

EX LIBRIS

NERVE WOUNDS.

*SYMPTOMATOLOGY OF PERIPHERAL NERVE
LESIONS CAUSED BY WAR WOUNDS*

BY

J. TINEL



ANCIEN CHEF DE CLINIQUE ET DE LABORATOIRE DE LA SALPÊTRIÈRE

PREFACE BY

PROFESSOR J. DEJERINE

AUTHORISED TRANSLATION BY

FRED ROTHWELL, B.A., LOND.

REVISED AND EDITED BY

CECIL A. JOLL, M.B., M.S., B.Sc.LOND., F.R.C.S.ENG.

SENIOR SURGEON RICHMOND MILITARY HOSPITAL.

ASSISTANT SURGEON ROYAL FREE HOSPITAL.

LATE SURGEON-IN-CHIEF MAJESTIC HOSPITAL, CROIX ROUGE FRANÇAISE

NEW YORK
WILLIAM WOOD & COMPANY

MDCCCXVIII

RDS95
T5

W. W. CLARE

380212

PRINTED IN GREAT BRITAIN BY
WILLIAM CLOWES AND SONS, LIMITED
LONDON AND BECCLES

W. W. CLARE

EDITOR'S INTRODUCTION

My object in making Dr. Tinel's book available in English has been to fill a very definite gap in the literature of peripheral nerve lesions. I am, of course, aware that there are excellent manuals on the subject by British authors, but none of them appears to me to cover the ground so fully, so authoritatively, and so originally as Dr. Tinel's.

The continental clinic system makes it possible for the clinician to investigate a far larger number of cases than under our own individualistic methods. I hope that, with the return of peace, the clinic system, introduced in a modified form by my colleague, Mr. James Berry, at the Royal Free Hospital, will be continued and expanded.

I have endeavoured to adhere closely to Dr. Tinel's text. If, however, I have failed to reproduce his meaning, the responsibility is certainly mine, as his book is most lucidly written.

I have throughout preserved the term "griffe" rather than use the rather doubtful translation "claw," and in one or two other cases where translation did not appear to be helpful, I have retained the original word. I wish to thank Mr. Rothwell for great help in the revision of the proofs.

CECIL A. JOLL.

WIMPOLE STREET, W.

OCTOBER, 1917.

PREFACE

I AM pleased to be in a position to introduce to the medical public this work of my pupil Tinel on Nerve Wounds, for it is admirably adapted to the needs of the daily work of our military hospitals.

All surgeons and neurologists still remember how surprised they were, during the early months of the War, at the numerous cases of peripheral nerve wounds brought into our hospitals.

It was a big subject of which the few cases observed before war broke out had not enabled a complete study to be made; in addition, the uncertainty of our clinical and diagnostic knowledge of the nature of the lesions was complicated by the therapeutic aspect of the problem.

Suddenly we found ourselves confronted with so many facts unlike one another that it is easy to understand our hesitation in classifying and interpreting them, and above all in pronouncing them amenable or not to surgical intervention.

Indeed, we had first to establish the exact signification of the variable and differently associated symptoms met with in all these cases, to specify the diagnostic value of partial or total paralysis, of muscular hypotonia and electrical disturbances, of anæsthesia, paræsthesia, or pains in their various modalities; to throw light upon the problem of vaso-motor secretory or trophic disturbances, at times so intense, or at other times scarcely perceptible, and above all to connect each of these symptoms with the determining lesion. By close study of all these disturbances and of their evolution, my pupils and myself have been enabled to set up the main syndromes of nerve interruption, of compression, irritation or regeneration, and the syndromes of dissociated or partial lesions.

It was also necessary to study the nerve lesion itself, in order to understand the mechanism of interruption irritation or compression. It was specially important to become acquainted with the exact anatomical conditions which either permit of the regeneration of the nerve trunks or make this impossible. These problems have been solved by histological study and experimental investigation. We are now acquainted with the particular characters of neuromata and pseudo-neuromata; we know how the vicious cicatrices which I have called nerve keloids, and which set up a frequently insurmountable obstacle to the regeneration of the axis-cylinders, are formed; consequently, we are possessed of

histological information which either calls for or proscribes surgical intervention.

In a word, the same histological and experimental discoveries have enabled us to specify the normal conditions of operation; they have demonstrated the illogical nature and the uselessness of certain interventions, the utility and rationale of others; they have not only encouraged the practice of simple liberations and of nerve sutures, but they have also enabled us to throw light on many aspects of surgical technique.

For long months all the laboratories, clinics and neurological centres of our country have given themselves up to these investigations, thus carrying out a task which has completed the unwearied labours of former histologists, physiologists, and clinicians.

Whilst it must be confessed that all our problems have not yet been completely solved, and there are still many obscure points, all the same it may be affirmed that the main lines to be followed have now been traced. The time has come to unite in one book the many investigations which form the basis of this new work.

It must indeed be recognised that these ideas of nerve pathology, anatomy and physiology, have not yet gone far beyond the sphere of the neurological and surgical centres. Nerve wounds are still a mysterious and disturbing problem to many doctors. And yet it is important that these fundamental principles should be known to all. Nerve lesions must not continue to remain unknown in the routine of hospital life.

No longer must there be, for whole months, useless electrical or massage treatment of complete nerve sections, or the unnecessary excision of nerves simply compressed, irritated, or in a fair way towards natural recovery.

Regarding the prognosis of nerve wounds, or of the operations on them which are frequently necessary, we must not allow opinions to be established that are incorrect, discouraging in their pessimism, or dangerous in their optimism.

Above all, we must not regard as nerve lesions, functional paralysis and disability, the cure of which is so easy when a timely diagnosis has been made.

In a word, it is not sufficient that all doctors and surgeons should scrupulously conform to the indications of neurologists; they must also be co-workers. This is the best means of multiplying observations, of recording both clinical data and therapeutical indications, and of obtaining not only the best results for the wounded, but also a solution of problems on which full light has not yet been thrown.

It is for this reason above all that I regard the publication of the present work as necessary.

It will show doctors how almost all clinical problems may be solved by the aid of a few very simple facts of general anatomy and physiology.

I am glad to see once more verified the rule which I have always followed, namely, that you cannot have a good clinical neurology without exact anatomy.

We shall also see that we need only have recourse to the elements of histology and nervous physiology in order to deduce therefrom the logical rules of physical or surgical treatment.

Consequently, I cannot sufficiently congratulate the author of this work on his constant endeavours to call attention to the knowledge of anatomy, physiology or histology, necessary for an interpretation of the facts.

His remarkable qualities of exposition will also be noted. One must be a thorough master of one's subject to compile, from an enormous mass of observations and documents of every kind, a book that is alike perfectly clear and scrupulously exact.

The wealth and choice of the information offered, the carefully executed photographs, the numerous clear diagrams, make this volume a fine study in symptomatology, of great educational importance, and one which completely fulfils the purpose aimed at both by the author and by the publishers.

It is a pleasure for me to have encouraged the idea of this work and witnessed its realisation. Written, so to speak, in my very presence, it is a faithful *résumé* of the investigations entered upon in my service by all my fellow-workers of the Charcot Clinic.

J. DEJERINE.

PARIS.

CONTENTS

	PAGE
INTRODUCTION	xi

PART I

GENERAL SURVEY

CHAPTER		
I.	NERVE LESIONS IN WAR WOUNDS	1
II.	CLINICAL EXAMINATION OF A NERVE	17
III.	ELECTRICAL EXAMINATION	37
IV.	CLINICAL TYPES	60
V.	GENERAL DIAGNOSIS OF PERIPHERAL NERVE LESIONS	92

PART II

UPPER LIMB

VI.	MUSCULO-SPIRAL NERVE	99
VII.	ULNAR NERVE	132
VIII.	MEDIAN NERVE	170
IX.	ASSOCIATED PARALYSIS OF THE MEDIAN AND ULNAR NERVES	194
X.	MUSCULO-CUTANEOUS NERVE	197
XI.	THE CIRCUMPLEX NERVE	201
XII.	INTERNAL CUTANEOUS NERVE AND LESSER INTERNAL CUTANEOUS NERVE	205
XIII.	BRACHIAL PLEXUS	209
XIV.	ISCHÆMIC PARALYSIS OF THE UPPER LIMB	225

PART III

LOWER LIMB

XV.	SCIATIC NERVE	231
XVI.	SMALL SCIATIC NERVE	266
XVII.	ANTERIOR CRURAL NERVE	268
XVIII.	OBTURATOR NERVE	275

CHAPTER	PAGE
XIX. EXTERNAL CUTANEOUS NERVE OF THIGH	277
XX. GENITO-CRURAL NERVE	279
XXI. ILIO-HYPOGASTRIC NERVE	280
XXII. LUMBO-SACRAL PLEXUS	282
XXIII. DIAGNOSIS OF THE LESIONS OF THE LUMBO-SACRAL PLEXUS	294

PART IV

CONCLUSIONS

XXIV. PROGNOSIS AND TREATMENT OF PERIPHERAL NERVE LESIONS	297
XXV. SURGICAL TREATMENT	300
XXVI. ELECTRICAL TREATMENT	308
INDEX	313

INTRODUCTION

THE number of peripheral nerve wounds in warfare is considerable : this has been one of the surprises of the present war.

Lesions of the nerve trunks in traumatism of the limbs cannot be estimated at less than 18 to 20 per cent., and this proportion increases if we leave slight wounds out of account and consider serious traumatism frequently involving one or more nerves.

This consideration is most important ; in every wound all the nerves of the wounded limb must be systematically examined. An early diagnosis of nerve lesions will alone enable one fully to appreciate the gravity and consequences of the wound, to formulate an exact functional prognosis and institute proper treatment. By surgical intervention at the right moment, by judiciously employed electrical and mechanical treatment, an early diagnosis of nerve lesions will enable one to reduce to a minimum one form of incapacity following on war wounds. On the other hand, an imperfect knowledge of these nerve lesions may have grave results ; it may cause erroneous or unjust calculations as to the degree of disability the patient will suffer in the future, make the prognosis of the wounds worse by the absence of the necessary treatment, or render irreparable cases of paralysis which ought to have been cured.

Any nerve may be affected by war wounds ; speaking generally, statistics show a certain preponderance in nerves of the upper limb, amongst them the musculo-spiral nerve. Our own statistics enable us to form some idea of the relative proportion of the different nerves affected.

From the 639 cases investigated in this work, we reach the following results :—

UPPER LIMB.

Musculo-spiral	146
Ulnar	84
Median	67
Musculo-cutaneous	11
Circumflex	25
Lesions of the brachial plexus	27
Combined serious lesions of several nerves of the upper limb	48
Total	408

LOWER LIMB.

Anterior crural	11
Long saphenous nerve	14
Sciatic (trunk)	78
Internal popliteal nerve	29
External do. do.	37
Posterior tibial	18
Musculo-cutaneous	7
Anterior tibial	4
Short saphenous nerve	9
Obturator	1
External cutaneous	3
Ilio-inguinal nerve	1
Lumbo-sacral plexus	19

Total 231

The study of nerve wounds is based essentially on certain facts of general pathological anatomy, and on a perfect knowledge of the anatomy and physiology of the nerves.

The works of Waller, of Duchenne of Boulogne, of Philippeaux and Vulpian, of Weir Mitchell, of Létiévant; the more recent researches of Broca, Lejars, Claude and Velter, etc., have already thrown considerable light on the problems involved in the study of peripheral nerve lesions.

The innumerable cases observed during the war, however, have given this study considerable importance and expansion.

Since the outbreak of war, it has produced an enormous number of works from the various neurological centres. It is impossible to enumerate them all here: the illuminating writings of M. and Mme. Dejerine, inspiring the works of their pupils, André-Thomas, Jumentié, Mouzon, etc.; the brilliant investigations of P. Marie and his pupils, Meige, Foix, Mme. Athanassio-Benisty, etc.; the remarkable studies of Babinski and Froment; of Claude, of Sicard, and of their pupils or assistants; and the histological researches of Nageotte, etc.

The *Société de Neurologie de Paris* has fortunately grouped together all these fundamental investigations, which will be found published in the *comptes rendus* of this Society, and analysed in the valuable numbers of the *Revue Neurologique* devoted to war neurology.

To these patient and methodical investigations of neurologists have been added the works of surgeons, recorded and published for the most part by the *Société de Chirurgie de Paris*.

To this cordial and unceasing collaboration of neurologists and surgeons we are at present indebted for the possession of admirably exact and complete information on nerve wounds. It is almost a new science that has thus come into being since the war began, the results of which already surpass our most enthusiastic expectations and hopes.

NERVE WOUNDS

PART I

A GENERAL SURVEY

CHAPTER I

NERVE LESIONS RESULTING FROM WOUNDS

THE peripheral nerves may be wounded either directly or indirectly.

Directly, the wound may be made by a bullet or by a shell splinter, when the nerves are sectioned, torn, perforated or crushed by the projectile; they may be pierced by small splinters which remain within the nerve itself; they may also be contused by the shock, spitted by a bony

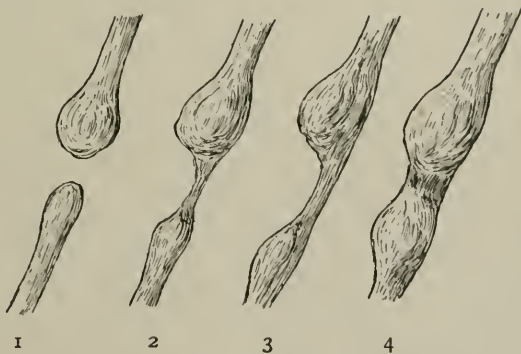


FIG. 1.—*Various types of nerve sections.*—1. Total section with separation of the segments. 2. Union of the segments by fibrous cord. 3. Partial section; persistence of a portion of the nerve. 4. Total section, union of the two segments by cicatricial formation. In every case there are found two swellings: *neuroma* on the central end, *glioma* on the peripheral end.

splinter, compressed by a fractured bone. They may be stretched or even torn away by violent traction: this frequently happens in lesions of the brachial plexus. Finally, they may be infiltrated by an interstitial traumatic hemorrhage of the nerve trunk, which itself is in a contused state.

Indirectly, the peripheral nerves may be surrounded by callus or shut in by cicatricial fibrous tissue.

The macroscopic lesions, resulting in these different ways may be reduced to a few types.

Complete or partial sections, with separation of nerve segments, or else with interposition of cicatricial tissue.

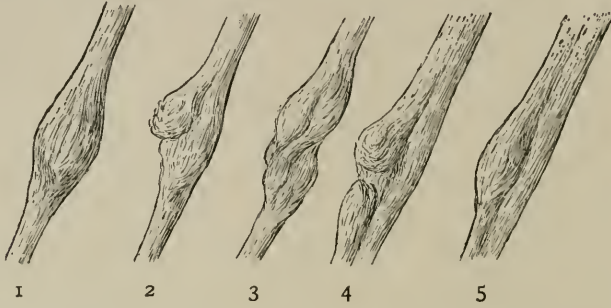

FIG. 2.—*Tearings and crushings*.—1. Total neuroma by crushing of the nerve.—2. Lateral neuroma by partial tearing. 3. Diffuse neuromatous formation. 4. Partial section. 5. Partial neuroma after crushing a portion of the nerve.

Tearings, crushings or perforations, attacking the whole or part of the nerve, with interstitial, total, central or lateral neuroma.

Compressions or strangulations over a greater or less extent; sometimes there is found strangulation by simple fibrous band, producing above the

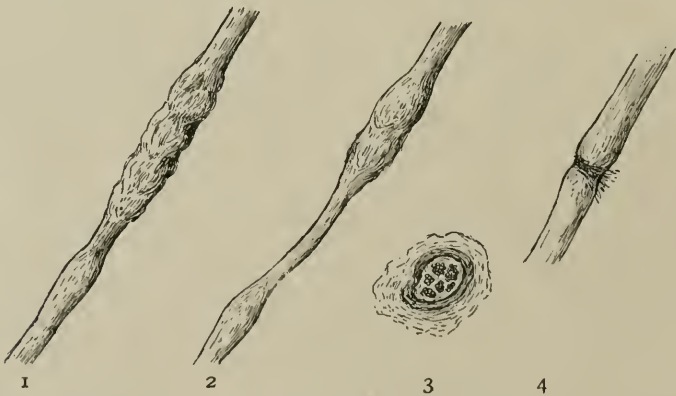

FIG. 3.—*Compressions*.—1. Compression in callus, the compression corresponds to the narrowed area, forming an insurmountable obstacle above which the contused nerve has produced a pseudo-neuroma. 2. Very tight compression; development of a neuroma above the obstacle. 3. Section at the upper part of the pseudo-neuroma showing thickening of the envelopes. 4. Simple constriction by fibrous cord.

constriction a swelling which may occasionally disappear immediately after the liberation of the nerve.

Contusions or attritions of the nerve are most frequently shown by

hemorrhagic or fibrous infiltrations, which probably correspond to two successive stages; in all likelihood it is the interstitial hemorrhage of the nerve for the most part which in the long run produces the fibrous infiltration.

Fibrous hemorrhagic infiltrations, like the compressions with which they are often allied, would seem to be the most frequent cause of nerve irritations of a neuritic type. All the same, there exist irritations, sometimes very intense, in which the macroscopic appearance of the nerve is absolutely normal. This is ordinarily the case in simple neuralgia and even in violent neuralgia of a causalgic type.

Almost always the wounded nerve shows not only lesions of the nerve itself but also important changes in its coverings and in the surrounding tissues; thickening of the neurilemma which may even constitute a voluminous fibrous sheath for the nerve; cicatricial fibrous

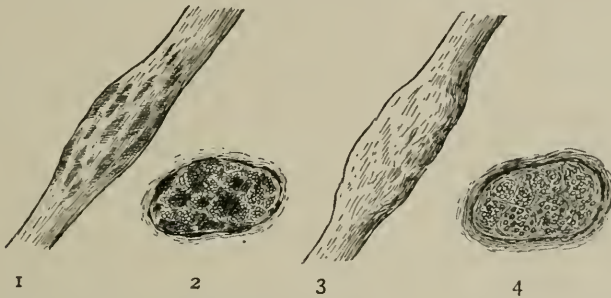


FIG. 4.—*Pseudo-neuromata resulting from bruising.*—1 and 2. Recent contusion of a nerve with hemorrhagic infiltration. 3 and 4. Long-standing bruise, with fibrous and neuromatous infiltration.

transformation by injury to the neighbouring connective or muscular tissues, often forming an enormous fibrous mass in which the nerve is as it were swallowed up and is frequently very difficult to recognise and isolate.

Every wounded nerve is habitually the seat of a more or less bulky *neuroma* or *pseudo-neuroma*.

We give the name *neuroma* to the tumour which essentially consists of the local proliferation and entanglement of the regenerated nerve fibres.

The *neuroma* invariably indicates an interruption of the nerve fibres and an obstacle to their progress. A *neuroma* is found on the central end of the sectioned nerves or else above the fibrous cicatrix resulting from a tearing or a perforation and opposing the regeneration of the axis-cylinder (Dejerine's "nerve keloid").

On the other hand, the tumours formed by thickening of the envelopes, by hemorrhagic or fibrous infiltration of the nerve, by proliferation of the neuroglial elements, are *pseudo-neuromata*.

Pseudo-neuroma resulting from bruising takes place in contusions and

compressions of the nerve ; the tumour which occurs on the peripheral end of a sectioned nerve is a pseudo-neuroma formed by proliferation of the neuroglial cells ; it contains no nerve fibres, but is really a *glioma*, as Nageotte has shown.

This distinction is important, for it results in very different therapeutic consequences. *The neuroma always indicates the presence of an obstacle to nerve regeneration*, it develops above this obstacle which must almost always be removed.

On the other hand, the *pseudo-neuroma* indicates an interstitial lesion, without proliferation of axis-cylinders ; the laminated sheaths which isolate the nerve fasciculi may be thickened, but they are not destroyed ; the compressed axis-cylinders may be injured or interrupted, but there exists no essential obstacle to their regeneration ; the integrity of the laminated sheath, on the contrary, insures conduction of the regenerated fibres ; there is never any occasion to make a nerve resection, at the most, a liberation may be needed ; spontaneous regeneration is almost certain.

HISTOLOGICAL STUDY

I.—PROCESSES OF DEGENERATION AND OF REGENERATION

A microscopical study of the wounded nerve enables us to analyse the processes of degeneration and regeneration of the nerve trunks.

Degeneration.—It is a fundamental and absolute principle that every interrupted nerve fibre undergoes centrifugal degeneration of the peripheral segment below the interruption. This is the phenomenon of *Wallerian degeneration*.

There is no exception to this rule : every nerve fibre separated from its trophic centre (the anterior horn cell in the case of the motor fibres, the cell of the posterior root ganglion in the case of the sensory fibres), inevitably degenerates ; even immediate suture of the nerve trunk cannot prevent this degeneration.

Experimental investigations have thrown light upon the successive phenomena which are seen during this degeneration of the peripheral segment. The axis-cylinder is seen to assume first a fibrillary appearance, then to split up into sinuous fragments, to become thin and finally disappear altogether.

At the same time we note the progressive transformation of the myelin ; it loses its chemical characteristics and comes to resemble the neutral fats, it also becomes stainable by Marchi's method. The myelin sheath swells in places and becomes irregular, sinuous and beaded ; it splits up into lumps or droplets and at last completely disappears, absorbed and eliminated by the leucocytes.

Lastly we witness a rapid multiplication of the nuclei of the sheath of Schwann, the proliferated cells of which unite with the neighbouring connective tissue cells and with the leucocytes to absorb the split-up myelin ; these are the granular bodies which effect a veritable clearing-up of the region, and, filled with the droplets of degenerate myelin, are eliminated by way of the lymphatic and the blood streams.

The interrupted nerve fibre then consists only of a vague protoplasmic frame, surrounded by the multiplied cells of the sheath of Schwann. This is an *empty sheath*.

Such, as a whole and in schematic fashion, is the process of Wallerian degeneration of the peripheral segment. It occurs within a few days, two to three weeks at most, culminating in the inevitable destruction of the nerve fibre below the interruption.

Whilst the peripheral segment is degenerating, the central end remains almost intact. Nevertheless it also undergoes slight degeneration, though confined to a few segments above the interruption ; the evolution of

this degeneration is almost the same as that of the peripheral segment. This is ascending or retrograde degeneration.

At the same time, the original nerve cell undergoes certain slight disturbances, an echo of the peripheral traumatism; these disturbances show themselves in the swelling of the nucleus and the chromatolysis of Nissl's granules. For some days this cell is itself incapable of entering upon the work of regeneration. Only after a few days does it resume its normal activity, and show its trophic function by the regeneration of the axis-cylinder.

Regeneration.—The *apparent* union of the sectioned nerves is very rapid; in three or four days at most it is brought about between the segments that remain in contact, by the proliferation of the cells of the sheath of Schwann. This soldering, however, of the separate segments is not regeneration, which is more tardy; it does not begin until a few days have passed and is effected only by the penetration and progressive descent of the axis-cylinders of the central end into the empty sheaths of the peripheral segment.

As in the peripheral nerve, so also among the scar tissue we have the proliferated cells of the sheaths of Schwann, cells of the neuroglia, which seem to attract and direct the regenerated axis-cylinders.

This directing action of the empty sheaths of Schwann on the axis-cylinders of the central end has been proved by numerous experiments; it is called *neurotropism*.

About the fourth day, we see the axis-cylinder of the central end dividing at its termination into very fine fibrils which slowly progress right to the level of the section, crossing the zone of retrograde degeneration.

They proceed across the "soldering," attracted and guided by the masses of neuroglia cells: they scatter about as though seeking the cellular cords representing the empty sheaths of the peripheral segment; they penetrate into these sheaths or course over their surfaces; they slowly advance into the nerve trunk, which they gradually reconstruct, and all of whose branches they follow to their motor or sensory endings.

Whilst these regenerated axis-cylinders are progressing, their myelin sheath is gradually being reconstructed and they insensibly resume their normal structure.

Only by this work of progressive regeneration, we must repeat, is the peripheral segment reconstructed; there is no other method of regeneration.

The axis-cylinders do not usually grow more than one or two millimetres per day in favourable cases; more rapid in the young and slower in those who are older. The consequence is that the regeneration of the nerve always demands considerable time. It must also be added that the restoration of the functions of the nerve takes place much later than its anatomic regeneration. It requires the reconstruction of the nerve terminations and their perfect functional adaptation.

All those cases in which, within a few days or even hours, the functional restoration of a sectioned nerve is stated to have taken place, are manifestly errors of interpretation, caused most frequently by the motor or sensory substitution of neighbouring nerves.

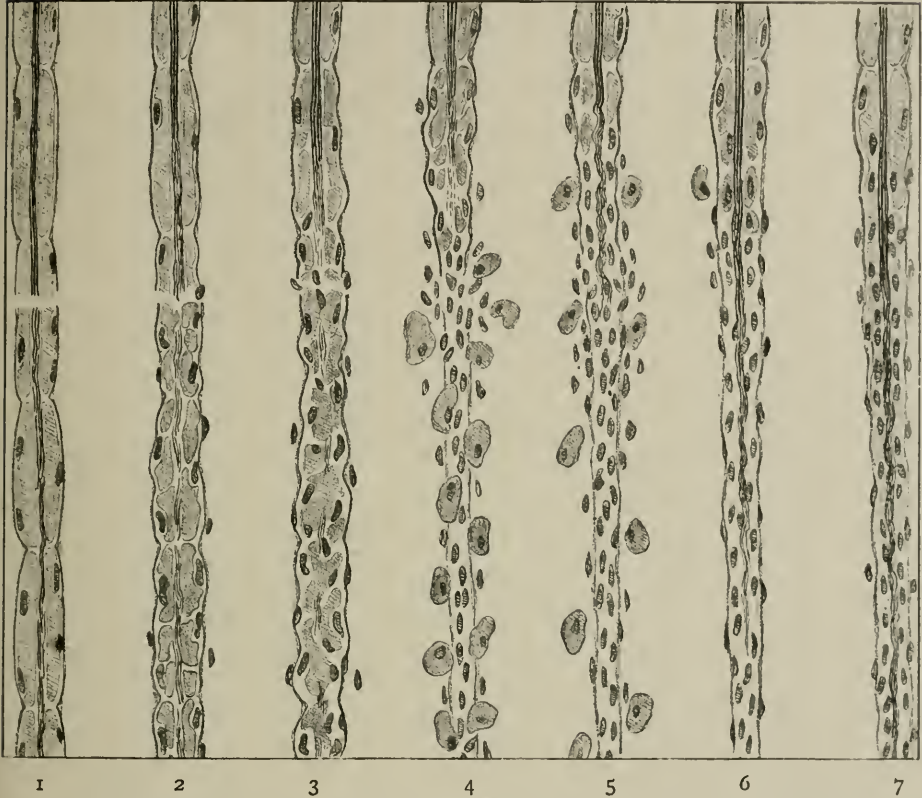


FIG. 5.—*Degeneration and regeneration of a sectioned nerve fibre.*—1. Fibrillation of the axis-cylinder and swelling of the myelin. 2. Segmentation of the axis-cylinder, swelling and displacement of the myelin. Proliferation of Schwann's sheath cells. 3. Disappearance of the axis-cylinder; myelin bulbs; proliferated connective tissue cells. Retrograde degeneration. 4. Formation of granular bodies; elimination of degenerate myelin by phagocytes. Soldering of fragments by proliferated connective tissue cells. Retrograde degeneration. 5. Beginning of regeneration in the central end. 6. Progression of the regenerated axis-cylinder in the empty sheath of the peripheral end. 7. Regeneration of the peripheral segment. Commencement of myelin reconstruction.

II.—DEFECTIVE REGENERATION—NEUROMATA

In order that regeneration of the peripheral segment may occur, the two segments must remain in contact with each other, or at all events at no great distance apart; it has been shown that regenerated axis-cylinders are capable of traversing a certain distance, attracted by the neurotropic of the peripheral end.

If the separation is too great, or if the axis-cylinders encounter an insurmountable obstacle between the two segments, regeneration of the peripheral segment is impossible.

The axis-cylinders of the central end proliferate, but, being incapable of reaching the sheaths of the peripheral segment, they wander about in the cicatricial tissue which impede their advance, they cluster at the extremity of the central end and constitute a veritable tumour, the "neuroma": or again, they are rolled upon one another in spirals and return to their starting point, tracing the curious figures described by Peroncito.

In these cases, there is an attempt at regeneration, though ineffective; it is abortive regeneration.

This fruitless regeneration, resulting from a bad coaptation of the segments, must not be mistaken for absence of regeneration. The latter, characterised by absence or delay of activity in the processes of regeneration, results solely from serious disturbances in the nutrition of the nerve cell or of the central segment; it is found only in aged subjects or those in poor health: in certain cases of neuritis, regeneration is also tardy and inadequate.

Consequently this is not as in the first case a simple accident, reparable by surgical intervention, it is an essential disturbance and has serious consequences.

III.—HISTOLOGICAL LESIONS CAUSED BY NERVE WOUNDS

We have summarily described the general processes of degeneration and regeneration, as elucidated by experimental investigations.

The knowledge acquired will enable us readily to interpret the variable and complex histological aspects, encountered in traumatic lesions of the nerves.

1. Section.—Section of the nerve trunks presents the simplest features for histological study.

We find on the central end a terminal neuroma, formed by the winding and rolling of the proliferated axis-cylinders: this is the classic amputation neuroma.

More or less bulky, this neuroma appears in section as made up of intricate nerve fibres or even of regenerated nerve fasciculi. Some, in longitudinal section, appear sinuous and irregular; the rest, sectioned transversely or obliquely, fill the clear spaces which seem hollowed out in the interstitial fibrous tissue.

All these nerve fibres are embedded in a fibrous tissue which is more or less dense, sprinkled with numerous cells resulting from the multiplication of the neuroglial cells of the sheaths of Schwann; these cells seem specially grouped along the nerve fasciculi of which they really compose the connective tissue framework.

The nerve fibres of the neuroma are already myelinised, but they are

irregular and often beaded ; we find in juxtaposition adult fibres, already bulky, and very slender and scarcely myelinised young fibres.

Above where they enter in the neuroma, the nerve fibres of the central end almost always show abnormal features ; some have undergone fibrillary transformation, others are irregular, and sometimes present a barbed aspect

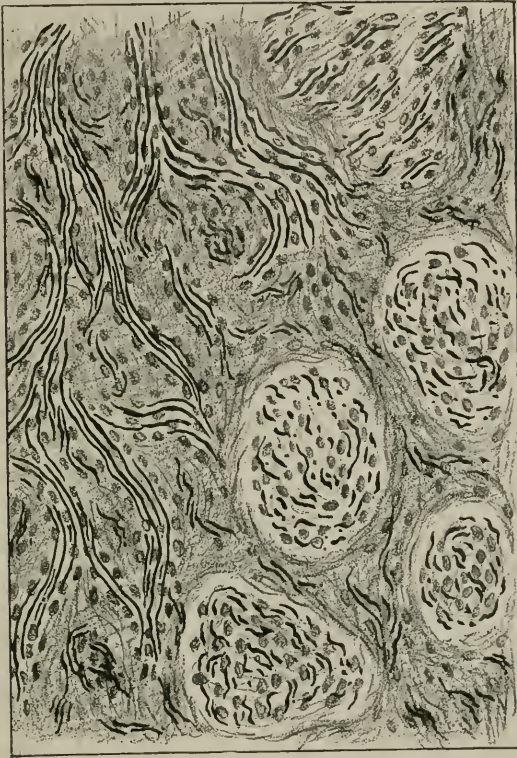


FIG. 6.—*Terminal neuroma of the central end.*—Twisting up, grouping and intermingling of the fasciculi of regenerated axis-cylinders. Certain fasciculi are sectioned longitudinally, others transversely. They are embedded in rather dense fibrous tissue, interspersed with the proliferated cells of the sheath of Schwann, the cellular columns of which accompany the nerve fasciculi.

of which we shall speak later ; others have undergone a kind of swelling of their myelin, giving them a vacuolated appearance.

To sum up, these features are but the remains of retrograde degeneration, or the manifestations of regenerative activity.

The peripheral segment also presents a swelling, usually less bulky, this is a false neuroma, a *glioma*, as Nageotte has shown, composed solely of the excessive proliferation of the cells of the sheath of Schwann.

These neuroglial cells are clearly to be seen, at the lower part of the glioma, set out in parallel groups corresponding with the site of the nerve fasciculi that have disappeared. At the upper part of the glioma, the cells

of the sheaths of Schwann usually constitute more bulky and irregular cellular masses, resulting from unrestrained proliferation. Groups and cellular masses are plunged in a fibrous stroma, which is more or less dense.

If the section is not too old, traces of degenerate nerve fibres may still be found in the form of "granular bodies" laden with myelin, or even with series of blocks of myelin still tracing the course of the nerve fibre.

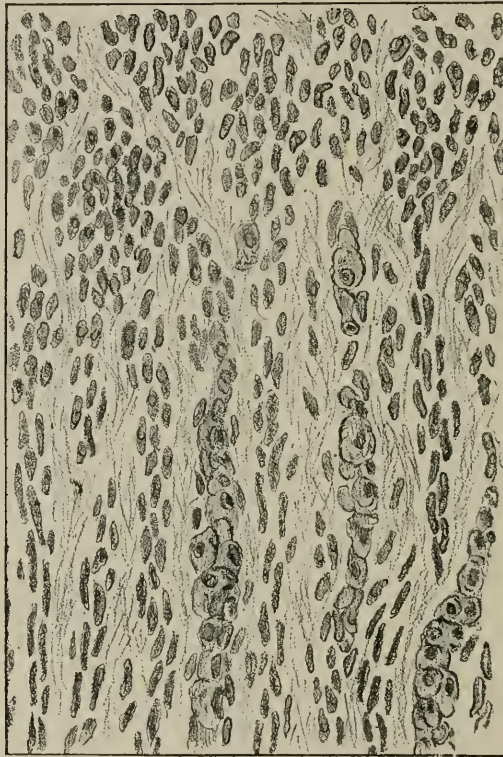

FIG. 7.—*Glioma of the peripheral segment.*—Absence of all nerve fibre. Simple proliferation of the cells of the sheath of Schwann, forming cellular columns which accompany the empty sheaths. Arrangement in cellular columns is fairly regular at the lower part of the glioma; at its upper part, in the neighbourhood of the section, the cells form bulky masses in which the fascicular arrangement is no longer recognised. Below, some granular bodies, laden with degenerate myelin, have not yet been completely eliminated.

2. Complete interruptions without break of continuity of the nerve.—The nerve is apparently not sectioned, but the traumatism, crushing or rending, has produced complete interruption of the nerve fibres. At the level of the wound, there is observed a more or less irregular neuroma, made up of cicatricial fibrous tissue, the proliferation of neuroglial cells, and the grouping of regenerated axis-cylinders.

In very schematic fashion, three different zones in this neuroma may

be described : a middle zone of nerve destruction and of fibro-cicatricial scar tissue constituting the obstacle, this is the nerve keloid of Dejerine ; an upper zone where the regenerated axis-cylinders are piled up and grouped above the obstacle ; and a lower zone of neuroglial proliferation

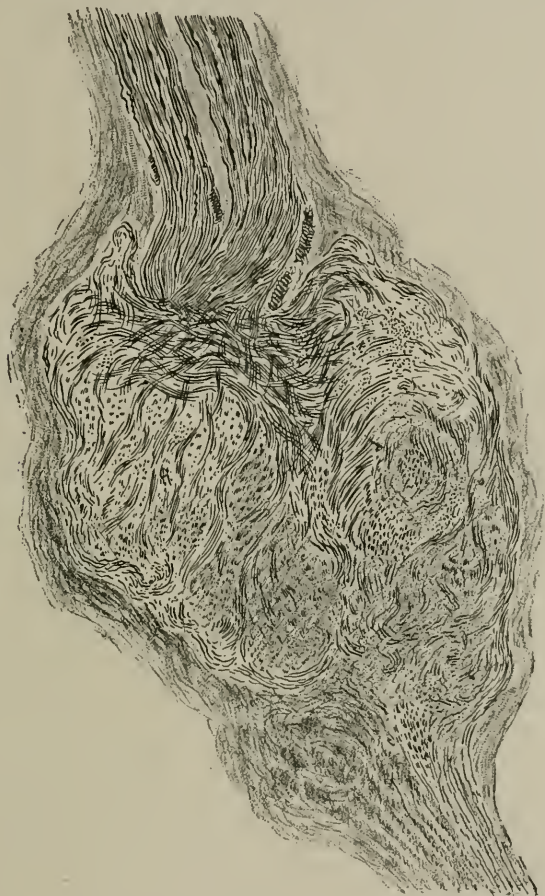


FIG. 8.—*Complex neuroma*.—Above, penetration of the central end, the majority of whose fibres have undergone fibrillary transformation. Some fibres are rolled in spiral form above the neuroma. In the middle part, neuroma made up of the intercrossing and grouping of axis-cylinder fasciculi (fibres sectioned longitudinally or transversely). In the lower part of the neuroma is found a denser fibrous tissue which probably represents the cicatrix of the wound. Below, the cells of the empty sheaths form cellular columns, the proliferation of which forms on the left a veritable glioma. On the right, a few regenerated fibres have succeeded in passing into the peripheral (semi-diagrammatic) segment.

where the cells of the sheath of Schwann form, in the neighbourhood of the wound, bulky and disorderly cellular masses, to resume in the lower part of the neuroma the more regular aspect of cellular columns corresponding to the degenerate nerve fasciculi.

In reality these three zones are seldom so distinct ; they are partly

confused and entangled, constituting a complex neuroma, in which it is difficult to distinguish what results from each of the three processes analysed: fibrous cicatrisation, regeneration of the central end and degeneration of the peripheral segment with cellular proliferation.

The notion, however, of the cicatricial fibrous obstacle interposed between the two segments is a very important one. Whether this cicatricial formation is clearly limited as is sometimes seen, constituting a sort of fibrous nucleus, or whether it is diffused and extends over almost

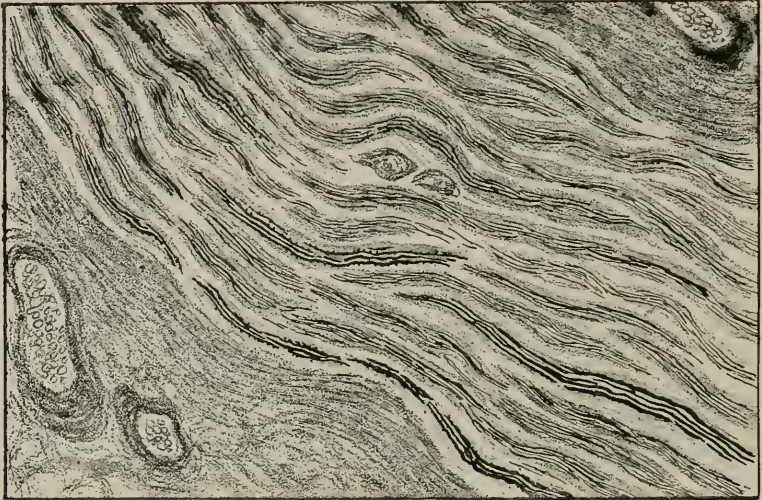


FIG. 9.—*Pseudo-neuroma resulting from bruising.*—Nerve fasciculus contained in a cicatricial fibrous mass. The nerve fibres are not interrupted, but they are greatly altered. Most of them have undergone fibrillary transformation and have lost their myelin. Others have preserved their normal volume: some are swollen, irregular, beaded; others have assumed a special appearance, bristling with thorns (which probably represent the dissociation and impregnation of the incisures of Lanteimann), barbed in appearance. The laminated sheaths which separate the nerve fasciculi are infiltrated and thickened, but they have not undergone any rupture which permits the egress of the axis-cylinders; by them the regenerated nerve fibres are readily conducted towards the peripheral end.

the entire neuroma, it always sets up an obstacle to the progression of the axis-cylinders; on the extent, thickness and density of the cicatricial fibrous tissue depends the regeneration of the peripheral segment.

If the nerve fibres are able to pass the obstacle or turn round it and rejoin the empty peripheral sheaths, spontaneous regeneration is possible; the neuroma is permeable to the regenerated axis-cylinders.

If the fibrous tissue is too dense or of too great extent, the neuroma is impermeable, spontaneous regeneration is impossible; surgical intervention must remove the obstacle and restore coaptation between the two segments by resection and suture of the nerve.

3. Pseudo-Neuroma resulting from Bruising.—In certain contusions

or compressions of the nerve, one may observe lesions that are not so deep.

What essentially characterises these lesions is that the laminated sheaths surrounding the nerve fasciculi are not destroyed, they may be infiltrated or thickened, but they have not undergone any rupture which could permit egress of the axis-cylinders and their budding outwards. The frame of the nerve is, on the whole, preserved.

The nerve fibres are seldom interrupted, but only injured at the level of the lesion. For instance, we find a simple swelling or fragmentation of the myelin, frequently even demyelination of the nerve fibres; the




FIG. 10.—*Hemorrhagic infiltration of a nerve by recent contusion: syndrome of severe nerve irritation. Hemorrhage in the sheath of the nerve and interstitial hemorrhage. Fibrillary separation of certain fibres, beaded transformation or barbed appearance of the other fibres. Integrity of the laminated sheaths (Bielchowski's method en masse).*

axis-cylinder may be irregular, beaded, or more frequently it is separated into a bundle of fine fibrils; very often we find a special appearance where the axis-cylinder seems bristling with thorns which probably represent the displacement and impregnation with silver of the incisures of Lantermann; a veritable barbed appearance of the nerve fibres.

There is always an interstitial infiltration of the nerve by a more or less dense connective tissue, with proliferation of the cells of the sheath of Schwann, or again we encounter small interstitial hemorrhagic effusions. The envelopes of the nerve are thickened, sometimes even the entire nerve is embedded in a cicatricial fibrous mass where it is extremely difficult to recognise it.

This causes increased volume of the nerve, an elongated or fusiform pseudo-neuroma resulting from the bruising.

In all cases, however, lesion of the nerve fibres is gradually confined to the traumatised zone; the sheaths of myelin may have disappeared at this level, without the axis-cylinders being interrupted; consequently there is no Wallerian degeneration of the peripheral segment; at the most, certain

fibres, more profoundly affected by the traumatism, end by degenerating. Most of the peripheral fibres do not degenerate; they simply indicate, by certain modifications of the myelin or the axis-cylinder, the disturbances to their nutrition caused by the local injury.

Though the more severe lesion of certain nerve fibres may have determined their complete interruption, the integrity of the laminated sheaths does not permit egress of the regenerated fibres; they cannot constitute a real neuroma; they are guided by the intact sheaths towards the peripheral segment.

These lesions resulting from bruising are not generally accompanied by complete paralysis; when this latter exists, it assumes the somewhat special characteristics of the paralytic syndrome of compression; it is usually incomplete, temporary, dissociated, irregular.

On the other hand, it is in these cases that we almost always encounter the syndrome of nerve irritation accompanied by trophic pains and disturbances.

The nerve fibres, having undergone simple partial and segmentary degeneration, may be reconstituted on the spot, without the necessity of regeneration by eruption of the central axis-cylinder. They may thus very rapidly regain their functions; this is what we find in certain cases of simple compression after surgical liberation of the compressed nerve.

Still it is not always so; when the lesions, without being completely destructive, are nevertheless very severe, regeneration seems to take place exactly as in cases of complete interruption; the young axis-cylinders proceeding from the central end gradually replace the affected, irritated and painful fibres of the peripheral segment. In these cases of severe neuritis, regeneration would seem to be particularly slow and difficult, as though the trophic function of the cell itself were disturbed *à distance* by the painful reactions of the affected nerve.

IV.—DISSOCIATED SYNDROMES AND PARTIAL LESIONS

The various lesions just investigated may frequently be found on the same nerve trunk, giving rise in these cases to dissociated syndromes, elucidated in the works of J. and A. Dejerine and Mouzon.

Thus, for instance, the same nerve may be interrupted in one of its parts and simply bruised or even intact at other points.

So also certain groups of nerve fibres may have escaped the more or less complete destruction of the nerve.

Again, a neuroma may be permeable or impermeable to regenerated fibres, or may even be partially permeable.

* * * * *

Whilst we are at the present time well acquainted with the histological processes of nerve interruptions and regenerations as well as of nerve

compressions and irritations, we must at the same time confess our complete ignorance regarding the syndromes produced by slighter traumatism.

Simple neuralgia from slight contusion of the nerve, painful syndromes of causalgia or of ascending neuritis, fleeting paralysis from temporary compression, are other obscure problems, of whose pathogeny we know nothing.

In some cases we meet with a few widely disseminated lesions; in many others, on the contrary, we find nothing to explain histologically the disturbances noticed; and one is often led to consider the hypothesis of disturbances arising from nerve inhibition, sympathetic reflexes, or irritation, *à distance*, of the motor or sensory cells which are related to the fibres involved.

DIAGNOSIS OF NERVE LESIONS

The different lesions which a wounded nerve may present are shown, on examination, by different syndromes. Most frequently they are

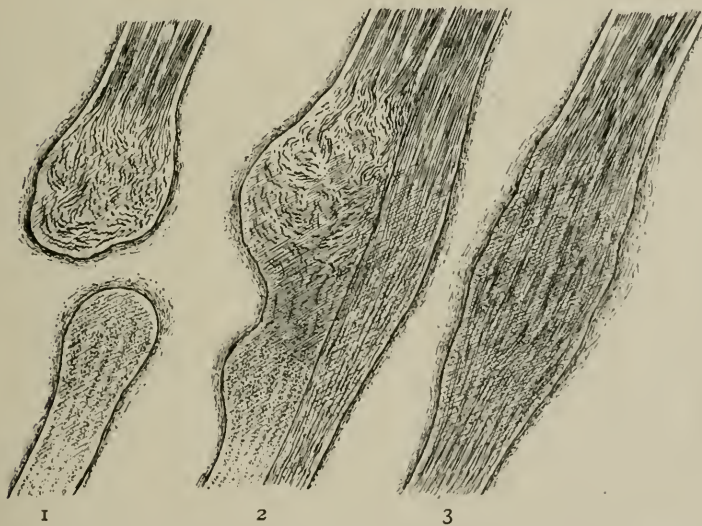


FIG. 11.—1. Total interruption. Neuroma, above; glioma, below. 2. Partial interruption with lateral pseudo-neuroma resulting from bruising. 3. Pseudo-neuroma resulting from bruising without interruption of nerve fibres. Rarefaction and fibrillation of axis-cylinders.

differentiated in a way clear enough to enable one, previous to any intervention, to form a tolerably exact diagnosis of the anatomical state of the nerve.

Thus it is by a clinical examination mainly that we must judge if an operation is necessary. (J. and A. Dejerine and Mouzon.)

Before any intervention takes place, we must find out if the nerve is

physiologically interrupted or not ; also if the interruption is partial or total and which fibres it affects.

It is necessary to recognise the signs of irritation of the nerve as a whole or of some of its fasciculi, indicating that while the nerve is preserved, the fibres are irritated.

Above all we must find out if the neuroma discovered by palpation is permeable or not to the regenerated fibres, *i.e.* whether or not signs of regeneration exist ; this is particularly important, as it indicates clearly surgical abstention or intervention.

It would be most imprudent to trust solely to objective signs made in the course of systematic interventions ; for the macroscopic state of the

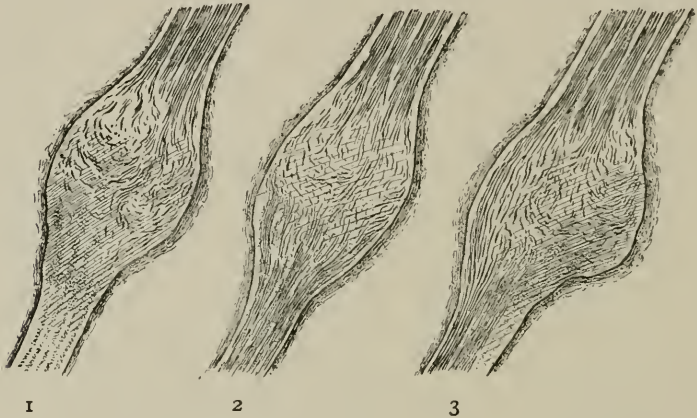


FIG. 12.—1. Neuroma impermeable to regenerated fibres. 2. Neuroma permeable to regenerated fibres. 3. Neuroma partially permeable with intact fasciculus.

nerve but imperfectly reveals its histological state, and above all the physiological state of the nerve fibres.

Naturally we must not neglect the objective examination and physiological exploration of the nerve exposed by intervention ; of all the processes suggested for this examination we shall find that there is only one that is logical and capable of being utilised : the electrical exploration of the exposed nerve as propounded and carried out by P. Marie and Meige.

It is the clinical examination, however, that must come first and supply the most important indications ; it is this that will decide if intervention is legitimate and will regulate beforehand the nature of such intervention.

CHAPTER II

CLINICAL EXAMINATION OF A NERVE

To be able to explore a nerve implies above all perfect knowledge of the anatomy and physiology of this nerve, its course and relations, the number and position of its branches, the muscles it supplies, and the cutaneous territory over which it is distributed.

The examination of a paralysed nerve should not be made until several weeks after the wound, if the best results are to be attained.

It must be made frequently, at intervals of several weeks, for the evolution of the symptoms is all important. One may often repent having operated too soon; there is never any inconvenience, so to speak, in postponing surgical intervention to two and even three months after the injury.

A nerve requires to be examined both minutely and methodically. The following system of examination may be advised—

I.—PRELIMINARY EXAMINATION AND HISTORY OF THE CASE

1. Examination of the wound.—The wound must first be examined, the orifice of entrance and that of exit located, and, following the course of the projectile, investigation made as to what nerve may have been injured.

It is important to reconstitute the exact position of the limb at the time of the wound, for anatomical relations may change according to the posture.

The bones situated in the neighbourhood of the wound should also be explored; the existence of a fracture makes possible the compression of the nerve in callus or its damage by a bony splinter.

Finally, it must be known whether or not there has been suppuration in the wound: from a suppurating tract may sometimes flow purulent matter capable of producing irritation in a neighbouring nerve.

2. Date of the wound.—Account must be taken of the time that has elapsed since the wound was received, for the symptoms may change considerably during the first few weeks.

Speaking generally, it is only two months after the wound that a clinical examination possesses its maximum value.

Indeed, during the early weeks, symptoms of inhibition may be mistaken for signs of destruction; paralysis or anæsthesia is often more extensive or complete than would be associated with the real lesion.

Again, a certain number of symptoms appear only after some time. Muscular atrophy, hypotonia, require several weeks to reach their height; the pains of nerve irritation frequently appear only after eight or ten days and sometimes increase for a whole month; formication in a nerve under pressure appears only about the fourth to the sixth week.

The electrical reactions of degeneration likewise frequently come about only after three or four weeks.

Too hasty an examination, then, would deprive one of a certain number of important signs; whereas it seems to be clearly proved that a delay of two or three months previous to surgical intervention is generally of no significance as regards the success of such intervention.

3. Investigation of the first sequelæ of the wound.—It is important to find out if paralysis has been immediate or has come about secondarily. In the first event, it is the nerve itself that has been directly injured; in the second, paralysis may result simply from compression by callus, from being embedded in a fibrous cicatrix, or even from the contact of a plaster apparatus; or again there may be the formation, around the nerve and in its very tissue, of a hematoma which has shown itself some hours after the wound and which would appear to be one of the frequent causes of nerve irritation.

Afterwards inquiry must be made into the phenomena which sometimes indicate immediately the presence of a nerve lesion.

Certain wounded men complain of an immediate and violent pain, suddenly traversing like a flash the entire extent of the nerve, whether it be the median, the ulnar or the sciatic. At other times the sensation is one of painful numbness.

In other cases, the nerve wound is accompanied by signs of motor irritation, such as a sudden cramp, a fleeting contraction in the region of the injured nerve, preceding the appearance of paralysis.

4. Evolution of nerve disturbances.—Inquiry will naturally be made as to the progressive increase or decrease of motor, sensory, or trophic disturbances.

The patient will be questioned as to the degree of functional inconvenience he experiences, as to his sensations of pain, of numbness and of formication.

Only after this previous examination and interrogation can one profitably make an objective examination of the nerve affected.

II.—CLINICAL EXAMINATION

I.—ATTITUDE OF THE PATIENT

All paralysis produces a characteristic attitude in repose or during action. Thus we have the droop of the hand in musculo-spiral paralysis, the *griffe** of ulnar paralysis, or steppage in lesions of the external popliteal nerve.

These attitudes will be studied in the case of each nerve.

It is important not to confuse paralytic attitudes with those resulting from functional inertia, psychic paralyses, contractures or cicatricial fibrous contractions.

II.—EXAMINATION OF VOLUNTARY MOVEMENT

The loss of power of voluntary movement of a muscle or a muscular group may vary from simple enfeeblement to complete paralysis.

Naturally, it is discovered by asking the patient to execute the necessary movements, and opposing to these movements, if they exist, a greater or less resistance.

In measuring the scope of active or passive movements, one may usefully employ either a "goniometer" with graphic representations (Lortat-Jacob and Sézary), or adopt the process of moulding the position of the limb with lead piping. These processes enable the evolution of paralysis to be readily followed.

Still, several important causes of error must be borne in mind.

(a) Complete paralysis may be mistaken for a considerable degree of weakening of a muscle, if movement takes place in an unfavourable attitude, particularly if the weakened muscle has to overcome the action of gravity.

For instance, a greatly weakened biceps or triceps can effect flexion or extension only when, the elbow being raised outwards to the height of the shoulder, the fore-arm is able to move horizontally. The extensors of the wrist, too, if greatly weakened, can raise the hand only if the arm remains hanging by the patient's side; very feeble contraction is then sufficient to impart to the hand a slight oscillatory movement.

These processes are particularly useful when trying to bring back the early movements which denote the disappearance of paralysis.

It is easy to find for each muscular group the attitude in which the feeblest movements are readily discernible.

(b) Make sure that the patient has thoroughly understood the order

* The term *griffe* refers to the claw-like attitude of the hand in certain nerve and muscle lesions.—(Ed.)

given ; all that is needed for this is to have the movement executed by the other limb.

(c) Also ascertain that inability to execute the movement is not caused by retraction or contraction of the antagonists, or by immobilisation of a joint.

The passive movements must consequently be studied.

(d) It often happens that the patient does not try to execute the prescribed movement, either from a sort of functional inertia which rather frequently follows on paralysis and artificially prolongs it, or from a conviction of inability, or even from ill intent.

This may readily be discovered, for even a powerless effort to execute the prescribed movement is always accompanied by the synergic contraction of the neighbouring and antagonistic muscles. If this contraction is lacking, one is justified in suspecting artificial incapacity.

(e) In all suspected cases electrical examination will enable us to judge of the reality of paralysis, for if we are dealing with functional inertia or psychic paralysis, the muscle readily contracts beneath the faradic current.

All paralysis in which faradic contractility is wholly retained must be suspected, unless we are dealing with cerebral lesion. Only, as we shall see, in some rare cases of slight compression of the nerve can faradic contractility be retained, in spite of genuine paralysis.

(f) On the other hand, one may deny the existence of real paralysis by attributing to a paralysed muscle the compensatory movements which the neighbouring muscles often succeed in effecting.

The study, then, of these functional compensations is very important, and should be made in the case of each nerve.

III.—EXAMINATION OF THE REFLEXES

Examination of the reflexes affords two classes of information.

We may study in a reflex the motor response which reveals the paralysis or the integrity of the muscle in question. This applies mainly to the study of the tendon reflexes. Peripheral paralysis of a muscle is accompanied by the disappearance of its reflex. The patellar reflex is abolished in paralysis of the anterior crural ; the Achilles reflex in paralysis of the sciatic ; the olecranon reflex in paralysis of the triceps ; the reflex of the extensors of the wrist in musculo-spiral paralysis, etc.

Whenever a paralysed muscle reacts by a reflex movement, it may be affirmed that we are dealing either with functional or with central paralysis.

In peripheral paralyzes we often find inversion of the reflexes, the paralysed muscle being incapable of responding to sensory excitation, a response of the neighbouring or antagonistic muscles is noticed. For instance, in lesion of the musculo-spiral accompanied by paralysis of the

triceps, percussion of the olecranon may cause slight contraction of the biceps; this is the inversion of the olecranon reflex. This reflex synergic contraction of the neighbouring or antagonistic muscles exists normally, though it is masked by the more vigorous response of the muscle directly stimulated; paralysis of this muscle makes it only the more manifest.

On the other hand, in a reflex one must consider sensory excitation; anæsthesia of the region excited is shown by abolition of the reflexes; this applies mainly to the cutaneous and periosteal reflexes.

In this case there is no response, either from the muscle appealed to or from the others; the reflex is suppressed at its source, not only in its motor expression.

The study, however, of the cutaneous and especially the periosteal reflexes is more delicate than that of the tendon reflexes and often supplies less exact information, on account of the possible diffusion of the sensory excitation and of the frequent superposition of several nerve regions especially in the case of deep sensibility.

We shall also study the different reflexes with their respective nerve regions.

IV.—OBJECTIVE EXAMINATION OF THE MUSCLES

(a) **Muscular atrophy.**—The muscular atrophy following a nerve lesion occurs rather slowly; it appears only after two or three weeks and gradually becomes more pronounced until the muscle is transformed into a thin fibrous cord.

It may be recognised by the contour of the muscular outline; it is mainly judged by comparison with the healthy side, and its progress may be followed by measuring the circumference of the limb.

Muscular atrophy also varies according to the nature of the lesion; it is more rapid and pronounced in sections than in simple compressions, and even more rapid still in certain nerve irritations.

It retrogresses somewhat slowly, and, though less marked, persists long after the reappearance of the movements.

It is increased by immobilisation of the limb, whilst it may be considerably checked by massage and a proper electrical treatment of the paralysed muscle.

Muscular atrophy in nerve lesions is a somewhat variable symptom and of secondary importance in the diagnosis. It should be distinguished from simple atrophy from prolonged inaction of the muscle and especially from reflex atrophy, which is secondary to the osseous, articular and tendon lesions.

(b) **Muscular tone.**—The study of muscular tone is very important, as J. and A. Dejerine and Mouzon have shown.

Tone is the state of latent and permanent contraction of the normal muscle at rest.

All paralyses by nerve lesions are accompanied by muscular hypotonia, but simple compressions are usually characterised by the retention of a certain degree of muscular tone, whereas complete interruption of the nerve after some time causes its total disappearance.

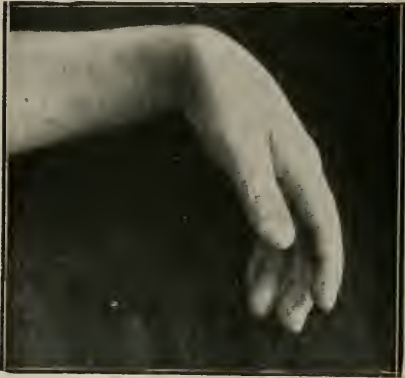

FIG. 13.—Complete hypotonia in interruption of the musculo-spiral nerve.

Nerve irritations, on the other hand, are not accompanied by very marked hypotonia; it is frequently less marked than in simple compressions.

On palpation, muscular tone may be recognised by the greater or less flaccidity of the muscular bellies.

It may more readily be studied by causing the antagonistic muscles to contract; then, if tone is maintained, a slight synergic swelling of the paralysed muscles is perceived.

The degree of tone is even better recognised by the attitude of the limb, for the disappearance of tone somewhat intensifies the paralytic

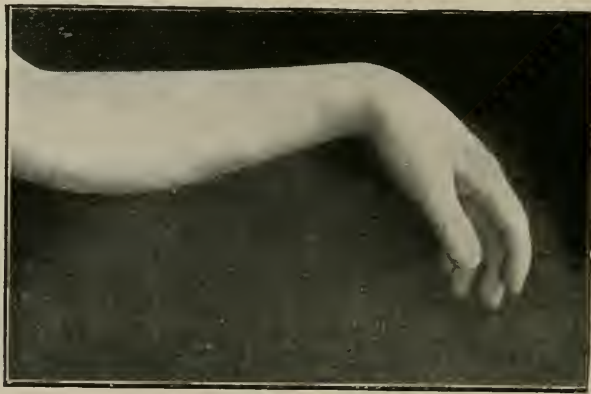


FIG. 14.—Return of muscular tone 73 days after suture, in the preceding case.

attitude. For instance, in musculo-spiral paralysis from simple compression, the hand remains hanging down at the end of the fore-arm, but if slight pressure is given to the hand, tending further to accentuate the flexion of the wrist—this accentuation is found to be possible since the hand was not flexed to its full extent—and if the pressure exercised is suddenly released, the hand rises slightly, elastically, owing to some

remaining muscular tone. In complete section of the musculo-spiral, however, flexion of the hand after a few weeks reaches the maximum permitted by the articular ligaments.

Disappearance of tone, therefore, is an important sign in favour of complete interruption of the nerve. (J. and A. Dejerine and Mouzon.)

It must, however, be noted that the prolonged inaction of a muscle, even in a certain number of functional paralyses, may be accompanied by hypotonia, which in time becomes considerable.

(c) **Mechanical contractility of the muscle.**—It is important to distinguish muscular tone from idio-muscular contractility. Percussion of a normal muscle produces a local and momentary swelling of the percussed muscular fasciculi, and that this is a genuine contraction is shown by more or less extended movements. This is the idio-muscular reflex.

Idio-muscular reflexes are always intensified in peripheral-nerve lesions, even though there is considerable hypotonia or even complete atonia.

This intensification of the mechanical contractility of the paralysed muscle is, as we shall see, comparable to the intensification of the contractility of the muscle under the galvanic current (galvano-tonus), when excitability of its nerve at the motor point has disappeared. Like contraction of the paralysed muscle under the galvanic current, the contraction provoked by percussion is slow. This amplitude and this slowness of contraction often permit a diagnosis of paralysis to be made. It constitutes a veritable “mecano-diagnosis” (André-Thomas). This is Sicard’s “mechanical myo-diagnosis.”

In a word, it may be said that, in a paralysed muscle, contractility from excitation of the nerve, whether voluntary or electrical, diminishes or disappears, whereas the contractility peculiar to the muscular tissue itself is intensified; the former is rapid and short, the latter is tardy in appearance and slow in its execution.

Mechanical contractility of the paralysed muscle, however, diminishes or even disappears in time, simultaneously with its galvanic contractility; the atrophied muscle, transformed into fibrous tissue, has then lost every kind of excitability.

(d) **Sensibility of the muscle to pressure.**—Every paralysed muscle is painless under pressure, unless there exists some nerve irritation. The total insensibility to pain and even the absolute insensibility of the muscle to pressure is one of the clear signs of complete interruption. (J. and A. Dejerine and Mouzon.)

On the other hand, pain of the muscular bellies under pressure is the best sign of nerve irritation; it is even more pronounced than pain of the nerve under pressure.

This pain may be extremely acute, rendering impossible all mobilisation or massage.

It may exist even when the muscle is not paralysed; then pressure on

the muscle frequently causes very painful though fleeting contractions and cramps. Voluntary contraction also causes violent pains, to such an extent that false paralyses may be noticed, resulting from immobilisation of the muscle through fear of pain.

Nerve pain in the muscles is very often accompanied by fibrous contractions.

(e) **Fibrous contraction of the muscles.**—Whereas compressions and especially nerve sections are accompanied by hypotonia, flaccidity and progressive lengthening of the muscles; nerve irritation, on the other hand, is almost always accompanied by muscular contraction with fibrous transformation.

A modification in the consistency of the muscle is then found; it becomes hard, fibrous, painful and adherent to the neighbouring tissues; certain muscles end by acquiring an almost woody consistence.

At the same time, this muscle has a tendency to contract. These muscular contractions progressively limit the excursion of the corresponding joint, modify and so far restrict the paralytic attitude as sometimes to mask it; finally, they induce the appearance of special attitudes, no longer reducible as the paralytic attitudes are, but fixed and frequently difficult to reduce by prolonged massage and mobilisation. The fibrous *griffes* of the ulnar and the median, the contraction of the posterior muscles of the leg, likely to lead to *pes equinus* and to necessitate tenotomy, are so many instances of these nerve contractions.

The muscular examination must always end in a search for fibrous contraction, by investigating the passive movements of the corresponding joints.

All limitation of articular movement is a sign of neuritis; impossibility of completely extending the fingers or completely flexing them; arrest of dorsi-flexion of the foot at right or obtuse angles, demonstrate nerve irritation of the median, ulnar, musculo-spiral or sciatic, associated or not with paralysis of these nerves.

One must naturally avoid confusing nerve muscular contraction with articular lesions and especially with the cicatricial contractions and adhesions of muscles or tendons, approximately ending in almost the same attitudes and the same limitation.

(f) **Muscular contraction and hypertonia.**—Lastly, certain cases of nerve irritation, mostly slight, are accompanied by a state of muscular hypertonia, sometimes going as far as real contraction; thus we meet with attitudes that are permanent and paradoxical, in some way the opposite of paralytic attitudes, reducible with difficulty and even at times almost impossible to overcome. The pain in the muscles under pressure, intensification of the idio-muscular reflexes, the sensory, vaso-motor or secretory disturbances met with in these cases, particularly the increase of the secretion of sweat (Babinski) show clearly the irritated condition of the nerve fibres.

Almost always, however, in these contractions, especially when permanent, we meet with an important functional factor; they are certainly emphasised and intensified by inaction of the patient.

V.—OBJECTIVE EXAMINATION OF THE INTEGUMENTS AND SUPPORTING TISSUES. TROPHIC AND VASO-MOTOR DISTURBANCES

After the objective examination of the muscles comes logically that of the other tissues, investigation of the various trophic and vaso-motor disturbances.

Speaking generally, we may lay down the principle that trophic dis-

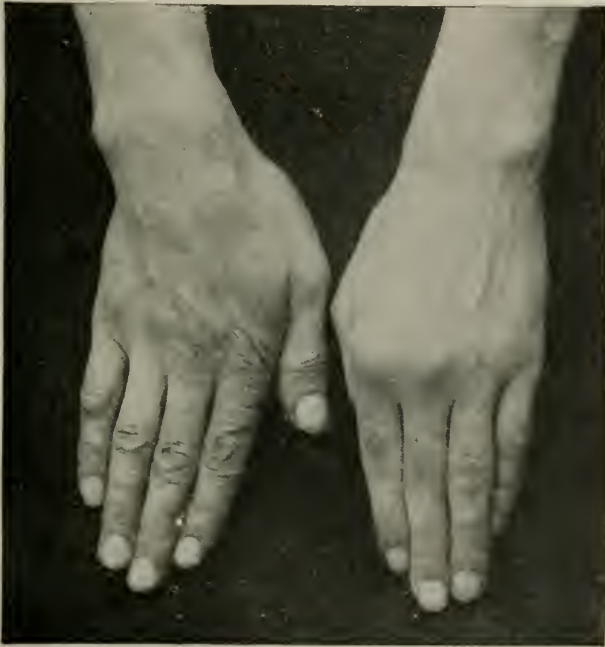

FIG. 15.—Cutaneous disturbances in a case of nerve irritation. (Note the smoothness of the fingers of the left hand and the disappearance of the cutaneous folds.)

turbances are either absent or very slight in almost all cases of nerve interruption or simple compression.

On the other hand, they are almost constant in nerve irritations.

(a) **Integuments.**—Examination of the integuments is by far the most important and may reveal very different disturbances.

Glossy skin is the most frequent; disappearance or diminution of the cutaneous folds, levelling of the papillary crests expressed by the smooth appearance of the finger-prints—constitute its main characteristics.

These disturbances always exist, though greatly diminished, in paralysis from section or simple compression.

On the other hand, they are most marked in cases of nerve irritation. In these cases we are struck by the glossy condition of the skin, its dryness and dull colour, the disappearance of the cutaneous folds, the fibrous consistence of the integuments which are adherent to the underlying tissue and difficult to mobilise: these disturbances, always more pronounced at the extremities, give the hand and foot a waxy and fixed aspect which is altogether characteristic.

(*b*) **Sweat reactions.**—The skin of paralysed hands and feet is often the seat of excessive sweating, of fetid odour. This sweating is mainly

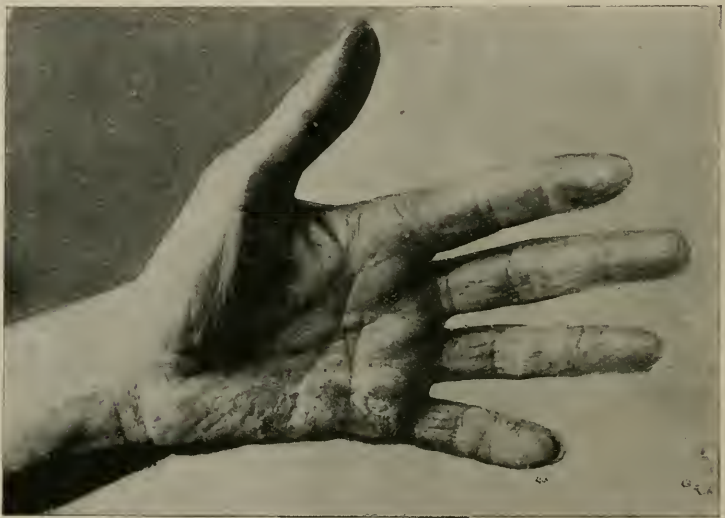

FIG. 16.—Cutaneous desquamation in the region of the ulnar (slight nerve irritation).

found in nerve irritations with slight neuritis and, above all, in neuralgia, occurring without complete paralysis.

Dryness of the skin is very important; it is found in most cases of nerve section and is sometimes accompanied by a fine branny desquamation which clearly delineates the cutaneous topography of the nerve. But it is also very pronounced in certain cases of nerve irritation, especially in severe cases with paralysis, where there is also found an abundant cutaneous desquamation in broad scales. The skin, thickened and indurated, assumes quite a rough, scaly, fish-skin appearance.

We may advantageously test for sweat secretions with the aid of chemical paper impregnated for instance with nitrate of silver, or more simply by using litmus paper; the slight acidity of sweat changes blue litmus paper to red. (Claude and Chauvet, Jumentić.)

(c) **Vaso-motor disturbances.**—Vaso-motor disturbances are practically inevitable in all nerve lesions.

In some cases we find pallor of the integuments, along with the dryness and thickening of the skin. It is mainly found on the palms of the hands and the soles of the feet, where the thickness of the integuments and their dull tint seem to mask the colouring of the deeper planes.

Cyanosis and redness of the integuments are far more frequent.

Cyanosis more especially indicates vaso-motor paralysis, acting upon the vaso-constrictor apparatus. It is exaggerated by a dependent position and by cooling; it rapidly diminishes and disappears if the limb is placed in an elevated position.

We need only compare the cyanosis and the pallor produced in the healthy limb and in the paralysed one, when placed alternately in dependent and elevated positions, to see that the paralysed limb becomes cyanosed more quickly and pales more rapidly than the healthy limb. The white spot, likewise produced by pressure of the finger, disappears more quickly on the paralysed limb.

In a word, these phenomena show the loss of tone of the vaso-constrictor muscles in the paralysed region.

In certain conditions, however, one may notice an apparently paradoxical phenomenon. If the cyanosed limb is not in too dependent a position, and the venous pressure not too great, vigorous rubbing with the nail often produces a white streak which slowly enlarges and may persist for one or two minutes. On the sound limb, however, the narrow white streak obtained by the nail rapidly disappears and gives way to the usual red streak. Probably this paralytic white streak results from the slow and prolonged contraction of the vaso-constrictor muscles, brought out by mechanical excitation. Like the other muscles, the paralysed muscular fibres of the small vessels seem to have lost their nervous excitability, whilst their idio-muscular contractility has become intensified.

On the other hand, redness of the skin is found especially in neuritic or slight neuralgic irritations, without paralysis. It is particularly marked in causalgia, and usually coincides with increase of the sweat secretions. Probably it corresponds to active vaso-dilatation.

Redness or cyanosis of the skin may in certain cases reach an extreme degree; for instance, we find the index finger in certain irritations of the median, and the little finger in certain lesions of the ulnar, assume a red, wine-coloured, œdematous and shiny aspect; the fingers are covered with chilblains. The special susceptibility of the paralysed extremities to chilblains must also be remarked.

Œdema is sometimes found in nerve interruptions; for the most part it would seem to be only the intensified swelling by stasis observed in prolonged dependent positions; this is an œdema of posture and disuse.

Along with cyanosis it sometimes produces appearances recalling that of the "succulent hand" in syringomyelia.

Then again, œdema is evidently the result of nerve irritation ; it may reach a considerable degree ; in these cases we have seen it rapidly disappear as the result of surgical intervention.

Finally, it will not be forgotten that œdema, like cyanosis, often results from vascular lesions associated with nerve lesions ; these must be systematically investigated.

In all these cases, the distribution of the vaso-motor disturbances is exactly spread over the cutaneous region of the affected nerves. Claude and Chauvet justly remark that this vascular topography is often more precise and exact, more in conformity with the anatomical region of the nerve, than the distribution of the sensory disturbances.

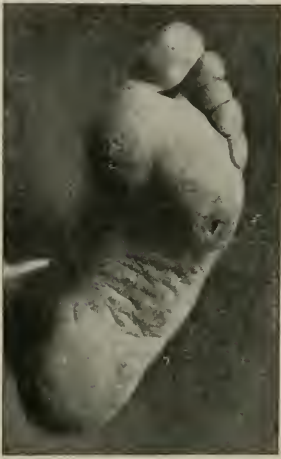

FIG. 17.—Ulceration in a case of complete interruption of the posterior tibial nerve.

(d) **Ulceration.**—Genuine ulceration is very rare in peripheral nerve lesions. Almost always we can find the exciting cause.

For instance, these are secondarily ulcerated bullous lesions, that have appeared after too hot a bath or after a too intense galvanic bath ; they have the characteristics of burns, and indeed they doubtless are burns appearing over a region of disturbed nutrition, or else ulceration caused by the pressure of an apparatus, or again we are dealing with a perforating ulcer on the sole of the foot, one which has developed as usual at the site of a corn and has certainly been caused by pressure in walking.

In all cases these lesions, though rare, are scarcely ever spontaneous ; the nerve lesion appears only as a predisposing cause by reason of the disturbances in nutrition which it calls forth. They would seem to occur both in cases of complete section and in nerve irritation.

(e) **Thermal disturbances.**—On the paralysed limbs there may be remarked a lowering or an elevation of the local temperature.

Actual persistent rise of the local temperature is found only in certain slight nerve irritations, with permanent vaso-dilatation and redness of the skin.

On the other hand, lowering of the temperature is very frequent. But this is really an artificial cooling, resulting, on contact with the air, from a less active circulation. The cooled limb slowly becomes warm in bed or if it is wrapped in wadding ; it almost regains its normal temperature but again cools more rapidly than the sound limb as soon as the surrounding temperature falls.

Marked and persistent cooling of a limb mainly results from the vascular lesions associated with the nerve lesion. It is then accompanied by chronic cyanosis, by œdema and the progressive fibrous infiltration which characterise ischæmic paralysis.

(f) **Skin appendages.**—Hypertrichosis is almost constant in all nerve lesions.

The nails are specially affected. Whilst, on the one hand, in simple sections or nerve compressions there is found only a simple transverse groove, changing place with the growth of the nail and thus marking the date of the paralysis; on the other hand, in nerve irritations there are found serious trophic affections of the nails; they are striated, split, laminated, thinned at the edges, curved like claws or deformed into the shape of a watch glass.

Frequently too they are atrophied, smaller than those of the opposite side, and this diminution, associated with cutaneous and bony atrophy, ends in a sort of tapering conical appearance of the last phalanx of the fingers.

(g) **Aponeuroses, tendons, synovial sheaths, bones and articulations.**—The trophic disturbances of nerve irritation also reach the deeper planes.

The thickened and contracted palmar fascia gives the impression of cords, to a certain extent reminding one of Dupuytren's disease; the indurated plantar fascia sometimes presents fibrous nodules, similar to those of alcoholic neuritis.

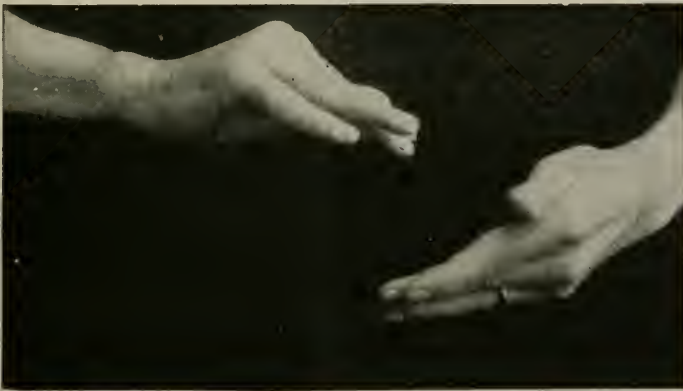

FIG. 18.—Ankylosing and deforming arthrites, chronic rheumatized type, with atrophy of the cellular tissue, by nerve irritation, without vascular phenomena, in a case of stretching of the two brachial plexuses. (Dejerine, *Presse Médicale*, 8 July, 1915.)

The thickened, indurated, contracted, synovial sheaths are attached to the tendons by adhesions which immobilise them, and, associated with neuro-muscular contraction, they determine the formation of fibrous claws.

The joint may undergo the same process of sclerosis, sometimes ending in actual fibrous ankyloses of the digital articulations.

The phalanges themselves, thickened at their ends, give to the articulations of the fingers a knotty fusiform appearance which in certain cases may recall the appearance of rheumatoid arthritis, or resemble the "radish bunch" of gonorrhœal rheumatism.

Osseous decalcification is a rather common phenomenon, existing in almost all nerve lesions, but also found in vascular disturbances and even after prolonged disuse of the limb through muscular or tendon lesions.

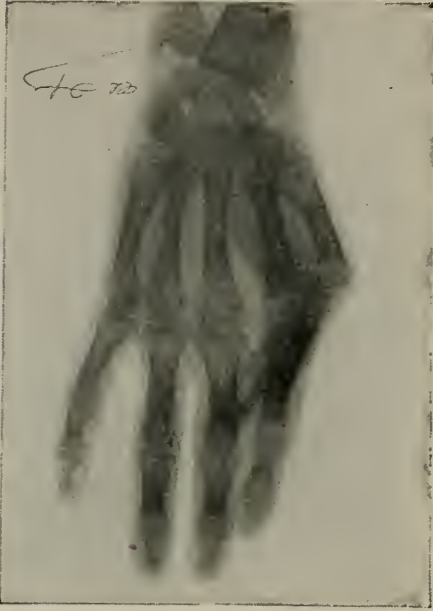

FIG. 19.—Radiograph of hand (palm facing). Note the decalcification of the metacarpals and of the phalanges of the thumb, the middle finger and especially the index finger.

Decalcification, however, is particularly pronounced in certain nerve irritations.

Lastly, we may meet with actual atrophy of the paralysed limb *en masse*. We have referred to the conical thinning of the digital extremities: it is possible to see, especially in certain cases of paralysis of the ulnar or of the posterior tibial, atrophy of hand or foot *en masse*: in these cases, with the muscular atrophy are associated the thinning of the skin, sclerous atrophy of the dermis and osseous decalcification and deformations of the nails.

In this analytical description we note how much more frequent and intense in nerve

irritations than in simple nerve sections are all trophic and vaso-motor disturbances. This is an important point, now well established, and on which we must insist.

There is only one condition capable of producing trophic disturbances as marked as neuritic irritation: the arterial obliteration causing ischæmic paralysis. Accordingly this must always be sought systematically, when we find ourselves confronted with considerable trophic disturbances; all the more so as it is frequently associated with nerve lesions, intensifying and modifying their clinical features.

VI.—OBJECTIVE EXAMINATION OF SENSIBILITY

Here we are not dealing with spontaneous pains, noticed by the patient, or with sensations caused by pressure on the muscles or nerve

trunks. It is a general questioning of the patient, an objective examination of muscles or nerve trunks, that supply us with this important knowledge.

We are now simply investigating the disturbances of objective, superficial and deep sensibility.

1. Cutaneous sensibilities.—Tactile, painful and thermal sensibility should be studied in succession.

In reality, this minute examination is not usually necessary, for the areas of the three sensibilities are usually almost identical. It may at the same time be stated that thermal anæsthesia is a little more widely diffused than painful anæsthesia and the latter than tactile anæsthesia.

But here again we are liable to an error of interpretation, for in the case of each sensibility we must distinguish the coarse sensation from the fine appreciation of the qualities of the sensation. This is the distinction, set up by Head, between protopathic and epicritic sensibility; the vague sensation of touch is to be distinguished from the clear appreciation of the nature of the contact and of its precise localisation; the rudimentary sensation of pain must be differentiated from the ability to distinguish the quality of the pain; the differentiation between hot and cold must be distinguished from an exact appreciation of moderate temperatures. These are so many special sensibilities, corresponding to terminal apparatuses all the more complex because they supply more precise notions; in nerve sections they disappear with a rapidity proportional to their complexity and become regenerated all the more slowly as they correspond to apparatuses more highly differentiated.

Practically, in the case of peripheral nerves, we may generally dispense with these minute examinations.

Exploration with a pin alone supplies all necessary information.

By a prick, the pin supplies both tactile and painful sensations; by the slight pressure it exercises, however faint, it affords practically adequate indications regarding deep sensibility.

Speaking generally, it is possible in an anæsthetic area to distinguish three main zones.

In the first zone, the patient feels nothing; there is complete superficial and deep anæsthesia.

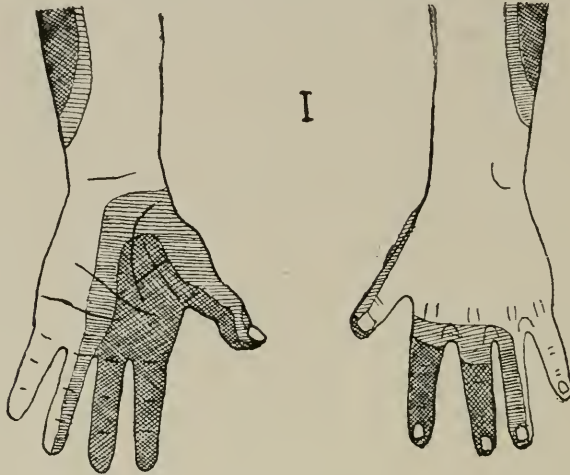
In the second zone, the patient perceives the prick of the pin as simple contact; he replies: "touch." Probably this sensation is mainly provoked by pressure of the point; it largely depends on deep sensibility; in this zone there is superficial anæsthesia with the retention of deep sensibility.

In the third zone, in the neighbourhood of the next nerve region, a true intermediate zone, the patient vaguely feels the pricking; he answers: "pricks a little." There is simple superficial, tactile and painful hypo-æsthesia; it is in this zone that slight cutaneous stimuli, with paint brush, hair, or piece of cotton-wool, begin to be clearly distinguished.

When we reach the intact sensory region of the neighbouring nerve,

the pricking is keenly felt ; the more so as there sometimes exists slight marginal hyperæsthesia.

20th January (139th day after the wound).



13th March (51st day after suture of the nerve).

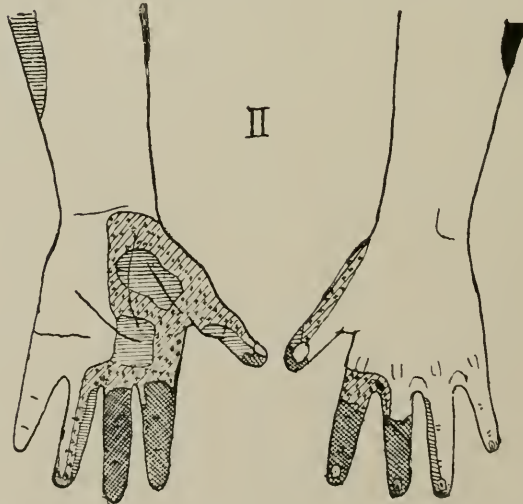


FIG. 20.—Examples of different disturbances of sensibility, simultaneous or successive, from nerve lesion.—Extent of the zones of anæsthesia and hypo-æsthesia to pin-prick, before and after nerve suture in a case of complete interruption of the median. In the cross hatched area, pricking provokes no sensation at all. In horizontal hatched area, pricking causes only a sensation of contact. In oblique hatched area with crosses : paræsthetic phenomena : hyperæsthesia to pain ; diffusion, irradiation, burning sensations, persistence of the sensation. Painful hyperæsthesia is specially marked where the crosses are replaced by dots.

In other cases, we find hyperæsthesia either to all modes of sensibility or to pain only, with hypo-æsthesia to the other sensibilities. This is what

may be called painful hypo-æsthesia : pin-prick, touch, heat and cold are then imperfectly distinguished ; all these stimuli, however, produce the same painful, badly differentiated and localised sensation, diffused, irradiated in the neighbourhood and persisting for a few seconds. This painful hypo-æsthesia is the most frequent form of paræsthesia encountered in nerve irritation.

It must not be confused with paræsthesia of nerve regeneration. Indeed, in the restoration of cutaneous sensibilities, we find at an early stage certain special phenomena, characterised mainly by a sensation of formication diffused, imperfectly localised, irradiated in the neighbourhood, persistent, rather disagreeable, provoked by every cutaneous stimulation and particularly by light stroking.

These cases of paræsthesia last long and may persist for several months.

2. Deep sensibilities.—There must be studied successively :

I. Sensibility to pressure ; the simplest and most practical instrument is the rounded end of a stylographic pen. Note if pressure is felt in the region of the nerve. We have seen that the simple pressure of a pin point suffices to rouse deep sensibility.

II. The sense of attitudes, which consists in finding out if the patient perceives the movements imparted to his various joints.

III. Bony or periosteal sensibility, which is discovered by means of a tuning fork placed on the bony projection, and whose vibrations are more or less distinctly perceived.

The study of deep sensibilities is less important than that of cutaneous sensibilities. It is subject to more causes of error, its results are less constant and the rôle of collateral substitutions is a greater one. The region of deep anæsthesia is always much more extended than that of cutaneous anæsthesia ; and we shall often find, for instance, that pressure applied at the level of an anæsthetic cutaneous region is fairly well perceived.

The disappearance, likewise, of deep anæsthesia is often somewhat earlier than that of cutaneous anæsthesia and may to some extent permit of our anticipating a speedy restoration.

In every case, after each examination, the exact area of the anæsthesia encountered, whether superficial or deep, must be drawn up, for the permanence and fixity of the anæsthetic region is one of the best signs of complete interruption. (J. and A. Dejerine and Mouzon.)

On the other hand, the region of anæsthesia is found to vary from day to day in cases of simple nerve compression.

During the regeneration, we see the concentric shrinking of the zones of anæsthesia.

Only by observation and comparison of the successive areas of

sensibility shall we be able to account exactly for the evolution of sensory disturbances ; this practice is the *sine quâ non* of a complete examination.

VII.—OBJECTIVE EXAMINATION OF THE NERVE

The objective examination of the nerve supplies three important indications :

1. Whether the nerve is painful on pressure or not.
2. The existence of formication provoked by pressure.
3. The possible discovery of a neuroma.

1. **Sensibility of the nerve on pressure.**—The nerve does not feel pain on pressure in all cases of section or simple compression.

On the other hand, it is very painful in neuritic or neuralgic irritation of a nerve trunk ; on pressure it is painful along its whole course below the lesion.

Sometimes the nerve is painful even above the lesion, but this is a somewhat rare complication.

Pain on pressure must be carefully differentiated from the sensation of formication also provoked by pressure and having a totally different significance.

2. **Formication provoked by pressure.**—When compression or percussion is lightly applied to the injured nerve trunk, we often find, in the cutaneous region of the nerve, a creeping sensation usually compared by the patient to that caused by electricity.

Formication in the nerve is a very important sign, for it indicates the presence of young axis-cylinders in process of regeneration.

This formication is quite distinct from the pain on pressure, which exists in nerve irritations.

The pain, indeed, which essentially indicates irritation of the axis-cylinders and not their regeneration, is almost always local, perceived at the very spot where the nerve is compressed, or at least magnified at this spot ; it always co-exists with the pain in the muscular bellies under pressure, very often the muscles are more painful than the nerve.

Formication of regeneration, on the other hand, is but little or not at all perceived at the spot compressed, but almost entirely in the cutaneous region of the nerve ; the neighbouring muscles are not painful.

As a rule, it appears only about the fourth or sixth week after the wound. It enables us to ascertain the existence of this regeneration and to follow its progress.

If it remains fixed and limited in one spot for several consecutive weeks or months, this is because the axis-cylinders in their regeneration have encountered an insurmountable obstacle and are forced to group together on the spot in a more or less bulky neuroma.

The fixity of formication on a level with the lesion and the complete absence of formication below the lesion would almost warrant our affirming

the complete interruption of the nerve and the impossibility of spontaneous regeneration.

If, on the other hand, the regenerated axis-cylinders can overcome the obstacle and make their way into the peripheral segment of the nerve, we see a progressive migration of the formication so provoked. Pressure on the nerve below the wound produces this sensation, and from week to week it may be met with at a spot farther removed from the nerve lesion. The presence of formication provoked by pressure below the nerve lesion warrants our affirming that there is more or less complete regeneration.

The zone of formication so brought out changes its place on the nerve at the same time that the axis-cylinders are advancing; it extends progressively towards the periphery at the same time that it disappears at the level of the lesion.

The "formication sign" is thus of supreme importance, since it enables us to see whether the nerve is interrupted or in course of regeneration, whether a nerve suture has succeeded or failed, or whether regeneration is rapid and satisfactory or reduced to a few insignificant fibres.

Formication lasts a tolerably long time; appearing about the fourth week, it persists during the entire regeneration, *i.e.*, for eight, ten, twelve months or more, gradually drawing nearer the extremity of the limb. It ceases only when the regenerated axis-cylinders have almost regained their adult stage.

Formication, however, may be absent, both on a level with the lesion and below it; this absence is an unfavourable prognostic point; it shows that nerve regeneration is taking place imperfectly, mainly because of general disturbances of nutrition.

3. Search for a neuroma along the track of the nerve.—Every nerve lesion tends to cause the formation of a neuroma at the injured spot. This is sometimes a simple fusiform thickening of the nerve, sometimes a real neuroma that is more or less bulky; at other times, the nerve is simply embedded in a cicatricial fibrous mass.

By careful palpation we often succeed in recognising the existence of these neuromatous formations; besides, the neuroma so compressed is frequently the seat of pain or formication which are provoked, according as the axis-cylinders which it contains are irritated or regenerating respectively.

Still, too much importance must not be attached to the information supplied by palpation. First, because there are many causes of error; muscular bundles, cicatricial nodules or enlarged glands, may easily be taken for a neuroma. Again, the discovery of a neuroma affords no information whatsoever as to the physiological state of the nerve; there are neuromata permeable to regenerated axis-cylinders, and others which permit the passage of no fibre whatsoever. This is the main point of the diagnosis, with a view to the prognosis and treatment.

Consequently, search for the neuroma, involving many causes of error, never indicates anything more than the seat of the lesion.

As we see, examination of the nerve logically terminates the clinical examination of the patient. It completes this examination and enables us to group together and interpret the various symptoms obtained by a study of the muscles and integuments.

CHAPTER III

ELECTRICAL EXAMINATION

THE electrical examination is the indispensable adjunct to the clinical examination.

To do this with precision often requires the aid of a specialist. Still, every clinical surgeon, with a little attention, method and practice, may make it in very simple and tolerably adequate fashion.

The well-established facts of electro-diagnosis have been for several years largely augmented and illuminated by modern works, especially by the application to human pathology of the investigation and the methods of electro-physiology.

For greater clearness we will divide this study into two parts.

1. A setting out of the classic methods of electro-diagnosis.
2. A *résumé* of the recent notions on electro-physiology which complete them and permit of our interpreting them.

I.—CLASSIC METHODS OF ELECTRO-DIAGNOSIS

Electrical examination essentially comprises two stages :

Examination by the faradic current ;

Examination by the galvanic current.

1. **Examination by the faradic current** may be done in two ways :

1. By the unipolar method, involving the application, on the nape of the neck or on the lumbar region, of a large indifferent electrode and the excitation of nerve and muscles by the small active electrode (negative by preference). It should be applied to the motor point of the muscle which generally corresponds with the point of entrance into the muscle of the nerve twig which supplies it.

2. By the bipolar method, in which we apply the two electrodes to the nerve or muscle to be examined, so as to include the motor point when separated by a few centimetres.

As a rule, the bipolar method is but little used in faradic examination of the muscles. In our opinion, however, it is simpler for making a rapid examination of the muscular groups ; it is the method illustrated by the works of Duchenne of Boulogne.

On the other hand, examination of the nerve is more difficult by this method, the result being that the unipolar method is almost always preferred.

In any case, a successive examination of nerve and muscles should be made, always employing a vibration of from one to three shocks per second.

Use will mostly be made of a thick wire coil, the resistance of which is no more than one to two ohms.

Examination of the nerve must be made carefully, as this is far more painful than examination of the muscles.

If possible, it should be done above and below the nerve lesion, note being taken of the jerks produced in the corresponding muscles.

Indeed, it may happen that the excitation of the nerve above the lesion causes no movement at all, whereas we note below the lesion a relative retention of excitability. In this case there are two possibilities: sometimes it is a recent lesion where the peripheral part of the nerve, separated from the central portion, has not had time to degenerate completely; or else, in certain cases of simple compression of a nerve trunk, the lesion is sufficient to arrest the transmission of nerve excitation, whilst not suppressing the trophic action of the centres on the peripheral segment of the nerve; the latter does not degenerate and partly retains its excitability: this is the phenomenon described by Erb in musculo-spiral paralysis by compression.

When excitation of the nerve above the lesion provokes contractions in the muscles supplied by it, we may naturally state that it is not interrupted, at any rate in all its fibres.

Faradic exploration of the muscles with the thick wire coil enables us to ascertain the entire series of disturbances, from simple hypo-excitability to complete faradic inexcitability.

1. Simple hypo-excitability is judged by comparison with the same muscle on the healthy side. It is necessary to sheathe the coil more deeply to obtain equal muscular contraction. This will be more easily recognised by seeking on each side for the excitation capable of causing very small contractions; this is the faradic threshold, which is measured according to the length of coil sheathed. It is unnecessary to remark that this method of measurement is very uncertain, even altogether incorrect, for the electric units produced by the coil are not at all proportional to the lengths of sheathing. It would be better to substitute for notation of the length of sheathing, notation in the quantity of electricity induced, a measure which is quite a relative one, and which some makers now inscribe on their coils.

2. Faradic inexcitability always accompanies complete peripheral paralysis. There is only one exception to this rule: the paradoxical phenomenon just mentioned in the slight and fleeting compressions of a nerve trunk.

Apart from this particular case, a rather rare one, all nerve interruption or prolonged compression is accompanied by faradic inexcitability. This is one of the essential features of the reaction of degeneration.*

If we use a sufficiently strong current, we often observe the contraction of the neighbouring and antagonistic muscles, produced by diffusion of the current. This is what is called antagonistic contraction. It has no other significance than to demonstrate by comparison the marked hypo-excitability or the complete inexcitability of the muscle involved.

Faradic inexcitability appears at an early stage; it is one of the first signs of the RD and persists for the entire duration of the paralysis. Faradic contractility reappears only very late, after the return of the first voluntary movements, as Duchenne of Boulogne has demonstrated. But, we must also remember, this law is only true if we use a wire coil of feeble resistance.

Examination of nerve and muscles by the faradic current is very important for the clinical surgeon, inasmuch as when complete faradic inexcitability is established, one is almost sure to find with the galvanic current a reaction of degeneration that is typical or at all events partial.

On the other hand, faradic examination enables us readily to distinguish organic peripheral paralysis from functional paralysis in which faradic contractility is always maintained.

There are but two exceptions, already mentioned, to this rule. On the one hand, very recent paralysis in which the RD has not yet come about; then we find faradic excitability rapidly disappearing. On the other hand, the slight nerve compressions, presenting the paradox of Erb, in which the nerve and muscles are excitable below the lesion, whereas the nerve is inexcitable above; in a few days or weeks we find the voluntary movements reappearing.

Apart from these two cases, all paralysis characterised by maintenance of a nearly normal faradic contractility is not peripheral paralysis. It is functional paralysis, hysterical or simulated; or else of central origin, from cerebral lesion or injury of the tracts in the spinal cord, and always accompanied by manifest objective symptoms, disturbances of the reflexes, Babinski's sign, etc.

* It is important to note that we are here speaking only of relative faradic inexcitability, which is determined with the ordinary instruments and the thick wire coil. Indeed, we shall see that this fact is only true if we modify the usual conditions of examination. Even if there exists complete faradic inexcitability with the thick coil, faradic inexcitability of the muscle is apparent only; we can always get contraction of the paralysed muscles either by utilising far more powerful coils or by greatly increasing the intensity of the original current or even by causing the muscles examined to undergo electrotonic modifications by the simultaneous passage of a galvanic current. Whenever, then, we speak of faradic inexcitability, we mean this relative excitability, for the thick wire coil.

Faradic examination also gives us other information of less importance: the faradic sensibility of skin and muscles. This sensibility seems to be the first to reappear during nerve regeneration.

* * * * *

In all this description, we have considered only the usual faradic examination, with the thick wire coil. To this method alone apply the classic ideas as to faradic excitability of the muscles.

On the other hand, if a coil of greater electro-motive force is used, a fine wire coil, for instance, the resistance of which may reach 800, 1200 ohms or more, we find important modifications.

Indeed, in certain cases, we may ascertain the persistence of a slight faradic contractility in spite of a very pronounced partial RD or even a complete RD; a rather strong excitation produces slight muscular contractions, sometimes very short, oftener slow, like those produced by the galvanic current on the degenerated muscle.

We may also see the return of faradic excitability as one of the first signs of nerve regeneration, when the RD is still complete, as shown by P. Marie, Meige and Mme. Bénisty. Consequently, investigation of faradic excitability with a fine wire coil might with propriety supply the place of investigation of galvanic reactions of regeneration, and one might follow the whole progression of faradic excitability up to the normal.

Later on we shall see how these apparently paradoxical results may be interpreted.

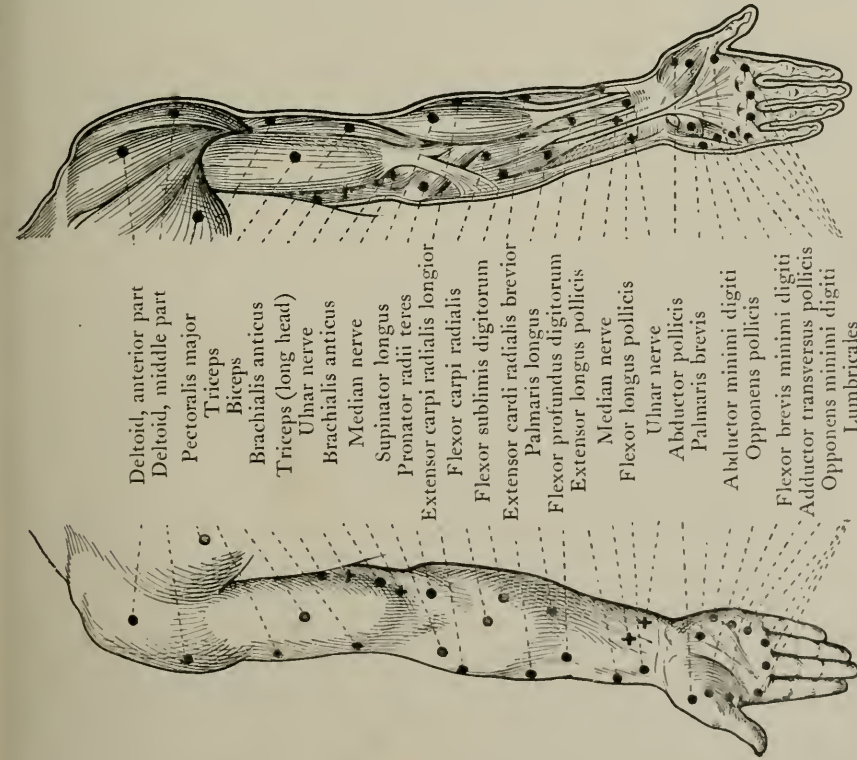In any case, this process of examination is not to be recommended.

It requires currents of relatively great intensity and consequently painful; the contractions obtained in the degenerated muscles depend not only on the intensity of the current, but also on the duration of the exciting wave, which is extremely variable; it depends on the characteristics of the coil, on the phenomena of self-induction, on the production of rupture sparks, which increase the duration of the passage of the current, etc.

This method, then, gives inconstant results and inaccurate information, it cannot be measured and so is greatly inferior to galvanic examination.

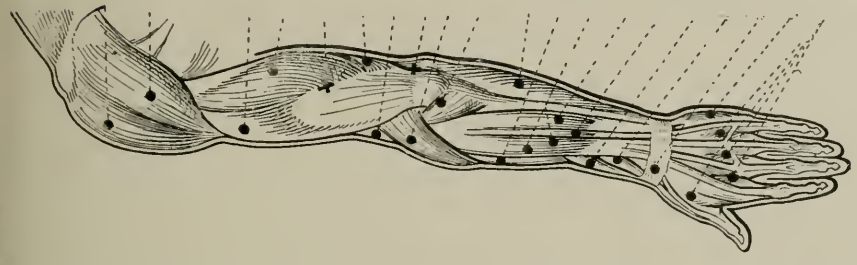
On the other hand, Babinski, Delherm, and Jarkovski have shown that it is possible to cause faradic contraction to reappear in paralysed muscles by associating with faradization the passage of a galvanic current into the limb. This latent faradic excitability seems to constitute an intermediate degree between hypo-excitability and utter inexcitability.

2. Examination by the galvanic current.—This examination may also take place by the unipolar or the bipolar method; but here the unipolar method is far preferable: one might almost say that it is practically the only one possible.



- Deltoid, anterior part
- Deltoid, middle part
- Pectoralis major
- Triceps
- Biceps
- Brachialis anticus
- Triceps (long head)
- Ulnar nerve
- Brachialis anticus
- Median nerve
- Supinator longus
- Pronator radii teres
- Extensor carpi radialis longior
- Flexor carpi radialis
- Flexor sublimis digitorum
- Extensor carpi radialis brevior
- Palmaris longus
- Flexor profundus digitorum
- Extensor longus pollicis
- Median nerve
- Flexor longus pollicis
- Ulnar nerve
- Abductor pollicis
- Palmaris brevis
- Abductor minimi digiti
- Opponens pollicis
- Flexor brevis minimi digiti
- Adductor transversus pollicis
- Opponens minimi digiti
- Lumbricales

MOTOR POINTS OF UPPER LIMB
(Anterior aspect).

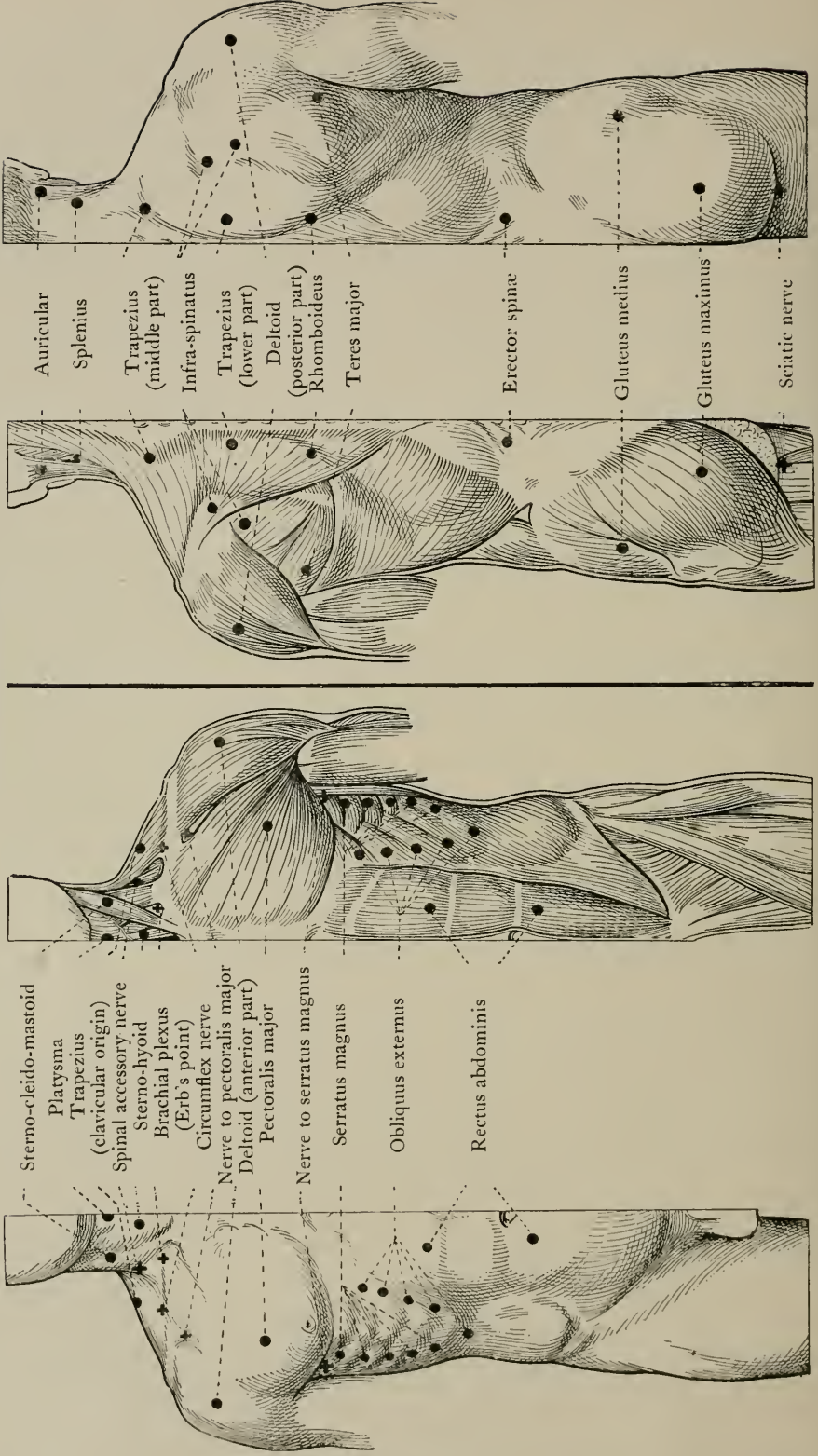


- Deltoid, middle part
- Deltoid, posterior part
- Triceps (external head)
- Triceps (long head)
- Musculo-spiral nerve
- Triceps (internal head)
- Supinator longus
- Ulnar nerve
- Extensor carpi radialis longior
- Anconeus
- Flexor carpi ulnaris
- Extensor carpi radialis brevior
- Extensor communis digitorum
- Extensor carpi ulnaris
- Extensor digiti minimi
- Extensor ossis metacarpi pollicis
- Extensor brevis pollicis
- Extensor longus pollicis
- Abductor minimi digiti
- Dorsal interossei

MOTOR POINTS OF UPPER LIMB
(Posterior aspect).

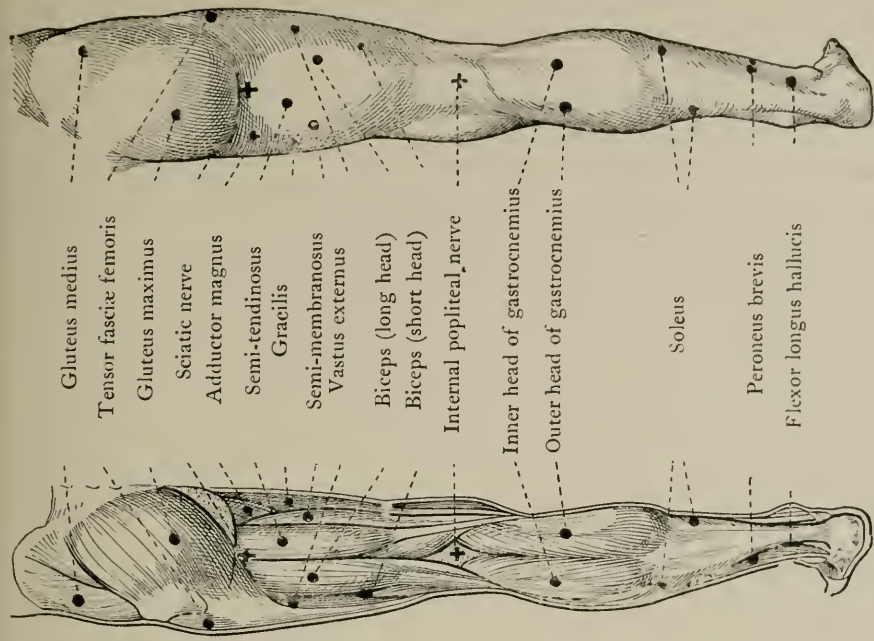
(From the *Nouvelle pratique Médico-Chirurgicale*, article "Electrodiagnostic," by Dr. Pariset.)

ELECTRODIAGNOSIS II.

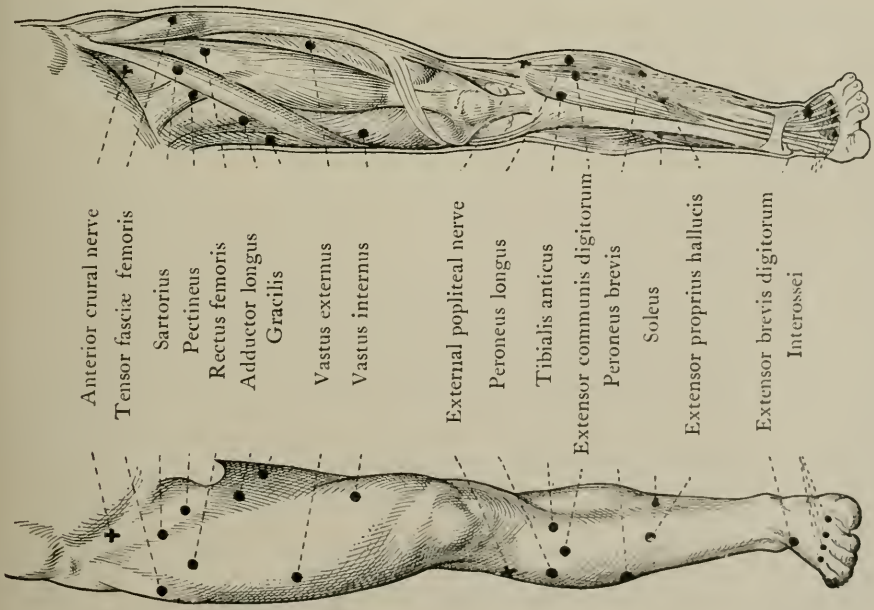


MOTOR POINTS OF TRUNK (Anterior aspect).

MOTOR POINTS OF TRUNK (Posterior aspect).



MOTOR POINTS OF LOWER LIMB
(Posterior aspect).



MOTOR POINTS OF LOWER LIMB
(Anterior aspect).

The examination is made with a large dorsal indifferent electrode and a small electrode applied to the motor points; this electrode is made positive or negative in turn by means of a current reverser (Courtade's key).

The nerve and the muscles supplied by it will be examined in turn.

It must be remembered that muscular contraction takes place only at the moment of the closing and of the opening of the current. The closing contraction, the stronger one, is generally the only one sought for. The contraction on opening the current, requiring greater intensity, is seen only in certain pathological states.

Three elements of muscular contraction under the galvanic current require special study.

1. The intensity of the current necessary to produce at the closing the minimum contraction; this is the threshold of excitation.

In an injured nerve, it will be possible to ascertain the diminution or disappearance of galvanic excitability. Galvanic inexcitability is the absolute rule in all cases of interruption of the nerve.

In the paralysed muscle, on the other hand, galvanic inexcitability is a very rare phenomenon; it is found only in cases where the degenerated muscle has finally lost all contractile structure and has become transformed into a mere bundle of connective tissue. This is the last stage, long delayed, of muscular degeneration.

Almost always we find in the paralysed muscle an apparent simple hypo-excitability. It can be measured by the number of milli-amperes necessary to obtain contraction, rising from one or two (the normal figure) to five, ten, or twenty-five milli-amperes.

The normal threshold of galvanic contraction varies according to the muscle and the patient; it must accordingly be sought by comparison with the healthy side.

On the other hand, it varies considerably according to the point of excitation of the muscle; from one, two, three milli-amperes by excitation of the motor point the figure easily rises to four, five, eight milli-amperes as soon as one moves from this point. Consequently, minute search must be made for the motor points of each muscle.

2. The pole capable of inducing, with the same current, the strongest contraction; or rather, the pole susceptible of inducing the minimum contraction with the weakest current.

We must therefore compare the negative threshold and the positive threshold.

Normally it is the negative pole which, on the closing of the current, induces the strongest contraction; this is expressed in the following formula:—

$$KCC > ACC.$$

If contraction is stronger at the positive pole, we have an inversion of the polar formula, and this is written—

$$ACC > KCC.$$

If the contractions are equal, there is said to be polar equality.

Certain muscles, particularly the supinator longus, the tibialis anticus, the peroneals, sometimes exhibit normally the phenomenon of inversion or of polar equality.

3. The form of contraction.

Normal contraction is rapid and short, a sudden flash.

In peripheral paralysis with degeneration, contraction becomes slow and delayed.

Frequently when compelled to use a current of considerable intensity, it is diffused over the neighbouring or antagonistic muscles. Then there is observed an initial short contraction of the antagonists, followed by slow contraction of the muscles involved. Sometimes it is difficult to distinguish this slow contraction from simple return of the stimulated antagonistic muscles to the normal state.

ELECTRICAL SYNDROMES

1. Syndrome of nerve interruption.—REACTION OF COMPLETE DEGENERATION.—In cases of peripheral paralysis both the faradic and the galvanic examination almost invariably give concordant results, the sum total of which constitutes the reaction of degeneration.

The typical and classic RD is made up of the following characteristics :

Faradic and galvanic inexcitability of the nerve ;

Faradic inexcitability of the muscle ;

Galvanic hypo-excitability at the motor point with polar inversion and slow contraction. As we shall see, this apparent galvanic hypo-excitability is due to inexcitability of the nerve twig involved at the motor point ; the muscle itself is really hyper-excitabile, especially at the beginning of the RD.

Of these three latter elements, it is slow contraction that seems to be of greatest importance. Without great hypo-excitability and without polar inversion, slow contraction seems sufficient to characterise the RD.

We must add to these characteristics what is somewhat erroneously called the displacement of the motor point ; this latter appears no longer to have its seat at the upper part of the muscle but to be approaching its lower insertion, being found at times even in the neighbourhood of its termination on the tendon. In reality, the muscle deprived of its nerve responds the better to electrical excitation from the fact that this latter affects a greater part of the muscular body. This is Doumer-Huet's longitudinal reaction, characterised by the fact that the muscle is more excitable at the level of the muscular body and especially in the neighbourhood of the tendon. This longitudinal excitation almost always occurs along the negative pole, even when there is complete RD, and polar inversion at the motor point.

The slowness of contraction to longitudinal excitation is often more

marked than to excitation at the motor point. It often persists even when excitation at the motor point of the muscle, in process of recovery, begins to give a quick contraction.

The longitudinal excitability of the paralysed muscle is greater than that of the healthy muscle. This is one of the facts that demonstrate the hyper-excitability of the paralysed muscle; its hypo-excitability is but apparent, resulting from the inexcitability of the motor twig supplying it; but the muscle itself, deprived of its nerve, is really more excitable than in the normal condition. This galvanic hyper-excitability of the muscle is often very marked during the first few weeks of paralysis.

It is also by longitudinal excitation that we most easily find the opening contraction: always stronger at the positive pole, in contradistinction to the closing contraction, it is easy to provoke only in cases of complete RD, with hyper-excitability of the paralysed muscle.

The reaction of complete degeneration is generally related to complete interruption of the nerve.

It does not come about all at once, but within a fortnight or three weeks; it gradually becomes more pronounced, passing through all the phases; by degrees the nerve loses all excitability; the muscle loses its faradic excitability with the thick wire coil and then with the thin wire coil, at the same time that galvanic hyper-excitability, polar inversion, slow contraction and longitudinal reaction become obvious.

Nerve regenerations, after complete interruption, act in exactly the opposite way. On examining the muscles, we find that galvanic hypo-excitability diminishes, that polar inversion becomes polar equality and then returns to its normal form; slow contraction gradually accelerates; we ascertain the reappearance of faradic sensibility and faradic contraction with the thin wire coil, then faradic contractility with the thick wire coil reappears, though generally tardily and preceded by the return of voluntary contractility.

The nerve also slowly resumes its normal excitability. As a rule the voluntary movements appear before the excitability of the nerve.

As the different muscles of the same nerve region resume their functions according as they are affected by the progression of the regenerated axis-cylinders, we note the first signs of improvement in those muscles supplied by the nerve nearest the origin of the limb. There result therefrom dissociations in the reaction of degeneration.

In a paralysed muscle we may also note the return of the normal reactions in some muscular fibres at the upper part of the muscle, around the motor point, whereas the lower fibres still present the RD and still respond to longitudinal reaction by slow contraction.

2. Syndromes of compression or irritation.—REACTION OF PARTIAL DEGENERATION.—The RD is usually incomplete or only faintly indicated

if there is no nerve interruption, in simple compressions or in cases of moderate nerve irritation.

Very different types of partial RD may be found.

Sometimes it consists of a simple widespread hypo-excitability of nerves and muscles to the faradic and galvanic currents.

At other times it consists of a faradic and galvanic hypo-excitability of the muscles, along with inexcitability of the nerve trunks. It is in these cases that we can at times observe the slowness of the contraction under the faradic current.

In other cases, there is lacking only one factor to the complete RD : the contraction is not very slow, or else, whilst slow to the positive, it is quick to the negative, corresponding to the slightest forms of the RD ; again it is the polar inversion that fails, or rather it disappears when we cross the threshold of excitation ; or again we find that longitudinal hyper-excitability fails.

3. Syndromes of fibrous transformation.—ELECTRICAL INEXCITABILITY OF THE MUSCLE.—In the complete RD, we have seen that galvanic excitability was retained ; apparently diminished if we seek excitation at the motor point, but in reality increased if we excite the muscular body itself or seek longitudinal reaction.

This excitability of the muscle may be seen to diminish or even disappear completely, at all events with currents of twenty-five to thirty milli-amperes, the only ones that can practically be utilised in electro-diagnosis.

This reaction of muscular hypo-excitability or inexcitability always indicates very profound lesions of the muscle ; it shows that the muscle has lost its contractile structure, and that it has undergone more or less a process of infiltration or one of fibrous transformation. This reaction is met with in certain cases of long-standing nerve interruption ; it appears more quickly in muscles left untreated by either massage or electricity.

Consequently it has a relatively serious prognosis. It should, however, be known that this muscle, even after fibrous transformation, may slowly regain its normal characteristics if the regenerated axis-cylinders reach it soon enough:

The syndrome of muscular hypo-excitability or of muscular inexcitability is found with quite special frequency in nerve irritation, which so often causes fibrous contraction and infiltration of the muscles.

It is often superposed on the RD, emphasising, sometimes to an enormous degree, the galvanic hypo-excitability of the muscles.

In other cases, it exists without the RD, it is then characterised by marked hypo-excitability of the nerves and muscles to the faradic and galvanic currents. It is found in these cases that, in contradistinction to the syndrome of the paralytic partial RD, the hypo-excitability of the muscle

to the faradic and to the galvanic currents at the motor point is not accompanied by the usual longitudinal hyper-excitability.

In certain cases, one may even ascertain the apparently paradoxical association of the following symptoms :

The nerves and muscles are almost incapable of being excited by the usual faradic and galvanic currents ; but violent faradic shocks, or galvanic currents at the motor point up to twenty-five or thirty milli-amperes produce rather feeble contractions of small areas, limited to a few muscular fibres ; we are surprised to find that these contractions are quick, without polar inversion.

As Huet has shown, this reaction after all has a relatively favourable prognosis. It shows that the muscle has undergone a more or less profound fibrous transformation, from lack of attention or else from nerve irritation ; but at the same time it indicates the persistence of healthy, or the arrival of some regenerated axis-cylinders and enables us to predict the slow restoration of motor functions.

4. Reaction of Exhaustion.—Sometimes we find in weakened muscles, and oftener during muscular regeneration, an indication of the reaction of exhaustion described by Jolly in myasthenia.

The muscle makes unequal responses to successive faradic excitations, or rather, if we utilise a somewhat rapid faradic rhythm, we find a contraction fail from time to time ; there are “misses” comparable to those of cardiac arrhythmia in myocardial lesions.

In other cases, if the muscle is excited by a rapid rhythm or a tetanising current, it is found to become rapidly inexcitable.

5. Myotonic Reaction—Lastly, in some cases of slight neuritis, usually accompanied with contraction, the muscles seem to be slightly hyper-excitabile under the faradic current ; tetanisation seems to take place with interruptions somewhat less rapid than in the normal state, which simply shows, after all, a certain prolongation of the contraction. This, however, is not the true myotonic reaction, which is mainly characterised by a tonic, lasting contraction, persisting after the cessation of galvanic excitation. It essentially characterises Thomsen’s disease and certain myopathies. It does not exist so clearly in cases of nerve lesion ; all the same, in recent cases of paralysis one may at times observe a faint contraction persisting during the passage of the galvanic current. This is the exaggerated manifestation of galvano-tonus, or galvanic hyper-excitability of the muscle, which exists in recent RD.

* * * * *

The disturbances of electrical reactions and the RD in particular essentially characterise peripheral paralysis, *i.e.* those which result—

From lesion of the motor cells of the spinal cord (poliomyelitis, hematomyelia, etc.) ;

From lesion of the anterior roots (inflammation of the roots, compressions, etc.) ;

From traumatic lesion of the plexuses or peripheral nerves ; from the polyneurites.

Functional, hysterical paralyses and paralyses of cerebral origin or resulting from lesion of the pyramidal tract (upper motor neurone) are never accompanied by important disturbances of the electrical reactions. At most there is slight hypo-excitability from muscular disuse.

At the same time, in sections of the cord, we may frequently note important electrical disturbances, as remarked by P. Marie and Foix, but they manifestly result from the reaction of the grave medullary lesion on the motor cells of the anterior horns below the lesion.

Only one affection is accompanied by electrical disturbances as profound and rapid as those of the peripheral nerve lesions, this is ischemic paralysis from arterial obliteration. Still, we see rather the syndrome of fibrous transformation of the muscles than the true RD ; inexcitability of the muscles comes on earlier and is more marked than the inexcitability of the nerve controlling it.

II.—SOME POINTS IN ELECTROPHYSIOLOGY

Modern investigations in electrophysiology now enable us to complete and interpret the information supplied by the classical electro-diagnosis.

Three important points stand out prominently :

1. The active pole—which is always the negative pole, at the closing of the current ;
2. The galvanic hyper-excitability of the muscle deprived of its nerve ;
3. The velocity of excitability or *chronaxie*.

1. Polar Action.—It now seems proved that the negative pole alone is capable of producing a closing contraction with the galvanic current.

Consequently, the contraction obtained by the positive pole in the paralysed muscles and characteristic of polar inversion of the RD, is falsely attributed to the action of this pole. It results from the action of a virtual, negative pole, appearing deep within the tissues and in the muscle itself.

1. As a demonstration, an interesting experiment made by Cardot and Laugier may be given.*

A frog's gastrocnemius and the nerve supplying it are placed in a small box made of paraffin wax, divided into two compartments by a partition traversed by the nerve. Thus there are two separate rooms, the one for the muscle, the other for the nerve, which passes across the partition and penetrates the muscle.

A wide indifferent electrode supports the muscle, a small active one surrounds the nerve.

* H. Cardot and A. Laugier. *Journal de Physiologie et de Pathologie générale*. Paris, 1912.

Each of these electrodes may be made positive or negative at will ; whenever the current is established, and in whatsoever direction, the muscle contracts.

We have to discover which is the active pole, and upon what it acts, nerve or muscle.

Now, Lapicque has shown that the velocity of excitability or *chronaxie* of a neuro-muscular system varies with the temperature. Thus, by varying the temperature of one of the two compartments, the variations of *chronaxie* can be studied and the problem solved.

Indeed, if the nerve compartment and the nerve itself are brought into different temperatures, with the negative pole we shall obtain corresponding differences of velocity ; if, on the other hand, we apply to the nerve the positive electrode, the velocity of excitability remains invariable, whatever the variations of temperature.

Conversely, if the temperature of the compartment containing the muscle is made to vary whilst maintaining the nerve at a constant temperature, we find that only excitation of the muscle by the negative pole is affected by the variations of temperature.

Thus it is demonstrated that the negative pole alone is active at the closing of the current for nerve and muscle alike, since the negative excitation alone is influenced by variations of temperature.

It has also been shown that, at the opening of the current, the positive pole alone is efficacious. But the opening contraction at the positive pole is usually not utilisable in electro-diagnosis. It requires an intensity eight to ten times greater than the closing contraction at the negative pole.

2. This principle that the negative pole alone is active at the closing of the current thus seems in formal contradiction to the results of the electro-diagnosis in the paralysed muscles, showing the existence of a polar inversion and of a closing contraction at the positive pole.

An experiment of Bourguignon * clearly shows that this contradiction is but apparent.

Thus, if we apply a small active electrode to a superficial nerve, close to muscular bellies independent of its motor supply (as, e.g., is the musculo-spiral nerve, in the groove of the biceps or the median at the inner surface of the arm), we obtain by a rather powerful negative or positive excitation very different results.

Excitation of the nerve by the negative pole will produce at the closing of the current a contraction in all the muscles it supplies in the forearm.

The closing excitation at the same point by the positive pole, however, causes no movement in the muscles supplied by the nerve. On the other hand, we notice a contraction in the neighbouring muscles, biceps and triceps.

Positive excitation, then, has not taken place in the nerve placed in contact with the electrode ; it has, however, affected *à distance* the muscles next to this nerve.

It is therefore proved that the positive pole in contact with the nerve is inactive. The motor response, *à distance*, of the neighbouring muscles

* Bourguignon. *Revue neurologique*, April 30, 1914.

is due to the existence of a virtual negative pole, which the real positive pole, applied to their surface, causes to appear in the neighbouring muscles.

This virtual pole, however, appearing deep in the tissues, along the course of the lines of force, naturally has not the density of the superficial pole represented by the small active electrode. Its action, consequently, is diffused; it falls upon the mass of the muscles and not in a precise energetic fashion on the motor nerve twig innervating them.

From these facts, the following conclusions may be drawn:—

The negative pole, at the closing of the current, exercises a direct, precise and limited action on the nerves and muscles with which it is in contact. Moreover, it causes to appear deep in the tissues a virtual positive pole, inactive and devoid of importance.

The positive pole, on the surface, acts indirectly at the closing, through the virtual negative pole which it causes to appear deep in the tissues. This excitation, therefore, is more diffused, indefinite and imperfectly limited; having less density, it requires a far greater intensity to produce the same results.

These facts enable us to explain the electrical reactions of a normal muscle and of a paralysed muscle.

(a) If we excite a healthy muscle at the motor point, we find that it contracts at the closing of the current, under the direct action of the negative pole, with a very small current; for instance, the threshold is at one to two milli-amperes. The excitation has acted directly, with great intensity, on the motor twig of the muscle. In these conditions it has produced the maximum of useful effect.

At the same point, with the same current, the positive pole is altogether ineffective. The intensity of the current must be sensibly increased to find the positive threshold, *i.e.* to cause to appear in the muscle a virtual negative pole, capable of producing, in spite of its diffusion, an equally strong excitation.

If the muscle is excited outside of the motor point, at the level of the muscular belly, or by longitudinal excitation, we at once see that greater intensity is needed to obtain the threshold of contraction. For instance, five, six, eight milli-amperes are needed to obtain the contraction. This is because excitation no longer acts directly on the motor twig but is diffused with less intensity in the muscle itself.

Again, we shall see that the muscle responds almost as well and often even far better to the positive pole. In this case it is excited by the virtual negative pole in its depth.

Thus we understand why we may find in a healthy muscle false polar equalities and false polar inversions, when the excitation does not bear exactly on the motor point, or when the real motor point is with difficulty accessible on the surface.

(b) In a paralysed muscle there is no longer any real motor point ; the nerve twig supplying it is inexcitable.

On the other hand, the muscle itself has retained its excitability ; we shall even see shortly that this excitability is usually increased. It contracts, however, only under the influence of a diffused current, distributed throughout the muscular belly, the density of which current, consequently, will be less great, whilst, in order to produce the same contraction as the excitation of the nerve, it will have to possess greater intensity.

In these conditions, the muscle makes a similar response when excited at the motor point or at a distance from this point ; by excitation of the muscular belly itself and especially by its longitudinal excitation we obtain even a stronger contraction than at the motor point : this is the phenomenon inaccurately designated as the descent of the motor point, or more correctly the longitudinal reaction.

If the negative electrode is applied to the muscle in its lower part or in the neighbourhood of the tendon, the current directly excites the muscular fibres throughout their whole length ; longitudinal reaction is thus almost always produced more readily by the negative pole.

If, on the other hand, the negative electrode is applied to the upper part of the muscle, near the motor point, the muscular fibres are excited only partially and feebly ; if we use the positive electrode, it causes to appear in the muscular body a virtual negative pole, the action of which on the muscular fibres is direct and far more effective than surface excitation ; we obtain polar inversion.

2. Hyper-excitability of the paralysed muscles.—GALVANO-TONUS.— Apparently the paralysed muscle is less excitable under the galvanic current than the healthy muscle. The contrary, however, is the case.

The paralysed muscle has lost its nerve excitability, *i.e.* it is impossible to excite at the motor point the nerve twig which normally responded to a very feeble current.

The muscle itself, however, has retained its excitability, which is more difficult to provoke than that of the nerve, on account of the diffusion ; consequently it requires greater intensity.

This electrical excitability of the paralysed muscle is frequently intensified, just as we have found its mechanical excitability intensified, as shown by the idio-muscular reflexes.

Only after some time, with the progress of muscular atrophy, the prolonged disuse of the muscle and the gradual disappearance of the contractile structure, do its electrical and mechanical excitability diminish and finally disappear.

There are two ways of accounting for this hyper-excitability of the recently paralysed muscle.

First, by investigating the threshold in the neighbourhood of the motor point ; the muscle usually responds to the positive pole.

Polar inversion takes place and we find that the positive threshold is often less raised on the paralysed muscle than on the healthy one.

Secondly, we can more easily recognise this hyper-excitability by longitudinal excitation. The muscle almost always responds to the negative pole, and this threshold of longitudinal excitation is always far less raised than on the healthy muscle.

In some cases there is also seen to appear the opening contraction which is difficult to obtain on the healthy muscle with bearable currents.

This hyper-excitability of the paralysed muscle, shown by longitudinal excitation, is particularly clear in cases of recent paralysis; it diminishes with the progress of the atrophy. It may even appear in muscles incompletely paralysed and thus demonstrate very slight nerve lesions. It disappears somewhat rapidly as soon as nerve regeneration manifests itself. It is sometimes called galvano-tonus.

A therapeutic effect results from this conception of the longitudinal hyper-excitability of the paralysed muscle.

It is logical to provoke by longitudinal excitation the contractions used in galvanic treatment; they are fuller, more complete and easier to obtain with feeble currents; the method of longitudinal excitation produces the maximum of effect with the minimum of current.

3. Velocity of excitability.—**CHRONAXIE.**—The conception of velocity of excitability, introduced into electrophysiology by Engelmann, Dubois, Weiss, Lapique, etc., has only of recent years found a practical application in electro-diagnosis.

It is, however, most important, as are also its practical consequences.

I. Velocity of excitability may be measured by the minimum duration of the passage of the galvanic current necessary to produce the threshold of contraction with the minimum intensity (for an indefinite duration of passage).

In order that a muscle may contract, there must be excitation of the muscle or nerve supplying it with a minimum of intensity; this is the threshold of excitation.

That this minimum current, however, may be effective, it must last some time; below this minimum duration the same current remains ineffectual; if this duration is increased, the muscular contraction obtained at the opening remains the same, however long the current takes to pass.

If we diminish the minimum duration of the passage of the current, there is no longer any contraction by the liminal current; contraction can be obtained only by increasing the intensity of the current.

This minimum duration of the liminal current, capable of determining the threshold of excitation indefinitely, is a measure of the velocity of excitability.

For practical reasons, most recent researches have utilised another

measure of velocity of excitability. First, the physiologists determine the threshold of excitation for a current of indefinite duration : this is the rheobase or rheobasic threshold of Lapicque. Then we seek the velocity of excitability for a current twice as intense as the rheobase. To this minimum duration of passage for a double intensity of the rheobase Lapicque gave the name of *chronaxie*.

The minimum duration of passage for the liminal current, and *chronaxie*, are two different measures of the velocity of excitability ; the former is about ten times greater than the latter.

The relation between duration and intensity of the liminal current is particularly important. For the same muscle of the same species in identical conditions it is invariable.

Consequently it supplies a mathematical and measurable basis for reckoning the excitability of a nerve or muscle.

It is also an extremely sensible method ; the works of Lapicque and his pupils have demonstrated the considerable variations of *chronaxie* according to the temperature and the different physiological and pathological states of nerves and muscles ; the slightest and most fleeting injuries of the nerve twigs are shown by considerable modifications of *chronaxie* ; the traction of a nerve trunk, its slight compression, the action of cocaine, ether, chloroform, etc. ; are immediately revealed by variations of the velocity of excitability, corresponding to fleeting modifications of the structure of the nerve. (Lapicque and Legendre.)

In spite of its importance, however, the fact of *chronaxie* has long enough eluded the researches of observers, for the durations of passage to be studied are extremely short. We may see this when we reflect that *chronaxie* of the frog's gastrocnemius muscle, for instance, at a temperature of 15°, is about three ten-thousandths of a second.

In man, we shall see that we may reckon at about or even below one-thousandth of a second *chronaxie* of the normal muscle ; its *chronaxie* is rapid : the paralysed muscle, on the other hand, easily reaches forty, fifty, sixty thousandths of a second ; thus it is excitable only by a relatively prolonged current : its *chronaxie* is slow. The difference is seen to be great ; nevertheless the results, even approximate, given by the different methods of research, are of considerable value.

* * * * *

The application of these facts to electro-diagnosis has hitherto encountered many difficulties, mainly resulting from the resistance of the skin and from the extreme variability of muscular excitability applied through the integuments.

Three processes have been advanced for reckoning the velocity of excitability : First, two indirect processes, that of Cluzet by discharges of condensers ; that of Bourguignon and Laugier by comparison of faradic excitability at the opening and closing of the induced current ; second, a

direct process, recommended by Lopicque, the simplification of the methods utilised in electrophysiology for measuring the duration of a very short galvanic current.

(a) DISCHARGES OF CONDENSERS (Cluzet).^{*}—Condensers of different capacity, but of the same voltage, discharge themselves according to a duration proportional to their capacity.

According to their capacity they may supply currents of variable duration.

It will be sufficient first to produce the voltage corresponding to the threshold of contraction for an indefinite current (rheobasic voltage). Then, if the condensers are charged at the same voltage, or rather at double the rheobasic voltage, we have only to find out the feeblest of the condensers capable of producing contraction. The measure of capacity of this condenser gives the duration of the discharge, consequently the velocity of excitability.

Practically, this method, of which we have simply set forth the barest schematic data, involves a certain number of difficulties arising mainly from cutaneous resistance which varies according to the intensity of the current and even, in the case of a current of constant intensity, according to the duration of this current. We shall find these same difficulties in all the methods proposed.

The results obtained, therefore, constitute only approximations; nevertheless they are sufficiently precise to reveal the slightest lesions and enable them to be expressed in figures, the value of which, relative though it be, is nevertheless great.

(b) THE PROCESS OF BOURGUIGNON AND LAUGIER.—RELATION BETWEEN THE INDUCED WAVES OF OPENING AND CLOSING.—It is well known that in an induction coil, when the primary current (inductor) is closed, there is induced in the secondary a current in the opposite direction; on the opening of the primary current there arises in the secondary a current of the same direction as the inductor current.

These two induced waves, of closing and opening, have not the same characteristics. Their direction is inverse, but this is of no great importance. On the other hand, they are unequal in duration and intensity; this gives them a different physiological action.

In the induced waves of closing and opening, naturally, the quantity of induced electricity is equal. The closing wave, however, is long, consequently its intensity is less; the wave of opening is short, and its intensity is greater.

This difference results from the way in which the current is set up; the closing current of the primary started in the induction coil is set up

^{*} Cluzet. *Lyon Médical*, 26 November, 1911; *Journal de Radiologie et d'Electrologie*, March 1914.

slowly, because of self-induction. The primary closing current and the resulting induced current are consequently prolonged and slowed down.

On the other hand, at the opening of the primary, no resistance of self-induction takes place, the wave resulting therefrom, both in the primary and in the induced, is short, almost instantaneous even, if care has been taken to extinguish the rupture spark which tends slightly to lengthen the opening wave.

In the induction coils usually employed in faradic excitation, only the opening wave, short and intense, is efficacious. The shortness of this wave explains why it is capable of exciting only the normal muscle, with rapid *chronaxie*. It is ineffective in the paralysed muscle, with slow *chronaxie*, unless its voltage is enormously increased by using an induction coil of adequate electro-motive force and considerable sheathing. This explains the contractions sometimes obtained in paralysed muscles by thin wire coils (usually of 800 ohms). With a coil of 1600, 1800, and even 3000 ohms, we can almost always obtain contraction of a paralysed muscle, but the intensity is very great and the excitation painful.

On the other hand, the opening wave is long, consequently it is capable both of exciting normal muscles with rapid *chronaxie* and degenerated muscles with slow *chronaxie*.

Thus, with the same coil, an adequately powerful one, we have two waves of unequal though constant duration, a short wave and a long one.

Let us first produce the threshold of excitation with the short opening wave, and note, by the sheathing of the coil, the intensity necessary for contraction. A healthy muscle, with rapid *chronaxie*, contracts with the short wave as soon as it reaches the rheobasic threshold with extremely small sheathing. A paralysed muscle, with slow *chronaxie*, will contract with the short wave only if it attains a far greater intensity, much superior to the rheobasic threshold with considerably greater sheathing.

Afterwards let us produce the threshold of excitation with the long closing wave. The healthy muscle will again contract when the rheobasic threshold has been reached; given the less intensity of the closing wave by reason of its longer duration, there will be needed a greater sheathing of coil than for the opening wave, usually almost double. The paralysed muscle, with slow *chronaxie*, will also be contracted by the long wave, when the threshold of excitation has been reached; *i.e.*, with an intensity somewhat higher than that of the healthy muscle and a scarcely greater sheathing.

In a word, for the healthy muscle, between the sheathing, consequently between the intensity of the opening and closing thresholds, there is a considerable divergence, explained by the smaller efficacy of the closing wave; in the case of the paralysed muscle the difference is considerably diminished, because owing to its slow *chronaxie* the paralysed muscle

requires, along with the short opening wave, a comparatively far greater intensity.

If we reduce to quantities (micro-coulombs, measured by the ballistic galvanometer), the value of the currents employed, we are able to establish a real indication, almost constant for one and the same coil, of the excitability of healthy muscles.

The lowering of the index gives the diminution of the constant of excitability of the muscle.

Below we offer an example, taken from Laugier.

Case of musculo-spiral paralysis from compression. Examination of the extensor carpi ulnaris.

OPENING (SHORT WAVE).		CLOSING (LONG WAVE).	
Distance of coils.	Quantities.	Distance of coils.	Quantities.
Healthy side . . .	14.375 cm. or 27.5 micro-coulombs.	7.75 cm. or	288 micro-coulombs.
Paralysed side . .	10.75 cm. or 98 micro-coulombs.	6 cm. or	431 micro-coulombs.

The index of excitability determined by the relation between the opening and closing amounts is respectively :—

Healthy side $\frac{288 \text{ micro-coulombs}}{27.5}$, or 10.5 normal figure for the coil employed.

Paralysed side $\frac{431}{98}$, or 4.4.

As we see, this indirect method of reckoning the velocity of excitability may give tolerably accurate results. It enables us to follow mathematically the entire evolution of a paralysed muscle.

Two things may, however, be brought against it.

First, it supplies only relative figures ; the constant varies according to the coil employed ; the constants of each coil must be determined and an examination made always with the same instrument.

Then, too, it is rather complicated ; the main difficulty arises from the fact that at the intensities at which the closing contraction manifests itself, the opening contraction is violent and practically unbearable. It is consequently necessary to eliminate it carefully either by working the interruptor by hand or by utilising Bourguignon's special interrupter enabling one to eliminate at will the opening contraction.

(c) Lapicque's *Chronaximètre*.—Lapicque recently issued the model of a simplified *chronaximètre*,* for clinical use.

This is a "rotatory mechanical rheotome, to which movement is communicated by a suitable heavy weight falling from a moderate height and carrying a light shaft by

* L. Lapicque. *Académie des Sciences, Comptes rendus*, t. clxi, p. 643, séance du 22 Novembre, 1915.

a wire placed over a pulley with decreasing radius; a pointer fixed perpendicularly on this shaft describes a circle at a velocity increasing as the square of the time: in this way, I have obtained at the end of the first turn, which alone can be used, an angle of 7° to 8° per thousandth of a second. Two specially made interrupters, worked in succession by the passage of the pointer, give clearly and securely (as experience has shown) current durations that can be regulated from a fraction of a thousandth of a second up to a tenth of a second."

It suffices first to determine the threshold of excitation to closing of the negative, for a current of indefinite duration. This is the well-known negative threshold of electro-diagnosis; the rheobase of the physiologists. Then we must, with the same current though of definite duration measured by the *chronaximètre*, try to find the minimum time necessary for obtaining contraction. This duration supplies directly the velocity of excitability.

We must remember that physiologists prefer to take as their starting point a double intensity of the rheobase.

That we may avoid too short durations, it is preferable in clinical electro-diagnosis to seek *chronaxie*, starting with the rheobase itself.

Perhaps the results are somewhat less precise, but the durations are longer and easier to reckon.

The variations in *chronaxie* revealed by this method between the healthy muscle and the paralysed muscle are enormous. Whereas a healthy muscle contracts at one to two thousandths of a second, and often far below one thousandth, *chronaxie* of a paralysed muscle, manifesting the RD, easily rises to forty, sixty thousandths of a second, and even more.

This difference is less easy to estimate than the delay and slowness of galvanic contraction, which, after all, are but the objective expression of the same phenomenon.

Without claiming the precision of an apparatus in physics, the *chronaximètre* enables us to estimate *chronaxie* of a muscle with tolerable rapidity; to reckon its degree of excitability and to follow by successive measurements its entire pathological evolution.

Nevertheless, it must be confessed that these researches, even simplified, are always too prolonged; several hours are often necessary for the methodical examination of the muscles of a single patient.

Muscles, too, in a state of prolonged inactivity, show a sensible diminution in their velocity of excitability. We readily obtain figures of eight and ten thousandths of a second in cases of hysterical paralysis or on the inactive antagonists of the paralysed muscle.

4. Selective excitation of paralysed muscles.—A second important application of the idea of *chronaxie* has been proposed by Lapicque.

In electro-diagnosis we are considerably impeded by contraction of the antagonistic muscles excited by diffusion. We may eliminate this contraction of the antagonistic muscles which have remained normal and limit excitation to the paralysed muscles alone by utilising a progressive current.

In 1907-1908 Lapique showed that if a current increases gradually to a constant intensity, the diminution of efficacy resulting from this retardation is smaller in proportion as *chronaxie* is slower.

When we are at the threshold of excitation, or even a little above, if the galvanic current gradually attains its constant intensity, in six or eight thousandths of a second, for instance, the normal muscles and nerves, with small short *chronaxie*, undergo no excitation whatsoever. The degenerated muscles, with slow *chronaxie*, on the other hand, are excited by a progressive current, even if this current reaches its intensity only in fifty or one hundred thousandths of a second.

We need then only introduce the current by degrees in order to limit contraction to the paralysed muscles alone.

Lapique produced this retardation by using condensers, placed in series. A condenser of two microfarads causes the current to take about six thousandths of a second to reach 95% of its constant intensity. By progressively introducing greater capacities, up to ten, twenty, thirty microfarads, if the hypo-excitability of the paralysed muscle necessitates the use of a more intense current, we finally suppress altogether the contraction of the healthy muscles, without in any way modifying the efficacy of the current in the paralysed muscle.

The same observation is of considerable importance in electrotherapy. Indeed, it is necessary to limit to the paralysed muscles, as far as possible, the contractions provoked by the current.

By utilising currents progressively, we shall do away with the contractions produced in the healthy muscles, and, without any pain, can utilise greater intensities.

This is obtained progressively with special interrupters, with metallic vibrators, or with immersion vibrators (Bergonić, Bordier, etc.) the use of which has recently been highly recommended.

CHAPTER IV

CLINICAL TYPES

THE most important and difficult problem to solve in peripheral paralysis is that of the nature of the lesion. This diagnosis requires surgical intervention or abstention ; it enables us to form a prognosis as to the future of the paralysis.

The minute study of the many cases of peripheral paralysis, undertaken since the outbreak of war in the various neurological centres, enables us to differentiate a certain number of clinical syndromes relating to various nerve lesions and involving diametrically opposed therapeutic solutions.

Along with J. and A. Dejerine and Mouzon we may describe four syndromes that are fundamental, typical and clearly characterised :

- Syndrome of interruption ;
- Syndrome of compression ;
- Syndrome of irritation ;
- Syndrome of regeneration.

To these must be added dissociated syndromes resulting from partial lesions of the nerve, and also complex syndromes produced by association in the same nerve of two or more of the preceding syndromes, in connection with the different or unequal lesions of the various fasciculi of which it is composed.

We may also add the syndrome of ascending neuritis, which is rather a complication than a consequence of nerve lesions.

In reality, however, the clinical manifestations of nerve lesions are even more varied and numerous than this enumeration suggests. A study of nerve wounds enables us continually to group new categories and distinguish new symptomatic forms. Irritation of the nerve trunks, in particular, direct or even ascending, is indicated in many different clinical pictures, sometimes by simple neuralgia, sometimes by violent pains, of a character special to the causalgia of Weir Mitchell ; sometimes by trophic disturbances which especially characterise neuritic forms, and sometimes even by states of muscular hypertonia which come under the heading of contracture.

Consequently, we shall have to dwell at some length on the manifestations of nerve irritation and the polymorphous symptoms it may call forth.

I.—SYNDROME OF INTERRUPTION

The syndrome of interruption occurs in cases of complete section of the nerve, in very severe compression, in tearing or bruising of the nerve with the formation of a fibrous cicatrix.

In all these cases, there is complete interruption of the nerve fibres; their peripheral segment, from the lesion on to the termination of the fibres, undergoes Wallerian degeneration and gradually disappears; their central segment, above the lesion, remains almost intact.

In favourable conditions, such lesions are capable of spontaneous regeneration. This will come about by a progressive growth of the axis-cylinders of the central end, which, crossing the obstacle, will slowly advance in the empty sheaths of the peripheral segment and end by completely reconstructing and regenerating the original nerve.

But, on the other hand, the obstacle is frequently insurmountable to the regenerating fibres; the segments of the sectioned nerve are not in contact, compression is too great, the cicatricial mass is formed of too dense fibrous tissue. In all these cases, the regenerating fibres springing from the central end will be unable to join the peripheral empty sheaths which serve them as conductors, they will group themselves at the level of the obstacle, forming a neuroma, or else will stray about in the neighbouring cicatricial tissue.

Thus, complete interruptions often call for surgical intervention: either decompression in certain cases, or, more frequently, nerve suture after resection of the injured segment. This intervention has no other object than the removal of the obstacle and the placing of the central and peripheral segments in contact with each other, so as to allow of easy regeneration.

The syndrome of interruption is characterised—

1. By immediate, complete, absolute and invariable paralysis of the muscles supplied by the interrupted nerve.

2. By a progressive and particularly rapid disappearance of muscular tone, culminating in complete muscular hypotonia. It precedes atrophy, which occurs more slowly.

3. By well-marked progressive and regular muscular atrophy.

In spite of hypotonia and atrophy, the idio-muscular reflexes are intensified, for a very long time at least, whereas the tendon reflexes are abolished. There is increase of mechanical contractility of the paralysed muscle.

4. By a reaction of degeneration which is gradually set up in about two or three weeks and culminates in the complete classical RD.

From the outset the nerve excited above the lesion no longer transmits any excitation to the muscles which it supplies.

For some days after the wound the nerve remains excitable below the lesion, then it rapidly loses all excitability.

The muscles also lose in a few days their faradic contractility (with the thick wire coil), then, much later, after a month or even more, their faradic excitability with the thin wire coil (the usual coils).

At the same time we have the disappearance of the motor point, polar inversion and longitudinal hypo-excitability. Galvanic contraction becomes slow, its appearance is retarded and its execution slackened.

5. By immediate, complete and invariable anæsthesia in the region supplied by the paralysed nerve.

Anæsthesia is a little more widely spread the first few days; its area gradually diminishes for some weeks owing to anastomotic substitutions;

then it remains definite and fixed. According to the case, it is somewhat variable in its characters; in principle, it is absolute, involving all the superficial and deep sensibilities, though this is true only for large areas of anæsthesia.

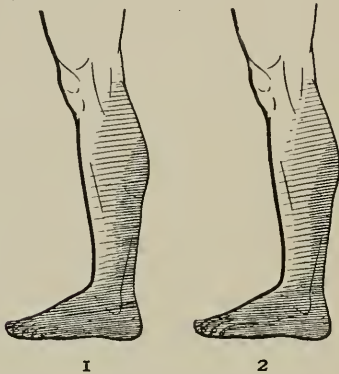


FIG. 21.—Example of fixed anæsthesia in complete interruptions. Section of the sciatic in middle part of thigh. 1. Examination on the 16th June, 1915, six weeks after the wound. 2. Examination on the 9th October, 1915.

Deep anæsthesia, indeed, is always, by reason of anastomotic substitutions, much less widely extended than superficial anæsthesia; it is, on the other hand, evoked by very slight cutaneous pressure: when the patient is pricked with a needle, and he feels simply the contact not the prick, this is because deep sensibility is involved. In the exploration process with the pin which we have recommended, the answer "touch" applies mainly to deep sensibility.

In these conditions, when the anæsthetised region is not very extensive, deep anæsthesia is never complete; the pressure of the pin is everywhere felt, the feeling of pain alone is abolished, and we have simple hypo-æsthesia.

6. By the absence of spontaneous, or induced pains by pressure on the nerve and the muscular bellies. Not only are the muscles not painful, but, as Dejerine has remarked, they are quite insensitive to pressure.

The nerve lesion itself is alone somewhat painful.

7. By the absence of formications caused by pressure on the nerve below the lesion.

On the other hand, we notice at the level of the lesion a focus of formications produced; they appear in a very limited zone which corresponds to the neuroma of the central end. The fixity of this zone, for weeks and months, is an important sign of complete interruption.

It must be remembered that formication appears as a rule only about the fourth or sixth week, and that it disappears in the end.

8. By the absence of trophic disturbances, except occasionally slight œdema, a little cyanosis and moderate hypertrichosis.

Serious trophic disturbances, cutaneous sclerosis, aponeurotic contractions, tendon and synovial adhesions, affections of the nails, arterial lesions, do not belong to the syndrome of complete interruption.

Still, one may meet with trophic ulcers, which are always secondary to a cutaneous injury; these are, for instance, plantar ulcers produced by walking, sores on the great toes or the dorsal surface of the foot occasioned by the foot-wear; ulcers on hand or fingers appearing as the result of a burn, an excoriation, or even at times a simple galvanic bath. After all, these are always accidental ulcers, favoured and prolonged by malnutrition of the tissues in the region of the interrupted nerve.

From this schematic description we conclude that—

(a) Several of the signs characterising the syndrome of interruption, such as the RD, atrophy, hypotonia, formication, etc., only come about gradually and after a certain time.

(b) Fixity of the symptoms is one of the important characteristics of the syndrome:

Fixity of paralysis;

Fixity of anæsthesia;

Fixity of the RD;

Fixity of formication.

(c) Complete interruption of the nerve fibres does not altogether exclude the possibility of their spontaneous regeneration without surgical intervention.

Consequently it is absolutely necessary to make a number of successive examinations at intervals of several weeks before making a formal diagnosis and deciding upon surgical intervention.

II.—SYNDROME OF COMPRESSION

Simple compression of the nerve takes place when the nerve fibres undergo lesions of such a nature that the voluntary nervous impulse, as well as the electric current, cannot pass, but without there being destruction of the axis-cylinder or centrifugal degeneration.

In a word, we have here a local disorganisation which momentarily causes to disappear the physiological conductivity of the nerve fibre; but this fibre is not dead; its peripheral segment is not degenerated; it is capable, after the disappearance of the injury, of being reorganised and

resuming its functions fairly rapidly. This is the syndrome produced in the momentary compressions of a nerve ; its classical example is musculo-spiral paralysis, called "a frigore," produced by compression of the nerve during deep sleep.

Sometimes this syndrome is found in the permanent compression of a nerve surrounded by a fibrous cicatrix or encased in callus, but without marked narrowing.

In these cases, however, permanent compression, compatible for a considerable time with anatomical survival of the nerve, may finally induce its progressive degeneration ; consequently, we may find a syndrome of compression being transformed into one of interruption.

On the other hand, the same injury may induce destruction of a certain number of more fragile nerve fibres and simple compression of the rest. This results in a mixed and very usual syndrome, one of incomplete interruption, where the symptoms of interruption are never fully seen, and where, nevertheless, we observe progressive regeneration, far slower than simple restoration of a compressed nerve.

The syndromes of momentary compression must be compared with the fleeting paralyses which often succeed grave injuries of the limbs, and which have been described as a kind of stupor of the nerves : these paralyses disappear after a few days, generally without any disturbance of electrical reactions revealing the tiny contusions or the state of shock in the nerve trunk.

The syndrome of compression is characterised—

1. By more or less complete paralysis, generally as complete as in the syndrome of interruption, more rarely partial and permitting of a few ill-defined movements.

2. By muscular atrophy, far more rapid and less intense than in complete interruption.

This atrophy may, however, become very intense, if compression persists.

3. By relative preservation of muscular tone which is one of the best signs of simple compression.

Still, one may also find muscular tone disappearing after a time ; this muscular atony, however, requires months, whereas it takes only a few weeks in complete interruption.

The idio-muscular reflexes are almost always intensified ; if they are normal it shows that the compression is very slight.

4. By a reaction of partial and always incomplete degeneration, far slower in taking place ; unless we have progressive interruption of the compressed fibres.

It is in slight compressions, particularly in musculo-spiral paralysis from temporary compression, that we may find the paradoxical electrical reactions we have already mentioned : nerve and muscles remain more or

less excitable by the faradic current below the lesion, whilst electrical stimulation of the nerve above the lesion causes no movement whatsoever in the paralysed region.

5. By anæsthesia, variable in intensity and extent; in general it is far more reduced and less pronounced than the anæsthesia of interruption; in any case it has no invariable fixity.

6. By the absence of pains at the level of the lesion, as also of pains in the course of the nerve or on pressure of the muscular bellies; these latter, however, may retain their normal sensibility to pressure.

7. By the absence of formication. This is altogether absent in simple and transitory compressions, as is musculo-spiral paralysis *a frigore*. If we find, in some cases of close and prolonged compression, slight

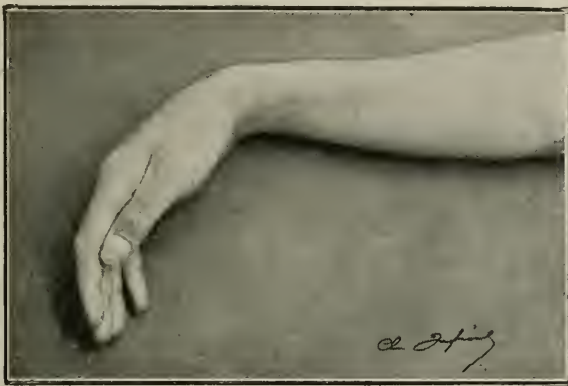

FIG. 22.—Attitude of the hand in a case of simple compression of the musculo-spiral nerve. The paralysis is the same as in cases of complete interruption, but the tone retained gives the hand a less drooping posture, one more resembling that of repose. Freeing of the nerve. First indication of movement 15 days after intervention. (J. and A. Dejerine and Mouzon, *Presse Médicale*, 18 May, 1915.)

formication of the nerve trunk under pressure, it indicates the destruction and the consecutive regeneration of some nerve fibres. In a word it is a case of incomplete interruption.

Whilst regeneration of the few interrupted fibres is taking place, we find the zone of formication extending over the tract of the nerve below the lesion, signifying the progressive advance of the axis-cylinders.

In other cases, the zone of induced formication remains fixed, limited to the level of the lesion. It is then to be feared that the constriction of the nerve, too great to allow of the passage of the regenerating fibres, will, in the long run, cause destruction of the fibres that have remained healthy.

8. The absence of trophic disturbances is even clearer in compression than in complete interruption. Usually we do not find in them the cyanosis and the slight œdema which may accompany the preceding type.

The syndrome of compression, like that of interruption, includes a certain number of characters noticed during the evolution of the symptoms and obtained by successive examinations.

Only after a few weeks' observation can one judge of the necessity for surgical liberation.

Moreover, the results of liberation are somewhat variable. In simple compressions we often find that the nerve regains in a few weeks, sometimes a few days, the whole of its functions.

In compression with incomplete interruption, the duration of restoration is evidently proportional to the nerve destruction.

The fibres momentarily or slightly compressed present only segmentary lesions, *i.e.*, limited to the affected point, and are not accompanied by degeneration of the peripheral segment. They need only undergo local restoration for the nerve impulse to pass into the peripheral segment which has remained intact and to supply afresh the paralysed muscles.

If the fibres are more deeply affected, the peripheral segment is injured secondarily, and the work of restoration must be carried on over the entire extent of the nerve.

The extreme variations we find in the time necessary for healing may thus be understood.

In almost every case of compression calling for surgical intervention, simple liberation of the nerve is usually sufficient. Resection and suture are called for only in cases where prolonged constriction has transformed the nerve into a mere fibrous strand; in these cases, the syndrome of compression had given place to that of complete interruption.

III.—SYNDROMES OF IRRITATION

Irritation of a nerve trunk may show itself by extremely varied and diversely associated symptoms.

We will describe schematically :

1. Serious nerve irritation ;
2. Slight nerve irritation ;
3. Irritation of a simple neuralgic form ;
4. A special neuralgic syndrome accompanied by violent pains and paroxysms ;
the causalgia of Weir Mitchell.

The phenomena of nerve irritation or neuralgia in a mixed nerve may be associated with paralysis, though they may also exist without total paralysis. It may even be stated that paralysis is exceptional in slight neuritic forms, and in neuralgic forms.

On the other hand, disturbances of irritation also show themselves in the sensory nerves or in the purely sensory branches of the mixed nerves.

I.—SYNDROME OF SERIOUS NERVE IRRITATION

This syndrome is found only in lesions of the mixed nerves which alone possess numerous vaso-motor and trophic fibres whose irritation produces neuritic disturbances.

It is almost always accompanied by paralysis ; this paralysis, however, is frequently less complete than in the preceding forms, for the nerve fibres are irritated, not destroyed. For instance, there persists a suggestion of voluntary movements or else a certain degree of electrical excitability. The RD is frequently partial.

Muscular atrophy is extremely variable. Whilst, for the most part, it is less marked by reason of the relative preservation of the nerve fibres, in other cases we find extremely rapid muscular dissolution.

Muscular tone is usually preserved, sometimes even intensified by fibrous infiltration of the muscles.

The idio-muscular reflexes are always intensified, although the fibrous transformation of the muscles may frequently mask them.

Trophic and painful sensory disturbances are the essential characteristics of neuritic types.

Whereas, however, motor disturbances occur immediately, pains and trophic disturbances are secondary.

After a few days the pain appears and it gradually becomes more pronounced for two or three weeks, to continue for months and then slowly disappear.

It is also after a few weeks that trophic disturbances appear, persistence of which often brings about definite lesions.

A.—SENSORY DISTURBANCES

Pains.—The main symptom is pain.

Spontaneous pains comparable to sensations of burning, pricking, muscular rending.

Pains intensified by movement and muscular contraction, by heat and more especially by cold, by cutaneous friction or by contact of the bed-clothes.

Pains occasioned mainly by pressure on nerve trunks and muscular bellies ; these pains are felt at the compressed point ; they also extend over the whole limb. Generally they are more acute on pressure of the muscles than of the nerve trunks.

Cutaneous hyperæsthesia.—The skin also is painful. In certain cases, it is true, we may note the presence of cutaneous anæsthesia, which, however, is found along with the pain on pressure of the deeper tissue. More

frequently, however, there is painful hyper-æsthesia, which usually coexists with a tactile and thermal hypo-æsthesia.

Indeed, touch, friction, cold and heat are but vaguely perceived ; even pricking is ill defined ; but all these cutaneous stimuli produce one and the same painful sensation, imperfectly localised and differentiated, diffuse, radiated, continuing several seconds and altogether characteristic.

B.—TROPIC DISTURBANCES

Trophic disturbances belong strictly to the syndrome of nerve irritation. In these cases we note the presence of œdema, cyanosis and hypertrichosis, already found in nerve interruption.

More especially do we find the whole series of severe trophic disturbances—

Extreme dryness of the skin, its fibrous infiltration and its desquamation in broad scales, or, on the other hand, the appearance of profuse fetid sweats, or again the condition known as glossy skin.

Nails curved, furrowed, split, cracked, claw-like.

Conical atrophy of the digital extremities.

Fibrous infiltration and contraction of the muscular bellies ; contraction of the tendons and aponeuroses, which lead to the formation of irreducible *griffes*.

Immobilisation of the tendons by fibrous invasion of the synovial sheaths.

Fibrous ankyloses of digital or carpal joints and of deformed joints reminiscent of rheumatoid arthritis.

A more rapid and pronounced bony decalcification than in any other type.

* * * * *

Pronounced neuritic types are therefore essentially serious, mainly by reason of their trophic disturbances.

Indeed, whilst the paralyses that accompany them are always destined to heal spontaneously or by liberation of the nerve, the pains that characterise them, however acute they may be, must inevitably diminish and disappear ; on the other hand, the fibrous and muscular contractions, the tendon immobilisations, the *griffes*, the articular scleroses, too often constitute refractory lesions which necessitate months or even years of painful mobilisation and of massage, and sometimes remain altogether irreducible.

Most of these severe neuritic types heal spontaneously, with the exception of the fibrous sequelæ of the healing process.

Spontaneous regression is indicated by the mitigation of pain and by the appearance of formication.

During the entire period of irritation, the nerve is painful, though there is no formication when pressure is applied. As soon as neuritis calms down, we note the appearance of formication at the level of the

lesion ; then, week by week, it is seen to descend along the tract of the nerve which, with the neighbouring muscles, ceases to be painful ; formation then gradually replaces in the nerve the neuritic pain, driving it forward, as it were. Speaking generally, the slowness of the regeneration in neuritic types is discouraging.

In obstinate cases, liberation of the nerve seems to give variable results ; sometimes it brings about a great and rapid improvement ; frequently it is ineffective. Probably the inconstant nature of the results is due to the character of the lesion ; irritation may be external to the nerve, or, on the other hand, may take place within it.

In certain particularly intense forms, where serious and definite trophic disturbances are to be feared, it is right to practise resection of the lesion and suture of the nerve. By this means, the pains are immediately dispelled, the evolution of trophic disturbances is suppressed and it is possible to practise massage, mobilisation and electrical treatment, all of which had been impossible before by reason of the intensity of the pains.

II.—ATTENUATED NEURITIC TYPE

We have described the grave forms of nerve irritation, but we must remember that its manifestations may be far more widely disseminated.

A little pain on pressure of the muscular bellies, a slight fibrous infiltration of the muscles, a few aponeurotic or tendon contractions, slight cutaneous sclerosis with adhesion of the integuments enable us to conclude that there is irritation of the nerve and therefore that it is incompletely interrupted.

Frequently slight neuritic disturbances may be dissociated. For instance, we may find pain on pressure of the muscles, with fibrous contraction but without pronounced cutaneous trophic disturbances ; this is the origin of some cases of *pes equinus*, from slight lesion of the sciatic. Muscular atrophy may be absent, we have even seen cases where slight irritation of the sciatic nerve was shown by actual hypertrophy of the muscles of the calf, accompanied by slight contraction and fibrous infiltration of the muscles, more bulky and resisting than on the healthy side. Moreover we shall see later what relations can be established between these disturbances and contractions from neuritis.

In these cases of neuritis affecting the muscular system we occasionally find neither hyperæsthesia nor even cutaneous hypoæsthesia ; whilst, on the other hand, the muscles are painful when pressed. The pain is deep, not on the surface.

In other cases aponeurotic contractions prevail, resulting in the formation of fibrous *griffes* ; sometimes nerve irritation is rather ill-defined and aponeurotic sclerosis so tardy that the nerve lesion may pass unnoticed.

For instance, we have seen cases of contraction of the palmar fascia, reminding one of Dupuytren's contracture, occurring slowly after a wound in the arm or the fore-arm and apparently inexplicable; the most minute investigation has been needed to discover, not only a certain degree of pain on pressing the nerve, but even slight formication along its course and hypo-æsthesia of its cutaneous area, thus proving slight irritation of the ulnar.

Sometimes again cutaneous trophic disturbances preponderate. In certain slight neurites of the musculo-spiral, for instance, attention is first attracted by the fibrous infiltration of the skin on the dorsal surface of the fingers, its adhesion to the first joints and the limitation resulting therefrom in flexion of the fingers.

Still, speaking generally, the exclusively cutaneous manifestation of trophic disturbances is more apt to accompany the neuralgic type which we will now investigate.

III.—SIMPLE NEURALGIC TYPE

Following on slight bruises of the nerve trunks, we often meet with more or less pronounced neuralgic syndromes.

No trophic disturbances occur, at most a few signs of cutaneous irritation. There is no paralysis, but only a certain degree of weakness and muscular atrophy, without appreciable modification of the electrical reactions.

Instead of anæsthesia, there is slight hyper-æsthesia to pin-prick in the area of distribution of the nerve.

The patient complains solely of more or less acute pains radiating along the course of the nerve, provoked mainly by the movements involving the lengthening of the limb, such as the extension at elbow, neck and knee in the case of the median and the sciatic, which are most frequently involved.

The muscular bellies are somewhat sensitive to pressure. The nerve trunks, however, are more so; and this pain is manifested above all at the points of election. On the sciatic are found all the Valleix points and Lasègne's sign; indeed, we are dealing with real injuries to the sciatic.

These traumatic neuralgias are often rather persistent, they may continue for several months and then disappear spontaneously.

Naturally their intensity is very variable, and every type may be found. They are syndromes of slight irritation, of a well-marked sensory type.

They are specially to be distinguished from the violent neuralgic syndromes of a particular character, for which must be reserved the name of "causalgia."

IV.—INTENSE NEURALGIC TYPE—CAUSALGIA

In 1864, after the War of Secession, S. Weir Mitchell described under the name of causalgia a particular neuralgic syndrome, characterised by its intensity, its long duration, its special pains and its habitual resistance to every therapeutic agency.

All the nerves may be attacked by causalgia, but it is particularly the median and the sciatic that produce this syndrome, doubtless by reason of the number, importance, and perhaps fragility or special nature, of their sensory or vaso-motor fibres.

Very seldom does causalgia appear immediately after the wound; almost always the pains supervene only after four or five days; they take three or four weeks to reach their maximum, and then continue for months, finally calming down very slowly.

Causalgia is essentially characterised by violent pains, compared by patients to a sensation of mingled smarting and burning (*καυσίς*, burning), or even, says Weir Mitchell, "to a red-hot file rasping the skin. . . . Its intensity varies from the most trivial burning to a state of torture that can hardly be credited.*

As a rule, it is localised at the termination of the nerve, at the palm of the hand in the case of the median, at the sole of the foot in the case of the sciatic; but it radiates simultaneously over the entire area of distribution of the nerve and even well above the lesion.

The pains are so greatly aggravated by movement, walking or the slightest shock, that certain patients resign themselves to almost complete immobility.

A slight touch on the skin, a pin-prick, heat, cold especially, and all cutaneous excitations, induce painful paroxysms which often continue for several minutes.

Accordingly these patients show the greatest anxiety when we want to examine the hand. And yet, whilst a gentle touch is atrociously painful, firm pressure of the integuments can scarcely be felt. By warning the patient beforehand, we may succeed in openly grasping his hand and examining it without causing him too much suffering. The pain is far more superficial than deep. "If it lasted long, it was referred finally to the skin alone," writes Weir Mitchell.

An even more curious fact,—keen emotions and sensations induce violent exacerbations of pain; a child falling, an unexpected letter arriving, a carriage appearing at the bend of a street, a door creaking, a sudden

* S. Weir Mitchell, Morehouse and Keen, "Gunshot Wounds and other Injuries of Nerves." Philadelphia, 1864, p. 101, etc.

Des lésions des nerfs et de leurs conséquences. Traduction Dastre, préface de Vulpian, Paris, 1874, p. 233, etc.

strong light, a glance down a staircase or through a window, are all so many causes calculated to provoke a painful paroxysm.

We now understand why those who suffer from violent causalgia have so distinctive an appearance: they look anxious, they are taciturn and irritable, they will not leave the house or speak or play, they lose both sleep and appetite. They walk daintily as though to avoid all shock; in some cases the hand is held behind the back, in others it is held in front, the healthy hand acting as a shield to protect the other from contact of every kind.

The dryness of the skin causes particularly painful sensations. To calm their sufferings and at the same time avoid contact with the air, the patients wrap the hand in compresses or padded gloves; moisture more than anything else gives them appreciable relief; they are often seen to surround the hand with a wet cloth constantly renewed.

"Most of the bad cases," says Weir Mitchell, "keep the hand constantly wet, finding relief in the moisture rather than in the coolness of the application. Two of these sufferers carried a bottle of water and a sponge, and never permitted the part to become dry for a moment. . . . One of these men went so far as to wet the sound hand when he was obliged to touch the other"; others "found some ease from pouring water into their boots."

Along with the pains which constitute the main symptom of causalgia, other less important disturbances must be mentioned. If there is no paralysis but at most a slight muscular weakening and atrophy, the vaso-motor and trophic disturbances are often a little more pronounced.

The skin, usually macerated by the moist state kept up, is smooth, warm and red, the *glossy skin* type described by Weir Mitchell. It is sometimes more dry than on the healthy side; though more frequently causalgia would seem to be accompanied by profuse sweats. The fingers are thin and slender; flexion of the last phalanx is often limited. The slightly striated nails, sometimes a little bent, are almost always of a dull yellow colour resembling ivory. They grow more quickly than in their normal state, and their rapid growth raises at the extremity of the finger a small cutaneous swelling, constant in all nerve irritations and particularly painful in causalgia.

The skin shows extreme hyper-æsthesia, entirely superficial, almost always passing beyond the cutaneous region of the nerve.

Strange to say, the vaso-motor disturbances, redness of the skin, dryness or exaggerated sweating, like hyper-æsthesia, often extend far beyond the cutaneous region of the nerve affected.

Those authors base their conclusions on this fact who tend to regard causalgia as the syndrome of irritation of the vascular nerves, supplied by the median or the sciatic to the arteries which they accompany, or even as a sympathetic syndrome indicating lesion of the peri-arterial plexuses.

In all cases, the refractory nature of these disturbances is disheartening. No treatment relieves them ; liberation of the nerve remains almost always ineffectual ; sedative electrical treatment obtains ease only for a few hours.

In these conditions, some authors considered the question of section of the nerve or the injection of alcohol above the lesion, but even these heroic measures may be ineffectual ; after resting for a few days, the patient again begins to suffer. Regeneration of the cut fibres seems to take place with extraordinary rapidity ; cutaneous hyper-æsthesia soon reappears and the muscles themselves rapidly regain all their excitability.

Further on, we shall study the various treatments proposed ; both failures and successes attend almost all therapeutic measures. The present therapeutic uncertainty is largely owing to our ignorance of the true mechanism of causalgia.

Not without a certain repugnance can we assent to cutting or alcoholising a nerve trunk which is not paralysed, and the regeneration of which, after intervention, is never certain.

Radiotherapy in certain cases has given remarkably soothing effects.

The paroxysmal symptoms of causalgia, the pains of an emotional type, the vaso-motor disturbances and the radiation of the symptoms beyond the region of the nerve clearly indicate a sympathetic syndrome. (Leriche, Meige and Mme Benisty.)

Denudation of the brachial artery and section of the sympathetic plexus surrounding it, recommended by Leriche, have given good results in obstinate cases.

V.—HYPERTONIA AND CONTRACTION FROM NERVE IRRITATION

We have already mentioned the cases in which slight nerve irritation produced simple contraction and fibrous infiltration of the muscles, without paralysis or strongly marked muscular atrophy. These are indisputable and well-known facts.

But it would also seem that irritation of a nerve trunk might produce states of muscular hypertonia, veritable nerve contractions, immobilising the muscles in a frequently paradoxical posture.

As a matter of fact, these contractions from neuritis are often of a more complex nature ; we shall study them later on.

IV.—SYNDROME OF REGENERATION

The syndrome of regeneration is seen in its purest form after nerve sections and nerve sutures ; it exists in the compressions, crushings or tearings which are accompanied by complete or partial interruption of

a nerve trunk ; it is also shown in cases of severe nerve irritation where the affected or irritated nerve fibres seem to have been gradually replaced by young and healthy ones.

Thus it indicates the slow progression of the regenerating axis-cylinders, coming from the central end, into the empty sheaths of the degenerated peripheral segment.

No interrupted or even severely injured nerve fibre can resume its functions except by this budding of the axis-cylinders from the central end.

The regeneration of a nerve is essentially a long and gradual process.

Again we must repeat that immediate or even rapid restoration of an interrupted and sutured nerve, however short the interruption, is theoretically and practically impossible. No fact of this kind has ever been ascertained by a neurologist ; all reported observations are errors of interpretation caused by compensatory movements or by phenomena of collateral sensibility.

The syndrome of regeneration, then, consists of the progressive reappearance of the functions of a nerve : motor, sensory, trophic functions and electrical reactions.

The beginning of restoration after a suture or a traumatic interruption of the nerve is never immediate ; the first signs of regeneration scarcely ever appear before the fourth or even the sixth week.

Any interruption of nerve fibres produces two kinds of phenomena. On the one hand, it is followed by the degeneration of the whole peripheral segment : Wallerian degeneration. On the other hand, it causes a series of profound disturbances in the central segment ; this is first an ascending degeneration of the nerve fibre above the lesion, a retrograde degeneration, which is always limited, and does not extend more than a few millimetres, and afterwards the reaction *à distance* on the original cell, shown under the microscope as the phenomenon of cellular chromatolysis. Only after this brief disturbance in the nerve does proliferation of the axis-cylinders of the central end and their advance towards the peripheral segment begin, and the first signs of regeneration become manifest.

Return of the functions of the nerve corresponds with progression of the axis-cylinders in the degenerated nerve ; consequently it follows a centrifugal course, *i.e.* restoration is first shown at the level of the muscles and integuments nearest the lesion, gradually and slowly extending to the more distant muscles and integuments.

This progress is not absolutely regular ; it often takes place in jumps, during periods of a few days when the regenerating activity manifests itself, followed by periods of rest.

In all cases regeneration is shown in the nerve trunk, in the muscles and in the integuments.

I.—SIGNS OF REGENERATION OF THE NERVE

In the nerve two signs of regeneration may be observed :

The appearance of formication called forth by pressure ;

The return of electrical conductivity.

The former comes about at a very early stage and is most important ; the latter is tardy, almost always following on the return of voluntary conductivity ; it is consequently devoid of interest.

The all-important sign is formication. We find that sudden pressure, or percussion of the nerve trunk, below the lesion, calls forth a sensation of formication in the cutaneous region of the nerve.

It appears about the fourth or sixth week. Then it gradually becomes more pronounced, and it is possible to follow, week after week, in the course of the nerve, the progress of this provoked formication, *pari passu* with the advance of the axis-cylinders. It extends towards the periphery, reaches the parts where the nerve divides, and ends after a few months by reaching the cutaneous region itself.

The more it extends and shows itself towards the periphery of the nerve, the less marked it becomes, finally disappearing at the level of the portions of the nerve which are nearest the lesion. Consequently, there is in the course of the nerve a wide zone of formication which can be brought on, spreads centrifugally, corresponds to the zone of growth of the young axis-cylinders and at last completely disappears when the nerve fibres have regained their fully formed state.

Let us follow, for instance, the progress of formication on a sciatic nerve sutured in the middle of the thigh : about the fourth week formication appears at the level of the suture ; about the eighth week it is ascertained to be a few centimetres below ; after three months it reaches the popliteal space ; at the fourth month we find it on the internal and external popliteal nerves at the upper third of the leg, but at the same time it has disappeared at the level of the lesion ; at the fifth month the nerve formicates on pressure from the popliteal space to the level of the malleoli ; finally, in the sixth month, it has reached the foot, but has disappeared as far as the upper third of the leg.

Formication is the best and almost the only sign of regeneration of the nerve ; for not only does it enable us to follow the progress of regeneration, but through its intensity, rapidity of migration and the region in which it appears, it even supplies exact information regarding the quality, extent or limitation of regeneration.

If the axis-cylinders stray and lose themselves in the tissues next to the lesion, formication reveals them ; thus, in an interruption of the musculospiral, André-Thomas was able to demonstrate the presence of stray axis-cylinders in the muscles of the forearm.

Any nerve that formicates below the lesion is a nerve in course of regeneration, either partially or wholly ; absence of formication over the

entire extent of a degenerated nerve trunk is an almost certain sign of absence of regeneration.

II.—SIGNS OF MUSCULAR REGENERATION

These are—

- The appearance of muscular tone.
- The return of muscular sensibility.
- The diminution of atrophy.
- The modification of electrical reactions.
- The return of voluntary movement.

Naturally all these signs take place muscle by muscle, one after another, in the order in which regeneration of the axis-cylinders reaches them; accordingly we find different results in neighbouring muscles; it might almost be said that we find in the same muscle different results according to the fasciculi examined.

The return of muscular tone seems to be the first sign of regeneration. It shows itself in the firmer consistence of the muscles on palpation, and especially in progressive modification of the paralytic posture of the limb, which loses any tendency to be excessive and approaches a state of normal rest.

The diminution of muscular atrophy is far more tardy; still, it may considerably precede the return of voluntary movements. Atrophy, however, does not completely disappear, except by massage, gymnastics and repeated electrical stimulation, until many months after the return of all the motor functions.

The appearance of muscular sensibility is perhaps the earliest sign after the return of tone. Nevertheless it follows regeneration so far that we may regard the coexistence of tone and muscular analgesia as a sure sign of regeneration after interruption of the nerve.

Electrical sensibility is perhaps the first to reappear; then comes sensibility to pressure.

The return of voluntary movement is the latest manifestation of regeneration.

At first it shows itself by a slight hardening of the muscle, which accompanies the efforts of the patient, and particularly the energetic contraction of the antagonistic muscles; no movement, however, is apparent.

Then there appear faint voluntary movements, necessitating considerable effort on the part of the patient and bringing into play the violent synergic contraction of all the muscles of the limb.

Finally the movements become definite but they long remain weak, awkward, clumsy and quickly exhausted, inducing rapid fatigue accompanied by slight trembling.

Only by daily exercise will patients regain the full range and dexterity of their movements.

III.—ELECTRICAL REACTIONS

During the entire regeneration, the electrical reactions are gradually modified.

These modifications seem to take place in somewhat variable order, according to the case.

Moreover, they are difficult to interpret, for certain of these electrical modifications seem clearly anterior to the arrival of the axis-cylinders in the paralysed muscles. Some patients, for instance, undergoing electrical treatment immediately after a nerve suture, show electrical signs of amelioration long before nerve regeneration can have reached the muscles; some, previously untreated, show almost complete electrical inexcitability and rapidly regain their galvanic excitability; in others we find that their galvanic hypo-excitability diminishes.

Probably massage and electrical treatment have simply improved the contractility of the paralysed muscles. These latter, from disuse and lack of attention, showed the early stages of fibrous transformation with the syndrome of muscular hypo-excitability, which the treatment causes to disappear gradually.

These, however, are modifications in quantity, not in quality; the RD, with all its characteristics, persists; it begins to be qualitatively modified only on the arrival of the axis-cylinders and after the reappearance of tone.

First of all, galvanic hypo-excitability is seen to diminish at the motor point; the closing contraction at the negative pole becomes stronger and finally equals the contraction at the positive. There is polar equality at the motor point; then the formula again becomes normal, the negative contraction stronger than the positive.

At the same time, longitudinal reaction becomes less clear; the muscle gradually loses its longitudinal hyper-excitability, its excitation at the motor point becomes predominant.

The contraction, however, remains slow for a very long time; still, it gradually accelerates, but whilst becoming shorter and shorter at the motor point, it remains slow to longitudinal excitation for a longer time.

The slowness of the contraction generally disappears completely only after the return of the first voluntary movements.

It is a generally recognised fact that faradic excitability reappears only after the voluntary movements.

This rule is true if the usual thick wire coils are utilised.

It is not true, as we have seen, if the muscle is examined with thinner wire coils of greater resistance and electro-motive force.

Thus, with the thin wire coils of the ordinary apparatus, we find, as P. Marie, Meige, and Mme Benisty have shown, that there exist muscular contractions which long precede the appearance of voluntary movements.

IV.—SENSORY SIGNS OF REGENERATION

Regeneration of the sensory functions takes place, like that of the muscular functions, by centrifugal extension.

1. Patients often complain of spontaneous sensations, more disagreeable than painful, which assume the form of shooting pains and especially of formication felt in the cutaneous region of the nerve.

These sensations often occur rather early, and generally it is not possible to regard them as a sign of cutaneous restoration.

Indeed, we are now considering excitation of the nerve itself, in process of regeneration; this is nothing else than the sign of spontaneous formication. Movements, muscular contractions, cutaneous pressure or slight touch, when transferred to the nerve trunk, induce formication of the axis-cylinders in process of regeneration.

At a later period there are observed sensations of cutaneous itching, soothed by scratching or friction; these seem to be connected with the paræsthesia we shall study shortly.

2. **Narrowing and disappearance of the zones of anæsthesia.**—The anæsthetised regions gradually shrink; but this progressive diminution mostly takes place from above downwards, following the growth of the axis-cylinders.

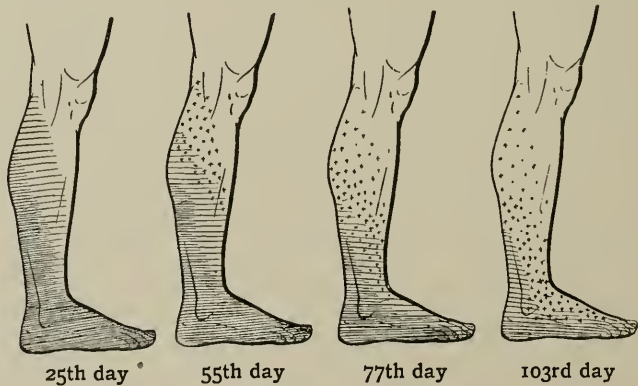


FIG. 23.—An instance of sensory restoration (after suture of the sciatic). There may be distinguished three schematic zones: a zone of total anæsthesia; a zone of hypo-æsthesia where pricking is felt as touch; a zone of hypo-æsthesia with paræsthesia of regeneration (cutaneous formication).

The return of the deep sensibilities is always earlier than that of the superficial ones; the slightest pressure of the skin is felt, whereas pricking, heat and cold are scarcely perceived.

As a rule, thermal anæsthesia is a little more protracted than tactile painful sensibility and is always more widespread. In certain cases and at certain stages of regeneration, this results in actual sensory dissociations.

Moreover, as the different sensibilities are restored, they gain both in

extent and in precision ; the gross sensations of touch, pain, heat and cold are first perceived ; then slowly these sensations become definite and allow of the appreciation of the qualities of contact, the characteristics of pain, the shades of temperature and the exact localisation of the sensations. It is this progressive restoration, doubtless corresponding to the regeneration of increasingly delicate terminal apparatuses, that has been most minutely described by Head, who differentiates the gross protopathic sensibilities from the finer, epicritic sensibilities.

3. **Paræsthesia.**—This name describes very special cutaneous sensations which are always found during nerve regenerations.

Generally these are sensations of formication, rather intense and at times very disagreeable, provoked by the slightest cutaneous excitation. They are produced by touch, pricking, heat, cold, and in particular by a slight stroking of the skin.

They are often retarded, at least on their first appearance ; *i.e.*, somewhat prolonged excitation is needed to produce them.

In general, they are diffused, radiated over the entire region in the vicinity of the excitation and over the course of the restored nerve.

Finally, they are persistent and are prolonged some seconds after the end of the excitation.

Paræsthesia ordinarily precedes the appearance of normal sensibility, so that no cutaneous excitation is yet clearly perceived, but all these excitations induce this same sensation of disagreeable, diffused, radiated and persistent formication.

The period of paræsthesia is prolonged. It gradually diminishes and its area becomes restricted as normal sensibility is restored.

Probably these special sensations are due to the presence in the dermis of the newly formed axis-cylinders, which penetrate there before the terminal apparatus is completed ; occasionally, however, they appear so early that they certainly precede the regeneration of the axis-cylinders ; their existence is then a paradoxical phenomenon, the interpretation of which we have so far been unable to find.

V.—DISAPPEARANCE OF TROPHIC DISTURBANCES

We have seen that muscular atrophy was both early in its appearance and slow in its completion.

Cutaneous, tendon, synovial, articular and other trophic disturbances which accompany neuritic forms are even more obstinate. Here too, we often have to deal with well-marked cases of very advanced fibrosis, the disappearance of which requires complete restoration of the tissues. Their cure is particularly long and difficult, sometimes even impossible ; neuritic types too often leave behind fibrous sequelæ, muscular contractions or tendon adhesions which are positively incurable.

V.—DISSOCIATED SYNDROMES

Dissociated syndromes correspond to partial or unequal lesions of the nerve trunks.

They are frequently met with in wounds of bulky nerves, particularly of the sciatic, but a minute analysis of the symptoms often enables us to recognise, in a nerve trunk of less importance, motor or sensory dissociations which point to partial lesions.

Consequently we may find partial lesions of a nerve manifesting themselves by dissociated paralysis confined to part of the muscles supplied by this nerve. Lesions of the external or internal part of the sciatic trunk, for instance, paralyse the region of the external popliteal nerve or of the internal popliteal nerve.

But, on the other hand, we may also find the association of unequal lesions in one and the same nerve, expressed by different syndromes.

There may be, for instance, complete section of the external fasciculi of the sciatic along with the hypotonia, degeneration, and fixity of formication which characterise the syndrome of interruption; and, in the region of the internal popliteal nerve, the return of tone, the partial RD, progressive formication and all the signs of regeneration which indicate a slighter lesion, capable of spontaneous restoration.

In another case, we may find associated with the syndrome of complete interruption over a part of the nerve trunk the painful symptoms and trophic disturbances which characterise nerve irritation of the neighbouring portion of the same nerve.

One may easily imagine all possible associations and find them exemplified.

The study of these dissociated types is of great importance. It enables us to determine the topographic constitution of a nerve; it shows that the internal or external, anterior or posterior fibres correspond to different muscular groups or sensory regions; it informs us what, in a nerve, is the position of the motor, sensory and trophic or vaso-motor fibres.

Consequently it confirms the theories put forward on the fascicular structure of nerves.

Further, this fascicular topography of the nerve trunks seems sufficiently definite to enable us, according to the analysis of symptomatic dissociations, to establish which is the wounded part of a nerve trunk. On these partially attacked nerves it will be possible to practise partial operations, to liberate, remove, and suture only the affected or destroyed part of a traumatised nerve whilst respecting the healthy fibres. It will be known beforehand that the external part of a neuroma is permeable to

regenerated axis-cylinders, whereas its internal part offers an insurmountable barrier to them.

We shall then be led, along the lines of the constitution and fascicular topography of the nerve trunks, in the direction of a fascicular, rational and economical surgery.

VI.—ASCENDING NEURITIS

Strictly speaking, ascending neuritis is not a type of traumatic nerve lesions, it is a complication and often a serious one.

It is characterised by the fact that the traumatised nerve not only degenerates rapidly towards its peripheral extremity, but undergoes a slow, progressive, ascending degeneration of its central segment.

Ascending neuritis seems due to the progressive ascent in the nerve, or the sheath of the nerve, of the toxic products or infectious agents of the focus of the wound.

Fortunately it is very rare, for it may culminate in definite degeneration of the nerve.

Ascending neuritis has most frequently as its starting point the persistence of an osseous focus of suppuration.

It is characterised by very acute and spontaneous pains, which radiate over the entire course of the nerve and even above the lesion. These pains are often sufficiently acute to enable the patient to trace on his limb the course of the nerve involved.

It is a continuous pain with paroxysmal crises, of a violent, distressing and intolerable nature.

The nerve is painful on pressure, not only at the level of the nerve and below it as in the syndromes of irritation, but also above the lesion.

We gradually see the slow ascent of this pain along the affected nerve. Frequently appearing in the vicinity of its termination, it ascends to the nerve trunk and finally reaches the origins of the nerve. It invades the plexuses which become painful, we may even find it extending right to the spinal cord and spreading to the nerves of the opposite side.

We likewise note the ascending advance of muscular atrophy and of paralyse, although these latter are usually incomplete. We see the progressive extension of the area of cutaneous anæsthesia or hyperæsthesia.

Slight ascending neuritis may stop in its progress and may retrogress, even after a considerable interval, especially when we have been able to carry out energetic disinfection or the removal of the initial focus which caused it.

Severe ascending neuritis, however, is usually continued for months and sometimes years; it seldom stops before reaching the plexus and the spinal cord itself. It causes pain, atrophy, and disabilities that are often permanent; section of the nerve above the lesion, amputation of the limb itself, to which one is sometimes reduced, are not always sufficient to stop

it if the infectious or toxic agent has already gone beyond the point of section.

Its exact nature completely baffles us, although the hypothesis of the ascent of infectious germs or of toxic agents in the nerve trunks or in their sheath seems very probable. We are almost completely helpless in its presence, for whilst experiments on animals show that it can be stopped by early section of the nerve trunks, this is a solution which one cannot adopt, apart from altogether exceptional cases.

APPENDIX

PARALYSIS, HYPERTONIA AND CONTRACTIONS FROM NEURITIS

Slight irritations of the peripheral nerves, capable, as we have seen, of inducing fibrous infiltrations and contractions of the muscles, may also induce a kind of muscular hyper-excitability, culminating in a state of hypertonia or even of genuine contracture.

We meet with a great number of contractures seemingly paradoxical, frequently succeeding slight injuries, which one might be tempted to regard as simple hysterical contractures. But if we minutely study these contractures, we note the presence of a certain number of characteristics indicating the existence of organic lesion, such as cyanosis, low temperature, profuse sweats, trophic disturbances of skin and nails, sensory disturbances clearly defined, slight modifications of the electrical reactions and mechanical excitability of the muscles. These disturbances have been specially studied by Babinski and Froment who, under the name of "reflex contractures," have clearly distinguished them from simple functional contractures.

These are the "painful contractures" described by Claude, the "*mains figées*" of H. Meige and Mme Ath. Benisty, the "*acro-contractures*" or "*acro-myotonies*" of Sicard.

It is extremely difficult to interpret these disturbances. All neurologists recognise the existence in these cases of the slight changes studied by Babinsky and Froment; they admit generally that these changes reveal the existence of slight organic lesions; some regard them as sympathetic or reflex disturbances, others as the result of slight neuritis. Most, however, refuse to admit the purely organic nature of these paralyzes or contractures; they interpret them as functional disturbances grafted on to slight organic lesions. It is, indeed, illogical and abnormal to find a simple sprain producing a paralytic club-foot or a permanent contracture of the foot; it is paradoxical to find that contracture of hand or arm, following a simple fracture of the radius or a superficial wound, may last for a period of eighteen months.

Amongst these accidents of a complex and ill-defined nature, it is now possible to distinguish a very clear group of paralyses and especially of contractures, of manifestly nervous origin, provoked by slight irritative lesions of a peripheral nerve.

But in almost all cases of clearly defined neurites, it is easy to prove the existence of a very important functional factor.

These neuritic paralyses and contractures are almost always functional associations. Nerve irritation is the origin of the disturbances found; it provokes the appearance of muscular hypertonia, of pains and sensory disturbances, of trophic, vaso-motor and secretory symptoms. But in most

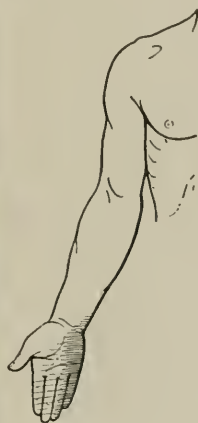
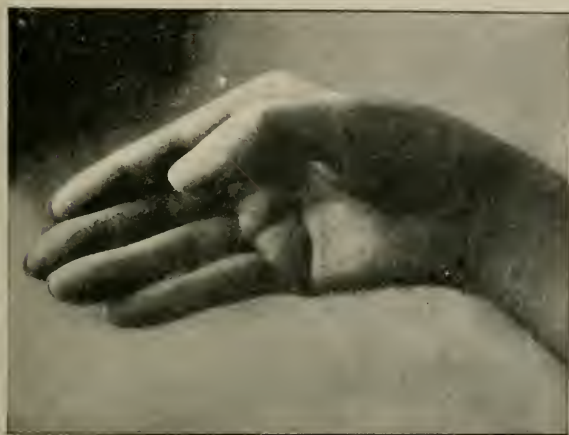
FIG. 24.—Contracture of the hand, immobilised in extension with flexion of the thumb; perforating wound of fore-arm. Almost complete anæsthesia of the ulnar; hypo-æsthesia of the median. Trophic disturbances of nails and skin; profuse sweats. (Slight neuritis of ulnar and median.)

cases it is the permanent immobilisation, the prolonged inaction, the auto-suggestion of impotence and the moral inertia of the patient that intensify, amplify and prolong these disturbances; it is the dread of pain that immobilises into a state of paralysis the limb affected with slight neuritis, it is inaction that transforms into obstinate contraction the neuritic hypertonia of the muscles, it is the inertia of the patient that enables neuritis to produce its maximum effect, to keep up the vaso-motor, thermal and trophic disturbances which we find in these cases.

We shall study more specially contractures caused by neuritis, which seem particularly frequent.

* * * * *

The first thing that strikes one is the paradoxical character of these contractures, in which the nerve lesion produces the exact opposite of the usual paralytic syndrome.

Sometimes they are simple states of muscular hypertonia, painless and rather easily reducible. To passive movements, the muscles affected

oppose only a certain elastic resistance, easily overcome: when they are reduced, we frequently notice the appearance of a kind of muscular tremor, comparable to the epileptiform tremor of the foot. Their rigidity becomes greater during active movements which become almost impossible for the patient. This hypertonia induces a permanent posture of the limb, the

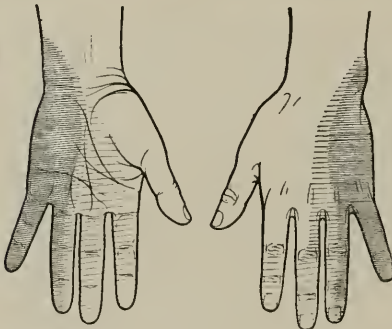
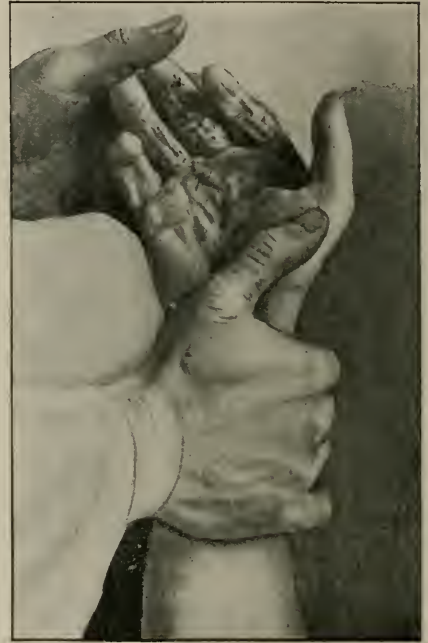
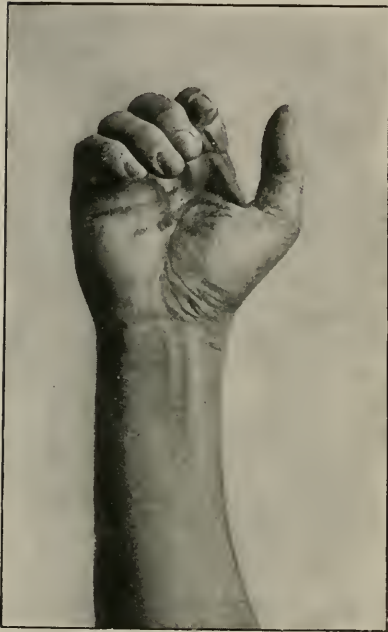
FIG. 25.—Contracture of the hand in flexion, after eleven months, caused by slight lesion of the ulnar and the median above the elbow. No paralysis, normal electrical reactions. Contracture mainly of the interossei, and contracture of the palmar fascia. It is possible to extend the hand without much difficulty; it remains extended without pain after contracture has been overcome, and gradually closes again in 5 or 6 hours. Almost complete anæsthesia of the ulnar, hypo-æsthesia of the median.

fixity of which is further increased by the inaction to which the patient too often resigns himself and which ends in complete loss of use.

In other cases, muscular rigidity produces permanent contractures, which persist for months and produce the most paradoxical attitudes. They offer enormous opposition to attempts at resistance. Seldom painful at

rest, they become extremely painful when an attempt is made to overcome them, and this very pain seems to increase their intensity.

When we have slowly and gradually succeeded in overcoming these contractures and bringing back the limb to its normal position, we find that,

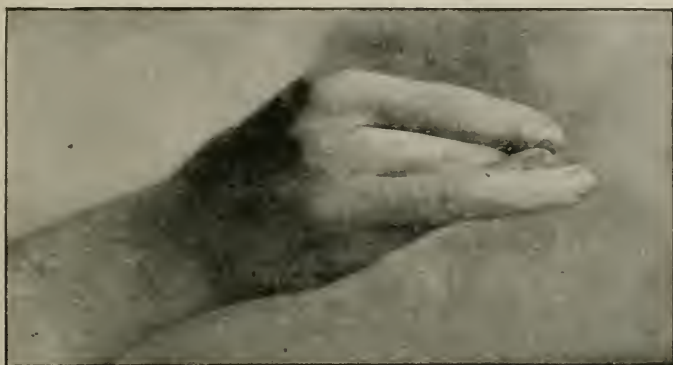

FIG. 26.—Contracture of the hand from slight lesion of the ulnar in the forearm. (Contracture of the interossei and of the hypothenar eminence.)

in a few minutes, a few hours, or even a few days, the muscles contract anew and the limb gradually resumes its original posture.

Many of these contractures are gradually intensified; through the relaxation of the antagonistic muscles and articular ligaments, they are found by degrees to adopt the most unusual postures.

These contractures almost always follow on slight wounds; at times appearing suddenly with the injury, more frequently coming about slowly, long after the wound is healed, they are invariably accompanied by nearly normal electrical reactions; the usual symptoms of nerve lesions are either scarcely perceptible or are altogether absent.

Still, a minute study enables us to detect in these "contractures from neuritis" a complete series of symptoms which combine to demonstrate the existence of an organic factor in the case.



FIG. 27.—Contracture of the hand owing to slight lesion of the ulnar in the forearm. The patient can bend only his thumb, index and middle fingers, and even these very imperfectly. Passive flexion is fairly easy. This figure represents the maximum of flexion possible. (Contracture of interossei and extensors.)

1. The contracted muscles frequently show, along with slight atrophy,

a state of mechanical hyper-excitability indicated by the intensification and slowness of the idio-muscular reflexes.

Electrical examination sometimes reveals a certain slowness of contraction in the shortened muscles.

Their special rigidity and the muscular tremor provoked by attempts at reduction often persist during slight chloroform anæsthesia. For instance, Babinski and Froment have succeeded in discovering by patellar clonus under anæsthesia, hypertonia of the contracted quadriceps. The tendon reflexes also often appear intensified during anæsthesia.

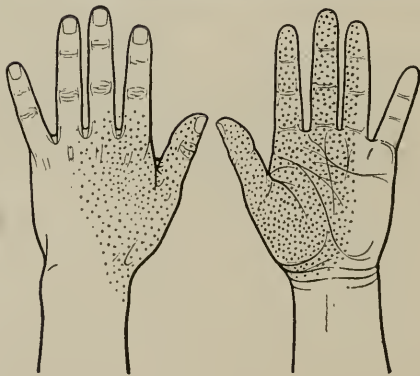
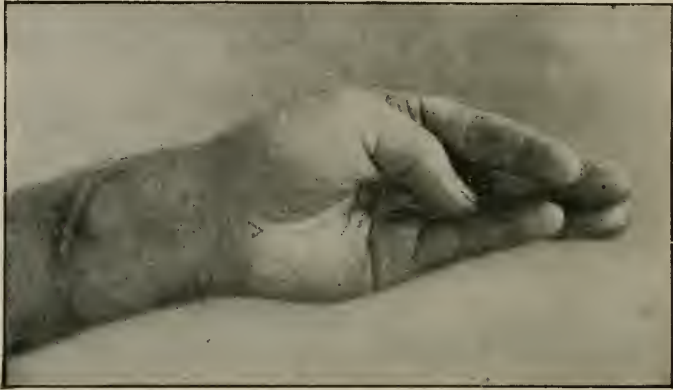

FIG. 28.—Contracture of the hand.—Hypertonia of all the muscles of the hand. The hand, at first contracted for eight months in complete flexion, has been contracted in extension after gradual opening of the fingers. Following on suppurating sore of the wrist, acute pains in the course of the median, musculo-spiral and even a little of the ulnar just above the elbow; hypoæsthesia in the area of the median and the musculo-spiral. (Probable ascending neuritis.)

These contractures are frequently accompanied by more or less pronounced trophic or vaso-motor disturbances, and by secretory disturbances in some cases.

Generally there exists a cooling of hand or foot, that may correspond to a fall of several degrees of temperature.

Frequently there are profuse sweats which sometimes produce actual maceration of the epidermis, and appear along with a special kind of redness of the skin, clearly localised in the region of the irritated nerve.

In other cases we have dull pallor of the integuments, with dryness of

the skin. At times, there is slight fibrous infiltration of the integuments, or else thinning of the skin which assumes the aspect of onion rind. Hypertrichosis is particularly frequent.

Then we have nail disturbances: their dull or sometimes striated appearance, their yellowish hue comparable with that of ivory, the cutaneous swellings which their rapid growth raises on the pulp of the fingers.

Finally, in some cases, we have slight contraction of the palmar or plantar fasciæ, showing the similarity of these cases to the neuritic syndromes we have already investigated.

3. Almost always there are pronounced sensory disturbances.

It is seldom that we do not find a more or less definite hypo-æsthesia

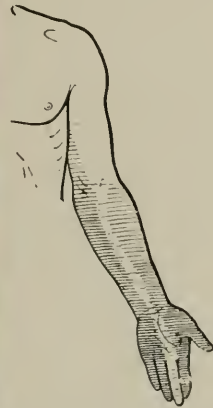
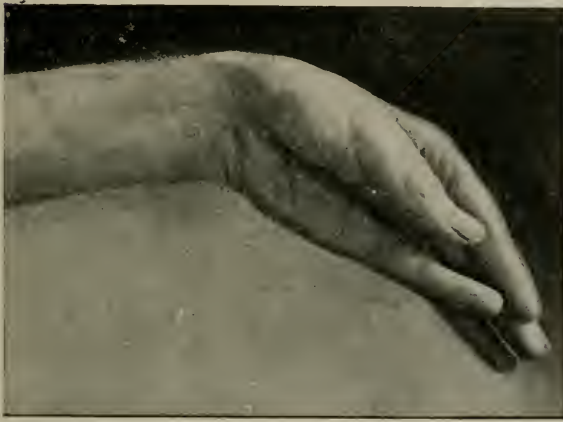
FIG. 29.—“Accoucheur’s hand” due to contracture of the muscles of the hand; after a fall producing fracture of radius. Thermal and vaso-motor disturbances, profuse sweats. Hypo-æsthesia on the region of C6, C7—and D1 (probable wrench of the brachial plexus).

in the region of the nerve involved; hyper-æsthesia, on the other hand, appears less frequently.

Almost always we find in the nerve itself pain on pressure, or the presence along its tract of provoked formications, which show slight irritation, or the regeneration in it of some injured fibres.

4. We must insist on the anatomical character of the changes observed. These contractures are generally clearly limited to the region of the nerves involved, or even to a portion of their area in case of partial lesions. Sensory, trophic and vaso-motor disturbances have also a precise topography.

In contradistinction to hysterical contractures, states of neuritic hyper-tonia are “contractures acquainted with anatomy.”

* * * * *

These contractures due to neuritis may be found in the region of all the motor nerves.

They would seem, however, to have been found with particular frequency in the region of the ulnar; hypertonia of the interossei, affecting all these muscles, or only certain of them, produces contractures of hands and fingers; association of the median causes the appearance of the "accoucheur's hand," described by Babinski, or flexed contraction of hand and fingers.

The musculo-cutaneous may be involved in certain contractures of the biceps. We have seen even the musculo-spiral induce contraction in hyper-extension of hand and fingers.

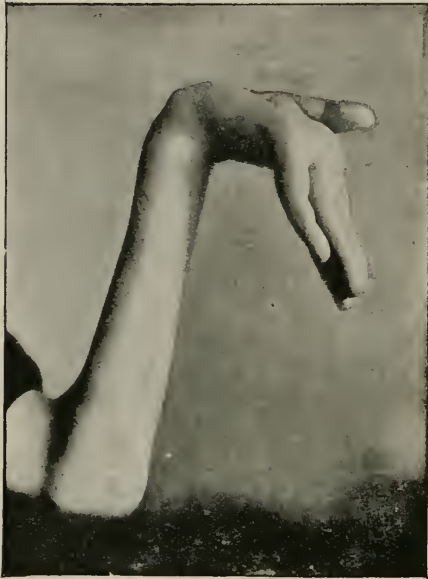

FIG. 30.—Contracture of extensors of hand and fingers; following on a wound of the hand crossing the thenar eminence; with prolonged suppuration. Progressive accentuation for a period of sixteen months. Acute pains in the course of the nerves of the fore-arm, particularly of the musculo-spiral. (Probable ascending neuritis of the musculo-spiral.)

Likewise with the lower limb, the anterior crural nerve seems responsible for certain contractions of the quadriceps, just as the sciatic is capable of provoking certain contractures of the posterior muscles of thigh, calf and foot. We find *pes equinus* and club-foot from contracture originating in hypertonia through slight irritation of the sciatic or its branches.

Lesions of the plexuses would also seem as though they must have been involved in certain cases. We have observed, for instance, a case of wrench of the sacral plexus, with hypo-æsthesia in the region of the fifth lumbar, first and second sacral; there existed a state of obvious muscular hypertonia of the posterior muscles of the thigh, as well as of the muscles of leg and foot. In contractures of hand and arm also are often

found sensory disturbances with root-distribution,—disturbances which indicate the irritation or wrenching of the cervical roots.

Whilst in certain cases contracture from neuritis is shown in the domain of an injured nerve, there are other more disturbing cases where the seat of the wound seems in no way to justify the appearance of neuritic troubles. These are particularly cases in which wounds of fingers, hand or foot are accompanied by extensive contractions.

These are slight ascending neurites, which spring from infection of the wound. Their presence is revealed principally by pain and formication

in the nerve trunks on pressure over a larger or smaller part of their course above the wound, by hypo-æsthesia or hyper-æsthesia of their cutaneous region, by atrophy of the muscles they supply, and often exaggeration of the muscular and tendon reflexes of their entire motor region.

There is another cause of contraction from neuritis : frost-bite.

Some forms of frost-bite are characterised by localised neuritis of the frost-bitten extremities. Sclerous infiltration, trophic disturbances of skin and nails, fascial contractions, the acute pain provoked by pressure on the muscular bellies, paralysis with faradic excitability of the muscles, are all so many proofs of the neuritic character of these cases. Whilst, however, these trophic and paralytic disturbances characterise severe cases of frost-bite, slight cases of neuritis may be shown by muscular hypertonia.

We have observed several cases of contraction appearing on frost-bitten limbs without any wound, accompanied by the same sweats, trophic, vaso-motor and slight sensory disturbances. Their more diffused distribution is often irregular ; for instance, we find jumbled together zones of hypo-æsthesia, of hyper-æsthesia, and of almost normal sensibility ; this is, so to speak, neuritis in islets, but the state of muscular hypertonia is as clearly defined as in neuritis over a systematised region.

* * * * *

However clear the organic signs noted in most cases, manifestly there often exists in the genesis of those contractions an important functional factor.

They scarcely ever appear except in patients who are resigned to them, and are flagrantly inactive ; they persist for an unconscionable time ; treatment improves, but rest and convalescence aggravate them ; we even find certain of these contractions, almost cured by electrical treatment and daily mobilisation, progressively reappear during convalescence. On the other hand, we may find others disappearing under the effect of treatment, whilst all the neuritic, vaso-motor, secretory and trophic disturbances, which seemed to give them birth, persist.

It would therefore seem that in most cases neuritis cannot produce such contractions without the aid of the prolonged immobilisation and muscular disuse which aggravate its consequences. We have been able to give a rather curious demonstration of this ; out of fifteen patients suffering from contraction due to irritation of the ulnar, with immobilisation of the interossei and of the hypothenar eminence, we found only two cases where there was contraction of the adductor pollicis ; the other thirteen patients had saved the thumb and succeeded in retaining its movements intact ; probably with a little effort and patience they might have avoided contraction of the other fingers, not so necessary for everyday use.

Treatment of contractions from neuritis is a particularly delicate matter. Energetic mobilisation accentuates them ; massage and electrical

stimulation are painful at times and unpleasant to bear; and yet it is impossible to allow the contraction to continue, the more so as there is almost always a tendency gradually to become more and more inactive from relaxation of the antagonists and of the articular ligaments.

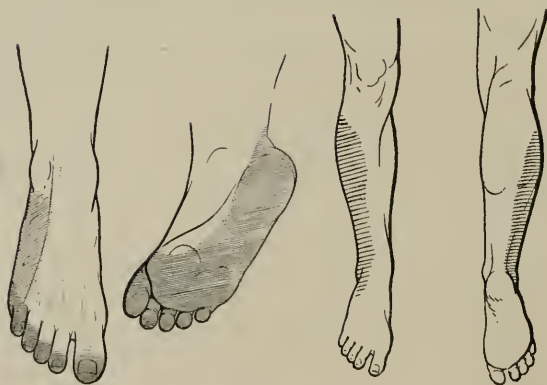
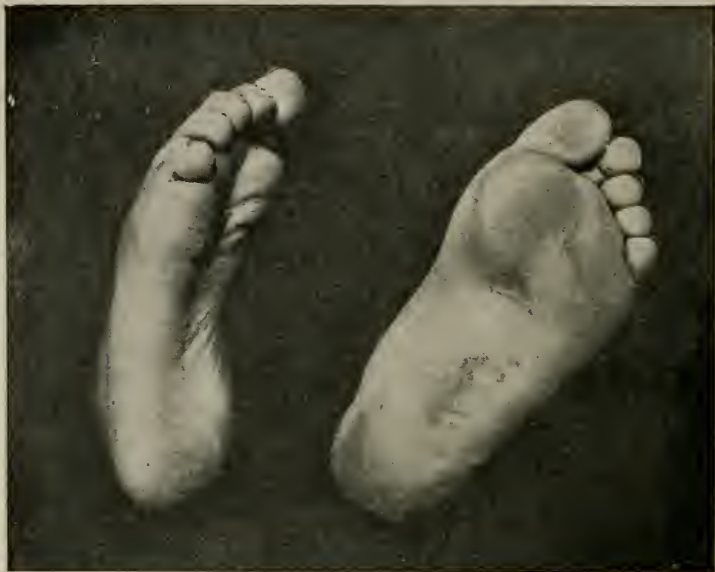
FIG. 31.—Club-foot from contraction following on sprain, after eighteen months! In the right foot is contraction of all the plantar muscles as well as contraction of the tibialis posticus which causes club-foot. Disturbances of sensibility revealing slight neuritic lesion of the external popliteal and more particularly of the internal popliteal nerves. (Compare with the healthy left foot.)

We have been very successful in bringing about gentle, progressive and continuous mobilisation by the aid of improvised appliances. An associated treatment consists of hot baths with faradic current; these give the best results. Indeed, a very hot and prolonged bath causes these contractions to become remarkably supple; if there is introduced into the bath a moderate faradic current, interrupted by the metronome, its vasodilator action is further increased, at the same time very gentle massage is

applied to the contracted muscles ; an undulatory faradic current would certainly be even better.

One condition, however, is indispensable in the cure of these cases ; perseverance and good will on the part of the patient. Indeed, the treatment of these contractions is long, wearisome and often painful. Too frequently the patient becomes discouraged, resigned to the disuse of his contracted limb, and then he ceases to contribute to the treatment the

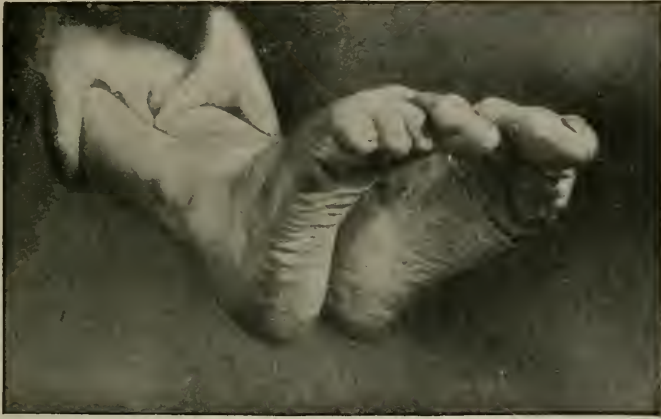
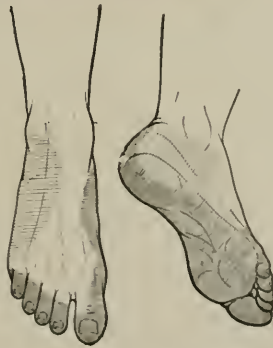
FIG. 32.—Claw-like contraction of the feet following on frost-bite, with signs of slight neuritis and cutaneous hypæsthesia.

main factor, after all—his personal quota of exercises and active movement.

It must not be forgotten that, though slight neuritis is the initial cause of contraction, it is frequently disuse, inertia or indifference on the part of the patient that enables it to get a hold on him. Though this contraction, at the end of several months, has become so irreducible as to prevent all voluntary movement, such is not the case when it first shows itself. Probably in most cases, daily exercise, patient mobilisation, sincere efforts to recover the use of the limb would rapidly have dispelled contraction.

We discover this by noting the various results of treatment according to the moral condition of the patient. Whereas some rapidly improve by a treatment they follow with interest, others submit to it without confidence and unwillingly, they take no interest in the results, make no effort of their own, and, quite unconcerned, allow contraction to follow its course. The treatment, therefore, of these disturbances essentially involves a moral factor, just as their pathogeny introduces an important functional factor.



CHAPTER V

GENERAL DIAGNOSIS OF PERIPHERAL NERVE LESIONS

WE shall not dwell long on the differential diagnosis of peripheral traumatic paralysis, for in the course of our clinical sketch of the subject under consideration, we have drawn attention to the main errors possible.

1. It must be remembered that this study is confined to injuries of the peripheral nerves from wounds, so that we may at once eliminate :

(1) Central paralysis, cortical monoplegias, following traumatism of skull or brain—characterised moreover by the absence of atrophy and electrical disturbances, exaggeration of the reflexes, progressive change to a spastic state, predominance of paralysis or of anæsthesia at the periphery of the limb, absence of the peripheral type of distributing anæsthesia.

(2) Paralysis by cord lesions, compression, crushing, or hematomyelia.

The same spastic symptoms, indicative of lesion of the pyramidal tract, characterise paralysis related to cord lesions.

Compressions of the cord are nevertheless accompanied by compression of the roots, so that we find, in addition to the spastic signs of spinal cord paraplegia, signs of paralysis of the peripheral type which correspond to the roots included in the compression.

On the other hand, hematomyelias which sometimes follow a simple vertebral concussion or a sort of gaseous embolus by decompression (paralysis from shell shock) are often limited to the grey matter of the cord. They cause in this case, from a lesion of the anterior horns, paralytic signs of the peripheral type, analogous to those of poliomyelitis. For instance, we may meet with hematomyelias limited to the first and second sacral segments, which are somewhat similar to paralysis of the sciatic.

Almost invariably, however, the history of a spinal injury, the greater diffusion, at first, at all events, of the paralytic signs, and the habitual coexistence of some slight indications of pyramidal irritation are all elements which help the diagnosis.

On the other hand, these hematomyelias are often accompanied by lesions of the posterior horns, with disturbances of sensation ; but these disturbances are arranged with root distribution ; they have neither the intensity nor the precise limitation of peripheral anæsthesias ; almost invariably they are dissociated, and then we note along with a more or less

marked diminution of thermal and painful sensibilities, a relative preservation of tactile sensibility and an almost complete integrity of deep sensibility.

(3) Peripheral, spontaneous, progressive polyneurites; these have naturally all the signs of peripheral paralyses: flaccidity, hypotonia, muscular atrophy, and disturbances of electrical reactions; they often show sensory disturbances or pain and the fibrous contractions of nerve irritation; they are almost always bilateral and symmetrical.

(4) Root inflammation, caused by inflammation of the meningeal sheaths surrounding the spinal nerve roots. Almost always sensory or sensory-motor, seldom purely motor, inflammation of the nerve root of lower or upper limb are alike spontaneous and progressive. They often owe their origin to syphilis, sometimes to tuberculosis, more rarely to infectious meningitis such as cerebro-spinal meningitis. The root distribution of motor and sensory disturbances, the radiating pain provoked by coughing and sneezing, the signs of concomitant meningeal irritation revealed by lumbar puncture, generally enable us to recognise them.

2. The most important diagnosis concerned with the group of functional paralyses. They are extremely frequent, and we continually find it necessary to differentiate them from peripheral nerve lesions.

This matter of false—or rather artificial—paralyses is extremely important.

(1) Following on war wounds, there are found typical hysterical paralyses, the main characteristics of which must be remembered.

At first they are almost always striking by reason of their paradoxical nature, the evident disproportion between the importance or the site of the wound which is frequently a slight one, and the extent of the paralytic disturbances.

They are widespread and absolute; nor is there found in the patient any attempt at compensation.

They correspond to no definite anatomical region, but attack an entire limb or segment of a limb; they do not paralyse a movement but rather a function.

Almost invariably they are accompanied by widespread, absolute paradoxical anæsthesia, corresponding to no nerve region but rather affecting a whole line or segment of a limb. These are segmentary anæsthesias, clearly limited by a circular line; glove, boot, leg of mutton, etc., types of anæsthesia.

They are not associated with muscular atrophy, loss of tone, disturbances of the reflexes or trophic disturbances.

Still, we see that there occurs in the long run a sort of muscular hypotonia from disuse; we also at times note a slight cyanosis which may be due to prolonged disuse or to the dependent posture.

The electrical reactions of nerves and muscles are normal or almost

normal. It is possible to detect a slight hypo-excitability in muscles long paralysed.

These paralyses are almost always accompanied by a special frame of mind, characterised by an absence of effort.

There appears to exist so absolute a conviction of paralysis, so great a certainty of its incurability, that the patient comes to take no interest in his paralysed limb, he does not seem anxious to recover.

And yet these paralyses may be rapidly and thoroughly cured if the patients are placed under appropriate treatment, the main elements of which are isolation, patient psychotherapy, energetic faradisation and motor re-education.

Apart, however, from these well-established hysterical paralyses, there are many functional paralyses which must be recognised.

(2) Paralyses from prolonged inaction or loss of the habitual muscular movements.

As a sequence of muscular wounds, fractures necessitating prolonged immobilisation, tendon lesions or articular injuries, we may have pseudo-paralyses due to prolonged disuse of the muscles. These are caused by dread of pain or by a sort of loss of the habitual use of the muscle, or even by the simple conviction of incapacity.

Nevertheless, electrical reactions are normal; faradisation of the muscle provokes its energetic contraction and demonstrates to the patient the possibility of movement; faradic treatment, energetic if need be, rapidly effects a cure.

(3) Pseudo-paralyses from pain.

With these cases must be compared muscular incapacity provoked by pain, the wounded man ceasing to contract his muscles.

(4) Pseudo-paralyses from contraction of the antagonists, rendering movement impossible.

(5) Functional paralyses from prolongation of organic paralysis.

In certain cases we find that paralysis is protracted when caused by nerve lesion even after the nerve has regained its functions and the electrical reactions have become normal.

These functional paralyses are after all only an exaggeration of muscular incompetence, seen in wounded men who recover their lost function.

They are specially frequent after nerve lesions accompanied by nerve irritation, because in these cases the dread of pain and a certain degree of fibrous transformation of the muscles are associated with the auto-suggestion of incompetence.

Faradisation again provides the means of diagnosis and treatment.

(6) Functional paralyses from anæsthesia.

In these cases, the rôle of auto-suggestion is even more manifest. We are now concerned with paralyses following on lesion of a sensory nerve.

The most frequent example is afforded by lesion of the median at the

lower third of the fore-arm ; this nerve has become almost entirely sensory, having to supply only the motor twigs to the thenar muscles and to the lumbricales ; now, we find an inexplicable paralysis of flexion in the first three fingers. The patient, noticing that there is anæsthesia in hand and fingers, concludes that they are powerless and ceases to move them.

The same thing is met with in the lower lesions of the anterior tibial or of the musculo-cutaneous.

Here, too, faradisation shows integrity of the muscles and the functional nature of the paralysis.

3. In a third group we may place the osseous, muscular, and tendon lesions.

(1) Paralyzes from pseudarthrosis.

(2) Pseudo-paralyzes resulting from muscular destruction.

(3) Pseudo-*griffes* produced by muscular or tendon contraction. For instance, the ulnar pseudo-*griffe* produced by contraction of the flexors of the last two fingers or the pseudo-paralysis of the external popliteal nerve, resulting from fibrous contraction of the calf or of the Achilles tendon, with production of *pes equinus*.

(4) Pseudo-paralyzes of hand or fingers produced by cicatricial adhesion of the tendons, or following on the tendon adhesions which nerve irritations produce.

(5) Reflex muscular atrophies, following on a neighbouring fracture or arthritis or on simple contusion of the muscle.

(6) Pseudo-paralyzes from hypotonia and muscular stretching.

The type of these is furnished by the pseudo-musculo-spiral paralysis following on hypotonia and stretching of the extensors of the wrist. It may be found following contusion of the fore-arm, after lesion or section of the tendons, producing a sort of accidental tenotomy, or even as the consequence of a prolonged defective posture. For instance, we have found it following hysterical paralysis of the hand which began ten months previously ; in another case after fracture of the humerus and the wearing for six months of a sling supporting the fore-arm and allowing the hand to droop at the wrist ; in these two cases, voluntary raising of the hand by the lengthened extensors of the wrist was possible, though at the cost of so great an effort that the hand permanently retained the posture of musculo-spiral paralysis and the patient had given up holding it extended.

This muscular hypotonia caused by a vicious posture is a distinct factor in artificial prolongation of musculo-spiral paralysis. It proves the necessity in this paralysis of an apparatus to keep the hand permanently extended.

Muscular hypotonia is also accompanied by almost normal electrical reactions ; it is cured after a somewhat prolonged faradic treatment ; in extreme cases, plication or shortening of the tendons may even be indicated.

(7) Contractions, whether the result of muscular irritation, defensive

immobilisation, a prolonged posture or a simple hysterical manifestation, occasionally produce postures which might be mistaken for those of paralysis.

Especially may they be mistaken for nerve irritations and fibrous infiltration of the muscles or the accompanying tendon contraction.

It is fairly easy to recognise the elastic resistance of contractions to the attempts at mobilisation, very different from the fibrous resistance of the contracted muscles. These contractions disappear under anæsthesia. Still, we have seen that very often they had as their initial cause a slight nerve irritation.

4. Ischæmic paralysis.—Ischæmic paralysis, resulting from vascular obliteration is sometimes most difficult to distinguish from paralysis caused by nerve lesions, and especially from syndromes of nerve irritation shown by fibrous contractions, tendon adhesions and *griffe* postures.

Ischemic paralysis is sometimes found following ligature or thrombosis of the great arteries, such as the axillary, the sub-clavian, the brachial, the femoral or the popliteal; it may also appear after dressings and especially after bandages too tightly applied.

It is essentially characterised by ischæmia with cyanosis, cooling and trophic disturbances of the wounded limb. There is nothing, however, more variable than the extent of these disturbances, with like lesions, in different patients.

Whereas the majority of normal subjects, after ligature of the axillary or the sub-clavian, for instance, simply present fleeting ischæmic disturbances of the hand, with the same lesion, others show marked signs of permanent ischemia, generally limited to the hand though sometimes extending over a considerable segment of the upper limb.

Ligature also of the femoral or popliteal may, according to the patient, be well borne or may provoke the appearance of ischæmic paralysis of the foot or even of the leg.

These differences of ischæmic disturbances, considerable in extent and intensity are rather difficult to interpret. Probably the previous state of the peripheral arteries, the ease or difficulty of arterial substitutions by collateral circulation, and perhaps especially the nerve lesions associated with the arterial lesions, play an important rôle; nevertheless the problem of the pathogenesis of ischæmic paralysis is not completely solved.

At all events, we may describe two phases that occur in the evolution of this syndrome.

In the first phase there is only an œdematous infiltration of the affected limb, together with cyanosis and cooling.

In the second, after an average of two to three months, we see the fibrous transformation of this œdema.

This progressive sclerous infiltration, which makes the sub-cutaneous cellular tissue puffy, invades the dermis, contracts the muscles, hardens the

aponeuroses, submerges the tendons and synovial sheaths in a veritable fibrous mass, gives the tissues a woody consistence and finally transforms the hand into a kind of fibrous bat.

All the movements are suppressed or considerably reduced by fibrous immobilisation; the glossy skin, desquamating here and there in broad scales, without papillary crests and reliefs, is cold and purple, sometimes a shining red; the deformed, cracked, curved nails take on the appearance of shapeless claws; the bones become extremely decalcified; the woody contraction of all the tissues produces wide-spread atrophy of the limb, the fingers have a fusiform appearance; the osseous projections, the prominence of muscles or tendons, the cutaneous creases, the articular swellings disappear and become atrophied, submerged in the progressive fibrous infiltration.

With this special and characteristic appearance are associated certain signs.

1. Ischæmic paralysis is accompanied by the disappearance or considerable diminution of the radial pulse in the case of the hand, of the dorsalis pedis artery and of the tibialis posticus in the case of the foot.

2. The arterial blood pressure undergoes similar diminution. Whereas, for instance, we find by Pachon's oscillometre an antibrachial pressure of 16-8 on the healthy side, we shall find on the affected side a pressure of 10-8, or of 9-8 shown by extremely feeble oscillations. In ischæmic paralysis of the entire lower limb following on the obliteration of the common iliac, we have even found an entire absence of blood pressure or of the slightest oscillation.

Still, in certain cases of ligature of the axillary, we meet with considerable diminutions of pressure, without serious ischæmic disturbances.

3. Ischæmic paralysis is almost always painful, accompanied by spontaneous pains with such characteristics as burning, formication, or unpleasant tingling.

Deep pressure, the contact of heat and especially of cold, are often very painful. All the same, there are ischæmic paralyses almost free from pain.

4. In contrast with this painful sensibility which mainly appears to be deep-seated, we usually observe considerable anæsthesia or hypo-æsthesia of the skin, affecting without dissociation all the superficial sensations, tactile, painful, thermal.

Anæsthesia predominates at the extremity of the limb and gradually decreases towards its origin; consequently it has a segmentary topography.

5. The electrical reactions of the infiltrated muscles are profoundly disturbed. We may find typical reactions of degeneration, and particularly enormous hypo-excitability, sometimes even the abolition of all electrical excitability; this is rather the syndrome of fibrous transformation of the muscles; the muscles react only to a very intense current, but we do not note any polar inversion; often, too, stimulation of the nerve at a distance provokes the movements more readily than does excitation of the muscle.

It is often difficult to diagnose these ischæmic disturbances, not from simple paralyzes by nerve section or compression, but more especially from muscular contractions, trophic disturbances and fibrous *griffes* of nerve irritations.

Moreover, the association of nerve lesions with arterial obliterations is very frequent; the median and ulnar nerves, with the brachial artery; the popliteal artery, and the internal popliteal nerve are very often affected by one and the same wound; it may be that the association of nerve lesions is an important factor in ischæmic paralysis. In several cases of ischæmia from lesion of the brachial, involving the median and the ulnar, we have seen ischæmic disturbances becoming enormously increased in the region of the affected nerve.

Bonamy and Verchère have reported a very interesting case in which ischæmia of the hand resulting from lesion of the axillary was accompanied by gangrene of the hand and fingers in the region of the musculo-spiral, which was itself slightly injured.*

Nevertheless, in a general way, the diagnosis of ischæmic disturbances and nerve lesions may easily be made along the following general lines:—

We find in ischæmic paralysis no peripheral nerve topography whatsoever.

On the other hand, the distribution of ischæmic disturbances is essentially segmentary and centrifugal.

All disturbances, cyanosis, cooling, fibrous infiltration and anæsthesia are preponderant at the extremity of the limb; they gradually and regularly diminish as we approach its root.

Finally, the diagnosis of ischæmic paralyzes is far from being as favourable as that of the peripheral nerve lesions. These paralyzes are severe and often incurable lesions, producing permanent incapacity.

Still, this principle must not be set up absolutely, for in certain cases a well-conducted and sufficiently prolonged treatment by means of hot baths, permanent hot-wrappings, massage, mobilisation and galvano-faradic baths may cause rapid retrogression of the symptoms. For months and even years, these patients are capable of progressive improvement which at times surpasses the most sanguine hopes and expectations.

* Bonamy and Verchère. "A Case of Gangrene of the Fingers and Hand in the Region of the Musculo-spiral." *Société des Chirurgiens de Paris*, 21 May, 1915.

PART II

UPPER LIMB

CHAPTER VI

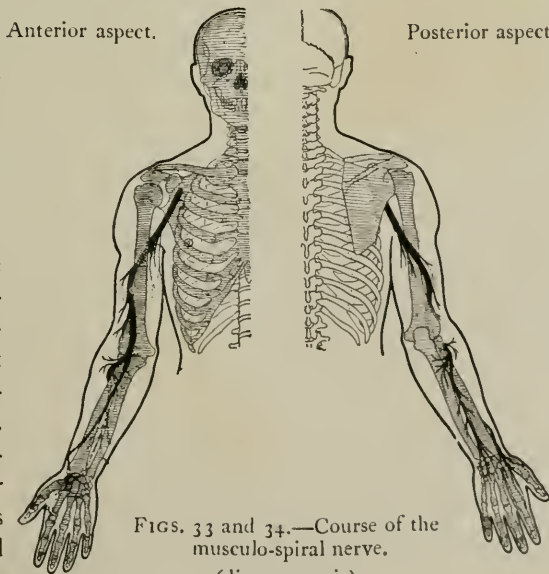
MUSCULO-SPIRAL NERVE

PARALYSIS of the musculo-spiral nerve is by far the most frequent ; for not only may the nerve be affected directly like the other nerves of the upper limb, but it is very often surrounded and compressed in the callus of fractures of the humerus ; it may also be accidentally compressed at the level of the axilla by pressure of crutches (crutch palsy) or on the posterior surface of the arm by pressure of a sharp edge during deep sleep (Saturday night palsy).

ANATOMY OF THE MUSCULO-SPIRAL NERVE

The musculo-spiral nerve, along with the circumflex, has its origin from the posterior cord of the brachial plexus.

It crosses the armpit behind the vasculo-nervous bundle ; then it plunges obliquely towards the posterior part of the arm and describes round the diaphysis of the humerus the spiral semi-circle which brings it over the external surface of this bone. Along this course it appears on the posterior surface of the humerus in the space comprised between the inner and outer heads of the triceps and covered by its long head.



FIGS. 33 and 34.—Course of the musculo-spiral nerve. (diagrammatic).

After passing round the humerus, the musculo-spiral appears on the

external border, then on the antero-external surface of this bone, lying on the fibres of origin of the brachialis anticus. In its spiral tract round the humerus it is very often affected by fractures of this bone or surrounded by callus formation.

It descends into the muscular interspace separating the supinator longus from the biceps, right to the line of the crease of the elbow.

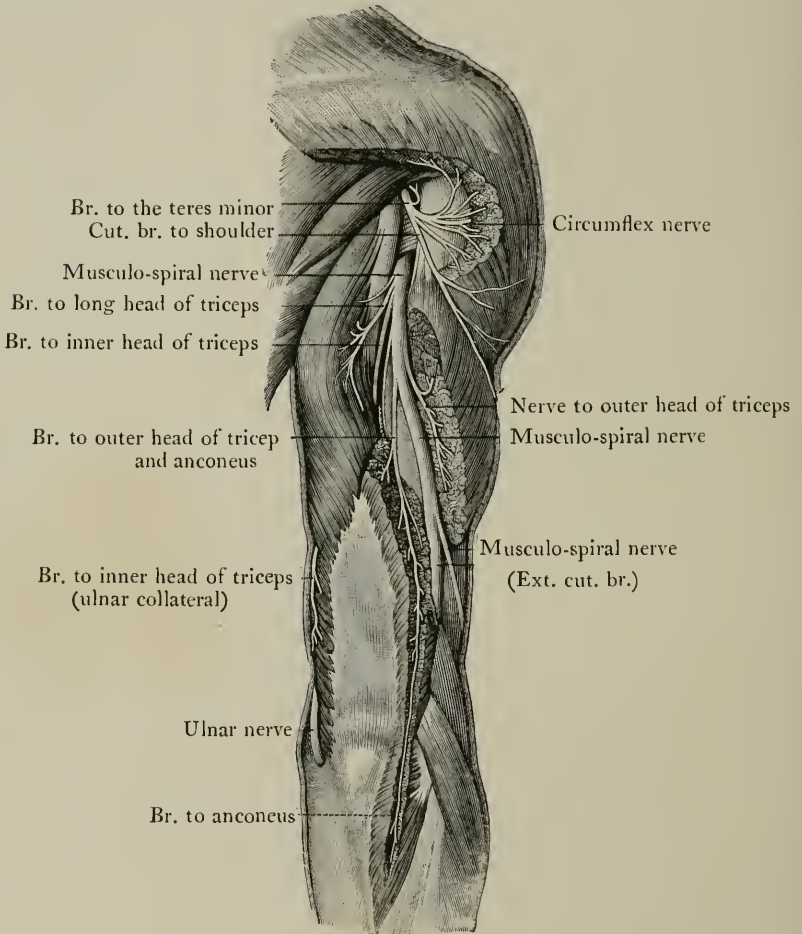


FIG. 35.—Musculo-spiral nerve on posterior surface of arm and fore-arm.
(After Sappey.)

It then divides into its two terminal branches—

1. The anterior branch, the less important, exclusively sensory, follows the direction of the nerve, proceeding along the internal edge of the supinator longus and covered by it.

At the lower part of the fore-arm, it passes outwards under the tendon of the supinator longus, passes round the external edge of the radius,

becomes subcutaneous and appears at the dorsal surface of the wrist, where it divides into three branches, intended for the sensory innervation of the dorsal surface of the hand.

2. The posterior branch, a very important one, passes round outside the neck of the radius, traverses the supinator brevis, then proceeds

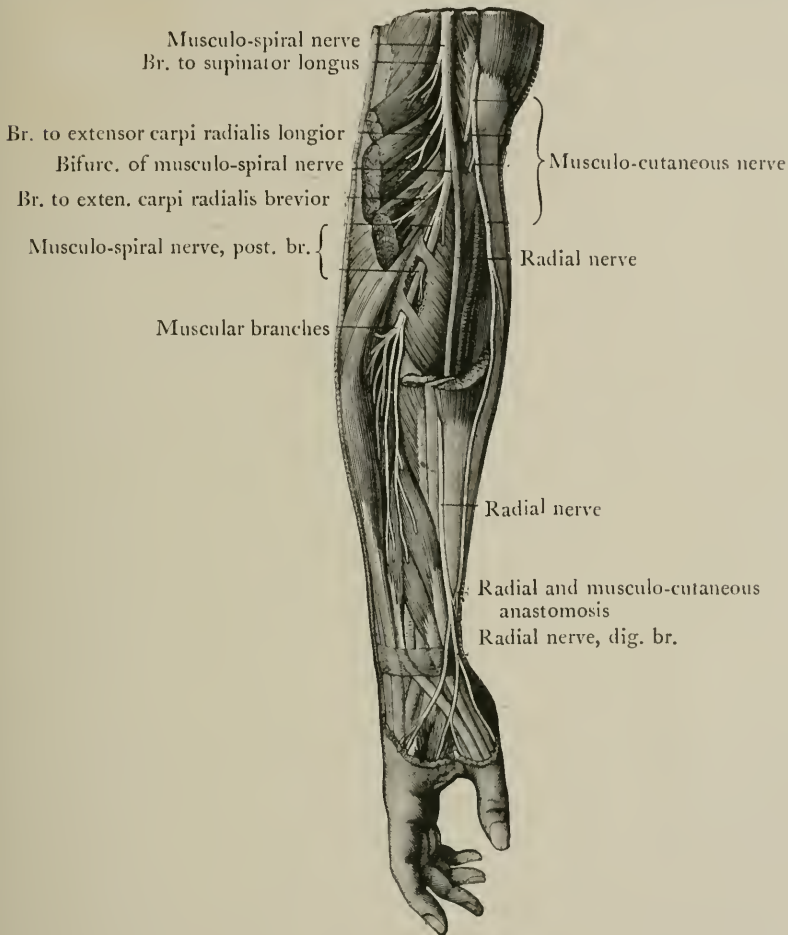


FIG. 36.—Musculo-spiral nerve or posterior surface of arm, fore-arm and hand.
(After Sappey.)

between the superficial layer and the deep layer of the posterior muscles of the fore-arm, supplying all of them with motor branches.

Under the name of posterior interosseous nerve, this branch, applied to the posterior surface of the interosseous ligament, extends right to the level of the wrist. The terminal branches are distributed over the periosteum and the articulations of the carpus and the metacarpus; we shall see that their trophic rôle is a particularly important one.

MOTOR BRANCHES

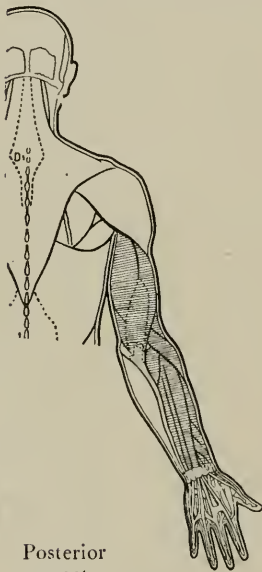
The musculo-spiral is above all a motor nerve. It gives off in turn the following motor branches:—

1. Below the axilla at the posterior surface of the arm: the nerve to the long head of the triceps; the nerve to the inner head; the nerve to the outer head, which extends down to the anconeus.

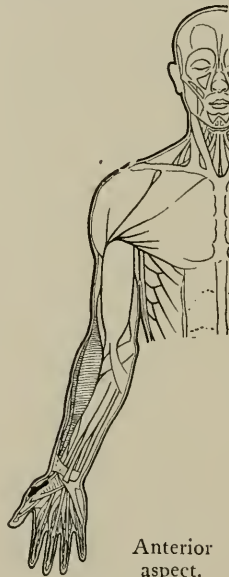2. In the bicipital furrow: the nerve to the supinator longus; the nerve to the extensor carpi radialis longior.

3. In passing round the neck of the radius, the posterior branch supplies: the nerve to the exterior carpi radialis breviar and the branches to the supinator brevis.

4. On the posterior surface of the arm, this same branch supplies:



Posterior aspect.



Anterior aspect.

FIGS. 37 and 38.—Motor distribution of the musculo-spiral.

the nerve to the exterior carpi ulnaris; the nerves to the extensor communis digitorum and to the extensor proprius digiti minimi, then descending, the nerves to the extensor ossis metacarpi pollicis, to the extensor longus pollicis and to the extensor brevis pollicis manus; the nerve to the extensor indicis.

5. Finally, the anterior branch sometimes supplies the thenar eminence with a little branch which participates in the innervation of the abductor pollicis

(the median supplies the principal innervation to this muscle).

This nerve twig has no great importance; all the same it explains the very slight atrophy of the abductor sometimes found in musculo-spiral paralysis.

SENSORY BRANCHES

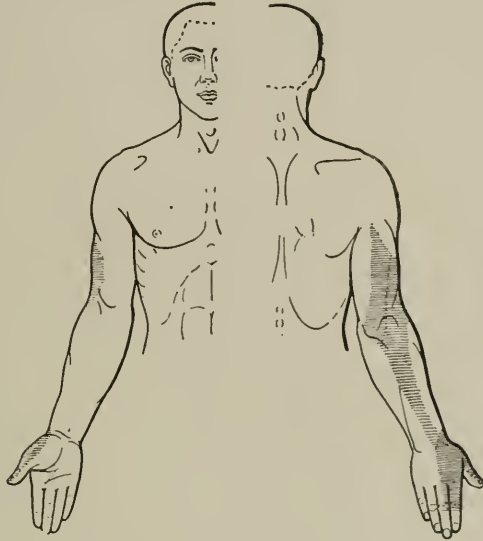
The sensory contribution of the musculo-spiral is of slight importance. We may describe its three branches—

1. Internal cutaneous branch to the arm which is given off at the

lower part of the axilla and goes to supply the postero-internal part of the arm as far as the olecranon.

2. External cutaneous branch, which is given off from the musculo-spiral just when it passes round the external edge of the humerus and is distributed: to the postero-external surface of the arm; and to the posterior surface of the fore-arm, in the form of a narrow band, lying between the areas of the musculo-cutaneous and internal cutaneous.

3. The anterior branch of the musculo-spiral is predominantly sensory. It terminates on the dorsal surface of the wrist in three branches which supply sensation to the external part of the thenar eminence, to the external part of the dorsal surface of the hand, to the entire dorsal surface of the thumb, to the dorsal surface of the index up to the second phalanx, to half the dorsal surface of the middle finger up to the second phalanx (the dorsal surface of the last phalanges of these two fingers is supplied by the median).



FIGS. 39 and 40.—Sensory distribution.

ANASTOMOTIC BRANCHES

The musculo-spiral nerve presents no important anastomosis with the other nerves. Its sensory fibres alone anastomose with the sensory fibres of the other nerves at the confines of its cutaneous region. These are terminal anastomoses.

We meet, however, at the lower third of the fore-arm, with a small twig of union between the sensory branch of the musculo-spiral and the musculo-cutaneous.

PHYSIOLOGY OF THE MUSCULO-SPIRAL NERVE

MUSCULO-SPIRAL PARALYSIS

I.—MOTOR SYNDROME

The musculo-spiral nerve is essentially the nerve of extension.

1. Paralysis of musculo-spiral nerve is essentially paralysis of extension.

Extension of the fore-arm on the arm by the triceps.

Extension of the hand on the fore-arm by the radial extensors on the outer side and by the extensor carpi ulnaris on the inner side.

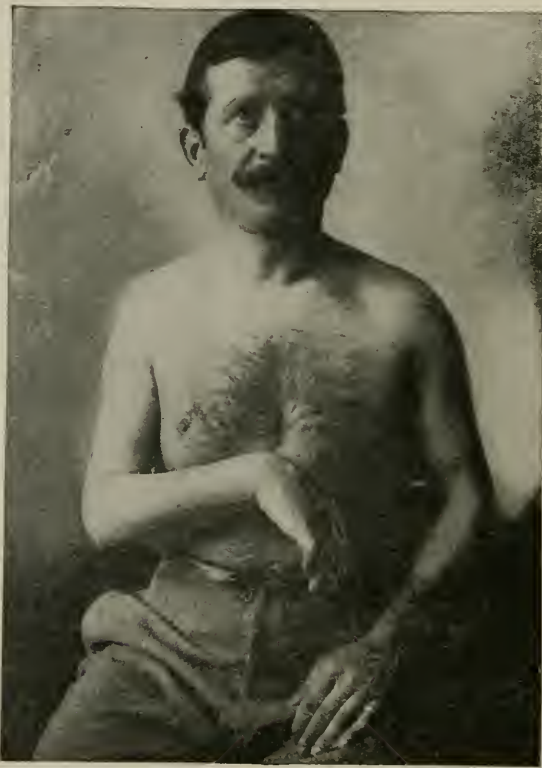

FIG. 41.—Attitude in musculo-spiral paralysis.

Extension of the fingers on the hand by the extensor communis and by the extensors of the thumb, the index and the fifth fingers.

This paralysis results in a special deformity: the fore-arm half flexed on the arm, the hand drooping, the fingers half flexed by the tonic action of the flexors.

But paralysis of the extensors of the fingers involves only the first

phalanges; if we artificially raise the first phalanges, we find that the patient can easily extend the second and third phalanges.

For, while the extensor tendons continue right to the last phalanx of the fingers, they really act along their deep surface, on the head of the first phalanx, a close adhesion limiting their action to the extension of the first phalanges upon the metacarpus alone.

It is the interossei that extend the second and third phalanges upon the first by the tendinous slips which they send to the extensor tendons.

Thus, orthopedic appliances intended to correct musculo-spiral paralysis have no need to extend more than the first phalanx.

2. Musculo-spiral paralysis is accompanied by paralysis of extension of the thumb.

3. The extensor carpi ulnaris muscle, which is an extensor of the hand on the fore-arm, also produces a movement of adduction of the hand.



FIG. 43.—Extension of second and third phalanges on the first, by the action of the interossei in musculo-spiral paralysis. This patient, suffering from musculo-spiral paralysis and possessing considerable articular laxity of the fingers, succeeded, in spite of the droop of hand and fingers, in producing with his interossei a hyper-extension of the second and third phalanges.

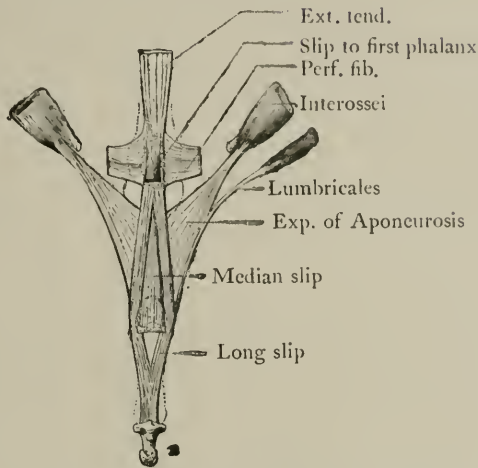


FIG. 42.—Tendons of the common extensor; connexions (deep aspect).

We see that the exterior tendon sends to the first phalanx a slip of insertion which limits its action to this phalanx alone. The slips intended for the second and third phalanges are affected by the lumbricales and the interossei.

Consequently, abduction is weakened, though it remains possible through the flexor carpi ulnaris (ulnar nerve). It then occurs along with flexion of the hand, in default of the synergic antagonism of the extensor carpi ulnaris.

4. We also have paralysis of supination (supinator brevis).

At the same time a slight degree of supination by means of the biceps persists, but this is possible only if the fore-arm is flexed.

5. Sign of the supinator longus.—Although supplied by the

musculo-spiral, the supinator longus is not an extensor ; it is not even a supinator, in spite of its name. It is rather a flexor of the fore-arm on the arm, almost as powerful as the biceps ; that it is supplied by the musculo-spiral nerve is quite an anomaly, since it really belongs to an altogether different physiological group, that of the flexors.

It contracts, synergically with the biceps, in every flexion of the fore-arm, standing out prominently.

The disappearance of this synergic contraction of the supinator longus is one of the best signs of peripheral musculo-spiral paralysis. Indeed, it is not found in root or spinal cord paralyses which are confined to the root region of the musculo-spiral (essentially the seventh cervical), whilst



FIG. 44.—Normal subject. Contraction of the supinator longus accompanying contraction of the biceps.



FIG. 45.—Musculo-spiral paralysis. The supinator longus does not contract synergically with the biceps.

leaving untouched the upper root group (deltoid, biceps, brachialis anticus and supinator longus, which depend mainly on the fifth and sixth cervicals).

As we are aware, contraction of the supinator longus is retained in saturnine paralysis, of the musculo-spiral type.

Any musculo-spiral paralysis where the supinator longus is untouched should at once attract attention. If this dissociation is not due to lesion of the nerve below the branch which it supplies to the supinator longus, then we are dealing with pseudo-musculo-spiral paralysis, through root or spinal cord lesion, polyneuritis, or hysterical paralysis.

6. In musculo-spiral paralysis we note a considerable diminution of energy in flexing the fingers. This, however, is not a real weakness, but results from the faulty attitude of the flexed hand ; contraction of the

flexors can take place powerfully only if the antagonists put the hand in extension. If the hand is artificially raised, the fingers will regain their full power of flexion.

II.—SENSORY SYNDROME

The musculo-spiral nerve is but very slightly sensory, its region is confined to the posterior part of the arm, a tract on the back of the fore-arm and a part of the dorsal surface of hand and fingers.

It must be added that anæsthesia of the internal cutaneous branch is scarcely noticeable and is very rare, since it occurs only in lesions high up in the axilla.

The external cutaneous branch is more frequently affected, particularly in fractures of the humerus; still, we can just discern on the external surface of the arm and behind the fore-arm a small area of hypo-æsthesia,

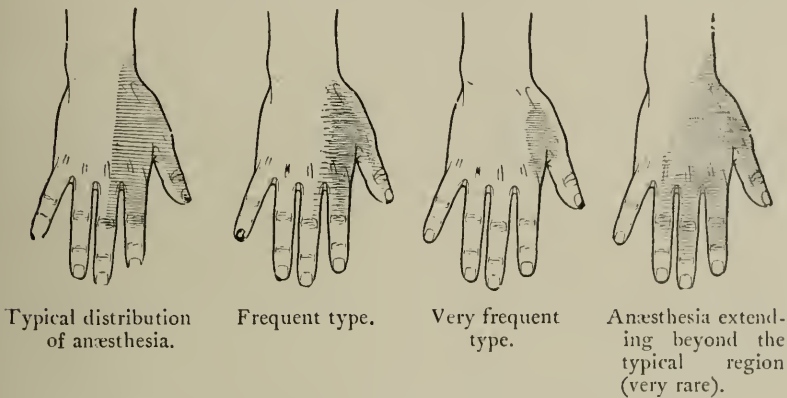


FIG. 46.—Types of anæsthesia from lesions of the musculo-spiral.

so restricted is its sensory rôle and so great the overlapping of neighbouring nerves.

Anæsthesia in musculo-spiral paralysis is not often found anywhere else than on the hand. Seldom does it reach the typical distribution of the musculo-spiral, far more seldom does it go beyond it. Most frequently it limits itself to a very restricted part comprising the dorsal region of the first and the second metacarpal.

It is often very slight, sometimes even it can scarcely be seen; in any case, it is exceptional to find complete anæsthesia in this region; at most we have more or less marked hypo-æsthesia.

In this same region is found formication, brought out by pressure on the nerve; it exists even in cases where anæsthesia is scarcely discernible. It even appears at times in lesions of the posterior branch, showing the presence therein of sensory fibres.

III.—TROPIC SYNDROME

In musculo-spiral paralyses we frequently find an abnormal projection of the bones of the carpus, forming the dorsal swelling of the carpus.

Probably this is due to simple relaxation of the carpal ligaments with slight subluxation of the os magnum and of the semi-lunar, rather than to genuine trophic disturbance. In some cases, and especially in neuritis, it seems to be produced by an actual teno-synovitis of the extensor tendons.

It is in neuritic forms that we find the real trophic disturbances, attacking the integuments, the synovial sheaths, the metacarpo-phalangeal and digital articulations.

It would seem extremely probable that this trophic rôle is due partly to the posterior branch of the musculo-spiral, for it is found even in cases



FIG. 47.—Dorsal swelling of the carpus.

where neuritic irritation acts exclusively on this branch.

The nails are very slightly affected in neuritis of the musculo-spiral. We know that its innervation is limited to the first phalanges. Vascular disturbances are usually very slightly marked; most frequently they are lacking; in any case they never possess the definite character of the vascular disturbances of the median and the ulnar.

In some cases of musculo-spiral paralysis we find œdema of the dorsal surface of the hand. This is rare, though it is met with both in nerve sections and in nerve irritation; its appearance is certainly favoured by the drooping attitude of the hand.

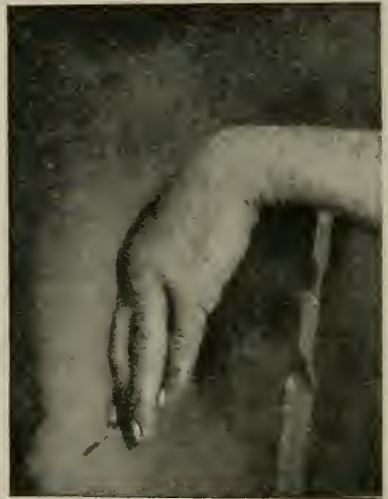

FIG. 48.—œdema of the hand in a case of musculo-spiral paralysis (section of the nerve).

TYPES OF MUSCULO-SPIRAL PARALYSIS

These types should be studied :

1. According to the seat of the lesion and the topographical distribution of the paralysis ;
2. According to the clinical type produced by the lesion : interruption, compression, nerve irritation or regeneration.

TYPES ACCORDING TO THE SEAT OF LESION

I.—TOTAL PARALYSIS OF THE MUSCULO-SPIRAL

This is produced by lesions of the nerve at the lower part of the axilla and by crutch palsy.

It is characterised by paralysis of the triceps, along with abolition of the olecranon reflex, in addition to all the other symptoms of musculo-spiral paralysis.

We note the complete disappearance of the movements of extension of the fore-arm on the arm ; paralysis, atrophy and RD of the triceps.

After all, it is very seldom found in its pure state, for the musculo-spiral nerve supplies its first tricipital branches immediately below the axilla. It is seen more frequently in musculo-spiral paralysis associated with that of the circumflex or of the other nerves of the arm resulting from axillary lesions.

Paralysis of the triceps easily passes unperceived unless sought for systematically ; indeed, when at rest, it is not indicated by any special attitude. It is always accompanied by exaggerated passive flexion of the elbow.

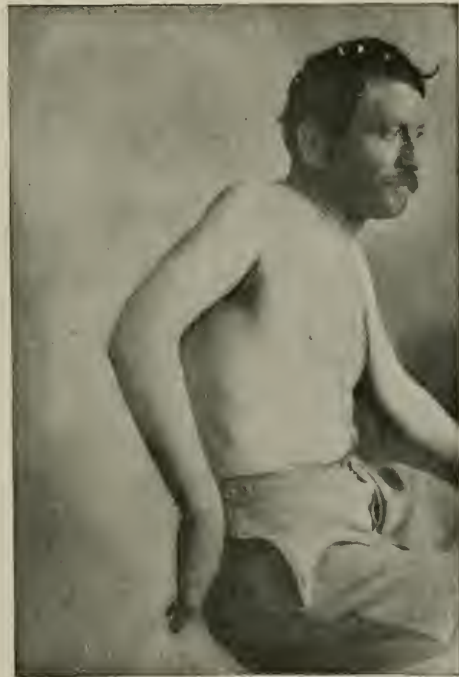

FIG. 49.—Paralysis of the triceps. Lesion at the base of the axilla. The patient, on trying to extend the fore-arm on the arm, succeeds only in raising the arm outwards and backwards by contraction of the deltoid (circumflex) ; the fore-arm hangs vertically.

II.—PARTIAL PARALYSIS OF THE TRICEPS

The triceps is supplied by three different branches : branches to the internal head, to the long head, and to the external head.

Lesions between these branches may produce partial paralysis of the triceps.

In such cases we have to deal with a nerve lesion very high up, at the postero-internal surface of the arm. We always find paralysis of the outer head and of the anconeus, with more or less complete integrity of the inner head and the long head, the branches of which originate quite close to each other, one or two centimetres above the branch to the outer head, which also supplies the anconeus.

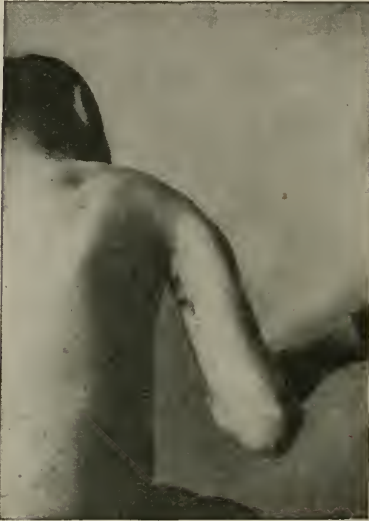

FIG. 50.—Dissociated paralysis of the triceps. Integrity of the long head and of the inner head; paralysis, atrophy and RD of the outer head. The patient is making an effort to extend his arm, against resistance.

It is often difficult to detect the existence of this partial paralysis of the triceps, for extension of the fore-arm persists, and is scarcely diminished at all. Only by palpation of the

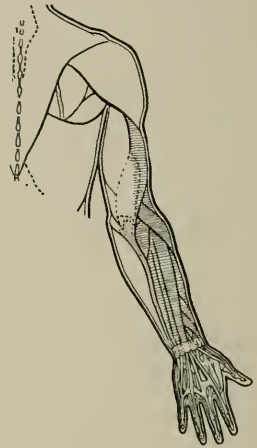

FIG. 51.—Musculo-spiral paralysis with dissociated paralysis of the triceps.

contracting muscle can we recognise the flaccidity and atrophy of the outer head. Faradic examination by the bi-polar method also shows the persistence of contraction in the case of the inner head and the long head, their disappearance in the case of the outer head.

The olecranon reflex is retained.

The external cutaneous branch makes its appearance below the tricipital branches; its participation is indicated by a faint narrow tract of hypo-æsthesia on the posterior surface of the fore-arm.

III.—MUSCULO-SPIRAL PARALYSIS ABOVE THE SUPINATOR LONGUS.

This is the classic and most frequent type of musculo-spiral paralysis, that produced by wounds on the external surface of the arm, simple compression of the nerve on a sharp edge, fractures of the shaft of the

humerus with involvement of the nerve in the callus or in the surrounding tissues. Secondary involvement in callus of a musculo-spiral nerve originally intact is theoretically possible; it must, however, be quite

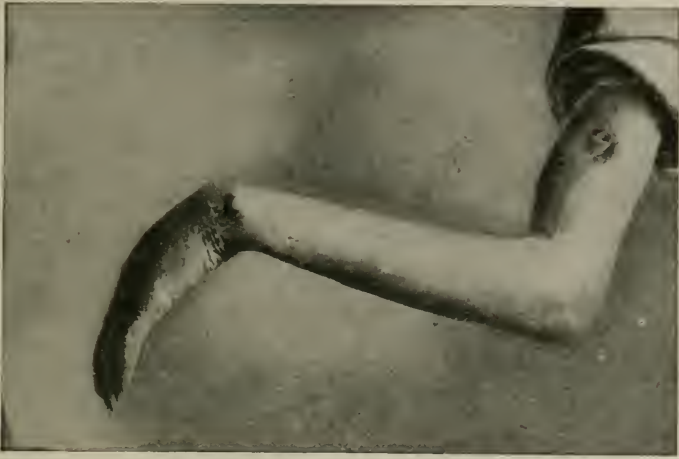

FIG. 52.—Wounds on the external surface of the arm with fracture of the humerus. Typical musculo-spiral.

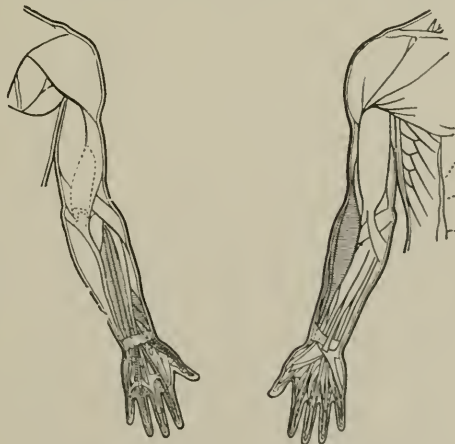
exceptional; for we have always found that paralysis occurs immediately with the wound.

Musculo-spiral paralysis is characterised at this level by inaction of the supinator longus, the radial extensors, the extensor carpi ulnaris, and the extensors of the fingers, causing the typical flexed attitude of the hand and of the first phalanx of the fingers.

The olecranon reflex is retained.

The triceps is of course untouched, as is the anconeus.

Although this small muscle is situated below the olecranon, in the posterior compartment of the fore-arm, it is no more than a prolongation of the triceps and is supplied by the branch to the outer head.



Posterior aspect. Anterior aspect.

FIGS. 53 and 54.—Musculo-spiral paralysis below the triceps.

Its integrity is indicated by no special attitude or movement, but it may be a cause of error in electrical examination. Indeed, if we try to

obtain faradic excitability of the posterior muscles of the fore-arm, the anconeus, excited by diffusion, often responds by slight contractions which may be taken for a response of the radial extensors or of the extensors of the fingers.

The external cutaneous branch, which emerges on to the external surface of the arm, may be affected by the lesion or remain untouched, as the case may be. Its interruption, moreover, is shown only by a slight and faint narrow tract of hypo-æsthesia, on the external surface of the elbow and descending on to the posterior surface of the fore-arm.

We must remember that if the musculo-spiral nerve is found to be enclosed in callus, it is sometimes rather difficult to bring about the sign of formication at the level of the lesion. It is necessary to make on the callus a few slight taps, capable of transmitting the shock to the enclosed nerve.



FIG. 55.—Paralysis of the supinator longus. The muscle no longer contracts synergically with the biceps.

Lesions of the musculo-spiral nerve by involvement in callus are particularly likely to induce symptoms of nerve irritation, along with pains caused by pressure on nerve and muscles, trophic disturbances of integuments and digital articulations, tendon adhesions limiting the passive flexion of the fingers. These are cases which call for liberation of the nerve, and the sooner this is done, the more satisfactory will be the results obtained.

Operations on the musculo-spiral nerve at this level, sutures and liberations alike, are particularly liable to be followed by secondary involvement in the callus or in cicatricial fibrous tissue, by reason of the proximity of the fractured bone. This is the main cause of lack of success after operations. Accordingly it is usually necessary, more than anywhere else, to surround the nerve with a muscular or fatty envelope, and at an early stage to massage and mobilise the scar.

IV.—MUSCULO-SPIRAL PARALYSIS BELOW THE SUPINATOR LONGUS

Lesions at the lower part of the bicipital furrow, direct traumatism or fracture of the epicondyle, may affect the musculo-spiral immediately below the branch to the supinator longus.

There is then complete paralysis of extension of hand and fingers, but

the supinator longus is untouched and contracts synergically with the biceps.

Several times we have found this type in neglected fractures of the epicondyle with a fibrous loop enclosing the nerve at the level of the line of the fracture. The integrity of the supinator longus might have made one regard it as a functional paralysis.

Still, it must be remembered that the branches to the supinator longus and to the extensor carpi radialis longior arise near each other from the trunk of the nerve itself, whereas the twig to the extensor carpi radialis brevior has its origin much lower from the posterior interosseous; accordingly there will often be observed weakening of the supinator longus accompanied by paralysis of the extensor carpi radialis longior. More frequently if the lesion is in the vicinity of the joint we note the integrity of the supinator longus, simple weakening of the extensor carpi radialis longior and paralysis of the extensor carpi radialis brevior; electrical examination enables us easily to dissociate these symptoms.

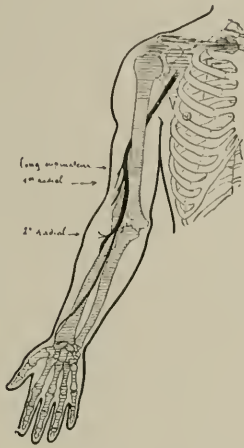


FIG. 56.—Origin of the branches to the supinator longus and to the radial extensors.

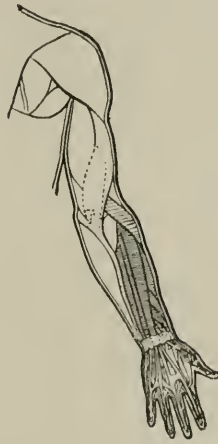

FIG. 57.—Integrity of the supinator longus, weakening of the extensor carpi radialis longior, paralysis of the extensor carpi radialis brevior.



FIG. 58.—Integrity of the supinator longus. Atrophy and paralysis of the radial extensors. Wound inflicted at the middle part of the furrow of the supinator longus.

V.—MUSCULO-SPIRAL PARALYSIS BELOW THE RADIAL EXTENSORS

In this case, the lesion is of the posterior branch alone, below the joint or else on the outer surface of the neck of the radius or even at the posterior surface of the fore-arm.

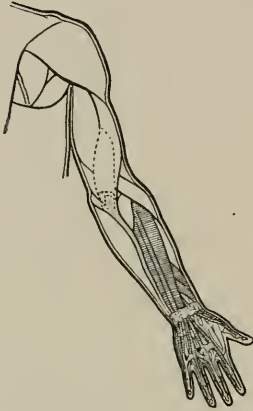

FIG. 59.—Integrity of the radial extensors. We find paralysed: The superficial layer of muscles, extensor carpi ulnaris and extensor communis digitorum, covering the deep layer made up of the extensor ossis metacarpi pollicis, the extensors of the thumb and of the index.

The anterior branch is untouched; consequently there are no sensory disturbances in the hand.

Raising of the hand is possible but the extensors of the fingers and the extensor carpi ulnaris are paralysed.

If there is considerable hypotonia of these latter muscles, we may see the contraction of the radial extensors raising the hand by giving it a deviatory movement outwards; this is because their traction takes place on the radial side of the hand and must normally be balanced by the synergic contraction of the extensor carpi ulnaris on the inner side of the wrist.



FIG. 60.—Wound on the posterior surface of the arm. Integrity of the radial extensors. Extension of hand on fore-arm possible. Paralysis of the extensors of the fingers.

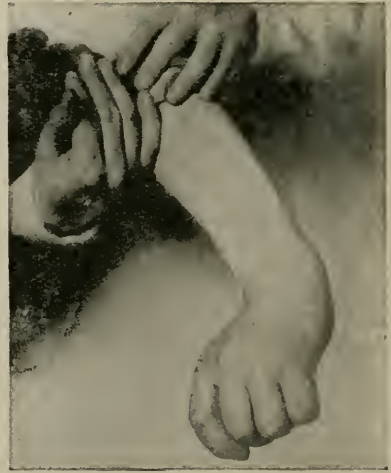

FIG. 61.—Contraction of the radial extensors is no longer balanced by synergic contraction of the extensor carpi ulnaris; the hand deviates towards the radial side.

VI.—DISSOCIATION OF THE EXTENSOR COMMUNIS DIGITORUM

Below the radial extensors and the supinator brevis a lesion of the posterior branch of the musculo-spiral may affect the extensors of the fingers.

The extensor communis, however, receives its supply by several twigs corresponding to the different muscular fasciculi.

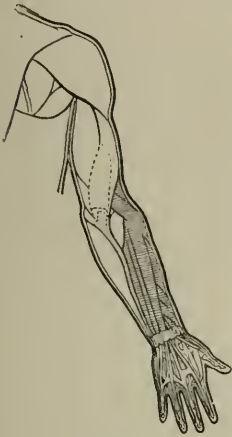

FIG. 62.

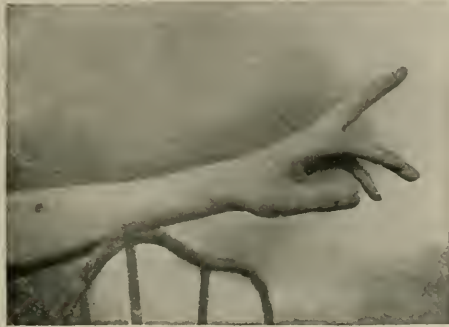

FIG. 63.—Dissociated paralysis of the extensor communis digitorum. Integrity of the extensor of the middle finger.

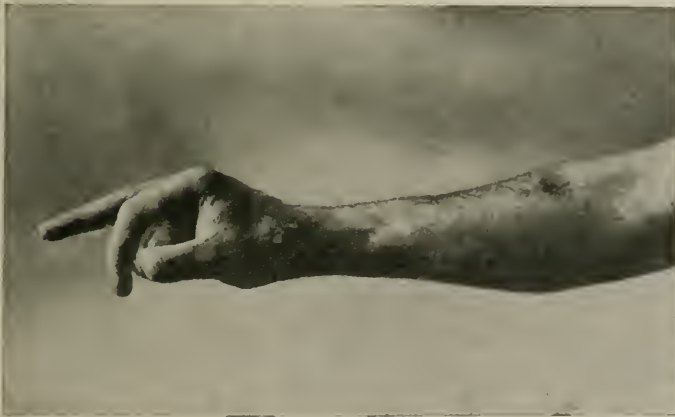

FIG. 64.—Dissociated paralysis of the extensor communis digitorum. Integrity of the extensor of the middle finger.

The extensor fasciculus to the middle finger may be untouched whilst the underlying fibres are affected, and we find extension of the middle finger persisting when the other extensors are paralysed.

VII.—MUSCULO-SPIRAL PARALYSIS BELOW THE EXTENSOR COMMUNIS DIGITORUM

Below the branches intended for the extensor communis digitorum, a twig of which almost always terminates at the extensor of the little finger, the posterior branch of the musculo-spiral supplies the extensor ossis metacarpi pollicis, the long and short extensors of the thumb and the extensor indicis.

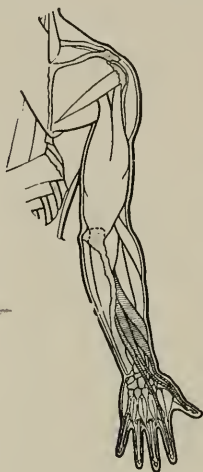

FIG. 65.

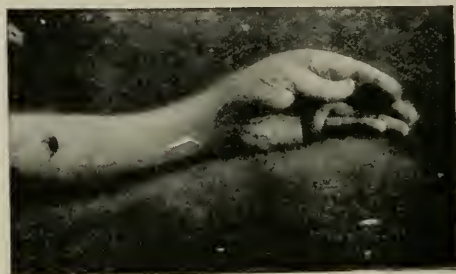

FIG. 66.—Paralysis of the extensors of the thumb by wound at the middle third of fore-arm.

Consequently we may have isolated paralysis of these muscles from a lesion of the musculo-spiral at the middle of the fore-arm.

VIII.—DISSOCIATED PARALYSIS OF THE MUSCULO-SPIRAL

Partial fascicular lesions of the musculo-spiral are rare. However, we meet with certain cases which occasion dissociated paralysis.

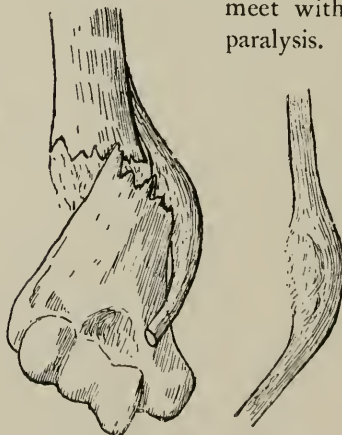


FIG. 67.—Dissociated paralysis of the musculo-spiral, not affecting the supinator longus and the radial extensors.

We may quote two types of these lesions—

1. The musculo-spiral nerve crushed by a bony fragment of the humerus, level with the furrow of the biceps, seemed to present symptoms confined to its inner part. There was absolute paralysis of the extensors and extensor carpi ulnaris, along with complete RD; on the other hand, the supinator longus and the radial extensors had retained some voluntary movements, very slight faradic excitability without galvanic polar inversion and also without slow contraction.

The modified operation performed on this nerve was followed by a rapid return of the functions in the case

of the supinator longus and the radial extensors, whilst paralysis of the extensors and of the extensor carpi ulnaris persisted three months after the operation.

2. In another case the musculo-spiral was bruised on the external surface of the humerus, the contusion apparently involving only the posterior and external part of the nerve.

There was found to be complete paralysis of the supinator longus and the radial extensors with considerable atrophy and a complete reaction of degeneration, whilst the voluntary mobility of the extensors of the fingers was fully retained along with normal electrical reactions.



FIG. 68.—Contusion on the external surface of the arm; dissociated paralysis of the musculo-spiral, integrity of the extensors; paralysis of the radial extensors and of the supinator longus. No operation; persistence of this paralysis three months after the first examination. The patient is photographed just as he is extending his fingers, usually flexed in an attitude of repose.

Thus there would appear to exist in the musculo-spiral, as in all the other nerves, a fascicular topography. It is somewhat difficult to determine it precisely, mainly perhaps on account of torsion of the nerve, which at each stage modifies the position of the different fasciculi.

But still it must be admitted that we find: on the outer side, and from front to back, the anterior cutaneous branch, the supinator longus, the radial extensors; on the inner side, from front to back, the extensor carpi ulnaris and the muscles of the thumb, the extensor communis, the supinator brevis. (J. and A. Dejerine and Mouzon.)

According to MM. Pierre Marie and Meige, we find the extensors of the wrist on the inner side, the extensores digitorum within and behind, the supinators on the outer side.

FORMS OF MUSCULO-SPIRAL PARALYSIS ACCORDING TO THE
NATURE OF THE LESION

I.—SYNDROME OF COMPRESSION

This is characterised, especially in musculo-spiral paralysis, by partial preservation of muscular tone for a long period.

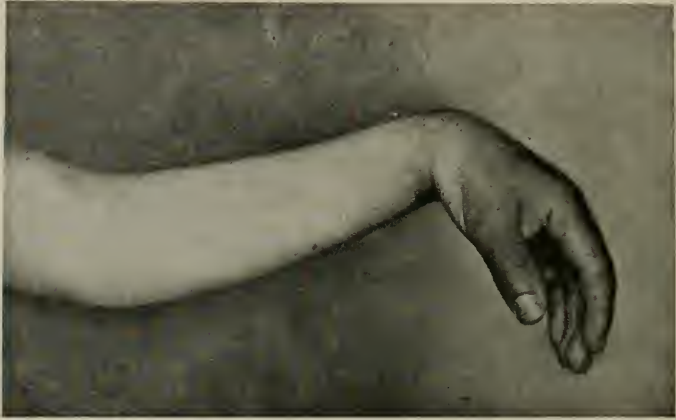

FIG. 69.—Simple compression of the musculo-spiral ; paralysis "a frigore."
Persistence of muscular tone.

The droop of the hand is slight, very little if at all more pronounced than in the position of simple muscular repose.

If we press on the hand, we may intensify the flexion ; if we cease

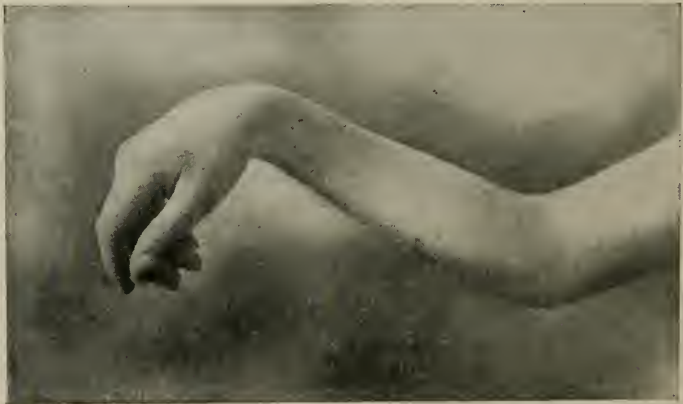

FIG. 70.—Compression of the musculo-spiral in callus. Persistence of muscular tone.

pressing, the hand is seen to resume its original attitude, as a result of the muscular elasticity.

In the long run, however, we find hypotonia becoming pronounced, and the hand assuming the attitude of complete interruption.

With the conservation of tone is associated the relative absence of muscular atrophy, the incomplete character of the RD, and the persistence of a slight degree of muscular sensation.

It is in slight cases of compression of the musculo-spiral that we may sometimes find by electrical examination the paradoxical preservation of faradic contractility of the nerve and muscles below the lesion.

The prognosis of these forms is particularly benign; the cure comes about spontaneously in a few weeks, being accelerated by electrical treatment.

II.—SYNDROME OF INTERRUPTION

In complete interruptions, on the other hand, we find that muscular atony rapidly appears and becomes more marked.

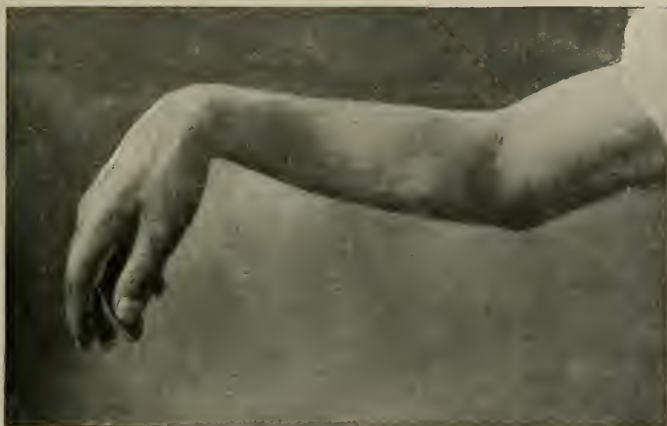

FIG. 71.—Complete section of the musculo-spiral (a separation of 3 cm. between the two segments) at the upper part of the furrow of the biceps. Hypotonia very pronounced.



FIG. 72.—Complete interruption of the musculo-spiral, by compression by callus in a fracture of the humerus. Hypotonia very pronounced.

The droop of the hand at the wrist is complete : pressure on the back of the hand does not intensify this attitude nor is it followed by an elastic return to the normal attitude.

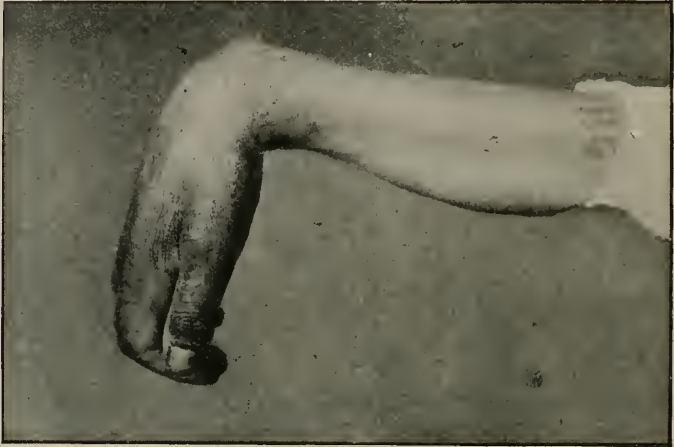

FIG. 73.—Complete interruption of the musculo-spiral, nine months previously. Crushing of the nerve and involvement in callus of fractured humerus. Extreme hypotonia.

On the other hand, atrophy of the muscle and RD rapidly appear ; muscular analgesia is complete.

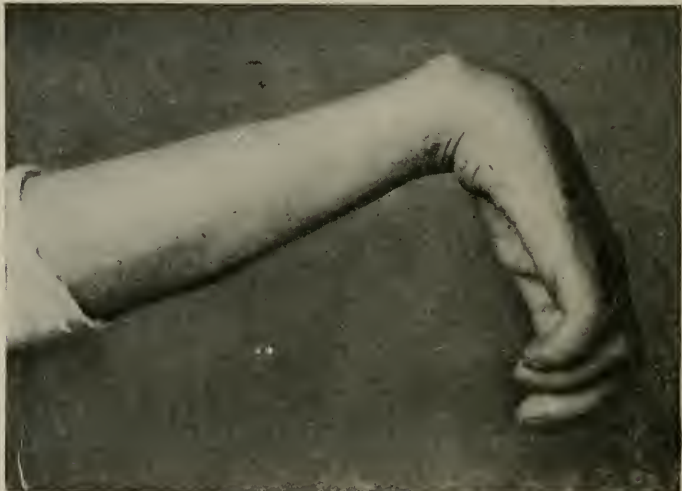

FIG. 74.—Section of the musculo-spiral on the outer surface of the humerus. Complete hypotonia. (In this case there also exists a very slight ulnar *griffe*.)

No great reliance must be placed on the fixity of anaesthesia, for it is

well known that anæsthesia may be extremely reduced in musculo-spiral paralysis.

Still, in spite of the slight importance of sensory disturbances, on pressing the nerve at the level of the lesion, it is always found that formication manifests itself on the dorsal surface of the thumb and of the second metacarpal.

Muscular hypotonia, after some months of complete interruption, may reach an extreme degree: the articular ligaments relax, the tendons lengthen; flexion of the hand reaches an angle of 90° and even more; the hand is no longer simply flexed, it is hanging loose; the flexors have ended by losing all action and now exhibit functional inertia from disuse, which in certain cases might make one think they were paralysed, had they not retained their normal electrical reactions.

III.—SYNDROME OF NERVE IRRITATION

Nerve irritation in the musculo-spiral nerve is very frequent, and important to investigate, for it involves a somewhat serious prognosis by reason of the tendon adhesions and articular limitations which it pro-

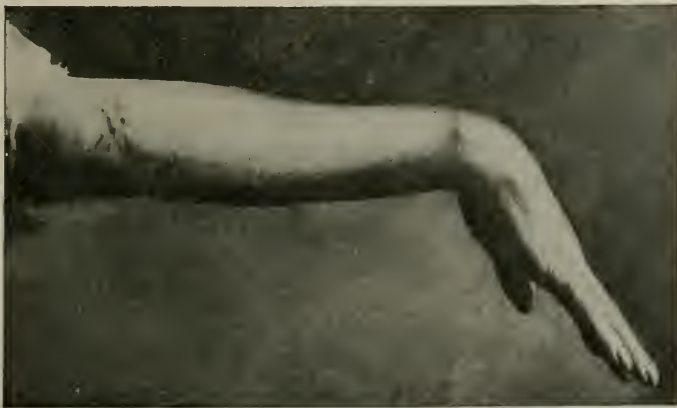

FIG. 75.—Nerve irritation of the musculo-spiral. Droop of the hand less pronounced. Extension of the fingers by contraction of the extensors and adhesion of their tendons to the dorsal surface of the hand.

duces. Still, it is often disregarded, as it is unaccompanied by the acute intolerable pains which characterise neuritis in other nerves.

The musculo-spiral, we must repeat, is but slightly sensory; its irritation consequently is not expressed by the painful syndrome of neuritis in the ulnar and especially the median. The nerve is at most slightly sensitive; the point where the posterior branch crosses the neck of the radius is found to be particularly painful to pressure; the antibrachial muscular masses are somewhat tender if pressed; occasionally we find slight hyper-æsthesia of its cutaneous region.

But whilst sensory disturbances are reduced to these scattered manifestations, trophic disturbances, on the other hand, are very important.



FIG. 76.—Nerve irritation. Tendency to hyper-extension of the first phalanges. Considerable limitation of flexion, active or passive. Acute pains caused by attempts at flexion.

The attitude is different; the droop of the hand is less pronounced, flexion of the wrist is diminished by fibrous adhesion of the tendons and contraction of the extensor muscles which are sometimes felt to be indurated, infiltrated, and painful under pressure. No longer have we the half-flexed fingers usual in musculo-spiral paralysis; they remain extended on the hand, held in place by their contracted tendons.

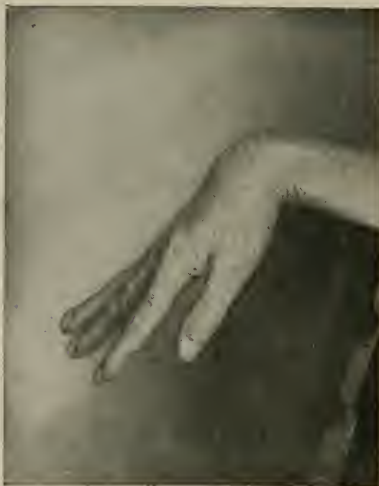

FIG. 77.—Nerve irritation. Spontaneous hyper-extension of the fingers. Impossibility of flexion.

Adhesion of the extensor tendons to the dorsal surface of the carpus and fingers is such that it considerably limits or even makes impossible flexion of the fingers, whether active or passive. Even if pressure be exercised on the dorsal surface of the hand, the attitude of the rigid fingers may be seen intensified in hyper-extension.

The aspect of the hand is characteristic: fibrous infiltration of the dermis, desquamation of the epidermis in fine scales, adhesion of the skin on the dorsal surface of the fingers and particularly at the level of the first digital articulations, disappearance of

the cutaneous creases, swelling of the digital articulations or rather tapering of the fingers are very pronounced, they sometimes recall the appearance of chronic blennorrhagic rheumatism or of certain types of arthritis deformans. The nails, however, are simply curved, far less affected than in neuritis of the median and the ulnar. For it is known that dorsal innervation of the last phalanges is mainly supplied by the palmar nerves.

All these disturbances not only exist on the first fingers, in the cutaneous region of the musculo-spiral, they extend to the entire hand and fingers, being pronounced in the case of thumb, index and middle fingers. This

inclines one to think that they are due mainly to irritation of the posterior branch of the musculo-spiral, which, as we know, is distributed over the five interosseous

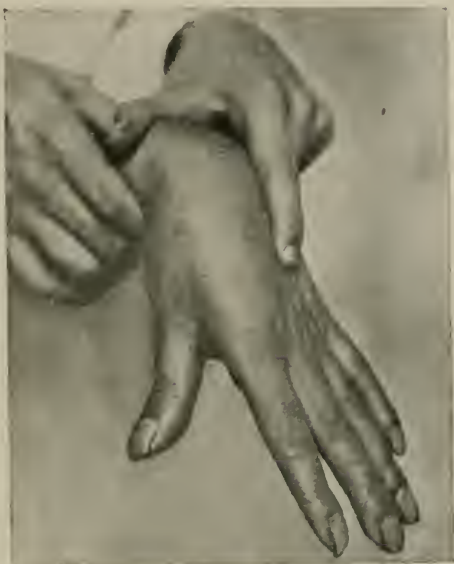

FIG. 78.—Nerve irritation. Hyper-extension of the fingers caused by pressure on the dorsal surface of the hand.

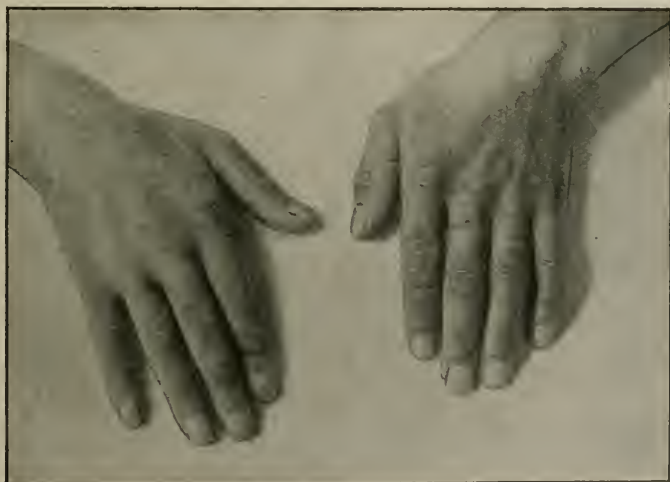

FIG. 79.—Nerve irritation of the musculo-spiral. (In this case the wound is located at the middle third of the fore-arm.) No musculo-spiral paralysis, except slight weakening of the extensors of thumb and index finger. Severe irritative lesions in the hand. Smoothness and fibrous infiltration of the skin, rigidity of the fingers and tendon adhesions. It is impossible to flex the fingers.

spaces. Moreover, one may see all the trophic disturbances of neuritis of the musculo-spiral in isolated wounds of the posterior branch of the musculo-spiral, in the fore-arm, even at its lower part or almost at the wrist, below all its motor branches.

Neuritis of the musculo-spiral is particularly serious on account of its consequences; for, even after healing, when the muscles have lost their fibrous consistence and regained their functions, we find the persistence

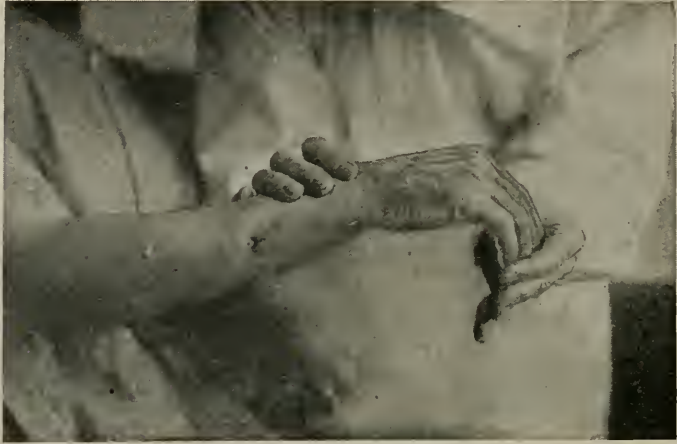

FIG. 80.—Neuritis of the musculo-spiral, healed three months previously. All the movements have reappeared, atrophy has lessened, the pains have disappeared. After three months of massage and mobilisation, however, flexion of the fingers is still extremely limited, however energetically it is attempted; the extensor tendons are united to the dorsal surface of the metacarpals and the digital articulations. Mobilisation of the fingers is extremely painful.

of flexion of the hand and fingers resulting from adhesion of the tendons united to their synovial sheaths and from the fibrous infiltration of the peri-articular tissues; these fibrous sequelæ, refractory to mobilisation and massage, continue for months and years; they may constitute actual infirmity, accompanied by almost total incapacity of the hand.

SYNDROME OF REGENERATION

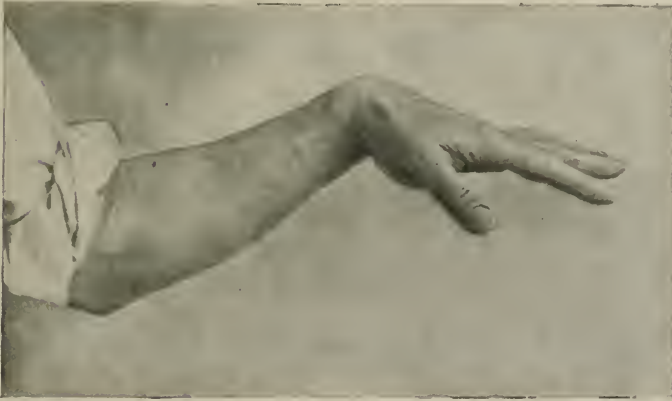Regeneration of the muscles takes place from above downwards, following the path of the axis-cylinders, unless a partial obstacle to the regeneration of a nerve fasciculus create a dissociated paralysis.

Then we find the muscles successively resuming their movements; supinator longus, radial and other extensors.

But when paralysis has lasted some time, prolonged flexion of the hand produces an actual lengthening of muscles and tendons. This lengthening of muscles lasts for a considerable time, and we find that patients, who have recovered the movements of their radial and other extensors are

temporarily incapable of executing simultaneously the movements of these two muscular groups.

“When I wish to raise my hand,” says the patient, “I cannot raise my fingers. When I wish to stretch out my fingers, I am compelled to bend my hand !” And, as a matter of fact, the extensor tendons, when



FIGS. 81 and 82.—Impossibility of simultaneous extension of hand and fingers. Two attitudes of the same patient after regeneration of the musculo-spiral (divided at the external surface of the arm, sutured on the 10th of June, 1915. Photographed 20th December, 1915).

lengthened, are powerless, unless the patient stretches them by previous flexion of the wrist.

The extensors of thumb and index are, as a rule, the last to resume their functions.

To assure oneself of the complete cure of musculo-spiral paralysis, one may request the patient to extend his hand in the position adopted when taking an oath or ask him to stand at attention, his little finger touching

the outer seam of the trouser leg; any defect of the musculo-spiral is indicated by the impossibility of effecting the complete supination thus called for. (Pitres and Testut.)

DIAGNOSIS OF MUSCULO-SPIRAL PARALYSIS

Three main causes of error must be mentioned.

1. Destruction of the muscles of the fore-arm, a frequent occurrence. In these cases, which are usually somewhat complex, loss of muscular substance, cicatricial adhesions and a certain degree of functional inertia of the traumatised muscles are associated most frequently with the nerve lesions in causing loss of motion.

Speaking generally, there takes place secondarily a cicatricial contraction

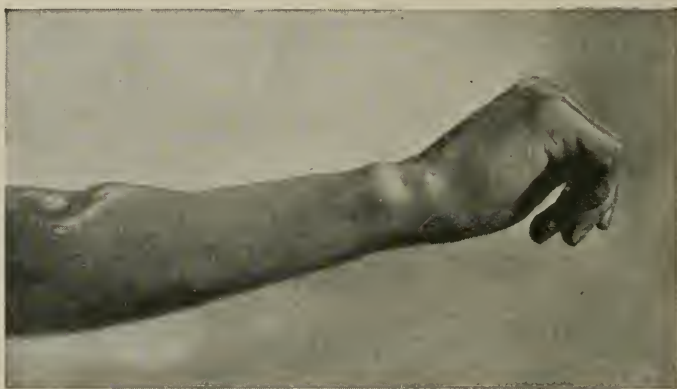

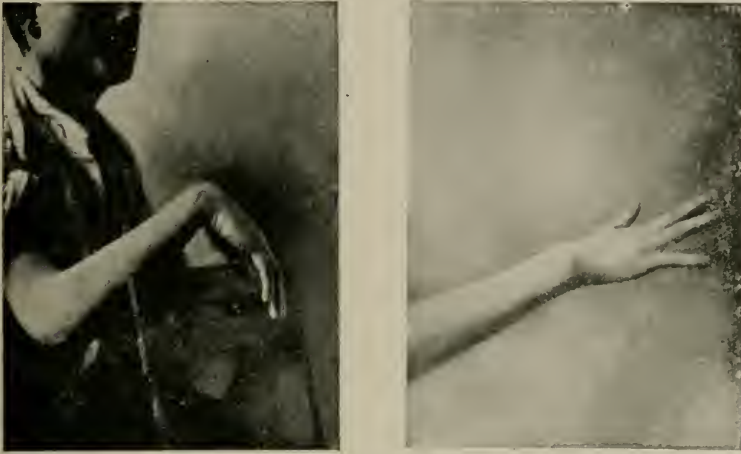
FIG. 83.—Large wound on the posterior surface of the fore-arm. Almost complete destruction of the radial extensors and of the extensor communis. Cicatricial contraction of the radial extensors causing immobilisation of the hand in a state of extension. Droop of fingers is complete, although what remains of the muscle has retained its faradic excitability.

of the wounded muscles which does away with the paralytic attitude and renders the extended hand motionless.

2. Hypotonia and lengthening of the radial extensors and other muscles by traumatism or prolonged mal-position, or again, traumatic lengthening of their tendons.

Violent bruises and injuries of the antibrachial muscles, or even simply—a still more curious thing—the prolonged attitude of the hand in a state of flexion, often induce so pronounced a muscular hypotonia of the radial extensors and other muscles that the result is very similiar to musculo-spiral paralysis. But, though the patient appears in the attitude characteristic of this paralysis, though he experiences great difficulty in raising his hand and especially in keeping it extended, still, these movements are possible; they may be called forth by the will, or, if need be, by faradisation.

This muscular lengthening slowly improves with the use of faradisation, exercise and massage; in obstinate cases, shortening or plication of the tendons of the radial extensors may be practised. (Delorme.)



FIGS. 84 and 85.—Wound on the antero-internal surface of the arm. No paralysis at all, but a comminuted fracture of the humerus. Prolonged immobilisation. *Sling worn for 13 months!* . . . Attitude of musculo-spiral paralysis with extreme hypotonia of the muscles. Voluntary motion, however, is retained; at the cost of considerable effort the patient is able to raise his hand.

Simple contusions also, crushing or section of the tendons of the radial extensors, whilst tending to lengthen them, bring about a similar attitude and the same difficulty in extension of the hand.

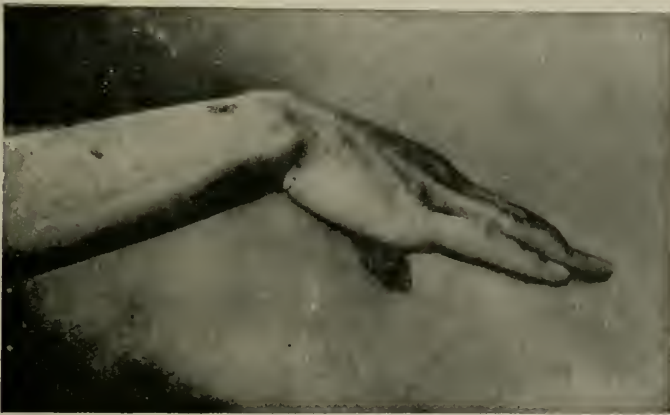

FIG. 86.—Wound on dorsal surface of the wrist with contusion and lengthening of the tendons of the radial extensors.

3. Hysterical paralysis of the hand almost always presents itself under the guise of musculo-spiral paralysis.

It is soon seen, however, that flexion is impossible, just as extension is. The persistence of electrical reactions, segmentary anæsthesia, the mental state of the subject, the disproportion between wound and paralysis, even absence of any wound, readily enable a diagnosis to be made.

Still, we must not trust to electrical examination alone, for it often happens that, in musculo-spiral paralysis *a frigore*, as a result of compression during sleep, the muscles have retained their normal electrical reactions. This is the paradoxical phenomenon described by Erb. It would appear that nerve-compression, sufficient to interrupt the voluntary nerve impulse, is not sufficiently pronounced to cause degeneration of the axis-cylinders. The latter continue normal below the lesion; the

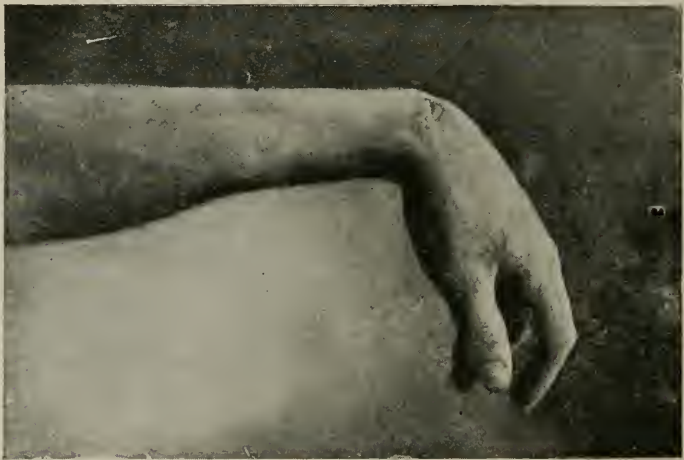

FIG. 87.—Crushing of the radial tendons and extensors at the level of the wrist caused by the kick of a horse. Lengthening of the tendons. Attitude of musculo-spiral paralysis has persisted for 6 years. Voluntary extension of hand and fingers is possible, though at the cost of considerable effort.

nerve and muscles below the lesion have retained their normal electrical reactions; nevertheless, voluntary paralysis is complete, the supinator longus does not contract with the biceps. Finally, electrical stimulation of the nerve at the upper part of the arm causes contraction of the triceps but produces no movement whatsoever of the antibrachial muscles. Thus, a slight compression arrests the nerve impulse as does electrical excitation, without interrupting the trophic action of the nerve cells in the cord on the peripheral axis-cylinders.

This is important; ignorance of the fact would expose one to the risk of regarding as functional, musculo-spiral paralysis resulting from compression, although the rapid cure of these slight compressions within a few weeks, their motor character and the sign of the supinator longus enable them to be easily recognised.

TREATMENT.

Apart from the therapeutic ideas we may hold common to all nerve lesions, in the case of musculo-spiral paralysis, we must insist on the



FIGS. 88 and 89.—Slight wound at the level of the wrist. Hysterical paralysis of the hand of 12 months' standing. Attitude of musculo-spiral paralysis. Persistence of electrical reactions.

necessity of keeping the hand in an extended position, even hyper-extended, during the whole period of the paralysis.

We apply either a plaster splint, an armband or leather glove, or a spring appliance of which many models are to be obtained.

The application of rubber bands or springs to the first phalanges will permit of extension of the fingers.

To obtain elevation of the first phalanx is sufficient, since the last two are extended by the interossei.

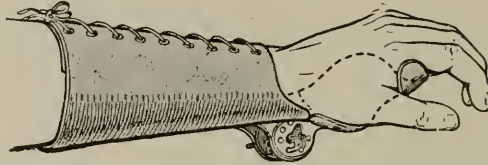


FIG. 90.—Hinged support allowing the hand to be maintained in the desired position by altering the angle with the fore-arm. Aluminium splint fixed by broad leather armlet to the fore-arm. (Apparatus of Pierre Marie and Meige.)

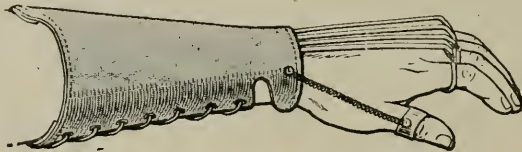


FIG. 91.—Spring appliances intended to correct incapacity of the extensor muscles of the hand and fingers in musculo-spiral paralysis. The apparatus is fastened to the fore-arm by a long leather armlet. It permits of flexion of fingers and hand (which are preserved), it also permits of objects being grasped. A leather ring fixed to a spring keeps the thumb apart. (Apparatus of Pierre Marie and Meige.)




FIG. 92.—Lemoing's glove (imitated from Sollier's apparatus). A steel plate forming a spring is applied to the palmar surface which it elevates; small springs produce extension of the fingers by traction on leather rings. With this apparatus, patients are able to write and to roll cigarettes.

All these appliances not only enable a patient to use his hand and fingers and thus avoid weakening of the flexors through inaction, they also do away with muscular lengthening from the prolonged flexed position.

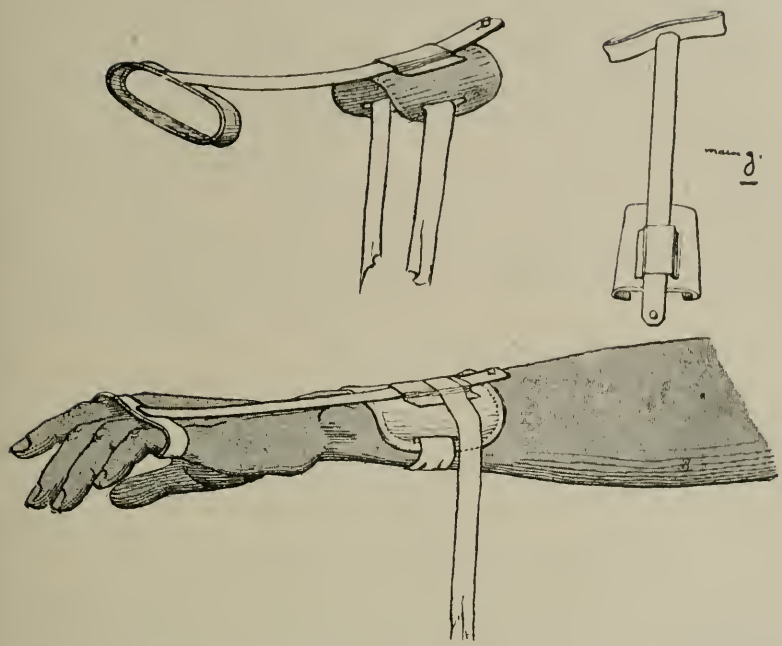


FIG. 93.—Léri and Dagnan-Bouveret apparatus for musculo-spiral paralysis.

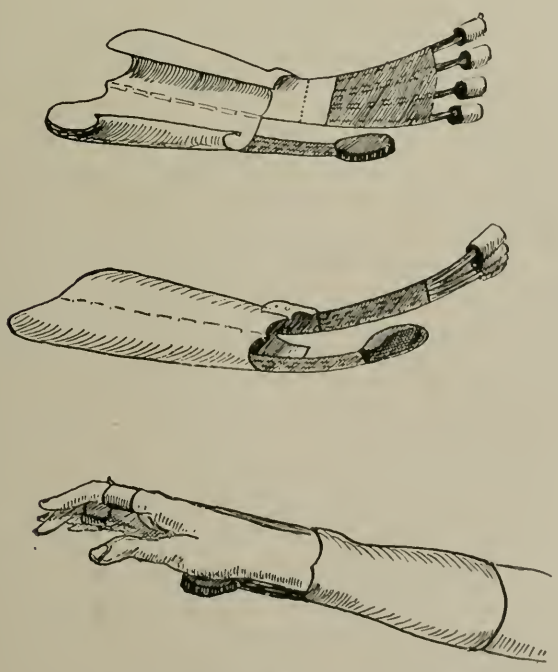


FIG. 94.—Apparatus of Mauchet and Anceau.

CHAPTER VII

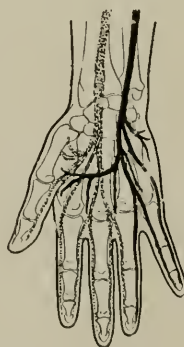
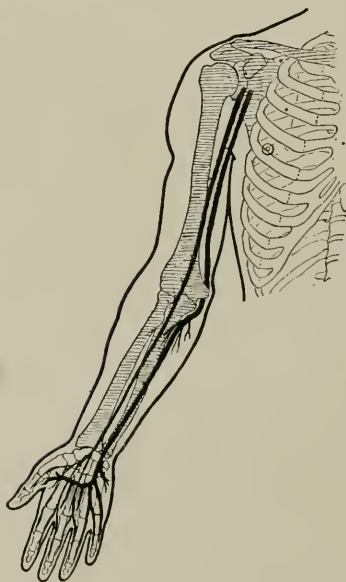
ULNAR NERVE

ANATOMY

THE ulnar nerve is supplied from the lower roots of the brachial plexus (eighth cervical root and first dorsal).

It is given off from the inner cord of the plexus along with the inner head of the median, a little beyond the internal cutaneous and the lesser internal cutaneous.

It traverses the axilla and descends to the inner side of the arm, behind the median nerve and the brachial artery. It is closely united with them as far as the lower third of the arm; this is why we so frequently find associated, at this level, lesions of the median, the ulnar and the brachial artery. The internal cutaneous, which is more superficial, descends internal to and in front of the neuro-vascular bundle.



FIGS. 95 and 96.—Course of ulnar and median (diagrammatic).

then into the epitrochlear groove.

In the fore-arm it passes round the inner side of the elbow to reach the anterior region of the fore-arm. It passes under the flexor carpi ulnaris and then descends along its external edge resting on the flexor profundus, and covered by the epitrochlear muscles and the superficial flexor.

It thus descends along the flexor carpi ulnaris right to the pisiform ; it is here confined in the carpal canal, of which it occupies the inmost part.

At this level it gives off its two terminal branches—

Superficial palmar branch (sensory).

Deep palmar branch (motor).

MOTOR BRANCHES

The ulnar supplies no branch whatsoever to the arm.

To the fore-arm it supplies—

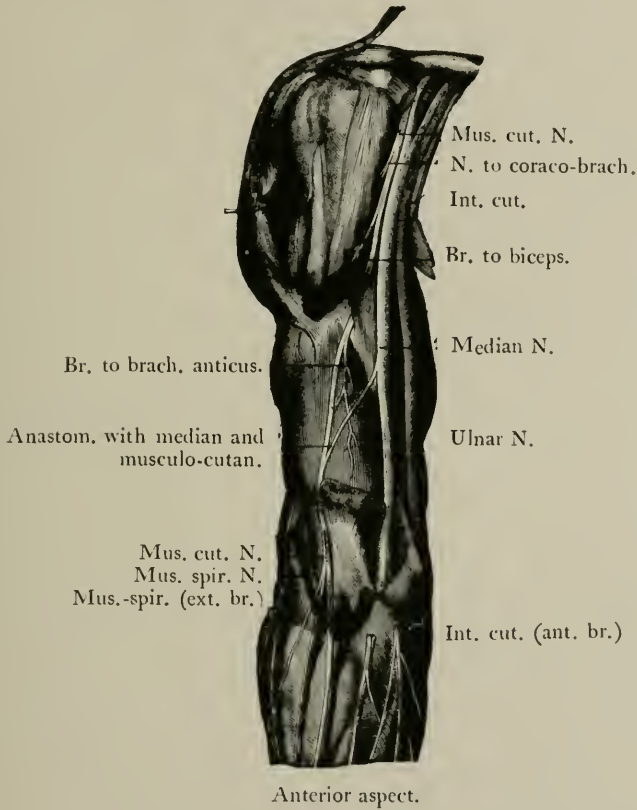


FIG. 97.—Deep nerves of the arm (after Sappey).

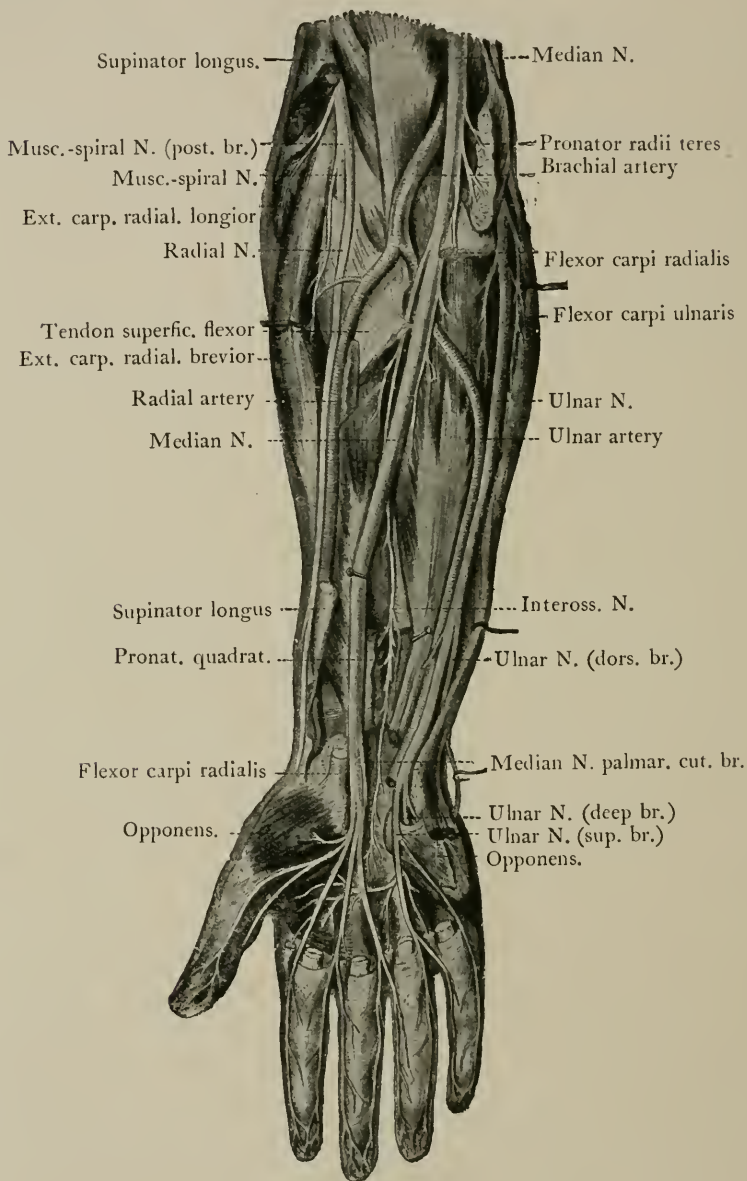
1. The nerve twig to the flexor carpi ulnaris.
2. Two motor branches for the two internal fasciculi of the flexor profundus digitorum.

To the hand. The deep palmar branch alone is motor.

It supplies—

1. Three nerve twigs destined for the three muscles of the hypothenar eminence ;
2. The nerves destined for all the interossei, both palmar and dorsal ;

its internal branch supplies the digital collateral twig to the inner side of the little finger. Its external branch supplies digital collateral twigs to the contiguous sides of the little and ring fingers.



Anterior aspect.

FIG. 98.—Deep nerves of fore-arm and hand (after Hirschfeld).

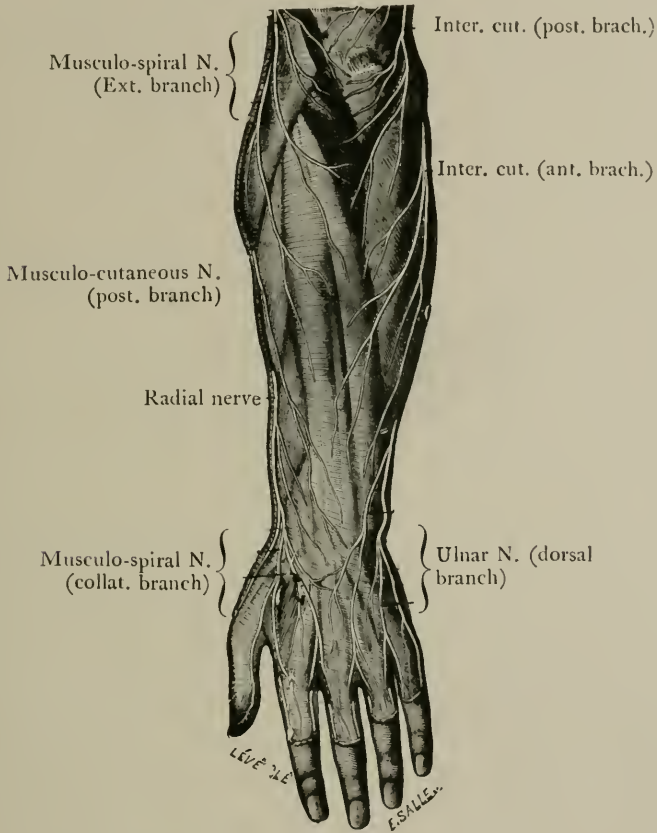
3. The nerves destined for the adductors of the thumb and for the inner head of the flexor brevis pollicis.

SENSORY BRANCHES

In the hand, the superficial palmar branch is exclusively sensory.

Its internal branch supplies the digital collateral twig to the inner side of the little finger, its external branch supplies digital collateral twigs to the contiguous sides of the little and ring fingers.

In the fore-arm the ulnar supplies—



Posterior view.

FIG. 99.—Superficial nerves of fore-arm and hand (after Sappey).

1. The branch to the ulnar artery which begins at the middle third of the fore-arm, follows the ulnar artery, becomes subcutaneous at the level of the wrist and goes on to supply the skin of the inner side of the wrist and of the hypothenar region ;

2. The dorsal cutaneous branch of the hand begins at the middle third of the fore-arm, passes over the inner border of the ulna, and becomes dorsal ; it distributes itself over the skin of the dorsal region of wrist and hand. On its inner side it supplies—

The dorsal digital collateral of the little finger ;

The dorsal digital collaterals of the little finger and the contiguous margin of the ring-finger ;

The digital collateral of the outer side of the ring-finger and the contiguous margin of the middle finger.

It must be observed that the dorsal collateral nerves, supplied by the ulnar, become spent, as do those supplied by the musculo-spiral, towards the extremity of the first phalanx. It is the palmar collaterals which supply the dorsal surface of the last two phalanges.

Still, an exception should be made for the little finger, supplied as far as its extremity by the dorsal collaterals of the ulnar, just as the thumb is supplied right on to its extremity by the dorsal collaterals of the radial.

VASO-MOTOR, TROPHIC AND ARTICULAR BRANCHES

The ulnar supplies twigs to the articulation of the elbow, to the ulnar artery, to the articulations of the carpus, to the palmar aponeurosis and to the interosseous spaces.

We shall find that the trophic rôle of this nerve is important.

PHYSIOLOGY OF THE ULNAR NERVE

MOTOR SYNDROME OF ULNAR PARALYSIS

The ulnar nerve supplies :

1. The flexor carpi ulnaris and the two internal fasciculi of the flexor profundus ;
2. The muscles of the hypothenar eminence ;
3. All the interossei and the inner two lumbricales ;

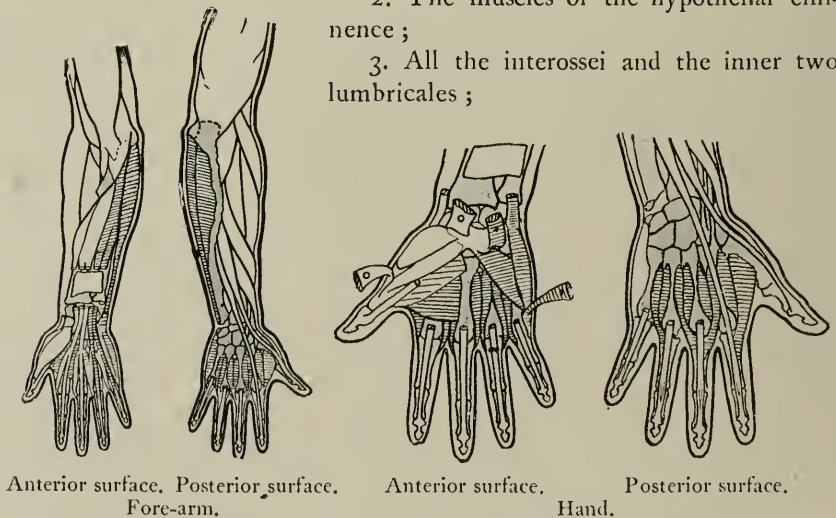


FIG. 100.—Motor supply of the ulnar.

4. The adductors of the thumb, and, partially, the short flexor of the thumb (inner head).

1. The flexor carpi ulnaris is at the same time a flexor of the hand on the fore-arm and an adductor of the hand.

If it is paralysed, flexion of the hand remains possible through the flexor carpi radialis and palmaris longus (median nerve), but in this movement the tendon of the flexor carpi ulnaris is no longer felt to contract.

Adduction of the hand is also possible by the extensor carpi ulnaris (musculo-spiral nerve), but it is greatly weakened and is accompanied by hyper-extension of the hand.

In the normal state, the tonicity of the flexor carpi ulnaris produces a slight inclination of the hand to the ulnar side; its paralysis produces a slight inclination of

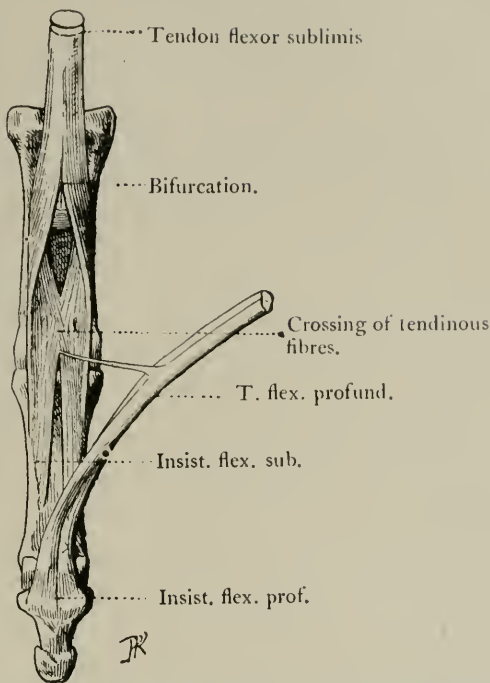


FIG. 101.—Flexor tendons and their insertions. The superficial flexor is inserted into the second phalanx, the flexor profundus into the third.

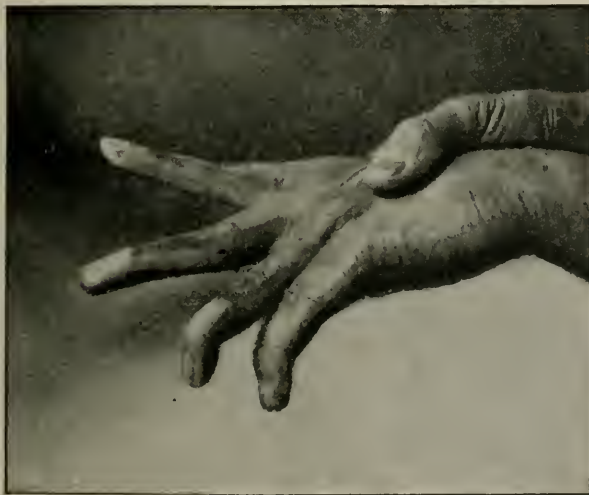

FIG. 102.—Action of flexor profundus in a patient suffering from paralysis of the median, accompanied by a certain degree of articular rigidity of the fingers offering some resistance to flexion. The strong contraction of the flexor profundus causes primarily flexion of the last phalanges of the two inner fingers.

the hand towards the radial side.

2. Paralysis of the two inner heads of the flexor profundus is shown only by diminished flexion in the last two fingers.

It will be remarked that flexion of the second phalanx on the first is easily brought about (action of the superficial flexor inserted into the second phalanx). On the other hand, flexion

of the last phalanx on the second only takes place in the case of the last two fingers (action of the flexor profundus inserted into the third phalanx).

Complete flexion of the fingers is still possible, in spite of ulnar paralysis. If it is weakened, this is not so much from lack of contraction of the flexor profundus as from paralysis of the interossei, which are the true flexors of the first phalanges on the metacarpus.



FIG. 103.—Action of the interossei; flexion of the first phalanx, extension of the last two phalanges.

1. The interossei are flexors of the first phalanges on the metacarpus and extensors of the second and third phalanges on the first.

In ulnar paralysis, if we request the patient to flex his fingers, we note that flexion of all the phalanges is not simultaneous. The action of the interossei—flexors of the first phalanx—is totally absent; flexion first takes place in the last two phalanges, then the first phalanx is flexed as though by progressive rolling up of the fingers, by traction of the flexor muscles. At this last stage, however, flexion is very weak.

Isolated flexion of the first phalanges, with extension of the last two, is impossible.

The lumbricales muscles, however, of the index and the middle finger (median nerve), may partially supply or make good, for these fingers, the action of the interossei; they are capable of flexing feebly the first phalanx of these fingers and of extending the last two.

3. Muscles of the hypothenar eminence.

—Paralysis of these muscles is indicated by atrophy of the hypothenar eminence; by the disappearance of the vertical puckering of the skin produced by the palmaris brevis; by loss of the appropriate movements of the little finger produced by the abductor, the flexor brevis and the opponens minimi digiti.

4. Interosseous muscles.—All the interossei, both dorsal and palmar, are supplied by the ulnar.

Their paralysis is by far the most striking change produced by lesions of the ulnar, for their rôle is most important.



FIG. 104.—The palmar interossei are adductors of the fingers.

2. The palmar interossei are adductors of the fingers.

The dorsal interossei are abductors of the fingers.

Consequently, the paralysed subject can neither separate his fingers nor bring them together.

This statement, however, admits of several limitations. Observation of these disturbances is difficult and requires much care; if certain precautions are not taken, one may altogether misinterpret an ulnar paralysis, masked as it is by substituted movements.

Indeed, the extensor communis digitorum (musculo-spiral nerve) is also an abductor. The patient may therefore separate his fingers with his extensors, but forcible extension of the fingers is also noticed.



FIG. 105.—The dorsal interossei are abductors of the fingers.

On the other hand, the flexors of the fingers are adductors: consequently the patient may draw together the separated fingers, on condition, however, that he flex them slightly.

Lateral movements by the interossei are accompanied neither by

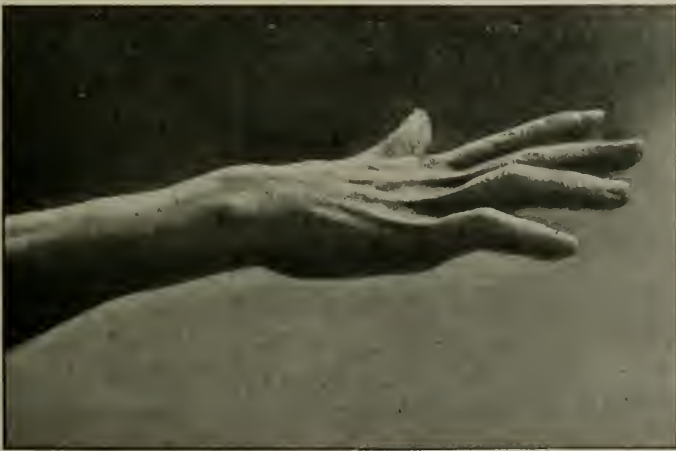

FIG. 106.—Ulnar paralysis; abduction of the fingers is still possible by the action of the extensors (musculo-spiral nerve). The projections produced by contraction of the extensors are clearly seen.

extension nor by flexion. They must be sought for by placing the hand on a table or a plane surface and working them in a strictly horizontal plane.

Even in these conditions we note that approximation of index and middle finger is possible through the action of their lumbricales and the extensor of the index which is slightly adductor; only the last two fingers cannot approach each other. This loss of adduction on the part of the fifth finger is often the only sign that shows complete paralysis of the ulnar; it is the only movement which cannot possibly be simulated.

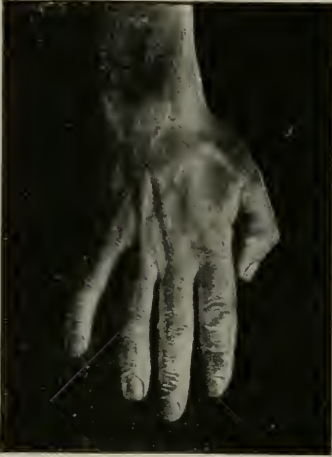

FIG. 107.—Ulnar paralysis; adduction of the outer two fingers remains possible by the lumbricales. Adduction of the fifth is impossible.

5. **Thenar eminence.**—The ulnar supplies entirely the adductors of the thumb, and partially the flexor brevis.

Paralysis of the adductors can easily be discovered. Apart from the characteristic atrophy of these muscles paralysis of the adductors is recognised by the prehension sign or the thumb sign of Froment.

In order to grasp a small object, a sheet of paper, for instance, between the thumb and the index, two movements are possible. Either the paper is firmly grasped between the body of the thumb and the base of the half-flexed index; thumb and index are closely applied over each other, mutually fitting into each other; prehension is energetic, resulting from the contraction of the adductor of the thumb and from the inner head of the flexor brevis (ulnar nerve),—or the object is taken between the extremity of the



FIG. 108.—Position of the thumbs in forcible prehension, in the case of a wounded man afflicted with left ulnar paralysis. (Froment, *Presse Médicale*, 1915.)

thumb and that of the index set opposite each other to form a sort of pincers, prehension is then weaker though more delicate; it is effected by the action of the opponens (median nerve) aided by the flexor longus pollicis.

In ulnar paralysis, the latter type of prehension is retained; to it the

patient almost always has recourse. The former type of prehension by adduction is abolished or rather it is very feeble; the patient cannot firmly hold the paper which he grasps and which the slightest traction causes to slip through his fingers. This is why he usually has recourse to prehension by opposition.

However, a slight degree of adduction is generally retained; thanks to the long extensor of the thumb; but this action is feeble, and is then accompanied by an obvious extension and rotation outwards of the thumb.



FIG. 109.—Paralysis of ulnar nerve with contraction of the fingers in a state of flexion. Adduction of the thumb applied against the index by the action of the long extensor of the thumb (musculo-spiral) which is seen to project. (H. Claude, R. Dumas and R. Polak, *Presse Médicale*, 1915.)

SENSORY DISTRIBUTION—SENSORY SYNDROME

The sensory region of the ulnar is far more definite and far more extensive than that of the musculo-spiral. It comprises :

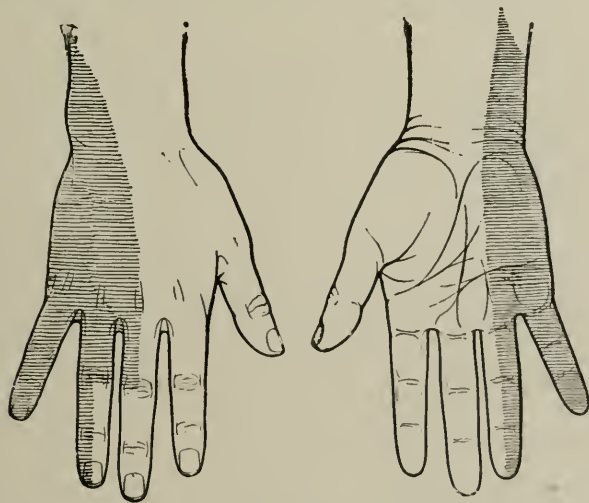


FIG. 110.—Sensory region of the ulnar (diagrammatic).

1. On the anterior surface, the entire inner edge of the hand, separated from the region of the median by a vertical line passing through the middle of the ring-finger.

It passes some centimetres upwards to the lower and inner part of the fore-arm.

2. On the dorsal surface, the entire ulnar edge of the hand, as far as to a vertical line passing along the middle of the middle finger.

It also extends upwards some centimetres on to the ulnar border of the fore-arm.

The anæsthesia arising from section of the ulnar is almost always very

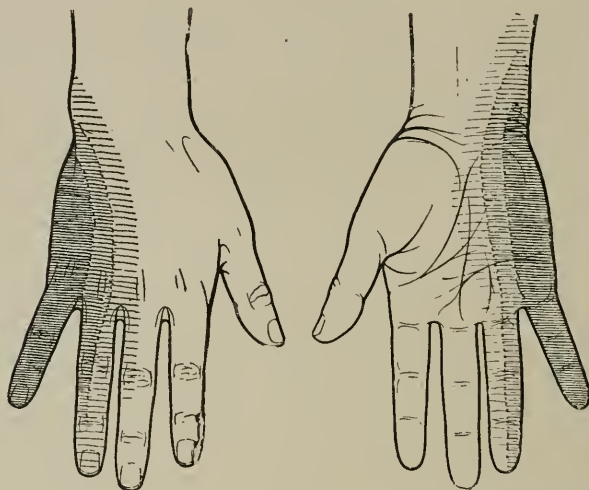


FIG. 111.—Anæsthesia in complete section of the ulnar, the three zones correspond to the answers given by the patient, on examination by pin-prick :

1st zone, he replies : "nothing."

2nd zone, he says : "touch."

3rd zone, he says : "pricks a little" (simple hypo-æsthesia).

(Semi-diagrammatic.)

complete, affecting both the superficial and the deep sensibilities, mainly in the case of the fifth finger and the ulnar edge of the hand.

As we approach the middle line, we notice the existence of deep sensation and tactile hypo-æsthesia, which, however, are rarely seen on the ring-finger and dorsal surface of the middle finger, as a result of overlapping by the median nerve.

TROPHIC AND VASO-MOTOR SYNDROME

The trophic rôle of the ulnar nerve is an important one.

We are not now studying the muscular atrophy which naturally accompanies paralysis of the muscles and gives to the hand the characteristic appearance of ulnar paralysis.

We must also neglect for the moment true dislocation of the hand which sometimes happens, in sections of the ulnar nerve, from atrophy of the interossei and relaxation of the intermetacarpal ligaments and carpal

aponeuroses—permitting hyper-extension of the first phalanges and abnormal mobility of the metacarpals on one another.

Finally, we shall not insist on the important trophic disturbances which accompany neuritis of the ulnar. They show that trophic action does not simply extend to the inner part of the hand, but that it may also reach the entire palmar fasciæ as well as the synovial membranes and fibrous tendon sheaths of the flexors of middle finger and index; consequently going far beyond the cutaneous region of the nerve. This is readily understood when we remember the course of the deep palmar branch which would seem to play an important trophic rôle.

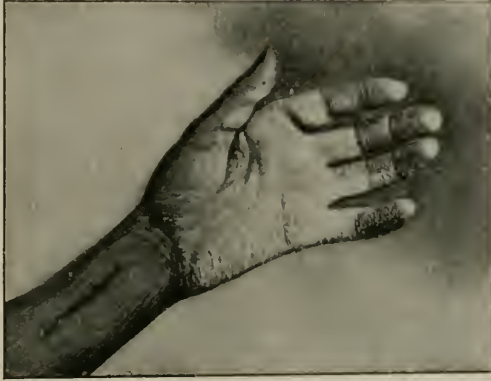

FIG. 112.—Lesion of the ulnar at the middle part of the fore-arm. Complete interruption, no neuritic disturbances. Scaly desquamation of the skin in the cutaneous distribution of the nerve.

Simple suppression of the functions of the ulnar, in complete section of the nerve, for instance, often shows cutaneous trophic disturbances and interesting vascular changes.

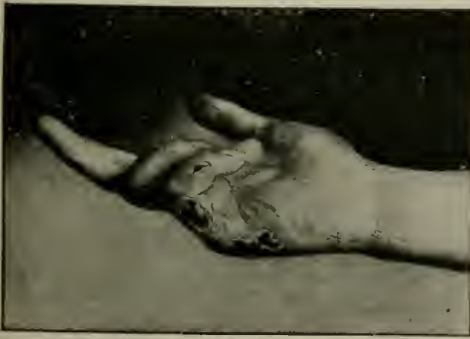

FIG. 113.—Section of the ulnar above the epitrochlea. Trophic ulcers that have appeared as a result of a simple galvanic bath, of slight intensity (10 to 15 milliamperes).

Very frequently there is found a state of dryness of the skin throughout the entire distribution of the nerve; it is sometimes accompanied by a branny desquamation or even by an active scaly appearance, limited to the cutaneous region of the ulnar.

In complete interruptions of the ulnar, we may find ulcerations, readily provoked by slight injuries, burns, chilblains, galvanic baths, etc. Their slow rate of healing is a sign of special fragility of

the skin and of insufficient trophic action.

Finally we often notice a certain degree of redness or cyanosis in the inner two fingers and particularly in the fifth. This appearance is sometimes extremely pronounced; we see the little finger swollen, shining with a bright red or a dark violet tint, which would almost suggest a vascular

obliteration. These vascular disturbances are chiefly found in those who are predisposed to cyanosis of the extremities; they are really no more than a local exaggeration, favoured by vaso-motor paralysis.

We may compare with this fact the frequency of chilblains found in predisposed subjects, in the distribution of the nerve.

TYPES OF ULNAR PARALYSIS

The ulnar being essentially a nerve of the hand, the disturbances of which are rarely manifested except in movements of the fingers, there is no occasion to examine in detail, as in the case of the musculo-spiral nerve, the syndromes resulting from lesion of the nerve at different levels.

Whatever the seat of the lesion, the posture and the motor disturbances are approximately the same. The various syndromes result mainly from the nature of the injury, complete or incomplete interruption, nerve irritation or dissociated lesion. In passing, we will simply indicate the slight differences which distinguish injuries of the nerve above the epitrochlea from interruptions in the fore-arm below the flexor carpi ulnaris and the flexor profundus muscles.

I.—SIMPLE COMPRESSION OR RECENT INTERRUPTION OF THE ULNAR

Paralysis of the ulnar is often difficult to recognise in these conditions; it is frequently overlooked because of the numerous muscular substitutions we have studied above.

It must be remembered that flexion of the fingers is preserved by means of the superficial flexor and the two external tendons of the flexor profundus (median). Minute examination is needed to see that it was weakened: this weakening is the result, first, of paralysis of the two inner heads of the flexor profundus (flexion of the third phalanx on the second does not take place); second, of paralysis of the interossei, powerful flexors of the first phalanx. This causes great difficulty in performing movements that require considerable flexion of the first phalanges along with extension of the other two (difficulty and fatigue in writing).

Extension of the last two phalanges on the first (interossei) is still possible, though feeble, in the case of the index and the middle finger by means of the lumbricales (median).

Separation of the fingers (dorsal interossei) may be effected by substitution of the extensors.

Adduction of the fingers (palmar interossei) is possible, though weak, by the action of the flexors, or laterally, by the lumbricales of the index and the middle finger.

Adduction of the thumb has disappeared (although imperfectly replaced by substitution of the long extensor), but opposition still exists (median),

and a methodical examination is required to distinguish them, by investigation of the prehension sign of the thumb.

In these conditions, ulnar paralysis may frequently pass unnoticed on a superficial examination.

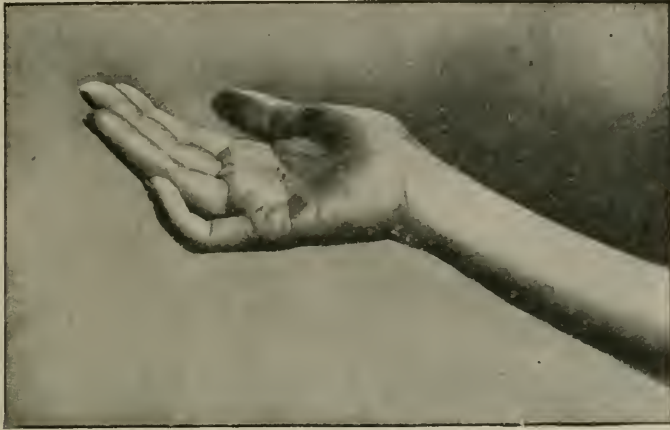

FIG. 114.—Complete section of the ulnar above the epitrochlea (photograph taken two months after the wound). Hand in a state of rest, simple type of ulnar *griffe*.

The position is not so clearly characteristic as one might expect from the classical description.



FIG. 115.—Same figure as above, with maximum extension.

Ulnar *griffe* is often scarcely perceptible.

The hand is somewhat flattened; the hypothenar eminence is slightly atrophied, as are the adductors of the thumb.

We see when the hand is at rest that the fifth finger is slightly flexed, also the fourth, though in less degree.

This slight flexion of the inner two fingers is due to suppression of the interossei, extensors of the last two phalanges; the fingers become flexed owing to the tone of the superficial flexor.

If the patient is requested to extend vigorously his hand and fingers, the attitude is not much more characteristic.

We note that extension is not absolutely complete; the hand is but partially extended. The fifth digit is still slightly flexed, as well as the fourth; but the other fingers are extended, and we must test their resistance when extended to ascertain that extension of the last two

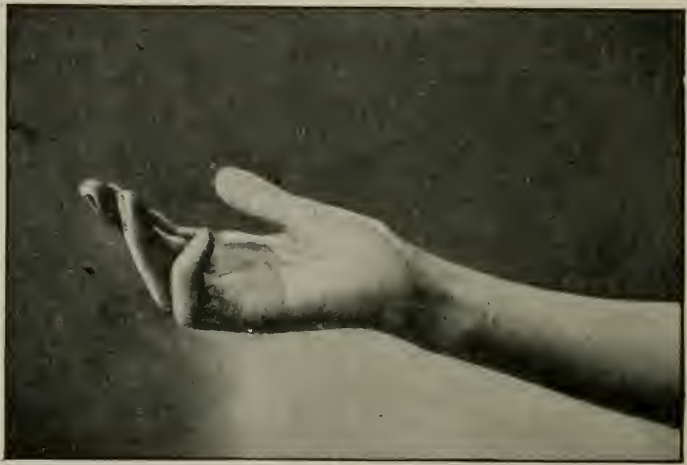

FIG. 116.—Lesion of the ulnar above the epitrochlea (complete section three months previously). Typical ulnar *griffe* which gradually appeared about six weeks after paralysis. Note the marked flexion of the second phalanx on the first, whilst the third is but slightly flexed on the second. Tonic action of the superficial flexor (second phalanx), paralysis of the flexor profundus (third phalanx).

phalanges is very feeble, and merely the result of contraction of the lumbricales.

Nevertheless, if ulnar paralysis persists long enough, hypotonia of the interossei becomes pronounced, and there takes place the typical ulnar *griffe* with semi-flexion of the fourth and particularly the fifth fingers. This flexion affects almost exclusively the second phalanx (superficial flexor); the third phalanx (flexor profundus) remains almost fully extended.

* * * * *

The description just given of ulnar *griffe* in recent sections or compressions of the nerve, applies mainly to injuries above the epitrochlea.

If the nerve is injured below the motor branches which it supplies to the flexor profundus and extensor carpi ulnaris, the position of the hand is slightly different.

The ulnar *griffe* occurs earlier and is more pronounced. It becomes obvious owing to preservation of the flexor profundus. (J. and A. Dejerine and Mouzon.)

No longer does it consist of simple flexion of the second phalanx on the first; the third phalanx is also flexed.

The rôle of the flexor profundus in ulnar *griffe* is clearly shown in the course of nerve regeneration; thus, in a section of the ulnar above the epitrochlea, we find ulnar *griffe* but faintly perceptible, as long as the flexor profundus remains paralysed; then, with the growth of the axis-cylinders and the return of tonicity and contractility in the flexor profundus the claw-like attitude of the last two fingers is seen to take shape and to become pronounced.



FIG. 117.—Ulnar paralysis (nerve in course of regeneration) through lesion of the nerve above the epitrochlea (complete section, suture of the nerve two months after the wound); ulnar *griffe* has gradually appeared acquiring the typical form, about two months after the wound. Three months after suture, it has become modified by progressive flexion of the third phalanx, the flexor profundus having regained its tone and its functions. (Note the projection of the tendon of the flexor carpi ulnaris.)

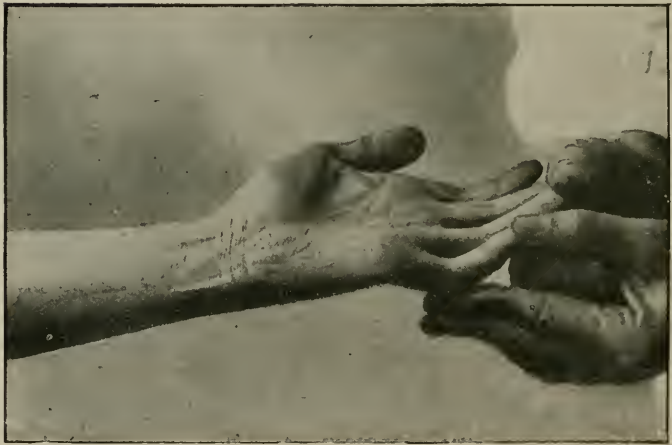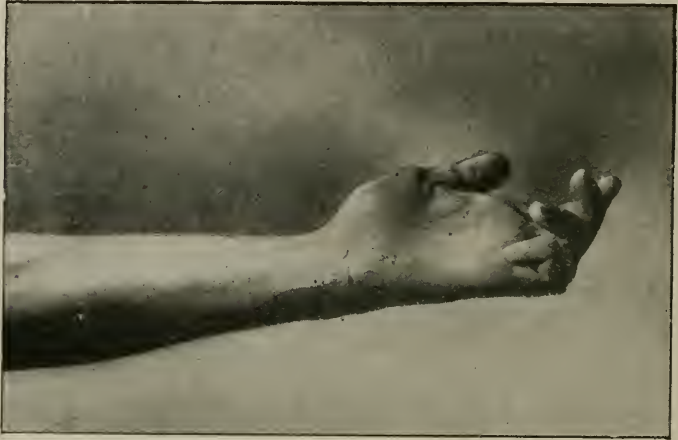Finally, adduction with flexion of the hand, which is effected by the flexor carpi ulnaris, is of course retained.

* * * * *

In all these cases, ulnar *griffe* caused by recent injury of the nerve, whether resulting from lesion above or below the flexor profundus, is always slight; it is, moreover, essentially a soft, supple, easily reducible *griffe*. (J. and A. Dejerine and Mouzon.)

It is due entirely to loss of power and tone of the interossei; there is no fibrous contraction whatsoever keeping the fingers flexed, as may happen sometimes in complete and long-standing interruptions. We do not find the fibrous, intractable, irreducible transformation which characterises the

ulnar *griffe* of nerve irritation, resulting from contraction of the muscles and tendons, from fibrous transformations of the palmar aponeurosis and the adhesions contracted between the tendons and their synovial sheaths.



FIGS. 118 and 119.—Ulnar *griffe* caused by complete section of nerve in fore-arm (5 months). This is a soft, easily reducible *griffe*, as in all cases of complete interruption, with the exception of very slight flexion of the fifth finger caused by fibrous contraction of the tendon.

It may be established as an almost absolute principle that every fibrous *griffe* is of neuritic origin, without complete interruption of the nerve ; it is always accompanied by pain on pressing the muscles and nerve trunk and by some trophic disturbances.

II.—SYNDROME OF PROLONGED COMPLETE INTERRUPTION

It is somewhat difficult, during the first two or three months, to distinguish the syndrome of interruption from that of compression, which moreover is far rarer in the ulnar than in the musculo-spiral.

The main points in this diagnosis are, as in the other nerves, the far greater rapidity and intensity of hypotonia and muscular atrophy; the fixity of sensory disturbances, the more rapid and complete appearance of the RD; the existence of formication in a fixed zone, at the level of the lesion, and the analgesia of nerve and muscles.

After two to three months, however, complete interruption is more



FIG. 120.—Hyper-extension of the last two fingers (by hypotonia of the interossei) in prolonged ulnar paralysis.

strikingly shown by muscular atrophy and by the greater hypotonia of the interossei.

1. This hypotonia of the interossei is at times so pronounced and accompanied by so much articular relaxation that abnormal movements are produced.

First, we have hyper-extension of the first phalanges, brought on without effort, when the patient tries to extend his fingers or when an attempt is made to obtain this hyper-extension by passive movements; it may be quite extraordinary in certain patients. Indeed, Duchenne of Boulogne has shown that the action of the interossei alone, forming by their tendons a sort of band on the dorsal surface of the metacarpals, opposes hyper-extension of the fingers.

This hyper-extension may be limited to or most pronounced in the last two fingers; but it may also show itself in the last three or even in all

four fingers when the lumbricales of index and middle finger become incapable of fulfilling their function as substitutes for the interossei.

Atrophy and laxity of the articular ligaments is in these cases associated with hypotonia of the muscles.

Palpation of the hand shows such relaxation of the inter-metacarpal ligaments as enables the bones of the metacarpo-phalangeal articulations to move freely upon one another, affording a sensation of extreme laxity and genuine dislocation of the metacarpus. This articular laxity is far greater in the ulnar part of the hand, though it should be noted in the normal state that there is greater laxity in these same articulations of the fourth and fifth meta-carpals.

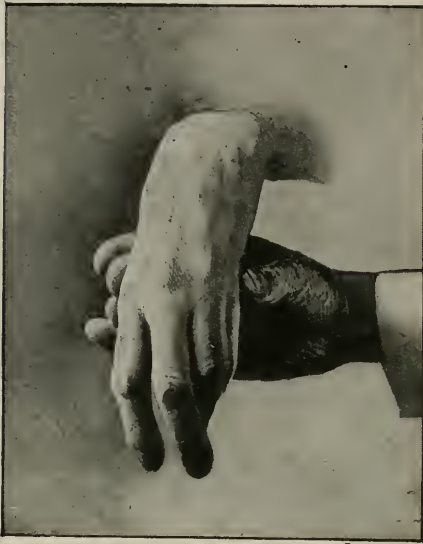

FIG. 121.—Dislocation of the metacarpus. Lateral compression of the hand gives it a cylindrical form.

2. At the same time, ulnar *griffe* becomes pronounced, as a result of increasing hypotonia of the interossei; it assumes the

appearance described by writers on the subject. The last two fingers are



FIG. 122.—Long-standing (5 months) ulnar paralysis, complete interruption above the epitrochlea, typical *griffe*.—Flexion of second phalanx only.

flexed almost completely into the palm of the hand, and this attitude is even

more marked if the nerve is affected below the flexor profundus. In this case also, the third phalanx naturally participates in the flexion.

Flexion of the last two fingers affects the middle finger slightly, owing to the slips of the palmar aponeurosis which unite the third and fourth fingers at their bases; and if the lumbricales finally weaken in their resistance, the index also becomes flexed, thus producing a sort of incomplete three-fingered or even four-fingered *griffe*.

We find that the lumbricalis of the middle finger, normally supplied by the median, may also sometimes be supplied by the ulnar.

In all cases this *griffe* remains flaccid and reducible.

It is solely, we must repeat, nerve irritation of the ulnar that creates the irreducible *griffes*. Still, in some cases, we see that there occurs a slight fibrous contraction of the flexor tendons, which fixes the fifth

finger and to some extent also the ring-finger, in a moderate curvature.

In all these cases of complete and long-standing interruption, we are struck by the relative unimportance of trophic disturbances. The skin is dry and often becomes the seat, on the palmar surface especially, of a sort of branny desquamation; but the integuments remain supple, the nails are not deformed, and the articulations re-

tain their mobility. Only vascular disturbances, and particularly cyanosis which is distinctly confined to the region of the affected nerve, can be seen; the frequency of chilblains, the easy production of accidental ulcers and the slowness of their cicatrisation alone bear witness to the important effects upon nutrition of the tissues.

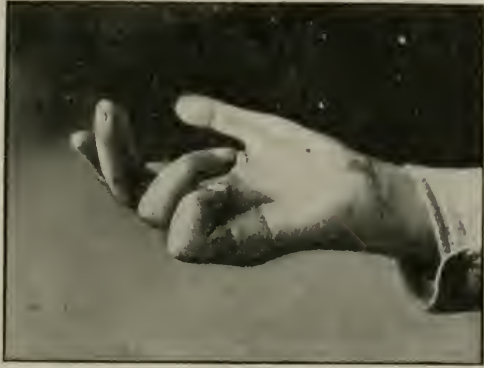

FIG. 123.—Long-standing (three months) ulnar paralysis (lesion at the middle third of fore-arm), complete interruption, accentuation of typical *griffe*.

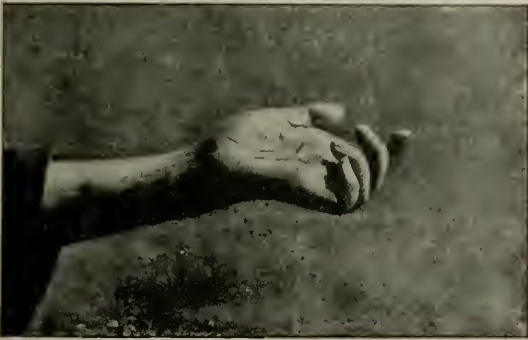

FIG. 124.—Long-standing (five months) ulnar paralysis (lesion at the upper third of fore-arm), three-fingered *griffe* through weakening of the lumbricales or perhaps innervation by the ulnar of the second lumbricalis, ordinarily supplied by the median.

In some cases, however, we have found extremely important vascular disturbances of the little finger, which becomes swollen and shining, and offers an almost black cyanotic appearance, as though caused by a sort of

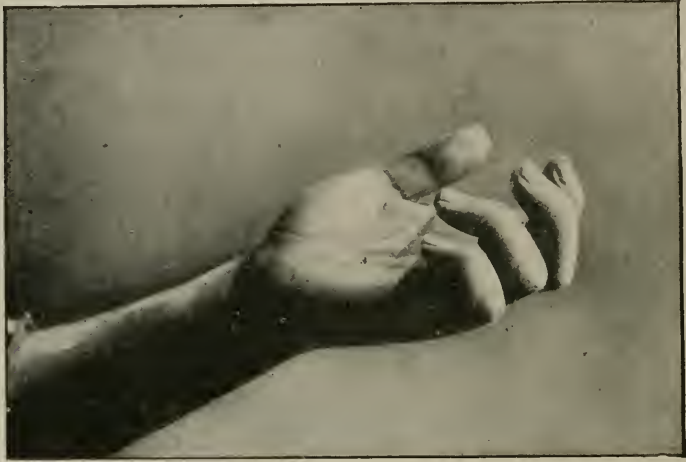

FIG. 125.—Long-standing (six months) ulnar paralysis (wrist wound, complete section), four-fingered *griffe* from weakness of the lumbricales; flaccid *griffe*.

exaggerated paralytic stasis. Possibly, in these cases, disuse of the hand may have favoured the appearance of such intense vascular disturbances.



FIG. 126.—Hyper-extension of the first phalanges in preceding case, from relaxation of metacarpo-phalangeal articulations, hypotonia of interossei and projection of extensors.

They are never found in patients treated by massage, mobilisation and electricity.

3. Lastly, muscular atrophy is pronounced. The flattening of the hypothenar eminence is complete; paralysis of these muscles, particularly of the palmaris brevis, does away with the creases of the skin and its vertical contraction. The atrophied interossei produce on the dorsal surface of the hand actual intermetacarpal furrows; exaggeration of these furrows may produce quite a skeleton hand; the adductors of the thumb disappear, leaving between thumb and index a deep depression in which palpation of the first interosseous space reveals nothing but a thin muscular sheet almost devoid of substance.

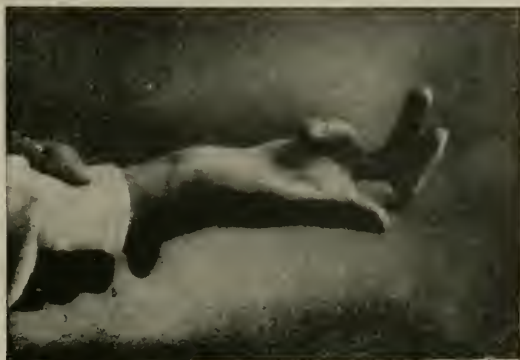

FIG. 127.—Atrophy of the hypothenar eminence.

The thenar eminence in its deep layers, becomes flattened, the thumb lies close against the index on the same plane though twisted somewhat outwards, bringing its palmar surface on to the outer side of the index (predominance of the opponens).

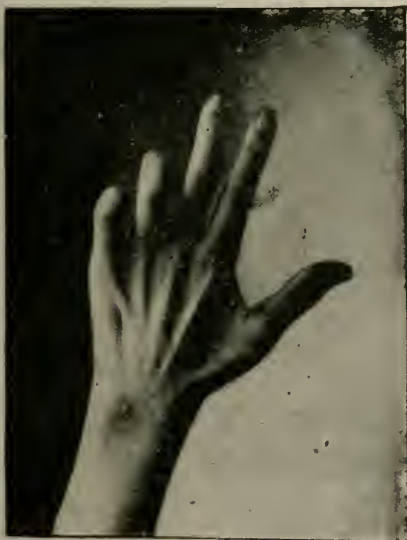

FIG. 128.—Atrophy of the interossei.

It is in these cases of atrophy and extreme hypotonia of the adductors of the thumb and inner slip of the flexor brevis, that we sometimes meet with the attitude described by Jeanne.* This is a sort of thumb *griffi*, characterised by extension of the first phalanx and by semi-flexion in the second.

The adductors of the thumb and the flexor brevis are, like the interossei, though to a less degree, flexors of the first phalanx and extensors of the second, through the dorsal slip which they send to the extensor

tendons.

This attitude, however, is rare, for the external slip of the flexor brevis (median), which has the same action, is usually capable of correcting it.

* Jeanne. *Société de Chirurgie*, 17 March, 1915.

Atrophy of the interossei, so clearly significant of paralysis of the ulnar, persists long after the cure of this paralysis.

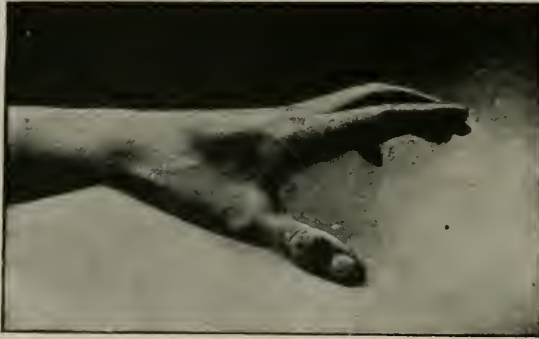

FIG. 129.—Atrophy of the adductors of the thumb.

It is nerve irritation that, more than anything else, creates the fibrous *griffes* of the ulnar.

In these cases, to a more or less marked extent, we find spontaneous pains in the distribution of the nerve, pain caused by pressure on the nerve trunk, painful anæsthesia of the skin, or even complete hyper-æsthesia; pressure on the antibrachial muscles and especially on the hypothenar eminence, and compression between two fingers of the adductors of the thumb, cause very keen suffering.

The painful syndrome is more or less pronounced, as the case may be; it seldom, however, attains the degree of certain cases of neuritis of the median. It may be found without very evident paralysis, though it is almost always accompanied by important trophic disturbances.

The scaly condition of the skin, infiltration of the dermis, woody atrophy of the muscles and the split curved state of the nails, are more or less striking.

The more rapid growth of the nails raises the pulp of the finger into a small sub-ungual and frequently

persists long after the cure of this paralysis. It also exists in certain incomplete lesions of the ulnar and enables us to recognise them, even in the absence of definite paralysis.

III.—SYNDROME OF NERVE IRRITATION

It is nerve irritation that, more than any-

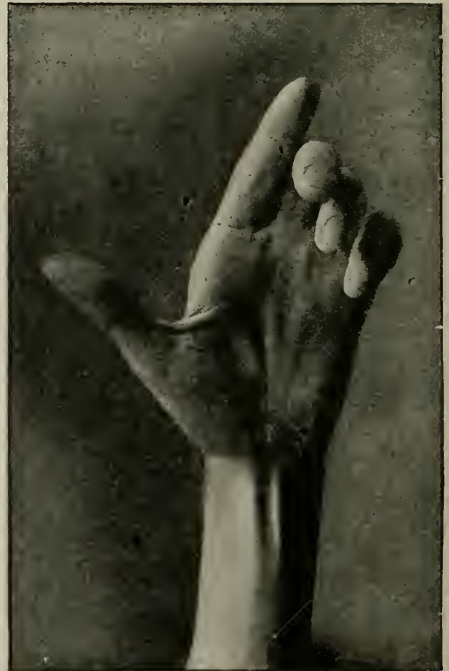

FIG. 130.—Neuritic ulnar *griffe*, fibrous and inextensible; pain by pressure on the hypothenar and interosseous muscles. Maximum extension. Contraction of the flexor tendons.

painful tumour, the presence of which is an indication of neuritis, however slight.



FIG. 131.—Contraction of the palmar aponeurosis in a neuritic ulnar *griffe* (four-fingered *griffe*).

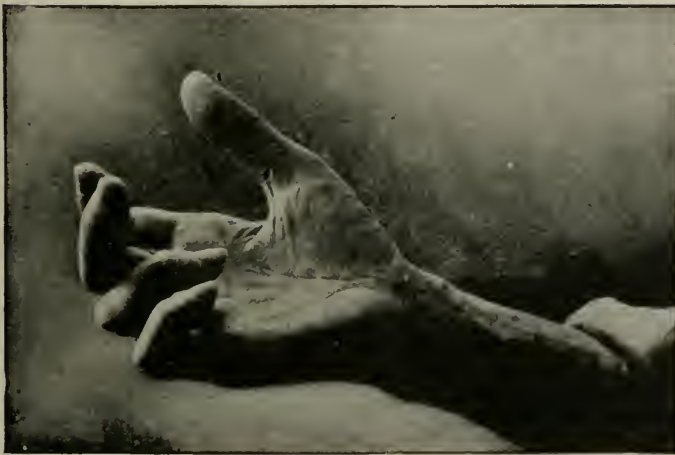

FIG. 132.—Neuritic, irreducible, ulnar *griffe*; contraction of flexor tendons and palmar aponeurosis.

The main points to note, however, are: fibrous contraction of the flexor tendons, adhesion of the tendons to the synovial sheaths, thickening and fibrous contraction of the palmar aponeurosis, comparable to Dupuytren's contracture, the prominences of which stand out like whipcord.

These lesions emphasise, intensify and render irreducible the attitude of ulnar *griffe*.

It may be affirmed that every fibrous and irreducible ulnar *griffe* is a sign of more or less pronounced nerve irritation.

This is easily demonstrated; whenever we find a fibrous, inextensible, or even moderate *griffe*, we need only pinch between two fingers the mass of hypothenar muscles or the adductors of the thumb, to cause a very acute sensation of pain.

Frequently the *griffe* is confined to the ulnar part of the hand and reaches only the ring-finger and the fifth finger; at most it involves the

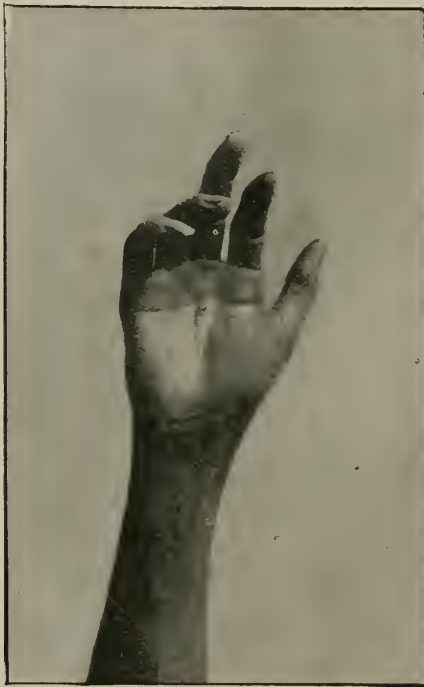

FIG. 133.—Neuritic *griffe* of ulnar without paralysis of the interossei, combined with fibrous infiltration of the palmar aponeurosis and contraction of the flexor tendons.

trophic fibres form a distinct fasciculus which the lesion can reach, whilst leaving the motor fibres untouched.

For instance, we may mention the case of a patient afflicted with

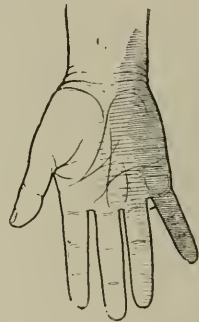


FIG. 134.—Disturbances of sensibility in the same case of neuritis combined with fibrous *griffe*, without paralysis.

middle finger in slight flexion. Sometimes also it invades the entire palmar aponeurosis and produces a veritable three-fingered or four-fingered *griffe*.

Neuritis of the ulnar may show itself without paralysis, or with only partial paralysis, either owing to the fact that the slight irritative lesion has not touched the motor fibres, or that the

lesion of the ulnar at the middle third of the fore-arm. There was no paralysis of the interossei, for the muscles possessed their normal electrical reactions and the patient was able to do all the movements, though not to the full extent. On the other hand, along with complete anæsthesia in the ulnar area, there was nerve irritation producing fibrous transformation of the sub-cutaneous cellular tissue and of the palmar aponeurosis, contraction of the flexor tendons and adhesion to the synovial sheaths. To such a degree was this the case that, in spite of the integrity of the interossei, their movements were rendered painful and strictly limited by the fibrous transformation of the hand in its ulnar part.

In another case, a slight lesion of the ulnar only after some months

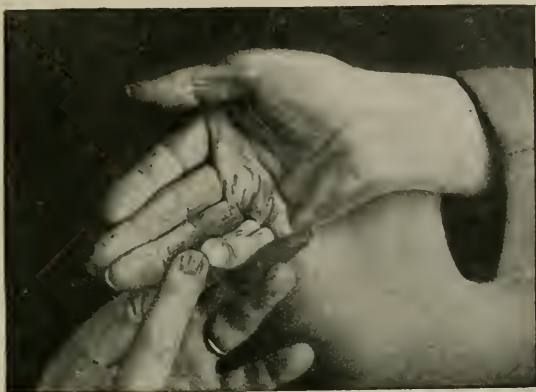

FIG. 135.—Contraction of the palmar aponeurosis which has gradually appeared after slight irritation of the ulnar. No paralysis; scarcely perceptible hypo-æsthesia. The little finger is habitually flexed on the hand; the semi-flexion here represented can be obtained only by exercising very strong traction which raises beneath the skin the knotty projections of the contracted aponeurosis.

produced a slow and progressive contraction of the palmar aponeurosis, exactly comparable with that of Dupuytren's contracture, which, after all, is probably due to nothing more than slight neuritis of the ulnar or of its component cervical roots.

We shall soon see that slight neuritis of the ulnar may frequently cause states of muscular hypertonia or of contraction, producing paradoxical attitudes. We ought to mention the special tendency of the ulnar nerve to cause, through slight irritation, contraction of the muscles of the hand; this nerve is found to be affected in most of the cases that produce the "accoucheur" type of hand. These states of hypertonia, however, through irritation of the ulnar, are really somewhat complex: we will study them separately, after the diagnosis of ulnar paralysis.

Nerve irritation of the ulnar is often a serious complication, certainly more serious than total interruption. Whereas paralysis from complete

interruption readily permits of the use of the hand, owing to the many substitutions, neuritis of the ulnar renders the patient quite powerless. After suture, the interrupted ulnar nerve will gradually regain its functions, whilst neuritis may create irreparable fibrous contractions.

IV.—NEURALGIA OF THE ULNAR

Slight lesions of the ulnar are sometimes indicated by painful syndromes, of the simple neuralgic type, associated or unassociated with motor disturbances but not accompanied by the trophic disturbances which characterise nerve irritation. This neuralgia of the ulnar is seldom as intense as that of the median. There may, however, be found, more especially in lesions affecting the ulnar at the upper part of the arm, painful syndromes of the causalgic type; intensity of the pain, extreme hyper-æsthesia of the skin, radiation of the pain over the whole limb even above the lesion, the provocation of pain by the slightest contacts or even by vivid impressions and emotions: all these recall the characteristics of median causalgia.

V.—DISSOCIATED SYNDROMES

Like all the other nerves, the ulnar is composed of distinct fasciculi, destined for a special trophic, sensory or motor region.

Investigation of the many cases observed during the war has enabled us to outline the study of this fascicular topography.

The possibility of partial lesions producing dissociated syndromes is one result of this investigation.

For instance, a lesion of the ulnar nerve in the arm, affecting the external part of the nerve, may cause nothing more than paralysis of the flexor profundus and of the flexor carpi ulnaris, leaving the interossei untouched. On the other hand, lesion of the nerve in its internal, superficial part, may be indicated solely by paralysis of the interossei and of the hypothenar eminence, the flexor profundus and the flexor carpi ulnaris being preserved.

The mutual positions of the principal fasciculi are thus known by superposition of various clinical cases, as also by direct electrical stimulation of the fasciculi of the nerve in the course of surgical operations. (P. Marie and Meige.)

It is now known that, above the elbow, the fibres destined for the flexor carpi ulnaris and for the flexor profundus, as well as those destined for the adductor of the thumb, occupy the external part of the nerve, and consequently lie on the inner surface of the humerus.

On the other hand, the sensory fibres and the motor fibres destined for

the hypothenar eminence and for the last interossei, occupy the internal part of the nerve; they are therefore superficial and more exposed to be affected by partial traumatisms. (Dejerine.)

This arrangement probably explains why certain lesions of the nerve above the elbow are accompanied by more or less marked ulnar *griffe*—according as the fasciculi destined for the flexor profundus have been attacked or not. Ulnar *griffe* will be more pronounced in cases where the flexor profundus is untouched; indeed, it collaborates with the superficial flexor in flexing the second and third phalanges of the fingers whose extensors are mainly the interossei.

In the fore-arm also are found lesions confined to the internal part of the ulnar nerve, which are characterised by intense sensory and trophic disturbances, along with relative preservation of the interossei; in these cases, it is again the muscles of the hypothenar eminence and the interossei of the last spaces that are most affected. On the other hand, the fibres destined for the interossei of the first spaces and for the adductors of the thumb appear to occupy the external part of the nerve.

According to J. and A. Dejerine and Mouzon, then, we may sum up as follows the fascicular topography of the ulnar. From within outwards we find—

1. The sensory cutaneous branches and the branches of the hypothenar eminence, entirely superficial.
2. The fasciculi destined for the interossei representing the deep palmar branch of the ulnar. The fibres destined for the different interosseous muscles are also arranged in layers from within outwards: the fibres of the last interossei are the most internal.
3. The fibres of the adductors of the thumb occupy on the fore-arm the most external position; this muscle, indeed, represents the interosseous of the first space. On the arm, it is also external, though still covered by the fibres of the flexor carpi ulnaris and of the flexor profundus.
4. The fasciculi of the flexor carpi ulnaris and of the flexor profundus which occupy at the level of the arm the most external part of the ulnar nerve.

In the case of the ulnar, as of all the other nerves, one cannot help being struck by the way in which the fascicular topography is identical with the root topography of the sensory and motor regions. There is, so to speak, in the nerve a sort of relative lengthening of its root constitution; for instance, the fibres destined for the adductors of the thumb which seem mostly to originate in the eighth cervical root are more external than the fibres of the hypothenar eminence, supplied by the first dorsal root.

We here give as an instance of dissociated syndromes the following two contrasted cases, a study of which has proved to J. and A. Dejerine and Mouzon the fascicular topography of the ulnar.

FIG. 136.*—State of soldier Vid . . ., 2 Nov., 1914, 74th day after his wound—Keloid occupying the internal third of the right ulnar nerve in the arm (partial lesion). (Shown at the *Société de Neurologie*, 3 June, 1915.)

Soldier Vid . . ., of the 1st Zouaves, wounded on the 8th Sept., 1914, at Sézanne, by Mauser bullet (?). The ball crossed the inner region of the right arm, two fingers' breadths above the epitrochlea. Immediate ulnar paralysis. There can be felt, through the skin, along the track of the bullet, an indurated swelling of the ulnar nerve.

Operation, 21 Dec., 1914 (104th day after the wound), by Dr. Gosset. Indurated swelling, 6 to 8 mm. long, forming a projection on the inner surface of the ulnar nerve, along the track of the bullet. This projection was adherent to the skin. It was first cut off flush with the inner surface of the nerve. Then the indurated nucleus, which seemed to act as a kind of root in the interior of the nerve itself, was extracted. After extraction of this nucleus, there was found to be a notch on the inner third of the ulnar. The fasciculi, which were interrupted at the level of this notch, were not sutured.

Slow progress as regards movement, with appearance of amyotrophy, following suture, and coinciding with the first phenomena of motor restoration. Scarcely any amelioration in the disturbances of objective sensation, five and a half months after the operation.

a, Attitude of the hand at rest (disturbances of tone). Note :

1. That the hand remains inclined towards the ulnar side, the normal type (good tone of the flexor carpi ulnaris).
2. That there exists a certain degree of "ulnar *griffe*." This attitude seems due to the tone of the flexors of the last two fingers, and particularly of the deep flexors, which is greater than the tone of the corresponding interossei.
3. That atrophy seems more pronounced in the hypothenar eminence than in the adductors of the thumb.
4. That abduction of the little finger is possible (with reference to the axis of the hand), this abduction is very slight.
5. That there is no actual hyperkeratosis whatsoever in the distribution of the ulnar, which is anæsthetic.

b, Maximum flexion of the fingers. Note :

1. That prominence of the flexor carpi ulnaris above the pisiform persists.
2. That the phalanges of the last two fingers are flexed as well as those of the first two.
3. That flexion of the first phalanx is far more pronounced in the last two fingers than in the first two.

c, d, e, f, Muscular contraction in voluntary movements, in resistance movements, and by electrical stimulation.

Black: no appreciable voluntary contraction, no contraction in any of the muscles to electrical stimulation of the nerve above the injury (diadynamic stimulation). Total RD in all these muscles.

Hatching: voluntary contraction takes place; it is only slightly diminished. Contraction to electrical stimulation of the nerve above the lesion. Partial RD (faradic excitability is less manifest in the interossei of the last interspaces than in those of the first). The hatchings are closer, to indicate that voluntary contraction is less.

Dotted: slight weakening; electrical hypo-excitability, without RD.

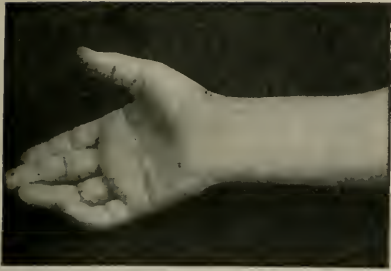- g, h*, Cutaneous sensibility to pin-prick. *i*, Osseous sensibility to tuning-fork.
j, Articular sensibility to passive attitudes.

In black: complete cutaneous and osseous anæsthesia; attitudes are not recognised.

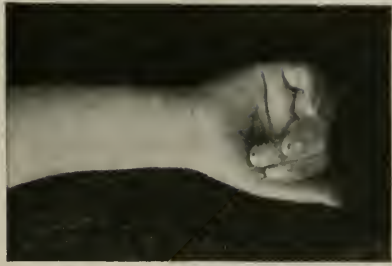In horizontal hatching: anæsthesia to pain.

In oblique hatching: osseous hypo-æsthesia (the hatching is closer, to indicate that sensation is less, compared with the opposite side).

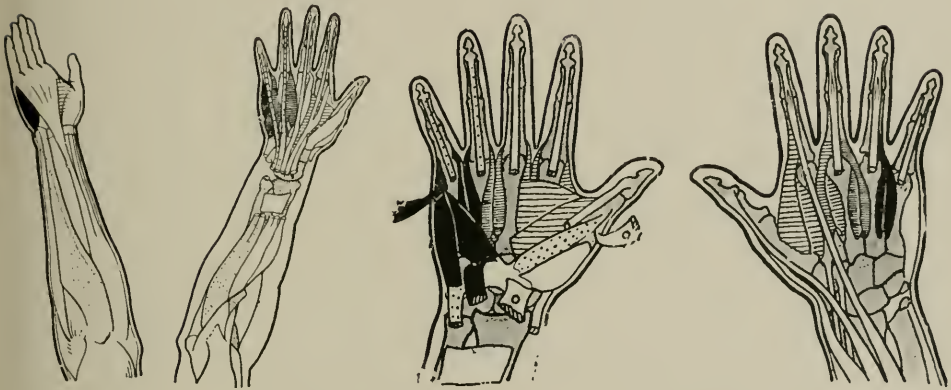
* Figures 101 and 102 and legends are taken from the article by J. Dejerine, Mme. Dejerine, and J. Mouzon, *Presse Médicale*, No. 40, 30 August, 1915.



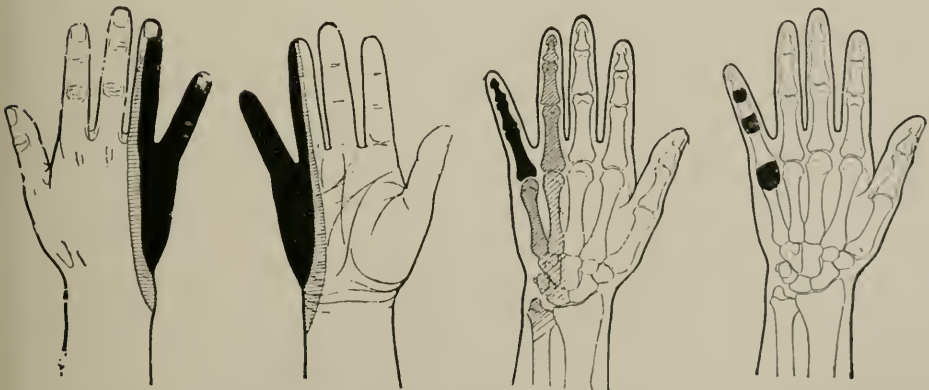
a, Attitude of the hand at rest.



b, Maximum flexion of the fingers.



c, d, e, f, Voluntary and electrical contractility of the muscles.



g, h, Cutaneous sensibility to pin-pricking.

i, Osseous sensibility to tuning-fork.

i, Articular sensibility to passive attitudes.

FIG. 137.—Case of Corporal Chev . . . 30 April, 1915, 71st day after his wound. Compression of external surface of left ulnar nerve in the upper arm (partial lesion).

Corporal Chev . . . of the 228th Infantry, wounded on the 18th Feb., 1915, at Suzanne (Somme), by the bursting of a shell. The projectile traversed the inner region of the left arm, four fingers' breadths below the armpit. Suppuration of tract and drainage. Ulnar paralysis seems to have been immediate, but for several weeks movement of the arm was rendered almost impossible by reason of the pains set up in the last two fingers, doubtless connected with the pulling on the nerve. These pains had almost disappeared at the time the wounded man entered the hospital.

Operation, 17 May (88th day after the wound), by M. Gosset. Ulnar nerve bent on a very hard fibrous cord which strongly compressed its external surface, and was stretched between the external edge of the biceps and the outer bend of the biceps. Resection of this cord. The nerve was normal in calibre, aspect and colour, with the exception of a slight swelling and hardening (interstitial sclerosis) of its external part.

a, Attitude of the hand at rest (disturbances of tone).

Note : 1. That the hand, in its entirety, is deviated towards the radial edge (atrophy of flexor carpi ulnaris).

2. That there is no trace of "ulnar griffe." On the other hand, the flexion folds of the phalanges of the last two fingers are less obvious (the tone of the interossei of the last two outer spaces is greater than that of the corresponding slips of the flexor profundus).

3. That atrophy of the adductors of the thumb, at the thenar eminence, seems more pronounced than atrophy of the hypothenar eminence.

4. That abduction of the little finger (as regards the axis of the hand) is very marked; this abduction seems connected, on the one hand, with the favourable tone of the muscles of the hypothenar eminence, and, on the other hand, with the tonic action of the extensor tendons, whose rôle as abductors is intensified when the hand, as in this case, finds itself deviated towards the radial border.

5. The considerable hyperkeratosis that exists throughout the entire paræsthetic region of the ulnar nerve, and which extends right to the region of the median.

b, c, Maximum flexion of fingers.

Note : 1. That projection of the flexor carpi ulnaris above the pisiform is quite absent.

2. That there is no flexion of the last phalanx in the case of the last two fingers, and only imperfect flexion in the case of the middle finger.

3. That flexion of the first phalanx of the fingers is effected better than in the case of Fig. 101, and also better in the latter fingers than in the former (the outer interossei are more weakened than the inner interossei).

d, e, f, g, Muscular contraction in voluntary movements and movements of resistance, and by electrical stimulation.

Black: no appreciable voluntary contraction; doubtful contraction to electrical stimulation of the nerve above the lesion; partial RD.

Hatching: voluntary contraction is possible, though diminished. These muscles contract to electrical stimulation of the nerve above the lesion (diadermic stimulation); partial RD. (The hatching is closer, because voluntary contraction is less.)

Dotted: slight weakening; electrical hypo-excitability, without RD.

h, Articular sensibility to passive positions: no disturbance whatsoever. *i*, Osseous sensibility to tuning fork. *j, k*, Cutaneous sensibility to pin-prick.

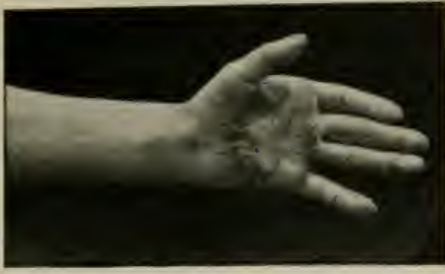In oblique hatching: painful hypo-æsthesia to pin-prick; slight bony hypo-æsthesia.

In oblique cross-hatching: paræsthesia.

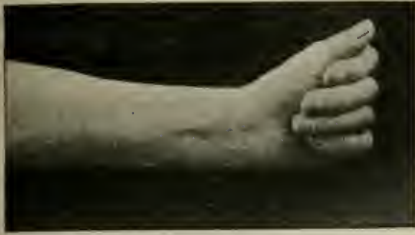In oblique dotted-hatching: very painful paræsthesia.

Dotted: painful hyper-æsthesia, strictly so-called (no enlargement of Weber's circles) osseous hyper-æsthesia.

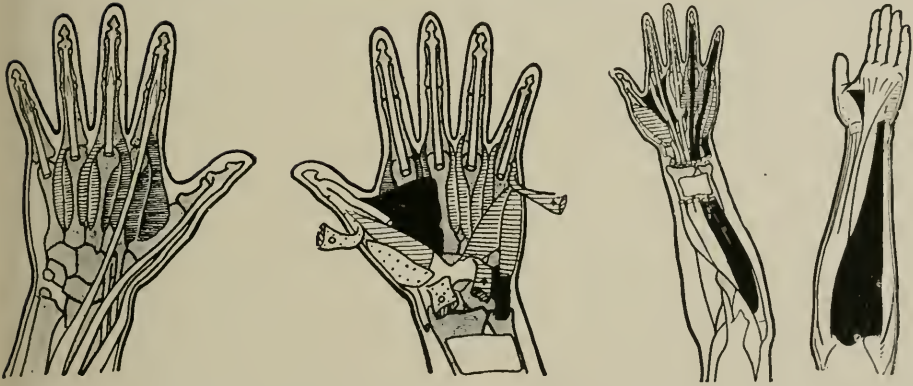
A comparison of Figs. 101 and 102 shows that, deep in the ulnar nerve on the arm, the general arrangement of the fasciculi seems to be as follows: from within outwards, the cutaneous sensory (dorsal and palmar) branches along with the branches to the hypothenar eminence—then the deep branch of the nerve, the branches of the last interosseous spaces being within, those of the last spaces further without, those of the adductors of the thumb still further; and lastly, on the outer surface of the nerve the fasciculi for the flexor carpi ulnaris, and for the flexor profundus (inner slips).



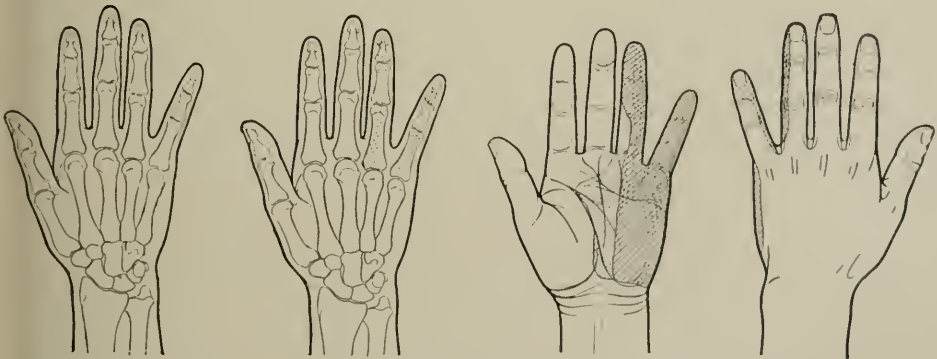
a, Attitude of the hand at rest.



b, c, Maximum movements of flexion of fingers.



d, e, f, g, Voluntary and electrical contraction of muscles.



l, Articular sensibility to passive attitudes.

i, Osseous sensibility to tuning-fork.

j, k, Cutaneous sensibility to pin-prick.

DIAGNOSIS OF ULNAR PARALYSIS

Diagnosis of ulnar paralysis requires little more than the indication of a few causes of error.



FIG. 138.

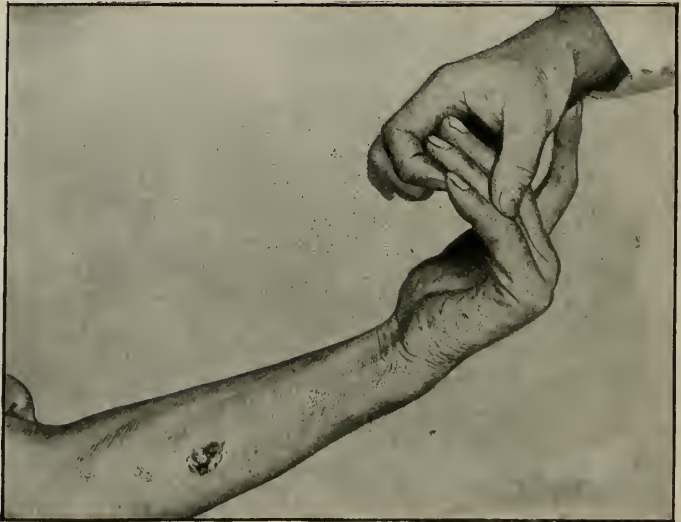

FIG. 139.—False ulnar *griffe* by cicatricial contraction of the flexors of the last two fingers. Relax the contracted muscles, flexing the fingers on the hand or the hand on the wrist, to obtain reduction of *griffe*.

1. Note the frequent absence of the typical ulnar *griffé*, which may be scarcely perceptible.

Nothing is easier than to be mistaken regarding paralysis of the ulnar, and perhaps more particularly as regards complete paralysis through lesion of the nerve above the epitrochlea; indeed, it is in this case that *griffé* is least pronounced, owing to paralysis of the flexor profundus.

It should be remembered that almost all movements of the ulnar may be reproduced by substitutionary movements. True, these are far weaker, but a superficial observation might lead us to imagine that we were dealing with simple paresis of the nerve. Lateral adduction alone of the fifth finger cannot be substituted; this is almost the only movement which is absent in certain cases.

2. Just as we may be mistaken in ulnar paralysis so may we regard as an ulnar *griffé* the simple cicatricial contraction of the flexors of the last two fingers.

In this case, indeed, there is a real resisting *griffé*, apparently inextensible, and therefore reminding one of the fibrous *griffé* in nerve irritation.

It is felt, however, when employing traction in order to straighten the *griffé*, that the resistance is in the fore-arm, not in the hand; the traction movements raise like cords the contracted muscles and draw on the scar.

Finally, if care is taken to flex the fingers on the metacarpus, or the hand on the fore-arm, free play is given to the contracted muscles and it is noticed that the *griffé* is completely reduced, without deformity of the fingers.

It is unnecessary to add that the hypothenar eminence and the inter-ossei show no sign of atrophy.

3. Finally, we must insist on certain contractions appearing in the ulnar distribution. They often give rise to appearances which might be mistaken for ulnar *griffés* and paralyses.

CONTRACTIONS RESULTING FROM SLIGHT NEURITIS OF THE ULNAR

Contractions of the hand constitute a very special, important and interesting chapter in the study of irritations of the ulnar.

Indeed, there are often found, following slight wounds of this nerve, states of muscular hypertonia or even of real contraction, to which we have already called attention.

Whilst all slightly irritated motor nerves seem susceptible of producing analogous syndromes, the ulnar would appear to produce them with special frequency. As the median seems to respond very frequently to slight irritations of its sensory fibres, producing the causalgic syndrome, so the ulnar seems to manifest greater susceptibility of its motor fibres and to react readily to their irritation, producing the hypertonic syndrome. It is

generally a case of direct lesion of the nerve, sometimes indirect compression or lengthening by traction; in other cases, the nerve seems irritated by a process of slight ascending neuritis.

We note in every case the appearance of muscular hypertonia, frequently amounting to contraction, and immobilising the hand in a fixed attitude.

All the muscles have retained their normal electrical reactions, but they are contracted. Active movements are impossible, passive movements are difficult and meet with considerable resistance of an elastic type which is non-fibrous and almost always painful. As a rule, the pain disappears as soon as contraction is overcome and the movement carried out; left to itself, however, the hand, either immediately or more slowly, in a few minutes or in a few hours, regains its original condition.

One might pronounce this to be a case of hysterical contraction, did not the attitude of the hand show distinct localisation in the distribution of the ulnar; pain in the nerve under pressure, formication caused by percussion, anæsthesia or hypo-æsthesia of the cutaneous area, vaso-motor, sweat or trophic disturbances, mechanical and often electrical hyper-excitability of the contracted muscles, all these clearly demonstrate the irritative origin of these hypertonic syndromes.

* * * * *

Nothing could be more variable than the contracted attitudes produced by irritation of the ulnar; indeed, the different muscles supplied by this nerve have antagonistic functions, and according as any particular group is preponderant we find altogether different attitudes. Nor must it be forgotten that contraction becomes fixed and intensified by immobilisation. Contraction in flexion, for instance, becomes contraction in extension, if after overcoming it we immobilise it in this attitude. We may consequently see in one and the same patient different attitudes succeeding one another. The main types we will now review.

Sometimes we have contraction of the muscles of the hand, producing the "accoucheur's hand" type described by Froment and Babinski. The fingers are pressed against one another or even intercrossed by contraction of the palmar interossei; the thumb is immobilised by the adductors, the little finger is kept in a state of forced adduction.

As a rule, contraction does not affect the thumb and is even at times confined to the hypothenar eminence; the little finger is in forced adduction and obliquely crosses the anterior surface of the other fingers.

In all cases, there is immobilisation of the fingers in extension by the action of the interossei on the second and third phalanges.

We also find that certain cases in which it is impossible to flex the fingers, particularly the last two fingers, are due to contraction of the interossei.

Immobilised when extended, these fingers do not offer to passive flexion

the fibrous and articular resistance which we find in certain cases of

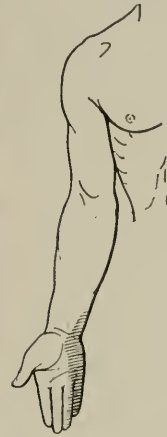

FIG. 140.—Contraction limited to the hypothenar eminence with slight contraction of the palmar interossei. Ulnar hypo-æsthesia. Hypo-æsthesia of the internal cutaneous. Pain and formication in the nerve as far as the armpit. Very pronounced trophic change in the little finger nail. Compression of the ulnar and of the internal cutaneous at the level of the armpit, or slight traction on the lower roots of the brachial plexus.

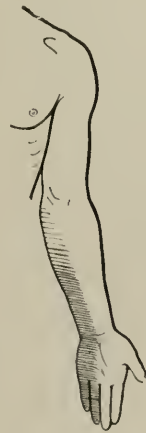
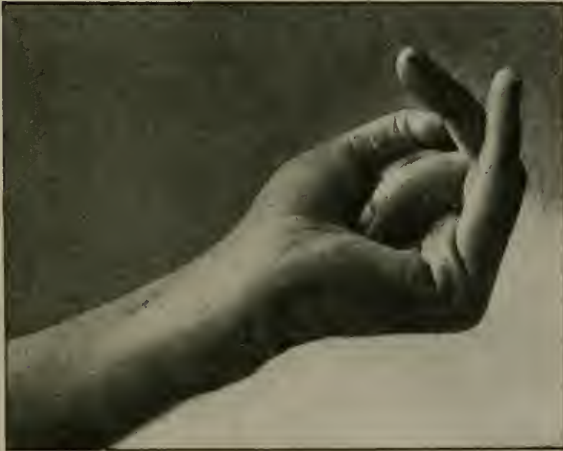
FIG. 141.—Contraction with extension of two fingers; maximum of voluntary movements. The fingers may very readily be flexed, but they immediately resume their original attitude as though moved by a spring. Lesion of the ulnar above the epitrochlea. Ulnar hypo-æsthesia with hypo-æsthesia of the internal cutaneous. Originally the patient had contraction in flexion of the last two fingers; after opening of the hand and immobilisation in extension for several weeks, contraction in extension occurred.

neuritis. Voluntary flexion of the first phalanx is possible and sometimes

even exists permanently, thus showing full movement of the interossei. Passive flexion of the last two phalanges is possible and even tolerably easy, affording the impression of elastic resistance, but left to themselves the fingers at once resume their initial attitude as though moved by a spring, or else they regain it slowly after a few minutes.

In other cases we find contraction of the hand along with flexion of the fingers; of this two typical varieties may be described. Sometimes we have flexion of all the fingers by the interossei; flexion then almost exclusively affects the first phalanx; the second and third are but moderately flexed. In these cases there is often more or less pronounced contraction of the palmar aponeurosis, the existence of which intensifies

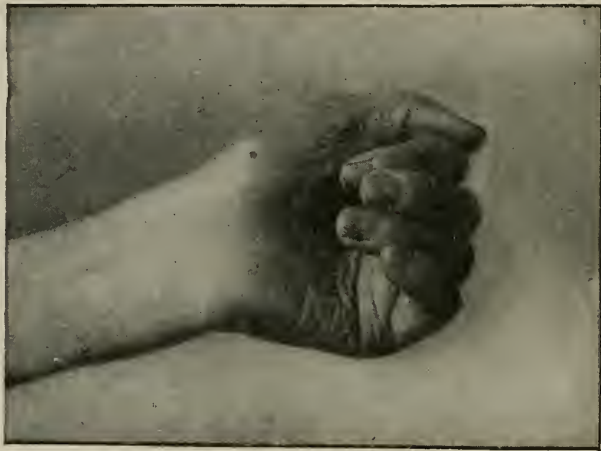

FIG. 142.—Contraction of the hand in flexion. Slight wound of the ulnar in the middle part of the arm. Liberation of nerve two months after the wound. Contraction, which appeared some weeks after the wound, has become exaggerated after operation. Complete ulnar anæsthesia. Slight hypo-æsthesia of the median. Contraction of the palmar aponeurosis. Passive extension of the hand is possible though painful; consequently the hand remains extended, voluntary flexion impossible; in a few hours it resumes its original flexed attitude.

flexion of the fingers as well as resistance to passive movements; it clearly indicates irritation of the nerve trunk.

Soon after we note flexion of the last two fingers on the hand through contraction of the flexor profundus, producing an attitude which resembles, though somewhat exaggerated, that of ulnar *griffe* in paralysis accompanied by neuritis.

Whilst in all these contractions there undoubtedly exists a motor nerve irritation which causes them, still this is not the main factor, perhaps in most cases it is not even the most important factor.

As a rule, this irritation acts only by causing a sort of muscular hypertonia, an actual predisposition to contraction. What more than all

else favours, maintains, and intensifies this neuritic contraction in almost every case, is immobilisation. From the time when they are slowly, patiently, and regularly mobilised, these contractions diminish and finally disappear.

We are justified in thinking that they would not exist for the most part if we had practised this daily mobilisation from the outset, and if the patient had not shown a certain amount of indifference, or even willingness, in allowing contraction to take place.

This is proved by the habitual preservation of the movements of the thumb; even when there is contraction of the interossei, the adductors of the thumb almost always escape contraction and retain their movements



FIG. 143.—Flexion of the last two fingers by contraction of the flexors. The attitude may be thought to be due to muscular contraction, for the wound has affected the fore-arm in its inner part. All the same, there is no cicatricial muscular contraction; complete extension may be obtained without great resistance, and the attitude is reproduced several minutes afterwards. Pain in the ulnar when pressed on in the middle part of the arm, hypo-æsthesia of its cutaneous area, simultaneous contraction of the adductors of the thumb, cyanosis of the little finger, profuse sweats noticed in the ulnar part of the hand, point to involvement of the ulnar nerve, probably irritated by a process of ascending neuritis.

which the patient finds indispensable in using his hand: out of fifteen cases of contraction in the region of the ulnar, only twice have we found immobilisation of the thumb by the contracted adductors.

It must be remembered that these neuritic contractions are almost always partially functional; great care must be taken to prevent their appearance or persistence by practising mobilisation on the patient at an early stage and above all by requiring that he himself should do everything possible.

Once contraction has been established, massage, hot baths, mobilisation under warm water, the faradic bath with metronome rhythm, have invariably given excellent results.

CHAPTER VIII
MEDIAN NERVE

ANATOMY

THE median nerve originates in the brachial plexus from two heads: the outer head, coming from the outer cord along with the musculo-

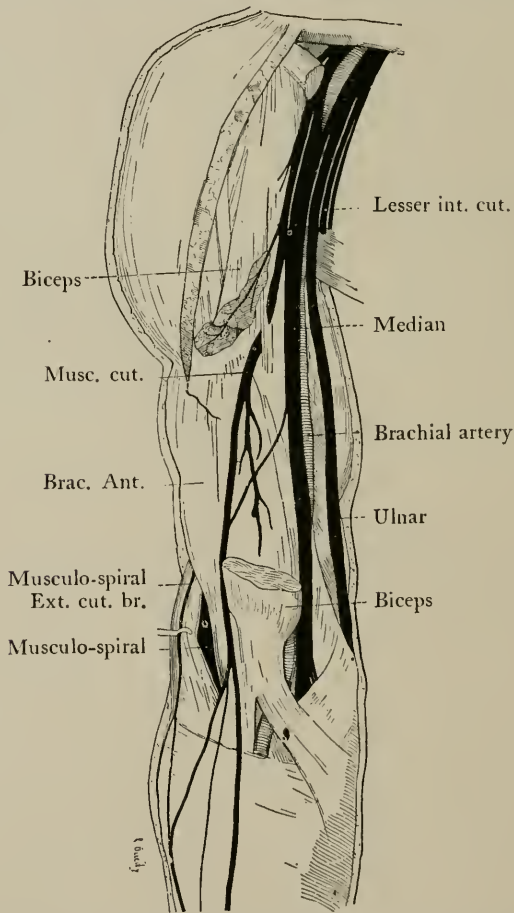


FIG. 144.—Deep nerves of the arm (after Hirschfeld modified).
 Anterior aspect.

cutaneous, brings to it fibres of the sixth and seventh cervical roots; the

inner head, coming from the inner cord trunk, along with the ulnar, supplies it with fibres from the eighth cervical and of the first dorsal.

The median nerve descends into the armpit in front of the axillary artery. It proceeds along the inner side of the arm, lying against the inner side of the biceps, in front of and outside the brachial artery, which,

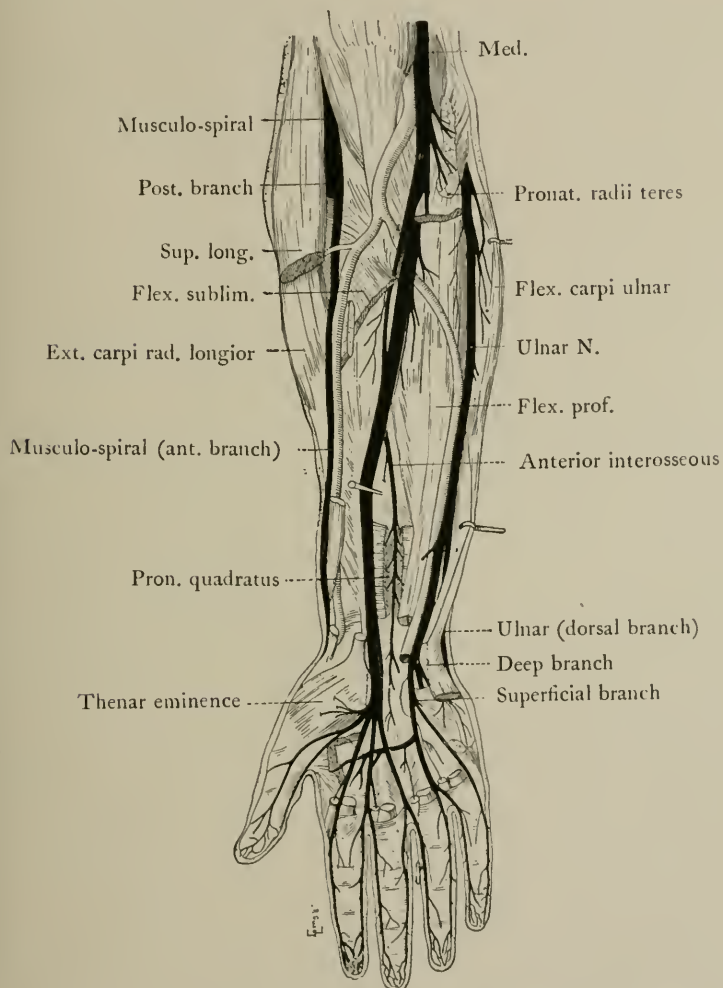


FIG. 145.—Deep nerves of the fore-arm and nerves of the hand (after Hirschfeld).

at its lower part, crosses its deep surface and becomes external to it. It proceeds in front of and outside the ulnar, which is closely united with it as far as the lower third of the arm.

At this level, the ulnar separates itself from the median to reach the epitrochlean groove which is behind, whilst the median slightly inclines

outwards in order to draw nearer to the middle line of the upper limb at the bend of the elbow.

In the fore-arm, it proceeds between the two heads of the pronator radii teres, and disappears beneath the superficial flexor. It descends in the middle line resting on the flexor profundus, covered by the superficial flexor. Below the fleshy body of this muscle, at the lower part of the fore-arm, where it becomes superficial, it appears between the tendons of the flexor indicis and the tendon of the flexor carpi radialis.

It passes on to the wrist under the annular ligament of the carpus ; occupies the anterior compartment of the radio-carpal canal, and divides into its terminal branches : the inner trunk and the outer trunk.

MOTOR BRANCHES

The median nerve does not supply any branch whatsoever to the arm, except a few twigs for the brachial artery and the articulation of the elbow.

I.—All the branches of the median in the fore-arm are exclusively motor, except the palmar cutaneous branch, which appears a little above the wrist and is destined for the hand.

1. Upper nerve to the pronator radii teres.

2. Nerves to the superficial muscles of the fore-arm, destined :

For the pronator radii teres (lower nerve).

For the flexor carpi radialis and palmaris longus.

For the superficial flexor.

All these branches originate close to the elbow (Cruveilhier) ; but some accessory twigs also become detached lower down, particularly for the flexor of the index.

3. Nerves of the deep layer, comprising :

A branch which supplies the two external heads of the flexor profundus ;

A branch destined for the flexor of the thumb ;

A branch which descends, under the name of anterior interosseous nerve, in front of the interosseous ligament, supplies the pronator quadratus and reaches the proximate articulations of the carpus, where it ends.

II.—In the hand, the median nerve supplies :

1. The muscles of the thenar eminence by three branches, originating in its external branch and destined :

For the abductor of the thumb ;

For the opponens ;

For the flexor brevis.

The median does not supply the adductors of the thumb, which the ulnar supplies in the same way as the interossei.

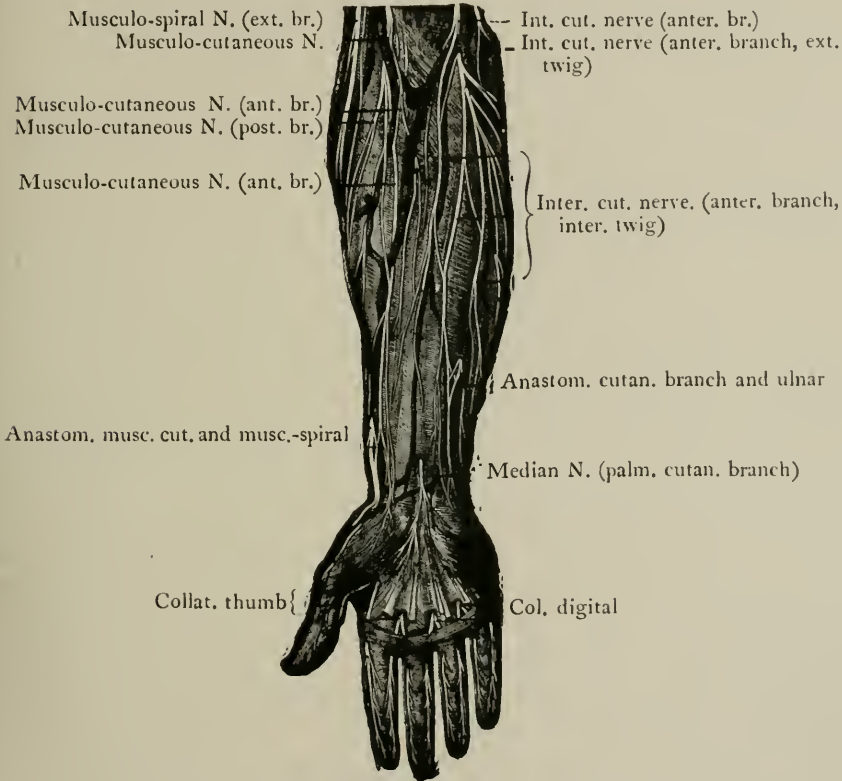
It also supplies only the superficial part of the flexor brevis ; the deep head is supplied, partially at least, by the ulnar.

2. The first two lumbricales, by branches originating in its inner branch. Occasionally it also supplies the third lumbrical.

SENSORY BRANCHES

Whereas in the fore-arm the median nerve is exclusively motor, in the hand it is mostly sensory.

1. **Palmar cutaneous branch.**—This collateral branch appears a little above the wrist and disappears in the skin of the thenar eminence and of



Anterior aspect.

FIG. 146.—Cutaneous nerves of fore-arm and hand. (After Sappey.)

the palm of the hand, which it supplies as far as the middle palmar crease.

2. The external terminal branch of the median, from which also originate the motor branches of the thenar eminence, supplies :

- The external digital collateral nerve of the thumb ;
- The internal digital collateral nerve of the thumb ;
- The external digital collateral of the index.

3. The internal terminal branch supplies through the inter-digital nerves of the second and the third space :

The internal digital collateral of the index and the external collateral of the middle finger ;

The internal collateral of the middle finger and the external collateral of the ring-finger.

All the digital collaterals of the fingers, except those of the thumb, successively send out a dorsal branch for the second phalanx and one for the third phalanx, so that, in the case both of the median and of the ulnar, the dorsal surface of the last two phalanges is supplied by the palmar nerves : the thumb and the fifth finger alone form an exception to this rule.

ANASTOMOTIC BRANCH

It is useless to enumerate the terminal anastomoses of the median along with the musculo-spiral, the ulnar, or the musculo-cutaneous. Unlike those of other nerves they have no interest for the clinician. This is not so in the case of the anastomosis supplied to the median by the musculo-cutaneous, at the middle of the arm. Probably it supplies the median nerve with the motor fibres coming from the sixth and seventh cervical roots ; it is the more developed in proportion as the external root of the median is slighter ; and so its persistence, in the complete sections of the median above it, would explain the possible preservation of some nerve fibres supplying the flexor carpi radialis and the pronator radii teres.

The median also receives in the arm and the fore-arm some slight anastomotic twigs from the ulnar nerve, capable of supplying occasionally substitutionary fibres to the flexor profundus of the middle finger.

PHYSIOLOGY

MOTOR SYNDROME

I.—The median nerve in the fore-arm is exclusively motor.

It controls :

1. Pronation by the pronator quadratus and the pronator radii teres.

Babinski found that, in paralysis of the median, electrical stimulation of the biceps produces supination more pronounced than in the normal state as a result of lack of antagonism of the pronator radii teres.

2. Flexion of hand on fore-arm by the flexor carpi radialis, etc.

Nevertheless, in paralysis of the median, slight flexion of the hand is still possible by the flexor carpi ulnaris, and the synergic contraction of the supinator longus and of the extensor ossis metacarpi pollicis.

3. Flexion of the fingers by the superficial flexor and the flexor profundus. In spite of paralysis of the median, flexion of the last two fingers remains possible by means of slips of the flexor profundus supplied by the ulnar.

The fingers which cannot be flexed in paralysis of the median are the thumb, the index and middle finger.

Flexion is absent in the last two phalanges only ; the ulnar being capable,

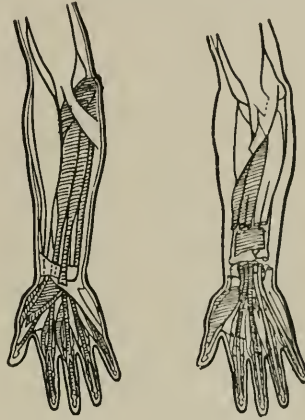


FIG. 147.

FIG. 148.

Muscles supplied by the median in the fore-arm.

FIG. 147.—Superficial layer. Pronator radii teres. Flexor carpi radialis. Palmaris longus. Superficial flexor.

FIG. 148.—Deep layer. Pronator quadratus. The two external fasciculi of the flexor profundus. Flexor of the thumb.

through the interossei, of flexing the first phalanges of middle finger and index on the metacarpus.

On the other hand, in spite of the typical anatomical descriptions, the middle finger can frequently be flexed in paralysis of the median. This is not only owing to the aponeurotic fibres which unite the flexors of the middle finger to those of the ring-finger, but to actual muscular contraction. It must of

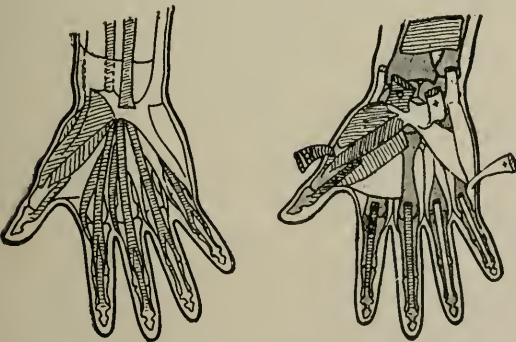


FIG. 149.—Superficial layer.

FIG. 150.—Deep layer.

Muscles supplied by the median in the hand.

FIGS. 149 and 150.—Abductor pollicis. Opponens. Flexor brevis pollicis. The first two lumbricales.

those of the ring-finger, but to actual muscular

necessity be admitted that the flexor profundus of the middle finger is very often supplied, partially at least, by the ulnar.

II.—In the hand the median nerve supplies all the muscles of the thenar eminence, except the adductors and the deep head of the flexor brevis.

Paralysis of the median is mainly characterised by loss of the opposition and flexion movements of the thumb, whilst adduction persists.

The patient can grasp an object firmly and press it between the first phalanx of the thumb and the base of the index, but he cannot pinch it between the end of the thumb and the last phalanxes of the index; still less between the thumb and the end of the other fingers.

On the other hand, the thumb is capable of slight external rotation.

Nevertheless, energetic contraction of the adductors enables it frequently to move to the ulnar edge of the hand, by crawling, so to speak, against the base of the fingers. This is the pseudo-opposition of the thumb described by H. Claude, facilitated by lack of tone in the other thenar muscles and by articular laxity.

The flexion movements of the thumb are completely suppressed (long and short flexors); still, a slight flexion movement of the second phalanx is occasionally possible, by means of the deep head of the flexor brevis.

The median also supplies in the hand the first two lumbricales, but paralysis of these muscles is fully compensated for by integrity of the interossei and causes no motor disturbance whatsoever.

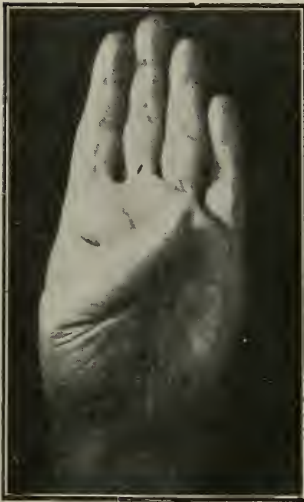

FIG. 151.—Pseudo-opposition in paralysis of the median. The thumb in its course inwards approaches the little finger; skimming the base of the fingers. Then the little finger is bent inwards to reach the extremity of the pulp of the thumb. (Claude, Dumas, and Porack, *Presse Méd.*, 10 June, 1915.)

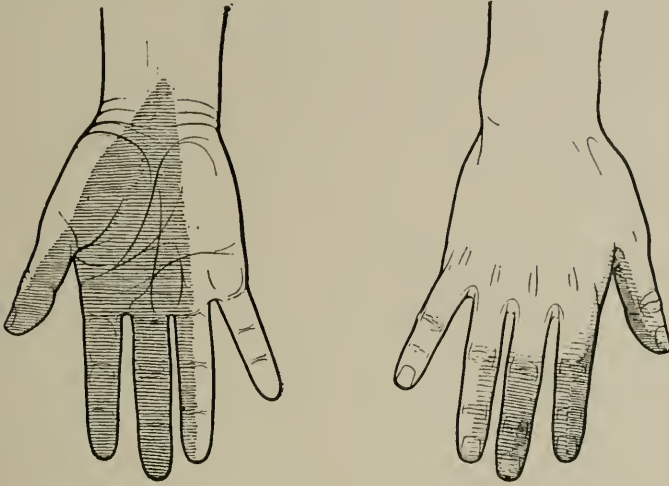
SENSORY SYNDROME

The sensory region of the median comprises :

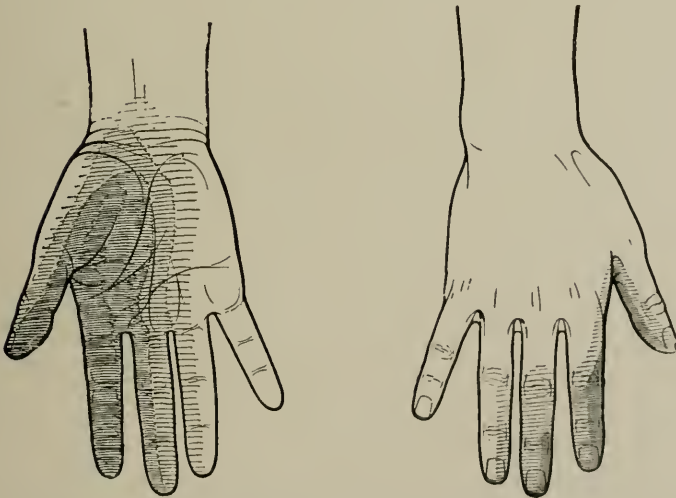
1. The external part of the palm of the hand, though without reaching the outer side of the thumb ;
2. The palmar surface of thumb, index and middle finger : the external half of the ring-finger ;
3. The dorsal surface of the second and third phalanges of the index and the middle, and the external half of the ring-finger.

In the median, however, as in the ulnar, total anæsthesia is usually

confined to a portion only of this region, almost always to the index; it gradually becomes less pronounced as we approach the regions of the ulnar and the radial.



FIGS. 152 and 153.—Anatomical region of the median.



FIGS. 154 and 155.—Usual topography of sensory disturbances of the median. Three diagrammatic zones: complete anæsthesia, pronounced hypo-æsthesia, and slight hypo-æsthesia.

TROPHIC SYNDROME

Trophic disturbances of neuritis of the median, affect the palm of the hand far less than do those of the ulnar; they are confined chiefly to the

fingers, particularly the index and the middle finger ; they affect the thumb to a less degree and the ring-finger but slightly. They act mainly on the second and third phalanges as well as on the nails of these fingers, the deformities of which are obvious and persistent.

Apart from the various neuritic disturbances we shall study later on, we may note in simple lesions of the median, the cyanosis and redness of the innervated fingers, chiefly the index ; dryness of the skin, or, on the other hand, profuse sweats in the cutaneous region of the nerve, also a tendency to chilblains.

Finally, in very rare cases, we may note the appearance, at the end of the fingers, of ecchymoses, or occasionally of small ulcers, caused by various mechanical or chemical irritants.

Muscular atrophy in cases of paralysis of the median is shown mainly by the flattening of the lower part of the fore-arm following atrophy of the pronator quadratus.

CLINICAL FORMS OF LESIONS OF THE MEDIAN NERVE

In the case of the median, even more than of the ulnar, it is not easy to differentiate between complete interruption and simple compression.

Muscular hypotonia is difficult to establish ; muscular atrophy of the epitrochlear and thenar muscles is more rapid and pronounced in nerve interruptions, but sometimes it is not easy to judge, by reason of the preservation of the flexor carpi ulnaris and of the internal fasciculi of the flexor profundus. The main signs of interruption are the early appearance and the intensity of the electrical disturbances, the constancy of anæsthesia and the fixity of formication which is found at the level of the lesion.

We will study in succession :

1. Paralysis of the median above the epitrochlear muscles ;
2. Lesions of the median below the epitrochlear muscles ;
3. Dissociated paralysis of the median.
4. Neuritis of the median.
5. Causalgia of the median.

I.—COMPLETE PARALYSIS OF THE MEDIAN IN THE ARM ABOVE THE EPITROCHLEAR MUSCLES

Paralysis of the median is not shown when at rest by any special attitude. It is revealed solely by movement. Pronation is impossible, however little resistance is offered to it ; flexion of the hand on the wrist, which is very feeble, occurs only by means of the flexor carpi ulnaris ; flexion of thumb, index and middle finger is impossible ; they remain

extended if the patient tries to shut his hand, whereas the last two fingers are strongly flexed by the flexor profundus alone.

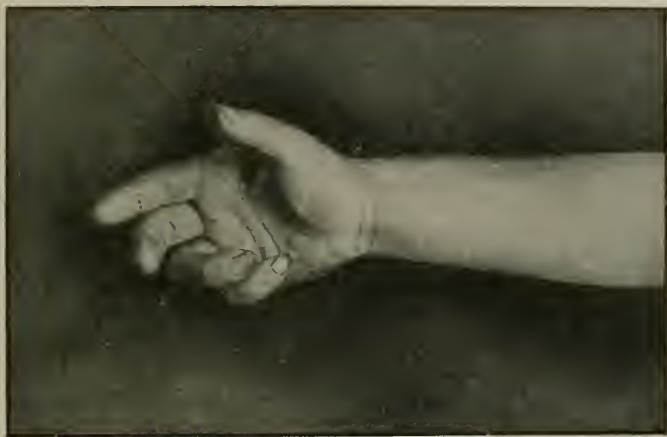

FIG. 156.—Paralysis of the median nerve. Complete interruption above the epitrochlea. Maximum flexion of the fingers.

We must, however, qualify some of these statements.

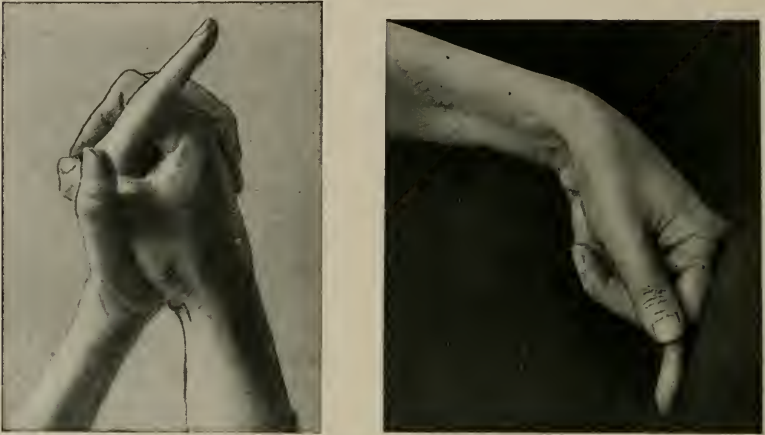On the one hand, the middle finger may often be slightly flexed, being affected by movement of the ring-finger, on account of the apo-



FIG. 157.—Complete paralysis of the median nerve (resection and suture at the middle third of the arm). The interossei are capable of flexing the first phalanx. Flexion of the last two, however, is impossible. (In this case, flexion of the middle is possible, by the flexor profundus, which is sometimes supplied by the ulnar.)

neurotic slip which unites their extensor tendons on the dorsal surface of the hand. It frequently happens that flexion of the middle finger is almost complete when the ulnar supplies a branch to its flexor profundus.

On the other hand, the interossei are capable of flexing the first



FIGS. 158 and 159.—Complete paralysis of the median nerve. Impossible to flex the index finger.

phalanx of index and middle finger on the metacarpus, but the last two phalanges remain extended.



FIG. 160.—Paralysis of the median (first sign). On the left side, the patient cannot bring the thumb in front of the middle finger as on the right side. (Claude, Dumas, and Porack, *Presse Méd.*, 10 June, 1915.)

It is easy to eliminate the cause of error produced by the action of the interossei and to show that flexion of the second and third phalanges is impossible by requesting the patient to intertwine the fingers of both hands and then to close them. It is noticed that the index finger and the thumb remain extended, that flexion of the middle finger is slight, whereas the last two fingers can be flexed strongly. (Pitres.)

Again, if the patient is ordered to flex his hand on his wrist and his fingers on his hand, we notice extension of the index finger; this would seem to be an irrefutable sign of paralysis

of the median. (M. and Mme. Dejerine.)

Even more simply we may firmly fix the first phalanx of the index

finger and ask the patient to flex the others ; alternatively, his hand resting flat on a table, the patient is asked to scratch the table with the nail of the index finger. (Pitres and Testut.)

Finally, the thumb has lost all its power of flexion and opposition. If the patient is ordered to close his fist, it is found that the thumb remains extended and cleaves to the index finger instead of being flexed in opposition in front of the other fingers (first sign). (H. Claude.)

There may sometimes be observed manifest dissociation in paralysis of the epitrochlear muscles ; the pronator radii teres, the flexor carpi radialis, and the palmaris longus have partially retained their movements and still



FIG. 161.—Dissociated paralysis of the median. Integrity of the pronator radii teres, the flexor carpi radialis, and the palmaris longus, which become prominent at the wrist.

preserve slight faradic contractility, whilst the flexors are paralysed. This dissociation may be found in three forms.

1. As the result of lesion of the nerve at the bend of the elbow, below the twigs destined for the pronator radii teres, the flexor carpi radialis and the palmaris longus.

2. From lesion of the nerve at the level of the arm, giving rise to a dissociated syndrome. We have observed this several times, but it cannot be affirmed that lesion of the nerve is partial in all these cases. Indeed it may be remembered that the anastomosis coming from the musculocutaneous brings fibres of the fifth and sixth cervicals to the median, most of these fibres, actual aberrant fibres of the external root of the median, seem destined for the pronator radii teres and the flexor carpi radialis, indeed we shall see (brachial plexus) that the external and superior root of the median evidently to a large extent supplies the pronator radii teres, the flexor carpi radialis, and the palmaris longus.

3. This dissociation is also noted in the course of progressive regeneration of the nerve ; the flexor carpi radialis, the palmaris longus, and the pronator radii teres regain their movements before the other flexors.

II.—PARALYSIS OF THE MEDIAN IN THE FORE-ARM BELOW THE EPITROCHLEAR MUSCLES

Lesion of the median in the fore-arm is indicated solely by paralysis of the thenar eminence and by anæsthesia of the hand.

These disturbances are exactly similar to those found in total paralysis of the median ; still, it is well to study paralysis of the thenar muscles a little more closely, and to compare it with ulnar paralysis.

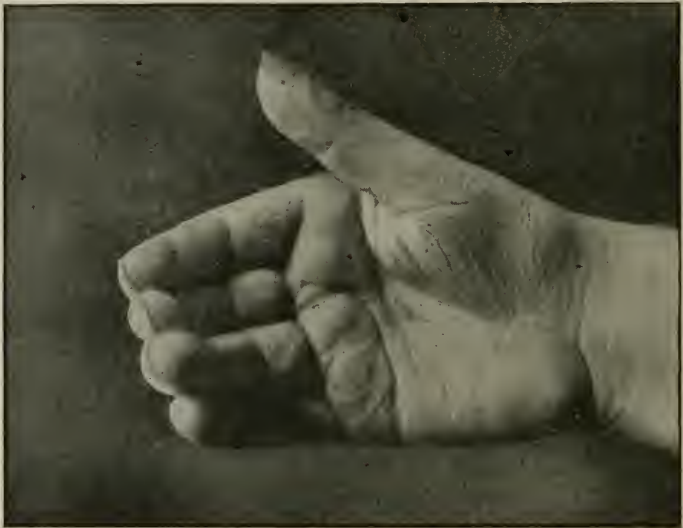

FIG. 162.—Atrophy of the thenar eminence in paralysis of the median.

If paralysis is of long standing, atrophy of the thenar eminence is very obvious, but the paralysis is chiefly shown by atrophy of the abductor and of the opponens ; it induces flattening of the thenar eminence ; a flat area or even a depression running parallel to the first metacarpal, replaces the normal projection. This atrophy is superficial ; it is not, as in ulnar paralysis, atrophy of the deep muscular layers (adductors of the thumb and deep head of the flexor brevis). Owing to integrity of the flexor longus pollicis, flexion of the thumb is not abolished.

The only movement which is really absent is that of opposition ; still it is sometimes difficult to discover this. Indeed, if the patient is asked to touch with the extremity of the flexed thumb the extremity of some other finger, it is found that the movement is possible ; this is not done, all the

same, by frankly setting the one against the other, it is effected by flexion of the thumb in the hand and flexion of the fingers over its extremity ; thumb and fingers no longer meet at the pulp, as in normal opposition, but on their dorsal or lateral side ; it is a case of pseudo-opposition.

Finally, although the flexors are entirely retained, we must here note



FIG. 163.

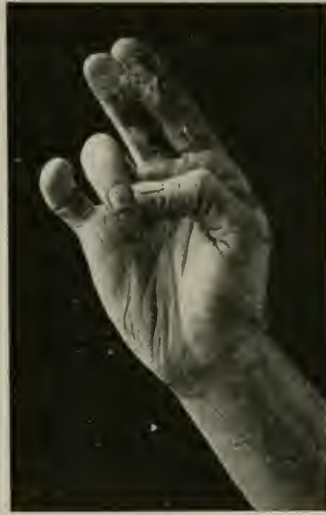

FIG. 164.

FIG. 163.—Normal opposition in a healthy subject. The fingers are completely and really opposed ; rotation of the thumb is complete.

FIG. 164.—Pseudo-opposition in a case of section of the median at the wrist. The fingers are opposed at their sides. The thumb is flexed by its own flexor, supplied in the fore-arm, far above the wound.

the frequency of their functional paralysis, a pseudo-paralysis caused by anæsthesia of the hand : no longer feeling his fingers, the patient thinks that they are paralysed and does not even attempt to use them. We shall return to this point when we discuss diagnosis.

III.—DISSOCIATED PARALYSES OF THE MEDIAN

The median, like the ulnar, may show partial lesions and dissociated paralyses.

We have mentioned the relative preservation of the pronator radii teres, the flexor carpi radialis, and the palmaris longus sometimes found even in certain complete interruptions of the nerve in the upper part of the arm ; possibly in these cases the motor fibres originate in the anastomosis of the musculo-cutaneous. All the same, more complete dissociations may be found.

In certain cases, for instance, there is found to be complete paralysis of

the flexors supplied by the median ; flexion of the index finger is impossible ; flexion of the other fingers takes place solely through the fasciculi of the flexor profundus which is supplied by the ulnar. The pronator radii teres, however, the flexor carpi radialis, the muscles of the thenar eminence, and, above all, the opponens have retained their movements ; the flexor longus pollicis is weakened but not wholly paralysed.

In these cases, the lesion affects the inner part of the nerve.

We have noted three cases of this dissociated form ; the first two were

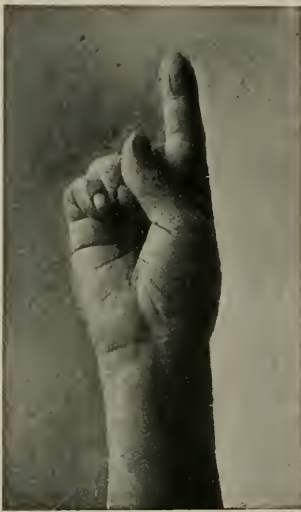

FIG. 165.

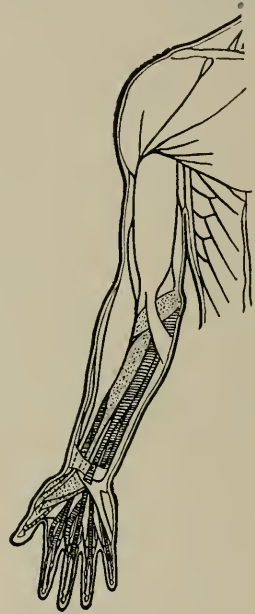

FIG. 166.

FIG. 165.—Dissociated paralysis of the median nerve. Paralysis of the flexors. Integrity of the flexor carpi radialis, of the palmaris longus, of the pronator radii teres, and of the opponens. Wound in the middle of the arm affecting only the inner part of the nerve.

FIG. 166.—Fascicular topography of the median. The inner part supplies the flexors. The outer part supplies the pronator radii teres, the carpi radialis, the palmaris longus, and the thenar eminence.

accompanied by no sensory disturbance whatsoever ; in the third, there was somewhat pronounced anæsthesia of the distribution of the median.

In other cases, where the lesion affects the nerve at its external border, it is rather the muscles of the thumb, the pronator radii teres and the flexor carpi radialis that are paralysed, the existence of sensory disturbances is not invariable.

It would thus appear that the fibres destined for the pronator radii teres, the flexor carpi radialis, the flexor pollicis and the muscles of the thenar eminence occupy the outer part of the median nerve.

The fibres that supply the flexors, on the other hand, are the most internal.

The sensory fibres probably hold an intermediate position, since either of these motor syndromes may involve injury to them.

According to the researches of Pierre Marie, A. Gosset and H. Meige, on applying local electrical stimulation to the nerve trunks, there are in the median nerve, in the arm, four distinct groups of motor fibres :

Pronator muscles in the antero-external region of the nerve.

Thenar muscles in the posterior region.

Flexor muscles of the carpus in the postero-internal region.

Flexors of the fingers in the antero-internal region.

IV.—NEURITIS OF THE MEDIAN

An essential distinction must be drawn between neuritis of the median, accompanied by considerable trophic disturbances, and neuralgia of the median, both frequent and distinctive, to which the name of causalgia has been given.

Nerve irritation of the median is characterised, as is that of all other nerve trunks :

1. By spontaneous and often very acute pain ;

2. By pain on pressure of the nerve trunks and muscular bellies ;

3. By painful hypo-æsthesia or even by cutaneous hyper-æsthesia ;

4. By important trophic disturbances culminating in *griffe* of the median.

We again find in these cases cutaneous trophic disturbances, scaly desquamation of the skin, and fibrous infiltration of the dermis ; but we must especially note two orders of symptoms : disturbances of the nails and the formation of *griffe*.

The nails of thumb, index and middle finger are always considerably affected in neuritis of the median.

In the pronounced form, the nails are striated, both longitudinally and transversely, bent into actual claws ; they grow extremely fast, and their rapid development raises between the nail and the digital pulp a small cutaneous swelling which, provoked and increased by the growth of the nail, is frequently the seat of somewhat acute pain.

Trophic disturbances of the nails in neuritis of the median are absolutely constant and very well defined. Sometimes even, in slight

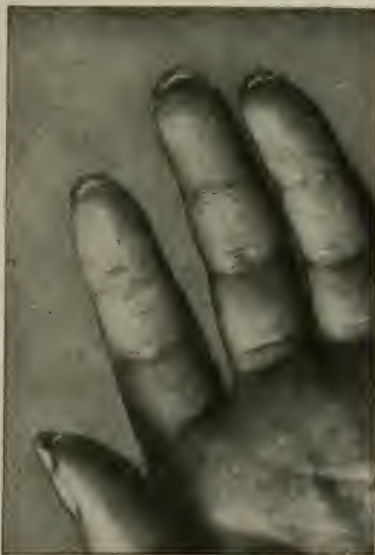

FIG. 167.—Sub-ungual swelling in neuritis of the median.

nerve irritation, the nails alone are affected, and it is their special incurvation that enables us to recognise the existence of this irritation.

Griffe of the median, in neuritis of this nerve, is far from being as

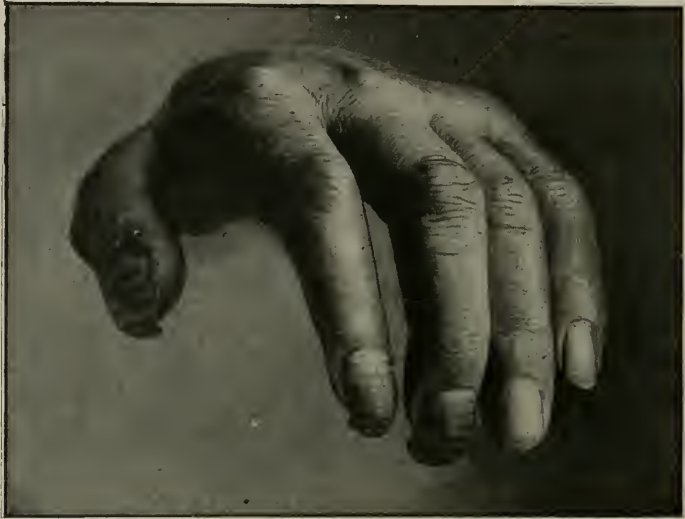

FIG. 168.—*Griffe* of the median caused by neuritis. Deformity of the nails. Glossy skin. Atrophy and fibrous infiltration of the last two phalanges, especially of the index.

constant and intense as ulnar *griffe*. Still, it is occasionally found, or suggested at all events.

It consists of fibrous contraction of the flexor tendons and synovial



FIG. 169.—Incurvation of the nails in slight neuritis of the median. Immobilisation of the finger in extension.

sheaths, immobilising thumb, index and middle finger in moderate though irreducible flexion. This flexion is most pronounced in the last phalanges; contraction of the palmar aponeurosis is but faintly perceptible and its

relative integrity contrasts with the intensity of its disturbances in neuritis of the ulnar.

Griffe of the median in flexion is not altogether constant; for in cases of slight neuritis we often find immobilisation of the fingers in extension along with adhesion of the skin to the dorsal surface of the fingers and fibrous transformation of the digital articulations. Neuritis of the median in these cases somewhat resembles neuritis of the musculo-spiral: but whereas articular sclerosis is more marked in the case of the first digital articulation, on the other hand, when the musculo-spiral is involved in neuritis of the median, it is the second and third digital articulations that are specially affected.

As in all other cases of nerve irritation, the fibrous sequelæ left by

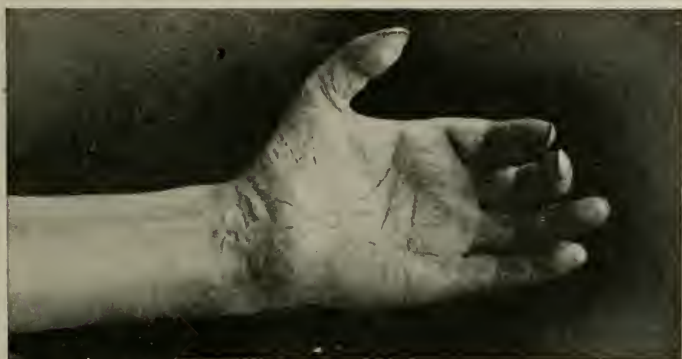

FIG. 170.—Neuritic *griffe* of the median.

irritation of the median persist long after the paralysis has been cured and may even terminate in irreducible deformity.

Neuritis of the median is found both in lesions of the nerve, in the arm, and in irritations below the elbow, even at the wrist.

It may exist apart altogether from paralysis, but, as a rule, in such cases, it somewhat resembles, in the slight degree of trophic disturbances and the intensity of painful phenomena, neuralgia of the median in its causalgic form. This we shall now study.

V.—CAUSALGIA OF THE MEDIAN NERVE

Nerve irritations of the median assume with the utmost frequency and intensity the type of the causalgia of Weir Mitchell; to such an extent is this so, that causalgia has been regarded as peculiar to this nerve.

Whilst this fact may not be altogether correct, whilst other nerves, particularly the sciatic and chiefly the internal popliteal, are capable of presenting the same disturbances, none the less is it true that causalgia of the median is by far the most frequent and characteristic.

It almost invariably accompanies slight lesion of the nerve, without paralysis or anæsthesia, but appearing all of a sudden and accompanied by almost purely painful symptoms and a minimum of trophic disturbances.

* * * * *

Immediately after the wound pain manifests itself, but it gradually increases during the following days, usually reaching its culminating point after ten or twenty days.

Patients complain of terrible, intolerable, persistent, paroxysmal pains both day and night ; these pains are essentially localised in the hand, but they spread over the upper part of the arm, even though the wound is in the fore-arm or the wrist.

The pain is a special and a violent one, characterised by a sensation of persistent burning, whence the name of *causalgia* (*καυσίς*, burning).

Cold, heat, the slightest contact, cause the most atrocious pain. What patients most dread is contact with the air and dryness of the hand ; tepid water often relieves them, and we see them wrapping round their hands moist cloths which they constantly renew. It is also to be noted that profuse perspiration of the hand frequently takes place.

It is not only cutaneous excitations of the hand that cause painful paroxysms, movement of any kind is painful ; simple swinging of the hand when walking causes intolerable recrudescences in these patients. Strong emotion, an approaching

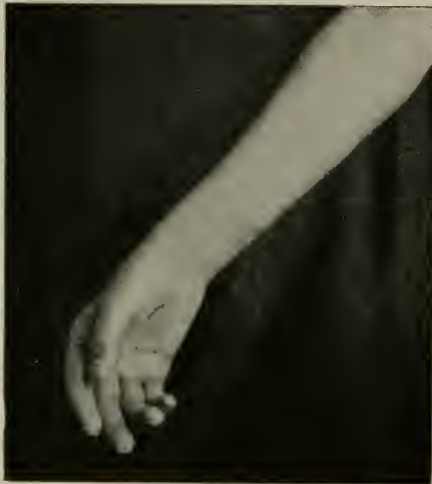

FIG. 171.—Position of the hand at rest. This is not a paralytic posture ; but immobilisation caused by pain. (Dejerine.)

carriage, an unexpected sound, the banging of a door, a brilliant light, the dizzy sense of void in a staircase ; any of these may bring on a terrible and painful crisis.

Thus we find in these patients special symptoms : emaciated by reason of insomnia and loss of appetite, they are gloomy and peevish, they will neither talk nor go outside, they seek solitude, silence and obscurity ; they walk slowly, with short steps, to avoid all shock ; if any one approaches them, they slink away, carefully protecting the hand from all contact by concealing it behind the back, or placing the other arm round it as a shield. The hand is carefully enveloped either with a glove or with wet cloths, which some of them keep renewing, even during conversation.

If these patients are examined, we are surprised to find that there is

no paralysis ; the hand is simply immobilised as a result of pain. Nor is there complete anæsthesia, though often very intense and painful hyper-æsthesia ; more than this, whereas the slightest touch of the skin causes intolerable suffering, firm pressure on the integuments is not very painful, pressure on the muscles of the fore-arm is not at all painful, that on the nerve but slightly, except near the hand. It is excitation of the surface that is painful, not deep excitation as in cases of neuritis.

Trophic and vaso-motor disturbances are insignificant and of a rather special nature.

Usually the skin is not thickened as in cases of neuritis ; on the contrary it is thin, smooth and glossy, with an onion-rind appearance. It is often red and almost always moist.

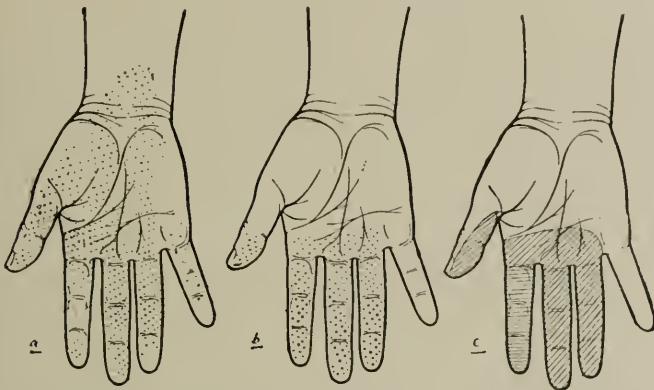


FIG. 172.—Topography of the disturbances of objective sensibility. These disturbances extend beyond the cutaneous region of the median. *a*, Hyper-æsthesia to slight contact (wisp of cotton wool). *b*, Hyper-æsthesia to pin-prick. *c*, Hypo-æsthesia to heat. *Oblique hatching* : the heat is less distinctly felt. *Horizontal hatching* : the heat is not recognised as such. (J. and A. Dejerine and Mouzon, *Presse Méd.*, 8 July, 1915.)

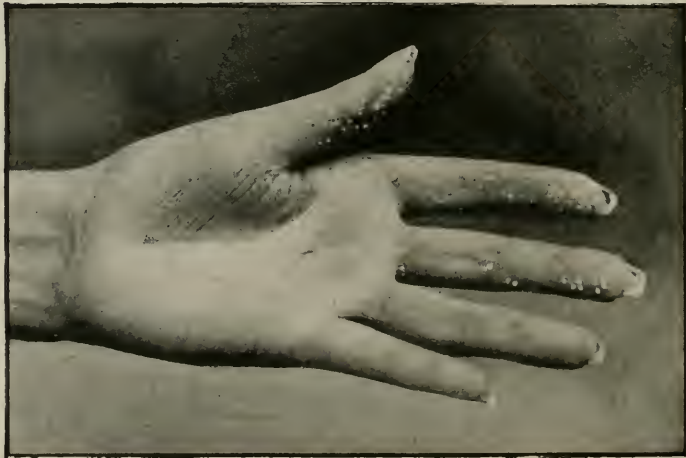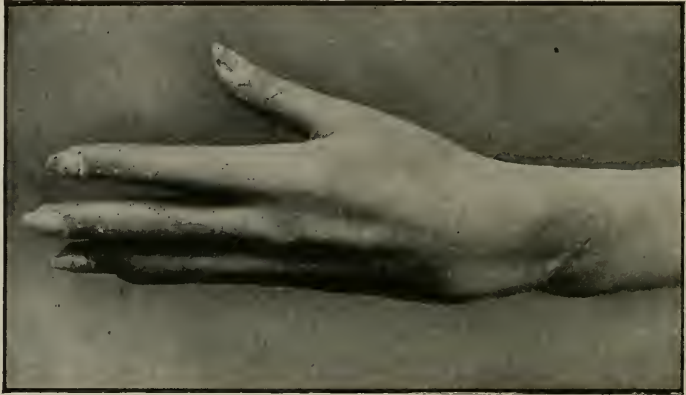There is neither sclerosis of the dermis, fibrous contraction nor articular immobilisation ; the nails are curved as in neuritis, but they are thin and smooth, not thickened, split or striated. Moreover, they grow rapidly and produce behind the pulp a slight cutaneous swelling which is extremely painful.

After a few months there can be seen taking place considerable atrophy of the extremities of index and middle finger, thin, tapering and conical extremities which terminate in quite small and almost triangular nails.

Whilst the trophic disturbances usual in cases of neuritis are absent in causalgia, special lesions are found from time to time ; we have seen small subungual ecchymoses or more frequently small cutaneous phlyctens, comparable to sudamina which, on rupture, left a very painful punctiform cicatrix. It would seem that the thinness and fragility of the integuments, the constantly damp condition and perhaps more especially the maceration

of the continually moistened epidermis, favour the appearance of these trophic disturbances.

There are cases of causalgia in which neurotic lesions are more manifest; accompanied by dryness of the skin, scaly desquamation, fibrous infiltration of the dermis and a tendency to ankylosis of the last phalanges.



FIGS. 173 and 174.—Causalgia of the median nerve. Tapering of the fingers, atrophy, thinness of the skin, profuse sweat. Sudamina followed by ulceration. Rapid growth of nails and sub-ungual swellings.

Causalgia of the median is very refractory to treatment; it continues for eight, ten, or even fifteen months, before diminishing and finally disappearing. Massage has no result whatsoever, galvanic electrical stimulation with the positive pole, and iodine or salicylic ionisation cause only a few hours' relief; in these conditions it may readily be understood

that there has been strong temptation to practise resection and suture or alcoholisation (Sicard) of the affected nerve.

At the same time, one hesitates before subjecting these patients, who are not paralysed, to the risks of nerve suture.

Radiotherapy to the nerve itself or to the roots frequently alleviates causalgia, but it only dispels the painful paroxysms and does not calm the continuous dull pain.

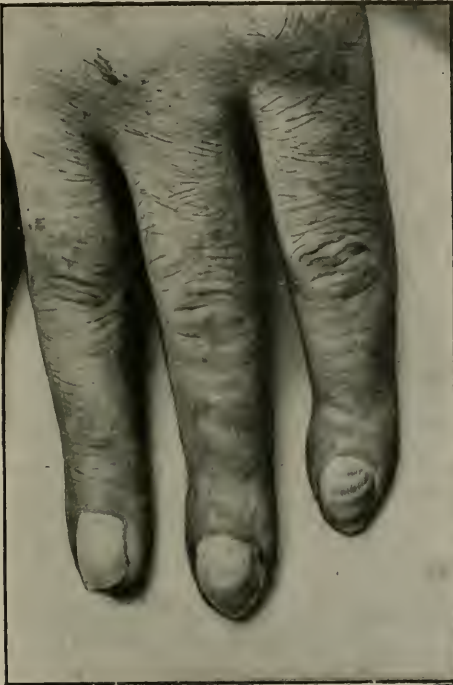

FIG. 175.—Causalgia of the median nerve, with incurvation of the nails, conical atrophy of the last phalanges, fibrous infiltration of dermis and digital articulations. (Compare index and middle finger with the comparatively unaffected ring-finger.)

Moreover, its effect is not constant.

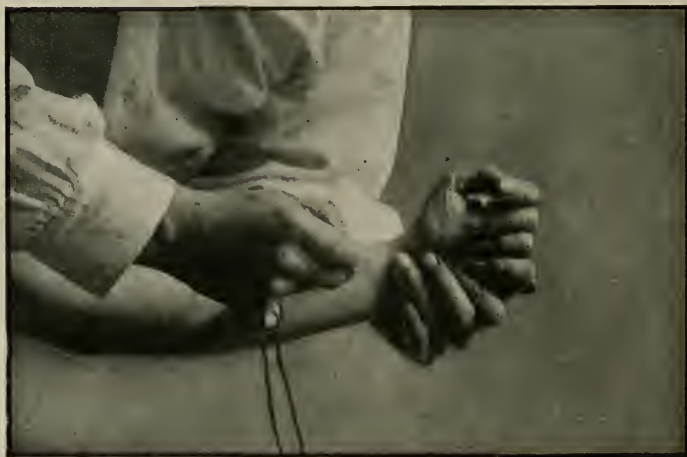At present, there is a tendency to regard causalgia as a sympathetic syndrome. Undoubtedly vaso-dilatation or vaso-constriction of the skin, profuse sweats, and the recrudescence of pain through emotion, call forth the idea of sympathetic disturbances. (Leriche, Meige and Mme. Bénisty.)

In causalgia caused by wounds at wrist or in the fore-arm, we have found disturbances throughout the entire region of the cervical sympathetic, with narrowing and vaso-constriction of the entire brachial artery whose calibre was not more than two or three millimetres and whose pulsations were almost non-existent; there was also slight numbness of the surface on the same side, a diminution of sweat, vaso-motor disturbances in the ear on the affected side, manifestly proving the existence of reflex excitation of the cervical sympathetic.

All these facts may justify the intervention proposed by Leriche : denudation of the brachial artery and resection of the sympathetic plexus surrounding it. We have performed this operation several times with favourable results in cases refractory to all other treatment.

DIAGNOSIS OF PARALYSIS OF THE MEDIAN NERVE

We need not insist on the possibility of overlooking paralysis of the median, either above the epitrochlear muscles, when flexion of the first



FIGS. 176 and 177.—Pseudo-paralysis of the median. Lesion of the nerve in the forearm. Cutaneous anæsthesia and atrophy of the thenar eminence. Although the flexors are intact, the patient cannot close his hand completely. Faradisation of the flexors readily produces movement. Cure effected by a single treatment.

phalanges by the interossei might incline one to believe in the possibility of some slight action of the flexors, or below the epitrochlear muscles, where all the disturbances are reduced to cutaneous anæsthesia and to the loss of opposition of the thumb.

Wounds of the fore-arm, in which the median nerve is affected, very often cause, from injury to the muscles, a weakening or even complete incapacity of the flexors of the fingers, that might erroneously be attributed to nerve lesion.

To avoid this error, we must remember that the flexors receive their nerve twigs very high up, immediately below the bend of the elbow; moreover, the muscles weakened by the wound retain more or less their normal electrical reactions and above all their faradic excitability.

It is also known that there is frequently associated with these wounds a certain degree of functional paralysis due to prolonged inaction.

Here we would point out a somewhat frequent cause of error, to which allusion has already been made. We refer to functional paralysis of the flexors of the thumb, the index and the middle finger, following lesion of the median in the fore-arm and caused by anæsthesia of the hand.

We have met with several of these very curious cases in which the patient thinks that his fingers are paralysed because he neither feels them nor even attempts to use them.

We need only contract the flexors by means of the faradic current to recognise the functional nature of this paralysis, prove to the patient the possibility of movement, and effect a speedy cure.

CHAPTER IX

ASSOCIATED PARALYSIS OF THE MEDIAN AND ULNAR NERVES

It is necessary to make a special study of the associated paralyses of the median and the ulnar. These paralyses are very frequent, and are




FIG. 178.—Paralysis of the median and the ulnar—"flat hand."

caused by lesions in the upper arm, where both nerves are close to each other.

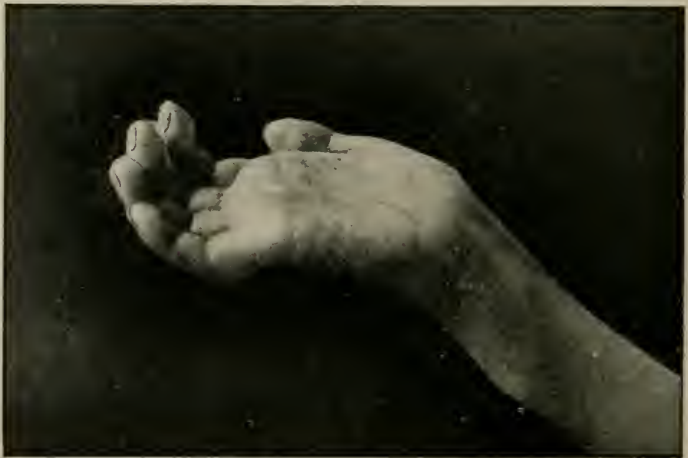

FIG. 179.—Paralysis of the median and the ulnar. Hyper-extension of the first phalanges by contraction of the extensors. This movement induces semi-flexion of the second and third phalanges (paralysis of the interossei).

In these cases we note the association of the two paralytic syndromes, also complete loss of the movements of flexors and interossei.

Atrophy of the epitrochlear muscles is complete ; the massive atrophy of the thenar and hypothenar muscles produces the " flat hand " appearance.

Owing to atony of the flexors and interossei, the efforts to extend the fingers readily induce an attitude of hyper-extension of the first phalanges, along with semi-flexion of the second and third.

Particularly important are the curious substitutionary movements found in most cases and first mentioned by H. Claude.

Flexion of the hand on the wrist is theoretically suppressed ; all the same, it is for the most part possible, by substitution of the extensor ossis metacarpi pollicis and the short extensor of the thumb.

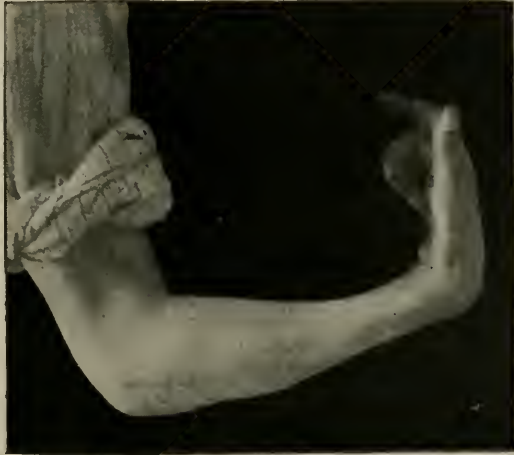

FIG. 180.—Flexion of the hand by the extensor ossis metacarpi pollicis and by the short extensor of the thumb. (Claude, Dumas, and Porack, *Presse Méd.*, 10 June, 1915.)

Finger-flexion is logically impossible. Patients, however, are capable of performing certain flexion movements ; to such an extent is this the case, that it is difficult to believe that both nerves are paralysed.



FIG. 181.—Pseudo-flexion of the fingers. In paralysis of the median and the ulnar, by forcible straightening of the carpus and mechanical traction of the flexor tendons.

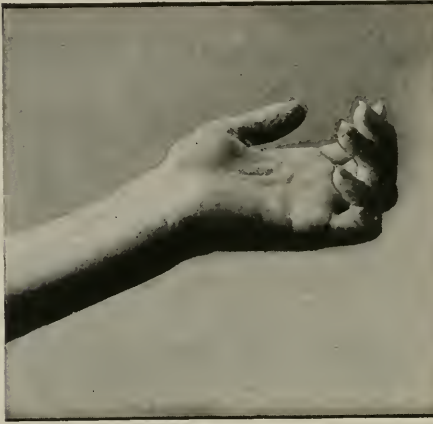They succeed in flexing the fingers by forcibly raising the hand with the radial extensors ; the effect of this hollowing of the hand is to stretch the flexor tendons on the pulley, as it were, of the radio-carpal articulation, and consequently to exercise traction on the fingers, in a purely mechanical way.

Again, in raising the hand, the patients allow their fingers to droop under the action of gravity, and this still further emphasises the flexion attitude. This may be seen by turning upwards the palm of the hand ; the action of gravity ceases, and the fingers, being flexed only by the hollowing of the hand, fall back into a state of moderate flexion.

It is unnecessary to add that this artificial flexion of the fingers is extremely feeble and cannot be made use of by the patient.

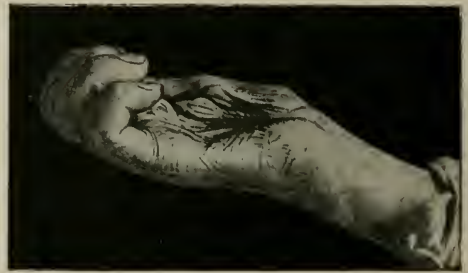When regeneration begins in the median and ulnar nerves, there is observed the progressive appearance of a special four-fingered *griffe*, supple and reducible, characterised by flexion of the last two phalanges on the

first: it is produced by tone of the flexors of the fingers, deprived of the antagonism of the interossei, extensors of the last two phalanges.



FIGS. 182 and 183.—Paralysis of the median and the ulnar in course of regeneration. The “flat” hand has become transformed into a four-fingered *griffe* once the flexors have regained their tone. (Soft and reducible *griffe*.) Note the projection of the flexor carpi radialis.

Finally, simultaneous irritation of the median and the ulnar causes a complete neuritic fibrous four-fingered *griffe*; flattening of the thenar and hypothenar eminences, atrophy of the interossei, and flexion of the last two phalanges, all give the hand the typical appearance of the “ape-like hand.”



FIGS. 184 and 185.—Neuritic *griffe* of the median and the ulnar—“simian hand.” Fibrous four-fingered *griffe*. Tendon contraction. Contraction of the palmar aponeurosis.

CHAPTER X

MUSCULO-CUTANEOUS NERVE

THE musculo-cutaneous nerve originates along with the external root of the median from the outer cord of the brachial plexus. Its fibres arise almost solely from the fifth and sixth cervical roots.

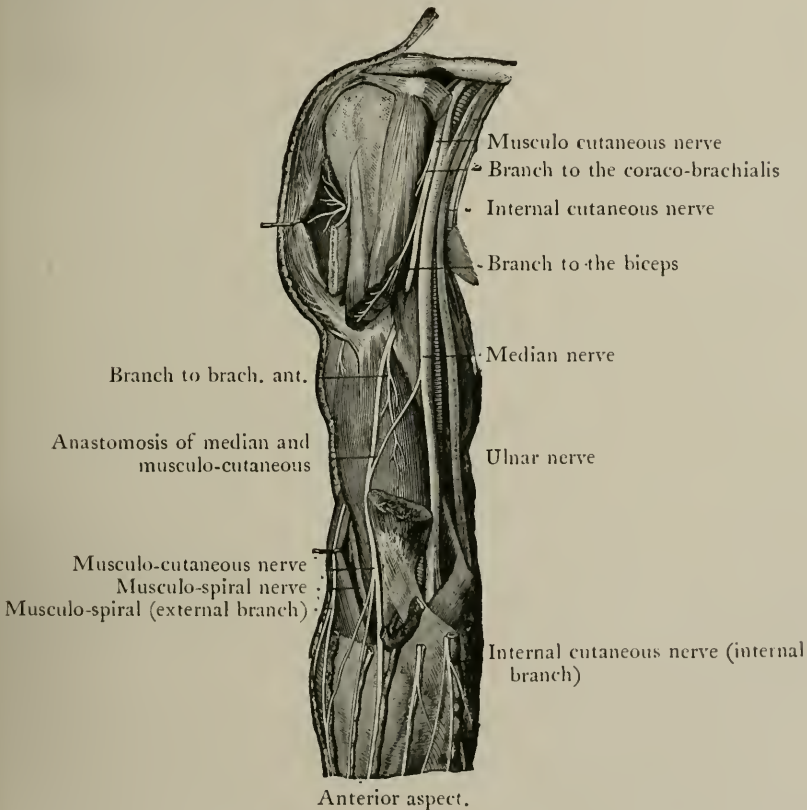


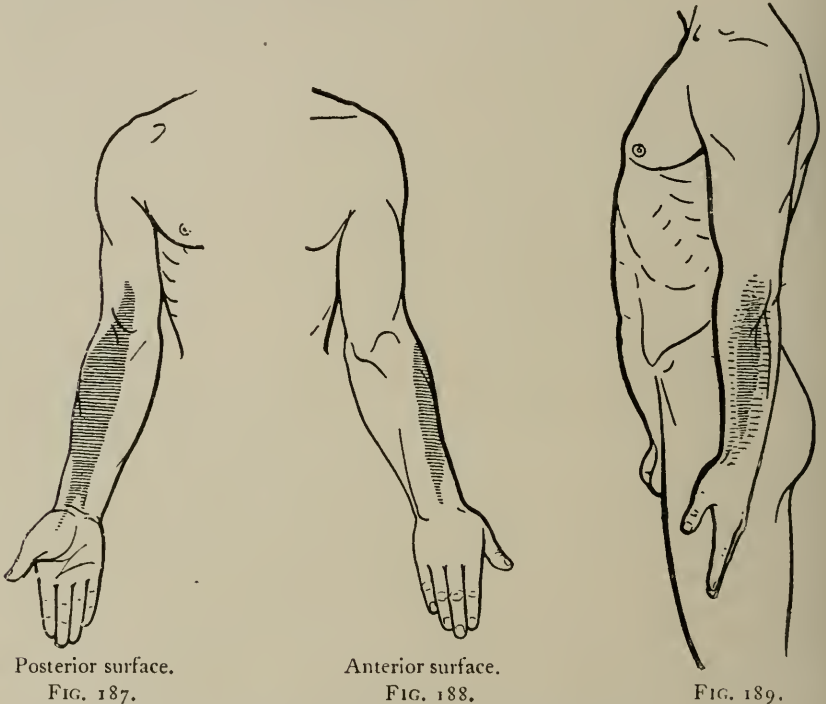
FIG. 186.—Deep nerves of arm (after Sappey). The biceps has been resected to lay bare the musculo-cutaneous nerve.

At its origin in the armpit, the musculo-cutaneous nerve is situated above and outside the median and the axillary artery. It remains adherent to the median, as far as the union of the upper third and the middle third of the arm.

At this level it suddenly changes direction, passes obliquely outward, crosses the coraco-brachialis, and descends obliquely in front of the brachialis anticus, covered by the biceps, supplying motor branches to these three muscles.

It is under the biceps that the anastomotic branch breaks away, uniting the musculo-cutaneous to the median nerve; rising again obliquely it enters this nerve, reaching it at the middle third of the arm.

Probably it often brings to the median aberrant motor fibres issuing from the fifth and sixth cervical roots.



Posterior surface.

FIG. 187.

Anterior surface.

FIG. 188.

FIG. 189.

FIGS. 187 and 188.—Sensory region of musculo-cutaneous nerve.

FIG. 189.—Cutaneous anæsthesia in complete section of musculo-cutaneous nerve.

Afterwards the musculo-cutaneous nerve appears on the external surface of the biceps, plunges underneath the edge of the supinator longus, and becomes sub-cutaneous near the bend of the elbow; it then divides into its two terminal branches, anterior and posterior, which descend in parallel lines on to the antero-external surface of the fore-arm, supplying the skin.

BRANCHES

1. Along the first part of its course, the musculo-cutaneous supplies only motor-branches:

The nerves to the coraco-brachialis.

The nerves to the biceps.

The nerves to the brachialis anticus.

2. Beyond the biceps, the musculo-cutaneous is no more than a sensory nerve where two parallel branches of the bifurcation supply the antero-internal part of the fore-arm right to the vicinity of the wrist.

3. Lastly, the musculo-cutaneous, apart from its terminal anastomoses, sends out an important anastomotic branch to the median, meeting the



FIG. 190.

FIG. 190.—Substitution of the paralysed musculo-cutaneous by the musculo-spiral. Energetic flexion of the fore-arm on the arm by the supinator.

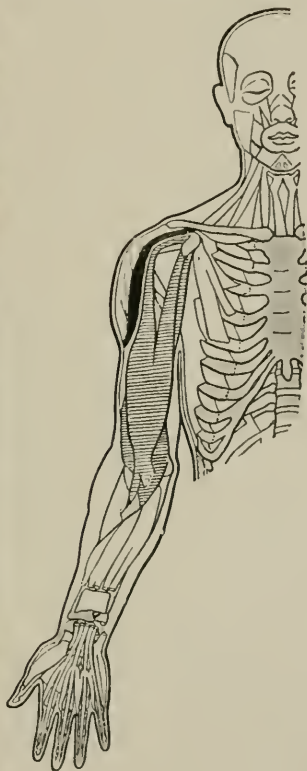


FIG. 191.

FIG. 191.—Muscles supplied by the musculo-cutaneous. Coraco-brachialis biceps; brachialis anticus. The deltoid is cut in order to expose the deep muscles.

latter about the middle of the arm. It seems to be proved that, speaking generally, this branch brings to the median supplementary fibres of the fifth and sixth cervical roots; it may fail in this; the thinner the external head of the median, the more developed this branch is.

PHYSIOLOGY—PARALYSIS OF THE MUSCULO-CUTANEOUS

MOTOR SYNDROME

The musculo-cutaneous is the nerve whose sole function is to supply the flexors of the fore-arm on the arm.

Its interruption determines paralysis and atrophy of the coracobrachialis, the biceps and the brachialis anticus ; these last two are flexors of the fore-arm on the arm.

It must not be imagined that paralysis of the musculo-cutaneous does away with the flexion of the elbow. This is still possible, even forcibly, by the supinator longus (musculo-spiral), the flexor rôle of which is thus proved.

Paralysis of this nerve may thus easily be disregarded if we confine ourselves to making a simple flexion of the fore-arm without endeavouring to obtain real contraction of the biceps and without exploring its electrical reactions.

SENSORY SYNDROME

The musculo-cutaneous supplies the integuments of the antero-external part of the fore-arm and passes slightly on to its postero-external surface.

Nevertheless, we must not expect to find so extensive a state of anæsthesia in lesions of this nerve. The musculo-spiral behind, and the internal cutaneous on the inner side, overlap it considerably and largely reduce the region of complete anæsthesia, which is restricted to a tract extending over the antero-external part of the fore-arm.

CHAPTER XI

THE CIRCUMFLEX NERVE

THE circumflex nerve is generally regarded as a collateral branch of the brachial plexus.

By reason of its size and importance, however, we may, with Sappey, regard it as a terminal branch of this plexus, becoming detached along with the musculo-spiral from the posterior secondary trunk. Most of its fibres originate in the fifth cervical root.

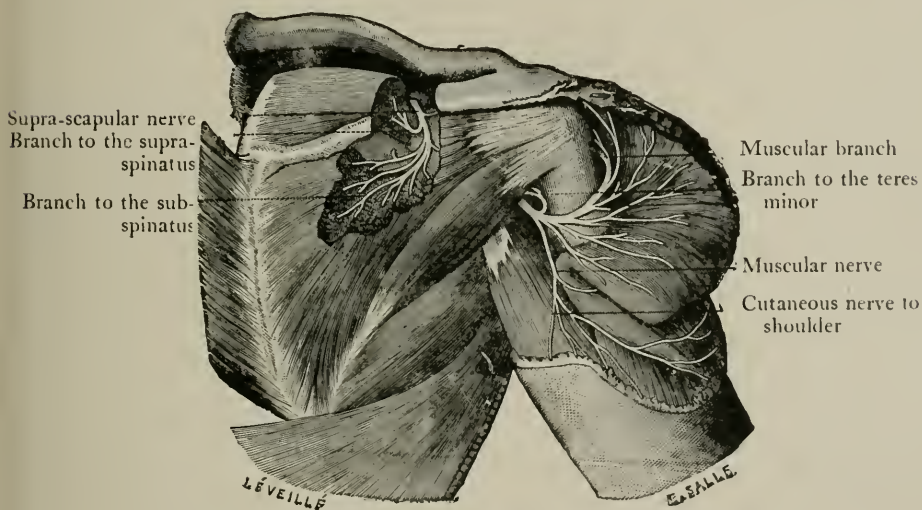


FIG. 192.—Circumflex and supra-scapular nerves. (After Sappey.)

It springs from the brachial plexus, about the middle of the axilla; at this level it is situated behind the axillary artery, and outside the musculo-spiral nerve.

It immediately proceeds downwards and outwards, and passes towards the posterior part of the shoulder accompanied by the posterior circumflex artery; it passes into the interspace circumscribed by the neck of the humerus outwards and forwards, the long head of the triceps within and behind, the lower edge of the subscapularis and of the teres minor above, the upper border of the teres major below (quadrilateral square of Velpeau).

It thus passes round the posterior surface of the surgical neck of the humerus and reaches the deltoid on its deep surface.

BRANCHES

Apart from the articular branches and from certain fibres supplied to the subscapularis, the only important offshoots supplied by the circumflex are the deltoid branches and the cutaneous branch to the shoulder.

1. The deltoid branches issue from the circumflex nerve after it has

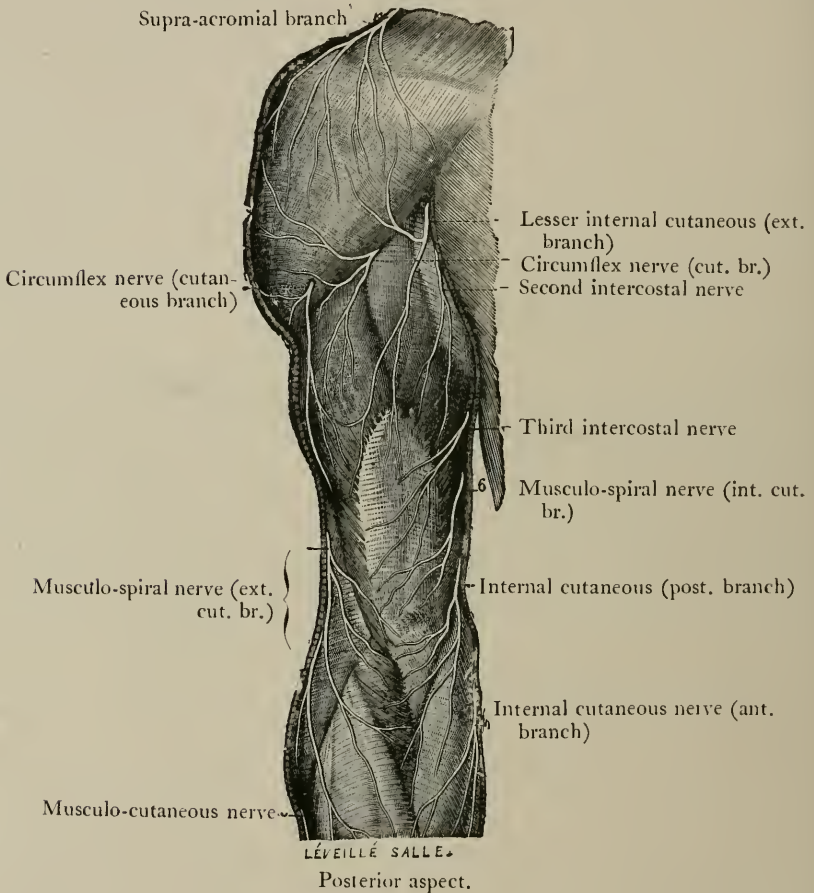


FIG. 193.—Superficial nerves of shoulder, arm and elbow. (After Sappey.)

reached the neck of the humerus. A distinction is made between the ascending and the descending branches, which successively become detached to supply the different portions of the deltoid.

This distribution is arranged in vertical segments, from behind forwards. Thus we see that certain lesions of the nerve, on the external surface of the shoulder, for instance, may produce dissociated paralyses of the circumflex; the anterior and exterior fasciculi, clavicular and acromial, are paralysed, whilst the posterior scapular fasciculi are untouched.

2. The cutaneous nerve of the shoulder is a collateral sensory branch, which breaks away from the circumflex after its passage into the quadrilateral space; it proceeds downwards and outwards, and emerges between the deltoid and the long head of the triceps. Then it divides into ascending and horizontal branches which supply the cutaneous covering for the shoulder, and in descending branches which are distributed over the integuments of the external surface.

PARALYSIS OF THE CIRCUMFLEX

Paralysis of the circumflex is not met with in direct traumatism of the nerve only, it also appears in fractures of the surgical neck of the humerus by embedding or compression of the nerve; it may follow dislocation of the

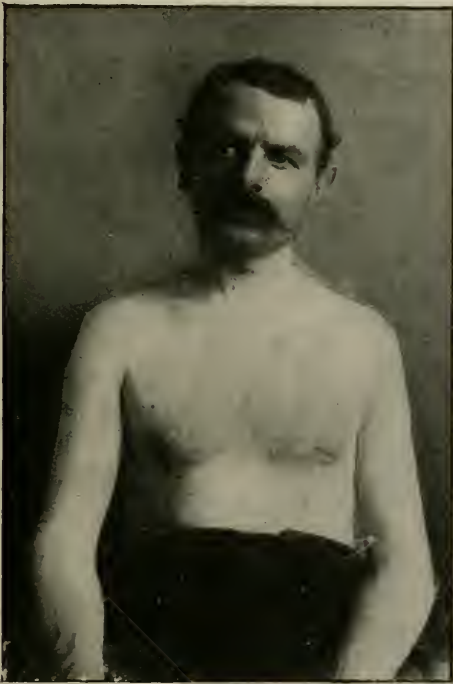


FIG. 194.—Paralysis of the circumflex. Atrophy of the deltoid.

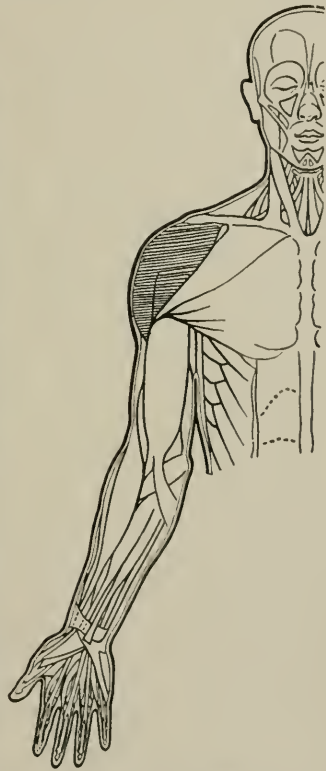

FIG. 195.—Motor area of the circumflex.

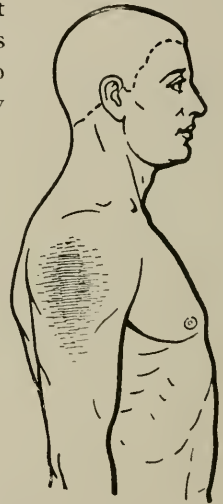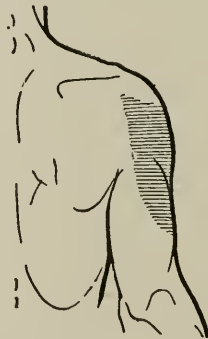
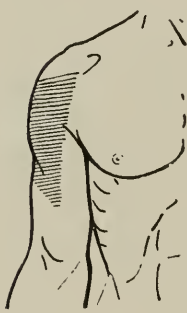
shoulder, owing to traction on or contusion of the nerve; all the same, it would appear that in most of these cases we are dealing with the lesion of the upper roots of the brachial plexus, stretched or torn away by the dislocation (Duval and Guillain); in reality, they are cases of root paralysis of the brachial plexus, affecting the fifth cervical root.

Lesions of the circumflex are shown solely by paralysis of the deltoid and by sensory disturbances of the shoulder.

Paralysis of the deltoid produces loss of power to raise the arm outwards (by means of the acromial fasciculi), forwards (clavicular fasciculi), and backwards (scapular fasciculi).

The disturbances thus produced are all the more serious because substitutionary movements scarcely exist at all in the case of the deltoid. The supra-spinatus alone is capable of slightly raising the arm outwards and forwards, with rotation inwards; this movement is extremely feeble, and is incapable of introducing any effective substitution for paralysis of the deltoid.

The arm remains hanging almost loose alongside the body; in vain does the patient attempt to raise it; he contracts his shoulder muscles and the supra-spinatus succeeds in making only a faint movement of abduction; he contracts the serratus magnus, but the swinging movement imparted to the shoulder-blade is nullified by the utter flaccidity



FIGS. 196 and 197.—Anatomical sensory topography of the circumflex nerve (cutaneous nerve of the shoulder).

FIG. 198.—Actual anaesthesia in section of the circumflex.

of the deltoid; finally, he partially detaches his arm artificially, by raising his shoulder and bending his thorax in such a way that the arm is, as it were, raised by the ribs on which it is resting.

At the same time atrophy of the deltoid flattens the shoulder and relaxes the joint capsule, which often exhibits an abnormal degree of laxity.

SENSORY DISTURBANCES

Sensory disturbances are somewhat reduced in paralysis of the circumflex. Seldom do we find complete anaesthesia; as a rule, we simply have more or less pronounced hypo-aesthesia of the external surface of the shoulder.

CHAPTER XII

INTERNAL CUTANEOUS NERVE AND LESSER INTERNAL CUTANEOUS NERVE

THE internal cutaneous nerve and the lesser internal cutaneous are very seldom affected separately ; on the contrary, they often share in the lesions of the median and the ulnar, on the inner surface of the arm.

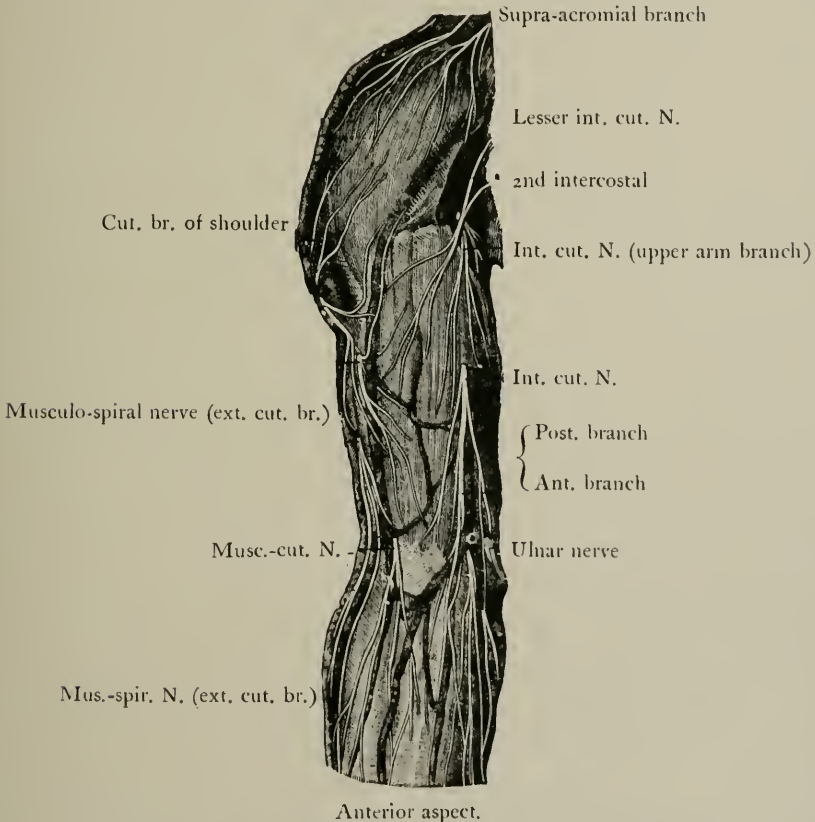


FIG. 199.—Cutaneous nerve of shoulder and arm. (After Sappey.)

These are exclusively sensory nerves, originating in the lower secondary trunk slightly internal to the ulnar.

The internal cutaneous descends to the inner part of the arm internal

to the median nerve, in front of the ulnar nerve; on reaching the middle of the arm, it perforates the deep fascia and becomes superficial. Then it proceeds along the basilic vein and at the bend of the elbow divides into its terminal branches which are distributed over the inner and anterior part of the fore-arm.

At the base of the axilla, it supplies the cutaneous branch to the upper

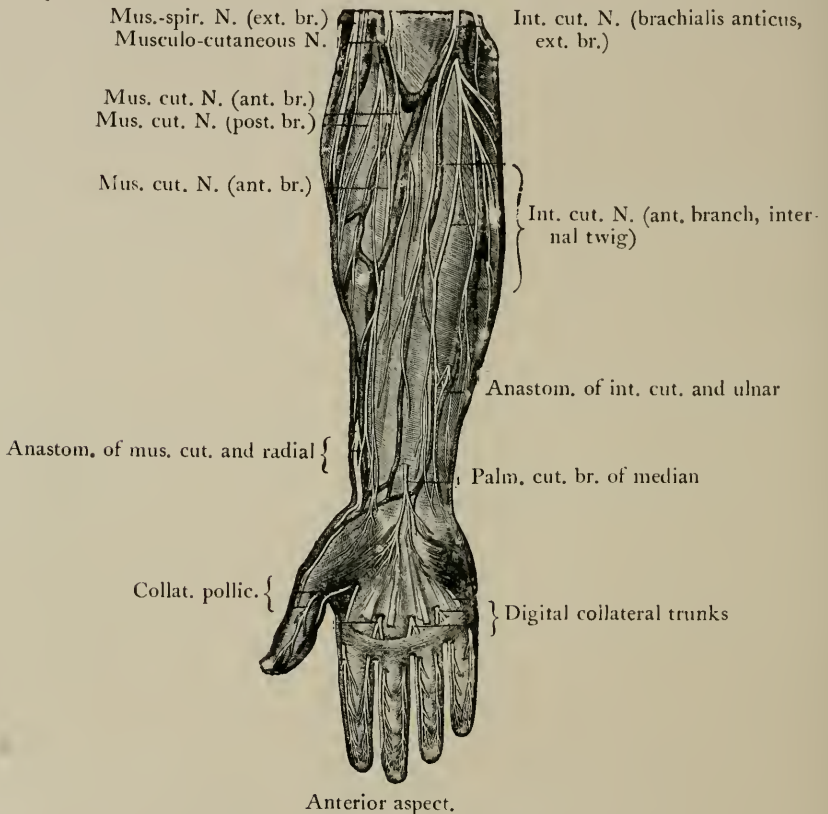


FIG. 200.—Superficial nerves of fore-arm and hand. (After Sappey.)

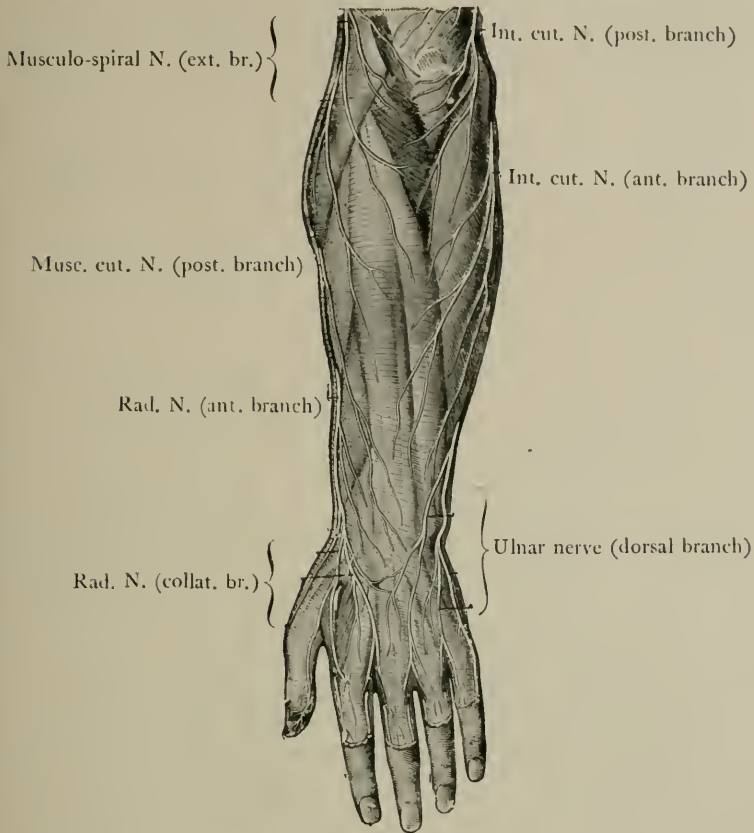
arm, which is distributed over the inner surface of the arm, as far as the bend of the elbow.

The lesser internal cutaneous perforates the deep fascia at the upper third of the arm and is distributed over the skin of the inner surface of the arm behind the region of the internal cutaneous (cutaneous branch to the arm) and right to the level of the epitrochlea.

A lesion of the internal cutaneous, usually associated with that of the median and more especially of the ulnar, is shown by slight hypo-æsthesia of the inner surface of the fore-arm.

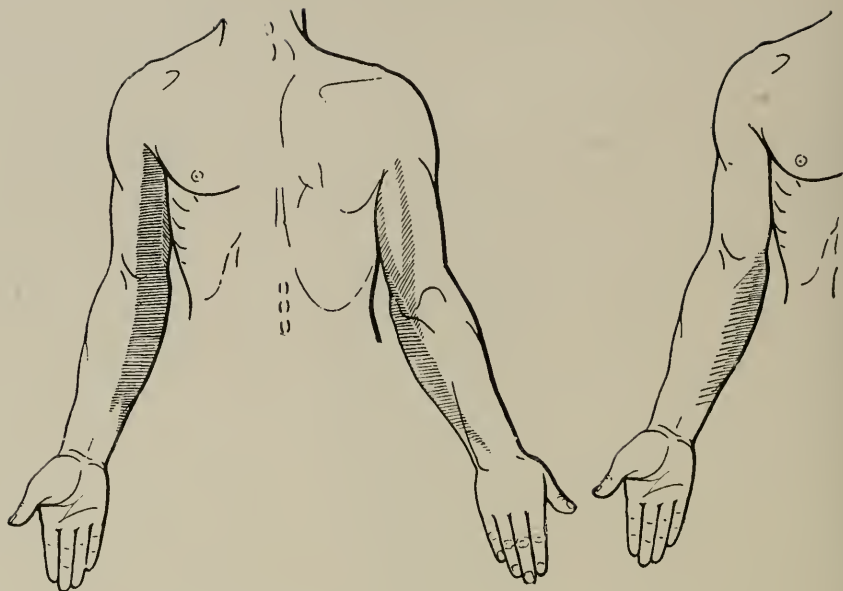
Only lesions which involve the nerve in the neighbourhood of the axilla are accompanied with hypo-æsthesia on the inner surface of

the arm; and even this hypo-æsthesia is greatly lessened owing to the proximity of the lateral cutaneous branches of the second and third intercostal nerves.



Posterior aspect.

FIG. 201.—Superficial nerves of fore-arm and hand. (After Sappey.)



FIGS. 202 and 203.

FIG. 204.

FIGS. 202 and 203.—Cutaneous topography of the internal cutaneous and the lesser internal cutaneous (oblique hatching). The perforating branches of the second and third intercostal nerves supply a triangular area on the postero-internal surface of the arm, in the region of the lesser internal cutaneous.

FIG. 204.—Sensory disturbances in lesions of the internal cutaneous.

CHAPTER XIII

BRACHIAL PLEXUS

THE brachial plexus consists of the fifth, sixth, seventh, and eighth cervical roots and the first dorsal.

All these roots make their way towards the apex of the axilla, the

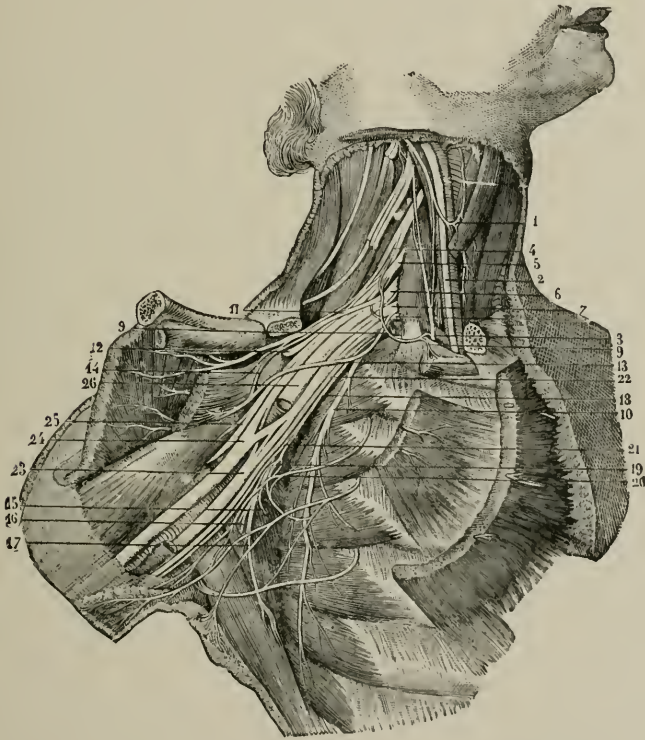


FIG. 205.—Brachial plexus and its collateral branches. (After Hirschfeld.) 1. Ansa hypoglossi. 2. Pneumogastric nerve. 3. Phrenic nerve. 4, 5, 6, 7. Fifth, sixth, seventh and eighth cervical roots. 8. First dorsal root. 9. Nerve to the subclavius. 10. Nerve to serratus magnus. 11. Nerve to pectoralis major. 12. Sub-scapular nerve. 13. Nerve to pectoralis minor. 14. Anastomoses of nerves of pectoralis major and pectoralis minor. 15. Lower branch to sub-scapularis. 16. Nerve to teres major. 17. Nerve to latissimus dorsi. 18, 20, 21. L.I.C. 19. Its anastomosis with the lateral cutaneous branch of the second intercostal nerve. 22. Internal cutaneous nerve. 23. Ulnar nerve. 24. Median nerve. 25. Musculo-cutaneous nerve. 26. Musculo-spiral nerve.

higher ones taking an obliquely descending course, the lower ones following a direction almost horizontal.

The brachial plexus thus spreads out into the sub-clavicular region in the form of a triangle, with vertebral base and axillary apex.

Near the vertebral column, the roots of the plexus, set in tiers and separated from one another, may be affected separately by traumatism, whereas wounds in the axillary region almost invariably cause important injuries that affect several trunks.

CONSTITUTION OF THE BRACHIAL PLEXUS

There are many individual variations in the constitution of the plexus ; at the same time, we can give a tolerably simple diagrammatic description of it.

I.—PRIMARY TRUNKS

The fifth and sixth cervical roots unite to constitute the upper trunk.

The eighth cervical and the first dorsal join to constitute the lower trunk. The seventh cervical of itself forms the middle trunk.

II.—SECONDARY TRUNKS

Each of the primary trunks soon divides into two branches, the one anterior, the other posterior.

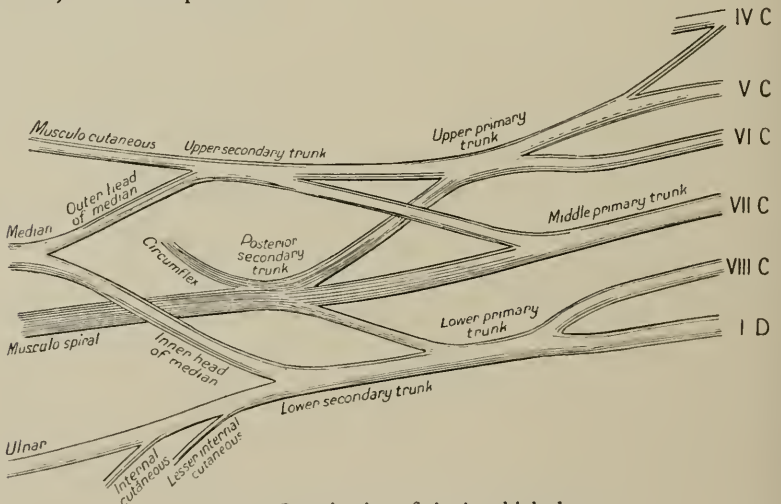


FIG. 206.—Constitution of the brachial plexus.

The anterior branches of the upper trunk and of the middle trunk unite to form the upper cord which is to produce the musculo-cutaneous nerve and the external or superior root of the median.

The anterior branch of the lower trunk constitutes of itself the inner

cord, which produces the ulnar and the inner root of the median as well as the internal cutaneous and lesser internal cutaneous.

The three posterior branches unite to form the posterior cord which supplies the circumflex and afterwards constitutes the musculo-spiral nerve.

CONNEXIONS OF THE BRACHIAL PLEXUS

On leaving the intervertebral foramina, the roots of the brachial plexus penetrate into the space separating the scalenus anticus from the scalenus medius.

Then they cross obliquely the lower part of the supra-clavicular fossa and converge towards the middle of the clavicle. It is slightly outside the

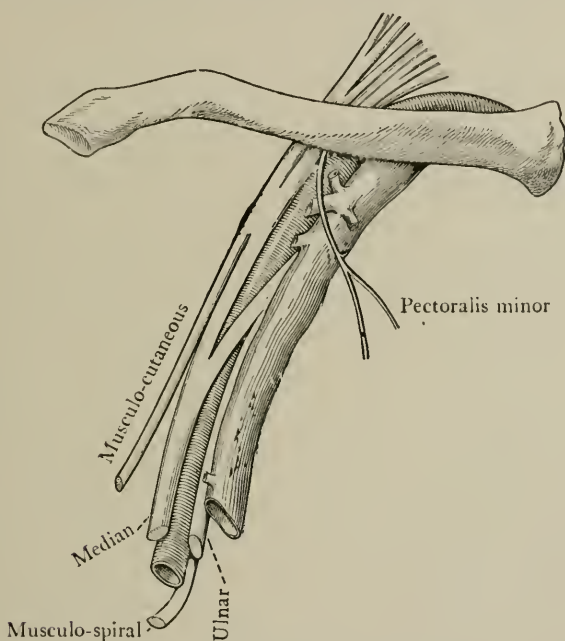


FIG. 207.—Connexions of the brachial plexus at the level of the axilla.

scaleni that the primary trunks appear. Thus the supra-clavicular area is essentially that of the primary trunks and of their branches of division.

Below the clavicle are found the cords which soon produce the nerves of the upper limb.

The important relation of the brachial plexus with the axillary artery and vein are well known.

Situated at first external to, and a little behind the axillary artery, which separates them from the vein situated more internally, the nerve trunks are all around the artery; the musculo-cutaneous is outside and above, the median in front and outside, the musculo-spiral behind; the

ulnar runs between the artery and the vein; the inner head of the median, passing between the artery and the vein, crosses the anterior surface of the artery.

Traumatism which affects the brachial plexus will accordingly affect the different groupings of nerve fibres, according to the level of the wound.

We must remember that the brachial plexus may somewhat diagrammatically be divided into four regions.

In the region of the scaleni, and even a little outside this zone, are found the roots of the plexus.

The supra-clavicular fossa corresponds to the region of the primary trunks.

Behind the clavicle and in the upper part of the axilla, are found the secondary cords. In the lower axillary region appear the nerves of the upper limb.

It is necessary to add that the nerve fibres all converge upon the axilla; at this level, lesions of the plexus will often be severe and very extensive, affecting several nerve trunks and simultaneously affecting the axillary vessels. Wounds of the supra-clavicular fossa, especially those of the region of the scaleni, on the other hand, affect isolated nerve trunks; most frequently they induce partial lesions and dissociated root paralyses; the artery and the axillary vein, situated much lower, behind the clavicle, are more rarely affected.

BRANCHES OF THE BRACHIAL PLEXUS

Along its course the brachial plexus sends out a certain number of important collateral branches.

1. The nerve to the rhomboids which separates direct from the fifth cervical root.

2. The nerve to the serratus magnus, which originates in the fifth and sixth cervical roots, crosses the entire posterior surface of the brachial plexus and descends along the mid-axillary line, adhering to the thoracic wall.

3. The supra-scapular nerve, springing from the higher primary trunk crosses the supra-clavicular fossa, reaches the supra-scapular notch passing beneath the ligament which converts into a foramen the supra-scapular notch whilst the supra-scapular vessels pass above it. It thus penetrates into the supra-spinous fossa, passes round the spine of the scapula and terminates in the infra-spinous fossa.

It supplies the supra and infra spinati.

4. The upper branch to the subscapularis, originating in the upper trunk.

5. The nerve to the subclavius rises generally in the anterior branch

of the upper trunk and supplies an anastomotic branch to the phrenic (loop of Henle).

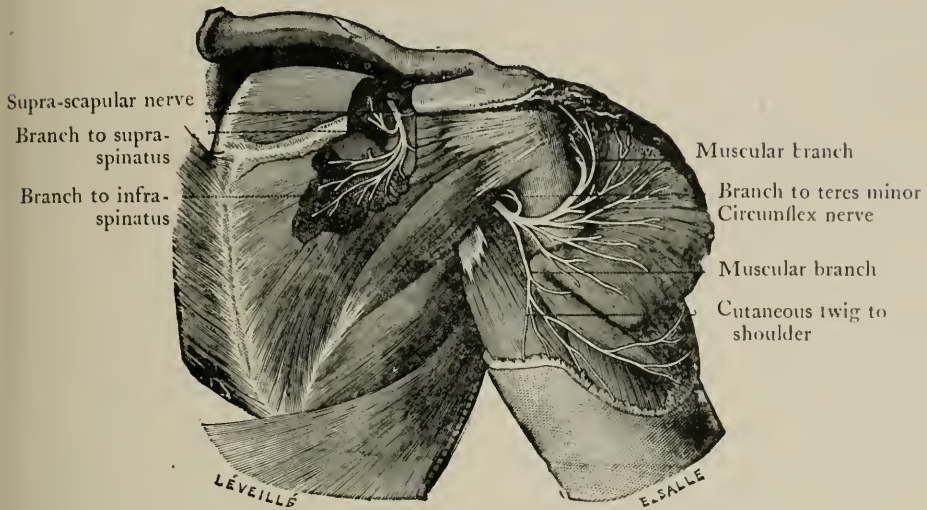


FIG. 208.—Circumflex and supra-scapular nerves. (After Sappey.)

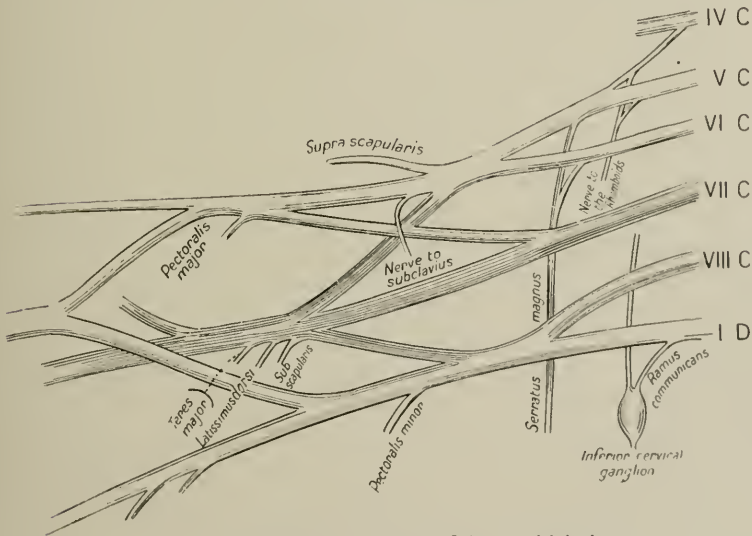


FIG. 209.—Collateral branches of the brachial plexus.

6. The nerve to the pectoralis major (external anterior thoracic) separates from the upper cord behind the clavicle.
7. The lower branch to the subscapularis.
8. The nerve to the teres major.
9. The nerve to the latissimus dorsi.

These three nerves become detached almost at the same level from the posterior cord, near the origin of the circumflex.

10. The nerve to the pectoralis minor (internal anterior thoracic) has its origin in the lower cord.

We must remember that the nerves to the rhomboids, to the supra-spinatus and the infra-spinatus, to the subscapularis (upper branch) and to the pectoralis major, originate successively from the fifth and sixth cervical roots and from the primary and secondary trunks following them. They thus belong to the higher root group.

The nerves to the latissimus dorsi and the teres major as well as the lower branch to the subscapularis originate in the posterior cord.

The lower trunk supplies only the nerve to the pectoralis minor.

All the cervical roots, on leaving the intervertebral foramina, send out a communicating branch to the cervical sympathetic. The branch from the first dorsal root is particularly important, for it carries to the lower cervical ganglion of the sympathetic the cilio-spinal fibres destined for the innervation of the pupil.

LESIONS OF THE BRACHIAL PLEXUS

The brachial plexus, like all the nerves, may be affected directly by a wound, compressed by a foreign body, a bony callus, a cicatricial fibrous mass, or even a simple hematoma of the supra-clavicular fossa or of the axilla. But it may also be wrenched by traction on the upper limb, or by violent downward traction of the shoulder, with or without dislocation.

Wounds of the brachial plexus may affect the roots or the primary trunks as well as the secondary trunks and their branches of division.

Somewhat variable and often complex syndromes result, of which only a very summary description can be given.

They differ mainly from the syndromes produced by wounds of the peripheral nerve trunks in the fact that there is a different distribution of motor and sensory disturbances. In the case of the roots and primary trunks, we have radicular distribution; in the case of lesion of the secondary trunks we have a distribution midway between that of the roots and of the peripheral nerves.

We shall study in succession :

1. The radicular syndromes resulting from lesion of the roots or primary trunks; these result from lesions above the clavicle and affecting the nerve trunks, either in the supra-clavicular fossa, or between the scaleni, on the sides of the vertebral column, or even on a level with the intervertebral foramina.

2. The plexus syndromes strictly so called, corresponding to lesions of

the secondary trunks and of their branches; these result from lesions affecting the clavicular region or the upper part of the axilla.

We have already remarked that the roots and primary trunks are frequently affected separately, producing partial paralysis of the brachial plexus. The secondary trunks, on the other hand, closely adhering to one

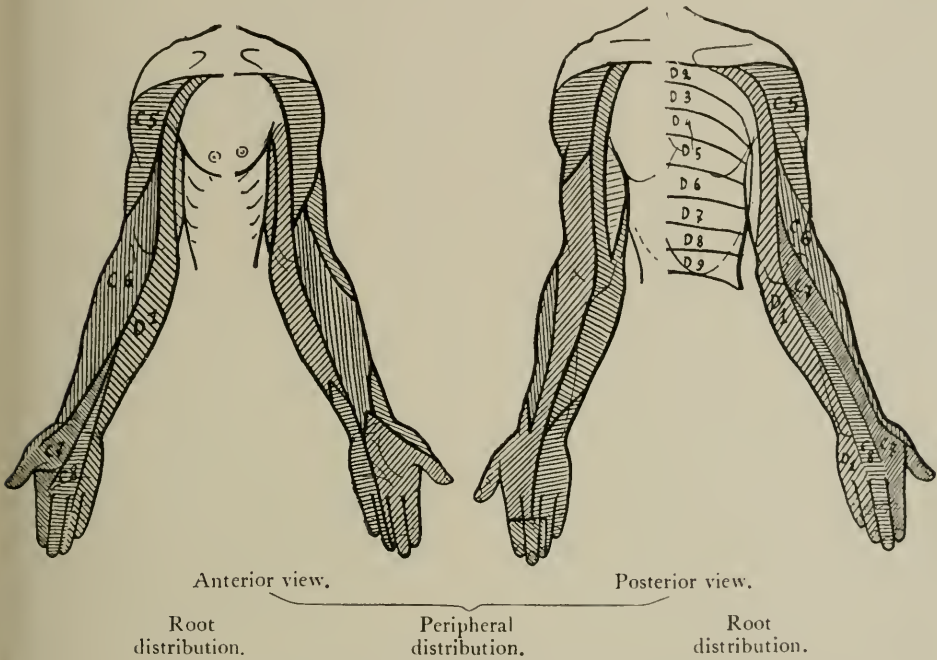


FIG. 210.—Root and peripheral sensory regions.

The radicular sensory regions are indicated by horizontal lines, parallel to the axis of the limbs.

another, are more frequently affected as a whole and often produce complete paralysis of the brachial plexus; still, it is possible to find among them syndromes of partial lesion. On the other hand, the close relations of the secondary trunks with the axillary vessels explain the frequent association of lesions and vascular syndromes which complicate strikingly any clinical investigation.

I.—RADICULAR SYNDROMES (ROOTS AND PRIMARY TRUNKS)

The general character of the radicular syndromes is essentially the root distribution of motor and sensory disturbances.

On the other hand, however, a great number of muscles are supplied

by two and often three different roots ; consequently, partial paralyses of these muscles will often be found.

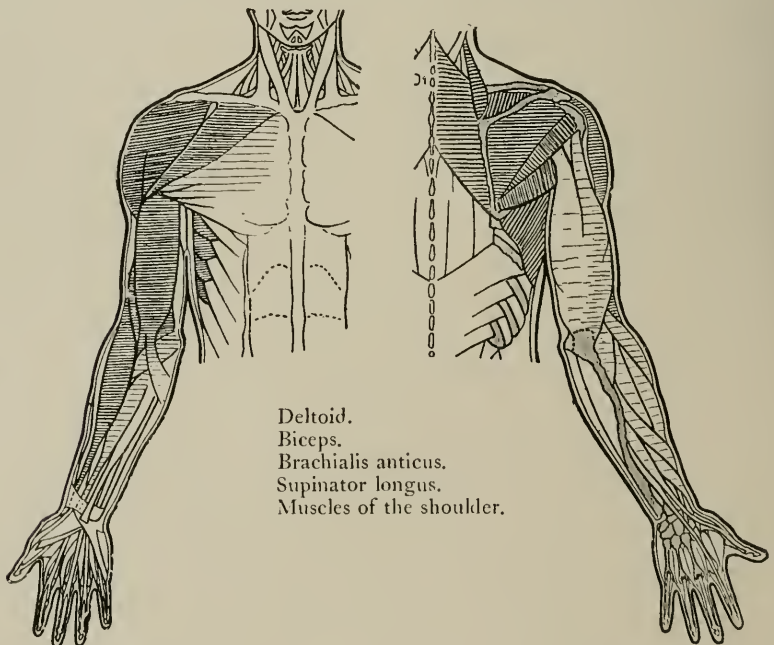
Between the roots, too, there are extensive sensory substitutions ; anæsthesia therefore resulting from radicular lesions is frequently less obvious than anæsthesia from lesions of the trunks.

We shall describe diagrammatically three partial radicular syndromes, corresponding to lesions :

1. Of the fifth and sixth cervical roots—upper radicular group comprised in the upper primary trunk.
2. Of the seventh cervical root and the middle radicular trunk.
3. Of the eighth cervical root and the first dorsal—lower radicular group, comprised in the lower radicular trunk.

I.—UPPER RADICULAR GROUP, FIFTH AND SIXTH CERVICALS. (ERB-DUCHENNE SYNDROME)

1. Lesions of the upper radicular group are characterised essentially by paralysis of the following muscles, supplied by its terminal branches ;



Anterior view.

Posterior view.

FIG. 211.—Upper radicular group. Motor topography.

Deltoid (circumflex nerve).

Biceps and brachialis (musculo-cutaneous nerve).

Supinator longus (musculo-spiral).

We need not insist on the nature of these paralyzes, which have already been studied. We simply call attention to the fact that flexion of the fore-arm on the arm is completely suppressed, since the biceps and the supinator longus are both paralysed.

2. There is also found paralysis of the following muscles :

Pectoralis major (clavicular head only).

Supra-spinatus and infra-spinatus.

Subscapularis.

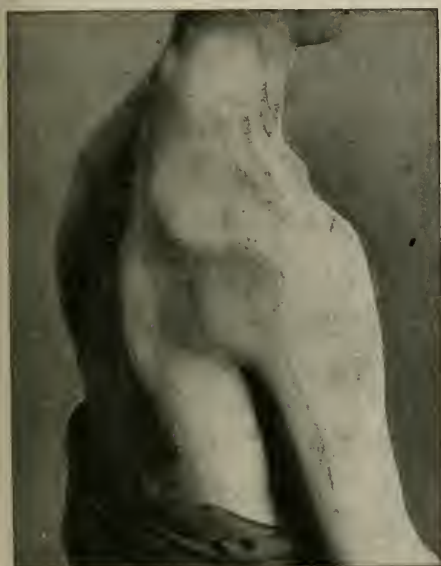

FIG. 212.—Upper radicular paralysis from wound in the cervical region. Atrophy of muscles of the shoulder, deltoid, supra-spinatus, infra-spinatus, rhomboideus major and minor, serratus magnus ; displacement of the shoulder-blade.

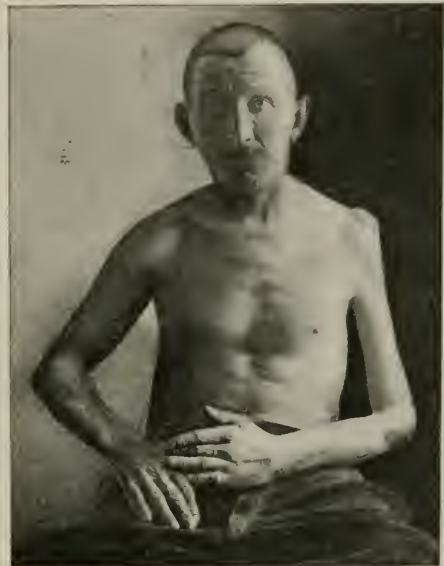

FIG. 213.—Upper radicular paralysis from wrenching of the fifth and sixth cervicals. Atrophy of shoulder, of biceps, brachialis anticus and supinator longus. Impossible to flex the elbow or raise the shoulder.

Teres major, the nerves of which originate in the upper primary trunk or its branches.

If the lesion affects the roots near their origin we even find paralysis of the serratus magnus, of the rhomboids, and the levator anguli scapulæ.

There results atrophy of all the scapular muscles, displacement of the shoulder-blade, giving the appearance of winged scapula (rhomboids and levator scapulæ) and the almost absolute impossibility of imparting to the shoulder-blade the balancing movements which might slightly compensate for paralysis of the deltoid (serratus magnus).

3. Finally, the upper radicular group partially supplies the following muscles : coraco-brachial ; triceps ; radial extensors and supinator brevis ; pronator radii teres and flexor carpi radialis ; the extensor and flexor muscles of the thumb.

These muscles will be slightly weakened.

4. Sensory disturbances, which take place over an area parallel to the axis of the limb, are never characterised by so complete an anæsthesia as that of trunk lesions. We find a rather well-defined area of hypo-æsthesia occupying the regions C-5 and C-6; it extends over the outer surface of the arm and the fore-arm; it does not reach the hand, but at most extends on to the base of the first metacarpal.

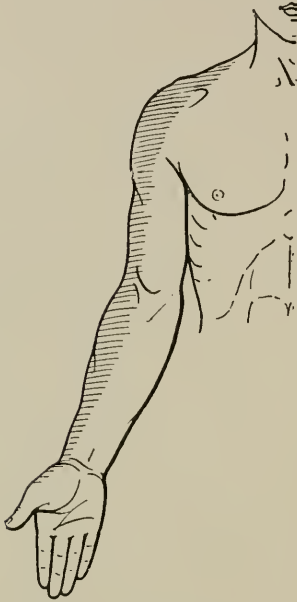


FIG. 214.—Upper radicular paralysis. Hypo-æsthesia C-5 and C-6.

The supinator jerk, from percussion of the styloid process, is abolished.

II.—MIDDLE RADICULAR SYNDROME

Paralysis of the seventh cervical or of the middle radicular trunk, is essentially characterised by paralysis of the muscles supplied by the musculo-spiral nerve, with the exception of the supinator longus, which is untouched.

The triceps, weakened, is not completely paralysed, for, as we remember, it is partially supplied by the sixth cervical.

There also persist some very feeble movements of the extensors and the extensor ossis metacarpi pollicis (supplied partially by C-6) and even slight movements of the extensor indicis and the extensor minimi digiti (C-6 and C-8).

The syndrome produced is almost exactly that of saturnine paralysis accompanied by similar integrity of the supinator longus.

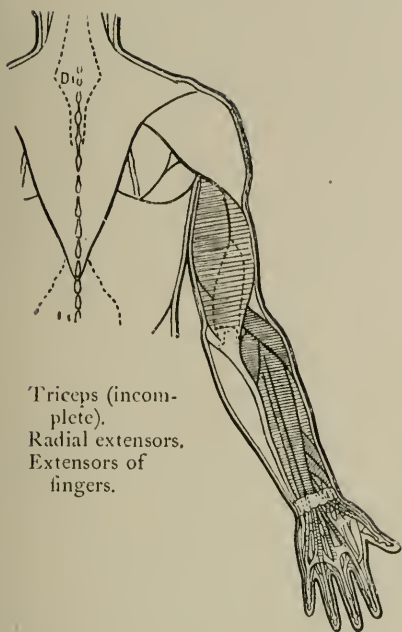
The sensory region of the seventh cervical is extremely restricted. It comprises at the most a small tract of slight hypo-æsthesia extending over the dorsal surface of the fore-arm and the external part of the dorsal surface of the hand.

The olecranon reflex is abolished or inverted.

III.—LOWER RADICULAR GROUP (ARAN-DUCHENNE SYNDROME)

Lesion of the eighth cervical root and of the first dorsal or of the lower primary trunk is characterised by paralysis of the flexores digitorum, the flexor carpi ulnaris, the interossei, the thenar and hypothenar eminences.

Summarising, we may state that the muscles supplied by the median belong to the region of the eighth cervical, whereas the ulnar principally carries fibres of the first dorsal.



Triceps (incomplete).
Radial extensors.
Extensors of fingers.

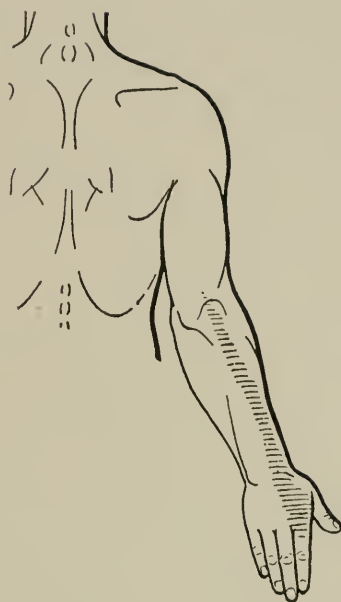

FIG. 216.—Middle radicular group.
Sensory topography.

FIG. 215.—Middle radicular group (seventh cervical). Motor topography.

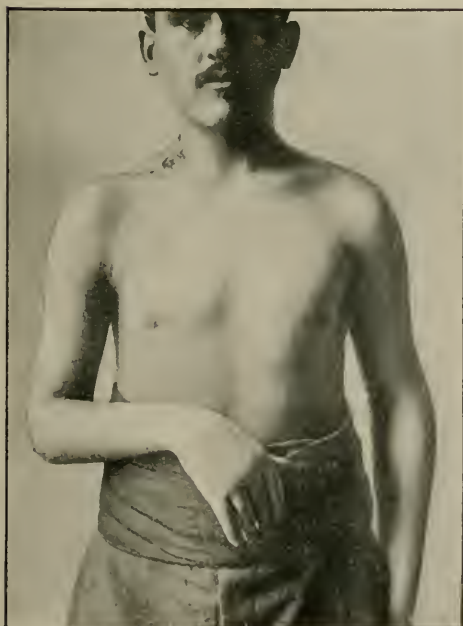

FIG. 217.—Middle radicular paralysis from wound of the cervical region.

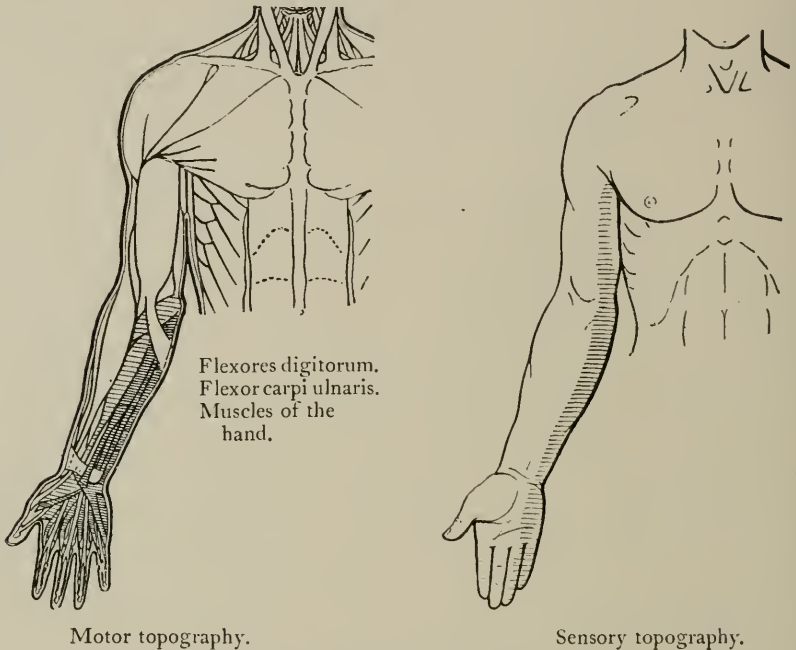
Considerable weakening of the triceps. Paralysis of the radial extensors and extensores digitorum; attitude of musculo-spiral paralysis. (Lesion of the seventh cervical.)

In this case the sixth cervical has also been affected, for though the deltoid is almost untouched, the biceps is weakened and the supinator longus almost completely paralysed, whereas it ought to be wholly untouched in paralysis limited to the seventh cervical.

Integrity of movements in bending the fingers. Weakening of pronation and flexion of the hand (pronators, flexor carpi radialis, palmaris longus, sixth and seventh cervicals).

Hypo-esthesia, somewhat more extended in an isolated lesion of the middle radicular trunk, occupies a track covering the external part of the fore-arm and stretching forwards and backwards almost to the middle line of fore-arm and hand.

A lesion of C-8 and D-1 reproduces very nearly the appearance of associated paralysis of the median and the ulnar with flattened hand or simian *griffe*, according as we have complete interruption or nerve irritation.



FIGS. 218 and 219.—Lower radicular group C-8 to D-1.

The muscles of the thenar eminence, however, particularly the abductor pollicis, receive some fibres of C-7 and even of C-6; the abductors of the thumb seem to be supplied mainly by C-8, in contradistinction to the other interossei, for which D-1 seems predominant.

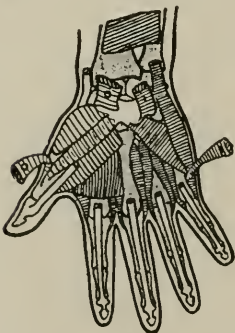


FIG. 220.—Motor topography. Muscles of the hand.

Lastly the pronator radii teres and the flexor carpi radialis receive, mostly through the external root of the median, fibres coming from C-6 and C-7. They are largely unaffected in lower radicular paralyses.

Sensory disturbances are characterised in lower root lesions by a band of hypo-æsthesia of the inner side of the limb.

On the internal surface of the arm, we note the integrity of the triangular region supplied by the second and third dorsals.

Into this tract of hypo-æsthesia, however, on the inner side of the arm,

there fits the triangular zone responding to the second and third dorsal roots.

The ulnar periosteal reflex is abolished.

OCULO-PUPILLARY SYMPATHETIC SYNDROME

It may be remembered that the communicating branch supplied to the lower cervical ganglion by the first dorsal root carries to the cervical sympathetic the fibres of the cilio-spinal medullary centre.

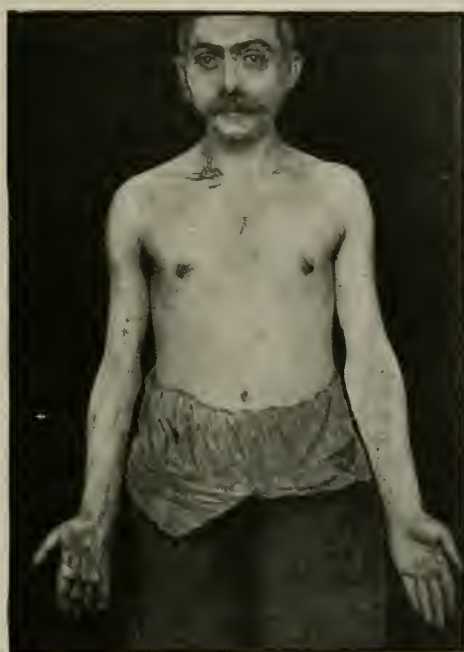

FIG. 221.—Lower radicular paralysis from wound in lower cervical region, with fracture of the clavicle. Integrity of the deltoid, biceps, supinator longus, triceps and extensor muscles. Paralysis and atrophy of the epitrochlear muscles; persistence of the movements of flexor carpi radialis and especially of the pronator radii teres. Paralysis and atrophy of all the muscles of the hand. The lesion, of a neuritic type, has determined fibrous contraction of the flexores digitorum and of the palmar aponeurosis; trophic disturbances of the nails.

If this branch is destroyed by traumatism, as is usually the case in the traumatic wrenching of the roots, we have the oculo-pupillary syndrome described by Mme. Dejerine-Klumke. This consists of myosis, enophthalmos and contraction of the palpebral fissure of the corresponding eye. However, it is not found in the lower radicular lesions alone; it may be noticed after lesions higher up, affecting the upper cervical roots. But in these cases it does not come from the radicular lesion itself; it is

produced by direct lesion of the cervical sympathetic chain, affected by traumatism at the same time as the cervical roots.

TOTAL RADICULAR PARALYSIS

Total radicular paralysis—as produced mainly by tearing of the brachial plexus owing to violent traction on arm or shoulder—is characterised by

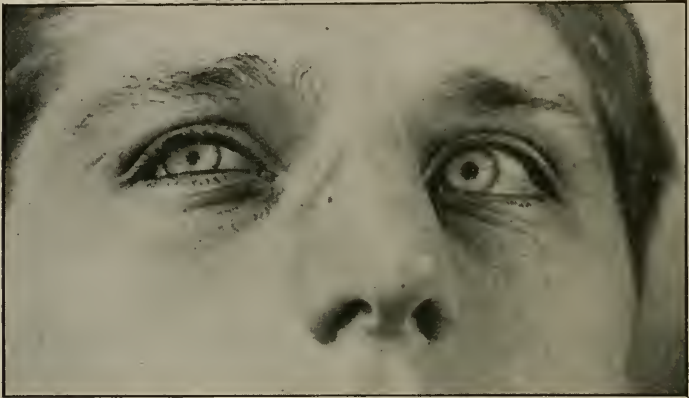

FIG. 222.—Oculo-pupillary syndrome from lesion of the first right dorsal root (Dejerine-Klumpke syndrome). Sinking in of the eye; constriction of the palpebral fissure, myosis.

complete paralysis of the upper limb. Anæsthesia is complete on hand and fore-arm, there is sensation, however, on the upper part of the shoulder (fourth cervical) and on the inner surface of the arm where is found the triangular zone supplied by the second and third dorsal roots.

The oculo-pupillary phenomena previously described (first dorsal) naturally form part of this syndrome.

II.—TRUNK SYNDROMES OF THE BRACHIAL PLEXUS

The syndromes produced by lesions of the secondary trunks and their branches of division closely resemble peripheral syndromes.

Three partial types may be described :

1. Syndrome of the upper secondary trunk, corresponding to paralysis of the musculo-cutaneous and of the outer head of the median.
2. Syndrome of the posterior secondary trunk (musculo-spiral circumflex trunk), characterised by complete paralysis of the circumflex and the musculo-spiral.
3. Syndrome of the lower secondary trunk, corresponding to paralysis of the ulnar and of the inner head of the median, along with lesion of the internal cutaneous, and of the lesser internal cutaneous.

As we see, these syndromes consist of the associated paralysis of two or more peripheral nerves.

We must lay stress on the topography of the inner and outer heads of the median. In paralysis of the upper secondary trunk (outer head of the median) we have found complete paralysis of the pronator radii teres and almost complete paralysis of the flexor carpi radialis, accompanied by weakening of the flexor pollicis and of the opponens.

Again, in another case of lesion of the lower secondary trunk (inner head of the median), there was paralysis of the flexores digitorum, with preservation of some degree of flexion of the thumb and of opposition,

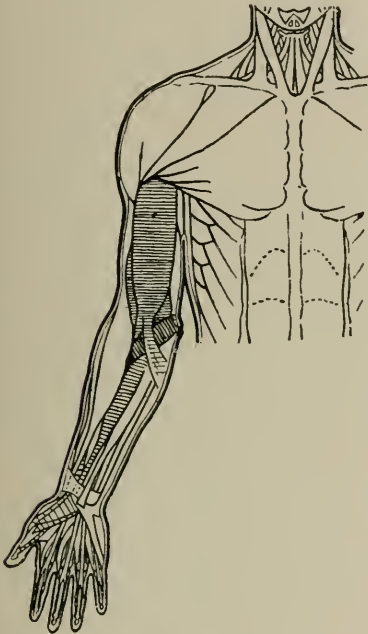


FIG. 223.—Syndrome of the upper secondary trunk comprising the outer head of the median.

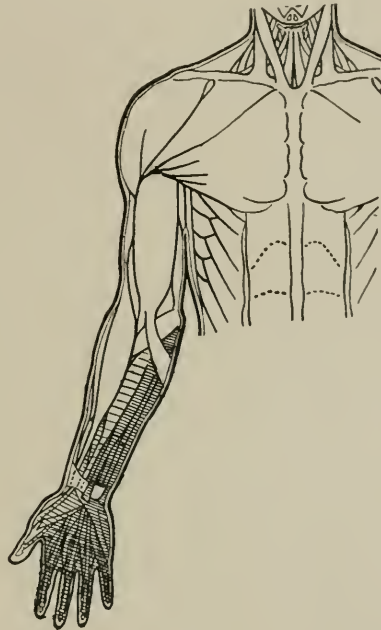


FIG. 224.—Syndrome of lower secondary trunk comprising the inner head of the median.

almost complete integrity of the flexor carpi radialis and complete integrity of the pronator radii teres.

The cases, moreover, of partial lesion of the brachial plexus behind the clavicle and at the level of the axilla are not very frequent ; more often we find important lesions affecting almost all the branches of the plexus. Still, these branches are unequally affected, and, as time goes on, we may find that complete paralysis at the outset becomes dissociated paralysis when the less affected branches have resumed their functions.

Finally, association with vascular lesions is extremely frequent, introducing into the clinical picture the complication of more or less pronounced symptoms of ischæmic paralysis.

In this chapter we have contented ourselves with giving a general and systematic summary of the syndromes of the brachial plexus. It is possible, of course to find the most diverse associations ; we also meet with every clinical variety corresponding to the nature of the lesion : syndromes of complete interruption, of compression, nerve irritation forms, or simple neuralgic syndromes.

There is no need to describe them ; their characteristics are exactly the same as those of the various peripheral syndromes.

CHAPTER XIV

ISCHÆMIC PARALYSIS OF THE UPPER LIMB

ISCHÆMIC paralysis of the upper limb is too frequently connected with nerve wounds, and even when clearly defined is so difficult to diagnose that we feel compelled to devote an entire chapter to it.

As a rule, it follows obliteration or ligature of a large artery, *e.g.* subclavian, axillary or brachial artery. Nevertheless, we have found ischæmic paralysis following obliteration of the radial and ulnar arteries, we have even met with a very singular case, after obliteration of the radial artery in the anatomic snuff-box, accompanied by ischæmia of hand and fingers.

Ischæmic paralysis may also be seen after prolonged contraction of the upper limb ; plaster of Paris applied too tightly is the most frequent cause of such paralysis.

The mechanism of ischæmic paralysis caused by obliteration of an arterial trunk is far from being clear. Only a few obliterations of arteries are accompanied by ischæmic phenomena. For instance, out of thirty-two cases of ligature of the axillary and sub-clavian, we have found no more than five cases of genuine ischæmic paralysis, some others complained of slight signs of ischæmia, probably transitory ; most of them showed no disturbance whatsoever.

In a similar lesion, such as ligature of the axillary, the extent of the ischæmic region may vary considerably ; we have seen paralysis affect only the hand or rise as far as the elbow.

In these cases, the integrity and distribution of the collateral circulation constitute an important individual factor. In most cases free from paralysis, we quickly observe the reappearance of the radial pulse, momentarily suppressed by ligature ; the arterial blood-pressure becomes almost normal.

On the other hand, we sometimes find cases where arterial anastomoses are lacking, where the radial pulse does not reappear ; nevertheless, there are but few ischæmic phenomena, or none at all. For instance, we have seen two patients who, three months previously, had submitted to ligature of the axillary ; in both cases the radial pulse was suppressed ; both had almost identical vascular tension, *viz.* scarcely any at all ; and yet the symptoms observed were totally different.

By the Pachon sphygmomanometer, the first had a tension of 17-8 on the healthy side ; of 9-8 with scarcely any oscillations on the ligature side ; however, there was but slight cyanosis and cooling of the hand.

The second on the healthy side had a tension of 22-9 ; on the paralysed side the tension was 11-9 with very faint oscillations, though perceptibly stronger than in the former case ; he presented an instance of complete ischæmic paralysis accompanied by fibrous transformation of the hand.

Probably the elasticity of the vessels, the presence or absence of atheroma, the phenomena of vaso-motor spasms play an important part in these cases, as well as the nerve lesions so often associated with arterial lesions.

In addition to real ischæmic paralysis, mention must be made of the more or less obscure syndromes of ischæmia from arterial obliteration which often accompany nerve lesions : particularly lesions in the brachial plexus at the level of the axilla and wounds of the median and ulnar on the inner side of the arm.

CHARACTERISTICS OF ISCHÆMIC PARALYSIS

We may describe two phases in the evolution of ischæmic paralysis.

1. In the first phase we note œdematous infiltration of the ischæmic regions.

The hand is cold, either simply cyanosed or of the reddish tint of the lees of wine; it is infiltrated with a soft swelling which is not confined simply to the sub-cutaneous cellular tissue, but spreads over the muscles, giving them a sort of pasty consistence; the skin is infiltrated and thickened, though remaining dull and dry.

Movement is not completely abolished, and the patient can still, though with considerable trouble, move his fingers slightly. Passive movements also are still possible, although the resistance caused by fibrous transformation of muscles and articulations is quickly developed.

Sensation has not altogether disappeared ; we even find, as a rule, the coexistence of very marked hypo-æsthesia and of painful hyper-æsthesia : patients complain of a numbed feeling in the hand ; all stimuli of touch or pain-provoking heat are incompletely perceived, badly localised, and above all, imperfectly differentiated ; but each of these stimuli gives rise to a very painful sensation.

Deep sensation is somewhat better retained than superficial sensation.

Finally, these patients often complain of acute pains : burning or freezing sensations with formication or numbness of the hand ; deep pressure, cutaneous stimuli and cold more especially intensify these sensations ; heat mostly calms them somewhat, and the patients carefully wrap the hand in warm gloves or cotton-wool.

Sensory disturbances gradually increase from the root to the extremity of the limb, their topography is therefore vaguely segmental.

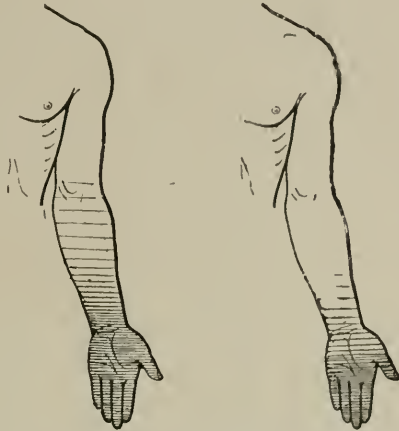
2. In the second phase, we see fibrous transformation of the infiltrated tissues.

After a few weeks, œdema begins to diminish; but the subcutaneous cellular tissue, the aponeuroses, the tendons, are gradually embedded in a veritable fibrous mass; the muscles become puffy, they harden, atrophy, contract and gradually acquire a woody consistence.

The skin becomes smooth and shiny, of a violet or even vivid red colour, it is thin, dead-looking, hard and adherent to the subjacent tissues; the nails bend in like claws, the fingers taper off and sometimes become incurved, following the fibrous contractions, the projections of the muscular bellies disappear.

After the slightest traumatism we may find cutaneous ulcers of a dry sloughy type, their cicatrisation is often a very long process.

All active or passive movements disappear progressively; anæsthesia



FIGS. 225 and 226.—Topography of anæsthesia in two cases of ischemic paralysis.



FIG. 227.—Ischæmic paralysis following ligature of the axillary. Fibrous transformation of the hand.

appears and becomes complete; the pain also calms down; and the hand is gradually transformed into a sort of fibrous, rigid, inert and insensitive appendage.

In true ischæmic paralysis the hand is habitually extended, the fingers

slightly flexed, but in the case of associated nerve lesion, it may be flexed in a fibrous *griffe*, which recalls, in pronounced or distorted form, the neuritic *griffe* of the median or the ulnar.

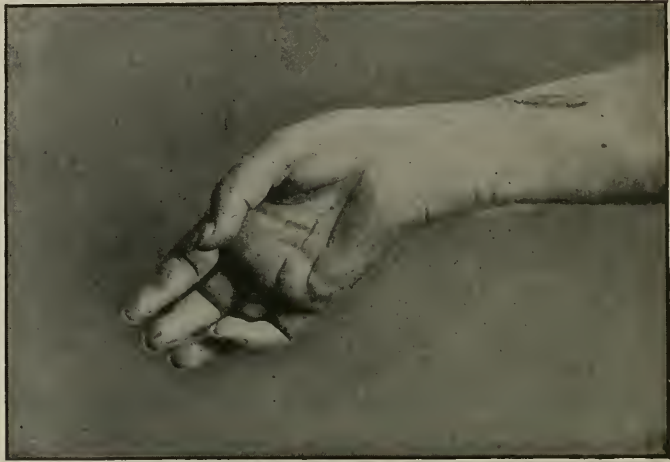

FIG. 228.—Ischæmic paralysis following the crushing and obliteration of the brachial artery. Fibrous transformation of the hand.

Too frequently ischæmic paralysis is incurable, but considerable improvement may be obtained by permanent warm covering, hot baths, prolonged massage and mobilisation and galvanic or faradic electrical stimulation.

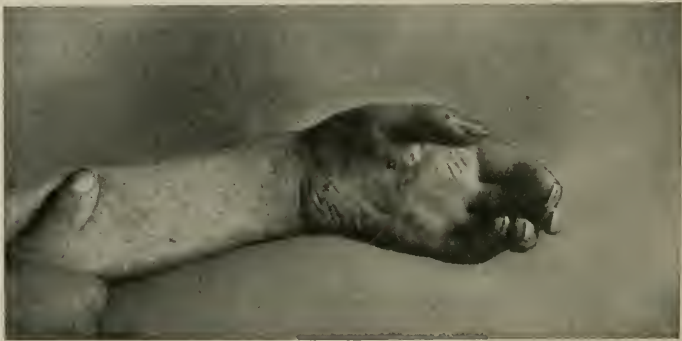

FIG. 229.—Ischæmic paralysis from lesion of the axillary with association of nerve disturbances. Fibrous hand, completely immobilised in the position of ulnar *griffe*.

DIAGNOSIS

Ischæmic paralysis is distinguished from nerve lesions by the following characteristics :—

1. Distribution of motor and sensory disturbances corresponding to no peripheral nerve topography. On the contrary, it is segmentary.

All these disturbances are pronounced at the periphery and gradually diminish towards the root of the limb.

2. The special puffy or wooded consistence of all the tissues.
3. Suppression of the radial pulse.
4. In some cases it is even possible to ascertain that there is no real paralysis : a few imperfect movements continue for a long time : we find

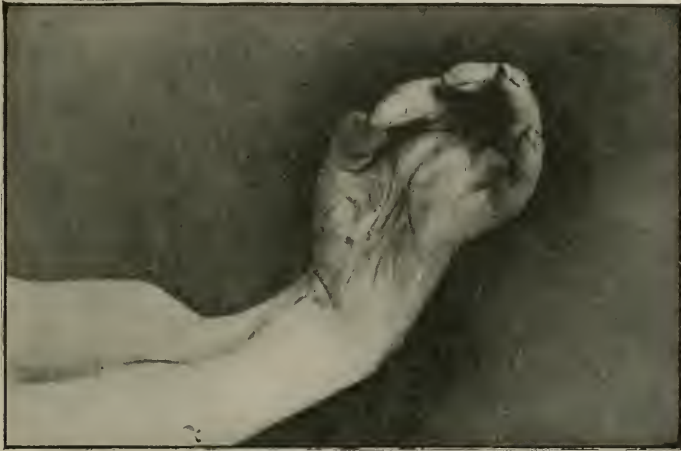

FIG. 230.—Ischæmic paralysis from lesion of the brachial artery.
Associated with median *griffe*.

that the muscles are not really paralysed but are immobilised by fibrous infiltration.

5. Electrical reactions likewise are somewhat different : there is no polar inversion, but enormous hypo-excitability which speedily becomes complete inexcitability ; as long as electrical excitation is capable of causing muscular contraction, we can obtain this movement by exciting the nerve from a distance or at the motor point, as well as by excitation of the muscle itself.

PART III
LOWER LIMB

CHAPTER XV
SCIATIC NERVE

THE sciatic is by far the most frequently affected nerve in the lower limb. The bulk of its trunk, the length of its course, the number and importance of its branches which supply the greater part of the lower limb, render it particularly vulnerable.

ANATOMY OF THE SCIATIC NERVE

The large sciatic nerve is the longest and most widely distributed in the human body.

It originates in the fourth and fifth lumbar roots, through the medium of the lumbosacral cord, and more particularly in the first, second and third sacral roots; it represents "the sacral plexus condensed in one nerve cord." (Cruveilhier.)

All its original branches are united at the level of the sciatic notch.

It passes round the ischial spine and descends in the posterior part of the buttock between the ischium and the greater trochanter, covered by the mass of the gluteal muscles and the pyramidalis, and also below this muscle by the lower part of the gluteus maximus.

It descends in the posterior part of the thigh into the interspace comprised between the semimembranosus and the semitendinosus within, and the biceps without. It rests on the posterior surface of the femur which is covered by the insertions of the adductors and by the vastus externus.

It becomes superficial at the upper end of the popliteal space, in the neighbourhood of which it divides into its two terminal branches—the external popliteal and the internal popliteal.

The level at which this division takes place is extremely variable; it

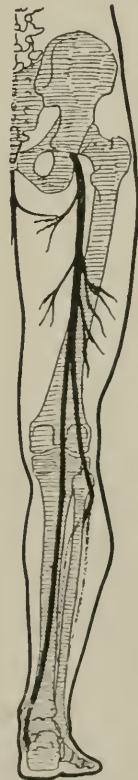

FIG. 231.

may be very high, sometimes these two branches rise as far up as the pelvis, distinct from each other yet in close apposition, in gun-barrel fashion.

COLLATERAL BRANCHES

Along its course, the trunk of the great sciatic nerve supplies :

1. The upper nerve to the semitendinosus, which arises very high up, immediately below the tuberosity of the ischium.

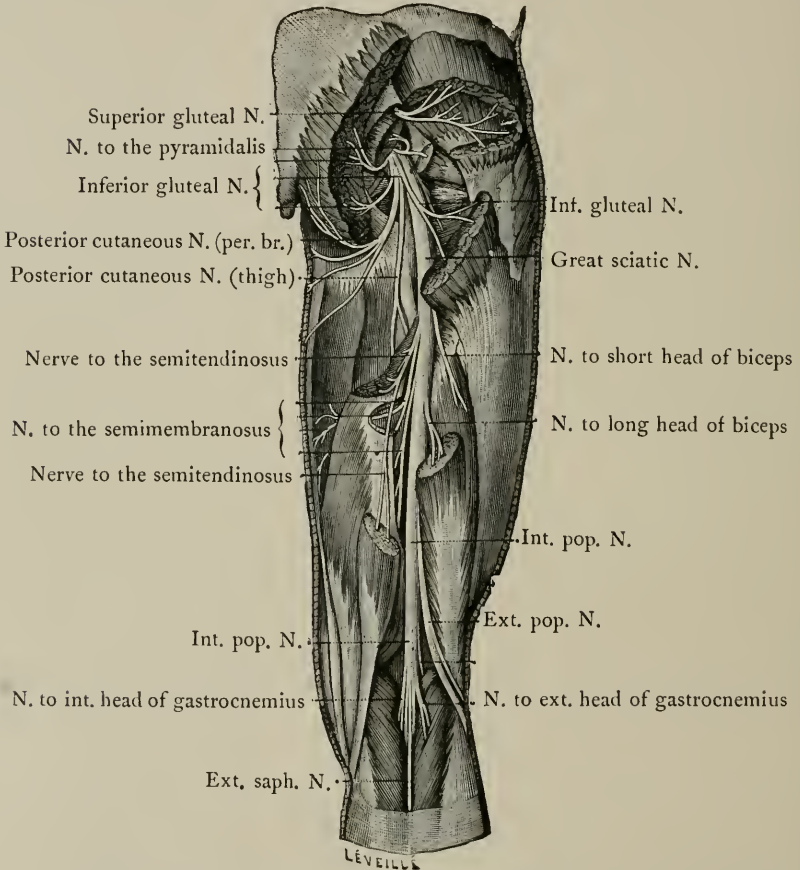


FIG. 232.—Sciatic nerve and its collateral branches in buttock and thigh.
(After Sappey.)

This is the reason why the semitendinosus is often untouched in lesions of the sciatic.

2. The nerve to the long head of the biceps which appears at a very variable level, most frequently in the middle region of thigh.

3. The nerve to the semimembranosus which originates at the same level and often from the same trunk as the nerve to the biceps.

4. The nerve to the short head of the biceps, the origin of which also varies considerably, being usually a little below the nerve to the long head.

To these collateral branches must be added another supplied by the sciatic to the adductor magnus and the upper articular nerve of the knee.

There is no need to dwell on the function of these muscles, all being flexors of the leg on the thigh.

Sufficient to note that the order in which these branches break away from above downwards explains the frequent weakening of the biceps in lesions of the sciatic, whereas the semimembranosus and especially the semitendinosus are more frequently untouched.

TERMINAL BRANCHES

The division branches of the sciatic nerve really constitute two distinct nerves, antagonists of each other: the external popliteal, the nerve of extension, homologous to the terminal part of the musculo-spiral, and the internal popliteal, the nerve of flexion, more widely distributed and representing both the median and the ulnar.

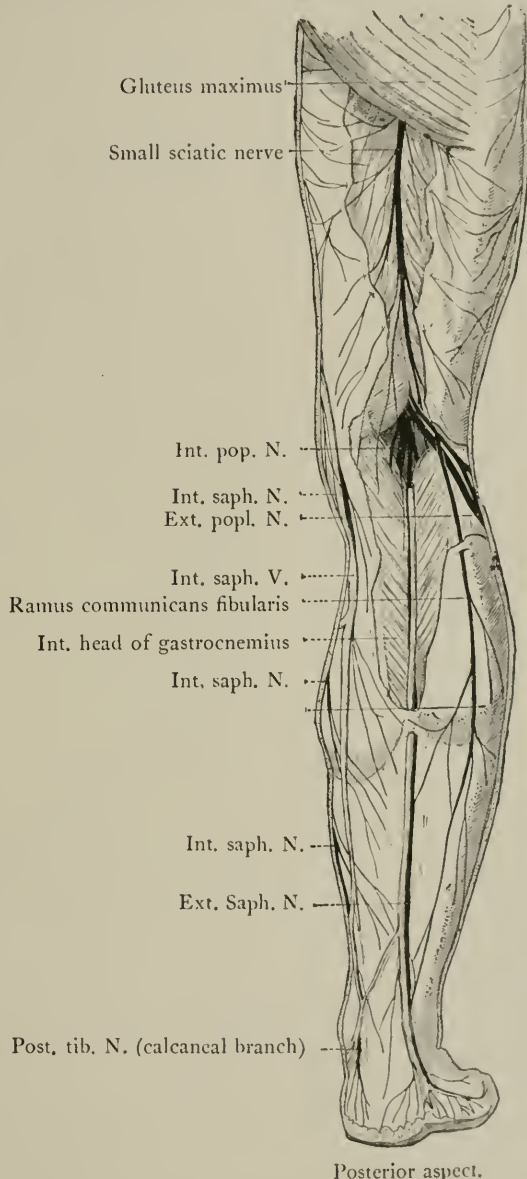


FIG. 233.—Superficial nerves of the lower limb. (From two sketches by Hirschfeld.)

I.—EXTERNAL POPLITEAL NERVE

The external popliteal breaks away in the neighbourhood of the upper end of the popliteal space.

It proceeds along the internal border of the biceps, crosses the outer tuberosity of the tibia covered by the external head of gastrocnemius, passes behind the head of the fibula, and goes round the neck of this bone to reach the antero-external region of the leg. At this level it is very superficial, resting directly on the periosteum of the fibula where it may be

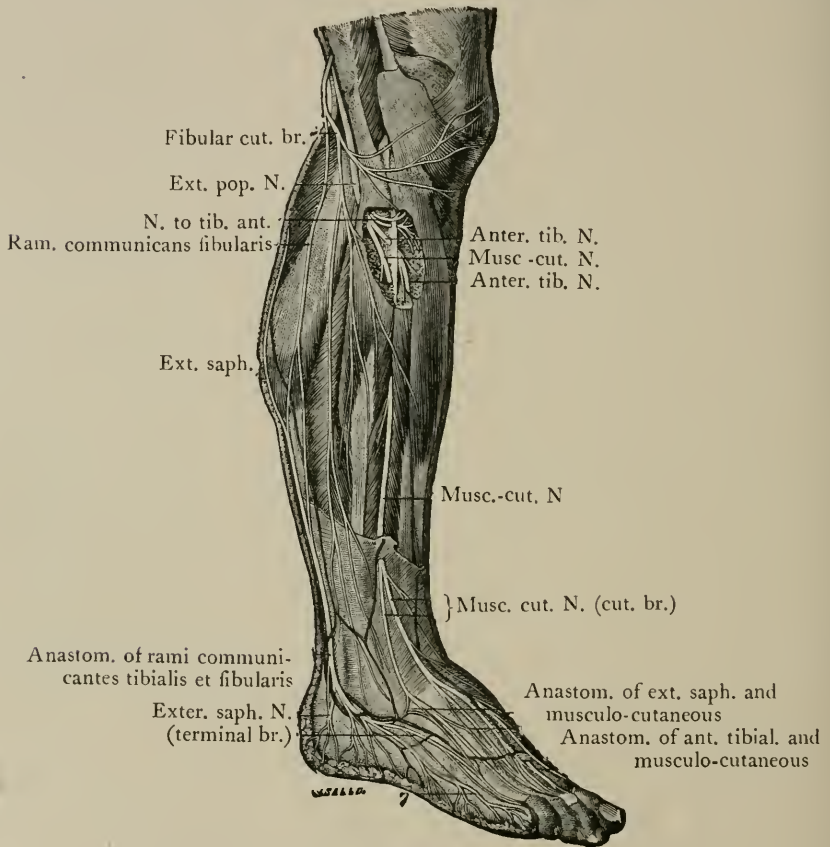


FIG. 234.—External popliteal nerve. (After Hirschfeld.)

involved in case of fracture; it is immediately covered by the aponeurosis and the skin.

It penetrates into the antero-external compartment of the leg, passing along a musculo-fibrous canal formed by the origins of the peroneus longus. Inside this canal it divides into its two terminal branches.

COLLATERAL BRANCHES

After sending out an articular branch, the external popliteal supplies :
 1. The ramus communicans fibularis which descends upon the posterior

surface of the external head of gastrocnemius and is distributed to the skin of the external and posterior region of the leg and the heel. At this level it anastomoses with the external saphenous (internal popliteal).

2. The peroneal cutaneous branch or external cutaneous nerve of the leg, which appears at the same level as the former and descends outside it,

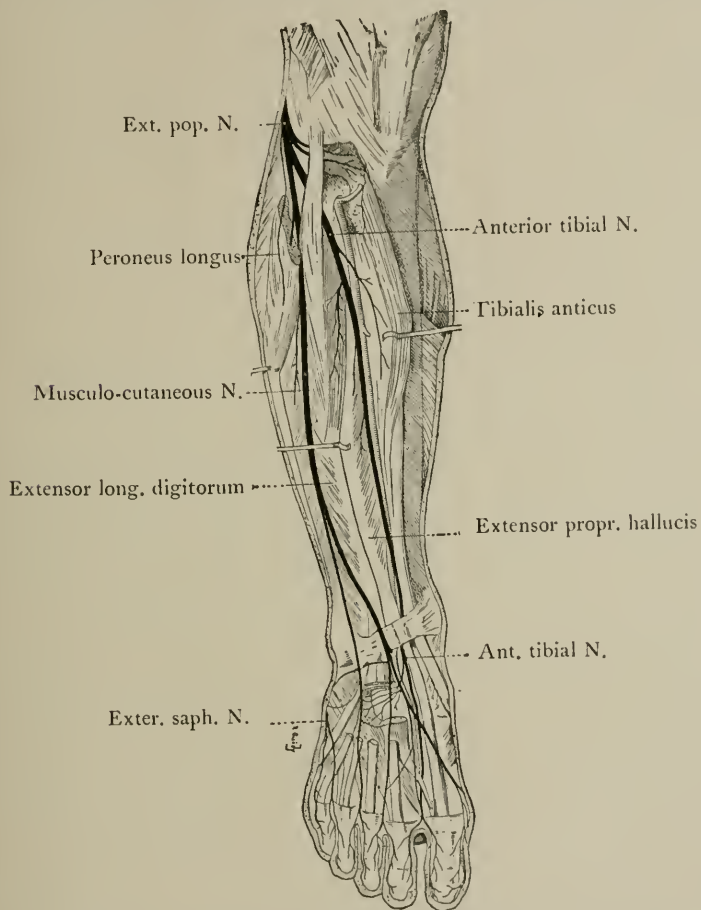


FIG. 235.—Musculo-cutaneous nerve and anterior tibial nerve.
(After Hirschfeld, simplified.)

distributing itself over the upper part of the antero-external region of the leg.

TERMINAL BRANCHES

1. **Anterior tibial nerve.**—This nerve penetrates into the compartment of the extensors, and descends at first outside, then in front of, and later internal to the anterior tibial artery, it then lies deeply in the muscular interspace that separates the anterior tibial on the inner side from the

extensor communis, and later, from the extensor proprius hallucis on the outer side.

At the level of the annular ligament of the ankle, the nerve passes beneath the tendon of the extensor hallucis, appears on its external border and splits up into its terminal branches.

The anterior tibial nerve supplies from its collateral branches :

1. The tibialis anticus by means of two branches, superior and inferior.

2. The extensor communis digitorum pedis ;

3. The extensor proprius hallucis.

At its termination, it divides into two branches, external and internal.

The internal branch, more widely distributed, proceeds along the first intermetatarsal space, covered by the extensor brevis digitorum, and anastomoses in the most variable fashion, with the terminal branches of the musculo-cutaneous.

The external branch is divided into several shoots which also proceed along the second, third and fourth intermetatarsal spaces and anastomose with the branches of the musculo-cutaneous.

It supplies the motor innervation of the extensor brevis digitorum.

The anterior tibial shares but feebly in the sensory innervation of the dorsal surface of the foot. It mainly supplies articular and periosteal twigs ; its branches of cutaneous sensibility, when they exist, are merged in the branches of the musculo-cutaneous. Still, in certain cases, it is possible to meet with a distinct sensory region for the anterior tibial occupying the dorsal surface of the first metatarsal and of the great toe, and especially the first inter-metatarsal space.

2. **Musculo-cutaneous nerve.**—The musculo-cutaneous separates at an acute angle from the anterior tibial, amidst the fibres of origin of the peroneus longus.

In passing through this muscle, it reaches obliquely the interspace between the extensor communis on the inner side, the peroneus longus and the peroneus brevis lying on the outer side.

It becomes superficial at about the lower third of the leg.

In its course the musculo-cutaneous supplies :

The peroneus longus and the peroneus brevis.

It supplies cutaneous twigs to the lower part of the antero-external region of the leg.

It finally divides at the lower third of the leg into two terminal branches.

1. The internal dorsal cutaneous nerve of the foot, which supplies the internal collateral of the great toe.

The first dorsal interosseous nerve, which produces the external collateral of the great toe and the internal collateral of the second toe.

The second dorsal interosseous nerve, which supplies the external collateral of the second and the internal collateral of the third toe.

2. The middle dorsal cutaneous nerve, which supplies only the dorsal intersseous of the third interspace and its two collateral branches.

It must be noted that the fourth dorsal intersseous nerve comes from the external saphenous (internal popliteal).

As in the hand, the dorsal collaterals do not reach the extremity of the

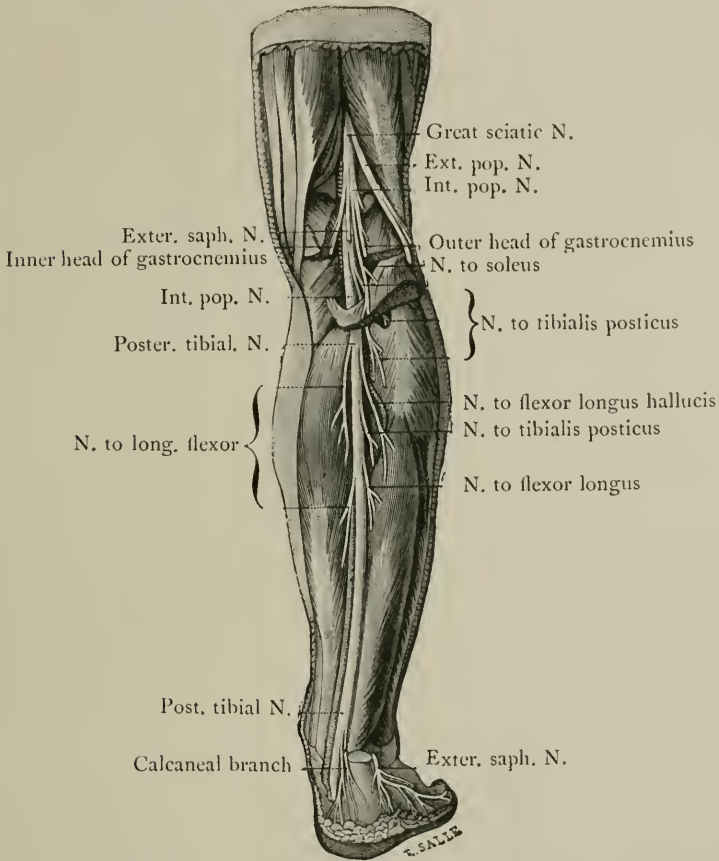


FIG. 236.—Internal popliteal nerve and posterior tibial nerve. (After Sappey.)

toes. The unguis phalanx is supplied by dorsal branches coming from plantar collaterals.

II.—INTERNAL POPLITEAL NERVE AND POSTERIOR TIBIAL NERVE

More bulky than the external popliteal, the internal popliteal nerve is continued in the direction of the trunk of the sciatic.

It traverses the popliteal space and is given off in the angle formed by the biceps and the semi-membranosus, passing downwards below into the

space between the two heads of the gastrocnemius and passes under the aponeurotic arch of the soleus. In this course it is in relation to the popliteal vessels; we then find from without inwards and from behind forwards the nerve, the vein and the artery. The arch of the external saphenous vein opens into the popliteal vein, crossing the posterior and internal surface of the nerve.

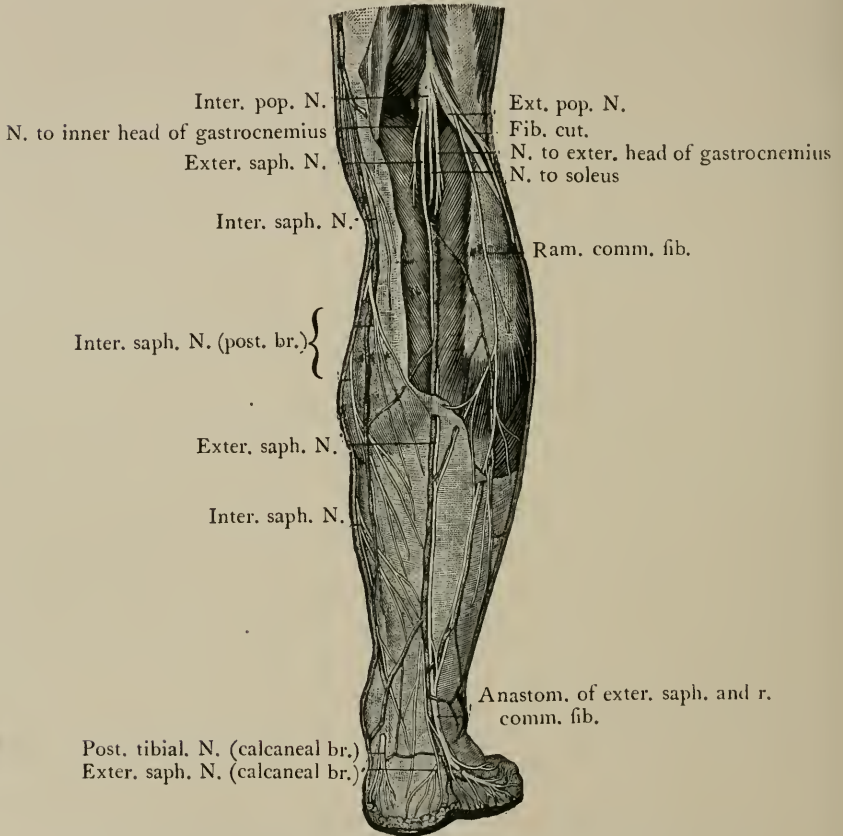


FIG. 237.—External saphenous nerve and ramus communicans fibularis.
(After Hirschfeld.)

Starting from the fibrous arch of the soleus, the internal popliteal takes the name of posterior tibial.

The posterior tibial nerve descends between the superficial layer and the deep layer of the posterior muscles of the leg. It lies in the cellular interspace separating the tibialis posticus from the flexor communis digitorum; it closely adheres to this deep muscular layer by means of the deep or sub-solear aponeurosis; it is covered by the soleus and afterwards by the Achilles tendon.

The posterior tibial artery, originating in the popliteal trunk,

crosses the anterior surface of the nerve and becomes internal. Thus the nerve descends almost midway between the posterior tibial artery on the inner side, and the peroneal artery on the outer side.

At the level of the instep, the nerve and the posterior tibial vessels appear in the internal retro-malleolar groove; the nerve is behind the artery and internal to it, *i.e.* deeper and more closely adherent to the bone covered by the tendon of the flexor longus.

It is in this retro-malleolar groove, at the entrance of the calcanean groove which forms its continuation, that the posterior tibial nerve divides into its two terminal branches, the internal and the external plantar nerves.

COLLATERAL BRANCHES

1. In the popliteal space, the internal popliteal supplies a certain number of muscular branches:

1. The nerve to the inner head of gastrocnemius.
2. The nerve to the outer head of gastrocnemius.
3. The nerve to the soleus.
4. The nerve to the plantaris.
5. The nerve to the popliteus with muscular and vascular branches and a branch to the interosseous membrane.
6. It also supplies articular branches grouped by Cruveilhier under the name of posterior articular nerve of the knee.

7. Finally, it supplies an important sensory branch, the external saphenous nerve or tibial saphenous which is given off at the upper or middle part of the popliteal space, rejoins the external saphenous vein at the upper part of the leg, and descends with it in the middle line, being covered by the superficial aponeurosis which ensheaths it in a fibrous canal.

At the lower part of the leg, it appears on the outer side of the Achilles tendon and at this level receives an important anastomosis from the ramus communicans fibularis. It finally reaches the outer edge of the foot, describing a curve round the outer malleolus.

The external saphenous nerve sends out no sensory twig to the upper part of the leg.

It supplies cutaneous branches to the lower part of the leg, in the malleolar region (external calcanean nerves); in front of the malleolus it anastomoses with the musculo-cutaneous.

Near the tuberosity of the fifth metatarsal, it divides into two terminal branches: the outer one becomes the external dorsal collateral of the fifth toe; the inner one, the nerve of the fourth interosseous space, supplies the internal collateral of the fifth toe and the external collateral of the fourth toe.

2. At the level of the leg below the fibular arch of the soleus, the posterior tibial nerve which continues the internal popliteal supplies :

- The tibialis posticus ;
- The flexor proprius hallucis ;
- The flexor communis digitorum.

It also supplies vascular branches, articular branches for the tibiotarsal

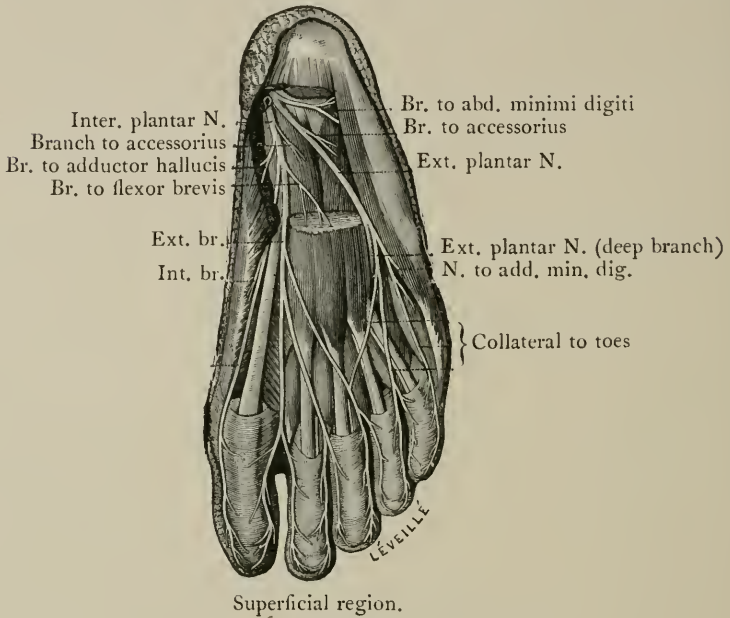


FIG. 238.—Plantar nerves. (After Sappey.)

articulation and sensory branches of but slight importance : the internal supra-malleolar branch and the internal calcanean nerve.

TERMINAL BRANCHES

The two terminal branches, the internal and external plantar nerves, reach the sole of the foot by the retro-calcanean groove and separate at an acute angle, making their way towards the inner and outer sides of the foot.

They proceed between the two muscular layers of the sole of the foot ; covered by the belly of the short flexors ; lying on the accessorius which separates them from the interossei and on the tendons of the flexor proprius hallucis and the flexor communis digitorum.

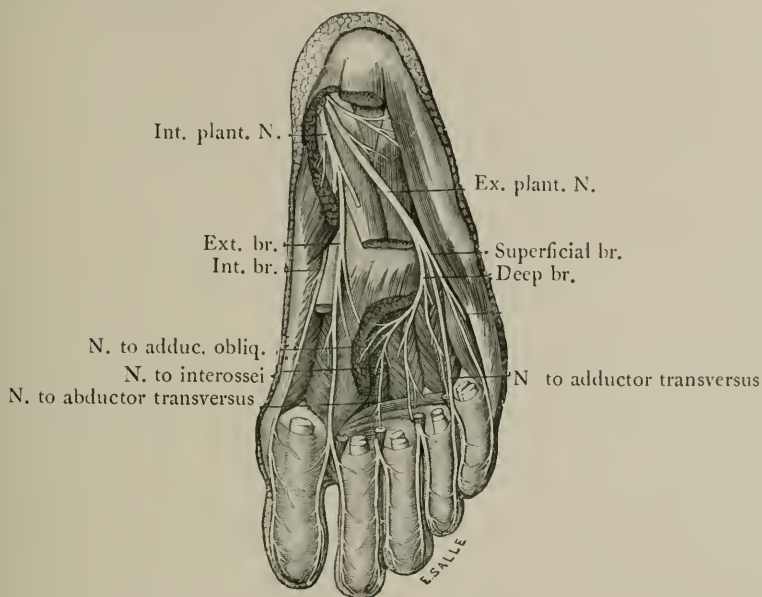
Their respective distribution somewhat resembles that of the median and ulnar in the case of the hand.

1. **Internal plantar nerve.**—Apart from its articular branches, the internal plantar nerve supplies both muscular and cutaneous branches.

The muscular branches destined for the muscles are :

- Abductor hallucis ;
- Flexor brevis hallucis ;
- Flexor brevis digitorum pedis ;
- Accessorius.

The cutaneous branches are of two orders. Firstly, simple collateral branches which perforate the plantar aponeurosis and supply the plantar integuments from the os calcis to the base of the toes. These are the plantar cutaneous nerves.



Deep dissection of the foot.
 FIG. 239.—Plantar nerves. (After Sappey.)

Secondly, terminal branches, two in number :

The internal branch which supplies only the internal plantar collateral of the great toe ;

The external branch which supplies the first, second and third interdigital nerves and the plantar collaterals springing from them. The third interdigital nerve receives from the external plantar nerve an anastomosis analogous to that supplied by the ulnar to the median.

It is the plantar collaterals that supply, by means of their dorsal branches, the dorsal surface of the unguis phalanges.

2. External plantar nerve.—The external plantar nerve also supplies both muscular and cutaneous branches.

1. By its collateral muscular branches it supplies the abductor minimi digiti pedis and the flexor brevis minimi digiti pedis.

Its deep terminal branch curves inwards and penetrates the deep

compartment of the sole, then, like the deep branch of the ulnar, it proceeds to supply all the plantar interossei, including the adductor transversus and the adductor obliquus and all the dorsal interossei, by means of its perforating branches.

2. On the other hand, the superficial terminal branch of the external plantar is sensory ; it supplies :

The external collateral of the little toe ;

The fourth interdigital nerve with its collaterals ;

An anastomosis to the third interdigital nerve (internal plantar).

The plantar collaterals, through their dorsal branches, provide the dorsal innervation of the ungual phalanx.

PARALYSIS OF THE SCIATIC

Before studying paralysis of the sciatic in its entirety, we will study separately the paralyzes of each terminal branch, the external popliteal and the internal popliteal.

I.—PARALYSIS OF THE EXTERNAL POPLITEAL

MOTOR SYNDROME

The external popliteal supplies the muscles of the antero-external compartment of the leg :

The tibialis anticus ;

The extensor longus digitorum pedis ;

The extensor proprius hallucis ;

The extensor brevis digitorum is supplied by the anterior tibial ; the peroneus brevis and the peroneus longus are supplied by the musculo-cutaneous.

Paralysis of this nerve is indicated by suppression of the elevation and extension movements of the foot* and of the toes, by the abolition of internal rotation and of elevation of the internal border of the foot, movements produced by the tibialis anticus ; by the loss of external rotation, of abduction and of elevation of the external border of the foot, movements produced by the peroneal group.

To those main disturbances is added the collapse of the arch of the foot normally maintained by the tendon of the tibialis anticus and of the peroneus longus. The tibialis posticus (internal popliteal) supports and raises only the inner portion of the plantar arch.

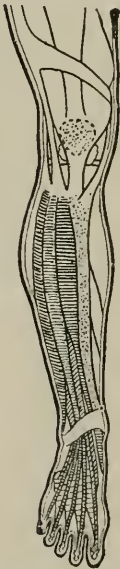


FIG. 240.—Muscles supplied by the external popliteal.

* We use the expression "extension of the foot" for the dorsal raising of the foot, comparing it with the synergic movement of raising or extending the toes, and from analogy between the functions of the extensor of hand and fingers, and the external popliteal.

By flexion of the foot we mean the movement of lowering the toes, analogous with flexion of the hand.

This paralysis results in a drooping of the foot with the toes pointing towards the ground, and in a characteristic gait : steppage.

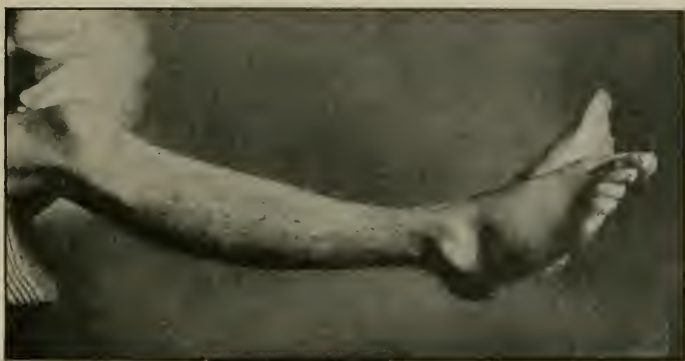

FIG. 241.—Paralysis of the external popliteal. Atrophy of the antero-external group. Foot-drop, with dorsal tumour of the tarsus.

The toes are flexed from the loss of the antagonism of the extensors.

As Pitre and Testut have observed, we may easily detect the existence of paralysis of the external popliteal by asking the patient, who is seated, to raise his toes and keep them clear of the ground, the heel remaining on the ground.

Paralysis of the external popliteal is easy to recognise. Later on we shall see what are the possible errors in diagnosis.

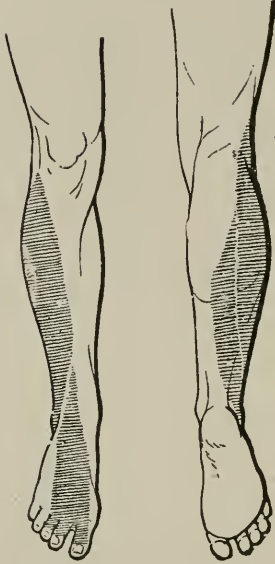
Here we will mention only one of these : the possibility of attributing to the tibialis anticus the slight power of adduction possessed by the tibialis posticus, either voluntary or resulting from electrical stimuli. To avoid this error, it is sufficient to raise the foot and keep it at right angles ; in this position the smallest contractions of the tibialis anticus are indicated both by adduction and by raising the foot ; there is distinctly perceived beneath the skin the rising of the tendon : *adduction movements* without raising the foot are produced by the tibialis posticus.



FIG. 242.—Steppage in paralysis of the external popliteal.

SENSORY SYNDROME

The complete sensory distribution of the external popliteal comprises a broad tract occupying the entire antero-external surface of the leg and a part of its posterior surface; it spreads over the dorsal surface of the foot with the exception of the internal and external borders and the ungual phalanges.



FIGS. 243 and 244.—Sensory distribution of the external popliteal, comprising: the peroneal cutaneous branch (external surface of the leg); the ramus communicans fibularis (posterior surface); the anterior tibial and the musculo-cutaneous (dorsal surface of the foot).

In this sensory distribution several zones must be distinguished.

The antero-external surface of the leg is supplied by the peroneal cutaneous branch, the posterior part by the ramus communicans fibularis; the musculo-cutaneous is distributed only over the lower region of the leg and the dorsal surface of the foot. To this latter region are confined the sensory disturbances observed when the lesion of the external popliteal is below the first two branches; this, indeed, frequently happens, for the ramus communicans fibularis and the peroneal cutaneous branch have their origin rather high in the upper region of the popliteal space.

Moreover, we must not expect to find complete anæsthesia; it is not constant, and when it exists is to be found only at the middle of the external surface of the leg and on the dorsal surface of the foot.

TROPIC AND VASO-MOTOR SYNDROME

Occasionally we find dorsal œdema of the foot, pallor or cyanosis of the integuments; cutaneous desquamation, hypertrichosis.

In some cases we have found traumatic ulcers on the back of the foot, produced by the boot; their extremely slow cicatrisation is a sign of trophic disturbances.

Finally, if foot-drop is considerable and hypotonia prolonged, we may observe a sort of tumour on the dorsum of the tarsus, comparable with the dorsal tumour of the carpus in musculo-spiral paralysis.

As a rule, however, trophic and vaso-motor disturbances of the external popliteal are of slight importance, the result of substitution by the internal popliteal.

I.—CLINICAL FORMS OF PARALYSIS OF THE EXTERNAL POPLITEAL

As in the case of all nerve trunks, we may find the syndrome of complete interruption or of simple compression.

The syndrome of complete interruption is characterised :

By complete and rapid loss of muscular tone, intensifying the foot-drop ;

By rapid muscular atrophy ;

By the localisation of the resulting formication to a definite area ;

By permanence and fixity of anæsthesia as well as by the absence of paræsthetic zones.

In the syndrome of compression we note the opposite characteristics, particularly the prolonged persistence of muscular tone.

If nerve regeneration takes place, we follow the progression of formication along the paralysed nerves simultaneously with the reappearance of muscular tone.

We may also meet with syndromes of nerve irritation, with cutaneous trophic disturbances, tendon adhesions, scaly desquamation, pain by pressure on muscles and nerve trunks, muscular fibrous contractions which limit the passive flexion of foot and toes and consequently diminish steppage.

These neuritic, or even simple neuralgic syndromes, however, are somewhat rare. The external

Before the operation.	The 95th day after suture of the nerve.
<i>a</i>	<i>b</i>

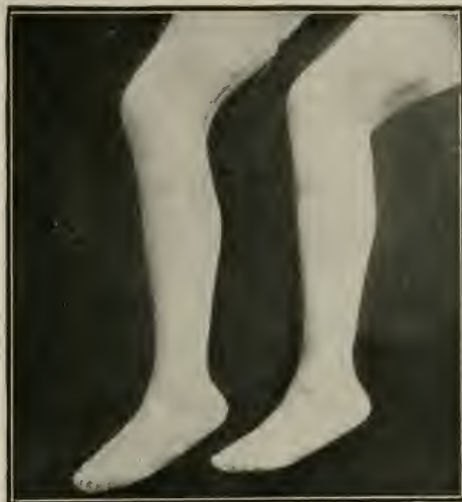

FIG. 245.—Attitude of the right foot when walking, before and after nerve suture in a case of paralysis of the external popliteal with syndrome of complete interruption in section of the nerve by shell splinter (Captain C—). *a*. Muscular atony and droop of foot and basal phalanges of toes before nerve suture ; foot swinging, equinovarus, dorsal swelling of the metatarsus. Photograph taken on the 66th day after the wound. *b*. Return of tone showing attitude of the foot on the 95th day after suture of the nerve ; the foot is no longer swinging, walking is easier, running is possible, pes equinus less pronounced, the varus has almost disappeared ; the basal phalanges are no longer drooping but extended on the metatarsals ; dorsal swelling of the metatarsus has disappeared. So far there is neither elevation movement of foot nor extension movement of the first phalanx of the toes, but in the horizontal position the Captain can carry out very marked abduction of the foot accompanied by elevation of its external edge (contraction of the peroneals). (J. and A. Dejerine and Mouzon. *Presse Médicale*, 10 May, 1915.)

popliteal, like the musculo-spiral, and in contradistinction to the internal popliteal, is not a very sensitive or painful nerve.

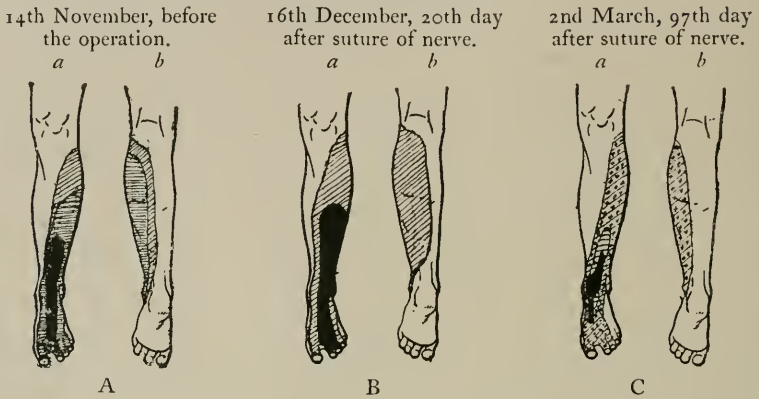


FIG. 246.—State of sensibility to pin-prick before and after suture of the nerve in a case of paralysis of the external popliteal by complete section of the nerve (Captain C—). Note in B the appearance of a small zone of paræsthesia on the dorsal surface of the first interosseous space. *Black*: pricking causes no sensation. *Horizontal hatching*: pin-prick is felt simply as contact. *Oblique hatching*: diminished sensibility to touch and pin-prick. *Oblique hatching with points and crosses*: hypo-æsthesia with intermittent hyper-æsthesia; *the crosses* indicate delayed persistent sensations, with diffusion, irradiations and errors of identification, *the points* indicate that the sensation of pin-prick is, in addition, particularly disagreeable (*paræsthesia*). (J. and A. Dejerine and Mouzon. *Presse Médicale*, 10 May, 1915.)

Finally the external popliteal may be affected by dissociated lesions and partial paralysis.

We will relate two instances of these.

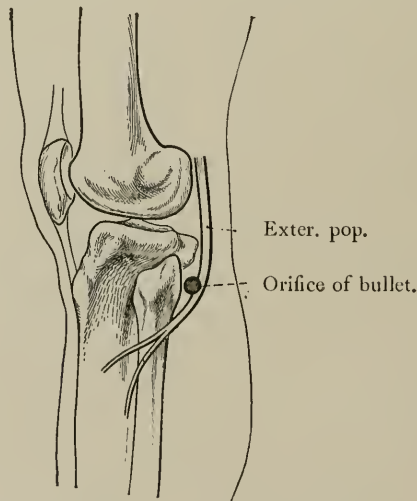


FIG. 247.—Dissociated paralysis of the external popliteal affecting solely the fibres of the anterior tibial.



FIG. 248.—Sensory distribution of the anterior fibres of the external popliteal (same case as Fig. 247).

In the first case a bullet had struck the anterior part of the external popliteal, behind the head of the fibula. The muscular group of the anterior tibial was paralysed; the peroneal muscles were not affected. The internal part of the distribution of the musculo-cutaneous was devoid of sensation.

In another case, a small shell splinter, embedded in the external and posterior part of the external popliteal, almost at the same level, caused paralysis accompanied by nerve pains in the peroneal muscles alone, together with hyper-æsthesia of the external part of the cutaneous distribution.

We may therefore conclude that, behind the head of the fibula, the fibres destined for the anterior tibial are in front, the fibres of the peroneals are behind. In the thigh, the fibres destined for the tibialis anticus form the most external group of the external fasciculi of the sciatic nerve which represent the external popliteal. This position corresponds to the very high root origin of the nerve fibres to the tibialis anticus (fourth lumbar).

II.—PARALYSIS OF THE ANTERIOR TIBIAL NERVE

The anterior tibial nerve may be affected separately after bifurcation of the external popliteal.

Its paralysis exactly reproduces the type of dissociated paralysis which we have just been studying.

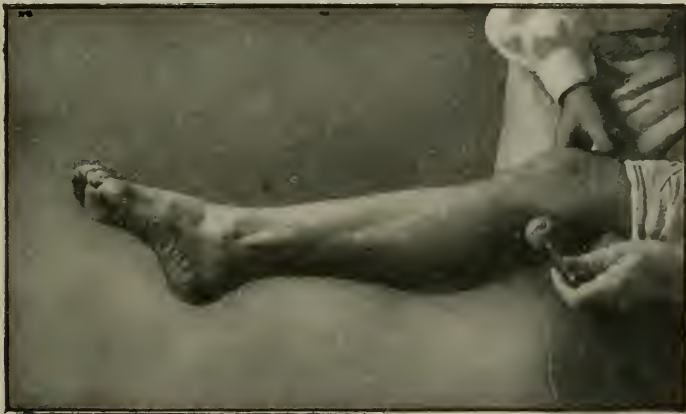

FIG. 249.—Paralysis of the anterior tibial nerve. Foot-drop with steppage. Integrity of the musculo-cutaneous. Retention of lateral movements by the action of the peroneals. Faradic excitation of the external popliteal nerve causes only the projection of the peroneal tendons, without raising of the foot and the toes.

The extensors and the tibialis anticus are paralysed, whereas the peroneals are untouched.

Cutaneous anæsthesia is almost absent; the anterior tibial is but slightly sensory, it possesses no distinctive region of its own, for its

cutaneous branches anastomose with the branches of the musculo-cutaneous. Its terminal branches are more specially articular and periosteal, comparable to the terminations of the posterior branch of the musculo-spiral. At most there is slight hypo-æsthesia of the dorsal surface of the foot, more pronounced near the inner edge, and more especially a small triangular region of anæsthesia behind the first interdigital space.

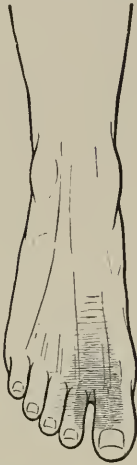

FIG. 250.—Sensory distribution of the anterior tibial.

The anterior tibial nerve may also be affected below the branches destined for the tibialis anticus and the extensor longus.

Here we have isolated paralysis of the extensor of the great toe, which remains flaccid and half flexed, whilst the other toes can easily be raised.

Finally, paralysis of the external popliteal and of the anterior tibial is always accompanied by paralysis of the extensor brevis digitorum muscle which is supplied by the anterior tibial nerve; it is recognised mainly by flaccidity of the muscle and disappearance of its faradic contractions; for after all the accessorius is but an accessory synergic muscle of the extensors of the toes.

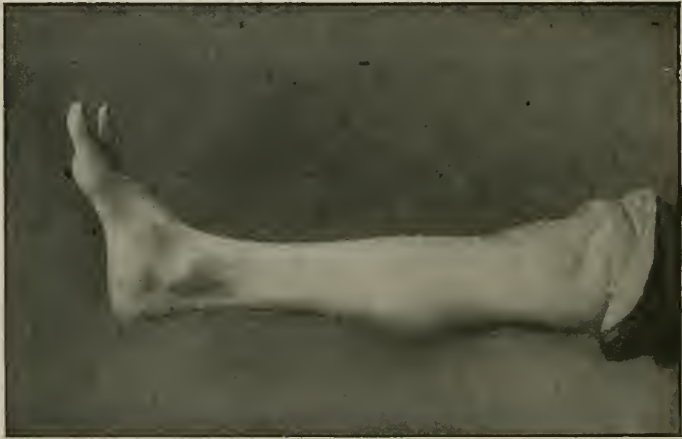

FIG. 251.—Isolated paralysis of the extensor of the great toe, caused by lesion of the anterior tibial at the middle of the leg. The patient can easily raise the other four toes.

III.—ISOLATED PARALYSIS OF THE MUSCULO-CUTANEOUS

Isolated lesion of the musculo-cutaneous nerve is shown by paralysis of the peroneals, with loss of abduction, of rotation outwards and of elevation of the external edge of the foot.

Raising the foot is still possible by means of the extensors and the tibialis

anticus, but, since antagonism of the peroneals is lacking, they are accompanied by a rotation inwards, by adduction and elevation of the inner edge, effected by the tibialis anticus. If there is considerable hypotonia of the peroneals, paralytic talipes varus may result, and the patient walks on the outer edge of the foot.

The musculo-cutaneous nerve is sometimes affected below the peroneals, in its sensory part. This lesion is indicated solely by anæsthesia of the cutaneous area which comprises almost

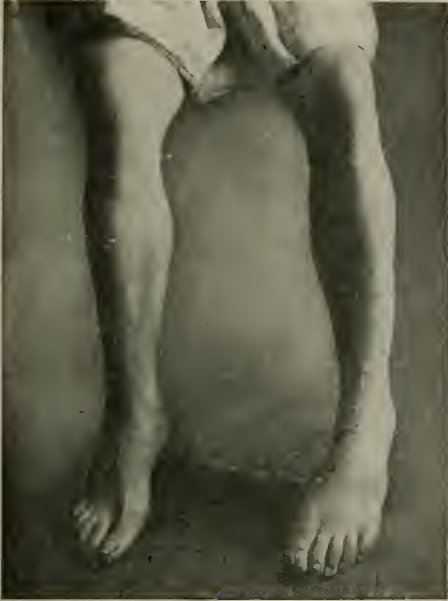

FIG. 252.—Isolated paralysis of the musculo-cutaneous, producing, on the left, a deviation of the foot inwards (paralytic talipes varus).

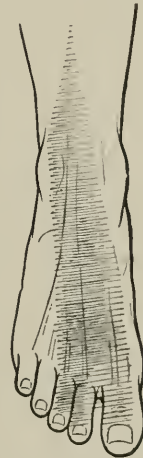

FIG. 253.—Sensory distribution of the musculo-cutaneous.

the entire sensory distribution of the external popliteal on the dorsal surface of the foot, with the exception of the small interdigital triangle of the first interspace specially supplied by the anterior tibial.

It sometimes happens that the pain caused by pressure on a terminal neuroma or by confinement of the nerve in a cicatrix, or even by simple formication of regeneration in the neuroma and the branches of the nerves, renders the wearing of boots or shoes and especially of leggings painful.

We have noted several cases of somewhat severe neuralgia of the musculo-cutaneous, injured in the middle or the lower part of the leg; one particularly painful case even necessitated resection of the neuroma and embedding of the central end deep in the tissues.

II.—INTERNAL POPLITEAL AND POSTERIOR TIBIAL

I.—INTERNAL POPLITEAL

MOTOR SYNDROME

Lesions of the internal popliteal produce paralysis of all the posterior muscles of the leg and of all the plantar muscles.

There results disappearance of the movements that produce flexion or lowering of the foot (gastrocnemius and soleus)—

Abolition of flexion of the toes by the muscles :

flexor longus hallucis,
flexor longus digitorum,
flexor brevis digitorum.

Collapse of the plantar arch, in its inner part (tibialis posticus) together with considerable weakening of rotation and adduction movements, incompletely carried out by the tibialis anticus.

Loss of adduction and abduction of the toes (adductors and abductors of the first and fifth toe, dorsal and plantar interossei).

Nevertheless, at first, walking does not appear to be greatly impeded. Paralysis of the internal popliteal may pass unnoticed on a superficial examination.

All we see is that the patient puts his foot flat down ; that he does not lift the heel from the ground ; that he cannot rise on his toes.

The patient, when seated, is unable to raise his heel by using his toes as a fulcrum. (Pitres and Testut.)

The internal plantar arch is flattened out, being deprived of the support of the tibialis posticus, whilst the antagonism of the peroneals on the other hand raises the outer edge. The patient thus walks on a sort of splay-foot, heavily, without elasticity or spring, and with a degree of uneasiness which is rapidly increased by fatigue of the antagonists.

At rest, the foot is extended, passive hyper-extension appears and may become extreme, as soon as the tone of the muscles of the calf disappears.

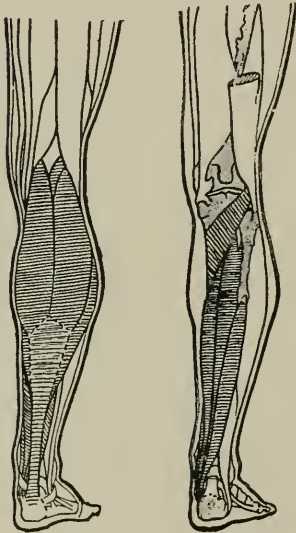


FIG. 254.

FIG. 255.

FIG. 254.—Muscles supplied by the internal popliteal. Superficial layer, gastrocnemius, soleus, plantaris.

FIG. 255.—Deep layer. Popliteus. Tibialis posticus. Flexor longus digitorum. Flexor proprius hallucis. These last three muscles are supplied by the posterior tibial below the fibrous arch of the soleus.

The toes are in simple extension or even in hyper-extension, according as the tone of the flexors and interossei persists or not.

When the patient attempts to raise and stretch his toes, we sometimes find a curious attitude of extreme hyper-extension of the toes, caused by the

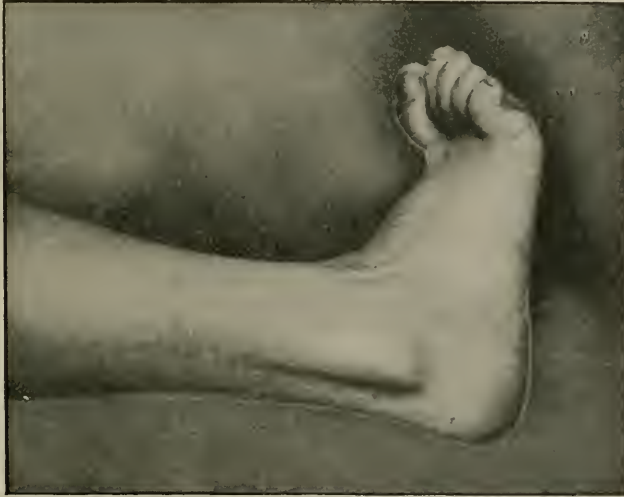

FIG. 256.—Paralysis of the internal popliteal. Hyper-extension of the toes by contraction of the extensors and loss of tone of flexors and interossei.

predominating action of the extensors deprived of the antagonistic tone of the flexors of the toes and of the interossei.

Both the Achillean reflex and the plantar reflex have disappeared.

SENSORY SYNDROME

The sensory region comprises the entire plantar surface; the back and lower part of the leg up to about the middle third; the outer edge of the foot and the outer part of its dorsal surface limited by a line which joins the third interdigital space; the dorsal surface of the last phalanx of the toes.

If the trunk of the sciatic is injured below the origin of the external saphenous, the external edge of the foot and the part close to its plantar surface naturally retain their sensibility.

TROPHIC AND VASO-MOTOR SYNDROME

In simple paralysis, as the result of compression or complete interruption, trophic and vaso-motor disturbances are almost entirely absent. It is seldom that we find cyanosis of the toes or pronounced cutaneous disturbances; plantar hyper-hydrosis, however, is somewhat frequent; the

frequency of chilblains on the toes is also to be noted, as is the readiness with which mechanical ulcers appear on the plantar surface.

We have several times found superficial sores of this kind, caused by injuries from the boots, at the level of the metatarso-phalangeal articulations.

In neuritic types, however, trophic disturbances are very great, affecting the skin, the muscles and the plantar aponeurosis; they also affect the toenails which are not touched by the external popliteal.

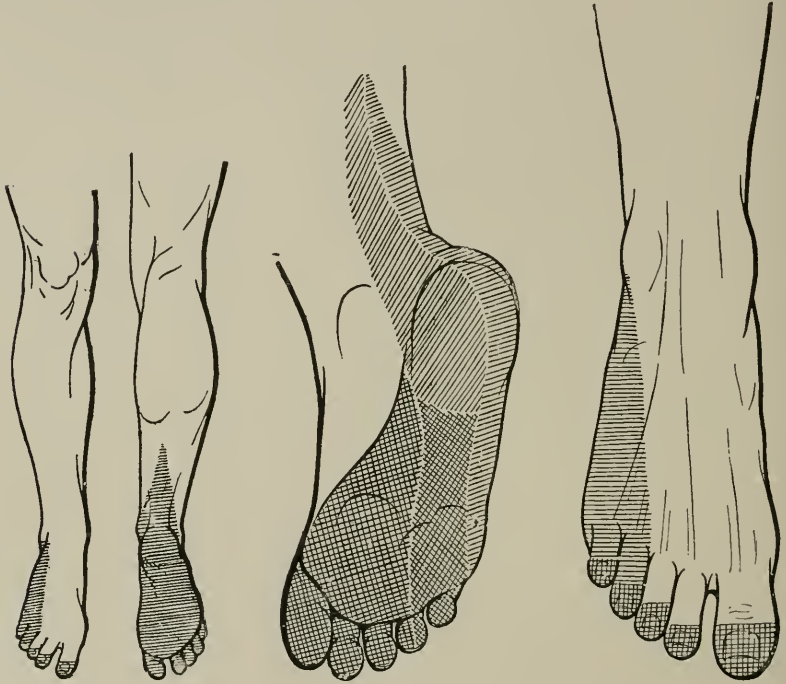

FIG. 257.

FIG. 258.

FIG. 259.

FIG. 260.

FIGS. 257, 258, 259, 260.—Sensory area of the internal popliteal comprising: the external saphenous; external surface of the instep (*horizontal hatching*), outer edge of the foot, dorsal surface of the foot to the third intermetatarsal space. The posterior tibial, cutaneous branch (*oblique hatching*). The external and internal plantars (*crossed hatching*) which supply, on the dorsal surface, the last phalanx of the toes.

In the case of the internal popliteal we may say the same as for the external; trophic and especially vaso-motor disturbances are less pronounced in isolated paralysis of this nerve than in complete paralysis of the sciatic. Probably they are modified by substitution of the external popliteal.

CLINICAL TYPES

We meet with both compression and interruption types in lesions of the internal popliteal. Interruption types, moreover, are by far the more frequent; there is no need to insist on the characteristics by which they are

to be recognised : early hypotonia and atrophy, fixity of sensory disturbances, clearness of RD, fixed location of formication, insensibility to pain

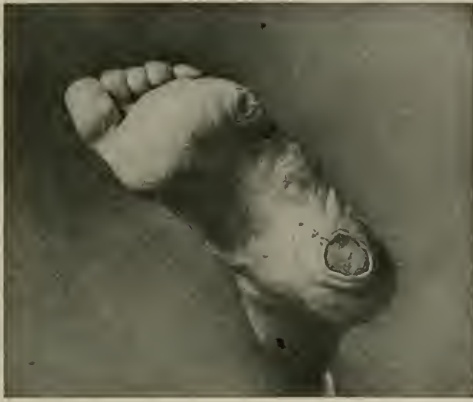

FIG. 261.—Ulcers on the sole of the foot in a case of interruption of the posterior tibial.

by pressure on the muscles of the calf and on the muscle masses in the sole of the foot, as well as on the nerve along its entire distribution.

In contradistinction to the external popliteal, the internal popliteal is frequently the seat of neuritic or neuralgic lesions capable of reproducing all the syndromes of irritation studied in the case of the upper limb.

The slight neuritic type, often without complete paralysis, though accompanied by pain on pressure on the nerves and muscular bellies, always causes slight fibrous contraction of the Achilles tendon gradually producing a certain degree of pes equinus.

The grave neuritic types are rather frequent, accompanied by intolerable pains, suppressing sleep and necessitating the use of morphine; pressure on the nerve trunks, and especially on the muscles of the calf and on the plantar muscles, causes violent pains.

Trophic disturbances are very marked. Along with scaly desquamation, fibrous infiltration of the skin,

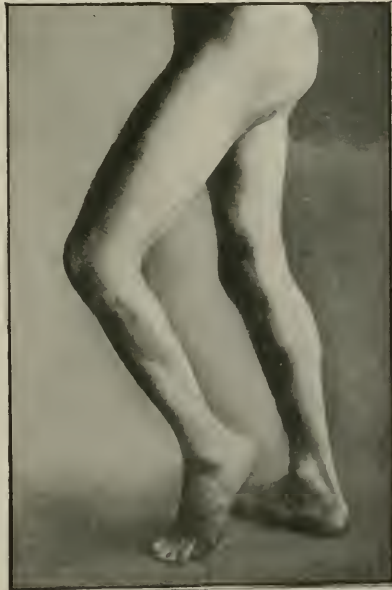

FIG. 262.—Fibrous contraction of the calf and pes equinus caused by slight neuritic lesion of the internal popliteal at the upper part of the popliteal space.

and the claw-like curve of the nails, we find that grave deformities supervene.

Fibrous contraction of the calf soon immobilises the foot in a state of forced flexion, suppresses the movements of the antagonistic extensors and very often renders necessary, after cure of the neuritis, tenotomy of the Achilles tendon. Contraction of the plantar muscles and of the plantar aponeurosis along with formation of fibrous cords and nodes, ends in the claw-like attitude of the foot, and will necessitate, for a few months after cure, both massage and mobilisation of the foot, sometimes even surgical section of the aponeurotic fibres and of the contracted flexor tendons.

Neuritis of the internal popliteal, when intense, is a very serious type, capable of producing irreducible deformities; it is certainly more serious

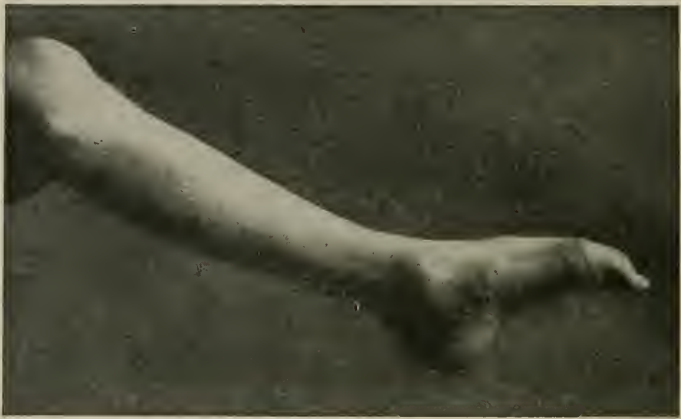

FIG. 263.—Fibrous contraction of the calf and pes equinus. Contraction of the flexors and of the plantar aponeurosis, producing fibrous *griffe* of the toes—neuritis of the internal popliteal.

in its consequences than section of the nerve. Consequently, in two particularly serious cases, we did not hesitate to practise resection of the lesion and suture of the nerve. Six weeks afterwards, these two patients were walking without a stick, though there was paralysis of the internal popliteal; the immediate disappearance of the pains had permitted of massage and mobilisation of the limb, thus effecting a cure without trophic disturbances or fibrous contractions.

The simple neuralgic type, accompanied by pain on pressure on the nerve trunks and also plantar hyper-aesthesia, is serious only because of the very long time it takes to cure.

Neuralgia of the internal popliteal frequently assumes the type of causalgia. Next to the median, this is the nerve most frequently affected. In these cases, we find the same absence of paralysis; trophic and vasomotor disturbances are still less pronounced; but the pains are often terrible. These are the special violent pains affecting the entire limb

with a burning sensation, caused by the slightest cutaneous touch far more than by deep pressure, above all, provoked by the most trifling emotions.

Partial lesions of the internal popliteal produce dissociated syndromes which enable us to set up the following fascicular topography; we find, from within outwards, the external saphenous nerve, then the plantar nerves, the nerve to the inner head of gastrocnemius; then further out are the fibres to the tibialis posticus, to the flexor longus digitorum pedis, the calcanean branches and the superficial branch of the external plantar nerve. (J. and A. Dejerine and Mouzon.)

II.—PARALYSIS OF THE POSTERIOR TIBIAL NERVE

From the fibrous arch of the soleus onwards the internal popliteal assumes the name of posterior tibial. This nerve is very often affected by traumatism in the calf or perforating wounds in the leg, though paralysis of the nerve is frequently overlooked. Indeed, the gastrocnemius and the soleus, supplied by the internal popliteal, have retained their movements; the muscles of the deep layer, tibialis posticus, flexor communis digitorum pedis and flexor proprius hallucis, which receive their branches from the posterior tibial at the upper part of the leg, are usually untouched. Thus, all disturbances are practically reduced to paralysis of the plantar muscles and partial anæsthesia of the sole of the foot. In all wounds of the leg, systematic inspection should be made of the attitude of the foot and the electrical reactions of the plantar muscles; a simple faradic examination will generally reveal neglected plantar paralysis.

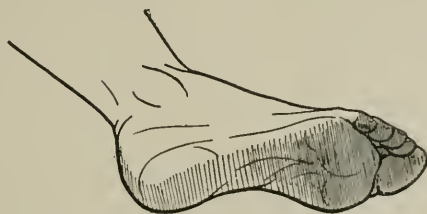


FIG. 264.—Anæsthesia caused by lesion of the posterior tibial.

The attitude of the foot is rather characteristic. First, it is a hollow foot, since atrophy of the plantar muscles intensifies the concavity of the plantar arch, which is supported by the tendons of the tibiales and the peroneals.

Frequently too it is an atrophied foot, owing to the disappearance of the thick mass of the plantar muscles; in some cases, after a time we may see atrophy of the foot, which appears to be smaller, thinner and shorter than the normal foot.

The toes form a special kind of *griffe*; the first phalanx is hyperextended on the metatarsus by the pull of the extensors and by the inaction of the flexor interossei of the first phalanx; the second and third phalanges, on the other hand, are strongly flexed by traction of the flexor longus digitorum.

The toes thus seem to be bent back upon themselves, forming a sort

of Z, the pulp lying on the ball of the toes formed by the metatarsophalangeal articulations.

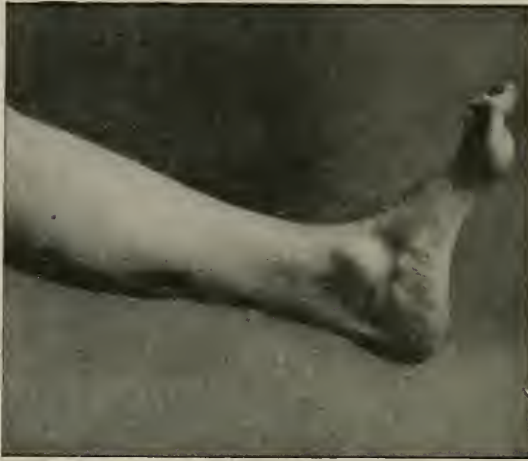
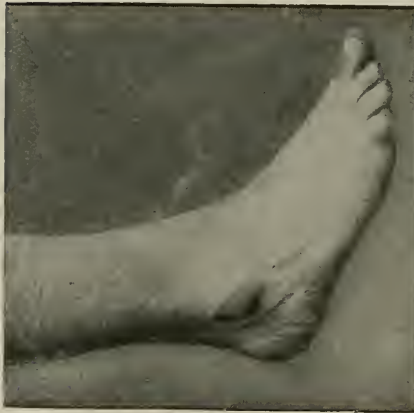
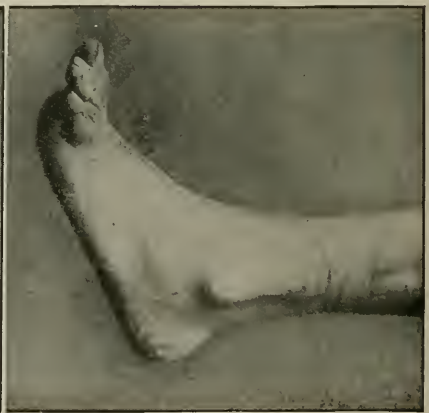FIG. 265.—Atrophy of the plantar muscles caused by lesion of the posterior tibial at the lower part of the leg.



FIG. 266.—Pes cavus with hyper-extension of the toes caused by lesion of the posterior tibial.



Normal foot.



Paralysed foot.

FIGS. 267 and 268.—Attitude of the foot in paralysis of the posterior tibial. On the right, left foot paralysed in characteristic attitude. Hyper-extension of the first phalanx, hyper-flexion of the second and third phalanges; projection of the metatarsophalangeal articulations which constitute the anterior end of the arch. On the left, compare the normal right foot of the same patient.

The adduction and abduction movements of the toes are suppressed by paralysis of the interossei.

The posterior tibial nerve possesses the same trophic activities as the internal popliteal.

Its interruption results in the frequent appearance of plantar ulcers caused by injuries from the boot ; superficial sores which often take a very long time to heal. Its irritation brings out the same nerve disturbances, particularly fibrous contraction of the plantar aponeurosis, with *griffe* of the toes and muscular sclerosis.

Like the internal popliteal, it may be the seat of violent causalgia and of prolonged neuralgic pains.

III.—EXTERNAL SAPHENOUS NERVE

Of all the branches of the internal popliteal, the external saphenous alone deserves special mention, for it may be affected in its superficial course on the posterior surface of the calf.

Its interruption causes anæsthesia, limited to the external retromalleolar region, to the external half of the heel and to the outer border of the foot. It is followed by the usual phenomena of regeneration accompanied by unpleasant formications and cutaneous paræsthesia which may cause pain along the course of the nerve if anything is worn on the foot.

On the other hand, irritation of the nerve is often the cause of painful heel, along with cutaneous hyper-æsthesia so painful at times that the patient does not dare to set his heel on the ground and walks with difficulty, carrying the weight of his body on the inner portion of the metatarso-phalangeal articulations.

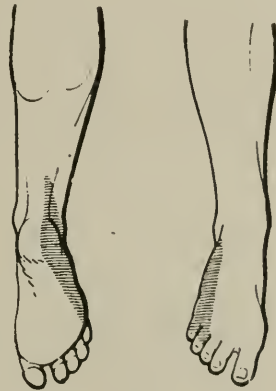


FIG. 269.—Sensory area of the external saphenous nerve. Note that the anæsthesia does not reach the extremity of the last two toes.

III.—PARALYSIS OF THE SCIATIC TRUNK

Lesions of the great sciatic nerve simply combine paralysis of the internal popliteal with that of the external popliteal. Atrophy is complete. Progress, however, is possible, with a steppage gait, but the foot, in an absolutely swinging condition, is no more than an insensible inert appendage supporting the weight of the body, thanks to the rigidity of the lower limb, a rigidity maintained by the hamstring.

In these cases, there is considerable and often widely diffused atrophy of the leg, the sensory, trophic and vaso-motor disturbances are more pronounced, for collateral substitution is no longer possible.

To paralysis of the muscles of leg and foot may be added paralysis of the posterior muscles of the thigh supplied by the collateral branches of the sciatic.

These muscles receive their motor branches at different and somewhat variable levels.

The semi-tendinosus, supplied wholly at the upper portion of the thigh, below the sciatic notch, is scarcely ever injured.

The semi-membranosus and the long head of the biceps, supplied a little below, are sometimes paralysed.

The short head of the biceps, the motor twig of which is given off at the middle of the thigh, is very often affected; paralysis is indicated by appreciable weakening of the biceps.

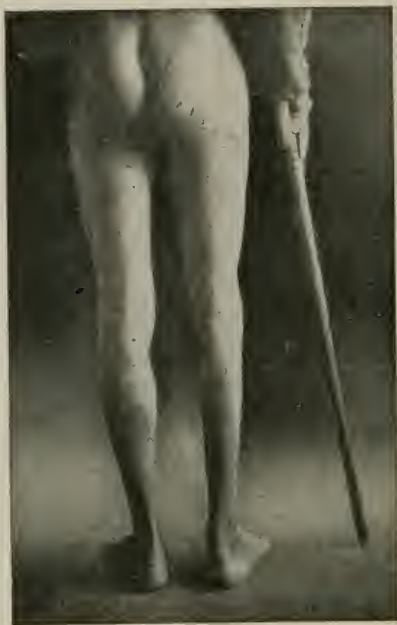

FIG. 270.—Lesion of the sciatic (complete interruption at the level of the sciatic notch). Wound 13 months old. Considerable atrophy of all the muscles of the leg. Paralysis of the posterior muscles of the legs, except the semi-tendinosus.

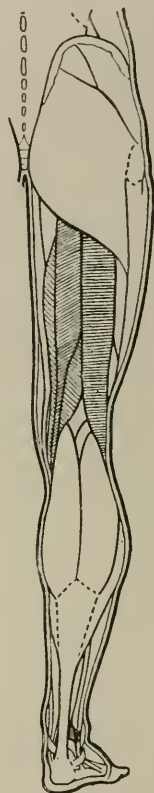


FIG. 271.—Muscles supplied by the trunk of the sciatic itself. On the outer side is the biceps, semi-tendinosus and semi-membranosus.

Preservation of the semi-tendinosus suffices in all these cases to assure persistence of flexion of the leg on the thigh, the abolition of which is therefore exceptional.

The sciatic nerve, like its branches, may be interrupted, compressed or irritated. Injuries of this nerve may produce all the paralytic, neuritic, neuralgic and causalgic syndromes which we have already studied.

The neuritic types are extremely frequent, affecting either the whole or only part of the nerve distribution. They are indicated by the usual

trophic disturbances, fibrous infiltration and desquamation of the skin, profuse sweats or dryness of the integuments; sclerosis of the dermis; muscular, tendon, and aponeurotic contractions. They may immediately be recognised, simply by pressure on the calf or the sole of the foot, which is extremely painful; whilst almost invariably they culminate in fibrous contraction of the calf, combined with pes equinus, and sometimes even in fibrous *griffe* of the toes.

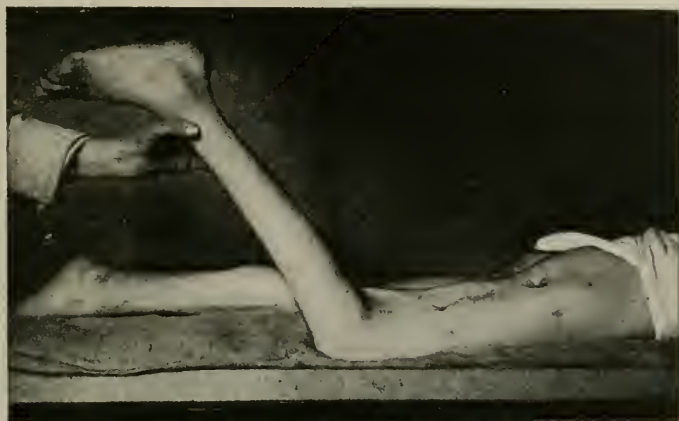

FIG. 272.—Complete interruption of the sciatic at the upper part of the leg. Paralysis of the biceps and of the semi-membranosus. The unaffected semi-tendinosus is capable of producing considerable flexion of the leg on the thigh. Here its tendon shows as a very obvious projection on the inner side of the popliteal space. Absence of contraction of the biceps, the tendon of which is invisible on the surface.

It must be remarked that vaso-motor and trophic disturbances of the neuritic types are usually more pronounced in lesions of the trunk of the sciatic than in wounds of the internal popliteal or of the external popliteal, doubtless because of the impossibility of substitution.

In some cases we find that simple contusion of the sciatic nerve gives rise to persistent neuralgia, veritable traumatic sciatica, the cure of which is a very long process. The nerve is painful under pressure at the level of Valleix's points; Lasègue's sign is almost always present, and we often note slight hypertonia of the muscles of the calf, shown by a raising of the heel, just as in common sciatica (Souques), suggesting true pes equinus.

Lastly, certain cases of slight neuritis of the sciatic produce the appearance of actual contractions: contraction of the posterior muscles of the leg and contractions of the calf, intensified and aggravated as usual by disuse on the part of the patient and culminating in permanent flexion of the knee with more or less pronounced pes equinus.

What particularly characterises the sciatic is, by reason of its bulk, the frequency of partial lesions and of dissociated syndromes.

It must not be forgotten that bifurcation of the nerve takes place at an extremely variable level, sometimes at the middle or even the upper

part of the thigh. There are indeed cases in which the two branches of the nerve issue from the sciatic notch separate, and pass on together, arranged in gun-barrel fashion.

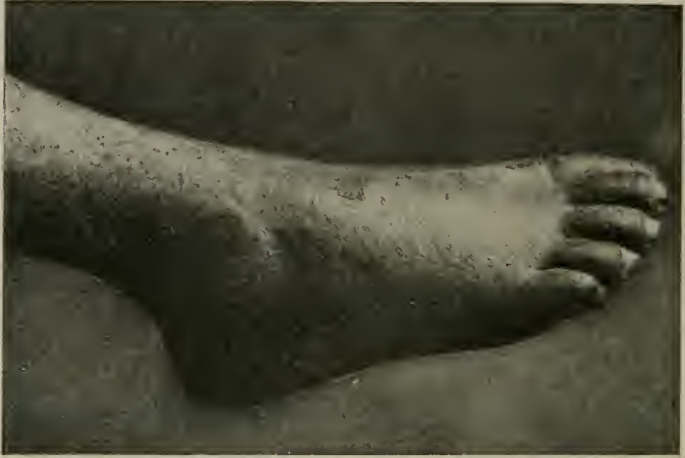

FIG. 273.—Severe neuritis of the sciatic nerve. Edema of the foot, fibrous infiltration of the dermis, cyanosis, cutaneous desquamation.

Even united in a single trunk, the fibres of the internal popliteal and of the external popliteal retain their relationship, being grouped together at the internal and external part of the nerve.

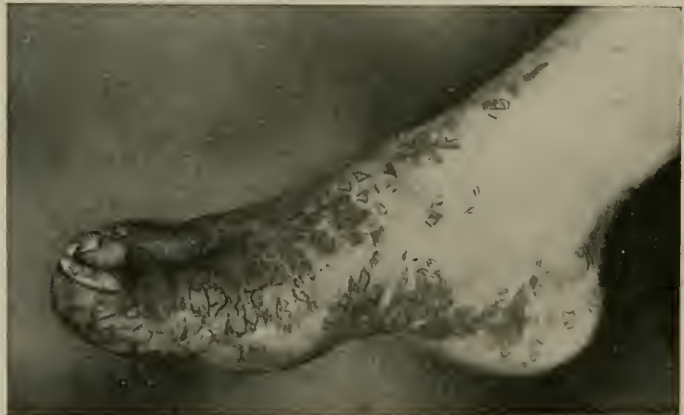


FIG. 274.—Neuritis of the sciatic. Predominant cutaneous disturbances scaly skin peeling off in broad flakes (integrity of the distribution of the internal saphenous). Trophic disturbances of the nails.

We may then observe the most varied dissociations and combinations resulting from lesion of the sciatic. A few instances may be given.

In some cases we have complete paralysis of the internal popliteal or

of the external popliteal, accompanied by simple weakening of the other nerve.

In other cases, paralysis is complete in the nerve distribution of both nerves, but whereas it remains unchanging in the region of one of the nerves, we find, in the other, that a syndrome of progressive regeneration appears. Even before the muscles show the slightest sign of improvement, the sign of formication indicates this difference in evolution. We find, for instance, at the level of the lesion, a definite area of formication, unchanging and localised in the sole of the foot ; on the other hand, we see

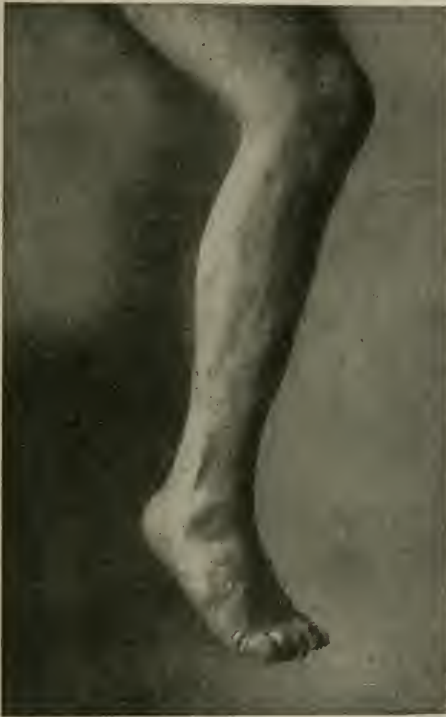

FIG. 275.—Contraction of the calf with pes equinus, caused by slight irritation of the sciatic at the upper part of the thigh.

advancing below the lesion a zone of induced formication which is localised on the dorsal surface of the foot ; the conclusion we arrive at is that there exists an insurmountable obstacle to the fibres of the internal popliteal, whereas the fibres of the external popliteal nerve are in process of regeneration.

We may find the association of simple paralytic disturbances in the region of one of the nerves, and of neuritic or neuralgic irritation in the region of the other. Still, it must be remembered, in such cases, that the neuritic symptoms of the internal popliteal are always far more intense and

obvious ; the signs of irritation of the external popliteal, always more widely distributed, are not apparent at first ; they have to be sought for.

The frequency and diversity of these dissociated syndromes of the sciatic are a matter of importance, for a precise diagnosis of the nature and seat of the lesion will frequently enable us to carry out partial and conservative interventions, these being specially easy in the case of the sciatic.

DIAGNOSIS OF PARALYSIS OF THE SCIATIC AND ITS BRANCHES

The various forms of paralysis of the sciatic are easy to recognise.

The seat of the wound in the course of the nerve, the topography of the paralysed muscles, their atrophy and faradic inexcitability enable us to determine the existence of the lesion and to eliminate all the causes of error, which we will now enumerate :

Hysterical paralysis, or rather the group of functional paralyses, constitutes the chief difficulty in diagnosis.

They are frequent and extremely variable as to their cause. Sometimes we are dealing with genuine hysterical paralysis or simply with the functional inertia of wounded muscles ; sometimes after the recovery of a nerve lesion, the paralysis persists—this is a functional condition, the result of prolonged disuse of the muscle. The incapacity results from the pain, contracture or retraction of the antagonistic muscles.

In all cases, a simple electrical examination with the faradic current will suffice to show the functional nature of the paralysis.

We may also easily recognise cases of incapacity caused by the partial destruction of the muscles or by section of the tendons ; first, by the site and character of the wound ; secondly, and above all, by electrical examination. The muscular fibres which have escaped the more or less complete destruction of a muscle still retain some faradic contractility, unless there exists an associated nerve lesion. The divided muscles also contract, and the contraction, not transmitted to the tendon, may be regarded as a definite sign that they have been cut.

Lastly, the contractures and the fibrous cicatricial scleroses of the muscles, and in particular the almost constant contractions of the calf resulting from a wound of the gastrocnemius, or of the tendo Achillis, or of the os calcis, may easily be mistaken for neuritic fibrous contraction ; but the distinctive pain in cases of neuritis on pressure on the nerve trunks and muscular bellies is here lacking, and the muscles have retained their faradic contractility, though this is often difficult to determine in retracted or contracted muscles.

Sometimes a diagnosis of the various organic paralyses of the lower limb is a little more difficult.

Frequently peripheral neuritis appears almost identical with complete or dissociated paralysis of the sciatic. In addition to the typical forms of polyneuritis, of which the diphtheritic is the most frequent, certain forms of neuritis peculiar to war must be mentioned; of these we have found three groups: polyneuritis resulting from trench dysentery, polyneuritis



FIG. 276.—Complete hysterical paralysis of the right lower limb, following a superficial perforating wound of the buttock. Slight muscular atrophy from prolonged inaction (16 months), normal electrical reactions, normal reflexes. Complete anæsthesia of the lower limb. The patient, incapable of using his right lower limb, hops along on his left leg with the help of a stick, leaving his right leg to drag behind him.

from frost-bite, polyneuritis from asphyxiating gases, two instances of which we have localised to the region of the external popliteal. The first and third are generally painless, neuritis from frost-bite, on the other hand, is very painful, being accompanied by trophic disturbances together with contraction of the plantar aponeurosis and of the plantar muscles.

In all these cases, the disturbances are mostly bilateral and symmetrical, though they may predominate on one side; the electrical reactions are

profoundly affected—though, as a rule, the tibialis anticus is more or less untouched, just as the supinator longus is, in saturnine musculo-spiral paralysis. Finally, the absence of a wound and the history of the case are usually sufficient to determine the diagnosis.

Lesions of the sacral plexus often reproduce the picture of complete or of dissociated paralysis of the sciatic; when we come to study the lumbosacral plexus, we shall set forth the special characteristics of these root paralysees.

Lumbo-sacral hematomyelia, caused by lumbar *commotio* or simply by shell explosion, may also cause errors in diagnosis, but the root distribution of the motor and sensory disturbances, the almost invariable association of sphincteric disturbances, and, above all, the dissociation of sensibility join with the history in clearing up the diagnosis.

We shall return to this point in diagnosing root paralysis, the main difficulty of which lies in cases of hematomyelia.

Cortical paralysis, limited to the lower limb and following on wounds of the cranium, may in certain cases be mistaken for paralysis of the sciatic. These cortical monoplegias, which are flaccid and spasmodic in succession, are characterised by the absence of peripheral signs, the integrity of the muscles and their normal electrical reactions, exaggeration of the reflexes, Babinski's sign and the combined flexion of thigh and trunk. We are far more likely to mistake them for hysterical paralysis than for paralysis of a peripheral nerve.

Lastly, ischæmic paralysis of the foot, resulting from too tight a bandage or from arterial obliteration, may sometimes be very difficult to diagnose, the more so as it is rather frequently associated with nerve lesions.

As in paralysis of a neuritic type, we observe pains that are violent, spasmodic and evoked by pressure; there are seen marked disturbances of electrical reactions and objective disturbances of sensibility. The absence of the topography characteristic of peripheral nerve lesion, the frequent preservation of an attempt at contraction, the considerable fall of temperature, the cyanosis and fibrous infiltration of the foot, the suppression of arterial pulsation, the segmentary distribution of muscular and sensory disturbances diminishing from the periphery towards the root of the limb; all are important signs that enable us to connect these paralysees with their cause.

TREATMENT OF PARALYSIS OF THE SCIATIC

Steppage constitutes the main functional drawback in paralysis of the trunk of the sciatic or of the external popliteal. It is important to minimise this, just as we minimise the wrist drop in musculo-spiral paralysis, in order to diminish the incapacity of the patient, and especially to avoid the stretching of the muscles of the antero-external group.

This is easily effected either by surgical boots or shoes, or by the application of spring contrivances; or, more simply still, by the traction, on the front part of the foot, of a spring or elastic, fastened either to a girdle or to a shoulder strap.

Types of apparatus
suppressing steppage.

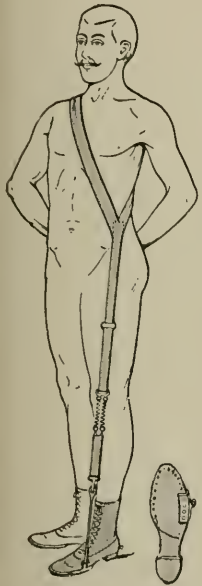


FIG. 277. (P. Marie
and H. Meige.)

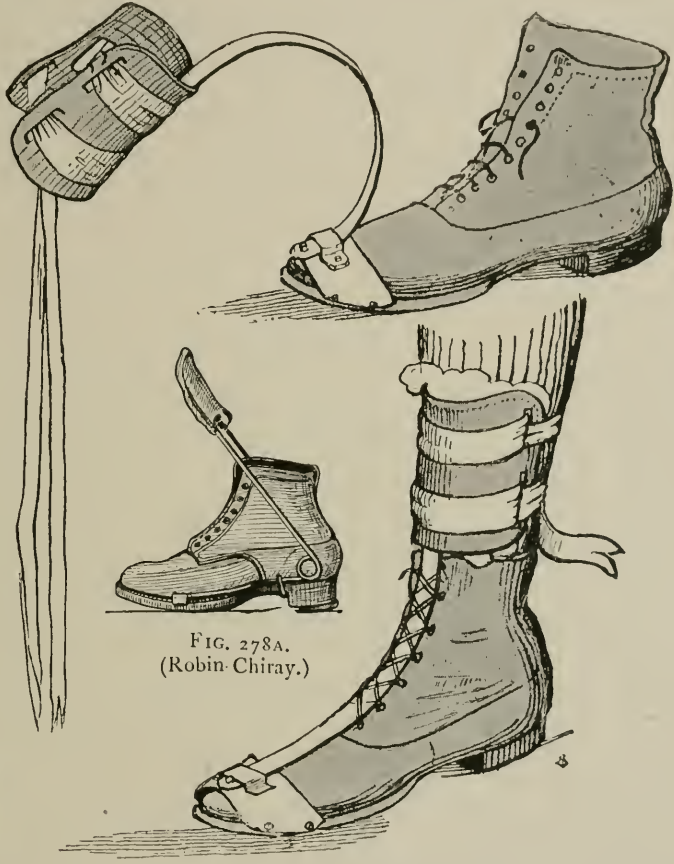


FIG. 278A.
(Robin-Chiray.)

FIG. 278. (A. Lévi.)

It is really surprising to find that patients, supplied with these very simple contrivances, can take moderately long walks without much fatigue; in spite of their paralysis they complain of only a very slight degree of incapacity.

CHAPTER XVI

SMALL SCIATIC NERVE

THE small sciatic nerve has its origin in the first, second, and third sacral roots.

It issues from the pelvis, along with the great sciatic nerve and the

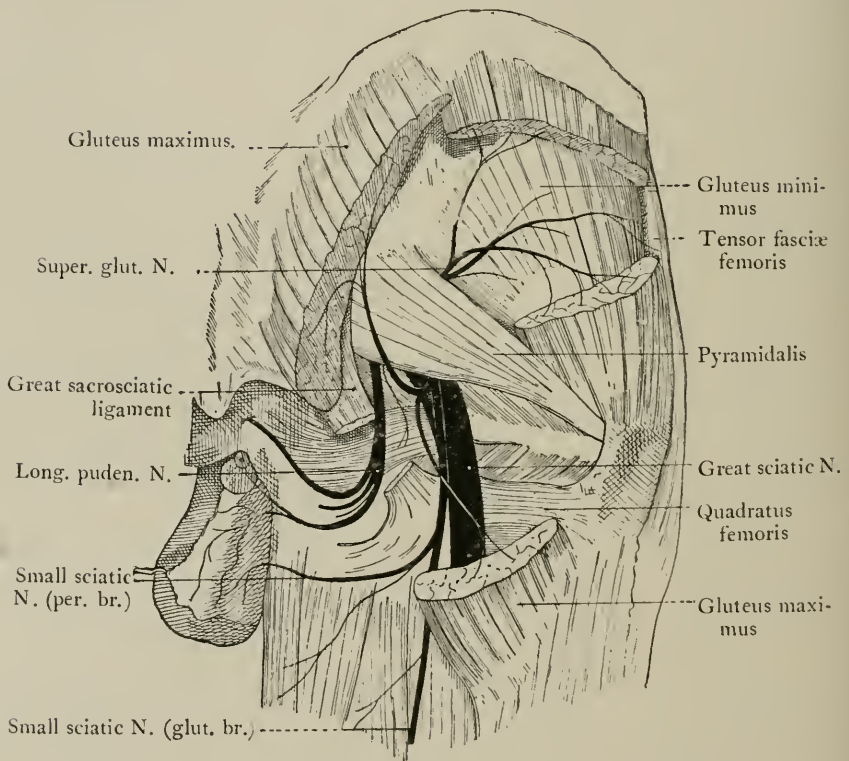


FIG. 279.—Nerves of the gluteal region. (After Hirschfeld, simplified.)

inferior gluteal nerve (sacral plexus). Moreover, the inferior gluteal nerve and the small sciatic are often described as the two branches of one and the same trunk.

The posterior cutaneous nerve descends, internal to the great sciatic, between the biceps and the semi-tendinosus as far as the middle part of the popliteal space, where it divides into its two terminal branches.

COLLATERAL BRANCHES

Along its course, it sends out a series of collateral branches :

The gluteal branches, two or three in number, which turn round the lower edge of the gluteus maximus to be distributed over the skin of the lower and outer part of the buttock ;

The perineal branches which are given off at the same level and are distributed over the skin of perineum and scrotum ;

The femoropopliteal branches which appear at variable levels and are distributed, on the inner and the outer side, over the skin of the posterior part of the thigh.

TERMINAL BRANCHES

1. A superficial branch which descends right to the middle of the calf, distributed to the integuments ;

2. A deep subaponeurotic branch which proceeds along the external saphenous vein and anastomoses with the external saphenous nerve, about the middle part of the calf.

The posterior cutaneous nerve of the thigh is thus wholly sensory.

Its destruction is indicated solely by anæsthesia of the posterior surface of the thigh and of the upper part of the calf.




FIG. 280.—Sensory distribution of the small sciatic nerve.

CHAPTER XVII

ANTERIOR CRURAL NERVE

THE anterior crural nerve is formed by the union of three roots springing from the second and particularly the third and fourth lumbar.

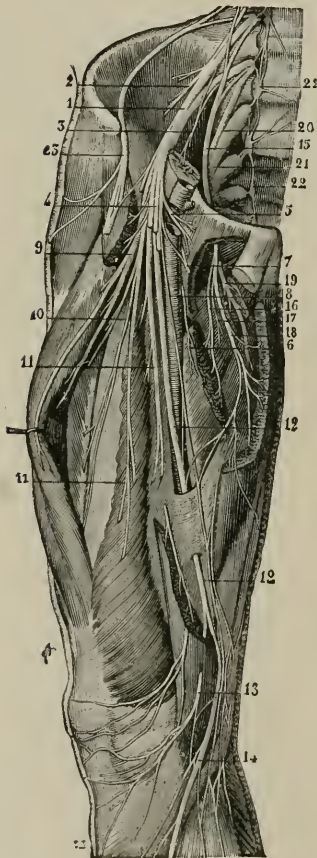
These roots unite near the iliac crest, at the level of the outer edge of the psoas.

The nerve crosses obliquely the iliac fossa, in the angle formed between the psoas and the iliacus.

It passes under Poupart's ligament outside the vessels from which it is separated by a portion of the psoas.

It is under Poupart's ligament that it divides into its many terminal branches, diverging in every direction across Scarpa's triangle.

The course of the nerve trunk then is very short; this fact explains why paralyses of this trunk are so few.



COLLATERAL BRANCHES

In its intra-pelvic course the anterior crural supplies the iliacus and the psoas; it also supplies a branch to the femoral artery and the nerve to the pectineus.

FIG. 281.—Anterior crural nerve and obturator nerve. (After Sappey.) 1. Anterior crural nerve. 2, 3. Nerve to the ilio-psoas. 4. External musculo-cutaneous nerve. 5, 6, 7. Internal musculo-cutaneous nerve. 8. Branch to the femoral artery. 9, 10, 11. Nerve to the quadriceps. 12. Internal saphenous nerve with 13, its patellar branch and, 14, its tibial branch. 15. Obturator nerve. 16. Branch to the adductor longus. 17. Branch to the adductor brevis. 18. Branch to the rectus femoris. 19. Branch to the adductor magnus. 20. Lumbo-sacral trunk. 21. First sacral root. 22. Abdomino-pelvic sympathetic. 23. External cutaneous nerve.

TERMINAL BRANCHES.

The anterior crural expands into a considerable number of branches which frequently originate in two common trunks and which we may, with Sappey, reduce to four groups.

1. The external musculo-cutaneous nerve supplies a single muscle, the sartorius, by means of several twigs (short and long branches). It supplies three cutaneous branches :

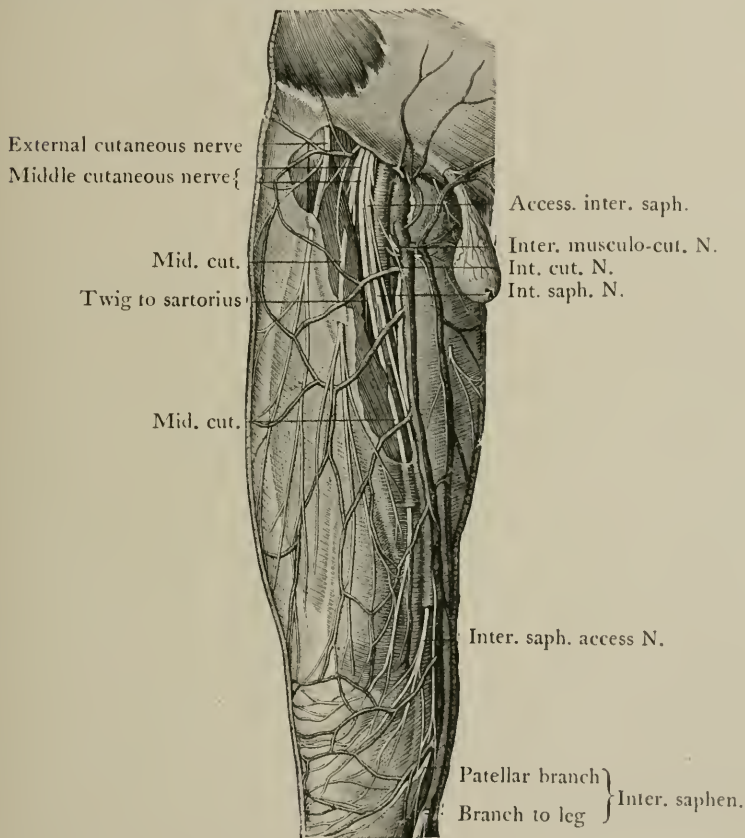


FIG. 282.—Cutaneous branches of the anterior crural. (After Sappey.)

The upper cutaneous perforating branch (middle cutaneous) which passes through the sartorius and is distributed over the antero-external part of the thigh internal to the external cutaneous nerve with which it anastomoses ;

The lower cutaneous perforating branch (middle cutaneous) which descends along the sartorius and perforates it at about its middle third, to be distributed in the supra-patellar region ;

The accessory branch of the internal saphenous, one branch of which

remains close to the internal saphenous vein, and the other the deeper one, follows the femoral artery; both become superficial at the lower and inner part of the thigh and supply the inner side of the knee.

2. The internal branch whose muscular branches pass behind the femoral vessels and are distributed to the pectineus and to the adductor longus.

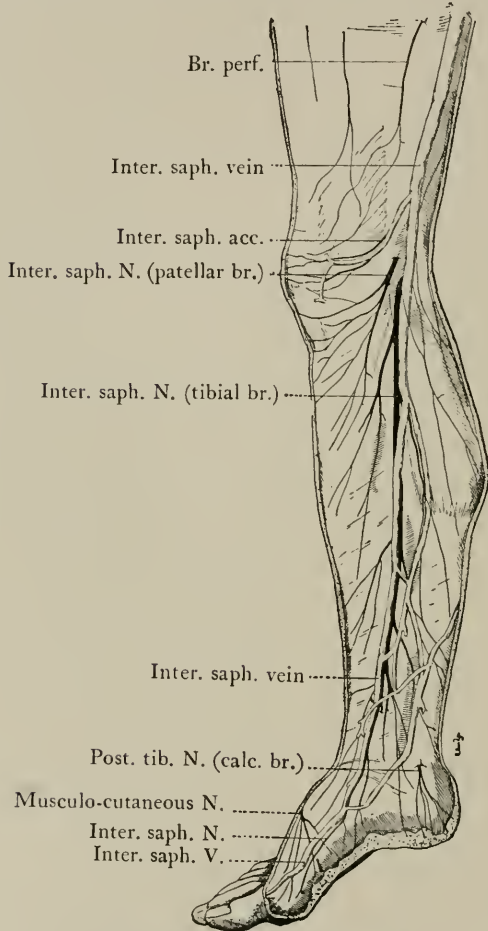


FIG. 283.—Internal saphenous nerve.
(After Hirschfeld.)

The cutaneous branches which pass in front of the vessels are distributed over the upper and inner part of the thigh and anastomose with the cutaneous branches of the obturator.

3. The nerve to the quadriceps from which originate :

The branch to the rectus femoris ;

The branch to the vastus externus ;

The branch to the vastus internus ;

The branch to the crureus.

4. The internal saphenous nerve rejoins the femoral artery and descends into the sheath of the femoral vessels in front of the artery which it crosses obliquely so as to lie internal to it.

At the lower part of the thigh, near the opening in the adductor magnus, it leaves the vessels, perforates the anterior wall of Hunter's canal and proceeds along the inner side of the knee.

Becoming subcutaneous at the level of the internal tuberosity of the tibia, it lies along the internal saphenous vein which its main terminal (tibial) branch accompanies right to the inner side of the foot.

Its collateral branches, of but slight importance, are :

The femoral cutaneous branch ;

The tibial cutaneous branch ;

The internal articular branch to the knee.

It has two terminal branches :

The patellar or anterior branch, which breaks away at the inner side of the knee and supplies the supero-internal part of the leg.

The tibial or lower branch, which proceeds along the internal saphenous vein and accompanies it throughout its entire course, supplying branches to the whole inner surface of the leg.

Its posterior branch is distributed over the internal malleolar region.

Its anterior branch passes in front of the malleolus and is distributed on the inner side of the foot as far as the base of the first metatarsal.

PARALYSIS OF THE ANTERIOR CRURAL NERVE

Paralysis of the anterior crural nerve is comparatively rare. This nerve has quite a short course which corresponds solely to the point at which it crosses the pelvis, where it is protected by the pelvic girdle. Immediately under Poupart's ligament it opens out into its terminal branches and if the nerve is injured, in Scarpa's triangle, only some of its terminal branches are affected.

Paralysis of this nerve, therefore, is generally the result of pelvic injuries.

Injury to the anterior crural nerve is shown solely by paralysis of the pectineus, of the sartorius and of the quadriceps, accompanied by loss of extension of the leg on the thigh.

Atrophy of the crureus, absence of its power of extension, loss of its normal electrical reactions and abolition of the patellar reflex are so many signs that enable us to recognise paralysis of this nerve.

As a rule, the patient can walk, but he does so with his leg stiffened by contraction of the tensor fasciæ femoris, and the gracilis, for the lower limb, thus maintained in a kind of hyper-extension, easily bears the weight of the body ; but if the slightest flexion takes place, the crureus muscle ceases to function and the patient sinks down on to his suddenly flexed knee. He has also a special way of walking; advancing the healthy limb, he brings up the paralysed one, plants it on the ground in hyper-extension, maintained by contraction of the tensor fasciæ femoris and of the gracilis, and, on this unstable support, again begins to advance the healthy limb.

As in fracture of the patella, walking backwards is

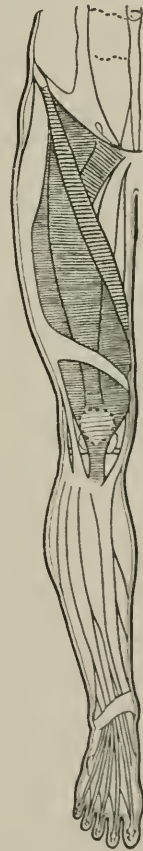
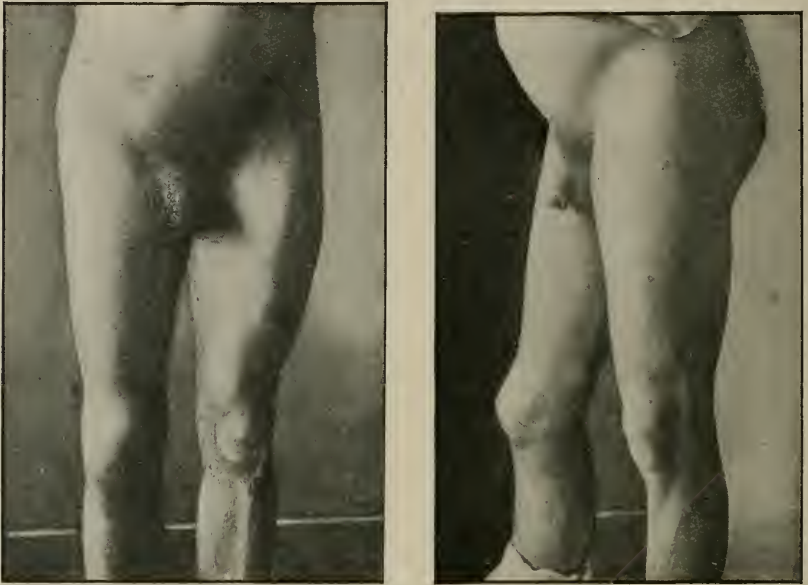

FIG. 284. — Muscles supplied by the anterior crural: sartorius, pectineus, quadriceps.

as easy as walking forwards is difficult, for in this case the knee remains in a state of permanent hyper-extension.

A frequent cause of error must be mentioned in summing up anterior crural paralysis. We sometimes imagine that voluntary muscular contractions persist just as we may observe electrical pseudo-contractions of the paralysed crural triceps. This error originates in the voluntary or electrical contraction of the tensor fasciæ femoris (superior gluteal nerve),



FIGS. 285 and 286.—Paralysis of the right anterior crural nerve by intra-pelvic lesion, above Poupart's ligament ; slight consecutive hydrarthrosis of the right knee.

which thrusts inwards the triceps and imparts to it a transverse pull by means of its aponeurotic slip.

It must not be forgotten that paralysis of the anterior crural is often accompanied by hydrarthrosis of the knee, probably caused partly by the slight and oft-repeated injuries which this articulation now has to sustain and partly by the hyper-extension necessary for walking.

Disturbances of sensibility are localised on the anterior surface of the thigh and on the inner surface of the leg.

A special study must be made of these latter disturbances and of lesions of the internal saphenous.

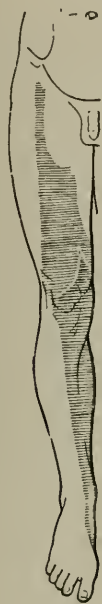LESIONS OF THE INTERNAL SAPHENOUS NERVE.

Of all the branches of the anterior crural nerve, the internal saphenous is the only one the lesion of which is of special interest, since lesion of

the other terminal branches causes no more than partial paralysis of the sartorius and the crural triceps.

The long course of the internal saphenous exposes it to frequent lesions capable of producing the various syndromes of simple anæsthesia, neuralgia from nerve irritation, or even actual causalgia.

Its distribution covers the entire inner surface of the leg and spreads upwards on to the antero-internal surface of the knee. It extends over



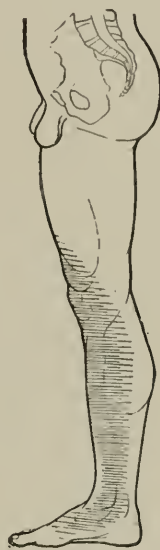Anterior surface.

FIG. 287.



Posterior surface.

FIG. 288.



Inner surface.

FIG. 289.

FIGS. 287 and 288.—Sensory region of the anterior crural. Above the knee, region of the anterior crural proper. Below the knee, region of the internal saphenous.

FIG. 289.—Sensory disturbances in complete interruption of the internal saphenous nerve in Scarpa's triangle.

the internal malleolar region and over the inner side of the foot, to end near the first metatarsal.

It is often somewhat enlarged in its upper part by simultaneous lesion of the branch accessory to the internal saphenous, which follows in the thigh the same course as the internal saphenous and is also affected as a rule.

Neuralgia of the internal saphenous is at times so violent as to cause considerable inconvenience in walking.

DIAGNOSIS

The diagnosis of paralysis of the anterior crural must be made from functional paralysis and from reflex muscular atrophies which generally

follow fractures of the femur and particularly lesions of the knee joint.

Particular care must be taken in dealing with lesions of the lumbar roots or with lumbar hematomyelias, which we will study along with the syndromes of the lumbo-sacral plexus.

CHAPTER XVIII

OBTURATOR NERVE

THE obturator nerve originates in the lumbar plexus from the second, third, and fourth lumbar roots.

It appears internal to the psoas, passes behind the common iliac vessels and proceeds along the brim of the inlet right to the subpubic groove, covered by the parietal peritoneum.

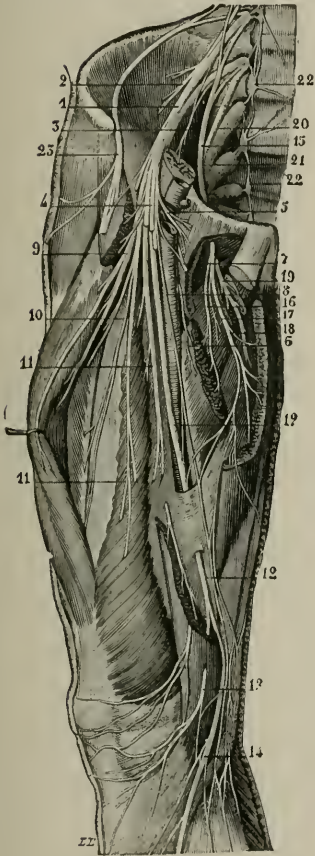
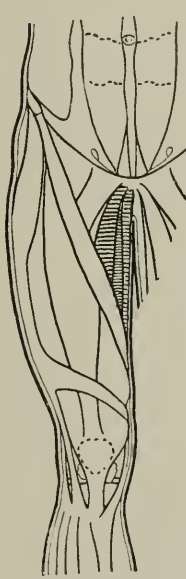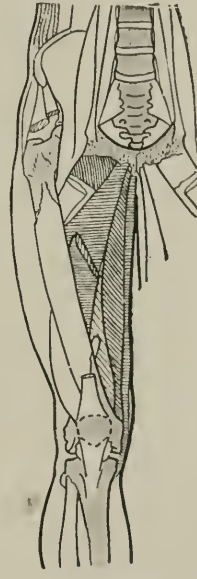


FIG. 290.



Superficial layer.

FIG. 291.



Deep layer.

FIG. 292.

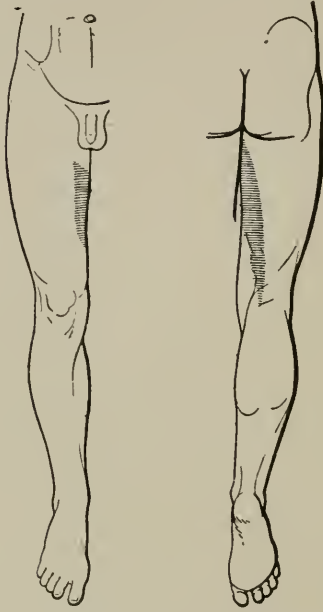
FIG. 290.—Anterior crural nerve and obturator nerve. (After Sappey.) 1, Anterior crural nerve. 2, 3, Nerve to the ilio-psoas. 4, External branch of anterior crural nerve. 5, 6, 7, Internal branch of anterior crural. 8, Branch to the femoral artery. 9, 10, 11, Nerve to the quadriceps. 12, Internal saphenous nerve, with 13, its patellar branch and 14, its tibial branch. 15, Obturator nerve. 16, Branch to the adductor longus. 17, Branch to the adductor brevis. 18, Branch to the gracilis. 19, Branch to the adductor magnus. 20, Lumbo-sacral cord. 21, First sacral root. 22, Abdomino-pelvic sympathetic. 23, External cutaneous nerve.

FIGS. 291 and 292.—Muscles supplied by the obturator nerve. Superficial layer: adductor longus, adductor magnus, gracilis. Deep layer: the sartorius, the crural triceps and the pectineus (crural nerve) have been removed, and the adductor longus (obturator nerve) has been cut to show the obturator externus and the adductor brevis, as well as the lower part of the adductor magnus and of the gracilis.

On leaving the obturator foramen or even in the subpubic groove it divides into its terminal branches.

BRANCHES

In its pelvic course it supplies chiefly the branch to the obturator internus.



FIGS. 293 and 294.—Sensory region of the obturator.

There are two terminal branches—
 1. **Superficial branch**, which passes in front of the adductor brevis and then winds below the adductor longus.

It supplies at this level :

The branch to the gracilis ;

The branch to the adductor brevis ;

The branch to the adductor longus ;

A cutaneous branch which is distributed over the supero-internal surface of the thigh and anastomoses with the internal saphenous.

2. **Deep branch**.—This, on the other hand, passes behind the adductor brevis and supplies the adductor magnus on which it rests.

The obturator nerve is essentially the nerve of adduction of the thigh. Its secondary function is to rotate outwards and to flex the thigh on the pelvis.

As a rule, adduction is not completely paralysed in lesions of the obturator nerve, for the adductor longus receives secondary innervation from the anterior crural ; the adductor magnus also receives some twigs from the sciatic.

Sensory disturbances appear in a triangular area occupying the inner surface of the thigh.

Lesions of the obturator are even more rare than those of the anterior crural ; like the latter it has a somewhat short trunk, also very effective protection is afforded it by the bones and muscles of the pelvic girdle.

CHAPTER XIX

EXTERNAL CUTANEOUS NERVE OF THIGH

THE external cutaneous nerve originates in the second and third lumbar roots.

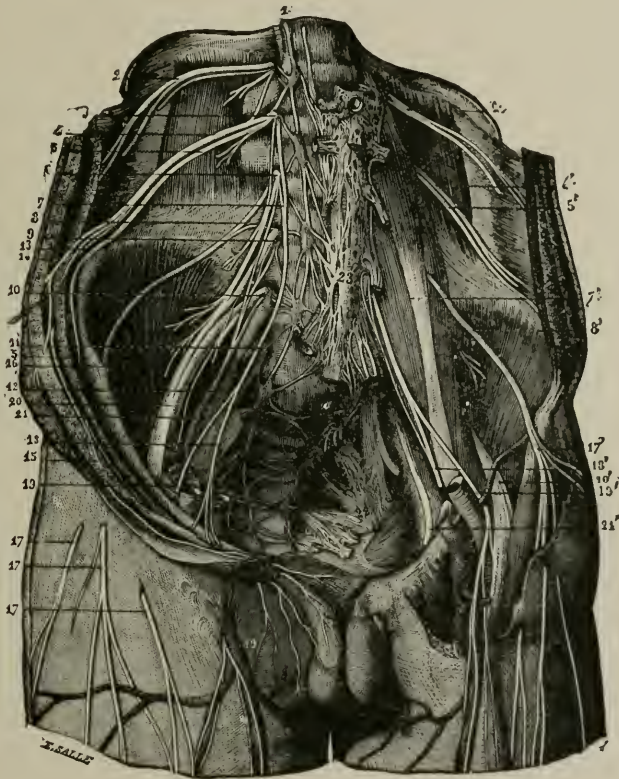
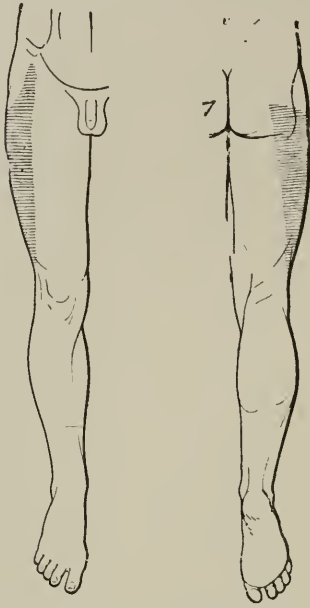


FIG. 295.—Lumbar plexus and collateral branches. (After Hirschfeld.) 1. Great abdominal and pelvic sympathetic. 2, 2'. 12th dorsal root. 3. 1st lumbar root. 4, 4'. Ilio-hypogastric. 5, 5'. Ilio-inguinal. 6. 2nd lumbar root. 7, 7'. Genito-crural. 8, 8'. External cutaneous. 9, 10, 11. 3rd, 4th, 5th lumbar roots. 12. Lumbo-sacral cord. 13. Perforating branch of the ilio-hypogastric. 14. Its abdominal branch. 15. Its genital branch. 16, 17, 17'. The trunk, gluteal and femoral branches of the external cutaneous. 18. Genital branch, and 19, 19', crural branch of the genito-crural. 20, 20'. Anterior crural nerve. 21, 21'. Obturator nerve.

It emerges from the outer edge of the psoas, crosses the iliac crest, and

goes on its way lying on the inner surface of the pelvis a little below the iliac crest, pressed against the iliacus by the parietal layer of the peritoneum.



FIGS. 296 and 297.—Sensory region of the external cutaneous.

It issues from the pelvis through the notch between the antero-superior iliac spine and the antero-inferior iliac spine.

It then divides into a posterior or gluteal branch which is destined for the integuments of the supero-external part of the buttock and into two femoral branches distributed over the skin of the outer part of the thigh.

Anæsthesia of this nerve covers a region corresponding to the outer part of the thigh; its irritation, which is rather frequent, causes the appearance of a somewhat special neuralgia covering the entire outer surface of the thigh, rendering painful the contraction of the extensor fasciæ femoris, and known ever since the description given of it by W. Roth (1895) under the name of neuralgia paræsthetica.

Several cases have been mentioned of lesion of the external-cutaneous accompanied by painful irritation of the causalgic type.

CHAPTER XX

GENITO-CRURAL NERVE

THE genito-crural nerve originates almost exclusively in the second lumbar root.

It makes its way forwards across the fibres of the psoas, emerges on the anterior surface of this muscle, and descends, parallel to this latter, right to the antero-inferior iliac spine, below which it passes under Poupart's ligament. It divides into two terminal branches :

1. The external or crural branch passes under Poupart's ligament outside of the iliac vessels to which it is applied, separated consequently from the anterior crural nerve by the tendon of the psoas.

It perforates the fascia in front of the vessels and becomes superficial, afterwards it spreads over the integuments of the antero-internal surface of the thigh.

There it supplies a small sensory region, oval in form, covering almost the whole of Scarpa's triangle.

2. The internal or genital branch breaks away from the former before passing under Poupart's ligament ; it bends back inwards to reach the inguinal canal through which it passes together with the vas deferens.

It penetrates into the scrotum and is distributed over the skin of the scrotum and to the contiguous area of the inner surface of the thigh.

Lesions of the genito-crural nerve are very rare ; they show themselves, for the most part, in sensory disturbances. We have met with lesions that irritate the nerve, in the course of wounds of the abdominal wall, manifesting themselves by painful hyper-æsthesia at the root of the thigh and in the scrotum.

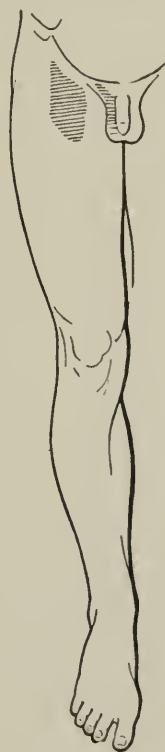

FIG. 298.—Sensory region of the genito-crural.

CHAPTER XXI

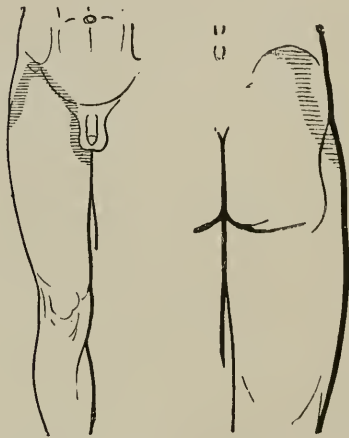
ILIO-HYPOGASTRIC NERVE

THE ilio-hypogastric continues the first lumbar root and makes its way obliquely towards the iliac crest, passing along its upper border, lying between the internal oblique and the transversalis abdominis.

1. It gives off along its course a perforating branch which appears above the gluteus maximus and supplies the outer and upper part of the buttock.

2. It supplies a musculo-cutaneous branch or abdominal branch which gives some motor twigs to the internal oblique and to the transversalis, and is distributed, by way of a perforating branch, over the skin of the lower part of the abdomen.

3. The third—genital—branch proceeds along the upper surface of Poupart's ligament, lying in the depth of the abdominal wall, between the transversalis and the internal oblique.



FIGS. 299 and 300.—Sensory region of the ilio-hypogastric.

It thus enters the inguinal canal and emerges to spread out at the external

inguinal ring into branches which are distributed over the supero-internal part of the thigh.

ILIO-INGUINAL

The ilio-inguinal appears as a collateral trunk of the ilio-hypogastric.

It originates in the first lumbar, proceeds like the latter along its lower border, supplies a few muscular branches to the internal oblique and the transversalis, and joins the ilio-hypogastric before leaving the inguinal canal.

The ilio-hypogastric and ilio-inguinal* together really act as a true intercostal nerve: their oblique course in the depth of the abdominal

* The description of these two nerves differs in some particulars from that current in English Text-books.—(Ed.)

wall, the motor branches supplied to the muscles of the abdomen, the two lateral perforating cutaneous branches, and their terminal branch issuing from the inguinal canal, represent the three perforating branches of the intercostal nerves.

Their sensory region consists, as does that of the intercostals, of an oblique tract which passes along the margin of the pelvic girdle but spreads over the root of the lower limb at the points where the three perforating branches emerge. The result of this is a sinuous tract corresponding to the similar sinuosities of the twelfth intercostal nerve.

CHAPTER XXII

LUMBO-SACRAL PLEXUS

FROM the lumbo-sacral plexus all the nerves of the lower limb originate. It consists of two distinct parts: the lumbar plexus, formed by the first four roots; the sacral plexus, consisting of the fifth lumbar root, and the first, second and third sacral.

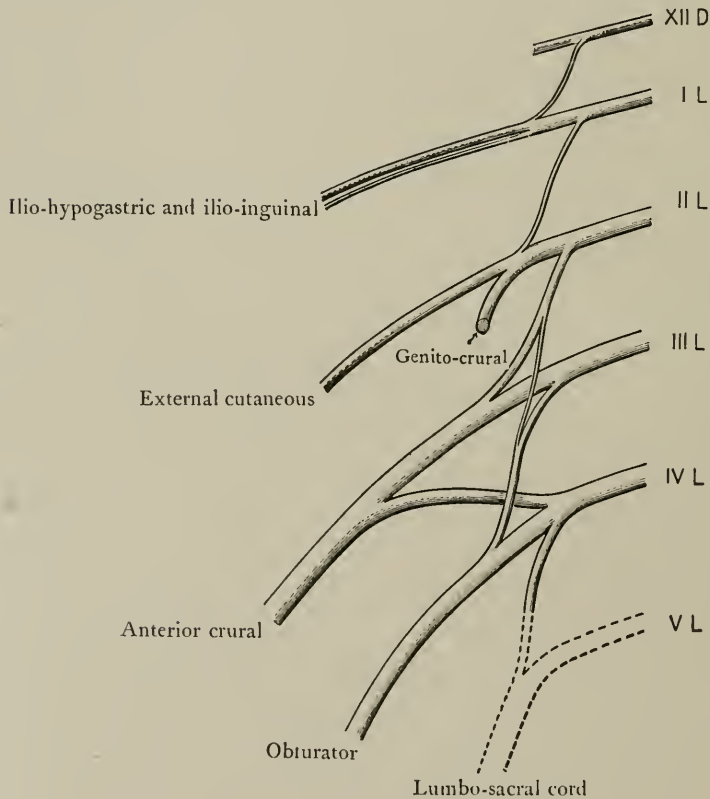


FIG. 301.—Lumbar plexus.

All the roots of these plexuses are united to one another by vertical anastomoses, which form actual nerve loops from which the trunks that constitute the peripheral nerves are given off.

LUMBAR PLEXUS

A very simple description of the common types of lumbar plexus may be given.

The first lumbar root gives off the ilio-hypogastric and the ilio-inguinal with the aid of the anastomotic loop originating in the twelfth dorsal.

The second lumbar root supplies the external cutaneous and the genito-crural, with the aid of the anastomotic loop originating in the first lumbar.

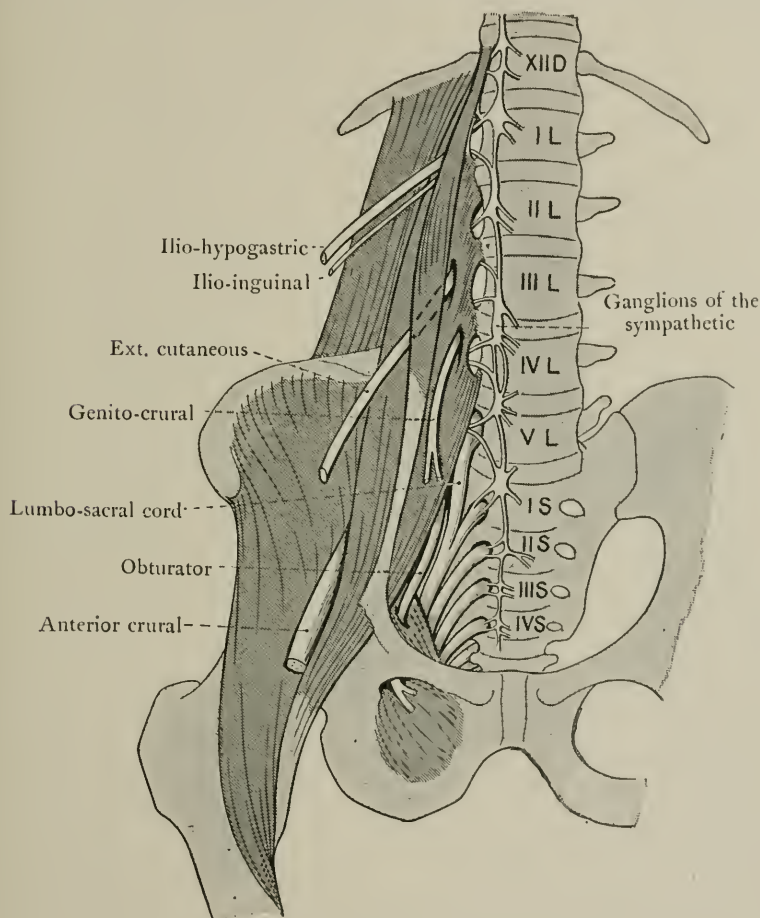


FIG. 302.—Connections between the lumbar plexus and its branches.

The anterior crural nerve is for the most part formed of the fibres originating in the third lumbar, but it also receives an important contribution from the second lumbar and even a more important one from the fourth lumbar.

It is the fourth lumbar that supplies the obturator which also receives fibres from the third and even from the second lumbar.

From the fourth lumbar there also breaks away an anastomotic loop which unites with the fifth lumbar to constitute the lumbo-sacral trunk, the upper root of the sacral plexus.

The lumbar plexus is covered, on the sides of the vertebral column, by the belly of the psoas muscle.

Through the fasciculi of this muscle emerge the different nerves formed by the plexus; the ilio-hypogastric and ilio-inguinal above and the

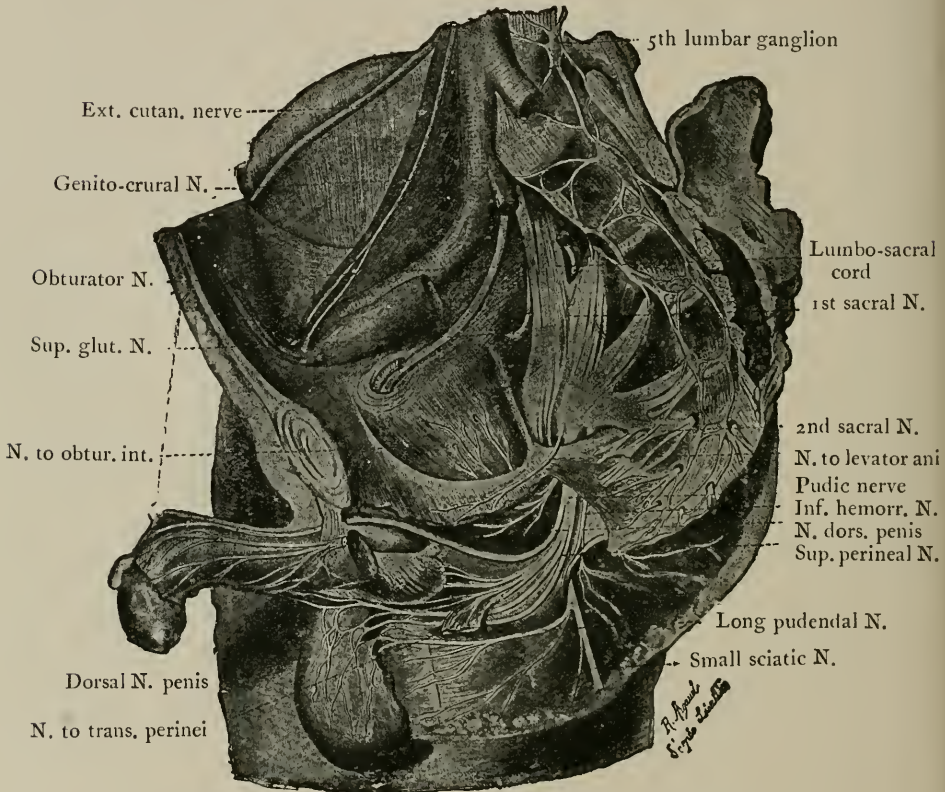


FIG. 303.—Sacral plexus. (After Hirschfeld.) Collateral branches.

anterior crural below appear on its external border, the external-cutaneous on its anterior surface, the genito-crural and the obturator on its internal border.

The collateral branches of the plexus are of slight importance; they are the branches supplied to the quadratus lumborum and to the psoas by the first two lumbar roots.

SACRAL PLEXUS

The sacral plexus consists essentially of the fusion of the lumbo-sacral cord (fifth lumbar and an anastomotic branch of the fourth lumbar) and

of the first three sacral roots, in one bulky trunk: the great sciatic nerve.

It supplies several important collateral branches:

1. The superior gluteal nerve, which originates in the lumbo-sacral cord and the first sacral, issues through the great sciatic notch, passes above the pyramidalis, and proceeds between the gluteus minimus and the gluteus medius, divides into an ascending branch and a descending branch which penetrates into the tensor fascia femoris. It supplies the gluteus minimus, the gluteus medius and the tensor fasciæ femoris;

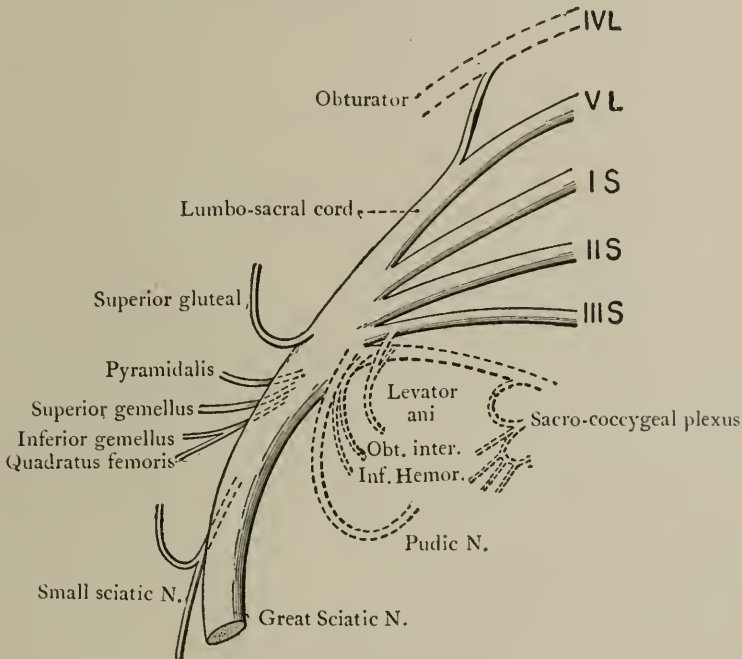


FIG. 304.—Sacral plexus.

2. The nerve to the obturator internus, which also originates in the lumbo-sacral cord and the first sacral, proceeds forwards into the inferior rectal space and supplies the obturator internus muscle;

3. The nerves to the pelvi-trochanteric muscles which are given off from the first, second and third sacrals, and are distributed to the pyramidalis, the quadratus femoris, and the gemellus superior and gemellus inferior muscles;

4. The inferior gluteal nerve, which originates in the fifth lumbar and the first and second sacral, accompanies the great sciatic nerve and appears with it below the pyramidalis, to split up on the deep surface of the gluteus maximus which it supplies by means of a series of ascending and descending branches.

It is to the somewhat frequent union of this nerve trunk with the

posterior cutaneous nerve of the thigh that we sometimes give the name of small sciatic, regarded in this case as a terminal branch of the lumbosacral plexus.

As a matter of fact, however, the great sciatic alone includes in itself all the branches of the plexus of which it is the sole terminal trunk. It is,

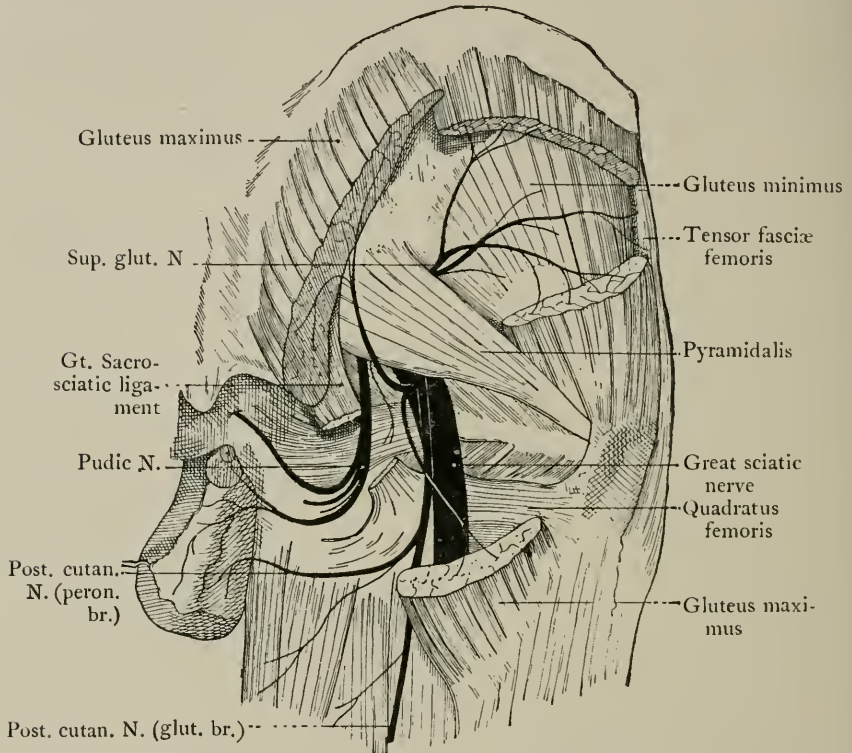


FIG. 305.—Nerves of the gluteal region. (After Hirschfeld, simplified.)

according to Cruveilhier's expression, "the sacral plexus condensed in one nerve trunk."

The collateral branches of the sacral plexus, along with the great original trunks of the sciatic, constitute quite an inextricable network of nerves which covers the entire posterior surface of the pelvic cavity.

PUDENDAL PLEXUS

The anastomotic loop, which unites the third to the fourth sacral, forms with this latter root and the loop of the fifth sacral the origins of the pudendal plexus.

This plexus supplies several collateral branches and a terminal branch: the pudic nerve.

The collateral branches are distributed:

To the levator ani and the ischiococcygeus;

To the sphincter ani and the skin of the anal margin (inferior hemorrhoidal or anal nerve).

The pudic nerve, terminal branch of the plexus, issues from the pelvic cavity below the pyramidalis, internal to the sciatic; it crosses the ischio-rectal fossa in the aponeurotic sheath of the obturator internus; at the level of the tuberosity of the ischium it divides into its two terminal branches, the perineal nerve and the dorsal nerve of the penis.

RADICULAR SYNDROMES OF THE LUMBO-SACRAL PLEXUS

The roots of the lumbosacral plexus are not only affected by traumatism of the pelvic cavity, they may also, and perhaps more frequently, be found injured in their long intra-spinal course. Indeed, they form, in the whole of the spinal canal which stretches below the first lumbar vertebra, a compact bundle, *cauda equina*, from which they break away one after the other to reach the inter-vertebral foramina. Along this course, they are successively intra-dural and extra-dural. We must remember that the cul-de-sac of *dura mater* ends in the vicinity of the second sacral vertebra.

Fractures of the spine, depressed fracture of the sacrum, bullets or shell splinters penetrating into the spinal canal, always affect several roots at once, producing the different syndromes of the *cauda equina*.

There is no occasion to consider here, as in the case of the brachial

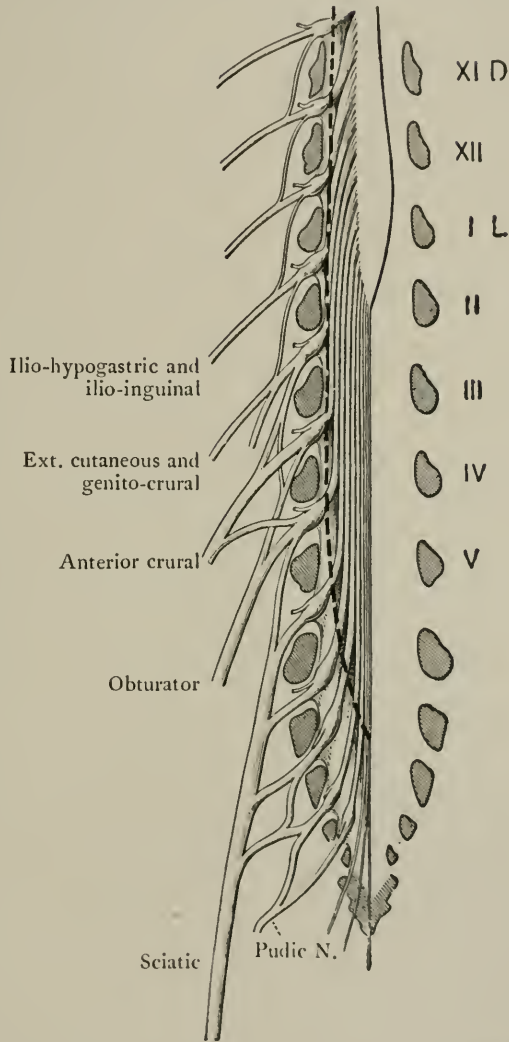
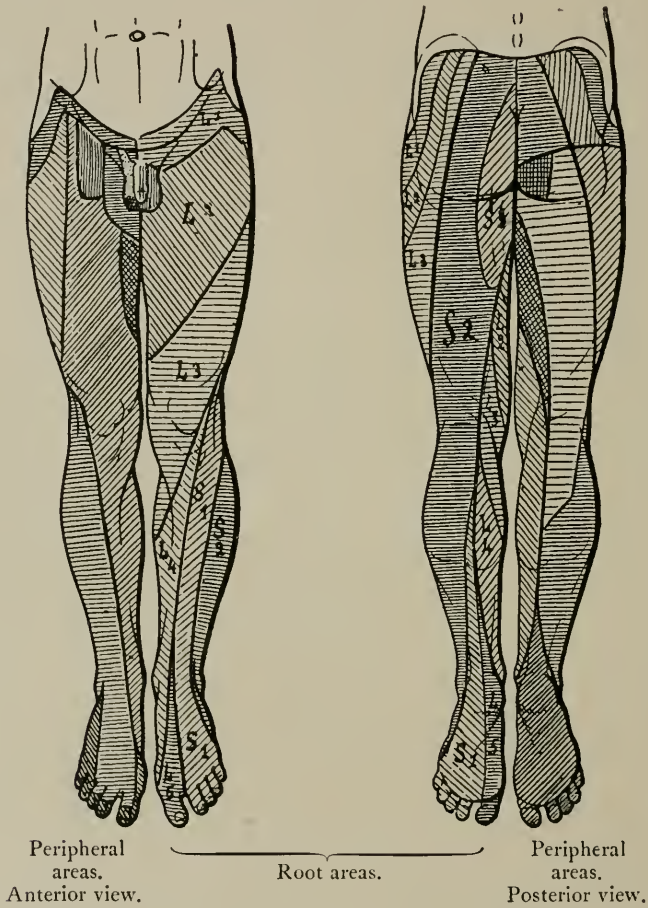


FIG. 306.—Intra-spinal course of the lumbosacral roots; *cauda equina*. The dural cul-de-sac is dotted.

plexus, root and trunk syndromes. It is sufficient to compare the principal root syndromes of the lumbo-sacral plexus with the syndromes of the peripheral nerves.

Whether intra-spinal or extra-spinal, lesions of the roots may be recognised by their special root topography.



FIGS. 307 and 308.—Lumbo-sacral plexus. Sensory topography. Peripheral and radicular areas.

The peripheral nerves always contain fibres coming from several roots; consequently, the root lesions will for the most part give rise to dissociated peripheral paralyses. On the other hand, almost all the nerves receive their supply from several roots, consequently no complete paralysis will be observed unless several roots are injured at the same time.

Disturbances of sensation, likewise, are characterised by a different

topography from the peripheral distribution ; they appear in the form of longitudinal tracts almost parallel to the axis of the limb in the case of the sacral and lower lumbar roots, arranged obliquely in the case of the upper lumbar roots which constitute a sort of transition from the almost horizontal topography of the dorsal roots.

Lastly, the motor and sensory roots may be injured independently of one another in the spinal canal ; we then find dissociation between the motor and the sensory areas.

LUMBAR ROOTS

The upper roots of the lumbar plexus (first and second) have only a very secondary motor rôle ; they supply a few fibres to the psoas, to the quadratus lumborum, to the lower part of the transversalis abdominis and to the anterior muscles of the thigh. Injury does not cause

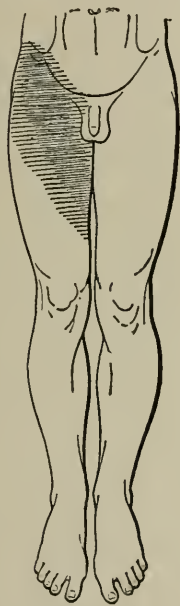


FIG. 309.—Root topography in lesion of the first and second lumbar roots.

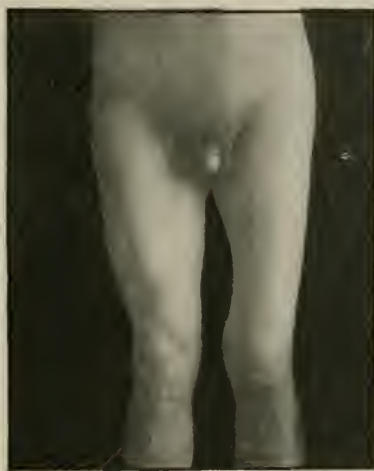

FIG. 310.—Associated paralysis of the anterior crural and of the obturator, caused by injury of the third and fourth lumbar roots.

paralysis, but simply an enfeebled condition of these muscles.

Their sensory region comprises the outer surface of the buttock and of the root of the thigh ; it spreads over the anterior surface of the thigh and passes slightly beyond, on to the upper part of the outer surface.

The lower roots of the lumbar plexus (third and fourth lumbar and fibres from the fifth lumbar), on the other hand, occupy a very important motor region. It comprises all the anterior and internal muscles of the thigh ; the crural triceps, the pectineus and the sartorius, through the

anterior crural nerve ; the adductors and the gracilis through the obturator nerve.

Injury to these roots affects both the area of the anterior crural and that of the obturator, giving the atrophied thigh a special appearance, as though it were strangled in its middle part.

Finally, the fourth and fifth lumbar roots supply a certain number of fibres to the glutei, to the tensor fasciæ femoris, to the posterior muscles of the thigh and to the muscles of the leg, which may consequently be slightly weakened.

Among the muscles in which atrophy and weakness consequent on lesions of the fourth and fifth lumbar roots are manifested, we must specially note the tibialis anticus ; the extensor communis digitorum and the extensor proprius hallucis, as well as the inner head of gastrocnemius, also receive lumbar fibres, though fewer in number.

Though dependent on the external popliteal, the tibialis anticus is almost entirely supplied by the fourth and fifth lumbar roots ; atrophy and paralysis in lesions of the lower part of the lumbar plexus are almost complete ; its preservation also in lesions of the first and second sacral roots contrasts strikingly with the complete paralysis of the peronei. It acts as the supinator longus muscle

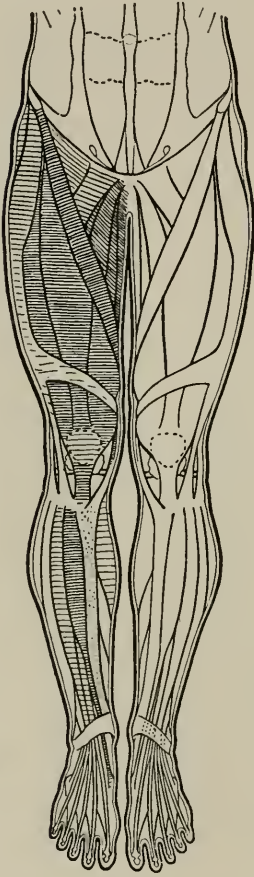


FIG. 311.

FIG. 311.—Muscles supplied by the third, fourth and fifth lumbar roots. Note that the tibialis anticus is supplied almost solely by lumbar fibres. The extensors and the inner head of gastrocnemius receive only a few fibres.

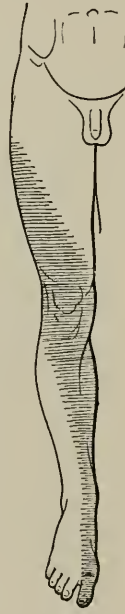

FIG. 312.

FIG. 312.—Sensory area of the third, fourth and fifth lumbar roots.

the homologue—does in the upper limb. Like this muscle also it belongs to the upper root group of the limb.

The sensory area of the last lumbar roots spreads obliquely over the outer surface of the thigh, the anterior and inner surface of the knee, and the whole inner surface of leg and foot. The patellar reflex, which

corresponds essentially to the third and fourth lumbar roots, is always abolished, both by anæsthesia of the point of origin of the reflex and by suppression of the motor response.

SACRAL ROOTS

The fibres of the first two sacral roots are distributed over the region of the great sciatic nerve, with the exception of the tibialis anticus which is exclusively supplied by L₄ and L₅; the other muscles of the leg also receive a few fibres from the lumbar roots; this participation of the lumbar roots is particularly obvious in the case of the extensor longus digitorum, the extensor proprius hallucis and the inner head of gastrocnemius. On the other hand, the peronei and the outer head of gastrocnemius would appear to be almost exclusively supplied by sacral fibres.

In the foot, it is the muscles of the internal compartment, the abductor and the flexor brevis hallucis, that appear to receive the principal supply, though an unimportant one, of lumbar fibres. On the other hand, the adductores hallucis and the interossei seem to be entirely supplied by the sacral roots.

We thus see in what main respects root innervation is distinguished from peripheral innervation in the lower limb.

Indeed, we often meet with lesions affecting the third, fourth and fifth anterior lumbar roots: the symptoms observed are those of paralysis of the anterior crural and of the obturator, and we are at first somewhat surprised to find associated therewith both paralysis of the tibialis anticus and weakening of the extensores digitorum, belonging to the region of the sciatic. Frequently the tibialis anticus appears to be profoundly affected in lesions connected solely with the fourth lumbar.

In the same way, inverse dissociation is found in lesions of the first and second sacral roots; at first they seem to spread over almost the whole region of the sciatic and we are surprised to find that the tibialis anticus

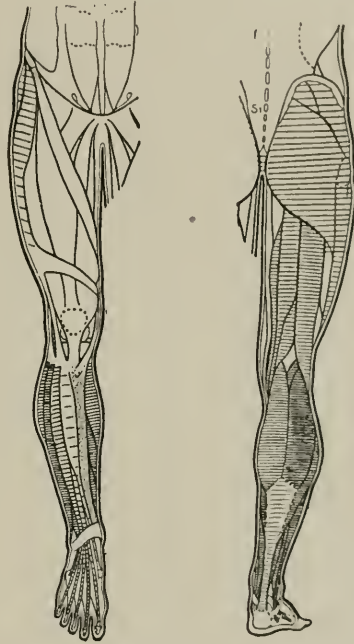


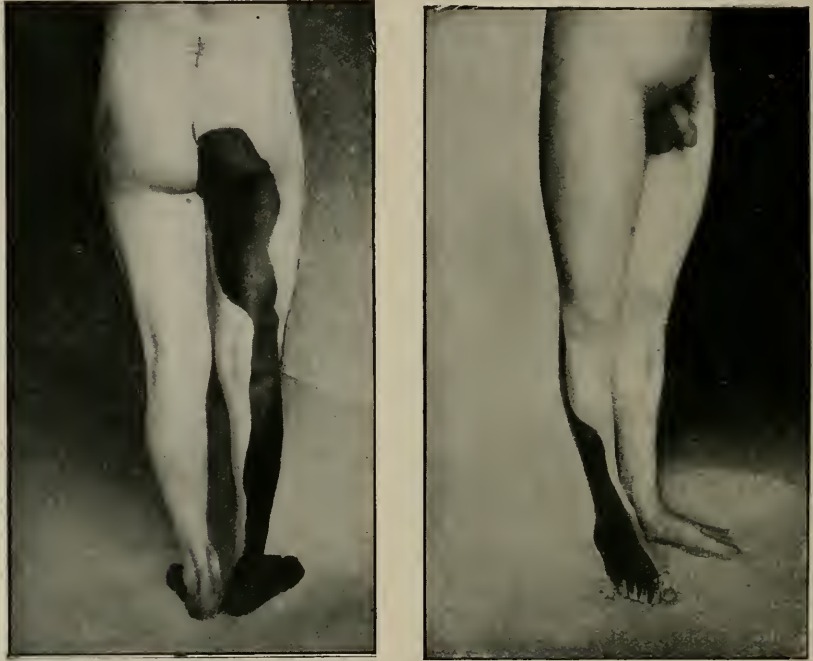FIG. 313.

FIG. 314.

FIGS. 313 and 314.—Muscles supplied by the first and second sacral roots. Note the almost complete integrity of the tibialis anticus and the partial preservation of the extensors.

is not touched at all, that some faint movements of the extensors are possible, and that there are even some very feeble contractions of the inner head of gastrocnemius and of the muscles of the great toe.

Sensory disturbances of the first and second sacral roots occupy a broad tract which, after spreading over the posterior surface of the buttock, extends obliquely to the external surface of the knee and leg, passes on to the anterior surface of the leg and covers both the dorsal surface and the plantar surface of the foot as far as the first intermetatarsal space.



FIGS. 315 and 316.—Lesion of the first, second and third sacral roots. The anæsthetic region has been painted with tincture of iodine. The lesion of the third sacral root adds to the topography of the first and second, the inner region of the buttock and a small postero-external tract on the thigh. Paralysis of all the muscles of the leg, with the exception of the tibialis anticus which is scarcely touched. There are also some slight movements of the extensor hallucis and of the extensor communis; a faint suggestion of contraction of the inner head of gastrocnemius and of the flexor brevis hallucis.

In this same region, when there is irritation of the roots, we find hyper-æsthesia or the trophic disturbances characteristic of neuritic lesions.

The Achilles reflex (first and second sacral) is in every case abolished.

The third sacral root is distributed over the inner part of the buttock; it descends on to the posterior surface of the thigh, as far as its middle, occupying a triangular tract just internal to the region of the second sacral.

When the fourth and fifth sacral roots are injured, it results in

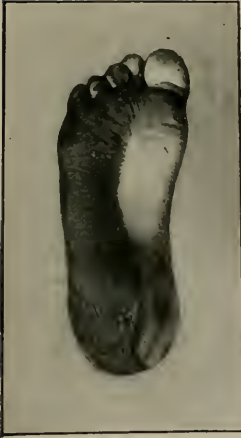

FIG. 317.

FIG. 317.—Plantar anaesthesia in the preceding case. The line of demarcation passes through the first intermetatarsal space and the first interdigital space.

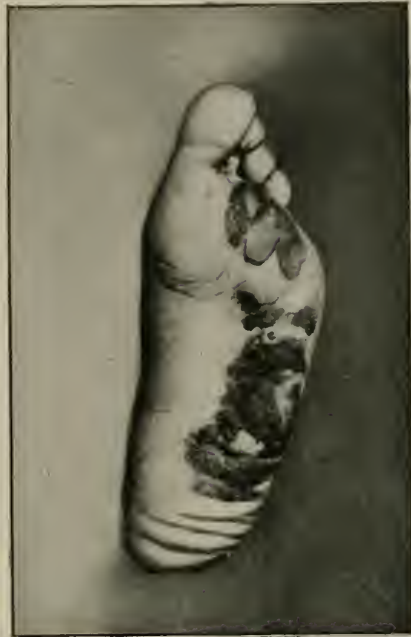

FIG. 318.

FIG. 318.—Cutaneous desquamation with root topography in irritative lesion of the first and second sacral roots (*radiculitis*).

incontinence of urine and fæces, due to paralysis of the sphincters; vesical paresis, paralysis of the levator ani and of the bulbo-cavernosus and ischio-cavernosus muscles.

The patient is no longer aware of the passage of urine and fæcal matter.

Anæsthesia affects the inner part of the buttock and a tract down the posterior surface of the thigh, which constitutes the area of the third sacral, it reaches the perineal and anal region, the penis, the lower part and posterior surface of the scrotum; the root of the penis and a portion of its dorsal surface as well as the root and anterior surface of the scrotum receive fibres from the twelfth dorsal and the first lumbar, and are not anæsthetic.

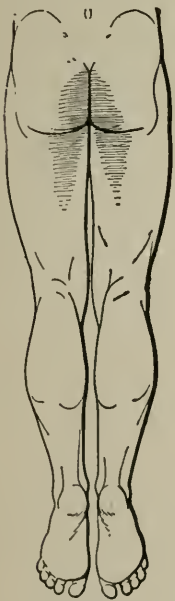

FIG. 319.

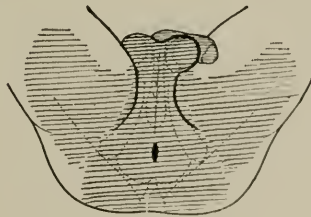


FIG. 320.

FIG. 319.—Area of the third sacral root. Lesion of the sacral canal at the level of the third spinous process.

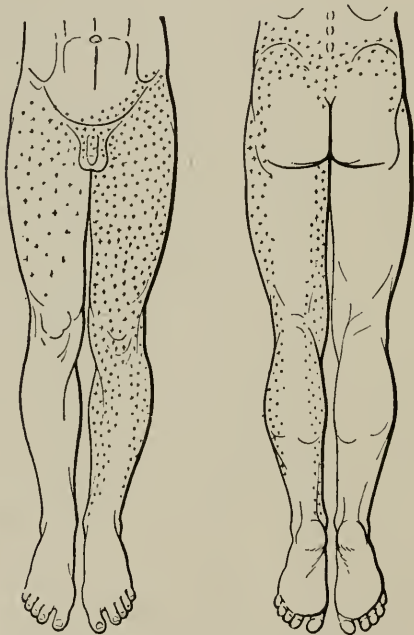
FIG. 320.—Area of the third, fourth and fifth sacral roots.

CHAPTER XXIII

DIAGNOSIS OF THE LESIONS OF THE LUMBO-SACRAL PLEXUS

THE only important diagnosis to be studied is that of lumbo-sacral hematomyelia. Indeed, these lesions are not uncommon in injuries of the lumbar region: wounds from bullets or shell splinters, fractures of the

vertebral column, lumbar contusions; they may even result from the explosion of a shell or a mine close at hand; they are paralyzes, probably caused by compression and sudden decompression, and accompanied by slight medullary hemorrhage or air-emboli.



FIGS. 321 and 322.—Slight hematomyelia affecting chiefly the left lumbar segments and leaving untouched the sacral segments. Characterised mainly by anæsthesia to heat and cold; thermal sensations are scarcely perceived at all; but cold and pin-prick cause a very painful sensation which the patient compares to burning.

Hematomyelia of the lumbo-sacral enlargement has a somewhat analogous symptomatology to the lesions of the plexus. It produces flaccid paralysis accompanied by muscular atrophy and reaction of degeneration resulting from lesion of the cells of the anterior horns of the cord; this paralysis is distributed like root paralysis, for each motor root corresponds exactly to a cord segment.

As a result of lesion of the posterior horns, they are accompanied by sensory disturbances, the topography of which is almost the same as that of root anæsthesia.

Diagnosis, however, is possible as a rule.

In the first place, it depends on the site of the wound; for whereas the *cauda equina* descends into the canal, from the third lumbar vertebra

to the second sacral, the lumbar enlargement of the cord corresponds rather to the first and second lumbar vertebræ.

On the other hand, hematomyelia as a rule is a more diffused process, producing a topography less clearly circumscribed than in root lesions. Paralysis, like anæsthesia, is not often restricted to a very clearly circumscribed region, it encroaches slightly upon the neighbouring regions, or else it does not affect certain muscles or certain cutaneous zones in the attacked region, thus indicating the unequal distribution of the hemorrhagic focus. It is likewise rather rare for disturbances to be strictly unilateral, generally there are to be found on the healthy side some motor or sensory disturbances showing a certain degree of bilateral spread of the hemorrhagic process.

Finally it must be remembered that hematomyelia is almost always localised in the grey matter of the cord ; it attacks chiefly the anterior and posterior horns of the cord, scarcely touching at all the layer of white matter.

Whilst a lesion of the anterior horns is shown by the flaccid and atrophic paralysis which always indicates lesion of the lower motor neurone, a lesion of the posterior horns gives rise to a very important and wholly characteristic symptom: the dissociation of sensibility. In lumbar hematomyelia we often find anæsthesia to painful and thermal stimuli (posterior horns) contrasting with the relative integrity of tactile sensibility and above all with the preservation of deep sensibility (posterior columns).

The clear dissociation of sensibility, as in syringomyelia constitutes a pathognomonic sign of hematomyelia: no peripheral or root lesion is capable of producing it.

In some cases we may observe even more systematised dissociations. For instance, we may find that sensibility to pain is retained, whereas sensibility to heat and cold is manifestly lessened ; frequently heat and especially cold are not clearly perceived but give rise to a painful sense of burning instead.

Lastly, in slight cases of hematomyelia, the cord lesion may reveal itself simply by hyper-æsthesia to pin-prick, to heat and to cold, thus causing a painful, widely diffused and persistent sensation.

The prognosis of hematomyelia, especially of slight hematomyelia, is

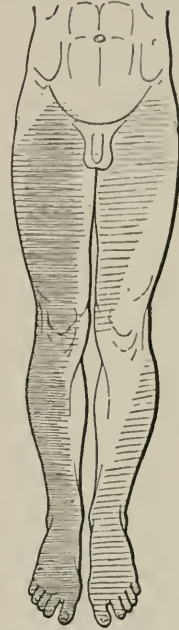


FIG. 323.—Lumbar hematomyelia. Hypo-æsthesia. On the right, a region resembling the distribution of the lower lumbar and the sacral roots. On the left, a region resembling the distribution of the first and second lumbar, and of the fifth lumbar, the first and second sacral. Dissociation of sensibility. Thermal and painful anæsthesia. Relative conservation of tactile sensibility; almost complete integrity of sensibility to pressure and of the other deep sensibilities.

generally far more favourable than that of root lesions. In a few months, even sometimes in a few weeks, we see a progressive diminution of the region of paralysis and anæsthesia.

Improvement often passes on to complete cure, but anæsthesia may persist, or even more commonly, well-defined paralysis.

PART IV

CONCLUSIONS

CHAPTER XXIV

PROGNOSIS AND TREATMENT OF PERIPHERAL NERVE LESIONS

At the present time, basing our opinion on a very large number of observations made since the beginning of the war, we are justified in affirming that the prognosis of peripheral nerve lesions is on the whole favourable.

Every peripheral nerve affected by traumatism tends to regenerate, provided the general condition of the patient enables him to contribute towards this restoration. It is this wonderful aptitude of the nerves towards regeneration by fresh shoots from the axis-cylinders, that explains the considerable number of spontaneous cures.

Surgical intervention itself has no other aim than to favour this natural regeneration, by suppressing the obstacle to the progress of the nerve fibres and bringing about coaptation of the segments of the divided nerve, *i.e.* of the central segment containing the nerve fibres along with the peripheral segment, the empty sheaths of which are alone capable of guiding the axis-cylinders in their regeneration.

The wide-spread destruction of the peripheral nerves is also reparable by nerve grafting which reconstructs the anatomical continuity of the supporting tissues, the conductor of the regenerating fibres.

According to our personal statistics, we may estimate at between sixty and seventy per cent. approximately the number of spontaneous regenerations without surgical intervention ; at the same time, there are a certain number of these, between ten and twenty per cent., which in our opinion would have gained by such intervention ; a simple liberation or even a nerve suture, if performed at the right time, would in all probability have permitted of a more rapid and complete restoration.

We are now speaking of cases in which the neurological examination, made only from eight to ten months after the wound, shows a nerve manifestly to be on the way to recovery, though this may be slow and

incomplete ; naturally in such cases one hesitates to have recourse to any intervention not absolutely necessary and which would compel the patient to begin all over again the regenerative process painfully carried through in the course of the preceding months. After all, such cases should become exceptional if the neurological examination is always made in good time.

Consequently those cases of nerve lesion that necessitate surgical intervention, whether liberation or suture, do not appear to be more than thirty or forty per cent.

Results naturally vary according to the intervention practised. Still, we may lay it down as a general principle that the liberation of a nerve, when this is indicated, should always be successful ; if such is not the case, it is because resection and suture were necessary, and intervention should be resumed.

The results of nerve suture have been very much questioned ; to us, however, there does not appear to be any doubt at all on the matter. Nerve suture practised under favourable conditions almost invariably succeeds. Out of one hundred and eight cases of nerve suture or grafting which we have been able to follow up, there are only fourteen failures ; *i.e.* fourteen cases in which there appears no sign of regeneration of the peripheral segment ; all the rest are on the way to a more or less rapid and complete regeneration, and consequently warrant us in looking forward to their cure : up to date we have had twenty-two cases of practically complete restoration.*

Accordingly we may estimate at from twelve to fifteen per cent. approximately (12.9 per cent. in our statistics) the cases of failure after nerve suture.

We must add that the statistics here given do not deal solely, as one might think, with only favourable cases, operated on at the right time and under favourable conditions, but with *all* the cases we have investigated.

Early intervention does not appear to be an indispensable condition ; we have witnessed the success of nerve sutures practised thirteen and fifteen months after the wound ; it is quite possible that suture might successfully be attempted long after this period. Nevertheless, there can be no doubt but that early sutures are followed by more rapid regeneration.

A favourable prognosis for peripheral nerve lesions is, as we see, confirmed by these figures. More than half the patients are cured spontaneously ; almost all surgical interventions are attended with success.

The number of irreparable nerve wounds would certainly appear not to exceed from eight to ten per cent. ; either because surgical intervention has encountered insuperable difficulties or because the general condition

* Most of these cases were operated on at Le Mans by M. Delagènière, whom we take this opportunity of thanking for his valuable advice.

of the patients has either annulled or made difficult the work of regeneration. Amongst the factors contributing to failure, mention must be made of alcoholism; two cases of nerve suture carried out under the best of conditions were succeeded by no sign of regeneration whatsoever in patients manifestly alcoholic.

The figures we have cited, more particularly the proportion of successes registered after nerve suture, may perhaps seem surprising. They are nevertheless correct, and may be compared with those of other neurological centres, particularly that of Professor Dejerine at the Salpêtrière.

If they appear to clash with other published statistics, we affirm that this is because people are always too precipitate in speaking of the failure of surgical intervention. It must not be forgotten that the regeneration of a nerve is invariably an extremely prolonged task. Under the most favourable conditions, and in the case of young patients, the progress of the axis-cylinders is not more than one to two millimetres per day; the appearance of the first voluntary movements also takes place long after the penetration of the axis-cylinders into the paralysed muscle. Consequently, to affirm, three, four, or six months after nerve suture, the failure of intervention because no movement shows itself, is a serious error, to be attributed to nothing else than impatience on the part either of the observer or of the patient; besides, motor restoration is invariably the most tardy of all.

We shall realise much more correctly the progress made if we try, on the contrary, to discover the sensory signs of regeneration; the sensibility of the nerve to pressure and its characteristic formication, the sensibility of muscular bellies, cutaneous paræsthesia, etc.

The sign of formication is here specially important, since it enables us, after a few weeks, to note the appearance of the axis-cylinders beyond the suture, and to follow their progressive advance in the peripheral trunk. It permits not only the observer but also the patient to follow the work of restoration step by step; it proves to him the success of surgical intervention, gives him confidence and patience, and thus becomes an important moral factor in the cure.

CHAPTER XXV

SURGICAL TREATMENT

I.—INDICATIONS FOR OPERATION

To lay down the indications for operation is assuredly the most delicate problem in war neurology.

Apart from a few special cases, it would appear as though we ought to reject the principle of prompt and systematic intervention for every wound of the peripheral nerves.

Indeed, we have seen that the majority of nerve lesions, about sixty or seventy per cent., were susceptible of spontaneous regeneration; even the diagnosis of complete interruption of a nerve trunk does not inevitably imply the necessity of intervention, for even in these cases spontaneous regeneration is often possible.

The only fact which necessarily calls for intervention is the absence of regeneration of the peripheral segment, or else the defective, difficult or partial character of the regeneration.

Consequently, before deciding to operate, we must make absolutely certain, by successive examinations, that regeneration is either not taking place at all or is progressing badly. It is scarcely ever possible to obtain such certainty in less than two, three or even four months after the wound.

Besides, as we have already seen, this delay as a rule is in no way prejudicial to the success of intervention.

Manifestly this recommendation must not be accepted as absolute; there are cases in which prompt operation is necessary, especially in simple compression and severe neuritis.

I.—TIME OF INTERVENTION

We discovered that two or three months at least were often necessary to establish the necessity of intervention.

On the other hand, an operation must be carried out as soon as possible, once its necessity has been recognised.

Regeneration is assuredly more rapid and easy when the operation is not delayed too long.

Still, it must not be forgotten that, even twelve or fifteen months after nerve interruption, suture may be performed successfully.

II.—CHOICE OF INTERVENTION

As clinical reasons alone can indicate the necessity of intervention, so it is mainly by a clinical examination that the nature of the intervention will be decided.

No intervention must take place until we have obtained every item of clinical information to prove the existence of complete interruption or simple compression, of a total lesion or a partial change, of regeneration that is non-existent or is simply difficult to effect.

Assuredly this clinical information will not always suffice in deciding upon a suture or a liberation; account must naturally be taken of the lesions encountered during intervention as well as of operative possibilities; though clinical reasons above all others are the most important. A thorough preliminary examination, or rather a series of minute examinations, almost invariably enable one to decide upon the kind of intervention necessary.

Moreover, information given by the anatomical state of the nerve is often somewhat difficult to interpret.

Evidently no hesitation will be felt in the presence of a complete section, of a particularly dense nerve cicatrix or of bulky neuromata.

It must always be remembered that all neuromatous formations imply the existence of an obstacle, above which the regenerated fibres, unable to reach the peripheral segment, shrivel up. It is therefore always necessary to remove the obstacle by liberation if it is external to the nerve and by resection if it is interstitial.

In many cases, however, less clearly characterised, anatomical examination of the nerve is not sufficient to solve the problem.

Indeed, it is a matter of absolute importance to find out if there is simple extrinsic compression or an interstitial obstacle; if the lesion has destroyed the continuity of the nerve fibres or has changed them locally; if the obstacle is permeable or not to the regenerating nerve fibres. This information cannot be supplied by anything but a clinical examination.

In this connection, however, the electrical and histological examination of the nerve, exposed during the operation, has been recommended.

Direct electrical examination of the nerve trunk has been carried out by P. Marie, H. Meige, and Gosset by using a small sterilisable metallic electrode* which allows of separate excitation of the different fasciculi of the nerve above and below the lesion. We may thus ascertain if these fasciculi have remained excitable.

Evidently this method is capable of affording very important information, though of itself alone it is insufficient. It proves very clearly that certain fasciculi, or even the entire nerve, have not been touched by the

* Pierre Marie, *Bull. de l'Acad. de Méd.*, meeting of 9 February, 1915.

lesion ; in addition, it has undoubted value by reason of the positive information it gives. The negative information, however, has not the same value ; electrical stimulation of the nerve shows no reaction whatsoever and consequently has no value at all if it acts upon sensory fasciculi or upon motor fasciculi in course of regeneration. We cannot therefore conclude, because a nerve or a nerve fasciculus is incapable of being excited, that it is not in course of spontaneous regeneration ; electrical excitability of the nerve is, as we know, one of the most tardy signs of regeneration ; the sensibility of the nerve to pressure, formication, the return of tone, the appearance of paræsthesia are earlier signs. Thus, by taking account only of electrical inexcitability, we should run the risk of resecting and suturing healthy sensory fasciculi and motor fasciculi, well advanced in regeneration.

Histological examination of the nerve, by an actual operative biopsy, has been recommended by A. Sicard.* This method consists in removing a few particles of nerve tissue from the peripheral segment below the lesion and there trying to discover, from rapid staining with osmic acid, the existence of myelinised nerve fibres.

This method is far more questionable even than the former :

1. The existence of nerve fibres in the examined fragments does not prove that the other fasciculi of the nerve are in the same condition ; the absence of fibres in the fasciculus examined is no proof that the other fasciculi are also affected.

2. Staining with osmic acid reveals only myelinised fibres ; now the young fibres in course of regeneration consist, at the outset, of the axis-cylinder alone.

3. It is to be regretted that we cannot obtain any certainty of the integrity of a nerve fasciculus except by subjecting it to the traumatism of a biopsy and suppressing some of its fibres.

As regards the process of injecting methylene-blue into or above the neuroma, in order to demonstrate its permeability to the axis-cylinders, this would seem to be a very doubtful course to adopt.

II.—SURGICAL INTERVENTIONS

There are but three interventions possible on a nerve trunk :

Liberation ;

Suture ;

Grafting.

1. **Liberation.**—Liberation consists essentially in dissection of the nerve and in ablation of the causes of compression, bony callus, fibrous tissue or cicatricial bands.

The operation is a very delicate one, and is really satisfactory only if

* A. Sicard, Imbert. Jourdan, and Gastaud, *Acad. de Méd.*, meeting of 16 February, 1915.

we succeed in completely stripping bare the nerve cord and liberating from all adhesions the delicate neurilemma sheath surrounding it.

This intervention is really permissible only when it restores a mobile, free and supple nerve, in the interior of which there is found no obstacle to regeneration.

It is naturally indicated in all cases of simple compression: it may be practised in cases of ordinary neuritis. Its success is all the more likely when intervention is prompt.

As a rule, liberation of the nerve is ineffective in cases of severe lesions of the nerve trunk along with rupture of the laminated sheath, cicatricial nerve keloid and formation of exuberant neuromata; in these cases, either the cicatricial obstacle is permeable to the regenerating axis-cylinders and intervention is then useless, or else the obstacle does not allow of the passage of the axis-cylinders and liberation will not make it permeable.

Seldom does liberation succeed in severe and long-standing cases of neuritis. Almost always in such cases there are interstitial lesions of the nerve, and on these liberation has no effect.

In all doubtful cases, remember that *a good complete suture is far better than a bad liberation.*

2. **Suture.**—Nerve suture is indicated in all cases of complete interruption of nerve fibres where no satisfactory regeneration has taken place.

There is but one way of suturing a nerve trunk, and that is by bringing into contact the healthy extremities of the interrupted nerve trunk and sewing them *end to end*.

Suture, then, essentially presupposes resection of the cicatricial obstacle and of all tissues which might impede the progress of the axis-cylinders.

We should bring into contact with each other a central end, containing healthy and regularly arranged axis-cylinders, and a peripheral end, offering for the growth of nerve fibres supple and readily permeable sheaths.

Any suture that does not fulfil these conditions is defective and almost invariably condemned to failure. All the same, if necessary, we may sew a supple peripheral segment on to a neuroma richly supplied with axis-cylinders; but we risk serious disturbances in the arrangement of the nerve fasciculi, the systematisation of which is thus left to chance.

On the other hand, by suturing the two healthy segments, *if we very carefully avoid all torsion of the nerve*, we put exactly in their right places the different motor and sensory fasciculi and do away with all risk of defective regeneration.

Such a suture almost invariably involves considerable shortening of the nerve, a process which we shall be able to assist by flexion of the neighbouring articulations, as indicated by Delorme.

The most effective suture is that which produces the best contact with a minimum of traumatism for the nerve trunk. Speaking generally, it is better to content oneself with a few stitches—silk or linen thread or even

catgut—inserted in the neurilemma.* If the suture is tight and we are compelled to go through the nerve, it is preferable to use only catgut, strong enough not to tear and readily reabsorbable so as to leave no element of irritation in the middle of the axis-cylinders.

As a rule, there is no occasion to dread secondary rupture after nerve suture. By experiments made on animals, we know that union of the central and peripheral segments is extremely rapid, owing to the proliferation of the neuroglial cells; it appears to take place from the fourth day onwards (Dustin).

Lastly, suture must ensure simple coaptation between the segments which it unites; a tight suture which crushes against each other the shrivelled nerve extremities exposes the axis-cylinders to the risk of going astray (Nageotte). Rather than incur this risk, it is better to leave between the segments a space of one or even two millimetres, easily filled in by the neuroglial proliferation.

Suture as thus interpreted is certainly the best operation for all serious nerve lesions in which, along with an almost or wholly complete interruption, there exists an obstacle to regeneration.

In our opinion, it may even be recommended in certain cases of grave neuritis from interstitial lesions, hemorrhages or fibrous infiltration. In these cases it is better to run the risks of suture than to see the evolution and prolongation—in spite of a liberation, which, after all, is never efficacious—of fibrous contractions and trophic disturbances which are so difficult to cure.

3. Nerve grafting.—When the distance between the segments of the nerve trunk is too great to permit of direct suture, *the only legitimate operation is nerve grafting*, as recommended by J. and A. Dejerine and Mouzon.

This consists in uniting the segments of the interrupted nerve by the interposition of fragments removed from a sensory nerve. The musculocutaneous, which to a considerable length may be removed from the leg, is the nerve to which preference is given.

One, two, or more of these fragments, united in a bundle by catgut passed through them, are sewn on both sides to the central and peripheral segments. Regeneration would seem to take place through the graft somewhat more slowly than, though almost as effectively as, by direct suture.

All other grafting processes are more or less defective.

Suture by division into two is inevitably partial, since it suppresses part of the nerve. In any case, if this suture is practised, it is always the peripheral segment which must be divided. Division of the central end should be altogether condemned, since it inevitably interrupts half of the axis-cylinders. The divided fragment also should be completely detached and sewn *end to end* with the two segments of the interrupted nerve.

* Catgut should be used exclusively in nerve suture.—(Ed.)

Pseudo-graftings by interposition between the nerve segments of some tendon fibres, fragments of aponeurotic sheaths, catgut threads intended to serve as conducting wires (?) are wholly illogical and inevitably condemned to failure.

There is nothing but nerve tissue that can serve as a conductor for regenerating axis-cylinders.

Defective operations.—All that we have said about the main principles of nerve regeneration is sufficient to show how illogical and ineffective are certain methods once strongly recommended.

All lateral sutures must be condemned that do not make continuous the axis-cylinders of the central end and the empty sheaths of the peripheral end; lateral implantations, sutures by division into two of the upper segment, transplantations of one nerve into the other, and more especially transplantations of a motor nerve into a sensory one are almost always useless and often mischievous operations.

We must condemn the ablation of the lateral neuromata; such intervention is purposeless since it merely removes the extremity of the regenerating nerve fibres above an interruption without supplying a guiding channel for these fibres; the removed lateral neuroma will inevitably form again on the same spot, as does a neuroma in the case of an amputation.

“Combing” of the nerve must also be condemned; it neither liberates nor restores anything but merely effects a chance division into sections of a few nerve fibres, the regeneration of which thus becomes a matter of uncertainty. The only “combing” which can be advocated in some cases is the longitudinal incision of the sheath at the level of the interstitial hematmata occasionally found in cases of violent contusion.

Partial operations.—For partial lesions, however, we are sometimes led to practise partial operations. For instance, we may simply suture an interrupted bundle of a partially untouched nerve. Moreover, such interventions can only be made on the big nerve trunks.

They may be effected by cleavage of the nerve; its untouched part is bent back loop-fashion to allow of direct suture of the segments shortened by removal.

In these cases it is better, when reuniting the cut bundle, to have recourse to grafting, except in the case of the big nerve trunks, such as the sciatic.

Isolation of the nerves.—Care must be taken lest liberated or sutured nerves should again be embedded and compressed by the fibrous tissue of the scar. Several methods of preventing this have been recommended.

Isolation of the nerve by an aponeurotic flap, a muscular bed, a fatty covering, has been proposed; catgut has been rolled round the nerve; it has been enveloped in a peritoneal flap or a layer of amnion; attempts

have even been made to wrap round it a thin sheet of aluminium or of rubber ; the two united fragments have been brought into a segment of a vein or an artery ; a few drops of gomenol have been injected around the nerve. . . .

In our opinion, these practices are almost always useless, and even harmful in many cases, especially as regards the use of foreign bodies.

It must be well understood that the laying bare of the nerve to a considerable extent and the rolling round it of an isolating plate of any kind involves the risk of diminishing vascularisation from the surrounding tissues and thus compromising regeneration.

If we would rightly endeavour to do away with cicatricial fibrous formations round the nerve, we must not forget that fibrous tissue may develop at the expense of all the tissues ; muscle, fat, peritoneum, amnion are as likely to be transformed into cicatricial tissue as the connective tissue itself.

We give it as our opinion, therefore, that none of these practices, speaking generally, are to be adopted. There is but one exception to this rule, and that is when the liberated or sutured nerve happens to be in contact with bony or periosteal surfaces capable of involving it secondarily ; the most frequent instance is that of the musculo-spiral liberated from the callus of a fractured humerus.

In these cases we can and ought to effect isolation of the nerve in the vicinity of callus or a bony projection ; the best method is certainly the interposition of a muscular—or better still a fatty—layer.

But in all other cases we look upon these proceedings as both useless and harmful.

The best means of avoiding cicatricial fibrous formations is :

1. To avoid operating in a septic area ; a nerve operation, as far as possible, should take place only after complete cicatrisation of the wound and when all inflammatory reaction is at an end.
2. To make a very careful hemostasis, blood infiltration being one of the main factors in secondary fibrous formations.
3. To practise mobilisation and massage of the cicatrix very carefully and in good time.

Alcoholisation of nerve trunks (Sicard).—The failure of all kinds of treatment and the continuance of intolerable pain in certain cases of severe neuritis, more especially in causalgia, have led certain authorities to attempt the physiological interruption of the nerve.

In several cases, resection and suture of the nerve have been practised. This succeeds quite well in serious cases of neuritis complicated with trophic disturbances, though failure has resulted in cases of causalgia ; the painful nerve recovers with extreme rapidity, and the causalgic syndrome usually reappears after a few weeks.

Sicard * has recommended alcoholisation of the nerve trunks, effected by injecting above the lesion a solution of sixty per cent. alcohol. This injection of one to two cubic centimetres is made in the nerve itself, after surgical exposure.

There is thus produced by local neuritis a physiological interruption of the nerve, which, according to Sicard, would often appear to reach only the more fragile sensory fibres. Sicard, Pitres, Grinda, Godlewski, Benoît, and Morel state that they have been successful with this method.

Denudation of the arteries (Leriche).—For the treatment of causalgia, Leriche † advocated arterial denudation and resection of the perivascular sympathetic plexus.

This operation is based on the special nature of the pain in causalgia, which is attributed to irritation of the sympathetic twigs supplied by the nerve to the neighbouring artery, or else supplied to the nerve by the periarterial sympathetic plexus.

Causalgic symptoms would appear to be largely sympathetic in their nature, although the interpretation of these symptoms is probably somewhat complex.

We rather think there exists sympathetic irritation of a *reflex* nature, for we have found such irritation extend over almost the entire region of the cervico-dorsal sympathetic, even in the case of lesion of the median at the wrist (pain over the entire area of the median, constriction of the brachial artery, diminution of the pulse, numbness of the lower part of the face, and diminution of sweating at this level, intermittent redness of ear on the affected side, etc.).

Under these conditions, resection of the sympathetic plexuses which surround the brachial artery would result in the suppression of the reflex reactions of the sympathetic which give neuralgia its distinctive characteristics.

At all events, this procedure has given some results in obstinate cases. The same intervention has been proposed for the femoral artery in causalgia of the lower limb.

Sicard, *Presse Médicale*, 1 June, 1916.

† R. Leriche, *Presse Médicale*, 20 April, 1916.

CHAPTER XXVI

ELECTRICAL TREATMENT

ELECTRICAL treatment may fulfill three main indications ; it may :

1. Maintain contractility of the paralysed muscles.
2. Accelerate regeneration.
3. Soothe the pain.

1. The principal rôle of electrical treatment in paralysis is to maintain contractility of the paralysed muscle until voluntary contraction returns. The passing of the current attains this object by artificially bringing about contraction of the muscle.

The current to be used, therefore, is that which will most readily and with least intensity produce muscular contraction.

In case of reaction of degeneration, the muscle is capable of being excited only by the galvanic current. There is polar inversion at the motor point ; at this point, then, the positive pole would give the best contraction with the least intensity. On the other hand, however, longitudinal excitation is invariably greater than excitation through the motor point ; it is almost always *stronger at the negative pole*. Practically, then, longitudinal excitation by the negative pole will be used to bring about contraction of the muscle. The galvanic current causes contraction only at the closing and the opening of the current, consequently a rhythmic current will be utilised, one capable of producing somewhat slow interruptions (metronome or undulatory).

We have seen that the gradual application of the current did not lessen its action on the paralysed muscles, whereas it suppressed the excitation of the healthy antagonistic muscles. Besides, it is less painful than the sudden application of the current, and permits of greater intensities being utilised without pain. Consequently it will be a good thing always to effect this gradual application, either by employing condensers set in series (Lapique) or by the use of metallic undulators.

Thus a gentle and easily borne contraction will be obtained, limited almost exclusively to the paralysed muscles and not diffused into the healthy antagonistic muscles.

If there is no RD, the muscle can be excited by the faradic current ; once the muscular groups can be contracted under the faradic current, we

shall be able, with a moderate intensity, to utilise this current in effecting contraction.

First we shall utilise the brief contractions, caused by the coil interrupter ; then later we shall have recourse to interrupted tetanisation, set to rhythm by the metronome, or, better still, by an undulator, though always to a very slow beat.

In any case, whether muscular contraction is caused by the galvanic or by the faradic current, only a moderate effort must be required from the paralysed muscle. As a rule, a few daily contractions are sufficient ; care must be taken not to overwork a muscle disturbed in its nutrition, which would react by atrophy to an electrical treatment which is too strong.

2. The simple passing of the electric current appears capable of hastening the regeneration of the nerve, maintaining the nutrition of the tissues and facilitating the resolution of the cicatricial fibrous tissues.

For this purpose, the galvanic current, with negative pole and of moderate intensity, about ten or fifteen milliamperes, is generally employed. Consequently a simple galvanic bath, lasting from fifteen to twenty minutes, can be made to precede the few rhythmic excitations intended to maintain its contractility.

Mention must also be made of the favourable influence of the faradic current of feeble intensity, produced by stout wire coils. This current produces phenomena of vaso-constriction followed by intense, deep vasodilatation and appearing extremely favourable to the nutrition of the tissues as well as to regeneration.

The rhythmic faradic bath is particularly useful in the treatment of cicatricial contractions, of muscular fibrous infiltrations, of cutaneous adhesions and of the articular fibrous ankyloses produced by neurites, as well as of contractions from nerve irritation.

We may advantageously bring about the association of the galvanic and faradic currents under the galvano-faradic form ; this association allows of excitation of the paralysed muscle whilst avoiding its fibrous transformation ; it is by far the best treatment for muscular atrophy.

3. The galvanic current is a wonderful pain-allaying sedative, though this property is possessed only by the positive pole. The negative pole, on the other hand, is an excitant.

This current is utilised most frequently in the form of positive pole galvanic baths, with intensities varying, according to the case, from five, ten, twenty, or even twenty-five milliamperes.

Better results are frequently obtained from prolonged baths of extremely feeble intensity ; for instance, with three and four milliamperes lasting several hours we have obtained sedative results that shorter baths of greater intensity could not have given.

Ionization.—Salicylated or iodised ionization has been employed with

widely varying results in the treatment of neuritic pains and fibrous formations.

Some good results have been obtained by ionization (1% KI solution, negative pole) recommended by Bourguignon. The diminution of pain effected is sometimes remarkable, though inconstant and often fleeting; the lessening of fibrous *griffes* and muscular contractions is a more constant result.

Diathermy.—Diathermy may also be serviceable in painful and sclerosing neuritis, and in states of ischæmia accompanied by fibrous transformation.

Radiotherapy.—Radiotherapy is often very useful in the treatment of painful neuritis. The results we have obtained confirm the statistics published by Cestan and Descamps; * though in our opinion radiotherapy has acted rather upon violent neuralgias of a causalgic type than upon the duller pains of nerve irritation. We have seen cures effected more especially in several cases of causalgia of the median nerve; though frequently the violent painful paroxysms alone have disappeared whilst the dull pains continued.

Improvement is sometimes shown after the first treatment; in other cases, it appears only after seven or eight treatments.

It is no rare occurrence to find a momentary recrudescence of the pain, a possibility of which the patient must be warned.

Radiotherapy may take place either on the nerve lesion itself and the course of the affected nerve or on the roots and spinal ganglia which supply the nerve. On this point we are unable to afford any precise indication, for each of these methods has given favourable results after the other has failed.

It is probable that radiotherapy applied to the lesion acts on the inflammatory element in the nerve, interstitial infiltration and connective tissue proliferation caused by irritation; radiotherapy applied to the ganglia and roots would seem to be indicated when the pain results from the state of reflex hyper-excitability of the ganglion cells which appears to be present in causalgia.

MECHANOTHERAPY—MASSAGE—GYMNASTICS—PROSTHESIS

However great the therapeutical resources of electricity in all its forms, we must not forget that massage and mechanotherapy are absolutely necessary to supplement them.

To maintain the contractility of a paralysed muscle, to prevent its fibrous transformation, massage is perhaps as important as electrotherapy. *Daily massage should be given to every paralysed muscle.*

* R. Cestan and Descamps. Radiotherapy in the treatment of certain traumatic lesions of the nervous system. *Presse Médicale*, 25 November, 1915.

A fortiori massage is indispensable in nerve irritations that have a tendency to fibrous contraction of the muscle, to cutaneous adhesions and to articular sclerosis; it must be given in spite of the pain, unless this latter is really intolerable. The same may be said of mobilisation which should be practised daily in cases of neuritis accompanied by a tendency to fibrous ankylosis. A great number of neuritic *griffes*, of articular fibrous ankyloses and muscular contractions might easily be avoided by daily mobilisation.

In cases of neuritis both massage and mobilisation are invariably more easy and efficacious as well as less painful after the limb has been subjected to a hot bath, or better still, a hot bath and faradic current combined.

In addition to the passive mechanotherapy represented by massage and mobilisation, we must also insist on the importance of the active mechanotherapy effected by gymnastics.

This latter also maintains the contractility and nutrition of the paralysed muscles; it helps forward a return of the earliest movements after regeneration; it facilitates and provokes the important substitutionary movements in the case of paralysed muscles; it mobilises the articulations and integuments.

Gymnastics of the wounded limbs, in every form, both general and particular, is thus of the utmost importance. One must have witnessed the disastrous results of prolonged immobilisation in cases of peripheral paralysis and neuritis to understand the supreme importance of active movements. Inactivity of the wounded limbs and moral inertia of the patient form the main cause of the irreducible deformities, the neuritic contractions, the functional paralyses that accompany or follow organic paralyses.

Finally, it is often necessary to make use of appliances of an elementary prosthetic nature, both in order to keep the limb in its right place and to permit of its being used in a normal fashion; this is principally the case with apparatus intended to correct flexion of the hand in musculo-spiral paralysis and also steppage in paralysis of the external popliteal. Other appliances have as their object the avoidance of fibrous contractions and of the appearance of *griffes*.

All these appliances should be removable without any difficulty; they may readily be improvised with the aid of elastics or springs.

SCLEROLYTIC MEDICINAL TREATMENT

And lastly, some mention must be made of the treatment of nerve wounds by thiosinamin or fibrolysin (salicylate of thiosinamin).

It is logical to utilise the sclerolytic quality of thiosinamin in the treatment of the cicatricial fibrous lesions compressing the injured nerve or creating an interstitial obstacle to regeneration of the axis-cylinders.

P. Cazamian * has mentioned good results thereby ; in several instances he would appear to have effected the disappearance of the nerve tumour and also a certain functional improvement.

The following formula may be utilised—

Thiosinamin	15 grammes,
Antipyrin	7'5 grammes,
Distilled water	q.s. to 150 grammes,

in subcutaneous, or better still, intra-muscular injections. Twenty-five or thirty consecutive injections in doses of two cubic centimetres, either daily or every other day.

Thiosinamin would seem to be specially indicated in syndromes of compression, neuromata of attrition and neuritic types, where fibrous infiltration of the nerve, being interstitial, is inaccessible to surgical treatment ; it would also appear as though it had a favourable action on the fibrous sequelæ in cases of nerve irritation, which are so difficult to mobilise and require so long a time.

* Cazamian. *Presse Médicale*, 11 November, 1915.

INDEX

A

- ACTION, polar, in electro-physiology, 49
 Alcohol, injection of, 306
 Anæsthesia, deep and cutaneous, 31-33
 chloroform, 86
 complete ulnar, 168
 from lesion of posterior tibial, 255
 in complete section of ulnar, 142
 in lumbar hematomyelia, 295
 in musculo-spiral paralysis, 107
 in section of circumflex, 204
 of cutaneous area, 166
 of external cutaneous nerve of thigh,
 277
 of hand, 193
 peripheral, 92
 segmentary, 93, 97
 thermal, 78
 André-Thomas, xii, 75
 Anterior crural nerve,
 collateral and terminal branches, 268-
 271
 diagnosis of paralysis of, 273
 paralysis of, 271-272
 Anterior tibial nerve, paralysis of, 247-248
 Aponeuroses, 29
 Apparatus, Sollier's, 130
 of Léri, 265
 of Léri and Dagnan-Bouveret, 131
 of Marie and Meige, 265
 of Mauchet and Anceau, 131
 of Robin-Chiray, 265
 Appendages, skin, 29
 Aran-Duchenne syndrome, 218
 Arteries, denudation of, 307
 Athanassio-Benisty, xii, 73, 77, 82, 191
 Atropy, massive, 30
 muscular, 21

B

- BABINSKI, xii, 40, 82, 86, 88, 166
 Benoît, 307
 Bergonié, 59
 Bielchowski, method of, 13
 Bordier, 59
 Bourguignon, 50, 55, 310

- Brachial plexus, 209
 branches of, 212-214
 connexions of, 211
 lesions of, 214-215
 primary and secondary trunks, 210
 radicular syndromes (roots and primary
 trunks), 215-224
 Broca, xii

C

- CARDOT, 49
 Causalgia, 66, 187-191
 Cazamian, 312
 Cestan, 310
 Charcot clinic, vii
Chronaxie, 53-59
Chronaximètre of Lapicque, 57-58
 Circumflex nerve, 201
 branches, 202-203
 paralysis of, 203-204
 sensory disturbances in paralysis of, 204
 Claude, xii, 82, 176, 181, 195
 Club-foot, 88, 90
 Cluzet, 55
 Compression of nerve, 2
 Contractility, mechanical, of muscle, 23
 Contraction, fibrous, of muscles, 24
 club-foot from, 90
 from nerve irritation, 73
 Contracture, 83
 from neuritis, 88-91
 functional, 86, 91
 of hand in flexion, 84
 of interossei and hypothenar eminence,
 85
 Contusion of nerve, 2
 Cruveilhier, 231, 239
 Current, faradic, 37-40
 galvanic, 40-45

D

- DECALCIFICATION, 30
 Degeneration, Wallerian, 5, 13, 61, 74
 Dejerine, xii, 3, 11, 14, 15, 21, 23, 33, 60,
 62, 65, 117, 147, 159, 160, 180, 183,
 189, 245, 246, 255, 304

Delherm, 40
 Delorme, 302
 Descamps, 310
 Desquamation, cutaneous, 310
 Diagnosis of nerve lesions, 15
 Diathermy, 310
 Disturbances, cutaneous, 25
 thermal, 28
 vaso-motor, 27
 Doumer-Huet, longitudinal reaction of, 45
 Dubois, 93
 Duchenne of Boulogne, xii, 37, 39, 149
 Dupuytren's contracture, 70, 156, 157
 Dustin, 304

E

ELECTRICAL treatment in paralysis, 308-309
 Engelmann, 53
 Erb, paradox of, 39
 Erb-Duchenne syndrome, 216
 Examination, faradic, 37-40
 galvanic, 40-45
 Excitability, latent faradic, 40
 Excitation, selective, of paralyzed muscles, 58-59
 External cutaneous nerve of thigh, 277-278
 External plantar nerve, 241
 External popliteal nerve, 233
 clinical forms of paralysis of, 245
 collateral and terminal branches, 234-237
 motor syndrome, 242-243
 paralysis of, 242
 sensory syndrome, 244
 trophic and vaso-motor syndrome, 244
 External saphenous nerve, 257

F

FIBROUS infiltration of muscles, 70
 Foix, xii, 49
 Fornication, 18
 provoked by pressure, 34
 Froment, xii, 82, 86, 166

G

GALVANO-TONUS, 52
 Genito-crural nerve, lesions of, 279
Glioma, 1, 4, 9-11, 15
 Glossy-skin, 72, 97
 Godlewski, 307
 "Goniometer," 19
 Gosset, 301
 Grafting of nerve, 304
 Granular bodies, 5
Griffe, 19, 24, 68-69, 96, 98, 145-169, 255, 257, 310, 311
 Grinda, 307
 Gymnastics, 310

H

HÆMATOMYELIA, 92
 Head, 79
 Henle, loop of, 213
 Histology, 5-15
 Hunter's canal, 270
 Hyperæsthesia, 32, 69
 Hypertonia, 73
 Hypertrichosis, 29
 Hypoæsthesia, 32, 33
 Hypothenar eminence, atrophy of, 138

I

ILIO-HYPOGASTRIC nerve, 280-281
 Ilio-inguinal nerve, 280-281
 Indications for operation, 299
 Integuments, examination of, 25
 Internal cutaneous nerves, 205
 lesions of, 206-207
 Internal plantar nerve, 240
 Internal popliteal nerve, 237-239
 collateral and terminal branches, 239-242
 grave neuritic type, 253
 motor syndrome, 250-251
 sensory syndrome, 251
 simple neuralgic type, 254
 slight neuritic type, 253
 trophic and vaso-motor syndrome, 251-252
 Internal saphenous nerve, lesions of, 272-273
 Ionization, salicylated, in treatment of neuritic pains, 109-110
 Ischemic paralysis, 96-98, 223
 of upper limb, 225-229

J

JARKOVSKI, 40
 Jeanne, 153
 Jolly, 48
 Jumentić, xii

K

KELOIDS, nerve, v, 3, 11

L

LANTERMANN, incisures of, 12, 13
 Lopicque, 53-59
 Lasègne's sign, 70, 259
 Laugier, 49, 55-57
 Lejars, xii
 Lemoing's glove, 130
 Leriche, 73, 191, 192, 307
 Lesser internal cutaneous nerve, 206

Létiévant, xii
 Liberation of nerve, 302
 Ligament, Poupart's, 268, 272, 279
 Lumbar roots, 289-290
 Lumbo-sacral plexus, 282-286
 diagnosis of the lesions of, 294-296
 radicular syndromes of, 287-289

M

MARCHI, 5
 Marie, P., xii, 40, 49, 77, 117, 130, 301
 Massage, 310
 Mechanotherapy, 310
 Median nerve,
 anastomotic branch, 174
 anatomy of 170
 causalgia of, 187-193
 complete paralysis above epitrochlear
 muscles, 178-182
 diagnosis of paralysis of, 192
 dissociated paralysis of, 183-185
 motor branches, 172
 motor syndrome, 175
 neuritis of, 185-187
 paralysis below epitrochlear muscles,
 182-183
 sensory branches, 173
 sensory syndrome, 176
 trophic syndrome, 177
 Median and ulnar nerves, associated para-
 lysis of, 194-196
 Meige, xii, 40, 73, 77, 82, 117, 130, 191,
 301
 Morel, 307
 Motor points, 41, 42, 43
 descent of, 52
 Mouzon, xii, 14, 15, 21, 23, 33, 60, 65,
 117, 147, 159, 160, 189, 245, 246, 304
 Muscle, mechanical contractility of, 23
 fibrous contraction of, 24
 sensitivity to pressure, 23
 Muscles, interosseous, 138
 Muscular atrophy, 21
 contraction and hypertonia, 24
 tone, 21-22
 Musculo-cutaneous nerve, 197
 branches, 198, 199
 isolated paralysis of, 248-249
 motor and sensory syndromes, 200
 paralysis of, 200
 Musculo-spiral nerve,
 anastomotic branches, 103
 anatomy of, 99
 diagnosis of musculo-spiral paralysis,
 126
 dissociated paralysis of, 116
 dissociation of extensor communis digi-
 torum, 115
 motor branches, 102
 motor syndrome, 104
 paralysis above supinator longus, 110

Musculo-spiral nerve—*continued*
 paralysis below extensor communis
 digitorum, 116
 paralysis below radial extensors, 114
 paralysis below supinator longus, 112
 paralysis of, 104
 partial paralysis of triceps, 109
 sensory branches, 102
 sensory syndrome, 107
 syndrome of compression, 118
 syndrome of interruption, 119
 syndrome of nerve irritation, 121
 syndrome of regeneration, 124
 total paralysis of, 109
 treatment, 129
 trophic syndrome; 108

N

NAGEOTTE, xii, 4, 9, 304
 Nails, changes in, 29
 Nerve, sections of, 1, 7
 anatomy of, 99-103
 dissection of, 302
 grafting, 303
 isolation of, 305-306
 liberation of, 302
 musculo-spiral, 99-131
 physiology of, 104-117
 suture of, 302
 Nerves, musculo-spiral, 99
 anterior crural, 268
 circumflex, 201
 external cutaneous nerve of thigh, 277
 genito-crural, 279
 ilio-hypogastric, 280
 internal cutaneous, 205
 lesser internal cutaneous, 206
 median, 170
 musculo-cutaneous, 197
 obturator, 275
 sciatic, 231
 small sciatic, 266
 ulnar, 132
 Nerve trunks, alcoholization of, 306
 Neuritis, ascending, 81-82
 paralysis, hypertonia and contraction
 from, 82-91
 Neuroma, 1-4, 7-16, 35-36
 Neurotropism, 6, 7

O

OBTURATOR nerve, 275
 superficial and deep branches, 276
 Oedema, 27
 of hand, 108
 Operations, defective and partial, 305
 choice of, 301
 indications for, 300
 time of, 300

P

- PAIN, spontaneous, 65
 provoked by pressure, 65
- Palsy, crutch, 99
 "Saturday night," 99
- Paralysis, 18-30
 apparatus for, 130-131
 central, 92
 diagnosis of, 164-165
 from pseudarthrosis, 95
 functional, 93-96
 hysterical, 97
 ischaemic, 96
 musculo-spiral, 104-128
 pseudo-, 95
 simple compression of, 144
 treatment of, 129-130
 ulnar, 136-165
- Peripheral nerve lesions, prognosis and
 treatment of, 297-299
- Peroncito, 8
- Pes equinus, 24, 69, 88, 95, 253, 259, 261
- Petres, 243, 250, 307
- Philippeaux, xii
- Pole, action, 50
 negative, 51
 positive, 51
- Posterior tibial nerve, paralysis of, 255
- Prosthesis, 311
- Pseudo-*griffe*, 164
- Pseudo-neuroma, 2, 3, 4, 12, 15
- Pudendal plexus, 286-287

R

- RADIOGRAPH of hand, 30
- Radiotherapy, 191, 310
- Reaction of degeneration, 39
 complete, 45
 partial, 47
- Reaction, sweat, 26
 longitudinal, 52
 myotonic, 48
 of exhaustion, 48
- Reflexes, 20
- Revue Neurologique*, xii
- Roth, W., 278

S

- SACRAL roots, 291-293
- Schwann, sheath of, 5, 13
- Sciatic nerve, anatomy of, 231
 collateral and terminal branches, 232-
 233
 diagnosis of paralysis of, 262-264
 paralysis of, 242-257
 treatment of paralysis of, 264-265
- Sciatic trunk, paralysis of, 257-262
- Sclerolytic medicinal treatment of nerve
 wounds, 311-312

- Sensitivity, of muscle to pressure, 23
 attitude, 33
 cutaneous, 31
 deep, 33
 of nerve on pressure, 34
 osseous, 33
- Sheaths, synovial, 29
- Sicard, xii, 23, 82, 191, 302, 306, 307
- Small sciatic nerve, collateral and terminal
 branches, 266-267
- Société de Chirurgie de Paris*, xii
- Société de Neurologie de Paris*, xii
- Steppage, 243, 257
- Stimulation, unipolar, 37
 bipolar, 37
- Surgical intervention, time of, 300
 choice of, 301-307
- Suture of nerve, 303-304
- Syndrome of nerve interruption, 45, 61-63
 dissociated, 80-81
 of compression, 46, 63-66
 of fibrous transformation, 47
 of nerve irritation, 67-73
 of regeneration, 73-79

T

- TENDONS, 29
- Tenotomy, 24
- Testut, 243, 250
- Thenar eminence, 140
 atrophy of, 182
- Thiosinamin in treatment of nerve wounds,
 311-312
- Thomsen's disease, 48
- Tone, muscular, 21, 22, 23
- Treatment, electrical, 308
- Triangle, Scarpa's, 268, 273, 279
- Trophic changes, 25, 65, 68, 69, 80

U

- ULCERATION, 28
- Ulnar nerve, anatomy, 132
 contractions resulting from slight neu-
 ritis of, 165
 dissociated syndromes, 158
 motor branches of, 133-134
 motor syndrome of ulnar paralysis, 136
 neuralgia of, 158
 neuritis of, 165
 physiology of, 136
 sensory branches of, 135-136
 sensory syndrome, 141
 simple compression or recent interrup-
 tion of, 144
 syndrome of prolonged complete inter-
 ruption, 149
 syndrome of nerve irritation, 154
 trophic and vaso-motor syndrome, 142

Upper limb, ischaemic paralysis of, 225
 characteristics of, 226-228
 diagnosis of, 228-229

V

VALLEIX, points, 70, 259
 Vaso-motor changes, 27
 Velpeau, quadrilateral square of, 201

Velter, xii
 Vulpian, xii

W

WALLER, xii
 Weir Mitchell, S., xii, 66, 71-72, 187
 Weiss, 53
 Wound, examination of, 17
 date of, 17
 investigation of first sequelæ of, 18
 nerve disturbances of, 18

THE END

14 DAY USE
RETURN TO DESK FROM WHICH BORROWED

BIOLOGY LIBRARY

TEL. NO. 642-2532

This book is due on the last date stamped below, or
on the date to which renewed.

Renewed books are subject to immediate recall.

~~DEC~~
~~NOV~~ 2 1968

NOV 17 1968 10

LD 21A-12m-5,'68
(J401s10)476

General Library
University of California
Berkeley

380212

RD595

T5

UNIVERSITY OF CALIFORNIA LIBRARY

