



This is a digital copy of a book that was preserved for generations on library shelves before it was carefully scanned by Google as part of a project to make the world's books discoverable online.

It has survived long enough for the copyright to expire and the book to enter the public domain. A public domain book is one that was never subject to copyright or whose legal copyright term has expired. Whether a book is in the public domain may vary country to country. Public domain books are our gateways to the past, representing a wealth of history, culture and knowledge that's often difficult to discover.

Marks, notations and other marginalia present in the original volume will appear in this file - a reminder of this book's long journey from the publisher to a library and finally to you.

### **Usage guidelines**

Google is proud to partner with libraries to digitize public domain materials and make them widely accessible. Public domain books belong to the public and we are merely their custodians. Nevertheless, this work is expensive, so in order to keep providing this resource, we have taken steps to prevent abuse by commercial parties, including placing technical restrictions on automated querying.

We also ask that you:

- + *Make non-commercial use of the files* We designed Google Book Search for use by individuals, and we request that you use these files for personal, non-commercial purposes.
- + *Refrain from automated querying* Do not send automated queries of any sort to Google's system: If you are conducting research on machine translation, optical character recognition or other areas where access to a large amount of text is helpful, please contact us. We encourage the use of public domain materials for these purposes and may be able to help.
- + *Maintain attribution* The Google "watermark" you see on each file is essential for informing people about this project and helping them find additional materials through Google Book Search. Please do not remove it.
- + *Keep it legal* Whatever your use, remember that you are responsible for ensuring that what you are doing is legal. Do not assume that just because we believe a book is in the public domain for users in the United States, that the work is also in the public domain for users in other countries. Whether a book is still in copyright varies from country to country, and we can't offer guidance on whether any specific use of any specific book is allowed. Please do not assume that a book's appearance in Google Book Search means it can be used in any manner anywhere in the world. Copyright infringement liability can be quite severe.

### **About Google Book Search**

Google's mission is to organize the world's information and to make it universally accessible and useful. Google Book Search helps readers discover the world's books while helping authors and publishers reach new audiences. You can search through the full text of this book on the web at <http://books.google.com/>


LANE MEDICAL LIBRARY STANFORD STOR  
D1531 .H92 1872  
Observations in myology : including the



24503377249

250  
mcr

**OBSERVATIONS IN MYOLOGY.**



**OBSERVATIONS IN MYOLOGY.**



D1531  
H92  
1872

The following observations, with the exception of those on *Uromastix spinipes*, are reprinted from the sixth volume of the *Journal of Anatomy and Physiology*. They furnish numerous illustrations of the unity which underlies the great variety of animal forms. I have, however, refrained from entering upon the theories associated with that great principle. Much remains to be done to furnish a clear and sufficient exposition of the morphology of the muscular system; and many of the views here given may require to be modified, as, indeed, some of them are modifications of views before given by myself.





.

## CONTENTS.

	PAGE
<b>CRYPTOBRANCH</b> . . . . .	1
Fascial investment . . . . .	2
Fascia and muscles of tail . . . . .	8
Muscles of trunk . . . . .	9
,, hind limb . . . . .	18
,, fore limb . . . . .	31
,, head . . . . .	43
Nerves of head . . . . .	45
Spinal nerves . . . . .	47
<b>UROMASTIX SPINIPES, Notes of muscles of</b> . . . . .	61
<b>LEPIDOSIREN ANNECTENS</b> . . . . .	65
Fascial investment . . . . .	66
Ventral muscle . . . . .	67
Dorsal muscle . . . . .	76
Nerves of head . . . . .	79
<b>DOG-FISH, Muscles of</b> . . . . .	83
<b>CERATODUS, Muscles of</b> . . . . .	91
<b>PSEUDOPUS PALLASII, Notes of muscles of</b> . . . . .	99
<b>DISPOSITION OF MUSCLES IN VERTEBRATE ANIMALS</b> . . . . .	105
Dorsal muscles . . . . .	115
Ventral muscles . . . . .	117
Muscles of limbs . . . . .	142



# THE MUSCLES AND NERVES

OF THE

## CRYPTOBRANCH.

---

BEING so fortunate as to obtain the fine specimen of the great Japanese Salamander which died recently from a gash across its throat in the Zoological Gardens, in Regent's Park, and having the advantage of my friend and assistant Mr Anningson's skill for its dissection, I felt that the opportunity of making a more careful examination of the muscles of the animal with their nerves than had hitherto been done was not to be lost. Hyrtl, in his *Cryptobranchus Japonicus*, 1865, does not describe either the muscles or the nerves, and Drs F. J. J. Schmidt, Q. J. Goddard, and van der Hoeven (*Aanteekeningen over de anatomie van den Cryptobranchus Japonicus*, Haarlem, 1862) do not give any account of the spinal nerves.

The chief interest in the muscular system of this animal (and the other Urodelans) consists in the massing together of the several muscles, or rather the imperfect segmentation and individualization of them; so that it affords us, to some extent, a natural means of ascertaining the relationships of the muscles of the higher animals to one another, and so of grouping them. In instituting the comparisons requisite for this, it is difficult to exercise sufficient caution, and to avoid the errors which the necessities of nomenclature and the straining for over-exactness of homological interpretation are apt to induce. Especially is this the case if our views are warped by any theory we are disposed to favour. Such influences work upon us imperceptibly; and to be altogether free from them is more than is to be expected, even if it is to be desired. Facts will gravitate from their chaos, and they do so in some minds more quickly, in some in better order than in others; and while we gain the good, we

must abide by and beware of the evils of the tendency. I express these thoughts because they have been present with me throughout the investigation of the Cryptobranch.

#### FASCIAL INVESTMENT.

The muscles of the trunk, tail, and limbs, are covered by an investment of fascia or tough areolar tissue, which is connected with the transverse intermuscular septa of the trunk and tail more closely than with the muscles, and from the deeper strata of which processes pass between the muscles, and are attached to the bones. One of these processes (Fig. 1) forming a sheet or lamina on either side, near the mesial line above, dips downwards, covering the edge of the dorsal muscle, and meets its fellow of the opposite side along the line of the spinous processes of the vertebræ to which the two are attached. They thus enclose a triangular interval between them and the superficial stratum, which is continued across the middle line; and this interval contains fat, and affords a convenient passage for blood-vessels. A similar disposition exists along the ventral mesial line and along the lateral lines in the tail, as we shall find presently. Superficially it is connected with the skin and with the muscular fibres passing from point to point of the skin; and, which is very important to remark, it is closely connected with the *trapezius*, *latissimus dorsi* and the fore part of the *pectoralis*, as well as with the *subcutaneus colli*, the *depressor mandibulæ*, and the *constrictor faucium*. I say closely connected, because the fibres of these muscles are interwoven with and so take origin from it, and in this respect differ from most or all of the other muscles of the trunk and limbs. In front the fascial investment is continued dorsally, over the head to the margins of the upper jaw; and, ventrally, it is attached to the margin of the lower jaw.

The interior of the trunk is lined by a similar investment (*fascia transversalis*), somewhat more compact, though thinner than that on the exterior, which is connected with the transverse septa extending through the inner layer of the abdominal muscles. It is continued forwards to and along the base of the skull above, and, beneath, over (deeper than and attached

to) the branchial cartilages and the hyoid, to the inferior maxilla. Behind it forms a thick fascial stratum inside the pelvis, with which it is connected; and it is continued, between the caudal ventral muscles on the two sides, to the hæmal spines of the caudal vertebræ, where it blends with the mesial ventral process of the external fascial investment<sup>1</sup>.

Though thus described as an external and internal investment, these fascial strata are parts of one fibrous system continuous at the oral and anal ends of the animal, and connected with each other along the length of the animal by intervening septa—fibrous, cartilaginous, and osseous—which, though histologically varying, are members of the same system, and in the interspaces between which lie the muscles with their blood-vessels and nerves.

In Fishes and in the *Lepidosiren* the external fascial investment is, especially at the sides of the body, scarcely developed as a separate stratum, and the transverse intermuscular septa pass through it into the skin and bind the skin with its appendages closely to the lateral muscle. Near the upper and lower edges and immediately over the lateral septum it is more free and more easily detached; and there is frequently subcutaneous muscle present at these parts.

### FASCIA AND MUSCLES OF TAIL.

The tail is the simplest part of a vertebrate animal. It consists merely of axially disposed bony pieces or vertebræ which are moveable upon one another, of the muscles which move them, of the nerves which excite and regulate the movements, and of the vessels which carry the nutritive materials to and fro. In *Urodelans*, as in *Fishes*, the movements of the bony pieces are restricted, or nearly so, to one plane—a vertical movement in a horizontal plane—and the disposition of the muscles is very simple. The muscles, indeed, composed of longitudinal parallel fibres, are arranged as in the *Fish* in two flat masses, one on either side of the tail, which may be named after their homologues in the *Fish*, the ‘great lateral muscles.’ They are

<sup>1</sup> These fascial investments, external and internal, are described by Schmidt, Goddard, and van der Hoeven, though not quite in same manner as above.

separated from one another, that is, the lateral muscle of the one side is separated from that on the other by membranous septa passing vertically in the mesial line above and below from the vertebræ; and ossifications extending into these septa above and below constitute the 'neural' and 'hæmal' spines.

Each lateral muscle is, as in the Fish, divided into an upper or 'dorsal' and a lower or 'ventral' muscle by a horizontal membranous septum—which may be called the 'lateral septum'—stretched from the sides of the vertebræ nearly midway between the upper and lower edges of the animal, and ossifications extending into these septa on the two sides would constitute 'transverse' or 'lateral' processes. Such ossification however has not taken place except in the fore part of the tail.

Each of the septa (Fig. 1) as it approaches the surface splits into two laminæ which extend in opposite directions beneath the skin and meet and unite with the adjacent laminæ of other septa. Thus the laminæ resulting from the splitting of the neural septum are spread out, right and left, upon the dorsal muscles, and meeting the ascending laminæ from the lateral septa, form sheaths enclosing the dorsal muscles. The same is the case with the laminæ of the ventral septum; and the four muscles, the two 'dorsal' and the two 'ventral' of the two sides, are enclosed in sheaths, more or less distinct, formed by the laminæ of the neural, ventral and lateral septa.

Finally (Fig. 2), the four longitudinal caudal muscles—the two dorsal and the two ventral muscles—are divided transversely by septa, extending with more or less obliquity backwards or forwards from the intervals between the several vertebræ to the enclosing sheaths just described and the skin. So that each of the longitudinal muscles is transversely segmented into pieces corresponding with the several vertebræ. These transverse septa are tough and form as it were part of the muscle itself, being connecting media between the ends of the muscular fibres of the segments. They are not disposed in true vertical planes, but form slight curves with the convexity backwards above and below the lateral septum<sup>1</sup>.

<sup>1</sup> Schmidt, Goddard, and van der Hoeven count 46 of these tendinous inscriptions, 14 or 15 in the trunk, and the remainder in the tail, where the muscular intervals between them are narrower.

It is worth while to remark that the intervals or channels between the diverging laminae of the longitudinal septa are occupied by fat, and serve as recesses for the passage of blood-vessels, which are thus arranged in four longitudinal trunks or systems—a 'dorsal,' a 'ventral' and two 'lateral.' The interval in the ventral septum is thicker than in the other parts, and the fat-mass occupying it is larger and extends in upon the stunted or bifurcated hæmal spines. A transverse system of blood-vessels lies upon the transverse septa; and the several transverse vessels being connected with the four longitudinal trunks form communications between them, and discharge their blood into them.

In addition to the four fat-masses disposed with the longitudinal series of vessels are four deep fat-masses lying beneath the four lateral muscles, and lying therefore above and beneath the transverse processes and lateral septa. The nerves, as they pass from between the vertebræ transversely to the muscles, cross superficially with regard to these deep fat-masses.

The several fat-masses serve the purpose of giving size and lightness to the tail, making it a large and, by reason of the muscles, powerful propelling organ. Each attains its maximum thickness near the middle of the tail and diminishes towards the tip.

The caudal muscles therefore consist of a 'dorsal' and 'ventral' muscle on each side, passing from behind forwards, and transversely segmented by the membranous septa and the vertebral processes running into it.

The several parts, muscular and other, of the animal above the level of the lateral septa present but little variety in different regions of the tail, or indeed in the different regions of the animal. Accordingly the dorsal muscle extends in the simple form I have described along the whole length of the tail and indeed onwards through the abdominal and thoracic regions to the head.

The parts of the animal beneath the level of the lateral septa, on the contrary, undergo various and extensive modifications in consequence of the presence of the limbs and the abdominal thoracic and cervical viscera, which are all placed in the ventral division, that is in the division of the animal beneath the plane



of the transverse vertebral processes and the transverse or lateral septa connected with those processes. The effect of these modifications is seen in the fore part of the ventral muscle of the tail. Behind and in the greater part of its extent it, like the dorsal muscle, is simple. Anteriorly, however, it is more or less interrupted and broken up by the proximity of the pelvis and hind limb.

The upper portion of it encounters the ilium, which is developed in the middle of the thickness of one of the transverse septa; and the middle stratum of this portion of the muscle is interrupted by or inserted into it and constitutes the *ilio-caudal* muscle. The superficial stratum is continued forwards over the ilium, and being expanded, together with the rest of this part of the animal for the accommodation of the viscera, contributes to the formation of a layer of the abdominal muscles. The deepest stratum is continued forwards beneath the ilium, is similarly expanded, and joins the deepest stratum of the abdominal muscles.

The undermost part of the ventral muscle, the part lying next to the ventral fat-mass, becomes separated from the remainder as it approaches the pelvis and hind limb, loses the transverse inscriptions, and divides into three. Of these one—'*ischio-caudalis*'—situated nearest the middle line and the most superficial, arises from the extremities of the hæmal spines and is inserted into the hindermost margin of the ischium<sup>1</sup>; a second division—'*caudo-cruralis*'—arises a little more laterally from the hæmal spines and arches and loses itself in the superficial stratum of the hinder part of a broad muscle (Figs. 8 and 9), which is passing from the pelvic shield to the hind limb. It cuts this muscle nearly at right angles, and being inserted tendinous into it produces a tendinous inscription in it. A portion, however, of the caudo-crural does not lose itself in the broad muscle just mentioned, but is continued on along the hinder aspect of the thigh and leg into the musculo-tendinous

<sup>1</sup> It arises rather from the side of the ends of the hæmal processes, being separated from the muscle of the opposite side by the fat-mass which lies upon (beneath) the middle parts of the extremities of the hæmal processes.

The intervals between the hæmal spines are occupied by short antero-posterior '*interspinous*' muscles, which form part of the ventral muscle, and the marginal fibres of which are continued into the *ischio-caudalis*.

mass of the sole, and so on to the extremities of the digits. It may be called '*caudo-pedalis*,' and it constitutes a continuous muscle reaching from the middle of the tail to the ends of the toes. Its fibres are partially interrupted by a tendinous inscription, and it is joined beyond that point by a portion of the muscle arising from the ischium in which there is no tendinous inscription. (Fig. 10.)

The third division—'*caudo-femoralis*'—arising somewhat more laterally and deeply from the hæmal arches, is inserted by a strong tendon into the middle of the under (plantar) surface of the femur.

This disposition of the caudal muscles corresponds with that in the other Urodelans<sup>1</sup> (Axolotl, Menobranch and Newt) which I have examined; the only difference being, that in these the upper and larger—the iliac—portion of the ventral muscle does not afford so thick a covering stratum to the ilium, and consequently that bone, occupying as it does in Cryptobranch the plane of one of the intermuscular septa, approaches nearer to the surface. Internally the ilium is, as in Cryptobranch, lined by a deep stratum of the caudal muscle which is continued into the abdomen.

The TRANSVERSE INSCRIPTIONS or 'sclerotomes' which, in these animals, as in the fish, divide the lateral muscles into so many 'myotomes,' serve the purpose of binding the muscles throughout their whole length and depth to the vertebral column, preventing their starting from the column towards the arc of the curve, or their having a tendency to do so, when the tail is bent to one side or the other under their contraction; also by preventing the continuity of the muscular fibres, and by diffusing among many the force of the pull consequent on the contraction of any one, they add greatly to the strength of the whole. It is obvious that if each muscular fibre had been continued from end to end of the animal, and, further, had been required, as must be the case in these animals, and in fishes especially, to contract in its whole length simultaneously for the purpose of effecting those energetic violent flexures which produce the dartings and leaping of these animals, it would have been liable to rupture under its own force. The interruption however of the fibre by an inscription common to it with others diffuses the pull of the several parts of each fibre among many, and enables them all better to combine in a simultaneous effort. The arrangement does not interfere with the nerve-supply because each myotome receives its own nerves from its own division of the spinal cord through its vertebral foramen, in addition to the filaments from the lateral nerve which travels along the lateral septum to the tail and then

<sup>1</sup> It corresponds also generally with the account given by Mr Mivart of the Menopoma and Menobranch, *Proc. Zool. Soc.* April 22 and June 24, 1869.

breaks up into branches (p. 47). When, however, as in the case of the caudo-femoral, caudo-crural, &c., a part is segmented from the rest for the purpose of independent action requiring independent nerve-supply, then, partly for the better distribution of the nerves through its substance, the inscriptions disappear, the continuity of the muscular fibres being established through them so as to cause their obliteration. It is probable also, taking into account the peculiar vibratory or successional manner of action of the several parts of a fibre by which sustained contraction is effected, that continued action may have relation to continuity of independent fibres; whereas violent sudden efforts are associated with interruption of fibres, or, as in the case of the heart, with interlacing and intercommunication of fibres, which would have much the same effect. Practically, at any rate, we find where sustained action is required the muscular fibres are parallel and uninterrupted, but where sudden violent efforts are needed the fibres are interlaced and communicating, or are segmented by transverse tendinous inscriptions.

It is obvious that just as the extension of the muscular fibres through or over the tendinous inscriptions would cause fusion or ankylosis of the myotomes, and the occurrence of this partially and in varied ways will lead to varied dispositions and divisions and complications of the muscular structure: so the extension of the tendinous inscriptions through or over the myotomes would cause fusion or ankylosis of the sclerotomes; and the ossification of the thus extended sclerotomes may lead to varied prolongations and complications of the bony skeleton.

I have mentioned incidently that the limb-girdles and the limbs are placed beneath the lateral septa in connection with the ventral parts of the lateral muscles and have little or no relation to the dorsal parts, that the same is the case with the ribs, and that the iliac bones are, like the ribs (pp. 6 and 10), the result of ossifications in the ventral transverse intermuscular septa. It does not hence follow that the iliac bones are precisely the serial homologues of the vertebral ribs or 'pleurapophyses.' An objection to that view is presented by the fact that there intervenes in the Cryptobranch and other Urodela, between the iliac bones and the vertebral transverse processes on either side, a distinct bone which must correspond with a rib, and which in Menobranch has the elongated characters of a rib. This, together with the ventro-mesial position and relations of the pelvic bones and their freedom from the vertebral column in some animals (Whales, Snakes and Lepidosiren), indicate a serial correspondence with the skeletal formations in the sternal rather than with those in the vertebral ('pleurapophysial') region of the visceral wall. I avoid applying the term 'hæmapophysial' to the former because I think it by no means clear that the visceral cavity and its wall are to be regarded as identical with the hæmal canal and its wall. Indeed, as stated above, the lining of the visceral cavity (*fascia transversalis*) in the Cryptobranch is continued from the interior of the pelvis beneath the hæmal arches of the tail where it blends with the subhæmal septum; and the position which a backward or caudal prolongation of

the visceral cavity would occupy appears to be that occupied by the ventral or subhæmal fat-mass. If this view is correct the visceral wall represents a stratum superficial to that of the hæmal wall; and the hæmapophyses, instead of being in the same plane and corresponding with the lower parts of the visceral wall, or, instead of being expanded to the level of those parts—the pelvis, linea alba, sternum and sternal ribs, shoulder-girdle, and hyoid apparatus—are rudimentary or abortive in the visceral region. The representatives of them are to be sought in the fibrous structure covering the aorta and its branches, and lining the crura of the diaphragm, not in the subvisceral part of the wall of the visceral cavity.

### THE MUSCLES OF THE TRUNK.

The muscles of the trunk may clearly be regarded as, in part at least, formed by an extension of the caudal muscles forwards. Like these they are divided by a 'lateral septum' into a 'DORSAL' and a 'VENTRAL' series; and the former present very little difference from those in the tail. The septum is continued from the extremity of the tail forwards, beneath the *latissimus dorsi* and the muscles passing from the dorsum of the head and spine to the scapula and over the neck, as far as the head. The fibrous sheet which forms it slants from the exterior somewhat upwards to the upper surface of the ribs and transverse processes, so that the dorsal series of muscles overlaps the ventral to a slight extent: and owing to the greater expansion of the inferior or ventral part of the trunk, in comparison with that of the upper or dorsal part, the lateral septum is here situated nearer to the dorsal than to the ventral edge of the animal.

The TRANSVERSE SEPTA, a serial continuation of those in the tail, are directed from the median line above, at first very obliquely outwards and backwards through the inner part of the dorsal muscles; gradually, as they pass over the ribs they become less oblique, describing a curve with the convexity backwards, and near the lateral septum they are almost transverse. Beneath the lateral septum they are continued with slight obliquity backwards, and then again become transverse, thus forming in the ventral region a gentle curve with the convexity backwards, like that which is seen in the dorsal and in the ventral muscle of the tail. The direction therefore is not

so zigzag as in the fish, or quite so much so as represented by van der Hoeven. Viewed from the interior of the trunk they are seen to be directed from the mesial line, on either side, over the several intervertebral substances, obliquely backwards and outwards, upon the bodies of the vertebræ and over the ribs, in a direction corresponding with that of the transverse septa on the corresponding part of the exterior. Indeed they are a continuation of them through the thickness of the animal. They are easily traced down to the ribs, and the ribs appear to be the result of ossification occurring in them, beneath the plane of the lateral septum, that is, in the ventral parts of them. Beyond the extremities of the ribs the direction is rather suddenly changed, becoming more transverse; and towards the middle line they are, as on the exterior, quite transverse. (Fig. 4.)

#### DIRECTION OF THE MUSCULAR FIBRES.

In the DORSAL series (above the lateral septum) the direction of the muscular fibres is parallel with the axis of the animal. As in the tail, they simply pass between the transverse intermuscular septa and between the vertebral processes, and show no distinct indications of grouping into distinct bundles or muscles. They are moreover not interrupted by the presence of the limb-girdles. They require therefore no special description.

In the VENTRAL series (beneath the lateral septum) however the case is different. The intermuscular septa preserve their serial order, that is, follow one another in regular succession, as in the dorsal series, and are continued through the entire thickness of the muscular wall of the abdomen, and the muscular fibres pass from septum to septum, being limited to the intervals between the septa; but the muscular wall is expanded to cover the abdominal cavity and accommodate the viscera, and it is interrupted, or partially interrupted, by the limb-girdles; moreover, the direction which the muscular fibres take between the septa varies in different *parts* of the abdominal wall, and at different *depths* of the same part. The difference in direction at different *depths* causes a more or less distinct division into *planes*; and the difference in direction at different *parts* of the

abdominal wall causes a more or less distinct division into *sectors*.

Near the exterior the muscular fibres are directed, between the transverse intermuscular septa, from before backwards, and ventrally towards the *linea alba*. This disposition distinguishes them from those of the subjacent layer which take a different direction, and gives rise to a stratum constituting an '*obliquus externus*' muscle. The obliquity is most marked near the lateral septum. At a distance from that it gradually diminishes, and near the mesial line the fibres acquire an antero-posterior or straight direction, and constitute a superficial layer of the '*rectus abdominis*.'

In the stratum next subjacent the fibres are directed from before backwards, and dorsally towards the lateral septum, and thus is constituted an '*obliquus internus*.' The obliquity is here also more marked near the lateral septum diminishing towards the mesial line; and the fibres here acquiring an antero-posterior or straight direction constitute a deeper layer of the '*rectus*.'

The '*rectus abdominis*' is therefore simply the resultant of the altered direction of the fibres of the internal and external oblique, and consists of two layers which may, to some extent, be separated from each other, and which are continuous respectively with the external and internal oblique muscles<sup>1</sup>. (Fig. 7.)

In the deepest stratum of all the muscular fibres with their intermuscular septa extend, under the surface of the bodies of the vertebræ, as far as the middle line. In this situation they are directed antero-posteriorly or straight, and constitute what may be designated a '*subvertebral rectus*'<sup>2</sup>. More laterally, where they lie beneath the ribs and are connected, by means

<sup>1</sup> It would be more strictly correct to say that the *obliqui* are the resultant of an altered direction of the fibres of the *rectus*, and the two layers which they form are consequent on the difference in the direction which their fibres respectively take in their variation from the antero-posterior course of those of the *rectus*.

This fusion of the external and internal oblique muscles with the *rectus*, which I have indicated diagrammatically in Fig. 7, was pointed out by Mr Mivart in his description of the *Menopoma*, *Proc. Zool. Soc.*, April 22, 1869, p. 258, as well as in that of the *Iguana*, *Proc. Zool. Soc.*, 1867, p. 770.

<sup>2</sup> This muscle is described as *rectus trunci internus* by Schmidt, Goddard, and van der Hoeven; but they do not mention its connection with the *transversalis*. By Mivart it is regarded, in *Menopoma* (*Proc. Zool. Soc.*, April 22, 1862, p. 260), as part of the *retrahens costarum*.

of the intermuscular septa, with the ribs, they acquire a slant from behind outwards as well as forwards, and constitute a series of '*depressores costarum*.' More laterally still the obliquity increases to an almost transverse direction. This part of the stratum is the '*transversalis abdominis*.' Towards the linea alba it degenerates into a fascial layer, which is continued above (on the deeper aspect of) the *rectus abdominis* to join its fellow in the middle line.

The nerve-trunks lie in the chief part of their course behind the intermuscular septa, between the internal and the middle muscular planes, *i.e.* between the *subvertebral rectus*, the *depressores costarum* and the *transversalis*, on the one side, and the *internal oblique* on the other. (Fig. 4.)

It will thus be perceived that the muscular fibres lying nearest to the mesial plane of the animal, ventral as well as dorsal, are directed antero-posteriorly, corresponding with the axis of the trunk, and constitute so many pairs of '*recti*,' '*supra-vertebral*,' '*sub-vertebral*,' and '*sub-abdominal*,' whereas the fibres more laterally situated are oblique, and constitute *obliqui* and *transversi*. This accords with the directions in which the muscular forces are required to operate in the mesial and lateral planes.

It will be perceived further that the several abdominal muscles are essentially one, transversely segmented, muscular mass, that the stratification or segmentation into planes is simply the result of the variation in the direction of the fibres at different depths, and that the *recti* differ from the *obliqui* and *transversi* only in the circumstance that this variation in direction at different depths has not occurred in and near the mesial plane of the animal where they are situated. In the Fish where the variation in direction does not commonly take place at any part, not being required by the form and movements of the animal, the '*rectus*' character pervades the whole of the ventral muscular system of the trunk, and there are no *obliqui* and *transversi*.

Lastly, the stratification, even in the lateral parts of the Cryptobranch and other Urodelans is incomplete, intermediate between the condition of the Fish and that of the higher vertebrates, forasmuch as it affects only the muscular fibres, and does not extend to the intermuscular septa. In Birds and Mammals,

where more independent action, not only of the several strata, but of the several parts of each stratum, may be presumed to take place, the stratification is more complete, and the septa have in great measure disappeared. Still even in them the sub-abdominal *rectus* retains commonly more or less of the original septal and unstratified type. The persistence of these characters in it contrasting so markedly with the alterations which have been wrought in the more lateral muscles, and the consequent complete separation of the one from the other, mask the natural relations of the several abdominal muscles, and make us overlook the fact that they are all derivatives from one simple antero-posteriorly disposed muscular mass.

#### DESCRIPTION OF THE ABDOMINAL MUSCLES.

*The obliquus externus* (Figs. 2, 3, 5, 7) may be described as arising from the extremities and outer surfaces of the ribs from the second to that just in front of the pelvis, inclusive, by digitations, of which the foremost are very distinct. Further backwards the digitations are less distinct, and the muscular fibres arise partly from the lateral septum as well as apparently, to some extent, from the fascial tissue covering the dorsal muscles; this however is not quite clear. Joined by a more superficial portion from the ventral surface of the thorax<sup>1</sup>, it extends over the side of the abdomen to the middle line and the edge of the prepubic shield and cornu. The fibres, for the most part oblique, are near the middle line antero-posteriorly disposed, blended with, or constituting the superficial layer of the *rectus*. The hinder part of the muscle, dorsally, is not very defined, being partly attached to the ilium and partly lost in fascial tissue: ventrally it is attached to the edge of the prepubic shield and cornu superficial to the *pyramidalis*: and it is strongly attached to the spinous or marsupial tubercle which projects forwards from the hinder part of the edge of the prepubic shield. It is also continued into the *gracilis*, which arises from the under surface of the prepubic shield and pubes; and it is attached to the ala of the ilium, while some of the fibres passing over it are lost in fascial tissue; and between the ilium and the *gracilis* or pubes it is

<sup>1</sup> This is the pectoral muscle, see p. 32.



continued into the fascial tissue, which spreads over the dorsal aspect of the thigh, knee and leg. A deeper portion extends from between the anterior edge of the ilium and the pubic spine as a fibrous process, which acquires close connection with the hip-joint. (Fig. 2. *e, o'.*)

If it is traced in the opposite direction, it may be described as radiating from the sides of the prepubic cartilage and the pubes, anteriorly and dorsally. The fibres nearest the middle line run forwards as *rectus*, having a slight connection with the sternum, and are continued beneath, *i.e.* superficial to the coracoid of the same side, forming the superficial thoracic portion mentioned above. Some of these are lost upon the fascial tissue of the coracoid; but the greater number diverge laterally and are attached to the humerus, contributing largely to the formation of the *pectoralis major*. The fibres of the oblique situated more laterally than these take a deeper course, above the coracoid, and are attached to the extremities of the ribs as far forward as the second. Thus the fore or under part of the scapular arch (the hinder portion of the coracoid) projects back between the '*recto-pectoralis*' and the '*obliquus*' divisions of the oblique muscle. The fibres of the oblique arising still more laterally, are directed with increasing obliquity upwards to the ribs, the lateral septum, and the dorsal fascia, and backwards to the ala of the ilium and the fascial tissue of the thigh.

It will be understood that this, which we call a single muscle, is composed of successional series of fibres or myotomes passing from rib to rib and from transverse line to transverse line, the transverse lines being continuous with the ribs.

*Obliquus internus.* (Figs. 2, 4, 5, 7.) If the fibres of the external oblique are cut through, the subjacent stratum of fibres taking a different direction, *viz.* from behind forwards and inwards and constituting the *obliquus internus*, is disclosed without difficulty, forasmuch as the change in direction takes place abruptly.

The internal oblique is more massive than the external oblique, and more obviously a continuation of the iliac part of the caudal ventral muscle. Indeed that muscle, or great part of it, is continued forwards into the internal oblique, the ala of the ilium, which constitutes the notable line of demarcation

between the two, not being seen on the exterior or the interior, and being, as before said, apparently an ossification in the thickness of the intermuscular septum.

The *internal oblique* may be described therefore as arising from the upper part of the ala of the ilium, from the iliac part of the caudal ventral muscle passing above and beneath the ala of the ilium, and from the several ribs, as far forwards as the fourth, in a deeper plane than the external oblique. Its origin does not however extend so far forwards by two ribs as that of the external oblique. The fibres are, in the lateral part of the animal, directed obliquely from behind forwards and inwards, or mesially between the intermuscular septa; but near the ventral mesial line they take a more antero-posterior direction, constituting the deep stratum of the *rectus*. The hindmost fibres in this manner join or contribute to the rectus, in front of the prepubic cartilage and cornu, and are therefore not attached directly to the pubes. Anteriorly it is continued beneath the abdomen and thorax into the neck passing above, that is deeper than, the coracoid to the branchial cartilages and the hyoid. Its mesial part—the part forming the deeper stratum of the rectus—when passing above the coracoid comes into contact with and is attached to the deeper plate of the sternum<sup>1</sup>, the edge of the plate being received among its fibres; and between this point and the hyoid apparatus, it forms the *sterno-hyoid*. As it travels forward in the neck it is joined, near the hyoid, by a narrow muscle from the anterior edge of the scapula, which is the *omo-hyoid*. (Fig. 5, *o. h.*) Or, the relations of the omo-hyoid to the internal oblique may be more clearly expressed by stating that as the latter muscle proceeds backwards from the hyoid a portion is detached to, or acquires an attachment to, the fore part of the scapula and forms the omo-hyoid.

The hinder and inferior margin of the internal oblique pass-

<sup>1</sup> The sternum (Fig. 5) is a very rudimentary structure, consisting of a broad heart-shaped plate of cartilage, with the rounded apex directed forwards; and it is deeply notched or cleft on either side anteriorly for the reception of the edges of the large coracoids. So deeply is it cleft that it might be regarded as consisting of two plates, a superficial and a deeper, blended in the middle line and behind. It is the deeper plate which is involved at its margin in the internal oblique. The clefts on the two sides are not quite in the same plane, that of the left side extending a little beneath that on the right side. This permits the edge of the left coracoid to pass superficially to or beneath the right.

ing from the ilium to form the deeper stratum of the rectus, is tolerably defined; and there is an interval between it and the retiring angle of the pubes and prepubic shield, which is occupied by the *Pyramidalis*. (Fig. 2. *Py.*) The fibres of this muscle, arising from the anterior edge of the pubic shield and the tubercle or spine<sup>1</sup> which bounds that edge laterally, pass forwards and inwards to the edge of the prepubic cartilage and cornu, and some of them are continued further forwards, blending with the edge of the *rectus*. It lies between the external oblique and the transversalis, its outer margin being parallel with, though at a short distance from, the inner margin of the internal oblique. Its fibres take the same direction as those of the internal oblique and are in the same plane with them and appear to belong to the same series. In the Axolotl this is proved to be the case by the continuity between the two, that is, by the absence of the interval which separates them in the Cryptobranch.

The *Transversalis* (Fig. 4) is connected with the ribs and the transverse intermuscular septa in a still deeper plane. Near the vertebral column the direction of its fibres is nearly antero-posterior, and they are with difficulty distinguished from those of the internal oblique; still the division between the two is marked by the passage of the nerves. More externally their slant first resembles then exceeds that of the fibres of the internal oblique (from behind forwards and inwards), and finally they become almost transverse. At about an inch and half from the mesial line, at a part that is corresponding with the formation of the *rectus* in the manner I have described, the muscular

<sup>1</sup> The relation of the muscles shows this lateral prepubic tubercle to be the homologue of the spine of the pubes in man, and of the marsupial bone in marsupials. I have dissected the muscles of this part carefully in the Wombat, Paracayon, and Echidna, and find that the external oblique fibres forming the outer columns of the external ring are inserted into the outer edge of the marsupial bone, whereas the fibres forming the internal column pass across to the base of the marsupial bone of the opposite side and interlace with the corresponding fibres of the opposite side. The *pyramidalis* muscle, which is large in most of these animals, arises from the inner edge of the marsupial bone, and extends forwards and inwards in front of the rectus and behind the external oblique to the middle line, becoming blended with the rectus posteriorly so as not to be easily distinguished from it. In these animals, with the exception of the Wombat, the internal oblique has no connection with the marsupial bone and the *pyramidalis*, but passes deeper than they, and deeper than the rectus. In the Wombat a few of the hindmost fibres of the internal oblique are connected with the marsupial bone.

fibres of the *transversalis* end in a tendinous sheet which is continued above (deeper than) the *rectus*, to join its fellow in the middle line. Anteriorly the *transversalis* takes origin from the ribs as far forwards as the internal oblique; and it forms a thin sheet passing above the coracoids and the sternum. It is separated from the coracoids by the internal oblique; but it comes into contact with the deeper surface of the sternum near the mesial line. A space is here left uncovered in consequence of the fibres of the internal oblique being limited to the margin of the deeper plate of the sternum, and the *transversalis* accordingly is attached here. In front of this it blends with the internal oblique or is lost in areolar tissue. Towards the hinder part of the abdomen it is inserted into the upper surface of the prepubic cartilage and cornu in a manner corresponding with its attachment to the upper surface of the sternum; and it is traceable within the pelvis in company with the deepest stratum of the internal oblique into connection with the caudal muscle.

Where the fibres of this deepest or *transversalis* stratum of the abdominal muscles lie beneath the ribs passing from rib to rib, directly or through the medium of the intermuscular septa in which the ribs lie, and passing from the sides of the vertebral bodies to the ribs, they constitute a series of *depressores costarum* (Fig. 4, D, C); and where they lie beneath the bodies of the vertebræ they constitute what I have called a *subvertebral rectus*. In the former situation (where they form the *depressores costarum*) they slant from behind forwards and outwards like the fibres of the internal oblique; but in the latter situation (where they form the *subvertebral rectus*) they take a more antero-posterior direction. The subvertebral rectus is continued forwards beneath the bodies of the cervical vertebræ and is attached to the skull, so constituting a *longus colli* and *rectus capitis*. It will be understood that there is no line of demarcation between these several muscles, the whole—*transversalis*, *depressores costarum*, *subvertebral rectus*, *longus colli*, *rectus capitis*—being one continuous sheet of muscular fibres, with transverse septa or inscriptions, extending beneath the vertebral column, forwards, as far as the head, backwards, into the caudal muscles, and continued laterally beneath the

internal oblique to the ribs, the ventral mesial line, the pre-pubic cartilage, and the sternum.

Mesially, beneath the vertebral bodies, the muscle is separated from that of the opposite side by an interval in which lie longitudinal subvertebral vessels. Branches from these vessels pass transversely between the several vertebral bodies and the subvertebral rectus supplying both, and are continued as 'intercostal' and 'lumbar' vessels in company with the nerves, behind the intermuscular septa, between the transversalis and internal oblique.

There can, I think, be little doubt that the *crura* of the *diaphragm* in Mammals are formed by the lumbar parts of the *subvertebral rectus* bending downwards on the sides of the aorta and encircling it, and that the lateral parts of the diaphragm are in like manner formed by the inflection of the lateral parts—the *depressores costarum* and *transversalis* parts—of the same sheet.

A series of muscular fibres extending forwards to the head in the plane of, and taking the same antero-posterior direction as, those of the external and internal oblique near the vertebral column and forming a continuation of them, constitute the *scaleni* and the *recti laterales*. They pass between the transverse processes, between the ribs and between the intermuscular septa, and are separated from the *rectus capitis* (the anterior part of the subvertebral rectus) by the emerging nerves.

### MUSCLES OF THE HIND LIMB.

The muscles of the hind limb are, in accordance with the chief movements of the several parts of the limb, arranged in two series, one upon the plantar and the other upon the dorsal aspect of the limb; and in the furrows between the two, along the anterior or tibial and the posterior or fibular edges, are contained the chief blood-vessels and nerves of the limb. This at least is the case in the thigh; in the leg and foot they lie more near the middle of the dorsal and plantar aspects of the limb between the superficial and the deep strata of the muscles.

## PLANTAR MUSCLES OF THIGH.

In the thigh the plantar mass arises from both surfaces—the upper or abdominal and the inferior surfaces—of the under or sub-costal parts of the broad pelvic shield, that is, from the region of the pelvis situated on the ventral or plantar side of the hip-joint, and consisting of the ischium and the pubes. The mass is continued anteriorly into the *obliquo-rectus* muscle of the abdomen, and posteriorly is connected with the *caudo-crural* muscle. It thus intervenes between and connects (or may be regarded as an extension of) the mesial portions of the ventral muscles of the abdomen and the tail.

It is divided into two STRATA. Of these the SUPERFICIAL is a large, broad, unsegmented, and thick mass. It arises from near the mesial line of the large pelvic shield in nearly its whole length, from the insertion of the *ischio-caudal*, behind, to the *external oblique*, with which it is blended, in front. The greater part of it (all of it except the fibres presently to be mentioned as joining the *caudo-pedal*) is inserted into the upper two-thirds of the anterior (tibial) edge of the tibia inclining to the plantar aspect. It is the great flexor and adductor muscle of the leg, and corresponds with the *gracilis*, *semitendinosus* and *semimembranosus*. About one-third from its origin it is joined nearly at right angles by the fibres of the *caudo-crural* (p. 6, Fig. 8), which, or the greater number of them, terminate, tendinous, in its hinder and superficial part, causing a tendinous inscription in it.

The hinder part in which the caudo-crural thus terminates appears to correspond with the *semitendinosus*, the anterior superficial part being referable to the *gracilis* and the deeper part to the *semimembranosus*; and I cannot but suspect that the inscription thus formed may afford a more probable explanation than has yet been given of the remarkable inscription in the *semitendinosus* of man. If it be so it is a curious illustration of how far back in the animal series we may search for the explanation of peculiarities in the human frame, and, further, of the fact that minor features may appear or reappear and be the only trace of those conditions in the general plan of development which seem to have been their cause; for I need scarcely say that of the *caudo-crural* muscle itself there is no trace in man.

A bundle of the fibres of the hinder part of the muscular mass we are considering, unmarked by an inscription, joins a

similar bundle from the *caudo-crural*, which is to some extent marked by an inscription, and they together form the *caudo-pedal* (Figs. 3 and 10). This runs down the back of the leg and expands into the fascia of the leg and sole, reaching to the extremity of the digits. There is thus one continuous muscle extending from the middle of the tail to the ends of the digits, deriving occasional fibres in its course from the pelvis, and, as we shall find, from the femur, the leg-bones, and the tarsus.

The DEEPER STRATUM of the plantar mass is in three parts. A middle part arises beneath (deeper than) the preceding from the under surface of the pelvic shield. It is large, covers the obturator hole, and receives the nerve emerging from that hole. It is inserted into the tibial side and middle line (*linea aspera*) of the plantar surface of the femur and into a line passing from the *linea aspera* to the tibial condyle. It represents the *adductors* and the *external obturator*. A hinder—ischio-femoral—part arising from the hinder edge of the ischium is inserted rather above and behind the preceding into the projection on the fibular side of the upper end of the femur. It represents the *quadratus femoris*, the *gemelli*, and the *internal obturator*. It is separated from the contiguous edge of the dorsal muscular mass, or the ilio-femoral portion of it, by the sciatic nerve, which lies between them, as it passes from the interior of the pelvis. An anterior—supra-pubic—portion representing the *pectineus* (Fig. 2, *Pect.*) arises from the whole of the upper or abdominal surface of the pubes, behind the pubic spine and the *pyramidalis*, not therefore from the prepubic cartilage. It here extends as far as the middle line, meeting its fellow of the opposite side. It is a large muscle, passes over the anterior edge of the pubes and the inner part of the hip-joint, and is inserted into the *linea aspera* and tibial side of the plantar surface of the femur in conjunction with the middle portion. Moreover, it expands over the dorsal surface of the lower third of the femur, immediately above the knee-joint. It here extends round the fibular side of the femur, as far as the plantar or popliteal surface, and therefore nearly embraces the lower part of the shaft of the femur. Where it passes over the fore part of the pubes it is separated from the middle, or adductor, portion of its stratum by a prolongation of the tendon

of the external oblique which extends from the spine of the pubes, along the anterior margin of the pubes, to the hip-joint<sup>1</sup>.

#### DORSAL MUSCLES OF THIGH.

The dorsal muscular mass is, above, connected with the supra-coxal part of the pelvis, *i. e.* with the ilium. Below, it is partly connected with the femur and partly extends upon the leg. This causes a division, as in the plantar mass, into a SUPERFICIAL or ILIO-CRURAL and a DEEP or ILIO-FEMORAL STRATUM.

The SUPERFICIAL STRATUM is divided into three long bands or sectors. The inner (Fig. 2, *R, v*), arising by a flat tendon from the pelvis over the hip-joint, external to the *pectineus*, descends over the anterior or tibial part of the knee close to the joint, and passing beneath the origin of the *tibialis anticus* from the femur is inserted into the dorsal surface of the head of the tibia, close to the knee. I name this *rectus femoris internus*, and judge that it corresponds with the so-named muscle in Birds. It has no distinct representative in mammals, though its insertion nearly resembles that of the *sartorius*. It acts as an extensor of the leg.

<sup>1</sup> This is not the *ligamentum teres*. Indeed, I do not find so distinct a representative of that ligament either in the hip or the shoulder as figured and described by Hyrtl (Tab. v. fig. 3, and Tab. vi. fig. 1). In the femur and the humerus the cartilage forms a broad horse-shoe belt over the somewhat flattened upper end of each; and into the concavity of the crescent on either side, which is thus left uncovered by cartilage, the capsule of the joint ascends higher than at other parts of the circumference of the bone. The fibrous tissue of the capsule is also rather thick at these parts and so forms ridges, as it were, projecting into the joint, and passing from the head of the bone upwards and downwards, to the ilium and to the ischium in the case of the hip, and to the scapula and to the coracoid in the case of the shoulder. Suppose the ends of the cartilage horse-shoe to be prolonged in either instance and to meet forming a circle, enclosing a central dimple, and cutting off from the rest of the capsule the projecting portion of it inserted into that dimple, a veritable *ligamentum teres* would be formed. This might take place either above or below. It does so below, towards the ischium, commonly in the hip; and in the shoulder, a projection of the capsule forming the gleno-humeral ligament towards the upper or scapular side presents an approach to the same thing, and is a reminder of the parts in the Cryptobranch. In the *Journ. of Anat.* iv. 23, I have called attention to a recess and dimple in the astragalus of Unau and of Ai. They are similar to these in the humerus and femur of Cryptobranch; and with these are associated in each animal a similar approach to the formation of a *ligamentum teres* from a part of the posterior peroneo-tarsal ligament which ascends into the recess and dimple.

If this is, as I believe, the true explanation of the *ligamentum teres*, we must regard that ligament as merely a detached portion of the capsule of the joint, and not, as has been suggested, the representative of a tendon or other structure.



The middle sector (Fig. 2, *Gl. 2*) arises from the outer surface of the ilium, half an inch from the hip-joint, and descends as a broad strap-like muscle over the thigh and over the middle of the knee, superficial to the inner sector and the origin of the dorsal leg-muscles from the femur. It does not acquire any attachment to the upper end of the tibia, being separated from it and from the knee by the dorsal muscles of the leg, extending up to the femur; but it expands over those muscles and sends a process deeper, between the *tibialis anticus* and the *extensor digitorum*, which is attached to the lower end of the tibia and expands upon the ankle. I name this part of the ilio-crural stratum, '*gluteo rectus*,' believing it to represent the *gluteus maximus* (if there is any representative of that muscle in Urodelans) and the *rectus femoris* of mammals.

The outer sector (Fig. 2, *B*) arises from the ilium just beneath the preceding, and so close to it that it may almost be said to arise by a common tendon with it; it descends along the fibular side of the thigh and terminates in a broad tendon which, insinuating itself between the peroneus muscle and the fibula, is inserted into the upper third of the shaft of that bone. The peroneal nerve (Fig. 10, *P*) crossing beneath it, runs along its upper edge to the dorsum of the leg. The relation of the nerve, as well as the insertion of the muscle, indicate this outer or ilio-fibular sector to be the *biceps flexor cruris*; and it affords an example, not uncommon, of a muscle which belongs to the dorsal or extensor series becoming, by virtue of its position upon the side of a joint, an adjunct in its action to the plantar or flexor group. It is accompanied, in the distal part of its course, by a distinct spindle-shaped muscle (Fig. 10, *F, f*), which arises, by a tendon, from the plantar aspect of the femur, just beneath the insertion of the tendon of the caudo-femoral, and is inserted tendinous into the middle third of the shaft of the fibula beneath the tendon of the biceps. This femoro-fibular muscle appears to represent the short or femoral origin of the *biceps*.

The DEEPER or ILIO-FEMORAL STRATUM of the DORSAL mass covers the iliac part of the hip-joint. It arises from the outer and anterior surface of the ilium near the joint, between the *pectineus* anteriorly and internally and the *ischio-femoral* posteriorly and

externally, being separated from the former by the origin of the *internal rectus* and from the *ischio-femoral* by the sciatic nerve. It moreover extends a little upon the internal surface of the ilium, and still further upon the adjacent internal surface of the ischium, where it reaches behind the *pectineus* as far as the middle line. It is inserted into the fibular side of the middle of the *linea aspera*, close to the *caudo-femoral* and the *femoro-fibular* and close to the adductors, which are inserted into the tibial side of that line. Its attachment extends also from the *linea aspera* upon the fibular side of the plantar surface of the femur. Its origin from the ilium extends on either side of, or rather, in front and behind the origin of the *gluteo-rectus* and *biceps*: and the part in front of those muscles, lying upon the front of the hip and the ilium, appears to correspond with the *iliacus internus*, while the part lying behind those muscles and lying upon the back of the hip and the ilium appears to correspond with the lesser *glutei* and the *pyriformis*.

It must be remarked that the ilium is chiefly occupied by the attachments of the caudal and abdominal muscles—the internal oblique more particularly—and little space is left for the *glutei*. They are accordingly almost abortive. The *gluteus maximus* is absent, unless it is, as I have supposed probable, blended in the part of the ilio-crural section which I call *gluteo-rectus*; and the other *glutei* are very small; and in order to gain sufficient space for attachment they extend upon the inner surface of the ilium, and still more upon that of the ischium, thus spreading beyond their proper area and encroaching upon the territory appertaining to the plantar muscles, more particularly occupying the ground from which the internal obturator usually arises. This, at least, I suppose to be the case. It must however be stated that the muscles immediately surrounding a ball-and-socket joint in such an animal as the Cryptobranch somewhat resemble the capsule of the joint itself in the mode in which they invest it, and in the imperfection of their segmentation; so that the division into separate muscles is rather arbitrary, and the nomenclature proportionately uncertain.

It will have been remarked that the deeper parts of the extensor cruris, viz. the *vasti* and *crureus*, which are such constant elements in higher animals, do not exist in the Cryptobranch, and the lower space of the femur usually devoted to their origin is occupied by the insertion of the *pectineus*, while the upper part does not give attachment to any muscle.

The dorsal aspect of the thigh is covered by areolar or

fascial tissue in addition to the muscles above enumerated; and this is an extension of or is continuous with the hinder portion of the external oblique between the ala of the ilium and the spine of the pubes.

#### PLANTAR MUSCLES OF LEG AND FOOT.

Below the knee the plantar aspect of the limb is occupied by a broad thick pronato-flexor mass, extending from the femur to the ends of the toes, and with some difficulty distinguishable into parts—strata and sectors. It arises from the plantar surface of the fibular side of the limb, namely, from the fibular condyle of the femur, from the fibula in its whole length and the fibular side of the tarsus, being continuous with the *abductor minimi digiti*. Superficially, it is blended with the *caudopedal*, extends over the sole and divides into five tendons, which pass to the terminal phalanges of the five digits. Detachments from the deeper surfaces of these tendons pass to the first and second phalanges; and still deeper parts of the muscle are inserted into, as well as arise from, the proximal and distal row of tarsal bones and the metatarsals. The chief direction of the fibres is from the fibular towards the tibial side of the limb as well as downwards. Near the surface the fibres are nearly vertical and have, in the main, a flexor action. Traced more deeply they are, for the most part, more oblique; and the deepest of all are transverse and act simply as pronators.

The mass is partially divided into a SUPERFICIAL and a DEEP STRATUM, with the chief nerves of the back of the leg and sole running between them. The two strata are however blended together above and still more below.

The SUPERFICIAL STRATUM (Figs. 10 and 11), which is the part blended with the caudo-pedal, extends from the fibular condyle and the fibula to the ends of the digits. Its fibres have in the main a vertical direction, and exercise in the main a flexor function. It corresponds apparently with the *gastrocnemius*, *soleus* and *plantar fascia*, and with the *plantaris* and *flexor brevis digitorum* (the last two should be regarded as one, forming a *flexor sublimis digitorum*<sup>1</sup>). I will recur to the dis-

<sup>1</sup> The terms '*sublimis*' and '*profundus*' are greatly to be preferred to '*brevis*' and '*longus*' in designating these flexor muscles of the digits; because,

position of its divisions in the digits after describing the *flexor profundus*.

The DEEP STRATUM is disposed in an interesting manner. Its fibres are more oblique and have more of a pronator function than those of the superficial stratum. It is composed, *first* and chiefly, of a mass of fibres (Fig. 11, *Pr. p*) derived, slightly, from the fibular condyle of the femur in conjunction with those of the superficial stratum, but, chiefly, from the fibula and the fibular part of the tarsus—the two fibular tarsal bones—and slightly from the adjacent tarsal bones. They are directed downwards and inwards to the distal row of tarsal bones, to the metatarsal of digit I. and slightly to the metatarsals of II. and III., and also join the deeper surface of those divisions of the superficial stratum which pass to the flexor tendons of digits I. II. and III. This mass may be called '*pronator pedis*'<sup>1</sup>: it appears to combine the representatives of the *tibialis posticus* and those portions of the *flexor digitorum profundus* which we call the *flexor longus pollicis* and the *accessorius*.

A *second* part of the DEEP STRATUM (Fig. 11, *Fl. pr.*) still lying beneath the nerves is a long, thin muscle, quite separate in its upper part, which arises from the upper end of the fibula, descends upon the main mass of the deep stratum (the *pronator pedis*), the fibres of which cross obliquely from the fibula beneath it. Having reached the tarsus it expands, trumpet-like, beneath it and divides into five muscular bundles to the five digits. I have said that it lies, in the leg and in the proximal part of the tarsus, superficial to the *pronator pedis*; but its insertion into the digits is deeper; and in order to reach this deeper plane it, or rather the part of it destined to digits I. II. and III., curls round the fibular edge of the part of the *pronator pedis* passing to the *flexor sublimis*, so as to come into

in conjunction with the *plantaris*, which is really the upper or crural part of it, the *flexor sublimis* (*brevis* usually termed in man) is quite as long or longer than the *flexor profundus*; and the relation of the *flexor sublimis* to the *plantaris*—a cardinal point in the anatomy of the muscles of the leg illustrated in most mammals—is ignored or rather concealed by the term '*brevis*' of human anatomists.

<sup>1</sup> I call the muscle '*pronator pedis*' to facilitate subsequent descriptions, and because the name indicates an important part of its function; but even in this animal it has a flexor action, especially the fibres of it joining the *flexor sublimis*, and its representatives in the higher animals, in which pronation and supination of the foot do not take place, have a flexor action only.

close proximity with the tarsus. As it expands beneath the distal row of tarsal cartilages to reach the digits on the tibial side, it crosses the insertion of the *pronator pedis* into those cartilages, and itself acquires a connection with the cartilages, sending some fibres to them and deriving some fibres from them, and some of its fibres are here blended with those of the *pronator pedis*.

In *Menopoma* (Fig. 13) the interruption by the projecting tarsal cartilage is more complete than in *Cryptobranch*; so that the long band descending the leg is inserted there, or nearly so, and short muscles to the digits take their origin there. It seems not improbable that the *flexor profundus* is compounded of detachments from short flexor muscles arising from the tarsus with a detachment from the *pronator pedis* inserted into the tarsus; and may it not be that the fibrous mass, or sesamoid ossicle so commonly found in the tendon of this flexor and in its homologue of the fore limb, is a representative of the skeletal structure which in these animals intervenes between the upper and the lower parts of the muscle, and which becomes detached with the muscular fibres when the continuity of the two parts of the muscle is established?

Further, are not sesamoid ossicles in other parts similar detachments from the bones near which they lie?

Each of its five digital bundles subdivides into three, a middle and somewhat superficial part which is inserted into the base of the proximal phalanx, and two lateral parts which are attached to the sides of the metacarpal. The subdivision, which passes to the fibular side of met. v. is thin; and the division which passes to the pollex subdivides only into two, one to the middle and the other to the fibular side of the proximal phalanx. This muscle represents in the main that portion of the *flexor digitorum* which we usually call the *flexor longus digitorum*. I say in the main, because the representatives of the two parts of this stratum, which I have designated *pronator pedis* and *flexor profundus digitorum*, are, in other animals, variously blended to make up the *flexor hallucis*, *flexor longus digitorum*, and the *accessorius*.

The arrangement of each of the divisions of the *flexor subl. digitorum* resembles generally that of the divisions of the *flexor profundus digitorum* just described. Each (Fig. 11, a) subdivides into three, of which the two lateral pass to the sides of the approximated ends of the metacarpal bone and the proxi-

mal phalanx, while the middle portion passes on to the second or terminal phalanx. That at least is the case in digits I. II. and V., which have only two phalanges. In digits III. and IV., which have three phalanges, the middle portion again subdivides into three, of which the lateral parts are attached to the sides of the penultimate phalanges, while the middle parts go onwards to be inserted into the terminal phalanges. So that digits I. II. and V. have the same complement of muscles as III. and IV., but the second tripartite division does not take place in them.

There are in the individual digits some exceptions to this arrangement which should be mentioned. Thus, in digit I. the tendon sends only one offset to the middle of the proximal phalanx, and then passes on to the terminal phalanx. In III. the penultimate phalanx is treated like the proximal in I. receiving only one offset to its middle from the tendon on its way to the terminal phalanx. In V. the tendon detaches the usual lateral offsets to the approximated ends of the metacarpal and the proximal phalanx, and subsequently detaches an offset to the middle of the same phalanx before its insertion into the base of the terminal phalanx.

These points are deserving of special notice, because the lateral offsets are probably the representatives of the *lumbricales*, and the median offsets are probably the representatives of the *retinacula* not unfrequently found in Mammals, and usually observable in connection with flexor tendons of the toes in Birds.

The *third* part of the DEEP STRATUM (Fig. 14, *Pr. t.*) lies beneath, deeper than, the others, and is separate from them and composed of fibres still more obliquely, indeed almost transversely, directed. They form a square muscle, passing from the shaft of the fibula across the interosseous space to the shaft of the tibia. It may be called '*pronator tibiæ*.' The upper fibres<sup>1</sup> have a slight inclination from the fibula downwards, while the

<sup>1</sup> Some of the uppermost fibres are attached quite to the top of the fibula. In Scine the upper part, slightly separate from the rest, arises by a tendon from a sesamoid behind the knee common to it with the descending tendon of the caudo-femoral and the two strata of the flexor mass; and through the medium of this sesamoid and the fibrous bands that unite it with the condyle, the upper part of the *pronator tibiæ* derives its origin from the fibular condyle, and corresponds with the *popliteus* of mammals.

lower fibres have a slight inclination upwards, crossing behind the upper.

*Tarso-metatarsales* (Fig. 12) are a series of short thick muscles passing from the under surface of the distal row of tarsal bones to the under surface of the metatarsals near the base. Each, like the flexors of the digits, divides into three, but the lateral portions are rather more prolonged upon the metatarsals than are the middle portions. In digit I. the middle portion is wanting, and the laterals are very delicate. In digit v. the division into three parts is scarcely to be made out.

*Metacarpo-phalangei* (Fig. 12) arise from the under surface of the metacarpals near the insertion of the middle portions of the tarso-metatarsals, and in some instances are continuous with them. They are present in all the digits, and are inserted into the bases of the proximal phalanges, close to, and blended with, the tendons of the *flexor digitorum longus* inserted at the same parts.

*Phalangei* (Fig. 12) are present only in digits III. and IV. (the digits with three phalanges). They arise from the under surface of the proximal phalanges, and are inserted into the bases of the second phalanges blending with the parts of the tendons of the *flexor digitorum sublimis* which are attached here. There is a slight thickening in the tendons as they pass under the joints suggestive of a sesamoid body.

In higher animals the *phalangei* are absent, and the *interossei* (p. 30), the *tarso-metatarsales*, and the *metatarso-phalangei* are blended in the *short flexors* and *interossei*.

*Adductor minimi digiti* is a piece of the flexor mass extending from the lower end of the fibula to the fibular side of the tarsus and the base of met. v.

#### DORSAL MUSCLES OF LEG AND FOOT.

The muscles on the dorsal aspect of the leg and foot form a supinato-extensor mass corresponding antagonistically with the pronato-flexor mass on the plantar aspect, and, like it, consisting of a superficial and a deep stratum. There is however a less amount of muscular substance, and less complexity in its disposition and subdivision.

The SUPERFICIAL STRATUM arises by one broad tendon from the dorsal surface of the fibular condyle of the femur. It soon divides into three parts or sectors—a 'tibial,' a 'fibular,' and an 'intermediate.'

The tibial sector—*tibialis anticus* (Fig. 15, *T. a.*)—is inserted along nearly the whole of the fore part of the tibia. Its more superficial fibres extend over the ankle, and are inserted into the dorsal surface of the proximal tarsal bone on the tibial side.

The deeper fibres of the intermediate sector—*extensor longus digitorum* (Fig. 15, *E. d.*)—are united to and inserted with those of the preceding into the tibia. The more superficial portion divides over the ankle into five broad tendons which reach the terminal phalanges of the five digits, and send down detachments from their deeper surface to the proximal phalanges. Moreover at each notch between the divisions into the five tendons a process passes into the interval between the subjacent metacarpals, and bifurcating extends a short distance along their contiguous sides and is inserted into them, so that traction of the muscle has the effect of approximating the digits.

A delicate detachment (Fig. 15, *E. d.*) from the fibular side of the muscle in close apposition to a similar detachment from the fibular sector, forming a *peroneus tertius*, is inserted into the proximal tarsal bone on the fibular side.

The outer or fibular sector—*peroneus*—is inserted into the fibula in nearly its whole length, with the exception of the slip just mentioned, which contributes to form the *peroneus tertius*. This muscle is therefore, in the Cryptobranch, derived from both the *peroneus* and the *extensor digitorum*. Some few of the fibres of the *peroneus*, it should be added, extend over the end of the fibula, and are continuous with the fibres of the *abductor minimi digiti*.

The DEEP STRATUM exists as a separate layer only at the lower part of the leg and on the foot. It consists of two parts.

(1) *Supinator pedis* (Fig. 15, *S. p.*), a narrow band which arises from the dorsal surface of the lower end of the fibula, and crosses the ankle and tarsus obliquely to the base of the tibial side of the metatarsal bone of digit II. (Digit I. is absent in the hind limb.)



(2) *Extensor brevis digitorum* arises from the dorsal surface of the tarsus, more particularly on the fibular side, and is inserted into the under surface of the extensor tendons as they pass over the digits. A slip detaches itself from the tibial side of this muscle and joins the supinator pedis.

*Interossei metacarpales* occupy the proximal parts of the intervals between the metacarpals, passing nearly transversely between the adjacent sides of the several bones. Their free edges are defined and curved or semilunar, the fibres descending a little along the sides of the metacarpals, but they do not reach the phalanges.

### MUSCLES OF THE FORE LIMB.

The fibro-cellular or fascial tissue which covers the dorsal muscles and extends upon the ventral muscles and upon the head is thicker over the dorsal muscles than elsewhere, and is especially thick near the head. It here furnishes attachment or origin to muscles passing upon the scapula and the throat.

There are four muscular sheets thus arising placed beneath one another and distinct from each other. The most superficial (*subcutaneus colli*, Fig. 5, *S. c. C.*), the thinnest and least defined, is a cutaneous muscle the representative of the *panniculus carnosus* and the *platysma myoides*. Behind, it reaches as far as the *latissimus dorsi*. Anteriorly and ventrally it meets its fellow in the middle line, and is attached along the inner side of the edge of the lower jaw. Near the angle of the jaw its deeper surface is joined by the fibres of the myo-hyoid radiating above it. Under the *subcutaneus colli* is the *depressor mandibulae* and then the *constrictor faucium*.

The deepest is the *trapezius* (Fig. 6, *Tr.*), which arises from the fascia covering the dorsal muscle opposite the scapula and as far forward as the skull, also from the occipital bone above the insertion of the dorsal muscle, and round the side of that insertion from the lateral part of the occipital. This last part of its origin is very deep, reaching with the lateral septum to the base of the skull, and probably represents the *cervico-humeral* of certain mammals. The fibres converge to be in-

served into the anterior edge of the scapula, the upper edge of the precoracoid, and the retiring angle between the scapula and the precoracoid.

*Levator scapulæ* (Fig. 6, *L. sc.*) is a long narrow muscle arising by a delicate tendon from the base of the skull close to the insertion of the subvertebral rectus, indeed looking like a derivation from it, and inserted into the middle of the outer surface of the suprascapula above the origin of the *dorsalis scapulæ*.

It arises from the skull in this animal and the other Urodelans probably, because of the proximity of the scapula to the head. It is a very definite muscle in them, and attached only to and near the angle of the scapula. In Saurians, where the clavicle reaches this angle, the muscle creeps upon it forming a *levator claviculæ*; and rudiments of the same are sometimes met with in Man and other mammals.

*Serratus magnus* (Fig. 4, *S.*) arises by two bundles from the fore parts of the ends of the second and third ribs, the two foremost origins of the external oblique being from the hinder parts of the ends of those ribs. It is inserted into the under surface of the upper and also of the anterior part of the supra-scapula.

The *omo-hyoid* (Fig. 5, *O. h.*) passes from the anterior edge of the scapula beneath the *trapezius* to the side of the ventral muscle advancing forwards to the hyoid, with which it is blended<sup>1</sup>.

These are the four muscles which pass from the trunk to the scapula.

The muscles of the fore limb, like those of the hind limb, may be classed as flexor or 'palmar,' and extensor or 'dorsal;' and, after the manner of the hind limb, of those which pass from the shoulder-girdle to the limb, the palmar muscles take their origin from the coracoids, or subglenoid part of the girdle, and the dorsal muscles arise from the scapular or supraglenoid part of the girdle. Here, however, as in the hind limb, the muscles are not bound within rigid barriers, functional or territorial, but may be found to stray or glide more or less across their

<sup>1</sup> In Menobranch the long precoracoid cartilage lies upon the omo-hyoid, and this muscle as it passes back beneath it divides into two, one portion going over the anterior, and the other over the posterior, edge of the base of the precoracoid to its outer surface, where they are inserted.

frontier lines into other districts, and sometimes pass from an extensor to a flexor office.

#### ON THE PALMAR ASPECT OF THE GIRDLE AND ARM.

The *pectoral* (Fig. 5, *P.*) is derived almost entirely from the superficial stratum of the obliquo-rectus of the abdomen, and is continuous with it. Where the fibres diverge from the trunk-muscle and take their independent course over the coracoid and to the humerus, they lose the tendinous inscriptions, *i.e.* in the last four inches of their course. A few fibres are derived from the sternum; and as the muscle passes over the hinder part of the coracoid it acquires some addition from muscular fibres which arise from the coracoid. It is inserted into the radial edge of the radial tubercle near the upper end of the humerus, none of the fibres extending beyond this tubercle. Its anterior edge is continuous with fascial tissue superficial to the precoracoid and extending over the neck<sup>1</sup>.

The coracoid and precoracoid cartilages in this animal are very large and form a considerable part of the glenoid cup; and the muscles arising from them are numerous, almost surround the head of humerus, and are difficult of interpretation. They arise chiefly from the outer surface or the edge, and are as follows.

1. A broad thin muscle, arising from the outer surface of the sternal or epicoracoid edge of the coracoid superficial to the *biceps*. It crosses the muscular fibres of the *biceps* superficially and transversely and converges to be inserted into the summit of the upper part of the radial tubercle of the humerus, just above the pectoral. It may be called *epicoraco-humeral* (Fig. 17)<sup>2</sup>. Some of its superficial fibres are blended with those of the under surface of the pectoral, and it is not improbably the representative of the *pectoralis minor* of mammals.

<sup>1</sup> This is the fascial investment already spoken of (p. 2) as covering the body. Schmidt, Goddard, and van der Hoeven, speak of the connection of the pectoral with the sternum and coracoid, but do not mention its relation to the external oblique, or to the fascial tissue.

<sup>2</sup> It corresponds, I think, with that described under this name in the *Echidna*, by Mivart. *Trans. Linn. Soc.* xxv. 383.

2. *Precoraco-brachial* (Fig. 17, *P. c. b.*), arises from the whole of the outer surface of the precoracoid cartilage, with the exception of the marginal part. It lies in the same plane with the *epicoraco-humeral*, indeed is almost continuous with it, and is inserted, in close connection with it and with the pectoral, into the radial side of the uppermost part of the radial tubercle of the humerus<sup>1</sup>.

3. *Coraco-brachialis longus* (Figs. 17 and 18, *C. b. l.*) is the largest of the muscles arising from the coracoid. It arises from the hinder edge of the coracoid and divides into two portions. Of these, the larger and inner or lower division is inserted into the ulnar edge of the humerus for a quarter of an inch above the internal condyle: the other division, being nearly as large, is partly inserted into the side of the long tendon of the biceps, while a bundle of its fibres is continued on over the elbow, and is inserted into the ulna near the joint.

This last-described division must represent the short or coracoid origin of the biceps in Man. There is no trace of it in Menobranch Axolotl or Newt. The muscle in them though large is confined to the humerus in its insertion.

4. *Coraco-brachialis brevis* (Fig. 17, *C. b. br.*) arises from the coracoid close to the shoulder-joint, between the preceding muscle and the joint, and also from the external surface of the hinder part of the coracoid near the joint. It passes beneath the *biceps* to the ulnar side of the humerus near the shoulder-joint, and to the base of the ulnar side of the radial tubercle of the humerus beneath the *coraco-brachialis superficialis*. It corresponds with the ordinary mammalian coraco-brachial.

The median nerve passes between these last two; while the ulnar vessel, and in animals where it is present the ulnar nerve also, continues its course behind both.

<sup>1</sup> This muscle is called *subclavius* by Mivart, in his description of Menopoma and Menobranch, *Proc. Zool. Soc.* 1869, pp. 265 and 460, though he regards it as the same as that named by him *epicoraco-humeral* in the Echidna. The relations of the muscle to the mammalian *subclavius* do not appear to be sufficiently clear to induce me to follow in the application of that name to it; and it arises from the precoracoid rather than from the epicoracoid part of the girdle. In Menobranch it is inserted into the summit of the radial tubercle, and its under surface is blended with the supra-scapular which makes its appearance in that animal though quite absent in Cryptobranch.

5. *Coraco-brachialis quartus (subscapularis)* arises from the margin of the coracoid and also of the scapula forming the inner edge of the glenoid cup, extending from the origin of the *coraco-brachialis brevis* to and over that of the triceps and also a very short distance upon the adjacent inner surface of the scapula. It separates the origin of the *coraco-olecranal*is from the capsule and from the origin of the *triceps*. The latter expands somewhat into the capsule, and so separates this muscle behind from the capsule. With that exception it is in immediate contact with the capsule which is thin under it. It is inserted into the upper part of the humerus behind the preceding, that is, just behind the ulnar edge between the *coraco-brachialis brevis* and the inner or third origin of the triceps. Indeed some of its fibres are continuous with the former of those muscles in front, and with the latter behind.

This muscle spreading itself to a greater extent upon the internal surface of the scapula in some animals becomes the subscapular. It is called subscapular by Mivart in *Menopoma* and *Menobranch*. In the latter animal its extension upon the inner surface of the scapula is rather more decided than in *Cryptobranch*.

6. *Coraco-olecranal*is arises, by a tendinous band, from the edge of the coracoid, near the joint, internal to the middle of the preceding muscle, which separates it from the joint. It soon becomes muscular, descends the ulnar side of the arm dorsally, joins the triceps and is inserted with it into the inner side of the olecranon.

This coracoid accession to the *triceps* is common in Reptiles as well as in Urodelans. It results from the large relative size of the coracoid, and reminds us of the accession which the *quadriceps extensor cruris* in these animals receives in the form of what I have called *internal rectus* from the inner side of the front of the hip-joint. Only, in consequence of the difference in the rotation of the two limbs, the extensor of the forearm being directed backwards, gains its accession from the back of the shoulder-girdle, while the extensor of the leg being turned forwards gains its accession from the front of the pelvic girdle.

The *coraco-olecranal*is is also an example of the deviation of a member of the flexor series to an extensor function: just as the *biceps flexor cruris* is an instance of the deviation of a member of the extensor series to the flexor function, the office in each instance being determined by the position and attachment.

7. *Coraco-radialis*, or *biceps* (Fig. 17, B.), arises from the

external surface of the coracoid, between the epicoraco-brachial (*pect. minor*) and the short coraco-brachial, as a fan-shaped muscle, the fibres of which pass across the short coraco-brachial and soon converge into a long tendon, which runs down beneath the pectoral. Having passed the pectoral it receives the fibres of the long coraco-brachial, passes over the elbow-joint, and is inserted into the palmar surface of the upper end of the radius close to the joint. It is supplied by the nerve which perforates the scapula and which supplies also the superficial coraco-brachial.

I find the *biceps* corresponding with the above and distinct from the *brachialis anticus* in Menobranch, Newt, and Axolotl. In the Newt the long thin tendon is more closely related to the *brachialis anticus*, but does not seem to derive muscular fibres from it. As above mentioned, it does not in any of these animals derive fibres from the *coraco-brachialis longus*.

The *Brachialis anticus* arises from the radial side of the radial tubercle of the humerus, close, but on the opposite side of the tubercle, to the insertion of the pectoral, and beneath the insertion of the *dorsalis scapulae*<sup>1</sup>. It passes along the shaft of the humerus, deriving no fibres from it, passes over the elbow superficial to the *biceps* tendon, and is inserted about equally into the radius and ulna. Its foremost fibres are inserted into the ulnar side of the radius at a short distance from the joint, nearly in the situation corresponding with the middle of the insertion of the supinator longus in ourselves. Its hinder half, passing between this radial insertion and the insertion of the *biceps*, is attached to the adjacent palmar surface of the ulna.

#### ON THE DORSAL ASPECT OF THE GIRDLE AND ARM.

The *trapezius* already described, (p. 30).

*Latissimus dorsi* arises from the fascial tissue over the dorsal muscle, extending, forwards, nearly to the head, overlying the hinder part of the trapezius and, backwards, half way to the pelvis. It is a thin muscle and its edge is not very defined in

<sup>1</sup> I may observe that neither in this nor in the hind limb is the surface for attachment of muscles increased by intermuscular septa extending from the sides of the humerus and femur.

front or behind. The fibres converge and are blended with the upper part of the scapular origin of the *triceps*. Through the medium of it some are connected with the hinder margin of the scapula near the glenoid cavity; but it has no direct attachment to the scapula, and we cannot trace any of its fibres to the humerus.

In these animals, in Reptiles and Birds, the *lat. d.* overlaps the *trapezius*; the reverse being the case in mammals.

*Dorsalis scapulæ* (Fig. 17, *D. s.*) arises from the outer expanded surface of the supra-scapula. It is a long trumpet-shaped muscle, and is inserted into the radial side of the radial tubercle of the humerus beneath the insertion of the *pre-coraco-brachial*.

This is in Cryptobranch the only muscle, with the exception of the few fibres of the *subscapularis* above mentioned, passing from the scapula to the humerus. In Menobranch there is in addition a muscle, blended with the deeper part of the precoraco-brachial, which represents the *supra-scapular*. The *dorsalis scapulæ* must represent, in the main, the *infra-spinatus*. Its superficial part, probably, becomes in other animals developed so as to contribute to the scapular part of the *deltoid*, and its hinder part is segmented as the *teres minor*. The *clavicular* part of the *deltoid* corresponds probably, to some extent, with the superficial fibres of the *precoraco-brachial*. Thus the clavicular and scapular parts of the *deltoid* come into relation with the *trapezius*, which is, in Urodelans, inserted into both precoracoid and scapula. They overlie the *supra-* and *infra-spinatus* and *teres minor* muscles, and have insertion corresponding with that of the *precoraco-brachial* and *dorsalis scapulæ*. The two parts are not uncommonly separate.

The few fibres of the *subscapularis* constitute the only appearance of muscle upon the whole of the large extent of the concave under surface of the coracoids and scapula, so that the surface is free to play upon the convex outer surface of the ventral muscle on which it lies.

*Triceps* arises by a tendon from the posterior edge of the scapula, immediately behind the joint and in close connection with the capsule, which indeed it strengthens by expanding upon it. It soon becomes muscular and is joined by the *latissimus dorsi*. A second head arises from the radial side of the humerus at the base of the tubercle, and a third from the hinder and ulnar aspect of the humerus. These all unite; and the muscle is inserted into the olecranon, being joined by the *coraco-olecranal*is.

PALMAR MUSCLES OF FOREARM AND HAND<sup>1</sup>.

On the palmar aspect of the forearm the muscles form, as on the plantar aspect of the leg, a pronato-flexor mass, which is partially divided into two strata.

The SUPERFICIAL STRATUM (Fig. 18) is in three sectors. A radial sector representing the *Pronator teres* and the *Flexor carpi radialis*, large and thick, passes from the anterior or palmar part of the ulnar condyle, commencing close to the joint and extending a little way up the humerus above the condyle, crosses the forearm obliquely, and is inserted into an oblique line on the radius, which passes across its palmar surface from the ulnar to the radial edge, and into the radial edge as far as the wrist, also into the radial side of the two radial cartilages of the wrist. The upper edge of its insertion is immediately below that of the *brachialis anticus*. The deepest portion of the muscle, arising from the condyle close to the joint and passing to the ulnar edge of the radius, that is, to the upper part of the oblique line just mentioned, is in close contact with the *pronator quadratus* and at its insertion is blended with it, but is separated from it nearer the origin by the nerve (ulnar nerve) passing from the median nerve to the ulnar side of the forearm. This deepest portion of the muscle, which obviously corresponds with the ulnar origin of the *pronator teres* in man, is slightly separated from the rest by the branch of the median to the *flexor digitorum sublimis*<sup>2</sup> (see Fig. 18).

*Flexor digitorum sublimis* (Fig. 18, *Fl. d. s.*) forms the middle sector. It arises from the inner part of the ulnar condyle of the humerus, covering the preceding sector at this part. It soon lies on the same plane with it, occupies the middle of the forearm and receives an accession in the form of a portion arising by a flat tendon from the middle of the ulna (Fig. 19, *Fl. d. s.*) on the radial side of the *flexor carpi ulnaris*. The fibres of this portion join the under surface of the ulnar side of the general

<sup>1</sup> I apply the term 'hand' to the distal segment of the fore limb simply for the convenience of distinguishing it from the distal segment of the hind limb.

<sup>2</sup> In the Seine this portion, similarly related to the nerve and arising from the condyle beneath the rest of the muscle, is quite separate in its whole length, forming a *pronator intermedius*, and, serially, corresponding precisely with the *popliteus* in ourselves.



mass. It terminates over the carpus in a broad tendon, which is joined by a portion of the deep stratum, and divides into four tendons to the four<sup>1</sup> terminal phalanges. The disposition of the tendons corresponds almost precisely with that of its homologue in the hind limb (p. 26). Each subdivides into three, two lateral and a middle, the two lateral pass to the sides of the approximated ends of the metacarpal and the proximal phalanx, while the middle portion passes on to the second or terminal phalanx. In digit iv., which has three phalanges, the middle portion again subdivides into two, of which the deeper is attached to the base of the second phalanx, while the superficial runs on to the terminal phalanx.

*Flexor carpi ulnaris* (Fig. 18, *Fl. c. u.*) arises from the inner condyle in conjunction with the *flexor digitorum*, and is inserted along the lower two-thirds of the ulna and into the proximal ulnar carpal bone; and some of its fibres are continued into the *abductor minimi digiti* which extends along the side of the metacarpus to the ulnar side of digit v.

The DEEP STRATUM arises from the plantar surface of the ulna commencing a little below the elbow-joint, also from the cartilages forming the middle or radial part of the carpus, but not those quite on the radial side. The fibres pass partly into the under surface of the radial part of the *flexor sublimis digitorum* and, partly, to the metacarpal and to the distal carpal bone on the radial side, also to the ulnar edge of the radius.

More accurately described the arrangement of the components of this stratum is as follows in three parts—*Pronator radii quadratus*, *Pronator manus*, and *Flexor profundus digitorum*.

1. *Pronator radii quadratus* (Fig. 18, *Pr. q.*) arises from the upper part of the palmar surface of the ulna near the radial edge, and is inserted along the ulnar edge of the radius, its uppermost fibres blending at their insertion with the deepest fibres of the superficial layer (*pronator teres*). The upper fibres have some obliquity downwards from the ulna to the radius, the lower fibres are more transverse, and rather behind the upper.

<sup>1</sup> Of the four digits in this limb digit iv. only has three phalanges, the remaining digits ii. iii. and v. having each but two phalanges.

The position of the muscle on the same level with the next portion of the deep layer indicates, as does the passage of the large branch of the median behind it, that it is a segment from the deep stratum rather than a third and hinder stratum which one might at first be disposed to regard it, and which view the position of its correspondent in the hind limb rather favours. By the connection of the muscle with the lower part of the *pronator teres* a continuity between the two muscles and between the two strata is established above. It is not so large, does not descend so low as its correspondent in the hind limb, and it is not placed behind the plane of the deep flexor stratum as the *pronator tibiæ* is in that limb. The difference in the last particular is caused by the greater size of the *pronator tibiæ* as well of the deep flexor stratum in the hind limb, so that the one comes to overlie the other.

2. The largest portion of the deep stratum, which I will call '*pronator manûs*' (Figs. 18 and 19, *Pr. m.*), arises from the radial side of the palmar surface of the ulna, beneath the preceding, and from the middle carpal cartilages. Its superficial fibres run into the radial part of the under surface of the *flexor sublimis*, just as the fibres from the ulnar origin of that muscle run into the ulnar part of its under surface. Its deeper fibres are inserted into the distal radial carpal bone and the base of the metacarpal of II. and III.

3. The *flexor profundus digitorum* (Figs. 18 and 19) is a flat band arising from the upper part of the palmar surface of the ulna between the *pronator quadratus* and the *flexor carpi ulnaris*. Like the corresponding band in the hind limb, it is completely segmented from the other muscles, and descends vertically. It passes deep, is connected with the distal carpal cartilage near the base of digit IV. detaching some fibres to the cartilage, and acquiring some from it; indeed the cartilage projects up through the muscle. The muscle now spreads out fan-like, and sends a division to each of the four digits. Each division is inserted chiefly into the base of the proximal phalanx, and a lateral detachment passes to one or both sides of the metacarpal. The division which passes to digit II. encounters another distal carpal cartilage, which also projects up through it, some of the muscular fibres passing to the cartilage and some passing from it. This trumpet-like muscle does not, as in the hinder limb to so great an extent, curl beneath the level of the pronator portion of the stratum (the *pronator manûs*),

because that portion is in the fore limb smaller, not arising from the ulnar part of the carpus; and the trumpet-like part of the *flexor profundus digitorum* is more on the same level with it, and lies on its ulnar and distal sides. Still the portion to digits II. and III. does, as in the hind limb, curl beneath the superficial fibres of the *pronator manûs* which pass into the under surface of the *flexor sublimis* going to those digits.

The short muscles resemble those in the hind limb (p. 28).

*Carpo-metacarpales* pass from the distal row of the carpals, each to the sides and middle part of its metacarpal. The middle are shorter than the lateral fibres, to give space for the

*Metacarpo-phalangei* which pass from the middle of the palmar surface of the metacarpals to the bases of the proximal phalanges.

*Phalangeus* is present only in digit IV. passing from the proximal to the second phalanx.

#### DORSAL MUSCLES OF FOREARM AND FOOT.

On the dorsal aspect of the forearm and hand the muscles form a 'supinato-extensor' mass, corresponding, serially, with the 'supinato-extensor' mass in the leg and foot, and, antagonistically, with the 'pronato-flexor' mass in the leg and foot, and in the forearm and hand. Like those, they are partially divisible into a superficial and a deep stratum.

The SUPERFICIAL STRATUM arising from the dorsal surface of the radial condyle and the adjacent part of the humerus, preponderates over the deep stratum more than is the case on the palmar aspect. It is in three sectors, a 'radial,' an 'ulnar,' and an 'intermediate.'

The radial sector representing the *supinator longus* and *brevis* and the *extensores carpi radiales* is the largest. It arises from nearly the whole of the part of the humerus mentioned, and is inserted into the whole of the dorsal surface of the radius. A portion of its fore part extends over the wrist-joint and carpus, and is inserted into the ulnar side of the base of met. II. representing the extensor *carpi radialis longior*<sup>1</sup> (Fig. 17, *Ext.*

<sup>1</sup> In Menobranch it runs on to the radial carpal bone, but not to the metacarpus.

c. r.). The upper and deep part, which might be regarded as appertaining to the deep stratum, represents the *supinator brevis* and the part lying between these two, and inserted into the radius nearer the wrist, represents the *supinator radii longus* (Fig. 17).

The middle sector (*extensor digitorum sublimis*) arises from the humerus, superficially to the radial sector. Passing down the forearm and over the carpus, and receiving upon its under surface fibres from the *extensor digitorum brevis*, it divides to the four digits, passing to the terminal phalanges<sup>1</sup>.

The ulnar sector (*extensor carpi ulnaris*) arises on the ulnar side of the other sectors, is inserted into nearly the whole of the shaft of the ulna, and a portion runs on to the ulnar side of the carpus.

The greater proportion of the fibres therefore pass from the humerus to the ulna instead of, as in most higher animals, from the ulna to the carpus. A similar deviation from the disposition in higher animals also is presented to a still greater extent by the corresponding stratum in the hind limb, the fibres of which pass largely from the femur to the tibia and fibula, instead of as in Man all passing from the leg to the foot.

The DEEP STRATUM is absent from the upper region of the forearm, except the part of it blended with and forming the deeper portion of the radial sector just described as representing the *supinator brevis*.

The uppermost part of the deep stratum, with that exception, arises from the dorsal surface of the lower end of the ulna, and crossing over the back of the radius and the carpus and the *extensor carpi radialis*, is inserted into the radial side of the base of met. II. It represents the *extensor poll. primus*. It may be best called '*Supinator manus*' (Fig. 17, *Sup. m.*).

This is a better term than that of '*rotator carpi*' which I applied to the same muscle (*Journal of Anat.* iv. 48). It is one of the most constant muscles in the forearm, is the serial homologue of the muscle which I have called *supinator pedis* (p. 29), and, like it, is in the same plane with and in a higher level than the *extensor brevis* and often connected with it.

<sup>1</sup> In Menobranch and in Saurians it stops, like its homologue in the hind limb of those animals and of Aī, at the metacarpus, being inserted there in three portions; and small muscles arising from the metacarpus, close to its insertions, constitute the only extensors of the digits, and pass to the terminal phalanges.

The *extensor digitorum brevis* or *profundus* is a broad thin muscle arising from the proximal row of carpal bones, and joining the under surface of the *extensor digitorum sublimis* just above its division. It is connected with the preceding by a slip from the lower end of the ulna, which passes with it to the under surface of the ulnar part of the *extensor digitorum sublimis*.

*Interossei* are directed between the metacarpals descending rather lower on the ulnar than on the radial sides of the several bones.

The similarity in the disposition of the muscles in the middle and distal segments of the fore and hind limb is very closely in accordance with the similarity in the general structure and functions of the limbs. In each they constitute a 'pronato-flexor' mass upon the palmar or plantar aspect, and a 'supinato-extensor' mass upon the dorsal aspect; and the segmentation of these masses is much alike in each.

Especially in this so in the case of the SUPINATO-EXTENSOR mass, of which the division into two strata is equally distinct in each limb, and the *superficial stratum* arising from the condyle of the femur or humerus on the 'tibial' or 'radial' side, is in three parts, of which the middle passes to the digits, while the laterals are attached to the bones of the leg and forearm, and run on to the tarsus and carpus. The *deep stratum* in each limb is composed of a supinator of the foot or hand continuous with a short extensor of the digits.

In the PRONATO-FLEXOR MASS there is rather more difference in the two limbs, which is referable chiefly to the fact that segmentation is somewhat more advanced in the fore limb. In it the *superficial stratum* is more separate from the deep, though the two are still blended above and below; and the superficial stratum presents the three sectors—'radial,' 'ulnar' and 'intermediate'—which is not the case in the hind limb, where the muscular force is concentrated chiefly upon the flexion of the distal parts, and is less expended on the pronation of the tibia. This stratum moreover in the hind limb receives an accession from the tail and from the pelvis. With that exception the origin in the two limbs is alike—from the fibular condyle of the femur, and the fibula in the one, and from the ulnar condyle of the humerus, and the ulna in the other. The *deep strata* in the two correspond with an exactness which is scarcely modified by the difference in the number of the digits, each consisting, after the pattern of the dorsal antagonistic stratum, of a pronator of the foot or hand continuous with a deep flexor of the digits.

There is, however, this difference between the antagonistic deep strata, viz. that a distinct vertical band or strip is in both limbs segmented from the whole length of the pronator portion, and joined more or less completely to the short flexors constituting that which I have called the deep flexor of the digits; whereas, in the dorsal aspect, the short or deep extensor is connected only with the lower edge of the supinator.

## MUSCLES OF THE HEAD. (Figs. 5 and 20.)

I have already (p. 30) described the *subcutaneus colli*. Beneath it is the *depressor mandibulæ*, presently to be noticed. Next lies the *constrictor faucium*, which arises from the fascial tissue between the *depressor mandibulæ* and the *trapezius*. Narrow at first, it radiates out beneath the neck and the hinder part of the broad interval between the mandibular rami and meets its fellow of the opposite side at the middle line.

The *Mylo-hyoid* arises from the hinder extremity of the cornu of the hyoid and the ligament<sup>1</sup> which connects the hyoid cornu with the suspensory apparatus of the jaw, as well as from the suspensory (glenoid) cartilage where it projects behind between the mastoid and the pterygoid bones, but not from the angle of the jaw itself, being separated from it by the insertion of the digastric. It passes forwards and radiates on the deeper surface of the subcutaneous muscle, and in connection with it is inserted into the inner part of the ramus of the lower jaw.

*Genio-branchial*, a long muscle, passes from the hinder part of the posterior branchial cartilage to the hinder surface of the lower jaw, at a little distance from the middle line.

*Branchio-hyoid*, a thick muscle, arises from the hinder part of the posterior branchial cartilage, its origin being by tendinous fibres from the deeper surface of the cartilage and by numerous muscular fibres which almost entirely enclose the cartilage; it arises also from the hinder part of the anterior branchial cartilage, and runs forwards to be inserted into the approximated parts of the basis and cornu of the hyoid.

*Intermandibular* consists of fibres passing transversely across the middle line from one side of the lower jaw to the other beneath it.

*Temporal* is a large muscle arising by a broad tendon from the frontal and parietal bones, near the middle line of the skull, and by a thick portion running backwards in the groove

<sup>1</sup> In the back of that ligament there is a distinct though small piece of cartilage (stylo-hyal) between the extremity of the cornu (cerato-hyal) of the hyoid and the mastoid part of the suspensorial cartilage. Hyrtl found no cartilage in this ligament, though he mentions one as present in *Menopoma*.

internal to the suspensory apparatus (the squamous bone and the ridge in the parietal upon which it abuts) to the dorsal spines of the three foremost vertebræ, from which it arises by means of a strong tendon. It forms a thick mass, bounding the orbit behind, and filling up the wide pterygoid fossa on the side of the skull, but not deriving many fibres from the bones there. The fibres converge to be inserted into the upper surface of the lower jaw, and particularly the inner or 'surangular' part of it, a little in front of the articulation with skull. Some of the fibres arising from the pterygoid probably represent the *external pterygoid* muscle.

*Masseter*, a thick muscle, arises tendinous from along the upper surface of the bone ('squamous,' as it appears to me), forming the upper part of the suspensorium, and descends to be inserted into the outer surface of the lower jaw, for an inch in front of the joint.—A considerable mass of muscle arises from the anterior surface of the suspensorium and is inserted into the upper surface of the jaw between the temporal and the mastoid. It is partly separated from the masseter by areolar tissue, in which branches of the third division of the fifth pass outwards to the side of the head and to the lower jaw. Its fibres are, however, blended to some extent with those of the masseter and of the temporal; and I cannot tell whether it should be regarded as appertaining more particularly to either, or to both, or as constituting a distinct pterygoid muscle.

*Digastric*, a strong muscle, arises from the retiring angle between the suspensorium and the back of the skull behind, near the auricular opening, and from the edges of the squamous, the mastoid, the parietal and exoccipital as well as the cartilage which they there surround. At its origin it is between the origin of the masseter from the squamous bone and the insertion of the dorsal muscle of the trunk into the exoccipital (Fig. 20). It lies on the groove of the mastoid along the back of the suspensorium, and is inserted into the hinder part of the angle of the lower jaw, just above the depressor maxillæ; but a distinct and strong bundle of its fibres passes on tendinous behind the jaw along the hinder surface of the suspensory ligament of the hyoid to the cornu of the hyoid. It is here overlapped by the mylo-hyoid, or those fibres rather of it which

are attached to the suspensory ligament of the hyoid and the suspensory cartilage of the jaw.

The close connection of these parts—angle of jaw and its suspensory cartilage—with the cornu of the hyoid and its suspensory ligament, together with the insertion of the digastric into the angle of the jaw and the hyoid cornu, are interesting and important in relation to the remarkable course of the digastric to the hyoid and to the jaw, in ourselves.

*Depressor Mandibulæ* arises two inches behind the head from the fascial tissue, near the middle line, beneath the *subcutaneous colli*, between it and the *constrictor faucium*, forms a band about half an inch broad, the fibres of which converge to be inserted tendinous into the extremity of the jaw close to the preceding.

#### THE NERVES OF THE HEAD (Fig. 20).

The tough areolar tissue of the animal and the numerous accompanying veins rendered the dissection of the nerves difficult.

For an account of the nerves in the cranial cavity, I may refer to Figure 22 and the description of it.

THE OPTIC passes from the skull by a separate foramen, through the orbit, to the eye. Mr Anningson, in careful dissection of both orbits, could not discover the third, fourth, or sixth nerves in the orbit. The third and fourth were however found in the cranial cavity very small, and are represented in Fig. 22. Schmidt, Goddard, and van der Hoeven state that the sixth is a branch from the fifth in the orbit. This we did not find.

The three divisions of the FIFTH nerve are quite distinct.

The first, or OPHTHALMIC division, and the second, or SUPRAMAXILLARY, escape from the skull by a common hole, though separated by a fibrous band.

The OPHTHALMIC is a large nerve, crosses above the optic, gives a *supra-orbital* branch, which passes to the integuments above the eye, and which, on its way, supplies nerves (*ciliary*) to the eye. Soon after entering the orbit, the ophthalmic detaches a large branch which runs beneath the eye, and at the



margin of the orbit joins a long branch from the third division of the fifth. The resultant trunk passes through an infra-orbital hole, and is the *infra-orbital* nerve. Many small branches are given off by both nerves before they unite. The ophthalmic also, immediately after crossing the optic, gives a branch (*nasal*) to the nose.

The SUPRA-MAXILLARY, or second division of the fifth, runs along the floor of the orbit beneath the optic nerve and divides into branches, which pass inwards to the nose and forwards to the maxilla.

The INFRA-MAXILLARY, or third division of the fifth, emerges through a large hole at the front of the base of the suspensorial projection for the jaw, between the temporal and masseter muscles, and gives branches to both. Its *dentary* branch runs outwards beneath the masseter muscle, between it and the muscle arising from the front of the suspensorium which it supplies, then dips down to the lower jaw, and enters it by two branches through two foramina. A branch of the infra-maxillary runs forwards over the temporal muscle, on the outer side of the eye, gives off numerous branches upon the upper jaw, and joining a branch of the ophthalmic, as above described, forms the infra-orbital. A branch passes backwards beneath the masseter where it comes into contact with the seventh nerve, communicates with it, runs outwards with it, and turns forward along the outer side of the ramus of the lower jaw.

The SEVENTH nerve emerges from the skull in the retiring angle between the suspensorium and the occiput, and divides into two chief branches. One of these pierces the digastric muscle, supplies it, the depressor mandibulæ, the subcutaneous colli, and the constrictor faucium. The other chief branch passes beneath the digastric upon the suspensorium and along it, communicates with the branch of the fifth which has come beneath the masseter to this point, passes over the ramus of the lower jaw, and runs along beneath it supplying the mylohyoid and the subcutaneous colli, and reaching the intermandibular muscle. A branch also passes along the side of the lower jaw in company with the branch of the third division of the fifth.

The *Vagus* on its first appearance in the neck is large, and

immediately gives off branches to the *branchio-hyoid* muscle and probably to the other branchial muscles (though these were not made out), small branches to the *digastric* and *depressor mandibulae*, the *constrictor faucium*, and a large branch to the *trapezius*, also a long LATERAL nerve, which runs backwards along the lateral septum, in company with the lateral vessels, continuing its course to the tail without, apparently, giving off any branches. Having arrived at the tail, it gives off branches and communicates with the other nerves.

The branches above mentioned correspond with branches in ourselves from the 7th and 9th, and with the spinal accessory.

The office of the lateral nerve is probably to harmonize and produce simultaneous action of the several segments of the lateral muscle. It differs in the Cryptobranch from the same nerve in the Fish in that its distribution is limited to the lateral muscle of the tail, which indicates that the simultaneous powerful contraction of the parts of the lateral muscle in this animal are confined to or take place chiefly in the tail.

### THE SPINAL NERVES.

The several spinal nerves, emerging through the neural foramina behind the transverse vertebral processes, cross above (dorsally, with regard to) the deep lateral vessels which traverse the holes in the roots of the transverse processes, and lie above the lateral septum. They supply the several segments of the trunk-muscles, taking their course behind the respective fibrous septa or inscriptions, and in addition send nerve-trunks to the limbs. Each nerve, immediately after its emergence from the vertebral foramen, above the lateral septum, divides into a POSTERIOR or DORSAL, and an ANTERIOR or VENTRAL SPINAL nerve (Fig. 21). The former divides into branches, which are directed upwards and outwards, in front and behind the articulating processes, to the dorsal muscles and the skin. The cutaneous branch (Fig. 21, *C*.) runs in front of the articulating processes outwards with a slight inclination upwards, behind the rib and the transverse septum passing dorsally from it, to the skin. The muscular branches radiate into the surrounding dorsal muscle. The ANTERIOR SPINAL or VENTRAL nerves (*v*) pass through the lateral septum

so as to come into contact with the *subvertebral rectus* and its prolongations, and take their course behind the several ribs and the transverse intermuscular septa, and supply the ventral muscles, the skin and the limbs.

The first cervical nerve (SUBOCCIPITAL) passes through a foramen in the atlas direct to the foremost portion of the *subvertebral rectus* and the adjacent dorsal muscle. The second cervical nerve passes to the next portion of the *subvertebral rectus*, and a branch traversing that muscle reaches the 3rd nerve and so enters into the formation of the brachial plexus.

The BRACHIAL PLEXUS (Fig. 4) is formed by branches from the 3rd, 4th, 5th and 6th spinal nerves, with that just mentioned from the 2nd.

The third cervical nerve, joined by the branch from the second, divides into four. No. 1 joins the fourth spinal nerve. No. 2 passes in front of the precoracoid and is lost apparently in the areolar tissue and skin of that region. No. 3 traverses the coracoid hole and supplies the *coraco-brachialis superficialis*, the *biceps*, and perhaps the *coraco-brachialis brevis*. No. 4 supplies the *omo-hyoid*.

Its branches correspond with some of those which in man pass from the upper part of the cervical plexus, and form the EXTERNAL CUTANEOUS or MUSCULO-CUTANEOUS mass; and they correspond serially with the OBTURATOR nerve in the hind limb. The branch to the *omo-hyoid* is to be associated with the absence of a hypoglossal nerve: at least we could not discover that nerve in the dissection of the neck or in the interior of the skull.

The fourth spinal nerve crosses behind the origin of the external oblique from the second rib, is connected with the third and fifth nerves by commissural trunks, and gives off scapular branches, which pass beneath the scapula (SUBSCAPULAR) also to the *latissimus dorsi*, *dorsalis scapulae* and *precoraco-brachial* muscles, and a cutaneous branch (CIRCUMFLEX) to the outer side of the arm.

The nerves to the last two muscles might be designated SUPRA-SCAPULAR because they supply the muscles (*dorsalis scapulae* and *precoraco-brachial*) which must, in part any rate, answer to the muscles (*infra- and supra-spinatus*), which are, in ourselves, supplied by the supra-scapular nerve. It is interesting to observe the nerves in this animal taking a course, behind the scapula to supply the

muscles on the dorsum of the scapula, corresponding with the course, behind the ilium, which is usually taken by the *GLUTEAL* nerves in their passage to the muscles on the dorsum of the ilium.

The same nerve supplies the *triceps*, and perforating the long and the outer heads of that muscle descends, as the *MUSCULO-SPINAL* or *RADIAL*, between them and the humerus, then between the triceps and the brachialis anticus, and then between the latter and the extensor muscles arising from the outer condyle. It supplies those muscles, and divides into two branches (Fig. 17), of which one perforates the extensor mass of muscles, becomes superficial, and runs along the radial edge of the forearm and the radial side of digit II. (digit I. is missing): the other branch crosses deeply, between the extensor mass and the radius, to the back of the forearm, where it communicates with a posterior interosseous branch from the median and with the posterior ulnar branch of the median (the branch that is of the median which has descended through the triceps). It then descends the back of the forearm, under the extensor muscles, perforates the *supinator manus*, and divides, supplying the apposed sides of digits II. and III., also the apposed sides of digits III. and IV. (Fig. 17).

The course and disposition of this nerve corresponds closely with those usually presented by the radial in higher animals, even to the share it takes in supplying the digits. It is derived from the middle of the brachial plexus in connection with the circumflex and subscapular, and is distributed exclusively to the muscles upon the dorsal aspect of the limb.

The fifth spinal nerve is connected by a commissural branch with the fourth, and receives the greater part of the sixth, that nerve merely sending off, besides, a cutaneous branch. It passes between the origins of the external oblique, from the 3rd and 4th ribs, and supplies branches to the *pectoralis* and *coracobrachialis longus* and probably *brachialis anticus*, though the branch was not traced to that muscle. High in the arm it sends a long nerve (*POSTERIOR ULNAR*, or, better, *INFERIOR MUSCULO-SPINAL*) which, turning outwards to the back of the arm, perforates the short or ulnar origin of the *triceps* and descends through the triceps to the radial side of the olecranon. This nerve (Fig. 17) then pierces the *extensor carpi ulnaris*, and

having reached its deeper surface and communicated with the radial and with the posterior interosseous from the median, runs along the dorsal surface of the ulna, then over the carpus, supplies the small muscles in that situation upon the carpus and metacarpus, and is distributed to the ulnar side of digit v. and the apposed sides of digits iv. and v.

The main trunk of the fifth spinal nerve continues its course as the MEDIAN on the inner side of the arm. It passes over the upper surface of the humeral portion of the *coraco-brachialis longus*, between it and the *coraco-brachialis brevis*, keeps beneath the bicipital portion of the former muscle, and passes over the elbow between the tendon of the biceps, which is inserted into the radius and the portion of the *coraco-brachialis longus* which is inserted into the ulna. At the elbow it divides into two trunks, an ANTERIOR ULNAR and a MEDIAN, both of which disappear beneath the mass of flexor muscles arising from the inner condyle.

The ULNAR trunk (Figs. 18 and 19) takes its course through the flexor mass on the forearm, between the superficial stratum arising from the condyle and the ulna and the deeper stratum arising from the ulna and supplies both strata. One of its nerves passes to the *flexor dig. subl.* through the *pronator teres*, or proximal part of the condyloid stratum, just as the median in man passes between the condyloid and the ulnar origin of that muscle. Its terminal branch travels down between the *flexor subl. dig.* and the *flexor prof.* and, partly, also under cover of the *flexor carpi ulnaris*, supplying them in its course to the wrist. It runs over the carpus, supplies the ulnar side of dig. v., dips down between the muscles to dig. v. and, like the external plantar nerve in the hind limb, curls in beneath the *flexor profundus dig.*, and passes across towards the radial side of the limb, between that muscle and the *metacarpophalangei*, supplying the latter. At the interval, between digits v. and iv., it sends down a branch which supplies the apposed sides of those digits, and at the intervals between iv. and iii. and between iii. and ii., it communicates with the branches of the median which are passing to supply the apposed sides of iv. and iii. and iii. and ii.

The MEDIAN (Fig. 19) trunk takes a still deeper course be-

YASALI ZHA!

neath the *pronator quadratus*, supplying it, then over the front of the carpus beneath the *flexor profundus*, where it divides into three nerves, one supplying the muscles of the base of digit II. and perhaps passing on to the radial side of that digit; the second supplying the apposed side of digits II. and III., and the third supplying the apposed sides of digits III. and IV. The second and third nerves last mentioned each receives a twig from the terminal branch of the ulnar which runs across the metacarpal bones and muscles.

The ULNAR nerve always arises from the plexus in company with the MEDIAN, and not uncommonly forms one trunk with it, not separating from it till the forearm. In the Cryptobranch the dorsal or posterior part of it shows a tendency to associate itself in its course with the radial or dorsal nerve-trunk of the limb forming the inferior musculo-spiral, which corresponds in mammals to the posterior branch of the ulnar in the fore limb, and to the external saphenous in the hind limb. The palmar or anterior part of the ulnar carries with it the muscular branches usually given off directly from the MEDIAN; and the trunk of the MEDIAN is continued on in a deep plane as the ANTERIOR INTEROSSEOUS to the carpus and digits.

#### NERVES TO THE HIND LIMB.

The nerves to the hind limb are derived from four spinal nerves (*a, b, c, d*). Of these the foremost (*a*) sends a branch to



(*b*) and runs downwards as the OBTURATOR nerve, pierces the *pectineus* where it is taking origin from the interior of the pelvis, traverses the small obturator hole in the pelvic shield, and supplies the adductor muscles arising from that shield. Whether it extends to the superficial stratum (*gracilis*, &c.) there situated, could not be ascertained with certainty. A branch from it however passes backwards to join the branch of the sciatic, which enters the hinder (*flexor cruris*) part of that stratum.

This connection with the sciatic is interesting in relation to the fact that the correspondent of the OBTURATOR nerve in the fore limb—the perforator of the coracoid or MUSCULO-CUTANEOUS—supplies in part or wholly the flexors of the forearm.

The second nerve (*b*) sends a branch to unite with the third and fourth (*c* and *d*) in forming the sciatic and then descends, over the brim of the pelvis upon the *iliacus* muscle, as the ANTERIOR CRURAL nerve. It supplies the *internal rectus*, the *iliacus* and the *pectineus*. A long branch from it (INTERNAL SAPHEOUS) takes a deep course between the *pectineus* and the femur to the tibial side of the limb, where it emerges between the *gracilis* and *internal rectus* and descends on the tibial side of the knee and leg.

The deeper course down the thigh than in ourselves of the SAPHEOUS nerve is consequent on the extension of the *pectineus* downwards nearly to the knee (p. 20), so that the nerve has to pass under it to reach its wonted place of emergence.

The third and fourth nerves (*c* and *d*) pass from the spinal column, the one in front and the other behind the level of the ilium, unite and are joined by a branch from the second nerve (*b*) to form the SCIATIC, which emerging between the *ischio-femoral* and the *gluteus* or *pyriformis*, gives off several branches to the surrounding muscles, dorsal and plantar—to the *pyriformis*, *glutei*, *gluteo-rectus* and *biceps*, to the *caudo-femoral*, *caudo-crural* and *caudo-pedal*, and to the hinder part of the *flexor cruris* (*semitendinosus* and *semimembranosus*).

It gives off also the MUSCULO-SPIRAL or PERONEAL nerve (Fig. 10), which descends in the thigh under cover of the *biceps*, supplying it and passing above or in front of it at the knee, then runs beneath the *peroneus*, between it and the fibula, to join a large branch from the ANTERIOR TIBIAL and supply the *peronei* and the *extensor digitorum longus*. It descends on the front of the leg beneath the *ext. digitorum* superficial to the *extensor hallucis* and on the fibular side of the *extensor brevis*, and sends nerves to the fibular side of digit v. to the apposed sides of digits IV. and v., and ends in a nerve which joins the branch of the anterior tibial in the interval between digits III. and IV.

The PERONEAL or MUSCULO-SPIRAL nerve answers to the RADIAL or MUSCULO-SPIRAL of the fore limb, and not at all to the ULNAR, though its name might seem to imply the contrary. The differences between the musculo-spirals in the two limbs, that is between the peroneal and the radial, are dependent chiefly or entirely upon the difference in the direction of the rotation in the two limbs causing a variation in the direction best adapted for the nerve-course. This is probably the reason that the PERONEAL does not traverse the whole thickness of the *quadriceps*, but only that part segmented from it which becomes the *biceps*. Indeed where the rotation of the limb is complete, as in Man, the nerve does not traverse even the *biceps*, as it does in these lower animals, but only gets under cover of it or keeps along its hinder edge. For the same reason the nerves to the *quadriceps* pass in front of the pelvis as ANTERIOR CRURAL, while those to the *triceps* pass behind the shoulder-girdle bound up in the RADIAL.

The SCIATIC nerve (Fig. 10) then divides into two, which in the left limb pass on the two sides of the *femoro-fibular*, and are joined by a connecting trunk beyond it, so as to encircle the muscle. (In the right thigh the sciatic trunk passes on the tibial side of the femoro-fibular and divides subsequently.) The outer division (EXTERNAL POPLITEAL) supplies the *femoro-fibular*, sends a (SURAL) branch to the stratum of the flexor mass arising from the fibular condyle, passes between the condyloid and fibular part of the superficial stratum, descends between the two strata along the fibular edge of the *flexor profundus digitorum* (Fig. 11) between it and the origin of the *flexor sublimis* from the fibula. It passes beneath the tarsus, curls over (deeper than) the *flexor profundus*, and then runs across the metatarsus as far as digit II. between the *flexor-profundus* and the *metatarso-phalangei*. In its course it supplies the fibular portion of the *flexor sublimis*, the whole of the deep flexor stratum (*tibialis posticus*, *flexor profundus*, *flexor-hallucis* and *accessorius*), the small muscles in the sole, the fibular side of digit V., the apposed sides of IV. and V. Between digits III. and IV. and between II. and III. it joins branches from the POSTERIOR TIBIAL, and the combined nerves supply the apposed surfaces of these digits.

The inner division (INTERNAL POPLITEAL, Fig. 10) in the left limb pierces the *caudo-femoral* close to its attachment to the femur (in the right limb it passes on the fibular side of this tendon going between it and the *femoro-fibular*). It gives off



a long branch which descends, gives filaments to the lower part of the flexor cruris (*semitendinosus* and *semimembranosus*), perforates it, and runs down on the tibial side of the leg and foot, accompanying the internal saphenous towards, and probably upon, the tibial side of the hallux. The latter part of its course corresponds with that of the superficial branch of the radial nerve upon the radial edge of the forearm. The next branches from the internal popliteal, in conjunction with branches from the external popliteal, supply both strata of the flexor mass. The nerve (Figs. 10 and 11) passes deeply beneath (in front of) the flexor mass and the *pronator tibiæ* or *popliteus* which it supplies, gives off the ANTERIOR TIBIAL, descends as POSTERIOR TIBIAL behind the tarsus and metatarsus, and divides into two branches, which, joined by branches from the external popliteal, supply the intervals between digits I. and II. and II. and III.; also, probably, the deep muscles on the tibial side of the sole.

The ANTERIOR TIBIAL nerve supplies the *tibialis anticus*, descends over the ankle and tarsus, and divides into two nerves; one passes superficially to the *extensor hallucis* over the tarsus towards, and we believed to, the interval between and the apposed sides of digits I. and II.; the other passed beneath the *extensor hallucis*, supplying it, and divides into nerves to the apposed sides of digits II. and III. and of III. and IV., these nerves being joined by the terminal branches from the peroneal.

The similarity in the course and disposition of the EXTERNAL and INTERNAL POPLITEAL nerves and their plantar branches with the course and disposition of the ULNAR and MEDIAN nerve and their palmar branches is what might have been anticipated from the similarity of the muscles in the corresponding parts of the leg and forearm. Dorsally the supply of the tibial digits, wholly or partly, by the anterior tibial derivation from the POSTERIOR TIBIAL nerve in this and other animals, would scarcely have been expected from anything in the construction of the hind limb. The anterior tibial nerve is in the fore limb represented in Cryptobranch by the branch of the MEDIAN passing dorsally to join the radial and inferior musculo-spiral. The fibular digits are supplied by the MUSCULO-SPIRAL (peroneal) of the sciatic and the ulnar digits by the inferior MUSCULO-SPIRAL branch of the median: the only difference being that the nerves to the outer digits in the fore limb keep company with the main nerves of the limb (median or median and ulnar) longer than their correspondents in the hind limb keep company with the sciatic. Or,

it might be said, the MUSCULO-SPIRAL in the hind limb detaching itself from the main trunks carries with it the dorsal nerves of the fibular digits. In ourselves the dorsal nerve of the ulnar digits—the 'INFERIOR MUSCULO-SPIRAL' as it may be called—keeps company with the ULNAR NERVE to the middle of the forearm, and the dorsal nerves of the fibular digits (the external saphenous) is derived partly from the MUSCULO-SPIRAL or PERONEAL, and partly from the POPLITEAL.

The chief differences from the corresponding nerves in Man, in addition to those just mentioned, are (1) the deeper position of the digital branches in the palm and sole beneath, instead of superficial to, the flexor tendons. In the fore limb the branches to the ulnar digits are derived from the deep palmar branch of the ULNAR instead of from a superficial branch; and those of the radial digits come from the INTEROSSEOUS which (in Cryptobranch) forms the main trunk of the MEDIAN, instead of coming off near the elbow by a branch which separates from the interosseous upon the FLEXOR PROFUNDUS, and the size of which causes it to be regarded as the main trunk. (2) In the hind limb the EXTERNAL POPLITEAL is, in Cryptobranch, like the ULNAR, continued to the digits; whereas in Man the course of the nerves to the fibular digits is not along the fibula, with the nerve which accompanies the peroneal artery, and which is the representative of the ULNAR nerve, but with the POSTERIOR TIBIAL, which is the representative of the MEDIAN, till they reach the foot, where they separate, and form the EXTERNAL PLANTAR nerve.

An interesting feature in the nerves of this animal and its allies as compared with those of higher animals is the simple structure of the BRACHIAL and CRURAL PLEXUSES, which may be associated with the imperfect segmentation and specialization of the action of the limb-muscles. The office of these plexuses, we may conclude, is to ensure that harmony and those nice balancing modifications in the degree of action of the muscles—the opponents as well the co-operatives—upon which the adjustment and proper direction of the movements of the limbs depend. This, it may be inferred, is effected by such an arrangement of bundles in the plexuses that a certain number of the filaments of any nerve presiding over one muscle, or set of muscles, are distributed among the nerves destined to each of the other muscles or sets of muscles; so that an impression transmitted to one muscle or set of muscles is in duly ordered degree communicated to each of the other muscles. Where, consequently, the muscles are numerous, the interchanging branches between the nerves requisite for this purpose will be numerous and form a complicated plexus; and where the muscles are few the plexus will be proportionately simple. The same object may be attained by intercommunicating filaments between the nerves in the distal parts of the limb, or by two or more passing to the same muscle. Thus the ninth and the cervical nerves intercommunicate before supplying the *omo-hyoid* in ourselves, while the *sterno-mastoid* and *trapezius* are each supplied by

branches of the spinal accessory and of the cervical nerves passing separately into them; and the communicating branches above described between the obturator and sciatic, and between the median, radial, and posterior ulnar at the back of the forearm, indicate that the offices performed by the proximal plexuses in ourselves are, to a greater relative extent, performed by distal plexuses or communications in the Cryptobranch.

The course which the nerve-current follows, like that of the blood-current, is, in each case, probably regulated or greatly modified by convenience; and a nerve in its way to a particular muscle takes usually the most direct course, and may attach itself to one set of nerves or another, according as either lies more across its path. I have already alluded to the difference in rotation of the fore and hind limbs as a cause of difference of distribution of the nerves in the two. The rotation in each limb attains its maximum in ourselves, and causes the divergence of the nerves in the two limbs to be greater than in the Cryptobranch. For examples; the extensors of the leg and of the forearm are both in that animal chiefly supplied by nerves passing behind the respective girdles; in Man the nerves to the extensors of the forearm pass behind the scapula, whereas those to the extensors of the leg pass in front of the pelvis.—In Cryptobranch, the nerves to the muscles on the dorsum of the scapula and to the pectoral pass behind the shoulder, and those to the muscles on the dorsum to the ilium and to the gracilis pass behind the hip; in Man the scapula being thrown as well turned more backwards, the nerves (pectoral and suprascapular) to the corresponding muscles in the fore limb pass in front of the shoulder, while those in the hind limb (obturator and gluteal) pass behind the hip.—In Cryptobranch the nerves on the palmar and plantar aspects of the two limbs below the elbow and knee present scarcely any difference. In Man the nerves to all the digits of the hind limb proceed together in the posterior tibial nerve as far as the ankle; the companion of the peroneal artery, which is the representative of the ulnar nerve, is a mere muscular branch; whereas, in the fore limb, the nerves to the ulnar digits take their course down the forearm in the ulnar nerve quite separate from the nerves to the other digits, which are bound together in what we call the median nerve. These points indicate, as do the variations observed in this and other animals and in man, that nerve-course is somewhat too arbitrary or too much regulated by convenience in each instance for us to be able to rely upon the disposition of nerves as at all sure guides to the discernment, in difficult cases, of the homological relations of muscles and other structures.

## DESCRIPTION OF FIGURES.

They are all representations of dissections of the Cryptobranch unless it is otherwise specified.

Fig. 1. Transverse section through tail. *F.*, fascial investment covering the part, ensheathing the ventral and dorsal lateral muscles and sending down laminae to the vertebral processes. *D.f.*, dorsal fat-mass in triangular space between fascial laminae on either side descending to dorsal spines and superficial lamina passing across. *V.f.*, and *L.f.*, ventral and lateral fat-masses similarly situated. *S.l.f.*, supra-lateral fat-mass with posterior spinal nerve curling from beneath it. The infra-lateral fat-mass is similarly situated.

Fig. 2. Muscles of the left side of the tail, hinder part of abdomen, and dorsal aspect of left thigh. *D.*, dorsal muscle of tail. *V.*, ventral muscle of tail. The lateral septum is seen between these two. *I.c.*, The iliac part of ventral muscle (Ilio-caudal) passing over the ilium (*I.*) and continued into the internal oblique (*I.O.*). *E.O.*, external oblique which has been partly divided and reflected upwards and downwards to expose the internal oblique and transversalis. *E.O'*, the part of external oblique attached to the spine of the pubes and extending upon the hip between (*Gr.*) gracilis and (*Pect.*) pectineus. *Tr.*, transversalis exposed by reflection of external oblique and removal of part of internal oblique. *Py.*, pyramidalis. *Il.*, iliacus. *Gl.r.*, gluteo-rectus. *B.* biceps. *R.i.*, rectus internus. *T.a.*, tibialis anticus. *Ext.d.*, extensor digitorum. *P.*, peroneus.

Fig. 3. Right side of hinder part of abdomen, of tail and right hind limb shewing the caudal muscles and the extension of the external oblique into the fascial tissue on the dorsum of the thigh. *D.*, dorsal muscle of tail. *I.c.*, ilio-caudal. *C.f.*, caudo-femoral. *C.cr.*, caudo-crural. *Isch.c.*, ischio-caudal. *E.O.*, external oblique reflected from around the ilium to show its connection with the ilium (p. 13). *E.O<sup>A</sup>.*, external oblique of the left side inserted into the edge and horn of the prepubic cartilage.

Fig. 4. Interior view of the muscles on the left side of the under surface of the back of the abdomen with the nerves of the brachial plexus. *V., V.*, right sides of the bodies of the vertebræ uncovered. *I.v.* inter-vertebral substances. *S.v.R.*, sub-vertebral rectus. *D.C.*, depressores costarum. *Tr.*, transversalis. *I.O.*, internal oblique seen in shadow through the hole cut in the transversalis. *N.*, Nerve lying between transversalis and internal oblique. In the upper part of the drawing are two separate portions of the internal oblique which arise from the fourth and fifth ribs. *C.*, coracoid. *P.C.*, pre-coracoid. *S.*, serratus. *Tr.*, trapezius. *L.S.*, levator scapulae. *C.f.*, constrictor faucium. *V.*, Vagus nerve.

*O. h. N.*, omo-hyoid nerve coming from the third cervical nerve. 6, the sixth cervical nerve, the hindmost contributor to brachial plexus, indicated by a dotted line where it is covered by the transversalis. It is seen in front of the transversalis joining the fifth cervical nerve.

Fig. 5. Under surface of fore-part of trunk, neck and shoulders. *E. O.*, external oblique passing into (*P.*) pectoral. The right pectoral and external oblique have been reflected with the coracoids showing *I. O.*, internal oblique attached to upper plate of (*S.*) sternum (p. 15); the lower plate is exposed beneath it. *Sc.*, scapula. *C.*, coracoid, *P. c.*, pre-coracoid. *C. b. br.*, coraco-brachialis brevis. *C. o.*, coracolecranalis. *O. h.*, omo-hyoid. *P. c. b.*, precoraco-brachial. *Ep. c. b.*, epicoraco-brachial. *D. s.*, dorsalis scapulæ. *B. H.*, Basi-hyoid with cartilaginous nucleus, behind its middle, in the branchio-hyoid ligament. *C. H.*, cornua of the hyoid. *E. C.*, entoglossal cartilage. *B<sup>1</sup>, B<sup>1</sup>*, first branchial arches with the copula (*C.*) between them. *B<sup>2</sup>*, second branchial arch. *S. c. C.*, subcutaneous colli divided and reflected to either side and seen passing under and attached to the ramus of the jaw. *M. H.*, the mylo-hyoid. *D. M.*, depressor mandibulæ. *D.* digastric. *S. H.*, foremost part of internal oblique or sterno-hyoid passing to (*C.*) copula and entoglossal cart. *G. b.*, genio-brachial. *B. H.*, branchio-hyoid. *I. M.* inter-mandibular.

Fig. 6. Deep view of under-surface of neck with right fore-limb. *S. v. R.*, subvertebral rectus passing to base of skull. *L. sc.*, levator scapulæ. *Tr.*, trapezius inserted between pre-coracoid and scapula. *D. sc.*, dorsalis scapulæ. *S. C.*, subcutaneous colli. *Cr. f.*, constrictor faucium. *D. M.*, depressor mandibulæ. *D.*, digastric. *C.*, coracoid. *P. C.*, pre-coracoid.

Fig. 7. Diagrammatic representation of abdominal muscles more particularly of the external (*E. O.*) and internal (*I. O.*) oblique and the rectus. *E. O. R.*, the external layer of rectus formed by the fibres of the external oblique. *I. O. R.*, the deeper layer of rectus formed by the fibres of the internal oblique. *Tr.*, transversalis.

Fig. 8. Muscles of tail and left hind-limb: the latter has been turned up so as to shew the plantar surface. *D.*, Dorsal, and *V.*, ventral muscles of tail separated by the lateral septum. *I. c.*, ilio-caudal. *Isch. c.*, Ischio-caudal. *C. f.*, caudo-femoral. *C. cr.*, caudo-crural. *C. p.*, caudo-pedal. *I. f.*, ilio-femoral, or biceps. *F. f.*, femoro-fibular, or short portion of biceps. *P.*, pubes. *Gr.*, gracilis. *St.*, semitendinosus. *T. a.*, tibialis anticus. *Fl. d. s.*, flexor digitorum sublimis.

Fig. 9. Plantar aspect of left hind leg and foot. *C. p.*, caudo-pedal. *Fl. t.*, flexor tibiæ (semitendinosus, &c.). *Fl. p.*, flexor mass of foot. *Fl. d. s.*, flexor digitorum sublimis divided and reflected upwards and downwards. *Pr. p.*, pronator pedis, or part of flexor mass inclined to tibial side of foot with its superficial fibres running into under-surface of flexor dig. subl. *Fl. d. p.*, flexor digitorum profundus. *N.*, nerve to sole lying on *Fl. dig.* *Abd.*, abductor minimi digiti.

Fig. 10. Muscles and nerves on plantar aspect of left hind limb. *I.*, internal surface of ilium with fibres of internal oblique passing to and from it. *C. f.*, caudo-femoral. *C. cr.*, caudo-crural. *C. p.*, caudo-pedal joined by portion from ischium. *Fl. c.*, flexor cruris. *Gl. r.*, gluteo-rectus. *B.* biceps. *F. f.*, femoro-fibular. *S.*, sciatic nerve passing beneath ilium and sending nerves to above muscles. *P.*, peroneal nerve. *E. P.*, external popliteal. *I. P.*, internal popliteal. *Pr. p.*, pronator pedis. *Fl. d. p.*, flexor digitorum profundus. *Fl. d. s.*, flexor digitorum sublimis, of which the lower part has been removed.

Fig. 11. Muscles and nerves on plantar aspect of leg and foot. *Fl. c.*, flexor cruris. *a. a. a.*, flexor sublimis, divided and reflected upwards and downwards (p. 26). *Fl. p.*, flexor profundus. *Pr. p.*, pronator pedis. *E. P. N.*, external popliteal nerve. *I. P. N.*, internal popliteal nerve.

Fig. 12. Deep muscles of sole. *Fl. d. s.*, flexor digitorum sublimis turned up, and the lower part removed, shewing the cut edge of fibres which passed into *Fl. d. s.* *Fl. d. p.*, flexor digitorum profundus divided, the lower part removed. *Pr. p.*, pronator pedis rising at the lower part to join *Fl. d. s.* *T. m.*, tarso-metatarsals. *M. p.*, metatarso-phalangei. *Ph.* phalangei. *I.*, interosseus. *Abd.*, abductor minimi digiti.

Fig. 13. Back of leg and sole of Menobranch dissected to shew the flexor digitorum profundus nearly divided in two, the tarsal cartilage intervening between its crural and its pedal parts. *Fl. d. s.*, flexor digitorum sublimis. *Pr. p.*, pronator pedis.

Fig. 14. Deep dissection of plantar aspect of right hind leg shewing *Pr. t.*, pronator tibiæ. *Fl. c.*, flexor cruris reflected. *C. p.*, caudo-pedal. *Fl. d. s.*, flexor sublimis reflected upwards. *Pr. p.*, pronator pedis reflected; below it is blended with flexor subl. *Fl. d. pr.*, flexor profundus. *T.*, lower end of tibia. The fibular and posterior tibial nerves are shewn, the latter passing in front of pronator tibiæ.

Fig. 15. Muscles on dorsal aspect of left leg and foot. *C.*, condyles of femur. *I. R.*, internal rectus. *T. a.*, tibialis anticus passing to tarsus; *T. a'.* tibialis anticus inserted into tibia. *Gl. r.*, tendon of gluteo-rectus passing to lower end of tibia between extensor digitorum and tibialis anticus; *E. d.*, upper part of extensor digitorum turned to one side. *E. d'.*, portion of extensor digitorum joining peroneus (*P.*) *E. d''.*, extensor digitorum reflected downwards. *S. p.*, supinator pedis. *E. d. br.*, extensor digitorum brevis. *E. d. br'.*, slip from extensor brevis to supinator pedis. *Abd.*, abductor minimi digiti.

Fig. 16. View and letters similar to preceding. *I.*, interossei.

Fig. 17. Muscles of left forelimb, with the radial and inferior musculo-spiral nerves seen in the back of the forearm. *C.*, coracoid. *P. C.*, pre-coracoid. *S.*, scapula. *E. p. c.*, epicoracoid muscle. *P. c. b.*,

pre-coraco-brachialis. *B.* biceps, detached from the scapula and turned back to shew (*C. b. br.*) the coraco-brachialis brevis. *C. b. l.*, coraco-brachialis longus. *Pect.*, pectoral. *Tr.*, trapezius. *L. s.*, levator scapulae. *D. s.*, dorsalis scapulae. *Br. a.*, brachialis anticus. *Ext. c. r.*, extensor carpi radialis. *Ext. d. s.*, upper and lower parts of *Ext. d. sublimis*, of which the greater portion has been removed. *Ext. c. u.*, extensor carpi ulnaris. *Sup. l.*, supinator longus. *Sup. br.*, supinator brevis. *Sup. m.*, supinator manûs. *Ext. d. br.*, extensor digitorum brevis.

Fig. 18. Muscles of right forelimb. *C.*, coracoid with (*Ep. c. b.*) epicoraco-brachialis. *B.*, biceps. *H.*, humerus. *C. b. l.*, coraco-brachialis longus, with divisions to biceps, to ulna, and to condyle of humerus. *Pect.*, pectoral, divided and thrown outwards. *Br. a.*, brachialis anticus. *Fl. c. r.*, flexor carpi radialis. *Pr. t.*, pronator teres perforated by the nerve to (*Fl. d. s.*) flexor digitorum sublimis, which has been divided and reflected upwards and downwards. *Fl. c. u.*, flexor carpi ulnaris. *Fl. d. p.*, flexor digitorum profundus. *Pr. q.*, pronator quadratus. *Pr. m.*, pronator manûs. *R.* radius.

Fig. 19. Muscles and nerves on palmar aspect of right forearm and hand. *Fl. d. s.*, flexor sublimis digitorum divided and reflected upwards to the humerus and towards the ulna and downwards at its attachment to the digits. *Fl. d. p.*, flexor digitorum profundus radiating to the digits with the carpal cartilages appearing through it. *Pr. m.*, pronator manûs divided and reflected. *Pr. t.*, pronator teres. *Fl. c. r.*, flexor carpi radialis. *Pr. q.*, pronator quadratus. *P.* phalangeus. *U.*, ulnar nerve and branches. *M.*, median nerve.

Fig. 20. Muscles and nerves on the upper part of the head. *T.*, temporal muscle of right side; on the left side the upper part of the muscle has been removed leaving only the part near the insertion. *M.*, masseter. On the left side the upper part has been removed (exposing the suspensorium with the dentary nerve in front and the seventh nerve behind); and the lower part has been turned back to shew its insertion into the lower jaw and the dentary nerves passing into the jaw. On the right side a branch of the third division of the fifth is seen emerging from beneath the masseter and joining the seventh. *7a.* Conjoined branch of 7th and 5th—the submental nerve. In the left orbit are seen the ophthalmic nerve near the inner part of the orbit giving off the ciliary nerve and the supramaxillary, with the optic crossing from the inner side of the orbit over the latter. *H.*, hinder end of the hyoid cornu with (*St.*) styloid cartilage between it and the jaw. *D.*, dorsal muscle extending to head.

Fig. 21 represents a piece of the side from which the lateral muscle (*L.*) has been partly removed to shew one of the spinal nerves emerging from the vertebral foramen just behind the rib (*R.*) and dividing into anterior or intercostal or ventral (*V.*) and posterior branches. *C.* cutaneous nerve from the latter. The posterior branches pass in front and behind the articulating processes to the

Fig. 4.

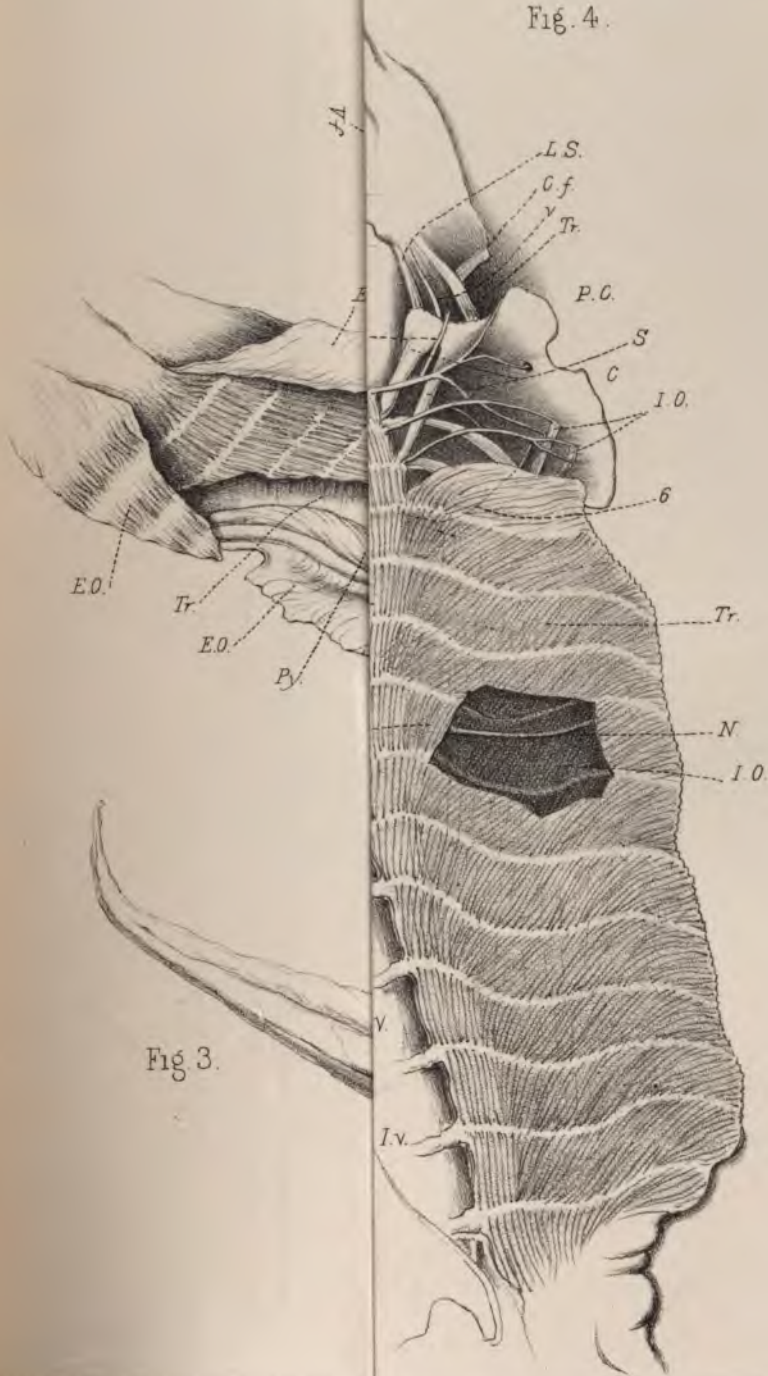


Fig 3.





Fig. 5.

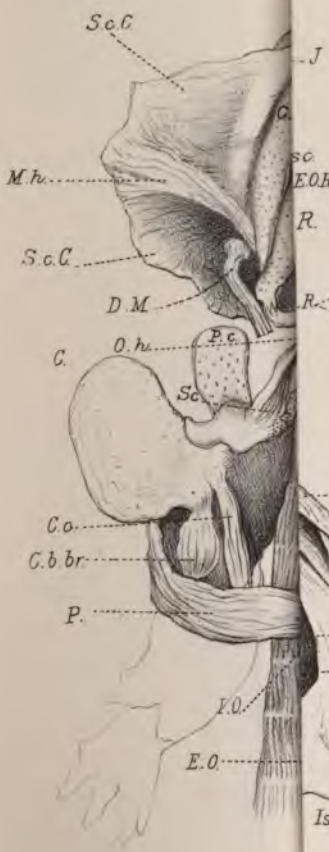

Fig. 7.

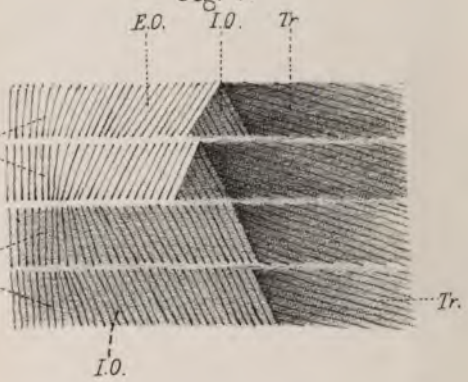
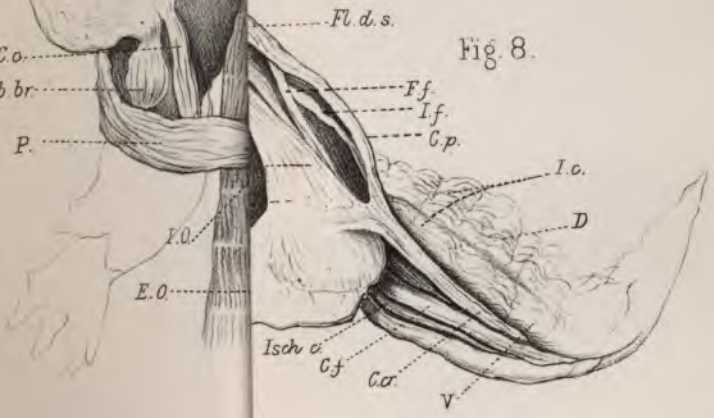


Fig. 8.



III

IV

Fig 10.

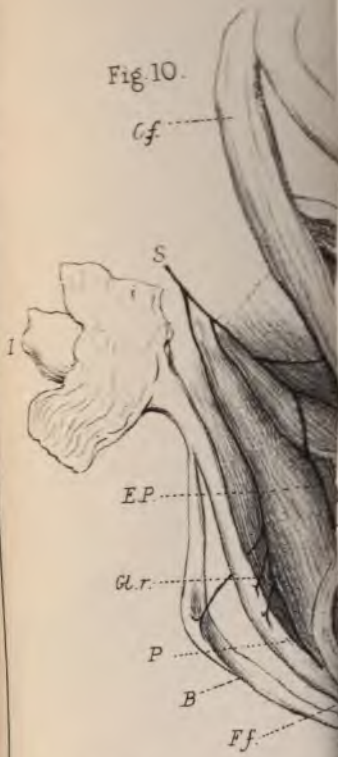

Fig 13.  
Menobranch

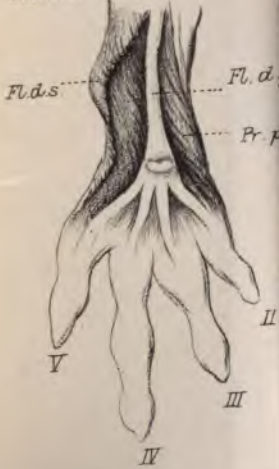

Fig 12

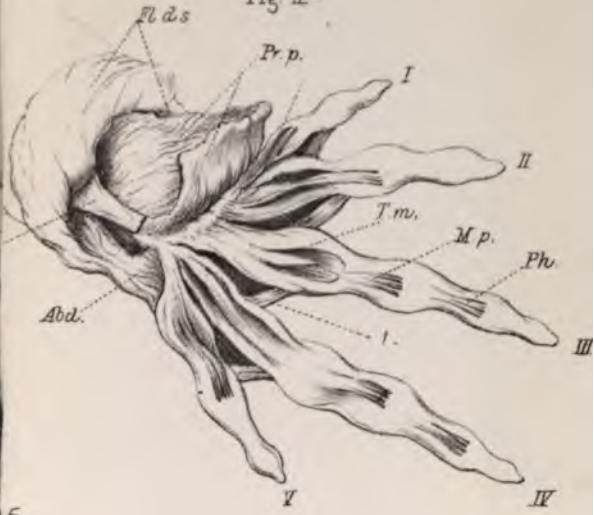


Fig 16.

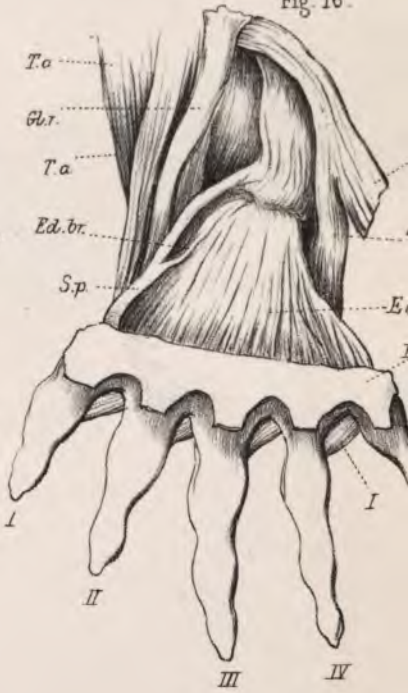




Fig. 5

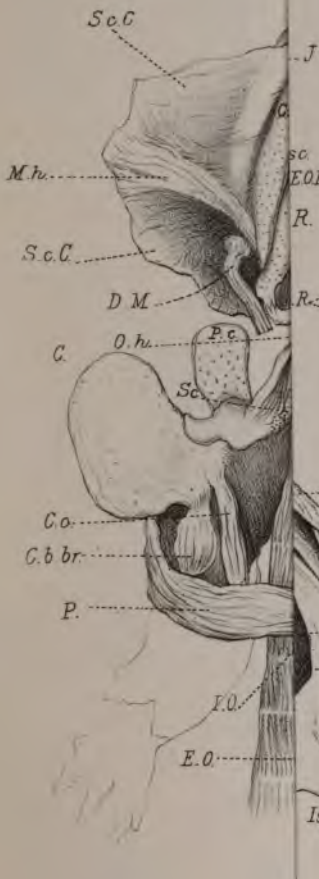

Fig. 7

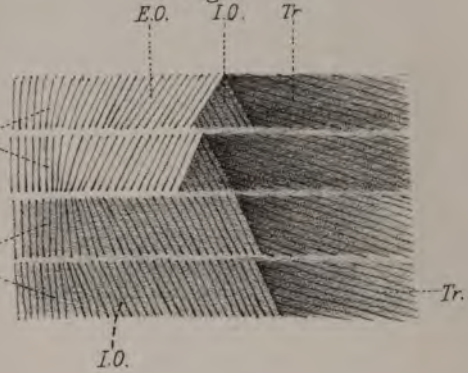
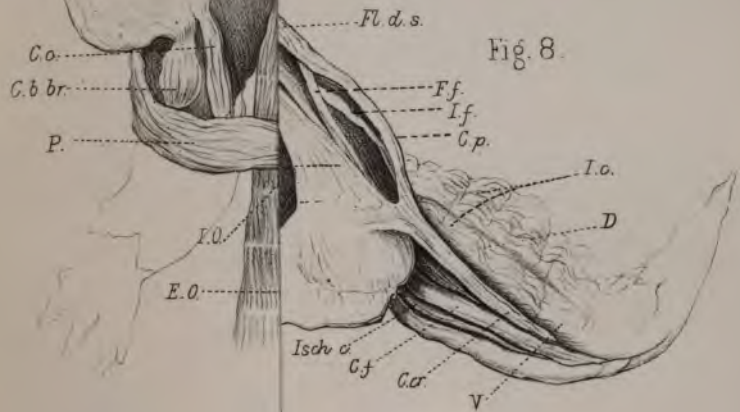


Fig. 8



III  
IV



dorsal part of the lateral muscle. The anterior branch runs along the hinder border of the rib. *I.*, inscription in the dorsal muscle.

Fig. 22. View of the brain and cerebral nerves in situ, the upper part of the skull and the meninges with the fine areolar tissue which occupied the large interval between the dura mater and the skull having been removed. 1. The olfactory nerve expanding into the cerebral hemisphere (Schmidt, G. and V. der H. judged that there was a cavity in the hemisphere. In my specimen the part was too soft for this to be decided). The hypophysis was very large and occupied a distinct digital fossa on the upper surface of the basis cranii. There was also a Pineal Gland but much smaller. 2. The optic nerve passing from beneath the hemisphere. The two optic nerves are quite separate from one another, and do not cross, each running direct from the hemisphere to the orbit of the same side. 3. The third nerve (*motor oculi*) passing from beneath the hemisphere. 4. The fourth nerve passing from the strand at the side of the third ventricle. The third and fourth nerves escape through small foramina in the dura mater and apparently accompany the ophthalmic part of the fifth. 5. The fifth nerve passing from the side of the forepart of the brain bounding the fourth ventricle: it expands into the Gasserian ganglion as it enters the dura mater. 7. The seventh nerve passes from the side of the back of the brain bounding the fourth ventricle and divides into the portio dura and the auditory part. 8. Two nerves passing from the medulla oblongata, meeting as they enter a common hole in the dura mater and skull, and forming the eighth nerve. The anterior of the two is probably the glosso-pharyngeal, and the small nerve seen joining the vagus from behind is probably the representative of the spinal-accessory. They are so regarded by Schmidt, G. and V. d. H., who also describe a nerve which they traced through an anterior condyloid foramen as the 9th or hypoglossal nerve. We could not discover any representative of the 9th nerve in the cranial cavity.

---

The following notes of the dissection of UROMASTIX SPINIPES, made since the rest of these dissections and observations were in type, and inserted here to fill up a blank space in the sheet, are of interest in reference to the remarks made in other parts of these pages.

The *rectus abdominis* is very wide, underlying all the middle part of the abdomen. Anteriorly, it is continued, through the medium of the long hindmost costal rib, into the *pectoralis*. This costal rib (or costal and epicostal combined, for it presents in the abdominal strata more superficially than the other costæ) answers to one of the septa, at once separating and connecting the *rectus* with the *pectoralis*. Posteriorly, the *rectus* is attached to the large recurved spine of the pubes; and, by means of a tendinous arch or septum extending between the pubic spine and symphysis, it is continued into the *gracilis*. More laterally, it is connected with a tendinous arch,

answering to Poupart's ligament, between the pubic and the iliac spines. This tendinous arch is, behind, continued into the tissue covering the muscles of the thigh. One of these, answering apparently to the *sartorius*, takes origin from it and passes down over the inner side of the fore part of the knee. A muscle, which appears to be the *quadratus lumborum*, is attached to the anterior and deeper surface of this arch<sup>1</sup>. The septa in the *rectus abdominis* are very wide; and the intervening muscular bundles extend somewhat irregularly into them, reminding us of the septa and muscular fibres in the hinder part of the Tadpole's tail (see p. 112). Towards the lateral region of the abdomen the muscular fibres encroach more upon the septa, and finally obliterate them and, acquiring an oblique direction, form the *obliquus externus*, which is thus seen to be continuous with the *rectus*. It covers the lateral region of the abdomen.

Radiating from the pubic spine, deeper than the *rectus*, inwards and forwards, is a large thick *pyramidalis*, resembling that muscle in Bats and Marsupials. Its fibres meet those of the corresponding muscle of the opposite side, the hindmost being nearly transverse; and the foremost, directed forwards and inwards, extend about one-third of the distance to the sternum. Laterally, it is continuous with a delicate sheet the fibres of which are directed forwards and inwards and constitute the internal oblique<sup>2</sup>.

The dissection of the submaxillary region, in relation especially to the morphology of the *digastricus*, is very interesting. A broad muscle—a hyo-mental—is continued forwards from the hyoid. It very soon divides. The outer portion is inserted into the side of the mandible, just in front of the masseter, and represents evidently the anterior portion of the *digastricus*. The inner portion is continued forwards to the mental part of the mandible, and represents the genio-hyoid. Deeper than these is the *genio-hyo-glossus*. The *sterno-hyoid* is easily separated into two layers. Both are connected, behind, with the episternum and clavicle in a deeper level than the sterno-mastoid, and, in front, with the hyoid. The superficial of the two layers is in the plane of the digastric and genio-hyoid, which appear, therefore, to be a continuation of it, though the connection is broken by the hyoid taking the place of the inscription between them.

The subcutaneous muscle of the neck (*subcutaneus colli*) is in two sheets. The superficial is composed of transverse fibres (*transversalis*

<sup>1</sup> This connection of the *sartorius* and the *quadratus lumborum* with the tendinous arch, and so with one another, may be associated with the fact that the *sartorius* in *Oryzeteropus* (*Journ. of Anat.* II. 311) extends over the *iliacus* and the *quadratus lumborum* as far as the ribs.

<sup>2</sup> There is no diaphragm; but the deep pigmentary stain of the lining membrane of the visceral cavity terminates in a line nearly corresponding in position with the line of attachment of the mammalian diaphragm; and, in the upper or dorsal part of the visceral cavity, in this line, a fold of the membrane projects as a mesentery to the oviducts. The hinder layer of this fold is deeply stained like the rest of the abdominal portion. The anterior layer is less deeply stained and, so, resembles the thoracic portion.



*colli*), passing from the mesial dorsal to the mesial ventral line. The deeper sheet is composed of oblique fibres, passing from the dorsal line, mesially and forwards, and constituting a *cervici-submaxillaris*. Anteriorly and superiorly, a thickening of the latter, composed of fibres passing from the back of the skull to the angle of the jaw, behind the masseter, forms a *depressor mandibulae*, which is thus separated from the *digastricus* by the *masseter*. Anteriorly and inferiorly, in the submaxillary region, it, blended with the *transversalis colli*, or superficial sheet, passes superficially to the hyoid and the origins of the digastric and genio-hyoid. It then sends a very delicate fascial or cellular sheet, superficial to the digastric, and is continued, superficial to the genio-hyoid, to the mental part of the mandible. But the main portion of it extends, deeper than the *digastric*, between it and the *genio-hyoid*, to the inner surface of the mandible, along the side of which it is implanted, above the *digastric*, so constituting the *mylo-hyoid*. The digastric accordingly passes through a ring-like or oval aperture in the *subcutaneus colli*, where the latter dips between the genio-hyoid and the digastric to form the mylo-hyoid.

A delicate muscle arises from the mastoid part of the skull behind the quadrate bone, and beneath the sterno-mastoid. It passes mesially and forwards, and is lost in the deeper surface of the *subcutaneus colli* beneath the hyoid. This would seem to represent the hinder portion of the digastric<sup>1</sup>.

There is not any direct continuity between the temporal muscle and the dorsal muscles of the neck. The latter, as they advance forwards, divide into two planes. Those in the superficial plane are inserted into the hinder edge of the overarching posterior horn of the parietal bone; and those of the deeper plane are inserted into the hinder edge of the exoccipital. The temporal muscle, extending backwards beneath the parietal, arises from the whole of the under surface of its posterior horn, and so comes into close relation with the dorsal muscles; but it is covered and separated from them by a membranous layer.

**FORE LIMB.** The *biceps brachii* arises in two distinct portions from the coracoid; one, tendinous, from near the proximal part, the other, muscular, more laterally from the anterior part. They evidently correspond with the coracoid and glenoid origins in man. The more lateral origin is biventral, being at first muscular, then becoming tendinous where it passes under the pectoral, and being again muscular, lower down, before it joins the median portion. The *brachialis anticus*, which is large, arising from the front of the lower part of the humerus, joins the *biceps* at the lower part of

<sup>1</sup> In the Frog (*Rana mugiens*) this hinder part of the *digastric* is continued into the hinder edge of the thick *mylo-hyoid*; and some of its fibres are traceable forwards, upon the deeper surface of that muscle, towards the mental part of the mandible. In this animal the thick *mylo-hyoid*, which is limited to the submaxillary region, and is free from the hyoid cartilage, engrosses the *subcutaneus colli* and the *hyo-mental* including the fore part of the *digastric*. The *genio-hyoid* is distinct and deeper.

the arm; and the conjoined tendon is inserted into the radius and ulna.

The *flexor sublimis digitorum* is a short flat muscle arising from the lower end of the ulna. It divides into five parts, one to each digit. Each part is, superficially, continued into a sheath which covers the deep flexor and the palmar aspect of the digit; and, more deeply, it gives rise to the usual perforated tendons which embrace and nearly encircle the deep flexor tendon on their way to their insertion. These tendons are inserted, two in number, in digit I. into the first phalanx, and in digit II. into the second phalanx. In digit III. a single tendon passes, on the ulnar side of the deep flexor, to the ulnar side of the second phalanx; and two tendons pass in the usual manner to the third phalanx. In digit IV., one tendon passes to the ulnar side of the second phalanx; a second tendon passes to the ulnar side of the third phalanx, and a third to the radial side of the fourth phalanx. In digit V., two tendons pass, in the usual manner, to the second phalanx. The muscular belly in the fore arm, which usually appertains to the *flex. subl.*, in this instance terminates in a tendon which joins the ulnar margin of the deep flexor.

The *flexor profundus* is arranged much as usual. Its tendon in the palm is broad and thick, with the ossicle commonly found there; and it bears a sheet of muscular fibres, which divides into *lumbricales*, upon both its surfaces. The superficial *lumbricales* are three, one to each of the middle three digits. That to digit II. passes on the radial side, and unites with the tendons of the *flexor sublimis* close to their insertion. That to digit III. passes on both sides of the digit and gives off two tendons, of which one blends with the single tendon of the *flexor sublimis* on the ulnar side; and the other, passing on the radial side, blends with the radial one of the two distal tendons of the *flexor sublimis* near its insertion. That to digit IV. passes on the ulnar side of the digit to join the proximal ulnar tendon of the *flexor sublimis*. The deep *lumbricales* are also three, and pass to the bases of the proximal phalanges of the middle three digits.

The two lateral digits (I. and V.) have each a short flexor arising from the carpus and passing to the base of the first phalanx. These evidently are parts of the same series as the deep *lumbricales*. But they have remained attached to the carpus, and become separated from the flexor tendon; whereas the deep *lumbricales* have separated from the carpus and remained attached to the flexor tendon. A connecting link is furnished by a small *accessorius*, a thin flat muscle, which arises from the ulnar side of the carpus and is inserted into the deep surface of the flexor tendon close to, and almost continuous with, the deep *lumbricales*.

The *interossei* are eight, one on the ulnar side of digit I., one on the radial side of digit V., and one on each side of each of the other digits; there being no abductors of digits I. and V. They run along the sides of the digits; and their margins are connected with the margins of the extensor tendons. These last are derived from the short extensor muscles which cover the metacarpus; the ordinary extensor stopping, as usual in Saurians, at the metacarpals.

**HIND LIMB.** The internal *rectus femoris* joins the inner part of the *quadriceps* near the knee, lying external to the *sartorius*. The *caudo-pedal* passes down between the two heads of the *gastrocnemius*, and blends with their tendon superficially. This tendon is broad, attached to the sides of the tarsus and continued into the *flexor sublimis digitorum*. The two heads of the *gastrocnemius*, arising from the two condyles of the femur, are quite distinct. The *fl. prof. dig.* arises from the outer condyle of the femur; so do the *peronei*. The *per. l.* is not continued into the sole, but is attached to the fibular side of the tarsus and is blended with the tendon of the *gastrocnemius*. Neither of the flexor tendons are therefore, above, continued into the internal rectus. The *tibialis anticus* covers the inner side of the tibia. The *tibialis posticus* arises, exclusively, from the fibula. The disposition of *flex. subl.* and *prof. digitorum*, of the *lumbricales*, superficial and deep, of the *accessorius* and the *interossei*, closely resembles that in the fore limb.

---

THE MUSCLES OF LEPIDOSIREN ANNECTENS,  
WITH THE CRANIAL NERVES. (Pl. V. figs. 23 to 27.)

THE muscular system of *Lepidosiren* presents<sup>1</sup>, as might be expected, many interesting features of an intermediate condition between that of the Fish and that of the Urodelan.

The great lateral muscle, as in those animals, is divided by a lateral septum passing, from before backwards, nearly midway between the dorsal and the ventral edges, into an upper or 'dorsal' and a lower or 'ventral' muscle. Each of these is also subdivided into myotomes by transverse fascial inscriptions or 'intermuscular septa' which are more simply disposed than in most Fishes, forasmuch as they run from the lateral septum, in nearly straight lines or with a slight anterior curve, upwards and downwards, to the dorsal and ventral edges. Traced, from the external fascia, into the substance of the dorsal muscle the septa pass, in oblique planes, forwards and inwards to the dorsal spines and the fin-rays; and those in the ventral muscle pass also obliquely forwards and inwards, to the ribs, hæmal spines, and fin-rays, where these exist, or to the internal surface of the ventral cavity and there blend with the internal or transversalis fascia.

<sup>1</sup> The specimen of *Lepidosiren Annectens* from which these notes were taken was nineteen inches in length. It was dissected chiefly by Mr Anningson, partly by myself.

## FASCIAL INVESTMENT.

The EXTERNAL or SUBCUTANEOUS FASCIA covering the lateral muscle is not, as in Cryptobranch, loose, permitting movement of the skin upon the muscle, but, as in Fishes though not quite in the same degree, compact and closely united with the derma on the one side and with the intermuscular septa on the other. It is separated from the skin by a thin stratum of pigmentary areolar tissue; and its union with the intermuscular septa is still more close. Hence it is with difficulty dissected off as a continuous sheet. Forasmuch as all, or nearly all, the fibres of the lateral muscle terminate in and arise from the septa, they are, through the medium of the septa, brought into relation with one another, with the vertebral system on the one side, and with the dermal system on the other. This is an important point; and the continuity of the parts or layers of the outer wall of an animal body thus established must be borne in mind in considering the relations of the muscles, and their subdivisions, to one another and to the dermal and vertebral systems.

Along each edge (upper and lower) of the animal, in the forepart, where the mesial fin is absent, the fascia of either side blends with that of the opposite side and is intimately united with the cutis externally. The median sheet resulting from the blending dips between the lateral muscles of the two sides. The upper one impinges upon and unites with the dorsal spines and other vertebral elements; and the lower blends with the hæmal spines or with the fascia transversalis.

In the region of the mesial fin (dorsal, caudal, subcaudal and anal, for they are continuous) the disposition is somewhat different. At the base of the fin the fascia on each side divides into two laminæ (Fig. 23 *B*). Of these one, superficial or subcutaneous, accompanies the derma upon the fin and is lost with it on the delicate horny fibres of the fin. The other lamina, retaining its connection with the lateral muscle, passes over the edge of that muscle, between it and the fin covered by its fin-muscle, and so reaches the neural or hæmal spines and the fin-rays resting upon them. It here becomes blended with those spines as well as with the intermuscular septa which are here passing into the spines and fin-rays. Thus the fin with its muscles is

enclosed in the interval between the superficial and deep fascial laminæ of the two sides, in the same manner as the dorsal, ventral and lateral fat masses in *Cryptobranch* (p. 5). There is however this difference, that the fat masses in *Cryptobranch* occupy continuous channels which are not broken or subdivided by the transverse septa extending into or across them; whereas the channel for the mesial fin of *Lepidosiren* is, in the line of each fin-ray, interrupted by the transverse septa of the lateral muscles of the two sides, extending through and transversely subdividing the fin-muscles and joining and blending with the fin-ray. The same disposition is observable in other fishes and is illustrated by *Ceratodus* (see p. 93). In the case of the pectoral and ventral fins the fascia is continued beneath the skin upon the muscular covering of the fins.

The INTERNAL or 'TRANSVERSALIS' FASCIA, lining the abdominal space and closely applied to the ribs, is distinct and strong. It is particularly strong in the region corresponding with that of the *depressores costarum* of other animals. A thin layer of it bends inwards upon the cesophagus, behind the pericardium, forming a rudimentary post-cardiac diaphragm. The fascia itself, or the greater part of the thickness of it, passes upon and is closely connected with the pericardium, and is, with the pericardium, attached strongly to the hinder and inner surface of the coracoid arch inferiorly. Superiorly it is thinner, and is accompanied upon the front of the pericardium by a distinct detachment of fibres from the internal surface of the ventral muscle, which thus forms a precardiac or post-branchial musculo-fascial diaphragm. Internally, the transversalis fascia is, in the greater part of its extent, in contact with the peritoneum. Externally, it lines the ventral muscle and is connected with the external fascia by the intermuscular septa passing obliquely between them. Inferiorly, it passes beneath the edge of the ventral muscle and blends, as just stated, with the external fascia. Behind the pelvis it forms a sheath upon the bowel passing to the anus. (Fig. 23, G.)

#### THE VENTRAL MUSCLE

presents nothing remarkable in the tail.

In the abdominal region, in about the middle third of the space between the lateral septum and the ventral mesial line

(Fig. 23), the fibres of the outer stratum present a slight but distinct obliquity, from before backwards and downwards (towards the mesial line), as they pass between the several septa. This disposition to the formation of an *obliquus externus* muscle is most marked in the middle of the space indicated. It diminishes above and below; and in the third of the muscle next the lateral septum, as well as in the third next the mesial line, the fibres are 'recti.' The removal of the superficial—external oblique—stratum shews an obliquity, to a like degree, but in a different direction, in the subjacent stratum. (Fig. 23 A.) The fibres there pass from before backwards and upwards (towards the lateral septum) and form an *obliquus internus*. In this instance also the oblique direction disappears in the upper and lower thirds of the muscle. The fibres there run antero-posteriorly, and the tendency to division into planes is lost. This gentle effort, as it were, at the formation of oblique muscles is an interesting corroboration of the remarks made (p. 11) with reference to the cleavage of these muscles in Cryptobranch, exhibiting as it does a still lower grade of stratification than we found in that animal. (See also *Ceratodus*, p. 92.) There is no appearance of a third or *transversalis* stratum; and there are no muscular fibres in a deeper plane than the ribs. This is also the case in most Fishes, though in some (*Bream* and *Dace*) there is a thin muscular layer beneath the level of the ribs; and the nerves lie upon its outer surface.

In describing the external fascia, I have mentioned that a superficial layer of it is continued upon the exterior of the mesial fin and that another layer passes beneath it; so that the rays and muscles of the fin are enclosed between the two layers and are separated from the lateral muscle by the deeper of them: also that the intermuscular septa are continued into the fin and blend with the rays, so causing a transverse segmentation of the fin. The fin-muscles are contained in the fascial partitions thus made, and consist of a layer of fibres parallel with the fin-rays, resting with one end upon the lateral muscle, or rather upon the fascia which separates them from it, and with the other end expanded upon the fin. The greater number of the fibres arise from and lie along the lines of the septa and the rays, as shewn in Fig. 23, where the alternating thicker and thinner parts of the muscle thus produced are well displayed, and

the thicker parts are seen to be in or near the lines of the septa of the lateral muscle and of the fin-rays. Now, the septa are disposed with regard to the fibres in the same way as they are with regard to the lateral muscle; and they connect the divisions of the fin-muscle with one another, and with the lateral muscle, much in the same way that they connect the several divisions of the lateral muscle itself. The chief difference consists in the direction of the fibres of the fin-muscle, which is at right angles, or nearly so, to that of the fibres of the lateral muscle. This causes the one series to be segmented from the other; and the action of the two being distinct leads to their being further separated by the fascial layer passing between them. At the forepart of the dorsal fin the fibres of the fin-muscle extend a short distance, on either side, upon the surface of the lateral muscle between the two layers of fascia. They do this more widely in some Fishes, becoming thus subcutaneously expanded upon the dorsal muscle; and they are still more segmented from it<sup>1</sup>.

The relations of the ventral muscle to the ventral-fin are simple and interesting. The chief part of the muscular fibres of the fin are derived from the slanting postero-lateral edge of the pelvis<sup>2</sup>, above and below the acetabulum, and indeed all round the joint. These (Fig. 23 *E*) descend upon the whole circumference of the fin, ensheathing it and blending with the fascial tissue beneath the skin and with the fibrous perichondrial tissue which invests and unites the series of cartilaginous pieces that form the cylindrical tapering skeleton of the fin. To these are superadded fibres from the adjacent part of the ventral

<sup>1</sup> See, further, the description of the relation of the fin-muscles to the lateral muscle in *Ceratodus* (p. 92).

<sup>2</sup> The pelvis is of somewhat diamond shape. The posterior angle is prolonged slightly into an obtusely pointed process. The anterior angle runs forwards as a smooth styloform process, an inch and a half long, and occupies a channel in the fascia formed in the same manner as the channel for the mesial fin above described, a circumstance which is not a little confirmatory of the view I have expressed (*Journ. of Anat.* v. 59) respecting the serial homologous relations of the mesial and lateral fins. The lateral angles of the diamond run out into horn-like processes, and are connected with or continued into the transverse septa of the lateral muscles on the two sides. Near the hinder part of the cartilage, on either side, is the articular facet for the first cartilage of the fin. See Fig. 23.

In Owen's Memoir, *Linn. Trans.* xviii, Tab. 23, as well as in the *Anat. Vert.* i. Fig. 47, the pelvis is represented and described with the styloform process directed backwards.

muscle, which converge from before and from behind and blend with them. There is no line of demarcation between the fibres derived from the pelvis and those derived from the ventral muscle. Some of the latter proceed from the next adjacent septa before and behind; and some are derived from more distant septa. As represented in Fig. 23, the lowest and hindmost of the ventral fibres passing upon the fin are segmented from the rest of the ventral muscle and are uninterrupted by septa for a greater distance than those situated higher up. Between the converging bundles from before and behind is seen an interval (*F*) in which the nerves run, from beneath the edge of the ventral muscle, over the outer edge of the pelvis and the acetabular joint, upon the fin.

As it approaches the forepart of the animal, the ventral muscle (and this will be found to be the case also with the dorsal muscle) gives off a superficial stratum which is thin and partly membranous (Figs. 24 and 26). Its disposition is as follows: it separates from the deeper stratum of the ventral muscle a little behind the level of the pectoral fin, at one of the septa, and is thenceforward connected with the deep stratum only by loose areolar tissue; so that it is easily dissected away. This is especially the case near the middle line. It retains the transverse septa and, advancing forwards, expands as a continuous sheet upon the shoulder-girdle and the hinder aspect of the base of the fin. It is also continued forwards upon the lower jaw, the gill cover and the opercular bones; and it spreads in this direction upon the surface of the dorsal muscle, becoming blended with the fascia of that muscle and so reaching the dorsal median line. It may be called the SUPERFICIAL BRACHIO-CEPHALIC STRATUM of the ventral muscle, to distinguish it from the deeper stratum of the same muscle which also passes to the limb-girdle, limb and head, and which may be called the DEEP BRACHIO-CEPHALIC STRATUM.

The upper portion (*L. d.*) of this superficial brachio-cephalic stratum—the portion, that is, nearest to the lateral septum,—a little in front of the line of separation from the deep stratum, is inserted into the upper, or scapular, part of the shoulder-girdle, which forms a conical projection above the fin, and into



the upper part of the first cartilage of the fin, which may be regarded as representing the upper or humeral segment of the forelimb of higher animals. Some of the fibres also blend with the other muscles of the fin. This portion of the stratum represents, therefore, the *latissimus dorsi*.

The next portion (*P*) of the stratum, a little more ventrally situated, is attached to the under-surface of the fin and its first cartilage, and to the anterior edge of the shoulder-girdle (the coracoid) beneath the fin. The coracoid is here covered by an extension of the mucous membrane of the branchial chamber, and contributes to form the wall of the branchial passage, and of the slit-like branchial opening; and the mucous membrane extends a short distance upon the surface of the muscle which accordingly contributes, with the coracoid, to form the hinder wall of the passage leading to the branchial chamber. This portion of the stratum corresponds with the *pectoralis major*. It is really continuous with the *latissimus dorsi*: but the fibres establishing the continuity between the two, and attached to the girdle and the fin in the immediate neighbourhood of the glenoid cavity, form a very thin sheet; and an axillary interval is easily made between the pectoral and the *latissimus dorsi* portions of the stratum.

Still more ventrally or mesially, the fibres of the superficial brachio-cephalic stratum pass onwards and form a superficial cervical muscle (*cervicalis superficialis*). The lateral fibres run beneath and in front of the branchial opening; and, covered by the skin externally and lined by the mucous membrane internally, they form the margin of the gill cover and the anterior wall of the passage leading to the branchial chamber. They (Fig. 24, *Sp. br.*) moreover spread out over the branchial chamber and, in front, come into contact with and are attached to the opercular bones<sup>1</sup> and the side of the skull; while, above,

<sup>1</sup> There are distinctly two opercular bones as represented by Peters. One, the inferior or *suboperculum*, situated behind the angle of the mandible, is triangular, with its apex directed forwards and continued into a narrow tendon which is attached to the inner surface of the lower part of the dentary bone, about the middle; and it blends there with the fibres of the mylo-hyoid muscle. The other, the superior bone or *operculum*, is smaller, more elongated, and extends up between the preceding and the hinder surface of the suspensorium.

Owen (p. 336) mentions only the superior. Huxley, *Anatomy of Vertebrate Animals*, p. 170, mentions the superior as operculum and the inferior as a 'branchiostegal ray' carried upon the hyoidean arch. It is however connected

they arch over the branchial opening and radiate into the fascial tissue covering the dorsal muscle (Fig. 24, *Tr.*). Here the hindmost fibres, bending backwards, are inserted into the upper and anterior surface of the scapula above the fin; and some pass on into the fin. These returning fibres therefore meet the fibres of the *latissimus dorsi* advancing to the same part. They—so much of this part of the stratum as lies above the branchiæ—appear to represent the *trapezius*<sup>1</sup>; while the fibres lying below and upon the branchiæ, and advancing forwards to the skull, may be regarded as representing the *sterno-cleido-mastoid*<sup>2</sup>. Dissecting away the fibres which radiate upon the dorsal muscle, I find some beneath them, running below the level of the lateral septum and inserted into the supra-scapular bone, which is here deeply seated, also into the ligament which connects that bone with the scapula<sup>3</sup>.

The dipping down of the deeper fibres of this layer, which I suppose to represent the *trapezius* and *sterno-mastoid* among other muscles, towards the cervical transverse processes accords with the disposition of the *cervico-humeral* muscle in many mammals, and affords an explanation of that which has seemed to be an aberrant feature of this muscle, viz., that in its upper part it is in close relation with the *levator scapulae* and might be thought to belong to it; whereas, below, it is in close relation with the *trapezius* and claims even more distinctly to appertain to it. It is further interesting to remark that in the Crocodile the *sterno-mastoid* runs to the cervical transverse processes; and a deep band of the *trapezius* does the same<sup>4</sup>.

with the lower jaw and the operculum rather than with the hyoid; and its opercular relations are confirmed by the disposition of the corresponding bone in *Ceratodus*. This is described as suboperculum by Günther in his excellent paper on the *Ceratodus*, *Phil. Trans.* 1871, p. 525.

<sup>1</sup> It is named *levator scapulae* by Owen, but is too superficially placed for that muscle.

<sup>2</sup> These, at least, are the muscles which they chiefly represent. There are, however, other muscles in different animals which must be derived by segmentation from the same source, such as the *constrictor faucium*, *depressor mandibulae*, *levator arcuum*, *subcutaneus colli*, from the superficial surface, and, more deeply, the *rhomboids*, *masto-scapular*, *cervico-humeral*, &c.

<sup>3</sup> This bone is quite distinct, as described by Peters. For further account of fibres, similar to those above mentioned, see description of Dog-fish (p. 86).

<sup>4</sup> In the Dog-fish (p. 86) all the fibres pass beneath the lateral septum, and none expand upon the dorsal muscle.

In that animal the several gill-openings cause a greater separation between the upper and lower parts of the muscle than is caused by the single transverse slit-like opening in *Lepidosiren*, and I have accordingly named the part above the gill-openings *cervicalis superficialis superior*, and the part below them *cervicalis superficialis inferior*.

The most ventral or mesial portion of the superficial brachio-cephalic stratum, separating a little from the portion last described, passes beneath the floor of the mouth and is inserted along the inner and lower edge of the circle of the lower jaw, also strongly to the cornu of the hyoid<sup>1</sup>, near the angle of the jaw, and less strongly along the upper edge of the cornu, and to the suboperculum. Here it is blended with the subopercular fibres of the last described (sterno-cleido-mastoid) portion. This portion of the stratum (Fig. 26, *M. h.* and *S. c.*) represents the *mylo-hyoid* with part of the *subcutaneus colli* or *platysma*. The transverse septa cease on a level with the angles of the jaw; and the fibres in front of that take a more transverse direction, are less closely connected with the skin, and are less stained with pigment than in the hinder regions of the stratum. The stratum is here, for a short distance, in two layers (Fig. 26, *S. c.* and *G. h.*). In the deeper of these, which is a more direct continuation of the superficial stratum of the ventral muscle, the fibres have an antero-posterior direction. It is inserted near the symphysis of the jaw only; and just behind the symphysis it is in immediate contact with the mucous membrane of the mouth, which is reflected upon it from the rudimentary hyoid and tongue and then passes from it to the symphysis. In the superficial layer (*S. c.*) the muscular fibres are more transverse, and are inserted into the ramus of the jaw and the cornu of the hyoid as well as into the symphysis. It is this superficial layer which more distinctly represents the *mylo-hyoid* and the *subcutaneus colli*, while the deeper layer (*G. h.*) may represent, in part, the *genio-hyoid*<sup>2</sup>; but the two layers are blended in front, near the symphysis, as well as behind at their junction with the septum of the ventral muscle from which they both spring.

It should be added that some of the fibres of the superficial layer, lying between those which I call *subcutaneus colli* and those which I call *mylo-hyoid*, radiate from, as well as are inserted into, the angle of the jaw and the adjacent cornu of the hyoid; and the fibres passing from the latter point, beneath the body of the jaw, to the symphysis form a hyo-mental (p. 137) and appear to represent the anterior belly of the *digastric* (Fig. 26, *D*).

<sup>1</sup> The cerato-hyoid. There is no basi-hyoid.

<sup>2</sup> They are so named by Owen in the description of Figs. 4, 5, and 6.

The DEEP BRACHIO-CEPHALIC STRATUM of the VENTRAL MUSCLE (Fig. 26, *D. v.*), the part that is beneath the whole of the superficial stratum just described, is far thicker than it and is marked by septa in its whole length. In its course it encounters three bones in succession; each of which is in the line of one of its septa and is involved in it.

The first of these bones (Fig. 26, *R*) is a stout cylindrical elongated bone, articulated by a broad trochlear surface with the cartilage of the base of the skull just behind the opening for the vagus nerve, and running down into the substance of the lateral muscle. This bone in form, position and relation to a septum, resembles a rib; and it probably is to be regarded as a rib, although it is much larger than any of the succeeding ribs. This view is confirmed by the fact that a short thick muscle here separates itself from the rest of the deep stratum of the ventral muscle and passes from the bone in question to the under surface of the scapular part of the shoulder-girdle, representing pretty clearly the *serratus*<sup>1</sup>. The nerve to the fin takes its course beneath the edge of this muscle, between it and the muscles attached to the coracoid, holding therefore the same relation to it as the brachial nerves in other animals do to the *serratus*.

This deep stratum of the ventral muscle next comes into contact with the coracoid which is connected with one of its septa, much in the same manner as the ribs are connected with the septa of the ventral muscle, that is to say, the coracoid is an ossification in the deepest part of the septum. Many of the muscular fibres are inserted into it, representing the *costo-* and *sterno-coracoids* (the ribs and costal cartilages being represented by the septa behind the coracoid). The greater portion of the fibres, however, run beneath, superficial to, the coracoid on to the hyoid, constituting a deep cervical (*cervicalis profundus*) muscle (*C. p.*). Some of these are inserted, tendinous, into the hyoid near the middle line. Some terminate in a tendinous

<sup>1</sup> I am glad to find that the view I have formed of this peculiar bone from its muscular relations in *Lepidosiren* is confirmed by Günther, in his description of the corresponding bone in *Ceratodus*, *Phil. Trans.* 1871, p. 529. Various views have been entertained of it, the last being that by Mr Parker (*Shoulder-girdle and Sternum*, p. 21, and Pl. II, Fig. 1), who regards it as a 'pharyngo-branchial' bone, and a small cartilage attached to its middle as a 'small unossified second pharyngo-branchial.'

band which is continued round the anterior part of the hyoid, near the middle line, and is inserted into the dense tissue there, in the place of a glosso-hyal, which causes a median elevation in the floor of the mouth, behind the symphysis of the jaw, and constitutes a rudimentary tongue. The more lateral fibres, curling beneath the coracoid, are folded over the median part of the muscle between the coracoid and the hyoid, giving a thick rounded edge to the muscle in this situation, and are inserted into the upper surface of the middle of the hyoid. The result of this disposition is a thick strong coraco- or ventro-hyoid, a representative of the sterno-hyoid, which serves powerfully to draw the hyoid backward, deepening the cavity of the mouth and raising the gill-cover. To some extent, therefore, it acts antagonistically to the superficial stratum, part of the office of which is to compress the opercular apparatus. It is disencumbered from other muscles by complete segmentation, and by an investment of loose areolar tissue, so as to be enabled to act freely and fully upon the hyoid.

The pharyngeal muscles of higher animals are represented, or partly represented, by a delicate layer of fibres—a *hyo-pharyngeus*—passing backwards from the hyoid, on either side of the mesial line, and radiating upon the mucous membrane of the pharynx. They meet and blend with a similar layer of fibres passing forwards from the coracoid and, in like manner, radiating upon the pharynx and the under-surface of the branchial chamber. These sub-mucous layers, specially segmented from the deep surface of the ventral muscle, resemble and are derived in the same manner as the subcutaneous layers which are specially segmented from its superficial surface, and which constitute the *platysma* and the *panniculus carnosus* of Mammals.

A short strong fan-shaped muscle—*stylo-hyoid*—radiates from inner surface of the hyoid<sup>1</sup>, near its upper end, to the under surface of the back part of the suspensorium, behind the auditory capsule, where it has a broad insertion.

<sup>1</sup> The hyoid (cerato-hyoid) rests upon the auditory cartilage, and is connected with the base of the skull by a tough ligament, and with the inner side of the angle of the jaw by a strong stylo-, or better, hyo-maxillary ligament.

## DORSAL MUSCLE.

The superficial stratum of the dorsal muscle, separating in the same manner and nearly at the same part of the animal as that of the ventral muscle, soon becomes in great part membranous, passes over the side of the head, and is attached to the end of the suspensorium just above the glenoid cavity, to the lower jaw a little in front of its angle, to the tooth-like hinder projection of the maxillary bone and to the edges of the pre-maxillary and frontal bones<sup>1</sup>. It represents the *temporal fascia*; and muscular fibres are attached to or detached from both its surfaces. Those which are connected with its superficial surface are continued into, or are more or less connected with, the superficial stratum of the ventral muscle. It is thus connected with the muscles already described as representatives of the *trapezius* and *sterno-mastoid*; also with the two following muscles situated in front of those last-mentioned and, like them, appertaining rather to the superficial ventral stratum; though their description is more conveniently given here.

These two muscles are superficial and thin, and lie upon the extension of the dorsal fascia to the suspensorium and mandible. They are separated from one another only by a fascial line from which the fibres of both arise; so that they might be regarded as one. The hinder of the two, which I will call *levator operculi* (Fig. 24, *L. o.*), radiates, from the angle of the mandible and the fascial line just alluded to, backwards upon the superior opercular bone and the interval between the two opercular bones where it blends with the pre-branchial (sterno-cleido-mastoid) part (*Sp. br.*) of the ventral muscle. The anterior of the two muscles (Fig. 24, *D. m.*) is also attached to the angle of the mandible, to the fascial line and to the suspensorium. Its fibres are directed more forwards upon the dorsal fascia. Its position is not unlike that of the masseter; but the masseter is represented by another muscle. On the whole, it rather corresponds with the *depressor mandibulæ*, or with that portion of it which, in some animals, arises from the

<sup>1</sup> Müller (s. 245 and Tab. vi.) describes in *Bdellostoma* a similar extension of the dorsal muscle forwards over the side of the head to the tentacles. It was connected by a ligament with the hyoid and the upper part of the skull.

suspensorium; while the portion which, in Cryptobranch and many others, arises from the dorsal fascia and the cervical spines is probably represented, in Lepidosiren, by some of the fibres of the levator operculi and of the supra-branchial (trapezius) muscles.

One or two points deserve attention here. *First*, the mode in which the superficial and the deep strata of the dorsal and of the ventral muscle are blended, rendering it difficult or impossible to say where the one begins and the other ends, or to refer precisely the respective muscles to the one or the other. This blending seems, on the whole, to result from an extension of the ventral upon the dorsal stratum; and we find the same thing often occurring, behind the fore limb, in the spreading of the latissimus dorsi towards, or to, the vertebral spines. *Secondly*, the superficial and the deep strata, ventral and dorsal, are blended respectively in the ventral and dorsal muscles behind; both strata may contribute to the formation of the same muscle, as we shall presently find in the case of the temporal muscle. *Thirdly*, the superficial pre- and supra-branchial stratum which we have been considering as a derivative chiefly from the ventral muscle, presents itself in Lepidosiren in a simple, but from its connections very suggestive form, warranting, I think, the view I have taken that it is the representative, not only of the *trapezius* and *sterno-mastoid*, but of the numerous other muscles segmented in different ways in different animals, and passing upon the shoulder, the neck, the branchial apparatus and the jaw, so as to meet their varied requirements. *Fourthly*, it is interesting to note, in connection with the relation of the superficial strata of the lateral muscle in other parts and other animals to the so-called membrane bones, that the superficial stratum of the dorsal muscle is in Lepidosiren blended with the periosteum of the membrane bones of the upper and anterior regions of the skull. Further, some of these bones partially enclose the eye and form the orbit, from which, or its periosteum, the muscles of the eye arise. The ocular muscles in Lepidosiren surround the optic nerve. They may be clearly distinguished as four *recti* muscles of which the external is the largest; they are distinctly traceable to the periosteum in which, as just said, the dorsal stratum ends; and they are thus brought into continuity with the superficial stratum of the dorsal muscle and shewn to be derivatives from, or prolongations of, this part of the great lateral muscle.

The reflection of the superficial stratum brings into view the DEEP DORSAL STRATUM which is thick and composed of fibres passing forwards to the skull. A partially segmented conical portion of it, commencing about the third vertebra, and expanding as it advances forwards, forms the *temporal* muscle (Fig. 25, *T*). It passes over the suspensorium, filling

up the lateral concavity of the skull. It is covered by the superficial stratum (the temporal fascia), as well as by the overhanging cranial bones into which that stratum is inserted. It derives a large accession of fibres from these structures which form its covering, as well as from the parts of the skull upon which it lies. It constitutes the hinder wall of the orbital space; and its fibres converge to be inserted into the coronoid process of the mandible, which is well developed, rising up behind the dentary plates that cover the forepart of the edge of the jaw.

The large size and extensive attachments of this muscle correspond with the thickness of the mandible, with the secure mode in which it is articulated with the skull and with the strong dentary plates which it carries. Its relation to the dorsal muscle, foreshadowed in *Cryptobranch* (Pl. IV. Fig. 20), and clearly made out in *Lepidosiren*, is of great interest as establishing the direct continuity of the muscles of the jaw with the lateral muscle.

The under surface of the temporal muscle, at and in front of the suspensorium, is confluent with the *masseter*. The division between the two is, however, indicated by the passage of the branches of the third division of the 5th nerve; and the latter muscle, though really a continuation of the temporal, may be described as arising from the forepart of the suspensorium and the inner surface of the temporal fascia; and it is inserted into the outer side of the coronoid process, beneath the temporal muscle, and into the outer side of the jaw near the coronoid.

Muscular fibres, arising from the forepart of the coronoid process, and partly continuous with those of the temporal muscle, radiate forwards upon the mucous membrane of the mouth, beneath the *retractor anguli oris*, and constitute a *buccinator*.

A stout *retractor anguli oris* (Figs. 24 and 25, *R. a. o.*) arises from the extremity of the suspensorium and the adjacent inner surface of the temporal fascia, also by a strong tendon from the outer side of the mandible in front of the angle. It is lost in the tough tissue about the angle of the mouth. It appears to represent in part the *depressor anguli oris* and perhaps the *Zygomatichi*.



## CEREBRAL NERVES. (Fig. 27, also Fig. 25.)

I subjoin a short account of the cerebral nerves of Lepidosiren, dissected by Mr Anningson.

The OPTIC nerve emerges from a small foramen in the forepart of the side of the skull beneath the frontal bone. It is accompanied and surrounded by the four *recti* muscles. Special nerves to these muscles (the third, fourth, and sixth) were not found.

The FIFTH nerve passes, in three divisions, through three foramina situated in the cartilage forming the anterior wall of the skull beneath the edge of the squamous bone.

The uppermost or OPHTHALMIC division (*Ophth.*) passes, deep, along the inner wall of the orbit, crosses over the optic nerve, gives off ciliary and oculo-motor nerves, and divides into three branches at least. One (*fronto-nasal, f. n.*) is joined by a branch from the supra-maxillary, and is distributed upon the inner side of the nasal process of the skull, upon the surface of that process, and upon the adjacent part of the head. A second branch (*nasal, n.*) traverses the inner wall of the orbit to the nasal cavity. A third branch reaches the floor of the orbit and unites with a branch of the supra-maxillary to form the *infra-orbital* nerve (*i. o.*) which is distributed in the upper lip.

The SUPRA-MAXILLARY division (*S. m.*) gives off three chief branches, a 'fronto-nasal,' an 'infra-orbital' and a 'muscular.' The *fronto-nasal* (*f. n'*.) pierces the upper part of the temporal muscle (Fig. 25 *f. n'*.), and runs upon its surface, beneath the temporal fascia and beneath the edge of the fronto-nasal process. There it joins the fronto-nasal branch of the ophthalmic division. The second or *infra-orbital* branch (*i. o'*.) runs beneath the maxilla just in front of the orbit and joins the *infra-orbital* branch of the ophthalmic. The third, or *muscular*<sup>1</sup> branch (*t.*) passes into and is lost in the temporal and masseter muscles, and appears to be the only nerve to those muscles; at least no branches could be traced into them from the next division.

The INFRA-MAXILLARY division escapes from the skull in two branches separated by membrane but traversing one foramen. One of these gives off a *nasal* nerve (*n'*.) which pierces the temporal muscle and runs beneath the temporal fascia (Fig. 25 *n'*.), passes to the nose, partly joins the nasal branch of the ophthalmic and is partly distributed to the cheek. This branch gives off a buccal nerve (Figs. 25 and 27 *b.*) which is also distributed to the cheek. The other, or mandibular, branch (*m.*) of this division is the larger of the two. It inclines downwards and forwards, passes over the upper edge of the mandible, between its coronoid and articular parts, runs beneath the strong external ligament of the joint and between the temporal and masseter muscles. Having gained the outer surface of the jaw it divides into three nerves. Two of these (Figs. 25 and 27 *l.*) are labial

<sup>1</sup> This muscular branch, as well as the *infra-orbital*, is in Cryptobranch derived from the *infra-maxillary* (p. 46).

branches supplying the integuments on the exterior of the jaw and lip; and the third penetrates the jaw between the dentary and the articular parts.

The SEVENTH nerve traverses a hole in the cartilage on the under surface of the skull, near the forepart of the suspensorium, in front of the origin of the stylo-hyoid muscle. It runs outwards between that muscle and the skull, gives off branches to the stylo-hyoid and to the muscles upon the opercular bones. One large branch (7') passes forwards between the suspensorial cartilage and the squamous bone, meets the labial branch of the infra-maxillary, accompanies it over the edge and upon the outer surface of the mandible, and blends with one of the branches of it going to the lower lip. Another large branch (7'') passes beneath the suspensorium, supplies the depressor mandibulæ, perforates the strong stylo-maxillary ligament, and runs external to the ligament connecting the inferior opercular bone with the mandible. It continues its course under the shelter of the dentary bone, close to the mucous membrane, between it and the mylo-hyoid. Finally (7'''), it pierces the mylo-hyoid, curls over the edge of the jaw, and blends with the lower of the two infra-maxillary branches to the lip.

Peters represents this as the third division of the 5th. Its foramen is in front of the usual position. Still it is quite beneath the skull; its branches are distributed much in the same manner as those of the seventh nerve in *Cryptobranch* (p. 46), and the three divisions of the 5th are quite distinct in *Lepidosiren*.

The blending of the branches of the several divisions of the fifth with one another, and of the branches of the infra-maxillary division with those of the seventh—their imperfect isolation—is of much interest, in connection with the want of isolation of the oculo-motor nerves in these animals. It is also interesting in relation to the union which in ourselves is established between the supra- and infra-maxillaries and the seventh through the medium of the *corda typani* and other petrosal nerves. The object, whatever it may be, which is attained by the blending of the branches in these animals is in ourselves effected, apparently in part, through the medium of the sphenopalatine and otic ganglions.

It is remarkable that the supra-maxillary supplies the chief if not all the branches to the temporal and masseter muscles. The upper portion of the infra-maxillary, though passing through the same foramen with the rest of that division, corresponds with branches of the supra-maxillary division in other animals.

The EIGHTH nerve or VAGUS emerges from a hole in the side of the skull behind the suspensorium, the auditory cartilage being between it and the seventh nerve. It immediately breaks into branches. Of these some pass to and supply the branchiæ and some pass to the pharynx. One of the branchial nerves (that to the 5th branchia) runs along the branchial arch to near the middle, passes between the pericardium and the coracoid, penetrates the ventral muscle and runs backwards, beneath the skin, near the ventral mesial line. A *coraco-hyoid* nerve runs downwards, behind the



Fig. 2

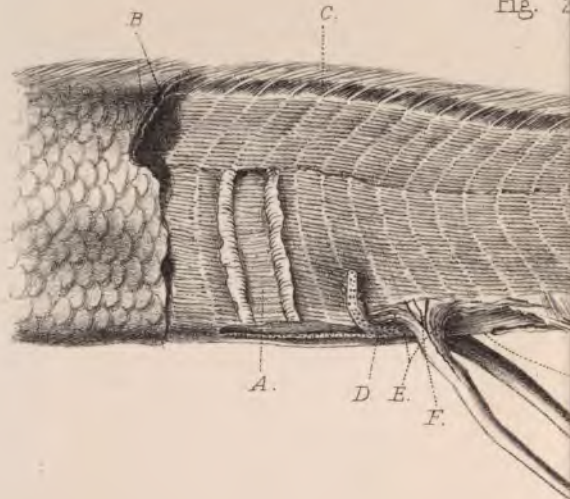
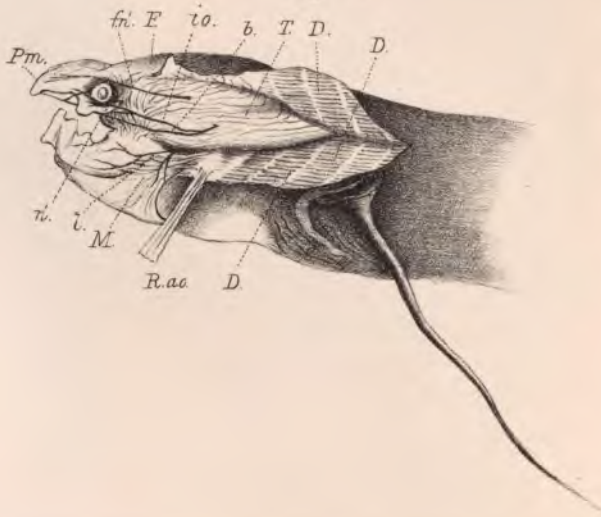


Fig 25.



n.  
-i.o'  
n'  
z.  
m.  
z.

branchiæ, nearly parallel to the preceding, and enters and is distributed in the deep stratum of the ventral muscle between the coracoid and the hyoid. The *Pneumo-gastric* passes backwards to the lungs and along the œsophagus. The *Lateral* nerve is the largest division of the vagus. It sends a branch upwards, behind the suspensorium to the deep part of the dorsal muscle. It then runs directly backwards upon the dorsal surface of the peculiar bone (the large first rib) and the other ribs, and the lateral septum, continuing its course immediately beneath, or in the deepest part of the substance of, the dorsal muscle.

## DESCRIPTION OF FIGURES. PL. V.

Fig. 23. The part of the animal in the neighbourhood of the ventral fins. The skin and the fascia have been removed to shew the dorsal and ventral muscles with the lateral septum between them. The fibres of the ventral muscle, midway between the lateral septum and the mesial line, are oblique from before downwards and backwards. Those of the subjacent stratum (exposed at *A* by dividing the superficial stratum along the interval between two of the transverse septa and reflecting it forwards and backwards) are, in the same region, oblique from before backwards and upwards. *B*, the edge of the fascia seen to split at the base of the dorsal fin. *C*, the muscles of the dorsal fin thickest in the neighbourhood of the transverse septa, and these overlying the ray-bones. *D*, the pelvic cartilage with its anterior styliform process lying in a fascial sheath, and its ascending lateral horn. *E*, ventral muscle continued in front and behind upon the fin. *F*, nerves converging upon the dorsal aspect of the fin. *G*, lower part of the intestine ensheathed by the fascia transversalis and terminating in the cloaca which is on the left of the mesial line. (It is usually on one side or the other in this animal, as observed by Peters, *Müller's Archiv*, 1845, p. 9. It was on the left side in Owen's specimen.) The muscles on the anal fin resemble those on the dorsal fin.

Fig. 24. Superficial layer of muscles on left side of fore part of body, fin and head. *D*, superficial stratum of dorsal muscle continued into temporal fascia which is continuous with frontal bone (*F*). This fascia has been cut away in front where it was attached to (*N*) the nasal bone, (*Pm.*) the premaxillary bone, (*N. c.*) the nasal cartilages, (*M*) the maxillary bone, (*De.*) the dentary part of the lower jaw, and (*An.*) the angular part of the lower jaw. *T*, temporal muscle. *R. a. o.*, retractor anguli oris. *L. d.*, latissimus dorsi. *P*, pectoral. *Sp. br.*, supra-branchial, or cervicalis superficialis, portion of ventral muscle. Behind the last is the slit-like branchial opening, which is bounded behind by the coracoid with the fibres of the ventral muscle passing to its edge and the coraco-brachial fibres (*C. br.*) running from its edge upon the fin. Between the latissimus dorsi and the pectoral

is the axilla. *Tr.*, trapezius.  $O^1$  and  $O^2$ , inferior and superior opercular bones. *L. o.*, levator operculi. *D. m.*, depressor mandibulæ.

Fig. 25. Similar view to the preceding in which the superficial dorsal layer (*D. D.*) and the temporal fascia have been divided longitudinally and reflected upwards and downwards exposing (*T*) the temporal muscle. *M*, the masseter with the branches of the third division of the fifth nerve emerging from between it and the temporal muscle. *R. a. o.*, retractor anguli oris, arising from the suspensorium. *F.*, frontal bone. *Pm.*, premaxillary bone. *F. n'*, fronto-nasal branch of the supra-maxillary division of the fifth nerve; *i. o'*, infra-orbital branch; *n'*, nasal branch of infra-maxillary; *l*, labial, and *m*, mandibular branches of the infra-maxillary.

Fig. 26. Deep dissection of throat showing disposition of ventral muscle. The superficial stratum (*S. c.*) of lighter colour has been partly divided on the left side and reflected towards the jaw, where, on its under surface *M. h.*, the mylo-hyoid, is seen attached to the jaw and the hyoid, and also forming (*D*) the anterior part of the digastric. *C. b.*, coraco-brachial. *N*, nerve passing to the ventral aspect of the fin. *P*, pectoral. *M. m.*, mucous membrane reflected from hyoid and rudimentary tongue upon superficial stratum of ventral muscle. *S. c.* and *G. h.*, the two layers of the superficial stratum of ventral muscle. *C. p.*, cervicalis profundus, or deep stratum of ventral muscle between (*C*) the coracoid and the hyoid. *R*, thick rib-like bone exposed by dividing part of deep stratum of ventral muscle.

Fig. 27. Right side of skull of Lepidosiren, from which the muscles have been cleared away to show the nerves. The optic is not shewn. *Ophth.*, the ophthalmic of the fifth; *f. n.*, its fronto-nasal branch; *n*, its nasal branch; and *i. o.* its infra-orbital branch. *S. m.*, the supra-maxillary division; *t*, its temporal or muscular branch; *f. n'*, its fronto-nasal branch; *i. o'*, its infra-orbital branch. *I. m.*, the infra-maxillary division; *n'*, its nasal branch; *b*, its buccal branch; *m*, its large mandibular branch giving off (*l*) labial branches to outer side of mandible. *7'*, the branch of the seventh accompanying the mandibular branch of the fifth; *7''*, the branch of the seventh to the depressor mandibulæ (*D. m.*), which is continued beneath the mylo-hyoid and curls beneath the jaw reappearing (*7'''*) to supply the lip. *Sq.*, the squamous bone. *S. o.*, the supra-opercular bone. *I. o.*, the infra-opercular bone. *C. h.*, the coraco-hyoid muscle. *D. m.*, the depressor mandibulæ. *L*, the external lateral ligament of the jaw.

THE MUSCLES OF THE SMOOTH DOG-FISH (*Mustelus levis*). (Pl. VI., Figs. 28 to 33),

FIGURE 28 represents the dorsal aspect of the fore part of the animal, and shews the obliquity of the transverse septa in the upper half (*M. D.*) of the DORSAL muscle, the *mesio-dorsal* muscle as it is sometimes called. In the lower or *latero-dorsal* half (*L. D.*) of the dorsal muscle, the septa form a series of gentle curves with anterior convexity; but in the upper half they are projected forwards into angles, which increase to extreme acuteness as the muscle approaches the head, more so than could be represented in the drawing. The upper lines of the angles are the more oblique and larger, running twice as far backwards as the lower lines or more. There are also a few return septa near the dorsal edge; and the angles formed by these, with the upper lines just mentioned, are prolonged backwards into extremely fine points which are lost in the mesial septum. The pointed extremities of the several angles formed by the union of the septa are thicker than the rest of the septa and show a gradual transition into tendons, some of which are fully developed and run along as distinct delicate tendons for considerable distances without any accompanying muscular fibres; and they are inserted into the median dorsal septum or into the vertebral processes lying in or near the septum. These prolonged tendinous apices of the converged and united septa closely resemble the delicate tendons of the dorsal muscle so remarkably developed in Snakes, and are obviously the representatives of them, rendering it clear that the tendons and the septa are homologous structures.

The muscular fibres situated between the very oblique septa do not retain their antero-posterior direction, but run with some obliquity in a penniform manner.

Turning attention to the VENTRAL muscle, a broad median portion—the medio-ventral portion (*M. V.*), of paler colour than the rest of the lateral muscle, is seen to overlap the more lateral—the latero-ventral—portion, covering it as far as the in-

verted angles formed by the ventral septa. It has a defined edge and is easily separated from the lateral portion, there being a distinct, though delicate, layer of areolar tissue between the two. This at least is true as regards the muscular fibres, which in both portions are throughout directed antero-posteriorly. The intermuscular septa are, however, continuous and hold the two portions in close relation with each other; and behind, near the ventral fin, the two are blended in the common ventral muscle. In the drawing the middle portion is shown partially reflected; and the subjacent lateral portion is seen in shade.

The median portion, which corresponds with the *brachiocephalic* portion of the lateral muscle, superficial and deep, of *Lepidosiren* (p. 70), increases in breadth and distinctness as it advances forwards, and is inserted into nearly the whole length of the shoulder-girdle and into the fin. A little behind the fin it gives off a *superficial stratum*, which, however, is much less segmented from the deep stratum than is the corresponding structure in *Lepidosiren*. The upper portion of this stratum, representing the *latissimus dorsi* (*L. d.*), is inserted into the scapular part of the girdle, and expands upon the dorsal surface of the root of the fin reaching to its anterior edge. Upon the fin it lies upon, and to some extent blends with, the proper muscle of the fin. In the drawing it is represented as partly reflected from the fin-muscle. The lower portion of the stratum, representing the *pectoralis* (*P*), is inserted into the coracoid part of the girdle, and extends slightly upon the under or ventral surface of the fin, becoming, in some measure, blended with the proper muscle of the fin. An intermediate or *axillary* portion of the stratum forms a furrow, in which the edge of the fin is received. It is inserted into the girdle and into the fin, behind the joint of the fin with the girdle.

I may here remark that the upper or scapular end of the girdle is prolonged into a pointed process, which runs over the lateral septum and projects in between the fibres of the dorsal muscle, where it terminates in a ligament which is lost in one of the transverse septa, not far from the lateral septum. I do not, however, find that any of the fibres of the dorsal muscle are inserted directly into the scapula.

Before reaching the lateral septum and the dorsal muscle



the scapula lies upon the upper part of the ventral muscle—the latero-ventral muscle—and its lower edge is connected with one of the transverse septa of this muscle. Moreover, some of the fibres of the muscle pass into its under surface, constituting a *serratus*. These are continuous with fibres of the same muscle farther forward, which pass, from a deep level of the lateral septum, backwards to the under surface of the scapula, and are inserted there, constituting a *levator scapulae*.

Reverting to the *pectoral* part of the mesio-lateral muscle, which I have described as being inserted into the coracoid, I should add that the more superficial fibres (Fig. 29) are inserted not into the coracoid but into the transverse septum lying between the coracoid and the skin (the coracoid is developed in the deeper part of this septum, which may therefore be called the 'coracoidal' septum). Through the medium of this septum it is continued onwards into a superficial cervical muscle, which may be called '*cervicalis superficialis inferior*.' This last is a thin muscle without septa; and its fibres radiate forwards and outwards. Anteriorly, they pass superficially to the hyoid, acquiring reinforcements of fibres from the mesial line, and are attached to the lower margin of the mandible and also to the hyoid near the angle of the mandible. Posteriorly, they expand, to some extent, upon the fin, as well as are continuous with the pectoral. Laterally, they pass beneath the branchial chamber, are connected slightly with the branchial cartilages, and extend into the gill-covers between the branchial openings. Antero-laterally, between the foremost gill-opening and the jaw, they pass over the fore part of the branchial chamber. Here, as well as between the several branchial openings, they are continued upon the dorsum of the animal as far as the lateral septum, forming what may be called the '*cervicalis superficialis superior*.'

This superior muscle is quite as strongly marked as that on the under surface of the throat and branchial chamber. It may be described as arising on the dorsum of the animal and extending downwards to meet the inferior muscle. Taking this view of it, we find it to arise from the projecting upper and back part of the skull, from the anterior edge of the scapular part of the shoulder-girdle near the fin and, slightly, from the

dorsal surface of the fin, where it represents the *trapezius* and meets the *latissimus dorsi*, also from the lateral septum between the shoulder-girdle and the skull. In the last situation the fibres are traceable down, beneath the septum, to the lateral parts of the vertebræ and to the fibres of the deep portion of the ventral muscle passing forwards to the skull. The fibres descend forwards and outwards, over the branchial chamber and the gill covers, and are continuous with the ascending fibres of the *cervicalis superficialis inferior*. They pass over and are slightly connected with the branchial cartilages in the same manner as the fibres of the last-named muscle are related to these cartilages beneath.

The points of difference between the *superficial brachio-cephalic stratum* in this animal and in *Lepidosiren* (p. 70) are slight, and are caused partly by the difference in the gill openings. The segmentation from the deeper part of the stratum behind the girdle is less distinct in the Dog-fish; and the stratum in front of the girdle does not, in this animal, expand over the dorsal muscle as it does in *Lepidosiren*. There is further not that distinctly segmented deeper layer of the superficial stratum in or near the mesial line which I have called 'genio-hyoid' in *Lepidosiren* (p. 73). The *cervicalis superficialis inferior* I suppose to represent, as in *Lepidosiren*, the inferior part of the *subcutaneus colli*, the *sterno-cleido-mastoideus*, the *mylo-hyoideus*, the anterior belly of the *digastricus* and the *genio-hyoideus*; while the *cervicalis superficialis superior* represents the superior part of the *subcutaneus colli*, the *depressor mandibulae*, the *levator arcuum*, the *trapezius* with the cervico-humerals and rhomboids.

Beneath the *cervicalis superficialis sup.*, which has been partly cut away in Fig. 28, is seen a strong muscle (*Levator scapulae*) arising from the lateral septum and from the sides of the vertebræ beneath it. The fibres pass backwards and downwards to be inserted into the under surface of the scapula where they meet the fibres of the lateral muscle, which I have called *serratus*, coming forwards to the same cartilage.

The division and reflection of the *cervicalis superf. inf.* from the middle line, as represented, on the right side in Fig. 29, brings into view the continuation of the deeper layer of the ventral muscle, which may be called *cervicalis profundus* (*C. p.*), from the fore part of the coracoid to the hyoid and the glossal cartilage. It constitutes a thick well-defined muscle,

like its homologue in *Lepidosiren*, and presents transverse septa corresponding in number and position with the branchial cartilages. At its origin this muscle, like the *cerv. superf.*, is connected with the coracoidal septum as well as with the coracoid; and it extends with the septum for some little distance upon the ventral aspect of the fin. The proper muscle of the fin also derives origin from the septum as well as from the coracoid. The septum therefore brings into relation and gives origin to the *cervicalis sup. inf.* and the *cervicalis prof.* in front, and to the *pectoral, ventral, and fin muscle* behind, linking them all together and to the coracoid<sup>1</sup>.

The fin-muscle upon each surface is, in consequence of the different direction of its fibres, like the muscle upon the median fins (see pp. 69, 92), in great measure segmented from the extensions of the lateral muscle which spread upon the fin.

We have traced the superficial stratum of the ventral muscle (*cervicalis superficialis*), over the shoulder-girdle and over the superficial branchial cartilages, and the deep stratum (*cervicalis profundus*) forwards from the coracoid to the hyoid. The deepest stratum of the ventral muscle passes from the deep surface of the girdle upon the deep branchial cartilages<sup>2</sup>. Superiorly, beside the bodies of the vertebræ, it is continued from one cartilage to another, and from the uppermost cartilage to the base of the skull, forming a continuous series of alternating cartilages and muscles, like the ribs and the intercostals. Furthermore some of the fibres are reflected from the hindmost branchial cartilage upon the œsophagus, contributing to the

<sup>1</sup> The course of the nerves to the fin accords with the disposition of the muscles, as compared with those of *Lepidosiren* and of higher animals. They all pass behind the girdle, except one which penetrates the edge of the girdle immediately behind the point of articulation of the fin. They traverse the ventral muscle in a line behind this point, having above them the part of the ventral muscle attached to the scapula which I have designated *serratus*, and having beneath them the part of the ventral muscle attached to the coracoid, and forming a deeper stratum than the pectoral, which represents the *costo-coracoid*.

<sup>2</sup> The deep branchial cartilages, five in number, commence above, that is beneath the vertebral bodies, by flattened, slightly curved ends, in close contact with the mucous membrane of the pharynx. At the level of the sides of the bodies of the vertebræ they suddenly thicken and turn downwards, running round, in contact with the pharynx, to the median line, where they coalesce with those of the opposite side. The superficial branchial cartilages are nearly subcutaneous, separated from the skin by the fibres of the superficial cervical muscles only. At their upper or vertebral ends they are connected by fibrous tissue with the deep cartilages; and their lower ends expand and underlie the deep cartilages which are also expanded.

muscular coat of that tube and forming a *diaphragm* between the branchial and pericardial chambers. Some of the fibres also pass from the œsophagus to the vertebral column.

The muscular coat of the œsophagus is further augmented by a small muscle on either side which extends, from the base of the skull and the foremost vertebræ, upon the upper flat ends of the branchial cartilages and upon the œsophagus.

A second or post-cardiac *diaphragm* is formed by a layer of the fascia transversalis reflected from the hinder edge of the girdle upon the œsophagus. It is not accompanied by any muscular fibres.

**VENTRAL FIN (Fig. 30).** The dorsal muscle (*Gl.*) of the ventral fin is broad and square-shaped, and in part continuous with the superficial strata of the ventral muscle, whereas, behind, it overlies the ventral muscle and is easily dissected from it. It thus affords a good example of transition from continuity with the lateral muscle to superposition with regard to it. As it descends upon the fin it blends with the proper muscles of the fin and extends also upon the clasper. It represents the *gluteus maximus*, together, probably, with the *sartorius* and *tensor vaginae femoris* (see also *Ceratodus*, p. 95). I do not trace any of the fibres of the caudal part of the ventral muscle into the back of this fin-muscle or into the back of the fin or the clasper. The caudal muscle is, however, largely inserted into the pelvis, behind, as is the ventral abdominal muscle in front. Near the mesial line the pelvis quite interrupts the ventral muscle, cutting off the caudal from the abdominal part, and lying in contact with the visceral cavity. More laterally, however, the pelvic cartilage is imbedded in the ventral muscle, the fibres of which are continued, on both its superficial and deep surfaces, from the caudal to the abdominal region.

The following description of three transverse sections of the animal, together with the drawings (Figs. 31, 32 and 33) and the accounts of them at p. 90, shew the relations of the lateral muscles to the septa, to the vertebræ and their processes and to the median fins.

A transverse section of the animal through the anterior

dorsal fin (Fig. 31) shows the lateral septum (*L. s.*) passing from the laterally projecting margins of the body of the vertebra, quite on a level with its lower surface which is flattened or slightly concave. It first takes a sweep downwards, then ascends to the part where it appears on the surface.

Beneath it, the ventral muscle is extended over the abdominal cavity and presents one thick oblique septum (*C*) indicating the commencement of the medio-ventral part of the muscle (*M. V.*). Above the lateral septum septa radiate from the middle of the neural arch about the position of the articulating processes. There is no neural spine, or a very short one. The median neural septum is continued, from the summit of the neural arch, to the cartilage of the fin, and there splits into the septa (*A. A.*) which separate the fin-muscles, on the two sides, from the lateral muscles. These last-mentioned septa resemble the other septa of the lateral muscle, though they are rather thicker; and their relations indicate the fin-muscle to be a segment of the lateral muscle. The cartilaginous fin-ray extends far beyond the fin-muscle into the fins; and its extremity is embraced by the horny subcutaneous fibres of the fin, which pass on either side of it.

In a section (Fig. 32) through the posterior dorsal fin and the anal fin the lateral septum is seen passing from the side of the hæmal canal, at a point below the body of the vertebra, about corresponding with the point, above, from which a septum passes from the side of the neural canal, a point, that is, answering to the articulating processes. The neural spine is somewhat pronounced, as is also the hæmal. The cartilaginous rays extend into the hæmal as well as into the dorsal fin.

In a section (Fig. 33) through the caudal fin the relations of the lateral septum to the hæmal canal correspond with those in the section just described. The neural and hæmal spines, especially the latter, are much more prolonged, extending quite to the bases of the respective fins; and the horny filaments of the fins embrace their ends, much as, in the dorsal fin, they embrace the free ends of the cartilaginous rays. These rays are here absent, and there are no fin-muscles.

Thus the neural and hæmal spines are reciprocal with regard to the cartilaginous rays. When these are developed

and penetrate between the lateral muscles the spines are short or abortive; and, on the contrary, when the rays are abortive, the spines run on into the fins.

DESCRIPTION OF FIGURES. (Pl. VI.)

Fig. 28. Dissection of the upper surface of the fore part of the Dog-fish, to show the angular prolongations of the septa of (*M. D.*) the medio-dorsal part of the lateral muscle. *L. D.*, the latero-dorsal part of the same. *L. V.*, the latero-ventral, and *M. V.*, the medio-ventral. *Lat. d.*, latissimus dorsi, which has been partly reflected from the fin-muscle. *P.*, pectoral. *C. s. s.*, cervicalis superficialis superior, its supra-branchial portion. *D. F.*, the dorsal fin.

Fig. 29. Dissection of the under surface of the fore part of the Dog-fish. *M. V.*, the medio-ventral portion of the lateral muscle. *P.*, its superficial, or pectoralis, layer advancing to the fin and to (*C. S.*) the coracoidal septum. *C. s. i.*, the cervicalis superficialis inferior, which, on the left side of the animal, is in situ, but, on the right side, has been reflected to shew (*C. pr.*) the cervicalis profundus, and the superficial branchial cartilages. The hinder fibres of the cervicalis *pr.* are seen passing upon the fin and connected with the fin-muscle. *G. H.*, the glosso-hyal. *C. H.*, cerato-hyal. *B.*, branchiostegal rays.

Fig. 30. Side view of a portion of the hinder part of the Dog-fish to show the relation of the dorsal muscle (*Gl.*) of the ventral fin (*V. F.*) to (*L.*) the lateral muscle. *P. D. F.*, the posterior dorsal fin. *Cl. Cl.*, the claspers.

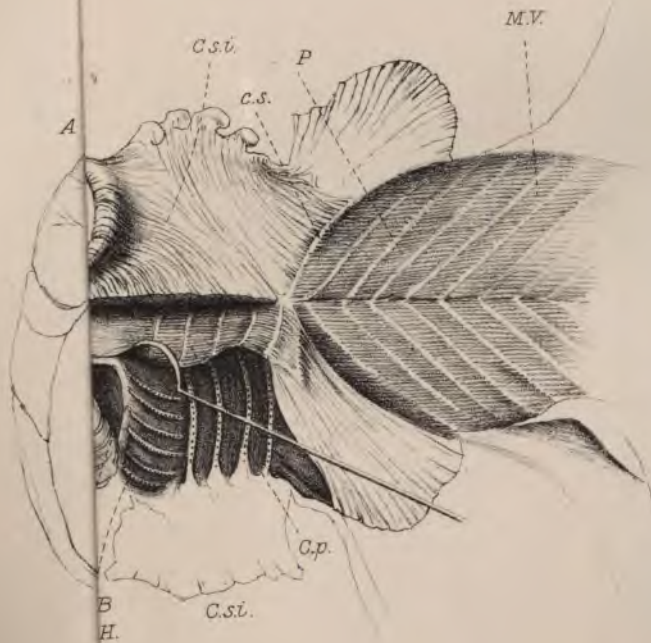
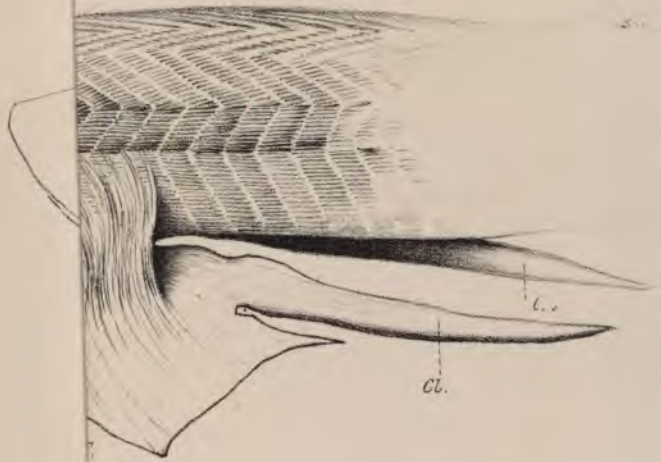
Fig. 31. Section through the anterior dorsal fin and the body wall. *L. S.*, lateral septum. *A.*, septum between the dorso-lateral muscle and the fin-muscle, passing to the root of one of the cartilaginous fin-rays, and continued on, as a median septum, to the dorsal spinous process. *A'*, similar septum to the fin-ray above. *B.*, septum from neural arch separating *D. L.*, the dorso-lateral muscle from *M. D.*, the medio-dorsal muscle. *C.*, septum between (*V. L.*) the ventro-lateral and (*M. V.*) the medio-ventral muscle. The parts of the vertebra which are ossified are distinguished from the cartilaginous parts by not being dotted.

Fig. 32. Section through the post-dorsal (*P. d. F.*) and the anal (*A. F.*) fins. *V.*, the ventral muscle behind the part where it is divided into medio-ventral and ventro-lateral. *D.*, septum between the ventral muscle and the anal fin and fin-muscle. *A.*, septum between the dorsal muscle and the dorsal fin and fin-muscle.

Fig. 33. Section through the caudal fin showing the prolongation of the neural and hæmal spines into the fin. *L. S.*, lateral septum. *N. S.* is the divided end of an overhanging neural spine; and *H. S.* is the divided end of an underlying hæmal spine.

Fig. 30.

P.D.F.







THE MUSCLES OF CERATODUS. (Plate VII. Figs.  
34 to 38<sup>1</sup>).

LATERAL AND MESIAL FIN-MUSCLES.

THE lateral muscle presents the usual general piscine characters. There is, however, none of the superficial, soft, coloured stratum often found over and near the lateral septum<sup>2</sup>. The ventral intermuscular septa simply slant from the lateral septum backwards and downwards to the ventral line. Traced inwards they pass obliquely forwards to the ribs, or to the transversalis fascia in the trunk, and in the tail to the hæmal spines and the median septum. Near the pectoral girdle the direction of their slant is reversed. The dorsal intermuscular strata, at first, slant backwards and upwards from the lateral septum; then they curve forwards to the line at which the dorsal fin-muscles impinge upon the lateral muscle. Here the direction is again suddenly changed; and they slant backwards and upwards, through the fin-muscle, with a greater obliquity than they present near the lateral septum. The septa in the muscle extending upon the side of the dorsal median fin are distinctly continuations of the septa of the lateral muscle, though their direction is somewhat different. The same disposition is observed throughout the tail; except that as they are traced backwards the curves of the septa disappear; and in the hinder part of the tail the septa extend as straight lines, obliquely backwards and upwards, through the dorsal part of the lateral muscle and onwards, with merely an increase of obliquity, through the fin-muscle. In like manner the septa of the ventral part of the lateral muscle, behind the anus, merely acquire an increased slant backwards when they traverse the muscle upon the sides of the median fin.

Near the lateral septum the fibres of the lateral muscle, ventral and dorsal, take an antero-posterior direction, a direc-

<sup>1</sup> For the opportunity of dissecting this animal I am indebted to the kindness of Prof. Flower, of the Royal College of Surgeons. It was dissected for me by Mr Anningson. The anatomy of Ceratodus, with the exception of the muscles, has been fully described by Dr Günther, in an admirable paper contained in the *Phil. Trans. of the Roy. Soc.* for 1871.

<sup>2</sup> This was also absent in Lepidosiren and Ceratodus. See obs. p. 106.

tion that is parallel with the direction of the septum and of the axis of the animal. As they become more distant from the septum they acquire a slant; the fibres of the ventral muscle inclining a little downwards and backwards and those of the dorsal muscle a little upwards and backwards. Near the ventral mesial line the direction of the fibres is again antero-posterior; but near the dorsal mesial line the fibres still retain a slight obliquity. Dissected from without inwards the fibres of the deeper parts of the ventral muscle are found to preserve much the same direction as do those near the exterior; that is, no difference is traceable which would indicate an incipient division into external and internal oblique, such as was observed in *Lepidosiren* (p. 68) and more markedly in *Cryptobranch* (p. 11). We notice that as they approach the interior they become intermingled with an increasing number of threads of fibrous tissue which take the place of the muscular fibres. In some places a tolerably distinct stratum of these, passing from rib to rib or septum to septum, lies upon the transversalis fascia. There are no muscular fibres beneath the level of the ribs to represent a transversalis muscle. This decreasing proportion of muscular fibres towards the interior of the abdominal wall is interesting as an indication that the development of its muscular tissue become less active as we approach the interior (see obs. on the Tadpole, p. 113).

The intermuscular septal planes being continued into the muscle of the median fin, it follows that the muscular planes are likewise so continued, and that the fin-muscle is an extension of the lateral muscle. There are, however, some distinguishing points. First, the direction of the fibres is different. The fibres of the fin-muscle are nearly parallel with the fin-rays, that is, have a much more vertical course than those of the dorsal muscle; and the change in direction takes place suddenly, the fibres of the fin-muscle impinging upon those of the dorsal muscle at an angle which approaches to a right angle. Hence the one set are segmented from the other; and a layer of the superficial fascia, as described in *Lepidosiren*, and shewn in Fig. 31 of Dog-fish, passes between them, covers the edge of the lateral muscle, and meets its fellow in the mesial line, or comes into relation with the fin-bones and the vertebral spines; while

the other, or outer, layer is continued upon the surface of the fin-muscle and the fin. The fin-muscle and fin are continued in a channel between the two fascial layers just mentioned, and are transversely segmented by septa crossing the channel and continuous with the transverse septa of the lateral muscle. The fin-ray bones are ossifications in the meeting-points of the septa of the two sides in the median line; just as the spinous processes and ribs are ossifications in the median or other parts of the transverse septa of the lateral muscle. The fin-muscle is accordingly divided into bundles, which correspond in number with the interspinous and fin-ray bones; and each bundle is inclosed in a fascial sheath which separates it from the adjacent bundles as well as from the lateral muscle. Each bundle also is composed of fibres running parallel with the fin-ray and springing from the surrounding sheath, chiefly from the basal part of the sheath which rests upon the lateral muscle, but partly from the septa which separate them from the fibres of contiguous bundles.

The superficial or EXTERNAL FASCIA is unusually thick. It is connected by areolar tissue with the derma on the one side-face, and with the septa of the lateral muscle on the other; these connecting it, as in *Lepidosiren* and *Cryptobranch*, with the fibres of the lateral muscle and with the deep, or internal, or *transversalis fascia*. It is also continuous with the *transversalis fascia* along the ventral edge of the animal; and, in the abdominal region, the blended fasciæ of the two sides are united in the median line, forming a median septum. Behind the pelvis the blended superficial and deep fasciæ on the one side are separated from those of the other by the bowel passing between them to the anus; and a sheath formed by them is continued upon it (see also Fig. 23, G).

#### MUSCLES OF PELVIC AND PECTORAL FINS.

The cartilaginous pelvis, with its smooth anterior, or pre-pubic, styliform cartilage and its lateral cornua, resembles that of *Lepidosiren* (p. 69 and Fig. 23); but the cornua are shorter, and each is forked (Fig. 34 C), terminating in two blunt prongs,

into the hinder of which two intermuscular septa converging are inserted. Behind, the pelvis terminates in a semilunar edge, with a condyloid projection on either side for the articulation of the paddle-like fin<sup>1</sup>.

The styliform process is enclosed in a sheath of the blended fasciæ, as in *Lepidosiren*. The cornua lie in the lateral muscle, the fibres of which are attached to their anterior and posterior surfaces. The under surface of the pelvis is covered, on each side, by a thick muscular mass, the fibres of which are parallel with those of the lateral muscle, though they are separated from them by a cleft. This mass is divided into two nearly equal portions—a median or 'plantar' and a lateral or 'dorsal,' and the line of division between them corresponds with, and is a continuation of, the line of the inferior edge of the fin. The dorsal or lateral portion (*Gl.* Fig. 34) passes upon the dorsal or outer surface of the fin; and the plantar portion passes upon the ventral or inner surface of the fin nearly to its extremity<sup>2</sup>. Each, in its course upon the pelvis and upon the fin, is marked by transverse inscriptions, like those of the caudal lateral muscle. These inscriptions are transverse upon the proximal thick part of the fin; but, on the more distal part of the fin, they become oblique, slanting from the middle or axial line of the fin, backwards and outwards towards the margin of the fin. They correspond with and overlies the lines of division of the axial cartilage of the fin into pieces; and they extend over the rays which pass, in a penniform manner, from those lines. They do not extend between the pieces of the axial cartilage so far as the margin of the fin, but only about half-way from the axis to the margin. In the intervals between them the muscular fibres are directed longitudinally, parallel, that is, with the axis of the fin. In the more marginal parts of the fin the muscular fibres slant off obliquely, from the middle longitudinal set, which form the proper muscle of the fin, towards the margin; and the two sets are to some extent segmented from each other, in the same

<sup>1</sup> Günther, *l. c.* p. 535 and figures. In *Cryptobranch* the prepubic cartilage is not continuous with the pelvic cartilage, as in *Ceratodus* and *Lepidosiren*, but jointed to it by fibrous tissue. It is also less cylindrical and small, and bifurcates anteriorly into two flat unsymmetrical horns.

<sup>2</sup> I use the words 'plantar' and 'dorsal' in reference to those portions of the fin-muscle, to indicate their correspondence with the respective groups of muscles passing to the hind limb in higher animals.

manner as the muscles of the median fin of the body and tail are segmented from the adjacent parts of the lateral muscle, but less distinctly. Towards the extremity of the fin the distinction between the two sets becomes less marked; and, at last, the middle set of fibres are continued without interruption to the edge of the fin (Fig. 34). This similarity in the construction of this almost uniquely bipinnate fin or paddle and in the arrangement of its muscles, to the construction of the tail and to the arrangement of the muscles of the tail, is highly interesting. It is strongly confirmatory of the view I have formed, from the dissection of this animal and *Lepidosiren*, that the muscles of the mesial fin are derivations from the lateral muscles, presenting varying degrees of continuity with, or segmentation and separation from, them.

The muscle on the dorsal surface of the fin is not derived entirely from the girdle. It receives a direct accession from the lateral muscle in the form of fibres which converge, from several of the segments of the lateral muscle, upon the fin, and which blend in one of the septa of the fin-muscle (Fig. 34, *G'L*). Of these fibres the foremost, running parallel or nearly so with those of the lateral muscle, are continued uninterruptedly into them. The hinder fibres, crossing that muscle more at an angle, are segmented from it, lie upon its surface, and are without difficulty dissected from it, affording, like the corresponding muscle in the Dog-fish (p. 88, Fig. 30), another illustration of gradual segmentation in consequence of increasing difference of direction.

The accession to the dorsal fin-muscle represents not uncertainly the sheet of the ventral muscle extending upon the dorsal aspect of the corresponding limb in higher animals, which may be partially or wholly interrupted by the ilium growing through it, and which becomes more or less segmented into *sartorius*, *tensor vaginae femoris*, and *gluteus*. The part of the muscle derived from the pelvis represents the deeper *glutei*, &c.

In like manner the muscle on the ventral aspect of the fin is not derived altogether from the plantar and internal or mesial portion of the sub-pelvic mass just described. It is joined by bundles of fibres from the deep surface of the hinder or ischiatic part of the pelvis; and, moreover, some of the fibres from

the lower edge of the ventral muscle passing forwards from the tail (*Pl.* Fig. 36) are reflected into it.

This accession to the plantar fin-muscle from the caudal part of the ventral muscle may be regarded as representing the caudo-appendicular series of Urodelans which are variously segmented into caudo-pedal, caudo-crural and caudo-femoral.

The disposition of muscles upon the pectoral fin, which is also a bipinnate paddle, resembles closely that of the muscles upon the ventral fin, except that they are formed altogether by fibres passing from the girdle, there being no accessions from the lateral muscle, no correspondents, that is, with the *latissimus dorsi* and *pectoralis*. The fibres that arise from the scapular part of the girdle—the part above the joint with the fin—form a 'scapulo-brachial' muscle, which passes upon the dorsal aspect of the fin; and the fibres that arise from the coracoid part of the girdle—the part beneath the joint with the fin—form a 'coraco-brachial' muscle which passes upon the ventral aspect of the fin.

#### BRACHIO-CEPHALIC MUSCLES.

Traced forwards the ventral muscle does not give off, as in *Lepidosiren*, a superficial brachio-cephalic muscular stratum; though the superficial fascia, which represents it, is continued forwards over the girdle to the jaw. A representative of the cervical or cephalic portion (*cervicalis superficialis*) of this muscular stratum is, however, found in front of the pectoral limb-girdle in the form of a muscular layer composed of fibres or bundles passing transversely, or in a slightly curvilinear manner, over the gill-cover (Fig. 34, *C. s.*). Traced upwards these fibres do not reach the lateral septum, but are attached to the girdle (the scapular part of it) above the fin, to the supra-scapula, and the backwardly projecting cartilaginous occipital angle of the cranium. Anteriorly, they encounter and are attached to the opercular and sub-opercular bones, the hinder ends of which project into and interrupt the layer, and to the lower jaw. Inferiorly, they extend beneath the throat, and are lost in the extension of the superficial fascia. By this means only they acquire connection

with the rest of the ventral muscle. They take chiefly a transverse direction, and bear close resemblance to the corresponding *cervicalis superficialis* of *Lepidosiren* and Dog-fish. The reflection of it, as in Fig. 37, shews it to be inserted strongly into the cerato-hyoid cartilage (*C. Hd.*), also into the jaw near its angle, as well as into the opercular bones, and into the body of the jaw (*M*) between the angle and the symphysis. There are not any fibres running forwards from the hyoid to the symphysis and corresponding to those which in *Lepidosiren* (p. 73) I have supposed to represent the anterior belly of the digastric.

This muscle is mentioned, and partly described by Günther, p. 525. Lying beneath the outer or posterior half of the suboperculum, closely united with and projecting beyond it, so coming into relation with the fibres of the muscle just described, is a remarkable plate of cartilage, represented at *S. o. c.* Fig. 37, which is not mentioned by Günther. It is quite separate from all the cartilages of the skull, and is connected only with the suboperculum, though lying near the hinder edge of the cerato-hyoid cartilage. There is not any similar cartilage under the operculum; for the small cartilage described as pre-operculum by Günther is quite separate from the operculum.

Beneath the *cervicalis superficialis*, near the middle line, is the muscle which I have described in *Lepidosiren* (p. 71, and Dog-fish, p. 85), as the deep layer of the *cervicalis superficialis*. In this animal it is more separate from the remainder of the *cervicalis sup.* than it is in *Lepidosiren*; and it constitutes a distinct *genio-coracoid* (*G. c.* Fig. 37). It is flat, ribband-like, and attached behind to half-an-inch of the anterior edge of the coracoid cartilage, and of the epicoracoid-bone (p. 106), near the middle line. It extends, forwards, to the under-surface of the hinder edge of the mandible near the symphysis. It passes beneath the hyoid, and is not connected with it; still its fore-part may, and probably does, represent the genio-hyoid of other animals or the hyo-mental (p. 137).

THE DEEP LAYER OF THE BRACHIO-CEPHALIC EXTENSION is disposed much as in *Lepidosiren*. It first, in its lateral part, encounters the peculiar bone, or first rib, which appears to be formed in the lateral part of one of its septa. From the anterior and outer surface of this bone is given off a thick muscle

(*serratus*), which is a continuation of this stratum, to the under-surface of the scapula. A little more anteriorly and near the middle line the brachio-cephalic is inserted into the coracoid cartilage and the epicoracoid septum which quite interrupt it. In front of the coracoid it is continued as a thick muscle, but without septa, to the hyoid forming a *coraco-hyoid*, the representative apparently of the sterno-hyoid. The middle part is inserted into the base of the cone-shaped glosso-hyal by a flat tendon which passes beneath the basi-hyal. The fibres of its lateral part, which are situated in rather a deeper level, are inserted into the basi-hyal.

#### DESCRIPTION OF THE FIGURES OF CERATODUS (Pl. VII.).

Fig. 34. A side-view of the animal, shewing *D*, the dorsal, and *V*, the ventral muscle, and the lateral septum between them.

*P*, the styloform prepubic cartilage turned out of its median sheath, and inclined upon the left side of the ventral muscle. *C*, cornua of pelvic cartilage. *Gl.*, dorsal-fin muscle passing from the pelvis, upon the dorsal surface of the ventral fin. *Gl'*, accession to dorsal-fin muscle from lateral muscle. *A*, the anus. *S. F.*, the superficial fascia reflected from the outer-surface of the ventral muscle. It joins (*T*) the transversalis fascia coming from the inner-surface of the ventral muscle. The two united are continued upon the bowel. *O.*, opercular bone. *S. O.*, sub-opercular bone. *C. s. s.*, cervicalis superficialis superior muscle (its supra-branchial portion) passing over gill-cover. *C. Br.*, coraco-brachial mass passing upon the ventral aspect of the fin. *S. Br.*, scapulo-brachial muscle passing upon the dorsal aspect of the fin.

Fig. 35. A piece of the lateral muscle with one of the myotomes dissected out to shew the sclerotome, or intermuscular septum, *I. M.*, passing inwards and forwards above and below the lateral septum to *F*, the fin-ray bone, and *R*, the rib, in which it terminates, as well as in the side of the body of the vertebra between them. *R'*, a rib in front. The transversalis fascia is seen between the two ribs with an outer coating of tendinous fibres which slant, from above downwards (ventrally) and forwards, in a direction that is different from those of the muscular fibres above them, and corresponding with that usual in internal intercostals or depressores costarum. The cut ends of the fibres of the ventral muscular bundles are seen in front of the gap; whereas the dorsal fibres have been cleared away in the corresponding situation, and the under-surface of the septum next adjacent has been there exposed.



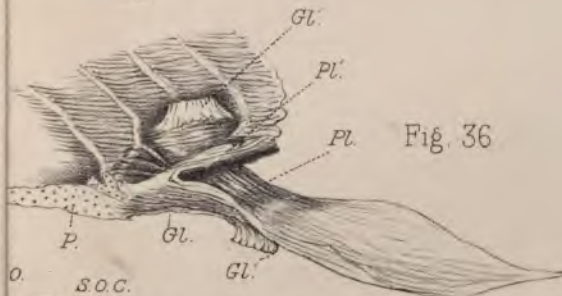


Fig. 36

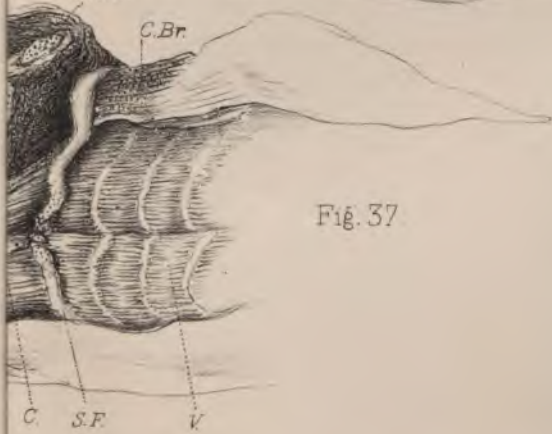


Fig. 37



Fig. 36. The pelvis and fin with part of the lateral muscle. *P*, the prepubic cartilage. *Gl.*, the dorsal muscle from pelvis to fin, and *Gl'*, the accession to it from the ventral muscle. The latter has been divided and reflected to shew *Pl.*, the plantar muscle from the pelvis to the fin, and *Pl'*, the accession to it from the caudal part of the ventral muscle.

Fig. 37. Dissection of the deeper muscles in the under-surface of the throat. *V*, the ventral, or brachio-cephalic part of the ventral muscle. *S. F.*, superficial fascia passing over *C*, the coracoid to *S*, the symphysis of the mandible. *C. s. s.*, cervicalis superficialis superior inserted into, *S. o.*, the sub-operculum. *S. o. c.*, the sub-opercular cartilage. *C. h.*, the cerato-hyal, and *M*, the mandible. *C. H.*, the coraco-hyal inserted into *G. h.*, the glosso-hyal, and *B. h.*, the basi-hyal. *G. c.*, the genio-coracoid of the right side. *G. c'.*, the genio-coracoid of the left side turned back in its middle and hinder part. *C. Br.*, coraco-brachial.

Fig. 38 shews the connection of the fore part of the ventral or brachio-cephalic muscular mass, and its septa with the coracoid. *C. C.*, the coracoid cartilage. *C'*, the epicoracoid bone. The muscular fibres have been left near the middle line, but dissected away more laterally to shew the septa which here slant, from the surface, backwards and inwards. The foremost septum is continued into the coracoid. The next has the peculiar rib-bone, *R*, projecting into it. It is continued into that bone. *C. Br.*, the coraco-brachial muscle extending from the girdle, beneath the joint with the fin, upon the ventral surface of the fin. *S. Br.*, scapulo-brachial muscle extending from the girdle, above the joint with the fin, upon the dorsal surface of the fin.

---

## NOTES ON THE MUSCLES OF THE GLASS-SNAKE.

### *Pseudopus Pallasii*<sup>1</sup>.

THE hind-limb is a mere slight scaly projection from the margin of the ventral articular plate, where the latter is being rounded off to form the anterior wall of the cloaca. The pelvic girdle is attached, above, to the transverse process of one vertebra<sup>2</sup>.

<sup>1</sup> This animal was dissected for me by Mr Anningson.

<sup>2</sup> The ilium extends a little above the transverse process; and the inner side of the ilium is applied upon the extremity of the transverse process (the second behind the last rib); a ball and socket is formed, the round end of the transverse process being received in a shallow socket in the ilium; and there is a synovial cavity with a thick surrounding capsule. The arrangement permits the lower ends of the two pelvic bones to swing backwards and forwards upon an axis traversing the transverse processes of the two sides. This movement is

Beneath, it is free in the abdominal wall, i. e., not connected with that of the opposite side. The small osseous limb marks, by its point of connection with the pelvis, the division between the iliac and the pubischiatic, or ischiatic, parts of the pelvis.

The *rectus abdominis* is a more distinct and continuous sheath than in the Snakes I have seen. It is joined by the successive bundles of the *obliquus externus abdominis* passing from the ribs into its upper or abdominal surface. Traced back it is quite interrupted by, or inserted into, the pubischiatic bone; and the hindmost division, or bundle of the external oblique muscle is inserted with it, and above it, i. e. deeper than it, into the same bone.

Examined more carefully the *rectus abdominis* (*longissimus abdominis* of Fürbringer<sup>1</sup>) is found to be composed, *first*, of bundles directed, forwards and outwards into it, from the extremity of the ribs and the costal cartilages, the hindmost of the bundles being attached to the mesial part of the pelvic bone (they resemble detached portions of external intercostal muscles); *secondly*, of bundles passing backwards and downwards, into it from the ribs nearer the vertebræ. These two sets of bundles lie in the same oblique lines; and they are confluent in the substance of the rectus. That muscle may therefore be said to be formed, either of bundles passing from the ribs near the vertebræ into it, travelling for a distance in it, and then leaving it to be attached to the free ends of the ribs and the costal cartilages; or, it may be described as being formed of fibres which take the opposite direction, that is, arising from the free ends of the ribs, joining it, and then leaving it to be inserted into the ribs near the vertebræ<sup>2</sup>.

These bundles run chiefly into the deeper surface of the

restricted by a fibrous band connecting the ilium with the transverse process next in front of it, the transverse process that is next behind the last rib. In an articulated skeleton in the Cambridge Museum the ilium is connected directly with the transverse processes of two vertebræ.

The limb consists of one longer bone next the pelvis, carrying a smaller bone, a mere nodule, upon its end. These bones should scarcely be named tibia and femur. They are as much representatives of the other limb-bones as of these two.

<sup>1</sup> *Die Knochen und Muskeln der Extremitäten der schlangenähnlichen Sauriern*, von Max Fürbringer. Leipzig, 1870.

<sup>2</sup> This is the case also in Snakes; though in them the bundles are finer and run more into the scutes, and form a less distinct antero-posterior muscle.

*lateral* part of the rectus. Its more mesial part is formed, wholly or nearly, of antero-posteriorly directed fibres<sup>1</sup>.

Behind the pubischiatic bone is a continuation of the series of external oblique muscular fibres, backwards, to the cloaca and into the caudal muscle on the side of the cloaca, so constituting an *ischio-cloacalis* and an *ischio-coccygeus*. These, it will be understood, are separated from the *rectus* and the *obliquus* by the pelvic bone.

Radiating forwards and inwards to the middle line from the median extremity of the pubischiatic bone is a *pyramidalis*. It is quite distinct, though thin; and it is broad. It lies along the inner side of the rectus; and the *pyramidales* of the two sides occupy the space on the ventral surface of the abdomen which is left uncovered by the *recti* diverging as they pass backwards to the pubischiatic bones<sup>2</sup>. This muscle is not described by Fürbringer.

The *gracilis* passes from the pubischiatic bone, where it is partially continuous with the *rectus abdominis*, into the inner or plantar side of the limb, and is attached to both the bones of the limb. Beneath the *gracilis* some deeper fibres, passing from the pubischiatic bone to the upper limb-bone, represent the *adductors*.

The deeper stratum of the abdominal muscle, the stratum, that is, beneath the level of the *obliquus externus* and the *rectus*, which extends more laterally than they, and in which the ribs are situated, and which therefore corresponds with the *obliquus internus*, if traced backwards is found to pass, in great measure, superficial to the ilium, into the ventral caudal muscle. Some fibres are, however, inserted into the ilium; and a tolerably distinct part of it passes, from the hindmost rib, to the ilium, constituting a *quadratus lumborum* and representing serially the intercostals.

If this internal oblique stratum is traced forwards, from the tail, a larger number of its fibres are found to be inserted into the hinder edge of the ilium, constituting an *ilio-caudal*; and one distinct bundle of fibres is found to pass

<sup>1</sup> These might be described as a *third* set. They are, however, probably continuous indirectly with the others.

<sup>2</sup> See similar disposition in *Pteropus*, *Journ. Anat.* III. 301.

beneath the ilium and to terminate in a tendon which runs on into the abdominal muscles; so that though the ilium lies deep it does not lie quite so deep as it does in Snakes, the ventral muscle being partially inserted into it and even partially travelling beneath it.

When the layer of the abdominal muscle travelling over the ilium is divided, a muscle is seen passing from the outer surface of the ilium upon the upper limb-bone. It is a representative of the deep *glutei*.

We do not discover any part sufficiently distinct to deserve the name *rectus femoris*; though such a muscle is described by Fürbringer.

The *transversalis* stratum of the abdominal muscles is represented by a sheet of muscular fibres passing from the sides of the bodies of the vertebræ, forwards and laterally, upon the under surface of the ribs, so forming *depressores costarum*. Some of these are traceable beneath three or four of the ribs. They decrease in thickness as they extend laterally; and they are scarcely traceable beneath the mesial parts of the ribs. The nerves lie between them, on the one side, and the ribs and the more superficial strata, on the other side. There is no *sub-vertebral rectus*. The *rectus capitis* is strong, arising from the anterior five or six vertebræ, also from the side of the hæmal spines of the three foremost vertebræ, and is inserted into the lateral part of the occipital. It encroaches upon the region usually occupied by the *longus colli*. These two muscles are however, as before shewn (p. 17), segments from one sub-vertebral mass.

#### BRACHIO-CEPHALIC MUSCLES.

NEAR the girdle the components of the *rectus abdominis* muscle radiate and separate into planes. The most superficial passes over the sternum and girdle, beneath the throat, over the lower jaw and side of the neck, and is lost in the tissue upon the back of the neck and head, thus constituting the *subcutaneus colli*.

Next beneath this, and crossing the direction of its fibres, is a tolerably defined muscle, the *depressor mandibulæ (cervici submaxillaris)* of Fürbringer, arising from the fibrous tissue

over the cervical spines and running, forwards and downwards, to the side of the angle of the lower jaw.

A little in front of the clavicle these two muscles are blended in a transverse inscription about two lines in length. This is supposed to be a representative of the acromion by Rudinger. It extends also through the subjacent stratum.

The next plane, partially interrupted by attachment to the sternum and clavicle, is continued forwards. Its more mesial portion runs under the clavicle, beneath the throat, to the hyoid and lower jaw as superficial *sterno-hyoid* (Fürbringer) and *genio-hyoid*, *hyo-mental*, and *mylo-hyoid*. The more lateral part—*sterno-cleido-mastoid*—a flat band slightly connected on its deeper surface with the clavicle<sup>1</sup>, runs to the back of the suspensorium (squamous or mastoid). It is superficially interrupted or divided into two—an anterior and a posterior part—by the inscription above mentioned.

More laterally still, that is, above the sterno-mastoid and rather on a deeper level than it, arising from the anterior edge of the upper, and scapular part of the clavicle, and on the same level with fibres of the sterno-hyoid and continuous with it, is a muscle which is called by Fürbringer a part of the sterno-mastoid, but which appears to me more properly to be called *trapezius*. It passes forwards to be inserted into the back of the suspensorium, immediately behind the sterno-mastoid, with which it is more closely connected near the skull than it is near the girdle.

These constitute the SUPERFICIAL BRACHIO-CEPHALIC STRATUM; those next described constituting the DEEP BRACHIO-CEPHALIC STRATUM.

The third, or deepest plane of the ventral muscle passing to the girdle, consists, *first*, of a broad muscle passing from the first rib, in nearly its whole length, to the hinder edge of the deeper surface of the scapula; *secondly*, of a broad bundle from the mesial part of the second rib to the hinder edge of the

<sup>1</sup> It is rather remarkable that the clavicle in its upper or scapular part is in, that is interrupts, this plane. Whereas in its lower or sternal part it lies beneath it, and interrupts the deepest plane of the brachio-cephalic mass. The superficial sterno-hyoid muscle passes quite superficially with regard to the clavicle, with the exception of a few of its lateral fibres which are continuous with the trapezius, and which are attached to the clavicle; whereas the deep sterno-hyoid is interrupted by the clavicle.

scapula; *thirdly*, of a narrower longer bundle from the mesial part of the third rib to the hinder edge of the coracoid near the sternum and to the sternum. It passes on also over the coracoid to the clavicle. *Fourthly*, a long thin band is attached to the coracoid. It runs nearly straight backwards over about a dozen ribs and, finally, blends with the intercostals. Of these, the first two appear to belong to the 'serratus' group, and the last two to the 'costo-coracoid' group. The absence of a limb precludes the opportunity of ascertaining whether the nerves to the limb pass, as they usually do, between the two groups<sup>1</sup>.

The *levator scapulæ* is a continuation of this plane onwards from the anterior edge of the upper part of the scapula, beneath the *trapezius*, to the transverse process of the first cervical vertebræ.

A *sterno-hyoideus profundus* (Fürbringer) passes from the anterior edge of the sternum to the hyoid. It is not distinctly continuous with any of the preceding. It is interrupted by the clavicle; and the hinder part of it is called *episterno-clavicularis* by Fürbringer. A few fibres passing from the sternum to the coracoid constitute a *sterno-coracoideus*.

*Sterno-costalis (triangularis sterni)* radiates, from a tendinous attachment to the hinder surface of the sternum, upon the deeper surface of several of the foremost ribs: it is in the stratum of the transversalis. There is no trace of diaphragm.

*Scaleni* are continuations forwards of the muscles between and upon the ribs to the cervical transverse processes. One slip reaches the lateral part of the occipital.

*Latissimus dorsi (trapezius of Fürbringer)* is small and thin, arising from the spines of five or six vertebræ behind the girdle. It is in the same plane with the *trapezius* but does not reach it. Its fibres converge; and the flat muscle formed by them passes over the dorsal surface of the scapula, lying upon the scapular cartilage but deriving no fibres from it, and is inserted into the hinder edge of the clavicle.

Near the scapula it is joined by a bundle from the *rectus abdominis*, which is a serial continuation of the bundles passing, from the lateral part of the *rectus*, to the ribs near the vertebræ.

<sup>1</sup> Nos. 2 and 3 are described by Rüdinger as *Pectoralis minor*, by Fürbringer as *sterno-costo scapularis*.



## ON THE DISPOSITION OF MUSCLES IN VERTEBRATE ANIMALS.

THE locomotory system of a vertebrate animal consists, fundamentally, of a successional series of alternating transverse skeletal and muscular planes which extend nearly through the outer wall of the animal. I say *nearly* through, for in and around the axial line, and in the immediate mesial plane, this alternation does not exist. The skeletal elements here form a continuous structure composed, in the axial line, during the early foetal state, and persistently in the Lancelet, of a simple cartilaginous notochordal streak, but usually, at a later period, of cartilaginous or osseous pieces articulated directly together or connected by ligamentous material. This vertebral column extends throughout the whole length of the animal; and cartilaginous or osseous processes run out from it, or in connection with it, more or less transversely, and serve as levers to aid the muscles besides fulfilling other purposes. It is obvious, however, that these processes must, in proportion to their length and unyielding character, limit the range of movement of the axial pieces upon one another and so lessen the flexibility of the animal. Accordingly, in the circumferential regions, especially in the directions in which movement is most required, the skeletal parts are not osseous or even cartilaginous, but are membranous and composed of fibrous plates extending from the axial osseous or cartilaginous structures to the skin. This may be the case throughout the whole of the muscular stratum as in the Lancelet, where the membranous septa extend from the skin down to the notochordal sheath and blend with it. The muscular planes occupy the intervals between the osseous processes and between the fibrous plates, the latter being continuous with the osseous axial pieces and their processes.

<sup>1</sup> The anatomical points mentioned in this paper, unless otherwise specified, are all from notes, published in the *Journ. of Anat.*, or in manuscript, of dissections made by Mr Anningson or myself. I have not been able to investigate the now copious literature of the subject so much as I could have wished.

This arrangement is found most distinct in the simplest parts of the lower vertebrates, as throughout the Lancelet and in the caudal region of Fishes and Urodelans. The structure of that region, with its longitudinal divisions caused by the dorsal, neural and lateral septa, and its transverse divisions caused by the transverse septa, has been described in the *Cryptobranch* (p. 3)<sup>1</sup>.

The transverse skeletal planes, membranous, cartilaginous and osseous, are sometimes called 'sclerotomes' and the trans-

<sup>1</sup> I should observe that the angular spaces left between the longitudinal divisions are not always, as in *Cryptobranch*, occupied by fat. In the Fish the dorsal and ventral furrows are often partly occupied by the dorsal and anal fins (see pp. 68, 89); and the lateral furrows are commonly occupied by muscular fibres which bear the transverse septa, but which are more closely connected with the skin, and peel off with it more easily than the rest of the lateral muscle. These fibres are more vascular than ordinary muscular fibres; and in a piece which I examined from a Dace they contained more oil than the other muscles. Stannius (*Handbuch der Zoologie*, II, 112) says that they, in addition, present microscopically the appearance of tissue in process of conversion into muscle. I did not find that to be the case. With the exception of the excess of oil, they presented the usual microscopic characters of striped muscle.

Stannius (II, 93) uses the terms 'epaxonalisch' and 'hypaxonalisch' to indicate the muscles above and below the axial vertebral line. Huxley (*The Anatomy of Vertebrate Animals*) uses the terms 'episkeletal' and 'hyposkeletal' to indicate the muscles situated respectively above and below the endoskeleton, and developed from above and beneath the protovertebræ. Strictly speaking, however, all the muscles are *interskeletal*; forasmuch as the intermuscular septa extend, from the transversalis fascia to the skin, through the entire thickness of the muscular layer which appears to be primarily and essentially one, and which is, for aught we know, all developed from the same embryonic protovertebral stratum; and the skeletal tissues undergo chondrification and ossification in certain parts only and in certain planes. The parts in which these changes take place are chiefly in and near the axial line. The plane in which chondrification and ossification occur is almost exclusively the middle one; and ossification without chondrification—i. e. from membrane—is most frequent in the superficial muscular plane; though it may take place much deeper, as in the instances of the parasphenoid, or sub-basal, bone and the vomer. I am not here speaking of the epidermal, or superficial dermal, tissues which may also be changed into horny matter, cartilage or bone. The ossifications in this epidermal layer are as distinct from those in the outer, or subcutaneous, muscular plane as these are from the chondrifications and ossifications in the middle muscular plane, or more so; and I do not think this distinction has been quite sufficiently kept in mind. It must not be forgotten that the 'cartilaginous,' the 'membranous,' and the 'epidermal' ossifications may be blended, and that the two former are particularly liable to be so. Indeed, those that begin in cartilage are usually enlarged by the addition of membrane bone. Histologically, there is perhaps no essential difference between the two.

It is, I think, far better to reserve the prefix 'epi' to designate the bones—membrane bones—which are formed, usually, though as above mentioned not always, in the superficial muscular or subcutaneous strata, and thereby distinguish them from the subjacent cartilage bones with which they are often closely related. Thus the 'episternals' and the 'epicostals' are indicated to be bones found in the tissue overlying the sternum and the costæ; and the 'epicoracoids' are bones or bony plates formed over, or upon, perhaps blended with, the coracoids.

verse muscular planes between them 'myotomes.' Very rarely, however, are the planes truly transverse. They commonly slant with more or less obliquity, backwards or forwards, from the axial line towards the circumference. An additional and more perplexing element of confusion is imported by the membranous or fibrous portions of the sclerotomes—the intermuscular septa as they are called—not preserving a uniform direction, but slanting first one way then another, first backwards and then forwards, or vice versâ, as they are traced from the upper or dorsal edge of the animal. Thus they acquire a more or less waving or zigzag line; and their superficial margins come to deviate considerably from the lines of their deeper margins and the lines of the osseous vertebral processes to which they are attached. Moreover the several curves or angles so formed may be produced to a great length. Especially is this the case near the mesial line, above—in the 'mesio-dorsal' part of the lateral muscle. Here the angles of the septa are often prolonged to a considerable distance; and in some Fishes (Bream and Dog-fish) they are, near the surface, thickened into tendons with the muscular fibres on the two sides of each passing obliquely between it and the adjacent septa, which has the effect of allowing the traction of a large number of muscular fibres to be brought to bear upon a given point or points (p. 83, Fig. 28). Where this occurs the intermuscular septa cease to run directly into the skin or to retain their close connection with it; for the cutaneous terminal filaments become converted into loose areolar tissue. Hence the tendinous septa as well as the intervening muscular planes, near the dorsal median line, in the Fishes above mentioned and in others, are allowed to glide with greater freedom beneath the skin than are the more lateral and ventral muscles, which are bound to the skin by the intermuscular septa running from the axial osseous structures into it.

A further change consists in the isolation of the prolonged and tendinous superficial parts of the septa from one another, and, to a greater or less extent, from their muscular contingents, as well as from the deeper and the superficial structures; so that they run alone to their destinations and

admit of traction without hindrance. This is effected by the conversion of the surrounding connecting structures into loose tissue, as just mentioned in the case of their isolation from the skin. Such a condition we find developed to perfection in the numerous delicate muscles and tendons which lie along the sides of the dorsal spinous processes of Snakes.

Thus, by comparatively simple stages of transition, the elongated longitudinal dorsal muscles are brought into relation with, or reduced from, the simple primary transverse muscular strata; and it is to be remarked that while this change takes place, usually in some degree and in many instances to the extent I have mentioned, in the upper or 'mesio-dorsal' part of the lateral muscle, the transverse disposition is commonly maintained through the visceral region, at any rate in the opposite and lowest, or 'mesio-ventral' part of the same muscle. Witness the transverse direction of the septa when they are persistent in the *rectus abdominis* and in its extensions into the neck and the tail.

So much for the variations in the fibrous plates or septa of the skeletal structure. Then, with regard to the muscles between them. These, in the simple condition, occupy the intervals between the septa and are composed throughout of fibres passing, antero-posteriorly, from one septum to another. Through the medium of the septa the fibres of one compartment are connected with those of the adjacent compartment, and also with the subcutaneous fascia and the skin, as well as with the osseous structures of the skeleton and the internal or transversalis fascia. I have already mentioned that where the septa are very oblique the muscular fibres between them usually take an oblique direction also.

Sometimes the fibres at one part of the thickness of the lateral muscle take an oblique direction different from those at another depth. This alone is sufficient to cause a cleavage into planes; and the cleavage usually extends through the septa as well as between the muscular fibres, so causing the separation of one or more superimposed muscular sheets which are thus rendered capable of moving upon one another<sup>1</sup>.

<sup>1</sup> The cleavage of a muscle into two planes, in consequence of a difference in the direction of its superficial and deep fibres, is well illustrated in the *pectoralis*

The Cryptobranch (p. 10) and the Lepidosiren (p. 68) offer examples of the cleavage being confined to the muscular elements without involving the septa. When the cleavage involves the septa these may remain (p. 70). Commonly they disappear, more or less completely, throughout the thickness of the muscular substance. A continuity, or ankylosis of the muscular fibres of the several compartments is thus established; and all trace of the primary, transversely segmented, myotomic arrangement is obliterated<sup>1</sup>.

Even without an alteration in the direction of the muscular fibres a cleavage into superficial and deeper planes may take place; and it may take place completely or partially. Thus a superficial stratum of muscular fibres, having the same or a different direction from those beneath them, may be quite severed from the deeper strata. It may retain here and there connection with the skin only, so forming, as is the case with portions of the pannicle, a purely 'cutaneous' or as commonly designated 'subcutaneous' muscle; or it may retain, at one or more places, a connection with the deeper strata of the muscle or, through remnants of the transverse septa, with the osseous skeleton. Thus it may be, as numerous varieties of the pannicle shew, a 'musculo-cutaneous' or 'osseo-cutaneous' muscle<sup>2</sup>. Lastly, a given layer may be severed from the deeper strata in a part only of its length, and may retain a connection, through the septa, which as already mentioned are equivalent to tendons, at both ends, either with the subjacent muscle or with the subjacent skeleton; witness some of the dorsal muscles, the muscles passing to the girdles, and many others. That is to say, a superficial or cutaneous stratum may be segmented more or less completely from the rest of the muscular system; and various strata of

*major* of *Cyelothurus* (*Journ. Anat.* iv. 25), and still better in that of the Wild Cat, in which there are no less than four layers.

<sup>1</sup> This is exemplified even in the Myxinoid fish *Bdellostoma*; and the contrast between the absence of inscriptions, or '*ligamenta intermuscularia*,' in the oblique muscles, and their presence in the straight muscles, is well shewn in Tab. I. accompanying Müller's well-known paper, *Abhandl. Berlin. Akad.* 1834.

<sup>2</sup> In *Pteropus* (*Journ. Anat.* iii. 299), the cutaneous muscles are connected with the skull, the sternum, the coracoid, the pelvis, and the femur, thus presenting unusually numerous and good examples of 'osseo-cutaneous' muscles. They are also remarkably well developed and have several osseous connections in the Hedgehog.

the remaining deeper portion may be more or less completely segmented from each other.

It is a very common thing for the muscular fibres to miss, that is, to pass over or under, one or more septa, as in the case of the erector spine and the subcostals. In these instances, and others of the like kind, the muscular fibres are continued through, or are ankylosed through, the septal tissue which has disappeared as such, owing to the embryonic tissue of the intermuscular septa undergoing the same histological change as the muscular parts. See p. 113.

A muscular plane, or any part of it, may also be divided longitudinally into portions or sectors by cleavages similar to that by which itself was separated from the strata above or beneath it.

Thus from the simple primary, transversely segmented, lateral muscle, on either side of the animal, the various muscular forms may be elicited. Moreover the differences in the muscular systems of different animals, and in different though serially homologous parts of the same animal, may in great measure be explained by variations in the number of the strata or of the sectors, or by variations in the depths at which the several strata have been detached, or in the points at which the several sectors have been separated. Hence, although general correspondence may be indicated, precise homology must not be too closely pressed.

The processes which I have mentioned may be recapitulated as follows: 1, varieties in the inclination and direction of the septa; 2, prolongation of the angles of the septa caused by increased inclination and flexure; 3, separation of the thus prolonged septa with their appended muscular fibres, individually or in groups, into independent muscles; 4, variation in the direction of the muscular fibres; 5, cleavage into planes and into sectors reaching to various depths; 6, fusion or ankylosis of the muscular segments by the establishment of continuity through the septa.

In the three highest orders of vertebrates, if we exclude the vertebral processes, the ribs, the hyoid and the limb-girdles, which are ossifications in the deeper parts of the septa, and the tendons of the dorsal muscles, which are modifications of the septa, the intermuscular septa are represented only, or chiefly, by the

inscriptions in the *rectus abdominis*, *biventer cervicis*, *digastric* and *omo-hyoid*, by occasional inscriptions in the *sterno-hyoid* and *sterno-thyroid*, by the clavicle or the inscription which, in carnivora and some others, is substituted for it between the *trapezius* and the *deltoid*, and by Poupart's ligament.

The fibres in these animals retain their simple antero-posterior direction between the successive skeletal septa in the instances of the *interspinales* and *intertransversales* and in the *recti-abdominis*, though in the last some of the septa have been obliterated. In the *semispinales* the fibres run obliquely between the successive skeletal structures and also in the *intercostales*. In these last, the direction of the obliquity varying at two parts of the depth between the successive ribs, two strata are formed resembling the two strata of external and internal oblique between the successive ribs and septa in the abdomen of Cryptobranch (p. 10). These and other variations will, however, be mentioned as we proceed.

Reverting to the plan of the construction of the locomotory system of a vertebrate animal, we have found it to consist of a series of transverse, alternating, skeletal and muscular planes or discs, traversed by an antero-posterior axial line, the whole being enclosed in an external fascial sheet which is also part of the skeletal system and which lies beneath the skin. A transverse section shews that each disc is in two lateral halves applied, as it were, upon the axial line which is formed by the notochord or the vertebral bodies. Each half constitutes one side of the animal. Owing to the obliquity with which the planes or discs slant from the axial line, a transverse section passes through both the muscular and the skeletal planes and shews their relative disposition. Such a section indicates the locomotory system of an animal to consist on each side of a fascial, or skeletal, tube enclosing a muscular cylinder, which last is traversed by transverse or oblique, fascial or skeletal planes. The approximated sides of the skeletal tubes are flattened against each other, above and below the axial line; and becoming fused here in great part of their extent they form mesial septa passing, dorsally and ventrally, from the axial line.

This is well illustrated by the section of the tail of a Tad-

pole (Fig. 41)<sup>1</sup>, in which the fascial walls on either side, ascending and descending from the notochord and enclosing the neural and hæmal canals, meet and so form the dorsal and hæmal septa. These run peripherally into the upper and lower membranous edges of the tail, where they are joined by the fascial layers from the exterior of the lateral muscle. Thus each membranous edge of the tail is composed, essentially, of four sheets—the two mesial sheets which are blended together and form the septum, neural or hæmal, and the two external, or lateral, sheets which are derived from the superficial covering, or fascia, of the lateral muscle. It is interesting to observe that at the

<sup>1</sup> The specimens of *Pseudis* Tadpole, from which the drawings were made, were kindly sent me by Mr Mivart.

Description of Figures of the *Pseudis* Tadpole (Pl. VIII.).

Fig. 39.—Side view of the animal, shewing the lateral muscle of the tail. This at the hinder part is in interrupted fragments, which are serially arranged in rows with wide septa between the rows. Further forwards the muscular fibres are more developed, filling in the rows and diminishing the intervals between them. A pin (*C*) is placed in the cloacal opening; another, above *B*, is in the branchial opening. Above, and in front of the branchial opening, is the eye. The small hind limb is seen on the hinder wall of the visceral cavity, or rather in the furrow between it and the tail, above *L*.

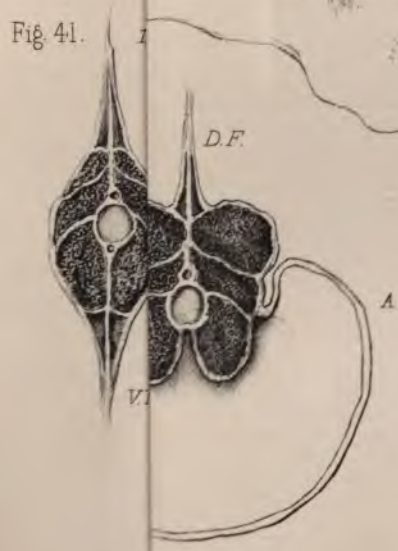
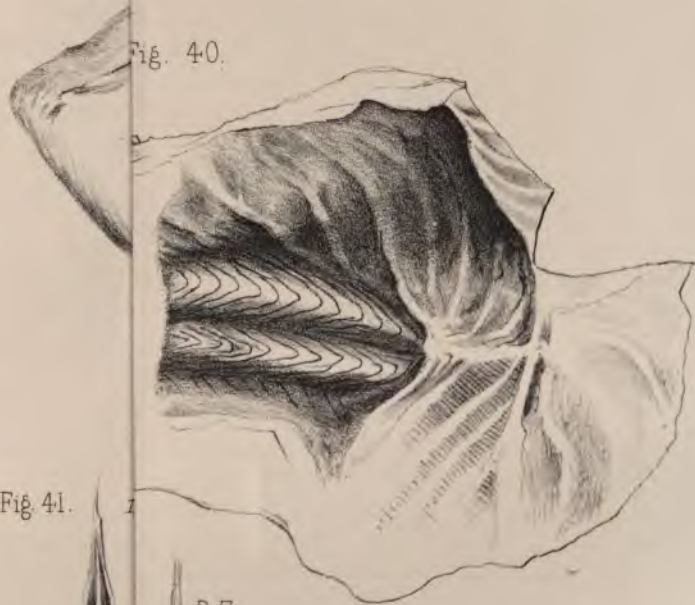
Fig. 40.—The visceral cavity laid open in a specimen more advanced where the cavity is more elongated. The transversely marked ventral portions of the lateral muscle are seen extending, from the tail, along the sides of the bodies of the vertebra, and projecting into the visceral cavity, with an interval between them leading down to the hæmal passage which has ceased to be a covered canal, and is merely a channel. The wall of the visceral cavity has been turned back; and the commencing development of its muscle is shewn, in isolated tracts, by fine muscular fibres arranged in rows between broad, white (septal) lines.

Fig. 41.—A transverse section at about the middle of the tail. The large central circle is the notochord, with a small neural canal above and a small hæmal canal below.—*D. F.*, the dorsal, or neural, membranous fringe.—*V. F.*, the ventral, or hæmal, membranous fringe. The neural septum extends from the notochord up the middle of the one, and the hæmal septum down the middle of the other. The sides of both are formed by extensions of the membrane covering the lateral muscle. The base of each, between the mesial septum and the external membrane, is occupied by soft succulent tissue which is separated from the lateral muscle by an offset from the external enveloping membrane.

Fig. 42.—A section through the animal, made at the back part of the visceral cavity, and seen from in front. *D. F.*, the dorsal fringe with the neural septum descending, through its middle, to the neural canal and the notochord. Beneath the latter is the hæmal passage at the bottom of a deep channel between the lateral muscles of the two sides, or, rather, between the plates of the hæmal septum, which have not coalesced, and which separate the hæmal channel from the lateral muscles. Beneath this channel is, *C*, the cloacal tube. *A* is the wide posterior cul-de-sac of the abdominal wall, with the muscular fibres beginning to be developed in rows between the paler lines, which indicate the future septa.

Fig. 43.—A section farther forwards. *A*, the abdominal, or visceral, wall ascends, is reflected, higher on the sides of the lateral muscle, reaching to the dorsal part of that muscle. The hæmal channel is wider and forms part of the visceral cavity.







extremity of the tail (Fig. 39), as well as along its upper and lower edges, the membranous sheets alone exist, the muscular fibres being absent; so that the mesial and external membranous plates are in contact. A little in front of the extremity of the tail the muscular fibres begin to appear, in patches, separating the external from the mesial plates. The patches are in broken rows; still they succeed one another in serial order. Gradually, as they are traced forwards, the rows are filled up and the membranous interspaces between them become reduced to the narrow intermuscular septa; while the muscles, increasing in thickness, acquire the semicircular or ovoid form which is seen on either side of the median line in a transverse section (Fig. 41). It is thus perceived that the membranous, or intermuscular, element is the first formed, that the muscular fibres are produced, or added in it, that the intermuscular septa and fascial sheets are remnants of it, and that these give way, in greater or less degree, before the force of muscular development.

Usually, in other animals, ossification takes place, to a greater or less extent, around the notochord, giving rise to the bodies of the vertebræ, and extends into the ascending and descending mesial laminæ, forming the neural and hæmal arches and spines. In Fishes (Figs. 31, 32 and 33) it also often extends into these laminæ, where they stretch, like the membranous fringe of the Tadpole's tail, beyond the confines of the lateral muscle. Thus are formed the fin-ray bones, which, like the septa, are double, actually or potentially; and muscular fibres are formed upon them. These have the same relations to the membranous laminæ, and the same segmentation, as the fibres of the lateral muscles, and are, indeed, extensions of them, though they take a different direction, and are, consequently, segmented from them (p. 69).

In front of the tail, in the visceral region, the mesial hæmal laminæ are kept apart; and the visceral cavity is formed between them. In other words, they are spread out over it, and form the *fascia transversalis*. This separation of them may, in the hindmost region of the visceral area, be confined to the marginal part of the hæmal septum: thus, in Fig. 39 of the Tadpole, the cloacal tube and aperture are seen to lie at the junction of the membranous caudal fringe with the

abdomen; and they are the result of a want of adhesion of the mesial laminæ which form that fringe. In the Fish the cloacal fissure, or separation, of the mesial laminæ, usually extends deeper into the region of the hæmal spines, which are, accordingly, bifurcate and arch transversely over this part of the visceral cavity instead of, as in the tail, occupying a median position, and each pair being fused into a single process. In front of the cloacal region, and through the rest of the visceral cavity, with occasional exceptions near the head, the separation of the mesial laminæ extends down to the vertebræ, splitting the hæmal arches of the two sides quite asunder, and laying the hæmal canal open to the visceral cavity. Towards the fore part of the visceral cavity the mesial laminæ and the hæmal arches are pressed so far upwards upon the vertebral bodies that the arches come to occupy the place of ribs.

The wall of the visceral cavity is thus formed by the separated and expanded hæmal plates, and not merely by those parts of the plates upon which, in the tail, the lateral muscle is formed, but by those parts also which form the membranous hæmal fringe in the Tadpole's tail, and in which the subcaudal or anal fin is formed in the Fish. In the Tadpole it is chiefly this latter, membranous, fringe-like part which becomes expanded; for the lateral muscle (the ventral portion of it) is continued, without much alteration, from the tail, forwards, through the abdomen<sup>1</sup>, as represented in Figs. 40, 42 and 43. These figures further shew the manner in which the membranous part is spread out and is reflected upon the sides of the lateral muscles, so as to give greater space for the contents of the visceral cavity; and they shew the mode in which the development of the abdominal muscles is commencing in the thickness of the wall by broken serial rows of muscular fibres with intervening septal lines, upon which the muscular transformation gradually encroaches, in the same manner as the development of the lateral muscle is progressing at the end of the tail (Fig. 39). Further, in Fig. 40, an extension from the sides of the lateral muscle is seen to be proceeding into the hinder part of the abdominal wall. In the Fish, the part of

<sup>1</sup> It is reduced and becomes the *quadratus lumborum* in the Frog.

the hæmal plate in which, in the tail, the lateral muscle is developed becomes, in the abdomen, more expanded than it does in the Tadpole, and forms, at any rate, the ventro-lateral (*V. L.*, Fig. 31) portion of the body-wall. It is not improbable that the part in which, in the tail, the anal sub-caudal fin is developed is continued forwards into the abdomen as the mesio-ventral (*M. V.*, Fig. 31) portion of the body-wall. Of this, however, I cannot be sure, the two parts (*V. L.* and *M. L.*) being, as we might expect from their development in one continuous hæmal plate, blended into one 'lateral' muscle<sup>1</sup>. There can, however, be little doubt that, as pointed out by me, in a paper "on the Homology of the Mesial and Lateral Fins of Fishes," in this *Journal*, Vol. v., the ventral and pectoral fins and their muscles are formed from the same serial elements as the sub-caudal or anal fins and their muscles.

I will now consider, briefly,

#### THE DORSAL MUSCLES OF THE TRUNK,

that is, the muscles situated above the lateral septum. These, though numerous, in accordance with the number of the vertebræ that require to be moved upon one another, do not present much variety or much interest in different animals. In the Fish the dorsal mass from which they are derived indicates a division into an upper or 'mesio-dorsal' and a lower or 'latero-dorsal' part. This division corresponds on the whole with that into the *spinalis* and *longissimus dorsi* and the *sacro-lumbalis* parts in higher animals. Such incipient longitudinal segmentation is less marked in Cryptobranch, Perennibranch, and Lepidosiren, than it usually is in Fishes. It is seen again in the Salamanders.

The dorsal muscles may be arranged, as follows, in two divisions:

*First*, those in which the fibres retain the primary antero-posterior direction and pass between corresponding parts of contiguous or distant vertebræ. Those connected with contiguous

<sup>1</sup> Supposing this view to be correct, the sternal ribs and the sternum would be serial representatives, not of the hæmal processes but, of the osseous elements of the subcaudal fin—the fin ray-bones—of the Fish.

vertebræ are commonly designated in accordance with the parts of the vertebræ between which they pass. Thus they are called '*Interspinales*,' '*Intertransversales*,' and '*Interobliqui*' or '*Interaccessorii*.' The foremost of them is the *Rectus capitis posticus minor*. They are developed in proportion to the mobility of the parts between which they pass, that is, they are most developed in the neck and loins, and least in the back. In the back the *intertransversales* and *interspinales* are sometimes merely ligamentous. In the more superficial members of this series the fibres sometimes leap over one or more segments to a distant point. This is caused by the superficial fusion of two or more septa, owing to the non-development of muscular fibres between them, or by the superficial obliteration of one or more septa from the extension of muscle-development through them, producing, in the one case, an elongation of septum or tendon, and, in the other, an elongation of muscle. In this manner are formed the *spinalis dorsi* and *spinalis colli* and the several parts of the *erectores spinæ*. The last, it may be observed, often overlap, to some extent, and are connected with the ventral parts of the skeleton, viz., the iliac bones and the ribs, parts, that is, which lie beneath the lateral line.

The *second* division includes the muscles in which the fibres have an oblique direction and pass between non-corresponding parts of contiguous or distant vertebræ, for instance, from transverse process to spine, or from spinous process to transverse process. The obliquity is therefore in two directions, giving rise to two sets, the fibres of which cross one another. In the one set the fibres pass from spinous processes *outwards* and *forwards* to the transverse processes; and in the other set, which is on the whole in a deeper plane, the fibres pass from the transverse processes *inwards* and *forwards* to the spinous processes. The more superficial, spino-transverse or *outwardly* directed, set comprises the *obliquus capitis inferior*, and the *splenius capitis* and *colli*. The deeper, transverso-spinous or *inwardly* directed, set comprises the *obliquus capitis superior*, the *complexus* with the *biventer*, the *semispinalis colli* and *dorsi*, the *multifidus* and *rotatores spinæ*.

The dissections of Cryptobranch (Fig. 20) and of Lepidosiren (Fig. 25) show conclusively that the *temporal* muscle is a pro-

longation of the dorsal muscle forwards from the neck, beside the cranial neural arches, over the suspensorium, to the lower jaw, and that the temporal fascia is the continuation of the fascial aponeurosis of the dorsal muscle. They render it probable that the *masseter* and *external pterygoid*, and also the ocular muscles, are an extension of the same series. According to this view the temporal ridge which, in most vertebrates, shuts off the masticatory muscles from the rest of the dorsal system, may be regarded as an ossification of, or an ossification extending into, a transverse intermuscular septum, an ossification, that is, in the superficial stratum of the dorsal muscle passing upon the head.

The *ligamentum nuchæ* and the interspinous ligaments, as well as the ligamentous bands tying the skin to the several spinous processes, are modifications of the longitudinal median septum which I have already (pp. 66, 112) described.

The modifications of the dorsal muscle in the tail do not require any special description. It may be sufficient to remark that in cases where the pelvis is absent or rudimentary, as in the Porpoise, the portion of it called *erector spinæ* is continued uninterruptedly from the lumbar to the caudal region.

#### THE VENTRAL MUSCLE

is subject to much greater modifications in the different regions of its course than is the dorsal. In the hinder part of the tail it much resembles the dorsal muscle of the same part; but, anteriorly, the symmetry between the muscles above and below the lateral line is destroyed by the expansion of the ventral muscle over the visceral cavity, by the formation of the limb-girdles in its substance, and by its relation to the limbs. Travelling forwards it first comes into relation with the openings of the alimentary, urinary, and genital organs, and detaches muscles to them. It then encounters the pelvis and hind limb, which, more or less, interrupt and make demands upon it. Next it is expanded, and the direction of its fibres is modified, by the visceral cavity. Then the shoulder-girdle and forelimb, the branchial and hyoidean apparatus, the larynx and pharynx, the lower jaw and the face necessitate modifications

to meet their several requirements, which vary in different animals, and which lead to almost infinite diversities in the disposition of the several parts of the muscle.

The ventral muscle, and this is important, not unfrequently overlaps the dorsal muscle. Such is described by Müller to be the case in *Bdellostoma*<sup>1</sup>; and superficial fibres or strata of it are often prolonged into the tissue over the dorsal muscle, so reaching the dorsal spines, or are continued as distinct muscles to this region (see pp. 13, 72, and Fig. 24). This occurs especially towards the fore part of the trunk, and is exemplified particularly in Snakes (Fig. 44); and this extension contributes to the formation of the superficial muscles of the neck, throat and face, as well as to those of the limb-girdle and limb.

While the superficial strata of the ventral muscle thus overlap the dorsal muscle, and reach to the dorsal median line, the deeper strata, as represented by the intercostals and the ribs, are commonly, to some extent, overlapped by it; so that the lateral margin of the dorsal muscle is received between the layers of the ventral muscle.

In the simplest condition, as in the ordinary teleostean fish, the ventral muscle does not undergo much change in its different parts. The two fascial hæmal plates, as has just been shewn, which line the apposed sides of the ventral muscle, in some parts of the tail coalesce beneath the hæmal spines, and form a median osseo-membranous septum, extending from the hæmal spines to the skin. At other parts they are separated by the caudal or anal fins. At the foremost part of the tail they are also separated; and the commencement of the visceral space exists between them, but walled off from the hæmal space by the hæmal arches still bridging over the latter. Further forward the separation is greater, the osseous hæmal arches disappear, the hæmal and visceral cavities are laid into one, or are divided only by membrane. The ventral muscles of the two sides are pushed asunder; and the separated membranous hæmal plates which line them are named the *fascia transversalis*. Ossifications in the inner parts of the transverse septa which pass from the fascia transversalis, through the lateral muscle, to the external fascia and the skin, form the ribs.

<sup>1</sup> *Abhandl. der Akad.* Berlin, 1834, s. 245. It may be observed also that in *Bdellostoma* (*l.c.* p. 246) the superficial fibres of the ventral muscle, in the interval between the head and the hinder opening of the gills, cross the median line and are continued from either side upon the surface of the ventral muscle of the opposite side, where they are lost in the superficial fascia. This, however, is quite exceptional.



The latter thus correspond serially, or nearly so, to the hæmal spines, split and pressed asunder, and to the sides of the hæmal arches. If an interval is left between the ribs and the transversalis fascia, in which muscle is developed, it constitutes the *transversalis* muscle, or it may constitute the *levatores*, or, more commonly, the *depressores costarum*, according to its position<sup>1</sup>; and when this muscular sheet extends beneath the bodies of the vertebræ it constitutes the *subvertebral rectus* (p. 11).

The mesial edges of the ventral muscles, inferiorly, are separated and covered by *fascia transversalis* continued round each into the *external fascia*. Behind, there is an interval between the contiguous edges of the ventral muscle, thus covered by fascia, which permits the passage of the alimentary tube to the anus. A layer of the fascia (Fig. 23, *G*) accompanies the tube and binds it to the skin; and some muscular fibres may be developed around it forming a sphincter.

In front of the anus the pelvic bones lie between the *fascia transversalis* and the ventral muscle, or in the substance of the deeper layers of the ventral muscle, in the same plane, that is, as the ribs. The fins project between the mesial edges of the ventral muscle; but marginal portions, or (Bream) a larger amount of the deep stratum, of that muscle are attached to the pelvic bones, constituting a '*retractor*' or '*protractor*;' and more superficial portions constitute what are sometimes called '*carinales*' muscles. In some Fishes (*Ceratodus*) portions of the ventral muscle extend upon both surfaces of the fin. The pectoral fin projects at a more lateral point; and the ventral muscle is attached more largely to its girdle which, like the pelvic bones, occupies the same relative position, with reference to the thickness of the abdominal wall, as the ribs. From it the ventral muscle is continued forwards to the hyoid and the head.

<sup>1</sup> In the Bream, Dace, and some other Fish, there is a sheet of muscular fibres passing from the vertebræ forwards and downwards internal to the ribs, that is, taking a direction corresponding to the internal intercostals and subcostals of mammals, and to the internal intercostals, *depressores costarum* and *transversalis* of Cryptobranch. In *Ceratodus* (p. 92) I have described tendinous fibres taking the same direction. Some are attached to the ribs nearest to their point of origin, others to more distant ribs. The nerves are external to this sheet. Towards the fore part of the body of the Dace fibrous bands take the place of these subcostals.

The median third or half of the ventral muscle is not unfrequently distinguished from the remainder in Fishes by the mere transverse direction of its septa. In some, as the Dogfish (Fig. 28), it is segmented from the remainder, in great part of its extent, and overlaps it. In Mammals also it is separate, as *rectus*, and is enclosed in a sheath formed by prolongations of the lateral portions of the ventral muscle, or their tendons, to the mesial line. Its continuity with the lateral parts of the ventral muscle has been shewn in Cryptobranch (p. 11), and in Lepidosiren (p. 68). In Cryptobranch, however, it must be observed that while the more superficial or *oblique* strata of the ventral muscle are continued into the *rectus*, the deepest or *transversalis* stratum, separating itself from the others, passes upon the deeper surface of the *rectus* to the middle line; and in Mammals the *rectus* is ensheathed by tendinous extensions from the deep, or peritoneal, and the superficial, or cutaneous, divisions of the ventral muscle which pass, upon its peritoneal and cutaneous surfaces, to the middle line. Though we are in the habit of thus referring the walls of the sheath of the *rectus* to the expansions of the lateral parts of the *ventral* muscle, we may, with equal right, assume them to be deep and superficial strata of the *median* part of the ventral muscle, that is, derivations from the *rectus* itself. And as, on the one hand, they retain their continuity with the lateral parts of the muscle, so, on the other hand, do they retain their connections with the *rectus*, or middle stratum of the same, through the transverse inscriptions which extend from it into them.

As already intimated the ventral muscle is disposed in three chief planes or strata which are in variable degrees distinguishable in different animals and in different parts of the same animal. Of these, the middle—or internal oblique—plane is that in the septa of which the pieces of the true or cartilage skeleton are for the most part developed: the external—or external oblique—stratum is connected with the external fascia and the skin, and is that in which the pieces of the dermal or membrane skeleton are for the most part developed: and the internal—or transversalis—plane is connected with the internal or transversalis fascia and the viscera, much in the same way as the external plane is connected with the external fascia and the skin. The connection with the viscera, however, is in great part interrupted by the formation of the visceral cavity. Primarily all the planes are continuous or, rather, form one plane from the skin to the visceral

tube. It remains so in the Leech. In the Earthworm the transverse septa still connect the visceral tube and its muscles with the dermal sheet and its muscles. In higher animals the visceral cavity interrupts the septa; and they are restricted to the dermo-muscular layer, except near the oral and anal apertures, and in the situation of the diaphragm or diaphragms, where the inner layer or layers of the dermo-muscular sheet bend in towards and come into contact with the visceral sheet of the animal. In the Fish the dermo-muscular sheet is, for the most part, in one undivided plane, with the septa extending throughout it and connecting the skin with the fascia transversalis. In Batrachians the muscular part is more separate from the skin on the one side, and the fascia transversalis on the other; and the stratification of the muscular part into the three planes above-mentioned is commencing.

We will first take the INNERMOST—the TRANSVERSALIS—STRATUM of the ventral muscle, the stratum that lies internal to or beneath the osseous skeleton, or between the innermost parts of the skeleton, and internal to the chief nervous and vascular trunks. In most Fishes (though not in all, p. 119) it is absent, or partial or rudimentary, being represented by tendinous or fascial structures and scarcely distinguishable from the *fascia transversalis*. It may enter with that fascia into the formation of the *post-cardiac diaphragm*; and it is sometimes (Dog-fish) a main constituent of the *pre-cardiac diaphragm*. In Cryptobranch we have found it very extensively disposed beneath the ribs and the rest of the wall of the abdominal cavity, forming the *depressores costarum* and the *transversalis* muscle. It also lies beneath the vertebral column, from the pelvis to the head, forming the *subvertebral rectus*; and there is no *diaphragm*. In higher animals it seldom is present as a continuous sheet in this last situation; but portions of it remain, forming the *longus colli*, the *rectus capitis anticus*, the *crura* of the *diaphragm* and the *retractor ani*. On the interior of the lateral parts of the abdomen and thorax it is usually present in animals above Fishes, forming the *transversalis* muscle and the *depressores costarum*<sup>1</sup>, also the internal *intercostals* and the *triangularis sterni*<sup>2</sup> with the *subcostals*. It is continued, with more

<sup>1</sup> These last are strongly developed in Snakes, and are quite segmented from the *transversalis* with an interval between them and it, in which the *levator costarum* appear.

<sup>2</sup> The *triangularis sterni* and the *transversalis* are sometimes continuous in Man, as remarked by Stannius, Rosenmüller and Meckel.

or less interruption, within the pelvis and is then gathered in around the bowel as a pelvic diaphragm, or *levator ani*, some of its fibres being reflected into, and some continued into, the muscular coat of the bowel. In some instances—Pseudopus P. (p. 101), Cryptobranch (p. 17) and others—a part of it is continued on into the subcaudal muscles. In Mammals a stratum is inflected from the ribs, or gathered in like the *levator ani*, upon the alimentary tube, forming the lateral portions of the post-cardiac *diaphragm* which, in continuity with a remnant of the subvertebral portion (the *crura*), constitutes a septum shutting off the thoracic from the abdominal regions, but with apertures, like those in the pelvic diaphragm, for the passage of the œsophagus and the vascular and neural trunks. The *psosas magnus* and *parvus* also appear to be derivatives from this stratum<sup>1</sup>, as well as some fibres of the *cremaster*.

It will be evident that the direction of the fibres of this stratum varies much in different parts of its extent, being antero-posterior where it lies under the vertebral column, oblique where it lies under or between the ribs, transverse where it forms the abdominal wall, and converging where it is inflected upon the viscera; and in proportion to the diversity in the direction of their fibres the several parts are segmented from each other.

In Cryptobranch it is throughout, or nearly, traversed by septa, and is so held in continuity with the *transversalis fascia*, on the one side, and the rest of the ventral muscle and the components of the osseo-cartilaginous skeleton on the other. In higher animals, however, the septa for the most part disappear in its substance and upon its surfaces. They still abide forming the lines of separation between the digitations of the *transversalis* muscle and the *diaphragm*, as well as between the members of the internal intercostal series, blended in the latter situation with the costal periosteum or perichondrium.

The *internal* or *transversalis fascia* is in contact with the greater part of the extent of the internal surface of the *transversalis* stratum and is gathered in with it to form the *levator ani* and the post-cardiac diaphragm. Thus it lies upon the anterior

<sup>1</sup> In the Guinea Pig the *psosas parvus* passes with the *ps. magnus* and the *iliacus* over the pubes to the lesser trochanter of the femur.

and posterior surfaces of both those diaphragms and reaches and is continued upon the alimentary tube<sup>1</sup>. From the anterior surface of the *levator ani* it is reflected upon the rectum and the bladder; and from the posterior surface it is continued to the integuments of the anus and the superficial fascia of the perineum. The part of the internal fascia behind the gathering-in of the *levator ani* forms the true pelvic fascia lining the obturator muscle; and it is stretched beneath the pubes as the triangular ligament. The part of the internal fascia in front of the diaphragm lines the intercostals and the ribs and is gathered in, in front of the first rib, as the precardiac diaphragm, or the deep cervical fascia, between the thoracic and the cervical regions. The internal fascia is also continued upon the inner surface of the cremasteric projection of the transversalis muscle, forming what is called the *fascia propria* of the spermatic cord. Just in front of the pubes, in Man and some other animals, the internal fascia is separated from the *transversalis* muscle which there passes with the internal oblique in front of the *rectus*.

The MIDDLE—the INTERNAL OBLIQUE—STRATUM is the most persistently intra-skeletal of the three strata of the ventral muscle; and the intermuscular septa traversing it are, in many places, solidified by conversion into cartilage and bone. Thus, the ribs and sternum, the limb-girdles and the hyoid are developed in it, and chiefly in its inner layers, though they may, and occasionally do, the limb-girdles more particularly, grow through the other strata and come into contact with the *fascia transversalis*, on the one side, and with the skin, or the *fascia superficialis*, on the other.

In the abdomen this stratum forms the *internal oblique*, the *quadratus lumborum*<sup>2</sup>, the *rectus*<sup>3</sup> and the *pyramidalis*<sup>4</sup>. The

<sup>1</sup> In Fishes these diaphragms are chiefly formed, so far as they are represented at all, by the fascia alone. The sheet passing upon the bowel near the anus represented in *Lepidosiren* (Fig. 23) is the only representative of the pelvic diaphragm.

The post-cardiac diaphragm is wanting in Saurians as well as Ophidians (Stannius, 105). In some birds, as *Apteryx*, it is well developed in its crural, or vertebral, and costal parts, but is deficient in front, where the heart projects through it.

<sup>2</sup> This muscle is carefully described by Carus, *Beiträge zur vergleichend. Muskellehre, Zeitschrift für Zoologie*, III. He regards it as part of the ventrolateral system; he says it is absent in Birds, but present in Chelonians, Ophi-

complete segmentation of the *quadr. l.* from the stratum, above, and of the *rectus* and *pyramidalis*, beneath, is due to the sudden alteration in the direction of their fibres from that of the fibres of the *internal oblique*. The relations of this muscle to both are nearly the same, a layer of it being continued upon the superficial, and another layer upon the deep surface of each; and these layers, forming sheaths for the *rectus* and *quadr. l.*, are in contact, and more or less blended, with the superficial (external oblique) and deep (transversalis) strata of the ventral muscle.

In the thorax the middle stratum forms the series of *external intercostals*. The direction of the slant of the intercostal muscles might indicate the external layer to belong rather to the superficial, or external oblique stratum and the internal intercostals to belong to this middle stratum. But, as we have already found, the fibres in different parts of the same stratum are disposed in very variable directions; and the relations to the intercostal nerves and blood-vessels are stronger grounds for classing the external intercostals with the internal oblique and

dians, Saurians and Batrachians; that in Man it sometimes passes to the body of the 11th dorsal vert. and to the 11th rib, in the Buffalo to the 4th hinder dorsal vert. and ribs. In some animals, as Hyrax (see Meckel), it advances still further forwards. In Cryptobranch its representative is not segmented from the rest of the ventral muscle, but, like that of the *rectus*, is continuous with it. In *Pseudopus Pallasii* it is distinctly a serial correspondent and extension of the intercostals passing from the hindmost rib to the iliac bone (p. 101).

<sup>3</sup> The relations of the *rectus* to the several strata of the ventral muscle vary a good deal. Primitively, as in *Lepidosiren* and most Fishes, it is continuous, and on a level, with the whole thickness of the ventral muscle. In *Cryptobranch* it is so with the middle and external strata only, while the internal stratum passes above it. In Snakes a deep part of it seems to be represented by thickening of the intercostal fibres near the extremities of the ribs. Some of these thickened bundles pass from rib to rib, and some from one rib to another at a greater distance. And in them, and more clearly in *Pseudopus P.* (p. 100), it, or the chief part of it, lies on a plane superficial even to the external stratum the fibres of which pass into its deeper surface. In Mammals it is completely segmented from all the strata, and lies in the greater part of its course between the layers of the middle stratum.

Müller, *Abhandl. der Berlin. Akad.* 1834, p. 345, and Tab. I, describes and represents the *rectus* as distinct from, and covered superficially by, the *obliqui* in *Bdellostoma*. This is, however, unusual in Fishes.

<sup>4</sup> The *pyramidalis* appears to have special relations to the marsupial bone, and to the spine and crest of the pubes, which are the representatives of that bone; and its presence as an independent muscle is probably to be associated with the tendency to the presence of this as an independent bone (foot-note on p. 16). Functionally, it seems to assist in strengthening the suprapubic region of the abdominal wall; and it is well developed in animals (female *Pteropus*, *Journal Anat.* III. 301, and *Pseudopus P.*, on page 101) in which, in consequence of an interval between the pubic bones, the *recti* muscles diverge and leave this part of the abdomen comparatively unsupported.

the internal intercostals with the transversalis stratum.—The *levatores costarum* which, like the external intercostals, are overlapped by the dorsal muscle, may also be ranged as members of the middle ventral stratum<sup>1</sup>.

The *rectus* is usually continued forwards on the external surface of the sternum and costal cartilages, not unfrequently as far as the first costal cartilage, constituting a *rectus thoracis*. Other longitudinal muscles are sometimes (Aï, Cyclothurus, Otter, &c.) developed, lying also beneath (superficial to) the ribs, more laterally than the rectus, and constituting what may be designated *recti thoracis laterales*<sup>2</sup>, to distinguish them from, and mark their relation to, the *rectus thoracis*. These muscles approach or alternate with extensions of the *scaleni* backwards. The *rectus* may (Cyclothurus and Otter) be crossed superficially by a *sterno-costal* muscle passing from the sternum, obliquely forwards and outwards, to the ribs and approaching the *scaleni*. All these belong to the middle or internal stratum of the ventral muscle and are merely illustrations of varying cleavage and segmentation in accordance with varying direction of fibres.

From the ribs the middle stratum is continued forwards laterally to the cervical transverse processes as *scaleni*. These are separated from the *rectus capitis* and *longus colli* of the internal stratum (p. 121) by the cervical nerves. As just hinted, they often extend upon the exterior of the ribs, meeting the *recti th. laterales* and the *sterno-costales*<sup>3</sup>. Anterior to the *scaleni* is the *rectus capitis lateralis*. Nearer the mesial line, inferiorly, the middle stratum is continued forwards to the hyoid<sup>4</sup>, thyroid,

<sup>1</sup> In Snakes, these last are much developed and extend over a greater range than in other animals, for the purpose of assisting in progression; and there is commonly to be found a series of internal *levatores costarum*, situated external to the outer part of the *depressores*, crossing those muscles and appearing in the interval between them and the *transversalis*. Their position would indicate them to belong to the internal stratum; but the nerves which lie external to the depressors and the *transversalis*, pass internal to the levators. It may be added that the nerves in these animals do not confine themselves to the intercostal spaces opposite which they escape from the vertebral canal, but, in some instances, cross over one or more ribs, passing between the ribs and the *transversalis*.

<sup>2</sup> One of these has been so named by Macalister, in his description of Aï, *Annals and Mag. of Nat. Hist.*, June 1869.

<sup>3</sup> In the Green Monkey the *scalenus* is continued into the *rectus*.

<sup>4</sup> The inscriptions in the ventral muscle running forward to the hyoid,

tongue, jaw and pharynx as *sterno-hyoid* and *sterno-thyroid*, as *hyo-glossus* and *genio-hyo-glossus*, and as *hyo-* and *thyro-pharyngeus*, or middle and inferior *constrictors* of the pharynx. These come into relation with muscles ascending to, or descending from, the skull, which probably also belong to the same stratum, viz. *stylo-glossus*, *stylo-hyoideus* with the hinder portion of the *digastricus*<sup>1</sup>, *stylo-pharyngeus*, superior *constrictor* of the pharynx, as well as the faucial and palatal muscles.

From the outer surface of the middle stratum muscles are detached to the shoulder-girdle. Those passing to the part of the girdle above the glenoid cavity (the scapular part) constitute the *costo-scapular* or *serratus* group. They consist of one or more muscles attached to the ribs, interdigitating and sometimes connected by continuity of fibres with the external oblique, so as to present strong claims to be regarded as part of the same stratum with it; but in their course they are deep; and they are inserted into the deeper surface of the margin of the scapula, on one or two sides, between the *sub-scapularis* and the other muscles which are inserted into, or near, the margin of the scapula. Anteriorly, this group is prolonged into the neck as the *levator scapulae* which is not unfrequently continuous with the *serratus*, and as the *omohyoid*<sup>2</sup>. The muscular

present in *Lepidosiren* and others, are not unfrequently represented by one inscription near the middle of the *sterno-hyoid*. This inscription is continued into the *omohyoid* with which the *sterno-hyoid* is sometimes continuous; and it is usually persistent in the latter muscle, in Man, where it makes a bend towards the clavicle. Stannius speaks of an extension of the *rectus* to the tongue in Triton.

<sup>1</sup> In the Porpoise this part of the digastric only is present passing from the hinder part of the temporal to the hyoid. It is called occipito-hyoid by Rapp, *Die Cetaceen Zoologisch-anatomisch dargestellt*, s. 132, and by Stannius, *Müller's Archiv*. 1849, s. 7, but is regarded by Stannius as the posterior belly of the digastric. For account of the anterior part see page 136.

<sup>2</sup> The *omohyoid* may be, as in *Phoca*, continuous with the *sterno-hyoid*, forming a broad muscle inserted into the sternum, the ulnar tubercle of the humerus and a fascial band between the two. It may, as in *Seiue*, be attached to the clavicle as well as to the scapula; and the *sterno-hyoid* is in that animal attached to the interclavicle, or episternum. Tendinous traces of the clavicular attachment bend it towards the clavicle in Man, and are, partly or entirely, the cause of the persistence of the inscription or interruption in its muscular fibres. Though in the same plane with the *levator scapulae*, it is separated from it by the situation of the branchial opening, which also separates the members of the superficial brachio-cephalic stratum (the *sterno-mastoid* and *trapezius*) that overlie this region. In the Hippopotamus it passes from the side of the basi-hyal and the sub-hyoidean septum to the under surface of the occipito-humeral part of the *trapezius* which it joins at an angle, and is united to it by an inscription. The foremost fibres run on without any definite inscription to



derivations from this layer, which pass to the girdle beneath the glenoid cavity, are the *sterno-* or *costo-coracoids*. When the coracoid is abortive, the *costo-clavicular*, called *subclavius*, may take the place of the *costo-coracoid*<sup>1</sup>; and when both coracoid and clavicle are abortive, the member or members of the group may pass to the under surface of the scapula, constituting the *costo-* or *sterno-scapulars*<sup>2</sup>. Thus, spreading beyond their usual limits, these may come into close relation with the serratus group. Or the serratus, extending lower down than usual, may come into close relation with the costo-coracoids. Still the two groups—the costo-scapular and the costo-coracoid or costo-clavicular—are, I believe, always separated by the nerves to the limb passing between them.

These two groups of muscles passing, respectively, to the scapular and to the coracoid or the clavicular parts of the shoulder-girdle, together with the muscles passing forwards to the hyoid, tongue and jaw, constitute that which I have designated (pp. 74, 97) the DEEP BRACHIO-CEPHALIC STRATUM of the VENTRAL MUSCLE. In animals (Snakes and Urodelans), in which the inferior wall of the thorax is not closed in by the sternum and the costal cartilages, the middle, or cephalic, part of the stratum may be continued onwards, uninterrupted, to the hyoid and the mandible, but it is not segmented from the superficial stratum (Fig. 44 and description); or (Fishes, Figs. 26 and 38) it may be interrupted by the coracoids extending athwart the middle line and uniting with one another, and may then be segmented from the superficial stratum.

Traced backwards from the abdomen, the middle stratum

the humerus. In the Pig it passes over the anterior edge of the scapula to the upper edge, and is connected by fibrous tissue with the radial tubercle of the humerus and the deltoid muscles.

<sup>1</sup> These two do not coexist, when the coracoid is large, the muscle passes from the sternum or rib to it, and forms a *sterno-* or *costo-coracoid*. When the coracoid is short the muscle, if present, passes from the rib, or the first or (Orycteropus) second costal cartilage and perhaps the sternum, to the clavicle constituting the *subclavius*. It may, as it does in *Orycteropus* and *Scine*, extend on to the scapula. In the Porpoise the *subclavius* passes from the first rib, near the sternum, to the coracoid; and the *pect. minor* passes from the second rib to the humerus. Stannius, "Beschreibung der Muskeln des Tümmers." *Müller's Archiv*, 1849, s. 14 and 16, calls the former of these *pect. minor*, and the latter *costo-humeralis*.

<sup>2</sup> The sterno-scapular may coexist with the subclavius. Thus Macalister found the subclavius quite separate from the sterno-scapular and inserted into the clavicle. In such case the muscle is divided into two.

of the ventral muscle encounters the pelvis and is interrupted by it<sup>1</sup>. Its continuations backwards from the pelvis constitute the *ilio-* and *ischio-caudales*<sup>2</sup>, the deep *sphincter-ani*, the *erector-penis*, *compressor-urethræ* and *transversus-perinei*, besides the extensions upon the hind limb around the hip-joint to be subsequently mentioned.

I pass now to the disposition of the EXTERNAL STRATUM of the VENTRAL MUSCLE which has the external oblique muscle of the abdomen as its most steady representative, and which I, therefore, sometimes call the EXTERNAL OBLIQUE STRATUM. As already stated, it is the stratum in which the ossifications, not preceded by cartilage, most frequently occur. The 'membrane bones' thus formed are commonly in the situation of the septa, and, therefore, overlie the 'cartilage bones' formed in the septa of the middle stratum. Sometimes they are blended with them, the two being ossified together, or the one may serve as a substitute for the other. Thus the epicostals<sup>3</sup>, the episternum<sup>4</sup> and the epicoracoid, or clavicle,

<sup>1</sup> It must not be forgotten, that the rudimentary pelvic bones of Ophidians lie, or rather project upwards, internal to the *transversalis*. Perhaps they originate in the internal oblique stratum, and grow through the *transversalis*, just as in many animals the ilium presents through the external oblique stratum, and as in the Dog-fish, the scapula pushes its way into the dorsal muscle (Fig. 28). In *Pseudopus P.*, the ilium, though deep, is not quite so deep as in Snakes, a considerable part of the ventral muscle is inserted into, or interrupted, by it, and a distinct strip of the muscle passes beneath it (p. 101).

<sup>2</sup> The ischio-caudal, and the ilio-caudal are, to some extent, serially homologous, respectively, with the costo-coracoid, and the costo-scapular (*serratus m.*); and the nerves to the hind limb pass between them, as do the nerves to the fore limb between the last-named muscles.

The shoulder-girdle, like the pelvic girdle, varies in the depth at which it is placed, and also remarkably in the size of its coracoidal part, and in its connection with the rest of the skeleton above and below. In Fishes the coracoid part is imbedded in the deep stratum of the ventral muscle; but in *Cryptobranch*, the coracoid, notwithstanding its size, has little direct connection with the ventral muscle, the deep layers of which pass clear of it and above it. In Birds and Reptiles its connection with the deep ventral stratum is re-established by the costo-coracoid muscles. In Mammals the connection is chiefly, through the medium of the *pectoralis minor*, with a deep layer of the pectoral or superficial stratum of the ventral muscle.

<sup>3</sup> In *Hatteria* the epicostals are more numerous than the costals, occupying not only the lines over them, but the interspaces between those lines: see Günther, *Phil. Trans.* 1867, p. 608, whose description I have in most points verified.

<sup>4</sup> I much prefer the old term, 'episternum' to that of 'interclavicle', proposed by Mr Parker; because it expresses not only its position, but its nature as a bone formed in the membranous tissue upon the sternum, at the same time that it refers it to the same series as the epicostals and the clavicle.—It will be perceived that, for the same reason, I use the term 'epicoracoid' to designate, not the cartilage or cartilages lying between the coracoid and the sternum, but the

are formed, respectively, over the costals, the sternum and the coracoid, and the lower jaw is formed over Meckel's cartilage. We have seen that this stratum is, in Fishes, closely connected with the skin by the transverse and longitudinal septa passing through the compact intervening external fascia.

A superficial layer of the stratum is often, more or less completely, segmented from the rest, and, retaining its connection with the skin, or with the superficial fascia or both, constitutes cutaneous or subcutaneous muscles to which the names *pannicle*, *platysma myoides*, &c. are given. They may retain their original connection not only with the rest of the external ventral stratum, but also with the deeper strata, and with the cartilage bones. Thus they, in some instances, are united to the ribs and the sternum, the vertebral spines and the limb-bones. They often correspond, and are more or less blended, with the several divisions of the rest of the stratum, and will therefore be best considered in relation with them. They commonly extend over the lateral septum, spreading upon the dorsal muscle, and reaching the dorsal mesial line. This also we shall find to be the case with the rest of the stratum. Or, which is much the same thing, the components of this external stratum of the ventral part of the lateral muscle are confluent with superficial dorsal fibres, and form one stratum with them; so that it might be called the 'external ventro-dorsal', or, better, the 'external lateral' stratum, that is, the external stratum of the entire lateral muscle<sup>1</sup>. See Diamond Snake (Fig. 44)<sup>2</sup>.

membrane bone, or clavicle, formed upon it, and often in close connection with it.

<sup>1</sup> This extension of the external stratum of the ventral part of the lateral muscle, over the lateral line and over the dorsal part of the muscle, to the vertebral spines is due, perhaps, to the expansion of the visceral cavity, laterally and upwards, as seen in the section of the Tadpole (Figs. 42 and 43).

<sup>2</sup> Description of Fig. 44, Pl. ix.—THE DIAMOND SNAKE.  
Dissection of the fore part of a Diamond Snake.—The pin is inserted into the fore part of the cerato-hyoid cartilage which is seen running back among the muscles. The drawing shews the bundles of the external oblique arising partly from the lateral septum, and partly from the fascial tissue on the surface of the dorsal muscle and passing, downwards and backwards, into the antero-posteriorly directed fibres of (*r.*) the rectus abdominis. Traced forwards, the rectus is seen giving off the bundles of the external oblique. Anteriorly, it expands into a muscular sheet, in the middle of the thickness of which the hyoid is involved. This runs forwards to the lower jaw, covers the under part and sides of the throat, expands upon the side of the head and neck, and extends over the dorsal muscle to the cervical spines. A set of its bundles more distinct than the others runs to the angle of the mouth, constituting a *retractor oris*.

This expansion is a continuation of the entire thickness of the ventral mus-

In the abdomen the stratum is chiefly represented by the external oblique which extends upon the exterior of the thorax, and the fibres of which often blend with the fibrous tissue over the dorsal muscle. Anteriorly, it is continued, or its superficial fibres are continued, with a variable amount of interruption, into a 'superficial brachio-cephalic' sheet which extends to the face and head, which is distorted by encountering the fore limb and its girdle, and the fibres of which converge upon the limb, as though, like the skin, they had been pushed before it as it grew out from its girdle. Hence, opposite the limb, the fibres are directed transversely, from the ventral and dorsal mesial lines, upon the limb; whereas, before and behind, they have a more oblique or antero-posterior direction.

As it advances towards the fore limb the inferior, or ventral, part of the superficial brachio-cephalic sheet resolves itself into the *pectoralis major*, the fibres of which converge upon the radial edge of the humerus, inclining to the plantar aspect; the superior, or dorsal, part of the sheet resolves itself into the *latissimus dorsi*, the fibres of which converge upon the ulnar side of the humerus, and are often, to some extent, blended with the muscles on the dorsal aspect of the limb. I say, to some extent, because the prolongations upon the middle and distal segments of the limb of both the inferior and superior parts of the sheet show an inclination to the plantar aspect, which is a consequence of the position and flexures of the limb. The two—*pectoralis* and *lat. d.*—may (Lepidosiren, p. 71) be united and pass as a continuous sheet upon the radial and ulnar margins and upon the intermediate, plantar or axillary, that is, the posterior aspect, of the shoulder and limb. More commonly they are separated by the axillary interval; or, connecting axil-

cle, and contains therefore the elements of all the muscles covering the under part and sides of the neck, and passing between the thorax, hyoid and jaw. It represents, in short, the whole of the brachio-cephalic stratum of Lepidosiren and Dog-fish,—the *cervicalis profundus*, that is, as well as the *cervicalis superficialis*;—and it includes therefore the factors of the sterno-mastoid and trapezius, the platysma, constrictor faucium, &c. A continuation of it backwards would represent the pectorals and latissimus dorsi as well as the serratus.

Though its hinder edge seems to be marked off from the oblique, yet its connection, and the connection of the oblique with the rectus, and the fact that the oblique bundles cease where this more continuous expansion begins, shew that it is a serial continuation of them, of the parts of them more especially which extend upon the dorsal muscles.

lary bands, may remain as a result of imperfect segmentation<sup>1</sup>. The term 'achselbogen' has been applied to them. The term 'axillary' is that by which I will designate them.

The *costo-alaris* (*costo-anconeus*) of the Bird is an interesting example of one of these 'axillary' muscles, being segmented from both the *pectoral* and the *latissimus dorsi*, and passing from the ribs, between the two, near to the *serratus*, along the inner side of the arm, to or near the inner condyle of the humerus. In the Swan I found part of it elastic, where it occupied the hinder fold of the axilla, and traced it along the ulnar margin of the wing, and in the retiring angle beneath the carpus, to the skin and tissue binding the skin to the ulnar phalanges. Thus it presents interesting antagonistic homological affinities to the *tensor plicae alaris*; and by its near relation to the *serratus* on the deeper side, and by its blending with the cutaneous muscles and the skin on the superficial side, it is an interesting relic of the primitive union of the several strata.

The relation of this brachial, or hinder part, of the superficial brachio-cephalic sheet to the rest of the external oblique stratum varies a good deal. In many animals, for instance, the *pectoral* is a continuation of the whole thickness of the *external oblique*, or of the whole or great part of the *rectus*. In Cryptobranch it is almost entirely derived from these. In others, it is a superficial stratum only of the oblique, extending perhaps to the pubes. In others again it arises from the outer surface of the aponeurosis of the oblique; and in Hatteria it appears to arise from between its layers<sup>2</sup>. In Man it is usually continuous with the oblique by means of only a few muscular fibres. In the Hippopotamus it is largely continuous with the subcutaneous muscle over the oblique; whereas in Birds its origin is so confined to the sternum and the clavicle that we should little have thought of regarding it as an extension of the abdominal stratum, had our attention been limited to its anatomy in them. In like manner the *latissimus dorsi* is, in some, confined to the neural spines, in others extends upon the ilium; and, not unfrequently, it derives origin from the hinder ribs, where it may (Seal) meet, and be united with, the *pectoral*. In the Porpoise its origin is confined to the 5th, 6th and 7th ribs<sup>3</sup>.

<sup>1</sup> A good illustration of these axillary muscles was presented this winter by a female subject in the dissecting-room of this University. A slip from the lower edge of the *pectoralis*, and another from the anterior edge of the *latissimus dorsi* in each arm, ran through the axillary space and, meeting, were inserted together into the fascia covering the *coraco-brachialis*.

These connecting bands are commonly large in Carnivora. They are usually formed by an extension of the *latissimus dorsi*, or parts of it, beneath the axilla, to the pectoral muscle and the pectoral ridge of the humerus; while another part of the *lat. d.* runs along the inner side of the triceps to the inner condyle forming the *dorsi-epitrochlien*.

<sup>2</sup> *Phil. Trans.* 1867, p. 609. In Pteropus, *Journ. Anat.* iii. 300, it is in three separate parts, an abdominal, a sternal, and a clavicular.

<sup>3</sup> The variation in the mode in which cleavage of strata may take place is illustrated by the fact, that in Birds and Reptiles the *lat. d.* usually overlaps the

All this hinder, post-brachial, portion of the external stratum of the lateral muscle may be covered by a superficial, or subcutaneous, layer, which varies much in thickness, and which may be connected with one or all of the divisions of the stratum, sometimes reciprocating with them in size and thickness, as in the Hippopotamus. Like them it converges upon the arm; and, accompanying the pectoral more particularly, it may be lost in that muscle, or it may be inserted into the humerus or the coracoid.

It is often a muscle of such size, and of so powerful action upon the arm, and radiates from the arm so widely upon the flank, that I have<sup>1</sup> described and named it as *brachio-lateral*. Sometimes it, or part of it, lies upon and is closely united with the *latissimus dorsi*; or it may be (Hatteria) continuous with its lower edge. Sometimes (Manis) it is difficult to separate from the skin on the one side and the external oblique on the other<sup>2</sup>. As mentioned above, it forms part of the *costo-alaris* of the Bird.

Traced forwards into the pre-brachial or cervical region the SUPERFICIAL BRACHIO-CEPHALIC STRATUM, which we are considering, is, after a certain interruption caused, partly, by the shoulder-girdle, and, partly, by segmentation from alteration of the direction of its fibres, continued as a superficial cervical sheet—*cervicalis superficialis*. It covers the neck, from the shoulder-girdle to the skull, and from the ventral median line to the

*trapezius*, the reverse being the case in Mammals. In the Rabbit the two muscles are continuous.

<sup>1</sup> *Journ. Anat.* iv. 27.

<sup>2</sup> The superficial, cutaneous layer is well developed in the Porpoise, where it spreads upon the fins, under the abdomen, and under the sheath of the penis; and in the female it passes beneath the mammary gland, detaching fibres which encircle the lower dilated part of the duct, so as to compress it during suckling. It attains its maximum in the Hedgehog, being connected with the frontal and occipital bones, the lower jaw, sternum and humerus, and the dorsal and caudal spines, and forms a thick sphincter around the body beneath the line where the bristles terminate.

In the Guinea Pig both *pectoral* and *trapezius* are continuous with the pannicle. In the Pig, and many Animals, the brachio-lateral part extends over the thigh. In the Hippopotamus it is very largely developed, forming a thick mass over the abdominal muscles, which are almost dwarfed or supplanted by it, though quite distinct from it; it extends over the thigh and the knee; and it is also continued into the pectoral.

In Snakes the continuity of strata is manifested and maintained by the bundles of the oblique abdominal muscles passing from the ribs directly into the ventral scutes, which are thus enabled to act as organs of locomotion. Some of the bundles running horizontally for a distance, from scute to scute, constitute (pp. 125, 139) a superficial or subcutaneous *rectus*.

lateral line; and it commonly extends, in a muscular form, beyond the lateral line, to the dorsal median line. Anteriorly, it is connected with the whole circumference of the skull, and sends superficial prolongations over it. It is well exhibited in *Lepidosiren* (Figs. 24 and 26), Dog-fish (Figs. 28 and 29), and *Ceratodus* (Figs. 34 and 37), and I have named the ventral part of it, lying beneath the level of the gills, *cervicalis superficialis inferior* (*C. s. i.*), and the dorsal part of it, lying above the level of the gills, *cervicalis superficialis superior* (*C. s. s.*). These two parts are, however, continuous upon and above the gill-cover; and the superior or dorsal portion (*C. s. s.*) seems rather to be an extension from the inferior or ventral portion (*C. s. i.*), just as the ventral and dorsal portions of the post-brachial part of the same stratum are often continuous, and the latter seems to be an extension from the former.

In animals like those just mentioned, where there are gills with the attendant opercular structures, the *cervicalis superficialis* is but a thin expansion, and does not present any distinct segmentation beyond that—often not very distinct, into *levatoros*, *depressoros*, &c. *arcuum*—which is requisite for the movements of the branchial apparatus. Where, however, the gills are abortive it acquires increased thickness and is stratified and segmented.

A superficial layer forms the *subcutaneus colli* or *platysma* which covers the neck and is prolonged forwards upon the face and head, where it blends with and is continued into the facial muscles, the auricular muscles and the *occipito-frontalis*. It is prolonged backwards upon the thorax and fore limb to an indefinite extent, blending with the *brachio-lateral* and, like it, finding its way to the osseous structures of the limb. As in the case of the *brachio-lateral*, portions of it may blend with, or supplant, segments of the subjacent layer.

In some instances it is continuous with the *trapezius*; and in *Pteropus* it takes the place of the cervical portion of that muscle<sup>1</sup>. A remarkable detachment from between its dorsal and its ventral

<sup>1</sup> Macalister finds that the muscle, which thus in Bats supplants the cervical part of the *trapezius*, is supplied not by the spinal accessory, but by cervical nerves and the seventh nerve.

portions, blended with a similar detachment from the deeper layer (from the contiguous edges of the pectoral and *trapezio-deltoid*), forms the *tensor plicæ alaris*, better called *cervico-alaris*. This, partly composed of elastic tissue, extends along the radial edge of the wing in Bats and Birds, and reaches the skin and subcutaneous tissue of the radial digits. It is thus (as mentioned p. 131) the antagonistic homologue of the *costo-alaris*.

The deeper layer of the *cervicalis superficialis* develops into the *sterno-cleido-mastoid* and the *trapezius*, the former representing the ventral, or sub-branchial, part of the layer, and the latter representing the dorsal, or supra-branchial part<sup>1</sup>. They are very regular muscles, but vary in their range of attachment at both ends. The *sterno-cleido-mastoid* is sometimes confined to the sternum and then is called sterno-mastoid. Sometimes it is inserted, by a narrow tendon only, into the mastoid, instead of by a broad musculo-tendinous termination as in Man<sup>2</sup>. Sometimes the portion connected with the clavicle is separate, forming a cleido-occipital. The *trapezius*, instead of the extensive origin from skull, cervical and dorsal spines, overlapping the *latissimus dorsi*, which it has in Man, may (Pteropus and Birds) have much more limited origin. It may, in the absence of the clavicle, be inserted (Cryptobranch) into the anterior edge of the scapula and the precoracoid or (Aī) the coracoid; or it may be continued as *trapezio-deltoid* to the humerus<sup>3</sup>. When this last occurs, there is usually an inscription remaining between the *trapezius* and the *deltoid*, in the deeper part of which a rudimentary clavicle is often present in Carnivora.

From beneath the *trapezius* the *rhomboids*<sup>4</sup> are segmented,

<sup>1</sup> The interval between the two in Raccoon is partly bridged over by fibres passing from the trapezius to the sterno-mastoid, reminding us of the epi-branchial fibres connecting the *superior* and *inferior cervicales* parts in Lepidosiren and Dog-fish.

<sup>2</sup> In a Fawn I found it extending over the lower jaw to the orbital edge of the maxilla, occupying that part of the area of the superficial layer. In Crocodile it passes beneath the *trapezius* to the transverse process of the 4th cervical vertebra, where it comes into contact with the middle ventral stratum represented by the *levator scapulae*.

<sup>3</sup> In Manis it extends over the *biceps* and brachial vessels to the internal condyle of the humerus.

<sup>4</sup> The *rhomboid* in Owl and Kite extends from all the lumbar and dorsal spines to the hinder edge of the scapula, dwarfing the *trapezius*. In Apteryx it is said by Owen to be wanting. It is present in the Crocodile, but I have not met with it in any lower animal; sometimes it blends with the *latissimus dorsi*. *Journ. Anat.* iv. 33.



also apparently the *serrati postici*, as well as the *masto-humeral* and *masto-scapular*. Though the last two might perhaps be said to be segmented from the deep surface of the sternomastoid, yet they usually blend below with the trapezius or deltoid, or pass to the scapula or humerus. Also another muscle is segmented from the trapezius, which I have in former papers named *cervico-humeral*, and which is an interesting reminder of the fact that in *Lepidosiren* (p. 72) and *Dog-fish* (p. 86) some of the deeper fibres of the layer are traceable to the lateral septum and, beneath it, to the lateral parts of the vertebræ; for the *cervico-humeral* arises, not like the *trapezius* from the vertebral spines, but from the transverse processes of the atlas or other cervical vertebræ, near to the *levator scapulæ*, or even (Hedgehog) from the fore part of the ring of the atlas, or (Guinea Pig and Rabbit) from the basi-occipital. It descends upon the shoulder to the clavicle, acromion, or humerus, or blends with the trapezius or deltoid. Thus, though it is associated with the *levator scapulæ* in its origin, it is associated with the *trapezius* in the latter part of its course; and it is evidently a representative, in Mammals, of those fibres of the stratum which, in *Lepidosiren*, detach themselves from the rest of the stratum and bend in, deeply, to the sides of the vertebræ. In the Hippopotamus the *cervico-humeral* arises by a round tendon from the back of the exoccipital, behind the digastric and stylo-hyoid, joins the *trapezius*, forming its fore part, and runs on to the deltoid ridge of the humerus. It is not separated from the deltoidal, or lower, part by any inscription. It is joined by the omo-hyoid which loses itself in this muscle. It is called *masto-humeral* by Gratiolet. A separate large portion arises by a strong tendon from the under surface of the transverse process of the atlas and spreads upon the dorsum of the scapula. The *trapezius* passes over the large transverse process of this vertebra without deriving any fibres from it.

Between the two layers of the cervical part of the superficial brachio-cephalic stratum, just described—the *superficial* layer which is forming the *subcutaneus colli*, and the deeper layer which forms the *sterno-mastoid* and *trapezius*—other

muscles are developed in different animals, to which the names *cervici submaxillaris*, *depressor mandibulae*, *mylo-hyoideus* and *genio-hyoideus* are given. These vary a good deal; and the first two are absent in higher animals. I have said that they are found between the two layers; but the genio-hyoid, which lies near the middle line, is perhaps rather to be regarded as segmented from the deeper surface of the superficial layer. The most remarkable member of this series is the anterior belly of the digastric. It lies in a more superficial plane than any, yet is continued, through the medium of a tendon or inscription, into the posterior belly which runs, in company with the stylo-hyoid, beneath the sterno-mastoid, to a deeply situated spot of the temporal bone, just behind the styloid process.—The peculiar conformation and disposition of this muscle in Man, and the inscription which in many lower animals is substituted for the tendon between its two muscular portions, have excited much attention and been the cause of many surmises. I believe the real explanation of it to be that it is composed of two muscles or muscular portions derived from the two strata of the brachio-cephalic muscle. The hinder portion is, together with the stylo-hyoid, a derivative from the deep stratum, which it will be remembered is an extension of the middle or internal oblique stratum of the ventral muscle; and the anterior portion is a derivative from the fibres of the *cervicalis superficialis* layer, which lies next above the *subcutaneus colli*. It is an instance of a portion of a deep stratum retaining continuity through the medium of a septum with a portion of a superficial stratum. The septal remnant, which is a remnant of the hyoidean, or sub-hyoidean, septum (the septum, that is, in which the hyoid is formed), is the tendon of connection between the two portions and the band which holds them to the hyoid<sup>1</sup>.

<sup>1</sup> It may be observed, as affording some confirmation of the relation described in the text between the anterior belly of the digastric and the mylo-hyoid, that they are both supplied by the mylo-hyoid branch of the 5th nerve; whereas the posterior belly of the digastric and the stylo-hyoid are both supplied by the 7th nerve. I do not however attach much importance to this.

In this derivation of the digastric from the elements of deep and superficial strata, we are reminded of the same thing in the *cervico-humeral* just mentioned, and in the *costo-alaris* (p. 131).

The dissection of the Hippopotamus<sup>1</sup> (Figs. 45 and 46) affords an interesting illustration and confirmation of these views. The *subcutaneus colli* (*S. c.*) under the neck is of great thickness, as is the case with the subcutaneous muscles on the under surface of the body generally; and it appears at first sight to terminate in front in a thick defined border extending, on either side, upon the middle of the large mandibular protuberance into which the masseter (*M.*) is inserted. The muscle at and near this border is further thickened by transverse fibres crossing from one side of the face, over the mandibular protuberance, to the other side. Close examination, however, shews that the anterior border is not so defined as at first sight appears; for the edge is connected by fibrous tissue, which is the sub-hyoidean septum<sup>2</sup>, with deeper-lying muscle, a broad, thick *hyo-mental* (*A. M.*), which passes forwards, from the septum just mentioned, to the mandible on the side of the bulging symphysis. By means of this septum the *hyo-mental* is continuous, behind, with the superficial fibres of the *sterno-hyoid* (*St. H.*) which is a large thick muscle, on its deeper surface, with the basi-hyoid bone, and, on its superficial surface, with the edge of the *subcutaneus colli*<sup>3</sup>. Above it, and deeper than it, is the *mylo-hyoid* (*M. H.*) Above this is (*G. H.*) the *genio-hyoid*, and deeper still is the *genio-hyo-glossus*. These are disposed as they usually are in Mammals. The *stylo-hyoid* arises, tendinous, from the outer side of the tooth-like exoccipital process, soon expands into a muscular belly which is, partly, inserted into the hyoid, on a

<sup>1</sup> Description of Figures of the HIPPOPOTAMUS and the CAT (Pl. IX.).

Figs. 45 and 46. Dissections of the muscles beneath the floor of the mouth of a Hippopotamus which died three days after birth.—*I. M.*, the inferior maxilla, with its large submental protuberance uncovered.—*L.*, the upper lip.—*S. c.*, *subcutaneus colli*.—*M.*, Masseter.—*H. M.*, *hyo-mental* entire on the left side, but divided on the right side, and, in Fig. 46, reflected.—*D.*, anterior part of digastric running parallel with, and blended near the jaw with, the *hyo-mental*.—*M. H.*, *mylo-hyoid* divided and partially removed to expose *G. H.*, the *genio-hyoid*.—*F. A.*, the facial artery.—In Fig. 46, the *subcutaneus colli* has been removed, exposing the hinder part (*D'*) of the digastric, also *S. H.*, the *stylo-hyoid* which is seen to be continuous with the *hyo-mental*.—*St. M.*, *sterno-mastoid*.

Fig. 47.—Similar dissection in Cat. *S. c.*, the *subcutaneus colli*, or *platysma*, has been divided and pulled aside to shew (*D* and *D'*) the anterior and posterior parts of the digastric, with the inscription between them which is the sub-hyoidean septum. The anterior part of the digastric is seen to occupy the position occupied by the *hyo-mental*, as well as by the anterior part of the digastric, in the Hippopotamus.—*M. H.*, the *mylo-hyoid*.—*St. H.*, *sterno-hyoid*.

<sup>2</sup> It is called by Gratiolet, *Recherches sur l'Anatomie de l'Hippopotame*, p. 246, the *raphé-sous-hyoidien*.

In the Flying Squirrel Macalister found that the digastric had two separate bellies and a central round tendon which was continued across, from side to side above the hyoid bone, as an arch from which the anterior bellies arose. This tendinous arch was the sub-hyoidean septum. I have met with a similar arrangement in the body of a man, in the University dissecting-room, this winter.

<sup>3</sup> Gratiolet (p. 299) describes it as *le second faisceau* of the digastric. It is in the plane of the digastric; its mandibular insertion is blended with the insertion of the digastric, and it occupies the place of the anterior belly of that muscle in Man. A *hyo-mental* is present in some Bats, according to Macalister.

level with the mylo-hyoid and the genio-hyoid and, partly, is continued on into the lateral edge of the hyo-mental. The *digastric* (*D*) arises, by a tendon, from near the extremity of the same process as the stylo-hyoid, passes internal to the stylo-hyoid, expands into a belly which, about on a level with the hyoid, is interrupted by a transverse inscription<sup>1</sup>. In front of this (*D*) it runs parallel, and on the same level, with the hyo-mental and is inserted, behind the hyo-mental, and continuously with it, into the lower edge of the body of the jaw, midway between the symphysis and the angle.

The facial artery (*F. A.*) passes, as usual, beneath the stylo-hyoid and digastric, and runs along the outer and posterior side of the digastric, over the side of the jaw, between the digastric and the fibres of the masseter which are curling round the anterior border of the protuberance to be inserted into its inner side and edge.

The points shown by this dissection are, first, the connection of the *subcutaneous colli* with, and its termination at, the hyoidean septum. Secondly, the presence of a hyo-mental muscle superficial to the mylo-hyoid, extending from the hyoidean septum to the symphysis of the jaw, and the continuity of some of the fibres of the *stylo-glossus* with it. Thirdly, the position of the anterior belly of the *digastric* (*D*), in front of the inscription, on a level with, and on the side of, a part of the same stratum with the hyo-mental, and, indeed, continuous with that muscle, and forming a lateral portion of it. It is clear that the inscription in the digastric is a part of the sub-hyoidean septum, and that the hinder, deeper, belly (*D'*) of the digastric is, by the medium of this inscription, continued into the lateral part of the hyo-mental, which forms the anterior belly; just as some of the fibres of the stylo-hyoid are continued into the middle part of the same muscle. In Man the lateral portion of this hyo-mental is absent; and it is the median portion which forms the anterior belly of the digastric. Hence the insertion of the digastric is near the symphysis of the jaw. The shifting insertion of the digastric into the jaw is thus explained by the circumstance that its anterior belly may be formed by different parts of the hyo-mental in different animals; and the inscription, usually observable, even when the muscle is straight, indicates the line of connection of the portion of the deep, or masto-hyoid, and the superficial, or hyo-mental strata which combine to make up the muscle. The hyo-mental portion, anterior to the inscription, or remnant of the sub-hyoidean septum, is a part of the superficial brachio-cephalic stratum; and the masto-hyoid portion, behind the inscription, is a derivative from the deep brachio-cephalic stratum.

<sup>1</sup> Gratiolet, whose account corresponds in other respects with that in the text, observes that the muscular fibres are not interrupted by any tendinous inscription. It is, however, quite distinct in the young (3 days old) animal from which my description is taken.

In the Cat (Fig. 47), as in many others, the *digastric* is a straight muscle, slightly constricted and crossed by a distinct inscription where it passes the hyoid, with which it is unconnected. Then it expands to be inserted into the whole of the inner surface of the body of the mandible between the symphysis and the masseter. There is no *hyo-mental*.

Fig. 45.

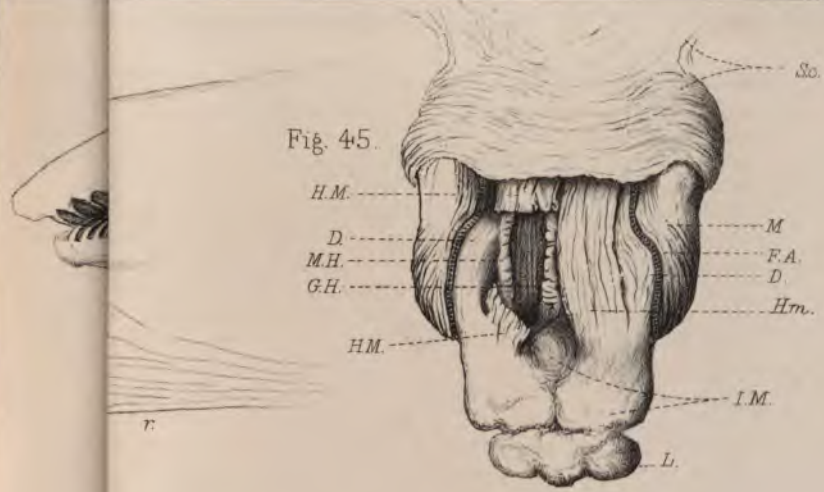
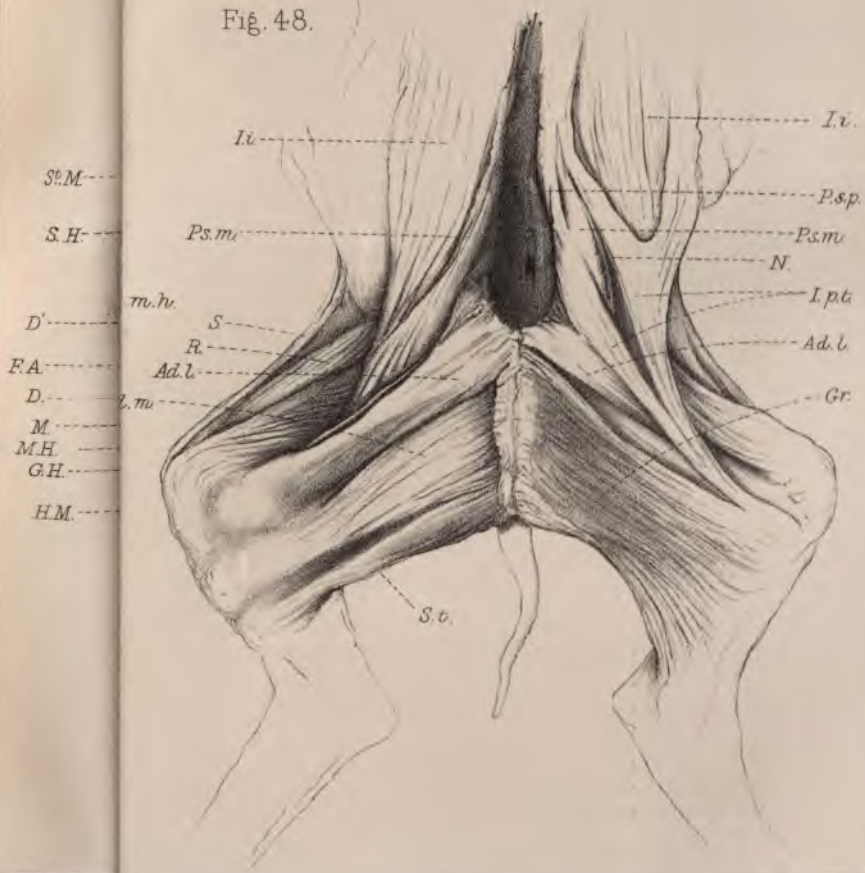

Fig. 48.





It is worth while to remark that the hyo-mental in the Hippopotamus is, together with the anterior belly of the digastric, supplied by the mylo-hyoid branch of the fifth nerve which runs between them and the mylo-hyoid muscle.

In the limbless Saurians (*Pseudopus*, P.) the *rectus abdominis*, which forms the median part of the superficial stratum of the ventral muscle in the abdomen, is not separated from the cervical (*sterno-mastoid*) part by an intermediate, thoracic, transversely disposed (*pectoralis*) part, but is continued directly on into it, or with only some interruption of the deeper fibres by the clavicle. In Snakes the foremost bundles of the external oblique muscle arise from the mastoid process, and run backwards towards the ventral scutes, beneath which they form a superficial *rectus*. Thus they represent the sterno-mastoid muscle in the same manner as do the corresponding fibres in *Pseudopus* P. For a short distance near the head the *obliquus* is overlaid by a superficial, thin muscular sheet extending from the cervical spines to the mandible and the scutes immediately behind it. This is described as being divided into *cervici submaxillaris* and *depressor mandibulæ*; and it corresponds evidently with part of the *cervicalis superficialis* of *Lepidosiren* and Dog-fish. But it is not interrupted by branchial openings; and it is not segmented from the subjacent layers of the ventral muscle, at least it does not present a stratification from them; although such separation may be indicated by the presence of the hyoid in the thickness of the sheet (see Fig. 44 and description<sup>1</sup>).

Traced backwards the superficial (external oblique) stratum of the ventral muscle is continued upon the hind limb, with more or less interruption by the limb-girdle; and it ensheaths the femoral segment much in the same manner as the humeral segment of the fore limb is ensheathed by a projection of the anterior prolongation of the stratum<sup>2</sup>. Ventrally, it is continued

<sup>1</sup> Some of the fibres of this—the *cervici submaxillaris*—part of the stratum are described by Prof. E. d'Alton (Beschreibung des Muskelsystems eines *Python bivittatus*, *Müller's Archiv*, 1834, s. 355) as attaching themselves to the hyoid, forming a 'Nackenzungenbeinmuskeln.' He also describes a 'Rückwärtszieher' of the hyoid running obliquely and superficially from the cervical spine to the hyoid. Some fibres of the cervici- or masto-submaxillaris attaching themselves to the quadrate, he calls 'Zurückzieher' of that bone. It is an extension of these upon the mandible which forms the *depressor mandibulæ*.

<sup>2</sup> In certain Snakes the ventral muscles form a funnel-shaped process investing the base of the claw, which is the counterpart of the funnel-shaped

into the *gracilis*, which is; manifestly, a serial repetition of the *pectoralis*, and which, like that muscle, is chiefly attached to the pre-axial edge of the limb. Dorsally, it is continued into the *gluteus maximus*, which is the serial repetition of the *latissimus dorsi*, and which, like that muscle, is attached to the post-axial edge of the limb and blends with the dorsal muscle (the *quadriceps*) on the first segment of the limb. Both these muscles (*gracilis* and *gluteus*) incline to the plantar surface of the middle and distal segments of the limb, as do the *pectoralis* and *latissimus dorsi* in the fore limb, and for the same reason. The middle part of the external oblique layer is continued into the *tensor vaginae femoris* and the *sartorius*, which are the representatives of the *deltoid* muscle, and which are cut off, wholly or in part, from the *obl. ext.* by the ala of the ilium, as the *deltoid* is wholly or in part cut off from the *trapezius* by the spine of the scapula. The opposed edges of the *sartorius* and the *gracilis*<sup>1</sup> are not commonly so approximated to each other as are those of the *deltoid* and *pectoralis*. In the interval between them, as well as upon them, the oblique muscle is continued into the fascia of the thigh; and the thickening called 'Poupart's ligament' at the crural arch, where the oblique passes into the femoral fascia, is probably a remnant of the pelvic septum; and an ossification in it would form the serial homologue of the clavicle<sup>2</sup>.

These muscles and fasciæ are sometimes covered by an extension of the brachio-lateral muscle (p. 132), which may (*Pteropus*) acquire an attachment to the femur; just as in

investment carried upon the fore limb of higher animals and segmented into *pectoralis*, *latissimus dorsi*, and *trapezio-deltoid*. Commonly the interruption of the components of the stratum by the pelvic girdle is greater than that by the shoulder-girdle. Thus the *gracilis* is often quite separated from the rest of the ventral muscle; though in some animals, as Cryptobranch, its continuity with the caudal and abdominal parts of the stratum is sufficiently clear: whereas the *pectoralis* is usually to some extent, and often very extensively, continuous with the external oblique, or the rectus, or both. So, the *sartorius* and *tensor vaginae femoris* are rarely (they are in *Ai*) continuous with the external oblique; though the *deltoid* often is continuous with the *trapezius*.

<sup>1</sup> In the Rabbit the *sartorius*, arising from Poupart's ligament, is continuous with the *gracilis*.—In *Ai*, Manis, Pig, and others, the *sartorius* and *tensor v. f.* are continuous with the *gluteus*; and in Pig the *biceps* also is continuous with them.

<sup>2</sup> Probably the marsupial bone, formed from cartilage in the deeper part of this septum, corresponds with the sternal end of the clavicle, which, its epiphyseal nucleus at any rate, is formed in cartilage.



the fore limb the subcutaneous muscle dips down to and is united to the humerus.

Behind the limb the external stratum is continued upon the tail and there blends with the middle stratum. Its superficial or subcutaneous layer forms the external *sphincter ani*. In some animals (Hedgehog) it is firmly inserted into the caudal vertebræ.

The following is a review of the serial or successional homological relations of the parts of the external stratum of the ventral muscle thus far discussed. The *gluteus max.* is serially homologous with the *latissimus dorsi*. The *tensor vag. f.*, the *sartorius*, the *femoral fascia* and part of the *obl. ext.*, with the *deltoid* and *trapezius*; Poupart's ligament representing the clavicle, and the ala of the ilium representing the spine of the scapula. The *gracilis* with the *pectoralis major*. The middle part of the *external oblique* and the superficial fibres of the *rectus* with the *sterno-cleido-mastoid*, and (between the sterno-mastoids) with the *mylo-hyoid*, the anterior belly of the *digastric*, the *hyo-mental* and the superficial fibres of the *sterno-hyoid*. The *rhomboids* and *serrati postici* have no homological representatives; and there are no structures in the tibial and fibular borders of the hind limb sufficiently segmented to compare with the *tensor plicæ alaris* and the *costo-alaris*; though the *sartorius* or some of its fibres nearly corresponds with the former, and the *caudo-pedal* with the latter. The *external sphincter ani* may be said to be serially homologous with the *orbicularis oris*; but the subcutaneous muscles generally do not admit of homological comparison.

The relations of the ventral muscles to the alimentary tube are therefore as follows:—The internal stratum is gathered round, continued into and reflected upon it as *levator* and *retractor ani* and is gathered round it as post- and sometimes as pre-cardiac diaphragm. The middle stratum forms the internal *sphincter ani*, and is continued into the tongue as *genio-hyo-glossus* and *hyo-glossus*, and is continued upon the pharynx as *thyro-* and *hyo-pharyngei* or *constrictores*. The external stratum forms, by its superficial layer, the *orbicularis oris* and other circum-oral muscles, and the *sphincter ani externus*.

The disposition of the ventral muscle in these three, oblique and transverse, planes is a visceral feature, is co-extensive, that is, with the visceral region or nearly so. It extends from the anus to the head, but not behind the anus, even in *Bdellostoma*, Snakes and other limbless animals. When the limb-girdles are present, either with or without the limbs, the planes are broken up by and partially lost on them; and when they are not present the planes are blended in the caudal muscles. In the Porpoise the *recti*, and with them the *obliqui interni* and the *transversi*, diverge and pass, on the sides of the bones supposed to be rudimentary pelvic bones, to the transverse vertebral processes in which they terminate about on a level with the vent; while the *obl. externi* terminate in a defined edge a little in front of

the bones just mentioned. It will be understood that the stratification is no necessary accompaniment of the visceral region. It does not usually take place there in Fishes; and in higher animals it is often obscure or imperfect in certain parts, rendering it difficult or impossible to decide with certainty from which of the strata a given muscle is derived.

#### MUSCLES OF THE LIMBS.

It has already been shewn that limb-girdles are, like the ribs and costal cartilages, formed in the transverse intermuscular septa of the ventral muscle, and in that part of the thickness of the septa which is in the plane of the middle or internal oblique stratum. They sometimes grow through the outer stratum and project subcutaneously; and the pelvic bone in Snakes lies, beneath the internal stratum, in juxta-position with the fascia transversalis. Essentially, however, they belong to the middle stratum; and the muscles passing from them upon the limbs may be regarded as derivatives from this stratum, as serially homologous, that is, with the muscles passing from septum to septum, or from costa to costa, in front and behind them.

It has also been shewn that the external stratum—the stratum of the external oblique muscle—is prolonged upon the limbs in the form of a more or less complete funnel-like investment of each limb. This is seen in its simplest condition in the Snakes that are possessed of claws. It is also well seen in *Lepidosiren*, where it consists of a simple sheath, interrupted, it is true, in front, by the branchial opening, yet surrounded by and extending along the fin; and different forms of it are exhibited in different animals. There are, therefore, derivatives of the two outer strata of the ventral muscle, at any rate, contributing, and largely, to the muscular basis of the limbs.

A limb is usually composed of a series of cartilaginous or osseous pieces serially arranged and moveable upon one another, of which the fin of *Lepidosiren* is one of the simplest examples; and the instance of the paddle of *Ceratodus* has shewn that the muscular fibres pass from piece to piece, indeed that the muscular tissue of the limb is, in the primitive form, segmented into transverse planes corresponding with the axial cartilaginous, or

osseous, segments, thus resembling the disposition of the muscles in the trunk, and more particularly in the tail, of simply constructed animals. But, as we have found in the trunk, the muscular fibres, the superficial fibres more particularly, are often not confined to their particular segments. They commonly break through the intervening barriers, or intermuscular septa, and range on to more distant segments, blending with the muscles of those segments. Hence the muscles of any division of a limb consist, usually, of three layers. *First*, and deepest, are the fibres of the segment itself, the 'intrinsic' fibres; of these the proximal series are the bundles passing from the girdle to the first segment of the limb: *secondly*, the fibres derived from distal segments, the 'extrinsic' fibres; and *thirdly*, and most superficially, the fibres derived from the ventral muscle, the superficial 'ventro-appendicular' fibres. The components of these three layers are blended together in a variety of ways, rendering it often difficult or impossible to distinguish to which layer they appertain.

In the simplest condition, as that of *Lepidosiren*, the cartilaginous or osseous pieces of the limb are joined to one another by simple tissue, and are moveable in any direction; and the muscular fibres are uniformly disposed around the joints, the deepest, or 'intrinsic', fibres forming a sort of circular capsule, and being blended on the exterior with the 'extrinsic' and the 'ventro-appendicular' fibres. When movements in particular directions are required, the conformation and structure of the joint is proportionately modified, and the muscular fibres are arranged and segmented, more or less distinctly, into bundles or muscles to effect the object. In the case of the proximal joint of the limb—that of the first cartilage or bone with the girdle—the movement is, on the whole, circumductory or in any direction; and the muscles are disposed around the joint in a nearly circular manner. Usually, however, even here, certain movements take place more frequently or more freely than others; and the muscular fibres are accordingly arranged in groups, or muscles, having more or less independent action. In the distal parts of the limb the movements are commonly much more restricted, are limited indeed, nearly or quite, to one plane, which is, speaking generally, the same for all the joints

of the limb. They all admit of flexion towards the palmar or plantar or ventral aspect, and of extension towards the dorsal aspect. Supposing the limbs stretched, as in their primitive condition, horizontally in straight lines and at right angles, from the trunk, then all the joints admit of flexion towards the ventral surface of the trunk and of extension to the horizontal line. At the wrist and ankle the extensor movement may, in some animals, be carried beyond that line (in Man the foot has come to be placed at a right angle with the leg); and the same is the case at the joints with the girdles where, as just said, other movements are also permitted. In all the joints, however, except that with the girdle, the movement is nearly restricted to the plane indicated. Hence the muscles are arranged in two sets, one upon the 'flexor' or 'ventral' aspect, which may also be called 'palmar' in the fore limb and 'plantar' in the hind limb, and the other set upon the 'extensor' or 'dorsal' aspect; and there is, speaking generally, a corresponding arrangement of the nerves.

It must not, however, be supposed that the arrangement is rigidly adhered to. Marginal portions of the ventral series occasionally (witness the *lumbricales*) stay upon the dorsal aspect and serve as extensors; and more frequently marginal portions of the dorsal series incline over the sides and upon the ventral aspect and serve as flexors, and perhaps become united with the flexors.

That there is a similarity, a general homological correspondence, between the muscles of the fore and of the hind limbs, as well as between the limbs of different animals, is self-evident. Their outer sheets are projections of serially homologous portions of the ventral muscle carried upon similar outgrowths from serially homologous ossifications in the ventral intermuscular septa<sup>1</sup>. The dorsal muscles of one limb and in one animal correspond, though not unexceptionably, with the dorsal muscles of the

<sup>1</sup> The septa in which the corresponding limb-girdles are formed are not, numerically, the same in the different orders of vertebrates. The scapular girdle, for instance, in the Fish is developed in a septum close to the head; whereas in the Bird it occupies a septum far removed from the head. So, the position of the pelvic girdle, though presenting a steady relation to the hinder part of the visceral cavity and the termination of the alimentary canal, varies greatly in its distance from the scapular girdle, owing to the variation in the number of intervening muscular and intermuscular planes in different animals.

other limb and in other animals; and the same with the ventral series. There is, moreover, often an antagonistic similarity between the ventral and dorsal muscles, according with the similarity in the action requisite to produce the flexor and the extensor movements. In short, the similarity of muscular disposition about the several joints, in the same or the different limbs of the same or different animals, is, as we might expect, generally proportionate to the similarity of the form, movements and position of the joints and of the force required<sup>1</sup>. Differences in these are sometimes, indeed not unfrequently, associated with such varieties in the combination of embryonic germs as to defy attempts at an exact homological comparison.

Two important features of difference which serve to modify the muscular relations in the two limbs at once suggest themselves as being present to a greater or less degree in most animals. First, the superficial position and the mobility of the shoulder-girdle, as compared with the pelvis; and associated with these are the variability and instability of the subglenoid parts of this girdle, and the frequent presence of a clavicle. The shoulder-girdle and its muscles often, indeed commonly, deviate from their simple primitive form and relations much more than do the pelvic girdle and its muscles; and they are liable to much greater variations in position—fore and aft and in the depth of plane at which they are situated—and in their relation to the other parts of the osseous skeleton. In one animal the shoulder-girdle is joined to the head, giving it, in the opinion of some anatomists, a claim to be regarded as an appendage to the skull; in another animal it is joined to the vertebral spines; in a third to the vertebral bodies; in a fourth to the sternum; and in a fifth it is free from all these. These varieties in the girdle involve a greater amount of variety in the muscles connecting it with the rest of the trunk and passing from it to the limb, than is the case with the muscles of the pelvis. There is, however, in connection with the latter, the varying development of the tail, which leads to considerable

<sup>1</sup> I do not mean to assert that all muscular varieties are thus teleologically determined; but it is very generally so; and it is not easy to adduce unquestionable exceptions.

variation in the muscles passing between this part of the body and the pelvis and hind limb.

The second great feature of difference is the difference in the rotation of the two limbs; the dorsal surface of the thigh and knee being directed forwards, while that of the arm and elbow is directed backwards<sup>1</sup>. In the hind limb the leg and foot are involved in the same rotation as the thigh and knee. But the forearm and hand undergo a rotation in a different direction to that of the arm by means of the proation of the radius; so that the dorsal surface of the hand is directed the same way as the dorsal surface of the foot. The effect of these rotations is that the radial—or pre-axial—edge of the humerus looks outwards, and the tibial—or pre-axial—edge of the femur looks inwards. This leads to a difference in the insertion of some of the otherwise homologous muscles at the upper ends of the two bones, for instance, the radial tubercle of the humerus presenting on the outer side of the limb, receives the muscles from the dorsal aspect of the scapula and exceeds the ulnar tubercle in size; whereas the fibular tubercle of the femur rises into strong relief beneath the dorsum of the ilium, and receives the muscles which arise from that surface and exceeds the tibial tubercle in size.

I may observe that such a variation in the locality of the insertion of corresponding tendons in the two limbs, and indeed in the same limb in different animals, is by no means uncommon. It is seen in the instances of the extensor muscles of the leg and forearm, in the *extensores carpi radiales*, the *biceps brachii*, *latissimus dorsi*, &c. Too much importance has, I think, been attached to the insertion of a muscle as a guide to its homology: and the statement that the insertion is more to be depended upon, in this respect, than the origin is scarcely supported by observation.

We have already (p. 139) traced the ventro-appendicular muscles from the ventral muscle to the limbs, and pointed out their serial homological relations. It remains to follow them upon the limbs. Normally, or primitively, they spread, as in *Lepidosiren*, and less distinctly in *Ceratodus*, over the whole surface of each limb, forming an outermost muscular covering of the limb; and they are still seen to expand upon the distal segments in many even of the higher animals, especially in

<sup>1</sup> See my *Obs. on the Limbs of Vertebrate Animals*, p. 16.

the hind limb. But they are often reduced, in their course down the limb, to fasciæ or areolar fibres, and often are arrested by insertion into a projecting process of bone at some higher point; or they blend with, and are lost in, the subjacent strata.

To take first the 'palmar' and 'plantar', that is, the 'ventral' divisions of the ventro-appendicular muscle, which we call, respectively, *pectoralis* and *gracilis*. Each extends along the pre-axial edge of its limb, inclining to the palmar, or the plantar, surface. Each reaches sometimes to the distal segment, but is usually interrupted or lost earlier; and each blends in variable degrees with the subjacent muscles. The *pectoralis* is commonly arrested at the radial tubercle of the humerus; but, sometimes (*Orycteropus*), part of it accompanies the *biceps* to the radius, or (*Otter* and *Wild Cat*), together with some fibres of the trapezio-deltoid, accompanies the *brachialis anticus* to the ulna, or (*Seal*) expands into the fascia of the forearm and so reaches the hand. It is, in some instances, free from the subjacent muscles, and in others is blended with the coracobrachials, or is connected with them by means of the *pectoralis minor* (see p. 156). The *gracilis* is rarely, if ever, arrested at so early a point as the pectoral. It is commonly inserted into the tibia, occasionally (*Pteropus*) blending with the *semitendinosus*, and, now and then (*Unau* and *Ai*), joining the *biceps flexor cruris* and acquiring an attachment to the fibula. It often extends down the inner side of the tibia, over the ankle and foot, spreading upon the dorsal and plantar surfaces of the foot (*Seal*). It is in some instances free from the subjacent adductors; in others (*Cryptobranch*) it is scarcely segmented from them.

The 'dorsal' divisions of the ventro-appendicular muscle have often a wider range than the 'ventral' both in their connection with the trunk and in the area of the limbs which they cover; and they are commonly sectorially segmented in some degree. The dorsal surface, as seen most distinctly in the fore limb of *Dog-fish* (Figs. 28 and 30) and in the hind limb of *Ceratodus* (Fig. 34), and the post-axial edge of the limb, may be regarded as their legitimate destination; but they not unfrequently spread, over both the pre-axial and the post-axial edges, upon the ventral surface of the limbs. They are, consequently, attached to various points. In the cylindrical (*Lepidosiren*), or

rudimentary (Snakes), state of the limbs, they are not segmented from the palmar and plantar portions of the sheet, and are not themselves longitudinally or sectorially cleft.

In the fore limb there are usually two sectors of the dorsal division; one—the *trapezius*—converging from the dorsal aspect of the head and of the front of the trunk, and the other—the *latissimus dorsi*—converging from behind, upon the limb. The *trapezius* sector in branchiate animals (pp. 71, 86) is interrupted and devoted to the gill apparatus, and scarcely reaches the limb. In some animals, devoid of gills (Cryptobranch), it does not extend beyond the anterior edge of the scapular and the coracoid parts of the girdle. In others (certain Mammals) it runs on to the radial tubercle of the humerus, or to the radius, or even (Otter<sup>1</sup>) to the ulna, joining the flexors of the forearm. It usually presents an inscription as it passes over the shoulder. This inscription is the superficial part of the septum in which the girdle is formed; and, in Mammals, the anterior edge of the scapular part of the girdle, called the 'spine', commonly grows through the septum, so occupying the inscription, and bisecting the upper or supra-scapular part of the muscle, transversely, into posterior, or *deltoid*, and anterior, or *trapezius* parts. In the lower, or coracoidal, part of the septum the case is somewhat different. Sometimes the inscription (*i. e.* the remnant of the septum in the muscle) remains, and marks the division into *trapezius* and *deltoid* parts. Sometimes it is nearly obliterated. Sometimes it becomes ossified into a 'clavicle' or 'epi-coracoid' (p. 128), the ossification being (many Carnivora) confined to the deeper tract of it and limited in extent, or extending through the thickness of the muscle, and ranging, from the acromial end of the spine of the scapula, to the sternum<sup>2</sup>. The most important varieties, therefore, in this

<sup>1</sup> In an Otter the foremost fibres of the *trapezius*, continued as *deltoid* with an intervening inscription, and accompanied by some fibres of the *pectoralis*, descended in front of the *brachialis anticus* to the ulna.

<sup>2</sup> In Lizards the clavicle extends along the anterior edge of the scapula to its base. In Ai it is attached to the coracoid. In Fishes it is large, closely applied upon the coracoid, and meets its fellow in the middle line; but it is not certain that ossification ever extends from the coracoid into it. It seems in this respect to bear to the coracoid somewhat similar relations to those which the supra-, or better epi-, scapular bones (Parker's supra-clavicles) bear to the scapula. I have spoken of the clavicle as an ossification in one of the muscular septa of the brachio-cephalic stratum, corresponding with the epicostals. But it should be added that it is situated at a deeper level than they, in the deeper



trapezio-deltoid sector are; *first*, that in which it does not extend below the anterior edge of the girdle; *secondly*, that in which it extends beyond the edge of the girdle and its septum down to the humerus or forearm; *thirdly*, that in which it is divided transversely, in part or the whole of its width, into two distinct muscles by ossification extending from the edge of the scapular part of the girdle into the septum which traverses it and by ossification arising independently over the coracoidal part of the girdle. The portion of the *trapezius* which, in Cryptobranch, is inserted into the anterior edge of the scapula is, in Mammals, continued, beyond that edge, which grows up as the spine, into the scapular portion of the *deltoid*; and the portion which, in Cryptobranch, is inserted into the coracoid is, in Mammals, continued, beyond the coracoidal septum, or the clavicle which may form in it, on into the clavicular portion of the *deltoid*. These two portions of the *deltoid* are not unfrequently separate.

The sector in the hind limb, corresponding to the trapezio-deltoid, is recognisable as a distinct element only behind the pelvic girdle, where it forms the *sartorius* and the *tensor vaginæ femoris*. These are usually cut off from the *external oblique* part of the ventral muscle lying in front of them, which, or part of it, may be supposed to correspond to the *trapezius*, by the edge of the ilium; and they thus answer, serially, to the scapular portion of the *deltoid*. The *sartorius* is sometimes (Unau and Ai), like the *deltoid*, inserted into the pre-axial edge of the first bone of the limb; but, usually, it runs into the second bone. In other words, the *sartorius* usually continues its course on to the tibia, but is occasionally arrested at the femur<sup>1</sup>; whereas the *deltoid*, or part of it, occasionally (Orycte-

instead of in the superficial part of the stratum, as seen in Ps. Pallasi, and also in Carnivora, where the rudimentary clavicle is found in the deeper part of the septum between the trapezius and the *deltoid*. It has not unfrequently connections with the muscles of the subjacent stratum—the *subclavius* and the sterno- and omo-hyoids. It is extended between two cartilage bones, of which one (the sternum) is in a deep level. According to Gegenbaur, it is not without claim to a cartilaginous origin itself at one part; and it has a cartilaginous epiphysis. In short, it appears to afford an example of remarkable blending of the superficial membranous and the deeper cartilaginous ossifications, the former preponderating from a very early period, and in some instances, probably, constituting the only basis of the bone.

<sup>1</sup> The *sartorius* sometimes (Hippopotamus) runs down the middle of the dorsal aspect of the thigh, over the patella, and is lost there. In the Heron it

ropus) continues its course on to the radius, but usually is arrested at the humerus. The course of the *tensor v. f.* into the fascia does not distinctly correspond with anything in the fore limb. It is present only in Mammals, and is often wanting in them. The *sartorius* may (Rabbit) extend, along Poupart's ligament, to the *gracilis*, as the *deltoid* often extends, along the clavicle, to meet the *pectoral*. This is, however, rare; and the intermediate space between the two muscles in the retiring angle of the bend of the groin, where there is no 'point d'appui' for muscular action, is usually occupied by fascia. That fascia is, accordingly, the serial representative of the clavicular portions of the pectoral, deltoid, and trapezius, Poupart's ligament being the serial septal representative of the clavicle.

The posterior sector of the dorsal portion of the ventro-appendicular muscle in the fore limb—the *latissimus dorsi*—is, like the pectoral, a very general appurtenance to the fore limb in animals above Fishes. Even in Fishes it is sometimes (Dog-fish, Fig. 28) represented by a thin stratum segmented from the ventral muscle and passing upon the dorsum of the fin, the pectoral being in like manner segmented and passing upon the palmar surface of the fin. In *Lepidosiren* (Fig. 24) we have seen the *latissimus dorsi* and the *pectoralis* travelling forwards as a continuous sheet constituting the hinder part of the superficial brachio-cephalic stratum. In this animal the *latissimus dorsi* is attached to the scapular part of the girdle in addition to passing upon the fin; and in Dog-fish it is barely segmented from the deeper (*serratus*) part of the stratum which is also attached to the scapula. In Man, and some other animals, it still retains the scapular connection; and, as before (p. 130) remarked, it often retains its connection with the pectoral by axillary bundles passing from it to that muscle. It is traceable to variable points in the limb. In *Lepidosiren* its fibres run on with others to the extremity of the fin. In Urodelans it is blended with the *triceps*; and more or less of this union is often found in Mammals. In Saurians and Birds it passes, between the scapular and humeral origins of the triceps, to the radial edge of the humerus. In Mammals, passing internal to the triceps more separate from the *gluteus* than in most Birds, and some of its fibres are traceable into the *gastrocnemius*.

ceps, it is inserted into the ulnar edge of the humerus, sending often a *dorsi-epitrochliæ* down to the ulnar condyle, or (Cyclothurus) extending along the fascia of the forearm to the ulnar side of the carpus<sup>1</sup>, or (Manis) running into the *flexor sublimis digitorum*, or (Rabbit) into the *flexor carpi ulnaris*.

This muscle thus affords a very interesting illustration of the varying points at which a ventro-appendicular muscle becomes arrested in different animals, and the varying muscles of the deeper strata with which it becomes blended or, rather, with which it retains its connection.

It is worthy of remark that the fibres of this muscle, and also of the pectoral and, though less frequently, those of the deltoid, often cross one another in a remarkable manner; those which arise most posteriorly passing behind the others to an insertion in front of them, so causing a sort of twisting or folding-in of the lower edge and, sometimes, leading to a cleavage in the plane of the muscle. I have before called attention to this point (p. 108 and *Journal of Anat.* iv. 35).

The corresponding sector in the hind limb—the *gluteus maximus*—has relations as varying as those of the *latissimus dorsi*. Its connection with the ventral muscle is well exemplified in Dog-fish (Fig. 30), and *Ceratodus* (Fig. 34), as well as the mode in which, in a primitive condition, it extends upon the limb, and blends with the proper muscles of the limb<sup>2</sup>. From these animals upwards the connection with the ventral muscle rarely reappears<sup>3</sup>. Thenceforwards its chief attachment is to the ilium (which appears through the ventral muscle like the spine of the scapula) and to the neural spines and arches of the caudal vertebræ. In the lower animals it is often, as we have seen in *Cryptobranch*, so united with the *extensor cruris* as to be with difficulty distinguished from it; and in Birds it blends with that muscle in the thigh. The same connection exists, to a greater or less extent, in Mammals; though sometimes, as

<sup>1</sup> Representing the *costo-alaris* of the Bird (p. 131).

<sup>2</sup> It is not quite correct to speak of the muscle referred to in these animals as the *gluteus* sector only; forasmuch as it represents, rather, the entire undivided dorsal portion of the ventro-appendicular sheet. In Mammals also it is often undivided.

In anurous Batrachians and Saurians, this dorsal portion is a not distinctly segmented muscle.

<sup>3</sup> In *Manis* the dorsal portion of the ventro-appendicular muscle is largely developed, blending above with the external oblique and reaching to the lumbar spines, and below extending over the buttock and the fore and outer parts of the knee and thigh.

in Man, the connection is with the fascia covering the *quadriceps*. Like the *latissimus d.* it is, in addition, often inserted into the post-axial line of the femur; but it does not follow its homologue by occasionally passing, between the divisions of the extensor muscle, to the pre-axial line. It sometimes ranges along the margin of the ilium to unite with the *tensor v. f.* and the *sartorius*, so obliterating the division between the two sectors; and on the limb it often reaches the fibular malleolus and side of the foot.

Before concluding the account of the ventro-appendicular muscles, it is necessary to mention certain derivatives from the ventral muscle of the tail which belong to this series, some of which are not represented in the fore limb.

Of these, the first and most superficial is that which I named *Caudo-pedal* in the description of the Cryptobranch. It occupies an intermediate position between the *gluteus* and the *gracilis*, and descends along the plantar surface of the limb to the distal parts, blending with the flexors of the digits. In Fishes it is not distinctly represented; and in animals above Reptiles it is lost or represented only by fascial tissue in its upper part. Its lower part in these animals is probably represented by the *plantar fascia*, or the superficial layers of the plantar fascia, and, perhaps, by the superficial layers of the *tendo-Achillis* and by some fibres of the *gastrocnemius*. In the fore limb of Birds it seems to be serially represented by the *costo-alaris*, or its superficial fibres, which, as I have before said, is the antagonistic homologue of the *cervico-alaris* (*tensor plicæ alaris*). Such antagonistic homologue to the caudo-pedal in the hind limb we do not find. It would be represented by fibres from the external oblique, between the *sartorius* and the *gracilis*, passing down to the distal region of the limb<sup>1</sup>.

Beneath, and connected with, the caudo-pedal is the *caudo-cruval* of Cryptobranch, which fuses with the adducto-flexor mass passing to the leg, and more particularly with that part

<sup>1</sup> In Crocodiles a large muscle passes from the hindmost projecting point of the ilium; and at the ham its tendon is, partly, connected with the deeper muscles and, partly, extends superficially down to the foot. A segment of it internally joins the *gracilis*. Externally, it is in contact with the *biceps* and *gluteo-rectus*. I suppose it is the representative of the *caudo-pedal*, starting from the ilium as a fixed basis instead of from the caudal vertebræ.

of it which represents the *semitendinosus*, thus giving rise to, or causing the persistence of, an inscription which I have (p. 19) supposed to represent the inscription found in that muscle in Man and some Mammals<sup>1</sup>. The only trace of serial homologue in the fore limb to the caudo-crural would be fibres of the hinder portion of the pectoral, or fibres of the oblique or rectus, joining the biceps brachii. But none of them so coalesce with that muscle as to cause an inscription in it.

Both the caudo-pedal and the caudo-crural lose the transverse inscriptions where they separate from the ventral muscle in the tail; but there is in the retiring angle between the tail and the hind limb in Saurians a thick transverse fascial band, which I suppose to be an inscription between the caudal and the crural parts of these ventral, or ventro-appendicular, muscles, and which seems to correspond, antagonistically, with Poupart's ligament, and so, serio-antagonistically, with the clavicle.

Still deeper, and belonging to a deeper plane, is the *caudo-femoral*, which is usually present in ovipara above Fishes, and is sometimes designated *agitator caudæ*. It is inserted into the femur, and is, in varying degrees, blended with the deep muscles of the thigh—the *adductors* and the *semimembranosus*—and sometimes with the origin of the flexors of the foot and toes, affording an interesting example of the prolongation of the deeper strata of the ventral muscle to the distal parts of the limb.

The caudal derivations, which form so important an element in the muscular system of the hind limb of Urodelans and some Reptiles, are present, though less strongly developed, in Birds, and are not uncommonly met with in Mammals. Thus the *semitendinosus* sometimes derives its chief origin from the sacrum. In the Otter and Raccoon, the *caudo-crural* is more distinctly represented by a muscular slip derived partly from the spinous and partly from the transverse processes of the caudal vertebræ. It joins the hinder surface of the *semitendinosus*, and is prolonged with the posterior fibres of that muscle

<sup>1</sup> In some large-tailed Mammals (Cyclothurus and Manis) the *semitendinosus* retains the caudal as well as the pelvic factors. I have not, however, found the inscription in any of these.

to the inner side of the heel. The caudo-femoral is also represented in the Otter by a thin muscle, arising from the transverse processes of the caudal vertebræ, passing internal to the sciatic nerve, and into the middle third of the linea aspera, between the *gluteus* and the adductors and distinct from both. The *pyriformis* and *quadratus femoris* muscles are both present in this animal. In the Rat a caudo-femoral muscle passes from the sacrum, beneath the *gluteus*, to the internal condyle and the post-condyloid bone, between the *addr. m.* and the *semimembranosus*. It lies near to, and in the same plane with, the *ischio-caudal*. The antagonistic homologues of the two (*caudo-femoral* and *ischio-caudal*) are probably the *psoas magnus* with its neighbour the *psoas parvus*.

#### THE MUSCLES PASSING FROM THE LIMB-GIRDLES TO THE LIMBS

may be regarded as extensions of the deeper strata of the ventral muscle—as deep ventro-appendicular muscles—forasmuch as the girdles are ossifications in the deeper level of the ventral inter-muscular septa. They share the surface of the girdles with the fibres of the ventral muscle which pass backwards or forwards to the adjacent trunk segments. Hence the extent of their attachment to the girdles varies inversely with the extent of attachment of the direct fibres of the ventral muscle. Where the latter are numerous, as on the ilium of *Cryptobranch*, the muscles passing from the bone to the limb are few. Where, on the contrary, the range covered by the direct ventral fibres is small, as in the pubischium of *Cryptobranch*, the size of the muscles passing to the limb is considerable. In like manner the extent of their attachment to the first segment of the limb reciprocates with that of the origin of the muscles passing to the second segment. Thus, in *Cryptobranch*, the *pectineus* engrosses the whole of the dorsal surface of the femur; whereas in most animals that surface is occupied by the extensor of the leg, and the *pectineus* is compressed within narrow limits. It may be inferred that the corresponding embryonic factors are, in some instances, employed in the

building up of the one series of muscles and, in other instances, of the other series.

These muscles surround the joint of the first limb-segment with the girdle in a more or less circular, or capsular, manner. Usually, however, they are arranged in two divisions, or groups, in each limb. The one group passes from the outer, or posterior, surface of the girdle, beneath the joint, to the ventral or under surface of the limb, constituting a palmar or coraco-humeral series in the fore limb and a plantar or pubischio-femoral series in the hind limb. The other group passes from the outer, or hinder, surface of the girdle, above the joint, to the dorsal surface of the limb, constituting a dorsal or scapulo-humeral series in the fore limb, and a dorsal or ilio-femoral series in the hind limb<sup>1</sup>. These groups do not adhere strictly to their respective limits. They sometimes extend from the outer surface, over the margins, upon the inner surface of the girdles; and they sometimes extend from the area of the girdle beneath the joint to the part above it, and *vice versa*. Moreover, in accordance with the difference in the rotation in the two limbs, the insertion of corresponding muscles may be on the one—the pre-axial or radial—side in one limb, and on the opposite—the post-axial or fibular—side in the other limb. It not unfrequently is found, in the case of each of the several groups, that it is imperfectly segmented from the superficial ventro-appendicular stratum on the one surface, and from the muscles which pass on to the next segment of the limb on the other surface.

In animals above Fishes the CORACO-HUMERALS, or, as they are more generally called, CORACO-BRACHIALS, are commonly divided into segments which vary in number and size with the number and size of the coracoid processes; and they are sometimes absent when these processes are abortive, as in Mole, Cyclothurus and Seal. They arrange themselves in two divisions. *First*, those which lie superficially with regard to the *biceps brachii* muscle and which pass to the radial tubercle

<sup>1</sup> These are seen in their simplest form in *Ceratodus* (Fig. 34), where the coraco-brachial and the scapulo-brachial muscles are seen extending from the respective parts of the girdle upon the ventral and dorsal surfaces of the pectoral fin. The arrangements are similar in the hinder fin; and there are additions from the ventral muscle.

of the humerus immediately above the level of the *pectoralis major* and also extend beneath that muscle. These constitute a superficial or pre-axial division. *Secondly*, those which lie beneath the *biceps* and pass to the ulnar tubercle and ulnar side of the humerus. These constitute a deep or post-axial division.

The superficial division comprises the *epicoraco-humeral* and the *precoraco-humeral*, and probably the *supra-spinatus*, the *levator humeri* and the *pectoralis minor*. All these, with the exception of the last, which I will consider separately, may, I think, be regarded as parts of one muscle which occupies, essentially, the precoracoid process and might be called the precoraco-humeral muscle. It may spread upon the edge of the coracoid on the one side, and be segmented, so forming an *epicoraco-humeral*; and it may spread upon the supra-spinal space of the scapula on the other side, so forming a *supra-spinatus*. In Cryptobranch (p. 52), where the precoracoid processes are large, the *precoraco-humeral* muscle is well developed; and the *epicoraco-humeral*, in the same plane with and scarcely segmented from it, spreads over the edge of the coracoid; but there is no *supra-spinatus*. In Menobranch the latter muscle is present, in addition to the other two; but its edge is continuous with that of the *precoraco-humeral*. In the Scinc the *precoraco-humeral* and the *supra-spinatus* are large and separate; but there is no *epicoraco-humeral* extension of them over the broad origin of the *biceps*. In the Crocodile the *precoraco-humeral* is large, arising from the precoracoid process—from the outer surface and the anterior edge, and also from the deeper surface of that process—much as the *pectineus* often arises from the corresponding surfaces of the pubes. It is nearly on a level with *pectoralis* on the one side, and the *deltoid* on the other, and is inserted between them. The *supra-spinatus* is small, lies partly beneath it, and is imperfectly segmented from it. There is no distinct *epicoraco-humeral*, the surface of the coracoid, internal to the origin of the *biceps*, being closely covered by the *pectoralis* which derives some fibres from its edge, from the place, that is, where the *epicoraco-humeral* usually arises. In the Bird the precoracoid process does not run out distinctly. It is bent down with the coracoid



to the sternum, forming an acute angle with the sternum; and the *precoraco-humeral* muscle follows it, together with the *epicoraco-humeral* factors. These, or some of them, extend upon the sternum and form the *levator humeri* or *pectoralis tertius*<sup>1</sup>, as it is sometimes called. In Mammals the *supra-spinatus* and the *pectoralis minor* are the representatives of this division.

The fibres of the epicoraco-humeral part of this superficial, pre-axial, or supra-bicipital, division of the coraco-humerals lie immediately beneath the *pectoralis major* in its whole course. I have remarked that in Cryptobranch its superficial fibres are blended with the under surface of the pectoral, and that in Crocodile the fibres that correspond with it form part of the origin of the pectoral. It thus, to some extent, occupies the place of the *pectoralis minor*; and if we suppose it continued upon the under surface of the pectoral, and in variable degrees segmented from that muscle, it would quite correspond with the ordinary mammalian *pectoralis minor*, the proper insertion of which appears to be the radial ridge or tubercle of the humerus. It is, however, in Man and some animals, arrested wholly, or (Rat), partially, at the coracoid and is often quite segmented from the *pectoralis major*. Thus, I conceive the *pectoralis minor* to be formed from factors of the *pectoralis major*, which, or some of which, represent the *epicoraco-humeral* of Urodelans, Reptiles and Monotremes, and that it also in part represents, indeed is the nearest representative of, the *levator humeri* of Birds<sup>2</sup>.

<sup>1</sup> Also the *secundus* when both are present.

<sup>2</sup> This view is in accordance with the fact that the *levator humeri* sometimes absorbs the *supra-spinatus*, or derives an accession of fibres from the upper surface of the scapula, as well as with the occasional passage in Man, as noted by Macalister, Wood and others, of the *pectoralis minor* over the coracoid process beneath the coraco-acromial ligament where it has been found to blend with the *supra-spinatus*, or with the capsule of the joint, or to pass directly to the head of the humerus. It harmonizes also with the close relation of the *supra-spinatus* to the tendon of the *biceps*, a relation corresponding with that of the *epicoraco-humeral* to the *biceps* in Urodelans and Reptiles.

It however is not quite in accordance with the view of Prof. Rolleston, *Trans. Linn. Soc.* xxvi. 609, that the *subclavius* is the homologue of the *levator humeri*. I have before (p. 127) given reasons for thinking that the *subclavius* is an extension of the middle stratum of the ventral muscle and is the serial homologue of the *costo-coracoid* muscle. It lies in front of, or above, the *costo-coraco-clavicular* ligament; and when it is prolonged beyond the range of the clavicle, it usually expands upon the *supra-spinatus* or the dorsum of the scapula, forming the *sterno-* or *sterno-costo-scapularis*, as it does in Hippopotamus and some other animals. Sometimes, however (Pig), it reaches the radial tubercle of the humerus; but its destination is rather to the dorsum of

The deeper, post-axial, or sub bicipital, coraco-humerals arise from the coracoid beneath the biceps, as best seen in Reptiles. They may be traced, in these animals, taking origin from the under and hinder surface of the coracoid and spreading upon the under surface of the scapula, where a portion of them forms the *subscapularis*. In Mammals, this muscle is quite segmented from the others<sup>1</sup>. They are inserted into the ulnar edge of the humerus; it is inserted into the ulnar tubercle. The one next below the *subscapularis*—the *coraco-brachialis*—is generally present and is inserted into the middle of the shaft. The passage through it of the external cutaneous or musculo-cutaneous nerve indicates a tendency to division; and in several Mammals (Rabbit, Proboscis Monkey and Jerboa) the upper segment is inserted separately into the ulnar tubercle, forming a *superior coraco-brachialis*. In Amphibians, Reptiles, and Monotremes there is commonly a third segment, an *inferior coraco-brachialis*, which extends to the ulnar condyle; and the brachial artery with the median nerve passes between it and the middle coraco-brachialis.

The PUBISCHIO-FEMORALS are less variable in number and size than their homologues just described, owing to the greater uniformity of the pubic and ischiatic bones in comparison with the coracoids. Like the coraco-humerals, they arrange themselves into superficial or pre-axial and deep or post-axial divisions, which pass, respectively, to the tibial and fibular edges of the femur; but the two are not so separated at their origin by the intervention of the prolonged portion which forms the flexor of the leg, as the two divisions of the coraco-humerals are separated by the prolonged portion of them which forms the *biceps* flexor of the forearm.

the scapula than to the humerus in the instances in which there is no clavicle, or when it extends beyond that bone.

The *pectoralis minor* would seem to be conducted as it were to the thorax in Mammals by the costo-coracoid ligament which usually separates it, above, from the subclavius, and which may be, as suggested by Gegenbaur, a remnant or representative of the extension of the coracoid to the sternum in ovipara.

In Pteropus (*Journ. Anat.* III. 301) a deep portion of the pectoral, which may be the *pect. minor*, arises from the clavicle. In the Rabbit, besides being connected with both tubercles of the humerus, it spreads over the *supra-spinatus*, and is inserted along the whole length of the spine of the scapula.

<sup>1</sup> In the Dog the *subscapularis* is partly blended with the *supra-spinatus*, and in the Mole with the *teres major*.

The superficial, or pre-axial, division of the pubischio-femorals comprises muscles arising from the os pubis (which is probably the representative of the precoracoid), and from part of the surface of the ischium (which is probably the representative of the coracoid). Owing to the large relative size and fixity of the bones from which they arise, and the heavier work which usually devolves upon the hind limb, they are ordinarily larger and more numerous than their correspondent the *precoraco-humeral* with its appendages, the *supra-spinatus* and the *epi-coraco-humeralis*, in the fore limb.

The *pectineus* is perhaps the most constant segment or muscle of the division, and it answers in many respects, serially, to the *precoraco-humeral*. It arises from the os pubis, and not unfrequently extends, over the anterior edge, upon the deep surface of the bone, much as the *precoraco-humeral* in Crocodile extends, over the anterior edge of the precoracoid, upon its deep surface. We have found the *pectineus* in Cryptobranch spreading over the dorsal surface of the femur, even to its fibular side. Usually, however, its insertion is limited to the upper part of the tibial line of the femur (the tibial edge of *linea aspera*). Where the ala, or anterior edge of the ilium, grows into prominence, an extension of this pubischio-femoral division spreads upon and occupies the anterior, or deeper, surface of the ala, constituting the *iliacus internus*<sup>1</sup>, in the same way that an extension of the superficial coraco-humerals spreads upon the anterior surface of the spine of the scapula, and constitutes the *supra-spinatus*. Behind the *pectineus* lies the *adductor* mass, which is variously segmented in different animals and which is perforated by a vessel that in some animals becomes the main vessel of the leg and foot. It sometimes (Hippopotamus, Fig. 48, and others) extends upon the tibial side of the leg; and, we shall find presently, it often has intimate relations with the flexors of the leg<sup>2</sup>.

<sup>1</sup> In Saurians the *iliacus int.* ranges, like the *pectineus* in Cryptobranch, but to less extent, over the dorsal surface of the femur, approaching the fibular side. In Mammals it is restricted to the tibial side.

<sup>2</sup> The adductor mass not unfrequently extends across the popliteal surface of the femur to the fibular line of the *linea aspera*; and a considerable part of it is probably derived from factors which, in the fore limb, range themselves with the post-axial division of the coraco-brachials.

The view just given of the morphological relations of the *iliacus internus* derives perhaps some confirmation from the fact that in the Hippopotamus, and other artio-dactyles and some other animals, there is an extension into the pelvis of one of the superficial muscles of the thigh—the *ilio-prétibien* of Cuvier. At least near the knee this muscle lies in the plane of the *sartorius* and the *gracilis* and seems, in some instances, to belong to the one, and in some, to the other of these two. In a Hippopotamus<sup>1</sup> the muscle I am alluding to was, near the knee, joined with the *gracilis*. Ascending, it diverged from it and divided into two portions. Of these, one was inserted into the inner edge of the brim of the pelvis, blending there with the lower part of the *psaos parvus*. The other portion expanded over the *iliacus internus*: the middle part of this was lost in the fascia covering that muscle; and the lateral parts, separating fork-like, approached and blended with the *psaos parvus* near its origin, on the one side, and with the outer fibres of the *iliacus int.* on the other side<sup>2</sup>. The *pectineus* was not distinctly segmented from the *adductors* in the Hippopotamus.

A remarkable derivation from this series of muscles, and apparently from the *pectineus*, is the *internal rectus* of Saurians and Birds. In the Cryptobranch we noticed the *pectineus* extending over the dorsal surface and fibular side of the femur; and the *internal rectus* would seem to be an extension of the lowest part of this, over the knee, beneath the *quadriceps*, into continuity with the flexors of the digits, an extension similar to that of a portion of the *peroneus*—the *p. longus*—over the ankle, through the sole, to the metacarpal of the hallux, or to that of the *tibialis anticus*, in Unau, over the inner side of the foot, into the flexor of the digits.

The deep, or post-axial division of the pubischio-femoral mass, which is inserted into the fibular edge of the femur and the fibular trochanter, is segmented into the *quadratus femoris*, the *gemelli*, and the *obturator externus* and *internus*. The

<sup>1</sup> Fig. 48 represents the muscles of the fore and upper part of the thigh and of the front of the pelvis, in a young Hippopotamus. *Il. i.*, *iliacus internus*.—*Ps. p.*, *psaos parvus*.—*Ps. m.*, *psaos magnus*.—*N.*, the anterior crural nerve.—*I. p. t.*, *ilio-prétibien*.—*Ad. l.*, *adductor longus*.—*Gr.*, *gracilis*.—On the right side, the *gracilis* and *ilio-prétibien* have been removed, bringing into view more fully the *psaos magnus*, the *iliacus internus* and the *adductor longus*, also shewing (*Ad. m.*), the *adductor magnus* passing to the tibia, and (*S. t.*) the *semitendinosus*.—*S.* the *sartorius*.

<sup>2</sup> This extension upon the *iliacus* is described by Gratiolet in his *Mémoire*, p. 287, as the *Sartorius*. There is, however, a muscular band passing from the ant. spine of the ilium over the front of the patella, which appears to represent the *sartorius* and the *tensor vag. femoris*; occasionally the *gracilis* itself extends over the *pectineus*, and so comes into relation with the *ilio-prétibien* above, as this muscle comes into relation with the *gracilis* below.

*obturator internus* appears to result from an extension of the mass round the posterior edge of the ischium upon its internal surface, resembling the extension which we not unfrequently find of the *pectineus* upon the internal surface of the pubes; and the two divisions of the pubischio-femoral mass may thus meet on the internal surface of the pubischium. This extension of the *obt. int.* corresponds serially with the extension of the coraco-humeral mass upon the posterior and inner surface of the coracoid, a prolongation of which (p. 158) beneath the scapula forms the *subscapularis* and corresponds with the prolongation of the *obt. int.* beneath the ilium.

Instead of saying that the *obturator internus* is formed by an extension of the pubischio-femoral mass round the edge of the ischium upon its internal surface, it would be more correct to say that the fibres of the ventral muscle developed upon the inner surface of the pubischium blend posteriorly with, and so form an extension of, those on the outer surface. We sometimes find that they take a different direction, and blend with the muscles in front of the pubischium. Thus in Saurians they join the members of the pre-axial division and, uniting with the *pectineus* and *iliacus internus*, create an extension of those muscles in that direction. Again in Birds they take a third course and, converging to the fore part of the obturator foramen, run forwards, through it, to the fibular condyle.

This remark is applicable to other instances in which I speak of an extension of a given muscle over any particular territory. That extension is commonly effected by the fibres which belong to and are developed in the territory mentioned blending with the muscle which is extended over it. Accordingly, it will be commonly found that the nerve-supply to the so extended part of the muscle is derived from the sources which appertain to the region which it covers. I do not therefore attribute much importance to the fact of the internal obturator muscle being associated in its nerve-supply with the gemelli and quadratus, while the external obturator muscle is in the same way rather associated with the adductors and the gracilis.

The SCAPULO-HUMERAL and ILIO-FEMORAL muscles are, respectively, situated upon the dorsum of the scapula and of the ilium, and are, in the main, inserted into that surface of the proximal part of the limb, in each case, which is directed dorsally. This, in the primitive piscine condition of the limb (see Dog-fish and *Ceratodus*), is the dorsal surface. In most higher animals, however, the radial tubercle and edge of

the humerus, and the fibular tubercle and edge of the femur, are turned into the position most favourable for their reception<sup>1</sup>.

In the fore limb the scapulo-humeral mass is, in most of the lower animals, represented by a single muscle, diffused upon the dorsal surface of the fin in Fishes, but in Urodelans and Reptiles converging into a tendon implanted into the radial edge or tubercle of the humerus and called *dorsalis scapulæ*. This in higher animals is commonly segmented into *infra-spinatus*, *teres minor*, and *teres major*. It is probable that some of its superficial elements, which in certain cases apply themselves to the last-named muscles, in other cases apply themselves to and contribute to the formation of the *deltoid*. Hence we find the latter muscle occasionally (Phoca) encroaching upon the territory of these muscles and dwarfing them. The *infra-spinatus* and *teres minor* are sub-deltoid segments. But the *teres major* may rather be regarded as a *sub-latissimus dorsi* segment, forasmuch as it applies itself often to the under-surface of that muscle. At the same time it is more steadily connected than the *lat. d.* with the ulnar ridge of the humerus<sup>2</sup>. Both the *teres major* and the *supra-spinatus* sometimes (Pig) extend over the respective margins of the scapula upon the under-surface, and derive fibres which usually appertain to the *subscapularis*. The *teres major* does so more particularly; and its relation to this territory is also shewn by the fact that it and the hinder part of the *subscapularis* muscle are sometimes supplied by the same subscapular nerve.

The ilio-femoral mass forms the deep *gluteus* which is sometimes one muscle, but is often segmented into the *gluteus medius* and *minimus* and the *pyriformis*. The last is, in many instances, continuous with the *gluteus medius*. It commonly extends upon the under-surface of the ilium and upon the

<sup>1</sup> This I think is the real explanation of that difference in the insertion of those corresponding muscles in the two limbs which has caused so much difficulty in determining their homological relations. The view is confirmed by the observation that the muscles arising from the dorsum of the scapula are not strictly tenacious of their connection with the radial tubercle; some of them at least in Birds and Lizards passing to the ulnar tubercle, or the ulnar edge of the humerus.

<sup>2</sup> In Scine it passes to the ulnar side of the humerus, quite separate from the *lat. d.* In Manis it is very large, blended with the *lat. d.* at its origin, and accompanies it to the inner condyle of humerus, the olecranon and the forearm.

sacral vertebræ. It lies beneath the *gluteus max.* bearing, at the origin, a relation to it similar to that of the *teres major* to the *lat. d.*; and the gluteal vessels and nerves pass between its anterior edge and the ilium, just as the posterior branches of the subscapular vessels and nerves pass between the anterior edge of the *teres major* and the scapula<sup>1</sup>.

Thus the deep or girdle portion of the ventro-appendicular muscle in each limb divides itself more or less distinctly into sectors corresponding generally with, and often to some extent blended with, the sectors of the superficial stratum of the same muscle. The *coraco-humerals* in the fore limb, and the *adductors* in the hind limb, lie beneath, and are often respectively blended with, the *pectorals* and the *gracilis*. The *dorsalis scapulæ* presents similar relations to the *trapezio-deltoid*, and the *teres major* to the *latissimus dorsi*; and the same may be said, though less markedly, respecting the relations of the other corresponding muscles in the hind limb, viz., of the deep *glutei* with the *obliquus*, *sartorius*, and *tensor vaginæ femoris*, and of the *pyriformis* with the *gluteus maximus*.

#### THE FLEXORS AND EXTENSORS OF THE FOREARM AND LEG

are in each instance formed, *first*, by intrinsic muscles, that is, muscles arising from the humerus and femur; *secondly*, by extensions of the deep ventro-appendicular stratum, that is, by muscles arising from the girdle; and, *thirdly*, by extensions of the superficial ventro-appendicular stratum; and the muscles from these three sources are more or less blended. In the simple limbs of Fishes they form only one unbroken layer. Some amount of segmentation takes place in most other animals; but, owing to the simple nature of the movements they effect, the complications and varieties in these muscles are not very great or numerous.

The intrinsic flexors are represented by the *brachialis anticus*<sup>2</sup>

<sup>1</sup> See reasons, in *Journal of Anat.* v. 85, for regarding the *teres major* and the *pyriformis* to be serially homologous.

<sup>2</sup> In Hippopotamus the *brach. ant.* is wanting, the space on the outer side of the humerus from which it usually arises being occupied by the *sup. longus* which is large, and acts as simply a flexor. It might almost be described as *brach. ant.* inserted into the lower two-thirds of the radius instead of, as usual, into the ulna. The blending of the elements of these two into one is remarkable. The muscle winds round the back of the humerus to the inner side, and has a broad

in the fore limb, and by the short portion of the *biceps*—the *femoro-fibular*—in the hind limb. The latter is sometimes inserted low down in the leg (Cryptobranch and Cyclothurus)<sup>1</sup>. In other cases it meets and blends with the *biceps flexor cruris*, and is called the 'short' or 'femoral head of the biceps.' It is not unfrequently wanting. Both these are usually inserted into the post-axial bones of the limb—the ulna and fibula. The intrinsic dorsal or extensor muscles are represented by the parts of the *triceps* and of the *quadriceps* which arise from the humerus and the femur. They, in the fore limb, usually converge to the ulna and, in the hind limb, to the tibia.

The deep ventro-appendicular flexor—the flexor derived from the girdle—in the fore limb is the *biceps*, which presents variable degrees of continuity with, and segmentation from, the *brachialis anticus*, and which is further brought into continuity with the intrinsic series by means of muscular derivations from the humerus in the Bird, and not uncommonly, in other animals, including Man in whom they occur as a variety. These are generally from the ulnar side of the humerus; while the *brachialis anticus* extends chiefly from the radial side, between the deltoid and the triceps. The coracoid origin of the *biceps* and its relation to the coraco-humeral muscles have been already (p. 155) described. Those relations were found to be very close in Cryptobranch (p. 33), and they shew the *biceps* to be an intermediate between the *coraco-humerals* and the *brachialis anticus*, continuous with either or both, and uniting them into one group, which extends from the coracoid, along the ulnar and palmar surface of the humerus, to the radius and ulna<sup>2</sup>. When the coracoid reaches to the sternum the origin of the *biceps* is broad, expanding, fan-like, as it ascends; and sometimes

origin beneath the inner tubercle. It thus dwarfs both of the humeral origins of the triceps. It is supplied by the radial nerve.

<sup>1</sup> *Journ. Anat.* vi. 22 and iv. 56.

<sup>2</sup> They are all usually supplied by one nerve—the musculo-cutaneous—which is the homologue of the coracoid nerve of Reptiles, and the serial homologue of the obturator nerve. The *brachialis anticus* is sometimes (Pteropus) found to be in direct continuity with the coraco-humeral. In Scinc the *biceps* derives two factors from the humerus, which occupy the position of the *brachialis anticus*. They are so named by Rüdinger, see p. 35, and *Journ. Anat.* ii. 301, iii. 338, iv. 37.



(Owl) it shews a tendency to divide into two—an outer, or glenoid, and an inner, or coracoid part. The division is complete in most Mammals; and the coracoid part forms the more superficial element of the muscle. Where the coracoid is very short, however (Manis), the division may disappear. The *biceps* is inserted into either or both of the bones of the forearm.

In the hind limb the flexor derived from the girdle, omitting for the present the consideration of the *biceps* to which I will revert, may, as in Cryptobranch, be blended, in its whole length, with the adductor mass; and it is often united with it to some extent. It however has rarely, or never, any connection with the femoro-fibular muscle (the short portion of the *biceps*). It is in most animals divided, in its whole length, into two. Of these the *semitendinosus* is usually the more free from the adductors<sup>1</sup>, is the more superficial, is inserted lower down on the tibia, and is the representative of the coracoid part of the *biceps brachii*. The other—the *semimembranosus*—is the deeper, represents the glenoid part of the *biceps brachii*, and is more connected with the adductors, presenting every degree of cohesion to them. It has also, as have the adductors, varied relations with the *caudo-femoral* which sometimes (some Birds<sup>2</sup>)—blends with it, sometimes (Cryptobranch) runs to the femur quite separate from it, and sometimes (Saurians) sends a long tendon, separate from the *semimembranosus*, down to the back of the fibular side of the tibia, or to the fibula, or to a sesamoid just above the fibula, from which the flexors of the foot and digits arise<sup>3</sup>.

<sup>1</sup> It retains a connection with the *gracilis* in Pteropus. In Seal the *semitendinosus* and *semimembranosus* remain one muscle, as their serial homologue the *biceps brachii* sometimes does in Mammals.

<sup>2</sup> In the Owl the *semimembranosus* and *adductor* are one muscle, which is joined by the *caudo-femoral*, and is partly continuous with the *gastrocnemius*. In the Swan the *caudo-femoral* joins the *adductor*, which is separate from the *semimembranosus* and is inserted into the *linea aspera* only. In the Gull the *caudo-femoral* is inserted into the femur unconnected with either the *semimembr.* or the *adductor*, which are separate; and the latter is partly continuous with the *gastrocnemius*.

<sup>3</sup> In the Dog the *semimembranosus*, arising from the tuber ischii, divides into two nearly equal portions. Of these one is inserted as usual into the tibia; and the other is inserted into the inner side of the lower part of the femur in the locality usually occupied by the *adductor magnus*. It is there blended with a tendon derived from the *add. longus*, and some fibres are inserted into the sesamoid of the inner head of the *gastrocnemius*. So that the sesamoid behind the internal condyle is a meeting-point between the *adductors* and the inner

The intrinsic extensors are represented by the parts of the *triceps extensor brachii* and the *quadriceps extensor cruris*, which arise from the humerus and femur, and which are very constant (except in Cryptobranch) and are subject to but little variety. The deep ventro-appendicular, or girdle, element is furnished by the scapular origin of the *triceps*, and by the *rectus femoris* or iliac origin of the *quadriceps*. Both these are connected with the dorsal surface of the girdles near the joints with the limbs; but the rotation of the fore limb usually directs the origin of the *triceps* to the hinder edge of the scapula, and the rotation of the hind limb directs the *rectus femoris* to the anterior edge of the ilium<sup>1</sup>. The superficial ventro-appendicular element is furnished in the fore limb by the *latissimus dorsi*, which in Cryptobranch is quite lost in the *triceps* and, in other animals, is partly blended with it; though, in Man and some Mammals, it passes to the humerus and has no connection with the *triceps*<sup>2</sup>. In the hind limb this element

head of the *gastrocnemius*; just as the sesamoid behind the external condyle is a meeting-point in Lizards between the tendon of the *caudo-femoral* and the outer head of the *gastrocnemius*.

Some of the fibres of the tendon of the *adductor magnus* in ourselves are continued into the internal lateral ligament, and so reach the tibia. In Ai and Manis some fibres of the *semimembranosus* join the *add. m.* above the knee. In the Jerboa the two muscles are inseparably united, and are inserted by a continuous tendon into the femur, the tibia, and the side of the knee. In the Rabbit the *adductor* is inserted into the tibia, as well as into the femur. In the Hippopotamus the *semimembr.* continues in union with the adductor as far as the knee.

<sup>1</sup> In Bats the rotation of the hind limb is the reverse of what is usual; and in Pteropus I found the *rectus* arising from behind the acetabulum. *Journ. Anat.*, III. 312.

The *triceps* in Manis extends in conjunction with the *supinator longus*, upon the dorsum of the scapula and to the spine, lying over the *teres* and *supraspinatus*: and, in Batrachians and Reptiles, the *triceps* derives an origin, behind, from the coracoid, as, in the same animals, the *quadriceps* derives an origin in front from the pubes. In Scinc the long portion of the *triceps* divides, one part passing external to the *teres major* upon the dorsum of the scapula, and the other upon the under surface of the shoulder-joint and the coracoid.

In Phoca (*Journ. Anat.*, II. 302) a portion of the *triceps (dorsi-epitrochlien)*, blended above with the scapular origin, and arising from the angle of the scapula, passes by the olecranon, along the ulnar side of the paddle, to the 5th digit. It forms a sort of intermediate between the *triceps*, the *teres major*, the *latissimus dorsi*, and the *costa alaris* of Birds, linking them all together and being linked by the two last to the ventral muscle.

For the parallel between the relations of the *triceps* to the radial nerve and those of the *biceps flexor cruris* to the peroneal nerve, see p. 53.

<sup>2</sup> The mode in which the *lat. d.* blends with the *triceps* in Cryptobranch explains its varied relations with that muscle—its passing in some instances on one side and in some on the other side of the scapular origin for instance—the fact being that its fibres are in some animals diffused in the *triceps*; in

is furnished by the *gluteus maximus*, which, in Birds, is blended with the quadriceps, and which, in Cryptobranch and other Batrachians, does not exist as an element distinct from the *rectus*<sup>1</sup>. In Mammals it partly expands into the *fascia* overlying the *quadriceps*, and partly is inserted into the fibular line of the femur. Sometimes it extends upon the outer side of the leg to the ankle and foot.

I have shewn (p. 22) that in Cryptobranch the long, or chief, portion of the *biceps flexor cruris* is a derivative from the *gluteo-rectus*, that is, from the blended, or unsegmented, superficial and deep ventro-appendicular extensions upon the dorsum of the limb; and that it inclines upon the lateral surface and plantar aspect of the limb, so as to acquire a flexor action. It often shews traces of this its origin. It retains its connection with the ilium in Lizards and Birds, being overlapped by the *gluteo-rectus* in the latter. In Mammals also it is often continued upon the ilium through the sacro-sciatic ligament. Not unfrequently it has more direct connection with that bone; and in some it extends, in close relation with the *gluteus*, upon the caudal vertebræ<sup>2</sup>. The inclination of this segment from the dorsal to the plantar aspect of the limb, and at the same time from an extensor to a flexor function, is probably due to the direction of the rotation of the limb. Accordingly, there is an absence of any distinct representative of it in Bats; and the nearest approach to the formation of a similar muscle in the fore limb is presented by the *dorsi-epitrochlien*—by such a one especially as we find in the Seal (see foot-note, p. 166). It

some they converge to and penetrate it at one point, in some at another; and in some they converge to, and pass on one side of it.

<sup>1</sup> In Birds there is no distinct *rectus femoris*; that is to say, this part of the quadriceps is not segmented from the *gluteus* or, as it might be called, *gluteo-rectus*. This is also the case in Urodelans (p. 22) and is paralleled by the imperfect segmentation of the *latissimus dorsi* from the scapular origin of the *triceps* in these animals (p. 36).

<sup>2</sup> In *Orycteropus* and Otter, the *biceps* arises from the ilium, ilio-sacral ligament and sacrum. In a wild Cat it was joined near the middle by a slip from the caudal vertebræ just behind the *gluteus*. In a tame Cat this slip, broad at its origin, was continued by a thin tendon which passed between the *vastus externus* and the *biceps* to the *fascia* on the outer side of the knee. In the Rabbit the chief origin of the *biceps* is from the sacral and caudal vertebræ; and it expands over the fibula and outer side of the leg, as far as the heel, without being inserted into the fibula. In Hippopotamus its disposition resembles that in the Rabbit; but it is more blended with the *gluteus* and has an insertion into the fibula. In Seal it reaches to and blends with the extensor tendons on the dorsum of the foot.

seems in many cases to be segmented from the *gluteus*, much in the same manner as the dorsi-epitrochlien is segmented from the *latissimus dorsi*.

Portions of the *triceps*, at the lower part of the arm, are not unfrequently segmented on one or both sides, constituting the *anconeus externus* and *internus*. A similar segmentation does not take place in the case of the *quadriceps*.

A sesamoid is very often developed in the lower end of the *quadriceps* and occasionally (Pteropus) in the lower end of the *triceps*. In the Wombat and a few other Marsupials the usual tibial sesamoid—the patella—is absent and a sesamoid—the fabella—is found upon the upper end of the fibula. We may connect this with the relation just described between the *biceps* and the *quadriceps*. The fabella can scarcely be regarded as the homologue of the patella, being connected with a different bone and a different part of the dorsal muscle. It presents more claim to be the serial homologue of the sesamoid in the *triceps*, situated above the olecranon which is the homologue of the large process growing from the upper part of the fibula in Monotremes. The connection of the fabella with an outlying portion only of the dorsal femoral muscle, whereas the supra-olecranon sesamoid is connected with the middle portion of the dorsal humeral muscle, is explained by the fact that the greater part of the femoral muscle is directed upon the tibia, whereas the greater part of the humeral muscle is directed upon the ulna.

The insertion of the *triceps* into the ulna while the *quadriceps* is inserted into the tibia has caused, in the mind of some anatomists, an unwillingness to admit the serial homological relation of the two muscles. The force of this objection, however, diminishes as we learn more of the manner in which the points of insertion as well as of the origin of muscles are liable to variation and to wander from one bone to another.

To sum up as thus far traced. The dorsal extension of the ventral muscle upon the hind limb gives rise to the *gluteus magnus*, the *tensor vaginae femoris* and the *sartorius*, to the *rectus femoris* and the long part of the *biceps*, to the *pyriformis* and the *glutei*. The like extension upon the fore limb gives rise to the *latissimus dorsi* and the *trapezio-deltoid*, the long head of the *quadriceps* with the *dorsi-epitrochlien*, to the *teres major* and *minor* and the *infra-spinatus*. The plantar extension of the ventral muscle upon the hind limb gives rise to the *gracilis* and the adductors, including the *iliacus internus* on the one side and the *obturator*, *gemelli* and *quadratus femoris* on the other, together with the *semitendinosus* and *semimembranosus*.

The same upon the fore limb gives rise to the *pectorales* and the coraco-brachials, including the *supra-spinatus* on the one side and the *subscapularis* on the other, together with the *biceps*.

#### MIDDLE AND DISTAL SEGMENTS OF THE LIMBS.

The muscles on the ventral (palmar and plantar) and on the dorsal surfaces of these segments of the two limbs are, in each instance, as we learn from the lowest orders of Vertebrates (see Figs. 23, 24, 34 and 36 and Cryptobranch), in their primitive state, in one mass which is connected with, that is to say, is to some extent continuous with, the prolongations of the ventral muscle upon the limb. In animals above Fishes, in all of which a uniform plan of segmentation of the limbs is followed, each mass (palmar or plantar and dorsal) is usually attached to the bone of the upper segment of the limb and to the several bones of the middle and distal segments. In accordance with the feathering manner in which the limbs, especially in the lower animals, are pressed upon the ground and withdrawn from it, the fibres on the palmar and plantar surfaces are directed from without, inwards as well as downwards, take their origin chiefly from the post-axial (ulnar or fibular) condyle and the post-axial side of the limb, and constitute a 'pronato-flexor' mass in each limb; while the fibres on the dorsal aspect, having a supinato-extensor action, take a similar direction, passing downwards and inwards from the post-axial side of the limb, and in some instances, in the hind limb, from the dorsal part of the post-axial condyle of the femur. In the case of the fore limb, however, the ulna, rising into the olecranon, commonly shuts off the supinato-extensor mass of muscles from the post-axial condyle of the humerus, and causes it—the deep as well as the superficial layer of it—to spread upon the preaxial condyle and the preaxial edge of the humerus. A certain method of division of these masses into planes and sectors is common to them all, and is also common to them in most animals; though there are of course many varieties in detail. A part of either of the masses which associates itself with one plane or one sector in a certain limb or animal may be otherwise disposed in other cases; but the deviations are

on the whole fewer and less than might have been anticipated. As a general rule each mass is divisible into a superficial and a deep stratum; and the superficial stratum is divisible into three sectors—two lateral and a median—though the division is by no means equally complete in all instances, that is to say, in some animals, as Cryptobranch, the segmentation is much less advanced than in others. It is usually less distinct in the pronator-flexor mass of the hind limb than in the several other masses. There is considerable variation in the extent to which the several masses are blended with the muscles of the upper segments of the limbs and with the extensions of the ventral muscles—the ventro-appendicular muscles—upon the limbs. The blending of the muscles of the upper segments is more observable on the palmar and plantar than on the dorsal aspects, because the dorsal projections of the elbow and knee commonly interrupt the continuity between the muscles above and below those joints.

#### PRONATO-FLEXOR MASSES.

The superficial stratum of these in Cryptobranch is very imperfectly segmented from the deep strata in both limbs; and in the hind limb it shows very little trace of division into sectors. In that limb it is a simple scarcely segmented mass extending from the fibular condyle and the fibular side of the limb upon the tarsus and digits. Superficially, it is continuous, through the medium of the *caudo-pedal*, with the superficial prolongation of the ventral muscle. This connection is in Lizards maintained only by a delicate tendon, and in higher animals does not exist; but the extensions of the *gluteus* and *biceps* are often substituted for it. The deeper (caudo-crural and caudo-femoral) prolongations of the ventral muscle are directed chiefly to the tibial side of the limb and do not commonly connect themselves with the pronato-flexor mass. Such a connection is however, as already mentioned, established in some Lizards by the descending tendon from the caudo-femoral running into the sesamoid above the fibula, from which the flexors of the foot and toes in part arise; and in some Birds there is a similar connection of the same muscle with the inner head of the *gastrocnemius*

through the medium of the *semimembranosus*. In *Manis* the inner head of the *gastrocnemius* derives fibres from the *adductor magnus*; and we know that this muscle is sometimes intimately connected with the caudo-femoral in the animals in which the latter is present. Moreover, the *rectus internus* in Birds and Lizards is continued over the condyles of the femur into the fibular origin of the superficial flexor of the digits, affording a good illustration of the manner in which, from the primitive unstratified unsegmented homogeneous envelope of the limb-skeleton, special forms are evolved.

Continuing the investigation of this superficial stratum of the pronato-flexor mass in the hind limb, in the which, as just said, the caudo-pedal is blended, we find it in the lower animals where the foot is in a plane with the leg extending, for the most part, to the digits. As the heel grows out, however, the superficial pronato-flexor stratum becomes concentrated upon and more or less interrupted by it.

The *plantar fascia*, which represents the pedal part of the caudo-pedal, may thus become isolated—cut off by the projecting os calcis—from the crural fascia and from the superficial layers of the *tendo-Achillis* and *gastrocnemius*, which appear to represent the crural part of the caudo-pedal. The pedal part of the *flexor sublimis digitorum* may become, in like manner, cut off from the crural part, the former acquiring the name of *flexor brevis* and the latter that of *plantaris*. The rest of the stratum, uniting itself with the caudo-pedal and inserted into the os calcis, forms the *tendo-Achillis* with the *gastrocnemius* and *soleus*. The degree however of this calcareal interruption of the superficial pronato-flexor stratum varies. The *tendo-Achillis* is sometimes continued into the plantar fascia; and the continuity of the *flexor sublimis digitorum* from the femur to the digits, as well as its connection with the plantar fascia, is very frequent<sup>1</sup>. In ourselves the principle of concentration of force upon the heel is carried to the utmost. The pedal and crural parts of the stratum are quite isolated from one another by the os calcis; and addi-

<sup>1</sup> In *Phoca* (*Journ. Anat.* II. 314). The elements of the *flexor sublimis* are derived from the *plantaris*, the *gracilis*, the *flexor profundus* and the *tibialis posticus*. In *Unau* also it derives a factor from the *tibialis posticus*. These are interesting remnants of the primitive common basis from which the several muscles were segmented.

tional power is brought to bear upon the heel by the origin of the *soleus* from the tibia and by the great development of the bellies of the *gastrocnemius*.

Thus considered, the *gastrocnemius* consists of the blended factors of the *caudo-pedal* and of the superficial layer of the pronato-flexor mass, some of which—the *soleus* elements—pass from the fibula, with occasionally factors from, or a connection with, the caudo-femoral. Most of these descend from the fibular side of the limb. In Amphibians the fibres that do so make up the whole muscle; and there is nothing to correspond with, or represent, the inner or tibial head of Birds and Mammals. This makes its appearance in Saurians as a thin muscular band descending from the lower edge and outer surface of the superficial plantar mass of the thigh—the part which represents the *gracilis* and *semitendinosus*—to the tibial side of the surface of the *gastrocnemius*. In Birds the tibial origin is connected rather with the portion which forms the *semimembranosus* or the *adductor*; and it acquires also a connection with tibial condyle of the femur. In Mammals the relation to the muscles descending from the thigh is lost, and the connection with the femur only remains, supplemented in Man by an origin from the tibia which constitutes the inner or tibial portion of the *soleus*.

The spreading of the *gastrocnemius* upon the fore part of the tibia in Birds, where it in some (Heron and Gull) is partially blended with the *sartorius*, is another illustration of the connection or continuity of the flexor with the extensor, or the plantar with the dorsal, muscles, and of the encroachment of one group upon the area of the other, of which we have seen so many instances. This portion of the muscle, though separated from the remainder by the *semitendinosus* passing between it and the internal condyloid head, is supplied by the popliteal nerve.

The blending of the *sartorius* with the *gastrocnemius* above mentioned is an interesting example of that continuity of the extensor and flexor muscles of the same limb, which is more remarkably exemplified, in a deeper stratum, by the continuity of the *internal rectus* with the *flexor digitorum*. Both subserve the same purpose, viz., that of assisting the action of the femoral flexors of the foot and toes during the condition of forced flexion of the knee which is so often and long maintained in Birds, and during which those flexors are much relaxed and less capable of acting upon the digits.

In the fore limb the superficial stratum of the pronato-flexor



mass never acquires an origin from the radial condyle, such as would correspond with the tibial head of the gastrocnemius which we find in the hind limb of Birds and Mammals. The covering fascia, strengthened by prolongations from the *pectoral* and *biceps*, perhaps also from the *latissimus dorsi*, and sometimes strengthened by muscular fibres derived from the ulnar condyle which constitute the *palmaris longus*, is the representative of the caudo-pedal. The most distinct example of a prolongation of the ventral muscle upon the palmar aspect of the fore limb—the most distinct serial correspondent, in short, of the caudo-pedal—is, however, as stated p. 131, furnished by the *costo-alaris* of Birds<sup>1</sup>.

Forasmuch as the carpus retains in all animals the flattened form, there is not here, as in the hind limb, a tendency to concentration upon a heel-bone thrown up in the middle, or an interruption of the several muscles by such a process. The components of this stratum are, therefore, more equally disposed upon the surface as they descend, than those of the hind limb; and they present a more distinct division into ulnar, radial and intermediate sectors. Of these the ulnar sector (*flexor carpi ulnaris*<sup>2</sup>), inserted into the cuneiform (with the pisiform) bone which is the homologue of the os calcis, is the chief representative of the *gastrocnemius* and *soleus*. In the intermediate sector, the *palmaris l.* expanding into the palmar fascia, where it blends with fibres of the *flexor carpi ulnaris*, represents the superficial part of the *gastrocnemius*; and the *flexor sublimis digitorum*<sup>3</sup> represents the *plantaris* and the *flexor brevis*

<sup>1</sup> I have said that the *costo-alaris* is to some extent the serial representative of the *caudo-pedal*, and that the *palmaris l.* is also a like representative of the same muscle. An interesting exemplification of the relation of these parts is afforded in *Phoca* by the *palmaris l.* which, instead of arising as usual from the condyle of the humerus, passes upon the olecranon and blends with a portion of the *triceps* coming from the angle of the scapula, which again is in close connection with the *latissimus dorsi*; and it spreads like the *costo-alaris* upon the ulnar side of the carpus and hand. The similar exemplification in *Manis* afforded by the direct continuity of the *latissimus dorsi* with the palmar fascia and the *flexor subl. dig.* has already been pointed out.

<sup>2</sup> The *fl. c. u.* is not subject to much variety. It sometimes (*Unau* and *Cyclothurus*) spreads across the wrist superficially, meeting an expansion from the *supinator longus*; or (*Phoca*) it spreads beneath the *palmaris l.*; or it blends with the latter muscle or with the annular ligament. In the *Proboscis Monkey* it meets the *sup. l.*; and the expansion formed by them lies superficial to, and can be dissected off from, the fascia of the forearm.

<sup>3</sup> The *fl. d. s.* is partially interrupted at the carpus in *Pteropus*; and the *palmaris l.* in *Ai.* In *Scine* the *fl. d. s.* is tendinous at the wrist and expands

*digitorum* which, as already shewn, are the upper and lower parts of the *fl. s. dig. pedis*. In the hind limb, the last-named muscle becomes, in higher animals, almost pushed out of the field, being reduced to the slender *plantaris* by the increasing *gastrocnemius*. But in the fore limb its homologue is in the ascendant and absorbs a great part of the fibres of the stratum at the expense of the *flexor carpi ulnaris* and also of the *palmaris l.*, which latter dwindles or disappears. The tibial sector of the superficial stratum in the hind limb shares the fate of the other parts of the stratum; indeed it is altogether absorbed by the heel-muscle. In the fore limb the corresponding sector is large, is partly inserted along the radius, forming the *pronator radii teres*, and partly into the carpus or metacarpus, forming the *flexor carpi radialis*.

Thus, granting that the *plantaris* is represented by the *flexor digitorum sublimis*, the elements of the stratum which, in the hind limb, are made to converge into the *tendo-Achillis* are, in the fore limb, divided into the *palmaris longus*, the *flexor carpi ulnaris* and the *flexor carpi radialis* with part of the *pronator teres*. Moreover the *palmaris l.*, instead of being interrupted at the carpus, is continued into the palmar fascia; just as the homologous part of the stratum in the hind limb is continued into the plantar fascia in those animals in which the tarsus retains its primary simple, flat, carpus-like form.

I have before (pp. 37, 38) pointed out evidences of the continuity of the upper (*pronator teres*)<sup>1</sup> part of the radial sector of the superficial stratum with the deepest (*pronator quadratus*) part of the deeper stratum; and the lower or *flexor carpi radialis* part of the sector is, in most animals above Urodelans, separate from the *pronator teres* and takes a deep course in the hand<sup>2</sup>. Now we find in the hind limb that the whole of the representatives of this sector—the representatives, that is, of the *pronator teres* and the *flexor carpi radialis*—or

into a second muscle below the wrist; thus closely simulating the *plantaris* and *fl. d. s.* in the ordinary mammalian hind foot.

<sup>1</sup> The ulnar origin of the *pronator teres* in Man (also in the Chimpanzee and Rabbit) is an interesting remnant of this continuity. In the Bird (Kite) the muscle is in two distinct parts, both arising from the humerus. Some of the branches of the median nerve pass between, some above and some below, the two parts. The branches passing between them are distributed to the *fl. c. u.* and the *fl. dig. pr.* and represent, therefore, part of the ulnar nerve. See disposition of the muscle and its relation to nerves in the Cryptobranch, p. 37.

<sup>2</sup> In the Bird the *flexor carpi radialis*, like its serial homologue—the *tibialis posticus*—lies deep in its whole course. It arises from the ulna only and not from the humerus. See varieties of insertion into scaphoid and mets. I., II., and III. *Journ. Anat.*, IV. 42. In Phoca it is inserted into the scaphoid and Met. I. with a slip to Met. II.; in the Pig into Met. III.; in the Proboscis Monkey into Mets. II. and III.

such of them as are present, viz., the *popliteus* and the *tibialis posticus*, are situated in a deep level, nearly in the same level with the *pronator tibiae quadratus* with which indeed the *popliteus* is sometimes merged. That is to say, the radial sector, though chiefly in a superficial level, is continued into a deep level through the medium of certain fibres of the *pronator teres* and through the tendon of the *flexor carpi radialis*; whereas the tibial sector, composed of the *popliteus* and the *tibialis posticus*, lies throughout in a deep level.

Indeed, the greatest and most essential features of difference with regard to this region in the two limbs is caused by the fact that the *flexor carpi radialis*, which in the hand lies in as deep a level as does the *tibialis posticus* in the foot and evidently corresponds with it, becomes in the forearm part of the superficial stratum and is attached to the condyle of the humerus; whereas the *tibialis posticus* continues its deep course in the leg and does not reach the femur at all. The plane of segmentation of the two muscles, which is the same in the hand and foot, differs in the forearm and leg. So that, although the two tendons might be regarded as serially homologous, the two muscles can scarcely be said to be so. Properly viewed, however, they furnish a good illustration of the way in which certain nearly corresponding muscles in the two limbs (and the remark applies to muscles of the same limb in various animals) are differently segmented from the parent mass. They afford further evidence that homological rule is not so rigidly followed in development as we may be disposed to think, and that we must not be too severe in our attempts to institute homological comparison.

The variation that occurs in the division of the strata and in the amount and disposition of the fibres attaching themselves to either stratum, is also shewn by the fact that in the lower animals the fibres of the radial and ulnar sectors are in great part inserted into the radius and ulna, so becoming flexors of the forearm upon the arm; and superficial prolongations only of them pass on to the carpus; whereas in higher animals the ulnar sector arising partly from the ulna is continued in its entirety to the carpus, and the radial sector divides into two parts, of which one—the *pronator teres*—is inserted into the radius, and the other—the *flexor carpi radialis*—is continued to the carpus.

The differences in the two limbs evidently have relation to the necessity that exists in higher animals for moving the foot forcibly as a whole for the purpose of driving the body onwards. This is accomplished by throwing the whole or the greater part of the strength of the superficial stratum of the pronator-flexor mass, including the elements of the caudo-pedal, upon the projecting lever furnished by the os calcis, and by applying a portion of the deeper stratum of the mass (*tibialis posticus*) to the same end as well as to the pronation of the limb; whereas in the fore limb the whole of the deep stratum, except the *pronator quadratus* and a considerable part of the superficial stratum, is available for the movements of the digits, and so subserves more directly to prehension and the requirements of the will. In the hind limb

the muscular mass becomes absorbed by the elevator of the heel, and in the fore limb it becomes absorbed in the flexors of the digits.

Not only does the superficial flexor of the digits in the fore limb absorb nearly all the elements of the middle sector, and push the *palmaris l.* (the representative of the middle or superficial part of the gastrocnemius, including the caudopedal) nearly or quite out of the field; but it not unfrequently happens that it in turn gives place, in great measure, to the deep flexor. Thus it may be reduced (Hatteria), much like its homologue in the hind limb of Man, to a mere thin muscle, arising near the wrist from a ligament extended between the *os pisiforme* and the *os naviculare*, or (Unau) it may be a mere slip from the deep flexor, or it may (Phoca) be imperfectly segmented from the *palmaris*<sup>1</sup>.

As a prelude to further analysing and reducing the pronato-flexor masses and entering upon the consideration of their deeper strata, we must remember the numerous skeletal moveable parts in the distal region of each limb, and must conceive an unsegmented chaotic muscular mass passing from above downwards, and dropping fibres upon and deriving

<sup>1</sup> In Carnivora, where it is usually small and often imperfectly segmented from the *palmaris*, the superficial fibres of its tendons commonly blend with the palmar fascia and pass into the pads and the skin; and the deeper fibres form the perforated tendons to the phalanges. In the hind limbs of a Dog and of a Cat some of these fibres to the pad were derived from the *fl. prof.* and passed between the tendons of the *fl. subl.* Delicate muscular slips also passed from the deep to the superficial flexor tendons in the sole of these animals.

In Jerboa the *flex. subl.* passes to the three middle digits only; the other digits (i and v) receiving delicate muscular superficial flexors from the supernumerary carpal ossicle which is present in that animal. These, like the same muscular Hatteria, remind us of the usual disposition of the *fl. subl.* in the hind limb. In Guinea Pig the superficial flexor sends the greater part of its tendon to join the *fl. prof.* The superficial flexor to digit v. is formed on the radial side by a tendon from *fl. prof.* and on the ulnar side by a small muscle arising from the palmar fascia. In short, the varieties in the segmentation of these muscles are very numerous.

In the Heron and some other birds, the *fl. d. s.* is little more than a tendon passing, from the int. condyle and the cuneiform bone, to the fascia and the proximal phalanx (it passes to the second phalanx in the Swan). In the Jackdaw it is a muscular slip from the *flexor carpi ulnaris*. In the Rock it is a separate small muscle arising by a tendon from the int. condyle and passing partly into the *fl. c. u.* and partly to the proximal phalanx of the digit. See varieties in disposition and relations between the deep and superficial strata, *Journ. Anat.* iv. 43. In Manis the superficial flexor passes to the pollex and is continuous above with the *latissimus dorsi*.

fibres from the several skeletal parts after the manner which is suggested by the anatomy of the limbs in Fishes and in Cryptobranch.

In the Cryptobranch, segmentation has gone to a certain extent. Take the hind limb. *First*, the superficial fibres pass the farthest, extending from the femur, indeed from the tail, to the terminal phalanges, and they form a superficial stratum; still this stratum is very imperfectly separated from the deeper portion of the mass. *Secondly* (Figs. 9 and 11), a band is segmented from the deep part of the mass and is directed upon the bases of the digits, forming a *flexor profundus digitorum*. *Thirdly* (Fig. 12), several small deep bundles are segmented, passing from one skeletal part to another near by, so constituting 'intrinsic' muscles—*tarsometatarsales*, *metatarso-phalangei*, *phalangei* and *intermetatarsales* or *interossei*. The residuum of the mass constitutes what I have called the *pronator pedis* (Fig. 10). And there is a similar arrangement in the fore limb.

In higher animals the proximal skeletal parts move less upon one another; and the *flexor profundus* grows at the expense of the other components of the deep stratum first mentioned, the germs of which are either absorbed or dwarfed by it, except those of the *interossei*. The *pronator pedis* also in part blends with it; the tarsal portion of its origin forming the *accessorius*<sup>1</sup>, and the fibular portion of it forming the *flexor hallucis*. This last joins the deeper surface of the *flexor profundus*, and may be destined, as its name implies, chiefly

<sup>1</sup> In Proboscis Monkey the *accessorius* is united with the tibial flexor (*flexor prof.*) only.

The union of the two strata is sometimes (Unau) retained by the blending of the *accessorius* with the *soleus*, and also by a slip in the same animal from the *tibialis posticus* to the *flexor sublimis*. In *Orycteropus* also the *tib. post.* sends a slip to the *plantar fascia*; and in Unau it sends a slip to the superficial flexor tendon of digit iv.

In *Phoca* the *tibialis posticus* retains its connection with the elements of the short flexor muscles of digit i.

I have already (footnote on p. 176) mentioned slips from the deep to the superficial flexor of the digits; and, in *Phoca*, Otter and Raccoon, slips pass from the *accessorius* to the superficial flexor tendons or to the *plantaris fascia*.

In the Rabbit the *tibialis posticus* curls over the inner side of the scaphoid bone and terminates in the extensor tendon of digit ii., thus contrasting with the termination of the *tibialis anticus* in the *flexor digitorum* which we have marked in Unau, *Journ. Anat.* iv. 66.

to the hallux; or it may form part, and even the greater part, of the tendons to the other toes<sup>1</sup>.

The elements of the *pronator manus* become disposed of in much the same way as those of the *pronator pedis*; but they rarely contribute an 'accessorius'<sup>2</sup> origin from the carpus, corresponding with the *accessorius* muscle in the foot. They become, however, more closely blended with the *flexor profundus digitorum* above, than do their homologues in the leg; that is to say, the ulnar origin of the *fl. dig.* does not retain its individuality so much as does the fibular origin in the hind limb; and when a *flexor longus pollicis* is segmented it is so from the radial side<sup>3</sup>.

In this arrangement of the parts in the fore limb of higher animals we note more deviation than in the hind limb from the primitive simple condition. In the hind limb the pronato-flexor fibres chiefly take an oblique direction, from the fibular side downwards and inwards, and combine the movement of pronation with that of flexion. In the construction of the fore limb provision is made that each of those movements should take place in a greater range and each more independently of the other than the hind limb. For this purpose the muscular fibres are arranged into two more distinct sets, a pronator set passing to the radius and a flexor set passing to the digits; and the latter take a more vertical

<sup>1</sup> It is not an uncommon arrangement, in Monkeys especially, for the tibial flexor to pass chiefly to digits III. and IV., the fibular flexor passing chiefly to the other digits; and the *lumbricales* then commonly arise from both. In Proboscis Monkey the *fl. tib.* passes to digits II. and V., and the *fibularis* to I., III., and IV.; and, which is very unusual, the two muscles are not blended in any part of their course but are quite distinct.

<sup>2</sup> In some Saurians (Scinc) a muscle arises from the cuneiform bone and passes to the deeper surface of the tendon of *fl. d. s.*, representing the *accessorius*.

<sup>3</sup> In the wild Cat the *fl. prof.* is large, dwarfs the *fl. sublimis* and derives origin from the internal condyle, the ulna and the radius; and each of the tendons, traced upwards, acquires fibres from the several origins, the tendon to the pollex acquiring as many fibres from the condyloid and ulnar as from the radial origin. In the Dog the radial portion passes chiefly into the tendon to the pollex, the ulnar portion chiefly into the tendon to digit V., and the condyloid portion chiefly into the other three tendons. It is seldom, however, that the radial portion to the pollex is so completely segmented as in Man.

Such varieties are very significant with reference to the mode of development and the homological relations of muscles. They shew great diversity in the arrangement and blending of corresponding embryological germs without any obvious purpose, a tendency to variety within the range permitted by the high controlling forces which ensure the requisite subservience to utility.

course; indeed, they scarcely shew any indication of crossing from the ulnar towards the radial side.

The deepest part of the *pronator manus* mass becomes the *pronator quadratus* which, below, may (Scinc) extend upon the carpus and, above, may reach and blend with the *pronator teres*.

The elements of the tarso-metatarsals (or carpo-metacarpals), the metatarso- (or metacarpo-) phalangeals and the phalangeals follow those of the *pronator pedis* (or *manus*) in uniting with, or retaining their union with, the *flexor profundus*. Advancing forwards, however, they often separate from it, and, attaching themselves to the sides of the phalanges, form the *lumbricales* from their lateral parts and the *retinacula* from their middle parts. The phalangeals are probably included in the latter, but occasionally remain separate and often disappear. Hence the *lumbricales* are commonly found chiefly upon the deep surface of the angles between the tendons of *flex prof.*, and are often nearly or quite continuous with the *accessorius*. In the cases of the lateral digits, I. and V., their elements remain in part or wholly upon the metatarsals and form the short flexors. For this reason the *lumbricales* are not usually present on the tendons to these digits, or one only is present, lying upon the tibial (or radial) side of the tendon to digit V. More rarely there is one on the fibular (or ulnar) side of the tendon to digit I<sup>1</sup>.

To put it in another way, the *lumbricales* and *retinacula* may be regarded as parts of the common flexor mass, which, instead of becoming segmented into metatarso-phalangeals and phalangeals, retain their connection with the flexor tendons and are separated with them from the tarsus and metatarsus; but they are not detached from the phalanges to which they accordingly pass from the flexor tendons. Their connec-

<sup>1</sup> In some animals (Scinc) the *lumbricales* pass from both sides of the several tendons of the *fl. prof.* to both sides of the digits. In the foot of Pteropus there are eight *lumbricales*—one on the fibular side of the hallux, one on the tibial side of digit V., and one on each side of each of the other digits. Usually, in Mammals, they arise only from the approximated sides of the tendons (or, as commonly described, from the clefts between the tendons); and the fibres, instead of following the two sides of the several tendons and forming eight muscles as in Pteropus, are combined into four (the two in each cleft fusing into one) which pass to the tibial (or radial) side of the four outer digits.

tion with the extensor tendons in Man and some Mammals is a reminder of the blending of antagonistic muscles into a common sheath which we have found, as illustrated by Lepidosiren, to be one of the features of the primitive limb<sup>1</sup>.

Not only does the *flexor profundus* thus absorb or retain annexed to it these various elements of the deep stratum of the pronato-flexor mass; it also, in most animals above the Salamanders, retains its connection with the terminal middle portion of each digital division of the superficial stratum, or superficial flexor, so passing on to the terminal phalanx; while the lateral portions of the superficial flexor tendons, disconnecting themselves from the middle terminal portion, stop at a preceding phalanx. In this way the deep flexor comes to perforate the superficial flexor, which splits, allowing it to pass<sup>2</sup>.

Here I may observe that the ordinary mode of disposition of tendons passing along the digits is that each tendon approaching a joint divides into three. Of these the lateral parts are attached to the phalanx immediately on the distal side of the joint; and the middle part runs onwards to the next joint, where a similar process is repeated. This is best seen in the digits of Birds and Reptiles where there are more than two phalanges, and is well illustrated in the Plate of the Whale's fin by Prof. Struthers (*Journal Anat.* vi. Pl. vii.). It is seen also, according to the view just given, to be exemplified in the usual arrangement of the tendons of the superficial and deep flexors of the digits; these being regarded, as they may be in each digit, to be segments of one flexor prolongation upon the digit. This flexor prolongation first detaches from its sides the *lumbricales* to the first phalanx, runs on, and in like manner detaches the slips of the *flexor sublimis* to the second phalanx, repeating the same process according to the number of phalanges, and finally reaches the terminal phalanx.

#### THE SUPINATO-EXTENSOR MASSES.

The division of the superficial stratum of this mass, in each limb, into three sectors is more generally found to be distinct

<sup>1</sup> In Pteropus (*Journ. Anat.* iii. 306) the *lumbricales* lie in their whole length along the tendons of the *fl. prof.*; and one of these tendons is, for a space, interrupted by muscular fibres.

<sup>2</sup> This continuation of parts of the deep flexor stratum into a superficial region is of like kind to that which has been just mentioned in the instance of the *flexor carpi radialis* passing from a deep level at the wrist to a superficial level in the forearm.



than in the pronato-flexor masses. In some of the lower animals the three sectors arise from the humerus, or the femur, and are inserted by their deeper fibres into the bones of the middle segment of the limb; while their superficial fibres pass on to the distal segments. Owing, however, as before mentioned, to the convexity of the elbow and knee-joints in this direction, they are more cut off from continuity with the muscles above than are the antagonistic pronato-flexor masses. Indeed, in the hind limb, the connection of the supinato-extensor muscles with the femur is commonly reduced to a single tendon. In ourselves it is lost altogether, and the fibres are all directed from the leg-bones downwards, instead of passing, in part, from the femur to the leg-bones.

Traced downwards the middle sector of the supinato-extensor mass varies but little in either limb. It commonly extends upon the digits, forming the *extensor digitorum sublimis* (*communis*), and sometimes reaches to the terminal phalanges. Not unfrequently it does not pass upon digit i. Sometimes it fails to reach digit v.; and in some instances (AI, Lizards, and Menobranch) it extends no farther than the metatarsus or metacarpus.

The inner—tibial or radial—sector is, in Batrachians, partly inserted into the tibia or radius, and partly runs on to the inner side of the distal segment. In the fore limb it sometimes (Saurians) reaches no farther than the lower end of the radius. Commonly, in Mammals, a segment only of it is inserted into the inner edge of the radius, constituting the *supinator radii longus*, which may extend to the inner edge of the pollex, or may spread upon the palmar surface of the forearm<sup>1</sup>. Other segments, passing close to the carpus and inserted into the metacarpals, constitute the *extensores carpi radiales* (*longior* and *brevior*)<sup>2</sup>. These divisions do not take place in Birds, where the

<sup>1</sup> This muscle is often so disposed as to afford an example of a muscle belonging to the extensor group acquiring, from its position, a flexor action. It is absent in the Rat, Rabbit, Hedgehog, Mole, some Ruminants and others. In Hippopotamus, as already said (footnote on p. 163), it is very large, its origin extending high on the humerus, in the space, external to the deltoid, which is usually occupied by the *brachialis anticus*; and it acts as a flexor of the forearm.

<sup>2</sup> Where there is only one of these it commonly passes to Met. III. (*Journ. Anat.* iv. 45). The second tendon is inserted into Met. II. The insertion of these radial carpal extensors may reach to Met. IV. and V. (*Journ. Anat.* III.

entire sector is continued to the carpus; neither do they take place in the corresponding sector (*tibialis anticus*<sup>1</sup>), in the hind limb of Mammals and Birds.

The outer or fibular and ulnar sector—the *peronei* and *extensor carpi ulnaris*—usually pass over the ankle or wrist, and each is inserted into the outer side of the metatarsus or metacarpus. They often detach, in each limb, tendons to the *ext. dig.*, which cross beneath the tendons of that muscle, and run along their outer sides to the terminal phalanges. Sometimes they appear to form a group intermediate between the *ext. sublimis* and the *ext. profundus digitorum*<sup>2</sup>. In the foot a further division not unfrequently takes place. One of the segments

308). In Phoca it is inserted into Mets. I. and II.; this variation having relation to the large size of the pollex in that animal.

<sup>1</sup> In a Dog, however, I found a slip given off from the fibular side of the *tib. ant.*, joining a slip from the *ext. prof. (brevis) dig.* and inserted into Met. II. There was also another slip from the *ext. prof.* inserted into Met. III. In the Pig the *tibialis ant.* is very small; and the *ext. dig.* sends tendons to Mets. II. and III. and to the int. cuneiform as well as upon the digits.

In the Hippopotamus the arrangement is peculiar. The *tib. ant.* has extensive origin from the upper end of the tibia, the capsule of the joint and the patella, nearly encircling the *ext. dig.*, to which it sends a slip. It is inserted into the inner side of the internal cuneiform bone and into Met. II. The *ext. dig. sublimis (longus)* arises by a strong tendon from the fore part of the ext. condyle and, after appearing from beneath the superficial part of the *tib. ant.*, divides into a superficial and a deep portion. The former, passing in front of the annular ligament, expands into the tough tissue beneath the skin of the dorsum of the tarsus, and acquires an attachment to the bones on both sides of the tarsus. The deeper portion, passing under the annular ligament, divides into two tendons: one, connected closely with the preceding in the leg, is inserted into the cuneiform bones and Mets. II. and III.; the other divides into four tendons to the terminal phalanges of the four toes. The portions of this muscle which are inserted into the tarsus and metatarsus, passing both above and beneath the annular ligament, are described by Gratiolet as appertaining to the *tibialis ant.*; but they arise from the femoral condyle with the *ext. dig.* The *peroneus brevis* is not inserted into the metatarsus, but divides into two tendons which join the fibular side of the tendons of the *ext. subl.* to digits IV. and V. The deep layer in Hippopotamus consists of an *ext. hallucis*, arising from the fibula, perforating the tarsal insertion of *ext. dig. subl.*, and lost upon the second phalanx of dig. II. (there are three phalanges to this digit): also of an *ext. profundus (brevis)* arising from the os calcis and dividing to the four digits. Thus, digit II. has three extensors,—*ext. subl.*, *ext. prof.*, and *ext. hallucis*,—a combination, that is, of the extensors which are usually distributed to digits I. and II.

The *extensor digitorum* in the fore limb sends off a slip corresponding with the superficial part of *ext. dig. pedis*; but it is lost in the tissue beneath the annular ligament instead of passing over it. There is no deep (short) extensor of the digits.

The *extensor carpi radialis* presents a striking resemblance to the metatarsal division of the deep portion of *ext. dig. subl.* of the foot above described. It is large, connected on the one side with the *ext. dig.* and on the other with the *sup. r. l.* It is inserted by a broad tendon into the bases of Mets. III. and IV.

See description of *extensor secundus* and *supinator manus* in footnote on p. 185.

<sup>2</sup> I have described this group as *extensor secundus digitorum*. *Journ. Anat.*, II. 307.

(the *peroneus tertius*) runs to the dorsal surface of the metatarsus and sends offsets to the *extensor digitorum*, which form the *ext. secundus* group just referred to<sup>1</sup>; while two segments run, one (*peroneus brevis*) behind the malleolus to the outer or fibular side of the tarsus, and the other (*peroneus longus*) is prolonged over the fibular edge of the tarsus, beneath its plantar surface, to the metatarsals, often as far as that of the hallux. The two last-mentioned segments thus acquire a flexor action. The course of the *peroneus longus* from the extensor aspect, over the fibular edge, upon the plantar aspect, to the inner side of the foot is paralleled (as suggested, p. 160) by that of the *internal rectus* of Birds and Saurians<sup>2</sup>. Nothing distinctly answering to this plantar extension of the *peroneus longus* is found in the fore limb. In it the whole of the sector passes upon the dorsal aspect, or the ulnar edge of the carpus or the metacarpus. It does, however, sometimes incline to the palmar aspect<sup>3</sup>.

The *abductor minimi digiti* is segmented from the lower end of this sector and constitutes a continuation of it upon the ulnar, or the fibular, side of the distal part of the limb; and, in like manner, the *abductor pollicis* or *hallucis* is a continuation, more or less distinctly segmented, of the radial or the tibial sector upon the pollex or the hallux.

The foregoing observations shew that each of the three sectors of the superficial sheet of the supinato-extensor mass, in either limb, may be imperfectly segmented from the others, and that each may extend upon the digits, or may be, partly or wholly, arrested at a more proximal point of the distal segment of the limb.

<sup>1</sup> The *extensor secundus* is formed by the *peroneus brevis* in Hippopotamus.

<sup>2</sup> In Birds the *peroneus l.* takes a more superficial course. Its origin extends over the *tibialis anticus*, meeting the tibial origin of the *gastrocnemius*; and its tendon forms part of the *flexor sublimis digitorum*, and also joins the sesamoid body through which the tendons of *fl. dig. pass.* In some animals it takes origin from the femur as well as from the fibula.

<sup>3</sup> In Birds the ulnar segment of the *extensor carpi ulnaris*, arising from the back of the ulna and supplied by the radial nerve, is inserted into the metacarpal (rv.) and is so placed as to exert a distantly flexor action, thus resembling the *peroneus brevis*. This is very decided in the Swan and the Kite. In the Hippopotamus the *ext. c. u.*, which is composed chiefly of tendon or fascia with a few muscular fibres, approaches the palmar aspect of the ulnar side of the forearm, and is inserted into the large pisiform bone, with the *flexor carpi ulnaris*, so as to combine with it in flexing the carpus.

See divisions of *ext. c. u.* resembling those of *peroneus*. *Journ. Anat.* rv. 45.

The deep strata of the supinato-extensor masses correspond generally with those of the pronato-flexor masses. They pass from the fibula and the tarsus, or the ulna and the carpus (in the fore limb from the humerus also), inwards and downwards, to the tibial or the radial side of the foot or the hand, and to the digita. They are frequently in some degree blended, above and below, with the several sectors of the superficial stratum.

In the hind limb the most persistent part of the stratum is the lowest part—the *extensor brevis*, or rather *profundus digitorum*—which may arise from the tarsus, or the fibula, or both. Its tendons blend with those of the *extensor sublimis*, passing to their under-surface and margins, or frequently to their outer margins only. When (Aī and Lizards) the *ext. subl.* does not extend upon the digits, the *ext. pr.* takes its place, constituting the chief or sole extensor of the digits. It is in the digits sometimes blended with the *interossei*. It is, not unfrequently, united with the peroneal tendons which passing upon the digits form the *ext. secundus*; or the peroneal sector may supply digit v. to the exclusion of the *ext. prof.*; or that digit may be omitted by both. In Cryptobranch (p. 29, Fig. 15), a small portion of this deep stratum, a small muscle, that is, passing from the fibula, continuous with the *extensor profundus* and inserted into the tibial side of the metatarsus, is a *supinator pedis*, which corresponds with the *supinator manus*.

In Unau and Aī this portion extends higher and forms part of the *tibiulis anticus*<sup>1</sup>. In most Mammals this highest part of the deep supinato-extensor stratum is not implanted with the *tibialis ant.* into the tarsus. It does not, therefore, form a *supinator pedis*, but it runs on to the hallux, forming the *extensor hallucis*, and standing in the place of a division of the *extensor digitorum sublimis*. Thus the hallux derives two tendons from the deep stratum, one from the *ext. dig. prof.*, and one from a higher part of the stratum; instead of, as in the case of the adjacent digits, having one tendon from each stratum.

In the fore limb the disposition is often, in some respects,

<sup>1</sup> *Journ. Anat.*, iv. 66. A lower segmented portion in these animals runs from the extremity of the fibula to the internal cuneiform bone. The still lower segment, arising from the tarsus, forms the *ext. dig. prof.*

different. The upper part of the stratum commonly preponderates over the lower, and often extends up to the outer condyle of the humerus. Passing from this point upon the upper part of the radius it constitutes the *supinator radii brevis*<sup>1</sup>. Lower down, passing from the ulna to the radial edge of the carpus or metacarpus, it forms (Cryptobranch, Fig. 17) the *supinator manus*, commonly called *ext. ossis met. pollicis*. Lower still, as in the hind limb, it passes in one or two portions upon the pollex, which take the place of a division of the *ext. digit. subl.* Still lower, it may send tendons to digit II. and perhaps to other digits, so forming an *extensor profundus*<sup>2</sup>. These tendons join the outer or ulnar sides of the tendons of the *ext. subl.* Towards the ulnar side of the hand these tendons are usually absent; and their place is sometimes supplied by offsets from the ulnar sector of the superficial stratum above-described, forming an *extensor secundus*; in the same way that the tendons of the *ext. profundus* in the hind limb are sometimes supplanted by offsets (*extensor secundus*) from the peroneal sector<sup>3</sup>.

It is evident, in short, that the muscles in the fore limbs of Mammals, which we are in the habit of designating *extensores pollicis, indicis, &c.*, are really elements of the *extensor profundus*; and they correspond with the *extensor profundus* of the foot, but take their origin from a higher point of the

<sup>1</sup> This is absent in Rabbit, Pig and some others. It has a sesamoid bone near its origin in Manis.

<sup>2</sup> In Hatteria the muscle is described by Dr Günther (*Phil. Trans.*, 1867, p. 614) as composed of fibres "arising from the distal half of the ulna and spreading over the bones of the carpus to which they are attached: the fibres nearest the radial margin are collected into a tendon which is inserted into the metacarpal bone of the thumb." It is covered by an *extensor communis dig.*; and an extension of it to the phalanges of the digits would have constituted an *extensor profundus (brevis) dig.* corresponding nearly with the ordinary *ext. pr. (br.) dig. pedis*.

<sup>3</sup> In the Hippopotamus an *extensor secundus* in the fore limb arises from the ulna and passes to the ulnar sides of the terminal phalanges of digits iv. and v., joining the sides of the tendons of the *ext. subl.* and precisely corresponding with the distribution of the *peroneus brevis* in that animal.

The deep stratum in the Hippopotamus is concentrated into one muscle, the *supinator manus (ext. poll.)* which is small, arises from the ulna, and passes between the *ext. dig.* and the *ext. c. r.*, then, over the latter, to the rudimentary trapezium into which it is inserted. In appearance and position, in its upper part, it resembles what I have described in this animal (footnote, p. 182) as the *ext. hallucis*; but its insertion is different, and it passes over, instead of perforating, the *ext. c. r.* It corresponds precisely with the *supinator pedis* of the Cryptobranch above mentioned.

limb. The uppermost of the group—the *extensor ossis metacarpi pollicis*—being inserted into the radial side of the carpus, and sometimes of the metacarpus, is better designated *supinator manus* or *carpi*. It, in conjunction with the true *extensores pollicis* on the one side, and the *extensores carpi radiales* with the *supinatores radii* on the other, constitute the radial sectors, deep and superficial, of the supinato-extensor mass; and they correspond with the tibial sectors of the same mass in the hind limb which is resolved, in different animals, into *extensores hallucis*, *supinator pedis* or *tarsi* and *tibialis anticus*. The chief difference consists in the freer segmentation of the mass in the fore limb, in accordance with the freer movements of the several parts. Thus in Mammals the *extensores carpi radiales*, the *supinatores radii*, and the *supinator manus* have their homologous elements, so far as they are developed in the hind limb, all blended in the *tibialis anticus*, from which the *extensor hallucis* is, in some instances, barely segmented. Another difference in the disposition of the stratum in the two limbs of most Mammals consists in the attachment of the fibres of a considerable part of the stratum in the hind limb to the tarsus—the origin, that is, of the *ext. prof.* from the os calcis. A similar disposition is, however, met with in the fore limbs of many Reptiles and in some Mammals<sup>1</sup>.

Usually (though not in so primitive a form as that of the Cryptobranch, p. 41) the elements of the deep extensor stratum, like the elements of the deep flexor stratum, are continued upon the phalanges farther than those of the superficial stratum. Thus, as already seen, the superficial extensor in Menobranch, Lizards and Aï stops at the metacarpus. In the Bird's wing it is inserted into the first phalanges<sup>2</sup>. In Mammals the greater part of it is inserted into the second phalanges; whereas the

<sup>1</sup> *Journal of Anatomy*, iv. 47.

<sup>2</sup> In Birds there are commonly only two rows of phalanges in the wing. In the Swan, where there are three rows, the superficial extensor is still inserted into the first row; and the deep extensor, which arises by two portions (a superficial and a deep) from the radius, is chiefly inserted into the second row and sends on a delicate slip to the third. This is the case also with the *interossei*.

In the Bird's foot, on the contrary, the superficial extensor reaches the terminal phalanges; the deep extensor, when present, joins, as in Cryptobranch, the deep surface of the superficial extensor; and the *interossei* are inserted into the proximal phalanges.

elements of the deep stratum arising from the carpus or tarsus, and the radius and ulna, or the tibia and fibula, as well as the elements of the still deeper—the interosseal—stratum, are continued to the distal phalanges.

When factors of the *superficial extensor* are continued onwards with prolongations of the deep stratum to the terminal phalanges, they are usually derived from the marginal parts of its digital tendons, the middle part of each tendon being inserted into the more proximal phalanx. Also when the tendons of the superficial extensor reach to the terminal phalanges, without such prolongations of the deep stratum, it is still their marginal parts that do so. Thus in the lateral or fibular digit of the Swan's foot the extensor tendon passes over the first phalanx without being attached to it. It then divides into three; of which the middle is inserted into the second phalanx, and the two lateral components pass onwards. The tendon resulting from their union is, in like manner, again subdivided; the middle portion being inserted into the third phalanx, and the two lateral portions running onwards and meeting to be inserted into the fourth phalanx.

This disposition is the reverse of that of the antagonistic tendons on the flexor aspect. In their case (as mentioned at p. 180), the deeper and more prolonged tendon occupies the middle position, and continues its course in that position onwards to the terminal phalanx, while the superficial tendon is inserted into one, or commonly both margins of a more proximal phalanx. Also when the superficial and deep flexor are fused into one, and that one subdivides to supply the several phalanges, it is usually the middle part which is the more prolonged; and it never receives any marginal additions from the deeper strata.

The *interossei* in the simple limbs of some of the lower animals, as Cryptobranch, are mere bands passing across between the metacarpals or metatarsals, drawing the digits together and antagonising the abductors of the marginal digits. In higher animals, where the metacarpals and metatarsals admit of very little movement to and from one another, the transverse direction of the *interossei* is changed for a course more parallel with the digits; and they extend upon the phalanges and, in many instances, blend

with the extensor tendons. Their proper complement, when thus arranged, is one on each side of each digit; and their action, as flexors, extensors, adductors or abductors, depends upon the part of the phalanges or their tendons to which they are attached. The resultant of their combined action, especially in the simple transverse mode of disposition, is to approximate the other digits to the middle one. Practically, however, they are usually so arranged and co-ordinated that they effect lateral inclination of the phalanges in both directions. Those which incline the other digits towards the middle one are commonly situated near to the plantar or the palmar aspect, and are associated in action with the flexor muscles of the digits, even though they may be blended with the extensor tendons; and those which incline the digits from the middle one are situated nearer to the dorsal aspect, and are associated in their action with the extensor muscles. In many animals the lateral inclination of the phalanges is very slight, being limited to slight separation of the digits in extension and approximation during flexion. The *interossei* in them grow towards the palmar or plantar aspect, appear all to be associated with the flexors of the digits, and are sometimes aided by an additional, or second, series developed beneath, i.e. superficial to, them<sup>1</sup>.

<sup>1</sup> The *interossei* in the hind limb of the Hippopotamus are one on the plantar surface to each side of each digit. They arise from the heads of the metatarsals and the sheath of the *peroneus l.*, and pass to the sides of the sesamoid bodies and the sides of the first phalanges. In addition to these eight are two, larger and more superficial than the others, arising from the sheath of the *peroneus*, and passing to the apposed sides of digits II. and V., adducting those two to each other strongly. There are no dorsal *interossei*.

In the fore limb the arrangement is the same: viz. the eight small muscles lying close upon the metacarpals and the two larger muscles, adductors of digits II. and V., arising from the middle of the carpus. There are, besides, two abductors of II. and V., the one arising from the scaphoid and the other from the pisiform bone. These are barely represented in the hind limb by small muscles passing from the cuboid and the internal cuneiform bones.

The two adductors in both limbs resemble the palmar *interossei* of Man.

There is in each limb only one *lumbricalis*. It arises from the superficial surface of the *flexor profundus* before the division to the digits, and runs to the preaxial side of the fourth digit.



# INDEX.

## A

Abductor digiti, 28, 38, 183  
 Accessorius, 25, 26, 64, 178  
 Adductors, 20, 101, 159  
 Alimentary tube, relations of muscles to,  
 141  
 Ankylosis of muscles, 107  
 Axillary muscles, 84

## B

Biceps cruris, 22  
     brachii, 34, 63, 155  
 Brachialis ant., 35, 63  
 Brachio-cephalic stratum, 70, 74, 84  
     96, 102  
 Brain of Cryptobranch, 62  
 Branchio-hyoid, 43  
 Buccinator, 78

## C

Carinales, 119  
 Carpo-metacarpales, 4d  
 Cat, digastric in, 138  
 Caudal muscles and fascia, f  
     fat masses, 5  
 Caudo-crural, 6, 19, 152  
 Caudo-femoral, 7, 153  
 Caudo-pedal, 7, 20, 65, 152  
 Ceratodus, muscles of, 91; pelvis, 93;  
     fin, 94  
 Cervicalis superficialis, 71, 85, 96, 132,  
     139  
     profundus, 74, 86  
 Cervici-submaxillaris, 63, 102, 136, 139  
 Cervico-humeral, 30, 72, 135  
 Clavicle, 148

Compressor urethrae, 128  
 Constrictor faucium, 30, 72  
     pharyngis, 126  
 Coraco-brachial, 32, 155  
     olecranalis, 34  
     radialis, 34  
 Costo-coracoid, 74, 104, 127  
     alaris, 131, 132  
 Cremaster, 122  
 Cryptobranch, muscles, 1; fascia, 2;  
     nerves of head, 45, 61; spinal nerves,  
     47; sternum, 15  
 Cutaneous muscles, 30, 75, 109

## D

Deltoid, 140, 148  
 Depressor anguli oris, 78  
 Depressor mandibulae, 30, 45, 63, 72,  
     76, 102, 136, 139  
 Depressores costarum, 12, 17, 102, 119,  
     121  
 Diamond Snake, 129  
 Diaphragm, 18, 88, 104, 121  
 Digastric, 44, 62, 63, 73, 126, 136  
 Dog-fish, 83  
 Dorsalis scapulae, 36  
 Dorsal muscle, 5, 76, 83, 111, 115  
 Dorsi-epitrochlaen, 131

## E

Epicoraco-humeral, 32  
 Epicostal, epiclavicle, &c., 128  
 Episterno-clavicularis, 104  
 Erector penis, 128

- Extensor digitorum subl., 29, 41, 181  
 prof., 30, 42, 184  
 carpi rad., 40, 181  
 uln., 41, 182  
 pollicis, 41  
 hallucis, 184
- F
- Facial muscles, 133  
 Fascia superficialis, 2, 66, 93, 119  
 transversalis, 2, 8, 67, 93, 113,  
 118  
 Flexor dig. subl., 24, 37, 64, 65  
 prof., 25, 39, 64, 65, 177  
 carpi rad., 37  
 uln., 38  
 hallucis, 25  
 pollicis, 178  
 Foot, muscles of, 177  
 Frog, digastric in, 63
- G
- Gastrocnemius, 24, 65  
 Gemelli, 20, 160  
 Genio-branchial, 43  
 coracoid, 97  
 hyo-glossus, 62, 126, 137  
 hyoid, 73, 97, 103, 137  
 Glutei, 23, 88, 102, 140, 151  
 Gluteo-rectus, 22  
 Gracilis, 13, 19, 61, 101, 140, 147
- H
- Hæmapophyses, 9  
 Hippopotamus, muscles of, 137, 160  
 Homological review of muscles of limbs,  
 141  
 Hyo-mental, 97, 103, 137  
 pharyngeus, 75, 126  
 glossus, 126
- I
- Iliacus, 23, 159  
 Ilio-caudal, 6, 101, 128  
 Infra-spinatus, 36
- Inscriptions in rectus, &c, 109  
 semitendinosus, 153  
 Intermandibular, 43  
 Interossei, 30, 42, 64, 187  
 Ischio-caudal, 6, 19, 128  
 coccygeus, 101  
 cloacalis, 101
- L
- Lancelet, muscles in, 105  
 Lateral muscle, 4, 65, 114  
 Latissimus dorsi, 35, 71, 84, 86, 104,  
 130, 140, 148, 150  
 Lepidosiren, muscles of, 65; pelvis, 69;  
 opercular bones, 71; first rib, 74;  
 nerves, 79; branchial cart., 87  
 Levator operculi, 76  
 costarum, 119, 125  
 ani, 121, 122  
 scapulæ, 31, 85, 126  
 arcuum, 72, 133  
 Ligamentum teres, 21  
 nuchæ, 117  
 Limb-girdles, nature of, 8  
 Limbs, disposition of muscles in, 142  
 Longus colli, 17, 102  
 Lumbricales, 27, 64
- M
- Marsupial bone, 16  
 Masseter, 44, 78, 117  
 Masto-scapular, 72, 135  
 humeral, 135  
 Metacarpo-phalangei, 40  
 Metatarso-phalangei, 28  
 Muscle, development of, in Tadpole's  
 tail, 113  
 Mylo-hyoid, 43, 63, 73, 103, 137  
 Myotomes, 107
- N
- Nerves, intercostal, 12  
 of Cryptobranch, 45  
 of Lepidosiren, 79; fin, 87.

## O

- Obliquus externus, 11, 13, 62, 68, 100  
internus, 11, 14, 68, 123  
Obturator, 20, 160  
Occipito-frontalis, 133  
Ocular muscles, 77  
Omo-hyoid, 15, 126  
Opercular bones of Lepidosiren, 71  
Ceratodus, 97

## P

- Pannicle, 30, 75, 109, 129  
Pectineus, 20, 159  
Pectoralis, 13, 14, 32, 61, 71, 84, 108,  
130, 140  
minor, 32, 104, 157  
Pelvis of Lepidosiren, 69; of Ceratodus,  
93; of Pseudopus P., 99  
Peroneal nerve, 22  
Peronei, 29, 65, 182  
Phalangei, 28, 40  
Plantaris, 24  
Plantar fascia, 24  
Platysma, 30, 73, 75, 128, 133  
Popliteus, 27  
Poupart's ligament, 62, 140  
Pectoraco-brachial, 33  
Pronator manus, 39, 179  
pedis, 25, 177  
tibiæ, 27, 39  
teres, 37  
quadratus, 38, 179  
intermedius, 37  
Pseudopus Pallasii, muscles, 99, 139;  
pelvis, 99  
Psoas, 122  
Pterygoid, 117  
Pyramidalis, 13, 16, 62, 101, 123  
Pyriformis, 23

## Q

- Quadratus femoris, 20, 160  
lumborum, 62, 101, 123  
Quadriceps, 23

## R

- Rectus abdominis, 11, 15, 19, 61, 100,  
102, 108, 120, 123, 139  
subvertebral, 11, 17, 102, 119,  
121

- Rectus capitis, 17, 102, 121  
lateralis, 125  
femoris, 22, 102  
femoris internus, 21, 65, 160  
thoracis, 125  
Retinacula, 27, 179  
Retractor anguli oris, 78  
ani, 121  
Rhomboid, 72, 134  
Rotator carpi, 41

## S

- Sartorius, 62, 88, 140, 149  
Scaleni, 18, 104, 125  
Sclerotomes, 7, 106  
Semimembranosus, 19  
Semitendinosus, 19, 153  
Septum, lateral, 4, 9, 89  
neural and hæmal, 4, 66, 89  
transverse, 4, 65, 92, 107;  
uses of, 7  
coracoidal, 87  
in fin of Ceratodus, 94  
Serratus, 31, 74, 85, 104, 126  
posticus, 135  
Skeletal planes, 105  
Soleus, 24  
Sphincter ani, 128, 141  
Sterno-hyoid, 15, 62, 103, 126, 137  
cleido-mastoid, 72, 77, 103, 134,  
139  
coracoid, 74, 104, 127  
costal, 104, 125  
scapular, 127  
thyroid, 126  
Stylo-hyoid, 75, 126, 137  
glossus, 126  
pharyngeus, 126  
Sternum of Cryptobranch, 15  
Subclavius, 127, 157  
Subcostals, 121  
Subcutaneous colli, 30, 62, 72, 73, 133  
Subscapularis, 34, 126, 158  
Supinator pedis, 29, 184  
manus, 41, 185  
longus, 40, 181  
brevis, 40, 185  
Supra-spinatus, 157

- T
- Tadpole, tail of, 111  
 Tarso-metatarsales, 28  
 Temporal, 43, 63, 77, 116  
     fascia, 76  
 Tendons derived from septa, 107  
 Tensor plicæ alaris, 131  
     vaginæ femoris, 88, 140, 149  
 Teres minor, 36  
 Tibialis ant., 29, 65, 184  
     post., 65  
 Transversalis abdominis, 12, 16, 68, 102,  
     118
- Transversalis colli, 62  
 Transversus perinei, 128  
 Trapezius, 30, 72, 77, 86, 103, 134, 148  
 Triangularis sterni, 104, 121  
 Triceps, 36
- U
- Uromastix spinipes, 61
- Z
- Zygomatichi, 78

