

Egypt (1 ex. dt. I-II + atlas dt. I-II (1/10))
+ 2 ex. dt. I + atlas dt. I

MINISTRY OF FINANCE, EGYPT.

SURVEY DEPARTMENT.

THE
ARCHÆOLOGICAL SURVEY OF NUBIA.


REPORT FOR 1907-1908.


PLATES ACCOMPANYING VOLUME II.



CAIRO:
NATIONAL PRINTING DEPARTMENT,
1910.

KARL W. HIERSEMANN, LEIPZIG





Digitized by the Internet Archive
in 2008 with funding from
Microsoft Corporation

MINISTRY OF FINANCE, EGYPT.

SURVEY DEPARTMENT.

THE
ARCHÆOLOGICAL SURVEY OF NUBIA.

REPORT FOR 1907-1908.

PLATES ACCOMPANYING VOLUME II.



CAIRO:
NATIONAL PRINTING DEPARTMENT,
1910.

DT
135
N8A5
v. 2
plates



1121940

LIST OF PLATES.

PLATE I.

The Biga Cemetery.

- a.* Vault 5 : 145.
- b.* Vault 5 : 145, contracted burial.
- c.* Vault 5 : 100.
- d.* Small vault 5 : 117, superstructure with lamp-niche.
- e.* Small vault 5 : 98, back end.
- f.* Small vault 5 : 22, entrance.

PLATE II.

Early Dynastic Period.

Examples of disturbance.

- a.* Grave 7 : 340, central plundering.
- b.* Grave 7 : 340 (on Plate, 7 : 370 by misprint), untouched legs.
- c.* Grave 7 : 335, plundered.
- d.* Grave 7 : 324, body turned over.
- e.* Grave 7 : 320, heads plundered.
- f.* Grave 7 : 104, accidental disturbance.

PLATE III.

Early B-group Graves.

- a.* Grave 7 : 149, looking south.
- b.* Grave 7 : 229, looking east.
- c.* Grave 7 : 222, looking south.
- d.* Grave 7 : 207, looking south.
- e.* Grave 7 : 257, covered with halfa (grass).
- f.* Grave 7 : 250, ostrich feathers.

PLATE IV.

Early Dynastic Period.

Undisturbed multiple burials.

- a.* Grave 7 : 317, first view.
- b.* Grave 7 : 317, top burial.
- c.* Grave 7 : 317, second burial.
- d.* Grave 7 : 317, lowest burial.
- e.* Grave 7 : 346, upper skeleton.
- f.* Grave 7 : 346, lower skeleton.

PLATE V.

- a.* Grave 7 : 202, from the south.
- b.* Grave 7 : 224, from the east.
- c.* Grave 7 : 204, from the west.
- d.* Grave 7 : 190, with copper axe, from the south.
- e.* Grave 7 : 147, goatskin covering.
- f.* Grave 7 : 151, Negro.
- g.* Grave 7 : 150, goatskin and matting.

PLATE VI.

Burials of C- and E-groups.

- a.* Grave 7: 161, plundered.
- b.* Grave 7: 162, unplundered.
- c.* Grave 7: 156, superstructure.
- d.* Grave 7: 164, E-group.
- e.* Grave 7: 156, burial.
- f.* Grave 7: 148, E-group.
- g.* Grave 7: 182, E-group.
- h.* Grave 7: 181, E-group.

PLATE VII.

- a.* New Empire pit 7: 7, bones in pit.
- b.* Executioner's trench 7: 11, looking down.
- c.* Executioner's trench 7: 21.
- d.* Roman fort, trench filled with bricks.
- e.* New Empire chamber 7: 13, section of débris.

PLATE VIII.

- a.* Tomb 2: 1,063, superstructure.
- b.* Tomb 2: 1,063, filling.
- c.* Tomb 2: 1,063, burial.
- d.* Grave 2: 381.
- e.* Grave 2: 892.
- f.* Superstructure, 2: 431.
- g.* Grave 2: 53: A, burnt bones.
- h.* Graves 2: 119-120.
- i.* Grave 2: 160.

PLATE IX.

- a.* Grave 17: 26, dogs.
- b.* Grave 17: 15, Late Predynastic.
- c.* Grave 17: 27, Early Dynastic.
- d.* Grave 17: 48, B-group.
- e.* Grave 17: 1, Early Dynastic.
- f.* Grave 17: 103.

PLATE X.

- a.* Grave 17: 7, remains of wooden coffin.
- b.* Grave 17: 7, skeletons.
- c.* Graves 17: 58 and 59.
- d.* Grave 17: 5.
- e.* Grave 17: 50, plundered.
- f.* Grave 17: 78, plundered.

PLATE XI.

X-group Graves.

- a.* Tomb 15: 46, entrance-block.
- b.* Tomb 15: 46, burial.
- c.* Tomb 15: 47, burial.
- d.* Tomb 15: 44, burial.
- e.* Tomb 15: 40, entrance-block.
- f.* Tomb 15: 40, burial.
- g.* Tomb 15: 36, entrance-block.
- h.* Tomb 15: 36, burial.

PLATE XII.

X-group Graves.

- a.* Grave 23:1, Late Predynastic.
- b.* Grave 23:19, Late Predynastic.
- c.* Grave 23:45, Early Dynastic.
- d.* Grave 23:12, B-group.
- e.* Grave 22:159, C-group.
- f.* Grave 22:70, ram burial.

PLATE XIII.

- a.* Grave 30:38, upper body.
- b.* Grave 30:38, lower body.
- c.* Grave 30:2, upper body.
- d.* Grave 30:2, lower body.
- e.* Grave 30:3, plundered upper body.
- f.* Grave 30:36, two dogs.

PLATE XIV.

- a.* Grave 30:6, B-group.
- b.* Grave 30:15, C-group.
- c.* Grave 30:21, New Empire.
- d.* Grave 30:17 (on Plate, 30:10 by misprint), New Empire.
- e.* Mud-cut chamber 36:78 (on Plate, 36:18 by misprint), Roman period.
- f.* Mud-cut chamber 36:26, Roman period.

PLATE XV.

- a.* Grave 40:33.
- b.* Grave 40:65.
- c.* Grave 40:73.
- d.* Grave 40:15.
- e.* Grave 40:11, double beehive type.
- f.* Grave 40:55 (on Plate, 50:55 by misprint), recess grave.

PLATE XVI.

Late Predynastic Burials.

- a.* Grave 43:62, recess grave.
- b.* Grave 43:64, recess grave.
- c.* Grave 44:22.
- d.* Grave 44:20.
- e.* Grave 44:8.
- f.* Grave 44:5.

PLATE XVII.

Early Dynastic and B-group Burials.

- a.* Grave 45:254, unplundered.
- b.* Grave 45:400, plundered.
- c.* Grave 45:403, double burial.
- d.* Grave 45:236.
- e.* Grave 45:405.
- f.* Grave 45:498, burial tied in bundle.

PLATE XVIII. Varieties of Cranial Forms met with in Nubia.

- Fig. 1, 2, 3. Early Dynastic crania from Cemetery 17, described on page 30.
- Fig. 4. Early Dynastic cranium (17).
- Fig. 5. A small Egyptian cranium (New Empire).
- Fig. 6. A small alien cranium (from Cemetery 5 at Biga).
- Fig. 7. An Egyptian woman's (15 : 47) cranium from an X-group cemetery.
- Fig. 8. A short alien cranium from the Christian cemetery at Biga.
- Fig. 9. A cranium of abnormal shape (probably pathological) from the Byzantine cemetery (2) on Hesa.

PLATE XIX. Varieties of Cranial Forms met with in Nubia.

- Fig. 1. The commonest type of alien Christian buried in Biga (5).
- Fig. 2. Another alien type (from Cemetery 42).
- Fig. 3. A type of dolicocephalic alien (from Cemetery 5).
- Fig. 4. A small round type of alien cranium from Biga, female.
- Fig. 5. A Negress from Biga.
- Fig. 6. Another example of the type seen in Fig. 4, male.
- Fig. 7. A Negress from the Byzantine cemetery (2) on Hesa.
- Fig. 8. An alien from the same cemetery (2).
- Fig. 9. A Dynastic Egyptian with exceptionally well-filled skull.

PLATE XX. Varieties of Cranial Forms met with in Nubia.

- Fig. 1. A Byzantine Nubian skull.
- Fig. 2. Another example of the same type.
- Fig. 3. A negroid woman (5 : 39).
- Fig. 4. A negroid Nubian woman, perhaps with some alien admixture (Christian 36 : 43).
- Fig. 5. A curiously distorted (probably pathological) cranium from Hesa.
- Fig. 6. Another example of the Hesa Nubian type.
- Fig. 7. Skull of Dynastic Egyptian type (22 : 141).
- Fig. 8. The cranium of one of the tall negroid men (E-group) buried near Shellal (71 : 82).
- Fig. 9. Woman's skull of Egyptian alien mixed type from the Byzantine cemetery at Markos.

PLATE XXI. Profiles of Skulls met with in Nubia.

- Fig. 1. A New Empire cranium (see Pl. XVIII, Fig. 5) conforming to Predynastic type.
- Fig. 2. An Archaic Egyptian skull (see Pl. XVIII, Fig. 1) pathologically expanded as a result of hydrocephalus.
- Fig. 3. Dynastic Egyptian (see Pl. XX, Fig. 7).
- Fig. 4. Another example of Dynastic type, probably not pure (see Pl. XX, Fig. 9).
- Fig. 5. The short-skulled type of alien Christians from Biga (see Pl. XIX, Fig. 4).
- Fig. 6. The commoner type of Biga aliens with massive sphenoid crania (see Pl. XIX, Fig. 1).

PLATE XXII. Profiles of Skulls met with in Nubia.

- Fig. 1. Another example of the short-skulled type of Biga aliens.
- Fig. 2. A Negress from the same cemetery (compare Pl. XIX, Fig. 5).
- Fig. 3. The dolicocephalic alien type (see Pl. XIX, Fig. 3).
- Fig. 4. Another alien type (see Pl. XIX, Fig. 2).
- Fig. 5. A Dynastic Egyptian woman (see Pl. XIX, Fig. 9).
- Fig. 6. An alien from Cemetery 2 (see Pl. XIX, Fig. 8).

PLATE XXIII.

- Fig. 1. Skull of a tall negroid man, E-group (see Pl. XX, Fig. 8).
- Fig. 2. A negroid woman (see Pl. XX, Fig. 3).
- Fig. 3. Another example of the commonest type of Christian aliens in Biga.
- Fig. 4. The same skull.

PLATE XXIV. Contrasts in Facial Forms from Nubia.

- Fig. 1. A Dynastic Egyptian.
- Fig. 2. An Archaic Egyptian.
- Fig. 3. A Christian alien from Biga.
- Fig. 4. An alien woman from Biga (see Pl. XVIII, Fig. 8).
- Fig. 5. An E-group man (7 : 165).
- Fig. 6. An X-group man (15 : 37) : shows distinctly alien traits of the Biga type.
- Figs. 7, 8, 9. Three Negro types from the Christian cemetery on Biga.

PLATE XXV. Contrasts in Facial Types from Nubia.

- Fig. 1. An alien from Hesa (see Pl. XXII, Fig. 6).
- Fig. 2. An Egyptian (see Pl. XXII, Fig. 5).
- Fig. 3. A Negress from Hesa.
- Fig. 4. The short-skulled Biga type, male (see Pl. XIX, Fig. 6).
- Fig. 5. The female of the same type (see Pl. XIX, Fig. 4).
- Fig. 6. Negress from same site.
- Figs. 7, 8, 9. Three examples of hybrids of the alien and Negro types shewn in Figs. 1 to 6.

PLATE XXVI. Contrasts in Facial Types from Nubia.

- Fig. 1. A Byzantine Egyptian, probably mixed with alien of the type seen in Fig. 6 (see Pl. XXI, Fig. 4).
- Fig. 2. An Egyptian man from Cemetery 22 (see Pl. XXI, Fig. 3).
- Fig. 3. A Negress from Cemetery 25.
- Fig. 4. The big-skulled type of Christian alien (5).
- Fig. 5. The short-skulled type of alien Christian (5).
- Fig. 6. The alien type from Cemetery 42.
- Figs. 7, 8, 9. The Negro-alien hybrids.

PLATE XXVII. Contrasts in Forms of Faces and Mandibles from Nubia.

- Figs. 1, 2, 3. Alien types from Christian cemeteries.
- Fig. 4. A Negroid man of the X-group (15 : 43).
- Fig. 5. Another type of Negroid X-group man (15 : 18 : A).
- Fig. 6. An alien-Negro hybrid from a Christian cemetery (34 : 50).

- Fig. 7. The form of mandible typical of the most numerous group of Christian aliens from Biga.
Fig. 8. The mandible of a Negress of the same epoch.
Fig. 9. The mandible of the short-skulled type of Biga aliens.
Fig. 10. An Egyptian mandible with its racial characters exhibited in an extreme form.

PLATE XXVIII.

- Fig. 1. The right half of the cranium of a Biga alien split in mesial sagittal section to show the large groove for the middle meningeal vein.
Fig. 2. Head of a Ptolemaic mummy in profile.
Fig. 3. Facial aspect of the same.

PLATE XXIX.

- Fig. 1. Adult male skull (7 : 10) with healed fracture of the right nasal bone. This skull also shows the supra-orbital grooves arising from foramina situated unusually far from the orbital margin.
Fig. 2. Skull of a man (24 : 1 : F) shewing a depressed fracture of the frontal bone. The evidence of its ante-mortem infliction are well-marked, and no repair had taken place.

PLATE XXX.

- Fig. 1. Skull of a woman shewing a small patch of localized periostitis.
Fig. 2. Skull shewing a curious condition of the bones caused by the gnawing of some insect.

PLATE XXXI. Diagrams representing a series of left orbits viewed from in front.

- Fig. 1. Orbit shewing reduction of the speno-maxillary fissure (43 : 53).
Fig. 2. Orbit of one of the alien people buried in Biga cemetery shewing a deficiency of the posterior orbital wall (5 : 82 : 1).
Fig. 3. Orbit shewing failure of the alisphenoid to meet the malar, causing a gap in the posterior orbital wall (2 : 197).
Fig. 4. Orbit shewing enlargement of the speno-maxillary fissure (43 : 133).
Fig. 5. Example of deficiency of the posterior orbital wall in an alien from Biga cemetery (5 : 82 : F).

⇒ **PLATE XXXII. Cases of fusion of the atlas vertebra to the occipital bone.**

The skull shewn in Fig. 5 is an example of pathological fusion, the atlas having united to the skull as a result of spondylitis deformans. (Six figures).

PLATE XXXIII.

- Fig. 1. Mummy (24 : 1 : H') shewing the little parcels of embalmed viscera in the body-cavity.
Fig. 2. Mummy (24 : 1 : L') shewing the general disorder of the parts of the skeleton.
Fig. 3. Mummy (24 : F') shewing in the abdominal cavity a mass of epidermis peeled off the hands and feet.
Fig. 4. Hand of a Ptolemaic mummy shewing the lines of incisions across the finger where the skin has been divided.

PLATE XXXIV.

- Fig. 1. Head (24 : 110 : C) shewing the stick passed into the foramen magnum.
Fig. 2. The mummy of a child (24 : 1 : C) in which the head was fixed to the body by a stick thrust into the foramen magnum.
Fig. 3. Head (24 : 110 : C) shewing the turns of bandage which kept it fixed to its artificial neck.

PLATE XXXIV a.

- Fig. 4. False arms of a mummy (24 : 1 : 1).
Fig. 5. False arms (24 : 1 : 1) split open to shew the fibula and inverted radius around which respectively they were built up.

PLATE XXXV.

- Fig. 1. Bundle of shed epidermis taken from the body-cavity of a Ptolemaic mummy.
Fig. 2. The cranium of a Ptolemaic mummy from Cemetery 14, opened by a horizontal saw-cut. It shows the ethmoidal aperture made by the embalmers to remove the brain.
Fig. 3. Hands of a mummy, showing the fixing of the skin and nails by means of thread wound round the fingers.
Fig. 4. Head showing the torn edges of the scalp, and the fixation of the artificial neck.
Fig. 5. A mass of resin from the thorax of a young woman embalmed in Ptolemaic times. Numerous maggots and beetles are embedded in the mass.

PLATE XXXVI.

- Fig. 1. Skull from the "executioner's trench" at Shellal, shewing an extreme degree of distortion caused by pressure in the grave.
Fig. 2. Bones distorted by grave-pressure. A radius and a fibula, which have become bent in the grave, are photographed alongside normal bones from the same burial.

PLATE XXXVII.

- Fig. 1. Posterior fossa of the skull (45 : 236) shewing large abnormal foramen.
Fig. 2. Upper jaw of a Negress (2 : 810) shewing accessory dental masses and fourth molar pits.
Fig. 3. Upper dental series of 23 : 60 X, shewing an additional tooth erupted in the palate.
Fig. 4. Contrasted dental series in bodies 7 : 154 and 7 : 151.

PLATE XXXVIII.

- Fig. 1. Honeycomb-like condition of the roofs of the orbits. Skull from Cemetery 5.
Fig. 2. Abnormal condition of the elbow-joint (2 : 687).
Fig. 3. Abnormal forms of sternum.
Fig. 4. Skull of a hyrax found in a New Empire pit at Shellal.
Fig. 5. Left os innominatum of a female pelvis which contained the bones of a foetus. Some characters of the bone are distinctly masculine.

PLATE XXXIX.

- Fig. 1. Splints *in situ* upon the right forearm of a girl of the Byzantine period from Biga (5) cemetery.
Fig. 2. Splints on right forearm cut open.

PLATE XL.

- Fig. 1. Splints *in situ* on the left forearm of the same girl.
Fig. 2. Splints on the left forearm opened to show their composition.

PLATE XLI.

- Fig. 1. Prolapse of the intestine in a girl from the Byzantine cemetery (2) on Hesa (2 : 63 : D).
Fig. 2. Adhesion band of old appendicitis from body in Cemetery 2.
[The photograph shows the sacrum, lumbar vertebræ, cœcum and appendix and the ascending colon, partly hidden by great omentum.]
Fig. 3. Sword-cuts of the skull which caused death. Ptolemaic period (24 : 103 : A).
Fig. 4. Ante-mortem fracture of the skull : portions of the broken bone were embedded in the embalming material in the cranium. Ptolemaic period (3 : 19 : A).
Fig. 5. The fractured jaw of a Prehistoric Egyptian shewing blood-staining (7 : 257).

PLATE XLII.

- Fig. 1. Sword-cut of skull with blood-staining of bone (24 : 1 : H').
Fig. 2. Ante-mortem fracture of the skull (7 : 257). The brain mixed with hair and fragments of broken bone was found inside the cranium.
Fig. 3. Sword-cuts of cranium and face which caused death (24 : 1 : H').
Fig. 4. Old depressed fracture of the skull (7 : x).

PLATE XLIII.

- Fig. 1. Extensive fracture of a woman's skull, excellently healed. Byzantine (Hesa, 2 : 63 : F).
Fig. 2. Healed sword-cut on the back of the skull. Roman Period (7 : 11).
Fig. 3. Skull with sword-cut of the forehead, inflicted just before death. Byzantine (Hesa, 2 : 652).
Fig. 4. Skull with healed fracture of the left supra-orbital margin (Hesa 2 : 1162).
Fig. 5. Woman's skull with a punctured wound of the right parietal bone (2 : 122 : B).

PLATE XLIV.

- Fig. 1. Skull shewing aneurismal opening in base of skull.
Fig. 2. Circular ulceration of frontal bone.
Fig. 3. Similar ulceration of the parietal bone.
Fig. 4. Beetle-eating of innominate bone.

PLATE XLV. Six examples of the deformities caused by osteo-arthritis :—

- Fig. 1. In the upper cervical spine ;
Fig. 2. In the lumbar spine ;
Fig. 3. In the head of the femur ;
Fig. 4. In the knee ;
Fig. 5. In the elbow and a finger, and
Fig. 6. In the heads of the humeri.

PLATE XLVI.

- Fig. 1. New joint formed between the shaft of the femur and the innominate bone after separation of the epiphysis of the former.
Fig. 2. Osteitis deformans in case of long-standing dislocation of the upper end of radius.

- Fig. 3. Arthritis deformans of elbow.
Fig. 4. Fusion of bones and wrist caused by osteo-arthritis (24 : 1 : R').
Fig. 5. Right and left humeri, side by side, to show great shortening of the latter caused probably by early separation of the upper epiphysis and secondary development of arthritis deformans (7 : 182).
Fig. 6. Inflammatory condition of upper end of radius (7 : 188).

PLATE XLVII.

- Fig. 1. Result of fracture of both bones of the forearm, when natural splinting is destroyed (17 : 17).
Fig. 2. A series of healed fractures of the forearm.
Fig. 3. Necrosis of humerus in a child.
Fig. 4. Fracture of neck of right humerus healed with a minimum of shortening. (Compared with the normal left bone).
Fig. 5. Abnormal conditions of lower ends of radius and ulna.

PLATE XLVIII.


- Fig. 1. Old-standing cases of separation of the upper epiphysis of the femur.
Fig. 2. Fracture of the right femur.
Fig. 3. Femur affected by some inflammatory condition.
Fig. 4. Another femur more severely affected.
Fig. 5. Fracture of the femur pelvis, sacrum and lumbar vertebræ (5 : 91 : A).

PLATE XLIX.

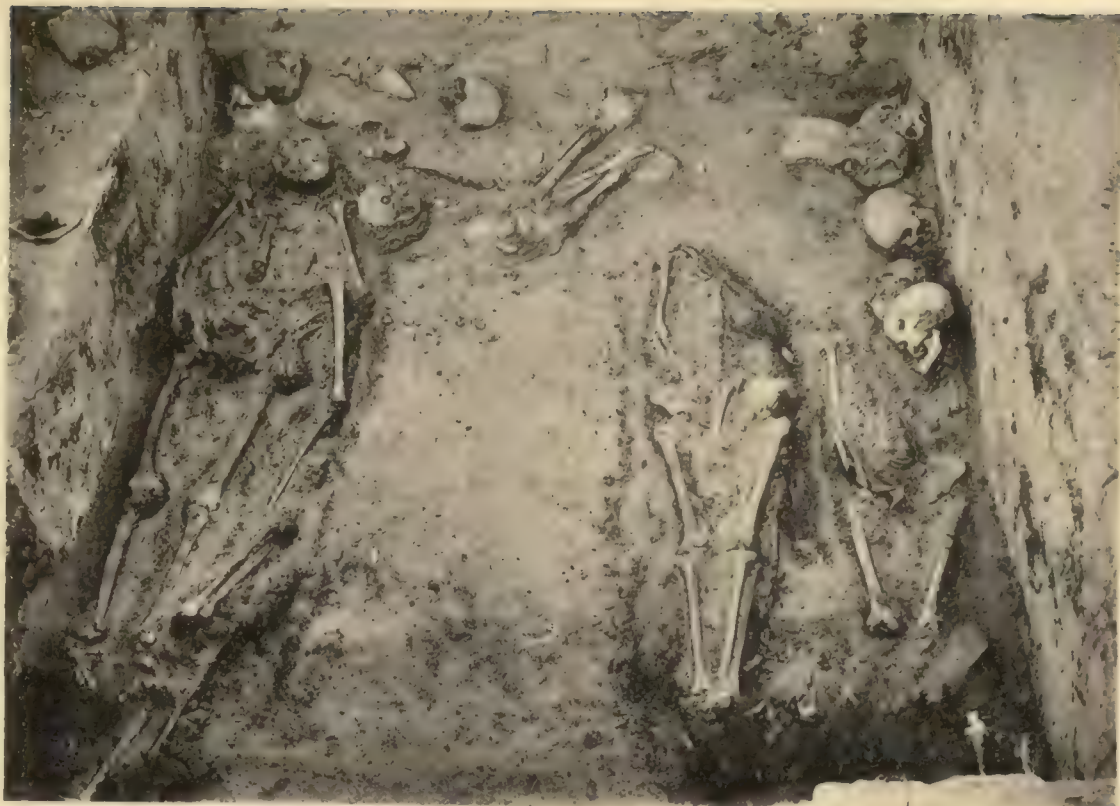- Fig. 1. Fracture of the ilium in a man of the Predynastic period.
Fig. 2. Fracture of the pelvis in a woman of the Christian period (40 : 76).
Fig. 3. Fracture of the pubis in a woman of the Christian period.
Fig. 4. Fracture of the scapula in a man of the New Empire period (7 : 1).
Fig. 5. Fracture of the scapula in a woman of the Christian period. (24 : 5 : D).
Fig. 6. Fracture of the sternum in a man of the Ptolemaic period (41 : 18 : C).
Fig. 7. Fractured ribs from the same case (41 : 18 : C).

[In Figs. 1, 4 and 5 the lines of fracture have been marked in ink.]

Imp. Nht. 4457-1910-500 br.



d. Small vault 5: 117, superstructure with lamp-niche.



a. Vault 5: 145.



e. Small vault 5: 98, back end.



b. Vault 5: 145, contracted burial.



f. Small vault 22, entrance.



c. Vault 5: 100.

The Biga Cemetery.


To indicate the state of the remains of the alien Christians buried in Cemetery 5



a. Grave 7 : 310, central plundering.



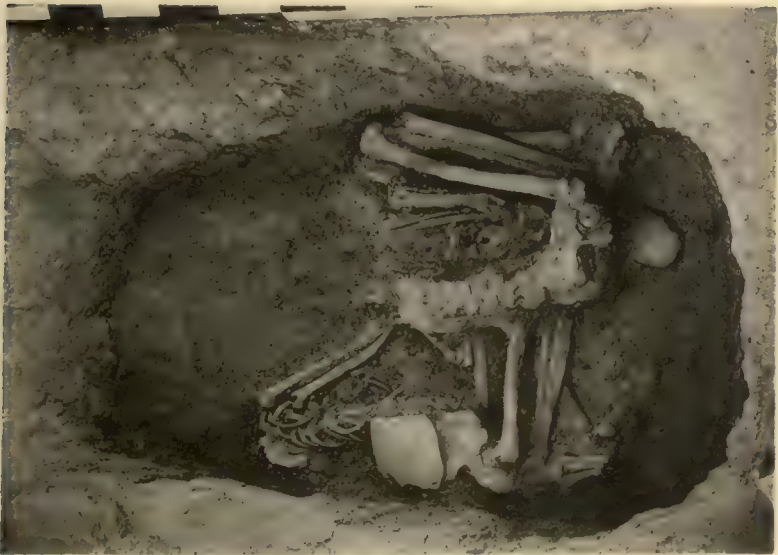b. Grave 7 : 370, untouched legs.



c. Grave 7 : 335, plundered.



d. Grave 7 : 324, body turned over.



e. Grave 7 : 320, heads plundered.

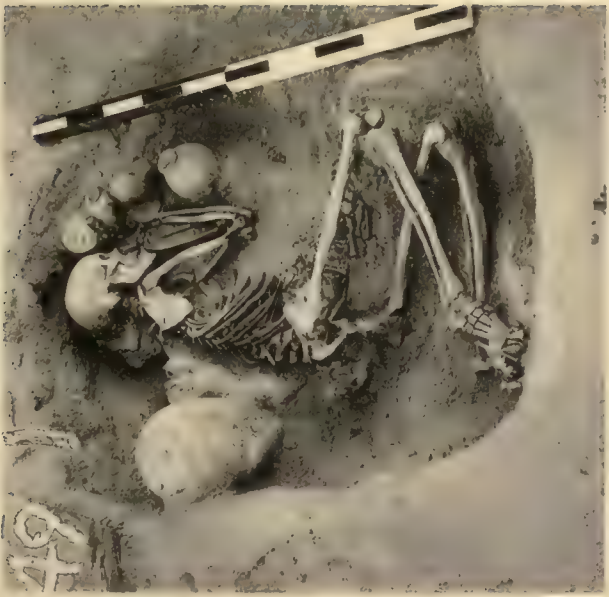

f. Grave 7 : 104, accidental disturbance.

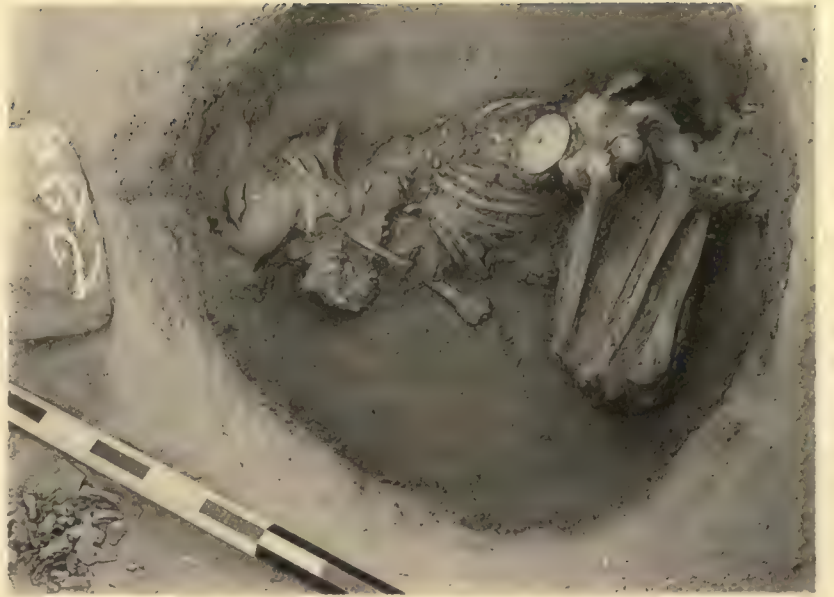Early Dynastic Period,

Examples of disturbance.

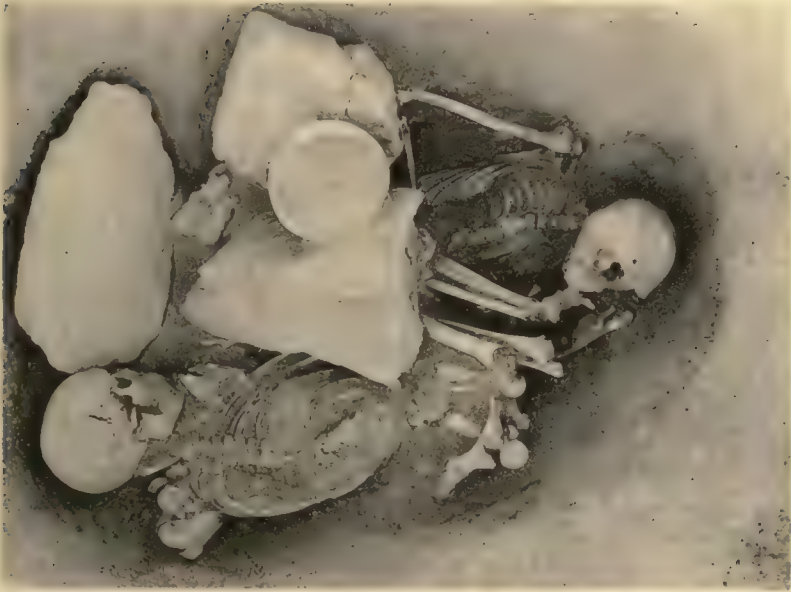To illustrate the damaged and fragmentary condition of the remains in most of the Early Dynastic graves.



a. Grave 7 : 149, looking south.




b. Grave 7 : 229, looking east.



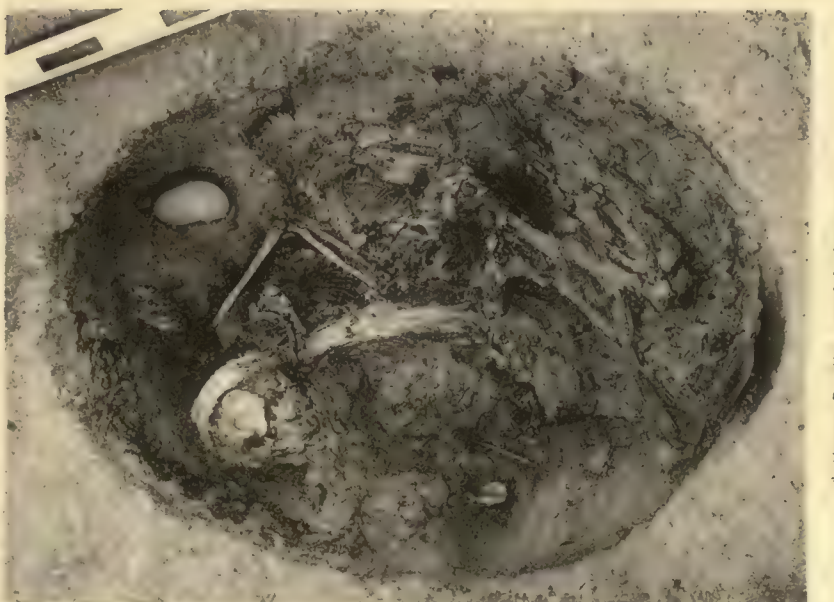
c. (rave 7 : 222, looking south.



d. Grave 7 : 207, looking south.



e. Grave 7 : 257, covered with halfa (grass.)



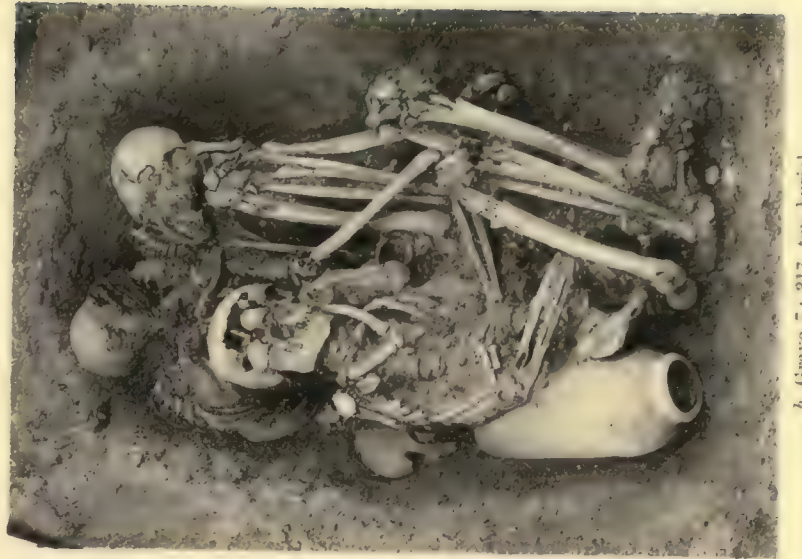f. Grave 7 : 250, ostrich feathers.

Early B-group Graves.

These are typical examples of the state of the Archaic Nubian remains.



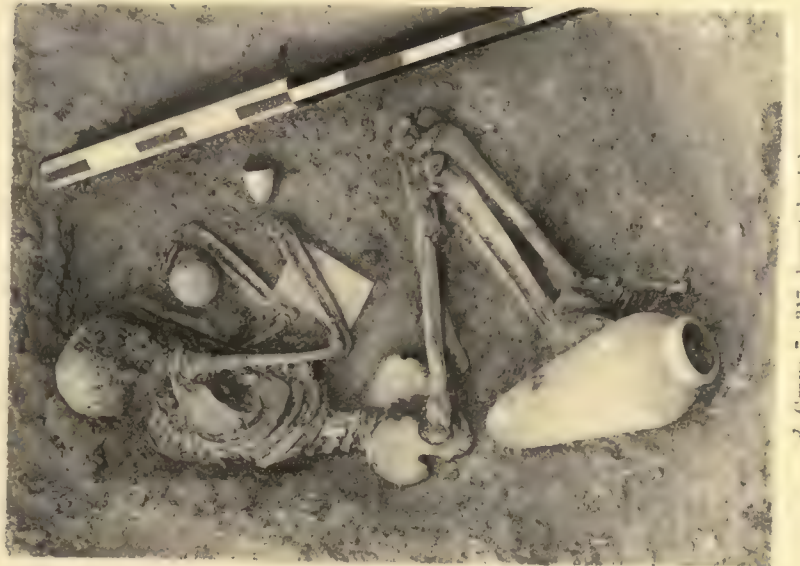a. Grave 7: 317, first view.



b. Grave 7: 317, top burial.



c. Grave 7: 317, second burial.



d. Grave 7: 317, lowest burial.



e. Grave 7: 346, upper skeleton.



f. Grave 7: 346, lower skeleton.

Early Dynastic Period.

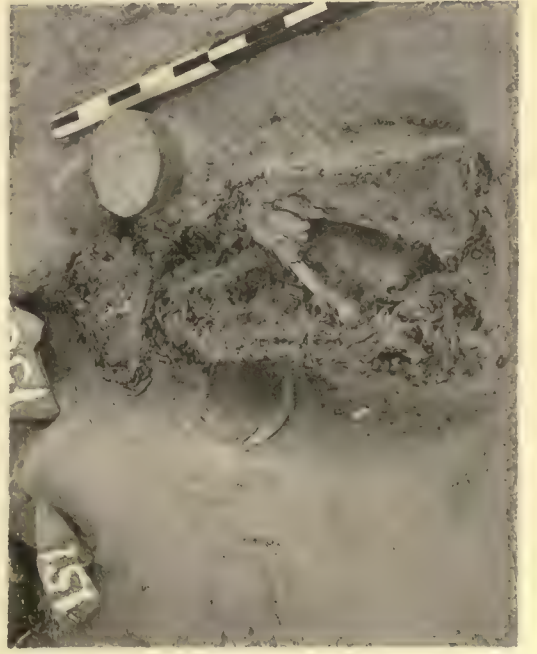
Undisturbed multiple burials.



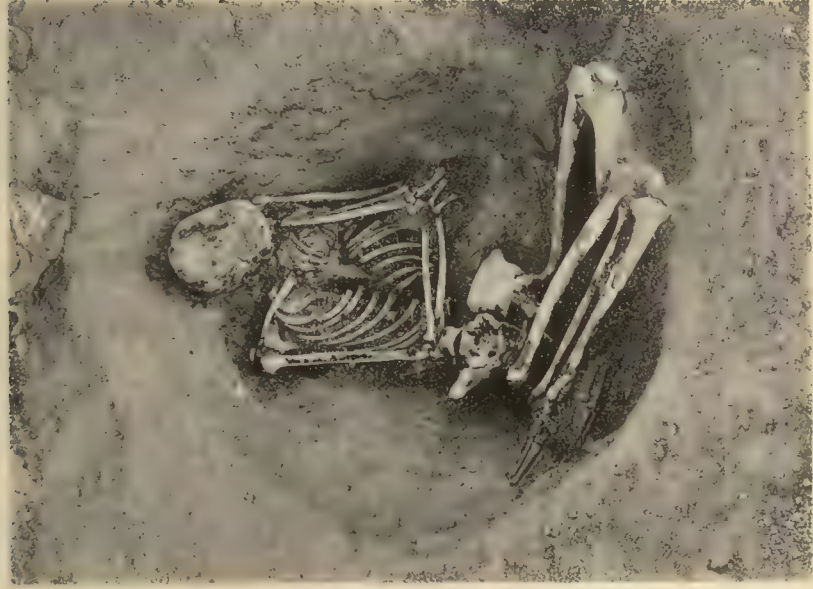e. Grave 7 : 147, goatskin covering.



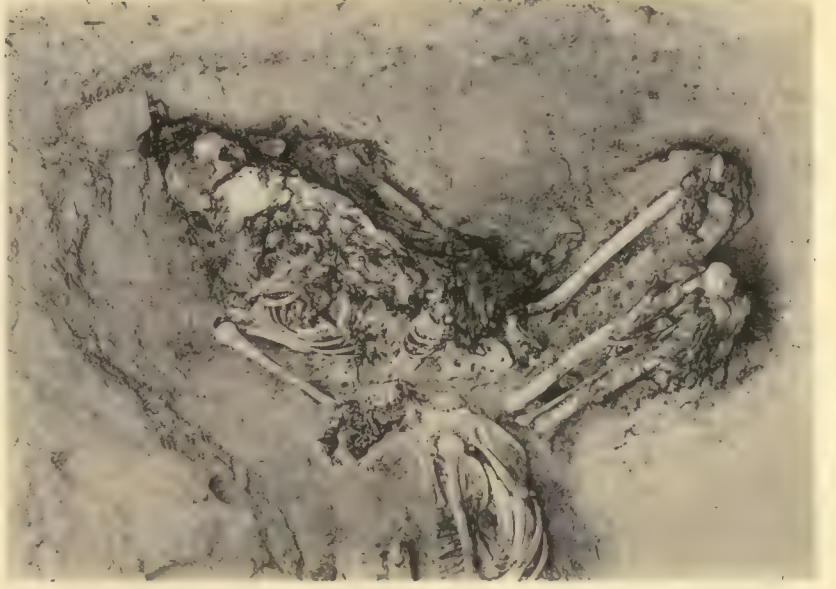f. Grave 7 : 151, Negro.



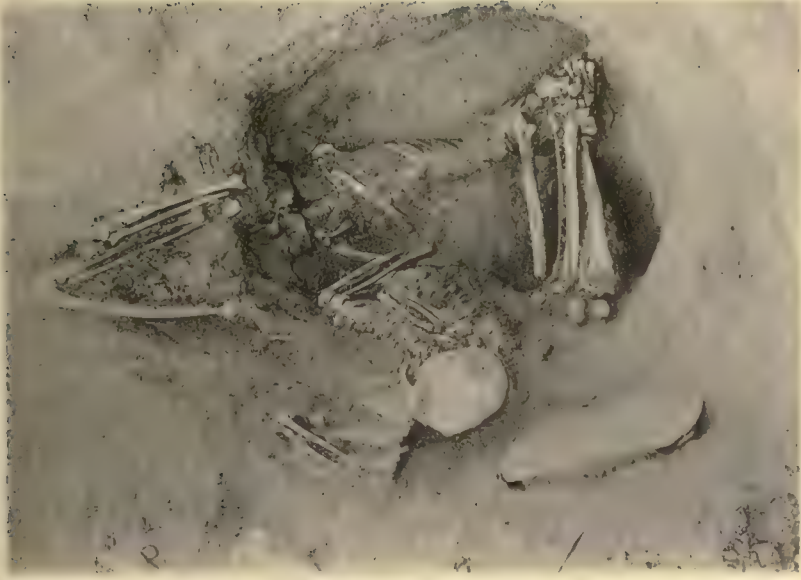g. Grave 7 : 150, goatskin and matting.



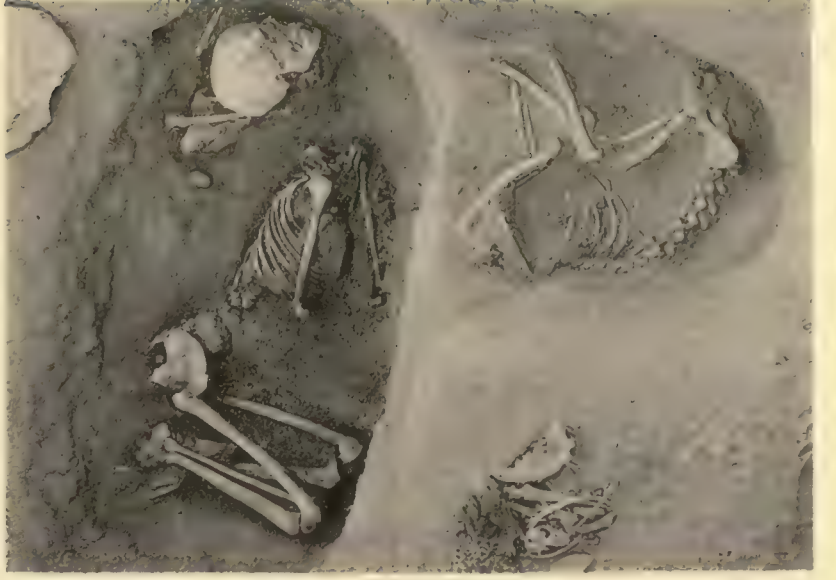c. Grave 7 : 204, from the west.



d. Grave 7 : 190, with copper axe, from the south.



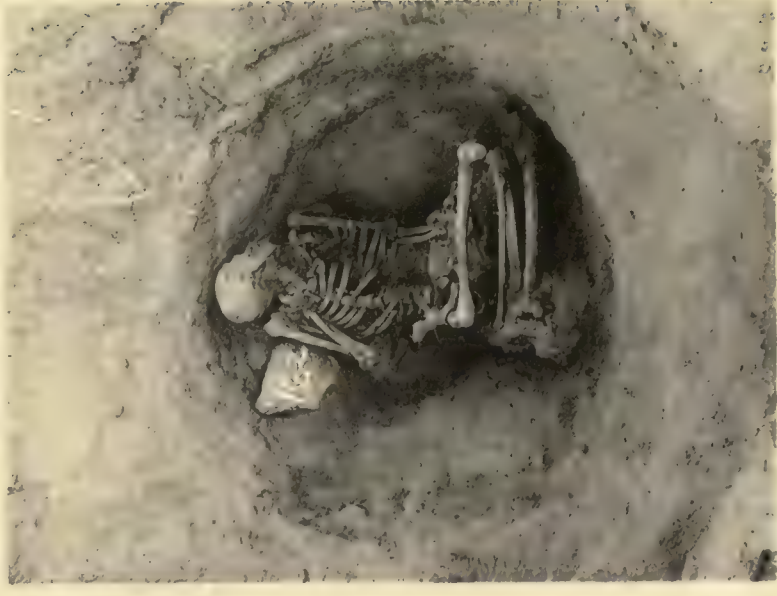
a. Grave 7 : 202, from the south.



b. Grave 7 : 224, from the east.



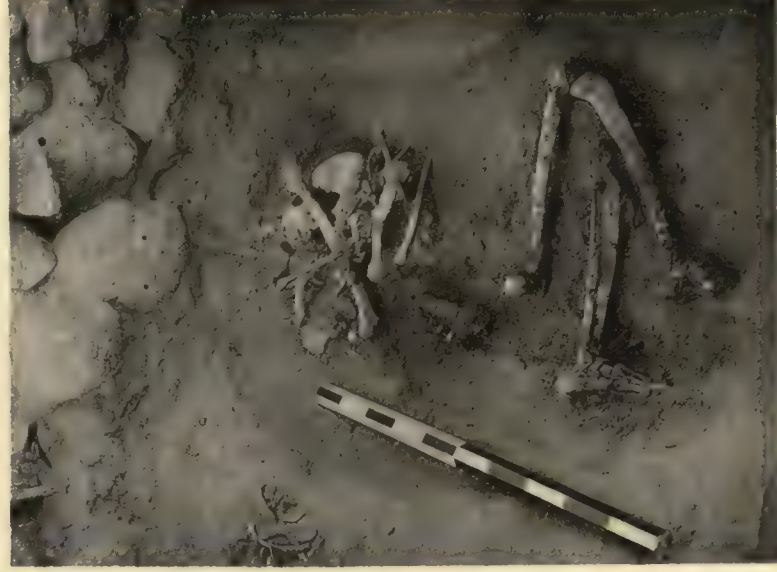a. Grave 7 : 161, plundered.




b. Grave 7 : 162, unplundered.




c. Grave 7 : 166, superstructure.




d. Grave 7 : 164, E-group.



e. Grave 7 : 156, burial.



f. Grave 7 : 148, E-group.



g. Grave 7 : 182, E-group.




h. Grave 7 : 181, E-group.




b. Executioner's trench 7 : 11, looking down.



a. New Empire pit 7 : 7, bones in pit.



c. Executioner's trench 7 : 21.



d. Roman fort, trench filled with bricks.



e. New Empire chamber 7 : 13, section of débris.



a. Tomb 2 : 1,063, superstructure.



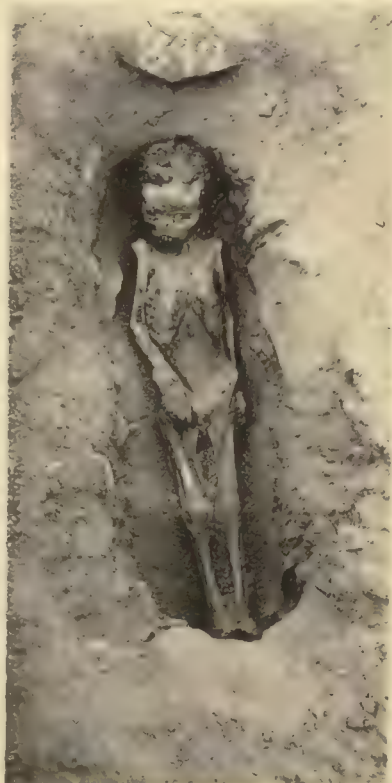b. Tomb 2 : 1,063, filling.



c. Tomb 2 : 1,063, burial.



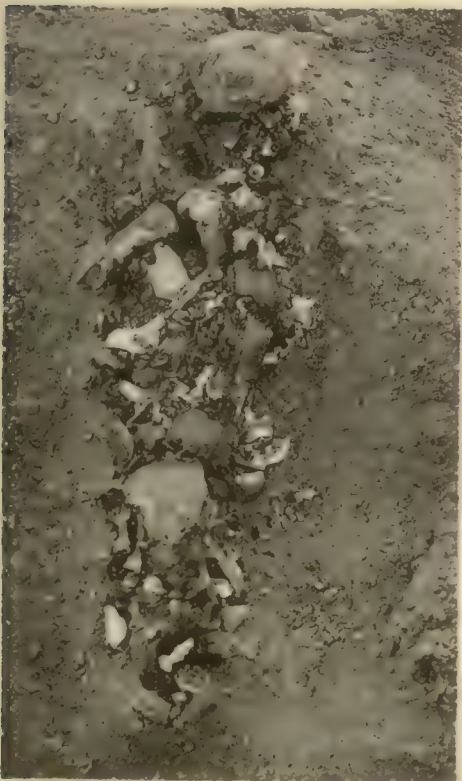d. Grave 2 : 381.



e. Grave 2 : 892.



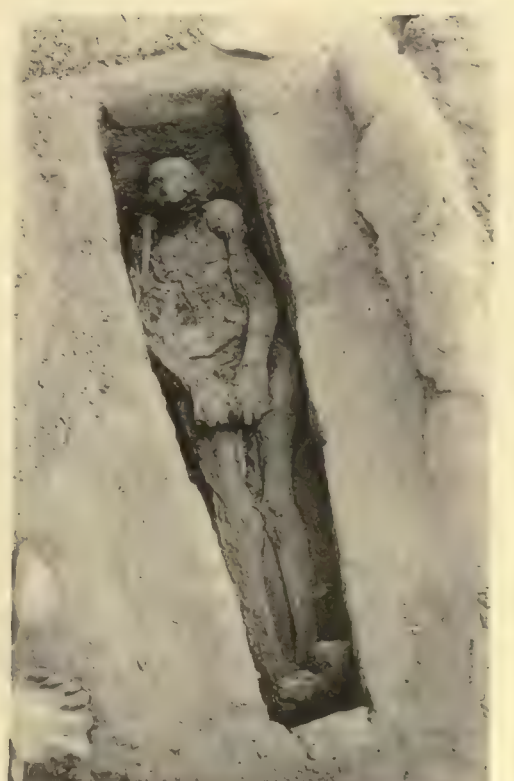f. Superstructure 2 : 131.



g. Grave 2 : 53 : a, burnt bones.

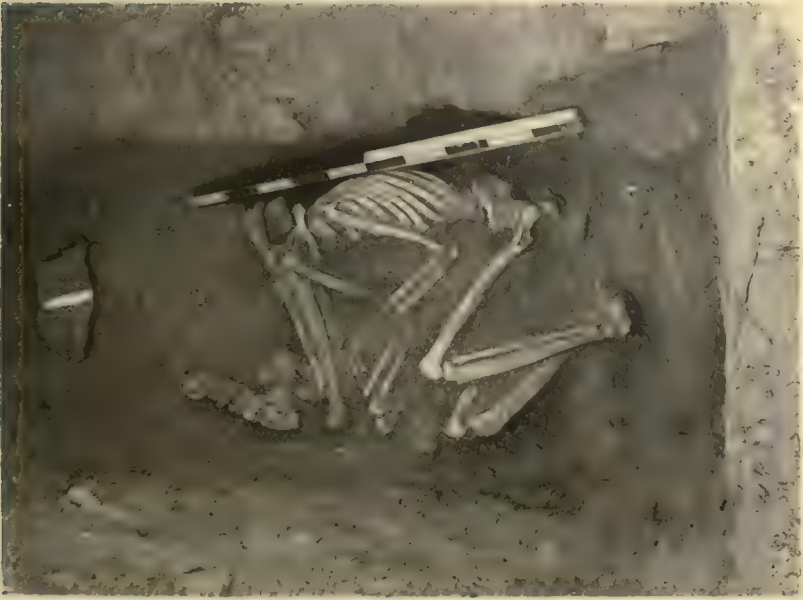

h. Graves 2 : 119-120.



i. Grave 2 : 160.

Samples illustrating the various states in which the human remains were found in the Byzantine cemetery on the island of Hesa.



e. Grave 17 : 1, Early Dynastic.



c. Grave 17 : 27, Early Dynastic.



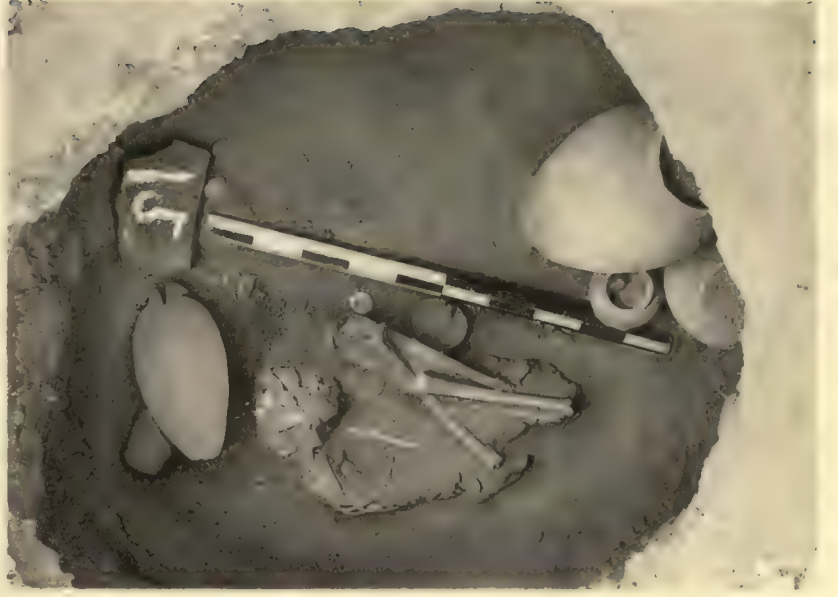a. Grave 17 : 26, dogs.



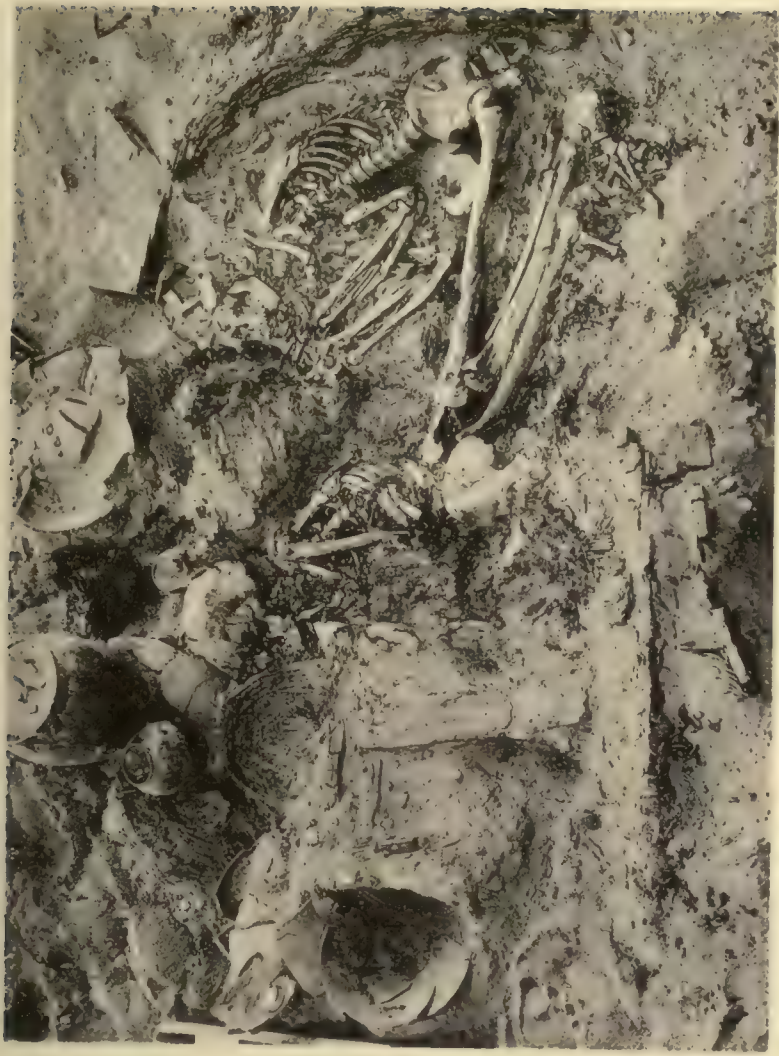f. Grave 17 : 103.



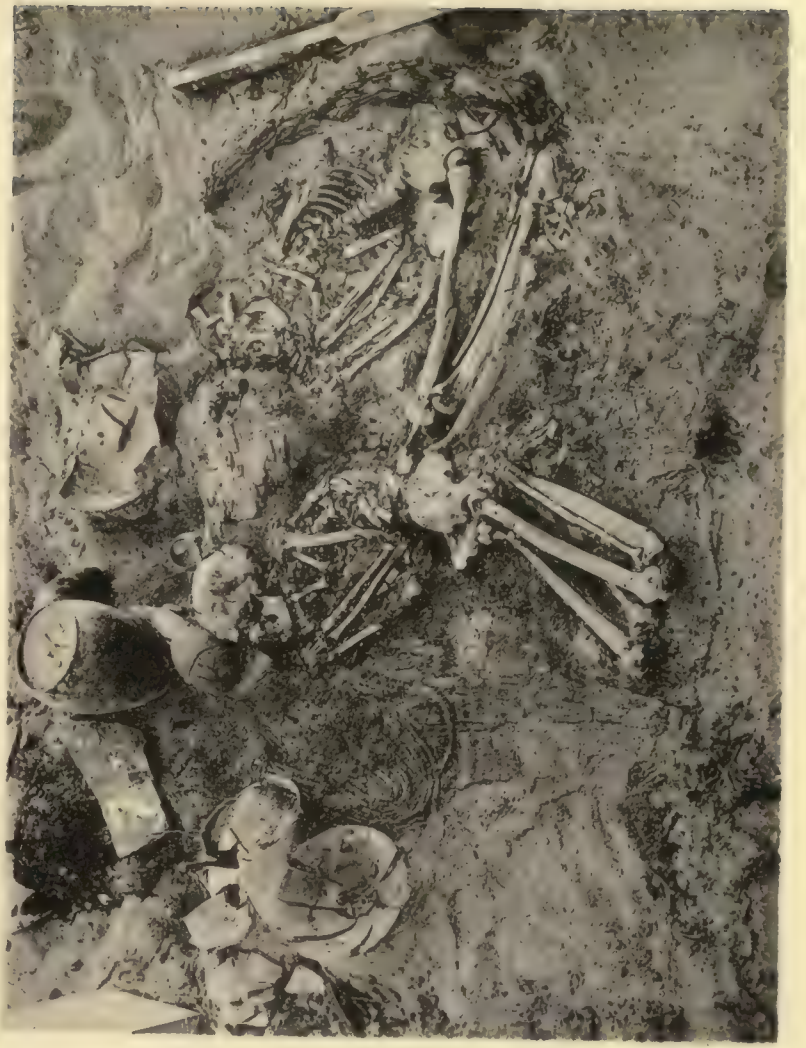d. Grave 17 : 48, B-group.



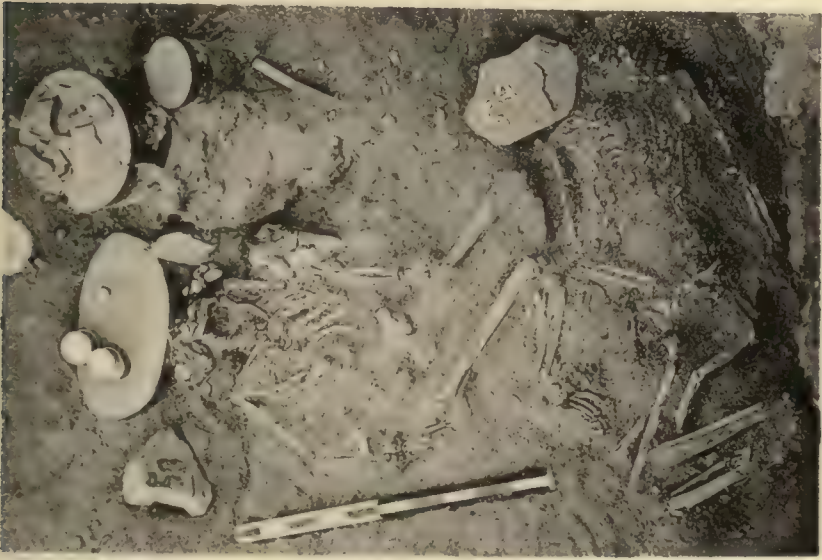b. Grave 17 : 15, Late Predynastic.



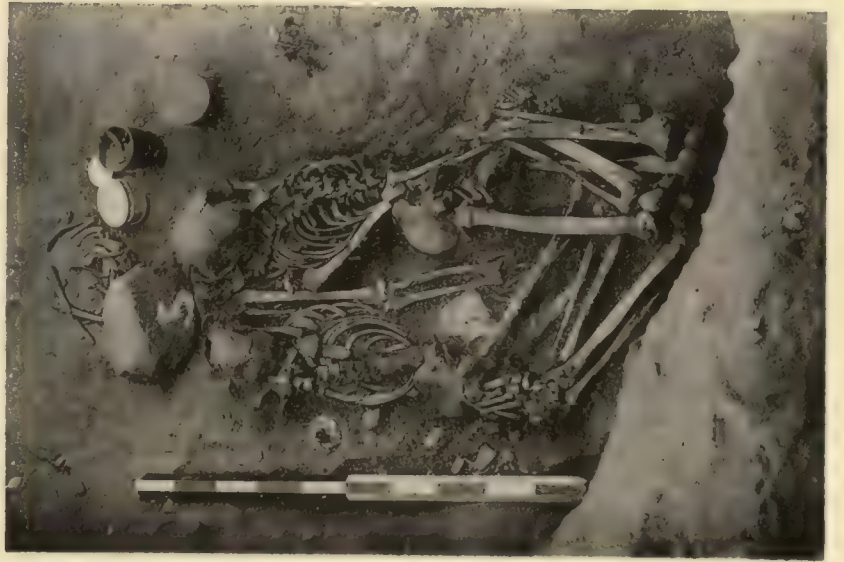a. Grave 17: 7, remains of wooden coffin.



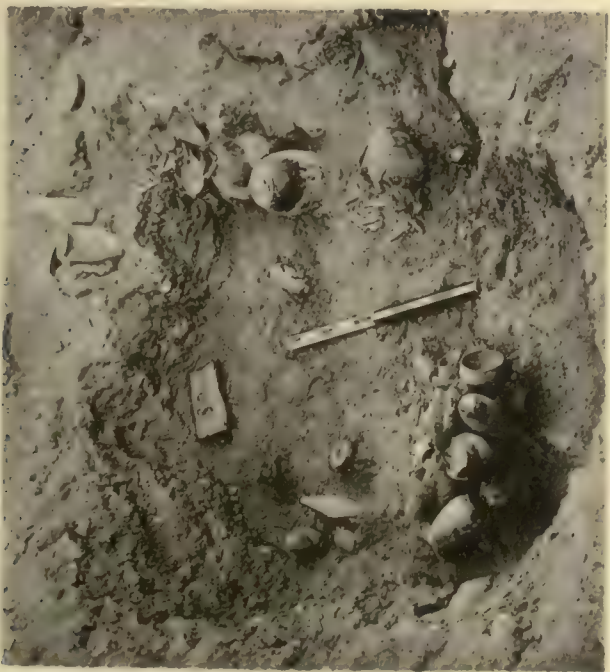b. Grave 17: 7, skeletons.




c. Graves 17: 58 and 59.



d. Grave 17: 5



e. Grave 17: 50, plundered.



f. Grave 17: 78, plundered.



a. Tomb 15:46, entrance-block.



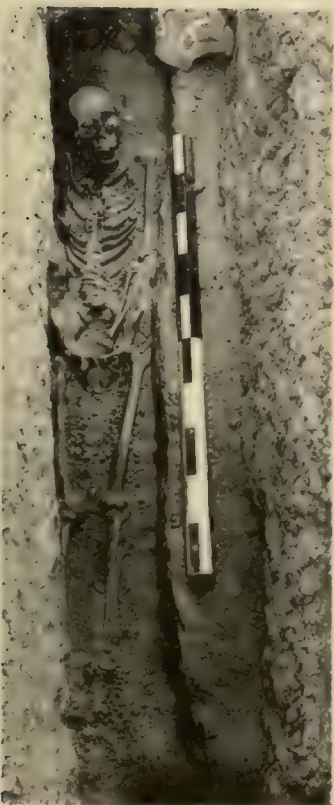c. Tomb 15:47, burial.



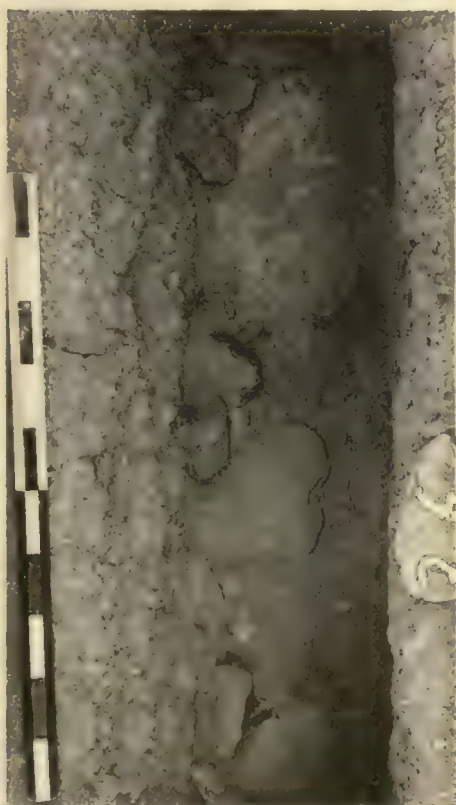
b. Tomb 15:46, burial.



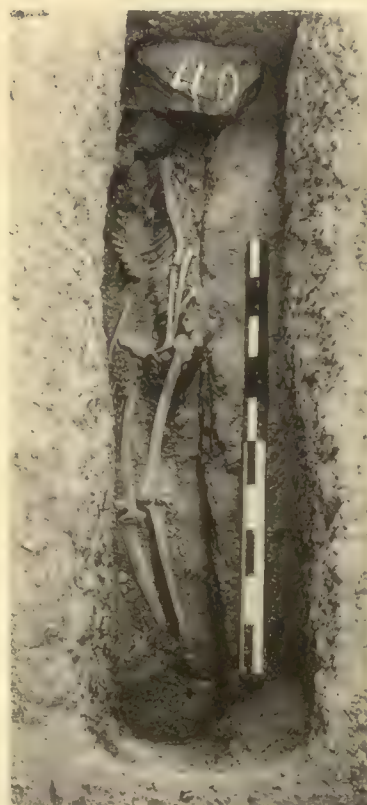d. Tomb 15:44, burial.



h. Tomb 15:36, burial.



g. Tomb 15:36, entrance-block.



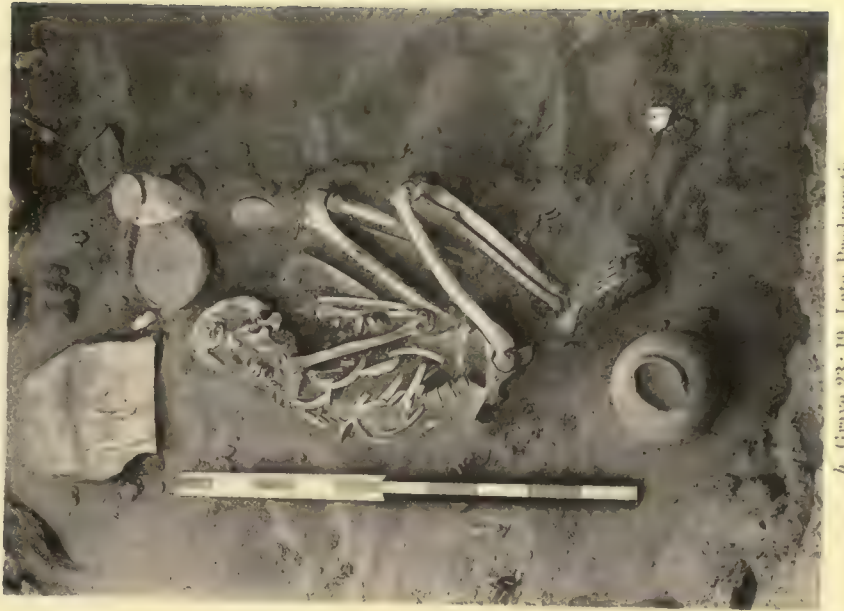f. Tomb 15:40, burial.




e. Tomb 15:40, entrance-block.



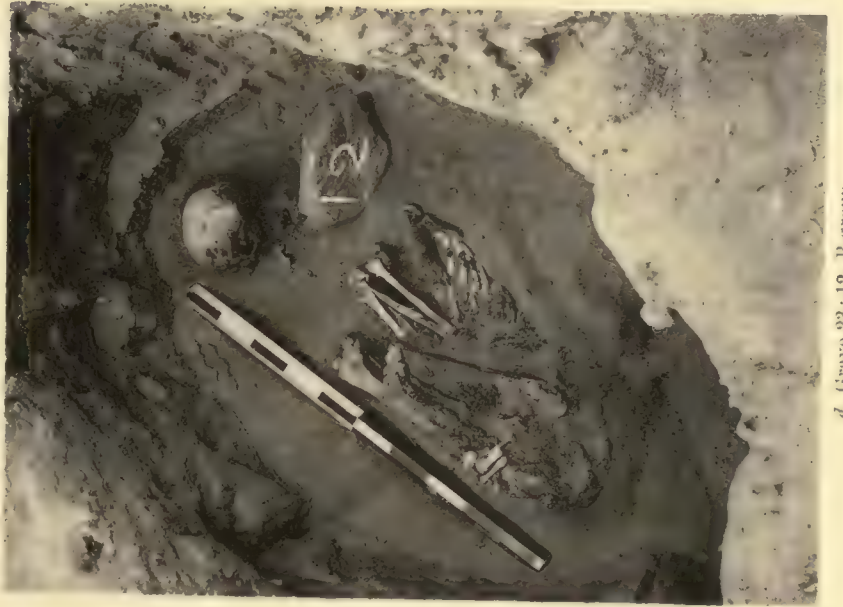a. Grave 23: 1, Late Predynastic.



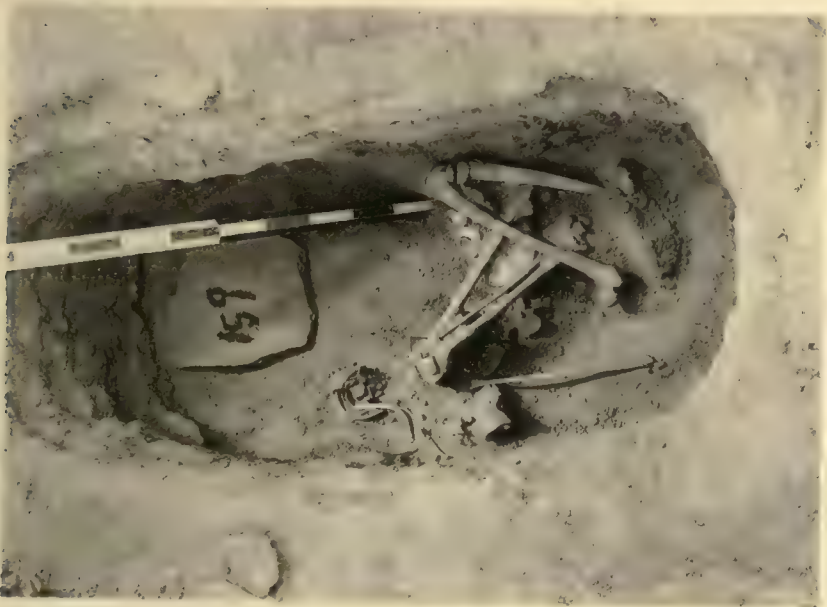b. Grave 23: 19, Late Predynastic.



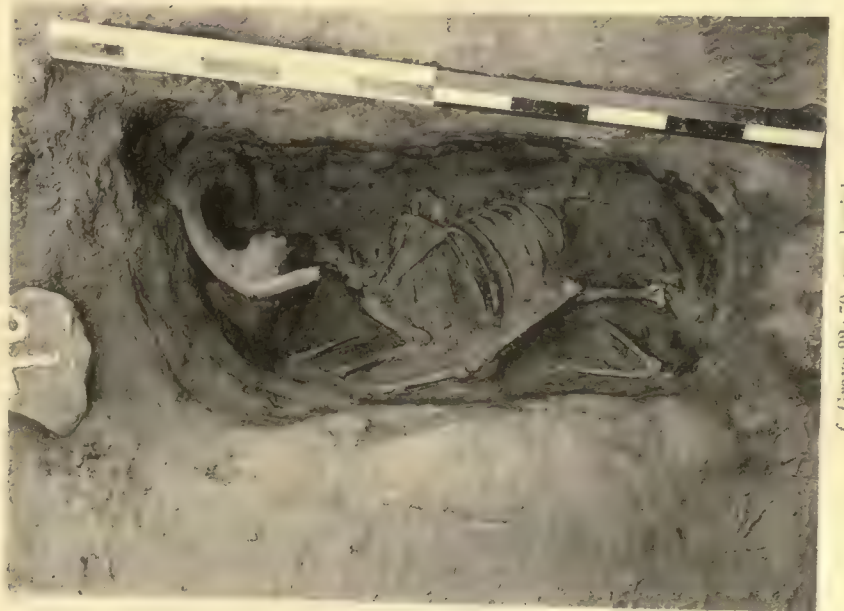c. Grave 23: 45, Early Dynastic.



d. Grave 23: 12, B-group.



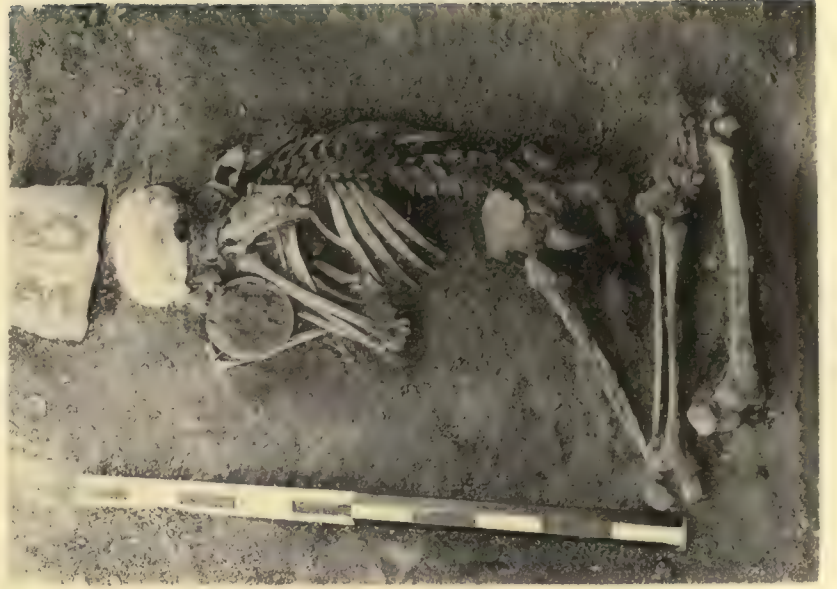e. Grave 22: 159, C-group.



f. Grave 22: 70, ram burial.



a. Grave 30: 38, upper body.



b. Grave 30: 38, lower body.



c. Grave 30: 2, upper body.



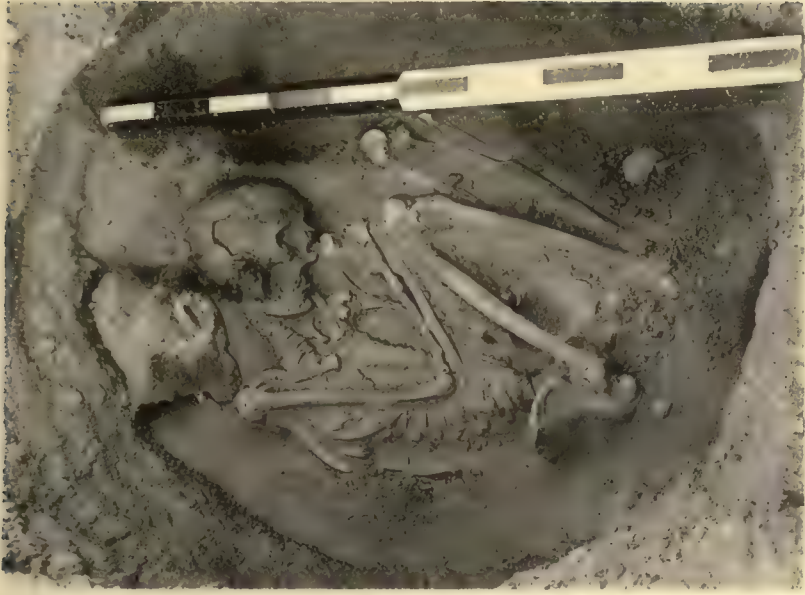d. Grave 30: 2, lower body.



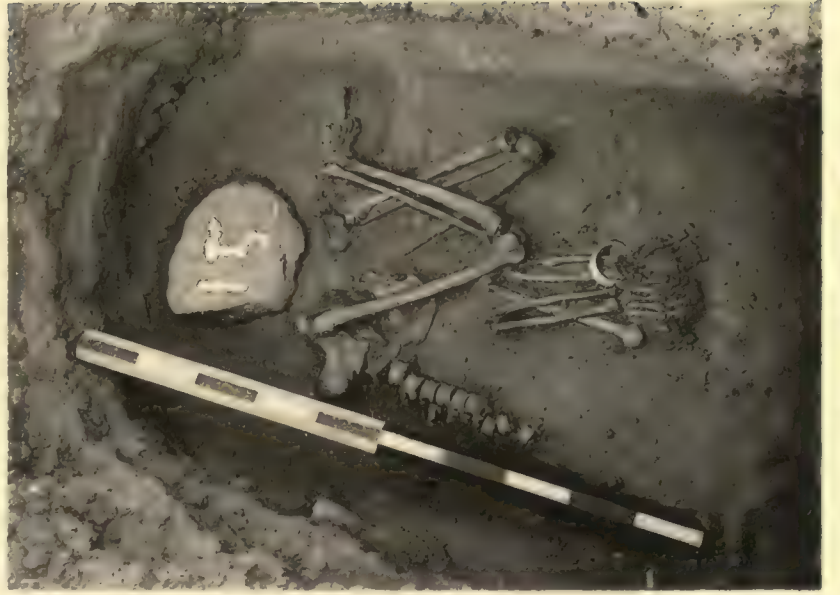e. Grave 30: 3, plundered upper body.




f. Grave 30: 36, two dogs.



a. Grave 30:6, B-group.



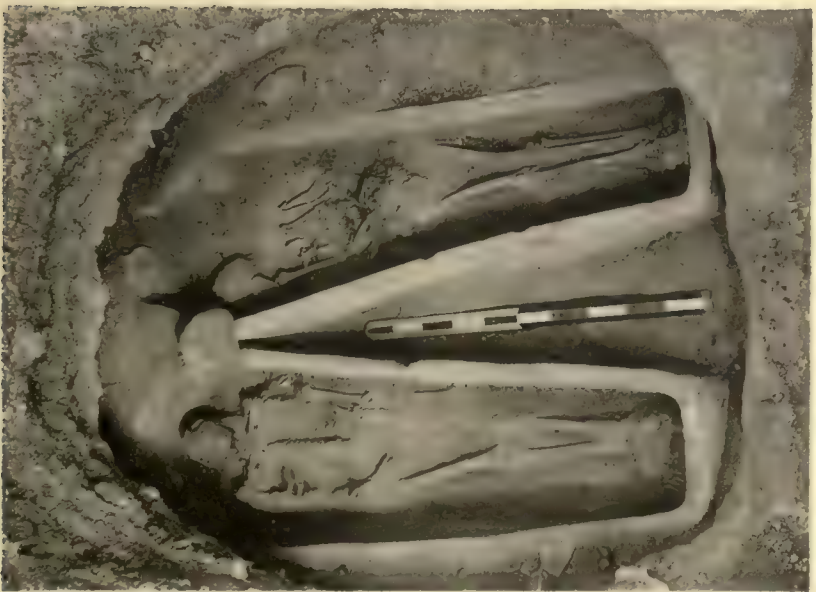b. Grave 30:15, C-group.



c. Grave 30:21, New Empire.



d. Grave 30:10, New Empire.



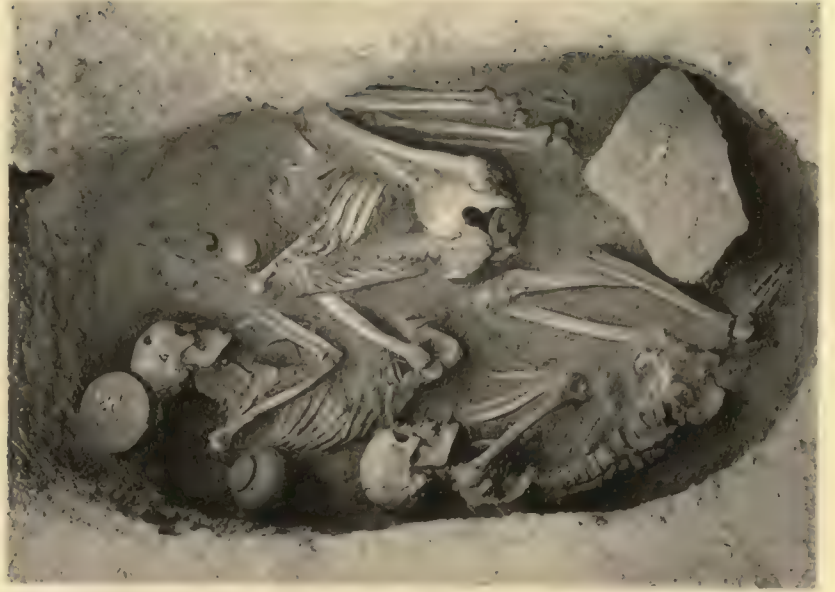e. Mud-cut chamber 36:18, Roman Period.



f. Mud-cut chamber 36:26, Roman Period.



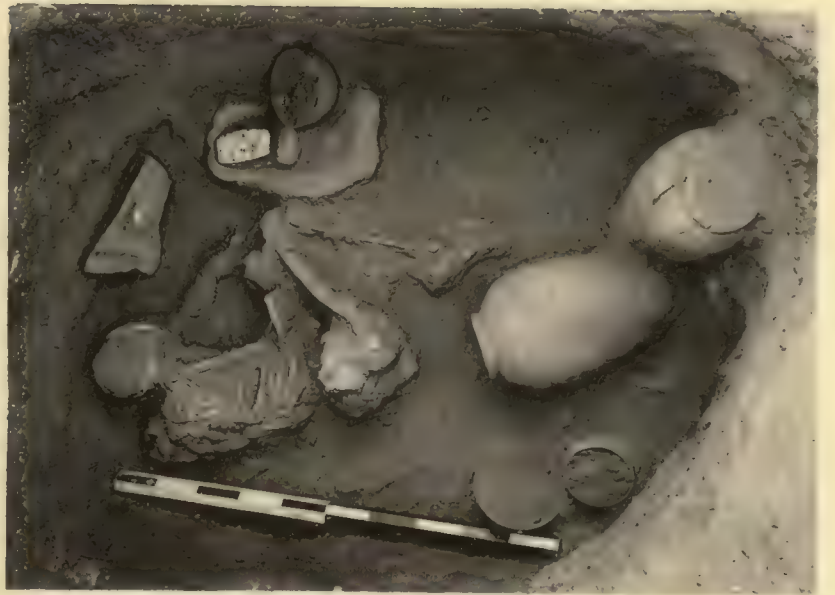a. Grave 40 : 33.



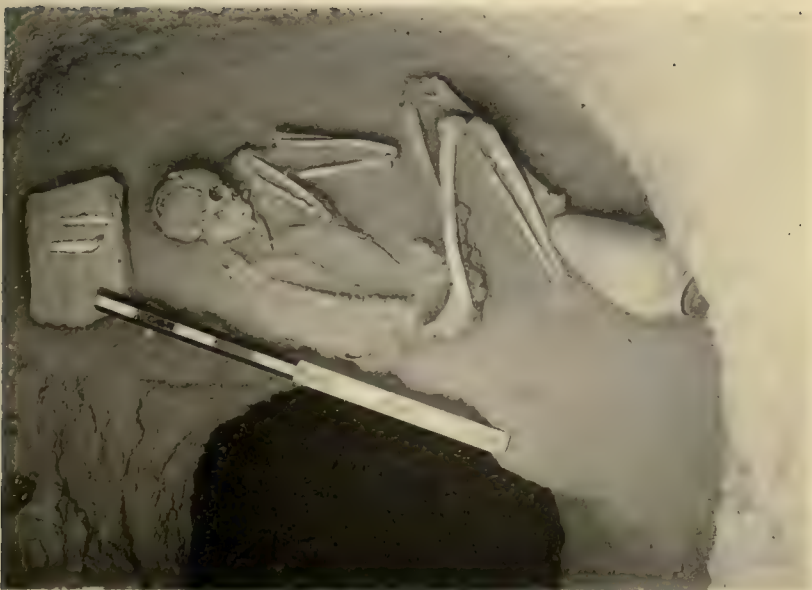b. Grave 40 : 65.



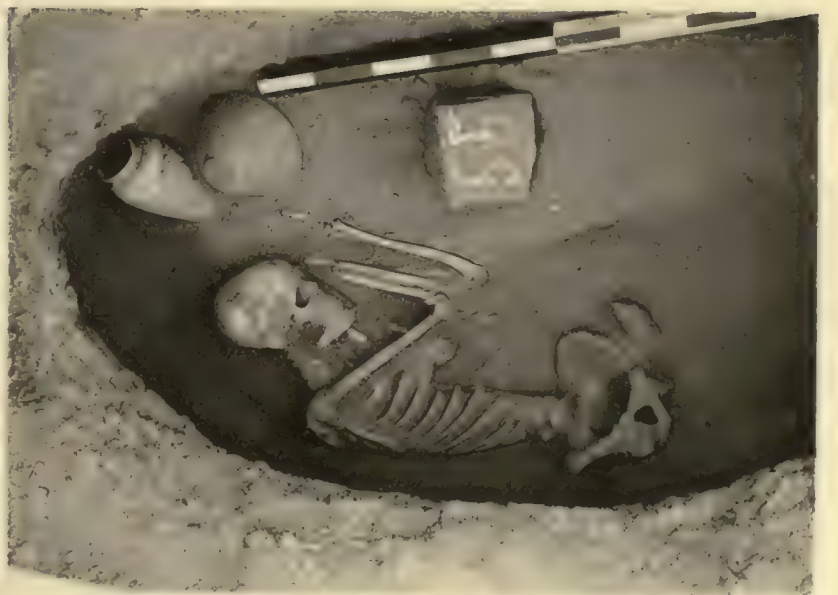c. Grave 40 : 73.



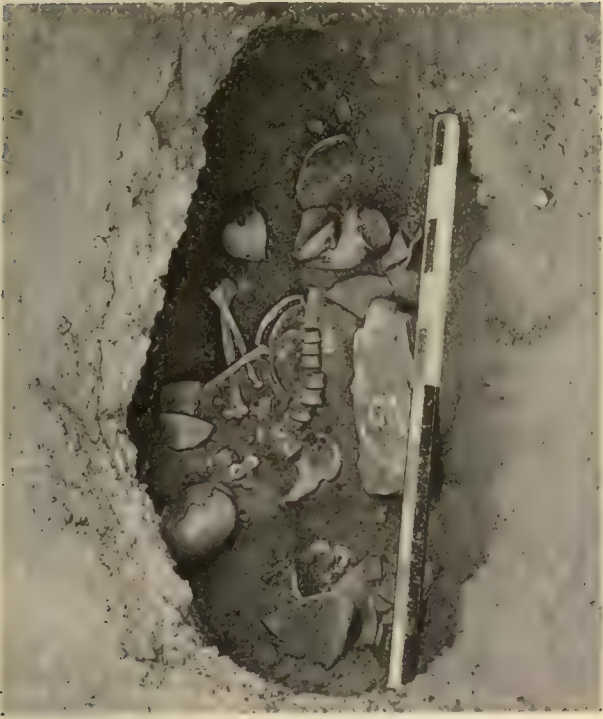d. Grave 40 : 15.



e. Grave 40 : 11, double beehive type.



f. Grave 50 : 55, recess-grave.



a. Grave 43: 62, recess-grave.



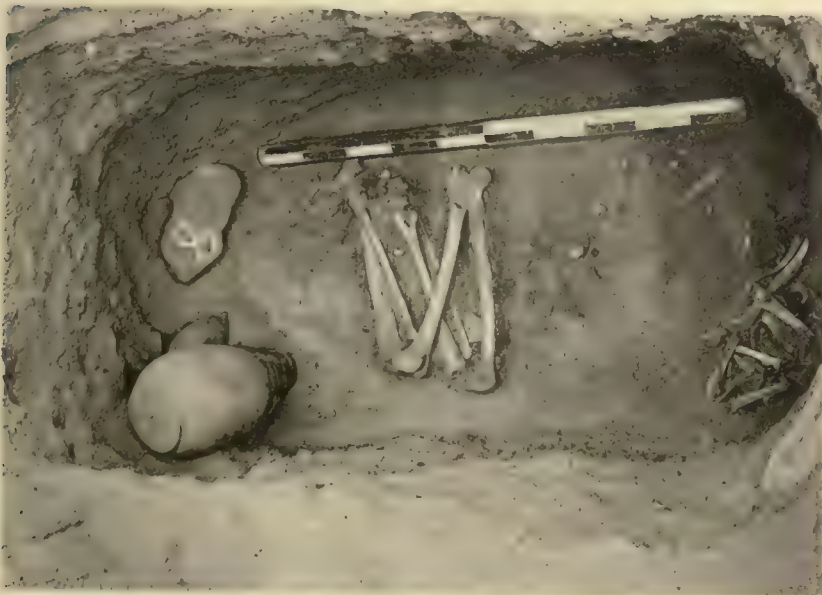
b. Grave 43: 61, recess-grave.



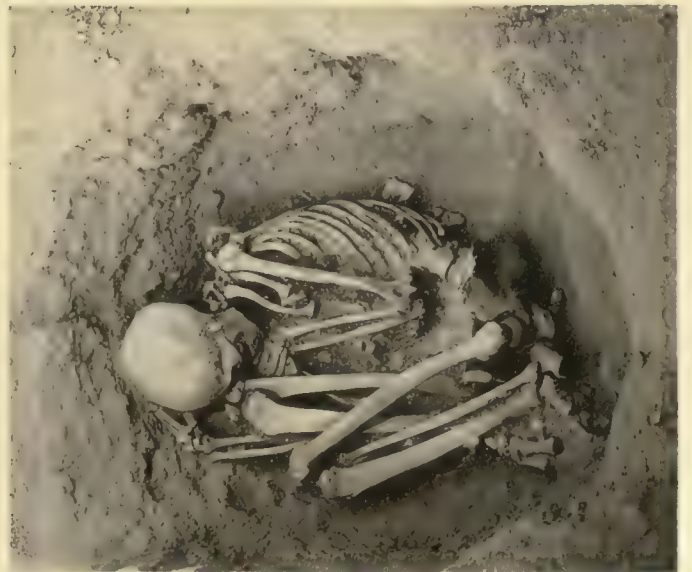c. Grave 41: 22.



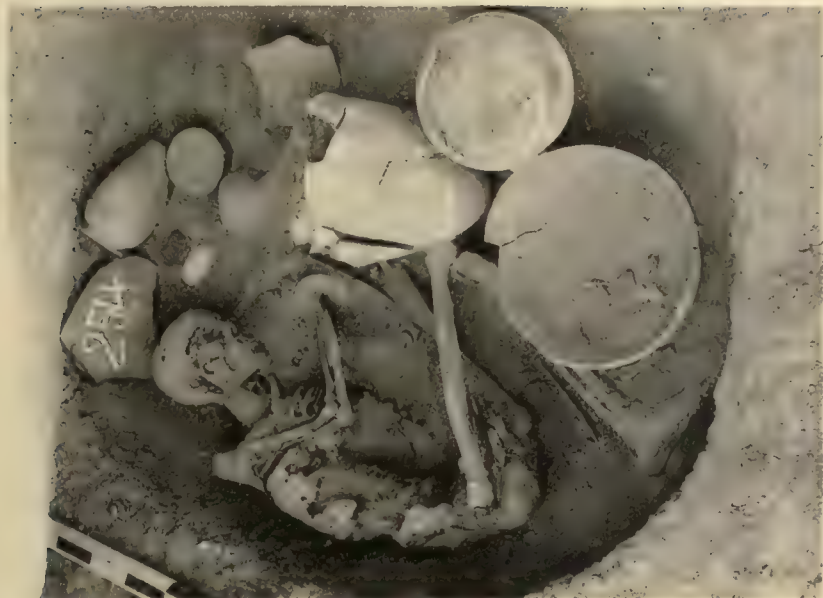d. Grave 41: 20.



e. Grave 44: 8.



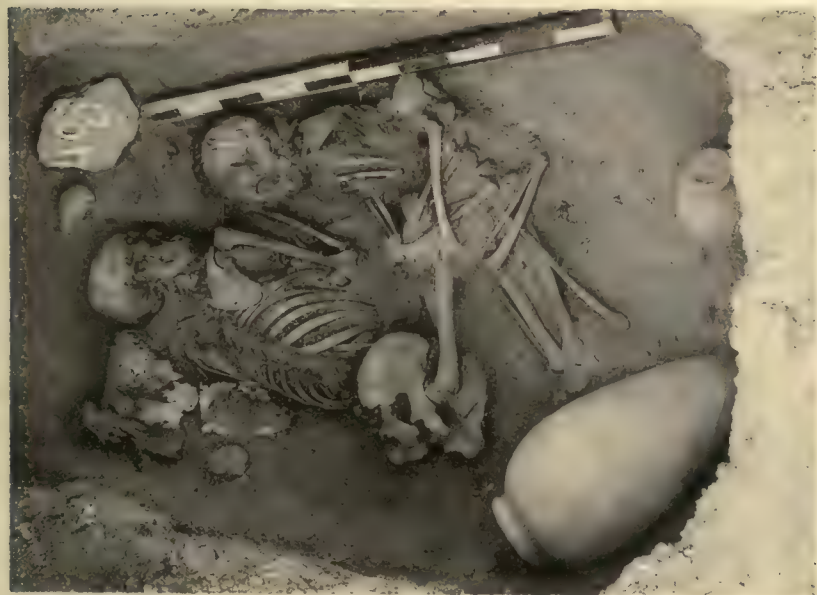f. Grave 44: 5.



a. Grave 45 : 254, unplundered.



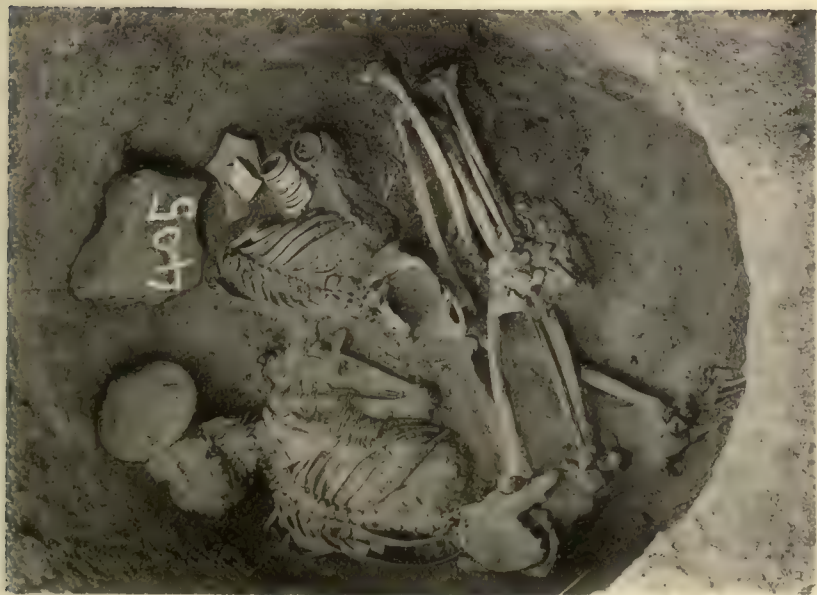b. Grave 45 : 400, plundered.



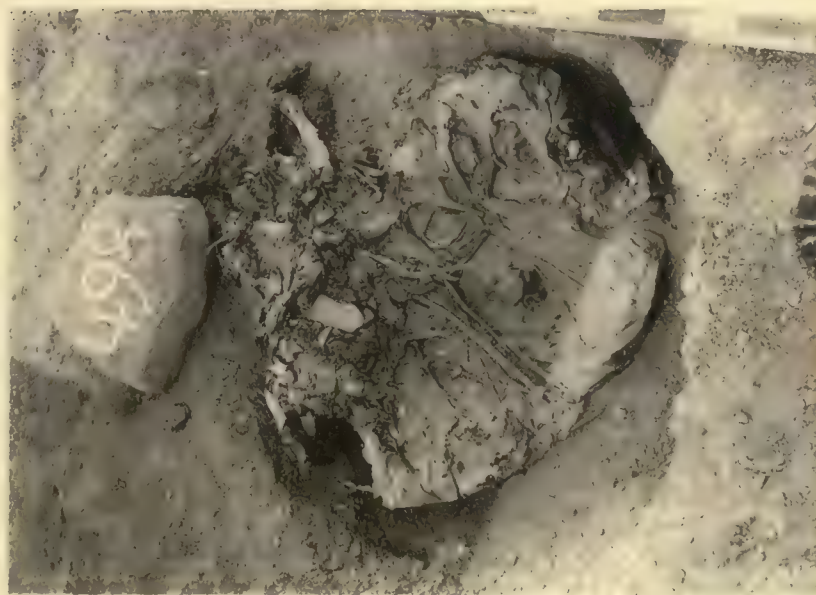
c. Grave 45 : 403, double burial.






d. Grave 45 : 236.

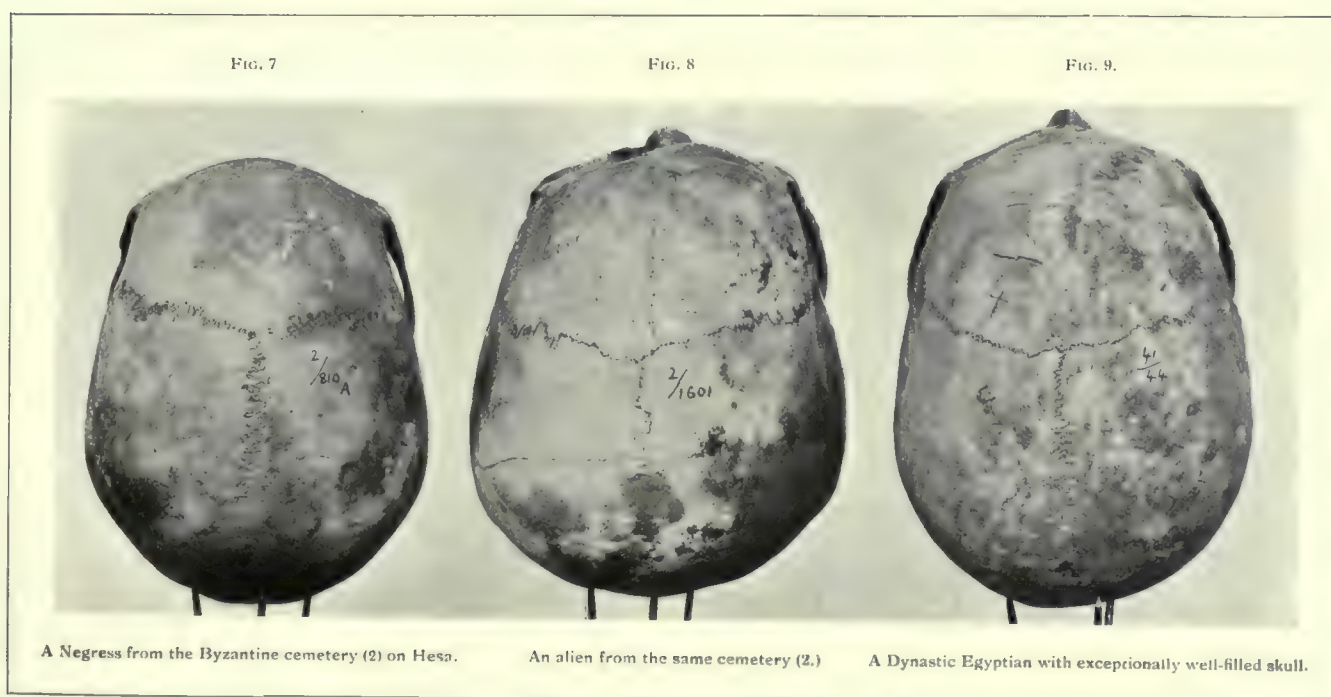




e. Grave 45 : 405.



f. Grave 45 : 408, burial tied in bundle.







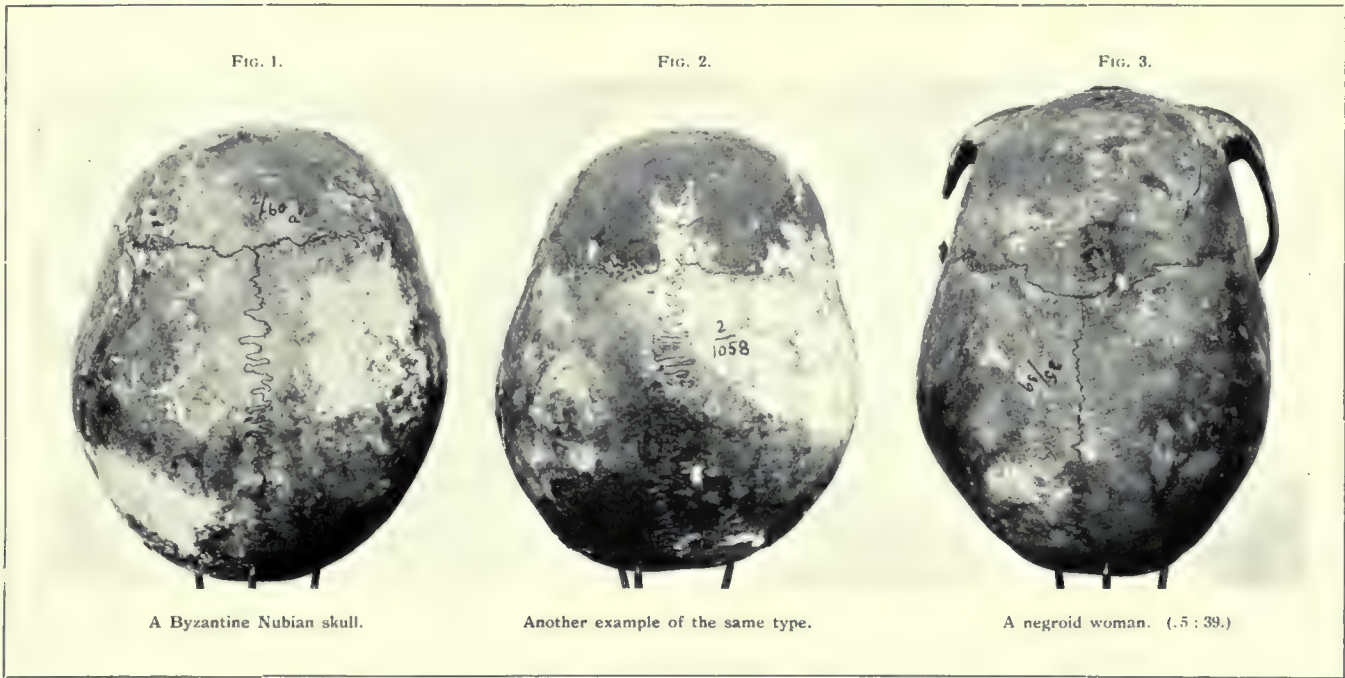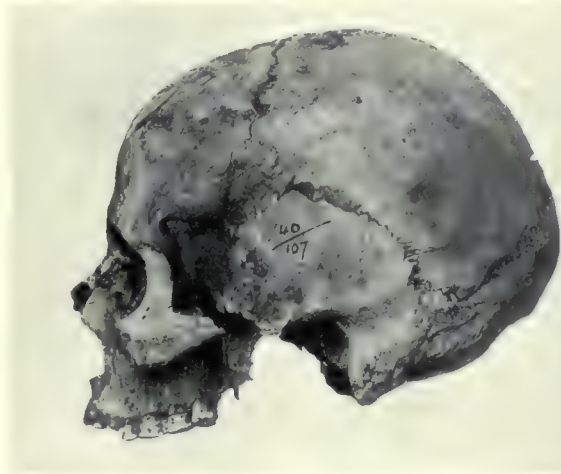
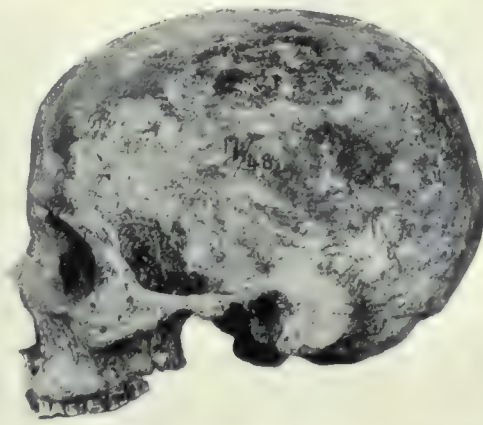


FIG. 1.



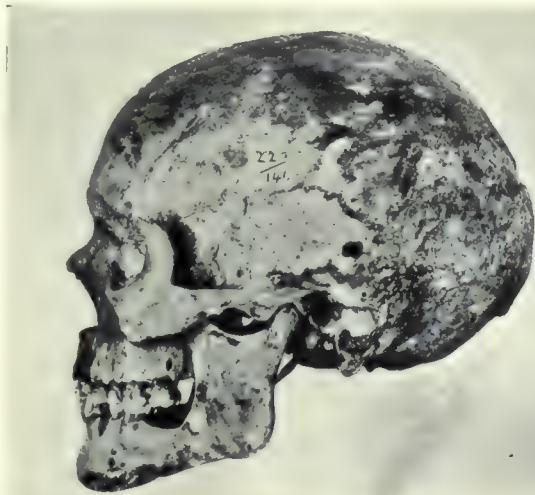A New Empire cranium (see pl. xviii, fig. 5 conforming to Predynastic type.

FIG. 2.



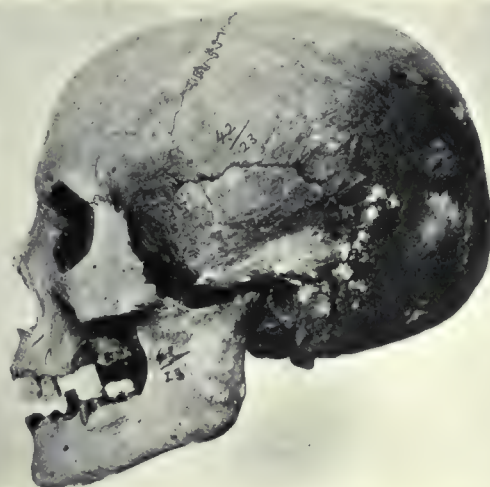An Archaic Egyptian skull (see pl. xviii, fig. 1) pathologically expanded as a result of hydrocephalus.

FIG. 3.



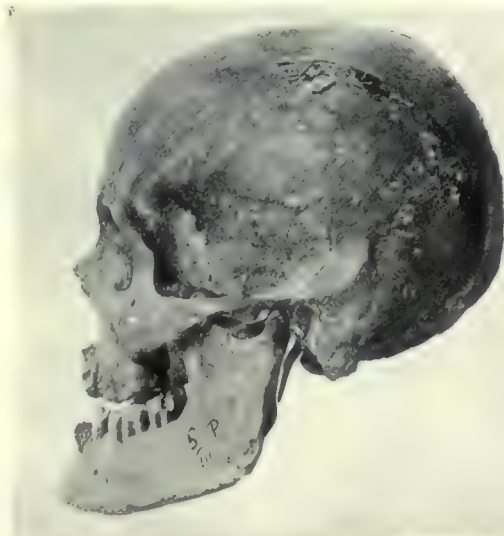Dynastic Egyptian (see pl. xx, fig. 7.)

FIG. 4.



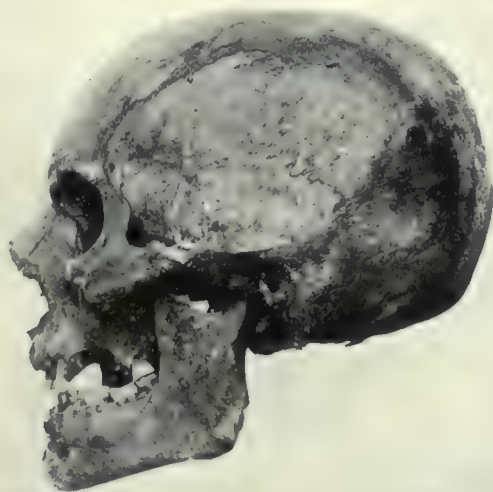Another example of Dynastic type, probably not pure (see pl. xx, fig. 9.)

FIG. 5.



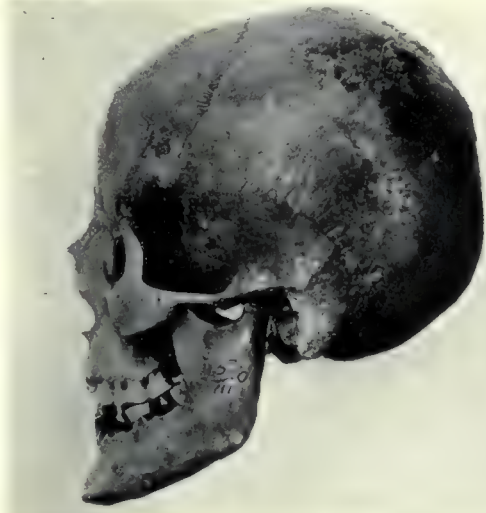The short-skulled type of alien Christians from Biga (see pl. xix, fig. 4.)

FIG. 6.



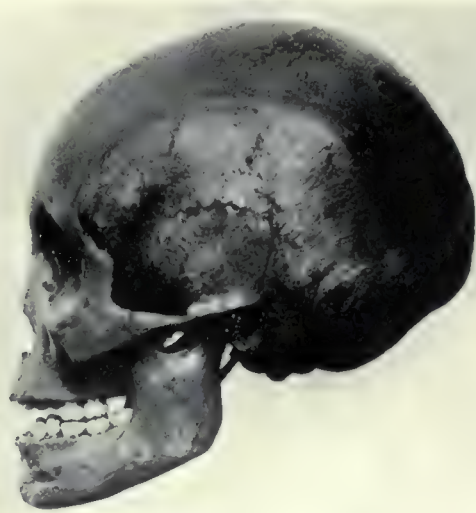The commoner type of Biga aliens with massive sphenoid crania (see pl. xix, fig. 1)

FIG. 1.



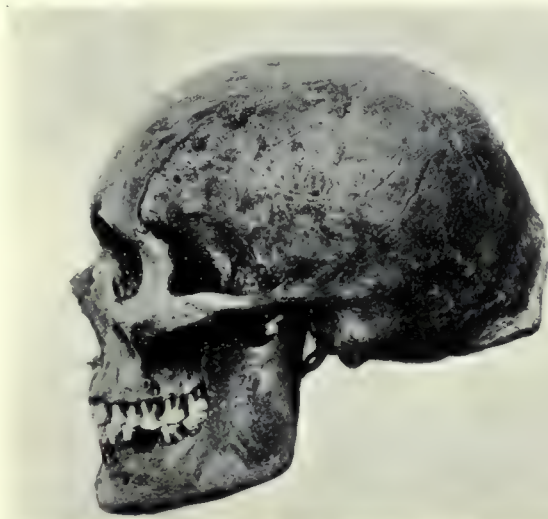Another example of the short-skulled type of Biga aliens.

FIG. 2.



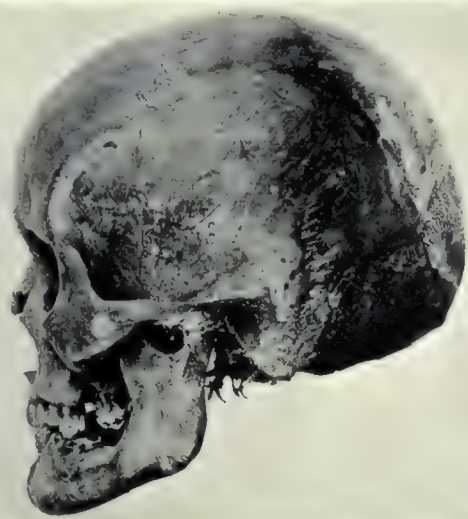
A Negress from the same cemetery (compare pl. xix, fig. 5.)

FIG. 3.



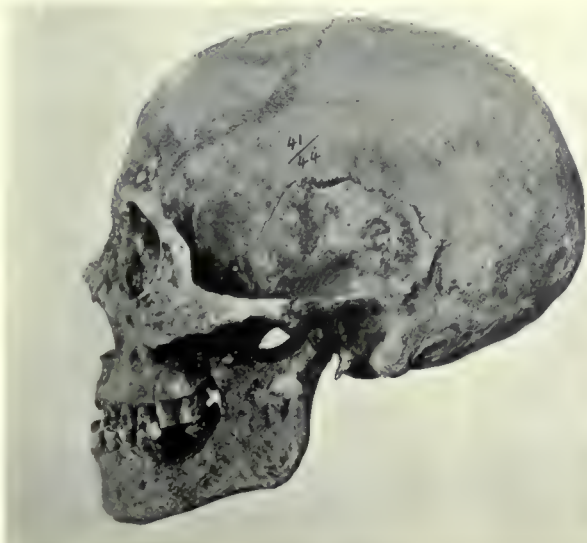The dolicocephalic alien type (see pl. xix, fig. 3.)

FIG. 4.



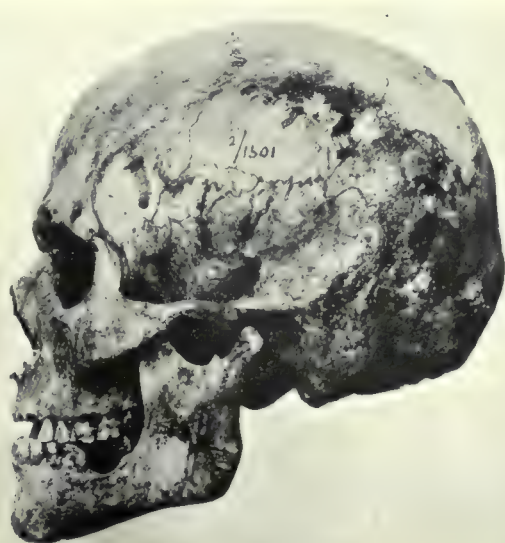Another alien type (see pl. xix, fig. 2.)

FIG. 5.

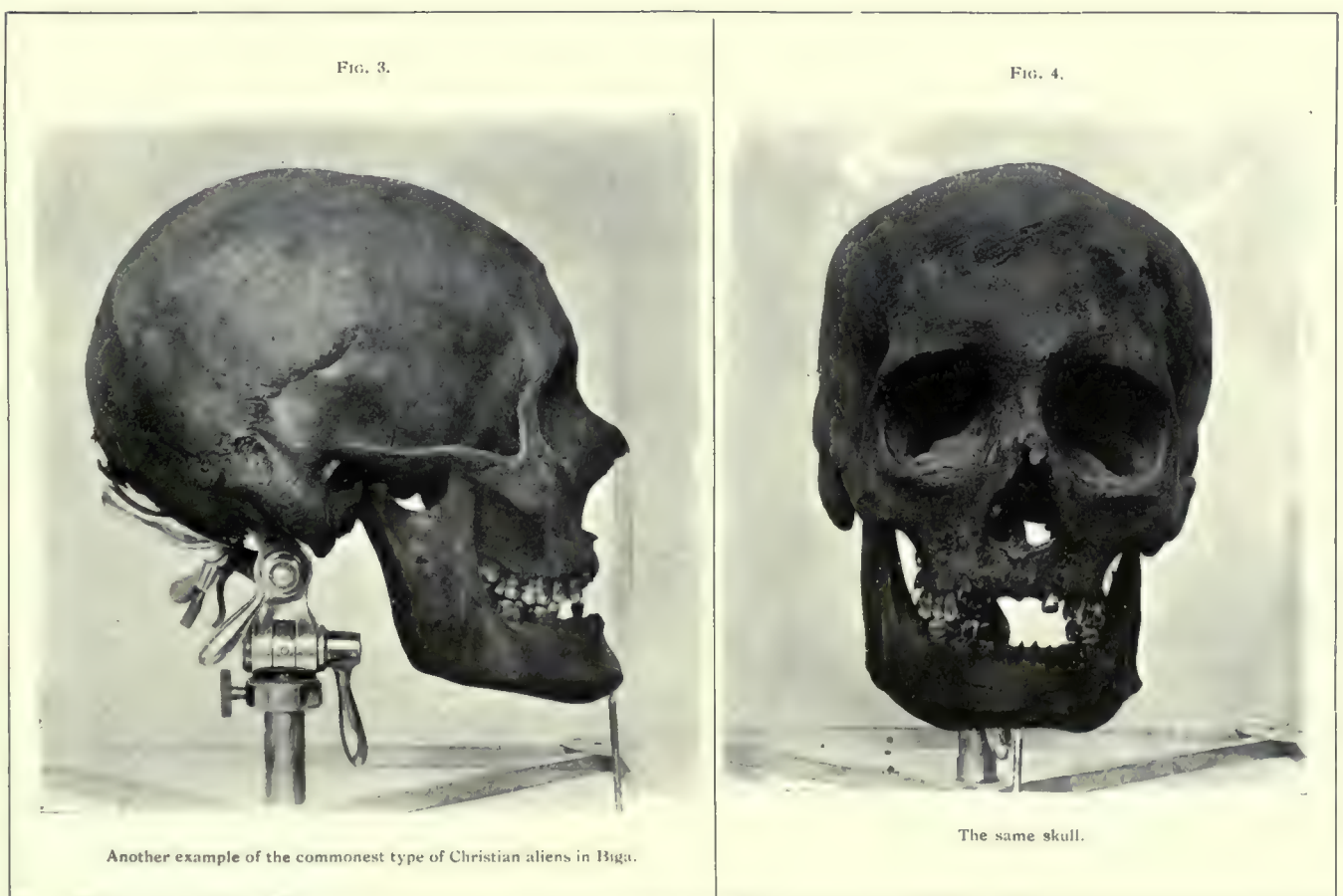
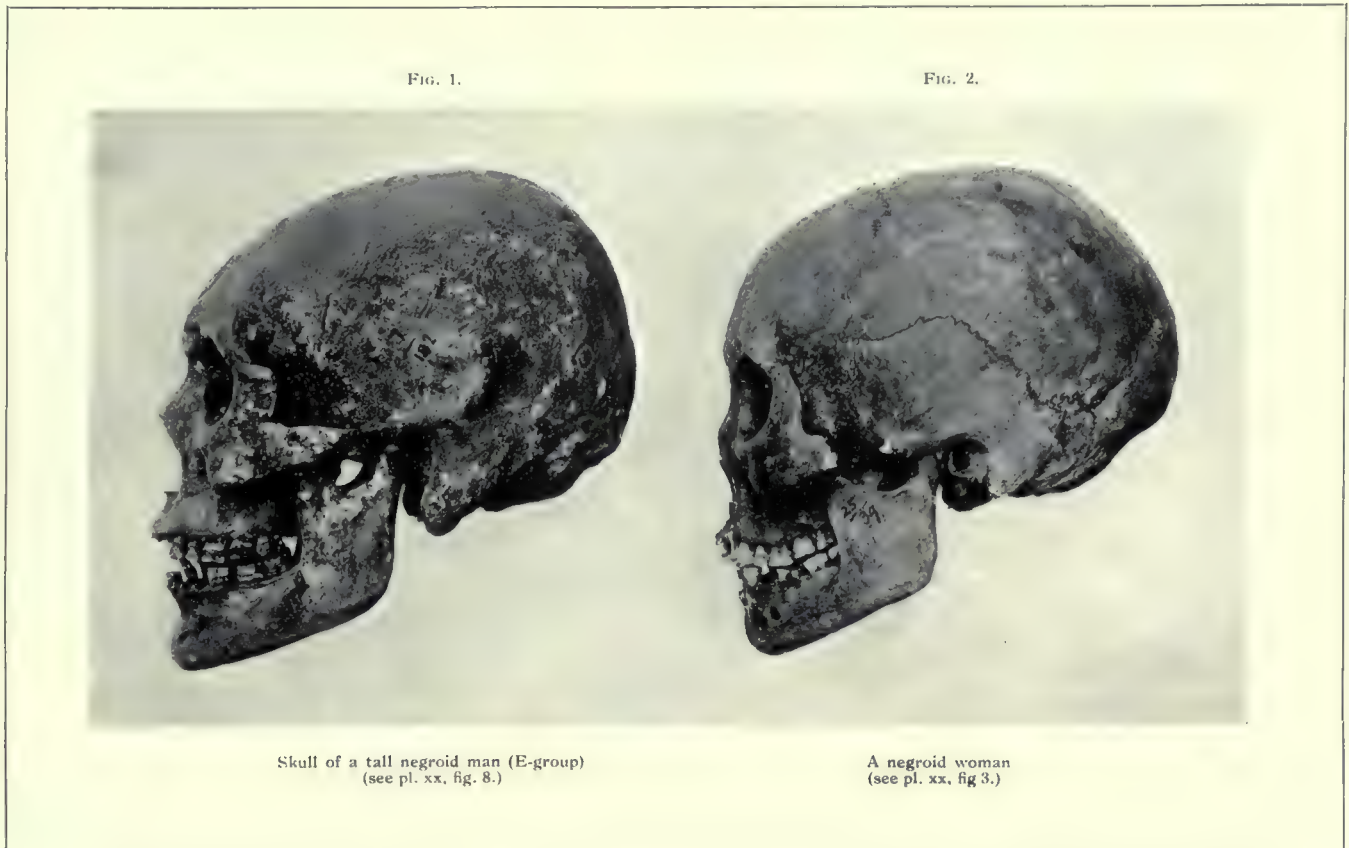

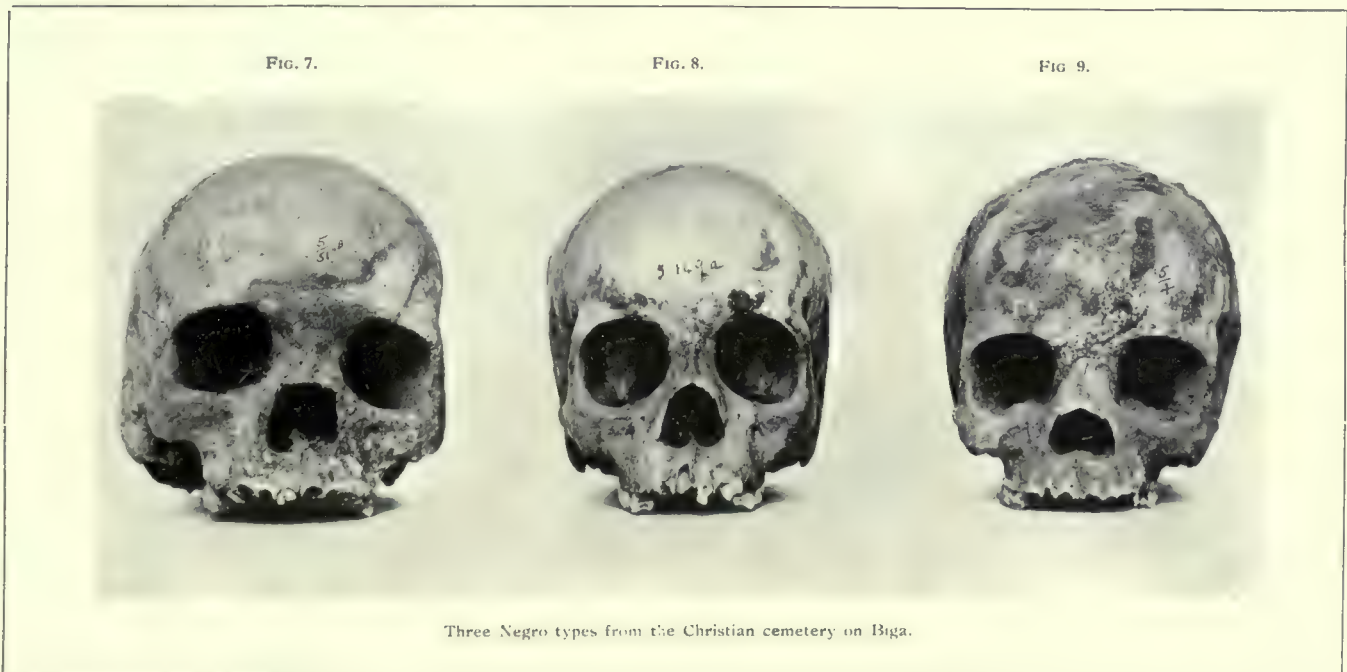
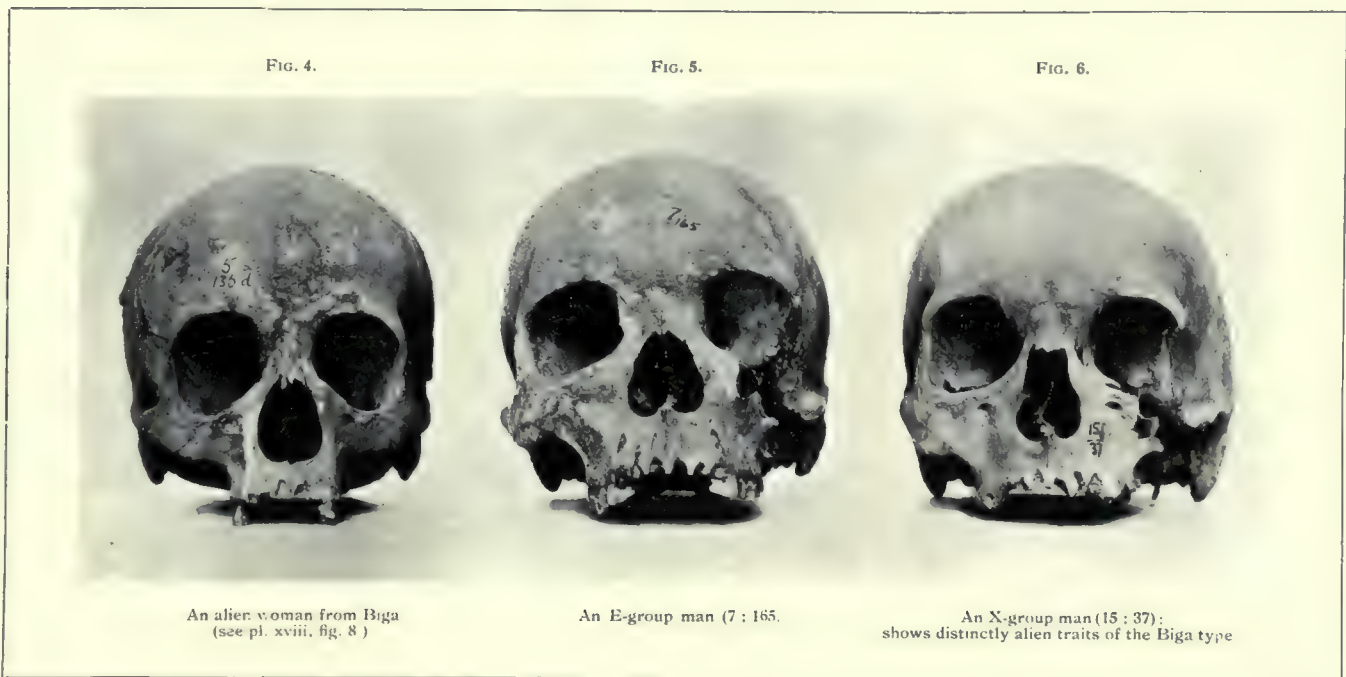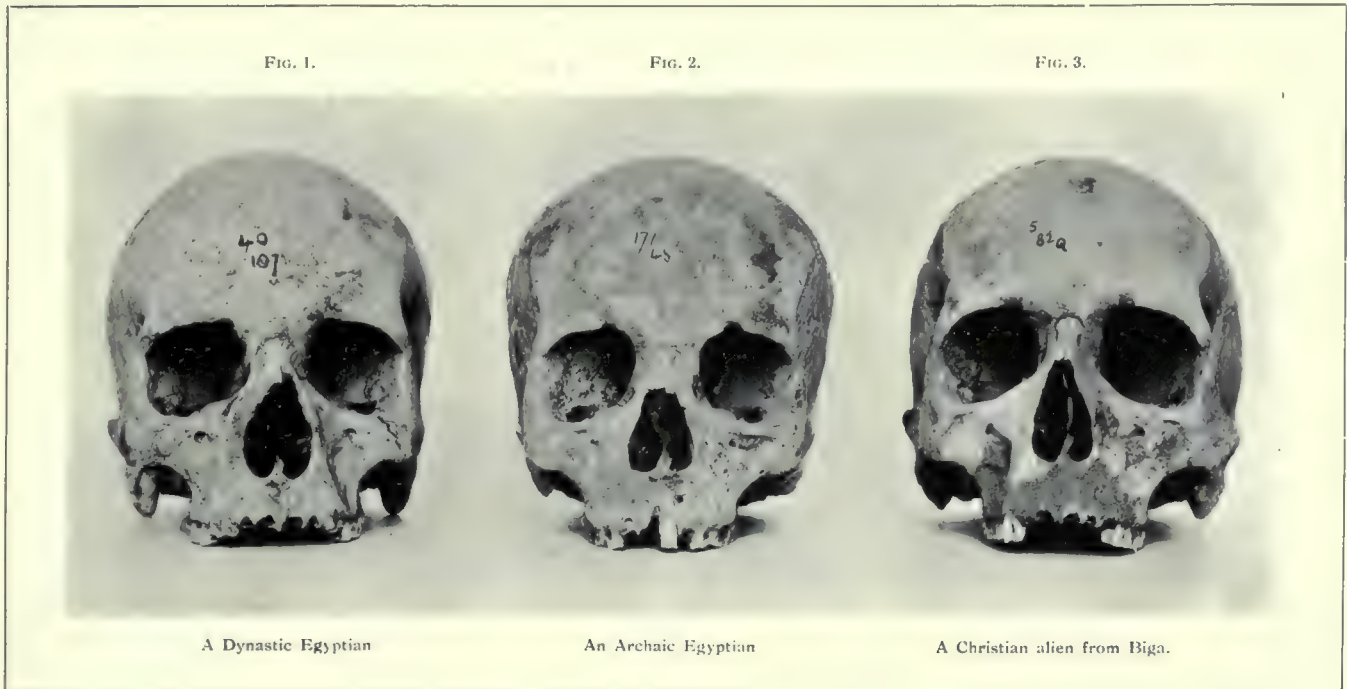A Dynastic Egyptian woman (see pl. xix, fig. 9.)

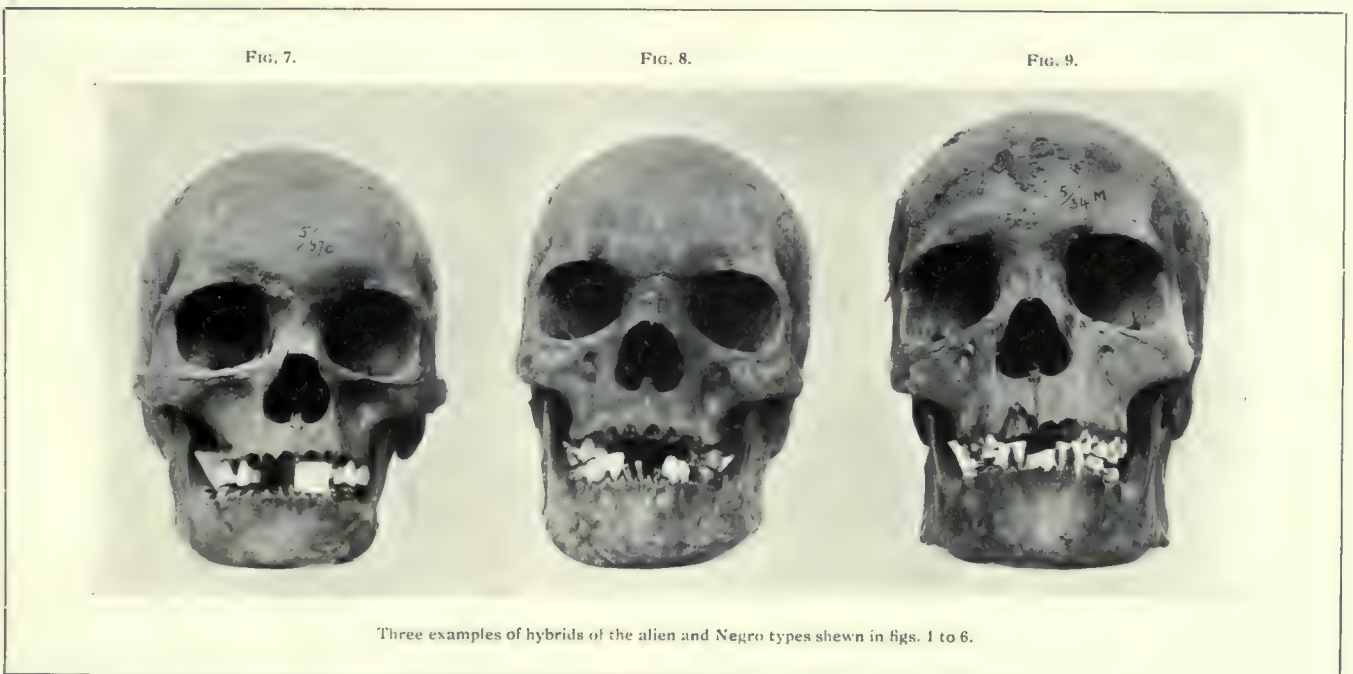
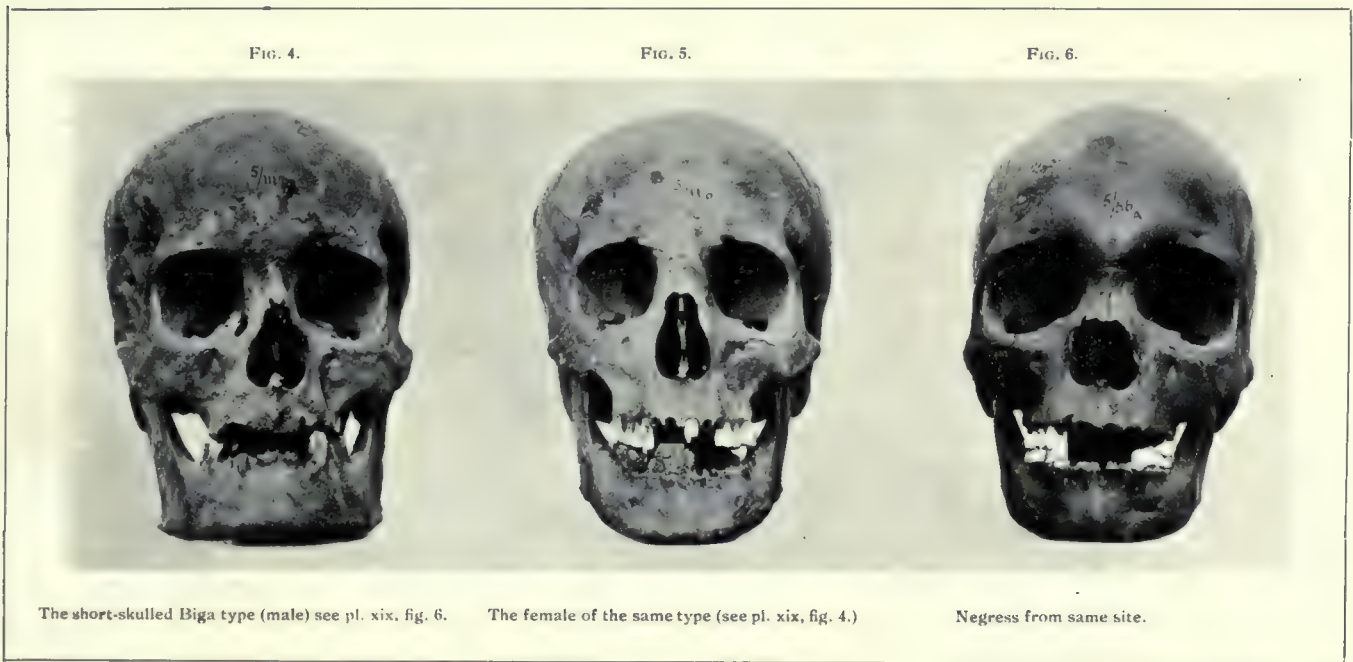
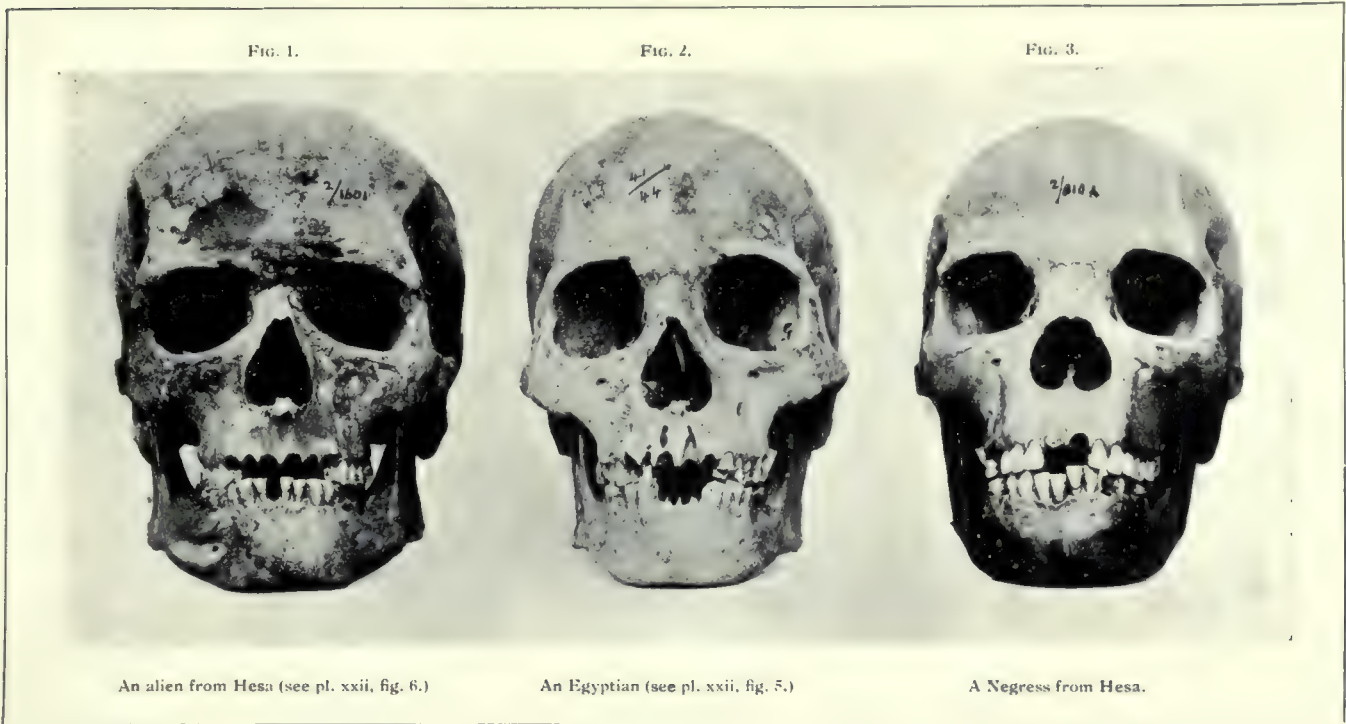
FIG. 6.

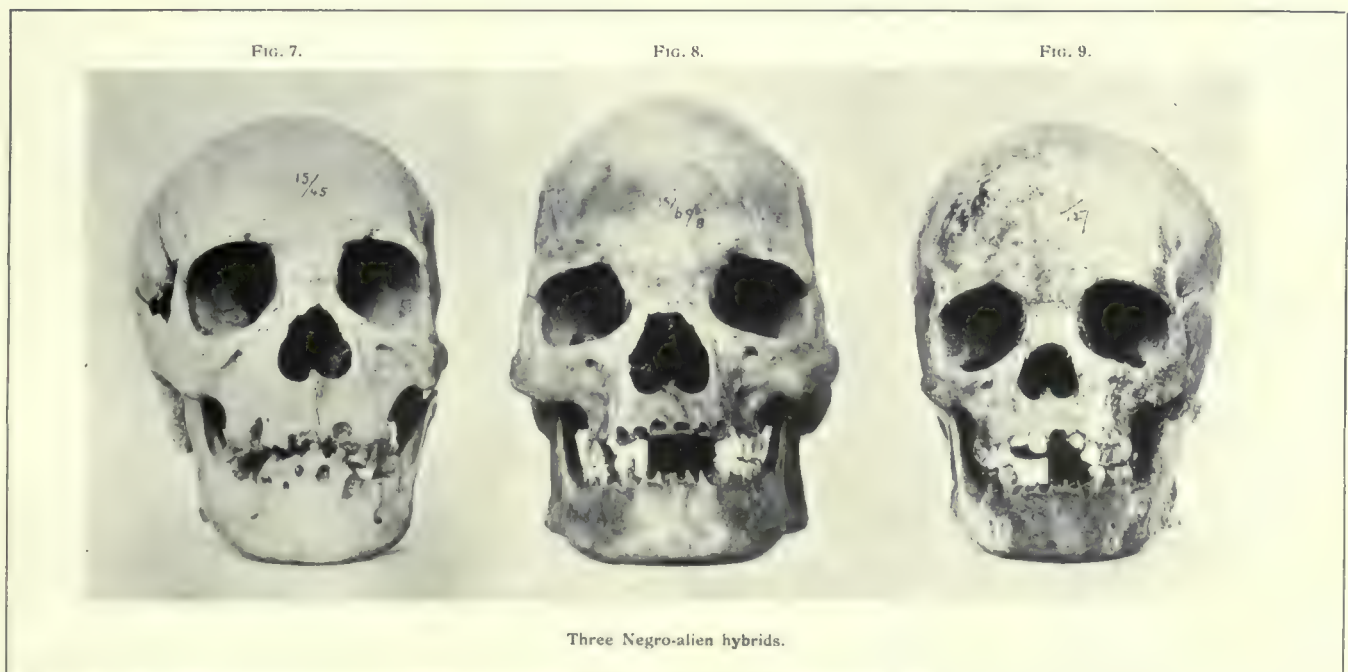
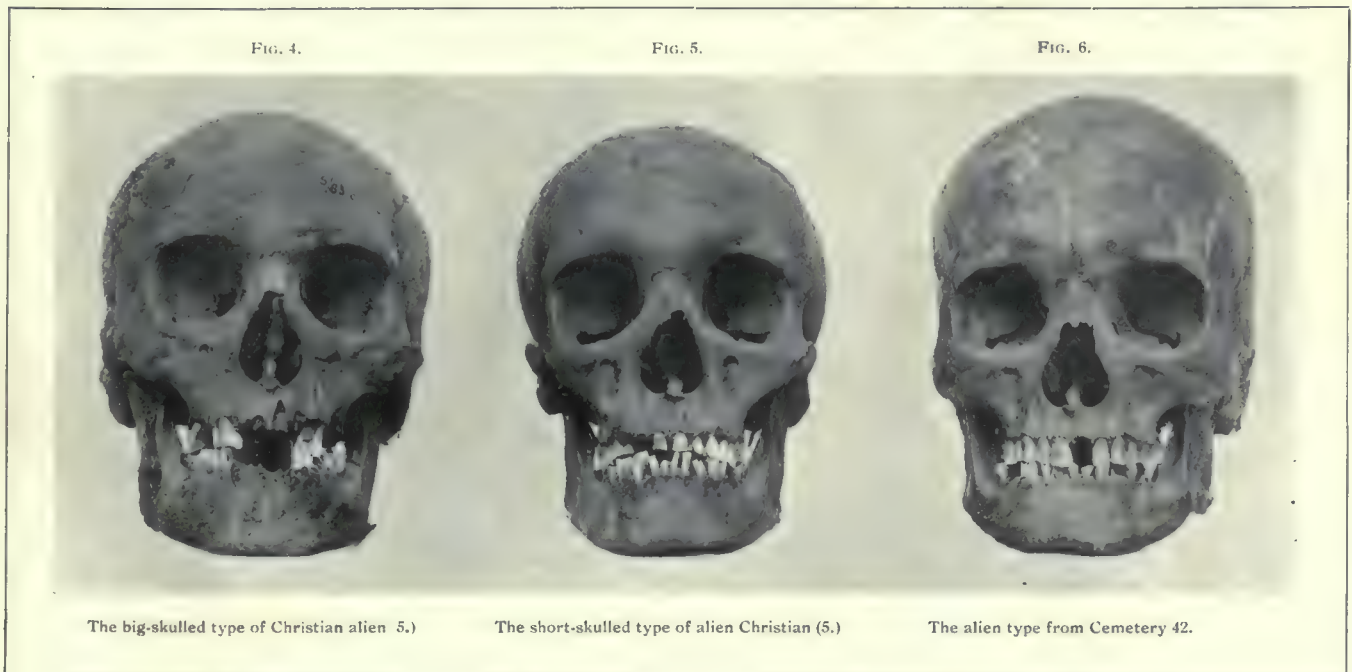
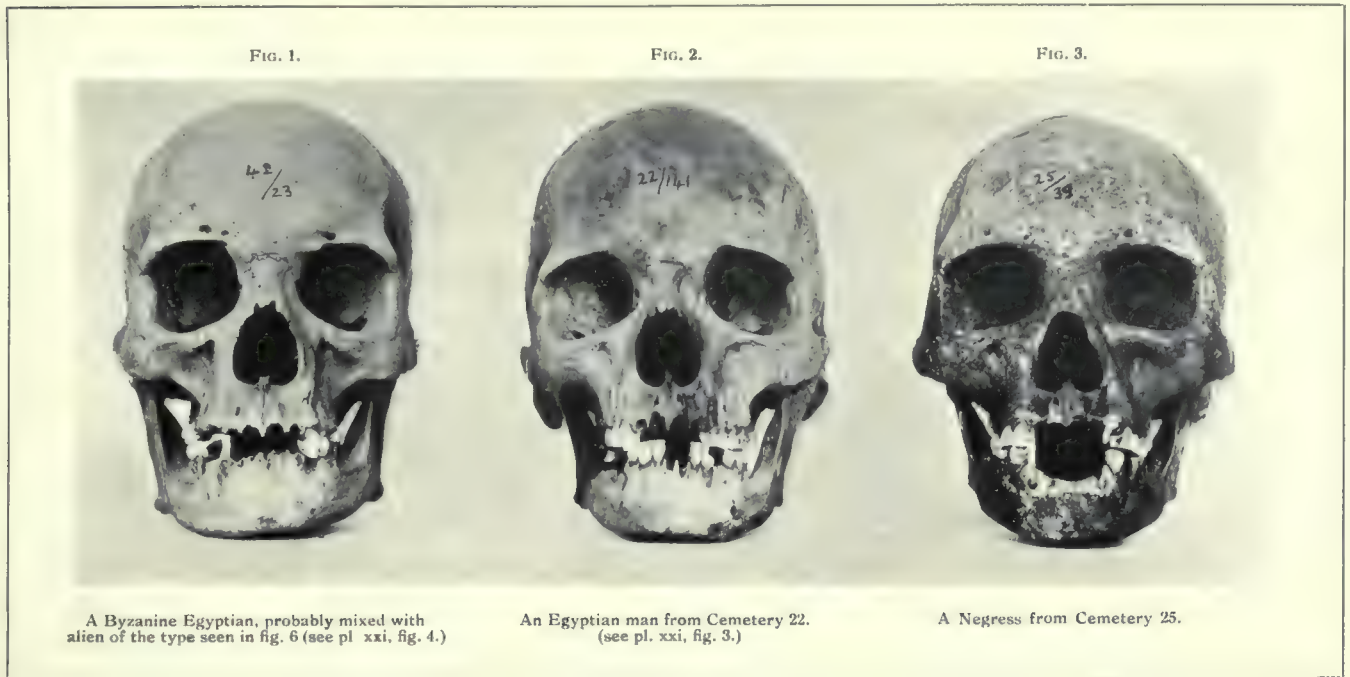


An alien from Cemetery 2 (see pl. xix, fig. 8.)









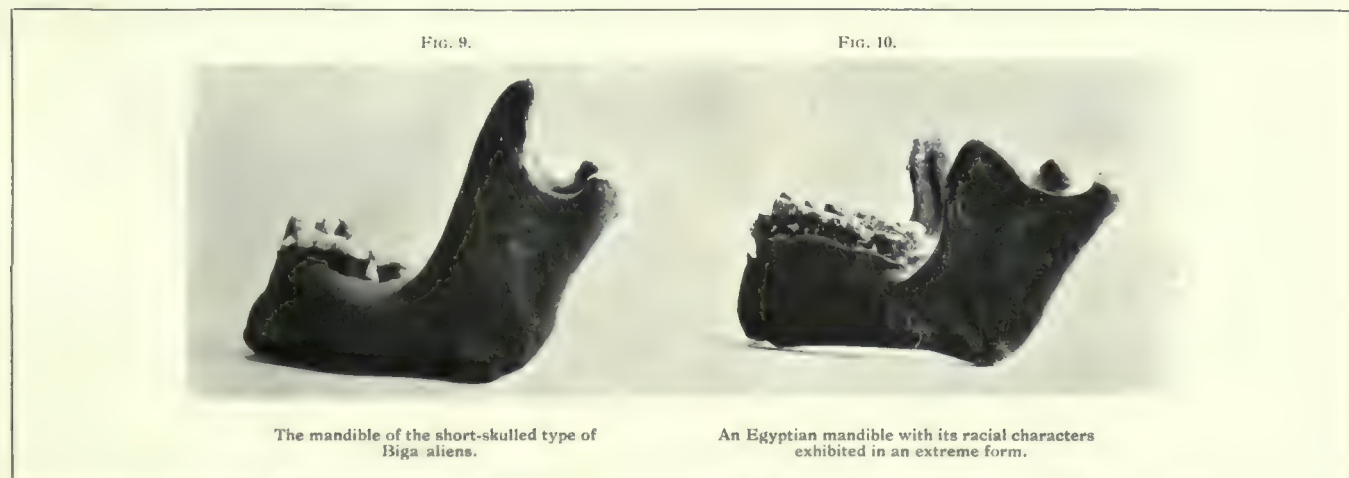
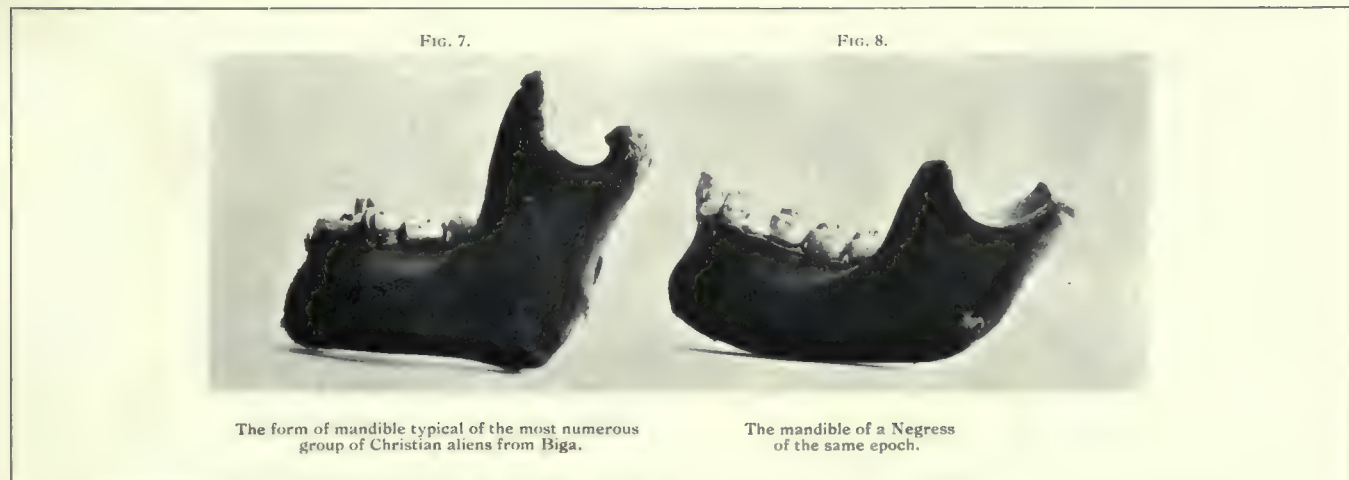
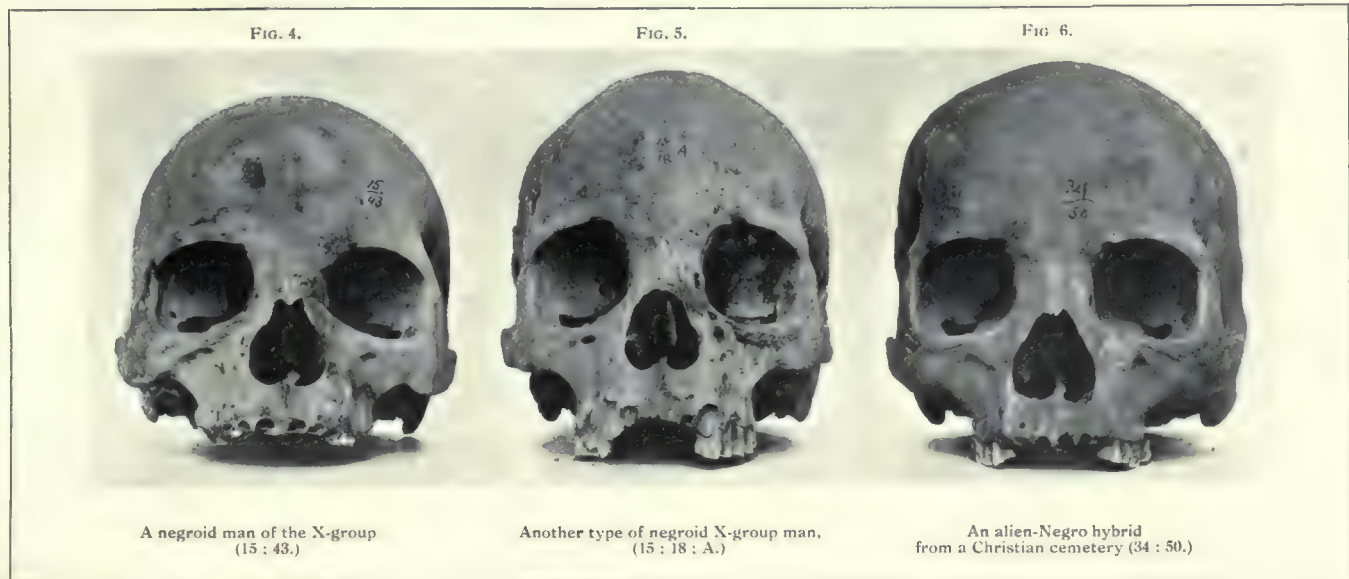
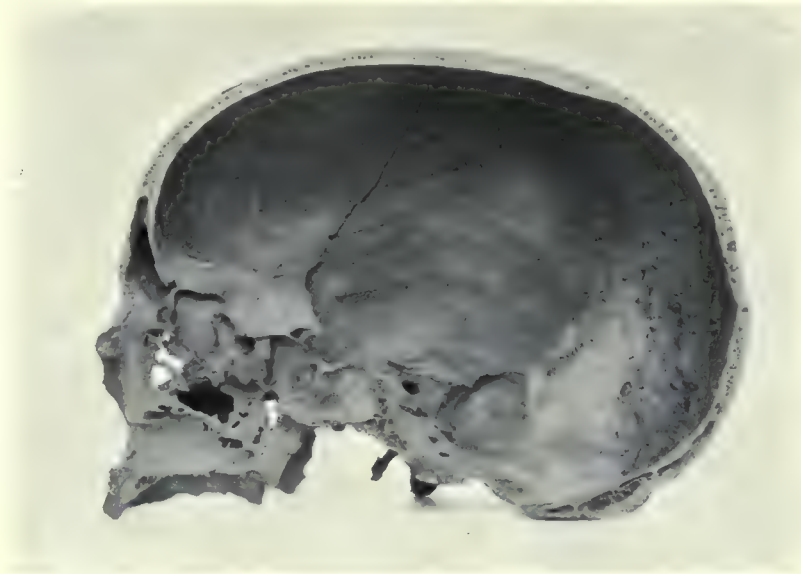


FIG. 1.




The right half of the cranium of a Biga alien split in mesial sagittal section to show the large groove for the middle meningeal vein.

FIG. 2.



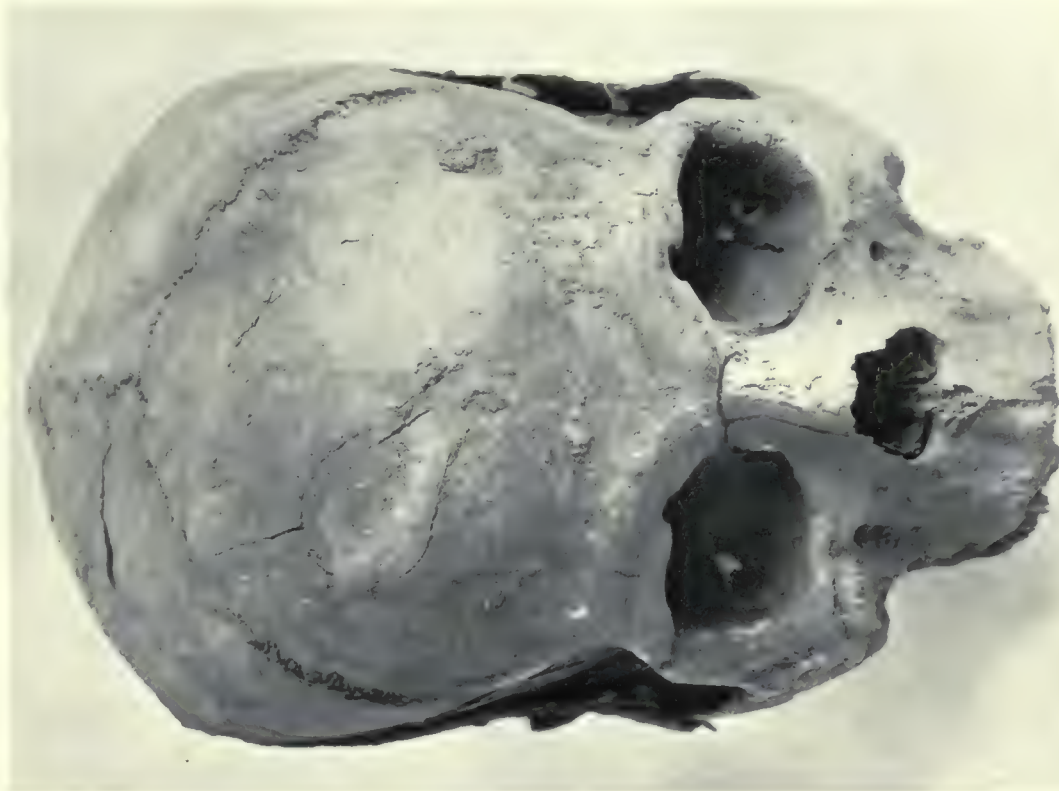
Head of a Ptolemaic mummy in profile.

FIG. 3.



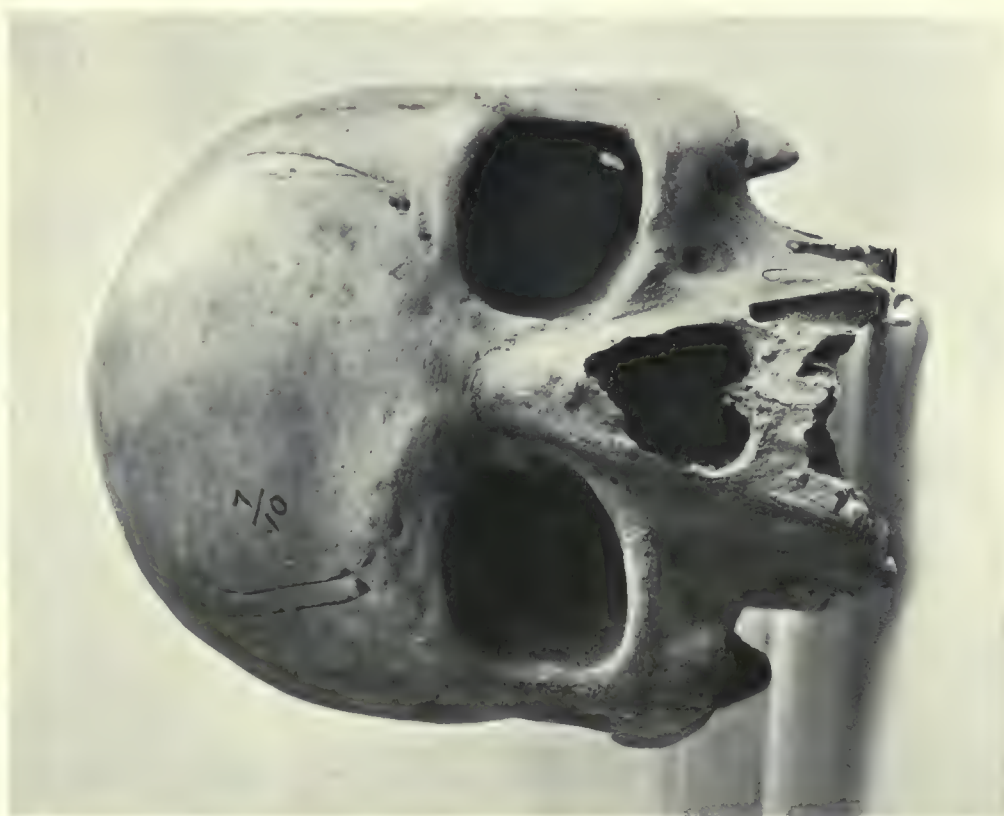Facial aspect of the same.

FIG. 2.



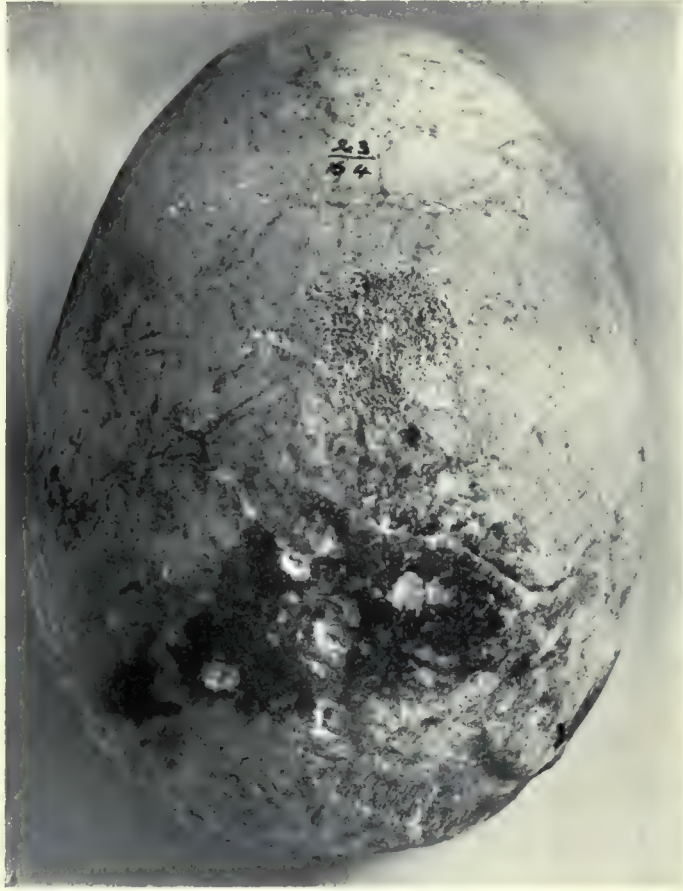Skull of a man (24 : 1 : F) showing a depressed fracture of the frontal bone. The evidences of its ante mortem infliction are well marked, and no repair had taken place.

FIG. 1.



Adult male skull (7 : 10) with healed fracture of the right nasal bone. This skull also shows the supra orbital grooves arising from foramina situated unusually far from the orbital margin.

FIG. 1.



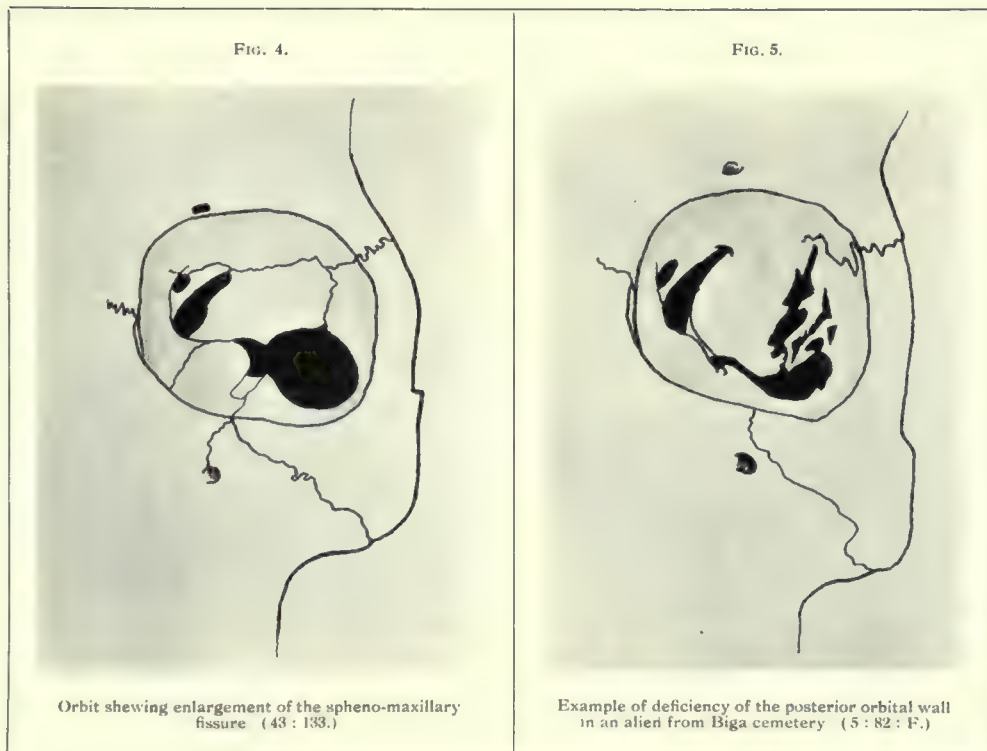
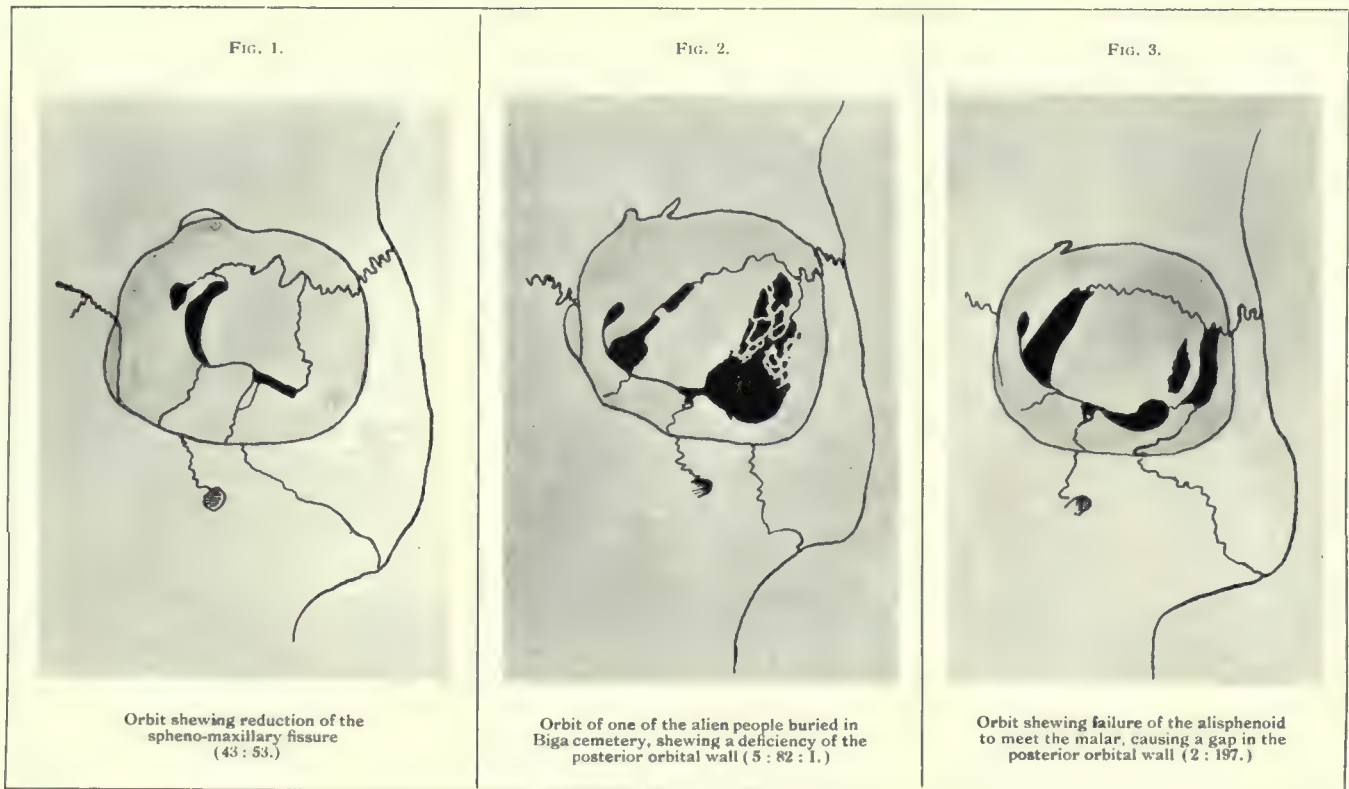
Skull of a woman shewing a small patch of localised periostitis.

FIG. 2.



Skull shewing a curious condition of the bones caused by the gnawing of some insect.

Diagrams representing a series of left orbits viewed from in front.



Cases of fusion of the atlas vertebra to the occipital bone. The skull shown in fig. 5 is an example of pathological fusion, the atlas having united to the skull as a result of spondylitis deformans.

FIG. 1.

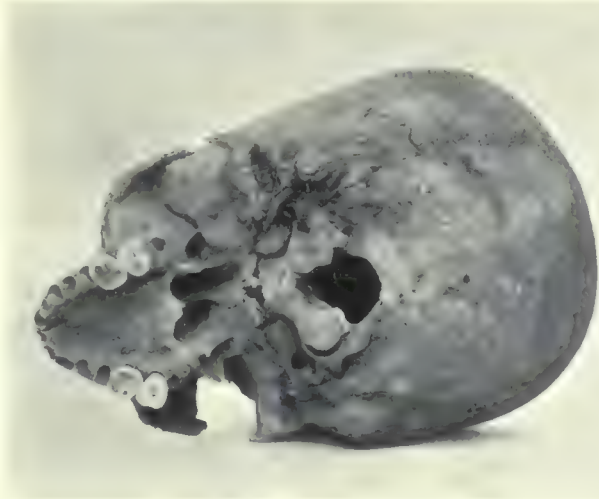

FIG. 2.

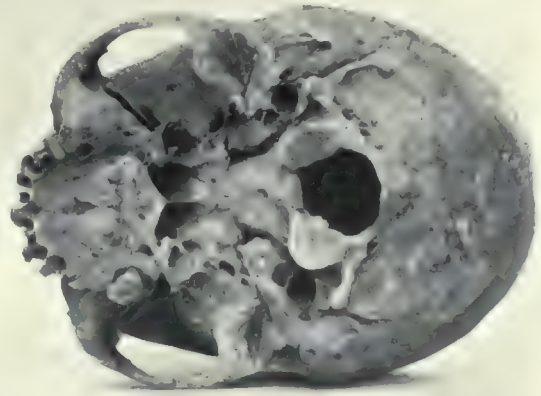


FIG. 3.

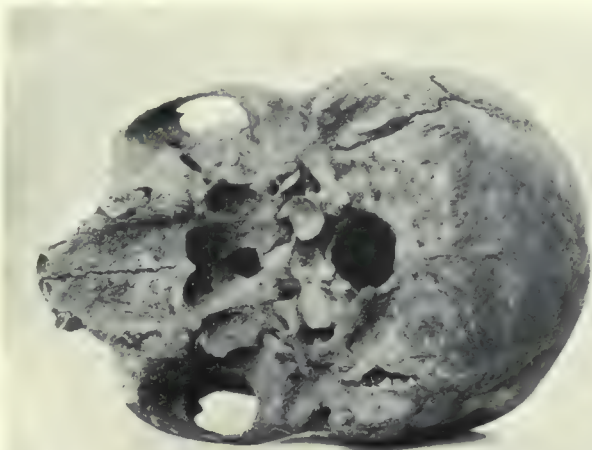


FIG. 4.

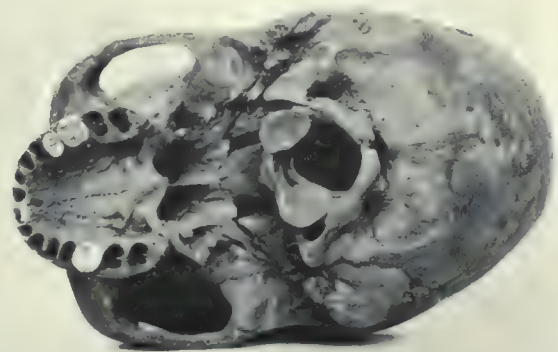


FIG. 5.

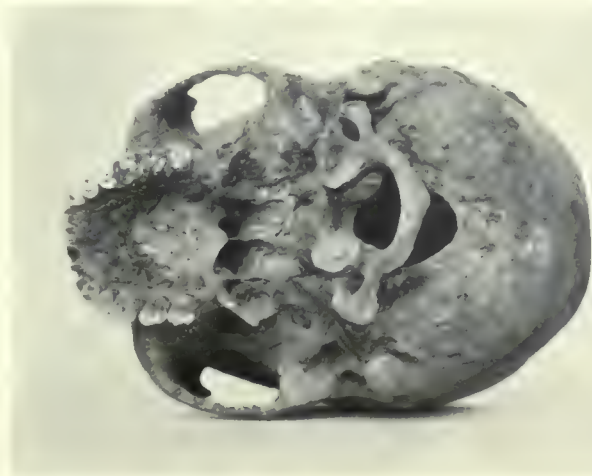


FIG. 6.

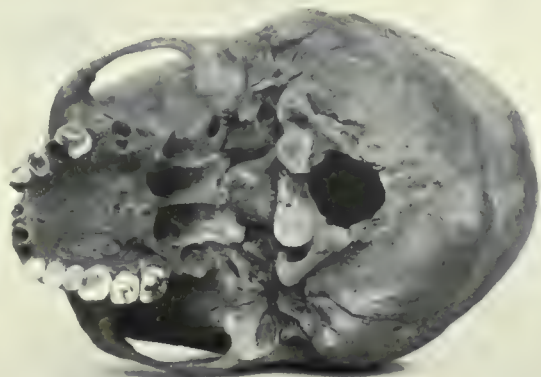
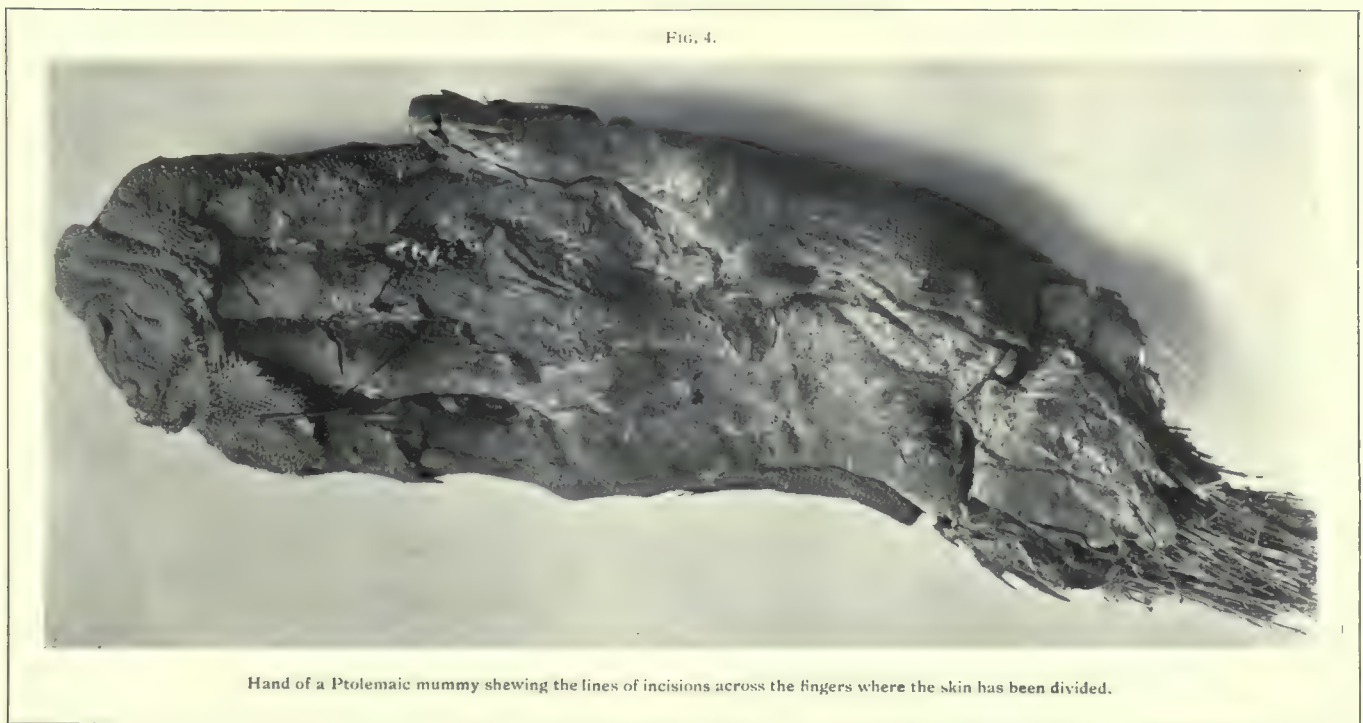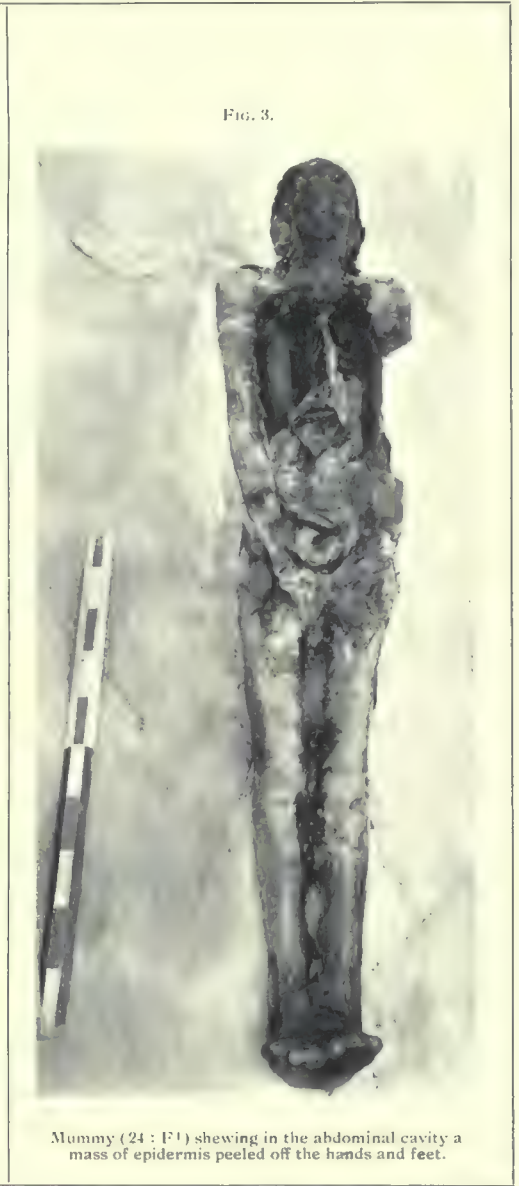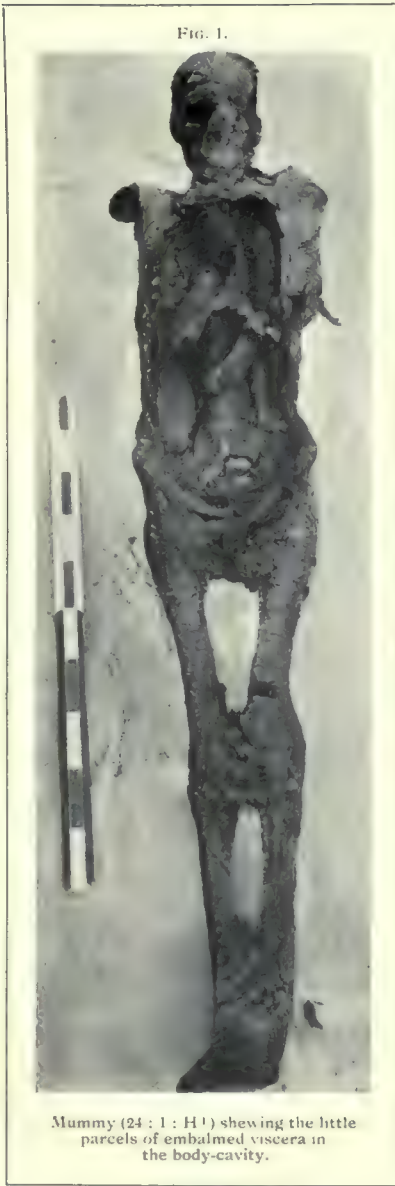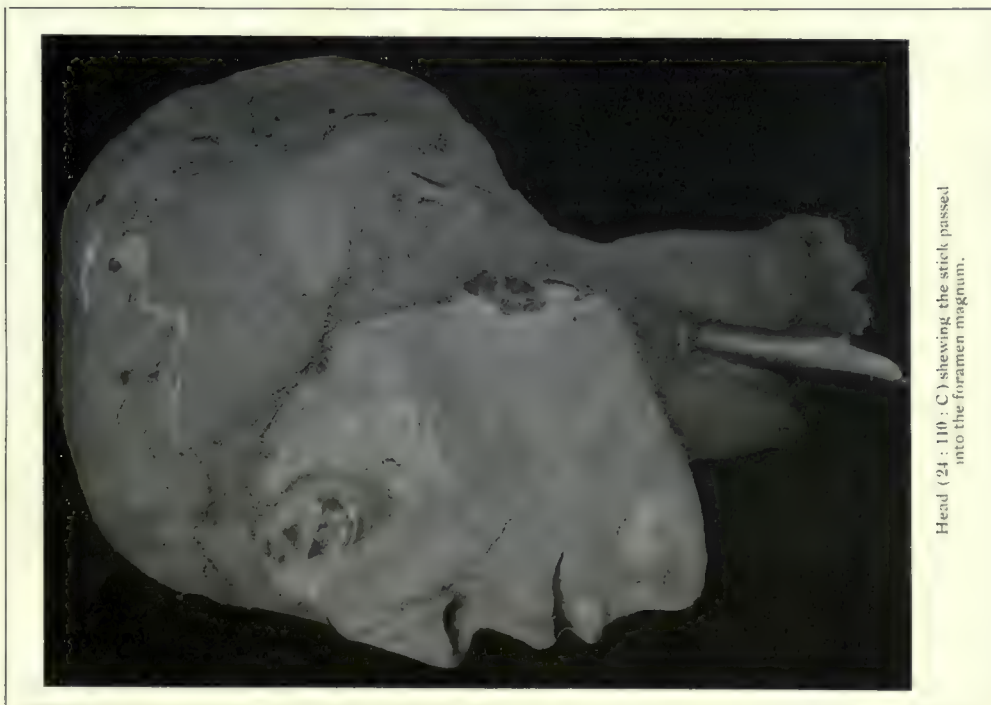


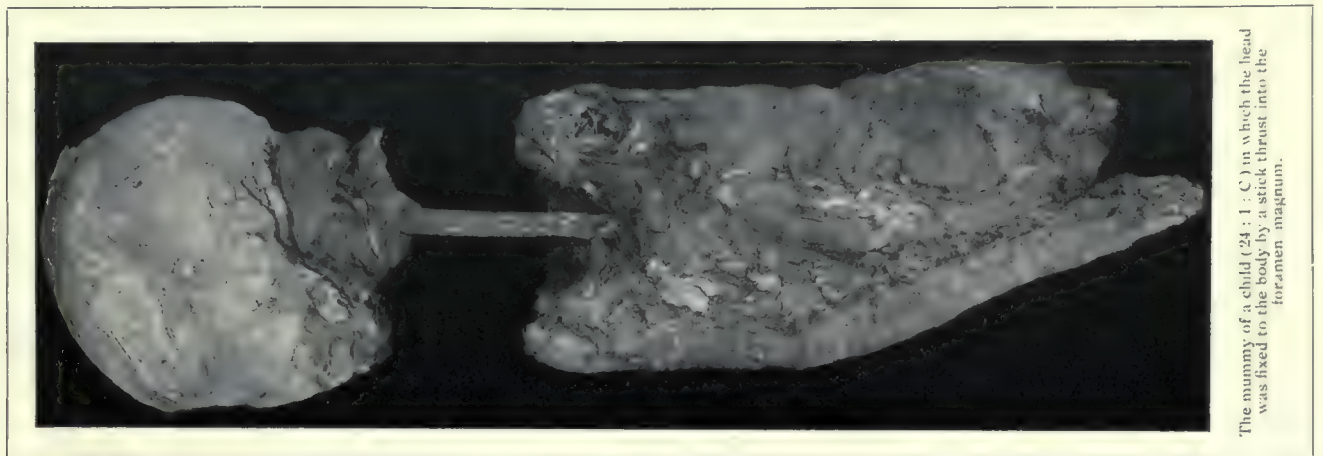


FIG. 1.



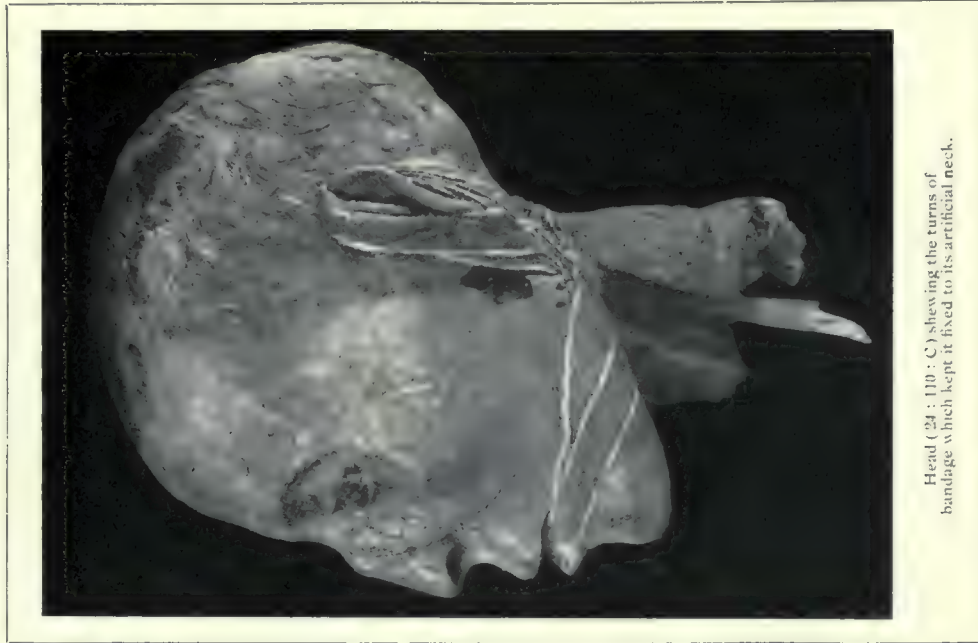Head (24 : 110 : C) shewing the stick passed into the foramen magnum.

FIG. 2.




The mummy of a child (24 : 1 : C) in which the head was fixed to the body by a stick thrust into the foramen magnum.

FIG. 3.



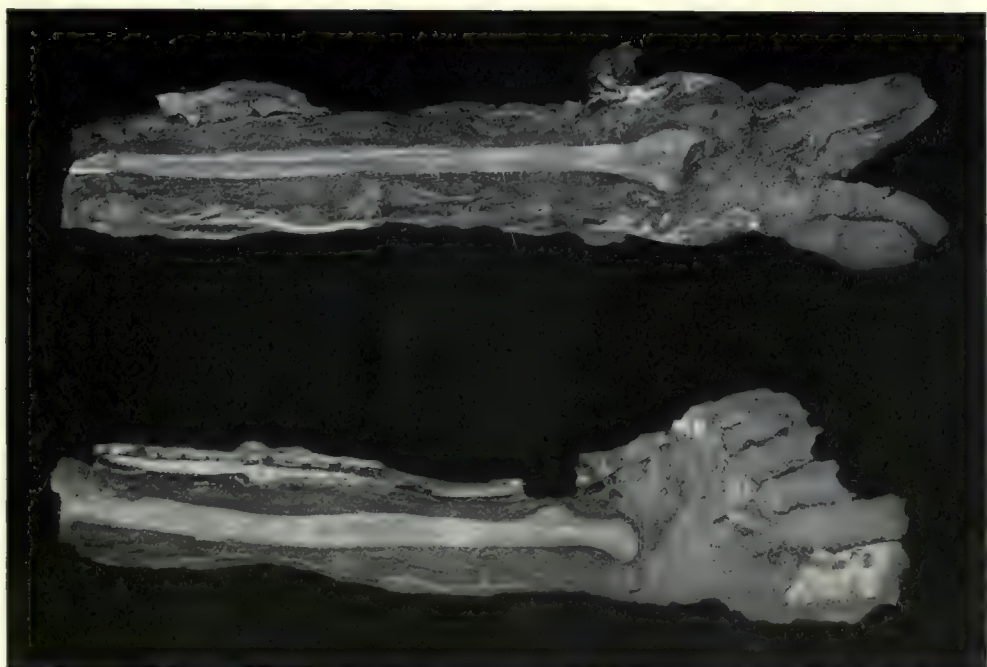
Head (24 : 110 : C) shewing the turns of bandage which kept it fixed to its artificial neck.

FIG. 4.



False arms of a mummy (24 : 1 : 1)

FIG. 5.



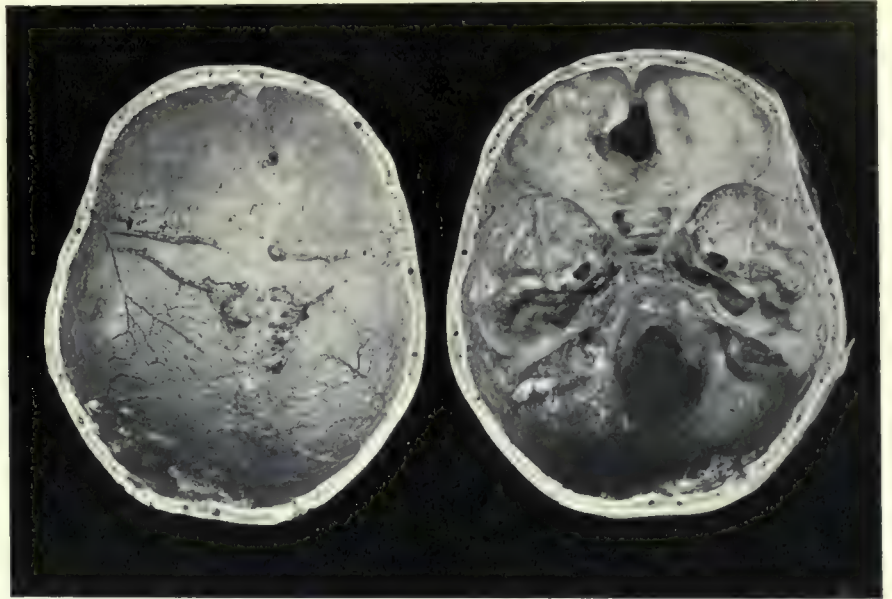
False arms (24 : 1 : 1) split open to shew the fibula and inverted radius around which respectively they were built up.

FIG. 1.



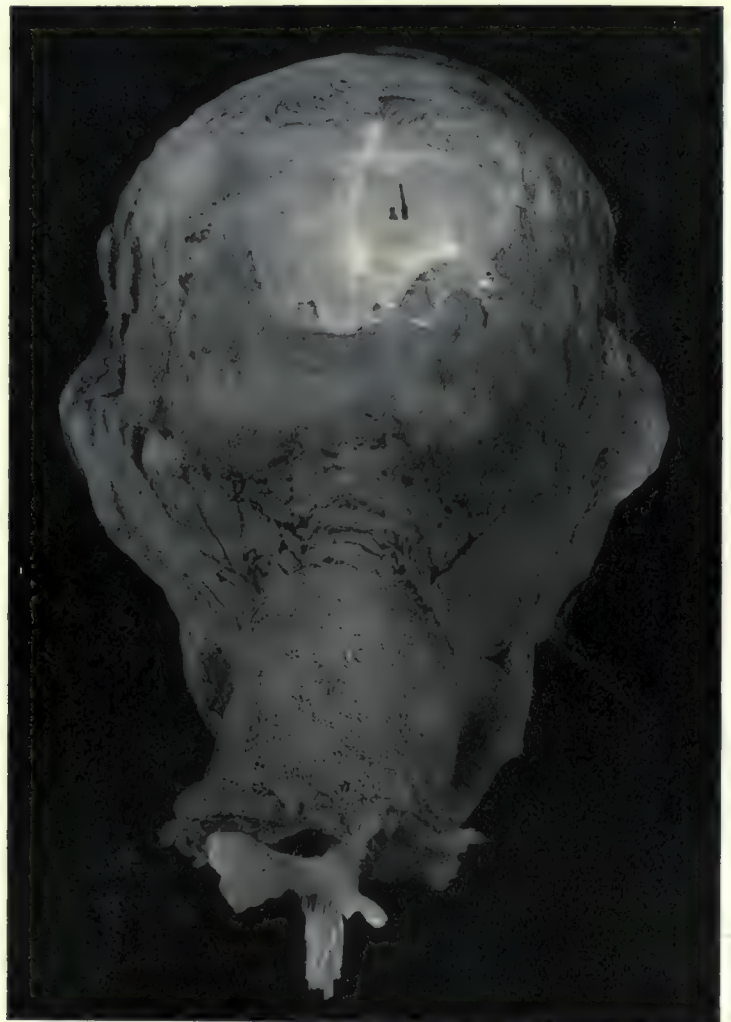
Bundle of shed epidermis taken from the body-cavity of a Ptolemaic mummy.

FIG. 2.



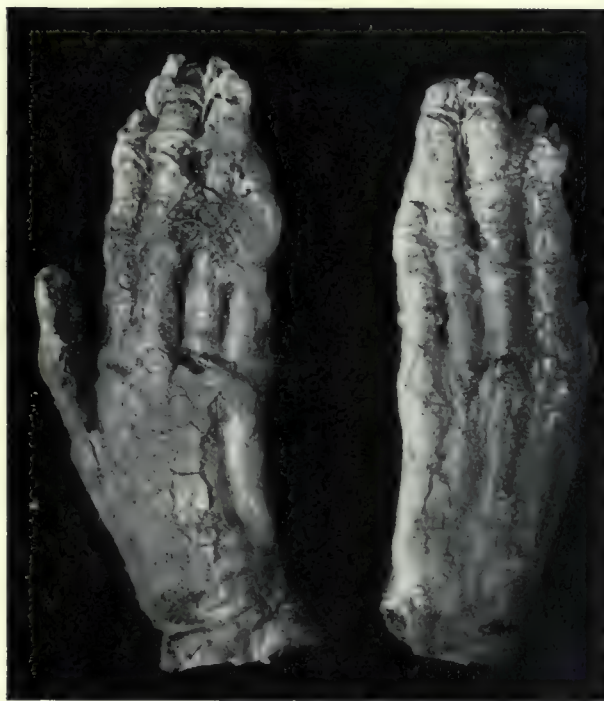The cranium of a Ptolemaic mummy from Cemetery 14, opened by a horizontal saw-cut. It shows the ethmoidal aperture made by the embalmers to remove the brain.

FIG. 4.



Head, showing the torn edges of the scalp, and the fixation of the artificial neck.

FIG. 3.



Hands of a mummy, showing the fixing of the skin and nails by means of thread wound round the fingers.

FIG. 5.

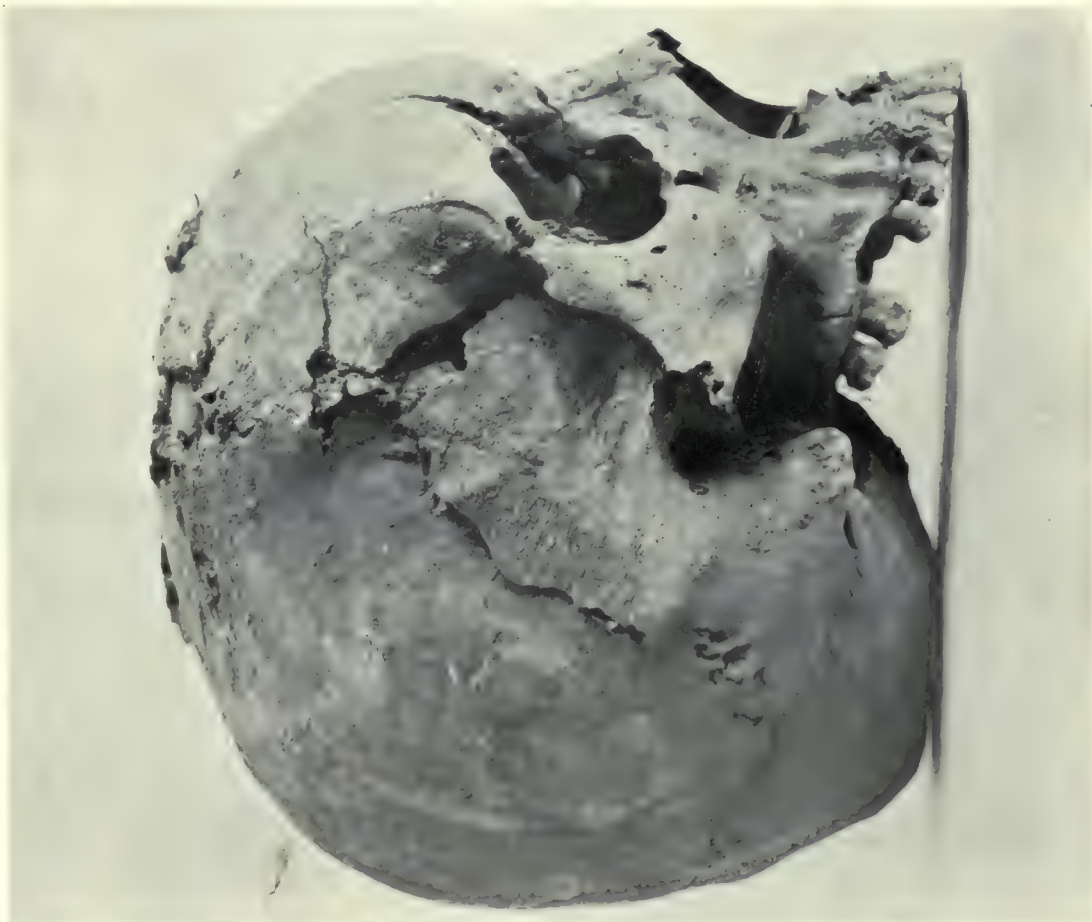


FIG. 2.



Bones distorted by grave-pressure. A radius and a fibula, which have become bent in the grave, are photographed alongside normal bones from the same burial.

FIG. 1.



Skull from the "executioner's trench" at Shellal, showing an extreme degree of distortion caused by pressure in the grave.



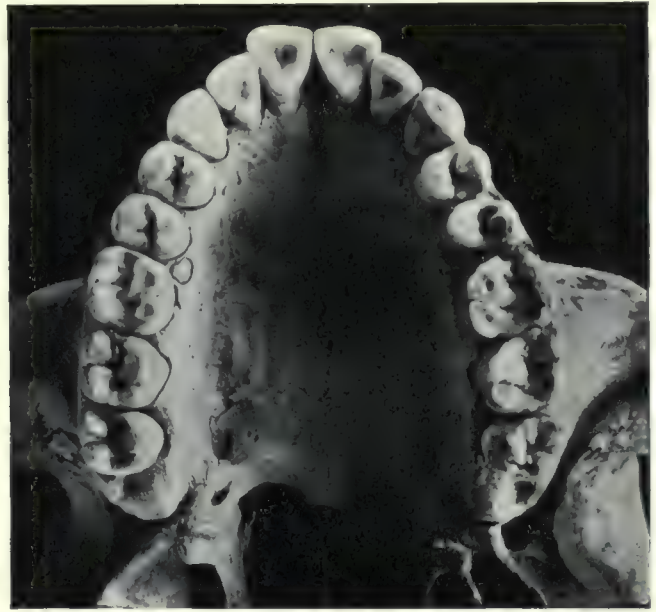


FIG. 1.



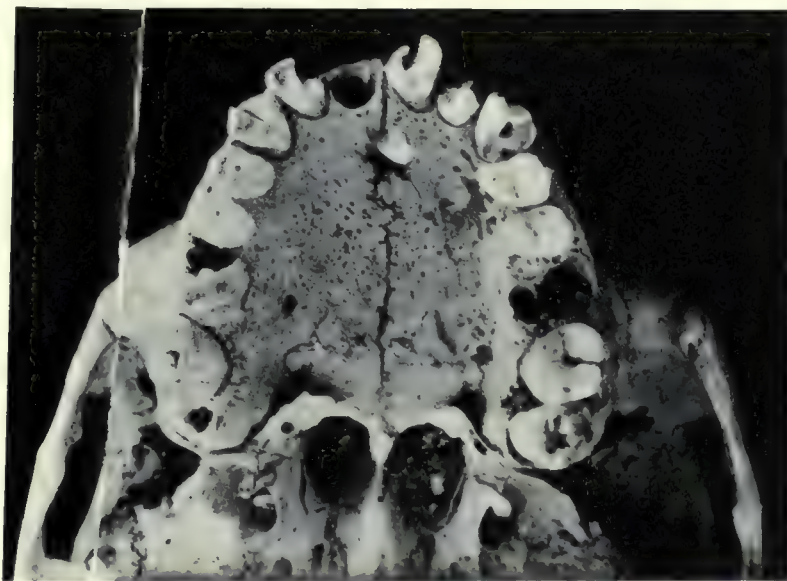
Posterior fossa of the skull (45 : 236) shewing an abnormal foramen.

FIG. 2.



Upper jaw of a Negress (2:810) shewing accessory dental masses and fourth molar pits.

FIG. 3.



Upper dental series of 23 : 60 X, shewing an additional tooth erupted in the palate.

FIG. 4.

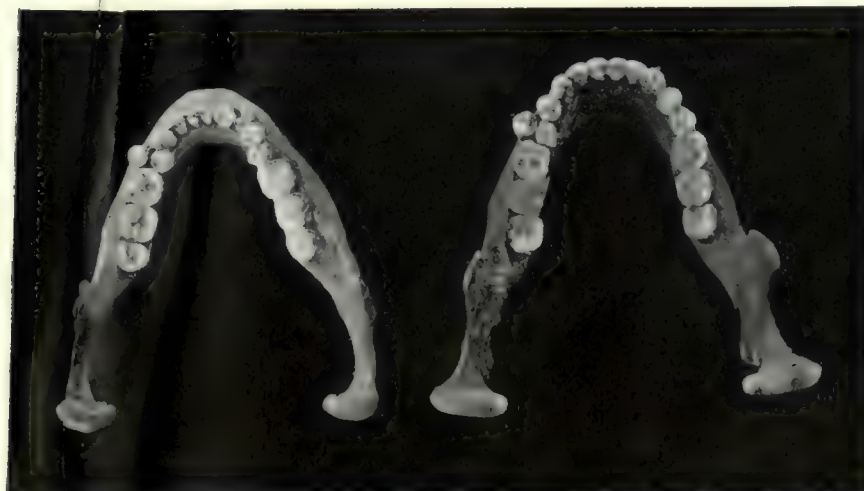
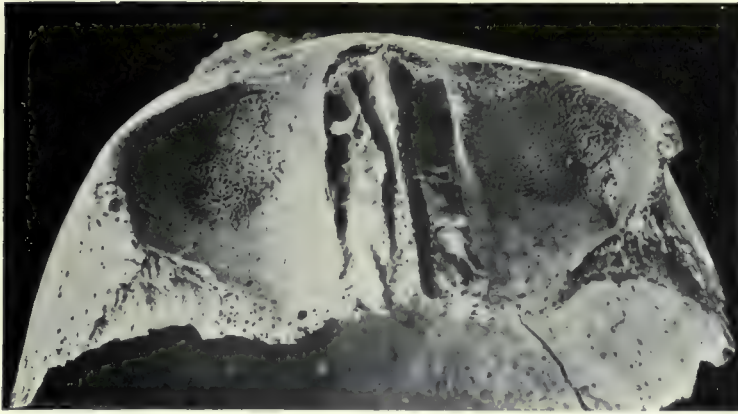




FIG. 1.



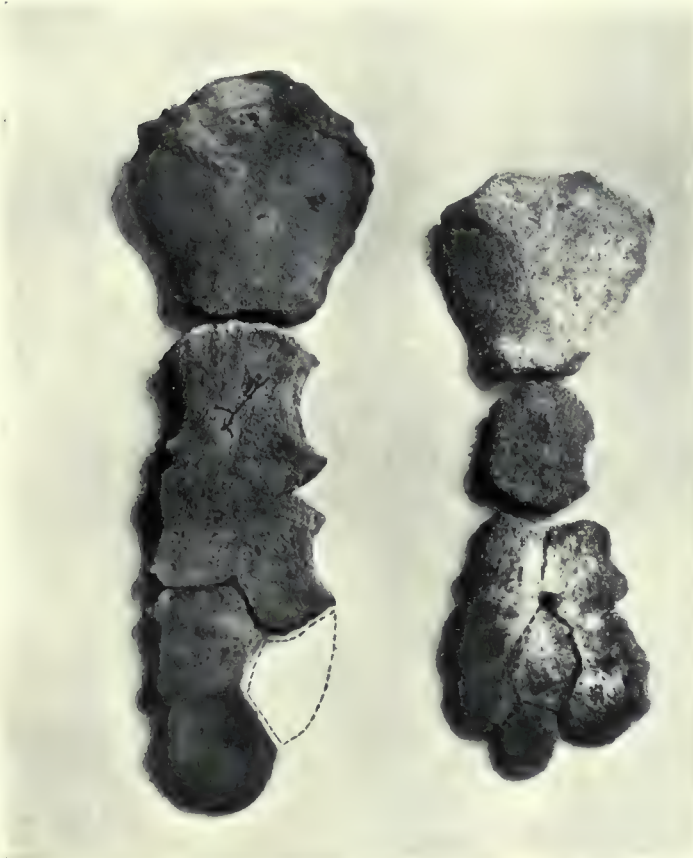Honeycomb-like condition of the roofs of the orbits. Skull from Cemetery 5.

FIG. 2.



Abnormal condition of the elbow-joint (2 : 687.)

FIG. 3.



Abnormal forms of sternum.

FIG. 4.

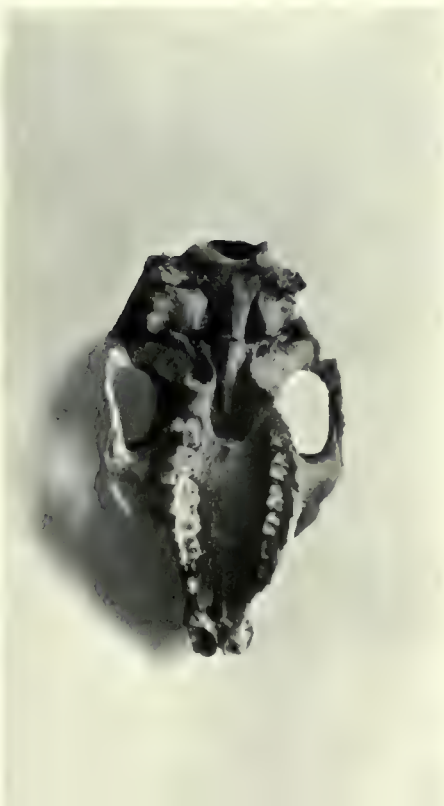

FIG. 5.



FIG. 1.



Splints *in situ* upon the right forearm of a girl of the Byzantine period from Biga (5) cemetery.

FIG. 2.



Splints on right forearm cut open.

FIG. 1



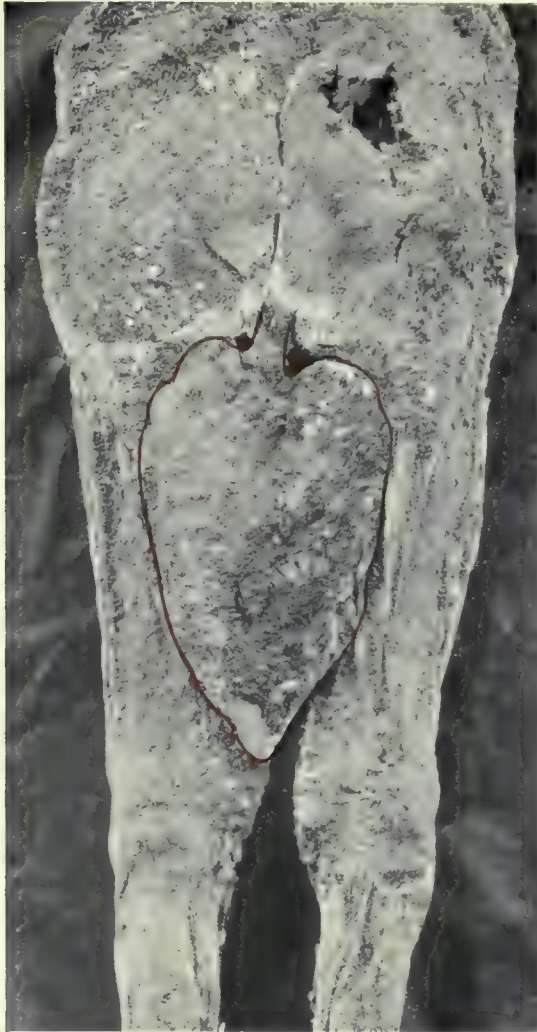Splints *in situ* on the left forearm of the same girl.

FIG. 2.



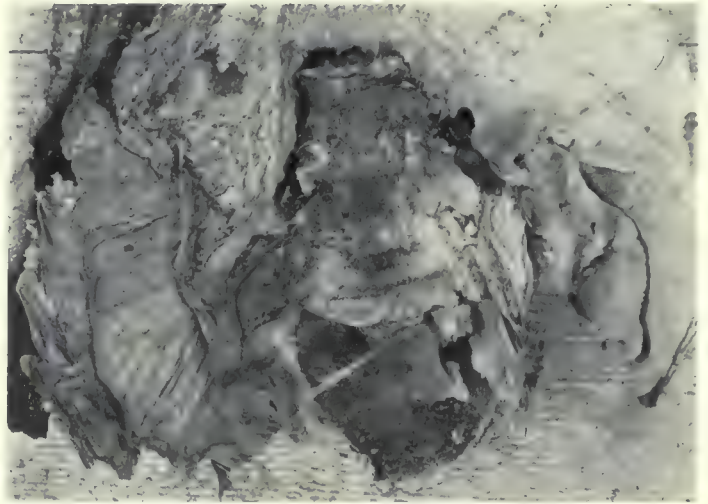
Splints on the left forearm opened to show their composition.

FIG. 1.



Prolapse of the intestine in a girl from the Byzantine cemetery (2) on Hesa (2 : 63 : D.)

FIG. 2.



Adhesion band of old appendicitis from body in Cemetery 2.

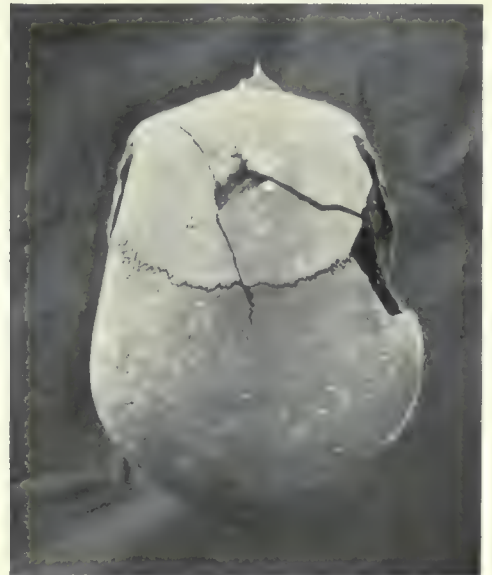[The photograph shows the sacrum, lumbar vertebrae, caecum and appendix and the ascending colon, partly hidden by great omentum.]

FIG. 3.



Sword-cuts of the skull which caused death. Ptolemaic period (24 : 103 : A.)

FIG. 4.



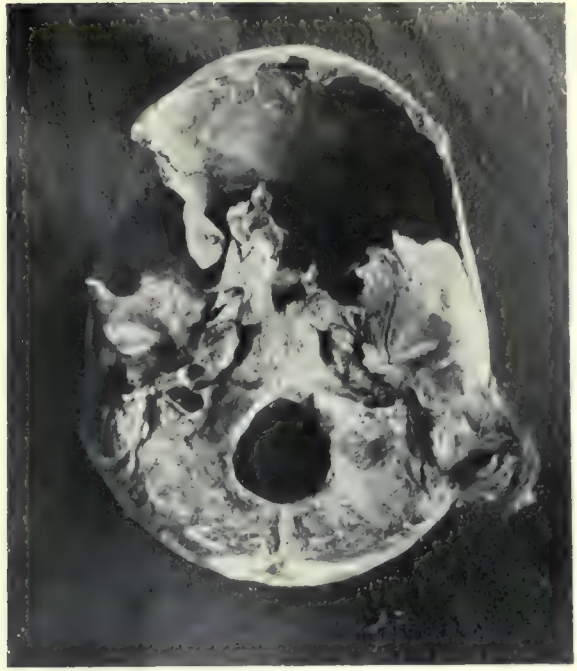Ante-mortem fracture of the skull: portions of the broken bone were embedded in the embalming material in the cranium. Ptolemaic period (3 : 19 : A.)

FIG. 5.

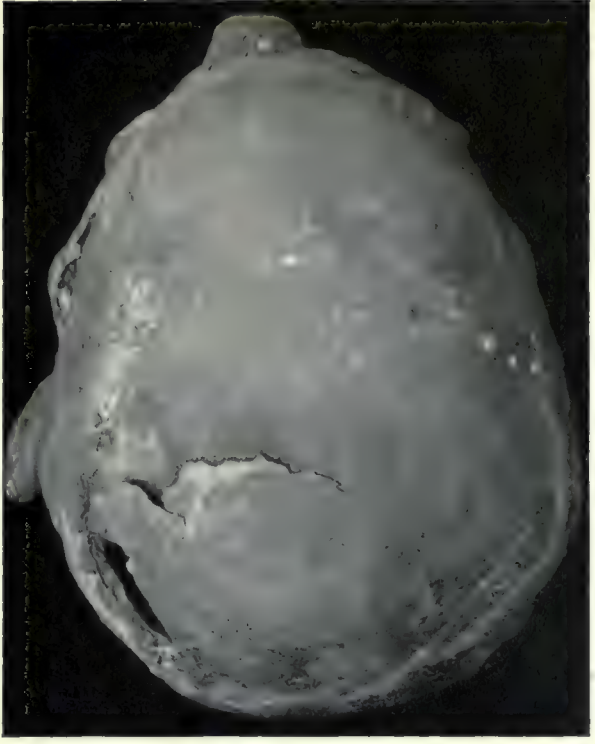


The fractured jaw of a Prehistoric Egyptian shewing blood-staining (7 : 257.)

FIG. 2.

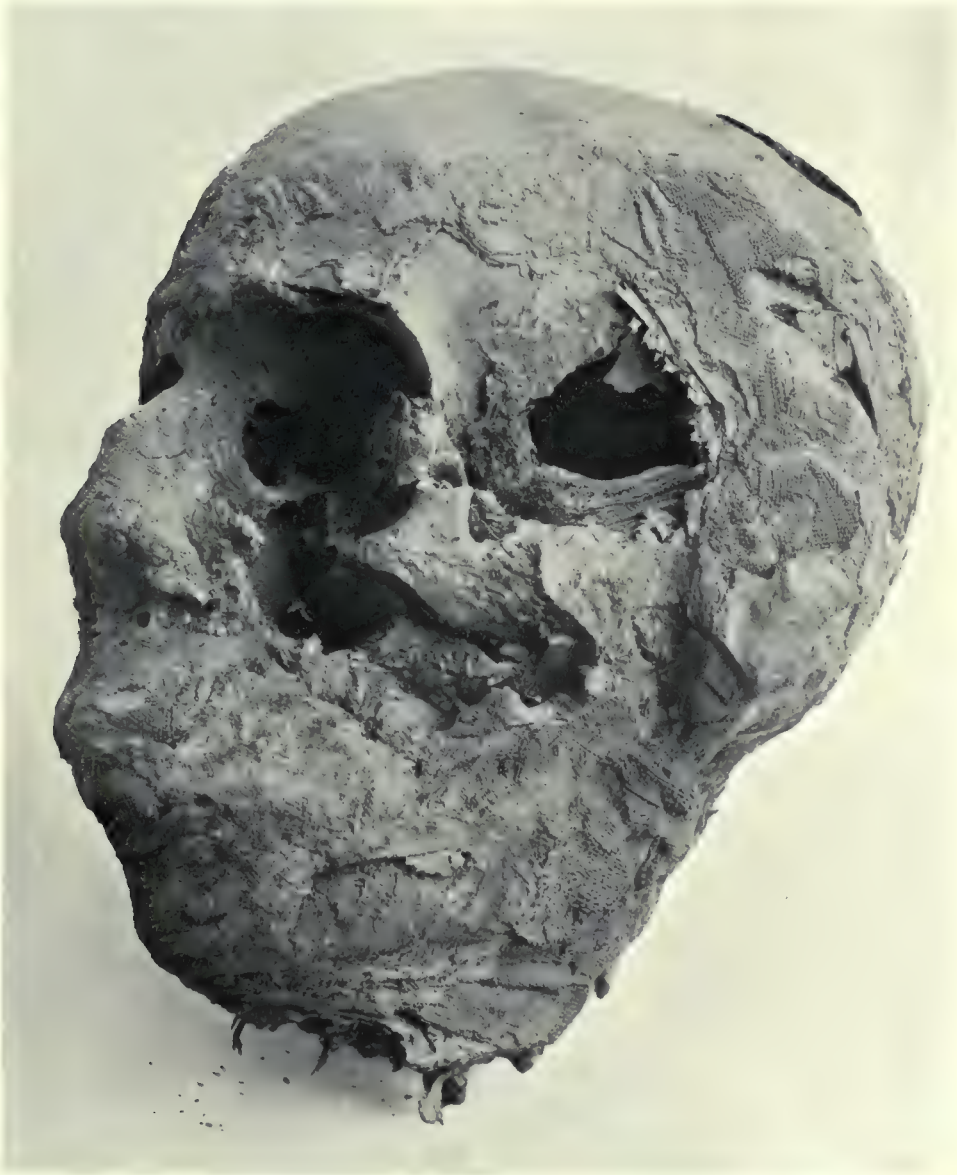

Ante-mortem fracture of the skull (7 : 257.)
The brain, mixed with hair and fragments of the broken bone,
was found inside the cranium.



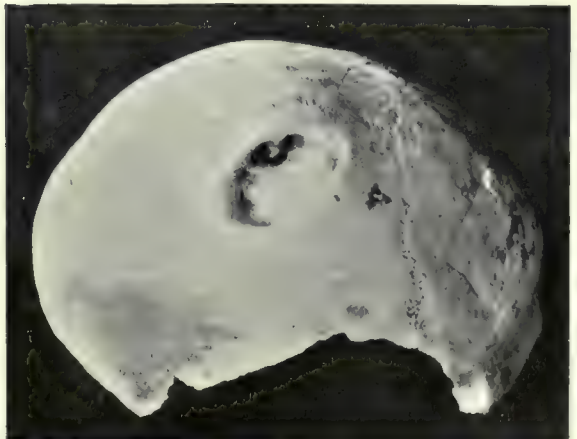
Sword-cut of skull with blood-staining of bone (24 : 1 : H'.)

FIG. 3.



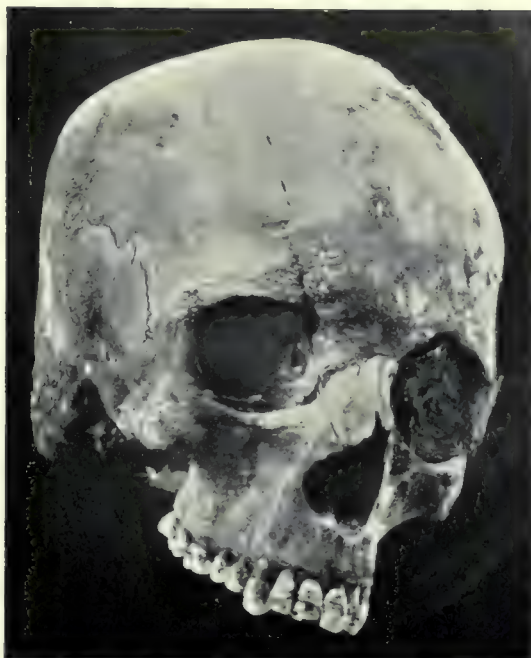Sword-cuts of cranium and face which caused death (24 : 1 : H'.)

FIG. 4.



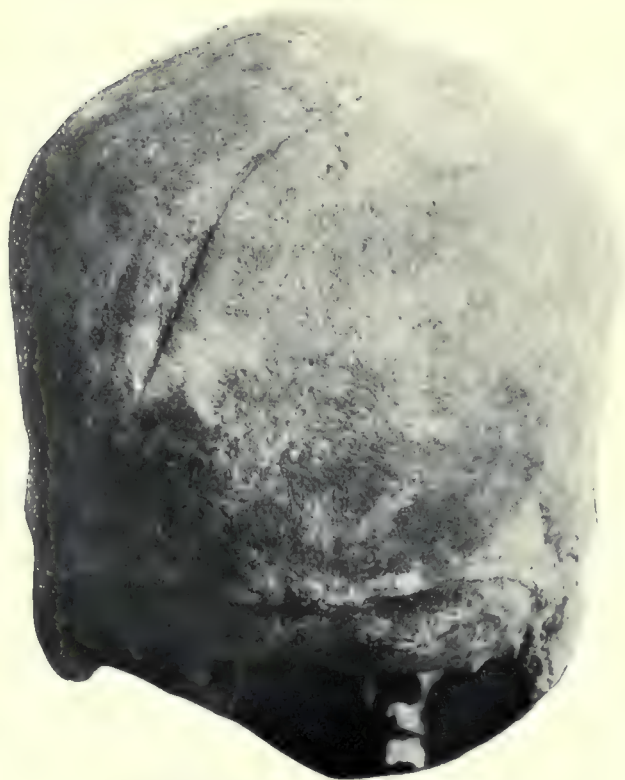Old depressed fracture of the skull (7 : 257.)

FIG. 1.



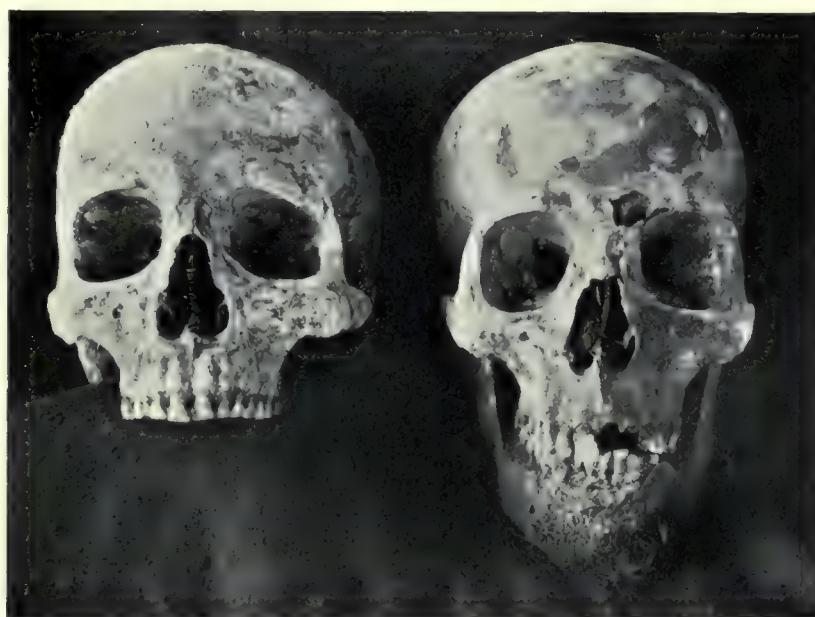Extensive fracture of a woman's skull, excellently healed.
Byzantine (Hesa, 2 : 63 : F.)

FIG. 2.



Healed sword-cut on the back of the skull.
Roman Period (7 : 11.)

FIG. 4.




Skull with healed fracture of the left supra orbital margin (Hesa, 2 : 1162.)

Skull with sword-cut of the forehead, inflicted just before death. Byzantine (Hesa, 2 : 682.)

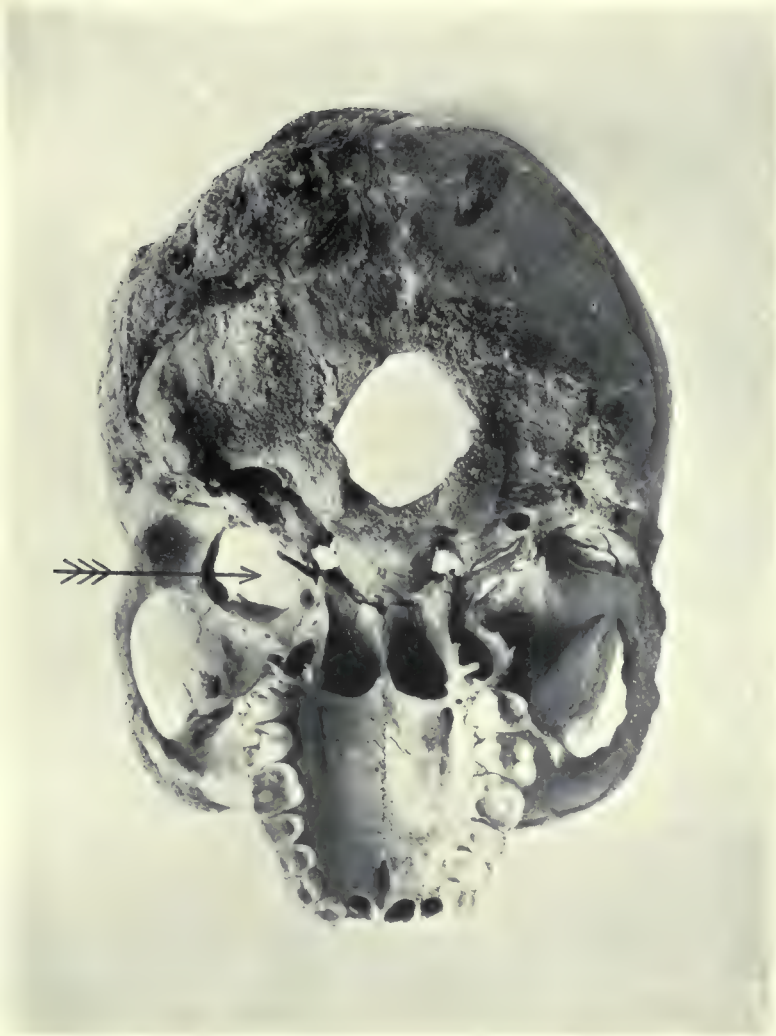FIG. 3.

FIG. 5.



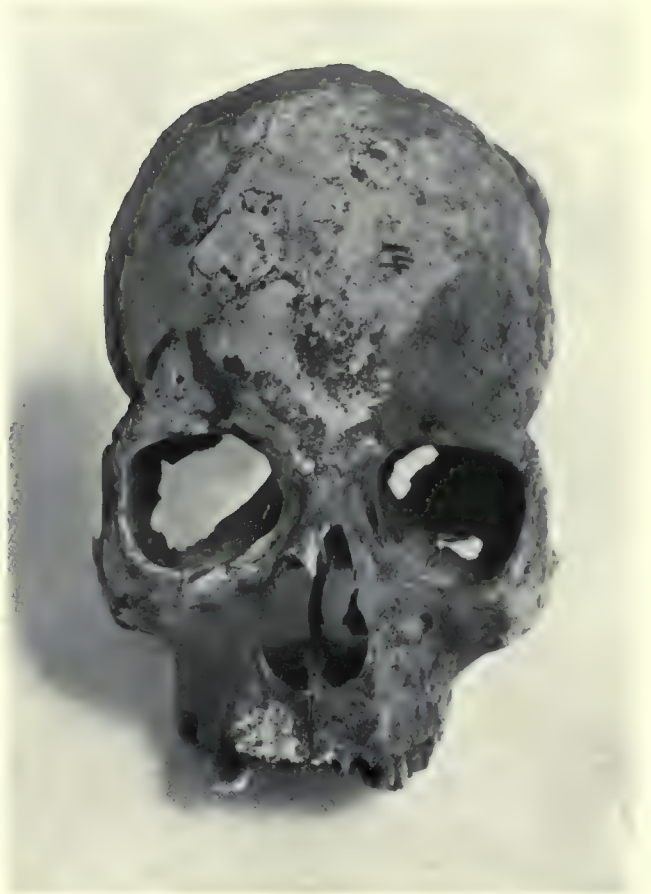Woman's skull with a punctured wound of the right parietal bone (2 : 122 : B.)

FIG. 1.



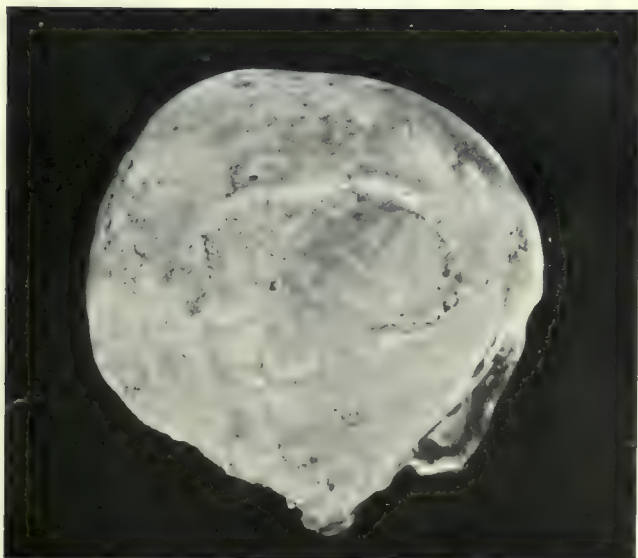
Skull shewing aneurismal opening in base of skull.

FIG. 2.



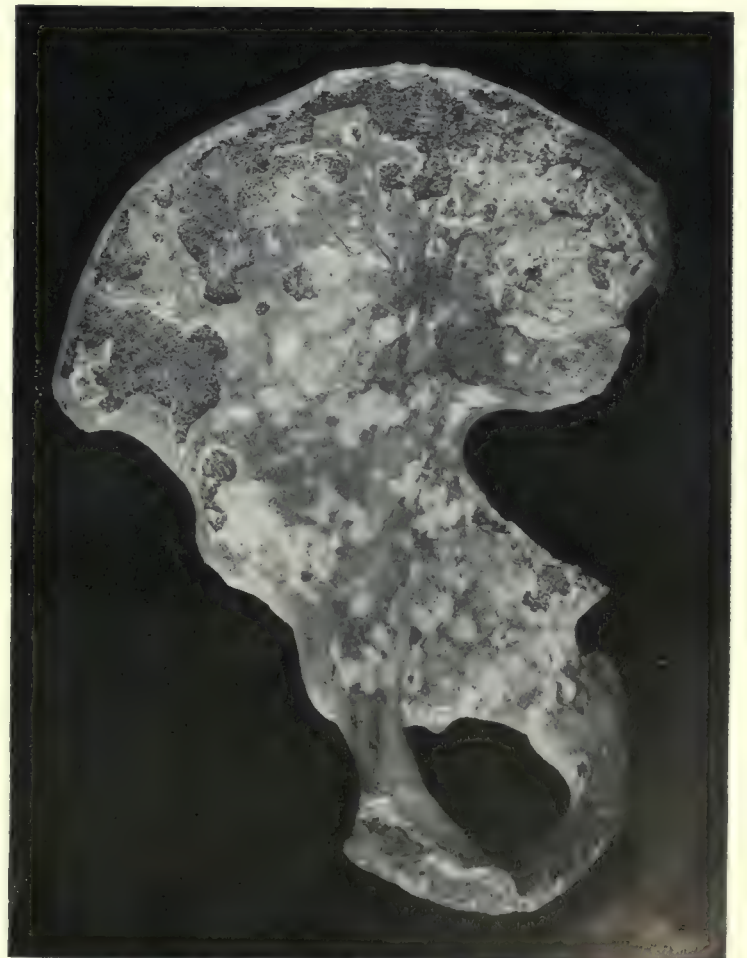Circular ulceration of frontal bone.

FIG. 3.



Similar ulceration of the parietal bone.

FIG. 4.



Beetle-eating of innominate bone.

FIG. 2.

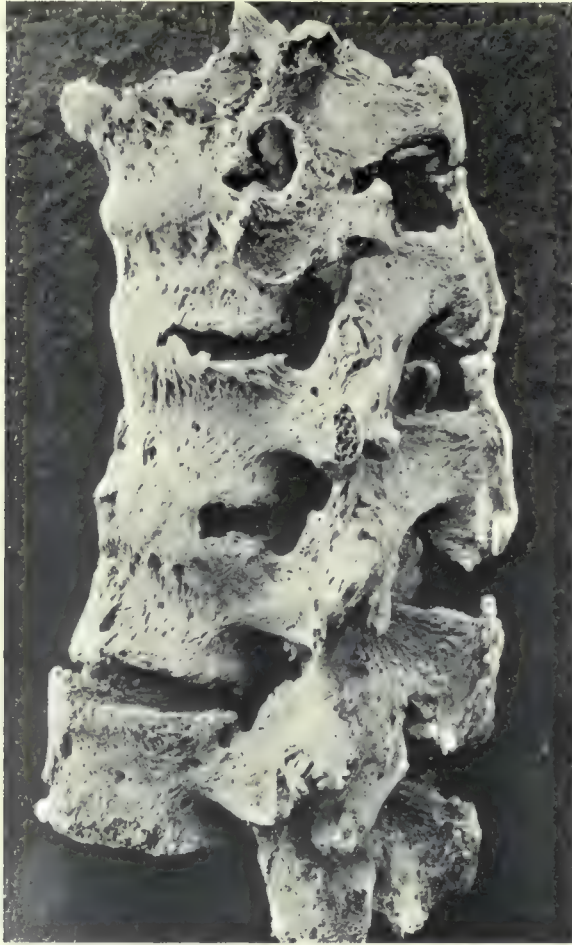

FIG. 3.

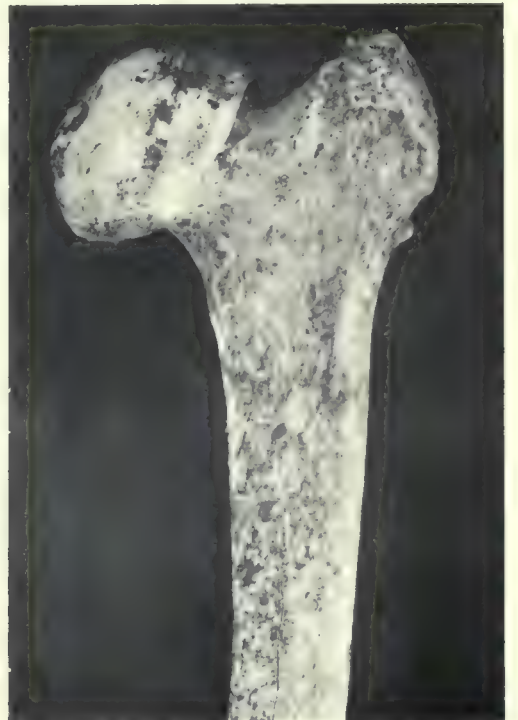

FIG. 1.

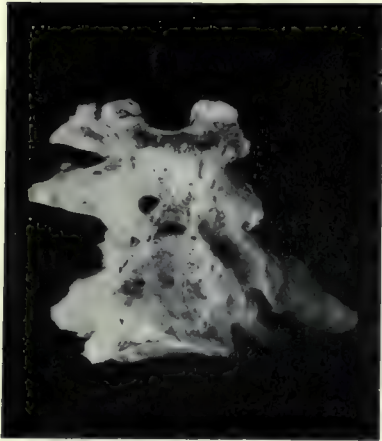


FIG. 4.

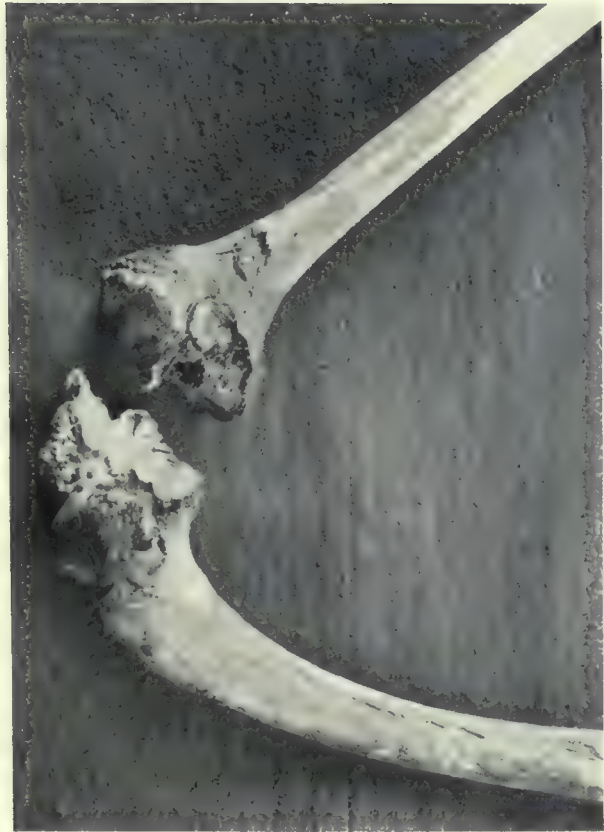
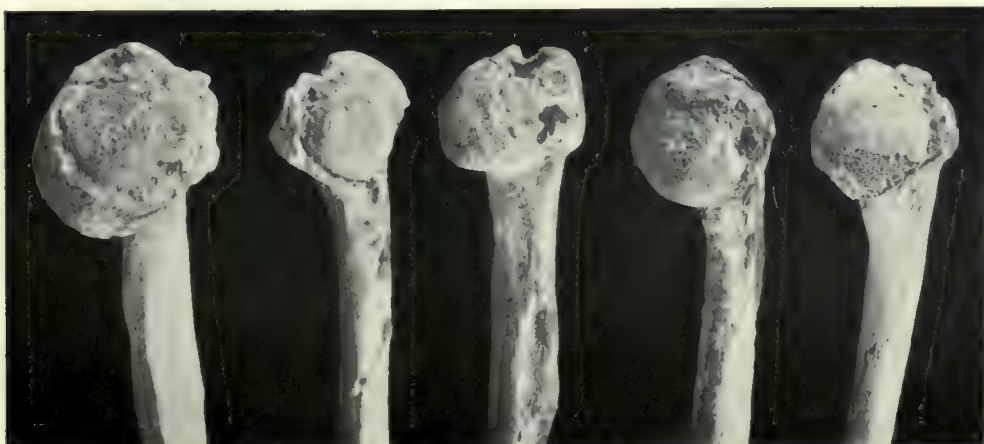
FIG. 5.



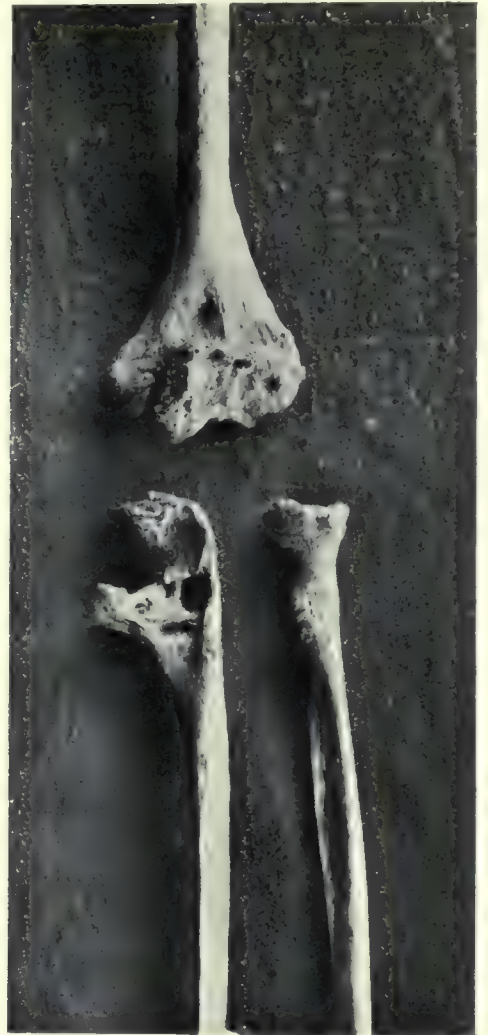FIG. 6.



SIX EXAMPLES OF THE DEFORMITIES CAUSED BY OSTEO-ARTHRITIS :—

(1). In the upper cervical spine; (2), in the lumbar spine; (3), in the head of the femur; (4), in the knee; (5), in the elbow and a finger and (6), in the heads of the humeri.

FIG. 3.



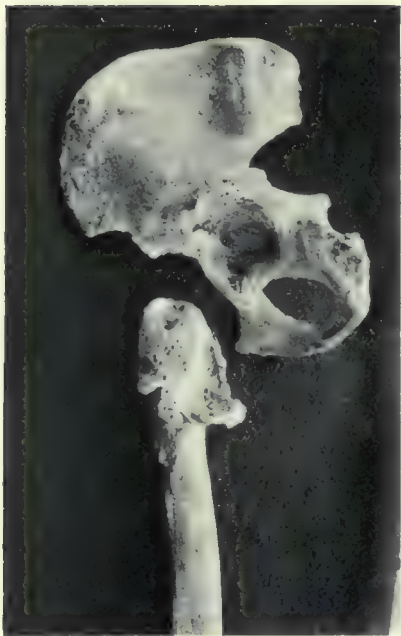Arthritis deformans of elbow.

FIG. 2.



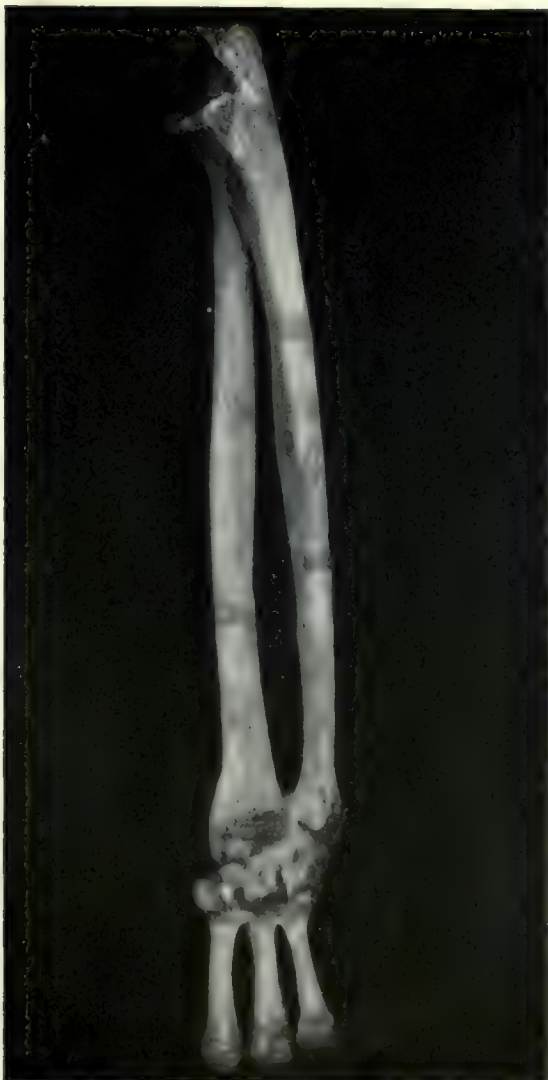Osteitis deformans in case of long-standing dislocation of the upper end of radius.

FIG. 1.



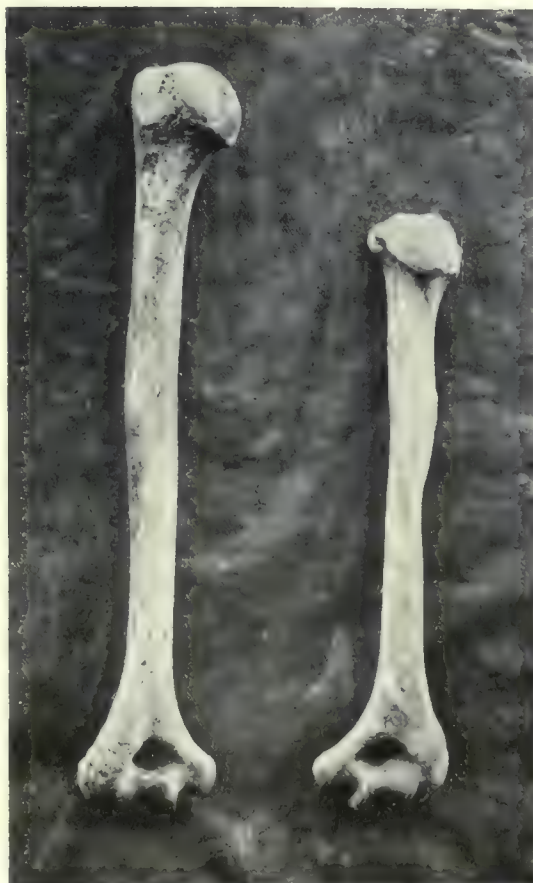New joint formed between the shaft of the femur and the innominate bone after separation of the epiphysis of the former.

FIG. 4.



Fusion of bones of wrist caused by osteo-arthritis. (24:1:R¹.)

FIG. 5.



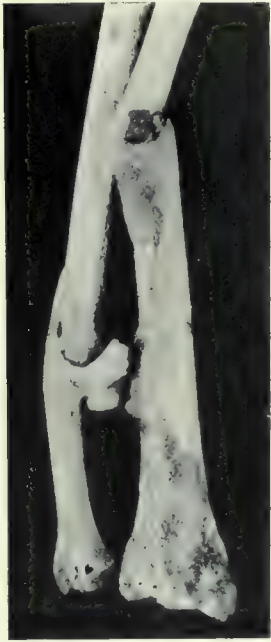Right and left humeri, side by side, to show great shortening of the latter caused probably by early separation of the upper epiphysis and secondary development of arthritis deformans.

FIG. 6.

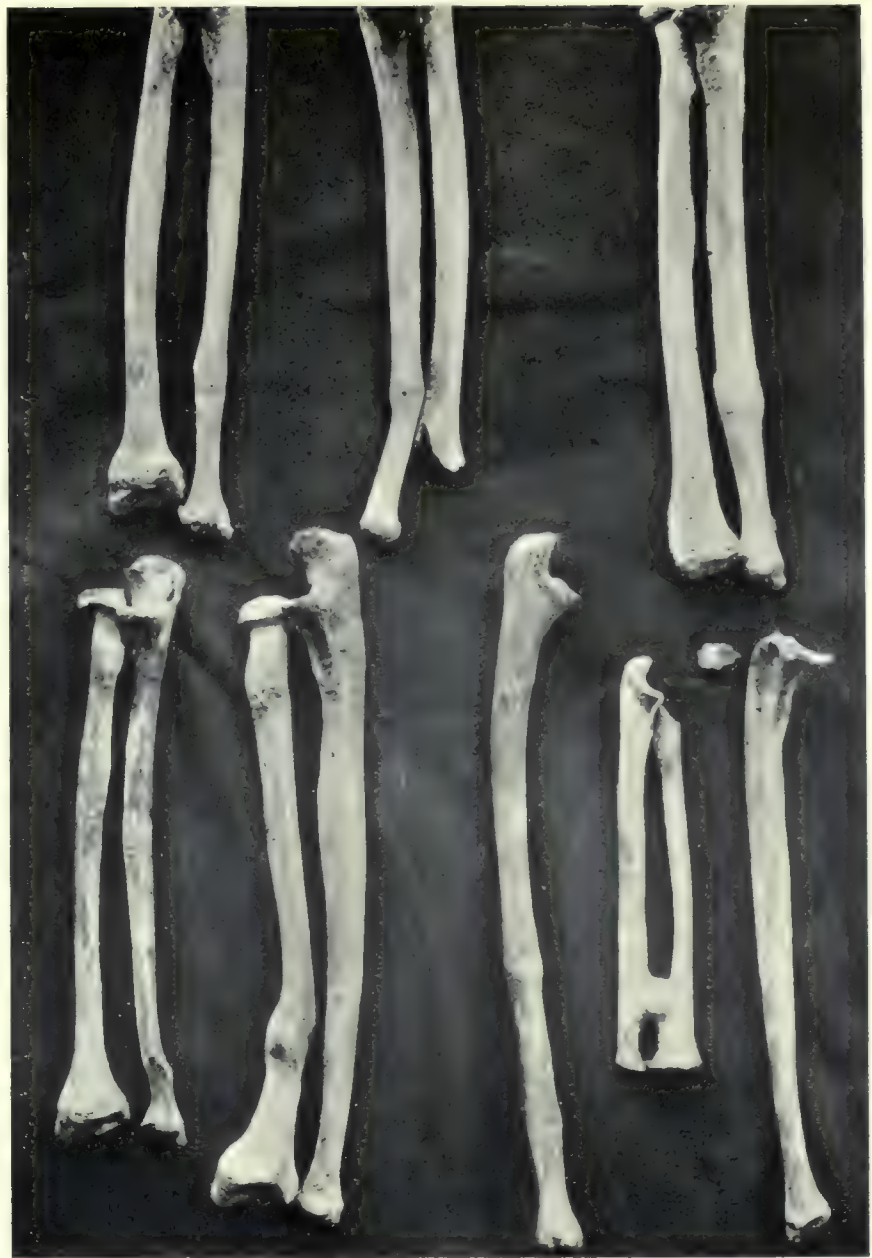

Inflammatory condition of upper end of radius. (7:188.)

FIG. 1.



Result of fracture of both bones of the forearm, when natural splinting is destroyed (17 : 17.)



A series of healed fractures of the forearm.

FIG. 4.




Fracture of neck of right humerus healed with a minimum of shortening. (Compared with the normal left bone.)

FIG. 5.



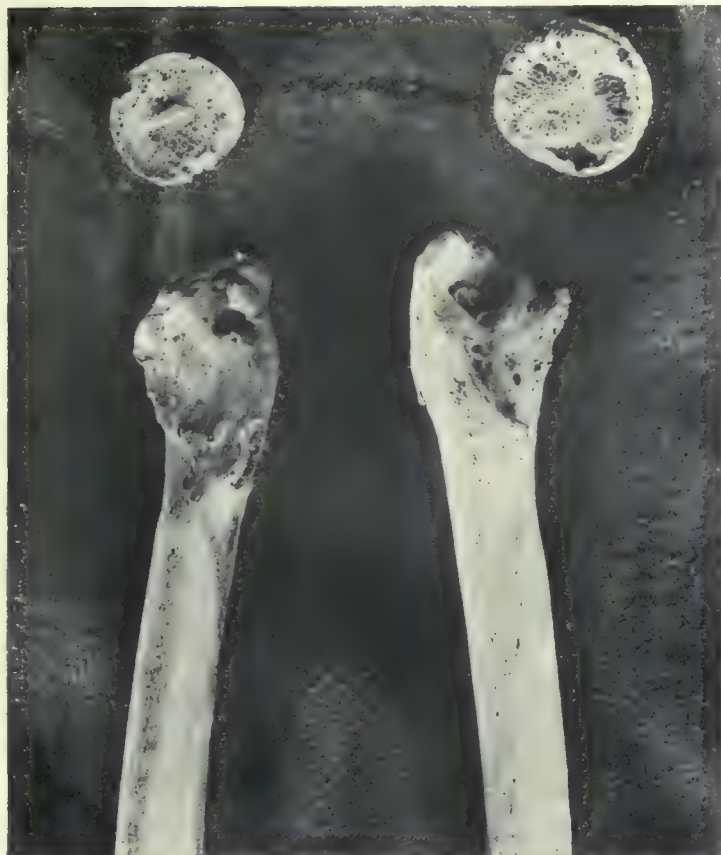Abnormal conditions of lower ends of radius and ulna.

FIG. 3.



Necrosis of humerus in a child.

FIG. 1.



Old-standing cases of separation of the upper epiphysis of the femur.

FIG. 2.




Fracture of the right femur.

FIG. 3.



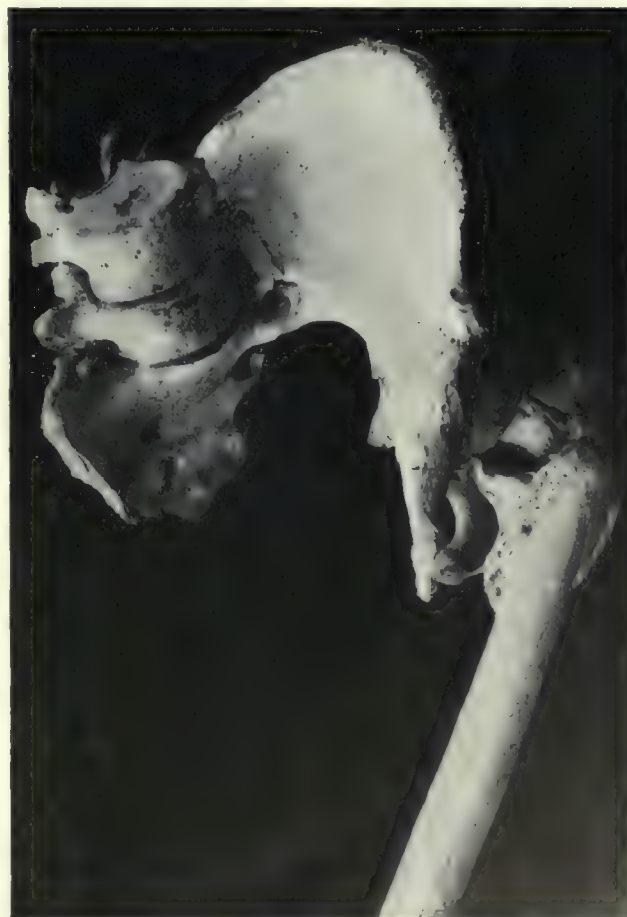Femur affected by some inflammatory condition.

FIG. 4.



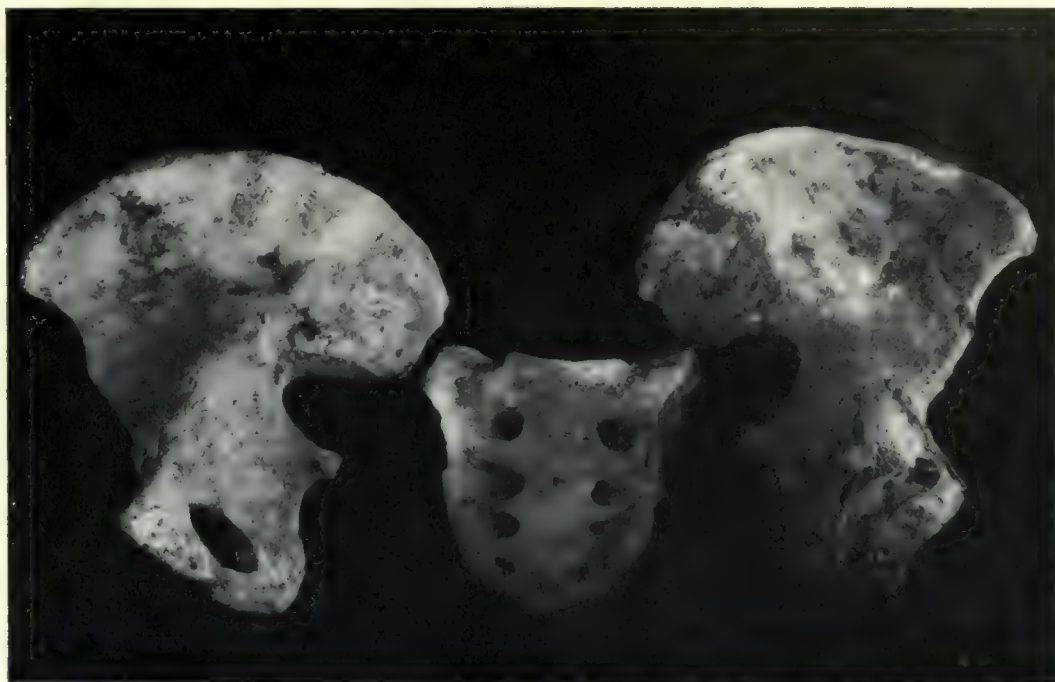
Another femur more severely affected.

FIG. 5.



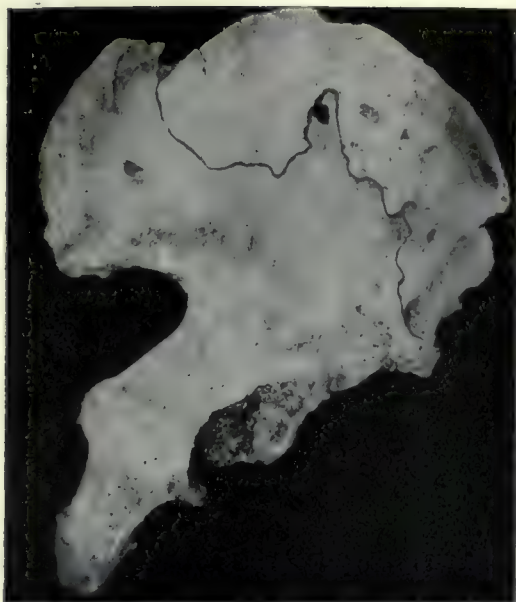
Fracture of the femur, pelvis, sacrum and lumbar vertebrae (5:91: A.)

FIG. 2.



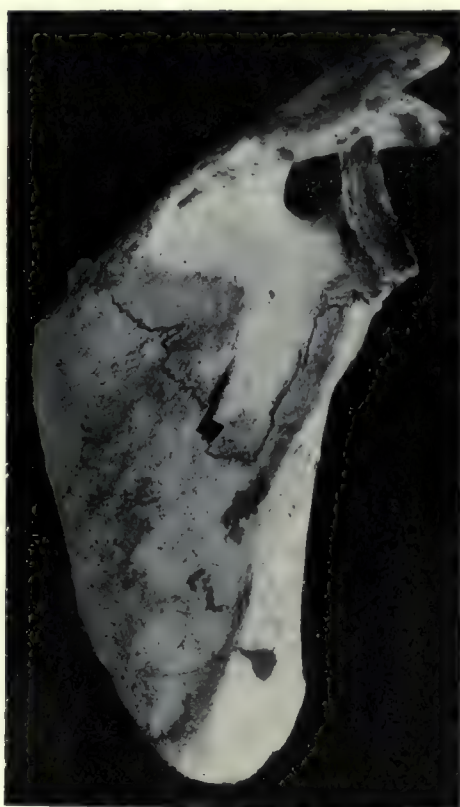Fracture of the pelvis in a woman of the Christian period (40:76.)

FIG. 1.



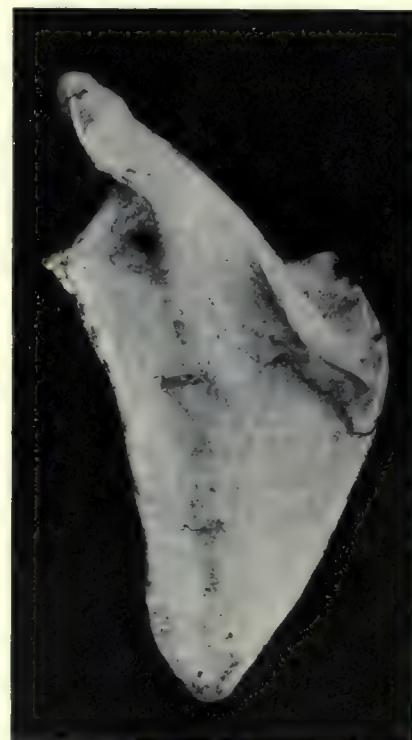Fracture of the ilium in a man of the Predynastic period.

FIG. 4.



Fracture of the scapula in a man of the New Empire period (7:14.)

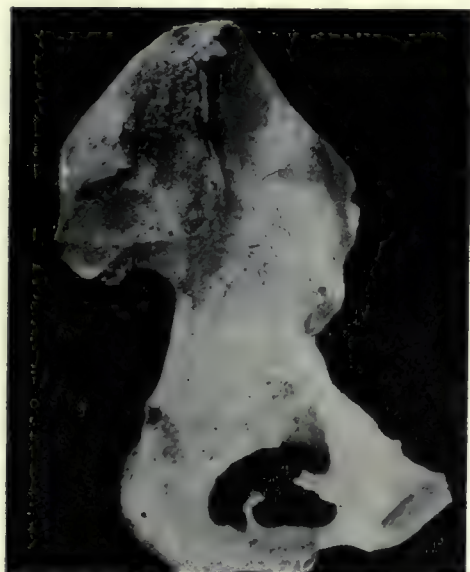FIG. 5.



Fracture of the scapula in a woman of the Christian period (24:5:D.)

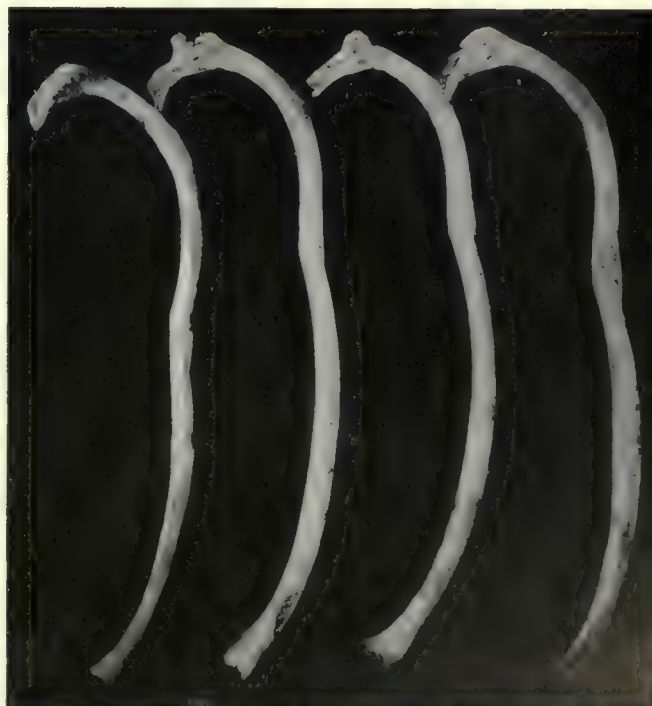[In Figs. 1, 4 and 5 the lines of fracture have been marked in ink.]

FIG. 3.




Fracture of the pubis in a woman of the Christian period.

FIG. 7.



Fractured ribs from the same case (41:18:C.)

FIG. 6.



Fracture of the sternum in a man of the Ptolemaic period (41:18:C.)

DT
135
N8A5
v.2
Plates

Egypt. Maṣlahat al-Misāḥah
The Archaeological Survey
of Nubia; report for 1907-1908

FRINDAL C. 200

PLEASE DO NOT REMOVE
CARDS OR SLIPS FROM THIS POCKET

UNIVERSITY OF TORONTO LIBRARY
