

UNIVERSITY OF TORONTO



3 1761 01053704 1

Digitized by the Internet Archive
in 2008 with funding from
Microsoft Corporation

52

A

1132

PRACTICAL AND SYSTEMATIC

TREATISE

ON

FRACTURES AND DISLOCATIONS.

BY

A. J. HOWE, A. M., M. D.

PROFESSOR OF SURGERY IN THE ECLECTIC MEDICAL INSTITUTE.

FOURTH EDITION.



CINCINNATI:
JOHN M. SCUDDER:

1891.



RD
101
H68
1891

Entered According to Act of Congress in 1870, by JOHN M. SOUDER, in the Clerk's office
of the District Court for the Southern District of Ohio.

CONTENTS.

PART I. FRACTURES.

	PAGE.
PREFACE.....	11
CHAPTER I.	
General Observations upon the Nature and Treatment of Fractures...	17
CHAPTER II.	
Signs of Fracture.....	22
CHAPTER III.	
Process of Union.....	29
CHAPTER IV.	
Non-union, or False-joint after Fracture.....	36
CHAPTER V.	
Defective Union.....	41
CHAPTER VI.	
General Remarks in Regard to the Treatment of Fractures.....	43
CHAPTER VII.	
Reduction of Displaced Fragments.....	49
CHAPTER VIII.	
Apparatus for the Treatment of Fractures.....	52
CHAPTER IX.	
Re-dressings.....	64
CHAPTER X.	
Movements allowed a Patient.....	66
CHAPTER XI.	
Management of Compound Fractures.....	67
CHAPTER XII.	
Diastasis, or Separation of an Epiphysis.....	72
CHAPTER XIII.	
Fracture of the Cranium.....	74
CHAPTER XIV.	
Fracture of the Inferior Maxillary.....	80
CHAPTER XV.	
Fracture of the Hyoid Bone and Laryngeal Cartilages.....	88
CHAPTER XVI.	
Fracture of the Vertebrae.....	91

	PAGE.
CHAPTER XVII.	
Fracture of the Ribs and Costal Cartilages.....	95
CHAPTER XVIII.	
Fracture of the Clavicle.....	104
CHAPTER XIX.	
Fracture of the Scapula.....	110
CHAPTER XX.	
Fracture of the Humerus.....	117
CHAPTER XXI.	
Fracture of the Ulna.....	137
CHAPTER XXII.	
Fracture of the Radius.....	145
CHAPTER XXIII.	
Fracture of the Bones of the Hand.....	161
CHAPTER XXIV.	
Fracture of the Pelvic Bones.....	165
CHAPTER XXV.	
Fracture of the Femur.....	171
CHAPTER XXVI.	
Fracture of the Patella.....	215
CHAPTER XXVII.	
Fracture of the Leg.....	221
CHAPTER XXVIII.	
Fracture of the Bones of the Foot.....	249

PART II: DISLOCATIONS.

CHAPTER I.	
General Considerations.....	225
CHAPTER II.	
Dislocation of the Jaw.....	290
CHAPTER III.	
Dislocation of the Vertebrae.....	297
CHAPTER IV.	
Dislocation of the Ribs.....	303
CHAPTER V.	
Dislocation of the Clavicle.....	305
CHAPTER VI.	
Dislocation of the Scapula.....	310
CHAPTER VII.	
Dislocation of the Humerus.....	314

CONTENTS.

v

PAGE.

CHAPTER VIII.

Dislocation of the Radius and Ulna at the Elbow..... 335

CHAPTER IX.

Dislocation of the Wrist..... 349

CHAPTER X.

Dislocation of the Phalanges..... 355

CHAPTER XI.

Dislocation of the Femur..... 359

CHAPTER XII.

Dislocation of the Patella..... 388

CHAPTER XIII.

Dislocation of the Tibia..... 391

CHAPTER XIV.

Dislocation of the Tibio-fibular Articulations..... 397

CHAPTER XV.

Dislocation of the Ankle..... 399

CHAPTER XVI.

Dislocation of the Bones of the Foot..... 400



ILLUSTRATIONS.

FRACTURES.

FIGURE.	PAGE.
1. Partial or "green-stick" fracture.....	27
2. Specimen of broken ribs.....	33
3. Method of union when fragments overlap.....	35
4. Brainard's perforator or drill.....	39
5. Method of making a "reverse" in a spiral reversed bandage.....	53
6. Bandage of strips.....	55
7. Lined splint material.....	58
8. Moulded gutta-percha splints.....	58
9. Carved wooden splints.....	58
10. "Wire breeches".....	59
11. Adhesive strips to make fast to the leg, for purposes of extension.	60
12. Double inclined plane fracture box.....	61
13. Welch's double inclined apparatus.....	62
14. Burge's fracture bed.....	63
15. Compound fracture of the leg... ..	67
16. Separation of the lower epiphysis of the humerus.....	73
17. Fracture of the lower jaw.....	80
18. Pasteboard splint for moulding to the chin.....	84
19. Moulded pasteboard splint for the chin... ..	84
20. Dressing for fracture of the inferior maxillary.....	84
21. Application of silver wire to adjacent teeth.....	85
22. Fractured rib.....	69
23. Union of broken ribs....	100
24. Fracture of the Sternum.....	102
25. Fracture of the Clavicle.....	105
26. Deformity after fracture of the clavicle.....	107
27. Posterior view of Fox's dressing for fracture of the clavicle.....	108
28. Anterior view of Fox's dressing for fracture of the clavicle.....	108
29. Fracture of the shoulder blade.....	111
30. Fracture of the acromion.....	112
31. Fracture of the coracoid process.....	113
32. Fracture of the neck of the scapula.....	114
33. Humerus, divided into thirds.....	117
34. Carved and hinged splint for the shoulder.....	119
35. Fracture of the surgical neck of the humerus.....	120
36. Woven wire splint for fractures about the shoulder.....	121

FIGURE.	PAGE.
37. Fracture of the shaft of the humerus.....	123
38. Dressing for fracture of the shaft of the humerus.....	124
39. Diastasis, or separation of the lower epiphysis of the humerus...	126
40. Double fracture of the humerus.....	126
41. Deformity after fracture of the humerus.....	128
42. Fracture of the epitrochlea.....	129
43. Fracture of the external condyle of the humerus.....	129
44. Fracture of both condyles of the humerus.....	129
45. Fracture of the internal condyle of the humerus.....	130
46. Dressing for fractures of the condyles of the humerus.....	131
47. Fracture of the olecranon and coronoid processes of the ulna	137
48. Dressing for fracture of the olecranon.....	138
49. Fracture of the shaft of the ulna.....	142
50. Fracture through upper extremity of the radius.....	147
51. Shows action of rotating muscles of forearm	148
52. Fracture through middle of the shaft of the radius.....	148
53. Union of radius and ulna after fracture.....	149
54. Barton's fracture of the radius.	150
55. "Silver fork" appearance of the arm after Colles' fracture of the radius.....	151
56. Colles' fracture of the radius.....	152
57. Splints and dressing for treatment in Colles' fracture of the radius.	155
58. Single splint for treating Colles' fracture of the radius.....	156
59. Fracture of both bones of the arm.....	157
60. Comminuted fracture of both bones of forearm.....	158
61. Dressing for fracture of the bones of the forearm.....	159
62. Fracture of the bones of the hand.....	162
63. Fracture of a phalanx of the finger.....	163
64. Fracture of the os innominatum	166
64. Section of the head and neck of femur.....	173
65. Fracture of the neck of the femur within the capsule.....	179
66. Consolidation after fracture of neck of the femur.....	180
67. Ligamentous union after fracture of the neck of the femur.....	181
68. Excess of callus after extra-capsular fracture of the femur.....	182
69. Bony union after fracture of the neck of the femur.....	184
70. Fracture of the greater trochanter at its extremity.....	185
71. Fracture of the cervix femoris and greater trochanter.....	185
72. Fracture of the trochanter major.....	186
73. "Wire breeches" applied.....	188
74. Fracture of the shaft of the femur.	192
75. Straight splint in the treatment of fractures of the femur.....	195
76. Extension obtained by means of adhesive strips.....	197
77. Dressing for fractures of the femur... ..	198
78. Union of fragments of femur with overlapping.....	199
79. Weight and pulley for making extension.....	199
80. Burges' fracture apparatus applied.....	200
81. Fracture of the upper third of the femur.....	201
82. Fracture of the lower third of the femur.....	207
83. Fracture of the femur just above the condyles.....	208

FIGURE.		PAGE.
84.	Fracture of the internal condyle of the femur.....	212
85.	Fracture of both condyles of the femur.....	212
86.	Wire appliance for treating fractures near the knee.....	213
87.	Fracture of the patella.....	216
88.	Ligamentous union after fracture of the patella.....	218
89.	Dressing for fracture of the patella.....	219
90.	Fracture of both bones of the leg.....	222
91.	Fracture of both bones of the leg at the same point.....	223
92.	Fracture of both bones of the leg near the ankle.....	225
93.	Handkerchief hitch just above the ankle, for making extension.	229
94.	Gaiter appliance to the ankle, for making extension.....	229
95.	Adhesive strip fastening to the leg, for making extension.....	230
96.	Dressing for fracture of both bones of the leg.....	230
97.	Fracture box, for treating the leg after both bones are broken....	231
98.	Fracture of both bones of the leg, showing consolidation of fragments.....	232
99.	Fracture of the tibia alone....	237
100.	Dressing for treating the leg after fracture of the tibia.....	238
101.	Double fracture of the fibula	241
102.	Potts' fracture of the fibula.....	242
103.	Fracture of the fibula and dislocation of the ankle	243
104.	Dressing for Potts' fracture of the fibula.....	245
105.	Dupuytren's dressing for Potts' fracture.....	246

DISLOCATIONS.

106.	Dislocation of the lower jaw.....	209
107.	Appearance of the face produced by dislocation of the lower jaw.	292
108.	Dislocation of the head of the humerus inwards (subcoracoid)...	317
109.	New socket formed under the coracoid process.....	321
110.	Subglenoid dislocation of the humerus.....	326
111.	Subspinous dislocation of the humerus.....	329
112.	Dislocation of the elbow.....	336
113.	Dislocation of the elbow.....	338
114.	Dislocation of the head of the radius forwards.....	342
115.	Dislocation of the head of the radius backwards.....	343
116.	Dislocation of the carpus backwards.....	350
117.	Dislocation of the carpus forwards.....	351
118.	Dislocation of the first phalanx of the thumb forwards.....	355
119.	Dislocation of the head of the femur upwards and backwards, upon the dorsum of the ilium.....	361
120.	Manner of reducing dislocations of the femur by the manipulating plan.....	373

FIGURE.	PAGE
121. Dislocation of the head of the femur downwards, into the thyroid foramen.....	377
122. Dislocation of the femur forwards, upon the pubes.....	381
123. Dislocation of the patella.....	388
124. Dislocation of the tibia.....	391
125. Lateral dislocation of the knee.....	394
126. Dislocation of the foot outwards.....	400
127. Dislocation of the foot backwards.....	403

P R E F A C E.

The improvements and modifications which have recently taken place in the management of fractures and dislocations, and the fact that the ordinary text-books to be found in every physician's library contain too little on the nature and treatment of these lesions, and the special treatises too much, have induced me to venture upon the task of preparing a work specially adapted to the wants of the great mass of medical men.

Accidents involving fractures and dislocations commonly fall into the hands of the nearest and most available practitioners, who may need practical suggestions in regard to the most approved methods of treating this class of injuries, especially as such accidents frequently involve great professional responsibility.

On account of the roller bandage being too often applied improperly, I have endeavored to enforce a due consideration of the dangers attendant upon its careless application; and have urged the importance of employing as light dressings in each lesion as are compatible with efficiency.

Lotions of various kinds which have generally been used in the treatment of fractures do not meet with my approval, for the reason that they induce vesications and render the patient uncomfortable in many ways. A bandage which is occasionally wetted will not maintain equable pressure, and may become the source of perilous constrictions.

In treating fractures of the lower extremities, neither the double inclined plane nor the long straight splint, secures satisfactory results, therefore I have recommended the "natural

method" of producing extension and counter-extension. The cleverly constructed specimens of mechanical art which have lately been invented to obviate shortening, may gratify the taste of those who have ample means to invest in novelties; but the majority of medical men can not afford to purchase more apparatus than may be absolutely needed, consequently I have depicted and commended the simplest methods of treating fractured limbs. I have not advised the use of any appliance that could not be extemporized from materials to be found in every farm house. "Sets" of splints and appliances serve to make a show in a physician's office, but only a few pieces in each are of any practical utility, even if furnished in assorted sizes. A moulded or carved splint, though made especially to fit a case under treatment, will soon become inapplicable from increase or subsidence of swelling. A splint carved into grooves and ridges with the design of conforming to the natural outline of the arm, wrist, and hand, is calculated to deceive the unwary into the neglect of more simple means, which, if rightly applied, will answer better purposes. It is therefore advised that the surgeon construct from thin boards of soft wood, such splints of requisite width and length as each case may demand.

I have designed most of the illustrations, and in no instance is a topic introduced for the purpose of exhibiting an old picture; and no subject is distorted to meet the requirements of obsolete diagrams.

IN PART SECOND, well directed efforts to reduce dislocations by what has been called the "manipulating plan," are encouraged as a substitute for the more dangerous method of overcoming displacements by the aid of pulleys and other mechanical means for multiplying force. Since the introduction of anæsthesia into surgical practice, there is less need of violent measures to replace luxated bones. It is now known that obstacles to the easy return of a displaced bone, consist essentially in tense tissues which can generally be rendered lax by

changing the position of the dislocated limb. However, it is not to be understood, if a displaced bone can not be reduced by manual dexterity alone, that no other means are to be tried. But the manipulating plan in intelligent and persevering hands, has been so generally successful, that it would be rash to try harsher means until repeated and varied trials of the "physiological method" have failed.

In preparing this work on Fractures and Dislocations, I have taken the liberty of drawing from every available source of information, and have not always given credit for material employed. This omission did not arise from a reckless disposition to appropriate the ideas of others; but in an early attempt to give each author his due, I found that A had drawn from B, and B from C, and so on, and therefore I abandoned an undertaking which at best must have been imperfect, laborious, and unsatisfactory.

In presenting this book to the profession, it is with no inflated estimation of its merits; indeed I know it has glaring defects,—some of which may be placed to a lack of time for carefully correcting and amending what has been prepared amid countless interruptions, and during the busiest of professional life. Whether it will accomplish what I have designed, time and readers must decide. It is offered as a guide to the multitude of practitioners scattered through the country, who have comparatively limited facilities for becoming acquainted with the best methods of treating a class of injuries which often baffle the most experienced surgical talent.



PART I.

FRACTURES.



CHAPTER I.

FRACTURES.

GENERAL OBSERVATIONS UPON THEIR NATURE AND TREATMENT.

THE bones preserve the outline of the human figure, giving support and protection to the soft tissues; and serve the purpose of levers upon which muscular force is displayed. Having a large proportion of earthy matter in their composition, they are necessarily brittle, breaking under the influence of unusual forces, directly or indirectly applied.

When a muscle, tendon, ligament, or other soft structure, is mechanically separated, the injured part is said to be torn, ruptured, or lacerated; but the forcible separation of a bone into two or more pieces, is always called a *fracture*.

Bones are organized structures; when they are broken, the reparative processes can mend or consolidate the fragments, rendering a fractured arm or leg as strong as ever in the course of a few weeks. That the uniting forces may be as efficient as possible, the fragments of bone must be kept in apposition.

The healing action firmly joins the pieces after they have been adjusted and retained in their places; and it is the office of the surgeon to place the broken parts in their right position, and to hold them there by the use of such appliances as the nature of each case demands.

Fractures vary in extent and direction, and the forces acting upon the fragments produce a variety of deformities, therefore it becomes important to draw distinctions between them, and to lay down some definite rules for their recognition and successful management. The principles of diagnosis and treatment have become so well established that the surgeon who fails to perform his duties according to the most approved rules, is held responsible for such defects and deficiencies as are justly chargeable to his negligence or ignorance;

and the practitioner of medicine and surgery cannot undertake to treat a fracture without placing his professional reputation in jeopardy, and assuming the risks of vexatious and expensive litigation.

Fractures are primarily divided into two classes, the *simple* and the *compound*. In a simple fracture the lesion is uncomplicated with injuries of the soft tissues. A compound fracture has for its essential character a wound of the skin, with which the fracture communicates. There are two ways in which the wound may be produced at the time of the accident:—from without, by the direct force which fractures the bone; or from within, by the end of one or both fragments being thrust through the soft parts, either by the continuance of the original force, or by the weight of the body. The latter mode is the more frequent; consequently compound fractures are more common in the leg than in any other part of the body. If caused by direct force the contusion will be considerable, and likely to be followed by inflammation, suppuration and sloughing; if simply incised or lacerated by the protrusion of a sharp fragment of bone, the wound may unite by first intention, converting the compound into a simple fracture. It may be remarked in this connection, that a fracture, simple at first, may be rendered compound by ulceration of the skin over a broken subcutaneous bone, as in oblique fracture of the tibia; and by the formation and bursting of an abscess at the seat of injury.

The *partial* fracture exists only when a portion of the bone breaks, the fracture stopping before it extends completely through its substance, so as to leave the fractured portions still continuous in some part with the rest of the bone. This has been graphically called the “green-stick” fracture. In the *complete* fracture all continuity is destroyed, and the portions of bone are separated from one another: in the former kind the limb seems to be bent, while in the latter there is generally, though not always, more or less displacement of the fractured ends, giving the limb an angular, twisted and strongly marked deformity. The partial fracture is exceedingly rare, the complete very common.

A fracture is said to be *comminuted*, when the bone is broken into many small pieces, some of which are often completely separated from the periosteum, losing all source of nourish-

ment, and requiring to be removed either naturally or artificially, before the other fragments can unite.

A *complicated* fracture denotes the additional lesion of an important blood-vessel or nerve, or the extension of the fracture into a neighboring joint. Fractures are not unfrequently attended with such serious complications that death is the result. If a fracture extend into a joint, the high degree of inflammation, and the interference of the reparative material, often bring about partial or complete ankylosis. A compound fracture is necessarily complicated: the flesh is lacerated or contused, rendering the injury very serious in its nature. A fracture complicated with much bruising and laceration of the soft parts, requires a long period to undergo reparation. The primary shock, and the subsequent suppuration, tell upon the patient's health; and the pus and debris about the ends of the bones, prevent a speedy union of the fragments.

The fragments of a simple, uncomplicated fracture, ordinarily become consolidated in five or six weeks; yet as many months may be consumed in the repair of a compound injury with perverse complications.

The direction a fracture takes may be *oblique* or *transverse*, though the line of separation, in a strict sense of those terms, is rarely the one or the other. The manner in which the injury is received, has some influence over the direction of the fracture. Direct violence produces fractures more transverse than oblique; and an indirect force, as when a person in a fall, strikes upon the feet and receives a fracture of the leg, favors obliquity in the line of separation, especially if the fracture occurs to the shaft of the bone. Fractures near the extremities of long bones, and in the flat, and irregular shaped, as the scapulæ and vertebræ, are apt to be more transverse than oblique.

When the lines of separation radiate from a central point of the bone, at which the violence was received, they are regarded as *stellate*; and when the broken ends of bone are full of spicula or serrations, which may interlock like opposing teeth, the fracture is *dentate*.

The course of the fracture has a bearing on the reduction of the fragments, and their retention in apposition. Transverse fractures, especially if they be dentate, when once reduced, are not easily displaced; and these conditions often present obstacles to ready reduction. If the line of separation be oblique the

reduction is not difficult, but there is a disposition on the part of the fragments to slide past each other.

As may naturally be supposed, all bones are not equally liable to fracture. Some are more exposed to injury than others, and some are increased or diminished in strength by their shape. It is plainly observable that the long bones are the most frequently fractured, while the short ones are comparatively seldom broken, and always by direct violence.

There are certain morbid conditions of the bones which render them unusually fragile. Rickets, caries, necrosis, cancer, scrofula and syphilis, may so affect the bones that they are liable to break from very slight causes. A dozen fractures, occurring at different times, and from trivial forces, have been treated in a boy under twelve years of age. Three of them were of the right humerus, and occurred in the act of throwing a stone. Esquirol possessed the skeleton of a woman, in which the traces of more than two hundred fractures, occurring at different periods, could be counted. The peculiar liability to fracture in the bones of certain individuals does not necessarily retard the uniting process. In some instances the recovery is unusually rapid. Stanley records one case, however, in which it was difficult to obtain a union.

There is a tendency to fracture in old people, from the fact that their bones become chemically altered; the earthy matter predominates over the animal, a condition which favors brittleness. In young people, the disproportion in the component parts is reversed; the animal matter predominates, so that the bones bend under the weight of the body, or under the action of the muscles. Children with bow-legs usually have a deficiency of lime in the skeleton.

A disproportion between the strength of the bones and the power of the muscles also predisposes to fracture. Great muscular development, coupled with a rapidly acting nervous system, may prove too powerful for slender bones. The humerus and the femur have both been broken simply by muscular exertion. The olecranon, patella, and the os calcis are levers which, while enduring violent and sudden forces from the muscles acting upon them, are occasionally broken. Few bones are placed at such disadvantage for resisting muscular action.

Tables drawn up to exhibit the comparative frequency of fractures in the different bones, vary somewhat. According to

some authors the ribs are the most frequently fractured; the clavicle standing next in the order of frequency; the radius taking the third place; the humerus the fourth; the femur the fifth; the fibula the sixth; and the tibia the seventh. Both bones of the leg are broken at the same time more frequently than either singly. According to my own observation and experience the radius is the most frequently broken, the clavicle next, and the ribs take the third place.

When a bone breaks at the point where force is applied the fracture arises from *direct* violence; a fracture of the radius or humerus arising from a fall on the hand, is said to be by counter-stroke (*contre-coup*), or *indirect* violence. A person falling from a height and striking upon the feet, does not sustain a fracture of the calcaneum or metatarsal bones, but the force is transmitted through the foot to the tibia, or even through it to the femur, and acts indirectly to a degree that severs one of those long bones at a weak point. The radius commonly gives way, from indirect violence, near its lower extremity; the humerus at the external condyle; the femur just below the trochanters, the tibia through its lower third. The fibula is often broken by a twisting force in the fall of the body to the ground after the tibia has yielded to the counter-stroke. It is reasonably supposed that muscular tension has something to do with fractures commonly considered as taking place from indirect violence, for a dead body may be let fall the same distance and it will receive no broken bones from the counter-stroke. The loose and passive condition of the bodies of drunkards seems to shield them from fractures while sustaining fearful falls.

A person in falling from a height, often seizes at some object to arrest his descent, or strikes some object on the way down, either of which imparts a whirling motion to the trunk, so that in accounting for the injury upon the theory of counter-stroke, the compound motion should be estimated.

The great degree of bruising of the soft parts, with ecchymosis, is sufficient in some situations to prevent the fracture from being discovered. This is often the case in crushing injuries of the hand or foot. Direct violence of a crushing nature, applied near the joints, may break the articular surfaces, causing effusions and swelling which tend to obscure the real nature of the injury.

CHAPTER II.

SIGNS OF FRACTURE.

The symptoms of fracture are quite distinct and reliable. The patient hears a snap at the time of receiving the injury, and feels such a piercing pain, that the nature of the lesion is impressed upon the mind of the sufferer. Loss of power in the part implicated, and unnatural mobility at the point of injury, causing the limb to assume unusual twists and angular deformities, are peculiar to fracture. Crepitus, when it can be elicited, is the most decisive of all the signs of fracture.

The *snap*, whether heard by the patient, or by persons who chance to be near, is a symptom of some value, though the sound may be produced by other causes, such as the rupture of tendons, ligaments, or the breaking of a stick or other foreign substance at the time the injury is received. It is almost impossible for a fracture to occur without a loud and distinct snap being produced, yet the sound is heard in only a small proportion of cases.

Pain is not a reliable sign of fracture, for it is sometimes slight, being scarcely complained of unless motion be imparted to the fragments. However, in most instances, the pain is so acute and agonizing that it calls forth cries of distress, eliciting the deepest sympathy. In fractures that have existed several hours, the swelling having checked the preternatural mobility and masked the deformity, the pain which may be produced by motion, becomes a valuable diagnostic sign. If the finger be passed slowly and carefully over the whole length of the suspected bone, the absence of all pain on pressure proves its integrity, unless the parts have been subjected directly to external violence. On the contrary, the existence of pain, more or less severe, at a circumscribed spot, would afford strong presumptive evidence of fracture.

Loss of power in a limb is not necessarily a diagnostic sign of considerable importance. A patient with a fractured radius can often use the hand to the astonishment of by-standers who afterwards learn the true nature of the injury; a broken fibula does not always restrain a patient from walking; and a man with a fractured cervix femoris has been known to use the limb with a freedom truly puzzling. The impaction of the fragments and the interlocking of the serrations may account in part for these seeming anomalies or inconsistencies.

It is certainly true that in most instances fractures inflict a notable hindrance, or an entire incapacity, of motion in the limb. The patient generally expresses his inability to use the fractured limb, and refuses to make even moderate effort, being intuitively conscious of the loss of power.

The *swelling* attendant upon a fractured-injury may take place immediately, or not be marked for several days. At the instant of fracture there is often, but not always, an effusion of blood around the fragments, and an extravasation into the surrounding tissues, constituting strictly an internal ecchymosis, which may not betray itself unless the tissues are laid open. This effused or extravasated blood, especially in elderly patients, finds its way gradually to the integuments at quite a distance from the seat of injury, discoloring the limb to an extent which excites alarm.

In fractures communicating with a joint, the blood mixes with the synovial fluid, and contributes not a little to the general tumefaction. The swelling following a fractured patella may be so great that, if the injury be not seen for two days after the accident, it is very difficult to determine the nature of the lesion. The same obscurity attends fractures into, or near all the joints, if the patient be not examined soon after the accident has occurred.

Preternatural mobility is a characteristic sign of fracture. To develop this decisive diagnostic symptom one fragment must be held fixed while the other is moved in different directions; the limb is then observed to bend, the angle being at the seat of fracture, indicating, at once, a solution of continuity in the bone. In the clavicle, the mere weight of the shoulder will produce the angle, and if the arm be grasped and moved up and down the mobility can be readily discovered.

Motion can be easily produced in the shafts of the long bones, which have been fractured, but it is not so readily demonstrated when the solution of continuity is near joints. The portion of bone connected with the articulation, is so small or short, that it can not be easily fixed so the long fragment can be moved upon it. And then, the natural movements of the joint in such immediate proximity to the fracture, tend to obscure the mobility peculiar to the lesion. In fracture of the radius through its carpal extremity, very little mobility can be developed by manipulation of the parts.

Displacement of the fragments is betrayed by the change in the form of the limb; often an experienced surgeon can at a glance divine the nature of the injury by the deformity. It would be unsafe to trust too much to first appearances; the deformity might be due to luxation or to a severe contusion.

If a fractured limb present a bend or angle at a point where none should exist, the sign is valuable. One fragment resting in front or to one side of the other, constituting a salient projection which can not only be seen, but felt as the fingers are pressed along the bone, is quite decisive as to the nature of the injury; deformity by rotation, as when the hand or foot is twisted around into an awkward position after fracture of the arm or leg, indicates what kind of an injury has been sustained. Shortening of a limb, which can generally be determined by measurements between prominent points in the skeleton, is a sign of great value in establishing a diagnosis. If there be no displacement, the spicula of the fragments hold each other interlocked, so that no shortening is perceptible. Fractures of the olecranon, patella, and os calcis, are apt to be attended with a considerable degree of *separation* between the fragments. Muscular action is the cause of this displacement, and it always produces more or less deformity after fractures; it twists fragments of the fibula away from each other; and in fractures of the forearm, it drags the fragments of the radius and ulna into contact with one another, and if the pieces of bone be not kept in their proper relations, all the fragments may be so united as to prevent rotation.

Crepitus is a grating sound, produced by rubbing one fragment of bone against another. It is the most positive of all the signs of fracture, though, unfortunately as a diagnostic

symptom, it cannot always be elicited on account of the interlocking of the ends of the fragments.

If there be much separation between the fragments, as there usually is in fractures of the patella, crepitus can not, for obvious reasons, be elicited; and extensive overlapping is also opposed to the production of crepitation. A coagulum of blood, piece of muscle, or other soft tissue interposed between the ends of broken bones may interfere mechanically to prevent crepitus; and many other conditions are opposed to the success of efforts designed to elicit crepitation.

It often happens in fractures through the neck of the thigh bone, that free motion can be produced, yet no crepitus is elicited, one portion of bone being drawn up beyond the other. In these cases if the limb be extended, so as to bring the ends of the fragments in apposition, and the leg be rotated, a distinct crepitus can be obtained.

In the majority of fractures the crepitus can be distinctly felt and heard; therefore as a sign of fracture it is extremely valuable. To the patient and bystanders, who hear the crepitation, the sound is particularly convincing. The surgeon enjoys a double satisfaction in the sound, for it not only gives decisive evidence of the nature of the injury, but proves that the fragments are in juxta-position, no muscle or other structure intervening.

The snapping of tendons, and the crackling of emphysematous tissues, resemble slight or indistinct osseous crepitus, yet the surgeon, manipulating the injury, *feels* rather than hears the crepitation, and judges or discriminates by that sense. Crepitus can be made most distinct soon after the reception of a fracture; the changes which take place in the course of the inflammatory stages of the injury, and the healing process, thwart all efforts to elicit crepitation.

Fractures are often dangerous injuries. The violence producing them may be of such a nature as to lacerate the soft tissues, and to inflict the most serious wounds. The sharp ends of the fragments sometimes sever or puncture large blood-vessels, and destroy the integrity of important nerves, subjecting the parts involved to the dangers of gangrene or extensive sloughs. Not unfrequently an injury involving a fracture, is of such a serious nature that amputation becomes imperative. Fractures extending into the joints always excite

the gravest apprehensions; they may turn out well, yet there is no certainty of a perfect result. Partial or complete ankylosis is a common sequence of fractures involving an articulation.

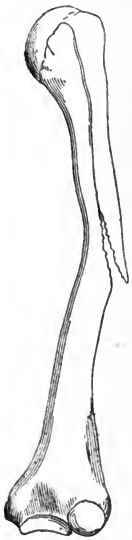Other injuries often simulate fractures, therefore the surgeon must discriminate between the symptoms of dislocations, sprains, fractures, and other lesions. A differential diagnosis cannot always be made out until the patient is placed under the influence of chloroform. The peculiarities of dislocation must be well understood, or the differences between the signs of the two injuries will not be apparent. It must be known that a fractured limb is characterised by unusual mobility, and that a dislocated one is unnaturally rigid; that a fractured bone is easily reduced but it will not stay in place, and a dislocated one is difficult to reduce, but once returned to its normal position, it will generally stay there. An examination and comparison of the most prominent processes, in fractures near the joints, may preclude error of diagnosis. In a severe bruise or strain the real condition of the injury can be determined by a negative method of examination and reasoning. If it be satisfactorily demonstrated, in a doubtful case, that neither a fracture nor a dislocation exists, the logical conclusion is that the lesion is a sprain, bruise, or contusion.

Children sometimes receive serious injuries that are exceedingly difficult to recognize. They are unable to tell how the hurts were received, or to give an intelligent explanation of the pain or other conditions of the parts implicated in the injury. Their fright, sobs, and agitation, thwart the best directed efforts to understand the nature of the accident; sometimes it is best to postpone the examination until the child has recovered from its nervous condition.

Incomplete fracture, when it exists, and that is seldom, must necessarily be confined to the young. The bones of old subjects, from the amount of earthy matter in their composition, break like a dry stick. The bones of the arm are most liable to the partial or "green-stick" fracture (Figure 1). The humerus, during childhood, has been found bent. It then offers considerable resistance to straightening or reduction. The child is averse to motion in the limb, and guards it against subsequent injury. An attempt at quick and forcible reduction may complete the fracture.

Fissure of a bone is commonly an obscure injury to diagnose. In most instances of suspected fissure the evidence must be founded on what is little better than conjecture. The bone could not well be fissured without tearing the periosteum and the medullary membrane; and the suffering would be long continued. The danger of these cases is illustrated by an example from Duverney. A man received a kick from a horse on the center of the left tibia. This was followed by severe pain and sloughing of the skin, which, however, readily healed, and the patient went about as cured. Three months later he was again confined to his bed by the accession of sudden, acute pain. After much ineffectual treatment by emollients, the bone was exposed, and a long deep fissure was found, the edges of which were raised twice, giving exit, on the second occasion, to pus. Subsequently the bone was trephined, and an abscess laid bare in the medullary cavity.

FIG. 1.



Partial, or 'green stick' fracture.

Railway accidents produce fractures which, from their complications, and serious nature, deserve to be considered by themselves. The severer forms of injury, from the paralyzing character of the shock, and the number of parts implicated in the lesion, are apt to terminate fatally. An arm or leg, suffering from fracture by a railroad accident, is generally so badly bruised and mashed, that it may require amputation.

In 1868, Dr. C. E. Witham, of Walton, Iowa, was called to take professional charge of a man who received a fracture of both bones of the forearm while shackling cars. In the course of twenty hours from the time of the accident, reaction having taken place in the entire body except the injured limb, which remained cold and pulseless, the doctor in consultation with two other physicians, decided to amputate the arm. The injury was of such a crushing character that it was presumed the limb would slough, and greatly endanger the patient's life. The three medical men in council, had no misgivings in regard to the requirements of the case. There seemed to them an imperative necessity for amputation, and they accordingly removed the limb. The patient made a good recovery, and for the time appeared satisfied with the opera-

tion; but some rival physicians got possession of the amputated limb, and injected the arteries; the vessels proved to be untornd, at least they sustained an injection. The young man who had lost the arm was made to believe that his limb had been needlessly sacrificed, and, therefore, sued Dr. Witham and his associates, for damage to the extent of ten thousand dollars.

A breakman on a freight train gets a leg or an arm broken by the moving cars, or receives a crushing injury by being thrown from his position. The shock may be so great that he will never react; or he may die from a multiplicity of injuries, that do not manifest themselves at first. A question arises, in the contemplation of these terrible injuries, what is best to be done? Ordinary rules applicable in surgical injuries, fail to meet the exigencies of the cases. A conservative course, which in ordinary accidents succeeds so well, too often fails in these dangerous injuries. To attempt to save a limb that has suffered a compound, comminuted, and complicated fracture, may result in the sacrifice of life.

Threshing machines, sorghum mills, and other modern agricultural implements, to say nothing of the powerfully moving machinery of our great manufactories, are constantly producing fractures and other injuries which tax the skill and ingenuity of the most experienced surgeons.

If the principal arteries and nerves of a limb be lacerated or severely injured, the hope of recovery without amputation quite frequently proves illusive. However, in doubtful cases it is well to wait for reaction and other recuperative signs. There is danger in resorting immediately to operative measures. While a patient might not know that he had lost a limb through surgical incompetence, there is an awful responsibility in the procedure which a lively conscience could not easily endure. "Did I sacrifice a limb that might have been saved?"

CHAPTER III.

PROCESS OF UNION.

The dearth of opportunities for examining broken bones during their various stages of repair, has prevented that thorough knowledge of the changes taking place from day to day during the healing process, which is so interesting and instructive. Experiments upon animals have contributed something to a better understanding of the subject, yet varying conditions have stood in the way of rigid comparisons. In man, a steady unvarying course of repair is not to be expected in all cases. One person with fracture of the tibia may walk on the limb in five or six weeks from the accident: another person, with a similiar fracture, and every condition seemingly as favorable, may not walk for three months: in fact, no bony union may take place, the patient having to hobble about for the rest of life with a false-joint at the seat of fracture, the connection between the fragments being ligamentous and not osseous.

In the simplest forms of fracture, where the periosteum is not much damaged, and the soft tissues are not severely bruised, the healing process sets in earlier and terminates sooner, than in compound, complicated, and comminuted fractures. The effusion of considerable blood is an obstacle to early efforts at repair. If the periosteum be stripped from the fragments, and torn into shreds, the course of recovery will necessarily be prolonged.

During the first few days the inflammatory action runs high, and the swelling and local disturbances create serious trouble. The swelling may commence as soon as the accident occurs, or come on anytime within a day or two. The violence of the inflammatory action may be reached on the second day, but there is no marked subsidence for five or six days. This

may be called the inflammatory stage of the difficulty. For the succeeding five days the swelling subsides, and a great part of the effused blood—the debris of the injury—is removed; during the next five days there is an effusion of plastic material, of jelly-like consistence, which is to be elaborated into a firmer bond between the fragments. Fifteen days have now passed, and the union is a “rope of sand.” If the parts be cut into and examined, the extravasated blood will be gone, an abundance of unorganized lymph will be seen between and about the fragments of bone, and the muscles and other soft tissues adjacent to the injury will seem to be glued together. The lymph is yellowish white, but the surrounding structures under the influence of the reparative action, have a pinkish hue, the reddish color coming from minute blood-vessels which are pushing their way into the newly forming material. Although the blended soft tissues around the bone assist in giving firmness to the parts, the fragments themselves move about as freely as when the fracture first occurred.

Half of the time ordinarily consumed in the treatment is now passed, and the real work of repair is but just begun. During the next five days the plastic lymph becomes organized into cells and fibrous bands. By the twentieth day the fragments are bound together by this newly formed connective tissue, so that there is considerable firmness established between the ends of the fragments and the surrounding structures. The limb at this time will bend, but has not the mobility peculiar to a recent fracture.

From the twentieth to the twenty-fifth day the osseous corpuscles are deposited in the meshes of the fibrous connection. The new bony material is thrown out first and most rapidly from the periosteum and the medullary membrane, but is not placed with much regularity. At first there is an excess of corpuscles at one point, and a deficiency at another; but by the twenty-fifth day, in a young patient, under favorable circumstances, the bony connection is sufficiently abundant and consolidated to sustain itself without artificial assistance. The osseous union is not yet complete; in places there is too much of the fibrous, and not enough of the bony material; and there is not that complete consolidation which proves to be unyielding. In fractures of the leg, the osseous union

is often so imperfect by the thirtieth day, that the uniting material may yield, allowing of shortening in cases inclined to overlap. I recently took off a dressing from a fractured femur that had been on thirty days. There seemed to be perfect consolidation of the fragments, and careful measurement showed that the legs were of equal length. The patient, a lad of ten years, began to move about on crutches, and gradually to press the foot of the lame side to the ground. In two weeks after the fracture-dressings were removed, I again made a measurement, and found that the fractured limb was fully a half inch shorter than its fellow. As the measurements in both instances were made with scrupulous exactitude, the conclusion to be drawn was that the dressings were removed before the ossification was sufficiently complete or consolidated to resist the normal muscular tension.

It is of the utmost importance that the surgeon understand, as nearly as possible, what is going on from day to day in the process of repair in a fractured bone. The differences of activity at the various ages of life, and the modifying influences arising from the kind of fracture, and from the region of body injured, to say nothing of general health, and minor considerations, render certainties out of the question, and leave a wide scope for conjecture and speculation.

The most experienced surgeon can not, from manipulation or the appearances of the limb, determine positively when a fracture-dressing may be removed. If every part of the treatment has been satisfactory, and there be no known reason why the healing processes have not accomplished what they usually do in a given time, it may be presumed that a good union has been effected in four, five, or six weeks, as the particular case might seemingly require. If there be mobility, crepitus, or other signs of non-union at a time when a complete result ought to be expected, it would be certain that the fracture-dressing should be continued for a week or two, but there is no way to determine just how many more days the treatment ought to be continued, nor could it be positively determined whether a union would ever occur. After four, five, or six weeks have elapsed from the reception of the injury, and upon the removal of the dressing the limb is found to be firm at the point of fracture, the presumption is that union has taken

place, and the surgeon would feel justified in laying aside the usual retentive supports.

When the fragments do not accurately correspond, the uniting medium occupies externally the angle between them, and extends partly into and across the medullary canal. When they completely overlap, and even when there is an interval between them, provided it is not too great, the same rule prevails. The reparative material simply extends between them, bridging over the interval, and filling up all angles and irregularities. It does not cover the free ends of the fragments, nor occupy the medullary canal.

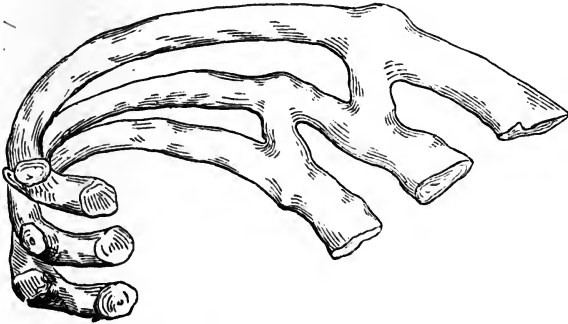
According to Dupuytren, the method of union in broken bones is by a superabundance of reparative material at the seat of fracture, called "provisional callus." It may be likened to the mass of solder employed to join the ends of two pieces of leaden pipe, or to a "ferule" on a whip-stock. The reparative material used to blend or weld the ends of the fragments, and not carried away by absorption at a period more or less remote, takes the name of permanent, "definitive," and uniting callus.

Mr. Paget holds that the mode of union through the agency of a provisional callus, is peculiar to the process of reparation in animals whose broken bones are in constant motion, or not fixed by dressings. He teaches that the only bones which normally and constantly unite by this process, in man, are the ribs, the motions of which can not be fully restrained. Occasionally it is seen in the clavicle and humerus; rarely in the tibia, fibula, and other bones. In children, whose motions it is not easy to restrain, the "ensheathing" callus is quite frequent; according to Hamilton, almost constant.

Dupuytren entertained the idea that the provisional callus was intended as a temporary support during the mobile stages of repair. It is now known that a "provisional" callus is not necessary in the union of broken bones; and only exists in cases where it is impossible to restrain motion in the fragments. The accompanying cut, (Fig. 2), from a specimen in my possession, shows that in the union of fractured ribs, where respiration keeps up constant motion of the fragments, there is not only a large amount of provisional callus, but bridges of bone reaching from one rib to another along the course of the intercostal muscles, are built up as if to support, or to

steady, the moving fragments. I have another specimen from a leg, in which both bones were broken near the ankle, and a long, curved spur of new-made bone was sent backward from

FIG. 2.



Union of broken ribs, with "bridges" of bone in the course of the intercostal muscles.

the tibia, at the seat of fracture, to the tendo Achillis, as if to gain support from that rather stable tendon. The excessive production of callus thrown out in the repair of fractures in the neighborhood of joints, especially of the hip-joint, is a strengthening buttress pushed out to give stability to moving parts.

When a broken bone is not accompanied with much injury to the surrounding soft tissues, and there is no displacement; and when the fragments are steadily held in place, without motion or disturbance, there is no ring or ferule of reparative material employed in the union; but the opposed broken surfaces of the fragments unite without ridge or outside callus, by a process akin to that called "first intention" in wounds.

It is still a question whether the intervention of *cartilaginous material* ever exists, or is necessary, in the last stages of repair in broken bones. In young subjects and in the inferior animals the presence of cartilaginous tissue has been observed, but as there are numerous instances in which its presence is not constant, the necessity for its existence is questionable. In adults the intervention of cartilage is exceedingly rare; and union without any perceptible callus is the rule, and not the exception, in well treated cases.

The agency of *granulations* in the repair of compound fractures becomes almost a necessity. In the union of simple

fractures, especially if inflammation be restrained within ordinary ranges, no granulations are interposed.

In the majority of cases the reparative material employed in the union of fractures, is similar to that employed for the repair of soft tissues by adhesion. This material is supplied from the vessels of the surrounding tissues, and by those of the bone and of the periosteum. The vessels of the medullary membrane also contribute a share in the work of furnishing supplies. If the fragments be kept at rest and in strict apposition, the reparative material is found chiefly, if not entirely, between them. When from irritation, motion, or want of apposition between the fragments, it extends outside the broken ends of the bone, it gets between the periosteum and the bone, and even into the adjacent tissues. The diagrams in *Paget's Surgical Pathology*, which represent the periosteum as having been separated from the bone to allow, as it were, room for the "ensheathing" callus, may faithfully represent the ideas of the author, but they do not represent the true healing state. The reparative material gets upon the outside or external surface of the periosteum, as well as between that membrane and the bone. The reparative material extends into the medullary cavity, but never between the medullary membrane and the bone.

The shaping or *modelling* of the excess of reparative materials after the union is complete, is a work of time. All rough and unnecessary projections are removed by absorption; the sharp points left by the overlapping of ill-uniting fractures, whether deep or superficial, are first softened by the disappearance of their earthy matter, and subsequently removed, and the rough surfaces rounded off. The pressure and friction of the muscles, are the chief agencies in the work of polishing and absorption.

In fragments that overlap, a hard bony cap covers the ends of the fragments, and the compact walls resting against one another, (Fig. 3), and the cancellous tissue of both communicate, the new connecting material being more vascular and spongy than the walls of the old bone.

Although the dressings can generally be removed with safety in from four to six weeks, ossification is rarely completed before the ninth or tenth week after the injury. In infants the time of union is reduced to fifteen or eighteen days;

in old age two or three months are required to consolidate the fragments. If the fragments overlap or rest faultily with one another, the time of reparation is greatly retarded; in cases of double fracture, in which it is difficult or impossible to prevent riding, the work of repair is always tedious.

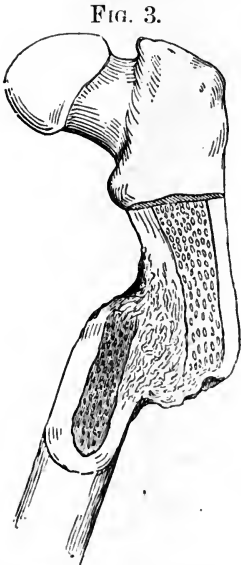

FIG. 3.

Shows unifying medium where the fragments overlap.

Compound fractures require about three times as long a period to complete the union as the simple. Fractures from gunshot wounds, on account of damage to soft parts, and the comminution of the bone, are exceedingly tedious in the process of cure. When there has been actual loss of bone, as by the removal of splinters, or comminuted portions, the time occupied in the restoration is very much prolonged.

A fracture extending into a joint is never followed by reunion of the articular cartilage. The bone unites, leaving an interval between the borders of the cartilage, which may or may not fill with fibrous tissue. Sometimes a ridge of osseous material projects into the space between the broken cartilage, which, by interfering with the functions of the joint, favors ankylosis. In fractures penetrating the articulations, the synovial membrane becomes thickened by inflammation, the sheaths of passing tendons get blocked up with effused and organized plastic lymph, so that considerable stiffness, if not genuine ankylosis, is likely to follow. Passive motion after the bony fragments have united with osseous material, is the proper method of restoring the functions of the joint.

CHAPTER IV.

NON-UNION OR FALSE JOINT AFTER FRACTURE.

It is a fortunate circumstance in the history of broken bones, that the fragments rarely fail to unite through the medium of osseous material. The process of union may be delayed or completely arrested at any period of its progress. And as there is no precise time when consolidation is effected, a tardy union should not be looked upon as evidence of a total lack of uniting capacity between the fragments. If there be no bony union in ten or twelve weeks after fracture, the surgeon begins to grow uneasy in regard to the result, and to cast about for the cause of the delay or inability.

Certain fractures frequently fail to unite by osseous material. The neck of the femur, within the capsular ligament, seldom unites by bony union; the patella, from the fragments being held at a distance apart by the contraction of the quadriceps muscle, often makes only a fibrous connection of its fragments; the olecranon and the coronoid processes of the ulna omit the osseous union for a similar reason; the condyles of the humerus occasionally fail to effect a bony consolidation with the shaft, when free motion is not restricted by a proper dressing. But these bones, having special causes for failure to unite, do not come so particularly under consideration in this place.

When there is failure to unite in fractures which ordinarily consolidate in the usual time, the defect may be regarded as pseudarthrosis from extraordinary causes. In such cases a soft ligamentous substance remains between the ends of the fragments, and shows no disposition to become ossific. In rare instances no ligamentous substance is formed. The ends of the fragments become smooth and rounded, constituting a

real false joint. The ends of the bones move freely against one another, being retained in their place by a kind of capsule, which is lined with synovial membrane.

Ununited fractures are so exceedingly rare that some experienced surgeons never met with a case. Lonsdale found but four or five cases out of four thousand fractures treated at Middlesex Hospital, London. Liston met with only one case in his own practice. Hamilton estimates that one case does not occur in five hundred fractures. According to Norris' tables, the humerus and the femur are bones most liable to non-union. This circumstance goes to show that motion has much to do with the failure to unite. When the tibia alone is broken, it rarely fails to obtain bony union, yet after a fracture of both bones of the leg, false joint stands next in frequency to similar defects in the humerus and femur.

The *constitutional* causes of non-union include all those conditions in which the powers of the system are much impaired. Old age, pregnancy, lactation, syphilis, scurvy, and especially the extreme debility of shattered inebriates, have been observed as causes retarding osseous union. Patients having been subjected to courses of mercury, and other prolonged devitalizing treatment, suffer from retarded union after fractures, and sometimes wholly fail to obtain consolidation of their broken bones. Larrey frequently saw, in his extensive campaigns, cases of false-joint that he attributed to poor diet, and kindred causes. Dropsical subjects suffer from pseudarthrosis, and very generally from retarded union.

The *local* causes of ligamentous connections and false-joint, are numerous and varied. Disease of the bone, the presence of a foreign substance, separation of the fragments, and motion, are the most prominent. Obstruction to the circulation, whether from morbid conditions, or tight bandaging, always retard and may prevent bony union. Immovable dressings, especially if applied too tightly, obstruct the local circulation and delay the healing processes. A tight bandage, made uncomfortable by the use of anodyne, refrigerant, and stimulating lotions, produces an anemic condition of the limb that opposes rapid and satisfactory recoveries. Consolidation of the fracture is arrested by a faulty application of the bandage or dressings. I have seen an arm above the elbow bandaged so tightly that the hand and forearm were nearly strangulated.

Such a radical interference with the nutrition of the limb must obstruct or wholly arrest the reparative action.

The appearance of a fractured limb in which the work of repair has been suspended, is peculiarly striking. The wasted flesh, the scaly and dead condition of the cuticle, the puffy or flabby state of the member, are always observable, and indicate the greatly enfeebled nutritive action.

Fatty degeneration in a limb partially paralyzed, though not previously mentioned by any author, is a cause of baffled reparation. In one case of this kind, I was unable to establish a bony union for five months. Even then the consolidation was effected with such imperfect material that the woman sustained a second fracture within a year. She died of general debility in a few months after the second accident, and at the time of her death there had been no progress in the work of repair.

To repeat, movement of the fragments, whether due to the patients' restlessness, to some defect in the apparatus used, or to any other cause, is the obstacle which most directly interferes with union. In forty-four cases investigated by Norris, movement of the broken ends was clearly made out in twenty-two and strongly suspected in several others.

Numerous measures have been devised for the cure of pseudarthrosis. If there be a constitutional vice, an attempt should be made to correct it, or so modify it that the recuperative powers of the system may be sufficient to heal the broken bones. The local means devised for the successful management of ununited fracture, are numerous and varied; but the object of all is the same, namely, to excite action in the parts around the ends of the fragments and to make them throw out material proper for their consolidation. Blisters, friction, rasping, removal of the fractured ends, setons, drilling of the bones, and other means have been tried, and with various degrees of success. Blisters can accomplish but little, as the effect of the irritation does not reach deep enough; rubbing of the sluggish fragments roughly together may arouse a new action which will result in union; the opening of the fracture, and rasping the broken ends of the bone, has been recommended, though the results are not flattering; excision of the rounded and polished surfaces has been performed with success; the seton applied by passing a long flat needle, armed

with a skein of silk, either between or close by the ends of the bone, and kept there till sufficient action is produced in the part to cause the adjacent textures to be excited to throw out the proper reparative material, has been highly recommended.

Dressing the leg—in the event of the non-union being in one of the lower extremities—with a firm support of splints and bandages, and putting the patient on crutches to exercise in the open air, is an excellent method of improving the general health, and of arousing sufficient action in the limb to start or re-establish the healing process. Bearing some weight upon the leg produces friction between the fragments, and promotes vital activity. Exercise on crutches, with gentle use of the fractured leg, might remove or press out of position a piece of ligament, muscle or other soft tissue that had effected a lodgement between the fragments of bone.

Drilling the bone near the fracture for the purpose of inserting ivory pegs, around which a silver wire or hempen cord fastens the fragments in contact, has succeeded in establishing a union in a few instances; but the method has also failed.

The late Dr. Brainard, of Chicago, suspected that the drilling accomplished more good than the pegs and fastenings, therefore he tried perforating the sluggish fragments at their ends, with an awl or perforator. The instrument devised by him has a stock that admits of a change in the size of the

FIG. 4.



Brainard's perforator or drill.

drills, though that is a complication not absolutely necessary. His directions for using the instrument are as follows: "In case of an oblique fracture, or one with overlapping, the skin is perforated with the instrument at such a point as to enable it to be carried through the ends of the fragments, to wound their surfaces, and to transfix whatever tissue may be placed between them. After having transfixed them in one direction, it is withdrawn from the bone, but not from the skin, its direction changed, and another perforation made, and this operation is repeated as often as may be desired." Two or

three perforations, according to Dr. Brainard, are enough to commence with ; more may be tried if the first fail to accomplish the object designed. After the perforations have been made, the limb should be dressed as in a recent fracture, and kept at rest for several weeks before observations are made to determine whether consolidation has commenced or perfected a union. Of all the means devised and recommended for the treatment of ununited fractures, the plan of Dr. Brainard has been attended with the greatest degree of success. It is easy to put in practice, as any awl or drill which can be trusted to perforate bone, will answer the purpose. The point of an awl which makes few chips is preferable to others.

Non-union is not so distressingly inconvenient as might be supposed. In the leg it is the worst ; but even there a heavy leather apparatus, with side-irons, or a mechanical support of some kind, can be worn, which will enable the patient to walk tolerably well. In the arm, the functions of the member are generally preserved in a good degree, and the limb is not without strength and general usefulness.

The freshening of the ends of the fragments can be accomplished by cutting the skin and fascias over the fracture, pulling the edges of the wound apart with retractors and then cutting off the smooth extremities of bone with pliers ; even a saw can be used in the freshening process. The affair is then like a compound fracture, and can be treated successfully with a firm dressing. If the tibia be the subject of non-union the foot must be kept flexed on the leg till consolidation is known to have taken place. It is astonishing how much can be gained by strapping the foot in a flexed state to the leg above. The manœuvre can be accomplished with a long loop of adhesive plaster, the middle going under the ball of the foot or the toes, and the ends extending to the calf of the leg.

CHAPTER V.

DEFECTIVE UNION.

Some united fractures are subject to frequent and long-continued pain, analogous to the neuralgia of cicatrices in soft parts; others are kept irritable by an exuberance of callus which piles up in ridges about the seat of injury.

There are three species of deformity resulting from mal-union: Junction with permanent displacement, angular, rotatory, or shortening; union of two contiguous bones, as of the radius and ulna; and projection of one of the fragments.

Angular deformity can sometimes be remedied by gradual compression. This may be applied with a common fracture apparatus, and by mechanical contrivances suited to the individual case. A splint may be placed opposite the concavity of the angle, and the bone drawn toward it; or it may be fixed to one fragment on the convex side, and perform the part of a lever to which the other is to be drawn by means of bandages; or, the projecting angle may be pressed between two opposing splints. The bandages must be kept tightened in order that the pressure may be maintained. The pressure may be begun as late as five or six weeks after the fracture is received, and be kept up for several weeks. Ordinary extension, combined with pressure, aids in the straightening process.

Re-fracture has been resorted to in cases of distorted union. This is to be done gradually with the hands and the knee, and not violently with a mallet or quick motion across the edge of a board or bedstead.

There is some danger of breaking the bone in the wrong place, though the callus generally yields in preference to a new place. This tendency to break through the callus arises from the fact that in those cases requiring refracture, the union is apt to be irregular and otherwise faulty. Refracture is not to

be attempted in a consolidation over six months old. The new fracture is not attended with a deficiency of healing power; in many cases the reparative process in the effort at reunion, seems to have been accelerated.

After the union of two contiguous bones, as of the radius and ulna, an attempt to effect a separation of parts not belonging together, should be made in cases promising relief. A patient under chloroform does not suffer from the force the surgeon applies. An assistant, to steady the shoulder and elbow, gives the surgeon an opportunity to exert great pronating and supinating power upon the arm.

A projecting point of bone at the seat of fracture, is generally rectified in a great measure by the ordinary pressure of the soft tissues upon the part. In very objectionable instances the salient point of bone may be cut down upon, and removed with the saw or bone nippers.

Chronic pains at the seat of fracture may be modified by the application of stimulating liniments, and by the use of flannel bandages. Enlarged capillaries and varicose veins, are also relieved by the bandaging.

When partial ankylosis takes place at the knee or elbow joints, it is generally good surgery to put the patient under the influence of an anæsthetic, and with force separate the fortuitous connections. After a well executed operation of this kind, passive motion should be kept up for several weeks in order to thwart attempts at re-union, and to favor a restoration of the functions of the joint. In cases of ankylosis, if recent, and free from other complications, an attempt to regain motion is seldom attended with harm, and is often followed with happy results. However, little good will be accomplished unless passive motion be brought to bear several times a day for weeks and even months. I have made satisfactory gains in lessening ankylosis after six months have elapsed. Nature is ready to favor any efforts directed to the perfection of her plans or tendencies.

CHAPTER VI.

GENERAL REMARKS IN REGARD TO THE TREATMENT OF FRACTURES.

The treatment of fractures consists in reducing the broken ends of bone to direct apposition, and in keeping them in place until consolidation is effected. There are some cases in which there is no call for reduction, the relative position of the fragments being unchanged by the accident. In such instances the surgeon has only to maintain the parts involved in the injury, at rest, and to guard against displacement.

These general statements render the subject apparently simple, for they make no allusion to the various complications which render this branch of surgery one of great responsibility. In the ordinary discharge of those professional duties which fall to the lot of the country practitioner of medicine and surgery, there are none so trying and difficult to perform successfully as those pertaining to the management of broken bones. The inexperienced physician may avoid performing what are ordinarily considered surgical operations, but if called to a fracture he does not feel like shirking the responsibilities of the case. A medical man would lose caste, and be considered timid, if he should decline to take charge of a fracture, though he knows that the public holds him pecuniarily responsible for the result of the treatment. There is a wrong sentiment in every community in regard to the duties and responsibilities of a physician, called to take charge of fractures. The medical practitioner has a right to decline any case he pleases on the ground of inexperience on his part.

It is not absolutely necessary that a fracture be "set" the very hour it is received. The patient can be made comparatively comfortable until the services of an experienced surgeon, who is willing to assume the responsibilities of the case,

can be secured. The people should be made to understand that a fractured bone needs, for its skillful management, the highest order of surgical ability. A man maimed or maimed for life by a crooked or shortened limb, is often a striking exhibition of professional incompetency. The victim of a blunderingly prescribed dose of medicine may go to the grave and be forever unseen, or fortunately recover, bearing no evidence of malpractice, but a bad piece of surgery follows the author of it like "a shadow," reminding him of inattention and indiscretion.

It is not to be understood that a competent surgeon never has any unfortunate cases; very far from it. Even the most experienced are charged with malpractice, and sometimes justly. If a young practitioner expects to treat fractures, he should spare no pains to thoroughly inform himself upon all such injuries, and especially upon those that are oftenest followed by defects and deformities leading to malpractice suits. He should study the nature of rotation in the forearm, and the causes that lead to its arrest in the treatment of fractures of the radius and ulna; he will learn the necessity of being guarded in his prognosis when about to engage in the treatment of a fracture of a condyle; he must not be too certain of a fortunate result in fractures of the shaft of the femur, though the nature of the injury be very plain; overlapping and consequent shortening will have to be battled all through the healing process; in a plain fracture of the tibia, he is not to be satisfied that the diagnosis is complete till the fibula, its whole length, has been carefully examined and pronounced intact; finally, he is to master that frequent injury, fracture of the fibula just above the malleolus, complicated with dislocation of the tibio-tarsal articulation.

In the management of surgical cases the physician is held responsible for an *average* result. In other words, he must exhibit as much skill and attention as are *ordinarily* displayed by the profession at large. The term "ordinarily," as used in this connection, is susceptible of no precise or inflexible definition; hence there must always be difficulty in applying its import or meaning in every case.

In a rural district, where opportunities for treating and observing surgical cases are necessarily limited, a less degree of skill must pass as *ordinary*, than in cities and large towns

where exist greater facilities for observation and experimental knowledge. Besides, the country practitioner is not expected or required to have at hand for all emergencies, the most novel instruments and appliances; or to leave his business and spend time and money in seeking them, granting that he knows what is best or most approved. If the physician exercises ordinary skill, care and caution, and makes good use of materials within reach, or manages the case well, taking all circumstances into consideration, he is not pecuniarily liable for an unfortunate result. This is not written as an apology or excuse for ignorance, blundering and inattention, which are never pardonable, but to place the question of pecuniary responsibility in the light in which it is held by the courts.

If medical men were to be held strictly accountable for the results of injuries and surgical operations, few practitioners would hazard their reputation and property in cases involving the dangers of alleged malpractice. Patients would call in vain for surgical aid at a time when professional services might be of vital importance.

FIRST ATTENTIONS TO THE PATIENT.

A person with a fracture of the upper extremity, can support the injured member with the sound hand, and seek a surgeon himself, or go home, and have one summoned to his assistance. A patient will carry his own broken arm with more steadiness than any assistant. Walking produces less motion between the fragments, than riding.

When a fracture occurs to the bones of the leg or to the femur, the patient is not able to walk. The pain attendant upon being removed home from the place of accident, is often intolerable. The following is the language of that famous surgeon, Ambrose Pare, who, just as he was going on board a boat, had his left leg broken by the kick of a horse: "Having received the blow, and dreading lest the horse should repeat it, I made a step backward; but suddenly falling to the ground, the broken bones stuck out, piercing the flesh, the stocking, and the boot; from which I felt the most intolerable pain. Very soon I was carried to the boat, to be taken to the other side, that I might be dressed. But the jolting thus caused nearly killed me, since the broken ends of the bones tore the flesh, and those who bore me were unable to fix them.

On landing I was carried to a house in a village, with even greater suffering than I had endured in the boat; for one carried my body, another my leg, and another my foot; and in walking along they did not keep in step. At length, however, I was laid on a bed to take breath; and here, while the dressings were in preparation, I found myself in perspiration all over; had I been plunged in water I should not have been more thoroughly wetted." The great surgeon, Percival Pott, had a similar experience to that of Pare. Falling from a horse in Southwark, in the suburbs of London, he broke his leg, and the jagged end of the bone pierced the skin. Estimating the suffering he would undergo if carried home in a carriage, he sent for men, and some poles suitable for supporting his body. He purchased a door, and made the men nail the poles to it; once mounted upon this improvised litter, he rode home in comparative comfort, though his sufferings altogether were intense.

A door or shutter taken from its hinges, constitutes a ready litter, upon which a patient with a broken leg can ride home without serious jolting. A carriage is difficult of ingress and egress; a wagon, with its bottom covered with straw or a bed, is a pretty good ambulance, and is oftener employed than any other means of transportation.

The patient having been brought near the bed, the clothing should be carefully removed. While the broken leg is steadied, the seam of pants is ripped the whole length, so the garment can be removed without difficulty. The patient is now ready to take the bed, and to have the limb dressed.

POSITION A FRACTURED LIMB SHOULD TAKE.

A great deal of discussion has arisen among surgeons in regard to the position a limb should take in order to assist in the reduction of the fracture, and to facilitate the healing process.

In fractures of the upper extremity, it is almost invariably the custom to keep the elbow at a right angle, the forearm being supported in a sling. There is but one exception to this rule, and that is in fracture of the olecranon. In this particular lesion the arm must be kept fully extended to relax the triceps, and to favor apposition of the fragments.

In the lower extremities the attitude of partial flexion is that admitting of comfortable repose. Pott claimed that from the muscles arises the whole difficulty of reduction—the resistance depending upon the position of the limb, by putting them in a state of tension. To avoid this tension the limb should be so placed as to relax the muscles, that they may offer the least possible resistance. Such a position is that of semi-flexion.

Desault took an opposite view. He contended that in semi-flexion there is difficulty in making the necessary extension on the broken bone; that in such a position there is an impossibility of accurately comparing the two limbs; that it favors derangements of the fracture while the patient has a movement of the bowels. He also urged the impracticability of firmly fixing the leg in a flexed position; and the trouble of adopting this method when both limbs were broken; and, lastly, the results of experience were against it. Bichat asserted that what was gained by relaxing one set of muscles, was lost by the tension of others.

Dupuytren, in reviewing the subject, announced that while extreme flexion would stretch the extensors, and complete extension made tense the flexors, partial flexion was a position of ease, which is the best condition for reduction.

Malgaigne asserts that experiments made upon the dead subject could not settle the question of the most desirable attitude, for the cadaveric rigidity is quite different from vital contractions. "Muscular action can not be studied except where it exists; hence experiments must be made of necessity upon the living subject." He alleges that complete extension, like complete flexion, is a fatiguing and painful position when kept up a long time.

Boyer says: "Sometimes the difficulty of the reduction arises from the forced extension of the limb and the unequal stretching of the muscles; it may be obviated by putting the limb in a state of semiflexion."

A patient with a fractured leg which confines him to the horizontal position, can be attended with the least trouble if he be placed on a narrow bed, a mattress of cotton or hair being used instead of feathers. A number of pillows, to cushion and support aching and uneasy parts, can be put to good use. Bags, holding a peck or more, made of strong cloth

or drilling, and filled with nice dry sand, are exceedingly useful to put under the knee, if semiflexion be adopted, or to bolster the limb at any point. Several of these sand-bag supports may be needed to wedge up the trochanters, and to prevent the limb from becoming everted. The heel which grows restive under pressure, is generally put at ease between two small sand-bags.

The weight of heavy bed clothes can be kept from the foot and limb, by means of hoops taken from a keg. Two half hoops can be fastened in the middle, and then twisted a little from one another at their free ends, so as to form a four-legged screen for the foot, knee, or other part of the limb.

To prevent the trunk from sliding down the bed, a perineal band may be used. This can be fastened to the head of the bed, and be made to serve as counter-extension, to oppose ordinary extension, which is made downward from the knee, leg, or foot. A firm piece of buckskin forms the best perineal band. It is soft, unirritating, and strong. A belt of drilling or firm muslin, padded to prevent irritation at points of pressure, will answer the purpose.

The elevation of the foot of the bed by placing blocks or bricks under the foot-posts, is a method of getting up counter-extension, now considerably in use. The extending strips or apparatus for extension, being made fast to the foot-board, the inclination of the body toward the head of the bed, is a simple manner of accomplishing what otherwise would require a perineal band, and other disagreeable and complicated machinery. This plan was devised by Dr. Van Ingen, of Schenectady, N. Y. He called it the "Natural extension." To avoid unpleasant sensations from having the head too low, high pillows may be used. The elevation of the foot tends to prevent œdema and congestion of the limb.

CHAPTER VII.

REDUCTION OF DISPLACED FRAGMENTS.

Before any efforts are made to reduce or adjust the displaced fragments, it is best to prepare and have at hand, splints, bandages, compresses, and such appliances as may be needed in the dressing. Every effort to pull and squeeze a fractured limb, is attended with intense pain; and repetitions of purposeless manipulations may do harm to the parts involved in the injury.

Everything being ready for the dressing, the reduction may be made, if any be required. In many instances there is no displacement, consequently no reduction is requisite. Inexperienced practitioners give every limb, before they place it in a fracture apparatus, an energetic pulling, and not a few vigorous twists, *to reduce*, perhaps, what does not need reducing. It is folly to suppose that the extent, direction, and displacement of every fracture can be accurately determined by an examination. The depth of the fractured bone, and the swelling of the soft parts, may preclude a satisfactory diagnosis. The usual signs of fracture having been observed, and comparisons made with the other limb, the existence of displacement can be pretty accurately determined. Shortening or overlapping of fragments can generally be overcome by extending and counter-extending forces applied by the hands of assistants. In obstinate cases of muscular contraction, chloroform may be used to overcome it, and to put the patient into that insensible condition which admits of free manipulation and examination of injured parts.

As soon as sufficient extension has been made to overcome the resistance of the muscles, the ends of the broken bone are to be placed as nearly as possible in their natural relations.

This is called adjusting, setting, or coaptating the broken bones; and is generally supposed to be a very skillful manœuvre, though not half so difficult to perform, as to keep the bones in place when once adjusted.

In fractures of subcutaneous bones it is generally easy to see when the extension is sufficient, and the coaptation perfect. The sudden restoration of the natural outline of the limb is pretty good evidence of the mutual adaptation of the fragments. Measurements and comparisons with the opposite limb, afford valuable aid in determining the relations of the fragments; and are decisive when other evidences of reduction fail.

In the event of a serrated or impacted fracture, it is necessary to extend the limb beyond its natural length, and then, by partial rotation, to coax the fragments into apposition. If soft parts intervene between the fragments, they are generally released by extension and rotatory manœuvres.

As a general rule, the sooner reduction is effected after the accident, the better. Some surgeons recommend that the reduction be delayed for three or four, or even ten or twelve days, or until inflammation has subsided. No reparative process of a substantial nature being yet commenced, the position of the fragments during that period does not interfere with the delayed reduction, nor affect the final result. However, immediate reduction has great advantages. It restores the patient to comparative comfort, and diminishes the dangers of spasmodic twitchings and other evils resulting from the malposition of the parts.

When reduction is delayed for several days after the accident, the fragments become more or less fixed by effusions into the surrounding tissues; and the muscles, accustomed to a new position, offer considerable resistance to a change.

If the surgeon is not called for three or four days after the reception of the injury, or until the inflammation is at its height, it may be advisable for the time to use such remedies as tend to lessen the inflammatory action, and to put off the reduction until the parts are more manageable. The disturbance of an irritable injury, when much inflammation and excessive ecchymosis exist, has provoked convulsions, uncontrollable twitchings, and even tetanus. On the other hand, according to Velpeau, neither inflammation, nor spasm, should

induce any delay; so far from that, immediate reduction is the quickest and surest method of alleviating them.

Malgaigne declares that, on account of muscular contraction and spasm, he has been frequently thwarted in his efforts at reduction, even with good assistants, and therefore has been obliged to resort to mechanical means to multiply force. As he says nothing about the relaxing effects of chloroform, it is probable that he did not use the agent. Under the influence of profound anæsthesia, few patients will be met whose muscular condition can resist well directed efforts at reduction.

Several surgeons have been obliged to saw off the protruding fragment in compound fracture, before a reduction could be effected. Cases treated in that manner have been reported as doing well, union taking place as readily as in ordinary compound fracture. Of course, there would be as much shortening as there was length of bone removed, yet that would be moderate in most instances.

In managing a compound fracture the finger is to be employed to ascertain if there be present in the flesh detached pieces of bone that need removing. To leave such pieces would endanger non-union, prolonged suppuration, and other serious troubles. When a fragment of bone protrudes through a wound in the flesh, it is best to enlarge the aperture in the integument, in order to secure reduction. A large wound in the skin heals about as quickly as a small one. Besides, an opening of considerable size the more readily admits explorations with the forefinger. And if detached fragments, that may perish, be present, the external wound offers an excellent opportunity to extract them. In a comminuted fracture the opening made in the flesh is indispensable to a right understanding of the situation of affairs.

CHAPTER VIII.

APPARATUS FOR THE TREATMENT OF FRACTURES.

Much ingenuity has been displayed in the invention and construction of apparatus for treating fractured bones. The apparatus for retention includes bandages, splints, junks, mechanical contrivances for maintaining extension, immovable dressings, together with belts, adhesive plaster, woven wire, and various means to enable the surgeon to manage special cases.

Bandages, or *rollers*, as they are sometimes called, can be made of several different materials. Those most commonly used are made of old sheets, or unbleached muslin. Flannel makes an excellent bandage. It is elastic, and does not slide, one fold over another, as freely as cotton fabrics.

An arm-bandage should be at least two inches wide, and eight yards long; a leg-bandage, two and a half inches wide and ten yards long; and a rib-bandage, five inches wide and twelve yards long. There is no inflexible rule governing the dimensions of bandages, yet it is of considerable importance that the width and length of a bandage be properly adapted to the part to be treated. A bandage which is to extend from the hand to the elbow, or from the foot to the knee, need not be so long as indicated above. A bandage should be cut off as soon as enough has been used; no advantage is gained by making more turns than are necessary.

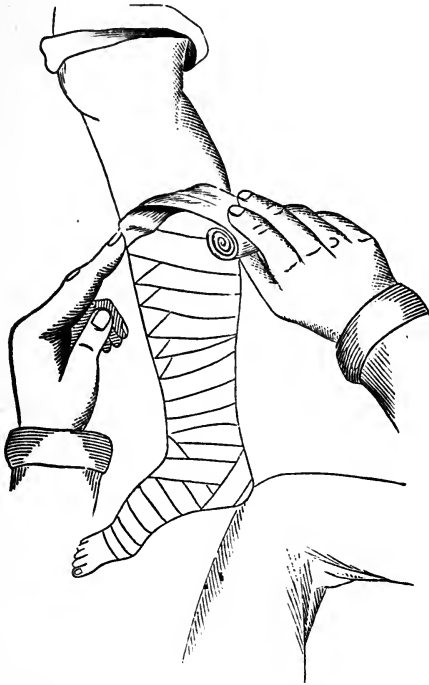
All bandages should be rolled into a firm, even, and compact mass. This may be done perfectly well with the hands, or upon the knee, after the roll is started. An assistant may take the kinks and twists out of the strip as it is being rolled.

A bandage which is used with plaster of Paris, to constitute an immovable dressing, ought to be made of coarse muslin, so as to retain the gypsum in its meshes.

As far as practicable, the bandage ought to be made of one continuous piece, or with few joinings; and the selvages should always be torn off. In a word, the surfaces and edges of the bandage ought to be as smooth and even as they can be made; and there should be nothing which can press unequally upon the limb, to constrict or irritate it in any way.

In applying a roller it is desirable to secure the end of the bandage by the first turn or two, in order that the proper traction may be sustained without slipping. A turn is generally taken around the wrist or ankle for no other purpose but to fix the commencement of the bandage.

FIG. 5.



Method of making a "reverse" in a spiral reversed bandage.

When a bandage is to rest in contact with the skin, it should be applied flatly to the surface—there should be no creases nor puckers. Where the part to be bandaged is of nearly uniform calibre, as, for example, the forearm a short distance above the wrist, the roller may be carried around the

limb circularly, forming what is called a "spiral bandage." Each turn of the roller ought to overlap about a third of the preceding one, and no intervals or gaps be left between the turns. But the conical outlines of the human limbs do not readily admit of the simple application of the circular bandage. It becomes necessary, therefore, to apply the roller by making "reverses," (Fig. 5), or to adopt some other plan suited to the contour of the limb. It is not easy to describe in words the method of making "reverses," but the accompanying illustration shows how they are made.

In a fracture dressing it often becomes necessary, in order to exert a considerable degree of pressure on a particular point, to place a wad of lint or folded cloth, called a compress, underneath the bandage. The pad or compress is to be of a size and shape to fit or suit the part pressed upon; and some care must be exercised to confine the compress to the spot where the extra pressure is needed.

When the arm is bandaged, the limb should be covered from the fingers upward to the elbow or shoulder; and the leg, when properly bandaged, is covered from the toes upward to the knee or hip. This will prevent the hand or foot from becoming swollen and œdematous.

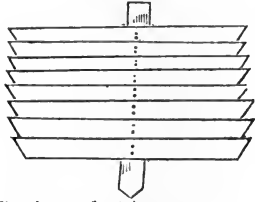
When a bandage is used to give support or to make pressure, great care should be taken that it is not so tight in any part as to cause constriction. Cases are on record in which the most disastrous results have been brought about by a bandage being drawn too tightly. Limbs have sloughed extensively, or become mortified, requiring immediate amputation, for no other reason than that the bandage which was intended to give even and gentle support, has been applied with so much pressure as to stop the circulation, and to establish gangrene.

It is the duty of the surgeon to dress a fractured limb for the first time as if he expected it to swell. This may save him the trouble of being called to loosen the bandage, and the patient a great amount of needless suffering.

As a general rule, a bandage ought not to be applied underneath a splint. The splint should be well padded with raw cotton, tow, or soft cloth, then wound with strips of muslin, and laid next the skin.

MANY-TAILED BANDAGE.—This is made of strips long enough to go once and a half around the limb. These, to the number of fifteen or twenty, may be laid, before application, in regular order, from above downward, one overlapping the other for about a third of its width. The strips may be kept in their places by a longitudinal band, stitched to their centre.

FIG. 6.



Bandage of strips, or many-tailed bandage.

When the bandage has been prepared, the limb is laid upon it, or the strips, arranged upon a piece of pasteboard, are slipped under the limb; and then each separate piece is made to encircle the limb, beginning with the lowest, the ends being brought up, one on each side, and crossed in front. One end of the last piece only needs pinning; the others are held

by the overlapping. This has been called the bandage of Scultetus, and is convenient in compound fractures, as the lacerated tissues can be examined without disturbing the limb the ends of the bandage being laid off for the time, and then returned to their places.

Another similar bandage is made by taking a piece of cloth long and broad enough to envelop the limb, and tearing it on each side into tails, leaving a few inches in the middle untorn, to support the tails or strips. The ends are brought around the limb, and lapped, as in the bandage of Scultetus.

BANDAGES PREPARED WITH STARCH, ETC.

What is called an “immovable apparatus,” is generally made by saturating the bandages surrounding the limb with a liquid which, after it is dry, gives a great degree of solidity to the dressing. By means of this the patient is sometimes enabled to leave his bed in a few days after he has met with a fracture of the leg, or even of the thigh, and to go about on crutches during the time that union is taking place.

The *starch-bandage* may be made as follows: The starch is mixed with water until it forms a thick paste. The surgeon,

having at hand rollers, lint, strips of pasteboard, and the basin of paste, lays a piece of broad tape along the front surface of the space to be bandaged, (for a purpose to be presently explained), and then begins the application of the dressing. A common roller, made of muslin or flannel, is run upon the broken part, whether foot, ankle, leg, or thigh, and an assistant, with a brush or swab, applies the starch-paste to the bandage as it goes on. Strips of pasteboard, leather, or other bracing material, are dipped in the paste, and then laid along the limb upon the first layer of bandage, to strengthen the dressing; over these splints another roller is applied, the assistant all the time using as much paste as may seem sufficient to stiffen and consolidate the dressing. Even the third roller may be employed in this way to give additional strength to the dressing.

Extension and counter-extension should be kept up by some of the means already indicated, for thirty or forty hours, when the dressing becomes hard and immovable. If in the course of a few days, it be found that a subsidence of swelling has left the dressing loose, the piece of tape laid on the limb at first, may be used to lift the hardened case from the skin, so it can be ripped open the whole length. The same means may be used to free the constriction in the event of swelling. Suetin devised scissors, one blade having a probe point, to slit up the starch-bandage, and to cut a hole in it to correspond to the sore in a compound fracture. A grooved director and a bistoury will answer the purpose of the scissors.

If the limb shrinks away to a considerable extent, the old apparatus should be removed, and a new one put on. An immovable dressing is to extend to the knee in case of fracture of the leg; and to begin above the knee and extend to the body, in case of fracture of the femur—the knee-joint being left free in both instances. The ankle-joint may be covered, the dressing beginning at the toes. Lint should be carefully packed between the ankle and the tendo-Achillis, on each side, that the dressing may not bear too heavily on the prominences of the joint.

GYPNUM BANDAGE.—A plaster of Paris bandage has the same general features as the starch-apparatus. A coarse roller of muslin is thoroughly dusted with the powdered gypsum, and

then applied to the limb. While the bandage is being put on, it should be moistened and freely dusted with the dry powder in order to strengthen or stiffen the application. It is well to wrap the limb in flannel or soft lint before applying the gypsum bandage. This precaution may save troublesome irritation. Three rollers, well powdered while being applied, generally make a stiff, immovable apparatus.

The advantage of gypsum over starch is that it dries or "sets" immediately. On the contrary, it is heavier and not so easily cut away in the event of its being too tight or too loose. When plaster of Paris is used, extension should be kept up by assistants for a few minutes, or until the stiffening ingredient has become solid.

The immovable apparatus is frequently employed in hospitals and public institutions, but it has not been extensively used in private practice. There seems to be no good reason why it is not more commonly adopted, as every house contains starch, and the other means needed to complete the dressing.

SPLINTS.


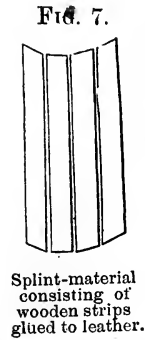
Splints are made of various substances, according to the caprice of the surgeon, or the nature of the materials at hand. Wooden splints are by far the most commonly used in country practice; and, in the majority of instances, they are the best.

From time to time splints of various materials have been introduced, so that a surgeon in a large city can make his choice among a number of appliances, and select that which he may fancy, or is best suited to his purpose.

The country practitioner derives little instruction and consolation, in case of emergency, from illustrations and teachings which deal only in "patent splints" and complicated contrivances that can not at the time be obtained. With a few practical suggestions he can, if moderately ingenious, make from thin boards all the splints he may need, or, at least, construct a temporary appliance which will do till the village car-

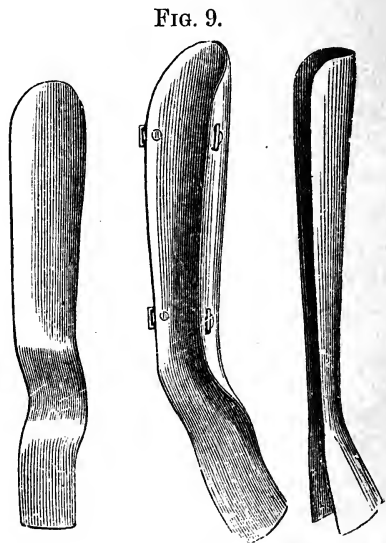
penter can furnish him with a more suitable apparatus. A shingle, a piece of lath, a cigar box, sole-leather, binders' board, pieces of tin, and other materials adapted to the purpose, can be pressed into service. A surgeon of expedients is rarely baffled through want of appliances. Strips of bark, or even a trough of bark taken from a sapling, can often be used with great satisfaction in dressing a fractured arm or leg. Surgical instrument makers keep for sale *lined splint*-material, which consists of thin board sawed into parallel strips, and held in place by a piece of pliable leather glued to one side. Splints cut of any desired length and

width, from the lined material, can be used in two ways: to envelope an arm or thigh, as a concave splint, the leather acting the part of a hinge between the strips; and, with the wooden side toward the limb, to answer as flat splints for the forearm or leg.



Moulded gutta-percha splints.

Splints of *gutta-percha* are easily moulded to the contour of the body. Cut into proper shape and size, they may be softened in hot water, and then made to fit the part to receive them.



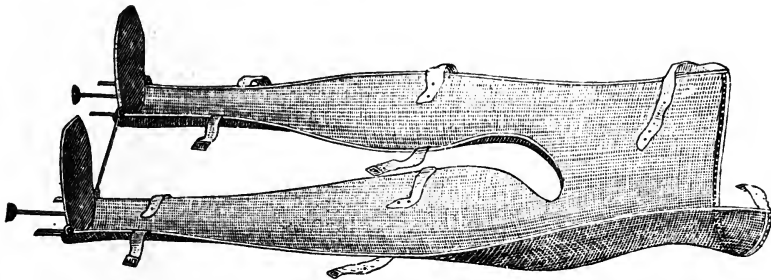
Carved wooden splints.

What are ordinarily called "carved splints," several of which are represented in the accompanying diagram, are made from thin boards, and bent into desired shapes, the wood having first been rendered pliable by the action of steam. These appliances are cut and moulded into various lengths and shapes to fit the arms and legs, and fitted with hinges to span the joints. Appliances of this kind are put up in "sets," and sold about the country, by Welch, Day, and other manufacturers of such wares.

Although such curiously fashioned and highly polished pieces of surgical mechanism, make a display, it is plain that they constitute a Procrustean bed, to which patients of all sizes and shapes must conform.

Woven wire has been cut, bent, and soldered into various forms for the support of fractured limbs. (Fig. 10.) The "Wire breeches," represented in the accompanying illustration, are a sample of the manner in which woven wire may be wrought to suit the purposes of the surgeon. This apparatus is one of

FIG. 10.



"Wire breeches."

the best that can be employed to treat fractures of the neck of the femur. The screw in the foot piece permits of making extension, and the shape of the upper extremity of the machine is such that the tuber ischii can easily rest against it for counter-extending support. The length of the limbs can be accurately compared while the patient is in the apparatus; and the wire extends so far above the hip-joint that the constant motion between the fragments is prevented. The patient can sit up in the apparatus; and by having its upper extremity raised upon a temporary support, the alvine evacuations can be re-

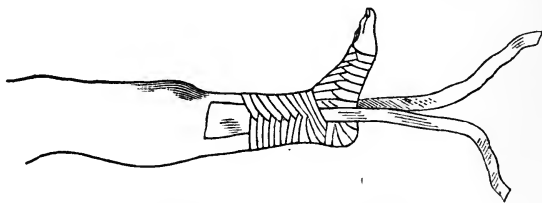
ceived in a bed-pan. The apparatus should be lined with thick flannel before the patient is put into it.

All the edges of the wire-gauze have a heavy wire soldered into them, to give the machine a *finish*, and proper firmness. The "wire breeches" were first devised for the treatment of hip-disease.

Concave and angular wire splints, of various patterns for the shoulder and other joints, have been in reputable use. They admit free ventilation, and are not particularly heavy.

ADHESIVE STRIPS.—One of the greatest improvements in the treatment of fractures of the leg, where it is necessary to effect and maintain extension and counter-extension, has been the introduction into use of adhesive strips, to take the place of a gaiter or other contrivance fastened upon the ankle. Every practitioner who has had occasion to make fast to the foot and ankle with the means formerly in use, fully appreciates the difficulties growing out of attempts to produce extension. Blisters, irritations and excoriations were the results of the gaiter and kindred appliances. Adhesive strips well applied, and carefully retained in place by the circular and oblique turns of other strips, keep their hold, and are borne with ease. The extending part of the dressing with adhesive strips, may be applied as follows: One long strip is cut, and

FIG. 11.



Adhesive strips applied.

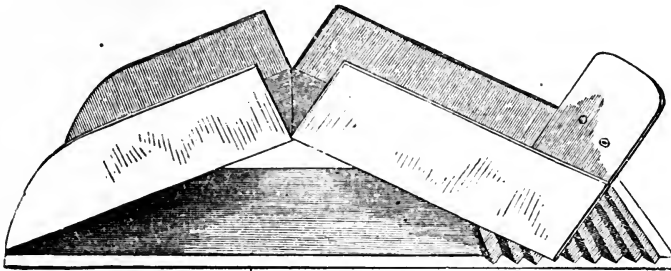
its two ends made to adhere to the sides of the leg and ankle, leaving a loop below the hollow of the foot. These ends will gradually slide down the limb unless they be bound in place by other strips, which are applied circularly about the leg and ankle, covering the two parts of the first piece at each turn. Finally, a strip or two may be applied diagonally to the others, to hold all firmly in place.

A block of wood may be placed in the loop to prevent pressure upon the ankle when the extending force is applied.

The strips will firmly adhere for months unless some alcoholic lotion be allowed to come in contact with them. They rarely need removing during the whole period of treatment.

A *double inclined plane* apparatus is one of the various contrivances to keep up a natural extension and counter-extension in fractures of the leg and thigh. It consists of two boards, hinged in the middle, and long enough to reach from the tuber ischii to the heel. There is a foot-board connected with the leg-piece; and this is sometimes made adjustable so it may be always placed in contact with the foot, whatever be the length of the limb. The double inclined plane is hinged at its upper extremity to a frame or board—the bed-piece—and is held flexed at any angle by notches in the lower end of the bottom board. (Fig. 12.) Side-boards may be nailed or hinged to the halves of the double inclined plane bed or bottom

FIG. 12.



Double inclined plane fracture box.

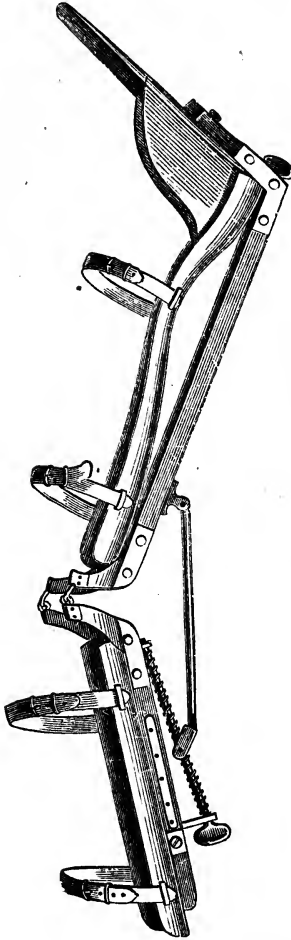
pieces, to form a fracture-box. Into this, cushions or sand-bags can be laid, and then the broken limb may be placed upon them, and secured by tapes and other supports.

Double inclined plane apparatus, with various modifications, has been in use for centuries. The weight of the body and thigh sliding down the upper plane, produces counter-extension, and the inclination of the leg down the lower plane—extension. Additional extending force is applied by means of the adjustable foot piece and screws.

Two pieces of board, hinged with leather in the middle, having a cord to reach from one board to the other, to hold them flexed, constitute an easily constructed double inclined plane, which may answer every purpose of a more complicated apparatus.

Fracture-beds are intricate and costly affairs, rarely constructed for patients in private practice. They are not extensively used even in hospitals. A description of one will answer for all. That of Amesbury is perhaps as good as any ever constructed. It consists of a horizontal frame, supporting three pieces of wood, or planes, hinged together, and long

FIG. 13.



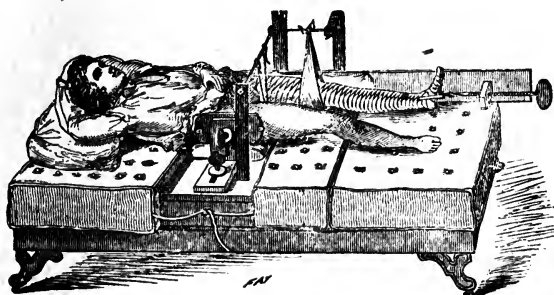
Welch's double inclined apparatus.

enough, when connected, for an adult to lie stretched out upon. The upper plane receiving the trunk, is raised at the bolster-end; the middle one, intended for the thighs, is made of two pieces sliding on one another so as to suit limbs of different lengths, and forms with the third piece a double inclined plane; this last, which supports the legs, has a foot-piece, used to confine the feet when it is necessary, and always serving to sustain the weight of the bed clothes. The upper of these planes is to be supplied with a thick mattress; the two others, with similar ones only half as thick. The middle one has an opening, with a basin fitted to it to receive the fecal evacuations; and the pelvis is fixed by means of a belt passing across the upper of the three planes. The hinges of the apparatus allow the different angles to be changed at

will. Burge's apparatus, (Fig. 14.) consisting of a bed, and an arrangement to make extension and counter-extension in treating fractures of the femur, is a useful piece of surgical and mechanical mechanism, but it is too complicated and expensive for ordinary use. The diagram presented to illustrate the appliance, shows that the machine could not be constructed for less than fifty dollars; and is made of so many different

materials that it would require a carpenter, blacksmith and upholsterer to construct the apparatus. Many intricate contrivances of varied merit have been pressed upon the attention

FIG. 14.



Burge's fracture-bed.

of the profession from time to time, but none have come into general use. If a surgeon were to possess all the different appliances devised to treat fractures, he would need extensive store rooms in connection with his office, to give them shelter.

The simplest and best method of exerting extension and counter-extension in the treatment of fractures of the leg and thigh, is to secure the limb to the foot of the bed by using adhesive strips upon the leg and ankle as an attachment for a cord to make fast to the lower end of the bed. Elevation of the foot-posts by means of blocks piled one upon another, to the height of eight or ten inches, secures a sliding inclination of the patient's body towards the head of the bed, and thus exerts both extension and counter-extension upon the broken limb. The force exerted is sufficient and easily borne. A restless child will bear this dressing without complaining. If splints be kept snugly applied to the fractured limb, the result will be recovery without shortening or other deformity.

CHAPTER IX.

RE-DRESSINGS.

After a fractured limb has been dressed, or "put up," to use a phrase of the London hospitals, it becomes a question when it should be *re-dressed*. According to some of the older authorities a definite time should be allowed to pass before the dressing is meddled with; and not a few timid followers of revered authority have permitted their patients to suffer needless torture, inflicted by swelling and tight bandages, because the prescribed time for re-dressing had not arrived.

Whenever a fractured limb undergoing treatment is painful, it is in danger, and should be undressed at once, that the cause of the distress may be ascertained and averted. If local pain and general uneasiness arise within twelve hours after the bandage or apparatus is applied, the limb should be re-dressed. An opiate or anodyne to allay the pain excited by the movements of the limb during the manipulations of dressing, may not be out of place, but repeated and heavy doses of any narcotic to allay the distress occasioned by the constriction of a tight bandage, may benumb the pain; yet while the wails of the patient are thus silenced, the dreaded gangrene may be doing its fatal work.

If the first dressing is well applied, and no swelling comes on to convert the retaining tapes and bandages into constricting cords, the compresses, splints and bandages may be left in place for several days. I have frequently left the dressings a week or ten days without interference. Frequent renewals, without substantial reasons for them, are worse than useless. They hinder the healing process, give the fragments an opportunity to play upon one another, and to overlap in cases where that condition is possible.

As soon as the swelling has subsided, and the shrinking of the limb permits the bandages to become loose, a renewal of the dressing should take place. It is probably best, in favorable cases, to re-dress once a week while the retentive treatment lasts. The limb may be looked at oftener. A case that is convenient to watch may be seen every other day; if it be at a distance, and circumstances do not favor any more attention than is absolutely necessary, a revisit and redressing once in ten days may do just as well as daily inspections. There is generally intelligence enough among the patient's friends to be entrusted with the execution of certain instructions pertaining to the case. If yellow blisters, or a livid color of the skin, show themselves between the folds of the bandage or anywhere beneath the dressings, the surgeon can be informed of the untoward condition. A too tight dressing can be loosened by cutting a few of the turns of the bandage partly or wholly in two; and, in the event of loosening, a few additional tapes can be tied around the dressing.

In fractures of the thigh or leg, the surgeon should, every time he visits the patient, compare the two limbs in regard to length, direction of feet, and general aspect. This can be done before the dressing is removed. The patient, while his limbs are inspected, should be made to lie on his back, straight in bed. A slight twist of the pelvis makes a great difference in the apparent length of the legs. With the trunk and limbs straight, accurate measurements with a tape or inelastic cord should be made from the symphysis pubis to the inner malleolus of both ankles. The placing of the two heels together and observing whether one is below the other, is a good test of the relative length of the limbs. If there be evidence of shortening, the dressing should be taken off, and the defect or displacement remedied. Re-dressings for such a purpose are always proper, even at the risk of disturbing the healing process. There is always an urgent necessity, on the part of both surgeon and patient, to avoid deformity if possible.

CHAPTER X.

MOVEMENTS ALLOWED A PATIENT.

After a fracture of the arm has been dressed, and the limb is suspended in a sling hanging from the neck, the patient can take moderate exercise upon his feet. Motion at the point of fracture, for obvious reasons, is to be guarded against. In fact, the patient, to avoid pain, is very likely to carry a broken arm with much care. If the dressing become loose, the motion between the fragments tends to establish false-joint.

After fractures of the femur, and of both bones of the leg, the patient must keep quiet in bed during treatment, unless an immovable apparatus be applied. In a fracture of one of the bones of the leg, the condition is different. The unbroken bone prevents shortening, and acts as a stay or support to the one fractured. A patient with a broken tibia or fibula well dressed, can go about on crutches.

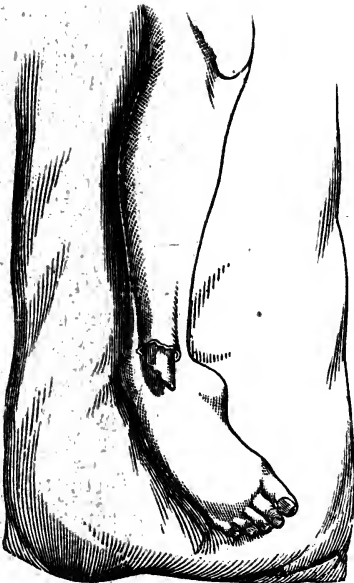
In fractures of the femur, it is dangerous for the patient to go on crutches, even if the immovable apparatus be employed. If the fracture be of the cervix, or through the upper third of the bone, it is difficult for the bed-pan to be used without imparting more or less motion to the fragments. A cord suspended from the ceiling, which can be grasped, enables the patient to raise himself with less motion than he can be raised by the efforts of assistants. If the patient is too feeble to raise himself, an assistant can do it by placing a hand in each loin, and lifting upwards and drawing backwards at the same time. This prevents the body from sliding down in bed, or the pelvis from descending upon the broken thigh. The body may also be kept from sliding downwards, by using a perineal band, which is to be tied to the head of the bed. A box or block so placed that the sound foot may press against it, in efforts to raise the pelvis, may be of considerable service.

CHAPTER XI.

MANAGEMENT OF COMPOUND FRACTURES.

The directions given by Ambrose Pare, himself an eminent surgeon, to his surgical attendant, when he received a compound fracture of the leg, are quite explicit. "If the wound be too small, enlarge it with a razor, that you may the more easily replace the bones in their natural position; and carefully explore the wound with the fingers, in order to remove such

FIG. 15.



Compound fracture.

fragments and bits of bone as may be completely detached and press out the blood which has become effused about the wound." This suggestion, to clear the cavity of the wound from blood and splinters, is generally to be followed. Small fragments isolated from the periosteum, are likely to create as much trouble as other foreign bodies in the flesh.

The wound once cleared of coagula, splinters, dirt, and other foreign substances, and the fragments adjusted, the treatment is much the same as in simple fractures. The dressing should be so applied as not to permanent-

ly cover and choke the wound, for it must have an opportunity for the free escape of pus and other fluids. When the immovable apparatus is employed, the wound, while the

dressing is being put on, is covered in ; but, after the dressing has become consolidated, a hole or door is cut so as to expose the wound.

The edges of the wound are not to be drawn together with sutures, but a piece of tin-foil, or a lead plaster, may be employed to shield the lacerated parts. As previously stated, the many-tailed bandage is well suited for the treatment of such injuries, inasmuch as the wound can be often exposed without disturbing the limb. Care must be exercised that flies do not deposit their ova in the saturated folds of cloth about the wound.

The immovable apparatus is not generally suitable for compound fractures. Unpleasant complications have too often arisen when it has been used. Malgaigne says of it: "Unhappily we have too much reason to fear pus will burrow between the integuments and the muscles, and between the muscles and the bones, endangering the limb and even the life of the patient. I once had to treat an old soldier, a stout, sanguine man, who fell from a ladder, and sustained a compound fracture of the tibia at its lower part. The immovable apparatus was employed ; on the eighteenth day it had to be removed on account of the insupportable fetor. Four days later, pus flowed abundantly from the heel. On the twenty-ninth day, the increased discharge and the excessive fetor made a fresh removal necessary ; the whole leg was pasty and flaccid ; a probe, introduced by the wound, passed up several inches between the two bones ; the tibia was denuded at its external face ; sinuses were formed in the limb above and below. Several surgeons regarded amputation as unavoidable. This, however, was postponed, and by great care, after three incisions had been made, and a long train of severe symptoms had been overcome, a satisfactory cure was effected by the end of six months."

The application of carbolic acid in a dilute form, to the wound of a compound fracture, is valuable to remove the fetor ; to prevent a profuse suppurative condition ; and to favor the formation of firm and healthy granulations.

TOPICAL AND CONSTITUTIONAL TREATMENT.

It was once customary to apply cerates, poultices, and fomentations to fractured limbs. At a later period in the history of surgery, it was a common practice to soak the dressings in laudanum, brandy, lead-water, camphorated liquids, and various other lotions. At the present day, dilute tinctures of aconite, arnica, and wormwood, are thought to be valuable applications; rum and whisky have always enjoyed a popular reputation for allaying inflammation in almost every kind of injury. Some practitioners order the frequent application of water to fracture dressings, with the object of cooling the inflamed tissues beneath.

The reasons adduced for employing cooling, stimulating, and anodyne lotions are not without plausibility, yet, in practice, it is found that more harm than good follows any kind of topical medication. A common muslin bandage creases upon being wetted, often rendering the dressing harmful; then, if allowed to dry, as is frequently the case, it will be too loose. Blisters are more likely to occur under wet dressings; eruptions and discolorations, with itching and other unpleasant sensations, are among the troublesome effects produced by lotions. I invariably find that fractured legs do the best when treated with dry dressings. Much is said by those whose experience ought to render them competent authority, about applying evaporating lotions to fracture injuries of the elbow, knee, and other large joints, yet the instances are few in which I could approve of such treatment.

The extensive ecchymosis that occasionally attends upon a fracture of the leg, excites dire apprehension on the part of the patient, yet the extravasation of blood and discoloration rarely result in any harm. Neither leeches nor stimulating lotions will prevent the spread of the discoloration, or remove the effused blood and serum.

If, upon the renewal of a dressing, it be found that large blisters exist, the bags of serum may be punctured, care being exercised that the subsequent dressing does not press upon the parts lest suppuration and sloughing follow. The surgeon should frequently re-dress a limb in a blistered condition, or watch it carefully until parts thus effected are sound.

Muscular twitching is occasionally a disagreeable complication which needs subduing. The application of chloroform to the limb may allay the difficulty; the internal use of an opiate has been attended with relief, though some patients of great nervous excitability grow worse under its administration. Chlorodyne has a far more desirable effect upon spasmodic conditions.

Distressing pain attendant upon the reception of a fracture, and the disturbance caused by the reducing process, ought to be assuaged by anodynes in doses gauged by the severity and continuance of the distress.

Febrile symptoms may be allayed by the use of aconite, or kindred agents. The evacuation of the bowels by the influence of an enema, or a mild purgative, frequently arrests feverish paroxysms. A hot skin may be cooled by the frequent use of the wet sponge. In case of "chills" and hectic, from exhaustive suppuration, iron, quinine, and the mineral acids may be employed to advantage.

The *diet* should be light for the first few days after the injury, but in the course of a week or ten days, it may be substantial and nourishing.

Excoriations on the nates arising from unsuitable beds, and a prolonged recumbent position, may generally be prevented by the use of a soft piece of buckskin to parts threatened with such a disagreeable complication. Air and water-cushions are useful in protecting parts irritable and excoriated from prolonged pressure of the bed.

CONVALESCENCE.

There is generally too little attention given to patients after the fracture apparatus is removed. The limb, though the broken bone has united, remains stiff, swollen, weak and tender. Compression and inaction have established a condition of atrophy; and the neighboring joints have lost their suppleness. A patient is very sensitive to this enfeebled state of the limb, and needs encouragement to make him exercise properly, and to employ those means which tend to re-establish the functions of the part. Extreme timidity prevents patients from giving their convalescing limbs a desirable

amount of action. There is an instinctive dread that the limb may be re-broken, or that it will not sustain the weight of the body.

It is a discreet precaution to keep patients who have sustained a fracture of the thigh, or of both bones of the leg, in bed for a week or two after the consolidation is known to have been established. As has been previously stated, there is yet danger of a gradual yielding of the newly-formed callus; yet during this confinement to the bed, the limb may be moved at the joints, and rubbed with the hand or coarse towels. At length the patient may venture upon crutches, and then to take gentle exercise with the support of a cane; and, finally, he will walk without any assistance, though with a limp in the gait even when there is no shortening or other deformity.

Sometimes a patient is so fearful of a fall or a second accident, that he has to be coaxed and urged into sufficient exercise to invigorate the limb. Liniments and douches are of questionable utility so far as medication is concerned, but their indirect effects may prove exceedingly advantageous. The patient is recreated while applying a liniment; and the circulation of the limb is improved by the friction employed in the application. There is a popular notion that certain penetrating or oleaginous liniments will impart suppleness to stiffened joints and rigid tissues; this prejudice may be turned to the advantage of the sufferer, for he will industriously employ any means that have ascribed to them the desired qualities.

Patients are to be impressed with the importance of employing considerable force in the flexion and extension of partially ankylosed joints; and of keeping up this action for weeks and even months in obstinate cases. Persevering efforts of this kind have accomplished wonderfully beneficial results.

Flannel bandages should be kept applied for weeks and months to legs inclined to swell, especially if the veins be varicose. At length the bandages may be laid aside, and elastic stockings worn continuously to keep the limbs in good condition. Elderly persons make exceedingly slow recoveries; and if of irritable temperaments, are querulous and despondent.

CHAPTER XII.

DIASTASIS, OR SEPARATION OF THE EPIPHYSIS.

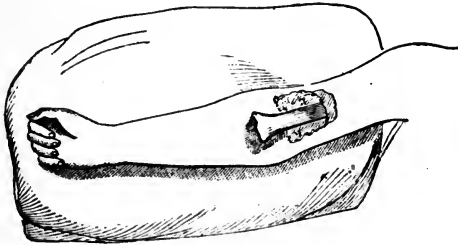
Strictly speaking, there can be no fracture without breaking of osseous material, yet the forcible separation of the epiphysis from the shaft of the bone, through the cartilaginous connection, in young subjects, is a lesion analogous to fracture. It is an accident that can not always be distinguished from fracture; and the treatment of the lesion should be the same as that directed for a broken bone. In the diagnosis of the case, clear and distinct crepitus will be wanting; but all the other signs of fracture may be present.

All the long bones, from birth to fifteen years of age, are subject to this peculiar injury. Both extremities of the humerus, radius, femur, and tibia, have been separated from the shaft, through the cartilages interposed in growing bones, between these distinct ossific parts. The separation may take place during the careless delivery of a child. The obstetrician, unless he bears in mind the dangers of diastasis, may, in attempts to bring down an arm or leg, sever the cartilaginous connections of the humerus or femur. If such an accident should occur, it would be known by the flaccid, mobile condition of the broken limb. Swelling and discoloration would soon exhibit themselves; and, in handling the child, the instability of the member would be observable. The limb would fall powerless into unnatural attitudes. Once discovered, the injury should be treated like an ordinary fracture.

I was once called to attend a lad of five or six years of age, who had separated the lower epiphysis (Fig. 16) of the humerus, by a fall upon the curbstone. The physician first summoned to take charge of the case, bandaged the arm so tightly that the soft parts, on the anterior aspect of the arm, sloughed. This was the state of the case when I was asked

to take charge of it. The shaft of the humerus protruded through the opening made by the slough, converting the lesion into something like a compound fracture. The protruding bone was denuded of periosteum, and pus was discharged through two sinuses above the main opening. The

FIG. 16.



Separation of the lower epiphysis of the humerus.

fortunate discovery of granulations upon the end of the protruding bone, suggested the idea of extending the limb until the projecting bone would sink into its natural place and position. Accordingly, the hand was suspended to the bed-frame above, so that the weight of the body, by extension, kept the bone where it ought to be, in the bottom of the wound. The period of recovery was prolonged, and attended with profuse suppuration, yet in the end the result was quite satisfactory, considering the condition of the limb.

Diastasis often takes place at the point of the elbow,—there is a partial separation of the epitrochlea. The injury is attended with great pain; and occurring in children whose joints are loose and who sob a great deal, the surgeon is puzzled to know what kind of an accident has happened. No crepitation can be elicited, and little displacement is apparent.

It is safe to manage these obscure and doubtful cases by placing an angular piece of binder's board on the posterior aspect of the limb, the ends extending three or four inches above and below the joint, and wrap splint and arm with a bandage. If a piece of binder's board eight inches long and three or four inches wide be cut into on each side, the incisions extending obliquely towards the centre of the material, the piece can easily be bent into a nest that quite accurately fits over the joint of the elbow.

CHAPTER XIII.

FRACTURES OF THE CRANIUM.

In the division of surgical subjects, fractures of the cranium, from the nature of the injuries and the peculiarity of their treatment, are always placed among wounds of the head. The gravity of such lesions depends essentially upon injuries and disturbances of the brain, therefore a consideration of the fracture alone would not reach the most important part of the subject. The treatment of fractures of the cranium is not based upon the ordinary rules pertaining to broken bones, but upon the brain-symptoms. Unaccompanied with cerebral complications, such fractures though almost always compound, are not to be interfered with. It is an established rule that simple fractures of the skull, even with depression, but without encephalic symptoms, are to be let alone. In the severer cases, the surgical interference chiefly consists in trephining, an operation performed in order to elevate or remove fragments of bone, and designed to relieve the brain-symptoms. Fractures of the cranium, then, will not receive attention in this connection. The bones of the face, though classed as belonging to the skull, may be broken without necessarily disturbing the brain; and require the same general treatment as fractures in other parts of the body.

FRACTURE OF THE ZYGOMATIC ARCH.

A fracture of the zygomatic process of the temporal bone is an exceedingly rare accident. A direct blow, as a fall upon the side of the head, is the kind of violence most liable to break this bony arch. Although very prominent and slender, the process is protected by coverings of integument, fat, fascia, muscle, and other soft structures.

A simple fracture of the zygoma is an unimportant injury, but a force that breaks the process of bone, is generally sufficient to do other mischief. Concussion of the brain is the frequent attendant of such a lesion. A depression of the arch interferes with the temporal muscle. The swelling that follows the injury also impedes the functions of the parts implicated.

TREATMENT.—In cases where the temporal muscle plays easily, and the depression of the arch is not distinct, no treatment is necessary, unless it be that employed in ordinary contusions. Duverney directs, in the event of depression of the arch, that the surgeon put his finger in the back part of the patient's mouth, against the inner surface of the cheek, and press the displaced fragments back into their natural line. An attempt to bring force against the inner surface of the zygomatic arch, by a finger in one's own mouth, shows that such a method of reduction is impracticable.

Ferrier brought the pieces to their natural level, by cutting down upon the fracture, and elevating them with a spatula.

In the only case I ever saw, the patient had been struck with a heavy chisel. A plain depression in the arch could be felt; and the sufferer could open and shut the mouth with difficulty. There was marked ecchymosis in the region hurt. The skin was broken, but there was no wound in the soft parts reaching to the bone. I pushed the point of a strong tenaculum beneath the depressed bone, and with a lever-like motion, forced the displaced fragment into line. There was a perfect recovery in six or eight weeks, no perceptible deformity following. The point of an instrument, like a carpenter's scratch-awl, might be employed as a lever to overcome the displacement.

FRACTURE OF THE OSSA NASI.

A not unfrequent injury is fracture of the nasal bones. It may be produced by the kick of a horse or mule, and by the forces of moving machinery. A circular saw might throw a block of wood with sufficient velocity to crush the bones of the nose. The handle of a windlass, while heavy weights are being raised, may slip out of the hand of a laborer, and so quickly take the reverse direction as to strike the workman across the bridge of the nose.

Violence producing fracture of the nasal bones, rarely stops with that injury. The ascending processes of the superior maxillary are adjacent to the ossa nasi, the central lamella, and cells of the ethmoid are directly beneath, and the vomer and turbinated bones not far away. The nasal duct may be lacerated, and the Schneiderian membrane is sure to be torn. The symptoms of fracture which amount to reliability, are displacement. This may elude observation, on account of the great swelling which immediately follows the accident, unless the surgeon presses his fingers deep into the tumefied tissues, and thus discovers that the nasal bones, wholly or in part, are depressed below their natural position. The profuse hemorrhage from the anterior nares, and other conditions generally attendant upon fracture of the nose, assist in the diagnosis, yet, without other evidence of fracture, the case would be likely to pass unrecognized. Ecchymosis and swelling, which extend to the eyelids, are the usual concomitants of contusions in the vicinity of the nose, and do not indicate the existence of a fracture. Even the introduction of a probe into the nostrils determines nothing positively, unless it forces one fragment against another, producing crepitus. The nasal bones may be broken and displaced, yet the fragments may be so wedged against one another, and between other bones, that no crepitus can be elicited. When the fracture is much comminuted, motion between the fragments can easily be given by holding the nose between the finger and thumb, and pushing it laterally, or from side to side. If a grooved director be carried up the nostril beneath the fragments, and the finger be held upon the outside injury, alternate motion given by either instrument may disclose crepitus, and a pretty clear idea of the state of the parts. In the event of a wound exposing the bones, it would not be difficult to discover whether a fracture had been received or not.

TREATMENT.—Diagnosis having been established, the surgeon's next duty is plain, though not easily accomplished in every instance. A profuse and persistent hemorrhage is to be arrested before dangerous syncope comes on. The displaced fragments of bone ought to be reduced, if possible, for no deformity is so noticeable as a flattened or distorted nose. A female catheter, grooved director, or other similar instrument, may prove a sufficiently firm lever when inserted in the nose,

to force the fragments back into place, but in some instances, a pen-handle, or piece of hickory wood whittled into the form of a pencil, may be required as a lever to elevate the bones from their depressed position. This elevator, first carried up one nostril, and then the other, to a point beneath the depression, then, being poised on the forefinger which rests on the upper lip, is made, by a lever motion, to pry the fragments into their normal position. Once replaced, the bones will stay where they belong. Pledgets of lint stuffed into the nasal cavities to prevent the bones from falling out of place, can not accomplish any good purpose. Petit remarks: "These plugs are only of use to contain the medicaments; and those who have thought of putting plugs of lint with the idea of supporting the bones, for fear they should be displaced, have never made the reduction of a single fracture of the nose: experience would have taught them that it requires more force to depress these bones that have just been replaced, than was necessary to raise them up with the elevator."

If the bones be much comminuted, the parts may be quite moveable and require some lateral support. This may be brought to bear by the use of small compresses, one placed on either side of the nose, and held there with strips of adhesive plaster.

In many accidents, the fracture of the nasal bones is the least important part of the injury. There may be emphysema, the air from the nostrils finding its way from cell to cell, or tissue to tissue, till the parts about the eyes and face are dangerously infiltrated; lachrymal fistula is another unpleasant complication; and the crista galli of the ethmoid bone may be forced upwards or to one side, and do serious harm to the brain, or structures within the skull.

A lateral deviation of the nasal appendage is not so objectionable a deformity as flattening or sinking down of the bridge, yet much care should be exercised from day to day, during the healing process, to prevent any lateral tendency. As soon as the swelling about the nose and eyelids subsides, any depression or lateral deviation can be readily detected; and if the injury be not more than two or three weeks old, the defect may be remedied. After consolidation of the fragments, no correcting operation should be adopted, so far as the position of the bones is concerned.

FRACTURE OF THE MALAR BONES.

The bones of the face may be broken by direct violence; and, when broken, the displacement is generally by depression. There will necessarily be a severe contusion, and not unfrequently a wound clear to the bone. No crepitation can be elicited, unless the comminuted fragments can be made to move against one another. The evidence of fracture is derived from displacement, and that is almost always by depression. The swelling, which arises rapidly, masks the bony displacement, so that the true condition of the parts has to be ascertained by indentations made with the fingers.

Although the malar bone is very prominent, and nearly subcutaneous, it is not easily broken, or forced out of place. In prize fights the projecting cheeks are especially exposed to blows, yet in the whole history of such "sports," not an instance of a broken malar has occurred. I have never been called to treat a fracture of this bone, but if I had an accident of the kind to manage, I should expect to treat it as I would a depressed zygoma. There is generally in connection with the fracture, a wound of the integument covering the bone, and through this an awl-like lever might be used to elevate the depressed fragments.

FRACTURE OF THE SUPERIOR MAXILLARY BONES.

Fragments by direct violence, are occasionally detached from the front portions of the superior maxillary bones. The nasal or ascending processes, as has already been indicated, may be broken by the same force that breaks the *ossa nasi*.

In a case that came under my observation, a man, in a fall from the loft of his barn, struck upon the tire of a wagon, and sustained a fracture of one superior maxillary. The break beginning in the median line and extending back to the incisive and canine fossæ, separated from the main bone a segment of the alveolar arch containing four teeth. There had been a tooth—the first molar—extracted, which perhaps weakened the bone at that point, and allowed the fragment the more easily to be turned into the mouth. The soft palate was

not much lacerated, therefore the piece of bone did not become completely detached from its connections. The upper lip was extensively bruised; and there were injuries to other parts of the body.

I had no difficulty in pulling the segment of the alveolar arch back into its place, and retaining it there. None of the teeth were loosened from their places, though there must have been some interruption to their nervous and vascular supplies. The wound received no dressing except a wiring together of the two front or incisor teeth. The loss of a tooth beyond the other extremity of the fragment, prevented the application of another wire at that point. The recovery was perfect, no defect or deformity following the injury.

Cases similar to the one described, are reported in several of our medical journals, and by Hamilton and Malgaigne in their Treatises. In the treatment of fractures of the superior maxillary, the rule is to save the detached parts if possible; and if the mucous membrane of a fragment be not entirely separated from that connected with the main part of the mouth, the union of the piece in its original place, may generally be expected. The separation of splinters in the operation of extracting teeth, is commonly final, there being no attempt to effect consolidation with the rest of the bone.

In the management of a fracture of the upper jaw, including a segment of the alveolus, it is well to wire the teeth together at the extremities of the fragment, and then bind the inferior maxillary against it, with bandages around the head and under the chin.

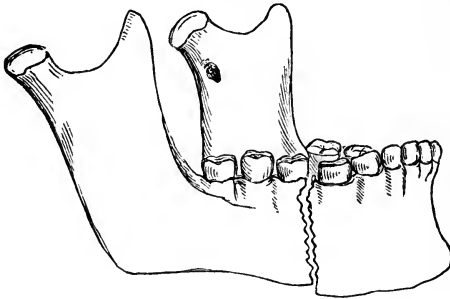
When a bullet enters the antrum, and carries with it small pieces of bone, the cavity must be cleared of the missile and the detached osseous fragments, or prolonged suppurative action will ensue. It is better to take care of such an injury well at first, than to wait until the complications are unpleasant, and perhaps dangerous. With a drill the antrum can be entered without incising the cheek. The lip is held up while the operator perforates the cavity of the jaw above the roots of the teeth.

CHAPTER XIV.

FRACTURE OF THE INFERIOR MAXILLARY.

The lower jaw, from its situation, is exposed to injury; and parts of the bone, which are thinly covered, receive blows with full force. However, the inferior maxillary, in shape and mobility, is signally protected against fracture. A heavy blow directly in front, tells powerfully upon the symphysis, as the bone does not have an opportunity to slide or otherwise escape the full effect of the stroke; but a blow upon the side of the jaw is decomposed by the lateral sliding of the bone.

FIG. 17.



Fracture of inferior maxillary bone.

The under-jaw is weakest at a point just in front of the insertion of the masseter muscles; at least, fracture takes place more frequently there than at any other place. Direct violence, as the kick of a horse, is the common cause of a broken inferior maxilla. Boyer maintains that the solution of continuity never occurs just at the symphysis. In two instances I have seen fracture in the median line. Plenty of similar cases have been reported. In adult age the

bone is very strong at the symphysis, yet the frequency of fracture at that point indicates that the strength of the bone may be overcome by a powerful blow centrally applied.

The bone is rarely broken in two places. A crushing kind of force, as where the face is run over by a loaded wagon, may inflict a double fracture. The neck of the condyle is rather slender, and, in a divided muscular action, in conjunction with a complication of forces acting in a fall, it may be broken. The coronoid process is so well protected by the zygoma and thick muscles, that a fracture of it must be exceedingly rare. The ramus may be separated from the body of the bone at the angle, or a little above.

Fracture of the lower jaw may be simple, compound, comminuted and complicated—the nature of the injury depending much upon the violence sustained. A segment of the alveolar arch, taking with it several teeth, is occasionally detached. In such cases, the gums and mucous membranes of the mouth are lacerated.

Bonn gives an account of a fracture in combination with dislocation of the lower jaw. The same force in one direction did not occasion the double injury, but a series of forces acting at different times and in different directions, as when a man, in falling from a high building, strikes a scaffolding on his way down, and receives one kind of injury, then as he reaches the ground covered with rubbish, sustains another kind of hurt or a multiplicity of injuries. It would be difficult to account for certain complicated injuries, except on the theory of the action of a variety of forces.

A jaw that has been weakened by ulceration around diseased fangs of teeth, may break under the force a dentist imparts in the act of extracting a neighboring tooth. I once saw a jaw that had been broken while a dentist was extracting the lower teeth to prepare the mouth for an artificial set. The bone was carious at the point of fracture; and had been thus rendered by an old fang that was completely hidden by the over-growing gum. Suspecting a diseased state of the bone, for the dentist assured me that he used only moderate force, I explored the fractured ends with a slender dental instrument, and discovered and dislodged the old fang. Suppuration kept up for three or four weeks, and then the fragments united as in an ordinary fracture of the jaw.

Muscular action has been known to produce fracture of the neck of the condyle. Professor Joseph Pancoast once met such a case in the Jefferson College Clinic. An old man suffered the lesion while in a paroxysm of violent coughing.

Mr. Holmes, of London, exhibited to the Pathological Society a specimen of a fractured portion of the neck of the lower jaw driven into the meatus auditorius externus. Violence producing fracture of the inferior maxillary, may be sufficient to crush the bones of the face, and to injure the brain.

In most of the instances coming under my observation, the direction of the fracture has been more transverse than oblique. This has not always been the experience of other observers. Reports of a great variety of cases show that the course of the fracture in this bone may be similar to that in the long bones.

When fracture occurs in the body of the jaw, the symptoms are plain, and distinctly indicate the nature of the injury. There is mobility of the parts, crepitus, and irregularity in the line of the teeth; the gums are torn and bleeding, the mouth is usually partly open, the saliva dribbles away, and the patient, in making known his wants and sufferings, utters words without allowing much motion of the mouth. One fragment rarely takes the same line as the other, but there is apt to be a rocking of the short piece, and a displacement above or below the long fragment, or overlapping as in fractures of the long bones.

When fracture occurs in the ramus, or about the neck, or coronoid process of the bone, the displacement is either considerable, or in such a situation as to be recognized with some difficulty. The pain at the point of injury, the mobility, and crepitus, are signs that might be expected, and when the latter can be heard or felt, it is not to be mistaken.

Sometimes the bone is splintered at the time of the fracture, or a small portion becomes carious afterwards, causing exfoliation to take place before the part will unite. Abscesses forming in connection with these cases are often very tedious and difficult to cure.

The tearing of the gum, a frequent complication in fracture of the lower jaw, is not to be considered fully in the light of a "compound" injury, for the laceration is within the mouth,

so that the healing process is not much prolonged by the wound in the soft tissues.

The *reduction* of fractures of the inferior maxillary is not generally attended with serious obstacles. Manipulation of the broken parts is most conveniently conducted while the patient is sitting on a stool or low chair, and the operator is seated behind him. Then the surgeon with the patient's head leaning against his breast, can with his thumbs and fingers press the displaced fragments into line. Any loosened tooth had better be removed, lest it interfere with perfect apposition of the fragments, and the healing process.

The surgeon, leaning over the patient, as indicated, has a good opportunity to feel any irregularities along the base of the bone, or want of harmony in the dental arches and planes. If the surgeon is unable to adjust the fragments by sitting behind the patient, he can have an assistant take his place to support and steady the head, while he, standing in front of the patient, has a better opportunity to manipulate the jaw.

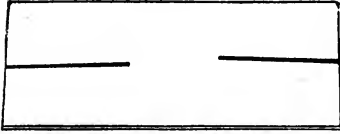
If a tooth is merely loosened, and is not in danger of getting between the fragments, or of interfering with the healing process, an attempt may be made to save it. Having had some trouble with a loose tooth I tried to save in one instance, I am not so "conservative" in my notions in regard to saving teeth as were my early teachers.

TREATMENT.—The common method of treating fracture of the inferior maxillary, is to fix the lower jaw firmly against the upper, either directly, or by placing two pieces of cork between the teeth, and then applying a bandage tightly under the chin and over the top of the head. The dressing is to be kept on for four or five weeks. During this time the patient must live on liquid food, or such as he can swallow without mastication. It is quite desirable that the nourishment should be rich and stimulating, therefore beef, mutton, and chicken broths, in which bread is soaked or softened, should constitute a part of the patient's diet.

The variety of "splints" and dressings devised to treat fracture of the inferior maxillary, is greater than necessary. In hospitals where gutta percha and other splint-material is at hand, such substances seem very satisfactory for moulding

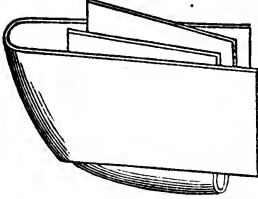
purposes. However, it is my design not to give undue prominence to means and methods only practicable in public institutions, or in large cities where almost any mechanical contrivance can be obtained at short notice; but to make such

FIG. 18.



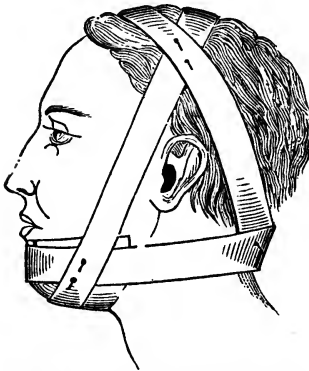
A piece of pasteboard, split at each end toward the middle, to be folded to fit the chin.

FIG. 19.



Pasteboard folded ready to be applied to the chin.

FIG. 20.



Pasteboard applied to chin, and held in place by a bandage.

suggestions and give such directions as may enable a practitioner in a rural district to fix up his case satisfactorily, with materials at command. A piece of pasteboard about eight inches long, and four or five broad, may be taken and split up the middle from each end to within an inch of the centre. The material is then to be dipped in warm water, to make it soft and pliable, and folded, as indicated in the wood-cut. The splint thus moulded can be applied to the chin; and by a little manipulation, it may be made to adapt itself closely to the part, so it shall give equal and uniform support. It may be retained in place by a four-tailed bandage, or a roller carried in front of the chin, and around the base of the head below the ear, then across the top of the head obliquely, and under the chin and over the head again, as depicted in the wood-cut. At the points where the turns of the bandage cross each other, pins should be used to

keep the dressing from slipping out of place. Gutta percha, cut like the pasteboard, and soaked in very hot water to make it pliable, may be used in the way just described. A firm piece of sole leather answers an excellent purpose. Tough bark is not without its desirable qualities in treating fracture

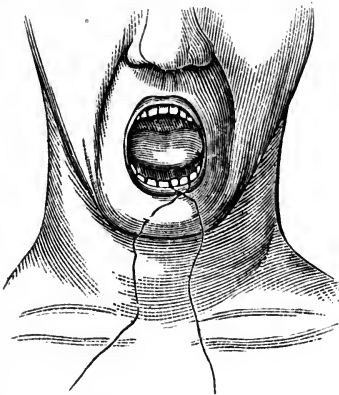
of the inferior maxillary when other means can not be commanded.

The employment of silver wire as a ligature to fasten together contiguous teeth on each side of the fracture, is the most reliable and satisfactory means of holding the fragments adjusted. A strong silk or hempen cord will do in place of the silver wire. Even an iron wire may be used in case no silver wire is at hand. In one instance coming to my knowledge, a piece of tough iron wire was used to twist together adjoining teeth in fragments of the under jaw, and it held its place for three weeks. At the end of that time no further retentive means were needed.

If silver wire be used, a large size, ordinarily employed for sutures, should be selected. There is generally space enough between the teeth, near the gum, for one end of the wire to pass readily. A piece from twelve to fifteen inches in length is long enough. After one end is carried through to the middle of the ligature, it may be bent, and pushed back out of

the mouth between the two teeth nearest the other fragment. Then, with the two ends of the wire in his hands, the surgeon can draw the pieces of bone together and hold them in apposition, by twisting the ends of the wire ligature around each other. After a secure fastening is made in this way, the free ends of wire may be cut with scissors, down to the twist. Finally, the rough end of the fastening may be bent with forceps, and thus kept from jaggging the lip.

FIG. 21.



Silver wire passed around two teeth adjacent to fracture of jaw, and ready to be twisted.

Forceps may be employed with advantage in carrying the wire between the teeth.

A silk or hempen thread may be passed between the teeth by the aid of a short needle. The wire may be carried twice around the necks of adjoining teeth, with the view of greater strength and security, but a single ligature is generally better than two.

If the tooth next the fracture be loose, or missing, the ligature may be made to surround the next in the row.

Where no teeth exist, the fragments may be perforated on each side of the fracture, and a silver wire ligature employed to fasten the pieces of bone together.

I have had such excellent success in ligaturing the teeth, and the results have been so satisfactory, that I feel like bestowing great praise upon this plan of joining the fragments in the treatment of fractures of the lower jaw. It permits free movements of the mouth, although mastication is not to be admitted. If the patient can not be trusted to keep the jaw pretty quiet after the teeth are wired together, it will be best to finish the dressing with the pasteboard cap for the chin, and the roller to keep it in place.

Ivory and metallic clamps to fit the chin, and others to bestride the alveolar arch, have been employed with success. Perhaps there may be instances where it is impracticable to use the wire suture; and a chin or clamp dressing is the only means left which can be employed. However, the pasteboard, gutta percha, or leather chin-piece, is never beyond reach.

I have seen cases where all means, except the wire ligature around the teeth, have failed to keep the fragments in apposition and at rest.

Fractures through the ramus, neck of the condyle, or coronoid process, can not, of course, be treated with the silver wire ligature. In such cases the chin dressing, with bandages, constitutes the only means that contribute to the support of the broken parts. Such fractures are beyond reach, and the fragments continue under the control of the masseter and pterygoid muscles. The coronoid process, as has been stated, is rarely broken; and even when fractured, the temporal muscle, on account of the great extent of its insertion, does not generally displace the fragment.

Delayed union and false-joint are occasional defects the surgeon has to encounter in the management of fractures of the lower jaw. One of the alleged reasons for these defects is that the saliva may have free access to the broken surfaces, dissolving and washing away the reparative material; but a more acceptable explanation is that the inferior maxillary is to some extent, a floating bone, subject to motion at every act

of speaking or swallowing. Want of steadiness in broken bones always delays union, or altogether prevents that result. In one of my cases, complete consolidation did not take place for over a year from the reception of the fracture. The mobility during the later period of the consolidating process, was very slight, and did not inconvenience the patient. The fracture was through the symphysis, and the accompanying injuries were so severe that there was little hope of a recovery for several weeks.

Allusion has been made to the use of corks between the teeth. These when used are designed to keep the jaws apart so that food can be taken. The corks should be wedge-shaped, and channeled above and below for the reception of the teeth. There are objections to any material used in this way. Even the gutta percha wedges recommended by Hamilton impart an unpleasant flavor to the mouth as long as they are worn. In one instance, where the teeth were too closely set to allow of nutrient fluids to be easily sucked between them; I used leaden wedges, channeled for the teeth, and curved to correspond with the arches of the jaws. I was well pleased with the part they served. These interdental splints are not needed in cases treated by fastening the fragments together with silver wire inserted between the teeth.

In the event of double fracture, a segment of one side of the jaw being detached, it may be difficult to use the wire far back in the mouth. However, if the front end of the detached piece of bone can be secured by suture to the long and more stable fragment, the result will generally be more satisfactory than when treated with chin splints and bandages.

When fracture of the jaw is left untreated during the period of union, the fragments do not rest accurately in apposition, but sufficient displacement exists along the dental arches to render mastication unpleasant. Afterwards the surfaces of the teeth wear unevenly, and become liable to early decay. Considering how easy it is to diagnose fracture of the inferior maxillary, it seems strange that so many cases are overlooked, and allowed to pass without treatment.

CHAPTER XV.

FRACTURE OF THE HYOID BONE, ETC.

The os hyoides is exposed not rarely to one kind of violence, viz., the grip of an antagonist. Other causes might be enumerated; but the one mentioned breaks the hyoid bone more frequently than all others together. The shape of the bone is such that the thumb on one side of the throat and the fingers on the other, tend to force the two great cornua towards each other. The fracture may take place through the body of the bone, or, as is oftener the case, through one of the branches.

While the head is bent forward, the hyoid bone is protected by the under jaw; with the head thrown back, the bone becomes exposed to blows, and other kinds of violence. Ollivier reports that a woman, fifty-six years of age, made a false step and fell, her head being thrown forcibly backwards. She received, from muscular action, a fracture of the greater cornu of the hyoid; and heard a distinct crack at the upper part of the left side of the neck, at the moment she fell. Dr. P. G. Fore, of Cincinnati, had a case, which was sustained by a direct blow, received in falling down stairs, a projecting brick inflicting the injury.

The signs of fracture of the hyoid are generally well marked. The snap is audible, and quite often heard by the patient; the pain, coming on immediately, is severe, and is quickly followed by notable external swelling; discoloration, the result of ecchymosis, appears sooner or later; and the patient can not speak or swallow without occasioning distress. Crepitation can not always be elicited, owing in part to the displacement, and in part to the difficulty of manipulating the fragments. The finger carried back along the floor of the mouth to the root of the tongue, may discover the rough ends of the fragments. The treatment consists more in combatting

inflammation, and enjoining a quiet, easy position, than in any kind of retentive dressing.

In the event of displacement, the finger of one hand is passed into the throat, and the other hand, externally, assists in adjusting the pieces. Once in place, the fragments are not generally drawn out of position, especially if the head be kept inclined forward, and in a state of repose. The patient may have to be fed through a tube for a few days. The recovery is generally complete in four or five weeks. Dr. George Harley, in Holmes' System of Surgery, reports a case of fracture of the hyoid bone, which illustrates the peculiarity of the symptoms, and refers to a bandage employed in the treatment. "On the 28th of March, 1856, a little girl, aged six years, while jumping, fell with her neck across the rail of an iron bedstead. She was instantly seized with a fit of coughing, great dyspnœa, an inclination to vomit, and a copious flow of saliva. The saliva was partly tinged with blood. When brought to us, which was almost immediately after the receipt of the injury, there was distressing difficulty of breathing, the face was of a livid blackness, and there were all the other symptoms of impending death by apnœa. On examining the neck, there was found a sharp body projecting beneath the skin. It was very angular and quite moveable. On close inspection it was found to be the displaced ends of the fractured hyoid bone. One end of the body rode over the other. By a little manipulation the fracture was reduced, and all the symptoms of impending suffocation, together with the copious flow of saliva, etc., rapidly subsided. A bandage was placed around the neck to keep the ends of the bone in their place; and with the exception of a smart attack of fever, which lasted three days, the child made an uninterrupted recovery, and without any deformity, except a slight fullness caused by the callus; but even this after a time disappeared."

In the case just cited, the fragments nearly perforated the skin; in some cases the sharp ends puncture the mucous membrane of the pharynx, pricking and irritating to an intolerable degree. Proper reduction consists in replacing the fragments so the ends shall be at a distance from sensitive parts. A handkerchief tied snugly around the neck would steady the muscles, and prevent, in some measure, the recurring inclination to swallow.

FRACTURE OF THE LARYNGEAL CARTILAGES.

The cartilages of the larynx are sometimes broken, the result of a blow or fall upon the front of the neck, or from a forcible squeeze of the throat. M. Ladoz has no doubt this fracture is produced exclusively by violence inflicted with the hands and nails. Plenck has seen a case in which the thyroid and cricoid cartilages were both broken by a fall against the edge of a bucket. Dr. Frank Hamilton reports a case arising from the kick of a horse.

Injuries of this kind are extremely dangerous to life, in consequence of impediments to respiration, either immediately after the injury, from displacements, and effusion of blood; or, subsequently, from emphysema, and œdematous infiltration. The neck has a swollen and distorted appearance, the voice is altered or entirely lost, and the act of swallowing is attended with difficulty. Cough supervenes, and the respiration becomes changed to a disagreeable whistling or crowing. The emphysema, by becoming general, is a serious complication, though the greatest danger is from rapidly approaching suffocation.

An attempt should be made to overcome the occlusion of the glottis, by cutting down upon the larynx, and even into it, that the infiltrated and œdematous tissues may be relieved, and the fragments of cartilage pushed into place.

A grooved director or small elevator, entered through a lacerated or artificial opening, is a serviceable instrument to raise and to adjust fragments. The emphysema, if confined to regions around the injury, is nearly harmless, and may be let alone. Punctures to relieve the infiltrated areolar spaces, will do some harm and no good. The introduction of a laryngeal tube, to breathe through, might be of service in cases where suffocation was imminent. Evaporating and anodyne lotions would be indicated to subdue or hold in check a high grade of inflammation.

CHAPTER XVI.

FRACTURE OF THE VERTEBRÆ.

Severe injuries and displacements of the bones of the back, are generally complicated, fracture and dislocation being liable to occur at the same time. It seldom happens, from the mechanism of the vertebral column, that a simple fracture or dislocation occurs as a distinct and uncomplicated lesion. In the cervical and lumbar regions, where motion is not restrained by the vertical articular surfaces, dislocation can occur without the absolute necessity of a fracture; but in the dorsal region, where the processes overlap, and are closely locked, simple dislocation seems impossible.

In the management of injuries about the extremities, it is exceedingly important to draw nice distinctions between fractures and dislocations, that the proper treatment for each may be applied understandingly; but in grave injuries of the back, the breaking of the tip end of a spinous or transverse process is not the serious part of the trouble. If dislocation exist, the displacement is to be overcome, but the gravity of the case depends upon the condition of the spinal cord. That delicate and important organ is liable to be compressed by the displacement of vertebræ; and the reduction of the bones is more to give relief to the cord than to get rid of a deformity.

Fractures of the vertebral bones coming from direct violence, arise mostly from blows; but they result from indirect violence, as when a man, in falling from a height, strikes upon the head or upon the nates. The parts hitting the earth may escape with bruises, yet the force is continued upward, and breaks some of the vertebral bones.

The throat, chest and abdomen protect from direct violence the vertebral chain of bones in front, therefore the force must come from the rear, or from above while the body is bent

forwards. A miller's carman, standing in his wagon, was receiving into it heavy sacks of corn, let down by ropes from the high story of a grocery; one of the sacks slipped, and in its descent, struck the neck and shoulders of the workman. The force fractured the spinal column at the fifth dorsal vertebra.

A heavy force, striking the back, making it suddenly bend beyond its ordinary incurvation, is very likely to wedge off some of the processes. In the dorsal region the imbrication or overlapping is so considerable that not much flexibility exists, but in the cervical and lumbar regions, there may be a good degree of incurvation without fracture.

EFFECT OF FRACTURE UPON THE SPINAL CORD.—A fracture of the vertebral column at any point between the occiput and the third lumbar vertebra, where the cauda equina begins, generally inflicts injury upon the spinal cord; and all the body below the fracture at once loses, more or less completely, both motive power and sensation. The great nerve center, being impinged upon, or compressed, loses its functions, and the parts depending upon it for nerve supplies, are paralyzed. The higher in the column the fracture occurs, the greater the part of the body affected—in other words, the graver the consequences. The fracture of a cervical vertebra makes the case extremely dangerous, owing to effects upon the spinal cord high up, where the respiratory nerves arise.

The length of time a patient will sometimes live after a fracture of the vertebral column, with all the distressing afflictions of paralysis, is quite astonishing. Persons have lived thirty years under such unfortunate circumstances. Even with the fourth cervical vertebra broken, a patient has lived more than a year. Mr. Page reports the case of a Scotch gentleman, twenty-six years of age, the heir to extensive landed property, who, while running on the edge of a terrace, accidentally fell upon a hard road beneath, a height of ten or twelve feet, and injured his neck. From that moment every part of the body, with the exception of the head, was completely paralyzed, the power of rotating the head being all that remained to him.

When a man has the spinal cord crushed or torn, so low down that respiration is not materially affected, it is not the direct injury and loss of function in parts below, that destroy

life. If the circumstances be favorable the fracture will consolidate and prevent motion dangerous to the cord if that remain intact; the parts paralyzed may become atrophied, but that does not prevent vital continuance. However, there are formidable causes which, sooner or later, exhaust the strength of the patient. Bed-sores on the hips, coupled with disorders of the urinary organs, by combined influences, at length make life succumb. A remarkable feature of the sores is that they form and extend with unusual rapidity. In a few days, before nurse or friends suspect any difficulty of the kind, large sloughs have separated from the regions of the sacrum and hips. The patient, feeling no pain in the region, does not ask to be turned in bed, hence the prolonged pressure and irritation upon one spot, which result in disorganization of the tissues involved.

Owing to the bladder being deprived of sensation, a condition which frequently results in over-distension of that viscus, and which calls for the repeated use of catheters, derangements of the mucous lining of the urinary tracks begin, and continue with varying phases till the gravest effects are impressed upon the system already weakened or seriously impaired from other causes.

In simple fracture of the spinous, transverse, and articular processes, as pictured in surgical works, the lesion does not generally appear formidable, but when the bodies of the vertebræ and the walls of the spinal canal, are broken, the prolonged and deplorable results tax the patience of friends and the ingenuity of the surgeon.

TREATMENT.—A patient with suspected fracture of the vertebræ should be taken home in an easy horizontal position, on a door or shutter; and, after his clothes are cut from him, he should be laid on a mattress. The surgeon should see that extension and such manipulation be employed as shall favor the return of any displaced fragments to their places. A slight change of posture may be all that is needed to correct a marked deformity.

Sand-bags should be prepared at once, and so employed as to sustain the attitude thought to be the most desirable. Common feather pillows answer a good purpose in bolstering up the head and shoulders, but the hips should be propped up

with something more substantial. Sand-bags will be found useful in every case, though the service of air and water-pillows is needed for parts inclined to slough. A piece of buckskin next to the integument is better than lint or other fine textures. In the event of sloughing, the use of carbolic acid to the raw surface is excellent. The agent corrects fetor, and hardens the tissues to which it is applied.

It is still a question whether any operative measures are ever justifiable, undertaken to relieve compression of the cord. The trephine has been employed with success in a few instances, though there seems to be no definite indication for its use. There is no sign to distinguish between the compression made by a piece of bone and that arising from effusions into the vertebral canal. The diagnosis depends more upon inference than substantial evidence, therefore the operation can never be performed under well grounded convictions.

If a surgeon meets a case in which the indications point emphatically to an operation, he should not hesitate to execute what that exceptional case requires. To be always governed by general principles deduced from the majority rule, leaving no latitude for exceptions, which may always exist, would impose undue restrictions upon a progressive science.

The pain arising from the fracture of a vertebra and from compression of the cord, is generally not severe, therefore the inexperienced practitioner may overlook the injury. If the patient after sustaining an injury of the back, be unable to move the legs, it is wise to look after a lesion of the spinal cord, and in doing so it is not best to turn and twist the trunk violently lest an additional injury be inflicted.

In some instances it is impossible to determine by manipulation whether fracture exists or not. During the examination of a patient having a broken back it is desirable to turn the body by lifting and pulling upon the sheet which is spread beneath the trunk. A rolling motion is thus imparted which does not disturb injured parts.

CHAPTER XVII.

FRACTURE OF THE RIBS, ETC.

The length of the ribs, their curved shape, together with their articulation to the sternum by means of elastic cartilages, contribute to their power of resisting forces, which otherwise would be continually causing fracture of these bones. Even as it is, with all their advantages for resisting fracture, such lesions are extremely common, forming about one-tenth of all fractures.

The elasticity of the ribs varies greatly with age; the young rarely suffer from broken rib, while in elderly people, whose bones have become unyielding and brittle, the injury is exceedingly frequent.

The anterior extremities of the ribs being more elastic and less firmly fixed than their vertebral ends, fractures of these bones occur less often in front of the middle than behind that point. A rib may break at a point remote from the part struck, for it will first bend to a certain extent, and then yield at the point where the flexibility ceases. A given amount of compressing force applied to the front of the chest of a young person, makes a rib snap away back near its angle; the same force, applied to the same spot on the thorax of an old subject, breaks the bone in its middle or more anteriorly.

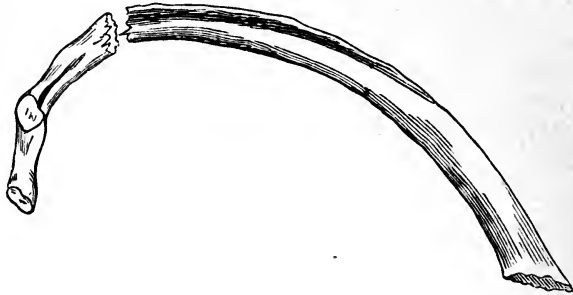
A direct force against the side of the chest, breaks a rib and carries the ends of the fragments inwards, lacerating the pleuræ and lungs. A force applied to the front of the chest, renders the rib more convex, or hoops it, so that when the fracture occurs the ends of the fragments will be directed towards the skin, and away from the viscera of the thorax.

If a person be thrown forcibly against any projecting point, like the corner of the table, one rib is broken; but the kick of a horse, or the crushing force of a carriage wheel,

generally breaks two or more of the costal bones. Several ribs are broken in severe injuries of the chest.

The fracture of a rib may be incomplete, the bone being simply fissured. In such cases there would be no displacement, though there might be angular deformity in a perceptible degree. In complete fracture of the ribs the periosteum

FIG. 22.



may not be torn, giving no opportunity for displacement or deformity. The intercostal muscles assist in steadying the fragments and in preventing displacement; and the bones are firmly fixed both in front and behind; consequently there is seldom much shortening or other displacement. The ends of the fragments resting against each other, are moved sufficiently by active respiration to elicit crepitus.

In the event of the thorax being caught between two opposing forces, and in severe and complicated accidents, fractures may be produced on both sides of the chest; though in the majority of instances, only one side becomes involved. A rib may be broken in two or more places, yet the long bones of the extremities suffer comminuted fracture much more frequently. The first rib being short, and protected by the clavicle, is seldom fractured; the last two, or floating ribs, on account of their natural mobility, scarcely offer resistance sufficient for a force to act on them; the ribs most frequently fractured are the upper false, and the lower true, these being the longest and the most exposed to injury.

A simple fracture of one or more ribs, uncomplicated with lesions of the lungs and other important structures, is not a dangerous injury; but when the pleuræ and pulmonary organs, to say nothing of the heart and large blood vessels, are in-

involved in the accident, the most serious consequences are to be feared: An analysis of 136 cases admitted into Guy's Hospital, during five years ending in 1860, exemplifies the relative proportion of complicated and uncomplicated fractures of the ribs; 108 were uncomplicated, of which 8 only had secondary inflammation, proving fatal in two instances from previous old-standing disease; 28 were complicated, 16 with emphysema, of whom four had symptoms of pneumonia, though all recovered, and of the remaining twelve, 6 died at once from fatal collapse, and 6 recovered. Of the latter, 3 had hæmoptysis and emphysema, and 3 extensive injury and severe inflammatory symptoms.

The ordinary symptoms of fractured ribs are quite clear and definable. The patient declares he felt something break, or give way; he feels acute pain at the seat of injury; and complains of a severe stitch in the side or catching of breath during a deep inspiration; the slightest attempt to cough disturbs the fracture, and gives rise to the sensation of grating; movements of the ribs on the affected side, and even on the sound side, on account of the consonance of action, are guardedly suppressed, and respiration is carried on through the movements of the diaphragm; the arm on the injured side is held steady and in such a position as to relax the muscles extending from that member to the thorax. Crepitation sometimes results from the motion of respiration, and can generally be produced by manipulating the chest. The hands placed on each side of the supposed seat of fracture, or on each side of the chest, and moved alternately, excite sufficient motion to elicit crepitus. When the fracture is situated very far back, it is more difficult to produce crepitation. The hand placed upon a point opposite the fracture, and made, by a sudden impulse, to impart motion by indirect force, sometimes causes a grating of the ends of the fragments. The ear placed against the seat of injury may detect crepitus, the patient being requested to cough while the auscultation is made. Crepitus, though an essential indication of fracture, is sometimes wanting, and its absence should not positively decide against the possible existence of such an injury. If there be spitting of blood, and escape of air into the cellular tissue, the evidence of fracture is quite convincing, even if no crepitus can be discovered.

The prognosis is generally favorable, though of course it will be modified according to the primary and secondary complications. In old and elderly persons, especially if they be at the time subject to bronchitis, asthma, or other forms of chronic disease, a guarded prognosis should be given, even if the fracture be uncomplicated. Such individuals often succumb, in the one instance, to shock from their low state of vitality; and in the other, to a kind of asphyxia from inability to free the lungs of the accumulated mucous secretion. The pleura is very liable to become inflamed, either from the fractured ends rubbing against it, or from a direct wound caused by a spiculum of bone lacerating it. The lungs themselves are not unfrequently wounded, and, as a consequence, take on serious inflammation. The cavity of the chest, between the pleuræ, may get filled with purulent fluids, and collapse of the lung result. The escape of air from a wound of the lung, may fill the chest and compress the organ, and find its way through rents in the pleuræ, to the cellular tissue external to the chest, a fact that may be known by a peculiar crackling felt when the skin is pressed on. The emphysema is at first confined to the side of the chest, and is situated near to the fracture; but gradually, as the patient goes on inspiring, fresh supplies of air escape, until it occupies an immense extent of surface, sometimes spreading over the whole body, even down to the fingers and toes. A moderate amount of emphysema is not especially dangerous, but when it encroaches upon the space needed for the action of the lung, and fills a great part of the superficial cellular tissue of the body, the respiration becomes impeded to a fearful extent, and the movements of the body, from the puffy swelling, uncomfortably restrained.

The intercostal artery, running just within the lower edge of the rib, is in some danger of being punctured or lacerated by the sharp end of a broken and depressed bone. Complicated accidents of this kind are exceedingly rare, but quite within the range of possibilities.

TREATMENT.—The local treatment consists in keeping the ribs in as perfect a state of rest as possible. The best plan to accomplish this object, is to apply long strips of adhesive plaster, extending from the spine to the sternum of the affected

side. Enough strips an inch and a half or two inches wide, must be used to cover a space several inches broad, the distance covered depending upon the number of ribs broken. These stay in place better than a bandage, and do not interfere with the movements of the sound side of the chest.

In those cases where the ends of the fragments sink in toward the pleura, and compression at two opposite points on the chest remote from the injury will pry the pieces of bone outwards, (a manœuvre that is practicable in some instances,) a wide flannel bandage may be used; also compresses at the points where the desired leverage can be obtained. The use of pasteboard and other splint-material to stay the broken ribs and to impede the normal motions of the chest, can accomplish very little substantial good.

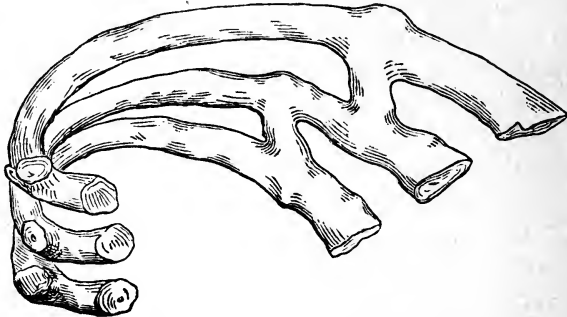
Some restless patients refuse to have any dressing applied, declaring that they can not endure the confinement imposed upon the respiratory organs. In nearly all cases coming under my observation and treatment, the restrictions placed upon the movements of the ribs by the adhesive strips, have been described as grateful. The sense of relief, and security against irregularity of respiration, have been acknowledged by patients thus treated.

Purulent collections in the cavity of the thorax, are to be removed by the use of the trocar, as in ordinary cases of empyema. The escape of air into the cellular tissue can not always be prevented. Well adjusted compresses around the thoracic opening, fastened in place with adhesive strips and a bandage, may arrest the further issue of air. In case the emphysema become wide-spread and troublesome, punctures may be made in the skin to let the air out. A compressed lung, from the collection of air in the cavity of the pleura, has been relieved by an incision made in the intercostal space some distance above or below the fracture.

To dull the acuteness of the pain, and to arrest the inclination to cough, the patient should be kept under the influence of opiates for several days. Gelsemium, aconite, veratrum, and other vascular and respiratory sedatives may be administered to advantage. Antimony and bloodletting are altogether too depressing and devitalizing to be employed, though they still are held in favor among the advocates of the theory that inflammation is an exalted state of the vital powers.

In four or five weeks from the reception of a fractured rib, the patient so far recovers that he can attend to his usual avocation, when all treatment may be suspended. Usually a large callus forms at the seat of fracture. This excess of reparative material is supposed to depend mostly upon the constant motion kept up by respiration.

FIG. 23.



Showing bridges of osseous reparative material deposited between broken ribs, in the course of the intercostal muscles.

In some instances the callus extends obliquely along the course of the intercostal muscles, and joins several ribs together with osseous bridges.

Want of bony union follows fractures of the ribs in a larger proportion of cases than in other bones. This defect is presumed to arise from the impracticability of keeping the fragments in a state of repose. Fortunately the state of false-joint is not attended with serious inconveniences.

Necrosis of one or the other of the fragments has been known to follow fracture and to become a chronic trouble. At a proper time exsection may be performed to get rid of the dead bone.

FRACTURE OF THE COSTAL CARTILAGES.

The sterno-costal cartilages may be broken by forces similar to those which fracture the ribs. In old age the cartilages become ossified wholly or in part, so that, by losing their ordinary elasticity, they do not escape being fractured. The lesion is so rare that it was scarcely mentioned till modern times. Magendie having observed five cases in two years, wrote a thesis upon the subject; Malgaigne states that he has

seen only three cases; and that at the Hotel Dieu, there was but one case in 2328 cases of fracture generally. He attributes this paucity to the probable omission of the lesion in the hospital returns.

The cartilage of the eighth rib has been most frequently broken; then, those immediately above it. One fragment is liable to overlap the other, which renders the diagnosis easy, and the parts may become united in that position. Osseous material consolidates the fragments. No subsequent ill effects are reported. Though the callus is bony, the original cartilaginous condition of the broken parts remains unchanged. The prognosis, in cases uncomplicated with serious internal injuries, is favorable. The diagnosis, unless one piece overlaps the other, is difficult. No true crepitus can be elicited, but the other symptoms are the same as in fracture of the rib.

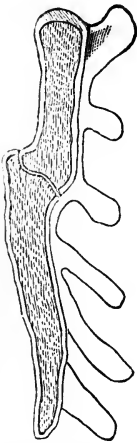
The treatment consists in applying adhesive strips, a foot or more in length, across the injured spot. The chest bandage is not required, though it may be used to modify the movements of the thorax in case pain is aggravated by the respiratory movements. Malgaigne found the bandage useless, but succeeded in keeping the fragments in apposition by the use of a light inguinal truss, with a soft compress. In twenty days the union was perfect, no inequality or deformity remaining.

FRACTURE OF THE STERNUM.

Crushing injuries that break the ribs and the vertebræ, are liable to fracture the sternum. The bone, by its articulation with the clavicles and the cartilages of the true ribs, yields sufficiently to escape fracture from ordinary violence; hence, uncomplicated fracture of the sternum is a rare accident. The elasticity of the costal cartilages and the ribs, which are like hoops, deadens the shock and decomposes the force of a blow. Separation of the manubrium from the gladiolus, is more frequent than true fracture through parts wholly osseous. In advanced age, when the original parts of the bone are completely ossified, the point corresponding with the primary division between the upper two pieces, proves to be the weakest. At least, fracture generally takes place at that point. (Fig. 24.) The course of the fractured line is across the bone

transversely ; and one fragment may be driven in so as to be overlapped by the other. There may be perceptible displacement without one piece getting behind the other.

FIG. 24.



Section of the sternum, showing fracture and displacement.

The causes of the injury are generally direct violence, though persons striking on the back, and having the body bend suddenly in a fall, have sustained fracture of the sternum. Chaussier reports two cases arising from muscular action, during parturition. The females were in labor with a first child, and threw back their heads, curving the body backwards. A celebrated vaulter, whilst bending his body backwards in the feat of raising a heavy weight with his teeth, broke the sternum.

The symptoms are: a sensation of breaking or cracking at the time of the accident, interference with respiration, and sharp pain at the seat of injury. Crepitation may be produced by manipulating the chest, or by movements of the body. The displacement, when any is present, is decisive in its character, but if the fibrous and fascial investments remain untorn, there may be no overlapping of the fragments. Swelling and effusions may obscure the usual diagnostic signs.

Fracture of the sternum may be complicated with laceration of the integuments, and severe injury of the thoracic viscera. The spongy nature of the internal structure of the bone, favors the formation of abscess. The pus, in such a case, would be more liable to collect or burrow in the mediastinal space than in the cavities of the pleuræ. Caries is not uncommon after fracture of the sternum ; and the pus and debris may cause trouble unless they readily find their way to the surface.

Longitudinal fracture of the sternum is excessively rare. A case is quoted by Malgaigne : A mason, aged 60, fell from a scaffold on some large stones, and received a longitudinal fracture of the sternum ; the left portion overlapped the right. Reduction was effected by drawing the arm to the side, and carrying it backwards, then pressing firmly on the middle of the right sternal ribs, making alternate movements from before backwards, so as to disengage the fragments ; at

the same time gentle pressure was made on the left or riding portion, so as to keep it on its own level. After reduction, a compress was applied, and maintained by a firm bandage. The case was successful at the end of six weeks; no deformity resulted.

TREATMENT.—The plan of treatment to be adopted in fracture of the sternum, is to prevent, as much as possible, motion taking place between the two portions of bone, whether they rest in apposition or not. If one fragment overrides the other, moderate efforts should be made to reduce them, which may be accomplished by manipulating the chest. But if reduction is impracticable by such means, it is not advisable to use hooks or elevators to raise the depressed piece. It is found by experience that overlapping does not prevent consolidation, or produce serious inconvenience, even if the pieces of bone unite, with one fragment depressed below the other.

Adhesive strips, applied vertically and transversely, prevent motion, and retain the fragments in contact with one another. A flannel bandage in some instances where respiration is attended with pain, may be used to surround and moderately compress the chest. The fabric is more elastic than cotton or linen, and one fold or turn will not slide upon another. The horizontal position, and moderate doses of quieting medicine, soon put the patient in a state of ease. Coughing, laughing, or sneezing, are instinctively avoided by the patient, therefore protests against such acts are useless.

Position sometimes affords considerable relief. A firm pillow or a large bag of sand placed under the back, to curve the trunk in that direction, puts extension and counter-extension upon the sternal fragments, favoring reduction, apposition, and repose of the broken parts.

Many persons possess such deformities of the sternum that the surgeon called to an injury of the central aspect of the chest, might, from the distorted appearances, be led to suspect fracture and displacement when neither existed.

CHAPTER XVIII.

FRACTURE OF THE CLAVICLE.


The clavicle is exposed to direct and to indirect violence; and the bone breaks from one influence about as frequently as it does from the other. Blows are always liable to be received, and the body is often thrown against unyielding substances, hitting the clavicle with direct forces which result in fracture. Falls upon the hand, the elbow, and especially upon the shoulder, impart forces sufficient to produce fracture; the radius, humerus, and scapula escape by conveying the shock or impulse along to the next bone in the order of articulation. The clavicle being slender and situated disadvantageously to take the violence communicated to it, breaks at its weakest or most severely tested point.

The two extremities of the bone are stronger than its central part, and are connected to the sternum and scapula by means of protecting ligaments, which render the ends capable of offering much more resistance than the middle of the bone, which has no such support.

When the fracture is occasioned by a blow, or by the body coming in contact with some hard substance, it is apt to be more serious in its nature and consequences, from the contusion and mischief done by the broken ends, than in fractures coming from indirect violence. The situation of the fracture in the majority of instances, is near the centre of the bone. When the fracture is not far from the extremities, the accident occurs near the acromion more frequently than in the immediate vicinity of the sternum. The parts of the bone between the curves seem to possess the least powers of resistance. When the clavicle is broken near its middle, (F'g. 25), or between the middle and the sternum, the inner fragment is usually retained in its place by the ligaments, and counter-

balanced muscular action ; and the outer fragment in some instances is drawn a little downwards, in others it is elevated above the inner. If the fracture be outside the middle of the

FIG. 25.



Fracture of clavicle near the middle of the bone, showing overlapping and angular deformity.

bone, the broken ends of both fragments are generally drawn upwards. Dr. R. W. Smith, of Dublin, in his "Treatise on Fractures in the vicinity of Joints," gives a description of several specimens of fractured clavicle, in all of which the fracture described was within two inches of the acromial extremity. According to his illustrations, the broken ends of both fragments were drawn upwards, except in one or two instances where the fracture occurred between the coraco-clavicular ligaments. By the action of the trapezius muscle the fragments were elevated until they formed nearly a right angle with each other, and large masses of osseous material (excess of callus) were poured around the seat of injury, even connecting the irregular bony mass with the coracoid process. The coraco-clavicular ligaments were either ruptured or lost in the excessive reparative material.

Fracture of the clavicle occurs at all ages of life ; it is met in infancy and extreme old age, and at all periods between. Males are more exposed by their habits and occupations, to blows, falls, and fatal accidents, therefore they more frequently suffer fracture of the clavicle than females.

The fracture may be simple, compound, comminuted, and complicated ; it may be transverse, oblique, or intermediate, partaking of both varieties so far as direction is concerned.

The prognosis, so far as prospects for a good use of the arm are to be considered, is favorable ; but so far as deformity is concerned, exceedingly unfavorable. Few fractures of the clavicle unite without more or less displacement. In most instances there is shortening either from angular deformity or from overlapping. This common defect arises from various causes. In some instances the dressing is not suitable, or is

not kept well applied; in others, the patient, not being much inconvenienced by the injury, fails to carry out the injunctions of his surgical attendant. It is needless to enumerate the causes of deformity. The weight of the arm dragging upon the shoulder and clavicle, tends to produce displacement, unless the member be well supported.

The symptoms of fracture of the clavicle are very evident in the majority of cases; the shoulder falls downwards and forwards, the level of the acromion being much lower on the injured than on the sound side. The shoulder and arm are nearer the chest, obliterating, apparently, the axillary space. One or the other of the fragments will be unusually prominent at the seat of fracture; and the overlapping and displacement can be distinctly seen and felt. Crepitus can generally be produced by taking hold of the shoulder and moving it up and down, while it is held outwards. As soon as the arm is left unsupported it falls downwards and inwards, producing the characteristic deformities. The patient experiences great pain in these forced movements, and in his own attempts to move the limb. He is unable to bring the hand across the chest to the opposite shoulder. The mobility observed at the point of fracture, when the arm is moved, is quite decisive as to the nature of the injury. In most instances the evidence of fracture is so clear that crepitus need not be sought. The appearance of the patient before the clothing is removed, is generally such that an experienced surgeon suspects at once the nature of the injury. An individual with a fractured clavicle, is careful to support the elbow of the injured side in the hand of the sound side. This is to take the weight of the limb from the parts involved in the fracture, and to keep the shoulder up in its natural position. The patient is generally conscious of the nature of the injury. He complains of numbness in the fingers, which may be produced by the pressure of one of the fragments on the axillary plexus of nerves. In some cases the pain is intense and sickening, while in others, very little distress is experienced.

TREATMENT.—The numerous contrivances devised and employed to treat fracture of the clavicle, indicate the difficulties in carrying out what is so plainly demanded. The shoulder is to be held upwards, outwards and backwards: to perform

this simple feat, a dozen kinds of apparatus are in practical use; and all seem to bear evidence of ingenuity. If a patient would submit to the confinement of lying on the back in bed for three or four weeks, the head being fixed on a pillow, and

FIG. 26.



Unsightly deformity following a badly treated fracture of the clavicle.

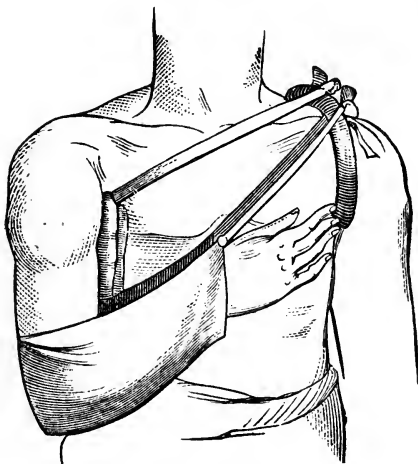
both arms confined to the side of the body, no special apparatus need be used. Young ladies, whose dresses expose the neck, and in whom it is particularly desirable to preserve the symmetry of the clavicle, may put this plan in practice. Men and boys will not submit to such restraints, therefore some method of treatment must be adopted to render them comfortable during the healing process, and allow them out-door exercise. A moderate amount of shortening and nodular deformity at the seat of fracture,

is not often minded by them, provided the arm is at length strong and useful.

The dressing of Dr. Fox, introduced in 1828, is much in use, and answers a very good purpose. It consists of a stout wedge-shaped pad, the thick end to be used upwards in the axilla of the injured side, to serve as a fulcrum over which the arm performing the part of a lever is drawn outwards by other parts of the dressing. A sling, like a ripped coat sleeve, made of strong cloth, extends over the forearm and elbow, and has tapes at each end; a stuffed ring is slipped on the sound arm quite over the shoulder. To this the tapes of the sling are tied, to lift the shoulder upwards and outwards. That the pad in the arm-pit may not escape from its place, its upper end should have a couple of tapes, one to tie to the ring in front, and the other behind the chest. The accompanying drawings explain the dressing better than words. If the surgeon, when he is first called to a case, can not wait for the dressing to be made, he can dress the arm with the handkerchief, and leave directions for the making of the wedge, ring, and sleeve-sling. The wedge may be made of strong cloth, and stuffed with cotton, tow, or hair. The upper or thick end should be packed densely with the stuffing, that it may fulfill

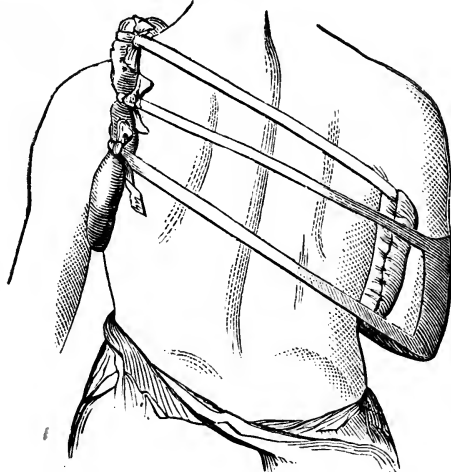
the purpose for which it is designed. The ring may be stuffed with cotton, wool, or hair. The sling needs no padding, yet it should be soft and yielding.

FIG. 27.



Front view of "Fox's dressing" for fracture of the clavicle.

FIG. 23.



Posterior view of "Fox's dressing" for fracture of the clavicle.

Very good results have been obtained with the handkerchief dressing. It consists in placing a long roll of cloth in the arm-pit as a fulcrum, and using a common cotton handkerchief as a sling to support the elbow, and hold the forearm up towards the opposite shoulder. The ends of the handkerchief are to be tied around the neck.

Dr. Lewis modified the dressing of Fox, using the pad and sling, with wide straps to cross the chest in front and behind. It is not superior to the Fox dressing.

Some years since, Dr. Huntoon introduced to the notice of the profession a dressing which he called his "Yoke-Splint," consisting of a yoke-shaped piece of wood, hollowed out on the under surface, so as to fit the neck and both shoulders. The ends extend some inches be-

yond the shoulder; and to which are attached two stuffed straps to pass through each axilla. These straps can be buckled so tightly as to elevate the shoulders, and carry them outwards and backwards, a handkerchief or other appropriate

sling supports the forearm and elbow in front of the chest. Such an apparatus will do for adults, but is unfit for children.

Long strips of adhesive plaster, carefully applied, constitute a good dressing to hold the arm and shoulder immovable in young and restless patients. The first piece is looped at one end around the upper part of the arm on the injured side, and then the rest of the strip extends across the back, and up over the shoulder of the sound side, to the front aspect of the thorax, adhering all the way. One end of the second piece of plaster is stuck to the posterior aspect of the arm on the injured side, and passes over the point of the elbow, ulnar part of forearm, and up across the sound shoulder to the back where it firmly adheres. This adhesive plaster roll is easy to apply, and will not get out of place. If well put on it will not have to be removed or renewed during the four weeks of healing.

Many years ago it was customary to place a pad in the axilla, and then envelope the arm, shoulder and chest in a very long bandage. This is now discarded on account of its confining the chest, and of the difficulty of keeping it in place.

About a year ago I adjusted a fractured clavicle with handkerchiefs. The patient was an old German, who received the injury by a fall on his shoulder in the street. Upon visiting him the second day I found the dressing had been thrown aside; and learned from the old man's son that his father had refused to have anything done in the way of treatment. The patient was thin of flesh, so that in the movements of the arm motion could be distinctly observed between the fragments. There was great angular deformity caused by the arm falling so low. No particular pain was complained of. The patient used his hand every day, though very carefully. I called once in a week or so to watch the progress of the healing process under no treatment. There was so much motion between the ends of the fragments, that I was afraid of non-union. At the end of three weeks from the date of the injury, a pretty firm callus had united the broken ends, though there was a salient projection of the fragments upwards. In five weeks the patient said he was well as ever, and claimed credit for success in his let-alone treatment.

CHAPTER XIX.

FRACTURE OF THE SCAPULA, ETC.

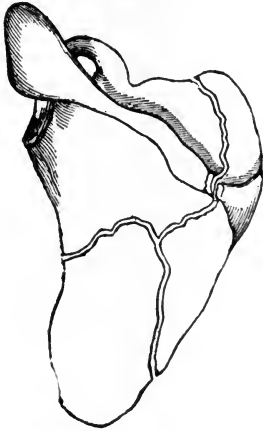
The shoulder-blade glides easily and freely in all directions, therefore it is well prepared to decompose forces or to yield sufficiently to escape fracture. Resting upon the convexity of the ribs and muscular cushions, the bone rarely suffers from lesions peculiar to more rigid and unyielding parts of the skeleton.

The scapula is deeply covered with muscles, except at points which project quite prominently. The spine of the bone, the acromion and the coracoid processes, though subject to muscular action and external violence, escape fracture with almost as much certainty as the blade itself. Fracture of the body of the scapula occurs in combination with other injuries when the trunk is severely crushed, as by the fall of a heavy weight upon it, or by the force of moving machinery. A fall backward upon some projecting point may produce fracture of the blade without the necessity of serious complications.

The thin plate of bone below the spine may be broken, the fracture being transverse, oblique, irregular, or stellated. Motion and crepitus are the two most important symptoms. The numerous muscles arising all along its flat surfaces, and crossing the line of fracture, prevent much displacement. Sometimes motion of the arm and shoulder will cause crepitus, which may be felt by laying the hand flat on the dorsum of the bone while it is being so moved. In muscular and fat subjects, and where there is little displacement, the diagnosis is often attended with difficulty, but in others the signs are quite plain and obvious. To ascertain if the spine of the bone be fractured, it will be necessary to press it forcibly with both hands while the patient's arm is carried backwards and forwards, to produce crepitus, and to disclose the line of separa-

tion. When the fracture extends through the body of the bone, including the spine, the course of the bony solution must be disclosed by movements imparted to the fragments, using the arm as a lever to incite the motions. Occasionally the body of the scapula is broken into several pieces. In such

FIG. 29.



Fracture of the blade of the scapula.

instances it is impossible to accurately trace the outlines of the fragments, or to retain the fragments in place by any kind of a dressing.

TREATMENT OF FRACTURES THROUGH THE BODY OF THE SCAPULA. — The fragments having been reduced as completely as possible by manipulation, a broad bandage or strip of adhesive plaster should be applied around the arm, chest and shoulder, (including the scapula), so as to hold the broken bone steady in one position, and prevent motion between the fragments by a shifting condition of the arm. The elbow should

be supported in a sling. Slight deformities from overlapping of the fragments, rarely do any harm. As soon as consolidation takes place, the functions of the limb are regained by use. Rough overlapping and irregular callus may, for a time, impede the easy action of the muscles, yet these contingent defects will not be permanent.

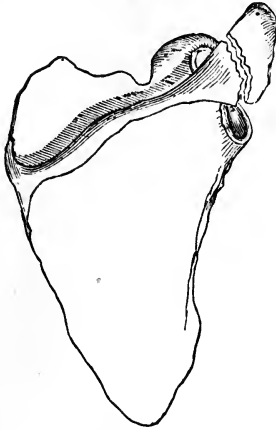
FRACTURE OF THE ACROMION PROCESS.

The acromion process being the most prominent part of the shoulder, is liable to be broken across when a blow is received directly from above, in falls upon the shoulder, and also, perhaps, by upward pressure of the head of the humerus, in falls upon the elbow or hand. The most frequent accident to the acromion, of a fractured nature, is the separation of the epiphysis in young subjects. The accompanying cut illustrates pretty nearly the line of separation. In cases of real fracture, the process is broken nearer the root than the apex. The ex-

treme tip may be broken off; and there may be genuine fracture in adults, at the epiphyseal line.

The most frequent cause of fracture of the acromion process, is by the person falling sideways against some hard resisting body, so as to strike the top of the shoulder as well as the side of it. Fracture from upward pressure of the humerus must be exceedingly rare. In cases reported, the cause was merely conjectured. The acromion, in the dry bone, appears weak and unsupported, but in its vital state, strengthened with muscles and fibrous bands, and sustained by ligamentous connections with the humerus and clavicle, to say nothing

FIG. 30.



Fracture of the acromion process.

of its sharing in the gliding character of the scapula, it is capable of offering great resistance, and generally escapes fracture.

The symptoms of fracture of the acromion are: dropping of the shoulder, and inability to raise the arm outwards, at a right angle with the trunk. The shoulder loses its salient prominence, its extremity being sunk. On passing the fingers along the spine of the scapula, towards the tip of the acromion, a sudden depression is felt at the seat of fracture, and mobility of the process itself can be perceived. On raising the arm so as to bring the fragments in apposition, all the abnormal appearances are lost; and crepitus, which is absent as long as the arm hangs down, can now be obtained. "In a fat person," says Lonsdale, "or where there is much swelling present, the nature of the accident is not easy to discover, owing to the difficulty of feeling the extremity of the process, and of distinguishing the exact point at which the motion and crepitus are produced. I lately saw a case of this kind, where the patient did not apply for relief for two days after the accident; the whole shoulder was greatly swollen, and it was impossible to say whether any fracture existed, or in what situation it might be, if one were present. As soon as the swelling subsided, however, the acromion was found to be

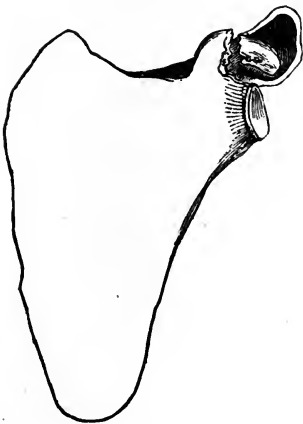
fractured, and to be depressed some way below the spine of the bone."

TREATMENT OF FRACTURE OF THE ACROMION PROCESS.—The principal indication is to support the elbow, so that the acromion may be raised by the head of the humerus: the handkerchief sling may be made to do this, care being taken to elevate the elbow, and to keep the arm straight across the front of the chest. The counterbalancing action of the trapezius and deltoid muscles, prevents lateral displacement. A roller of adhesive plaster, to wind round the neck and under the elbow and arm, stays in place better than any sling or common roller dressing.

The acromion, when fractured, does not always unite by bony union. The cause of this defect is supposed to depend upon a want of close contact of the broken ends. Probably that has more to do with the lack of osseous connection than any peculiarity in the situation of the process. To avoid non-union, is to make the head of the humerus hold the extremity of the acromion steadily upwards. If the broken surfaces can be brought in contact and held there, the consolidation will generally be complete and satisfactory.

FRACTURE OF THE CORACOID PROCESS.

FIG. 31.



Fracture of the coracoid process.

The coracoid process is short and very strong; it is well protected, and shares in the instability of the scapula; indirect violence can have but little influence upon it, therefore when broken, the process must be separated by a blow or direct force of some kind. The process derives some support from the coraco-clavicular ligaments, and is sheltered in its position by the clavicle and the head of the humerus.

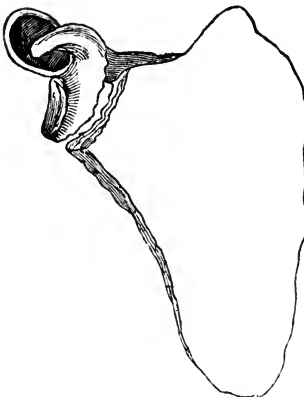
When the coracoid process is broken, the nature of the injury is discovered by the displacement downwards and forwards. The separated process of bone is displaced by the action of the three muscles that are attached

to it; motion in the process may be observed when the arm is moved in various directions. Crepitus can not be discovered unless the arm is so held as to relax the muscles, allowing the broken surfaces of the fragments to come together. Manipulation may then produce the grating sound. In injuries about the shoulder, the diagnosis is often made out by carefully observing the relative positions of the prominent points. The distance between the acromion and the coracoid processes, measured with the fingers and the eye, as compared with that found in the sound shoulder, is quite important in forming a conclusion, especially in distinguishing fracture of the coracoid process from fracture of the neck of the scapula.

TREATMENT.—A sling for the arm, whether it be a sleeve, a handkerchief, or the roller plaster, is the only dressing needed. This apparatus is designed to support the arm for the purpose of relaxing the biceps, coraco-brachialis, and pectoralis minor muscles. Bandages, compresses, etc., are not required.

FRACTURE OF THE NECK OF THE SCAPULA.

FIG. 32.



Fracture of the neck of the scapula.

The accompanying diagram shows pretty clearly what is meant by fracture of the neck of the scapula; it exhibits the line of fracture somewhere near its occurrence, taking with the free and separated piece, the coracoid process and the glenoid cavity and rim, and leaving joined to the blade or body of the scapula, the spine of the bone and its terminal acromion process. If the dried bone be examined, it will be readily seen where this isthmus or narrowed place is. The constriction makes the scapula appear weak at that part of the bone, but facts do not sustain this view in regard to fragility. There are very few, if any, specimens in the cabinets of Europe or America, showing that this fracture has occurred. Several surgeons competent to

recognize the injury have met with the fracture in the living subject. Duverney had an opportunity to examine one case in a woman who was killed on the spot from other injuries; he says, "On examining the left arm, I thought it was dislocated; I made an incision through the integuments and muscles, and opened the capsule; the head of the humerus occupied the cavity, but I then discovered the fracture of the neck of the scapula."

While a student of medicine, a young man came to the office of my preceptor, for treatment. The patient had, a few minutes before, fallen against a tree and pile of stones, while playing foot-ball. He supported the arm of the injured side with the hand of the sound side, as a person will who has a fracture of the clavicle or dislocation of the shoulder. After removing the clothing from the upper part of the body, I thought I recognized a dislocation of the right shoulder, and proceeded to reduce it in the usual way by manipulation. There was no difficulty in restoring the arm to its natural position, but it would not stay there; the head of the humerus would immediately, if not prevented, slide into the axillary space, leaving a hollow beneath the acromion. I tried to divine the cause of this perverse state of things, and conjectured that the head of the humerus did not slip back through the rent in the capsular ligament, but in some way folded the ligament in front of itself while returning to the joint. I was so certain of this condition that I considered the propriety of enlarging the rent with the point of a knife carried through the soft parts, down to the capsule. Fortunately I did not put the rash thought into execution, but began anew to consider the case. The arm was not rigid as it usually is when the shoulder is dislocated; but the limb had the mobility common to a fracture injury. Great pain attended the manipulations, and the tissues about the joint were soon swollen so as to render obscure some points that were at first quite prominent. However, I began to search for proofs of a fracture, and looked at a dried scapula and humerus, to help my diagnostic powers. The formation of the neck of the scapula suggested what might be the nature of the injury. I then turned to the patient, and hunted for the coracoid process. I found it held the same relative position to the head of the humerus that it normally did, but it

was a long way too far from the acromion which remained immovable in its usual place. I then reduced the head of the humerus to its normal position beneath the acromion, and found that the coracoid process had followed the head of the humerus, taking its place on the inside of the joint, at a proper distance from the acromion. To verify the new diagnostic conclusion, I moved the shoulder back and forwards, causing distinct crepitation; and allowed the displacement to occur again, in order that I might carefully note the relative position of the coracoid process to the humerus and acromion. Every point in the diagnosis became so plain that there could be no mistaking any one of them. The neck of the scapula was broken, and no other injury existed.

In the treatment I used a firm pad in the axilla, to keep the head of the humerus away from the chest, and held the elbow upwards with a sling. I also fastened the arm to the side of the chest, to obviate motion at the seat of injury. In four weeks the dressing was removed, and gentle motion allowed to the arm. The broken surfaces in this kind of fracture are small, therefore the apposition of fragments ought to be perfect, and the motion as much restrained as possible. Fox's dressing for broken clavicles is a desirable appliance for treating fracture of the cervix scapulæ.

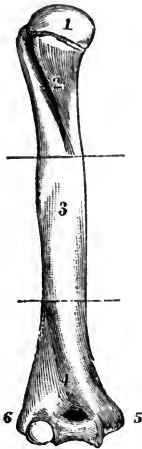
The two strips of adhesive plaster, each two inches wide and a yard long, so useful in treating fracture of the clavicle, are well adapted to retain the shoulder in place while treating fracture of the scapula of any variety. A loop a little larger than the arm is made to encircle the limb near the shoulder, and the rest of the strip crosses the back and passes over the shoulder to the chest. This is to hold the shoulder outward and backward. And the other strip, which is made to adhere to the posterior aspect of the arm, the elbow, and the ulnar part of the forearm, is to cross the sound shoulder and reach down upon the back, crossing the first strip. It is well to split this second strip where it passes the point of the elbow. The dressing keeps every part of the arm and shoulder snug and steady.

CHAPTER XX.

FRACTURE OF THE HUMERUS.

Anatomically the humerus is divided into the head, neck, tuberosities, shaft, and condyles; surgically, the bone is divided into the upper, middle, and lower thirds, and it has a surgical neck below the tuberosities. The anatomical neck is

FIG. 33.



Humerus divided into thirds by transverse lines. 1, head of bone; 2, upper third; 3, middle third; 4, lower third; 5, internal condyle; 6, external condyle.

marked by a slight constriction between the round head and the tuberosities. The condyles make up the lower extremities of the bone, including the articular surfaces, and the lateral projections which can be felt so prominently beneath the skin. The thin crests which extend from the condyles upwards until they are lost in the shaft of the bone, are called condyloid ridges. The shaft of the humerus extends from the tuberosities to the condyles. A deep groove between the tuberosities, is occupied by the tendon of the long head of the biceps. This brief description, together with the accompanying diagram, brings to mind many of the peculiarities of the bone, and will save calling attention

repeatedly to each part involved in fractures of the humerus.

FRACTURE AT THE ANATOMICAL NECK.

Pathological museums and autopsies furnish indisputable evidence of an occasional fracture through the upper extremity of the humerus, at a point where the bone is strong and well protected from external injuries. The fracture alluded

to is within the capsular ligament, no muscles having any connection with the articular fragment.

The lesion is generally produced by falls, the shoulder coming in direct and violent contact with the ground or some hard substance. In rare instances the evidence seems to be that great force conveyed upward from the hand and elbow, in falls upon those parts, has resulted in separating the head of the humerus from the remainder of the bone.

In the event of *impaction*, a condition in which the end of one fragment is driven into the cancellated tissue of the other, the broken structures lend support to each other, and by their intimate relation favor osseous union of the fragments. If there be no impaction, the head of the humerus is a loose piece of bone entirely within the capsular ligament, cut off from nutritive supplies, and free to move in every direction, even turning over so as to present its articular surface to the broken end of the lower or long fragment. Cases are reported in which the detached head of the humerus has become united to the shaft of the bone in every conceivable attitude. In rare instances, no consolidation nor union of any kind has taken place between the fragments, but the head of the bone has continued in the joint as a foreign body.

Bony union is effected in the majority of cases, yet with an excess of reparative material about the broken end of the lower fragment, and with such irregularities of surface that the function of the joint is impaired.

The *symptoms* of fracture at the anatomical neck of the humerus are mostly those attendant upon fractures of other bones. Pain, swelling, and inability to raise the hand, are common signs; the flattening of the shoulder, when present, may lead to the suspicion that a dislocation exists, therefore the distinctive features of the two injuries must be carefully compared. The displacement attendant upon fracture is easily overcome, yet the deformity is at once reproduced as soon as the limb is left to itself; a dislocated bone is not readily returned to place, but, having been restored to its normal position, it will stay there.

After fracture of the anatomical neck of the humerus, the arm is excessively mobile, and falls or hangs powerless by the side of the body; the depression beneath the acromion is not so great as in dislocation; and in rare instances the detached


head of the humerus can be fixed with the fingers, so that crepitus can be elicited. In dislocation of the shoulder the arm is rigid, with the elbow standing off from the side.

The *treatment* for fracture through the anatomical neck of the humerus, is quite the same as in all the fractures that occur about the shoulder-joint. The axillary pad as a fulcrum, the arm as a lever, and slings to force the displaced parts into position and to keep them there, comprise a suitable dressing. To prevent motion, the arm should be bandaged to the side. The sling or handkerchief to support the elbow and arm should not force the humerus powerfully upwards. As the excessive reparative material sent out from the lower fragment is sure to impede the movements and impair the functions of the joint, the surgeon should announce in advance, to the patient, what may be expected in the way of a cure. Passive motion, begun about four weeks after the accident, may help to restore the usefulness of the joint.

FRACTURE OF THE TUBEROSITIES.

Direct violence and muscular action are the only agencies that separate the tuberosities of the humerus from the body of the bone. Accidents of this kind are exceedingly rare,

FIG. 34.



Carved splint for the arm, and hinged to a shoulder piece

and liable to be confounded with other injuries about the joint. In dislocation of the head of the humerus, the three powerful muscles inserted into the greater tuberosity, may detach the lump of bone to which they are connected. In the dislocation outwards, the lesser tuberosity may be fractured in the same way, by the action of the subscapularis.

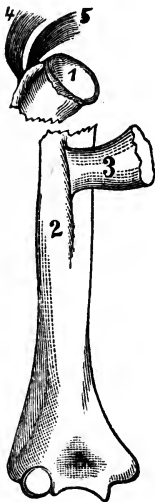
A satisfactory diagnosis could not be made out in such injuries unless the bony tubercles can be moved independently of the remainder of the bone. Pain, swelling, and aversion to movements of the arm, might cause the surgeon to suspect the existence of fracture, but the suspicion would not be well founded unless the fingers could feel the detached fragment, and make it grate against the surface from which it was detached.

The indications in the treatment are to keep the arm and shoulder at rest for three or four weeks. A concave splint that fits the shoulder, may be used to cover the injured region; and a sling employed to fasten the arm to the front of the chest.

FRACTURE OF THE SURGICAL NECK OF THE HUMERUS.

The constricted portion of the shaft of the humerus, just below the tuberosities, is a common seat of fracture. The line of separation is above the insertion of the pectoralis major and latissimus dorsi muscles; and is usually more transverse than oblique in direction. The amount of displacement is considerable, but varies in different cases. In characteristic examples the upper fragment is tilted upwards and outwards by the action of the muscles inserted into the greater tuber-

FIG. 35.



Fracture through the surgical neck of the humerus.

osity, the lower fragment is drawn inwards towards the axilla, by those inserted into the bicipital groove, while the various muscles extending from the scapula to the humerus below the line of fracture, produce shortening.


The symptoms are generally very evident and not liable to be mistaken for dislocation. When the arm is rotated, the head of the humerus remains motionless in the glenoid cavity. The mobility of the shaft or lower fragment is marked, and crepitus is distinct when extension is made, or the broken ends of bone are moved while in apposition. Fracture at the line of junction of the epiphysis, in young subjects, resembles true fracture through the surgical neck of the bone in old subjects. The only discoverable difference is a less marked crepitation in the cartilaginous separation. Fracture through the surgical neck of the humerus, in adults, is generally a half inch or more below the line where separation of the epiphysis occurs in the young.

If the injury be not seen until the parts have become excessively tender, and much swelling has supervened, fracture through the surgical neck will closely resemble dislocation of

the shoulder. However, in case of doubt and uncertainty, the patient may be put under the influence of chloroform, when the nature of the lesion can be determined. In case of fracture, the space beneath the acromion will be found filled with the head of the bone; the humerus will not stay reduced, but slide towards the axillary space as soon as left to itself; and great mobility at the seat of injury will be observable. All of these signs present unequivocal evidence of the existence of fracture.

From a consideration of the anatomy of the region, it would seem that a fracture through the surgical neck of the bone could not take place without marked displacement and deformity. In a small proportion of instances, however, there

FIG. 36.



A woven wire splint extending from the top of the shoulder to the ends of the fingers. It is useful to obviate motion between the fragments in treating fractures of upper end of humerus.

is no perceptible disjunction of the fragments, a state of apposition which is probably favored by the interlocking of serrations in the broken ends, and by the restraining influence of the tendon of the long head of the biceps. Malgaigne rarely met with displacement, though in this he differs widely from other experienced observers.

TREATMENT.—It is not always easy to reduce the fragments to a state of perfect apposition, owing to the shortness of the upper fragment, and the diverse action of the muscles attached to the two fragments. Extension and manipulation, aided when necessary by the relaxing effects of chloroform, will generally restore the broken ends to their proper places. A roller bandage may be used to envelope the limb from the fingers to the shoulder, to restrain muscular twitchings and to prevent congestion and swelling, yet this is not absolutely necessary. The primary bandage, as this is sometimes called, is going more and more out of use. A concave shoulder splint, made of leather, gutta percha, carved wood with a hinge, or woven wire bent and soldered to fit the parts, is quite essential for the outside of the limb. Two or three short board splints may be padded and laid on the inside of

the arm, reaching from the axilla to near the condyles. These, including the one that caps the shoulder, may be fastened in their places with tapes, or bandages. A firm compress is placed in the axilla, to prevent the upper extremity of the long fragment from inclining too much inwards, and a bandage fastens the elbow to the side of the body. The weight of the arm is to be left free to act as extending force. A handkerchief dropped from the neck is always convenient for the hand to rest in. No sling should be employed to support the elbow or weight of the arm.

It must be borne in mind that ordinary dressings for fractures through the middle third of the shaft of the humerus, and which reach only about as high as the seat of the injury, are not efficacious in restraining motion between the fragments. Such dressings get no hold upon the upper fragment and the scapula, therefore they can not steady the parts and prevent mobility.

There is some danger of false-joint, especially if motion at the line of separation be not thoroughly restrained. It is found that a fracture through the surgical neck of the humerus, does not become consolidated as soon as fractures lower down in the bone. The delay may be charged to the mobility, for the more quiet the fragments the sooner is the healing process accomplished.

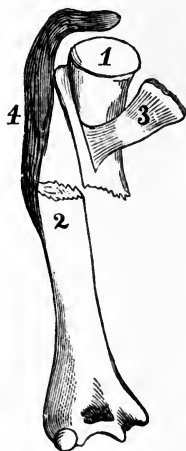
FRACTURES OF THE SHAFT OF THE HUMERUS.

All fractures occurring between the surgical neck of the humerus and the condyles of the bone, are commonly spoken of as fractures of the shaft of the *os humeri*. Such lesions are extremely easy to recognize, and are not usually difficult to treat. There is no joint near to mask the injury, nor companion bone, as in the fore-arm and leg, to obscure the diagnosis, or to modify the treatment.

Fractures of the shaft arise from direct and indirect forces; a direct force usually comes in the shape of a blow, or a fall upon some hard substance; the indirect acts upon a part of the bone remote from the point struck, as when a person falls with the arm extended from the body, the elbow being the part that receives the shock, but the shaft of the humerus, several inches from the point hit, may be the part to yield.

Direct violence, besides breaking the bone, commonly inflicts more or less injury to the soft parts, which is manifest in the bruising, discoloration, and ecchymosis; the indirect force

FIG. 37.



Fracture of the shaft of the humerus between the insertion of the pectoralis major and the deltoid muscles.

seldom produces much disturbance to the tissues in the vicinity of the fracture, though at the point receiving the shock, there may be serious contusions. Muscular action is often sufficient to fracture the humerus. I once treated a lad's arm which was broken while in the act of throwing a stone. The patient heard the bone "snap like the break of a dry stick," and his arm fell powerless to his side. The fracture was near the junction of the lower with the middle third of the bone. Fractures from muscular action are not uncommon; cases happening in different parts of the country are constantly being reported in the medical journals. It may be remarked that there is no particular point in the shaft of the

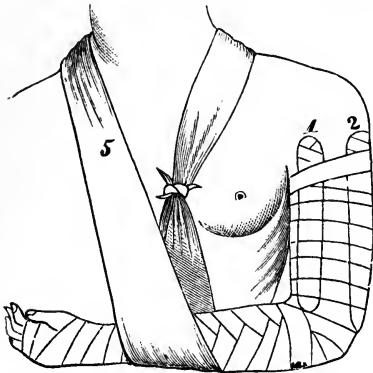
humerus that gives way to muscular force, for reported cases show that fractures from such causes occur at any point except through the articulating extremities.

The displacement following fracture of the shaft of the humerus, is not always appreciable, for the fractured surfaces may remain in contact, the serrations so interlocking as not to be easily moved from their apposition. In most instances, however, the contact is lost, and the muscles draw the fragments past one another. In some instances the angular deformity is great when there is no shortening; and the defect produced by rotating one fragment upon the other, may cause a more marked and awkward defect than either of the distortions just mentioned.

The distinctions between fractures above and fractures below the insertions of certain muscles, so far as the deformity is concerned, are of not much practical importance. The diagnosis is extremely easy whether the line of separation is transverse or oblique, or the broken end of the lower fragment rests upon the inside or the outside of the other, in the overlapping.

TREATMENT.—The fragments having been adjusted, four small, straight, well-padded wooden splints should be applied, one on each side of the arm, extending several inches above and below the seat of fracture, and retained in place by means of tapes tied around all. Over the whole, including arm, splints, and tapes, a roller bandage ought to be applied as it gives support to the dressing that can not be obtained by straps and buckles, or a multiplicity of ties. A primary

FIG. 38.



Dressing for fracture of the shaft of the humerus. 3, and 4, are not seen, and refer to two splints on the other side of the arm.

bandage, reaching from the fingers to the shoulder, before the splints are applied, is not necessary, although some surgeons contend that this is valuable to prevent excessive swelling and muscular twitchings. The splints may be padded with cotton, or wrapped with soft muslin. A sling dropped down from the neck is convenient for the fore-arm or hand to rest in. All mechanical contrivances for keeping up extension and

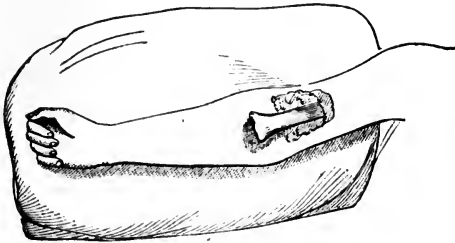
counter-extension, as Swinburne's apparatus, are open to such serious objections that they have fallen into disuse. The weight of the arm counteracts the retraction of the muscles. If there be slight overlapping in oblique fractures, no great trouble attends the defect. A shortened arm is not so objectionable as a shortened thigh.

In compound fractures of the humerus, the arm may be kept dressed with three splints. Tapes may be used instead of a bandage to keep them in place. The patient should keep in bed for a week or two, until the violence of the inflammation and the purulent discharge subside.

FRACTURES OF THE SHAFT OF THE HUMERUS JUST ABOVE THE CONDYLES.

Falls upon the hand or upon the elbow are not unfrequently attended with fracture of the humerus above the condyles, across the condyloid ridges. In young subjects, the separation of the lower epiphysis occurs in this region, and presents nearly all the characteristics of a true fracture. Figure 39 represents an injury of this kind rendered compound by a too tight dressing, which resulted in sloughing, and a protrusion of the broken end of the upper fragment. The epiphyseal

FIG. 39.



Separation of the lower epiphysis of the humerus, the injury rendered compound by a slough and protrusion of lower end of upper fragment.

fragment retained its place in articular connection with the radius and ulna. The case was treated, after it came into my hands, by extension, to enable the protruding bone to sink into place. The boy's hand was tied high up to the bedpost, so that the weight of the body in pulling downward, exerted the proper force to accomplish the purpose.

The humerus just above the condyles is very thin and prismatic, expanding laterally at the expense of its thickness or rotundity. This irregular shape undoubtedly weakens the bone in that region. A fall upon the elbow in a bent position, seems to be the most frequent cause of fracture at all ages. The powerful action of the muscles passing from the upper arm to the fore-arm usually tends to shortening and riding of the fragments. In most cases the lower fragment is drawn backwards and upwards by the triceps, producing an appearance similar to that caused by dislocation of both bones of the fore-arm backwards. The distal extremity of the upper frag-

ment projects in front of the arm, making a prominence just above the elbow on its anterior aspect; the olecranon projects backwards, forming a hollow space in the arm just above it, which corresponds with the unnatural fullness in front. The general appearance of the deformity is that of dislocation;

FIG. 40.



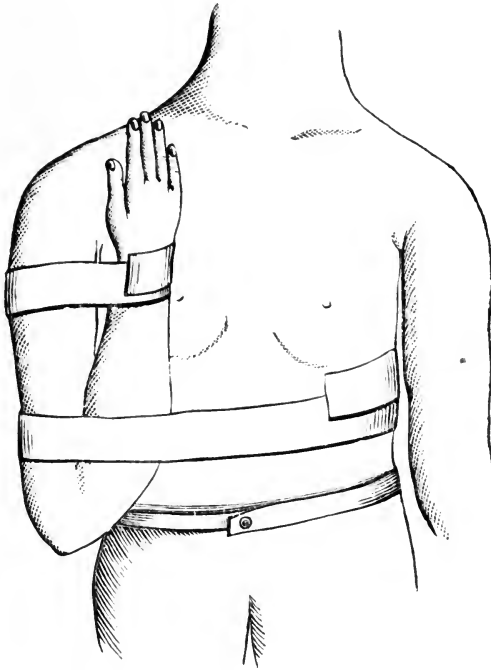
Double fracture of
the humerus.

and the restricted motion favors the same idea, though the immobility is not so marked as in dislocation. When doubt exists in regard to the nature of the injury, the distinction between fracture and dislocation can be drawn as follows: an extending force in case of fracture, competent to overcome muscular contraction, temporarily obliterates the deformity, but, as soon as the force is relaxed, the displacement reappears; in case of dislocation, it requires great force to restore the parts to position, and once in place they will stay there.

When the broken surfaces are brought in contact by extension and manipulation, and slight motion is imparted to the fragments, distinct crepitus is elicited. It will also be found, in the event of fracture, that the condyles, which can always be felt beneath the integuments, follow the radius and ulna in any motion imparted to the arm; and such movements are not in consonance with the lower end of the long fragment. In dislocation, the condyles continue as part of the humerus, and the olecranon is displaced backwards, forming a distinct prominence by itself, and the condyloid eminences are distinct from it. The distance from the acromion process to the internal condyle is less in the event of fracture than in dislocation.

TREATMENT.—The fracture being near the joint it is not easy to retain the fragments steadily in place. Reduction is to be effected, as already intimated, by grasping the arm with one hand, and the fore-arm with the other, making sufficient extension and counter-extension to overcome the muscular contraction. In this way the fragments may be brought into apposition. To keep them there the elbow should, with proper splints, and other dressings, be fixed at a right angle. A jointed wooden splint may be used if at hand or readily

attainable. If the fracture be just above the condyles, the fore-arm should be firmly flexed against the upper-arm and held there with strips of rubber adhesive plasters, as depicted in the cut below. The fleshy part of the fore-arm crowds the fragments into place, and holds them in conjunction, the strongly flexed limb acting as a splint to the broken humerus. In fact, there is no other way to keep the ends of the fragments in apposition. All jointed splints are a fraud—they will not accomplish what is needed. There is no danger of ankylosis at the elbow while the fragments are uniting, and there is no fear of false-joint through excess of mobility.

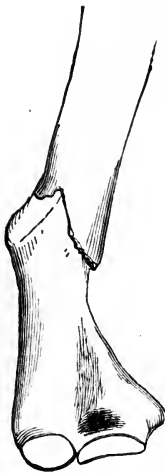

Special dressing for fracture of humerus above condyles.

The pressure of the lower end of the upper fragment upon the brachial artery, or the median nerve, may operate unfavorably upon the nutrition and functions of the forearm and hand. Several cases of alleged malpractice have been tried in different parts of the country, which grew out of the enfeebled condition of the parts below the fracture. It is worthy of remark, that distinguished surgeons, while giving testimony in these

litigations, have differed widely in regard to the cause of paralysis in the fingers, sloughing, etc. Some have declared that the defects were owing to injuries done to the artery and

FIG. 41.



Deformity after fracture of humerus through its lower third.

nerve by the broken end of the bone—conditions which no surgeon could always avoid; and others were of the opinion that tight bandaging, compresses, and a lack of adjustment of the fragments, were the causes of the difficulty. It is highly probable that in rare instances the trouble has been in the injury inflicted by the fragments, but in cases coming under my observation the defect has depended upon lack of proper reduction of the fragments, tight bandaging, and the injudicious use of splints and compresses.

If the fracture be oblique, and the sharp edge of the upper fragment project forward, as it is always inclined to do, the brachial artery and median nerve are about sure to be pressed out of place and irritated. However, if the reduction is perfect, and the dressing retains the fragments in place, the edges of the broken bone are covered by one another. Even if the apposition be made perfect at the time of dressing, a fresh displacement may take place in a few hours. Fracture just above the condyles must not only be well dressed in the first instance, but it must be carefully watched, and redressed as often as there is a suspicion that everything is not going right.

FRACTURES OF THE CONDYLES OF THE HUMERUS.

The condyles of the humerus are often fractured. They are much exposed to direct violence, and may be broken by indirect forces. The simplest form of such injuries is a separation of the tip of the inner condyle (*epitrochlea*), for the lesion does not involve the articulation. It may be occasioned by muscular action, though more commonly by direct falls upon the inner side of the elbow. The symptoms of this fracture are very evident, for the separated portion of bone can be easily

moved, and crepitus is elicited by the motion. The swelling may alter the appearance of the articulation, yet a close examination shows that the joint is unimpaired, and no marked

FIG. 42.



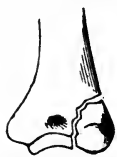Fracture of the epitrochlea.

displacement exists. The capsular ligament and ligamentous structures adhering to the fragment, keep it from leaving its position. The muscles arising from the epitrochlea may tilt the piece a little inwards, yet not sufficiently to require any special appliance to oppose the tendency. Very little treatment is required to secure a fortunate result. If the arm be carried in a sling for sup-

port, and to maintain semiflexion of the limb, a good recovery will be made. The accident occurs mostly in children, in whom the epitrochlea is connected only by cartilaginous material, the tip of bone being an epiphysis. Cases are reported in which the accident has happened to adults, and in whom the detached fragment has been drawn downwards an inch or more by the powerful muscles arising from it.

Fractures through the articular surfaces are of a more serious character. They may effect the inner or the outer condyle, extending from that part of the bone which meets the ulna or radius, and continue obliquely upwards

FIG. 43.

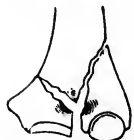

Fracture of the external condyle of the humerus.

and inwards, or upwards and outwards through the condyloid ridge, detaching a piece of bone somewhat as represented in the accompanying diagrams. In instances more or less rare, the two condyles are split apart, the line of fracture dividing so as to terminate in both condyloid ridges. This would constitute a comminuted and complicated fracture,

allowing the radius and ulna to be drawn up between the fragments, the displacement being in part a dislocation. In such a case the distance between the two condyles would be too great, and the arm would have the appearance of a fracture of the humerus just above the joint, or a dislocation of the elbow.

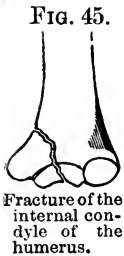FIG. 44.



Fracture of both condyles of the humerus.

In fractures through the internal condyle, involving the articular surfaces, the line of separation extends from the middle of the trochlea, or concave articular surface which receives the ulna, through the fossæ or depressions which receive the two upper processes of the ulna, and termi-

nates just above the epitrochlea. This fracture is generally caused by direct violence, the force of the blow in falls being received directly upon the condyle. It is an injury confined almost exclusively to childhood, and is not as common as fracture of the external condyle.

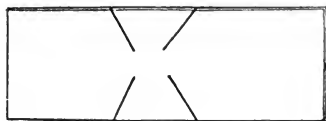
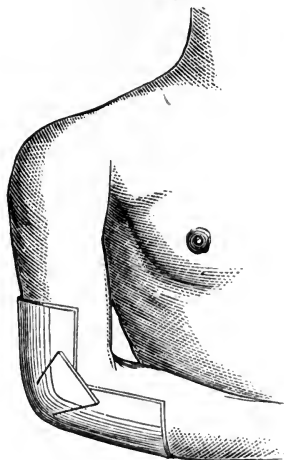


The displacement of the detached fragment is not great when the arm is semiflexed and in an easy position. The separated condyle can not be drawn downwards, for the ulna prevents such a displacement; the muscles arising from it will not permit of its being pushed or drawn upwards; and the ligaments are opposed to other malpositions. However, the fragment can be moved when grasped with the fingers, and made to follow the ulna in flexing and extending the arm. These movements are almost certain to produce crepitation. The distance between the condyles is generally increased a little, and there is a peculiar deformity noticed which is partly produced by the swelling, and partly by a twist in the arm. When the limb is grasped above and below the elbow, greater lateral motion can be imparted to the joint than could be if no fracture existed. This is a valuable diagnostic manœuvre in ascertaining a fracture of either condyle. These deflections do not determine which condyle is broken, but with a finger on each, while lateral movements are imparted to the joint, the point can be determined.

TREATMENT.—Anchylolysis, partial or complete, is the danger to be apprehended while treating fractures of either condyle. As has been stated, the displacement can not be great, therefore hard splints, compresses, and tight bandages are not required. However, few patients are satisfied unless the broken bone is “set,” and the injured part dressed with splints and bandages. To satisfy this popular demand is quite desirable when it can be done without detriment to the case. In hospitals, where patients are under the control of rigid professional directions, it may do to keep the arm resting on a pillow, without any dressing or treatment, except topical remedies to keep down inflammation. In private practice such a course would be severely criticized; and unless the medical attendant had a firm hold on the patient’s confidence, he would be in danger of being dismissed for pursuing such a

course. Fortunately for those who have to conform to popular prejudice, fractures of the condyles can be dressed with pliable splints and a bandage. A piece of pasteboard twelve inches long and six inches wide, should have two incisions made in each side to within an inch of each other, as

FIG. 46.



Quadrangular piece of pasteboard cut into at the sides to make it conform to the bend of the elbow, and the same applied to the arm.

indicated in the diagram. This may then be wetted, lapped and bent, so it will cover the flexed elbow, as seen in Figure 46. After the arm is manipulated, to overcome the displacement if there be any, and the limb is flexed to nearly a right angle, the pasteboard splint is applied, and a bandage reaching from the fingers to near the shoulder, is snugly made to envelope the limb. Great swelling usually attends fracture of the condyles, therefore some allowance should be made for that state if the arm be dressed before the swelling has reached its height. Once dressed in the way indicated, the arm may be carried in a long sling let down from the neck.

A gutta percha splint moulded to the flexed arm answers a good purpose. Sole leather cut, wet, and moulded, as indicated for the pasteboard splint, is perhaps as good material as can be employed. Angular wooden and metal splints are not desirable, on account of their unyielding nature. I have used an angular woven wire splint with much satisfaction, though it has its objections.

The arm should be redressed every two or three days, and oftener if great pain and swelling seem to demand it. At the end of two weeks the elbow should be subjected daily to gentle passive motion. In three weeks from the accident the dressing may be wholly removed, and more forcible passive motion imparted several times a day. If the limb be left to itself the joint is almost certain to become ankylosed, therefore it will not do to trust so important a proceeding to the patient.

The operation of forcibly flexing and extending the limb is attended with considerable pain; and the patient in attempting to follow directions is liable to be deceived as to the amount of motion imparted. Movements of the shoulder lead to the conclusion that the motion is in the elbow. When the arm is forcibly flexed or extended, it should be held to the maximum of those states for several minutes in order that the pressure imparted to the callus or excess of reparative material may stimulate absorption.

Voluntary motion, on account of the stiffness of the muscles, is of little value. In forced motion the joint seems to lock, as a hinge into which a nail has accidentally slipped, stopping the normal sweep of flexion. This impediment arises from the amount of uniting callus in the articulation, which interferes with the play of the hinge.

Passive motion should be kept up for a year, if sufficient range of motion be not obtained before that time. The patient should be directed to voluntarily put his fingers to his cravat, chin, mouth, and forehead every day. He can thus determine whether he gains in the extent of motion. I have, in several instances, taken an arm that was quite immovable when the dressings were removed, and restored it to perfect action in the course of a few months. I may add that I have never failed to establish a satisfactory range of motion in the elbow in cases of threatened or impending ankylosis following fracture of a condyle. There is scarcely a fracture of any bone which is followed with so many unsatisfactory results as a broken condyle of the humerus. Litigations are numerous in which attempts are made to recover damages from the surgeon who is unfortunate enough to be afflicted with unsatisfactory results. Some of our most experienced surgeons have refused to treat a broken condyle until the patient and the patient's friends are informed that the case would not be undertaken unless assurance be given that no litigation is to be commenced, or damages claimed in the event of ankylosis or other serious defect in the joint.

FRACTURE OF THE EXTERNAL CONDYLE.

The external condyle is broken more frequently than the internal, especially in adults. Children are extremely liable to fracture of either condyle, though the inner oftenest suffers. The external condyle is frequently broken by direct violence, as by a blow or fall; yet it may become disjoined by indirect violence, the hand receiving the shock of a fall, the force being conveyed from the hand through the radius to the humerus. Although authors have hitherto neglected to speak of the fracture as occurring from indirect violence, I have met with several examples of the lesion, in which the evidence was that no violence had been received except upon the open hand thrown out to break the fall. In September, 1868, I stood watching the work of some paperers, when one of the workmen, John Fordice, who stood on the head of a barrel, lost his poise, reeled, and fell to the floor. He broke the force of the fall with his outstretched hand, but received an injury of the elbow that gave an audible snap. Being present at the time of the accident, I had an opportunity to determine the nature of the lesion before swelling set in. The external condyle could be easily moved with the thumb and finger, and crepitus was distinctly produced by the motions imparted. The fragment was forced upwards, and the arm seemed deflected to the radial side, as well as inclined to remain in a position of partial flexion. The elbow gained in lateral mobility, and appeared wider between the condyles. In a few minutes swelling came on and obscured some of the signs that were marked at first. The fragment then was not so easily moved on account of the effusions in and about the joint, and the crepitus was not so plain. If I had not seen the man strike on his hand while falling, or had not examined the case for an hour after the injury, I might have suspected that some of the swelling and discoloration which came on at the seat of injury, was caused by the elbow striking heavily against some hard substance, and that the fracture may have been caused by direct violence. Persons who sustain fractures by falls are often confused, and not positive whether the elbow hit something heavily, or the force was received on the palm of the hand. Dislocations of the head of the radius

frequently occur from a fall received upon the hand. In one case reported by Hamilton, the dislocation occurred backwards in conjunction with fracture of the outer condyle. But in that case the patient was confident he struck the ground with the back of his elbow. It is not easy to conjecture how this double injury could arise from a single force applied all at once, to say nothing of the *backward* dislocation of the head of the radius.

TREATMENT.—The displacement being slight in almost every instance, there is no reduction to be accomplished. The arm should be dressed in the semiflexed position, and the same shaped pasteboard splint employed, as was recommended for fracture of the internal condyle. The passive motion should be commenced by the fifteenth day, and kept up daily for a week or two longer before the dressing is laid aside. If the muscles and soft tissues be much stiffened, and there be evidence of impending ankylosis, the arm should be forcibly flexed and extended several times a day until the functions of the articulation are fully restored. The services of some friend or strong member of the family should be secured to regularly perform this important part of the treatment, for there exists the same danger of bony ankylosis as in the repair of the other condyle. The arm should also be exercised in the motions of pronation and supination. In the process of reparation osseous material not only encroaches upon the fossæ of the humerus, but makes connections with the head of the radius, preventing the normal rotation of the fore-arm.

In rare instances the detached condyle fails to consolidate with the rest of the bone. Such a state does not impair the use of the limb to a degree that warrants the usual surgical interference devised to overcome false-joint or non-union.

In the event of ankylosis there may be exceptional cases in which, while the patient is under profound anæsthesia, attempts to break up the osseous connections might be justifiable. In October, 1867, Thomas Anson, of Indiana, came to me with ankylosis of the elbow following fracture of the external condyle. The arm was broken ten weeks previously, and had been treated in the usual way by the family physician. As near as I could learn, no particular directions had been given about passive motion to obviate ankylosis, but at the

end of four weeks, when the dressings were removed, the arm was allowed to remain in the same semiflexed position it had been made to assume during the treatment. I put the patient under the influence of chloroform, and broke the osseous bridges that joined the head of the radius to the consolidated external condyle. No great amount of inflammation followed the disjunction. Anodyne and evaporating lotions were kept on the joint for five or six days, and not much motion permitted, though no splints or dressings were used to overcome mobility. Finding that no severe inflammation was likely to arise, the joint was subjected to almost hourly exercises in flexion and extension. The patient went home on the tenth day after the operation, with directions to keep up the passive motion for weeks, and months if necessary. In a letter written six weeks after he left for home, he wrote that he could flex and extend his arm voluntarily, to a degree sufficient for all practical purposes.

Anchylosis of long standing should not be treated in this way, for the limb is not useless though the elbow be stiff, and attempts to break up the articular adhesions and connections might result in no substantial advantage. It is only while anchylosis is recent that a forcible disruption is justifiable. A successful attempt to sunder the adventitious structures has been made six or eight months after the reception of the original injury, and other efforts have failed at the expiration of three months.

Injuries of a crushing character inflicted upon the elbow, bruising the flesh and breaking the osseous structures of the articulation, are sometimes sufficiently grave to demand amputation. However, unless the brachial artery and median nerve are known to be lacerated, it is commonly prudent to wait a few days to ascertain what may then be the indications. There is generally no pressing necessity for haste after such injuries, though every sign of vitality has departed from the extremity, and gangrene is apparent.

If there be feeble pulsation at the wrist, and partial sensation in the hand, there is a possibility, if not a probability, of saving the limb. At any rate, a primary amputation, as it is called, should not be performed unless the limb, after reaction has taken place in the rest of the body, remains cold and cadaverous—pulseless and senseless. If sufficient vitality remain

to warrant an attempt to save the arm, a few days will disclose the fact whether the limb must be sacrificed to save life, and amputation can then be performed with not much greater risk than would have been incurred just after the accident.

In compound and comminuted fracture of the elbow, the finger may be used to explore the joint, to ascertain if any loose pieces of bone need removing. Small fragments completely disengaged, or cut off from nutritious supplies, are about sure to act as foreign bodies in the joint; and may do as much mischief as pieces of wood, cloth, or common gravel in their position. All such pieces of isolated bone should be removed, and the limb placed on a pillow, in an easy attitude, for several days. The parts implicated in the injury should be kept wet with water, and lightly covered. The fœtor may be corrected to some extent by the use of dilute carbolic acid. As soon as it becomes known that the limb can be saved, though with no hope of motion in the joint, the arm should take the position of semiflexion, as the member, when ankylosed, is the most useful in that attitude. Many an arm, condemned to amputation by surgical attendants, has been saved as a valuable limb, by the stubborn refusal of the patient to submit to what was professionally decreed. In one case, in which the joint was so opened that the finger could be passed through and feel the artery pulsating in front, Sir Astley Cooper proposed amputation, but the patient refused to submit to it, and his arm was saved and became useful.

A disposition to amputate after the reception of severe injuries is the peculiarity of those surgeons who have held commissions in the volunteer army. The inclination to lop off a lacerated limb springs from a desire to execute a notable operation, which may go to sustain a reputation for surgical ability. However, an old army surgeon is apt to be as conservative as the civil practitioner.

If a limb is to be a source of danger to life through prolonged suppuration, or from tetanic complications, it is well to amputate early; yet tetanus may generally be averted by placing injured parts in easy attitudes; and a perilous suppuration can not be determined for weeks, or perhaps months. Amputation after fractures is to be avoided if possible.

CHAPTER XXI.

FRACTURE OF THE ULNA.

The ulna, the companion of the radius in the skeleton of the fore-arm, does not constitute an important part of the wrist joint, but enters more largely than its fellow into the articulation of the elbow. The bone terminates at its upper extremity, in a prominent process—the olecranon—which is a lever for the action of the triceps. This process, behind the

FIG. 47.



Shows fracture of the olecranon and coronoid processes.

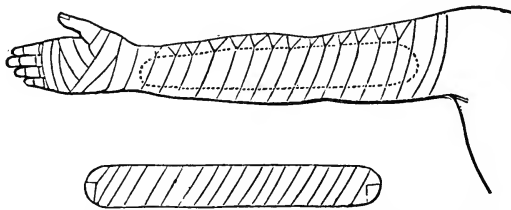
articulation, is thinly covered, and exposed to blows of sufficient severity to cause fracture. If the fore-arm be suddenly and forcibly extended, the olecranon, either by the action of the triceps or the violent contact of the humerus in extreme extension, is liable to be broken off from the rest of the bone. The summit or extreme tip of the process may be detached in extremely rare cases, though the fracture usually separates the greater part of the olecranon. In falls directly upon the part, the greater portion of the process is likely to be broken off. The line of separation is commonly transverse; and the displacement upwards in the direction of the triceps, renders the nature of the accident quite easy to understand. In some instances, where the ligamentous structures are untorn, and the arm has not been flexed, the displacement is scarcely perceptible. In most cases the process is retracted to so great an extent by the triceps, that every connecting medium must be torn through, the fragment being entirely under the control of the muscle. Flexing the arm puts the triceps on the

stretch, and necessarily widens the breach between the fragments. Displaced as the process usually is after fracture, it can be distinctly felt an inch or so above its ordinary location, and is easily movable from side to side. Power of voluntary extension is almost entirely lost after fracture of the olecranon, and pain is aggravated by movements of the limb. Swelling quickly follows the injury, and tends to obscure the diagnosis if the patient be not examined for several hours after the accident. Crepitus can not be elicited unless the arm be extended, and the triceps pressed downwards, so that the broken surfaces may be brought in contact.

In doubtful cases, when there is no apparent displacement, the finger placed upon the olecranon while the arm is flexed, will discover the line of separation which is always more or less marked by a lack of perfect apposition. If the arm be put into extreme flexion, the fragments are forced apart and a palpable depression is felt between them.

TREATMENT.—It is plainly evident that fracture of the olecranon is to be treated with the arm in a state of extreme ex-

FIG. 48.



Splint and dressing for fracture of the olecranon process.

tension; and a long splint reaching from near the shoulder to the hand, and bound to the front aspect of the limb, will keep the arm from being flexed. A roller bandage begun at the fingers should extend to the elbow; then another started near the shoulder is made in its turns to envelope the arm down to and including the elbow. The first prevents undue congestion and swelling, and the other forces the triceps downwards so that the detached olecranon may come in contact with the rest of the bone. The long straight splint is now placed on the front of the arm and fastened there by the turns of another roller. This dressing holds the limb in a straight position, which is somewhat awkward, but it is the only way the

broken surfaces can be brought into apposition and held there securely. As there is danger of severe inflammation in the joint, anodyne and evaporating lotions should be applied to the elbow for several days. The dressing may be taken off and re-applied occasionally during the healing process, though the joint should not be fully flexed for five or six weeks, lest the fragments be forced apart. At the expiration of that time, the state of the parts involved in the injury should be carefully observed, to ascertain whether the union of the fragments be osseous. If the consolidation be perfect, whatever of stiffness and ankylosis exist, should be overcome by passive motion. The arm should not be fully flexed at first, but there ought to be a gradual restoration of the functions of the joint. If the union be fibrous, which by some surgeons is thought to be the normal state after fracture of the olecranon, the connecting bands will be so short that the use of the limb is but slightly impaired. Extension can be performed even if the union be fibrous or ligamentous. In the event of false-joint, especially if the connecting bands be short, it is not best to attempt the establishment of bony union by any of the means usually employed for such purposes.

The only objections raised against dressing the arm in the extended position is, that if ankylosis does take place, the limb is not in a good attitude for service. It is justly claimed that if the joint is to be permanently stiff, the semiflexed position is far preferable to a straight attitude. However, it is found in practice that the cases in which complete ankylosis results, are extremely uncommon. If the articulation be severely injured at the time the fracture occurs, so that ankylosis seems inevitable, it might be wise to dress the arm in a position which would be most useful, for if the elbow be ankylosed it would make little difference whether the olecranon was consolidated or not.

It is recommended by Hamilton that moderate flexion and extension be performed every day, while the dressing is off, the finger pressing downwards upon the olecranon, to obviate ankylosis, but this increases greatly the risk of fibrous union, and opposes in a slight degree ankylosis which is very unlikely to occur.

FRACTURE OF THE CORONOID PROCESS.

Fracture of the coronoid process must be an extremely rare accident. The surgeons are few who have been positive that they have seen a case. Several cases have been reported, but full credence can not be placed in all of them. The accident is said to occur in connection with dislocation of the radius and ulna backwards, and sometimes perhaps without that complication. It has been stated by surgical writers that the action of the brachialis anticus would break the process; their language being that the muscle is inserted into the process, when in fact it is inserted below or at the base of that prominence of bone, and has no direct action upon it. The occasion for distrust in some of the reported cases comes from the anatomical error into which writers have so frequently fallen. In a malpractice suit tried in the State of New York, one of the surgical experts in his testimony in regard to dislocation of the radius and ulna backwards, stated that the brachialis muscle was inserted into the *apex* of the coronoid process. Mr. Liston, in his *Operative Surgery*, mentions the case of a boy who broke the coronoid process by the action of the brachialis muscle while hanging from a high wall. Notwithstanding our great regard for such high authority, it will be convincing to any one referring to the anatomy of the parts involved in the alleged injury and considering the action of the muscle upon the process while a boy was hanging by the arm, that no such lesion could take place. The boy's weight as he was suspended by the hand, would draw the coronoid process away from close contact with the humerus, and the brachialis anticus muscle, being inserted at the base of the process, also passing over it, would press upon its apex, the action tending to retain the bony prominence in place, and not to detach it, while the arm was in extreme extension. The coronoid process is not an epiphysis, with a cartilaginous connection with the shaft of the ulna during childhood; which is another circumstance opposed to the theory of fracture from muscular action, though it is declared by nearly all writers upon the subject, that children and not adults, are liable to the accident.

It is not denied that direct violence, as the passage of a wheel over the part, may break off the coronoid process; and it is quite certain that in dislocations of the ulna backwards, the point of bone is occasionally severed from its connections with the main part of the bone.

TREATMENT.—The dislocation having been reduced, for the fracture is presumed not to occur except in conjunction with that injury, the arm should be kept in a state of partial flexion to prevent a recurrence of the luxation. The limb may be bandaged from the fingers to a point above the elbow, and a compress employed to retain the detached process in place. This dressing can be employed for four or five weeks, though the articulation is to be gently exercised daily to prevent ankylosis. The difficulty of retaining so small a fragment steadily in position, and the scanty nutritive materials finding their way to the process after its violent separation from the shaft, would be liable to insure a ligamentous, and not a bony connection. If the detached process never obtained a firm connection with the shaft of the ulna, the osseous material poured out to consolidate the fragments, would constitute a barrier against repeated dislocations. The functions of the joint, under such circumstances, must be more or less impaired, for the elbow is liable to chronic defects after even moderate injuries. It is vastly more important to secure free motion to the joint, than to be striving for bony union, which would be utterly useless in the event of ankylosis.

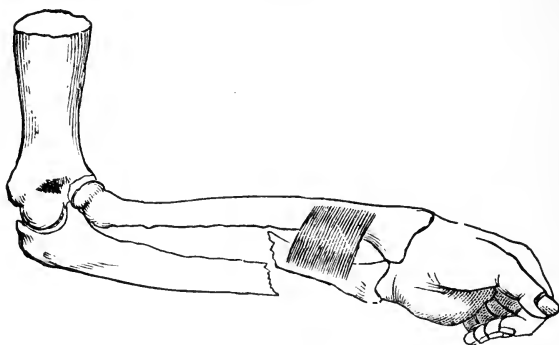
FRACTURE OF THE SHAFT OF THE ULNA.

The shaft of the ulna, when fractured singly, is always broken by direct force. If the radius be previously broken, the ulna may be brought under the influence of the indirect force, and be fractured by it. When the hand is extended in falls to save the head and trunk from violence, the radius, from the mode of articulation in the fore-arm, receives the force of the blow and either breaks just above the wrist, or conveys the shock to the humerus; thus the ulna is preserved from heavy concussion. The ulna is subject, then, to direct violence, either in striking against some hard body, or in

warding a blow aimed at the body. The arm is raised in protecting the head, to an attitude which presents its ulna side toward the threatening violence. Also in falling backwards, the arm is thrown in advance of the trunk to shield it from injury, and receives a violent shock on its ulnar side. While descending stairs, a slip of the feet forwards throws the body backwards, and the ulnar sides of the arms come directly against the edge of a step.

The situation of the fracture under such circumstances, depends of course upon the part of the bone struck. The lower half of the bone is smaller and weaker than the upper half,

FIG. 49.



Fracture of the ulna above the origin of the pronator quadratus, showing the action of that muscle upon the lower fragment.

and should consequently be most frequently broken, all other conditions being equal. A force producing fracture of the shaft of the ulna, is very liable to convert the lesion into one of a compound nature.

The symptoms of fracture are usually very prominent. The bone being thinly covered, the displacement is generally quite marked. However, in some instances, especially towards the upper extremity of the bone, the fragments may be interlocked, or held in place by the periosteum, so that no disjunction occurs. In fractures through the lower-portion of the bone, the upper fragment remains nearly in the place occupied before the fracture, owing to the firm and wide articulation at the elbow, and the lower fragment is drawn towards the radius by the action of the pronator quadratus muscle. If the upper end of the lower fragment take any other position, it is driven

there by the force that produced the fracture, and the muscular action was too feeble to restore it to the place it would take if uninfluenced by the paralyzing blow. When the broken ends are brought in contact, in the manipulations of the arm, crepitus is distinctly felt and heard. The power of rotation is impaired by fracture of the ulna, and in fact all the functions of the fore-arm are restrained by the swelling, pain, and loss of power attendant upon the lesion.

In May, 1865, I was called to Mollie Shannon, a stout Irish girl, who fell backward from a stool while hanging out clothes. The fall brought her upon a flight of back stairs, and she slid to the bottom, lighting upon a brick pavement. I saw her in a few minutes after the injuries were received. She was complaining bitterly of her arm near the elbow, and refused to allow me to examine it as thoroughly as I desired, on account of the pain which the slightest manipulation seemed to produce. I therefore gave her chloroform until I could handle the limb, and ascertain the nature and extent of the injury. A contusion about five inches below the elbow on the ulnar aspect of the arm, led to a critical examination of the bone beneath. I found a fracture of the ulna at that point, though not much displacement existed. There was swelling about the elbow, which, with a huge development of the muscles, rendered the nature of any injury in that region perplexingly obscure. The rigidity of the joint, and the peculiar twist, amounting to marked distortion, which the limb assumed, favored the idea of dislocation of the head of the radius. To this conclusion I at length arrived, though not with that certainty which fully satisfies the mind. After putting the patient under profound anæsthesia I succeeded in reducing the dislocation, and then the arm became supple, and the fracture of the ulna permitted of the plainest crepitation, which could not be elicited until the luxation was reduced. To understand how both injuries were produced is not easy, unless the ulna was broken against the sharp angle of the post at the head of the stairs, and at the time she fell from the stool; the dislocation of the head of the radius upon the anterior aspect of the condyle, must have been done when she landed at the foot of the stairs, where the great weight of her body came upon the injured arm, which, she said, "doubled up under me." The case made a good recovery.

TREATMENT.—It is not generally a difficult matter to reduce a simple fracture of the ulna. The broken ends, whether they project in one direction or another, or the upper fragment be in position and the lower dragged into the interosseous space, toward the radius, can commonly be manipulated into apposition without deviation from the natural course of the bone. The fragments once brought into line and properly adjusted, two padded board splints, wider than the arm, and reaching from the elbow to the fingers, are to be bound to the anterior and posterior aspects of the arm, while the hand is held half way between pronation and supination. No roller should be applied except the one that holds the splints in place. Any circular compression is extremely liable to press one or both fragments into the interosseous space, where they may unite to the radius, destroying the functions of pronation and supination. If the fracture be through the lower third of the bone, and the lower fragment is quite forcibly drawn toward the radius, two long, firm compresses should be laid between the radius and ulna, beneath the splints. These tend to wedge the bones apart. The width of the splints prevents anything but lateral compression. As the bandage, while it is being put on, passes across from one splint to the other, the upper and lower surfaces of the arm remain untouched, thus entirely obviating *circular* compression. After the arm is properly dressed, it may be carried in a sling. The redressings need not be frequent unless there arise a suspicion that all is not well. In the usual time, which is about four or five weeks, the dressings may be finally removed. False-joint after fracture of the shaft of the ulna is extremely rare. The callus is plainly felt for months, on account of the subcutaneous location of the bone.

CHAPTER XXII.

FRACTURE OF THE RADIUS, ETC.

The upper third of the radius, from its being buried deeply in muscles, is seldom fractured; the middle third is not broken any more frequently than the ulna; but the lower third is fractured more often than any part of any other bone in the body.

Fracture of the neck of the radius is admitted by every experienced surgeon to be extremely rare. Dr. Markoe, of New York, thought he met with a case in which the signs pointed inevitably to a fracture through the neck of the radius, but the autopsy showed that he had been mistaken. The injury proved to be a dislocation of the head of the radius forwards, and a fracture of the ulna near the elbow. The mobility of the parts and the crepitus which seemed to come from the radial side of the arm, led to the error of diagnosis. Mutter's cabinet in Philadelphia, contains a specimen of fracture through the neck of the radius, which I have examined. The history of the case is unknown. The fracture united with considerable deformity, which must have interfered considerably with the functions of the elbow.

In the winter of 1855, Mr. Noyes, of Boston, was thrown from a sleigh in Lowell, and received a severe injury about the elbow. He went to a hotel, and requested that a surgeon be called to treat his arm. The landlord sent for Dr. Nathan Allen, his family physician. Upon his arrival, the doctor examined the injury, and pronounced it a sprain. He applied a bandage to suppress the swelling, and ordered wormwood and rum as a topical application. Several professional visits were made Mr. Noyes while he was at the hotel, and assurances were given that in a few days the patient would be able to resume his business. After several weeks Mr. Noyes found

that he could not bend the elbow except in a very moderate degree; he could not carry his fingers to the chin, even if the head was bent to meet them. Accordingly he went to the late Dr. John C. Warren, of Boston, for an opinion in regard to the nature of the injury and the prospects of a cure. Dr. W. asked "who had treated the arm;" and upon being told that it was Dr. Allen, he would not look at the case, as Dr. A. was a professional brother in the Massachusetts Medical Society. Mr. N. then went to Dr. Kimball, of Lowell, a surgeon of some repute. Dr. K. examined the arm, and called his student's attention to what he called *a fracture of the condyle*. Mr. N. then went to Dr. Walter Burnham, of Lowell, also a surgeon of large experience, who pronounced the injury a fracture of the neck of the radius, which was ununited. Mr. N. now supposed that he had been maltreated by Dr. Allen, and sued him for damages. The case was tried at East Cambridge, in Middlesex County, in January, 1856, and resulted in a disagreement of the jury. The testimony given in court was singularly conflicting, coming as it did from some of the most accomplished and experienced surgeons in the State.

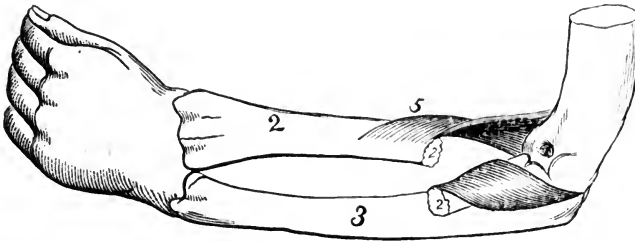
It was also a matter of surprise to Mr. Noyes that Dr. Kimball, who had directed his student to observe an old fracture of the condyle, should then under oath declare that the arm had never sustained a fracture. The real state of the limb, at the time of the trial was as follows: there was partial ankylosis at the elbow, flexion being greatly impeded, as has been stated; pronation and supination restricted; and a grating could be produced just below the elbow by passive efforts at rotation of the fore-arm. There was no evidence that the condyles of the humerus had ever been broken. The ulna seemed perfect in its processes and proportions, bearing no sign of fracture. The head of the radius was not dislocated, for it could be grasped with the thumb and finger, and plainly rotated, and it could be held still while the hand and lower extremity of the bone were rotated. These movements elicited a crepitating sound much like that heard in the motions of a false-joint. The evidence of fracture of the neck of the radius was reached by a logical necessity, on the application of a method of reasoning much resorted to in the diagnosis of diseases, viz., *reasoning by way of exclusion*. That there had been a fracture about the joint was quite plain, and as the humerus

and ulna were excluded from the possibility of having been fractured, the upper extremity of the radius alone remained unexcluded, and every symptom in the case indicated fracture of the neck of the bone, whether the injury had previously been met or not by surgeons high in authority.

In fractures of the head or neck of the radius, the arm should be flexed to relax the biceps which has its insertion just below the tubercle and tends to displace the upper extremity of the long fragment. The pasteboard splint recommended for fracture of the condyles of the humerus, would be excellent to steady and support the parts implicated in the injury. At the end of three or four weeks motion should be imparted to the joint to obviate ankylosis.

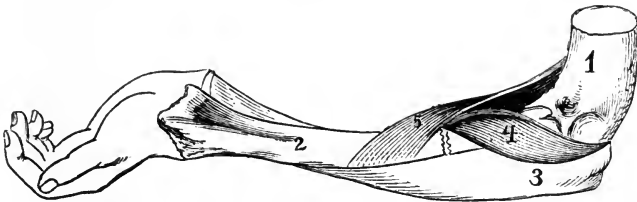
In fractures of the radius which very rarely occur between the attachment of the biceps and the insertion of the pronator radii teres, the fragments are acted upon by muscles exerting their forces in different directions. The supinator brevis rolls

FIG. 50.



Fracture of the radius between the insertions of the supinator brevis and pronator radii teres. The fragments are separated by the action of these muscles.

FIG. 51.



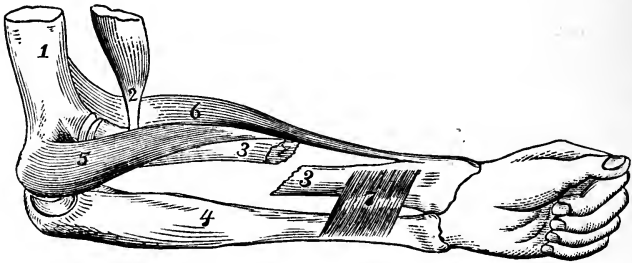
Arm supinated to bring the lower fragment into apposition with the upper.

the short, upper piece of bone outwards, and the antagonistic pronator pulls the lower piece inwards, somewhat as exhibited in Figure 50. Now, as the upper fragment is short and thickly covered with muscular tissue, it can not be moved from the position given to it by the supinator brevis; but the

lower fragment can be made to come in contact with the upper by the extreme supination of the fore-arm, as seen in Figure 51. To treat such a fracture successfully, the arm would have to be dressed in the attitude of extreme supination, and retained in that position until the consolidation of the fragments was sufficient to allow of rotation, and not endanger the breaking up of the callus. I have never treated but one case of the kind, which was produced by a pistol bullet, and in that I followed the course just laid down. The recovery was not rapid, for the injury was rendered compound by the bullet wound. Two splints made of thin boards, two inches and a half wide, and reaching from the elbow to the ends of the fingers, were bound in place by a roller while the arm was supine. The back of the hand was allowed to rest in a sling, strict orders being given to keep the thumb directed away from the body. The position was irksome at first, but in a few days it was maintained without effort.

Fracture through the middle third of the radius, below the insertion of the pronator radii teres, is generally caused by

FIG. 52.



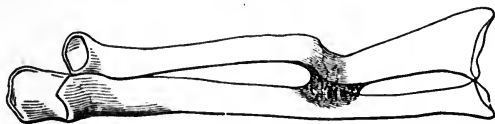
Fracture of the middle third of the radius. The biceps (2) tends to pull the upper fragment in one direction, and the pronator quadratus (7) the lower fragment into the interosseous space.

direct violence, and happens about as rarely as fracture through the middle third of the ulna. The diagnosis is unattended with difficulty. Rotation develops so much displacement that the ends of the fragments can be distinctly felt beneath the integuments. Crepitus can also be produced when the fragments are brought in contact and rubbed against one another. The inclination of the broken ends is to take a position in the interosseous space, approximating the ulna.

The treatment is the same as for fractured ulna in the same

region. Two straight splints, wider than the arm, to obviate circular compression, and padded to prevent excoriation of the skin, are to be bandaged to the dorsal and front aspects of the fore-arm. A compress placed under each splint between the bones, so as to force the fragments away from the ulna, tends to prevent the reparative material from soldering one or both broken ends to the ulna, as represented in Figure 53. If one or both fragments become welded to the ulna, the condi-

FIG. 53.



Consolidation of fragments of radius with the ulna, preventing rotation of the fore-arm.

tion is fatal to rotation. Ordinarily it is not necessary, in treating fractures near the middle of the radius, to use splints extending farther than from the elbow to the hand. These reach quite a distance above and below the line of fracture, so that no motion at the point of separation can take place if the splints be efficiently held with bandages. Figure 61 represents the splints padded and held in place with a couple of tapes preparatory to receiving the bandage.

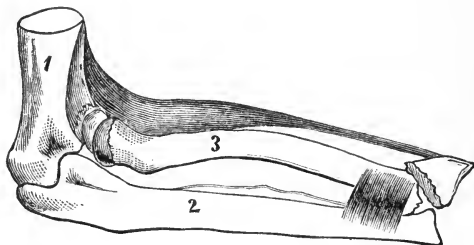
FRACTURE THROUGH THE LOWER THIRD OF THE RADIUS.

There is no part of the skeleton so subject to fracture as the lower extremity of the radius. The lesion occurs from indirect violence. The hand in a fall is put forth to arrest the progress of the descent, and to save the head and the trunk from serious blows and concussions. These uses are the occasion of so many fractures of the radius near the wrist. The expanded articular extremity of the bone receives the carpus, leaving the ulna free from the shocks sent along from the hand to the fore-arm. The lower end of the radius, though quite large, has a thin shell of hard bone upon the outside, and an abundance of cancellated structure within.

Several distinguished surgeons in this country and abroad, have written upon the nature, appearances, and treatment of

fractures occurring at the lower extremity of the radius, and a few of them have gotten their names associated with varieties of the injury. In 1814 Dr. Abraham Colles, of Dublin, published an article in the *Edinburgh Medical and Surgical Journal*, upon the peculiarities of a fracture commonly occurring about an inch from the carpal extremity of the radius; and since that time all fractures of the lower portion of the radius, except such as involved the articular surface of the bone, have been called "*Colles' fracture.*" In 1838, Dr. J. Rhea Barton, of Philadelphia, published an article in the *Philadelphia Medical Examiner*, on the subject of fractures of the carpal extremity of the radius. He called particular attention to such fractures as involved the articular surface of the bone, claiming that in many instances the line of separation was not so far from the wrist-joint as described by Colles. Since the publication of the article American surgeons have

FIG. 54.



"Barton's fracture" of the lower extremity of the radius. The action of the supinator longus and pronator quadratus is exhibited in the position of the fragments.

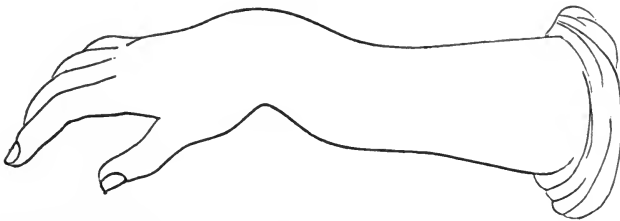
commonly called the injury, when the articulation is involved, "*Barton's fracture.*" Both writers have described injuries produced by the same causes, and presenting the same peculiarities. There is no difference between Colles' fracture and Barton's fracture, unless it be that the latter name belongs to such lesions as present a break extending to the carpal articular surface. In the production of both fractures the hand is thrown out instinctively to break the force of a fall, and when the carpus meets the earth or the resistance of anything stable, the momentum of the body causes a fracture at the weakest part of the bone.

The deformity following fracture of the radius near the wrist is observable, yet to an inexperienced person the nature of the difficulty is rather obscure. The swelling which rapidly

supervenies, masks the irregularities of the broken surfaces, and otherwise conceals the symptoms of fracture. The appearances of the parts may lead to the suspicion of radio-carpal luxation. If the hand and fore-arm of the patient be grasped and subjected to extending and counter-extending forces, the injured limb in case of fracture, will be made to assume its natural outlines and projections. In the event of radio-carpal dislocation, which is an exceedingly uncommon lesion, the deformities can not readily be overcome by such force; and when once in place the bones will stay there. The deformities attendant upon fracture are easily overcome, but they will immediately recur upon the relaxation of the reducing forces.

The peculiar appearance of an arm suffering from fracture of the carpal extremity of the radius, has been compared to the outline of a silver fork. The accompanying diagram represents it pretty well. An elevation presents on the wrist,

FIG. 55.



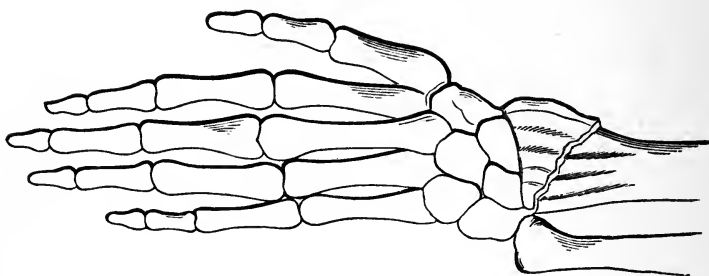
“Silver fork” appearance of the hand and arm after Colles’ fracture of the radius.

extending to the back of the hand. This dorsal prominence is nearly apposite or a counterpart to a deep sulcus or depression on the palmar aspect of the wrist. Higher on the front of the arm, above the sulcus, is a marked prominence. Besides these deformities, there is an abnormal projection of the lower extremity of the ulna, as if the carpus was dislocated laterally to the radial side. The muscles going to the thumb tend to pull the hand away from the ulna.

In seeking positive evidence of the fracture under consideration, crepitus becomes important. This valuable sign can generally be elicited by grasping the hand and arm, and imparting various movements to the wrist. The finger pressed upon the radius immediately above the articulation, while the movements just spoken of are made, will discover the sharp or rough edges of the broken ends of the fragments, or such

irregularities in the bone within an inch or two of the joint, as will be quite conclusive as to the nature of the injury, the direction of the line of fracture, and the size and shape of the lower fragment. The skeleton drawing in the accompanying diagram represents pretty accurately the line of separation

FIG. 56.



Fracture through the lower extremity of the radius, showing the tendency of the hand to slide away from the ulna.

just above the radio-carpal articulation. The short fragment is larger in some instances and smaller in others. It is well to bear in mind, while considering the relative positions the fragments take, that the supinator longus is inserted into the lower fragment, dragging it and the carpus attached to it, away from the ulna, and the pronator quadratus drags the lower end of the upper fragment toward the ulna, making the arm just above the wrist rounder, or less flattened, than usual.

Colles' fracture of the radius happens at all periods of life, from infancy to old age. Females not being so much exposed to the violent accidents of life as the other sex, suffer less from all kinds of fractures. In September, 1868, a gentleman and two ladies were thrown from a carriage, while riding on the Reading pike. The gentleman jumped before the carriage had fully upset, and landing heavily on one foot, received Pott's fracture of the fibula; the two ladies were hurled violently to the earth, with hands extended to save more vital parts, and each sustained a fracture of the right radius near the wrist. If sex had any bearing on these injuries, it must have been confined to the conduct of each in an emergency, the man preferring the risks of a leap to the more passive course of being thrown upon his hands and head.

The deformities following Colles' fracture present unmistakable characteristics, whether treated well or ill, or not

treated at all. Some years ago I examined the wrists of Mr. Coleman, an English gentleman, who on a voyage from Calcutta to New York, was thrown against some luggage by a violent lurch of the ship. He received the common fracture of the radius in both arms, and as there was no surgeon on the vessel, no treatment was instituted except the application of a wet cloth to keep down inflammation. Being injured off the Cape of Good Hope, it was several weeks before he arrived in port. It was then too late to have anything done to remedy the deformity. However, the wrists were fully as mobile and useful at the end of two months from the injury as they would have been if subjected to the usual treatment, and the deformities were not greater than in many cases which have passed through surgical hands. I was surprised to see no worse results in cases never treated.

The examination of cabinet specimens reveals the fact that there is more or less impaction in many cases, the upper fragment being driven into the lower. In one specimen belonging to me, taken from the arm of a man who was killed by a fall, the lower fragment is split into three pieces, the line of fracture running through the carpal articular surface; and to every appearance the comminution was produced by the impacting and wedging forces of the upper fragment. The primary fracture was about an inch above the carpo-radial articulation; the splitting of the lower fragment must have been of a secondary nature, and was probably produced by the impetus of the body after the hand had struck the earth and received the earliest lesion.

The symptoms of fracture of the radius near the wrist are, pain, swelling, greater or less inability to use the hand and arm, and all the deformities already described. Crepitus can not always be produced, though the cases are rare in which it can not be elicited by varied manipulation. In young subjects the results of well treated cases are quite satisfactory, but in elderly persons, some degree of ankylosis, and stiffness in the wrist and fingers, lasts for weeks, months, and even years. The sheaths of the tendons lose their slippery functions, and a troublesome sensitiveness chronically affects the hand and wrist.

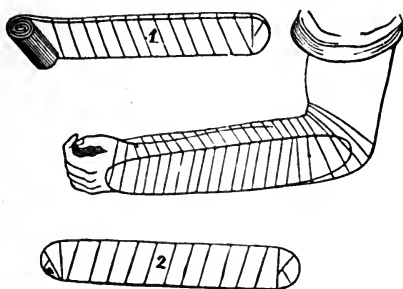
TREATMENT.—Many ingenious contrivances have been devised for successfully treating fractures through the lower

third of the radius. In fact, some of our works on fractures contain so many plans, with lengthily expressed approvals and objections, that the inexperienced reader finds some difficulty in selecting the most feasible plan. It is thought best, therefore, to describe a simple method of dressing the arm, which can be readily put in practice in the country, where a thin board, knife, and bandage can be obtained. The dorsal splint may be a piece of cigar box, two and a half inches wide and long enough to reach from near the elbow to the back of the hand. Before application it should be wound with strips of muslin or old cloth; the palmar splint may be whittled from the thin cover of a box, or from a shingle, or lath. Its shape may be something like the profile of the hand and arm, or like that represented by No. 1 in figure 57, which is broad near the lower end, and cut obliquely across, so that the upper or longest border corresponds with the thumb side of the hand. To this broad and obliquely cut extremity a compress large enough to fill the hollow of the hand, is bound. The compress may be made of a strip of bandage, compactly rolled. This is to be fastened in place by the same strip which is used to envelope the splint. The obliquity of the compress when the splint is applied, forces the hand to the ulnar side, thereby producing a degree of extension upon the lower fragment.

A compress is placed between the splint and the prominence of the arm on the palmar surface, and another small compress is placed on the prominence of the back of the wrist, under the dorsal splint. A piece of tape is tied around the splints near the hand, and another near the elbow, to retain the dressings thus far applied, in place. Extension is now made on the fingers to adjust the fragments; and the lower tape is tightened to prevent the displacement from recurring. Over the whole dressing thus far applied a roller bandage is snugly, though not tightly wrapped. Figure 57 represents the two splints before they are applied, and the arm after it is fully dressed. The fingers and thumb are left exposed, and can be used enough to prevent ankylosis, or even much stiffness. This dressing is simple in its construction, easily worn, and prevents motion between the fragments. I have obtained better results with it than with more complicated and expensive apparatus. The width of the splints must always exceed the width of the arm in order that there shall be no circular

constriction. No enveloping bandage is to be used upon the arm before the splints are applied. No water or other topical application is to be employed, for the wetting of the bandage

FIG. 57.



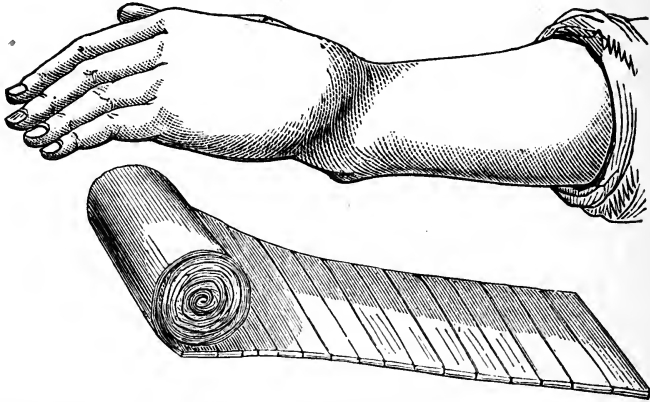
No. 1 is the palmar splint ready for use; and No. 2 the dorsal splint. The arm is represented as dressed in the treatment of "Colles' fracture" of the radius.

shrinks the cloth, and makes the dressing too tight. The limb should be seen the next day after the accident, and the bandage loosened if it seem to inflict pain or to arrest the circulation. It is better to re-dress the limb than to take any risk of mischief from strangulation. After the swelling has subsided, which will be in eight or ten days after the accident, the dressing may be left undisturbed for a week at a time. In four or five weeks, as a general rule, the consolidation will be complete, and the dressings may be laid aside. However, passive motion should be kept up for several weeks longer or until the functions of the fingers and wrist are re-established. Persons advanced in years are liable to neuralgic pains in the hand and at the seat of injury. This difficulty, if prolonged, and much troublesome, may be ameliorated by the use of stimulating and anodyne liniments. The excess of reparative material sometimes thrown out around the end of the upper fragment, constitutes a hard ridge at the seat of fracture, and seriously impedes the play of the tendons in that region. In time this excess of callus will be absorbed, leaving the parts nearly in their normal state.

An impending evil after fracture of the radius near the wrist, is false joint, which generally occurs where the patient has used the fore-arm at too early a period, or where motion at the wrist has not been guarded against during the treatment. Two ordinary straight splints, though they extend beyond the fingers, do not restrain motion at the seat of fracture

as well as the palmar splint, with its roller-like compress for the hollow of the hand. The dorsal splint resting upon the back of the hand also serves to check that tilting motion, with the lower end of the ulna for a pivot, which is so promotive of non-union of the fragments.

FIG. 58.



The arm exhibits the deformity attendant upon fracture through the lower extremity of the radius. A single splint, like the one represented, will answer to dress the fracture.

Some surgeons employ only one splint in the dressing for fracture through the lower extremity of the radius; and claim to have obtained good results from such an appliance. I have secured satisfactory recoveries from the single splint, with a roller bound obliquely upon the wide end, to rest in the hollow of the hand, but I prefer using also a dorsal splint.


If the dressing gets too loose, and the patient begins to use the hand before the consolidation is quite effected, the vital operations are perverted. Instead of continuing to furnish reparative supplies, they begin to remove the callus or uniting material, and make way for false-joint. In one case that came under my observation, the consolidation was nearly perfect on the twentieth day; there was plenty of callus, and every evidence of a complete repair. The patient now thought it was all useless to hamper his arm any longer, and assumed the responsibility of throwing aside the dressing and using the arm. At once the operations of nature became opposed to consolidation, and in a few weeks removed the reparative material and established a false-joint where there might have been consolidation by a week more of retentive treatment.

A little girl was brought to me not long since with an arm that had been fractured through the lower extremity of the radius five weeks previously. The medical attendant had dressed the limb in the usual way, but the dressing had been loosened by the child's mother, and taken off altogether before the physician had given directions for such a course. The little girl had used her arm at play, keeping up motion at the seat of injury where there should be absolute rest. The consequence was that the fragments failed to unite, though the upper fragment furnished an abundance of reparative material. I regarded it as not too late for an attempt to re-establish the healing process, so I put on the dressing recommended for the treatment of this fracture, employing starch paste at each turn of the bandage. In fact, the roller was employed up and down the arm two or three times, and the paste freely applied, as the wrapping continued, to constitute an immovable dressing. The rigid case thus constructed, was ordered to be worn six weeks at least. Consolidation followed, and a good result was obtained.

FRACTURE OF BOTH BONES OF THE FORE-ARM.

The radius and ulna are often broken at the same time. The injury is produced by direct violence. A blow, the passage of a wheel over the arm, and moving machinery, are the

FIG. 59.



Fracture of the radius and ulna. The same muscles are shown as acting upon the fragments as when one bone is broken.

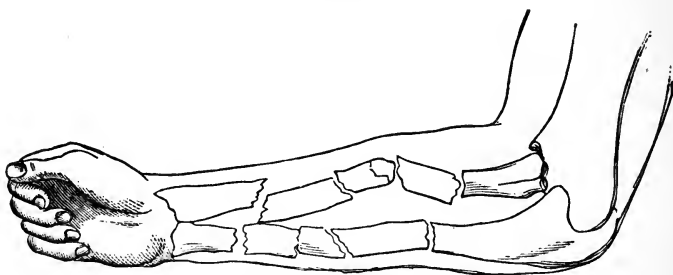
common causes. The middle and lower extremities of the bones are broken more frequently than the upper thirds which are protected in a measure by the deep coverings of muscles. In regard to the frequency of such accidents, the analysis of

tables shows that both bones of the fore-arm are oftener broken than the ulna singly.

The diagnosis is usually simple; the pain, loss of power, the unnatural bend in the arm, the separate mobility of the upper and lower fragments, and the crepitus, constitute signs which are too plain to be mistaken. The displacement of the fragments may not be observable in some instances, for the broken ends do not always become disengaged, but in most cases the deformity is so great as to indicate at once the nature of the injury. When there is overlapping of the fragments there must, of necessity, be shortening of the arm. The peculiar distortion produced by bending the limb near the seat of fracture, can not be misapprehended. Crepitus can be elicited by grasping the arm above and below the fracture, and rotating the limb while it is brought to its normal length and position by extension.

The tendency of the fragments is to sink into the interosseous space, where they will unite *en masse* unless well directed efforts are made to keep the ends of the two bones away from each other. In some instances one fragment will keep aloof from the others which incline to group. If the bones be broken conjointly and by direct violence, much damage may be done to the soft tissues, resulting in sloughs,

FIG. 60.



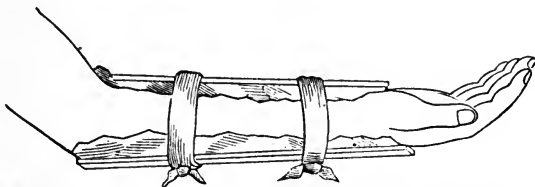
Comminuted fracture of both bones of the forearm.

protrusion of the fragments, and the most dangerous complications. Compound and comminuted fractures of both bones of the fore-arm have generally been considered a sufficient cause for immediate amputation, but such a course is not always necessary, as the following case will show. In October, 1865, Mr. William Moffit, living on Longworth Street in this

city, had his arm drawn between the rollers of a leather splitting machine. The crushing power to which the limb was subjected, broke the radius and ulna into fragments, each an inch or two in length, beginning near the wrist and extending to the elbow. The arm felt like a bag with pieces of broken ice in it. Some of the pieces of bone projected through the skin. Dr. E. N. Cushing, of Covington, Ky., was in my office at the time I was summoned to the case, and assisted in arranging and adjusting the fragments, and in dressing the limb. It is needless to say that it was utterly impossible to bring every fragment into perfect apposition at both ends, but the fragments of the two bones were pressed into rows, and the natural contour of the limb was well restored and preserved. Splints and bandages were used to keep the pieces and parts steadily in place. No severe pressure was applied through fear of gangrene. In less than two months the arm was freed from its dressings, and put under passive motion. The limb lost only a small share of its functions, and therefore became quite useful. Pronation and supination were partly lost; and the elbow and wrist did not recover their full extent of motion.

In treating fractures of both bones of the fore-arm, two splints reaching from the elbow to the wrist, and wide enough

FIG. 61.



Two splints, wider than the arm, and padded, are represented as tied in place with tapes preparatory to the reception of the roller or circular bandage.

to prevent circular constriction of the arm, are to be employed upon the front and dorsal aspects of the limb. Tapes may be used to retain the dressing in place until the fragments are coaptated, and everything is ready for the roller bandage. As in all other fractures of the fore-arm, no primary bandage is to go on next the skin. The constricting influence of such a bandage would force the fragments into the interosseous space where they are liable to unite in a group. The retentive bandage should be applied lightly at first.

Several cases are recorded in which the limb has had to be amputated, through the folly or carelessness of too tight dressings. There is time enough for snug compression after inflammation and swelling have subsided. Inexperienced surgeons often commit the error of strangling the local circulation by a tightly drawn retentive dressing. There is no other excuse for these repetitions in regard to the application of dressings to a broken arm, except in the fact that serious and fatal mistakes continue to be made by practitioners of medicine and surgery who have either not had an opportunity to read impressive lessons on the subject, or they are too heedless to learn what is enjoined but once.

A girl, Miss S., had her arm broken while at work at a printing press. The physician under whose professional charge the patient fell, wrapped the limb from the fingers to the axilla with new and thick drilling, and then ordered the wrappings kept wet all the time. Morphia and chloral were administered to keep pain in check. Two days after the injury I saw the case and advised amputation, as gangrene had appeared from the fingers to a distance above the elbow. My plan was rejected, and the late Dr. Geo. C. Blackman was invited to manage the case. The doctor said at once the arm could and must be saved, and the patient was taken to the Good Samaritan Hospital. In a few days the arm dropped from the scapula, unaided amputation having occurred at the shoulder joint. The separation was attended by no bleeding or other mishap. The cicatricial line was nicely puckered, and every feature of the reparative process was admirable. The dead arm gave issue to a horrible stench while the separation at the shoulder was going on, yet the surgeon had given his word that no amputation was necessary, and he was obstinate enough to stick to it. The case shows what the unassisted recuperative powers of the body will accomplish when left to themselves.

A similar case occurred in Lowell, Mass., twenty-five years ago. When the results of unskillful bandaging had appeared, surgeons gathered with the idea of amputating, but gave up their purpose on the ground that the patient would not survive the operation. In less than a week the head of the humerus dropped from its socket, and in two days more all the soft tissues became disconnected at the border of the axilla.

CHAPTER XXIII.

FRACTURE OF THE BONES OF THE HAND.

The bones of the hand, including the carpus, metacarpus, and phalanges, are seldom broken. The carpus has no long bones, but a group of eight pieces, rounded and angular, which are held together by ligaments and other fibrous structures, so that even if one or more were broken or crushed, there would be no particular displacement or special signs of fracture. It would be more in accordance with a rational division of subjects if fractures of the carpus were arranged under the head of wounds or severe bruises. The carpal bones can not be broken unless by direct violence of a crushing character, as by the passage over the wrist, of a cart-wheel, or by being caught between the bunters of rail-cars.

The *treatment* should consist in adjusting displaced parts as well as possible, and in using a bandage upon the hand, wrist, and fore-arm, to restrain motion. The topical use of anodynes and cooling lotions, would be indicated. In the management of a gunshot wound of the wrist, in which there must have been a crushing of one or more carpal bones, my patient exhibited signs of tetanus. Chloroform constantly applied to lint laid upon the wound, seemed to allay the nervous irritation.

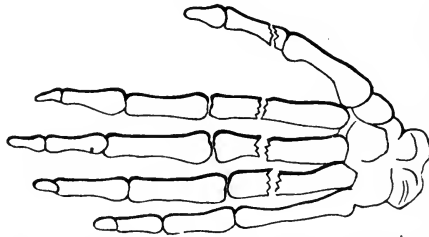
FRACTURE OF THE METACARPAL BONES.

Direct violence upon the back of the hand, and indirect force, as by blows upon the ends of the knuckles in pugilistic encounters, may produce fracture of one or more of the metacarpal bones. I have treated cases that were produced by both causes. Two years ago, John Benson, of West Virginia, came to my office one morning with the right hand swollen

and very painful. About sunrise that morning, he got into a fight with a negro deck hand on the Annie Laurie. He says he struck at his assailant, and missing him, his knuckle hit a box of freight; something in his hand cracked like a pistol, and his hand became too painful to use. At the middle of the metacarpal bone of the ring finger a tumefaction existed, and back and forward pressure produced motion between the fragments of the broken bone, and elicited crepitus.

In June last a boy came to my office from the printing department of Stannage & Co., and complained bitterly of his hand, which had been injured in a printing press. I found three of the metacarpal bones broken, and the first phalanx

FIG. 62.



Fracture of three of the metacarpal bones, and the first phalanx of the thumb. The hand was crushed in a printing press.

of the thumb. I applied to the hand and arm the palmar splint used for fracture of the lower extremity of the radius, and retained it in place with a bandage. The injury proved to be very painful, and the inflammation ran high. The back of the hand was kept wet with the tincture of aconite. At the end of three weeks the dressings were removed, at which time the consolidation seemed to be complete. However, the stiffness of the metacarpo-phalangeal joints was so great that forcible passive motion had to be employed for weeks, before the functions were sufficiently restored to allow of his voluntarily opening and shutting the hand. Slight displacement of the fragments toward the palm existed at the time I first saw the hand, and this deformity was not entirely overcome by the treatment. The boy was so stubborn and refractory that I could not carry out my plan of treatment fully. He objected to a moderately tight dressing, and would not submit to efficient passive motion. In treating fractures of the metacarpal bones, the plan of causing the hand to grasp a large

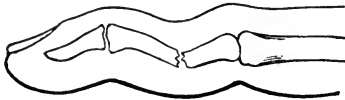
ball, and then binding a roller around the whole, as recommended by Sir Astley Cooper, is not so valuable as the palmar splint, with a roller compress bound to its end obliquely, to fill the hollow of the hand. This dressing leaves the fingers free, and prevents the ends of the fragments from sinking down toward the palm. If the metacarpal bone of the thumb be broken singly, the palmar splint having the roller compress attached, is the best apparatus that can be employed to give the fragments support and prevent motion and displacement.

FRACTURE OF THE PHALANGES.

From the exposed situation of the bones of the fingers, fracture of one or more of the phalanges is an occasional injury demanding consideration. Direct violence is by far the most common cause of the lesion, though a blow upon the end of a finger, as in attempts to stop or catch a ball, may produce fracture of the first or second phalanx.

A simple fracture of the finger may be produced by the great velocity of the force applied. The phalanges have been broken by a smart blow of a cane, though no resistance was offered on the opposite side of the fingers. A phalanx is seldom broken in more than one place, and generally near the

FIG. 63.



Fracture of a digital phalanx.

middle. A crushing force not unfrequently produces a comminution of the bone, including its articular extremities, and perforation of the integuments.

The symptoms of simple fracture are crepitus and mobility of the fragments; sometimes the shape of the finger will determine whether it is broken or not. If the flesh be mashed and the bone crushed, one of the joints of the finger is about sure to be involved; and the symptoms must depend very much upon the severity of the injury.

TREATMENT.—Simple fracture of a finger is to be managed on the usual plans followed in treating the long bones. A

narrow straight wooden splint is fastened beneath the finger, with a small compress against the point of fracture to support the ends of the broken bone, and to fill up the concavity which naturally exists between the joints. A strip of pasteboard laid upon the dorsal surface of the finger, offers moderate resistance to motion between the fragments, and serves to keep the bandage from constricting the integument. At the end of the third or fourth week, when the dressing is finally removed, well directed passive motion is needed to get rid of the stiffness which depends upon deposits of lymph in the sheaths of the tendons.

Broken fingers left to themselves, without treatment, do not turn out well. They become angularly deformed, deflected laterally, or rotated on their axis, constituting permanent deformities that are sources of much regret to the patient ever afterwards. I have been solicited to break a deviated finger, and attempt to straighten it. I have never seen a case that seemed to justify the measure, though such an operation would not always be unwarranted.

Compound fractures of the fingers, with mashing of the soft parts, can sometimes be brought into proper shape by the use of sticking plaster. Such injuries, however, do not properly come under the head of fractures, so far as adjustment and treatment are concerned, but must be managed according to the principles involved in the treatment of wounds.

CHAPTER XXIV.

FRACTURE OF THE PELVIC BONES.

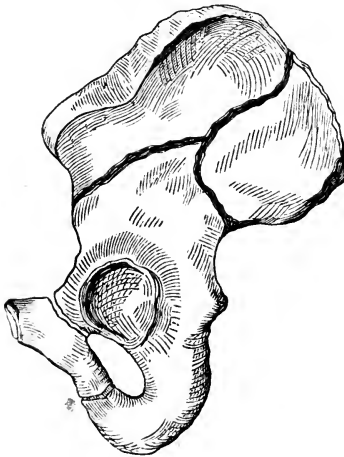
Crushing forces, as when a man is caught between heavy moving bodies, or strikes in the region of the hip at the termination of a long fall, may produce fracture of some part of the pelvic circle. The symphysis pubis has been separated by the throes of labor, though such an accident must be exceedingly uncommon. Several cases have been reported in which forcible separation of the two pubic bones occurred at the symphysis from injuries received while coupling cars, and in railway accidents generally. I was once called to see an old negro in Louisiana, who had been kicked by a mule in the region of the pubes. He was unable to urinate, and while introducing the catheter-I discovered a sinking in of the body of the os pubis on the left side, at a point outside of the spine of the bone. The line of separation must have extended into the thyroid foramen, though the ramus of the pubis did not appear to be broken. The fractured surface of the end of the outer fragment could be distinctly felt, but the other surface was too much depressed to be manipulated. No mobility existed, and on account of the swelling no deformity was observed until in the attempt at catheterism the left wrist discovered an irregularity of the parts. The patient was not aware that a fracture had been received, but supposed his bladder was ruptured. The urine was not bloody, and there was no evidence that severe internal injury had been inflicted. The depressed bone could not be brought back into place; yet some months afterwards I heard that the patient suffered no inconvenience from his injuries.

Fractures of the pelvic bones are not necessarily dangerous of themselves; but the terrible forces which produce them are apt to inflict greater or less injury to important parts in their

immediate vicinity. Fragments of bone may perforate the rectum and bladder, or do such mischief to the viscera of the pelvis as may seriously interfere with the functions of those organs. The gravity of such injuries can not always be determined at the earlier examinations. The crest of the ilium, and the anterior superior spinous process may be broken off by moderate forces, as by a kick from another individual, but the massive strength of the deeper parts and their protective coverings and connections, serve to shield them from the damaging influence of all ordinary forces.

In 1860, Andy Rice, in the employ of McHenry & Carson, fell through the hatches of four stories, and struck against hard substances in the cellar. He sustained a multiplicity of injuries, and fully recovered from all of them. At first he complained most of his left shoulder, which was dislocated. This I reduced without removing his coat or changing his position. Finding that he had several fractures I had him taken home. I there learned by examination that one femur was broken just below the lesser trochanter; that the under jaw was broken at the symphysis; that three ribs were fractured; and that the left os innominatum was broken into at least three pieces. It was difficult to determine just where

FIG. 63.



Fractures of the os innominatum.

all the lines of separation extended. The great arc of the ilium could be easily moved by taking hold of it, and the motions were attended with distinct crepitus. Its line of separation must have been nearly like the upper one represented in the accompanying figure. The movement of this piece gave little pain; but in attempts to diagnose the other fractures of the innominatum great distress was produced. The greatest degree of pain seemed to arise from motion imparted to the fragments of

the femur. The pubic part of the bone was certainly broken through the ramus and body. This left the femur articulated

to a large movable fragment of the innominatum, that was free from still another fragment which was firmly united to the sacrum. The costal segment was the most mobile, then the large piece that contained the acetabulum; the smaller fragment connected to the sacrum had no perceptible mobility, and the pubic fragment continued firm on account of its junction at the symphysis. The catheter had to be used a few times, but there was no blood in the urine. The symptoms were so terribly severe for more than a week that there seemed little ground for hope. The pelvis now has its natural shape, excepting a slight abnormal twist in the left os innominatum, which does not cause lameness.

The treatment of fracture of the pelvic bones consists in applying such bandages, straps, belts, or apparatus, as shall restrain all motion between the fragments. In the case of Andy Rice I used the "woven wire breeches," figure 10. This apparatus served several purposes: 1st, to keep up extension and counter-extension for the fractured thigh; 2d, to steady the pelvic fragments; and 3d, it proved useful in handling the patient during the six weeks of treatment.

A wide belt of strong cloth or leather to buckle around the pelvic region, serves to steady a simple fracture of the ilium, ischium, or pubes. The patient is unable to walk, or to assume the erect posture, if anything more than a salient point is broken from the pelvic bones. The powerful muscles acting upon any considerable fragment, would disturb it too much for active exercise.

Fracture extending into the acetabulum, seriously interferes with the hip-joint; and the diagnosis of such an injury must be exceedingly obscure. Cases have been dissected in which it had been demonstrated that a stellate fracture of the acetabulum was produced by a blow upon the trochanters of the femur, the force telling through the head of that bone.

FRACTURE OF THE SACRUM.

The sacrum, as a dry specimen, removed from its connections with the other pelvic bones, is not difficult to break, but in its normal state, wedged between the ossa innominata, and covered with ligamentous and other firm tissues, the bone is

in little danger of being broken. A kick or a powerful blow, such as may be received in a fall, might cause a fracture of the bone at any point, the line of separation running in any direction. The processes of the bone may be broken off, or a fracture may extend only as far as the central or spinal canal. In most instances, it is found that fractures of the sacrum extend through the lower third of the bone, and mostly in a transverse course.

If the lower fragment be carried in towards the rectum the functions of that tube might be seriously interfered with. A patient suspected of having a broken sacrum should be made to lie on the abdomen while an examination is going on, and an attempt made to overcome any considerable displacement. The finger carried into the rectum may be the only means of discovering the full extent of the mischief, and in correcting such deformity as lays within digital power. A lithotomist's scoop, or any instrument of proper proportions and strength, might be used in the rectum to press the deflected fragment back into place, care being used not to injure the soft parts.

The patient should keep quiet in the horizontal position for a few weeks, to allow the healing process to consolidate the fragments. The bowels should be kept in a soluble state during the treatment, to prevent accumulations of gas and stercoracious matter near the seat of the injury. Hamilton recommends that the bowels be kept constipated in order that the accumulation of hardened material in the rectum may press back into line the displaced fragment, and act as a splint on the inner surface of the bone. The suggestion is quite ingenious, but the practical working of the plan is questionable.

FRACTURE OF THE COCCYX.

A fracture of the cornua of the coccyx, and a partial dislocation of the bone inwards, constitute an injury, which is caused by a direct blow, kick, or other violence telling upon the bony appendage. The lesion has been reported as occurring from parturient efforts. If such be the case the subjects must have been sufficiently advanced in life to have the bone consolidated to the sacrum. In young women the mobility of the coccyx allows the bone to yield to forces brought to bear upon it during the last stage of labor.

I have never seen but one case of a broken coccyx; and this accident occurred to a man standing on the platform of a car as the train was suddenly put in motion by the engineer. The point or angle of the iron railing struck the passenger in the coccygeal region, and caused a sickening sensation from the severe shock to the nervous system. After receiving the injury the patient took a seat inside the coach, and although in severe pain, and complaining of a general uneasiness, he chatted with a fellow traveler, reaching home that night. Before morning he took a "chill;" and had his family physician summoned. He no longer complained of distress in the region hurt, but asked to be relieved of a sense of constriction in the bowels, and nausea at the stomach. Morphia was administered in large and repeated doses. This relieved him of the acute distress, yet he declared that there was some terribly deep seated disease about him that would terminate fatally. The bowels were evacuated by the influence of cathartics, and the bladder at length had to be relieved by catheterism. On the tenth day after the injury he died; and none of his medical and surgical attendants had suspected the true cause of death. An autopsy was held, at which I was present. The physician using the scalpel, remarked that he should first look for abscess of the liver, or for pus in or about that organ. Finding no cause for death in the viscera of the abdomen, and observing considerable redness in the pelvic colon, the perineum and anus were inspected. The discoloration in that region led to the suspicion that the difficulty had been somewhere about the lower end of the spinal column. The body being turned over, the signs of decomposition in the region of the coccyx were strikingly apparent. A careful dissection showed that the coccygeal horns or processes were broken, and the bone somewhat displaced inwards. The entire coccyx except the detached cornua, was blackened, and bore the appearance of having been dead for many days. An apparently trifling injury, which had not attracted the attention of several physicians in consultation, and which produced more general than local disturbance, terminated fatally. This case is not without parallel. Cloquet, Petit, and other surgical writers upon the subject of fracture and dislocation of the coccyx, speak of the dangers of caries, as if the bone, after serious lesions, was liable to mortification. Whether anything could

be done to arrest the tendency to necrosis, if undertaken promptly, is not demonstrated. It is plainly the duty of the surgeon, when called to a case of fracture of the coccyx, to overcome any inward displacement by manipulation, using the finger in the rectum; and to keep the patient at rest by the use of opium suppositories and such other local means of a quieting or stimulating character, as would afford relief and promote a restorative action in a severe bruise or other wound in that region.

It is not easy to diagnose fracture of the coccyx. Pain of a severe character might arise from shock or concussion, as, also, a general uneasiness, on account of the constitutional disturbance. With a finger in the rectum and the thumb on the coccyx, a great increase of mobility might be determined, as well as displacement; but crepitation, that distinctive sign of fracture, can not certainly be obtained, owing to the broken surfaces of bone being small, and the motion imparted not of a kind likely to cause rubbing of the broken parts against one another. It is not improbable that fracture of the coccyx has occasionally passed unobserved, or for a bruise in the region of the sacrum; and a severe concussion in that part of the body followed by sharp pain in attempts to walk, and during defecation, has been regarded as a case of coccygeal fracture. The great mobility of the coccyx in young subjects might contribute to the deception. Fracture arising from the displacing force of the child's head in parturition, is quite different in character from that produced by a kick or fall upon some projecting substance. The shock is much less when produced by the forward movements of a child's head. When produced by accidental violence there may be a vast excess of force over that actually required to break the bone; and this excess would naturally increase the dangers of the case.

CHAPTER XXV.

FRACTURE OF THE FEMUR.

The length of the femur and the exposure of the bone to a variety of forces, contribute to its liability to fracture. The muscles surrounding the femur afford a certain amount of protection against external shocks, yet this shielding influence is more than counterbalanced by the strain the bone receives from their action. The different fractures to which the bone is subject, and the complicated appliances recommended for their treatment, constitute a series of topics well calculated to overwhelm the student who first directs his attention to this branch of surgical study. Unless the diagnosis of such injuries be clearly made out, and the treatment necessary to the accomplishment of good results be clearly understood, and efficiently carried out, the most lamentable consequences may be expected. An imperfect conception of the nature of the accident, or a "trust-to-luck" management of the injury, will surely lead to the chagrin and disgrace of the surgical attendant, and to the permanent crippling of the unfortunate patient. No medical practitioner should assume the responsibility of treating a fractured thigh, unless he comprehends what is absolutely necessary to insure at least an average recovery. A perfect result cannot be attained in all instances, for the circumstances under which some cases have to be treated may thwart the best directed efforts of the surgeon. However, want of skill is the most common cause of bad recoveries.

The neck of the femur is placed at an oblique angle to the shaft of the bone, and in old age it more nearly approaches a right angle. This peculiar conformation in advanced life, together with an increased amount of cancellated tissue on the inner structure, renders the bone weak at a point subjected to considerable lever power.

The trochanters are stout processes of bone, but the greater of the two being subjected to direct violence in falls, and the lesser to the action of powerful muscles, they may be disconnected from the shaft, or forced into the central spongy structures.

The shaft of the femur is very long, offering forces a favorable opportunity to break it in pieces. The muscles exert great influence upon a bone which offers the advantage of such extensive lever power. Indirect forces received by the foot, and transmitted upward to the great curve just above the middle of the shaft of the femur, very frequently produce fractures at that point.

The condyles spread out into a broad base to give steadiness to the knee-joint, but they have so much spongy structure within, that they are not adapted to offer powerful resistance to direct forces. The resisting power of a bone must not be reckoned by its size, for the middle of the shaft, which is the smallest part of the bone, is probably the strongest.

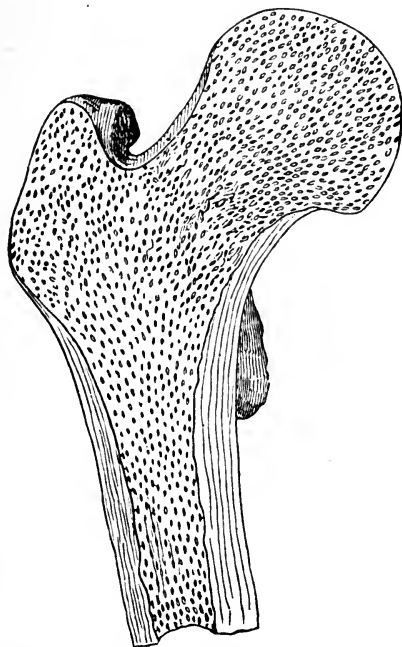
The causes which produce fractures of the thigh are numerous. When the direct force acts, it generally happens that the limb is crushed by some heavy weight falling upon it, or by a loaded wagon passing over it. When an indirect force acts, it is most frequently found that the person falls from a height, with the thigh in such a position that the bone snaps at a point remote from the part receiving the shock. An irregularity in the ground sometimes imparts a twist to the leg which may prove too great for the brittle neck of the femur. A person fancying he is treading upon level ground, takes a false step unawares, and the muscles not being employed to resist the impetus, or to counteract the accidental twist unexpectedly given to the limb, he receives a fracture of the neck of the thigh bone.

FRACTURE OF THE NECK OF THE FEMUR.

The neck of the thigh bone has been invested with unusual interest, both on account of the frequency of fracture occurring at that point, and the learned discussions that have taken place concerning the possibility and probability of bony union taking place here as in fractures through other parts of the bone. A quotation from Mr. Lonsdale expresses some of the reasons why frac-

tures through the cervix femoris are so frequent: "It is an accident that is met with chiefly in old people, and very seldom, indeed, in young. The structure of the bone in old people becomes altered, owing to the deficiency of the animal matter in it, causing the earthy to be in excess, which gives a brittleness to it, that does not exist in the bones of young people. This part of the bone is also naturally of a loose, cancellated structure, and when deprived of its animal matter, will become weak and ill calculated to receive any severe shock, either from the weight of the body, or from a blow directly applied to the part. There are other causes also which tend to produce fracture of this part of the bone.

FIG. 64.



Section of the head, neck, and upper extremity of the Shaft of the Femur, showing the inner cancellated texture, and natural shape of this part of the bone.

The muscles surrounding the hip-joint in old people waste, causing this part to become flattened, and to have comparatively little covering upon it; so that a fall upon the posterior part of the hip, which, in a younger person, in whom the muscles act as a cushion, might tell with little force directly on the trochanter, or neck of the bone, would in an old one,

where this cushion is absent, be sufficient to produce fracture. In old people, also, the whole body loses its elasticity, all the movements are heavier, and more awkward and less secure, so that falls are likely to take place from trifling causes, without the power of resisting them; for though a younger person might break his fall by the use of his arms, or by the strength and activity of his body generally, an old person can not, but falls like a dead weight, and the shock, of course, becomes much greater than it otherwise would be. All these circumstances taken together cause this kind of fracture to be much more frequent in old than young people."

Sex has something to do with the frequency of the fracture. In women the pelvis is wider, and the neck of the femur is longer, and it joins the shaft nearer a right angle than it does in men. Elderly females are apt to lose confidence in their pedestrian powers, which, so far as it goes, favors fracture; besides, their bones and bony supports are weaker or less developed than in the other sex, being therefore less capable of offering resistance to forces acting upon the skeleton. Elderly persons, if they fall heavily upon the trochanter, may sustain fracture of the neck of the femur. This kind of violence has been called direct, though it is not more so than when a person, in falling, or in taking a false step, sends a force from the foot up to the neck of the bone. Indirect violence, then, must be considered the common cause of fracture through the *cervix femoris*.

A fracture near the head of the bone, and wholly within the capsular ligament, is generally transverse, while the direction of the fracture is likely to be oblique, if it be near the trochanters, making the line of separation partially within and partially without the cavity of the joint.

It is quite essential to understand the place where the solution of continuity exists, for in a fracture near the head of the bone ossific union need not be expected, but in a fracture extending outside the femoral attachment of the capsular ligament, bony union may be reasonably expected, with a strong and useful limb. It will generally be found that fractures wholly within the capsular ligament, result in ligamentous unions; and that a break in the bone outside the ligament is about sure to end in osseous consolidation. In fractures partly within and partly without the ligament, as when the line of

separation is oblique, or irregular in its course, crossing the attachment of the ligament to the bone, the union is most likely to be osseous, though it may be fibrous.

Displacement has considerable to do with consolidation, though not so much as mobility. If the separation of the broken surfaces be so great that there is scarcely any contact, bony union is not to be expected; and if in addition to displacement, there be constant rocking of one fragment upon the other, efforts at consolidation are thwarted.

Much has been said about lack of reparative supplies afforded to the articular fragment, as if it were completely cut off from vascular connections, except through the ligamentum teres. In some instances, especially if the synovial membrane be torn, as it is likely to be, the head of the bone is completely isolated except through the round ligament. This theory in regard to scanty nutritive supplies, is supported by the fact that large quantities of reparative bony material are deposited around the end of the lower fragment, constituting an excess of callus, while the scantiest amount is accumulated about the end of the short or upper fragment. The symptoms of a fracture within the capsule are, shortening of the limb, eversion of the foot, motion between the fractured portions of the bone, crepitus, great pain about the joint, and inability to move the limb, or to bear the weight of the body upon it. The shortening is not marked directly after the reception of the fracture, but it increases from day to day till it reaches an inch or more. The shortening may be overcome by making extension, and as soon as this force is relaxed, the limb draws up again. It requires considerable care, and regard for accuracy, to ascertain whether one leg be longer than the other. A limb is often supposed to be shorter than the other, when the position of the patient's body produces the deception. Anybody can lie upon the back, and so twist the pelvis as to make one leg appear of a different length from the other. In the examination of a patient to ascertain the relative length of the limbs, the pelvis must be placed straight with regard to the transverse diameter of the body; for any obliquity in this direction will give a corresponding obliquity to the lower extremities, and cause one to appear longer than the other. The pelvis being quite straight, the two knees ought to correspond, and the two heels also, if both limbs are

of the same length. After observations have been taken, with the body carefully arranged as just indicated, measurements should be taken to determine exactly the amount of shortening, if any exist. The patient being placed in bed, and care taken that the shoulders and pelvis are parallel to one another, and the legs in conformity to the straight attitude, a piece of tape or inelastic cord is made to take the distance from the anterior superior spinous process of the ilium to the patella or external malleolus; or, what is better, from the symphysis pubis to the internal malleolus of each ankle. Any well defined and unvarying point in the body is as good as those indicated; the upper or lower extremity of the sternum, or the umbilicus, will answer as a point to commence the measurement. As the patella is rather moveable, it will be necessary to measure to the lower point of the bone when it is pulled upwards, in order to arrive at accuracy. Shortening alone is not a sure indication of fracture, for the limb may have been shrunken from childhood, or drawn up from dislocation, but in connection with other signs, this becomes valuable. In rare instances there may be fracture and no displacement, or shortening. Mr. Stanley relates the following case, which illustrates the point. "A man aged sixty, was knocked down in the street; he complained of pain in the hip, but there was neither shortening nor eversion of the limb, and its several motions could be executed with perfect freedom and power. A fracture was not suspected; the patient, therefore, was merely confined to his bed. In the fifth week from the date of the accident he died from another cause. No trace of injury was found in the parts around the hip joint, but small effusions of blood, apparently not recent, were discovered beneath the synovial and fibrous membrane, covering the neck of the femur, also beneath the synovial membrane covering the ligamentum teres. The head and neck of the bone were sawed through their middle, and in each portion a dark line, evidently occasioned by the effusion of blood, was seen extending through the bone at the base of the neck. A fracture was discovered extending along this line; but the broken surfaces were in contact, and the synovial and fibrous membrane covering the neck of the bone was uninjured." "In this case," Mr. Stanley very pertinently remarks, "if an attempt had been made to walk at the end of two or even three weeks

from the accident, a separation of the fractured surfaces, and consequent shortening of the limb, would have been the result."

Either from the natural inclination of the foot to gravitate outwards, or from the action of the rotator muscles, the foot, after fracture of the cervix femoris, is almost always found to be in a state of eversion. In extremely rare instances, mostly where the force producing the fracture violently twists the foot inwards, the limb may continue in that position. It is highly probable that *impaction* has considerable to do with the position of the limb in cases varying essentially from the usual attitude assumed after fracture of the neck of the thigh bone. The fragments may be interlocked, or the lower one may be driven through the capsular ligament, and held in an inverted position until extension frees one or both pieces from the entangled state. If the limb be somewhat *fixed* in an everted or an inverted position, there exists a mechanical obstacle to rotation either in one direction or the other.

When crepitation can be produced by motion imparted to the limb, it is conclusive of fracture; but in many instances this decisive and distinctive sign can not be produced. The round head of the bone and its free motion in the acetabulum require the least interlocking of the fractured surfaces to cause the lesser fragment to follow the natural movements of the larger. The articular fragment is so nearly concealed in the cotyloid cavity that it can not be seized and held fast while the other is made to grate against it. Crepitus can be elicited in nearly every instance of fracture of the neck of the femur, if the lower fragment be forcibly extended and carried through all the motions possible for the limb to take, yet a rash course, simply to produce crepitation, would not be justifiable. There are plenty of points to decide the question of fracture, even if crepitus be not sought.

It is not a little singular that a patient with a broken thigh bone can walk directly after receiving the injury. As a general thing the patient falls immediately upon the reception of the fracture; or, having received the fracture by the fall, he is unable to rise; yet there are notable instances in which patients have not only risen from the ground, but walked almost as if nothing serious had happened. These unusual powers after fracture, are difficult to be understood. Theo-

rists have attempted to explain them on the supposition of a firm impaction, and on the ground that the fragments were interlocked. It has also been claimed that in such cases the untorn periosteum holds the pieces in exact apposition. Usually the loss of voluntary power is complete, and the limb falls into a state of eversion characteristic of the injury.

Any one familiar with all the peculiarities of the limb after fracture of the cervix femoris, has observed the change of position assumed by the great trochanter. In the event of shortening, the bony prominence is drawn upwards, so that it occupies a site nearer the ilium; eversion throws it backwards; and impaction, when it exists, carries the process closer to the acetabulum, giving the limb a flattened appearance not seen in the sound thigh. Another notable feature of the trochanter is, that in rotating the limb the bony protuberance does not describe the segment of so large a circle as it does in its natural state.

PAIN AND SWELLING.—There is rarely much pain in what is called intra-capsular fracture, unless the limb be moved or disturbed by manipulation. Gently extended and propped up on each side, the broken limb is affected with little or no distress. However, any efforts to voluntarily move the limb, or any attempts to discover the nature of the injury by rude handling, are attended with severe pain. The swelling may be moderate, especially if no violence be done to the parts involved, except mere fracture.

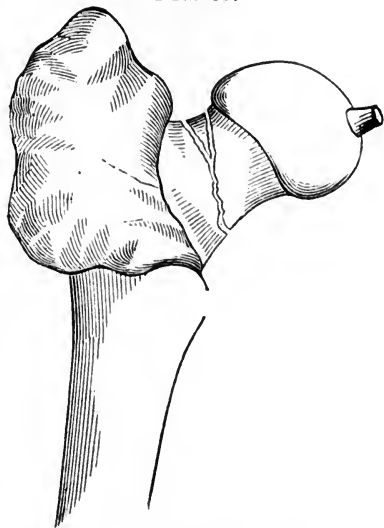
In many cases the normal size of the limb renders manipulation at the seat of injury quite useless; the diagnosis, therefore, is based more upon measurements, eversion, and other signs already indicated, than upon the senseless kneading that inexperienced practitioners are apt to apply directly to the parts about the hip joint suspected of fracture. If each diagnostic symptom be carefully considered, enough signs will be discovered to decide almost any case, though some signs of fracture may not be prominent. Generally it requires only a superficial examination to determine the nature of the injury; in rare cases the closest scrutiny is demanded to decide the matter. It is quite essential that the evidence of fracture be ascertained when it exists, in order that the treatment may be well directed. To confine a patient, hampered with fracture dressings, to the horizontal position for weeks and

months, under the supposition that a fracture exists when really it does not, would be quite unpardonable.

FRACTURE OF THE CERVIX FEMORIS WITHIN THE CAPSULE.

In a recent fracture of the neck of the femur within the capsule, the tissues immediately involved are reddened, and there is an abundant effusion of lymph, and not much extravasation of blood. The capsular ligament may preserve its integrity, and, also, the synovial membrane; these structures, however, are quite likely to be lacerated, especially the delicate coverings of the bone at the seat of fracture. In the course of a few days the presence of reparative material is discoverable, and osseous particles at length find their way to the borders of the fractured surfaces; yet before any bony matter is exuded, plastic lymph, floating in an abundance of synovial fluid and gathered in shreds

FIG. 65.



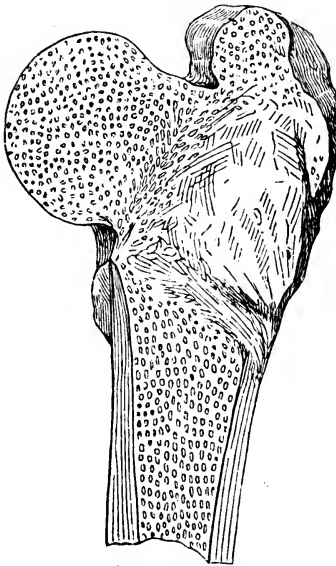
Fracture of the cervix femoris within the capsule.

to the torn tissues, shows a disposition to connect the fragments with fibrous bands.

In old cases, the capsular ligament becomes thickened, especially at its upper part, which has to sustain the weight of the body in walking, the long fragment pressing up against it for support at every step. In cases where no impaction exists, and no real progress is made towards osseous consolidation, a variety of conditions are found within the capsule of the joint; in some cases the organized bands of plastic material form a pretty firm connection between the fragments, the patient being able to walk with some assistance from cane or crutch; in other instances the fibro-ligamentous bands are slender or too long to be of any service as connecting media between the fragments; finally, the fractured surfaces may

mutually yield to one another, the short fragment becoming excavated and polished, and the cervical portion of the long piece rounded into a conical knob to fit into the cup-like cavity presented to it. Such a false joint would be a troublesome affair, yet not necessarily prevent the person from enjoying somewhat restricted locomotion. Absorption occasionally alters the broken parts in a wonderful manner. The short piece has been completely removed by the absorptive processes, and the upper end of the long fragment has been dissolved and removed, the absorption reaching into the greater trochanter, leaving nothing but the shaft of the bone which was steadied in place by the muscles inserted into it, and by the condensed tissue surrounding it. In the event of impaction, the cervical portion of the long fragment being driven into the cancellated structure of the head of the bone, the connection is so intimate that the pieces mutually steady each other, and favor bony consolidation.

FIG. 66.



Consolidation following impaction.

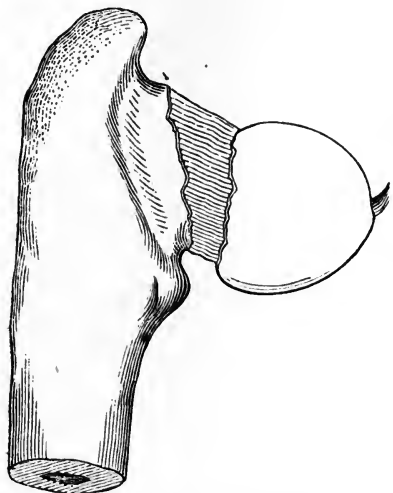
tion is so intimate that the pieces mutually steady each other, and favor bony consolidation.

A great deal of interest attaches, at the present time, to the question whether bony union ever follows fracture of the cervix femoris, the line of separation being wholly within the capsule. It is pretty generally admitted among surgeons who have studied pathological specimens, that such a fracture, if impacted, may result in consolidation; but if the break be simple, entirely within the capsule, and uncomplicated with impaction, or tearing of the capsular ligament, the union is most likely to be liga-

mentous and imperfect at that. Much ingenuity has been displayed in attempting to account for the lack of bony union; the fact that motion between the fragments can not be arrested by any ordinary apparatus, has some bearing on the question; the abundance of synovia secreted under the influence of prolonged irritation, diluting and otherwise impairing the qualities of the reparative materials, is adverse to

consolidation of the fracture; but the chief obstacle to repair seems to reside in the almost complete isolation from vessels and nerves, to which the head of the bone and remnant of the neck are subjected by the fracture. The ligamentum teres is a small band of dense white tissue, with scarcely a vascular

FIG. 67.



Ligamentous union following fracture of the neck of the femur within the capsule.

sign in it. An adequate supply of reparative material could not be expected to find its way through such attenuated channels. If the fragments could be maintained in perfect apposition for a few days it is possible that a direct union, similar to what is known as "first intention" in wounds of the soft tissues, might occasionally take place, which might in time ensure osseous consolidation. In some of those rare instances in which early union is known to have taken place after intra-capsular fracture, without

impaction, it is probable that the results followed perfect coaptation, freedom from motion, and the quick restoration of the usual channels of supply.

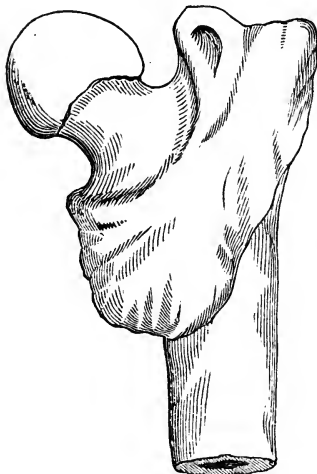
Where the line of separation is partly within and partly without the capsule, giving the otherwise isolated fragment an opportunity to get its supplies without drawing for them through the round ligament, the chances in favor of bony union are greatly increased.

EXTRA-CAPSULAR FRACTURE OF THE CERVIX FEMORIS.

In extra-capsular fractures, *i. e.*, where the line of separation is entirely outside the apparatus of the joint, the upper fragment having a good supply of vessels entering it by the many foramina so conspicuous in that part of the bone, the union is likely to be osseous. Even if the line of fracture extend slightly beyond or within the capsule, it does not seem to in-

terfere with consolidation in cases where the greater part of the fracture exists in the trochanter and that part of the neck immediately adjoining it. It is not uncommon, in falls upon the trochanter, for the fractured cervix to penetrate the cancellated structure of that great process of bone, and even to act the part of a wedge and split it. Sometimes the two trochanters are rent asunder by this wedge force, more or less impaction taking place in every instance. Specimens are in existence which show the line of separation to be through the trochanter major, the upper part remaining with the neck of the femur, and the lower with the shaft of the bone. In a greater number of cases, however, the fracture is multiple or comminuted, the trochanter being broken into several frag-

FIG. 68.



Excess of callus after extracapsular fracture of the femur.

ments, and the cervix femoris detached from all of them.

Although bony union is the rule, in extra-capsular fractures, the healing process is slow, and the consolidation of the cervix to the trochanteric fragments is more tardy than it is in fractures lower down. A notable feature connected with consolidation of fractures near the hip-joint is the great exuberance of ossific deposits, which interfere with the motions of the limb, and tend to deceive any one examining the parts with the object of ascertaining the original state of the injury.

Rough points in the reparative material render muscular movements painful; and may inflict permanent lameness upon the patient. These ledges of bone may become rounded off in time, yet their complete obliteration need not be expected.

The symptoms of extra-capsular fracture very closely resemble those manifested by fracture within the capsule; there is shortening, eversion, inability to move the limb, and the other signs peculiar to fractures in general. If the great trochanter be involved in the fracture, the mobility of the fragments, and the attending crepitus, would be distinctive of extra-capsular lesion. In the extra-capsular variety the

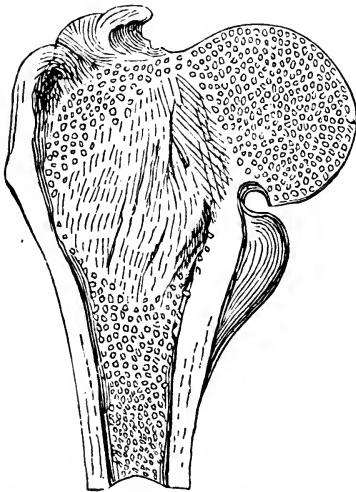
shortening of the limb is immediately to the extent of an inch or more, while in the other variety the shortening rarely reaches its maximum for several days.

The accidents which are most liable to be confounded with fractures of the neck of the femur, are dislocations of the head of the femur upon the pubes, severe contusions of the hip, paralysis, and absorption of the neck of the thigh bone from chronic arthritis. A fracture of the acetabular cavity, the bottom being driven into the pelvis, the head of the femur following, may present features leading to the suspicion that the cervix femoris is broken. However, a critical consideration of each symptom, and a careful analysis of each group of signs, will lead to a rational solution of almost every case. If the surgeon is not able to determine the exact course of the fracture in every case it is practically of very little importance, for the treatment is substantially the same for all fractures in the vicinity of the joint. The real nature of obscure cases can only be determined after death. Very few suits, for alleged malpractice, have grown out of imperfect recoveries after fractures of the neck of the femur, for the reason that even the most experienced surgeons are averse to giving a positive opinion in regard to obscure injuries about the hip joint. In a recent case of severe injury in the vicinity of the hip joint, where great pain and swelling are in the way of a satisfactory examination, it is best to put the patient under the influence of chloroform, when a more thorough exploration can be carried on.

Some very interesting specimens of defective and deformed femurs are in existence, which have been selected and preserved to show that bony union will take place after intracapsular fracture. Sir Astley Cooper had gained the reputation of having taught that ossific union could never take place if the line of fracture was wholly within the capsule. Certain other surgeons took a different view of the question, and hunted the museums and graveyards for thigh bones which tended to disprove the teachings accredited to Mr. Cooper. The specimens were sawed through and through in order to display the white line of ivory hardness that seemed to mark the consolidation of the fragments. Many of the specimens supposed to represent the line of union, were cast aside as spurious, and as representing the effects of chronic arthritis,

or fracture partly outside the capsular ligament. The numerous specimens were narrowed down by professional criticism to a half dozen, more or less, of bones that furnish evidence of having been broken within the capsule, and afterwards consolidated. The late Prof. R. D. Mussey obtained a few pathological specimens of the thigh bones, which offered quite convincing proof of having been fractured within the capsule, and of osseous union following the injuries. These specimens were taken to Europe and exhibited to distinguished surgeons there for the purpose of eliciting opinions concerning the evidence of fracture and subsequent consolidation. It is a verity that "doctors disagree," and in regard to the morbid marks borne by the bones in question, there was not a unity of opinion. Of one specimen which had been regarded as clearly indicating the line of osseous union after fracture within the capsule, Mr. Cooper said there never had been any fracture in the case, or, if there had, the line of separation had run outside the capsular ligament. Mr. John Thompson, of Edinburgh, declared "upon his truth and honor" that a fracture had never existed in the specimen, but the changes in

FIG. 69.



Bony union after intra-capsular fracture;—
with evidence of impaction.

the shape and appearances of the bone were due to chronic inflammatory action and absorption. Other pathologists abroad believed that the bone had been fractured. American surgeons who have examined the specimens generally agree in the opinion that intra-capsular fracture once existed in them. There is also a specimen of the same kind in the Wistar and Horner Museum of Philadelphia, and one belonging to Prof. Willard Parker, of New York. Prof. H. H. Smith, of Philadelphia, thinks that Dr. Parker's specimen does not

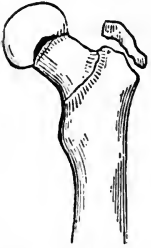bear positive evidence of fracture; or, if a line of separation did exist, it must have been partly extra-capsular. In a specimen of mine, exhibited by figure 69, the primary frac-

ture was undoubtedly intra-capsular, but impaction must have taken place, as indicated by the disturbance of the cancellated structure of the trochanters. As before stated, the impaction of the fragments favors consolidation in a variety of ways, therefore such specimens are not legitimate evidence in settling the question of osseous union after simple, uncomplicated intra-capsular fracture.

FRACTURES OF THE GREATER TROCHANTER.

Fracture of the trochanter major, uncomplicated with fractures of the neck or shaft of the femur, is an extremely rare accident. Only a few cases have fallen under the notice of surgeons, and some of these were not discovered or verified until after death. The accompanying diagram represents a simple fracture of the process, uncomplicated with more extensive lesions of the bone.

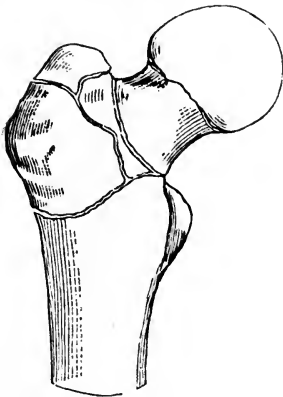
FIG. 70.



Fracture of the extremity of the greater trochanter.

A splitting of the trochanter which is produced by impaction in connection with fracture of the cervix femoris, is more properly considered as a part of the injury to the neck of the bone.

FIG. 71.



Comminuted fracture of the cervix femoris and of the trochanter major.

Heavy falls upon the hip may produce a chipping off of the the tip of the trochanter, to a greater or less depth; and age has not so much to do with the injury as it has with fractures of the cervix femoris. The break is not always characterized by displacement, for the fibrous structure covering the process may continue untrorn, and hold the fragment in place. If the enveloping fibrous tissue be lacerated the fragment will be drawn some distance away from the rest of the bone, by the muscles inserted into it. In such a case the detached fragment could be felt in its mobile state, though it would be difficult to bring it in contact with the other fragment unless the limb, carried into

extreme abduction, sufficiently favored apposition to allow of contact. Once brought into place the piece might be rubbed against the broken surface it originally left, and be made to produce crepitus.

The exposed position of the great trochanter leads to the conclusion that the process might be frequently broken, but experience does not sustain the inference. Probably, if the neck of the femur could better maintain its integrity under severe shocks, the trochanter would be the more frequently broken. As it is, the yielding of more fragile parts, saves the trochanter.

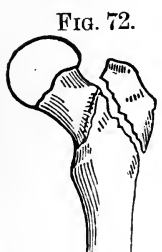

FIG. 72.
Fracture of the trochanter major.

In the event of fracture, separating the greater part of the process, the pain, swelling, and deformity might lead to the supposition that some more important lesion had been sustained, therefore a careful diagnosis should be entered into before a conclusion is drawn. A patient with a broken trochanter might not be fortunate enough to secure bony union, though the detached fragment be kept at rest, and in a state of partial apposition. The horizontal attitude of the body, with the fragment drawn downwards by means of adhesive strips applied while the leg is abducted, is about all that can be done to secure a favorable result.

TREATMENT OF FRACTURES OF THE NECK OF THE FEMUR.

Substantially the same kind of treatment is indicated for all kinds of fractures about the neck of the femur, whether the line of separation be intra or extra-capsular, or partly within and partly without the capsule, including impaction and splitting of the greater trochanter. The points to be overcome are shortening, eversion, and mobility. The object to be gained in intra-capsular fracture is a short and firm ligamentous union, and if consolidation incidentally incline to take place, it should be favored by the treatment; in extra-capsular fracture osseous union may be reasonably expected, and proper dressings favor the desired result. However, the kind of patients liable to fracture of the neck of the femur is such, that confinement to the horizontal position, and the irritation

produced by dressings, are not borne without complaint and opposition. Some old people are so restive under the restraint of fracture dressings that they will assume the responsibility of throwing them all off. I well remember, in my professional beginnings, of having spent an hour or two in dressing an old man's thigh who had broken his cervix femoris by stepping on his grandchild's playthings. I congratulated myself upon the success of having dressed the limb so skillfully. The next morning I called to see how my surgical case progressed, not doubting but all was right. My patient appeared at ease and composed. Upon asking him how the leg was doing, he said, "I could not endure your traps an hour, so I threw them aside, and put in practice my own plan, which you can inspect but not interfere with." The apparatus for producing extension and counter-extension, with all additional straps, and trappings, were gone, and the patient had placed the tendo-Achillis of the fractured limb between the toes of the sound foot; and thus he produced moderate extension, prevented eversion, and maintained the limb in a state of ease. He absolutely refused to have any dressings applied to the limb, and kept up his novel plan of treatment quite steadily for weeks. He at length got up with a useful limb, consolidation having taken place, though there was shortening to the extent of an inch or more, and much stiffness about the hip-joint, owing in part to an excess of callus, or "buttress of bone," thrown out near the trochanteric lines.

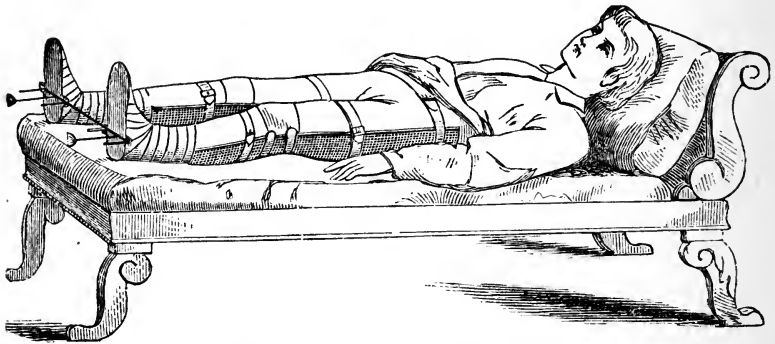
Experience teaches that a great amount of extension should not be made even if the shortening be not entirely overcome; first, because patients can not endure the forces applied; and, second, because the fragments are found not to rest in apposition if subjected to much traction. The eversion can be easily overcome by the judicious use of sand bags or other easily pressing props.

The long splint, so called, which reaches from the foot to near the armpit, or the long double splint, extending from the axillæ down on each side of the body and along the outsides of the legs to a foot-piece, requiring perineal bands to secure counter-extension, is painful to wear, even insupportable in many instances.

A wide belt of cloth buckled around the hips, with a notch near the anus to facilitate evacuations, serves a good purpose

in steadying the broken cervix, especially if the patient be placed on a firm mattress, with the knee moderately flexed over a large sand bag. This arrangement can be made still more complete by strapping the lower part of the thigh or the ankle to the foot of the bed, raising the posts a little by putting bricks under them, to give the patient's body a slight inclination toward the head of the bed. I have treated patients in this way quite comfortably for them and satisfactorily to myself. The "wire breeches" figure 10, fill the most indica-

FIG. 73.



The "wire breeches" applied.

tions of any species of apparatus yet invented for the treatment of fractures through the cervix femoris. It should be well padded to obviate excoriations, and made so nearly to fit the body and limbs as to be comfortable. Extension is made from the foot-piece, and counter-extension against the tuberosities of the ischium. The apparatus allows the patient to be bolstered up in bed, without imparting much motion to the fragments; and it has an opening left between the leg pieces for evacuations of the bowels to pass. I have used the "wire breeches" in two or three cases, and secured the happiest results.

Cases are reported as having been successfully treated by placing the limb over a double inclined plane made of pillows or junk. This is an easy attitude, and the plan is so simple that it may be readily put in practice under almost any circumstances. The inexperienced practitioner is apt to think, because fracture of the neck of the femur is a serious lesion, that a complicated apparatus is demanded for its treatment. The

quicker he dismisses such an idea the better it will be for himself and patient. Death has ensued from the confinement of feeble and aged persons in a too rigid and "scientific apparatus." If a patient does not bear the straight splint or any other, without becoming exhausted by the restraint and horizontal position, all dressings should be laid aside, and attention paid to comfort and general recuperation. No particular kind of dressing, then, can be carried out in all cases. The surgeon must consider the condition of his patient before applying the treatment, and modify it from time to time as circumstances seem to demand. A young person can generally endure such restraint as shall favor consolidation, and some old people bear up remarkably well under confining influences for weeks together. The diet should be nourishing and easily digested; the bowels need not be disturbed by frequent evacuations; and an anodyne may be taken to allay severe pain.

The question may arise among those who have few opportunities to treat fractures of the cervix femoris, either within or without the capsule, or through the trochanters, why an effort need be made to distinguish one fracture from the other, since the same kind of treatment is recommended for all of them? Practically it is not of vital importance to discriminate between the different forms of lesion, and to trace the line of separation with the idea that nothing serviceable can be done till the course of the fracture has been established beyond a doubt; yet it is an accomplishment worth possessing to be able to tell the patient that the case is one of intra-capsular fracture, and that such injuries generally unite with ligamentous material, and that permanent lameness may be expected; or, that the fracture is one of the extra-capsular variety, and ossific union may reasonably be anticipated. In a mixed or doubtful case the best surgeons must acknowledge the imperfection of the art of diagnosis and the uncertainty of the result of the injury, even when scientifically treated. Impaction is a condition favorable to bony union; and impaction generally arises from a heavy fall on the trochanter, driving the cylindrical and perhaps sharpened cervix into the cancellated structures of the expanded part of the bone.

It is to be borne in mind that an intra-capsular fracture generally occurs in old subjects, from a trip of the foot on the carpet, or from some trivial cause, and commonly not from a

fall on the trochanter; that the shortening, eversion, and other familiar signs attend extra-capsular fractures, and are therefore not differential or distinctive in character; but in a simple fracture wholly within the capsule, the limb appears flabby, powerless, immovable, and as if paralyzed, with the whole expression altered.

In extra-capsular fractures, whether impacted or not, bony union may be expected, though the excess of callus employed in the repair of the injury, is likely to impede motion, and to create considerable local deformity. In the event of shortening after consolidation, the defect may be partly remedied by a higher heeled shoe. Exercise facilitates the removal of irregular and sharp projections, and helps to restore strength to the limb, and confidence in putting it to use.

When called to take charge of a fractured hip, the surgeon should place himself right with the patient and friends by explaining the nature of the injury, and the probabilities of a good or imperfect result. The prognosis should be carefully guarded, for old people frequently die from the irritation and restraint consequent upon fracture of the femur. Bed sores upon the sacrum and sloughs upon the heel render the patient's sufferings exceedingly irksome. Loops let down from the ceiling where the patient can grasp them with the hands, to assist in movements of the body, serve an excellent purpose. Little comforts are highly appreciated, and if brought about by the surgeon's suggestions they add to his reputation for skill and attention. A piece of buckskin large enough to cover the excoriated hips of a bedridden patient, may save a great deal of distress, and contribute much to the healing of irritated and ulcerated parts. Dressed deer-skin, with the hair left on, is often exceedingly agreeable. The soft leather is much more comfortable to the irritated skin than any kind of cloth.

FRACTURES OF THE SHAFT OF THE FEMUR.

Fractures occurring below the lesser trochanter, and above the condyles, properly belong to the shaft of the bone. The line of separation is not confined to any particular locality, but is found in the upper, middle, and lower thirds. The point a little above the center of the bone is more liable to

yield to indirect violence than any other. The greatest number of cases coming under my observation presented a fracture a few inches below the trochanters. The bone has generally a little sharper curve in that region than pervades the entire shaft, which may be the reason that the accident occurs so often at that point. It has been a question whether the shaft of the femur is broken most frequently by indirect violence, as in falls, when the person strikes upon the feet, and has the force transmitted upwards to the thigh bone; or by direct violence, as a blow, or the passage of a wheel over the limb. The prevailing impression among surgical writers upon the subject, is that the direct application of force breaks more femurs than indirect agencies.

Those who have had limited experience in the management of broken femurs are exceedingly prone to talk of oblique and transverse fractures of the bone, as if one or the other variety was certain to take place; and as if being particular in calling attention to the direction of the line of separation was an indication of wisdom concerning the subject. As has already been stated in another place, it is seldom that a fracture is wholly oblique, or wholly transverse, but an irregular and mixed condition prevails, the line of separation being oblique in some places and transverse in others. The broken surfaces in a fractured femur, present many serrations which may interlock and prevent overlapping, but the general course of the line of separation partakes of a predominant obliquity in the majority of cases. Unless the fracture be compound, one fragment being driven out through the flesh, the direction of the line of separation is not always easy to determine, for the depth of the soft tissues is too great to admit of such a discrimination.

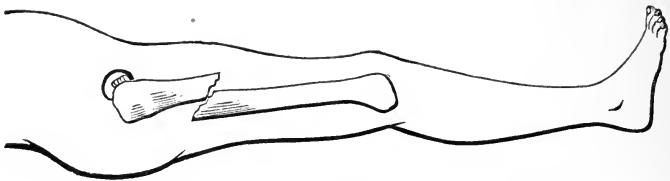
The prevailing opinion seems to be that it is exceedingly difficult to treat successfully an oblique fracture; the presumption being that broken surfaces with much obliquity favor overlapping, and surfaces fractured transversely, if held in apposition, will prevent overriding and the attendant shortening. However, it will be found of very little importance practically whether the line of separation be transverse, oblique, or a compound of the two directions. If the limb be properly treated there will be little or no shortening; and if managed improperly there will be shortening, though the line

of separation be transverse. If the accident occur from direct violence, the line of separation between the fragments is more transverse than oblique; and if the fracture arise from indirect violence the greater will be the obliquity.

FRACTURES OF THE UPPER THIRD OF THE SHAFT, BELOW THE TROCHANTERS.

Quite a common place for fracture of the femur to occur is at a point a few inches below the trochanter minor. It is a place where the muscular forces greatly influence the relative positions of the fragments, and oppose in some degree the influence of the dressings. There is always considerable displacement whether the fracture be oblique or transverse. The lower fragment is drawn upwards, backwards, and a little inwards, and the upper fragment is drawn forwards, and a little outwards, causing an overlapping of two or three inches, with the position of the fragments as represented in the accompanying diagram. The lower fragment sometimes acts upon the

FIG. 74.



Fracture through the upper third of the shaft of the femur, showing the tendency of the fragments to overlap.

upper, making it project forwards and outwards, contributing to produce angular distortion. Sir Astley Cooper and his followers have attributed this position of the upper fragment solely to the action of the psoas and iliacus muscles. "And," says Mr. Cooper, "to prevent this horrid distortion two circumstances ought strictly to be observed; the one is, to elevate the knee very much over the double inclined plane; and the other, to place the patient in a sitting position, supporting him by pillows during the process of union." The distortion, however, is in some measure due to the forces acting on the lower fragment, and to a certain degree upon the forces which produced the injury. The psoas, iliacus, and pectineus mus-

cles tend to elevate the lower end of the upper fragment, but not to the extent claimed by Mr. Cooper.

Muscular action being deprived of its normal influence upon the bone in consequence of the fracture, exerts forces upon the fragments of a rotatory character, so that the periphery of one piece does not correspond to that of the other piece. It is difficult to discover this defect, and to remedy it, although the limb will not be restored perfectly to usefulness if such a defect exist.

The symptoms of fracture of the shaft of the femur below the trochanters are similar to those met in other fractures of the long bones. Pain, swelling, and deformity are prominent characteristics; inability to move the limb or to bear weight upon it, is a necessary condition; great mobility at the seat of injury may be expected, as well as crepitus when the broken surfaces are made to confront one another. The shortening is marked, amounting in some instances to several inches. Impaction is very rare, therefore the shortening is due to overlapping and angular deformity. Eversion of the foot is generally observable, as if the limb naturally inclined to roll outward, falling powerless and subject alone to gravity. In rare instances the lower fragment is found in front of the upper, a position into which it may have been forced by the power which produced the fracture. And when the upper fragment is thus behind the other, the psoas and iliacus do not tilt the lower end of the upper fragment forward, making a marked prominence on the anterior aspect of the thigh, except in cases where the breaking force threw the fragments into that position. In such instances there is no force in the muscles competent to radically alter the position of the fragments or to change their relative positions.

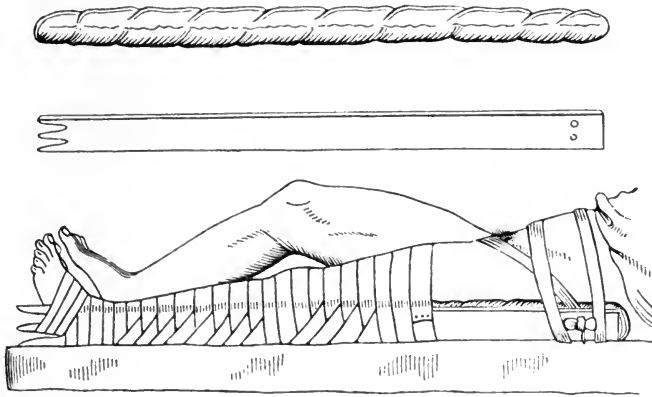
TREATMENT.—There are two distinct attitudes in which the leg may be placed in the management of fractures below the trochanters: one is the straight position of the limb, and was always employed, so far as is known, until Percival Pott, a little more than a century ago, came out with his “physiological” notions in regard to the position the limb should be made to assume during the treatment of fractures of the thigh. Mr. Pott claimed that the muscles caused displacement of the fragments while in a state of tension, and therefore sug-

gested that their contractile forces could be neutralized by posture alone ; and he proposed to flex all the parts involved in a fracture in order to secure apposition of fragments without the employment of force. For instance, if he wished to treat a patient with a fractured femur, he flexed the leg upon the thigh, and the thigh upon the abdomen, and kept the limb in that position for several weeks, using no splints, junks, or other mechanical contrivances to keep the fragments at rest, and to perform extension. This bold and seemingly rational plan created a revolution in the ideas of English surgeons ; and among its able supporters was Sir Astley Cooper, who added mechanics to physiology. He placed the flexed limb upon a double inclined plane, by which the muscles were relaxed, the weight of the leg on an inclined plane established extension, and the weight of the body and the upper part of the thigh, produced counter-extension. The elevation of the lower part of the thigh made the lower fragment correspond to the pitch the upper fragment generally assumed. Mr. Amesbury, a little later, modified the simple double inclined plane of Cooper, by adding to it means for producing active extension and counter-extension. American surgeons have improved upon the splint of Amesbury, though all involve the physiological principle adopted by Pott, and the additional mechanical principle of Cooper. At length a reaction took place in the minds of European and American surgeons ; and though the straight and the flexed plans of treating fractures of the thigh are both in reputable use, the method of treatment with the long straight splint is followed in nearly all the hospitals at home and abroad. In the rural districts of this country the double inclined plane apparatus is in common use. Whether the Pott and Cooper plans have certain captivating ideas in connection with them that readily persuade the country practitioner ; or the "sets" of fracture splints and appliances, all of which embrace a double inclined plane apparatus, with attractive illustrations to show the practical workings of the splints, now hawked about from town to town, contribute to the belief that all eminent surgeons employ such in their practice, are subjects of interesting inquiry. That truly great and illustrious surgeon, the late Dr. Valentine Mott, never "reacted," or went back to the straight attitude for a fractured thigh. He once said to his class, in my hear-

ing, that if he should ever be so unfortunate as to sustain a fracture of the femur, he should insist on having it treated upon the double inclined plane.

The straight splint is a piece of board nearly an inch thick, and about four inches wide, pierced with two holes at its upper end, and notched two or three times at its lower end, and long enough to reach from the borders of the axilla to four inches below the foot. The splint should be well padded its whole length; and the pad should be pierced

FIG. 75.



The "straight splint" applied. The cushion to be used between the splint and the patient's limb, is represented by the upper object of the wood-cut.

with holes corresponding to those in the splint, so that the ends of the perineal bands may slip through them easily, and be loosened or tightened as occasion may require. The perineal band may be a silk pocket handkerchief, a wide strip of buckskin, or any belt of strong and unirritating material. It is to be long enough to reach through the perineum between the genitals and the thigh, one end extending in front, along the groin, and the other behind the buttock, to the holes in the splint through which the two ends pass, to be tied in a bow-knot. In applying the apparatus, the surgeon, after adjusting the fracture, takes the perineal band and applies it to the patient's perineum, bringing up one end in front of, and the other behind this part of the body. He then lays the splint along the outer side of the affected limb, against a long cushion to protect tender parts, and proceeds to fasten the foot to the notches in the lower end of the appliance. Before doing this, it is a good plan to bandage the foot and ankle

with a flannel roller in the ordinary way, to protect them from the pressure of the splint, and to prevent them from swelling; or, instead of this, the foot may be enveloped in a layer of cotton-wool. The surgeon should then take a muslin roller, and make a few turns round the foot and ankle in the form of a figure-of-8, so as to obtain a firm hold; after which he should carry the bandage in a regular way round the ankle and through the notches in the lower end of the splint, so as to fasten it securely to the foot. He should then get an assistant to make extension from the foot while he draws the perineal band tight, and ties it in a bow on the outer side of the splint. In order to keep the apparatus in position it is sometimes necessary to apply a bandage over both the leg and splint from the foot upwards as far as the thigh, and also to put a few turns of a broad roller round the patient's chest. The thigh on each side of the seat of fracture may have a piece of splint material or pasteboard bound to it with tapes to make the broken parts feel more secure. This dressing, if well applied, and no serious complaints are made, may stay on for weeks, even till bony union has taken place. If at any time after its application, the dressing produce general uneasiness, it may be removed, and the fault, should any be found, corrected. The patient gets up with more general stiffness of the joints after this straight dressing has been employed, than after a double inclined plane splint has been used.

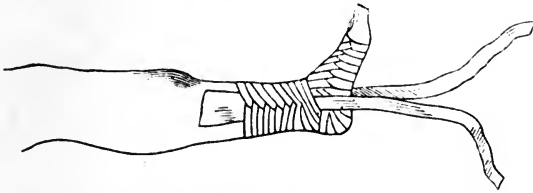
The straight splint is irksome at first, owing in part to the great restraint imposed upon so considerable a portion of the body. However, in a few days the patient gets over the feeling of being rigidly confined, and passes the remainder of the time without much complaint.

A great deal may be done toward keeping the fragments in apposition, by simply attending to the position of the limb, without the application of any splint. If the patient has a good degree of self control, he may be laid on his back, and the limb can be kept straight by the use of several sand bags placed along the leg from the hip to the foot.

Extension may conveniently be made by fastening the ends of long pieces of adhesive plaster to the sides of the leg, with the ends extending below the sole of the foot; the pieces should reach nearly to the knee, and over these other strips should be applied in a circular manner till the leg is enveloped

as if in a bandage. The circular strips prevent any slipping or yielding when power is applied, and distribute the pressure falling upon the circumference of the limb. A short block of

FIG. 76.



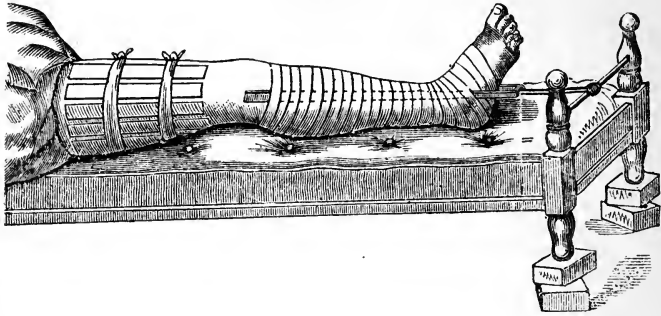
Strips of adhesive plaster applied to the leg longitudinally, and held from slipping by the circular wrapping of other pieces of the same material.

wood a little longer than the width of the ankle may be placed in the loop after the long loose ends are tied together, to prevent the downward strain from compressing the tissues on the sides of the joint. Around this block and the loop a cord may be fastened, which then extends over the foot of the bed, and sustains a weight. The extension thus produced need not be so great as to distress the patient. Moderate but constant traction upon the limb is all that may be desired.

After the foot and leg have been arranged with the extending apparatus, the thigh demands separate attention. The fragments should be adjusted while assistants are producing temporary extension and counter-extension with their hands; and then four or five common wooden splints a foot long, and two inches wide, made of lath or thin boards, and evenly wrapped with cloth, are to be placed at a little distance from one another, parallel with the course of the femur, and reaching above and below the line of fracture; where they are to be firmly bound with tapes. Over all of these a roller or many tailed bandage is to be snugly applied. This part of the dressing prevents mobility between the fragments, and contributes to the comfort of the patient. The limb may be made still more comfortable by placing a sand bag under the knee to flex it a little. Extension may be made by fastening the limb to the foot of the bed by means of a cord reaching from the loop of adhesive strips to the lower bed rail, and then raising the foot of the bed upon a couple of bricks to give the patient's body an inclination toward the head of the bed. This is the easiest and most natural method of securing ex-

tension and counter-extension without complicated apparatus. Any desired amount of extending and counter-extending power can be secured by this arrangement. If the foot of the

Fig. 77.



The splints upon the thigh prevent motion between the fragments of the femur; the adhesive strips upon the leg and ankle make a comfortable fastening to the limb; the fastening is secured to the bed rail; and the foot of the bed is raised on blocks or bricks to incline the patient's body in the opposite direction.

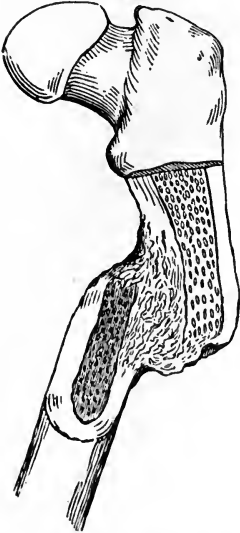bed or lounge be raised high enough to have the patient's body incline effectively in the opposite direction or toward the head of the bed, great extending force may be brought to bear upon the limb. I have such confidence in this manner of treating a fractured thigh that I feel like urging its use upon my professional brethren. Very few perfect results can be secured by the use of the long straight splint; and the double inclined plane apparatus which goes with almost every "set" of splints or fracture appliances, does not give general satisfaction.

About one-third of all cases of fracture of the shaft of the femur, as ordinarily treated by physicians and surgeons of every grade of skill turn out favorably, or without perceptible or appreciable deformity; another third of all cases treated exhibit so little shortening or other defects that in the course of time they fail to attract personal or professional attention; the remaining third are so seriously defective, either from shortening or other deformities, that the patient is temporarily or permanently compelled to walk lame, or forever made a cripple.

The defect is generally shortening which comes from overlapping of the fragments; and, in addition, there may be angular deformity, as seen in the following diagram. The shortening in the cases attracting attention, which constitutes

about one-third of all fractures of the shaft of the femur, amounts to three quarters of an inch. No shortening which is less than half an inch attracts attention or proves a serious source of complaint; but in rare instances the overlapping reaches several inches.

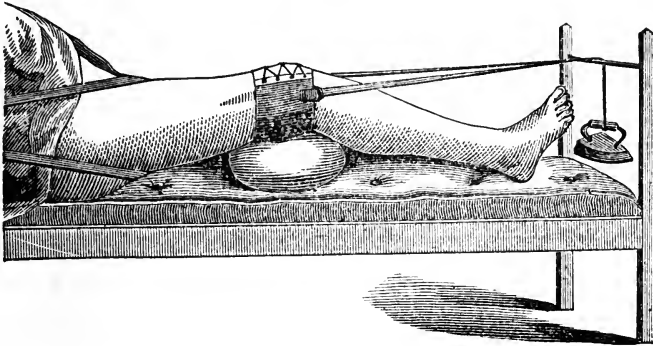
FIG. 78.



Union of the fragments with shortening, and angular deformity.

In several mal-practice suits in which I have been called to give testimony as an expert, I have found the shortening to be from one to three inches. In addition to the shortening there has generally been angular deformity, and excess of callus which seriously interfered with the functions of the limb. In some of these malpractice cases the fault seemed to result from surgical incompetency; and in others the defect may have arisen from untoward circumstances beyond the control of the professional attendant.

FIG. 79.



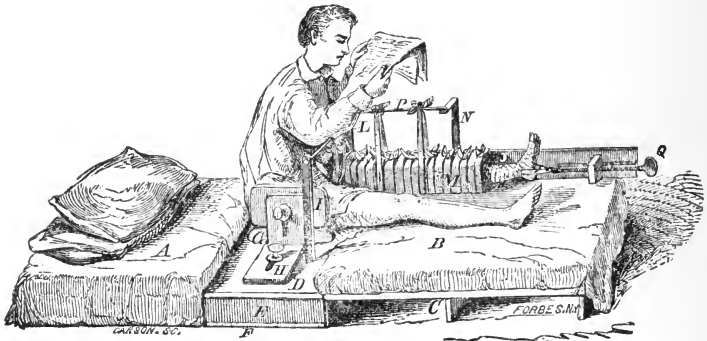
Extension by means of a weight and pulley; counter-extension is produced by a perineal band which may be fastened to the head of the bed.

WEIGHT AND PULLEY FOR MAKING EXTENSION.—Another method of applying extension in the treatment of a broken femur, consists in employing weight to a cord which reaches from the loop of adhesive strips over the foot rail of the bed. The fastening to the limb may be made with a piece of belt

leather secured to the thigh above the knee with lacings. This leather band may have loops fastened to each side of it, from which cords extend over the foot of the bed for the purpose of sustaining weight. It is well to have the knee gently flexed by means of a sand bag or cushion placed under the joint. Instead of producing counter-extension with a perineal belt, the foot of the bed may be raised on blocks, to give the patient's body an inclination in the direction of the head of the bed. This dressing is not complete without straight splints are bound to the thigh; and sand bags used to obviate rotation.

Mr. Burge, of New York, has invented an apparatus for treating fracture of the femur, which is represented by the accompanying diagram. The machine has been successfully employed in some of the New York hospitals. It holds the

FIG. 80.



Burge's fracture apparatus applied.

limb in the straight attitude, but allows the patient to take the sitting posture; and provides for the escape of alvine evacuations without disturbing the fragments of bone. Various intricate contrivances have been devised to treat fractures of the femur, but it is questionable whether they are superior to the more simple plans already described. The most of them are too costly for the ordinary practitioner who might not have an opportunity once in ten years to put one of them in practice. To study the different parts entering into the Burge apparatus, for instance, would require more time than to dress a limb with more simple means. To a practitioner inexperienced in the different machines invented to treat fractures

of the thigh, the diagrams representing such apparatus in works on surgery, offer more confusion than illustration. The fracture beds of Jenks, Daniels, Burge, and others, cost from fifty to a hundred dollars, therefore the surgeon of limited pecuniary means could ill afford to possess one or more of them.

A fractured femur needs to be treated with retentive means for a period of six or eight weeks in the young and vigorous, and for ten or twelve weeks in patients advanced in years. A limb may appear firm, as if consolidation had taken place at the end of five weeks, yet it is not safe to lay aside the dressings and trust the patient on crutches lest shortening occur. As has been remarked in another place, the uniting material continues soft and yielding for many weeks after osseous consolidation between the fragments seems to

have been effected. Many a surgeon of large experience in treating fractures has discharged his patient with one leg as long as the other, and has been astonished some weeks after to find that shortening had taken place. It may be remarked in this connection, that there is no way to determine when the fragments are so far consolidated that shortening will not take place. Experience shows that the uniting medium generally becomes unyielding at the expiration of ten or twelve weeks after the reception of the fracture. In young patients seven or eight weeks may be long enough to continue the retentive dressing. I have never had occasion to censure myself for keeping a fractured thigh in its dressing too long; but several times I have regretted having laid the apparatus aside too soon.



FIG. 81.

Consolidation after fracture through the upper third of the femur, showing some permanent enlargement at line of union and slight angular deformity.

After the fracture has become consolidated there remains at the seat of injury an enlargement which may annoy a nervous patient. This hypertrophy comes mostly from the excess of reparative material employed in the healing process. At first the lack of perfect apposition of the fragments may present some sharp and jagged edges, which

will irritate the soft tissues, and paralyze the muscles to some extent, but in time the rough points will be removed by absorption, and the enlargement will be forgotten.

A moderate degree of angular deformity will not prove a serious impediment to locomotion, therefore it should not be meddled with in old cases. Unless the defect be very great, any attempt to break the femur over again is not justifiable. In extreme angular deformities an awl or drill may be used to perforate the bone at the point of union, until there is so little osseous material left that it can, with proper apparatus, be pressed into line, or re-broken, when the limb can be treated in the straight attitude until the fragments re-unite. It may be incidentally remarked, that the lameness dependent upon shortening, generally diminishes. The twisting of the pelvis and the vertebral column tend to conceal the defect. A higher heeled shoe worn on the lame side will improve the gait.

FRACTURES OF THE MIDDLE THIRD OF THE FEMUR.

The middle of the shaft of the femur is broken about as frequently as those parts of the bone near the extremities; and when a fracture exists near the centre of the bone, the manner of treatment does not differ essentially from that demanded at points some distance from the middle line. The same forces which break the femur at points higher or lower in the bone, may produce a fracture of the middle third; and the signs of the injury could not be substantially different from those in fractures through other parts of the bone. There would be inability to move the limb, eversion of the foot, shortening, angular deformity, and crepitus when the broken ends of the fragments were brought in contact. The mobility at the seat of the injury would be so marked that even the unprofessional observer could not fail to recognize the nature of the lesion. The line of separation between the fragments may be oblique, transverse, or intermediate between those directions, partaking in part of each. There is the same tendency for the fragments to overlap, producing shortening, as after fractures higher up or lower down the shaft of the femur. The same dressing will be required as for a fracture

just below the lesser trochanter; there will be the same danger of defects and deformities as in fractures at other points in the bone; and it will require about the same length of time for the reparative forces to effect consolidation of the fragments. "These fractures," says Malgaigne, "when simple and without displacement, unite in forty or fifty days; sometimes they require two or three months, when the fragments overlap one another, being in contact only by their lateral surfaces. When the two ends can not be made to oppose one another, so as themselves to counteract the muscular contractions, it is impossible to preserve the normal length of the limb, whatever be the apparatus or method employed. There has been too much discrepancy of opinion among surgeons in regard to this. Hippocrates gives the idea that the shortening can always be obviated; Celsus goes to the opposite extreme, declaring that a thigh once broken must ever remain shorter than its fellow. At a period by no means remote from our own, Desault claimed to cure all fractures without shortening, and his journal contains several such cases. In imitation of him many surgeons have varied, corrected, and improved apparatus for permanent extension, and have announced as complete successes from them. I must, however, state positively that I have never obtained anything of the kind, either with contrivances of my own, or with those of others, or even when I have invited the inventors of such apparatus to apply them in my wards. I have more than once examined persons said to be cured without any shortening, but always discovered such shortening by actual measurement. Some have deceived themselves in regard to the merits of their treatment; they have happened to meet with fractures in which there could be no overlapping on account of an interlocking of the serrations, and imagined they had corrected a shortening which never existed. In short, when the fragments remain in contact, or when we can replace them and keep them so by means of their serrations, it is easy to cure a fracture of the femur without shortening; in the absence of these two conditions the thing is simply impossible.

"Several distinguished surgeons of the present day, recognizing this impossibility, have abandoned the idea of permanent extension. They allege moreover that an overlapping of even as much as an inch is of slight consequence, and involves no

limping. I can not entertain this view. I have seen persons walk very well with one-third of an inch shortening, but with more than this they either limp, or must wear a thick soled shoe; or possibly their halt is masked by a lateral inclination of the spine. Hence we see how grave a fracture, with overlapping, must always be, and what caution we should observe in giving a prognosis."

Although the upper fragment rides usually upon the lower, and the tension of the muscles seems to favor the flexed or "physiological position" recommended by Pott, Cooper, and others, many of the most experienced surgeons of the present day, both in Europe and America, employ the long straight splint, instead of the double inclined plane, to treat fractures near the middle of the thigh. To the latter plan, Desault makes the following objections: "the difficulty of making extension and counter-extension while the limb is in a state of flexion—the impossibility of comparing, with precision, the injured thigh with that of the sound side, in order to judge of the regularity of the conformation—the uneasiness which this position continued for a long time occasions, although at first it may appear natural—the inconvenience and painful pressure of a part of the trunk upon the great trochanter of the injured side—the derangement to which the limb is exposed when the patient goes to stool—the difficulty of fixing the limb sufficiently to prevent movements of the femur—the evident impossibility of this method when the two thighs are fractured—lastly, experience so little favorable in France to this position." Such were the motives, says Lonsdale, which determined Desault to have recourse to it no more, after having tried it on two patients, one of whom had a considerable shortening, in spite of the most scrupulous attention.

The objections to a flexed condition of the limb over a double inclined plane, as offered by Desault, are unworthy so eminent a surgeon. The experiment upon only two patients was too limited for a weighty argument; and then to say that experience was against the position, shows that prejudice exercised an undue influence over his mind. It is unfortunate that no tables are drawn up to show under which plan of treatment the least amount of shortening occurs.

I have had the best success with cases managed with a sand bag under the partially flexed knee, and extension applied

from the leg by means of adhesive strips, the counter extending force being derived from the descent produced by elevating the foot of the bed. A firm mattress is quite essential to the carrying out of several points in the treatment. In a soft feather bed it is quite impossible to bolster up the leg to obviate eversion, and to determine how the dressing is accomplishing its various objects. On a mattress every indication can be fulfilled, and every defect watched and guarded against. I believe in securing every advantage that can be derived from position. Even while using the long straight splint, the limb may be made fast to the foot of the bed, and the body given an inclination toward the head of the bed by elevating the lower parts as already indicated. However, there is no necessity for complicating the means if the straight splint accomplishes all that may be desired. Experience teaches that very few cases of fracture of the shaft of the femur can be trusted without some kind of extending and counter-extending forces being employed clear through the course of treatment.

The double inclined plane fracture appliance of Amesbury, and kindred contrivances, may possess principles which, if carried into execution by surgeons possessing mechanical skill, might secure the happiest recoveries; but the complications of the machines often confuse the professional attendant, and lead him to trust more to the apparatus than he would to a contrivance easier to be understood. I recently saw a patient under treatment for fracture near the middle of the femur; and the double inclined plane splint of artistic construction was performing its part so badly that I asked the doctor what he designed to accomplish with the appliance? He appeared unable to explain what the machine ought to perform, yet expressed confidence in the powers of the apparatus to avert deformity in the limb. If he had understood what the broken femur needed, he could have used almost any method to accomplish the object; but having no rational theory in regard to the wants of the case, he trusted blindly to the virtues of the appliance. The thigh-piece of the splint was so short that the body of the patient, bolstered up with pillows and other material, slid down against the apparatus, producing an angle and overlapping at the line of fracture, which would not have occurred if the limb had laid straight on a mat-

dress, no dressing being employed. The splint was so defective, or was so faultily applied, that the case was damaged by the treatment. In a soft bed, with the narrow double inclined plane splint toppling about, and the body pressing down against the fracture, there is little hope of a reputable cure. The double inclined plane under such circumstances is infinitely inferior to the long straight splint of Desault. With the "physiological method" so imperfectly or wretchedly put into practice, it is no wonder a reaction in favor of the old-fashioned straight dressing took place.

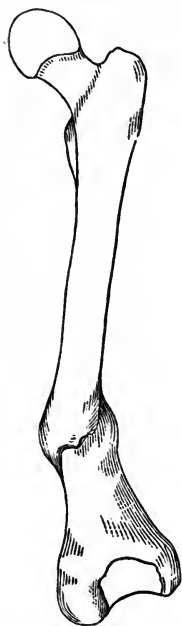American surgeons have displayed much ingenuity in constructing apparatus for treating fractures of the leg. Not less than half a dozen have gotten their names associated with splints. Dr. Wm. Gibson introduced an apparatus with a couple of long splints reaching from the axilla down on each side of the trunk and legs to a foot-piece, to which the feet of the patient were secured. This kept both legs parallel and the body straight with them; and prevented lateral twisting and swaying, and served as a kind of litter to raise the patient for defecation. The foot-piece could be moved up and down on the straight pieces, and held at any desired place by means of holes and pegs. The upper crutch-headed extremities rested in the axillæ, and the movements of the foot-board downwards secured the necessary traction. Dr. Joseph Harts-horne used a similar apparatus, though only one splint reached the arm-pit, the other being placed on the inside of the broken leg, reaching to the perineum, with a crutch-like head to prevent excoriation. The foot-piece was moved by means of a wooden screw passing through a cross-piece. None of these more or less ingenious contrivances are so simple and effective as the adhesive plaster extending apparatus, with elevation of the foot of the bed for counter-extension. Besides, this method leaves the thigh free to be dressed with common retentive means.

In fractures somewhere near the middle of the thigh, the immovable or starch dressing may be applied about the eighth day, and then the foot can be released from powerful traction. A compound injury is to be treated like a simple fracture, except the puncture in the flesh is to be left open to facilitate discharges.

False-joint is an unfortunate termination, which may happen in any case of fracture of the long bones, and in the practice of any surgeon. No display of skill will absolutely obviate non-union, though a well applied retentive apparatus, after proper adjustment of the fragments, is believed to favor consolidation.

FRACTURE OF THE FEMUR JUST ABOVE THE CONDYLES.

Fractures of the femur above the condyles, in the lower third of the bone, are not rare; they are generally produced by direct causes, though indirect violences, as heavy falls upon the feet, may break the femur at any point. The direction of the line of separation is rarely transverse or fully oblique. Cases are reported in which the line of separation has been nearly transverse; and others in which the obliquity was uniform all the way through, the broken surfaces exhibiting only minute serrations. The circumference of the bone increases from near the middle of the femur to the widest part of the condyles, and as the periphery increases the cancellated tissue augments, making so much spongy material in the lower extremity of the bone that the upper fragment may be driven into it, producing a state of impaction.

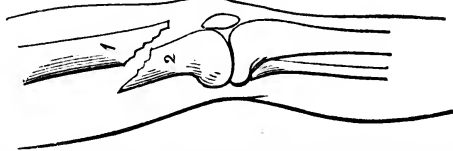


United fracture of the femur through its lower third, with overlapping and angular deformity.

In a simple fracture without penetration or impaction, the upper fragment usually occupies a position in front of the lower, producing shortening. There has been some speculation in regard to the influences which produce this position of the fragments. The action of the gastrocnemius upon the condyles, which project backwards, forming levers of considerable length, is the principal reason why the lower fragment is tilted so powerfully backwards. It is no uncommon occurrence for the lower end of the upper fragment to encroach upon the normal position of the patella, and even penetrate the synovial cavity beneath that bone, making

a complicated injury quite serious in its nature. The upper fragment occasionally gets pushed out through the flesh, producing a compound fracture. In 1865 I was called to Peter Mecklin, a German laborer, who fell from a high bank in a quarry. He struck, in his fall, upon a projecting rock, and then fell several feet further to a plane landing. His comrades found him with the broken femur pushed through the soft structures on the inside of the knee. I saw the patient in about two hours after the injury, and observed the broken end of the upper fragment still protruding; the lower fragment was in place so deeply buried in flesh that its fractured end could scarcely be outlined by manipulation. After stripping the leg of pants and boot, an attempt was made, by means of assistants, to extend the limb sufficiently to allow the protruding bone to go back into place, but such efforts were in vain. I then sent for chloroform, and, when the anæsthetic arrived, I put the patient profoundly under its influence, and exerted powerful traction upon the limb. This course proved successful; the bone went back into place in apposition with the other fragment. Although the fracture was marked with considerable obliquity, the consolidation took place with not more than a half inch shortening. I saw one case of compound fracture of the shaft of the femur in its lower third, in which the resistance to a return of the fragment, balked the efforts of two quite accomplished surgeons, in their efforts at reduction. The end of the fragment was finally sawed off, to allow it to go back through the rent made in the flesh. It is possible that such a proceeding might be justifiable in extremely rare cases, but it should be avoided if possible.

FIG. 83.



Fracture of the femur just above the condyles, which shows the tendency of the lower fragment to encroach upon the popliteal space.

The broken end of the lower fragment being tilted backward by the action of the gastrocnemius, its sharp edge may do harm to the vessels and nerves of the popliteal region. Paralysis of the foot, and aneurism of the artery, are said to

have followed such an injury. Malgaigne in his criticisms upon what Boyer says of the backward movement of the lower fragment, declares that such a displacement is purely imaginary. Hamilton reports a case treated by a surgeon of Lockport, N. Y., in which parts of the foot sloughed after fracture of the femur just above the condyles; and there seemed to be great danger of death to the leg. All the dressings were thrown off, and efforts made to restore vitality to the leg. The limb recovered with shortening, and the loss of the toes and part of the foot. The surgeon at length sued the father of the patient for the recovery of his professional bill. The case was litigated on the ground that the dressings had been so tight as to impede the circulation and to invite gangrene. The surgeon got judgment in his favor on the testimony of several distinguished surgical witnesses who declared that the sloughing arose from injury done to the nerves by the lower fragment of the femur, and that no amount of skill and attention could have averted the evil.

In fractures so near a large joint the dangers are greater than when the femur is broken at a distance from its articulations. If the upper fragment is dragged down against the patella the injury may be followed by a high grade of inflammation, and ankylosis.

The symptoms of fracture just above the condyles, are generally marked; the pain, swelling, inability to move the limb or to bear weight on it, necessarily attend the accident. Crepitus may be produced if the broken surfaces can be rubbed against one another, but in the event of much overlapping the grating will be absent. In cases of many hours standing, the swelling obscures the characters which declare themselves so plainly just after the accident occurs. However, the angular deformity which is very great, or can be made so by manipulating the limb, is a convincing sign of fracture. The lateral mobility which does not belong to the knee, is another conclusive diagnostic sign.

TREATMENT.—It seems unnecessary, after what has already been said concerning the treatment of fractures of the shaft of the femur, to give anything more than general directions for the management of fractures just above the condyles. The reduction can sometimes be easiest effected by flexing the

leg, and putting the arm just above the calf, for the purpose of making extension. A straight downward pull upon the heel and foot exerts traction upon the gastrocnemius, thereby tending to tilt the broken end of the lower fragment backwards. If the fragments can not be adjusted without the influence of an anæsthetic, there should be no hesitancy in its early employment.

Cures effected with the aid of the long straight splint are not very satisfactory; shortening to the extent of one or two inches being a common result, to say nothing of other glaring defects. The long straight splint, for the purposes of effecting extension and counter-extension, has many advocates, but it finds little favor with me in the treatment of such injuries; the double inclined plane apparatus does better, yet it has its objections. It is better to envelope the thigh with retentive splints, the pieces of lath or thin board being laid longitudinally with the limb, across the fractured line in the bone, where they are to be bound in place with tapes and bandages. Extension can be made from the leg and ankle by means of adhesive strips, using the weight and pulley, or raising the foot of the bed on blocks after making the limb fast to it. To relax the muscles of the thigh and leg a large sand bag or cushion is to be placed under the knee to keep it permanently flexed. The limb may also be bolstered up and kept in a straight line by means of several sand bags placed along its sides at places where support is needed. Whatever be the dressing applied, it should be employed for six or eight weeks, and even longer in old subjects. After the extending and retentive appliances have been laid aside, no weight should be borne upon the limb until several weeks more have elapsed lest overlapping and angular deformity take place from yielding of the new formed callus or uniting medium. During this convalescing interval gentle motion should be kept up at the knee to obviate stiffness and ankylosis, and the limb may be rubbed with stimulating liniments to restore the normal activity of the muscles. Until consolidation takes place and while the retentive dressings are in use, measurements and comparisons of the two limbs should be often made. The general contour and condition of the leg should be observed at every visit, and any deviation or defect guarded against by re-adjustments of the appliances, or by changing the entire

plan of treatment if deemed necessary. The state of the circulation in the foot, and the condition of the skin where dressings bear heavily, must not be neglected. A tight wrapping can generally be loosened by cutting part way through a few turns of the bandage; and a loose dressing may be made tighter by the application of a few additional strips employed as ties. The surgical attendant must bear in mind that the tendency of a broken thigh is to deformity, and that the perverse inclination must be constantly and efficiently opposed, leaving nothing to "luck" or hazard.

FRACTURE OF THE CONDYLES OF THE FEMUR.

Fracture of one or both condyles is, fortunately, a rare accident, for the injury is attended with dangers of a serious nature. The knee-joint is exceedingly intractable when subjected to the influence of disordered action. Effusions into the articular structures are attended with great distress and constitutional disturbance.

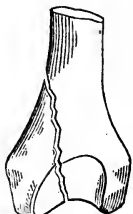The force which breaks a condyle of the femur may be direct, as when a heavy weight falls upon the knee; or it may be indirect, as when a person in falling strikes in such a way as to have the violence communicated to the side of the femur which did not receive the primary impression. The disengaged fragment may include the articular surface of the inner or outer condyle and four or five inches of the condyloid ridge, terminating in a point at its upper extremity. One condyle is broken about as often as the other, though the inner is less protected from direct violence.

The muscular forces exerted upon a broken condyle are antagonized to a great extent; the two vasti pull upwards and the gastrocnemius downwards. The lateral and crucial ligaments are opposed to much displacement, unless both condyles give way, allowing the central wedge-shaped shaft in its course downwards, to force them asunder.

I have the specimen of a fractured internal condyle which was taken from the leg of Thomas R., a laborer, who lost his life by falling to the bottom of a well, which was being dug. In the descent the knee hit against the edge of a heavy tub attached to a windlass used in raising the earth which was

being excavated. The line of separation in the broken bone begins near the centre of the articular concavity at the lower end of the bone, and extends upwards and inwards about five

FIG. 84.

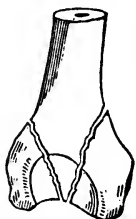


Fracture of the internal condyle of the femur.

inches, terminating in the condyloid ridge. The broken surfaces are rough with the usual spiculæ, but bear no marked irregularities. The separated condyle was not displaced by the force which produced the fracture.

The symptoms of a broken condyle are not marked and palpably distinctive, though the diagnosis can be determined by a careful manipulation of the parts. The pain, swelling, and inability to bear weight on the limb, are features that could not well be absent. The joint in its normal state admits only of the hinge motion, backward and forward, but after fracture of either condyle the lateral motion which can be imparted to the joint clearly indicates the nature of the injury. The separation of the epiphyseal extremity of the bone in a young subject, might obscure the difficulty, as might a transverse fracture of the femur close above the condyles. Crepitus can be elicited in either kind of fracture, therefore the existence of that sign would not throw much light upon a doubtful case. However, when a condyle is separated from the rest of the bone the disengaged fragment can be grasped, and moved independently of the rest of the femur, and the movement is attended with a crepitating sound that corresponds with the motion. The increased width of the joint is another sign of some value, and should not be neglected.

FIG. 85.



Fractures of both condyles of the femur.

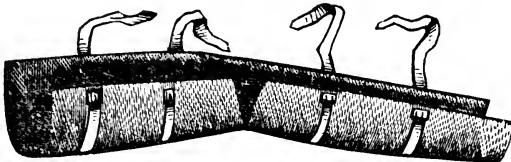
If the fracture be caused by the passage of a wheel over the joint, or by any violence of a crushing character, the lower extremity of the femur may be broken into several pieces, some of which may be so isolated from nourishing tissues that they will become foreign bodies, creating grave local and general disturbance. The suppuration attendant upon the discharge of such pieces of bone, exhausts the patient, and occasionally necessitates amputation to save life. The case of a boy with a compound fracture, is reported in *Braithwaite's Retrospect*, Vol. XV., in which a good recovery was made, though a piece of the ex-

ternal condyle worked its way out in the course of three or four months from the reception of the accident.

TREATMENT.—The gravity of the lesion requires more patience and skill to combat inflammation and to avoid the necessities of amputation than to adjust the fragments and to retain them quietly in place. Anodynes and cooling lotions must be topically used, and opiates administered internally. The employment of the long splint, which necessitates the straight attitude, is out of the question. If only one condyle is broken, and there is no displacement, the knee should be moderately flexed by being placed on a sand bag. If the foot is forcibly inclined to eversion, the tendency may be counteracted by other bags arranged along the outside of the limb.

In the event of a double fracture, both condyles being separated from the shaft, there is considerable shortening to be overcome. This can not be accomplished by using the straight apparatus of Desault, or the double-inclined plane splint in common use. A moderate degree of flexion is one of greatest ease and repose; and should anchylosis take place the limb is the most serviceable in that position. The use of adhesive plaster repeatedly described, is the easiest method of applying extending force, and the inclination of the body in the opposite direction, produced by elevating the foot of the bed, is the most comfortable manner of obtaining counter-extension. If the knee be too wide, a leather or pasteboard splint should be bound around the limb, enveloping the joint and a few inches of the leg and thigh. Should the soft parts be much bruised, no stiff dressing can be endured. As soon,

FIG. 86.



A woven wire appliance to support the leg after fractures near the knee-joint.

however, as the flesh wounds have sufficiently healed to receive a slightly compressing support, it may be employed to advantage.

Passive motion should be begun by the thirtieth day in a gentle manner at first, and kept up for months or until the

functions of the joint are fully restored, or recovered as far as practicable. Passive motion is as essential during the period of convalescence after fracture of a femoral as in the final treatment of a humeral condyle, but the knee will not endure the rough usage that can be imposed on the elbow.

In the earlier part of the treatment a tendency to deflection to the right or left is to be guarded against as well as shortening. The leather or pasteboard splints if allowed to extend above and below the knee, and if kept snugly bound in place with a bandage or multiple ties, operate against lateral deformity, and the extending and counter-extending forces resist the overlapping. Eversion of the foot and limb is prevented by the use of sand bags. Moderate flexion of the knee relaxes the muscles of the leg. The ordinary double inclined plane fracture box or appliance for the leg, constitutes a very serviceable dressing for treating a femur broken at the condyles. In a case of comminuted fracture of the lower extremity of the femur, including a severance of both condyles, which recently came under the treatment of Drs. Potter and Clarke, of Hamilton, O., the double inclined plane apparatus was used; and the result could not be more satisfactory. By the courtesy of the surgical attendants I was invited to see the case under treatment, and was pleased with the skillful management of the means employed.

CHAPTER XXVI.

FRACTURE OF THE PATELLA.

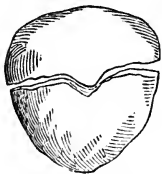
The patella is much exposed to direct violence, but the facility with which it slides in various directions, saves it from fracture. Indirect violence can not reach it; but muscular action exerts a powerful influence upon it. The size and shape of the bone contribute to its immunity from fracture.

The patella is a sesamoid growth in the tendon of the quadriceps extensor cruris muscle, and plays the part of a fulcrum and lever at the same time. In the former office it can not be crushed by muscular action; but in the latter capacity it may be snapped, the fracture running through the bone transversely. A blow may break it longitudinally, or crack it into several pieces. The patella is broken by muscular force more frequently than any other bone in the body. When the knee is slightly bent the bone is supported upon the condyles of the femur on its transverse axis only, becoming wholly a lever, and losing its character of fulcrum. Its upper edge is then elevated and unsupported, as well as its lower, which is held rigidly in place by the ligamentum patellæ. Under these circumstances the rectus femoris and its associate muscles, no longer act in a direction corresponding with the longitudinal axis of the bone, but nearly at right angles with it. In a violent effort to save the body from falling backwards, the bone may snap transversely. In one instance I knew a boy to break one of his patellæ while jumping a wide ditch. As he landed the body dropped down so as to bring the knee into extreme flexion, and he says the knee-pan snapped at that time. In that instance the conditions were not favorable to a fracture of the patella, for its position was such when the knee was excessively flexed, that its centre was unsupported, and the force acted in the direction of the vertical axis of the bone, and no leverage could be obtained upon

it. In order that the patella may be placed in the most favorable position for the muscular force to act upon it, the knee must be only moderately flexed; then the ligamentum patellæ holds the bone poised on its centre, between the condyles of the femur, and the muscles act upon its upper edge. Extreme force is not brought upon the patella when it plays the part of a lever, except a person in walking, slips with one or both feet, and in an effort to resist a fall, or to recover an equipoise of the body, he attempts to straighten the knee which has become partially flexed. It is just at this time that the patella is placed under the most favorable conditions for the muscles to act upon it; and it is at this moment that the muscles act suddenly in the most powerful manner. While the knee is bending it is instantly checked in its course of flexion, and changed to a state of extension. If the patella be poised on its articular apex, its integrity is severely tested; but if the leg be nearly straight or extremely flexed, the force acts in a straight line with the bone, and the tendon above or below the bone is put to a dangerous test. The patella is ordinarily strong enough to resist any muscular force that can be brought to bear upon it, but, as has been stated, if it be caught in a poised position between the condyles when great and sudden power is exerted on the part of the muscles, the bone is put to a disadvantageous strain, and may snap, as a short stick is made to break across the knee by the power of the hands.

A person in going down stairs may catch the heel or partially stumble, and in the effort to shun a fall receive a fractured patella. By far the most common cause of a broken patella is direct violence; the kick of a horse, the hitting of the bone against some solid substance in a fall, the blow of an axe, hammer, or implement violently hurled by moving machinery, are all well known causes.

FIG. 87.



Transverse fracture of the patella.

The symptoms of transverse fracture of the patella are prominent and unmistakable. The patient feels the sudden separation of the bone, and generally declares that he heard the snap attending it. He is unable to extend or advance the leg, and seems to be instinctively conscious of the nature of the injury. The lower fragment remains in place, being held there by the ligamentum patellæ;

but the upper fragment is drawn upward sometimes to the extent of several inches—generally an inch or two. The upper fragment can be found as the hand is slid down the thigh near the knee, and the fingers find a yielding depression between the fragments. Just above the lower fragment, the knee, when the leg is flexed, evidently has lost something which normally produces a fullness there.

No crepitus need be expected unless the leg be extended and the quadriceps be pressed powerfully downwards, so as to allow the fragments to reach each other: if once brought in contact by the above means the broken surfaces may be made to grate against each other.

Considerable swelling takes place from effusions of lymph and extravasation of blood. If the limb is not seen for several hours succeeding the accident, the swelling will mask some of the prominent symptoms, yet the fingers firmly pressed along the anterior aspect of the limb in the vicinity of the joint, will discover the upper fragment dragged upward, and the abnormal depression between the pieces. The furrow between the condyles will also be recognized if the fingers are pressed into that sulcus.

In an oblique fracture of the patella the signs of the lesion will be as apparent as in a transverse separation. In multiple or stellate fracture the fragments may not be displaced, but all will be held in position by the tendinous surroundings. In such a case crepitation could be readily elicited, and movements of the limb would cause sufficient irregularity of the pieces to be discoverable with the aid of the fingers. Flexion of the limb would produce separation of some of the fragments, as the quadriceps must take one or more pieces of bone along with it as contraction of the muscles ensues.

In a longitudinal fracture of the patella there may be lateral separation of the fragments, though the beveled and projecting condyles on each side tend to keep them in place. The action of the vasti muscles, pulling in opposite directions, the force being from the centre towards the sides of the limb, may separate the fragments when the leg is flexed.

One of the peculiarities of a fractured patella is that the fragments unite very frequently with fibrous material, and rarely consolidate with bony matter. The length of the fibrous bands depends upon the distance existing between the

fragments during the healing process. It is not uncommon to find the fibrous connection nearly an inch in length. In

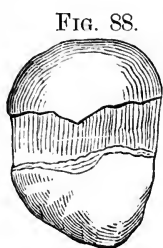


FIG. 88.

Ligamentous union
after transverse
fracture of the
patella.

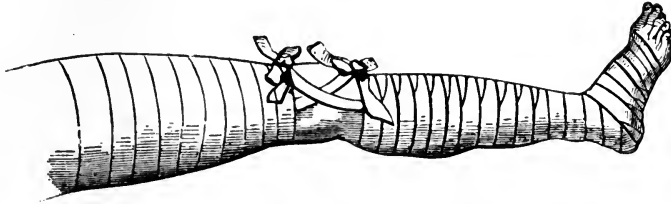
the case of Mary Adams, of Covington, Ky., who broke the right patella transversely by a tumble on some out-door steps, I secured a very short ligamentous union, so that she walked well at first, but in less than a year the connecting band had stretched, torn, or yielded, so that there were two inches between the fragments when the leg was forcibly flexed.

Dr. Coale presented to the Boston Society for Medical Improvement, a specimen of a fractured patella taken from a man sixty-five years old, the fracture having occurred ten years before. Dr. C. reports that the fragments at first were so closely united that no separation between them could be discovered; but subsequently they became disjoined at their outer edges one inch, and at their inner edges very much less.

TREATMENT.—The sooner the limb is properly dressed, after fracture of the patella, the easier it will be to accomplish the chief object of the treatment. The muscles attached to the patella are so powerful that their contraction goes on from day to day until at the end of a week or two a space of two or three inches between the fragments exists, though the separation of the pieces of bone may have been less than an inch at first. Immediately succeeding the fracture the two portions of bone can be easily brought into contact, whereas in the course of a few days the muscles have become so much contracted and accommodated, as it were, to their new position, that it is often quite impossible to elongate them sufficiently to bring the piece of bone connected with them down far enough to meet the lower portion: the consequence of which is, that direct apposition and consolidation are never obtained, but a kind of ligamentous or fibrous union is the result. It is generally believed among experienced surgeons that the great rareness of bony union in transverse fractures of the patella must be owing simply to the difficulty of keeping the fragments in sufficiently close apposition; if contact of the broken surfaces could be produced and steadily maintained for several weeks, bony union might be expected as in other fractures.

A modification of the dressing employed by Mr. Cooper is represented in the accompanying diagram, and may be applied as follows; carry a circular bandage from the toes to the knee, binding two strips of uniting bandage which are laid on the sides of the leg, the upper ends being left free for tying above the upper fragment when it is bandaged down into place. Another roller is to be applied, beginning at the upper part

FIG. 89.



Circular bandages above and below the knee serve to hold firmly in place two sets of uniting tapes which are to be tied above and below the fragments of the patella.

of the thigh and bandaging downward while an assistant with both hands near the knee pulls powerfully upon the quadriceps. The bandage secures and maintains the stretching and extension applied by the assistant. Two strips of strong cloth are to be laid upon the sides of the thigh, and covered by the spiral bandage, as was done below the knee. The free ends of the uniting bandages are to be tied above and below the fragments, a compress being placed where the knots are to rest. If the uniting strips be tied snugly, they exert a powerful influence towards bringing the fragments in contact. To finish the dressing a compress may be laid on the patella, and held in place by a few turns of a third roller, which also covers in the space between the other bandages and secures equal pressure the whole length of the limb. A long splint may be bound to the posterior aspect of the leg to prevent the slightest degree of flexion at the knee. The rectus femoris is freed from tension by elevating the leg on cushions or other supports.

The dressing just described operates very well when the bandages wholly prevent the ties from slipping, but practically it is found that they will not. To obviate that serious defect Dr. Sanborn, of Lowell, Mass., devised a modification of the old plan, using adhesive strips in place of the ties or uniting bandages. He recommends a strip of ordinary adhesive plas-

ter four feet long and two and a half inches wide to be applied to the anterior aspect of the limb from the upper portion of the thigh to the middle of the leg, leaving a free loop at the knee for purposes presently to be explained. The ends of the strip to within a few inches of the knee, are bound in place by a couple of rollers—one for the foot and leg, as in Cooper's dressing, and the other for the thigh. A hard roller compress is placed immediately above the upper fragment, and then a small stick, as a *twister*, is put through the loop, and revolved until great power is brought to bear upon the parts to which the adhesive strip is attached. This is an efficient and easily applied apparatus, and good results may be obtained from its use. I have employed it in one instance, with the addition of a single inclined plane to elevate the foot, and secured a bony union of the fragments.

If the fracture occurs from direct violence there will be danger of a high grade of inflammation and ankylosis. Cooling and anodyne lotions that will not interfere with the dressings, should be freely employed during the early part of the treatment. At the expiration of four or five weeks from the reception of the injury, passive motion is to be instituted, and kept up until the functions of the joint are restored.

In a case of vertical or longitudinal fracture the knee-joint should be enveloped in strips of adhesive plaster to retain the fragments steadily in juxtaposition. The tendency is to lateral displacement of the fragments in a moderate degree, and the adhesive strips are used to counteract it. Osseous union is pretty certain to follow this treatment. Arthritis and ankylosis are the most dangerous conditions to be guarded against.

I have never met with a case of a recurrence of the lesion after fracture of the patella, but such accidents are reported. I am inclined to think that there was no bony union in such cases, and that the "recurrence" was merely a tearing of the fibrous connection.

It is rare for a patient to recover entirely after having sustained fracture of the patella. In the event of fibrous union of the fragments the power of extending the leg is impaired; and bony union is generally followed by excesses of callus that impede the motions of the joint. A complete restoration of all the functions of the limb is a fortunate issue.

CHAPTER XXVII.

FRACTURES OF THE LEG.

The bones of the leg are parallel in direction, but quite different in size, shape, and function; the tibia is large, and by its broad articulation with the femur and tarsus, is evidently designed to support the weight of the body; the fibula is small, and is destined not to sustain weight, but to give attachment to many muscles, and its lower end contributes to the formation of the ankle joint. The tibia has broad articular extremities and a triangular shaft; the fibula has moderate sized extremities, and a slender prismatic shaft. The two bones have quite different offices to perform, yet they are so intimately associated in their anatomical relations that both are more frequently broken by a single accident than either is fractured separately. A force sufficient to break the tibia is generally powerful enough to reach the fibula and to break it also.

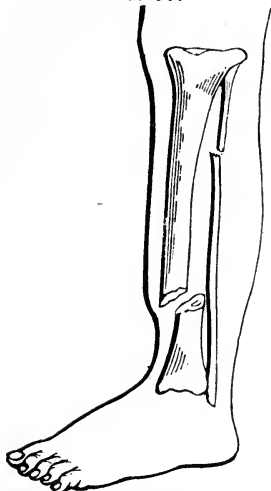
The tibia being thinly covered, is exposed to direct violence, and peculiarly liable to compound fracture; the fibula is pretty well buried in soft tissues, and when broken, its fragments rarely puncture the skin.

The causes of fracture of the leg are either direct, as the passage of a wheel over the limb; or indirect, as in landing heavily upon the feet, from a jump or fall. The relative frequency of these causes in the production of fracture has been variously estimated by different authors. Hamilton considers that four-fifths of them come from direct violence, while Malgaigne found that in sixty-seven fractures of the leg observed by him, thirty-six were produced by direct, and thirty-one by indirect violence. There are some parts of the tibia, as the head and lower extremity, that rarely yield from the influence of an indirect force; but when a person in a jump or fall

comes to the ground on his feet, the force is likely to act obliquely upon the shaft of the bone, and snap it across. Direct forces may fracture any part of the bone, for all parts are exposed to the influence of kicks, blows, projectiles, falling bodies, and moving machinery.

Both bones of the leg may be broken, as has just been stated, at the same time, or by the same accident; if the violence be direct the fracture may be on the same line in the two bones; if indirect, the tibia is liable to yield in its lower third, and the fibula somewhere above its middle. Peculiar

FIG. 90.



Fracture of both bones of the leg; the fibula through its upper, and the tibia through its lower third.

circumstances may allow the indirect force to break the two bones in the same line; and others may occur which cause the direct force to break each at different points.

When the indirect force acts, the fibula must almost always break after the fracture of the tibia has taken place, for the force continues on upwards and comes upon the fibula with the additional weight of the body of the person which is no longer supported by the tibia, consequently the whole stress tells on the slender fibula above where the other bone gave way, producing a fracture in its upper third. A violent and sudden twist of the ankle, which is force indirectly applied, may cause fracture of both bones just above the joint, the line of separation being nearly on the same level.

It is rare to find the fibula broken below the point of fracture in the tibia, even though direct force has caused the injury. If the leg be broken by a wheel passing over it obliquely, the fibula being struck at a point lower down than the tibia is hit, the line of separation in the two bones must correspond with the points subjected to violence.

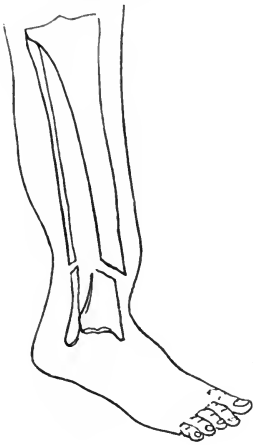The direction the fracture takes is much the same it is in the long bones generally: if the force be indirect, the oblique course prevails; if direct, the transverse. In most instances the line of separation is irregular, but inclining to the oblique. The tibia is most liable to exhibit a predominance of obliquity

in the line of its fractures; and the fibula shows a tendency to the transverse direction in the line of its separations.

Displacements may take place as in fractures of other bones, and from similar causes; in transverse fractures the fragments may not become disengaged, at least there is less tendency to displacement; in oblique fractures, on the contrary, there is nearly always overlapping, sometimes to a considerable extent, as when the fracture is caused by a fall on the feet from a height, for the force being more than sufficient to break the bones, continues to act, and so displaces them. Combined with this there is usually some rotatory displacement, due partly to the force received and partly to muscular action.

The signs of fracture in the bones of the leg, are generally well marked, though not always comprehended in their utmost significance. In other words, it may be plain that a fracture exists, but it is not generally an easy matter to determine whether one bone is broken or both, and what is the direction of the fracture, the extent of the injury in all its bearings and complications, and what obstacles are to be overcome in the treatment. The crepitus, mobility, and deformity are commonly detected upon the slightest examination. The tibia is so near the skin that the smallest amount of displacement is readily detected by passing the fingers along the course of the bone; the fibula is more deeply covered, yet thorough manipulation can not fail to discover the place where the separation exists. The surgeon, in examining a leg which has sustained a fracture,

FIG. 91.



Fracture of both bones of the leg on nearly the same plane, the result of direct violence.

should not be content with the discovery of a break in one bone, but he should carefully scrutinize the other. It has been already stated that a fracture of both bones in a single accident, is more common than the fracture of one bone singly, therefore in a given case the probabilities are always in favor of both bones having been broken. In the treatment of fractures of the leg it is of the utmost importance to de-

termine whether one bone is broken or two; if only one bone be broken there may be a rotatory or twisting kind of deformity, but there can be no serious degree of shortening; if both bones be broken, and the surgeon discover a fracture in one alone, and treat the injury according to his faulty diagnosis, the most serious consequences are sure to be the result.

In considering the displacement that occurs in fractures of both bones of the leg, it may be easy to determine, for instance, that the upper fragment of the tibia takes a position in front of the lower fragment; but to decide upon the relative positions of the fragments of the fibula may be attended with some difficulty. The force that displaces the fragments may be of two kinds,—it may come from muscular action pulling the lower fragment above the upper; or it may be that which causes the fracture, driving one portion of bone from its contact with the other after the break has occurred. It is more probable that the same force would go on acting after it has fractured the bones, than it should cease directly. When the fragments are once displaced by the force producing the fracture, the muscles exert an action upon them, and may oppose reduction.

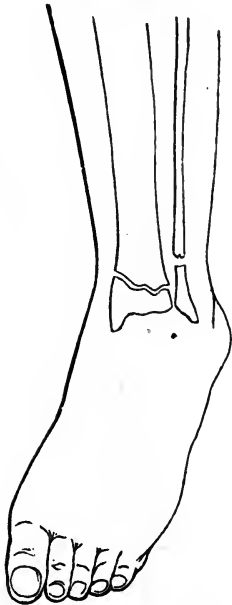
Overlapping is one of the most important and constant features in fractures of both bones of the leg. To recount all of the muscles that either produce or maintain the retraction would be simply enumerating the entire list that make up the motive power of the leg. The line of action is towards the knee, the broken ends of the lower fragments being pulled upwards past the fractured surfaces of the upper fragments. The weight of the limb causes a part of the angular and rotatory deformity, and the winding course of some of the muscles the rest of it. The direction of the force producing the fracture will always vary the line of the displacement; for, applied from the outside of the limb it will be disposed to displace the portions of bone inwards; and applied from the inside, it influences them in the opposite direction.

The fibula, in fractures of both bones of the leg, has very little influence upon displacement; the fractured ends present so small a surface that very little force destroys their apposition, and if the bone be broken into more than two pieces the muscles destroy their parallelism, so that perfect coaptation of the fragments is exceedingly rare.

In fractures very high up, near or through the head of the tibia, where they may be when direct force inflicts the injury, the displacement is slight, unless the fracture be much comminuted; for, in this situation the structure of the bone is cancellous, which causes it to break with a more irregular fracture, giving the surfaces a rough, uneven shape, by which the ends of the bone are locked within one another, and require a powerful force to displace them. Fracture through the head of the tibia, or through the lower extremity of it, is liable to be oblique or nearly vertical in its course, a circumstance that always renders it doubtful whether the knee or ankle-joints are not complicated in the injury, rendering the nature of the lesion much more serious than a fracture of the shaft of the bone.

Fracture of the internal malleolus and of the fibula a few inches above the joint, accompanied with partial or complete dislocation of the ankle, is an injury of a complicated nature, and is essentially the same as "Pott's fracture" of the fibula, with laceration of the deltoid ligament, and displacement of the tibia from the astragalus to a certain extent.

FIG. 92.



Fracture of the tibia and fibula near the lower extremities of those bones.

Fractures through the extremities of the bones of the leg are not easily diagnosed, especially if the patient be not examined until swelling has rendered the case obscure. These accidents are always accompanied with more ecchymosis and swelling than fractures at a distance from the joints, owing to the nature of the force that produces the injury, and to the fact that the articular structures are more or less injured at the same time, which causes the effusion to be greater than it otherwise would be. On July 6th, Dr. A. P. Freeman and myself were called to treat Mrs. Taylor, of West Covington, Ky., who had the evening before broken

her left leg just above the ankle. There was considerable swelling and discoloration twelve hours after the accident occurred. The general contour of the leg showed that a frac-

ture existed near the ankle, but the line of separation in both bones could not be determined without careful manipulation. Crepitus decided the nature of the injury, though it could not be ascertained at first whether the grating sound came from the tibia or fibula, or both. The concavity on the outside of the leg led to the suspicion that the fibula was broken, and lateral motion, with the finger on the suspected point, made the existence of fracture certain. Antero-posterior motion developed crepitus between the fragments of the tibia; and the fingers pressed upon the bone just above the ankle discovered the line of separation. It was easier to comprehend the break in the fibula than it was the certainty of fracture and the line of separation in the tibia. The deviation from the ordinary shape of the limb, consisting of some angular defect, a visible twist or rotatory deformity in the lower part of the leg, made it apparent that both bones had been broken. The line of separation in the tibia was too nearly transverse, and there was too little displacement to admit of overlapping, therefore whatever of deformity existed was overcome by extension made with the hands. Common thin board splints were wrapped with muslin, and applied to each side of the leg, and bound in place with encircling tapes and a roller, compresses being used to help secure the normal shape of the limb. In five weeks consolidation was complete, and no shortening or rotatory deformity remained. No extending force was used after the reduction, for none was required. The interlocking of the fragments of the tibia would not admit of overlapping.

In fractures of both bones of the leg near the knee, the line of separation can be discovered between the fragments of the fibula, but the course of the fracture-line in the tibia is often quite difficult to make out. The tibial fragments are apt to remain interlocked, owing to their broad surfaces, and to the little power of the muscles over them. Crepitus may sometimes be elicited, but it may not be easy to determine whether it is between the fragments of the tibia or fibula. If much displacement happens to be produced by the force which caused the fracture, or if the line of separation be oblique, the nature and extent of the injury are not difficult to understand.

Fractures of the bones of the leg remote from the joints, are attended with signs quite unmistakable. Crepitus is

easily produced, owing to the mobility that exists between the fractured portions. When the fracture exists in the tibia only, the same facility does not always exist, for the fibula then serves as a splint to a certain extent, and keeps the fractured ends of the tibia in apposition.

Crepitus, for various reasons, can not always be produced even when both bones are broken somewhere near their middle; but the angular deformity which can be produced by bending the leg in any direction, sufficiently demonstrates the nature of the lesion.

The inner and fore part of the tibia being quite superficial, a fracture of the shaft of the bone may at once be recognized by passing the finger along the anterior spine; for any irregularity along this surface will be easily discovered, and indicate the position of the fracture. The point of fracture in the fibula is not, as already stated, on the same level with that of the tibia, especially when the fracture is caused by indirect force; for the fibula is found to yield at a point somewhere above the place the tibia breaks. The most frequent kind of displacement in the fibula is inward toward the tibia, causing a depression which may be felt when the finger is pressed along the outside of the bone; and the ends of the tibia can not be displaced to any great extent without the ends of the fibula moving with them. Overlapping of the fragments of the tibia can not take place without the same amount of displacement occurs in the fibula.

TREATMENT OF FRACTURES OF BOTH BONES OF THE LEG.

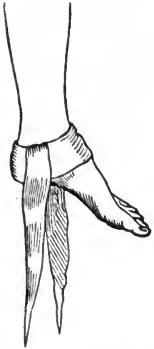As already indicated, when detailing the course pursued in the treatment of Mrs. Taylor's leg, extension and counter-extension are not always required in the management of fractures of both bones of the leg. However, if there be shortening, or an opportunity to overlap on the part of the fragments, as there almost always is when the fracture is through the shafts of the bones, those forces must be steadily and persistently maintained as long as a retentive apparatus is necessary, otherwise some degree of deformity will be inevitable. If there is a disposition to overlap, as there necessarily will be

when the fracture is oblique, the difficulty in preventing this deformity is exceedingly great. The surgeon may effectually reduce the fragments to their proper places, and carefully apply suitable means to retain them there, yet the tendency to overlap is so pressing that the pieces of bone will slip past each other, unless watched and guarded against with the utmost patience and skill. The facility with which the broken surfaces escape from one another, while the dressing is being applied, has been observed by every one familiar with such injuries. The force and dexterity required to effect reduction in the event of much overlapping, and in irritable patients whose muscles fly into a state of spasm as soon as the limb is touched, are far from trifling. The influence of chloroform is sometimes needed to accomplish a successful reduction. In reducing fractures of the leg, an assistant should be placed so as to fix the knee firmly, while the foot is grasped, and steady and well directed extension is made downwards, care being taken to unlock or disengage the fragments by gentle rotatory motion. In manipulations of a broken leg it should be borne in mind that large arteries, veins and nerves, pass along near the rough and sharp edges of the fragments, and may be seriously injured by careless handling of the limb.

It is the custom of some surgeons to allow a broken leg to remain several days under the influence of cooling and anodyne lotions, before an attempt is made at reduction. This course might do in a hospital where the patient has no choice of surgical attendants, but in private practice the most eminent practitioner is not sure of holding his case if he follow such a course. Policy, then, is against the practice, even if it have some points in its favor; but according to my experience there is no better time to adjust a fractured bone than as soon as it can be done conveniently. The muscles do not readily relax after they have been allowed to contract for several days; besides, the patient does not rest well with the limb in a broken and unsupported state. There is a feeling of insecurity in an undressed fracture that is absolutely tormenting; every motion of the body imparts pain and invites a spasmodic action of muscles in the vicinity of the fracture. If it be impossible to reduce a compound fracture on account of the muscular contraction and spasm, the influence of an anæsthetic will put the patient into such a state of relaxation that the

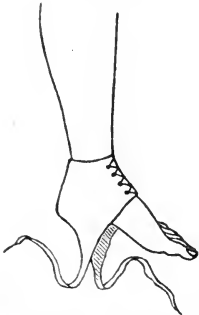worst case can be managed successfully. If the wound in the integument be too small for the protruding fragment to return, it may be enlarged slightly to take off the tension. The necessity for sawing off a piece of the bone in order to accomplish easy and speedy reduction, can rarely or never exist. However, it would be necessary to resect a point of the bone if it could not be returned to its proper position, yet such a procedure is to be avoided if possible. I can not endorse the following from Prof. Hamilton: "Resecting thus the end of an oblique fragment does not generally affect in any degree the length of the limb, or interfere with a prompt and perfect cure, but on the contrary it often is advantageous in every point of view."

FIG. 93.



Hitch made upon the ankle and foot with a handkerchief folded like a cravat.

FIG. 94.

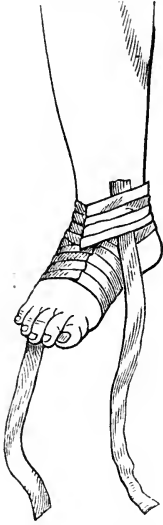

A gaiter-like appliance to make fast to the ankle.

The application of extending force in those instances where the overlapping demands it, taxes the ingenuity of those unaccustomed to make a "hitch" upon the foot. Barton's handkerchief, as it is sometimes called, may be employed as a means of making extension. It can be applied as follows: a handkerchief of good size being folded into a cravat, is so laid against the point of the heel that one-third of the handkerchief shall be on one side and two-thirds on the other; after which the longest end is to be carried round across the instep to the opposite side, where it takes a turn around the other extremity of the handkerchief, and is then carried under the sole of the foot to the other side of the ankle, where it takes a fold around the first turn. The two free ends reaching below the foot are to be used for making extension with whatever apparatus the surgeon chooses to employ. A gaiter has been one of the means of making fast to the ankle, when extension is needed; but if the fracture be near the ankle-joint, the folded handkerchief is not endurable without great suffering and excoriation. The heel and structures about the ankle are proverbially intolerant of pressure, and the accident renders them more so.

The adhesive strip fastening is the least objectionable of all kindred contrivances for making extension. The foot and ankle are to be covered in with narrow strips of adhesive plaster, then the vertical side strips of greater width are made to adhere partly to the skin and in part to the enveloping material, and, finally, over both a few encircling strips are applied, which complete the first stage of the dressing.

FIG. 95.

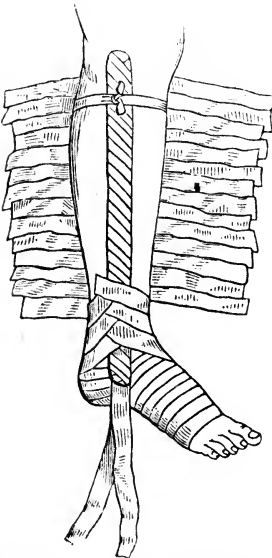


Adhesive strip fastening made to the foot and ankle, for the purposes of making extension.

The surgeon can take his choice of these three forms of making fast to the foot and ankle, but I much prefer the "hitch" by adhesive strips.

If the fracture be higher up, long pieces of adhesive plaster may be used and a firmer hold secured. A roller may be used to envelope the leg after the strips are applied if its compressing influence seems to be necessary, though I am not in favor of a bandage next the skin which may exert a constricting influence.

FIG. 96.



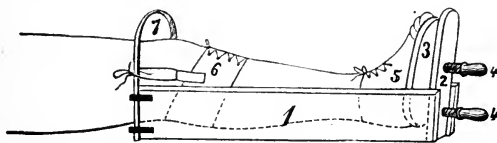
Dressing for the leg, after both bones are broken, in progress of application.

The next step in the dressing consists in applying the retentive apparatus, which may

consist of two wooden side splints, well wrapped; and over these the ends of a many tailed bandage may be lapped to hold them securely in place. Figure 96 shows the dressing in this second stage, with a few of the lower strips lapped across. Two or three encircling ties may be used to retain the splints in place until the full retentive influence of the many tailed bandage is brought to bear. A roller may be used instead of the bandage of strips. I prefer the roller in ordinary simple fractures; and the bandage of strips in compound injuries, for the latter is the easiest to be opened and closed when the wound is examined.

The next step in the dressing is to give the leg the position it is going to occupy, and to apply the extending and counter-extending forces. The double inclined plane apparatus is used by some surgeons to give the limb the flexed position and to secure not only what force there is to be obtained by this attitude, but to apply by means of ties and screws as much in addition as may be demanded. Other surgeons prefer the straight position of the limb, using a fracture box, as it is called, or a contrivance made of boards to reach along the sides of the leg, a bottom piece, a foot piece which is nailed to the bottom and side pieces, and a movable foot piece to which the gaiter, handkerchief, or the side strips of the adhesive application, are tied. If the double inclined plane be used, counter-extension may be left to the weight of the thigh and body, and extension made by lashing the foot to the movable foot-piece of the apparatus, and then drawing it steadily downwards by turning the screws, or by other means employed to accomplish the same object. To describe all the inventions and improvements of this kind introduced to the notice of the profession, would require more space than can be granted in a work of this kind. The accompanying cut represents an apparatus for making extension and counter-extension below the knee. The foot is fastened to the movable foot-piece by means of a gaiter; and the counter-extend-

FIG. 97



1, Side of fracture box; 2, bottom of fracture box; 3, movable foot-piece; 4, wooden screws to adjust foot-piece; 5, gaiter; 6, belt of leather encircling the leg below the knee, for counter-extending force; 7, hooped rod to sustain the force.

ing force is obtained by means of a piece of sole leather which is laced together after encircling the leg just below the knee. Some tapes extend from holes or loops in the upper edge of the leather band, to an iron rod, which is hooped, and has its two ends secured to the upper extremity of the box,—the hoop is made adjustable by means of a couple of wire loops driven into the upper ends of the sides of the box. The same

principle is applied to every apparatus of the kind, though many of these contrivances vary in general characteristics.

It is not necessary to employ a complicated apparatus to treat successfully fractures of both bones of the leg. The extending strips of adhesive plaster may be attached to the foot of the bed, and then counter extension can be produced by elevating the foot posts of the bedstead, as already recommended in the treatment of fractures of the thigh. If this method be adopted a sand bag should be placed under the knee, and other bags may be laid against the outside of the limb to thwart the tendency to eversion. In some instances the leg should be supported between two junk bags in order to take the weight of the limb from the heel which is liable to slough under prolonged though moderate pressure. If the ends of the splints press heavily at their upper or lower extremities, so as to threaten ulceration, cushions of cotton, hair, or wool should be placed under them. The limb must

FIG. 98.



Consolidation of the fragments after fracture of both bones of the leg, showing deformity.

be watched very narrowly, to prevent any morbid action from doing serious mischief. Vesication is a common condition after fractures of the leg; and the bladders of serum that form beneath the dressings, out of sight, may break and degenerate into ulcers and ugly sloughs. If the vesicles are very large and tense, they may be pricked to allow the serum to escape. These blisters commonly dry up in the course of a week or two, and leave no bad effects.

In a fracture of both bones of the leg, especially if the tibia be broken at one point, and the fibula at another, the tendency to overlap on the part of the fragments is considerable, therefore careful and persevering efforts must be made to obviate shortening. The accompanying diagram represents with scrupulous exactness the bones of the leg as found after having been under the treatment of a surgeon of more than ordinary skill and experience. The patient died of visceral disease in five months after receiving the fracture. The limb was three quarters of an inch too short, as may be judged by the

overlapping of the fragments, and there was angular deformity, besides some arising from rotation. The upper fragment of the fibula split, and the wedge shaped broken edge of the lower fragment was forced between the splinters. The injury occurred from indirect violence, the patient in a fall striking upon one foot. The consolidation between the fragments was found to be complete, but the rough points of the badly opposed fragments were little affected by the polishing process which at length makes such irregularities comparatively smooth.

Measurements during treatment should be frequently made to determine whether shortening is taking place. With the body straight, and the legs parallel, a tolerably correct comparison can be made between the lengths of the two limbs. However, it is more satisfactory to measure from the umbilicus or symphysis pubis to the inner malleolus of each ankle. If the patient be a woman the measurement may be made from the patellæ to the malleoli.

When the two limbs are side by side, any deviation of the broken leg, as by rotation, is quickly detected. As a sight is taken up the limb to the body the great toe should be on a line that strikes the inner edge of the patella.

The foot must be watched to see that the heel be not drawn upwards too much by the contracted condition of the sural muscles acting through the tendo-Achillis. When the obliquity of the fracture favors that kind of contraction, as well as a slipping backwards of the foot and whatever of leg is below the break in the bone, the inclination or tendency must be arrested by the dressings and the proper use of sand bags. If a cushion or junk bag be carelessly placed just above the fracture the weight of the leg would tend to displace the foot backwards.

In cases admitting of the leg resting upon its side, that position is favorable to ease and apposition. Some surgeons prefer to dress the leg with the view of having the limb gently flexed and laid upon its side. After fracture of one of the bones of the leg the limb may be placed in any attitude, for no extending apparatus interferes with free movements; but when both bones are broken, and there be danger of overlapping, the limb can not be freed from the machine or apparatus that has to be employed to secure extension.

In some instances it may do to lay aside the ordinary appliances, and to adopt the stiff dressing in their stead. The common starch dressing, when once dry, will obviate the tendency to shorten. However, the limb may shrink after it has been in the immovable dressing for a few days, affording opportunity for lateral displacement and shortening. I never feel satisfied with a starch dressing when both bones are broken. In exceptional cases, where it becomes necessary for the patient to be moved by carriages and railroads before consolidation of the broken bones has taken place, the immovable or stiff dressing should most certainly be employed.

Debilitated, dropsical, and broken down constitutions are exceedingly unfavorable to rapid bony union; and in an occasional instance no consolidation will take place. In 1862 a raftsmen on the river got his leg caught in some lumber and broke both bones in the lower third of the limb. He was taken to the house of Mr. Harrison, of Newport, Ky. I accepted an invitation to take charge of the case, and treated it in the ordinary way. In the course of ten days the limb took on a flabby, dropsical appearance, and presented evidences of defective vitality. At the end of four weeks from the accident, I perceived crepitus between the fragments, and the limb exhibited almost as much mobility at the seat of fracture as at first. The limb was redressed, and the patient who was seriously impaired in health from the excessive use of liquor and exposure, was put upon a stimulating and nourishing diet, and three glasses of ale a day were allowed him. He soon began to improve in general appearance, and the leg which was redressed once a week, showed more firmness and vitality. At the end of the eighth week the limb had stiffened at the point of fracture, very little deformity existing. I now put the leg in a starch dressing, and had the patient begin to take exercise on crutches. In four months from the reception of the injury, the patient walked to my office, using a cane to steady himself. There was no perceptible shortening, though the upper fragment of the tibia projected so it could be plainly felt. The consolidation seemed as perfect as in any case. During the early part of the treatment I was afraid of false joint, but the sequel showed that the case was to be looked upon as representing delayed or tardy reparative action.

FRACTURE OF THE TIBIA SINGLY.

As has been previously stated, a force which breaks the tibia is generally sufficient to snap the fibula also. However, the tibia is sometimes broken singly, the fibula remaining intact. Direct violence, such as the kick of a horse, or a blow from some hard body, may be the cause. James Buckingham, in January, 1864, slipped while stepping from the street to the sidewalk at the corner of Sixth and Elm Streets, and hit his leg five or six inches below the knee against the sharp corner of the curb-stone. He distinctly heard something snap, and immediately experienced great pain in the limb. He was near home and attempted to walk the distance, but the distress occasioned by an effort to use the leg compelled him to sit down. It was before daylight in the morning, and as nobody passed along to help him, he dragged himself home the distance of a square, on his hands and sound hip and leg. In an hour or so after the accident I found the tibia broken a few inches below the knee, and the fibula as sound as ever. The upper fragment projected a little, but there was no perceptible rotation of the leg below, or other deformity.

In 1867, Fritz Gorman, a lad of eight years, was hit by a runaway horse, on Front Street, and received an injury of the leg. I was called to the case, and found a fracture of the tibia three inches above the ankle, with the anterior sharp edge of the upper fragment protruding through the skin. The fibula had escaped fracture. These cases are mentioned, not as possessing any special interest; but to show what kind of forces may break the tibia alone. In the first case the patient said "the weather was so cold there must have been frost in his leg." There is a popular notion that the bones are more fragile when the weather is intensely cold. Probably this is an error founded on the fact that more fractures occur in frosty weather than at other seasons, the sufferers ascribing their misfortunes to osseous fragility and not to the slippery condition of everything frosted, where the real cause should be placed. It is possible that the highly contractile state of the muscles may, in cold weather, increase the frequency of broken limbs; and if it be a fact that intoxicated persons whose muscular system is in a loose, flaccid condition, can receive heavy falls and

enjoy an immunity from fractures, it becomes highly probable that a tense state of the soft tissues favors fracture.

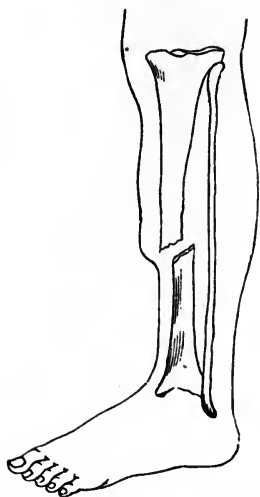
In fracture of the tibia the line of separation may be transverse, oblique, or irregular in its course. Being the result of direct violence in a majority of instances, the transverse variety prevails, especially if the fracture be near the extremities of the bone. I was once called by Dr. Wm. Sherwood, of this city, to see a case in his practice, in which the fracture extended transversely through the tibia within two inches of the knee-joint,—the fibula was not fractured. There was little or no displacement, and consolidation took place in five or six weeks. Direct violence was the cause of the injury. Dr. Van Ingen, for a while in this city, exhibited to me a drawing which he had made to represent an oblique fracture through the upper part of the tibia, the line of separation extending into the knee-joint. He says the case was treated by him successfully near Schenectady, N. Y. His diagram also showed a fracture of the inner condyle of the femur, which was a part of the same accident. It is possible he may have been mistaken in regard to the extent of the injury.

I once took professional charge of a teamster who, in jumping from his wagon to the ground, received a longitudinal fracture of the lower extremity of the tibia. The line of separation began in the articular surface of the lower end of the bone, and terminated two inches above the joint, disengaging a wedge-shaped splinter of bone, including the internal malleolus. The piece united without displacement or deformity, but the function of the joint was restricted by partial ankylosis, lasting a year or more. The patient ultimately recovered the full use of the limb. In fractures of the tibia through the lower third of the bone, the foot, including the leg below the fracture, is liable to exhibit a twist, indicating more distortion than might be expected after a fracture of only one bone of the leg. The twist in the limb is permitted by the length and slender state of the fibula, and its lateral mode of articulation.

The symptoms of fracture of the tibia alone, are quite distinct and easy of recognition, if the solution of continuity be anywhere near the centre of the bone, for the inequality at the line of separation will be felt when the finger is pressed along the spine of the bone; but if the break be near either

extremity, and the direction of the fracture line be transverse, without appreciable displacement, the diagnostic powers of the surgeon may be put severely to the test. The perfect contact of the fragments often prevents crepitation; and the existence of the fracture has to be inferred from the nature of the force applied, the sharp, circumscribed and persistent pain increased by pressure or an attempt to walk, and the local engorgement. If mobility and crepitus can be detected when the fragments are pressed in opposite directions the diagnosis of fracture is made out, but not of the tibia alone; for, the diagnosis is not complete until it is decided that the lesion is limited to the tibia, and that the fibula remains unbroken. When it is known that a fracture of the leg exists it is safe to consider both

FIG. 99.



Fracture of the tibia; the fibula remaining unbroken.

bones broken, until it is positively determined that the fibula is intact. The crepitus elicited may come from a fracture of one bone or both. To determine whether the fibula be broken the bone must be tested its entire length. The finger is to be pressed along its course slowly while the limb is carried backwards and forwards and laterally to develop a point in which there is mobility or inequality.

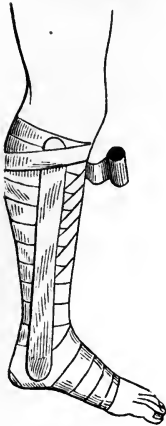bones broken, until it is positively determined that the fibula is intact. The crepitus elicited may come from a fracture of one bone or both. To determine whether the fibula be broken the bone must be tested its entire length. The finger is to be pressed along its course slowly while the limb is carried backwards and forwards and laterally to develop a point in which there is mobility or inequality.

TREATMENT OF FRACTURES OF THE TIBIA.—In most instances a fracture of the tibia alone can be managed with ease and success. The coaptation of the fragments when there is displacement, is generally not a difficult matter. If the projection of the upper fragment forward be considerable, it may require some tact to get it back into place. The influence of an anæsthetic may be employed to overcome muscular rigidity. The tendo-Achillis has been divided to overcome the spasm and contraction of the gastrocnemius and soleus, but such a course is rarely if ever necessary. I have never seen a case that demanded a section of the tendon to assist in reduction.

The twist or rotation which follows a fracture near the ankle is worse to overcome than the angular deformity following fractures of the tibia higher up.

In an ordinary case the limb from the toes to the knee may be enveloped, not tightly, in a common muslin roller to mod-

Fig. 100.



Splints being bound to the leg after fracture of the tibia.

ify swelling, congestion, and muscular action; two lath splints long enough to reach from the knee to the ankle may be laid on the sides of the leg, and bound there by another roller. If there be much tendency to the forward projection of either fragment a third splint may be laid upon the posterior aspect of the leg, and a compress upon the anterior surface of the limb near the fracture, and so placed as to bear upon the projecting piece of bone, though not at its very point. Side splints have been prepared with concavities to fit the form of the leg, and with holes near their lower ends to avoid pressure upon the malleoli. These carved and nicely constructed splints are applied with ease, and they answer an excellent purpose in most instances.

Almost every surgeon has on hand more or less of such appliances for treating fractures. He also keeps ready prepared a supply of rollers, raw cotton, adhesive plaster, and other material for emergencies. Some houses have so few comforts and implements, that the surgeon is greatly troubled to find material from which to construct splints and bandages. And on remarkable occasions, when from a railroad accident, or from the fall of a building, a dozen fractures may need attention at once, ample preparation for the extraordinary occasion redounds to the credit and advantage of the surgical attendants. However, if a practitioner of medicine and surgery be called to treat a fracture, and he be not prepared with the usual appliances, he should be competent to construct extemporaneously such splints and bandages as the necessities of the case demand. Sheets may be torn into strips, sewed together, and wound into rollers; splints can be whittled from lath or shingles, cigar boxes, and thin boards; pillows do for cushions and supports until bags of dry sand can be obtained.

After a fracture of the tibia has been dressed, the limb may be laid in a position favorable to ease and repose. The patient need not be confined to bed, but may lie upon a sofa or lounge. The limb may be flexed, extended, or laid on its side, just as the patient chooses. The fibula prevents shortening, and the splints, bandages, compresses, and other parts of the dressing obviate mobility, rotation, and angular deformity. Lotions shrink the bandages, and favor vesication of the skin, therefore it is generally better to allow the dressings to continue dry. An opiate may be needed to subdue pain during the first few days. The bowels should be moved every two or three days, and the diet, after the first week, ought to be quite nourishing.

The immovable dressing, of starch, or plaster of Paris, is suitable for treating fractures of the tibia. It may be well to keep the limb in an ordinary dressing for a week or ten days, or until the swelling subsides, and then it saves trouble to encase the leg in a stiff dressing, and let the patient go about on crutches. Even with the ordinary dressing the patient can get about on crutches without pain, or danger of mobility at the seat of fracture. However, no weight should be borne on the limb for five or six weeks after the accident. Consolidation to the extent of preventing mobility may take place in four weeks, but the callus is not sufficiently hard in all its parts to obviate deformity under great pressure. There can be no harm in keeping light splints and a bandage applied to the leg for a week or two after the ordinary time for undressing a limb has passed.

After fracture of the tibia extending into the knee-joint, the danger is ankylosis, therefore the limb should be slightly flexed, and placed on a pillow or between two sand bags so arranged as to support the knee and produce some lateral pressure. Lotions may be used for two weeks, then pasteboard, leather, gutta percha, or other pliable splints. In four or five weeks from the accident, passive motion ought to be begun and kept up for months, or until the joint recovers its functions.

In a longitudinal fracture of the lower end of the tibia, including the inner malleolus with the detached fragment, the foot and leg should be bandaged, and great vigilance exercised to prevent any lateral distortion at the ankle. If the

foot incline too much outward or inward, the tendency may be overcome with a properly applied splint, compresses, bandages and sand bags.

FRACTURES OF THE FIBULA.

The fibula being a slender bone, may be broken at any point, especially by direct violence. A smart blow upon the outside of the leg has been known to snap the fibula into fragments. But the most common cause of fracture in this bone is a sudden and violent twist of the foot outwards, which dislocates the ankle and breaks the fibula a few inches above the outer malleolus. The accident often arises from getting the foot caught in a hole or cleft while walking. Sir Astley Cooper fractured his right fibula by falling, after his foot was entangled between two pieces of ice. Booth, in his leap to the stage of the theatre, after shooting President Lincoln, had his foot powerfully deflected by having the spur on his boot catch in a displayed flag, and thereby sustained a fracture of the fibula.

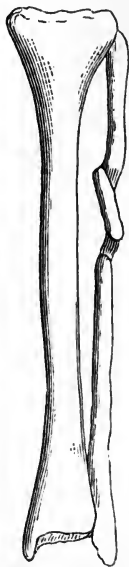
The frequency of fracture of the fibula and dislocation of the ankle from forcible abduction of the foot, is notable. Every experienced surgeon, when called to an injury of the leg at a point near the foot, at once examines the fibula just above the external malleolus, as if he expected to find the bone broken at that point. In fact the lesion is too common to escape the observation of any practitioner of moderate experience.

The office of the fibula is not to take part in supporting the weight of the body, but to strengthen and complete the mechanism of the ankle-joint upon its outside. The bone also serves to give attachments to a large number of muscles, and lends support to the tibia.

A kick, or smart blow of any kind, is enough to produce a fracture of the shaft anywhere between its two extremities. I have treated fracture of the fibula through the upper third of the bone which was caused by the rapid passage of an ordinary buggy wheel; and in another instance the kick of a steer was the cause. In both instances the men were able to walk after the injuries were received, though great pain attended the taking of each step. Considerable tumefaction

occurred at the seat of fracture; and, the upper fragment being driven inwards in both cases, I was able to detect the displacement by pressing the fingers along the course of the bone. The projecting end of the lower fragment stood out distinctly, and could be seen as a salient point, as well as felt. No particular mobility was discovered, but the foot could be

FIG. 101.



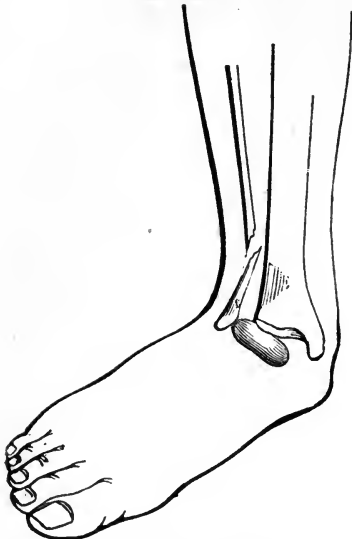Fracture of the fibula through its upper half; showing deflection of the central fragment.

rotated to a greater extent, or through a larger arc, than in the sound leg. Distinct crepitation was not elicited, for the broken surfaces could not be brought in apposition, though manipulation of the limb forced them in contact. The dressing in each case consisted of two padded side splints and a bandage. Both cases recovered without apparent deformity, or defect in the functions of the limbs.

The specimen represented in the accompanying diagram shows a double fracture of the fibula above the middle of the bone, and the central fragment deflected, probably by muscular action, from its normal course. The apposition is far from perfect, yet the reparative action formed an osseous connection between the fragments. The tibia shows no sign of ever having been broken. The double fracture may have been produced by the same kind of violence that would cause a single fracture. There was a slight deformity apparent in that part of the limb before a full dissection revealed the true state of the parts. The history of the case is not known. I have another specimen of the bones of the leg in which the tibia shows the marks of an old fracture three inches above its lower extremity, and the fibula a double fracture at about the junction of the middle and upper thirds, which shows a deflection of the middle fragment much as is seen in the above diagram. Probably both the tibia and fibula were broken at the same time, and by indirect violence. As previously stated, the most frequent fracture of the fibula is that caused by a twist of the ankle, which also ruptures the internal lateral or deltoid ligament,—a strong band that binds the inner malleolus down to the bones of the tarsus. The tibia being thus disengaged from its connection with the inner ankle, becomes

partially dislocated. This complicated injury, from having been particularly described by Mr. Pott, is called "Pott's fracture." His words are as follows: "I have already said, and

FIG. 102.



"Pott's fracture," or dislocation of the astragalus from the tibia, and fracture of the fibula above the ankle joint.

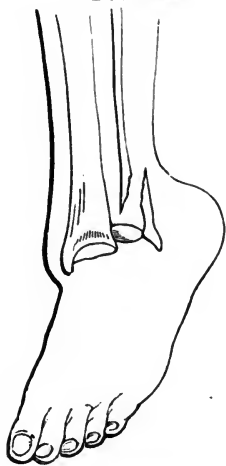
it will obviously appear to every one who has examined it, that the support of the body, and the due and proper use and execution of the office of the ankle, depend almost entirely on the perpendicular bearing of the tibia upon the astragalus, and on its firm connection with the fibula. If either of these be perverted or prevented, so that the former bone is forced from its just and perpendicular position on the astragalus; or if it be separated by violence from its connection with the latter, the joint of the ankle will suffer a partial dislocation internally; which partial dislocation can not happen,

without not only a considerable extension or perhaps laceration of the bursal ligament of the joint, which is lax and weak, but a laceration of those strong tendinous bands, which connect the lower end of the tibia with the astragalus and os calcis, and which constitute in a great measure the ligamentous strength of the joint of the ankle. This is the case, when by leaping or jumping the fibula breaks in the weak part, within two or three inches of its lower extremity."

Strictly in accordance with Pott's description, a simple fracture of the fibula through its lower third, whether by direct violence or other force, does not cover all the lesion he has described. In other words, "Pott's fracture" calls for laceration of the internal lateral ligament, and partial luxation of the tibia, as well as a fracture of the fibula three inches above the lower extremity. I have seen the fibula fractured through its lower third, by direct violence; and the astragalus remained in place, and the deltoid ligament escaped untorn; and I have also treated cases where the description of Pott was applicable

so far as the broken fibula and tibial displacement are concerned, but the inner malleolus was fractured instead of there being a laceration of the ligament which is attached to that process of bone. And in one instance, that of a boy of sixteen who had a splay foot and lax ligaments, the fibula was broken by forcible eversion or rotation of the foot outwards, and the tibial part of the articulation remained intact, as well as the ligamentous structures about the ankle joint. Still further, the fibula has been broken by powerful adduction or inversion of the foot, the bone yielding to the pressure of the astragalus against the external malleolus. Malgaigne affirms that there is no displacement (luxation) nor laceration of ligament, external or internal, when the fracture is caused by extreme adduction; that if any displacement be found it is secondary, being produced by the patient's attempt to walk. However, it must be admitted by every surgeon conversant with fractures, that in a large proportion of cases in which the fibula is broken a few inches above the external malleolus,

FIG. 104.



Fracture of the fibula above the ankle,
and dislocation of the tarsus back-
wards.

the internal lateral ligament is ruptured and the astragalus more or less displaced from its usual junction with the lower end of the tibia. Pott has described a complicated lesion that occurs in more than half of the injuries in which the fibula is broken near its lower extremity.

Fracture of the fibula through its lower third may also be complicated with a dislocation of the tarsus backwards. A person in falling from a height may strike on an inclined surface, or a hard substance that keeps the heel raised; and the force caused by the descent continuing, dislocates the foot backwards, and breaks the fibula a few inches

above the ankle by a lateral or twisting motion. In such an injury the lower fragment of the fibula follows the bones of the tarsus, and abandons all contact with the long fragment. This lesion is analogous to Pott's fracture, the foot being dislocated backwards, instead of outwards. The dislocation, in

both cases, is the leading feature of the injury. The foot, however, can be quickly replaced, while it requires several weeks' treatment to secure union between the fragments of the fibula.

The symptoms of what is called "Pott's fracture" are quite marked; yet the patient, as soon as the injury is received, often reaches down and twists the foot back into place, thereby overcoming those prominent signs which so clearly indicate the nature and extent of this complicated lesion. After the foot has been replaced the limb appears so natural in contour that the inexperienced practitioner may be led to suppose that no serious injury exists. I was once called to see Mr. Homan, printer, living then on Elizabeth Street, who had received a severe twist of the foot by having it caught in a crevice of the sidewalk. He suffered so much pain that he hired a passing hackman to carry him home. A physician of considerable surgical acquirements was called; but before he arrived the patient with his hand had overcome the distortion in his foot. The doctor examined the ankle, and pronounced the difficulty a sprain; he visited his patient every day for about a week, and ordered a lotion which was prescribed at his first visit, to be continued. Mr. Homan becoming dissatisfied with the progress of the cure, discharged his medical attendant, and invited me to take professional charge of the case. According to my usual custom when called to an injury of the ankle, I carefully hunted for fracture of the fibula just above the ankle. There was much swelling about the joint; and it was apparent when the two limbs were compared, that the injured leg presented a little greater concavity on its outside, above the ankle, than the other. The fingers in being pressed along the course of the fibula discovered at the point of preternatural concavity, a slight irregularity in the bone. Lateral rocking of the foot produced great pain, and caused crepitus. The forced rocking of the foot also developed mobility between the fragments, which the finger held upon the suspected point readily discovered. The foot could be rocked outward in a greater degree than is natural; and when once displaced in that direction it was inclined to stay in that position.

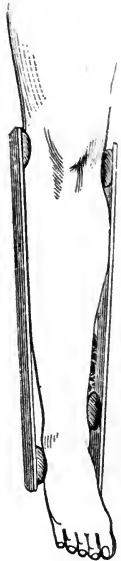In an ordinary case of Pott's fracture, the patient not having returned the foot to its normal position, the deformity will

appear like a dislocation of the foot outwards, though such an injury can not exist without fracture of the fibula. The pain and swelling are noteworthy signs, though not sufficiently distinctive in their character to establish a diagnosis. The fractured ends of the fibula will be driven or held in against the tibia, making a depression at the point of fracture. Persons having bad shaped feet, with a great concavity a little above the ankle, on the outside of the leg, and with the external malleolus projecting outward, giving great width to the articulation, are prone to have such lax deltoid ligaments that the foot can hardly be kept in place even when no fracture exists. A weak ankle of that kind makes a bad recovery after "Pott's fracture;" and the result is far from satisfactory even when good treatment is followed.

TREATMENT OF FRACTURES OF THE FIBULA.—A fracture of the fibula, not connected with dislocation of the foot, may be treated with a common lath splint laid along the outside of the leg, and a bandage to retain it in place. No shortening of the limb can occur, nor serious displacement of any kind, for the tibia is the chief bone in maintaining the stability of the leg. A patient with a fractured fibula above the lower third of the bone, can walk after the limb is dressed with a splint and bandage. However, it is always best not to use the leg except with the greatest care, and with the aid of a cane. The fragments need to be kept quietly in apposition in order that the union may be osseous.

Pott's fracture needs a skillfully applied dressing. After the reduction, which consists in twisting the foot into its natural shape, the leg may have applied to its inner and outer sides a couple of lath splints, two inches or more wide, and long enough to extend from near the knee to the sole of the foot. Under the lower end of the outside splint a firm compress is to be used to force or rock the foot inwards when the roller is made to perform its part of the work. The outside splint bridges

FIG. 104.

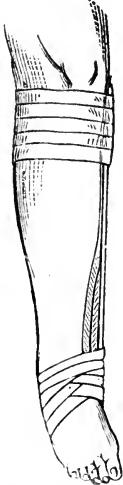

Splints and compresses ready for ties and bandages, to constitute a dressing for "Pott's fracture."

over the depression which exists where the broken ends of the fibula are, and prevents the turns of the circular bandage from dropping into it; and the pressure brought to bear upon the very lowest point of the external malleolus tends to force the broken end of the lower fragment away from the tibia and into its proper position. After the dressing is applied the patient may walk on crutches, using the maimed limb with care. In four or five weeks, consolidation may be expected to take place. The limb need not be undressed often during the treatment, for the fracture generally does well if properly treated in the beginning. No leeches or fomentations can be of much service, and they may do serious harm. Great pain may attend the injury for the first few days, yet an elevated position of the leg, and an easily fitting appliance favor a state of comfort and repose. An opiate given twice a day while the inflammation continues, keeps the patient from complaining. Any large blisters charged with serum may be pricked, and excoriated parts kept from pressure.

The dressing devised by Dupuytren, in his own language, "consists of a cushion, a splint, and two bandages. The cushion, made of cloth, and filled two-thirds with chaff, should be two feet and a half in length, by four or five inches in width, and three or four thick. The splint, from eighteen to twenty inches in length, two inches and a half wide, and three or four lines thick, should be made of firm and slightly flexible wood. Lastly, the bandage should be four or five yards in length. The cushion, folded upon itself in the form of a wedge, is applied to the inner side of the fractured limb, and laid upon the tibia, its base directed downwards, being applied upon the internal malleolus, not passing below it; its apex being above and upon the internal condyle of the femur. The splint applied along this cushion should pass below it, from four to six inches, and extend below the inner edge of the foot for three or four inches. These first pieces of the apparatus are fixed to the upper part of the leg, by a few turns of bandage directed from above downwards; in this state the splint, pro-

FIG. 105.



Dupuytren's folded cushion, splint and bandages for treating Pott's fracture of the fibula.

longed like a kind of lever below the base of the cushion, leaves between it and the foot a space equal to the thickness of the cushion, that is to say, from three to four inches. This extremity of the splint will serve as a 'point d'appui,' to bring the foot from without inwards. For this purpose the end of a second bandage is fixed to it, and then directed successively from the splint over the upper surface of the foot, upon its outer side, under the sole of the foot, upon the splint; then from this upon the instep and under the heel, to return again to the splint, and to be continued in the same manner until all the bandage is used; thus embracing in the same circles, which can be tightened at pleasure, the splint and the instep, and the splint and the heel alternately. The foot is brought into such a state of adduction that its external edge becomes inferior, the sole of the foot directed inwards, and its internal edge upwards."

It will be seen by the diagram, and be understood by the description, that the dressing of Dupuytren will accomplish the object for which it is designed. The splint is a lever, the pad a fulcrum, and the bandage through the power imparted to it, is the force to draw the foot inwards; and the action of the lower turns of the roller in drawing the lower end of the external malleolus inwards, necessarily tilts the broken end outwards, or away from the tibia, the space in the vicinity of the fracture being purposely left bare or uncompressed. So the broken ends, whether locked against one another or not, may be left unobstructed to return to their normal position.

I prefer using two splints, for they stay in place better than one, and constitute an even and firm dressing for the leg and ankle joint; in Dupuytren's dressing his upper bandage constricts the leg near the knee, and tends to press the lower end of the long fragment into the interosseous space. In the dressing I have recommended, a compress is used below the external malleolus, large enough to keep the outside splint from bearing on the malleolus itself; and another compress on the inner ankle to keep the inside splint from pressing on the internal malleolus, and to allow the foot to be rocked inwards without hitting the splint. There is no necessity for canting the foot too far inwards; an excess of inversion is not desirable.

In cases where no displacement is perceptible I dress the ankle with pieces of pasteboard and a bandage, to strengthen the weakened parts, so the patient may hobble about with the aid of a cane or crutch. I have seen very good recoveries made without any dressing.

If a patient recover from Pott's fracture, with a weak ankle, he can derive some benefit from a shoe with side irons fastened to it, such as is worn to correct weak ankles from other causes. Even a stiff boot or brogan lends some aid.

In the case of Harry Edwards, who in a leap from the cars in motion near Brighton Station, broke both bones of one leg, and the fibula a little above the ankle joint in the other, I used two strips of adhesive plaster an inch wide and fourteen inches long, to treat the latter fracture. One end of each strip was applied to the outside of the foot and ankle; and then the two strips were drawn under the heel and sole, and while the foot was twisted inwards, the other ends of the adhesive plaster were applied to the leg on its inner aspect. These strips prevented the foot from becoming everted; and as the patient had to be confined to his bed for several weeks on account of the fractures in the other leg, the broken fibula consolidated long before the other leg was well. The adhesive strips accomplished every purpose sought in a more complicated dressing.

Potts' fracture is exceedingly common, therefore the inexperienced practitioner should study its every phase. As much may be said of all fractures, yet the most frequent lesions are those the young physician should study first. As soon as a medical man has had a few fractures of the leg to treat, he studies such injuries all the closer, for he sees how important the simplest features become. Besides, he finds that good results are only obtained by thoughtful attention. There is no such thing as good fortune in the treatment of fractures of the leg. Every tendency is to deformity of some kind, therefore each defect and distortion is to be provided against at repeated dressing. In the management of such lesions, the surgeon can not afford to be careless or in a hurry. The patient's comfort and the reputation of the medical attendant hinge upon the application of sound sense to every part of the dressings.

CHAPTER XXVIII.

FRACTURE OF THE BONES OF THE FOOT.

The anatomical resemblance between the hand and foot, necessitates a similarity in the nature of the injuries peculiar to both. The tarsal bones are cuboid in shape, and contain a large proportion of spongy material; therefore they are subject to fracture from direct violence alone. The nature of the force producing a fracture of one of these bones must be of a crushing character, consequently the injury done to the soft parts will constitute the leading feature of the lesion. The os calcis partakes, to a certain extent, of the character of a long bone. At any rate, its projection backwards forms the arm of a lever which is acted upon by the powerful muscles of the calf of the leg, and may be fractured by them. The carpus has no bone which, from its shape, is subject to great muscular power. The astragalus, situated so as to receive the entire articulation of the lower end of the tibia, is necessarily subjected to immense forces, and occasionally crumbles under their influence. These two bones, then, may be broken by indirect violence, but the cuboid, scaphoid and three cuneiform bones can only be broken by the fall of a heavy weight upon them or by the passage of a wheel over that part of the foot which they occupy. The fracture can hardly be simple under these circumstances, for the force must bruise the soft parts practically to the extent of rendering the fracture compound.

The os calcis in a heavy person, who raises himself quickly upon the toes, is subjected to a powerful force, though the tendo Achillis is more likely to break than the bone. Either accident must be extremely rare, for few surgeons have ever met with a case. The projection of the os calcis posteriorly exposes the bone to direct violence. A miller of my acquaintance had his right os calcis broken by the end of a crowbar

which was violently hurled by the fall of a log from a wagon. He wore a low cut shoe, but it did not prevent the bar from inflicting upon the heel a telling blow.

The astragalus is broken by a thrust of the tibia against it ; as when a person jumps from a height and comes to the ground with the tibia placed vertically on the astragalus, the shock being sufficient to split or crush the bone. Mr. Lousdale reports a case of the kind coming under his observation : " The patient was treated for a severe sprain, there being no reason to suspect fracture ; the inflammation of the joint, however, was so great, and the man's constitution became so much affected, that the patient died on the twelfth day. The case was considered peculiar, from the severity of the symptoms ; on opening the joint, however, after death, the astragalus was found to be split, in two or three directions, which fully accounted for the constitutional disturbance, and for the other serious defects produced by it." An isolated fragment of the astragalus could not well escape from the joint without such serious disorganization as to endanger the articulation, to say nothing of perils to life.

In fractures of the os calcis, the strong plantar fascia prevents the disengaged fragment from being drawn far upwards by the gastrocnemius and soleus muscles, though surgical writers speak about the separated piece being drawn upwards several inches. In the case of Mr. Conklin, the miller, whose heel bone was broken by the iron bar, there was no marked separation of fragments, but the fullness in what is termed the hollow of the foot, was marked, and the heel seemed to be elongated. Manipulation discovered mobility and crepitus. The pain and swelling were considerable, though the patient claimed that the contusion produced by the missile, was the chief cause of the distress. The inability to walk was manifest as soon as an effort was made to take a step.

The treatment adopted in that case may be applicable in all similar cases. While the foot was moderately extended it was encased in strips of adhesive plaster until every part was covered in ; then two long strips were attached to the top of the instep by their lower ends, and then extended down on each side of the foot to the sole where they crossed each other and came up on each side of the heel and so on to the calf of the leg where they were made to adhere. These kept

the foot in a state of extension. The knee was flexed over pillows, and the limb was kept in a state of comparative repose for several weeks. The consolidation was complete, though the functions of the foot remained somewhat impaired. The point of the heel appeared to be raised a half inch or so.

The kind of apparatus commonly recommended is a slipper-like toe-piece nailed to a wooden sole or foot-board as a base for the application of mechanical forces; a pad is placed just above the heel, which has a long strap attached to it; this is first carried down through a ring in the wooden sole, through which it acts like the cord of a pulley, and then extends above the calf of the leg where it is confined by the circular turns of a bandage. The appliance is not equal in merit to the adhesive strip contrivance just described.

Fractures of the other tarsal bones admit of no apparatus to overcome displacement, and to prevent mobility; but the injury is to be treated like other severe injuries of the foot, no special regard being paid to the fragmentary state of one or more of the bones. The inflammation and suppuration are to be managed on the general principles involved in the treatment of wounds. Amputation is required sooner or later in some of the worst cases, though a laying open of the foot and the removal of isolated and carious fragments may save life and a more or less useful foot.


The metatarsal bones are less exposed and more exempt from fractures than the corresponding bones in the hand. The forces which break the metatarsal bones are the passage of a wheel, and the fall of heavy weights. Hermann Frieling, while removing a safe on Third Street, had his foot caught between the side of the safe and the door post, and received a fracture of the three outer metatarsal bones. He was carried home, and the boot was cut from his foot before I saw him. Swelling and discoloration marked the line where the sharp corner of the safe had pinched his foot. Crepitation was elicited by manipulation; there was no displacement discoverable. I placed a compress on the sole against the seat of injury and bandaged the foot. In ten days he walked upon his heel, with the assistance of a cane; and entirely recovered, without deformity or defect, in five or six weeks from the reception of the injury.

The fragments, after fracture of the metatarsal bones, are liable to project upwards, though the direction they take depends somewhat upon the force which produced the injury. If the healing process takes place with the ends of the fragments projecting upwards, the salient points are constant sources of irritation from the pressure of the boot or shoe; and if they sink downwards, so as to produce a prominence on the sole of the foot, the defect is still worse, for the points pressed upon in walking will be constantly tender. The phalanges of the toes are seldom broken. The first phalanx of the great toe is fractured more frequently than the bones of all the other toes taken together. The fall of a heavy weight upon the great toe, or direct violence quickly applied, is generally the cause of fracture of this digit. The other toes are so small and yielding that they commonly escape fracture though the great toe be caught and broken.

The signs of fracture in the first phalanx of the great toe are sufficiently marked for ready recognition. The displacement is generally inconsiderable, but mobility and crepitus can be elicited.

The treatment for fracture of the great toe consists in binding a splint to its under surface, and keeping the foot at rest during the period of reparation. Lonsdale says that fractures of the great toe are attended with great irritation, which affects the absorbents all the way to the groin, causing abscesses to form in different parts of the limb, and producing great constitutional disturbance. Probably these complications arise from the contusion which is apt to be severe when a toe is broken. Bruises of the great toe, if followed by deep suppuration, are attended with constitutional disturbances whether the phalanges be broken or not.

PART II.
DISLOCATIONS.



DISLOCATIONS.

CHAPTER I.

GENERAL CONSIDERATIONS.

The term Dislocation, or luxation, is employed to signify the sudden and forcible separation of the articular surfaces of two or more bones. The displacement is commonly caused by accidental violence, and is generally attended with laceration of the surrounding ligamentous and connective tissues.

Dislocations are injuries of frequent occurrence, and, if allowed to remain unreduced, they constitute a serious and lasting class of deformities; consequently the practitioner of medicine and surgery, who holds himself in readiness to assume the responsibilities of such lesions must give the subject of luxations a vast amount of careful study, or he will inflict permanent lameness upon those so unfortunate as to call for his services. Almost all physicians are ambitious to attend to surgical cases on account of the *eclat* arising from a quickly performed operation; but in order to accomplish satisfactorily all their laudable aspirations may crave, intense thought must be given to the mechanism and pathology of the joints. There is no such anomaly as a "natural bone setter," any more than there is a natural engineer or watch repairer. A man may have a love for the principles involved in nicely constructed machinery, and a desire to become a practical machinist,—a love and desire which constitute genius, but the possessor is not a finished artisan until he can practically apply the principles of the art or science—an attainment which is the result of prolonged study and persevering toil; a young man may feel an intense longing to master a ship, and study navigation for that purpose, which is a pre-

requisite to success, but he will never find the capitalist who will entrust a valuable cargo to his care until he has crossed the seas and learned the winds and the seasons, the currents and counter-currents of the ocean, and something of the varied influences known only to the practical navigator. Any claims for natural gifts in navigation would be treated with contempt.

A few individuals have gotten the credit of being natural bone setters, but their merits, so far as they go, depend more upon tact than skill; and the prevailing credulity of the people has given them more reputation for ability than might reasonably be expected from their limited success. A family by the name of Whitworth, in England, and another by the name of Sweet, in Connecticut, have assumed to possess these wonderful inborn qualities. For two or three generations, one or more of the male members of these families claimed to possess a secret power for reducing dislocated bones; and not a few persons of average intelligence give credence to these preposterous assumptions. Any uneducated man with a large endowment of boldness and self assurance, claiming to be a natural bone setter, could by giving every distorted joint coming in his way, a severe pulling and twisting, accomplish some cures; the successes would be heralded far and near, and the failures would pass unmentioned and unremembered, consequently he would soon gain considerable experience in handling defective joints, and if he proved to be a good learner he would acquire considerable skill in his pretended art. Having received no lessons in anatomy and surgery, success even in a single case would be accepted by the popular mind as positive evidence of innate powers. Love of the marvellous is so infatuating that every age will have to endure its quota of imposters. However, it is not to be denied that these charlatans have done some good indirectly. The fact that a dislocated bone could be reduced by manipulation, without the aid of pulleys and other instruments for multiplying force, led such discreet surgeons as Dr. Nathan Smith, to put the manipulating plan into successful practice.*

The Whitworths, Sweets, and others of their order, studiously keep to themselves their plan of operating, though

*See "Surgical Memoirs of Dr. Nathan Smith," by his son, Dr. Nathan R. Smith, of Baltimore.

competent observers declare that it is not essentially different from the plan now followed by the most intelligent portion of the profession. Being aware of their general incompetency in surgical science, these "natural bone setters" preferred to keep secret the little knowledge they possessed, hoping to retain this meagre advantage over those who in every other respect were their superiors. Probably a similar feeling actuated the Chamberlains to keep as a secret in their family a knowledge of the obstetric forcep. Such detested selfishness, by a law as unvarying as that of gravitation, will taint the name of those who in any branch of the healing art, withhold knowledge which accident or genius has placed within their power. Anything in medicine or surgery which will benefit our fellow men ought to be the common property of mankind; and he possesses a sordid spirit who from selfish motives will not promulgate a secret which will ameliorate the condition of the unfortunate. The dabbler in secrets is, by the common consent of all good men, branded indelibly with the disgrace that cleaves to the quack and the charlatan.

The manipulating plan of reducing dislocations is now well understood by those having a knowledge of the anatomy of the joints, and of the muscles, ligaments, and other structures involved in a luxation.

The use of anæsthetics in overcoming the rigidity of dislocated limbs, has also contributed to overthrow the old method of replacing a displaced bone by mechanical violence. In the present advanced stage of knowledge pertaining to dislocations there is little use for the pulleys, straps, hooks, and other appliances so indispensable a half century ago; and it is to be hoped that knowledge will still further advance, so that these contrivances shall be looked upon more as objects of curiosity and implements of torture than as the appliances of an enlightened profession; and that the cruelties practiced with them will be associated with those of the old Spanish Inquisitions.

It seems a pity that somebody before Dr. Nathan Smith's time did not take a hint from the Whitworths or Sweets, and study out and put in practice a principle of reduction in dislocations which was demonstrated by those charlatans to have an existence. Perhaps the spirit of the profession was too arrogant to receive suggestions from such a source. Unfortunately for the world, good ideas are often kept from seeing

the light on account of the illiberality of the influential classes.

The joints are generally encased in capsular ligaments; at some point there may be a thickening and a strengthening of the ligamentous tissues, and this augmentation may receive the designation of a distinct band of fibers, yet these several ligaments, as the anterior, posterior, and internal and external lateral, generally go to make up one continuous structure which encloses the entire articulation. In nearly all instances of dislocation this ligamentous bag or capsule is torn by the force that displaces the bone; in rare cases the ligament stretches sufficiently to allow the bone to remain partially displaced. The bone, after it has been forced through a rent in the capsule, is often dragged away from the opening, or so twisted by muscular contraction that it is no longer in a favorable position to return through the laceration. This is particularly the case with the shoulder and hip joints. But if the limb be carried to the attitude it was forcibly made to assume when the head of the bone escaped from the socket, the part protruding through the capsule will be in a favorable position to return. In attempts to reduce dislocations of the hip and shoulder the surgeon must seek to get the limb into that attitude; and if he succeeds, very little force will be required to complete the reduction. Direct violence rarely knocks a bone out of place; dislocations are generally produced by forces acting upon the displaced bone as a lever, some portion of the articular structures performing the part of a fulcrum. Muscular force assists in producing dislocations, and the power continuing prevents the return of the bone to its normal position. However, the antagonistic muscles, if given an opportunity to act advantageously, assist in all rational attempts at reduction. A proper appreciation of the construction of joints, and of the functions of muscles and other tissues surrounding them, has created a revolution in the art of reducing luxations. In the "Surgical Observations" of Dr. J. Mason Warren, page 354, the revolution is acknowledged to the following extent: "The use of ether has made a very great change in the practice pursued in the treatment of dislocations of the hip, which can now be very frequently reduced by normal assistance only, thus enabling us, in many cases, to dispense entirely with pulleys; and, by

successive movements of flexion, abduction, and rotation, to restore the head of the bone to its socket with remarkable facility." This is an acknowledgment from high authority in regard to a joint which, when dislocated, once called for extending apparatus of the most powerful kind. Dr. W. W. Reid, of Rochester, N. Y., who has written out an exceedingly clear plan for reducing dislocations of the femur by manipulation, says, in concluding his paper on the subject: "Dislocation of the hip on the *dorsum illi*, an accident so serious to the patient, and so formidable to all surgeons, is reduced with the greatest ease, in a few minutes, without much pain, without an assistant, without pulleys, without 'Jarvis' Adjuster,' or any other mechanical means, simply by flexing the leg upon the thigh, carrying the thigh over the sound one, upward over the pelvis, as high as the umbilicus, and then by abducting and rotating it." Dr. Reid has succeeded in reducing dislocations of the femur in several instances by the "natural plan," and therefore does not speak from a theoretical point of view alone. The plan has been carried into successful operation by a great number of surgeons, and always without failure when Dr. Reid's rules were followed. Jarvis' Adjuster, once so popular that the inventor could hardly fill orders as fast as they were given, has gone almost entirely out of use, and young surgeons rarely indulge in the expense of a set of pulleys. In my own practice I have found no case of recent dislocation that could not readily be reduced by manipulation, under chloroform. Our older works on dislocations, from Cooper to Hamilton, have a great display of illustrations to show how the pulleys should be applied in efforts to reduce luxations of the hip and shoulder, yet there is rarely, if ever, a necessity for following those directions. Perhaps the publishers of modern surgical works, whose illustrations belong mostly to the past, have been ambitious to make a numerical display of cuts, caring little whether they contributed to perpetuate a fundamental error in practice or not. Dr. Reid, in his essay, read at the annual meeting of the Monroe County Medical Society, in May, 1850, says, "Having witnessed, on several occasions, the *inquisitorial torture* inflicted upon the unfortunate patients—their screeching—their piteous begging to be released—the slipping of bandages—the yielding and re-adjusting of fixtures—the delay—the duration of

the operation, sometimes two or three hours,—the exhaustion of the patient, and after all, in some instances, a failure, and the patient a cripple for life, a profound horror and prejudice against the use of pulleys seized me (Jarvis' Adjuster had not then been invented), and I could not avoid the conviction that a great power was unnecessary, and that it must be misapplied. Preceptors, professors and authors were interrogated. The unanimous reply to all my queries was—'to overcome the contraction of the great muscles, which drew up and shortened the limb, viz., the glutei, triceps femoris, the iliacus internus and psoas magnus.' But do these same powerful muscles contract, and shorten the limb when there is fracture in the neck of the femur? Yes. And you tell me that one of the diagnostic symptoms between fracture and dislocation on the dorsum is, that in fracture the limb can be easily extended to its normal length, by the strength of one man, while in luxation it can not. Now why do these great muscles require so much more force to overcome them in one case than in the other? To this I could get no satisfactory or even plausible reply."

It will be seen that Dr. Reid looks upon the mechanical method of reducing dislocations of the hip as senseless in the extreme; and indicates a physiological plan which consists in giving the limb an attitude which relaxes the muscles, and places the bone in a position favorable to a return through the laceration in the capsule. To pull the limb straight downwards, as is done by mechanical appliances, renders some of the muscles rigidly tense, and constricts the neck of the bone with the untorn portion of the capsular ligament.

Every joint not being ball and socket, like the shoulder and hip, the same kind of manipulation will not succeed with them when dislocated, yet the principle of placing a bone in the exact attitude in which displacement was effected, is the position favorable to reduction. For instance, the first phalanx of the thumb is dislocated backwards by a force which throws it into extreme flexion, the bone being a lever to tear the capsular ligament, and the muscles a secondary force to draw it back after the usual points of resistance are overcome. The bone having been dislocated while in extreme flexion, returns to nearly its normal attitude as soon as the flexing force is removed, for the projecting articular rim has dropped into

a depression behind the head of the metacarpal bone. Now, to make extension straight forward would not effect reduction unless the force be great enough to rupture the yet untorn portion of the ligament which is rendered tense by the displacement of the phalanx. But if the thumb be carried into extreme flexion, where it was when luxation took place, the projecting rim is lifted from the depression spoken of, the untorn portion of the ligament is relaxed, and everything is made ready for the reducing manœuvre, which consists in the operator placing his thumb firmly behind the displaced phalanx where it is to perform the part of a fulcrum, while the dislocated thumb is used as a lever to pry the displaced bone into its normal position.

In the upper extremity the bone nearest the trunk is regarded by all authors as the one from which the distal bone is dislocated; for instance, the humerus is dislocated from the scapula, the radius and ulna from the humerus, and so on, but in the lower extremity the rule is not maintained by all; the femur is regarded as dislocated from the acetabulum, and the tibia from the femur, but several authors have changed the rule so far as the tibio-tarsal articulation is concerned. Cooper, Malgaigne, Hamilton, Gross, and others, regard dislocations of the ankle as displacements of the tibia forwards, backwards, etc. On the contrary, many prominent French, English, and German surgeons, adhere to the rule as applied to other joints, and speak of dislocations of the foot when the luxation is at the ankle.

There seems to be no valid reason for this exception to a rule that ought to be general; and it would have been creditable in Hamilton, Gross, and other American surgical writers, if they had lent their great influence toward correcting this manifest error in the manner of considering the subject.

Dislocations need to be considered in a variety of aspects; they have been divided into congenital and traumatic as general classes; and subdivided into the simple, compound, complicated, partial, complete, recent, ancient, primitive, and consecutive.

Congenital dislocation is a lesion intimately connected with malformations and defects of childhood, and does not legitimately belong to that great class of accidents ordinarily embraced under the head of luxations. Robert Smith, of

Dublin, reports a case of congenital dislocation of the jaw, in an idiot, and states that the upper jaw projected beyond the lower, and the mouth could be freely opened and closed; the reverse order of signs is observed in accidental luxations of that bone. Certain dislocations of the shoulder seen in young subjects are occasionally not complete luxations, but partial displacements arising from paralysis or irregular muscular contractions. Dupuytren looked upon these defects of the shoulder-joint as the result of arrested development in the bones constituting the articulation, the socket being mostly at fault. Chelius and Cruveilhier ascribe them to the position of the fœtus in the womb. Guerin considers them as the product of an active or primary retraction of the muscles, the remote cause of which is to be sought in the affection of some central part of the nervous system; and that they result from the same causes as club-foot, wry-neck, etc. I have seen a partial dislocation of the head of the radius, congenital in character, in a bright little girl having no other defects, excepting that one. The entire elbow joint was considerably involved in the imperfect development which permitted the luxation. By the fifteenth year the arm so far recovered, without treatment, that the limb was as useful as the other, and no apparent deformity existed.

Robert Smith reports several congenital dislocations of the wrist, in which there was defective development of the arm bones, and distortions of the carpus. His observations were founded upon dissections; and he criticises the speculations of Dupuytren and Cruveilhier in regard to cases of theirs which they regarded as the result of epiphyseal injury. A certain preternatural laxity of the soft tissues, brought about in some instances by nervous disorders and faulty nutrition is found in these cases of congenital luxations of the wrist, as well as of some of the other joints; and a large share of which will improve by growth and age. Some of these cases are not true dislocations, but partial luxations arising from extreme flexion and extension.

Congenital dislocations of the femur are occasionally met in defective organizations, or as Cruveilhier says, *vices de conformation*. He found in one case, in connection with club-feet and club-hands, a congenital luxation of both thigh bones; the fœtus died at birth, and was found to be without kidneys.

and testes, and marked with other deficiencies; the heads of the thigh bones were flattened, and the cotyloid cavities were shallow.

Dr. J. M. Carnochan, who has given considerable attention to infantile deficiencies, says that "Congenital defects occurring in the ilio-femoral articulation result from active morbid muscular retraction; that morbid muscular retraction itself is to be traced to a morbid condition of the central ganglionic mass of the cord; and this pathological condition is either located in the ganglionic mass, or conveyed thither by the incident-excitor nervous influence of the excito-motor apparatus of the medulla spinalis." This is not given with Prof. Carnochan's usual perspicuity.

The gait in congenital dislocation of the thigh on both sides, is peculiar and unmistakable; no other motion is like that which is occasioned by this lesion: it is a rolling motion of the trunk together with double lameness; and yet it is painless and rapid. In some instances the nervous defect is so great that the individual is compelled to move about in a go-cart, being unable to balance the body and move the limbs with any degree of certainty.

Congenital dislocations of the knee are generally sub-luxations resulting from abnormal muscular contractions; and, to be substantially benefited, require subcutaneous section of the ham-string tendons, and mechanical extension of the limbs.

Partial dislocation of the ankle, as a congenital defect, is a species of "weak-ankle," the ligamentous and fibrous tissues being too lax or undeveloped to sustain the lateral strain necessary to a firm joint. The foot seems to be affected with a variety of talipes, and flaps about with much uncertainty. A shoe with side irons extending up the leg, and fastened to the limb with a hoop and strap, affords some relief, and assists in a cure or substantial improvement.

Congenital dislocations, from what has just been said of them, are to be looked upon as the result of arrested or perverted development, and are not, except in rare instances, to be treated by a process of rapid reduction, like those luxations that occur suddenly from accident.

Traumatic dislocations are the forcible separation of the articular surfaces of two or more bones, in which the loss of power is instantaneous, and the luxated part is excessively

rigid. The names of the varieties have already been given. A *simple* luxation is unaccompanied with serious complications, though there is generally a rupture of the ligamentous structures. It may be caused by external violence, and muscular contraction. The humerus is often dislocated by the action of the muscles only. A convulsive condition has been known to produce dislocation of several of the joints. The term *compound* is applied to a dislocation, in connection with which the displaced bone is forced through the flesh and skin, or an opening is made in some other way, communicating with the cavity of the articulation.

A *complicated* dislocation is one in which there is a more extensive lesion than simple displacement or separation of articular surfaces: the term implies that the soft parts have been extensively lacerated, including nerves and blood vessels; or that a fracture has been produced in connection with the dislocation.

A *partial* luxation is one in which the articular surfaces are not wholly removed from one another, though the function of motion in the joint is temporarily arrested by the displacement. In such dislocations the ligamentous surroundings are not necessarily torn, the fibrous structures being sufficiently elastic to admit of the disjunction. The injury is somewhat rare; probably such displacements are occasionally reduced without the medical attendant fully understanding whether the luxation was incomplete or not.

In a *complete* dislocation the displaced bone is forced entirely clear of the other so far as corresponding articular surfaces are concerned, and finds lodgment in a new position, generally near the old situation, as when the head of the luxated femur rests against the border of the acetabulum. In a complete dislocation the capsular ligament is necessarily torn, and the head of the luxated bone escapes through the rent.

A *recent* dislocation is one that has not existed many weeks; in fact, a luxation of some joints is old at the end of a week, for it is not time alone that renders a dislocation old in a surgical sense. If such changes have taken place in the structures about the joint as to render reduction unsafe or impracticable, the dislocation is practically old though it have existed only a few days. A dislocation, then, may be considered recent, if it can be reduced without danger of rupturing im-

portant nerves, blood-vessels, and other structures which have become changed in their conditions by inflammatory action, or rendered unfit to assume their normal relations.

An old or *ancient* dislocation is one in which such changes have taken place in and about the joint as to render attempts at reduction unsafe and uncertain. It is not uncommon to meet with luxations which have escaped detection or passed unreduced for several weeks or even months; and the question arises whether an attempt to overcome the displacement is justifiable. The humerus has been replaced after being out six months and more, but to reduce a luxated elbow that had been out six weeks, would be to inflict an amount of injury that might result in death. Since the introduction of chloroform into surgical practice, well directed attempts at reduction of ancient dislocations have not been attended with those serious injuries that were wont to occur, and the efforts have been rewarded with far more successful results. By the manipulating plan the displaced bone is not so liable to be fractured, nor is the danger of rupturing blood vessels so great, as when no anæsthetic was used, and pulleys and other instruments for multiplying force were generally employed.

A dislocated bone generally remains in the place it originally took when luxation occurred; it may then be called a *primitive* dislocation, as distinguished from a luxation in which the displaced bone is made to abandon its original position and take up with another, which is called a *consecutive* dislocation. For instance, a man may have a dislocation of the shoulder, the head of the humerus being forced beneath the coracoid process; and in going home or in being removed from one place to another, the bone may get forced inside the process and be drawn up against the clavicle: the former would be a primitive, and the latter might be considered a consecutive dislocation.

Joints which admit the most extensive range of motion, as the ball and socket,—the shoulder and the hip—are the most frequently dislocated; the ginglymoid, as the knee and elbow—being more restricted in their motions, rarely get displaced. According to the tables of Malgaigne, the shoulder is dislocated oftener than all the other joints in the body. The hip has a deeper socket, and is not so much exposed to displacing forces as the shoulder. The vertebræ are so firmly bound in

place by ligaments, and prevented from displacement by complicated processes, that they seldom suffer luxation.

There are few physicians of ten years' experience but have met with dislocation of the shoulder; yet they may not have seen a luxation of any other joint. I once asked an old surgeon of extensive experience to give me a list of the dislocations he had been called upon to treat; and this is his report: Dislocation of the inferior maxillary, 2; of the cervical vertebrae, 1; of the clavicle, 2; of the humerus, 11; of the radius, 3; of the thumb, 3; of the fingers, 2; of the femur, 2; of the patella, 2; of the tibio-tarsal articulation, complicated with fracture of the fibula, 5; of the toes, 3. It will be seen that in his practice the shoulder was found dislocated far more frequently than any other joint, though the number is less than all the other luxations counted together. He had never seen a dislocation of both bones of the arm at the elbow, although it is not an extremely uncommon accident; and had never met with a complete dislocation of the knee, though he said he had found the joint in a painful and rigid state which he diagnosed as displacement of the semilunar cartilages.

Age has an influence upon the relative frequency of dislocations; the very young and the very old are not liable to such accidents; in middle life luxations most frequently occur. The elastic condition of the tissues in youth, serves to decompose forces tending to produce luxations, the pliant structures yielding sufficiently to avert the accident; in advanced age the bones become brittle, therefore they are more liable to be fractured than to be dislocated. Thus, if an individual seventy years old sustains a severe injury at the hip, a dislocation could scarcely be expected, yet a fracture of the neck of the femur would be highly probable. Elderly persons who suffer severe injuries of the shoulder, are most likely to sustain fractures of the clavicle, though dislocation of the humerus has been met in persons advanced in life.

The causes of dislocation are sometimes quite insignificant, or apparently so. A girl of sixteen dislocated the shoulder in attempting to throw the loop of a string over a peg a little higher than she could reach; another school girl dislocated the head of the radius while she and a companion were playfully swinging arms; the thumb has been luxated from seemingly trivial causes; the under jaw is frequently dislocated

while gaping; the patella may be displaced outwards when the patient had no reason to suspect even a mild form of injury. Muscular action in such instances seems to be adequate to produce luxation. If a bone has been dislocated once it is ever after liable to the same accident: at least, it is not uncommon for some joints to suffer dislocation a number of times.

External violence may operate directly and indirectly in producing luxations; thus, a severe blow upon the top of the shoulder may drive the head of the humerus downwards into the axilla; but if the hip be dislocated by a force received on the knee, the action is indirect. There are not many joints that can be dislocated by direct violence; the shoulder is one, and I have known the patella to be knocked out of place by a blow. A combination of forces most frequently produces a dislocation. For instance, the elbow is forced upwards until the humerus as a lever acts across the acromion as a fulcrum, to lacerate the capsular ligament; at this point in the progress of the injury the muscles jerk the head of the bone out of its normal relations with the joint. A drunken man whose muscles are in a state of relaxation, rarely sustains a dislocation though exposed to the action of forces that favor such injuries. In order to produce a luxation of the shoulder in a cadaver, the operator must first rupture the capsule of the joint by using the arm as a lever, then push the bone through the rent. Dead muscles will not complete the injury after the capsule has been lacerated and the bone is presented in a favorable attitude for displacement. When a bone is dislocated in life the limb is generally in such a position at the time of the accident that the antagonism of the muscles is for the moment destroyed,—one set being relaxed and another, whose action is in an opposite direction, put violently upon the stretch.

Symptoms.—Timothy Holmes, in his *System of Surgery*, says: “A complete dislocation is, in typical cases, attended with such very distinct symptoms, that when these are fairly detailed upon paper the reader is tempted to say that the injury is unmistakable. Yet the great number of old unreduced dislocations which are still seen, even in patients who have been from the first under medical supervision, proves that, notwithstanding the elaborate care with which the symptoms

of dislocation in general, and of each special injury in particular, have been described ever since the time of Astley Cooper, such mistakes can not always be avoided, even by well-informed and careful men; and it is no doubt true that errors in diagnosis on this head will sometimes occur to the best surgeons, in consequence of extreme depth of the parts, of great effusion and swelling over them, or of complication with other injuries; but with proper care such mistakes ought to be very seldom made even at the time of the accident, and attention to the subsequent progress of the case will always enable the surgeon to correct his error while there is yet a fair prospect of easy reduction." I take pleasure in being able to offer such distinguished testimony in favor of opinions so near in conformity with my own. In the malpractice suit of "*Larkin versus Jones*," tried at Marion, Grant Co., Ind., in April, 1869, I declared to the court that it was no rare or uncommon occurrence for physicians of average professional qualifications and experience, and of considerable surgical pretensions, to fail to discover dislocations, even when called early, and having opportunity to examine the case before swelling and other conditions tending to mask the real state of the injury, had come on. I cited cases of dislocation of the shoulder which had passed undetected through the hands of quite pretentious surgeons. This opinion was attacked as unsound, by Dr. Wm. Lomax, and other physicians of Grant County, who thought a dislocation of the shoulder would never be overlooked by a physician of ordinary skill and ability, though the injury be of two days' standing when first observed. All claimed to have had several cases of dislocation of the shoulder to treat, and denied ever having been in doubt in regard to the nature of the injury.

The general symptoms of dislocation are, great pain suddenly following the accident, loss of motion and rigidity in the articulation, change in the natural contour of the joint, shortening of the limb in most instances, loss of voluntary motion except to a limited extent and in certain directions, absence of crepitus, a disposition to remain in place after the luxated bone is reduced. Fractures have quite different symptoms; they are attended with pain and deformity, as are dislocations, but there is an increase of mobility, the existence of crepitus, the pain is not overcome by reduction, and the

displaced bone will not stay in place when adjusted. There are two distinct injuries, a fracture and a dislocation, of the shoulder, which closely resemble each other; a luxation of the humerus inwards appears much like a fracture of the neck of the scapula. The fracture allows of free passive motion, and crepitus can generally be produced after reduction; and when adjusted and left to itself the displacement readily occurs. In dislocation the arm is rigid, and will not admit of passive motion, and reduction having been effected the displaced bone will remain in its natural position without assistance, no crepitus can be elicited, and the coracoid and acromion processes maintain the same distance between each other.

Fractures of the neck of the femur are characterized by increased mobility and *eversion* of the foot; dislocation of the femur is attended with great rigidity and *inversion* of the foot.

Injuries about the other joints exhibit certain signs which indicate whether a fracture or a dislocation exists; and when luxated the natural axis of the bone is so changed that it no longer corresponds with its socket, there is intense pain where the head of the bone rests in its new situation, and the limb is greatly benumbed as well as rigid.

If the symptoms be not sufficiently distinctive to remove all doubts in regard to the nature of the accident, the patient may be put under the influence of anaesthesia, and then carefully examined.

PATHOLOGICAL ANATOMY.—In a recent dislocation it is found that the capsular ligament is torn, and more or less injury may be done to the adjacent tissues; muscles are sometimes severed from their attachments, ruptured, or stretched, according to the nature and extent of the displacement. The great nerves in the vicinity of the joint (such as the circumflex behind the shoulder) are often compressed or lacerated; hence severe pain at the time of the accident, and a succeeding paralysis of the parts supplied with these nerves, which is sometimes irremediable. Blood vessels may be pressed upon so as to obstruct the circulation in the limb. Dr. Goldsmith, of Louisville, reports a case of dislocation of the femur on to the brim of the pelvis so as to lie under the femoral artery. Remaining unreduced, in two months it produced a diffused aneurism of that vessel.

It is rare to find a simple dislocation of the ankle, for fracture of the fibula is almost a sure complication; and a backward luxation of the ulna is liable to be complicated with fracture of the coronoid process.

If the bones be restored to their natural position, all of these defects and lesions are soon repaired. The ruptured capsule heals, the stretched and lacerated muscles, tendons, and fibrous tissues regain, in a great measure, if not entirely, their former condition, and even the nerves which may have been contused or lacerated, may at length recover their wonted functions. To ensure perfect restoration it is necessary that the bone be not allowed to escape from its normal position while the recovery is made; a repetition of the luxation might prevent the healing of the rent in the capsule, and the return of strength to the disabled parts.

If, on the contrary, the dislocation remain unreduced, other changes, besides those which immediately attend the accident, necessarily follow. These arise from prolonged irritation and inflammatory action, as well as from efforts to establish a substitute for the old joint. The head of the dislocated bone forms for itself a cavity or new socket in the bone upon which it is thrown,—a cavity which is produced in part by absorption under pressure, and in part by deposits of osseous material around the forming socket. The new articular cavity has furnished to it something akin to synovial tissue, and the old socket becomes filled with fibroid structures. The ginglymoid articulations do not make so much progress towards establishing new joints as the ball and socket variety. In many instances complete ankylosis takes place,—a condition which is not uncommon in unreduced dislocations of the small joints.

The muscles and tendons directly influenced by a dislocated bone become materially and functionally altered; in some ancient dislocations, the relaxed muscles may be shortened or retracted to an extent that can never be overcome; the tendons get torn from their attachments and forced from their positions (as is often the case with the long tendon of the biceps); and from inflammatory action the various tissues may become blended in a mass, so that an attempt to break up these adhesions would be attended with laceration. Adventitious bony material has been found in these blended masses, as if the conservative vital forces were engaged in furnishing

osseous matter to repair a fracture or to construct a new articulation.

The head of the radius thrown upon the anterior or posterior aspect of the humerus, may unite by osseous or fibrous material so as to prevent rotation, as well as impede flexion and extension of the forearm. The backward dislocation of the ulna, if left unreduced, would be followed by such changes of various kinds, articular, ligamentous, and muscular, as to result in permanent deformity in a few weeks.

Evidence is furnished by dissection that in rare cases the rent in the capsular ligament so far unites in a few days that the hole which admitted the passage of the bone out of the joint, will no longer permit it to go back again. Hilton, in *Guy's Hospital Reports*, relates a case dissected three weeks after the accident, in which the rent in the capsule had so far healed as to prevent a return of the head of the bone. The femur, when left unreduced upon the dorsum ilii for two or three months, is prevented from returning to the acetabulum by a narrowing of the rent through which it escaped from the joint; but if well directed means be employed to reduce the bone to its proper position, the repaired ligament will so far yield as to allow the head of the femur to go back into place.

Structures thrown into disuse on account of the dislocation, undergo gradual atrophy; and any part of the organism, whether vessel, nerve, or bone, that is pressed upon, suffers marked alterations, if not entire obliteration.

When firm adhesion takes place between a large artery or vein and the dislocated bone, there is great risk of serious or even fatal consequences from laceration of such vessels during attempts at reduction. In Eve's "Collection of Surgical Cases" are a few reports of serious injuries following attempts at the reduction of luxations. They are all translations from French journals. "In one of them the attempts to reduce the dislocated joint produced a rupture of the axillary artery, gangrene, and subsequently, the death of the patient.

"In another, hemiplegia ensued, most likely in consequence of extravasation in the brain, from efforts used in the reduction; the paralysis gradually diminished, but the lower extremity never recovered its natural heat and sensibility, and the use of the arm was almost completely lost.

“ In a third case the dislocated shoulder was reduced thirty-eight days after the accident; immediately after the operation, emphysema supervened over the arm and a great part of the back; very soon afterwards violent headache and hemiplegia ensued, and proved fatal on the twelfth day. On examination, the brachial plexus was found extensively lacerated; at the sixth, seventh, and eighth cervical and the first dorsal vertebrae, the spinal cord was swollen, softened, and of a reddish-brown color.

“ In the fourth case, the reduction was followed by an enormous painful swelling of the extremity, the arm could never be used, and the fingers only retained a very small degree of sensibility and motion.

“ In a case of dislocated hip, the reduction was made very soon after the accident, and the head of the femur was very distinctly heard to slip into the cotyloid cavity; the patient died, however, five days after the operation. The anterior and exterior part of the hip was found ecchymosed; the pyriformis, gemelli, and quadratus femoris, the capsule and ligamentum teres were ruptured, and the cavity of the joint was filled with pus. In this case, the fatal termination was apparently rather the result of the dislocation, than of the reduction; the observations, however, of M. Faubert, show how cautiously the attempts at reduction ought to be made, and how necessary it is to consider whether a sufficient extending force can be used, without inflicting serious injury on the patient.”

It will be observed that extending force was relied on in these unfortunate attempts at reduction; and it is not even suggested that there may be an easier and safer way of reducing dislocations. I have known the humerus to be broken in a fruitless attempt to reduce an ancient dislocation with instruments for multiplying force. Such an instance occurred in this city a few years ago, but the surgeon did not see fit to report the case that the profession at large might be benefited by the lesson it conveyed.

Another unfortunate attempt to reduce an ancient dislocation of the shoulder (if the diagnosis was correct) was made in this city some years ago, and the surgeon (Dr. George C. Blackman) published an account of the case. The “*Western Lancet*” for November, 1856, contains the doctor’s version of

the nature of the injury, the operation to effect reduction, and the result. In a letter to the editor of that journal, he says:

“About the 10th ult., aided by yourself, I succeeded in reducing by manipulation, without the pulleys, a dislocation into the axilla, of eighty days' standing. The reduction was accomplished in a very few minutes, under the influence of chloroform and ether, and the next morning the patient left for the country, in a comfortable condition. Since that I have received no tidings from him. Encouraged by the result in this case, another patient, himself a physician, a tall, athletic man, and about fifty years of age, decided to submit to the same manipulation, although his arm had been dislocated for about sixteen weeks. The dislocation was downwards and inwards, and about the tenth week an unsuccessful attempt, by another surgeon, had been made with the pulleys, to which the force of six men was applied for two and a half hours. The patient being under the influence of chloroform and ether, aided by yourself, Drs. Fries, Cary, Graham and Kauffman, I commenced my manipulations, adducting, rotating, abducting, and elevating the arm. These efforts had been made for about ten minutes, and the least possible violence employed, when a tumefaction appeared in the pectoral region, which in a few minutes attained a considerable size. Supposing that the axillary artery was ruptured, as no pulse could be felt at the wrist, a ligature was immediately applied to the vessel at the upper part of its course. The operation was performed about 10 o'clock A. M., and compression of the pectoral region made by means of a sponge and broad roller. On removing this the next morning, the tumefaction had nearly disappeared. The patient continued comfortable, and about nine days after the application of the ligature, I was compelled to leave the city on a professional visit to Indiana. I left on Friday afternoon and returned on Monday morning, at which time I learned that my patient had died on Sunday morning, from hemorrhage at the seat of ligature. Two physicians, his most intimate friends, lodged in the same house with him, but before they reached his bedside the quantity of blood lost was so great that he sank exhausted in about two hours from the first and only attack of hemorrhage. Previous to my departure for Indiana, I had suggested to the physicians in charge, the importance of having compressed sponge at hand,

to be used in any emergency of the kind, but this was not used by the attendant; instead of applying pressure instantaneously, he went in search of the physicians, who, at that early hour in the morning were in bed. The time thus lost unquestionably led to the fatal catastrophe.

“I might refer you to numerous instances of success in the reduction of old dislocations—from two to six months’ standing—which have occurred since the days of Wiseman, but I propose to notice only the accidents by which some of these attempts have occasionally been followed. One of the earliest recorded, so far as we have been able to learn, is the case reported by Desault.

“During the effort of this surgeon to reduce an old dislocation, suddenly a considerable ‘*tumeur aerienné*’ appeared below the clavicle, which Desault attributed to the ‘*degagement de l’air amasse entre les cellules rompues du tissu cellulaire!*’ In a few days this tumor entirely subsided under the influence of ‘*astringents et une compression methodique.*’ Whether it was the result of a disengagement of air from the lacerated cells of the cellular membrane, as supposed by Desault, or of a rupture of blood vessels, we leave the reader to determine.

“It is somewhat singular that Desault should have met with two cases of this extraordinary phenomenon. Pellatan’s explanation, in our opinion, throws some light on this subject. In an attempt to reduce a luxation of four months’ standing, the same kind of ‘*tumeur aerienné*’ appeared. It was opened, and the hemorrhage from the torn artery was fatal.

“Malgaigne states that he is acquainted with but a single instance of an ‘*emphyseme veritable*’ following a reduction, and that is the one reported by Flaubert. The patient, a female æt. 70, screamed violently during the operation, and Malgaigne is disposed to believe that the emphysema was independent of the luxation, or the reduction.

“Malgaigne, himself, attempted reduction in a case of sixty-eight days’ standing, but was forced to discontinue his efforts in consequence of the sudden appearance of a tumefaction in the axilla, and on the shoulder. Ice was applied, and in the course of a few hours the swelling was arrested, and by the twenty-second day, the blood which he thinks came from ruptured muscular branches, was completely absorbed.

“ A case occurred to Flaubert, in which, besides the tumefaction, the pulse could not be felt at the wrist. The hand was cold, insensible, and immovable. The next day, however, the pulse returned to the wrist, and in the course of twenty-six days the effused blood was absorbed. Froriep lost a patient from a rupture of the axillary vein, which proved fatal in an hour and a half after the operation. The reader may find in the comprehensive treatise of Malgaigne, details of cases in which the axillary artery was ruptured. We pass over those observed by Verduc, Petit, Platner, Delpech, and that referred to by Sir Charles Bell, in his *Operative Surgery*. The late Dr. John C. Warren tied the subclavian to arrest the progress of an enormous aneurismal tumor in the axilla, the result of the reduction of a recent dislocation, and of supposed pressure of the operator's boot. In this instance the coats of the artery were so contused that sloughing took place during a fit of coughing, five days after the accident. In 1824, M. Leudet lost a patient at the hospital at Rouen. The dislocation was only of eleven days' standing, and was complicated with a fracture of the margin of the glenoid cavity, as in the two fatal cases which occurred in the practice of Prof. Gibson, of Philadelphia. The latter cases are too familiar to every surgical student to require particular mention in this place. Prof. Gibson, in connection with the report of the above cases, gives briefly the details of a fatal operation by David, of Rouen. The luxation had existed several months, and great force was employed in the reduction. This resulted in an inflammation, mortification, and death. Some years since, Lisfranc attempted the reduction in a case of four months' standing. He succeeded; but on visiting the patient an hour afterwards he was found dead. His death was attributed to cerebral congestion, as the autopsy showed the axillary artery, veins, and nerves uninjured. In the same volume, MM. Lenoir and Larrey refer to cases in which they have met with lesion of the brachial plexus, giving rise to paralysis, and yet these were recent cases, and the reduction was most readily accomplished. But I will not multiply cases of this kind; those already related will suffice, in the minds of many, to answer the question—At what period of time after a dislocation of the shoulder, is an attempt at reduction justifiable? When Prof. Gibson lost his first

patient, he wrote that 'should a case similar in external appearance to that of James Schofield again occur, I shall feel justified in adopting a similar course.' When he had lost his second patient, (John Langton), he expressed his views as follows: "The conclusions which I am now prepared to draw are directly the reverse of what I have stated in some of the foregoing pages; I am now disposed to condemn, in the most unqualified terms, all attempts at the restoration of ancient luxations of the humerus and other bones—except in cases where the patient is remarkably thin and debilitated, and where there has been little or no inflammation at the time of, or subsequent to the displacement.' At a meeting of the *Societe de Chirurgie* of Paris, July 3, 1850, M. Maisonneuve reported a case in which, after M. Velpeau had failed, he succeeded in reducing a luxation of the shoulder of twelve weeks' standing, and elated with this triumph over the veteran of La Charite, he asserts there are but few cases in which, with the aid of chloroform, we may not succeed. '*Quelles resistances y a-t-il a vaincre ici, en effet?*' he asks. '*Il n'y a presque pas d'engrenage; les muscles sont neutralises par le chloroforme; il ne reste donc que des adherences fibreuses: l'on pourra presque toujours les surmonter, ou les rompre.*' But these fibrous adhesions are not the only obstacles to overcome; where the tissues surrounding the head have become consolidated by inflammation, the axillary vessels and nerves must be in danger of laceration. Perhaps, however, as M. Maisonneuve suggests, this accident may be avoided by '*extensions preparatoires,*' as in the attempts to restore contracted limbs to their natural shape."

Cases attended with success are frequently reported, after the dislocation has existed from six weeks to as many months. Attempts attended with failures must be quite common, but accounts of them rarely get into print. If all the bad consequences had occurred in cases subjected to the action of pulleys and Jarvis' Adjuster, the blame might be mostly charged to those powerfully acting instruments, but where gentle manipulation alone was employed there have been some unfortunate results. In ancient dislocations of the shoulder, a joint that has been attended with a large proportion of unfortunate attempts at reduction, the arm should be subjected to such movements as would tend to detach the head of the humerus from any adventitious connections with the struc-

tures in the armpit. The surgeon can generally discover during these preparatory manipulations whether the adhesions are firm and extensive; and he will be governed somewhat by the evidence thus obtained. If the head of the dislocated bone can be rotated and moved freely in every direction without seeming to disturb the blood vessels of the axilla, there is very little danger of doing mischief in moderate attempts at reduction. I have seen a surgeon use his boot heel in the axilla as a fulcrum, and then exert all his strength in a violent and excited manner to effect a reduction by pulling and twisting the arm in all directions, without regard to method or reason.

If a vessel be ruptured, which is made known by a quickly forming tumor in the axilla, and by loss of pulse at the wrist if the main artery be torn, the grave question arises, What is then best to be done? Of course, any additional efforts to effect a reduction must be abandoned; and well directed measures promptly adopted to arrest the extravasation of blood. If it be certain that the axillary artery is ruptured, compression should be made upon the subclavian where it crosses the rib; and the force should not be relaxed for forty-eight hours or more. It is possible that in the course of time the blood already extravasated would form a firm coagulum and arrest the hemorrhage. Well directed and prolonged compression has resulted favorably; and ligation of the subclavian and axillary have, in the few instances performed, proved fatal. Certainly such want of success attending deligation, does not warrant a repetition of the operations, though we reason with ourselves that there can be no hope except in the ligation.

Generally a bone which has been dislocated, will remain in place when once returned to its natural position, especially if a little care be exercised in the use of the limb for a few weeks, or until it is presumed that the rent in the capsular ligament has healed, and the different tissues involved in the injury have returned to their normal state and relative conditions. However, in rare instances, there seems to be a disposition for the luxation to recur upon the most trivial opportunity. I once had a patient whose shoulder I reduced five times, at intervening periods of a few weeks; and the last time I kept the arm in a sling for two months as a safeguard against a recurrence of the accident. I had induced the

patient to keep the arm by the side for two weeks, but that length of time did not prove sufficient to prevent a recurring luxation. The patient was a woman about thirty years of age, who received the first dislocation—of the right shoulder—in a fall from a wagon; within a week she dislocated the arm again while sweeping, the hand being raised at the time and the elbow projecting outward from the body and upward; the third displacement occurred while fixing a window curtain as high as she could reach; the fourth happened in the act of saving herself from a fall; and the fifth and last, while hanging clothes on a line higher than her head. All of the accidents occurred within a period of six months; and in each instance there was no trouble in reducing the bone to place by ordinary manipulation, no chloroform being used. I began to suspect that the edges of the rent in the capsule had become covered with synovial membrane, and thereby offered an open and smooth passage-way for the escape of the bone from its normal position. The suspicion grew stronger from the fact that each succeeding reduction was attended with less and less trouble. Whether the rent ever closed I am unable to state; yet sufficient contraction took place in it during the long period in which the arm was bound to the side by means of a sling, to be a protection against another accident of the kind. Dr. Jay, of Marion, Indiana, once had a similar case to manage. He reduced a recurring dislocation of the shoulder several times; and at length the patient, upon having his arm re-dislocated, applied to another surgeon for relief. The second surgical attendant was not on friendly relations with the first, therefore he led the patient to believe that the displaced bone had never been properly reduced, and instigated him to commence a suit for the recovery of damages. The plaintiff, however, failed to get a decision in his favor.

In the September number (1869) of the *Western Journal of Medicine*, W. R. Thompson, M.D., of Vandalia, O., reports a case of recurring dislocation of the hip, which is not without interest. "April 9th, 1869, I visited a patient in conjunction with Dr. H. B. Nunemaker, for the purpose of reducing a dislocation of the head of the femur of three days' standing. Our patient, a boy, aged sixteen years, muscular and healthy, had been playing with a colt, which became unmanageable, running violently against him, dislocating the head of the

femur upward and backward, upon the dorsum of the ilium. The injured limb lay in a semi-flexed position, the heel abducted and the toes inverted, resting on the instep of the opposite foot. Measurement revealed about an inch and a half of shortening. The patient was put under the influence of chloroform, and the dislocation reduced by manipulation, (Reid's method). The first effort we made the head glided from its bed; the circular movement brought it under the acetabulum, converting it into a sub-pubic dislocation. The movement was then reversed, which brought the head of the bone to its first position on the dorsum ilii. The limb was again brought across its fellow, and the circular movement carefully made, at the same time guarding the head of the bone from passing around the socket. To our gratification the head passed in with an audible snap, the limb assuming its normal position. The patient was then placed in the horizontal attitude, and the injured limb secured to its fellow by means of a roller extending from the ankle to the knee. On the following day, on our first visit, the hip-joint was found to have been dislocated during the night. The boy, contrary to most positive orders, had attempted to raise himself up in bed, and at the same time turning partially around, threw the head of the bone out; the leg assuming the same position as when we first saw it. Again the patient was placed under the influence of an anæsthetic, and the luxation reduced as in the first operation. He was then secured firmly by means of a splint and bandage to the couch in which he lay, in order to guard against a third luxation. In this secured position he lay for seven days, doing well, except some slight peritonitis occasioned by other injuries received in conjunction with the first dislocation. During the night following the seventh day, he loosened the bandage which held his head and shoulders to the bed. Finding himself again free, his first impulse was to get up. (He seemed unable to appreciate his condition.) In this attempt he again threw the head of the bone out of the socket. This, in our opinion was easily accomplished. In the first place, there was an extensive laceration of the capsular ligament, allowing the head to glide easily from the socket; and secondly, the limb in its secured position to the splint and bed, with the shoulders and body free to move in the direction of the erect posture, and to the right. These

movements would, under the circumstances, certainly produce a dislocation (the left limb being the injured one). At our request, Dr. J. C. Reeve, of Dayton, Ohio, was called in counsel, in order to fortify ourselves against any subsequent trouble, in a legal point of view. The patient was again anaesthetized, and Dr. Reeve thought, upon first examination, there might be fracture within the capsular ligament; but, upon further investigation, coincided with our previous diagnosis. We then proceeded to reduce the luxation in the manner before mentioned, and with similar success. At the doctor's suggestion, the splint was reduced in width from five inches to three, and not to be secured to the bed, and the toe was everted to about seventy-five degrees—the foot abducted about four inches from the normal axis of the leg—the body was secured to the bed as was previously done. In this position he lay for three weeks, after which time the splint was removed and passive motion induced.

“At the time of writing the above, the boy was able to walk without crutches, though there is still some lameness—the foot is still in an abducted position, with the toe everted, giving him altogether an awkward appearance.

“In this case the difficulty did not consist in the reduction of the dislocation, but in retaining it in its normal position after reduction; and it is our opinion the injured limb should always be secured with a splint, the normal axis of the leg maintained, and the toe but slightly inclined outwards. It will be seen that the splint in this case was left on somewhat longer than would be required in the majority of cases.”

In the above case it seems strange that the toes remained everted and the foot abducted after the reduction was effected, unless the head of the femur was fractured or a notch was broken out of the rim of the acetabulum.

Case CCXV. of Dr. J. Mason Warren's *Surgical Observations*, was somewhat similar to that just quoted. The bone slipped out of place in a few minutes after it was reduced, while the limb was slightly raised for a more thorough inspection. The experiment of reduction and luxation was performed several times to see what was the probable cause of the easy recurrence. Slight crepitus showed that a fracture of the acetabulum or head of the femur existed, probably of the upper and back part of the cotyloid border. Hence, Desault's fracture

apparatus was employed for three weeks. At the end of that time the patient threw off the splint, and began to use his leg. While turning around the bone slipped from its socket, and in the course of a week the accident occurred a number of times upon the most trivial occasions. A permanent splint was then put on, and the leg kept quiet in a straight attitude for several months. After the fracture dressing was removed the joint slowly regained its mobility. Dr. Warren pertinently remarks that if the patient had passed into other hands when some of these recurrences of the dislocation took place "it might easily have been urged that the dislocation had never been reduced."

In cases of old dislocation of the shoulder, the accident recurring over and over again, there is little skill required in effecting a reduction. Some persons in whom the shoulder is so affected, have learned to reduce the dislocation for themselves, by reaching over a gate, taking hold of one of the lower bars, and hanging in this position, when the mere weight of the body is sufficient to restore the parts to their place. The non-professional brother of a patient of my acquaintance had learned the manner of reducing a frequently recurring dislocated shoulder, and performed this service whenever required. Some loose jointed children practice dislocating, wholly or in part, some articulation of the thumb or of the fingers; the reduction is performed with equal facility.

CAUSES OF DISLOCATION.—As has been stated previously, external violence and muscular contraction are the frequent and prevailing causes of dislocation. A blow upon the top of the shoulder, escaping the acromion but hitting the head of the humerus, may force the latter bone downwards, below the glenoid cavity, into the axillary or subglenoid space. It is possible that the femur, when the limb is in a state of abduction, may be driven downwards in the same manner, so that the head of the bone shall find a lodgment in the thyroid foramen. The patella is known to have been dislocated by a direct blow. Either end of the clavicle may be forced out of articulation by direct violence. I reduced a luxation of one condyle of the jaw, that was produced by a kick.

The indirect force most commonly produces dislocations, whether the articulation, at which the accident occurs, be of one

kind or another. A powerful force suddenly applied to the elbow, carrying the arm excessively upward, may rupture the capsular ligament of the shoulder joint, and thus open the way for a luxation. The hand thrown forward to break a fall, may receive a force which is safely transmitted through the carpus, and shaft of the radius, without fracture or dislocation of those parts, but the head of the radius may be wrenched from its connection with the external condyle. It is not always easy to determine the essential cause of dislocation; an injury is received in some unknown manner, which proves to be a luxation. The patient can not positively tell whether the violence was applied to the arm or to the shoulder, to the hand or to the elbow. A bruise upon some point remote from the luxation or directly upon the joint, may lead to a rational interpretation of the cause, yet there may be several contusions, and all be produced by forces independent of that which caused the dislocation. Generally a limb in a state of luxation is a little shorter than natural, though it may be longer; in most instances it is either longer or shorter, and rarely retains the same length as the other limb. In a dislocation downwards of the humerus (subglenoid) the arm is lengthened about two inches; if the head of the bone be thrown under the coracoid process (subcoracoid) the arm is lengthened about three quarters of an inch, and if the displacement extend inside the coracoid process the head of the humerus rises toward the clavicle and the arm is shortened. In dislocations of the hip, the leg is two or three inches shorter if the head of the femur be thrown upon the dorsum ilii, and the limb is longer if the dislocation be downward into the thyroid foramen. In dislocations of a ginglymoid articulation, the limb is rarely lengthened, and is generally shortened.

A dislocated limb always has a constrained and distorted appearance, which is diagnostic of the injury. A dislocation of the radius and ulna backwards resembles a deformity following a fracture of the shaft of the humerus just above the condyles, yet the rigid state of the parts involved in the dislocation, and the mobility in fracture, ought to be sufficiently marked to remove doubt in any case, to say nothing of other distinctive features in each.

The pain and disagreeable numb sensations attendant upon a recent dislocation, aid in the diagnosis, though such signs

are not sufficiently characteristic of the injury to settle a question involved in doubt. Not much can be determined by the swelling, for other injuries have that symptom in a greater or less degree, the amount not always depending upon the severity of the lesion.

Fractures near the joints and sprains resemble dislocations. A sprain is attended with pain, swelling, and stiffness which may be taken for the rigidity of luxation. However, a limb simply sprained can be made to move in all its normal directions, and no ugly deformity, beyond that caused by the swelling, can be discovered. In a fracture crepitus can almost always be elicited, a sign which is unmistakable. Dislocated joints and even those merely stiffened from disuse, may be made to yield a creaking, crackling noise, but it is not the sharp, harsh grating sound known as the genuine crepitation of fracture.

It is difficult to reduce a dislocated bone, and when reduced it will generally stay in place; not so in a difficulty consisting purely of a fracture. In the latter injury the reduction is easy, and the displacement returns to the parts as soon as left to themselves. For instance, a fracture of the neck of the femur is attended with shortening, and, in some instances, inversion of the toes—both marked features of dislocation of the hip, yet in the event of fracture the shortening could be readily overcome by moderate extension; and if this force was relaxed, the shortening would reappear. In the event of dislocation, the shortening could not well be overcome and the toes be brought into their natural attitude without reduction; and when the head of the bone was once replaced it would not leave its situation as soon as the limb was left to itself. In addition to these differential signs, the mobility in fracture and the rigidity in dislocation, are quite distinctive, and, therefore, valuable.

The sooner the investigation of an injury is held after an accident, the clearer will appear the differential signs; and the less distress will be inflicted upon the patient in establishing the diagnosis. If two or three days pass before the injury is seen by the surgeon, he will be balked by the swelling, the tenderness, and the tumid condition of the infiltrated tissues. It is advised by Malgaigne, in obscure cases, to insert a slender and well tempered needle through the tissues to the

articulation; and with its point explore the structures of the joint. If the head of the bone be in place the progress of the needle will be arrested; but, if out of place, the hollow space it once occupied will be reached, and the diagnosis established. It is far better to use an exploring needle than to remain in doubt concerning the nature of the injury. The point of penetration should be selected so as not to endanger the puncture of a large vessel or nerve.

Sensitive females, or those possessing peculiarly impressible nervous systems, may claim that they have a dislocated joint, and simulate luxation to an extent likely to deceive the unwary. The knee is the joint most liable to be attacked with such symptoms as are generally the result of hysterical complications. So irregular becomes the distribution of nerve influences that the parts about the joint may swell and become distorted, or waste as if struck with palsy. The patient claims to have slipped and displaced a bone, and ever after was unable to walk or even move the joint. Manipulations and passive motions are attended with excruciating pain. In some instances the rigidity of the articulation is well calculated to mislead, the physician being convinced that no lesion, other than luxation, could present such articular fixedness.

These neuropathic affections of the joints are called forth at first by the feelings and imaginings of the patient, who having once or twice given way to the belief that she is suffering from a dislocation or other serious lesion of the joint, deceives herself into the full conviction of having a real malady. This feeling indulged in for a few weeks or months, disturbs the nutritive functions of the part claimed to be displaced or disordered, and in time a real deformity exists, which is in danger of becoming permanent. If the surgeon be persuaded that no luxation or real defect exists, he may have chloroform administered and go through with the mock performance of reducing a dislocation, or of executing some important operation. Patients have thus been deceived into a cure which could not be accomplished in any other way.

GENERAL TREATMENT OF DISLOCATIONS.—From what has been previously written it will be seen that I am in favor of reducing dislocated bones by such gentle movements of the limb in certain directions as shall relax the muscles and bring the

head of the displaced bone into a position favorable to its return through the same rent in the capsular ligament, that permitted the egress. This is to be accomplished more by tact than by force—*arte non vi*. However, dislocations of the ginglymoid articulations can not be reduced without more or less force is used. The power is not to be employed rigidly in a straight line, but advantage is to be taken of the muscles, relaxing them as much as possible, and by twisting and rocking motions the impediments of bony prominences are to be overcome. For instance, in case of dislocation of the ulna backwards, extension from the wrist and counter-extension from the shoulder, with the whole arm in a straight attitude, will avail nothing, except it defeat the object to be accomplished, unless force enough be employed to break and tear through every obstacle. The knee is another joint, when luxated, that requires force to reduce it, yet the leg needs to be flexed, and the force used against the ham, and not upon the foot with the limb in a straight position. A little coaxing in the management of dislocations, often proves effectual when arbitrary force is obstinately resisted. Intelligent manipulation manifested in accordance with a good understanding of the anatomy and pathology of the articulation, will generally succeed in reducing a dislocation when brute force would fail or be attended with unnecessary suffering and lasting injuries.

The accomplished surgeon considers well every phase of each case, rarely allowing himself to be completely thwarted; if one method of reduction does not succeed, he tries another, being ever fertile in expedients and resources. He even enlists the power of the muscles to assist in the work of reduction. The expert bone-setter does not, when called to treat a dislocation, first look about for pulleys and other contrivances for multiplying force that he may violently drag the bone back into place, regardless of consequences. The ignorant and inexperienced are ever embarrassed; and in order to mask their inefficiency, they often resort to violent measures that are entirely unnecessary. Natural prominences about the joints have been taken for deformities; and a simply sprained articulation has been subjected to the stretching influence of Jarvis' Adjuster. The physician who has courage to acknowledge his incompetency to treat a surgical injury is a moral hero who will not go through the world with merits unrewarded.

The most skillful and experienced surgeon is often baffled or utterly thwarted in his efforts to reduce a dislocation ; and his failures teach him to be charitable in passing criticisms upon those whose opportunities to acquire and put in practice surgical knowledge have been necessarily limited.

With the patient under chloroform the majority of luxations will yield to well directed and persevering manipulation : if that fails, extension and counter-extension should be made by the hands of assistants, and while these forces are being applied, the surgeon should give proper directions, and endeavor with his own hands to rotate the limb or to impart such movements to it as shall favor reduction.

These efforts having failed, the surgeon may deem it advisable to resort to Jarvis' Adjuster, the pulleys, or some other contrivance for multiplying force. A strong cotton handkerchief, or a wide strip of firm muslin may be made fast to the wrist (if force is to be applied to the arm) by the common double slip-knot or what is called the " clove hitch," for the application of the extending force ; a wide towel or folded sheet put around the chest, just under the arm, will do for making the counter-extension. Two large staples or spikes driven into door posts or window sills, or any firm fastenings in a wood shed or back room, a few feet distance from one another, will answer for points to make fast to when everything is in readiness. Let the towel or sheet surrounding the patient's chest be tied to one spike or staple, and a strong cord or rope doubled upon itself, be tied between the other spike or staple and the extending handkerchief placed on the patient's wrist. A stick or cane inserted between the two thongs of the double rope may now be revolved as in a Spanish windlass, until the extending bands are made tort. It will be seen that great extending and counter-extending force can, in this way, be brought to bear upon the arm. The contrivance is so simple that it can be gotten up in a few minutes in any farm house ; and it serves all the purposes of costly blocks and pulleys. Since the discovery of anæsthesia and rational manipulation, there is seldom a call for such mechanical contrivances as constituted a necessary part of the surgeon's paraphernalia a half century ago. I have reduced dislocations in subjects of great muscularity, without assistance or appliances ; and although I have possessed a Jarvis' Adjuster for fifteen

years I have rarely put it into use. I begin to regard it as entirely superfluous.

It was formerly considered necessary to subdue muscular tension and to reduce the powers of the system by the use of warm baths, venesection and tartarized antimony; but the discovery of anæsthesia has entirely superseded those agents. The forcible, prolonged, agitating and painful attempts to reduce dislocations, which were common to older surgery, are scarcely heard of now. The old notion that the muscles had to be "tired out" by the prolonged traction of a number of men, or by various mechanical contrivances, some of them of the most ludicrous nature, which may be seen depicted in old books of surgery, has been almost entirely supplanted by more rational ideas and sounder principles.

In France an instrument called a dynamometer is used in connection with the pulleys, in order that the precise force employed may be accurately measured. This is a refinement that has not been introduced into American practice. Inasmuch as different degrees of force are required in individual cases, and it never having been ascertained how much force may be safely applied in a given case, the instrument could have no practical value.

It should be remarked for the benefit of those who may employ pulley force, that the surgeon is to watch the condition of the joint while the extension is being made; and as soon as the head of the bone seems to be opposite the empty articular cavity, he is to order the extension to be relaxed, and at the same time he completes the reduction by pressing or pulling the bone into place. If he fails to return the head of the bone to its normal position, and it sinks back into its new formed bed, the pulley force is to be renewed, and a fresh attempt made to return the bone at the nick of time when the assistant relaxes the extending cord. The handkerchief or bandage applied above the wrist, elbow, ankle, or knee, as a fastening to hitch the ropes to, may, in prolonged efforts at reduction, excoriate the constricted parts, and the wounds be followed by dangerous sloughing. It is to be borne in mind, therefore, that there are worse evils than a dislocated bone; and a surgeon might bring discredit upon himself by hopelessly ruining a limb, even if he succeeds in the reduction by the exhibition of unwarranted violence.

Reduction having been accomplished, the position of the replaced bone must be maintained by bandages, or slings, for a certain period; generally a week is sufficient to confine most of the joints; the shoulder should be kept in a state of repose for two weeks. High grades of inflammation require topical applications of evaporating and anodyne lotions. In the event of suppuration the pus should be evacuated at a proper time, and efforts made to prevent ankylosis.

Tenotomy has been performed in order to overcome what seemed to be the chief resistance to reduction. The tendo-Achillis has been subcutaneously divided to facilitate the return of the foot to its normal place when luxated backwards; and so have the tendons of the thumb been served to accomplish reduction. In regard to these operations I may say, that there is no serious objection to tenotomy if reduction can not be effected in any other way; but with the free use of an anæsthetic, it is not probable that such measures are ever necessary.

In compound and complicated dislocations there can be no definite rules which will reach many cases. The lesions are generally of such a serious and complex nature, that the surgeon must manage each according to its individual peculiarities. A joint badly crushed as well as dislocated, with injury of the passing vessels and nerves, may require amputation or resection to save life. However, there is generally no necessity for haste in resorting to extreme measures unless the disorganized condition of the limb demands prompt action. The conservative spirit of modern surgery has saved limbs that would have been sacrificed at once in Sir Astley Cooper's time. Loose pieces of bone deprived of nutritive connections should be removed in compound injuries, and then if the reduction be accomplished, and the joint treated like a fracture or in accordance with the demands of the case, a serviceable limb may be saved to the patient. Compound dislocation of the knee, complicated with fracture of the patella, and the condyles of the femur, generally demands amputation to save life. The dangers from primary shock, subsequent pyæmia, and irritative fever, constitute well grounded objections to any argument advanced in favor of attempting to save the limb.

If a dislocation be complicated with a fracture, the luxation should be overcome first, if possible, and then the fracture

may be treated as a simple injury, for a dislocated bone left until a fracture has united, is not easy to be returned to place. The older Warren, of Boston, once had a case of shoulder dislocation and fracture of the humerus on the same side; and he was unable to reduce the luxation until the broken bone was repaired. This course is commended by Malgaigne, and it even might be necessary when the fracture was so near the head of the bone as to render it impossible to overcome the dislocation until the fragments of the humerus had united so as to make a lever of the arm.

My experience with compound dislocations leads me to commend an attempt to save the limb without amputation. Two years ago I was called to an injured elbow in which the radius and ulna were projecting through the flesh on the posterior aspect of the arm. I gave the patient chloroform, and rather easily pulled the luxated bones into position. I dressed the limb in a semiflexed position, and left the wound in the skin as it was. Inflammation was held repressed by the use of cooling lotions, and the internal use of chloral hydrate. Considerable suppuration attended the healing process, and the elbow was somewhat stiff. In this case there appeared no excuse for amputation.

A boy was playing base ball and received a compound dislocation of the ring finger at the knuckle joint. It required great traction to pull the luxated bone into place. However, with force and manipulation I succeeded in the reduction. I bound the finger in splints, and kept the lesion wet with cooling lotions. In four weeks the finger was well, yet somewhat stiff at the injured joint. Passive motion for three months completely restored the functions of the joint.

I was once called to Dr. McKinney, of Defiance, O. He had received a compound dislocation of the ankle the day previously. Amputation had been advised, but I opposed such a procedure. The patient was a very large man and the injured limb swelled prodigiously. The dislocation was reduced, and the limb left without splints or other dressings except pledgets of lint laid upon the the wound. There appeared to be no disposition to a re-dislocation. The swelling of the leg was so great that phlyctenæ appeared and gangrene threatened. The patient made a good recovery, yet with restricted action of the ankle-joint.

CHAPTER II.

DISLOCATIONS OF PARTICULAR JOINTS.

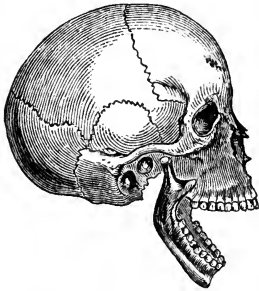DISLOCATION OF THE JAW.

The under jaw is articulated, through its condyles, with the glenoid cavities of the temporal bones. In each temporo-maxillary joint is a bi-concave fibro-cartilage, with synovial membrane on both surfaces, which facilitates the various motions of the articulation, and in a measure prevents luxation, for its elastic substance lessens shocks, and its shape deepens

the articular cavity. The glenoid cavities are bounded in front by ridges of bone called the eminentiæ articulares; and in laughing, yawning, and other forward movements of the lower jaw, the condyles rest upon these bony prominences; but the ligaments of the temporo-maxillary joints, prevent the condyles from dropping into the zygomatic fossæ in front of the eminentiæ articulares, or from becoming dislocated.

However, an extreme downward and forward motion of the jaw, as sometimes takes place in gaping, ruptures the ligaments, and luxation ensues. Muscular action, then, is sufficient to produce the lesion. Sir Astley Cooper reports the case of a boy who had his jaw dislocated by an apple forced into his mouth; and Dr. Physick, of Philadelphia, knew a woman to dislocate her jaw while scolding her husband. Dr. E. Andrews, of Michigan, reports a case in the *Peninsular Journal of Medicine*, in which a patient while vomiting from the effects of lobelia, received a dislocation of the jaw; other emetics of the same kind had been frequently taken, but no

FIG. 106.



Dislocation of the lower jaw.

ill effects had followed except a sensation of slight spasm at the joint. Malgaigne met with four cases of luxation of the jaw from vomiting, and five from convulsions. Dentists not unfrequently dislocate the jaw on one or both sides while engaged in extracting teeth, removing old fangs, and even while excavating and filling. Dr. Gilbert, of Buffalo, in a *Thesis upon Dislocation of the Inferior Maxillary*, relates a case of luxation of both condyles forward, under the zygomatic arches, which occurred while he was taking an impression of the lower alveolar ridges, for the purpose of making an artificial set of teeth.

Direct violence occasionally produces luxation of the lower jaw. A heavy lateral blow, or the kick of a horse or mule, the force being directed forwards as well as laterally, may dislocate one or both condyles.

Children and elderly persons are not subject to this accident, though a case in one of the extremes of age is occasionally reported. Nelaton found a dislocation of the jaw in a person above seventy, whose gums were toothless.

Luxations of the jaw occur most frequently in persons from fifteen to thirty-five years of age; and in females much oftener than in males. A laxity of the ligamentous structures about the articulations favors dislocation, whether the subject be of one sex or the other. As soon as the condyles become thrown slightly in front of the articular eminences, the jaw is spasmodically forced forward by the combined action of the masseters and internal pterygoid muscles.

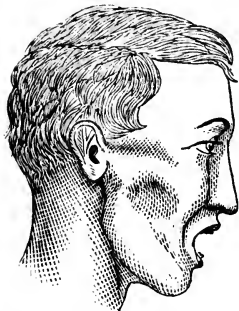A backward dislocation is impossible unless the osseous structure of the external ear is broken at the same time. Dislocation of one condyle forward, the other being left in place, is an accident of not extremely rare occurrence; though both condyles are much more frequently luxated in one injury.

The symptoms of dislocated jaw are so marked and characteristic, that, says Robert Wm. Smith, "were there not recorded cases to the contrary, we could scarcely suppose it possible that the true nature of the accident could be overlooked. * * The mouth remains widely opened, and the individual is unable to close it; the incisor teeth of the lower project beyond those of the upper jaw; the saliva flows from the mouth involuntarily and profusely; speech is difficult, and the pronounciation of labial consonants impossible; deglu-

tion can not be performed, and the motions of the tongue are limited.”

“The masseteric regions of the cheeks are flattened, a depression is observed in front of the auditory canal, immediately below the horizontal root of the zygoma, and the finger can be sunk into the parotid space. The coronoid process forms below the malar bone, a prominence which is very visible externally, but which is most distinctly felt through the mouth.”

FIG. 107.



Appearance of the lower part of the face produced by dislocation of the inferior maxillary.

“There is likewise an evident fullness in the temporal fossa, between the eyebrow and the ear, immediately above the zygoma. This prominence (which does not seem to have been noticed by any writer except Mr. Adams) appears to be thus produced: As soon as the condyle has cleared the articular eminence, it at once becomes placed upon a higher level than the apex of the coronoid process; it is elevated in the same proportion as the coronoid process is

depressed. It thus comes into contact with and pushes upwards the posterior fibres of the temporal muscle, which pass horizontally, or nearly so, over the pulley-shaped surface of the zygoma. To the displacement and stretching of these fibres over the upper surface of the condyle, the prominence alluded to is, I conceive, to be ascribed.”

The coronoid process can be felt through the cheek, or within the mouth; and the relation of the teeth is altered. The pain in a recent case is intense; but becomes mitigated in the course of a few days in cases left unreduced.

When one condyle is dislocated the anterior arch of the jaw inclines to the right or left side as the case may be, giving the lower part of the face a distorted appearance. The mouth is not held wide open, as in the double dislocation, but the parallelism of the teeth is destroyed, and the jaw is rigidly fixed in the distorted state.

When luxation of the condyles is left unreduced for several weeks or months, the chin gradually becomes elevated, the patient is enabled to close the mouth, the involuntary flow of saliva ceases, the faculty of speech is regained, and most of

the characteristic signs of the nature of the injury disappear ; but the projection of the chin, and the advance of the lower incisor teeth still remain, making the lower segment of the face rather unsightly. In fact, the general mobility of the jaw is never fully recovered, if the bone be left unreduced.

Mr. Hey, in speaking of dislocation of one condyle, does not admit that the chin is carried off to the side opposite the lesion, but declares that he could see no alteration in the position of the chin. The symptom most diagnostic, according to his description, is a small hollow or depression which can be felt behind the condyle that is dislocated ; and the other side is natural or free from any such empty space.

When the mouth is open to its utmost extent, the tips or extremities of the condyles rest on the articular eminences which bound the glenoid cavity in front ; and being poised on those eminences, the muscles have an opportunity to jerk the condyles in front of those ridges. Even if the masseters and pterygoids hold steadily, constituting a fulcrum, the chin depressing muscles, acting on the long arm of the lever, may readily accomplish the displacement of the condyles forward. This view of the mechanism of the under jaw, explains why gaping produces luxation oftener than all other causes combined. Besides, it is common for the muscles of the neck and face to act irregularly during the effort of yawning.

Reduction of a dislocated jaw has been effected after the bone has been out of place several weeks, and even months. There is no objection to an attempt being made at reduction, even if six months have elapsed from the time of the accident. However, it might be difficult to keep the bone in place after it had been luxated so long ; and after the implicated parts have become accustomed to their new relations, there is no longer a pressing demand for surgical interference. The best time to effect reduction is immediately after the accident ; and the patient, though unable to speak, is frantic for relief.

TREATMENT.—To reduce a dislocated jaw of recent occurrence no chloroform is generally needed. The patient is to be seated on a low stool, with his head resting against an assistant's breast ; the surgeon places himself in front of the patient, and inserts his thumbs, previously wrapped with pieces of cloth, into the mouth as far back as possible and

presses upon the lower molars, while the fingers beneath the chin elevate the anterior extremity of the dislocated bone. The thumbs, if they were strong enough, would depress the condyles below the articular eminences and the internal pterygoids would snap them into place; but the assistance of the fingers, acting on the anterior portion of the bone as a lever, is required to overcome the power of the temporal, masseter, and internal pterygoid muscles. Each thumb is not only a fulcrum, but it is made a power to depress the back part of the jaw and disengage it from the zygomatic fossa. By this double power exerted advantageously by the thumbs and fingers the reduction can generally be accomplished in a brief space of time. The jaw needs pulling forwards a little in the effort at reduction, in order to facilitate the escape of the projecting condyles from the cavities in which they have been resting. As the surgeon feels the movement that is to result in reduction, he quickly slips his thumbs between the teeth and cheeks to escape the effects of the sudden closure of the jaws. The first time I attempted this feat the side of each thumb was pinched into a "blood-blister."

If trouble is experienced in this attempt without chloroform, the patient may be brought under the influence of anæsthesia, when less force is required to effect the reduction, and the muscles being relaxed there is less danger of receiving a bite at the time the condyles slip into place.

Another method of reducing dislocations of the under-jaw is to place a couple of vial corks or pieces of soft wood as far back between the grinders as possible, each to perform the part of a fulcrum, and then with the hands or a strap beneath the chin, exert sufficient upward force to pry the condyles downwards to the level of the articular eminences where the muscles can pull the bone into place. This plan is executed while the patient sits on the floor, with his head resting between the knees of the surgeon who sits in a chair behind the person operated upon. M. Nelaton has reduced dislocations of the inferior maxillary, while standing behind his patient, by resting his fingers against the mastoid processes, and with his thumbs upon the projecting coronoid processes, forcing them downward to a point where the contracting muscles could finish the reduction. This manœuvre could hardly be

accomplished unless the patient were well under the influence of an anæsthetic.

An old plan was to use pieces of wood the size of a narrow ruler, as levers in the mouth to depress the angles of the jaw sufficiently to effect reduction. In the case of Mrs. Harts-horne who dislocated her jaw at the Sherman House, while gaping, I found it necessary to use a lever of wood to disengage one condyle. Her husband would not allow me to employ chloroform; and one of my thumbs was suffering from a sprain, so that I could not exert sufficient force to dislodge the condyle from its abnormal bed.

There is no objection to reducing one side at a time, if the operator has not power in his hands to accomplish the full reduction at once. The prudent surgeon will employ force with care, in reducing dislocations, and inflict as little damage upon the patient as possible. Relaxation should be guarded against by the use of a bandage over the head and under the chin to prevent the mouth being opened too wide either while eating, gaping, laughing, or sleeping. A handkerchief folded, and, after passing under the chin, tied on the top of the head, serves to prevent a wide separation of the jaws, and to remind the patient that the danger of relaxation still exists. The retentive means may be employed a week or ten days; and in the event of a second accident and successful reduction, the bandage should be worn for six weeks. The jaws are not to be so firmly closed by the retentive dressing as to prevent the taking of food.

I am acquainted with a case of recurring luxation of the inferior maxillary; and the patient himself, after having it reduced a few times, learned the art of replacing the bone. He generally employs a wooden roller of the diameter of a pen-holder, two inches and a half long, as a fulcrum between the molar teeth, while with the hands he elevates the chin and forces the jaw back into its sockets. He says the bone was first dislocated when he was young. A brother playfully struck him on the chin while he was in the act of gaping. Relaxation took place in a week after the first reduction; and the recurrence has been frequent ever since. He wore a gum elastic bandage over the head and under the chin for a year or more, and although the number of luxations decreased the casualty was not wholly prevented. Finding that the dis-

placement of the jaw at length gave very little pain, and that he could return the bone to place without difficulty, he took no further special precaution against the accident.

If an ancient dislocation of the inferior maxillary disfigured the patient, and was the source of pain and other serious annoyances, the subcutaneous section of the masseters might allow of reduction; and if there still existed formidable obstacles to a return of the bone, the temporal and internal pterygoids might be divided, leaving no muscular resistance to reduction.

Sub-luxation of the lower jaw is a species of displacement not exceedingly rare, especially in persons who possess a lax state of the ligaments. The difficulty is somewhat troublesome, for the patient is not able to close the mouth until the condyles are replaced. Sir Astley Cooper thought the accident depended upon the condyle slipping off from the inter-articular cartilage, but in a case I had an opportunity to examine, I was confident the cartilage followed the condyle, and its concave centre impinged on the articular eminence in front of the glenoid cavity. Bransby B. Cooper states that "the interarticular cartilage is always displaced with the condyloid process of the bone."

Very little skill is required to overcome a sub-luxation. Depression of the jaw, together with lateral motion, relieves the "hitch," and the muscles replace the bone, and the inter-articular cartilage. No ligament or other tissue is lacerated, therefore it is useless to employ a retentive dressing. Bathing the maxillary joints frequently in cold water or astringent lotions, might prevent a recurrence of the displacement. A spasmodic contraction of the digastric and genio-hyoid muscles while gaping in cold weather, has been regarded as a sub-luxation, but it is a difficulty quite distinct and different from articular displacement. The spasmodic state leaves the muscles sore beneath the chin, and in sub-luxation the soreness is confined to the region of the articulation.

CHAPTER III.

DISLOCATION OF THE VERTEBRÆ.

The intricate articular connections between the bones composing the spinal column, render uncomplicated dislocations of the vertebræ exceedingly rare. Sir Astley Cooper says: "I have never witnessed a separation of one vertebra from another through the intervertebral substance, without fracture of the articular processes; or, if those processes remain unbroken, without a fracture through the bodies of the vertebræ." Other surgeons and surgical writers have declared that a dislocation can not occur anywhere in the vertebral column without the concurrence of fracture; and any anatomical student who has attempted to disarticulate the vertebral chain in a fresh subject, has been impressed with the difficulties attendant upon such separation. The bones interlock and overlap to a degree that seems to forbid luxation; and the fibrous structures which bind the bodies of these bones and their processes together, seem to be stronger than the osseous material itself. However, there have been reported during the last few years a number of well authenticated dislocations of the vertebræ, in different regions of the column.

It is not extremely rare to find luxations of the vertebræ from disease, the process of displacement being gradual, and the result ankylosis or death. Some years ago I was called to a lady who had been having the head drawn forwards and to one side until the left ear rested between the nipple and the armpit of the corresponding side of the body. The extraordinary contraction had wrenched at least three of the cervical vertebræ from their articulations, and greatly distorted two others. But this and similar cases do not properly belong to the subject of luxations, for they do not occur sud-

denly from accidental violence, and are not amenable to the treatment usually employed to replace dislocated bones.

In 1856 I was summoned to an Irishman who had fallen from a chamber window to the ground, head foremost. I found the patient with his head twisted to one side and rigidly held in that position. He uttered cries of distress, and called lustily for relief: "A stitch in my neck, docther, a stitch in my neck." I took hold of his ears and endeavored to pull and twist his head into its natural position, but was unable to accomplish my object. I could feel a bony displacement to exist between the third and fourth vertebræ, by pressing my fingers into the soft structures of the neck, though I was unable to discover the exact nature or extent of the luxation. Perhaps another vertebra was implicated in the displacement. By the help of assistants who laid hold of the patient's head and feet and made powerful extension and counter-extension, together with some twisting motion, reduction, which was attended with an audible snap, was accomplished. The patient then moved his head and neck with ease and complained no more of sharp pain. He suffered from great soreness in the neck for a week or more, yet recovered without physical defect or lasting functional impairment. I am quite sure no process of bone was broken; and that the injury was a simple luxation, occurring between two or more of the cervical vertebræ.

The *Lancet* for '49 contains the report of a case of dislocation of the cervical vertebræ in a seaman, who in descending the fore-ladder caught his foot and fell forwards, striking on the right side of the head, without inflicting any wound on the scalp. "When taken up, he was found to be quite helpless, and on being brought into the sick-berth, the chief seat of pain was referred to the back of the neck, which, on examination, presented considerable irregularity of the spinous processes of the fifth and sixth cervical vertebræ, with a bulging of the muscles on the right side, corresponding to the position of the transverse processes of the above-named vertebræ." Head and neck rigid, face turned toward the point of the shoulder, and bent forward; respiration natural, and questions answered coherently, though there was considerable paralysis of the extremities. Extension and counter-extension with pressure made by the surgeon on the swelling of the

right side of the neck, reduced the dislocation. The reduction was followed by a restoration of impaired functions.

Mr. Lawrence, of London, says: "The possibility of the occurrence of complete dislocations of the vertebræ without fracture, has long been a disputed point among many of the first surgical writers. Boyer and Sir A. Cooper are of opinion that such an accident can not happen; and Delpech asserts, without qualification, that a careful examination of the form and situation of the bones must convince the observer that such accidents can not occur. The case of Charles Butcher, who slipped on some steps, while carrying a heavy load on his head, in the end proved that a vertebral luxation can occur. The accident was followed by complete insensibility, and loss of voluntary motion below the neck. Functions of the brain not disturbed; respiration apparently performed merely by the diaphragm; pulse weak and slow; body cold; penis in a state of erection. *No irregularity of the spinous processes could be observed.*" Death took place in four days after the reception of the injury. The autopsy revealed a luxation between the fourth and fifth cervical vertebræ: "After cutting away the muscles from the back of the spine, the cartilaginous surfaces of the superior articular processes of the fifth cervical vertebra came into view; they were exposed in consequence of the inferior processes of the fourth vertebra having been *completely dislocated forwards*, and remaining fixed in their unnatural position. The yellow ligaments connecting the laminae of the two vertebræ were torn through, and the bifid apex of the fourth spinous process, lay in close contact with the basis of the fifth. On the front of the column an unusual projection was observed, but the anterior longitudinal ligamentous expansion was entire. *The body of the fourth was completely detached from that of the fifth vertebra*, the connecting fibro cartilage being torn through, and *the body of the former projected by its whole depth in front of the latter.*"

M. Roberts, of Paris, reports the case of a carpenter who in attempting to raise a heavy scaffolding pole and at a certain point being unable to sustain it any longer, received its weight upon his back. The accident was immediately followed by complete paralysis below the point injured. No projection or irregularity could be discovered at the seat of the lesion; death occurred on the eleventh day. Dissection showed that

the fifth was separated from the sixth dorsal vertebra, the latter being driven inwards so as to encroach upon the mediaspinal space. The ligaments were torn, and the articular surfaces separated, between the two bones. There was no fracture of any process; and the displacement was sufficient to compress the spinal cord.

There are several cases of dislocation of the last dorsal on the first lumbar vertebra reported, but some of them will not admit of full credence. The case referred to in Schmuclier's surgical work, is one of this class.

The New York Journal of Medicine for 1852, contains the account of a case of dislocation and fracture of the dorsal vertebræ, which occurred in the practice of Dr. Graves, of New Hampshire. The injury was produced by the fall of a door, the man being under it in a stooping posture. The lower extremities were immediately paralyzed, and priapism took place, lasting several hours. At the seat of the injury, which was at the junction of the lumbar and dorsal vertebræ, there was a marked appearance of displacement of the parts, which seemed to arise from a fracture and dislocation, or a sliding of the body of one vertebra over another. The surgeon placed the patient on his belly, and fastened a folded sheet under his arms and another above his hips: chloroform having been administered, extending and counter-extending forces were applied by means of the sheets, and the displaced vertebræ were reduced. Paralysis continued until the sixteenth day, when slight sensation returned to the feet: during this time the urine had to be discharged by the daily employment of a catheter; and the bowels were occasionally moved by the assistance of enemata. In six or eight weeks the patient recovered the use of his limbs; and the normal evacuations took place without artificial aid. Galvanism was employed for several months; and ultimately the recovery was complete, though a prominence remained at the seat of injury.

The only suspicious circumstance about this case is that the falling door is reported to have struck the man "across the shoulders," and the dislocation is claimed to have been "at the junction of the lumbar and dorsal vertebræ." Perhaps a mistake crept into the report, as it was not made directly to the Journal by Dr. Graves, but came through the hands of Prof. Willard Parker, of New York. The case terminated

much more fortunately than similar injuries generally do, but this circumstance need not necessarily cast suspicion upon its authenticity.

Death has occurred from attempts to effect reduction in cases of vertebral luxations. There would evidently be more danger existing in cases complicated with fracture, for the fragments might be forced against the cord and do irreparable mischief. Dupuytren expresses a caution in regard to the treatment of spinal dislocations in the following language: "the reduction of these dislocations is very dangerous, and we have often known an individual to perish from the compression or elongation of the spinal cord which always attends these attempts."

Dr. Ayres, of Brooklyn, N. Y., reports in the *New York Journal of Medicine*, for January, 1857, a case of dislocation occurring between the cervical vertebræ from some unknown cause, as the man was drunk at the time he received the injury. The neck was rigid and exhibited a peculiar deformity which could not attend any lesion except luxation of one or more of the cervical vertebræ. There was no paralysis; but intense pain attended the displacement. Great difficulty was experienced in attempts to drink or swallow food. The œsophagus and larynx seemed to be pressed upon by the bulging forwards of several of the cervical vertebræ. The back of the neck was rendered excessively concave and the integument was thrown into folds as it is when the back of the head is forced back against the shoulders; the front of the neck presented a corresponding convexity. Between the spinous processes of the fifth and sixth cervical vertebræ, a marked depression could be felt, and this was the point at which the greatest distress was felt by the patient. Dr. Ayres, with several surgical assistants who concurred with him in the diagnosis, performed a successful reduction while the patient was under the influence of chloroform. Extension was applied to the head and counter-extension to the shoulders, and while the head was rotated and pressure made upon prominent points in the neck, the displaced bones returned to position, and the head and neck resumed their natural attitude and aspect. The difficulty of swallowing and expectorating soon passed off, and no lasting ill consequences followed the luxation or the reduction. This with several

other equally successful attempts at reducing dislocated vertebræ, shows that in all favorable cases, well directed efforts should be made to overcome the displacement.

The execution of criminals by hanging was designed to bring about death by dislocation and not by strangulation, as is often the case. If death takes place suddenly the transverse ligament of the atlas gives way, and the odontoid process of the axis becomes free to impinge upon the cord at a vital point. Besides the rupture of the transverse ligament and the odontoid displacement, the posterior atlo-axoidean ligament may be torn, permitting a separation of the atlas from the axis.

The playful but dangerous practice of raising a child by the ears, and asking it to "see London," has been attended with dislocation at the atlo-axoidean articulation and sudden death.

The dreadful and prolonged sufferings which follow dislocations of the vertebræ, are among the worst that can be inflicted upon the human body. All the complex horrors of paralysis are liable to follow these luxations, such as bed sores, artificial evacuations of the bladder and rectum, utter dependence upon others to have even necessary wants supplied, and the perversions of the secretions to an extent that renders every phase of life disagreeable, and death welcome.

In a dislocation of the last dorsal vertebra, which occurred in a laborer engaged upon the government buildings in this city, no reduction could be effected, and the patient lived twenty-seven days. The man did not suffer excruciatingly from the first, but was unable to move the pelvis and legs. He rode home and talked cheerfully all the way. He could not believe he was seriously or dangerously hurt, and wondered why he could not move his legs. The urine was drawn with a catheter for ten days, and then it began to dribble, and flowed incontinently till death. The bowels were evacuated by means of enemas, except when profuse liquid discharges escaped involuntarily. Bed-sores formed upon the hips, and at length the flesh on the legs became gangrenous in spots. Death occurred from exhaustion and septicæmia. An autopsy revealed the dislocation and a partial fracture of an articular process of the vertebra above the one displaced. The cauda equina was pinched by the dislocated bones.

CHAPTER IV.

DISLOCATION OF THE RIBS.

The ribs do not properly articulate with the sternum, therefore they can only be dislocated at their vertebral extremities. The separation of a rib from its cartilage, or of its cartilage from the sternum, ought to be regarded as a fracture and not as a dislocation. That condition of the chest ordinarily known as "chicken breast," depends upon a bending of the cartilages, and is not a luxation in the true interpretation of that word.

The *heads of the ribs* have firm connections with the bodies of the vertebræ, and their *tubercles* articulate with the transverse processes of the dorsal chain, rendering their displacement exceedingly difficult and necessarily rare. The lower ribs, embracing the false and floating, having less support, are the most frequently dislocated.

The displacement is necessarily inwards, though the force producing the dislocation may carry the rib above or below its normal position. The accident, when it occurs, is produced by direct violence, such as kicks and blows; and it would be extremely difficult to determine whether a fracture or luxation was the result. Depression, mobility, and pain, would be characteristic of either lesion. Crepitus would be indicative of fracture, yet one rib might be dislocated, and another broken. The fracture of a spinous or transverse process might furnish the crepitation, and lead to the conclusion that the injury did not involve dislocation. Last year I had an opportunity to examine the body of a man who died from kicks received while he was lying upon the ground. Several ribs were broken, some of them in two places, and the tenth and eleventh, on the left side, were dislocated.

Bransby Cooper reports the following case of a luxated rib :
"Mr. Webster, surgeon at St. Albans, when examining the

body of a patient who had died of fever, found the head of the seventh rib thrown upon the front of the corresponding vertebra, and there anchylosed. Upon inquiry, Mr. Webster learned that this gentleman, several years before, had been thrown from his horse across a gate, for which accident he had been subjected to the treatment usually followed in fractures of the ribs, and there is every reason to believe that it was at this time that the dislocation occurred."

Other dislocations of the kind may occasionally occur, but as there is no opportunity to verify the diagnosis until after the death of the patient, they remain undiscovered. And even if they were discovered, it would be a difficult matter to restore a displaced rib to its natural position. A bandage might be applied to the chest to restrain the costal movements and compel the patient to breathe mostly by the action of the diaphragm; and the region of the injury might be subjected to the influence of chloroform and aconite, or the subcutaneous action of morphia, and anodynes might be administered internally, but all this would be appropriate in fracture of the rib, hence there is no necessity for a differential diagnosis between the two injuries, as nothing would be gained by the discrimination. A patient, therefore, need not be subjected to distressing and perhaps dangerous examinations to determine whether fracture or dislocation of one or more ribs existed. To be convinced that the one or the other lesion had been received, is practically sufficient for the surgeon. There being several authenticated cases of costo-vertebral dislocations, a question on that point no longer exists: and the injury being necessarily serious the prognosis should be always guarded. In simple dislocation or fracture of the rib, without much injury to the thoracic viscera, a recovery may be expected; but with several ribs broken or dislocated, the result is problematical. A force which breaks or luxates several ribs is about sure to extend to the organs within, and inflict dangerous lesions upon them.

CHAPTER V.

DISLOCATION OF THE CLAVICLE.

The firm ligamentous connections of the clavicle to the sternum and the scapula give forces a better opportunity to break the bone than to dislocate it. The acromial extremity of the clavicle is the most completely covered with soft tissues; and in addition to the acromio-clavicular ligaments which form a capsule for the joint, the coraco-clavicular fasciculus of ligamentous fibres holds the clavicle in firm connection with the scapula. This strong articulation would seemingly prevent luxation, yet the joint suffers such a lesion more frequently than the sterno-clavicular articulation. Of twenty-three dislocations of the clavicle observed by Hamilton, five were at the sternal end and eighteen at the acromial (*scapular* dislocations). The movements at the articular extremities of the clavicle are of a *gliding* character and quite limited in range, so that it is impossible for the articular surfaces to undergo much change in their relation to each other, or that any of the ligaments can be put greatly on the stretch. *Ceteris paribus*, the greater the extent of motion in a joint, the greater the liability to dislocation.

The sternal end of the clavicle may be dislocated forwards, backwards, and upwards. The cartilage of the first rib prevents displacement downwards. The forward dislocation is the most frequent, and may be partial or complete. In the latter, the head of the bone, besides projecting forwards, is depressed below its natural level; in the incomplete, it is usually slightly raised.

Luxation of the sternal end of the clavicle is generally produced by a fall upon the point of the shoulder, the force driving the bone inwards or forwards. It is probable that the shoulder is carried a little backwards as well as inwards, or

the head of the clavicle would not slide out of its place, but break somewhere in its course. The nature and direction of the forces which produce dislocations of the clavicle are not always understood. Quite contrary causes have been alleged as producing these displacements.

SYMPTOMS.—The prominent head of the clavicle seen and felt in its abnormal situation, covered only by the integument, leaves no doubt as to the nature of the injury. Where the head of the bone should be there is a depression into which the finger may be thrust. The corresponding shoulder still holds its position a little back where it has been driven; the movements of the arm are restricted; and great pain is felt at the point of displacement. The sterno-cleido-mastoid muscle in the lower part of its course, is rendered salient; and the tension of the muscle draws the head slightly downwards and to one side, as in “wry-neck.”

Movements imparted to the shoulder sensibly affect the displaced head of the bone; raising the shoulder depresses the head of the clavicle, and depression of the shoulder elevates it; if the shoulder be forcibly carried backwards, the head of the clavicle drops into place, or is brought to a point favorable to reduction.

A fracture near the sternal end of the clavicle may exhibit deformities similar in appearance to dislocation of the head of the bone: and I have seen syphilitic enlargements, and periosteal tumors which closely resembled a luxation.

The displacement, if considerable or complete, has not occurred without laceration of the anterior and posterior sterno-clavicular ligaments, and the rhomboid could hardly escape being torn. The inter-articular cartilage may remain in connection with the sternum or follow the head of the clavicle.

TREATMENT.—It is not a difficult matter to bring the head of a dislocated clavicle to the point of reduction, by drawing the shoulder outwards and backwards, the surgeon's knee being placed between the scapulæ of the patient; but to press it completely into place and keep it there, quite baffles the best skill. The great disposition of the bone to slip out of place when successfully reduced, has led to the invention of many methods intended to keep it in its normal position. In most instances, no kind of retaining apparatus yet devised,

will effectually retain the bone in position. In most cases the reduction can not be accomplished, and in the few in which the bone is replaced, the luxation has again occurred in a few minutes, or a few days at most. Fortunately the utility of the limb is not substantially impaired, even if the bone continues unreduced.

The dressing ordinarily used for fracture of the clavicle is as useful as any to retain the head of the bone in place, and as a protection against a recurrence of the luxation. The shoulder is to be carried outwards and backwards, and kept fixed in that position. Sir Astley Cooper recommended an apparatus something like a common shoulder brace to carry out the indications. A pad in the axilla and a sling to support and steady the arm, constitute a serviceable appliance. A thoracic bandage, with a pad in the arm-pit as a fulcrum over which the arm acts as a lever to pry the shoulder outwards, has been employed with success. Velpeau bandaged the arm to the side, with the hand carried to the opposite shoulder. Nelaton recommended that pressure be kept upon the head of the replaced bone, and used a truss for that purpose, the pad being placed over the articulation and the spring passing under the axilla of the sound side. The dressing is to be worn and the pressure kept up for six weeks or two months.

Luxation of the Sternal End of the Clavicle Upwards.—This accident has only recently acquired an established place in surgical pathology; the older surgeons doubted the possibility of its occurrence. Malgaigne has collected five examples; and the Buffalo Medical Journal contains an account of another that happened in the practice of Dr. Rochester. They were all occasioned by a violent force that carried the shoulder downwards and inwards. The patient of Dr. Rochester was caught under the bar of a gateway while seated upon a load of wood, and had the shoulder forced downwards and a little backwards. The sternal extremity of the clavicle was driven upwards in the direction of the chin, until it rested on the thyroid cartilage, the displacement being followed by difficulty of breathing and loss of speech. The reduction was easily effected, but no kind of apparatus would retain the bone perfectly in place. The head of the bone always remained a little above and a half inch in front of its natural position, though the arm retained its usefulness.

The symptoms of this rare dislocation are very marked, the head of the bone being felt above the upper border of the sternum, and near the median line of the neck; a depression can be felt where the head of the bone belongs, and the space between the first rib and clavicle is increased. There is probably complete rupture of all the ligaments of the joint, as well as of the costo-clavicular. The reduction is readily effected by lifting the shoulder upwards, and carrying it outwards, the head of the bone at the same time being pressed down into position. Retention is difficult, if not impossible. In none of the cases yet reported has there been one of successful retention, though the displacement did not seriously impair the functions of the arm. The treatment after reduction consists in the use of such appliances as shall steadily retain the shoulder upward and outward. A pad in the axilla, and a sling to keep the elbow to the chest, with the hand drawn up towards the opposite shoulder, are the simplest and most effective means at command. It is difficult to maintain continued pressure downwards upon the head of the bone.

Dislocation of the Sternal End of the Clavicle Backwards.—A combination of forces, as in accidents of a crushing character, may displace the sternal end of the clavicle backwards, compelling the head of the bone to take a position behind its normal location. This dislocation is rare, yet several cases have been reported. If a force drive the clavicle inwards at the same time the backward luxation occurs, the head of the bone may press disagreeably and even dangerously upon the trachea and œsophagus.

The *Medical Times and Gazette* contains the account of a case which occurred in the practice of Dr. Morgan, at the Middlesex Hospital, in 1852. "A girl, ten years of age, was knocked down by a carriage, and appears to have been trodden on by one of the horses. On admission, she suffered much from dyspnœa, the head was inclined forwards and could not be raised without extreme pain. There were marks of bruising over the right shoulder and clavicle. Where the head of the bone should be, there was a depression into which the fingers might be thrust, and the articular surface of the sternum could be distinctly felt, while the head of the clavicle was evidently behind it.

“On placing the knee against her spine, and gently drawing the two shoulders backwards, the bone was easily restored to its proper place, causing obvious relief to the dyspnœa; but immediately on leaving hold of the shoulders, the bone fell back, and the dyspnœa returned. A splint was then placed across the shoulders, with a pad between it and the spine, the shoulders being drawn to the splint by a bandage; by these means the bone was kept firmly in its place, pillows being so arranged along the patient’s back that the splint should not feel uncomfortable. On the apparatus being fixed, she could lean her head backwards, and stated that her pain was much relieved. The splint was kept on for a fortnight; the bone then being quite steady in its place. She was allowed to remain in bed without any bandage. The articulation became in four weeks quite as firm as that on the other side; and the arm could be moved without causing any pain.” This report gives the cause of the dislocation, depicts the prominent symptoms, and offers a plan of treatment which proved successful, at least in that one instance. Other cases are reported which throw no additional light upon the character of the injury or its surgical management. In one or two instances in which reduction was never accomplished, the functions of the arm were not seriously impaired.

If an attempt be made to save a leg that has suffered compound dislocation of the knee, let there be free discharge from the wound, and perfect rest. Evaporating lotions would keep the injured parts cool, yet warm wet cloths would do best to keep off tetanus and some other dangerous complications. The danger comes from shock, suppuration, tetanus, and gangrene. The swelling is usually great and the pain fearful. Then it is to be considered that a patient with an open injury to the knee may seemingly do well for a few days, and then sink and die without apparent cause for the sudden change for the worse.

CHAPTER VI.

DISLOCATION OF THE SCAPULA.

Dislocations of the *scapulo-clavicular* articulations have generally been described as "*luxations of the acromial end of the clavicle*," but in order to establish uniformity in our nomenclature, which has now discarded such terms as "dislocation of the radius and ulna upon the carpus," "dislocation of the tibia at the ankle," etc., it seems necessary to consider the acromion process of the scapula as dislocated from the clavicle, the latter being the more fixed point and nearest to the trunk. Use will make this naming of the injury seem correct when it is once rendered familiar. Luxation at this joint is more frequent than at the sterno-clavicular articulation: In the great majority of cases the acromion is forced beneath the outer end of the clavicle; in rare instances the acromion is made to take a position above the clavicle; and in extremely rare accidents the displacement is carried so far that the coracoid process, as well as the acromion, takes a higher level than the clavicle.

The causes of the injury are falls upon the extremity of the shoulder, and kicks and blows upon the same point. Direct violence, applied to the scapula, generally produces the lesion, though if the shoulder be fixed, and a force come from the opposite side of the body in a way to tilt the outer end of the clavicle upwards, luxation may be produced by an indirect action.

The symptoms of dislocation of the scapula downwards, are tolerably well marked; the acromion is overlapped by the clavicle which projects sufficiently to be distinctly felt; the pain is severe, and the motions of the arm are restrained: the shoulder appears slightly depressed, and the arm somewhat lengthened, the deformity partaking few of the features of a dislocation of the humerus.

In complete luxation the ligamentous structures, including the coraco-clavicular ligament, are lacerated; and the soft parts covering the articulation may be bruised and torn. If the displacement be great the acromion is driven inwards beneath the clavicle so far that the end of the bone forms a prominence immediately under the skin outside the acromion.

TREATMENT.—By drawing the shoulder outwards and backwards, and pressing upon the outer end of the clavicle, the bones can easily be restored to their natural relations. There is always great difficulty in retaining them in position, owing to the narrowness and obliquity of the articulating surfaces, as well as the action of the clavicular portion of the trapezius muscle. However, the parts implicated in the displacement soon adapt themselves to their new relations, and the utility of the arm and shoulder is but little impaired. Notwithstanding the difficulty of retaining the bones in their natural relation, success has occasionally attended a well directed and prolonged effort. The ordinary dressing for fracture of the clavicle, consisting of a pad in the axilla and a sling to lift the elbow upwards and bring it inwards, is a proper retentive appliance. A thick compress placed upon the outer end of the clavicle, and bound down by a long strip of adhesive plaster reaching from the lower ribs posteriorly to the lower end of the sternum anteriorly, prevents a recurrence of the displacement, and with the rest of the dressing, helps to keep the articular surfaces steadily in apposition. The compress may be held in place by a strip of adhesive plaster passed over it and under the elbow of the same side. A short strip reaching from the compress to the side of the neck will prevent the other part of the dressing from slipping over the point of the shoulder. Various contrivances have been devised to keep the bones in their relative positions, but none of them have universally succeeded. The mobility of the scapula is the greatest obstacle to continued adjustment. Tourniquets have been recommended to retain the bones in apposition, the strap passing under the elbow and the pad resting on the outer end of the clavicle. Shoulder straps connected with a sling at a point where the elbow rests, have been employed by various surgeons, but with all the modifications ingenuity has called forth, no appliance has been invented which will satisfactorily fulfill all the indications.

Dislocation of the Scapula Upward.—What has been called “*infra-acromial*” dislocation of the clavicle, or the upward displacement of the scapula as regards the acromial extremity of the clavicle, is an exceedingly rare accident. Two opposing forces acting upon the clavicle and scapula, the one depressing the former, and the other elevating the latter bone, might produce the injury. In the case reported by Tournel, the patient was knocked down by a horse and trod on. In looking at the articulated skeleton it might seem that the scapula could not be dislocated upwards without at the same time fracturing the coracoid process, yet experiments upon the cadaver show that the shoulder-blade may be rocked outwards sufficiently to permit this acromio-clavicular displacement without breaking the coracoid process. The dislocation must be attended with rupture of the acromio- and coraco-clavicular ligaments. The general symptoms will be those attending ordinary injuries of the kind; and the special diagnostic marks will be as follows: the acromion stands out prominently, and on its inside a depression can be discovered with the fingers, the end of the clavicle being below the articular facette on the acromion. If much swelling has not taken place, the positions of the two bones can be accurately determined by careful manipulation.

TREATMENT.—Reduction is accomplished by drawing the shoulder outwards, and rocking the scapula gently to disengage the acromion from the end of the clavicle. These manœuvres are sufficient to bring the articular surfaces of the two bones into apposition. This form of acromio-clavicular dislocation, when once reduced, is not so troublesome as the other more common variety. The return of the scapula to its natural position presents the coracoid process as an obstacle to the descent of the clavicle. After reduction is accomplished, it is only necessary to secure the arm to the side of the thorax and prevent all motion at the shoulder for two or three weeks. A handkerchief extending under the arm of the injured side and tied across the neck on the sound side, will hold the scapula snugly to the thorax and prevent that tilting of the bone which favors the acromio-clavicular displacement.

Dislocation of the scapula upward and backward, so as to throw the coracoid process above the clavicle, is an accident

that was not recognized by the older surgical writers. The lesion is now generally called the *infra-coracoid* dislocation of the clavicle, though in accordance with our adopted nomenclature, as well as *in fact*, it is a scapular displacement. The pathology of this accident is not well understood, at least it has not been well described; and the cause of the injury is decidedly problematical. The force must be of a character to rotate the scapula and wrench it from its connections with the clavicle. In reality, the injury must be an exaggerated form of the upward dislocation of the scapula, that bone being forced outwards and upwards to a degree which throws the coracoid process above the clavicle, the latter bone being made to take a position in the axilla. Such a peculiar injury must be exceedingly rare; and it is not strange that its existence should be doubted. However, the most unaccountable accidents will occasionally occur to astonish the incredulous, and this may be one of them. It is easier to see how the bones can take that unusual position, than to understand the complex nature of the forces necessary to effect the displacement.

If I were called to treat such an injury I should attempt to reduce the dislocation by placing the knee in the armpit, and using the arm as a lever to bring the scapula back into place; the upward pressure of the knee would tend to dislodge the clavicle from the axilla and direct it back into place; while the scapula could be made to rotate in any direction by movements imparted to the arm.

CHAPTER VII.

DISLOCATION OF THE HUMERUS.

Dislocation of the shoulder is so common an occurrence that it is deserving of unusual attention. A practitioner of medicine and surgery will not pursue an active part in his profession for many years without being called upon to take charge of a shoulder luxation; though he may never encounter in a long career of practice, one-half the different dislocations described in his text books.

The humerus is dislocated, according to the tables of Malgaigne and several other authors, more frequently than all the other bones of the body together. This fact in itself is sufficient to demand for the subject the most profound consideration.

The peculiar structure of the shoulder-joint, the shallowness of its socket, the large size and globular form of the head of the humerus, the extensive movements and long leverage afforded by the arm, and its frequent exposure to injury in protecting the more important central organs of the body, are all circumstances which contribute to the facility and frequency of dislocation. On the contrary, the great mobility of the scapula, and the flexibility of the spinal column, which serve to transmit and decompose forces, operate as counter-balancing influences.

Age exerts a marked influence upon dislocations of the shoulder, the accident being extremely rare during childhood and old age, though I have met with an example in a child under a year old, and another in a woman over seventy. Mr. Watts, house-surgeon to Middlesex Hospital, treated a case of dislocation forwards in an infant fourteen days old. The accident most frequently occurs in adults from thirty to sixty years of age.

Strange though it may be, the pathology of this common injury is still imperfectly understood. Surgical writers of the French School, in seeking for distinctions and refinements, have contributed not a little to involve the subject in inextricable confusion. The student is apt to be discouraged when he finds his author has described eight or ten different forms of luxation peculiar to one joint. But, when he finds that there are only three principal displacements of the humerus to study, and that all other forms so elaborately described by some authors, are mere variations of one or the other of the three kinds, he is encouraged to enter upon the study of them with greater zeal.

The old method of describing the different luxations of the shoulder under the nomenclature of downwards, forwards, backwards, etc., often led to confusion, none of them indicating definitely the exact position of the head of the humerus. Names derived from the position the head of the bone in its new situation assumes in regard to certain well defined points on the scapula, are more concise, definite, and expressive. For instance, the "backward" dislocation is called the *subspinous* luxation of the humerus, the word in Italics indicating that the head of the humerus rests beneath the spinous process of the scapula; the "downward" dislocation is designated as the *subglenoid*, meaning that the head of the humerus is thrown beneath the glenoid socket; and the "forward" or "inward" dislocation, takes the name of *subcoracoid*, to show that the head of the humerus is forced beneath the coracoid process. And if the force be sufficient in any case to carry the displaced bone very far inwards or forwards, so it shall fall inside the coracoid process and beneath the clavicle, the luxation may be called *intra-coracoid* or *subclavicular*, to indicate definitely the extent of the displacement and the position the head of the humerus has assumed. This is a modification of the nomenclature adopted by Malgaigne; and it is hoped that the attempt to simplify the system will prove advantageous to the beginner in the study of this otherwise vexatiously complex classification. I shall commence with what I regard as the most frequent variety of luxations of the humerus.

Subcoracoid.—This is what the older writers have pronounced a dislocation forwards; and as a form or variety of displacement, embraces the *intra-coracoid* of Malgaigne, his two varie-

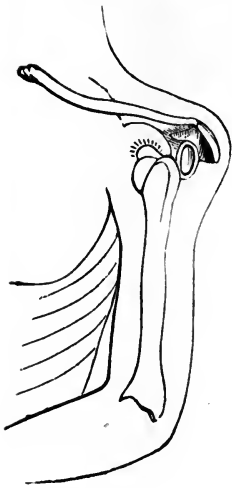
ties being brought under one head from the fact that the difference between them is rather of *degree* than of *kind*. If the critical reader is not satisfied with this manner of considering the subject, he may regard the terms employed as expressing subvarieties of one common form.

In each of the three varieties of dislocation the head of the humerus rests against the rim of the glenoid fossa. If the displacing force drives the head of the bone far inwards, so it shall rest inside the coracoid process, establishing the *subclavicular* variety, there may be some space between the glenoid rim and the humerus, though not as much as mere reasoning upon the subject would lead us to suppose. Dissections of the parts involved in the subclavicular dislocation show that rotations of the scapula and humerus bring the two bones into pretty intimate relations. If the *teres minor*, and the *infra- and supra-spinatus* muscles continue untornd, they will not permit the head of the humerus to remain at a distance from the glenoid border unless some obstacle intervène. Should the head of the humerus be forced within the coracoid process and there lodge or become fixed, the dislocation would be truly *intra-coracoid*, but such is not often the case.

For many years I have been inclined to dissent from the commonly accepted opinion in regard to the most frequent form of dislocation at the shoulder-joint. I critically examined every case coming under my observation, whether in the living or the dead subject. I frequently met with the subcoracoid variety, and rarely with the subglenoid ("downward"), though many of the lesions I carefully investigated and found to be subcoracoid, had been pronounced downward dislocations by surgeons of more than ordinary experience and ability. At length I was gratified while looking up authorities on this subject, to find that Malgaigne regarded the subcoracoid variety as happening more frequently than any other form of shoulder dislocation; and Mr. Flower, in his surgical contribution to *Holmes' System of Surgery*, says: "Of forty-one specimens of dislocation of the shoulder-joint, preserved in the different anatomical museums in London, as many as thirty-one undoubtedly belong to this form; and of fifty recent cases which have come under the observation of myself, or gentlemen in whom I can place perfect confidence, and of which I have full particulars, in forty-four the head of

the humerus was placed so closely beneath the coracoid process as to justify the appellation of 'subcoracoid.' In the face of these facts, it is difficult to understand how the wide-spread

FIG. 108.



Dislocation of the head of the humerus inwards (subcoracoid.)

error of regarding the subglenoid as the typical form of dislocation at the shoulder-joint, should have been so long maintained. A simple process of reasoning upon the anatomical structure of the part would suffice to show that, whenever the humerus is thrown from its socket, it will almost of necessity be drawn upwards until it is arrested either by the coracoid process in front, or the spine or acromion behind. Even in the dead subject, when dislocation is artificially produced by forcibly elevating the arm, while the scapula is fixed, the humerus is almost always drawn up close against the under surface of the coracoid process; *a fortiori*, in the living, must the action of the deltoid, coraco-brachialis, and biceps cause it to assume this position. The truth is, that nearly all

the cases of 'dislocation into the axilla,' or 'downwards,' described as so common by Sir A. Cooper, and all subsequent authors, have really been examples of this variety, to which the anatomical characters of the more rare 'subglenoid' dislocation have been erroneously applied."

In a case of alleged malpractice tried in Marion, Grant Co., Indiana, in April, 1869, between Larkin *versus* Jones, I was called to give testimony in relation to the injury sustained by the plaintiff. Mr. Larkin had fallen from a load of grain six months previously, receiving an injury of the shoulder. Dr. Jones was summoned to treat the injury two days after the accident, and, as he claims, was not permitted to make a satisfactory examination of the shoulder, the patient being peevish, and the parts involved in the injury greatly swollen and extremely sensitive. The doctor suspected the existence of a serious lesion, such as a fracture or dislocation, but left some liniment to allay the inflammation, and directions to be called again as soon as the swelling and tenderness sufficiently

subsided, to admit of a satisfactory examination. Mr. Larkin did not send for Dr. Jones again, nor any other physician, but let the arm go as it was for four weeks. He then exhibited his shoulder to Dr. Horn, who discovered the existence of a luxation, and sent the patient to Dr. Wm. Lomax for treatment. It was decided not to attempt reduction; and Mr. Larkin entered suit against Dr. Jones on the ground of neglect to discover a dislocation, and claimed ten thousand dollars as damages. At the trial Dr. Lomax and seven other practising physicians and surgeons of Marion, Jonesboro, and vicinity, testified that the injury sustained by the plaintiff was a downward dislocation (subglenoid) of the humerus; and that this was the common form of shoulder dislocation. In my testimony and cross-examination, I declared that the head of the displaced humerus in Mr. Larkin's injured shoulder, was resting beneath the coracoid process: and that this was the most common form of shoulder dislocations. The testimony was received with marked discredit by the medical friends of the plaintiff; yet the defendant was acquitted.

The head of the humerus in Larkin's case, could be distinctly felt beneath the coracoid process; and measurements from the acromion to the olecranon while the arm was flexed, showed that the arm was lengthened to the extent of half or three-quarters of an inch. If the dislocation had been downwards (subglenoid), it would have been lengthened an inch and a half, or more than the width of the glenoid socket. Subcoracoid dislocation may be produced either by a direct force applied to the head of the humerus, displacing it inwards and forwards, as a blow or fall upon the shoulder; or, more frequently, by forcible elevation of the lower end of the bone, such as may be caused by a fall upon the elbow or hand, when extended from the body. In those cases coming under my observation, the cause of the displacement has most frequently been a fall upon the elbow or hand, though in Mr. Flower's cases direct violence, as falls or blows upon the shoulder, produced dislocation in the most instances. It occasionally happens that the cause can not be definitely ascertained, the patient bearing marks of violence in several places, and not being able to decide what force produced the displacement. As a general rule, dislocations at any articulation, are rarely produced by a direct blow on the joint. Mr. Bryant, in

Cooper's *Surgical Dictionary*, states that, "in thirty-one out of thirty-four cases, the cause of the injury was a direct fall upon the shoulder, either forwards, backwards, or outwards. In two instances only of dislocation downwards, and forwards, was the bone displaced by a fall on the extended arm." Maligne says: "the subcoracoid luxation, which is the most common dislocation, is the effect of a direct blow on the shoulder, the arm not being raised." Warren in his *Surgical Observations*, expresses the opinion that when direct force, the arm being by the side, knocks the head of the humerus out of its socket, the rim of the glenoid cavity must at the same time be broken.

SYMPTOMS.—Certain symptoms, such as pain, want of motion, and swelling in the region of the injury, accompany all dislocations, but the subcoracoid variety of shoulder dislocation has a few characteristics peculiar to that form of luxation: the elbow projects from the side, and can not be made to approach the chest without causing pain; the movements of the forearm and hand are not much impaired, though the sensation of numbness which comes from pressure of the head of the humerus on the brachial plexus of nerves, is somewhat disagreeable. On comparing the two shoulders a striking change is observable on the injured side, especially if the patient be lean and the injury recent. The natural roundness is lost, the acromion appears remarkably prominent, and beneath it there is a depression into which the fingers can be pressed, proving that the head of the humerus has left its socket; and in some spare subjects, even the form of the glenoid fossa can be distinguished through the fibres of the deltoid. The axis of the humerus is evidently altered; instead of being directed to the glenoid cavity, it points to a spot internal, anterior to, and below it. If the head of the humerus rests on the point of the coracoid process, the arm, measuring from the acromion to the external condyle, and comparing it with the opposite side, is lengthened; if it presses in behind the coracoid process, or gets forced within that osseous projection, so as to become *subclavicular*, the arm is shortened. According to Mr. Flower, of forty-four cases of subcoracoid dislocation, the arm was elongated in nineteen, unaltered in eight, and shortened in seventeen; the greatest

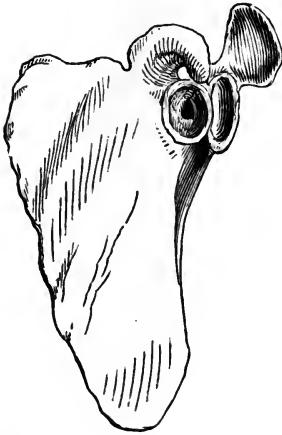
elongation being one inch, the greatest amount of shortening seven-eighths of an inch. Measurement of the vertical circumference of the shoulder, by carrying a tape over the acromion and under the axilla, always gives an increase of one to two inches over the uninjured side; an important diagnostic sign, common to all forms of dislocation of the humerus, as pointed out by Mr. Callaway, in his "Dissertation upon Dislocations and Fractures of the Clavicle and Shoulder-Joint." The head of the humerus can be distinctly felt beneath the pectoral muscles; the tumor produced by its globular form can be seen; and any movements imparted to it by rotating the arm can be both seen and felt. The head of the humerus lies on the anterior surface of the neck of the scapula, immediately below the coracoid process. The subscapular muscle is raised from the neck of the scapula, and stretched over the front of, or above the head of, the humerus. The muscles from the back of the scapula (teres minor, and infra- and supra-spinatus) are drawn tightly across the glenoid fossa, or one or more of them may be ruptured, or detached from the bone. In some cases, the greater tuberosity is broken off, and the muscles inserted into the fragment then drag it into the glenoid fossa. The tendon of the long head of the biceps, contrary to the views of Hamilton, is rarely broken asunder, or completely detached from its insertion. The great vessels and nerves are displaced inwards, the circumflex nerve being either stretched or compressed to an extent which frequently causes paralysis of the deltoid muscle. I have seen patients, years after a successfully reduced dislocation of the shoulder, who could not raise the arm beyond an angle of 45° or 50° , though all the other motions were perfectly restored.

The capsular ligament in complete dislocation, is torn sufficiently to allow the head of the humerus to escape through the aperture; and in those cases that will not stay in place after reduction is effected, there is a strong presumption that the edge of the glenoid rim is fractured.

When left unreduced a new shallow socket is formed upon the anterior surface of the neck of the scapula, partly by the absorption of old bone, and partly by the deposit of new, around its edge. The exact position of this socket varies according to the extent of the displacement; in some instances the new cavity is formed more or less at the expense of the

anterior portion of the glenoid fossa, which is gradually removed by absorption under pressure, so that the original socket is greatly encroached upon. A corresponding change

FIG. 109.



New socket formed under the coracoid process.

takes place in the head of the humerus; the part bearing upon the edge of the glenoid fossa, has a hollow excavated in it, the surfaces of the two bones in apposition accommodating themselves to each other, and thus a rude kind of joint, which allows of a certain amount of motion, is formed. The under surface of the coracoid process, especially near its tip, becomes smooth and eburnated, showing upon dissection that it has contributed to the formation of the new articulation.

In those cases where the head of the humerus is thrown within the coracoid process, constituting

the subclavicular variety, or the "intra-coracoid" of Malgaigne, the head of the os humeri being wholly on the sternal side of the coracoid process, sometimes coming forwards so as to appear just beneath the skin, and at others deeply buried in the subscapular fossa, the new socket is not formed on the rim or border of the glenoid fossa, and the globular extremity of the humerus maintains its accustomed shape. If the head of the humerus touch the inner surface of the blade of the scapula, a shallow depression is formed in that bone, and the head of the humerus is slightly flattened at a spot where the bones meet, and there becomes divested of its cartilage, though from friction the parts in articular contact become polished and hardened. If the greater tuberosity reach the anterior edge of the glenoid fossa, or any part of the coracoid process, the points of contact will soon show the peculiarities of a new articulation. In extremely rare cases the clavicle has exhibited a slight depression where the head of the humerus has reached it. How long it takes to form a new socket when the head of the humerus is forced to take lodgment outside its normal position, is not known, for the history of old dislocations is

seldom obtained. Probably it requires a year or more for the most of those changes to occur which are observed in ancient dislocations. In a specimen in St. Bartholomew's Hospital Museum, in which the luxation is said to have occurred three months before death, absorption of the anterior edge of the glenoid fossa has already commenced, and some bone is deposited in the margin of the new socket.

It is a singular circumstance that so many surgical writers should have regarded subcoracoid dislocations as "partial" in their nature, unless it came from the fact that Sir Astley Cooper, in his treatise on Fractures and Dislocations, which has been "authority" so long, described an incomplete luxation of the head of the humerus, of the subcoracoid variety. Hamilton, after reviewing and criticizing the opinions of those who claim to have had partial dislocations to treat, says: "I shall content myself with declaring that the existence of this or of any other form of partial luxation of the shoulder-joint, as a traumatic accident, has not up to this moment been fairly established; and that the anatomical structure of the joint renders its occurrence exceedingly improbable, if not absolutely impossible." It may be remarked, incidentally in this place, that in many of those cases which have been regarded as partial dislocations of the shoulder, the lesion consisted of a rupture or displacement of the long head of the biceps tendon, an accident which is characterized by a sufficient displacement of the head of the bone upwards and forwards between the coracoid and acromion processes, to give the deformity the appearance of a partial luxation. The long tendon of the biceps having its origin from the upper part of the rim of the socket, and passing over the head of the humerus and down through the bicipital groove of that bone, serves to bind the articular surfaces of the two bones in close apposition, consequently a rupture of this tendon would be followed by more or less displacement which might be regarded as incomplete luxation.

TREATMENT.—All scapulo-humeral dislocations of recent occurrence, can be successfully reduced by manipulation if the patient be thoroughly under the influence of chloroform at the time the effort to replace the humerus is made. In very many cases no anæsthetic is needed, but in muscular subjects,

especially if the injury be of two or three days' standing, it is useless to attempt a reduction before an advanced stage of anæsthesia is reached. The use of nauseants, fomentations, and other relaxing agencies, has been entirely superseded by anæsthesia. The pulleys, Jarvis' Adjuster, and other contrivances for multiplying force, have also lost their importance.

In a subcoracoid dislocation, as well as in other luxations of the shoulder, the projecting edge or rim of the glenoid socket is an obstacle to reduction; the stretched muscles and tense ligamentous structures also oppose a return of the displaced bone, unless the arm be carried into a position which relaxes those tissues. To attempt reduction by extension alone is sure to increase the strain on the already overstretched muscles and ligaments.

To proceed systematically, whether chloroform is used or not, let the patient lie upon a sofa, low bed, or the floor, and then the arm seized near the elbow is to be carried off from the body and elevated as much as possible; the fingers of the surgeon's other hand rest upon the shoulder to steady the scapula, and his thumb is pressed into the axilla, against the head of the humerus, to act in part as a fulcrum over which the patient's arm as a lever is made, by a quick downward movement, to pry the head of the bone from behind the projecting border of the glenoid socket, bringing the head of the humerus to a point where the force of the thumb and of the tense muscles will inevitably complete the reduction. The hand which has hold of the patient's arm near the elbow, should swing it slightly backwards and forwards while the arm is forcibly elevated, in order to disengage the head of the bone from its place of lodgment; and then, in bringing the elbow downwards to the side of the thorax, or across the front of the chest, the motion is to be imparted suddenly in order to be as effective as possible. The patient, if not under the influence of chloroform, always holds the muscles in a state of rigid resistance while the surgeon is manipulating the arm, therefore the quick motion is expected to put the patient off his guard. It is to be borne in mind that the forearm should be flexed on the arm while manipulation is going on, that the biceps may be relaxed.

If the first attempt at reduction fail, it will be because the scapula slips from the surgeon's fingers, and destroys the

leverage which is designed to lift the head of the humerus from behind the projecting edge of the glenoid fossa ; therefore another effort must be made, and the attempts repeated until success crowns the undertaking. Those who are not strong in the hands may use the heel (the boot being removed) as a fulcrum in the axilla or against the head of the humerus ; this leaves both hands free to execute the reducing manœuvres upon the arm. Some surgeons prefer to employ the knee in the armpit instead of the heel ; and to have the patient lie on the floor while the manipulation is performed. The return of the bone to the socket is generally accompanied with an audible snap ; and the natural mobility of the arm is restored at the same instant. In most instances the natural contour of the shoulder returns as soon as reduction is effected, but in rare cases the head of the humerus rests awkwardly in the socket, which, in addition to the swelling, gives the region a deformed appearance.

Reduction has been accomplished by extension and counter-extension, applied as follows : the patient lying upon his back, the surgeon seated by the affected side, places his heel well up into the axilla, so as to press upon the lower border of the scapula, and then with both hands hold of the wrist exerts all the traction he can command, all the while rotating the arm and endeavoring to engineer the bone back into place.

Surgeons owning Jarvis' Adjuster, and having employed it successfully in several instances, still have faith in its qualities, and persist in claiming that there are cases that can not be reduced without it as a means of exerting powerful extension and counter-extension.

I have never met with a recent dislocation of the shoulder that, in my present belief, could not have been reduced by manipulation, the patient being thoroughly under the influence of chloroform. In October, '68, I was called to Hamilton, O., to assist in the reduction of a subcoracoid dislocation of the humerus which fell into the hands of Dr. Markt. Several futile attempts had been made to effect a reduction ; and their failure, in my opinion, depended upon imperfect anæsthesia. The patient was a young German, of remarkable muscular development ; and possessed a nervous system that would bear an unusual amount of chloroform without being overcome.

I used eight or ten ounces of the best chloroform on a handkerchief held quite close to the nose before stertorous breathing was produced. As soon as that stage of profound anaesthesia was reached, the muscular system became relaxed, and reduction took place by the force of the hands alone.

In some cases which for some time resist the usual efforts at reduction, it is found that success attends modifications of the ordinary procedure; for instance, the arm is to be carried forcibly backwards as well as upwards, or it has to be extended by the force of two or three assistants, to effect some change in the position of the head of the humerus, or relieve it from the restraining influence of the untorn portion of the capsular ligament, or to perform some other feat more empirical than scientific, which shall so modify the relations of the parts involved in the injury, as may result in an easy replacement of the luxated bone. I have seen a person inexperienced in the management of dislocations reduce a displaced bone that had baffled a skillful surgeon for hours. However, there are not enough of such chance cases to justify an entire dependance upon the results of blundering.

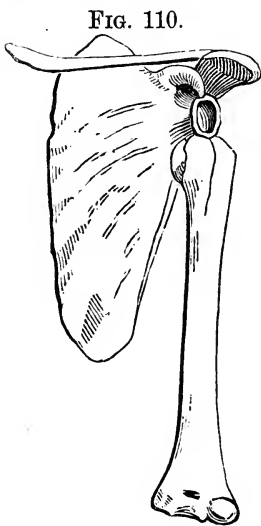
After reduction has been accomplished, the joint should be kept at rest for two or three weeks, the arm being placed in a sling, with the elbow bound to the side. It may be well to guard against elevating the elbow or throwing it outwards and upwards for several months. A recurring dislocation is a great perplexity, therefore it is best to follow precautions likely to prevent such accidents.

The subclavicular variety of dislocation is generally very difficult to manage. The coracoid process is an obstacle in the path leading to a return of the head of the humerus. The arm must be drawn downwards so the head of the humerus may pass clear of that process; and then manipulated as if the displacement were of the common variety. The heel in the space between the arm and the chest, with both hands exerting extension and rotation, will generally effect a dislodgment of the luxated bone, and successful reduction.

SUBGLENOID DISLOCATION OF THE HUMERUS

What is generally called the "downward," "downward and inward," and "axillary" luxation of the shoulder, is a displacement of the head of the humerus so that it occupies a position below the socket, the capsular ligament being torn at its lower part. This has commonly been regarded by surgical writers as the most frequent luxation of the humerus, but as I have already stated in another place, the lesion is far less frequent than the subcoracoid variety of shoulder dislocations.

The head of the humerus being thrown below the glenoid fossa, finds lodgment upon the inner border of the inferior costa of the scapula, somewhat as represented in the accompanying diagram (Figure 110).



Subglenoid dislocation of the humerus.

Why the globular head of the os humeri should ever become poised on the thin border of the blade-bone, is almost a mystery, but there it has been found in a few instances. Probably the untorn edge of the capsular ligament prevents the head of the humerus from rising up to a point beneath the coracoid process. An examination of the scapula shows that the inferior costa of the bone terminates in two crests, leaving a wide groove between them at a point corresponding with the cervix scapulae. In this scaphoid fossa the head of the humerus finds lodgment; and the inner of the two crests or borders of the groove prevents the humerus from sliding upwards. Mr. Flower says, that "In the only two specimens of unreduced dislocations of this kind that I have been able to find in the anatomical museums of London, a new osseous socket has formed for the head of the humerus on the upper part of the anterior border of the inferior costa of the scapula, encroaching considerably upon the lower and anterior part of the glenoid fossa. One of these has been figured by Sir A. Cooper, and its subsequent reproduction by other authors has

contributed much to confirm the error of regarding this as the usual form of dislocation at the shoulder. From examinations of specimens in museums, and from numerous recent cases, I should conclude that not more than one in ten of all dislocations of the humerus can properly be called subglenoid." There is a specimen in King's College Museum, (No. 1342), which is intermediate between subcoracoid and subglenoid.

The servile copying of diagrams from Cooper's work on Fractures and Dislocations, and the wording of the text to conform to the illustrations, has done much towards perpetuating errors even in recent works on Surgery. Old figures representing reductions of the humerus and femur by means of pulleys, and other appliances, showing how to employ extension and counter-extension as methods of reduction, have contributed more than any other influence to perpetuate barbarous practices in the application of force. Even if better methods of reducing dislocated bones are described in the text, many indolent practitioners will neglect the printed directions, and be governed only by the pictures which make deeper impressions than prosy descriptions.

The symptoms of subglenoid dislocation of the shoulder are not strikingly different from those manifested in the subcoracoid variety of luxation. The depression beneath the acromion process is greater; the arm is lengthened to the extent of the diameter of the glenoid fossa, unless, in being worked at, the head of the bone leaves the bifid ridge on which it usually rests and becomes embedded deeply in the subscapular fossa; and there is an inch or more of space between the head of the humerus and the coracoid process. Measurements are uncertain unless they be conducted with great care, both arms being made to assume the same positions while measured, allowance being also made for the rotated attitude of the injured arm. In this as in the subcoracoid variety of dislocation the patient is unable to make the hand of the injured side touch the sound shoulder; neither can the surgeon execute the manœuvre unless the patient be under the influence of chloroform; and then there would be danger of lacerating the tense tissues in the endeavor. The rigid condition of the arm, its ugly projection from the side, the painful numbness of the whole limb, and disposition of the patient to support the arm with the well hand, constitute signs that point pretty clearly

to some kind of a scapulo-humeral dislocation. The causes of subglenoid dislocation of the shoulder are direct violence upon the top of the humerus, falls upon the hand or elbow while the body is descending, and the forcible elevation of the elbow, making the acromion a fulcrum over which the leverage of the arm is sufficient to tear the capsular ligament on its under side and contribute to the displacement. Muscular action while the arm and elbow are quickly thrown upward, has been known to produce the "downward" luxation.

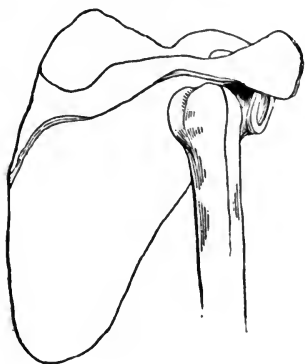
TREATMENT.—The management of a subglenoid dislocation does not differ essentially from that already laid down for the reduction of a subcoracoid dislocation. The arm is to be seized just above the elbow and carried forcibly upward and outward, and the scapula is to be fixed by the exertion of the fingers, while the thumb performs the part of a fulcrum and helps push the head of the humerus into place at the instant the quick downward and inward movement of the arm is executed. One attempt failing, several repeated efforts should be made, each being somewhat different from the preceding in order to give variety to the manœuvres. The heel or knee being placed in the axilla, both hands can be used in extending, rotating, and sweeping the arm from a position of extreme elevation to one of extreme depression alongside or across the chest. One hand holds the forearm flexed and the other guides the elbow. Chloroform should be freely employed in all cases that resist the first efforts or are extremely painful. If the surgeon sees the patient soon after the accident, he may be able to effect reduction without resort to anæsthetics. I have reduced a dislocated shoulder without even waiting to take off the patient's coat. I have seen the armpit severely bruised by the surgeon's boot in attempts at reduction; and here express my disapprobation of such rough usage. I have also seen the arm above the wrist and elbow terribly excoriated by the action of towels and straps employed in making extension. Proper care manifested during manipulation saves the patient from these painful and unsightly marks. A bold and efficient surgeon generally acquires the reputation of being rough, and he deserves this discredit if he heedlessly and heartlessly inflicts unnecessary injuries upon his patients. Skillful and gentle manipulations accomplish more in reducing

dislocated bones than brute force put forth without a rational method in view. The retentive dressing to be employed after reduction is effected, may be the same in all kinds of shoulder dislocations. The arm is to be suspended in a sling, and tied to the side for two or three weeks; and care exercised about elevating the arm for several months.

SUBSPINOUS DISLOCATION OF THE SHOULDER.

What has been generally called a "backward" luxation of the humerus, the head of the bone being forced from its usual position to one beneath the spine of the scapula, outside

FIG. 111.



Subspinous dislocation of the humerus.

of the glenoid socket, is an injury of uncommon occurrence. Out of 159 cases of scapulo-humeral luxation recorded in the Middlesex Hospital, three were of this variety. Its characters are so well marked, that it is not liable to be confounded with any of the others. There are said to be four good specimens, illustrating its effects, when left unreduced, in the different anatomical museums of London. The head of the bone, when dislocated backwards, would naturally rest on the neck of the scapula near the posterior

edge of the glenoid fossa, but in case the displacing force continued after the luxation was accomplished, the head of the humerus might be driven back two or three inches upon the dorsum of the scapula. In cases of great displacement the lesser tuberosity of the humerus is found to be separated (broken), or the tendon of the subscapularis is detached from its humeral connection.

In an unreduced dislocation of several years' standing, which I once had the opportunity to dissect, I found the part of the head of the humerus which rested against the posterior edge of the socket and the neck of the scapula, somewhat flattened and eburnated; and a new socket had formed, slightly excavating the blade, and considerably the base of the

acromion. There was very little osseous material thrown around the new socket. Pressure of the head of the humerus upon the posterior edge of the glenoid rim had caused some encroachment upon that segment or ledge of bone, but the articular face of the glenoid cavity had not been altered. The tendon of the subscapular muscle had been torn from its humeral attachment, and the old capsular ligament was thinned and in places lost by being blended with the other soft tissues of the region.

The head of the bone formed a marked protuberance beneath and outside of the acromion, giving the shoulder the appearance of being widened on that side; the depression between the acromion and the coracoid processes, was not marked, but could be distinctly felt by pressing the fingers into the old socket. The elbow was inclined to take a position a little more inward than natural. Whatever may have been the rigidity of the arm directly after the accident, or the restrictions upon a wide range of motion, at the time of the patient's death the limb could be moved freely in every direction.

The causes of subspinous dislocation would probably be falls upon the arm while the elbow is thrown forcibly in front of the chest. At any rate, this seems to be the only way a dislocation of the kind can be produced in the cadaver. The few surgeons who have had a case to treat were not generally able to ascertain the position of the arm when luxation occurred, or the positive and direct cause of the accident. Convulsive muscular action is said to have produced the luxation in one instance, and falls of various kinds in the others. The dislocation was not always discovered until days or weeks after the accident, yet reduction was accomplished in nearly every case, though the head of the bone had been displaced for a number of days before an attempt at reduction was made.

TREATMENT.—The rule for reducing this form of dislocation is to stand behind the patient who is seated in a chair or on a stool; the surgeon with one hand takes hold of the back of the arm near the elbow and forces it across the chest, in front, as far as it will go; he then puts the other hand on the top of the shoulder, the fingers resting on the acromion to steady the

scapula, and to lend efficiency to the thumb in the work of being a fulcrum and in pushing the head of the humerus into place when the patient's arm is suddenly swung backwards. This manœuvre, accomplished by both hands operating separately, will replace the bone, especially if the patient be thoroughly relaxed by the influence of anæsthetics.

Direct extension has proved effectual in reducing this dislocation. In fact, any dislocation of the shoulder may be reduced with the pulleys and other appliances for exerting great force, yet the mechanical resistance offered by the untorn portion of the capsular ligament, is such that the bone can not be replaced by extension without lacerating the tissues made more tense by the operation. Extension drags the head of the bone away from the opening in the ligament through which it escaped, and places the *caput humeri* in a position unfavorable to an easy return over the glenoid rim.

Mr. Flower gives the following plan which he has never known to fail: "The patient is seated on a high chair, which is placed about two feet from the post of an open doorway. The surgeon, leaning his back against the door-post, places one foot upon the side of the chair, and, with his knee pressed into the axilla and both hands upon the shoulder, steadies the patient's body. A jack-towel is then fixed by a clove-hitch knot to the patient's arm, just above the elbow; and by its means two or more assistants, placed on the other side of the doorway, make steady extension horizontally outwards." This plan is for reducing dislocations "downwards" and "forwards," but is open to the same objections as other contrivances to produce extension. It is found to be an unscientific plan for reducing dislocations, and though it will yet be followed by a few superannuated practitioners, the more rapid, and less dangerous "physiological" process, now so well understood, continues to gain favor, and rarely or never fails where success by any method is possible.

Compound Dislocation of the Shoulder.—It has been a question whether a compound dislocation of the shoulder should be reduced, or the head of the humerus resected. Although I have never had such an injury to treat at the shoulder-joint, I am persuaded that I should proceed at once with an attempt at reduction. If the head of the bone would not return through the hole in the skin I should enlarge the opening.

and then make a powerful effort at reduction. If this course failed it would then be in order to exsect the head of the humerus and enough of the shaft to facilitate a return of the bone to its place.

Dislocation of the Humerus, with Fracture near the Upper End of the Bone.—The older surgical writers declared that a dislocation of the shoulder, complicated with fracture of the humerus near its upper extremity, could not be reduced until the fracture had united. Dr. J. M. Warren, in his *Surgical Observations*, says, "I have had to treat several cases of dislocation of the shoulder, with fracture of the neck of the humerus. In two instances in which I was called while the muscles were still relaxed, and before the patient had recovered from the depressing influence of the shock, it was found possible to effect reduction by making extension of the shaft of the bone, at the same time working the separated head into its socket by firm pressure with the thumbs. In case reduction can not be thus effected, it is still a question whether the shaft of the bone should be carried back into the old socket, so as thus to make at once the best practicable joint; or whether it should be placed in apposition with the head, and an attempt made at reduction after such a lapse of time as may be thought sufficient for the union of the fragments to take place. The latter method was tried with success, by Dr. John C. Warren, on a young man, whose case he reported in the 'Boston Medical and Surgical Journal' for 1828. Immediate reduction having been attempted in vain, fracture-apparatus was applied. After seven weeks, extension was made with pulleys, and the dislocation reduced. The case is quoted by Malgaigne, who considers the precedent worthy to be followed in similar cases. I also attempted the same treatment in a case which occurred nearly twenty years ago; but, in the attempt to break up the adhesions which had formed during the six or eight weeks that had elapsed, the callus gave way, and the fracture was reproduced. The broken end of the bone was then placed in the glenoid cavity, and the patient recovered with a very useful arm. In another case which came under my notice, the arm had been paralyzed by fruitless attempts at reduction. I saw the patient, in consultation with other surgeons, at the end of seven weeks, when it was decided to leave the broken end of the bone in the

socket. I afterwards learned that the paralysis gradually passed off, and that the patient recovered the use of the arm."

If the fracture be at some distance from the head of the humerus the limb could be temporarily dressed firmly with splints, and then employed as a lever as if no fracture had occurred; and if the break be near the head of the humerus, the head itself might possibly be pushed into place by the power of the thumbs, especially if the patient be profoundly under the influence of chloroform. The first attempt failing, repeated efforts may be made every day for a week or more.

Dr. Watson, of New York, reported a case to the Academy of Medicine, in May, 1855, in which dislocation of the humerus existed, and a fracture near the head of the bone. The injury was produced by a blow from a steam engine; and the patient was not treated until the morning after the accident. A sweeping motion was given to the arm while the fingers were pressed against the head of the bone in the axilla, and reduction was effected. The arm was then treated for a successful cure of the fracture.

It remains a question in the event that attempts at reduction failed, whether it is best to adjust the fracture and retain the fragments in apposition until osseous union has taken place, trusting to a successful reduction of the dislocation at the end of six weeks, or after the fragments are presumed to be sufficiently consolidated to allow the arm to be safely handled in the manipulating process necessary to accomplish reduction; or to place the broken end of the shaft in the empty glenoid cavity, trusting to the usefulness of a joint obtained under such circumstances. I am inclined to the belief that it is best, if the reduction can not be effected at trials made during the first ten days, to treat the fracture with the broken ends in apposition, and at the expiration of six or seven weeks, or after consolidation of the fragments is presumed to have taken place, attempt to effect a reduction of the dislocation. It is well known that a dislocated shoulder, if left unreduced, at length regains a great part of its usefulness, or as much at least as an arm would have, which had a joint made of the fractured shaft placed directly in the glenoid socket.

In rare instances the fragments would fail to unite, a false joint being established. Such a termination would not be worse than a union of the fragments with the bone un-reduced; or a joint produced from the broken end of the long fragment of the humerus, the short fragment being left to itself in the axilla.

If a patient with a dislocated shoulder and fracture of the humerus near its upper extremity, be put profoundly under an anæsthetic, the short fragment can be manipulated with considerable ease, especially if the patient be not too muscular. I have recently had such a complicated injury in a lad twelve years of age. The accident happened by a fall from a horse that was frantically running away. The boy says the dislocation occurred first, and the fracture immediately afterwards. I laid the patient upon a low bed, and produced stertorous breathing with chloroform; and then manipulated the short upper fragment of humerus for nearly an hour. At length I got the position all right for a return of the head of the bone through the aperture in the capsular ligament, and with my thumb pushed the luxated part into its socket. At first the swelling and stiffness seemed to impede and balk my efforts, but the longer I worked the easier it was to render the conditions favorable to reduction. The arm was carried to position as if no fracture existed, and the fractured surfaces of the two fragments were kept in apposition during the movements. No other rules can be given in regard to the management of such a case. As soon as reduction of the luxation occurs the limb is to be carefully dressed to secure a good result from the fracture.

I have examined a case in which there seems to have been dislocation of the shoulder and separation of the epiphysis—head from shaft—in a little girl. The accident occurred more than a year previously, therefore I did not undertake to reduce the luxation. The head of the bone and the shaft had united at an angle that was beneficial rather than otherwise. The deformity was not great, and the functions of the limb were better than might be expected. The mother reported that the child was regaining the use of its arm very rapidly. It was easy to diagnose the injury, from the fact that the head of the humerus was out of its socket, and the angle alluded to presupposes fracture.

CHAPTER VIII.

DISLOCATION OF THE RADIUS AND ULNA AT THE ELBOW-JOINT.

Dislocation of the elbow, both bones of the forearm being displaced, is not a common accident, and occurs mostly in childhood and youth. The injury, according to statistical tables, is peculiar to boys between the ages of five and fifteen years. Of thirty-three cases observed by Hamilton, nineteen were in children under fourteen years of age.

Malgaigne concludes, from experiments upon the dead subject, and from careful examination and interrogation of patients who have met with the accident, that the most frequent cause of nearly every form of luxation at the elbow-joint, is a twist given to the ulna, which brings the coronoid process successively inwards, downwards, and backwards, and which may be produced by a fall upon either the internal border of the forearm, or the inner side of the olecranon. Other authors state that this injury is more frequently effected by a fall in which the palm of the hand comes into violent contact with the ground, so that the forearm is driven directly back under the lower end of the humerus. Hamilton has known one case to occur from a blow upon the back and lower part of the humerus.

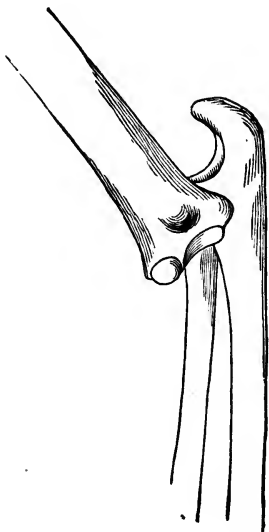
The bones may be displaced backwards, forwards, or to either side; there also may be intermediate forms, as backwards and outwards, and backwards and inwards. Each form may be partial or complete, and one or both bones may be displaced; or the ulna may be dislocated backwards as regards the lower end of the humerus, and the radius forwards. Some of these different forms of dislocation may be complicated with fracture of the olecranon or coronoid process of the ulna; either of the condyles of the humerus may be broken; and the injury may be compound.

The complex structure of the elbow-joint, and the depth to which portions of the articulation are buried in muscles, together with the great swelling to which all lesions of the parts are especially liable, render any of the injuries peculiar to the bones exceedingly difficult to diagnose. Fracture of the humerus just above the elbow takes the semblance of dislocations of both bones of the forearm backwards; fracture of either condyle may be mistaken for a luxation of one or both bones of the forearm; and a complication of fractures and dislocations may result from a single accident.

The elbow-joint is exceedingly liable to high grades of inflammation, and to ankylosis after a fracture implicating the articulation, or a dislocation. Many of the injuries peculiar to the elbow either pass unrecognized or are badly treated, therefore more deformities of this joint are to be met than of any other articulation. It is of the utmost importance, then, that the anatomy and pathology of the elbow be well studied.

Some forms of elbow dislocation are exceedingly rare: luxation of both bones of the forearm backwards and upwards is the most common of all of them.

FIG. 112.



Dislocation of radius and ulna backwards.

When this is complete, the coronoid process (if not fractured) is forced back into the olecranon fossa of the humerus. According to Malgaigne, this condition is not so common as the incomplete form, in which the process rests upon the trochlea of the humerus. The radius almost always maintains its relative position to the ulna, being held there by the orbicular ligament. All the ligaments of the elbow-joint, except the posterior, are generally torn in a dislocation of the radius and ulna. The *symptoms* in this dislocation of both bones of the forearm backwards, are marked and characteristic; the limb is in a semi-flexed

state, and rigid; the elbow seems to be thicker antero-posteriorly, and the olecranon projects backward in a marked de-

gree, reaching above the condyles of the humerus; the triceps tendon stands out conspicuously, though it is not tense; the forearm generally exhibits a twisted appearance, inclining strongly to pronation. When the hand is rotated the head of the radius, behind the humerus, can be felt rolling in its usual relation with the ulna. Anteriorly, as if embedded in the flesh of the forearm, the lower end of the humerus can be felt, with the tendon of the biceps and the brachialis anticus muscle stretched over it. Any attempt to flex or extend the elbow is found to be painful and quite impracticable. In front the forearm is shortened to a noticeable extent, while the posterior aspect retains its usual length. The fingers are moderately flexed, and can not be moved with ease; they are also benumbed by pressure on the nerves above.

If great swelling has taken place before the injured limb is seen, and any doubt arises in regard to the nature of the lesion, it may assist in the diagnosis to bear in mind that only one injury appears like a dislocation of both bones of the forearm backwards, and that is fracture of the humerus just above the condyles, and the distinction between the two injuries may be drawn as follows: in dislocation the arm is rigid, and the deformity can not be overcome without reduction, which is accomplished with difficulty, and when once replaced the bones will stay there; while in fracture, there is great mobility at the seat of injury, the reduction is accomplished with comparative ease, and when the reducing force is discontinued the deformity will at once be reproduced. Besides, in the event of fracture of the humerus, crepitus can readily be elicited.

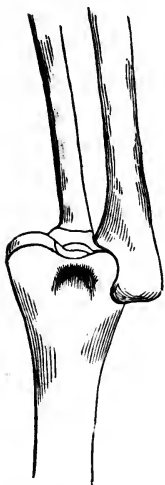A *lateral* displacement of the bones of the forearm at the elbow may be readily recognized by the peculiarities of the deformity. In most instances the luxation is incomplete, *i. e.*, both bones are not thrown so far laterally, as to have no contact with the articular surfaces of the lower extremity of the humerus. In the *outward* dislocation, which is the most common, the radius does not touch the articular surface of the condyle, but the ulna rests upon the spot the radius usually occupies.

The joint is rigid, and semi-flexed, with the hand inclined to pronation. The elbow-joint has an unsightly appearance, which is characteristic of the lesion. In the outward disloca-

tion of the two bones, the head of the radius can be distinctly felt under the skin, and the internal condyle projects most strikingly, the epitrochlea and even a part of the trochlea being distinctly felt.

If the lateral displacement be *inwards*, both bones of the forearm are not forced completely clear of the articular surfaces of the lower end of the humerus, but the radius reposes

FIG. 113.



Dislocation of the radius and ulna inwards. The head of the radius rests on the trochlea and the ulna on the epitrochlea.

in the trochlea, and the ulna upon the epitrochlea. In some cases the head of the radius might rest in front of the trochlea, or fall back into the olecranon fossa. In all of these dislocations much injury is sustained by the ligaments, muscles and nerves,—the ulna nerve being particularly exposed to bruising or compressing forces.

Dislocation of both bones of the forearm forwards has been denied as being possible, unless there was first a fracture of the olecranon process; but Velpeau, Monin and Denuce, have each reported a case, establishing the existence of such an injury, whether it can be accounted for or not by any process of reasoning. In Velpeau's case the accident occurred by the passage of a carriage wheel over the arm. When first seen by the surgeon, both bones of the forearm were found in front of the lower extremity of the humerus, the radius reposing in the coronoid fossa, and the olecranon upon the condyloid ridge, the ulna being carried upwards and a little outwards. According to Denuce, the summit of the olecranon rests against the inferior part of the trochlea of the humerus, and the head of the radius is below and somewhat separated from the external condyle; the prominence of the olecranon disappears from behind the joint, and on each side the condyles of the humerus are unusually prominent. The joint is rigid, and the arm is flexed at least to a right angle.

The several dislocations of the elbow are not always clearly defined as distinct displacements. In some instances the luxation is partially lateral and partially backwards, or forward so far as the radius is concerned, and lateral as regards the ulna. In these extraordinary accidents, the violence is probably of a

twisting nature, or partakes of complex motions, the patient being unable to define the cause with much clearness. A surgeon looking on when the accident occurred, might not be able to describe how it was produced.

TREATMENT.—When both bones of the elbow are dislocated, their reduction is not generally attended with much difficulty, especially if chloroform be brought into requisition. In the backward dislocation, the surgeon may be able to replace the bones by placing one hand against the forearm near the elbow, and pressing with all his might while with the other hand grasping the patient's wrist he employs extension, and at the same time uses the limb as a lever—the other hand being a fulcrum—to disengage any locking of elevations and depressions, and to force the bones of the arm into their relative positions. Sir A. Cooper recommended that the patient sit in a chair, and the surgeon, resting his foot upon the edge of the seat, places his knee upon the inner side of the elbow-joint, while he grasps the wrist with his hands; he then bends the elbow slowly, but forcibly at the same time pressing with his knee upon the upper part of the radius and ulna, so as to disengage their articular surfaces from the lower end of the humerus. Mr. Skey advocates that one assistant hold the upper arm, and another pull steadily upon the wrist, and as soon as the coronoid process is brought below the level of the trochlea of the humerus, the muscles are powerful enough to bring the bones into their natural place.

In those cases where much difficulty is experienced in the reduction, it is probable that the lateral ligaments, remaining untornd, act as powerful obstacles to a return of the bones to their normal positions. If there be reason to suppose that these ligaments oppose reduction, and the obstacles can not be overcome in any other way, the joint must be extended beyond the straight attitude, in order to tear the most unyielding bands, and then reduction may be easily effected.

The treatment after reduction consists in keeping the arm in a sling for two or three weeks, and applying anodynes to the joint to suppress high grades of inflammatory action, each day employing passive motion as a preventive of ankylosis.

It may be of importance to mention that surgeons of great experience have failed to detect dislocation of both bones of

the forearm backwards; and they have also gone through with the forms usually employed to effect reduction, and supposed they had accomplished their object, yet have left the bones unreduced. If these mistakes happen to accomplished surgeons, the inexperienced practitioner of medicine and surgery should be particularly on his guard against erroneous conclusions.

If a month or more has elapsed before reduction is attempted, great difficulty will be encountered in the endeavor to replace the bones. Cases are on record in which reduction was accomplished after the displacement had existed for five or six months. The successful cases are about sure to be reported, and the larger proportion of attempts which turn out as failures, never get into print. Death has occurred from violent attempts to reduce recent and ancient luxations of the elbow. However, failures and unfortunate results should not deter a surgeon from making well directed efforts in favorable cases, even if several months have elapsed from the time of the accident, for the number of successful results is quite large, establishing the principle that a fair trial is legitimate.

In lateral dislocations of both bones of the forearm, reduction is to be accomplished by extension and lateral pressure, the soft tissues being first relaxed by the use of chloroform. If the luxation be not purely lateral, but combined with some backward displacement, the restoration of the bones to their proper places is to be accomplished by varying the direction of the forces applied. No set rules are applicable for every case, consequently the surgeon has to rely to a greater or less extent upon his own ingenuity and resources. My experience in treating dislocations of the elbow, has taught me that no plan, rule, or method, will invariably prove successful; but if one course failed, I at once made trial of another, and in the end have always succeeded, except in one instance which was in trying to reduce a case of six months' standing. I have never seen a dislocation of both bones forward, but if I should, it seems to me that I could replace the bones by having assistants make extension and counter extension while I used the force of my hands in pulling the humerus forwards and pushing the forearm backwards. I have yet to be convinced that a dislocated elbow needs only to have its untorn ligaments relaxed by position of the limb, to secure an easy reduction.

If the lateral ligaments be lacerated the anterior and posterior parts of the capsule are too loose to offer much resistance.

Dislocations of the elbow should be reduced as early as possible after the reception of the injury. If the bones be left displaced for a number of days, the inflammation runs so high that changes of an unfavorable character take place in the joint, leading sometimes to permanent defects in the articulation. A luxation of three weeks' standing is more difficult to reduce at the elbow, than one of six weeks at the shoulder.

DISLOCATION OF THE HEAD OF THE RADIUS.

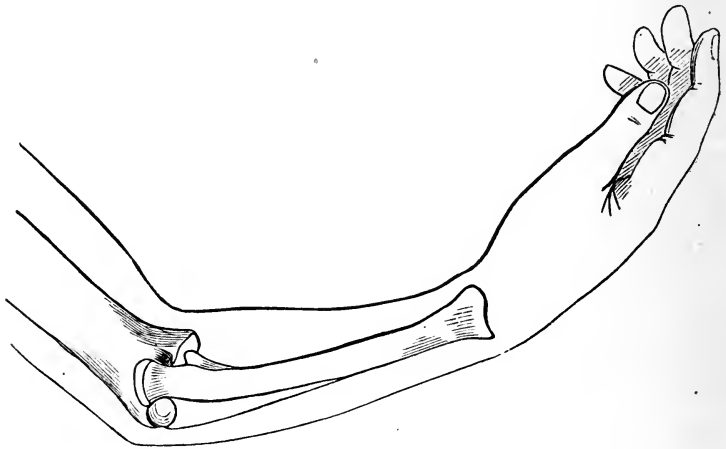
The head of the radius has a double articulation, radio-humeral, and radio-ulnar; and it can not be displaced to any great extent without a rupture of the external lateral and orbicular ligaments, losing its articular connection with the external condyle of the humerus, and the sigmoid notch of the ulna. The accident is one peculiar to youth, though it may occur in adult life. It is generally produced by a fall upon the palm of the hand, the direction of the force acting in a manner favorable to the dislodgment of the upper end of the radius from its articular relations; a sudden jerk or twist imparted to the hand has been known to luxate the head of the radius; and a fall or blow upon the elbow may displace the bone. In one case that came under my observation, the boy fell from a high wall sideways, the body whirling as the hand met the ground; in another case a boy had his elbow caught in a swinging gate in such a way as to force the head of the radius from its normal position to one behind the external condyle; and I have treated a third case that happened in a scuffle. The patient said the other boy fell on him while his arm was confined underneath his body.

The radius may be displaced forwards, backwards, and directly outwards. The forward dislocation is far the most common; the backward less frequently; and the outward exceedingly rare. In children of a lax condition of the fibrous structures, a partial dislocation or *sub-luxation*, the ligaments not being torn, is a common occurrence. Such a displacement is not attended with pain, the child throwing the head of the radius into a state of deformity, and returning it again with-

out any particular discomfort. As the child advances in years the ligaments increase in firmness, so that the defect no longer exists.

In the *forward* dislocation, the head of the radius is found in front of the external condyle of the humerus; the forearm is fixed in a moderately flexed state, either prone, or half way between pronation and supination. Bending of the elbow is prevented by the head of the radius coming in contact with the front of the humerus; and complete extension causes

FIG. 114.



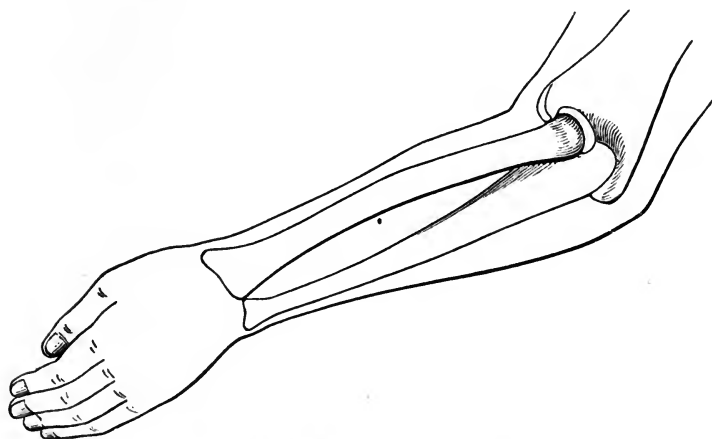
Dislocation of the head of the radius forwards.

pain. The head of the radius can be defined in its new position, and when the hand is rotated, it can be seen and felt to follow those movements. The whole forearm presents a peculiar and characteristic twist, which is occasioned by the altered situation of the upper end of the radius. The tendon of the biceps stands prominently forwards in the bend of the elbow; and the finger can be pressed into a depression at the point vacated by the head of the radius.

The *backward* displacement is characterized by that peculiar attitude of the limb which denotes the nature of the injury, though the position of the head of the radius can not be determined positively without careful examination. The forearm is semi-flexed, and held fixed in a state of pronation, unless the internal condyle be broken in the same accident, which is not an uncommon complication. The head of the radius

can be felt behind the external condyle, quite superficial, the finger being easily pressed into the cup in the upper end of the bone, and be made to feel the button-like termination which plays in the orbicular ligament.

FIG. 115.



Dislocation of the head of the radius backwards.

Dislocation of the head of the radius *outwards*, must be a form of displacement rarely met, for there are only two or three cases reported by American surgeons, and only four by Paul Denuce, who may not have been correctly informed in regard to them all. Before his "Memoire" was published (1854) dislocations of the head of the radius were supposed to be confined to the forward and backward displacements. It may even now be a question whether the outward dislocation is not a modification of one or the other of the two well defined displacements of the head of the radius. Dr. Willard Parker reports a case of outward dislocation in the *New York Journal of Medicine* for March, 1852, stating that a child four years old fell down stairs "backwardly, with the right arm twisted behind the back, in such a position that the whole weight of her body came upon her arm."

It is plain that the head of the radius can not be displaced outward to any considerable extent without a rupture of the upper end of the interosseous ligament, as well as a laceration of the orbicular, external lateral, and the capsule enclosing the articulation. A force competent to commit that damage,

would be likely to produce fractures and other injuries to adjoining parts.

TREATMENT.—It is not generally a difficult matter to reduce dislocations of the head of the radius, though the bone is not easily kept in place when once the barriers to displacement have been broken down. A great many prosecutions to recover damages for malpractice have grown out of the fact that a recurrence of the dislocation is very common. The non-professional suppose that a bone is not properly reduced or skillfully treated after reduction, if it gets out of place in a few days or weeks after it has passed through a surgeon's hands; and there are also plenty of medical wisecracks who believe or pretend to believe about the same thing. A few days ago a father brought his son into my office, and asked me to examine the lad's arm. I suspected the motive, and soon satisfied myself by inquiries that my suspicion was well founded. A physician of respectable talents had treated the arm six weeks previously, for dislocation of the head of the radius; in three weeks from the accident the bone was found to be displaced, and the father then took the patient to another physician, who said that the arm had not been properly treated, that the luxation had never been reduced. This statement made the parent believe he had been imposed upon by an incompetent medical attendant; and he at once took steps toward entering a suit for damages. I returned the bone to its natural position, and bound a compress in front of the head of the radius, the dislocation being forwards. Having assured the father that a dislocation of the head of the radius was liable to recur, and that the physician who first treated the injury had probably reduced the dislocation properly, he went away contented, and abandoned his intention to prosecute.

In a forward dislocation, the wrist is to be grasped with one hand, and the elbow with the other, and while the forearm is moderately flexed, considerable supinating force will effect reduction, especially if the thumb be used to push the head of the radius into position. If this manœuvre, several times attempted, do not succeed, powerful extension and counter extension may be employed, the thumb pressing hard upon the displaced bone. It is probable that either plan would prove successful even without chloroform, but if the patient be mus-

cular and the resistance considerable, anæsthesia should be brought into service.

There exists some difference of opinion in regard to the attitude of the arm while reduction is being attempted. Cooper applied a supinating force with extension, and Denuce directs that the arm be kept in a state of pronation while extension is made. It is to be presumed, however, that the advocates of several distinct plans have succeeded in their favorite methods; I am satisfied that the reduction can be effected by several distinct manœuvres, though in all it is essential that there be pressure of the thumb on the head of the radius to steady it, to help direct it into place, and to perform the part of a fulcrum when the arm is used as a lever to force the reduction of the displaced bone.

In the backward luxation the forearm needs flexing and pronating at the same time that powerful thumb pressure be brought to bear upon the head of the radius to force it into its normal position. Gross says that the reduction is to be effected by flexion and supination. As long as there exist such discrepancies in regard to the direction the forearm is to take in facilitating reduction, it will be safe for the inexperienced practitioner to try one method, and if that fails, to resort to another. In the single backward dislocation I had to treat, I pronated the hand, and forced the radius into place with my thumb, the reduction being accomplished easily.

The outward dislocation needs no special rules for its reduction. Extension and rotation of the forearm inwards will place the bones in a favorable position, as regards one another, for the pressure of the thumb or fingers to return the bone to place.

After the reduction of either form of dislocation the arm should be dressed with pasteboard splints, with the forearm neither flexed nor extended. Some surgeons employ a stiff angular splint to prevent motion at the joint. After sufficient time has elapsed for the torn ligaments to heal, the dressings are to be removed and passive motion instituted. It will be well if the patient does not completely flex or extend the limb for several months.

DISLOCATION OF THE ULNA BACKWARDS.

Displacement of the ulna singly is a recognized injury among surgical writers, though both bones of the forearm are more likely to be dislocated together, than the ulna alone, from the fact that the radius is more strongly bound to the ulna than to the humerus. A force, then, which is competent to luxate the ulna backwards, must almost of necessity carry the radius with it. In the few cases reported, of dislocation of the ulna backwards, the radius was displaced to a certain degree, if not fully luxated. In the case reported by Sir Astley Cooper, the radius went with the ulna to the extent of having to form a new socket for itself on the external condyle.

Pirrie's Surgery contains a brief account of a case of backward dislocation of the ulna which occurred in the practice of Gosset. Even in this there must have been as much lateral displacement as backward, for the coronoid process lodged on the internal condyle, and the radius may have been partially displaced. As has been previously stated, in injuries of the elbow the best surgeons may be deceived in regard to the nature and extent of a given lesion.

The signs of dislocation of the ulna backward would be great rigidity of the articulation, and a marked projection of the olecranon behind the joint. If the ulna has been forced backwards singly, the orbicular ligament would have to be lacerated, as well as a part of the interosseous, to allow the radius to remain in its normal place.

Reduction was accomplished in Gosset's case, "by extension and counter-extension applied by two persons pulling in opposite directions, and by the pressure of the olecranon process downwards and outwards, while the forearm was suddenly flexed." In other words, the same method of reduction was employed as is commonly recommended to replace both bones of the forearm when they are luxated backwards.

DISLOCATION OF THE LOWER END OF THE RADIUS FROM THE ULNA.

Hamilton, following Sir A. Cooper, and Malgaigne, has spoken of forcible separation of the radius and ulna at their inferior articulation, as dislocation of the lower end of the ulna from the radius; but in accordance with the nomenclature employed in describing luxations in other joints, this injury should be regarded as a dislocation of the radius. The ulna is the fixed bone, the radius moving upon it, the displacement, therefore, is of the latter from the former.

The accident, as an uncomplicated lesion, is one of extreme rarity. Sir A. Cooper does not mention having met with a single case; and other surgeons of the most extensive experience, have never seen an example of the injury. Malgaigne has a report of several cases, though some of them were complicated with fracture, and others may have been mistaken for that kind of injury.

The displacement may be caused by excessive pronation or supination of the hand, as by wringing clothes, or seizing a child by the hand as it is falling, giving the arm a violent twist.

The displacement is accompanied with rupture of the saciform ligament, and as the hand goes with the radius, the carpal connection with the ulna is broken, allowing the styloid process of the ulna to form a marked prominence, if it does not actually pierce the skin.

The displacement may be forwards or backwards; the former is the most common accident. In the *forward* dislocation the hand is held firmly in a state of pronation, with the fingers somewhat flexed; the axis of the little finger no longer corresponds with the ulna; and the wrist has a peculiar contorted appearance not met in any other injury.

The reduction is to be effected by extension applied to the hand, supinating it at the same time. The radius and ulna must also be pressed into their natural relations with each other, while the extending and supinating forces are applied.

In the *backward* dislocation the signs of the displacement are in some respects the reverse of those in the other variety of luxation; the hand is powerfully supinated, the fingers

being moderately flexed, and the wrist having a peculiar twist in it which is not a deformity belonging to a fracture.

The reduction is to be accomplished by extension and pronation exerted upon the hand, while an effort is made to press the two bones into their normal relations with each other.

As there is great liability to a recurrence of either form of luxation, while the torn ligaments remain ununited, the forearm and hand should be dressed with the same appliance recommended for the treatment of a fracture through the lower extremity of the radius. The dressing should be worn for two or three weeks, and then the arm ought not to be subjected to pronating and supinating forces for six or eight weeks more.

In a case of alleged malpractice that never came to trial, I had an opportunity to see how medical men of considerable experience will differ in regard to the nature of a surgical injury. The defendant in the case was charged with not having discovered and treated a dislocation of the ulna from the radius, the allegation being that the young woman was seriously damaged by said neglect. The prosecutrix had been thrown from a wagon, and in the fall sustained an injury of the wrist. The physician having the case in charge did not discover a lesion beyond that of a sprain, and applied a bandage to the hand and wrist, and ordered arnica applications. In the course of a few months a peculiar and marked laxity of the ligaments of the wrist came on, so that the patient could voluntarily make an awkward deformity at that joint. In some of these forced attitudes or positions, the limb appeared as if the hand and radius had been forcibly separated from the ulna, or that the ulna had been torn loose from the radius, hence the charge of malpractice. Before the trial came off the girl saw several eminent surgeons in the country, and all advised her to drop the suit on the ground that no real luxation existed, but that her wrist had been so injured that the soft tissues, especially the ligaments, were rendered unnaturally pliant or yielding; that loose joints in any part of the body were not uncommon, particularly in the young. There was evidently an hysterical complication which in some instances will produce queer conditions of the body.

Six physicians of the place were ready to swear that dislocation existed, but the limb at length became as useful as the other, and scarcely more deformed.

CHAPTER IX.

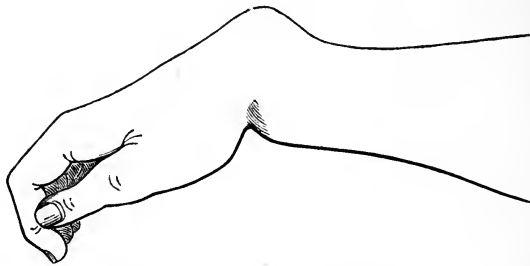
DISLOCATION OF THE WRIST.

The older surgical writers, back to the time of Hippocrates, regarded dislocation of the hand or carpus from the lower end of the radius and ulna, as an accident of frequent occurrence, but within fifty years it has been ascertained that the injury is exceedingly rare, and that most of those lesions once regarded as dislocations are now presumed to have been fractures of the lower extremity of the radius. This error of diagnosis was suspected by Pouteau, and positively avowed by Dupuytren who gave the subject great attention. It is a matter of no little surprise that the surgeons of a century ago so often met with dislocations of the wrist, and that Dupuytren and his followers should have found so few. Although it is quite evident that fractures of the inferior extremity of the radius were once thought to be luxations of the wrist, the bold assumptions of Dupuytren have not been fully sustained by critical observers of more recent times. Dislocation of the carpus upon the radius and ulna is undoubtedly a rare form of accident, yet the lesion is proved by dissection to have had an existence. In some instances the dislocation has been compound, and in others it is complicated with fracture of the rim of the articular cavity at the lower extremity of the radius.

The displacement may be in either of two directions, backwards or forwards. In the *former* variety the carpus is thrown upon the dorsum of the wrist, and the ends of the radius and ulna form an abrupt prominence on the palmar aspect of the carpus. The general aspect of the wrist is that of fracture of the radius, yet a careful examination of the parts will determine the difference between the two injuries. In fracture of the radius the deformity can be mostly overcome by seizing

the hand and making extension, and when this force is removed and the limb is left to itself unconstrained, the deformity at once returns; in dislocation of the wrist backwards,

FIG. 116.



Dislocation of the carpus backwards.

great reducing power is required to restore the parts to their normal places, and when once reduced they will stay in place.

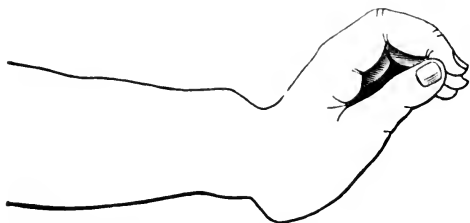
In September, 1863, Peter Sullivan, a laborer, while excavating a bank of earth in the vicinity of the city, fell from a ledge six or eight feet in height, and struck on the knuckles of his right hand which grasped the bowl of a large briarwood pipe. He sustained a severe injury of the wrist, compelling him to abandon his work and come to the city for surgical attention. He walked to the street railroad and then rode to my office. I found the wrist appearing much as it does in fracture near the lower extremity of the radius, though with sufficient difference in several respects to institute a more thorough investigation of the lesion. The wrist was too rigid for fracture, the elevation on the back of the wrist was too abrupt for the usual dorsal tumor attending a broken radius, and the palmar lump was too near the hand. The fingers were flexed; and the styloid processes of the radius and ulna could be felt occupying the same plane, which is not the case in fracture. The arm just above the dorsal tumor maintained its usual width and flatness, and was not rounded as it is found after fracture of the radius through its lower extremity.

I attempted to reduce the dislocation, for such it was, by taking the patient's hand in mine, and making extension; but he complained so much of pain as soon as I used any force, that I administered to him enough chloroform to deaden his sensibilities and to relax his muscles to some extent. I then

made extension with one hand, first flexing the wrist a little to get the thumb of the other hand so it could both act as a fulcrum as I applied extension and push the carpus forward into its relative position with the radius and ulna. I had to use considerable force to effect reduction which was announced by an audible snap. I then dressed the wrist in a bandage for a few days, when the patient claimed to be well, and I lost sight of him. In this case I endeavored to ascertain whether the muscles or the untorn ligaments opposed reduction; and could not solve the question, though it seemed to me that the tendons and their sheaths offered the greatest obstacles.

A dislocation of the carpal bones *forwards* is an injury more seldom met than the backward displacement. The accident is produced by falls, the hand so striking as to force it into extreme extension. The displacement is easily recognized by the character of the deformity. The lower extremities of the radius and ulna form a well marked projection backwards

FIG. 117.



Dislocation of the carpus forwards.

and the carpus forwards. The styloid processes of the two forearm bones are so prominent and well defined that no mistake could be made in regard to the nature of the injury. The wrist and hand are rigidly stiff, and can not be made to assume their natural relation in regard to the forearm, as in case of fracture.

There are some congenital defects of the wrist which present the appearances of dislocation, but they are quite different from an ordinary luxation produced suddenly by violence.

Reduction of a dislocation of the carpus forwards is to be produced by bending the hand a little more backward so as to place the thumb well against it in the capacity of a fulcrum and to help press the bones into place when extension is made

by the surgeon, grasping the patient's hand in his own and making powerful extension. After reduction is accomplished the wrist may be treated to a cooling and anodyne lotion, and used with care until the lacerated ligaments are healed.

DISLOCATION OF THE BONES OF THE CARPUS FROM ONE ANOTHER.

There is a popular notion that some of "the little bones in the wrist" may get out of place; and in fact, it has been shown by dissection that the carpal bones may be displaced. The head of the os magnum suffers a partial luxation from the cavity formed for it by the scaphoid and semi-lunar bones. The displacement, observed mostly in females of a lax condition of the ligaments, is caused by forced flexion of the wrist, either in falls, or from accidents in which a severe twist is given to the hand and wrist. The nature of the injury is recognized by an unnatural projection on the dorsum of the carpus, which increases when the wrist is flexed, and diminished when it is extended.

The reduction can generally be effected by pressure upon the tumor, especially if extension be made at the same time upon the fore- and middle-fingers. When once reduced the bone should be held in place by a compress and bandage.

Richerand once met with a luxation of the os magnum which happened to a woman in the throes of labor. She seized the edge of her mattress and squeezed it forcibly, turning her wrist forwards. She heard something snap, and a tumor immediately formed on the back of her wrist, which gave her great pain. The extended hand showed no deformity, and the difficulty never received any treatment. Chopart reports having seen a similar case; and Bransby Cooper says: "I have known the os magnum to be dislocated backwards from its articulation with the scaphoid and lunar bones. The subject of this accident was a carpenter, an out-patient of my colleague, Mr. Callaway. In this case, the appearance was that of a hard fixed tumor on the dorsal surface of the carpus: the man described the injury to have been originally caused three years before, by a very forcible grasping exertion of the hand. The displacement frequently recurred, and he

could generally slip the bone back into its place by pressure of the thumb."

Similar dislocations of some of the other carpal bones have been recorded. Erichsen mentions having seen dislocations of the semilunar and pisiform bone. The latter was displaced by an effort to lift a heavy weight, and the bone was drawn up the arm to the distance of nearly an inch by the flexor carpi ulnaris.

A case is reported by Maisonneuve, of simple dislocation backwards of the second row of carpal bones from the first, caused by a fall from a height of forty feet. The nature of the injury was verified by dissection.

The different bones of the carpus are so firmly bound together with ligaments, and so strongly held in place by passing tendons, that no ordinary accident is likely to displace one or more of them. A blow of the nature of a driven punch, and a gunshot wound, very frequently displace these bones, but the nature of the injury differs essentially from ordinary dislocations, and has no claims to be considered in this connection.

DISLOCATION OF THE METACARPAL BONES.

Displacement of the metacarpal bone of the thumb from the os trapezium, either forwards or backwards, is possible, though the injury is not common. The backward luxation is the most frequent, and is caused by a fall upon the thumb, throwing it into a state of extreme flexion. The forward dislocation may be caused by a force throwing the thumb violently backward, or by direct violence. In a case coming under my observation the displacement was caused by the fall of a heavy rock which struck the metacarpal bone of the thumb near its carpal extremity, and forced it inwards or forwards. The soft tissues covering the bone at the seat of injury were severely bruised, but the dislocation was not thus rendered compound. The injury was recognized by pressing the fingers into the depression caused by the displacement, and by other ordinary signs of luxation. Chloroform was administered, when by extension and pressure in the hollow of the hand against the projecting bone in that region, the reduction was accomplished. The backward luxation is the

easiest to reduce, though the assistance of anæsthesia may be needed in successful attempts to reduce either form of the injury.

Malgaigne has collected accounts of dislocations which happened to three other of the metacarpal bones. In one of them, Bourguet's case, the carpal extremity of the metacarpal bone of the index finger was displaced forwards by a great and sudden force being applied to the back of the hand. A great depression at the point of luxation indicated the nature of the injury. Reduction was effected by extension applied to the finger and pressure made in the palm near the thumb. In the case seen by Roux, there was a backward luxation of the metacarpal bone of the great finger. The accident happened in a mine, from the explosion of blasting powder. The prominence of the bone on the dorsum of the hand indicated the nature of the difficulty. Reduction was effected by extension, and pressure on the displaced bone. There was always a tendency to relaxation when the hand was straightened. Hamilton mentions having seen one case of luxation of the metacarpal bones of the index and great fingers, the accident being caused by a blow given with the fist or clenched hand. It was an old case, the bones becoming relaxed after having been reduced.

The carpo-metacarpal articulation of the thumb closely resembles a ball and socket joint, hence a luxation would have to be managed on principles that govern the overcoming of dislocations of the shoulder and hip. In other words, the articular head of the bone would be forced through a rent in the capsular ligament; and a return of the bone must be through the aperture of escape. The reduction is not to be brought about by forcible extension and counter-extension, but by the manœuvre of placing the thumb in the attitude it assumed when luxation occurred, and then prying the head of the bone into place, the operator's thumb being used as a moving or sliding fulcrum in the application of forces. And because the leverage is so restricted it is not easy to overcome this dislocation. In fact, the feat is nearly impossible unless the patient be put under the influence of an anæsthetic.

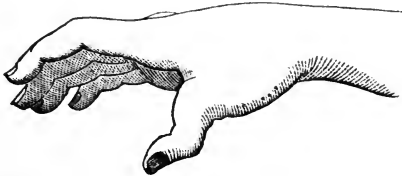
CHAPTER X.

DISLOCATION OF THE PHALANGES.

DISLOCATION OF THE FIRST PHALANX OF THE THUMB.—This injury is of frequent occurrence; especially the backward displacement, the end of the first phalanx being thrown upon the extremity of the metacarpal bone. The cause is generally a fall upon the end of the thumb, or upon the last knuckle of that digit. The symptoms are so distinctly marked that there is no danger of error in the diagnosis. The pain is great; there is inability to move the joints of the thumb; and the bones being sparsely covered, the displacement becomes strikingly apparent.

The reduction is not difficult, though the older surgical writers speak of subcutaneously dividing the lateral ligaments of the joint, and the tendons of the flexor muscles. I have reduced this dislocation several times, and have never found

FIG. 118.



Dislocation of the first phalanx of the thumb forwards.

any serious trouble in the operation. In either form of displacement I extend or flex the luxated digit to get my own thumb well placed against the end of the dislocated bone, then I make extension and at the same time push the phalanx into place. I have never yet met a case that required the use of a tape, or other appliance to fasten upon the thumb, as a

means of obtaining a better hold for the purpose of making extension.

Mr. Flower says : " After a fair trial of all the above measures, reduction has still been unaccomplished in so many cases, that both the cause of the difficulty and the means by which it ought to be overcome, have become a standard subject for research and speculation among surgeons of all countries. Although much difference of opinion has certainly existed upon this point, the majority of writers have agreed that the flexor brevis pollicis muscle is in some way the chief obstacle to reduction. Dissection of dislocations artificially produced upon the dead subject, shows that when the phalanx is completely carried on to the dorsal surface of the metacarpal bone, the two attachments of the flexor brevis, with their contained sesamoid bones, slip over its wide head, and tightly embrace its neck. It is evident that the bone can only be disengaged from this situation with difficulty. The only successful way hitherto devised to overcome this, is the subcutaneous section of one, or even both of the tendons of the muscle. The cause of occasional failure of even this somewhat severe proceeding is, I believe, the difficulty of effecting a complete division of all the opposing fibres. I have found, in the dead subject, that a division of the fascia which connects together the two sesamoid bones, by allowing the tendons to separate from each other, quite up to their insertion, materially facilitates reduction, without resorting to the section of the muscle itself; but I have not yet had an opportunity of trying this on the living." Dr. Humphrey, also on anatomical grounds, recommends an endeavor to draw the sesamoid bones forwards, by means of blunt hooks inserted through an incision in the skin.

Hamilton failed in one case to effect reduction, though he used chloroform, and the " Indian puzzle." The parents of the girl would not allow the flexor tendons and lateral ligaments to be divided, so the patient had to go with the thumb still dislocated. If a surgeon of his ability and experience failed to effect reduction, there are occasionally cases that will baffle the skill of the most expert.

I hold to the opinion that there is something radically wrong in the usual manner of applying the reducing forces. The dorsal dislocation is produced by forced flexion of the

thumb ; and as soon as the displacement occurs, the digit returns part way from this extreme flexion. Now, in a rational attempt at reduction, the thumb should be carried to the extreme point of flexion, and the thumb of the surgeon should then hold the displaced bone so it can not slip when the patient's thumb is extended. It is clear that by this manœuvre the surgeon's thumb acts the part of a fulcrum, while the patient's digit is employed as a lever to pry the dislocated bone into place. In the palmar dislocation, the reverse of the above movements should be followed. Dislocation takes place from forced extension, and then the thumb falls back towards its normal attitude ; reduction, therefore, is to be accomplished by tilting the digit backwards to the point it was forced to assume before luxation occurred, and then the displaced end of the phalanx being held rigidly while flexion is made, success attends the manœuvre. At least the plan is right, and if it fail once it may be tried again, and repeated until the reduction is accomplished.

DISLOCATIONS OF THE FIRST PHALANGES OF THE FINGERS.—The first phalanx of the index and little fingers are more frequently luxated than the corresponding bones of the great and ring fingers. The more exposed positions of these digits contribute to the frequency of the accident, though such lesions are quite rare. I have seen a forward dislocation of the forefinger, which was caused by the digit being caught in a cog-wheel ; and a dislocation of the little finger backwards, which was produced by the explosion of powder in a flask. The deformity in both cases was quite distinct, especially in the little finger. The abrupt projection of the displaced bone was distinctly seen and felt. In the forefinger the nature of the injury was not so apparent, though by a little manipulation the displacement became too evident to be mistaken.

The reduction was effected by extension and a pushing of the bones into place, the luxation being managed on the plan of first tilting the luxated digit backwards in the forward displacement, and forwards in the backward displacement, the reason for which being already given in the directions for reducing the first phalanx of the thumb.

Dislocation of the terminal phalanx of the thumb, or of the second and third phalanges of the fingers, is an accident easily recognized. Falls or blows upon the ends of the digits com-

monly produce the displacement. The reduction would be reasonably easy if a firm hold were practicable. Although the "Indian puzzle," a cylinder of basket-work, made to appear like a snake in the act of swallowing the finger, is highly recommended to secure a fastening, yet I have had no occasion to use the cunningly devised toy for the purpose of applying adequate extension. The strength of my own fingers has thus far proved sufficient to effect reduction.

The violence done to the digital articulations in cases of dislocation, is apt to be followed by a high degree of inflammation, endangering the condition of ankylosis. In rare instances, complicated with severe injuries to the joint and its investing tissues, it may be best to amputate, to avoid tetanus and other serious complications.

The game of base-ball has greatly increased the number of phalangeal luxations. Such extreme exertion is given to the act of catching a hard, heavy, and swiftly moving ball, that injuries to the fingers are not thought of, hence the frequency of digital dislocations. And the lesion is frequently of the compound character, therefore the more serious. The luxation is commonly produced by the ball being received on the end of the finger extended to guide the missile into the hollow of the hand. The injury may occur at either of the phalangeal joints, and at the metacarpo-phalangeal articulations. The displacement is attended with keen pain, yet excited players have been known to keep on with the game after a dislocation had been sustained.

In the management of a dislocated finger after reduction has been effected, little need be advised except that the injured digit be allowed to rest a few days under cooling lotions, and then begin passive motion to prevent ankylosis. In most instances, unless the cartilages be crushed, the injury will be overcome without permanent stiffness.

It may be well to remark that if ankylosis must take place, the finger should be kept in a partially flexed state. A stiff finger in an extended or straight attitude is an awkward affair.

CHAPTER XI.

DISLOCATION OF THE FEMUR.

Powerful forces are often brought to bear on the shaft of the femur as a lever to dislodge the head of the bone from its deep socket. The capsule of the joint is strong, and its anterior and inferior aspects are strengthened by that aggregation or reinforcement of fibres, called the ilio-femoral ligament, to say nothing of the protecting influences of the ligamentum teres and the cotyloid ligament.

According to the statistics of Malgaigne, collected at the Hotel Dieu, the hip stands next to the shoulder in the relative frequency of displacements.

There were, of 491 cases of dislocation,—of the

Shoulder.....	321		Fingers.....	7
Hip.....	34		Jaw.....	7
Clavicle.....	33		Knee.....	6
Elbow.....	26		Radius.....	4
Foot.....	20		Patella.....	3
Thumb.....	17		Spine.....	1
Wrist.....	13			

These tables show that about ten dislocations occur at the shoulder-joint where one happens to the hip, yet the latter articulation is more frequently luxated than the thumb or jaw which are generally supposed to be specially liable to such accidents. It is possible that the statistics of Malgaigne do not justly represent the relative liability of each joint to luxation; yet tables collected in other Hospitals show that the hip-joint is one which often suffers luxation.

The lesion is more common to men than women, for the obvious reason that males are most exposed to such violence as produces these graver accidents of life; and the injury is mostly confined to ages ranging from twenty to forty-five, embracing a period of life devoted to enterprises fraught with danger. The earliest recorded age at which dislocation at the

hip has occurred, is eighteen months, and the oldest, eighty-six years. During childhood a force competent to dislocate the femur would be more apt to separate the epiphyses of the bone; and after the age of fifty, the bones become so brittle that fracture of the neck of the femur is more liable to occur than displacement of the head of the bone from the acetabular cavity.

Much has been written concerning spontaneous dislocation of the hip arising from disease of the joint during early life, but complete luxations from such a cause must be exceedingly rare; and they are of a nature not to be considered in this connection. According to Cooper, persons have existed who possessed the power of voluntarily dislocating their hip, and again reducing it. Paralysis of the muscles on one side of the joint, has been known to effect dislocation in the opposite direction.

Dislocation of the coxo-femoral articulation resulting from violence, may occur in four directions:

1st. The head of the bone may be forced upwards, and more or less backwards, upon the *dorsum ilii*.

2d. Far backwards, and slightly upwards, into the great ischiatic notch. This is really a modification of the preceding and not a distinct form of luxation.

3d. Downwards and inwards, into the obturator foramen.

4th. Upwards and inwards, upon the body of the pubes.

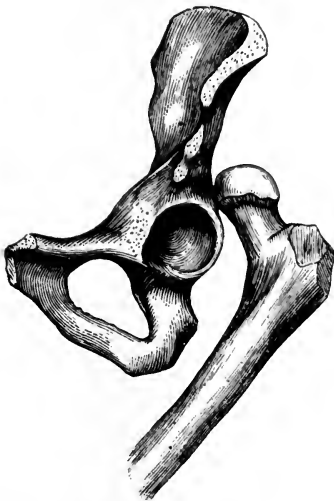These last two displacements belong to one form, viz., the dislocation inwards, the range upwards to the pubes, and downwards to the thyroid foramen depending much upon the direction of the force received, or some modifying circumstance. The same observation may be made concerning the first two mentioned forms of displacement, it being positively known that the head of the bone may occupy both positions in a single accident, or during attempts at reduction. There is no precise spot where the head of the bone always rests when dislocated, but a wide range is given to the position occupied. The different attitudes assumed by the toes and foot in different cases clearly indicate that the head of the femur is subject to considerable variety of position.

The relative proportion of the different varieties of displacement, is, according to Sir A. Cooper, the following: in twenty cases of all kinds, there will be twelve on the *dorsum ilii*, five

into the ischiatic notch, two into the obturator foramen, and one on the pubes. Or, considering only two varieties of displacement, there will be seventeen backwards, and three forwards, showing a vast preponderance in the backward direction. In seventeen cases observed by Malgaigne, eleven were either iliac or ischiatic, four pubic, and two obturator, or eleven backwards and six forwards. Of the 104 cases collected by Hamilton, eighty-three were backwards, and twenty-one forwards, or in the ratio of four in the former direction to one in the latter.

BACKWARD AND UPWARD DISLOCATION.—In the common dislocation backwards, the head of the femur wholly leaves the articulation, and takes a position on the outside of the socket, resting on the dorsum of the ilium, or between the glutens maximus and medius, or as far back as the pyriformis muscles. The great displacement necessitates the rupture of the teres and capsular ligaments. The small rotator muscles are

FIG. 119.



Dislocation of the head of the femur upwards and backwards, upon the dorsum of the ilium.

put greatly on the stretch, or are more or less lacerated. The luxation is attended with considerable effusion of blood in and about the joint, and the parts implicated in the injury are apt to bear marks of violence.

The *symptoms* of the dislocation are strongly marked, and characteristic of the injury: the limb is shortened from one to three inches, commonly from an inch and a half to two inches; it is inverted, slightly flexed, and inclined forwards and inwards, the toes resting on the opposite foot near the ankle; the great trochanter is tilted forwards, giving a full appearance over

and just above the acetabulum, and the head of the femur, in thin persons, can be felt beneath its gluteal covering, in its new position. The limb is rigid, and can not be elongated, extended, or abducted without great pain; it may be flexed, adducted, and rotated inwards, in a moderate degree, without

creating much distress. It is useful in determining the position of the head of the bone, to have the patient take the erect attitude, standing on the sound limb. The great toe of the luxated limb will then approach the instep of the opposite foot, and the knee will press against the opposite thigh somewhat above the patella. The pain in the region of the dislocated hip, extending to the knee and foot of the affected side, is intense, and the patient carefully guards against all motion.

The *causes* of dislocation of the coxo-femoral articulation are of a multiple character, though the displacement is usually produced by a fall, in which the force coming in contact with the foot or knee, carries the limb in front of its fellow and as high up as the abdomen and perhaps to the thorax, the femur being converted into a lever of the first power, the anterior edge of the acetabulum constituting a fulcrum, the head and neck of the bone being the short arm of the lever, which overcomes the weight or resistance, which is the capsular and other ligaments. If the pelvis be held firmly in the cadaver and the flexed leg and thigh be forced into extreme adduction or across the lower part of the trunk, the coxo-femoral ligaments will be heard to snap; and if an outward force, exerted parallel to the femur, be now imparted to the limb, to correspond with a power that would come from living muscles, the backward dislocation will be accomplished. It is difficult for me to understand how the outward dislocation can be produced in any other manner. It is possible that the fall of a mass of earth or other heavy weight, upon the back whilst the body is bent forward in a stooping posture, may produce the backward dislocation of the hip, but it seems to me the violence must be done to the joint by the thigh being doubled under the descending trunk, the lower end of the femur acting as a lever to pry the head of the bone out of its socket. In December, 1867, Gus. Bovine, living on Freeman St., fell in a tobacco manufactory on Sixth Street, and struck his right knee against a tobacco hogshead that laid upon its side under a hatch through which the fall occurred. A couple of his fellow workmen, who were standing near when the accident happened, said they distinctly heard the breaking sound in the joint as distinct from that of the collision. Be this as it may, the outside of the knee was bruised, showing the point hit; and when the patient was raised from the prone position in

which he lay, the dislocated thigh was found at a right angle with the trunk, and beneath the lower part of the abdomen. When I saw the patient first he had been taken to his home; and his leg occupied the usual position that it does in dislocation of the hip: the great toe was resting on the tarsus of the opposite foot, the knee pressed the thigh of the well limb, just above the patella, the great trochanter was rotated forwards and occupied a position nearer the anterior superior spine of the ilium than natural, and the normal contour of the region of the hip indicated luxation. By rotating the limb, while the fingers were pressed down upon the head of the bone, its rotundity could be discovered and the motion distinctly felt. The leg was stiff, and many of the muscles appeared tense and others relaxed, so that the limb felt as if under the influence of distorting forces. I gave the patient chloroform, and reduced the displacement by the "physiological" or manipulating plan.

When a femur is recently dislocated upon the dorsum of the ilium, the shortening is more apparent than real. If the patient rest straight upon the back, and the legs be arranged parallel with each other, and perpendicular with the trunk, measurements will show that the dislocated leg is not more than an inch shorter than its fellow. But it is impracticable to bring the limbs parallel with each other unless the patient be under the influence of an anæsthetic, and then the dislocated leg will have a strong inclination to flex, and twist inwards. If the dislocation be left unreduced for several days, it will be found that the shortening of the limb has increased from one inch to two inches.

DIAGNOSIS IN THE BACKWARD LUXATION OF THE FEMUR.—The common signs of dislocation of the femur backwards have been already noticed, but the fact has not been mentioned in this connection that there is a slight resemblance between the features of a luxated hip and those which belong to a fracture of the neck of the femur within the capsular ligament. In the shortening of the limb they agree, but in almost every other respect they differ. In fracture, the limb is everted, and more moveable than in dislocation; it is also capable of elongation by moderate extension, but becomes shortened on the remission of the extending force. Fracture occurs mostly in old people, and from slight causes; and cre-

pitus is a sign indicating the nature of the injury when that sound can be obtained, and it generally can be elicited by slight rotation of the limb whilst extension is being applied. In comparatively rare cases the limb is inverted after fracture, so that in this peculiar feature resemblance to dislocation exists, yet the remaining characteristics of the two injuries—the differential signs—are generally plain and distinctive. Robert Wm. Smith, in his *Treatise on Fractures in the Vicinity of the Joints*, Case XXIX, reports as follows: “Patrick Murphy, æt. 80, transverse serrated fracture of the neck of the femur external to the capsule, at the line of junction of the cervix with the shaft of the bone: a second fracture detached the trochanter major, which was drawn upwards and backwards, carrying with it the insertions of the pyriformis, gemelli, and obturator muscles. The trochanter minor was likewise separated from the shaft of the femur, and along with it, the insertion of the psoas and iliacus internus; a large quantity of blood was poured out between the fragments, and among the muscles around the joint. The limb was shortened two inches, the foot inverted, and the entire limb in a state of adduction; the trochanter major could be felt upon the dorsum of the ilium, a little above the situation of the sciatic notch. This case was at first supposed to have been an example of luxation upon the dorsum of the ilium. The patient died upon the fourteenth day after the accident.” The case is reported to show that a comminuted fracture of the upper extremity of the femur may resemble a dislocation in so many respects as to be mistaken for that injury, even by surgeons of the greatest experience and acumen. However, Mr. Smith does not state whether the limb was rigid as in dislocation, and no mention is made of the diagnostic manœuvre of extending the limb to ascertain if it could be easily elongated, and if so, whether upon relaxing the force the shortening would be resumed. These differential signs, taken in connection with the advanced age of the patient, ought to decide a doubtful case. It is presumed that the faulty diagnosis resulted from placing too much importance upon the adduction and inversion.

Fracture of the acetabulum is another injury which permits the limb to assume many of the aspects peculiar to dislocation of the hip. Several examples of the kind are given by Cooper, Malgaigne, Earl, and others. The shortening and in-

version of the limb which characterized some of these cases, was due either to the head of the bone being driven through the acetabulum into the pelvis, or to its escape from the acetabulum through the superior and posterior border of that cavity. In the event of a fracture of the cotyloid border, allowing the head of the bone to escape, the reduction would be comparatively easy, but there being no obstacle to a recurrence of the displacement, the dislocation would be repeated as soon as the extending and restraining forces were removed. Arthritis, rheumatism, contusion, spasm of the muscles, and other injuries and complications of a pathological character, may be mistaken for dislocation, and be treated accordingly. It may be remarked that some mysterious defects about the coxo-femoral articulation, which were not dislocations, yet treated as such by presumptuous "bone-setters," have been benefited by their senseless manipulations.

Dislocations of the hip have been overlooked, owing to some complication or perplexing circumstance. Fergusson's Surgery contains the following example: "A young woman, about her full time of pregnancy, had a severe fall, and was carried to bed in a helpless condition; labor came on immediately after, and she had a difficult time. A severe rheumatic fever, as it was supposed, came on, and for some weeks her life was despaired of." Mr. Fergusson was asked to see her when she was comparatively well, about three months after the accident, and then, for the first time, a dislocation of the hip was detected. The same surgeon also relates another case, where a dislocation of the hip was complicated with a fracture of the femur in its lower third, and the dislocation was not detected till it was too late to attempt its reduction.

The *ischiatric* variety of the backward dislocation is not a primary form of displacement, but consecutive to the luxation upon the dorsum ilii. The same kind of violence which produces the ordinary backward and upward dislocation, may also throw the head of the bone a little farther backward into the great ischiatic notch, where the head of the bone rests on the pyriformis muscle and against the sacro-sciatic ligaments. The symptoms are substantially the same as those belonging to the iliac dislocation, though the shortening is not so great; the distance between the great trochanter and the anterior superior spinous process of the ilium is increased (instead of

diminished, as in the primary variety of the backward dislocation), and the head of the femur is too deeply buried in the ischiatic region to be felt, except in very spare subjects. In a patient who came under the observation of Dr. Gross, the head of the femur could be distinctly felt in the sciatic notch, "rolling under the finger when the limb was rotated upon its axis." The author does not state whether the patient was emaciated or not, though it is presumed from this circumstance that he was. Taking all the symptoms of ischiatic dislocation into consideration, it will be observed that this variety of displacement causes somewhat less deformity in the limb than the dorsal luxation: thus the shortening rarely exceeds a half inch, the point of the great toe rests on the top of the great toe of the sound side, the knee projects but slightly beyond the other, and the adduction, inversion, and flexion, are less than in the other variety. The limb is fixed, and all voluntary movements are lost. It is quite probable that one variety of the luxation is sometimes mistaken for the other. Mr. Cooper says that the ischiatic dislocation is "most difficult both to detect and reduce," there being less deformity and less fixture of the limb than in any other of the displacements of the thigh-bone. "This obscurity (says Mr. Syme,) is much increased by attempts to effect reduction, since a moderate degree of extension almost entirely removes the shortening and the inversion, which are usually considered the most characteristic symptoms. I think it, therefore, of consequence to state, that there is another feature of the injury which, according to my experience, is never absent—always well marked—and not met with in any other injury of the hip-joint, whether dislocation, fracture, or bruise. This is an arched form of the lumbar part of the spine, which can not be straightened so long as the thigh is straight, or in a line with the patient's trunk. When the limb is raised, or bent upward upon the pelvis, the back rests flat upon the bed; but as soon as the limb is allowed to descend, the back becomes arched as before. By attention to this symptom, I have been enabled to recognize the existence of dislocation into the ischiatic notch, when it had been unnoticed by others; and on one occasion, when it was supposed that the replacement had been effected through powerful extension by the pulleys."

Whether the ischiatic dislocation be consecutive upon the dorsal displacement or not, it is quite certain that in attempts to reduce one variety of dislocation the other may be produced. Many cases are reported in which the efforts at reduction baffled the surgeon by the tendency of the head of the bone to slip from the dorsum ilii to the sciatic notch, and *vice versa*; and even from the latter point to the thyroid foramen. The CCXVII. of Warren's Surgical Cases, is an instance of the kind. The patient was thirty-six years old; he sustained the dislocation while attempting to lift another man; he fell in making the effort, and the weight of the lifted man came against the thigh and pelvis. For twenty-three days the injury was supposed to be a sprain; at the end of that time the patient walked a mile and a quarter to a railway station, and took the cars for Boston, where he came under the treatment of Dr. Warren in the Massachusetts General Hospital. The limb was found to be shortened two inches, and more movable than is generally the case—a circumstance which may have arisen from the exercise the limb got in the walk to the station. The patient was etherized, and subjected to the action of pulleys, but the effort failed. Reid's plan was then tried, which also failed, the only effect being to carry the head of the bone from its old position on the dorsum of the ilium, to a new one in the foramen ovale. It was now brought back to the point it originally occupied, and the pulleys were again tried; and by lifting the trochanter and rotating the limb suddenly outwards, the head of the bone slipped into its normal place with a snap.

The New York Journal of Medicine for 1855, contains the report of a similar shifting state of the head of the femur in attempts at reduction. The case happened in the New York Hospital under the practice of Dr. Markoe. The patient, seven weeks previous to the unfortunate attempt at reduction, received the dislocation of the femur upon the dorsum ilii, by a fall from a rail-car while it was in motion. He was put under the influence of ether and Reid's method was tried. "The head of the bone descended as usual, until it came opposite the lower margin of the acetabulum, but from that point, as the limb was brought down, it slipped on to the foramen ovale. The manipulation was repeated several times, with all care, varying the degree of abduction at the various trials,

but without success. It was impossible to make the head rise over the lower border of the acetabulum so as to slip into its place. After numerous thorough and careful trials, the manipulation was abandoned and the pulleys ordered to be applied. Before this was done, it was thought best to place the head of the bone on the foramen ovale, and from that point to try and reduce it by the usual method recommended by Sir Astley Cooper. The head was accordingly placed on the foramen, and while the upper part of the thigh was grasped by an assistant and lifted strongly outwards, I took hold of the ankle and made extension and adduction. The head seemed not to move at all under this force, and while making strong adduction a crack was heard, everything became loose about the joint, and on examination it was evident that a fracture of the cervix had taken place, leaving the head on the foramen ovale. There was nothing further to be done, but to put the limb up in the straight apparatus, hoping that, if we could obtain union, he would have as useful a limb as those ordinarily left by fracture of the cervix, and certainly a better limb than if the dislocation had been untouched."

TREATMENT.—Quite a revolution has occurred in recent times in regard to the best method of reducing dislocations of the coxo-femoral articulation. Our older works are profusely illustrated with appliances for exerting great force in the reducing process. Pulleys are the principal means recommended for applying extension. They are used in the following manner: the patient is placed on his back upon a lounge, table, or bench, in a locality where strong hooks or staples, within a few feet of the patient's position, can be fixed to a door-post or some immovable object. A long towel or stout piece of muslin, several yards long, is carried between the limbs so that its middle shall rest on a soft compress placed against the perineum, and its ends, the one passing over the groin, and the other over the buttock, are to be tied together and slipped over the hook or staple which is beyond the patient's head; the pulleys are made fast to the hook or staple which is a few yards below the patient's feet, and reaches to a wide leather strap buckled or laced around the thigh just above the knee, or to a towel fastened by a clove-hitch, surrounding the limb **at** the same point, the skin being protected previously with a

wet wrapping cloth. The hooks or staples should be secured at points in the room, so that the extending and counter-extending forces shall be on a line with the axis of the patient's body. Everything ready, the free end of the cord in the multiplying pulley may have traction gradually made upon it, till the head of the bone has approached the acetabulum. The surgeon now uses his hands, or a towel around the upper part of the thigh, to direct the head of the bone into its place. Sometimes the foot or knee may be seized at the proper time during the extension, and such rotation imparted to the limb as shall secure reduction. It is said that when pulleys are used the head of the bone slips into the acetabulum without any audible snap, so that there are no means of judging whether the bone is in its place, except by relaxing the extension, unloosening the apparatus, comparing the length of the two limbs, and ascertaining that the relative position of the trochanters to the spines of the ilia are alike. However, if the surgeon have hold of the limb while extension is being made, he will, while aiding the reduction of the bone, recognize its return to the proper place. The head of the bone having been returned to its socket, and the apparatus removed, the natural contour of the limb, and the movements of the joint, will be found perfectly restored, which are reliable tests of reduction.

In 1845, Prof. Gilbert, of Philadelphia, published in the *American Journal of Medical Sciences*, a method of multiplying extending force which is effective and more simple in its application than pulleys. It is a mechanical appliance which can be commanded on almost every occasion, even in a rural district. It consists in the utilization of a "twisted rope." The patient is first arranged as for the use of pulleys; then, after the perineal belt or towel is secured beyond the patient's head to a hook, staple, or substantial object, and the band of cloth or leather is made to surround the thigh above the knee, a bed-cord, clothes-line, or other strong-rope, is doubled and made fast to the extending band, and again to a hook or staple within a few yards of the patient's knee, in the axis of the limb. A stick is now passed between the doubled or redoubled rope at a point equidistant from the staple and the patient's knee, and used as a double lever to twist the thongs or strands, thereby producing steady but powerful extension.

The limb is to be managed by the surgeon in every respect as it should be whilst pulleys are applied.

The method of reducing a dislocated femur by manipulation, has been practised from the earliest times; but no systematic and well described and defined method of this character was known to the profession until quite recently. In the translated works of Hippocrates, the following language is used in regard to the manipulating plan: "In some the thigh is reduced with no preparation, with slight extension directed by the hands, and with slight movement: and in some the reduction is effected by bending the limb at the joint, and making rotation." In the "Chirurgical Treatises" of Richard Wiseman, published in 1676, the directions for reducing a dislocated femur, show that the "physiological" principle of replacing the bone was pretty clearly understood, and put into successful practice. "If the thigh-bone be luxated inwards, it may be reduced by the hand of the surgeon, viz. : he must lay one hand on the thigh, and the other on the patient's leg, and having somewhat extended it toward the sound leg, he must suddenly force the knee up toward the belly, and press back the head of the femur into its acetabulum, and it will snap in. For there is no need of so great extension in this kind of luxation; for the most considerable muscles being upon the stretch, the bowing of the knee aforesaid reduceth it." Daniel Turner, who published his *Art of Surgery* in 1742, must have been familiar with a manipulating process of reducing coxo-femoral dislocations, for he gives rules, which indicate a knowledge of such a method. In the *Edinburgh Medical Commentaries* for 1776, he reports a plan of reduction which Surgeon Thomas Anderson seems to have hit upon when present at a case of dislocation, to reduce which pulleys were unsuccessfully employed. He says: "I was convinced that attempting the reduction in the common method, with the thigh extended, was improper, as the muscles were all put on the stretch, the action of which is, perhaps, sufficient to overbalance any extension we can apply. But by bringing the thigh to near a right angle with the trunk, by which the muscles would be greatly relaxed, I imagined that the reduction might more readily take place, and with much less extension.

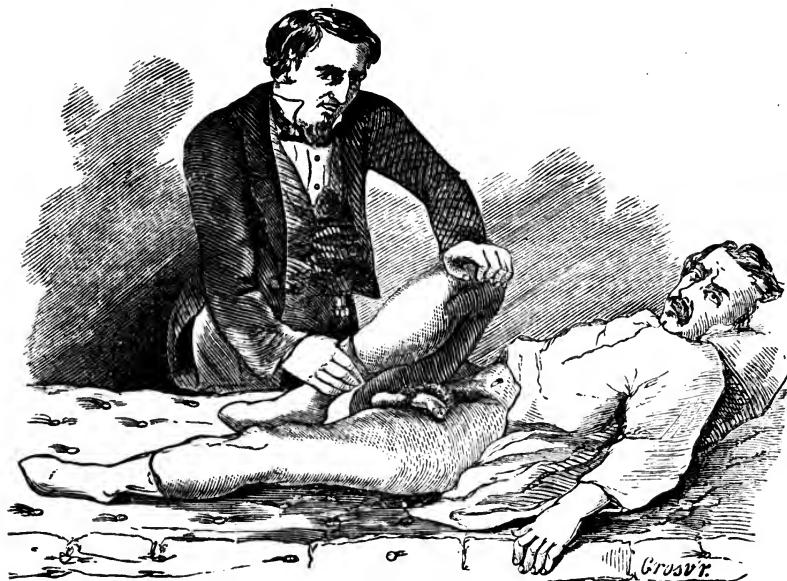
“When I made this examination, he was lying on a table on his back. I raised the thigh to about a right angle with the trunk, and with my right hand at the ham, laid hold of the thigh, and made what extension I could. From this trial I found I could dislodge the head of the bone. At the same time that I did this, with my left hand at the head and inside of the thigh, I pressed it toward the acetabulum, while my right gave the femur a little circular turn, so as to bring the rotula inwards to its natural situation; and on the second attempt, it went in with a snap observable to the gentlemen standing around, but more so to the poor man, who instantly cried out he was well and free from pain. His knees could then be brought together; the legs were of the same length, and the foot in its natural situation. The knees were kept together for some time with a roller, to confine the motion of the thigh; and in three weeks he was at his work, without the least stiffness in his joint.” Thirty or forty years later, or as early as 1815, Dr. Nathan Smith, a surgeon well known at that time throughout New England, was in the habit of reducing dislocations by a manipulating plan, for in a case of alleged malpractice in which he was an expert, he affirmed in the following language: “I do not think that the mechanical powers, such as the wheel and axle, or the pulleys, are necessary to reduce a dislocated hip, or any other dislocation.” The same doctrine he used to teach to his classes, as Professor of Surgery; and some of his pupils have been known to carry his instructions into successful execution. According to an article published in the *Boston Medical and Surgical Journal* for May, 1840, Dr. Luke Howe, a former pupil of Dr. Nathan Smith, remembered and practiced the teachings of his preceptor. Dr. Howe says, in reporting a case: “The patient was permitted to lie on his back on the bed where I found him, the knee of the luxated limb turned in and over the other. I raised the knee in the direction it inclined to take, which was towards the breast of the opposite side, till the descent of the head of the bone gave an inclination of the knee outwards, when I made use of the leg, being at a right angle with the thigh, as a lever to rotate the latter, and turn the head of it inwards. It then readily returned to its socket, with an audible snap. During this operation, the two assistants who had been placed to make the lateral extension and counter-exten-

sion, if ultimately required, were directed to draw moderately at their towels. How much of the success of the operation is to be imputed to their extension, and the rotation of the thigh by the leg, I am unable to determine; but as Dr. Smith succeeded without the aid of either, and as the head of the femur seemed to descend by an easy and natural process, I am inclined to believe that all that is necessary in such cases, is to elevate the knee, when the ilium, the muscles attached to it, and perhaps the ligaments, become the natural fulcrum, over which the thigh, as a lever, acts to bring the head down and inwards into the socket." In 1833, Dr. Wooster Beach, in his "Treatise on Surgical Diseases," described a process of reducing dislocations of the femur, which depended upon manual dexterity, and is correct in many particulars. It is as follows: "Instead of its being performed by extension and counter-extension, it is done by a compound movement. The patient must be placed upon a table, upon the floor, or a bed, upon his back; then the practitioner seizes the dislocated leg, and flexes or bends it a little, taking hold principally of the knee with one hand and the ankle with the other. After having very much flexed the leg upon the thigh, for the purpose of constructing the leg into a lever, he carries it a little outward; in the next place the thigh is to be gradually abducted; and lastly, the operator freely pushes the leg upward upon the pelvis, by the knee, toward the face, inclining the knee a little to the opposite side."

In the August number, 1851, of the *Buffalo Medical Journal*, Dr. W. W. Reid, of Rochester, N. Y., published an account of his method of reducing dislocations of the thigh, which does not differ essentially from those already quoted, except that the rules laid down are definite and practicable. His directions are as follows: "Place the patient on his back, on a low firm table, the floor or ground is better; let the operator stand or kneel on the injured side, and seize the ankle with one hand, and the knee with the other; then flex the leg on the thigh; next strongly adduct it, carrying it over the sound one, and at the same time, upward over the pelvis by a kind of semicircular sweep, as high as the umbilicus; then abduct the knee gently; turn the toes outward, the heel inward, and the foot across the opposite and sound limb, making gentle oscillations of the thigh, when the head of the bone will slip

into its socket with a slight jerk and an audible snap, and the whole limb will slide easily down into its natural position beside the other. In a recent case the whole operation can be accomplished in less time than it can be described."

FIG. 120.



Manner of reducing dislocations of the femur by the "manipulating plan."

Dr. Reid reduced three dislocations upon the dorsum ilii successfully, and had no failures; and since the publication of his "plan," many other surgeons have followed it, and generally with the happiest results. Some failures are reported as having attended efforts at reduction; but it is possible, if not probable, that the manipulation was not conducted skillfully or perseveringly. If the limb be not elevated or lifted well at the time the sweep outward is given, the head of the bone may slide from its position, and not enter the socket. In some instances the head of the femur slips down into the thyroid foramen; and in a few cases it has slid outward into the ischiatic notch. If one attempt at reduction fails, another should be undertaken; and even a half dozen or more trials may be made, each being varied to some extent. Dr. Bigelow thinks that the ilio-femoral ligament, which is an accessory band of fibers to strengthen the capsule on its anterior aspect,

plays an important part as an obstacle to reduction, and in shifting the head of the femur from one position to another; and in certain cases he recommends that the luxated limb be used as a lever to lacerate the capsular ligament still more, to facilitate reduction. As the tense untorn portion of the capsule is often the chief obstacle to reduction, the suggestion may be put into practical operation in some instances. It is clear that the manipulating method of reducing dislocations consists in placing the luxated limb in an attitude which shall relax tense tissues whether they be muscular or ligamentous. At last, after repeated failures, the pulleys may be tried, for prejudice against such appliances should not prevent their being used as a *dernier resort*. And even after the pulleys have been tried and proved inefficient, the manipulating plan may again be resorted to with success. I should recommend the employment of ether or chloroform in every instance, unless there existed a contra-indication, or positive aversion, to its use.

A case reported by Dr. Markoe, illustrates what has just been stated: "The first opportunity which presented itself for the trial of the new method, was in the case of an Irish laborer, who was brought into the New York Hospital, November 30th, 1852, with a luxation of the right thigh. He had been struck, a short time before admission, by the cow catcher of a passing railway train, and thrown some distance, and in his fall, probably, the accident was produced. The symptoms were those of the dislocation on the dorsum ilii, the head lying rather lower down and nearer the ischiatic notch than usual. The thigh was shortened about two inches, tended across the other, with the ball of the great toe of the injured limb touching the instep of the other foot, fixed in its position, and the head of the femur was felt in the position above described when the thigh was rotated on its axis. In addition to this injury, he had received a compound fracture of the left leg, three inches above the ankle, together with a good deal of bruising of other parts of his body. The patient was etherized to the extent of complete relaxation, and Jarvis' Adjuster was applied. It broke on the first trial of extension, and was laid aside. This mischance suggested the trial of Dr. Reid's plan, which was accordingly adopted. The operator, Dr. Buck, after bending the leg upon the thigh, gradually

adducted the thigh, while at the same time it was being flexed upon the trunk. Carrying the limb thus bent at the knee, and strongly adducted over the sound thigh, by a gradual sweep over the abdomen, and then slowly and steadily abducting the limb so as to carry the knee outwards, making at the same time a rocking motion by moving the leg backwards and forwards, had the effect of dislodging the head of the femur from its new position, and making it approach the acetabulum; but it did not enter the socket. From the position above indicated, the limb was now brought down slowly toward a straight position, still kept in a state of forced adduction. This last manœuvre seemed to have a very powerful influence in forcing the head toward the acetabulum, but the whole proceeding was completed without success. It was observed, however, that the head had been moved a little higher on the dorsum than it was before. The same manipulation was now again practised more deliberately and more carefully than before, and as the limb was being brought down abducted, we had the satisfaction of seeing and hearing the reduction effected by the head of the bone slipping into its socket. All deformity had disappeared, and the motions were free in all directions. The other injuries were properly attended to, and the recovery from the effects of the luxation was rapid and satisfactory." Dr. Warren, in his "Surgical Observations," Case CCXX, reports having to modify the method of Reid before reduction was accomplished. After having made the knee describe a segment over the abdomen, the head of the femur slipped partially around the socket, but did not enter that cavity, thus altering the seat of the dislocation, though not effecting reduction. The ankle was now seized and moderate extension applied, yet this did not accomplish the object, though a noise was heard as if reduction was effected. The leg, however, retained the abnormal shortening. The limb was again extended with considerable force, and the trochanter was lifted by the surgeon's hand, when the bone went into place with an audible snap. In this case the movements given to the limb by the "physiological" method, brought the head of the bone to the border or rim of the acetabulum, and simply required being pushed from this lodgment into the cavity.

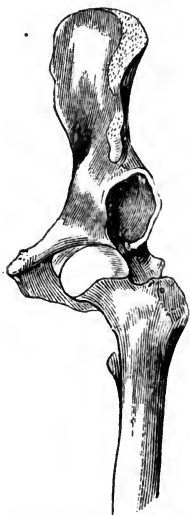Displacement into the ischiatic notch can be overcome by the same class of manipulations. It is only a variety of the backward dislocation, consisting mostly in degree of displacement—*i. e.*, the head of the femur is thrown farther outwards or backwards than it is in the dorsal luxation. To effect reduction the leg is to be flexed on the thigh, the thigh on the abdomen, the knee being made to rest on the belly as high as the umbilicus; and then takes the outward sweep till the thigh comes to a right angle with the trunk, the surgeon lifting upon the limb so as to help the head of the femur to approach the socket, and to enter it as the leg is allowed to slide down into a position beside its fellow. If the manœuvre is not a success, the dislocation will have been changed from an ischiatic into a dorsal displacement. And the rules already given for the reduction of that luxation will then be applicable. According to the *London Medical Times and Gazette*, for August, 1856, Mr. Wormald succeeded with the manipulating plan in a case that had been dislocated six weeks, and in which the pulleys had been repeatedly used in vain.

A few cases of serious injury are reported as having occurred from the manipulating plan of reducing dislocations, though in not so large a proportion of instances as in the method by extension. Violent handling of a dislocated thigh may result in fracture of the neck of the femur; or, the head of the bone in changing its position, as it sometimes does, may rupture muscles or do other mischief that may result in abscess and caries. It should be borne in mind as an established principle peculiar to the plan of reducing dislocations of the thigh by manipulation, that the knee, after the leg is flexed on the thigh, is to be carried in those directions only which offer the least resistance, and then reduction will generally be effected, and no mischief arise from the manœuvres. After the limb has taken the sweep over its fellow, up toward the face of the patient, it is to be abducted more than to a right angle with the trunk, then it is to be gently oscillated and lifted with a strong force, when the surgeon will either perceive that reduction is being accomplished, or that the effort is a failure, the head of the bone sliding around the base of the socket. If the surgeon feels that the attempt is a failure, while the limb is yet in a state of flexion, he need not bring the foot and knee down parallel with the other limb, but re-

peat the manœuvre from the point the failure is perceived. This will save the head of the bone and the trochanters from ploughing the soft tissues so extensively in different directions.

DISLOCATIONS DOWNWARDS AND INWARDS, INTO THE OBTURATOR FORAMEN; OR, INWARDS AND UPWARDS, UPON THE PUBES.—In the dislocation downwards, the head of the femur is forced into the obturator foramen, rupturing in its descent the round and capsular ligaments, and putting upon the stretch the

FIG. 121.



Dislocation downwards into the thyroid foramen.

psaos and iliacus muscles, as well as the glutei and the pyriformis. The head of the bone rests upon the external obturator muscle, and indents the obturator membrane. This injury is produced by forced abduction of the limb, as when a heavy weight falls upon the hips of an individual while the body is bent; or by a fall from a horse, the foot becoming entangled in the stirrup. Pirrie knew of a case caused by a person jumping out of bed in haste; the right foot became entangled by the blankets while the left foot reached the floor. The luxation has also been known to occur while a person was entering a carriage, one foot being on the ground, and the other on the step of the vehicle, just as the horses suddenly started. In fact, any accident by which the thighs become suddenly and violently

separated from each other, may produce the dislocation of one or both femurs into the thyroid foramen. In most of the instances reported the displacement has been caused by the fall of heavy weights upon the hips, crushing the individual to the earth, one or both thighs being forced outwards. The leverage of the shaft of the femur, under such circumstances, brings the head of the femur to the lower segment of the socket, ruptures the capsular ligament at that point, and forces the bone through this rent, down into the foramen ovale.

SYMPTOMS.—The limb is held rigid, and takes a position in advance of the other; it is lengthened to the extent of about two inches; and the foot is not turned either inward or out-

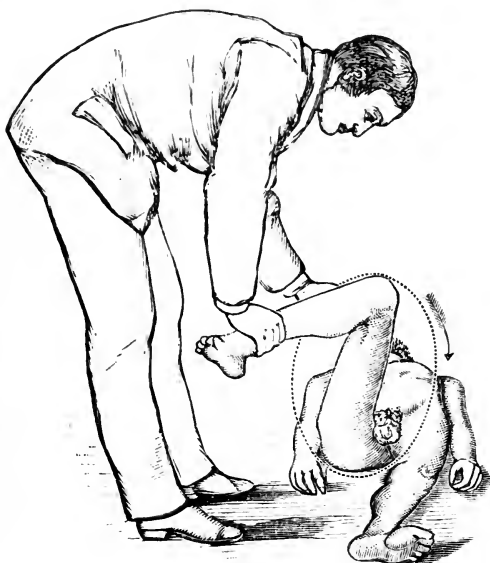ward; the trochanter major is less prominent than natural, the body is **bent** forwards and inclines to the injured side by the tension of the muscles. The limb can be abducted, but can not be made to approach the other without exciting intense pain and numbness. No form of fracture produces these symptoms.

TREATMENT.—No pulleys or kindred appliances are required to effect reduction. The patient is to be placed on the sound side, and then the surgeon grasps the foot and knee much as he would in attempting a reduction with the head of the bone on the dorsum ilii; he flexes the leg on the thigh, and carries the limb into a position of extreme abduction, or to the point it was made to assume when the dislocation occurred. One hand now clasps the knee, and forces it into extreme abduction, while the other hand placed on the inside of the thigh near the body, pulls the head of the bone upwards and outwards, into the socket. If the surgeon be not strong enough in his hands to accomplish this manœuvre successfully, he can employ assistants to help him execute his plan. A towel surrounding the thigh near the trunk and pulled outwards and upwards by assistants, while the surgeon sweeps the knee inwards, may prove of signal service. A serious objection to assistants is, that they may direct the head of the bone around and not into, the socket, converting one variety of dislocation into another. This accident has several times occurred. It may not be amiss to remark, that should such an accident occur, the head of the bone must be brought back into its original position before an attempt at reduction is again made, in order that the head of the femur may be in the best place to re-enter the socket through the rent in the capsular ligament.

In the case of Mr. Ashfield who dislocated his left femur into the thyroid foramen, by being thrown from his horse while descending Kemper Lane, in September, 1868, I first flexed the leg upon the thigh, then carried the limb outwards and upwards, into extreme abduction, as the first step in the proceeding: I next placed my foot, from which the boot had been previously removed for the purpose, against the perineum or between the ramus of the ischium and the upper extremity of the thigh, and used it as a fulcrum, while with my hands I brought the limb over across its fellow, when the head of the

bone slipped into place with an audible snap. The reduction was accomplished much more easily and expeditiously than I anticipated. The patient was under chloroform, and resting upon the back on the floor, during the effort to replace the bone.

The picture below is from Bigelow's illustrations, but the dart representing the direction points in the wrong way. The limb, in a flexed state, should be rotated outward, and *not inward*, as represented. The rule is the following: *Flex the leg to a right angle with the femur, and flex the thigh enough to relax all the muscles. Then with one hand on the leg and the other on the thigh, circumduction with rotation outward is to be imparted to the limb.* This raises the head of the femur from its bed in the foramen ovale, and the muscles pull it into the acetabular socket. The manœuvre is easy, and attended with success. The rotation is not in the direction of the dart in the diagram.



"Reduction of obturator dislocation by rotation and circumduction inward."—Bigelow.

(The dart points in the wrong direction.—H.)

I have verified what has just been stated in several trials, hence I know what I am talking about. In one instance the head of the femur had been in the thyroid foramen for more than a year. The leg was three inches *too long*, and much restricted in motion. While the patient was under chloroform I rotated the limb forcibly, to break up fortuitous adhesions; then I felt and heard such bands break. I then flexed the leg to a right angle with the thigh; then with my right hand on the leg, and my left on the thigh, I rotated the limb *outward*. This lifted the bone from the thyroid foramen, and the strained muscles pulled it upward and into joint. The reduction was attended with an audible snap. The limbs became of equal length at once, and all deformities disappeared.

The cotyloid notch in the lower border or walls of the socket, offers an easy passage way for the return of the head of the femur from the thyroid foramen to the acetabular cavity. This circumstance in the construction of the socket, greatly facilitates the process of reduction. Sometimes the return of the bone to the socket is effected by some slight movements of the limb imparted by a non-professional attendant. The powerful muscles put upon the stretch by the displacement, are ready to lend their force in returning the bone as soon as a little rocking or rotation is imparted to the limb, to disengage the head of the bone from obstruction in the way of reduction.

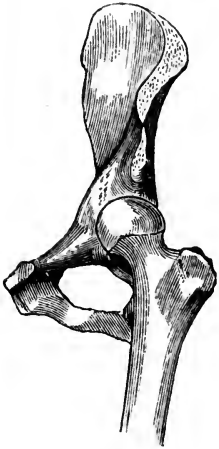In reducing any variety of hip dislocation, the inexperienced surgeon can remember to carry the limb in those directions only which are assumed most easily. For instance, the leg is to be flexed as far as it will go readily; then the knee is to be carried outwards and upwards in a state of abduction until some resistance is offered to the sweep in those directions, the limb reaching nearly to the thorax in some cases before its course is arrested; finally, the thigh, with the leg flexed behind it, is to be moved inwards and downwards, across the opposite thigh, completing the manœuvre which is to result in the return of the head of the bone to its natural socket. If the thigh be carried too high, the knee reaching the thorax, there is danger of throwing the head of the femur, not into its socket, but around the acetabulum, into the ischiatic notch. Experience shows that the thigh may be safely carried to a right angle with the trunk, and not endanger the slipping of

the head of the bone below the socket and backward towards the ischiatic notch. Markoe carried the knee too high in one instance, and converted the thyroid into an ischiatic dislocation.

According to the North-Western Medical and Surgical Journal, for 1852, the late Dr. Brainard, of Chicago, reduced a dislocation of the femur, which had been displaced into the thyroid foramen, by using a piece of wood, well padded, as a fulcrum, between the thighs, and employed the luxated limb as a lever to pry the head of the bone into place. Before he tried this plan, the pulleys and Jarvis' Adjuster had been used unsuccessfully.

DISLOCATION UPWARDS AND INWARDS UPON THE PUBES.—Although this is called a dislocation upon the pubes, the head of the femur rests more upon the ilio-pubic groove outside the psoas and iliacus muscles, hence Malgaigne has called it the ilio-pubic luxation, a term which better designates the position of the bone, than that employed by Cooper and his followers.

FIG. 122.



Dislocation forwards upon the pubes.

It is an extremely rare form of dislocation, few cases of the kind having been observed, and, of course, still fewer dissected. It is a forward variety of displacement, and does not occur more frequently than what is sometimes called the perineal dislocation, a form of luxation in which the head of the femur is thrown far forwards and finds lodgment upon the ramus of the ischium.

The ilio-pubic dislocation may be caused by a misstep, or a throwing of the body backwards to save a fall when the foot is placed in a hole in the ground, or upon an unstable substance. Any force which suddenly carries the thigh outwards and rotates it at the same time, tends to produce this form of dislocation. The fall of a bank of earth, or the wall of a building, striking the back or hips when the body is bent, in such a way as to force one thigh backwards twisting it behind the other, may also produce the luxation under consideration.

SYMPTOMS.—The limb is everted, abducted, and shortened to the extent of an inch or more. The buttock is flattened, the trochanter is nearer the anterior superior spine of the ilium than natural. The hemispherical head of the femur can be felt upon the horizontal ilio-pubic bar, outside the femoral vessels. As some of these signs exist in common with fracture of the neck of the femur, their differential peculiarities should be pointed out. In fracture, crepitus may be elicited, and motion in various directions may be easily imparted to the limb, the eversion of the foot may be overcome by moderate force, the limb can readily be pulled down or extended to its normal length, and the head of the bone being in the socket can not be felt. In dislocation, though there be shortening and eversion of the foot, there is no crepitus, the limb is rigid, the eversion and shortening not being easily overcome; and the head of the bone may be distinctly felt in the groin. The thigh, in dislocation, is slightly flexed, and stands off from its fellow, which is not the case in fracture of the cervix femoris.

TREATMENT.—Powerful extension may effect reduction, especially if a towel be put around the thigh near the body, and great force be used in pulling the upper extremity of the limb outwards or away from its fellow. If this plan should fail, the patient may be placed on his sound side, on the floor or a low bed, and the leg flexed on the thigh and the limb abducted to a point nearly at a right angle with the trunk, and then adducted much as in the manner directed for reducing dislocation into the thyroid foramen. By this manœuvre the head of the femur may be dislodged from its position on the ilio-pubic bar, and returned to the socket. If pressure can be made on the head of the bone, so as to help it towards the acetabulum, while the rotating or adducting sweep of the knee is made, the reduction is more sure to attend the effort.

All surgeons who have reduced dislocations “upon the pubes” do not agree in their manner of operating; one claims to have proceeded nearly in the course indicated above; and another manipulates the limb much as directed in reducing a dislocation upon the dorsum ilii. But how success could attend adduction before the thigh is first abducted to bring the head of the bone to the rim of the socket, is more than I can comprehend, unless the dislocation be “incomplete,”

the head of the bone being simply dislodged from the socket, and resting on the rim of the acetabulum. In this, as in other dislocations of the thigh, the limb should be carried in those directions offering least resistance, and then the operator can hardly go astray, even though he has made a faulty diagnosis.

ANOMALOUS DISLOCATIONS OF THE HIP-JOINT. — Among the so-called anomalous dislocations of the hip may be mentioned the *upward* displacement, the head of the bone being made to occupy the notch between the anterior superior and the anterior inferior spines of the ilium; or the head of the bone may rest immediately above the margin of the acetabulum, on a level with the anterior inferior spine of the ilium, and to its outside. These are displacements that belong to the *backward* variety, if the head of the bone be outside of the iliac spines; and to the *forward* variety, if the head of the femur be in front of those processes; and must be treated according to the rules, plans, and methods, laid down for successfully managing those forms of luxation.

Downward dislocations vary from the ordinary forward or backward dislocations, just as do the upward luxations. Ollivier gives a description of one of these forms of dislocation, which was met in 1819, but not published till 1823; a blow upon the inner aspect of the thigh near the knee, drove the limb violently outwards, where it remained in a rigid state of abduction, slightly flexed and rotated inwards; the head of the bone could not be felt anywhere, and there was a hollow in the situation of the great trochanter. By imitating on the dead subject the mode in which the displacement took place, the surgeon found that the head of the bone was thrown immediately below the acetabulum, and behind the cotyloid cavity, upon the tuberosity of the ischium or into the lesser sciatic notch. Mr. Keate, in the *Lancet*, reports a similar case, which was caused by a horse falling backwards with his rider into a narrow ditch. The reduction was accomplished by first bringing the head of the bone into the thyroid foramen, and then into the socket. It is probable that many of these so-called anomalous dislocations were *primarily* either forward or backward, varying according to circumstances in the upward or downward direction; and that new and additional forces compelled the head of the bone to take a position in a secondary or consecutive location quite at variance with the ordinary

displacement. This view is in accordance with the well known conversion of a dorsal into an ischiatic or thyroid luxation, while manipulating the limb in legitimate attempts at reduction.

AFTER-TREATMENT.—After a dislocated femur has been reduced, a long splint reaching from the foot to the thorax, or at least above the hip, tied to the trunk at its upper extremity, to the thigh at its middle, and to the foot or ankle at its lower end, should be worn for three or four weeks, or until it is presumed that the rent in the capsular ligament is healed, and other injuries about the joint have been repaired. The splint keeps the joint motionless, thereby preventing those movements that favor re-dislocation. Locally applied sedatives may restrain high grades of inflammation that might result in abscess and other serious complications.

ANCIENT DISLOCATIONS OF THE COXO-FEMORAL ARTICULATION.—There is no set time at which a reduction of a dislocated hip may not be attempted, though there is not much hope of success after three or four months have elapsed from the reception of the accident. Malgaigne reports having known a dislocated hip to be successfully reduced after the head of the femur had been displaced for a whole year. In March, 1856, Dr. Blackman, at the Commercial Hospital, in this city, reduced a dislocation of the hip that was of six months' standing. The reduction was accomplished by the manipulating plan. Dr. Dupierris, a Cuban surgeon of distinction, also reduced a dislocation of the femur, which had been received more than six months previously. The operation was performed by manual dexterity, and not by the aid of pulleys or other appliances for multiplying force.

Such results at late periods after the accidents occurred, warrant the attempt at reduction, even if several months have elapsed from the time the luxation is received. Though the acetabular cavity be partially filled during the long absence of the head of the femur, the return of that bone will soon re-establish all the functions of the joint.

It would not be wise to consider these successful efforts at reduction, in ancient dislocations, as establishing a rule, for in all probability many unsuccessful attempts, even in cases of not more than two or three months' standing, have been made; and because they proved to be failures, they passed unreported.

It would be safer, then, to consider these successes in the reduction of dislocations of six months' standing, as exceptions, and the unreported failures as constituting the rule.

CONGENITAL DISLOCATIONS OF THE HIP.—These constitute a class of difficulties that, as a general rule, can not be remedied by the ordinary methods of reducing luxations, therefore they are not strictly admissible in this connection. In the majority of such instances there is some osseous defect about the articulation, to say nothing of lax ligaments and muscles. Occurring mostly in children of a scrofulous and flaccid condition, or those having a soft and yielding state of the bones, the acetabular walls become elongated upward, or the head of the femur absorbed to an extent that displacement is a necessity, and can not be fully remedied.

PARTIAL DISLOCATIONS OF THE FEMUR.—Occasionally cases will be met, especially in the young, where there is some strange defect of the coxo-femoral articulation which resembles a dislocation in many respects, yet no positive evidence exists that the head of the femur completely leaves its socket. In some instances it seems probable that the head of the bone rests on the edge of the acetabular cavity, being prevented from descending on the slope outside the cavity by the untorn state of the capsular ligament, yet it does not seem possible that in anything like a normal state of the fibrous tissues the capsular ligament will stretch sufficiently to allow the head of the femur to rise out of its deep socket and take a position on the border of the cavity and there rest poised until absorption, under pressure, has formed an imperfect cup for the point of the bone to move in, and not be liable to escape, either inside or outside the true articular cavity. However, surgeons of unquestioned ability have reported incomplete luxations of the femur, giving the lesion a legitimate place among hip-joint dislocations. It is probable that some mistake has arisen in regard to the nature and extent of the injury, yet when a limb bears several of the prominent signs of dislocation, and no other lesion is suspected, it would naturally be pronounced luxated. There are some mysterious defects more or less peculiar to the coxo-femoral articulation, that may require a long course of inquiry and investigation to clear up. About a year ago I was called to see a little girl who had been hurt in the street, and was unable to walk

home; she had complained of something breaking or giving way in her hip, and her physician went through with a variety of manipulations, and claimed to have reduced a dislocation. At the time I was called, two weeks after the reception of the injury, the trochanter was very prominent, the leg was rigid, inverted, and to all appearance an inch or two shorter than the other.

The parents remarked that if the limb was ever dislocated the bone was still out of place, for it had presented the same appearance ever since the accident, notwithstanding the doctor's claims to having effected reduction. Movements imparted to the limb gave great pain; there was no crepitation, or other marked sign of fracture; the head of the femur was not outside the socket, though it seemed lifted part way out, and could not be made to return. I interpreted the symptoms as indicating inflammation of the joint, the head of the bone being raised in the socket by swelling, effusions, or morbid products in the bottom of the socket. The girl now walks about, with the foot inverted, the limb apparently shortened, though a twist in the pelvis prevents that feature from being observable; she is a little lame, but is improving in her gait and general appearance. I think there never was in her case, any form of traumatic dislocation, but that she labored under a species of hip-disease.

DISLOCATION OF THE HIP COMPLICATED WITH FRACTURE OF THE FEMUR.—Under extraordinary circumstances the head of the femur may be dislocated, and then, in the same accident, the neck of the bone or upper extremity of the shaft, may be broken. The London and Edinburgh Monthly Journal of Medical Science, for December, 1843, contains an account of such an injury, which was verified by a dissection made after the patient's death, which occurred twelve years after the reception of the injury. The dislocation was of the pubic variety, and the head of the femur was completely disengaged from the neck and shaft of the bone. It is not stated in the report whether any attempt had been made to reduce the dislocation, during which the neck of the femur may have been accidentally broken. It is not improbable that in some instances the femur is broken in attempts at reduction; and the complication may not have been recognized or acknowledged. In the event of dislocation and fracture of the femur in the

same accident, a judicious attempt should be made to push the head of the bone into the socket, before the fracture is treated. If the effort fail, the question would arise whether it is best to seek a union of the fragments, or, if the fracture was through the neck of the bone, to preserve the limb in as natural a position as possible, and expect only such a state of the parts as exists in a case of non-union after fracture of the cervix femoris. If the fracture was through the shaft of the bone at some distance from the cervix, and the reduction of the dislocation could not be accomplished, a good union of the fragments should be secured, and then an attempt might be made to replace the head of the bone, as in an ordinary case of ancient or chronic dislocation. The attempt at reduction should not be made until the fracture has been treated eight, ten, or twelve weeks, the age and vigor of the patient influencing the time consumed in the treatment.

In connection with the diagnosis of dislocated femurs, it must be borne in mind that in luxation upon the dorsum ilii, the back arches prominently upwards as the patient rests upon a table or level surface; and the muscles of the thigh are baggy underneath, and tense or drawn down to the bone on top, or on the front aspect of the femur. In a dislocation into the thyroid foramen the muscles and tendons on the inside of the thigh near the groin are tort. It is to be remembered also that a consecutive dislocation upon the dorsum ilii, the luxation being first into the foramen ovale, must be reduced by carrying the head of the femur back to the thyroid foramen, then into place. When the head of the femur has passed from the foramen ovale to the dorsum ilii, it can not go directly into the socket, for no aperture exists through which it can pass, but it must retrace its steps—it must go back by the route taken in the beginning.

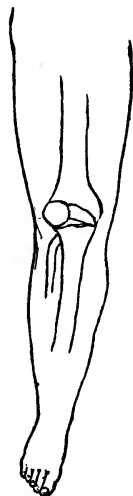In reducing dislocation of the hip, the patient is handled best on the floor, with a quilt for a bed. If one kind of manipulations do not succeed, the surgeon is to take a rest, and reconsider all the conditions of the case. He is to question himself whether or not a consecutive dislocation has not intervened since the first occurred. The surgeon commencing the introductory manipulation may convert a primary into a secondary or consecutive luxation.

CHAPTER XII.

DISLOCATION OF THE PATELLA.

The patella may be dislocated laterally, *i. e.*, outwards or inwards; and the bone has been forced upon its edge. It can not be dislocated downwards; nor upwards without a rupture of the ligamentum patellæ. The outward displacement is not an uncommon accident, but the other forms are quite rare. Muscular action is the most common cause of the displacement, though direct violence, as a blow upon the knee received

FIG. 123.



Dislocation of the patella outwardly.

in a fall, has been known to force the bone from its natural position. Young women of lax ligaments, whose wide hips, and approximating knees, throw the patella inside of a line drawn from the tubercle of the tibia, where the ligamentum patellæ is inserted, to the centre of the origin and action of the quadriceps muscle, are most liable to this accident. It is obvious that the muscles which, in going to their insertion, are made to swerve inwards to embrace the patella, would in their contractions tend to displace that bone outwards. There are several varieties of the outward displacement; the bone may be partially luxated or thrown so far outwards that the inner articular half of the patella would rest upon the outer condyle; and owing to the obliquity of the surfaces in contact, the outer edge of the bone is made to project prominently. In a complete dislocation, the patella is thrown wholly outside the most prominent point of the external condyle, and the inner edge of the displaced bone is made to project forward. The capsule of the joint is more or less

lacerated by the complete luxation. The *inward* dislocation, which is a rarer form of injury, is generally produced by direct violence, and not by muscular action. Blows received in falls, are the common cause.

In the dislocation edgeways the patella is turned on its axis, so that the articular surfaces of the patella face inwards, and the front surface outwards, the outer edge of the bone being buried in the fossa between the condyles.

There is no difficulty in detecting the nature of these displacements; the patella can be easily felt in its unnatural position, the bone being forced upon its edge or too far inwards, or outwards. The knee after luxation of the patella is partially flexed and too firmly fixed to admit of voluntary motion. Any attempt to move the limb is attended with great pain. In the lateral dislocation the width of the knee is increased; and the position usually occupied by the patella presents a depression to be both seen and felt. In April, 1860, I was called to see a boy on Fifth Street, opposite the Market House, who in falling down stairs hit his left knee against the corner of a box, and received a dislocation of the patella inwards. The mother who was near when the accident occurred, carried the boy up stairs, and tried to make him stand and walk; but he complained that his knee was broken, and he could not use it. I found the leg considerably flexed, rigid, and excessively painful. After taking off the patient's pants, I recognized the nature of the injury at once; and proceeded without delay to replace the bone. I encountered more resistance to a return of the bone than I had anticipated. At first I attempted to extend the limb to relax the quadriceps, but could not do it without eliciting the sharpest cries from the patient. I found the patella would not readily slip over the high edge of the inner condyle, so I sent for chloroform, and when the patient was well under its influence, I had no trouble in pulling the patella outwards into its place, the fingers being strong enough to lift it to a point where the action of the muscles would replace the bone.

TREATMENT. — The outward displacement may generally be overcome by slight movements of the joint, and firm pressure made against the outside of the bone; but the displacement inwards, and the edgeways dislocation, are more difficult to replace or return to position. In these forms of dis-

placement great force is required to effect reduction, and all movements are attended with extreme pain, therefore the quieting and relaxing effects of an anæsthetic should be brought into requisition. A case is reported by Dr. Gazzom, of Pittsburg, Pa., in which a man in a wrestling match was thrown, and was unable to rise on account of the patella having been dislocated upon its axis, the edge of the bone resting in the sulcus between the condyles. Varied and repeated attempts at reduction failed; the doctor, by the advice of another physician, divided subcutaneously the ligamentum patellæ close to the tubercle of the tibia, and then made efforts at reduction but failed; bleeding to syncope was tried, yet the bone could not be adjusted; the next day the leg was flexed on the thigh, and the thigh on the pelvis, and then the leg suddenly straightened, according to the suggestion of Dr. Watson, who placed his patient in a chair, and then taking his foot upon the shoulder, flexed the knee a little by the forward inclination of the body, and then suddenly extended the leg, the hands being used to help execute the manœuvre. This plan succeeded with Dr. Gazzom upon a fourth trial.

Mr. Flower had a case in a lad who fell between the seats of a theatre gallery, the patella being forced half way round and turned up edgeways, between the condyles of the femur and the head of the tibia. The limb was extended, and all attempts at reduction by bending the knee, manipulating the patella, etc., were unavailing. Chloroform was then administered, and the bone easily replaced.

If the ligamentum patellæ be ruptured or extremely relaxed, the patella may be displaced upwards. This could not be legitimately considered a dislocation, but a rupture of the tendon. Such an injury should be treated in every respect as if it were a fracture of the patella.

It is often difficult to keep a patella, which has once been dislocated, in place; therefore when the bone is once reduced, an elastic knee-cap should be worn, or an apparatus with a ring or disc on the side the dislocation has occurred. Side irons extending a few inches above and below the knee, jointed in the middle, and having a semi-circular iron band at each end to surround the posterior half of the leg and thigh, and straps to buckle over the front part, may be worn to strengthen the joint and to prevent re-luxation.

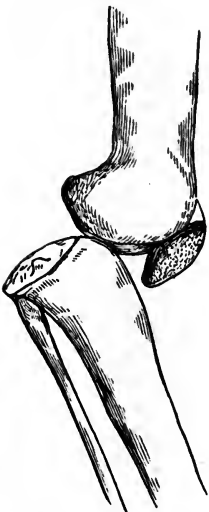
CHAPTER XIII.

DISLOCATION OF THE TIBIA.

The tibia may be dislocated forwards, backwards, and to either side, though it is seldom displaced in any direction. The articular surfaces at the knee-joint being large, and the connecting ligaments exceedingly strong, luxation can not be produced without great displacing power be brought to bear.

The lateral dislocations are frequently partial, but the forward and backward luxations are generally complete, the tibia being also rotated in some degree upon its axis.

FIG. 124.



Dislocation of the tibia backwards,

In the *backward* dislocation the head of the tibia forms a projection in the ham, and a deep depression exists in front of the knee, below the protuberant condyles of the femur. The lower end of the patella follows the tibia, and thus becomes placed horizontally, with its anterior surface looking downwards and its upper margin forwards. The limb may be straight or forcibly extended. The muscles about the knee are nearly all put upon the stretch, and the vessels and nerves of the popliteal space are compressed. If the tibia be thrown entirely behind the articular surfaces of the condyles, the crucial ligaments will be torn, and other tissues about the joint stretched or lacerated.

The backward luxation is generally produced by direct violence applied to the upper and front part of the tibia when the knee is bent.

TREATMENT.—When the patient is under chloroform there is no great difficulty in reducing the bone by manipulation. If ordinary manipulation fail, an assistant may hold the thigh upon the arm of a sofa, foot-board of a bed, or any projecting ridge, while the surgeon extends the leg if it be flexed, or flexes it if in a state of extension, at the same time pulling the leg into position. It is rarely necessary to make use of pulleys or other appliances for exerting powerful extending and counter-extending forces. The hands of another assistant to push the tibia forward and the femur backward, might aid in the work of reduction.

Dr. Rose, in the Provincial Medical Journal, reports being present when a woman had the tibia dislocated backwards by a fall occasioned by a carriage being driven furiously against a ladder on which she was standing. The knee was rigidly held in a state of fixed extension. The patient being relaxed from the shock of the injury, the doctor had no difficulty in pressing the displaced bones into position; and in the course of a few weeks, under the influence of local antiphlogistic treatment, the woman made a successful recovery.

The *forward* dislocation of the tibia is a rare accident, and presents features quite the reverse of the backward displacement: the tibia and patella project forwards, and the condyles of the femur produce a swelling in the ham. The popliteal artery and nerves are compressed to the extent of endangering gangrene; the ligaments about the joint are lacerated; and the limb is more or less shortened and extended. The projection of the leg bones in front and the femur behind, clearly indicate the nature of the displacement.

The causes of this injury in cases reported, have been the stepping into a ditch while carrying a heavy weight; the falling of a heavy spar on a man's back, the knee being forced to give way under the weight and shock; and direct blows. Malgaigne is of the opinion that neither the forward nor the backward dislocation of the tibio-femoral articulation is complete, though it would be difficult to account for the shortening in the cases reported, if the luxations were only partial.

October 10th, 1860, I was called by Dr. Adams, of Covington, Ky., to see a negro boy who received an injury of the knee by falling into a coal barge anchored in the Licking river. The boy in falling backwards struck the edge of a projecting

board, which hit just above the calf of his right leg. The upper part of the leg was driven forwards, and the condyles of the femur were prominent in the popliteal space. The forward dislocation of the tibia was unmistakable; and its reduction was effected by manipulation, while the lower part of the thigh projected over a chair. The leg was found in a forcibly extended position. The boy received other injuries of a serious nature, but ultimately recovered perfectly from all. His left ulna was broken by direct violence through its upper third, and it was thought that the eighth rib was broken near its angle.

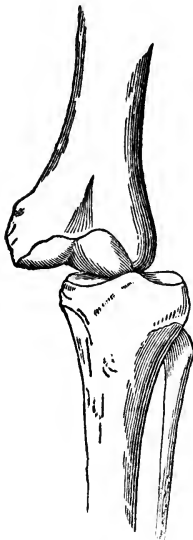
Dr. Sanborn, of Lowell, Mass., reports through the Boston Medical and Surgical Journal, for 1856, a case of dislocation of the tibia forwards which was produced by moving machinery in one of the factories of the city, the man being caught in a belt and carried round a shaft, the leg hitting the timber above at each revolution. At first sight the limb seemed to be broken in many places; it was shortened by several inches and shapeless; a closer examination proved that no fracture existed, but a complete dislocation of the tibia forwards, the condyles of the femur being driven down beneath the gastrocnemius muscle; and the tibia rose up in front, forming a marked projection. An assistant held the pelvis, and the surgeon grasped the ankle and drew the leg downwards to its proper length; and the bones then slipped into place. The patient made a satisfactory recovery.

The treatment of the forward dislocation is to be managed on precisely the same principles as the backward luxation; the patient is to be put under the relaxing and stupefying effects of chloroform, and then the surgeon extends the leg and pushes the displaced bones into their natural relations. If he is unable to accomplish reduction alone, he can engage the strength of assistants to good advantage. In those cases of forward and backward dislocations which obstinately oppose reduction, it is not improbable that the lateral ligaments, when they escape untorn, offer the chief resistance. To overcome these obstacles the leg would have to be forcibly flexed or extended to relax the tense tissues. If the leg was found in a partially flexed condition, it would have to be flexed still more; if in a state of extension, it should be extended even

beyond the straight attitude, before the displaced bone would slide into place.

The *outward* and *inward* dislocations of the head of the tibia, as has already been stated, are, on account of the width of the knee-joint, only partial. A violent twist of the leg, coupled with the displacing force the leg often sustains in a fall of the body, and the effects of moving machinery, are accounted as the common causes of lateral dislocations of the tibia. The signs of the displacement are too strongly marked to pass

FIG. 125.



Lateral dislocation of the tibia.

undetected. There is no shortening, but the limb is rigid, slightly flexed, with the foot inverted or everted as circumstances may direct. The prominent projections laterally of the femur to one side, and the tibia and fibula to the other, exhibit the true state of the injury. The width of the joint is greatly increased, and the limb will almost always present a twisted appearance, there being some rotation of the tibia upon its axis. The accident can not occur without considerable laceration of ligaments, and straining of muscles.

TREATMENT.—Lateral dislocations of the knee are reduced with greater facility than any other luxation of importance in the body. An assistant holds the thigh fixed, and the surgeon makes extension and pushes the head of the tibia in the direction favoring a return of the bones to their natural positions. After reduction is accomplished, the joint must be kept perfectly motionless for two or three weeks, and the ordinary remedies employed for preventing or subduing inflammation. Passive motion, which would be serviceable in preventing ankylosis, might also interfere with the healing of the lacerated ligaments; therefore it should be employed with due regard to the state of all the parts implicated.

DISPLACEMENTS OF THE SEMILUNAR CARTILAGES.—Chronic inflammation of the knee-joint, caused by a strain, or other injury, is sometimes followed by thickening of the semilunar

cartilages, and by elongation of the ligaments which connect them with the tibia; and it may create other difficulties with the internal working of the joint, so that the cartilages may become displaced by some trivial effort in the use of the foot. For the time the patient falls, or is unable to walk until the limb is gently flexed and twisted, when the defect is overcome, and the leg resumes all its functions without evidence of serious impairment. This injury has passed among surgical writers and teachers as a sub-luxation of the semilunar cartilages, though little is positively known in regard to the pathology of the difficulty. It is possible that the cartilages do become slightly displaced, so that some part of their structure gets pinched between the condyles of the femur and the head of the tibia. Surgeons have declared that they have found the cartilages projecting outwards at some part of the articulation. In a few instances what was supposed to be a displacement of the semilunar cartilages, has turned out to be loose or false cartilages in the joint. M. Gimelle has related a case of this kind, the mistake being corrected by Larrey who cut into the joint and removed the foreign body.

In some patients, either from lax ligaments, or a predisposition to joint affections, the knee is constantly tender and unstable. A slight twist imparted to the joint in walking, or even while turning in bed, is followed by sickening pain, and acute arthritis. The difficulty may be regarded in most instances as a morbid sensibility of the joint structures which will pass off in the course of time, even if nothing be done; but it would be judicious to put such patients on tonic and restorative treatment to remove any constitutional dyscrasia, and to bathe, and galvanize the knee. If in any case there existed evidence of displacement, whether of cartilage or bone, the limb should be extended, flexed, and rotated, until the parts displaced resumed their proper positions and functions. I have seemingly relieved a difficulty of this kind by flexing the knee to its utmost, then suddenly straightening the limb, repeating the operation with the addition of a slight rotatory movement. "Natural bone-setters" have occasionally gained great advantages by imparting to a disordered joint certain movements of this kind.

Whether anything like reduction is effected or not, some degree of synovitis will attend the injury, which needs to be

subdued by proper management. As all such difficulties of the joint are liable to be repeated sooner or later, an elastic knee-cap should be worn for months or even years.

Compound dislocation of the knee is one of the most dangerous accidents that occur to a limb. Besides the injury to the soft parts, which must be considerable, large articular surfaces are exposed to the influences of the air, and subjected to those changes which begin in shock and end in suppuration. The popliteal artery, veins and nerves, are stretched, or torn, so that complications of the most dangerous character can scarcely be escaped. In most instances it would not be advisable to attempt to save the limb; though, if the subject of the accident be vigorous, and the vessels and nerves apparently not much injured, an attempt to save the limb would be justifiable. However, the entreaties of the patient or those of his friends, who can not comprehend the extreme dangers of a compound dislocation of the knee, should not, in a severe case, deter the surgeon from expressing his views in decisive terms, nor swerve him from his plain path of duty. Many a timid, vacillating, or too easily influenced surgeon has, when too late, regretted having trusted to the recuperative powers of nature in severe injuries of the knee-joint. Amputation, or even resection, seems a harsh and uncompromising measure to adopt in case of compound dislocation of the tibio-femoral articulation, yet the more experience a surgeon has the less he is disposed to trust to any conservative course in the management of compound lesions of the knee.

CHAPTER XIV.

DISLOCATION OF THE TIBIO-FIBULAR ARTICULATIONS.

Separation of the tibio-fibular connections must be extremely rare, for two principal reasons: 1st, no considerable force can be so directed as to tell effectively towards separating these bones; and 2ndly, the interosseous ligament, together with the ligamentous fastenings between the tibia and fibula near the extremities of these bones, render their disjunction exceedingly difficult. If all the ligaments connecting these two bones be preternaturally relaxed some displacement of the fibula would be admissible, without, however, presenting a dislocation in the ordinary acceptation of the term. Dislocation of either end of the fibula may attend a fracture of the tibia; but as a distinct lesion, unaccompanied with fracture, the fibula is seldom disengaged from its articular relations with the tibia at either of its extremities. The *upper* end of the fibula is reported to have been displaced forwards and backwards.

In the *forward* dislocation, three or four examples of which have been collected, there was doubt whether muscular action or direct violence produced the displacement, though it is probable that the latter cause was the true one, inasmuch as little muscular force can be exerted in the forward direction upon the upper extremity of that bone. In the extreme flexed state of the limb, as in a squatting attitude, the thigh presses the upper end of the fibula forwards, and the muscles arising from the anterior aspect of the upper half of the bone, also tend to displace it forwards. With these forces at work, and a direct blow coming at the same time, the head of the fibula might be thrown in front of its normal position.

The signs of this displacement are tolerably plain. The head of the fibula is not in its natural position, but its presence is discoverable near the ligamentum patellæ; the biceps flexor cruris, which is inserted into the head of the bone, is put upon the stretch; and the natural contour of the leg just below the knee, is lost.

TREATMENT.—Dislocation of the head of the fibula forward, is reduced by extending the leg and rotating the foot outwards, the surgeon at the same time pressing the bone back into its natural position. Rest for a couple of weeks will allow the torn ligaments time to heal.

Dislocation of the upper end of the fibula *backwards* is a rarer accident than the forward displacement. Direct violence is the chief cause, though the action of the external hamstring muscle might assist in the luxation. Malgaigne has reported a case or two in which muscular action and direct force seemed to have produced the displacement. The head of the fibula was thrown behind its usual position, and could there be distinctly felt beneath the skin. The reduction is accomplished by flexing the leg to relax the biceps, and then the bone may be pushed into its normal place. Unless the leg is kept flexed at the knee for two or three weeks there is danger that the luxation may be reproduced. A compress bound against the posterior aspect of the bone, will assist in keeping the head of the fibula in its natural position.

Dislocation of the lower end of the fibula from its tibial connection has been reported. The displacing force of a passing wheel, might throw the lower end of the fibula back toward the tendo-Achillis; and a similar force acting upon the bone while the leg was resting upon its anterior aspect might possibly effect a forward displacement. Either variety of luxation would be difficult to overcome. While the foot was rocked inwards the surgeon should make an effort to push or pull the bone into place. Once restored to its natural position there would be no particular danger of a reproduction of the lesion.

CHAPTER XV.

DISLOCATION OF THE ANKLE-JOINT.

Following the nomenclature heretofore adopted, luxations at the ankle will not be regarded as dislocations of the lower end of the tibia. In all other dislocations the *distal* part of the limb is assumed to be displaced, though it may not be strictly correct in all instances. The foot may be held fixed, and a displacing force throw the tibia forward on the astragalus, the tibia being the bone displaced: the same thing may happen to other joints. For example, the arm may be caught and held immovably, while a force twists the body until the scapula is displaced from the head of the humerus. This circumstance does not do away with the fact that the injury, so far as surgical recognition is concerned, is a dislocation of the humerus. Those who contend for exceptions to ordinary rules, as applied to dislocations, gain nothing, and contribute their support to what can be correct only a part of the time. Indeed, in not a few instances neither form of language could be strictly correct, for the displacement is mutual, *i. e.*, a double force produces the dislocation,—one drives the tibia forwards, for example, and the other propels the astragalus backwards in the same accident. It is absurd, then, to destroy the harmony of nomenclature by adherence to an exception which presents no compensating advantages.

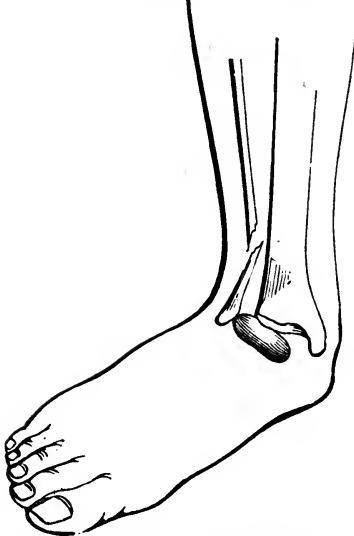Dislocations of the foot at the ankle-joint take place in four directions; and, mentioned in the order of frequency, they stand as follows: outwards, inwards, backwards, and forwards.

In the *outward* dislocation, the injury is commonly complicated with a fracture of the fibula a few inches above the malleolus. The foot is strongly everted, the outer edge of the sole being elevated, and the inner resting on the ground. A

depression exists at the seat of fracture, and the internal malleolus projects prominently.

The injury is produced by a violent twist or wrench of the foot outwards, as in stepping on the outer edge of the foot the

FIG. 126.



Dislocation of the foot outwards.

sole comes down upon a rolling stone or a projection of frozen earth. It is often caused by a fall, the weight of the body being received on the outer half of the sole, giving the leg a cant inwards. This injury has already been described in the chapter on fractures of the fibula; one part of the accident rarely occurs except in combination with the other. In extremely rare instances, the fibula may be broken just above the ankle-joint, without dislocation of the astragalus; and occasionally the foot may be luxated, partially or completely, with-

out the fibula being broken. However, the double form of injury is to be expected in the majority of cases. Besides the fracture of the fibula, either the internal malleolus is broken, or the internal lateral ligament (deltoid) is torn. If the lower end of the tibia be broken, as well as the fibula, and the foot thrown outwards with these two inferior fragments, the injury is not legitimately a dislocation, but a fracture of both bones of the leg. Boyer relates a singular case in which the dislocation of the foot was not attended with fracture of the fibula, but with displacement of that bone at its upper extremity. It is possible for the foot to be thrown outwards, the fibula not suffering fracture but separation from the tibia at the peroneo-tibial articulation. Such accidents have occurred, unless there has been some mistake on the part of those who reported them.

The ordinary form of the accident is sometimes adjusted by the patient before the surgeon has an opportunity to examine the parts implicated in the accident. Finding his foot in an

awkward state of deformity, the patient reaches down and twists it back into place; and then after being carried home, he has his ankle bathed in liniments, believing the injury only a sprain, and does not send for a surgeon until he finds that the difficulty is more serious and tedious than at first anticipated. Called several days after the accident and the return of the foot to nearly its natural position, the surgeon must not be misled by the patient's opinion of the case; but should seek the depression in the course of the fibula an inch or two above the ankle, and rotate the foot to elicit crepitation. Though the parts be swollen, a careful examination will reveal the nature of the injury. If asked the question, the patient will remember having, with his own hands, twisted the distorted foot into position. In the event of dislocation, without fracture of the fibula, the reduction is too difficult for the patient to accomplish, and the surgeon will then find the parts involved in the injury just as the accident left them.

TREATMENT.—The outward dislocation of the ankle, as has already been intimated, is not difficult to overcome. In most cases the surgeon, after flexing the leg on the thigh to relax the gastrocnemius, can with his hands press the foot into its natural position. It may facilitate the operation by gently rocking the foot while moderate extending force is applied. After reduction is accomplished, two side splints are to be used, with a compress between the lower end of the outside splint and the external malleolus, or the outside of the foot just below the malleolus, as recommended in the treatment of "Pott's fracture" of the fibula. In some instances, where the internal lateral ligament is torn across, as it generally is, the ankle will remain weak, with a tendency for the foot to turn out too much, especially when a step is made upon an uneven surface.

Hamilton reports two cases in his work on Fractures and Dislocations, in which the reduction could not be effected on account of some obstacle in the articulation, which may have arisen from fracture of the lower extremity of the tibia, the small fragment being in the way of reduction. He also reports having amputated the limb for compound dislocation of the foot outwards; and a dissection exhibited a fracture of the outer part of the articular surface of the tibia, the wedge-

shaped fragment occupying a position in the joint adverse to reduction.

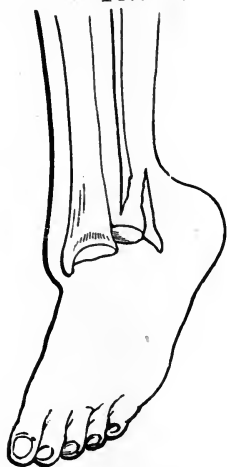
When the top of the astragalus has slipped away from the articulating surface of the tibia, and lodged in the channel between that bone and the outwardly displaced external malleolus, the reduction can not be exceedingly difficult to effect; and if the displacement could not be overcome by ordinary means, the inference would be that a piece of the outer side of the tibia had been chipped off, and dropped down between the astragalus and the main fragment of the tibia, either maintaining the upright attitude or turning over upon its side and becoming an obstacle in the capacity of a wedge.

The dislocation of the ankle *inwards* is a rare accident, and must occur from a forcible rocking of the foot upon its axis in a direction calculated to split off the internal malleolus, and to stretch and tear the external lateral ligaments of the joint. In this injury the foot is thrust inwards, so that the outer edge of the sole meets the ground, and the inner edge is raised, making the bottom of the foot present toward the opposite foot. The lower end of the fibula, or the external malleolus, projects very prominently; the width of the joint is increased; and the internal malleolus is displaced and moves with the astragalus. In a case that recently came under my observation, the internal malleolus was broken, and the fibula was fractured three inches above its lower extremity. If I had not seen the deformity before it was overcome, I should have been disposed to believe that the luxation had been originally outwards, and that in the efforts at reduction, the foot had been rotated too far inwards. The accident happened by a fall from a building, the foot striking among some rubbish. It is not improbable that the displacement was primarily outwards, breaking the fibula above the ankle, and the internal malleolus, by the strain on the deltoid ligament; and that by a further descent of the body the foot received an inward cant which threw it in that direction beyond its usual limit.

TREATMENT.—The inward dislocation of the ankle is always reduced with ease. If the patient has not turned the foot into place with his own hands, the surgeon has only to seize the foot and make extension, at the same time rotating it outwards. No powerful forces are required to replace the luxated bones, or to adjust the displaced fragments. The healing pro-

cess will occupy four or five weeks, and during this time the two leg splints should be worn, with a compress between the inside of the foot, below the malleolus, and the lower end of the splint. Any rotation or distortion of the foot is to be corrected during the time the dressing is worn, by the judicious use of adhesive strips, which in their application are to begin at the base of the great toe and cross the hollow of the foot obliquely, along the course of the peroneus longus muscle, and thence over the external malleolus and up the leg on its anterior aspect. The position of the foot can be regulated by the proper employment of strips of adhesive plaster, even if no splints be applied, though the use of splints keeps the ankle from turning laterally in either direction. If the fragment embracing the internal malleolus unites to the rest of the bone by osseous consolidation, the cure will generally be satisfactory; but if it make only a ligamentous connection the ankle must always remain weak.

FIG. 127.



Dis-location of the foot backwards:

Dislocation of the foot *backwards* may take place in a leap from a carriage in motion, or from a fall in which the heel catches or the toes meet something solid, the impetus of the body carrying the leg forwards. The displacement is generally accompanied with a fracture of the fibula just above the ankle, the lower fragment, constituting the external malleolus, remaining in contact with the astragalus. The tibia takes a position in front of the astragalus, on the navicular and cuneiform bones.

The symptoms of this accident are a shortening of the anterior part of the foot and a lengthening of the heel. The toes are pointed downwards, and the extremity of the tibia forms a projection in front of the ankle. The tendo-Achillis is arched, and the tendons on the top of the foot are tense and sharply defined.

TREATMENT.—This variety of dislocation is commonly reduced without much difficulty, though considerable extending

force is required before the bones of the leg and foot can be pulled and pushed into their proper positions. The flexing of the leg on the thigh relaxes the gastrocnemius muscle, therefore an assistant should put his arm under the lower extremity of the thigh, to make counter-extension, while the surgeon makes extension with one hand on the patient's heel and the other on his toes. The dressing and after-treatment should be much like that recommended for treating the lateral dislocations of the ankle. Due regard must be exercised for the fracture of the fibula.

In some cases it may be found difficult to maintain the parts in place after reduction is accomplished. However, if the foot is kept flexed on the leg, and the heel made to support the weight of the limb, the tendency to displacement is mostly overcome. In cases where the heel will endure pressure, and the anterior part of the leg near the ankle, some additional retentive means may be employed. If the foot and leg be placed in a box, with the heel suspended on a strip of buckskin, another strip of the same material may be made to press on the front of the leg by passing the ends through two holes bored in the sides of the box below the level of the limb, and then tied over the top of the box. Great watchfulness is needed to prevent a slough of the heel, for such a complication is frequent, and its effects tedious and distressing.

Dislocation of the foot *forwards* is the rarest form of displacement occurring at the ankle-joint. The injury arises mostly from falls, the foot meeting the ground with the toes elevated, and there remaining fixed while the descent of the body carries the leg bones down behind the summit of the astragalus. One of the best described cases is that of Mr. R. W. Smith, in the Dublin Quarterly Journal of Medical Science, for May, 1852. The subject of the accident was a sailor, who, while assisting to raise a very heavy cask on board ship, having at the same time one leg much flexed on the foot, and the thigh on the leg, was struck by the falling of a cask just above the knee, forcing the distal end of the tibia backwards from off the astragalus on the upper and posterior surface of the calcaneum. The symptoms of this accident were, a lengthening of the dorsum of the foot to the extent of one inch, and a shortening of the leg to the extent of half an inch, the two malleoli being so much nearer the ground. The projection of

the heel had disappeared, and the tibia formed a remarkable projection in front and to the inner side of the tendo-Achillis. The fibula was uninjured; but the extremity of the inner malleolus received a fracture.

The only accident with which this could be confounded is a fracture of the tibia immediately above the ankle-joint; but the situation of the malleoli would be decisive of the nature of the injury. "In the few cases of this accident which have been published," says Mr. Carsten Holthouse, "reduction was not effected, and the patients remained very lame; but there seems to be no reason why cases of this description, if seen early and properly recognized, should not be reduced in a similar manner to the lateral dislocations, and treated in all respects similarly."

A dislocation of the foot forwards could not take place without extensive laceration of nearly all the ligamentous structures about the joint; and the tendons passing behind the two malleoli are put greatly upon the stretch, and may drop from their sheaths into the mortise-like excavation usually occupied by the astragalus.

TREATMENT.—The forward luxation of the foot can not be overcome without well-directed and vigorous efforts on the part of the surgeon and assistants. The aid of chloroform in relaxing the muscles is invaluable; and the patient should be made to take the agent until he is profoundly under its influence. The injured limb should then be flexed at the knee, and held by an assistant; the foot is to be extended by the hands of another assistant; and the surgeon pulls the leg forwards and pushes the foot backwards. If several efforts of this kind prove unsuccessful, the most unyielding tendons may be divided subcutaneously, to facilitate the reduction. Once in place, great care must be exercised to prevent a recurrence of displacement. The weight of the limb must not rest on the heel, but on the leg above the ankle. The limb should be kept at rest for several weeks, or until it is presumed that the torn ligaments have united.

CHAPTER XVI.

DISLOCATION OF THE BONES OF THE FOOT.

Says Mr. Robert Wm. Smith, in his *Treatise on Fractures, etc.*, "The mechanism by which the bones of the foot are secured against the effects of external violence, is so complete and powerful, that we seldom have opportunities of witnessing luxations of the bones of the tarsus from one another, or their displacement from the metatarsal range."

The os calcis has been dislocated from its relations with the astragalus, and in the same injury the scaphoid bone has been disconnected from its astragaloid relations, these bones with the rest of the foot going backwards, causing the head of the astragalus to take a position upon the instep, where it forms a tumor, projecting almost through the skin. The foot is shortened in front of the leg, and the heel is elongated. An example of this injury is reported by Macdonnell, in the *Dublin Journal*. On the 6th of August, 1838, Mr. Carmichael was riding at a brisk trot when his horse suddenly fell. To prevent being pitched forwards, he threw himself back in the saddle, and strongly extended his legs to meet the ground. The shock of this descent was accordingly received upon the anterior extremities of the metatarsal bones, especially the metatarsal bone of the great toe of the right foot, which alone came to the ground. The following were the symptoms: "The toes were turned outwards, the inner edge of the foot forming an angle of about 30° with its natural direction; the sole was slightly turned outwards, and the outer edge slightly elevated. The concavity of the tendo-Achillis posteriorly was manifestly increased, and the heel lengthened. On grasping the soft parts between the tendo-Achillis and tibia, we found the distance between these parts much greater than in the other foot. The absence of the hard projection, which

would have been formed by the upper articulating surface of the astragalus, had it passed backwards with the other tarsal bones, was evident. The malleoli were perfectly defined. Below and before the inner there was a hard prominence, over which the skin was tense, formed by the inner surface of the astragalus brought into relief by the dislocation, and the slight eversion of the sole of the foot. Much the most striking part of the deformity consisted in a prominence on the dorsum of the foot. Immediately in front of the tibia it presented a flat surface broad enough to receive the finger, and from which there was an abrupt descent upon the anterior part of the tarsus. Over this projection, caused by the head of the astragalus, the integuments were so tense that it was evident a very small additional force would have driven it through the skin. Lastly, on taking the distance from the point of the internal malleolus to the extremity of the great toe with a tape-measure, I found it to be nearly exactly an inch less than the distance between the same points in the left foot. We could detect no fracture. The foot could be flexed and extended, but it occasioned great pain." To understand this dislocation better, it must be considered that the astragalus retains its normal connections with the tibia and external malleolus, and becomes disconnected from the calcaneum and scaphoid bones, they passing backwards.

The reduction of such a dislocation is to be effected by the strength of the surgeon's hands, the patient being anæsthetized, and his leg flexed and managed by an assistant, who pulls the tibia, fibula, and astragalus backwards, and the surgeon, with one hand on the patient's heel and the other on his instep, exerts extension and a forward movement of the foot. Some twisting and rotation of the foot facilitate the return of the displaced bones to their normal relations.

Dislocation of the calcaneum and the other bones of the foot *forwards*, the astragalus alone being left in connection with the bones of the leg, is an exceedingly uncommon accident. Malgaigne finds but one example, and that is reported by M. Parise. The injury happened to a quarryman who, while at work, with his left foot resting on a block of stone, and his right on the ground, was thrown forcibly forwards by the falling of a mass of stone; the thigh being at the same time strongly flexed on the trunk, the leg on the thigh, and

the foot on the leg. The following symptoms were observed : the foot was flexed ; the projection of the heel had disappeared ; and the bones of the leg with the astragalus in its normal relation with them, were found behind the calcaneum, or were resting upon its posterior extremity. As no crepitus was discoverable it was presumed that the injury was a dislocation ; but the pain and the swelling were so great, that a complete examination could not be made, and reduction was not attempted. Nine months afterwards the condition of the limb was as follows : the foot was flexed at a right angle with the leg, its point inclined inwards, and its inner border slightly depressed ; it was elongated in front of the bones of the leg, and the projection of the heel was completely effaced. At the level of, and a little below the malleoli, posteriorly, was a bony projection, which pushed backwards the tendo-Achillis beyond the heel. Above this projection there was another less marked, formed by the posterior and inferior margin of the tibia ; the malleoli were not separated from each other, nor did they present any traces of fracture. The extensor tendons of the toes were stretched over the instep, and beneath these on the outer side was a projection, which appeared to be the head of the astragalus, and immediately in front of this a depression. Flexion and extension of the ankle-joint existed to a limited extent.

It is possible that this displacement could not be overcome, but if chloroform had been administered, it is quite probable that a surgeon to pull the foot backwards, and an assistant to pull the leg forwards, might have accomplished reduction. Flexion of the leg and extension of the foot, would favor a return of the bones to their accustomed places.

Dislocation of the foot *sideways* at the calcaneo-astragaloid joint, is apt to be incomplete and compound ; the astragalus rests on a portion of the os calcis, and is not thrown upon its side, as it would be if the dislocation were complete. Forced adduction and abduction are the principal causes of these lateral dislocations of the calcaneum.

In the *outward* dislocation the foot is abducted, the outer border of the sole being raised, and the inner resting on the ground. The external malleolus is buried in the fossa caused by the eversion of the foot, and the inner malleolus and the head of the astragalus project unnaturally inwards. In thir-

teen examples of this variety of dislocation collected by Broca, nine were compound, and in six the fibula was broken.

The *inward* dislocation at the calcaneo-astragaloid joint, presents deformities similar to the varus form of club-foot; the foot is inverted, and its inner border raised. The head of the astragalus and the external malleolus project beyond the outer border of the foot, and a deep depression exists below. On the inside of the foot an elongated projection, formed by the inner border of the calcaneum, completely masks the internal malleolus. The scaphoid bone can be felt nearer to the os calcis than natural, and thus the inner border of the foot is shortened and rendered somewhat concave, while the outer is lengthened and made unnaturally convex.

The widest difference seems to exist in the difficulties encountered by the several surgeons who have reported cases of dislocation of the bones of the tarsus. Probably the kind and degree of displacement are not always the same; and it is possible that all cases were not managed with the same amount of intelligence and perseverance. In not a few instances the ligaments of the tarsus, and the tendons passing from the leg to their insertions in the foot, act as mechanical impediments to the return of the displaced bones; in extremely rare cases, they may become insuperable obstacles to reduction. In those cases in which it is apparent that the tendons offer the principal resistance to reduction, it is advisable to divide subcutaneously the tendo-Achillis, and perhaps the tibialis anticus and posticus.

In some dislocations about the foot and ankle it is extremely difficult to determine the exact nature of the injury, one lesion so much resembles another. There are deformities attendant upon fractures in the immediate vicinity of the ankle, that appear like those following luxations of the bones of the tarsus, therefore the surgeon should exercise his powers of discrimination if he would escape making a faulty diagnosis. Those injuries which are compound, do not present so many difficulties in the way of a correct solution of the mystery. It would not ordinarily be easy to diagnose a rotation of the astragalus, in which the upper or trochlear surface presented inwards, and its outer surface upwards; but if the accident leave an opening to the bone the insertion of the finger might determine exactly the nature of the displacement.

According to the results of cases collected by M. Broca. it is much safer to let a dislocated tarsal bone, which can not be reduced, remain in its abnormal position than to attempt to remove it; and amputation, which has so many times been adopted at once after some of the tarsal dislocations, should not be considered as long as there existed a possibility of escaping gangrene, and other serious complications. In accidents of a crushing character, breaking and displacing the bones, and compounding the injury by lacerating the soft tissues, no special rules can be given which would be generally applicable, yet in the management of such injuries, the accomplished surgeon who is accustomed to act in emergencies, and is governed by the general principles of his science, knows as well what the necessities of each particular case demand, as if he had just studied a written direction for the treatment of such a case.

The astragalus, when it is displaced, may become so completely isolated from nutritive connections, as to be in danger of necrosis. Under such circumstances, it would be better to extract the bone at once, than to leave it where by prolonged irritation it might jeopardize the limb, or even the life of the patient.

Mr. Burnett, in the London Medical Gazette, for 1837, describes the case of a gentleman who, in taking a leap while fox-hunting, dislocated the scaphoid bone from its connections with the cuneiform bones. A wound three inches in length was made in the instep through which the scaphoid and part of the astragalus protruded. By making steady pressure on the bone for fifteen minutes it was reduced. The wound healed, and the patient recovered the free use of the foot. Piedagnel was unable to reduce a displaced scaphoid that came under his observation; and the bone being broken longitudinally, and the accident compound, he amputated the foot.

In the case of Walker, reported in *The Medical Examiner*, for 1851, the scaphoid was forced forwards and upwards, as a stone is forced from an arch. By bending the foot downwards, the surgeon was enabled to press the projecting and displaced bone back into its normal position.

Malgaigne has not seen a case of dislocation of the cuboid bone, nor has he confidence in the reports of those who claim to have met with the accident. The assertion of Piedagnel,

that the bone may be displaced in three directions, is probably based upon speculation, as other surgeons, since his time, have enjoyed great opportunities for observing such displacements, if they were of even rare occurrence, and no well authenticated accident of the kind has been reported. There seems to be nothing in the shape of the bone, or in its connections, to prevent displacement; and that is probably why it has been stated that the bone may be dislocated downwards, inwards and upwards.

The internal cuneiform bone may be luxated from its scaphoid connection in an upward and inward direction, as if influenced by the action of the tibialis anticus muscle; and its anterior extremity may also be forced from its metatarsal relations, though in conformity with the nomenclature adopted in this work, such a displacement must be considered as a luxation of the metatarsal bones. All three cuneiform bones have been luxated upwards, the deformity being marked, and the diagnosis easy, on account of the bones being thinly covered on the dorsum of the foot. The reduction, when the internal cuneiform is displaced singly, or the three together, is not difficult. The foot is seized in such a way that the hands bend the anterior part of the foot downwards, and the thumbs press the bone or bones back into place.

DISLOCATION OF THE METATARSAL BONES.

Robert Wm. Smith, of Dublin, makes the following appropriate remarks: "When we reflect upon the admirable mechanism of the foot; when we consider the beautiful construction of its arches, the peculiar forms of the tarsal bones, the extent of their articulating surfaces, and their mode of adaptation to each other; when we also take into account the number and strength of the ligaments which bind them together, the arrangement of the muscles, tendons, and tendinous expansions in the plantar region, and the very slight degree of motion which is permitted to the bones;—when we reflect upon all these conditions, we find, that in the mechanism of this solid, but at the same time, highly elastic fabric, nature has adopted every provision calculated to ensure strength, and immunity from external violence.

“Notwithstanding, however, these numerous and varied sources of security, the bones of the foot occasionally suffer displacement, when subjected to the influence of great external force.”

Sir Astley Cooper observes: “The metatarsal bones I have never known luxated; their union with each other, and irregular connection with the tarsus, prevent it; and if it ever happens, it must be a very rare occurrence.”

Mr. Robert Smith, whose words have just been quoted, twice had an opportunity of ascertaining by *post mortem* examination, that the metatarsus, and internal cuneiform bone, were dislocated upwards and backwards, the luxations having remained unreduced many years. The appearance of the foot in both instances indicated pretty clearly the nature of the accident. The heel preserved its natural relations to the bones of the leg; but the foot in front of the ankle-joint was shortened an inch or more; the inner edge of the foot was elevated, and the outer depressed; the sole of the foot exhibits a rounded appearance, and the dorsum a transverse prominence, situated about an inch below and in front of the ankle-joint. Upon examining the skeleton of the foot, the metatarsal bones, and the internal cuneiform, were found dislocated upwards and backwards upon the tarsus. The accident which effected the displacement was a fall from a horse.

In the second example the history of the case was not ascertained. The patient died of malignant disease of the abdomen at the Richmond Hospital; and as he did not walk lame, no inquiry was made concerning the condition of the foot which appeared simply fore-shortened in front of the ankle-joint. The appearance of the foot in every particular, was like that of the other just described. Dissection showed that the second, third, fourth and fifth metatarsal bones, and the internal cuneiform bone, were dislocated upwards and backwards upon the tarsus. Ankylosis had taken place between the tarsus and metatarsus, and osseous buttresses had been thrown out to assist in the consolidation. Mr. Smith thinks the dislocation is liable to occur “when a person, in falling or leaping from a considerable height, alights upon the anterior part of the foot. Under these circumstances, the limb is submitted to the operation of two forces operating in opposite directions; one, the weight of the body and impulse of the fall, tending

to depress the tarsal bones; the other, the resistance of the ground, tending to displace the metatarsus upwards; the articulating surfaces thus glide past each other, and the anterior part of the foot is then drawn backwards, and the aspects of its surfaces altered by muscular action."

In the injuries just described it will be observed that the first metatarsal bone--the one to which the great toe belongs--was not dislocated, strictly speaking, but, as it went upwards and backwards it followed the rest of the metatarsal row, and the internal cuneiform bone, to which it maintained its normal connections.

Mr. Smith thinks that the two cases of dislocation of the metatarsus upon the tarsus related by Sanson, as having happened in the practice of Dupuytren, may have been strictly such, but he inclines to the opinion that the internal cuneiform bone preserved its connections with the first metatarsal bone; and if that condition was overlooked, he regards it as not the slightest disparagement to the judgment of that great surgeon. The two cases dissected by Smith were found unreduced; and it is not known whether attempts at reduction were ever made. Dupuytren found it impossible to reduce the bones to place in the two cases coming under his treatment.

In a case of dislocation of the metatarsus under the tarsus, reported in the *Dublin-Quarterly Journal of Medicine*, 1854, as falling to the practice of Mr. Tuffnell, in the Dublin City Hospital, reduction was not accomplished, though the most powerful and persevering efforts were made. The accident happened to a trooper whose horse fell upon the soldier's right leg and foot, crushing them against the ground. In six months after the accident the patient was able to walk upon the heel and outside of the foot, but could not bear any weight upon the sole on account of the burning, lancinating pain excited by the endeavor.

Dr. Hershey, of Williamsville, N. Y., in 1856, reported to the *Boston Medical and Surgical Journal*, a dislocation of the first, second, and third metatarsal bones upon the tarsus. The accident occurred to a young man who was suddenly dismounted from a horse. The reduction was accomplished as follows: an assistant made counter-extension upon the heel, and the surgeon grasped the anterior extremity of the foot with both hands, made extension, bent the toes downwards,

and with his thumbs pressed the projecting bones back to their natural position.

A lateral dislocation of the metatarsal bones *outwards* is reported by Dr. Gross, to have occurred in the practice of Drs. Green and Swift, of Easton, Pa. The accident happened to an elderly gentleman who, in falling down a flight of stairs, sustained the injury. The metatarsal bones were all forced laterally outwards to the extent of a half inch or more; and the foot is reported to have been *shortened* and twisted.

The reduction was accomplished by extension, and pressure in directions calculated to return the displaced bones to their natural positions.

DISLOCATION OF THE PHALANGES OF THE TOES.

The great toe is dislocated at the metatarso-phalangeal articulation much more frequently than the other toes. Of twenty-two cases, confined to the first row of phalanges, reported by Malgaigne, the great toe suffered luxation in nineteen instances; and in the three other cases, all the toes were dislocated at once. The displacements are generally, if not always, upwards, the phalanges being forced upon the metatarsal bones.

Partial displacements of the toes are common; and compound luxations are more frequent than in displacements at other joints. There seems to be a certain analogy between the dislocation of the first phalanx of the great toe, and that of the corresponding phalanx of the thumb; and a similar difficulty is experienced in the reduction. As both joints are organized on the same general plan, it would be strange if the like causes did not produce like effects, the same kind of resistance being offered in both articulations. In the only case of dislocation of the great toe at its metatarso-phalangeal articulation, that has come under my treatment, I met with no serious obstacles to a ready reduction. Extension was made upon the toe by an assistant, and with my hands around the sides of the foot to exert counter-extension, pressure with the thumbs against the projecting and displaced phalanx, effected reduction. In the event of failure after employing all ordinary means, it would be justifiable to divide the oppos-

ing barriers, whether they be ligaments, or tendons, or both, though such a course should be avoided if possible.

Dislocation of the second row of phalanges, is an accident of extremely rare occurrence. Reduction, by means of extension and pressure, has not been difficult in the few cases reported.

The terminal bones of the toes have been luxated; and the accident, as with other dislocations of the toes, generally arises from falls received in horseback exercise. A crushing force so directed as to double the toes under the foot, is the one which commonly produces displacement of one or more of the phalanges. The pain attendant upon the displacement is severe; and the deformity denotes the character of the injury. Reduction may be accomplished by the ordinary manipulation required to reduce displaced digital extremities.



INDEX.

PART 1. FRACTURES.

	PAGE
Acromion process, fracture of the.....	111
Adhesive strips, for making extension.....	60
Apparatus for treating fractures.....	52
Appliances, defects of, in fractures of the femur.....	205
adhesive strip, as a fastening to the leg.....	230
handkerchief, as a fastening to the leg.....	229
gaiter, as a fastening to the ankle.....	229
Astragalus, fracture of the.....	249
Attitude of limb in treating fractures of the femur.....	193
Bandages.....	52
Brainard's perforator, for treating false-joint.....	39
Burges' fracture-bed.....	63
Burges' fracture apparatus for treating fractures of the femur.....	200
Calcaneum, fracture of the.....	250
Callus, soft and yielding after apparent consolidation.....	31
provisional.....	32
yielding nature of, after fractures of the femur.....	201
Capsule of hip-joint.....	179
Carpus, fractures of the.....	161
Cartilages, costal, fracture of the.....	100
laryngeal, fracture of the.....	90
Cervix femoris, fractures of the.....	172
scapulæ, fracture of the.....	114
Clavicle, fracture of the.....	104
Coccyx, fracture of the.....	168
Condyles of the humerus, fractures of the.....	128
of the femur, fractures of the.....	211
Convalescence.....	70
Costal cartilages, fracture of the.....	100
Coracoid process, fracture of the.....	113
Cranium, fractures of the.....	74
Crepitus as a sign of fracture.....	24
Dangerous complications in fracture injuries.....	25
Defective union after fractures.....	41
Diastasis, or separation of epiphysis of the humerus.....	125
or separation of epiphyses in general.....	72
Differential signs of fracture and dislocation.....	26
Direct and indirect forces as causes of fracture.....	21
Direction of the line of separation, as oblique, transverse, etc.....	19

	PAGE.
Dislocations, (see Part Second).....	255
Division and subdivision of the subject of fractures.....	18
Dressings.....	52
Dupuytren's splint and fracture dressing.....	246
Epiphysis, separation of.....	72
Epiphysis of the humerus, separation of the.....	125
Exercise allowed a patient treated for fracture.....	66
Extension, adhesive strips in making.....	60
Fracture, general observations upon nature and treatment of.....	17
division and subdivision of subjects of, as simple, compound, partial, complete, comminuted and complicated.....	18
direction of the line of separation in, as oblique, transverse, etc.....	19
comparative frequency of. in different bones..	20
causes of, as direct and indirect violence.....	21
signs of, as pain, mobility, crepitus, etc.....	22
incomplete or "green-stick".....	26
with dangerous complications.....	25
rendered serious by railway accidents, etc.....	27
apparatus.....	52
beds.....	62
process of union and method of repair in.....	29
non-union after.....	36
defective union after.....	41
responsibility in the treatment of.....	44
management of compound.....	67
of the cranium.....	74
of the zygomatic arch.....	74
of the nasal bones.....	75
of the malar bones.....	78
of the superior maxillary.....	78
of the inferior maxillary.....	80
of the hyoid bone.....	88
of the laryngeal cartilages.....	90
of the vertebræ.....	91
of the ribs.....	95
of the costal cartilages.....	100
of the sternum.....	101
of the clavicle.....	104
of the scapula.....	110
of the acromion process.....	111
of the coracoid process.....	113
of the neck of the scapula.....	114
of the humerus.....	117
of the anatomical neck of the humerus.....	117
of the tuberosities of the humerus.....	119
of the surgical neck of the humerus.....	120
of the shaft of the humerus.....	122
of the humerus just above the condyles.....	125
of the condyles of the humerus.....	128
of the internal condyle.....	129
of the external condyle.....	133

	PAGE.
Fracture, of the ulna (olecranon process)	137
of the coronoid process of the ulna.....	140
of the shaft of the ulna.....	142
of the radius.....	145
of the shaft of the radius.....	148
of the radius, (Colles').....	150
of the radius, (Barton's).....	150
of the carpus, metacarpus and hand.....	161
of the phalanges.....	163
of the pelvic bones, as ilium, ischium and pubes.....	165
of the sacrum.....	167
of the coccyx.....	168
of the femur.....	171
of the neck of the femur.....	172
of the cervix femoris within the capsule (intra-capsular).....	179
of the neck of the femur outside the capsule (extra-capsular).....	180
of the trochanter major.....	185
of the shaft of the femur.....	190
of the shaft of the femur just below the trochanters.....	192
of the shaft of the femur just above the condyles.....	207
of the condyles of the femur.....	211
of the patella....	215
of both bones of the leg.....	221
of the tibia, singly.....	235
of the fibula.....	240
of the fibula, Pott's.....	242
of the bones of the foot.....	249
of the astragalus.....	249
of the os calcis.....	250
of the metatarsal bones.....	251
of phalanges of the toes.....	252
Femur, fracture of the	171
fracture of neck of the.....	172
fracture of the shaft of the.....	202
fracture of the condyles of the.....	211
Fibula, fractures of the	240
Pott's fracture of the.....	242
and tibia, fracture of the.....	221
Gaiter, fastening upon the ankle.	229
General observations upon the nature and treatment of fractures	17
General treatment of fractures.	43
Gibson's apparatus for treating fractures of the thigh	206
Gypsum dressing	56
Hand, fractures of the	161
Hamilton, in regard to mobility at seat of fracture	127
Humerus, separation of its lower epiphysis	73
fracture of the.....	117
fracture of the anatomical neck of the.....	117
fracture of the tuberosities of the.....	119
fracture of the surgical neck of the.....	120
fracture of the shaft of the.....	122

	PAGE.
Huntoon's yoke-splint for treating fracture of the clavicle.....	108
Hyoid bone, fracture of the.....	88
Ilium, fracture of the.....	165
Incomplete, or "green stick" fracture.....	26
Immovable fracture dressing.....	55
Impaction in fractures of the neck of the femur.....	177
Innomiatum, fracture of the.....	165
Ischium, fracture of the.....	165
Jaw, fractures of upper.....	78
Jaw, fractures of lower.....	80
Laryngeal cartilages, fracture of the.....	90
Levis' dressing for fracture of the clavicle.....	108
Ligamentous union after fracture of the neck of the femur.....	181
Ligament, capsular, of the hip-joint.....	179
Ligamentous union after fracture of the patella.....	218
Malar bone, fracture of the.....	78
Malgaigne and others on shortening after fracture of the femur.....	203
Management of fractures.....	43
Many-tailed bandage.....	55
Maxillary, superior, fracture of the.....	78
inferior, fracture of the.....	80
Metatarsus, fracture of the.....	251
Mobility as a sign of fracture.....	22
"Natural method" of producing extension.....	48
of applying extension in treating fractures of the femur.....	198
Nasal bones, fracture of the.....	75
Neck of scapula, fracture of the.....	114
Neck of femur, fracture of the.....	172
Olecranon process of ulna, fracture of the.....	137
Osseous fragility.....	20
Paget, ensheathing callus of.....	34
Partial fracture (incomplete).....	26
Patella, fracture of the.....	215
Pelvic bones, fracture of the.....	165
Phalanges of the hand, fracture of the.....	163
of the foot, fracture of the.....	252
Pott's fracture of the fibula.....	242
Pubes, fracture of the.....	165
Radius, fracture of the.....	145
fracture of the neck of the.....	145
fracture of the shaft of the.....	148
Colles' fracture of the.....	150
Barton's fracture of the.....	150
Reduction of fractures.....	49
Re-dressings of fractures.....	64
Responsibility in the treatment of fractures.....	44
Ribs, fracture of the.....	95
Sacrum, fracture of the.....	167
Sand bags in the treatment of fractures of the leg.....	47
Scapula, fracture of the.....	110
Shoulder blade, fracture of the.....	110

	PAGE.
Signs of fracture.....	22
differential, of fractures and dislocations.....	26
Silver wire to fasten together fragments of lower jaw.....	85
Smith, of Dublin, on fracture of the clavicle.....	105
Spinal cord, injuries of the.....	92
Splint, long straight, for treating fractures of the thigh.....	195
Dupuytren's	246
Starch bandage, treatment of a case with.....	234
Sternum, fracture of the.....	101
Swinburne's method of making extension.....	124
Tarsal bones, fractures of the.....	249
Tibia, fracture of, singly.....	235
Thigh bone, fracture of the.....	171
Treatment of fractures.....	43
Trochanter, fracture of the.....	185
Ulna, fracture of the olecranon process of the.....	137
fracture of the coronoid process of the.....	140
fracture of the shaft of the.....	142
Union of fractured bones.....	29
by "first intention".....	33
defective	41
ligamentous, after fracture of the neck of the femur.....	181
ligamentous after fracture of the patella.....	218
Weight and pulley for extension.....	199
"Wire breeches".....	59
in the treatment of fracture of the neck of the femur.....	188
Zygomatic arch, fracture of the.....	74

PART II. DISLOCATIONS.

Ancient dislocations, dangers in attempts at reduction of.....	271
Ancient dislocation of the hip-joint.....	384
Ankle, dislocation of the.....	399
Axillary vessels, dangers of rupture of, in attempts to reduce ancient dis- locations of the shoulder.....	273
Beach on the reduction of dislocations of the hip by manipulation.....	372
Blackman on the reduction of ancient dislocations of the shoulder.....	272
Carpal bones, dislocation of the.....	352
Carpus, dislocation of the.....	349
Cartilages of the knee, displacements of the.....	394
Causes of dislocations	281
Clavicle, dislocation of the.....	305
Dislocation, general consideration of the subject.....	255
an injury of frequent occurrence.	255
division of the subject of.....	261
congenital.....	261

	PAGE
Dislocations, traumatic.....	263
partial.....	264
ancient.....	265
dangers in attempts at reduction of.....	271
relative frequency of.....	266
symptoms of.....	267
alleged malpractice following.....	268
recurring, of the shoulder.....	277
causes of.....	281
general treatment of.....	284
compound.....	288
of the inferior maxillary.....	290
of the vertebræ.....	297
of the ribs.....	303
of the clavicle.....	305
of the scapula.....	310
of the humerus.....	314
of the shoulder.....	314
of the humerus, with fracture.....	332
of the elbow.....	335
of the head of the radius forwards.....	341
of the head of the radius backwards.....	343
of the ulna backwards.....	346
of the radius from the ulna.....	347
of the wrist.....	349
of the carpal bones.....	352
of the metacarpal bones.....	353
of the phalanges of the fingers.....	355
of the thumb.....	355
of the fingers.....	357
of the femur.....	359
of the hip.....	359
of the hip, anomalous.....	383
of the hip, ancient.....	384
of the hip, congenital.....	385
of the hip, partial.....	385
of the hip, and fracture.....	386
of the patella.....	388
of the tibia.....	391
of the knee.....	391
of the knee, compound.....	396
of the tibio-fibular articulations.....	397
of the fibula.....	398
of the ankle.....	399
of the bones of the foot.....	406
of the metatarsus.....	411
of the phalanges of the toes.....	414
Elbow, dislocation of the.....	335
Femur, dislocation of the.....	359
Fibula, dislocation of the.....	398
Fingers, dislocation of the.....	357

	PAGE.
Foot, its dislocation outwards.....	399
dislocation of the bones of the.....	406
Frequency of the different dislocations.....	266
Gibson on the reduction of ancient dislocations.....	275
Gilbert's substitute for the pulley force.....	369
Hip, dislocations of the.....	359
dislocation of the, with fracture of the femur.....	386
congenital dislocation of the.....	385
recurring dislocation of the.....	278
Humerus, dislocation of the.....	314
with fracture.....	332
ancient dislocations of the.....	272
Hysterical affections simulating dislocations.....	284
"Indian puzzle".....	358
Jarvis Adjuster.....	286
Jaw, dislocation of the.....	290
Joints, comparative frequency of dislocations at the.....	359
Jones' case of alleged malpractice.....	268
Knee-pan, dislocation of the.....	388
Knee, dislocation of the.....	391
displacement of the semilunar cartilages of the.....	394
compound dislocation of the.....	396
Larkin versus Jones, suit for alleged malpractice.....	268, 317
Ligaments of joints.....	258
untorn portions of.....	260
Luxation, see Dislocation.....	255
Malpractice—Larkin versus Jones.....	268, 317
Markoe on the reduction of dislocation of the hip.....	374
Manipulating plan for reducing dislocations of the hip, history of the.....	370
Metacarpus, dislocation of the.....	355
Metatarsus, dislocation of the.....	411
"Natural bone setters".....	255
"Natural plan" of reducing dislocations of the hip, by Reid.....	259
Paralysis following dislocation of the vertebræ.....	300
Patella, dislocation of the.....	388
Pathology of dislocations.....	260
Phalanges of the fingers, dislocation of the.....	355
of the toes, dislocation of the.....	414
Pulleys, on the use of, in reducing dislocations.....	259, 368
Pulley force, Gilbert's substitute for.....	369
Radius, dislocation of the.....	342
from the ulna.....	347
Reid's manipulating plan of reducing dislocations of the hip-joint... 259,	372
Recurring dislocation of the hip.....	278
Relative frequency of dislocations.....	266
Ribs, dislocation of the.....	303
Scapula, dislocation of the.....	310
Semilunar cartilages of the knee, displacements of the.....	394
Shoulder, recurring dislocation of the.....	277
ancient dislocations of the.....	272
dislocation of the.....	314

	PAGE.
Spanish windlass for multiplying force.....	286
Smith, Dr. Nathan.....	256
Sweet, "a natural bone setter".....	256
Tarsal bones, dislocation of the.....	406
Tarsus, dislocation of the.....	399
Tenotomy to facilitate reduction of dislocations.....	288
Tibia, dislocation of the.....	319
Tibio-fibular dislocation.....	397
Thumb, dislocation of the.....	355
Ulna and radius, dislocation of the, at the elbow.....	335
dislocation of the, backwards.....	346
Vertebra, dislocation of the.....	297
Warren on dislocation of the hip.....	375
Whitworth "a natural bone setter".....	256
Wrist, dislocation of the.....	349

COMPLETE
DESCRIPTION AND PRICE LIST
OF
MEDICAL BOOKS

PUBLISHED AND FOR SALE

BY

JOHN M. SCUDDER,

228 COURT STREET,

CINCINNATI, O.

1888.

Any book in this list sent post-paid on receipt of price.



AS a school of medicine we profess to have a distinctive practice, unlike either our old school or homeopathic neighbors. We claim to use different remedies, or in different form and dose, and for different effects. We boldly claim a more successful practice than either of our competitors, and this claim can only be based upon different principles, a different therapeutics, and a different materia medica.

We must, therefore, have distinctive books which clearly state *our* methods of practice. Old-school works will not serve this purpose, neither will homeopathic. With the pretensions we make, if we can not show that we have such works, and depend upon them, we are frauds of the first magnitude.

In the early days of Eclecticism, the need of text-books was clearly seen, and great sacrifices were made to furnish them. The writers toiled without pay, and to publish the earlier works they practiced the most rigid economy for years to command the money. By these means we had Beach's works, Jones and Morrow's Practice, King's Dispensatory, and some others. The making of books was not an easy nor a profitable job.

Now we have a full list of text-books, or books of reference, and by frequent revision they are kept fully up to our practice of to-day. They have been very successful, more so than any American books in the market, and this is the best evidence of their value. They are bought by all schools of medicine, and when bought they are brought into active use.

THE
ECLECTIC PRACTICE OF MEDICINE.

By JOHN M. SCUDDER, M. D.

The best recommendation of this work comes in the statement, "*twelfth edition.*" It is *the* authority of our school of medicine, and thousands of sick are daily treated according to it. Thus far it has proven sufficient, and it has given a success that others have failed to obtain.

Twelfth edition, revised: 8 mo., 816 pp., Sheep; \$7.00 post-paid; \$6.00 post-paid to Journal Subscribers.

THE
PRINCIPLES OF MEDICINE.

By JOHN M. SCUDDER, M. D.

This is a study of the elements of disease and the principles of cure. It is the basis of our practice, and, as we think, of the practice of the future. It gives a rational basis for medical practice.

Fifth edition; 8 mo., 352 pp., Sheep; post-paid, \$4.00.

THE
ECLECTIC PRACTICE IN DISEASES OF CHILDREN.

By JOHN M. SCUDDER, M. D.

If there is one thing more than another that we take pride in, it is our success in the treatment of children. The teaching of pleasant remedies, in small doses, for direct effect, has relieved thousands of children from the horrors of "regular" medicine.

Fifth edition; 8 mo., 486 pp., Sheep; post-paid, \$5.00.

A PRACTICAL
TREATISE ON THE DISEASES OF WOMEN.

ILLUSTRATED BY

COLORED PLATES AND NUMEROUS WOOD ENGRAVINGS.

By JOHN M. SCUDDER, M. D.

WITH A PAPER ON THE DISEASES OF THE BREAST, BY ROBERT S. NEWTON, M. D.
Late Professor of Surgery in the Eclectic Medical Institute of Cincinnati.

This work has stood the test of twenty years, and as revised it gives our treatment of to-day.

Fourteenth edition, revised: 8 mo., 534 pp., Sheep; post-paid, \$4.00.

Specific Medication and Specific Medicines

By JOHN M. SCUDDER, M. D.

Eleventh edition, fourth revision; 12 mo., 432 pp., Cloth; Price, \$2.50.

SPECIFIC DIAGNOSIS.

By JOHN M. SCUDDER, M. D.

Seventh edition; 12 mo., 388 pp., Cloth; Price, \$2.50.

These companion volumes have had a larger sale than any other medical works in this country. They appeal to the feeling every thinking physician cherishes that there must be something certain in medicine, if it can be discovered. They have had a very marked influence upon medical practice, not only of our own school, but also on regular medicine and homeopathy.

THE AMERICAN ECLECTIC
MATERIA MEDICA AND THERAPEUTICS.

By JOHN M. SCUDDER, M. D.

Tenth edition: 8 mo., 748 pp., Sheep: post-paid, \$6.00.

THE ECLECTIC
PRACTICE OF MEDICINE FOR FAMILIES.

By JOHN M. SCUDDER, M. D.

Twenty-first edition; Cloth, \$300; Sheep, \$4.00; half Morocco, \$5.00.

This work contains all of medicine that a family should know. It is anatomy, physiology, hygiene, practice, materia medica, surgery, and obstetrics. It is concise, plain and correct, and will not lead to household drugging. Liberal offers to agents. Write for terms.

ON THE
REPRODUCTIVE ORGANS AND THE VENEREAL.

By JOHN M. SCUDDER, M. D.

WITH COLORED ILLUSTRATIONS OF SYPHILIS.

Second edition; 8 mo., 393 pp., Sheep; post-paid, \$5.00.

OUR PROF. JOHN KING, WHO HAS BEEN A TEACHER FOR NEARLY HALF A CENTURY, IS TOO WELL KNOWN TO REQUIRE MORE THAN A CATALOGUE OF HIS BOOKS. THEY ARE AS FOLLOWS:

THE AMERICAN DISPENSATORY.

WITH SUPPLEMENT BY J. U. LLOYD.

Tenth edition: Sheep: Price, \$10.00.

DIAGNOSIS and TREATMENT of CHRONIC DISEASES

1700 pages; Sheep; Price, \$10.00.

THE AMERICAN ECLECTIC OBSTETRICS.

Fourth edition: Sheep: Price, \$6.50.

WOMAN, HER DISEASES AND THEIR TREATMENT

Fourth edition; Sheep: Price, \$3.50.

UROLOGICAL DICTIONARY.

Sheep; Price, \$3.00.

PROF. HOWE IS RECOGNIZED AS ONE OF THE ABLEST TEACHERS IN THIS COUNTRY, AND AN OPERATING SURGEON WITH BUT FEW PEERS IN THE WEST.

THE
ART AND SCIENCE OF SURGERY.

Revised edition; 8 mo., 886 pp., Sheep; Price, \$7.00.

Diagnosis and Treatment of Dislocations and Fractures

Third edition; 426 pp., Sheep; Price, \$4.00.

MANUAL OF EYE SURGERY.

8 mo., 204 pp., Cloth; Price, \$2.50.

THE CHEMISTRY OF MEDICINES.

PRACTICAL.

A text and reference book for the use of students, physicians, and pharmacists. Embodying the principles of chemical philosophy, and their application to those chemicals that are used in medicine and in pharmacy, including all those that are official in the Pharmacopœia of the United States. With fifty original cuts. By J. U. LLOYD, Professor of Chemistry and Pharmacy in the Eclectic Medical Institute, Cincinnati, O.; corresponding member of the College of Pharmacy of the City of New York; associate author of the Supplement to the American Dispensatory; author of the Pharmacy and Chemistry of the Student's Pocket Medical Lexicon.

One volume; large 12 mo., 451 pp.; Cloth, \$2.75; Leather, \$3.25.

OTHER BOOKS NOT PREVIOUSLY MENTIONED.

ON INHALATIONS. John M. Scudder. Cloth.....	\$1 00
PATHOLOGICAL ANATOMY. J. A. Jeancon. 25 parts, \$1.00 per part, or bound complete, Cloth.....	30 00
GRAY'S ANATOMY. Sheep, 7.00; with Colored Plates,	8 25
HOLDEN'S ANATOMY. Oil-cloth.....	4 50
DUNGLISON'S DICTIONARY. Sheep.....	7 50
THOMAS' MEDICAL DICTIONARY. Cloth, \$5.00; Sh'p,	6 00
HUXLEY AND YOUMAN'S PHYSIOLOGY. Cloth...	1 60
CLEVELAND'S LEXICON.....Cloth, \$1.00; Leather,	1 25
STEELE'S PHYSICS.....	1 17
TENNY'S NATURAL HISTORY.....	1 38
HUXLEY & YOUMAN'S BIOLOGY.....	1 50
BASTIN'S BOTANY.....	2 50
FOSTER'S PHYSIOLOGY.....Cloth, \$3.25; Sheep,	3 75
PITZER ON ELECTRICITY.....	1 00
MERRILL'S MATERIA MEDICA.....	4 00
CLARK'S DISEASES OF WOMEN. Sheep.....	4 00

Any other medical book, not enumerated in this list, sent post-paid on receipt of publisher's price.

J. M. SCUDDER,
CINCINNATI, O.





PLEASE DO NOT REMOVE
CARDS OR SLIPS FROM THIS POCKET

UNIVERSITY OF TORONTO LIBRARY

RD	Howe, Andrew Jackson
101	A practical and
H68	systematic treatise on
1891	fractures and dislocations

BioMed

