



THE LIBRARY
OF
THE UNIVERSITY
OF CALIFORNIA
LOS ANGELES

GIFT OF

SAN FRANCISCO
COUNTY MEDICAL SOCIETY



Digitized by the Internet Archive
in 2007 with funding from
Microsoft Corporation

“WITH all our varied instruments of precision, useful as they are, nothing can replace the watchful eye, the alert ear, the tactful finger, and the logical mind which correlates the facts obtained through all these avenues of information and so reaches an exact diagnosis.”

W. W. KEEN.

4284

PRINCIPLES AND PRACTICE

OF

PHYSICAL DIAGNOSIS

BY

JOHN C. DACOSTA, JR., M. D.

ASSOCIATE PROFESSOR OF MEDICINE, JEFFERSON MEDICAL COLLEGE; ASSISTANT VISITING
PHYSICIAN, JEFFERSON HOSPITAL; HEMATOLOGIST, GERMAN HOSPITAL; CONSULTING
PHYSICIAN, NORTHWESTERN GENERAL HOSPITAL; FELLOW OF THE COLLEGE
OF PHYSICIANS OF PHILADELPHIA; FELLOW OF THE AMERICAN
ACADEMY OF MEDICINE, ETC.

WITH 243 ORIGINAL ILLUSTRATIONS

THIRD EDITION, THOROUGHLY REVISED

PHILADELPHIA AND LONDON

W. B. SAUNDERS COMPANY

1915

Copyright, 1908, by W. B. Saunders Company. Reprinted June, 1909, and
September, 1910. Revised, reprinted, and recopyrighted September,
1911. Reprinted August, 1913. Revised, reprinted,
and recopyrighted November, 1915

Copyright, 1915, by W. B. Saunders Company

PRINTED IN AMERICA

PRESS OF
W. B. SAUNDERS COMPANY
PHILADELPHIA

Biomedical
Library

WB

200

D118p

1915

TO THE MEMORY OF
MY UNCLE
JOHN MEIGS, Ph. D.
HEAD MASTER OF THE HILL SCHOOL

624180

PREFACE TO THE THIRD EDITION

By selective deletion and recasting of the text it has been possible to keep the size of this new edition within bounds and to preserve the original character of the previous printings, despite the addition of considerable new matter chiefly dealing with technical methods, and with diseases of the lungs, the heart, and the stomach. To keep abreast of the recent advances in physical diagnosis the subjects of vertebral percussion, sphygmomanometry, electrocardiography, and gastric radiography receive due attention; mediastinal pleurisy, the lobar type of bronchopneumonia, and the acute pulmonary edema of chlorin gassing are described; and auricular fibrillation, auricular flutter, ventricular fibrillation, and the various cardiac arhythmias are discussed from a clinical standpoint.

The author is indebted to Dr. W. F. Manges for several new radiographic plates; to Dr. T. A. Cope and Dr. E. B. Krumbhaar for a number of original electrocardiograms; and to Mr. J. V. Alteneder for the other illustrations. To his publishers appreciation is due for their willingness to substitute new printings for the revision called for two years ago and unavoidably delayed until the present time.

PHILADELPHIA, *November, 1915.*

PREFACE

THE purpose of this book is to present, within reasonable compass, the principles of physical diagnosis, and to apply this means of research to the study of thoracic and abdominal diseases. To meet the requirements of junior students, especial consideration is given to clinical anatomy and to the origin, mechanism, and meaning of normal physical signs; while in order to guide those farther advanced in the study and practice of medicine, the subjects of pathology and diagnosis are accorded commensurate prominence. Throughout, a consistent endeavor is made to keep in view the prime importance of interpreting morbid objective data, individual or grouped, on the basis of pathologic cause and physical effect, and to analyze such findings in the light of a full clinical inquiry. In the section dealing with technic the theory and practice of the simpler direct methods of physical examination are explained in detail, and also certain instrumental procedures adapted to routine bedside investigation. Useful laboratory information, in so far as it applies to the diagnosis of particular lesions, is discussed in connection therewith, but an account of special laboratory technic, not being germane to the plan of this work, is omitted.

The subject matter of the following pages is based primarily upon the author's lecture-notes, and the views expressed were molded largely by ten years' clinical and teaching experience in internal medicine and study of pathology, aided and supplemented by much information derived from acknowledged authorities and from contributions of merit found in text-books, monographs, and periodical literature. Information gleaned from these sources has been duly accredited in the text, save in the case of facts that by time and usage have become a matter of common scientific knowledge.

Care has been taken to secure an adequate number of original illustrations that will prove helpful to the reader, those representing various clinical conditions having been reproduced from photographs of patients observed in the Jefferson Hospital and in the Philadelphia General Hospital, and those showing pathologic lesions having been made from Kaiserling preparations by Dr. R. C. Rosenberger and Dr. John Funke, of the pathological staffs of these institutions. Recknagel model-studies and figures standardized to Cunningham have been utilized for many of the diagrams by Mr. E. F. Faber and by Mr. J. V. Alteneder. The sphygmograms and cardiograms are the work of Dr. George Bachmann, and the radiographic plates were made by Dr. W. F. Manges. For the coöperation so cordially extended by these gentlemen hearty thanks are herewith returned.

The author takes pleasure in acknowledging the aid rendered by his wife in lightening the task of proof-revision; in thanking Dr. S. A. Munford for many useful criticisms and suggestions relating to technical questions; and in expressing appreciation of his publishers' numerous courtesies and liberal policies.

CONTENTS

SECTION I

	PAGE
METHODS AND TECHNIC OF PHYSICAL EXAMINATION.....	11
Inspection.....	12
Palpation.....	12
Percussion.....	12
Auscultation.....	22
Thoracometry and Cyrtometry.....	29
Sphygmomanometry.....	31
Sphygmography and Cardiography.....	37
Electrocardiography.....	43
Paracentesis.....	47
Fluoroscopy and Radiography.....	65
The Tuberculin Reaction.....	67

SECTION II

EXAMINATION OF THE THORAX.....	70
Clinical Anatomy.....	70
Normal Landmarks.....	71
Topographic Lines and Areas.....	74
Pathologic Types.....	77
Local Asymmetry.....	86
Respiratory Movements.....	92
Anomalies of Respiration.....	95
Dyspnea.....	100
Cyanosis.....	104
Venous Enlargement and Tortuosity.....	104
Edema of the Thoracic Wall.....	106
Glandular Enlargement.....	109
Pain in the Thorax.....	117

SECTION III

EXAMINATION OF THE BRONCHOPULMONARY SYSTEM.....	122
Clinical Anatomy.....	122
Inspection.....	128
Palpation.....	130
Percussion.....	135
Auscultation of the Lungs.....	151
Respiratory Sounds.....	152
Vocal Resonance.....	159
Adventitious Sounds.....	160
Splashing Sounds.....	169

SECTION IV		PAGE
DISEASES OF THE BRONCHOPULMONARY SYSTEM AND MEDIASTINUM.....		171
Acute Catarrhal Bronchitis.....		171
Chronic Catarrhal Bronchitis.....		174
Fibrinous Bronchitis.....		175
Bronchial Asthma.....		177
Bronchiectasis.....		179
Bronchostenosis.....		183
Pulmonary Congestion.....		185
Pulmonary Edema.....		188
Pulmonary Hemorrhagic Infarction.....		190
Catarrhal Pneumonia.....		192
Croupous Pneumonia.....		198
Chronic Interstitial Pneumonia.....		213
Acute Pneumonic Phthisis.....		216
Chronic Ulcerative Phthisis.....		220
Fibroid Phthisis.....		234
Pulmonary Syphilis.....		237
Emphysema.....		240
Hypertrophic.....		241
Atrophic.....		246
Compensatory.....		246
Acute Vesicular.....		247
Interstitial.....		248
Atelectasis.....		248
Pneumonoconiosis.....		252
Pulmonary Abscess.....		255
Pulmonary Gangrene.....		257
Pulmonary Neoplasms.....		260
Actinomycosis.....		264
Echinococcus Cyst.....		265
Pleurisy.....		266
Acute Fibrinous.....		267
Serofibrinous.....		268
Purulent.....		278
Circumscribed.....		281
Chronic Adhesive.....		283
Hydrothorax.....		285
Hemothorax.....		286
Chylothorax.....		287
Pneumothorax.....		287
Pleural Neoplasms.....		295
Mediastinitis.....		296
Mediastinal Lymphadenitis.....		298
Mediastinal Neoplasms.....		301

SECTION V

EXAMINATION OF THE CARDIOVASCULAR SYSTEM.....	308
Clinical Anatomy.....	308
Mechanism of the Circulation.....	311
Inspection and Palpation.....	315
Percussion.....	350
Auscultation.....	355
Adventitious Sounds.....	372
Endocardial Murmurs.....	372
Exocardial Sounds.....	380
Vascular Murmurs.....	392

SECTION VI

	PAGE
DISEASES OF THE CARDIOVASCULAR SYSTEM.....	396
Pericarditis.....	396
Acute Fibrinous.....	396
Serofibrinous.....	398
Purulent.....	401
Chronic Adhesive.....	402
Hydropericardium.....	406
Hemopericardium.....	406
Pneumopericardium.....	406
Cardiac Hypertrophy.....	407
Cardiac Dilatation.....	414
Myocarditis.....	417
Acute Endocarditis.....	421
Chronic Endocarditis.....	427
Mitral Regurgitation.....	434
Mitral Stenosis.....	439
Aortic Regurgitation.....	449
Aortic Stenosis.....	457
Tricuspid Regurgitation.....	462
Tricuspid Stenosis.....	465
Pulmonary Stenosis.....	467
Pulmonary Regurgitation.....	471
Congenital Cardiac Disease.....	473
Aneurism of the Aorta.....	476
Aneurism of Thoracic Aorta.....	476
Aneurism of Abdominal Aorta.....	493

SECTION VII

EXAMINATION OF THE ABDOMEN AND THE ABDOMINAL VISCERA.....	495
Clinical Anatomy.....	495
Topographic Lines and Areas.....	498
Methods of Abdominal Examination.....	500
Clinical Types of Abdomen.....	503
Local Abdominal Enlargements.....	509
Abdominal Movements.....	512
The Skin and Subcutaneous Tissues.....	513
Fluctuation.....	515
Tactile Friction and Thrills.....	516
Pain in the Abdomen.....	516
Examination of the Stomach.....	519
Examination of the Intestines.....	532
Examination of the Liver and Gall-bladder.....	539
Examination of the Pancreas.....	549
Examination of the Spleen.....	550
Examination of the Kidneys.....	557
INDEX.....	563

PHYSICAL DIAGNOSIS

SECTION I

METHODS AND TECHNIC OF PHYSICAL EXAMINATION

IN the common acceptance of the term, physical diagnosis relates primarily to the objective study of disease by the four cardinal methods of inspection, palpation, percussion, and auscultation, the successful practice of which depends upon the intelligent exercise of the examiner's senses of sight, feeling, and hearing. In suitable instances certain clinical instruments are used as an aid and a supplement to these means of inquiry: the thermometer, to take the patient's temperature; the stethoscope, to facilitate auscultation; the tape-measure, calipers, and cyrtometer, to determine diameters, circumferences, and shapes; the exploring needle, to obtain specimens of body-fluids; and the tonometer, the sphygmograph, and the electrocardiograph, to study the blood-pressure and other details of the circulatory system.

In addition to the foregoing methods of physical diagnosis the clinician has at his disposal a number of technical procedures that require training in the use of special instruments of precision and in laboratory technic, and upon the intimate correlation of the data derived from both these sources, bedside and laboratory, a finished diagnosis must be based. Although, in a broad sense, the diagnostic application of the Röntgen-ray and analyses of the urine, blood, sputum, gastro-intestinal contents, and body-fluids belong to the subject of physical diagnosis, the technic and principles of these procedures are too highly specialized to receive more than parenthetic reference in the following pages, which deal purely with the theory and practice of physical diagnosis at the bedside, with reference to the study of thoracic and abdominal lesions.

INSPECTION

Inspection, or visual examination of the patient, is the first, and in some instances the all-important, step in a routine physical examination. "We make more mistakes by not looking than by not knowing" is an aphorism of Edward Jenner that every beginner in the study of physical diagnosis should take as a maxim. To neglect or to gloss over careful inspection of the patient deprives one of a means of information for which skill in percussion or in auscultation cannot compensate.

A general inspection shows the individual's appearance, body conformation, and gait; the approximate height and weight; the condition of the muscular and adipose structures; and the marks of various cachexias and of scarring or eruptive diseases. Inspection of a circumscribed area, with the patient's clothing removed, may betray at a glance some organic lesion, or at least may give a clue to be verified by other procedures. The facies of pneumonia, of phthisis, and of Bright's disease, the barrel chest of emphysema, and the throbbing tumor of aneurism are familiar examples of diseases that in time indelibly stamp their subjects with visible signs so characteristic as immediately to direct the clinician along correct lines of inquiry.

PALPATION

Palpation, or examination by means of the tactile sense of the fingers and the palms of the hands, is employed in studying various vibrations referable to the bronchopulmonary system (fremitus), to the cardiovascular apparatus (thrill), and to the serous surfaces (friction). The palpating hand can also appreciate the wavy impulse of pent-up fluid agitated by striking its delimiting parietes (fluctuation), and can recognize rhythmic throbbing of cardiovascular origin (pulsation). The site, size, shape, mobility, resistance, and tenderness of a local area of the body are also determined principally by the tactile sense of the examiner's hand.

The special technic of inspection and palpation in the examination of various regions and organs is described subsequently.

PERCUSSION

Percussion is the act of striking or tapping the surface of the body so as to elicit sounds of diagnostic utility, the clinical value of this method depending upon the fact that different anatomic structures, when struck by the finger-tips or with a suitable instrument, give rise to different sounds, the acoustics of which vary accord-

ing to the physical properties of the parts percussed. Fundamentally, all percussion-sounds are either *resonant* or *dull*, of which essential properties there are several modifications, notably, *hyper-resonance*, *tympany*, and *flatness*, together with several other special shades of sound not exactly expressed by any of these terms. By noting the character of the sounds and the degree of resistance over the region percussed, one is able to judge the density of the underlying structures and to delimit the boundaries of parts containing different volumes of air.

The percussion blow may be struck either with the finger-tips (finger percussion) or with a small hammer (instrumental percussion). By the method known as *mediate percussion* the sound is elicited by laying a finger (pleximeter finger) flat upon the part and tapping it with one or two fingers (plexor fingers) of the other hand; or a small rubber plate may be used as a pleximeter and a specially devised percussion hammer as a plexor. In the practice of *immediate percussion*, little used at the present time, the part is tapped without the intermediation of a pleximeter.

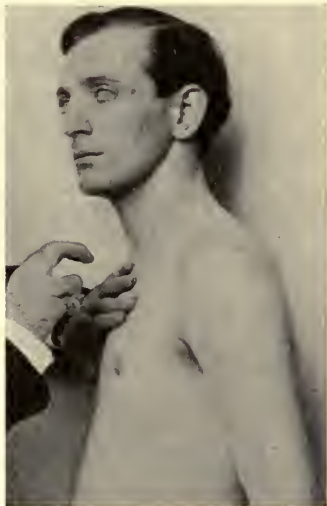

Fig. 1.—Technic of mediate percussion.

Percussion, though exploited by Auenbrugger in 1761, did not come into general use until half a century later, when, in 1808, Corvisart's researches, prompted largely by the teachings of Stoll, crystallized the diverse and fantastic theories and methods of percussion into a tangible, concrete means of clinical inquiry. Piorry and Barry, the advocates of instrumental percussion, and Skoda, who, in 1839, correlated the various percussion-sounds with correct physical factors, were conspicuous figures in the development of Auenbrugger's principle, now so indispensable to diagnosis.

Technic.—It is best to percuss the bare surface of the body, though a thin covering of underclothing does not materially interfere. Muscular relaxation, natural breathing, and an unconstrained posture, either erect or prone, as the circumstances direct, are requisites for the best results.

In performing **mediate finger percussion** (Fig. 1) the palmar

surface of the middle finger of the left hand is laid upon the surface of the body and sharply struck with the tip of the middle finger of the right hand, the plexor finger being crooked so as to deliver a perpendicular blow, which should fall upon the dorsal surface of the pleximeter finger at the base of the nail or at the middle of the second phalanx. Four precautions are to be observed: the pleximeter finger must be kept in firm, close, accurate contact with the surface of the body; the force of the percussion strokes must be as equal as possible; the blow must be delivered entirely by a movement of the wrist, with the elbow rigid and immovable; and the action of the plexor finger must be rapid, accurate, and rebounding. The force of the stroke is strong or light, according to the situation of the organ or lesion percussed, whether deep or superficial. (See Fig. 77.) Too forcible percussion, even of a deep-seated structure, is to be guarded against, since it may set up such intense vibrations outside of the circumscribed area that a confusing commingling of sounds is produced. The more forcible the percussion-stroke, the firmer should be the pressure of the pleximeter finger, and vice versâ. The pleximeter finger should be kept parallel to the outline of the part to be delimited. A few careful strokes will demonstrate the characteristics of the sounds and of the resistance much better than a long succession of blows. Prolonged percussion dulls one's auditory and tactile perceptions, just as long-continued looking at the two tints in a hemoglobinometer blunts one's color-sense.

Goldscheider's method of *threshold percussion* may prove useful in outlining the cardiac and hepatic borders, the technic consisting of tapping lightly with the finger upon a glass rod pleximeter one end of which, fitted with a rubber cap, rests upon an intercostal space, the rod meanwhile being held at an angle to the surface of the thorax and parallel to the borders of the organ thus to be delimited. This method of percussion possesses the advantage of confining the percussion vibrations to a very restricted area, and affords accurate data at the hands of one skilled in its use.

Immediate percussion is performed by directly striking the surface with a plexor (finger or instrumental), or of delivering a series of sharp slaps with the flat of the hand. The method is distinctly inferior to mediate percussion, owing to the defective sounds produced and also because it robs the examiner of definite tactile impressions, so essential in judging the character of sounds. Immediate percussion is employed chiefly in demonstrating extensive areas of dulness and tympany, in eliciting the cardiac and the pulmonary reflexes, and in the practice of auscultatory percussion (*q. v. i.*).

Palpatory percussion is a combination of palpation and percussion affording tactile rather than auditory impressions, which are elicited by gently striking the pleximeter finger with the *pads* of the plexor fingers, the latter being kept almost straight, so as to produce more of a pushing impact than a perpendicular blow, this peculiarity being the more emphasized by continuing the plexor-pleximeter pressure for a few moments after the stroke. Rebounding piano-hammer strokes are to be avoided, and the arc of the percussion push should not exceed one or two inches (2.5 to 5 cm.). Although perhaps a superior method of examination for those

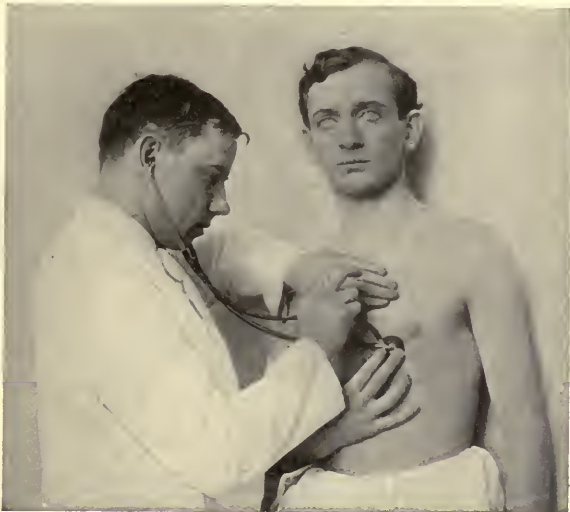

Fig. 2.—Technic of auscultatory percussion.

skilled in its technic, palpatory percussion is in no sense a substitute for ordinary mediate percussion in routine work.

Auscultatory Percussion.—Auscultatory or stethoscopic percussion is the act of listening to the percussion-sounds with a stethoscope applied to the part under examination, instead of directly judging the sound in the ordinary manner. It is adapted especially to outlining various solid and hollow organs, such as the heart, the liver, the spleen, the stomach, and the colon; in determining the limits of effusions and consolidations; and in circumscribing cavities and tumors. By auscultatory percussion of a superficial echinococcus cyst it is sometimes possible to distinguish a deep, sonorous sound of hydatid resonance.

In auscultatory percussion the chest-piece of a binaural stethoscope is placed over the part to be delimited,¹ where it is held in position by the patient or by an assistant, while the examiner, listening through the instrument, begins to percuss very gently at several points encircling the organ and well beyond its outer boundary (Fig. 2). Continuing the percussion toward the organ, along converging lines centering at the chest-piece of the stethoscope, the sounds become distinctly louder and altered in pitch and in quality when the periphery of the organ is reached. A line joining these

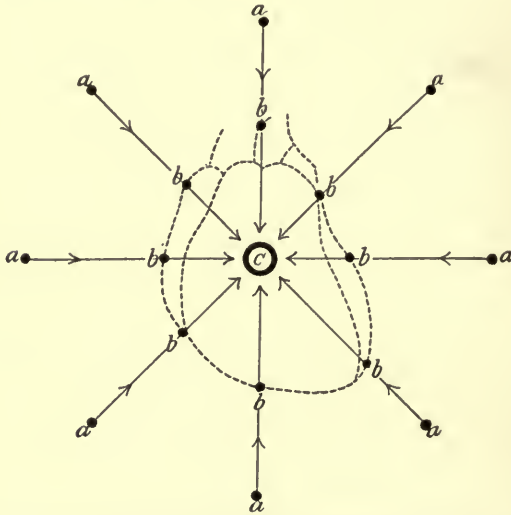


Fig. 3.—Illustrating the technic of auscultatory percussion: *a-b*, Percussion lines; *b*, points of acoustic change; *c*, chest-piece of stethoscope.

several points of acoustic change corresponds to the limits of the organ in question (Fig. 3).

Several modifications of this, the usual, technic of auscultatory percussion also enjoy more or less vogue, and perhaps merit confidence. Thus, the sound may be produced by direct stroking of the surface with the finger-tips, instead of by actual percussion—*stroke auscultation*; by rubbing the fingers up and down, a grooved wooden stick applied perpendicularly to the surface—*rod auscultation* (Reichmann); or by tapping with one forefinger the second

¹ Le Fevre prefers to auscultate the percussion-sounds with the chest-piece of the stethoscope held just above the point of percussion, but not touching the surface, in order to eliminate the vibrations of the bony thorax.

joint of the other forefinger applied perpendicularly to the part—*Korányi's method*. The substitution of a vibrating tuning-fork for the plexor finger has been suggested (Warder), the examiner noting the changes in the intensity and quality of the musical vibrations as the fork passes over the surface toward the part under investigation.

Attributes of the Percussion-sound.—Four different acoustic properties, *quality*, *pitch*, *duration*, and *intensity*, are to be recognized as clinically important attributes of the percussion-sound. Since verbal description can convey but an inadequate idea of these fundamental sound elements, each one must be studied practically by the student in order to appreciate their individual peculiarities. Their every-day application will be understood when they are referred to later, in connection with the questions of resonance, dulness, and other phases of the percussion-sound. The *resistance* offered to the pleximeter (or percussed) finger is also of the greatest utility in determining the nature of the region examined.

By the term *quality* is meant that essential element by which the particular source of a given sound is distinguished, whether it be a vocal, an instrumental, or other tone. Thus, this quality, timber, or tone-color enables one instantly to discriminate between a masculine and a feminine voice, between the sounds of a bass-drum and a snare-drum, and between the tones of a fife and an oboe, a piano and an organ, and other musical instruments. Physically, the quality of sounds is determined by the type of vibrations by which they are generated, the more complex vibrations giving rise to sounds of greater individuality than those of simpler character. It is this element of quality, then, that is the clue to the origin and nature of different sounds, which cannot be judged by criteria such as pitch, intensity, and duration.

The *pitch* of a sound is an acoustic attribute thoroughly appreciable only by those who are gifted with a "musical ear." It was Austin Flint who first called attention, in 1852, to the value of pitch variations in the acoustics of percussion and respiratory sounds. Variations in pitch are governed by the rate of the vibrations set up in the part percussed, and the more rapidly these vibrations occur, the higher the pitch, and vice versâ. The deep rumble of the basso and the high "A" of the soprano exemplify extremes of low and of high pitch respectively, while by their quality the sounds are recognized as the male and the female human voices. Other conditions being the same, a tense muscular thorax yields a percussion sound of higher pitch than a relaxed, thin chest, and the same is true

of a small thorax in comparison with a large one. Similarly, higher pitched sounds are afforded by small than by large air-containing viscera, cavities, and consolidations, by muscle than by lung, and by pleural effusion than by pulmonary infiltration.

The *duration* of a sound, which is an element of subsidiary importance, expresses simply its length or continuance. Duration and pitch are intimately related, in that the lower the pitch, the longer the duration, and vice versâ. For instance, normal low-pitched pulmonary resonance is of longer duration than the sound obtained by percussing over a high-pitched patch of pneumonic or tuberculous consolidation.

Intensity, or volume, also of secondary importance, refers to the degree of fulness, loudness, or amplitude of a sound. It goes hand in hand with the foregoing attributes, pitch and duration, especially with the latter—the longer the duration of a sound, the greater its intensity. Thus, normal pulmonary resonance yields a more intense sound than a consolidated area, while, on the other hand, the sound over a small cavity is feebler than that over an extensive excavation. The intensity of a sound is determined by several factors, of which the most important are the force of the percussion stroke, the amount of air contained in the part percussed, and the thickness and resiliency of the intervening structures.

Sense of Resistance.—The resistance appreciated by the pleximeter finger when the percussion blow is delivered is, to the experienced clinician, quite as certain a guide as the actual sound elicited. This resistance is a particularly useful clue in ill-defined pulmonary consolidations in which exaggerated fremitus, frank dulness, and definite auscultatory signs are wanting, and in such instances a high-pitched sound with an increased feeling of resistance is often conclusive evidence. Percussion of the thigh gives a good example of greatly increased resistance, and over the colon, an illustration of diminished resistance. The resistance is strikingly exaggerated over a pleural effusion, well marked over a consolidated lung, and usually diminished over a pneumothorax. As a general rule, it may be stated that tactile resistance increases *pari passu* with the extent to which the air contained in an organ is replaced by liquid or solid matter, and with the increase in the tension of the parietal structures.

Tonal Properties of the Percussion-sound.—*Resonance.*—If an air-containing organ, such as the lung, be percussed, the sound elicited has a clear, soft, resounding quality, a moderately low pitch, and a well-sustained duration and intensity. This typically *resonant* sound, or pulmonary resonance, though pure and clear, lacks the harmony

and consonance of a true musical note, for it is caused by the vibrations of air-columns, which, owing to the peculiarities of the bronchopulmonary structures, lack precise rhythm and equality of sound-waves.

Tympany.—If an air-containing organ, such as the stomach, be percussed, a clear, hollow sound is produced, differing chiefly from pulmonary resonance in having a distinctive drum-like quality. This *tympanitic resonance*, or *tympany*, is a typical musical note, since it is due to rhythmic vibrations of sound-waves of equal length occurring within an empty cavity bounded by thin, smooth, elastic walls.

Hyperresonance.—Percussion of an overdistended lung, as in hypertrophic emphysema, creates a sound which, though it retains the quality of normal pulmonary resonance, differs from it in possessing greater intensity and lower pitch. Such a sound approaches tympany, yet it cannot be so designated, because it lacks the true tympanitic or drum-like quality. The compromise term, *hyperresonance*, is, therefore, applied to this tone, used to signify the various shades of exaggerated resonance not amounting to actual tympany.

Independent of the above-mentioned physical causes is the sound elicited by percussion over a bony structure, which, when struck, vibrates resonantly by virtue of its inherent resiliency, and emits a sound termed *osteal resonance*. The qualities of the osteal tone are well illustrated by percussion over the sternum. Auscultatory percussion over an echinococcus cyst yields a peculiar low-pitched sonorous tone, known as *hydatid resonance*, provided that the cyst is superficial, and contains a thin liquid inclosed within resilient walls. This sound is due to the same factors responsible for hydatid fremitus (*q. v.*), of which it is the tonal equivalent.

Certain forms of modified resonance—*amphoric*, *cracked-pot*, and *vesiculotympanitic*—are discussed in connection with the special circumstances under which they occur. (See p. 146 *et seq.*)

Dulness and Flatness.—These two words express varying degrees of impaired resonance, ranging from the trifling impurity of sound due to a slight diminution of air in a part, to the absolute deadness found over an entirely airless structure. Flatness is the acoustic acme of dulness, and between the two extremes numerous tonal gradations exist, designated, for convenience sake, as *impaired resonance* and *relative dulness*.

The terms dulness and flatness are not to be used synonymously: the former is applied to a sound which, though impaired, still retains some element of resonance, and the latter to a sound to which even the faintest trace of resonance is foreign. A dull sound indicates that the air-content of the part within range of percussion is dimin-

ished, but not absolutely abolished, the latter condition being betrayed by flatness. For example, the percussion-sound over a patch of pneumonic hepatization is dull, not flat, inasmuch as the consolidated lung is not entirely deprived of air, owing to the fact that the communicating bronchi and many groups of unimplicated vesicles contain a sufficient volume of air to emit a feeble shade of resonance. On the other hand, a pleural effusion, being quite airless, affords pure flatness without a suspicion of resonance.

According to their acoustic attributes, it will be noted that, as the dull percussion-sound approaches flatness, the quality hardens, the pitch rises, the intensity and duration diminish, and the resistance increases. A slight elevation in pitch plus increase in the resistance over the part percussed is one of the earliest signs of impaired resonance, and, since it is usually appreciable before the development of frank dulness, the finding is most pertinent.

The resonant quality of an air-containing part is materially modified by the degree of tension existing in its walls, which, to resound resonantly, must be sufficiently relaxed to vibrate freely under the impact of the percussion blow. Up to a certain point of mural tension the sound remains clear, but if the tension be raised beyond this "resonant point," the purity of the sound disappears and it becomes dulled and toneless. In a similar manner undue lowering of the mural tension dulls a resonant sound.

The pitch of resonance varies according to the volume of air contained in the part emitting the sound: the pitch of pulmonary resonance, for example, rises as the air-content of the lung is lessened by the encroachment of a consolidation, as in croupous pneumonia; the pitch of the note is higher over the small intestine than over the large gut.

The intensity and the duration of resonance are determined by the force and the length of the sound-waves within the part percussed: other conditions being equal, the larger the air-space within the organ, the louder and the more lasting the sound evoked by percussion.

Aside from the influences of mural tension and air-volume in modifying the resonance of an air-containing part, the force of the percussion blow and the vibratory properties of the tissues within its range are also determining factors of the sound produced.

Spinal Percussion.—Spinal percussion is not without value in the study of obscure lesions of the lungs and mediastinum lying close enough to the spine to damp its vibrations, but too far from the thoracic wall to produce definite dulness thereupon. Healthy verte-

bræ emit osteal percussion-sounds *sui generis* in quality, and of a degree of resonance corresponding to the extent to which the bone vibrations are affected by adjacent anatomic structures. The accompanying diagram (Fig. 4) shows a clinical modification of Korányi's spinal zones, each affording, in health, distinctive percussion findings which are variously altered by morbid processes of the thorax and abdomen. Thus, the normal dulness of the uppermost zone diminishes vertically in hypertrophic emphysema, but lengthens in

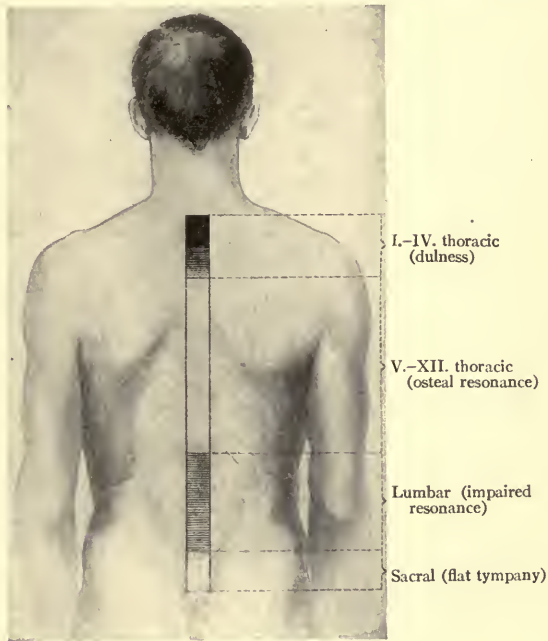


Fig. 4.—Spinal percussion zones.

mediastinal neoplasm and in thoracic aneurism. Pulmonary consolidation may appreciably dull the osteal resonance of the thoracic zone, while fluid within the pleural sac causes dulness at the base of this region and extending thence upward to a height commensurate with the volume of the effusion. (See Grocco's Triangle, p. 273.) A tumor of the abdomen (*i. e.*, hepatic, splenic, or pancreatic) may substitute absolute dulness for the normal impaired resonance of the lumbar zone and even obliterate the flat tympany below. Spinal percussion is usually performed with the aid of a soft-rubber plexor and

vulcanite pleximeter, the latter being placed over the spinous processes, but the writer prefers to use ordinary mediate finger percussion in order to judge tactile resistance as well as tonal changes.

By percussion of the vertebral tips and the upper interscapular region Ewart has mapped out a paravertebral ovoid subresonant area between the first and the fifth thoracic spines, extending vertically for 110 mm. and having an equatorial diameter of 90 mm., each lateral boundary being equidistant from the midline. This ovoid patch contracts laterally with deep inspiration and commensurately expands with expiration. In apical phthisis and pleurisy its respiratory excursions are restricted and its symmetry is altered, and in hypertrophic emphysema, in addition, the size of the patch is greatly diminished. Extension of dullness in this region, with modification of the normal ovoid shape, has been reported in tracheobronchial adenopathies, in pericardial effusion, in extensive enlargement of the left auricle, in aortic aneurysm, and in enlarged thymus.

Vertebral reflexes (Abrams) are demonstrable by the percussion of appropriate spinous processes, whereby contraction and dilatation of the deep viscera are provoked if the organs in question be healthy. Upon this fact depends the clinical utility of the test, which consists of outlining the organ, by topographic percussion, both before and after vertebral concussion, and of comparing the size of the two boundaries. In health, percussion of the lower five thoracic spines should enlarge, and of the vertebra prominens should diminish, the cardiac and aortic areas of dullness anteriorly, while percussion of the upper three lumbar vertebræ should reflexly contract the normal areas of the liver, the spleen, and the stomach. Spinal reflexes are usually evoked by delivering a few sharp blows with a plexor upon the spinous processes, the outline of the organ before and after this manœuver being judged by auscultatory percussion.

AUSCULTATION

Auscultation, as applied to clinical examinations, is the act of listening to physical sounds, normal and pathologic, either by the aid of an instrument known as a stethoscope, or by applying the ear directly to the part. This method of research is employed chiefly in investigating the condition of the respiratory system and the heart, but in certain instances it gives useful data relating to the arteries, the veins, and the abdominal organs. Although Hippocrates, who observed that liquid within an air-distended pleural cavity splashed audibly when the subject's body was suddenly

shaken, was, in a strict sense, the first to practise auscultation, this procedure did not enjoy clinical vogue until the time of Laennec's publication, in 1819, of his *Traité de l'Auscultation médiate*. In this masterpiece Laennec described his new invention, the stethoscope, and dealt with the mechanism of auscultatory signs and their application, especially to diseases of the heart and the lungs, his conclusions upon these subjects becoming the acknowledged standard upon which subsequent studies were based. Of the many investigators to whom our present knowledge of auscultation is due, the names of Skoda, of Gerhardt, of Traube, and of Wintrich deserve noteworthy prominence.

Auscultation, like percussion, may be either *mediate* or *immediate*, according to whether or not a stethoscope is employed, and of these two methods, the former is chosen in the great majority of routine examinations. In the exceptional instance, however, the naked ear appreciates certain sounds that are ill defined, if not quite imperceptible, with a stethoscope, so that to be equal to emergencies of this sort one must train one's self in the technic of both methods of auscultation. As Connor has pointed out, faint, high-pitched sounds are indifferently transmitted by closed tubes, particularly by tubes with flexible walls, from which fact it follows that certain cardiac murmurs of high pitch, blowing quality, and feeble intensity, as well as vesicular sounds of similar characteristics, are heard more clearly by auscultation with the naked ear than by using a stethoscope, particularly one of the binaural pattern with two flexible rubber ear-tubes.

Stethoscopic auscultation is of value chiefly in the investigation of circumscribed lesions of the respiratory, cardiovascular, and abdominal organs, since under such circumstances it is important to exclude every extraneous noise interfering with the peculiarities of the sound under analysis. Owing to their contour, certain areas of the body (*i. e.*, the supraclavicular and infraclavicular fossæ and the upper axillæ) can be examined satisfactorily only with a stethoscope, while this instrument also comes into play when the patient's modesty, or perchance disregard of personal hygiene, forbids the direct application of the ear to the body, even if some covering be interposed.

The Choice of a Stethoscope.—In the practice of mediate auscultation the choice of that form of stethoscope best suited to the needs of the user is the first essential of success. Naturally, this question must be decided largely upon personal grounds, although in the selection due weight should be given to certain acknowledged advantages peculiar to the various patterns of the instrument.

Two forms of stethoscopes are in general use—the *binaural* or *double*, modified to a greater or less extent from the design originally suggested by Camman; and the *monaural* or *single*, modeled after the original instrument invented by Laennec. The binaural instruments designed by Bowles, by Sansom, and by Arnold are well adapted to general clinical work, while Hawksley's monaural stethoscope is the simplest and most convenient pattern of this type of instrument.

The *Bowles stethoscope* consists of a steel, cupped chest-piece, fitted with a hard-rubber diaphragm, and communicating, by means of flexible rubber tubing and a Y-coupling, with two metal conducting tubes provided with ear-pieces and connected by an adjustable steel spring (Fig. 5). The standard disc-shaped chest-piece is made in two sizes, of which the smaller is preferable, owing to its restriction of the auscultatory area and to its accurate adaptation to depressed areas, such as the intercostal and supraclavicular spaces. For such purposes the small disc is just as satisfactory as the special "flat-iron" chest-piece devised for this sort of work. Bowles's stethoscope is convertible into an ordinary binaural by replacing the metal chest-piece by a hard-rubber bell, also furnished with the instrument.




Fig. 5.—The Bowles stethoscope.

Personally, the author prefers to use a Bowles stethoscope, equipped with *soft-rubber* ear-pieces,¹ a 1½-inch (3.75 cm.) rubber-capped disc, and 15-inch (37.5 cm.) lengths of the best grade of flexible catheter tubing (No. 14, E). The rubber cap, which prevents slipping of the chest-piece and negatives metallic tones, can be cemented to the disc with strong fish-glue. The catheter tubing, of the dimensions specified, is a perfect

¹ Made by C. H. Liverpool & Co., Boston, Mass.

conductor of sounds, and so flexible that it cannot kink. It is sufficiently long to allow adjustment of the chest-piece to any part of the back of a patient lying in dorsal decubitus, without disturbing the subject—a distinct advantage when examining a bed-ridden person too ill to be turned on the side. Thus equipped (Fig. 5), the




Fig. 6.—Sansom's binaural stethoscope.

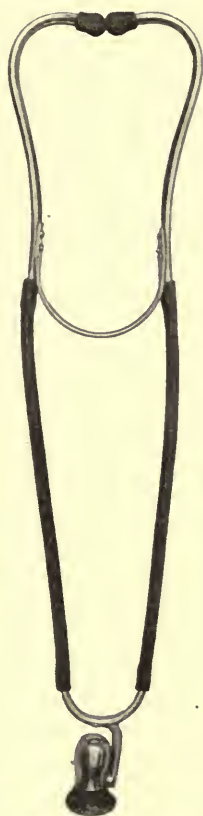

Fig. 7.—Arnold's phonophore.

instrument can be depended upon to amplify sounds without undue exaggeration, to conduct them with great purity and clearness, and to facilitate the analysis of circumscribed adventitious sounds.

Sansom's stethoscope (Fig. 6) embodies all the good points of the older types of binaural stethoscope, none of which, it may be added, is so satisfactory for routine work as the instrument devised by Mr.

Bowles. All follow the same general principle—having a metal frame adjusted to the examiner's head by the pressure of a spring, and provided with ear-pieces and conducting tubes terminating in a chest-piece made of hard rubber, of wood, or of metal. In most binaurals the metal work and the rubber tubing are too light, the ear-pieces ill fitting, the chest-pieces defective, and the springs difficult to adjust properly. If a folding stethoscope (Fig. 6) be preferred, one should take care to select a model that can be opened and closed without straining the spring and frame, and that is provided with a spring joint of stout construction and of firm locking action which does not rattle when the instrument is in use.

Arnold's phonophore (Fig. 7), made in both binaural and monaural models, is especially helpful in listening to faint high-pitched sounds, which, as a rule, it transmits very clearly; to other sounds, however, this instrument seems to lend a hollow, somewhat metallic quality, and, to one unaccustomed to its use, an unnatural intensity. The phonophore is excellently made, having soft-rubber ear-pieces, heavy metal and rubber tubing, and a resonating steel chest-piece the sharp edge of which is fitted with a rubber cushion.

The *differential stethoscope* is a form of instrument equipped with two separate chest-pieces communicating, by individual conducting tubes, one with the right and the other with the left ear of the auscultator. It is of service, say those who use it, in timing and in detecting quality differences of cardiac murmurs produced synchronously at different valve areas, by applying one chest-piece to one area and the other to another locality, and discriminating between the differences in the tone and rhythm of each.



Fig. 8.—Hawksley's monaural stethoscope.

Hawksley's monaural stethoscope (Fig. 8) consists of a hard-rubber ear-plate screwed into a rigid metal tube flaring at its other extremity into a bell-shaped chest-piece, or fitted with a detachable bell made of vulcanite or of ebony. This pattern of stethoscope is preferred by some clinicians, notably by those of the older school, who claim that it transmits sounds with more distinctness, greater purity, and less artificial intensity than instruments of the binaural model.

The single stethoscope, though excellent in some respects, is inconvenient and fatiguing to use while examining a patient confined to bed, and is unsuited for auscultating the upper thorax and the lower

abdomen. It is not clear that the single stethoscope serves any purpose not better served by an instrument provided with flexible tubing and two ear-pieces.

Technic.—The posture of the patient, dictated by the nature of the examination, should be as unconstrained, relaxed, and easy as possible. This is no minor essential, especially in a self-conscious, nervous, or feeble person, to whom even the simple procedure of auscultation may be an ordeal sufficient to excite unnatural breathing, artificial muscular rigidity, and curious cardiac irregularity, all of which defects are exaggerated by a constrained, uncomfortable position. As in percussing, auscultating should not be needlessly prolonged.

In *mediate auscultation* the stethoscope should be applied to the naked surface of the body, for, unless preternaturally gifted, the average physician is unable to detect delicate acoustic differences through the patient's clothing, the rustling and creaking and dulling effect of which may effectually modify, if not entirely mask, important auscultatory findings.

The chest-piece of a binaural instrument should be applied lightly and evenly to the surface over the area under examination, being approximated thereto by the pressure of one or two fingers, which must not bear too heavily, lest the undue pressure thus exerted extinguish certain ill-defined sounds audible only when the stethoscope rests lightly upon the surface. As Sewall points out, stethoscopic pressure with the chest-piece of an instrument designed to transmit purely by air conduction has a distinct effect upon the character of the auscultated sounds, which are made up of two separate components—visceral tones and mural vibrations. Of the two, the latter generally predominate, and are more or less effectually effaced by firm pressure. In general, stethoscopic pressure, when it does not quite annul the voice sounds and the respiratory murmur, dulls them, raises their pitch, and lends to them a tinge of the bronchial tone, modifications due perhaps to pressure-dampening of the fundamental lower vibrations of the parietes. This modification is particularly true when pressure is made over the lower part of the thoracic wall. Emerson has shown that sounds produced at the parietes (*i. e.*, faint tones of the heart; indistinct murmurs of mitral obstruction; the fetal heart-beats) are easily damped by the pressure of the stethoscope, while certain transmitted sounds (*i. e.*, high-pitched râles; blowing cardiac murmurs) are made clearer thereby. With a monaural stethoscope, held in position by the pressure of the examiner's head, it is espe-

cially difficult to observe these niceties of adjustment, and, moreover, when firm pressure is necessary, the chest-piece is likely to indent the subject's chest and cause considerable discomfort. Whichever model is used, the chest-piece must be held snugly in contact with the skin, so that the auscultator will not be confused by hearing extrinsic noises, amazingly magnified, which otherwise leak in; in emaciated subjects and in those with very narrow interspaces it is sometimes necessary to use a soft-rubber chest-piece to insure an air-tight contact.

Only the tyro need be warned against confusing with adventitious sounds certain rude, jarring noises due to slips in technic, such as movements of the examiner's fingers over the metal parts of the stethoscope, accidental contact of the rubber tubing with nearby objects, and friction between the chest-piece and a dry, hairy skin. In addition to these extrinsic sounds, one must recognize various noises produced by contraction and respiratory movements of the surface muscles, particularly of the upper anterior thorax.

Transmanual auscultation, suggested by Riesman to facilitate the timing of cardiac murmurs, consists of auscultating through the hand laid over the precordia, whereby, if the apex-beat be palpable, it is possible to feel the systolic impact of the heart and to hear an endocardial murmur at the same time and place. With a Bowles stethoscope there is no difficulty in distinguishing cardiac sounds through the intervening hand, and this combined method of palpation and auscultation is of distinct value, especially in differentiating presystolic and systolic bruits generated at the mitral orifice of the heart.

Acromion auscultation (Abrahams), with the bell of the stethoscope applied to the outer end of the clavicle, is useful in studying obscure apical sounds which are amplified and well transmitted by the conducting properties of the underlying bone.

The technic of *immediate auscultation* is obviously too simple to call for detailed description, though it is not, perhaps, out of place to suggest that the auscultator should invariably cover the region under examination with a thin towel or other suitable material before applying the ear to the part.

Phonometry.—The method of *phonometry*, by means of which the examiner aims to ascertain the condition of different organs by the tone of a tuning-fork placed on the surface, deserves recognition as a useful clinical aid. As elaborated by Habershon, by Benedict, and more recently by Cantlie, the examiner auscultates with a bin-aural stethoscope over a solid or a hollow organ to the vibrations

of a tuning-fork applied to the surface of the body over such an organ, and systematically moved so as to cross its outer boundaries. When this occurs, the sound originally heard suddenly grows faint or is quite inaudible, as the vibrations pass from the auscultated area to neighboring parts, and the observer is thus enabled to delimit the part by pencilling upon the skin the points at which this change of sound occurs. A fork with a narrow blunt handle and with long vibrating prongs tuned to a note of G sharp serves best for general purposes. Tuning-fork auscultation is applied to the outlining of pleural effusions of fluid, and to delimiting solid organs such as the liver, the heart and the spleen, and air-filled viscera like the stomach and the large intestine.

The term *autophonometry* is applicable to a procedure based upon vibrating sensations appreciated by the subject when the handle of a vibrating tuning-fork is applied to the surface of the body, this method having been used to demonstrate pulmonary consolidations, as well as in the study of certain lesions attended by diminished cutaneous sensibility. Stritch has shown that the patient feels these vibrations most distinctly when the instrument is placed over a dull area of the thorax, less distinctly when over an impaired area, and least over normal pulmonary resonance. When a tuning-fork is placed upon various subcutaneous bony prominences (*i. e.*, the sternum, malleoli, styloid process of the ulna, and nails of the fingers and toes) the vibrating sense is commonly abolished, often before cutaneous sensibility is impaired, in patients affected with peripheral neuritis, locomotor ataxia, spinal caries, syphilis of the cord, and diabetes mellitus.

THORACOMETRY AND CYRTOMETRY

The tape-measure and calipers, which should be graduated in inches and in centimeters, are employed for measuring various circumferences and diameters, especially of the thorax and abdomen, for ascertaining the size of surface lesions, and for defining the exact position of local physical signs with reference to fixed anatomic landmarks.

Thoracometry, or mensuration of the thorax, has for its chief objects the determination of the girth and the several diameters of the chest. In taking the girth, the tape should incircle the chest horizontally at the level of the nipples, and the measurements noted during respiratory repose, extreme inspiration, and extreme expiration, the difference between the last two expressing the

chest expansion, which ordinarily amounts to from two to five inches (5 to 12.5 cm.) in a healthy man. Various stethometers, indicating the thoracic excursions upon a graduated dial, are available for measuring the chest expansion, but the simple tape-line is quite as accurate as any of these instruments. Comparative measurements of the two halves of the chest are made by half-circling each side from midsternum to midspine, care being taken to follow precisely the same horizontal level and to apply the tape with equal tension on both sides. In comparing the semi-circumferences thus obtained, allowance must be made, in right-handed persons, for at least a one-half inch (1.25 cm.) greater measurement on the right than on the left side. In measuring abdominal girths the tape is generally passed horizontally around the belly at the level of the umbilicus.

It is convenient to take as the vertical diameter of the chest the distance from the highest point of the axilla to the lowest level of the costal margin, and to measure the two horizontal diameters at the level of the nipples; the anteroposterior diameter is found by applying one point of the caliper to the median line of the sternum and the other point to a vertebral spine, and the transverse diameter by caliper-ing the chest between two corresponding points upon the lateral walls in the midaxillæ.

Cyrtometry, or the procedure of outlining body-curves, is applicable chiefly to determining the shape of the thorax in cross-section. For this purpose numerous more or less elaborate cyrtometers have been devised, none of which is more satisfactory than a simple instrument made of two narrow, flat strips of soft lead, each two feet (60 cm.) in length, and hinged together with a bit of rubber tubing. Having adjusted this hinge to the spine, the chest is incircled horizontally by the strips, which, being flexible, can be molded accurately to the body; having thus taken an impression of the entire circumference of the chest, the strips are removed by slipping them from their rubber connection, each section retaining the contour of the surface to which it was molded. A pencil tracing of the strips after their removal gives a graphic transverse section of the chest, and may be the means of revealing deviations from the normal contour too trivial to attract attention on casual inspection. Cyrtometry is useful both as a means of initial diagnosis and in studying, from permanent records, the progress of thoracic development and retrogression in persons affected with chronic pulmonary lesions.

SPHYGMOMANOMETRY

Sphygmomanometry, or the instrumental estimation of the arterial blood-pressure, shows the degree of arterial tension with far greater accuracy than simple feeling of the pulse affords, and serves also to confirm the details of the sphygmographic tracings. The sphygmomanometer, used for gaging the tension, is based upon the principle of measuring with a manometer the degree of pressure required to obliterate the pulse of a part distal to a given point of constriction, the result being expressed in millimeters of mercury. A pneumatic constricting armlet, an inflating apparatus, and a mercurial manometer comprise the essential working parts of the instrument, of which the model designed by Nicholson is well suited for clinical work, inasmuch as it registers both systolic and diastolic pressures, and is accurate, simple, and portable. Rogers' aneroid sphygmomanometer, which registers the pressure by an aneroid gage, is much simpler than any of the mercurial manometers, and is sufficiently accurate for routine clinical work. Hill and Barnard's sphygmometer is useful for determining roughly the systolic pressure, in much the same way that one sometimes estimates a hemoglobin percentage with a Tallquist scale, instead of with a more elaborate hemoglobinometer.¹

Technic of Sphygmomanometry.—The working parts of *Nicholson's sphygmomanometer* are housed in a metal case, the lid of which, when raised, locks automatically and firmly supports the whole device (Fig. 9). When shut, the instrument fits into a leather case, with the armlet and inflating bulb, and can be conveniently carried in a coat pocket. The apparatus consists of a steel mercury reservoir, fitted above with a metal Y-connection for the inflation device and terminating below in a glass mercury tube, alongside of which is mounted an adjustable scale showing millimeter divisions. A soft pneumatic armlet, for application to the patient's arm, is connected by rubber tubing to one end of the Y-connection, to the other end of which fits a tube leading from the inflation bulb, which carries a stop-cock and a delicate needle-valve for controlling the pressure within the armlet. Before adjusting the latter it is customary in hospital work to place the

¹ Nicholson's sphygmomanometer (Precision Thermometer and Instrument Co., Philadelphia) costs \$15.00; Rogers' (Taylor Instrument Companies, Rochester), \$25.00; and Hill and Barnard's sphygmometer (J. J. Hicks, London) sells for \$3.10 plus duty. The original Riva-Rocci sphygmomanometer, and the modifications thereof suggested by Erlanger, Mummery, Martin, and others can be furnished by Hawksley and Son, London.

subject in dorsal recumbency, with the arm, relaxed and bared to the shoulder, supported by a pillow at the level of the heart. The inflation device having been applied to the arm, with the rubber bag over the brachial artery, the remainder of the armlet is wound smoothly around the arm and the end tucked under the last turn, so as to hold it in place when pressure is established. The con-

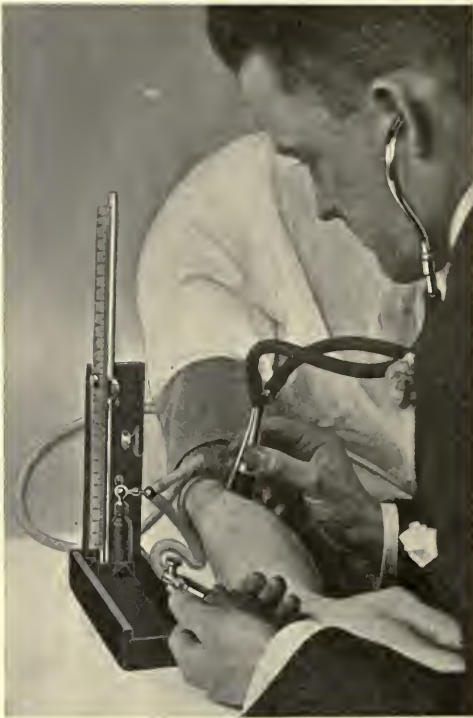

Fig. 9.—Nicholson's sphygmomanometer. The auscultatory method of estimating blood-pressure.

nection between the inflation device and the mercury chamber having been made, the zero mark of the scale is adjusted to the level of the top of the mercury column in the glass tube, and inflation is begun, with the stop-cock parallel to the tube and the needle-valve closed. Air is thus forced into the armlet until the radial pulse, meanwhile being palpated with the examiner's disengaged hand, is extinguished. When the pulse at the wrist is no

longer appreciable, the release valve is cautiously opened until the mercury column (now high in the tube) begins to fall. The level reached by the mercury column *at the moment the pulse reappears* indicates the systolic pressure, which in the healthy adult usually ranges between 120 and 140 mm., rarely exceeding the latter figure in a young man, and being from 25 to 50 points lower in children under two years old. As the mercury falls its oscillations progressively increase to an acme and then diminish, the *base line of the maximum oscillation* being taken as the degree of *diastolic pressure*, which varies normally from about 90 to 110 mm. in adults, or approximately 30 points lower than the systolic pressure. This reading should not be made until the mercury column has had time to adjust itself after each fall, several fluctuations being observed at the various levels. The difference between the systolic and the diastolic figures represents the *pulse pressure*, a value normally approximating from 20 to 30 mm.

The *auscultatory method* (Korotkow) has of recent years largely replaced the original palpatory or oscillatory technic, just described. It is carried out by stethoscopic auscultation of the artery at a point below the cuff, while gradually releasing the pressure upon the vessel, the primary object being the detection of the following series of sounds as the compressed artery refills with blood, with the escape of air from the armlet: (1) A loud clear tone, coincident with the first inflow of blood into the relaxed vessel; (2) multiple murmurs generated by local blood eddies; (3) a secondary sharp sound, changing gradually to (4) an indistinct dull tone, caused by mural vibrations and followed by (5) complete silence, as the normal relations of blood volume to vessel lumen are restored. The height of mercury column when the first clear tone is heard is taken as the systolic pressure, which by this method is some 10 or 15 points higher than by the palpatory; and the figure registered at the time of the dull, muffled tone is generally conceded to indicate the diastolic pressure. The special stethoscope and tambour¹ devised by Oliver is most useful in determining blood-pressures by the auscultatory method.

Rogers' sphygmomanometer (Fig. 10) consists of an aneroid manometer registering on a dial reading from 0 to 300 millimeters Hg, and of an armlet containing a rubber pressure-bag and connecting, by two rubber tubes, with the gage and with an inflating bulb. The tube leading from the latter is provided with a release valve,

¹ Price, \$6.25, duty paid (Hawksley & Son, London).

for relieving the armlet compression. The armlet, to be applied like a roller bandage, is held in place by tucking the small free end under the preceding fold, the pressure produced by the inflating bulb being sufficient to keep it snugly adjusted to the subject's arm during the observation. The aneroid gage is then suspended from a hook on the outer face of the armlet, and the two rubber tubes are connected, one with the gage and the other with the inflation bulb. To obtain the systolic pressure, the armlet

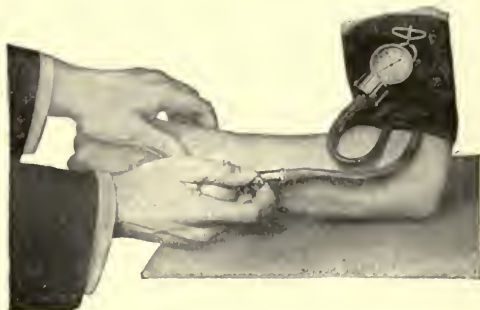

Fig. 10.—Rogers' sphygmomanometer. The palpatory method of estimating blood-pressure.

is inflated by means of the bulb until the compression thus produced obliterates the radial pulse, after which 1 or 2 c.c. additional pressure is added. Now, by careful manipulation of the release valve, air is permitted to escape until the radial beats reappear, the figure registered on the dial at this exact moment representing the systolic pressure. To gage the diastolic pressure the air is released very slowly until the dial indicates a maximum range of oscillations, whereupon the valve is quickly closed, and the minimum oscillation figure taken as the diastolic value. Rogers' sphygmomanometer reads within about 5 mm. of the figures of the mercurial instruments, over which it possesses the advantages of greater simplicity, ease of operation, and adjustability for differing barometric conditions.

Hill and Barnard's sphygmometer consists of a glass gage graduated in millimeters, and fitted, by a short length of rubber tubing, to a small rubber ball contained in a silk bag (Fig. 11). The gage is closed at one end by a metal cap pierced by a small orifice, which, by manipulating a screw, can be opened and closed. By means of this device a fluid meniscus can be produced within the lumen of the

tube by placing its open end in water (or in ink) and screwing the column up and down until the top of the fluid reaches the zero mark. This accomplished, the rubber ball is distended with air, connected with the gage, and, covered with the palm of one hand, pressed down

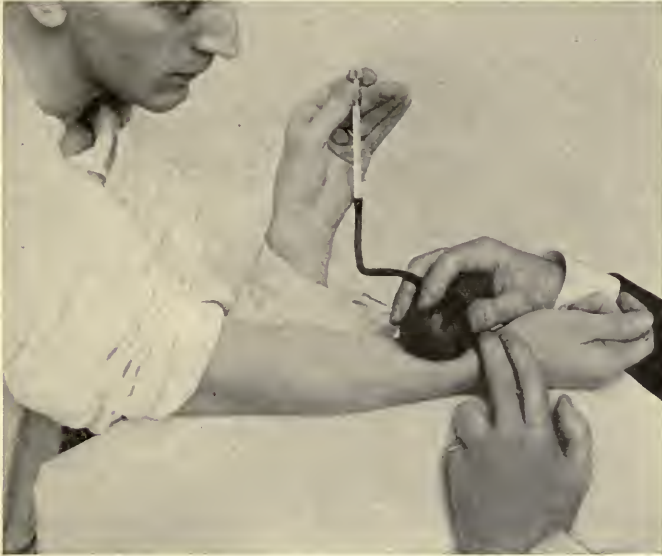


Fig. 11.—The Hill-Barnard sphygmometer.

firmly upon the subject's radial artery, the beats of this vessel being meanwhile felt with a finger of the examiner's other hand at a point peripheral to the rubber ball. The figure indicated by the fluid *when the radial pulse is obliterated* is taken as the *systolic pressure*. Hill and Barnard's instrument is not, of course, intended to do the work of the more accurate armlet-and-bulb sphygmomanometer, but its simplicity and extreme compactness recommend its employment when only a general idea of the blood-pressure value is desired, and under circumstances when a more elaborate method of sphygmomanometry is impracticable.

To insure accuracy, the blood-pressure should be investigated only when the subject is absolutely at rest, both physically and mentally, for no reading shows a true value unless obtained when the influence of transient circulatory stimuli can be excluded—muscular tension, intellectual effort, excitement, fear, all raise arterial pressure. Smoking a strong cigar may do the same, but alcohol

has no material effect, save when taken too liberally, in which event the pressure falls perceptibly. Comparative estimates should be made under precisely similar conditions, relating especially to the subject's posture, to the time of day, and to the technic of the armlet application and other details.

The practical application of sphygmomanometry and the pathologic variations of arterial blood-pressure are considered subsequently. It is sufficient here to associate *hypertension* with arteriosclerosis, cardiac hypertrophy, renal sclerosis, and the toxic states attending gout, plumbism, syphilis, and other specific infections. Prominent factors of *hypotension* include shock, hemorrhage, vomiting, diarrhea, anemia, enteric fever, tuberculosis, and various lesions of the heart marked by myocardial enfeeblement and dilatation.

The term "energy index" (Barach) is used to indicate the total efforts per minute exerted by the cardiovascular system. This figure, which in health approximates 20,000 mm. of mercury, is calculated by multiplying the sum of the systolic and the diastolic pressures by the pulse-rate. Tigerstedt judges the actual pumping efficiency of the heart by dividing the pulse-pressure by the systolic pressure; the figure normally reads from 25 to 35 per cent.

Hoffmann, in 1906, suggested the use of the sphygmomanometer in the study of the *pulsus alternans* (*q. v.*), in which type of arrhythmia a systolic manometer pressure may be reached which obliterates the alternately feeble impulses, and thus halves the pulse-rate at the wrist. In such instances the auscultatory method of tonometry affords at high pressures but one-half of the tones audible when the armlet is deflated.

By Oliver's method the *venous pressure* can be estimated merely by noting at what height above the level of the cardiac apex the veins on the dorsum of the hand collapse, when the hand, with fingers extended, is held vertically and slowly raised. If the subject has prominent veins, it is easy to distinguish their sudden collapse, which occurs normally at a height of $\frac{1}{2}$ inch above the apical level. The height, in inches, at which this occurs above the apex is multiplied by 2,¹ to indicate—and with surprising accuracy—the venous pressure in millimeters of mercury.

Although no direct proof of a venomotor nervous system is available, recent physiologic work suggests the hypothesis that a mechanism of this sort exists, comparable to the general vasomotor

¹ One inch, or 25.5 mm., represents about 2 mm. Hg (1.985), reckoning the specific gravity of the blood and of mercury as 1.060 and 13.57, respectively.

system (Yandell Henderson). The studies of Hooker show that the normal venous pressure and the alterations in arterial pressure are independent. With laboratory instruments Howell approximates the normal venous pressure of the adult at about 7.5 cm. of water; while Hooker's figures read 10 to 20 cm. during the day and 7 to 8 cm. during sleep at night. High readings are common in arteriosclerosis and in the failing compensation of various cardiac diseases; well-compensated lesions, whether muscular or valvular, produce no deviation from the normal figure.

SPHYGMOGRAPHY AND CARDIOGRAPHY

Graphic records of arterial and venous pulse-waves, of the cardiac apex-beat, and of other pulsations upon the surface of the body are obtainable by the use of special instruments devised for the purpose of registering surface undulations. For recording these different pulsations synchronously, some form of polygraph is necessary, such an instrument consisting essentially of a series of delicate levers, each tipped with a stilet and attached to a separate tambour, communicating by rubber tubing with a cup-shaped capsule or receiver, which, when placed over a pulsating area, transmits the undulations thereof to its respective stilet. The latter rests upon the surface of a strip of smoked paper, driven by clockwork at uniform speed past the stilet point, whose oscillations are thus scratched upon the carbonized film as a graphic tracing. A chronograph, or time-marker, is also useful in accurately indicating the time-incidence of the several tracings. The polygram made in this manner is suitably labeled by writing upon its smoked surface with a dry point, after which is flooded with tincture of benzoin or with negative varnish, hung up until dry, and subsequently filed with the case-history.

Technic of Sphygmocardiography.—Of the several polygraphs now in vogue, Jaquet's model is to be preferred for clinical work if its high cost is not prohibitive,¹ since this instrument is compact, comparatively easy to operate, and capable of registering three synchronous tracings, which, though they may seem miniatures of those made by a large laboratory kymograph, show all essential details. Marey's polygraph,² practically unused in this country, is an accurate, though somewhat bulky, instrument, of more moderate price. Gibson's clinical polygraph,³ which takes four simultaneous

¹ Price, \$130.00, duty paid (Arthur H. Thomas Co., Philadelphia).

² Price, \$120.00, duty paid (Charles Verdin, Paris).

³ Price, \$146.40, duty paid (T. Hawksley, London).

ink-tracings on glazed paper, is even more expensive than either of the two just mentioned. Dudgeon's sphygmograph,¹ adapted to recording but a single tracing, is used for making sphygmograms of the radial pulse. Equipped with Mackenzie's polygraph attachment, it will serve to register synchronously the radial beat and one other pulsating area, such as the jugular vein, the cardiac apex, or an aneurism. Mackenzie's ink polygraph² traces three separate records upon a strip of white paper.

Jaquet's sphygmocardiograph (Fig. 12) is provided with a small metal plate which rests upon the subject's radial artery, and is

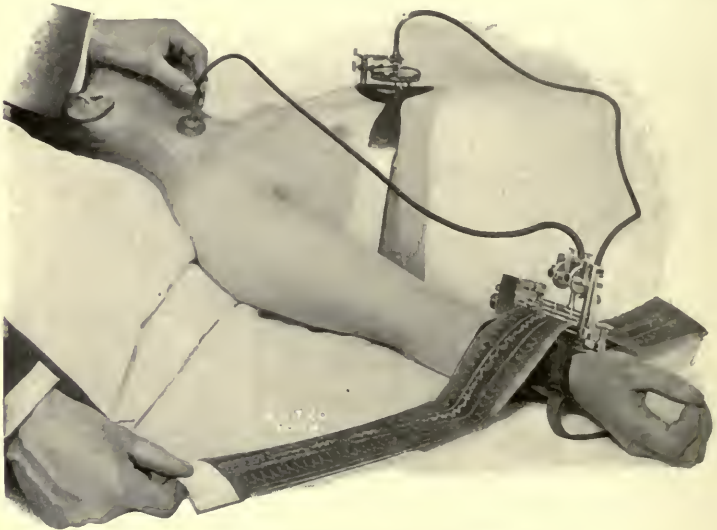


Fig. 12.—Jaquet's sphygmocardiograph.

attached to a delicate lever system carrying at its free end a light stilet for registering the movements of the radial pulse; a second stilet and lever system plays upon a tambour on the instrument, and leads, by a rubber tube, to a special receiver designed for the cardiac apex (or other surface pulsation), being adjusted thereto by a chest-strap; a third registering mechanism, of similar construction, communicates with a cup-shaped receiver used for transmit-

¹ Price, \$20.00, duty paid (T. Hawksley; also J. J. Hicks, London). Biggs's time-marker, registering one-fifth second intervals, and designed for attachment to Dudgeon's sphygmograph, is furnished, at a cost of \$9.00, by Messrs. G. Horstmann and Sons, Bath, England.

² Price, \$84.00, duty paid (S. Shaw, Padiham, England).

ting the jugular impulse. The three stilets simultaneously register upon a strip of smoked paper, which, by means of a roller and guide wheels revolved by clockwork, travels past the writing points so as to register their oscillations, definite time intervals meanwhile being marked by a chronograph stilet. The driving and time-marking mechanisms are controlled by levers, and the pressure of the radial plate is regulated by a milled screw.

Having fitted the cardiac receiver to the apex-beat and strapped the frame of the instrument snugly to the patient's wrist, as shown by the illustration (Fig. 12), the leather cuff is adjusted so as to bring the metal plate beneath the frame directly over the radial pulse-beat, the site of which has been previously marked with an anilin pencil. The smoked paper is then inserted between the roller and guide wheels, and the clockwork started in order to carry the strip along until the three stilets rest upon its surface, when its progress is halted. The cardiac receiver is connected with its appropriate tambour, and the jugular receiver placed in position and similarly coupled to the instrument. When the three stilets rise and fall with proper amplitude, indicating satisfactory registry of the different undulations, the operator starts the chronograph and again sets the paper strip in motion and allows it to run its entire length, while an assistant catches the tracing as it passes from the roller and guide wheels, so that it emerges smoothly and evenly from the instrument. Having finished the tracing, the driving power is stopped and the strip benzoinated or varnished, as described above.

Dudgeon's sphygmograph, for tracing the radial pulse-waves, is provided with a single lever mechanism similar to the corresponding arm of the sphygmocardiograph, for which, indeed, Dudgeon's device served as a model to be elaborated by the incorporation of additional stilets, receivers, and a chronograph. The accompanying picture (Fig. 13) shows the correct adjustment of the sphygmograph, held in position by a band and clamp, so that the metal plate of the registering lever presses upon the exact point where the radial artery beats most forcibly. Substitution of the standard metal plate by a slightly larger one attached to a more resilient spring has given, in the author's hands, much more satisfactory tracings than can be obtained with the original model of the instrument. It also simplifies the technic to tie the sphygmograph to the wrist with a flat elastic band, as Mackenzie advises, rather than to attempt to hold it in place by means of the orthodox strap and clamp. Glover uses an ordinary tourniquet fitted with a cloth band, to each free end of which is sewed a metal clip, to be inserted into the slots where the wrist-bands are

attached in the original model. Having adjusted the instrument so as to establish correct oscillations of the stilet, the smoked paper strip is set in motion and the tracing completed in the manner noted above.¹ While this is taking place the patient's forearm should rest upon a firm table, being supported by folded towels or similar pads so placed that the limb is kept relaxed and immobile, while the fingers, held in a position of moderate flexion, likewise must be kept perfectly still.

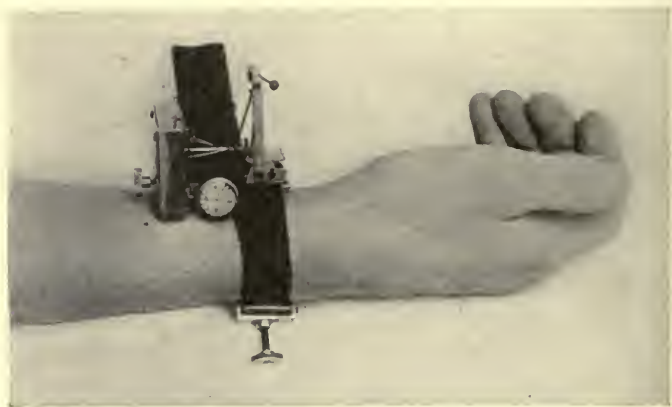


Fig. 13.—Dudgeon's sphygmograph.

Interpretation of the Normal Sphygmocardiogram.—The above diagram (Fig. 14) illustrates the normal undulations recorded by a simultaneous tracing of the pulsations of the carotid artery, the cardiac apex, and the right external jugular vein, the synchronous points on these three waves being marked by the numbered ordinate lines.

The *arterial sphygmogram*, typified by the carotid tracing, shows an almost perpendicular *upstroke* (3), due to a sudden rise of blood-pressure, followed by an oblique *downstroke* (4-5), corresponding to the fall of pressure. A line drawn through the lowest points of the upstrokes, termed the *base line*, normally follows a virtually horizontal course. The upstroke (anacrotic limb) is coincident with ventricular systole, the pulse-wave arising therefrom being so sharp and abrupt that it produces a continuous and almost vertical

¹ Tracings in ink on white paper can be made by fitting the Dudgeon stilet with Macfie's glass writing point, made by Messrs. Down Bros., 21 St. Thomas's Street, London.

line on the sphygmogram. The downstroke (catacrotic limb) is much more oblique, for it mirrors the comparatively slow fall of blood-pressure, and this line shows two distinct undulations: one known as the *tidal* (predicrotic) *wave* (4), due to secondary contraction and expansion of the artery immediately after its systolic distention; and a second, termed the *recoil* (dicrotic) *wave* (5), caused by the recoil of the blood-column, whose retreat aortaward is suddenly

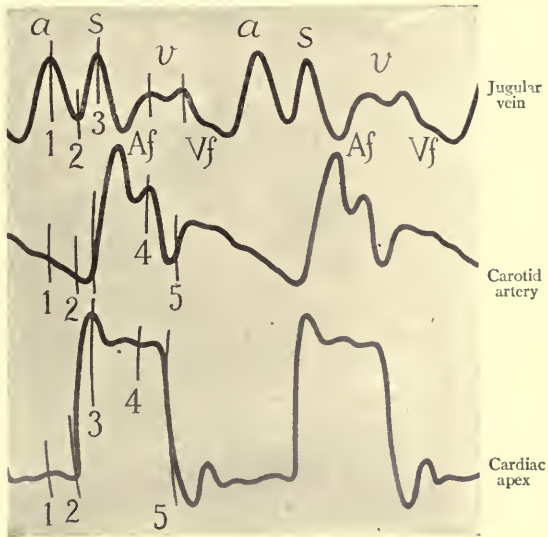


Fig. 14.—Simultaneous tracings of the normal arterial, venous, and cardiac pulsations (Sphygmocardiogram by Dr. G. Bachmann).

checked by the closure of the aortic valve. Apart from these two normal oscillations of the downstroke, this line may also show miniature waves referable to the inherent elasticity of the arterial wall. The *apex* of the normal arterial tracing, or the angle between the upstroke and the downstroke, is acute, while of the two minor downstroke waves, the recoil is more conspicuous than the tidal.

The *cardiogram*, shown by the above tracing, consists fundamentally of a perpendicular *upstroke* (2-3) and an oblique *downstroke* (5). The former marks the beginning of ventricular systole, and may be preceded by a minor wave, due to systole of the left auricle; ordinarily, the cardiogram fails to show this auricular undulation, the immediately preceding diastolic phase of which is difficult, if not impossible, to register in finer detail. The summit beyond

the *apex* (3) is known as the *systolic plateau*, and is formed by a gently sloping line, usually rippled by one or more subsidiary waves, due to ventricular contractions. Chronologically, the systolic plateau corresponds to the impact of the heart against the parietes during ventricular systole, and from this summit the downstroke drops, with moderate obliquity, to the base line. The curve rising immediately after the downstroke (5) coincides with ventricular diastole, the first part of this line timing the active, and the latter part the passive, period of this phase, which, graphically, is the actual beginning of the upstroke.

The *venous sphygmogram*, illustrated by the jugular tracing, is composed of three distinct waves corresponding to various movements of the right side of the heart, and constituting the so-called "physiologic venous pulse." The first of these waves (a), the *auricular* or *a-wave*, is presystolic in time, being coincident with the contraction of the auricles, and is due to the centrifugal impact of the venous column consequent to the slowing and sudden arrest of its onward flow. The second wave (s), commonly termed the *systolic*, is synchronous with the beginning of ventricular systole, or with the so-called "protosystolic period" of this chamber, when the tricuspid valve suddenly projects into the cavity of the right auricle and thus creates a reverse wave in the veins.¹ The third wave (v), known as the *ventricular*, is also systolic in time, but it occurs distinctly later than its protosystolic predecessor, for it accompanies the latter phase of ventricular contraction. The peculiar double curve of this undulation is produced by the sudden upward movement of the tricuspid valve and by the ascent of the auriculoventricular diaphragm to its resting position—events consequent to the relaxation of the papillary muscles at that period when the intraventricular tension exceeds the intra-auricular. The notch after the a-wave (2) marks relaxation of the auricle; that following the s-wave (Af) indicates auricular diastole; and that succeeding the v-wave (Vf) designates ventricular diastole and the passive period of the cardiac cycle.

Clinical Value of Sphygmocardiography.—Accurate technic and intelligent interpretation of the tracing together make this

¹ Mackenzie and his school term this second ascent (s) the "carotid wave," and attribute it to the communicated impact of the carotid artery. While admitting that this may be one of the factors of the s-wave, the arterial impact cannot be the sole cause. The s-wave unquestionably precedes the systolic line of the carotid pulse in the majority of accurate kymograms; it has been repeatedly traced under circumstances absolutely precluding every possibility of a transmitted arterial throb (Bard, Cushny, Morrow); and, moreover, its disappearance has been noted after experimental inhibition of the ventricle (Porter).

method of unquestionable value, the all-important personal equation receiving, of course, due consideration in the individual instance. To regard sphygmocardiography as a pleasing bedside pastime is perhaps as great an error as to expect a ready-made diagnosis from every smoked slip. The arterial pulse tracing neither can nor should supplant the trained finger in studying the size, volume, and mural condition of the vessel, but it does provide a permanent record of the pulse's rate, force, and rhythm, which thus can be crystallized on a single slip of blackened paper, together with numerous minor oscillations too delicate to be felt. Simultaneous tracings (*i. e.*, carotid, jugular, and precordial) indicate, as no other method of research can, disturbances of the auriculoventricular relations, asynchronism of ventricular contraction, and other cardiac arrhythmias for the diagnosis of which a comparable sphygmogram is indispensable.

The characteristics of individual pulse tracings and their diagnostic significance in certain cardiovascular disorders are detailed in Sections V. and VI.

ELECTROCARDIOGRAPHY

With the electrocardiograph it is possible to study graphically the electric currents generated by the contracting heart, and thus to identify with great accuracy certain cardiac irregularities, notably those due to defects of conductivity, to premature systoles of the auricles and ventricles, to sinus disorders, and to paroxysmal tachycardia.

The electrocardiograph now in general use was perfected by Einthoven, on lines originated by Kölliker and Müller, in 1856, and consists essentially of a delicate filament of silvered quartz stretching between the poles of an electromagnet activated by a storage-battery and wired to electrodes attached to the subject.¹ The current traversing this filament at right angles to the lines of force of the electromagnet's magnetic field deflects it according to the direction of the current. The shadows of these oscillations obtained by illumination with an arc light and magnified by a Zeiss objective and a system of condensing lenses are focussed upon a photographic film, driven at fixed speed, which, after proper development, constitutes the clinical electrocardiogram. The delicate movements of the filament attributable to "skin

¹ The duty-free price of the Edelmann electrocardiographic outfit with the Einthoven string galvanometer, electrodes, illuminating system, photographic registering apparatus, and other accessories is \$1031; the Cambridge instrument, complete, costs \$1611, duty free. (A. H. Thomas Co., Philadelphia.)

currents" are compensated by projecting, by means of a rheostat, sufficient current from a dry cell exactly to neutralize such deflections, and the tension and sensitiveness of the filament are also adjustable, usually so as to secure a 10-millimeter deflection with the passage of a 1-millivolt current.

The patient, who must be warm, relaxed, and absolutely at rest, is included in the electric circuit by electrodes commonly consisting of zinc vessels containing warm salt solution in which the extremities are immersed, or of strips of metal enveloped in




Fig. 15.—Cambridge electrocardiographic outfit.

absorbent material saturated with saline and applied to both arms and one leg of the subject. The course of the current thus led off is termed a "lead," or "derivation," designated by the Roman numerals I, II, III, etc., according to the parts of the patient to which the electrodes are attached. Kraus and Nicoli have plotted six different leads, all of which afford different electrocardiograms, but for clinical purposes only three are in general use, as follows: Lead I, current from right arm and left arm; lead II, current from right arm and left leg; and lead III, current from left arm and left leg. Lead II gives the most useful record in the majority of electrocardiograms (Fig. 16*b*).

Interpretation of all of the electrocardiographic waves is still an unsettled point, but the correctness of Einthoven's conclusions as to the conspicuous deflections is generally conceded. These waves, with his letterings, represent auricular systole at *P*, ventricular systole at *Q*, *R*, *S*, *T*, the conduction of the auriculo-ventricular impulse from *P* to *R*, and the diastolic period between *T* and *P* (Fig. 16*a*).

By means of these simple alphabetic symbols the following pathologic variations of sequence, size, and incidence of the

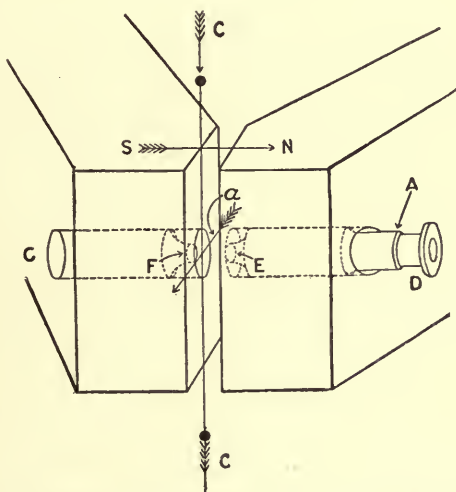


Fig. 16.—Lewis's diagram of the string galvanometer: *A*, Microscope for observing the movements of the string of silvered quartz (*C*) suspended in the field of the electromagnets (*S N*); α , direction of current's movements, at right angles to the magnetic field; *C F*, electric light and condenser.

principal waves of lead II of the electrocardiogram may be designated:

1. Irregular incidence, but normal sequence, of waves: tachycardia; sinus arrhythmia.
2. Prolonged *P*-*R* interval: sluggish impulse conduction from sino-auricular node to ventricle.
3. Prolonged *Q*-*R*-*S* complex: delayed impulse conduction through ventricle.
4. Replacement of *P*-wave by fine oscillations: auricular fibrillation.
5. Multiple *P*-waves in *R*-*T* interval: auricular flutter.

6. Small or inverted *P*-wave, with premature *P*-, *R*-, and *T*-waves: auricular premature systole.

7. Large *P*-wave: auricular hypertrophy; left ventricular dilatation.

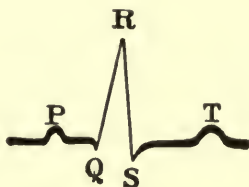


Fig. 16a.—Diagram of the normal electrocardiogram: *P*, Auricular systole; *P*-*R*, conduction-time of impulse from auricle to ventricle (0.12 to 0.17 second); *Q*, beginning of ventricular systole; *R*, basal ventricular activity; *S*, apical ventricular activity; *T*, end of ventricular systole; *T*-*R*, diastolic period.

8. Large prolonged *R*-wave, with deep *S* depression: ventricular premature systole. (*R*-wave inverted in lead III, if left-sided, and in lead I, if right-sided.)

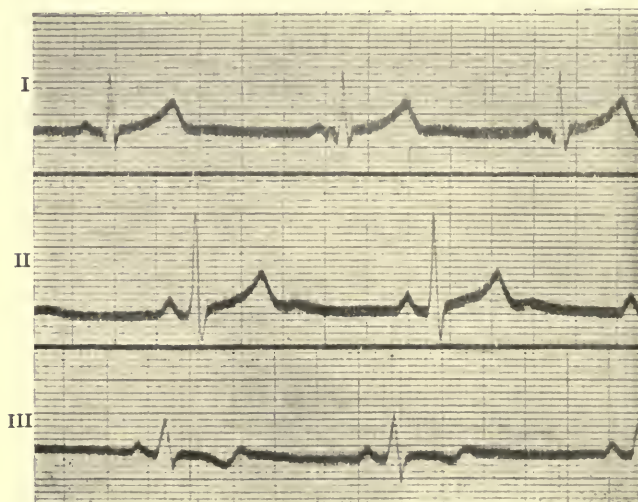

Fig. 16b.—Normal electrocardiogram. Leads I, II, and III of a normal heart.

9. Small *R*-wave: ventricular hypertrophy. (*R*-wave inverted in lead III, if left-sided, and in lead I, if right-sided.)

10. Simple inversion of *R*-wave: deep, forced inspiratory effort; subphrenic pressure.

11. Small *R*-wave: cardiac dilatation (inconstant).
12. Large *T*-wave: vigorous ventricular contraction.
13. Small or inverted *T*-wave: feeble ventricular contraction.

The diagnostic value of the more specialized electrocardiograms in various lesions of the myocardium and of the cardiac valves is duly considered in Section VI (p. 396 *et seq.*).

PARACENTESIS

Pathologic fluids and other material for laboratory study are obtained by puncture, or paracentesis, made with a hollow needle or a small trocar, ordinarily attached to a small syringe or connected with a vacuum bottle, by means of which the specimen can be readily aspirated. It is a good rule always to be prepared, when the occasion arises, to remove a foreign fluid as soon as it is detected, so as to spare the patient a subsequent operation. In consequence, exploratory punctures, though primarily diagnostic, are likewise potentially curative. In this manner pathologic fluids within the pleura, pericardium, and peritoneum, as well as the contents of cysts and abscesses, may be evacuated; the spinal canal tapped; the spleen and liver explored; and occasionally the consistence and nature of obscure tumors determined.

Technic.—Paracentesis must be carried out under rigid asepsis, the field of operation being scrubbed with a 1 : 1000 mercuric chlorid solution, cleaned with soap-suds, rubbed with alcohol, and finally doused with sterile water, after which a sterile dressing is applied and allowed to remain in place until the time of the puncture. The needle, syringe, and other apparatus are to be sterilized, preferably by boiling, and the operator's hands must be surgically clean.

The site of puncture having been chosen (*v. i.*), the needle is introduced steadily but rapidly, and without any boring or lateral twist, until a sensation of suddenly diminished resistance and free mobility is perceptible, indicating that the point has passed through the parietal structures. To prevent damage from too deep a puncture, the operator should grasp the needle with the thumb and forefinger just above its point, while piercing the comparatively resistant tissues of the surface. After withdrawal of the needle the wound is dried, covered with a bit of sterile gauze or cotton, and sealed with aristol-collodion. Only exceptionally, as noted below, is general anesthesia indicated, local anesthesia by ethyl chlorid or by eucaïn being usually sufficient to deaden the pain of the puncture.

For withdrawing a small amount of fluid it is best to use an exploring syringe of about 6 c.c. capacity, fitted by a length of flexible rubber tubing to a hollow needle, the length and caliber of which are regulated by the situation and nature of the lesion to be explored (Fig. 17). For routine work it is well to have needles of three different sizes: 56, 45, and 30 gage, and $2\frac{1}{2}$ inches (6.2 cm.), 3 inches (7.5 cm.), and $3\frac{1}{2}$ inches (8.7 cm.) in length, respectively. In lieu of a special aspirator, an ordinary hypodermic needle may sometimes be employed with success.

When considerable fluid is to be removed, it may be allowed to drain off spontaneously through a coarse hollow needle or cannula (30 to 36 gage), or aspirated into a vacuum bottle. For aspirating a large effusion most clinicians use Potain's apparatus, consisting of a set of three hollow needles, a trocar-cannula, and a graduated vacuum bottle and exhaust pump (Fig. 18). To the bottle are fitted two rubber tubes, each having a separate stop-cock, one tube leading to an aspirating needle and the other to the pump, used to create a partial vacuum within the bottle and thus to exert suction through the hollow needle. The latter, having been inserted to the proper depth, is connected with the aspirating bottle, from which most of the air has been pumped out, the vacuum thus created being maintained by the closure of both stop-cocks. Suction is established by opening the needle stop-cock (the pump-cock remaining closed)

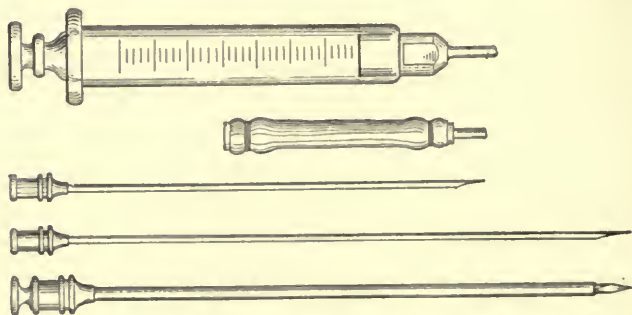


Fig. 17.—Aspiration syringe and needles.

just sufficiently to start a slow flow of liquid into the bottle. If it be necessary to interrupt the aspiration for the purpose of decanting the fluid and reëxhausting the air within the bottle, the needle-cock must remain closed meanwhile. Failure to insert the needle to a sufficient depth commonly accounts for a "dry tap," the remedy for which is obvious, while a sluggish, intermittent flow may be due

to blocking of the needle's lumen by a flake of fibrin, to unusual thickness and viscosity of the exudate, or to feeble aspiration force. These last obstacles can generally be overcome by reinserting the needle in a different direction after having partly withdrawn it and cleared its bore with a sterile wire, by the use of a needle of larger caliber, or by exhausting more air from the bottle. Having finished the aspiration and measured the fluid withdrawn, a portion for subsequent examination is poured into a sterile container, or the vacuum bottle itself is taken directly to the laboratory.



Fig. 18.—Potain's aspirator.

The laboratory report should embody data relating to the following points: (a) The *physical properties* of the fluid—specific gravity, color, odor, transparency, consistence, coagulability, and amount of sediment; (b) *chemic examination* of the filtrate, including tests for albumin, serum-globulin, and mucin; for sugar and urea; and, occasionally, for sarcolactic acid, succinic acid, allantoin, and inosite; (c) *microscopic examination*, for the detection of blood-corpuscles, epithelial and endothelial cells, crystals, necrotic tissue, ray fungi, hydatid hooklets and membrane, trypanosomes, piroplasmas, amebas, and pathogenic bacteria, which, if not demonstrable by direct examination, may be identified by culture and by animal inocula-

tion; (d) *cytodiagnosis*, whereby the number and character of the cells in the fluid are determined. For the technical details of these procedures the reader should consult a treatise on clinical laboratory methods.

Pleurocentesis.—Puncture of the pleural cavity usually calls for the use of a rather coarse needle and a Potain aspirator, for in the majority of instances this operation is a curative measure, necessitating the removal of much fluid. The site of puncture is determined by the size of the effusion, and should lie well below the upper level of the fluid. The sixth interspace in the anterior axillary line,

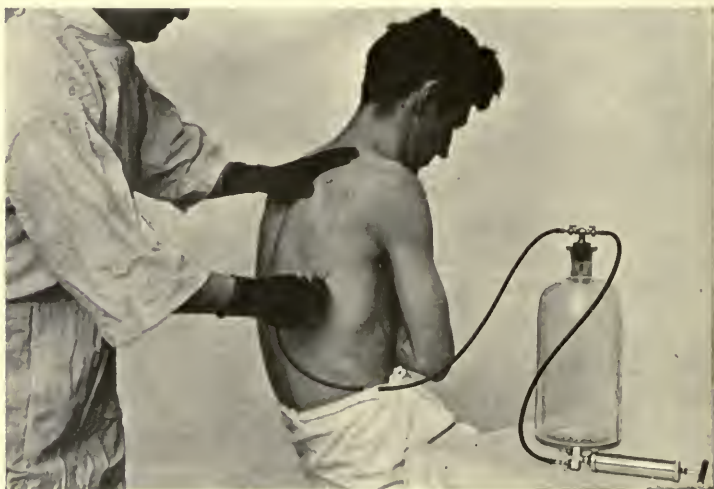


Fig. 18a.—Pleurocentesis.

the seventh interspace in the midaxillary line, and the eighth interspace midway between the latter and the scapular line are the points of election suitable in most effusions of average extent (Fig. 19). Too high a puncture may lacerate the lung above the effusion, while if the needle be inserted at too low a level, it may penetrate the complementary pleural space, or tear the diaphragm, the liver, or the spleen.

If possible, the patient, who must limit respiratory excursions, should sit upright during the operation, with the arm of the affected side swung across the chest so that the hand rests upon the opposite shoulder, thus widening the intercostal spaces. The puncture site having been chosen, the needle should be thrust directly through

the middle of the proper interspace, thus avoiding the possibility of wounding an intercostal artery and of lacerating the costal pericostium. The effusion must be aspirated slowly, for its sudden withdrawal is not unattended by risk, chiefly from the sudden recession of the dislocated heart and from abrupt refilling of the previously

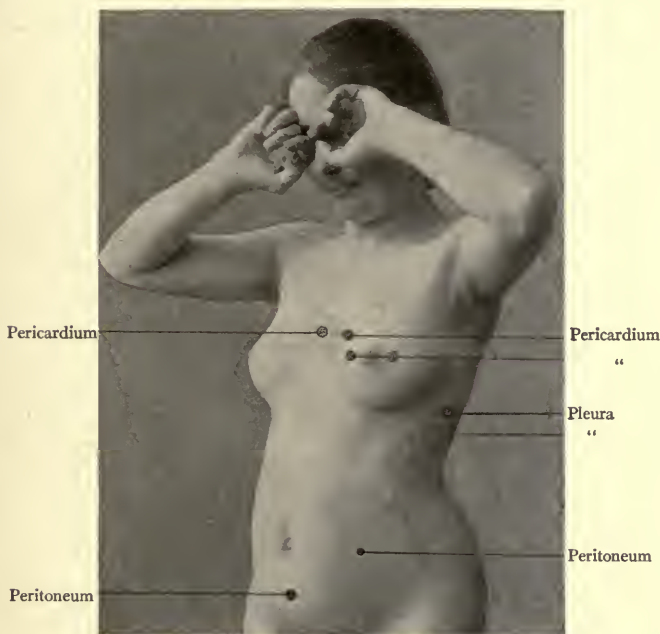


Fig. 19.—Points of election for paracentesis of the thorax and abdomen.

collapsed blood-vessels of the lung. Aside from sealing the puncture wound, the affected side requires no attention, for it seems better to permit free movement of the thorax than to restrict it by strapping, as was formerly considered good practice. After the patient has passed three or four days in bed subsequent to the paracentesis, it is advisable to hasten expansion of the deflated lung by means of respiratory exercises. This is accomplished preferably by the use of a Wolff apparatus, whereby the patient, by blowing a measured volume of water alternately from one bottle into another, exerts a respiratory effort against a given degree of resistance.

In that type of encysted effusion known as "blocked" pleurisy (*pleurésie bloquée*) ordinary aspiration fails to liberate the fluid, in

which event two needles may be used, one for drainage and the other for forcing sterile air into the pleural pocket, thus driving out the contained liquid.

The amount of fluid to be withdrawn at one sitting depends essentially upon the manner in which the subject bears the aspiration; in general, however, the volume should be too little rather than too great. If all goes well, it is safe *slowly* to drain off at least a liter—if this much exists—or, in the case of a massive effusion, as much as one and one-half liters, removing the remainder a day or two later. If the patient coughs, gasps, and complains of pain in the chest, faintness, and suffocation, and if the blood-pressure falls notably, the aspiration must be temporarily suspended, or, if these symptoms persist, permanently abandoned, at least for the time being. It is not always necessary to aspirate a large volume of intrapleural fluid, for the withdrawal of a small amount (10 to 20 c.c.) may stimulate absorption sufficiently to dispose of the remainder by way of the lymphatic apparatus.

Artificial pneumothorax is a remote accident, and one arising only in consequence of gross carelessness—air cannot enter the pleura if the needle and bottle be properly connected, and if the needle stop-cock be opened only when a satisfactory vacuum exists within the bottle. To assure this last essential the suction power and the valve action of the bottle should always be tested with sterile water before using the instrument of the patient. Sudden death of the subject during paracentesis, a most unusual accident, has been referred to extreme inhibition of the heart, due to irritation of the vagus and to vasomotor and respiratory paralyses from grave depression of the vasomotor and respiratory centers.

Capps and Lewis have drawn attention to the danger of exciting a vasodilator reflex by irritation of the pleura, in consequence of which death may occur after a period of rapid and extreme decline of arterial tension, attended by shallow and hurried respiration and by other symptoms of collapse. Such an accident should be guarded against by making the puncture with great care and by avoiding unnecessarily deep penetration and irritation of the pleura with the needle; the emergency, should it arise, is best treated by adrenalin transfusion.

A form of autotoxemia resembling so-called “serum illness,” and characterized by albuminuria, fever, arthritis, and urticarial rashes, is a very remote sequel to pleural paracentesis. Albuminous expectoration also may follow the operation, but this accident need not be feared if the fluid has been drained off slowly and with care.

Examination of a pleural fluid has for its chief object the differentiation of an edematous transudate from an inflammatory exudate, both of which may have precisely the same transparency and yellowish hue, yet within certain limits are distinguishable by differences in specific gravity, protein content, coagulability, and microscopic elements. A *transudate*, which resembles lymph, usually has a specific gravity of 1015 or lower, contains not more than 2.5 per cent. of albumin, and, unless mixed with blood, does not coagulate spontaneously. Microscopically, it shows little or no fibrin and a few endothelial cells derived from the pleural wall; blood-cells are found, if hemorrhage coexists, and fat-droplets, if the fluid be chylous. An *exudate* generally shows a specific gravity of 1018 or higher, contains at least 4 per cent. of albumin, and clots promptly and completely. Microscopically, a dense fibrin network is found, and also degenerated endothelium, leukocytes, erythrocytes, and perhaps cholesterol crystals; pathogenic bacteria may or may not be demonstrable in the stained specimen, according to the nature of the underlying inflammatory process. Although difficult to apply clinically, Zagoumenny's rule generally holds true, viz., that the alkalinity of exudates is less than that of the patient's blood, while the alkalinity of transudates is about the same as that of the blood.

Some exudates are frankly purulent or putrid, and, therefore, undeniably of inflammatory and infectious origin; some are hemorrhagic, in which case either a tuberculous or a cancerous factor may be at work; some are eosinophilic, as in tuberculosis, rheumatic fever, and a wide variety of other diseases; and some are milky or opalescent, for which peculiarities the presence of fat-droplets or of delicate albumin granules may account. In general terms it is true that the protein content of both dropsical and inflammatory fluids largely depends upon the site of the effusion, and is higher, as a rule, in pleural fluids than in those drawn from the peritoneum.

Cytodiagnosis is useful principally in determining the nature of a bacteria-free fluid, and is based upon investigation of the number and character of the cellular elements observed in a stained film of the effusion. The relative proportions of lymphocytes and polynuclear leukocytes, and also the erythrocytes and the cells derived from endothelial surfaces and from neoplasms, serve as the criteria for deductions, which relate chiefly to the differentiation of tuberculous and non-tuberculous effusions.

A differential count showing *lymphocytosis*, or a predominance of mononuclear leukocytes, suggests either a mild or a subsiding inflam-

mation, or some non-inflammatory process. Chronic tuberculous exudates are thus characterized, save during their incipiency and when active inflammatory complications supervene, under which circumstances the polynuclears are unduly numerous.

A count affording *polynucleosis*, or a preponderance of polynuclear leukocytes, generally denotes a well-defined and active inflammation of acute infectious origin, due, for example, to streptococci, staphylococci, pneumococci, or meningococci, and if such a process be of striking intensity, there will possibly be many necrotic cells and much detritus.

Endotheliocytosis, by which is meant an undue relative or absolute increase in the number of endothelial cells, is the general rule in non-inflammatory transudates, and in such fluids both lymphocytes and polynuclears, particularly the latter, are in the minority.

The detection of *cancer cells*, many with mitotic figures therein, in a fluid that also contains small bits of tissue of distinctively cancerous structure, points to the malignant origin of the effusion. Caution must be observed, in the absence of corroborative cytologic findings, in attempting to differentiate true cancer cells from endothelial elements, an unnatural number of which, free and *en plaque*, Sahli speaks of finding in most effusions of cancerous character.

Inoscopy may demonstrate tubercle bacilli in an effusion giving negative bacteriologic findings when examined by ordinary methods of film-staining. The technic of inoscopy, as elaborated by Jousset, consists of digesting the coagulum of the suspected liquid with pepsin and hydrochloric acid, centrifugalizing the liquefied mass, and preparing films from the sediment, to be stained by the Ziehl-Gabbet method and examined microscopically.

Pericardicentesis.—Puncture of the pericardial sac is not to be undertaken lightly, inasmuch as a slight technical slip may irreparably damage the heart; but, with due care, the operation is practically without danger. Curative pericardicentesis is indispensable in dealing with a bulky effusion showing no tendency to undergo resorption, and in a condition of this sort the physical signs are so unmistakable that a merely diagnostic puncture is neither indicated nor justified.

With the subject sitting upright or semiprone and restricting respiratory movements as much as possible, the needle is introduced through the middle of an interspace at a point within the area of cardiac percussion flatness. The instrument is then pushed inward along a horizontal plane while piercing the muscle, after which its

point is cautiously directed inward until a sense of abolished resistance marks its entrance to the pericardial sac. Ordinarily, the fifth left intercostal space between the midclavicular line and the extreme outer limit of effusion flatness is by far the most satisfactory site for puncture, though some prefer the fourth or the fifth left interspace, either close to or at least one inch (2.5 cm.) from the sternal border, so as to clear the internal mammary artery, which parallels the breast-bone at a distance of from $\frac{1}{4}$ to $\frac{1}{2}$ inch (0.6-1.25 cm.) from its margin (Fig. 19). In a very large effusion the freest drainage is sometimes secured by tapping the pericardium through the fourth right interspace close to the sternum (Dobert), or through the left costoxiphoid angle (Osler), thrusting the needle upward and backward and hugging the costal margin.

In order to avoid causing sudden relief of the extracardial pressure, the fluid must be drained away slowly and in limited amounts, not more, for example, than 3 or 4 ounces (90-120 c.c.) at a single séance, which may have to be repeated subsequently if the effusion be of considerable volume. The wound made by the needle requires no attention other than the treatment advised above.

Examination of the pericardial fluid, by the methods just alluded to, decides the type of the effusion in question, whether it be the dropsical serum of hydropericardium, the bloody effusion of hemopericardium, the milky liquid of chylopericardium, or the inflammatory exudate of pericarditis. The physical properties and other characteristics of liquid effusions obtained from the pericardial sac, being essentially like those of corresponding pleural liquids, do not require separate consideration (*v. s.*).

Paracentesis Abdominis.—*Diagnostic puncture* of the abdominal cavity is sometimes indicated in the investigation of abdominal cyst, circumscribed abscess, and solid tumor, and under such circumstances the needle virtually fills the dual office of instrumental palpation and aspiration. Hydronephrosis, subphrenic abscess, and cysts of the ovary and pancreas may come within reach of the exploring needle, but it is safer to cut down on a distended gall-bladder than to attempt its puncture, owing to the tendency of bile to escape into the peritoneum after the withdrawal of the needle. In making the puncture the operator guides the instrument so that it unquestionably penetrates the mass aimed at, and in this attempt great care is to be observed to prevent peritoneal contamination, either through a breach in the punctured part, or by leakage of infected material from the eye of the needle. The latter is used in connection with an aspiration syringe, and should be of small

caliber (about 50 gage), of high tensile strength, and of sufficient length to penetrate deeply. In the diagnosis of pneumoperitoneum Herrick's method of paracentesis with a blunt trocar and laterally perforated cannula is good practice. The cannula, being connected by rubber tubing with a wash-bottle containing water, transfers the free peritoneal gas to the liquid, the bubbling of which gives an ocular proof of gas.

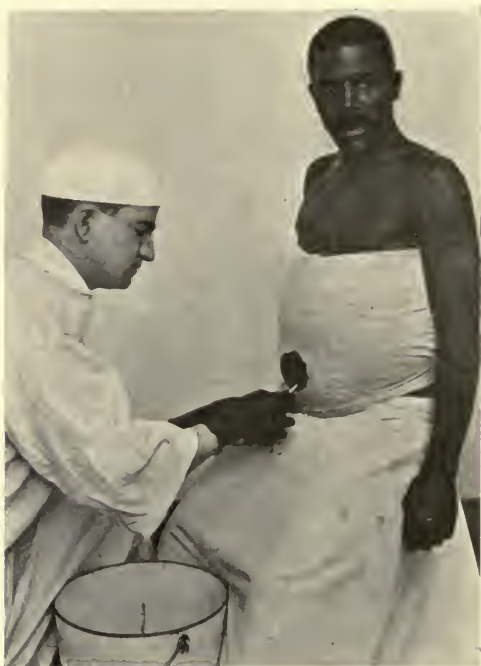

Fig. 19a.—Paracentesis abdominis. Inserting the trocar and cannula.

Therapeutic puncture of the peritoneal cavity for the relief of ascites is usually made alongside the median line of the abdomen, at a point midway between the pubic symphysis and the umbilicus; or at Munro's point, midway between the umbilicus and the left anterior superior iliac spine (Fig. 19). Inasmuch as the deep epigastric artery lies dangerously close to the latter point, Lian's site of election for puncture (the junction of the outer and middle thirds of an umbilico-iliac line) may seem a safer situation for

introducing the trocar. The patient should be placed in a sitting posture, or, if bed-ridden, propped up in a semireclining attitude, so as to favor gravitation of the fluid to the lowest level of the peritoneal cavity. Having found that the subject's bladder is empty, and that the intestines are out of the way, a sterile muslin binder is fitted snugly around the abdomen, by which device uniform parietal pressure is applied while the fluid is es-



Fig. 19b.—Paracentesis abdominis. Fluid draining away, with trocar withdrawn and cannula in position.

caping. This binder, reaching from the lower epigastrium to the pubis, should be provided with a window in front and with interlacing tails behind, the former corresponding to the field of operation and the latter being used for traction. The puncture is made with a trocar and cannula, the former being withdrawn when the peritoneal sac is entered, and the fluid allowed to flow through the tube into a receptacle beside the patient. As the transudate drains off, commensurate support is given to the abdominal

wall by an assistant who stands behind the patient and, by taking up the slack of the interlacing tails, keeps the binder tightly applied to the abdomen as its size diminishes. This not only facilitates the flow, but to some extent wards off troublesome syncope, due to the sudden rush of blood from the periphery to the overdilated, toneless abdominal vessels. Syncope from too rapid withdrawal of the fluid can be averted by the use of a cannula of proper size (about 35 gage), and by stopping the flow with the finger, from time to time, should the patient complain of vertigo or faintness. An apparently dry abdomen sometimes still yields a surprisingly large quantity of fluid when the point of the cannula is directed downward and swept about, while the subject bends far forward, compresses the abdomen laterally with both hands, and contracts the abdominal muscles. After the cannula is removed and the wound sealed, as above directed, a tight abdominal binder is applied, and the patient put to bed for about twenty-four hours.

Buth's method of gradual evacuation is suitable if one fears the effects of the pain of puncturing with a large trocar or the danger of shock from too rapid a drainage of a massive effusion. This calls for the use of a "capillary trocar" and a cannula about $\frac{3}{4}$ inch (8 cm.) long and a diameter approximating $\frac{1}{16}$ inch ($1\frac{1}{4}$ mm.), with lateral perforations near the end introduced into the peritoneum and with a bulbous extremity for attaching a rubber tube. The instrument having been introduced in the usual manner, its point is directed downward through the belly wall, and after withdrawing the trocar and fitting a length of drainage-tubing to the end of the cannula, the fluid is allowed to drain into a receptacle alongside the patient. The fluid, which if fibrinous will not flow at all through such a small cannula, is usually evacuated at the rate of from 1 to $1\frac{1}{2}$ quarts (1 to $1\frac{1}{2}$ liters) per hour, and with a minimum of discomfort to the patient.

Drainage of the abdominal cavity, if skilfully done, is quite without danger, and may be repeated time and again in the same individual with perfect immunity from by-effects, as many an old alcoholic with a hard liver can testify. Even in preantiseptic days the harmlessness of repeated punctures of the belly was recognized, if one may judge by Algernon Ashton's description of a century-old English epitaph, which naively sets forth that the deceased "was tapped 97 times, and had 461 gallons of water taken from her, without ever lamenting her case or fearing the operation."

Examination of the fluid obtained by abdominal puncture aims to distinguish ascitic transudates from peritoneal exudates, by the

criteria already mentioned (*v. s.*), and to identify fluids aspirated from ovarian, echinococcus, hydronephrotic, and, rarely, pancreatic cysts.

Ovarian cysts have a most variable composition, their contained fluid being commonly viscid and turbid or colloid, but exceptionally resembling a thin, watery transudate. The specific gravity ranges from about 1005 to 1050, according to the richness of the albumin content, and the color may be amber, greenish, brightly sanguineous, or chocolate brown. The cystic fluid is of alkaline reaction, and contains, in addition to albumin, metalbumin, the presence of which is believed to be diagnostic. In a questionable fluid the absence of fibrin points to an ovarian cyst rather than to ascites. Urea and uric acid are sometimes found in considerable amount, and microscopic examination shows blood-cells and blood-pigment, degenerated epithelium, and often colloid masses. In an ovarian dermoid, hairs, squamous epithelium, fat, and cholesterolin are the significant findings.

Echinococcus cysts yield a clear alkaline fluid having a specific gravity usually not exceeding 1010, and containing a large amount of sodium chlorid, little or no albumin, a variable quantity of glucose, and, sometimes, inosite and succinic acid. The foregoing composition of the cyst fluid is greatly altered should it be contaminated by pus or by blood, in the event of which the diagnosis must be made entirely with the microscope. This shows distinctive echinococcus scolices, hooklets derived therefrom, and fragments of cyst membrane, with such minor findings as eosinophile cells, cholesterolin and hematoidin crystals, and fatty cells.

Fluid from *hydronephrotic cysts*, if uncontaminated, may be either clear and watery, or amber tinted and cloudy, and generally ranges in specific gravity from about 1010 to 1015. The detection of renal epithelium in the fluid is proof positive of hydronephrosis, while the presence of a considerable amount of urea and uric acid is suggestive, but not conclusive, since both these substances are commonly found in the contents of ovarian and pancreatic cysts, and urea is demonstrable in both inflammatory and mechanical effusions. Apart from these details, there is nothing to be learned from the microscopic examination.

From a *pancreatic cyst* of recent origin and rapid development one expects to obtain an alkaline fluid of low specific gravity and hemorrhagic character, containing a characteristic tryptic ferment, owing to the presence of which the fluid, despite its alkaline reaction,

has the property of digesting egg-albumen. This most distinctive proof of a pancreatic fluid is supplemented in some instances by the demonstration of diastatic and fat-splitting ferments, whose significance is, however, in nowise pathognomonic. In an old cyst the tryptic ferment is rarely obtained, for it tends to disappear as the lesion ages. Albumin, uric acid and urates, cholesterin, and blood-pigment are other common constituents of cysts of the pancreas.

Lumbar Puncture.—This procedure, popularized by Quincke, consists of tapping the subarachnoid space below the termination of the spinal cord, with the dual object, diagnostically, of obtaining a sample of cerebrospinal fluid for examination and of determining

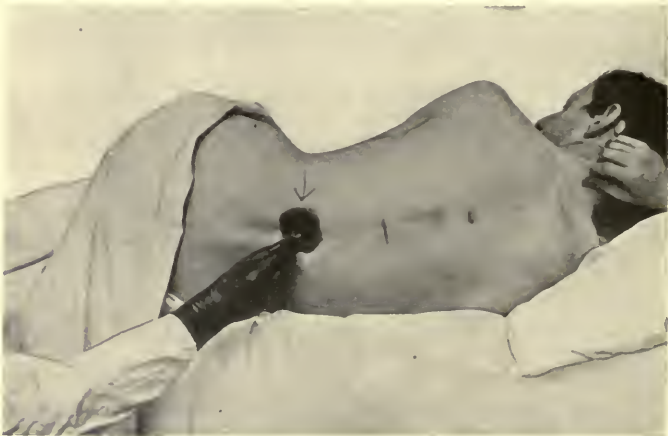


Fig. 19c.—Lumbar puncture. Inserting the needle in the fourth lumbar interspace.

the degree of intraspinal pressure. Therapeutically, lumbar puncture is a means of relieving undue cerebrospinal tension, of draining the spinal canal and irrigating it locally, of administering meningitis serum and salvarsanized blood-serum, and of producing spinal anesthesia. The puncture may be made either with a stilet needle devised for the purpose, or with an ordinary hollow needle of about 45 gage and three or four inches (7.5 to 10 cm.) in length.

The patient is placed in lateral decubitus, back toward the operator, with thighs flexed upon the abdomen and trunk bent well forward so as to widen the intervertebral spaces. Or the patient may sit facing the back of a chair, with the trunk arched passively forward and the arms and legs relaxed. General anesthesia

is usually indicated in young children, but in adults it is unnecessary. By preference the puncture is made between the spines of the fourth and fifth lumbar vertebræ, for here the spinal cord, terminating at the level of the second lumbar vertebra, cannot be lacerated. The fourth lumbar interspace is crossed by a horizontal line connecting the highest points of the two iliac crests. At this level and at a point about one-half inch (1.25 cm.) to one side of the midspinal line the needle is thrust through the skin and cautiously pushed upward and inward until it enters the spinal canal, at a depth varying from about $\frac{3}{4}$ inch to $1\frac{1}{2}$ inches (2 to 4 cm.) in children, to twice these distances in adults. As a rule, the fluid drips from the



Fig. 19d.—Lumbar puncture. Collecting the cerebrospinal fluid after paracentesis.

needle as soon as the point enters the subarachnoid space, and can be collected in a sterile tube as it flows out, drop by drop. If aspiration be necessary, the suction must be very slow and gentle, for fear of mechanically injuring the delicate spinal structures. Danger of damage by the needle's point is minimized by using a flexible rubber coupling between the mouth of the needle and the syringe. A "dry tap" may sometimes be made productive by cautiously withdrawing the needle a short distance and reinserting it, by moving the patient's head and neck backward and forward and straightening the spine, or by passing a sterile wire through the bore of the needle to dislodge clots and fibrin flakes therein. The pressure of the

cerebrospinal fluid is roughly estimated by noting the velocity with which the first few drops escape from the open end of the needle, hypotension being indicated by a forceless dribble, and hypertension by a streaming forth, of the fluid. Deviations from the normal pressure (about 5 to 7 mm. Hg.) are detected accurately by a small mercury manometer. When the operation is finished and the needle withdrawn, the puncture wound is dressed with sterile gauze or sealed with cotton and collodion, and the patient kept in bed for the ensuing twenty-four hours or longer.

Normal cerebrospinal fluid, of which from 5 to 10 c.c. ordinarily can be withdrawn by lumbar puncture, is an alkaline fluid of low specific gravity (1006 to 1008), and having the transparent, limpid appearance of distilled water, or, less commonly, being of a faint yellowish hue. It contains a small amount of protein, chiefly in the form of serum-globulin, and also chlorids, traces of urea and cholin, and a copper-reducing substance akin to, if not identical with, glucose. Microscopically, an occasional endothelial cell and leukocyte, and often numerous erythrocytes, derived from the puncture, are found.

The *volume* of the fluid is generally increased, in some cases even a hundredfold, and its flow proportionately accelerated, in meningitis, hydrocephalus, intracranial tumor, paresis, and certain infectious diseases. It may be blood streaked as the result of apoplexy, turbid and yellow in purulent meningitis, yellowish-green in jaundice, and delicate blue after the administration of methylene-blue. The specific gravity of the fluid rises decidedly as the consequence of meningeal inflammation, and it is usually higher than normal in paretics. The *chemic composition* of the fluid deviates from the normal in certain disorders, and, in general terms, such variations are of diagnostic utility. The protein content, which tends to rise after repeated tapings, may also be excessive in lesions responsible for a large increase in the cellular elements of the fluid, but it cannot be held that the protein-cell relation is always constant or proportionate. Albumin is appreciably increased in purulent meningitis, paresis, intracranial tumor, and apoplexy. An undue amount of cholin in the cerebrospinal fluid indicates disintegration of nerve tissue, and in general paresis, epilepsy, multiple sclerosis, alcoholic neuritis, and beri-beri this product of decomposition is commonly encountered. The chlorids are diminished in uremia (Carrière), and in this intoxication there is usually an increase of the urea, albumin, phosphates, and sulphates of the fluid. The reducing agent normally present in the cerebrospinal fluid is frequently absent in

pyogenic meningitis and in cerebrospinal meningitis, but in the acute stages of tuberculous meningitis and in poliomyelitis it is demonstrable. In diabetes mellitus, as a rule, this substance is decidedly increased, usually in close relation to the degree of glycosuria.

The potassium content of the cerebrospinal fluid obtained before death is in general higher in acute than in chronic lesions of the cerebrospinal system, but no relation exists between the potassium content and the cellular richness and globulin reaction of this fluid (Rosenbloom; Andrews).

Cyodiagnosis is of some value in differentiating certain acute and chronic types of meningeal disease. Thus, when the clinical picture suggests acute meningitis, a lymphocytosis implies tuberculous as the factor, rather than the meningococcus, pneumococcus, streptococcus, staphylococcus, or other bacteria, in all of which a polynucleosis is the rule. Meningitides of long standing and those nearing recovery cannot, however, be judged by this criterion, for in such instances there is ordinarily a definite lymphocytosis. In cerebrospinal syphilis, tabes, paresis, uremia, and other lesions that excite infiltration of the meninges a lymphocytosis is also to be expected. In view of the foregoing facts it is obvious that cyodiagnosis of the cerebrospinal fluid can be relied on only when interpreted in relation with all the other clinical findings of the case in question. The detection of cancer-cells in the cerebrospinal fluid has led to the antemortem diagnosis of carcinoma of the central nervous system (Widal). The presence of many erythrocytes and lymphocytes in a yellowish fluid of high coagulability is a syndrome suggestive both of dural sarcoma and of meningomyelitis.

Bacteriologic examination of the cerebrospinal fluid includes the microscopic study of stained cover-glass films prepared from the centrifugalized sediment, supplemented, in appropriate cases, by suitable cultural methods. Thus one can differentiate with absolute surety true meningococcus cerebrospinal fever from meningitides due to the streptococcus, staphylococcus, pneumococcus, tubercle bacillus, and other bacteria. The offending bacterium can usually be identified by direct examination of the stained specimen, animal inoculation being called for only exceptionally. Even in tuberculous meningitis, contrary to current belief, the tubercle bacillus is found in from 75 to 90 per cent. of all cases, if the spreads be made from the delicate coagulum of the fluid (G. Canby Robinson). In pneumonia Rohdenburg reports a high percentage (87 per cent.) of positive cultures in fatal cases, with a fair proportion (34 per cent.)

in those recovering. In trypanosomiasis the *Trypanosome gambiense* persists in the spinal fluid long after it has been driven from the blood and the glands by the use of atoxyl.

The presence of a positive Wassermann reaction in the cerebrospinal fluid is of great value in the diagnosis of syphilis of the central nervous system, and in paresis and tabes a positive colloidal gold test is helpful.

Visceral Paracentesis.—Exploratory puncture of the *spleen* has become a routine clinical measure among those who deal with tropical splenomegaly and with obscure malarial infections, and the procedure is also of great utility in certain cases of abscess and of hydatid disease. In enteric fever splenic puncture is scarcely justifiable, in view of the adequacy of other less perilous methods of diagnosis. Hemophilia and active congestion of the organ forbid splenic puncture. Using a very delicate hollow needle (not larger than 56 gage), the spleen is pierced either through the tenth left intercostal space in the midaxillary line, or, if it be greatly enlarged, at a convenient point below the left costal margin. During the operation, which must be done quickly, the patient should hold his breath, so as to minimize the risk of tearing, with the point of the needle, the parenchyma of the organ or its capsule. These possible accidents, which may be followed by hemorrhage, peritonitis, and even splenic rupture, are more prone to occur when the spleen is soft and friable, as in enteric fever, than when it is hard and compact, as in ague cake.

Puncture of the *liver* is generally made under general anesthesia, the organ being entered by a very fine needle passed through a right lateral or posterior interspace, well below the upper level of hepatic flatness, *i. e.*, the seventh or eighth interspace in the right axillary space. Hepatic puncture has settled the diagnosis in many a case of pyogenic or amebic abscess, and of echinococcus infection of the liver; it should not be attempted in acute yellow atrophy, nor under the circumstances noted above as contraindications to puncture of the spleen.

Puncture of the *kidney* is attempted only when a large renal swelling can be made out just beneath the abdominal wall, exploratory laparotomy being a more satisfactory means of inquiry in most instances.

Puncture of the *lung* is occasionally helpful in detecting and in orienting pulmonary and bronchiectatic cavities, and in obtaining therefrom secretion for laboratory examination. For this purpose a long, fine needle and aspiration syringe should be used, the puncture being made where the surface signs suggest an excavation, the subject

meanwhile controlling thoracic movement. If the needle-point, after penetration of the lung, can be freely swept through a considerable arc, a large cavity is suggested, though a surer guide is the aspiration of a large amount of offensive secretion; if, however, the patient has freely expectorated just before the paracentesis is made, a cavity may yield no fluid whatever. A bronchial or pulmonary cavity, rather than empyema, is indicated by the aspiration, from a comparatively deep level, of a mixture of air and mucopus containing elastic fibers and other microscopic evidences of tissue disintegration.

FLUOROSCOPY AND RADIOGRAPHY

Examination by means of the Röntgen ray, though more often corroborative of other findings than primarily diagnostic, has a distinct place in physical diagnosis which no student of this subject can afford to ignore. The average internist cannot hope, nor does he desire, to have more than a bowing acquaintance with *x*-ray technic, but it is highly desirable that his familiarity with radiosopic shadows and radiographs should be sufficiently thorough to permit intelligent association of his clinical impressions with the views of the trained specialist in *x*-ray work.

Technic.—Detailed consideration of *x*-ray *technic* and of the risks inseparable therefrom is not germane to the plan of this book, and for this information treatises dealing with this highly specialized subject should be consulted. It may, however, be stated that the equipment required for this work includes some source of electric current, derived from an ordinary incandescent-light service, from a storage battery, or from a static machine; a coil capable of converting this current into one of greatly increased power (save when the electric supply is generated by a static machine); and an *x*-ray tube, consisting of a glass vacuum bulb inclosing a positive and a negative pole, made of platinum and wired to the current generator. The current, passing through the tube, jumps the vacuum gap from the positive to the negative pole, and produces luminous rays having the property of penetrating ordinarily opaque substances and of creating shadows visible with the aid of a fluoroscope, and permanently recordable upon a sensitized photographic plate.

Fluoroscopy.—The fluoroscope, devised for the direct inspection of the shadows during röntgenization, consists of a pyramidal hood with an apex provided with an opening for the observer's eyes and a base made of a fluorescent screen which becomes luminous when acted upon by *x*-rays. With the area to be examined interposed

between the *x*-ray tube and the fluoroscope the shadows cast by dense substances within the body cavities and other parts are clearly visible upon the surface of the luminous screen. The examinations should, of course, be conducted in a dark-room, in which the examiner ought to remain long enough to acquire a keen perception of faint shadows, before attempting to judge them with the fluoroscope.

Radiography.—Except when effusions are being investigated, in which event the upright position is preferable, radiographs of the chest and abdomen are made with the subject in recumbency, the body being turned so as to bring the lesion to be photographed directly over a sensitized plate placed beneath the adjacent parietal parts. In thoracic work the scapulæ are to be swept outward by the patient clasping the hands over the head, and the subject cautioned to make as little respiratory movement as possible. The correct posture having been assumed, the *x*-ray tube is adjusted and the exposure made, the resulting negative and print therefrom being carefully examined, in the light of the other clinical findings, and with the aid of a skilled radiographer's opinion.

Applied to internal medicine, the Röntgen-ray is helpful chiefly in the examination of the thoracic organs, and in some instances lesions of the heart and great vessels, bronchopulmonary system, and mediastinum are revealed only by this means. In such examinations fluoroscopy is superior to radiography, for it is a comparatively simple procedure to inspect the chest contents with a fluoroscope, while a photographic negative takes longer to make, and, unless instantaneously exposed, is blurred by the cardiac and respiratory movements. In abdominal work, on the other hand, radiography usually gives more accurate data than the fluoroscope, but neither is dependable unless the gastro-intestinal tract is practically empty at the time of the examination. Recently great advances have been made in the differentiation of gastric and duodenal lesions by the study of serial radiographs made at fixed intervals after the patient's ingestion of a draft of bismuth-buttermilk. The *x*-ray's field of usefulness in abdominal diagnosis also includes the detection of calculi, especially of the kidney and of the urinary bladder, and, with less certainty, of the gall-bladder and ducts. The shape and size of the abdominal organs, as well as the presence of new growths that may invade them and other intra-abdominal structures, are also demonstrable by the *x*-ray.

The normal and pathologic *x*-ray pictures of the thoracic and abdominal organs, and their application to the diagnosis of special lesions, are referred to later, in connection with other physical signs.

THE TUBERCULIN REACTION

Here may be mentioned the several types of the tuberculin reaction observed in different forms of tuberculosis, and, properly employed, capable of serving as valuable, sometimes indispensable, clues in the diagnosis of obscure cases.

Koch's tuberculin test consists of the hypodermic injection of a definite quantity of tuberculin, whereby moderate fever and other systemic disturbances are produced in a tuberculous subject, whereas in a healthy person no appreciable symptoms arise. Ordinarily, this test is resorted to only after all other methods of diagnosis have failed, for there is always a possibility, remote though it be, that the injection of tuberculin, by profoundly depressing the body's resistance, may light up latent tuberculous foci. Koch's old tuberculin (T. O.) is generally used for diagnostic purposes, the conservative initial dose being 0.2 mg., which, if insufficient to cause a reaction, should be followed, at intervals of a few days, by successive doses of 1, 3, and 5 mg., until a reaction occurs. Experience has shown that if this routine be followed by negative results, no reaction will occur with the higher dosage (10 mg.) advocated by some investigators. A positive reaction occurring after a second or a third injection has not the same clinical value as a primary positive finding, for the first injection may, by a sensitizing process, cause a non-tuberculous subject to react.

The criterion of a positive tuberculin reaction is fever, which should amount to at least $1\frac{1}{2}^{\circ}$ F. within from ten to twenty-four hours after the injection; such by-effects as rigors, aching, nausea, vomiting, and hemoptysis, while suggestive, do not constitute, in the absence of a rise of temperature, a positive reaction. As a rule, the subject's fever and indisposition disappear within from twenty-four to thirty-six hours after their onset.

The **cutaneous tuberculin test** of von Pirquet relates to an afebrile local reaction produced in the tuberculous subject by inoculation of the skin with tuberculin, after the manner employed in cow-pox vaccination. The "vaccine" consists of Koch's old tuberculin, diluted with 1 part of a 5 per cent. solution of carbolic acid in glycerin and 2 parts of normal saline solution. Two drops of this mixture are placed on the skin of the arm, about 2 inches (5 cm.) apart, and through each drop an abrasion is made by means of a sterile needle. A control inoculation is then made in the neighborhood with normal saline solution. If the reaction be positive, the site of inoculation will show, within twenty-four or forty-eight hours, an areolated

papule about one-half inch (1.25 cm.) in diameter, and of a bright red color, which later deepens, and, fading during the course of a few days, sometimes leaves a pigmented area at its site. Rarely, turbid vesicles appear, and occasionally a small urticarial patch springs up at the point of inoculation. The control inoculation, of course, shows none of the changes just noted.

Von Pirquet's test is of little practical value in diagnosing tuberculosis in the adult, since positive reactions are not unusual in those who have passed the age of puberty, despite the fact that the subject is symptomatically free from all tuberculous taint. This is as one would expect, since few of us reach this period of life without having been at some time infected with Koch's bacillus. In children the test is more useful, and its value increases in direct relation with the youth of the child. From these remarks it is obvious that the cutaneous reaction is a delicate indicator of latent tuberculosis, in which, it must be added, positive results are obtained much more constantly than in active lesions.

Calmette's ophthalmoreaction is the specific conjunctivitis excited by the instillation of a weak solution of tuberculin in the eye of a tuberculous subject, no such reaction being produced by this test in a person free from tuberculous taint. One minim of a c.5 per cent. glycerin-free solution of dry tuberculin¹ is dropped into the inner canthus of the eye, whereupon, if the subject be tuberculous, acute congestion of the conjunctiva, with redness and swelling of the lacrimal caruncle, develops, usually within from three to six hours after the instillation, and, finally, in intense reactions, the conjunctival surfaces become bathed with a profuse puriform exudate within the next six hours or so. In the exceptional instance both eyes are inflamed (S. H. Long). The inflammation thus produced generally abates within twenty-four or thirty-six hours, and entirely disappears by the end of three or four days. It is attended by free lacrimation and by a sensation of moderate heat and burning in the instilled eye. The ophthalmoreaction is contraindicated by any sort of ocular lesion whereby the integrity of the eye is impaired, nor is it to be employed when there is reason to suspect a very active form of tuberculosis, for here the unduly low conjunctival resistance plus the irritant effect of the tuberculin might lead to serious local damage. The aggravation of a preëxisting ocular lesion by the instillation of

¹The test solution is marketed in glass capsules, and also in the form of discs, one of which, dissolved in 1 c.c. of sterile water, makes a 1 per cent. solution. For fear of exciting too violent a reaction it is better to use a tuberculin solution of one-half this strength.

tuberculin may result in violent conjunctivitis, iritis, corneal ulceration, or pannus.

The intensity of the reaction has no fixed relation to the severity of the tuberculous infection: incipient and mild cases rarely fail to react, while only about 50 per cent. of severe infections are positive. A positive reaction obtained at a second test, in the eye unaffected by the primary instillation, is of no clinical value whatever, for under such circumstances the development of conjunctivitis indicates merely the local sensitizing action of the earlier instillation, whereby the conjunctiva may react to tuberculin, even if the subject be perfectly healthy. Conjunctival congestion, it is interesting to note, is lighted up by the subcutaneous injection of tuberculin in a patient having recently reacted to the ophthalmic test.

Moro's reaction consists of the eruption of pale or of red papules over a cutaneous area after the application thereto of an ointment made of 5 c.c. of old tuberculin and 5 gm. of anhydrous wool-fat. A reaction of this sort has virtually the same significance as a positive von Pirquet's test.

SECTION II

EXAMINATION OF THE THORAX

CLINICAL ANATOMY

THE thorax consists of a bony framework formed by the sternum, the ribs, the vertebræ, and their cartilages, invested by a musculature of varying density; it incloses the esophagus, trachea, bronchi, lungs, heart, and great vascular trunks, and surrounds at its base the important viscera of the upper part of the abdominal cavity. The bony thorax is shaped like a truncated cone, whose superior aperture is

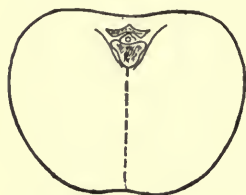


Fig. 20.—Transverse section of a normal adult thorax.

formed by the upper border of the sternum, the first ribs, and the first thoracic vertebra, the inferior aperture being floored by the diaphragm. A cross-section of the normal adult thorax is elliptical (Fig. 20), the transverse axis being decidedly longer than the anteroposterior; in the young child, however, the two axes are practically equal, and this is also the case in certain types of chest deformities

resulting from pathologic processes. (See *Pathologic Types of Thorax*, p. 77.)

The average vertical measurement of the normal chest is 13 inches (32.5 cm.) in men, and 11.8 inches (29.5 cm.) in women, the anteroposterior diameters being 7.7 and 7 inches (19.2 and 17.5 cm.), and the transverse diameters 10.5 and 9.8 inches (26.2 and 24.5 cm.) for the respective sexes (Bessenen). Fourmentin's "thoracic index" (anteroposterior diameter \times 100 \div transverse diameter) equals, in the normal man, 72 (Woods Hutchinson). The normal chest expansion varies from 1½ to 4 or 5 inches (3.8 to 10 or 12.5 cm.), while the circumference, according to Otis's measurements, averages 34 inches (85 cm.) in men and 29.5 inches (73.7 cm.) in women. The respiratory capacity of the average male thorax is approximately 3.3 liters (201 cubic inches), or about 20 c.c. for each centimeter of stature.

A perfectly symmetric chest is rare, although conspicuous deviations from the normal contour are seldom met with, except in those who have acquired local muscular overdevelopment, usually as the result of their occupation or a similar cause. The one-sided chest fulness of the blacksmith and of the iron puddler and the drooping shoulder of the hod-carrier are familiar types of this sort of asymmetry. Aside from such influences, however, the right half of the chest is generally somewhat larger than the left half in right-handed persons, and there are few adults, even in perfect health, that do not show a moderate dextral inclination of the dorsal spine. In those who are left-handed the asymmetry is, of course, left sided.

NORMAL LANDMARKS

Study of the thoracic organs is facilitated by the use of the normal landmarks, bony and muscular, upon the walls of the chest, as well as by the aid of a number of arbitrary lines drawn upon its surface. Having detected a given sign, it is first oriented in a certain area of the thorax, and then more accurately localized by determining its precise relation to one of these fixed anatomic landmarks and to a surface line. For example: "A systolic pulsation in the fifth left intercostal space, one-half inch to the right of the left midclavicular line," technically describes the situation of the normal apex-beat of the heart.

The *clavicles* are conspicuous landmarks upon the anterior chest-wall: a moderate prominence of these bones is not incompatible with good health, and even bilateral deepening of the fossæ above and below the collar-bones may exist, without the slightest implication of the pulmonary apices. Unilateral depression in one of these regions, on the contrary, is extremely significant of an apical lesion, especially if the sunken area expands laggingly and imperfectly during respiration. The sternal ends of the clavicles correspond to the level of the disc between the second and third thoracic vertebræ. The depressed area below the junction of the middle and outer thirds of the clavicle, between the pectoralis major and the deltoid muscles, is known as *Mohrenheim's fossa* (Fig. 21).

Lloyd Jones has noted that in right-handed adults the right clavicle is tilted more than the left, that in the left-handed the left clavicle is tilted more than the right, and that in the ambidextrous the clavicles slope equally.

The *sternum*, bounded above by the suprasternal notch and below by the "pit of the stomach" (scrobiculus cordis), is the seat of two important surface-markings: the *angle of Louis* (angulus Ludovici) and the *xiphisternal joint* (Fig. 21). The angle of Louis

is a transverse ridge, always palpable and usually visible, formed by the articular surfaces of the manubrium and the gladiolus, and corresponding in front to the level of the second costal cartilage, and behind to the third thoracic vertebra. Since this prominence indicates the position of the second rib, it serves as an accurate landmark in counting the ribs. The xiphisternal articulation (Fig. 21) is situated just below the sternal end of the seventh costal cartilages and corresponds to the disc between the ninth and tenth thoracic vertebrae.

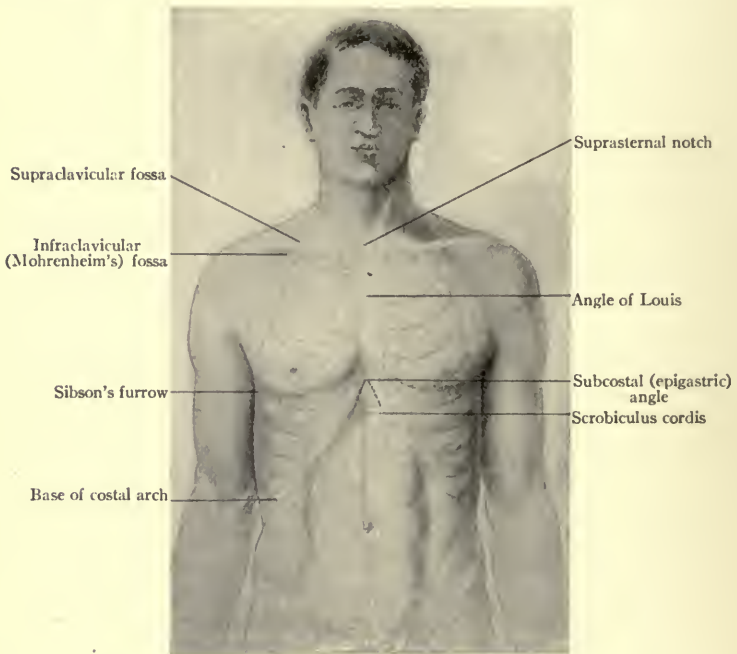


Fig. 21.—Normal thoracic landmarks

The *ribs* and *intercostal spaces* are usually taken as the horizontal topographic lines, the number of an interspace being that of the rib immediately above it. Owing to the obliquity of the ribs, their sternal ends are at a lower level than their vertebral: the first rib in front is in the plane of the fourth rib behind, and the anterior level of each of the next five ribs (second to seventh, inclusive) corresponds to the posterior level of the fourth rib below it. The first seven (true) ribs articulate individually with the sternum, but the lower five (false) lack this direct attachment to the breast-bone. In the well-developed adult the ribs are visible only upon the lateral walls of the lower

chest. The upper ribs run horizontally outward from their sternal attachments, but as the epigastrium is approached their obliquity increases, so that the *epigastric* or *subcostal angle*, formed by the substernal divergence of the costal margins, is approximately an angle of 70° (Fig. 21). With inspiration the subcostal angle is more obtuse than with expiration, owing to the exaggerated obliquity of the ribs during the latter period of breathing.

In counting the ribs on the *anterior chest-wall* Louis' angle and the lower border of the pectoralis major muscle (Sibson's furrow) are accurate indices to the second and the fifth ribs, respectively. It is much easier to find the first rib by counting upward from the former landmark than by direct palpation backward and downward under the clavicle. The lowest part of the costal arch corresponds to the cartilage of the tenth rib. *Laterally*, the highest visible slip of the serratus magnus muscle is a guide to the fifth rib. *Posteriorly*, the scapula extends from the second to the seventh rib inclusive, the inner end of its spine being at the level of the third thoracic spine and its inferior angle corresponding to the seventh thoracic vertebra. The scapulæ do not stand out prominently from the normal thorax, but lie snugly against it. The "scaphoid scapula" (Graves), with concave vertebral borders, is generally considered a normal variation and not a developmental anomaly, as formerly believed. Other bony landmarks useful in counting the ribs in the back are the seventh cervical vertebral spine (*vertebra prominens*), directly below which is the joint of the first thoracic vertebra and the first rib. The free tips of the eleventh and twelfth (floating) ribs correspond to the spines of the eleventh and twelfth thoracic vertebræ, and are palpable outside the erector spinæ muscles. Each thoracic spine from the second to the ninth inclusive corresponds in number to that of the rib next below it serially; the tenth spinous process is opposite the tenth interspace.

The upper intercostal spaces, of which the second usually is the widest, are readily palpable, especially in front, but it is sometimes a difficult matter to feel the lower interspaces, owing to their narrowness.

The *nipple* in a man usually lies between the fourth and the fifth ribs, about 4 inches (10 cm.) from the center of the sternum. A woman's nipple is situated somewhat below the center of the mammary gland, which covers the chest-wall from the second to the sixth or seventh ribs, and from the sternal border to the anterior limit of the axilla. The female nipple is not a reliable surface-marking, owing to the variable size and shape of a woman's breast.

TOPOGRAPHIC LINES AND AREAS

In connection with the foregoing anatomic landmarks the clinician makes use of a number of imaginary vertical lines, drawn parallel to the long axis of the torso, these lines, in their order from sternum to spine, being as follows:

The *midsternal* (anterior median) *line*, passing through the middle of the sternum, from the cricoid cartilage above to the tip of the xiphoid appendix below. Prolonged downward, this line divides the abdomen laterally and ends in the middle of the symphysis pubis.

The *sternal* (lateral sternal) *line*, paralleling the lateral border of the sternum, and continuous below with the line of the costal arch.

The *parasternal line*, drawn midway between the sternal line and

The *midclavicular* (mammillary, nipple) *line*, let fall from the middle of the clavicle. Projected downward this line crosses the costal arch at the level of the ninth costal cartilage, and is continuous with the vertical Poupart line, which terminates in the middle of Poupart's ligament. This line, although commonly termed "mammillary," rarely passes through the nipple, frequently running wide of this point in the male, and almost invariably doing so in the female.

The *anterior axillary line*, running downward from the anterior fold of the axilla.

The *midaxillary line*, drawn from the middle or apex of the axilla.

The *posterior axillary line*, dropped from the posterior fold of the axilla.

The *scapular line*, falling perpendicularly through the inferior angle of the scapula.


The *midspinal* (posterior median) *line*, corresponding to the middle of the spinal column.

For an ordinary clinical examination the ribs and interspaces are sufficiently definite horizontal landmarks, although in certain instances it may be advisable, for the sake of technical description, to localize a physical sign with relation to certain imaginary horizontal lines. Drawn across the long axis of the trunk, these lines may be indicated:

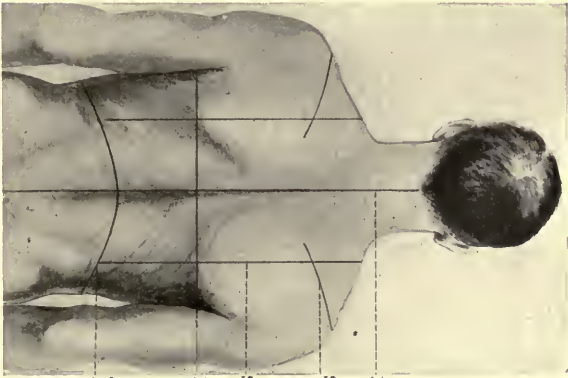
The *cricoclavicular line*, drawn from the cricoid cartilage of the larynx to the point upon the clavicle crossed by the upward projection of the anterior axillary line.

The *clavicular line*, following the course of the clavicles.

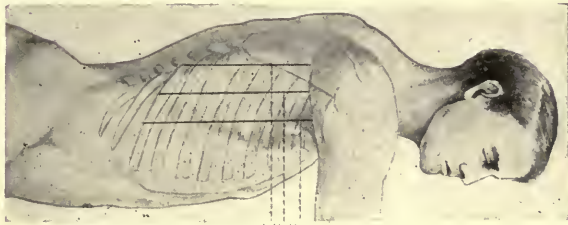The *third costal line*, drawn from the third chondrosternal articulation to the anterior axillary line.



Clavohavicular
 Clavicular
 Midsternal
 Sternal
 Parasternal
 Midclavicular
 Anterior axillary
 Third costal
 Sixth costal
 Costal arch
 Infracostal



Midsapinal
 Scapular
 spinal
 Scapular
 Infracapular
 Twelfth
 thoracic



Anterior
 Mid
 Posterior
 }
 Axillary

Fig. 22.—Topographic lines of the thorax.

The *sixth costal line*, drawn from the sixth chondrosternal articulation to the posterior axillary line.

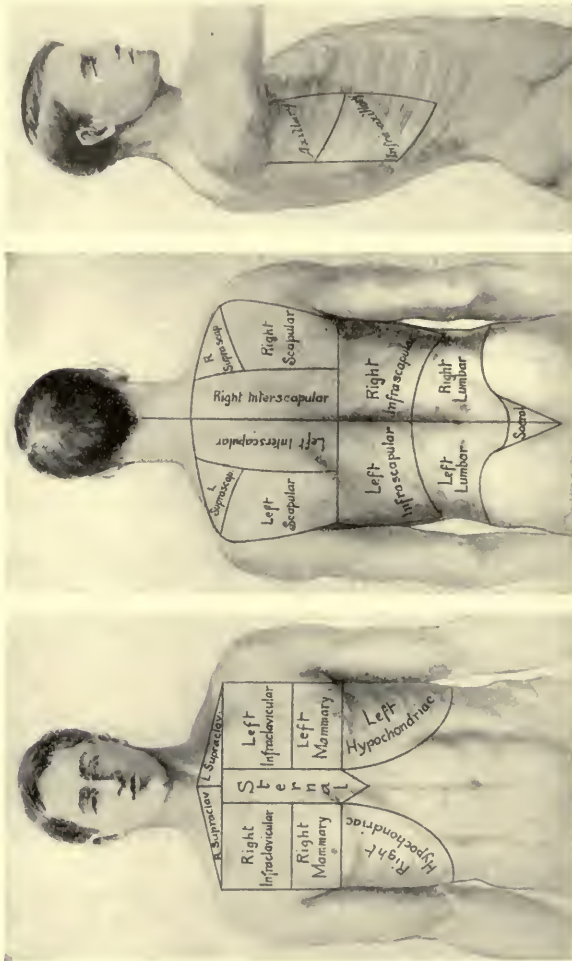


Fig. 23.—Topographic regions of the thorax.

The line of the *costal arch*, continuous with the sternal line and following the costal margin.

The *infracostal line*, connecting the lower borders of the tenth costal cartilages.

The *scapular spinal line*, corresponding to the spines of the scapulæ.

The *infrascapular line*, at the level of the inferior angles of the scapulæ.

The *line of the twelfth thoracic vertebra*, curving outward and downward from the spinous process of this bone to the posterior axillary line.

The following *topographic regions* (Fig. 23) may be mapped out upon the surface of the chest by the use of the foregoing lines:

The *sternal region*, corresponding to the sternum, extending vertically from the suprasternal notch to the tip of the xiphoid process, and horizontally between the sternal lines.

The *supraclavicular region*, or the triangular space over and above the clavicles, bounded externally by the cricoclavicular lines.

The *infraclavicular region*, bounded above by the clavicle, below by the third costal line, externally by the anterior axillary line, and internally by the sternal line.

The *mammary region*, lying between the third and sixth costal, and the anterior axillary and sternal, lines.

The *hypochondriac* or *inframammary region*, lying below the sixth costal line, being limited internally and below by the line of the costal margin, and externally by the anterior axillary line.

The *axillary region*, extending from the apex of the axilla to the sixth costal line.

The *infra-axillary region*, from the sixth costal line to the costal margin, the lateral boundaries of both axillary areas being the anterior and posterior axillary lines.

The *suprascapular* and the *scapular regions* overlie the supraspinous and the infraspinous fossæ of the scapula respectively; the *interscapular region* includes that part of the back between the scapulæ; and the *infrascapular region* extends, between the right and left posterior axillary lines, from the inferior scapular line to that of the twelfth thoracic vertebra.

PATHOLOGIC TYPES OF THORAX

Of the several types of bilateral abnormalities of the thorax, some are so constantly associated with definite diseases as to serve as almost certain clues to these conditions, while others betray simply retarded or erratic physical development. The first group includes the forms of chest peculiar to phthisis, to hypertrophic emphysema, to rickets, and to syringomyelia; the second group comprises those

observed in the thin, undeveloped individual and in the woman that laces too tightly.

The Phthisical Thorax (Pterygoid; Paralytic; Alar).—The typical chest of the phthisical subject appears long, emaciated, deficient in expansion, and often shows circumscribed areas of flatness and of retraction (Figs. 24 and 25). The common belief, current since the days of Galen, that the phthisical thorax is shallow and flat, is true of some cases, but in others, especially in those with lesions far advanced, the anteroposterior diameter is greater than normal

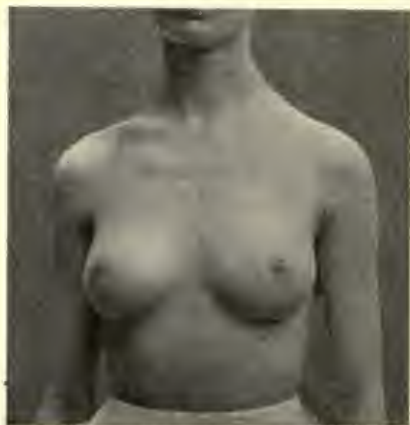

Fig. 24.—The thorax of incipient phthisis (Jefferson Hospital).

and the transverse outline of the chest deep and round (Woods Hutchinson) (Fig. 26).

The neck is likely to be long and slender, the larynx conspicuous, the clavicles prominent, and the supraclavicular and infraclavicular areas abnormally and unequally deep. The angle of Louis forms a prominent transsternal ridge, and the ribs, separated by unusually wide intercostal spaces, incline sharply downward from the sternum and as sharply bend upward again

as they approach the spine. The subcostal angle, owing to this increased obliquity of the ribs, is extremely acute. The shoulders generally slope, and the scapulæ, instead of hugging the back, stand out like a pair of wings—hence the term, “winged” or “alar” scapulæ. The chest showing the foregoing group of changes has also been labeled the “expiratory form of thorax.”

The phthisical thorax must not be mistaken for the emaciated chest of a patient convalescent from some acute febrile disease, such as enteric fever; in the latter instance, while the emaciation of the thoracic parietes may be striking, the chest does not show the slightest evidence of actual structural deformity.

The Emphysematous Thorax (Inflated, Barrel-chest).—The thorax of hypertrophic (large-lunged) emphysema is short, deep, overdistended, and frequently bulged out in the central portion, so that it conforms more or less to the shape of a cask—the so-called

“barrel-chest” (Fig. 27). This peculiarity is most striking when the emphysematous enlargement affects especially the upper pulmonary lobes, being less evident when the process is diffuse and when it implicates chiefly the lower part of the lungs. Fig. 29 shows a transverse section of the typical “barrel chest.”

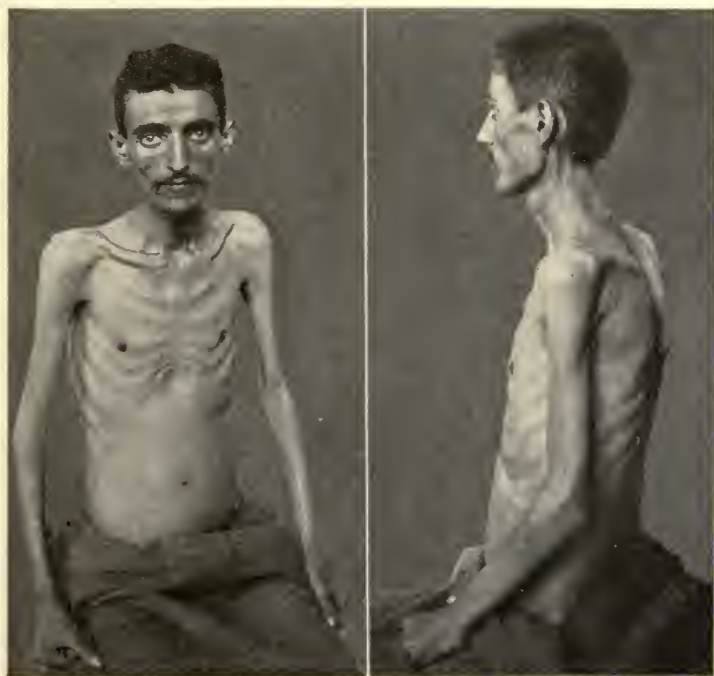

Fig. 25.—The thorax of advanced phthisis (Philadelphia General Hospital).

The neck is usually short and thick, and the shoulders elevated, squarely set, and bent forward. The angle of Louis is prominent, the sternum distinctly protruded, and the upper intercostal spaces widened, while those of the lower thorax are narrowed and drawn in during inspiration. The ribs run horizontally from the sternum, and in consequence the subcostal angle is obtuse. The respiratory movements of the emphysematous chest are highly characteristic, the excursion being

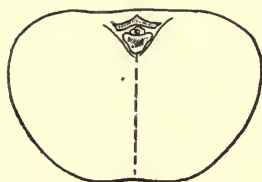


Fig. 26.—Transverse section of a phthisical thorax.

highly characteristic, the excursion being

vertical and rigid, as if all the structures of the thorax were welded together and rose and fell *en masse*.

The "inspiratory form of chest" is a term also applied to a thorax having these characteristics, and the presence of such a deformity is almost proof positive of hypertrophic pulmonary emphysema, although it must be borne in mind that these changes do not neces-

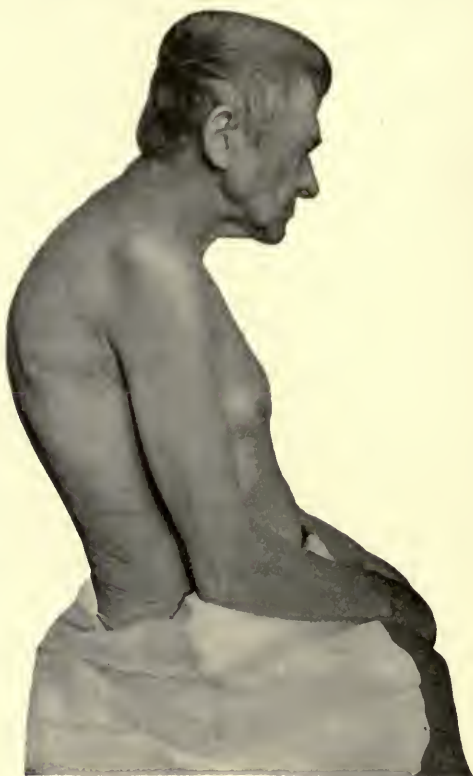

Fig. 27.—Emphysematous thorax (Philadelphia General Hospital).

sarily develop in every case. Kyphosis may superficially resemble the "barrel chest," but in ordinary "hump-back" the costosternal peculiarities and the vertical type of chest movements are absent.

The Thorax of Atrophic Emphysema.—This is the small, contracted type of chest met with in subjects of atrophic (small-lunged) emphysema, and is the direct consequence of senile atrophy of the lungs. The thorax is abnormally diminutive, shallow, and peculiarly

deformed by bowing of the shoulders, by depression of the sternum, clavicles, and ribs, by exaggerated costal obliquity, and by narrowing of the lower interspaces. The respiratory excursion is greatly

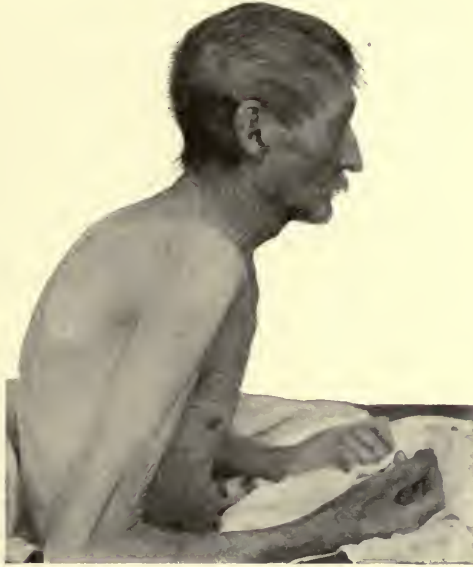

Fig. 28.—The thorax of atrophic emphysema (Jefferson Hospital).

restricted, for the chest-wall is rigid, and inspiratory sucking in of the supraclavicular and the intercostal spaces may occur. The musculature of the chest is generally wasted and flabby, in keeping with the other marks of senility shown by the patient.

The Rachitic Thorax.—In rickets the causes of the chest deformity are threefold: direct muscular action upon the soft bony structures, pressure upon these parts by the enlarged viscera, and the influence of atmospheric pressure. These combined factors tend to produce lateral compression, with relative increase in the anteroposterior diameter of the thorax, and to favor the formation of various local flattenings, prominences, depressions, and lineal markings upon its

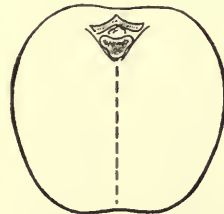


Fig. 29.—Transverse section of an emphysematous thorax.

surface. Fig. 31 illustrates a cross-section of a common type of rachitic chest.

The most distinctive single sign of rickets is the so-called *rachitic rosary*, which consists of a beaded line paralleling each sternal border

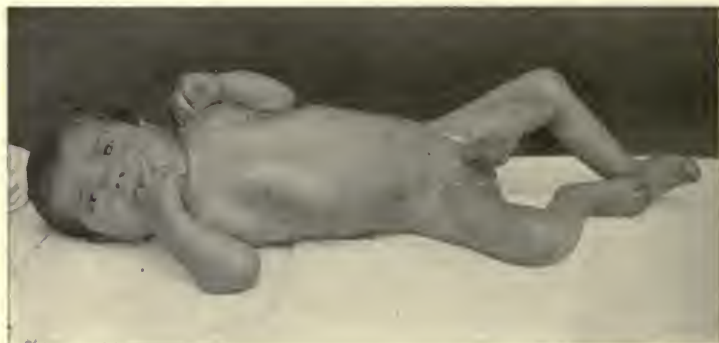

Fig. 30.—The rachitic thorax (Jefferson Hospital).

and corresponding to the course of the chondrosternal articulations. This double line of prominences, due to thickening of the costal cartilages, is to be felt in almost every rickety child, and in advanced cases it is also clearly recognizable on inspection. Another important sign of rickets, and one scarcely less characteristic than the rosary, is an apparent shortening of the clavicles, with a marked exaggeration of their curves.

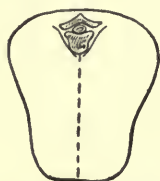


Fig. 31.—Transverse section of a rachitic thorax.

Prominence of the thoracic spine (*kyphosis*) is a familiar type of vertebral deformity, and frequently the vertebral column is bent forward (*lordosis*) and twisted laterally (*scoliosis*) (Fig. 32). In some cases the spine remains flexible, but in others it is found to be fixed and rigid. The vertebræ may or may not be thickened, and sometimes they are studded with sharply pointed, conspicuous spinous processes.

The **pigeon-breast** (**chicken-breast**; **pectus carinatum**; **keel breast**) is a common type of deformity met with in advanced rickets (Fig. 33). The anteroposterior diameter of the chest is unduly increased, the lateral thoracic walls are compressed, the sternum is pushed forward so that it projects like the keel of a ship, owing to

the stress upon the flexible chondrosternal joints (Fig. 34). The

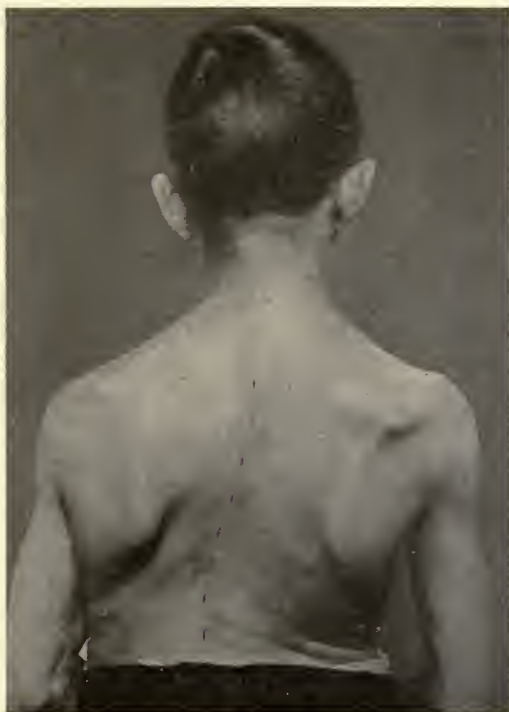

Fig. 32.—Thoracic deformity due to spinal curvature (Jefferson Hospital).

lower margins of the ribs are often distended or flared outward, partly by the intra-abdominal pressure exerted by such factors as ascites, tympanites, and enlarged liver and spleen, and partly by the traction of the diaphragm. A transverse groove, or furrow, extending from either side of the ensiform cartilage and curving downward and outward toward the axillæ is also found in most cases of rickets; this furrow corresponds approximately to the insertion of the diaphragm, and is known as *Harrison's sulcus* or *furrow*.

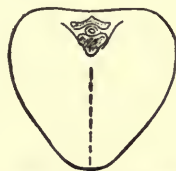

Fig. 33.—Transverse section of a pigeon-breast.

The **funnel-breast** (*Trichterbrust*; *pectus excavatum*) is also sometimes found in rickets, especially when adenoid and tonsillar

hypertrophies coëxist. It is characterized by a depression of the lower part of the sternum, extending from the tip of the xiphoid, perhaps as high as the middle of the gladiolus. This deformity is not essentially rachitic, for it may be congenital, secondary to non-rachitic diseases, or acquired as the result of pressure upon the lower sternum. The funnel-breast of the cobbler (*Schusterbrust*), due to constant pressure of the last against the lower part of the sternum,

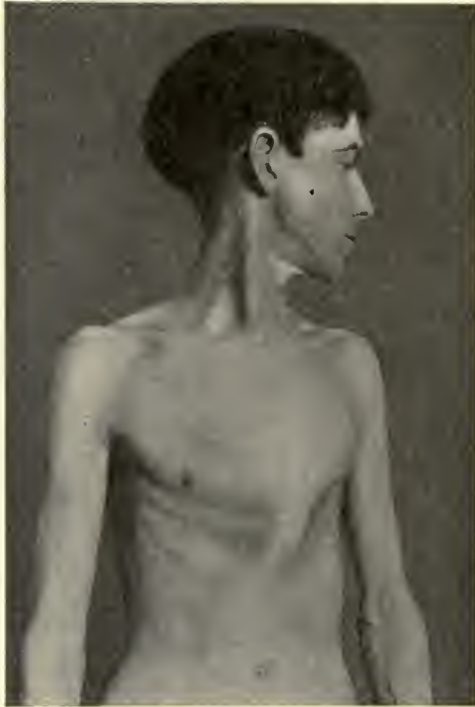

Fig. 34.—The pigeon-breast (Jefferson Hospital).

shows a concavity limited to the lower gladiolus and to the ensiform, if not to the latter process alone (Fig. 35).

The Flat Thorax.—This type of thorax is shallow and broad, although the length is not abnormally increased. It is distinguished chiefly by the conspicuous flatness and breadth of the anterior chest-wall and by the absence of the normal

forward curve of the ribs, but the structural peculiarities of the phthisical thorax, noted above, are lacking. To be flat-chested does not necessarily condemn one to phthisis, but it is at least suggestive of a predisposition to this disease.

The Fusiform Thorax.—Habitual tight lacing narrows and elongates the thorax, immobilizes the lower ribs, and contracts their intercostal spaces. In consequence of this compression

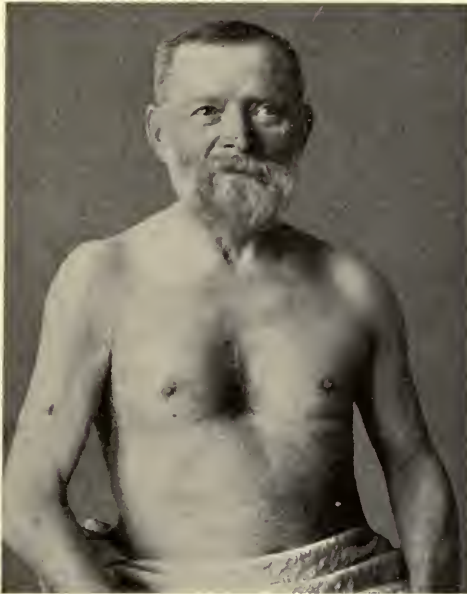

Fig. 35.—Funnel-breast, due to the pressure of a cobbler's last (Philadelphia General Hospital).

of the lower thorax the chest loses its normal conic shape, and is molded into a more or less fusiform or spindle-shaped structure, the waist-line decreases in circumference, and is lowered at the expense of the flanks, the vertical extent of which is considerably lessened. Exaggerated upper thoracic breathing, upward displacement of the thoracic organs, ptosis of the abdominal viscera, and atrophy of the spinal muscles are the principal structural changes which, in the extreme instance, may result.

The Boat-shaped Thorax.—In syringomyelia there may be noted a median depression of the upper anterior wall of the thorax, extending as far downward as the level of the fifth rib. The chest, hollowed out in this manner, has been termed the “*thorax en bateau*” by Marie, from its rude resemblance to a boat.

The Thorax of Progressive Muscular Atrophy.—In the adult this myopathy may account for a most singular deformity, the thorax being converted into a roughly box-shaped structure whose perpendicular walls project some distance beyond the surface of the flanks, which are immoderately concave. The waist, having an atrophied musculature, contrasts strikingly with the contour of the chest, and appears abnormally constricted and slender—the “*taille de guêpe*” (“wasp waist”) of Landouzy and other French writers. Other hall-marks of this type of thorax are loss of the normal curve of the chest-walls, extraordinary obliquity of the ribs, especially at the base, where their course is almost vertical, and general wasting of the thoracic muscles.

The Gutter-chest.—As the result of antenatal and postnatal developmental defects the chest may be disfigured by the presence of a narrow, shallow, vertical gutter or groove corresponding to the median line of the sternum. This peculiarity, dubbed the “*thorax en gouttière*” (Féré; Schmidt), is due to an exaggerated forward convexity of the costal cartilages, owing to which their sternal extremities are closely approximated and the sternum pressed backward so as to form a narrow longitudinal median furrow.

LOCAL ASYMMETRY OF THE THORAX

Aside from the foregoing bilateral thoracic deformities, there are various defects of contour that may affect either one entire side or a circumscribed area of the chest. The anomalies due to lesions of the thorax and of the upper abdomen, described in the four groups given below, are to be distinguished from those secondary to disease of the spine, the consideration of which belongs to the subject of orthopedic surgery.

Unilateral Bulging (Fig. 36).—Enlargement of one side of the thorax generally produces a leveling or a bulging of the intercostal spaces on the affected side; indeed, this obliteration of the interspaces may exist alone, and, if so, carries practically the same significance as an actual overdistention of the chest. Fig. 37 shows

the outline of this type of thoracic deformity. One-sided distention is met with in large pleural effusions, in pneumothorax, in neoplasms

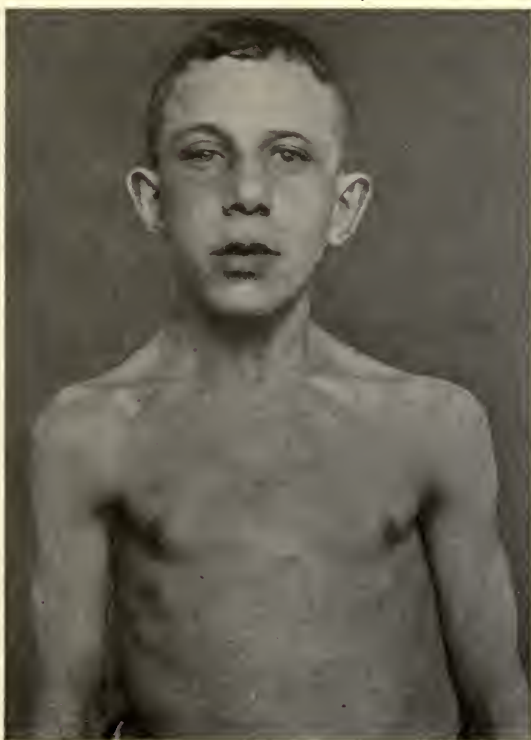

Fig. 36.—Unilateral enlargement of the thorax (Jefferson Hospital).

of the lung and the pleura, and in compensatory emphysema of the lungs secondary to lesions of the opposite side. If due to this last

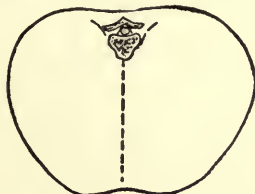


Fig. 37.—Transverse section of a unilaterally enlarged thorax.

cause, the contrast between the two halves of the chest is espe-

cially striking, for here the emphysematous distention is brought into comparison, not with a normal opposite side, but with a shrunken, diseased one.

Unilateral Contraction (Fig. 38).—Unilateral flattening or contraction of the chest, if extensive, causes lowering of the

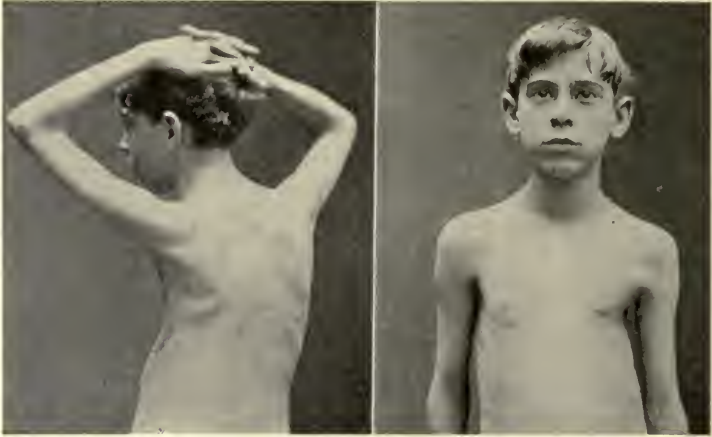

Fig. 38.—Unilateral retraction of the thorax due to empyema (Jefferson Hospital).

shoulder and narrowing of the intercostal spaces on the affected side, together with more or less spinal curvature and twisting in this direction. The contracted side is smaller than normal, while the opposite side is often found to be vicariously enlarged

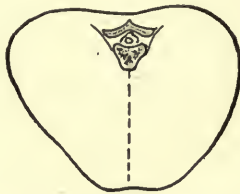


Fig. 39.—Transverse section of a unilaterally retracted thorax.

(Fig. 39). Chronic pulmonary tuberculosis, interstitial pneumonia, wide-spread pleural adhesions, and chronic compression of the lung by pleural effusions are the most important factors of this sort of deformity. In rare instances unilateral contraction of the thorax may arise from pulmonary collapse due to the obstruction of a main bronchus by a tumor or by a foreign body.

Circumscribed Prominences.—Local swellings or prominences upon the chest-wall, attributable to a wide range of causes, are seen most commonly upon the anterior surface, but they are by no means restricted to this part of the thorax. Bulging in the cardiac region (Fig. 40) may mean enlargement of the heart, pericardial effusion, pneumopericardium, or forward dislocation of the heart by the pressure of an aneurism or a new-growth. It is in young children that bulging of this part of the chest is most frequent and most noticeable. Aneurism of the aortic arch, by a process of erosion, may push through the overlying structures and, in course of time, cause a local tumor, simulated, at least superficially, by an

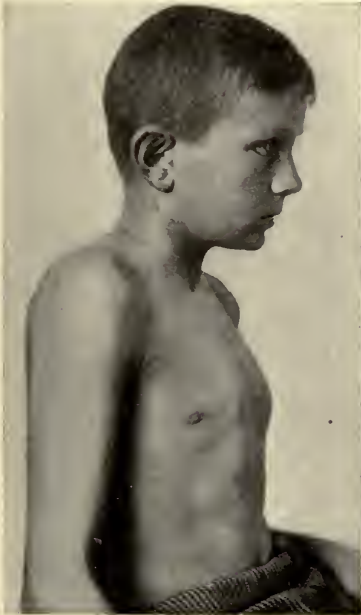

Fig. 40.—Precordial bulging due to cardiac hypertrophy (Jefferson Hospital).

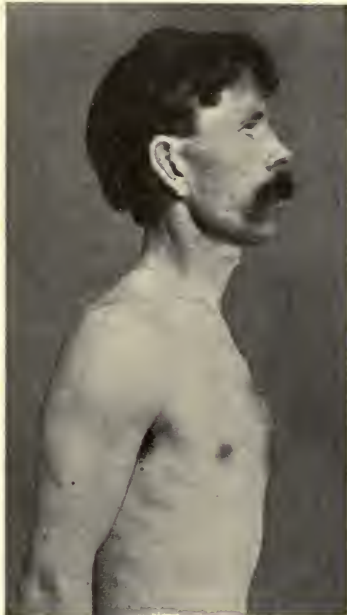

Fig. 41.—Sternal bulging due to aneurism of the aortic arch (Jefferson Hospital).

abscess of the soft parts or by the simple irregularity in the contour of the sternal or the costochondral surfaces (Fig. 41). It is also possible, at first glance, to mistake an aneurism of the descending aorta for a left lateral twist of the spinal column. By pressure, a greatly enlarged liver may produce decided distention of the lower right thorax, while a splenic tumor may similarly bulge the left side

(Fig. 42). Hypertrophy of the breast in a male adolescent (Fig. 43) is a curious anomaly sometimes encountered. As already noted, the clavicles and the scapulæ stand out prominently in the phthisical thorax. Prominence of either scapula may be caused by a scoliosis and by paralysis of the serratus magnus muscle, while the left scapula may be tilted outward by the backward erosion of a large aneurismal dilatation of the descending thoracic aorta. Tumors of the chest-wall, the lungs, and the pleura, empyema necessitatis, pulsating pleurisy, tuberculous disease of the bony thorax, mediastinal and subphrenic abscesses, and, rarely, hernia of the lung, are also capable of pushing out the chest-wall within a restricted area. An encysted pleural effusion, while it causes no local bulging, may obliterate the intercostal spaces over its site. Myxedema may account

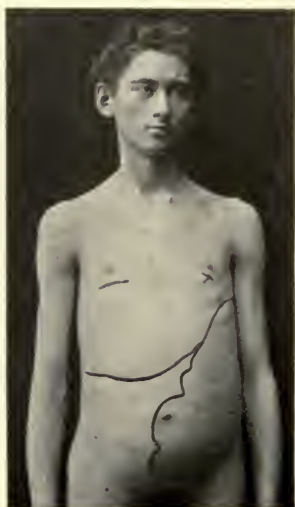

Fig. 42.—Thoracic and abdominal enlargement due to splenic tumor (Jefferson Hospital).

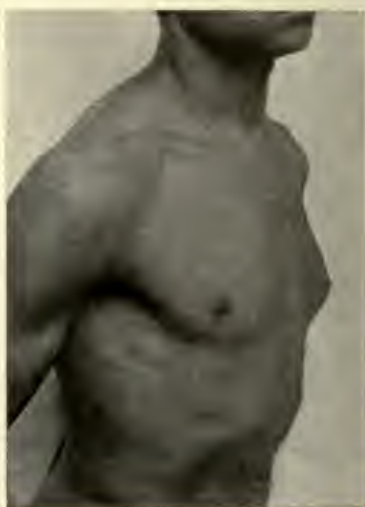

Fig. 43.—Hypertrophy of the left breast in a male adolescent (Jefferson Hospital).

for supraclavicular fibrofatty deposits—Verneuil's pseudolipomata. Subcutaneous emphysema is recognized as a gaseous, crackling swelling which tends to disappear by absorption, and which is secondary to the rupture of some air-containing organ, or to a penetrating wound.

Local Depressions.—The principal intrathoracic factors of local depressed and flat areas upon the surface of the thorax are apical

tuberculosis, circumscribed pleural adhesions, and superficially seated pulmonary cavities. (See Figs. 24, 45, 46.) Among other



Fig. 44.—Lateral compression of the thorax (Jefferson Hospital).

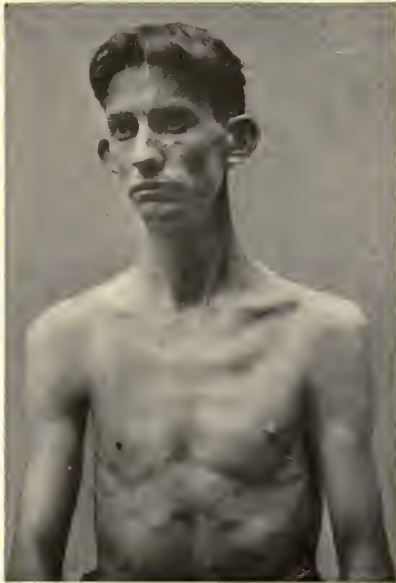

Fig. 45.—Local retraction of the thorax due to pulmonary fibrosis and pleurisy (Jefferson Hospital).

causes of such deformities may be mentioned atelectasis, bronchiectasis, fractured ribs, cicatrices consequent to rib resection and to

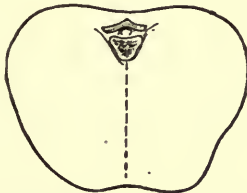


Fig. 46.—Transverse section of a locally retracted thorax.

healed empyema necessitatis, and atrophy or removal of a breast or of the musculature of the chest-wall.

RESPIRATORY MOVEMENTS OF THE THORAX

The student must become familiar not only with normal respiratory movements of the chest, but also with the abnormalities of breathing symptomatic of pathologic conditions. This information is acquired by observing the frequency, the rhythm, and the type of the thoracic movements, the degree and character of the chest expansion, and the extent and freedom of the diaphragm excursion. The adequacy of blood oxygenation, as shown by the color of the patient, is an intimate correlative of these signs, with which it will be considered below.

Normal Respiratory Movements.—The *respiratory cycle* consists of an active inspiratory effort and a passive expiratory phase, followed by a pause, the relative duration of the two movements being thus expressed : inspiration : expiration : : 5 : 6. The respiratory-pulse ratio averages about 1 : 4. In adults the *normal respiratory frequency* is from 16 to 24 to the minute (Hutchinson), while in children the average ranges from 44 in the new-born to 26 in the five-year-old child (Quetelet). Normal breathing is usually regular and quiet, but its rhythm and tranquillity may be deranged by mental disturbances, by muscular exertion, and by fatigue. The respirations may be timed either by simply watching the chest movements or by palpation, with the hand applied to the lower part of the thorax.

The *movements* of the two sides of the chest are synchronous, and, except for a trifling physiologic overfulness of the right half, practically symmetric.¹ Each inspiration increases all the diameters of the chest, and is attended by ascent and forward projection of the sternum, by ascent and eversion of the ribs, and by bulging of the upper epigastrium; with expiration the decrease in the chest diameters is accompanied by retrocession of the parietes and by reappearance of the normal epigastric hollow. The movements of inspiration are performed ordinarily by the diaphragm, intercostals, scaleni, serrati postici, and levatores costarum; but extraordinary efforts in breathing call into play the following accessory muscles: pectorales, quadratus lumborum, serratus magnus, sternomastoid, latissimus dorsi, infrahyoid, and erector spinæ (Cunningham). The movements of expiration are due principally to the elasticity of the lungs, the ascent of the diaphragm, the weight of the chest-wall, and, in difficult, forceful deflation of the lungs, to the auxiliary action of the intercostal, triangularis sterni, and upper abdominal muscles.

¹ Most women, according to Ransome, show a greater respiratory movement of the left side of the chest.

The *type of respiration* differs normally in the two sexes, and is also influenced by the age of the individual. Thus, in women *costal* or *thoracic* breathing is the rule, which means that respiration is carried on chiefly by the upper part of the thorax, the scaleni and the upper intercostals being actively brought into play and the sternum and upper ribs conspicuously elevated and projected, while the epigastrium remains immobile, or, at the most, moves but moderately. In men and in children of both sexes, on the contrary, respiration is of the *abdominal* or *diaphragmatic* type, being performed mainly by the action of the lower part of the thorax and of the diaphragm, whose descent causes bulging of the epigastrium during inspiration.

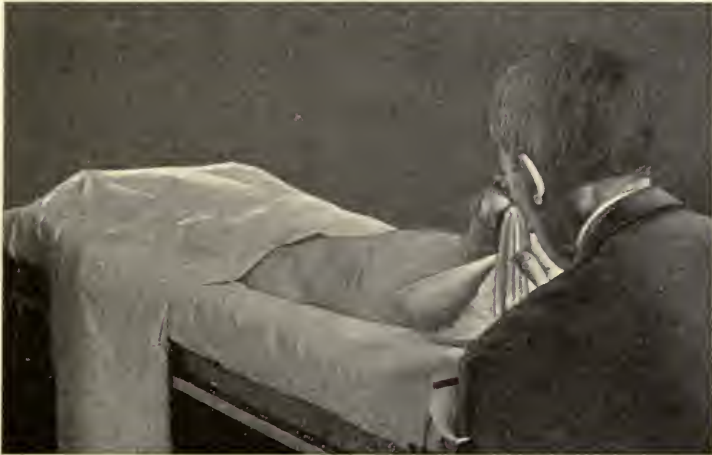

Fig. 47.—Technic of determining Litten's diaphragm sign.

In women of advanced age, whose chests have become rigid and fixed, more or less tendency toward abdominal respiration is also seen.

The Diaphragm Phenomenon.—The normal inspiratory descent of the diaphragm is recognized as a faint, although perfectly appreciable, shadow which travels vertically down the lower axilla during each full inflation of the lungs, from the sixth to the eighth or ninth intercostal spaces. This so-called *diaphragm phenomenon* (*Litten's sign*) is shown most distinctly by placing the subject in dorsal decubitus, with the feet toward a window and the arms extended above the head, the observer standing behind or at the side of the bed, in the position indicated by the accompanying picture (Fig. 47). The shadow, which ordinarily has a vertical course of three or four inches

with each deep inspiration, is explained by the inspiratory separation of the diaphragm from the thoracic wall, an act that increases the extent of the complementary pleural sinus and exerts suction upon the intercostal spaces below the inferior border of the lung. Naturally, the diaphragm shadow is virtually imperceptible during expiration.

Litten's sign is present in practically every healthy individual, except in those who are overmuscular or overfat, and it shows that the excursions of the diaphragm, the lung, and the pleura are unrestricted. Conditions interfering with such movements partly or entirely abolish the diaphragm shadow upon the affected side, as is the case in pleural adhesion and effusion, basal pneumonia, extensive emphysema, pneumothorax, and neoplasms of the lower part of the thoracic cavity. To some extent subdiaphragmatic abscess, enlargement of the liver and of the spleen, and extreme distention of the abdomen by fluid, gas, or solid tumors act in a similar manner, while in many cases of incipient phthisis the shadow is more or less indefinable. In paralysis of the diaphragm the phenomenon is totally abolished, and in persons whose chest expansion is restricted the sign is difficult of detection. The presence of edema of the chest-wall effectually obscures the phrenic shadow.

Respiratory Alterations of the Subcostal Angle.—The study of the diaphragm shadow should always be supplemented by determining the presence of any unnatural change in the subcostal angle, as shown by Hoover's method of combined inspection and bimanual palpation with the thumbs symmetrically placed along the costal borders to serve as indicators of their divergence from, or convergence toward, the median line. This simple maneuver shows that with an identical limitation of inspiratory excursions, in both basal pneumonia and in pleural effusion, there is divergence of the costal borders in the former and convergence in the latter. In pleural adhesion simple restriction is the rule, without definite change in the subcostal angle. Inspiratory divergence, with consequent widening of the subcostal angle, is observed in paralysis of the diaphragm, in subphrenic abscess, and in hepatic enlargement, while in emphysema, in pneumothorax, and in large-sized pericardial effusion the reverse occurs. In the foregoing the respiratory changes noted correspond to the affected side. Cardiac enlargements may alter the respiratory excursion of either the left costal margin or of both borders, the left being affected in left-sided enlargements, and both, with symmetric narrowing of the subcostal angle, in an enlargement in the median line, as commonly occurs in mitral stenosis.

Unlike Litten's diaphragm phenomenon, the movements of the costal borders are not obscured by either a thick layer of fat or by muscular overdevelopment of the subject, and, therefore, their study deserves wide clinical application in the differentiation of lesions of the lower thorax and of the upper abdomen.

ANOMALIES OF RESPIRATION

Under this caption are included the various disturbances of the respiratory excursion distinguished chiefly by deviations from its normal extent, frequency, and rhythm.

Reversal of the Respiratory Type.—Costal breathing in a man and abdominal breathing in a woman, being just the reverse of the respiratory type normally occurring in the two sexes, are to be regarded as distinctly anomalous. Exaggeration of the type of breathing peculiar to either sex is to be interpreted in the same light.

Costal breathing is associated with conditions that restrict the movements of the diaphragm, such as diaphragmatic pleurisy and paralysis, extensive pericardial effusion, emphysema, ascites, tympanites, abdominal tumor, and peritonitis. Exaggeration of the respiratory movements of the upper thorax attends various forms of dyspnea, notably those of hysteric origin.

Abdominal breathing, prevailing because of some mechanical impediment to the free movements of the chest, occurs in bilateral pleural effusion, in massive pneumonia, in calcareous disease of the chest-wall, and in scleroderma. Spinal paralysis, tetanus, and strychnin poisoning also throw the work of the thoracic movements upon the abdomen. The conditions noted below as factors of deficient expansion, owing to the painful breathing they excite, also favor more or less the abdominal type of respiration.

Sternomastoid Breathing.—Undue contraction of the sternomastoid muscles is noticeable whenever the respiratory function suffers any extraordinary stress, and, therefore, such action is a common sign in most forms of dyspnea (*q. v.*). So conspicuous are the contractions of this muscular group in the dying state that this action has been termed a "veritable death's call" (R. H. Chase).

Alterations in the Degree of Expansion.—A *general deficiency* in the expansion of the chest, or shallow breathing, may be simply a personal peculiarity, and hence is without definite import; more often, however, it is suggestive of either latent or active pulmonary tuberculosis, especially if flat-chestedness coexists. Feeble expansion is perhaps best illustrated by the thoracic immobility

incident to such conditions as collapse, acute syncope, trance, and the adynamia of acute febrile diseases. The overdistended thorax of the emphysematous subject can expand but slightly, and the mobility of the chest is impaired by laryngeal or tracheal stricture, and by paralysis or spasm of the respiratory muscles and of the diaphragm. Deficient chest expansion from ossification of the costal cartilages (*Bryson's sign*) often occurs in Graves' disease. Painful breathing limits the respiratory excursion, which is restricted for this reason in pleurisy, pericarditis, peritonitis, intercostal neuralgia, rheumatism, and diseases of the chest-wall.

Wavy and uneven expansion, or a peculiar undulatory type of respiratory movements, frequently develops during the adynamia of the so-called "typhoid state."

Deficient expansion and inspiratory retraction of the interspaces sometimes coexist, as in stenosis of the upper air-passages and in diffuse bronchopneumonia, in which conditions inflation of the lungs is performed with great difficulty. Retraction of the lower interspaces with a simultaneous bulging in the supraclavicular regions is a distinctive finding in advanced emphysema. Bronchial stenosis, atelectasis, and pleural adhesion are factors of unilateral, and of limited, circumscribed intercostal retraction.

Unsymmetric expansion, characterized by a one-sided deficiency of the respiratory movements, is commonly met with in conditions that mechanically interfere with the movements of the affected lung—pleural effusion, wide-spread pleural adhesion, massive pneumonia, pneumothorax, and tumor of the lung; while a lung crippled by tuberculosis, by cirrhosis, or by atelectasis also fails to inflate and deflate normally. Either a foreign body lodged in a main bronchus or a tumor constricting its lumen can account for unilateral interference with expansion on the side implicated. Right-sided restriction of breathing may be symptomatic of hepatic enlargement, and left-sided, of hypertrophied spleen.

Circumscribed deficiency of expansion, showing as a local patch of immobility upon the chest-wall, is significant of some limited lesion of the lung, pleura, or pleuropericardium. Immobility and lagging in an infraclavicular space suggests tuberculosis, pneumonia, or adhesive pleurisy in this region; if it affects the lower part of the thorax, basal pneumonia or diaphragmatic pleurisy is to be thought of; and if it be localized in the region of the heart, pericardial adhesions are to be suspected.

A *general increase* in the expansion of the chest occurs as the physiologic effect of hard exercise, attends various emotional states, and is

seen in certain forms of dyspnea. The vicarious overaction of one lung or of a part of one lung is the underlying cause of a *unilateral* or *circumscribed* increase in expansion.

Alterations in the Frequency of the Respiratory Movements.—Simple *rapid breathing*, or *polypnea*, usually attended by shallowness of the respiratory excursion, occurs normally in young children, and is the physiologic result of active exercise, although in the latter instance the breathing is deep, as well as rapid. Accelerated respiration is also met with in neurotics, in many of the acute fevers, and in pulmonary lesions, such as pneumonia and tuberculosis, which not only diminish the aërating surface of the lungs, but also elaborate toxins that probably stimulate the respiratory center.

Slow breathing, or *oligopnea*, occurs in many conditions of coma, collapse, and shock from various causes; in cerebral tumor, apoplexy, and meningitis; in poisoning by opium, chloral, chloroform, aconite, and antimony; and, occasionally, in bronchial asthma. The association of arhythmic and difficult respiration is discussed under *Dyspnea* (*q. v.*).

Respiratory Arrhythmia.—*Simple irregularity*, often temporary, in the rhythm of the respiratory movements is not necessarily pathologic, since it is often referable to trivial psychic disturbances. It is, on the contrary, a sign of grave import in apoplexy, uremia, meningitis, cerebral tumor, lesions of the medulla, and in states of collapse. Respiratory arrhythmia may also accompany chorea, and frequently is found in pneumonia and in atelectasis, being evidenced in these last two conditions as a distinct post-inspiratory pause.

Jerky respiration, characterized by a series of spasmodic interruptions of inspiration and expiration, is in some instances purely hysteric, but in others it is attributable to some one of the factors of restricted respiration referred to in a preceding paragraph. (See p. 95.) Chorea, asthma, hemiplegia, and rabies are additional causes of this respiratory peculiarity.

Cheyne-Stokes respiration is characterized by periodic disturbances of the respiratory rate, rhythm, and volume, alternating with intervals during which breathing entirely ceases, these two contrasting phases recurring in regular cycles. Thus, one of these quiescent intervals (period of apnea) is followed by slow and shallow respirations, which progressively increase in both frequency and in volume until they reach an acme (period of dyspnea), after which they gradually become slower and shallower until, having ceased entirely, another quiescent period begins (Fig. 48). The length of the two periods is variable—a few seconds to one or even two minutes for the dyspneic phase,

and as long as one minute for the apneic. Sighing and snoring sometimes attend the deep respiratory efforts just preceding the acme of dyspnea, and cyanosis is a familiar objective symptom at this time. The difference between Cheyne-Stokes, normal, and




Fig. 48.—Cheyne-Stokes respiration; upstroke: inspiration; downstroke: expiration. The small waves in the period of apnea are due to the heart-beat (Pneumogram by Dr. G. Bachmann).

shallow respiration is graphically shown by Fig. 49. It is of some importance to recall Eyster's observation, that arterial hypertension accompanies the dyspneic period of Cheyne-Stokes respiration due to cerebral compression, while in that due to cardiorenal dis-

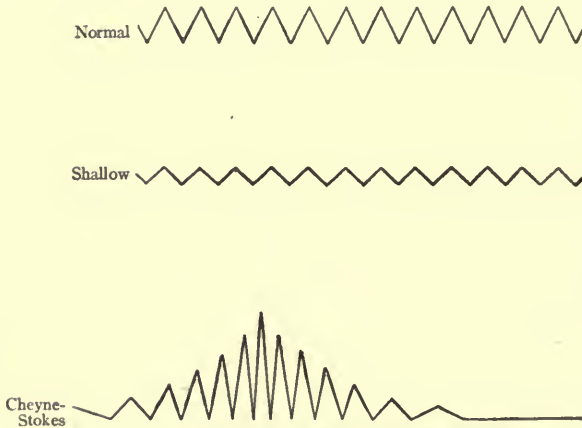


Fig. 49.—Normal and pathologic types of respiration.

ease and other factors the blood-pressure rises during the apneic stage. As a rule, the pulse-rate appreciably shows during apnea, but in some cases the reverse occurs.

The persistence of Cheyne-Stokes respiration ranges from a few hours to as long as several weeks, or, in the extreme case, several

months. The patient sometimes becomes insensible during the phase of apnea, but regains consciousness as breathing is resumed. This type of respiration also may occur in coma, as well as in ordinary sleep.

Cheyne-Stokes respiration invariably has a grave, although not necessarily a fatal, significance. It may attend almost any profoundly comatose state, but its presence especially suggests factors such as apoplexy, cerebral tumor or softening, meningitis, uremia, diabetes mellitus, opium-poisoning, and fatty heart or other degenerative cardiac lesions. With less frequency it is observed in the typhoid states of various acute infectious diseases, in general paralysis, and as the result of embolism and of hemorrhage. Cheyne-Stokes' respiration is due to diminished irritability of the respiratory center, but whether this can be accounted for simply by fatigue (Rosenbach's belief) or by faulty oxygenation (Traube's view) is a moot point.

Meningeal respiration consists of recurring periods of apnea, ranging from five or ten to twenty or thirty seconds' duration, and separated by intervals marked by irregularity of rhythm and of force. The apneic periods recur irregularly, and commonly are preceded or succeeded by a deep sighing respiration. This respiratory anomaly, also known as *Biot's respiration*, is particularly suggestive of meningitis, but it may be symptomatic of the same factors to which typical Cheyne-Stokes respiration is referable.

An extraordinary example of voluntary apnea in a young athlete, who held his breath for ten minutes and ten seconds, is recorded by Saxton Pope.

Stertorous respiration, or snoring, caused by the vibrations of a relaxed soft palate, occurs usually, but not exclusively, during either sleep or coma. It is a well-known sign of profound sleep in many healthy persons who sleep with their mouth open, and is heard with great constancy in the condition known as "mouth-breathing," consequent to tonsillar hypertrophy, postnasal adenoids, quinsy, and postpharyngeal abscess, the noisy snoring of this last-named condition having been dubbed the "hen-cluck" stertor. Of the more serious factors of stertorous breathing, one should remember paralysis of the soft palate, and the comatose states of uremia, apoplexy, diabetes mellitus, asphyxia, opium-poisoning, pulmonary edema, epilepsy, and cerebral compression.

Stridulous respiration, denoting stenosis of the larynx or trachea, is audible, especially during inspiration, as a medley of harsh, hissing, or whistling vibratory sounds, the production of which is due to some local lesion of the parts or to a primary interference with the functions

of the laryngeal muscles. Thus, stridor is commonly the result of inflammatory turgescence, edema, diphtheria, neoplasm, and of a foreign body in the larynx or trachea. Or it may relate to the laryngeal spasm of spasmodic croup, laryngismus stridulus (child-crowing; thymic asthma), locomotor ataxia (laryngeal crisis), tetanus, or strychnin-poisoning. In other instances irritation of the inferior laryngeal nerve by the encroachment of an aneurism, a neoplasm of the mediastinum or trachea, a mass of enlarged bronchial glands, or a dislocated heart is the exciting cause of stridor. Respiration through a tracheotomy tube produces a rasping sound not unlike that made by filing the teeth of a saw—hence the term, *stridor serraticus*. The stridor of tracheal stenosis is also known as the “leopard’s growl.”

DYSPNEA

Dyspnea means difficult or labored respiration, and these laborious efforts to breathe are the distinctive hall-mark of the sign, irrespective of any coëxisting disturbances of the respiratory rate, rhythm, and depth. When dyspnea is striking, the respiratory movements are obviously embarrassed, as shown by the overaction of the accessory muscles of respiration upon which demand is made, and the patient’s anxious face, dilated pupils, moist skin, dry tongue and lips, gaping mouth, dilated alæ nasi, and cyanosis constitute a very distinctive clinical picture of the extreme respiratory distress. When the dyspnea is so urgent that the subject can breathe only when in an upright position, the term *orthopnea* is used.

Labored inspiration, with natural expiration, the effort here being made to inflate the lungs, is known as *inspiratory dyspnea*; but when, on the other hand, expiration is interfered with, the effort being made to deflate the lungs, the condition is one of *expiratory dyspnea*. When both inspiration and expiration are labored,—and this is, by far, the commonest type,—the term *mixed dyspnea* is employed. According to the nature of the underlying factor or factors, dyspnea is either *constant* or *paroxysmal*. When the patient is conscious of shortness of breath, *subjective dyspnea* exists; while in *objective dyspnea* the labored breathing is apparent to the examiner, although the patient is not necessarily distressed thereby.

Types of Dyspnea.—Aside from the dyspnea arising from purely functional causes, the most important clinical types are those attributable to anemia, toxemia, stenosis of the air-passages, and organic lesions of the lungs and the cardiovascular system. These causes, together with others of minor interest, may be considered briefly under the following headings.

Functional Dyspnea.—Any form of *active muscular exercise* may be responsible for a temporary dyspnea of the mixed type, such as that illustrated by the labored, deep, and hurried breathing of the oarsman after a hard row, or of the sprinter after a hundred yards' dash. Temporary congestion of the pulmonary capillaries best accounts for this form of dyspnea, though it may be true that there is some irritation of the respiratory center by circulating toxins elaborated by abnormally active tissue metabolism. Trifling exertion, insufficient even to hurry the respiration of a normal person, is often sufficient to embarrass seriously the breathing of those affected with incipient phthisis, imperfectly compensated cardiac disease, chronic bronchitis, emphysema, anemia, and obesity.

The *functional neuroses* account for a similar kind of dyspnea, as in persons of a nervous temperament, especially neurotic and hysteric women, whose shortness of breath is distressing enough to amount to an actual dyspnea, despite the fact that no more tangible cause than simple excitement or emotion is apparent. Perverted action of the respiratory center has been suggested as the explanation of the dyspnea in such cases.

Anemic Dyspnea.—In high-grade anemia the diminished oxygen content of the blood leads to difficult breathing and to increased frequency and depth of the respiratory movements, in order thus to compensate for the oxygen deficiency by an unusually thorough oxygenation of all the available hemoglobin. The degree of a purely anemic dyspnea stands in direct relation to the extent of the hemoglobin loss, being more decided in pernicious anemia, in chlorosis, and in acute leukemia than it is in the ordinary forms of secondary anemia. Here also may be mentioned the dyspnea due to the breathing of impure air, as illustrated by the form of respiratory distress known as "mountain sickness," caused by breathing air deficient in oxygen, and by the extreme dyspnea, if not the asphyxia, of coal-gas poisoning, in which carbon monoxid replaces the oxygen of the circulating blood.

Toxic Dyspnea.—In *active fevers* rapid, difficult breathing is likely to develop from the effect of the attendant toxemia, as well as from irritation of the respiratory center by abnormally warm blood. *Uremic dyspnea*, observed in the nephritides, may be a sign of uremic intoxication, but it also must be referred to such additional factors as cardiovascular disturbances and to inflammatory and mechanical implication of the bronchopulmonary apparatus. In general, the uremia of renal disease is the evidence of an attempt of the lungs to compensate the existing acidosis, and to a less extent it is

a sign of increased excitability of the respiratory center. So-called "renal asthma" is an unfortunate term, generally confounded with the breathlessness of nephritis, though it must be admitted that an occasional instance of true bronchial asthma is possibly of uremic origin. Renal dyspnea is frequently paroxysmal, but it may be of a continuous type, with or without Cheyne-Stokes breathing and cyanosis. *Diabetic dyspnea*, or Kussmaul's *air-hunger*, is commonly of the mixed type, and is characterized by deep, but not unduly rapid, respiratory excursions, with or without cyanosis. It frequently ushers in an attack of diabetic coma during which it may become transformed into Cheyne-Stokes respiration. This precomatose form of dyspnea is explained partly by the toxic action of the diabetic acidosis and partly by the fact that the oxygen capacity of diabetic blood is subnormal. Toxemia plus hemolytic reduction of the oxygen content of the blood is the credible factor of the dyspnea incident to malignant jaundice, hepatic cirrhosis, insolation, and the malarial chill.

Obstructive and Mechanical Dyspnea.—It is convenient here to consider the varieties of respiratory difficulty symptomatic of stenosis of the air-passages, of mechanical interference with the thoracic movements, and of spastic or paralytic lesions of the respiratory muscles.

Stenosis of the upper air-passages, in that it obstructs the free entrance of air to the lungs, is a prominent cause of inspiratory dyspnea characterized by slow, deliberate, deep respiratory efforts, which tend to overcome the obstruction much more effectually than does hurried, shallow breathing. When the grade of stenosis is so extreme that the efforts of inflation actually rarefy the pulmonary air, inspiratory retraction of the lateral walls of the thorax and of the epigastrium is noticeable, and the lower intercostal spaces, the supra-sternal notch, and the supraclavicular regions are sucked in with each deep breath. Stridor, as noted in a foregoing paragraph, is also a noteworthy sign of stenosis of the upper air-passages. Of the conditions responsible for respiratory stenosis, the following are important: tonsillar enlargement and retropharyngeal abscess; membranous, edematous, and inflammatory occlusion of the larynx; laryngismus stridulus, croup, and paralysis of the dilators of the glottis; and stenosis of the larynx, trachea, or main bronchus by cicatrix, foreign body, neoplasm, glandular enlargement, or aneurism. In young children alarming paroxysms of dyspnea and respiratory stridor may be excited by the pressure of a thymus hyperplasia upon the trachea.

In extreme bronchial obstruction there is wide-spread blocking of the bronchioles by swelling, spasm, or exudate, and in consequence rapid breathing and urgent expiratory dyspnea occur, marked by great prolongation of expiration, cyanosis, and perhaps by stridor. This is especially prone to occur in the diffuse catarrhal pneumonia of young children, in bronchial asthma, and in fibrinous bronchitis of the smaller tubes.

Mechanical restriction of the thoracic movements provokes dyspnea, commonly of the mixed type, attended by accelerated breathing, and by compensatory overaction of the unaffected side, in unilateral interferences. The causes underlying this variety of dyspnea are practically those of deficient expansion (*q. v.*), namely: conditions provocative of painful breathing; rigidity and deformity of the bony thorax; intrathoracic tumor and paralysis of the respiratory muscles; pleural collections of gas or fluid; and upward displacement of the diaphragm by enlarged abdominal viscera, tumor, meteorism, or ascites.

Pulmonary Dyspnea.—Diminution of the respiratory surface, due to diseases of the pulmonary parenchyma, is attended by dyspnea and rapid breathing, the degrees of which are determined chiefly by the extent to which pulmonary ventilation is crippled. In some instances the attendant toxemia is also actively concerned, and in others some of the additional factors of dyspnea enumerated above are partly responsible. Pulmonary dyspnea may be met with in any form of consolidation, collapse, or distention of the lungs, of which good examples are furnished by croupous pneumonia, tuberculosis, edema, infarction, fibrosis, and neoplasm; by atelectasis due to catarrhal pneumonia and to pericardial or pleural effusion; and by the overinflation of the vesicles in hypertrophic emphysema. In the last-named disease a highly distinctive expiratory dyspnea prevails; in most of the others there is difficulty with both inspiration and expiration.

Cardiac Dyspnea.—The dyspnea of uncompensated cardiac disease depends upon general circulatory stasis, by fault of which the system is overcharged with venous blood, the oxygen tension being lowered with a consequent increased stimulation of the respiratory center. Owing to this defect, the lungs become rigidly fixed in the position of extreme inspiration, on account of the great overdistension of the pulmonary capillaries with blood. These two circumstances excite the rapid, shallow, arhythmic dyspnea which develops in various structural lesions of the heart, but especially in mitral disease, during the stage of broken compensa-

tion. The associated bronchitis, with its abundant catarrhal secretion, aggravates the respiratory distress already existing. Sudden, acute engorgement of the pulmonary capillaries gives rise to urgent dyspnea and cardiac irregularity—the condition misnamed “cardiac asthma,” which is to be clearly distinguished from true bronchial asthma and from uremic dyspnea.

CYANOSIS

Cyanosis betrays a deficiency of oxygen and an excess of carbon dioxid in the capillary circulation, and is recognized as a dusky blue or even purple discoloration of the skin and the mucous membranes. This discoloration tends to show most decidedly in relatively transparent parts remote from the chest—the tips of the fingers and toes, the knees and ankles, and the lips, nose, cheeks, and ears. Cyanosis blended with pallor gives to the skin a livid hue, and combined with jaundice, an extraordinary greenish tint.

The factors of *general cyanosis* relate to the faulty oxygenation of the blood in the lungs, and to any obstruction of the venous return flow productive of congestion within the veins. Like dyspnea, cyanosis may accompany disorders of the cardiovascular or respiratory system, capable of exciting the foregoing disturbances. Aside from such causes as these, cyanosis is symptomatic of vasomotor paralysis and of the methemoglobinemia consequent to poisoning by acetanilid or by nitrobenzol. Permanent cyanosis with splenomegaly and polycythemia constitutes the syndrome of Saundby and Russell, chronic cyanotic polycythemia.

Local cyanosis is produced by either partial or complete obliteration of a venous trunk by thrombosis or by external pressure, in consequence of which blueness develops in the part distal to the constriction.

VENOUS ENLARGEMENT AND TORTUOSITY

Actual overfulness of the veins upon the surface of the thorax is to be distinguished from the conspicuous venous trunks so commonly observed in the thin-skinned blond and in those who are greatly emaciated. In a healthy person one occasionally meets with a general dilatation and even with an abnormal tortuosity of the cutaneous veins of the chest, a peculiarity best explained by ascribing it to a congenital weakness of the venous walls. More often, however, venous enlargement is traceable to either a general or a local interference with the venous circulation, due, for instance, to right-sided cardiac

weakness, to thrombosis, and to mediastinal growths (Figs. 50 and 51). The direction of the venous flow is determined by stroking the enlarged vein so as to empty the blood therein, and then noting the direction from which the collapsed vessel refills when the pressure is removed. Or the vein may be compressed with the finger-tip and the relation of the resulting turgescence to the point of constriction observed (*cf.* p. 514).

Enlarged *mammary veins* may arise from several different causes: they are not uncommon during the late stages of pregnancy and during lactation; they are also associated with many cases of malignant disease of the breasts; and they may betray an obstruction, by

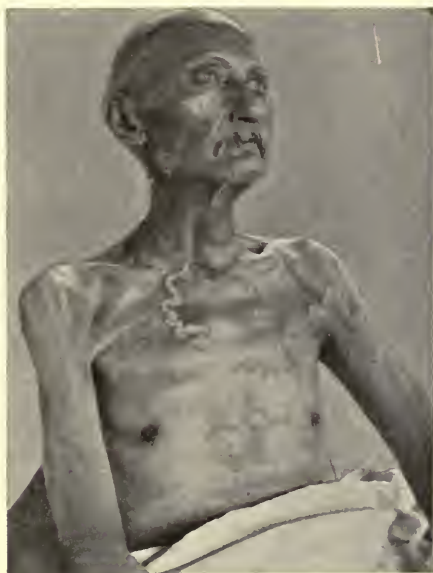

Fig. 50.—Venous tortuosity of the thoracic wall (Episcopal Hospital).

the pressure of a thoracic aneurysm or a new-growth, to the venous return of blood from the breasts.

A ramification of small venules over the *upper chest*, with prominence of the jugulars, is sometimes found in tuberculous enlargement of the bronchial glands. Abnormal fulness of the superficial veins in the neighborhood of the *sternum* suggests mediastinal tumor; of which such a sign is one of the early clinical manifestations (Fig. 50). The pressure of a tumor or of a cicatrix in the axilla may account for overdilatation of the veins of the *upper arm* on the

affected side (Fig. 52). A purplish fringe of dilated veins coursing symmetrically along the *costal arch* is a familiar finding in right ventricular dilatation, in atrophic cirrhosis of the liver, and in chronic adhesive pleurisy. In portal vein engorgement and obstruction

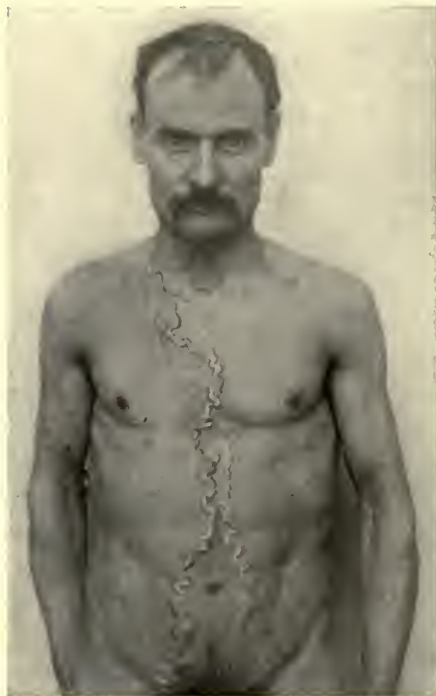

Fig 51.—Venous engorgement of thoracic and abdominal walls (Jefferson Hospital).

the greater part of the entire *lower thorax* is sometimes encroached upon by the upward extension of the dilated veins of the upper abdominal region.

EDEMA OF THE THORACIC WALL

This is easily detected by its tumid appearance and by the fact that the tissues pit upon pressure and retain temporarily the imprint of the finger. *Local edema*, perhaps with some discoloration, may be a sign of impending perforation in empyema necessitatis or of abscess of the parietes; but purulent pericarditis, mediastinal abscess, pulmonary hydatid, aneurism of the aortic arch, and angioneurotic edema must also be recalled as possible factors. Occlusion of the

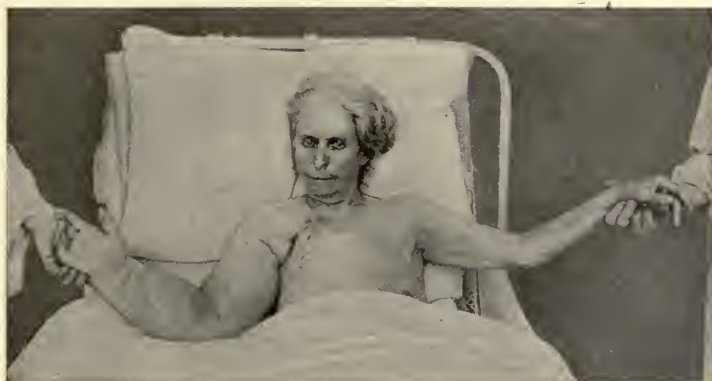


Fig. 52.—Edema of the arm, due to lymphatic obstruction (Jefferson Hospital).

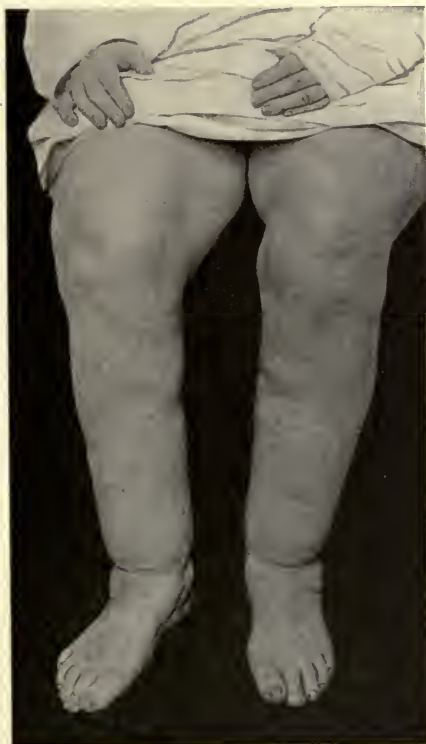

Fig. 53.—Edema of the lower extremities (Jefferson Hospital).

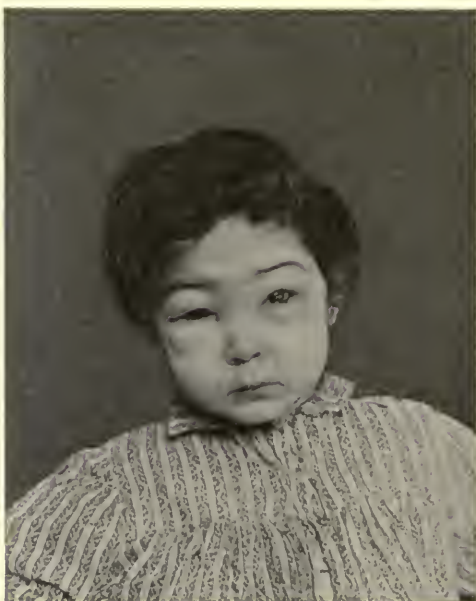

Fig. 54.—Nephritic edema of the face (Jefferson Hospital).

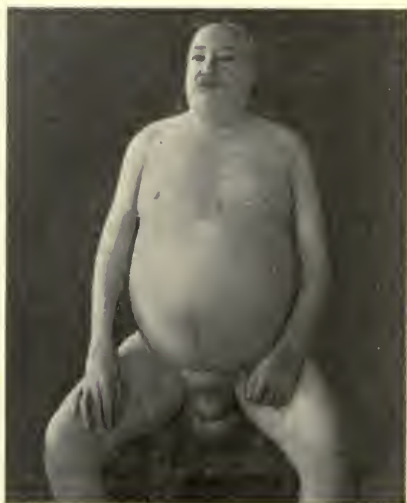

Fig. 55.—Cardiorenal anasarca (Jefferson Hospital).

superior vena cava may account for persistent edema of the thorax, neck, and upper limbs, with cyanosis and compensatory dilatation of the superficial veins. *General edema* affecting the greater part of the surface of the chest, is referable to some form of anasarca, for the cause of which the heart, the liver, and the kidneys should be examined (Fig. 55). In this connection that form of congenital dropsy known as *fetal erythroblastosis*, a defective hemogenesis with anasarca and fluid in the body cavities, should be recalled.

GLANDULAR ENLARGEMENT

Routine examination of the neck and axilla should be made, in order to detect glandular swellings symptomatic of such lesions as simple adenitis, tuberculosis, syphilis, malignant tumors, benign

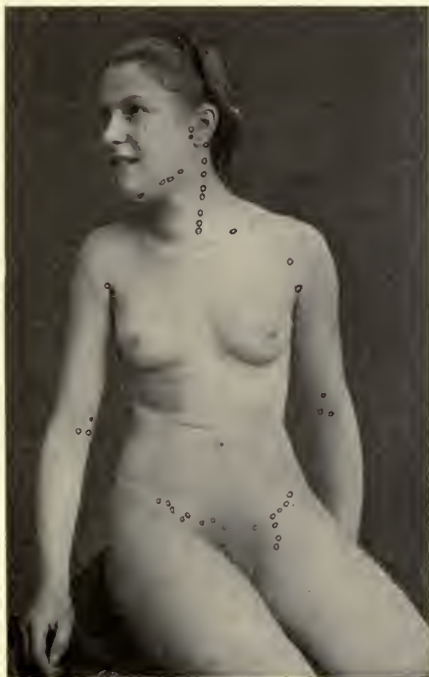

Fig. 56.—Common sites of superficial glandular enlargements.

lymphoma, leukemia, and Hodgkin's disease. The *cervical glands*, lying along and beneath the sternocleidomastoid muscle, are the

favorite site of simple acute adenitis tending to end by resolution, and met with in the specific fevers of childhood and in local infections of neighboring parts. Of the former class of factors, measles, scarlatina, diphtheria, glandular fever, and pertussis are important examples; and of the latter group of causes, dental caries, stomatitis, tonsillitis, and otitis. The *submaxillary glands* are frequently the earliest site of tuberculous adenitis, which in the course of time tends to implicate the other lymphatics of the neck (Fig. 59). Scrofulous glands are prone to early softening, suppuration, and fistulation, and are often accompanied by definite signs of tuberculosis of the lungs and bronchial glands. These glands are also a favorite site for



Fig. 57.—Benign tumor of the neck (Jefferson Hospital).

the growth of a local benign lymphoma, a tumor of this type being strictly limited to a single group of glands, and forming a dense, painless swelling which does not caseate, suppurate, nor adhere to adjacent parts (Fig. 58). Vincent's angina, diphtheria, mumps, stomatitis, actinomycosis, and infections of the mouth and adjacent structures are among the other factors of submaxillary adenitis. The *occipital glands* are commonly enlarged in syphilis, being recognized as a group of painless, freely movable masses of cartilaginous

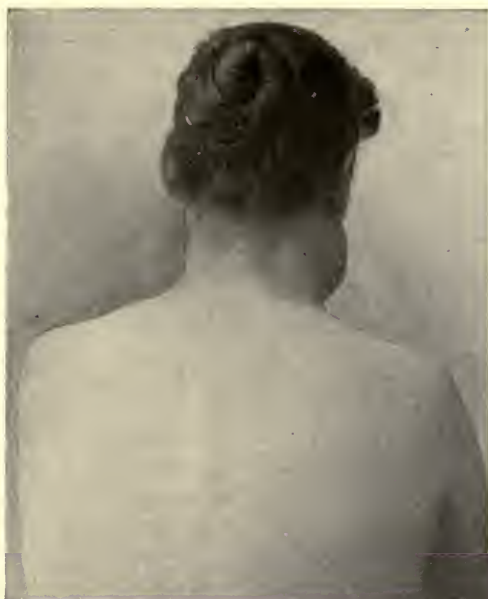

Fig. 58.—Lymphoma of the cervical glands (Jefferson Hospital).



Fig. 59.—Bilateral tuberculous enlargement of the cervical lymphatic glands (Jefferson Hospital).

hardness and moderate size. Whenever such masses are felt, the examiner should look for the initial lesion and search for inguinal

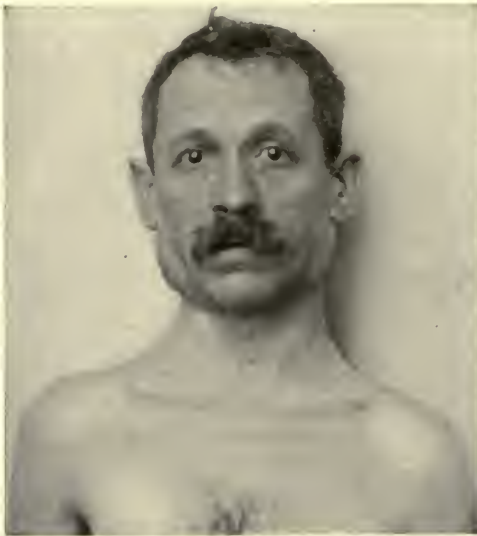

Fig. 60.—Bilateral sarcomatous enlargement of the cervical lymphatic glands (Jefferson Hospital).

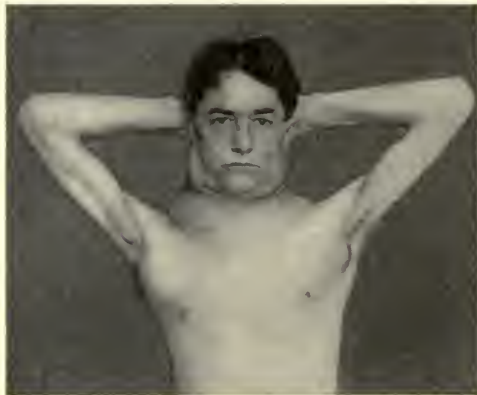

Fig. 61.—Generalized glandular enlargement in Hodgkin's disease (Jefferson Hospital).

adenitis and for supratrochlear kernels just above the internal condyle of the humerus. The posterior cervical glands are pecu-

liarily susceptible to enlargement in r otheln, and the occipital glands are affected in irritation and inflammation of the scalp. Enlargement of the *parotid gland*, aside from mumps and neoplasms, may be secondary to septicemia, pneumonia, enteric fever, and similar infections; to lesions of the abdomen and pelvis; and to facial paralysis.



Fig. 62.—Cystic enlargement of the thyroid gland (Jefferson Hospital).

Enlargements of the *axillary glands* (Fig. 61) may be secondary to vaccinia, infected wounds, general septicemia, and bubonic plague; they are part and parcel of the general glandular hyperplasia of Hodgkin's disease and of leukemia; and, like many of the lymphatic chains heretofore mentioned, they are sometimes symptomatic of malignant tumors. The extensive glandular tumors of Hodgkin's disease and of leukemia are in nowise distinctive, from a clinical standpoint, but the blood-report furnishes an easy means of differentiation: normal or but moderately anemic blood in the former, and either myelemla or lymphemia in the latter. A malignant neoplasm of the lymphatic structures, if

cancerous, is to be regarded as secondary to a primary growth in another situation—in the mouth, the upper air-passages, or the mediastinum, if the cervical lymphatics are implicated; in the breast, if the axillary glands are large. A sarcomatous gland-

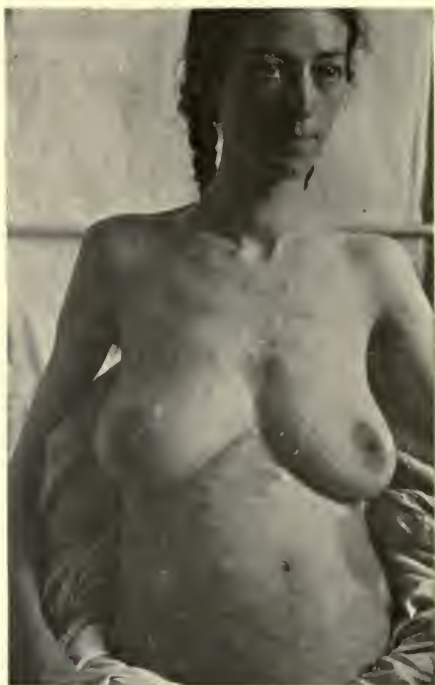

Fig. 63.—Subcutaneous nodules in a case of general sarcomatosis (Jefferson Hospital).

ular swelling is likely to be fixed and immovable, and tends early to infiltrate, inflame, and ulcerate adjacent tissues. The soft parts about a lymphosarcoma may pit upon pressure, if, indeed, they do not seem abscessed, and the tumor is sometimes covered by a maze of tortuous, congested cutaneous veins.

Enlargement of the *lateral thoracic glands* in the midaxilla is suggestive of tuberculosis, either pulmonary or bronchial. Zebrowski found this type of adenitis in 20 per cent. of all cases of phthisis, usually on the side of the affected lung. Other factors of enlarged glands in this site include simple hyperplasia, malignant neoplasms of the lung, pleura, mediastinum, liver and stomach, lymphatic leukemia, and Hanot's hepatic cirrhosis.

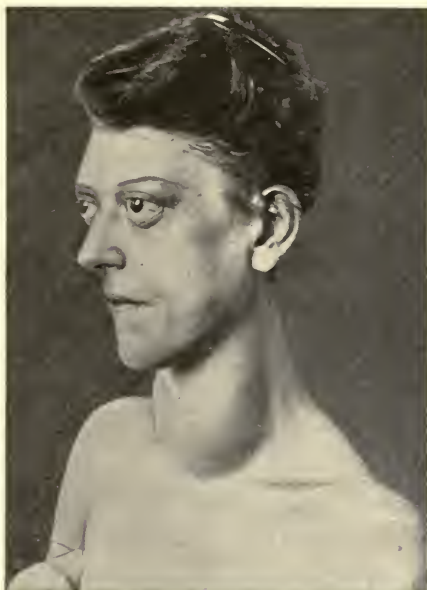

Fig. 64.—Thyroid enlargement in Graves' disease (Jefferson Hospital).

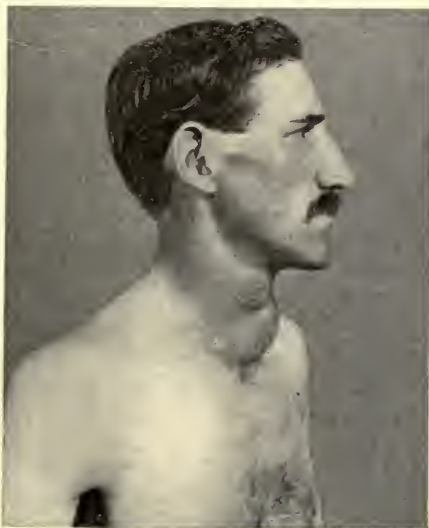

Fig. 65.—Thyroid enlargement in Graves' disease (without exophthalmos) (Jefferson Hospital).

Enlargement of the *thyroid gland* shows as a globular swelling, more often of irregular than of symmetric contour, situated between the larynx and the suprasternal notch, and intimately attached to the trachea, with which it moves during deglutition (Fig. 62). Such a tumor generally proves to be goitrous, either simple cystic or exophthalmic, the ordinary bronchocele being attended by no ill effects save perhaps those due to pressure, while in Graves' disease one expects to find three other cardinal signs—tachycardia, exophthalmos,

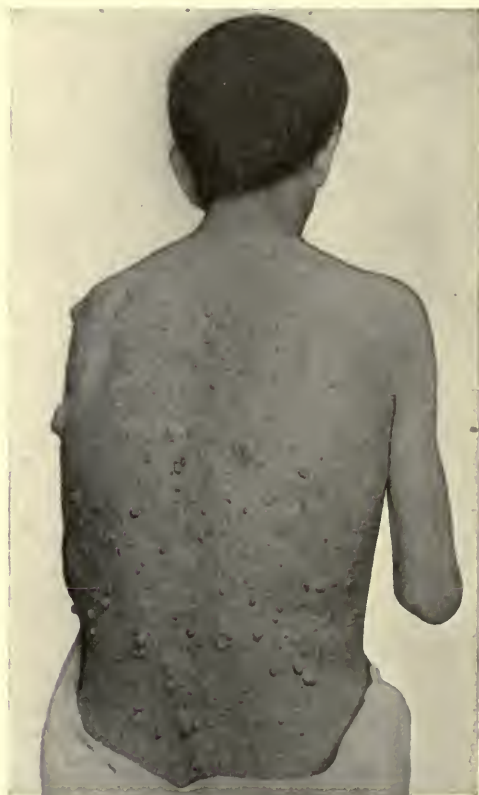

Fig. 66.—Multiple fibroma (molluscum fibrosum) of the back (Philadelphia General Hospital).

and tremor (Figs. 64 and 65). Less commonly the enlargement is due to acute thyroiditis, abscess, tuberculosis, neoplasm, or acromegaly. Puberty in girls, menstruation, and pregnancy all may be accompanied by a moderate, transient swelling of the thyroid

gland, excited by acute congestion. Myxedema, in the form of either cretinism or Gull's disease, is characterized by atrophy of the thyroid, and this also is true of the exceptional case of acromegaly.

PAIN IN THE THORAX

Pain in the chest may be symptomatic not only of diseases of the thorax and its contents, but also of lesions affecting more remote regions, such as the gastro-intestinal and the genito-urinary tracts, the peritoneum, the spine, and other parts of the nervous system. Such extrathoracic factors as these are to be recalled in deciding the origin of pains affecting the thorax. Of the many localized chest pains, those referred to the apex of the lung, the sternum, the breast, the precordia, the back, and the lower thoracic regions have, in many instances, more or less definite significance; but, as a rule, the various unclassified pains felt in other areas of the chest are most ambiguous clues (Fig. 67).

Pain in the *right shoulder* is occasionally an accompaniment of aortitis and of aneurism of the innominate artery, but more often it is due to some disease of the liver or of the bile-ducts. Possible factors of pain in the *left shoulder* include diaphragmatic pleurisy, distention of the colon, gastritis, gastrectasis, duodenal ulcer, and suprarenal lesions.

At the *apex of the lung* pain is commonly elicited in apical tuberculosis, owing to the attendant pleurisy.

Sternal pain may mean bronchitis, enlarged bronchial glands, or bronchial obstruction by a foreign body; aortitis, aortic valvulitis, aortic aneurism, or angina pectoris; and mediastinal inflammation, abscess, or tumor. Pain in this situation is also very common in gastric disorders, in syphilis, and in diseases of the bone itself.

Pain in the *precordia*, which is quite as likely to be extracardiac as cardiac, has among its numerous factors functional and organic cardiac disease, aneurism of the aorta, angina pectoris, neuralgia, myalgia, and disorders of the stomach and the colon.

Pain in the *breast*, aside from that due to diseases of the mammæ, may be associated with menstruation, pregnancy, and lesions of the uterus and the ovaries. Pleural pains, as in the pleurisy of croupous pneumonia, are also ordinarily referred to this region.

Pain in the *right hypochondrium* suggests especially diseases of the liver and the bile-passages, malignant growths of the pancreas, the hepatic colon, or the duodenum, and aortic valve defects; in the *left hypochondrium*, pain may be due to diseases of the spleen, impaction of the splenic colon, inflammation, ulceration, dilatation

and prolapse of the stomach, and aneurism of the abdominal aorta. As likely causes of pain in either hypochondrium pleurisy, pneumonia, subphrenic abscess, peritonitis, gastric cancer, renal

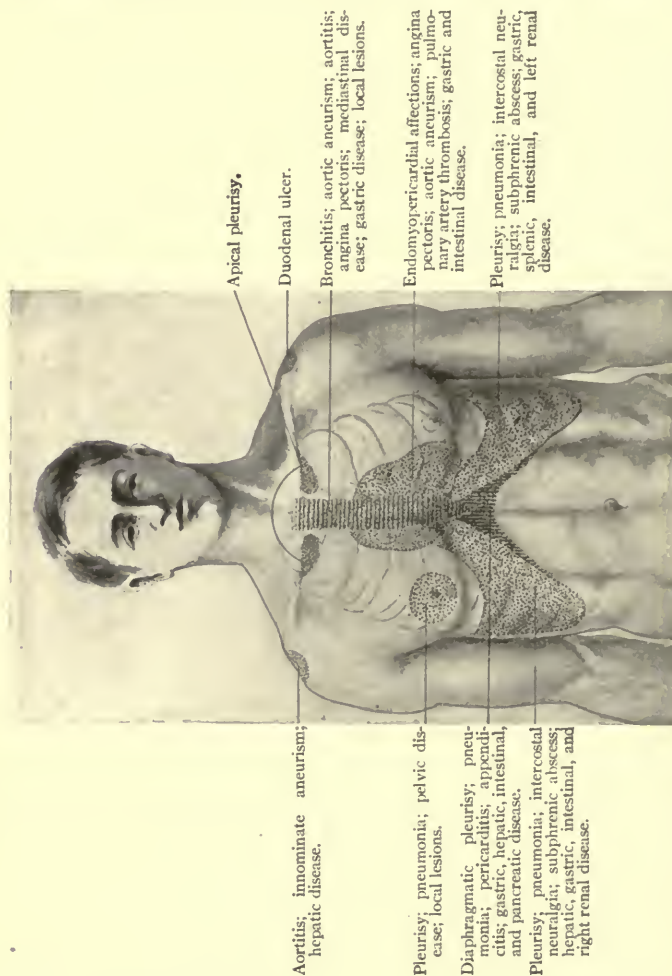


Fig. 67.—Areas of tenderness and pain on the anterior and lateral thoracic walls.

colic, and nephroptosis are to be recalled. Pain localized along the upper part of the *costal arch* may be symptomatic of diaphragmatic pleurisy, or it may come from the strain of long-continued coughing or retching.

Pain in the *lateral wall of the thorax* is particularly significant of pleurisy, pleurodynia, and intercostal neuralgia, and in this region may also be felt the pain of pericarditis, thoracic aneurism, mediastinal disease, and lesions of the vertebræ. Herpes zoster accounts for exquisite pain in the lateral thorax, especially on the right side. The discomfort attending gaseous distention of the stomach and colon, as well as that of fecal impaction of the colon, is also referred to the side of the chest in many instances. Indefinite pains in the side are a common complaint in hysteric and in anemic states.

Pain in the *posterior thoracic wall* (Fig. 68), if localized between the

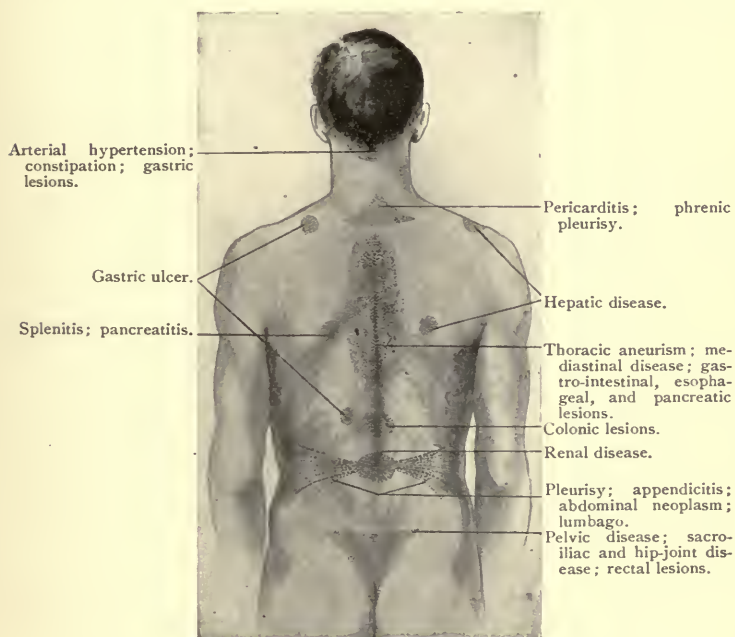


Fig. 68.—Areas of dorsal tenderness and pain.

scapulæ at the level of their spines, may mean either pericarditis or diaphragmatic pleurisy; at the inferior angle of the left scapula, splenitis; and at the inferior angle of the right scapula, disease of the liver. In phthisis an interlobar pleurisy commonly provokes a dull ache, changed by coughing to a sharp, lancinating pain alongside the spine, at the level of the second or third thoracic vertebra, or the point corresponding to the inner border of the oblique fissure between the upper and lower pulmonary lobes. Pain between the scapulæ is

frequently due to some disorder of the stomach, such as overdistention, inflammation, or ulceration; tenderness at the left of the spine at the level of the eleventh and twelfth thoracic vertebræ is frequently elicited in gastric ulcer. The gnawing pain of an aneurism of the descending aorta is felt between the left scapula and the spinal column.

Here also may be mentioned the principal factors of pain in the loin and in the sacral region. Aching and pain in the *lumbar region*, usually radiating to the flanks, constitute a familiar symptom in lumbago, lumbar neuralgia, dysmenorrhea, lithemia, and in con-

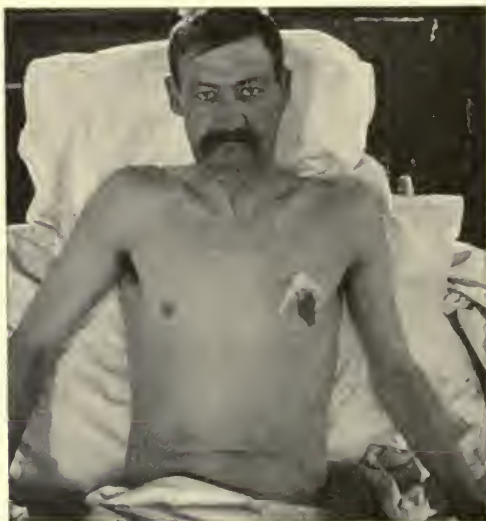

Fig. 69.—Empyema necessitatis (Jefferson Hospital).

ditions of simple exhaustion and neurasthenia; it may be a sign of a more grave disorder—renal lesions, lumbar abscess, appendicitis, hernia, and abdominal aneurism or neoplasm; or it may be referred to diseases of the bladder, the prostate, the perineum, and the rectum. The lumbar region is the favorite seat of the dragging ache excited by a mass of feces within the colon, and of the pain which attends many of the acute febrile infections.

Pain in the region of the *sacrum* is a finding which points pertinently to diseases of the pelvis and its viscera, and one which also suggests sciatica, sacral neuralgia, sacro-iliac disease, coxalgia, inflammation, ulcer, cancer of the rectum, and diseases of the testes.

Of the foregoing, sciatica and lesions of the pelvis and the rectum also reflect pain to the outer and posterior aspects of the thigh. In the *coccygeal region* pain is attributable to such factors as coccygodynia, hemorrhoids, proctitis, and fissure or fistula of the rectum.

Scars.—Scarring of the chest-wall and of the neck is to be carefully investigated, for such marks are sometimes a valuable clue in identifying questionable cases of syphilis and of tuberculosis. The cicatrix left by a healed perforative empyema, by a rib resection, by a trauma, or by a burn may also throw light upon the patient's condition. The pitting of variola and of varicella, the tough, thick, flat scars of lupus, and the minute depressions of acne are also rather distinctive.

Other signs, noted on inspection of the cutaneous surface in general, rather than that of the thorax in particular, relate to the temperature and moisture of the skin, to deviations from its normal color, such as pallor, flushing, undue redness, jaundice, and pigmentation, and to the presence of petechiæ, ecchymoses, and various eruptions.

Clubbed or Drumstick Fingers.—Extreme incurving of the nails, thickening of the joints, and bulbous enlargement of the tips of the terminal phalanges are the hall-marks of this deformity, observed in various chronic diseases of the heart and the bronchopulmonary system, and in conditions of habitual cyanosis. Phthisis, bronchiectasis, empyema, chronic adhesive pleurisy, pulmonary stenosis, and cardiac septal defects are prominent factors of drumstick fingers, which, with less frequency, also occur in rickets, hepatic cirrhosis, gastrectasis, and myxedema. Clubbing of the fingers, with bilateral enlargement of the hands, feet, and long bones, is distinctive of Marie's hypertrophic pulmonary osteo-arthritis, a form of toxic osteoperiostitis incident to various purulent lesions of the bronchi, lungs, and pleura.

SECTION III

EXAMINATION OF THE BRONCHOPULMONARY SYSTEM

CLINICAL ANATOMY

The Lungs.—The lungs are a pair of roughly pyramidal organs, closely approximated to the walls of the pleural cavity, their bluntly convex apices occupying the pleural domes, and their broad, concave

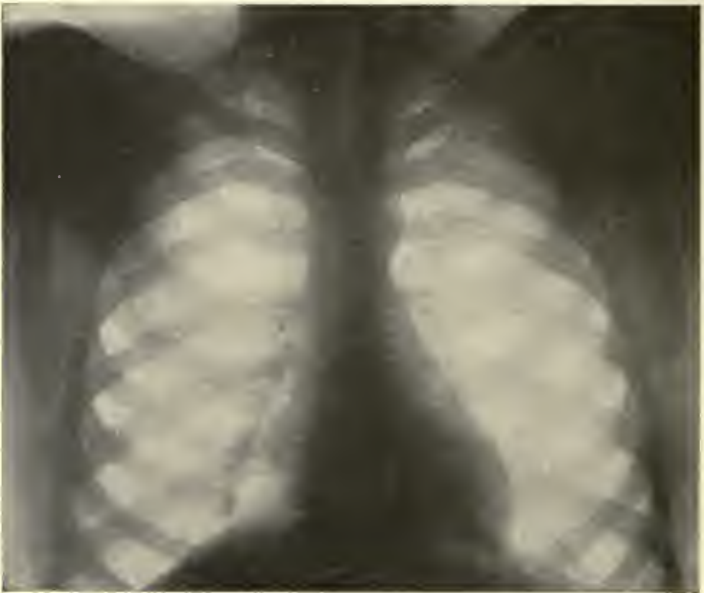

Fig. 70.—Radiograph of the normal thorax. (Plate by Dr. W. F. Manges.)

bases resting upon the diaphragm. Of the two lungs, the left is somewhat longer, narrower, and less voluminous than the right.

The *outer* or *costal surfaces* of the lungs, which are convex, are closely adapted to the inner pleural surfaces of the ribs and the intercostal spaces. The *inner* or *mediastinal surfaces* bound the mediastinum

and are deeply indented, especially on the left side, to afford room for the heart. Above and behind this hollow space is the wedge-shaped *hilus* of the lung, within which the bronchi, the pulmonary artery, pulmonary veins and nerves, the bronchial vessels, and the lymphatics communicate with the lungs. These structures, entering and leaving at the hilus, constitute the *root of the lung*, which lies opposite the fourth, fifth, and sixth thoracic vertebræ. The inner pulmonary surfaces are grooved on the right side for the superior vena

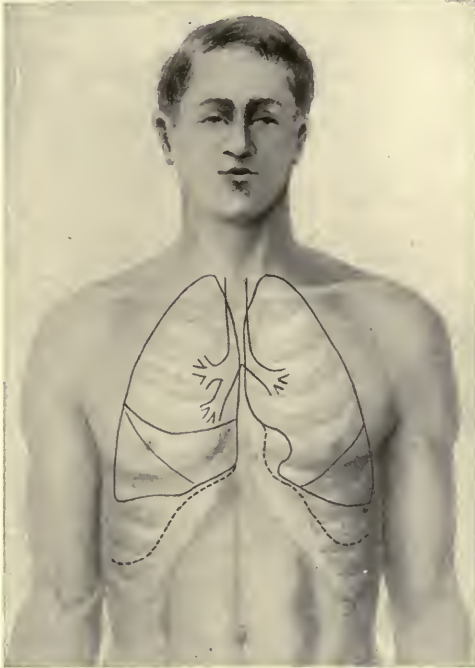


Fig. 71.—Anterior surface topography of the lungs, bronchi, and pleuræ.

cava, the vena azygos major, and the innominate vessels; and on the left side for the aorta, the subclavian artery, and the innominate vein. Anchored only by its root and ligamentum latum pulmonis, each lung is otherwise unattached to its pleural space, in which, therefore, it has unhampered motility.

The *apices* of the lungs rise from $\frac{1}{2}$ to $1\frac{1}{2}$ inches (1.25 to 3.75 cm.) above the clavicles, the right apex being about $\frac{1}{2}$ inch (1.25 cm.) higher than the left. From the apex the *anterior border* of the *right lung*

is traced by a line running through the sternoclavicular articulation to the midsternal line, at the level of the second chondrosternal joint, from which point it drops vertically downward to the level of the sixth costal cartilage. The *anterior border* of the *left lung* corresponds to that of the right as far down as the fourth costal cartilage, but at this level it curves outward along the lower border of the fourth rib as far as the parasternal line, then drops vertically downward to the upper border of the fifth rib, and courses inward to a point upon the

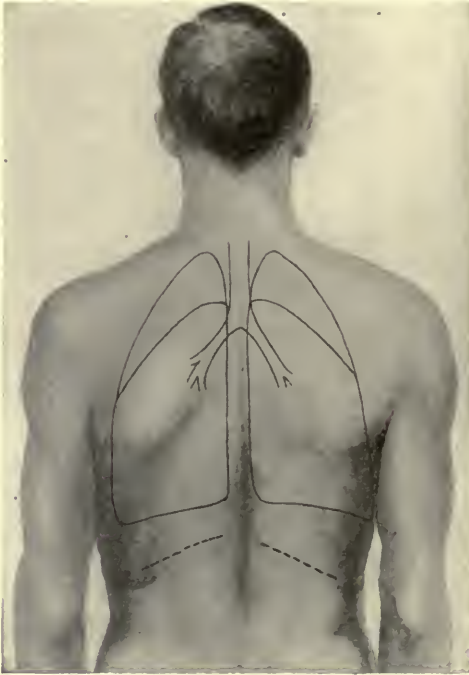


Fig. 72.—Posterior surface topography of lungs, bronchi, and pleuræ.

upper border of the sixth costal cartilage, just inside the parasternal line. This notched contour of the left anterior pulmonary margin overlies the right ventricle, which, uncovered by lung tissue, corresponds to the area of superficial cardiac dulness, or cardiac flatness.

The *lower borders* of the lungs are represented by a line running outward from each lower extremity of the anterior border, and, coinciding with the sixth rib in the midclavicular line, the eighth rib in the midaxillary line, the tenth rib in the scapular line, and the tenth

thoracic vertebra in the midspinal line. Since the inferior margin of the right and the left lung may be considered identical clinically, the foregoing surface-marking applies to each.

The three lobes of the *right lung* are indicated by the courses of its oblique and horizontal fissures, while the two lobes of the *left lung* are separated by its single fissure, the oblique. The position of the *oblique fissures*, which is the same in each lung, is marked by

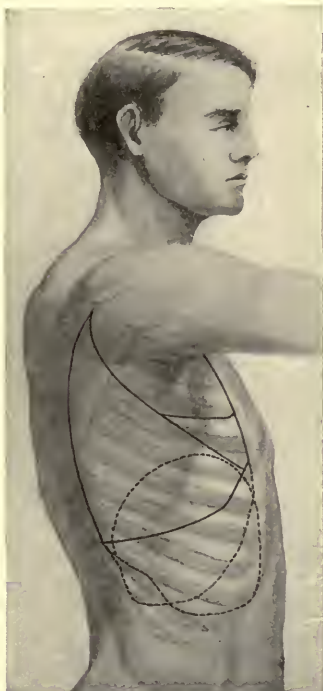


Fig. 73.—Right lateral surface topography of the lungs and pleuræ.

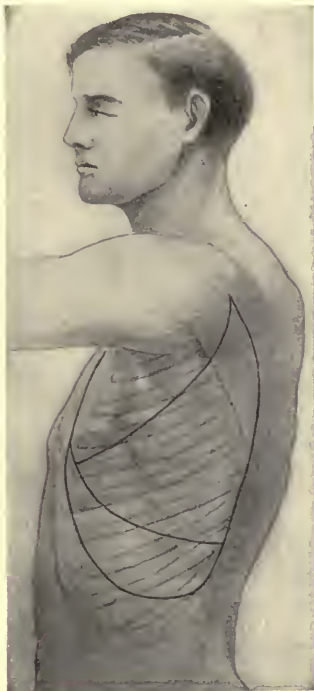

Fig. 74.—Left lateral surface topography of the lungs and pleuræ.

a line beginning at the second thoracic spinous process, continuing downward and forward through the root of the scapular spine to the fourth rib in the midaxillary line, and terminating at the lower border of the lung at the sixth costal cartilage, just inside the parasternal line. The line of the *horizontal fissure* of the right lung begins at the anterior pulmonary border at the level of the fourth costal cartilage, and extends outward below the fourth rib as far as the midaxillary line, where it joins the oblique fissure.

Making use of these interlobar landmarks, the following limits of the pulmonary lobes can be mapped out upon the surface of the body: The *right anterior thorax* overlies the upper lobe from the supraclavicular space to the fourth rib; the middle lobe, from the fourth to the sixth ribs; and a triangular portion of the lower lobe, below and outside the latter level. Upon the *left anterior thorax* the upper lobe extends downward as far as the junction of the sixth costal cartilage and the lower pulmonary border, below which level the lower lobe extends to the left. Upon the *right lateral thorax* the point at which the midaxillary line crosses the fourth rib marks the junction of the upper, the middle, and the lower lobes. The same point upon the *left lateral thorax* divides the upper and the lower lobes of the left lung. Upon the *posterior thorax* on each side the greater part of the upper lobe lies above the scapular spine, below which is the lower lobe, extending downward to the level of the tenth thoracic vertebra.

The Bronchi and Trachea.—The *trachea* begins at the lower border of the cricoid cartilage, enters the mediastinal space at the level of the seventh cervical vertebra, and terminates by division into the right and left primary bronchial tubes, at the level of the root of the scapular spine posteriorly, or at the angle of Louis anteriorly. The *bronchi* extend obliquely downward and outward from the bifurcation of the trachea to the root of each lung, the right bronchus entering the corresponding lung at a somewhat higher level than the left. The right bronchus differs from the left in being shorter, of larger diameter, and of more vertical course—hence the relatively exaggerated physical signs over this tube, as well as its greater predilection for foreign bodies that pass below the division of the wind-pipe. The bronchial lymphatic glands, which are especially numerous near the tracheobronchial junction, extend along each bronchial tube toward the root of the lung. These glands, when tuberculous or otherwise diseased, may, by pressure, inflammation, and infection, seriously implicate the bronchi, the trachea, the esophagus, and the pericardium.

The Pleuræ.—The pleural cavities, which contain the lungs, are lined each with a separate pleural membrane, one layer being in intimate relation with the thoracic parietes (parietal pleura), and a second layer closely investing the lungs (visceral pleura). The *parietal pleura*, though a continuous membrane, is arbitrarily divided into several parts (cervical, costal, diaphragmatic, mediastinal), corresponding to different areas of the thoracic chamber. The significance of these artificial divisions of the pleural covering is self-

evident. The *visceral pleura* closely adheres to the lung, both upon its external and interlobar surfaces, and at the pulmonary root it becomes continuous with the mediastinal part of the parietal pleura.

The surface line of the *right pleura* extends anteriorly from the sternoclavicular articulation to the level of the second chondrosternal joint at the left of the midsternal line, whence it continues downward to the ensiform process, and then is deflected to the right, crossing the lower border of the seventh rib in the midclavicular line, the tenth rib in the midaxillary line, and the upper border of the twelfth thoracic vertebra at the spine. The line of the *left pleura* descends from the left sternoclavicular joint parallel to the course of the right pleura, running beneath the outer third of the sternum as far as the fourth rib; at this level, however, it turns obliquely to the left sternal edge, beneath which it resumes a vertically downward course to a point in the middle of the sixth costal cartilage; thence the line follows, at a somewhat lower level, the same course as the pleural line of the right side to the vertebral column. Posteriorly, both pleuræ parallel the spine from the first to the twelfth thoracic vertebra.

The space lying between the two pleuræ beneath the sternum corresponds to the situation of the anterior mediastinum. The apex of the pleural cavity, inclosing the pulmonary apex, is bounded by a pyramidal line running from the sternoclavicular joint to meet the posterior pleural border at the level of the first thoracic vertebra posteriorly. The slight outward deviation of the left anterior pleural line below the fourth rib exposes the pericardium to immediate contact with the sternum. The recess intervening between the lower pulmonary and pleural borders is known as the *complementary pleural space*; this sinus, largely occupied by the lungs when they are fully inflated, during their deflation varies in depth from $1\frac{1}{2}$ to $3\frac{1}{2}$ inches (3.75 to 8.75 cm.), being deepest on the lateral chest-wall, and extends vertically from about the sixth to the seventh rib in the midclavicular line, from the eighth or ninth to the tenth rib in the midaxillary line, and from the tenth to the twelfth thoracic vertebra in the midspinal line.

The Mediastinum.—The intrapleural space, extending from the sternum to the spine, and partitioning the cavity of the chest into two lateral compartments inclosing the lungs and pleuræ, is termed the mediastinum thoracis, or the mediastinal space. The pleural surfaces surrounding this space are continuous with the costal pleuræ above the superior outlet of the thorax, while at its base the mediastinum is attached to the diaphragm. The important structures inclosed by the mediastinum include the heart and its great vascular

trunks, the trachea, esophagus, and thoracic duct, the thymus gland or its remnants, the bronchial and mediastinal glands, and the pneumogastric and phrenic nerves. It is convenient, for the sake of clear description, to divide the mediastinum into four arbitrary spaces,—superior, middle, anterior, and posterior,—upon whose anatomic differences the interpretation of mediastinal physical signs is to be based.

The *superior mediastinum* lies above the pericardium, and is bounded anteriorly by the manubrium sterni, posteriorly by the bodies of the first four thoracic vertebræ, inferiorly by a line drawn obliquely from the lower border of the fourth thoracic vertebra to that of the manubrium, and laterally by the mediastinal pleuræ. This section of the mediastinum contains the aortic arch, and the innominate, left common carotid, and left subclavian arteries; the upper part of the superior vena cava and the innominate veins; the trachea, esophagus, and thoracic duct; the remains of the thymus gland and the superior mediastinal glands; and the phrenic, pneumogastric, left recurrent laryngeal, and cardiac nerves.

The *middle mediastinum* comprises the enlarged central portion corresponding to the pericardium and heart, in addition to which this space also contains the ascending aorta and its branches, the pulmonary artery, the lower part of the superior vena cava and the vena azygos major, the bronchial lymphatic glands, and the phrenic nerves with their accompanying vessels.

The *anterior mediastinum* is a triangularly shaped space between the sternum and the pericardium, extending vertically from the lower border of the manubrium to the sixth or seventh costal cartilages. It incloses merely a group of lymphatic glands, the anterior mediastinal, embedded in areolar tissue.

The *posterior mediastinum*, which is virtually a downward extension of the superior space, lies between the posterior surface of the pericardium and the spine, and corresponds to the bodies of the eight lower thoracic vertebræ. The contents of this space are the descending thoracic aorta, the azygos veins, the esophagus, the thoracic duct, the pneumogastric nerves, and the posterior mediastinal lymphatic glands.

INSPECTION

Inspection bears importantly upon the diagnosis of pulmonary diseases, the evidences of which are in some instances clearly shown by anomalies in the configuration of the chest and in the character of its respiratory movements. Cyanosis, edema, lymphadenitis, and enlargement of the superficial veins are additional signs, often-

times secondary to lesions of the lungs. These physical signs have been dealt with in the preceding section (p. 104 *et seq.*), and, therefore, require no further mention here.

The examiner should investigate the thorax systematically from every point of view—from the front, from the sides, from behind, and from above downward, standing behind the patient and looking down over the clavicles. The patient, preferably stripped to the waist, is placed in such a position that the light falls directly upon the surface to be examined, save when some inconspicuous sign, such as a small patch of deficient expansion or an ill-defined pulsation, is sought for, in which event oblique illumination is better. The importance of routine inspection of the chest cannot be insisted upon too emphatically in every case in which there is reason to suspect a pulmonary disorder.

The **respiratory turgescence** of the cervical veins is sometimes an aid in the diagnosis of infiltrations and new-growths of the anterior mediastinum. Normally, forcible expiration with the mouth and the nares closed (Valsalva's method) dilates these vessels equally on either side, but should the intrathoracic venous trunks be compressed, the cervical veins on the affected side dilate sooner and more conspicuously than those on the opposite side of the neck.

The pressure of a mass of enlarged bronchial glands may cause venous **suffusion of the neck** when the patient's head is forced far backward in the median line, thereby exerting upon the air-tubes sufficient traction to force the glandular tumor against the cervical vessels.

Circumscribed areas of pulsation, aside from those of precordial origin, elsewhere described (p. 321), are met with in certain diseases of the lungs and pleura. Pulsating pleurisy, usually of the purulent type, may account for a throbbing or an undulation in one or more interspaces, almost invariably on the left side, between the second and the sixth ribs. An intrathoracic pulsating neoplasm, by encroaching upon the inner chest-wall, may also produce a rhythmic surface throb. A large cavity of the left lung, which abuts directly against the heart, may, by conduction of the cardiac impulse, account for a systolic throbbing over the lower lobe posteriorly (Steven).

Displacement of the larynx, recognized by deviation of the pomum Adami from its median position, occurs in consequence of intrathoracic lesions that either drag or push the trachea from its normal course. Extensive pleural effusion, pneumothorax, thoracic aneurism, mediastinal neoplasm, pulmonary excavation, and even a circumscribed dilatation of the aortic arch are to be thought of as possible factors of this deformity. Displacement of the larynx

by an adjacent growth (*i. e.*, a thyroid tumor) is readily distinguished from that due to the conditions just noted.

Inequality in the size of the pupils is a pertinent sign in certain diseases of the lungs and pleura, as in unilateral phthisis, pleurisy, and other lesions exciting irritation of the sympathetic nerve, as shown by a relatively wider pupil on the affected side. Gröber emphasizes the significance of deviations from the normal expiratory contraction and inspiratory dilatation of the pupils. With Valsalva's method of breathing the dilatation of one pupil with expiration (bilateral contraction being normal) suggests a circumscribed lesion on the same side; while if both pupils dilate (instead of contracting), bilateral disease is to be inferred—inferred, but not assumed, for the value of these pupillary signs is to be decided only in the light of a full clinical inquiry. The absence of such changes by no means warrants the exclusion of thoracic disease.

PALPATION

In examining the lungs the sense of touch is used chiefly to study various sorts of fremitus, or vibrations felt over the pulmonary structure, the pleuræ, and the bronchi when the subject speaks, breathes, or coughs, as the case may be. In addition, palpation not only confirms the signs afforded by inspection, but in many instances it proves even more definite, as, for example, in recognizing deficiencies of expansion and local asymmetry so slight as to be overlooked by the eye. Different chest pains and areas of circumscribed tenderness—pleural, neuralgic, muscular—are traced to their proper sources by palpation with much greater surety than when the patient's statement alone is relied upon. Tracheal tugging, to be described subsequently, is occasionally detected when adhesions exist between the trachea or the large bronchi and a neoplasm of the mediastinum, though more commonly this sign is symptomatic of aneurism of the aortic arch (*q. v.*).

In performing palpation the hands should be applied, palms downward, to the naked skin, and moved from place to place methodically, so as to cover the entire surface of the thorax, care being taken to compare the differences of the two sides, especially at the apices and at the bases. Aimless, wandering palpation is worse than none at all, and unless the examination be systematic and comparative, the results will be misleading and confusing. Lagging respiratory movements at the apex are readily appreciated if the examiner stands behind the patient with his index- and middle fingers applied to the supraclavicular and infraclavicular spaces, respectively (Fig. 75)

Deficient expansion at the bases is best determined by facing the patient with the hands closely pressed against the curve of the lower dorsolateral regions of the chest. To gage the general chest expansion, the examiner should stand at the subject's side, placing one hand upon the sternum and the other between the scapulae.

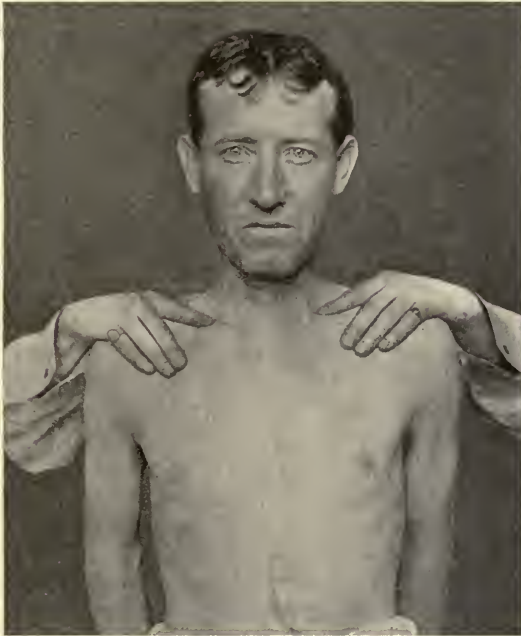

Fig. 75.—Technic of palpating the pulmonary apices.

Vocal Fremitus.—Vocal fremitus is the tactile vibration appreciated by the hand applied to the chest-wall while the patient is speaking aloud. The vibrations thus felt arise in the vocal cords, whence they travel via the trachea, the bronchi, the vesicular structure, and the parietes to the surface of the thorax, where they are recognized as a peculiar purring vibratory sensation.

In eliciting vocal fremitus the palm of the hand is pressed firmly against the bared chest of the patient, who is instructed to repeat, in a deep voice, "ninety-nine," or to count "one, two, three" a number of times, the resulting vibrations being appreciated by the palmar surfaces of the examiner's fingers. Or, as Berkeley suggests, the sound of "ōō," as in "moon" or "rood," is excellent for tactile purposes. Ulnar palpation, or the application of the ulnar side of

the hand, is recommended by some clinicians, but it seems far inferior to the palmar method, owing to the much less delicate tactile sensibility of the side of the hand as compared to that of the fingers. Comparative tests of the fremitus of both halves of the chest should always be practised, in order to detect slight differences.

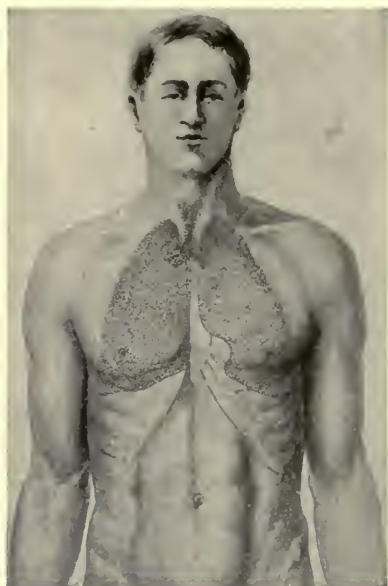


Fig. 76.—Comparative intensity of vocal fremitus, vocal resonance, and respiratory sounds over the anterior thorax.

The intensity of the vibrations depends upon the loudness and the pitch of the voice, and upon the conducting qualities of the structures between the larynx and the palpator's hand. It is more intense in adults than in children; in men than in women; in persons of loud, low-pitched, harsh voice than in those whose voice is quiet, high-pitched, and soft; and in the thin, spare individual

than in one whose chest is muscular, fat, or edematous.

The comparative intensity of vocal fremitus over different regions of the chest is shown by Figs. 76 and 77.

Normally, vocal fremitus is relatively exaggerated over the right side of the thorax, especially in the infraclavicular and interscapular regions. This disparity between the fremitus of the two sides is explained partly by the larger caliber and the less acute bronchotracheal angle of the right bronchus, and partly by the fact that the tube leading to the right upper lobe arises closer to the trachea and at a higher point than the corresponding left tube—anatomic differences by virtue of which the volume of vibrations is greater, their route shorter, and their transmission less impeded within the bronchus of the right lung than within that of the left. The intimate anatomic relation of the trachea and the right lung is another factor of right-sided exaggeration of the fremitus, as recently shown by Fetterolf. Lateral decubitus also influences the intensity of the voice vibrations, the side of the chest in contact with the bed affording a perceptible increase of both vocal fremitus and resonance, together

with a commensurate modification of pulmonary percussion resonance and a slight exaggeration of the respiratory murmur.

The vocal fremitus is faint over the scapulæ, the sternum, and the female mammæ, owing to the interference of these parts with the conduction of the vibratory waves. These latter are, of course, absent over the areas of the thorax corresponding to the immediate contact of the heart, liver, and the spleen. On the other hand, the voice vibrations are clearly conducted by the clavicle, and can be distinctly palpated as far as its outer extremity.

Increased Vocal Fremitus.—This is found in croupous pneumonia, diffuse catarrhal pneumonia, tuberculous infiltration, infarction, and fibrosis, since consolidations such as these conduct vibrations with undue power; the same thing occurs in the case of a dense intrathoracic neoplasm situated near a bronchus. An interpleural fibrous band will telephone voice fremitus through a pleural effusion, notwithstanding the non-conducting properties of the latter (*v. i.*). Increased pulmonary tension, which favors clear transmission of the sound-waves, explains the exaggerated fremitus incident to congestion of the lungs. A cavity, either pulmonary or bronchial, amplifies the voice vibrations and, therefore, increases the fremitus, but to act thus as a resonating chamber the cavity must be near the surface and of considerable size, with resilient walls and a patent bronchial communication.

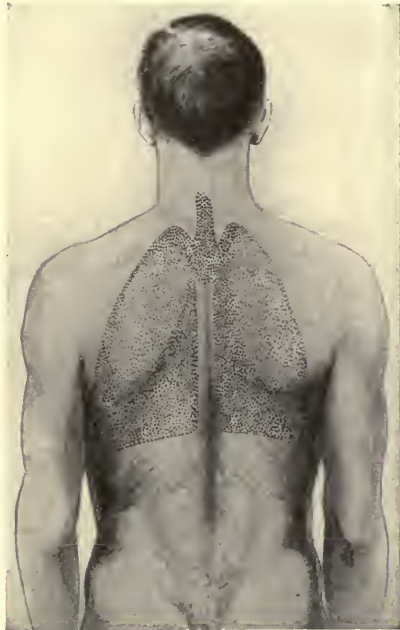

Fig. 77.—Comparative intensity of vocal fremitus, vocal resonance, and respiratory sounds over the posterior thorax.

Decreased Vocal Fremitus.—Modifications of vocal fremitus, ranging from slight enfeeblement to actual abolition of the vibrations, occur as the result of subnormal pulmonary tension, pleural effusions and thickening, and bronchial obstruction. Hypertrophic emphysema, which diminishes the tension and the resiliency of the lungs,

weakens the transmission of the voice vibrations, but scarcely to the extent popularly supposed, and, by a similar mechanism, pulmonary edema has the same effect on fremitus. A plural cavity containing either air or liquid interferes with vocal fremitus, in consequence of the non-conducting properties of the effusion and because of the associated pulmonary relaxation. A greatly thickened pleura or one bathed in a thick, buttery exudate also weakens the vocal vibrations. If any part of the bronchial tubes be blocked, the vocal fremitus over the pulmonary area communicating with the occluded part of the bronchial tree is correspondingly diminished. This occurs as the result of spasm of the tubes, inflammatory swelling of their mucosa, and mechanical obstruction of their lumen by a foreign body or by the pressure of an aneurism, a neoplasm, or a glandular mass. Or the occlusion may be spastic or exudative, as in diffuse catarrhal bronchitis, fibrinous bronchitis, and asthma. It is important to note that in croupous pneumonia, despite the consolidation, vocal fremitus may be completely abolished over the pneumonic lobe if the bronchus leading thereto happens to be plugged with a mass of fibrin.

Rhonchal Fremitus.—The vibrations of coarse bronchial and tracheal râles are sometimes felt upon the surface of the chest, especially during inspiration. This rhonchal or bronchial fremitus is to be looked for in bronchitis and in asthma, and is particularly common in the bronchitis of young children. It is, of course, abolished by bronchial occlusion, and is influenced by coughing and by deep respiration. Occasionally tactile fremitus due to cavernous râles is appreciable over pulmonary and bronchial cavities.

Succussion Fremitus.—This sign, the tactile equivalent of the Hippocratic succussion sound, may occur over a pleural cavity containing air and fluid when the subject's chest receives a sudden jar, so as to splash a wave of fluid against the inner chest-wall.

Tussile Fremitus.—The palpable vibrations excited by coughing are known as tussile or tussive fremitus. They are of trifling clinical value, save perhaps in cases of aphonia, in which it is impossible to elicit vocal fremitus.

Friction Fremitus.—Tactile vibrations corresponding to the pleural friction-sound are sometimes detected over roughened pleural surfaces when the patient takes a deep breath. This pleural friction fremitus feels superficial to the palpating hand, is affected by firm pressure and by forcible respiration, and has a fine, rasping, or even creaking quality, according to the character of underlying pleural lesion. (*Cf.* Pericardial Friction, p. 389.)

Increased Resistance and Fluctuation.—The increased surface

resistance over pleural thickening, pleural effusions, and pulmonary consolidations is appreciable by palpation as well as by percussion. Less commonly the resistance is increased by the diminished elasticity of the lungs incident to extreme emphysema and to pneumothorax. Increased rigidity of the thoracic parietes causes a corresponding increase in the degree of resistance upon the surface.

In exceptional cases pitting and even circumscribed fluctuation due to an affection of the lungs or pleura can be felt upon the surface of the thorax, as in the preperforative stage of empyema necessitatis, and in pulmonary hydatid cyst, inflamed and about to fistulate through the chest-wall. Under the latter circumstance *hydatid fremitus* is sometimes demonstrable by laying the fingers, widely separated, over the swelling, and sharply percussing upon one of them, whereupon a delicate thrill, due to the impact of the daughter cysts, is appreciated by the other three fingers. This so-called hydatid fremitus or thrill must be distinguished from *muscular fremitus* (Barnabei) arising from fibrillary muscular contractions set up by manual stimulation. Such fremitus is especially prone to occur in the abdominal muscles in connection with conditions of excessive intraperitoneal tension, and, unlike true hydatid fremitus, can be excited at will, merely by deep, kneading palpation.

PERCUSSION

Percussion of the lungs gives information relating to the extent of the pulmonary or vesicular resonance and its pathologic modifications, due to lesions of the lungs and their pleural investment, such lesions including consolidation, collapse, overdistention, and excavation of the vesicular structure, together with pleural thickening and collections, gaseous or fluid, within the pleural sacs.

The general rules regarding the patient's symmetric posture, muscular relaxation, and quiet respiration (see p. 27) are to be observed, in order successfully to practise pulmonary percussion. In examining a bed-ridden person perfect anatomic symmetry of the parts is a preliminary essential to the best results, whether the subject be in the dorsal, the ventral, or the lateral decubitus. In percussing the *anterior chest-wall* of a patient in the upright position his head should be kept in the median line, with the arms hanging naturally at the side, so as to poise the trunk symmetrically (Fig. 1). In percussing *the back* the subject should bend well forward from the waist, and fold the arms across the chest, in order to tilt forward the scapulæ, thus flattening the posterior thoracic wall and exposing as large an area of it as possible; or the patient may lean

forward in the position illustrated below (Fig. 78). The *lateral regions* of the thorax are made accessible by having the subject raise the arms, with the clasped hands resting upon the top of the head. Percussion of the *apices* is not an easy matter, owing chiefly to the dulling effect of the thick musculature of the neck, and to the adjacent tympanicity of the trachea. The apices may be percussed from before, with the little finger applied as a pleximeter to the supraclavicular space above and parallel to the clavicle (Fig. 79), or from behind, with the pleximeter finger pointing toward the sternoclavicular joint (Fig. 80).

In *comparative percussion* the areas to be contrasted should be percussed during the same respiratory stage, the force of the blow,

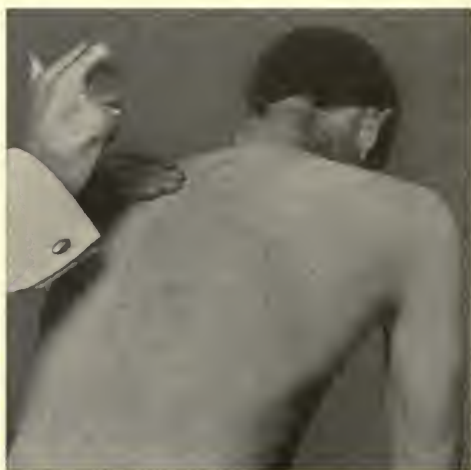

Fig. 78.—Technic of percussing the posterior thorax.

the pressure of the pleximeter finger, and the other details of the percussion technic being identical. Furthermore, the comparable parts must be of similar anatomic structure—the sound obtained over an interspace should be compared with that elicited over a corresponding interspace, not with the sound over a rib or over a dense muscle.

By *respiratory percussion* certain respiratory differences in the percussion sounds can be judged by percussing over the same area while the subject holds the breath, first, after deeply inflating, and then after similarly deflating, the lungs. Normally, when the breath is held after a full inspiration, the sound is of greater resonance, more volume, and higher pitch than that elicited after a forced expiration,

these differences being particularly clear on the right side, below the clavicle and above the scapula.

Normal Pulmonary or Vesicular Resonance.—The distinctive hall-mark of pulmonary resonance is its quality, which, being *sui generis*, is comparable only to the sound excited by the vibration of healthy pulmonary tissue having an air-content distributed through innumerable minutely divided alveolar spaces. Experience alone

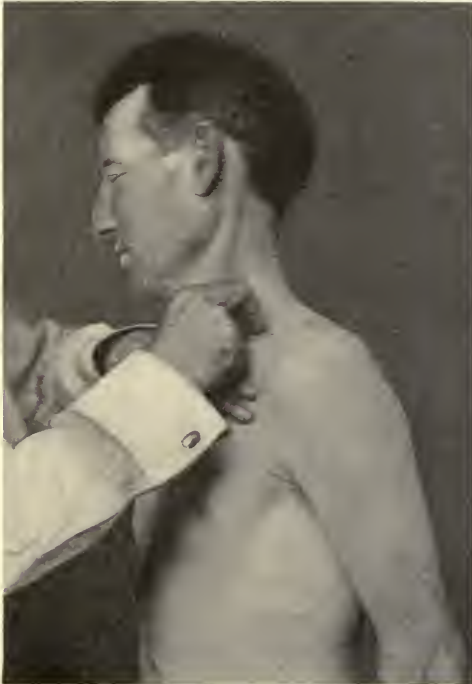

Fig. 79.—Technic of percussing the pulmonary apices.

will enable one to recognize this characteristic vesicular quality, which dominates the pulmonary percussion sound, irrespective of its pitch, intensity, and duration. These acoustic details of resonance have been considered in a preceding section. (See p. 17.)

Certain *regional differences* in normal pulmonary resonance, due entirely to physiologic causes, must be clearly distinguished, in order not to misinterpret the results of percussion of the lungs. Modifications of the percussion sound, perfectly normal in one region of the

chest, may be pathologic when found in a different area, so that the significance of any given sound rests upon its variance from the sound afforded by the part in health.

The clear, low pitch and vesicular quality of pulmonary resonance are typically illustrated by percussing in the upper axillary region above the fourth rib, and this is also true of the middle of the infra-

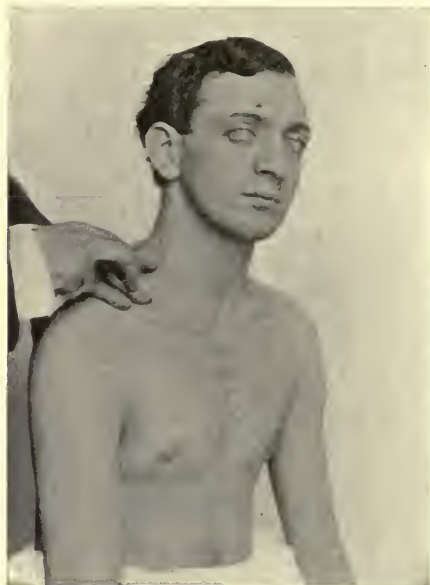

Fig. 80.—Technic of percussing the pulmonary apices.

clavicular region; at the sternal end of this region, however, the resonance of the lung blends with the osteal tone of the sternum and with the tympanic element of the underlying primary bronchi and trachea. Owing to the anatomic peculiarities of the right bronchus and to the encroachment of the large blood-vessels upon the right pulmonary apex (Norris; Fetterolf), the percussion sound is somewhat higher pitched and less typically vesicular in the right than in the left infra-clavicular area. To a minor degree these differ-

ences are also found in the supraclavicular regions, at the inner portions of which one must reckon with tracheal tympany.

Anteriorly, on the right side, the dulling effect of the liver is encountered in the midclavicular line below the fourth rib, and in the anterior axillary line below the sixth rib. On the left side, below the fourth rib, the dullness of the heart modifies the pulmonary sound within the midclavicular line, while between this line and the axilla the influence of gastric tympany is apparent below the fifth rib. On both sides resonance is obscured over the site of the great pectoral muscles and the mammary glands. *Laterally*, hepatic dullness on the right side, and gastric tympany (perhaps, also, splenic dullness) on the left side, modify the resonance of the lower axillæ. *Posteriorly*, the percussion sound is nowhere so resonant as it is anteriorly, this being especially noticeable above and over the scapulæ, where the dead-

ening effect of the bone is obvious. In the other regions of the back resonance is more or less obscured by the thick musculature, the spine, and the underlying solid viscera.

Aside from the foregoing differences, it must be remembered that pulmonary resonance is obscured wherever the thorax bears a dense investment of muscle or of fat, and also that undue rigidity of the bony thorax lends impurity to the percussion sound. Postural compression of one side of the thorax may cause dulness due to mechanical suppression of parietal vibrations. (See p. 133.)

Normal Limits of the Pulmonary Borders (Figs. 71, 72, 73, and 74).—The position of the pulmonary borders is determined by percussion while the subject's lungs are in a state of median inflation, *i. e.*, during respiratory repose. The *upper borders* are outlined by percussion over the supraclavicular spaces, where the apices project, in health, from $\frac{1}{2}$ to $1\frac{1}{2}$ inches (1.25 to 3.75 cm.) above the clavicles. The *lower borders* are mapped out by percussing vertically downward along the midclavicular, the midaxillary, and the scapular lines, from typical pulmonary resonance to the levels of hepatic flatness on the right side, and to gastric tympany and the flatness of the spleen, the kidney, and the lumbar muscles on the left side. The lower border of the right lung extends to the sixth rib in the midclavicular line, to the eighth rib in the midaxillary line, and to the tenth rib in the scapular line, hepatic flatness lying below these levels. The lower border of the left lung extends in the midclavicular line to the sixth rib or interspace, below which there is the sound of gastric tympany, while the lateral and the posterior levels of the left lower border are practically the same as those of the right lung. The *anterior borders* of the lungs are too closely approximated to be separated by percussion, and the excessive vibrations of the sternum, beneath which these borders lie, also forbid their delimitation. The peculiar curve of the precordial border of the left lung bounds the area of cardiac flatness lying at the left sternal margin, between the fourth and sixth ribs. (See Cardiac Percussion, p. 350.)

In early childhood the lower pulmonary borders are higher, and in advanced life lower, than the above mean levels, the difference in each instance amounting to about 1 inch (2.5 cm.). Changing from the dorsal to the lateral decubitus depresses the lower border of the uppermost lung about $1\frac{1}{2}$ inches (3.75 cm.) in the axilla, and changing from the dorsal to the erect posture elevates the lower level $\frac{1}{2}$ inch (1.25 cm.) anteriorly.

Changes in the Mobility and Position of the Pulmonary Borders.—The *mobility of the lungs* is gaged by the excursions of the pulmonary borders, as shown by their positions during extreme

inspiration and expiration. In the healthy adult the vertical excursion of the lower border above and below the mean is about $1\frac{1}{2}$ inches (3.75 cm.) anteriorly, and 3 inches (7.5 cm.) laterally, the inspiratory convergence of the anterior borders encroaching upon precordial flatness practically to the point of obliteration. Restriction, in part or absolute, of this excursion is noted should the lungs be overdistended, infiltrated, or hampered by adhesions or by mechanical pressure. Thus, emphysema, consolidations, fibrosis, adhesive pleurisy, and excessive intra-abdominal pressure, by limiting the normal pulmonary excursions, are attended by unnaturally small differences between the inspiratory and the expiratory levels of the pulmonary borders, and in such instances the axillary diaphragm shadow is correspondingly obliterated. (See Litten's Sign, p. 93.)

The **extent of the pulmonary resonance** is determined by the position of the pulmonary borders during respiratory repose, deviations from the normal boundaries being either general or circumscribed, according to the nature of the pulmonary lesion responsible for such changes.

A *general extension* in the area of pulmonary resonance is met with in hypertrophic emphysema, in which all the normal boundaries of the lungs are overstepped, the apical resonance rising to an unnatural height above the clavicles, the basic resonance encroaching upon the upper zone of hepatic dulness, and the resonance of the anterior borders extending partly or completely over the cardiac area ordinarily uncovered by the lungs. It is in this region especially that an emphysematous extension of the borders is likely to be most readily detected. A similar extension of the pulmonary borders may attend an asthmatic paroxysm, fibrinous bronchitis, and dilatation of the lungs consequent to uncompensated cardiac disease. Circumscribed emphysema is associated with extension of the pulmonary resonance corresponding in situation and extent to the seat of the lesion. The lower pulmonary borders not uncommonly sag below their normal level in Glénard's disease.

Decrease in the extent of pulmonary resonance, if general, may be symptomatic of atrophic emphysema; if local, some lesion provocative of pulmonary retraction and shrinkage is suggested. Diminution in the height of the apical resonance, unilateral or bilateral, points to phthisis or to pleural adhesion. Elevation of the lower borders, with apparent extension of the vertical hepatic dulness, may be symptomatic of pleural retraction or of tuberculous or atelectatic contraction of the lung. Unilateral elevation of the lower pulmonary border is also observed in pneumothorax, pleurisy with effusion,

paralysis of the diaphragm, and upward displacement of this muscle by excessive subphrenic pressure. Fibroid retraction affecting the anterior borders of the lungs may account for an unduly large area of cardiac dulness.

Dulness and Flatness.—Impaired pulmonary resonance, with a corresponding increase in resistance, denotes airlessness, absolute or relative, in the structures within range of the percussion impact, or, as Weil expresses it, the acoustic sphere of action. This may be due to infiltration of the pulmonary parenchyma, to fluid within the pleural sac, to thickening of the pleura, or to a neoplasm situated directly beneath the chest-wall. Thus, dulness is found in croupous pneumonia, diffuse coalescing catarrhal pneumonia, phthisis, a telecta-

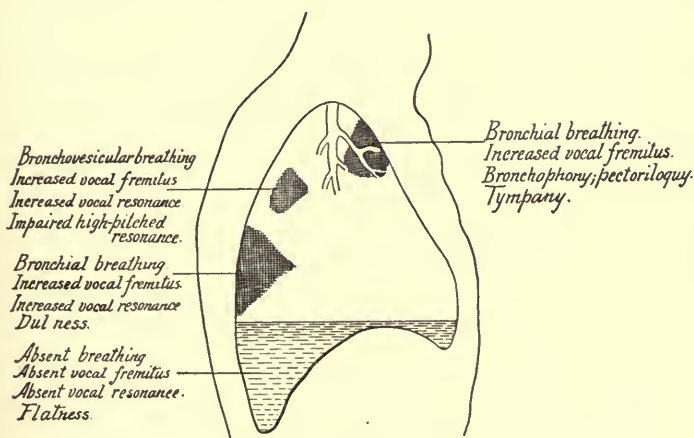


Fig. 81.—Physical signs in pulmonary consolidation and in pleural effusion.

sis, congestion, edema, cirrhosis, and in destructive processes of the lung, such as abscess, gangrene, and new-growths. The percussion sound is dulled to the degree of flatness as the result of pleural effusion, pleural thickening, enlarged bronchial glands, and neoplasms of the pleura and of the mediastinum (Fig. 81).

The degree of dulness depends upon the volume of air in the parts percussed, upon their size and situation, and upon the force of the percussion stroke. Other things being equal, the larger, more superficial, and more densely consolidated the lesion, the more marked the degree of dulness. The influence of the above factors is well shown by comparing the sounds produced by strong and by light percussion over pulmonary infiltrations of different size, situation, and distribu-

tion (Fig. 82). The percussion stroke may be too light to elicit the dulness of a deeply seated extensive consolidation, since with light percussion the vibrations fail to reach the airless area and, therefore, elicit only the resonance of the intervening normal vesicular structure. Strong percussion, the sphere of which includes the consolidated patch, at once reveals the latter by an impairment of the

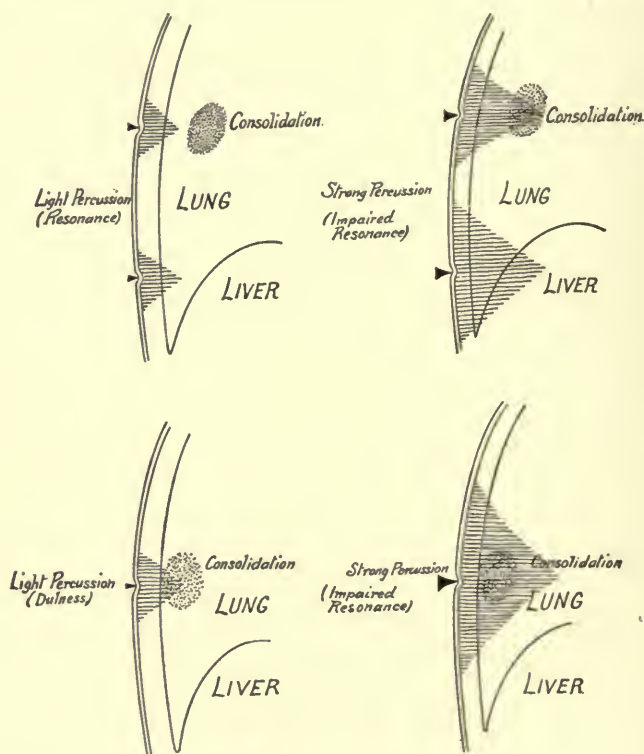


Fig. 82.—The effects of variable percussion force.

resonance. Percussion may be too strong to bring out the dulness of a small superficial infiltration, should the blow be of sufficient force to set up vibrations in the lung tissue behind and around the patch, the dulness of which is thus obscured by the predominant resonance of the vesicular sound. Under the same circumstance, if the percussion stroke be light, so as to affect only the infiltrated area, the latter's dulness will be demonstrable. Neither light nor strong per-

cussion may avail in eliciting the dulness of diffuse disseminated areas of infiltration, owing to the prevailing resonance of the surrounding pulmonary tissue, whereby the dulness is so effectually masked that it escapes notice. This is particularly true if strong percussion be made, for the more forcible the blow, the more intense the vesicular vibrations. Analogous to this is the neutralization of dulness from consolidation by the undue resonance of the adjacent relaxed or vicariously distended lung.

The situation of a dull or a flat area has a certain clinical bearing upon the character of the underlying lesion, although deductions based upon such a premise are to be made only in correlation with other physical signs. Thus, *apical* impairment of the percussion sound is most suggestive of tuberculosis; equality of the sound at both apices points to an incipient left-sided infiltration, since in health the upper right lobe shows relative impairment. (See p. 126.) A second important factor of apical dulness is the so-called apex pneumonia, which occurs especially in children. *Sternal* and *parasternal* dulness, generally near Louis' angle, is found in mediastinal tumors large enough to have encroached anteriorly upon the inner surface of the sternum, and laterally upon the anterior borders of the lungs. The dulness of tumors of the lungs and the pleura cannot be referred definitely to any distinct topographic region. Dulness or flatness at the *base* posteriorly, if not obviously due to enlargement of the liver or the spleen, is commonly a sign of croupous pneumonia, fluid within the pleural cavity, and pulmonary edema, infarction, or hypostatic congestion. Basal flatness shifting with the subject's change of posture occurs in pleural transudates, such as hydrothorax and hemothorax; rarely, if ever, does an inflammatory pleural exudate gravitate in this manner. *Paravertebral* dulness, if bilateral, should prompt a search for atelectasis and its exciting factors, or for hydrothorax. In pleural effusion a triangular patch of paravertebral dulness above the level of the twelfth rib may be demonstrable on the unaffected side—*Grocco's sign*. (See p. 273.) Impairment in the *interscapular area* is significant of enlargement of the bronchial glands, as well as of aneurism of the descending aorta, which causes dulness between the vertebral column and the left scapula. Dulling of the normal tympany in *Traube's space* may be due to fluid within the left pleural sac, and to enlargements of the heart, liver, or spleen, while in pericardial effusion, adhesive pericarditis, right pleural effusion, pleural thickening, and basal pneumonia the normal resonance of Ebstein's *cardiohepatic angle* may be obliterated. Dulness in the *axilla* is commonly a sign of pulmonary infarction.

Unilateral dulness, of a peculiar wooden quality, over the greater part of one lung, is often met with in pulmonary cirrhosis, and multiple patches of impaired resonance are sometimes to be detected in catarrhal pneumonia, miliary tuberculosis, and pulmonary syphilis.

Hyperresonance and Tympany.—Exaggeration of pulmonary resonance indicates that the structures within the percussion sphere contain an abnormally large volume of air, that their mural tension is altered, or that they conduct clearly the hyperresonance of adjacent air-containing parts, according to the character of the exciting cause of the altered sound. Thus, hyperresonance is met with as the result of vesicular emphysema, bronchopulmonary cavities, pneumothorax,

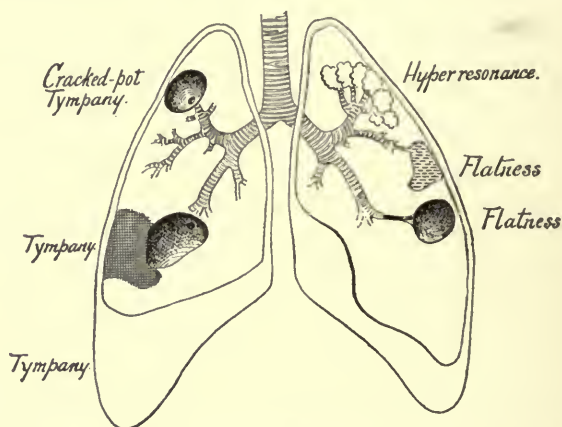


Fig. 83.—The effect of pulmonary cavities, pneumothorax, and emphysema upon the percussion sound.

parabronchial consolidations, and pulmonary relaxation consequent to mechanical or to parenchymatous changes (Fig. 83).

The increased resonance of *hypertrophic emphysema*, dubbed "band-box resonance," is explained by the unduly excessive volume of air within the lungs, and by the state of pulmonary relaxation due to permanent overdistention and destruction of the alveolar tissue. In the condition termed *compensatory emphysema* hyperresonance is elicited over the lung vicariously dilated in consequence of crippling of the opposite lung. The exaggerated resonance expressive of these emphysematous changes is a commingling of the vesicular and the tympanitic qualities, of abnormally increased intensity and duration, and of a pitch rising in proportion to the predominance of the tympanitic quality—the *vesiculotympanitic resonance* of Flint. Acoustic-

ally, this sound is essentially similar to the resonance of Skoda, described below.

Pulmonary hyperresonance commonly accompanies the extremes of life—as in the young child, whose lungs, owing to their great elasticity, are prone to temporary dilatation from simple respiratory overaction, as, for example, during a fit of crying; and in the very aged, whose lungs, in consequence of senile changes, are in a state of relaxation. In scoliosis circumscribed patches of compensatory hyperresonance may be found opposite to the vertebral convexity (Gray).

Conditions of *pulmonary relaxation* secondary to compression and to parenchymatous disease of the lungs may account for a decided increase in the resonance of the percussion sound, owing to the diminished tension of the vesicular tissues. This sort of hyperresonance, termed *Skodaic resonance*, is elicited by percussion over the compressed lung immediately above a pleural effusion or an extensive basal pneumonia; less readily it can be detected over the relaxed pulmonary tissue adjacent to an intrathoracic neoplasm, an enlarged heart, or a large pericardial effusion. Upward displacement of the diaphragm, secondary to excessive intra-abdominal pressure, crowds the lungs upward and lowers their tension to a degree provocative of greatly exaggerated resonance. In the formative stage of obstruction atelectasis hyperresonance is found over the area corresponding to the patch of airless relaxed lung. In acute febrile states a general hyperresonance, presumably due to diminished pulmonary tension of toxic origin, has been described by Samuel West as an “acute pulmonary tympanites.”

Hyperresonance dependent upon parenchymatous changes in the lungs develops in the congestive stage of croupous pneumonia, in pulmonary edema, and in pulmonary infarction, all of which lesions lower the tension of the vesicular structure.

It should be borne in mind that the hyperresonance observed in the foregoing conditions is incidental only to the stage of pulmonary relaxation, for when the affected lung becomes consolidated, dulness at once appears. This transition from hyperresonance to dulness occurs, for example, in compression atelectasis so soon as the vesicular structure becomes infiltrated or carnified, and in croupous pneumonia when the stage of red hepatization sets in.

Pulmonary and *bronchiectatic cavities*, inasmuch as they act as air-containing resonating chambers, furnish a tympanitic percussion sound whose tonal characteristics vary with the physical properties of the excavation and the adjacent parts. It is important to understand that a cavity affords typical physical signs only when it is super-

ficial, filled with air, and resilient, with a free bronchial outlet. A large cavity may be so deeply buried in the parenchyma of the lung as to escape recognition, even by the most vigorous percussion; while a much smaller cavity, if it be superficial, can generally be detected by gentle percussion. When the air within a cavity is replaced by liquid, the primary tympany changes to flatness, which becomes more and more marked as the resonating chamber of the cavity is thus abolished. Should the cavity be emptied by expectoration, the primary tympany reappears, and a similar transition from tympany to flatness to tympany may occur as the result of the lodgment and the dislodgment of a tight mucous plug in the cavity's bronchial outlet. The mural resiliency of a cavity is also an important determining factor in the character of the tympanitic sound: in two cavities of equal size, the one having the more relaxed walls affords the lower pitched and intenser sound. It is common to find a dull undertone to the tympany over a pulmonary cavity adjacent to a patch of pulmonary infiltration or of pleural thickening (Fig. 83).

Over a *pneumothorax*, or an effusion of air within the pleural sac, loud tympany, perhaps of a metallic tone, is heard on percussion, provided that the mural tension is not excessive. If this be so, the percussion sound, although unnaturally intense, is dull and muffled and toneless. Pneumothoracic tympany frequently extends far beyond the anterior and the inferior borders of the lung, owing to the tendency of the air to fill the complementary pleural sinus. Therefore, the tympany encroaches upon the dull areas overlying the heart, the liver, and the spleen, from whichever quarter the effusion spreads. Upward extension of the hyperresonance also takes place, for the lung above a pneumothorax is relaxed by the upward pressure of the intrapleural air: in the extreme instance the entire side of the chest emits an intensely tympanitic percussion sound. Since a pneumothorax eventually excites pleural effusion into the air-distended sac, the tympanitic area sooner or later is underlaid by a zone of flatness, which, unlike the flatness of a simple inflammatory exudate, shifts with the subject's change of position (Fig. 81).

Parabronchial consolidations conduct the normal percussion tympany of the large bronchi and the trachea, tympany from this cause being demonstrable by percussing over tuberculous and pneumonic consolidations lying between the larger bronchi and the inner surface of the thorax (Fig. 81).

Amphoric Resonance.—This is a variety of tympany characterized by a prolonged empty, echoing sound of high pitch and distinctive metallic quality. It may be fairly well imitated by flapping the

cheek with the finger when the mouth is closed and moderately distended with air, or by tapping the side of an empty jar—hence the term, “jug sound.”

Amphoric resonance may be demonstrated by forcible percussion over an air-containing cavity of fair size and superficial situation, with smooth, thin, moderately tense walls, and a small outlet, or none at all. Pneumothorax and tuberculous cavities occasionally, though by no means frequently, afford tympany of this peculiar echoing character.

Cracked-pot Resonance.—This form of tympany is recognized by its distinctive chinking quality, which has been likened to the muffled chink of coins (*money-chink resonance*), and to the sound produced by striking the side of a cracked metal jar (*cracked-pot sound*; *bruit de pot fêlé*). This sound may be counterfeited by clasping the hands so as to form a cavity, and striking them sharply against the knee, thus suddenly expelling, with an audible “chink,” a jet of air through the constricted orifice between the opposed palms. The essential element of the cracked-pot sound is the sudden expulsion of air from a cavity through a small opening, and this noise blends with the ordinary tympany of the cavity to produce the characteristic sharp “chink.” To elicit the sign, strong percussion should be made during expiration, the patient’s mouth being open when the blow is struck.

Interpreted in connection with other physical signs, the cracked-pot sound is an important indication of a cavity, but as a single isolated finding, it is of most uncertain utility. It is to be heard, especially at an apex, over a superficial cavity with tense, though resilient, walls, and a free bronchial outlet, and at the base over a pneumothorax communicating with the air by a fistula leading either into a bronchus or through the chest-wall (Fig. 83). The sound is also sometimes elicited over an acutely congested lung, as well as over the relaxed, compressed pulmonary tissue above the upper level of a pleural effusion. A highly resilient normal chest, if percussed with considerable force, may emit a spurious cracked-pot sound, produced by the rush of the escaping air plus the loud sound of pulmonary resonance. It is not uncommon to find this in the young child, particularly during the act of crying, which, by narrowing the glottis, impedes the egress of the air-columns set in motion by the percussion blow. As already pointed out, a cracked-pot sound may be closely imitated should the pleximeter finger not be closely applied to the surface of the chest when the percussion blow is delivered.

Special Tonal Changes of the Percussion Sound.—Several

distinctive alterations in the pitch, intensity, quality, and permanence of the percussion sound have been described as aids in determining not only the initial diagnosis of solid and hollow pulmonary lesions, but also, in the case of the latter, in gaging the size and the shape of the cavity, the amount of its contained fluid, and the patency of its communication with the external air.

Wintrich's Sign.—Percussion over a cavity gives clearer, louder, and higher pitched tympany when the patient's mouth is open than when it is closed. This change of note, known as *Wintrich's sign*, is found over superficial cavities and over pneumothorax, in either of which conditions a free bronchial communication is essential for its production, the mechanism of which consists in the transmission of the percussion vibrations to the tracheal air-columns, and thence

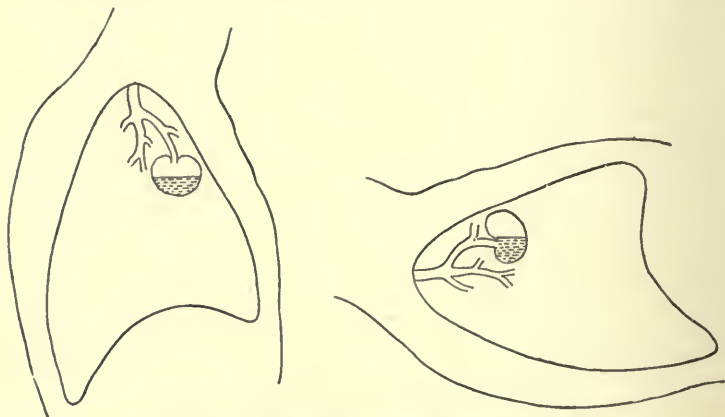
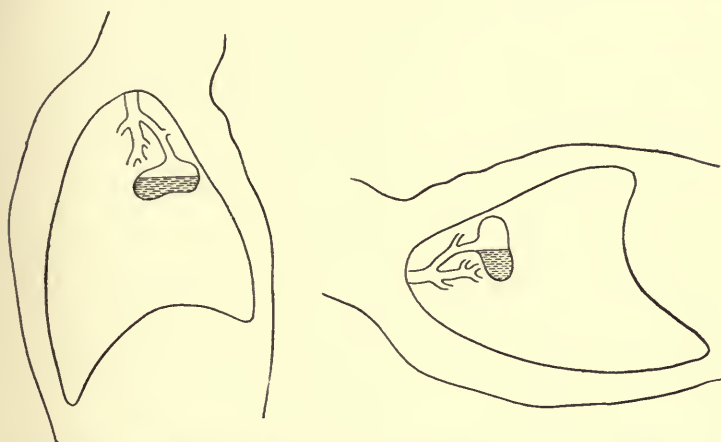


Fig. 84.—Wintrich's interrupted change of note.

to the mouth, where they are amplified and resonated by the action of the pharynx. In eliciting Wintrich's change of note the examiner's ear should be kept directly beneath the open mouth of the patient, who is instructed to elevate the chin, to protrude the tongue, and to inspire forcibly, even beyond the ordinary acme of inspiratory excursion. The sign can be fairly well imitated by percussing over the trachea, first with the subject's lips tightly closed and then with them wide agape.

If Wintrich's sign appears and disappears, depending upon the posture of the patient's body, the change is termed *Wintrich's interrupted change of note*. This sign indicates a cavity containing fluid, which shifts as the subject changes his position, so that the bronchial outlet is alternately occluded and left unobstructed (Fig. 84).

Williams' Tracheal Tone.—Percussion over an infiltrated or a compressed apical lesion may show an alteration of note similar to that of Wintrich, the sound changing from dulness, when the patient's mouth is closed, to clear high-pitched tracheal tympany when the mouth is open—the *tracheal tone* of Williams. An analogous tonal alteration has been found by Hoover when the upper part of the sternum is percussed in cases of anterior mediastinal new-growth, aneurism of the ascending aortic arch, and large pericardial effusion; and, according to Gröber, tympany with a Wintrich tone change is demonstrable in tumors of the posterior mediastinal space. The production of Williams' tracheal tone in the foregoing lesions depends



Low-pitched tympany with subject erect.

High-pitched tympany with subject recumbent.

Fig. 85.—Gerhardt's sign.

upon the transmission of the percussion waves to the trachea, whose air-columns, thus agitated, lend a tracheal quality to the sound primarily excited in the area percussed.

Friedreich's Sign.—Inspiratory elevation and expiratory lowering of the pitch of cavity tympany is known as *Friedreich's sign*, which requires for its production physical conditions identical with those responsible for Wintrich's change of note. Respiratory change of pitch is attributed to variations in the mural tension of the cavity and in the size of the chink of the glottis, which occur with the act of breathing. Unless associated with other more definite indications of a cavity, Friedreich's sign is likely to be misleading—a similar respiratory change of pitch, differing from it chiefly in degree, may

be readily demonstrated by vigorous percussion over the normal lungs, owing to differences in pulmonary tension during inspiration and expiration. (Cf. Adherent Pericardium.)

Gerhard's Sign.—This is a change of note relating to the shape of a pulmonary cavity, and consists of an alteration in the pitch of the percussion tympany, occurring when the patient's posture is changed. In order to afford this change of pitch a cavity must be partly filled with fluid, have unequal axes, and have an unobstructed bronchial outlet. Under these circumstances the pitch of the tympany is lower when the long axis of the cavity is horizontal than when it is vertical, (Fig. 85). Thus, a cavity with a long horizontal axis emits a lower tympany when the patient sits erect than when he lies upon the back, while one with a long vertical axis affords

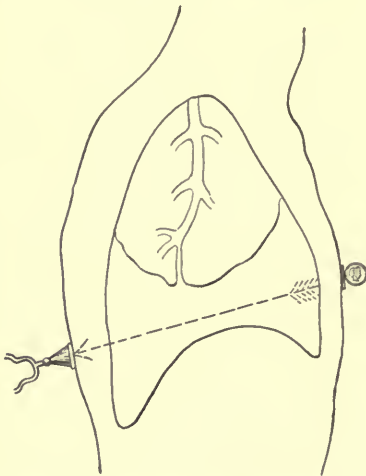


Fig. 86.—Mechanism of bell tympany.

higher pitched tympany under the same conditions of posture. An identical change of pitch, known as *Biermer's sign*, may be elicited over a hydro-pneumothorax, in which condition the percussion tympany is low pitched when the patient is recumbent and high pitched when he is erect, since in recumbency the long horizontal axis of the pleural cavity is increased by the gravitation of the fluid. Of these two signs, Biermer's is the more constant. This is so because the pleural cavity more readily provides the necessary acoustic conditions than a pulmonary excavation—

the former frequently serves as a simple oval resonating chamber, while the latter is ordinarily of exceedingly irregular shape, with several axes of unequal length.

Bell Tympany.—In pneumothorax a distinctive metallic echo (*bruit d'airain*) may be elicited by a special sort of auscultatory percussion known as Gairdner's coin-test (Fig. 86). This consists of auscultating over the lower thorax posteriorly, while an assistant percusses at the same level anteriorly, using the edge of one large silver coin as a plexor and the flat surface of another as a pleximeter. If the pleural sac be filled with air, the impact of the two coins is

heard as an echoing metallic ring, not unlike the distant sound of a hammer and anvil or of a chime of bells. It is also possible to hear the bell sound over a large, empty, superficial pulmonary cavity having the resonating properties of a pneumothorax.

Here may be mentioned the transmission of the metallic click of two coins, demonstrable by the above technic in pleural effusions (Pitres's *signe du sou*). This sound, however, wholly lacks the chiming tone so typical of pneumothorax, being harder, more "chinky," and less echoing. The tone is simply dull when fluid and consolidation coëxist.

The Lung Reflex.—Not infrequently a circumscribed area of pulmonary resonance becomes decidedly hyperresonant after prolonged and vigorous percussion, this alteration of sound being ascribed to a temporary dilatation of the lung, excited reflexly, beneath the part percussed. Abrams has described, under the term *lung reflex*, this sort of circumscribed hyperresonance resulting from local irritation of the surface of the chest by the application of heat, cold, friction, and mustard, which apparently provokes dilatation of the vesicular tissue beneath the irritated surface area.

AUSCULTATION OF THE LUNGS

Auscultation is the means of studying the normal respiratory sounds and their pathologic modifications, of judging the character of the voice resonance, and of detecting sundry adventitious sounds produced in the bronchopulmonary structures and in the pleura. Either the mediate or the immediate method may be employed, according to the examiner's preference—there are those who believe that poorly defined chest signs, such as very fine crepitations and distant pathologic breathing, can be detected most easily by applying the ear directly to the chest, and there are those who, accustomed to using a stethoscope, can judge respiratory sounds most accurately with this instrument. The exceptional instances in which the naked ear serves better than the stethoscope have been referred to in the preceding section. (See p. 23.)

To obtain trustworthy results, the patient should breathe regularly, tranquilly, and somewhat more deeply than normal, thus fully inflating and deflating the lungs, while the examiner auscultates systematically over the different areas within the pulmonary borders. The sounds thus elicited are analyzed and compared with those afforded by deeper, more forcible respiration, which in some instances is necessary to develop tangible findings. To avoid the production of extraneous noises within the upper air-passages, the patient is

instructed to breathe with the mouth partly open, the cheeks and nares being relaxed, and to guard against forcible, noisy respiration. These essential precautions, though of themselves simple, are not easy to put in force, for the average subject is not readily taught how to breathe properly.

THE RESPIRATORY SOUNDS

The respiratory sounds audible over the normal thorax conform to two principal types, *vesicular* and *bronchial*, to which may be added, for convenience sake, a subsidiary variety, which combines the characteristics of both, the *bronchovesicular*. Each of these types of breathing is audible, in health, only in certain definite regions of the chest, and, this being so, the substitution of one

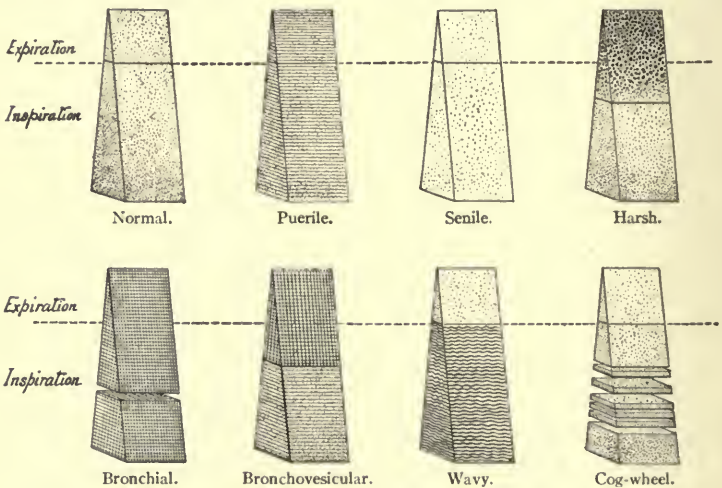


Fig. 87.—Normal and pathologic types of the respiratory murmur.

respiratory type by another (such as the existence of bronchial or of bronchovesicular breathing in a region normally affording a pure vesicular sound) is to be regarded as pathologic.

Vesicular Breathing.—The normal vesicular murmur is a soft, rustling, breezy, low-pitched sound, whose inspiratory and expiratory cycles blend so imperceptibly that no distinct interval of silence separates them (Fig. 87). The inspiratory phase best illustrates the distinctive breeziness, the low pitch, and the moderate intensity of the sound, for during the expiratory phase the quality is a trifle harder

and more blowing, the pitch higher,¹ and the intensity decidedly less—in fact, the expiratory sound may be so weakened that it is practically inaudible. The ratio of the inspiratory to the expiratory sound is 3 : 1. Normal vesicular breathing may be imitated with tolerable accuracy by breathing naturally with the lips held in the position of pronouncing the letter *f*. It may be heard in its typical character over the left infraclavicular, the infrascapular, and the axillary regions, where only alveolar tissue lies directly beneath the auscultator's ear.

To account for the origin of the vesicular murmur several theories have been suggested, no one of which appears to be wholly adequate. Baas' theory assumes that the sound is merely a modification of the blowing sounds of the larynx and the trachea, which become softened, muffled, and otherwise altered by their conduction through the bronchopulmonary structures. But, according to Sahli, the local movements of the pulmonary parenchyma also account for certain elements of the vesicular sound. Together, these two hypotheses serve as a better explanation than the original theory of Laennec, that the sound was due to the friction of the air-currents in the bronchioles and the infundibula, or than Bueri's hypothesis of the impact of central and peripheral air-columns.

Bronchial Breathing.—Bronchial breathing is distinguished by its loud, blowing, tubular quality, high pitch, and the distinct interval of silence which separates inspiration and expiration (Fig. 87). Of the two breath-sounds, expiration is generally more intense, higher pitched, and more distinctively tubular. The duration of the respiratory phases is about equal, if, indeed, expiration is not decidedly the longer, and neither carries even the faintest trace of that soft, quiet breeziness peculiar to the normal vesicular murmur. The bronchial respiratory sound may be elicited in the healthy adult by auscultation in those areas of the thorax lying directly over the larynx and the trachea—the suprasternal notch, the upper sternal region, and the lower cervical vertebræ. As Barach points out, both bronchial respiration and bronchophony are audible at the acromial end of the clavicles, owing to the excellent conducting properties of these bones. The bronchial tone may be counterfeited by breathing deeply with the mouth fixed, so as to pronounce the syllable "*hu*" or the consonant "*ch*."

Bronchial breathing is merely the unmodified sound of the laryngo-tracheal murmur, which is a glottidean tone due to the passage of air-columns, during inspiration and expiration, through the glottis

¹The truth of this statement, originally made by Austin Flint, in 1852, must be apparent to one that judges sound by intelligent auscultation, despite the view expressed by some that the pitch of expiration is *lower* than that of inspiration.

into the wider caliber of the windpipe above and below, with the consequent production of air-eddies and their reflection both upward toward the pharynx and downward through the trachea and the larger bronchial tubes.

The detection of bronchial breathing over areas of the lung to which this sound is foreign signifies that in such areas the vesicular structure is in a condition of infiltration, compression, or excavation, in consequence of which the bronchial tone, normally enfeebled by healthy pulmonary tissue, is conducted to the surface of the chest with unimpaired intensity and quality. This type of respiration, therefore, is met with in pneumonic and tuberculous consolidations; in pulmonary and bronchiectatic cavities with a free bronchial outlet; and in pulmonary compression and collapse secondary to pleural effusion, neoplasm, and aneurism. (See Figs. 81 and 83.) Other conditions that account for bronchial respiration are edema, abscess, gangrene, infarction, cirrhosis, syphilis, cancer, and actinomycosis. A mass of enlarged bronchial glands or a mediastinal neoplasm situated in intimate relation with the larger air-tubes and the thoracic parietes may distinctly transmit to the latter the bronchial tone.

Full respirations are essential to bring out all the characteristics of bronchial breathing, as can be demonstrated by auscultating over a consolidation, while the subject takes alternately shallow and deep breaths.

Cavernous and **amphoric breathing** are two subvarieties of bronchial respiration, distinguished by certain peculiarities in their quality and pitch. *Cavernous breathing* is distinguished by its deep and hollow quality, low pitch, and usually, but not invariably, by the fact that expiration is of lower pitch than inspiration. A superficial cavity with resilient walls and a patent bronchial outlet is the usual factor of this sort of breathing, such a cavity being either pulmonary or bronchiectatic, and due to tuberculosis, abscess, or gangrene. The proximity of an area of infiltration to the excavation may add to the cavernous tone a high-pitched tubular bronchial quality during expiration, and to this modification Flint has applied the term *bronchocavernous respiration*. A patch of healthy lung surrounding a cavity may ingraft its vesicular quality upon the cavernous sound, and thus produce a hybrid type of breathing known as *vesiculocavernous*. The distinctions between these two subvarieties of cavernous breathing, though hypothetically plausible, are too finely drawn to be appreciated save by one who possesses a most cultivated sense of acoustics.

Amphoric breathing is recognized by its characteristic musical, metallic, echoing quality, which replaces the hollow tone of pure

cavernous and the tubular blowing of typical bronchial respiration. The sound produced by blowing gently into the mouth of an empty vessel closely imitates the musical quality of amphoric breathing, which is the auscultatory complement of the amphoric percussion-note and of the bell-tympany elicited over pneumothoracic and large pulmonary cavities. The pitch of the foregoing types of breathing depends chiefly upon the size of the cavity, being higher the smaller the size of the resonating chamber, and vice versâ.

A minor subvariety of bronchial breathing, known as *Seitz metamorphosing respiration*, is distinguished by an inspiratory murmur beginning as a tubular bronchial sound, and ending as either a cavernous or an amphoric tone. Less commonly, this change of quality affects expiration or both respiratory phases. This bronchocavernous breath-sound is afforded by a cavity having a small patent bronchial outlet. Over tuberculous infiltrations there is sometimes to be heard a type of breathing beginning as a vesicular and ending as a bronchial or bronchovesicular sound—the “veiled puff” (“*souffle violé*”) of Laennec.

Bronchovesicular Breathing.—This type of respiration, as its name suggests, is a mixture of the bronchial and vesicular murmurs, such as may be heard in those areas of the normal thorax where the range of auscultation includes the sounds of both the large bronchi and the vesicular structure. It is audible, therefore, over and alongside the sternum at the level of Louis' angle, and over the interscapular spaces on each side of the spine, at the level of the third or fourth thoracic vertebra, these being the situations where the primary bronchi, covered by an intervening layer of vesicular tissue, lie close to the surface of the chest. The sound is louder and decidedly more bronchial in tone on the right side, owing to the anatomic peculiarities of the right bronchus.

The inspiratory phase of bronchovesicular breathing is purely vesicular, or, less commonly, tinged with a bronchial tone, while expiration is of a more bronchial character. Expiration is as long as, if not longer than, inspiration, which, aside from its shorter duration, is the quieter and the lower pitched of the two sounds. No matter what be its finer acoustic variations,—and their number is legion,—so long as respiration affords this blending of the bronchial and vesicular sounds, the term bronchovesicular is applicable, or, if one chooses, a synonymous adjective like rude, sub-tubular, indeterminate, or transition (Fig. 87).

Pathologically, bronchovesicular breathing occurs as the result of pulmonary lesions that conduct the bronchial tone to the surface of the chest, along with more or less of the normal vesicular murmur

(Fig. 81). This acoustic condition is fulfilled by small, disseminated consolidations separated by unimplicated vesicular structure, as in catarrhal pneumonia and incipient phthisis; by a large area of consolidation or excavation adjacent to healthy lung, as in central croupous pneumonia, tuberculous infiltration, and pulmonary or bronchiectatic cavities overlaid by normal pulmonary tissue; by an area of compressed, atelectatic lung, such as the zone of pressure atelectasis lying directly above a pleural effusion. The bronchial element of bronchovesicular breathing may diminish or disappear, should the bronchial tube communicating with the infiltrated or excavated patch be obstructed by secretion, while the vesicular element may be similarly modified, should the tube leading to the healthy vesicular area be blocked. Bronchovesicular respiration is especially significant of some pathologic factor when it is elicited over parts of the lungs well removed from the normal sites of this type of breathing, but these areas are by no means exempt from consolidative processes.

Prolonged Harsh Expiration.—Reversal of the inspiratory-expiratory ratio, with harshness and impurity of the expiratory sound, denotes some impediment to the free egress of the bronchopulmonary air-columns during the act of breathing, and, in general terms, it may be stated that the greater this interference, the more decided the impurity and the lengthening of the sound (Fig. 87). At the left apex prolonged high-pitched expiration is exceedingly suggestive of tuberculous infiltration, while a prolonged low-pitched expiratory sound, audible over the greater part of both lungs, is found in the chronic bronchitides of emphysema and asthma. Undue prolongation and harshness of the expiratory murmur is to be expected as a physiologic sign over the upper part of the right lung.

Puerile or Exaggerated Breathing.—An exaggeration in the intensity of the vesicular murmur is known as exaggerated, harsh, rough, or puerile breathing. This type of respiration is physiologic in children below the age of puberty, being more pronounced the younger the child; in the healthy adult it is audible above and below the right clavicle, and frequently also at the left base posteriorly (Cabot). A thin, elastic chest-wall magnifies the vesicular murmur, perhaps to the degree of puerility, while a thick, rigid chest blocks the transmission of the sound.

Pathologically, puerile breathing is elicited over a lung that is variously overacting in consequence of crippling of the opposite lung by a wide-spread congestion, infiltration, effusion, or neoplasm; or over a circumscribed portion of a lung that is overworked, so as to compensate for a lesion elsewhere in the same lung. Catarrhal

obstruction of the smaller bronchi is a most important cause of harsh, rough breathing, owing to the stenotic interference with the movements of the bronchiolar air-columns attending this affection. Dyspneic overaction of the lungs, such as that incident to active muscular exertion or to uncompensated cardiac disease, may also account for abnormal intensity and harshness of the breath-sounds.

Puerile and bronchovesicular breathing are, superficially, not unlike, but they differ in that the former, though loud and harsh, is untainted by the bronchial tubular tone and is not attended by any disturbance in the normal inspiratory-expiratory ratio. These differences also serve to differentiate bronchial breathing, should it prove a source of confusion.

Senile or Feeble Breathing (Fig. 87).—Enfeeblement of the vesicular murmur, or senile breathing, is common in the aged and in states of asthenia and debility, as the result of defective pulmonary resiliency and of weak respiratory movements. Normal lungs may emit suppressed, distant sounds simply because the subject breathes so quietly that the vesicles are improperly inflated with inspiration.

In disease a senile type of breathing is symptomatic of many different conditions relating to defective distention of the pulmonary alveoli and to the non-conduction of the normal pulmonary murmur. In paralysis of the respiratory muscles and in painful affections, such as acute pleurisy, pleurodynia, and trauma of the chest, it is natural to expect suppressed, quiet breathing, because of the limited thoracic expansion. In bronchial obstruction, as by foreign body, pressure, or secretion, diminution of the respiratory murmur is elicited over that part of the pulmonary parenchyma supplied by the stenotic tube, the general rule holding true that the higher the location of the obstruction, the larger the area of enfeebled sound. Imperfect vesicular distention, weakening the breath-sounds, may occur in chronic adhesive pleurisy, owing to restriction of the pulmonary excursions by dense fibrous bands; in hypertrophic emphysema, because of the rigid, overinflated condition of the vesicles; in the first stage of croupous pneumonia, when the lungs are engorged and fixed and abnormally tense; in atelectasis (due to either obstruction or compression) for the reason that the affected area receives no air supply and is too relaxed to vibrate. In disseminated tuberculous infiltration the respiratory sounds may be weakened as the result of hypertension of the non-tuberculous portions of the lungs and from circumscribed catarrhal stenosis of the small bronchi (Sahli), though more commonly this type of infiltration is betrayed by bronchovesicular or by harsh, impure breathing. The respiratory sounds are

suppressed in some cases of active congestion, edema, and cirrhosis of the lungs, and in those forms of massive pneumonia in which a fibrinous exudate blocks a large part of the bronchial lumen.

Enfeeblement of the respiratory sounds, by fault of their poor conduction to the surface, is found when a liquid or a solid media is interposed between the lungs and the chest-wall. The sound is damped in this manner by extensive pleural effusions, by pleural thickening, and by intrathoracic new-growths not continuous with the pleuropulmonary surfaces. In pneumothorax the breath-sounds become weak and indistinct when the bronchial outlet of the cavity is obstructed.

Absent Breathing.—Total suppression of the respiratory murmur occurs as the result of any change acting as an effectual barrier to the conduction of bronchopulmonary sounds to the surface of the chest. Any factor of senile breathing, therefore, may altogether suppress the breath-sounds, should it produce the essential acoustic conditions of such a change. The most important causes of totally absent breath-sounds are pleural exudates and transudates, bronchial and bronchiolar obstruction, closed pneumothorax, and pulmonary cavities filled with liquid—conditions which, it is obvious, may block all sound vibrations at some point between their origin in the glottis and the surface of the thorax (Fig. 81).

Cog-wheel or Interrupted Breathing.—In this type of breathing the inspiratory murmur is interrupted by a series of short, jerky pauses, or it is composed of a succession of undulatory, wavy sound modulations; less commonly these peculiarities are audible during expiration. More or less exaggeration and impurity of the whole vesicular murmur frequently accompanies the foregoing changes, although they may also be attended by suppression of the breath-sounds (Fig. 87).

Circumscribed cog-wheel breathing indicates catarrh of the finer bronchi, with obstruction to the free movements of the bronchiolar air-columns and irregular inflation and deflation of the lobules supplied by the inflamed tubes. This change is commonly found in early phthisis, of which cog-wheel respiration (especially if localized at the apex) is a most suggestive physical sign. Generalized cog-wheel breathing over the whole thorax is due simply to intermittent contractions of the respiratory muscles, and it means, therefore, nothing more serious than fatigue, nervousness, chest pain, or perhaps incomplete paralysis of the muscles concerned in breathing.

VOCAL RESONANCE

Vocal or voice resonance, which bears the same relation to auscultation as does vocal fremitus to palpation, has the same physical origin as its tactile equivalent, and is modified by pathologic processes identical with those that influence the latter. The audible and tactile fremitus, then, correspond, under both normal and abnormal conditions, and hence are corroborative in the study of the laryngo-tracheal voice vibrations by the senses of touch and of hearing.

In eliciting vocal resonance the stethoscope should be placed over a region of the chest not immediately adjacent to the main bronchial tree, while the patient repeats "ninety-nine" or "one, two, three," with his lips turned away from the auscultator's ear. Normal vocal resonance sounds like a confused, buzzing hum that carries no trace of articulate sound—it is merely an indistinct, far-away vibration, which seemingly arises within the depths of the thorax, and never conveys to the examiner the clean-cut, sharp pronunciation of the words uttered by the speaker. Auscultation just above the lower pulmonary borders typically illustrates these peculiarities of the sound. The resonance of the voice, like its fremitus, is normally exaggerated over the site of the large air-passages, and is modified by the pitch and intensity of the subject's voice and by the conducting qualities of the thoracic parietes.

Increased Vocal Resonance.—As a pathologic change, increase in the intensity of the voice resonance depends upon pulmonary infiltration, excavation, or compression, and upon bronchiectatic cavities, the several underlying causes of which have already been enumerated (Fig. 81). *Bronchophony*, or the bronchial voice, is the term used to express an exaggeration of vocal resonance so striking that it seems as if it were produced just beneath the chest-wall, though, in spite of its intensity, bronchophony invariably remains a confused, inarticulate rumble. Normally, this bronchial sound is audible over the course of the trachea and primary bronchi. *Pectoriloquy*, a refinement of bronchophony, is the transmission of *articulate* speech to the surface of the thorax, where not only the spoken words, but also their syllables, are heard with a clear, distinct intensity. *Whispering pectoriloquy*, or the conduction of the articulate whisper through the chest-wall, is a still greater refinement of bronchophony, and stands for the acme of increased vocal resonance, in which the sound conduction is exquisitely developed. Pectoriloquy, either spoken or whispering, is most suggestive of a cavity, but it is not restricted to such a lesion, as Laennec believed, since it is not

infrequently audible over an area of pulmonary infiltration or compression. Page proposes the word *bronchiloquy* to express the high-pitched pectoriloquy due to a consolidated lung, and the term *caverniloquy*, for the low-pitched pectoriloquy afforded by a cavity, while he designates as *amphoriloquy* the intense amphoric voice-sounds which correspond to the amphoric percussion-note and respiration. *Egophony* is a form of bronchophony characterized by a peculiar quavering nasal tone, comparable to the bleating of a goat. This sign, whose mechanism is not understood, is sometimes heard just above the upper level of a pleural effusion, and also above various pulmonary infiltrations. Its clinical significance does not differ from that of the ordinary bronchial voice.

Baccelli's sign, or the transmission of whispering pectoriloquy through a serous, but not through a purulent, pleural effusion has been used as a point of differentiation between these two conditions, but on insufficient grounds, for though absent over an empyema, the whispered voice is also inaudible over many serous effusions of large volume.

Decreased Vocal Resonance.—Enfeebled, sometimes absent, voice resonance is to be expected as the result of emphysema, bronchial occlusion, thickened pleura, pleural effusions, and the other causes of diminished tactile fremitus referred to in a preceding section. (See p. 133.)

ADVENTITIOUS SOUNDS

In addition to the several modifications of the vesicular murmur just described, certain superadded, foreign sounds arise in consequence of pathologic changes affecting the bronchial tubes, the pulmonary parenchyma, and the pleura (Fig. 88). The following classification of these abnormal or adventitious sounds is sufficient for clinical purposes:

RÂLES.

<i>Dry</i> :	{	Sibilant.	Small bronchi.
		Sonorous.	Large bronchi; trachea.
<i>Moist</i> :	{	Crepitant.	Air-vesicles; infundibula.
		Subcrepitant.	Bronchioles.
		Mucous.	Bronchi; trachea; cavities.

PLEURAL FRICTION.

Pleural surfaces.

SPLASHING SOUNDS.

Succussion sounds.

Pleural or pulmonary cavity.

Metallic tinkle.

Pleural or pulmonary cavity.

Extraneous sounds produced upon the surface of the body may prove sources of error in diagnosis, from their resemblance to intrathoracic adventitious sounds, such as harsh breathing, râles, and friction. Of these extraneous noises, perhaps the commonest are the so-called *muscle sounds*, which are comparable to a series of low, distant, muffled rumbles or to an interrupted humming, audible during both the active and the quiescent stages of breathing. Those heard during active respiration are generally attributable to the movements of the thoracic musculature or to friction between the patient's skin and the stethoscope; they naturally

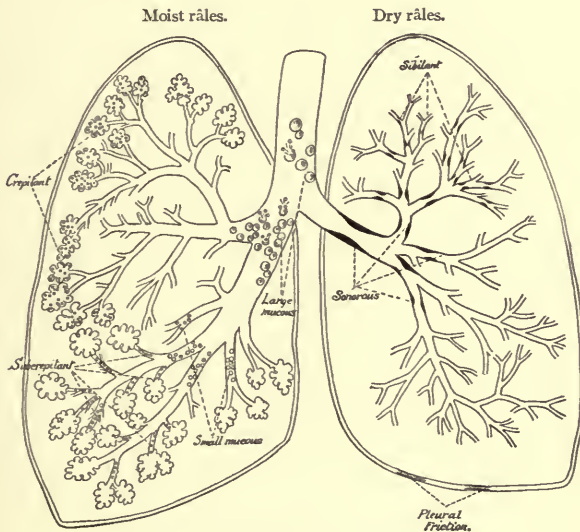


Fig. 88.—Mechanism of râles.

disappear when the patient stops breathing. Those heard when the subject's chest is motionless are usually referable to fibrillary muscular contractions or to pressure upon muscular bundles by the chest-piece of the stethoscope; they cease when the latter is applied gently and evenly, and when immediate is substituted for instrumental auscultation. Crackling sounds, due to the application of the stethoscope to a dry, hairy surface (*hair crepitus*), may remind one of crepitant râles; but these false crepitations are equally loud and clear with both inspiration and expiration, may be produced at will by the improper adjustment of the stethoscope, and disappear

when the hairy part is moistened before the chest-piece is pressed against it.

Râles.—In a clinical sense the term *râle* includes those adventitious vibratory noises due to interference with the free movements of the air within the bronchopulmonary structures by the presence of fluid or by a constriction of the bronchial lumen. According to the absence or the presence of liquid at their site of origin, râles are classed as either *dry* or *moist*; and according to their anatomic seat of production, as *bronchial*, *vesicular*, and *cavernous*; or, should they originate in the upper air-passages, as *buccal*, *laryngeal*, and *tracheal*.

In general, it may be said of bronchopulmonary râles that they convey to the examiner the impression of arising deep within the lungs, that they are likely to be disseminated as well as circumscribed, that they are prone to disappear, to reappear, and to alter their situation as the result of deep inspiration and coughing, and that their characteristics are unaltered by external pressure over their site. Furthermore, as Ransom has pointed out, some individuals suffering from bronchial catarrh whose chests are quite free from adventitious sounds so long as they stand upright, show abundant râles directly they assume the lateral decubitus.

Dry Râles.—These are dry, snoring, whistling, or musical sounds of variable pitch, intensity, and quality, arising within the bronchi and the larger air-passages as the result of constriction of their lumen, due commonly to a turgescient mucosa, to spasmodic contraction of the muscularis, to mechanical obstruction by masses of viscid, tenacious secretion, and, rarely, to extrabronchial pressure.¹ In the tubes thus narrowed the air-columns, as they rush past the barrier into the wider lumen beyond, set up vibrations recognizable by the ear as râles, and by the hand as rhonchal fremitus (Fig. 88).

It is convenient to classify dry râles, according to their acoustic properties, into two general groups—sonorous and sibilant. *Sonorous râles* are coarse, loud, low-pitched, snoring sounds arising within the large and the medium-sized tubes, while *sibilant râles* are distinguished by a shrill, high-pitched quality or by a soft, cooing tone, and, as a rule, are produced within the smaller bronchi. Exceptionally, however, sibilant sounds may originate within the medium-sized tubes, should their caliber be greatly narrowed.

The sudden and forcible rupture, by the air-current, of delicate threads of mucus stretching across the bronchial lumen may account for the production of dry râles endowed with a peculiar snappy,

¹The word *rhonchus* (L., *rhonchus*, a snoring or snorting) is frequently used as a synonym for the term *dry* râle, particularly by English writers.

crackling quality, while the simple vibrations of similar mucous threads may cause rhonchi having a musical quality. The vibrations of a loosened bit of bronchial membrane produce a peculiar "flapping" râle of exceedingly dry quality, termed the "*bruit de drapeau*." (See Fibrinous Bronchitis, p. 176.) In interstitial emphysema coarse crepitations and sounds like small mucous râles have been noted, as the result of the action of the respiratory movements upon the bubbles of air imprisoned in the interalveolar walls. This so-called *emphysematous crackling* is very like the sound of the precordial emphysematous murmur, but the former corresponds to the respiratory excursion and the latter to the heart-beats. Interalveolar crackling differs from intra-alveolar crepitation in being coarser, drier, and unrestricted to the latter part of the inspiratory cycle of breathing.

Moist Râles.—These are the various moist, crackling, bubbling, or gurgling sounds, produced in the air-tubes and in the pulmonary parenchyma by the movement of air through collections of fluid or by the separation of agglutinated vesicular and infundibular walls. Such sounds, which have a distinctively moist or sticky quality, may be classified, according to their size, as *crepitant*, *sub-crepitant*, and *mucous* (Fig. 88).

Crepitant Râles.—Crepitant or vesicular râles are due to the forcible separation of the vesicular and infundibular walls by the inspiratory air-columns. When these parts, glued together by a viscid or fluid secretion during their expiratory deflation, are forcibly separated by their inspiratory inflation, a series of exceedingly delicate crackling sounds is produced, the quality of which depends largely upon the density of the agglutinating material, viscid mucus affording a sticky sound and thin fluid a correspondingly liquid sound. The theory that the crepitant râle is really a form of pleural friction and not a vesicular sound at all, fails to carry conviction, and the weight of opinion is strongly against the intrapleural origin of the sound. Owing to the mechanism of their production, it is obvious that crepitant râles occur during the latter part of inspiration, at which time full inflation of the vesicles occurs, with a consequent tearing apart of the adherent mucosa;¹ and, since all the agglutinated vesicles do not inflate simultaneously, these râles are audible not as a single, isolated sound, but as a succession of crepitations or a shower of râles. The crepitant

¹Very exceptionally, crepitations are audible during expiration, as in certain lobular infiltrations, in which, by fault of an impermeable bronchiolar obstruction, the expiratory air-columns may be forced *backward* from a patch of healthy lung into a collection of catarrhal alveoli whose agglutinated walls are thereby distended with distinct crepitation.

râle may be tolerably well imitated by rolling a lock of hair between the thumb and fingers held close to the ear, or by throwing a pinch of salt upon a hot stove.

Crepitant râles are audible in croupous pneumonia during the stage of engorgement (*crepitus indux*) and during the stage of resolution (*crepitus redux*), at which periods of the disease the pulmonary vesicles are partly filled with an exudate. Vesicular crepitations are also heard in catarrhal pneumonia, in tuberculous infiltration, and in the early stages of pulmonary edema, infarction, and atelectasis. *Atelectatic crepitations* over the bases and borders of the lungs are common in persons who breathe superficially, either from habit or from weakness, as, for example, in those of advanced age, whose breathing is habitually shallow, and in bed-ridden patients, whose alveoli are more or less deflated and unduly moist through disuse and posture. In such instances a brief shower of fine crepitations will usually be heard when the subject takes a few deep inspirations of sufficient force to separate the walls of the collapsed vesicles and infundibula; ordinarily, these atelectatic râles disappear after the first few deep breaths, but exceptionally they persist.

Subcrepitant Râles.—These are moist bronchiolar sounds, audible during both inspiration and expiration, and due to the force expended by the air-columns and by the pulmonary excursions upon the contents of the ultimate bronchial tubes. Owing to the influence of these combined forces, deposits of viscid secretion are snapped apart and torn from the bronchiolar mucosa, minute bubbles of thin liquid are exploded, and the sticky walls of some of the finest tubes are alternately agglutinated and separated. The moist subcrepitations produced in this manner are clicking or bubbling or crackling sounds, which, though fine, are obviously coarser than the delicate crepitations of vesicular origin. They are not unlike the succulent sounds caused by agitating a mouthful of saliva with the tongue, when the teeth are kept in contact and the lips apart.

Subcrepitant râles indicate the presence of pathologic secretion (serous, serofibrinous, purulent, or hemorrhagic) within the bronchioles, and they are, therefore, to be sought for in catarrhal pneumonia, in which they are referable to an exudative bronchiolitis; in the third stage of croupous pneumonia, when the bronchioles contain a liquefied alveolar exudate, and hence afford the so-called *râle redux*; and in pulmonary edema, hemorrhage, and abscess, in consequence of which the fine tubes are flooded with serum, blood, and pus, respectively. In incipient phthisis a sharp, high-pitched, clicking sound, known as the *mucous click*, is frequently audible

during deep inspiration, this râle being essentially a subcrepitation indicative of a tuberculous catarrhal bronchiolitis. *Atelectatic subcrepitations*, due to the inspiratory separation of partly collapsed and agglutinated bronchiolar walls, may occur under the conditions responsible for vesicular crepitations of this nature (*q. v. s.*).

Mucous Râles.—The respiratory passage of air through accumulations of serum, pus, or blood in the larger air-passages produces various sized bubbling and explosive sounds, designated as mucous râles. Such râles ordinarily arise within the bronchi, less commonly within the trachea and the larynx, and, like their bronchiolar counterpart, the subcrepitant râle, are audible during inspiration, expiration, or both; their size, intensity, and pitch vary according to the diameter of the tube in which they originate. With air-columns of equal strength and with a secretion of the same density, the mucous râles of the primary bronchi and the upper respiratory passages are coarser, louder, less numerous, and lower pitched than those of the medium-sized bronchial twigs, between the primary tubes and the bronchioles. Clinically, these râles are usually defined as *large*, *medium-sized*, and *small*, according to the impression which their sound conveys to the mind of the auscultator. Large-sized mucous râles are well illustrated by the coarse, intratracheal blubbering sounds of the "death-rattle"; smaller types of these râles, by the more delicate bubblings heard in bronchitis.

Coarse *gurgling râles* are produced by the passage of air through the fluid within a pulmonary or bronchiectatic cavity, whose bronchial outlet lies below the upper level of the liquid secretion that partly fills the excavation, the ebb and flow of air through the fluid exciting a series of gurgling, bubbling noises which frequently have a reverberating, metallic quality (Fig. 89). Similar râles may be elicited over a large bronchus flooded with a profuse watery secretion (Fig. 88). The size and the pitch of gurgling râles, whether pulmonary or bronchial, are largely determined by the size of the cavity in which they originate, the coarseness of the sound increasing and its pitch lowering, the larger the size of the resonating chamber. Gurgling râles are most clearly heard during deep, forcible inspiration, and after the act of coughing, in advanced phthisis, in bronchiectasis, and, rarely, in the exudative stage of bronchitis.

The *pulmonary fistula sound* or the *water-whistle noise*, as it is also called, is demonstrable in some cases of valvular pneumothorax (both hydropneumothorax and pyopneumothorax) in which the opening of the pulmonary fistula lies below the upper level of the fluid within the pleural cavity. This being the case, the respiratory

movements of air through the liquid may set up a series of bubbling, gurgling râles, not infrequently endowed with a metallic, ringing quality.

Cardiopneumatic râles, or moist sounds synchronous with the cardiac action and usually of subcrepitant or of crepitant character, are occasionally audible over infiltrations of the lung immediately adjacent to the heart. Under this circumstance râles in the bronchiolar and alveolar secretion may be generated, partly by the direct impact of the heart and partly by the sudden variations of intrathoracic pressure attending systole and diastole.

Pleural Friction.—In health respiratory excursions of the moist, smooth costal and pulmonary pleuræ are noiseless, but when the

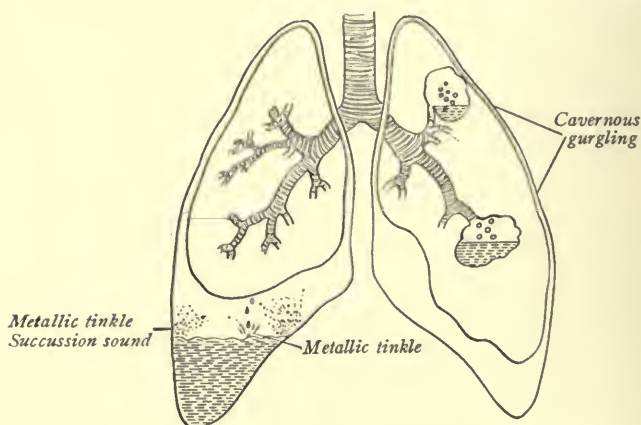


Fig. 89.—Mechanism of cavernous râles and splashing sounds.

pleural surfaces are abnormally dry and rough, as in fibrinous pleurisy and in tuberculosis, their movements against each other are attended by a sound known as *pleural friction*, whose quality and intensity vary greatly, according to the degree and extent of the lesion. (See Fig. 88). The friction-sound is in some instances merely a delicate crepitation, almost indistinguishable from a vesicular râle; in others it resembles a silken rustle; while in still others it sounds like a loud rasping rub or like the crunching of dry snow underfoot. It is more likely to be an interrupted than a continuous sound, and for this reason it may resemble, at least superficially, the jerky noise of cog-wheel breathing (*q. v. s.*). Moreover, it is a superficial and often quite circumscribed sound, intensified by the pressure of the stethoscope, practically uninfluenced by the act of coughing, and sometimes

accompanied by a distinct tactile fremitus. Friction is audible during both inspiration and expiration, but ordinarily it is most distinct toward the close of a deep inspiration. Although limited to no single area of the thorax, pleural friction is generally most distinct in the lower axillary region on the affected side, and just below the scapular angle (Fig. 90). Should a patch of friction disappear after having once been detected, it is frequently possible to demonstrate it again by Abrams' method of auscultating over the site of the lesion while the subject sweeps the arm of the affected side



Fig. 90.—Common auscultatory site of pleural friction.

upward over the head, thus moving the two pleural surfaces in a direction just opposite to that of ordinary respiration.

Pleural friction is heard over the site of an acutely inflamed dry pleura, but it is obscured when sufficient exudate accumulates to lubricate and separate the inflamed membranes; with the resorption of the exudate, however, the sound reappears, as the *frictio redux*, which, as a rule, is louder than the primary rub. In chronic dry pleurisy the persistence of the friction-sound is determined by the chronicity and the progress of the lesion. Other factors that tend to destroy the normal moist and smooth state of the pleuræ,

and hence provoke the friction-rub, are tuberculosis, neoplasms, and profuse diarrhea, such as that of Asiatic cholera, which inspissates the pleural cavities. It is possible that certain creaking sounds, virtually identical with those of genuine pleural friction, may arise from inflammatory changes in the intercostal muscles whereby intermuscular friction is excited (Coplin). The presence of miliary tubercles beneath the pleura may be sufficient to produce a soft, delicate crepitation, to which Reisman has given the name *subpleural crepitation*. Inflammation of the two reflected surfaces of the complementary pleura, as well as subphrenic peritonitis and perihepatitis, account for friction-rubs, not infrequently associated with tactile fremitus, over the lower right thorax below the sixth rib anteriorly, the eighth rib laterally, and the tenth rib posteriorly. (See Auscultation of the Abdomen.) A dry, rubbing sound over the scapula, known as *shoulder-blade friction* (Duchenne), may be due to the friction of this bone against the ribs, normal or necrosed; while a similar sound in the same situation is sometimes indicative of what Gee describes as *shoulder-joint friction*, this sound being influenced by manipulation of the subject's arm and becoming louder as the ear approaches the articulation.

Perez's sign, friction sounds or crackles most intense over the midsternum on movement of the subject's arms at the shoulder-joint, may be either a dry pericardial or pleural rub generated by mechanical traction, or it may represent merely the transmission of an articular motor crackle. Ewart emphasizes the importance of clearly differentiating the origin of this sound by careful auscultation with a view of localizing it to the shoulder-joint or to an intrathoracic area, and by noting the effects of articular movements and of respiration upon the vibrations.

Pleuropericardial friction is audible, most commonly toward the left border of the precordia, from the effect of the cardiac impact against the adjacent pleural surfaces, roughened by fibrinous inflammatory deposits. Obviously, such sounds are synchronous with the movements of the heart, and it is also true that they bear a distinct relation to the respiratory phases. If the roughening implicates the pericardial and the pulmonary reflections of the pleura, the friction diminishes or quite disappears at the end of deep *expiration*, for during the recession of the deflated pulmonary border over the heart the two inflamed surfaces are not in contact (Fig. 91). If, on the other hand, the lesion be situated upon the pericardial and

the costal pleuræ, the friction becomes enfeebled or lost at the end of forced *inspiration*, or when the inflated pulmonary border inter-

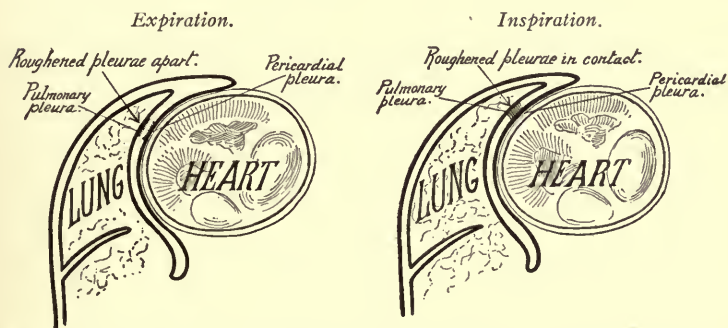


Fig. 91.—Mechanism of pleuropericardial friction, audible during inspiration, but inaudible during expiration.

venes to separate the two roughened membranes (Fig. 92). The differentiation of this pleuropericardial or extrapericardial friction




Fig. 92.—Mechanism of pleuropericardial friction, audible during expiration, but inaudible during inspiration.

and that of pericardial origin is described elsewhere. (See Pericardial Friction, p. 389.)

SPLASHING SOUNDS

Succussion Sounds.—The presence of air and fluid within a body cavity is determined by *succussion*, or the act of suddenly shaking the subject so as thus to create audible waves, recognized as *succussion sounds* (Fig. 89). These sounds are best appreciated by stethoscopic auscultation, but sometimes they are audible at some distance from the

subject, who, indeed, may be conscious of the splashing sensation. Succussion sounds are highly suggestive of air and fluid within the pleural cavity, their association with pneumothorax having been first described by Laennec—though Hippocrates was unquestionably the discoverer of intrathoracic splashing (*Hippocratic succussion sound*), he misinterpreted it as a sign of empyema. The sounds, which generally have a hollow, metallic tone, are most commonly detected in hydropneumothorax, less frequently in pyopneumothorax, and exceptionally they are audible over a large pulmonary cavity containing fluid. Splashing sounds arising within the stomach and the large intestine are distinguished from those of intrapleural origin by an analysis of the associated physical signs and the localization of the sounds. Exceptionally a succussion wave can be recognized by palpation.

Metallic Tinkling.—This sound, also termed the “falling-drop sound” (*gutta cadens*), resembles the hollow, metallic tinkling of drops of water falling from a height upon the surface of the fluid within a partly filled cistern (Fig. 89). A metallic tinkle is constantly audible in hydropneumothorax and pyopneumothorax, in which conditions it is provoked by deep breathing, loud speaking, coughing, and changes in the subject’s posture. Several credible factors have been advanced to explain this physical sign: the dropping of fluid from the edges of the moist, retracted lung above upon the surface of the pleural effusion below; the explosion of moist râles at the outlet of a pulmonary fistula situated above the level of the fluid; and the bursting of small bubbles upon the surface of the effusion. Metallic tinkling must be distinguished from the metallic consonating râles to be heard over a pulmonary cavity, from the reverberations of transmitted bronchial râles, and from the succulent sounds arising in a pneumothoracic fistula.

SECTION IV

DISEASES OF THE BRONCHOPULMONARY SYSTEM AND MEDIASTINUM

ACUTE CATARRHAL BRONCHITIS (*Acute Tracheobronchitis; Acute Bronchial Catarrh*)

Clinical Pathology.—The term acute bronchitis, or tracheobronchitis, is applicable to a catarrhal inflammation, either general or circumscribed, affecting the mucosa of the trachea and bronchial tubes, but not extending to the bronchioles. Should the latter also be implicated (bronchiolitis), extension to the air-vesicles (vesiculitis) is certain to occur, which two changes together constitute bronchopneumonia. The designation of this condition as a “capillary bronchitis” is unwarranted on pathologic grounds.

The changes in the tracheobronchial mucosa consist of a primary hyperemia and moderate tumefaction, with degeneration and desquamation of the epithelium, followed by swelling and hypersecretion of the mucous glands. As a rule, the exudate that bathes the inflamed membranes is mucous or serous, though it may have a more or less purulent character. According to the intensity of the process, a variable number of round-cells infiltrate the mucosa and submucosa, but, save in extremely severe cases, this process does not permeate far into the bronchial walls. Ordinarily, the inflammation subsides without complications or sequelæ, and the mucosal swelling promptly disappears, the epithelium regenerates, the infiltrations are absorbed, and the secretions are removed by expectoration, leaving the mucous membrane of the affected parts intact and normal. Less commonly, the disease becomes chronic, and leads to extensive denudation and ulceration of the mucosa, and perhaps to permanent structural changes in the walls of the bronchi.

Acute bronchitis is usually secondary to a catarrhal inflammation of the upper air-passages, which, by extension downward, invades the trachea and the bronchial tree; or, it may be symptomatic of some infectious disease—measles, influenza, enteric fever, malarial fever,

pertussus, phthisis, or pneumonia. The direct inhalation of irritant vapors, the insufflation of contaminated material from the upper respiratory tract, and the lodgment of a foreign body in an air-passage are additional factors of bronchial inflammation. A fulminant type of bronchitis, with a primary outpouring of thin frothy mucus followed by a secretion of thick mucopurulent matter, attends the asphyxial stage of chlorin gassing, numerous examples of which have been reported among the troops of the British Expeditionary Force in France during the present Continental war; and in fatal cases intense pulmonary congestion and edema, with multiple patches of acute marginal emphysema, are the usual sequelæ (Herringham). Fungus tracheobronchitis, due to various identified and non-determined fungi, is frequently met with in the tropics. The chronic bronchitides attending gout, cardiorenal disease, asthma, and emphysema have from time to time ingrafted upon them acute exacerbations, which to all intents and purposes may be regarded as attacks of acute bronchitis.

Physical Signs.—*Inspection.*—In simple acute bronchitis the information gained by inspection is more likely to be negative than positive. The thoracic expansion is symmetric, no anomalies of the respiratory movements are found, and the normal rhythm and rate of breathing remain undisturbed, except for a moderate polypnea, accompanied by a proportionate increase in the rapidity of the pulse, when the attack is attended by considerable fever. Actual dyspnea is seldom seen, save in the event of bronchiolitis and of severe sub-sternal pain.

Palpation.—Vocal fremitus, as a rule, is normal, although it may be temporarily diminished or quite cut off over a circumscribed area of the lung, should the bronchus leading to such an area be plugged by a bit of secretion; when the obstruction is expelled by coughing, however, the voice vibrations immediately reappear. Rhonchal fremitus is palpable, especially during active inspiration, when the tubes contain considerable secretion.

Percussion.—Normal pulmonary resonance is unimpaired, so long as the inflammation is restricted to the larger bronchi, but should it extend to the bronchioles and the neighboring alveoli, as it is prone to do in the extremes of life, patches of dulness, usually first detected at the bases, appear. As the result of alveolar overinflation, areas of moderate hyperresonance are sometimes demonstrable, particularly over the upper regions of the chest.

Auscultation.—The respiratory murmur may be normal, enfeebled, or harsh: normal, so long as the air-currents traverse the bronchi without hindrance; enfeebled, if not, indeed, absent, if the lumen of

a tube be blocked by secretion; and harsh, often with prolongation of expiration, if the bronchial caliber be decidedly narrowed by a swollen, secretion-laden mucosa. Vocal resonance behaves like vocal fremitus. Bronchial râles are audible during both inspiration and expiration, and can usually be made to appear and disappear by instructing the patient to cough deeply and to breathe forcibly. In the early, dry stage of bronchitis low-pitched, sonorous, and piping sibilant râles predominate, but later, as the liquid secretion accumulates, numerous mucous bubblings are also audible, the two types of adventitious sounds persisting so long as the air-tubes are narrowed by inflammation and filled with secretion.

Diagnosis.—Acute bronchitis presents a group of distinctive physical signs—harsh breathing and widely disseminated dry and moist bronchial râles, with no impairment of the normal tactile fremitus and pulmonary resonance. Add to these findings a history of having “taken cold,” and of coryza, hoarseness, substernal pain, and cough, with little or no fever, and the diagnosis is complete.

The possibility of mistaking *pulmonary tuberculosis* for simple bronchitis should always be thought of, since incipient phthisis may show little else than bronchitic signs, which, if persistent, are highly suggestive. In doubtful cases apical localization of such signs is to be sought for, the sputum stained for tubercle bacilli, and a minute study made of the expansion, fremitus, resonance, and breath-sounds.

Bronchopneumonia, in affording little else than a chestful of widely disseminated bronchial râles, may closely resemble a simple acute catarrh affecting especially the smaller bronchi. But in bronchopneumonia, despite the absence of tubular breathing and dulness, it is often possible to distinguish, amid the medley of rhonchi, the fine subcrepitant and crepitant râles betraying bronchiolar and alveolar implication, together with undue prolongation of expiration and unnatural hyperresonance. When these distinctive evidences of multiple small lobular consolidation are not apparent, the diagnosis must rest upon such details as urgent dyspnea, cyanosis, and hyperpyrexia, which are conspicuous signs of a bronchopneumonic process.

Occasionally, *croupous pneumonia* is counterfeited by a bronchitis that begins abruptly with a chill, considerable fever, and blood-stained expectoration, and in such cases the wide-spread distribution and bronchitic character of the physical signs and the absence of evidences of lobar consolidation indicate bronchial inflammation.

Exceptionally, the early symptoms of some *infectious disease* are temporarily masked by a coëxisting bronchitis, as in certain cases of enteric fever, malarial fever, pertussis, and measles. In such

instances the experienced examiner, without waiting for a complete clinical picture to develop, is frequently able to identify the associated infection by finding some one distinctive sign, such as a positive blood-culture in typhoid, the presence of parasites in malaria, a mononucleosis in pertussis, and Koplik's spots in measles.

CHRONIC CATARRHAL BRONCHITIS (Chronic Bronchial Catarrh; Winter Cough)

Clinical Pathology.—In chronic bronchitis the bronchial mucosa shows a variable degree of persistent hyperemia, together with epithelial denudation, granular changes, and foci of ulceration. There is also round-cell infiltration, either implicating merely the mucous and submucous tissues, or extending through the entire bronchial wall, and perhaps leading to peribronchitis and peribronchial adenitis. In the course of time serious defects in the tubes tend to supervene—destruction of the mucous glands, local patches of atrophy and hyperplasia, areas of necrosis and ulceration, and bronchiectatic dilatations of various shape and size. Emphysema is a practically constant, and cirrhosis a common, associated pulmonary change. The retained bronchial secretion may consist of thin, serous fluid, glairy mucus, mucopus, or fetid purulent matter.

Chronic bronchitis is sometimes traceable to a single attack of acute bronchial inflammation incident to some one of the acute infections, but more often it is but the relic of repeated bronchial catarrhs. The familiar "winter cough" of old persons means simply the annual lighting up of an old bronchitis that has smouldered, quiescent, during the warm months. In many instances, if not in most, the cause is primarily cardiac, renal, pulmonary, arterial, or gouty. Aneurism of the aortic arch is also to be recalled as a possible cause of intractable bronchial inflammation.

Physical Signs.—The physical signs of chronic bronchitis are in no sense distinctive, for they depend not only upon the changes in the bronchial mucosa and wall, but also upon the character of the associated lesions, pulmonary, cardiovascular, or renal, as the case may be. In general, the findings resemble those of the acute type, but they are not so constant, clear cut, or well defined, and in most cases the coëxisting emphysema and asthma conspicuously modify the physical signs.

Inspection and palpation show, sooner or later, that the chest is overdistended, that the respiratory movements are restricted and labored, and that vocal fremitus is feebler than normal. *Percussion*, though frequently showing nothing abnormal, may yield a general

hyperresonance referable to habitual overdilatation of the vesicular structure. *Auscultation* reveals undue expiratory prolongation, a confusing commingling of normal, feeble, and harsh breathing, and various sized dry and moist bronchial râles, indicative of different degrees of dry and exudative inflammation within, and spasmodic stenosis of, various parts of the bronchial tree. Should there be patches of collapsed lung at the bases, as is commonly the case, basal crepitation can be distinguished.

Diagnosis.—Having diagnosed chronic bronchitis by the foregoing signs, it is important to determine whether the process be primary or secondary to some organic disease, and also whether it be associated with emphysema, asthma, bronchial dilatation, or other complications.

Aside from simple chronic bronchitis, the following three special varieties are of clinical interest: *Dry catarrh*, or Laennec's *catarrhe sec*, distinguished by scanty, tenacious sputum, by severe fits of coughing, and by its common association with emphysema; *bronchorrhea*, in which there are severe paroxysms of cough, productive of astonishingly large quantities of bronchial secretion, consisting either of mucopurulent matter, or, less commonly, of thin, frothy, odorless mucus—the so-called *mucous catarrh*, or Laennec's *catarrhe pituiteux*; *fetid* or *putrid bronchitis*, characterized by disgustingly fetid expectoration, composed largely of pus, detritus, fatty acids, bacteria and various fungi, and frequently containing minute yellowish-brown masses—*Diltrich's* or *Traube's plugs*. Rigors, fever, anemia, emaciation, and similar evidences of septic poisoning may develop in fetid bronchitis, and in some instances extensive damage to the bronchial walls, pulmonary infection, and embolic lesions of distant organs occur. True fetid bronchitis should not be diagnosed by the odor of the sputum alone, for the stench may be quite as bad in bronchiectasis, pulmonary abscess, gangrene, tuberculosis, and perforative empyema.

FIBRINOUS BRONCHITIS (Plastic Bronchitis)

Clinical Pathology.—This rare type of bronchial inflammation is distinguished by the formation, within the finer bronchial tubes, of fibrinous casts which become detached and are expectorated in the form of small gray or yellowish plugs or molds. These plugs can be teased out into dendritic bronchial molds, of either tubular or solid structure, and composed usually of mucin, but rarely of fibrin. With these masses erythrocytes, leukocytes, epithelial cells, and Charcot-Leyden crystals are incorporated, and to their dendritic extremities Curschmann's spirals are commonly attached. The

bronchial surface where the membrane forms is not conspicuously affected: pallor or hyperemia of the mucosa, its epithelium either remaining intact or being denuded, and moderate tumefaction and infiltration of the submucosa being the ordinary changes.

Physical Signs.—*Inspection.*—Paroxysms of urgent dyspnea and coughing, perhaps with cyanosis and hemoptysis, are the noteworthy signs during the loosening and subsequent expectoration of the casts. Should one of the larger bronchial passages be obstructed, there may be inspiratory retraction of the lower intercostal spaces on the affected side.

Palpation.—Ordinarily, the voice vibrations are unaltered, save in the event of bronchial occlusion and as the result of a complicating pneumonic consolidation, the fremitus being enfeebled or abolished in the former and exaggerated in the latter. When bronchial râles are plentiful, their vibrations are appreciable to the palpating hand.

Percussion.—The percussion sound over the lungs may be resonant, hyperresonant, or frankly dull, according to the condition of the vesicular structure—whether normal, emphysematous, or consolidated. Ordinarily, however, there is more or less general exaggeration of the normal pulmonary resonance.

Auscultation.—In uncomplicated cases the respiratory murmur is either suppressed or harsh, with a prolonged expiratory phase. Unnatural sharpening and intensity of the breathing should prompt a careful search for a patch of lobular or of lobar consolidation. Many moist and dry râles are audible, notably the peculiar dry “bruit de drapeau,” due to the oscillations of bits of partly detached bronchial membrane. (See p. 163.)

Diagnosis.—The physical signs of bronchitis and the expectoration of branching molds of the smaller bronchi, together point to fibrinous bronchitis, but, aside from these distinctive findings, it is well also to investigate the patient's previous history. Two types of the affection are recognized: a *chronic recurrent form*, apparently idiopathic, and characterized by paroxysms tending to recur periodically year after year, at approximately regular intervals; and an *acute form*, of rarer occurrence and graver outlook, which commonly complicates one of the febrile infections, and is distinguished by dyspneic paroxysms of alarming severity, ushered in by a sharp attack of bronchitis, and attended by fever and rigors.

True fibrinous bronchitis of the foregoing types is to be distinguished from certain conditions sometimes attended by the accumulation of fibrin, membrane, or blood within the bronchial tubes. Fibrinous molds of the bronchi, for example, are occasionally expectorated in pneumonia, diphtheria, phthisis, chronic cardiac disease,

and after paracentesis of a pleural exudate. The sputum may contain blood coagula in bronchopulmonary hemorrhage, and fungus casts in pulmonary aspergillosis.

BRONCHIAL ASTHMA (Spasmodic, Essential, Idiopathic, or Catarrhal Asthma)

Clinical Pathology.—The respiratory neurosis, known as bronchial asthma, is distinguished clinically by recurrent, often periodic, paroxysms of dyspnea, cough, and viscid expectoration, accompanied by inspiratory thoracic rigidity and overdistention, and by depression and restricted mobility of the diaphragm. Spasm of the bronchial muscles, commonly attended by hyperemia and swelling of the mucosa of the smaller tubes and by a peculiar viscid bronchiolar secretion, chiefly explains the asthmatic attack. The bronchial spasm of itself is sufficient to interfere with the passage of air through the finer tubes, and the blocking of their lumen by a turgescient mucosa and by clumps of sticky mucus still further increases the difficulty. In addition, as Alexander Morison points out, there is also a relative, if not an actual, impediment to the ingress of air, and an actual impediment to its egress, owing to the great increase in the relative volume of residual intrapulmonary air existing during the asthmatic seizure. Repeated attacks of asthma lead to the development of chronic bronchial catarrh, emphysema, and dilatation of the right heart, and the changes incident to these complications and sequelæ are the important pathologic findings of this neurosis.

In a person predisposed to asthma the paroxysms may be precipitated by an almost endless diversity of causes—by emotional disturbances, fatigue, and similar factors having a central action; by climatic peculiarities, irritating dust, unpleasant odors, and the respiratory strain of violent coughing, laughing, or sneezing, which probably produce bronchial stimulation; by reflex waves propagated from distant parts, as in the attacks excited by nasal lesions, dyspepsia, and utero-ovarian disorders. Sometimes asthma supervenes after bronchitis, pertussis, or pneumonia, and sometimes it is directly related to vagus irritation depending upon mediastinal pressure.

Physical Signs.—*Inspection.*—During the attack the patient's chest is in a state of undue inspiratory distention, the respiratory movements are labored, limited, and inefficient, and the excursion of the diaphragm is greatly restricted. Beginning as a mere oppression in breathing, the dyspnea becomes more and more urgent until, as the acme of the paroxysm is reached, orthopnea supervenes,

bringing into active play the auxiliary muscles of respiration, and compelling the subject to rush to an open window in his desperate fight for air. At this stage of the attack frequently there are cyanosis, subnormal temperature, and a feeble running pulse; inspiration amounts to little more than a series of short, jerky gasps, while expiration is laboredly prolonged and wheezy, the whole picture being one of acute expiratory dyspnea, for deflation of the lungs is the main difficulty. As the acme of the attack passes, often with a violent fit of coughing, the breathing becomes easier, the cyanosis disappears, and the patient, exhausted, may fall into a deep sleep. The cough, until this time tight and unproductive, now loosens and the patient expectorates copiously, much to the relief of the respiratory distress. Early in the attack the sputum is scanty, and consists largely of little pearly beads of glairy mucus (*Laennec's "perles"*), which, when unrolled, are found to be bronchiolar casts having a peculiar spiral structure. These so-called *Curschmann's spirals* are composed of strands of mucin twisted into a tight coil in whose meshes numerous leukocytes (especially eosinophiles), bronchiolar epithelium, and perhaps Charcot-Leyden crystals are entangled. Some of these spiral bodies are provided with a clear, translucent core, probably composed of a filament of transformed mucin. As the cough loosens, with the decline in the intensity of the paroxysm, the now abundant sputum becomes of a mucopurulent character, and no longer contains the Curschmann spirals. Blood-streaked sputum is common in severe paroxysms attended by active bronchitis.

Other physical signs sometimes observed during an attack of asthma include erythema, urticaria, and angioneurotic edema of the upper extremities (J. S. Billings, Jr.). Very exceptionally, cervical emphysema is produced by the violent strain of coughing.

Palpation.—During the paroxysm the pulmonary overdilatation and the bronchial obstruction together enfeeble, if not abolish, vocal fremitus; during the interval, provided that permanent emphysema does not exist, the voice vibrations are normally transmitted. Pronounced rhonchal fremitus is a familiar tactile sign. The pulse is likely to be feeble, rapid, and intermittent or, indeed, imperceptible during inspiration, and the cardiac apex-beat may be effectually obscured by the overdilated pulmonary tissue.

Percussion.—The percussion sound is abnormally resonant over both lungs, except, in some instances, at the bases, where impaired resonance from atelectasis may be detected. Should decided emphysematous distention of the lungs exist, the normal areas of hepatic, cardiac, and splenic flatness are correspondingly encroached upon.

Auscultation.—The respiratory murmur and the cardiac sounds are masked by a pandemonium of râles, loud and sonorous tones commingled with shrill and cooing sounds, occurring early in the attack, while small and coarse mucous bubbling is audible during and after the acme of dyspnea. The patient, as Salter happily expresses it, wheezes “as if a whole orchestra of fiddles were tuning in his chest,” and oftentimes the râles are so loud that they are distinctly heard some distance from the patient’s chest; dry râles and mucous sounds tend to persist, after the acute seizure is past, so long as secretion remains within the bronchial passages. The alterations in vocal resonance correspond to those of vocal fremitus.

Diagnosis.—An asthmatic paroxysm is clearly recognized by the physical signs, of which urgent expiratory dyspnea, hyperresonance, loud rhonchi, and viscid, pearly sputum form a distinctive group. These signs, plus the case-history, serve to separate asthma from *acute bronchitis*, *pleurisy*, *phthisis*, and *pneumonia* attended by excessive dyspnea, cyanosis, and restricted movements of the chest.

Pertussis, with its sudden attacks of difficult breathing, is not unlike asthma, but in whooping-cough the characteristic “crow,” the laryngeal cough, and the *inspiratory* type of dyspnea are distinctive criteria.

Certain forms of *toxic dyspnea*, as well as anemic shortness of breath, are readily differentiated from bronchial asthma, when the physical signs and the patient’s history are studied. So-called renal, cardiac, and anemic “asthmas” are misnamed—“dyspnea” is the proper term for such disturbances, which are in no way related to true bronchial asthma.

BRONCHIECTASIS (Bronchial Dilatation)

Clinical Pathology.—Bronchiectasis is a circumscribed or a general dilatation of the bronchial tubes, of which two principal types are recognized: the *cylindric*, or *fusiform*, which affects the entire bronchial circumference, usually of the larger bronchi; and the *saccular*, or *globular*, in which the lesion consists of a pouch-like expansion or of a series of pockets, commonly implicating the smaller tubes (Fig. 93). The term *bronchiolectasis* is used to designate that uncommon condition of extensive dilatation of the bronchioles met with almost exclusively in the young child. *Bronchiectasis universalis*, also a rare form of the disease, is a congenital affection, in which one entire bronchial tree is converted into a series of irregular sacculations.

Bronchiectasis is most commonly situated at the pulmonary bases, except in the tuberculous form, which ordinarily is apical. Unilateral

dilatation is a shade more common than bilateral, and in the former, implication of the right and the left bronchi occurs with about equal frequency. In bilateral bronchiectasis the lesion is prone to be much more extensive in one bronchial tree than in the other.

Acquired bronchiectasis is due primarily to weakening and lowered resiliency of the bronchial wall, which gives way under the stress of increased internal pressure or from external traction, and thereby

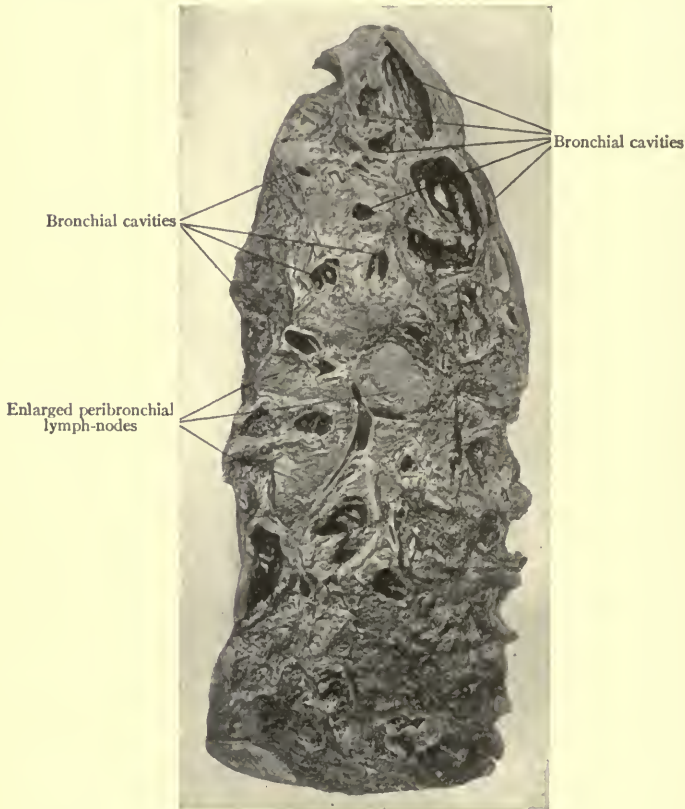


Fig. 93.—Bronchiectasis (Jefferson Hospital Laboratories).

enlarges the bronchial lumen wherever such damage exists. Inflammatory mural changes, the strain of coughing, the pressure of a large volume of intrabronchial secretion, and the traction exerted by peribronchial adhesions are the exciting factors essential to the formation of the ectases. The most important affections in which they develop

secondarily include chronic bronchitis, tuberculosis, pleurisy, croupous and catarrhal pneumonia, influenza, pulmonary cirrhosis, atelectasis, emphysema, and bronchial obstruction from external pressure by foreign bodies.

The pathologic changes in the dilated tubes are extremely variable, according to the character, degree, and duration of the disease. In active, acute cases the mucosa has the familiar appearance of acute bronchial inflammation. In bronchiectases of decided chronicity, however, the damage is much more extensive at the seat of ectasis, as shown by wasting of the muscular and elastic coats, by fibrous thickening, and by ulceration of the mucosa. Indeed, in some instances little or no trace of the bronchial structure remains, the lesion consisting virtually of one or more irregular pulmonary cavities, with smooth linings and thick fibrous walls—the so-called “trabecular bronchiectasis.” Sometimes, despite extensive distribution of the lesions, there is but a scanty secretion within the bronchi; but ordinarily the dilated portions are filled with mucopurulent material, swarming with bacteria and containing desquamated epithelium, and perhaps erythrocytes and bits of necrotic tissue, from the decomposition of which elements arises an intolerable fetor. Away from the seat of the dilatation the bronchi show, in variable degree, the changes of chronic bronchitis. In the neighborhood of a bronchiectatic lesion pleural adhesions and thickening commonly exist, and the lung may show patches of compression atelectasis, fibrosis, lobular consolidation, and emphysema. Pulmonary abscess and gangrene, purulent pleurisy, peritonitis, and cerebral abscess are other complications occasionally traceable to infection from the bronchiectatic secretion. Hypertrophic pulmonary osteo-arthropathy develops in certain cases of bronchiectasis, as the result, so Marie believes, of irritation of the osseous structures by toxins evolved in, and absorbed from, the bronchial lesions.

Physical Signs.—In a considerable proportion of cases no definite physical signs are demonstrable, owing to the small size and deep situation of the lesions and to the abundance of their contained secretion. Relatively large, empty ectases near the surface (or, if deep seated, surrounded by consolidated lung) afford the signs of a pulmonary cavity, more frequently basal than apical.

Inspection.—The subject of extensive bronchiectasis may show no traces of such a condition, or he may breathe laboriously, appear cyanotic, become emaciated, and wear the hectic facies of septic poisoning. The signs of Marie’s disease (enlargement of the hands and feet with bulbous clubbing of the terminal phalanges) should be carefully looked for in all cases of suspected bronchial dilatation.

The thorax, if at all abnormal, shows areas of deficient expansion, contraction, and emphysematous enlargement, with corresponding alterations in the respiratory excursion over these parts. The fluoroscope may reveal the site of the dilatation, a well-defined opacity being produced by an empty cavity, and a dark, circumscribed shadow by one filled with secretion.

Palpation, Percussion, and Auscultation.—Over an accessible empty bronchiectatic cavity one expects to find increased vocal fremitus, a tympanitic (perhaps “cracked pot”) percussion sound, bronchophony which may amount to clean-cut whispering pectoriloquy, cavernous or amphoric breath-sounds, and moist cavernous râles or gurgles. With more or less constancy it is also possible to demonstrate the various special tonal changes of the percussion sound indicative of a cavity. (See p. 144.) The foregoing signs, however, disappear when the dilatation becomes filled with secretion or when the communicating bronchus becomes obstructed, but they reappear when the cavity is emptied and the tube cleared, as by a paroxysm of coughing. The tendency of the physical signs thus to come and go is most suggestive of a bronchiectatic cavity. Aside from the purely cavernous signs, those relating to coëxisting bronchitis, emphysema, and pleuropulmonary fibrosis are commonly ingrafted upon the clinical picture, and, indeed, it is not at all unusual for such findings to predominate. In some instances the heart is dislocated, by traction, toward the site of the dilatation.

Diagnosis.—Bronchiectasis is suggested by a history of chronic bronchitis or of a fibroid lung or pleura in a person who tells of the periodic and copious expectoration of foul-smelling mucopurulent sputum. After standing in a conic vessel, such sputum separates into two strata, the lower consisting of a granular sediment of pus, débris, fatty acids, and hematoidin crystals, and the upper of a thin, mucoid liquid overlaid by dirty froth. With a history of this sort, the diagnosis is confirmed by the demonstration of a basal cavity whose special physical signs are influenced by cough, expectoration, and posture, but which do not alter perceptibly so as to denote progressive increase in the size of the original excavation, even after the lapse of a considerable period.

Fetid bronchitis and bronchiectasis require differentiation, since in both affections the patient may expectorate large quantities of evil-smelling, purulent material. In questionable cases the detection of a basal cavity is conclusive, but the presence of wide-spread bronchitic signs is merely suggestive—small, deeply seated bronchiectases (which perhaps are part and parcel of a putrid bronchitis) defy

recognition, at least with any degree of certainty. It is sometime of use to remember that in bronchiectasis there is more likelihood of severe constitutional symptoms and of "evacuative" cough and expectoration, while in fetid bronchitis the expectoration is practically continuous.

Empyema with a fistulous bronchial outlet sometimes accounts for the sudden expectoration of a mouthful of foul, purulent matter, but here there are unmistakable physical signs of a pleural effusion, and also a helpful case-history.

If *pulmonary actinomycosis* be suspected, owing to the fetor of the sputum, the latter should be examined microscopically for characteristic ray-fungus granules. The physical signs of bronchiectatic and *pulmonary cavities* are discussed under Phthisis, Pulmonary Abscess, and Pulmonary Gangrene. (See pp. 218, 256, and 259.)

BRONCHOSTENOSIS (*Stenosis of the Bronchi; Bronchiarctia*)

Clinical Pathology.—Narrowing or stricture of the bronchial lumen depends upon numerous factors relating either to obstruction within, or to external pressure upon, the tubes. In the former class of causes are included swelling of the bronchial mucosa, fibrinous and membranous plugs, foreign bodies, broncholiths, neoplasms, tuberculous lesions, and syphilitic cicatrices. To the latter group belong factors such as tracheobronchial adenitis, pleuropulmonary fibrosis, solid tumors, cysts, and abscesses of the mediastinum, aneurism of the thoracic aorta, large pleural and pericardial effusions, and extreme dilatation of the left auricle.

According to the character of the underlying cause, bronchial stenoses are attended by more or less bronchitis, by local necrosis and ulceration, and by inflammation of the peribronchial structures. When a bronchus of some size is completely occluded, the pulmonary structure supplied by the stenotic tube is rapidly deprived of air by absorption, and in consequence the airless portion of the lung relaxes, and sooner or later collapses, this change being termed *obturation atelectasis*. In some instances the obstruction virtually serves as a ball-valve, allowing no air to enter the lung during inspiration, but not interfering with its egress during expiration. The clinical features of bronchial stenosis vary greatly with the character, degree, and site of the constriction, and, hence, with the nature of its bronchopulmonary sequelæ, especially those affecting the distal portion of the lung. If a primary bronchus be obstructed, the entire lung of the same side is crippled; if a smaller sized tube be blocked, the circum-

scribed patch of the lung beyond is affected; while in bronchiolar stenosis, unless it be very extensive, the resulting lobular airlessness is usually masked by the emphysematous condition of the surrounding pulmonary tissue.

Physical Signs.—On *inspection* there is obvious dyspnea, principally of the inspiratory type, ranging in intensity from moderate shortness of breath to extreme orthopnea with cyanosis. The respiratory movements are hurried, restricted, and inadequate, especially on the affected side, and they cause overaction of the auxiliary muscles of breathing. Inspiratory retraction of the lower ribs and interspaces on the side of the lesion is observed in case the residual air is notably exhausted and rarefied. Blocking of a large bronchus tends to provoke vicarious exaggeration of the thoracic movements on the opposite side. The foregoing signs are usually accompanied by paroxysmal cough, either dry and hard, or productive of sputum of variable amount and composition. *Palpation* reveals enfeebled or abolished vocal fremitus over the lung lying peripheral to the obstruction, which interferes with, or entirely damps, the transmission of the voice vibrations. Furthermore, the coëxistence of vesicular dilatation in the neighboring pulmonary structure is an associated factor of diminished tactile fremitus. *Percussion* gives no noteworthy findings, save in the event of atelectasis or of wide-spread emphysema, which may yield, respectively, dullness or hyperresonance. It sometimes happens that the normal inspiratory exaggeration of the percussion sound is ill defined, if not quite imperceptible. On *auscultation* loud sibilant and sonorous râles and numerous mucous sounds generated in the bronchial exudate are audible at the site of the constriction, while over the lung beyond the latter the respiratory murmur and vocal resonance are enfeebled or abolished.

Diagnosis.—The association of inspiratory dyspnea and cough with circumscribed bronchial râles and a patch of airless lung indicates bronchial stenosis, the character of which is to be determined by finding the exciting cause of the lesion in the instance in question. *Laryngeal obstruction*, directly diagnosed by laryngoscopy, is accompanied by hoarseness, urgent dyspnea, harsh, stridulous breath-sounds, and unnaturally extensive movements of the larynx during respiration. *Tracheal obstruction*, which does not distinctly alter the voice, may also provoke stridor, and is commonly attended by orthopnea and by limited movements of the larynx.

PULMONARY CONGESTION (*Hyperemia of the Lungs*)

Clinical Pathology.—*Acute or active congestion* of the lungs is characterized by an intense engorgement of the pulmonary capillaries, commonly of both lungs, attended by the accumulation of blood-serum within the air-vesicles and by more or less swelling and shedding of their epithelium. A lung thus affected is larger, firmer, and less resilient than normal, of a dark-red color, and deficient in, though not wholly deprived of, air; it pits on pressure, and on section yields

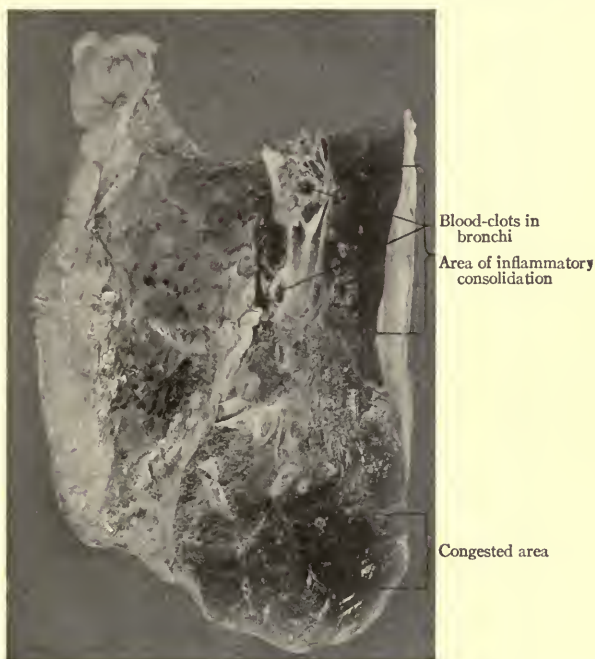

Fig. 94.—Pulmonary congestion (Jefferson Hospital Laboratories).

a considerable amount of bloody serum. Since acute pulmonary congestion commonly leads to exudative inflammation, of which it is, in reality, the first stage, and also tends to set up transudative processes, it is impossible always to recognize any clearly defined distinctions between these conditions. Such a condition of "active fluxion," typified by the stage of engorgement in an extensive croupous pneumonia, may be excited by exposure to extremes of heat and cold, by the inhalation of irritating vapors, by violent exercise,

and by toxemia due to the presence of poisonous substances in the blood; congestion doubtless also exists in the pulmonary types of vicarious menstruation. *Wouillez's disease*, or the "acute idiopathic pulmonary congestion" of the French school, is probably nothing but an abortive form of pneumonia, terminating before the stage of consolidation. *Collateral congestion* or *fluxion* is a form of hyperemia affecting portions of the lung adjacent to some local pulmonary lesion, as in infarction, pneumonia, phthisis, and bronchitis. It arises in consequence of a local circulatory disturbance, and implicates, to a greater or less extent, the pulmonary structure not primarily diseased.

Chronic or passive congestion of the lungs develops as the result of habitual stasis of the pulmonary circulation due to various conditions mechanically interfering with the return of blood to the heart, or enfeebling the cardiac force. *Mechanical congestion*, ultimately leading to a change in the pulmonary parenchyma known as *brown induration*, is a common sequel of valvular and mural disease of the left heart. When thus affected, the lungs are the seat of permanent fibrosis and pigmentation, being abnormally large, unduly firm, and of a dark-brown color. The connective and elastic tissues are increased, the capillaries are distended and tortuous, and the air-vesicles contain a catarrhal exudate filled with desquamated alveolar epithelium and leukocytes studded with pigment-granules. The extensive pigmentation, so characteristic of this type of chronic congestion, is due to hemolysis which causes erythrocytic disintegration, some of the blood-pigment thereby liberated being ingulfed by the alveolar epithelium and by leukocytes and removed by expectoration, while other particles are deposited, via the lymph-channels, in the pulmonary parenchyma.

Hypostatic congestion, affecting the dependent parts of the lungs, is referable to a feeble heart plus the effect of gravity and deficient expansion of the pulmonary tissue. It occurs with frequency in various febrile and asthenic conditions that necessitate prolonged recumbency, and in such states it shows a special predilection for the bases posteriorly. It may also attend lesions of the brain, morphin-poisoning, and comatose states in general, and the bases of the lung may show this sort of congestion as a consequence of pressure exerted by intra-abdominal effusions and tumors. Hypostatic congestion is more active a process than the mechanical form, and, unlike it, does not set up a fibrous overgrowth. The air-vesicles are choked with blood-cells and the products of their destruction and with desquamated epithelium and serum. The congested areas are boggy

with blood, abnormally heavy, practically airless, and dark red or even black-red in color, resembling, in the extreme example, the tissue of the spleen—hence the expression, *pulmonary splenization*, commonly applied to this change. Should edema and inflammation be ingrafted upon this primary engorgement, a state of *hypostatic pneumonia* is said to exist.

Physical Signs.—*Acute Congestion.*—The physical signs naturally vary with the intensity and distribution of the process, as well as with the presence or absence of coëxisting edema and inflammation in and near the congested area. If the fluxion be circumscribed, the evidences are much clearer, by comparison with the healthy lung, than if it be widely disseminated.

Inspection ordinarily shows either a flushed face or cyanosis, dyspnea, polypnea, restricted respiratory movements, cough, and perhaps hemoptysis, should the engorgement be very intense. On *palpation*, the vocal fremitus, if altered at all, is found to be moderately increased. The *percussion sound* is of higher pitch than normal, and the resistance to the pleximeter finger is somewhat exaggerated; or the defective resonance may still more closely approach actual dulness. *Auscultation* reveals either suppressed, feeble breath-sounds, or a harsh respiratory murmur, whose expiratory phase is comparatively high-pitched, prolonged, and blowing. Fine crepitant râles are audible when the vesicles contain serum.

Chronic Congestion.—In chronic congestion of the mechanical type the most striking signs commonly relate to the underlying cardiac defect, which in most instances consists primarily of mitral stenosis, regurgitation, or both, later succeeded by right ventricular enlargement.

Inspection shows, apart from the cardiac findings, habitual and distressing dyspnea, which in time becomes true orthopnea, with decided cyanosis and a variable degree of anasarca. The respiratory excursions, which are hurried, are notably freer at the apex than at the base of the lungs. There is cough, productive of considerable thin sputum, often frothy and blood-streaked, and charged with blood-pigment, both free and contained within alveolar epithelial cells—the so-called “heart-disease cells.” *Palpation* over the bases gives tactile fremitus of varying grades—feeble, in a simple passive congestion, and increased, if much fibrosis has developed. *Percussion* elicits basal dulness, and above it a generally hyperresonant sound is frequently distinguishable. On *auscultation*, enfeebled, harsh, or even bronchial breathing is audible, according to the degree of congestion and attendant changes existing in the individual case.

Simple congestion tends to obscure the breath-sounds, while dense induration of the lung intensifies them. Crepitations indicate the presence of intravesicular fluid. In *hypostatic congestion* the requisite conditions usually exist to bronchialize the respiratory murmur, to impair resonance, and to cause mucous bubbling at the bases, but in dealing with this condition one also must always search for physical signs due to associated edema and to pneumonia.

Diagnosis.—In detecting a pulmonary congestion the patient's history gives fully as important data as the physical signs, so that in every suspected case a thorough inquiry should be made for some primary factor capable of surcharging the lungs with blood, either by precipitating an active fluxion, or by impeding the return flow of blood to the left heart. This question having been decided, it is not difficult to interpret correctly the significance of dyspnea, cyanosis, cough, and frothy, bloody sputum, accompanied by basal signs of deficient aëration and incomplete consolidation. Congestion of the lungs versus *croupous pneumonia* is considered in connection with this infection. (See p. 211.)

PULMONARY EDEMA (Pulmonary Dropsy; Serous Infiltration of the Lung; Serous Apoplexy of the Lung; Pneumochysis)

Clinical Pathology.—In pulmonary edema the air-vesicles, their walls, and their communicating bronchioles are flooded with a serous or a serosanguinolent transudate, and in consequence of this dropsical condition the affected tissue becomes partly deprived of air, swollen, boggy, and pale. On section, the cut surface exudes a thin, frothy fluid, clear or tinged with blood, and containing a variable number of blood-corpuscles, alveolar epithelial cells, and pigment-granules. When edema is associated with congestion, as so often is the case, hyperemic discoloration is apparent, and when consolidation coëxists, the lung is of a gelatinous consistence and appearance. The bronchi contain thin, frothy, blood-tinged or decidedly hemorrhagic fluid, and the peribronchial lymphatic glands are in some instances preternaturally soft. Unless inflammatory complications are also present, the pleural surfaces show no noteworthy changes. Pulmonary edema, which may be either general or local, ordinarily implicates the lower lobes. Coplin, in a study of 2030 autopsies, found the lungs edematous in 20 per cent., the process being unilateral in 9 per cent., and affecting the right lung a shade more frequently than the left. When circumscribed to the neighborhood of a pneumonic or other inflammatory lesion of the lung, an edema is designated as

collateral, focal, or inflammatory. As the result of passive pulmonary hyperemia *congestive edema* is prone to develop in the dependent portions of the lungs. An *acute fulminating edema* of the lungs and bronchi is occasionally met with, especially in conditions of arterial and renal sclerosis, the edematous changes being attended by intense diffuse engorgement and by a copious outpouring of richly albuminous fluid containing numerous leukocytes. Vasomotor disturbances linked with a disproportionately forcible action of the right ventricle is supposed to excite this type of edema, which may rapidly cause death, though it sometimes recurs repeatedly in the same individual. The apparent determining factors of pulmonary edema are hypertension of the pulmonary circulation, plus a relative weakness of the left ventricle, together with a hydremic blood-mass and undue permeability of the capillary walls. Sudden vasomotor paresis also is a plausible explanation in some instances.

General edema and congestion of the lungs are frequently associated conditions, and have numerous factors in common—sepsis, toxemia, cardiac failure, exposure, and irritation of the bronchopulmonary mucosa. Edema is to be looked for as the terminal event in many illnesses, notably in nephritis, cardiac affections, grave anemias, cerebral diseases, acute infections, and cachectic states. It develops collaterally in connection with many cases of pneumonia, phthisis, abscess, and infarction of the lungs. Exceptionally, pulmonary edema is an embarrassing sequel to etherization and to thoracentesis, as well as a complication of angioneurotic edema of the surface of the body.

Physical Signs.—*Inspection* shows dyspnea, cyanosis, and restriction of the respiratory excursions of a degree commensurate with the extent of the edema and the character of its primary cause. There is cough, often painful, and productive of copious gushes of frothy, thin, serous or blood-tinged fluid. Ordinarily, unless some essentially febrile disease coexists, there are no signs of fever. *Palpation* over the water-logged, inelastic lung detects little or no vocal fremitus, while above it rhonchal vibrations are commonly felt. With the onset of an acute edema the *pulse* is full, bounding, and of extraordinarily high tension, but later this gives way to feebleness, arrhythmia, and virtual pulselessness. *Percussion* yields dulness and increased resistance over the dropsical area, with progressive upward extension of the impaired resonance as the process spreads. In exceptional cases of fulminating edema, however, the presence of extensive lobular overdistention and of bronchial paralysis may cause general hyperresonance, despite the flooded vesicles—the so-

called *paradoxic percussion sound* of Huchard. *Auscultation* detects enfeebled respiratory and voice sounds, and numerous fine moist râles over the dependent parts of the lungs. These râles, of vesicular and bronchiolar origin, have a distinctive liquid quality, and are diffused, "like a rising tide," through the lungs as the edema spreads. They are masked by intense, coarse, liquid bubbling sounds when the larger bronchi fill with the transudate.

Diagnosis.—Having found some adequate determining cause, the association of basal dulness, suppressed respiratory sounds, and distinctively liquid râles, with labored breathing, cough, and abundant serous expectoration, is good evidence of pulmonary edema. A terminal edema, it should be recalled, may develop stealthily, with few, if any, clinical phenomena save those obtained by percussion and auscultation. Acute fulminating edema provokes alarming dyspnea and cyanosis, and is likely to arise without warning or obvious cause, in persons apparently in good health, the symptoms resembling, at least superficially, pulmonary infarction, acute bronchial spasm, and certain inflammatory processes of the lungs and pleuræ.

Bronchial asthma, like acute pulmonary edema, is paroxysmal, recurrent, prone to be nocturnal, and attended by dyspnea and cough, but in asthma the patient usually has an accurate premonition of the attack, which supervenes progressively, and gives a history of long-standing bronchitis and emphysema, while the physical signs relate to a characteristic type of expiratory dyspnea, to scanty, viscid expectoration charged with Curschmann's spirals, to general thoracic hyperresonance, and to a predominance of dry bronchial râles.

The differentiation of acute edema of the lungs from *infarction*, *pneumonia*, and *pleurisy* is detailed under these last-named subjects. (See pp. 192, 198, and 268.)

PULMONARY HEMORRHAGIC INFARCTION (Pulmonary Apoplexy; Pneumorrhagia; Embolic Pneumonia)

Clinical Pathology.—When an embolus or a thrombus plugs a terminal branch of the pulmonary artery and the resulting anastomosis is insufficient adequately to carry on the circulation, extravasation of blood takes place into the neighboring air-cells and their septa, thereby producing the pulmonary lesion known as hemorrhagic infarction. The obstructing emboli are commonly derived from clots lodged within the right heart, which has become dilated and thrombotic as a consequence of mitral obstruction, or from clots within one of the systemic veins; in certain instances pulmonary

artery thrombosis has been found to be the exciting cause of an infarct. The area of infarction is usually of pyramidal shape, with well-defined margins and base directed toward the periphery of the lung; such patches may be either single or multiple, and their size ranges from a few centimeters in the longest axis to an extravasation diffused through virtually an entire lobe (Fig. 95). Recent infarcts are dense, firm, almost airless, and of dark-red color, which in time changes to a dingy brown hue. Microscopically, the air-vesicles and bronchioles are gorged with blood-cells and the intervesicular walls infiltrated with the same elements. The pleura bordering

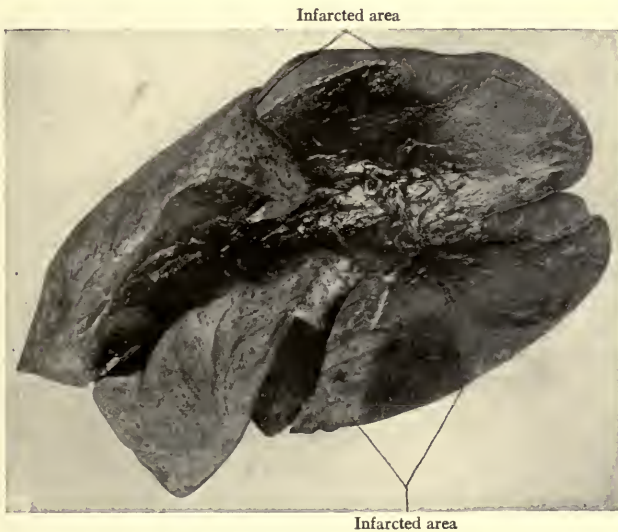


Fig. 95.—Pulmonary infarction (Jefferson Hospital Laboratories).

upon the infarction rarely escapes plastic inflammation, and may exude a copious effusion into the pleural sac, while the adjacent lung shows a variable degree of congestion and edema, if not, indeed, pneumonic changes. An uncomplicated sterile infarct, after absorption of the effused blood has occurred, generally leaves a brownish or slate-colored scar, though it is not impossible for the affected area to become entirely restored, leaving no visible trace of the infarction. A septic infarct may be the starting-point of abscess or of gangrene, which latter is capable of fistulating into the pleural cavity and establishing a pneumothorax.

Physical Signs.—The physical signs of pulmonary infarction are substantially those of a compact local consolidation modified by concurrent congestion, edema, and pneumonia, and in the individual case they vary according to the size, number, and situation of the infarcted areas and the circulatory derangements thereby produced. In general, it may be stated that an infarct must have a peripheral extent of at least five square centimeters to afford definite percussion and auscultatory data, and that in central infarctions examination of the chest gives no certain information. On *inspection* there is more or less labored, painful, and hurried respiration with cough and hemoptysis, while, exceptionally, syncope and convulsions attend the development of an extensive infarction. If sterile, the latter is usually not associated with fever, but if infected, the familiar objective symptoms of sepsis ensue. *Palpation, percussion, and auscultation* afford, in typical examples, exaggerated vocal fremitus, dullness, bronchial breathing, bronchophony, pleural friction, and numerous crepitant and subcrepitant râles over a sharply defined circumscribed area commonly situated posteriorly over a lower lobe. These signs, even though no inflammatory complications exist, are subject to material modifications, due chiefly to the damping of voice vibrations by flooded bronchi, and to the masking of crepitations by loud râles.

Diagnosis.—In a patient suffering from mitral disease or other lesion from which emboli may be derived, the abrupt onset, without fever, of acute respiratory embarrassment, sharp pleural pain, bloody expectoration, and the physical signs of a clearly delimited patch of pulmonary solidification are sufficient for the diagnosis. Infarctions due to septic emboli are recognized primarily by similar signs, and later by those relating to abscess or gangrene of the lung, as well as by the “pump-handle” temperature, recurrent rigors, sweats, and rapid emaciation accompanying these grave affections. Small deep-seated infarctions, be they single or multiple, rarely give rise to anything more definite than dyspnea, cough, and moderate hemoptysis. The distinctions between infarction of the lung and *croupous pneumonia* are given under the latter infection. (See p. 198.)

CATARRHAL PNEUMONIA (Bronchopneumonia; Lobular, Disseminated, or Peribronchial Pneumonia; Suffocative Catarrh)

Clinical Pathology.—Catarrhal pneumonia is primarily an inflammation of the bronchioles and alveoli of the pulmonary lobules, leading to their partial or complete consolidation and to consecutive

hyperemia, collapse, and overdistention of the neighboring vesicular structures (Fig. 96). If the bronchopneumonic process be widely disseminated, involving the fusion of multiple lobular lesions, an entire lobe may be converted into an almost airless mass of solidification. Almost invariably the initial lesion consists of inflammation of the terminal bronchioles, which rapidly invades the corresponding vesicles of the bronchiolar territory; in exceptional instances only

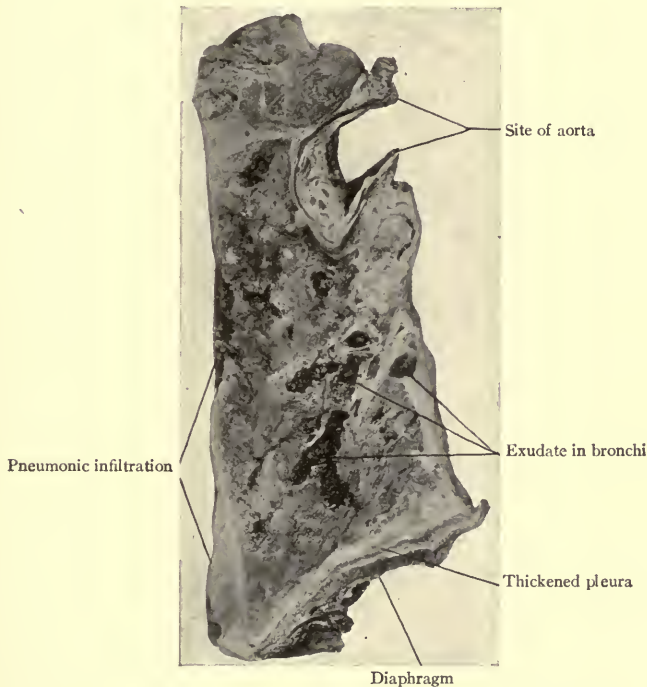


Fig. 96.—Catarrhal pneumonia (Jefferson Hospital Laboratories).

does the inflammation first arise within the vesicles, from primary disease of the septa. No special microorganism of catarrhal pneumonia has been isolated, and the disease may be excited by numerous varieties of bacteria, such as the pneumococcus, streptococcus, staphylococcus, pneumobacillus, and the bacilli of influenza, diphtheria, leprosy, and tuberculosis, the resulting infection being far more frequently mixed than pure.

The lung of catarrhal pneumonia varies considerably in gross

appearance, according to the acuteness and distribution of the bronchiolar and vesicular changes. Taking a well-marked acute case as an illustration, the organ, as a whole, is swollen, lacks resiliency, is unduly resistant (though not wholly deprived of air), and has a curiously mottled appearance, due to the presence of consolidative, congestive, collapsed, and overdistended areas. The bronchopneumonic patches consist of red, non-crepitant, firm, nodular masses, surrounded by a hyperemic zone, these areas, as resolution ensues, turning gray and undergoing softening and absorption, with ultimate restoration of the inflamed foci. Purple spots of atelectasis, usually sunk below the surface of the lung, are particularly numerous at the base, although these evidences of lobular collapse may also be thickly distributed through the greater part of a lobe. Pale zones of emphysema impinge upon the pneumonic patches, and also affect the upper portions and the anterior borders of the lungs. On cross-section through a lobule three characteristic zones are distinguishable, from within outward: the central distended bronchiole, choked with viscid mucopurulent material; a middle zone of vesicular consolidation, at first presenting a red or grayish-red, dense surface, which is more commonly smooth than granular, but later becoming paler, softer, and stippled with small purulent areas; and an outer zone of atelectasis, composed of collapsed, airless vesicular tissue, matted together by low-grade inflammation. Under the microscope the air-vesicles and bronchioles are found to be distended with an exudate, wholly or almost devoid of fibrin, and rich in desquamated epithelium, leukocytes, and bacteria, with but few, if any, erythrocytes. Leukocytic infiltration of the alveolar septa and the walls of the terminal tubes is present to a greater or less degree. If resolution progresses favorably, the inflammatory products soften and are disposed of by expectoration and resorption, and restoration of the epithelial surfaces takes place. If resolution be defective and infection ensues, tuberculosis, abscess, or gangrene may be implanted upon the vulnerable bronchopneumonic areas.

Important concomitant pathologic changes of catarrhal pneumonia include pleurisy and pleural petechiæ, congestion and inflammation of the larger bronchi, and edematous swelling of the peribronchial glands. Empyema, meningitis, and septic arthritis are the more common complications, which, as a class, are rare, while exceptionally the cardiac muscle and the endocardium are inflamed.

As a rule, catarrhal pneumonia arises secondarily, and this type of the disease is usually of streptococcal origin; primary cases ordinarily are either pneumococcal or pneumostreptococcal. The dis-

ease is most common in the extremes of life, for at these two periods the bronchovesicular mucosa is unusually susceptible to inflammatory processes and the respiratory musculature too enfeebled to insure thorough expulsion of the bronchiolar secretions. Catarrhal pneumonia is a grave menace to life in many of the acute infections, notably in measles, diphtheria, pertussis, scarlatina, variola, and enteric fever, and it is also prone to develop in subjects of nephritis, organic cardiac affections, malignant disease, rickets, emphysema, and other debilitating and resistance-lowering conditions. Tuberculosis, syphilis, anthrax, and other specific foci in the lungs are attended by catarrhal inflammation of a lobular type, and the same is true of the several forms of pneumokoniosis. *Deglutition* or *aspiration pneumonia*, due to the insufflation of minute foreign particles, is met with in various comatose states (*i. e.*, uremia and apoplexy) in which the sensitiveness of the upper respiratory passages is abolished. Owing to this defect, fine bits of contaminated matter (food-particles, for example) may be sucked into the bronchi, whose secretion carries the infection downward into the terminal bronchial twigs, and thence to the alveoli. Aspiration pneumonia is the common type of pneumonitis in the new-born, and it also develops as the result of infection from operations about the mouth and upon the upper air-passages, as well as in laryngeal and esophageal cancer. *Ether pneumonia*, so called, is generally of the lobular variety, and may prove of grave consequence in an otherwise successful operation. The accident doubtless arises from a number of causes—the action of the ether in chilling, irritating, and lowering the resistance of the bronchopulmonary structures, the insufflation of infectious matter from a contaminated inhaler, and the exposure of the patient while on the operating table.

Physical Signs.—*Inspection.*—Inspection is of the utmost clinical value, for fulminating cases sometimes run so rapidly fatal a course that tactile and auditory signs fail to develop, or do so most indefinitely. Dyspnea, cyanosis, and distressing cough are the objective symptoms to which attention should be especially directed. The dyspnea, with corresponding cyanosis, is noticeable from the beginning of the attack, and, as the pulmonary lesion spreads, becomes progressively more acute, the patient gasping for breath with loud, jerky, rapid respiratory efforts, which do but little to satisfy the call for oxygen. In the so-called “suffocative catarrh,” ending in death from asphyxia and cardiac paralysis, these evidences of deficient aëration are most strikingly exhibited. A persistent and distressing “grunty” cough, usually unproductive and often painful, begins

early and lasts through the acute stages, though in fatal cases it may abate, despite the persistence of the other signs, a few hours before death. The patient's flushed cheeks and dry, hot skin are visible signals of the existing pyrexia. In the event of extensive basal confluence of the lobular consolidations, inspiratory drawing in of the lower ribs and interspaces is observed.

Palpation.—Vocal fremitus is exaggerated if the lesions be sufficiently confluent and superficial to conduct the voice vibrations to the surface of the chest. Widely disseminated and deep infiltrations, especially if separated and surrounded by emphysematous areas, do not increase tactile fremitus, but, on the contrary, may diminish it.

Percussion.—Early in the attack the percussion sound is unaltered, and in fatal cases it may remain so until the end. But as the infiltrations grow and extend toward the surface of the lung, scattered patches of impaired resonance, sometimes amounting to actual dullness, can be made out. Coëxisting emphysematous territories, however, may ingraft their quality upon the bronchopneumonic sound, so that dull hyperresonance is elicited. Above the site of consolidation, where there is vicarious overdilatation of the vesicles, the percussion sound is likely to be typically hyperresonant.

Auscultation.—The respiration is either bronchovesicular or purely bronchial, according to the conditions holding in the individual case—bronchovesicular, if the solid patches be small and well disseminated; bronchial, if they crowd one another or are confluent throughout a considerable part of the lobe. The seat of the lesion, whether central or peripheral, and the condition of the adjacent vesicular structure, whether normal, collapsed, or distended, are active modifying influences of the respiratory sounds. Distinct bronchophony, perhaps pectoriloquy, is audible over the consolidated lobules, the determining factors of these signs being substantially the same as those affecting vocal fremitus.

Subcrepitant râles at both bases, often associated with dry and piping sibilant sounds, are the most typical auscultatory findings in catarrhal pneumonia. Finer vesicular crepitations are also detected, so long as the lobular solidification is not complete, and in many instances there are the numerous dry and moist râles of a concomitant bronchitis of the larger tubes.

Diagnosis.—The gradual development of fever, rapid and labored breathing, cough and viscid expectoration, with subcrepitant and crepitant râles scattered over both bases, is highly characteristic, despite no distinctive modifications of the respiratory, vocal, and

percussion sounds. Especially significant are such signs when they supervene in connection with one of the acute specific infections, or during the course of some depressing chronic affection. Distinctly impaired resonance, bronchial breathing, and bronchophony, though classic signs, can be detected only when a considerable area of consolidated tissue lies within the range of auscultation and percussion, and in the average case of catarrhal pneumonia the diagnosis must rest upon the association of disseminated fine moist râles with high fever and acute respiratory disturbances. In the less frequent primary form of the infection, however, it is generally possible to map out circumscribed areas of consolidation which are peculiarly prone rapidly to clear up and to reappear in other regions.

An ambulant form of *confluent bronchopneumonia* of lobar type in young adults is described by Riesman, who summarizes its chief clinical features as cough, moderate fever, and a protracted course characterized by absence of initial chill and critical defervescence, ending in complete recovery. The physical signs relate to an extensive basal lobar consolidation—dulness, bronchovesicular respiration, and abundant showers of fine, moist crackling râles, frequently having a consonating quality.

From *croupous pneumonia* the secondary type of catarrhal pneumonia can be distinguished with ease, but the primary type only with difficulty, if at all. In the secondary form the gradual, insidious onset of the respiratory stress, the early bronchitic symptoms, the bilateral distribution of the chest signs, and the recovery, by lysis, stand in strong contrast to the abrupt onset, the predominant pleural symptoms, the unilateral lobar consolidation, and the critical termination of typical croupous pneumonia. The attempt to differentiate the latter from catarrhal pneumonia of the primary type must needs fail in those instances in which the lobular lesions rapidly fuse and spread, for here the onset is abrupt, the fever high, the sputum rusty, and the physical signs those of dense basal consolidation. In this quandary the susceptibility of young children, especially under the age of one year, to lobular rather than to lobar inflammations, the fleeting tendency of a lobular pneumonia, and its likelihood of becoming definitely multiple sooner or later, are to be remembered.

Catarrhal pneumonia versus *bronchopneumonic phthisis* is an important question to be decided, inasmuch as most of the lobular pneumonias incident to measles and whooping-cough are of tuberculous nature. Unfortunately, in many instances the differentiation must be postponed until the tuberculous inroads become unmistakable, or until the subject comes to autopsy. A tuberculous history, great

prostration, rapid emaciation, free sweating, recurrent hemoptysis, tubercle bacilli and elastic tissue in the sputum, and softening, especially apical, are the principal hall-marks of phthisical cases.

Acute bronchitis and catarrhal pneumonia can sometimes be distinguished only by taking into account the relative intensity of the fever, cough, dyspnea, and similar disturbances in the two affections, for in both the physical signs may, at least for a time, be practically identical. (See p. 173.)

CROUPOUS PNEUMONIA (*Fibrinous or Lobar Pneumonia; Pneumonitis; Lung Fever*)

Clinical Pathology.—Croupous pneumonia is an acute, self-limited, infectious disease, associated with a constant and characteristic pulmonary lesion of one or more lobes and with a distinctive clinical picture, due primarily to the effects of the specific pneumotoxin. After a period of intense congestion the pulmonary structure becomes consolidated by the intra-alveolar accumulation of a coagulable fibrinous exudate, which tends subsequently to undergo liquefaction and removal by resorption and by expectoration, thus resolving the consolidation and restoring the original condition of the affected lung. Pneumonia is due to invasion of the lungs by Fränkel's pneumococcus,¹ which not only evolves absorbable toxins in the local lesions, but itself enters the general circulation. It is still a moot point whether the infection arises by the inhalation of dried sputum charged with pneumococci or by auto-infection from the germs commonly resident in the healthy throat. Other bacteria with which the pneumococcus may be associated include Friedländer's pneumobacillus, the pyogenic cocci, and the bacilli of enteric fever, diphtheria, and influenza. These microorganisms, however, probably have no direct influence in exciting true croupous pneumonia, with the exception of the first-named bacterium, which is regarded as the exciting factor of a grave form of pneumonitis characterized by a tendency toward necrosis and suppuration—"Friedländer pneumonia."

As a rule, pneumonia is unilateral, and implicates the greater part of one lobe, particularly the lower right lobe; less commonly an entire lung is affected, an extensive consolidation of this type being somewhat more frequent on the right than on the left side. The relative incidence of the commoner sites of primary pneumonic lesions is illustrated by analysis of the statistics of 1500 cases studied

¹ Discovered by Sternberg, and by him named *Micrococcus Pasteuri*.

by Ashton and Landis, by Osler, and by G. W. Norris, which shows that the right lung was attacked in approximately 52 per cent. of cases, the left lung in 35 per cent., both lungs in 14 per cent., and the apex of one or of both lungs in 14 per cent. In the Philadelphia General Hospital, about 25 per cent. of the pneumonia patients have consolidation of the right lower lobe, 22 per cent. of the left lower lobe, 12 per cent. of the entire lung, and less than 2 per cent. crossed pneumonia.

The situation of the local lesion may account for decided contrasts in the clinical features of different cases of pneumonia, and in consequence of this, numerous special forms of the disease have been exploited from time to time, usually without valid reason. Certain pathologic variations, however, merit separate mention, and of such the following seem of practical importance. *Apex pneumonia*, in which the initial consolidation invades an apex of the lung, generally on the right side, is met with more commonly in the child than in the adult, is frequently provocative of grave toxemia attended by striking cerebral symptoms, tends to resolve slowly, and always suggests the possibility of tuberculosis. *Double pneumonia*, implicating both lungs, is especially prone to affect the lower lobes, while *crossed pneumonia*, or bilateral lesions of an opposite base and apex, more often begins in the right upper and left lower than in the left upper and right lower lobes. *Central* or *core pneumonia* is the term applied to a pneumonic patch deep within the lung, perhaps so remote from the surface that no definite physical signs are afforded, or, when present, are not recognizable until several days after the initial chill. Should the pneumonitis spread in the form of a vertical slab of solidification, the designation *stripe pneumonia* is applicable. *Superficial pneumonia* is so named because in this variety the process primarily affects the surface of the lung directly beneath the pleura, and hence the physical signs of the pneumonic lesion are peculiarly easy of detection and the evidences of the concurrent pleurisy conspicuous. (See Pleuropneumonia, p. 203.) *Wandering pneumonia* is a form of the infection that slowly and persistently creeps through the lungs, successively attacking lobe after lobe, either by direct continuity (*pneumonia errans*), or by the establishment of independent foci (*pneumonia migrans*) remote from the original lesion; a lung thus implicated may show simultaneously all stages of the pneumonic process, and the symptoms therefrom are likely to be protracted, disorderly, and grave. The adjective *massive* is applied to that form of pneumonia in which not only the alveoli, but also the bronchi, of a lobe, or even of an entire lung, are choked with a fibrinous exu-

date, and in this rare condition the auscultatory physical signs are effectually negated by the extensive bronchial obstruction. The physical signs of a massive pneumonia are very similar to those of pleural effusion.

During its evolution the pneumonic lesion passes through three principal stages: congestion, red hepatization, and gray hepatization, with which it is possible to correlate more or less distinctive physical signs. Pathologically, these three stages are not always sharply defined, for a lung attacked by a rapidly spreading pneumonic inflammation may be the seat of every possible phase of the process simultaneously.

The *stage of congestion* or *engorgement*, usually lasting less than twenty-four hours, begins as an intense inflammatory engorgement of the interalveolar capillaries with the subsequent leakage of serum hence into the adjacent air-cells. The latter, when this stage is fully developed, are partly filled with a serous exudate containing a few leukocytes and erythrocytes, together with swollen, granular epithelial cells shed from the alveolar wall. Macroscopically, the lung appears enlarged, dark red in color, and abnormally moist; although denser than normal and of diminished resiliency, the pulmonary tissue still crepitates, and contains sufficient air to keep it afloat when placed in water.

In the *stage of red hepatization* or *dense consolidation*, of about four or five days' duration, the initial capillary engorgement still persists, the interalveolar walls are infiltrated and edematous, and the alveoli, hitherto the seat of but a moderate exudate, are now completely filled with a highly coagulable serofibrinous exudate, rich in fibrin and full of erythrocytes, leukocytes, bacteria, and desquamated epithelium (Fig. 97). On section, the lung appears unduly dry, although when scraped with a knife a small amount of sanguineous fluid mixed with minute fibrinous masses exudes along the track of the blade; the cut surface is stippled with numerous granular areas corresponding to the alveolar and bronchiolar coagula of fibrin. The area thus consolidated and enlarged is of a deep-red or brownish-red color, resembling a piece of liver—hence the appropriate term, red hepatization; the tissue of the lung tears easily, and is so dense and so airless that it neither crepitates nor floats.

As *gray hepatization* and *resolution* supervene, the consolidation becomes gray or grayish-yellow in appearance, being either of a fairly uniform tint or mottled with patches of persistent red hepatization (Fig. 98). The lung is smaller, moister, and less granular than in the immediately preceding stage, and, as resolution advances, the vesic-

ular tissue becomes correspondingly crepitant; elastic, and less friable. These gross changes indicate subsidence of the primary capillary engorgement, active leukocytic infiltration of the interalveolar walls, and gradual shrinkage, softening, and liquefaction of the exudate. The character of the latter is now altered by the disappearance of the erythrocytes and of the dense fibrin network,

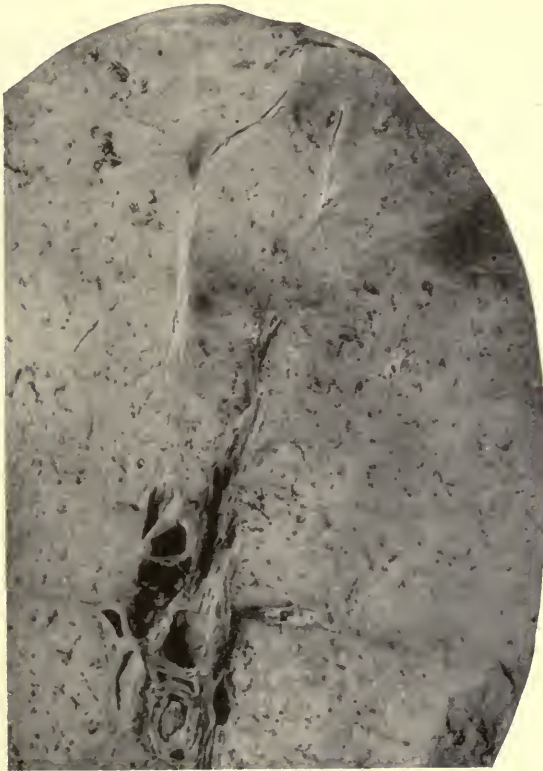

Fig. 97.—Croupous pneumonia; stage of red hepatization (Jefferson Hospital Laboratories).

and by the influx of many leukocytes which, so to speak, clean up much of the bacterial and cellular detritus of the vesicles by phagocytosis. The exudate, having undergone fatty degeneration and dissolution, is finally disposed of by the lymphatics and by expectoration, complete resolution of the pneumonic area and adequate aëration of the lung being effected within a fortnight or sooner, in favor-

able cases. Occasionally gray hepatization is succeeded by a *stage of purulent infiltration*, in consequence of which the consolidated parts take on a yellowish color from their permeation by an abundant purulent exudate, and become soft, boggy, and exceedingly friable. Pus-cells flood the alveoli and extensively infiltrate the pulmonary connective tissue, as the result of which the lung ultimately may be



Fig. 98.—Croupous pneumonia; stage of gray hepatization (Jefferson Hospital Laboratories).

riddled with abscesses of various size, should the process persist unresolved.

Delayed resolution of the consolidation is said to exist when, despite the subsidence of the active pneumonic symptoms, the physical signs indicate the persistence of an exudate undergoing slow, imperfect liquefaction and removal from the alveoli. In simple delayed resolution weeks may pass before the consolidation entirely disappears and the function of the lung is restored. On the other hand, the lung may never clear up, but, by fault of a fibroid overgrowth starting

in the interalveolar structures, become the seat of a *dense cirrhosis* which obliterates the air-cells and greatly contracts the pulmonary parenchyma. In other cases *pulmonary abscess* is the sequel of a delayed resolution, and, rarely, *gangrene* develops. *Tuberculosis* may follow pneumonia, should the latter light up a quiescent tuberculous lesion. "The instances of caseous pneumonia and softening which have followed an acute pneumonic process have been from the outset tuberculous" (Osler).

Fibrinous pleurisy is a practically constant accompaniment of pneumonia, save in deep-seated central lesions that resolve without reaching the surface of the lung. Usually the inflammation attacks the pleura contiguous to the pneumonic area, but it may also rapidly extend over the non-pneumonic lobes. Indeed, pleurisy may be so dominant a feature as to justify the use of the old term "pleuropneumonia." Ordinarily, the pleurisy clears up as the pneumonia undergoes resolution, but it may result in permanent adhesion and thickening of the pleural surfaces, in a richly fibrinous effusion so large as to require aspiration, or in an empyema removable only by free incision. *Catarrhal bronchitis* commonly is associated with pneumonia, and in many cases there is inflammatory enlargement of the bronchial glands. The larger bronchial tubes contain an abundant serous fluid with a variable amount of fibrinous material, and the smaller tubes traversing the pneumonic area may be choked with tough plugs of fibrin. Inflammation of the endocardium and pericardium are important and not very infrequent complications of pneumonia. *Endocarditis* is the commoner of the two, and more especially implicates the valves of the left than of the right heart, particularly attacking those leaflets whose vulnerability has been heightened by chronic valvulitis. The pneumococcus infection may be quiescent and inconspicuous, or it may light up a most virulent malignant endocarditis, with striking toxemia, symptoms of septic embolism, and signs of valve destruction. *Pericarditis* is particularly prone to occur in infantile pneumonia, especially of the left lung. It may follow a relatively benign course, or it may result in the collection of a serofibrinous or purulent effusion of sufficient volume to produce unmistakable physical signs. Actual *myocarditis*, sufficiently advanced to attract attention, rarely occurs, save as the result of prolonged, intense attacks, but the heart muscle not infrequently shows cloudy swelling, or, rarely, more advanced degeneration. *Arthritis* is sometimes seen in association with pneumonia, especially in the young; the joint swelling may precede the pneumonia, appear during its height, or develop after defervescence. Other complica-

tions of pneumonia of infrequent incidence include meningitis, neuritis, peritonitis, croupous gastritis and colitis, acute gastric dilatation, venous thrombosis, otitis media, and parotid bubo.

Physical Signs.—*Inspection.*—The pneumonic facies is characterized by an anxious, alert expression, by flushed cheeks and shining eyes, by crops of herpes about the lips and nose, and by inspiratory gaping of the nostrils. Cyanosis is sometimes observed, but, as a rule, it is not conspicuous; and in the bilious type of the disease jaundice develops, often most intensely. The patient generally lies upon the affected side, and breathes rapidly, laboriously, and painfully, owing to the action of the pneumotoxin, to restriction of the aërating surface of the lungs, and to pleural pain. Very commonly respiration is punctuated by a peculiar and quite distinctive “expiratory grunt.” The dyspnea, though urgent, rarely amounts to actual orthopnea. The respiratory rate may be two, three, or even four times more rapid than normal. The typical pneumonic cough is frequent, dry, and painful, hence repressed. The chest movements are limited on the affected side, especially in extensive consolidations and in those accompanied by wide-spread pleurisy. On the unaffected side there are vicariously exaggerated respiratory movements, and the same thing is to be noted over the upper lobe of a lung extensively consolidated at its base. This condition also may mechanically restrict the diaphragm excursions on the side of the lesion, but in other instances pleural or diaphragmatic inflammation accounts for an absence of the normal diaphragm shadow. The cardiac impulse may be transmitted with undue force by dense consolidation of the thin wedge of the left lung which extends downward in front of the pericardium.

The *sputum* at first is generally mucoid, but as hepatization sets in, exceedingly viscid, tenacious matter, often streaked with bright red blood, is expectorated, generally with great difficulty; later the sputum tends to become of red-brown hue, or “rusty.” The sputum may be tinged yellow or green when jaundice coëxists, and is thin and dark colored, like prune-juice, in asthenic subjects; it is abundantly mucopurulent when there is severe attendant bronchitis, and conspicuously hemorrhagic in severe sthenic cases; in the aged, in the very young, and in the debilitated little or nothing may be expectorated. After crisis copious puriform sputum is the rule, none at all, the exception. Microscopically, pneumonic sputum consists chiefly of erythrocytes, leukocytes, alveolar and bronchial epithelium, small bronchiolar casts of fibrin, and pneumococci, ordinarily mixed with other microorganisms.

By *x-ray examination* with a fluoroscope the detection of a shadow toward the center or lower part of the lung is most suggestive, particularly if, on subsequent examinations, such a shadow be found to change in accordance with the extension and resolution of a pneumonic area. Especially in central pneumonias is the *x-ray* able to reveal consolidated patches too deep to give convincing percussion signs. In most instances the fluoroscope also indicates a restricted diaphragm excursion on the pneumonic side, and in some it shows cardiac displacement and even right-sided enlargement.

Palpation.—The rapid, restricted respiratory movements and the unevenness of expansion noted on inspection are clearly recognized by the palpating palm, by which pleural friction is also occasionally appreciated. As the vesicles fill with the exudate, vocal fremitus increases, reaching its acme with complete hepatization and becoming normal again with the resorption of the exudate. It is important to remember that vocal fremitus may be entirely cut off by a coëxisting pleural effusion or by the obstruction of a bronchus leading from the pneumonic patch.

The *pulse*, full and bounding at the beginning of the attack, tends progressively to diminish in volume and in force as the infection progresses. The rate of the pulse ordinarily corresponds to the degree of pyrexia, but the usual pulse-respiration ratio is greatly disturbed, commonly ranging from 2 or 3 to 1, and, in exceptional cases, being practically equal. A pulse-rate exceeding 120 is a grave omen, save in children in whom a much greater frequency does not necessarily imperil life. From 150 to 170 is the usual pulse-rate in young children and infants affected with lobar pneumonia.

Excessive rapidity of the pulse, irregularities of volume, and arhythmia are danger signals, especially when they appear before crisis.

The blood-pressure in the average case of pneumonia shows no noteworthy changes, but a striking hypotension is an unfavorable sign. Gibson's rule is but approximate: "When the systolic pressure in millimeters does not fall below the pulse-rate in beats per minute, the fact is of good augury; when the pulse-rate per minute is higher than the millimeters of blood-pressure, the equilibrium of the circulation is seriously disturbed."

Percussion.—During the stage of engorgement exaggerated resonance, commonly of a Skodaic quality, is found over the affected lung, and a similar hyperresonance is also elicited above the level of a hepatized area. In pneumonia of an upper lobe Wintrich's sign (heightened pitch and increased intensity of the hyperresonance when

the patient's mouth is open) is frequently demonstrable, and a cracked-pot percussion sound is not uncommon. As the hepatization progresses the dulness becomes correspondingly pronounced and the resistance to pleximeter finger appreciably increases, but as resolution occurs these signs gradually disappear and sooner or later are replaced by normal pulmonary resonance—soon in the average case; late in the exceptional one, in which, despite a typical crisis and no unfavorable symptoms, the days may lengthen into weeks before the defective resonance wholly disappears. Over a central pneumonia dulness develops both slowly and imperfectly, and, should such an infiltration resolve without invading the periphery of the lung, nothing more definite than a moderate impairment of resonance may be detected. In extensive unilateral consolidations the opposite lung is vicariously hyperresonant. The area of cardiac flatness may extend unduly beyond the right border of the sternum, and frequently the percussion limits of the liver and the spleen are enlarged.

Auscultation.—Early during the stage of engorgement the respiratory murmur ordinarily is feeble and suppressed, but as the infiltration progresses the sound becomes harsher and more exaggerated, until the vesicular element is replaced first by bronchovesicular breathing, and later, when there is well-defined hepatization, by loud and tubular bronchial breathing. The latter's great intensity, high pitch, and distinctive "hu-u-u" quality are most conspicuous over a consolidation adjacent to a large, perfectly patent bronchial tube, and sometimes the amplification of the bronchial tone is so great that it is audible some distance away from the pneumonic focus. Usually bronchial breathing cannot be detected over a deep-seated central consolidation, nor is it audible if the bronchi be occluded, as by a fibrinous plug or by the generalized obstruction of a massive pneumonia. As resolution proceeds, the respiratory sounds lose their bronchial character, become bronchovesicular again, and finally acquire the breezy vesicular quality. The intensity of the voice resonance corresponds to that of the vocal fremitus, bronchophony, and perhaps whispering pectoriloquy being heard over a consolidated area, and, less commonly, even egophony.

Crepitant râles, in volleys or showers, are audible at the end of inspiration during the stages of engorgement and of resolution, the *crepitus redux* of the latter period being at first mingled with, and then replaced by, larger moist râles due to the outpouring of secretion into the smaller bronchi. Pneumonia in an emphysematous subject may afford no crepitant râles whatever, because the alveoli are so dilated and their walls so rigid that there can be no

mural adhesion and separation during expiration and inspiration respectively. In young children crepitations are sometimes difficult to appreciate, owing to inadequate inspiratory excursions of the thorax. Since the vesicles and infundibula are distended by a fibrinous exudate during the stage of red hepatization, crepitant râles are then inaudible, save perhaps for an occasional isolated crackle produced in a vesicle which has escaped complete filling. Pleural friction-sounds, however, are not infrequently heard at this time, as well as during the other stages of the disease. Moist and dry râles, indicating concurrent local or general bronchitis, are often a prominent associated sign, and such sounds have an extraordinarily sharp, resonant quality (*consonating râles*) when they arise within bronchi invested by compactly consolidated lung.

The *cardiac sounds*, at first intense and clear, become distant and impure during the height of the fever, and relative murmurs denoting dilatation of the mitral and tricuspid orifices sometimes develop. So long as the right ventricle reacts adequately to the stress imposed by the intrapulmonary hypertension, the pulmonic second sound is accentuated and of unduly high pitch. Gradual weakening of the pulmonic second sound is an important sign of right ventricular dilatation consequent to the pulmonary engorgement, actual enfeeblement of the valvular tone being foreshadowed by a lowering of its vicariously heightened pitch, to which change J. M. Anders ascribes great value as the earliest indication of right heart failure. Irregularities of rate, rhythm, and force appear, as the strength of the heart flags under the influence of the fever and the pneumotoxin. Sudden death may occur, without warning, from acute dilatation or from pulmonary thrombosis. Recent studies by Porter contradict the former view that the circulatory failure in pneumonia is largely ascribable to vasomotor paresis.

Diagnosis.—Frank croupous pneumonia is easily recognized, for in no other disease is there a more distinctive clinical picture, of which the facies, the painful cough and dyspnea, the rusty sputum, the abnormal pulse-respiration ratio, and the orderly development of physical signs of lobar engorgement, consolidation, and resolution are the noteworthy features. As a rule, these signs follow a severe initial chill, and are accompanied by high fever reaching its acme within a few hours and continuing high, with trifling fluctuations, for from about five to ten days, when it abruptly drops, by crisis. During this febrile period such laboratory findings as hyperinosis, leukocytosis, iodophilia, pneumococcemia, and striking deficiency of the urinary chlorids constitute important corroborative evidence.

After crisis the urgent symptoms of the infection rapidly abate, the normal pulse-respiration ratio is reëstablished, the signs of consolidation clear up, and the abnormal blood and urine changes disappear.

Atypical pneumonia, however, is not so well defined, and the symptomatology outlined above is subject to extraordinary modifications according to the ruling factors at work in the individual case, of which influences the most important relate to the virulence of the invading bacteria, the age, habits, and resistance of the patient, and the presence or absence of coëxisting disease. Such factors as these must automatically recur to one who would deal successfully with the diagnosis of a disease capable of appearing in the many different guises which pneumonia may assume. From a clinical viewpoint, the following aberrant types of pneumonia are of sufficient importance to call for special consideration.

Larval Pneumonia.—This is a mild, abortive, ephemeral type of the disease, with trifling symptoms and poorly defined physical signs, lasting but a few days and terminating usually by a most rapid crisis. In this class belongs the *one-day pneumonia*, which clears up by the second day after the onset of the initial symptoms. Many cases of so-called *epidemic pneumonia*, extensively prevailing in institutions, also conform to this type, though by no means is this invariably true, inasmuch as in certain epidemics of this sort the symptoms are severe, particularly those relating to the nervous and the gastro-intestinal systems. Epidemic pneumonia is frequently characterized by slow infiltration, by the rapid supervention of gray hepatization, and by a tendency toward connective-tissue overgrowth in the lungs.

Toxic Pneumonia.—In contrast to the above there is a toxic or typhoid pneumonia, which is distinguished by grave toxic symptoms referable to a bacteremia, either pneumococcic or mixed. Early and striking prostration, serious cardiac failure, excessive diarrhea, tympanites, stubborn headache, delirium, and conspicuous nervous symptoms serve in such instances to divert attention from the real cause of the toxemia, which masquerades as enteric fever with severe initial pulmonary lesions. This *typhoid pneumonia*, which is merely pneumonia plus the "typhoid state," is to be distinguished from *pneumotypus*, or enteric fever complicated at the outset by a croupous pneumonia which dominates the clinical picture for the first week or two. In typhoid pneumonia such evidences as early pneumococcemia, persistently negative Widal tests, deficient urinary chlorids, and absence of a roseola, together with the critical disappearance of both signs and symptoms, serve to rule out a concurrent Eberth

infection and to stamp the condition true pneumonitis with grave toxic manifestations. In pneumotyphus, on the other hand, the expected crisis fails to occur, as it should do in uncomplicated pneumonia within a fortnight, and by the end of this period, at the very latest, the distinctive evidences of enteric fever, hitherto overshadowed by the pneumonia, begin to appear, as the pulmonary consolidation undergoes resolution and the enteric lesions approach maturity.

Aside from these two forms of true toxic pneumonia, dulness at the right base posteriorly, due solely to an intense hepatic congestion and in no way related to a pulmonary consolidation, has been described by Lesieur and Marchand as a frequent finding at the height of the disease in uncomplicated enteric fever.

Certain cases merit the term *bilious pneumonia*, owing to the prominence of jaundice, yellowish or greenish sputum, hepatic engorgement, and obstinate vomiting; some of these are possibly true examples of toxemic jaundice, and run a severe, often fatal, course, while others are simply pneumonia with an associated obstructive jaundice, the coëxistence of which does not materially affect the subject's chances of recovery.

Infantile Pneumonia.—True croupous pneumonia in infants and young children, though commonly attended by alarming nervous symptoms, is of surprisingly low mortality. Convulsions and vomiting may replace the initial chill, and delirium, hyperpyrexia, abdominal pain, and diarrhea are conspicuous symptoms. In children old enough to expectorate, the sputum is more likely to be scanty and mucoid, than profuse and rusty, in character. In about one-half of all cases of infantile pneumonia the patellar reflex is abolished during the stage of acute pyrexia; frequently the knee-jerk is lost before the development of the chest signs, and ordinarily it returns with crisis or shortly afterward. Apical pneumonia is much more common in children than in adults, the spread of the consolidation and its subsequent resolution are less rapid, and the occurrence of pericarditis and of acute arthritis is more frequent.

Senile Pneumonia.—Pneumonia in the elderly subject has an extremely high death-rate, and commonly begins without an initial chill, the onset being gradual and ill defined. The leading features of the attack consist of great prostration, cardiac asthenia, moderate fever, little or no chest pain, and slight cough, productive of scanty sputum, perhaps of a "prune-juice" appearance. Usually the physical signs, which are prone to be of a fleeting, wandering character, are not well marked, and, indeed, they are sometimes quite effectually masked by a preëxisting emphysema; resolution, when it

does occur, is prone to progress slowly and imperfectly, and not infrequently terminates in abscess or in gangrene.

Alcoholic Pneumonia.—In the pneumonia of alcoholic subjects the symptomatology suggests delirium tremens rather than to pulmonary consolidation, for the clinical picture is made up of insomnia, incoherent muttering, and terrifying hallucinations, which develop insidiously, with little or no cough, fever, or chest pain. The expectoration is frequently like prune-juice, and may be quite copious. The physical signs, however, are usually characteristic, so that one cannot be excused for overlooking a pneumonic lung simply because the patient happens to be raving in mania à potu. In the majority of alcoholics pneumonia is equivalent to a death-warrant.

Traumatic Pneumonia.—This term is used to designate a form of pneumonia secondary to violent injury of some part of the body near or remote from the lungs, or arising in consequence of direct laceration of the pulmonary tissue. The affection may occur indirectly, from lowered vital resistance produced by the injury, and in such instances the pulmonary lesion may not supervene until the subject has been bed-ridden for some weeks; or the pneumonia may be the direct consequence of a damaged lung, in which event it develops within a few days after the accident. *Contusion pneumonia* is a variety of pneumonitis excited by a violent blow upon the chest-wall.

Intercurrent and Terminal Pneumonia.—In various acute specific infections, notably diphtheria, influenza, tuberculosis, enteric fever, typhus fever, bubonic plague, and malarial fever, pneumonia develops as a secondary, sometimes as a terminal, process. As the latter, it is also met with in certain chronic diseases, of which diabetes, arteriosclerosis, and chronic lesions of the heart and kidneys are typical examples. Intercurrent and terminal pneumonias are not uncommonly masked by the symptoms of the primary disease, and tend to pursue a more or less latent course, lacking the dramatic invasion, the characteristic febrile stage, and the clear-cut physical signs of a frank primary pneumonitis; indeed, in many instances the existence of pneumonia is determined only after repeated and systematic physical examinations, and, sometimes, not until autopsy. In view of these facts one must, aside from the laboratory side-lights, often base the diagnosis upon somewhat equivocal evidence—moderate fever, slight increase in the pulse and respiration rates, and trifling cough, with impaired resonance, feeble respiration, and a few crepitations at the base of a lung.

Aspiration and ether pneumonias, being nearly always of the lobular type, are dealt with under catarrhal pneumonia. (See p. 192.)

Aside from the preceding atypical varieties of croupous pneumonia there remain for diagnostic consideration a group of thoracic diseases and certain acute infectious processes which, to a greater or less degree, resemble the subjective and objective symptoms of lobar consolidation. The first group comprises pulmonary congestion, edema, infarction, phthisis, catarrhal pneumonia, pleural effusion, and bronchitis; and to the second belong meningitis and peritonitis.

Acute pulmonary congestion, in so far as the clinical picture is concerned, is to all intents and purposes the initial stage of croupous pneumonia; it is distinguished from the latter by its short duration, by the absence of lobar consolidation, and by the non-development, in orderly succession, of the attendant pneumonic phenomena. In this connection "one-day pneumonia" and Woillez's "idiopathic congestion" (*q. v.*) are to be recalled.

Hypostatic congestion usually causes dulness, harsh respiratory sounds, exaggerated fremitus, and crepitant râles at the bases, but these signs are bilateral, and, as a rule, they develop without active fever, rusty sputum, or herpes in a patient prostrated by some long illness accompanied by enfeeblement of the heart and by circulatory stasis in the dependent portions of the lungs.

In *acute pulmonary edema* there is usually some obvious cardio-renal defect to explain the suddenly developing respiratory stress and the distinctive serous, frothy expectoration. The physical signs, in contrast to those of pneumonia, are bilateral, not unilobar, and tend rapidly to spread upward over both lungs from the bases; vocal fremitus and respiratory sounds are suppressed, not exaggerated; percussion resonance is impaired, not abolished; and the adventitious sounds consist of various sized liquid râles, in place of fine vesicular crepitations and pleural friction. Fever is absent, except in the so-called inflammatory edema.

In differentiating *pulmonary infarction* and pneumonia the discovery of a source of embolism, such as mitral disease or femoral phlebitis, is a valuable diagnostic asset. Like pneumonia, infarction gives rise to sudden dyspnea, cough, pleural pain, hemoptysis, and, if the infarcted area be extensive, to physical signs of a dense basic infiltration of the lung. Unlike pneumonia, infarction is attended by moderate, if any, fever, and by frankly hemorrhagic and fluid expectoration, while the consolidated patch is sharply circumscribed and does not undergo the progressive evolution of a pneumonic lesion. Evidences of pulmonary abscess or gangrene are to be expected when the infarction is due to an infected embolus.

Acute diffuse bronchitis, in the exceptional instance, develops most abruptly, with chill, fever, dyspnea, and even hemoptysis, but here the resemblance to pneumonia ends, for the physical signs point conclusively to inflammation of the tracheobronchial tree, without dulness or crepitations at the bases of the lungs.

The differentiation of croupous pneumonia from *catarrhal pneumonia*, *acute pneumonic phthisis*, and *pleural effusion* is considered in connection with these diseases. (See pp. 192, 216, and 268.)

Meningitis is counterfeited by certain cases of pneumonia, especially by the so-called "cerebral pneumonia" of children, in whom the attack is ushered in by a convulsion, headache, restlessness, delirium, and a variable degree of cervical rigidity. Add to this group of symptoms herpes, leukocytosis, and arthritis, and a highly suggestive picture of cerebrospinal meningitis is produced. In the type of pneumonia under discussion, however, such a train of events means simply an intense meningeal congestion, and is associated with the signs of lobar consolidation, not uncommonly at the apex. *True meningitis*, when it complicates pneumonia, ordinarily develops at the height of the febrile stage, and is attended by distinctive symptoms—delirium, vomiting, persistent occipital headache, irritability, tremor, stupor, and painful retraction of the muscles of the neck and the back. The muscular reflexes are primarily exaggerated, but later abolished, and in some instances strabismus, ptosis, pupil changes, and various paralyses occur. Kernig's sign (inability to extend the leg when the thigh is flexed at right angles to the trunk) is of practical importance. Lumbar puncture may prove conclusive, the cerebrospinal fluid thus obtained showing gross changes, cytologic abnormalities, and bacteriologic findings distinctive of meningeal inflammation excited by the pneumococcus, meningococcus, streptococcus, tubercle bacillus, or other microorganisms. (See page 62.)

Peritonitis is simulated by pneumonia in which vomiting, hyperpyrexia, abdominal pain, and more or less distention, tenderness, and rigidity of the belly-wall are conspicuous early symptoms. A clinical picture of this sort, which is not unusual in a child, may counterfeit, according to the locality of the pain, appendicitis, gastric ulcer, or cholecystitis, and it is safe to regard every bellyache in a child as a potential sign of trouble above the midriff. Irritation of the pleural filaments of the lower intercostal nerves is responsible for this variety of reflected abdominal pain, traceable to its true source by an analysis of the patient's clinical history and by physical examination of the lungs, which ordinarily reveals pneumonia of the lower lobe or lobes and wide-spread pleurisy.

CHRONIC INTERSTITIAL PNEUMONIA (*Fibroid Pneumonia; Fibroid Lung; Fibroid Induration; Pulmonary Cirrhosis or Sclerosis*)

Clinical Pathology.—Interstitial pneumonia is a chronic inflammation of the pulmonary connective tissue, attended by fibrous overgrowth and subsequent contraction leading to permanent sclerotic changes in the bronchopulmonary structure (Fig. 99). According to the conditions prevailing in the individual case, the process originates in the peribronchial tissues, alveoli and their walls, interlobular

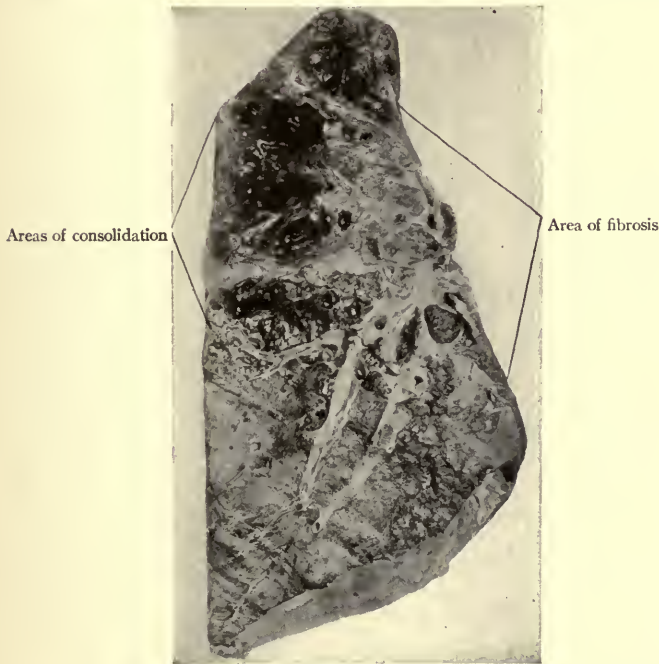


Fig. 99.—Chronic interstitial pneumonia (Jefferson Hospital Laboratories).

septa, or pleura, and develops subsequently into either a diffuse or a circumscribed fibrosis of variable extent.

Diffuse interstitial pneumonia, commonly of unilateral distribution, but exceptionally implicating both lungs, not infrequently follows bronchopneumonia, and begins as a luxuriant peribronchial fibrosis spreading through the interlobular septa to the alveolar walls, and ultimately invading an entire lobe, or even the whole lung. More

rarely the fibrosis is the relic of a faultily resolved croupous pneumonia, in which organization of the persistent intravesicular exudate and a fibrous overgrowth in the intervesicular septa combine to produce the condition termed "gray induration" at the site of the pneumonic infiltration. In other instances the cirrhotic changes are secondary to plastic inflammation of the pleura, whence fibrous bands penetrate the lung by way of the septa between the lobules and along the peribronchial lymphatics; or a pleural thickening and contraction may progressively compress the adjacent lung and set up interstitial changes in the atelectatic territory. Compression atelectasis, as by neoplasm or by aneurism, and also pulmonary syphilis are capable of initiating a more or less diffuse fibrosis of the lungs. The cirrhotic lesions arising primarily from irritation by dusts are considered in connection with Pneumokoniosis (p. 252), and the fibrosis due to tuberculosis is described under Fibroid Phthisis (p. 234).

The cirrhotic areas consist of dense, pigmented collections of gray cicatricial tissue disseminated throughout the organ, commonly by peribronchial radiations between the lobules and the lobes, and in the extreme case converting, by contraction of the fibrous overgrowth, the lobe or even the lung into an airless, sclerotic mass of extraordinarily small volume. At autopsy a lung thus damaged may be reduced to a compact, indurated mass of fibroid material the size of a cantaloupe, lying against the spinal column. In consequence of this unilateral shrinkage the thorax on the fibroid side is strikingly contracted and otherwise distorted (see Fig. 45), and the heart, which is hypertrophied, especially on the right side, is drawn toward the focus of the cirrhosis, along with the other mediastinal contents. The bronchi are generally dilated, and the air-vesicles are quite obliterated in the fibroid areas, while elsewhere both these structures show a variable degree of catarrhal inflammation. In the non-fibroid parts of the affected lung and throughout the other lung compensatory emphysema develops, and the pleural surfaces are thickened and adherent, in cases of pleurogenous origin, though they may escape injury in primary pulmonary fibroses.

Aside from the foregoing lobar type, there are instances in which the fibrosis, though extensive, conforms more closely to a lobular distribution, the process consisting essentially of a commingling of numerous indurated patches and intervening areas of emphysema. This variety of interstitial pneumonia, inasmuch as it is characterized by multiple discrete lesions situated usually at the bases and deep within the lungs, does not ordinarily cause the conspicuous medias-

tinal displacement and chest deformity so distinctive of a massive, confluent cirrhosis.

Circumscribed interstitial pneumonia, or local fibrosis, is sharply restricted to a limited area, and arises in consequence of some local damage to the pulmonary structure. The process is to be regarded as virtually reparative in character, for its tendency is to encompass the primary injury with an impermeable capsule of contracting connective tissue, and thus to stay the spread of infection, if not, indeed, to extinguish the lesion completely. Fibrous scars of this sort mark the sites of structural injuries of the lungs due to factors such as tuberculosis, gumma, abscess, gangrene, actinomycosis, echinococcus cyst, and neoplastic growths.

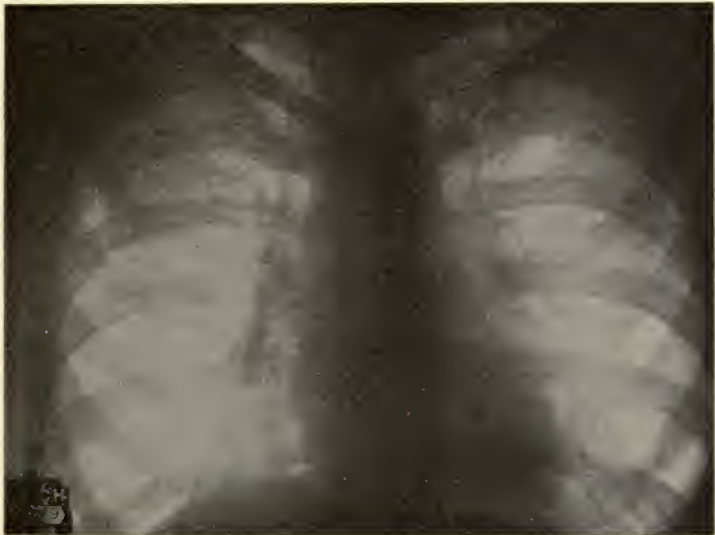

Fig. 100.—Radiograph of chronic interstitial pneumonia (*cf.* Fig. 70). Note dense shadows of fibrosis through the right lung. (Plate by Dr. W. F. Manges.)

Physical Signs.—Since the physical signs of interstitial pneumonia are essentially those of its clinical counterpart, fibroid phthisis, their detailed discussion will be taken up in connection with this form of tuberculosis. (See p. 235.) It suffices here to note that the clinical picture is made up of thoracic distortion and restricted respiration on the affected side, with enlargement and overaction of the opposite side; that the heart is displaced toward the site of the lesion and the anterior pulmonary borders may be retracted from the precordia; that over the cirrhotic areas increased vocal fremitus, dulness or flatness, and either

suppressed or harsh breathing are found, while the overdistended monic second sound, with the subsequent development of the murmur of tricuspid relative insufficiency, indicates the strain upon, and the inevitable failure of, the right ventricle.

Diagnosis.—Upon the foregoing signs, plus a story of cough, dyspnea, and mucopurulent, perhaps bloody, expectoration, persisting for many years without notably impairing the subject's strength, the diagnosis of chronic interstitial pneumonia is based, and the opinion thus formed is made still more tenable when there is a past territories afford hyperresonance and exaggerated breath-sounds. In pleurogenous fibrosis friction is to be looked for, and over areas of great pleural thickening, deadening of the voice and respiratory sounds. The cavernous signs of bronchiectasis are sometimes demonstrable. Accentuation and ultimate enfeeblement of the pulmonary history of pneumonia, pleurisy, syphilis, or local damage to the lung, to account for the initial cirrhotic changes. In a doubtful case the *x*-ray generally affords a certain means of diagnosis (Fig. 100). The differentiation of pure pulmonary cirrhosis from so-called fibroid phthisis, which is not always possible when positive bacteriologic findings and a clear history are wanting, is referred to under the latter affection. (See p. 234.)

ACUTE PNEUMONIC PHTHISIS (*Phthisis Florida*; *Galloping Consumption*)

Clinical Pathology.—This acute type of pulmonary tuberculosis, popularly known as "galloping consumption," consists of a rapidly spreading caseous pneumonia or bronchopneumonia, which is commonly secondary to a primary apical focus of infection (Fig. 101). The vesicles and bronchioles are the seat of intense inflammatory changes, and are filled with an inflammatory exudate which, owing to its tuberculous character, does not readily undergo softening and expulsion, but becomes caseated; the vesicular and bronchiolar walls in the affected areas are infiltrated and thickened, and their blood-supply is obliterated. With the spread of the infection from its original site to adjacent vesicles and bronchioles, there is rapid implication of the entire lobule, whence the process spreads to adjacent lobules, either by coalescence of their lesions or by direct extension. The size of these patches of tuberculous consolidation varies greatly in the individual case, according to the virulence of the infection and the resistance of the subject. In the so-called *pneumonic type* of the disease there is a diffuse, apparently uniform consolidation of a lobe or even of an entire lung, the changes

closely resembling those of croupous pneumonia, both in their lobar distribution and, it may be, in the fibrinous character of the alveolar exudate. In other cases, those of the *bronchopneumonic type*, the lesions are more widely disseminated, and conform, both in their lobular distribution and in the presence of a catarrhal exudate, to the changes produced by bronchopneumonia. In their early stages the tuberculous foci are recognized as white or grayish areas showing,

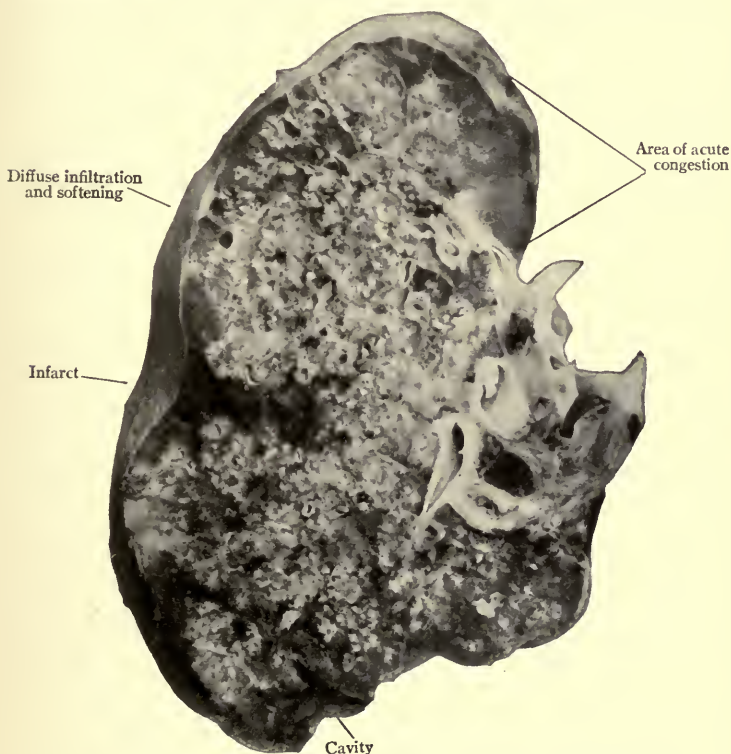


Fig. 101.—Acute pneumonic phthisis (Jefferson Hospital Laboratories).

on microscopic examination, the histologic structure of tubercles; in their later stages, as caseation progresses, their color becomes more and more yellow; and ultimately, owing to softening, secondary infection and discharge of the contents of the tubercles, the lung may become riddled with cavities, generally of small or moderate size. Isolated miliary tubercles also are commonly demonstrable, especially toward the apices and beneath the pleura, which is generally thickened and covered with a fibrinous or a caseous exudate. The

bronchi are more or less acutely inflamed, enlargement of the bronchial glands is virtually constant, and the lungs show atelectatic and emphysematous changes. Pyopneumothorax, from perforation of the pleura by a tuberculous nodule, is a complication of considerable frequency.

Physical Signs.—*Pneumonic Type.*—The physical signs are essentially those of lobar consolidation, commonly of an upper lobe, and exceptionally of an entire lung. On *inspection*, it is seen that the patient's face bears the pneumonic flush and that the breathing is hurried; or there may be urgent dyspnea, with more or less bluish pallor and inspiratory gaping of the nostrils. The spit-cup is likely to contain viscid mucoid material or typically rusty sputum, in which tubercle bacilli may or may not be found. *Palpation* yields exaggerated vocal fremitus over the consolidation, and sometimes reveals areas of restricted motility not noticed on inspection. *Percussion* shows dulness, preceding the development of which the percussion sound may have been decidedly hyperresonant. On *auscultation* over the affected area enfeebled breath-sounds and vesicular crepitations are heard in the early stages, succeeded by bronchovesicular and finally by bronchial breathing, and by intense bronchophony, as the consolidation progresses. These physical signs are practically those of ordinary croupous pneumonia, but, unlike them, they fail to clear up, critically, at the end of a five- or ten-day period. On the contrary, the consolidated areas soon begin to soften, to ulcerate, and to become excavated, in consequence of which cavity signs supervene and the sputum is charged with elastic fibers and teems with tubercle bacilli. This state of affairs may continue for ten or twelve weeks before the patient dies, but more commonly vital damage to the lungs is accomplished within six or eight weeks, or, in the exceptionally fulminant case, within a fortnight. Occasionally the acute progress of the process is modified, and the disease runs its subsequent course as a chronic pulmonary tuberculosis, generally of the ulcerative type.

Bronchopneumonic Type.—This form of acute phthisis, which is generally bilateral, is ushered in with predominant signs of an acute bronchiolitis—numerous sibilant and subcrepitant râles scattered over both lungs. As the smaller tubes fill with cheesy material and the vesicles of the communicating lobules undergo catarrhal changes, definite evidences of the tuberculous bronchopneumonia are apparent. On *inspection*, the patient's dyspnea, cyanosis, and panting respiration attest the stress of his fight for oxygen. *Palpation* discovers scattered patches, especially apical, of increased vocal fremitus, over which *auscultation* affords bronchovesicular or even tubular breathing, bronchophony, and subcrepitant and crepitant râles.

Jürgensen's sign—the delicate crepitation of pleural tubercles—is sometimes demonstrable. These signs, instead of abating after two or three weeks, as is the rule in non-tuberculous bronchopneumonia, persist and are subsequently overshadowed by evidences of softening and excavation of the caseous foci. Sometimes the picture of the typhoid state supervenes, and the subject survives but three or four weeks; but in other instances, despite the gravity of the disease, an extraordinary remission occurs after the patient has been prostrated for several weeks, the physical signs becoming transformed into those of chronic phthisis with multiple cavities and considerable fibrosis.

Diagnosis.—For a time *croupous pneumonia* may be faithfully counterfeited by acute phthisis of the pneumonic type, owing to its sudden onset, initial chill, high fever, cough, and evidences of lobar consolidation. At an early period there may be absolutely no means of differentiation, although primary implication of an apex, slow extension of the consolidation, and a remittent type of fever are more suggestive of tuberculous than of pneumococcus pneumonitis. The early detection of tubercle bacilli in the sputum is, of course, all important, but often this is not possible, and the same is apparently true of the ophthalmotuberculin reaction. The disease runs its course unchecked past the time of a pneumonic crisis without undergoing a critical defervescence, but, on the contrary, becomes more and more alarming, the high fever persisting and showing greater fluctuations, the pulse-rate quickening, drenching sweats occurring, and the sputum, previously rusty or mucopurulent, becoming of yellowish and greenish hue and laden with tubercle bacilli and perhaps bits of elastic fibers. The infection now appears in its true light, especially as by this time the patient's emaciation and toxemia are pronounced and the lungs show unmistakable signs of softening over the areas primarily consolidated.

In the bronchopneumonic type the differentiation from *non-tuberculous bronchopneumonia* is frequently called for, since the chief early symptoms are urgent dyspnea, cough, a chill or repeated rigors, high fever, a rapid pulse, and the physical signs of diffuse bronchiolitis. In some cases, however, hemoptysis is the initial symptom, and it is possible to find tubercle bacilli early; but generally these are later signs, and one must wait for softening of the tuberculous foci, to be sure of the diagnosis, though the progressive emaciation of the patient gives no uncertain hint. A tuberculous family history and a recent attack of measles or of pertussis are in favor of the tuberculous character of any obscure bronchopneumonia.

The wide-spread bronchitis of certain cases of *enteric fever* may require discrimination, but in this disease the development of an orderly sequence of typhoid symptoms, plus the lack of distinctive tuberculous physical signs, will effectually settle the question.

CHRONIC ULCERATIVE PHTHISIS (Slow Consumption)

Clinical Pathology.—This form of phthisis, which is primarily a chronic tuberculous pneumonitis, serves to illustrate every possible phase of damage which the lungs may suffer from invasion by the tubercle bacillus and by associated secondary bacterial infection. In the well-advanced case a most diverse group of lesions develops, ranging from minute miliary granules to extensive areas of destruction due to excavation and to fibroid overgrowth. To such a condition the lay term, "consumption of the lungs," is singularly applicable (Fig. 102).

In the majority of cases there can be no question that the infection is of bronchogenic origin, arising in consequence of the inhalation of tubercle bacilli, which lodge in the terminal bronchi or, less commonly, in the larger bronchial tubes. In the first instance the bacteria directly excite a caseous bronchopneumonia and also penetrate the bronchioalveolar epithelium, thus initiating the growth and distribution of tuberculous foci in the surrounding connective tissue. These two lesions, though theoretically distinct, rapidly merge into a single focus, whence dissemination of the infection to other parts of the lungs is effected by the lymphatic vessels and by secondary aspiration of tuberculous material into the finer bronchial twigs. Exceptionally, the initial phthisical lesion is ingrafted upon a preëxisting inflammation of the larger bronchi, which become the seat of tuberculous inflammation and ulceration, whence the bronchiolar and alveolar structures become secondarily infected, by aspiration. The bronchial glands are likely to be the seat of miliary and caseous lesions, terminating perhaps by calcification or by suppuration, often with the most disastrous results.

Aside from its origin by inhalation, pulmonary tuberculosis may also arise from infection through the alimentary canal, for tubercle bacilli swallowed and taken into the intestines are able to penetrate, without exciting a local lesion, the intact mucosa of the gut, and are carried hence, by the lacteals and the thoracic duct, ultimately to lodge in the capillaries of the lungs. Children are especially susceptible to infection along this path, which, though traveled in a considerable proportion of all cases of phthisis, cannot be regarded as

the only portal of entry, to the exclusion of the older inhalation theory of infection via the air-passages.

As tuberculous foci age, more and more of the lung tissue becomes invaded by the disease, and less and less distinction is possible between the tubercles and the adjacent spots of caseous pneumonia. Excessive proliferation of connective tissue is the rule in the neighborhood of the tuberculous lesions, and in many such areas this reparative process is actually obliterative, in that it finally converts the tubercles into a dense cicatrix, or encapsulates them with a thick, fibrous wall,

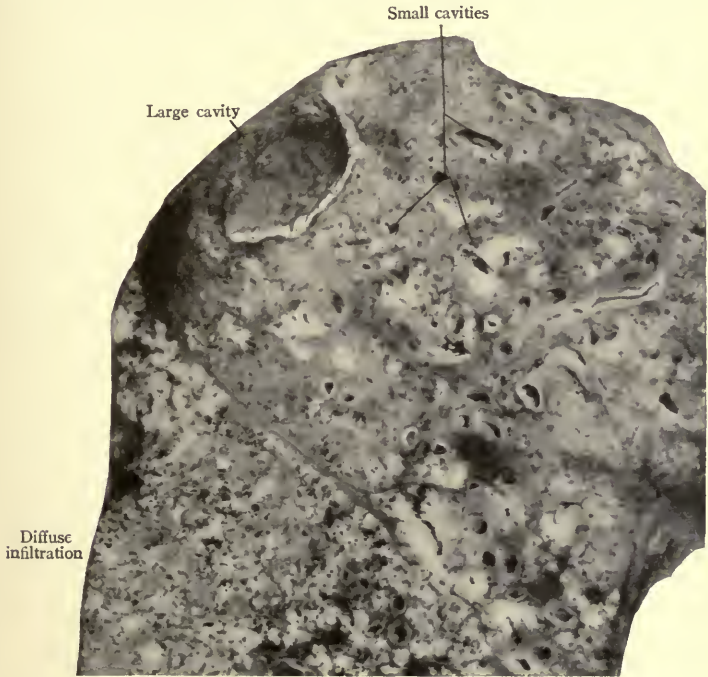


Fig. 102.—Chronic ulcerative phthisis (Jefferson Hospital Laboratories).

which later becomes still more impermeable through calcification. A cheesy spot thus thoroughly inclosed or obliterated is, to all intents and purposes, healed, but should the fibrous envelop be too delicate, the infective material, even after a long period of latency, may penetrate the barrier and thus light up afresh the disease. Hand in hand with these reparative changes the degenerative necroses of the tubercles progress, as shown by their tendency to undergo cheesy softening, liquefaction, and ulceration, the final result being the formation of

cavities, many of which find a bronchial outlet by ulcerative extension. The wall of such a cavity is formed of a fibrous overgrowth lined by a pyogenic membrane, and its contents consist of foul mucopurulent secretion swarming with both pyogenic and tubercle microorganisms and laden with caseous masses, elastic tissue, degenerate epithelium, and blood- and pus-cells. A cavity may enlarge by the process of chronic ulcerative erosion kept up by the combined action of pyogenic cocci and tubercle bacilli; and several moderate-sized cavities may fuse into a single large excavation, or they may form a chain of communicating chambers. Some cavities are but one or two centimeters in diameter, while others destroy practically an entire lung. A blood-vessel that has escaped thrombotic obliteration within a cavity is to be regarded as a possible source of serious, even fatal, hemorrhage, the blood issuing either from a breach eroded in the vessel-wall, or from the rupture of an aneurismal dilatation of a vessel (*Rasmussen's aneurism*) in the lining membrane of the cavity or bridging it from wall to wall. It is obvious that in a cavity with no bronchial outlet such a hemorrhage is not betrayed by hemoptysis, this accident being a so-called "concealed hemorrhage" of phthisis. Aside from the foregoing types of cavity, there are those of bronchiectatic origin, due to the dilatation of small bronchi weakened by tuberculous ulceration and distended by accumulations of secretion pent up within the diseased tubes. These have been referred to in the discussion of bronchiectasis. (See Fig. 93).

The pleura in a case of chronic ulcerative phthisis rarely, if ever, escapes injury, either in the form of a simple dry pleurisy with adhesion and thickening, or as a tuberculous invasion by miliary and caseous foci. Pleural effusions and pyopneumothorax are likewise to be reckoned with in numerous instances. The non-tuberculous pulmonary tissue is generally overdistended in its endeavor vicariously to offset the crippling effects of the phthisis, and in many areas atelectasis and compression of the lung are apparent.

About 1 per cent. of all cases of pulmonary tuberculosis is attended by chronic valvular disease of the heart, which only exceptionally is of tuberculous nature, and the latter is true also of pericarditis, a rare complication usually arising secondarily by extension from the pleura or from a cavity. Tuberculosis of the heart muscle is exceptional, but myocardial degeneration is common. The size of the heart is commonly smaller than normal in phthisical subjects, and this change is variously attributed to factors such as congenital anomalies, general cardiovascular hypoplasia, and the effects of habitual inspiratory restriction. Right-sided dilatation occurs as the result of long-standing pulmonary fibrosis and asso-

ciated changes which strain the right ventricle; and in such cases loss of compensation and the onset of cardiac failure hastens the progress of the pulmonary infection.

Mitral regurgitation is by far the commonest valvular defect in phthical patients. It has little or no effect upon the pulmonary lesion, although if compensation be good it may retard its progress (Lawrason Brown). Pulmonary stenosis, in that it causes persistent pulmonary anemia, predisposes to phthisis; while the effect of mitral stenosis, which sets up a constant congestion of the lungs and concentrates in them the immunizing agents of the blood, is supposed to be more or less antagonistic. Aortic disease is more commonly associated with latent than with active types of pulmonary tuberculosis.

In incipient phthisis lowered blood-pressure with acceleration of the pulse-rate is the rule, and as the disease advances both signs grow more conspicuous, owing to degeneration of the myocardium from the effect of the tuberculous virus.

Aside from the secondary infections that may attack various parts of the respiratory tract, the important complications of phthisis include tuberculosis of the intestines, kidneys, lymphatic glands, meninges, and ischio-rectal abscess.

Usually the initial lesion of chronic ulcerative phthisis develops in the upper lobe of one lung (most commonly the right) at a point one or one and one-half inches (2.5 to 3.75 cm.) below its extreme apex (Kingston Fowler), whence the process tends to spread downward on the same side, and later to the apex of the opposite lung, as the result of which method of extension the apical lesions are likely to be older and more advanced than those of the bases. Exceptionally, the starting-point of the disease is in a lower lobe, such instances occurring more commonly in children than in adults. Clinically, the earliest physical evidences of phthisis are demonstrable either anteriorly, just below the center of the clavicle and below the outer third of this bone in the first and second interspaces, or posteriorly in the supraspinous fossa. Infection of the lower lobe begins posteriorly at a point about $1\frac{1}{2}$ inches (3.75 cm.) below its summit (Kingsley), the physical signs of such an invasion being found at a spot opposite the fifth thoracic vertebra, whence they spread downward and outward along the line of the vertebral border of the scapula, when it is elevated by having the subject place the hand upon the opposite shoulder with the elbow raised above this level.

Although no case of phthisis can be expected to run a clinical course, divisible into fixed, well-defined stages, it seems best, when examining a suspected case of this disease, to have in mind certain

arbitrary periods of the infection, so as intelligently to correlate the physical signs with the underlying pulmonary lesions. It is, therefore, convenient to divide the disease into three periods, which, it is perfectly obvious, must overlap, merge, and variously dominate the clinical picture, according to the peculiarities of the process in the individual patient. The *first period*, which includes the stage of initial tuberculous deposits, may exist for some time and yet afford no definite physical signs; and in this category belong the so-called "incipient" cases, with suspicious histories and negative or trifling signs, as well as those with clear evidences of one or more circumscribed, limited areas of infiltration. The *second period*, corresponding to the wider dissemination and softening of the infiltrations, comprises cases with single or multiple lesions undergoing degenerative changes, the objective symptoms of which are conspicuous. The *third period*, that of cavity formation, affords signs of pulmonary excavation and extensive fibrosis, with extension of the infiltration and softening originally determined.

Physical Signs.—*Inspection.*—In incipient cases one must often be content to gain information from minor stigmata rather than from characteristic hall-marks of the disease. Typical illustrations of such stigmata have been perpetuated in Botticelli's pallid angels, and in Rosetti's and Burne-Jones's lanky beauties, whose wistful, pained faces, long, slender necks, and stooped, flat-chested trunks are highly suggestive of early phthisis. As Iwai has shown, supernumerary breasts are twice as common in phthisical as in healthy women. The characteristics of the phthisical or alar type of thorax will be found in a foregoing section. (See p. 78.) In this connection it is interesting to note that *Rothschild's sign* (preternatural flattening and mobility of the sternal angle) is frequently demonstrable long before the first signs of infiltration appear. Ankylotic rigidity of the spinal column, especially of the thoracic and lumbar segments (*Lorenz's sign*), also is found in a considerable percentage of patients with incipient phthisis.

Progressive loss of weight is a prominent early finding, which, as the disease advances, becomes correspondingly more conspicuous, the emaciation sometimes attaining a most extraordinary degree. (See Fig. 25, p. 79.) In some persons phthisis may be active for a prolonged period without apparently making inroads upon the general health and nutrition. A striking phase of the present European war is the physical fitness and ability for stress shown by the large number of tuberculous soldiers among the armies engaged. Guilhaud even goes so far as to describe a form of phthisis characterized

by obesity, regarding it as readily curable and not incompatible with longevity.

The trained eye appreciates the pertinence of the tuberculous facies; an oval face, with delicate or pinched features; bright, appealing eyes, with dilated, perhaps unequal, pupils and snow-white scleras; and, as the disease progresses, respiratory dilatation of the nasal alæ and bright-red hectic flushes upon either cheek (Fig. 103). Gee's trenchant remark, "we should never see anemia without thinking of phthisis," should serve as a maxim for daily use in dealing with chest cases, although blood deterioration ordinarily does not occur until malnutrition and sepsis have long been at work.

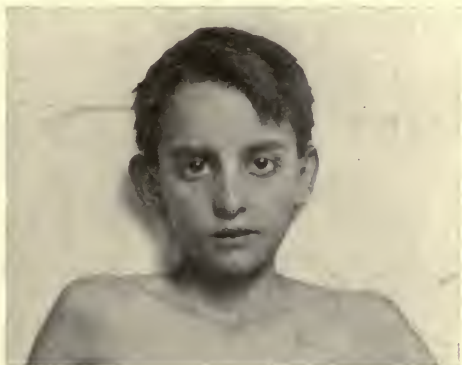

Fig. 103.—The phthisical facies (Jefferson Hospital).

Incipient apical disease is early betrayed by deficient expansion and flattening of one infraclavicular space, the former defect usually being more easily recognized by palpation than by inspection (*v. i.*). Lagging or complete respiratory immobility of the acromion process on the affected side is another early sign of real value. Diminished pulmonary elasticity plus spasmodic muscular contraction accounts for these early physical signs, and if persistent the combined factors lead to actual degeneration of the muscles affected, according to Pottenger's studies. The trapezius and the sternocleidomastoid muscles are notably smaller, softer, and shorter on the affected side in unilateral apical lesions.

As softening and fibrosis increase the neck apparently lengthens, the supraclavicular and infraclavicular regions deepen conspicuously, and the clavicles become abnormally prominent; the interspaces sink in, the ribs overlap, the scapula on the affected side

tilts outward, and circumscribed areas of immobility, flattening, and retraction appear upon the chest-wall, the expansion of which progressively diminishes as the result of the pulmonary destruction and the pleural pain. These changes, consisting essentially of reflex muscle spasm and atrophy, are largely attributable to disorders of the thoracic sympathetic ganglion and to irritation of the vagus, the brachial plexus, and the phrenic and intercostal nerves (Pomeroy; Balint; Jessen). In extensive unilateral lesions the opposite half of the thorax may be vicariously overdistended.

More or less restriction of Litten's diaphragm shadow on the affected half of the thorax may be evident, generally in consequence of pleural pain; and reversal of the physiologic respiratory type is a common anomaly of breathing in incipient tuberculous deposits.

A diffuse cardiac impulse, visible in the second, third, and fourth left interspaces, is commonly found in advanced tuberculosis of the left apex, in consequence of fibrous retraction of the lappet of lung from its normal site between the heart and the thoracic wall. Displacement of the apex to either side (more frequently to the left) occurs very frequently, as the result of either traction or pressure.

Not infrequently a delicate tracery of small venules courses over the lower part of the anterior chest-wall, and many phthisical subjects are disfigured by a downy growth of hair, by dirty brownish patches of tinea versicolor, especially upon the back, and by chloasmic discoloration (*chloasma phthisicorum*) of the face. In tubercular children with a tuberculous family history Gibson has noted the frequent occurrence of numerous visible venules upon the chest and face, associated with undue prominence of one or both jugulars, the vessels thus overdistended failing to show a normal inspiratory collapse. In apical tuberculosis a collection of delicate red or purple lines is commonly observed in the skin over the apex of the lung—the "striæ vasculares" of Francke, attributed to permanent engorgement of the cutaneous blood-vessels due to toxins derived from an underlying focus of pulmonary infection. Lombardi has described as an early sign of apical phthisis the formation of small bluish varicosities near the lower cervical and the upper thoracic vertebral spines, and Sabourin has noted depressed ecchymotic spots in the dorsolumbar regions. The association of zona and of erythema nodosum with phthisis is a well-known clinical sign.

Clubbed fingers, and perhaps true examples of Marie's osteoarthropathy, are familiar findings during the later stages of the disease. (See p. 121.)

Since tuberculous lesions produce x-ray shadows corresponding to their location, size, and density, the use of the fluoroscope and the

radiograph is of real value in the diagnosis of phthisis, as well as in tracing its progress. In incipient cases haziness or mottling of an apex is shown by the fluoroscope, and in some instances a more or less disseminated darkening over the greater extent of the diseased lobe. Sometimes the shadows cast by a group of enlarged bronchial glands give the first clue to the tuberculous process. The movement of the diaphragm is more restricted on the affected than on the sound side (*Williams's sign*), and, even in very early cases, inspiratory traction of the heart toward the diseased lung may be recognized. The "cough phenomenon," or the lightening of an

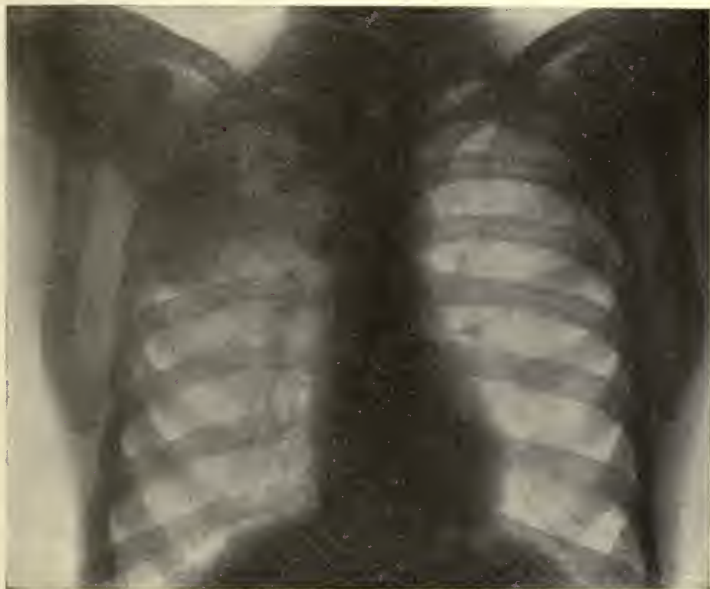

Fig. 104.—Radiograph of phthisis (*cf.* Fig. 70). Early stage, showing apical infiltration and glandular lesions. (Plate by Dr. W. F. Manges.)

apical shadow as the subject coughs, does not occur in an infiltrated apex, but this change, which is due to full inflation of the lungs, is constant in health and in atelectasis of the apex. The practical utility of these findings, which may anticipate the other physical signs, is obvious, provided that they are correctly interpreted. Failure to obtain an *x*-ray shadow from an incipient lesion that affords clear physical signs occasionally is met with in recent infiltrations of very slight density.

At a later period of the disease, when the tuberculous foci are denser and more wide-spread, their shadows are correspondingly deeper and

more clear-cut, oftentimes because of their contrast with the exceptional clearness of the neighboring emphysematous pulmonary tissue. A large cavity, if empty, produces a pale area, with peripheral darkening; if filled with fluid, it casts a definite homogeneous shadow. Röntgen-ray examination does not reveal the presence of a small cavity in the midst of an area of fibrosis. The accompanying radiographs (Figs. 104, 105, and 106) serve to illustrate the shadows cast by various degrees of tuberculous infiltration.

Palpation.—In early phthisis deficiencies of expansion so slight

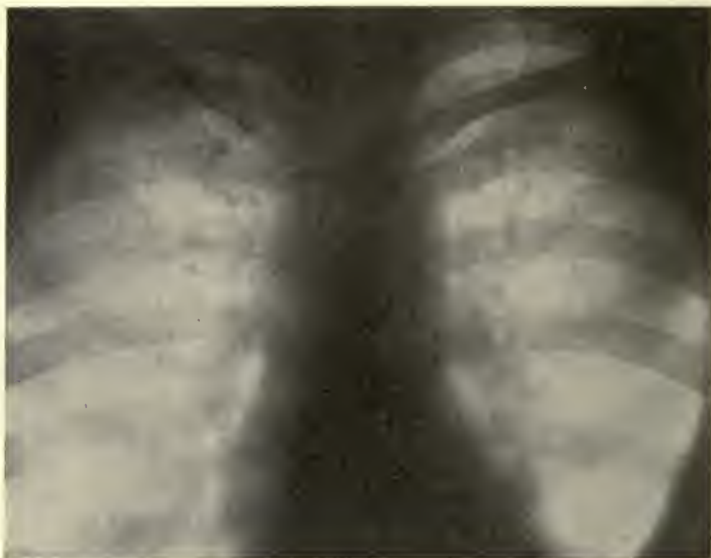

Fig. 105.—Radiograph of phthisis (*cf.* Fig. 70). Advanced stage, showing dense consolidation of right apex, with disseminated infiltration and fibrosis of both lungs. (Plate by Dr. W. F. Manges.)

as to escape the eye are frequently appreciable by palpation, and this is true particularly of apical lagging, which is most readily detected by palpating the clavicular regions from behind, as elsewhere described. (See Fig. 75).

Vocal fremitus is exaggerated over infiltrated areas not too deep seated, nor too effectually covered by emphysema, atelectasis, or thickened pleura. In view of the relative increase of vocal fremitus at the right apex, it follows that equal intensity of the fremitus at both apices denotes either undue increase on the left side or abnormal decrease on the right. Other conditions being the same,

the more compact the infiltration, the better its conduction of the voice vibrations. Over an empty superficial cavity vocal fremitus is greatly magnified, but over one filled with liquid or having a plugged bronchial outlet the vibrations are entirely abolished. It is occasionally possible to feel succussion waves over a large, smooth-walled excavation containing thin fluid secretion.

Mensuration and cyrtometry of the chest, save as a means of recording striking deformities, are generally dispensed with in the examination of a phthisical thorax, which in the advanced stages of the disease shows subnormal expansion, unusual measurements of the semicircumferences, and deviations from the normal depth and breadth.

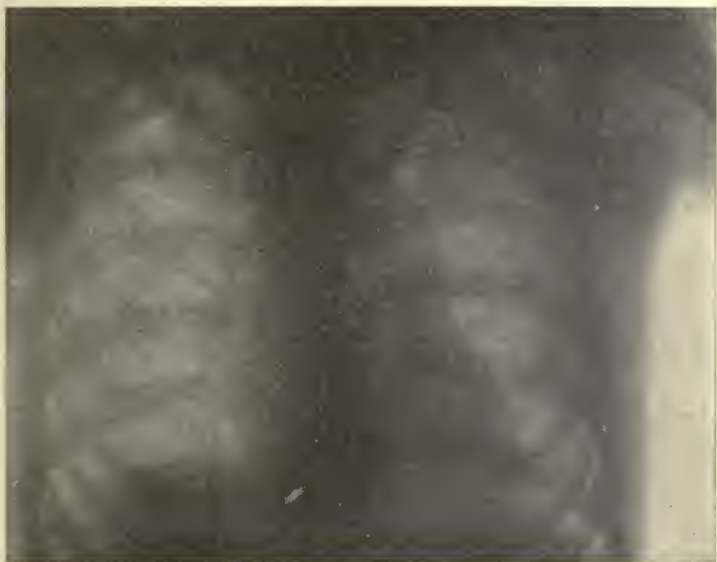

Fig. 106.—Radiograph of phthisis (*cf.* Fig. 70). Far-advanced stage, showing dense infiltration of both lungs, especially at the apices. (Plate by Dr. W. F. Manges.)

In many instances unilateral enlargement of the axillary and superficial cervical glands on the side of an apical lesion may be detected long before it becomes active. These glands, which Fernet believes to be affected secondarily to the pulmonary process, are small, movable, painless, and, strangely enough, tend to disappear as the primary infiltration of the apex lights up. Occasionally the subcutaneous lymphatic glands of the fourth and fifth interspaces in the axillary regions are distinctly palpable. Quite different from such indolent

adenopathies are the soft, ulcerative forms of tuberculous adenitis which may serve as the determining factor of phthisis.

Percussion.—The clavicular, suprascapular, and interscapular regions should be examined for the earliest indications of impaired resonance, which consist of a percussion sound of unduly high pitch and brief duration, associated with a sense of increased resistance over the part percussed. These evidences of moderate infiltration are gradually accentuated as the consolidation increases in density and in extent, until finally the sound becomes frankly dull and the resistance extreme. But every phthisical lung does not, during its incipient period, alter the percussion sound in this manner, for normal resonance is not incompatible with a deep-seated compact infiltration of considerable size entirely surrounded by healthy lung, nor with a superficial area of disseminated foci. The presence of an apical emphysema also is to be recalled as a potential factor of negating the dulness of a consolidation in this region. In attempting to judge trifling apical differences it is important to draw conclusions after comparative percussion of the two sides, and sometimes impaired resonance of one apex is elicited only by respiratory percussion, while the subject holds the breath after a full inspiration.

Apart from the demonstration of actual dulness at the apices, the attempt should be made to map out the respiratory rise of the lungs in these regions, by percussion over the supraclavicular regions from behind. (See Fig. 80, p. 138.) The roughly triangular area of pulmonary resonance, which normally extends $\frac{1}{2}$ to $1\frac{1}{2}$ inches (1.25 to 3.75 cm.) above each clavicle (Philip), is more or less contracted by the lung shrinkage due to apical disease. Especially significant of incipient phthisis, according to Minor, is a retraction, or outward dislocation, of the inner border of the apex, which, in health, runs upward from the sternoclavicular joint to a point $1\frac{3}{8}$ inches (4 cm.) internal to the free edge of the trapezius, and thence drops obliquely to the lower border of the second thoracic vertebra. Extraordinary skill in percussion is obviously necessary to detect this slight apical deviation.

As the tuberculosis spreads through the lungs, the dulness correspondingly extends, acquiring, over areas of dense fibrosis and pleural thickening, a characteristic wooden quality quite different from the dulness of airless lung. In contrast to this, a decided hyperresonance may be found over a caseous infiltration undergoing rapid softening.

A cavity affords either tympany or flatness, depending upon whether it be empty or filled with fluid. (See Fig. 83.) The "cracked-pot sound" and the amphoric "jug-sound" are also to be sought for, as well as the several special tonal changes described by Wintrich,

Williams, Friedreich, and Gerhardt. (See p. 148) *et seq.*) In Landis's experience at the Phipps Institute, cavity tympany is elicited in about 70 per cent. of cases in which excavation exists. It is sometimes possible to empty an apical cavity by gently rapping upon the overlying chest-wall with a hard instrument, such as an ivory paper-knife, the effect being to excite a coughing fit which expels the secretion within the cavity and thereby develops cavernous signs—Erni's *signe du tapotage*.

In most cases of phthisis—and also in numerous other diseases—sharp immediate percussion of the upper anterior chest causes a peculiar muscular contraction, known as myoidema, appearing either as a hard, nodular swelling at right angles to the course of the muscle, or as a linear groove running in the direction of the muscular fibers.

Auscultation.—Over a patch of beginning infiltration the inspiratory murmur may be either feeble and distant or loud and harsh, the former indicating imperfect entrance of air into the tuberculous area, and the latter, consolidation dense enough to conduct some of the bronchial tone. The expiratory murmur is relatively rough, harsh, and prolonged. In incipient phthisis of the right apex J. S. Billings, Jr., finds that exaggerated respiratory and voice sounds are sharply restricted to the apex, while a similar intensification from physiologic causes is audible over the entire upper lobe.

As the infiltration extends, the respiration becomes bronchovesicular, and finally bronchial, as the last vestige of the vesicular element is replaced by a tubular, blowing quality. Laennec's "veiled puff," recognized as an abrupt bronchial tone toward the end of an inspiration beginning as a vesicular sound, is a somewhat distinctive early sign; and respiration of the interrupted or "cog-wheel" type is quite common, though by no means pathognomonic of phthisis. Over parts of the lung affected by compensatory distention, exaggerated breathing is distinguishable.

Over a cavity of fair size several modifications of bronchial breathing are audible, of which the hollow cavernous and the echoing amphoric types are the most distinctive; over a small cavity the breathing is more likely to be purely tubular. Seitz-metamorphosing respiration, a tubulocavernous sound, usually inspiratory, is a less easily appreciable sign, occasionally heard over a cavity with a small bronchial outlet.

Vocal resonance is increased over infiltrated and excavated areas of the lung, and of the latter, whispering pectoriloquy is one of the most constant physical signs; it may, however, also be symptomatic of a dense peribronchial solidification. Clear pectoriloquy is very

commonly heard in this condition when the stethoscope is applied to the tips of the upper thoracic vertebræ (see p. 301).

Fine moist râles, pleural friction, and cavernous bubbling are the most pertinent adventitious sounds of chronic ulcerative phthisis. At an early stage moist bronchiolar subcrepitations, still finer vesicular crepitations, and delicate pleural friction-sounds are to be expected; or, should the bronchiolar mucosa be dry and swollen, piping sibilant râles are found rather than moist sounds, though the two are often intermingled. In some instances a single sharp mucous click is the first evidence of the tuberculous bronchiolitis. The foregoing râles are chiefly, if not altogether, inspiratory, and are usually much influenced by coughing and by deep breathing; their persistence at an apex is one of the earliest, most convincing indications of tuberculosis in this region. Boeri advises auscultation immediately after active massage of the supraclavicular regions, as a means of identifying delicate apical crepitations otherwise inaudible; or they may be developed by instructing the patient to cough lightly at the end of expiration.

If an area of pulmonary infiltration near the heart be forcibly joggled by the cardiac impact, audible vibrations may be set up in the exudate within the bronchioles and infundibula of the diseased area, thus producing so-called cardiac or cardiopneumatic râles. By a similar mechanism air may be driven from the finer tubes with an audible systolic whiff, known as a cardiorespiratory murmur.

Pleural friction, which is generally demonstrable throughout the disease, may be restricted to the pleural layers overlying the heart, in consequence of which the sound conforms to the rhythm of pleuro-pericardial friction (*q. v.*). Pleural thickening, it is to be remembered, may be so extensive as to mask exaggerated fremitus, as well as to dull the percussion sound over an otherwise tympanitic area. Vascular murmurs, due to the pressure of a thickened pleura, are occasionally demonstrable over the subclavian arteries in tuberculosis of the apex.

As softening progresses and secretion accumulates within the larger bronchi, coarse mucous râles become audible, and, should dry bronchitis coëxist in other parts of the tubes, snoring rhonchi are also heard.

Over a cavity containing liquid there are various sized moist bubbling and gurgling sounds of cavernous or amphoric quality, but a dry cavity affords no such physical signs. To cavernous râles, deep and active inspiration may add a sharp, clean-cut quality, described by Skoda as consonating or resonant, and metallic râles thus modified bear some resemblance to the metallic tinkle of hydrothorax, from

which, however, they are readily distinguished by the associated physical signs. Exceptionally, a cavity of large size furnishes a succussion sound similar to the pleural splash. Cavernous râles may also be of the cardiopneumatic type, in case an area of consolidation riddled with small cavities happens to be bound down to the heart by dense pleural adhesions. (See p. 166.) The transmitted sounds of the heart, and frequently of murmurs, should they exist, are clearly heard over large apical cavities.

Under the term *laryngeal crepitus* Remouchamps describes a fine grating respiratory sound, detected, even in incipient phthisis, by placing the ear a few inches from the open mouth of the subject, who meanwhile breathes deeply, with the chin elevated and extended. By this manœuver a bruit, comparable to the scratching of a pen upon a rough surface, is audible during respiration, especially with expiration. The sound is due presumably to the laryngeal amplification of adventitious sounds arising in the diseased tissues of the lung.

Diagnosis.—No sign, however trivial it appears, should be disregarded in the study of a case of possible incipient phthisis, for the diagnosis of which pulmonary physical signs alone may be wholly inadequate. Advanced cases, on the contrary, present no such difficulty, but a tuberculous lesion whose inroads afford convincing physical signs is correspondingly hard to arrest, and in such an event the physician may be able to do little save advise the patient to put his house in order against the inevitable finality.

In some instances a beginning infiltration is betrayed by deficient expansion, exaggerated voice fremitus and resonance, a high-pitched percussion sound, an impure respiratory murmur, and a few fine moist râles over a circumscribed area, generally at an apex. In others there is merely an enfeebled or a harsh respiratory sound, with perhaps an occasional mucous click or a few subcrepitations. For the patient's sake, it is better to regard as tuberculous these evidences of a local bronchiolitis, if they persist at an apex, despite negative sputum examinations and an unaltered percussion sound, and in doubtful cases of this sort tuberculin may clear up the diagnosis at once. Aside from the local physical signs, it is essential to take into account many other evidences of the more or less active inroads of the tuberculous process—habitually rapid pulse, afternoon fever and shivering, spontaneous sweating, indolent adenitis, cough and huskiness of the voice, persistent nasopharyngeal catarrh, capricious appetite and chronic indigestion, slight secondary anemia, and progressive languor and loss of weight. Very commonly the chief symptoms are those of chronic bronchitis or of pleurisy, while sometimes

hemoptysis is the first evidence found. Some patients exhibit an extraordinary degree of tolerance to the constitutional effects of the tuberculoxin, and are not conscious of any decided ill health until the lungs have become extensively damaged; and in others the pulmonary lesions are overshadowed by symptoms relating to tuberculosis of other parts of the body.

Malarial fever may be simulated by phthisical attacks of chills, fever, and sweats, closely conforming to the paroxysms of ague, but the chest signs, the result of the blood and sputum examinations, and the patient's history furnish conclusive data for differentiating the two infections.

Chronic bronchitis must be carefully distinguished from those forms of pulmonary tuberculosis having marked signs of bronchial implication. In ordinary chronic bronchial catarrh it is common to find the chest more or less emphysematous, with general hyperresonance, diminished fremitus, feeble breath-sounds, greatly prolonged expiration, and numerous dry and moist bronchial râles of various size.

The discrimination between *bronchiectasis* and a tuberculous cavity is always difficult and frequently impossible. Basal cavity signs that persist without becoming exaggerated, paroxysms of coughing productive of fetid sputum containing no tubercle bacilli, absence of apical infiltration, and little or no disturbance of the patient's strength and nutrition are findings in favor of a non-tuberculous bronchial dilatation. The bronchiectatic "evacuative cough," which empties the cavity, must be distinguished from the phthisical "Morton's cough," which empties the stomach, often so repeatedly and effectually that the patient's nutrition suffers.

A careful examination of the lungs is sufficient to identify cases of tuberculosis which masquerade as *chlorosis*, *secondary anemia*, and *chronic gastric catarrh*. Phthisis versus *pulmonary abscess* and *gangrene* is discussed elsewhere. (See p. 255 *et seq.*)

FIBROID PHTHISIS (Tuberculofibrosis or Fibrotuberculosis of the Lungs)

Clinical Pathology.—The predominant lesion in this variety of phthisis consists of a dense fibrous overgrowth whereby the tuberculous areas are compressed, encapsulated, and finally segregated or obliterated. The affection is one of decided chronicity, and develops apparently in subjects of great vital resistance, infected with tubercle bacilli of moderate virulence, owing to which conditions this conservative cirrhosis destroys the tuberculous foci, limits their dissemination, and in some instances effectually arrests the progress of the

initial phthisical disease. In lungs cirrhused in this manner the original tubercles are entirely effaced, or else are recognizable merely as encapsulated areas of sclerosis and as partly obliterated excavations. The latter, as in ulcerative phthisis, occasionally are of considerable size, and contain infective material which, in the course of time, may break through the cavity wall and contaminate the surrounding structures. Other cavities, of smaller size, may be compressed into long, slender fistulous passages drained by neighboring bronchial tubes—the *cicatrices fistuleuses* of Laennec.

Ultimately, the fibroid changes, although primarily reparative in character, become so exaggerated as seriously to interfere with the pulmonary function, for they progressively encroach upon the alveolar tissue, thus decreasing the respiratory area and exciting compensatory dilatation of the non-fibroid vesicles, and in time produce an extreme degree of induration and contraction of the pulmonary structure. In the event of extensive pleuropulmonary adhesion and contraction, conspicuous deformity of the thoracic wall develops.

Fibroid phthisis is ordinarily a sequel of the chronic ulcerative type of the disease or of a tuberculous pleurisy, but it may be secondary to other forms of tuberculosis of the lungs; or there may be a primary fibrosis, subsequently becoming tuberculous. The process usually implicates both lungs, and tends to become most extensive at one of the apices. Few sufferers from fibroid phthisis escape bronchiectasis, mainly because of the frequent incidence of dense fibrous adhesions which exert traction upon the bronchial walls. In consequence of the habitual obstruction to the pulmonary circulation that exists, cardiac hypertrophy, particularly of the right ventricle, sooner or later supervenes.

Physical Signs.—*Inspection.*—The pulmonary contraction inevitably changes the contour of the thorax, drags the heart from its normal site, and disturbs the respiratory excursions, especially where the fibrosis is wide-spread and complicated by extensive pleural thickening and by bronchiectasis. On the affected side, the respiratory movements are restricted, perhaps to the point of practical obliteration, while the opposite half of the chest, provided that it has escaped extensive fibrosis, is vicariously enlarged. The thoracic wall is flat and depressed, either as a whole or locally; the shoulder droops; the clavicular areas are unduly deep; the interspaces are narrowed or even effaced by the crowding together and overlapping of the ribs; and the diaphragm is elevated above its normal level. In the extreme instance the spinal column inclines toward the shrunken side. The heart is usually drawn toward the affected area, the apex-beat being displaced toward the right axilla by fibrosis of the right lung, and

toward the left axilla by a left-sided lesion; in the latter the impulse of the heart is frequently visible upon the chest-wall from the second to the fifth interspaces. Owing to the enlargement of the right heart there are bulging of the lower part of the sternum

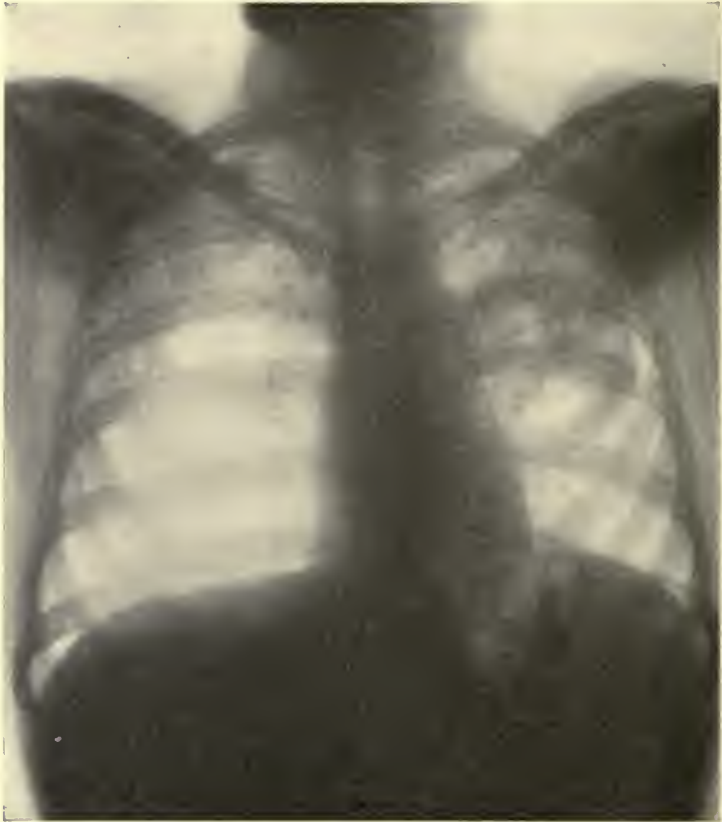

Fig. 107.—Radiograph of fibroid phthisis. Extensive fibrosis of left lung, with corresponding cardiac displacement. (Plate by Dr. W. Manges.)

and pulsation in the epigastrium and, in the upper interspaces to the right of the sternum.

Palpation.—The intensity of the local fremitus varies according to the character of the associated pulmonary and pleural lesions. Although the voice-sounds are clearly conducted by cirrhotic lung tissue, they are often diminished in fibroid phthisis, owing to the influence of pleural thickening, emphysema, bronchial obstruc-

tion, and retraction of the lung from the chest-wall. Over apical cirrhosis there is usually exaggeration of the fremitus, but over a central lesion no such alteration is appreciable.

Percussion.—Wooden dulness and a sense of extreme resistance to the pleximeter finger are elicited over the fibroid areas, especially when there are great pleural thickening and costal overlapping. Hyperresonance is the rule on the emphysematous side, as well as over circumscribed patches of overdistended lung adjacent to the seats of fibrosis. Circumscribed hyperresonance or pure tympany at the base of the lungs suggests an empty bronchial dilatation, and, at the apex, a pulmonary cavity.

Auscultation.—Various degrees of bronchophony and bronchial breathing are audible, ranging from the slightly increased vocal resonance and bronchovesicular breathing of a partly cirrhused area, to the clear pectoriloquy and bronchial or amphoric breathing of a compact fibrosis or of a cavity. Such changes are likely to be more marked at the apices than at the bases, where feeble respiration and many moist râles are ordinarily found. Other râles are also to be looked for, owing to the common association of bronchitis, tuberculous softening, and pleurisy. As the right heart dilates, the murmur of tricuspid incompetency appears, and the pulmonic second sound, previously accentuated and ringing, gradually weakens.

Diagnosis.—With a deformed chest, cardiac displacement and right-sided enlargement, wooden dulness, intensified respiratory and voice-sounds, and signs of pulmonary softening or excavation, the diagnosis is generally clear. With nothing more than physical signs of fibrosis as a guide, the question of fibroid tuberculosis versus non-tuberculous interstitial pneumonia arises, and in making this distinction one is frequently forced to depend finally upon the results of sputum examination and the tuberculin reaction. The detection of bilateral lesions, together with the fact that the patient has or has had fever, sweats, loss of weight, and other suspicious systemic symptoms, are suggestive of the tuberculous character of the process.

PULMONARY SYPHILIS (Syphilitic Pneumonia or Fibrosis; White Pneumonia; White Hepatization of the Lung; Pulmonary Albinism)

Clinical Pathology.—Pulmonary syphilis deserves careful consideration, not on account of its common incidence, for it is rare, nor because of its distinctive physical signs, for there are none, but rather because of its close clinical resemblance to certain non-syphilitic affections of the bronchopulmonary system, from which the differentiation of true lues of the lung must be attempted.

Gummata, interstitial fibrosis, and white hepatization of the vesicular structures are the essential pathologic changes of this rarely diagnosed condition, of which two sharply defined types, the acquired and the congenital, are generally recognized. In *acquired syphilis* of the lung the lesions are of gummatus and fibroid character, the former, though very rare, being by far the more distinctive of the two. Although they may invade any part of the lung, gummata are most often situated toward the root, near the larger bronchi, or, indeed, these tubes may be directly implicated by the granulomata, and in consequence are likely to become the seat of stenosis and of traction diverticula. Ordinarily, a gumma does not exceed 3 or 4 inches (7.5 to 10 cm.) in greatest diameter, and consists of a gray or yellowish caseous mass, inclosed by a fibrous capsule, either resilient and translucent or rigid and dense, according to the age of the lesion. Necrosis and liquefaction of a gumma, with its rupture into a bronchus, leads to cavity formation, and absorption and cicatrization of the syphilitic focus results in scarring at its site. Interstitial fibrosis is sometimes associated, and, exceptionally, it appears to develop as a primarily leucic process, quite independent of gummatus growths. As a rule, the fibrosis begins at the root of the lung, and extends peripherally along the interlobular and interlobar septa, but occasionally it spreads in the reverse direction, being of pleurogenous origin. The condition is virtually a chronic interstitial pneumonia (*q. v.*), commonly of a lobar type, and attended by the pathologic changes in the vesicular structures, bronchi, and pleura incident to an ordinary cirrhosis of the lung. Acquired pulmonary syphilis may lack distinctive features, for a gumma may exactly resemble a caseous tuberculous mass, and a syphilitic cirrhosis does not differ from cirrhoses due to other factors. In the first instance the differentiation depends upon the presence of the tubercle bacillus, the syphilitic treponema almost never being found in a gumma; while in the second instance the most available differential criteria are the patient's history and the question of cutaneous scars and visceral lesions. *Congenital syphilis* of the lung is typified by a condition known as *white pneumonia of the fetus*, characterized by hyperplasia of the intervesicular walls and proliferation of the cells lining the vesicles, with consequent obliteration of the vesicular structure through various areas, scattered or diffuse, of the lung or lungs. The affected parts teem with *Treponema pallida*, and, owing to the hyperplasia, become anemic, airless, and consolidated, being distinguishable as firm, non-crepitant, grayish-white territories, described as white hepatization of the lung. White pneumonia is found in the fetus, in still-born infants, and in those born alive, but in the last named no stress of respiratory

effort, however strong, is sufficient to inflate the consolidated areas. Gumma affects the congenitally syphilitic lung but very rarely.

Physical Signs and Diagnosis.—That acquired syphilis of the lung is attended by no distinctive thoracic signs must be apparent when the nature of the several pulmonary lesions is considered. According to the conditions predominating in the individual case, the physical signs ordinarily suggest chronic ulcerative phthisis, bronchostenosis, bronchiectasis, or pulmonary fibrosis.

Phthisis is counterfeited, not alone by signs of consolidation and perhaps of excavation, but also by the occurrence, with greater or less constancy, of cough, dyspnea, mucopurulent and bloody sputum, pleural pain, night-sweats, and emaciation. These last three symptoms are, however, comparatively infrequent, and, when present, are usually not striking—a circumstance of some consequence in favor of lues. But of far greater suggestiveness is the fact that the sputum invariably remains free from tubercle bacilli, in spite of its apparently tuberculous appearance and notwithstanding, in many instances, the clinical evidences of advanced consumption. Apparently, true syphilis organisms are never found in the sputum, judging from Rosenberger's analysis of 1210 collected cases. The reputed tendency of syphilis primarily to affect the middle lobe of the right lung, and the predilection of the right apex for tuberculous infection, are of minor, but not wholly negligible, significance. If the patient in past years has sown the wind so as now to reap a luetic whirlwind, syphilis, rather than tuberculosis of the lungs, is strongly suggested, this inference becoming the stronger if it be possible to identify the scar of the initial lesion, and to find signs of arteriosclerosis and of syphilitic processes elsewhere. Finally, so far as phthisis is concerned, the diagnosis may be settled by the tuberculin test: if positive, the lesion is tuberculous, though, unfortunately, this does not necessarily rule out coëxisting syphilis of the lung; but a negative reaction with tuberculin excludes phthisis, and by the same token indicates syphilis—beyond all question if it be associated with a strongly positive Wassermann reaction. If tempted to use potassium iodid as a therapeutic test, one should weigh the baneful effects of this drug in lighting up a tuberculous process against its action in subduing lues. Much the better plan is to anticipate improvement under the use of salvarsan.

Bronchial stenosis, due to the encroachment of gummatous nodules or to stricture by scar tissue, must be distinguished from bronchial occlusion by aneurism and by malignant tumor, especially sarcoma. Aneurismal pressure generally can be definitely proved with the aid

of the *x*-ray, even if the classic physical signs of this lesion be lacking. (See Aneurism, Section VI.) A history of syphilis and the existence of arteriosclerosis, it should be noted, favor aneurism as well as gumma. The following points are in favor of sarcoma rather than gumma: signs of consolidation in the anterior mediastinum prior to the onset of the bronchial obstruction; rapidly developing and often conspicuous symptoms, referable chiefly to the mediastinal vascular trunks and nerves; initial or secondary metastatic growths in parts remote from the thorax; anemia or cachexia of the patient, a clean personal history, and no scars or other relics of syphilis; and an unaltered clinical picture, despite the subject's saturation with iodids and mercury. Here also the *x*-ray may be of service, both in making the initial diagnosis and because of the fact that sometimes malignant growths diminish extraordinarily under persistent röntgenization, while gummata do not.

The physical signs of *syphilitic bronchiectasis* are in no wise distinctive, so that its differentiation from bronchial dilatation due to other causes rests upon other clinical evidence. The same is true of *syphilitic fibrosis* of the lung and its attempted discrimination from other types of chronic interstitial pneumonia.

Congenital syphilis of the lung is usually revealed only at autopsy, inasmuch as it is prone to affect still-born infants or those dying soon after birth. Occasionally white pneumonia is suggested by finding consolidative and other evidences of bronchopneumonia in a young baby showing unmistakable stigmata of congenital syphilis.

EMPHYSEMA

The word emphysema, literally meaning inflation, is applied, with an appropriate adjective, to several distinct, but frequently interdependent, pulmonary lesions of widely diverse character, affecting the vesicular and interstitial structures, either singly or together. Of the *vesicular type* of emphysema there are, according to current clinical nomenclature, four varieties: the *hypertrophic* or *large-lunged*, or a condition of chronic vesicular dilatation and septal wasting eventually leading to increased pulmonary volume; the *atrophic* or *small-lunged*, characterized by extreme and progressive atrophy of the vesicular structures, resulting in diminution of the pulmonary volume; the *acute vesicular*, in which a widely diffused overdistention of the lungs suddenly develops; and the *compensatory*, or a more or less circumscribed overinflation of the vesicles, either acute or chronic in character, and not primarily attended by permanent structural damage. The term *interstitial emphysema* is used to designate an accumulation of air in the interstitial connective tissues of the lung.

HYPERTROPHIC EMPHYSEMA (*Large-lunged, Pseudohypertrophic, Substantive, True, or Idiopathic Emphysema; Alveolar Ectasia*)

Clinical Pathology.—In this type of emphysema the lungs are permanently overinflated as the result of impaired pulmonary elasticity, combined with a state of persistent intravesicular hypertension (Fig. 108). The use of the adjectives hypertrophic and pseudo-

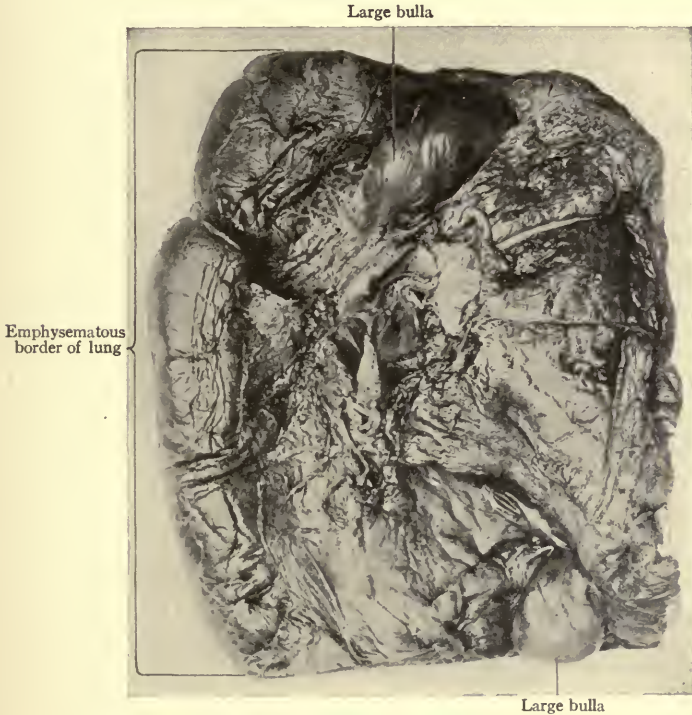


Fig. 108.—Pulmonary emphysema (Jefferson Hospital Laboratories).

hypertrophic to denote this form of emphysema relates merely to the enlarged volume of the lungs, and not to the predominant tissue changes, which are essentially atrophic. Impaired pulmonary elasticity may be an hereditary taint, whereby the elastic tissue of the lungs is inherently deficient or subnormally resistant; or the defect may be acquired through damage by processes inducing degeneration and atrophy of the elastic fibers, such as, for example, chronic bronchial catarrh, atheroma, and similar factors of disordered nutrition.

Given a predisposition of this sort, increased intravesicular pressure, especially when due to expiratory strain or overdistention, acts as the determining cause of emphysema. Emphysema is directly related to impaired alveolar ventilation, with an increase in the dead space of the lungs due chiefly to atonic elongation and broadening of the bronchioles and, in part, to bronchiolar spasm (Hoover).

Expiratory overdistention of the vesicles, the ruling factor in most cases, attends violent expiratory efforts associated with obstruction to the free outlet of the air-columns. Thus, in paroxysms of coughing the closure of the glottis plus the active pressure of the chest-wall together provoke inordinate tension within, and undue stretching of, the air-vesicles, especially toward the apices and along the anterior margins of the lungs, where the pulmonary structure, being poorly supported by the parietes, becomes the natural target of the violent gusts of air which, owing to the closed glottis, cannot escape by their natural channels. The poor support afforded by the intercostal muscles possibly has something to do with the development of emphysema in other portions of the lungs, which are successively approximated to the yielding interspaces during the progressive emphysematous changes in costal contour. Chronic bronchitis, asthma, and pertussis, chiefly in that they excite extreme intravesicular tension during expiration, are prominent causes of emphysema. In the light of modern studies (by Schmidt, Prettin, and others) the old belief that glass-blowers and players of wind instruments are peculiarly prone to emphysema must be regarded as a medical tradition.

Inspiratory overdistention of the vesicles apparently has little, if any, bearing upon the production of true large-lunged emphysema, though it is a most potent factor of the so-called compensatory variety (*q. v.*). It is, however, conceivable that a variable degree of vesicular dilatation might arise should relatively excessive inspiratory movements and shallow, imperfect expiration coëxist, as is the tendency when the thoracic resiliency is impaired by age or by disease.

Postmortem, the distinguishing marks of emphysematous lungs are their immoderate bulk, diminished weight, pale appearance, and disinclination to collapse; they convey a peculiar feathery sensation when handled, and their borders extend far beyond the normal limits, conspicuously encroaching anteriorly upon the cardiac and the hepatic areas. The emphysematous tissue fails to crepitate, pits easily on pressure, and is recognized beneath the pleura as a series of globular or irregular bullæ, ranging in size from a few millimeters to several centimeters, and, as a rule, attaining their maximum

development along the anterior inferior margins, at the root of the lower lobes, and at the apices of the lungs. Fig. 108 shows the appearance of these large emphysematous air-bladders along the pulmonary borders. On cross-section of a dry inflated specimen, the lung is found to be riddled with these enlarged vesiculo-infundubular compartments, both single and multilocular, formed by the rupture and coalescence of numerous individual over-distended vesicles. Microscopically, the changes relate to atrophy, thinning, and perforation of the intervesicular walls, obliteration of the capillary network therein, quantitative and qualitative deterioration of the elastica, and degeneration of the alveolar epithelium. Bronchitis and peribronchial thickening are virtually constant, and ectases of the finer bronchi are frequent associated changes. The pleura is generally dry and pale, and may show the white patches of Virchow's "pulmonary albinism." The rupture into the pleural cavity of an emphysematous bulla may set up pneumothorax. Owing to the stress imposed upon it by the impeded pulmonary circulation, the right side of the heart undergoes hypertrophy and dilatation, and occasionally a general cardiac enlargement supervenes; the pulmonary artery may be dilated and atheromatous. Various organs, notably the liver, spleen, and kidneys, show the familiar structural changes induced by chronic venous congestion.

Physical Signs.—*Inspection.*—The permanently overinflated "barrel chest," described in a preceding section (see p. 78), is distinctive of advanced cases of many years' development, although this deformity is by no means invariable. In certain subjects the costal cartilages are abnormally thickened and lengthened, corresponding to the "specific calcification" exploited half a century ago by Freund, as a primary and specific emphysematous change. Dyspnea, cough, cyanosis, and clubbing of the finger-tips are important objective signs which become more and more marked as the disease advances, with consequent loss of pulmonary elasticity, restriction of the respiratory surface, defective blood aëration, and exaggeration of the bronchitic lesions. When the right heart fails under the stress of the intrapulmonary hypertension, these signs become most striking, and are attended by jugular pulsation, general venous turgescence, and edema. Epigastric pulsation, due to the movements of a displaced and enlarged heart, is common, but the true apex-beat is obscured by the interposed mass of emphysematous lung. During respiration the thorax rises and falls *en masse* in a vertical direction, but fails to expand normally, despite the strenuous attempts of the auxiliary muscles to overcome the rigidity of the chest-walls. Litten's shadow begins at a lower level and is shorter than in the healthy

chest, owing to the abnormally low position and limited mobility of the diaphragm. In the exceptional instance this muscle is so extremely depressed and relaxed that its convexity lies toward the abdomen instead of toward the thorax. This inverted position of the diaphragm, whereby it serves as an expiratory rather than as an inspiratory muscle, gives rise to what is termed an inverse type of respiration. The fossæ above the clavicles and sternum and the upper intercostal spaces may be sucked in with deep inspiration, while the lower interspaces tend to become obliterated, or even to balloon outward, during expiration. Sudden inflation of both supra-clavicular spaces sometimes accompanies a coughing fit severe enough violently to distend the air-vesicles of the apices.

Palpation.—Bilateral enfeeblement of vocal fremitus is a characteristic tactile finding, its principal factors being the indifferent conducting properties of the lung, diminished resiliency of the thorax, and occlusion of the bronchi by secretion and by mucosal swelling. In some instances these causes, singly or combined, are capable of entirely cutting off the transmission of voice vibrations to the chest-wall. When decided bronchial catarrh coëxists, there is rhonchal fremitus. Ordinarily the apex-beat is impalpable at its normal site, but the systolic impulse of the right ventricle can be felt in the epigastric region. Both the liver and the spleen may be so large and depressed as to be readily palpable below the costal margin, and over the former, in the event of extreme dilatation of the right heart, venous pulsation is occasionally appreciable. Localized tenderness and pain in the region of the xiphoid is common, this so-called "epigastric spot" of pain being attributable to undue pressure within the right ventricle.

Percussion.—The percussion sound is loudly hyperresonant and the resistance generally is increased over the greater part of both lungs, but especially over the upper lobes anteriorly are these characteristics most clearly demonstrable. Strictly speaking, the sound is not a pure tympany, but rather tympany ingrafted upon a box-like tone—Biermer's "band-box resonance," or a commingling of vesicular resonance and tympany—Flint's "vesiculotympany." Percussion of the pulmonary borders at the apices, bases, and precordia shows that the unnatural resonance extends far beyond the normal limits of the lungs, and comparative percussion at the base reveals little or no inspiratory-expiratory difference in the levels of the pulmonary borders, indicating restricted excursion of the emphysematous lungs. The encroachment of the hyperresonance diminishes or entirely obliterates cardiac dulness, lowers the upper levels of the

hepatic and splenic areas, and extinguishes the pure gastric tympany of Traube's space.

Auscultation.—Enfeeblement of respiratory murmur, with low-pitched and notably prolonged expiration and short, silent inspiration, is the distinctive auscultatory finding. Expiration, whose duration equals or exceeds that of inspiration, may be either almost inaudible, or, if bronchitis and asthma coëxist, wheezy, harsh, and more or less masked by bronchial râles. Over the distended areas where the pulmonary elasticity persists the breath-sounds are vicariously exaggerated and puerile in character. Vocal resonance behaves like vocal fremitus (*v. s.*). A peculiar parchment-like crepitation, audible chiefly at the apices during forced inspiration, has been described in emphysema, the production of the sound being variously referred to the friction between subpleural bullæ and the costal pleura and to the crackling expansion of the emphysematous tissue, of which factors the former appears the more plausible. As the result of right heart failure, the liquid bubbling of pulmonary edema may be detected at the bases posteriorly. The cardiac sounds, owing to the interposed lung, are distant and muffled, and with the supervention of leakage at the right auriculoventricular orifice, a systolic murmur in the tricuspid area develops. The pulmonic second sound is accentuated during the phase of right ventricular hypertrophy, but weakens progressively as this chamber becomes inadequate and finally dilates.

Diagnosis.—Habitual cough, dyspnea, and cyanosis with bilateral thoracic distention, hyperresonance, a vertical type of respiration, and unduly prolonged low-pitched expiration admit of but one interpretation.

Simple *chronic bronchitis*, while it may give rise to cough, dyspnea, and somewhat prolonged expiration, is not attended by enlargement and increased resonance of the thorax, so long as it is unaccompanied by emphysema.

Pneumothorax, like emphysema, is attended by cough, labored breathing, and signs of defective blood aëration, but in the former the attack is most sudden and its severity most alarming, while in the latter the symptoms develop gradually and are not so urgent. The physical signs of pneumothorax differ from those of emphysema in being unilateral, not bilateral; the increased resonance more often amounts to pure tympany than to ordinary hyperresonance; the respiratory and voice-sounds, if not wholly abolished, are amphoric and echoing, instead of being merely enfeebled or wheezy. Moreover, air within the pleural cavity causes most conspicuous visceral displacement, and, when associated with a liquid effusion, is betrayed

by several distinctive signs—Hippocratic succussion sound, metallic tinkling, and basal flatness. Should air escape into the pleural cavity from an emphysematous lung, the physical signs of the latter condition will be suddenly replaced, on the side of the pleural perforation, by those of acute pneumothorax.

ATROPHIC EMPHYSEMA (Small-lunged Emphysema; Senile Atrophy of the Lungs)

This affection is essentially a senile atrophy of the lungs, which eventually shrink to a surprisingly small volume, and are converted into a mass of atrophic, functionless tissue permeated by air-spaces of various size, constructed of dilated, wasted, and ruptured infundibula and air-vesicles. The atrophied lungs are commonly the seat of deep pigmentation, and are not infrequently affected by local fibrosis, congestion, edema, and infarction. Progressive atrophy of the thoracic muscles accompanies the pulmonary wasting, until finally the chest, in strong contrast to that of hypertrophic emphysema, becomes abnormally small, and the course of the ribs extremely oblique, thus diminishing the thoracic diameters and capacity, and creating an acute subcostal angle; the respiratory movements are about equally restricted during both phases of respiration. The heart, like the lungs, is atrophied—it is not subject to undue stress, and, therefore, neither hypertrophies nor dilates.

The *physical signs* differ somewhat in detail from those of large-lunged emphysema. The dyspnea is inspiratory-expiratory, not chiefly expiratory; vocal fremitus is more likely to be exaggerated than enfeebled; the hyperresonance is often modified by fibroid deposits at the apices and by congestive and edematous changes at the bases. Owing to the pulmonary shrinkage the limits of the lungs are contracted, and in consequence there is an apparent increase in the extent of the cardiac and hepatic dulness, though both the heart and the liver actually may be smaller than normal.

The *diagnosis* of atrophic emphysema usually can be made at a glance, by noting the size and shape of the thorax and the evidences of senile changes elsewhere. Chronic cough and moderate dyspnea attend the development of the atrophic alterations.

COMPENSATORY EMPHYSEMA (Collateral, Complementary, Vicarious, or Local Emphysema)

When a circumscribed part of the lung is rendered impervious to air, other areas suffer undue inspiratory distention, in an endeavor to compensate for the loss of aërating surface in the crippled part, and the overinflated pulmonary tissue upon which this extra work

is imposed is said to be in a state of compensatory, complementary, or vicarious emphysema. The distended vesicles contain a considerable excess of air, and it frequently happens that this excess is not entirely expelled by the expiratory efforts, owing to some bronchiolar obstruction, by secretion or by a turgid mucosa, sufficient to prevent the free exit of air, but not necessarily interfering with its entrance. Thus, the intravesicular tension becomes progressively increased, and the air-cells more and more stretched, until, finally, should the underlying cause persist, permanent dilatation, with structural changes like those of true hypertrophic emphysema, is established. If, on the contrary, the factor of this vicarious distention is removed before the pulmonary elasticity is impaired and the vesicles irreparably damaged, their temporary overinflation entails no subsequent derangement of function.

Circumscribed vesicular dilatation takes place in the sound lung adjacent to areas of atelectasis, fibrosis, tuberculosis, and other lesions provocative of local airlessness of the pulmonary tissues, and in wide-spread adhesive pleurisy a corresponding degree of vicarious dilatation exists, especially along the anterior borders of the lungs. Compensatory emphysema of an entire lung is usually traceable to extensive cirrhosis, large pleural effusion, massive pneumonia, or pneumothorax of the opposite lung. As already intimated, the extent, character, and permanence of a compensatory dilatation of the lungs stands in direct relation to the nature and the duration of the underlying cause.

The *physical signs* over the affected area or areas vary with the extent of the process and the structural alterations wrought thereby. If there be simple acute dilatation with increased elasticity of the lung, as is often the case, hyperresonance, a harsh puerile respiratory murmur, with little or no prolongation of its expiratory phase, and exaggeration of vocal fremitus and resonance are the findings. If the process be of longer standing, impairing the contractile power of the lung, the signs are similar to those of generalized hypertrophic emphysema, restricted to the part implicated. The *diagnosis* depends not so much upon these signs, which, unfortunately, are in many instances obscure, as it does upon the patient's history and the detection of some satisfactory cause of the compensatory process.

ACUTE VESICULAR EMPHYSEMA (*Acute Pulmonary Distention*)

In certain cases of urgent dyspnea a sudden bilateral hyperdistention of the lungs sometimes occurs, due in part to excessive inspiratory stretching of the vesicles and in part to expiratory stress. The condition is one of simple functional pulmonary distention unat-

tended by atrophic changes in the vesicular walls, the increased volume of the lungs depending entirely upon a generalized dilatation of the air-cells. This so-called acute vesicular emphysema may develop, with striking abruptness, during acute diffuse bronchitis, bronchial asthma, pertussis, or cardiorenal disease, and in tracheal and laryngeal stenoses. The sprinter's "second wind," says White-locke, is presumably an acute type of physiologic emphysema, due to violent exercise. The *physical signs* are similar to those of hypertrophic emphysema, save that the right heart shows no evidences of habitual strain. (Cf. Acute Pulmonary Tympanites, p. 145.)

INTERSTITIAL EMPHYSEMA (Interlobular or Intervesicular Emphysema)

Interstitial emphysema, or an accumulation of air in the stroma of the lung, arises when, in consequence either of trauma or of violent expiratory strain, air escapes through a breach in the intervacular walls into the intervacular and interlobular tissues, where it collects in the form of bubbles ranging in size from about a millimeter to a centimeter or larger. These bubbles of air, if not absorbed, may work through the interstitial tissues to the surface of the lung, where they persist as little globules or as larger bullæ, freely movable beneath the pleura; exceptionally, the air burrows from the root of the lung into the mediastinum and thence upward along the trachea into the subcutaneous structures of the neck and the thoracic wall; or—and this also is uncommon—the pleura may be perforated and spontaneous pneumothorax produced. Air entering through a tracheotomy wound sometimes travels downward through the peritracheal and peribronchial tissues, ultimately collecting in the subpleural connective tissue. Apart from that variety due to wounds of the lung, interstitial emphysema is referable to alveolar rupture caused by violent fits of coughing, and by the excessive intrapulmonary tension incident to convulsions, parturition, and straining at stool.

Physical signs of interstitial emphysema are usually lacking, and the condition is discovered more often at autopsy than clinically. When the cellular tissue of the neck is infiltrated with air, one sometimes detects a subcutaneous emphysematous swelling which, on palpation, affords a curious sort of crackling sensation, while it has been asserted that a peculiar "crumpling friction-sound" can be heard over a collection of subpleural beads of air.

ATELECTASIS (Pulmonary Collapse; Apneumatosiis)

Clinical Pathology.—Atelectasis, or collapse of the lung, is met with either as an acquired condition or as a congenital defect, the latter being of but little interest to the internist. *Acquired atelectasis*

is due to factors depriving the lung of its normal content of air and effectually preventing its reinflation, either by obstructing the passage of air through the bronchi, by actual compression of the pulmonary structure, or by persistent inadequacy of expansion. *Obstruction atelectasis* is secondary to bronchial obstruction with absorption of the air in the vesicular territory beyond, and this type of pulmonary collapse is referable to occlusion of the bronchial lumen by mucosal swelling, viscid secretion, membrane, blood-clot, calculus, aspirated foreign bodies, cicatrices, and new-growths; or bronchial stricture due to external pressure, glandular, neoplastic, or aneurismal, may be the underlying cause of the atelectatic lesion. *Compression atelectasis* arises when the lung is subjected to pressure, such as that exerted by large pleural and pericardial effusions of liquid, pneumothorax, hypertrophy of the heart, and aneurism or morbid growth of the thorax; less commonly the pressure is subphrenic, as in the case of a large abdominal tumor or effusion, whereby the diaphragm is displaced upward and crowded against the pulmonary bases; and in the exceptional instance the compression is traceable to a crooked spine or to a deformed chest-wall. A variable degree of atelectasis, from habitual vesicular underinflation, also attends inadequate expansion of the lungs, whether due to simple shallow breathing, to prolonged dorsal decubitus, or to diminished irritability of the respiratory center.

Congenital atelectasis, met with in prematurely born and in weakly full-term infants, is characterized by imperfect inflation of the lungs after birth, owing to feeble respiratory movements or to bronchial occlusion by aspirated secretion. This type of vesicular collapse is either disseminated in numerous areas throughout both lungs, or implicates the greater part of a lobe or even of an entire lung, in the last event meriting the title *apneumatoxis*.

The appearance of an atelectatic lung varies with the extent and the chronicity of the process (Fig. 109). Multiple small foci of collapse, such as those incident to catarrhal pneumonia, show beneath the pleura as depressed blue or purple spots, each surrounded by a paler zone of vicariously dilated vesicles. An extensive area of diffuse collapse, due, for example, to the pressure of a large pleural effusion, consists of tough, dense, airless tissue, gray or of a light pink hue, and perhaps limited and bound down by fibrous bands and by a thickened, contracted pleura. The lung above the seat of atelectasis is compensatorily distended, and should the collapse be wide-spread, the lung is pushed upward and backward against the spinal column. If the cause be speedily removed and no inflammatory complications develop, the atelectatic area or areas may reinflate and the normal

function of the vesicles be completely restored, but if the collapse persists, irreparable damage to the lung occurs, and the deflated part becomes permanently deprived of air. In the latter event the compressed and intimately opposed intervesicular septa undergo infiltration with blood, whereby the affected part is converted into a dark,

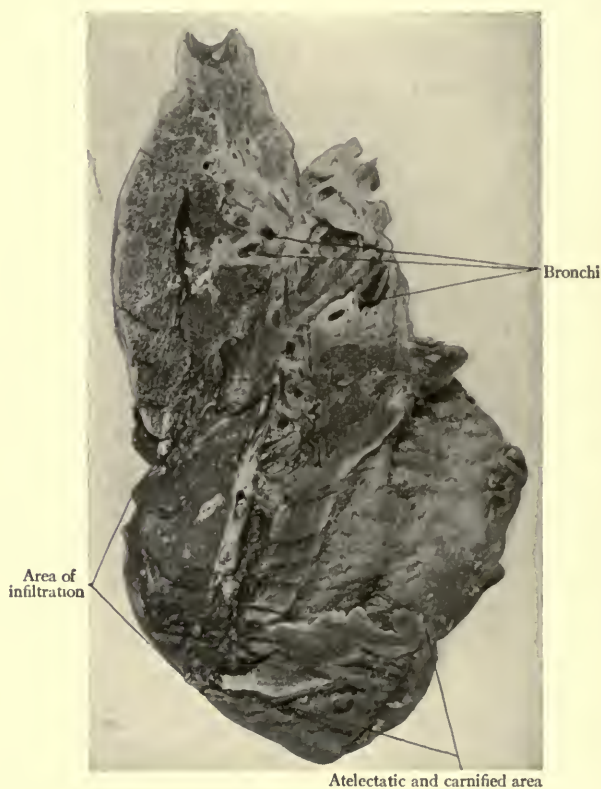


Fig. 109.—Pulmonary atelectasis (Jefferson Hospital Laboratories).

pulpy patch of splenization; later the epithelium of the air-cells degenerates, and the vesicles become coalescent and matted together by newly proliferated cellular tissue until, finally, the atelectatic focus is transformed into a mass of the consistence and general appearance of raw beef—*pulmonary carnification*. Subsequently this carnified tissue organizes, forming in the course of time a firm, contracted, pigmented patch of cirrhosis. As a rule, there are thickening and adhesion of the pleuræ adjacent to an atelectatic lesion, and the

bronchial tubes passing through it are inflamed, dilated, and otherwise altered structurally.

Physical Signs.—The physical signs of atelectasis are intimately blended with those of the exciting cause of the change, as, for example, the coëxisting catarrhal pneumonia, pleural effusion, or enlarged heart, and, furthermore, they are determined by the extent and the situation of the atelectatic area, as well as by the secondary changes existing therein and in the adjacent lung.

Inspection.—In extensive atelectasis there is extreme respiratory distress, as shown by the subject's rapid, shallow breathing, cyanosis, and inspiratory recession of the lower thorax and epigastrium. Indeed, in many instances these dyspneic phenomena are practically all that one finds, for deeply seated areas of collapse, if not far beyond the range of percussion and auscultation, produce signs whose identity is masked by the attendant compensatory emphysema and bronchial sounds.

Palpation.—Collapsed, toneless pulmonary tissue, being a poor conductor of vibrations, weakens vocal fremitus, but when the deflated area undergoes consolidation and becomes denser, the fremitus is clearly transmitted if not exaggerated. Pleural friction sometimes may be felt when the condition of the pleuræ is such that they grate noisily with the respiratory excursions.

Percussion.—As a rule, there is nothing more than emphysematous hyperresonance, save in the case of a circumscribed compact lesion near the surface of the lung; this, of course, impairs pulmonary resonance, and sometimes affords typical dulness, with undue pleximeter-finger resistance. If tightly compressed against a large patent bronchial tube, a large patch of atelectatic lung may give a tympanitic note, since, to all intents and purposes, the bronchus is an air-containing cavity, whose tone traverses, unaltered, the adjacent dense and airless pulmonary tissue.

Auscultation.—The respiratory murmur is generally suppressed, or quite lost, but over a dense peribronchial patch bronchovesicular or typical bronchial breathing may be heard. Provided that some air enters the collapsed vesicles, a few crepitant and subcrepitant râles are audible toward the end of deep inspiration. In bed-ridden subjects, with no pulmonary disease, atelectatic crepitations over the bases and the anterior borders of the lungs are very common, as the result of prolonged recumbency which, by interfering with adequate vesicular inflation, has allowed collapse and mural agglutination of some of the air-cells. With deep inspiration, however, the collapsed vesicles inflate, with the production of audible crepitations as their sticky walls separate. (See p. 164.)

Diagnosis.—As a foregoing paragraph suggests, in many instances the diagnosis of atelectasis must needs be inferential rather than evidential, being based upon such findings as respiratory distress, hyperresonance, and signs of some condition causative either of bronchial obstruction or of pulmonary compression. Small foci of collapse, even if numerous, give no tangible symptoms whatever so long as they are well compensated by the coëxisting vesicular dilatation. A dense circumscribed area of atelectasis furnishes the signs of consolidation—exaggerated fremitus, bronchophony, harsh or tubular respiration, and dullness, if the communicating bronchi remain open; respiratory silence and dullness, if the bronchi be plugged.

Here may be noted the lesion of *acute lobar atelectasis*, due to diphtheritic paralysis and to reflex inhibition of the phrenic movements after surgical operations; less commonly acute lobar collapse results from pneumothorax and from obstruction of the air-passages. In this “active lobar collapse of the lung,” described by William Pasteur, the main features include the abrupt onset of dyspnea, cyanosis, and thoracic pain attended by moderate cough and considerable greenish sputum; the physical signs point to unilateral lobar collapse, associated with a notable dislocation of the heart toward the affected side. As a rule, these active symptoms persist for but a brief period, and the deflated lung regains its former functioning power within a few days.

Atelectatic solidification is differentiated from *croupous pneumonia* by the absence of a distinctive pneumonic symptom-complex, and by contrasting the history and course of the two affections and the associated pulmonary changes incident thereto.

PNEUMONOCOONIOSIS

Clinical Pathology.—A combined fibrosis and pigmentation of the lungs, due to the inhalation of minute particles of dust, is known as pneumoconiosis, of which general process there are numerous special types, corresponding to the character of the aspirated material. Thus, *anthracosis* (coal-miner’s lung; black phthisis) is common among miners and stokers, who habitually breathe an atmosphere heavily charged with pulverous carbon (Fig. 110). *Siderosis* (knife-grinder’s phthisis; grinder’s asthma) results from the inhalation of fine particles of metal, especially iron and steel; this form of pneumoconiosis particularly affects grinders and polishers, who are exposed to the clouds of metal dust produced by the abrasion of metallic surfaces by a grindstone. *Chalicosis* or *lithosis* (grinder’s rot; stone-cutter’s phthisis) is due to the inhalation of mineral dusts

inseparable from the trades of stone-cutting, dressing, and polishing; to some extent those who suffer from siderosis also acquire more or less chalicosis, from breathing the fine dust abraded from the surface of the grindstone. *Kaolinosis* (potter's lung) develops from the aspiration of the dust of kaolin, a plastic clay used in making pottery. Millers, as well as those who handle tobacco, cotton, flax, furs, and other organic materials, are subject to inhalation cirrhoses from dust irritation. Of the preceding varieties of pneumoconiosis, that due to soot or coal-dust is the least destructive, and though a miner's lung may be densely carbonized throughout, severe structural changes do not necessarily develop in consequence. Furthermore, it is unquestionably a fact that anthracosis confers a relative immunity to pulmonary tuberculosis. The sharp, gritty particles of pulverized metal and stone are much more harmful, and lead not only to extensive interstitial fibrosis, but also predispose to tuberculous infection of the lungs, especially in the case of metal infiltrations. Oliver has drawn attention to the disastrous inroads of Rand miners' phthisis among gold miners in the Transvaal who breathe the air charged with quartz dust, and Robertshaw has emphasized the high mortality of ganister miners' disease, or a form of phthisis secondary to pneumoconiosis affecting miners of ganister, a flinty mineral composed chiefly of silica. The dusts of wool, fur, hair, and other organic substances are practically always contaminated by bacteria, and, therefore, are most likely to cause serious destructive processes, as well as interstitial fibrosis. Apart from their mechanical irritation, certain dusts also have a chemic action, and to this peril those engaged in the manufacture of paints, hats, and wall-paper are exposed, by being forced to breathe air full of dust charged with mercury, lead, or arsenic, as the case may be.

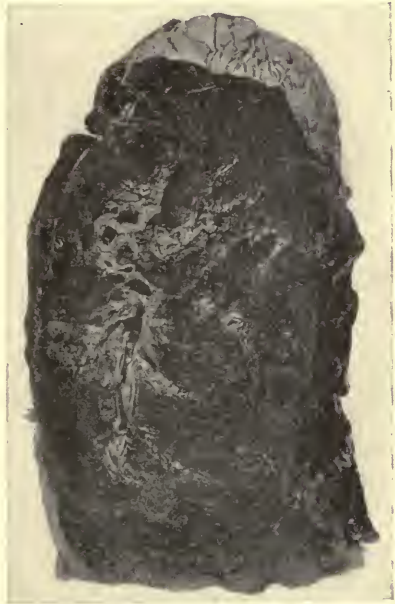

Fig. 110.—Pulmonary anthracosis (Jefferson Hospital Laboratories).

No one's lungs are wholly free from dust, it is true, but ordinarily little or none of it reaches the pulmonary interstices, for the coarser particles are excluded by the cilia of the upper air-passages, while finer dust deposited in the trachea and bronchi is there incorporated with secretion or ingulfed by mucous and alveolar cells and subsequently expelled by the action of the ciliated epithelium and by coughing and expectoration. But these protective measures, though adequate under ordinary circumstances, fail to prevent excessive deposits of finely granular inspired material within the lungs of persons who day after day are compelled to inhale heavily dust-laden air. Under such conditions numerous dust-particles escape removal from the air-tubes, and, either naked or phagocyted, penetrate the mucosa, whence they enter the lymph-spaces and are carried by the lymphatics permanently to lodge in the intervesicular and bronchiolar tissues and in the thoracic lymphatic glands. Especially abundant are the particles deposited in the peribronchial and periarterial lymphatic nodules, in the tissues of the interlobular septa under the pleura, and in the substernal, tracheal, and bronchial glands. Ordinarily, the granules go no farther than these adenoid structures, but exceptionally peribronchial glandular adhesions to the pulmonary veins open the door to the general circulation, with consequent pigmentation of the liver and spleen.

In all probability visceral pigmentation is also due, at least to some extent, to the transference of ingested dust-particles from the alimentary tract to the blood-stream, via the lymphatics and the thoracic duct, and, furthermore, the same mechanism accounts for some of the pulmonary deposits, though to a distinctly minor degree.

Although the pulmonary stroma can harbor an extraordinarily large amount of grit and other foreign particles for a long period without being damaged thereby, in time they irritate, provoke proliferation of the connective-tissue elements, and hence cause fibrous overgrowth. This process in the glands leads finally to their complete sclerosis, while the fibrous thickening of the intervesicular walls results in destruction of their blood-vessels and in obliteration of the air-vesicles, the affected tissues being thus deprived of air. As a rule, the cirrhosis begins in the peribronchial tissues, but ultimately it tends to invade other areas the fusion of which converts the lung into a more or less generally indurated mass; the infiltrations are likely to be most extensive and dense near the pulmonary apices. The lesions appear as scattered or diffuse patches of indurated, airless tissue traversed by thickened, catarrhal bronchial passages, and surrounded by a zone of emphysematous lung. Their color varies with the character of the infiltrated material—jet black, grayish

black, or slate color in the anthracotic lung; brick red or black in siderosis; and steel gray or unduly pale, perhaps with brown stains or stipples of altered blood-pigment, in chalicosis. Sometimes the fibroid territories become necrotic and cavernous (Charcot's *ulceres du poumon*), and sometimes the cavities erode into a nearby bronchus, whereupon infection takes place, with rapid enlargement of, and supuration within, the excavation. Implication of the bronchial tree, in the form of chronic bronchitis with mural thickening, invariably attends the foregoing changes; emphysema generally develops in the course of time; in some instances there are bronchiectases; and a variable amount of pleural thickening and adhesion commonly ensues. The right side of the heart is enlarged as the result of the cirrhotic process, and not uncommonly the organ is dislocated by fibrous traction.

Physical Signs.—The physical signs of pneumoconiosis are those of chronic bronchitis, emphysema, and chronic fibroid induration of the lungs, associated in some instances with bronchiectasis and with chronic ulcerative phthisis. The sputum, which may contain tubercle bacilli, usually is abundant, and of mucopurulent, sometimes fetid, character. It is blackened by coal-dust particles in anthracosis, reddened by bits of oxid of iron in siderosis, and shows fine silicate granules under the microscope in chalicosis.

Diagnosis.—In a person whose occupation necessitates the inhalation of dust, a history of years of bronchitis and emphysema ultimately followed by progressive cirrhosis of the lung, together with the distinctive appearance of the sputum, is unmistakable evidence of pneumoconiosis. Signs of pulmonary phthisis are also obvious in some cases, particularly in siderosis.

PULMONARY ABSCESS (*Purulent Pneumonia*)

Clinical Pathology.—Pulmonary abscess may arise in the various forms of aspiration pneumonia from infected particles sucked into the finer bronchi, wherein the contaminating material lodges and excites a supuration which extends to the contiguous vesicular structures. Occasionally, croupous pneumonia terminates in supuration of the lung, and, less commonly, this serious accident follows ordinary catarrhal pneumonia. Abscess of the lung due to the extension of some primary focus of infection, either by contiguity or by the lymphatics, is a potential complication in phthisis, pneumoconiosis, bronchiectasis, empyema, mediastinal abscess, esophageal cancer, hepatic abscess, and suppurating hydatid cyst of the lung or the liver. Stab wounds of the chest-wall, or even a presumably sterile

paracentesis, may carry pyogenic infection to the pulmonary tissue. In pyemic conditions the origin of pus foci in the lungs is traceable to emboli laden with pus-germs lodged in the terminal branches of the pulmonary artery.

Pulmonary suppuration may take the form of a solitary abscess of variable size, of multiple abscesses usually of small size, or of diffuse purulent infiltration. If of moderate extent, the purulent area sometimes is walled off from the surrounding lung by an impermeable fibrous capsule, but, on the other hand, practically an entire lobe may be invaded by a huge solitary abscess, developing either by the progressive spread of the primary focus or by the coalescence of several small points of pus. An abscess of the lung begins as an intense suppurative pneumonitis followed by softening, necrosis, and sloughing of the infected pulmonary tissue which, in consequence, undergoes excavation. The wall of the cavity, inclosing a collection of pus and disintegrated pulmonary tissue, is lined at first with ragged remnants of the necrotic lung and with inflammatory tissue, but later this lining ordinarily is replaced by a smooth pyogenic membrane, the contiguous lung being consolidated by infiltration and by a variable degree of fibrosis. Outside this none too firm a barrier the lung is more or less engorged, edematous, and hemorrhagic. Apart from the possibility of being isolated by encapsulation, a small abscess may ultimately heal by absorption of the purulent matter and by cicatrization, but, on the contrary, the infection may spread to other parts of the lung. Drainage is sometimes established by erosion into a bronchus; or the pus may invade the pleural cavity and cause empyema. Infected emboli giving rise to small, usually numerous, wedges of pus lying base toward and close to the pleura, are an especially common factor of this accident. It should be added that empyema is also attributable to infection through pleural membranes permeable by bacteria, but intact in the sense that no actual breach exists therein. Exceptionally, a channel is worn, via an abscess cavity, between a bronchial tube and the pleura, and under this circumstance pyopneumothorax almost inevitably supervenes. Pus diffused through the interstices of the lung, without the formation of circumscribed abscess, is accounted for by dissemination of pyogenic microorganisms by the lymph-stream.

Physical Signs.—Abscess of the lung affords definite thoracic signs only when it is of comparatively large size and superficial situation, in which event the objective signs of pulmonary consolidation and excavation are appreciable, together with corroborative evidence such as dyspnea, cough, "pump-handle" pyrexia, sweats, and emaciation. Signs of bronchitis and of pleurisy, both frequent concomitant

lesions, are commonly demonstrable, and in certain cases it is not difficult to find some primary affection, either within or remote from the lungs, to explain the pulmonary suppuration. The sputum is generally profuse, has a nauseatingly sweet and heavy odor, is of purulent character, and may contain, in addition to pus-cells and bacteria, shreds of elastic fiber and necrotic tissue from the lung. Copious gushes of expectoration sometimes occur when the secretion rising within an abscess cavity overflows into the bronchial outlet and in so doing provokes a fit of so-called "evacuative cough." When the suppurative process is composed of multiple small foci or is diffusely infiltrated, no clear physical signs can be looked for, and under these circumstances the symptoms of septic intoxication rule the clinical picture.

Diagnosis.—The character of the sputum, a clinical picture of septic poisoning, and physical signs of pulmonary softening and excavation appearing as a sequel to a primary lesion of the lung are the cardinal points of diagnosis. *Empyema* may be attended by constitutional symptoms like those of pulmonary abscess, and, should the purulent matter be discharged through a bronchus, the patient may suddenly cough up mouthfuls of pus, either practically pure or, rarely, fetid, but quite free from elements derived from disintegration of the lung. This fact, with the discovery of fluid in the pleura, shows the pleural origin of the pus. Abscess versus *gangrene* of the lung is referred to under the latter affection. (See p. 260.)

PULMONARY GANGRENE (*Necropneumonia*; Pulmonary Sphacelation or Mortification)

Clinical Pathology.—A dual factor is at work in producing gangrene of the lung: diminished vitality of the pulmonary tissue and infection of the devitalized part, the former being due to inadequate blood-supply and the latter to the invasion of pyogenic and associated bacteria. Subnormal tissue resistance must be regarded as the essential predisposing cause of gangrene, and this serves to explain the relative frequency of this grave affection in persons whose nutrition and defensive powers have been lowered by diabetes, alcoholism, chronic debility, and exhausting fevers, and its rarity in those whose health has not been undermined. Bacterial infection of *vascularized* pulmonary tissue generally means nothing more than abscess, at least primarily, but when the tissue's blood-supply is cut off, infection induces mortification. Important causes of pulmonary gangrene include aspiration and croupous pneumonias, abscess, cancer, and tuberculosis of the lung, bronchiectasis, and bronchial stenosis by

foreign body or by pressure of an aneurism or neoplasm, and contamination by some extrapulmonary necrotic process. Pulmonary embolism, particularly when septic, is likely to set up tissue death in the infarcted area beyond the clot, and this factor explains the occasional development of pulmonary gangrene in abscess of the middle ear, the mastoid, or the brain, in ulcerative endocarditis, in femoral thrombosis, and in acute febrile infections. Less commonly, sterile emboli account for a gangrenous lung.

Pathologically, there are two well-defined types of pulmonary gangrene: the circumscribed and the diffuse. *Circumscribed gangrene* may consist either of a single area or of multiple foci of dead pulmonary tissue of reddish-brown, greenish, or black appearance, and sharply delimited from the neighboring inflamed lung (Fig. 111).



Fig. 111.—Gangrene of the lung (Jefferson Hospital Laboratories).

As the tissue disintegration and solution proceed, the gangrenous patch softens and is converted into an excavation with rough, shaggy walls inclosing a fetid semifluid mass of necrotic débris. Bronchi near or within such a cavity are frequently eroded, and in consequence furnish an outlet for the putrescent material, and arteries traversing a gangrenous area become thrombotic and perhaps so worn that free hemorrhage takes place. The pulmonary tissue around a circumscribed gangrenous lesion is extremely hyperemic,

and more or less solidified by infiltration and by edema. As in abscess of the lung, a subpleural spot of gangrene excites pleural inflammation, thickening, and adhesion, and if the membranes be perforated, empyema, sometimes pyopneumothorax, supervenes. Intense bronchitis, generally of the putrid type, and inflammatory swelling of the bronchial glands are common complications of pulmonary gangrene. Aspirated particles of fetid bronchial secretion may excite gangrenous bronchopneumonia in either the affected or the opposite

lung. In some instances the mediastinum, the pericardium, or the abdomen is contaminated by the process of erosion, and embolic transference of the infection is not unlikely to occur, producing lesions of distant organs, for example, abscess of the brain. *Diffuse gangrene* of the lung, lacking the sharp line of demarcation so distinctive of the circumscribed form, sometimes arises by extension of the latter, or it may be a primary diffuse process consequent to pneumonia, bronchiectasis, putrid bronchitis, or pulmonary artery thrombosis. The greater part, if not the whole, of a lobe is transformed into a black or greenish mass of putrid necrosis, farthest advanced in the center of the lesion, whence the destructive changes gradually blend with those of the surrounding inflamed and consolidated lung. The diseased tissue at first is of firm, solid consistence, but later it becomes soft, pultaceous, and riddled with communicating cavities of various size. Fatal septicemia, septic thrombosis, hemorrhage, or pyopneumothorax is the sequel to be expected in this type of pulmonary gangrene.

Physical Signs.—Little can be learned from examination of the lungs unless the gangrenous area be extensive and near the surface, when, like abscess, it produces the physical signs of pulmonary solidification, softening, and excavation. Furthermore, it is almost invariably the rule also to find evidences of intense bronchial inflammation, pleurisy, and other attendant lesions either provocative of, or consequent to, the rotting lung. When a gangrenous area communicates with a bronchus, the patient's breath becomes horribly fetid and the sputum abundant, thin, and usually of a dirty greenish-brown hue. The sputum, too, smells vilely, for it reeks with decomposed tissue, pus, and putrefactive bacteria. On standing, it tends to separate into three layers: a dark granular sediment, a middle zone of thin liquid, and a top layer of mucopus. Microscopically, aside from shreds of necrotic pulmonary tissue and perhaps elastic fibers, the sputum ordinarily shows pus and red blood-cells, blood-pigment, Dittrich's plugs, fat-globules and fatty acid crystals, cholesterolin, leucin and tyrosin, swarms of bacteria, and, exceptionally, flagellate organisms and sarcinae.

Diagnosis.—The fetor of the breath and the character of the sputum are the two most distinctive features of pulmonary gangrene, which in typical instances is also attended by physical signs of pulmonary disintegration, by moderate fever and rapid pulse, by dyspnea, cough, and sometimes hemoptysis, by emaciation and prostration, and, in certain cases, by delirium. When the subject gives a history of diabetes or other debilitating disease and has suffered from some acute pulmonary lesion prior to the onset of this pertinent symptom

group, the diagnosis is reasonably certain. On the other hand, not infrequently the diagnosis of gangrenous lung must be made more by inference than by clinical proof, for in some instances there is neither foul breath nor necrotic sputum; in others these two diagnostic mainstays are referable to some non-gangrenous lesions; and in still others there are indefinite chest signs, or none at all. Thus, in the condition termed *latent pulmonary gangrene*, met with particularly in diabetics and in the insane, the patient's breath is untainted and the sputum odorless and mucoid, probably because the lung necrosis, though sometimes extensive, progresses leisurely, is well circumscribed, and does not open into a bronchus. In a case of this sort, affording possibly nothing but a suspicious history and signs of consolidation, an antemortem diagnosis of gangrene is not possible. Stinking breath and fetid expectoration may arise from purulent, decomposing lesions of the bronchi, lungs, and pleural cavity, without the coëxistence of gangrene.

In *pulmonary abscess* the breath is foul, but the odor is distinctively sweetish and not so fetid and heavy and penetrating as in gangrene; while the sputum, frequently coughed up in copious gushes, consists chiefly of pus, though it occasionally contains shreds of disintegrated lung.

In *putrid bronchitis* the breath is horribly fetid—only theoretically less so than in gangrene—but the foul sputum, abundant and seropurulent, does not contain pulmonary shreds nor elastic fibers.

Bronchiectasis taints the subject's breath with an odor of putrefaction only a shade less offensive and permeating than gangrene. This is true, notably, of saccular bronchiectases characterized by the periodic discharge of large quantities of sputum charged with putrescent matter and pus, but generally free from elastic fibers, save in the event of bronchial ulceration.

Advanced *pulmonary tuberculosis*, with cavities full of decomposing secretion, may be responsible for fetid breath and for foul sputum containing elastic fibers, but the breath, despite its disagreeable odor, has not the vile smell of gangrene, the sputum is filled with tubercle bacilli, and the patient usually shows unmistakable signs of apical excavation and of systemic inroads by the infection.

Bad breath incident to *ozena* and to *alveolar necrosis* obviously can be identified by examination of the nose and the mouth.

PULMONARY NEOPLASMS

Carcinoma.—Carcinoma, the most frequent type of pulmonary neoplasm, is rarely of primary origin, for the lung is usually invaded by the transference of a neoplastic process from an adjacent or a

distant initial lesion. In Stevens's analysis of more than 32,000 autopsies by various foreign reporters only 43 cases of primary pulmonary cancer are recorded. The tumor, commonly an encephaloid, may be situated in a neighboring structure, such as the pleura, esophagus, breast, or mediastinum, or in some remote part, like the liver, gastro-intestinal canal, or uterus, whence bits of the original tumor are carried, by the lymph or blood, to the lung, therein to lodge, proliferate, and replace the pulmonary tissue. A lung may also be attacked by a cancer originating in the mucous glands of the bronchi or possibly in the alveolar epithelium and eventually spreading through

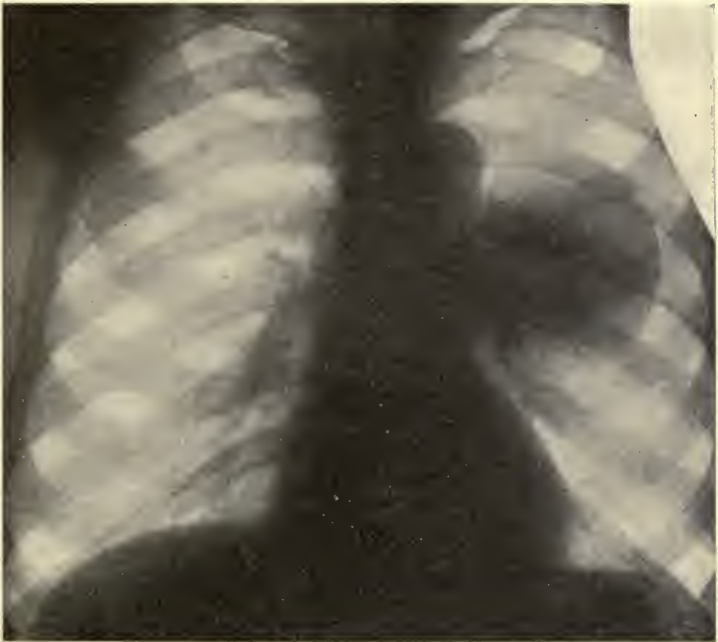

Fig. 112.—Radiograph of a pulmonary neoplasm. Anterior aspect, showing shadow of growth in left lung. (Plate by Dr. W. F. Manges.)

both lungs. Bilateral implication is the rule in growths of secondary type, and in primary cancer the tumor may either be confined to the lung originally affected, or spread to the other lung and to nearby structures. Primary carcinoma of the lung is decidedly more frequent in men than in women, and the lesion in many instances appears to be directly attributable to trauma; cobalt miners are

supposed to be exceedingly predisposed. Of the two sexes, women are the more susceptible to secondary cancer.

Malignant growths of the lung primarily cripple the organ's respiratory function by replacing the normal pulmonary tissue, and subsequently, as the neoplastic consolidation progresses, necrotic changes are prone to supervene both in the malignant areas and in other parts of the lung. In an extreme instance virtually an entire lung is invaded by the new-growth, ordinarily by the coalescence of numerous foci multiplying by local metastases from the parent lesion, but exceptionally arising by a more diffuse extension, radially or eccentrically, from the original deposit. In the immediate vicinity of the neoplastic areas the lung is collapsed, carnified, and edematous, and in other parts the vesicles are compensatorily dilated. When a malignant mass impinges closely against a bronchus, atelectasis and its unfortunate consequences arise in the corresponding vesicular territory; when a bronchus is perforated, bits of tumor tissue may enter the tube, to be coughed up and expectorated, or to be aspirated into other bronchial twigs, therein exciting bronchopneumonic processes and also secondary foci of the original tumor. Malignant areas communicating with a bronchial tube are most susceptible to bacterial infection, and hence to gangrenous degeneration and excavation, while the same thing may happen to patches of consolidated inflamed lung similarly situated. The growth may compress the gullet, the superior vena cava, the internal mammary artery, or the pulmonary vessels, giving rise to pressure symptoms similar to those found in mediastinal tumor. Pleural inflammation, setting up adhesions and thickening or attended by effusion, often of hemorrhagic character, is inevitable when the malignancy reaches the surface of the lung. In the rare event of pleural perforation pneumothorax, of course, ensues. With the extension of the malignant process beyond the confines of the lung, invasion of the tracheobronchial, mediastinal and cervical glands, the pleural membranes, and the opposite lung is the natural sequence.

The *physical signs* of pulmonary carcinoma naturally are subject to wide variance in the individual case, according to the site and size of the neoplastic infiltration and the bronchopulmonary damage thereby caused. Cachexia, though more or less apparent, tends to develop more slowly and less conspicuously in cancer of the lung than in cancer elsewhere situated. The superficial veins of the neck and thoracic wall may be distended abnormally in consequence of pressure upon the superior cava and internal mammary vein. The respiratory mobility of the affected side is sometimes restricted and the contour of the chest altered, being bulged and intercostally

widened by a massive growth, and retracted by one attended by dense fibrosis and adhesions or by pressure atelectasis. Vocal fremitus is very variable, being determined chiefly by the conducting properties of the neoplasm and the state of the surrounding vesicular structure. Dulness is afforded by a large, diffuse, superficial tumor; hyperresonance or tympany, by a cancerous excavation within range of the percussion strokes; and wooden flatness, by extensive pleural implication. Abnormalities of the respiratory murmur include suppressed breathing, due to a moderately disseminated growth; loud tubular respiration, produced by a large compact infiltration; and the amphoric tone of a cavity. Various râles, of bronchial, vesicular, and pleural

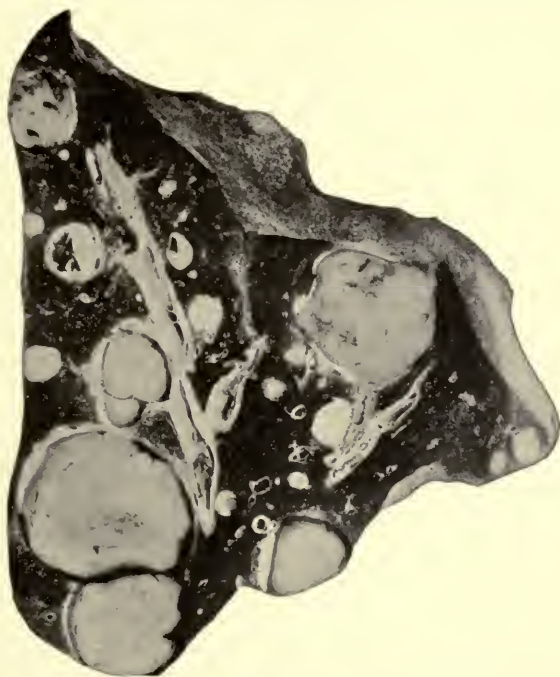

Fig. 113.—Sarcoma of the lung (Jefferson Hospital Laboratories).

origin, are audible when there is coëxistent bronchitis, congestion, edema, or pleurisy.

Sarcoma.—As a pulmonary growth sarcoma is distinctly less common than carcinoma, and, save in exceptional instances, is of secondary development, the initial tumor, according to West, existing in bone in one-third of all cases. Hypernephroma is followed by pulmonary metastasis of sarcomatous type in fully 60 per cent.

of cases (Wooley). As a rule, the growth is disseminated through both lungs. Pulmonary sarcoma is peculiar in two details: the long interval that may elapse in secondary cases between the appearance of the initial tumor and its metastasis in the lung, and its frequency in advanced life rather than in youth. A primary sarcoma of the lung, which usually is unilateral, is a very rare lesion, and commonly consists of an endothelioma originating in the pleura, or, exceptionally, in the lymph-follicles or blood-vessels.

The *physical signs* of pulmonary sarcoma do not differ from those of the other type of malignant disease of the lung discussed above, and, therefore, need not be further discussed.

ACTINOMYCOSIS

Pulmonary actinomycosis, though rare, is of clinical interest because of its more or less close resemblance to certain other pulmonary diseases, notably tuberculosis. The ray-fungus may invade the lung primarily, or may extend thereto by metastasis, by bronchogenic infection from a buccal lesion, or by direct extension from a neighboring focus. The process is essentially chronic, progressively destructive, and most unlikely to become arrested. Ordinarily, it is characterized by chronic diffuse bronchitis, attended by fetid mucopurulent sputum charged with actinomycetic granules. In such instances bronchopneumonic lesions sometimes develop, from the inhalation of contaminated matter, and set up a so-called miliary type of the disease, resembling in its general features miliary tuberculosis. The growth of fungous nodules in the lungs leads ultimately to obliteration of the vesicular structures and induces a condition of exudative catarrhal pneumonia; suppuration, softening, and excavation of the actinomycotic area occur; and in some cases perinodular fibrosis develops, which not only has a tendency to encapsulate the specific lesions, but also to spread through the adjacent interalveolar tissues. Thus, the greater part of an actinomycotic lobe may be converted into a dense fibrous mass, riddled with pus-cavities, traversed by fistulous tracts, and stippled with less mature foci in different phases of development. Extension of the process toward the pleura produces inflammation and adhesion thereof, and, in the course of time, after the invasion of these membranes, the chest-wall may become implicated or the abdominal cavity penetrated.

The *physical signs* of pulmonary actinomycosis are in no sense distinctive, for usually they resemble those of a stubborn catarrhal bronchitis, of a chronic bronchopneumonia with softening and excavation, or of an abscess of the lung. *Phthisis* in its various phases is

most often counterfeited, sometimes with surprising fidelity, by the general clinical picture, but in such a contingency the true nature of the symptoms is surely revealed by examination of the sputum. This contains the characteristic actinomyces granules ("sulphur granules"), consisting of minute yellow-brown or gray grains, which, when crushed, are found to be made up of an obscure central granular mass, from which radiate straight and undulating threads of mycelia, many showing club-like swellings.

ECHINOCOCCUS CYST

The lung or the pleura, particularly the former, is affected in about 8 per cent. of all cases of echinococcosis, the lesion commonly being secondary to an hepatic hydatid which has ruptured through the diaphragm or, exceptionally, reached the lung by way of the hepatic vein, inferior cava, and right heart. The development of a single cyst in one lung is more frequent than the growth of multiple cysts, either unilaterally or bilaterally, and in most cases the lower right lobe is the seat of the lesion. As the size of the cyst or cysts increases, corresponding compression of the lung is provoked, and the tumor may dislocate the mediastinal structures, encroach upon the pleural sac, and depress the diaphragm. Death of the cyst is likely to induce inflammatory changes resulting in suppuration, gangrene, and cavity formation; or the cyst fluid may become absorbed and inspissated, the wall atrophy, and the process undergo encapsulation by lime salts. So long as a hydatid lives and grows and remains of moderate size, neither irritation nor inflammation of the lung is likely to supervene. Should a cyst rupture, it generally does so into a bronchus, whereupon purulent material, bits of cyst membrane, hooklets, and free blood may be expectorated; less commonly it bursts into the pleura, causing pyopneumothorax; and exceptionally it suppurates through the chest-wall.

Physical signs are not demonstrable until the cyst attains considerable size, excites inflammatory changes, or ruptures. Suggestive, but not distinctive, signs include cough, dyspnea, hemoptysis, local bulging, restricted breathing, and a circumscribed dull area over which vocal fremitus, vocal resonance, and respiratory sounds are impaired or abolished. The heart and the liver may be displaced, and not uncommonly there are evidences of bronchitis, pulmonary consolidation, and pleural effusion. Over a large superficial cyst it is sometimes possible to detect hydatid fremitus and sonorous hydatid resonance (*q. v.*). Eosinophilia is an important sign of early, active echinococcosis. Exploratory puncture may give the correct clue to a puzzling group of physical signs, and the sputum

sometimes affords pathognomonic findings, such as hooklets and laminated membrane. (See p. 59.)

PLEURISY (*Pleuritis*)

The term pleurisy is applicable to numerous types of acute and chronic pleural inflammation that differ greatly in extent, intensity, and character, according to the circumstances prevailing in the individual instance. The lesion may be confined to a circumscribed area, or implicate the greater part of the pleural surfaces; its predominant character is fibrinous, serofibrinous, or purulent; and its origin is more frequently secondary and symptomatic than primary or idiopathic. For clinical study it is convenient to recognize the following main types of pleural inflammation, although, pathologically, such clear-cut distinctions are not always warranted: (a) *Acute fibrinous pleurisy*. (b) *Serofibrinous pleurisy*. (c) *Purulent pleurisy*. (d) *Circumscribed pleurisy*. (e) *Chronic adhesive pleurisy*.

By far the greatest number of cases of pleurisy are of the secondary or symptomatic type, arising most commonly from the extension of inflammatory diseases of the lungs and adjacent parts, of which lesions tuberculosis is of especial importance. Rarely does the pleura escape damage in this disease, though not always does it become actually tuberculous; less frequently a pulmonary tuberculosis is lighted up by a primary tuberculous focus of the pleura. To the group of pulmonary factors of pleurisy also belong pneumonia, infarction, abscess, gangrene, and neoplasm; while in other cases the process may arise by extension in consequence of disease of the pericardium, the peritoneum, the liver, or the bony thorax. Many pleurisies are traceable to such underlying conditions as rheumatic fever, nephritis, gout, syphilis, and alcoholism.

Of primary pleurisy, a comparatively rare condition, there is little to be said. A small minority of cases correspond to this caption—for example, those developing in a subject of low vital resistance after exposure to cold and dampness; but many apparently primary pleurisies are, in reality, of the secondary type, though the underlying factor may be masked. Bacteriologically, the tubercle bacillus, the pneumococcus, and the streptococcus are the three bacteria principally concerned as the causes of various forms of pleurisy, and of these organisms the first is the most frequent offender, the second the least harmful, and the last the most virulent. Less commonly pleurisy is referable to other microorganisms, notably to staphylococci, pneumobacilli, colon bacilli, typhoid bacilli, and diphtheria bacilli.

ACUTE FIBRINOUS PLEURISY (*Acute Dry or Plastic Pleurisy; Pleuritis Sicca*)

Clinical Pathology.—This form of pleurisy, which is more often confined to one or several circumscribed areas than generally disseminated, is accompanied by little or no accumulation of serum, the inflamed membranes, after a primary stage of acute injection, being coated with a scanty fibrinous exudate which obscures the normal glistening surface of the pleura and renders it dull, opaque, and lusterless. In a moderate inflammation with trifling proliferation of fibrous tissue, the exudate may soon undergo fatty degeneration and partial absorption, leaving merely small pearly patches of pleural thickening to mark the site of the lesion. If the inflammation be more active, however, the inflamed parts are covered by an abundant, thick lymph deposit, tending rapidly to become organized and thus ultimately to agglutinate the opposed pleural surfaces into a permanent fibrous union.

Physical Signs.—*Inspection.*—In order to ease the pain the patient, when erect, instinctively lowers the shoulder and relaxes the musculature on the affected side, and lies thereupon when confined to bed. The respiratory movements are shallow and the diaphragm shadow is obscured, especially on the pleuritic side; the breaths come and go in an uncertain, jerky, and painful manner; and the subject suffers from persistent, dry, and restrained cough. These objective symptoms of pleuritic pain are by no means constant, for, remarkable as it may seem, the patient, despite widespread pleural inflammation, may complain of no discomfort whatever. Dilatation of the pupil on the affected side, from sympathetic nerve irritation, is a finding of some suggestiveness.

Palpation and *percussion* are usually negative, save in the event of an abundant, thick exudate which may enfeeble vocal fremitus, modify the percussion resonance, and increase the tactile resistance of the area percussed. Distinct friction fremitus is sometimes palpable over the inflamed pleural surfaces.

Auscultation.—Friction-sounds are audible over the site of the lesion during the first few days of the disease, after which they disappear as the pleuritis subsides, usually with a more or less permanent adhesion of the inflamed pleural surfaces. In this type of acute pleurisy the friction, usually most distinct during inspiration, resembles a series of delicate, crepitating, jerky sounds, which, apart from their dry, superficial character, are very like the vesicular crepitation. The ordinary auscultatory site of pleural friction is shown by Fig. 90, p. 167. Pleuropericardial friction sounds, generated by the cardiac impact, are audible when the pleural surfaces adjacent

to the pericardium are roughened. (See p. 168.) The vesicular murmur, though frequently suppressed, shows no definite pathologic modification, and vocal resonance remains of normal degree.

Diagnosis.—The characteristic friction-sound is sufficient for the direct diagnosis of acute plastic pleurisy, irrespective of the patient's cough, respiratory distress, fever, and other objective symptoms. Routine chest examinations in subjects of various pulmonary disorders will reveal a surprisingly large number of unsuspected pleurisies, whose existence has provoked neither pain nor any other discomfort. It was doubtless the acute type of dry pleurisy that the great Dutchman, Boerhaave, had in mind when, more than two centuries ago, he spoke of "a sharp pricking inflammatory pain in the side, greatly increased in the act of inspiration, but abated in expiration, or by holding the breath," and when he referred to "a cough, which is almost incessant, and which, exciting great pain, is, therefore, stifled or suppressed by the patient."

Having discovered a pleural inflammation, it is important to decide, by further inquiry, if the lesion be uncomplicated, if it be symptomatic of some diathetic state, or if it be secondary to pulmonary pericardial, hepatic, or peritoneal lesion.

Both *intercostal neuralgia* and *pleurodynia*, in so far as pain is concerned, may closely simulate dry pleurisy, but in neither of these conditions is there friction or fever. *Intercostal neuralgia* is most commonly found in women who suffer from other nerve pains and are of the neurotic temperament, and the pain, which is lancinating and aggravated by motion, radiates along the course of the superficial branches of the intercostal nerves, whose points of exit (in the parasternal and axillary lines and at the bend of the ribs) are the seat of the most exquisite pain on palpation.

Pleurodynial pain, which is prone to occur in connection with other myalgic symptoms, is also intensified by motion, but it can be circumscribed to the intercostal muscles by making pressure over the interspaces. In the exceptional case *subphrenic peritonitis* (*q. v.*) is the source of friction-sounds audible over the lower part of the thorax.

SEROFIBRINOUS PLEURISY (*Pleurisy with Effusion*)

Clinical Pathology.—In serofibrinous pleurisy the primary changes are essentially those of the fibrinous type of the disease, except that they are usually more acute and more widely distributed; as a rule, they are unilateral. The affected surfaces are coated with a fibrinous exudate which, in some instances, consists merely of a thin, smooth, pale film, and in others of a thick, buttery deposit

of shaggy, ragged, honey-combed appearance. Attending these primary changes there is a free outpouring of inflammatory exudate, which gravitates to the lowest part of the pleural sac, save when, owing to the existence of pleural adhesions, it is hemmed in at a higher level. The amount of exudate poured out varies within the widest limits in different cases: ordinarily it ranges approximately between 16 and 64 ounces (480 and 1920 c.c.), but exceptionally it is decidedly larger—100 ounces (3000 c.c.) or more, or, as in Liebermeister's unique case, 245 ounces, *i. e.*, 7350 c.c. The exudate is composed of a coagulable albuminous fluid containing fibrin, blood-cells, swollen endothelial cells, uric acid, cholesterin, and sugar. These, as well as the other constituents of the exudate, have been described in a preceding section. (See p. 53.) If the fibrin content be moderate, the fluid is of a clear straw color and contains white fibrinous flocculi; if the fibrin be excessive, the exudate becomes turbid and is filled with numerous matted, curd-like masses of fibrin which tend to adhere to the pleural surfaces in thick, creamy layers.

The term *hemorrhagic pleurisy* is used when the exudate contains sufficient erythrocytes obviously to tinge it pink, red, or brown, such a change not becoming appreciable until the erythrocytes number at least 6000 to the cubic millimeter of fluid (Dieulafoy). Blood-stained effusions are very suggestive of tuberculosis and of cancer; less commonly they attend cardiac, renal, and hepatic lesions, the specific febrile infections, the several hemorrhagic diatheses, and various low asthenic states; and exceptionally they result from simple, though most intense, pleuritis. Hemorrhagic pleurisy is sometimes referable to the rupture of a vessel coursing through a false membrane organized upon the site of a recurrent pleural inflammation. True hemorrhagic pleurisy must be distinguished from an ordinary sero-fibrinous effusion accidentally tinged with blood by a tear in the lung made by an aspirating needle, and from the accumulation of pure blood in the pleural sac, or hemothorax (*q. v.*).

So-called *chyliform pleurisy*, distinguished by a turbid exudate of milky appearance, is met with in exceptional cases of both sero-fibrinous and purulent effusions, as the result of extensive fatty changes in the cellular elements of the exudate, which, microscopically, shows many fat-globules, fatty leukocytes and endothelium, and cholesterin crystals. Effusions of this type (*hydrops adiposus*), which are likely to be of tuberculous origin, of a primarily purulent nature, and of chronic duration, are to be distinguished from genuine chylothorax (*hydrops chylosus*), or the presence of pure chyle within the pleural sac (*q. v.*).

If the exudate be of considerable volume, the lower part of the

overlying lung is compressed, collapsed, and perhaps deprived of air and blood, while the pulmonary tissue above this zone of carnification is vicariously overdistended; in a very large and persistent effusion the pulmonary carnification may attain so extreme a degree that subsequent restoration of the lung is impossible. The mediastinum is dislocated toward the sound side, and the heart undergoes a similar displacement. The apex, though shifted, is never rotated (Osler), and its normal relative position to the base is not altered. The weight of a large effusion causes the diaphragm to sag abnormally low and restricts its respiratory excursions; if right-sided, the effusion depresses the liver, and if left-sided, the stomach, the transverse colon, and the spleen. In some instances the vascular trunks within the thorax are considerably pressed upon by the exudate. After the removal of the exudate, whether by absorption or by aspiration, there is a certain amount of connective-tissue formation at the site of the lesion, in favorable cases amounting to little more than a grayish area of moderate thickening or to limited adhesions of the opposed pleural surfaces.

The factors of serofibrinous pleurisy are virtually those of the fibrinous form, and, therefore, do not call for further mention. The importance of tuberculosis as an exciting cause, however, must be especially emphasized, for a large proportion of cases are tuberculous, either primarily or in consequence of infection from foci in the lungs, peritoneum, or other parts of the body.

Physical Signs.—*Inspection.*—The sharp pain of the præexudative stage excites both hurried and restricted breathing, which later, as the inflamed, sensitive pleural surfaces are bathed in the exudate, gives way to painless dyspnea, the urgency of which is related chiefly to the extent of the effusion; should there be patches of dry pleurisy elsewhere, however, painful respiration persists despite the effusion.

An extensive effusion causes moderate distention and decided immobility of the affected side, but comparative measurements of the two halves of the thorax will show that this increase of volume is actually much less than it appears, since it rarely amounts to more than 1 or 1½ inches (2.5 to 3.75 cm.). The lower intercostal spaces are unduly shallow or even quite effaced, so that the contour of the lower chest is smooth and rounded. In some patients the interspaces are wider than normal, but in young children they may be distinctly narrowed, by reflex contraction of the intercostal muscles—a sign described by Przewelski. The respiratory excursions of the affected side are considerably restricted and the diaphragm shadow of Litten is correspondingly abolished, while the opposite half of the thorax shows exaggerated expansion, as a matter of compensation. *Inspec-*

tion of the back may reveal a deviation of the spine toward the side of the effusion.

The cardiac impulse is dislocated upward and toward the unaffected side. In a left-sided effusion it may be visible in the epigastrium or to the right of the sternum, sometimes as far outward as the neighborhood of the right midclavicular line and as high as the fourth or the third interspace; should the apex be pushed directly behind the sternum, no impulse will, of course, be visible. In a right-sided

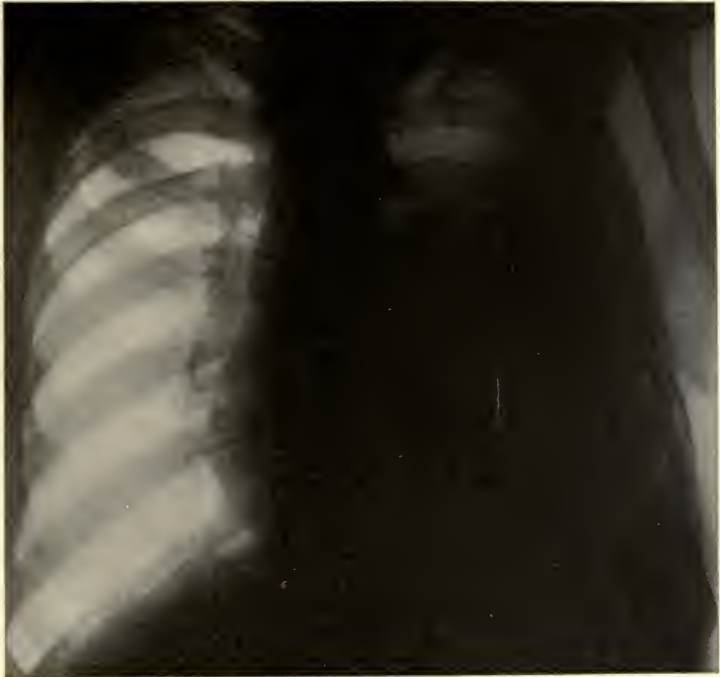

Fig. 114.—Radiograph of a left pleural effusion. (Plate by Dr. W. F. Manges.)

effusion the apex-beat may be displaced an interspace upward and carried outward to or even beyond the left midclavicular line. C. L. Greene has pointed out that the cardiac impulse approaches the median line with deep inspiration, and recedes therefrom with expiration, this sign being especially apparent in effusions of moderate size. It is demonstrable in some cases on ordinary inspection, but is more clearly recognized with the fluoroscope.

Fluoroscopic examination shows a shadow over the site of the effusion, and also indefiniteness of the costal and diaphragmatic

outlines, with abnormal depression and limited mobility of the latter. The lung above the effusion, if unduly dense, casts a correspondingly dark shadow, and the heart encroaches upon the unaffected side. The shadows cast by serofibrinous and by purulent effusions do not differ in density, according to Williams.

Palpation.—In the dry stage of the inflammation the voice-sounds are unaltered, but occasionally a friction fremitus is appreciable on palpation. Enfeeblement or total abolition of vocal fremitus is most convincing evidence of a collection of fluid within the pleura, but, unfortunately, this sign is not invariably obtainable, owing to the coëxistence of factors whereby tactile fremitus is exaggerated. Thus, despite the presence of a well-marked effusion, the voice vibrations may be transmitted through the liquid by bands of adhesions or by a bronchus dislocated against the chest-wall, while in other instances they may travel, via an overresilient parietes, from the sound to the affected side. It is in children especially that persistence of vocal fremitus is not to be regarded as incompatible with a pleural effusion. The fremitus is exaggerated over the site of the compressed lung above the effusion. Normal vocal fremitus reappears as the effusion diminishes in volume, except over areas where the thickening of the pleura is sufficient to damp the vibrations of the spoken voice.

Aside from showing the intensity of the vocal fremitus, palpation is useful in determining differences in the contour and the expansion of the two halves of the chest, in locating the cardiac impulse, and in ascertaining the level of the lower border of the liver. Reflex muscular contraction and rigidity below the twelfth rib on the pleuritic side is commonly appreciable (Ramond).

Percussion.—As an exudate accumulates within a pleural sac the percussion sound below the upper level of the liquid first becomes impaired, then frankly dull, and finally flat, as the fluid replaces pulmonary tissue. These auditory percussion signs are attended by a sense of increased resistance to the pleximeter finger, corresponding to the degree of airlessness of the area percussed, and in the typical case becoming so extreme that the finger perceives no trace of the normal parietal resiliency; under such circumstances the flatness acquires a high-pitched, wooden quality, most characteristic of fluid. Over the compressed and vicariously distended lung above the effusion Skodaic resonance is obtained.

A small effusion usually affords no physical signs anteriorly, being recognized by the appearance of a narrow zone of basal flatness posteriorly, which extends from the spine outward toward the axilla, and shows, with the patient in an upright position, an upper limit following a line of upward convexity. When an effusion attains

sufficient volume to produce signs anteriorly, its earliest effects are the substitution of flatness for normal hepatic dulness on the right side, and for normal tympany in the upper part of Traube's semilunar space, according to the side affected. Over a moderate effusion, reaching as high, say, as the fourth rib anteriorly, the upper level of the flatness follows an undulating line curving from behind forward, somewhat in the outline of the letter S—Ellis's "S-shaped line of flatness" (Fig. 115). Ellis's line, which corresponds to the line of contact between the exudate and the overlying lung, is lowest at the spine, whence it runs obliquely upward and forward in an S-shaped course toward its summit in the axilla, thence dropping abruptly downward and forward to the sternum, where it terminates at a slightly higher level than that of its spinal extremity. An effusion large enough to cause the foregoing sign usually produces either decided vertical extension of the area of hepatic flatness, or very definite obliteration of Traube's space, and more or less lateral and upward dislocation of the cardiac area. Persistence of tympany in Traube's area, despite signs of a left-sided effusion, suggests the formation of adhesions whereby the fluid is prevented from gravitating to the bottom of the pleural sinus.

Except at the base, where defective resonance is not unlikely to persist indefinitely, the transition from flatness to impaired resonance to the normal pulmonary percussion sound rapidly progresses over the site of the effusion as it subsides. Persistent areas of flatness, with absence of tactile vibrations, point to circumscribed permanent thickening of the pleura. Coincidentally with the above changes, it is found that the organs displaced by the effusion recede to their physiologic percussion limits.

Movable flatness, due to change in the posture of the patient, is rarely demonstrable in simple pleural effusion, and in those exceptional instances in which the change does occur the differences in the height of the flatness are very slight and of slow appearance. On the contrary, when the pleura contains both fluid and air, as in hydropneumothorax, shifting flatness is readily determined. In attempting to gage differences in the upper level of flatness by comparison of the surface markings of this limit in the erect and the recumbent positions, it is well to remember that the normal stretching of the skin when the subject's posture is altered shifts marks made thereon, and that apparent postural differences in levels of flatness are often referable merely to this resiliency of the integument.

Grocco's sign, or the presence of a triangular area of shifting dulness at the posterior thoracic base opposite the effusion, is a practically constant indication of free fluid within the pleural sac (Fig. 115).

This paravertebral dulness attends both small and large free effusions, and can also be detected in encapsulated pockets of fluid lying close to the spine; it cannot be demonstrated in interlobar pleurisy. Grocco's sign has been attributed partly to mutation of the vertebral vibrations by the pressure of the fluid against the spine, and partly to dislocation of the mediastinum toward the unaffected side. As a rule, the dull area is larger in effusions of the right than in those of the left pleural cavity.

In order to outline Grocco's triangle, the upper limit of the effusion and the lower limit of normal pulmonary resonance on the opposite side are first ascertained, with the patient in the

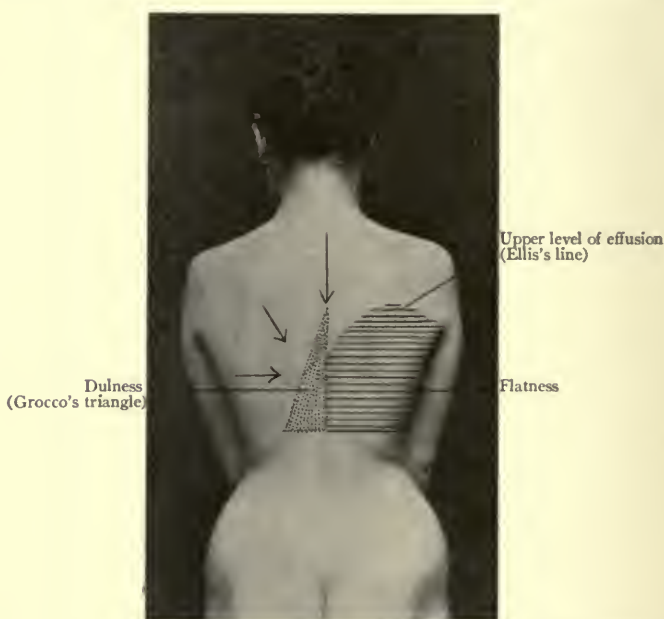

Fig. 115.—Grocco's paravertebral dulness in pleural effusion. Arrows indicate percussion lines to be followed in mapping out the dull area.

erect posture. The triangle itself is mapped out by percussing downward over the spine, horizontally inward along lines parallel to the spine, and obliquely inward toward the spine, surface markings, to be subsequently connected by a line, being made at the several points at which resonance is replaced by dulness (Fig. 115). The vertical side of the right-angle triangle thus erected corresponds to the line of the vertebral spines, extending from a

point somewhat higher than the upper level of effusion flatness to the lower limit of normal pulmonary resonance; the base coincides with the line of the latter on the unaffected side: the hypotenuse is formed by a line (sometimes showing a moderate outward convexity) joining the extremities of the vertical and base lines. The paravertebral triangle disappears or greatly contracts when the patient lies upon the affected side, and reappears when the erect position is resumed; it is not demonstrable after the removal of the effusion.

Subphrenic abscess may account for a paravertebral triangle of dulness on the opposite side, but here the dull area is low and broad, and not so prone to be influenced by posture. In *lumbar abscess* Ewart has detected a similar percussion finding that gave way to normal pulmonary resonance as soon as the pus was evacuated. *Ascites* sometimes produces a bilateral triangle of paravertebral dulness, differing from that due to a bilateral pleural effusion in being perfectly symmetric, of greater width, and of lesser height. In *abdominal cyst* paravertebral dulness has been found by Smithies, who also noted in *pregnancy* a roughly triangular dull patch, with a flat summit and convex hypotenuse, to the *left* of the spine.

Auscultation.—Partial or complete suppression of the respiratory murmur is the rule below the upper limit of the effusion, above which loud bronchovesicular or bronchial breathing is produced by the compressed lung. On the unaffected side there is a compensatory exaggeration in the intensity of the breath-sounds. Exceptionally, in the case of extreme pulmonary compression and bronchial occlusion by a massive effusion, practically no respiratory sounds are audible over the affected half of the thorax. In contrast to this, there are certain effusions, occurring especially in children, over which distant, though distinct, tubular or even amphoric respiration is heard, and in the face of such findings one must carefully exclude the possibility of a coëxisting pulmonary consolidation or cavity.

In general, the voice-sounds are weakened or quite obliterated by an effusion, save in those cases which afford bronchial breathing and, in consequence, a corresponding degree of bronchophony. The nasal bleating of egophony is frequently recognized near the upper level of percussion flatness. *Bacelli's sign* (the transmission of whispering pectoriloquy through a serous but not through a purulent exudate) is by no means distinctive; the whispered voice is inaudible in many serofibrinous as well as purulent effusions. As the volume of the fluid diminishes and the natural resiliency of the lung is restored, the normal respiratory and voice-sounds gradually reappear from above downward, both at the site of the effusion and in the lung above it.

During the first stage of the process auscultation over the dry, inflamed pleura reveals numerous friction-sounds (*frictio indux*), like those of acute fibrinous pleurisy, though generally of greater intensity and wider distribution. When the exudate is poured out these sounds, of course, disappear below the upper level of the fluid, above which, however, friction may continue to be heard, owing to patches of dry pleurisy here coëxisting. As the effusion diminishes, allowing the roughened pleural surfaces again to rub together with respiration, the primary friction-sounds reappear, as the *frictio redux*, and this sign may stubbornly persist for a long period after complete resorption has taken place, the sounds possibly acquiring a coarse grating or creaking quality suggestive of extensive pleural roughening.

Diagnosis.—There is no difficulty in recognizing a large effusion by this distinctive group of physical signs: unilateral immobility and overfulness of the chest, with absence of the diaphragm shadow; a zone of basal flatness over which tactile fremitus, vocal resonance, and respiratory sounds are abolished, and above which they are exaggerated and attended by Skodaic resonance; flatness in Traube's space and at one base a paravertebral triangle of shifting dulness; and various visceral displacements.

But the diagnosis is not always so clear as the above paragraph implies, for a moderate pleural effusion, particularly in a child, may afford two most significant indications of *croupous pneumonia*—bronchophony and bronchial breathing of the most exquisitely tubular type; while, on the other hand, there are certain cases of massive pneumonia which, by fault of bronchial occlusion, closely ape the auscultatory findings of a copious effusion. Though in the doubtful case the aspirating needle is usually the court of final appeal, it should be recalled that a severe initial chill, high fever, urgent dyspnea, herpes, rusty sputum, abnormal pulse-respiration ratio, and absence of visceral displacement are in favor of pneumonia. Another most important differential point is afforded by percussion, which in pneumonia shows that the resiliency appreciated by the pleximeter finger is of a much greater degree than that felt in pleural effusion, the percussion sound at the same time being of fuller volume and of lower pitch over a consolidation.

Should the diagnosis lie between inflammatory effusion and *hydrothorax*, it is to be recalled that the latter is not attended by fever, pain, or friction; that it is more commonly bilateral than unilateral; that it is usually associated with dropsy of other parts, of which sign some chronic lesion (especially of the heart or the kidneys) is the obvious factor. Paracentesis yields in hydrothorax a

fluid of lower specific gravity, smaller albumin content, and less coagulability than that due to an inflammatory exudate. (See p. 53.) Absence of voice and respiratory sounds and visceral displacements cannot be taken as criteria of differentiation, being common to both conditions; but, as a rule, the basal flatness of hydrothorax is capped by a horizontal, not an S-shaped, line. A point of some moment is the comparative ease with which movable flatness is demonstrable in hydrothorax, as contrasted with the great difficulty, usually the impossibility, of distinguishing such a sign in an inflammatory effusion.

In *chronic pleural thickening* the association of a restricted respiratory excursion, enfeebled breathing, deficient fremitus, and flatness at one base gives a close imitation of the physical signs of an effusion. But in thickened pleura the chest-wall is likely to be retracted and the heart drawn toward the affected side, while the opposite lung may be in a state of permanent overinflation; the flatness often acquires a peculiarly wooden quality and lacks a clean-cut marginal definition and S-curved summit; and no movable dulness alongside the spine can be mapped out. In pleural thickening, moreover, there are generally evidences of pulmonary fibrosis and a history of some primary disease to account for the pleural changes.

A large *pericardial effusion* may be distinguished from fluid within the left pleural sac by the following differences: in pericardial effusion the displacement of the heart is upward rather than to the right of the sternum; the flatness is roughly pyramidal in shape and corresponds to the outline of the distended pericardium, while immediately to the left, and perhaps also in the axilla, the percussion sound is Skodaic. Pulmonary resonance, rather than movable dulness, is found at the base posteriorly. Other signs pointing to pericardial effusion include apical weakness and basal intensity of the cardiac sounds, a feeble and sometimes paradoxical pulse, and the existence of dyspnea of a most extreme grade.

Enlargement of the hepatic area, as from abscess, cancer, or echinococcus of the right lobe, may account for a basal zone of flatness, with abolished fremitus and respiratory sounds, thereby suggesting a right-sided pleural effusion. But in these conditions the upper limit of flatness is likely to be horizontal, convex, or irregular (not S-shaped), the overlying lung does not emit Skodaic resonance, and the opposite posterior base fails to show a typical Grocco's triangle. If perihepatitis exists, it is not unusual also to hear a basal friction-sound *below* the upper boundary of the flatness, while in echinococcus disease it may be possible to elicit a distinctive hydatid fremitus.

Intrathoracic tumors may enfeeble fremitus and respiratory sounds, displace the heart, and dull pulmonary resonance so as to counterfeit a pleural effusion, except that their physical signs are not affected by postural changes, are not uncommonly **bilateral**, and are generally limited to the upper or middle thorax, being, therefore, underlaid by a strip of pulmonary resonance at the base. If the neoplasm be mediastinal, the signs are usually parasternal and attended by characteristic evidences of intrathoracic compression affecting the bronchi, esophagus, and great vessels and nerves of the mediastinum. The fact that tumors of the lungs and pleura are prone to excite a pleural effusion makes their recognition possible, in such instances, only after a careful analysis of the case-history and the diagnostic use of the aspirator.

PURULENT PLEURISY (*Empyema; Pyothorax*)

Clinical Pathology.—Empyema, or purulent pleurisy, is generally secondary to some preëxisting focus of infection, but exceptionally it is of primary origin, especially in children. The effusion may be purulent from the beginning, or the suppuration may be due to the contamination of a serofibrinous effusion (rarely, a dry, fibrinous pleurisy) by the bacteria of suppuration. In children pneumococcus infection, primary or metapneumonic, is the most active factor of purulent effusions, while in adults the streptococcus, pneumococcus, and tubercle bacillus, in this order of frequency, are the most common exciting causes (W. Watson Cheyne). Pneumococcus empyemas are more prone to spontaneous absorption than those due to other bacteria, with the possible exception of the bacillus of Eberth, as noted by Gerhardt, while purulent effusions referable to mixed infections are usually of graver character than those provoked by a single variety of microörganism. In establishing the origin of an empyema these factors should be rehearsed: pneumonia, tuberculosis, and other infectious processes of the lungs; infection by way of the blood- and lymph-vessels, as in the specific infections and in local lesions not directly contiguous to the pleuræ; and infection by erosive and gangrenous processes of the esophagus, stomach, liver, ribs, and vertebræ. Septic wounds of the chest account for some cases of empyema, which also can arise as a consequence of faulty asepsis during paracentesis.

The pathologic changes of empyema differ chiefly in degree from those of non-suppurative pleurisy, than which the former works the more serious damage. The character of the effusion is exceedingly variable, ranging from a thin, moderately opaque seropurulent liquid

of yellowish-green hue to a thick, creamy, yellow pus, the former separating on standing into a thin zone of leukocytes overlaid by a considerable quantity of clear serum, and the latter being of homogeneous consistence. In fetid cases the exudate emits a most offensive stench, and may have a brownish color. Fibrin, in the form of flakes or larger masses, is distributed through an empyematous effusion in variable amounts, the exudate in some cases being of a most decided fibrinopurulent nature. Microscopically, leukocytes are the most important constituent of the exudate, whose degree of purulence is proportionate to its richness in these cells; a variable number of erythrocytes, degenerate endothelium, fat-globules, and cholesterol crystals are also found, together with one or more of the varieties of bacteria mentioned above.

The pleural surfaces are actively inflamed and thickened by newly proliferated vascular connective tissue and by extensive leukocytic infiltration; they are covered with a dense, friable, grayish-yellow pseudomembrane or with a granulating pyogenic membrane; and sometimes show circumscribed areas, single or multiple, of necrosis. Through such breaches in the integrity of the pleura the pus spreads to other parts, whence it may, by the erosion of fistulous channels, find spontaneous evacuation—*empyema necessitatis*. The formation of a fistula between the pleura and a bronchus means the establishment of a pyopneumothorax; in other instances the pulmonary parenchyma becomes the seat of abscess or of extensive gangrenous destruction, these changes being especially prone to supervene in virulent putrid empyemas. Fistulation through an intercostal space, with discharge of the pus through the chest-wall, is also a common method of spontaneous evacuation. Less frequently the pus burrows into the esophagus, the stomach, the pericardium, the opposite pleura, the peritoneum, or even into such remote parts as the kidney, the lumbar region, and the groin, but only in most exceptional cases has this been observed.

Pulsating pleurisy, in which pulsations synchronous with the systolic impulse of the heart are palpable and generally visible in the intercostal spaces, particularly of the upper left chest, is a rare physical sign in pleural effusion. (See Fig. 125, p. 321.) It is met with especially in empyema (*pulsating empyema*), both as a true intrapleural pulsation and as a throbbing tumor in empyema necessitatis; it is seen exceptionally in non-purulent effusions, and occasionally it is found in connection with a coëxisting pneumothorax.

The mechanism of pulsating pleurisy has long been a moot point. Calvert logically explains the phenomenon by showing that the pleural

wall, distended by fluid and bordering upon a collapsed lung, lies in close contact with the thoracic aorta whose systolic expansions are taken up by the pleural wall and thereby transmitted to its weakest portion. If this happens to be external, its rhythmic stretching with each increment of pressure produces visible pulsations, synchronous with cardiac systole, upon the overlying surface of the chest.

The visceral displacements occurring in empyema are similar to those of a serofibrinous effusion, but they are usually more striking, owing to the greater weight of the purulent liquid; this factor plus the soft, relaxed state of the parietal structures around an empyema accounts for a relatively greater depression of the diaphragm and a more decided distention of the thoracic wall in this form of pleural effusion.

After the removal of the exudate, either instrumentally or spontaneously by absorption or by evacuation, the pleural surfaces continue to produce pus for a protracted period, and when this finally ceases, they are left irreparably injured. The damage is moderate in some cases, but in others there is inordinate pleural thickening with extensive pulmonary fibrosis, ultimately leading to contraction of the lung and to deformity of the affected side. (See Fig. 38.)

Physical Signs.—The physical signs of empyema do not differ materially from those of serofibrinous pleurisy, in so far as palpation, percussion, and auscultation are concerned, the findings afforded by these methods of research being identical, whether the effusion consists of serum or of pus. But inspection, at least in certain instances, furnishes signs of sufficient distinction to warrant separate mention, in view of the difficulty in discriminating between these two types of effusion, without resort to the aspirating needle.

In a severe case the dyspnea is most striking, and the patient's appearance betokens grave sepsis—anemic pallor, a hectic flush, sordes, mental apathy, low delirium, great prostration and emaciation, remittent fever, and recurrent drenching sweats. The enlargement of the affected side of the thorax is generally more noticeable than in an ordinary serofibrinous effusion, and the interspaces, instead of being merely obliterated, may even bulge outward between the ribs. Unilateral enlargement of the chest is common in children, owing to resiliency of the thorax, but this is not perceptible in adults, because of the rigidity of the mature thorax. The tissues of the chest-wall are sometimes boggy and edematous, and there may be either a discolored local area of distinct fluctuation that betrays the prefistulous stage of an empyema necessitatis, or, indeed, the fistula itself. The cardiac and the hepatic displacements

are likely to be more conspicuous than in serofibrinous cases, and the excessive weight of a copious empyema is capable of depressing and pushing forward the diaphragm to such an extent as to produce a well-marked tumor in the hypochondrium of the affected side. As a rule, Grocco's sign is strikingly shown in purulent effusions, and tubular breathing, rather than respiratory silence, is more common than in serofibrinous pleurisy.

In the vast majority of instances the differentiation of empyema and the other forms of pleural effusion can be made only by exploratory puncture, for which no other method of physical diagnosis is a satisfactory substitute.

Pulsating pleurisy may, at first glance, suggest *aneurism of the aortic arch*, but in the former the pulsations lie far outside the course of the aorta—between the third and fifth interspaces on the anterior or lateral surface of the thorax, almost invariably on the left side, and exceptionally behind; moreover, the thrill, bruit, cardiovascular changes, and pressure symptoms of aneurism are wanting.

CIRCUMSCRIBED PLEURISY

Aside from the local dry pleurisies and the free effusions just discussed, there are other pleuritides restricted to certain local areas of the pleural sac and which, because of this peculiarity, present physical signs difficult to appreciate and to interpret. Of these circumscribed types of pleuritis, the diaphragmatic, the encapsulated, and the interlobar deserve special consideration.

Diaphragmatic Pleurisy.—This type of pleural inflammation, implicating the pleural investments of the diaphragm and the lower pulmonary surface, is commonly attended by a serofibrinous effusion, though rarely the exudate is purulent, and exceptionally the process consists of a fibrinous or plastic inflammation. The condition is by no means of frequent incidence, in comparison with the ordinary forms of pleural effusion.

The *physical signs* of diaphragmatic pleurisy are usually overshadowed by the subjective symptoms, in view of which the diagnosis must rest chiefly upon the symptomatology of the onset and upon the character of the intense pain that monopolizes the clinical picture. The onset, which is most likely to be sudden, may begin with a chill, considerable fever, dyspnea, and perhaps vomiting. The pain, largely due to phrenic irritation or neuritis, is referred to the lower thoracic and the upper abdominal regions, particularly to the hypochondrium and epigastrium. Exquisite tenderness is elicited by pressure over the line of the diaphragm between the end of the tenth

rib and the ensiform cartilage, and also along the course of the phrenic nerve in the supraclavicular space at the outer border of the sternocleidomastoid muscle and often in the intercostal spaces at the sternal border. The pain is naturally much aggravated by the movements of respiration, and by the hiccough and vomiting that prove such distressing symptoms in many cases. The abdomen, though not distended, is acutely sensitive and resistant, especially on the side of the pleurisy.

Owing to the great pain the respiratory excursion is restricted and the breath-sounds are suppressed on the affected side, upper thoracic respiration being a conspicuous sign on inspection. Exceptionally, dry friction-rubs are audible in the region of the diaphragm, and if there be a fairly large effusion, a basal zone of flatness, with more or less depression of the liver or the spleen, may also be made out. Such visceral displacements are particularly prone to occur if the effusion be purulent, and in such an event one should look for edema of the chest-wall and for bulging of the lower interspaces.

Because of its violent onset, decided constitutional disturbances, and active abdominal symptoms, diaphragmatic pleurisy must be carefully distinguished from certain forms of the "acute abdomen," notably those due to gall-stone colic, to appendicitis, and to acute peritonitis, and in making this discrimination due weight must be given to the clinical history of the case in question. This having been analyzed, one may also succeed in detecting the basal friction, the typical areas of tenderness, and the unduly striking dyspnea, which together point surely to diaphragmatic pleural inflammation.

Encapsulated or Encysted Pleurisy.—In this variety of effusion, which is more commonly purulent than serofibrinous, the exudate, instead of being free in the pleural cavity, is limited by inflammatory adhesions to circumscribed areas, the fluid being thus walled off into a single encapsulated collection or into several pockets, either distinct and separate or communicating. The aspirating needle is the only certain means of detecting effusions of this sort, though their existence is suggested by the discovery of circumscribed physical signs of fluid.

Interlobar Pleurisy.—This term is applied to a type of local pleurisy in which the exudate, poured out by the inflamed pleural reflections between the lobes of the lungs, is confined by adhesions to the interlobar surfaces. A circumscribed exudate of this sort, which may be either purulent or serofibrinous, is commonly limited to the septum between the right upper and middle lobes, and, like other forms of walled-off effusion, usually cannot be diagnosed without resort to

aspiration. In interlobar empyema the pus sometimes fistulates into a neighboring bronchial tube, such an accident being betrayed by paroxysmal cough productive of a variable quantity of purulent sputum.

The *physical signs* of an interlobar effusion should be sought for along the course of the interlobar septa, the findings being sharply restricted to these lines if the fluid be near the surface, but being well below them if the process be deep. Circumscribed tenderness, absence of tactile fremitus and voice-sounds, pleural friction, feeble respiration, and dullness bordered by Skodaic hyperresonance, when localized near the levels of the fourth and fifth ribs, either anterolaterally or posteriorly, are suggestive findings that the Röntgen-ray and the exploring needle may clothe with certainty.

Mediastinal Pleurisy.—Effusions into the mediastinal space are of rare occurrence and ordinarily represent a postpneumonic complication, or they may be secondary to tuberculosis, to pulmonary abscess, or to an encysted diaphragmatic pleurisy. As a rule, such effusions are purulent rather than serofibrinous. The *physical signs* relate conspicuously to mediastinal pressure, consisting of the sudden onset of fever, substernal pain, dyspnea, and cough, and later, as the oppression becomes aggravated, orthopnea, rapid respiration, suffocative cough, dysphagia, laryngeal spasm, hoarseness, aphonia, and extensive congestion of the surface veins develop. Apart from this “mediastinal syndrome,” the objective findings are in no wise distinctive: they consist of an abolition of vocal fremitus, impaired resonance, and absent respiratory sounds in one infrascapular region, contrasted with intense percussion resonance, and perhaps bronchial respiration at the apex on the same side, with compensatory hyperresonance over the opposite lung. Aspiration is likely to fail as a diagnostic aid, because of the depth of the lesion and the density of the overlying lung.

CHRONIC ADHESIVE PLEURISY (Chronic Plastic or Fibrinous Pleurisy; Symphysis Pleuræ)

Clinical Pathology.—As a rule, this variety of pleurisy is a sequel of pleural effusion, beginning as an organization of the fibrous deposit left upon the pleural surfaces after the removal of the fluid exudate; less commonly it represents an agglutination and fibrosis of the pleuræ, secondary to an acute plastic pleurisy or developing as a slow, insidious, progressive lesion at no time betrayed by active symptoms. The visceral and parietal pleuræ are unduly thickened and inti-

mately united by dense fibrous masses, which, if there be sufficient respiratory movement, tend finally to yield to the incessant traction, whereby they are converted into tough interpleural cords; or the cicatricial overgrowth may weld the two pleural membranes into a single fibrocalcareous layer, sometimes so extensive as practically to obliterate the pleural cavity, especially if the corresponding lung be also diseased. In some instances there are small intrapleural loculi of fluid, in others traction bronchiectases develop, and in still others the lung becomes encapsulated by a rigid, contracting pleural investment. In consequence of the pleural lesions the excursion of the lung is limited and its function hampered; the pulmonary tissue undergoes extensive compression and fibrosis, the septa are penetrated by fibrous bands, interlobar agglutination may unite two or more lobes, and firm adhesions commonly develop, particularly at the bases and at the apices posteriorly. Exceptionally, chronic adhesive pericarditis and proliferative peritonitis coëxist.

Physical Signs.—*Inspection.*—In the average case one finds little else than a moderate degree of dyspnea, with slightly impaired mobility of the chest on the affected side, and not infrequently even such clues are wanting. But when the pleuræ are extensively implicated, the dyspnea becomes most striking, the respiratory movements are greatly hampered, the affected side expands but little, if at all, and may show a circumscribed area of flattening or retraction. (See Fig. 45, p. 91.) In cases following empyema the scar of the fistulous drain at once arrests the examiner's attention, and it is in examples of this kind that local deformities of the thorax, with drooping of the shoulder, overlapping of the ribs, and spinal deflection, become most conspicuous. (See Fig. 38, p. 88.) The heart may be drawn to the right or to the left, according to whether the traction is exerted by right- or by left-sided adhesions; and in old unilateral lesions compensatory enlargement of the opposite half of the chest tends to supervene. Apical adhesions that irritate the first thoracic sympathetic ganglion are betrayed by unilateral sweating or flushing of the face and by dilatation of the pupil. Evidences of venous stasis, from dilatation of the right heart, may appear late, in cases of great chronicity, and in such instances one commonly observes a network of delicate venous radicles curving across the lower anterior thorax.

Palpation.—The intensity of tactile fremitus varies with the peculiarities of the lesion in the individual case: it is ordinarily enfeebled or abolished over areas of simple pleural thickening, but despite this barrier to voice vibrations, the fremitus may be clearly conducted to the surface by bands of compact pleuropulmonary adhesions. Friction fremitus, of a coarse, grating quality, is appre-

ciable over patches of mobile pleural roughening. In moderately advanced cases the hand is more useful than the eye in detecting respiratory immobility, particularly circumscribed, of the chest-wall.

Percussion.—The thicker the pleuræ and the greater the pulmonary fibrosis, the less resonant the percussion sound over the parts affected. Resonance may be simply impaired, as shown by a slightly elevated pitch, shortened duration, and increased resistance; or there may be dulness of a peculiar wooden character, with most striking resistance to the pleximeter finger. Emphysematous percussion sounds over the opposite lung are familiar findings in advanced cases.

Auscultation.—The respiratory murmur and vocal resonance are enfeebled, especially at the base, in proportion to the degree of pleural thickening, of respiratory restriction, and of vesicular obliteration. Aside from these findings, many cases show the auscultatory changes of such coëxisting processes as pulmonary fibrosis and emphysema, bronchitis, and bronchiectasis (*q. v.*). Friction, if audible, is generally loud, leathery, and creaking.

Diagnosis.—The association of thoracic deformity and immobility with such signs as enfeebled breathing, diminished tactile fremitus, wooden dulness, and coarse friction makes a well-developed adhesive pleurisy an easily recognized condition. In doubtful cases, presenting a less clear-cut symptomatology, the patient's history and the careful study of the respiratory murmur and the percussion findings are to be relied upon as the chief diagnostic clues.

HYDROTHORAX (Pleural Dropsy)

Hydrothorax, or dropsy of the pleural cavity, is usually part and parcel of an anasarca due to chronic cardiac, renal, or hepatic disease or to high-grade anemia. The effused fluid is a simple clear transudate, of lemon-yellow color, poor in cellular elements, and containing little or no fibrin; the specific gravity rarely exceeds 1015, the albumin content is not more than 20 or 30 grams, and the formed elements are chiefly endothelial cells shed by the pleural surfaces. (See p. 53.) Here may be noted Péju's observation, that pleural dropsies occurring in subjects of anthracosis may consist of thin black fluid charged with carbon particles. Hydrothorax is generally bilateral, though unilateral effusions are also met with, chiefly in connection with chronic cardiac disease, in which right-sided hydrothorax, frequently preceding a general edema, is the rule, probably because of pressure on the vena azygos major by an enlarged right auricle (Baccelli). When stasis thus provoked extends to the vena azygos minor, effusion into the left pleural sac occurs, and in this manner a bilateral hydrothorax is established, the volume of which is usually greater on the right

side. Pressure by the dilated heart upon the pulmonary veins is the explanation of cardiac hydrothorax given by Fetterolf and Landis. In certain cases of Laennec's cirrhosis there is also a tendency toward right-sided hydrothorax, attributable, at least in part, to azygos compression by the enlarged veins of the esophageal plexus (Martini). Unilateral hydrothorax may be associated with local lesions of the same side (neoplasm, fibrosis, aneurism) that compress the great vessels at the pulmonary radix; it sometimes affects the free pleural sac opposite the one obliterated by universal adhesions; it occurs rarely (as "hydrops ex vacuo") in the pleuropulmonary space created by the recession of a tightly contracted lung; and it may exist as a loculated collection of fluid walled off by impermeable adhesions. In pure hydrothorax the pleural surfaces are not inflamed, though this change tends to supervene as the result of the chronic congestion, and the primary transudate, in such an event, acquires many of the characteristics of an inflammatory exudate.

The *physical signs* are those of intrapleural fluid, generally bilateral, unattended by pain and friction, and associated with clear evidences of the underlying disease. Dyspnea and cough in a dropsical subject should always prompt a search for fluid within the pleural sacs. The differences between the physical signs of hydrothorax and an inflammatory pleural effusion have been described under the latter. (See p. 276.)

HEMOTHORAX (Pleural Hemorrhage)

Hemothorax, or hemorrhage into the pleural cavity, results from accidents such as traumatism of the chest, rupture of an aneurism, erosion of a blood-vessel, and free vascular oozing incident to the hemorrhagic diathesis. The extravasated blood coagulates, the serum is rapidly absorbed, and the clot is deposited upon the most dependent surface of the pleura, whence, if uninfected, it is eventually removed by absorption, without giving rise to pleural inflammation. Infection, however, is not unlikely to take place, particularly in hemothorax due to wounds of the chest-wall or secondary to some erosive lesion that establishes a fistulous communication with the gullet or the larger air-passages, and in such cases the prompt onset of a purulent pleurisy is to be expected.

The *physical signs* relate to a rapidly accumulating pleural effusion, with or without evidences of actual pleuritis. These findings, correlated with the patient's clinical history and with the objective symptoms of acute hemorrhage and shock, are generally sufficient to warrant the diagnosis of hemorrhage into the pleural cavity.

CHYLOTHORAX (Hydrops Chylosus)

Chylothorax, or the presence of an effusion of chyle in the pleural sac, is a very rare affection, arising in consequence of a leakage of chyle from the thoracic duct or from a large intrathoracic lymphatic trunk. This accident may be of traumatic origin, or may be due to cancerous erosion, to lesions of the lymph-vessels, or to left subclavian venous thrombosis; rarely, it has been ascribed to filariasis. The effused fluid consists of a turbid, creamy emulsion of fat, having either a faintly sweetish odor or none at all, being peculiarly resistant to decomposition, and clearing on shaking with ether, but not doing so on centrifugalization. The specific gravity of the transudate ordinarily ranges between 1015 and 1020, and it contains approximately from 3 per cent. of albumin to twice this amount or more, together with a variable sugar content, and, inconstantly, fibrin and casein.

The **physical signs** of chylothorax are those of a pleural effusion, either unilateral or bilateral, and the diagnosis must be made by thoracentesis. True chylous hydrops, rather than a chyli-form effusion, is indicated by aspirating a creamy fluid yielding at least 0.2 per cent. of sugar, abundantly charged with very minute fat-droplets, and containing relatively few cellular elements. In contrast, a chyli-form effusion shows a lower sugar content, fewer and larger fat-particles, and a greater number of degenerate cells. When both types of effusion coëxist, as is sometimes the case, examination of the fluid is obviously of no avail, and in this contingency the differentiation, if one can be made, must needs rest largely upon the case history. Chylothorax is suggested when it is possible to identify some factor of chyle leakage: trauma, cancer of the pleura, thrombosis of the left subclavian vein, or, possibly, filarial infection; while chyli-form effusions, though also met with in pleural cancer, are likely to be associated with severe anemias, tuberculosis, chronic cardiac disease, and grave cachectic states. (*Cf.* Chyli-form Pleurisy, p. 269.)

PNEUMOTHORAX (Hydropneumothorax; Pyopneumothorax; Hemo-pneumothorax)

Clinical Pathology.—Pneumothorax, or the accumulation of air within the pleural cavity, is generally attended by an effusion of serum, pus, or, rarely, blood, and hence the more specific terms, *hydropneumothorax*, *pyopneumothorax*, and *hemopneumothorax* are appropriate, according to the character of the fluid.

Owing to the elastic tension of the lungs, the normal pressure within the pleural cavity (754 mm. of Hg) is about 6 mm. lower than that of the pulmonary vesicles and air-passages (760 mm. of Hg.), and in consequence of this difference, designated as "negative intrapleural pressure," the lungs are kept in close contact with the inner thoracic wall and the two pleural surfaces are intimately approximated. So soon, however, as a communication is established between the atmospheric air and the pleural sac, the latter sucks in sufficient air to satisfy its negative pressure, or, in other words, to equalize the intrapleural and the intrapulmonary pressures. In consequence, the lung, by virtue of its inherent elasticity, immediately recoils from the chest-wall and contracts, for its so doing is not now prevented by a high intrapulmonary tension, and the pleural cavity, whose membranes are no longer opposed, is widely distended by the aspirated atmospheric air. This constitutes pneumothorax. That pneumothorax does not invariably follow pleurotomy is due to increased pressure, referable to strong respiratory efforts, within the corresponding lung, whereby its contractility is overcome and the organ becomes overdistended. This not only insures adequate approximation of the two pleural surfaces, but may even cause protrusion of the lung through the breach in the chest-wall, and thus produce a pulmonary hernia.

Air enters and accumulates within the pleural cavity in consequence of numerous different factors, of which pulmonary tuberculosis is by all odds the most common. Fully 90 per cent. of all pneumothoraces are due to this cause (Weil; West; Walsh), the entrance of air usually being through a breach made in the pleura by a small interpleural or subpleural tubercle, or, less frequently, through the rupture of a pulmonary cavity lying immediately beneath the pleura. The favorite site of such perforations is toward the base rather than the apex of an upper lobe, especially on the left side. Empyema is also an important cause of pneumothorax, and in this disease the air commonly gains access through a bronchopleural sinus, while only exceptionally does it enter by the fistulous tract in the chest-wall created by an empyema necessitatis. Other destructive diseases that may produce pneumothorax, by the erosion of a fistula into the lung and bronchial tubes, include abscess, gangrene, cancer, and hydatid cyst of the lung, suppurative tracheobronchial adenitis, and bronchiectasis; while in certain instances the condition is referable primarily to esophageal erosion, to similar disease of the parietal structures, and to ulcerative lesions beginning in a subphrenic viscus (stomach, liver, intestine) and ultimately perforating the

pleura, as a rule, after first invading the corresponding lung. Pneumothorax has been known to follow violent respiratory effort and severe muscular strain, the stress of which is sometimes sufficient to rupture even a healthy lung, though more often a lung thus torn is found to be the seat of latent tuberculosis, emphysematous bullæ, infarction, or some other lesion that weakens its texture. Violent contusions and penetrating wounds of the chest-wall also account for the entrance of air into the pleural sac, and to the latter so-called traumatic type of pneumothorax the bungling use of the aspirating needle occasionally contributes a case. In an exceptional instance the pleural cavity fills with gas evolved by the *B. aerogenes capsulatus* growing in a pleural exudate.

Save for rare exceptions, the disease is unilateral, and the collection of air fills and thoroughly permeates the free space within one pleural sac—*general or complete pneumothorax*; occasionally, the air is circumscribed, by air-tight adhesions, to a part of the pleural cavity—*circumscribed or limited pneumothorax*: simultaneous distention of both pleural spaces, or *bilateral pneumothorax*, is a rare clinical curiosity in which the subject's life is a matter of hours. If the fistulous tract leading to the pleural cavity be patent and permits the free passage of air into and out of the pleural chamber, an *open pneumothorax* exists, and in this variety of the disease the intrapleural and atmospheric pressures are equal. Should the orifice become sealed, as by adhesions or by a bit of lymph, a *closed pneumothorax* is established, in which the intrapleural pressure either remains atmospheric or gradually becomes negative, if the excess air be finally absorbed. An opening provided with a valvular mechanism, which admits air with inspiration, but prevents its free escape with expiration, distinguishes a *valvular or ventilated pneumothorax*, a type associated with exceedingly high intrapleural tension. Primarily, the great proportion of all pneumothoraces are valvular, but the type of the disease is subject to change from time to time, because of the readiness with which structural alterations in the fistulous opening take place.

The immediate effect of pneumothorax is a great distention of the chest on the affected side, and on puncture of the pleural sac the air may escape with considerable force, if positive intrapleural pressure exists. If free, the lung on the diseased side is collapsed, contracted, and compressed, lying in a small, carnified mass along the vertebræ; if the lung be bound down by adhesions, it shrinks in a more irregular manner, according to the situation of the bands of traction. The mediastinum and its contents, unless firmly

anchored by adhesions, are displaced toward the sound side by the higher pressure in the pneumothoracic pleura; and by a similar mechanism the diaphragm, with the liver and spleen, is unduly depressed. Pleural effusion is an almost constant sequel in subjects that survive, the exudate being, in order of frequency, serofibrinous, purulent, or, exceptionally, hemorrhagic.

Physical Signs.—*Inspection.*—The affected side is distended and immobile, the intercostal spaces being effaced and the diaphragm shadow abolished, while in contrast to this the opposite half of the thorax shows exaggerated respiratory movements. The visible cardiac impulse is displaced toward the sound pleura, and the liver may bulge outward below the right costal margin. Distressful dyspnea, paroxysmal cough, cyanosis, rapid feeble pulse, and a state of suffocation and collapse are notable objective symptoms of acute general pneumothorax, but in cases of long standing the urgency of these signs is greatly modified.

Fluoroscopic examination reveals an abnormally clear and bright appearance of the affected side, with contrasting shadows of carnified lung above and of fluid below, in case these attendant conditions be sufficiently developed to obstruct the passage of the rays (Fig. 116). The mediastinal shadow lies far from its natural site, and the diaphragm is depressed and unnaturally immobile. In some cases the phrenic vault shows a downward convexity, and the normal inspiratory fall and expiratory rise of the diaphragm are reversed. If the displacements be unusually striking, as is the tendency in valvular pneumothorax with excessively high tension, practically nothing is seen with the fluoroscope save the clean-cut shadows of the ribs and clavicle against a bright background corresponding to the boundaries of the distended pleural sac.

Palpation.—Vocal fremitus is diminished or entirely lost over the air-distended pleura, though toward the apex there may be intense voice vibrations referable to pulmonary compression or consolidation. The liver, in right-sided pneumothorax, is palpable far below the costal margin, the displacement of this organ being, as a rule, much more conspicuous than in a simple fluid effusion within the pleura. Succussion fremitus (*v. i.*) is occasionally palpable when the pleura contains both air and fluid.

Percussion.—Generally, the percussion sound is unduly loud, sonorous, and hyperresonant; sometimes it is dull, muffled, and toneless; and exceptionally it is tympanitic or even amphoric. Normal pulmonary resonance, although rare, is not incompatible with the lesion in question. These differences, which relate to the typical

instance of general pneumothorax, are determined mainly by the degree of intrathoracic pressure existing in the individual case, and the character of the percussion sound serves to index the resiliency of the thoracic wall. Thus, despite the impracticability of differentiating the three forms of the disease by percussion alone, it is true that in valvular and in closed pneumothorax one expects to find sonorous hyperresonance or muffled dulness, according to whether the pressure be moderate or extreme;

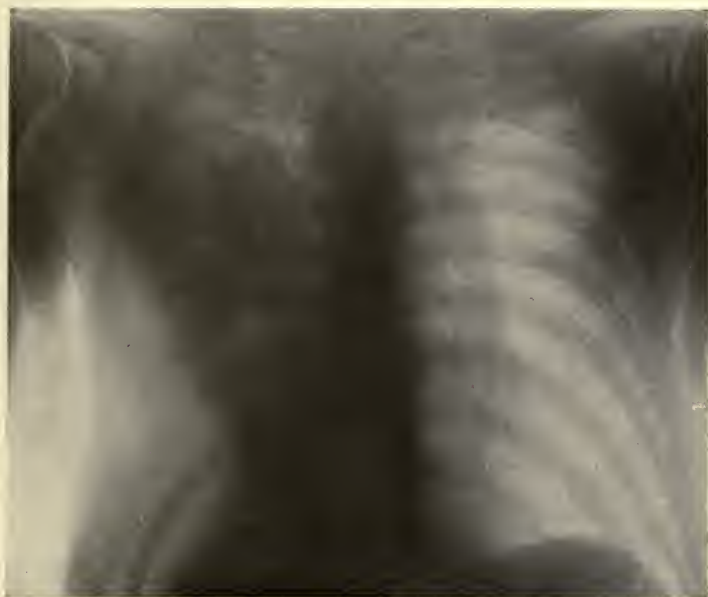

Fig. 116.—Radiograph of a left pneumothorax. Posterior aspect showing shadow of consolidated lung above the air-distended pleura. (Plate by Dr. W. F. Manges.)

while in open pneumothorax, where the intrapleural pressure is merely atmospheric, there may be the proper relaxation of the parietes to afford tympany. Cracked-pot resonance with Wintrich's sign may be elicited over a pneumothorax communicating with a patulous bronchus. The percussion resistance also varies with the elasticity of the chest-wall: commonly, a sort of "air-cushion" sensation is felt by the pleximeter finger, but should the tension be excessive, the resistance is almost board-like. The percussion sounds, whatever be their exact quality, are readily distinguishable from those found over the opposite—and perhaps vicariously hyper-

resonant—lung, and their extension beyond the median and inferior limits of the normal pleura is readily determined.

The coëxistence of fluid is revealed by a basal zone of flatness which readily shifts with changes in the subject's posture, this sign of movable flatness being much more evident and easy to detect in pneumothorax with fluid than in uncomplicated hydrothorax or in inflammatory effusion.

Auscultation.—Over the distended pleura the respiratory murmur is suppressed, often to the point of absolute silence; if at all audible, the breathing possesses a far-away amphoric tone or a distant bronchial quality, should the sound transmission travel by way of a patch of compressed lung abutting upon an open bronchial tube. Vocal resonance is distant and frequently amphoric and echoing. Over the unaffected side the respiratory and the voice-sounds are puerile and abnormally loud.

Four noteworthy adventitious sounds should be sought for in pneumothorax: the succussion splash (*succussio Hippocratis*) of Hippocrates; the coin sound (*bruit d'airain*) of Trousseau; the metallic tinkle (*gutta cadens*) of Laennec; and the pulmonary fistula sound (*water-whistle noise*) of Riegel. These important signs, indicating both air and fluid within the pleural sac, have been described in a preceding section, and, therefore, require no further comment in this connection. (See p. 165 *et seq.*) Other abnormal sounds, developed by the acts of coughing and deep respiration, consist of a medley of bubbling râles of ringing, metallic quality and of pleural, pulmonary, and bronchial origin.

The abnormal situations of the cardiac and hepatic percussion areas are generally well defined, especially in cases associated with excessively high intrapleural pressure: for example, a valvular pneumothorax, if left sided, may entirely obliterate cardiac dullness to the left of the midsternal line, or, if right sided, may depress the liver so that its upper border of dullness is at, if not below, the arch of the ribs. To a less striking degree the splenic area is depressed by the pressure of air within the left pleural cavity. In left pneumothorax Calvert has noted that an apex-beat invisible in recumbency becomes apparent when the subject leans forward so as to allow the mobile heart (for its pulmonary support is lost) to swing forward against the chest-wall.

Diagnosis.—The sudden onset of urgent dyspnea, cyanosis, and collapse is a most significant indication of acute general pneumothorax, particularly if this syndrome be observed in a phthisical subject. The principal confirmatory signs comprise unilateral dis-

tention, immobility, and hyperresonance of the thorax; diminished or absent vocal fremitus and resonance; abolished or distantly amphoric respiratory sounds; and remarkable displacement of the heart, liver, and diaphragm. If an effusion also exists, shifting dulness at the base will be found, as well as the peculiar ringing and metallic sounds so distinctive of air and fluid within a pleural sac. A circumscribed partial pneumothorax may afford no distinctive signs whatever—the so-called “mute pneumothorax” of Sabourin.

Pleural effusion, either exudative or transudative, is sometimes suggested by a pneumothorax attended by a collection of intrapleural fluid of sufficient volume to cause an extensive basal area of flatness, overlaid by dull hyperresonance and provocative of considerable visceral displacement; the fact that tubular or amphoric breathing above and respiratory silence below may be common to both conditions makes their discrimination still more difficult. In hydropneumothorax or pyopneumothorax, however, the thoracic distention is much more decided and the visceral displacements are more conspicuous than in simple effusion; the basal flatness has a perfectly horizontal upper level that readily shifts when the patient's position is altered; and such important auscultatory findings as the succussion sound, metallic tinkling, and the coin sound are generally demonstrable.

Certain cases of *unilateral emphysema*, secondary to wide-spread fibrosis of the opposite lung, in the course of time produce an enlargement of one-half of the thorax, which, on percussion, emits a sound whose intense hyperresonance is comparable to that found in pneumothorax, and in the face of such findings the presence of dyspnea, cyanosis, and cough makes the resemblance still closer. But despite these similarities, the differentiation is not difficult, when one contrasts the vertical excursions of the thorax, the expiratory type of dyspnea, and the attenuated (though still vesicular) respiratory murmur of emphysema with the thoracic immobility, the desperate suffocation, and the respiratory silence of pneumothorax. If these fundamental differences prove inadequate, the condition of the lung opposite the hyperresonant side and the presence of definite pneumothoracic adventitious sounds may furnish conclusive evidence.

One must occasionally distinguish circumscribed pneumothorax from a large superficial *pulmonary cavity*, owing to the resemblance between the percussion tympany and the metallic râles elicited in the two affections. A pulmonary excavation, rather than pneumothorax, is indicated by localization of the physical signs at or near the apex of the lung, by the presence of a circumscribed area of

intercostal immobility and retraction in this situation, and by finding little or no dislocation of the cardiac apex, which, if abnormally placed, is drawn toward—not pushed away from—the lesion. Additional evidence in favor of a cavity includes intense vocal fremitus, distinct pectoriloquy, and loud amphoric or cavernous breath-sounds, in contradistinction to the enfeebled respiratory and voice-sounds ordinarily detected in pneumothorax. Though such signs are most extraordinary, a large pulmonary cavity, if distended with air and partly filled with fluid, may yield succussion, metallic tinkling, and even the bell tympany of the coin test.

Subphrenic pyopneumothorax, a gas-containing abscess cavity situated between the diaphragm and the liver, counterfeits true pneumothorax, especially one circumscribed at the base of the chest. If the gaseous distention be excessive, the diaphragm is pushed up to a high level and the lung compressed, with the result that both physical signs and symptoms develop which intimately resemble those of an intrapleural effusion of air. In this differentiation the fluoroscope is most helpful, since it reveals, over a subphrenic pyopneumothorax, an abnormally high diaphragm shadow beneath the dome of which is a clear, luminous tract, indicative of air, and sharply contrasting with a horizontal zone of darkness corresponding to the underlying purulent collection. It is also of service to remember that a subphrenic abscess is usually a sequel of gastric or intestinal perforation (as in gastric or duodenal ulcer), in consequence of which the subphrenic space, more commonly on the left side, becomes infected by material and distended by gas derived from the gastrointestinal tract.

In a rare emergency it is necessary to differentiate pneumothorax and *diaphragmatic hernia*, for in this grave accident the stomach and gut, ballooned with air, may protrude through a rent in the diaphragm into the thoracic cavity, thereby faithfully reproducing the physical conditions and signs of air within the pleural sac. Evidence in favor of hernia includes the detection of gastro-intestinal rumbling and sibilant noises over the lower thorax, as well as the important fact that should the hernial protrusion suddenly recede, as it sometimes does, both signs and symptoms will disappear coincidentally. A history of injury is no sure criterion, since it may be the factor of either condition. Congenital hernia of the diaphragm is occasionally encountered.

A greatly *dilated stomach*, in so far as it can account for tympany, succussion sounds, tinkling noises, and embarrassed respiration, must be reckoned with as a possible mimic of left-sided pneumothorax.

But the previous history of the two conditions is radically unlike, and in gastric dilatation there is no distinctive combination of signs, such as unilateral distention of the thorax, descent of the diaphragm, compression of the lung, and conspicuous displacement of the heart.

PLEURAL NEOPLASMS

Carcinoma.—The great majority of pleural neoplasms are secondary to carcinoma of the lung, which invades the pleural membranes by direct extension; less commonly the cancer arises by metastasis from a primary lesion of the lung, breast, gullet, or thyroid. Unilateral implication is the rule, affecting the right pleura somewhat more commonly than the left. Ordinarily, the cancerous lesions consist of multiple nodules, first appearing along the course of the lymphatics and sometimes becoming so large as to excite active symptoms of intrathoracic pressure, to dislocate the mediastinum and its contents, and to bulge the chest-wall. Less commonly a diffusely disseminated type of growth is met with, the pleural membranes being densely infiltrated, welded together, and contracted, with the result that striking deformity of the chest ensues in the course of time. Cancer, as well as all other forms of pleural neoplasm, tends ultimately to excite inflammation of the pleura, generally with an effusion which in fully two-thirds of all cases is hemorrhagic.

The *physical signs* of secondary cancer of the pleura are referable chiefly to the primary pulmonary lesion (see p. 260), and secondarily to the presence of either a plastic or an exudative pleurisy. If the latter exists, as is usually the case, an exploratory puncture should be made, with a view to finding in the aspirated fluid erythrocytes, free fat, cancerous elements, and a considerable number of mitotic cells. As a rule, the fluid also contains relatively few lymphocytes and many large vacuolated endothelial cells, commonly occurring in plaques. (See p. 54.)

Aside from the important signs relating to the primary growth in the lung or some other locality, severe and stubborn pleural pain, cervical and axillary glandular enlargements, local chest deformity, and a cachectic appearance of the patient are to be regarded as important details of the clinical picture. The heart may be displaced either by effusion or by the growth, and dense adhesions may make the displacement permanent.

Of primary carcinoma of the pleura, little need be said, for the disease is more often discovered by the pathologist than by the clinician. So long as the pleura alone is implicated the physical

signs suggest merely a pleurisy, dry or effusive, for the constitutional evidences of malignant disease are not clearly defined. The development of metastases (*i. e.*, in the lung, liver, or superficial lymphatics) is of distinct diagnostic aid, if such findings be reviewed in the light of the pleural manifestations.

Sarcoma.—Sarcoma of the pleura is an exceedingly rare affection, and one impracticable to distinguish clinically from carcinoma, like which it is usually accompanied by hemorrhagic effusion, severe pain, deformity of the chest, and moderate, if any, cachexia. Invasion of neighboring and remote structures has been observed in the primary form, of which only about a dozen cases have been recorded. Secondary pleural sarcoma is also rarely met with, but the pleura appears to be more susceptible to sarcomatous than to cancerous implication by metastasis, in malignant disease primarily developing in other regions of the body.

MEDIASTINITIS

Simple acute mediastinitis is a rare affection, and its recognition during life can only be hazarded. If the inflammation does not subside by resolution, its usual termination, either a fibrous overgrowth or suppuration of the mediastinal tissues, may supervene, the clinical picture in each event being fairly definite. Though many cases must, unfortunately, be dubbed "idiopathic," in others a satisfactory cause is at hand, such as trauma and inflammation of the pericardium or of the mediastinal pleuræ; abrupt suppression of the menses is a doubtful factor.

Reliable *physical signs* are wanting in simple acute mediastinitis, the existence of which is suggested by the patient's history plus symptoms such as severe substernal and interscapular pain, persistent irritative cough, and moderate fever with rigors.

Chronic mediastinitis accounts for more constant and active clinical findings than the acute form, since it consists not only of a mediastinal fibrosis, but also of more or less extensive pericardial inflammation and adhesion. Syphilis is a prominent factor in such cases, and intensive treatment with salvarsan is most helpful, even in the face of definite pressure symptoms.

Following the classification of Thomas Harris, three pathologic varieties are recognized: those in which there are both external and internal adhesions of the pericardium, great increase of mediastinal fibrous tissue, and often caseation of the mediastinal lymphatic glands (the *indurative mediastinopericarditis* of

Kussmaul); those in which there are extensive external and internal adhesions of the pericardium, but little or no mediastinal fibrosis (the so-called *external and internal pericarditis*); and those in which there is decided mediastinal fibrosis attended by merely external pericardial adhesion (the true *chronic mediastinitis*).

Mediastinopericarditis is attended by great cardiac hypertrophy and dilatation, by chronic hepatic and renal congestion, and in some instances by proliferative peritonitis, perisplenitis, and a type of perihepatitis termed *pericarditic pseudocirrhosis* or *Pick's disease*. Bronchitis, pleurisy, and pulmonary fibrosis are familiar associated conditions, and ascites, with or without general dropsy, is prone to occur, especially as the result of cardiohepatic lesions, peritonitis, and venous obstruction due to mediastinal pressure.

The *physical signs* of chronic mediastinitis are referable mainly to the associated lesions of the heart and pericardium and to the sequelæ arising therefrom. On *inspection*, there is seen a variable degree of thoracic immobility and dyspnea, perhaps with cyanosis; dropsy, and engorgement of the cervical and thoracic veins. Inspiratory distention of the right external jugular vein is a suggestive though an inconstant sign: it indicates obstruction of the jugular return flow, due to compression of, or traction upon, the intrathoracic veins, and has been observed also in simple pericarditis, in pleurisy, and in mediastinal tumor. *Palpation* over the sternum, if roughly performed, may provoke lancinating pain. Of frequent occurrence is the paradoxical pulse, which weakens or completely disappears during inspiration, but this peculiarity is by no means distinctive of mediastinal fibrosis. (See p. 338.) *Percussion* shows, if the fibrosis be extensive, an abnormal area of dulness over and alongside the sternum, though such a finding is more often the result of the cardiac enlargement or of the mediastinal adenitis. On *auscultation* over the sternum one sometimes hears dry crackling mediastinal sounds and also the Eustace Smith hum (*v. i.*), while the râles of bronchitis and the friction-sounds of pericarditis and pleurisy generally coëxist. Evidences of cardiac dilatation and hypertrophy, of chronic adhesive pericarditis, and of hepatic (rarely, splenic) enlargement are also prominent details of the symptom-complex in many instances of chronic mediastinitis.

Suppurative mediastinitis, due to the invasion of pyogenic cocci, occurs in consequence of trauma and of ulcerative diseases of the air-passages and gullet; it results also from the extension of septic lesions of the cervical fascia, the tracheobronchial glands, the lungs, and the pleuræ; and it may be secondary to actinomycosis or to various

acute infectious diseases, notably erysipelas, enteric fever, variola, and pyemia. The suppuration thus set up may occur as a widespread purulent infiltration of the mediastinal tissues, or as one or more circumscribed abscesses. The former tends to run an acute and rapidly fatal course, attended by well-marked evidences of sepsis. The latter, if effectually walled in by a pyogenic membrane, often remains latent for a long period, and may even become absorbed or encapsulated; or the abscess may burrow through the mediastinal space and finally discharge through the line of least resistance—into the trachea, a bronchus, or the esophagus, through an intercostal space or downward along the spine, through the abdominal wall, or into one of the large blood-vessels. Tuberculous abscesses of the mediastinum are usually of limited extent, and do not give rise to severe systemic disturbances, save when secondary contamination with pyogenic microorganisms takes place. Cold abscess of the mediastinum can generally be traced to tuberculosis of the mediastinal glands, or to caries of the spine or chondrosternal structures. It is the general belief that it most frequently affects the posterior space, while the other spaces suffer chiefly from the acute form (Hare).

The *physical signs* of mediastinal suppuration are notoriously untrustworthy, being quite negative in small deep-seated lesions. However, in a large abscess of the anterior or superior mediastinum *inspection* not infrequently detects a dusky, hot, fluctuating and sometimes pulsating swelling in the sternal region, while exceptionally actual pointing of the pus through the chest-wall is observed. The cardiac apex is enfeebled and dislocated in relation to the size and situation of the purulent collection. On *palpation* tenderness over the sternum is elicited, and the local peculiarities of the swelling are appreciated; in some instances there is a paradoxical pulse. *Percussion* may demonstrate undue upward and lateral extension of cardiac dulness, and also, in a large abscess of the posterior mediastinum, a dull area between the scapulæ on either side of the spine. Evidences of mediastinal pressure (for a description of which see Mediastinal Tumors, p. 301) arise, should the situation and the character of the abscess be such as to crowd the important vessels, nerves, and other organs of the mediastinum. Such symptoms are, as a rule, not so conspicuous in abscess as in mediastinal neoplasm.

MEDIASTINAL LYMPHADENITIS

Adenitis, either simple or suppurative, frequently affects the mediastinal lymphatic glands, of which there are three principal

groups: those lying in the loose areolar tissue of the anterior space and also around the innominate veins, the aortic arch, and in front of the trachea; those situated along the esophagus and the aorta in the posterior space; and the bronchial group of the middle mediastinum. Of these, the last named is of peculiar interest, owing to its intimate relation with the bronchi and, through afferents, with the lungs and pleuræ.

Simple lymphadenitis, with engorgement and edematous swelling of the glands, attends practically all bronchopulmonary inflammations—bronchitis, bronchopneumonia, influenza—and occurs with especial frequency in the bronchitides of measles and pertussis. In the latter disease, indeed, the paroxysmal attacks of cough and dyspnea are interpreted by de Mussy as evidence of pressure by the enlarged lymph-nodes of the posterior mediastinum. Bronchial adenitis is an almost constant autopsy finding in pulmonary tuberculosis.

Suppurative lymphadenitis is generally of tuberculous origin, but it occasionally arises as the sequel of simple adenitis due to another factor. In some instances the suppuration is confined to the gland or group of glands primarily affected, and ultimately absorption of the pus and calcification of the lesion may take place; in other cases the pus burrows and finds an outlet, as by fistulation into a bronchus or into the esophagus; and in still others the infection may extend to the lungs and pleuræ, or mediastinal abscess may develop. In tuberculous adenitis the mediastinal focus of infection may account for the supervention of an acute miliary process and for phthisis, the former being due to the perforation of a vessel and the latter either to direct extension of the lesion or to the inspiration of tuberculous material which has eroded a channel into a bronchial tube. But pulmonary tuberculosis and glandular infection are by no means constant, even in long-standing tuberculous caseation of the lung—an example, Rist suggests, of allergy, like the acquired immunity of the buccal mucosa in phthisical subjects.

The *physical signs* of mediastinal lymphadenitis are rarely definite enough to be of much value, save in an occasional case of extensive enlargement of the anterior mediastinal glands, in which abolished tactile fremitus, respiratory silence, and dulness are detected over and alongside the sternum; or the glandular masses may exaggerate the bronchial sounds, combining bronchophony and intensified breath sounds with sternal dulness. In some instances the thoracic segment of the spine furnishes a group of most suggestive signs:

tenderness from the second to the seventh spinous tip; dulness over the fifth (normally resonant); and a patch of bronchial breathing and bronchophony at the level of the first. The writer is accustomed to place the same significance on the combination of hyperresonance with maximum tactile resistance as on the association

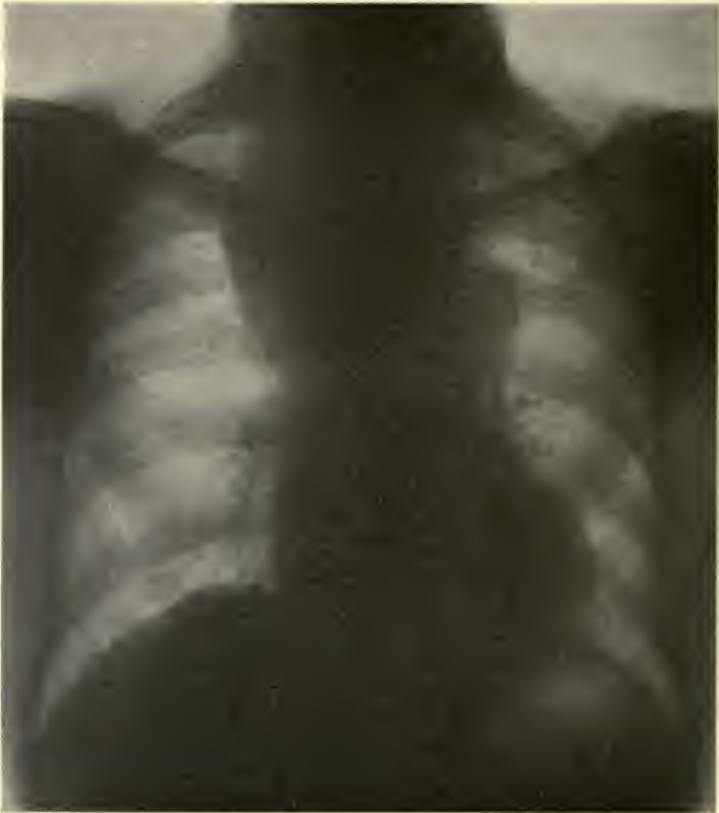

Fig. 117.—Radiograph of mediastinal lymphadenitis. (Plate by Dr. W. F. Manges.)

of hyperresonance with minimum tactile resistance in uncomplicated adenopathies. It is assumed, to explain this apparent paradox, that in the former instance the glandular mass exerts a dulling pressure, and that in the latter it conducts the predominant tracheal vibrations to the vertebral tips.

It is frequently possible to demonstrate *d'Espine's sign* of

tympany combined with exquisitely clear whispering pectoriloquy over the upper thoracic vertebral spinous processes, and this sign is dependable as an early and most constant clue to adenopathies which, by structure and situation, act as effectual transmission paths for sounds generated within the large air-passages.

Tracheobronchial tumors may compress the left innominate vein when the subject's head is stretched far backward, and thus produce a venous hum audible over the manubrium—*Eustace Smith's murmur*. Paroxysmal cough, dyspnea, hoarseness, and dilatation of the venules upon the anterior surface of the thorax are pressure symptoms of decided importance. In children persistent dry cough, with negative surface signs, may be referable to enlargement of the lymph-nodes at the tracheal bifurcation, especially those situated below the right bronchus. Herbert French attributes the cough in such cases to irritation of the phrenic nerve.

An x -ray examination usually reveals the presence of enlarged mediastinal glands, even at an early stage of their development (Fig. 117). The shadow cast by a group of hypertrophied bronchial glands suggests aortic aneurism, but an aneurismal shadow may show pulsation, and on inspection from various directions can generally be localized to some part of the aortic arch. In adult life the normal pulmonary radiograph ordinarily shows small isolated glandular shadows, for few persons reach maturity without at some time having been subject to a bronchopulmonary irritation whereby permanent adenoid enlargement is excited. In Fig. 70, a radiograph of a perfectly normal thorax, the shadows alongside the mediastinal area indicate this wholly benign type of glandular enlargement, which is without pathologic significance.

MEDIASTINAL NEOPLASMS

Clinical Pathology.—Sarcoma and carcinoma are the most important types of malignant tumors affecting the mediastinal spaces, the former being decidedly the commoner of the two and more likely to be of primary origin. Primary sarcoma may arise from the thymus gland or its remains, or from the lymphatic glands, the pleuropulmonary structures, and the mediastinal tissues; secondary tumors of this type are generally the sequel of an initial growth in some distant part. Primary carcinoma more commonly springs from the esophagus or the bronchopulmonary structures than from the thymus or connective tissue; secondary cancer of the mediastinum

is prone to develop in the neighborhood of the primary tumor. Among the rarer solid tumors of the mediastinum are included the simple lymphomata, and also growths of gummatous, fibrous, cartilaginous, osseous, and teratomatous character. Of cystic tumors, hydatids and dermoids are examples exceptionally observed. The anterior mediastinum is the most common situation of malignant disease, and here is the selective site of sarcomatous lesions; for the posterior space carcinoma apparently has a predilection. Not only does the mediastinal tissue become the seat of extensive malignancy, but its important organs as well as the neighboring structures also share in the change. Compression of the mediastinal vascular trunks, nerves, air-passages, and esophagus is produced, the pleuræ, lungs, pericardium, and even the heart may become implicated, and in some instances the growth encroaches upon the neck, extends through the diaphragm, or presses against the anterior or the posterior chest-wall. Metastatic spread of the original growth is also likely to take place via the blood or the lymphatic vessels.

For clinical study it is convenient to divide mediastinal tumors into two main groups: those of the anterior and superior mediastinal spaces, in which the physical signs overshadow the pressure phenomena; and those situated in the middle and posterior mediastina, in which the physical signs are subordinate to the pressure symptoms. It is perfectly obvious that this purely arbitrary classification is of limited applicability, since neoplasms tend progressively and erratically to invade the different mediastinal compartments, thus giving rise to a medley of symptoms relating partly to this and partly to that space. Despite this, in order to trace the origin of such symptoms, it is well to have a mental picture of these chief mediastinal compartments and of the effects produced upon their contents by the encroachment of morbid new-growths.

Physical Signs.—*Tumors of the Anterior and Superior Mediastinum.*—The principal signs of growths situated immediately beneath the sternum relate to the contour of the anterior chest-wall, to the consequences of compression or occlusion of the superior vena cava and the innominate veins, and to irritation of the superior laryngeal and sympathetic nerves.

Inspection.—It is of some interest to note that the subject of a malignant tumor in this situation is anemic rather than characteristically cachectic, and that emaciation, though it does occur, is not usually conspicuous until the disease has almost run its course. Clubbing of the finger-tips generally develops in cases of long standing.

Dyspnea is usually moderate, so long as the growth does not encroach far in a backward direction. As the result of persistent intrathoracic pressure the sternum finally gives way, and bulges outward to form a mound-like swelling (Fig. 118), or the growth may erode the chest-wall, appearing thereupon as a circumscribed node, of variable size, outline, and consistence, but tending ultimately to soften, to discolor, and to break down. Occlusion of the intra-

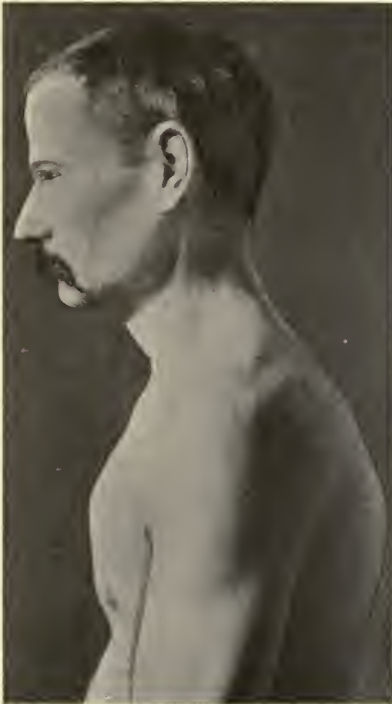

Fig. 118.—Bulging of the thorax in a case of mediastinal neoplasm (Jefferson Hospital).

thoracic venous trunks accounts for edema and for distention and tortuosity of the superficial veins of the face, neck, arms, and upper anterior chest-wall, bilateral phenomena of this sort indicating superior caval obstruction, and unilateral signs pointing to compression of an innominate vein or one of its tributaries. The illustration elsewhere shown (Fig. 51, p. 106) gives a good idea of the appearance of engorged superficial veins upon the surface of the

body. Inequality of the pupils is not a frequent sign in growths affecting the anterior mediastinum, owing to the posterior position of the sympathetic nerve. Hoarseness and loss of voice, from compression of the inferior laryngeal, are, however, very common findings.

Palpation.—Pressure over the sternum is painful to the patient, and palpation may detect a systolic pulsation over the tumor, the density of which ranges from stony hardness to soft edema. The lifting throb of a soft, overvascular tumor must be carefully distinguished from the expansile pulsation of an aneurism. Tactile fremitus is usually abolished over the growth and its infiltrative extensions. In some instances the primary growth is palpable in the suprasternal notch, and secondary glandular enlargements appear in the neck and in the axillæ.

Percussion.—There is an area of dulness or of flatness corresponding to the site of the tumor, in the immediate neighborhood of which hyperresonance is the rule. Abnormal modifications of the percussion sound are also likely to be found over other parts of the thorax, where associated pulmonary and pleural lesions exist.

Auscultation.—Ordinarily, the respiratory murmur is suppressed over the tumor and exaggerated over the adjacent lung, but sometimes the growth distinctly conducts, or even intensifies, the breath-sounds. Bronchial râles, pleural and pericardial friction-sounds, and systolic murmurs due to compression of the aorta and pulmonary artery are audible in certain cases. The cardiac sounds are frequently, though not invariably, obscure, muffled, and distant, particularly at the base.

Tumors of the Middle and Posterior Mediastinum.—In this situation growths, even of moderate size, cause signs referable mainly to compression of the vagus, the bronchi, and the gullet, while in some instances there are evidences of pressure upon the azygos veins and the inferior vena cava, as well as of extensive necrosis of the parts encroached upon.

Inspection.—True cachexia, emaciation, asthenia, and fever are more common than in lesions of the anterior mediastinal space. The patient is constantly dyspneic and subject to alarming paroxysms of orthopnea, stridulous breathing, brassy cough, and dysphagia, due chiefly to vagus irritation, but in part to compression of the bronchopulmonary structures. Syncope, vomiting, symmetric coldness of the extremities, and disturbances of the cardiac rate, rhythm, and force also occur as the result of what Gowers terms “vagal attacks.” The pulse, aside from its irregularity, is of feeble volume

bilaterally, if the aorta be compressed, while differences in the force of the two radials is noticed in the event of pressure upon the innominate artery or upon the left subclavian. Edema of the lower extremities, ascites, and engorgement of the surface tributaries of the inferior vena cava are visual evidences of constriction of this great venous trunk. Inequality of the pupils, and some-

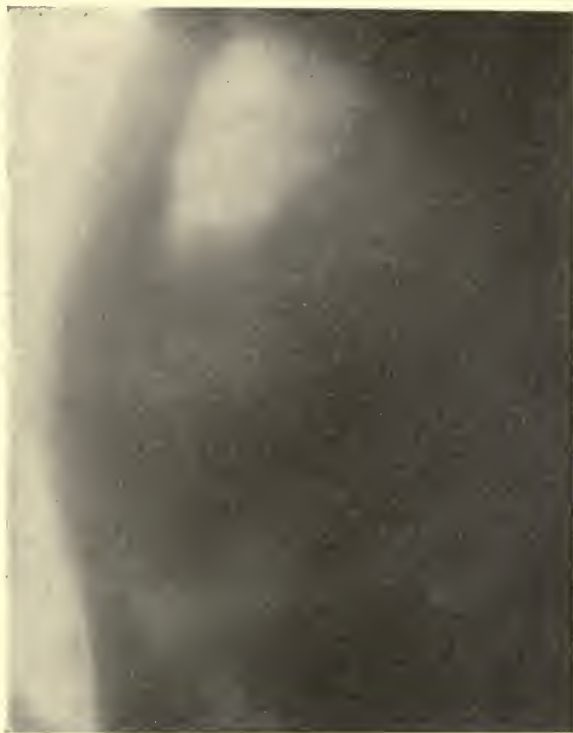

Fig. 119.—Radiograph of a mediastinal neoplasm. Lateral aspect, showing dense shadow in the anterior mediastinum, with infiltration of the sternum, and edema of the overlying chest-wall. (Plate by Dr. W. F. Manges.)

times unilateral circumscribed flushing and perspiration, betoken irritation of the sympathetic cord.

Palpation.—Considerable significance attaches to the sign noted by Graham Steell, who observed that the visible and palpable cardiac impulse covers an area almost coëxtensive with that of the entire heart, which, when encroached upon by a tumor of the posterior

mediastinum, appears to thrust itself forward *en masse* with every systole. In other cases, where this diffuse impulse is not present, the apex-beat may merely be tilted outward and downward away from its normal site.

Percussion.—Ordinarily, a tumor deep within the mediastinum is far beyond the reach of percussion, although should it extend backward against the posterior wall of the thorax, a patch of irregularly shaped dulness or flatness may be delimited in the interscapular region. It is not uncommon to find the basal flatness of intrapleural fluid, poured out usually as the result of an associated pleurisy, and exceptionally by fault of pressure stasis within an azygos vein. The percussion findings of pulmonary edema, excited by pressure upon



Fig. 120.—Radiograph of a mediastinal neoplasm. Anterior aspect, showing abnormal extension and density of the mediastinal shadow, with displacement of the heart. (Plate by Dr. W. F. Manges.)

the pulmonary veins, and of a distended right heart, due to pulmonary artery compression, are present in certain cases.

Auscultation.—Of especial interest in connection with neoplasm of the middle and posterior mediastina are the physical signs of bronchial occlusion, partial or complete. (See p. 184.) Aside from this, evidences of recurrent laryngeal nerve implication and of secondary

lesions of the lungs, pleuræ, and pericardium should be given due attention.

Diagnosis.—Usually it is not difficult to recognize mediastinal pressure, but it is quite another matter to prove that the pressure is due to malignant disease unless the case presents classic symptoms and signs. The association of persistent dyspnea, dysphagia, substernal and interscapular pain, venous obstruction, and nervous symptoms constitutes a syndrome scarcely to be misinterpreted, especially in the face of the physical signs of an intrathoracic tumor in a person who has steadily lost weight, failed in strength, and become anemic or cachectic. These signs having been obtained, in part or as a whole, it is perhaps justifiable to predict sarcoma when the lesion affects the anterior mediastinum, grows rapidly, attains a large size, and provokes striking local signs; and it seems also warranted to diagnose carcinoma when the growth occupies the posterior mediastinum, develops slowly, and is accompanied by few, if any, local manifestations. The radiograph is an invaluable aid in both the direct and the differential diagnosis, provided that its interpretation be sane and conservative. (See Figs. 119 and 120.)

Aneurism of the aortic arch is the lesion most often confused with mediastinal tumor, and, indeed, it is sometimes quite impossible to make the antemortem differentiation. Diastolic shock, tracheal tugging, cardiac hypertrophy, true expansile pulsation, and an absence of glandular enlargement are in favor of aneurism, and a history of syphilis, unduly severe pain, and temporary amelioration of the symptoms after the use of the iodids make this inference the stronger. Furthermore, an aneurismal swelling generally occupies a higher level upon the anterior chest-wall than a growth pushing forward from the mediastinum, and the development of the former is slower and the patient's lease on life longer, as a rule, than in malignant tumor. The fluoroscope reveals, in aneurism, a shadow that may clearly show expansile pulsation situated along the course of the aorta, while the shadow cast by a solid growth appears as an irregularly shaped extension of the mediastinal darkness which may or may not throb with cardiac systole.

The differentiation of malignant disease versus *gumma* of the mediastinum has been referred to elsewhere. (See p. 240.)

SECTION V

EXAMINATION OF THE CARDIOVASCULAR SYSTEM

CLINICAL ANATOMY

THE heart and its pericardial investment occupy the middle mediastinal space behind the lower two-thirds of the sternum, the long axis of the organ being almost horizontal, and its greater part projecting to the left of the median line of the trunk. The normal

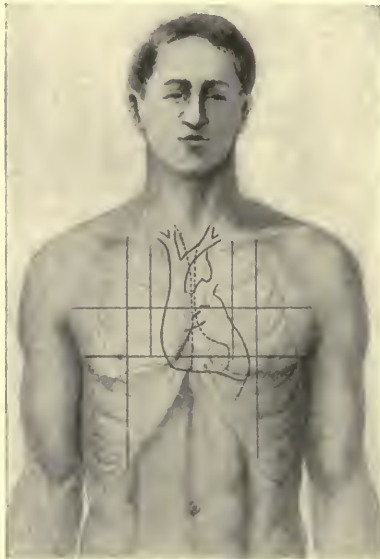

Fig. 121.—Surface topography of the heart.

adult's heart weighs approximately from 9 to 11 ounces (255 to 310 gm.), and shows maximum measurements of about 5 inches (12.5 cm.) in length, $3\frac{1}{2}$ inches (8.75 cm.) in width, and $2\frac{1}{2}$ inches (6.25 cm.) in thickness. The capacity of each ventricle is approximately $3\frac{1}{3}$ ounces (100 c.c.), according to Tigerstedt, and the auricles are capable of holding virtually the same volume of blood. The general shape of the heart is that of a blunt, somewhat flattened cone, having its base directed upward, its anterior convex surface placed upward and forward, and its comparatively flat surface facing downward and backward.

The pericardium consists of an outer fibrous and an inner serous layer, whereby the heart is completely enveloped, the viscus hanging free therein from its basal attachment to the great vessels; with the

fibrous layers of the latter the outer pericardium is continuous, while below it is anchored to the central tendon of the diaphragm. The inner pericardium is a closed sac formed by two serous layers: a parietal, which lines the fibrous pericardium, and a visceral, which covers the heart and is reflected therefrom along the great vessels. Like the heart, the pericardium is of a roughly conic shape, but unlike the cardiac cone whose base lies upward, the pericardial cone has its base directed downward.

The Precordia (Fig. 122).

—The term precordia, or precordial region, designates that area of the anterior chest-wall which overlies the heart, and corresponds not only to the part of the organ directly impinging upon the inner surface of the thorax, but also to the portion overlapped by the pulmonary margins. The precordia, therefore, includes within its boundaries both the area of cardiac flatness and the area of cardiac dulness (*q. v. i.*).

The relations of the heart to the chest-wall given below are those of the average normal adult, and more or less regional differences must be expected in the

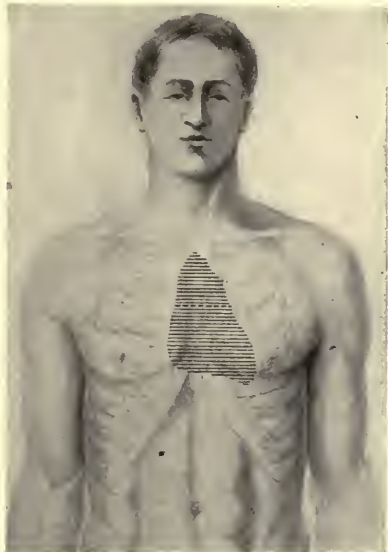


Fig. 122.—The precordial and supracardiac areas.

individual case, owing to the influence of age, the state of the thoracic musculature and bony structures, and the development of the lungs.

The **base** of the heart, consisting of the two auricles, lies in front of the descending thoracic aorta and the lower right pulmonary vein, being directed upward, backward, and to the right. It extends anteriorly from a point $\frac{1}{2}$ inch (1.25 cm.) to the right of the sternum to a point 1 inch (2.5 cm.) to the left of this bone, at the level of the upper border of the third rib; posteriorly, the base extends from the fifth to the eighth thoracic vertebra, inclusive. The *right auricle* lies beneath and somewhat external to the right half of the sternum, between the third and the sixth costal cartilages, but the greater part of the *left auricle* lies posteriorly, its appendage, beneath the second left intercostal space, being the only portion of this chamber to project toward the anterior surface of the thorax. The *auriculo-*

ventricular groove, separating the auricles from the ventricles, is indicated by a line extending from midsternum, at the level of the lower border of the third costal cartilage, to the sixth right chondrosternal junction.

The **right border** of the heart, formed by the right auricle, is represented by a line running from the right extremity of the base (upper border of the third rib, $\frac{1}{2}$ inch (1.25 cm.) from the sternum) to the sixth right chondrosternal articulation, and curving outward between these two points to attain a maximum convexity in the fourth intercostal space, which is crossed $1\frac{1}{2}$ inches (3.75 cm.) from the midsternal line.

The **left border** of the heart, corresponding to the left ventricle, follows a line curving slightly outward from the left extremity of the base (upper border of the third rib, 1 inch (2.5 cm.) from the sternum) to the anatomic cardiac apex (*q. v. i.*), situated in the fifth left intercostal space, in the midclavicular line. From somewhat to the right of this point the *interventricular groove*, dividing the ventricles, runs anteriorly upward to the third left chondrosternal junction.

The **lower border** of the heart, formed almost entirely by the right ventricle, though to a slight extent by the left ventricle, is mapped out by drawing a line from the apex to the lower extremity of the right border (sixth right chondrosternal articulation), which line crosses the xiphoid cartilage just below its sternal attachment.

The **cardiac valves and orifices** are included within the boundaries of a flattened circle, extending obliquely across the body of the sternum from the third left to the sixth right chondrosternal articulation (Fig. 134). From above downward the valves lie in the following order: *pulmonic*, at the upper border of the third left chondrosternal joint; *aortic*, beneath the left half of the sternum, at the lower border of the third costal cartilage; *mitral*, beneath the left half of the sternum, at the level of the fourth costal cartilage; and *tricuspid*, extending from midsternum, at the level of the fourth costal cartilage, to the fifth right chondrosternal junction. The foregoing landmarks refer only to the anatomic sites of the valves, the individual tones of which and the murmurs pertaining thereto are most clearly audible over that area of the thorax where the valve's chamber approaches closest to the surface. These sites, known as "valve areas," or "auscultatory areas," are referred to in connection with auscultation of the heart. (See p. 356.)

The Supracardiac Vascular Area (Fig. 122).—The great blood-vessels arising from the base of the heart lie within a rectangular area extending from the clavicles to the cardiac base line, and bounded on either side by vertical lines projected upward from the latter's

right and left extremities. This space, then, overlies the superior vena cava, the aortic arch, the innominate artery, and the innominate veins. The *superior vena cava* extends from the confluence of the innominate veins, at the right sternoclavicular joint, to its outlet into the right auricle, at the third chondrosternal articulation, the course of the vessel between these two points lying beneath and somewhat external to the right sternal edge. The *ascending aorta* lies behind the sternum between the third left chondrosternal junction and the second right costal (or aortic) cartilage. At this point the *aortic arch* commences, and runs thence obliquely upward and backward toward the fourth thoracic vertebra, where it becomes continuous with the descending thoracic aorta; the highest point of the aortic arch in the median line usually lies 1 inch (2.5 cm.) below the suprasternal notch, or at about the center of the manubrium. The *pulmonary artery* runs along the left sternal border beneath the second intercostal space and the second costal cartilage. The *innominate artery*, arising from the upper aspect of the aortic arch, runs obliquely upward to the right sternoclavicular junction, where it divides into the right subclavian and common carotid arteries; on the left side these two vessels spring from the aortic arch between its middle and posterior extremity, the common carotid coursing obliquely, and the subclavian running almost vertically, upward into the neck. Of the two *innominate veins*, the right lies under the inner extremity of the right clavicle, and the left, beneath the upper portion of the manubrium.

MECHANISM OF THE CIRCULATION

The Cardiac Cycle.—This term refers to the series of events that attend each beat of the heart, whose cycle, therefore, comprises the systole or contraction of the auricles, the systole or contraction of the ventricles, and the period of diastole or relaxation and passivity of both auricles and ventricles. In a clinical sense, the words systole and diastole, when used without a qualifying adjective, mean contraction and relaxation, respectively, of the ventricles. Normally, the systolic and diastolic phases on the right and left sides of the heart are precisely synchronous, the auricles contracting and relaxing at exactly the same moment, and the ventricles doing likewise. The entire cardiac cycle lasts 0.8 second, of which 0.1 second is occupied by the auricular systole, 0.3 second by the ventricular systole, and 0.4 second by the diastole of all four chambers. Acceleration of the cardiac action, which abbreviates each of these cyclic phases, especially affects the diastolic. The component parts of the cardiac cycle

and their relation to the cardiac sounds and impulses are graphically shown by the accompanying diagram (Fig. 123).

The origin and maintenance of the cardiac cycle are best explained by assuming an inherent automatic rhythmicity of the myocardium, whereby orderly waves of contraction are generated at the venous end of the heart and are conducted thence throughout the organ by its musculature. This *myogenic theory* of the heart-beat attributes to the cardiac muscular fibers the functions of "rhythmicity, excitability, contractility, conductivity, and tonicity" (Gaskill),

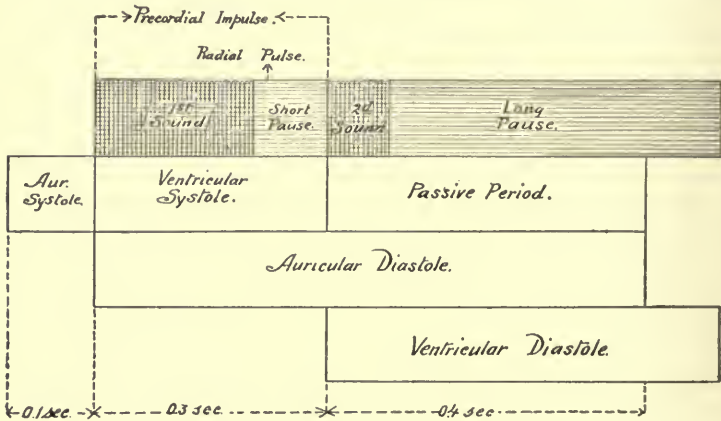


Fig. 123.—The events of the normal cardiac cycle.

whereby the heart can beat independently of nerve control, the vagus and the sympathetic nerves merely regulating the force and the rate of the contractions. These are probably excited directly by certain inner stimuli due to the action of ionized salts (especially sodium, calcium, and potassium ions) in solution in the juices of the tissues.

Opposed to the foregoing, the *neurogenic theory* of the heart-beat takes for granted that inner stimuli exciting cardiac contractions arise in the intrinsic nerve-cells of the auriculo-venous area, whence impulses travel, via nerve paths, to subsidiary nerve-centers, through which the auricular and ventricular contractions are activated. This theory, which is unsupported by positive proof, burdens the intrinsic cardiac nerves with the spontaneity, the orderly sequence, and the harmonious relations of the several events of the cardiac cycle.

The Cardiac Movements.—The earliest phase of the cardiac cycle is a quivering contractile movement at the mouths of the venæ cavæ and pulmonary veins, presumably initiated at the caval orifice

in a minute node of primitive tissue representing the remains of the sinus venosus—the sino-auricular node of Keith and Flack. Systole of the auricles immediately follows, as the peristaltic wave extends downward through the musculature of these chambers, to the auriculoventricular bundle of His, which arises from a node in the wall of the right auricle (Tawara's auriculoventricular node) and is distributed through the ventricular musculature. After a momentary delay as it crosses the auriculoventricular bridge of muscle, the contraction traverses the ventricles, first downward through the wall toward the apex, and finally inward to terminate in the papillary muscles.

The recent work of Kent suggests that cardiac impulses also may arise spontaneously in a mass of nodal tissue situated in the lateral aspect of the right auricle, and pass thence downward into the ventricles along a muscular channel connecting the upper and the lower chambers of the heart. In the event of the destruction of His' bundle it is possible that impulses are conducted to the ventricle along this right lateral bridge of Kent.

The ventricular systole thus excited is followed by auricular diastole, which begins as the earliest waves of contraction pass through the ventricles. The latter, after having ejected their contents into the arterial system, relax in diastole, and this final phase of the cycle is succeeded by a relatively long resting period which ushers in the next series of contractions at the auricular outlets of the great veins. During its contraction the heart twists forward upon its long axis from left to right, the ventricles harden, shorten, and thicken, and the apex, now pointed, tilts upward and to the right; the auricles diminish in size and recede, while the aorta and pulmonary artery distend and lengthen. With diastole the heart rotates backward and to the left, the ventricles become flaccid and globular, the apex becomes rounded and shifts downward and to the left; the auricles distend and protrude, and the aorta and pulmonary artery collapse and shorten.¹

With *auricular systole* the blood in the auricles is forced through the auriculoventricular orifices into the relaxed ventricles. Reflux into the venæ cavæ and pulmonary veins (which are not guarded by valves at their outlets) is prevented by several factors: chiefly by the

¹Williams and James have proved, by electrocardiographic tracings, that there may be a true reversal of the cardiac action, the ventricles contracting before the auricles and the impulses initiated in the lower chambers passing *up* His' bundle into the auricular muscle. Such a condition is referable to a prevailing dominance of the intrinsic ventricular rhythm over the normal sinus rhythm whereby the feebler stimuli of the latter are overshadowed.

low intra-auricular pressure,¹ but partly by the constriction of the venous orifices by the contraction of their muscular coats, as well as by the free outlet afforded the blood-stream by the widely dilated mitral and tricuspid openings.

The *ventricular diastole*, which coincides with the entire systole of the auricles and with the last part of their diastole, is due mainly to the inherent resiliency of these chambers. During this period the ventricles fill with blood, which gradually floats up the mitral and tricuspid curtains, so that they close, by the end of diastole, their respective orifices. Meanwhile the semilunar valves, kept tightly closed by the high arterial pressure, prevent leakage of blood from the aorta and pulmonary artery.

The *ventricular systole* now occurs, and the blood contained in the ventricles is pumped forward into the aorta and pulmonary artery, whose semilunar cusps are simultaneously forced open as soon as the pressure in the ventricles exceeds that in the arteries, this change of tension taking place immediately after the ventricles commence to contract. Regurgitation into the auricles cannot occur because the mitral and tricuspid valves, already approximated by the pressure of the blood distending the ventricles, are kept tightly closed by the impact of the reflux current excited by the contraction of these chambers. The contraction of the papillary muscles not only aids in perfectly apposing the margins of the cusps, but also prevents the eversion of the valves into the auricles. The aortic blood-column courses through all parts of the body, after which it is returned, by the *venæ cavæ*, to the right auricle, this complete circuit from the left ventricle to the right auricle being known as the *systemic* or *greater circulation*. The blood in the pulmonary artery is propelled through the lungs, whence it flows back, oxygenated, through the pulmonary veins, into the left auricle, this short circuit being termed the *pulmonary* or *lesser circulation*.

During *auricular diastole* the blood returns from these two circuits, for at this period of the heart's cycle the pressure in the *venæ cavæ* and pulmonary veins exceeds that in the auricles. The latter are distended by the volume of their contained blood, aided to some extent by the elastic traction exerted by the lungs, the auriculo-ventricular openings meanwhile remaining closed.

Arterial Tension.—The term blood-pressure designates the mural tension of the blood-vessels exerted by the lateral and radial

¹ The pressure in the ventricles, which at this time are in diastole, is also much lower than in the veins, being so low, indeed, that it is believed to exert a so-called "suction action" upon the entering blood-stream.

force of the circulating blood-stream, the degree of this pressure varying in different parts of the vascular path, according to their proximity to the heart. In this central pump the pressure reaches the maximum, in the arteries it diminishes, in the capillaries it becomes still lower, and in the veins it falls to a minimum; in consequence of these differences the blood-stream courses uninterruptedly through the body from its ventricular high-pressure outlets at the aortic and pulmonary orifices to its auricular low-pressure inlets at the mouths of the cavæ and pulmonary veins. In the venous channels the blood is impelled heartward by three factors: the initial cardiac force, the aspiration action of the heart and thorax, and the pressure exerted by the body musculature upon the valvular parts of the veins.

Arterial tension is maintained by the pumping force of the ventricles and by the peripheral resistance, and so long as these two factors work so as to equalize the vascular outflow and inflow of blood, the normal equilibrium of pressure remains undisturbed. The vasomotor system of nerves, aside from regulating the distribution of the blood-mass, is a most important factor in determining the height of the blood-pressure. Stimulation of the vasoconstrictors contracts the peripheral arterioles, and in so doing increases peripheral resistance, thereby raising arterial tension; paralysis or extreme exhaustion of the constrictors has an opposite effect. Stimulation of the vasodilator nerves, by dilating the arteriolar caliber and diminishing peripheral resistance, lowers arterial tension—a condition, it may be added, much more readily induced than increased tension, owing to the relatively greater susceptibility of the vasodilators to stimulating influences.

The acme of hypertension develops when a powerful, overacting heart impels the blood-column against the undue resistance excited by tight vasomotor constriction, while the lowest degree of tension is found when a feeble, toneless heart is linked with the minimized resistance resulting from extreme vasomotor dilatation.

INSPECTION AND PALPATION

It is convenient to discuss inspection and palpation of the cardiovascular apparatus together, rather than to make an artificial division of this dual method of research. The examiner should invariably preface his investigation of the precordial region by a careful inspection of the subject's facies, skin, and subcutaneous tissues, general nutrition, thoracic configuration, and respiratory movements. This

preliminary inquiry, the details of which have been considered elsewhere (p. 77 *et seq.*), is primarily directed toward the discovery of the more general objective symptoms of heart disease—pallor, cyanosis, and icterus; clubbing of the fingers, coldness of the extremities, venous tortuosity, and edema; and polypnea, dyspnea, and other forms of respiratory distress. Advanced disease of the mitral valve, for example, is suggested at first glance by the pasty, puffy, dusky face, the clubbed, cold fingers, and the panting respiration of the subject; coronary artery obstruction and aortic arteriosclerosis by a dull, ashen pallor—the “leaden overcast” of Sansom; while the association of violent arterial throbbing, urgent dyspnea, and an apprehensive facies, by turn pallid and flushed, spells Corrigan’s disease to the trained eye.

More definite information relating to the condition of the heart and blood-vessels is obtained by further inquiry, which should include the study of the precordial contour, the apex-beat, the presence or absence of unnatural pulsation and retraction, and the questions of thrills and friction fremitus. In looking for obscure pulsations and irregularities of contour it often proves most helpful to resort to K. H. Beall’s device of drawing with a skin pencil, upon the surface under investigation, a plaid figure composed of one-inch (2.5 cm.) squares, whose lines become obviously distorted by surface movements and irregularities not otherwise perceptible.

Semirecumbency is the best position for the subject to assume during routine inspection and palpation of the heart and great vessels, but it is frequently advisable to test the effect of gravity upon certain signs (pulsations, thrills, and tactile fremitus), by employing alternately the upright and the recumbent positions.

The influence of *bodily posture* upon cardiac physical signs has been succinctly summed up by William Gordon, who states that a change from the erect to the recumbent position: (a) raises and narrows the normal cardiac dulness; (b) greatly narrows the dulness of an enlarged heart; (c) dulls the first, and sharpens the second, cardiac sound; (d) exaggerates an accentuated pulmonic second sound and a reduplicated second sound; (e) intensifies hemic, mitral and tricuspid regurgitant, and aortic stenotic murmurs; (f) enfeebles the venous hum and the mitral stenotic bruit; and (g) leaves unaltered the murmur of aortic regurgitation.

The Precordial Contour.—*Bulging of the precordia*, disturbing the normal bilateral symmetry of the anterior chest-wall, is much more likely to occur in children than in adults, in consequence of the greater resiliency of the parietes during immaturity, and their

readiness to yield to intrathoracic pressure. (See Fig. 40, p. 89.) A prominent precordial region suggests pericardial effusion, enlarged heart, circumscribed pleural effusion, mediastinal tumor, or aneurism of the aortic arch, whereby the surface of the chest is mechanically, if not erosively, made to protrude outward. Less commonly, the deformity is traceable to some factor such as rickets, anterolateral spinal curvature, or inflammatory thickening of the surface structures.

Precordial flattening or depression, either general or local, may signify pericardial adhesions, in which event the change usually is best defined in the lower left parasternal area. Flattening of the precordia is also referable to left-sided pleural adhesions and to fibroid retraction of the left lung. The depression of the lower sternal region typical of the "funnel chest," the mesial sternal furrow of the "gutter chest," and the sunken breast-bone of the "boat-shaped thorax" have been referred to under Examination of the Thorax. (See p. 83.)

The Apex-beat.—In the healthy adult the apex-beat of the heart is recognized as a rhythmic local pulsation in the fifth left intercostal space, half an inch (1.25 cm.) internal to the midclavicular line, or $3\frac{1}{2}$ inches (8.75 cm.) external to the midsternal line. In young children the apex is commonly observed in the fourth interspace, and as far outward as the left midclavicular line; in short-chested subjects it may be similarly elevated; and in persons of advanced age and in those having a long chest it may beat at an unnaturally low level. The word *bathycardia* has been proposed by E. J. Janeway to signify a low position of the heart due to physiologic causes.

The apical pulsation is systolic in time, being synchronous with ventricular systole, and is ordinarily restricted to an area not more than an inch (2.5 cm.) in diameter. In health the right ventricle is to be regarded as the clinical apex of the heart, and to the systolic impact of this chamber against the inner thoracic wall the surface pulsation is due; the left ventricle, which is the anatomic apex of the heart, does not, unless enlarged, directly produce an appreciable pulsation of the overlying parietes. Usually the apex-beat can be both seen and felt, but it is by no means rare to find it invisible, though it is distinctly palpable as a gentle, pushing thrust appreciated by the finger-tip applied to the apex region. Deep inspiration slightly depresses, and forced expiration elevates, the site of the apex, which also shifts horizontally when the subject turns from dorsal to lateral recumbency, the deflection amounting to an inch or two toward the left when left lateral decubitus is assumed. Postural

mobility of the apex, which is greater in adults than in children, is especially apparent in subjects of cardiovascular disease.

Having identified the apex-beat, it is necessary to learn whether the impulse is situated normally or displaced, whether its force is exaggerated or enfeebled, and whether the area of pulsation is diminished or extended. These points are decided by combined inspection and palpation of the precordial region.

Displacement of the Apex-beat.—Of the numerous factors of apical displacement, the most important relate to enlargement of the heart by hypertrophy and dilatation, to dislocation of the organ by intra-thoracic traction or pressure and by ascent of the diaphragm, and to the collection of fluid within the pericardial sac. Aside from these causes, the effect of thoracic deformities and of visceral transposition on the site of the apex-beat is also to be recalled.

Upward apical displacement may indicate unduly great subphrenic pressure, in consequence of which the diaphragm, and with it the heart, rises to a high level, as in ascites, meteorism, gastric distention, and abdominal tumor; diaphragmatic hernia also may elevate the heart's impulse. Upward displacement, with more or less deviation of the apex to the left, occurs from effusion of fluid or of gas in the right pleural sac, adhesions of the left pleura and fibrosis of the corresponding lung, large pericardial effusion, and mediastinal neoplasm. A heart that has undergone considerable atrophy obviously is likely to pulsate at too high a site.

Downward apical displacement ordinarily is referable to pressure exerted by hypertrophic emphysema; less commonly the weight of an aortic aneurism or of a mediastinal tumor depresses the apex; or it may be dragged downward by an enlarged liver or by some form of visceral ptosis.

Right lateral apical displacement is generally attributable to such lesions as right-sided pulmonary fibrosis and pleuropericardial adhesions; to collapse of the right lung; and to the pressure of a left-sided pleural effusion or pulmonary consolidation. In congenital transposition of the viscera the apex-beat is to be looked for at a point in the fifth right interspace, near the midclavicular line—a condition of dextrocardia giving the so-called “mirror image” of the precordial and other regions.

Left lateral apical displacement, if practically horizontal, is especially significant of dilated hypertrophy of the right ventricle, whose strong epigastric and parasternal pulsations must not be mistaken for its actual apical impulse. The apex beats to the left of, and below, its normal situation in dilated hypertrophy of the left ventricle.

The *character* of the apex-beat as to force, extent, and rhythm varies both in health and in disease, so that should such deviations from normal be found, it is necessary first to determine if they are physiologic or pathologic, and, if the latter, to discover the lesion, cardiac or extracardiac, upon which they depend. In judging the force of the apex-beat, allowance is to be made for the facts that a thin chest-wall magnifies, and a thick chest-wall minimizes, the impulse; and that should the impact of the ventricle be directed against a rib rather than an interspace, the apex-beat naturally will be indefinable by inspection and palpation. The apex-beat may also be absent in an individual whose thorax is so deep that the heart fails to impinge against the inner thoracic wall.

Simple *exaggeration* of the force of the apical impulse may be due to nervous excitement, overexercise, indigestion, anemia, and the overuse of tobacco, coffee, tea, and alcohol. The "fluttering" of the heart complained of by the neurotic woman, and the precordial throbbing of the indiscreet coffee-drinker and smoker, are familiar illustrations of this type of apex overaction. It may accompany acute myocarditis, valvular disease, and left ventricular hypertrophy—in the last-named lesion the impact is not only forcibly heaving, but diffuse and displaced downward and to the left. Forcible throbbing of the apex attends the initial stages of many acute febrile diseases, and is seen in apoplexy. An apparently exaggerated apex-beat may be due to retraction of the left lung, whereby the heart is uncovered and hence pulsates against the chest-wall more forcibly and more extensively than in health.

An *enfeebled* or *absent* apex-beat should always arouse one's suspicion of cardiac dilatation, the relaxed ventricle either quite obliterating the impulse, or rendering it feeble, undulatory, and of a distinctively "slapping" character. The slow, deliberate systole of the left ventricle commonly associated with aortic stenosis may be so forceless as to give rise to no appreciable impulse in the region of the apex. Pericardial effusion, emphysema, and mediastinopericardial adhesions also are capable of weakening or negating the apical beat—pericardial effusion, by interposing a barrier of fluid between the heart and the thoracic wall; emphysema, by hemming in the whole anterior surface of the heart with a mass of overdistended lung tissue; and mediastinopericardial adhesions, by mechanically restricting the heart's excursions by the contraction of the fibrous bands by which the organ is anchored. Advanced myocarditis, myocardial degeneration, cardiac atrophy, and systemic shock and debility materially lessen the force of the apex-beat. Exceptionally,

every trace of the precordial impulse is obliterated by either a neoplasm or an inflammatory lesion of the anterior mediastinum, whereby the heart is pushed backward and its throbs are completely damped.

The *cardiogram* of the apex-beat (Fig. 124; *cf.* Fig. 14) may show unnatural deviations that serve, within reasonable limits, as criteria of disturbances affecting the rate, force, and rhythm of the

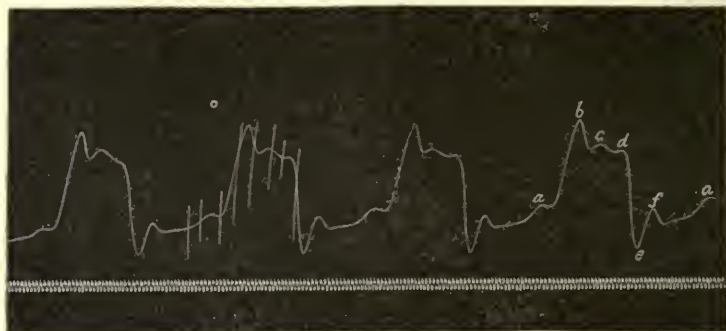


Fig. 124.—Normal cardiogram of the apex-beat: *a*, Auricular systole; *a-b*, upstroke (systole); *b*, apex; *b-c-d*, systolic plateau (cardiac impact); *d-e*, downstroke (diastole); *d*, aortic valve closure; *e-f-a*, ventricular filling. (Tracing by Dr. G. Bachmann.)

heart, more especially when interpreted in the light of simultaneous tracings of the radial and jugular pulsations. The cardiographic *upstroke* is, unfortunately, no certain index to the force of the ventricular systole, since a sudden, sharp impact of the heart, though the actual force be subnormal, may produce quite as high a rise as that due to a powerful contraction. Uneven spacing of the upstroke intervals, if instrumental defects can be excluded, means ventricular arrhythmia. *The apex*, if sharply acute, denotes rapid emptying of the ventricle, as the result, for example, of the double ventricular outlet established by fault of a mitral insufficiency; an obtuse, blunt apex indicates an opposite state of things, as in aortic stenosis. *The systolic plateau* corresponds in length to the duration of ventricular systole, and an unduly broad and horizontal wave in this situation suggests the deliberate systoles which accompany many cases of aortic stenosis. *The downstroke*, being related to diastole, follows a course the obliquity of which increases in correspondence with the prolongation of this phase. *The diastolic rise* ascends as a short, steep curve when diastole is sharp and sudden, but mounts gradually upward when the diastolic relaxation is prolonged. Vertical oscilla-

tions of the base line, it should be also noted, are explained chiefly by disturbances in the waves of the diastolic rise and fall between the systolic plateau and upstroke.

Abnormal Areas of Pulsation (Fig. 125).—Apart from pulsations directly referable to the apical thrust, those occurring in other parts of the precordia and in regions of the thorax adjacent thereto remain to be identified and interpreted in an etiologic light. Such anomalies

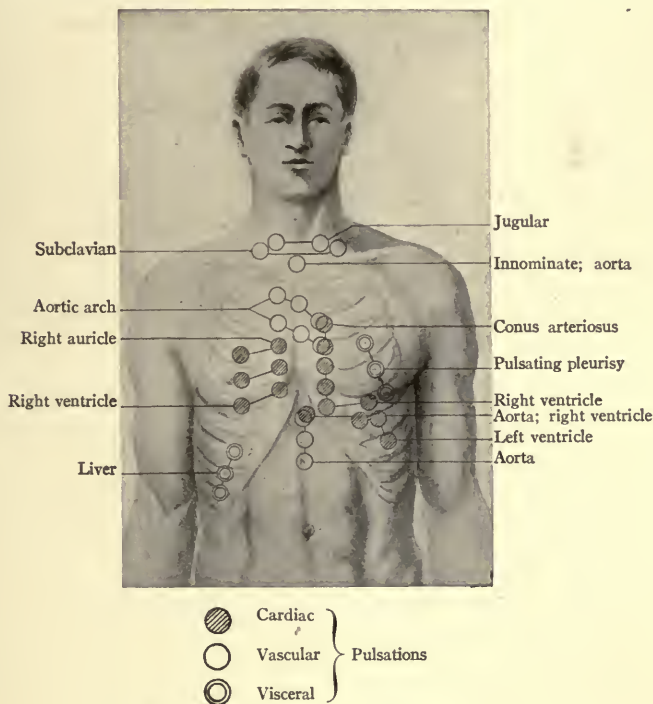


Fig. 125.—Areas of abnormal pulsation.

arise chiefly from lesions of the heart and large vascular channels, but they may also be due in many instances to a conduction of the normal cardiac and arterial impact by the medium of neighboring morbid structures. Like the apex-beat, these pulsations are often both visible and palpable, though some are palpable only; unlike the apex-beat, an extra-apical pulsation may have a distinctly expansile character and may be found over a local tumor upon the surface of the chest. Pulsations of cardiac origin are typically systolic in

time, but those of arterial and venous nature vary in time-incidence according to the mechanism whereby they are produced. The neck, the area corresponding to the base of the heart, the precordia and its vicinity, the epigastrium, and the region of the liver all should be examined for evidences of abnormal throbbing, whose rhythm is determined by comparison with the apex-beat.

Pulsations on either side of the *neck* may originate in the carotid artery or in the jugular vein. If carotid, it is recognized as a systolic throbbing along the course of the vessel from the sternoclavicular articulation to a midpoint between the angle of the jaw and the mastoid process. Pulsation in this site is due to much the same factors that account for a tumultuous apex-beat—neurotic influences, overexertion, and the abuse of tobacco and other heart irritants. Carotid pulsation is especially significant of left ventricular hypertrophy, with or without aortic leakage; of aneurism of the aortic arch; of exophthalmic goiter; of advanced arterial sclerosis; of cerebral hemorrhage; and of high-grade anemia. In rare instances the cause has been found to be an obliterative endarteritis of the descending portion of the aortic arch. Local expansile pulsation of a common or an external carotid artery may be due to a small aneurismal dilatation of the vessel.

Pulsation of the *jugular veins*, which is always more marked on the right side, is recognized as a throbbing along the course of these vessels upward over the clavicular belly of the sternocleidomastoid muscles. It is of the greatest importance to determine whether these pulsations are systolic, presystolic, or both. Systolic jugular pulsation is almost proof positive of tricuspid valve leakage, and indicates a ventricular, or positive type of venous pulse; presystolic jugular pulsation is not necessarily pathologic, and means an auricular, or negative, variety of venous pulse. Very exceptionally, it is possible to assign a factor other than tricuspid leakage to a systolic venous pulse, as, for example, aneurism implicating the superior cava, and also mitral regurgitation plus patent foramen ovale, both of which defects favor transmission of the ventricular impact through the venous columns emptying into the right heart. The differentiation and clinical significance of these two kinds of jugular pulsation are considered under the Venous Pulse. (See p. 346.)

Ordinarily, the venous pulse is observed only in the jugulars, but in extreme cases it may penetrate their smaller surface tributaries and extend to other extremal veins. The palpable hepatic pulse, described below, shows the extent to which the ventricular beats sometimes regurgitate through the veins.

Diastolic collapse of the jugulars (*Friedreich's sign*) occurs with frequency in chronic adhesive pericarditis; it has been attributed to a sudden emptying of these veins at the time of diastole, which allows the chest-wall, tightly drawn in by adhesions during systole, suddenly to relax and expand, and thus to exert an aspiratory action. *Collapse of a jugular vein*, if permanent despite pressure centrally applied, is significant of thrombosis of the lateral sinus.

Pulsation in the *episternal notch* may not be abnormal in the emaciated and in the aged, and it also may arise as the result of neuroses, anemia, and indulgence in stimulants. Other causes of a systolic pulsation in this area are dilatation of the transverse portion of the aortic arch, usually aneurismal; aneurism of the innominate artery; and exposure of the right subclavian artery by a contracted lung or conduction of its pulsation by a consolidated lung of the corresponding side. The existence of cervical ribs, and anomalies in the size and distribution of the vessels at the root of the neck are also among the possible causes of a systolic throb in this region.

Pulsation at or near the *base of the heart*, if not due simply to violent cardiac overaction, may mean aneurism of the aortic arch, or dilatation of the arch in consequence of atheroma or of Corrigan's disease. Systolic throbbing in the *first or second right intercostal spaces* near the sternal border is produced by aneurism of the ascending portion of the aortic arch; over the *angle of Louis*, at the level of the second rib, by aneurism of the transverse portion; and in the *second or third left interspaces*, by aneurism of the descending portion. Aneurismal throbbing in these sites, when typical, is attended by a distinct diastolic shock, and should it occur over a circumscribed bulging of the chest wall, has an expansile character. The impulse of the conus arteriosus of the right ventricle may account for a systolic pulsation near the left sternal edge as high up as the *second interspace*. Diastolic pulsation in the second left interspace near the sternal border is a common early sign of incipient pericarditis. Pulsation between the right sternal and midclavicular lines and between the *second and fourth interspaces* is sometimes due to displacement of the heart by the traction of a fibroid right lung, or by the pressure of left-sided pleural effusion, pneumothorax, or neoplasm.

Pulsation in the *precordial area* in the *third, fourth, or fifth interspaces* at the right sternal border may be caused by cardiac dislocation from any of the factors just mentioned, but it also commonly results from right auricular dilatation. An hypertrophied and dilated right ventricle may be the factor of throbbing immediately alongside the

left sternal border, between the *third and sixth interspaces* inclusive. Pulsating pleurisy, usually purulent, sometimes produces a throbbing or an undulation of one or several interspaces, almost invariably on the left side, between the *second and sixth ribs*, and between the left border of the precordia and the axilla.

Pulsation in the *epigastrium* depends upon a number of different factors, referable in the main to the heart, the gut, and the viscera of the upper abdominal zone. *Systolic* epigastric throbbing may be due simply to overaction of the heart, or to congenital shortness of the sternum, owing to which the anterior surface of the right ventricle beats against the soft structures of the epigastrium, rather than against bone. The same sign may indicate right ventricular hypertrophy and dilatation, or a displacement of the heart to the right by one of the causes enumerated above. *Postsystolic* pulsations originate in the abdominal aorta, commonly as the result of the so-called dynamic pulsation of this vessel, such as is encountered in neurasthenia and in severe anemia. Aneurism of the abdominal aorta, enlarged peritoneal lymphatics, tumors of the liver, stomach, gut, and pancreas, as well as tightly impacted fecal masses overlying the aorta, all may transmit the throb of this artery as an epigastric pulsation occurring a trifle later than the ventricular systole.

Pulsation of the *liver* is practically a pathognomonic sign of tricuspid regurgitation, though its occurrence in connection with this lesion is by no means constant. The throb of a pulsating liver is felt in the right hypochondrium (not merely in the epigastrium), below the lower costal border, and is most readily detected by bimanual palpation. The time of such a pulsation is tardily systolic, and its character is expansile—not merely a lifting thrust, like that of a liver jogged by a forcible heart-beat; it reflects the heart's impulse communicated, by fault of a leaky tricuspid orifice, through the inferior vena cava to the hepatic veins, with a consequent rhythmic distention of the liver directly after systole.

Abnormal Areas of Retraction.—*Broadbent's sign*, or a systolic retraction of the tenth and eleventh intercostal spaces below the left scapula, sometimes attended by a synchronous tug upon the eleventh and twelfth ribs, was first described by the younger Broadbent as an indication of chronic adhesive pericarditis, in which condition the diaphragm, anchored by dense adhesions to the pericardium, is dragged upward with each systole of the hypertrophied heart, so that the diaphragmatic attachments to the chest-wall are pulled inward and retracted (Fig. 126). This sign must be carefully distinguished from a similar systolic retraction due to

the tug of an hypertrophied or a greatly overacting heart, and met with especially in emaciated subjects, as Tallant has shown. Broadbent's sign is commonly attended by systolic retraction of the seventh and eighth ribs and intervening interspace near the left parasternal line, by systolic dimpling in the region of the apex, and by respiratory immobility of the epigastrium.

In aortic regurgitation a systolic retraction over the precordia, due to atmospheric pressure, is sometimes demonstrable; and in some cases of mitral stenosis a late diastolic retraction is visible in the

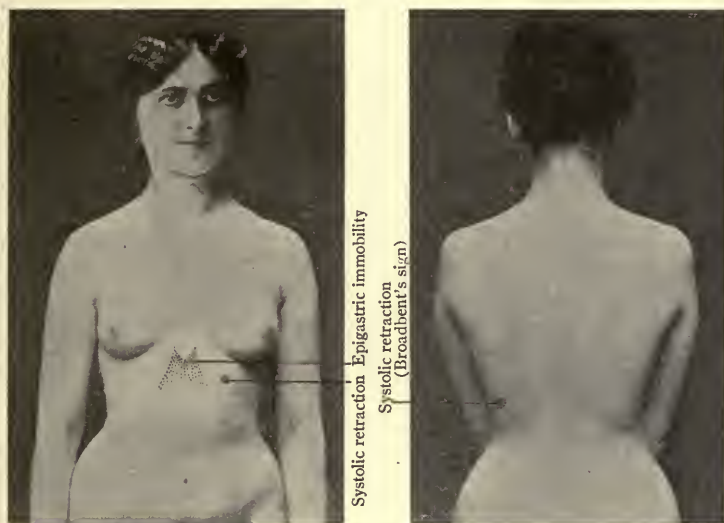


Fig. 126.—Local systolic retractions of the thorax due to adherent pericardium.

same situation. Recessions of this sort, which are due simply to sudden depression of the parietes provoked by strong pulsation, are to be discriminated from the cardiac tug exerted upon the chest-wall by an adherent pericardium.

Venous Engorgement.—*Circumscribed venous engorgements* arise in consequence of local interference with the venous current, the stasis thus established being shown by the distended, tortuous condition of the superficial veins draining the area peripheral to the point of obstruction. The undue prominence of the surface veins and their tendency to form anastomoses upon the anterior thoracic wall in cases of mediastinal tumor (Fig. 50), and the abnormal size of a venous trunk distal to a thrombotic obstruction, are exam-

ples of the changes wrought by local obstructions to the venous circulation.

Engorgement of the jugular veins occurs as a physiologic respiratory phenomenon and as the result of pathologic interference with the venous return flow into the right auricle. The normal inspiratory acceleration and expiratory delay in the venous current can be demonstrated by inspection of the external jugular veins while the subject breathes forcibly and deeply, from the effects of which the jugulars become appreciably fuller during expiration, or the period of normal venous retardation. The vascular stress incident to chronic cough and dyspnea exaggerates this respiratory phenomenon and ultimately creates permanent distention of the jugulars, as in asthma,

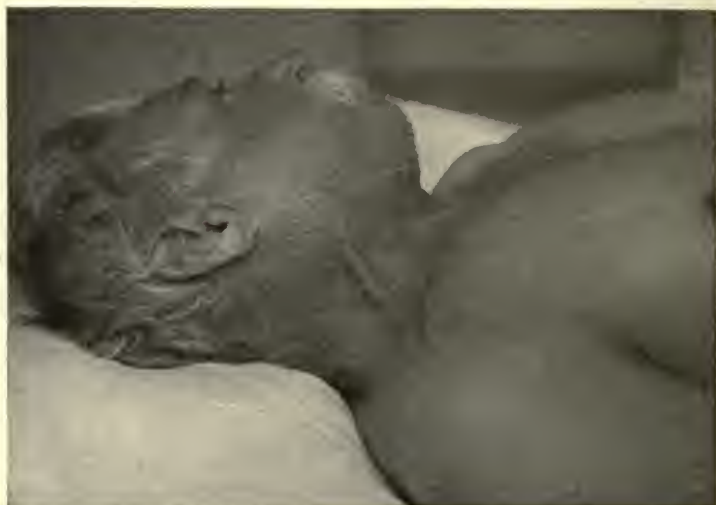

Fig. 127.—Jugular engorgement (Jefferson Hospital).

emphysema, and other chronic affections of the bronchopulmonary structures. Inspiratory overfulness of these veins—the reverse of their normal state—may accompany mediastinopericarditis and mediastinal tumor, indicating compression or traction of the intrathoracic venous trunks (*Kussmaul's sign*). Habitual jugular enlargement from lesions that obstruct the flow through the veins into the heart, suggests, if bilateral, cardiac dilatation or compression of the superior cava, the innominate or the jugular veins by aneurism or by mediastinal tumor; if unilateral, the sign points to compression of one innominate or jugular vein, as by a neoplasm or by an enlarged gland.

Enlargement and tortuosity of other superficial veins—notably, those of the upper thorax and the arms, the costal arch, and the upper part of the abdomen—have been specially dealt with elsewhere. (See pp. 105, 106.)

General venous engorgement, ultimately attended by edema of the congested parts, points to cardiac enfeeblement the precise character and degree of which are to be determined by examining the heart, especially the right side.

Thrills.—A thrill is the tactile equivalent of a murmur, and, like the latter, has a point of maximum intensity and a definite incidence in relation to the cardiac cycle. Thrills are excited by blood-eddies churned into vibrations by the same lesions that account for the production of murmurs, and are distinguished by the palpating hand as a fine or rough vibration, somewhat like the purr of a cat—hence the terms, “*frémissement cataire*” and “*Katzenschürren*.” In studying a thrill the palm of the hand or the finger-tips should be applied, with moderate pressure, to the surface of the chest, and the patient instructed not to breathe while the examiner times the occurrence of the sign, and notes its situation, extent, quality, and point of greatest intensity.

Thrills at the *base* of the heart may be symptomatic of aortic and pulmonary valvular defects, of aortic roughening, dilatation, and aneurism, and of Graves' disease. At the *second right intercostal space*, close to the sternal border, a systolic thrill, often carried upward into the carotids, is found in aortic stenosis and in roughened aorta; while if diastolic, and conducted down the sternum, a thrill in this site may denote aortic regurgitation. A systolic thrill in the *second left interspace* at the sternal edge occurs occasionally in pulmonary stenosis, and commonly in exophthalmic goiter; and a diastolic thrill in the same area may mean pulmonary regurgitation. Aneurismal thrills may be felt over the entire upper and middle precordia, and usually also in the arteries of the neck and in the episternal notch; in the latter depression the systolic thrill of a dilated aorta may also be perceptible.

Thrills at or near the *apex* of the heart are due generally to lesions of the mitral valves; less commonly they are transmitted from the base of the heart. If systolic, an apical thrill commonly indicates mitral regurgitation, or, very rarely, aortic stenosis; if presystolic, it is an almost certain sign of mitral stenosis, much less commonly being due to a Flint murmur of Corrigan's disease (*q. v.*); if diastolic, it may represent the conducted thrill of this last-named lesion.

Thrills over the *xiphoid and lower sternal region*, systolic in time, can be demonstrated in many cases of organic tricuspid regurgitation and of dilatation of the tricuspid orifice. Tricuspid stenosis sometimes accounts for a presystolic thrill in this situation.

Friction Fremitus.—Fremitus due to the rubbing together of roughened pericardial or pleural surfaces is perceptible as a delicate crackling or coarser creaking sensation, of a much more circumscribed and superficial character than that of a thrill.

Pericardial friction fremitus generally is distinguished by a to-and-fro rhythm, which, however, bears no definite relation to the heart-sounds; it is most distinctly felt, as a rule, between the second and fourth intercostal spaces, at and near the left sternal border; and it is exaggerated by pressure with the palpating finger and by making the patient bend forward. (See Fig. 159.)

Pleuropericardial friction gives rise to fremitus synchronous with the heart-sounds, being especially well related to the ventricular contractions; it is generally most distinct over the area corresponding to the tongue of lung overlapping the heart between the fourth and sixth ribs. According to the pleural reflection implicated, whether pulmonary or costal, pleuropericardial friction is palpable during either inspiration or expiration. (See Figs. 91 and 92.)

Tracheal Tugging.—Compression of the left bronchus by an aortic aneurism, and adhesions between an aneurismal sac and the trachea or bronchi, cause a slight descent of the windpipe with each pulsation of the aorta. This downward movement of the trachea is in turn transmitted to the larynx, the systolic depression of which is appreciated on palpation as a distinct tug synchronous with cardiac systole. Sometimes this indication of tracheal tugging (*Oliver's sign*) is visible, as well as palpable, and, exceptionally, it has a diastolic rhythm. The sign is elicited by supporting and elevating the cricoid cartilage with the thumb and forefinger, the patient meanwhile closing the mouth and raising the chin, so as to stretch the trachea and keep it tense. The tug can also be appreciated by grasping and elevating the body of the hyoid bone (M. L. Graves).

Tracheal tugging, though most suggestive of aneurism of the thoracic aorta, cannot be regarded as pathognomonic, inasmuch as it has been met with in simple dilatation of the aortic arch and in pulsating mediastinal sarcoma. Actual downward traction of the trachea is to be distinguished from a spurious tug due, for instance, to carotid, thyroid, or innominate pulsation.

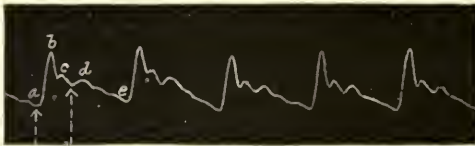The Arterial Pulse.—The pulse-beat corresponds to the wave of increased intra-arterial pressure excited by ventricular systole,

the tactile impressions thereby afforded being due to alteration in the shape and increase in the diameter of the artery's lumen. Of these changes the first, which alters the vessel's lumen from a flat to a circular shape, is the predominant factor of the pulse-beat, for the expansion of the artery is too insignificant to be appreciated by palpating a peripheral vessel, such as the radial artery.

The normal pulse beats at the rate of about 70 to 75 a minute in the adult male, being somewhat more frequent in women and much more so in children. The pulsations, which follow a rhythmic sequence, occur synchronously at both wrists, and are of well-sustained volume and moderate force. Save when the vessel is unusually large and superficial, its structure cannot be felt. A clinical analysis of the pulse requires minute attention to the following details: the condition of the arterial wall and the size of the vessel; the pulse-rate, rhythm, tension, and volume; and the bilateral symmetry of the pulses and their relation to cardiac systole.

Technic of Feeling the Pulse.—With the patient's forearm turned in partial supination and supported at the level of the heart, the first three fingers of the examiner's hand are pressed lightly against the radial artery at the wrist. The points to be investigated should be studied individually and with proper deliberation, for the feeling of the pulse is not merely a mechanical act, but one demanding both skill and experience linked with a keen appreciation of cardiovascular functions, normal and disordered, and the ability to correlate them with the tactile impressions perceived at the wrist. The condition of the *arterial wall* and the *size of the artery* are readily discovered by simple palpation and by "fingering" the vessel—which means gently sliding the pad of the finger across it transversely and along its course longitudinally, varying the pressure meanwhile so as to roll the artery against the bone. By these maneuvers, changes such as diminished elasticity, tortuosity, and mural irregularities, are made perfectly plain. The *pulse-rate* is ordinarily estimated by counting the number of beats felt during twenty seconds and multiplying them by three, but when the pulse is notably arrhythmic, slow, or fast, it is a better plan to count it for a full minute. Some clinicians calculate the rate of an excessively rapid pulse by indicating each beat by a lead-pencil dot, and subsequently counting the number of dots made during a stated period. A general idea of the *rhythm* of the pulse is gained at the time its rate is counted, and should irregularity be found, the type should be carefully identified by a further digital examination; supplemented, in suitable instances, by sphygmography. The *arterial tension* may be approximated by noting the pressure required to obliterate the pulse-beat, the

manner of obtaining this information consisting in gradually increasing the pressure of the proximal finger until the middle finger fails to feel pulsation, the distal finger meanwhile exerting firm pressure below, in order to block peripheral waves. The sphygmomanometer must, of course, be employed for accurate measurements of the blood-pressure. (See p. 31.) The *volume* of the pulse is judged by palpating with gentle pressure, at first uniform and then progressively increased, with a view to ascertaining the amount of distention that the artery undergoes with each systole of the ventricles. The *synchronism* and *comparative force* of the two radials are shown by bilateral palpation, while the relation of the pulses to cardiac systole is learned by simultaneous radial and precordial palpation.



Ventricular systole Aortic valve closure

Fig. 128.—Sphygmogram of the normal radial pulse: *a-b*, Upstroke; *b-e*, downstroke; *b*, apex; *c*, predicrotic (tidal) wave; *d*, dicrotic (recoil) wave. (Tracing by Dr. G. Bachmann.)

Clinical Significance of the Sphygmogram.—The following details of the *radial sphygmogram* serve as a basis for the interpretation of various changes produced by diseases of the cardiovascular system (Fig. 128; cf. Fig. 14). The special tracings, some of which have quite a distinctive relation to certain types of valvular disease and cardiac arrhythmia, are discussed in connection with these conditions in Section VI.

The Course of the Base Line.—The substitution of a wavy base line for one which runs a straight course is met with in conditions of dyspnea and subnormal blood-pressure, the undulations rising with expiration and falling with inspiration.

The Angle of the Apex.—A sharp apex with an unusually acute angle designates low arterial tension and a free peripheral blood-flow, while a blunt or rounded apex having an obtuse angle is a sign of high tension and obstruction to the peripheral circulation. The former accompanies the vigorous systoles and relaxed arterial tension of Corrigan's disease, and the latter is commonly due to arteriosclerosis, aortic stenosis, and aneurism. It is important also to remember that a blunt apex tracing is frequently the result of excessive tension of the sphygmograph spring or of a misfit between the metal pad of the instrument and the patient's artery.

The Spacing, Height, and Direction of the Upstroke.—Regular spacing of the upstrokes means rhythmic beating of the pulse, the rate of which may be determined either by counting the strokes of the stilet or by attaching a chronograph to the sphygmograph. Arrhythmia is shown by irregularity in the length of the upstroke intervals, which should be carefully measured with a pair of dividers in order to fix the degree and the type of the arrhythmia in the case in question. A spurious form of arrhythmia may be produced by some fault in the mechanism that drives the smoked paper slip, which if it travels too fast, imitates the closely spaced strokes of a rapid pulse, or which, if it moves too slowly, simulates the wide spacing of a slow beat.

The height of the upstroke is a rough index of the pulse volume, the stroke being either long or short according to whether the volume be ample or deficient. A perpendicular upstroke, the apex of which is very high above the base line, reflects vigorous contraction of the left ventricle. Decided obliquity of the upstroke suggests some impediment to the normally vigorous impact of the systolic blood-column, the slow distention of the arteries being referable to such factors as weakness of the left ventricle, high arterial tension, aortic stenosis, mitral insufficiency, or aneurism. In studying the upstroke it must always be remembered that this detail of the sphygmogram varies with the tension of the wrist-band and the spring of the instrument, as well as with the approximation, exact or imperfect, of the metal plate to the patient's artery.

The Strength of the Downstroke Waves.—A diminutive tidal wave indicates diminished force or volume of the arterial blood-flow, as, for example, in simple cardiac asthenia, in undue peripheral relaxation, and in regurgitant defects of the aortic and mitral valves. An exaggerated tidal wave, on the other hand, suggests high arterial tension, as in conditions attended by fibrosis and atheroma of the arteries. A feeble recoil wave occurs in high arterial tension, and the level of such a wave is abnormally high above the base line; in states of low tension this wave is comparatively well marked. Numerous oscillations and subsidiary downstroke waves are frequently observed on the tracing as a consequence of a high-tension pulse.

Changes in the Arterial Wall and Caliber.—The diminished resiliency of a sclerotic arterial wall conveys to the palpating finger a sense of increased resistance which becomes more and more striking as the fibrosis progresses, until finally the affected vessel is converted into a rigid, tortuous tube, either more or less symmetrically thickened or beaded with spots of local calcification. A sclerotic and a high-

tension vessel are distinguishable by suppressing the pulse-beat with the proximal and distal fingers, while the mural condition is examined with the middle finger. Since peripheral sclerosis does not necessarily imply similar implication of the deeper arteries,



Fig. 129.—Brachial arteriosclerosis. (Jefferson Hospital.)

such as the aorta and the coronaries, thickening of the radials alone does not warrant a diagnosis of general arteriosclerosis, to detect which all the accessible arteries, as well as the heart, should be examined.

Changes in the size of the vessel, due to increase in its caliber, are closely related to the volume of the pulse, to be referred to later, although personal peculiarities also account for variations in the size of the arteries, quite apart from cardiovascular influences.

Disturbances of the Pulse-rate.—Fundamentally, deviations from the normal pulse-rate are referable to defective function of the controlling nerves of the heart and to variations in arterial tension. Thus, the pulse beats with increased frequency if the sympathetic nerves of the cardiac ganglia are excited by stimulation, if the vagus loses its restraining influence through depression, or if the *vis a fronte* is lessened by subnormal arterial tension. On the contrary, the pulse-rate is slowed by depression of the sympathetic or of the ganglia, by stimulation of the vagus, and, usually, by the

increased effort of the heart provoked by high arterial tension.

Increase of the pulse-rate, giving rise to the *pulsus frequens*, is symptomatic of the abnormally rapid cardiac action known as *tachycardia* (Fig. 130, 1). Exceptionally there are persons who can voluntarily accelerate the pulse-rate, perhaps by a psychic influence upon the vagus and the accelerator nerves. Increased frequency of the pulse attends, with a certain parallelism, most febrile states, the pulse rising about eight beats above normal for each degree of fever, and in children attaining even a higher ratio. To this general rule there are numerous exceptions, notably yellow fever, tuberculous meningitis, pneumonia, and enteric fever, in all of which hyperpyrexia and a relatively slow pulse may coëxist. The same is often true of fevers complicated by uncompensated cardiovascular diseases. On the other hand, the pulse-rate is frequently found to be disproportionately high to the pyrexia in sepsis, phthisis, scarlatina, and acute miliary tuberculosis. Nervous disturbances commonly account for a rapid pulse, as in the neurasthenias, so-called irritable heart, nervous palpitation, paroxysmal tachycardia, and Graves' disease. Undue frequency of the pulse is also a familiar sign in locomotor ataxia, anterior poliomyelitis, acute ascending paralysis, cerebral concussion, vagus neuritis and compression, and sympathetic irritation. Pain, whatever its cause, generally accounts for tachycardia of more or less degree. Circulatory defects, due to valvular or mural lesions of the heart, to pericarditis, to cardiac displacement, and to the state of collapse, greatly disturb the pulse-rate, variously exciting increase or a diminution, as well as interfering with the normal rhythm. One looks for a quick pulse after hemorrhage, after aspiration of a large exudate, in the essential anemias, in Addison's disease, and in arthritis deformans. Other factors of abnormal pulse rapidity include the toxic effects of belladonna and aconite, and, in most persons, the immoderate use of alcohol, tea, coffee, and tobacco acts similarly, though in others just the opposite effect may be produced.

The *atropin reaction*, or an increase in the pulse-rate by the action of atropin on the vagus, is sometimes used by clinicians as a test of cardiac competency. If the integrity of the heart be unimpaired, the pulse-rate increases from 30 to 40 beats per minute within one-half hour after a hypodermic injection of from $\frac{1}{80}$ to $\frac{1}{25}$ grain of atropin, but in a subject of myocardial degeneration no such acceleration occurs. This test is used by Talley in cases of auricular fibrillation (*v. i.*) to determine whether vagal tone or cardiac muscle is the main factor, and he finds in such cases after full digitalization that atropin, after a preliminary period of slowing of the pulse,

subsequently accelerates it if the vagus be at fault, while a much less marked reaction is noted if the cardiac muscle be structurally diseased. A similar release of the vagal action has been observed in the slow pulse of meningitis (Roch and Cottin). Amyl nitrite, which has the advantage of instantaneous effect, has an action similar to that of atropin, and can be used as its substitute under identical conditions.

In judging a pulse-rate the accelerating influence of mental unrest, physical exertion, and the digestive period should be taken into account. It is not without interest also to remember that a normal pulse perceptibly quickens as the result of violent coughing, as well as after Valsava's experiment of forced expiration with the mouth and nose closed.

Auricular tachycardia is met with in auricular flutter, a condition in which the normal auricular contractions are replaced by




Fig. 129a.—Electrocardiogram of auricular flutter. (Tracing by Dr. E. B. Krumbhaar.)

abnormal impulses, of rapid rate and perfect rhythm, springing from auricular foci away from the sino-auricular node, and occurring at a rate of from 200 to 300 or more beats per minute. So accelerated are these new systoles of the auricles that true diastole of these chambers cannot take place, and ordinarily but a part of the contractions are shared by the ventricles, for many of the waves are blocked by the bundle of His. While the auricles beat at a 300-per-minute rate, the ventricles may beat but one-half or one-fourth as fast, though exceptionally a temporary (and dangerous) phase develops wherein the ventricular pulse equals the auricular rate. Chronic myocarditis, arteriosclerosis, and a history of rheumatism, syphilis, or gout are the common antecedents of this type of tachycardia, which is commoner in the aged than in the young. It is prone to persist for years, and, as Lewis points out, "a constant repetition of the same high pulse at intervals of weeks or months" strongly suggests the presence of such a lesion. In some cases the rapid auricular beats are clearly betrayed by jugular pulsations in the neck, and deep pressure in the carotid region, so as to irritate the vagus, causes an appreciable slowing and intermission of the arterial pulse. A full dose of digitalis acts similarly.

On the sphygmogram numerous *a*-waves of regular contour and

height fill the diastolic (*Vf*) period of the tracing, and the arterial waves vary in regularity and number, depending upon the integrity of the heart's conduction path. The electrocardiogram shows a multiplicity of small, sharp *P*-waves of undue rapidity

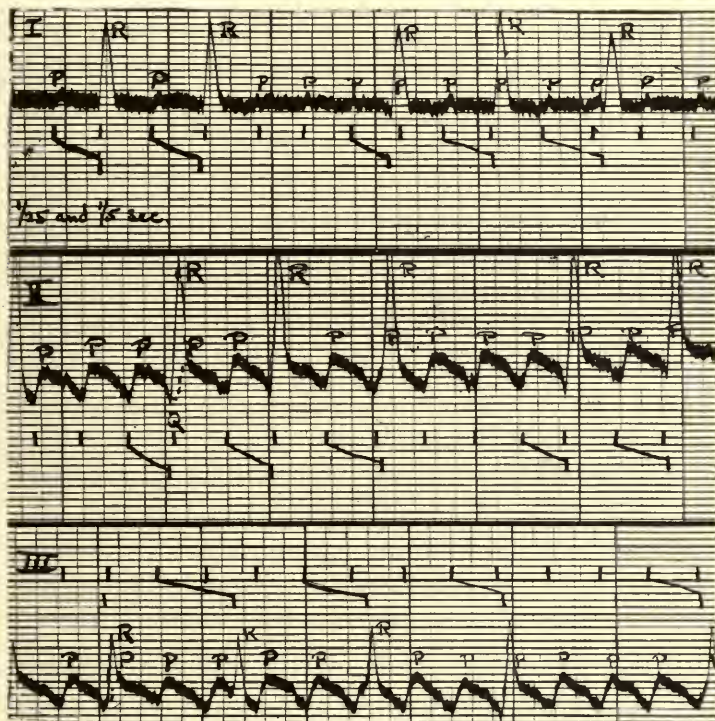


Fig. 129b.—Electrocardiogram showing leads I, II, III of auricular flutter with incomplete heart-block and extreme tachycardia. Note uniformity, definition, and incidence of *P*-waves, and irregularity and variable height of *R*-waves. Auricular rate 600, and ventricular rate 200, per minute. (Tracing by Dr. E. B. Krumbhaar.)

and striking regularity; or the oscillations immediately preceding the ventricular complex may be so rapid and delicate as to form merely a blurred streak before the *R*-waves (Fig. 129a). The latter are grouped irregularly, or are typical of an orderly incidence between every third or fourth auricular undulation, according to the degree of existing heart-block. The accompanying electrocardiogram (Fig. 129b) illustrates the irregularity of the waves in leads I, II, III in a case of auricular flutter with delayed and intermittent conduction of the impulses.

Paroxysmal tachycardia is a condition which arises in response to new and abnormal impulses originating in foci far removed from the sino-auricular node, whose action is overshadowed by that of the ectopic stimuli which excite a pulse-rate varying from 100 to 200 beats per minute, in paroxysms lasting from a few seconds to as long as many hours or even days. As a rule, this rapid rate is initiated in the auricle, less commonly in the ventricle, but in either event it remains rhythmic, despite variations in the force of the individual arterial pulse-beats. The paroxysms of tachycardia begin most abruptly and end with equal suddenness, and but immaterial acceleration of the pulse is provoked by physical exercise. Mental and physical stress, flatulence, and gastro-intestinal disorders usher in most attacks, and myocardial degeneration, coronary artery sclerosis, and mitral stenosis are familiar findings in those cases in which pathologic defects are found.

The arterial sphygmogram clearly indicates the onset of the paroxysm by a line of exceedingly rapid and small waves of equal height, often preceded by a few premature auricular systoles. The venous tracing shows corresponding rapidity, and may be either undisturbed or demonstrate obliteration of the *v*-waves by the *a*-waves. In the electrocardiogram there are numerous ventricular complexes which tend to encroach upon and even to obliterate the preceding *P*-waves, whose increased height and inversion are sometimes conspicuous.

Diminution of the pulse-rate, betrayed by the *pulsus rarus*, signifies an unduly slow cardiac action termed *bradycardia* (Fig. 130, II). In certain individuals this condition does not appear to be unnatural (Napoleon's pulse averaged but 40 beats per minute), and a pulse-rate of 50 or 60 a minute may exist habitually without being of itself incompatible with perfect health; any noteworthy diminution below these figures, particularly if it persists, calls for inquiry as to some pathologic factor. In studying the slow pulse it is essential to determine that the peripheral pulsations are a true index of the contractions of the heart: impairment of the cardiac power may be of such a character that only the alternate ventricular systoles are strong enough to produce a perceptible radial pulse, thus creating a fictitious *pulsus rarus*. An inordinately slow pulse is symptomatic of various disorders of the heart and blood-vessels, and of these factors it is well to remember fibroid and fatty heart, coronary artery sclerosis, general arterial sclerosis, aortic stenosis, and Stokes-Adams disease. Many nervous diseases are commonly attended by the *pulsus rarus*—meningitis, cerebral tumor and hemorrhage, depressed fracture of the skull, lesions of the

medulla and of the upper cord, epilepsy, mania, paresis, and myxedema. A slow pulse is generally found during the apneic period of Cheyne-Stokes respiration, in the postfebrile stages of many acute infections, in grave cachexias, in the toxemias of icterus, diabetes, uremia, ergotism and saturnism, and in poisoning by digitalis, strophanthus, convallaria, conium, and opium. Pain, which generally accelerates the pulse, and chronic indigestion, which acts similarly, may under certain circumstances considerably retard its frequency.

The combination of bradycardia, diminished pulse volume, and hypotension constitutes the *oculocardiac reflex* of Aschner, a phenomenon attributable to a true trigeminovagus reflex action. This trilogy of signs, notably the slowing of the pulse 8 to 10 beats a minute, occurs promptly in fully 70 per cent. of healthy subjects after firm compression of the eyeball with the pulp of the finger. The reaction is within normal limits in nervous bradycardia, in states of arterial hypertension, and in most cases of paroxysmal tachycardia, although Lian finds that it is sometimes possible to slow the heart in the last-named disorder by prolonged bilateral ocular pressure. The oculocardiac reflex is lost, as a rule, in tabes; and it is conspicuous in Graves' disease, in epilepsy, in gastrointestinal neuroses, and in various toxemias, notably in nicotine-poisoning. An "inverted" reflex, distinguished by an acceleration of the pulse after ocular compression, has been observed in incipient cases of exophthalmic goiter and in many emotional states.

Irregularity and Intermission.—The radial pulsations, which normally take place at regular intervals coincident with ventricular systole, are subject to various disturbances of rhythm consisting of irregularities and intermissions, conforming in certain instances to well-defined types. On the other hand, there are also pulse irregularities that lack definite sequence in their series of beats, and in which the tempo is much disordered, the individual beats being separated by a confusion of long and short intervals. Pulse irregularity indicates some impairment, either functional or structural, of the cardiac force, whereby its contractions deviate from their normal periodicity and generally also fail in power, the irregularities of time being attended by inequalities in the volume and power of the separate beats. As already intimated in a preceding paragraph, an intermittent pulse is not an infallible sign of an intermittent heart, since the systoles, though rhythmic, may not all produce an appreciable pulse at the wrist. The *pulsus intermittens*, a general term for intermissions of the peripheral pulse, must always be distinguished, by auscultation of the

heart, from the *pulsus deficiens*, in which the intermission depends upon actual failure of the heart to contract. An *allorhythmic* pulse is distinguished by rhythmic irregularities, or those in which the disordered pulse rhythm is definitely systematic and periodic (*pulsus inequalis periodicus*). To this type belong the bigeminal pulse (*pulsus bigeminus*), distinguished by two beats and a pause, and the trigeminal pulse (*pulsus trigeminus*), consisting of three beats and a pause, recurring in orderly succession, these peculiar allorhythmias being most commonly found in mitral disease, especially after full doses of digitalis or one of its congeners (Fig. 130, IV, V). The interruption of a rhythmic sequence of beats by a minor beat distinguishes the *pulsus intercidens*. In the alternating pulse (*pulsus alternans*) there is a series of strong and feeble beats alternating in regular succession. This type of pulse is most often found in the aged, and is a grave sign, in that it indicates a progressive exhaustion of the cardiac muscle, attending lesions such as arteriosclerosis, myocardial fibrosis, angina pectoris, and chronic nephritis. The use of the sphygmomanometer in clearly identifying the alternating pulse has been referred to elsewhere. (See p. 33.)

The paradoxical pulse of Kussmaul (*pulsus paradoxus*), characterized by bilateral enfeeblement or disappearance of the radial pulse during inspiration, is not distinctive of any special condition, though it is not uncommonly demonstrable in adhesive pericarditis, pericardial effusion, mediastinal inflammation and tumor, and extreme cardiac asthenia. Sometimes Kussmaul's pulse may be closely imitated at will simply by holding the breath after having taken a deep inspiration. Inspiratory disappearance of one radial pulse has been noted in adhesion of the subclavian artery to the pleura.

In seeking for a cause of an irregular pulse, it should be remembered that this peculiarity may be of no consequence whatever, especially when it appears temporarily. It is frequently traceable to emotional disturbances, physical strain, neurasthenia, indigestion, constipation, and the misuse of tobacco, tea, and coffee. Old people and young children sometimes have a persistently irregular pulse, with nothing tangible to account for it. But it is another story when, aside from these influences, the subject's arrhythmia is constant and associated with subjective symptoms and with signs of cardiac disturbance, under which circumstances one naturally investigates first the cardiovascular and then the nervous systems. These sources of an irregular pulse are referred to under Cardiac Arrhythmia. (See p. 363.)

Variations in the Tension, Volume, and Velocity of the Pulse.

—*Tension*.—The *tension of the pulse-wave* is regulated by the force

and rate of the ventricular systole and the volume of blood thereby propelled, by the degree of peripheral resistance, and by the elasticity of the arteries. Thus, a powerful, rapid heart and a well-contracted set of peripheral vessels together make for inordinately high tension—*hypertension*; while a feeble, slow heart and a toneless, relaxed vasomotor system give subnormal tension—*hypotension*. In most instances these factors are not so well balanced as in the academic illustrations just drawn, for, owing to their unequal action, the effects of certain factors tend to be neutralized by the influences of others—normal arterial tension may be preserved even in collapse, should the hypotension of the vasomotor depression be negated by the recuperative overaction of the heart. Usage establishes the terms *pulsus durus* and *pulsus mollis*, the former designating the

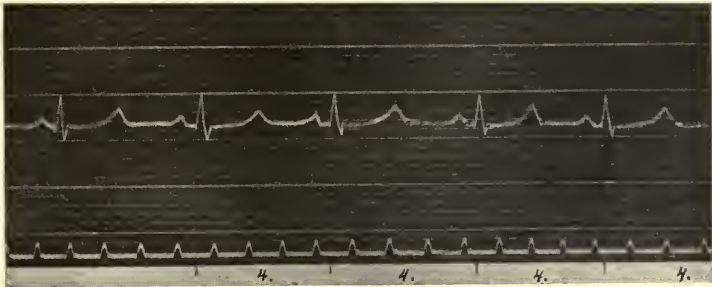
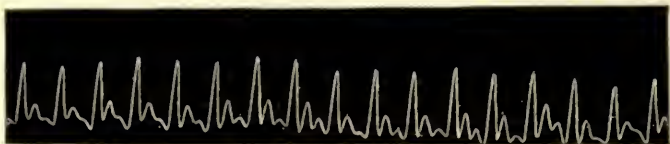


Fig. 129c.—Electrocardiogram of a case of arterial hypertension, showing the large T-wave of vigorous ventricular contraction. (Tracing by Dr. T. A. Cope.)

tense, hard, non-compressible pulse of hypertension, and the latter denoting the relaxed, soft, readily compressible pulse of hypotension (Fig. 130, VI, VII). Of the latter, two special types have been described: the extraordinarily soft and empty *gaseous pulse*, and *Mounerel's pulse*, soft, slow, full, and quite distinctive of the toxemia of icterus.


Clinically, it is desirable to estimate the maximum or systolic, the minimum or diastolic, and their difference or the pulse, pressures, data accurately obtainable only by using a sphygmomanometer. (See p. 31.) Only roughly is it possible to gage arterial tension by ordinary digital examination, though some general idea, later to be elaborated instrumentally, may be gained by compressing the radial artery in the manner described above, and by noting both the force of the pulse and the fulness of the vessel between the beats. Thus, with three fingers laid upon this vessel, the degree of pressure exerted by the proximal finger to obliterate the pulse approximates the




I. Pulsus frequens.




II. Pulsus rarus.




III. Pulsus inequalis.



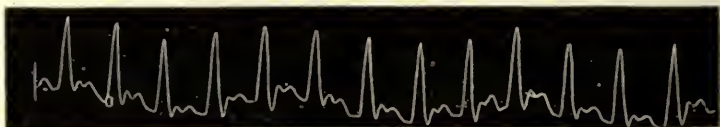
IV. Pulsus bigeminus.




V. Pulsus trigeminus.



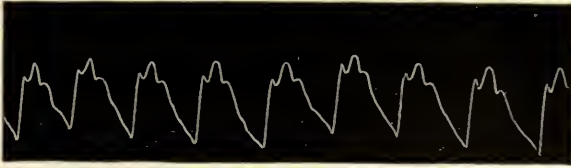
VI. Pulsus durus.



VII. Pulsus mollis.




VIII. Pulsus dicroticus.



- IX. Pulsus anacroticus.



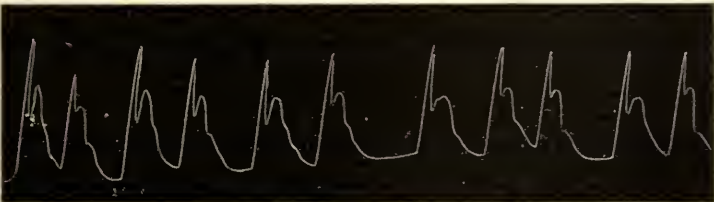
X. Pulsus bisferiens.



XI. Pulsus magnus.



XII. Pulsus parvus.



XIII. Pulsus celer.



XIV. Pulsus tardus.

Fig. 130.—Sphygmograms of pathologic types of the arterial pulse. (Tracings by Dr. G. Bachmann.)

systolic pressure, provided that the pulse under examination is not of too full a volume. Using the same technic, the diastolic pressure is suggested by estimating the force necessary to bring out the greatest impact of the pulse-beats, which, as the pressure of the fingers increases, gradually becomes stronger and stronger, attains an acme, and then diminishes. It is also worthy of note that a radial artery palpable between pulse-beats suggests hypertension, and that one which is indistinguishable indicates hypotension, the influence of fibrocalcareous changes being, of course, excluded.

In a pulse of low tension and usually of full volume the dicrotic or recoil wave is frequently appreciable, by gentle palpation, as a secondary impact immediately following the principal beat. This exaggeration of the normal dicrotic wave (*pulsus dicroticus*) is well shown in febrile states and exhaustion attended by extreme arterio-capillary dilatation, in uncompensated mitral regurgitation which restricts the ventricular output of blood, and in posthemorrhagic anemia severe enough to diminish the volume of arterial blood (Fig. 130, VIII). The pulse is described as *hyperdicrotic* when the dicrotic wave of the sphygmogram falls below the base of the systolic upstroke, and a pulse of this sort suggests very low tension and increased cardiac rate and force.

Occasionally, as the result of hypertension and tardy filling of the aorta (as in extreme aortic stenosis), the predicrotic or tidal wave is palpable just after the systolic beat (*pulsus bisferiens*). That this predicrotic impact is associated with high tension and is most distinctly developed by firm pressure upon the artery serves to distinguish it from the dicrotic wave, which accompanies low tension and is detected only by gentle or moderate pressure. A tracing of the *pulsus bisferiens* shows a double apex composed of upstroke and tidal wave, the latter sometimes being the more conspicuous (Fig. 130, X).

Another variety of high-tension pulse, also met with in aortic stenosis, is characterized by a notched upstroke or anacrotic limb, and hence is known as the *pulsus anacroticus* (Fig. 130, IX). The upstroke interruption of this type of pulse means, according to Mackenzie, "that the lever of the sphygmograph has been raised in the first instance slightly quicker than the following current of blood, and as the distending wave increases, the returning lever is caught and carried along to the summit." The anacrotic pulse, then, reflects augmented contractile power at the end of systole, and does not indicate a real interruption of the ventricular contraction.

In general, *hypertension* accompanies diffuse arterial sclerosis,

cardiac hypertrophy, angina pectoris, apoplexy, uremia, nephritis, and adequately compensated aortic regurgitation. *Hypotension* is to be expected as the effect of shock and collapse, extensive frank or concealed hemorrhage, acute febrile diseases, exhausting cachexias and anemia, primary myocarditis, cardiac dilatation, and valvular lesions, such as extreme aortic stenosis and mitral leakage, which diminish the ventricular output of blood with systole.

Volume.—The *volume of the pulse*, or the extent of the arterial expansion produced by the pulse-wave, varies with the size of the vessel's caliber and with the volume and force of the systolic blood-column. The more yielding the walls of the artery under the influence of the systolic blood-wave, the greater the volume of the pulse, of which the chief determining factors are, apart from the size and force of the systolic wave, the degree of intra-arterial pressure and the inherent tension of the arterial walls. In general terms, then, it follows that with an equal systolic output of blood, peripheral dilatation and hypotension increase, and that peripheral constriction and hypertension diminish, the volume, or size, or amplitude of the pulse. In health, aside from the physiologic exaggeration during inspiration, the individual pulse-beats are of equal volume (*pulsus equalis*), and, unless modified by anatomic peculiarities, there is also a similar bilateral symmetry. Inequalities of volume (*pulsus inequalis*) are generally associated with irregularities of rhythm and rate, the causes of which have been dealt with sufficiently in a foregoing paragraph (Fig. 130, III).

Increase of the pulse volume (pulsus magnus) commonly attends conditions provocative of subnormal arterial tension, and is recognized by the palpating finger as an unnatural expansion of the vessel at the time of the pulse-beat (Fig. 130, XI). Jerkily arrhythmic pulsations of undue volume are sometimes spoken of as the "caprizant" or "goat-leap" pulse. The full, bounding pulse of fevers, the large pulse of cardiac overaction or hypertrophy, and the momentarily voluminous pulse of aortic valve leakage typify the *pulsus magnus*. Overfulness of the artery during the interval between pulsations (*pulsus plenus*) indicates a large volume of blood within the vessel, irrespective of its size—a small, tense, contracted artery may be just as full, relatively, as one which is large, soft, and relaxed.

Diminution of the pulse volume (pulsus parvus) is attended by but slight stretching of the vessel-wall during the beat, and is not infrequently combined with arrhythmia and with increased arterial tension (Fig. 130, XII). A small pulse may depend upon deficient cardiac

force, or upon lesions that diminish the volume of blood in the peripheral vessels. The former accounts for the subnormal pulse volume in collapse, in conditions attended by malnutrition and exhaustion, and in the various functional and structural weaknesses of the heart; the latter explain the small pulse in stenoses of the aortic and mitral orifices, in aneurism, and in certain cases of profound anemia, the arterial blood-column being obstructed in the first instance, diverted in the second, and actually reduced in bulk in the last. The *arachnoid pulse*, small, thread-like, and running, is a good example of the excessive diminution of pulse volume symptomatic of extreme circulatory depression. A pulse whose volume and force gradually taper off has been described as the *decurtate* or *mouse-tail pulse*. Emptiness or collapse of the artery between beats is indicated by diminished amplitude of the pulse during such intervals (*pulsus vacuus*), and is dependent upon grave cardiac enfeeblement, or inadequate ventricular filling in mitral leakage, or an unsustained arterial blood-column due to aortic insufficiency.

Velocity.—The rapidity with which the individual waves rise and fall is referred to as the *velocity* or *celerity* of the pulse. A quick pulse (*pulsus celer*), or one whose undulations are abrupt, gives rise to a series of sharp tapping beats, which, irrespective of their volume, quickly recede from the palpating finger. Subnormal arterial tension is suggested by this type of pulse, the steep, high strokes of which are clearly shown by the sphygmographic tracing (Fig. 130, XIII). The trained observer has little difficulty in recognizing the *pulsus celer* without instrumental aid, if care be taken to differentiate the sharp bounding pulse of increased volume: the two may resemble each other in so far as the rise of the wave is concerned, but in the latter the pulse-wave, though sharp, lacks a rapid descent and is fairly well sustained. The *pulsus celer* may be symptomatic of arteriocardial relaxation, incident, for example, to fever, collapse, debility, and anemia, but its acme is attained in the *pulsus celerrimus* of Corrigan's disease, in which left ventricular hypertrophy, relaxed peripheral vessels, and a leaky aortic orifice combine to create a poorly sustained pulse-wave of extraordinary velocity and volume. A tardy pulse (*pulsus tardus*) rises and falls slowly and is well sustained, independently of the frequency of its beats. The impact of this pulse, which is to be expected when the arterial tension is high, conveys to the palpating finger the sensation of a slowly rising wave of rather prolonged duration and deliberate fall, which peculiarities are traced by the sphygmograph as a curve of moderate amplitude, oblique upstroke, rounded apex, and gently declining downstroke,

marked by feeble secondary oscillations (Fig. 130, XIV). Pure aortic stenosis is the factor of the most typical examples of the *pulsus tardus*, owing to the slow ventricular contractions and delayed passage of the blood-stream through the narrow aortic orifice. Arteriosclerosis, hindering the prompt rise and fall of the pulse-waves, is also an important cause of this type of pulse.

Asymmetry of the Pulses.—Conditions that impede the normal passage of arterial blood-waves from the left ventricle to the periphery disturb the bilateral symmetry of the pulse-rate and volume, by retarding and diminishing the waves beyond, and on the same side as, the lesion, which in the extreme instance may produce so decided an obstruction to the blood-current as practically to extinguish the pulse in the distal arteries of the surface. Inequalities of the pulses from such causes must be carefully distinguished from those due merely to abnormal distribution of the vessel or vessels under examination; and it is also to be recalled that the left radial pulse is generally stronger in right-handed individuals and in the ambidextrous.

Taking as criteria the radial arteries, delay and enfeeblement of one pulse at the wrist suggest aneurism, of the ascending aortic arch or of the innominate artery if the right pulse be modified, and of the transverse arch (to the left of the innominate's origin) or of the descending portion if the left pulse be altered. Aneurismal dilatation of the subclavian, axillary, or brachial arteries are also to be regarded as a possible, though rare, cause of suppressed peripheral pulsations on the same side, and a like asymmetry is referable to arterial obstruction by embolism or thrombosis, as well as to the pressure of cicatrices, faultily knit fractures, tumors, and intrathoracic effusion of fluid and of air. Retardation of both carotid pulses in comparison with the apex-beat is found in aneurism of the ascending aorta, while the right carotid beats later than the heart in aneurism of the innominate artery. Suppression of both femoral pulses may mean either aneurism of the abdominal aorta or, most exceptionally, congenital obliteration of this vessel; inequality in the force of the femorals suggests obstruction, as by thrombosis or tumor, of the feebly beating vessel; and delay of the femoral pulse, compared with the radial, suggests aortic aneurism below the arch.

The Capillary Pulse.—The *capillary pulse* of Quincke, which indicates transmission of the individual pulse-waves to the capillaries, is recognized as a systolic flushing and diastolic pallor of some peripheral part, such as beneath the finger-nail—hence the expression, *pulsus subungualis*. To show it in this situation the nail should be blanched by slight pressure on its tip, whereupon systolic

reddening of the pale subungual area is readily perceptible. The same thing can be seen upon the mucous membrane of the lower lip when it is everted and pressed upon with a glass slide, and along a line of hyperemia rubbed upon the forehead with some blunt instrument, such as the cap of a fountain-pen. If the ophthalmoscope be used, one can also observe a capillary pulsation of the retinal arteries.

Ordinarily, no pulse is visible in the capillaries, through which the blood trickles in a waveless stream, but under circumstances that increase cardiac force, diminish capillary resistance, and retard venous return flow, the pulsations of the heart permeate as far as the small arteries of the periphery and distend them with each systole. Essentially, the capillary pulse is the product of the *pulsus celer* and is associated with conditions of subnormal arterial tension. It is a valuable sign of aortic regurgitation, though it is not constant in this lesion, nor pathognomonic, since a capillary pulse is demonstrable in many conditions underlying the *pulsus celer*, *i. e.*, fever and anemia, and, moreover, it is occasionally noted in a presumably healthy person.

The Venous Pulse.—Ordinarily, the auricular contractions driving the blood-stream into the ventricles fail to create any appreciable backward wave within the *venæ cavæ* and pulmonary veins, since at this period of the cardiac cycle the auricular outlets of these vessels are so tightly contracted that a reflux cannot take place. When, however, the veins are unduly distended and their cardiac orifices correspondingly dilated, the contractions of the heart propel blood-waves not alone forward into the arteries, but also backward into the great venous trunks, the superior caval impulses being propagated into the veins of the neck, especially on the right side, which show pulsatile movements, either presystolic or systolic in time, according to the mechanism at work, as will be explained presently. Occasionally the backward waves are blocked by the valves just distal to the jugular bulb, and in this event a "bulbous pulse" is observed at the root of the neck, above the sternoclavicular articulation. But usually these valves leak, so that there is visible pulsation of the jugular veins, more prone to occur in the internal jugular than in the external, though the latter's pulsations are more readily detected, owing to its superficial situation. The venous pulse thus produced serves as a definite index to the action of the right auricle and ventricle.

The venous pulse should be studied while the patient is in recumbency, with the object of ascertaining its precise site, extent, and time relation to the events of the cardiac cycle. Pulsation of the internal jugular vein may be very similar to that of the carotid artery, but the jugular pulse-wave rises gradually and falls very suddenly,

frequently causing momentary recession of the overlying tissues at the site of the pulsation, while the carotid wave rises abruptly and forcibly but falls slowly and deliberately, and, moreover, is attended by unnatural arterial throbbing remote from the cervical region. A true venous pulsation travels upward from the root of the neck and produces distention and rhythmic throbbing of the vein, after it has been emptied from below upward by the finger, but if the pulsation be transmitted from the carotid artery, pressure over the vein distends it and exaggerates the pulsation above the point of constrict-

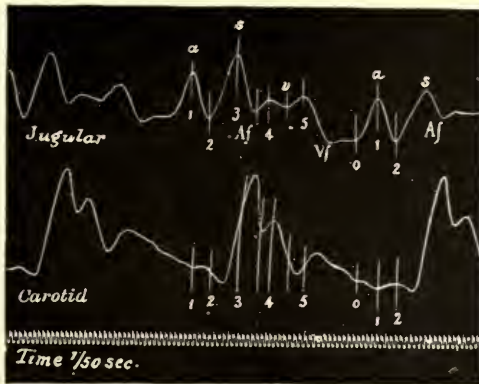


Fig. 131.—Sphygmogram of the normal venous and arterial pulses. (Tracing by Dr. G. Bachmann.)

tion below which the vessel collapses and becomes pulseless. These visual signs of the venous pulse, though suggestive, should be confirmed by means of a graphic tracing, in order to fix the exact time of the movements with relation to those of the heart, and by instrumental aid of this sort it is possible to determine these essential details, and to recognize two distinct types of the venous pulse, the *auricular* and the *ventricular*, which differ very materially, from a diagnostic and prognostic viewpoint.

The *auricular* or *presystolic venous pulse* is due to the contraction of the right auricle, and represents a physiologic or negative type of pulsation, for it may occur in the healthy subject in consequence of temporary venous distention, induced, for example, by prolonged holding of the breath. The sphygmogram of this type of pulse (Fig. 132) is distinguished by a succession of inordinately high auricular waves (*a*), timed well in advance of the carotid impulse, as shown by the lower tracing, made simultaneously with that of the jugular movements. The systolic wave (*s*), following the closure of

the tricuspid valve (3-4) is of comparatively moderate amplitude, and, after the period of auricular filling (*Af*), is succeeded by a single-peaked ventricular wave (*v*), after which the ventricular filling (*Vf*) commences, completing the diastolic phase. Comparing this sphygmogram with that of the ordinary jugular pulsations (Fig. 131; cf. Fig. 14), it is apparent that the chief characteristics of the auricular venous pulse are an exaggerated *a*-wave, a moderate *s*-wave, and a *v*-wave of pyramidal outline rather than doubly undulated. Clinically, this type of pulse means adequate nutrition, contractility, and force of the right auricle.

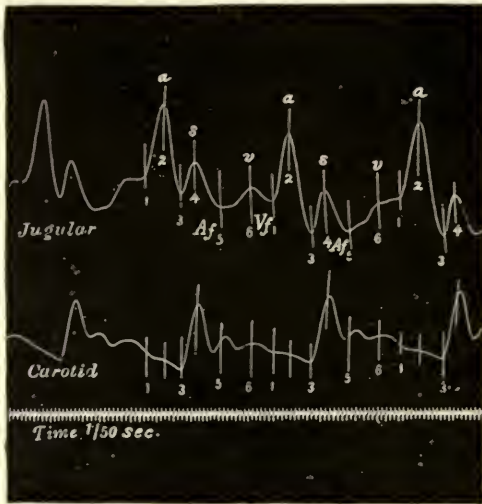


Fig. 132.—Sphygmogram of the auricular or presystolic type of venous pulse. (Tracing by Dr. G. Bachmann.)

The *ventricular* or *systolic venous pulse* is produced by the contraction of the right ventricle, and typifies the variety of pulsation sometimes described as pathologic or positive. It may indicate tricuspid leakage, whereby with each ventricular contraction a reflux blood-column is propelled back into the right auricle and thence into the venous tributaries of this chamber; or it may be due not so much to actual tricuspid leakage as to instant filling of the auricle, because of excessive intravenous pressure. The appearance of such a pulse suggests auricular enfeeblement, with comparatively well-sustained ventricular power, which, despite the coexistence of dilatation sufficient primarily to set up tricuspid regurgitation, is still strong enough to drive backward a forceful

reflux wave. The sphygmogram of the ventricular venous pulse (Fig. 133) shows an unnaturally high and blunt ventricular wave (*v*) synchronous with the midphase or late phase of systole, as indicated by the comparable carotid tracing. *Pari passu* with progressive enfeeblement of the right auricle, this *v*-wave becomes more and more conspicuous, encroaches upon the gradually diminishing curves of the *a*-wave, and finally replaces them completely. Thus, a prominent ventricular wave indicates not only tricuspid leakage and auricular hypertension, but also compensatory hypertrophy

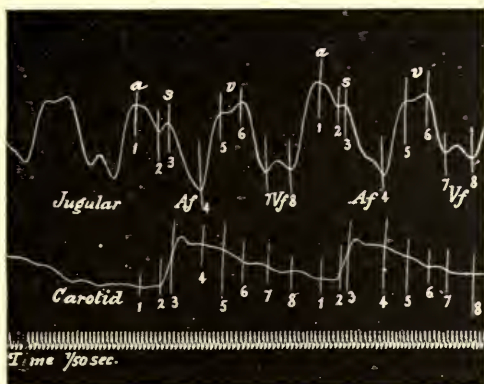


Fig. 133.—Sphygmogram of the ventricular or systolic type of venous pulse. (Tracing by Dr. G. Bachmann.)

of the right ventricle, and, therefore, it may be considered a good index of the nutrition and the pumping power of the ventricle. With a loss of this efficiency, the *v*-wave correspondingly diminishes, and, should advanced myocardial degeneration exist, this undulation does not appear on the tracing.

The Penetrating Venous Pulse.—A *penetrating* or *centripetal venous pulse* is sometimes demonstrable in the small veins of the extremities under conditions that allow the transmission of the arterial pulse to the venules. This type of pulse occurs most frequently, if not solely, in connection with Quincke's capillary pulse, of which it is merely an exaggeration, since the venous pulse depends upon a systolic arterial impact of sufficient force not only to jog the blood-columns within the capillaries, but also to penetrate the diminutive veins beyond them. Obviously, the penetrating venous pulse is a product of the *pulsus celer*, and hence it is to be looked for chiefly as a sign of aortic leakage, and also in states of extreme vascular relaxation (*v. s.*).

PERCUSSION

The beginner will be likely to regard cardiac percussion as a somewhat bewildering procedure, and even the experienced clinician cannot always rely upon its findings as incontestable. A cultivated ear, a sensitive pleximeter finger, and the strict adherence to a routine technic are essential for the best results, however experienced the examiner may be. Presupposing these preliminaries, it is possible, by percussion of the precordial region, to determine the situation, the size, and the shape of the heart; to detect the presence of an effusion within the pericardial sac; and to fix the position of the left anterior pulmonary border.

The Areas of Cardiac Flatness and Dulness.—Normally, two precordial regions, affording respectively flatness and dulness, can be distinguished by careful percussion of the heart: an inner area of flatness, over that part of the heart within the cardiac incisura of the left lung and lying directly against the chest-wall, without the interposition of pulmonary tissue; and an outer area of dulness, overlying that part of the heart separated from the chest-wall by the intervening pulmonary borders (Fig. 134). Of these two regions, which together compose the total precordial area, the inner is ordinarily designated as the area of absolute or superficial dulness, and the outer as that of relative or deep dulness, than which terms the words flatness and dulness seem clearer and more definite acoustically. The anatomic relations of these two zones are shown by Fig. 135.

The *area of cardiac flatness* is a triangular space overlying the right ventricle, and affording, on *gentle* percussion, flatness or absolute dulness, with decided resistance to the pleximeter finger. The right border (perpendicular) of this triangle follows the left sternal border from the fourth to the sixth costal cartilage; the left border (hypotenuse) extends from the fourth left chondrosternal articulation to the junction of the left parasternal line and the upper border of the sixth rib (about $\frac{1}{2}$ inch, or 1.25 cm. within the apex); and the lower border (base) runs from this point somewhat obliquely upward to join the lowest extremity of the right border, at the sixth chondrosternal junction. The base of the triangular flatness, inasmuch as it blends with hepatic flatness, cannot be mapped out by ordinary finger percussion. The principal object of mapping out the area of cardiac flatness is to decide if the left lung be either cirrhotic or emphysematous, since pulmonary retraction extends, and pulmonary overdistention restricts, this inner cardiac zone, while its extent is

not necessarily altered by changes in the size, position, and shape of the heart.

The *area of cardiac dulness*, surrounding the triangle of flatness, approximately corresponds to the anterior aspect of the heart, being the surface outline chiefly of the right ventricle, and, to a minor extent, of the right auricle and left ventricle. Over this area *strong* percussion affords dulness blended with pulmonary resonance, and attended by a correspondingly modified sense of resistance. From the cardiac base line (upper border of third rib) the outer dulness of the heart

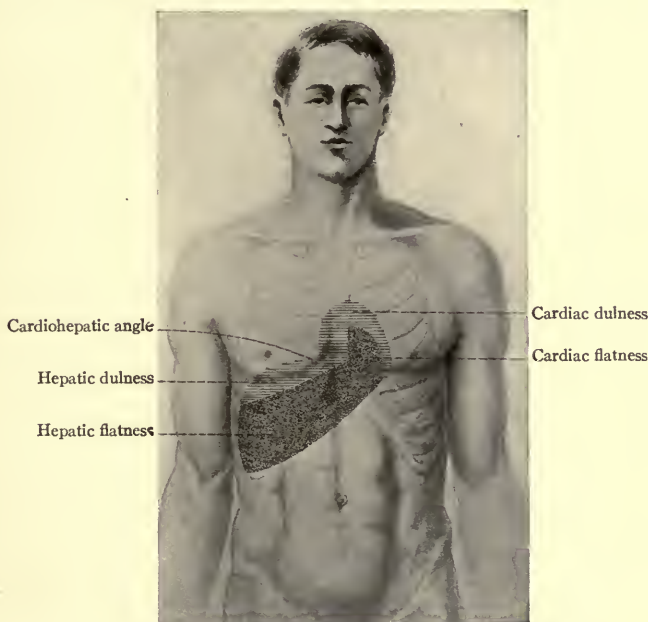


Fig. 134.—Percussion areas of cardiac flatness and dulness.

extends vertically along the right sternal border¹ to the sixth costal cartilage, whence it follows the lower border of the heart to the apex, and then curves upward, with an external convexity, to join the base line at the left sternal border. The area thus mapped out extends roughly $\frac{3}{4}$ inch (1.9 cm.) beyond the triangle of cardiac flatness, except at the lower border, where both have the same limit; it is impracticable to try to delimit the upper border from the area of

¹“In many cases the whole extent of the sternum furnishes such a loud tone that the deep cardiac dulness is really limited by the left sternal border” (Sahli).

vascular dullness. The junction of the horizontal limit of hepatic dullness with the right lateral line of cardiac dullness forms an approximate right angle of resonance in the fifth right intercostal space, close to the sternal border—the *cardiohepatic angle* of Ebstein.

Postural influences account for alterations in the extent of the lateral cardiac borders, the right border, when the subject changes from recumbency to the erect posture, shifting outward about half an inch (1.25 cm.), while the left border extends similarly for half this distance. It is obvious that these postural differences, relating to the normal heart, are greatly exaggerated when dealing with an enlarged heart.

The *area of vascular dullness*, overlying chiefly the aorta and the superior cava, extends between the sternal margins from the cardiac base line to the lower borders of the first costal cartilages. Normally, this area affords, on *moderately strong* percussion, impaired ostal resonance that shades off almost imperceptibly as Louis' angle is approached. Extension of the vascular area, especially upward and toward the right, with or without definite flatness over

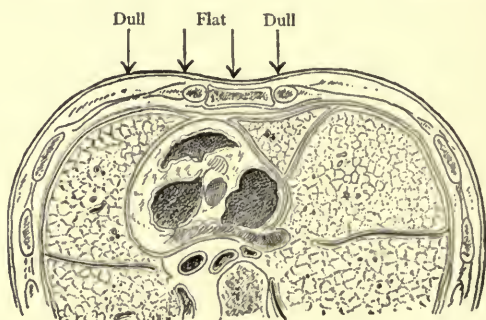


Fig. 135.—Transverse section of the thorax, illustrating the anatomic relations of the areas of cardiac dullness and flatness.

the sternum, is one of the earliest and most valuable signs of aneurism of the aortic arch and of extensive dilatation of this vessel.

Methods and Technic.—With the patient either semirecumbent or lying flat on the back, the examiner percusses from frank pulmonary resonance toward the precordia, carefully noting the tonal modifications and changes in resistance that occur when the outer and inner cardiac zones come within the percussion sphere. For clinical purposes it is generally sufficient to outline the upper level of the heart at the left of the sternum, and to mark its two lateral limits on either side of this bone. This is usually done by ordinary

finger percussion, though auscultatory percussion perhaps gives more dependable results and sometimes enables one to determine the upper (cardiovascular) and the lower (cardiohepatic) levels. Advocates of instrumental percussion claim that with an ivory or a vulcanite pleximeter all the cardiac boundaries can be accurately mapped out.

In outlining *cardiac dulness* percussion is carried downward from the left infraclavicular region along the sternal and parasternal lines, to fix the upper border; horizontally inward from the left axilla along the third, fourth, and fifth interspaces, to designate the left border; and, finally, from a resonant point in the right mammary region inward along the third, fourth, and fifth interspaces, to indicate the right border. The points along these percussion lines corresponding to the dulling of pulmonary resonance are then joined by a continuous line, to represent the total outer dulness of the heart, the upper sternal base line and the lower border being connected arbitrarily.

In mapping out the area of *cardiac flatness* the percussion strokes are directed from above downward midway between the sternal and parasternal lines; inward on the right side, at the levels of the fourth and fifth costal cartilages; and inward on the left side along the fourth and fifth interspaces. Proceeding in this manner, the percussion sound successively affords resonance, dulness, and flatness as the lungs, the lung-covered heart, and the exposed heart are traversed, in the order given.

The foregoing technic, which meets all ordinary demands, will reveal any undue extension of the lateral and lower left borders of the heart, indicative of this organ's enlargement. The accurate delimitation of the outline of a normal-sized heart is next to a physical impossibility—aside from the "personal equation," the continual movements of the heart and the depth of its outer margin, the individual differences in the thickness of the pulmonary borders, and the sonorous vibrations of the sternum make the attempt futile, in so far as the exact correspondence of the percussion outline to fixed anatomic landmarks is concerned. The same comment applies to percussion of the vascular area, the extension of which is betrayed chiefly by unnatural parasternal dulness. The diagram on the opposite page (Fig. 135) shows the anatomic difficulties that beset precise delimitation of the cardiovascular regions.

Increased Cardiac Dulness.—Extension of the area of cardiac dulness depends upon both intrinsic and extrinsic factors, the former relating to changes in the heart itself and in the pericardium, and

the latter to traction and pressure exerted upon the heart by adjacent structures.

A *general increase* in the area of cardiac dulness, particularly of the transverse diameter, is encountered in bilateral ventricular hypertrophy and dilatation, and a similar change is sometimes noted in moderate-sized pericardial effusion. Increased flatness, forming a roughly *pyramidal or pear-shaped* figure, is symptomatic of an extensive effusion into the pericardium; the apex of such a flat pyramid points upward, perhaps as high as the second interspace; the borders are sharply defined from the surrounding lung resonance; the boundaries usually extend laterally when the patient leans forward; and the cardiac apex is partly or completely obliterated. Extension of the *normal area* of the heart, without actual enlargement, may be due to cirrhotic shrinkage of the left lung, or to a neoplasm or an aneurism crowding the heart forward against the chest-wall.

Increase of cardiac dulness *to the right* is suggestive of hypertrophy and dilatation of the right heart, less commonly of moderate pericardial effusion, or of a greatly distended inferior vena cava. Such conditions dull the normal pulmonary resonance of Ebstein's cardiohepatic angle in the fifth right interspace at the sternal edge.

Increase of cardiac dulness *to the left and downward* is characteristic of left ventricular hypertrophy and dilatation, a lesion which also displaces the apex-beat in the same direction, and modifies its force according to the nature of the predominant myocardial condition.

Decreased Cardiac Dulness.—Atrophy of the heart accounts for a corresponding contraction of the surface boundaries of the organ, and in that rare lesion, pneumopericardium, the area of cardiac flatness is replaced by the tympany of the air-distended pericardial sac. In phthisis it is common to find the size of the heart smaller than normal, and Adler has described a form of congenital microcardia in hypochondriacal subjects. More commonly, however, diminution of the area of flatness is referable to some extracardiac cause—emphysema, which envelops the heart with a hyperresonant covering of overdistended lung; pleural adhesions, whereby a resonant pulmonary border may be permanently anchored directly in front of the heart; left-sided pneumothorax, whose clear tympany encroaches upon the triangle of cardiac flatness and perhaps displaces it toward the right. Simple gaseous distention of the stomach diminishes the flatness of the heart from below upward and, as W. Gordon has pointed out, gastric cancer reduces or even obliterates the cardiac flatness, in the recumbent position.

Recent x-ray studies have shown that the size of the normal

heart diminishes after muscular exercise, and is not increased by a state of temporary dilatation, as formerly believed. This fact has been proved conclusively by the researches of Nicolai, Zuntz, and numerous other investigators, who corroborate the pioneer work of Moritz on this subject. Of 100 subjects examined teleröntgenographically by Williamson, the vast majority of normal hearts responded to any exercise within their power by definite contraction, and even in pathologic hearts the same tendency was noted in one-half of the cases examined.

Displacement of the cardiac area is determined by the position of the heart's impulse, rather than by percussing out the dislocated area, and the circumstances under which the various cardiac displacements occur have been referred to at length under the Apex-beat. (See p. 317.)

AUSCULTATION

By auscultation of the precordial area one judges the intensity, quality, and rhythm of the cardiac tones, and determines the presence or absence of unnatural adventitious sounds of endocardial and pericardial origin. Like other methods of examination, auscultation of the heart must be carried out systematically, in order to afford the best results, the four different valve areas being studied in regular order so as to compare and correlate the various sounds. Thus, the mitral sounds are first investigated, and then the aortic, to ascertain the auscultatory findings relating to the left ventricle; while the sounds afforded by the tricuspid and the pulmonic valves are the key to similar signs pertaining to the right ventricle.

The heart-sounds should be auscultated with the patient in both the recumbent and the upright position, for posture has a decided modifying effect on certain heart-sounds, notably on endocardial murmurs, some of which can be made to appear and to vanish, virtually at will, by changing the subject's posture. (Cf. p. 316.)

The advantages of the binaural and the monaural stethoscope in cardiac auscultation, and the application thereto of the transmanual method of auscultation have been pointed out elsewhere. (See p. 28.) Abrahams suggests the use of stethoscopic auscultation of the voice sounds outside the upper and lateral cardiac boundaries as a substitute for percussion in delimiting these lines. The examiner, having placed the stethoscope in the interspaces over the pulmonary tissue several inches outside the conventional cardiac limits, auscultates while the subject repeats "ninety-nine" in a low voice, and, moving the bell of the instrument toward the heart, marks the several points at which the

pulmonary fremitus becomes inaudible and the sounds become extrastethoscopic. These points of lost vibration, which mark the transition from sound-conducting lung to non-conducting heart, are joined later with a line to represent the outer boundaries of the entire cardiac area (*v. s.*).

Auscultatory or Valve Areas.—Four different auscultatory areas, corresponding to the puncta maxima of the separate valvular sounds, are made use of in cardiac auscultation: the mitral, the tricuspid, the aortic, and the pulmonic (Fig. 136). These areas

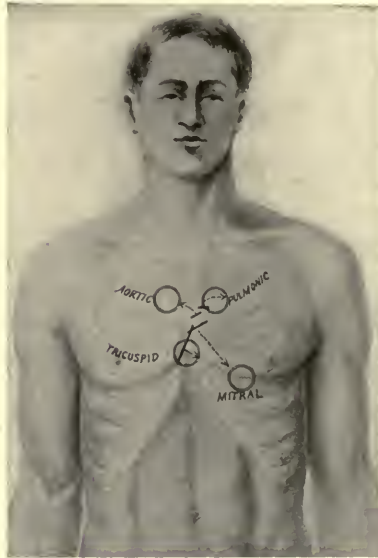

Fig. 136.—Auscultatory areas of the cardiac valves.

represent the points upon the precordia at which the sounds of the corresponding valves are most distinctly audible, and they do not overlie the anatomic seats of the valves, all of which lie in the immediate neighborhood of the third left chondrosternal articulation. (See p. 310.)

The *mitral area* is indicated by a circle about 1 inch (2.5 cm.) in diameter, centered at the cardiac apex, or at that point where the apical thrust of the heart impinges against the chest-wall during systole.

The *tricuspid area* overlies the lower end and right half of the sternum, from the fourth to the sixth or seventh costal cartilages, in which situation the right ventricle and the parietes are in close relation.

The *aortic area* is situated at the sternal end of the second right intercostal space and costal cartilage (aortic cartilage), where the aorta and the aortic valve approach nearest to the surface of the chest.

The *pulmonic area* is at the sternal end of the second left intercostal space, over the most superficial projection of the pulmonary artery and valve.

The Normal Cardiac Sounds.—Each beat of the heart is accompanied by two sounds, audible in the precordial area as tones having a distinctive grade of intensity and a *sui generis* quality. These

tones, which occur rhythmically and bear a definite relation to the events of the cardiac cycle, may be represented by the monosyllables *lūp-dūp*.¹ The *lūp*-element is the first sound of the heart, and is synchronous with ventricular systole, through about two-thirds of which phase it persists, ending in a gradual diminuendo. The *dūp*-element, following the first sound after a brief interval, is the second sound of the heart, and coincides with the closure of the semilunar valves and the beginning of ventricular diastole; it is relatively short, sharp, and of abrupt termination, and is separated from the succeeding *lūp*-sound by a comparatively long interval of silence (Fig. 137). Phonetically, the rhythmic succession of the



Fig. 137.—The normal cardiac sounds.

two sounds may be sketched: *lūp-dūp—lūp-dūp—lūp-dūp*, the interval between the two sound elements representing the short pause, and that between their recurrence the long pause, of the cardiac cycle. The diagram on page 312 shows the relation between the normal sounds of the heart and its cyclic phases.

The *first sound*, synchronous with the cardiac impulse and relatively more intense at the apex than at the base of the heart, is a musculo-valvular tone, due partly to the muscular rumble of the contracting ventricles, and partly to the sudden vibratory tension of the mitral and tricuspid valves at the time of their closure. The first factor accounts for the dull, prolonged, booming quality of the sound (muscular tone), and the second explains its tinge of high-pitched sharpness (valvular tone). Under normal conditions the character of the first sound is subject to individual variations, being, for example, shorter, higher pitched, and more valvular in slim, spare subjects than in those whose covering of muscle and fat is abundant.

The mitral first sound is more prolonged and a trifle lower in pitch than the tricuspid—a difference that can be detected by careful auscultation of the separate ventricular elements of the sound at the

¹With tolerable constancy it is also possible to distinguish, in perfectly healthy persons, a third cardiac sound, audible at the apex as a faint tone directly after the *dūp* of the second sound, or during the beginning of the diastolic period. Thayer suggests that this so-called "third heart-sound" may be caused by sudden tension of the mitral and possibly the tricuspid valve occurring during the protodiastolic phase. The sound, which is especially clear in the young, is sometimes accompanied by a synchronous impulse which may be both visible and palpable, is intensified by left lateral recumbency and during expiration, and is commonest in subjects with a slow pulse.

mitral and the tricuspid areas. This difference is especially noticeable in early life; it is to be explained possibly by assuming an intrinsically louder mitral sound, certainly by the fact that the lung between the apex of the left ventricle is too thin to affect the sound-waves arising within this chamber, while over the right ventricle it is thick enough to dampen the sound therein produced.

The *second sound*, caused by the closure of the aortic and pulmonic semilunar valves, totally lacks muscular tone, and is of a purely valvular character; normally, it is louder at the base than at the apex. In the young the pulmonic second sound is louder and higher pitched than the aortic; in middle life the intensity of the two sounds does not differ materially; and in advanced age the aortic element is the more striking. The gradual increase in the intensity of the aortic second sound is doubtless to be referred to the progressive rise in the aortic blood-pressure incident to maturity and to old age. Normally, the aortic tension is higher than the pulmonary, but this physiologic factor of a relatively louder aortic second sound is offset by the deep situation of the aorta and its valve, in contrast to the superficial position of the pulmonary artery and its valve.

In the majority of healthy subjects of all ages the cardiac sounds above the ensiform cartilage have a peculiar superficial scratching or crunching quality intensified by forward inclination of the trunk and by lateral decubitus. This sound, called "xiphisternal crunching" by M. Solis-Cohen, has a resemblance to pericardial friction, but it is regarded as a purely physiologic sign, referable perhaps to tensional changes in the loose areolar tissue of the sternopericardial ligament acted upon by the movements of the heart, as suggested by Bloomer.

Changes in the Intensity and Quality of the Cardiac Sounds.—The normal intensity, tone, and quality of the heart-sounds are variously modified in consequence of numerous factors intrinsically active or related to parts acoustically intimate with the heart. In attempting to judge these variations, due allowance is to be made for the influence upon the normal sounds of the muscular and adipose development of the subject—the thin-chested and cadaverous have relatively louder heart-sounds than the muscular and obese, or than the woman with generous breasts.

The intensity of both sounds is markedly *increased* in cardiac hypertrophy, since in this condition of overdevelopment both the muscular and the valvular components of the heart-tones are greatly exaggerated (Fig. 138). To a lesser degree the sounds are magni-

fied by simple cardiac overstimulation, due, for example, to transient mental excitement or to the effect of alcohol, coffee, and like stimulants; or the change may be incident to one of the cardiac neuroses, to Graves' disease, and to the effects of an incipient febrile affection. Pulmonary consolidations are capable of conducting the cardiac




Fig. 138.—Accentuation of both cardiac sounds.

sounds with abnormal intensity, while pulmonary fibrosis with shrinkage may expose the precordia, and thus make the sounds more superficial and apparently louder to the examiner's ear. Surgical emphysema of the tissues in front of the heart may greatly amplify the cardiac tones (Keats).

Intensified cardiac sounds with conspicuous *alteration of their quality* are audible when neighboring structures are so changed as to act as a resonating chamber for the normal tones. Thus, it is possible for the heart-sounds to be echoed as a loud, metallic, hollow ring by a distended stomach or gut, by a large, empty, clean-cut pthysical cavity, and by a pneumothorax.



Fig. 139.—Enfeeblement of both cardiac sounds.

Both sounds of the heart are *enfeebled* and muffled in myocarditis, in dilatation, and in the cardiac asthenia attending conditions of collapse, shock, paralysis, and great debility (Fig. 139). Pleural and pericardial effusions and hypertrophic emphysema, by covering the apex, also lessen the normal vigor of the sounds. In that rare clinical curiosity, pneumopericardium, the sounds are usually far away and faint; rarely they are louder than normal, amphoric, and bell-like. In high-grade anemic states it is common to hear sharp slapping cardiac sounds, which, though perhaps louder than in health, are, nevertheless, to be interpreted as irritably weak.

Accentuation of the First Sound at the Apex (Fig. 140).—That the first sound at the apex is likely to be exaggerated by nervous excitement, by physical exertion, and by flatulence should always be recalled in examining a patient for the first time. The turbulent character of this sound in the high-strung neurotic person or in the

dyspeptic is not, *per se*, to be construed as an evidence of disease. In ventricular hypertrophy, particularly of the left side, the first sound resembles a sustained, booming rumble, which, though often muffled and impure, gives one the impression of being more intense than normal. In dilatation of this cavity the first sound is short, sharp,



Fig. 140.—Accentuation of the first cardiac sound.

and high pitched, being not unlike the valvular tone of the second sound. A loud, high-pitched, snappy first sound at the apex is an important diagnostic sign of mitral stenosis. In incipient myocarditis, in the early stages of the acute febrile diseases, and throughout the whole course of the febriculæ, the apical first sound is commonly more or less accentuated and sharp.



Fig. 141.—Enfeeblement of the first cardiac sound.

Enfeeblement of the First Sound at the Apex (Fig. 141).—Diminished intensity of the apical first sound betrays weakness of the ventricles, which in some instances is so marked that the sound is practically inaudible. Shock, great anemia, collapse, vagus paretic, extreme cardiac dilatation, and myocardial degeneration (as in the typhoid state and in various forms of myocarditis) are factors by which the normal strength of this sound is modified. In mitral regurgitation the first sound is enfeebled, but this is difficult to detect because of the associated systolic murmur which partly or wholly masks the ventricular tone at the apex.




Fig. 142.—Accentuation of the second cardiac sound.

Accentuation of the Second Sound at the Base (Fig. 142). The character of the aortic and pulmonic second sounds at the base of the heart is of the greatest clinical value, since the former reflects

the strength of the left ventricle and the latter the vigor of the right ventricle. In judging the relative intensity of the two sounds their physiologic differences must always be considered in the light of a modifying element. Accentuation of the *aortic second sound*, the correlative of an intensified mitral first sound, is a sign of increased arterial tension within the aorta and the systemic circulation. This may arise from purely normal causes, such as temporary vasomotor stimulation, a simple overacting heart, and pregnancy. Or the loudness and ringing quality of the sound may depend upon arterial sclerosis, aortitis, nephritis, and atheroma, dilatation, or aneurism of the aorta. In hypertrophy of the left ventricle with competent aortic valve segments a similar accentuation is also audible. Accentuation of the *pulmonic second sound*, the basic equivalent of an intensified tricuspid first sound, develops in consequence of heightened pressure within the pulmonary circulation; it is excited by lesions that impede the blood-stream within the lesser circuit, as typical examples of which may be named pneumonia, and congestion, emphysema, and cirrhosis of the lungs. In hypertrophy of the right ventricle the pulmonic second sound rings loudly so long as the intraventricular pressure is not high enough to produce a "safety-valve" tricuspid leakage (*q. v.*).

Enfeeblement of the Second Sound at the Base (Fig. 143).—A weak, indistinct *aortic second sound* commonly results from myocardial degenerations of varying degrees of intensity, and from general




Fig. 143.—Enfeeblement of the second cardiac sound.

vasomotor relaxation, whereby the systemic blood-pressure is lowered; it may also be due to profound anemia, as in the posthemorrhagic form, involving a transient but real oligemia. In both obstructive and regurgitant valvular lesions of the left heart this sound is prone to become weak, if not inaudible: in mitral stenosis and in mitral regurgitation, because the tension within the aorta is too low to slam shut the aortic valve with normal force; in aortic stenosis, in consequence of the deliberate, noiseless closure of the sclerotic and stiff leaflets; and in aortic regurgitation, owing to the extensive valvular deformity and to the bruit of the diastolic murmur. Pulmonary lesions that impede the return of blood to the left side of the heart also account for a feeble second sound at the aortic cartilage.

Weakening of the *pulmonic second sound* is not a common physical sign, for the pressure within the lesser circulation is not so readily lowered as it is in the systemic circuit. Enfeeblement of this sound invariably supervenes when the right ventricle weakens and dilates, and it is, therefore, a distinctive and dependable index of this grave accident. Tricuspid regurgitation, when associated with right ventricular weakness, is the factor of a feeble second sound in the pulmonic area.

Reduplication of the Cardiac Sounds.—Reduplication or doubling of the first or the second sound of the heart, less commonly of both sounds, is heard under a number of circumstances whose direct bearing upon these phenomena is not always clear. Three distinct sounds in each cardiac cycle are audible when a single (first or second) cardiac tone is reduplicated; four sounds, when the doubling affects both tones. If the first sound be reduplicated, the precordial sounds may be imitated thus: *lür-rup-düp—lür-rup-düp*; if the second sound be doubled, the effect will resemble: *lüp-dür-rüp—lüp-dür-rüp*. Single reduplication is much more common than double, and splitting of the second sound more frequent than of the first.

In certain instances the reduplication simulates the hoof-beats of a galloping horse, and hence is termed variously *bruit de galop*, or *gallop rhythm*, or *canter rhythm*; in other cases it sounds not unlike the double beat of a snare drum—*bruit de rappel*. In the former, the doubled elements are divided by a brief pause; in the latter, they occur almost, though not quite, synchronously.

Reduplication of the *first sound* is almost invariably heard only at or near the apex, being audible at the base of the heart only as a rare exception (Fig. 144). It is not a true reduplication, but rather



Fig. 144.—Reduplication of the first cardiac sound.

an apparent doubling, the mechanism of which is probably not always identical. Asynchronism in the closure of the mitral and tricuspid valves, the presence of an obscure presystolic murmur, unduly strong auricular action, and vibration of the aortic wall are four possible causes of the doubling.¹ Systolic reduplication may be met with in mitral disease, in arterial sclerosis, in hypertrophy and

¹ For the many theories of systolic doubling the reader should consult the writings of Gibson, Barr, Sansom, Bramwell, Johnson, Hayden, Offenbacher, and Guttman.

structural degenerations of the heart, and in chronic adhesive pericarditis.

Reduplication of the *second sound* is most commonly heard at the base, but also at the apex, and at base and apex coincidentally (Fig. 145). Doubling at the base is commonly ascribed to asynchronous closure of the semilunar leaflets, caused by unequal tension in the general and the pulmonary circulations. Owing to this loss of balance, systole of the ventricle that must overcome the highest tension is delayed, and its semilunar valve closure is correspondingly tardy. This type of doubling may occur physiologically, from forced, full inspiration; it is pathologic when resulting from lesions upsetting the equilibrium of the pulmonary or the systemic circuits. Therefore, it may be symptomatic of obstructive lesions of the lungs, arterial sclerosis, left-sided valvular defects, myocarditis, hypertrophy, dilatation, and pericardial effusion. Reduplication of the second sound, heard at the apex, but *not* at the base, is apparent, rather than actual, and has a very different significance from the doubling just mentioned. It is an early and characteristic sign of mitral stenosis, and almost constantly develops in advance of the presystolic rumble of this lesion. The forcible entrance of the auricular blood-column produces a sudden, sharp tension of the mitral curtains, and this impact, occurring just after the second sound, counterfeits a doubling of the latter.



Fig. 145.—Reduplication of the second cardiac sound.

Arrhythmia.—Disturbances of the normal rhythm of the heart-beat may depend upon structural damage to the cardiac musculature, whereby its orderly contractions are interfered with, or they may be referable to erratic action of the vagus and sympathetic nerves. The former factor rules in the arrhythmia attending acute infectious processes, valvular disease, acute cardiac dilatation, chronic myocarditis, and fatty heart, while nervous influences are particularly active in the disordered rhythm incident to neuroses, great emotion, intracranial lesions, gastro-intestinal disturbances, certain toxemias, and the action of drugs like digitalis, aconite, and belladonna.

Simple arrhythmia of the heart's action is distinguished by various deviations from normal force and rhythm, and a heart thus affected may afford a medley of intense and feeble sounds so unequally spaced

and so diverse in other details as to defy comparison and description. Cardiac arrhythmia reaches a climax in that condition of extreme irregularity and palpitation so aptly termed *delirium cordis*, not infrequently met with in advanced valvular and myocardial disease. Disordered cardiac contractility may account for the presence of alternately loud and feeble heart-sounds, the tactile equivalent of this type of arrhythmia being a radial pulse whose beats are alternately strong and weak—the *pulsus alternans* (*q. v.*). Rhythmic irregularity of the heart is designated as *allorrhhythmia*.

Intermittence, or the omission of a beat, may be independent of simple irregularity, but the two are commonly associated. Genuine intermission, due to the actual omission of a ventricular systole, is to be distinguished from simulated intermission, wherein the contractions of the ventricle occur, though too feebly to produce a peripheral pulse. (*Cf.* p. 336.)

Respiratory arrhythmia is characterized by a periodic acceleration of the cardiac rate during inspiration and a slowing of the rate during expiration, and is a genuine example of “sinus arrhythmia” depending upon alterations in the tone of the vagus. In young children such an irregularity is peculiarly common with ordinary respiratory movements, and hence has been designated by Mackenzie as the “youthful type of arrhythmia”; in adolescents and in young adults it may be provoked by forced, deep respiration. Clinically, respiratory arrhythmias are recognized by their restriction to early life, their direct relationship to respiratory movements, and the perfect correspondence of the peripheral pulse, the precordial impulse, and the cardiac sounds. Sinus arrhythmias of this kind are not of serious import, and are promptly abolished by the administration of atropin and by other factors of rapid cardiac action, such as pyrexia and muscular exercise. They show, on the sphygmogram, virtually no variation of the height of the arterial peaks, and on the electrocardiogram no disturbance of sequential contractions—merely irregular incidence of the beats.

Extrasystolic Arrhythmia.—Extrasystoles, or premature contractions of the ventricles and the auricles, occur in consequence of isolated stimuli arising abruptly in parts of the cardiac musculature away from the specialized tissue of the sino-auricular node, where the normal contraction waves begin. Thus, with an increased irritability of the myocardium as a factor, numerous ectopic contractions are suddenly excited prematurely in relation to the normal systoles, and in consequence disturb the orderly sinus

impulses of the heart. This type of arrhythmia is commonest in men of advanced age, and in those who show evidences of myocardial degeneration and of valvular lesions; in many cases there is a past history of rheumatism, in others it is associated with a temperament of nervous unrest, or it may accompany apparently perfect health. The use of tobacco in excess, prolonged and fatiguing exercise, arterial hypertension, and digestive disorders are additional

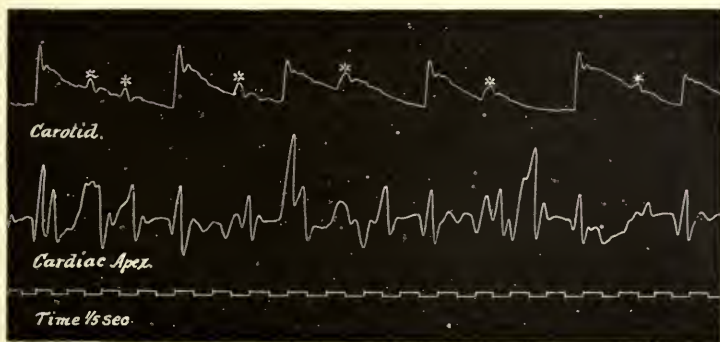


Fig. 146.—Sphygmocardiogram illustrating extrasystolic arrhythmia. Asterisks indicate extrasystoles. (Tracings by Dr. G. Bachmann.)

provocative causes of premature contractions, which ordinarily subside as the result of fever, deliberate apnea, recumbency, and moderate muscular exertion.

The occurrence of *ventricular extrasystoles*, wherefrom irregularity, inequality, and intermission of the heart's contractions arise, is an exceedingly common factor of disordered rhythm (Fig. 146). According to the law of maximal contraction (Marie; Bowditch) the heart, when stimulated to contract, does so with

its maximal power, regardless of the strength of the stimulus. Furthermore, each contraction thus excited completely exhausts for the moment the energizing material of the cardiac tissues essential for this act, and until this material again accumulates in sufficient quantity, fresh stimuli fail to excite a systole. Normally, this phase of cardiac excitability, termed the *refractory period*, begins just before the time of systole and persists throughout this period, the heart acquiring more and more sensitiveness as diastole progresses. Abbreviation of the refractory period and premature stimulation of a contraction, whether of physiologic or pathologic origin, result in an *extrasystole* timed soon after the normal beat. Should the extrasystolic refractory period overlap the time of the next physiologic stimulation, the ventricle, being at this time unresponsive, cannot react to the stimulus, and, in consequence, does not contract; *intermission* of a heart-beat therefore occurs. Extrasystolic arrhythmia may also conform to a regularly intermittent type, or allorhythmia, the superadded contractions occurring in groups of two or of three successive beats followed by a pause, and producing respectively the bigeminal and the trigeminal pulse. This variety of arrhythmia is illustrated by the sphygmograms IV and V shown on page 340.

Auricular extrasystoles are regarded as contractions excited by abnormal stimuli arising in the structure of the auricles, which, fatigued by these aberrant efforts, fail to respond to the immediately succeeding normal stimuli originating at the venous mouths. Each extrasystole of the auricle, therefore, is followed by a long pause, indicating quiescence of both auricles and ventricles, and this in turn is followed by the next normal contraction. Both the auricular and the ventricular types of extrasystole affect the cardiac sounds and the arterial sphygmograms similarly, but the jugular tracing of the auricular type clearly shows the premature auricular undulation, followed by a ventricular wave ushering in a period of passivity before the next normal contraction wave.

Auriculoventricular extrasystoles, in which the premature contractions are of nodal origin, are characterized by synchronous or almost synchronous contractions of the auricles and ventricles, and account for the irregularity known as *nodal* or *a-v rhythm*. Inasmuch as the contraction impulse is displaced from its normal situation at the sino-auricular node to a site in the junctional tissue (the *a-v* node), the normal *a-v* interval is disturbed, being either greatly abbreviated or indeed quite effaced, so that the excitatory waves reach the auricles and ventricles at the same in-

stant and thus excite synchronous contraction of all four cardiac chambers; if the ventricles contract before the auricles, the *v-a* interval is disturbed. To account for this type of arrhythmia it is assumed that the secondary nodal center initiates contraction either because of an abnormally slow sinus rhythm or that it does so because its inherent activity is disproportionately enhanced. While presenting no definite subjective symptoms, the jugular tracing registers an abbreviated *a-s* interval, a blending of the *a-s* waves so as to produce a bifurcated systolic peak, or an appreciable reversal of the *a-s* undulations. In the electrocardiogram inversion of the P-wave in leads II and III is the rule, owing to the change in the direction of the contraction impulse, and in some tracings it is superimposed upon the ventricular undulations *R*, *S*, *T*, which otherwise are unaltered.

Heart-block Arrhythmia.—Defective conductivity of the auriculo-ventricular muscular bundle produces a type of irregularity characterized by dissociation of the auricular and ventricular rhythms,




Fig. 146a.—Electrocardiogram of heart-block. (Tracing by Dr. T. A. Cope.)

occurring in three fairly distinct types: incomplete heart-block, complete heart-block, and Stokes-Adams' bradycardia.

In health the auricular systole takes place one-fifth of a second in advance of the ventricular, so that an increase in the time-interval between the auricular and ventricular contractions argues disturbed conductivity of His' bundle, the function of which is the conduction of the auricular contraction waves to the ventricles. When this muscular bridge is diseased (as by syphilis, fibrosis, or neoplasm) its conductile powers are crippled and a corresponding degree of dissociation of the auriculoventricular systoles is produced. Whipham describes a congenital form of heart-block, ascribed to developmental defects of the auriculoventricular bundle.

But the presence of pathologic alterations of the foregoing nature

does not invariably produce heart-block, for the cardiac conducting paths may be grossly implicated by disease without any consequent incoördination of the auriculoventricular contractions, in which group of cases the origin of the impulses in Kent's newly described node and their transmission along its connecting pathway are to be assumed (see p. 313). On the other hand, clinical heart-block may occur without pathologic changes in the bundle of His, the sino-auricular node, or Tawara's node, and the disordered rhythm in instances of this sort is usually referred to profound vagal depression.

The electrocardiogram of heart-block (Fig. 146a) shows clearly the dissociation of the auricular and ventricular beats, as demonstrated by the prolonged *P-R* intervals, the occasional intermission of the *R-T* waves, and the regular response of the ventricular peaks to every second or third auricular wave.

Incomplete heart-block is said to exist when some, but not all, of the auricular waves fail to reach the ventricles, which in consequence may occasionally miss a beat at irregular intervals, or may beat only with each second, third, or fourth systole of the auricles—a 2 : 1, 3 : 1, or 4 : 1 auriculoventricular rhythm, as the case may be.

Complete heart-block, or complete obstruction to the passage of the auricular waves, results in absolute dissociation of the auricular and ventricular systoles, which occur, each having a perfect rhythm of its own, independently of each other.

Stokes-Adams' bradycardia is a syndrome characterized by slow ventricular and rapid auricular rates of contraction, attended by syncope, epileptiform convulsions, and visible venous pulsations in the neck, which ordinarily occur twice or thrice oftener than the arterial pulse-beats.

Although first described by Thomas Spens, in 1793, this symptom-complex was not generally accredited as a clinical entity until half a century later, when Stokes' cases, in 1842, with the earlier work of Adams, in 1827, invested it with the eponym by which it is now known. Stokes-Adams' disease, which may occur at any age, is commonest in the male sex, and is attributable to infections such as syphilis, rheumatic fever, pneumonia, diphtheria, influenza, enteric fever, and to fatal anaphylaxis. Temporary examples of complete heart-block are also met with in uremia, and incomplete block is readily produced by overdigitalization of a rheumatic heart. The pathologic lesions affecting the specialized conducting tissues of His' bundle include gumma, neoplasm, atrophy, fibrosis, fatty degeneration, ulceration, and calcification; and the damage

to the heart in general consists of inflammatory changes in the cardiac muscle and its outer and inner investments, with or without sclerosis of the coronary arteries.

Fibrillation Arhythmia.—This type of gross irregularity depends upon fibrillation of the auricles, and in the heart so affected a medley of new stimuli arising at many different auricular foci replace the fundamental sinus rhythm, and produce a persistent disorder of cardiac rate. During these confused movements of the auricle this chamber remains stationary as a whole in wide diastole, but its muscular fibers throughout are extremely active and the wall “appears to be alive with movement, and rapid, minute, and constant twitchings and undulatory movements are observed in a multitude of small areas upon its surface” (Lewis). The ventricular contractions are wholly incoördinate with the auricular turmoil, since the regular succession of sinus impulses are mingled

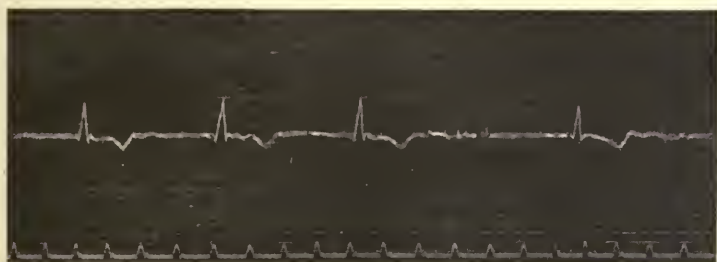


Fig. 146b.—Electrocardiogram of auricular fibrillation. (Tracing by Dr. T. A. Cope.)

with a confusion of stimuli which escape from the quivering muscle-fibers of the small chambers. According to the conducting properties of the *a-v* bundle, the rate and the rhythm of the ventricular contractions vary within wide limits and the arterial pulse is greatly disordered. Commonly, the ventricular contractions number from 100 to 140 per minute, or they may fall to as low as 40 or rise to as high as 200. Originally described by Mackenzie as a “nodal rhythm,” fibrillation of the auricles is now known to represent the birth of independent contraction stimuli in the auricular wall away from the sino-auricular node. This form of arrhythmia is found in fully one-half of all cases of mitral stenosis, and in many cases of advanced myocarditis and arterial sclerosis; in the exceptional case alteration in the sino-auricular node (inflammation, fibrosis, arteriosclerosis) is the underlying pathologic cause. Clinically, it underlies the *pulsus irregularis perpetuus* (*q. v.*).

A peculiarity found in most cases of auricular fibrillation is the wide variation of the maximal and minimal systolic blood-pressure figures—a range of from 30 to 60 mm., in Silberberg's experience.

In the electrocardiogram (Fig. 146*b*) the auricular *P*-wave is replaced by a series of very fine undulations, signifying the auricular fibrillations, while the *Q-R-S* waves are irregularly spaced and of variable height, denoting disordered rate and force, respectively.

Ventricular fibrillation, with gross disorder and incoördinate contractions of the musculature, also has been met with, as the immediate precursor of death, in light chloroform anesthesia, in lightning stroke, and as a sequel to auricular fibrillation. Death from this cause is usually sudden, and is preceded by disappearance of the radial pulse, and by an electrocardiogram recording complete sequential dissociation of the ventricular complexes.

Alternation Arhythmia.—This represents an irregularity in the force of the succeeding cardiac contractions, without deviation of the normal incidence of the beats, and, clinically, accounts for the *alternating pulse* (*pulsus alternans*), in which the beats, although regular in rate and occurrence, are alternately large and small. This anomaly depends upon variations in the quantity of blood expelled from the left ventricle by its alternately strong and weak contractions, and is explained by two different theories: (*a*) Incomplete ventricular systole, owing to persistence of the refractory period in a circumscribed area of the ventricular wall, which fails to contract while the other part of the muscle does so with enfeebled force (Gaskell; Hering); and (*b*) general ventricular hyposystole, with commensurately weak contractile force (Wenckebach). In either event the arterial pulsations are alternately strong and weak and the cardiac sounds correspondingly loud and obscure. Usually, sphygmocardiographic tracings more clearly show the alternating phases of this type of arhythmia than the curves of the electrocardiogram (Gravier), and auscultatory sphygmomanometry affords distinctive tonal changes. (See p. 36.)

Hemisystolic Arhythmia.—This extraordinarily rare disturbance is characterized by asynchronous ventricular contractions, or hemisystoles, and is met with in extreme mitral incompetence associated with excessive intrapulmonary hypertension. As the result of this stress, the right ventricle, gorged with blood and greatly overtaxed, makes a double systole, the second contraction representing an ineffectual attempt to overcome the circulatory stasis in the pulmonary circuit. By this mechanism a double apical first sound is produced, the second element of which is loudest over the right ventricle; a

double apex-beat is also created, but there is only a single arterial pulse-wave, inasmuch as the second impulse, being that of the right ventricle, cannot influence the systemic blood-stream.

Another type of hemisystole, excited by excessive digitalization, consists of independent contractions, first of the left and then of the right ventricle, this peculiarity having been attributed to the comparatively sluggish reaction of the right ventricle to digitalis and to the predominant effect of the drug on the left ventricle.

Prolongation of Diastole.—Prolongation of the second or long pause after the second sound converts the physiologic 3-4 time of the cardiac cycle into a 4-4 rhythm, the first half of which is occupied by the first and second sounds and the last half by the diastolic period of silence.

In this form of arrhythmia both the first and second sounds are shorter and higher pitched than normal, and become approximated by the shortening of the interval between them, while the diastolic pause is sustained through fully one-half the entire cardiac cycle. A prolonged diastole is suggestive of advanced myocardial disease, owing to which the ventricles, exhausted, ill-nourished, and tottering, have become almost too feeble to functionate; the sign may also be symptomatic of digitalization.

Embryocardia.—Unnatural frequency and equidistant spacing of the heart's sounds, from prolongation of the short, and abbreviation of the long, pause, is termed *embryocardia*. As the name suggests, it resembles the regular beating of the fetal heart, in that the two sounds are similar and, since both silences are of equal length, follow each other at regular intervals, like the tick-tack of a watch.

Embryocardia means striking cardiac enfeeblement, by fault of which the ventricles must labor hard, slowly, and almost fruitlessly to expel their contents. The presence of this sign in high-grade arterial sclerosis, in primary myocarditis, and during the acute infectious fevers generally indicates that complete heart failure is not far off.

An embryocardiac tick-tack may also be associated with simple tachycardia, in which event it is to be referred to a shortening of the long pause. Occurring under such a circumstance, the sign is not of grave import.

Pendulum Rhythm.—This consists of a succession of uniform cardiac tones, evenly spaced, equally intense, and not unduly accelerated, in consequence of which peculiarities the regular swing of a pendulum is more or less faithfully reproduced by the heart's two sounds. This anomaly of rhythm is met with in conditions of arterial hyper-

tension wherein ventricular systole is prolonged and the second sound correspondingly delayed, at the expense of the long pause.

ADVENTITIOUS SOUNDS

The normal cardiac sounds, in addition to undergoing rhythmic and tonal modifications, are also attended, if not wholly replaced, by certain superadded, adventitious sounds of pathologic significance, generated within the cardiac chambers and the blood-vessels, between the pericardial surfaces, and in the pulmonary structures contiguous to the heart. These abnormal sounds, for simplicity's sake, may be grouped as—(a) endocardial; (b) exocardial; and (c) vascular. *Endocardial murmurs*, or *bruits*, are of two principal types, organic and functional, the former arising from unalterable structural defects of the cardiac valves and orifices, and the latter depending upon myocardial enfeeblement and upon changes in the composition of the blood. *Exocardial sounds* comprise the dry rub of pericardial friction, the splash of the pericardial succussion sound, and the whiff of the cardiopulmonary murmur; other extracardiac sounds, primarily of pleural and pulmonary origin, include pleuropericardial friction and cardiopneumatic râles, the mechanism and meaning of which

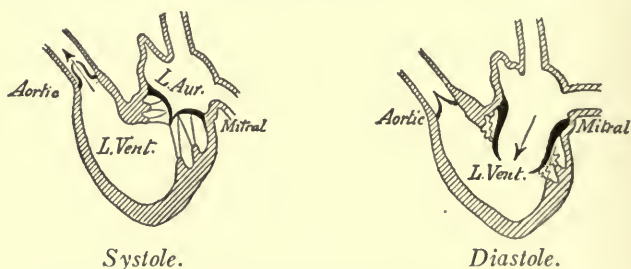


Fig. 147.—Mechanism of normal cardiac systole and diastole.

have been explained in another place. (See p. 166 *et seq.*) *Vascular adventitious sounds* are classified as either arterial or venous, according to their seat of origin, and of these sounds, the aneurismal bruit and the venous hum are the most important clinical examples.

ENDOCARDIAL MURMURS

Organic Murmurs.—No sound whatever, save the *lûp* of the first, and the *dûp* of the second, cardiac tone,¹ attends the passage of

¹ Practically, the so-called "third heart-sound," referred to on page 357, can be disregarded in routine examinations.

blood through the normal heart, since a column of blood coursing, at a normal velocity, through healthy endocardiac orifices and chambers does so without the formation of the current oscillations essential for the generation of murmurs. In other words, a normal endocardiac circulation is comparable, physically, to the flow of fluid through a tube of uniform caliber, and having smooth walls separated from the current by a film of liquid attached to them by the force of adhesion; under such conditions the smooth, uniform, silent flow of the fluid is assured. When, on the other hand, structural deformities of the valves and orifices exist, the blood-stream is churned into

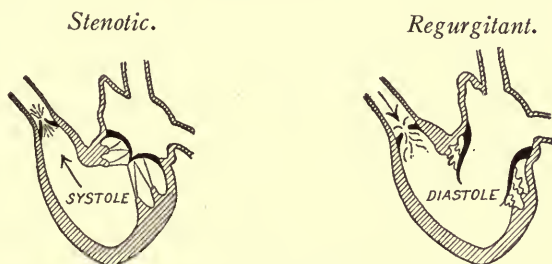


Fig. 148.—Mechanism of stenotic and regurgitant murmurs.

sonorous vibrations, just as fluid passing through a tube swirls about and is hurled into tiny jets should it be forced through a constriction of the tube's lumen into an expanded portion beyond. An orifice organically contracted and therefore obstructing the onward movement of the blood-stream (*stenosis*), or an opening deformed so as to allow the blood to leak backward (*regurgitation*) results, in either accident, in the passage of the stream into a larger cavity, already containing blood, and in consequence blood eddies and vibratory jets termed *fluid veins* (Savart's *veines fluides*) are produced (Fig. 148). These sonorous vibrations are conducted, with variable intensity, by the cardiac muscle and thoracic parietes to the surface of the chest, where they are audible as *murmurs* (*bruit; souffle*) and palpable as thrills. Inasmuch as a sluggish current of blood is not readily thrown into sonorous vibrations, despite the existence of deformed orifices and valves, the blood-stream must attain a certain degree of velocity in order to generate audible murmurs, in view of which the intensity of a given murmur indicates the condition of the circulatory force and does not, *per se*, denote the extent or gravity of an endocardial lesion. To some extent blood viscosity bears upon the production of murmurs, both organic and functional, since hypoviscosity and

undue dilution of the blood-mass favor the creation of vibrations therein. Matsuo finds that anemic murmurs, whose intensity is inversely proportional to the blood's viscosity value, disappear when this figure exceeds 3.0.

Clinical Attributes of Murmurs.—Having detected a murmur, it is next in order to determine its relation to the events of the cardiac cycle, its point of maximum precordial intensity and lines of transmission therefrom, and its quality, intensity, and other tonal characteristics. By this sort of analysis one attempts to decide whether the murmur is simply a functional accident or is a sign of endocardial disease, and if the latter be the finding, to discover the anatomic site, nature, and extent of the lesion, as well as its effect upon the structure and adequacy of the heart. In this inquiry the foregoing data are invariably to be correlated with signs relating to the size and position

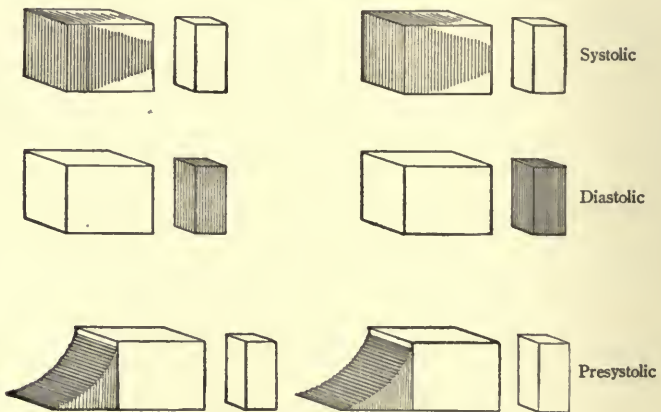


Fig. 149.—The rhythm or time of murmurs.

of the heart, to the character of the cardiac tones audible at the four valve areas, and to the condition of the arterial and venous circulations.

The Rhythm of Murmurs.—Endocardial murmurs correspond definitely to the events of the cardiac cycle, and occur during ventricular systole, ventricular diastole, and auricular systole (Fig. 149). The ventricular systole and diastole are taken as the clinical time-criteria of murmurs, those occurring with systole, accompanying or replacing the first sound, being termed *systolic*; those coincident with diastole, blending with or masking the second sound, being

known as *diastolic*; and those audible immediately before systole being called *presystolic*. A *post-systolic* murmur is audible toward the end of systole; a *protodiastolic* murmur occurs in the earliest part of diastole, directly after the first sound; and a *mid-diastolic* murmur corresponds to the middle of the diastolic period.

Murmurs are timed by determining their relation to the sounds of the heart, the visible apex-beat, or the palpable carotid pulsation; the radial pulse is not a correct index of ventricular systole, than which the pulse-wave at the wrist is appreciably later.

Puncta Maxima and Transmission of Murmurs.—An organic murmur is usually heard most distinctly over the precordial valve area corresponding to its seat of production, this site being known as the *punctum maximum*, or point of maximum intensity. Furthermore, if audible beyond this limit, a murmur tends to be conducted selectively along a restricted path termed its *line of transmission*, or area of propagation. The *puncta maxima* and transmission lines of different murmurs will be considered in detail later, but in general terms it may be here stated that the former are situated where the murmurous orifice lies closest, acoustically, to the surface of the thorax, and that the course of the latter is determined both by the direction of the blood-current and by the conducting properties of the structures lying between the source of the vibrations and the chest-piece of the examiner's stethoscope. The initial intensity of the bruit, its quality and pitch, and the velocity of the blood-stream are also to be taken into account as determining factors of a murmur's extraprecordial transmission.

The Intensity and Quality of Murmurs.—Like the normal heart-sounds, the distinctness of murmurs is modified by posture, as well as by the conducting properties of the thorax and contiguous parts. The acoustic characters and intensity of a murmur vary greatly, depending as they do upon the force of the blood-current and upon the extent and nature of the underlying lesion, the gravity of which can by no means be judged by criteria such as loudness and tonal attributes. However, generally speaking, a loud murmur means that the heart is well nourished and acting adequately, while, on the other hand, a feeble murmur suggests that the heart is weak, if not failing. This dictum is especially true when applied to an instance in which a murmur, once loud, bellows-like, and accompanied by a thrill, dwindles to a mere whiff, unaccompanied by the slightest tactile vibrations.

Progressive increase in the intensity of a murmur generally implies that the cardiac strength is correspondingly improved. Some

murmurs are so loud as to be heard distinctly by the patient, and others are so intense that they can be recognized by a bystander. A systolic or a diastolic murmur may simply blend with the first or second sound of the heart, and thus modify its normal quality, or it may be so loud as totally to obscure it, and the greater this replacement of the physiologic heart-sounds by the murmur, the more extensive the valve defect is likely to be. Thus, a distinct first sound plus a systolic murmur at the apex means that the mitral valve is not so crippled that it cannot close, though it may do so imperfectly; and, similarly, a persistent second sound with a diastolic murmur in the aortic area shows that the competency of the aortic leaflets is not totally abolished.

With reference to quality and pitch, a murmur may be described as soft, distant, and blowing; or rough, harsh, filing, and rasping; or rumbling, churning, and blubbery. Such adjectives as these, though by no means certain keys to the source of an endocardial murmur, have within certain limits a pertinent clinical bearing. For example, the typical mitral presystolic murmur is loud and rumbling or blubbery; the systolic mitral murmur, on the contrary, is generally soft and quiet and blowing. The systolic aortic murmur is usually loud, harsh, and rasping; but the diastolic murmur in this area is likely to be distant and subdued, if not, indeed, almost noiseless. These facts apply, of course, only to the characteristic case, to which exceptions are not uncommon.

The pitch of a murmur is likewise a most variable quality, being low and sonorous in some instances, and high and sharp in others. Like other bruits, a musical murmur, or one having a musical twang or plaintive tone, may be due to the vibrations of blood-eddies, but frequently it is produced by the fenestration of a valve, or by the vibrations of thickened chordæ tendineæ, of a delicate thread of fibrin, or of the thin free edge of a valve leaflet. According to Clément, increased rapidity of the intracardiac blood-flow is an important factor of the musical quality. Obviously, a musical murmur, *per se*, points to no single type of endocardial defect. Metallic, amphoric, echoing murmurs arise from the same conditions that lend these tonal qualities to the normal heart-sounds, the nature of which has already been discussed.

Peculiarities of quality and pitch are to be carefully noted when attempting to differentiate the adventitious sounds afforded by a heart tenanted by multiple murmurs, which, though audible at the same periods of the cardiac cycle, may differ radically in tone.

Functional Murmurs.—These bruits, like those of organic origin, are due to sonorous vibrations of the circulating blood-stream, but, unlike them, they do not depend upon permanent structural defects of the valve mechanism. To this sort of murmurs the adjectives inorganic, relative, accidental, and hemic are also applied, for they are produced by temporary myocardial weakness whereby the action of the valves is disarranged, or by dilatation of the conus arteriosus, or of the pulmonary artery. Diminished blood density, as mentioned above, contributes to the causation of functional murmurs, inasmuch as thinning of the blood favors the formation of eddies and jets in the circulating stream. Anemia, acute febrile affections, and extreme physical exhaustion are the principal factors of functional murmurs, of which the hemic bruit of chlorosis, the relative mitral incompetence of various specific fevers, and the relative tricuspid leakage consequent to excessive intrapulmonary tension are familiar examples. The presystolic murmur of Flint, met with in aortic regurgitation, is also, in a certain sense, relative or functional. (See p. 382.)

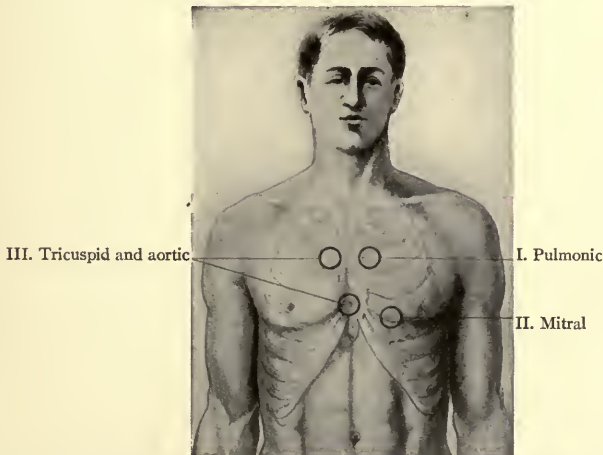


Fig. 150.—Comparative incidence of functional murmurs of the different valve areas. (Cf. Fig. 152.)

Functional murmurs, in their order of relative frequency, are audible at the pulmonic, mitral, tricuspid, and aortic valve areas, and in the vast majority of cases are systolic in time, faint and blowing in quality, and not conducted far beyond the precordia, though within this area they may imitate the transmission lines of organic

murmurs similarly timed and situated. Functional murmurs are not productive of cardiac hypertrophy, of distinctive pulse changes, or of consecutive alterations in the basic sounds of the heart. They, furthermore, have a transient, fleeting character, for they disappear with the removal of their exciting cause—when the blood-count improves, after the fever declines, or with the subsidence of the heart stress, as the case may be. A functional murmur of purely anemic character is ordinarily accompanied by a venous hum (*q. v.*).

The mechanism of functional murmurs is probably not identical in all instances. The *pulmonic* systolic bruit of anemic states, especially chlorosis, is best explained by assuming nutritional weakness of the myocardium, whereby the conus arteriosus dilates and leads to the formation of fluid veins within this portion of the right ventricle. The pulmonic area is also the site of an evanescent systolic murmur of functional type, occurring in emotional women, and termed the "psychic heart murmur." An *apical* systolic murmur, of transient duration, develops in many infectious diseases in consequence of toxic degeneration of the myocardium. This induces stretching of the left ventricle, undue enlargement of the mitral ring, and relative shortening of the papillary muscles, by fault of which defects the mitral valve fails to close tight during the ventricular contraction, and therefore permits the leakage of blood from the ventricle into the auricle with each systole (Fig. 151). This murmur of "relative" or "accidental" mitral incompetence disappears as the patient convalesces and the heart muscle regains its normal tone. A murmur of similar mechanism is frequently audible at the apex for a very brief period as a consequence of physical exercise severe enough to throw undue strain upon the left ventricle, by provoking excessive systemic arterial tension. Other murmurs, timed similarly, are audible at the apex as the result of the formation of audible blood-eddies within a dilated left ventricle, without leakage at the mitral orifice. A systolic *tricuspid murmur*, of relative type, may arise as the result of valvular disease of the left heart, whereby excessive intrapulmonary arterial tension is set up, thus dilating the right ventricle, and, by enlarging the tricuspid orifice, allowing tricuspid leakage. This so-called "safety-valve" murmur is really conservative, in that for the time it eases the high pressure within the right ventricle. (See p. 463.) Relative tricuspid regurgitation may also attend the obstinate obstruction of the pulmonary circuit accompanying certain chronic pulmonary affections. An *aortic* func-

tional murmur, if systolic, probably means dilatation of the left ventricle without stretching of the aortic ring, or, in other words, relative stenosis of the aortic orifice; or transient dilatation of the aorta may be the exciting cause of a systolic aortic bruit. The exceedingly rare diastolic functional murmur audible at the aortic area is best explained by assuming it to be the diastolic element of a venous hum (*q. v.*) conducted from the jugular veins downward into the superior vena cava.

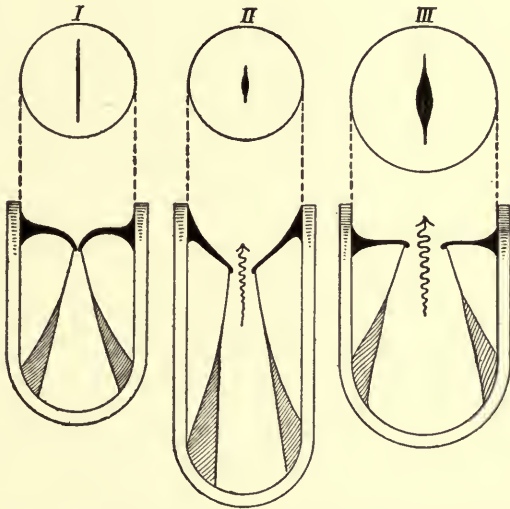


Fig. 151.—Mechanism of a functional murmur due to ventricular dilatation: I, Normal systolic coaptation of auriculoventricular leaflets; II, incompetence due to relative shortening of papillary muscles (chamber elongated); III, incompetence due to enlargement of mitral ring (chamber stretched horizontally).

The differentiation of organic and functional cardiac murmurs is generally possible, when all the clinical findings are given due weight, though in some instances one must withhold a definite decision, at least temporarily. For example, the apical systolic murmur so commonly arising in acute rheumatic fever may be symptomatic either of endocarditis, myocardial relaxation, or high-grade anemia due to the action of the rheumatic toxin, and under such a circumstance one cannot venture an opinion as to the character of the murmur until some time has elapsed—sufficient for the murmur to disappear, if functional, or for it to become supplemented by corroborative signs, if organic. The following table may prove helpful in

emphasizing the main points of difference between these two types of endocardial sounds.

	ORGANIC.	FUNCTIONAL.
<i>Time:</i>	Systolic, diastolic, or presystolic.	Almost invariably systolic.
<i>Punctum maximum:</i>	Varies with site of valve lesion.	Usually at pulmonic area.
<i>Transmission:</i>	Conducted selectively or circumscribed.	Rarely conducted beyond precordia.
<i>Myocardium:</i>	Permanent structural changes.	Heart not permanently altered in structure.
<i>Pulse:</i>	Often distinctive.	No characteristic change.
<i>Anemia:</i>	Not a factor.	Frequently an important factor.
<i>Previous history:</i>	Endocarditis, prolonged muscular strain, habitual arterial hypertension.	No history of organic endocardial disease.
<i>Basal cardiac sounds:</i>	Generally show distinctive changes.	No characteristic modifications.
<i>Duration:</i>	Permanent.	Transient.

The Analysis of Murmurs.—The particular defect indicated by a given endocardial murmur is ascertained by carefully analyzing the several attributes of the sound, and by correlating these data with a clear conception of the physical condition of the murmurous valve and orifice at the precise moment the sonorous vibrations are heard. The four different valve areas and transmission paths leading therefrom, therefore, are to be auscultated systematically, the examiner meanwhile being guided by these cardinal clues to the identity of organic murmurs in general: that at the mitral and tricuspid areas systolic murmurs mean incompetence, and presystolic murmurs, obstruction, of the auriculoventricular orifice; that at the aortic and pulmonic areas systolic murmurs indicate obstruction, and diastolic murmurs, incompetence, of the arterial outlet of the ventricle; and that, as a rule, the bruits of obstruction are intense and harsh and clear cut, while those of incompetence are relatively feeble and soft and indistinct.

With these facts in mind, it is convenient to investigate the individual murmurs heard over the precordia according to their relation to the four auscultatory sites thereupon. More detailed consideration, pathologic and clinical, of the individual endocardial lesions whereby murmurs are generated is given in Section VI. (See p. 427.)

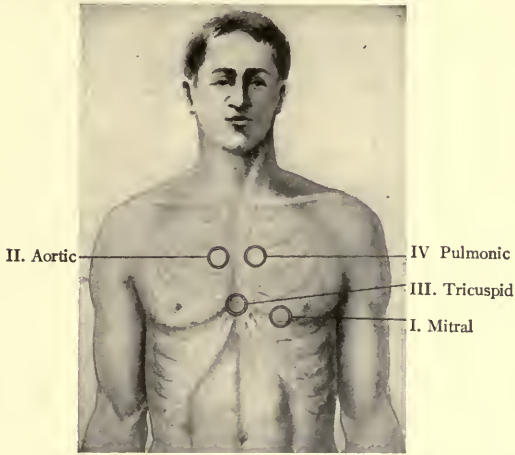


Fig. 152.—Comparative incidence of organic murmurs at the different valve areas. (Cf. Fig. 150.)

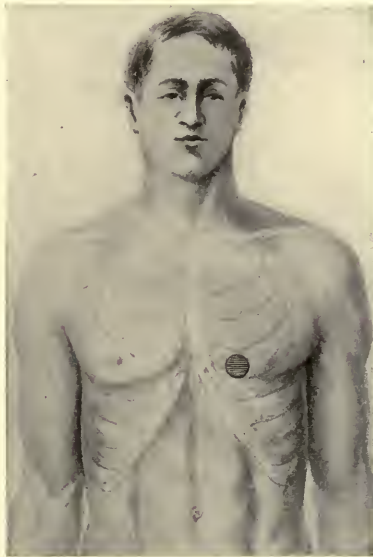


Fig. 153.—The mitral presystolic murmur.

Mitral Murmurs.—Murmurs due to lesions of the mitral orifice may be of either *presystolic* or *systolic* rhythm, the former being

audible just before the cardiac first sound and indicating obstruction, and the latter being synchronous with the first sound and signifying incompetence.

Mitral Presystolic Murmurs.—*Mitral stenosis* accounts for an apical murmur produced by contraction of the left auricle, whereby the blood-stream is churned into sonorous vibrations as it is forced through a constricted auriculoventricular orifice into the ventricle. The rhythm of this murmur corresponds to the end of ventricular diastole, at which period the auricle's contractile force and the velocity of the blood-current are greatest; less commonly, it occurs earlier in the diastolic period, in which case the vibrations depend more upon the suction action of the ventricle, which is most powerful at the beginning of diastole, than upon the driving force of the auricle.

The mitral stenotic murmur has its punctum maximum just above and within the apex of the heart, is virtually not transmitted thence, and is usually accompanied by a distinct apical presystolic thrill (Fig. 153). In its typical form the murmur is loud, harsh, and ingravescent or crescendo (*i. e.*, gradually increasing in loudness as it progresses), and terminates in a sharp, snappy first sound; less commonly, it is quiet and soft, as in the "suction force murmur" of the early phase of diastole. Disappearance of the bruit, in that it indicates failing power of the left auricle, is of unfavorable import. Associated signs of mitral obstruction include accentuation and reduplication of the pulmonic second sound, and doubling of the apical second sound. Mitral incompetence and obstruction frequently coëxist, and ultimately tricuspid incompetence may supervene, in consequence of the stress imposed upon the right ventricle.

The *presystolic Flint murmur* of aortic regurgitation is audible in the mitral area to which it is practically restricted. For its production dilatation of the left ventricle and incompetence of the aortic valve are regarded as the essential factors. Owing to the enlargement of the ventricular cavity, the anterior cusp of the mitral valve is displaced, during diastole, from its accustomed mural position, so that it projects into the rising tide of blood within the ventricle, and consequently becomes the target of two blood-streams coming from opposite directions—one regurgitating through a leaky aortic orifice and the other issuing (normally) from the mitral opening. By this mechanism vibrations of the cusp are set up toward the middle or end of diastole, with the generation of a presystolic murmur and thrill appreciable at the apex. Flint's murmur lacks the sharp apical first sound and the intense ingravescence of the bruit of true

mitral stenosis, and, moreover, is invariably associated with the lesion of aortic regurgitation (*q. v.*).

A *pericarditic presystolic rumble* is occasionally audible at and for some distance above the apex, in subjects of plastic pericarditis, especially in children. It is most likely that this sound represents an auriculosystolic (presystolic) friction-rub, symptomatic of pericardial adhesion; it is attended by none of the valvular tonal changes peculiar to the bruit of mitral stenosis of the organic type (*q. v.*).

Mitral Systolic Murmurs.—*Mitral regurgitation* is responsible for the vast majority of all systolic murmurs audible at the apex of the heart, the sound betraying incompetence of the left auriculoventricular orifice, by fault of which each contraction of the left ventricle forces a part of its contained blood backward into the left auricle. The murmur thus produced blends with or masks the first cardiac sound, is commonly of a blowing character, and from its apical punctum maximum is transmitted toward the left axilla and sometimes to the left scapular angle by the continuous pathway of conduction formed by the anterior papillary muscles and the ventricular wall (Fig. 154). Accentuation of the pulmonic second sound is an important concomitant sign of this defect, which, as stated elsewhere, may be due to endocarditic or sclerotic changes, or purely to ventricular relaxation, leading to disparity between the size of the mitral opening and of the valve-leaflets that should guard it. It is well to remember that

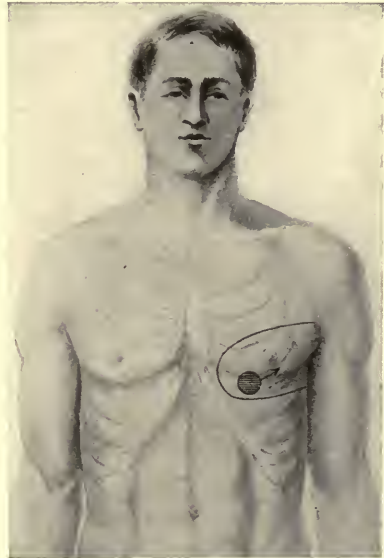


Fig. 154.—The mitral systolic murmur.

functional murmurs of mitral regurgitation vanish when the cardiac tone improves sufficiently to allow the mitral opening to resume its normal diameter, but that murmurs of organic mitral leakage are prone to become louder when the force of the heart increases.

Aortic Murmurs.—Both *systolic* and *diastolic* murmurs are audible in the aortic area in consequence of disease of the aortic

valve, those accompanying the first sound indicating obstruction, and those synchronous with the second sound, incompetence. Aortic systolic murmurs are more frequently due to sclerotic roughening and to dilatation of the aorta than to actual constriction of the orifice, while, less commonly, a systolic bruit in the aortic region means aneurism.

Aortic Systolic Murmurs.—True *aortic stenosis* causes a loud, harsh murmur at the aortic cartilage, the sound being transmitted thence into the arteries of the neck (Fig. 155). In typical instances the murmur is accompanied by a coarse thrill and the aortic second sound is notably enfeebled. Organic narrowing of the aortic orifice, at which fluid veins are agitated by each ventricular systole, explains the mechanism of this bruit, which rarely exists as an isolated lesion.

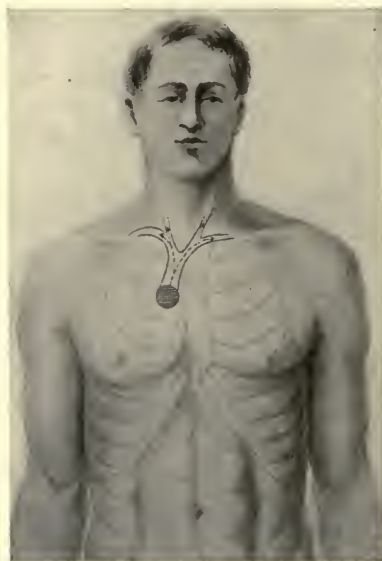

Fig. 155.—The aortic systolic murmur.

Aortic roughening, by all odds the commonest defect in this region, provokes a murmur of the same rhythm, site, and propagation as that of genuine stenosis, but it is not so frequently associated with a thrill, and the aortic second sound is loud, clear, and ringing. The mechanism of this bruit is shown by Fig. 163.

Aortic roughening, by all odds the commonest defect in this region, provokes a murmur of the same rhythm, site, and propagation as that of genuine stenosis, but it is not so frequently associated with a thrill, and the aortic second sound is loud, clear, and ringing. The mechanism of this bruit is shown by Fig. 163.

Dilatation of the aorta, producing a relative stenosis of the aortic orifice, and *aneurism of the aortic arch* produce systolic aortic murmurs, but in a dilated aorta one expects to find a corresponding area of local dulness, as well as an accentuated aortic second sound; while in aneurism there is usually no difficulty in discovering distinctive evidences of an aneurismal tumor. (See Fig. 163.)

Aortic Diastolic Murmurs.—Almost invariably these are symptomatic of *aortic regurgitation*, whereby the blood-column within the aorta falls backward, during ventricular diastole, through an organically incompetent orifice, and in so doing sets up a prolonged soft diastolic murmur, best heard at or below the aortic cartilage,

and propagated down the sternum and toward the apex or the left axilla. The five possible puncta maxima of this murmur are shown in the accompanying illustration (Fig. 156). Striking hypertrophy, and later dilatation, of the left ventricle develops in consequence of this lesion. *Relative aortic incompetence* is recognized by the presence of a diastolic aortic murmur like that of an organic regurgitation, and by the absence of the other hall-marks of the latter condition; relative leakage is, furthermore, attended by well-defined evidences of left ventricular dilatation and of enlargement of the ascending portion of the aortic arch. That, exceptionally, a diastolic *anemic bruit* may be clearly audible in the aortic area is a fact worth recalling.

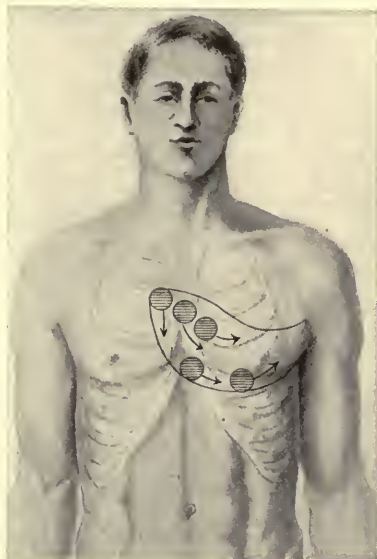

Fig. 156.—The aortic diastolic murmur.

Tricuspid Murmurs.—The tricuspid area affords both *presystolic* (stenotic) and *systolic* (regurgitant) murmurs, generated by a mechanism directly akin to that of corresponding adventitious sounds at the mitral orifice.

Tricuspid Presystolic Murmurs.—The punctum maximum of this extremely rare murmur, which never means anything but *tricuspid obstruction*, is at the base of the ensiform cartilage, either near the middle or along either border of the sternum, whence it is not conducted (Fig. 157). The murmur is like that of its mitral counterpart, both rhythmically and acoustically, and not uncommonly is accompanied by a presystolic thrill and by enfeeblement of the pulmonic second sound of the heart. A tricuspid presystolic murmur ordinarily signifies an acquired stenosis, though it may represent a congenital defect, either developmental or endocarditic.

Tricuspid Systolic Murmurs.—A tricuspid systolic murmur may be either circumscribed to its punctum maximum or conducted therefrom toward the right and upward (Fig. 158). Jugular pulsation of the ventricular or systolic type, hepatic pulsation, and

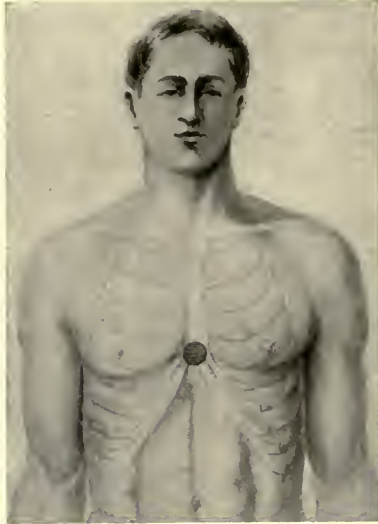

Fig. 157.—The tricuspid presystolic murmur.

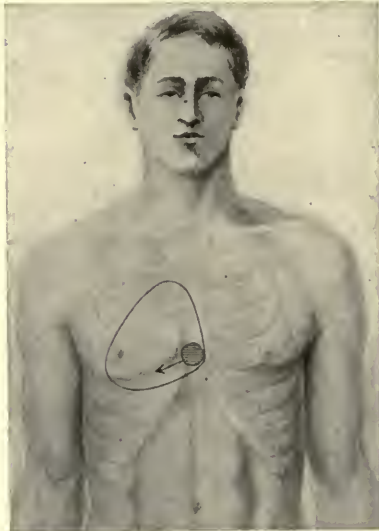


Fig. 158.—The tricuspid systolic murmur.

weakening of the pulmonic second sound are the important corroborative signs of this murmur of *tricuspid leakage*. This lesion is a very

common consequence of right ventricular dilatation, and, with less frequency, results from endocarditic deformity of the valve; in a limited proportion of cases the murmur is of anemic origin.

Pulmonic Murmurs.—Organic murmurs having their punctum maximum at the pulmonic area, like those of aortic origin, are either *systolic* and stenotic, or *diastolic* and regurgitant. Such murmurs are extraordinarily rare, though, as mentioned above, anemic bruits at the pulmonic orifice are not at all uncommon.

Pulmonic Systolic Murmurs.—Exceptionally, a *congenital stenosis* of the pulmonic orifice exists, to account for a harsh systolic murmur,

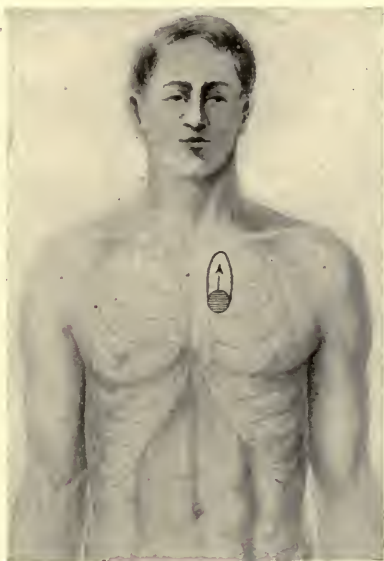

Fig. 159.—The pulmonic systolic murmur.

most intense at the pulmonic orifice and conducted upward toward the clavicle, or, if very intense, spreading over the upper left thoracic wall (Fig. 159). Impurity or suppression of the pulmonic second sound is a convincing attendant sign, and usually there is cyanosis, with more or less definite auscultatory evidences of other congenital cardiac defects, notably a pervious interventricular septum.

In addition to the pulmonic systolic murmurs of anemia and of organic constriction, similar sounds may arise from *relative stenosis* of the orifice, created by dilatation of the pulmonary artery immediately distal to its ventricular mouth, but in this condition the

murmur, which is likely to be soft and quiet, persists only so long as the arterial relaxation producing it lasts, and the patient is not cyanotic, but debilitated and poorly nourished.

In auscultating the pulmonic region one must not forget that this is the favorite site of a *cardiorespiratory murmur*, and that here also may be heard the bruits of *pulmonary artery stenosis*, of *aneurism*, and of a *patent interventricular septum*. In Section VI. the differentiation of these puzzling systolic murmurs is dealt with individually.

Pulmonic Diastolic Murmurs.—Organic *pulmonary regurgitation* is a clinical curiosity giving rise to a diastolic murmur of maximum

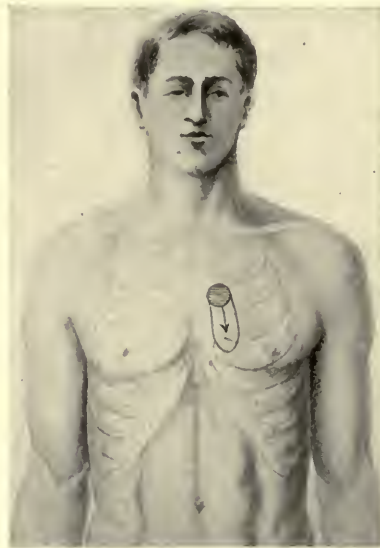

Fig. 160.—The pulmonic diastolic murmur.

intensity at the pulmonic area, and transmitted thence downward and sometimes toward the mitral region (Fig. 160). Also of rare occurrence is the diastolic murmur of *relative pulmonary incompetence*, or of leakage from stretching of the pulmonic ring incident to excessive pressure within the pulmonary artery. Aortic regurgitant murmurs are distinguishable only by a process of exclusion from these similarly timed murmurs of pulmonary regurgitation (*q. v. i.*).

Multiple Murmurs.—In organic disease of the endocardium two or more murmurs are commonly generated, owing to the tendency of endocarditic and sclerotic processes to attack more

than one valve, either simultaneously or consecutively. When they correspond to different periods of the cardiac cycle, it is comparatively a simple matter to recognize multiple murmurs by their different rhythms, but when the sounds are synchronous, their differentiation depends upon the detection of separate puncta maxima and lines of transmission, and upon careful study of individual sound-quality and other tonal attributes.

The basal "see-saw" bruit of *aortic obstruction* and *incompetence* is frequently associated with the apical systolic murmur of mitral leakage, and here, aside from differences in tone, rhythm, and maximum intensities, one observes three distinct lines of propagation—upward into the neck (aortic systolic), downward over the sternum (aortic diastolic), and toward the axilla (mitral systolic). A double lesion at the *mitral orifice* produces a rough presystolic apical rumble, continuous with a softer and longer systolic murmur, or apparently separated from it by a sharp, snappy cardiac first sound. In stenosis of *both mitral* and *aortic orifices* a presystolic apical and a systolic basal murmur are audible, the former being circumscribed at the mitral area, and the latter conducted upward. In the combination of *mitral stenosis* and *aortic regurgitation* the presystolic apical murmur of the former defect and the basal diastolic bruit of the latter sometimes commingle at the apex, but still are separable by their slight differences in rhythm and by their decidedly dissimilar quality and intensity. *Mitral* and *tricuspid regurgitation* in combination create a systolic murmur having a double punctum maximum, that of the mitral lesion being apical and that of the tricuspid, over the lower part of the sternum; between these two intensity points there lies a spot where neither murmur is distinct, as demonstrated by the clear mitral murmur on its apical side, and by the tricuspid bruit on its sternal.

Apart from differences in their several attributes, multiple murmurs must be discriminated largely by associated findings relating to structural changes in the cardiac chambers, to the peripheral pulses, to the pulmonary circulation, and to sequels such as edema, cyanosis, and dyspnea. Auscultatory findings without evidence of this sort can give but incomplete data regarding the character of a murmurous lesion and its effects upon the cardiovascular system.

EXOCARDIAL SOUNDS

Pericardial Friction.—Fibrinous roughening of the pericardial surfaces generates a friction-sound the characteristics of which are determined by the amount and viscosity of the exudate and by the

force of the cardiac impact. Ordinarily, this friction is most distinctly audible along the left sternal border, between the second and fourth interspaces (Fig. 161); less commonly it is most intense at or near the apex of the heart. The friction-sound is superficial, circumscribed, and usually increased by moderate, and perhaps obliterated by very forcible, pressure with the stethoscope; it is exaggerated when the subject bends forward in the upright position, and when he practises Valsalva's manœuvre of making forced expiratory efforts while the glottis is closed. The *rhythm* of pericardial friction is likely to be to-and-fro, corresponding to the movements of the heart rather than to the clinical cardiac tones with

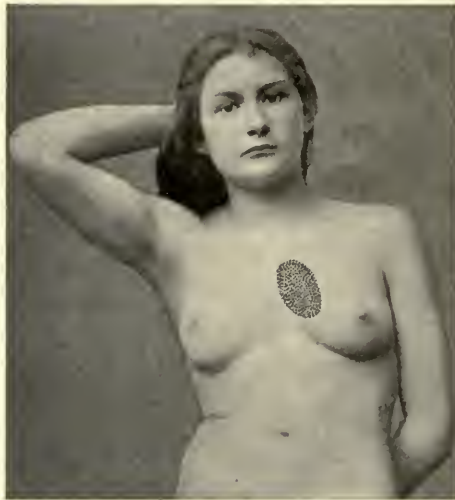

Fig. 161.—Punctum maximum of the pericardial friction-sound.

which it is not exactly synchronous; rarely, the sound is tripled by the addition of a presystolic element referable to auricular systole. The *intensity* and *quality* of a pericardial friction-sound vary greatly, according to the pathologic condition existing in the individual case: when greatly roughened and very dry pericardial surfaces are rubbed together by an overacting heart, the sounds thereby produced are loud, rasping, grating, or, indeed, not unlike the creaking of leather; when the exudate is moist and buttery, the sounds are fainter, and more liquid and clicking in quality. Pericardial friction is a curiously evanescent, inconstant sign, in that it may be detected one day and be absent the next, and may change its punctum maximum from

time to time. This point rises as an effusion collects, and should the exudate be of sufficient volume entirely to separate the two layers of the pericardial sac, the friction-sound may disappear, reappearing later, after removal or resorption of the fluid.

An *endocardial murmur*, in comparison with pericardial friction, is a softer, less superficial sound, accurately corresponding to an event of the cardiac cycle, and having a fixed punctum maximum and a definite line of transmission or area of localization; furthermore, pressure has no effect whatever upon an endocardial bruit, while Valsalva's experiment, as a rule, enfeebles it.

Pleuropericardial friction, though acoustically similar to a pericardial rub, bears a definite relation to the cardiac impulse and to the respiratory movements, is usually most intense at or just outside the pulmonary margin bordering on the triangle of cardiac flatness, and can be accurately circumscribed to the costal pleura or to the pericardial reflection, by noting the effect of full inspiration and expiration upon the sound. (See p. 168.)

Cardiorespiratory Murmurs.—When a segment of air-containing lung is compressed between the heart and the chest-wall the shock of the cardiac impulse may expel the air from the compressed pulmonary structure with sufficient velocity to create a precordial murmur, which almost invariably is of systolic rhythm. Such a sound is sometimes audible in apparently healthy subjects, especially in those whose cardiac action is tumultuous; pathologically, it is detected in emphysema, phthisis, external pericarditis, and massive pleural effusion, when in these conditions the anterior pulmonary margins (particularly the lingula of the left lung) are crowded, compressed, or adherent in front of the heart so as to receive the full force of the cardiac impact. Ordinarily a cardiopulmonary murmur resembles a short, subdued puff or whiff of air, but it may be relatively prolonged, loud, and rasping. It is evanescent in character, restricted to a limited area, intensified by deep inspiration and by forward inclination of the trunk, and variously modified by cough and by forced respiration. In children murmurs of this type account for two-thirds of all endocardial adventitious sounds.

The origin of diastolic cardiopulmonary murmurs is obscure, and probably the mechanism is not always the same. In some instances rapid aspiration of air into a patch of lung compressed during ventricular systole (Potain) serves as the most logical explanation, while in others the sound is best explained by assuming that adhesions between the lung and the heart or the aorta transmit a local suction force to the adherent lung at the period of cardiac diastole (Gallavardin; De Vivo). Should the portion of lung shar-

ing the heart's movements be the seat of an exudate or a transudate, moist cardiopneumatic râles also may be appreciable. (Cf. p. 166.)

Pericardial Succussion Sounds.—The presence of fluid and air within the pericardial sac, constituting that very rare clinical entity hydropneumopericardium, gives rise to a mélange of splashing, tinkling, gurgling, churning sounds audible over the precordia, and unmistakably produced by the movements of the heart. These sounds, also designated as the *metallic gurgle* and as the *bruit de moulin*, are sometimes so loud as to be appreciable at a distance from the patient; they may have a sharp metallic tone, and partly or entirely obscure the normal cardiac tones. Pericardial succussion sounds must be distinguished from somewhat similar noises created by the impact of the heart against the wall of an adjacent pulmonary cavity containing air and liquid, or against a left-sided hydropneumothorax.

VASCULAR MURMURS

Adventitious sounds may be heard over the larger arterial and venous trunks, occasionally in health, but more often in pathologic conditions. Such murmurs are explained by mural vibrations, by the formation of intravascular fluid veins due to a local anomaly of the vessel, and by the conduction of a bruit arising at a crippled cardiac orifice or within an aneurismal sac. Vascular murmurs may be systolic, diastolic, or to-and-fro; continuous or intermittent; and sighing, humming, musical, or harsh in quality, according to the factors of their production.

Arterial Murmurs.—If one of the larger superficial arteries (for instance, the carotid) be auscultated, the transmitted sounds of the heart are audible as dull, muffled systolic and diastolic beats, but if pressure with a stethoscope be made, so as to narrow the lumen of the vessel, the first sound becomes louder and distinctly murmurish, in consequence of the fluid veins formed by the local constriction (Fig. 162). By a similar mechanism an artery constricted by adhesions, by neoplasms, or by enlarged glands is also the seat of a systolic bruit.

A *systolic* murmur over the carotids is a confirmatory sign of aortic stenosis and of atheroma or aneurism of the aortic arch, the sound being conducted into the neck from its site of origin by means of the blood-current. A systolic murmur over the subclavian artery is sometimes audible in the healthy person, when the breath is held with the lungs fully inflated; and in apical phthisis a similar murmur may occur as the result of compression of the subclavian artery by a

fibrous band of adhesions. This subclavian murmur is usually most distinct on the left side, in the outer portion of the infraclavicular space. Systolic carotid and subclavian murmurs sometimes attend

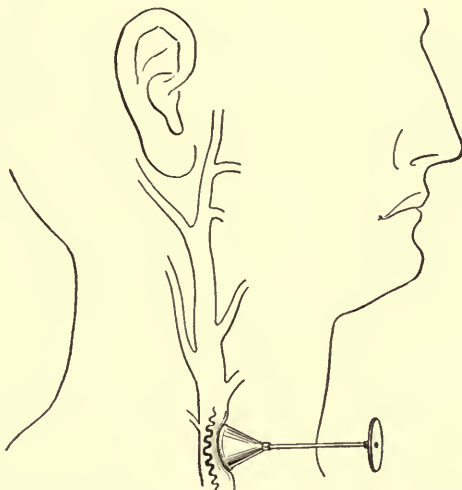


Fig. 162.—Mechanism of an arterial pressure murmur.

high-grade anemias. A *diastolic* murmur over the carotids and the subclavians is generally referable to the conduction of a bruit generated

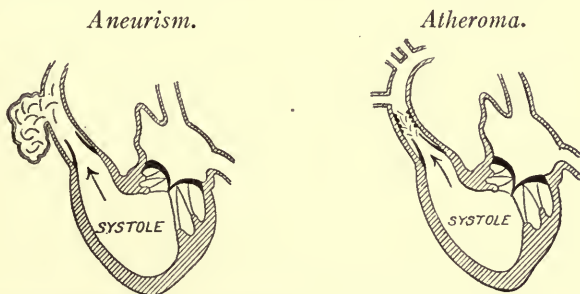


Fig. 163.—Mechanism of arterial murmurs due to aneurism and to atheroma.

at an incompetent aortic orifice, and a murmur of this sort is audible without the slightest compression of the vessel auscultated.

Duroziez's double murmur over the femoral artery is audible in many, but not in all, cases of aortic regurgitation. When the examiner

listens while the chest-piece of the stethoscope rests very lightly upon the vessel, a quiet dull systolic thud is heard, indicative of the sudden impact of the blood-column against the arterial wall; with moderate pressure a somewhat harsh, loud murmur, due to constriction of the vessel, replaces the thud first detected; and with still greater pressure, carefully graduated so as to produce just the proper degree of arterial constriction, the soft diastolic murmur of arterial reflux becomes audible. The double sound (normal systolic pressure murmur and diastolic reflux bruit) thus developed is designated as *Duroziez's sign*.

The Venous Hum.—This sound, also known as the *bruit de diable*, *nun's murmur*, and *humming-top murmur*, is heard most distinctly over the jugular vein at the inner end of the right supraclavicular space, whence, if the sound be intense, it may be transmitted to the base of the heart. In auscultation of the jugulars pressure upon the vessel must be avoided, for a fictitious murmur may be excited should the bell of the stethoscope compress the vessel sufficiently to constrict it, and thus to produce a fluid vein. Exceptionally a venous hum is audible over the courses of the lateral and longitudinal sinuses, over the liver, and over the subclavian and axillary veins.

A venous hum sounds not unlike the continuous musical souging of the wind through bare tree-tops, or the æolian-like buzz of a mass of telegraph wires swept by a breeze. More rarely it is fitful, intermittent, and blowing in character. The murmur has a rhythmic, crescendo quality during forced inspiration, at the time of cardiac diastole, and when the patient is in an upright position, for under these circumstances the jugular current heartward is accelerated. It is intensified when the patient turns the head sharply away from the examiner, thus compressing the vein and narrowing its lumen. There are several possible factors of the venous hum, none of which is a wholly satisfactory explanation of the sign. In anemia the hydremia no doubt plays a part, for thin blood flows with increased rapidity and tends to form whirling jets; but a more important factor in this condition is the nutritional relaxation of the walls of the veins, whereby rapid mural vibrations are provoked. Chauveau's theory is no longer seriously entertained—that in anemic states there is a sort of compensatory contraction of the veins because of the oligemia, except where the jugular bulb is attached to the cervical fascia, at which point a relative dilatation exists, and here fluid veins are formed. Lorrain Smith's work argues a decided increase of the blood-mass in chlorosis, and no great diminution of

it in pernicious anemia, and these are the very conditions of which venous hums are most frequently symptomatic.

The venous hum is not necessarily a pathologic sign, since it is present occasionally in perfectly healthy persons, especially in the young. It usually means anemia, however, and is particularly suggestive of chlorosis and of Addisonian anemia. No definite relation is apparent between the incidence and the intensity of the sign and the grade of the blood deterioration.

SECTION VI

DISEASES OF THE CARDIOVASCULAR SYSTEM

PERICARDITIS

RHEUMATIC fever is the most common single factor of pericarditis, although it is difficult to determine how active a cause it is, owing to the wide divergence in the percentages (6 to 75) given by different authorities; averaging these data, it seems safe to conclude that from 30 to 40 per cent. of all cases of rheumatism are attended by pericardial inflammation. This complication is prone to appear during the initial attack of rheumatism, and bears no constant relation to the number or intensity of the articular lesions, though it appears to be especially frequent when the joints of the upper extremity are attacked. Nephritis, gout, diabetes, and the hemorrhagic diseases are active exciting causes of pericarditis, which also not uncommonly attends pneumonia and scarlatina, and, with less frequency, other febrile infections, such as septicemia, erysipelas, variola, diphtheria, measles, and enteric fever. A pericardial inflammation may be secondary to pleurisy, bronchitis, tonsillitis, myocarditis, or valvular disease of the heart (especially aortic regurgitation), or it may develop in consequence of some neighboring or remote septic process—costal necrosis, mediastinal abscess or neoplasm, empyema, malignant endocarditis, gastric or esophageal ulcer, or peritonitis. Tuberculous pericarditis occurs both in a primary form and as a secondary process, usually in connection with pleuropulmonary tuberculosis. Chorea, even when unaccompanied by arthritic rheumatism, is not uncommonly the apparent cause of a pericardial inflammation. Traumatic pericarditis, mainly of surgical interest, sometimes supervenes in consequence of a penetrating wound of the heart or of a violent precordial contusion.

ACUTE FIBRINOUS PERICARDITIS (*Acute Plastic Pericarditis*)

Clinical Pathology.—In this type of pericarditis the visceral and parietal layers of the pericardium are covered, universally or in patches, with a fibrinous exudate attended by little or no serous effusion, the underlying serosa being dull, swollen, hyperemic, and

often ecchymotic. In recent cases of mild grade the fibrinous exudate is represented by a delicate pliable membrane of yellowish-gray color and readily detachable from the underlying serous surface, but in older lesions the deposit is thick, tough, and firmly adherent. Owing to the movements of the heart, the exudate presents a ridged or roughened or shaggy appearance, in some instances matted and meshed like two buttered surfaces which have been pressed together and then separated, while in other instances innumerable shreds of fibrin attached to the pericardium produce the peculiar shagginess distinctive of the so-called "hairy heart," known as the *cor hirsutum* or *cor villosum*. Myocardial inflammation occurs in severe cases and may be attended by dilatation, but in mild pericarditis no muscular changes arise.

Physical Signs.—*Inspection.*—This shows nothing characteristic, but it is commonly observed that the apex-beat is rapid, heaving, and unnaturally diffuse, that the respirations are hurried and irregular, and that the patient's face shows anxiety and pain. Diastolic pulsation near the second left interspace is a frequent sign in incipient cases (*v. i.*).

Palpation.—With more or less constancy vibrations produced by the to-and-fro rub of the roughened pericardial surfaces are felt, especially toward the base of the heart. This tactile equivalent of the friction sound is usually more intense when the subject is erect than when dorsal recumbency is assumed, and can sometimes be exaggerated by moderate, and obliterated by forcible, pressure with the palm of the hand. Unlike an endocardial thrill, pericardial friction fremitus is a very superficial vibration, does not exactly coincide with the cardiac beats, and has a peculiar grating quality quite unlike the purring vibrations of an eddying blood-stream. (See p. 328.)

Percussion.—In so far as it relates to the pericardial inflammation, percussion is wholly negative, although in the presence of cardiac dilatation, which may develop as a consequence, a corresponding extension of the precordial area can be mapped out.

Auscultation.—The pericardial friction-sound is characteristic of pericardial inflammation, if three other potential, though rare, factors of such a sound can be excluded: excessive dryness and viscosity of the pericardium, as in Asiatic cholera, and the existence of pericardial ecchymoses and milk-spots. Since the pericardial friction-sound has been discussed at length in another place (p. 389), it is sufficient here to note, in passing, that ordinarily the sign is most distinctly heard at the cardiac base and along the left sternal border; that it has a double rhythm not exactly synchronous with

that of the heart; that it resembles a surface sound, more or less influenced by local pressure and by the force of the cardiac impact; and that its quality ranges between that of a soft papery rustle and that of rude parchment-like grating or even of creaking leather—*bruit de cuir neuf*.

Diagnosis.—The friction-sound, precordial pain, and moderate fever are the three physical signs pointing to acute plastic pericarditis. An intense clanging accentuation of the pulmonic second sound (Turrettini's *éclat clangoreaux diastolique*) accompanies, if not precedes, the friction-sound in many instances, especially those in which the infection is circulatory rather than by extension from a pleuritis. The pleuropericardial friction-sound of *pleurisy* differs from a true pericardial rub in being most intense along the left edge of the heart, and in having the characteristics of a cardiopulmonary sound which is definitely affected by the different respiratory phases in the manner elsewhere explained. (See p. 168.) In differentiating a murmur of *endocarditis* the punctum maximum, area of transmission, pulse peculiarities, cardiac tonal changes, and attendant myocardial alterations are the dependable criteria. (See p. 374.)

SEROFIBRINOUS PERICARDITIS (*Serous Pericardial Effusion*)

Clinical Pathology.—In this type an initial stage of dry serositis is soon succeeded by the escape of an abundant serofibrinous effusion from the engorged capillaries, the serum thus poured out collecting within the pericardial sac and the fibrin being deposited upon the serous surfaces in the form of a coating of variable thickness and distribution. The effusion may be virtually a clear serous fluid, but, as a rule, it is more or less opaque from the presence of fibrin-flakes and leukocytes, while in conditions of cachexia, in tuberculosis, and in malignant disease the liquid is not unlikely to be blood stained. The volume of the effusion may range from a few ounces to 10 (300 cc.) or more; exceptionally, as in the case of gradually accumulating effusions, it amounts to, or even exceeds, a quart (1000 cc.). Chemically and microscopically, a pericardial exudate does not differ materially from inflammatory fluids derived from other serous membranes. (See p. 53.) Complete absorption of an effusion containing little or no fibrin may leave the pericardial serosa practically unimpaired, but as a rule sufficient plastic material remains after the absorption of the serous exudate to cause a variable degree of fibrous union between the opposed serous layers. Local deposits of organized fibrin are recognized as *milk-spots* or indurated white opaque areas on the visceral pericardium. The myocardium shows degenerative

or inflammatory changes, and endocarditis commonly coexists, usually in consequence of the same factor responsible for the pericarditis, but exceptionally arising by extension of the serosal inflammation through the myocardium.

Physical Signs.—*Inspection.*—In the young child a large effusion causes unnatural prominence of the precordia, but the more rigid chest-wall of the adult does not perceptibly bulge in this manner. The apex-beat, if not wholly obscured by the effusion, is visibly enfeebled and displaced from its accustomed site. Ordinarily, there is pulsation an interspace or two above the normal apical area,¹ though sometimes the apex-beat is lowered, owing to depression of the diaphragm by a copious, heavy exudate within the pericardial sac. In this event there may be also a local epigastric prominence (*Auenbrugger's sign*), due to descent of the left lobe of the liver. *Ewart's sign*, or prominence of the sternal end of the left first rib with elevation of the head of the clavicle, is a finding of some suggestiveness. Other associated signs, of variable constancy, include restriction or abolition of the diaphragm shadow, left unilateral diminution of expansion, and rapid, difficult breathing, sometimes amounting to orthopnea. There may be cyanosis or chalky pallor, engorgement of the veins of the neck, and pressure phenomena, such as extreme precordial oppression and pain, distressing cough, dysphagia, hoarseness, and even aphonia.

The detection by the fluoroscope of the normal inspiratory clear zone between the diaphragm and the cardiac apex is proof positive of no fluid in the pericardial sac. Little or no transmission of ventricular pulsation to the air bubble in the stomach is a röntgenoscopic sign upon which Maragliano lays stress in the diagnosis of an intervening mass of pericardial fluid.

Palpation.—The palpating hand confirms the findings noted by visual examination, particularly those relating to precordial fulness, the apical impulse, the respiratory embarrassment, and the altered anatomic relations on the left side. In some instances basal friction is palpable, despite the accumulation of considerable fluid in the pericardial sac.

The *pulse* is usually found to be of increased frequency, low tension, and disordered rhythm. Though by no means pathog-

¹To all intents and purposes this represents the apex beat, though, as Ewart insists, there is good reason, in some instances, to attribute the impulse to the impact of the body of the right ventricle. Calvert's recent researches show that the position of the heart depends chiefly upon its size, the apex remaining in the normal position so long as compensation is preserved and the size of the heart is unaltered, but being displaced backward and toward the right when, with failing compensation, the heart becomes unduly small by fault of a diminished blood-supply.

nomonic, the pulsus paradoxus, which dies out at the end of inspiration, is a sign of some corroborative value in the diagnosis of a large effusion. (See p. 338.)

Percussion.—Percussion reveals an unnaturally large area of cardiac flatness, which in a bulky effusion may conform to the outline of a pyramid having its base downward and its apex in the upper sternal region. Diminution in the size and alteration in the shape of this area of flatness are occasionally demonstrable when the subject changes from an erect posture to dorsal decubitus. The normal acuteness of the cardiohepatic angle is made obtuse by the sagging of the pericardial sac, and flatness is substituted for the resonance normally found in the fifth right interspace at the sternal border—*Rotch's sign*. An effusion of too moderate a size to produce well-defined precordial flatness will afford this suggestive area of flatness in the space between the borders of the heart and the liver. (See Fig. 134.) The upper inner angle of Traube's space may be encroached upon by an effusion of large volume. It may be possible to delimit an obtuse angle formed at the level of the third costal cartilage by the normal area of supracardiac vascular dulness and the left border of pericardial flatness—*Sibson's notch*. Compression of the lower lobe of the left lung by an effusion of large volume may produce, in the left infrascapular region, a small patch of dulness over which increased vocal fremitus, bronchophony, and bronchial breathing are detected when the patient sits erect, but not when he leans forward, lies in right lateral decubitus, or assumes the knee-chest posture (Bamberger; Pin); or there may be dulness, with abolished voice and respiratory sounds, at the base of the left lung alongside the spine (Ewart). In certain instances a circumscribed patch of bronchial breathing is audible in the right mammary region below the nipple. Compression of the left lung by a large effusion may account for a midaxillary area of dulness or of skodaic resonance, over which the voice and breath-sounds are either suppressed or greatly exaggerated, and this group of signs also is decidedly affected by postural changes.

Auscultation.—The cardiac sounds are indistinct, muffled, or inaudible, except at the base, where increased intensity of the second sound is the rule. Here also friction-sounds are prone to persist, in contrast to the auscultatory silence over the precordia below this level. With absorption of the exudate, however, a corresponding increase in the extent of the friction area is to be expected, with reappearance of the cardiac-sounds. The various modifications of the respiratory sounds audible over patches of compression atelectasis have been mentioned in the preceding paragraph.

Diagnosis.—Displacement and enfeeblement of the apex-beat, an enlarged precordial area of pyramidal outline, flatness in the cardiohepatic angle, muffling of the heart-sounds, and evidences of pulmonary compression are the principal diagnostic signs of an effusion in the pericardial sac.

In differentiating *cardiac dilatation* it is helpful to remember that the apex-beat of a dilated heart marks the extreme lower and outer limit of the cardiac outline, and does not lie well within this boundary, as it does in a pericardial effusion; and that the flatness of a dilated heart, though exceptionally pyramidal, is generally of ovoid shape, does not extend so high as the flatness of an effusion, and shades off gradually into the surrounding pulmonary resonance, so that no sharp line of demarcation between the two is appreciable, as is usually the case with effusion flatness. A history of chronic valvular disease or of myocarditis suggests dilatation, just as a story of rheumatic fever and acute plastic pericarditis is in favor of effusion. Neither the character of the apical impulse nor the effect of postural changes on the area of cardiac flatness is a reliable differential point; and the cardiohepatic angle may be dulled by a dilated right ventricle.

A left *pleural effusion*, especially when encapsulated near the heart, may suggest a pericardial effusion of large volume, but ordinarily a confusion of this sort is disposed of without difficulty. Pleurisy is indicated by the history of an acute stitch in the side, a pleural friction-sound, Grocco's sign, flatness over the anterolateral and generally the posterior regions of the thorax, and by the failure to discover such important pericarditic signs as basal friction, extension of precordial flatness, and enfeeblement of the cardiac tones. In the event of a puzzling group of physical signs, as in the case of coëxisting pericardial and pleural effusion, the x-ray may settle the diagnosis beyond all question.

Exceptionally, enlargement of the area of cardiac flatness is referable to *pulmonary retraction*, to *aortic aneurism*, or to *mediastinal neoplasm*, but none of these conditions creates pyramid-shaped flatness, and each of them is attended by physical signs and by a clinical history that, if intelligently reviewed, are sufficient for differentiation.

PURULENT PERICARDITIS (*Pyopericardium*; *Empyema of the Pericardium*; *Pericardial Abscess*)

Clinical Pathology.—This most grave variety of pericarditis, characterized by an effusion of pus within the pericardial sac, is more frequent in children than in adults, and generally is traceable to

pyemia, to some neighboring local purulent focus, or to an acute specific infectious process like pneumonia or tuberculosis. The exudate varies in character according to conditions prevailing in the individual case, being in some a thin limpid liquid and in others a collection of creamy material containing a minimal amount of serum and fibrin and composed chiefly of pus cells, the extraordinary number of which constitutes the striking difference between this and the ordinary serofibrinous type of effusion. The pus is but rarely absorbed spontaneously, although sometimes the more liquid portions are thus disposed of, leaving an amorphous mass of caseous matter tending ultimately to undergo calcification. Instrumental evacuation of the pus results in permanent adhesion of a variable area of the two pericardial layers, already unduly thickened and granular from the intense purulent inflammation by which they have been attacked. Spontaneous evacuation of a pericardial abscess, as, for example, by its discharge through the chest wall or into the mediastinal cavity, is a possible, but very remote, sequel, should the patient live. It is obvious that the myocardial changes in purulent pericardial effusions must be of greater intensity than those attending simple serofibrinous exudates, and in some instances purulent infiltration of the heart muscle takes place.

Physical Signs.—The aspirating needle is the only certain means of distinguishing a purulent from a serofibrinous pericardial effusion whose local subjective signs are practically identical. On academic grounds it is sometimes taught that extreme precordial bulging and hepatic displacement, with local edema or even discoloration, mean pus in the pericardial sac, but, clinically, this dramatic symptom-group virtually never appears. It is not unusual, however, to find great prostration, rapid emaciation, recurrent rigors, widely fluctuating fever, leukocytosis, and iodophilia in purulent cases, together with a history of some cause capable of setting up a purulent inflammation. But inasmuch as the foregoing evidence is more often equivocal than definite, pericardicentesis, in the vast majority of cases, is the key to the situation. (See p. 54.)

CHRONIC ADHESIVE PERICARDITIS (*Adherent Pericardium; Mediastino-pericarditis*)

Clinical Pathology.—Pericardial adhesions, formed by the organization of inflammatory material, ordinarily are the relic of a well-defined attack of acute pericarditis, but in some instances the fibrosis arises insidiously, with no authentic history of a primary inflammation. In either event the process is essentially of a chronic

nature, and, in accordance with its anatomic distribution, is separable into two principal groups, the internal and the external, which types, it is to be remembered, are frequently combined. *Internal pericardial adhesions*, confined to the pericardial sac, commonly exist as scattered fibrous strands or filaments connecting the parietal and visceral layers of the pericardium, which also is generally the seat of considerable thickening and induration. These strands vary in length according to their situation, being longest near the apex of the heart, where the cardiac excursions exert the greatest traction, and, as the result of this strain, a filament may be torn from one of its attachments, so that it dangles free in the pericardial cavity. In some cases the adhesions are represented merely by a few patches of simple union between the two membranes, and in others a moderate fibrosis of the pericardium, rather than actual adhesions, is the predominant lesion, conditions such as these often being quite symptomless and leading to no damage to the myocardium. In contrast to these relatively benign local processes, it occasionally happens that the parietal and visceral pericardium are universally adherent, thickened, and tightly welded into a single structure, the normal pericardial sac being, in consequence, entirely obliterated, and to this condition the term *adherent pericardium* is applicable. Investment of the heart by an unyielding bony capsule supervenes when an adherent pericardium undergoes calcification, as is the case in exceptional examples of this type of fibrosis. In early life the incessant compression exerted by a dense and firmly contracting adherent pericardium is capable of causing actual atrophy of the heart. *External pericardial adhesions*, almost always attended by internal union of the layers, may anchor the outer surface of the pericardium to the adjacent chest-wall, the pleura, the diaphragm, and the mediastinal structures—a most serious condition of *indurative mediastinopericarditis* (*q. v.*), tending to cause great hypertrophy and dilatation of the heart, advanced myocardial degeneration, and sometimes to provoke inflammatory implication of the subphrenic structures. The cardiac enlargement commonly but by no means invariably met with in the different types of chronic adhesive pericarditis, especially when external adhesions exist, is attributable to several factors: hypertrophy and subsequent dilatation may be due to mechanical interference with the movements of the heart, to compression stenosis of large arterial trunks, or to associated valvular defects, while pure dilatation is frequently set up by the coexisting myocarditis. The right ventricle, being relatively weak, thin-walled, and predisposed anatomically to external adhesions, is likely to be

damaged more seriously by these structural changes than the left ventricle.

Physical Signs.—*Inspection.*—Visual examination may discover practically all the important evidences of chronic adhesive pericarditis, or those referable to fixation of the heart to neighboring structures and to the direct tug upon different parts of the chest-wall produced by the contractions of the adherent organ. There may be no physical signs whatever of adherent pericardium, in the absence of adhesions between the external layer of the sac and the thoracic wall, diaphragm, and pleura. In the presence of extensive adhesions there is fixation of the apex-beat, which being restricted and bound down by fibrous tissue, cannot gravitate toward the dependent side when the subject changes from left to right lateral decubitus or vice versâ, nor can it descend at the close of a full inspiration. Systolic retraction of a small area of the thoracic surface in the neighborhood of the apex is also noted; rarely a similar recession of several interspaces and their corresponding costal cartilages to the left of the sternum, and even retraction of the lower part of this bone are perceived. Sometimes there is a decidedly undulatory precordial impulse—*Sander's sign*. J. F. H. Broadbent has described, as a pathognomonic sign of extensive pericardial adhesions, systolic retraction of the tenth and eleventh intercostal spaces in the left infrascapular region, and also, less commonly, of the seventh and eighth interspaces anteriorly—*Broadbent's sign*. (See p. 324.) Under the same circumstance Sir William H. Broadbent has noted that the normal epigastric movements during respiration are greatly hampered, if not quite abolished. *Friedreich's sign* (diastolic collapse of the jugular veins) and *Kussmaul's sign* (inspiratory jugular turbulence) are inconstant findings, in no wise distinctive of adhesive pericarditis. (See p. 326.) As the right ventricle fails, dyspnea becomes distressing, cyanosis appears, and edema and other forms of dropsy develop. Anasarca and effusions into the peritoneum and the pleura have been observed as the effect of pressure upon the large azygos vein (J. Lloyd Roberts).

Palpation.—Exceptionally, a diastolic shock is felt over areas that show systolic retraction, and this sign, due to the sudden rebound of the chest-wall directly after systole, is regarded as diagnostic. As in pericardial effusion, the pulse in adhesive pericarditis not uncommonly conforms to the paradoxical type. The fixed position of the apex-beat is clearly appreciated by palpation.

Percussion.—The area of cardiac flatness may be increased, commonly in all directions, the increase being referable both to the

enlargement of the heart and to fibrosis and retraction of the anterior margins of the lung. If the latter be anchored by pleuropericardial adhesions, comparative percussion will fail to show the diminution of cardiac flatness which occurs normally at the end of a full inspiration. Dulness in the cardiohepatic angle has been found in adhesive pericarditis, as well as in pericardial effusion (*q. v. s.*).

Auscultation.—There are no definite auscultatory evidences of true adherent pericardium, but in mediastinopericarditis there may be a peculiar creaking friction-sound audible over the sternum during up-and-down movements of the subject's arms (Perez; Babcock). (See p. 168.) A pericarditic friction-sound, not unlike the presystolic rumble of mitral stenosis (*q. v.*), is present in some cases, but not with any degree of constancy. In the presence of extensive adhesions pleuropericardial friction-sounds are commonly heard over the anterior pulmonary borders surrounding the body of the heart. The cardiac sounds are those of hypertrophy or of dilatation, according to which condition predominates.

Diagnosis.—Fixation of the apex-beat, immobility of the anterior pulmonary borders, systolic retraction and diastolic shock, cardiac enlargement, pericarditic friction, paradoxical pulse changes, and phenomena relating to the jugular veins form a combination of signs that unmistakably indicates chronic pericarditis with extrapericardial adhesions, and in such cases a history of previous pericarditis is usually obtainable, to make the diagnosis doubly certain. As noted above, simple internal adhesion of the two pericardial layers is essentially a latent process, giving rise to no distinctive symptoms nor physical signs. In doubtful cases—and these are numerous—one can venture only a provisional diagnosis, based upon a history of pericardial inflammation, and upon a clinical picture of chronic circulatory failure, respiratory distress, right ventricular dilatation, and, sometimes, friction-sounds over the precordia.

Pericarditic hepatic pseudocirrhosis, associated with ascites and with a hard, contracted liver, counterfeits ordinary alcoholic cirrhosis of this organ, especially in those cases in which the cardiac phenomena are latent or overshadowed by those of portal obstruction. In this differentiation, apart from the cardiac signs, Laennec's cirrhosis is suggested by a history of alcoholism or of syphilis, by a symptomatology characterized by long-standing gastro-intestinal catarrh, hematemesis, melena, and hemorrhoids, and by the appearance of ascites followed by edema of other parts. In contrast, Pick's pseudocirrhosis is indicated by a history of rheumatism, by symptoms referred to the heart, and by the onset of edema of dependent parts prior to the development of ascites.

HYDROPERICARDIUM (Pericardial Dropsy)

Hydropericardium is usually part of general dropsy, cardiac or renal, but it may arise in consequence of the pressure of an aneurism or of a mediastinal neoplasm. Under exceptional circumstances the fluid, instead of being a clear serum, is milky from the presence of chyle—*chylopericardium*. The transudate seldom attracts attention, for, being non-inflammatory and of moderate volume, it does not readily to provoke conspicuous objective symptoms. *Physical signs*, when present, include moderate dyspnea and perhaps precordial uneasiness, with the flatness of a liquid pericardial effusion which most readily shifts with changes of posture, and which is unaccompanied by friction, fever, pain, or precordial prominence. These peculiarities plus a story of cardiorenal disease and the discovery of subcutaneous dropsy or of hydrothorax, serve to differentiate hydropericardium from a pericarditic effusion.

HEMOPERICARDIUM (Pericardial Hemorrhage)

Hemopericardium, or free hemorrhage into the pericardial sac, is a rare and rapidly fatal accident, and one to be clearly distinguished from the hemorrhagic pericarditic effusions sometimes met with in tuberculous, cancerous, and cachectic subjects (see p. 398). Ordinarily hemopericardium is due to the bursting of aneurism springing from the intrapericardial portion of the aorta or from a coronary artery; exceptionally the blood pours out from a chamber of the heart ruptured by fault of advanced myocardial destruction; and sometimes the hemorrhage follows a wound of the heart. In any event the *physical signs* are those of effusion, and are attended (as well as overshadowed) by acute dyspnea, precordial pain, shock, and circulatory failure.

PNEUMOPERICARDIUM (Pyopneumopericardium; Hydropneumopericardium; Hemopneumopericardium)

Pneumopericardium, or the presence of gas within the pericardial sac, is almost invariably associated with a liquid effusion, usually purulent (*pyopneumopericardium*), sometimes serous (*hydropneumopericardium*), and exceptionally hemorrhagic (*hemopneumopericardium*). The affection usually depends upon the entrance of air through a traumatic breach or by way of a fistulous tract leading from a neighboring organ, but the pericardium may fill with gas generated by the decomposition of an exudate therein. Owing

to the practical constancy of bacterial contamination, purulent pericarditis is a very frequent complication. The direct effect of pneumopericardium is distention of the pericardial cavity with gas and with liquid, the former occupying the upper, and the latter filling the lower, part of the space. This distention, if decided, leads to embarrassment of the cardiac action and to displacements of the heart, lungs, and diaphragm similar to those met with in ordinary liquid pericardial effusions.

The *physical signs* vary with the degree of pericardial distention and with the character and the volume of the exudate. The precordial interspaces are leveled or bulged and the precordia itself may be unnaturally prominent; the apex-beat is obscure, if not wholly effaced, but it may become both visible and palpable when the subject leans forward so as to bring the heart closer to the parietes. There is tympany (perhaps with a metallic or a cracked-pot tone) over the upper part of the cardiac area, with flatness below, as the liquid effusion accumulates, the relative positions of these two areas being modified by postural changes. Auscultation, which affords most distinctive signs, reveals more or less pericardial friction intermingled with a medley of churning, splashing, tinkling sounds, among which can be distinguished the hard tone of the *metallic gurgle* and the liquid purl of the *bruit de moulin* (see p. 392). These adventitious sounds, synchronous with the movements of the heart, may effectually mask the cardiac tones, and the rising pericardial exudate has a similar effect. Extrême pneumopericardial distention is likely to cause great dyspnea, cyanosis, severe precordial oppression and pain, distressing palpitation, syncopal attacks, and a small, erratic pulse; but in less urgent cases the picture is very like that of pericarditis.

Pneumopericardium must be distinguished from *left pneumothorax* and from *gaseous distention of the stomach*, the differentiating points in the first instance being a displaced and pulsating cardiac area associated with metallic and splashing sounds of palpably respiratory origin, and in the second instance the disappearance of similar adventitious sounds immediately after the passage of a stomach-tube to remove the gas.

CARDIAC HYPERTROPHY

Clinical Pathology.—An adequately nourished heart subjected to habitually increased work in time undergoes hypertrophy, or an increase in its muscular structure, this enlargement being designated

as *general* or as *partial*, according to its distribution. Not infrequently a single chamber is affected, or the change may be restricted to one entire side or to a chamber on each side, while a still sharper limitation of the hypertrophy to a small local area of the heart is termed *circumscribed*. Pathologically, two well-defined types of cardiac hypertrophy are recognized: *simple hypertrophy*, or thickening of the cardiac wall with no deviation from normal in the size of the corresponding chamber; and, *eccentric hypertrophy*, in reality hypertrophy with dilatation, characterized by thickening of the wall with enlargement of the chamber. So-called "concentric hypertrophy," or thickening of the wall with diminution in the size of the cavity, is a fictitious condition, created no doubt by arrest of the heart's action during systole or by postmortem ventricular contraction.

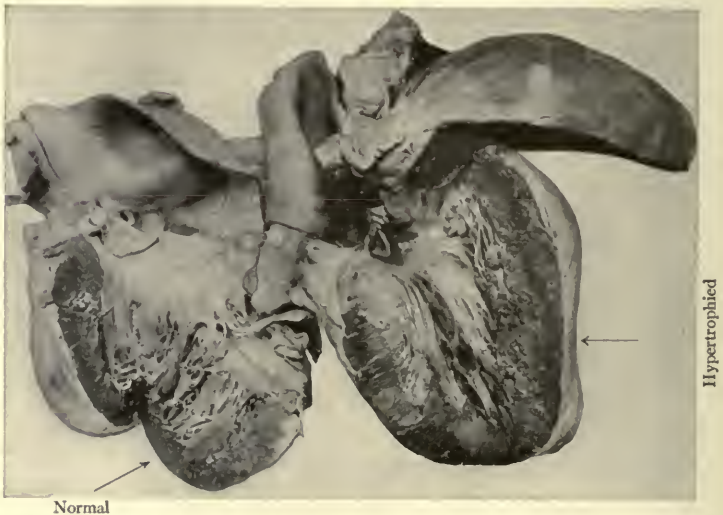


Fig. 164.—Comparative sizes of the ventricles in a normal and a hypertrophied heart (Philadelphia General Hospital).

The weight, size, and shape of a hypertrophied heart deviate from the normal according to the degree and site of the enlargement. In examples of moderate hypertrophy the normal average weight is commonly doubled, and in extreme instances is exceeded four- or five-fold, as in the enormous "ox-heart" hypertrophy, or *cor bovinum* (Fig. 164). Corresponding increase in the thickness of the cardiac walls develops, even in eccentric hypertrophies, despite the apparent parietal thinning referable to the coëxisting dilatation. The papillary

muscles and the muscular columns within the ventricles are thickened and diminished in resiliency. When there is predominant hypertrophy of the left ventricle, the heart becomes elongated and the apex unduly blunt and displaced downward and to the left; when the right ventricle is enlarged, the contour of the heart becomes more spherical than normal, the breadth being conspicuously increased and the lengthening less apparent; hypertrophy of both ventricles causes commensurate elongation of the organ, with unnatural flatness, breadth, and bluntness of the apex; and in hypertrophy of the entire heart both the length and the breadth are exaggerated,

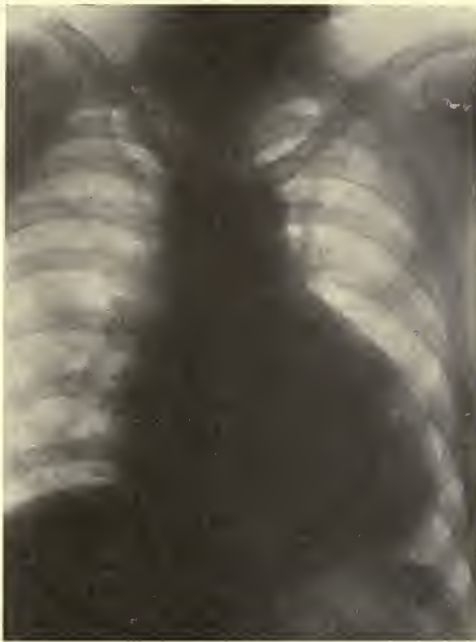

Fig. 164a.—Radiograph of cardiac hypertrophy and dilatation. (Plate by Dr. W. F. Manges.)

generally with approximate preservation of the normal contour. Pure hypertrophy deepens the color and increases the consistence and resistance of the cardiac muscle, but when fibrous and fatty changes coëxist, as is usually the case, the deep-red color of the hypertrophy becomes correspondingly paler, and the muscle undergoes more or less fibrous induration and fatty softening. The histologic changes in hypertrophy consist of an increase in the size of

the individual muscle-fibers, and, in all probability, of an increase in their number.

Left-sided and ventricular hypertrophies are more common than right sided and auricular, the four chambers of the heart being affected in the following order of frequency: left ventricle, right ventricle, right auricle, and left auricle. The causes of cardiac hypertrophy consist of arteriosclerosis, valvular and parietal affections of the heart, and persistent cardiac overaction due to various irritating influences.

General hypertrophy occurs in advanced age as the result of the increased peripheral resistance incident to senile arteriocalillary changes; it frequently attends myocardial fibrosis and adherent pericardium, which mechanically hamper the heart's movements; and it develops in conditions provocative of excessive cardiac frequency and force—*i. e.*, the tachycardia and palpitation excited by hyperthyroidism ("kropfherz"), by the neurosis termed paroxysmal tachycardia, and by nicotin, caffeine, and sexual excesses. Alcohol is an active cause of cardiac hypertrophy, since it not only stimulates the cardiac action and induces arteriosclerosis, but also, in the case of those who consume large quantities of malt liquors, adds to the heart's nutrition and increases its work by producing hydremic plethora. Prolonged physical exertion eventually leads to general hypertrophy, but especially to enlargement of the left ventricle. *Primary congenital cardiac hypertrophy* is, according to Virchow, in reality a diffuse myomatous neoplasia.

Left ventricular hypertrophy accompanies aortic stenosis, aortic regurgitation, and mitral regurgitation, for in the first lesion the ventricle labors hard to empty its contents, and in the other two it must propel an excessive volume of blood. Stenosis of the aorta and, less commonly, aortic aneurism, when they impede the main arterial current, are factors of left ventricular hypertrophy. Arterial hypertension in combination with mitral stenosis produces an extreme grade of left ventricular hypertrophy, even greater than that ordinarily met with in arterial sclerosis plus aortic lesions or chronic nephritis (Thomas Lewis). In states of arterial hypertension and general arterial sclerosis the left ventricle hypertrophies to overcome increased peripheral resistance.

Right ventricular hypertrophy is usually traceable to obstruction of the pulmonary circulation resulting either from mitral defects or from pulmonary cirrhosis, emphysema, or widespread pleural adhesions; less commonly, obstruction of the pulmonary orifice is the cause of the enlargement.

Auricular hypertrophy is invariably attended by dilatation; if left-sided, hypertrophy of the auricle means mitral disease, especially stenosis; while hypertrophy of the right auricle is generally due to intrapulmonary hypertension and its consequences, or, exceptionally, to organic tricuspid lesions.

Physical Signs.—*Left Ventricular Hypertrophy.*—On *inspection* the precordia may appear more prominent than normal if the subject be a child (Fig. 40, p. 89), and the apex-beat, which is violent and unnaturally extensive, is visibly displaced toward the left and downward. The precordial impulse is tumultuous, the arteries throb excessively, and in the extreme case the patient's body jogs rhythmically with every beat of the heart. *Palpation* demonstrates the powerful action of the enlarged heart, whose impact is appreciated as a deliberate, heaving thrust which counteracts the pressure of the examiner's palm and distinctly lifts it with systole. The *pulse* indicates high arterial tension, and is full, regular, well sustained, and of normal or somewhat diminished rate. *Percussion* reveals extension of the cardiac area, vertically upward, horizontally outward, and obliquely downward, the upper limit sometimes reaching to the second interspace, the left border extending well beyond the left midclavicular line, and the lower margin being at the level of the sixth or seventh interspace. *Auscultation* elicits a loud and prolonged mitral first sound at the apex, the tone in this situation being distinguished by the dull booming quality of its dominant muscular component. The aortic second sound is greatly accentuated, being loud and clear and ringing. In the event of unequal intraventricular tension (and this is common), the second sound is reduplicated, and in some instances there is also doubling of the first sound. In pure hypertrophy, to which the foregoing signs apply, murmurs are not audible.

Right Ventricular Hypertrophy.—*Inspection* discovers systolic pulsation in the epigastrium, at the left sternal border between the fifth and seventh costal cartilages, and sometimes at the right sternal border between the third and fifth cartilages. In extreme hypertrophy the lower sternal region and the apex of the epigastrium appear abnormally prominent. The apex-beat is diffuse, and displaced horizontally toward the left, with little or no depression. *Palpation* of the epigastrium commonly detects a heaving impulse just below the subcostal angle, most extraordinarily vigorous thrusts of the ventricle being here perceptible in the emaciated subject. The transmitted cardiac impulse occasionally palpable over the liver must be distinguished from true hepatic venous pulsation (*q. v.*).

The arterial *pulse*, aside from its somewhat diminished volume, presents no noticeable deviation from normal. On *percussion* the precordial limits are found to be expanded chiefly in a horizontal direction beyond the right sternal border, dulling the normal pulmonary resonance of the cardiohepatic angle and extending 1 inch (2.5 cm.) or so to the right of this landmark. *Auscultation* at the tricuspid area shows an intense, prolonged first sound, and at the pulmonic area a sharp, intense, sometimes reduplicated second sound. Murmurs do not arise, of course, so long as the valvular mechanism of the right ventricle remains unimpaired.

Auricular Hypertrophy.—This is invariably attended by dilatation of these chambers, and is recognized chiefly, if not entirely, by the discovery of some lesion of the auriculoventricular orifices capable of provoking undue intra-auricular pressure. *Left auricular enlargement* cannot be diagnosed by objective symptoms, but the demonstration of mitral disease (especially stenosis) is presumptive evidence in its favor. The left auricle, in exceptional instances, undergoes sufficient hypertrophy to damp the pulmonary vibrations, and therefore to impair percussion resonance at the left of the cardiac base, but it cannot possibly impinge upon the anterior chest-wall to produce visible or palpable pulsations thereupon, as is sometimes carelessly taught. (*Cf.* Mitral Stenosis, p. 443.) *Right auricular enlargement* is easier to distinguish, since well-marked examples are accompanied by presystolic pulsation near the sternal ends of the third and fourth right interspaces, by encroachment of cardiac dulness upon this territory, and by a forcible jugular pulse. The character of this venous pulsation is accurately fixed by the sphygmogram, which indicates an exaggerated wave of either auricular or of ventricular origin, as the case may be. (See Figs. 132 and 133.) The ability to auscultate the presystolic tone of a contracting hypertrophied auricle, right or left, is a gift possessed by few clinicians. Enlargement of the right ventricle and the signs of tricuspid leakage or obstruction, particularly the former, complete the clinical picture sketched by the signs just noted.

Diagnosis.—Pure cardiac hypertrophy is betrayed by a most distinctive group of signs: a full, regular, high-tension pulse, a deliberate heaving precordial impulse, displacement of the apex-beat, extension of the cardiac area, and a prolonged, muscular mitral or tricuspid first sound with ringing accentuation of the aortic or pulmonic second sound. The chamber or chambers chiefly affected by the myocardial overgrowth can be identified by reviewing more in detail the objective symptoms above enumerated. This can be

done more accurately by ordinary physical examination than by the electrocardiograph, which gives questionable tracings in many instances. It is, however, the rule to find in left ventricular hypertrophy inversion of the *R*-wave in leads II and III, and in right ventricular hypertrophy either a normal or an inverted *R*-wave in lead I and an enlarged *R*-wave in leads II and III.

Simple cardiac overaction may counterfeit hypertrophy, in so far as it gives rise to a bounding pulse, strong pulsation of the precordia and epigastrium, and intense heart sounds. Here, however, the similarity ends, since an excited heart does not alter the position of the apex-beat nor enlarge the cardiac area, and, furthermore, as soon as the heart quiets down the confusing signs disappear. *Bathycardia*, or an unnaturally low position of the heart, may be the cause of perceptible epigastric pulsation of excessive force.

The question of hypertrophy versus *cardiac displacement* must be settled, when the apex beats away from its natural situation, but if mere dislocation exists, the cardiac area, despite its abnormal situation, remains of normal size and shape. In dealing with a cardiac displacement, moreover, it is usually possible to discover the lesion that has either pushed or dragged the organ from its accustomed position. (See p. 318.)

Pulmonary cirrhosis, whereby the anterior margins of the lungs may be retracted so as to expose the parietal surface of the heart, is sometimes attended by vigorous precordial pulsation, by increase in the area of cardiac flatness, and by exaggeration of the cardiac sounds. In favor of this condition, rather than of true hypertrophy, are the absence of a typical booming first sound and of a ringing second sound, the failure to detect tumultuous action of the arteries, the inability to discover a satisfactory factor of hypertrophy, and the presence of definite pulmonary signs. If displaced, the heart tends to ride upward and toward the left, as the result of traction from these directions. In this connection it is well to recall the fact that cirrhosis of the lungs in time induces right ventricular hypertrophy and, ultimately, distention of this chamber. In the presence of extensive pulmonary emphysema it is sometimes impossible to elicit the physical signs of an enlarged heart, owing to the mass of dilated vesicular tissue which separates the heart from the chest-wall. *Apparent enlargement of the heart*, due to extension of its surface limits, may depend upon paracardial lesions, such as consolidation of the anterior pulmonary borders, circumscribed pleural effusion, mediastinal tumor, and aneurism of the aortic arch, though under such circumstances careful analysis of the subject's history and

physical signs suffices for an accurate differentiation. The same is true of certain *thoracic deformities* that may cause undue prominence of the precordial region.

The discrimination between *pericardial effusion* and a heart enlarged by dilated hypertrophy has been discussed under the former affection. (See p. 401.)

CARDIAC DILATATION

Clinical Pathology.—Dilatation of the heart, or an abnormal enlargement of one or more of its chambers, is due to stretching of its wall under the stress of overwork in excess of the organ's nutrition and muscular power. Intracardiac hypertension and diminished parietal resistance, singly or combined, are the essential factors which force the cardiac muscle to give way in this manner, either suddenly in consequence of an acute strain, or gradually after a prolonged period of overwork. In the great majority of instances the resistance of the myocardium is weakened by structural changes such as parenchymatous degeneration and interstitial fibrosis, but in others simple exhaustion of the cardiac muscle appears to be the sole predisposing cause of the dilatation.

Dilatation may exist alone or in combination with hypertrophy, and, like the latter, may be either a general or a partial change. *Dilatation with thinning* consists of an enlargement of the chamber with thinning of its wall, generally of acute development, and primarily excited by a sudden rise of pressure within the heart. Thus, acute distention, particularly of the right heart, sometimes results from the sudden increase of blood-pressure incident to inordinate muscular strain; the myocardium may suddenly yield and the corresponding chamber dilate under the intracardiac hypertension and overdistention due to traumatic valvular insufficiency; and acute dilatation may occur whenever the resistance of the myocardium is lessened by nutritive defects, and by the action of bacterial toxins.

Dilatation with hypertrophy denotes enlargement of the chamber with increase in the cardiac musculature, the wall being either of normal or of increased thickness. This type of dilatation, save when a degenerated hypertrophied heart suddenly gives way under acute strain, is essentially a chronic condition, and intimately associated with hypertrophy, of which it usually represents the secondary phase. Pure hypertrophy of the heart has certain limitations, fixed by nutrition, beyond which the overgrowth must cease and undergo retrograde changes, for want of adequate blood-supply through the

coronary arteries, either because these vessels are atheromatous or because of the rapid and disproportionate increase in the volume of the cardiac muscle. When this limit is reached, the cardiac wall yields to increased pressure from within, so that to the primary hypertrophy dilatation is now added. When finally dilatation can go no further, for to this change also there must be a limit, the chamber surrounded by the weakened muscle fails to empty itself with systole, is in consequence still more distended by residual blood, and becomes the starting-point of a stasis affecting that part of the circulatory system behind the dilated chamber. This means failure of compensation, the immediate effects of which are relative mitral leakage, left auricular dilatation, and engorgement of the lungs when the left ventricle fails, and tricuspid insufficiency, sooner or later followed by right auricular dilatation and general venous stasis, when the right ventricle yields. These accidents and the consequences thereto are considered in connection with lesions of the cardiac valves. (See p. 427.) In favorable cases primary dilatation of a cardiac chamber is followed by hypertrophy of its wall, in order thus to compensate for the impairment of cardiac strength, the duration, extent, and efficiency of this increased muscular power depending upon the circumstances prevailing in the individual instance. So long as the hypertrophy predominates sufficiently to ensure complete systolic discharge of the ventricular contents, stasis is warded off and the circulation does not suffer, but so soon as myocardial degeneration and intracardiac hypertension, one or both, become the prevailing change, secondary dilatation, leading to permanent circulatory embarrassment, inevitably supervenes.

Physical Signs.—*Left Ventricular Dilatation.*—*Inspection* shows enfeeblement of the apex-beat, which is displaced downward and to the left of its normal site. The impulse is either diffuse, forceless, and undulatory, or, in advanced dilatation, quite imperceptible to the eye. On *palpation* the apical impulse, if at all palpable, can be but vaguely felt as a somewhat abrupt tapping or slapping beat, utterly unsustained and lacking in strength. It is a common experience to encounter a visible apex-beat which cannot be palpated. The *pulse* is rapid, arrhythmic, and of diminished volume and tension, the individual waves being diminutive and easily extinguished by moderate pressure on the vessel (Fig. 165). *Percussion* defines an enlarged cardiac outline whose upper, lateral, and lower limits virtually correspond to those of left ventricular hypertrophy (*q. v.*). On *auscultation* the heart sounds are found to be feeble, impure, arrhythmic, and perhaps modified by coexistent murmurs. The

first sound at the apex is short, sharp, and high pitched, having lost most of its muscular tone, and acquired a valvular quality like that of the second sound. In the event of serious ventricular failure these two sounds, so acoustically alike, may be approximated by an abbreviated diastolic period, so as to reproduce the fetal cardiac rhythm termed *embryocardia*, while in some instances the irregularity conforms to the triple beat of *gallop rhythm*. (See pp. 362 and 371.) The tricuspid first sound shows no noteworthy deviation from normal. At the base of the heart the aortic second sound is weakened commensurately with the gravity of the left ventricular enfeeblement, while the pulmonic second sound, so long as the right ventricle is unimpaired, is relatively accentuated. Endocardial murmurs, when present, generally indicate relative mitral leakage, though

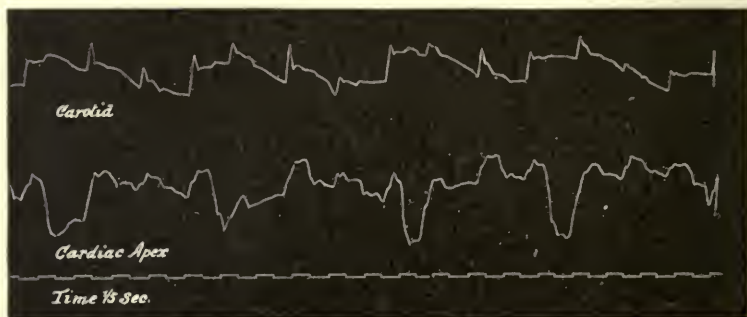


Fig. 165.—Synchronous sphygmographic tracings of the carotid artery and the apex-beat in a case of cardiac dilatation. (Tracing by Dr. G. Bachmann.)

preëxisting valvular disease should always be credited as a possible factor of the bruits.

Right Ventricular Dilatation.—On *inspection* and *palpation* one may note suppression of the normal apex-beat and undulatory pulsation corresponding to the parietal impact of the enlarged flaccid ventricle: below and on either side of the ensiform; outside the right sternal border between the fourth and seventh costal cartilages; and close to the left sternal margin between the second and fifth cartilages (Fig. 125, p. 321). The *arterial pulse* is affected by attendant conditions more than by the ventricular dilatation, being usually of increased frequency, small volume, disturbed rhythm, and low tension; the *venous pulse*, in the face of free tricuspid leakage, produces a sphygmogram having a high, blunt *v-wave* of the systolic or ventricular type. (See Fig. 133, p. 349.) *Percussion* defines the

right border of the heart well beyond the right sternal edge, with moderate horizontal extension of the cardiac area toward the left midclavicular line. On *auscultation* a more or less faint, abbreviated, sharply valvular tricuspid first sound is audible, and at the base the pulmonic second sound is enfeebled and obscure. The systolic bruit of relative tricuspid incompetence, with its striking attendant phenomena of venous stasis, is not unlikely to be a dominant physical sign, confirmative of the foregoing findings.

Auricular Dilatation.—The physical signs of this condition have been referred to on page 412, under its attendant change, auricular hypertrophy. In this connection it may be added that in the study of auricular enlargements the venous pulse tracing is most helpful in determining to what extent and in what manner the integrity and power of these cardiac chambers have become affected.

Diagnosis.—The diagnosis of cardiac dilatation rests upon the following distinctive signs: a feeble, wavy precordial impulse, an ill-defined, displaced apex-beat, a small, rapid, irregular arterial pulse, enlargement of the cardiac outline, and a weak though sharp first sound with an enfeebled second sound. The other evidence, relating to failing compensation and to back pressure and its consequences, is detailed in connection with valvular defects (see p. 432), and therefore need not be reconsidered here.

Dilatation and hypertrophy, save for the enlargement of the cardiac area common to both, are attended by diametrically opposed physical signs, as enumerated at length above. In attempting to judge which process predominates in an example of combined hypertrophy and dilatation, one should be guided mainly by a minute analysis of the cardiac sounds, by the presence or absence of relative regurgitant murmurs, by the condition of the arterial and venous pulses, and by a study stasis of phenomena. *Pericardial effusion* has been contrasted with dilatation of the heart on page 401.

MYOCARDITIS (*Carditis*; Granular Myocardial Degeneration; Myocardial Fibrosis; Myocardial Abscess)

Clinical Pathology.—*Acute Myocarditis.*—Under acute diffuse inflammations of the myocardium it is convenient to include in one group certain degenerative processes primarily affecting the muscular fibers, and in another group acute inflammations of the interstitial tissue, the former being designated as parenchymatous, and the latter as interstitial, myocarditis.

Acute parenchymatous myocarditis is to every intent and purpose identical with the condition known as “cloudy swelling” or “granular

degeneration" of the heart, in which the muscular fibers become swollen, lose their striation, and are loaded with albuminoid granulations, the heart muscle in consequence acquiring a dull gray appearance and an abnormally soft and edematous consistence. A slight degree of interstitial inflammation usually attends this predominant parenchymatous change, which, if unchecked, inevitably leads to fatty degeneration. Parenchymatous inflammation of the myocardium, toxic in origin, is a familiar cardiac complication in many active febrile and infectious states—*i. e.*, septicemia, enteric fever, pneumonia, rheumatic fever, scarlatina, gonorrhoea, influenza, and insolation; it arises in connection with exhausting cachexias; and it is sometimes consequent to endo- and pericarditis.

Acute interstitial myocarditis, also referable to acute infections and to inflammations of the endo- and pericardium, consists of an infiltration of the interstitial tissue with small round cells and leukocytes, together with vascular dilatation, and a variable degree of degeneration of the muscular fibers. This produces unnatural softening and grayish discoloration of the heart, either uniformly or locally, depending upon whether the inflammation is diffuse or circumscribed. A mild interstitial myocarditis may undergo perfect resolution, leaving the cardiac muscle undamaged, but severe cases probably terminate in unalterable fibroid myocarditis.

Acute suppurative myocarditis is generally due to the lodgment of infected thrombi in the branches of the coronary artery, less commonly to the direct extension of a pyogenic lesion of the endocardium or the pericardium. Various septic processes, such as malignant endocarditis, osteomyelitis, septic phlebitis, and puerperal fever, are the primary factors of this grave condition. The suppurative foci range in size from minute miliary points to abscesses as large as a centimeter or more in diameter, and may be either widely disseminated through the entire myocardium or restricted and circumscribed, notably to the anterior wall of the left ventricle. If small and few, the pus foci may become inspissated, absorbed, and cicatrized or calcified, but if there be extensive suppuration, and the subject survives, aneurism of the cardiac wall is a possible sequel. Or the pus may penetrate the pericardial sac or ulcerate into one of the cavities of the heart, exciting in the former instance fatal purulent pericarditis, and in the latter, metastatic abscesses of remote organs contaminated by septic emboli carried by the ventricular blood streams. An interseptal abscess may, by erosion, establish a communication between the ventricles or the auricles.

Chronic Myocarditis.—This type of heart disease, most common

in men of middle or advanced age, consists of a chronic interstitial inflammation of the myocardium terminating in fibroid induration. Usually the process is chronic from its inception, but sometimes it is the sequel of an acute myocardial inflammation or degeneration. Disease of the coronary arteries is undoubtedly the leading factor of chronic myocarditis, which ordinarily is the result of the nutritive defects consequent to obliterative endarteritis, although occasionally an area of anemic necrosis, referable to arterial thrombosis, is the starting-point of the lesion. In other cases the myocardial changes are due to the direct extension of chronic endocarditis or pericarditis, with predominant implication of the papillary muscles in the former event and of the outer surface of the myocardium in the latter. Fibrosis of the heart muscle is part and parcel of the retrograde changes incident to advanced age; it is excited by the irritant action of circulating toxic substances, as in rheumatic fever, malarial fever, syphilis, and as in alcoholism, nicotin-poisoning, plumbism, gout, diabetes, and nephritis; it develops after various acute infectious diseases, doubtless as a sequel of a primary interstitial myocarditis of intense grade; and, most exceptionally, it arises traumatically, as from an injury to the precordia.

The fibrosis may be so extensively distributed as to merit the term diffuse, or, as is more frequently the case, it may be more or less restricted, especially to the apical portion of the left ventricular wall, to the interventricular septum, and to the papillary muscles; in congenital cardiofibrosis, however, the apex of the right ventricle is the favorite site of the lesion. The affected areas are recognized as linear stripes and rounded patches of grayish-white induration, composed of connective-tissue bands paralleling the muscle-fibers, which eventually atrophy, undergo granular and fatty degeneration, and perhaps become wholly obliterated, in consequence of compression by the overgrowth. In rheumatic myocarditis the myocardial nodules of Aschoff are commonly found, existing as discrete microscopic areas of leukocytes and embryonal tissue, tending ultimately to form scars, and situated usually in the subendocardial parts of the septum in the left ventricular wall.

Associated changes of myocardial fibrosis include pressure stenoses of the aortic and pulmonary orifices produced by cicatricial contractions; mitral and tricuspid leakages due to fibroid shortening of the papillary muscles; chronic valvulitis and pericarditis; and obliterative endarteritis of the coronary vessels. Hypertrophy and dilatation are common sequels, but of these changes the attendant arteriosclerosis, valvular defects, and pericarditis are also im-

portant factors; or hypertrophy may occur merely as a compensatory overgrowth of the non-fibrous parts of the muscle. In cases of advanced myocardial disease there is a tendency toward thrombosis within the chambers of the heart, particularly in the auricular appendages and in the ventricles near the apex. Aneurism of the heart may arise, if a circumscribed patch of fibrosis becomes so weakened by degenerative changes that finally it yields and bulges under the incessant strain of intracardiac pressure.

Physical Signs.—*Inspection.*—In acute forms of the disease the patient's pallor, apathy, and breathlessness constitute a most suggestive trio of objective signs, or there may be a cyanotic countenance which betrays a lagging circulation. Subjects of myocardial fibrosis are notably affected by shortness of breath and distressing palpitation upon slight exertion. In suppurative myocarditis one should look for profound depression, collapse, symptoms of sepsis, and evidences of septic infarcts; and precordial pain is not unusual in this type of myocardial inflammation.

Palpation.—Enfeeblement of the cardiac impulse and a forceless, empty, and often arrhythmic pulse-beat are discovered by precordial and radial palpation, and, if there be considerable venous stasis, the liver and the spleen become palpably enlarged. In chronic cases a slow pulse is the rule, except in the event of advanced fatty changes or dilatation, which provoke undue rapidity and weakness of the beats.

Percussion.—Unnatural extension of the cardiac area, particularly in a horizontal direction, is found in cases associated with decided dilatation of the heart, but, naturally, this helpful clue to the recognition of the myocardial damage is forthcoming only in advanced cases.

Auscultation.—The tones of the heart are enfeebled, muffled, and impure in accordance with the gravity of the existing cardiac asthenia. Ordinarily the muscular sound is indistinct or even inaudible, so that the valvular quality of the heart's sounds predominates; or, as sometimes happens, the valvular tone, too, is suppressed, in which event it is difficult to auscultate any distinct cardiac sounds whatever. The systolic murmur of a relative mitral leakage, from stretching of the valve ring, is not uncommonly audible at the apex, and, should endocarditis or pericarditis coëxist, the adventitious sounds of these complications are also appreciable.

Diagnosis.—*Acute myocardial degeneration* is the natural inference when, during the course of an acute infectious process, dyspnea, pallor, vomiting, and precordial oppression and distress supervene, along with a rapid pulse of low tension and a muffled impurity of

the cardiac sounds. The discovery of a systolic (relative) murmur at the apex, of the percussion findings of ventricular dilatation, and of evidences of venous stasis change such an inference to a reasonable certainty. Suppurative myocarditis, though rarely diagnosed correctly during life, is suggested by extreme severity of the constitutional symptoms, by the existence of a septic etiologic factor, and by the occurrence of embolic processes.

Chronic interstitial myocarditis is prone to affect middle-aged men whose arteries have become sclerotic from the immoderate use of alcohol or from the effect of syphilis, gout, or similar poisons to the cardiovascular system. Or it may attack the clean-lived man of affairs long subject to the stress of a strenuous business or professional routine. In such subjects the important diagnostic details consist of hardening of the palpable arteries; a persistently high-tension pulse commonly deviating from the normal rate and rhythm; a comparatively feeble first apical sound of valvular quality and perhaps masked by a systolic murmur of mitral leakage; ringing accentuation of the aortic second sound, not infrequently attended by a systolic murmur of aortic atheroma and dilatation; and extension of precordial flatness indicative of enlargement of the left ventricle and of the ascending part of the aorta. In advanced cases the supervention of dilatation may transform the foregoing picture into one of cardiac breakdown. Other evidences, of arteriosclerotic character, that may be associated with the cardiac signs comprise interstitial nephritis, glycosuria, anginal paroxysms, intermittent lameness, and certain cerebral symptoms, such as vertigo, recurrent attacks of transient aphasia, palsy, and, exceptionally, of the Stokes-Adams syndrome—bradycardia, syncope, and convulsions.

ACUTE ENDOCARDITIS (*Valvulitis; Acute Mural Endocarditis*)

Clinical Pathology.—Acute inflammation of the endocardium, implicating chiefly the valves but to a less extent the mural serosa, may occur clinically as a *simple benign* type or as a *malignant* process. In this connection, however, one should recall Osler's assertion, that "so-called benign endocarditis kills in the long run a very much larger number of persons than the malignant form," for endocarditis, if it be not immediately perilous, tends to become so ultimately, in consequence of the sclerotic changes thereby provoked. Furthermore, there is no clear-cut pathologic demarcation between the two forms of inflammation, since they represent but different grades of intensity of the same infectious process.

Rheumatic infection is *par excellence* the factor of acute endocarditis, and the vast majority of instances are traceable to this poison, either in its frank arthritic form or in some one of its guises—tonsillar, choreic, or cutaneous. Conservatively, it is safe to believe that in adults articular rheumatism inflames the endocardium in from 25 to 35 per cent. of all cases, and that in children this incidence is doubled. Other causes that may light up an endocarditis include certain septic and pyemic processes: erysipelas, gonorrhoea, osteomyelitis, puerperal fevers, infected wounds, abscess; and many of the specific fevers, such as pneumonia, diphtheria, scarlatina, influenza, tuberculosis, and, less commonly, other infectious and eruptive diseases. As a terminal infection there is no doubt that a mild grade of endocardial inflammation commonly develops, nor is there any doubt that traumatism, unless attended by bacterial invasion, never

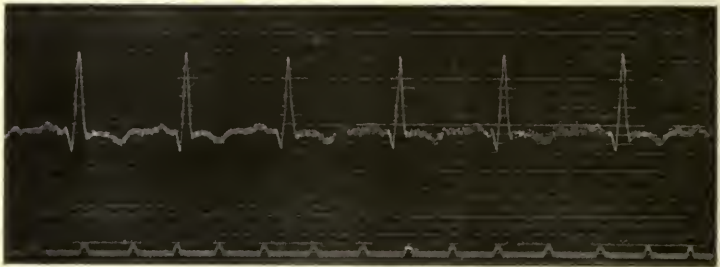


Fig. 165a.—Electrocardiogram of a case of acute endocarditis, showing deep Q-depression, large R-wave, inverted T-wave, and irregular prolongation of T, R interval. (Tracing by Dr. T. A. Cope.)

excites a vegetative endocarditis. Valve leaflets habitually exposed to the irritant effect of arterial hypertension are particularly prone to become inflamed and vegetative. The streptococcus, staphylococcus, pneumococcus, and gonococcus are the germs that have an especially close causal relation to endocarditis, while less commonly the lesion is excited by such bacteria as the bacillus of tuberculosis, influenza, or enteric fever, or by some other specific microorganism.

Simple acute endocarditis, as a rule, attacks the valves of the left side of the heart, the mitral, aortic, tricuspid, and pulmonic structures being affected in the order of frequency named. Lesions of the right side of the heart are generally of intrauterine origin, but it is probable that right-sided endocarditis during postuterine life is not such a rarity as was once supposed, though signs of such a condition are not frequently found, owing to the relatively greater tendency of resolution to occur in lesions of the tricuspid and pulmonic valves (*v. i.*).

Simple acute endocarditis has a special predilection for the lines of valve contact a short distance (about $\frac{1}{12}$ inch or 2 mm.) from the free margins, the auricular surface of the mitral leaflets and the ventricular aspect of the aortic cusps usually showing the earliest and most advanced alterations, which are primarily those of endothelial degeneration and are structurally of thrombotic character. The affected valves are the seat of local endothelial necroses, the swollen, abraded, and roughened surfaces becoming covered with a deposit of granular or fibrillar fibrin permeated by proliferating connective tissue and by infiltrated leukocytes. The *vegetations* developed in this manner appear as delicate or as coarse excrescences attached to the valves, and, if recent, of pinkish color and friable texture, or, if old, pale and of hard, warty consistence. Such vegetations, if small, soft, and delicately globular, merit the term *beaded excrescences*; those of greater size, denser character, and cauliflower-like or warty in form are well described as *verruucose excrescences*; and those of inordinate size and polypoid contour are referred to as *villous* or *polypous lesions*. The tissues of the affected valves show more or less inflammatory damage, leading to a corresponding degree of thickening, contraction, and puckering of the leaflets, whereby orificial stenosis and incompetence arise. Rarely, a simple acute endocarditis of the benign type undergoes resolution and leaves the valve functionally perfect; or it may undergo extensive necrotic and ulcerative changes; but ordinarily it results in the unalterable structural deformities distinctive of chronic valvular disease. The detachment of a valve thrombus or of a bit of necrotic tissue is a cause of embolism. Apart from the local lesion, acute endocarditis sets up a variable grade of myocardial inflammation and degeneration, which, indeed, may do more harm than the valvular defects. Pericarditis is also a familiar associated lesion—Sturges found it in 94 per cent. of cases in children, and in view of the frequency with which endo-myo-pericarditis coexists he purposes to apply the term *carditis* to the majority of acute endocarditides; or the term *pancarditis*, suggested by Jürgensen, seems even more appropriate. Laceration of a valve, rupture of a tendinous cord, aortitis, pleuritis, and pneumonitis are other possible complications, the first three being most exceptional.

Ulcerative or *malignant endocarditis* is generally due to streptococcal, staphylococcal, pneumococcal, or gonococcal infection, and, though commonly left sided, implicates the right heart more frequently than does simple benign endocarditis. The process is one of predominant necrosis and of subordinate repair, leading to exten-

sive and irreparable structural damage. This may take the form of ulcerative erosion resulting in more or less complete destruction of

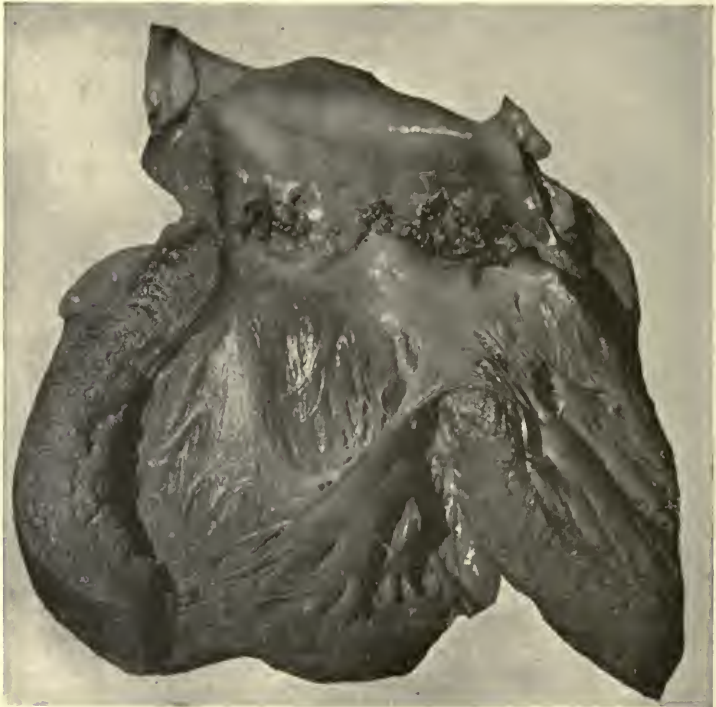

Fig. 166.—Malignant endocarditis, with extensive implication of aortic valves (Philadelphia General Hospital).

one or more valve cusps, in valve fenestration and aneurism, and in rupture of chordæ tendineæ; or ulcers may perforate a valve ring, produce septal perforation, and, penetrating the mural endocardium, set up a suppurative myopericarditis, perhaps terminating in cardiac aneurism or in rupture of the heart. Septic embolism is a grave danger associated with a mycotic process of this sort. In other cases the ulcerative changes are overshadowed by the formation of luxuriant vegetations springing from the valve mechanism and from the mural endocardium, the vegetative outgrowths commonly being attended by deep necrosis. If not leading to an immediately fatal outcome, the excrescences sometimes proliferate to a most extraordinary extent and ultimately may become coated with an unyielding, rigid deposit of lime salts.

Physical Signs.—*Inspection.*—In the average case of simple endocarditis there are no visible evidences of the lesion, unless, as exceptionally happens, the myocardial damage is grave enough to displace the apex-beat and to alter its force. It is in malignant cases particularly that signs of cardiac dilatation are likely to be observed, and in these instances the subject may show the inroads of profound septic poisoning.

Palpation.—Suggestive, but by no means characteristic, information is occasionally afforded by palpation. So long as myocardial integrity is unimpaired palpation, of course, shows nothing, but in the case of an acute valvulitis grafted upon an old valvular lesion abnormal variations in the force, extent, and site of the apex-beat, sometimes a thrill, and perhaps hepatic enlargement are to be looked for. The *pulse* is commonly increased in frequency, especially in febrile subjects, and may be altered in volume, in tension, and in rhythm.

Percussion.—Routine percussion of the cardiac areas, particularly those overlying the ventricles, is indicated in every suspected case of endocardial inflammation, irrespective of its benignancy or malignancy, in order thus to be able to detect the first indications of ventricular dilatation. In the absence of this change the percussion findings indicate no alteration in the extent of the normal cardiac outline.

Auscultation.—The earliest definite physical sign of simple acute endocarditis, in the great majority of instances, consists of an impurity of the first cardiac-sound at the apex, followed by a muffled prolongation of the tone, and finally succeeded by the development of a distinct, though usually soft and blowing, systolic murmur which is clearly conducted as far as the patient's axilla, and in time is attended by accentuation of the pulmonic second sound. This transition from a murmurish tone to an actual bruit having a well-defined area of propagation points to mitral regurgitation, the most common consequence of this type of endocardial disease. Less commonly, a muffled aortic second sound similarly is converted into a diastolic murmur, or the rough bruit of mitral stenosis may appear. The mere presence of a murmur, especially if it be basal, does not mean endocarditis, for such a sound is quite as likely to be anemic or relative as it is to be endocarditic. The criterion, then, is not the murmur, so much as the sequence of tonal changes attending its development. Furthermore, the inability to hear a murmur does not exclude valvulitis, which, if it does not fulfil certain physical conditions, creates no vibrations of the blood column.

Malignant endocarditis may afford auscultatory signs identical with those of the benign form, or there may be none at all. In certain cases, however, characterized by extensive and highly virulent endocardial damage, there are single or multiple murmurs peculiar in their tendency to change in *puncta maxima*, and in rhythm, intensity, and quality, affecting, as they do so, the character of the other cardiac sounds. To a single mitral murmur, for example, may suddenly be added an aortic bruit, as the mycotic process bridges the short endocardial path separating the two orifices. Myocardial impairment of the cardiac tones, the dry rub of pericardial inflammation, and the friction-sound of pleurisy are important consecutive findings in malignant infection of the endocardium.

Diagnosis.—In *acute simple endocarditis* the gradual supervention of a murmur attended by undue intensity of the pulmonic second sound and by signs of myocardial weakness is the chief diagnostic clue, which, unfortunately, is not available in every case. Due attention must also be paid to other suggestive clinical findings, such as moderate fever, rapidity of the pulse, precordial uneasiness (rarely, actual pain), and more or less respiratory oppression; while the patient's history, present and previous, is to be interrogated with a view to finding some factor of endocardial inflammation—rheumatism, tonsillitis, pneumonia, or similar infectious process. The distinction between true endocarditic murmurs and the adventitious sounds due to *anemia*, to *relative incompetence*, and to *plastic pericarditis* is considered at sufficient length in connection with these conditions. (See pp. 379 and 391.)

In certain cases of *malignant endocarditis* the development of erratic, changeable murmurs and of cardiac dilatation in an unmistakably septic subject provides satisfactory evidence of an endocardial ulceration. But in cases that do not conform to this cardiac type the local signs may be most equivocal, so that one must turn elsewhere for definite data, which in general refer to a condition of septic poisoning and in particular to pyemia, to the typhoid state, and to meningeal inflammation, according to the existing individual peculiarities. In studying such a varied symptomatology it is important first to discover the presence of some septic factor, either local or general, and to identify, by blood-culturing, the infective agent, after which investigation of the systemic damage wrought thereby is in order. This inquiry should be directed toward the presence or absence of chills, remittent pyrexia, progressive anemia, rapid wasting, extreme exhaustion, splenic enlargement, leukocytosis, iodophilia, and evidences of septic embolism. There is also a

puzzling group of cases that shows little else than moderate, often recurrent, fever and splenic enlargement, together with clear signs of chronic valvular disease. These cases, which may be acute, chronic, or relapsing in type, are especially liable to embolic accidents, and probably represent an active necrotic process implanted upon a preëxisting valvular sclerosis.

Enteric fever may closely resemble malignant endocarditis, in general symptomatology and in the existence of an endocardial (relative) murmur. Apart from the patient's previous history, these data bespeak typhoid: prodromal indisposition, gradual onset without a true rigor, relatively late prostration, specific findings from blood-cultures and from the serum test, and the orderly appearance of the distinctive symptom-complex of enteric fever by the end of the first week.

Malarial fever, although it may superficially ape malignant endocarditis, can scarcely prove a source of serious confusion, in the face of its distinctive hematologic picture—leukopenic mononucleosis, free pigment, and the malarial hemameba.

CHRONIC ENDOCARDITIS (Chronic Valvular Disease; Chronic Interstitial Endocarditis)

Clinical Pathology.—Chronic inflammation of the valvular and mural endocardium occurs both as a sequel of acute endocarditis and as a primary chronic sclerosis, in either event leading to deformities of the valves and orifices whereby regurgitant and stenotic lesions arise, and also to permanent alterations in the structure and functional efficiency of the cardiac muscle. More than one-half of all chronic valvular defects are traceable to rheumatic poison, and especially in childhood and in young adult life is this irritant the cause of the original endocardial inflammation. Langmead found signs of endocarditis in 87 per cent. of 133 rheumatic school children, and in approximately 3 per cent. of 2556 children examined, regardless of their past medical history.

Less commonly the permanent lesions are due to an acute endocarditis excited by some one of the numerous other factors referred to above. In the type of chronic valvular disease arising as a slow fibrosis the damage generally can be laid at the door of alcohol, syphilis, and muscular strain, which, singly or in combination, subject the valve mechanism to irritation by circulating toxins and by excessive arterial tension. Arteriosclerosis, nephritis, gout, malaria, diabetes, and plumbism act similarly.

The special manner in which the different valves are affected by chronic endocarditis and the important secondary cardiac changes

thereby set up are, for convenience sake, considered in connection with the several types of individual valvular lesions. (See p. 434 *et seq.*) It is sufficient here to summarize the pathologic findings of chronic valvular disease as follows: (*a*) Fibrosis, induration, and thickening of the valves and of their musculotendinous attachments; (*b*) contraction of the hyperplasia, resulting in curling and puckering of the valve edges, shortening and thickening of the chordæ tendinæ and papillary muscles, and orificial deformity, whereby faulty approximation of the cusps arises; (*c*) adhesion of the valve edges, restricting their movements and causing obstruction and leakage at the orifices they guard; (*d*) impregnation of the sclerotic structures with lime-salts, still further adding to their rigidity and mechanically interfering with their normal movement; (*e*) sclerotic thickening and calcification of the mural endocardium. The valves thus damaged are sometimes found to be beaded with simple inflammatory excrescences, and are prone, in the event of bacterial invasion, to

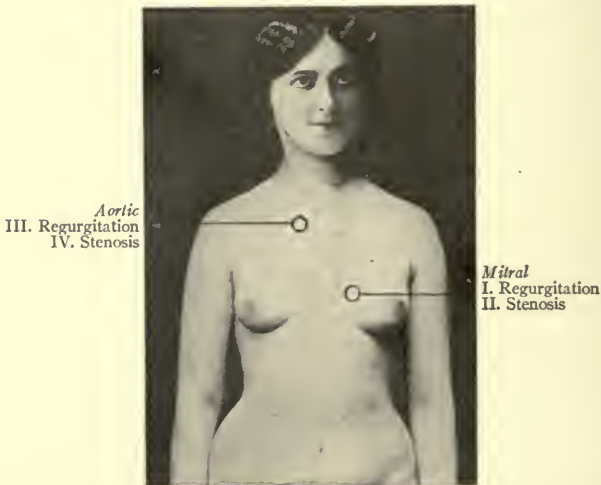


Fig. 167.—Relative incidence of regurgitant and stenotic lesions of the mitral and aortic valves.

become attacked by a malignantly necrotic process, or, if exposed to sudden violent strain, may rupture. Myocardial degeneration and inflammation are practically constant associated lesions which, as intimated before, give more concern to the clinician than do the underlying valvular defects.

Types and Relative Incidence of Valvular Lesions.—A valvular

defect acting as a barrier to the onward flow of blood is known as a *stenosis*, or an *obstruction*, and a deformity preventing the tight closure of a valve, and thus permitting backward leakage through the orifice into the chamber immediately behind, is designated as a lesion of *regurgitation*, *incompetence*, or *insufficiency*. Valvular lesions may be single, but more commonly they are either double or combined, a *single lesion* being either stenosis or regurgitation of one orifice, a *double lesion* meaning both stenosis and regurgitation at one orifice, and a *combined lesion* consisting of two or more defects at different orifices.

The valves of the left side of the heart are much more frequently implicated than those of the right side, defects of the tricuspid and pulmonic leaflets usually arising as sequels of left-sided disease, and but exceptionally representing acquired primary processes. Congenital valvular disease is right sided in the vast majority of instances. Mitral regurgitation is by all odds the most common single valvular defect, after which follow, in this order of frequency, mitral stenosis, aortic regurgitation,¹ and aortic stenosis (Fig. 167). The relative incidence of organic right-sided defects reads: tricuspid regurgitation, tricuspid stenosis, pulmonary stenosis, and pulmonary regurgitation. Of combined lesions, F. J. Smith has worked out this order of frequency: double aortic and mitral regurgitation; aortic and mitral stenosis; aortic and mitral regurgitation; double aortic and double mitral.

The comparative frequency of valvular defects at the four different cardiac orifices is illustrated by the following table, based upon the analysis of nearly 4000 collected cases:

	<i>Mitral.</i>	<i>Aortic.</i>	<i>Mitral and Aortic.</i>	<i>Pulmonic Tricuspid.</i>
Lockhart Gillespie. (1914 cases.)	58.5 per cent.	21.4 per cent.	19.2 per cent.	0.8 per cent.
T. G. Ashton. (1024 cases.)	60.6 "	21.5 "	17.0 "	1.0 "
Parrot. (1058 cases.)	58.6 "	35.9 "	0.5 "

From other data given by these and other authors, notably F. J. Smith and Middleton, too elaborate for quotation here, these general facts relating to chronic valvular disease may be deduced:

1. Including both sexes, mitral disease constitutes more than one-half of all cases; in men less than one-half, and in women more than three-fourths of valvular lesions are mitral.

¹ It is, perhaps, questionable which of these two defects is the more common, for their incidence is practically about the same. Most statistics, however, show that mitral stenosis is a shade the more frequent.

2. Including both sexes, aortic disease constitutes about one-fifth of all cases; it is three times as common in men as it is in women.
3. Double or combined lesions are found in about one-fifth of all cases; they are almost twice as common in men as in women.
4. Right-sided lesions constitute less than one one-hundredth of the total cases of valvular disease.

Primary Effects of Valvular Lesions.—In health the blood flows unimpeded through the chambers of the heart into the arterial, capillary, and venous channels, and thence back into the heart. Not only does the stream always flow in the same direction, but with each systole exactly the right volume of blood is emptied into the arterial system by the contracting ventricles, to maintain perfect circulatory equilibrium. This is ensured so long as the valves open and close properly and the size of the orifices remains normal, but the balance is immediately disturbed when valvular defects develop, which either obstruct the onward flow of the blood-stream or permit its reflux.

Valvular defects, whether they obstruct the blood-stream or allow it to regurgitate, primarily cause accumulation and stasis of blood in the chamber of the heart immediately back of the crippled valve, with the result that this chamber becomes habitually overdistended and dilated. The muscular walls then hypertrophy, in consequence of the increased work demanded of them, but ultimately they again tend to dilate, as they sooner or later weaken under the continued strain. The chamber primarily affected then gives out completely, and the back pressure extends to the other parts of the cardiovascular system, step by step. The predominance of one or the other of these structural changes in the cardiac muscle depends upon the peculiarities of the determining lesion and upon the extent and character of the retrograde changes in the myocardium. These influences will be discussed presently, in connection with the individual valvular lesions.

A condition of *compensation* is said to exist so long as the heart adequately responds to the demands made upon it to overcome, by increased work, the stress imposed by valvular defects. Thus, by virtue of its reserve force, the heart enlarges so as to equalize the circulatory disturbance by overcoming the stasis, and the conservative change, *compensatory hypertrophy*, supervenes (Fig. 168, II). Perfect compensation continues so long as the nutrition of the myocardium is sufficient to allow the development of hypertrophy adequate to maintain a normal cardiovascular equilibrium, and at this stage of a valvular disease the cardiac physical signs are the sole evidences of the lesion to be detected. It is important to bear in mind the fact

that during this period of perfect compensation drugs are not only not indicated, but their use may be distinctly injurious, no matter what be the character of the cardiac defect. *Ruptured or broken compensation* supervenes when the nutrition and reserve force of the heart fail to keep pace with the strain imposed by the valvular lesion, so that the circulatory balance becomes disturbed and the stasis aggravated. It is a change referable to myocardial enfeeblement and ultimate dilatation of the heart which develops, either gradually or abruptly, when the nutrition of the heart becomes so impaired that this muscle relaxes under the stress which hitherto it has been able to bear, and hence the total available cardiac force is

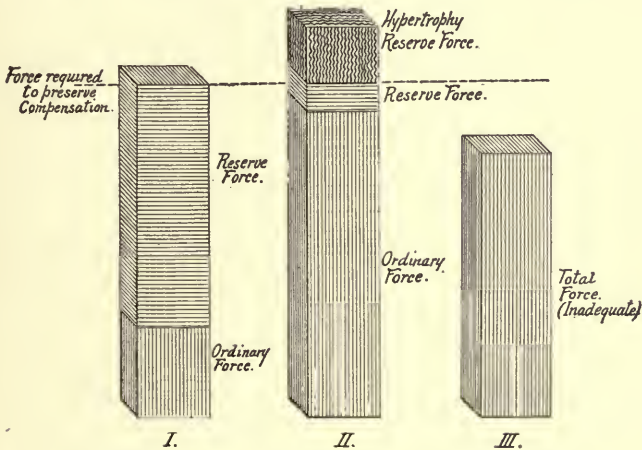


Fig. 168.—The effects of adequate and of ruptured compensation upon the force of the heart: *I*, Normal cardiac force; *II*, excess of cardiac force attending stage of adequate compensation; *III*, deficiency of cardiac force incident to stage of ruptured compensation.

inadequate for the maintenance of the normal circulatory balance (Fig. 168, *III*).

Ruptured compensation is betrayed not so much by distinctive cardiac physical signs as by groups of symptoms, more or less urgent, indicating circulatory derangements in different organs. For example, in left-sided valvular disease the brunt of the strain is felt by the lungs which become engorged as soon as the stasis and high tension extend backward from the left auricle and reach the pulmonary circulation. Later the congestion, via the pulmonary circuit, affects the right side of the heart, and ultimately extends even beyond its confines into the venæ cavæ, causing general venous engorgement.

Secondary Effects of Valvular Lesions.—The secondary effects of valvular disease develop in consequence of the back pressure of blood,

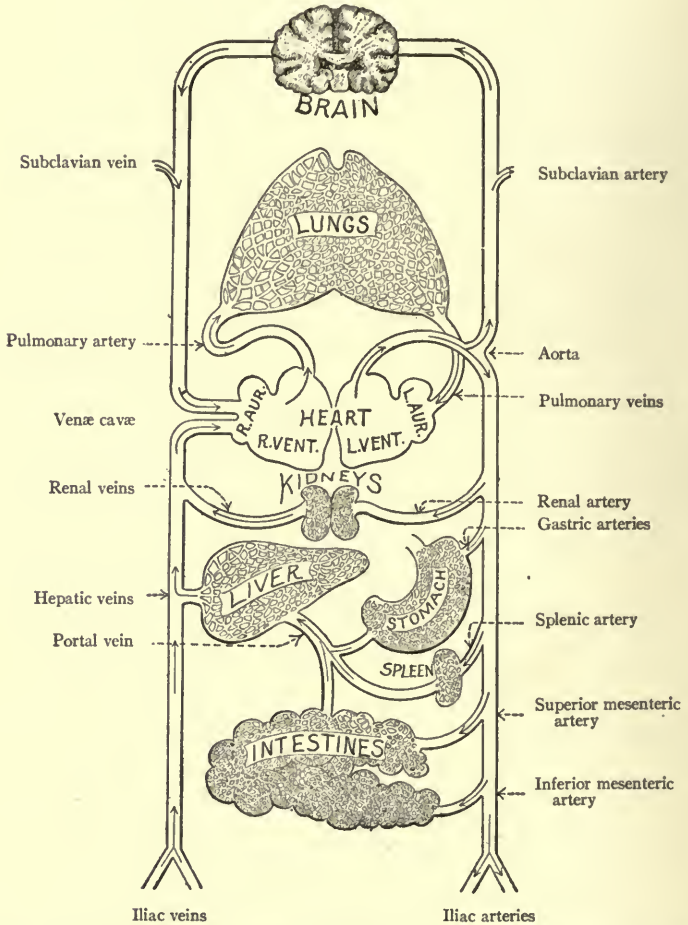


Fig. 169.—Mechanism of the stasis phenomena secondary to chronic valvular disease.

which in course of time causes venous congestion of different organs and parts of the body remote from the crippled heart. These signs of stasis are referred to the respiratory system, the gastro-intestinal

tract, the kidneys, the brain, and the great venous trunks. The mechanism by which these changes arise is illustrated in the accom-

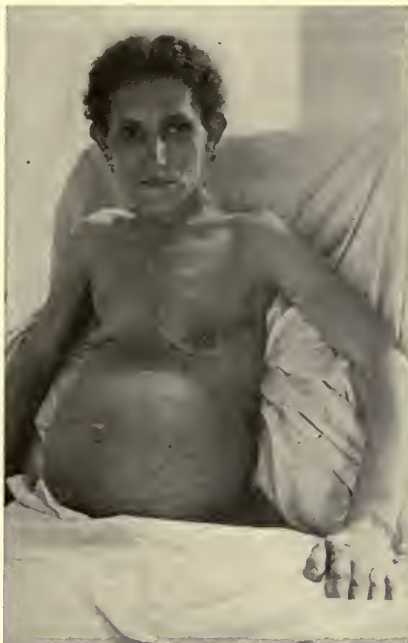

Fig. 170.—Appearance of a subject of chronic valvular disease during the stage of failing compensation (Jefferson Hospital).

panying diagram (Fig. 169), and their recognition may be facilitated by referring to the following symptom-groups:

- Bronchopulmonary:* Cough; dyspnea; orthopnea; hemoptysis; bronchitis; edema of lungs; passive congestion of lungs; hydrothorax.
- Gastro-intestinal:* Chronic gastric and intestinal catarrh; hematemesis; melena; hemorrhoids. Enlarged, tender, and pulsating liver; icterus. Enlarged and tender spleen.
- Renal:* Urine scanty, high specific gravity, high color, and containing albumin, urates in excess, and tube casts.
- Cerebral:* Headache; vertigo; faintness; syncope; phosphenes; insomnia; unpleasant dreams; drowsiness; delirium. Embolism; thrombosis; cerebral hemorrhage.
- Venous:* Cyanosis of face and extremities; clubbed fingers. Systolic jugular pulsation. Edema of extremities; ascites; anasarca.

The *special pathology, physical signs, and diagnosis* of the several varieties of chronic valvular disease will now be considered with relation to the individual lesions.

MITRAL REGURGITATION

Clinical Pathology.—This, the most common of all organic valvular lesions, is usually acquired during childhood, doubtless because at this period of life factors of endocarditis, such as rheumatism, chorea, tonsillitis, the exanthemata, and other infections, are prevalent. Less commonly leakage at the mitral orifice depends upon arteriosclerotic changes supervening in later life, as the result of nephritis, gout, syphilis, or the habitual use of alcohol. Traumatic

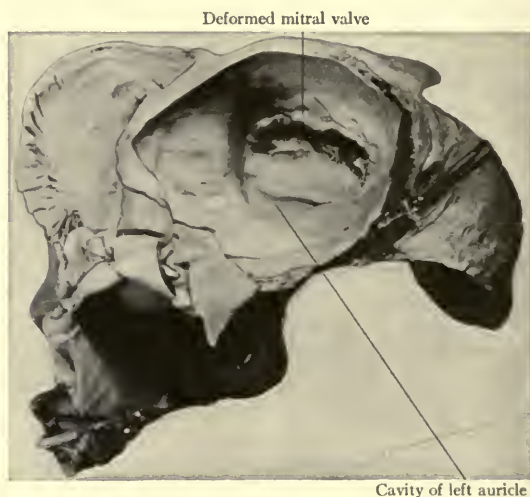

Fig. 171.—Mitral regurgitation (Jefferson Hospital Laboratories).

injury of the valve is a potential source of mitral regurgitation, and congenital defects, in the exceptional instance, account for the incompetency.

Interference with the accurate apposition of the mitral valve curtains results in imperfect closure of the mitral orifice, and, in consequence, leakage of blood from the ventricle into the auricle takes place during ventricular systole. This condition of mitral regurgitation is due fundamentally either to organic derangement of the valve mechanism or to muscular changes in the wall of the left ventricle, singly or combined. In the *organic type* (Fig. 171)

endocarditic induration and contraction of the mitral leaflets, with thickening, eversion, and fusion of their edges and perhaps adhesion to the ventricular wall, are ordinarily responsible for the faulty closure of the mitral orifice. Or the latter may leak because the cusps are prevented from closing tight by vegetations upon their surface, by the projection of calcareous plates at their base, or by sclerosis and contraction of the mitral ring. In extreme examples the valvular structures at the mitral orifice are virtually converted into a dense calcareous mass, and in this event there is obviously stenosis as well as regurgitation at the auriculoventricular opening. The foregoing changes are attended by more or less shortening and fibrocalcareous degeneration of the tendinous cords and papillary muscles, which possibly may even rupture. Exceptionally a valve leaflet is the seat of laceration, fenestration, or so-called aneurism. In the *muscular type* the leakage is due not to structural damage to the valves but to enlargement of the auriculoventricular orifice and to defective muscular action incident to myocardial enfeeblement and dilatation of the left ventricle. Febrile conditions, anemia, and myocardial inflammation and degeneration, by interfering with cardiac nutrition, are likely to cause this type of degeneration, which also may arise in consequence of ventricular enlargement secondary to habitual arterial hypertension or to aortic valvular lesions. Relative incompetence develops as the result of left ventricular dilatation, the mitral orifice being so stretched that its valve curtains fail to close tightly, and the ventricular walls being so distended as to drag upon the musculotendinous attachments of the valve segments and hence to prevent their perfect approximation. It is likely that the reflux thus permitted, if adequately accommodated by the pulmonary circulation, relieves the stress of a laboring left heart, by a mechanism comparable to that of the well-known "safety-valve action" at the tricuspid orifice in distention of the right ventricle. (See p. 463.) Muscular incompetence also may occur primarily from feeble ventricular systole, a defect leading to insufficient constriction of the mitral orifice and to deficient action of the papillary muscles, by fault of which systolic backward leakage of blood is permitted through the inadequately guarded mitral orifice.

As the result of mitral insufficiency both a normal supply of blood from the pulmonary veins and a reflux stream from the ventricle pour into and together overdistend the left auricle, which in consequence dilates, and, since expulsion of this large blood mass means additional effort, the auricular wall also undergoes compensatory

hypertrophy. The left ventricle becomes similarly dilated and hypertrophied, for of necessity it must receive and expel an abnormally great volume of blood. As the result of the auricular surcharging there are stasis and hypertension of the pulmonary circulation attended by dilatation, and, even by atheroma of the vessels, and finally, by brown induration of the lungs. By fault of the pulmonary engorgement the right ventricle is so strained and overworked that it dilates and hypertrophies, and when, after a variable period, the limit of hypertrophy is reached and dilatation predominates, the tricuspid valve leaks, permitting systolic regurgitation into the right auricle, which in turn dilates and hypertrophies in an endeavor to compensate the venous resistance. Hand in hand with this embarrassment of the right heart, systemic venous congestion progresses, sooner or later to set up chronic catarrh of the mucosal surfaces, transudative accumulations in the serous sacs and subcutaneous tissue, and visceral engorgement and induration. The cardiac muscle, meanwhile, enfeebled by the combined effects of undernutrition and overwork, is the seat of fibrous and fatty degeneration.

Physical Signs.—*Inspection.*—So long as the cardiac strength is adequate the patient's appearance is not suggestive of any valvular defect, but with the onset of venous stasis and failing compensation, dyspnea, cyanosis, especially of the lips, nose, and fingers, cough, watery or blood-streaked expectoration, and dropsy form a familiar group of objective symptoms. In cases of considerable chronicity one expects also to find more or less dilatation of the superficial veins of the face and upper chest, clubbing of the finger-tips, emaciation, and a facies picturing anemic pallor, an ashen-gray hue, or an icteroid staining.

The cardiac impulse is unnaturally extensive, and displaced downward and to the left as the result of the left ventricular enlargement, while if the right ventricle be hypertrophied there is visible epigastric pulsation. Exceptionally, in young children the hypertrophy is sufficient to produce outward bulging of the precordia, but in adults no such deformity occurs.

Palpation.—The impulse over the enlarged ventricles is either forcible and heaving or weak and undulatory, according to whether hypertrophy or dilatation predominates; over the liver there may be distinct pulsation, due in most instances to the violent impact of the right ventricle, but in some produced by the transmission of a systolic venous pulse. Palpation over or just above the cardiac apex sometimes, but by no means constantly, appreciates a delicate systolic

thrill, which is the tactile equivalent of the murmur heard on auscultation. In examples of extreme regurgitation it is sometimes possible to detect, by palpation of the chest-wall, diffuse pulsation of the lungs—the so-called “pulmonary pulse.”

The *radial pulse*, save perhaps for slight acceleration and hypotension, remains practically normal until the left ventricle fails, but when this happens the beats become notably deficient in volume, inordinately rapid, and irregular in rhythm and force. Ineffectual systole, or an occasional ventricular contraction too feeble to produce a radial impulse, is not infrequently detected by simultaneous palpation of the precordia and the wrist. The sphygmogram of such a pulse well illustrates its striking irregularity and low tension, the incidence of the curves being most erratic and their height unequal, with a vertical upstroke, sharp apex, rapidly falling downstroke, and low dirotic wave. (See Fig. 130, III and VII; p. 340.)

Percussion.—The area of cardiac dulness is increased horizontally and downward toward the left, owing to the bilateral ventricular enlargement, and occasionally it is possible to map out an upward extension of the basic outline corresponding to the situation of an enlarged left auricle. The size of the hepatic and splenic percussion areas is increased, as the result of venous obstruction.

Auscultation.—Mitral regurgitation gives rise to systolic murmur at or near the apex, whence the sound is transmitted toward the left, usually into the axilla and sometimes as far backward as the inferior angle of the left scapula (Fig. 154). The clear propagation of the sound toward the left depends upon the good conducting properties of the chordæ tendineæ, the papillary muscles, and the ventricular wall, and upon the efficiency of the mural vibratory path formed by the chest-wall.

Typically, the *punctum maximum* of this murmur is at the clinical apex of the heart, from which point the sound gradually grows fainter as the stethoscope is moved beyond the limits of the precordia, but exceptionally the murmur is so loud as to be audible far beyond these confines. In rare instances a mitral systolic murmur is heard most distinctly along the left sternal border, usually between the fourth and sixth costal cartilages, but occasionally as high as the second interspace. The murmur of a mitral leakage is more likely to be soft and blowing than harsh or rasping, and its distinctness is decidedly affected by the subject's posture, the sound often being clearer when the patient is recumbent. The duration of the murmur is variable: it may absolutely coincide with the first

sound, perhaps through only the first part of this period, or occur in the latter portion of systole, in which case a moderate grade of incompetence is suggested (Sahli). The longer the bruit the more conspicuous its diminuendo character, and the shorter the sound the more pronounced its "whiffy" quality.

The first sound at the apex is partly or wholly replaced by the attendant murmur, and within certain limits it is true that the greater the degree of the regurgitation the more effectually its bruit masks the first sound of the heart, which may, indeed, be quite inaudible. Accentuation of the pulmonic second sound, due to pulmonary congestion, is a valuable corroborative sign of mitral disease, while reduplication of the second sound at the cardiac base, from unequal tension within the two ventricles, is of some significance.

Diagnosis.—A systolic apical murmur propagated toward the left axilla, accentuation of the second pulmonic sound, and bilateral ventricular enlargement are the cardinal signs of mitral regurgitation. These signs, unmistakable during the stage of compensation, are more or less obscured later, when cyanosis, dropsy, erratic action of the heart, and other signals of cardiac break-down dominate the clinical picture.

In *relative mitral leakage* versus the organic type, the physical signs are often an uncertain guide, since if the mitral orifice be widely stretched by a dilated left ventricle, the thrill, murmur, and loud pulmonic second sound of an endocarditic reflux will be faithfully reproduced. Rosenbach's statement, that a late systolic murmur invariably means an organic structural defect of the left auriculo-ventricular opening, is helpful, but the clinical history, the question of secondary signs, and the subsequent behavior of the essential cardiac findings must largely mold the final decision. Most relative mitral murmurs, however, are comparatively quiet, poorly conducted, evanescent, unattended by accentuation of the pulmonic second sound, and unaccompanied by congestion of the lungs and of the right heart. They commonly develop in debilitated, anemic subjects during the course of some acute febrile infection or other exhausting disease that induces myocardial weakness, and the bruit completely vanishes when the tone of the cardiac muscle is restored. In a type of cardiac enfeeblement known as "Copenhagen heart" (Hielscher), common among habitual users of strong snuff, relative mitral insufficiency is readily provoked by exercise, and frequently is accompanied by palpitation, dyspnea, and a rapid pulse of high tension.

The murmur of *aortic stenosis* is sometimes audible at the apex, as well as at its punctum maximum at the aortic cartilage. But such a murmur, though timed like that of mitral regurgitation, usually has a harsh, rough tone clearly conducted into the carotids, and is accompanied by a basic thrill, by obliteration of the aortic second sound, and, not uncommonly, by a pulsus tardus or a pulsus bisferiens.

The distinctions between *tricuspid regurgitation* and a corresponding mitral defect are considered elsewhere. (See p. 389.)

MITRAL STENOSIS

Clinical Pathology.—Rheumatic endocarditis is unquestionably the most important factor of this variety of valvular disease, which ordinarily depends upon an insidious and progressive valvulitis, arising, in childhood, in connection with vague arthritic symptoms, and being first recognized during the second or third decade of life in those who, as young children, suffered from “growing pains” and other atypical manifestations of subacute or masked rheumatism. Less frequently mitral stenosis is traceable to an acute attack of rheumatic fever attended by well-defined endocarditis, and very exceptionally the lesion is to be regarded as congenital, being due in such instances either to fetal endocarditis or to developmental defect. Chorea is also a prominent cause of mitral valvulitis and narrowing, and the valvular irritation consequent to anemia and chlorosis, as well as the undue stress upon the mitral leaflets imposed by attacks of pertussis, may excite fibroid constriction of the mitral orifice. Pure mitral stenosis is a disease of children and young adults, rather than of advanced life, and is much commoner in females than in males, the former fact being generally attributed to the prevalence of rheumatism in the young, and the latter to the susceptibility of girls to rheumatism, chorea, and anemia. Persons of middle or advanced age occasionally acquire mitral stenosis of a sclerotic type, under which circumstances the lesion is but part of a general arteriosclerosis, and is commonly associated with chronic renal disease, gout, or syphilis. Rokitansky’s theory that mitral stenosis and pulmonary tuberculosis are antagonistic is generally regarded as tenable. The view that tuberculosis is an exciting cause of mitral obstruction, especially of those types characterized by slow development and progress, is supported by Potain and by Tessier. The association of mitral stenosis with cholelithiasis, which occurs in about one-fifth of all cases of this type of valvular disease, according to Brockbank, has never been satisfactorily explained.

The structural changes in mitral obstruction implicate mainly the valve leaflets, their tendinous and muscular attachments, and the basal ring of the orifice (Figs. 172 and 173). Of the valve defects, the two most distinctive types are known as Corrigan's "button-hole mitral" and the so-called "funnel-shaped stenosis," of which the former is the commoner in adults and the latter, in children. In the button-hole variety of obstruction the valve segments are fused, retracted, and greatly thickened, with the result that the mitral orifice is

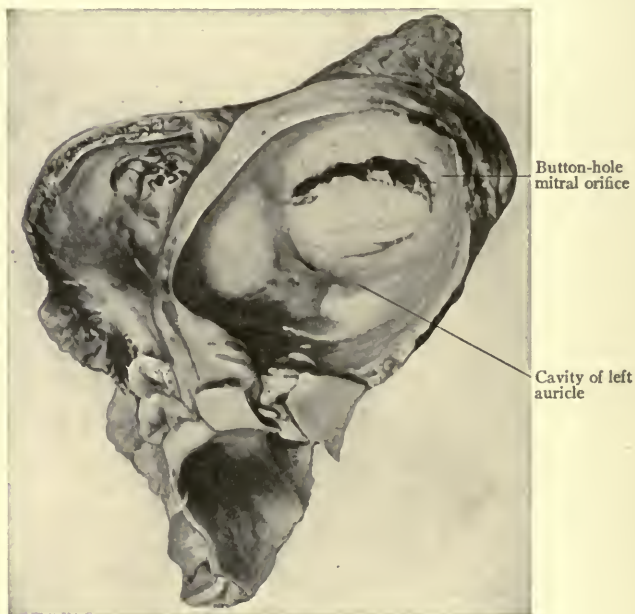

Fig. 172.—Mitral stenosis (Jefferson Hospital Laboratories).

converted into a mere narrow slit or a somewhat crescentic perforation; in the funnel-shaped stenosis the leaflets are intimately welded together, and, by sclerotic shortening of the chordæ tendineæ, pulled down into the cavity of the left ventricle in the form of a conic structure the large orifice of which points toward the auricle. In both these forms of obstruction the valve mechanism is further interfered with by more or less fibrous constriction of the mitral ring and by contraction and rigidity of the tendinous cords and papillary muscles, which, in extreme instances, appear to be attached directly to the valve leaflets, so striking is the shrinkage of the thickened cords.

In some instances, particularly those of congenital type, stricture of the orifice by contraction of the sclerotic and calcified basal ring, with little or no deformity of the leaflets, is the conspicuous change. In other cases the orifice is obstructed by vegetations situated upon the auricular surfaces of the leaflets just back of their free borders; the constriction may be due to irregular deformities of the cusps, depending upon fibrous contraction and the deposit of lime-salts; or, rarely, a calcareous plate projects from the basal ring into the lumen

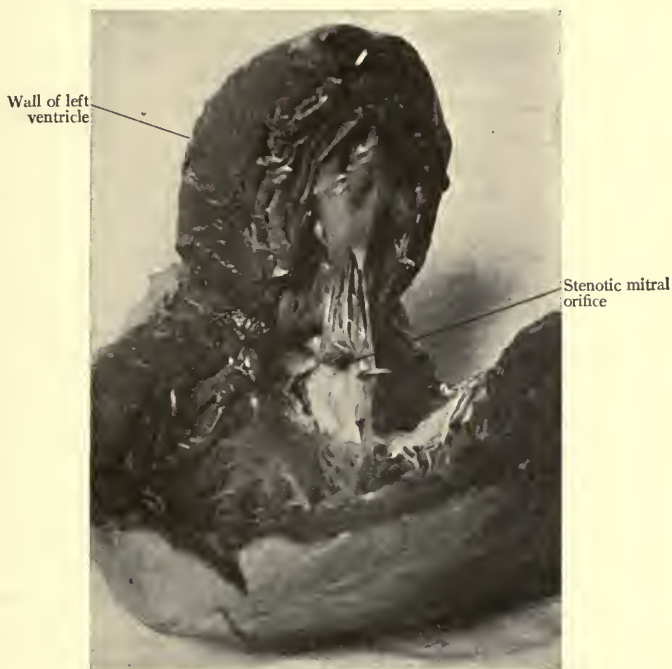

Fig. 173.—Mitral stenosis (Jefferson Hospital Laboratories).

of the orifice. Ewart mentions pedunculated thrombus attached to the left auricular wall as a cause of mitral obstruction, and he has also described a narrowing of the mitral orifice due to yielding non-indurative fibrosis, in which type of so-called "soft-valve stenosis" a murmur may never develop, owing, Ewart maintains, to the remarkable pliability of the valve mechanism.

A condition of *relative mitral stenosis* is said to exist when dilatation of the left ventricle is associated with no deviation from the normal

diameter of the auriculoventricular orifice. As a rule, left ventricular distention causes corresponding dilatation of the mitral ring, and hence relative mitral incompetence ensues, but should the ring fail to stretch, the orifice necessarily must be stenosed relatively to the inordinately large ventricular chamber beyond.

The immediate effects of mitral stenosis are felt by the left auricle, whose walls hypertrophy to a degree proportionate to the increased force the auricle must exert to drive the blood through the narrowed outlet into the ventricle. This primary auricular hypertrophy may ensure a satisfactory blood-supply to the left ventricle for a time, but usually not for a long period, as the auricle, having but indifferent muscular power, tends soon to dilate under the undue stress, in some instances enlarging to a most extraordinary degree—even to twice or thrice its normal capacity. In fully 50 per cent. of mitral stenoses the advanced myocardial degeneration attendant thereto ultimately causes auricular fibrillation, in which these chambers are maintained in wide diastole with their musculature incessantly quivering with fine fibrillary twitching movements, due to the independent origin of new impulses in many small areas, but never actually contracting through stimuli sent from the sino-auricular node (*v. s.*). Osler has shown that the dilated auricle may compress the left recurrent laryngeal nerve, exciting a group of pressure symptoms like those attending thoracic aneurism. (See p. 489.) This primary hypertrophy and secondary dilatation of the left auricle in mitral stenosis stand in strong contrast to the primary dilatation and secondary hypertrophy of this chamber in mitral regurgitation. When the left auricle fails, the pulmonary congestion consecutive thereto augments the work of the right ventricle, and this chamber now hypertrophies and then dilates, in its effort to overcome the stasis of the lesser blood circuit. This is unquestionably beneficial, in that the force of the hypertrophied ventricle is transmitted through the pulmonary circulation into the left auricle, raising the pressure therein, and thus aiding the feeble auricular contractions to drive the blood column onward through the stenosed mitral orifice. When finally the right ventricle fails, relative incompetence of the tricuspid valve is inevitable, and ultimately the right auricle, after a period of compensatory hypertrophy, dilates, with the disastrous consequences referable to general venous congestion. (See p. 432.) In pure compensated mitral stenosis the left ventricle, having less work than normal to perform, not only does not enlarge, but ordinarily diminishes in size, becoming atrophied, thin walled, and flabby, and appearing dwarfed

in comparison with the decidedly hypertrophied right ventricle. Left ventricular atrophy, then, is the familiar autopsy finding in uncomplicated mitral stenosis, notwithstanding the contention of some authors that the wall of the ventricle overdevelops in consequence of its undue efforts in performing diastolic aspiration of the auricular blood, with which act an obstructed mitral orifice interferes. When, however, compensation breaks and venous stasis is persistent and excessive, systemic arterial hypertension is thereby set up, and to overcome this resistance the left ventricle commensurately hypertrophies. It also does so, irrespective of broken compensation, in that class of cases in which persistent high tension accompanies the mitral defect. (See p. 410.) Left ventricular hypertrophy naturally attends double mitral lesions, as the result of the regurgitation.

Physical Signs.—*Inspection.*—Interference with the pulmonary circulation accounts for the chief objective evidences of mitral stenosis—early, persistent, and increasing dyspnea; cough productive of liquid, and frequently hemorrhagic, sputum; and cyanosis varying in degree from a slight dusky flush upon the cheeks to intense diffuse blueness of the face and extremities. Striking pallor of the skin and blanching of the mucous membranes, with other evidences of well-marked anemia and its consequences, are frequently seen in women who suffer from mitral stenosis. As a rule, edema is not so conspicuous as it is in mitral regurgitation, though it occurs, of course, when right heart failure leads to general venous stasis. Clubbing of the finger-tips, and, in children, unnatural prominence of the lower sternal area, are familiar signs in cases of long standing.

Systolic throbbing is visible in the epigastrium and lower part of the sternum when the right ventricle is considerably hypertrophied, and the impact of this chamber's conus arteriosus is occasionally perceptible, in thin-chested subjects, at the left of the sternum in the fourth, the third, or, rarely, the second interspace. Systolic jugular pulsation is noticeable when secondary tricuspid leakage is well established. The apex-beat, if strong enough to be seen, is found to occupy an approximately normal position.

Palpation.—In well-compensated mitral obstruction palpation at or just above the apex detects, with great constancy, a rough pre-systolic thrill occupying either the latter part or the whole of the diastolic period, and terminating in a short, sharp ventricular shock. Sometimes the thrill is not unlike the soft purring of a cat—hence the term, “*frémissement cataire*” of the French school; and, as a rule,

it is circumscribed to the neighborhood of the apex, and is intensified during expiration, by active exercise, and by left lateral decubitus. The discovery of this dual sign—presystolic thrill and systolic shock—is of itself proof positive of mitral stenosis. Other tactile signs to be noted in this lesion include a sharp impact in the pulmonic area, caused by the sudden closure of the pulmonic valve, and also the right ventricular pulsations alluded to above.

Preceding the stage of cardiac breakdown the *pulse*, though small, is of relatively high tension, and regular in rhythm and in frequency, the artery being of small size and full between beats, probably in consequence of contraction of the general arterial system to ensure its accommodation to the diminished ventricular output of blood. A radial tracing made at this period indicates a wave of small amplitude, characterized by an oblique upstroke, a blunt apex, and a gradually falling downstroke having a poorly defined dicrotic notch; later the sphygmogram shows most graphically the character of the various irregularities of rate, rhythm, and force noticed by feeling the pulse during the stage of disturbed compensation. These tracings, however, show nothing distinctive.

Percussion.—Owing to the right ventricular enlargement, the area of cardiac dullness extends considerably beyond the right sternal border, dulling Ebstein's angle and obliterating the pulmonary resonance for a considerable distance to the right of this point, between the third and the fifth interspaces. To the left of the sternum there may be dullness, generally within the midclavicular line, extending from the second or third rib to the apex, the greater part of this area corresponding to the site of the enlarged right ventricle. In mitral stenosis, with no hypertrophy of the left ventricle, the lower left cardiac limit is not unnaturally extended. According to Potain, the abnormally large left auricle of a pure mitral obstruction is capable of producing an oblong area of impaired resonance, about $4\frac{1}{2}$ by $2\frac{1}{2}$ inches (11.2 by 6.2 cm.) in extent, in the left interscapular region, and to the stabbing sensation provoked by strong percussion over this area Vasquez has given the name "auricular pain." Enlargement of the hepatic area supervenes in the late stages of mitral stenosis, in consequence of passive venous congestion of the liver.

Auscultation.—The auscultatory findings in mitral stenosis differ very radically according to the mechanical conditions prevailing during the progress of the lesion, in view of which Sir William H. Broadbent's plan of grouping the sounds and murmurs in three stages is most helpful (Fig. 174). In the *first* stage, that of ade-

quate compensation, auscultation at the apex affords three distinctive sounds: a rough, rumbling presystolic murmur, abruptly terminating in a sharp, snappy first sound,¹ and followed, after a prolonged diastolic interval, by a distinct, occasionally reduplicated, second sound.² Rarely, a short interval separates the murmur from the first sound, a peculiarity which Mackenzie attributes to delay in the transmission of the contraction stimulus between

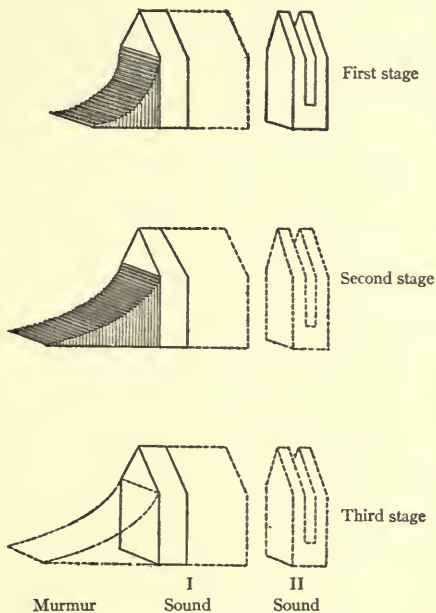


Fig. 174.—The murmur of mitral stenosis.

auricle and ventricle. At the base the pulmonic second sound is sharply accentuated and frequently doubled, while the aortic second sound either remains of normal intensity or is enfeebled.

¹The apical first sound may be reduplicated (from asynchronous mitral and tricuspid valve closure), but this peculiarity is of far less diagnostic moment than the sharp snappiness of the sound.

²This reduplication of the second sound *at the apex* (Sansom's "double shock sound") is attributed to sudden tension of the mitral cusps, primarily dependent upon increased intra-auricular pressure, whereby the blood-column is driven with undue velocity into the ventricle. Apical reduplication of the second sound, since it may precede the development of the presystolic murmur, is an important early sign of mitral obstruction.

The murmur occupies a short interval immediately before ventricular systole, and is distinguished by rolling, vibratory quality, by low pitch, and by gradually increasing intensity, or ingravescence, toward its abrupt termination. Its punctum maximum is just above and somewhat within the apex-beat, where, as a rule, the murmur is sharply localized, though in some instances its audibility extends, in the shape of a roughly pyramidal area, from midsternum to mid-axilla (Fig. 153). A mitral stenotic murmur, however, is never transmitted, in the ordinary sense of the word. Although generally ascribed to blood eddies created by the auricular contraction, there is also truth in Colbeck's belief that the bruit of mitral stenosis likewise may be due to vibrations excited in the long anterior mitral flap by the impact of the auricular blood stream.

Inconstancy and variation in intensity and duration are other peculiarities of this murmur, which is prone to appear and to disappear erratically in the same patient, and to become soft and indistinct and prolonged when the heart is beating rapidly. The sharp snappiness of the apical first sound corresponds to the systolic shock felt at the apex, and though both phenomena are obviously due to a common cause, their precise nature is a matter of much controversy; perhaps the best explanation assumes an incomplete filling of the left ventricle, whereby the contraction of the muscular wall, at first unopposed, is suddenly arrested by contact with the contained blood before the completion of systole.

The *second stage*, characterized by beginning failure of the left auricle and by hypertension of the pulmonary circuit, is accompanied by certain alterations in the character of the murmur, by increased intensity of the first sound, and by disappearance of the second sound at the apex. The murmur, hitherto a short continuous crescendo just before systole, now tends to become prolonged and wavy or actually interrupted. In other words, it now corresponds not only to the time of the auricular systole, but also to the time of the ventricular diastole, which creates a suction force at the mitral orifice sufficient to generate an additional sound during the early part of the diastolic period. It is this suction murmur, due to the diastolic recoil of the left ventricle, that accounts for the sound now audible at the beginning of diastole, before the appearance of the strictly presystolic bruit produced by the auricular force. The murmur audible at this stage may occupy the entire diastolic period, beginning immediately after the second sound and continuing up to the sharp first sound, as a continuous bruit having: (a) a mid-diastolic diminuendo and a presystolic crescendo; or (b) a double crescendo

wave; or (c) a mid-diastolic crescendo and a presystolic diminuendo. Should the ventricular suction-action be expended before the auricular contraction-force begins, the murmur will be actually interrupted at about the middle of diastole, so that it consists of two separate phases—one audible immediately after diastole and the other immediately before systole. Should the auricular force fail, but the ventricular suction persist, the strictly presystolic rumble will be suppressed, in which case but a single short sound, at the very beginning of the diastolic period, is detected. Should the pressure within the ventricle fall below that within the auricle, the characteristic presystolic rumble is replaced by a much softer diastolic diminuendo murmur generated at the narrow mitral orifice at the moment its valves open. In the event of auricular fibrillation, with the abolition of every vestige of the auricular contraction force, this diastolic murmur is commonly followed by a distinct period of silence just before systole, the adventitious sound being ascribed to the increased velocity of the blood flow during early diastole and the succeeding silence to the slowing of the current during late diastole. In general, Dagnini's statement is true, that early and mid-diastolic murmurs are more frequent in double mitral lesions than in pure stenosis. Aside from the changes in the murmur, the increased loudness and sharpness of the apical first sound and the disappearance of the second sound at the apex are clinically important signs. Maintaining that the second sound audible at the apex is the transmitted aortic (not pulmonic) tone, its disappearance in mitral stenosis is commonly attributed to two factors: first, weakening of the aortic second sound by the diminished tension of the aortic cusps consequent to the restricted output of blood by the left ventricle; and, second, non-transmission of this enfeebled aortic second sound to the precordia, owing to the backward displacement of the left ventricle by the hypertrophied and dilated right heart. Corresponding enfeeblement of the second sound in the aortic area, and accentuation, generally also reduplication, of the second sound in the pulmonic area are corroborative of the foregoing explanation.

The *third stage* is distinguished by striking enfeeblement or even total disappearance of the presystolic murmur, and when this happens, the short, sharp first sound is the sole auscultatory sign distinguishable at the apex, since already the apical second sound has been effaced. Coincidentally, the accentuation of the pulmonic second sound at the base disappears, and its aortic equivalent becomes still weaker. This stage of the lesion corre-

sponds to extreme dilatation of the left auricle and the right ventricle, and to auricular fibrillation, with the establishment of tricuspid leakage and, in consequence, lowering of the pressure within the pulmonary circuit and the left auricle. The force of the auricular contractions is now so lessened and the tension within the auricle is at so low an ebb that a murmur is no longer generated. However, should the heart regain its tone, as is not infrequently the case, the murmur may reappear, its persistence depending upon the mechanical forces active at different periods. In addition to the presystolic murmur, the majority of mitral stenoses also afford the systolic bruit of mitral regurgitation, and, during the advanced stage, a similar sound referable to secondary tricuspid leakage. Sometimes it is also possible to recognize the so-called "murmur of high pressure," indicative of relative pulmonary leakage. (See Relative Pulmonary Regurgitation, p. 473.)

Diagnosis.—A rough presystolic murmur and thrill, with a snappy first sound and a reduplicated second sound at the apex, are characteristic of mitral stenosis. Restriction of the murmur and thrill to the apical region and their ingravescient quality, accentuation of the pulmonic second sound at the base, enlargement of the right ventricle rather than of the left, and a small thready pulse are corroborative evidence not to be overlooked. Later, as the murmur and the second sound become indistinct and evanescent at the apex, the character of the other heart-sounds are the most definite guides. As the power of the heart wanes, the pulmonic second sound, for a long period accentuated, finally weakens at the base; and the aortic second sound, already lost at the apex, becomes almost inaudible in the aortic area; but despite all this, *the first sound still snaps sharply at the apex.* This sign, interpreted in the light of other clinical information, may be sufficient to warrant a diagnosis of mitral obstruction during the stage of broken compensation.

Discrimination between the *Flint murmur* of aortic regurgitation and the bruit of organic mitral constriction must sometimes be equivocal, for both are similarly timed, have a common punctum maximum, are restricted to the apex, and may be accompanied by the same sort of thrill. In a given case of Corrigan's disease with a basic diastolic and an apical presystolic murmur, the latter probably represents a spurious obstruction, if unattended by a systolic shock, a snappy first sound, an accentuated pulmonic second sound, and enlargement of the right ventricle. Moreover, a Flint murmur generally is less intense, rumbling, and ingravescient than the bruit of true stenosis, while the pulse does not become small and thready,

but retains its collapsing character. Syllaba advises, in studying doubtful cases, the use of digitalis, the action of which quiets or dissipates the murmur of Flint.

Tricuspid stenosis, though almost unique as an isolated lesion, must not be overlooked as a possible counterfeit of mitral obstruction, for a circumscribed presystolic thrill and murmur, with a sharp first sound, are common to both. These signs, restricted to the tricuspid area and attended by right auricular dilatation and venous congestion without pulmonary engorgement, warrant the diagnosis of tricuspid obstruction. In doubtful cases it is helpful to remember that in this affection, owing to the relatively weak contractions of the right auricle, the murmur is likely to be lower and less rumbling, while the tactile vibrations are less distinct than in its mitral counterpart; and also that, exceptionally, the liver shows presystolic (auricular) pulsation. When mitral and tricuspid stenosis coëxist the signs of the former usually so completely overshadow those of the latter that the right-sided defect escapes attention. When the tricuspid signs are well defined, one sometimes detects two thrills and two murmurs of virtually identical nature, save, perhaps, for differences in quality and pitch, and for the important fact that one is localized at the cardiac apex and the other at the base of the ensiform, between which puncta maxima lies a silent area over which neither bruit can be heard. Cyanosis, dropsy, and other evidences of venous obstruction are no criteria in distinguishing right- and left-sided auriculoventricular stenoses, nor is the character of the pulse a guide.

Pericarditis in children is occasionally followed by the development of a rumbling presystolic apical murmur, which Broadbent believes is "possibly a result of pericardial adhesions." This murmur, unlike that of true mitral stenosis, lacks a vibratory, crescendo character, and does not terminate abruptly in a snappy first sound; while the exocardial origin of such a bruit is suggested by its appearance after an attack of pericarditis and by its association with other physical signs thereof.

AORTIC REGURGITATION

Clinical Pathology.—This dangerous type of heart disease was first established as a clinical entity in 1832 by the brilliant Irish physician, Sir Dominick Corrigan, who termed the lesion a "permanent patency of the mouth of the aorta." Ordinarily, it affects men of middle age, and is the consequence of a gradual, progressive

sclerosis, of which unremitting muscular strain, alcohol, and syphilis, combined or singly, are the material factors; to some degree it is probable that plumbism and gout have a similar influence. The essential cause, then, of this type of heart disease consists of long-continued irritation of the aortic cusps, both by their exposure to excessive tension during diastole and by the action of circulatory poisons. This being so, it is easy to understand the predilec-

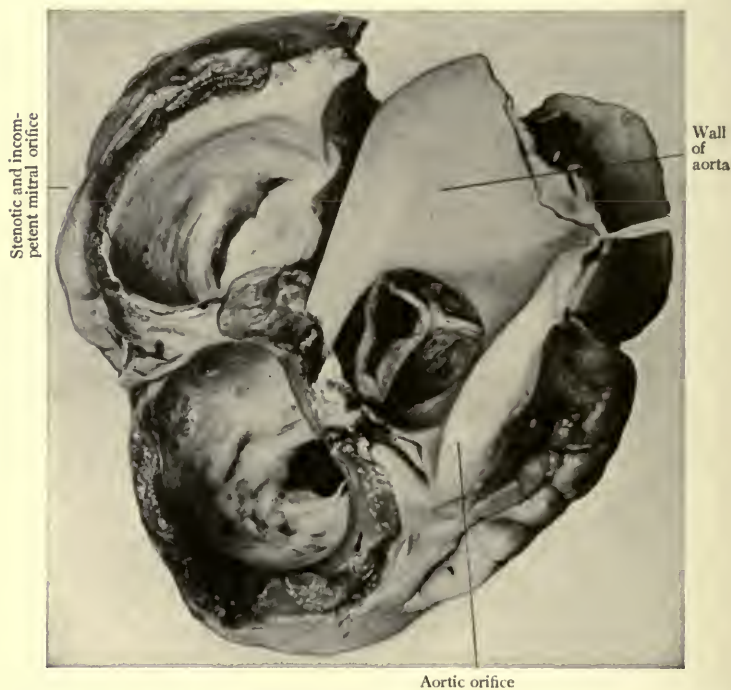

Fig. 175.—Aortic regurgitation and double mitral lesion. Aortic and auricular aspects (Jefferson Hospital Laboratories).

tion of aortic leakage for sailors, soldiers, stevedores, stokers, and other men whose occupations entail habitual muscular strain and whose tastes perchance run to alcohol and to venery. "Athlete's heart" and "jinrikisha heart" are medical slang for the aortic regurgitation occurring in the athlete, and in the rickshaw man of the Orient. Less commonly the aortic leaflets are damaged by endocarditis, whereby valvular induration, puckering, and adhesion, together with vegetation, erosion, and dense fibrocalcereous deformity, are the

various lesions provoked, according to the extent and malignancy of the inflammation. In regurgitation of endocarditic origin it is also true that males are more predisposed than females, but here middle age is not a prominent etiologic factor. Traumatic aortic regurgitation, from rupture of a leaflet, though very rare, occasionally follows a sudden violent strain; it is hard to believe that this accident can happen so long as the valve is normally resistant, though when damaged by sclerosis or erosion, a cusp is not unlikely to be torn or perforated under the stress of great muscular exertion or even by inordinate arterial hypertension. Exceptionally, the aortic orifice leaks because the valve is congenitally malformed, and in such instances it is usual to find sclerotic valvulitis with fusion of two cusp borders, and hence, conversion of the valvular apparatus into a double instead of a triple set of leaflets. Aortic regurgitation, whether sclerotic or endocarditic, is commonly attended by more or less stenosis, owing to the frequent coincidence of fibrous contraction at the aortic ring sufficient to obstruct the systemic blood-column passing through this aperture. The systemic arteries do not often escape fibrosis, owing to the circulatory wear and tear provoked by the powerful ventricular contractions, which, despite their force, are not always able properly to fill the arteries, if the aortic reflux be excessive. The circulation within the coronary arteries is greatly disturbed, and these vessels are damaged by sclerotic degeneration—defects leading to muscular degeneration of the heart. In many instances the first part of the aorta is the seat of fibrosis, atheroma, and calcification, whereby permanent dilatation is favored. So-called “dynamic dilatation” of the aortic arch, simulating the physical signs of aneurism and occasionally met with in Corrigan’s disease, is due merely to the violent systolic shocks of the voluminous blood-columns within a resilient and distensible aorta, having no actual enlargement of its caliber and no traces of mural disease.

Aside from the foregoing types of aortic reflux, essentially referable to valvular deformity, regurgitation also occurs into the ventricle when the aortic ring and the ventricular wall are so stretched that the leaflets of the valve fail to approximate during diastole. This so-called *relative aortic incompetence* is much less common than a corresponding leakage at the mitral orifice, since the aortic ring, being stouter and denser, does not readily enlarge to a caliber rendering perfect coaptation of its valve cusps impossible. Relative aortic incompetence follows stretching of the aortic ring secondary to myocardial degeneration, atheromatous dilatation of the aortic root, aneurism of the ascending arch of the aorta, and pressure stenosis of this vessel.

In aortic regurgitation the left ventricle bears the brunt of the damage, since with diastole this chamber receives not only its normal quota of blood from the auricle, but also the stream regurgitated from the aorta through the leaky semilunar cusps. Surcharged in this manner, the ventricle dilates in order to accommodate the undue blood volume, and hypertrophies so as adequately to propel its contents aortaward. This habitual overwork in time creates that extreme grade of eccentric hypertrophy of the left ventricle termed *cor bovinum*, or ox heart, the weight of which may be three or even four times that of the normal organ (Fig. 164). So long as this conservative hypertrophy predominates, the valvular lesion is compensated by the increased ventricular output thereby made possible, but inevitably dilatation gains the upper hand, owing to the pernicious action of the persistent ventricular overdistention and to myocardial malnutrition due to defective coronary blood-supply. When, finally, the ventricle gives way and no longer can pump sufficient blood into the

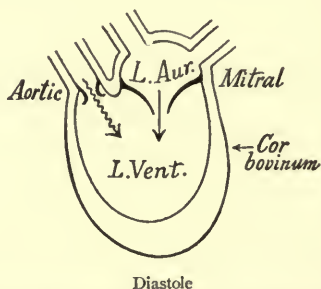


Fig. 176.—Mechanism of the murmur of aortic regurgitation.

systemic circuit to satisfy its demands, failure of compensation supervenes. Relative leakage at the auriculoventricular orifice occurs with systole, because of the strain upon the mitral ring, if, indeed, the valve's integrity is not already impaired by pathologic changes, and in consequence of this incompetence a wave of backward pressure is transmitted into the left auricle, the pulmonary veins, and the right heart, with the baneful effects already recounted in connection with mitral regurgitation. (See p. 435.)

Physical Signs.—*Inspection.*—Violent arterial throbbing is a noteworthy sign of Corrigan's disease, and in some instances one is almost justified in hazarding the diagnosis by this evidence alone. The pulsations, systolic in time and perhaps so vigorous as to jog the patient's head with every heart-beat (*Musset's sign*), are particularly

conspicuous in the carotid and subclavian arteries of the neck, in the temporals of the face, and in the brachials of the arm, while in the episternal notch an aortic throb is generally visible. Even the small arteries, such as the radial and the dorsalis pedis, may pulsate visibly, showing in miniature the powerful beats of the larger arterial trunks. If tortuous, a superficial artery, such as the brachial, may not only pulsate, but even become displaced and elongated with every beat—the *locomotive* or *movable pulse*. Penetration of the capillaries by the pulse-wave produces pulsation of these small vessels, to which the term *capillary pulse* is applied (see p. 345); and, rarely, the superficial veins, notably those of the hand and forearm, show postsystolic undulations created by arterial waves of sufficient force to penetrate the delicate venous radicles—the *penetrating, direct, or centripetal venous pulse*. (See p. 349.) Pulsation and tortuosity of the retinal arteries are sometimes visible with the ophthalmoscope. The precordial area heaves under the impact of the enlarged heart, and, in the case of a thin-walled, resilient thorax, it may show unnatural protrusion. A violent pulse in the abdominal aorta causes an epigastric throb. The apical impulse appears extraordinarily broad and powerful, and is displaced from one to three interspaces downward and outward toward, if not, indeed, as far as, the left anterior axillary line. In certain subjects atmospheric pressure produces a circumscribed systolic recession of the third and fourth interspaces between the left sternal and midclavicular lines, and in such instances a systolic thrill at the apex may be very closely counterfeited by costal vibrations set up by the violent and sharp cardiac impulse. These remarks apply to a well-developed example of aortic regurgitation with decided left ventricular hypertrophy, considerable reflux from the aorta, and marked arterial relaxation, but when such conditions do not obtain, it is obvious that suitable modifications of these visual signs are to be made. Pallor of the skin and mucous membranes is a common sign in aortic regurgitation, especially during the advanced stages, and, when compensation fails, cyanosis, dyspnea, cough, edema, and other evidences of venous obstruction supervene. Ague-like attacks not infrequently light up from time to time as a symptom of recurrent endocardial inflammation.

Palpation.—A heaving, tumultuous, lifting impulse of wide extent is perceived by laying the palm of the hand upon the precordia, but later, as dilatation predominates, this sign of ventricular hypertrophy is replaced by a feebler, less extensive, and somewhat undulatory pulsation. Occasionally there is a prolonged diastolic thrill at

the base of the heart, due to vibrations excited by the regurgitant blood-column; a systolic thrill in the episternal notch, if the aorta be greatly dilated; and a presystolic thrill near the apex, suggestive either of a Flint murmur or of a true mitral stenosis (*v. i.*). Rarely a distinct thrill may be felt over one of the smaller arteries, such as the brachial. A short, sharp diastolic impact in the region of the apex suggests sudden recoil of the left ventricle under the burden of a large volume of reflux blood. Rarely, it is possible to distinguish arterial pulsation over the liver, and, very exceptionally, over the spleen. One obtains a good idea of the general arterial overaction by grasping, with firm compression, the subject's arm just above the elbow, so as to obstruct the circulation and create an exaggerated distensive pulsation proximal to the constriction. (Beardsley.)

The *pulse* is very characteristic in most cases of aortic regurgitation; it is commonly known as the "Corrigan pulse," owing to its lucid description by Corrigan, but is also termed the "pulsus altus et celer," the "pulsus celerrimus," the "water-hammer pulse," the "collapsing pulse," the "receding pulse," and the "pistol pulse." In the radial arteries the pulse-wave rises suddenly and with extraordinary force, strikes the palpating finger with a momentary shot-like impact, and then instantly collapses, the strong impact representing the concussion of the large column of blood hurled aortaward by the hypertrophied left ventricle, and the quick collapse indicating the rapid depletion of the arteries due to diastolic reflux of the blood-column through the leaky aortic valve into the left ventricle. The Corrigan pulse, particularly its collapsing character, is exaggerated by raising the subject's arm vertically above the head, so as to take advantage of the force of gravity; its peculiarities are masked by arterial sclerosis of a grade sufficient to impair the resiliency of the vessels and hence their ability to carry an undue volume of blood. Dilatation of the left ventricle with mitral insufficiency also negatives this pulse, by weakening the ventricular systole and diminishing the output of blood. As the cardiac strength wanes the pulse quickens, weakens, and becomes irregular in time and in force, and occasional extra systoles of a tired ventricle become perceptible between the more forcible beats. An unduly long interval between the apical impulse and the radial beat indicates a prolonged ventricular systole.

The characteristic pulse tracing of aortic leakage indicates great amplitude, showing a high, abrupt upstroke, a sharp apex with an acute angle, and a rapidly falling downstroke, having a poorly defined, if not entirely obliterated, diastolic undulation. (See Fig. 130, XIII; p. 341.) The exaggerated amplitude and the sudden rise and

fall of the tracing, so distinctive of this sphygmogram, are materially modified by myocardial failure, by concomitant mitral incompetence, and by arteriosclerosis.

Recent experimental studies by H. A. Stewart indicate that aortic leakage is accompanied by a fall of systolic blood-pressure presumably due to increased capillary flow. Leonard Hill has proved that the systolic blood-pressure of the leg greatly exceeds that of the arm, a difference of from 50 to 100 mm. of Hg being not unusual, whereas in health this difference is seldom greater than 10 mm. Unduly low diastolic pressures with high pulse-pressures are the rule in the average case.

The palpatory method of sphygmomanometry is usually preferred to the auscultatory in aortic regurgitation, owing to the persistence of a murmurish tone during the phases ordinarily occupied by the sharp and dull sounds preceding and coinciding with the diastolic pressure stage. But, despite this confusing element of sound, it is rarely impossible to identify the dull tone of the minimal pressure. (See p. 33.)

Percussion.—There is downward and outward extension of the cardiac area, commensurate with the displacement of the apex-beat already noted, and, after compensation breaks, this area perceptibly broadens, the left limit of the dilated left ventricle extending upward and outward and its apical outline becoming blunt. Ultimately, the cardiac dulness may encroach well beyond the right sternal border, as secondary enlargement of the right ventricle progresses.

Auscultation.—During ventricular diastole a murmur is audible at the base of the heart whence it is transmitted, with variable distinctness, downward over the precordia, and, exceptionally, beyond this limit (Fig. 156). The murmur is peculiar in having no constant punctum maximum and no definite line of propagation common to every case, these two details of the sound varying with the nature of the structural changes predominating in the individual heart. The murmur usually is louder and more distinct at about the middle of the sternum at the level of the third rib rather than at the traditional aortic cartilage, or it may be heard most clearly along the left sternal border at some point between the third rib and the ensiform, while exceptionally the punctum maximum is at the apex. A sort of double punctum maximum is sometimes definable: one at the apex and the other at the aortic cartilage, between which two points the bruit is either quite inaudible or greatly suppressed.

The murmur may be propagated along one of three different lines: vertically downward along the sternum to the ensiform cartilage, obliquely downward toward the apex, or horizontally outward toward

the left axilla; occasionally an attenuated diastolic bruit is audible over the subclavian and the carotid arteries. The murmur begins with diastole, and its greatest intensity coincides with the second sound, after which it is prolonged, as a gradual diminuendo, generally throughout the entire diastolic period, but occasionally subsiding before its completion. The quality of the sound is more often soft and blowing than loud and rasping, and its pitch is tolerably high; rarely, it is distinguished by an unmistakably musical tone, in which event considerable valve laceration is suggested. The murmur may be so faint as to be almost inaudible—indeed, extensive leakage at the aortic orifice sometimes exists with no murmur at all—and its intensity is no criterion of the extent of the endocardial damage.

The aortic second sound is partly or wholly replaced by the murmur,

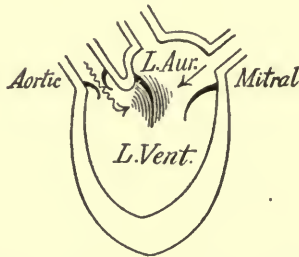


Fig. 177.—Mechanism of the Flint murmur of aortic regurgitation.

persistence of the second sound probably meaning a less serious aortic leakage than total masking of the tone by the murmur. In judging the intensity of the aortic second sound one should always auscultate over the carotid artery, in order to eliminate the pulmonic second sound, inaudible in this situation. The first sound at the base may be distinct and clear and loud, but more often it is obscured by a systolic bruit attributable to several causes—roughening of the aortic leaflets, atheroma or dilatation of the aorta, true stenosis of the aortic orifice, or anemia. The addition of this systolic sound produces the familiar “see-saw” or “to-and-fro” murmur of a double aortic lesion. At the apex the first sound is likely to be muffled, or perhaps overshadowed by the bruit of mitral leakage, either relative or organic. The apical second sound is unduly feeble, and not uncommonly tinged with the diastolic bruit reflected thence from the base. The rough presystolic murmur of Flint (see p. 382) is also audible at the apex in a certain proportion of cases—in about 50 per cent., says Thayer (Fig. 177). In certain instances

auscultation over the femoral artery reveals a sudden systolic thud coincident with the abrupt distention of the arterial wall by the impact of the blood-column, which sound, appreciable only when very gentle stethoscopic pressure is used, gives way to a physiologic constriction murmur when the pressure is increased. *Duroziez's sign*, consisting of this normal systolic bruit plus a diastolic murmur of arterial reflux, can often be developed by carefully graduating the pressure over the vessel until it is constricted to the exact degree essential for the creation of this distinctive double sound. (See p. 393.) Exceptionally, auscultation over the femorals reveals a faint double sound, not unlike that of the heart-beat—*Traube's sign*.

Diagnosis.—Arterial throbbing, a tumultuous apex-beat, collapsing radial and visible capillary pulses, enlargement of the left ventricle, and a diastolic aortic murmur, propagated downward and toward the left, unmistakably indicate Corrigan's disease, apart from the less constant corroborative signs of this lesion that also may be demonstrable. Subjects of aortic incompetence usually suffer from throbbing headache, vertigo, phosphenes, and tinnitus, while precordial pain, even true angina, is more common in this lesion than in any other type of valvular affection. Aortic disease, especially regurgitation, is not infrequently attended by most distressing mental symptoms—insomnia, dreadful dreams, melancholia, suicidal mania, and delirium. In this connection it may be noted that so-called "heart-disease delirium" may be counterfeited by the mental symptoms due to the toxic effect of digitalis, as H. O. Hall has pointed out.

The differentiation of aortic regurgitation from *pulmonary regurgitation* hinges upon the arterial phenomena and the nature of the cardiac structural changes, the details of which are dealt with in another place. (See p. 473.) In a preceding section (see pp. 378 and 391) the characteristics of diastolic *anemic* and *cardiorespiratory* murmurs sometimes audible at the base of the heart are considered.

The Flint murmur and the *mitral stenotic bruit* have been compared in the diagnosis of mitral stenosis. (See p. 448.)

AORTIC STENOSIS

Clinical Pathology.—Stenosis, like insufficiency of the aortic orifice, is more frequently attributable to a slow sclerosis than to frank endocardial inflammation, and is prone to affect men past the prime of life, in whom more or less general arterial fibrosis exists. In rare instances the obstructive lesion is the relic of an antenatal process. Pure aortic stenosis is the rarest acquired

valvular defect of the left heart, for in the vast majority of stenoses there is also reflux of blood through the orifice.

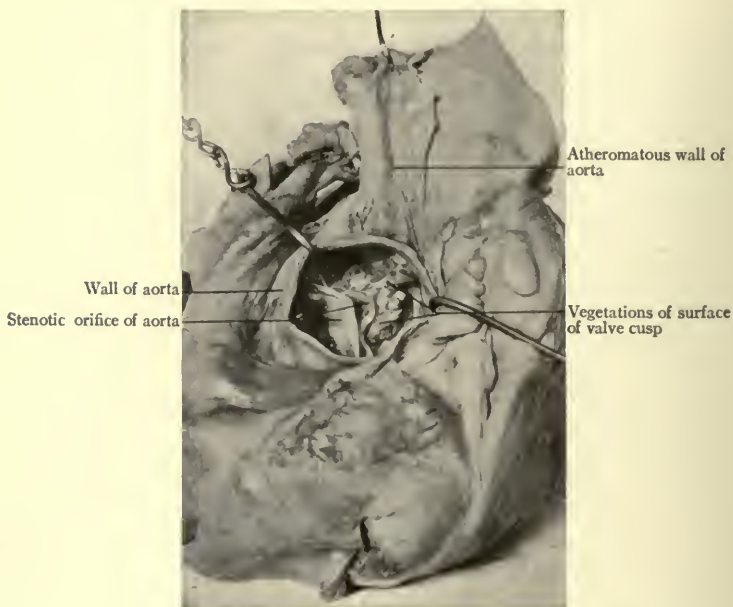


Fig. 178.—Aortic stenosis (Jefferson Hospital Laboratories).

Obstruction to the flow of blood from the left ventricle into the aorta ordinarily is due to rigidity and thickening of the semilunar

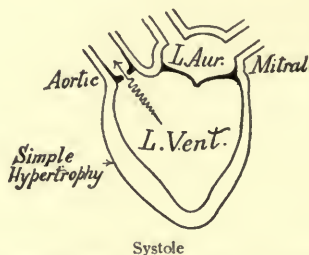


Fig. 179.—Mechanism of the murmur of aortic stenosis.

cusps, whereby they fail closely to hug the aortic wall during systole, and hence impede the outflowing blood-stream propelled by the ventricular contractions (Fig. 179). In some cases the orifice is

obstructed by vegetative excrescences, by simple adhesion of the valve borders, or by the formation, by fusion of the cusps, of a constricted funnel-like communication between the ventricle and the aorta. Calcification of the valve-leaflets, as well as vegetative and calcareous changes in the interventricular septum at the attachment of the aortic mitral cusp, may also develop. A type of aortic stenosis,

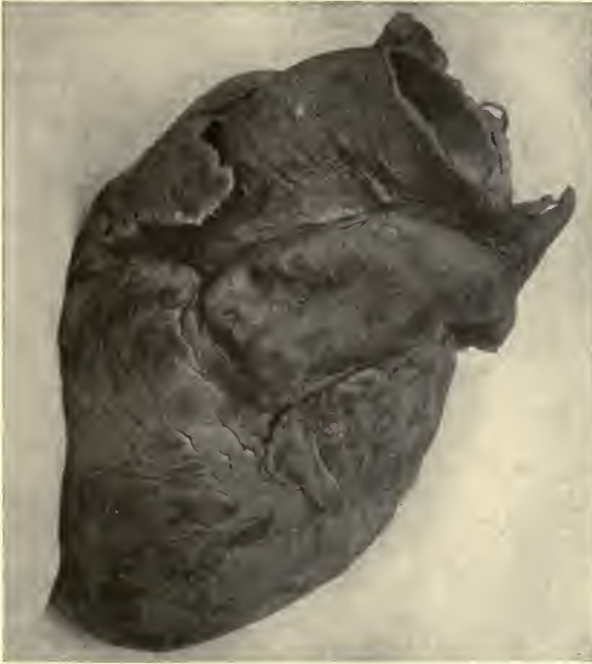

Fig. 180.—Dilatation of the aortic arch (Jefferson Hospital).

due not to valvular deformity, but simply to fibrocalcareous constriction of the aortic ring, also has been described. In congenital lesions it is the rule to find adhesion and thinning of the aortic cusps with little or no evidence of atheroma; or the defect may be a so-called *subaortic stenosis*, consisting of a constriction of the ventricular chamber by a ring of endocardial thickening situated below the aortic cusps—a process comparable to the conal type of pulmonary stenosis (*q. v. i.*). Occasionally, neither valve nor ring is

affected, but the aorta immediately beyond the latter is dilated—a condition known as *relative aortic stenosis*, though obviously “dilatation of the aorta” is the better term for the condition. The walls of the aortic arch are very commonly the seat of fibrocalcareous degeneration.

The immediate effect of aortic obstruction is a gradual and progressive thickening of the wall of the left ventricle, primarily unattended by dilatation. This change, one of so-called simple hypertrophy, is referable to the increased work thrown upon the ventricle in its endeavor to force the blood through an unduly narrow aortic opening. Later, however, the ventricle tends to give way under the incessant strain and to suffer myocardial degeneration, due to coronary artery occlusion, and in consequence it dilates, perhaps so decidedly that relative mitral leakage ensues, and in time the left auricle, the pulmonary circuit, and the right ventricle are affected by the back pressure.

Physical Signs.—*Inspection.*—The subject of aortic stenosis shows little or no evidence of a diseased heart so long as the left ventricle does not flag and the mitral valve remains tight, but when these structures give way signs of an embarrassed pulmonary circulation, already described, appear. Anemic pallor is likely to develop in the course of time, and in arteriosclerotic patients exaggerated prominence and tortuosity of the hardened surface vessels attract attention at first glance. The apical impulse, apparently of fair force, is dislocated obliquely downward and somewhat outward; or, as in old emphysematous individuals, the apex-beat may be looked for in vain.

Palpation.—With tolerable constancy a rather coarse systolic thrill, usually most intense at the aortic cartilage, is felt at the cardiac base, and, rarely, over the larger arteries near the surface. The apex-beat, if palpable, is regular, slow, deliberate, and heaving until the disturbing effects of left ventricular failure come into play.

The *pulse* of pure aortic stenosis (*pulsus tardus*) has a slow rate, moderate or small volume, normal rhythm, and prolonged, deliberate rise and fall. The tracing of such a pulse is quite distinctive, the wave being of diminished height, and composed of an unduly oblique ascent, a blunt apex, and a gradually falling down-stroke, with indistinct secondary oscillations. Or, the tracing may register the double apex of a *pulsus bisferiens*, suggestive of a double-phased contraction of the ventricle; while sometimes the notched upstroke of *anacrotism* is shown. (See Fig. 130, IX, X, XIV; p. 341.)

Percussion.—The downward and outward extension of cardiac dulness is proportionate to the degree of left ventricular enlargement, but in the average case of aortic stenosis the precordial limits are much more restricted than in Corrigan's disease. Impairment of pulmonary resonance at the right of the sternum may be detected as a late finding should secondary hypertrophy of the right ventricle occur.

Auscultation.—Aortic stenosis is attended by a systolic basic murmur having its punctum maximum at the aortic cartilage, whence it is transmitted into the carotid arteries, and in some instances over the entire precordia; most exceptionally, it is also audible alongside the spine, over the course of the descending thoracic aorta. Typically, the bruit is loud and rough and rasping; atypically, it is soft and blowing, or musical. The aortic first sound is likely to be masked by the murmur, particularly when this synchronous tone is notably harsh and intense. The aortic second sound is more or less muffled and enfeebled, sometimes to the point of actual extinction, this highly suggestive sign of aortic obstruction depending upon rigidity and thickening of the valve-leaflets. As a rule, the aortic second sound is still further obscured by a diastolic bruit, owing to the frequency of an associated leakage at the aortic orifice. The first sound at the apex is dully muscular in quality, and the second sound in this situation is indistinct, or perhaps blended with the transmitted bruit of a coëxisting reflux.

Diagnosis.—A systolic basic thrill, an aortic systolic murmur propagated into the neck, and impairment of the aortic second sound together determine the diagnosis of aortic stenosis, of which lesion moderate enlargement of the left ventricle and a pulse indicating slow, deliberate, and often double-phased ventricular systoles are highly corroborative. True aortic stenosis is unusual as an isolated defect, whereas aortic systolic murmurs, most often symptomatic of atheroma or dilatation of the aortic arch, or of some functional inadequacy of the heart, are very common.

Atheroma of the aorta may precisely simulate aortic stenosis in so far as the time, quality, and transmission of the bruit are concerned, but in atheroma a thrill is exceptional, suggestive pulse changes are lacking, arteriosclerotic hypertrophy of the left ventricle exists, and, most important of all, the aortic second sound rings clearly at the base of the heart. Well-defined arteriosclerosis is in favor of aortic atheroma, though the arteries are hard in many examples of stenosis.

Dilatation of the aortic arch, whether diffuse or aneurismal, also accounts for an aortic systolic murmur which is conducted into the

neck, as well as for a corresponding thrill, in many instances. In *simple dilatation* of the aorta one looks for systolic pulsation and unnatural dulness over the ascending aortic arch, throbbing in the suprasternal notch, a pulse of fairly good volume, and either accentuation of the aortic second sound or its modification by a bruit of concomitant aortic leakage. In differentiating *aneurism* of the aorta, attention should be directed to certain distinctive signs of this affection: an area of circumscribed dulness affording systolic pulsation and diastolic shock, a loud, low-pitched aortic second sound, and pressure symptoms affecting the pulses, the pupils, and the voice. The value of these findings as diagnostic criteria is dealt with more fully in another place. (See p. 489.) The discrimination between aortic stenosis and *mitral regurgitation*, *pulmonary stenosis*, and *patent ductus arteriosus* is given under these headings. (See pp. 439, 470, and 475.)

TRICUSPID REGURGITATION

Clinical Pathology.—Tricuspid regurgitation, due to organic valvular lesions or to relative muscular deficiency, is established when, during systole of the right ventricle, blood escapes thence through an incompetent tricuspid orifice into the right auricle, as well as forward into the normal outlet through the pulmonary artery. *Organic tricuspid regurgitation* is comparatively uncommon as a clinical finding, though it is not improbable, as Bramwell suggests, that the tricuspid leaflets are frequently invaded by inflammatory processes which abate without permanently crippling the valve mechanism, owing to the tendency of such lesions to undergo perfect resolution under the low pressure of the lesser blood circuit. The organic defects accountable for tricuspid leakage do not differ materially, either in origin or in kind, from those productive of mitral regurgitation, endocarditis and sclerotic degeneration of the cusps and their tendinomuscular attachments being the factors interfering with the integrity of the valve. Fibrous induration, thickening, and puckering of the valve segments, shortening of the chordæ tendineæ, and sclerosis of the muscoli papillares are familiar pathologic findings; or the free auricular border of the valve may be the seat of vegetations indicating endocardial inflammation of the acute or chronic benign variety, or of the malignant type; in the latter the mural endocardium is also most likely to be similarly implicated. Sclerotic degeneration is commoner at the tricuspid orifice than active inflammation,—just the reverse of the conditions prevailing at the mitral opening,—such changes supervening as the result of per-

sistent pulmonary hypertension, and consequently being secondary to mitral lesions (especially stenotic), left ventricular dilatation, arterial sclerosis, and chronic indurative affections of the lungs, all of which obstruct the pulmonary current, and by so doing excite habitually high tension within the right ventricle. Traumatic tricuspid leakage, due either to cusp laceration or to tendinous rupture, is most unusual, owing to the natural tendency of the right auriculo-ventricular sphincter to stretch and thus permit a "safety-valve" regurgitation, under sudden and acute intraventricular stress (*v. i.*).

Relative tricuspid regurgitation, consequent to muscular inadequacy, is an exceedingly common lesion, consisting essentially of right ventricular dilatation, stretching of the tricuspid ring, and relative shortening of the chordæ tendineæ and muscoli papillares, as the result of which the valve cusps cannot approximate accurately with systole, and hence permit reflux into the right auricle at this time. So-called "safety-valve regurgitation," a truly conservative condition, occurs at the tricuspid orifice when, as the result of increased pulmonary tension and distention of the right ventricle, the tricuspid sphincter enlarges so as to permit a backward leakage which relieves the stress upon the ventricular wall and lowers the tension of the pulmonary circulation. This natural tendency of the tricuspid valve automatically to ease the strain upon the right heart is well illustrated by the transient tricuspid leakage provoked by violent muscular exercise. Relative tricuspid regurgitation may attend true organic valvular disease, but it sometimes exists with perfectly healthy valves; its persistence is determined by the character of the underlying cause. Relative incompetence of the tricuspid valve from muscular deficiency of the right ventricle is a common secondary development in fever, anemia, toxemia, and other factors of myocardial relaxation, malnutrition, and degeneration; it accompanies conditions of heightened pulmonary tension consecutive to pulmonary fibrosis and emphysema, mitral disease, and left ventricular dilatation, and develops in consequence of pulmonary stenosis.

Physical Signs.—*Inspection.*—Free tricuspid leakage attended by right auricular dilatation cannot long exist without producing unmistakable evidences of an impeded venous circulation, such as cyanosis, edema, and distention and pulsation of the visible veins. Dyspnea and cough are also common features, either as forerunners of the right-sided heart failure, or arising indirectly from this accident, by the extension of the back pressure to the lungs through the systemic capillaries and arteries. The patient's cyanosis varies with the inadequacy of blood aëration existing in the individual case;

the edema, commonly beginning as dropsy of the feet and ankles, ultimately tends to implicate the serous sacs in the guise of ascites and hydrothorax, the latter being prone to affect the right pleural cavity. Turgescence of the small veins of the surface, in some instances most conspicuous, is detected by inspection of the upper anterior thoracic wall and the extremities. The external jugular veins are unnaturally distended, and, when emptied by pressure, fill from below; they may show the systolic pulsation of a positive venous pulse, the presystolic pulsation of a negative venous pulse, or a double jugular pulsation due to the coëxistence of both types of pulse. (See Venous Pulse, p. 346.)

Palpation.—There is epigastric pulsation, due to enlargement of the right ventricle, and varying in force with the strength of this chamber's contractions. Palpation of the liver discovers a positive venous pulse over this organ if the reflux venous waves created by the ventricular systoles are conducted thereto. The distinctive expansile property of this type of pulsation is to be distinguished from the mere lifting impulse of a liver jogged by the impact of a hypertrophied right ventricle; bimanual palpation, raising the liver with one hand and feeling its anterior surface with the other, is the most certain method of appreciating these differences.

The *pulse* of tricuspid regurgitation is in no wise characteristic, such irregularities as may exist being attributable to concomitant lesions of the left heart. A relatively feeble radial pulse on the right side suggests compression of the right subclavian artery by an enlarged right auricle (Popoff).

Percussion.—Owing to enlargement of the right heart, cardiac dulness extends unnaturally beyond the right border of the sternum and downward, while more often than not one also finds impairment of resonance due to enlargement of the left ventricle. Congestion of the liver produces lengthening of the vertical lines of hepatic flatness, the edge of the organ often reaching far below the costal margin.

Auscultation.—The murmur of tricuspid incompetence is most distinct over the lower part of the sternum, as a soft, blowing, systolic sound, which, though not propagated along hard-and-fast lines, is audible over a roughly triangular region lying between the tricuspid area, the right midaxillary line, and the manubrium (Fig. 158); inconstantly the bruit, enfeebled, is also heard in the neighborhood of the apex. The punctum maximum of the murmur is commonly situated at the conventional tricuspid area, but as the right ventricle undergoes changes in size and shape, the point correspondingly

shifts—to the xiphoid cartilage, to the left sternal edge over the fifth or sixth costal cartilages, or to the right sternal edge over the third, fourth, or fifth cartilages. The tricuspid first sound is masked by the attendant murmur, but only exceptionally is it entirely suppressed. In pure tricuspid leakage the pulmonic second sound is enfeebled; accentuation and reduplication suggest coëxistent left-sided disease. Auscultation over a pulsating cervical vein may reveal a systolic venous bruit. It is the rule to find at the apex signs of coëxisting mitral disease to which the right-sided leakage is secondary.

Diagnosis.—A systolic (ventricular) jugular and hepatic pulse, a tricuspid systolic murmur conducted toward the right, enfeeblement of the pulmonic second sound, enlargement of the right heart, and evidences of venous obstruction are the typical findings of this lesion. Moderate tricuspid leakage, so long as the tone of the right auricle is adequate, affords none of the foregoing venous phenomena, and in such an instance there may be merely a soft systolic whiff, audible over the lower part of the sternum. Furthermore, it is probably true that tricuspid regurgitation, especially of the muscular or “safety-valve” types, not infrequently gives rise to no physical signs whatever.

TRICUSPID STENOSIS

Clinical Pathology.—This exceedingly rare lesion may be of acquired or of congenital origin, and in either event is almost invariably associated with other cardiac damage, examples of pure isolated tricuspid stenosis being most unusual. The acquired form, making up the great majority of all cases, occurs most commonly during the second decade of life in women who give a history of rheumatic endocarditis, and who also suffer from mitral stenosis. The mitral affection, inducing protracted hypertension within the right ventricle, and hence irritation of the tricuspid segments, is the primary cause of many tricuspid stenoses, though there is good reason for believing that sometimes both auriculoventricular valves are simultaneously attacked by a wide-spread inflammation. Aside from stenosis due to well-defined inflammation of the endocardium, the defect occasionally arises in consequence of slow valvular sclerosis. In general, the structural changes affecting the tricuspid valve mechanism are similar to those of its mitral counterpart, except that on the right side of the heart the degree of constriction is likely to be less advanced, probably because the mitral lesion is usually primary and, therefore, older than the tricuspid defect, and, unlike the latter, tends to persist and to progress, rather than to undergo resolution.

Congenital tricuspid stenosis, the product of fetal endocarditis or of developmental anomaly, is less common than the acquired type. It is almost invariably attended by other defects of cardiac development—perforation of the ventricular septum, patency of the foramen ovale or the ductus arteriosus, and stenoses of other orifices.

Owing to the increased force the right auricle must exert in propelling its contents through the stenotic tricuspid orifice, the walls of this chamber hypertrophy and later dilate, for the myocardium weakens under the incessant stress, so that the auricle becomes habitually overfilled by residual blood, and, in most instances, overdistended by a systolic reflux stream from the right ventricle, due to concurrent tricuspid incompetence. Most extraordinary enlargement of the auricle and thinning of its walls are sometimes observed as the result of these several factors. The venous obstruction depending upon auricular failure has already been described. (See p. 432.) The effect of pure tricuspid stenosis is to diminish the size of the right ventricle, but, as a matter of fact, this chamber is nearly always found to be hypertrophied and dilated, in consequence of an attendant mitral lesion, which also accounts for the pulmonary congestion, when this exists. Arterial anemia develops should the right ventricular output of blood be inadequate for the needs of the pulmonary circulation, the left side of the heart, and the greater blood circuit.

Physical Signs.¹—*Inspection.*—Chronic cyanosis, well-defined turgescence of the surface veins, and persistent dropsy are most constant, yet not pathognomonic, signs of tricuspid obstruction. Assuming that the tricuspid orifice does not leak, there is jugular distention, unattended by systolic (positive) pulsation, though a presystolic (negative) flicker is sometimes visible should the force of the right auricle be sufficient to propel a backward venous wave.

Palpation.—Occasionally a short, purring, presystolic thrill, ending in a sharp, systolic impulse, is appreciable over the xiphoid appendix, but there is no epigastric throbbing so long as the right ventricle does not hypertrophy. The edge of the liver is palpable and, rarely, pulsatile below the right costal arch, and the skilful use of the kymograph may show a presystolic hepatic pulse wave, if the right auricle be hypertrophied (Mackenzie). The *pulse* in

¹ For the purpose of description, it is thought best to give the signs of a *pure* tricuspid stenosis. The reader should appreciate, however, that in actual practice this rare lesion, if met with at all, is nearly always attended by other valvular defects—by mitral stenosis in fully 90 per cent. of cases. Isolated tricuspid stenosis made up but about 7 per cent. of Herrick's 154 collected records of this affection.

the radials may exhibit no deviation from normal, or the beats may be accelerated, arrhythmic, small, and forceless.

Percussion.—Right auricular enlargement accounts for considerable extension of cardiac dulness at the base, particularly upward and to the right of the sternum. Hepatic dulness is increased commensurately with the existing degree of hepatic engorgement.

Auscultation.—A short, rough presystolic murmur, ending in a sharp first sound and restricted to the tricuspid area, is heard in obstruction of the tricuspid orifice. The punctum maximum of this murmur, which is not propagated thence, corresponds variously to the base of the ensiform or to either edge of the sternum, and, as in its mitral equivalent, the sound may be either strictly presystolic in time, or it may begin directly after the second sound, running through the entire diastolic period with a distinct crescendo just before the first sound. The cardiac tones at the base are enfeebled, should there be anemia of the pulmonary circuit, and, consequently, reduction in the volume of blood within the left heart.

Diagnosis.—A presystolic murmur and a sharp first sound in the tricuspid area, with enlargement of the right side of the heart, mean stenosis of the tricuspid orifice, provided that it is possible to exclude concomitant mitral obstruction (*q. v.*). The frequent coëxistence of the latter lesion, which masks the tricuspid signs, largely accounts for the common failure to recognize tricuspid stenosis during life. Corroborative evidence of tricuspid stenosis consists of cyanosis, edema, hepatic enlargement, turgid pulsating jugulars, and a presystolic thrill over the ensiform. According to the elder Broadbent, in the face of signs indicating pure mitral stenosis, the presence of extensive and persistent dropsy is sufficient grounds for believing that the tricuspid orifice is likewise obstructed.

PULMONARY STENOSIS

Clinical Pathology.—This very rare defect is almost invariably of congenital origin, being the most frequent form of valvular disease attributable to developmental imperfection or to fetal endocarditis. Ordinarily, the narrowing is due to adhesion of the cusps and contraction of the muscular sphincter, with more or less induration, thickening, and rigidity of the leaflets; but vegetative excrescences, in the exceptional case, may be virtually the sole cause of the obstruction. Or the stenosis may implicate the conus arteriosus, whose walls are thickened and indurated by a fibroid myocarditis excited by the extension of a primary endocardial inflammation. Rarely, endarteritic obstruction of the pulmonary artery is the initial seat of

the stenosis, and in some instances a fault of development results in the virtual occlusion of the first part of this vessel and also of the pulmonic orifice. In congenital cases the valvular defect is generally associated with other antenatal malformations, such as patency of the ductus arteriosus or the foramen ovale, and perforation of the interventricular septum; frequently the tricuspid orifice is likewise obstructed; and, from their very nature, many of the lesions causing pulmonary stenosis also cause incompetence of this valve. In the few recorded examples of acquired pulmonary stenosis benign and malignant endocarditis, gumma, and injury to the precordia have figured as the exciting causes. In endocarditic stenoses the acute specific infections, and especially the eruptive fevers, appear to be more active factors than rheumatism; this is equally true of regurgitant lesions at the pulmonic orifice, and in its relative insusceptibility to rheumatic valvulitis the pulmonic valve differs from the valves of the other cardiac orifices. In a pure pulmonary stenosis of moderate degree hypertrophy of the right ventricle is the primary, if not the only, structural change induced, but if the obstruction be extreme, or if it be combined with regurgitation, ventricular dilatation and relative tricuspid leakage soon supervene. This, of course, leads to embarrassment of the venous flow to the right auricle, the evidences of which have been sufficiently considered in a preceding paragraph. Pulmonary stenosis, whether congenital or acquired, is regarded as a predisposing cause of tuberculosis of the lungs, whose blood-supply and nutrition are interfered with by the obstruction to the blood flow from the right ventricle.

Dilatation of the pulmonary artery, the orifice remaining of normal size, establishes a condition of *relative pulmonary stenosis*.

Physical Signs.—*Inspection.*—Striking cyanosis, urgent dyspnea, and extensive venous turgescence commonly attend pulmonary stenosis of the congenital type, but in acquired cases with adequate compensation the breathing is not greatly embarrassed, anemic pallor is more conspicuous than cyanosis, and the other consequences of venous obstruction are not likely to become prominent. The epigastrium heaves systolically with undue force, owing to the impact of the hypertrophied right ventricle, and most writers speak of precordial bulging from the same cause.

Palpation.—The hand applied to the base of the heart appreciates a systolic thrill of variable quality and of maximum intensity in the pulmonic area, while palpation over the subcostal angle shows that the right ventricle is contracting with excessive force.

The *pulse* in the radials, though prone to become accelerated,

small, and arrhythmic, gives no specific indication of the valvular lesion under consideration.

Percussion.—An extension of cardiac dulness, relating primarily to right ventricular hypertrophy and later to right auricular dilatation, is an important corroborative sign of pulmonary stenosis. The hepatic area does not increase in size until the supervention of venous engorgement of the liver.

Auscultation.—Pulmonary stenosis creates a systolic murmur having its point of maximum intensity in the second and third inter-spaces at the left sternal border, and propagated thence upward toward the left clavicle, but not into the arterial trunks of the neck (Fig. 159). If the bruit be intense, its area of audibility may extend over a considerable part of the anterior chest-wall, but invariably it is more distinct on the left than on the right side, being conducted along the pulmonary artery and its branches rather than by the aorta. The murmur of pulmonary obstruction ordinarily is intense, rough, and superficial, effectually masking the pulmonic first sound, though exceptionally it is a feeble, soft, and distant tone. The pulmonic second sound is either muffled and impure, or entirely suppressed, but the sounds in the aortic area are likely to remain clear and distinct.

Diagnosis.—The direct diagnosis of pulmonary stenosis rests upon these cardinal signs: a harsh systolic murmur, perhaps attended by a thrill, in the pulmonic area, and thence reflected upward toward the clavicle, but not conducted into the neck; enfeeblement of the pulmonic second sound; and evidences of right ventricular hypertrophy. Information corroborative of this lesion includes, in congenital cases particularly, the presence of cyanosis, dyspnea, and venous turgescence, and, in numerous other instances, diminished volume and increased rate of the pulse, together with the demonstration of a tuberculous infection of the lungs and of systemic evidences thereof.

Only exceptionally does a systolic murmur in the pulmonic area mean organic stenosis of the pulmonic orifice, for this "region of auscultatory romance," as Balfour so aptly describes it, is the site of numerous bruits, both functional and organic, which have nothing whatever to do with a structural defect of the right semilunar valve-cusps.

Anemia is by far the most common factor of a pulmonary systolic murmur, and a bruit of this nature is likely to be soft and low-pitched, attended by a venous hum in the neck and by a sharp pulmonic second sound, but unattended by cyanosis and by hypertrophy of

the right ventricle; furthermore, an anemic murmur is peculiarly affected by postural changes, and, naturally, disappears when the patient's blood impoverishment improves.

In *relative pulmonary stenosis*, due to dilatation of the pulmonary artery, the pulmonic systolic murmur is more often soft and quiet than loud and harsh, the right heart is not enlarged, cyanosis is wanting, and the patient's appearance indicates malnutrition, debility, and general muscular flabbiness.

A *cardiorespiratory murmur* is frequently referred to the pulmonic area, but a sound of this sort resembles a sudden brief puff or whiff of air, lacks the harmonious vibratory tone of a genuine bruit, and is exaggerated by respiratory phases and by changes in posture favorable to intimate contact between the heart and the lung. As a rule, a cardiorespiratory murmur is systolic, though it may be diastolic; and while not incompatible with health, it often accompanies emphysema, in which affection both cyanosis and right ventricular hypertrophy may exist.

The *conus arteriosus* may be the seat of a systolic bruit, audible over the pulmonic area, should this part of the right ventricle be uncovered by a recession of the anterior edge of the left lung, due, for example, to its deficient inflation. In consequence of this each systole of the heart thrusts the conus directly against the thoracic wall, thereby flattening its anterior surface and agitating within the chamber blood eddies conducted forward by the blood-current.¹ This variety of murmur usually disappears when the patient takes a deep breath and holds it, thus intervening a cushion of inflated lung between the heart and the chest-wall. In addition to this point, it should be remembered that a functional murmur generated within the ventricular cone produces no enlargement of this chamber, nor is it attended by dyspnea or cyanosis.

Atheroma of the aortic arch and *true aortic stenosis* must be reckoned with as common factors of a systolic murmur in the pulmonic area, but the murmurs attending both these lesions are distinctly conducted into the carotid arteries—a fact alone sufficient to exclude pulmonary stenosis, though the differentiation is made doubly sure by detecting, in aortic atheroma, left ventricular hypertrophy, a ringing aortic second sound, and arterial sclerosis; and in aortic stenosis, left ventricular hypertrophy, a muffled or absent aortic second sound, and a *pulsus tardus*.

The murmur of *mitral regurgitation* may be clear and distinct in

¹Very gentle pressure upon the conus is sufficient to excite a murmur therein, as shown by the experiments of Thayer and MacCallum.

the pulmonic area, but the mitral murmur, though timed like that of pulmonary stenosis, is conducted toward the left axilla and supplemented by an accentuated pulmonic second sound, and in cases of organic leakage, the left ventricle becomes obviously enlarged, as well as the right side of the heart.

Aneurism of the aortic arch is sometimes mistaken for pulmonary stenosis, inasmuch as a rough systolic murmur and thrill are common to both lesions. If aneurism be suspected, one should search for the more distinctive signs of this condition, such as systolic pulsation and diastolic shock over a circumscribed dull area, a systolic carotid bruit, the aneurismal second sound, tracheal tugging, pulse inequality, and evidences of mediastinal pressure.

That rare lesion, *stenosis of the pulmonary artery*, generates a murmur indistinguishable from that of pulmonary obstruction, and, if the vessel be sufficiently stenosed, right ventricular hypertrophy and its sequels also supervene. In venturing to differentiate these two conditions, the character of the pulmonic second sound is a valuable guide, since this tone, enfeebled in stenosis of the orifice, is accentuated in stenosis of the artery, owing to the high pressure therein. The presence of systolic pulsation at the sternal end of the second left intercostal space and impaired resonance in this area are other findings in favor of arterial obstruction, and a similar significance attaches to the demonstration, in the upper part of the left lung, of a cirrhotic or tuberculous process to which constriction of the artery can be attributed.

The signs of a *perforate interventricular septum* are compared with those of a pure pulmonary stenosis on page 475.

PULMONARY REGURGITATION

Clinical Pathology.—Leakage at the pulmonic orifice arises in consequence of structural deformities of the valve or of undue stretching of the muscular sphincter, either of which defects is responsible for faulty approximation of the valve borders, and hence for the escape of blood from the pulmonary artery into the right ventricle during its diastole. Pure pulmonary regurgitation as an isolated lesion is the rarest variety of valvular disease, and, in its acquired form, is most commonly met with in young adults. *Organic pulmonary regurgitation* depends upon structural deformities of the valve mechanism analogous to those existing in aortic regurgitation, these changes being due to acute endocarditis more often arising in connection with the eruptive fevers and septic states than as the result of rheumatism; exceptionally the valve is damaged by pro-

gressive sclerosis. In congenital cases fusion of two of the valve-leaflets is the common factor of the incompetence, and with this lesion other developmental imperfections of the cardiac orifices and chambers are ordinarily associated. *Relative pulmonary regurgitation*, due to dilatation of the pulmonic orifice by abnormally high pressure within the pulmonary artery, is not of common occurrence, for the pulmonic ring, being firm and resistant, only exceptionally stretches under the stress of arterial hypertension. When the orifice enlarges so as to allow diastolic leakage of blood from the pulmonary artery into the right ventricle, either mitral disease or some indurative affection of the lungs should be looked for as the underlying cause of the intrapulmonary hypertension. The pulmonary artery, as well as the orifice, is more or less dilated and prone to undergo atheromatous changes. Exceptionally, relative pulmonary regurgitation indicates a purely functional rise of blood-pressure in the pulmonary artery.

Physical Signs.—*Inspection.*—There are no distinctive visual signs of this rare lesion, which, in its pure, organic form is attended by cough, dyspnea, cyanotic pallor, and other evidences of disordered pulmonary blood-supply and of arterial anemia; in the vast majority of instances the subject's appearance betrays engorgement of the lungs and general venous stasis incident to concomitant left-sided valvular defects and to secondary tricuspid incompetence. Systolic pulsation in the epigastrium and, perhaps, in the interspaces at the right sternal edge is visible when there is considerable enlargement of the right ventricle.

Palpation.—Occasionally it is possible to feel a basic diastolic thrill, having its greatest distinctness in the pulmonic area. Tumultuous throbbing in the epigastric region, and, not infrequently, a systolic, non-expansile hepatic pulsation, accompany the stage of right ventricular hypertrophy.

The *pulse* is not at all characteristic, though, as a rule, the radials are of small volume, low tension, and erratic rhythm.

Percussion.—Cardiac dullness is increased, especially to the right of the sternum, to an extent proportionate to the enlargement of the right ventricle, and, sooner or later, right-sided basal impairment due to dilatation of the right auricle supervenes. Until the tension within this chamber becomes excessive, there is no enlargement of the hepatic area.

Auscultation.—Pure pulmonary leakage gives rise to a soft (rarely, harsh and rasping) diastolic murmur in the pulmonic area, from which point of greatest intensity the bruit can be traced downward

along the left sternal border and toward the apex of the heart. The pulmonic second sound is enfeebled or lost, but the character of the other cardiac tones undergoes no primary alteration.

Diagnosis.—A diagnosis of pulmonary regurgitation is justified by the following combination of physical signs: a diastolic pulmonic murmur conducted down the sternum, impairment or obliteration of the pulmonic second sound without notable alteration in its aortic equivalent, right-sided cardiac enlargement, and a frequent, small arterial pulse. Ultimately, to these findings are to be added those relating to secondary tricuspid leakage and general venous engorgement.

Relative pulmonary regurgitation, of the type excited by the excessive engorgement of the lungs secondary to mitral stenosis, accounts for a diastolic pulmonic bruit described by Steell as "the murmur of high pressure in the pulmonary artery." This murmur is distinguished, aside from its association with a primary mitral defect, by a most evanescent character, for the sound appears and vanishes according to pressure variations within the pulmonary artery. The pulmonic orifice may be temporarily incompetent in consequence of pulmonary hypertension induced by violent exercise and by deep breathing. Cabot refers to persons in perfect health who were able, by prolonged holding of the breath, to produce a short, high-pitched diastolic murmur, best heard in the second or third left interspaces, and disappearing when respiration was resumed. The transient occurrence and the method of producing a functional murmur of this sort are sufficient denial of its organic nature, apart from the lack of consecutive structural changes in the heart.

Aortic regurgitation can beget a soft diastolic bruit having great intensity in the pulmonic area, and thence propagated downward like the murmur of pulmonary regurgitation. Corrigan's disease, however, is accompanied by an ox-heart, throbbing arteries, the water-hammer pulse, an obscure aortic, and a sharp pulmonic, second sound; while pulmonary regurgitation is associated with right ventricular enlargement, quiet arteries, a small pulse, a feeble pulmonic, and unimpaired aortic, second sound.

CONGENITAL CARDIAC DISEASE

Clinical Pathology.—Of the numerous forms of congenital heart disease, *pulmonary stenosis*, *defects of the interventricular septum*, and *patency of the ductus arteriosus* are of clinical interest, owing to their relative frequency as antenatal lesions and because they offer,

when existing singly, reasonably good opportunities for a diagnosis during life. Of purely pathologic interest are the structural changes relating to a *patent foramen ovale* (Fig. 181), and to *absence of the septa* between the auricles, the ventricles, or both. Congenital lesions of the *tricuspid*, *mitral*, and *aortic valves* have been sufficiently discussed under Valvular Disease.

Congenital malposition of the heart may take the form of *dextrocardia*, in which condition the heart lies on the right side of the thorax, thus giving a "mirror picture" of the normal physical signs,

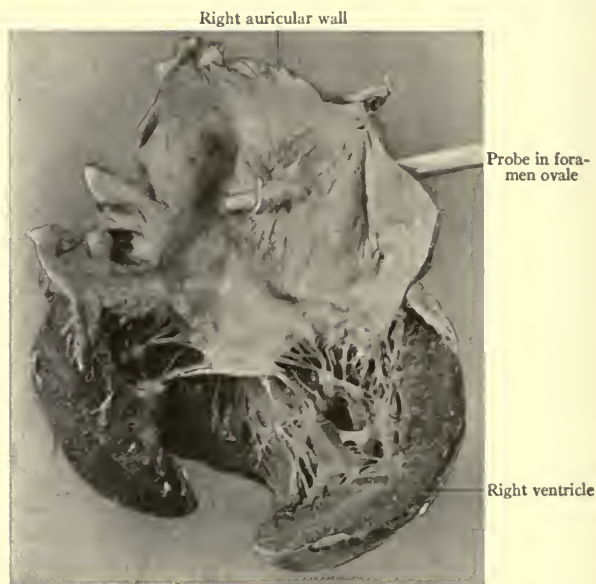


Fig. 181.—Patent foramen ovale (Philadelphia General Hospital).

and in this anomaly there is generally a corresponding transposition of the abdominal viscera, the combined abdominothoracic dislocation constituting a *situs viscerum inversus*. Persistence of the heart in its normal fetal position in the median line of the thorax is known as *mesocardia*. *Ectopia cordis*, or the situation of the heart outside the thorax, occurs in three forms: *pectoralis*, in which the heart, covered by the pericardium and integument or by the pericardium only, bulges through a midsternal fissure; *cervicalis*, or a displacement of the heart upward into the neck close to the lower jaw; and *abdominalis*, or subphrenic displacement of the heart downward into

the abdominal cavity. The last of these anomalies is not necessarily incompatible with many years of life, but in the other two postnatal existence, if at all possible, is of brief duration.

Anomalies of size comprise congenital *hypertrophy* and *atrophy*, the former ordinarily being the result of fetal endocarditis, and the latter part and parcel of a general cardiovascular hypoplasia sometimes incident to chlorosis and to lymphatism.

Transposition of the *aorta* and *pulmonary artery*, the former having a right, and the latter a left, ventricular origin, is a peculiarity of development commonly associated with a persistent arterial duct between the two transposed arterial channels. Communication of both aorta and pulmonary artery with the same ventricle, with or without malformation of the septa and the duct of Botallo, is a type of anomaly somewhat more common than the foregoing.

Physical Signs.—Congenital *pulmonary stenosis*, like the acquired form, generates a systolic murmur most intense in the pulmonic area, and thence transmitted toward the left clavicle, but not into the neck, of which leading sign a systolic basic thrill and hypertrophy of the right ventricle are strongly confirmatory. (See p. 467.)

A *pervious interventricular septum* is commonly combined with the foregoing lesion, and in this event its auscultatory signs are usually so overshadowed by the pulmonary murmur as to render it unrecognizable. An isolated septal perforation may be identified by finding a loud and harsh systolic bruit with its punctum maximum in the fourth left interspace, between the sternum and the midclavicular line, and highly characteristic in that it is a continuous sound running through the entire cardiac cycle (*Rogers' murmur*). A systolic thrill is not uncommonly palpable. During systole the intensity of this murmur is increased and the pitch raised, while with diastole it dwindles to a low, though distinct, rumble. The bruit has been likened to the rasping sound of a grinder's wheel when a knife is being sharpened. Hypertrophy of the right ventricle is the ordinary consequence of this defect, which, save for the absence of pulmonary congestion, accounts for objective phenomena like those of mitral stenosis.

Persistence of the ductus arteriosus has been recognized during life by the detection of a late systolic murmur, audible in the pulmonic area, and propagated toward the apex. This murmur, which appears immediately to follow, rather than exactly to coincide with, the first sound, is generally distinguished by a high pitch, by considerable intensity (especially during inspiration), and by prolonged duration. Accentuation of the pulmonic second sound and the presence of right ventricular hypertrophy are important secondary signs, while

paradoxical weakening of the pulse during inspiration, and systolic pulsation in the second left interspace also have been observed.

Patent foramen ovale, if an isolated lesion, may be wholly symptomless; under no circumstance does a pervious interauricular septum give rise to a distinctive clinical picture.

Diagnosis.—Congenital disease of the heart is indicated by a history of cyanosis from birth,—a “blue baby,” in lay vernacular,—with dyspnea and physical blemishes, such as dwarfed stature and clubbed fingers and toes. As a rule, physical exertion decidedly deepens the blueness. Given these general indications, the discovery of one of the above groups of signs may lead to the diagnosis of the precise defect. The very name, *morbis cæruleus*, applied to congenital heart lesions as a class, denotes the importance of cyanosis as a sign of these affections. It probably means imperfect aëration of the blood, despite attempts made to attribute it chiefly to venous stasis and to commingling of the arterial and venous currents. Cyanosis is most common and usually most striking in pulmonary stenosis, but it is by no means restricted to this lesion, and this is likewise true of the other signs just noted.

ANEURISM OF THE AORTA

ANEURISM OF THE THORACIC AORTA

Clinical Pathology.—Atheroma of the aorta and high blood-pressure are the almost invariable essential factors of aneurism of the thoracic aorta, which is prone to occur in men during the third and fourth decades of life, when, as Coats expresses it, “the period of greatest bodily vigor overlaps the period of beginning atheroma.” In other words, the lesion develops most commonly at that time of life when the cardiac force is greatest, while the vessel is impaired by a degenerative process, which, being incipient and, therefore, unattended by compensatory endarteritis, damages without attempting to repair its inroads. Syphilis is by far the commonest cause of the arterial degeneration, though bacterial toxins, infected emboli, plumbism, gout, and alcohol are also accredited factors of sclerosis whereby the artery is likely to yield, either gradually under the tax of persistently high blood-pressure, or suddenly in consequence of a violent muscular strain, as from lifting a heavy weight or from a hard fit of coughing. Under these conditions one or more of the impaired arterial coats may give way at the site of a focal or circumscribed atheroma, with subsequent pouch-like bulging of the arterial

wall and the formation of a saccular aneurism. In diffuse, fusiform aortic aneurism wide-spread atheromatous enfeeblement of the vessel-wall, without especially vulnerable local patches of degeneration, is to be assumed.

Of all cases of aortic aneurism, approximately three-fourths affect the thoracic division, the favorite site being the ascending portion of the arch, after which, in order of incidence, the transverse and descending portions, and the descending thoracic aorta are implicated (Fig. 182). *Saccular aneurism* produces the clearest physical signs, and is by far the most common type met with clinically, this variety constituting about 95 per cent. of the 570 cases of thoracic aneurism collected by

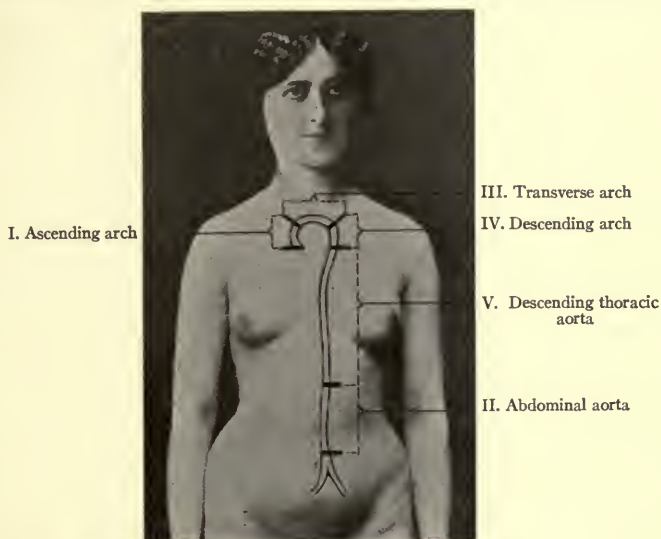


Fig. 182.—Relative site incidence of aortic aneurism.

Hare and Holder. *Fusiform aneurismal dilatation* of the aorta (Fig. 184) may attain a huge size without attracting attention. As a rule, there is but a single sac, which may be as small as a marble or as large as a football; exceptionally, the aorta is found to be studded with multiple sacculations. The changes in the wall of the aneurism comprise thinning and ultimate disappearance of the media from atrophy and destruction of the muscular and elastic fibers, and, subsequently, fibrous thickening of the intima and adventitia, the latter coat virtually forming the wall of the sac and frequently being matted by adhesions to neighboring structures. Eventually

every vestige of the three arterial coats may disappear and a sac be constructed of the surrounding tissues—*false aneurism*, in contrast to a *true aneurism*, in which at least one arterial coat persists. Or, a *dissecting aneurism* may arise, should a breach be torn in the intima through which the blood penetrates to bore a channel between the outer coats of the vessel; and if such a channel,

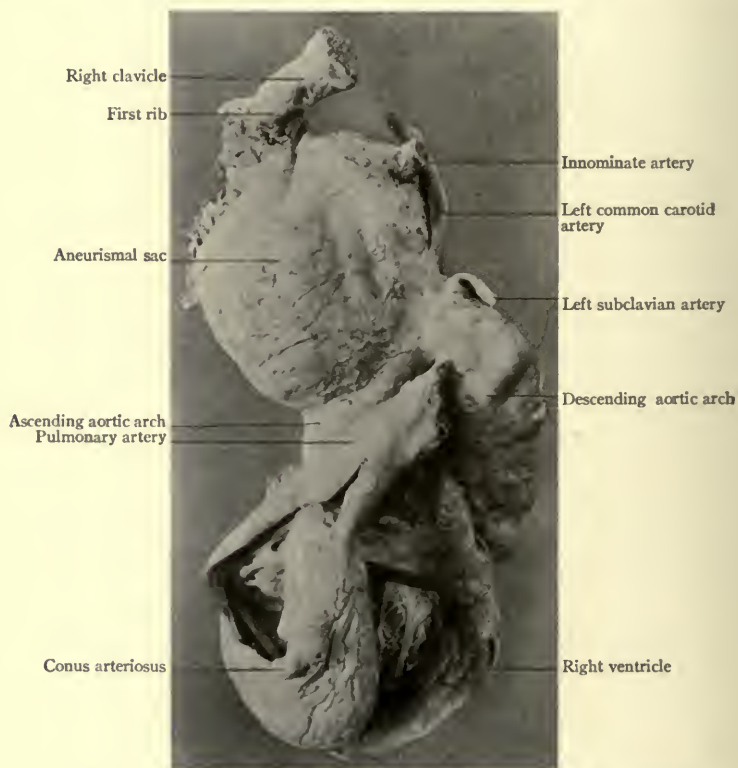


Fig. 183.—Saccular aneurism of the aortic arch (Philadelphia General Hospital).

instead of draining into the surrounding parts, leads back into the aorta by another opening in the intima, the curious anomaly termed *double aorta* is formed. An *arteriovenous aneurism*, effecting chiefly the peripheral vessels (Fig. 185), consists of an abnormal communication between an artery and a vein, the connection between the two vessels being either direct (*aneurismal varix*) or established

by an intervening sac (*varicose aneurism*). A laminated fibrinous clot usually occupies the interior of the aneurismal sac, which, indeed, may be wholly obliterated thereby, though rupture of the sac is the ordinary termination. This occurs most frequently into the left pleural cavity, and then, in this order of incidence, into the pericardium, right pleura, esophagus, and larger air-passages; less commonly the superior vena cava, the pulmonary artery, or the heart is penetrated, or the rupture may be external.

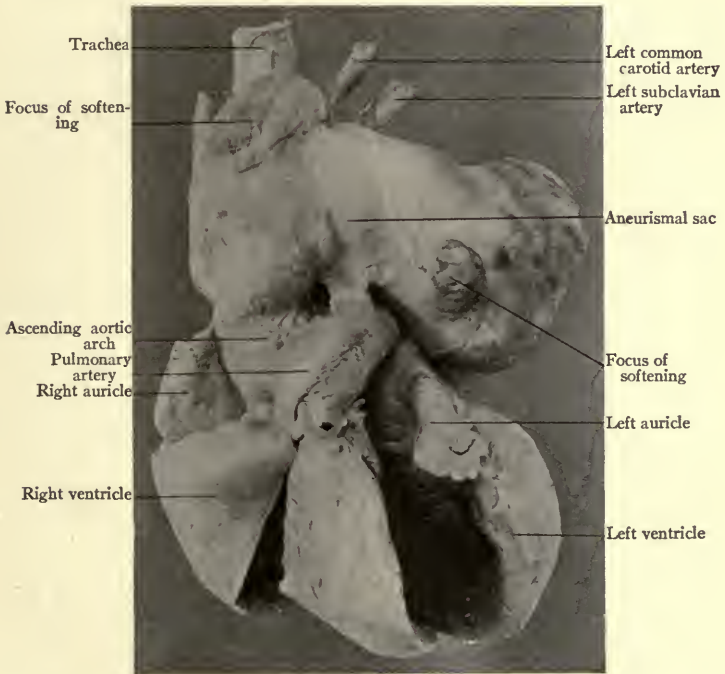


Fig. 184.—Fusiform aneurism of the aortic arch (Jefferson Hospital Laboratories).

Some aneurisms remain symptomatically latent for a long period, but ordinarily the enlarging sac encroaches upon the surrounding structures, displacing them and exciting therein various mechanical, inflammatory, and necrotic changes, due to compression. The bronchi and lungs are particularly liable to damage thus inflicted, which takes the form of bronchial ulceration, necrosis, stenosis, and ectasis, and of pneumonic, fibroid, and gangrenous processes in the

lungs; erosion of the bony thorax—ribs, sternum, vertebræ—is not uncommon; and pressure phenomena relating to the gullet and to the nerves and great vessels of the mediastinum are familiar findings. Aortic aneurism is commonly attended by cardiac hypertrophy, but it is questionable if the aneurism, *per se*, is the primary factor of the enlarged heart.

The study of thoracic aneurism is facilitated by localizing the lesion to some one of the following four clinical divisions of the



Fig. 185.—Arteriovenous aneurism (Jefferson Hospital).

artery: (a) *ascending arch*, or that portion of the vessel extending from the base of the left ventricle to the orifice of the innominate artery, and corresponding to the two anatomic portions termed the ascending aorta and the first part of the aortic arch; (b) *transverse arch*, between the innominate and the left subclavian arteries and including their mouths; (c) *descending arch*, lying between the left subclavian and the fourth thoracic vertebra; (d) *descending thoracic aorta*, occupying the posterior mediastinum between the fourth thoracic vertebra and the aortic opening in the diaphragm at the level of the twelfth thoracic vertebra. The surface topography of the thoracic aorta has been given on page 311.

Aneurisms of the *ascending aortic arch* usually arise from the convexity of the vessel above the pericardial limit, and pass forward and to the right, appearing in the neighborhood of the second and third right intercostal spaces and the sternum (Fig. 187), or they affect the concavity of the aorta, and give rise to physical signs along the left sternal

border. Or the dilatation may be intrapericardial, arising at or immediately above the sinuses of Valsalva, in which case rupture into the pericardium, causing instant death, is probable before the aneurism reaches a large size. Aneurisms of the ascending arch tend to cause striking cardiac displacement, to stretch the aortic ring so as to set up relative aortic leakage, and

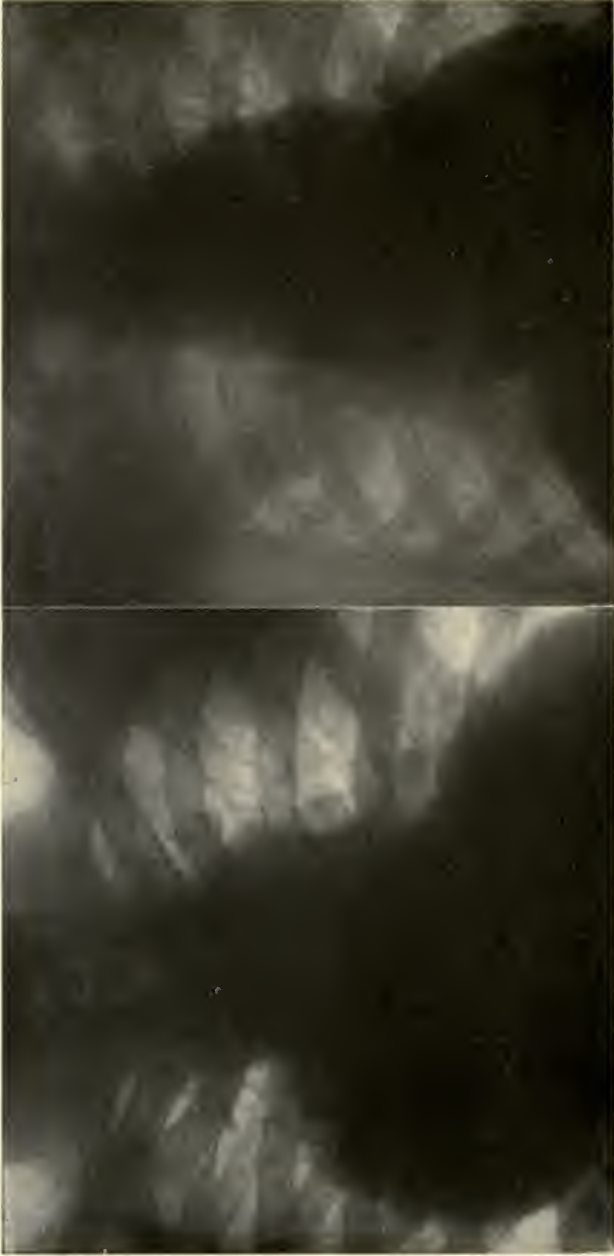to compress the superior (rarely, the inferior) vena cava, the subclavian vessels, the pulmonary artery, and the right recurrent laryngeal nerve. Rupture may take place into the right pleura, the pericardium, or, exceptionally, into the superior vena cava.

Aneurisms of the *transverse arch* commonly spring from the posterior wall of the aorta, and are more likely to extend backward toward the spine or to invade the pleuræ, than to press forward and erode the chest-wall beneath or alongside the sternum. Implication of both the ascending and transverse portions, which sometimes occurs, results in a tumor of extraordinary dimensions whose extension takes an upward and outward direction (Fig. 188). The structures particularly exposed to compression by an aneurism of the transverse arch are the trachea, esophagus, left bronchus, and left recurrent laryngeal nerve, and, less frequently, the sympathetic nerve and the thoracic duct. When the sac compresses, communicates with, or lies between the innominate, left common carotid, or left subclavian arteries; corresponding alterations take place in the carotid and radial pulses (*q. v.*). The potential causes of death in this type of aneurism include pressure-asphyxia, secondary pulmonary complications, and hemorrhage from rupture of the sac into the trachea, left bronchus, pleuræ, or posterior mediastinal space.

Aneurisms of the *descending arch* extend to the left and backward, and if they reach the surface, appear alongside the spine in the left interscapular region. The accompanying illustration (Fig. 189) shows the conspicuous deformity produced by such a tumor, which, owing to its deep situation, must attain an enormous size to cause surface signs. Nor are evidences of intrathoracic pressure well defined in the average case; the structures most likely thus to suffer are the esophagus, the thoracic duct, the spinal nerves, and the vertebræ, while less commonly the root of the left lung is compressed. Rupture into the esophagus, left pleural sac, or left bronchus, and consecutive lesions of the lungs are the ordinary causes of death in aneurism of this portion of the aortic arch.

Aneurisms of the *descending thoracic aorta*, usually situated just above the diaphragm, lie to the left or in front of the lower thoracic vertebræ and in close contact therewith. Pressure-erosion of these bones, irritation of the spinal nerves, and perhaps compression of the esophagus and pleuropulmonary tissues are to be looked for when the aneurism does not follow a latent course. Death by rupture of the sac into the pleura or the esophagus is the usual outcome of an aneurismal dilatation in this situation.

Physical Signs.—*Inspection.*—The chest-wall should be carefully



Ascending arch

Descending arch

Fig. 186.—Radiographs of aortic aneurism. (Plate by Dr. W. F. Manges.)

scrutinized with the object of finding an area of abnormal systolic pulsation, which is always highly suggestive of aneurism. The favorite sites of such pulsations are the anterior surface of the thorax, between the clavicle and the third rib, near the sternal border, especially on the right side (ascending arch), the suprasternal notch and the right supraclavicular space (transverse arch; innominate artery), and the left interscapular region near the spine (descending arch). Feeble pulsations—and these are by no means exceptional—are usually discovered only by most minute inspection of the questionable area from an oblique viewpoint; or by laying the finger-tips over the part and noting

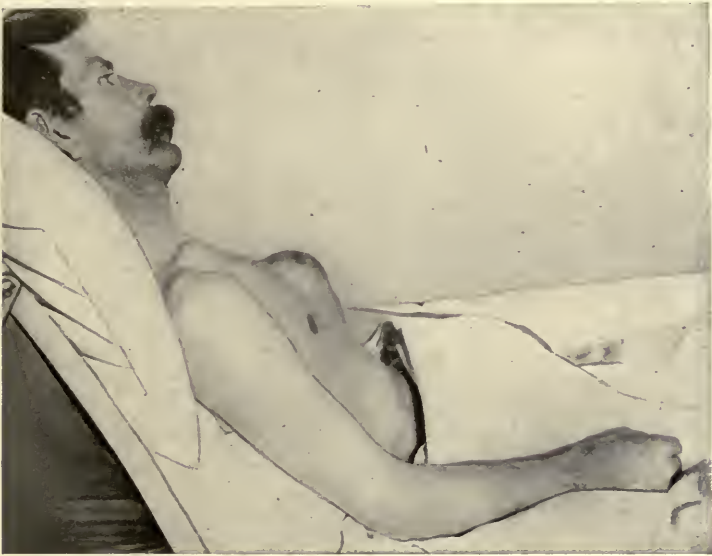

Fig. 187.—Aneurism of the ascending aortic arch (Jefferson Hospital).

their rhythmic elevation with each beat of the heart; or by observing that the barrel of a single stethoscope, whose chest-piece is applied to an interspace, is periodically tilted by a transmitted throb from beneath. On the other hand, sometimes the impulses are so strong as to cause an extensive circumscribed heaving of the chest-wall, apparent at first glance. According to the amount of erosion produced, a local bulging or even a definite tumor, each pulsatile, may appear, and over the swelling the tissues tend to become brawny, edematous, and stained purple or black with suffused blood, while later the surface structures may break down and a mixture of serum and blood

trickle from the sac. Figs. 187, 188, and 189 show the deformities produced by large aneurismal tumors which have eroded the chest-wall. The cardiac apex is crowded below and outside its normal site, and may beat tumultuously, owing to concomitant hypertrophy. Engorged veins upon the chest and upper extremities, edema of one arm, cyanosis, dyspnea, unequal pupils, and unilateral sweating are other objective phenomena

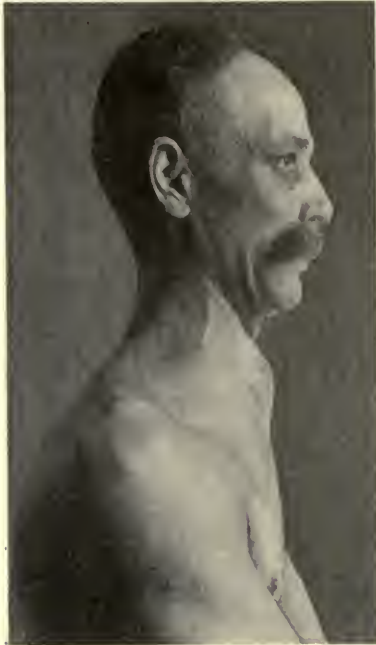

Fig. 188.—Aneurism of the ascending and transverse aortic arch and innominate artery (Jefferson Hospital).

whose prominence depends upon the degree and situation of the mediastinal pressure in the individual case. Signorelli attaches importance to wasting of the left sternomastoid muscle as a sign (due to nerve degeneration from pressure) of aneurism of the transverse and descending arch. The larynx may be immobilized, depressed, and displaced toward the left by a large aneurism of the ascending part of the aortic arch. (Boinet.)

X-ray examination with the fluoroscope is a great diagnostic aid, for it may clearly reveal a shadow to the right, to the left, or on both sides of the sternum in aneurism of the aortic arch, and in aneurism of the descending thoracic aorta this method of examination often is the only

means of securing definite data. Moreover, the x-rays show the extent of the cardiac dislocation consequent to pressure by the tumor, and, if the sac be resilient and comparatively clot-free, expansile pulsations are unmistakably shadowed upon the fluorescent screen.

Palpation.—The extent and character of the pulsation are best judged by palpation, which also may discover an abnormal throb too feeble to attract the eye. The palm of the hand appreciates either an obscure indefinite pulsation or a powerful lifting or heaving impact over the aneurism, according to its size and distance from the chest-

wall. If the latter be eroded, so that the sac projects externally as a tumor, a trio of valuable signs becomes available—expansile pulsation, diastolic shock, and systolic thrill. The expansile pulsation is due to the uniform distention of the sac with blood, and the sharp, short diastolic shock immediately following is produced by the sudden recoil of the aortic wall after its systolic distention. The thrill often associated with these two signs corresponds to systole and has a peculiar vibratory quality. The foregoing findings, practically pathognomonic of aneurism, indicate a resilient sac having comparatively fluid contents, and a tumor of this sort is not unlikely to be so soft and fluctuating that any manipulation, save the gentlest,

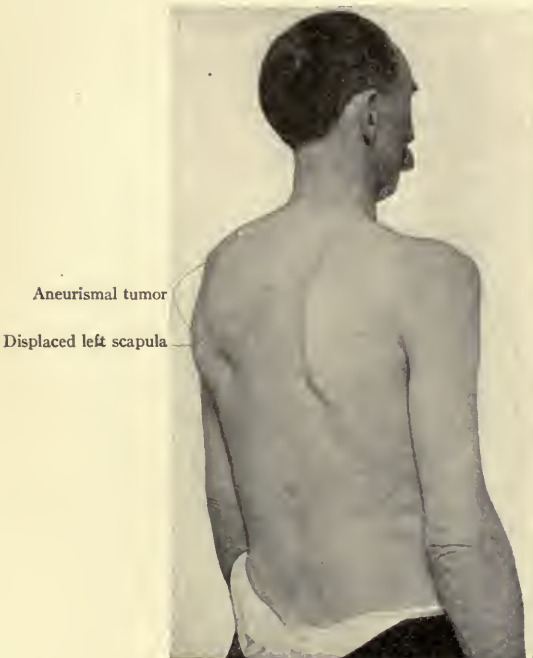


Fig. 189.—Aneurism of the descending aortic arch (Jefferson Hospital).

is interdicted, for fear of rupturing the fragile wall. These signs, of course, are not found over an aneurismal tumor having a rigid, thick wall, reinforced by a laminated clot so large and firm as to interfere with the generation and conduction of vibrations and to impair the sac's mural elasticity. When these conditions rule, the

consistence of the tumor will be firm and hard, and its pulsation a lifting impact. Tracheal tugging, though presumptive evidence of aneurism, especially of the transverse arch, is not distinctive, for a similar systolic depression of the windpipe is sometimes seen in simple dilatation of the aorta and in mediastinal neoplasm. (See p. 328.) An inversion of Oliver's sign, or a rhythmic *elevation* of the trachea with systole, has been described by Hirtz in aneurism springing from the convexity of the aortic arch. Aside from the spontaneous pain the patient suffers, local tenderness and sometimes excruciating radiations of pain are commonly provoked by pressure over the site of the aneurism: when, for example, the descending arch is implicated, tapping the upper thoracic vertebræ sets up aching of the spine and acute lancinating pain radiating thence over the left side of the thorax.

The *pulse* in the radial and carotid arteries is significantly modified by aneurisms of the ascending and transverse portions of the aortic arch, the nature of these alterations corresponding essentially to the situation of the sac. Aneurism of the ascending arch, situated between the aortic orifice and the innominate artery, but not compressing the

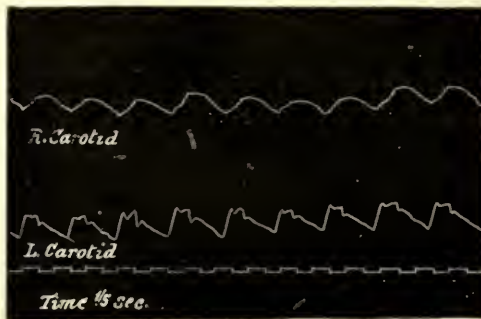


Fig. 190.—Synchronous sphygmographic tracings of the right and the left carotid arteries in a case of innominate aneurism. (Tracing by Dr. G. Bachmann.)

latter, obviously modifies both radials identically, and under this circumstance the right and left pulses at the wrist are perfectly synchronous and equal, though they are both likely to be delayed in comparison with the precordial impulse, and unnaturally full between beats, while the pulse-waves are of moderate amplitude, prolonged duration, and deliberate subsidence. Inequality in the time, volume, and tension of the two radial pulses suggests pressure upon, or obstruction within, either the innominate artery or the left subclavian artery by

an aneurism attached to some part of the transverse arch. If the innominate be obstructed or compressed by an aneurism lying between the orifice of this trunk and the left subclavian, the *right* radial pulse will be later, smaller, weaker, and softer than the left. If the left subclavian artery leads directly from an aneurismal sac, or if it be compressed by a dilatation of the transverse arch well to the left of the innominate's origin, the *left* radial pulse will exhibit the alterations just noted. The sphygmogram reproduced above graphically illustrates these pulse differences, so suggestive of aneurismal pressure (Fig. 191). Pulse changes in the carotid arteries like those affecting the radials also occur, inasmuch as innominate obstruction must check and diminish the current within the right common carotid and its branches, while factors acting on the left subclavian artery must similarly affect the adjacent left common carotid. It is quite apparent that an aortic aneurism distal to and well removed from the left subclavian artery cannot influence the pulses in the arms and wrists, though both femoral beats may be

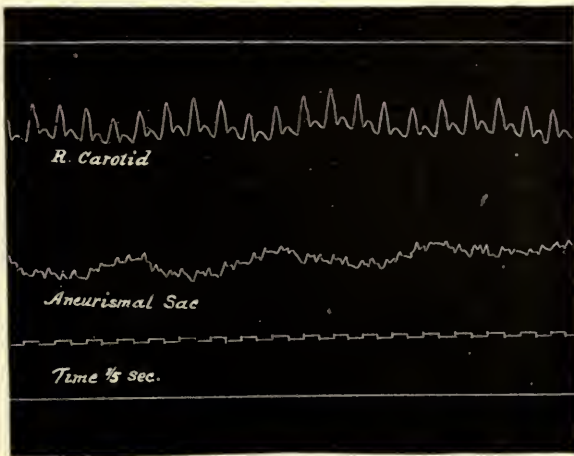


Fig. 191.—Simultaneous sphygmographic tracings of the carotid artery and of an aortic aneurismal sac. (Tracing by Dr. G. Bachmann.)

enfeebled and delayed, yet synchronous. Osler noted complete abolition of pulsation in the abdominal aorta in aneurism of the descending arch. In addition to noting the above important pulse deviations, one should not fail to study the condition of the arterial

walls, inasmuch as arteriosclerosis of the peripheral vessels is in favor of aneurism.

Percussion.—As an aneurism approaches the chest-wall percussion resonance is thereby impaired over an area corresponding to the site of the sac. Percussion is of unquestionable value in recognizing a beginning aneurismal enlargement of the ascending and transverse arch, in which an unnaturally broad zone of supracardiac vascular dullness, with proportionately increased tactile resistance, is frequently appreciable long before other physical signs appear. Later, as the sac enlarges, frank dullness, or even flatness, becomes well marked over and alongside the manubrium, in aneurisms of the ascending and transverse portions; and in the left interscapular region, near the spine, when the descending arch is greatly dilated. Obviously, a small intrapericardial aneurism lies beyond the range of percussion, and the same is true of an aneurism of the descending thoracic aorta, unless it be of great size.

Auscultation.—The presence or absence of a murmur over an aneurism is of very minor import, for it occurs with great inconstancy and is in no wise distinctive. A systolic bruit may be generated within an aneurismal sac, or within the aorta lying beyond and compressed by the dilatation (Fig. 163, p. 393); and in some cases a precisely similar murmur arises at a stenotic aortic orifice, and is transmitted thence into the sac and through the aorta. Here may be mentioned *Drummond's sign*: a rhythmic systolic whiff sometimes heard at the open mouth of a subject of aortic aneurism; *Sansom's sign*: a similar sound, audible with a stethoscope applied to the patient's lips; and *Glasgow's sign*: a systolic sound heard over the brachial artery. The foregoing oral signs must not be confused with Galvagni's *buccal souffle*: rhythmic systolic interruption of the expiratory sound audible at the subject's mouth, in paracardial pleurisy and in dilated hypertrophy of the heart, and attributed to the rush of intrapulmonary air columns expelled by the impact of the heart.

The most valuable auscultatory sign of aneurism is an intense and low-pitched diastolic sound over the aortic area, and usually audible for a considerable distance on both sides of the sternum. This distinctive sound is exactly synchronous with the palpable diastolic shock, and is probably due not so much to the snap of the aortic cusps, as to sudden tension of the aortic wall. A diastolic murmur of associated aortic regurgitation is frequently also audible, but despite this the aneurismal second sound usually persists, though it is modified by the attendant bruit.

Over the sternum loud tubular breathing is heard should the tracheal breath-sounds be conducted to the surface by an aneurism adjacent to the wind-pipe, while noisy and stridulous breathing may mean either stenosis of one of the larger air-passages or pressure paralysis of the recurrent laryngeal nerve. In some instances examination of the chest gives positive evidence of pulmonary atelectasis, consolidation and congestion, and of pleural effusion symptomatic of pressure upon a bronchus, the pulmonary tissue, the pulmonary veins, and the azygos veins, respectively.

Diagnosis.—Increase in the transverse vessel dulness and a barely palpable systolic pulsation at the level of the second interspace in a hard-working man with rigid arteries, and who confesses to syphilis or whose blood affords a positive Wassermann reaction, are highly suggestive of beginning aneurismal dilatation of the first or second divisions of the aortic arch—this, despite no murmur, thrill, tumor, nor pressure symptoms. In a case of this sort the *x*-ray sometimes furnishes invaluable positive evidence. At a later stage, when the aneurism nears the surface or erodes it, an area of circumscribed dulness or a definite tumor, heaving or expansile pulsation, a diastolic shock, the aneurismal second sound, the tracheal tug, a thrill, and a systolic murmur complete the clinical picture. Not only may the pulses of the two sides differ in time and in volume, but not infrequently, according to Williamson, there is a difference of from 20 to 30 mm. in the blood-pressure of the right and left peripheral pulses. The pupil on the side of the lower pressure is the larger, MacKinnon has found.

Pressure symptoms corroborative of these physical signs, and, indeed, in some instances the sole evidence of the lesion, are much more conspicuous in aneurism of the transverse and descending portions of the arch than in aneurism of the ascending part, a fact that prompted the elder Broadbent to term the former the "aneurism of symptoms" and the latter the "aneurism of physical signs." The pertinent symptoms due to pressure vary with the site of the compression, but a general summary of such effects may be expressed as follows: (*a*) pain, of boring, anginose, or radiating character; (*b*) dyspnea and dysphagia; (*c*) cough, bloody expectoration, huskiness, brassy voice, aphonia, and stridor; (*d*) inequality of the pupils, unilateral sweating, hyperemia, and pallor of the face; (*e*) engorgement of the superficial veins, with edema and suffusion of the upper extremities, neck, and face; and (*f*) the secondary lesions of the bronchopulmonary system referred to above. Hoesslin has noted stridulous expiration interrupted during dias-

tole as a result of pressure upon the trachea by an aneurismal growth.

Rupture of an aortic aneurism into the *superior vena cava*, forming an arteriovenous aneurism, is betrayed by the abrupt onset of urgent dyspnea, extreme engorgement of the cervical veins, and cyanosis and edema of the face and neck. These signs persist, should the subject live, and later the chest and upper extremities are disfigured by a maze of distended veins, while at the aortic area a vibratory systolic thrill, pulsation, and a variable murmur (systolic, double, or continuous) may develop. Rupture into the *pulmonary artery*, which is unlikely to prove so rapidly fatal as the accident just mentioned, causes a continuous roaring, vibratory bruit, accentuated during systole, most intense over the pulmonic area, and occasionally accompanied by a vibratory thrill, but not by pulsation. Preceding the appearance of this group of signs, the patient is suddenly attacked by an alarming paroxysm of dyspnea, substernal pain, cough, and hemoptysis, symptomatic of the actual perforation.

Aneurism of the *innominate artery* produces a pulsatile swelling at the right sternoclavicular articulation or in the suprasternal notch, with a systolic bruit over the tumor and conducted thence into the right, but not into the left, carotid. There may be duskiness and puffiness of the face, indicating pressure upon the left innominate and deep jugular veins; edema of the right arm, due to obstruction of the right subclavian vein; and dyspnea and dysphagia, in consequence of the sac's encroachment upon, and lateral dislocation of, the trachea and esophagus. Violent lancinating pain on the right side of the head, neck, and chest and down the right arm is excited by irritation of the cervical and brachial plexuses; hiccough and respiratory arrhythmia bespeak compression of the phrenic nerve; and pressure symptoms relating to the pupils, the larynx, and the vasomotor apparatus, indicate implication of the sympathetic and recurrent laryngeal nerves.

If the *common carotid artery* be the seat of a circumscribed aneurism, which is very rarely the case, the dilatation usually occurs on the right side near the bifurcation of the vessel, at the level of the thyroid cartilage, where a pulsating vascular tumor forms. Should the thoracic portion of the artery be implicated, pressure phenomena, similar to those just noted and corresponding to the side affected, sometimes supervene, and if there be pneumogastric irritation, vomiting, cardiac disturbances, and respiratory irregularities are to be expected.

Aneurism of the *subclavian artery* most commonly is situated in

the third division of this vessel's course on the right side, and shows as a pulsating swelling in the right supraclavicular fossa, at the subclavian triangle. Edema, pain, numbness, and loss of power in the corresponding arm may occur from pressure upon the subclavian vein and the brachial plexus; hebetude, vertigo, disordered vision, and venous engorgement, from interference with the jugular return flow; and respiratory disturbances and hiccough, from irritation of the phrenic nerve.

The systolic thrill and murmur of *aortic atheroma*, with the associated arteriosclerosis, suggest aneurism of the arch, but in the former condition the aortic second sound is high pitched and ringing, and there is no abnormal area of dulness, no systolic pulsation, and no diastolic shock. The differentiation of *aortic stenosis* and aneurism is considered under the latter lesion. (See p. 462.)

Non-aneurismal pulsations in the suprasternal notch and alongside the manubrium, due to cardiac displacement, enlargement, and overaction, are to be distinguished from an aneurismal throb in this locality. (See Fig. 125, p. 321.) Dynamic pulsation of the aorta may be distinctly felt and perhaps seen in the suprasternal fossa, and may even account for a forcible impact beneath the upper sternal area. Pulsation of this nature is commonly met with in neurotic, anemic women in whom no other signs suggestive of aneurism can be discovered, and, moreover, the thoracic pulsation is generally synchronous with violent throbbing of the abdominal aorta. Pulmonary retraction, enlargement of the right heart, cardiac displacement, and dislocation of the aorta by a crooked spine are additional causes of pulsation in the aortic area, but in such instances positive evidence of aneurism is lacking, other distinctive physical signs are demonstrable, and the previous history of the patient furnishes definite information. In general, non-aneurismal pulsations are strictly systolic and more or less diffuse, while an aneurismal throb is distinctly postsystolic, and frequently can be circumscribed to a very limited area of the chest-wall.

Aneurism may be suggested by *acute aortitis*, which is attended by retrosternal pain, dyspnea, precordial oppression, carotid throbbing, pulse irregularity, and, inconstantly, parasternal dulness due to aortic dilatation. In aortitis, however, the clinical picture develops most abruptly; bruit, thrill, and diastolic shock are lacking; and the blood-pressure of the two radials does not differ conspicuously. The aortic second sound, unlike the aneurismal, may have a peculiar valvular clanging quality, termed by Potain the *bruit de tabourka*, from its resemblance to the sound of the Oriental native drum of this

name. Inasmuch as both aortitis and aneurism are generally traceable to syphilis, a positive Wassermann test is not distinctive, but a röntgenograph may prove conclusive.

Aortic regurgitation may produce pulsation of the aorta, and impaired resonance at the sternal end of the second right interspace, due to moderate dilatation of the ascending arch. But in pure Corrigan's disease all the accessible arteries are found to beat tumultuously, an ox-heart is detected, a water-hammer pulse is common, and a characteristic diastolic bruit, with suppression of the aortic second sound, is audible. Though the coëxistence of aneurism and aortic regurgitation may be suspected, it is impossible to identify the former, save by the x-rays, unless cardinal signs and pressure symptoms are observed.

Empyema necessitatis resembles aneurism in that a pulsating tumor upon the chest-wall is common to both conditions. The site of an empyematous swelling is generally below and outside that of an aneurismal tumor, definite signs of fluid in the left pleura are found, thrill, diastolic shock, and expansile pulsation are wanting, and exploratory puncture shows pus. (See Fig. 125, p. 321.)

Cervical rib, by pressure upon the subclavian artery, may account for several significant aneurismal signs in the supraclavicular space—dull pulsating tumor, thrill, systolic murmur, and difference in the radial pulses, but in an instance of this sort the x-ray gives accurate evidence as to the real factor of the puzzling signs. In some cases of this sort the anomalous rib in time may actually produce fusiform dilatation of the blood-vessel.

Pulmonary tuberculosis must be distinguished from so-called "aneurismal phthisis," in which cough, dyspnea, hemoptysis, foul sputum, and other evidence of bronchial catarrh, bronchiectasis, and pulmonary infection predominate. Compression of a bronchial tube by a deep-seated aneurism springing from the posterior wall of the arch may account for such a symptom-group, the non-tuberculous nature of which is to be inferred if the sputum be habitually free from tubercle bacilli, if the ophthalmo-reaction be negative, and if there be no wasting or other constitutional symptoms of phthisis. In a case of this sort radioscopy may effectually settle the diagnosis.

Enlargement of the *thymus gland* may account for parasternal dullness in the first and second interspaces, especially on the left side, but dullness from this cause, unlike that of an aneurism, changes to resonance when the subject, heretofore sitting with the chin depressed, retracts the head to the fullest extent, thus

forcing the pulmonary margins upward over the gland (T. R. Boggs).

The differentiation of aneurism from *mediastinal neoplasm*, *adenitis*, and *abscess* is considered in another section. (See p. 307.)

ANEURISM OF THE ABDOMINAL AORTA

The abdominal aorta, being the target of a comparatively feeble impact by the blood column, is less commonly the seat of aneurism than the aortic arch. Although sometimes formed by the posterior or lateral wall, the sac usually springs from the anterior aspect of the aorta immediately below the diaphragm, in the region of the celiac axis, which is not infrequently also implicated; less commonly the dilatation is of the fusiform variety. The aneurismal tumor, as it enlarges, encroaches forward into the epigastrium and the left hypochondrium, upward beneath the diaphragm, backward against the spine, which may in consequence be eroded, and perhaps laterally as far even as the left flank. Barring those extraordinarily rare examples of spontaneous clotting, the sac, as a rule, bursts into the retroperitoneum, peritoneum, pleura, or intestine, while an arterio-venous communication with the inferior vena cava is a possible consequence. Some patients die of perforation or of gangrene-peritonitis, secondary to embolism of the superior mesenteric artery.

The **physical signs** of an accessible aneurism of the abdominal aorta are usually clear and well defined. *Inspection* shows forcible systolic pulsation in the epigastric area, where *palpation* detects a distinct tumor having a typically expansile pulsation and systolic thrill. On *percussion* it is sometimes possible to distinguish considerable impairment of abdominal tympany in the direction of the left epigastrium, and *auscultation* affords a systolic, if not a double, murmur over the site of the swelling. The *pulse* in the femoral arteries is likely to be unnaturally delayed and diminutive. Important *pressure symptoms* may arise, affecting, according to circumstances, the spine (vertebral and lumbar pain, paresthesia, paralysis); the diaphragm (dyspnea); the vagus (paroxysmal vomiting); the inferior vena cava (edema of the lower extremities; ascites); the esophagus and gut (dysphagia; intestinal obstruction); and the ureters and common bile-duct (renal and biliary colic).

The **diagnosis** of an abdominal aneurism is easily made when an expansile tumor can be felt beneath the belly-wall, this expanding property of the pulsation being radically different from the lifting throb of a normal aorta communicated to the surface by an overlying mass of feces or by an abdominal neoplasm; moreover, as

Osler insists, a solid tumor (*i. e.*, of the pylorus, pancreas, or liver) usually falls forward away from the aorta, and hence ceases to pulsate when the patient assumes the knee-chest posture, while an aneurismal pulsation is unaffected by this maneuver. The epigastric throbbing of a pulsating ventral aorta, ordinarily occurring in neurotic, anemic females, is never truly expansile, though when pressed upon, the vessel may generate a thrill and murmur.

SECTION VII

EXAMINATION OF THE ABDOMEN AND THE ABDOMINAL VISCERA

CLINICAL ANATOMY

UPON the surface the abdomen extends from the subcostal angle and costal arch to the pubic crest and folds of the groin, being bounded lateroposteriorly by the iliac crests, flanks, lower ribs, loins, and vertebral column. Internally, the abdominal cavity reaches from the diaphragm above to the pelvic outlet below. The shape of the abdomen varies greatly according to individual differences determined by age, sex, muscular development, and the amount of subcutaneous and omental fat; in general, it conforms to the outline of an ovoid bulged centrally, flattened anteroposteriorly, and longest vertically. Normally, the contour should follow a moderate convexity the gentle curve of which is exaggerated in either flank, and shows various linear depressions and local elevations corresponding to the anatomic structures of the parietes. In the average adult, however, this ideal is seldom realized, thanks to the deforming influences of corsets, childbearing, and sedentary habits. In a man under forty years of age the abdominal circumference at the navel should be from 2 to 4 inches (5 to 10 cm.) less than the thoracic circumference at the nipple, but during the next decade these two measurements tend to become equalized, until, at fifty, the girth of the average man's belly is as large as, if not larger than, that of his chest. (*Cf.* p. 70.) In a woman the maximum width of the abdomen is at a lower level than in a man, and the female waist line, as fixed by dressmakers' tradition, should be about 10 inches (25 cm.) less than the bust measurement. In a child the greatest abdominal width is in the upper flanks, and the belly, as a whole, is relatively large, owing to the disproportionate volume of the liver and to the small size of the pelvis, whereby the intestines and bladder are crowded upward.

As *anatomic landmarks*, useful in the physical examination of

the abdomen, there is available a number of parietal markings upon the base of the thorax and the belly musculature, while, in suitable instances, one is also guided by certain arbitrary points fixed upon the anterior abdominal wall with relation to underlying viscera (Fig. 192; cf. Fig. 21). The *upper abdominal region* presents two well-defined surface markings: the epigastric hollow of the *scrobiculus cordis*, or the pit of the stomach, which lies directly below the subcostal angle and is bounded laterally by the inner borders of the seventh costal cartilages; and the *costal arch*, diverging on either side

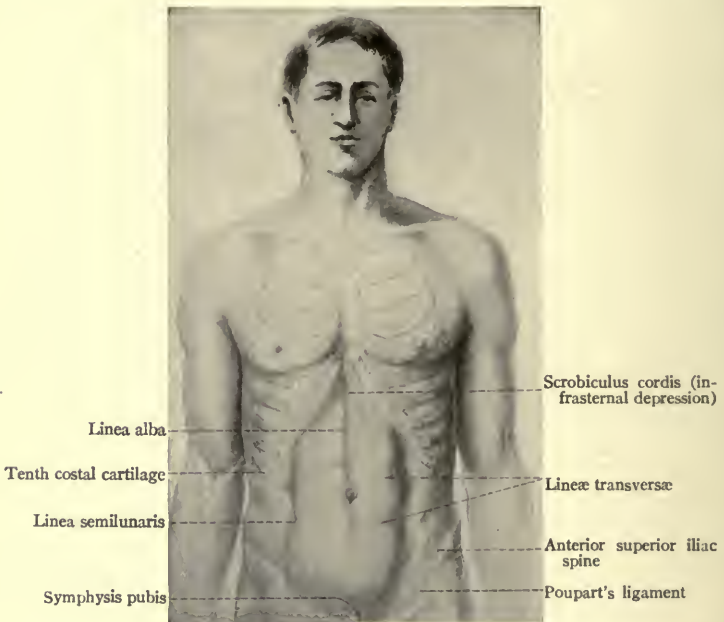


Fig. 192.—Normal abdominal landmarks.

from the apex of the subcostal angle and extending thence downward to its base formed by the tenth costal cartilage. By thrusting the finger-tips inward between this point and the iliac crest the free extremities of the eleventh and twelfth ribs can be palpated. The important bony landmarks of the lower abdomen are the *pubic symphysis* and the *anterior superior iliac spines*, with relation to which it is convenient to orient lesions of the lower abdominal zone. On either side of the symphysis lie the *pubic spines*, whence the *inguinal ligaments of Poupart* run upward to the anterior superior spines of the ilia. The most conspicuous anatomic point upon

the belly wall is the *umbilicus*, or *navel*, which, normally, lies in the middle line at about the level of the highest part of the iliac crests and opposite the body of the fourth lumbar vertebra. Like the nipple, the navel has a most variable site: it is considerably lower in children than in adults, and, naturally, shifts its position when the abdomen is overfat, wasted, distended, or pendulous (*v. i.*). The *linea alba*, or the vertical tendinous white line between the recti muscles, runs from the tip of the xiphoid process to the pubic symphysis, and can usually be identified as a narrow median furrow above the umbilicus, below which point its course, if perceptible at all, is indicated by a linear deposition of pigment (*linea nigra*), or, in men, by a matted line of converging hairs. In a well-muscled man two or three *lineæ transversæ* of the *rectus abdominis* are visible as horizontal furrows, at the level of the seventh costal cartilage, at the base of the costal arch, and just below the umbilicus. The *lineæ semilunares*, corresponding to the outer borders of the recti, extend downward, with a moderate outward curve, from the ninth costal cartilage to a point midway between the umbilicus and the anterior superior iliac spine, and thence to the pubic spine. In the obese abdomen horizontal *cutaneous flexion-folds* are frequently visible, one at the level of the umbilicus and another about an inch (2.5 cm.) above the pubes. The lateral walls of the abdomen between the thorax and the ileum form *the flanks*, which, lacking rigid osseous and muscular support, commonly form a moderate local bulging below the costal arch. Posteriorly, the abdomen is supported by the pelvic walls, the lower ribs, and the spinal column, whose median furrow extends downward to the *sacral triangle* or the shallow depression overlying the sacrum. The region of *the loin* includes that part of the back between the twelfth rib and the iliac crest.

The course of the *abdominal aorta* is indicated by a line directly to the left of the *linea alba* drawn from the ensiform to the level of the highest part of the iliac crest. At this level ($\frac{3}{4}$ inch, or 19 mm. below the navel) the aorta divides into the two *common iliac arteries* which diverge toward a point midway between the anterior superior iliac spine and the pubic symphysis. The *celiac axis* corresponds to a point on the aortic line about 4 or 5 inches (10 or 12.5 cm.) above the navel, and between these two levels, from above downward, lie the *superior mesenteric artery*, the *renal arteries*, and the *inferior mesenteric artery*. The *deep epigastric artery* follows a line extending from the umbilicus to the middle of Poupart's ligament. The *inferior vena cava*, lying to the right of the aorta, virtually

follows the surface markings of this vessel, its left common iliac branch being crossed by the right common iliac artery just below the aortic bifurcation.

TOPOGRAPHIC LINES AND AREAS

As an aid in determining the exact position of the abdominal organs and the lesions thereof the surface of the abdomen may be divided by two vertical and two horizontal lines into seven definite areas¹ (Fig. 193). The two *vertical* or *Poupart's lines* are indicated

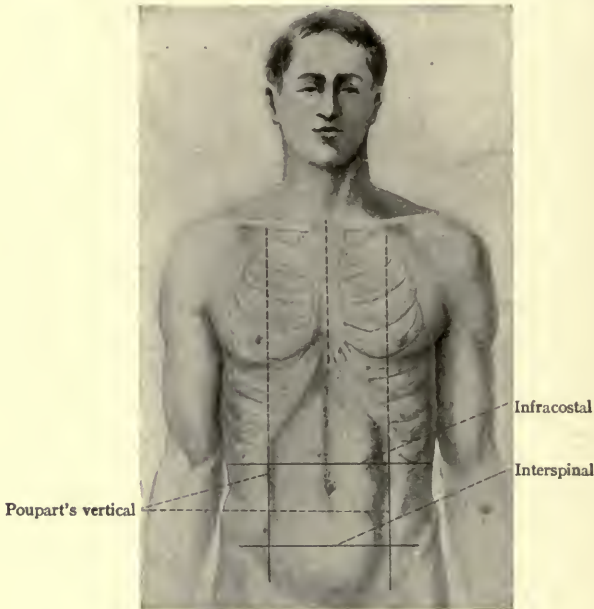


Fig. 193.—Topographic lines of the abdomen.

by the downward continuation of the right and left midclavicular lines, and extend perpendicularly from the tip of the ninth costal cartilage to a point on Poupart's ligament midway between the anterior superior iliac spine and the pubic symphysis. Of the two *horizontal lines*, the upper one, or the *infracostal*, joins the lower borders of the tenth costal cartilages and passes backward to meet the line of the twelfth thoracic vertebra at the posterior axillary line. The lower horizontal line, or the *interspinal*, connects the two

¹ The two abdominothoracic regions (*hypochondriac* or *inframammary*) are described in connection with Topographic Areas of the Thorax, on page 77.

anterior superior iliac spines and runs posteriorly to the vertebral column along the iliac crests. (See p. 77.)

The *topographic areas* (Fig. 194), delimited by the foregoing lines, are designated, from above downward, on the anterolateral aspects of the belly as follows:

The *epigastric region*, lying between the borders of the costal arch and the infracostal line, overlies the liver, gall-bladder, stomach, duodenum, pancreas, and kidneys.

The *umbilical region*, or the central rectangular area formed by the crossing of the horizontal and the vertical lines on the anterior abdominal wall. Beneath this surface area lie the transverse colon, small intestine, mesentery, greater omentum, and kidneys.

The *hypogastric* or *pubic region*, extending from the interspinal line to the pubic bone and bounded laterally by Poupart's lines. The hypogastrium corresponds to the coils of the ileum, the sigmoid flexure, the cecum (and frequently the appendix), the gravid uterus, and the normal bladder in the child, or the distended bladder in the adult.

The *lumbar region*, on either side of the umbilical area and between the infracostal and interspinal lines, the posterior continuations of which it lies between from Poupart's line to the spinal column. In the right lumbar region are the ascending colon, ileum, and right kidney, and in the left, the descending colon, jejunum, and left kidney.

The *iliac* or *inguinal region*, consisting of a triangular area in each groin bounded by Poupart's ligament, Poupart's line, and the interspinal line. The cecum, vermiform appendix, and ileum occupy this region on the right side, and the sigmoid colon, ileum, and jejunum, on the left.

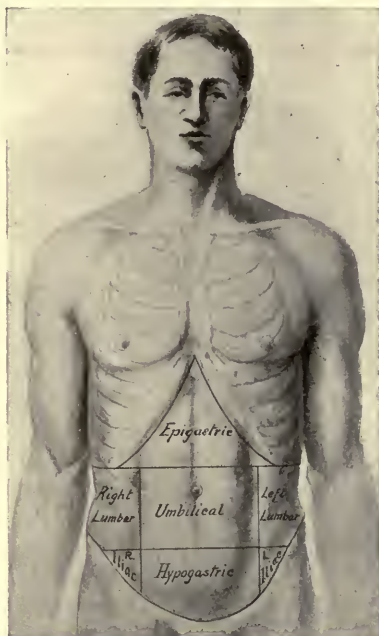


Fig. 194.—Topographic regions of the abdomen.

METHODS OF ABDOMINAL EXAMINATION

All four of the cardinal methods of physical diagnosis are applicable to the examination of the abdomen, according to the exigencies of the individual case, but in routine work inspection and palpation are chiefly relied upon, percussion being mainly a confirmatory step, and auscultation being resorted to only in exceptional instances. Mensuration is commonly used in connection with these procedures, to fix the exact position of pathologic signs, and to ascertain abdominal circumferences and surface distances. As already pointed out, the aspirating needle is sometimes indispensable in dealing with abdominal lesions, and occasionally this is also true of the *x-ray*.

The general principles of the preceding steps will be outlined below, and their special application under both normal and pathologic circumstances considered in connection with the examination of the different abdominal organs. (See p. 519 *et seq.*)

For a general examination of the abdomen, which should be bare from epigastrium to pubes, the *dorsal decubitus* is ordinarily chosen, the subject lying upon the back in an unconstrained, symmetric posture, with the knees drawn up and the shoulders elevated by a pillow, and breathing deeply with the mouth wide open. Attention to these details favors relaxation of the musculature, so essential for dependable results from visual and tactile examination. Stubborn rigidity of the belly wall, the bane of successful palpation, may have to be overcome by anesthesia or by the somewhat impracticable, though efficacious, expedient of immersing the patient in a warm bath. Small talk, to divert the patient's attention, will, however, generally induce sufficient muscular relaxation to allow a satisfactory examination.

The *erect position* is indicated in the investigation of certain types of abdominal enlargement and anomalies of contour, due, for example, to visceral prolapse, to tumor, or to sagging of the parietes. *Lateral decubitus* upon the unaffected side is useful in searching for unilateral enlargements, as of the liver and the spleen, and in comparing the postural changes of the percussion sound elicited with the patient in dorsal recumbency, as in intra-abdominal accumulations of fluid. The *knee-chest posture* is employed when attempting to palpate small abdominal masses and in testing the effect of gravity upon a pulsating tumor, which, if aneurismal, continues to heave despite the subject's genupectoral attitude, whereas, if the pulsation be transmitted from the aorta to an overlying tumor, it ceases when the pressure upon the vessel is relieved by this maneuver.

Inspection shows the size and configuration of the abdomen, the

condition of the skin and subcutaneous structures, and the character of various movements visible upon the surface. By this method of inquiry, then, the following details are investigated: deviations from the normal contour of the belly relating to its general enlargement or retraction and to local prominences; the color and nutrition of the skin and the presence or absence of edema, eruptions, scars, dilated veins, enlarged glands, and other subcutaneous nodules; and the movements of the parietes due to respiration, peristalsis, and cardiovascular pulsation. Perfect symmetry of posture is necessary, in order to recognize slight deviations from the normal contour of the abdomen, which should be inspected from several viewpoints—*anterior, oblique, and lateroposterior*—according to the requirements of the examination. The light should fall obliquely, not perpendicularly, upon the surface, so as to exaggerate trifling peculiarities of form and of movement.

Palpation not only confirms many of the signs obtained visually, but also is the means of investigating the sensitiveness of a part and the tension of the abdominal wall; of detecting tumors and fixing their site, mobility, and consistence; and of recognizing fluctuation, pulsation, thrills, and friction-rubs. An educated sense of touch is as important in studying abdominal lesions as is a trained ear in interpreting cardiac and pulmonary sounds. Muscular relaxation having been secured, the palpating hand is gently laid, palm downward, upon the surface of the abdomen, and, with firm but gentle pressure, the general contour of the underlying structures is determined. Taking advantage of the phases of expiration, when the abdominal wall is relaxed, a deep and sliding method of palpation, from right to left and from above downward, frequently enables one to outline with fair accuracy the stomach and the large intestine, if undue force is not used. Should a point of resistance be found, its shape, motility, and density are ascertained by deeper pressure with the fingers, still keeping the palm of the hand close to the surface and avoiding abrupt pressure with the finger-tips. This only tickles the patient and excites a local spasm of board-like rigidity. It may be added that a cold hand placed upon the belly will chill it into a similar contraction. The entire surface of the abdomen is covered in the manner described, the hand traveling consecutively over the different areas, the contents of which are meanwhile rehearsed by the examiner. Nervousness of the patient, abdominal tenderness, and fat, muscular, or edematous parietes are the principal difficulties that interfere with one's tactile appreciation. When the organs are not palpable because of ascites, it is well to try "dipping," which consists of a series of

sudden deep downward thrusts with the finger-tips over the enlargement sought for. This manipulation momentarily displaces the fluid overlying the obscure viscus or tumor so that it may be felt plainly.

Bimanual palpation of the abdomen is performed with the patient in dorsal decubitus, the examiner being seated by the bedside and palpating the anterolateral surface of the belly with one hand, while, with the other hand applied posteriorly, firm upward pressure is made against the relaxed structures of the loin and flank of the corresponding side. This procedure, aside from facilitating the palpation of fixed viscera like the liver and the spleen, is also useful in the tactile examination of movable solid bodies within the abdominal cavity—tumors, enlarged glands, and movable kidneys. In outlining solid intra-abdominal masses H. A. Kelly practises “bimanual vibratory palpation,” which consists of making a succession of rapid tremulous movements with the palpating fingers over the surface of the mass, whereby these tactile impressions are conducted to the underlying hand.

Mensuration is a valuable adjunct to the foregoing methods, in that comparative measurements of the abdominal circumference and of various surface distances indicate the progressive changes in the size of the belly that attended, for example, ascites, leukemic splenomegaly, and large neoplasms. The abdominal girth is usually measured at the level of the umbilicus, and from this point it is also convenient to compute mural distances, upward to the tip of the xiphoid, downward to the pubic symphysis, and obliquely to the anterior superior iliac spines.

Percussion of the abdomen is resorted to principally as a means of confirming the data obtained by inspection and palpation, in comparison with which percussion, as an individual method of inquiry, is of distinctly inferior value. According to the technic and principles elsewhere described (p. 12 *et seq.*), abdominal percussion is employed chiefly in delimiting the boundaries of the liver and the spleen, in detecting overdistention of the bladder, and in corroborating the visual evidences of meteorism and of fluid within the peritoneal cavity. Forced inspiration on the part of the patient, which depresses the viscera and approximates them to the abdominal wall, aids the judgment of percussion signs.

The normal tympany of the abdomen varies in intensity, pitch, and duration with the volume and pressure of air in the viscus percussed. If no disproportionate distention exists, the stomach emits louder, lower-pitched, and better sustained tympany than the intestines, and the same is true of the tympany afforded by the large gut in comparison with that of the small. Abdominal tympany is

exaggerated by meteorism, and variously impaired by factors such as emptiness and collapse of the bowels or by fecal masses therein, distention of the urinary bladder, fluid effusions, neoplasms, and enlargements of the various abdominal organs. Auscultatory percussion affords, in skilled hands, an accurate method of outlining the stomach, of discovering abnormalities in the size and position of the gut, and of localizing intra-abdominal tumors.

Auscultation is generally dispensed with in a routine examination of the abdomen, since its usefulness is limited to special conditions. The sounds audible over the abdomen are chiefly intestinal and gastric, less commonly frictional, and rarely of cardiovascular origin. The normal *intestines* are the seat of a medley of liquid gurgles and sonorous and sibilant cooing sounds caused by the rush of gas through the unequal lumen of the gut. Should the latter be stenosed such sounds are greatly intensified, provided that intestinal peristalsis persists. Over the *stomach* the transmitted heart and voice sounds are sometimes heard as hollow metallic echoes, and here also the bubbling and splashing of fluid within the stomach may be detected. In gastric dilatation and in fermentive gastritis these noises are exaggerated and intermingled with a curious sort of seething effervescence. The various kinds of *friction* are more often to be recognized by auscultation than by tactile sense. *Peritoneal friction*, which does not differ acoustically from the pleural rub, is generally excited only by respiration, although, rarely, active peristalsis of the gut is the exciting factor of the sound. The sounds of *tubercle friction* and of *gall-stone crepitus* possess a harsh crunching quality and are best elicited by combined auscultation and palpation. In infants and young children the respiratory sounds, as well as pulmonary and pleural adventitious sounds, are distinctly audible over the abdomen (H. L. K. Shaw). The abdominal auscultatory signs of *cardiovascular* origin include the fetal heart sounds and the uterine soufflé of pregnancy; the murmurs of hepatic cirrhosis and of splenomegaly; the bruits of aneurism and of compression of the abdominal aorta; and the hollow echo of a heart murmur transmitted downward and amplified by an air-filled viscus and by the telephonic properties of the parietes.

CLINICAL TYPES OF ABDOMEN

Several intra-abdominal affections account for conspicuous deviations from the normal size and shape of the abdomen, as in ascites, visceral ptosis, intestinal or peritoneal meteorism, and states of extreme inanition, in all of which the abnormal configu-

ration of the belly may present a most distinctive clinical picture. Abdominal enlargements belonging to this group are to be distinguished from those symptomatic of obesity and of pregnancy, which, for the sake of comparison, will be considered in connection with these pathologic types.

The Obese Abdomen.—In abdominal enlargement due to this very common cause the subcutaneous deposition of fat can be easily identified by rolling a fold of the skin between the fingers. Ordinarily the belly protrudes as a symmetric globular enlargement which depresses the navel, accentuates the cutaneous flexion-folds, arches the pit of the stomach, and encroaches upon the flanks and the pubes; or, should the musculature be relaxed and flabby, the abdomen may be pendulous, creased by deep transverse furrows, and lobulated by irregular islands of fat (Fig. 195).



Fig. 195.—The obese, relaxed abdomen (Jefferson Hospital).

The Scaphoid Abdomen.

—The scaphoid abdomen, or boat-shaped belly, typifies the extreme stage of abdominal retraction and wasting consequent to intestinal emptiness and contraction, to disappearance of the panniculus adiposus, and to tonic spasm of the parietal musculature. In the typical instance the abdomen is sunken or hollowed

out like a basin or a boat, whose sides closely correspond to the concavity of the bony pelvis. The flanks are deeply indented, the costal margins converge and thus narrow the subcostal angle, the xiphoid and Poupart's ligaments stand out conspicuously, and the iliac crests rise high above the surface of the sunken belly. The abdominal viscera and other structures are palpable as distinctly as if the subject were an anatomic model, and the area of normal abdominal tympany is greatly restricted, while pulmonary resonance usually extends below its normal limit.

Extraordinary bodily wasting commonly attends these abdominal changes, and to such extremes may the general emaciation progress



Fig. 196.—The scaphoid abdomen (Philadelphia General Hospital).

that the patient, as the accompanying picture testifies, literally may become a living skeleton (Fig. 196). The scaphoid abdomen is met with in its typical form in tuberculous meningitis, in chronic peritonitis, and in states of inanition incident to prolonged vomiting, chronic diarrhea, and stricture of the gullet or the pylorus. It has been observed also in simple meningitis, in cerebral tumor, and in the colic of plumbism.

The Abdomen of Pregnancy.—

Flattening of the hypogastrium, appreciable by or before the third month after conception, is the earliest visible change in the abdominal contour caused by a gravid uterus. By the fourth month this gives way to suprapubic fulness, which progressively increases and extends upward at the rate of about $\frac{3}{4}$ inch (1.9 cm.) each fortnight, until by the sixth month the swelling reaches the level of the umbilicus, and by the eighth month, the xiphoid. During the later months of gestation the abdomen presents a general enlargement, which, from an anterior aspect, with the subject erect, is of roughly pyriform shape, with the tapered end below, while the profile of the belly shows a symmetric protuberance more marked anteroposteriorly than laterally (Fig. 197). Primarily, the enlargement extends upward in the median line, but later a slight dextral deflection is commonly noted, and the shape is but slightly altered by postural changes. The flanks are uniformly

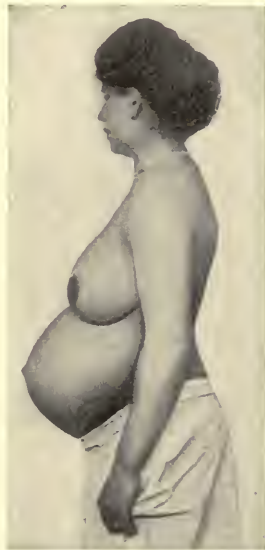

Fig. 197.—The abdomen of pregnancy (Jefferson Hospital).

rounded, the subcostal angle is moderately widened, and the navel, at first depressed, gradually rises to the surface, and finally pouts prominently. These changes, observed in primiparæ with firm abdominal walls, are naturally subject to modifications of contour in women whose parietes have been unduly stretched by previous childbirth or by visceral ptosis, under which circumstances anterior bulging and sagging of the dependent part of the abdomen are especially conspicuous. Of the numerous associated objective evidences of pregnancy, those of special interest to the clinician include the fetal cardiac sounds, the uterine bruit, abdominal ballotement, a palpable fetal outline, mammary changes, striæ gravidarum, and overfulness of the superficial veins.

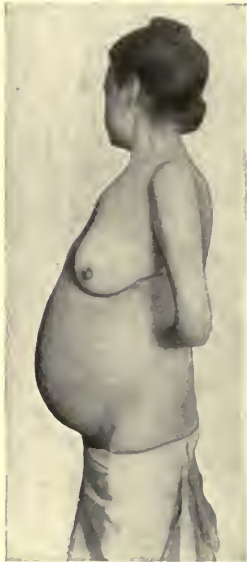

Fig. 198.—The ascitic abdomen (Jefferson Hospital).

The Ascitic Abdomen.—Alterations in the appearance of the abdomen due to ascites, or dropsy of the peritoneal cavity, vary with the volume of the contained fluid and the pressure thereby produced. If the effusion be moderate, nothing more definite is perceptible than slight bulging of the flanks with flattening of the belly's summit, in the dorsal posture, with unnatural fullness of the lower abdomen when the patient stands erect. The dependent parts afford a dull or a flat percussion sound which shifts with change of posture and consequent gravitation of the fluid and ascent of the buoyant intestines. With the subject in dorsal decubitus, the flanks are flat (fluid) and the summit of the abdomen is tympanitic (gut), but when the patient turns upon the side the opposite flank, originally flat,

will become tympanitic as the intestines float upward upon the surface of the gravitated fluid and lie directly beneath the parietes under the examiner's pleximeter finger. In the knee-chest posture both flanks give tympany, while the central part of the abdomen is flat. These percussion changes, it must be understood, may not be perceptible in a small effusion (of less than 50 ounces, or 1500 cc.), nor when it is so large as to prevent contact between the gut and the parietes.

If the effusion be of large volume there is a proportionately striking enlargement of the abdomen, in the form of a smooth, tense, uniform globular protuberance which curves downward from the

epigastrium, fills the flanks, overhangs the hypogastrium, and obliterates the umbilical fossa, if, indeed, the navel does not actually protrude from the surface (Fig. 198). The shape of the abdomen distended to such a degree is slightly, if at all, affected by postural changes, and, provided that the mural tension be not excessive, the fluid will give a distinctive wave of fluctuation, recognizable commonly by the eye as well as by the palpating hand. (See p. 516.) A pendulous abdomen full of free fluid bulges particularly toward the middle line, so as to produce a disproportionately elongated protuberance having a broad, sagging base, the shape of which visibly alters when the subject changes from the erect to the recumbent position. The abdominal cavity alone may be dropsical, as is generally the case in hepatic cirrhosis, in tuberculous peritonitis, and in Pick's disease; or the ascites may be part and parcel of an anasarca of cardiorenal origin, in which event the edema also invades the abdominal wall to a greater or less extent.

The Gaseous Abdomen.—The distention symptomatic of tympanites or meteorism may be most extraordinary, the abdomen becoming symmetrically ballooned in the form of a tense tympanic sphere which preserves the same contour irrespective of postural change, and whose pressure upon the diaphragm embarrasses the respiratory movements and disorders the cardiac action (Fig. 199; *cf.* Fig. 211). A veritable "wind bomb" in the belly is the apt description of this condition found in one of Ben Jonson's plays. The abdominal walls are universally taut, smooth, and shiny, the umbilicus is on

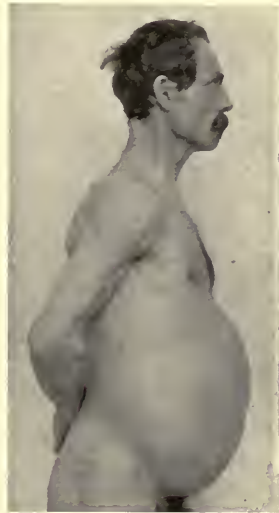

Fig. 199.—The gaseous abdomen (Jefferson Hospital).

a level with the surface or protrudes above it, and in the extreme case the lower part of the bony thorax projects anterolaterally. In gastro-intestinal meteorism it is sometimes possible to distinguish the contour and the peristaltic movements of the gaseous stomach and gut, but in meteorism due to the accumulation of gas within the peritoneal cavity the abdomen is uniformly enlarged and neither the outline of the gastro-intestinal tube nor any movement thereof is perceptible. (See p. 533.) The tympany of intestinal meteorism encroaches upon, displaces, and perhaps obliterates the

areas of hepatic and splenic flatness. In pneumoperitoneum the property of the intraperitoneal free gas to seek the highest level may afford a most distinctive alteration of the percussion sound when the patient turns from dorsal to left lateral decubitus. In the dorsal posture, despite the replacement of hepatic flatness by tympany anteriorly, dullness persists laterally in the right axillary region, but if the subject turns upon the left side this axillary dullness at once changes to tympany, inasmuch as the free gas rises to fill the space beneath the parietes created by the gravitation of the liver toward the dependent side.

Unfortunately, this changeable dullness in the axilla is not always demonstrable, for hepatic dullness may be wholly obliterated by a greatly distended colon. In such instances, then, the only certain means of differentiating pneumoperitoneum and intestinal meteorism is an exploratory puncture of the peritoneal cavity. (See p. 56.)

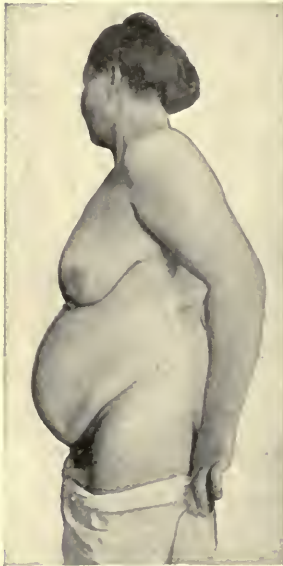

Fig. 200.—The gastroptotic abdomen (Jefferson Hospital).

The Gastroptotic Abdomen.—

When the subject stands erect, gastroptosis, or downward displacement of the stomach, produces a bulging that appears most conspicuous in the umbilical region, with deepening of the epigastrium, leveling of the umbilical depression, and a variable degree of flaccidity and thinning of the parietes (Fig. 200). In typical examples the abdominal contour is a fairly symmetric curve from the infracostal line to the pubes, the flanks are flat or even hollow, and each groin is seamed by a deep furrow paralleled above by a local saugage-shaped bulging of the belly wall. When gastrectasis, or dilatation of the stomach, coexists, as it usually does, the epigastric hollow is generally effaced rather than deepened, and unnatural fulness at the inner borders of the lumbar regions is also noticeable.

When gastrectasis, or dilatation of the stomach, coexists, as it usually does, the epigastric hollow is generally effaced rather than deepened, and unnatural fulness at the inner borders of the lumbar regions is also noticeable.

The Enteroptotic Abdomen.—Enteroptosis, or downward displacement of the intestines, is almost invariably associated with descent of the stomach and of other abdominal viscera, of which accidents, generically designated as *Glénard's disease*, relaxation of the

mesentery, peritoneum, and parietes is the exciting cause (Fig. 201). In the upright posture enteroptosis produces a most characteristic alteration in the size and shape of the abdomen, whose enlarged profile may be likened to that of a gourd or of a sagging sac, while the anterior aspect is roughly pear shaped, with an evenly rounded base. The anterior abdominal wall slopes gently downward from the epigastrium to the navel, where it bulges in all directions into a huge flabby paunch, full of distended and constipated gut, hanging far beyond and below the pubes, and overlapping laterally to form deep cutaneous folds, often painfully excoriated, which course obliquely upward as far as the summits of the iliac crests. There is unnatural flattening of the epigastric concavity and more or less effacement of the umbilical depression, and the abdominal wall is generally wasted, stretched, and disfigured by silvery striations. With the subject in dorsal decubitus, the outlines of the stomach and intestines may be distinctly visible, owing to the parietal thinning and relaxation, and in the extreme instance, there may be a hernial protrusion of the abdominal viscera through a separation between the recti abdominales. When enteroptosis and obesity are combined a most peculiar lobulated enlargement of the abdomen develops, characterized by a remarkable globular protrusion and sagging at the base, and by unusual depth of the lateral cutaneous creases. Enteroptosis is very commonly associated with downward displacement and unnatural mobility of the kidneys, and, less commonly, of the liver and spleen.

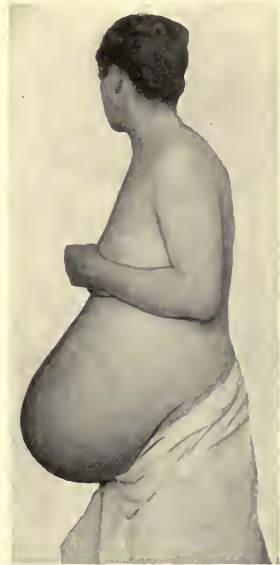

Fig. 201.—The enteroptotic abdomen (Jefferson Hospital).

LOCAL ABDOMINAL ENLARGEMENTS

In dealing with circumscribed enlargements of the abdomen, their general situation, whether in an upper, lower, central, or lateral zone of the belly, should be determined first, and then, for the sake of greater accuracy, their more precise relation to one of the arbitrary regions lying between the costal arch and the pubes. In such local-

izations, however, no hard and fast lines of demarcation are possible, since swellings occupying one region must, by their evolution, sooner or later tend to encroach upon neighboring areas. For example, the splenomegaly and hepatic tumor of Banti's disease primarily cause bulging below the costal arch, but ultimately the visceral enlargements distend the greater part of the abdomen, extending downward to the umbilicus, and perhaps into the iliac fossæ and pelvis. It is the *origin* of the swelling then, rather than its actual site, which is the important point to remember in studying a local abdominal enlargement.

Enlargements of the upper abdomen below the *right costal arch* are suggestive of lesions of the liver and gall-bladder—hepatoptosis, congestion, cirrhosis, amyloid disease, malignant and gummatous tumors, echinococcus cyst, and abscess of the liver; and lithiasis, empyema, or cancer of the gall-bladder. Or a swelling here may be due to a fecal or a malignant tumor of the ascending colon in the neighborhood of the hepatic flexure. Right-sided subphrenic pyopneumothorax may produce an immobile mass in the hepatic region

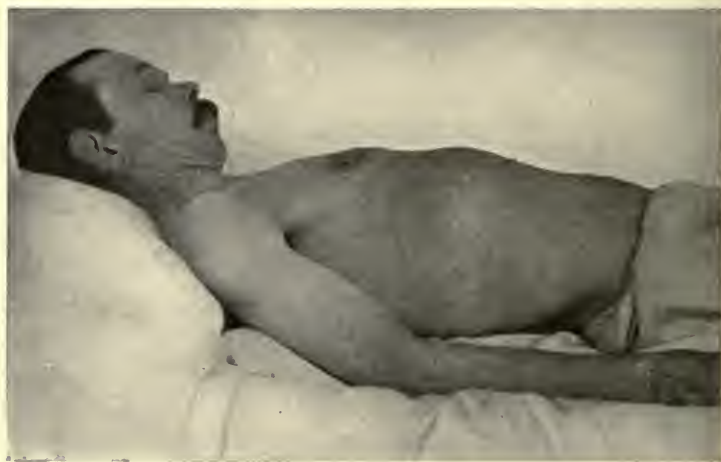

Fig. 202.—Epigastric tumor in a case of gastric cancer (Jefferson Hospital).

and perhaps in the epigastrium, and less commonly a distention of the upper right abdomen is traceable to nephroptosis, to an enlarged kidney, or to retroperitoneal adenitis.

Enlargements of the *epigastrium* are referable chiefly to a distended or a dilated stomach, and to neoplasms of the pylorus, left lobe of the liver, pancreas, transverse colon, and omentum. Aneurism of the abdominal aorta is recognized as a pulsatile tumor in the median

line of the epigastrium. To the right of this line an enlarged gall-bladder may be detected, and to the left, immediately above the colon, an effusion into the lesser peritoneal sac. Indurated masses in the epigastrium may prove to be retroperitoneal or mesenteric glands enlarged by tuberculosis, malignant disease, or pseudoleukemia.

Enlargements below the *left costal arch* may indicate splenomegaly, splenoptosis, gastric dilatation, or cancerous growths near the splenic flexure of the colon. Here also is the site of a left-sided subphrenic pyopneumothorax, of an effusion in the lesser peritoneum, and, occasionally, of renal tumor and nephroptosis.

Local enlargements in *either flank* commonly depend upon lesions of the uterus and adnexa—pyosalpinx, ovarian, uterine, and ligamentous tumors, and ectopic gestation; or a mass in one of the iliac areas may mean tuberculosis or malignant disease of the peritoneum, retroperitoneal growths, intussusception, renal tumor, or nephroptosis. A psoas abscess may bulge, fluctuate, and point in the groin either below or above Poupart's ligament, while an iliac abscess commonly appears above the outer end of this landmark. The *right flank*, at or near McBurney's point, is the common site of the palpable tumor of appendicitis, and in this region also may be found the tumors due to neoplasms of the cecum or ascending colon and to fecal impaction in these portions of the intestines. In the *left flank* similar obstructive lesions of the descending colon and sigmoid flexure are possible causes of a local swelling, additional factors to be borne in mind being splenomegaly and splenoptosis.

In the region of the *umbilicus*, a distention is suggestive of gastric dilatation and displacement; less commonly, of enteroptosis or of other visceral ptoses—a displaced spleen or kidney may be more conspicuous near the navel than it is in the epigastrium or in the flanks. The umbilical region is also the site of hernia and of the tumors caused by tuberculous peritonitis, and by neoplasms of the stomach, gut, omentum, and mesentery. In this region also appears most conspicuously the cup-shaped roof of the dome-like abdomen of ruptured extra-uterine pregnancy, described by Shulman.

Distention of the lower abdomen above the *pubes*, if not obviously a sign of pregnancy, may mean an overdistended bladder or, very rarely, physo- or hematometra. Additional factors of hypogastric swellings include the above-noted diseases of the female genital organs, the appendix, and the peritoneum, as well as inguinal hernia.

On inspection massive *abdominal tumors* may account for an apparent general enlargement of the abdomen, but by careful palpation and percussion such growths are traceable to a local origin—visceral, peritoneal, or glandular. It is especially the ovarian cyst, the preg-

nant or fibroid uterus, the leukemic spleen, the overfull bladder, and the cancerous gut and peritoneum which at first glance simulate a universal abdominal distention. In addition to these factors many others responsible for the various local enlargements mentioned elsewhere may, if exaggerated, also cause an apparent general distention.

In the distention due to an *ovarian cyst* the dome of the abdomen gives a dull percussion sound while the flanks on either side are tympanitic, these signs persisting when the subject turns from the dorsal to the lateral decubitus. The same is true of the *gravid uterus* and of *uterine fibroid*. In differentiating these three conditions, vaginal examination, the cautious use of the aspirator, and the history of the patient are important diagnostic adjuncts. A *leukemic spleen* may be readily mapped out by palpation and by the dulness over the upper and sometimes the lower left abdominal region, and in this disease the blood count is pathognomonic. The *distended bladder* forms a dull area encircled by a tympanitic zone in the lower mid-abdomen, which findings, it need scarcely be noted, vanish after catheterization. In the *cancerous intestines* and *peritoneum* the resistant, nodular character of the growths, their asymmetric distribution, and perhaps the presence of metastatic tumors furnish the important clues.

ABDOMINAL MOVEMENTS

The various movements of the abdomen to be noted on inspection relate to the respiratory excursions, to local areas of pulsation, and to peristalsis of the stomach and intestines. *Exaggerated* abdominal movements during respiration are generally due to some thoracic lesion which restricts the normal rise and fall of the diaphragm. *Enfeeblement* of such movements occurs as the effect of abdominal distention, pain, and paralysis, as, for instance, in ascites, meteorism, and tumors, in peritonitis, and in paralysis of the abdominal muscles. These causes, together with those of *local pulsations* in the epigastrium have already been considered. (See Anomalies of Respiration, p. 95, and Abnormal Areas of Pulsation, p. 321.) Here may be mentioned the rhythmic throbbing near the umbilicus, occasionally symptomatic of acute enteritis (Stokes).

Peristalsis of the stomach and gut may be visible under normal conditions in subjects with thin, flaccid abdominal walls, but more often it is a sign of marked gastric dilatation, perhaps with pyloric obstruction, or of stenosis of the intestine, with dilatation above the point of constriction. Exaggerated peristalsis also may be seen in overdistention of the gut associated with enteritis and with the

functional neuroses. Kussmaul's "peristaltic unrest" is simply an excessive peristalsis, betrayed by volleys of gurgles and rumbles of flatus (borborygmi), and chiefly affecting women whose neurotic temperament, tight stays, and overeating account for these embarrassing echoes. Visible peristalsis appears as a succession of undulatory movements travelling with a sort of worm-like motion across the belly—from left to right, if the peristalsis be of the stomach, and from right to left, if it be of the intestines. Peristalsis of the stomach is seen best in the epigastrium; of the large intestine, in the epigastrium and in the right or left flank, according to which section of the tube, transverse, ascending, or descending, be affected; and of the small intestines, in the region of the umbilicus. In this situation a circumscribed area of peristaltic gut, massed together coil upon coil, suggests stenosis at or near the ileocecal valve.

THE SKIN AND SUBCUTANEOUS TISSUES

The *nutrition* of the skin and structures beneath suffers decidedly in many wasting diseases, as examples of which may be cited tuberculous peritonitis, malignant disease of the abdominal viscera, and Asiatic cholera. In such conditions, in addition to obvious wasting of the abdominal wall, the skin is dry, furfuraceous, bloodless, and so inelastic that it may be pinched up and molded between the fingers like a ball of putty. In advanced senility and in the multipara the abdominal parietes are thin, toneless, and relaxed, and as the effect of long-continued distention the skin of the abdomen becomes tense, shiny, preternaturally dry, and even duskily blue in the dependent parts of the flanks. Increased thickness of the abdominal wall may be muscular, fatty, or edematous. *Edema* of this region is recognized as a boggy thickening which pits upon pressure like a soft apple, especially in the flanks and loins; it is commonly part of the anasarca

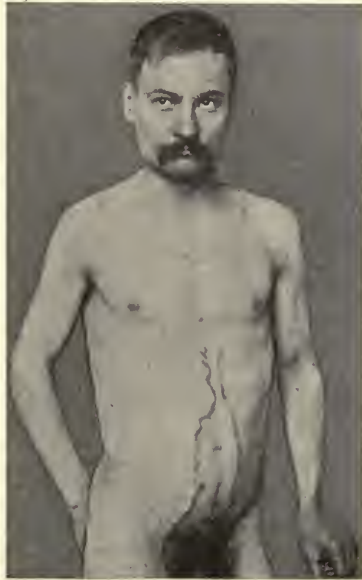

Fig. 203.—Venous engorgement of the abdominal wall (Jefferson Hospital).

of renal or cardiac disease, and may or may not be associated with ascites. Angioneurotic edema occasionally attacks the abdominal wall, appearing as an ephemeral local tumefaction, too tense to pit deeply and either blanched or of a scarlet hue. In the exceptional instance diffuse purulent infiltration may account for a widespread edematous thickening of the abdominal parietes.

As types of *color changes* in the skin of the abdomen and elsewhere there are to be recalled the saffron discoloration of icterus; the blue mottling of cyanosis; the dark pigmentation of Addison's disease, peritoneal tuberculosis, argyria, and vagabondism; the dirty brown or yellow patches of tinea versicolor; and the coppery macular areas of syphilis. Multiple white, silvery, or, rarely, pigmented *linear markings* upon the abdomen may have been caused by pregnancy, ascites, and various causes of chronic abdominal distention; generically, these streaks are designated as *lineæ albicantes*, or, if due to pregnancy, as *lineæ gravidarum*. The appearance of a white line upon the skin of the abdomen (*ligne blanche abdominale*) after friction with a blunt instrument is described by Sargent as an occasional finding in suprarenal insufficiency. *Scars*, aside from those due to accidents and to operations, may be the relic of a previous attack of syphilis, of a chancroidal bubo, or of a destructive skin disease. Venereal infection, tuberculosis, malignant disease, and injury by a sudden, violent strain are suggested when *enlarged glands* are discovered in the groin. Small, steel-gray points of *fat necrosis* are sometimes perceptible in cases of pancreatitis, and hard *subcutaneous nodules* may develop just beneath the skin in sarcomatosis and in cancer of the abdominal organs.

Enlarged and tortuous veins coursing over the abdomen are a valuable sign of venous obstruction, and generally mean Laennec's cirrhosis, although less commonly they result from portal vein thrombosis, ascites, or pressure by neoplasms upon the superior or inferior vena cava. The *caput Medusæ* of the gin-liver consists of a bunch of tortuous venules about the navel, and indicates portal obstruction, as the result of which there has been established a compensatory anastomosis between a para-umbilical vein and the superior epigastric veins (Sappey). By making pressure upon an abnormally dilated abdominal vein it is possible to determine whether the obstruction involves the superior or the inferior vena cava; if it be the former, the vein distends above the point of pressure, while if it be the latter, the fulness appears below the constriction. The flow within the enlarged veins radiating from the navel is away from this point.

Umbilical Changes.—The condition of the navel is not only a good index of the thoroughness of one's personal hygiene, but a collateral

sign of clinical moment. In an overfat abdomen the navel is retracted perhaps to the point of obliteration; it protrudes conspicuously in late pregnancy, umbilical hernia, and portal obstruction; and it is stretched and depressed in the abdominal fulnesses of early pregnancy, ascites, and new-growths. The navel may be the seat of inflammation and eczema, and in congenital umbilical fistula it may ooze a clear serous fluid. F. P. Henry regards peri-umbilical erythema as an important diagnostic sign in tuberculous peritonitis. A malignant neoplasm of the liver may rigidly immobilize the umbilicus.

Muscular Rigidity.—Increased resistance to pressure and actual spontaneous rigidity of the abdominal musculature are suggestive of either peritoneal irritation or inflammation. General rigidity of the belly wall is met with in acute general peritonitis, but a practically similar spasm also attends certain inflammations above the diaphragm, particularly croupous pneumonia and diaphragmatic pleurisy. Local muscular rigidity may point definitely to an inflammatory lesion of one of the abdominal organs—to appendicitis or to extensive typhoid ulceration, if it affects the right iliac region; to perisigmoid inflammation, if it be in the left iliac space; to cholelithiasis, gastric ulcer, or pancreatitis, if it be epigastric.

FLUCTUATION

The palpating hand seldom appreciates any decided tactile differences in the resistance of the gaseous and the liquid strata of an *ascitic abdomen*, but fluctuation, a certain sign of fluid, is demonstrable if a moderately large effusion be present. To obtain this sign the examiner palpates one flank and gently but sharply taps with the finger-tips the opposite side of the abdomen, an assistant meanwhile pressing firmly with his hand held edgewise in the median line, so as to cut off the vibrations of the abdominal wall. If fluid be present a distinct jog, due to a wave of liquid set in motion by the percussion, is felt by the palpating palm. Ascites does not invariably give this sign, for it may be impossible to agitate a liquid wave both in very slight and in very extensive dropsical accumulations. The percussion findings associated with this tactile sign of intraperitoneal fluid are described on p. 506.

Fluctuation of an *abdominal mass* indicates encysted fluid. The sign may obviously relate also to an iliac abscess or to an abscess of the abdominal wall. In other instances it is attributable to a distended bladder; to pregnancy, normal or extra-uterine; to ovarian, tubal, hepatic, or renal cyst or abscess; and to general effusions in the lesser, and encysted effusions in the greater, peritoneum.

TACTILE FRICTION AND THRILLS

In tuberculous peritonitis coarse *tubercle friction*, due to the rubbing together of peritoneal tubercles, is sometimes elicited by kneading the abdomen with the finger tips. In other forms of peritonitis, especially the chronic, fine *peritoneal friction* is occasionally felt over the upper part of the abdomen. Over the liver a palpable friction-rub during respiration suggests perihepatitis, secondary to hepatic abscess or cancer, or developing by the extension of pleurisy or of peritonitis. Subphrenic peritonitis likewise accounts for tactile friction in this area. Rarely, inflammation of the peritoneal covering of the spleen causes a similar rub over the splenic area. Perihepatic and perisplenic friction are most distinctly felt during full inspiration and disappear when adhesions form between the affected organs and the abdominal wall. Cholelithiasis may underlie two tactile signs localized to the region of the gall-bladder: palpable friction with respiration, excited by local inflammation of the peritoneum at the gall-bladder and of the adjacent hepatic peritoneal reflection (Gerhardt); and a grating gall-stone crepitus, due to friction of the calculi by palpatory manipulation.

Xiphoid crepitation, a tactile sensation akin to that of emphysematous crackling, is described by Galvagni as an evidence of peritonitis. It is elicited by pressure over the xiphoid tip and the upper costal arch, and is explained by the mechanical separation of peritoneal adhesions, as well as by the presence of subcutaneous bullæ created by gas-forming bacteria.

A *palpable thrill* in the epigastrium, with visible throbbing of a tumor, giving expansile pulsation and a systolic murmur, is found in aneurism of the abdominal aorta. Over an accessible hydatid cyst the so-called *hydatid thrill* or *fremitus* can be sometimes detected by palpatory percussion. (See p. 135.)

PAIN IN THE ABDOMEN

It is important to bear in mind that abdominal tenderness and pain relate not only to lesions of the abdomen, but also to disorders elsewhere situated, notably those affecting the thoracic organs and the spine. The acutely painful abdomen of pneumonia and the excruciating gastric crises of tabes dorsalis are two striking illustrations of pain reflected to the abdomen from remote regions, the examination of which should not be neglected in attempting to discover the true cause of a tender or an aching belly. Furthermore,

diseases of the abdominal organs frequently account for pain in regions far removed therefrom, as in the shoulder pains symptomatic of lesions of the liver and colon, in the tender spine of gastric ulcer, and in the painful testicle of stone in the kidney.

Generalized abdominal tenderness and *pain* usually is traceable to such conditions as gastro-intestinal disease, meteorism, peritonitis, irritant poisons, abdominal myalgia, or hysteria. Or when diffused through-

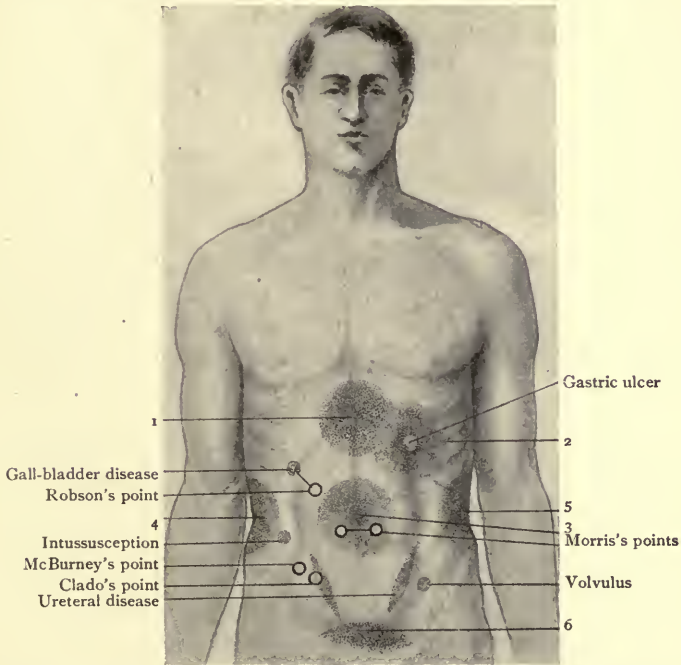


Fig. 204.—1. Diseases of stomach, gall-bladder, duodenum, transverse colon, and pancreas; abdominal aneurism; pneumonia; phrenic pleurisy; pericarditis; appendicitis; diabetes; uremia; eclampsia. 2. Diseases of stomach, splenic colon; enteroptosis, nephroptosis, nephralgia. 3. Diseases of intestines, omentum, mesentery, and peritoneum; lead colic; abdominal arteriosclerosis. 4. Diseases of liver, hepatic colon, and right kidney. 5. Diseases of spleen, splenic colon, and left kidney. 6. Diseases of urinary bladder and pelvic organs.

out the abdomen it may stand for the radiation of pain originating in one of the abdominal viscera or in some extra-abdominal structure, as in renal colic, appendicitis, dysmenorrhea, and diaphragmatic pleurisy, in which the pain, primarily circumscribed to the local lesion, secondarily spreads far beyond its original confines. *Circumscribed tenderness* and *pain* should be investigated with reference to its origin in, and reflection from, the organs and other struct-

ures corresponding to the several surface divisions of the abdominal wall, the findings thus obtained being interpreted in the light of a full clinical inquiry by other methods of examination (Fig. 204).

Pain in the *epigastrium* ordinarily is of purely gastric origin, as in neuralgia, inflammation, ulcer, or cancer of the stomach, but to this region the pain of diseases of the gall-bladder and gall-ducts also is commonly referred. In cholecystitis deep tenderness may be induced at the end of full inspiration if the examiner's fingers be thrust upward beneath the costal arch at the outer limit of the right epigastrium—*Naunyn's sign*. Epigastric pain may be symptomatic of duodenal ulcer or of an impacted transverse colon; of some pancreatic lesion, such as inflammation, hemorrhage, or carcinoma; of circumscribed peritonitis; of aneurism of the abdominal aorta; of myalgia of the abdominal musculature; or of vertebral disease. It is also to be recalled that severe epigastric pain is a common complaint in infantile pneumonia, diaphragmatic pleurisy, pericarditis, and rheumatic fever; and that it frequently accompanies visceroptosis and appendicular inflammation. Severe crises of epigastric pain are a well-known premonitory sign of diabetic coma, and less commonly accompany other intoxications, notably uremia and eclampsia.

Pain in the *umbilical region*, if not traceable to some one of the conditions just enumerated, may be indicative of enteritis, enteralgia, intestinal obstruction or ulceration, lead colic, general peritonitis, omental carcinoma, or mesenteric cyst. Here also may be the seat of pain in abdominal arteriosclerosis, angina pectoris, ureteritis, and embolism of the superior mesenteric artery. The girdle pain of locomotor ataxia, myelitis, and spinal meningitis encircles the body, as a painful sense of constriction, in the upper part of the umbilical rectangle. Two diagnostic points of pain on pressure are also situated in this area of the abdomen: *Mayo Robson's point*, at the junction of the outer and middle third of a line drawn from the ninth costal cartilage to the umbilicus, where tenderness indicates inflammatory lesions of the gall-bladder and ducts; and *Morris's point* of tenderness in appendicitis, situated $1\frac{1}{2}$ inches (3.75 cm.) from the navel on a line running thence to the right anterior superior iliac spine. Tenderness at this point and also at a corresponding point to the left of the navel suggests pelvic, not appendical, disease, in which the sensitiveness is right sided only.

Hypogastric pain relates principally to diseases of the urinary bladder, of which cystitis in particular, and also acute distention, calculus, tuberculosis, and neoplasm are accredited causes. In women uterine and ovarian disease, pelvic inflammation, and ectopic gestation are

also to be reckoned with as possible factors of pain above the pubes and in the lateral regions bordering thereupon. *Voillemier's point*, selected as the site for puncturing a distended bladder, is situated in the linea alba $2\frac{1}{2}$ inches (6.25 cm.) below the interspinal line.

Either *ileocolumbar region* may be the seat of maximum tenderness in abdominal pain due to colitis, hernia, varicocele, renal colic, floating kidney, or ovaritis. On the right side pain is suggestive particularly of intussusception, cecal impaction, enteric fever, and appendicitis; while left-sided pain in this area may indicate volvulus, sigmoid impaction, or pericolicitis sinistra. *McBurney's point* of appendical pain is situated in the right iliac region $1\frac{1}{2}$ inches (3.75 cm.) from the anterior superior iliac spine on a line drawn from this prominence to the umbilicus. *Clado's point*, having a similar significance, lies at the intersection of the right semilunar line by the interspinal line at the external border of the rectus abdominis muscle.

Pain in the *hypochondriac regions* and in the *loins* and *sacrum* has been dealt with in Section II. (See p. 120.)

EXAMINATION OF THE STOMACH

Clinical Anatomy.—The stomach occupies the left hypochondrium and part of the epigastrium, lying chiefly to the left of the median line in an almost vertical position, with the subject in the erect posture (Fig. 205). The old conception of the stomach's transverse position in the upper abdominal cavity must be revised by the newer truths of modern radiography, which shows radical differences in the topography of the organ according to the influences of posture, degree of distention, and amount of contained food. When empty and contracted the stomach is represented by a small pyriform sac filled with gas, and situated beneath the left dome of the diaphragm. This communicates with a collapsed tubular structure whose opposed walls for the greater part conform to the vertical plane of the body except near the midline, where they run almost horizontally. When fully distended the stomach is comparable in shape to an elongated gourd of virtually uniform diameter following the vertical-oblique course above indicated.

The *cardia*, or gastro-esophageal orifice, corresponds anteriorly to a point on the seventh left costal cartilage 1 inch (2.5 cm.) from the sternum, and posteriorly to the level of the ninth thoracic vertebra. The *pylorus*, or gastroduodenal opening, unlike the

cardia, is freely movable, and is situated, when the stomach is empty, in the median line 3 or 4 inches (7.5 to 10 cm.) below the xiphisternal junction, but when the stomach is distended the pylorus moves 2 or 3 inches (5 to 7.5 cm.) to the right of the median line; posteriorly, the pylorus is opposite the first lumbar vertebra. The pyloric region also includes a *vestibule*, directed upward to the right of the median line, and a *canal*, running thence upward, backward, and toward the right to project into the duodenum. The Addison-Cunningham transpyloric line, crossing the belly midway

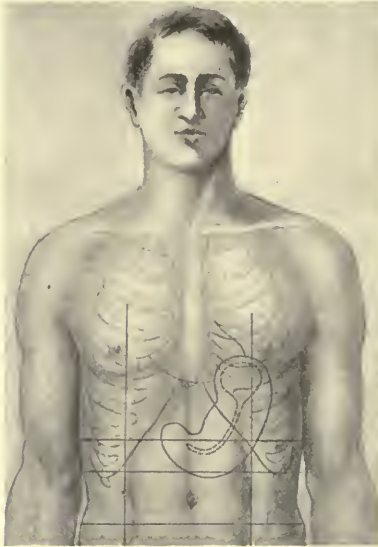


Fig. 205.—Surface topography of the stomach, when empty (inner broken outline), and in full distention (outer solid outline).

between the suprasternal notch and the pubic symphysis, bisects the pyloric end of the stomach. The *fundus*, or the rounded dome of the stomach to the left of the cardia, lies behind and somewhat to the left of the heart's apex, and occupies the left vault of the diaphragm. The *body*, lying entirely to the left of the median line, is situated either vertically or somewhat obliquely toward the right, according to the position of the trunk, whether upright or recumbent. The *lesser curvature*, or the upper concave border of the stomach, lies in the epigastric region, deeply situated be-

neath the lower border of the liver. In general, its course corresponds to that of the opposed wall of the empty contracted stomach. A distinct depression on the lesser curvature, the *incisura angularis*, separates the body from the pyloric portion. The *greater curvature*, or the lower convex border of the stomach, lies beneath the ninth costal cartilage at the left costal arch, and is situated at or slightly below the umbilicus in the median line of

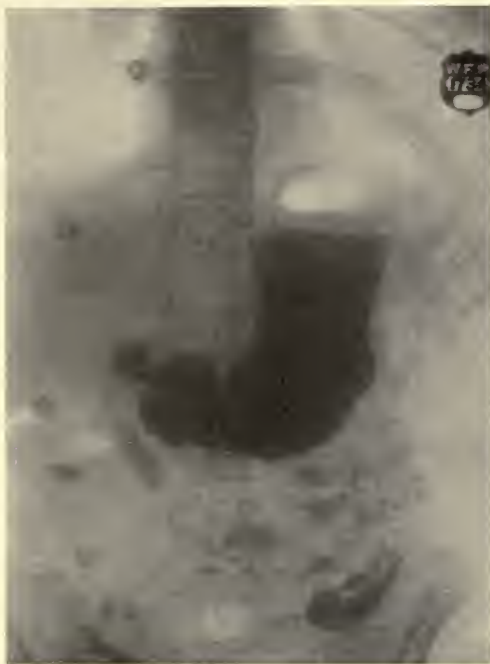

Fig. 205a.—Radiograph of the normal stomach in a state of complete distention. Cf. Figs. 206 and 207. (Plate by Dr. W. F. Manges.)

the abdomen. In children it is generally much lower, even below the level of the iliac crests.

Inspection.—Aside from the detection of *peristalsis* and of *pulsating areas* in the epigastrium, previously described (p. 324), inspection of the gastric region is useful in determining the *size* and the *position* of the stomach. In the thin subject it is sometimes possible to perceive the contour of the greater curvature and its respiratory rise and fall, even if the stomach be but moderately distended, and the outline of the lesser curvature may be visible if the organ be

greatly depressed. In other instances it is necessary to inflate the stomach, either with air by means of a bulb-syringe, or with carbon dioxid evolved from sodium bicarbonate and tartaric acid.¹ Artificial distention of the stomach may reveal a pyloric tumor otherwise invisible, while a phantom tumor due to a tightly contracted gastric musculature promptly disappears when the stomach is inflated.

When a patient whose stomach is dilated and displaced stands erect, the epigastrium becomes distinctly concave, and the lower central and lateral regions of the belly bulge forward and sag downward in the form of a flaccid globular mass bounded on either flank by a deep sulcus running obliquely downward toward the pubis from the iliac crests. In the dorsal decubitus the epigastric hollow becomes shallower, the abdominal prominence flattens, and the enlargement of the flanks is more conspicuous. (Cf. Figs. 200 and 201.)

Inasmuch as an enlarged stomach extends chiefly in a downward direction, the lower border is taken as a clinical index of the organ's size and site. A lower border well below the navel may safely be regarded as symptomatic of either dilatation or of displacement, for the differentiation of which other data are essential. In *gastrectasis* the pylorus is but slightly lower than its normal site below the right costal arch, the distance between the two curvatures of the stomach is greatly increased, and the lower border is depressed to the level of the navel or somewhat below it; while in *gastroptosis* the pylorus occupies the umbilical region, the distance between the stomach's curvatures is approximately normal, and the lower

¹ Mechanical inflation requires the introduction of a stomach-tube, to the buccal end of which is coupled a Davidson syringe, which is then manipulated until sufficient air has been pumped into the stomach. By this procedure the amount of gastric distention may be exactly controlled and the distressing symptoms of overinflation quickly relieved; it is, however, objectionable in patients to whom the passage of the tube is a trying ordeal, if not a positive danger. Carbon dioxid inflation, the best method for the average case, is accomplished by giving the patient a dram of sodium bicarbonate dissolved in half a tumblerful of water, followed at once by a dram of tartaric acid similarly diluted. The carbonic acid gas thus evolved in the stomach quickly distends the organ sufficiently for a satisfactory examination. This process of chemical inflation has been criticized chiefly because the gas generation cannot be controlled, and hence may cause cardiac embarrassment as well as active gastric distress from the irritant effects of the effervescence. Practically, overdistention is promptly relieved by the escape of gas through the cardia, whence it is disposed of by belching; or, in an extremity, the tube may be passed to relieve the pressure.

Organic cardiac disease, recent hematemesis, gastric ulcer and other factors that seriously weaken the gastric parietes are causes of possible danger in inflation of the stomach by either of the above methods.

border lies far below the navel, perhaps almost as low as the pubes. From this it is evident that the site of the pylorus, and not simply the position of the lower border of the stomach, is the criterion in distinguishing dilatation and displacement of the organ. These signs, it must be added, are always to be supplemented by a determination of the stomach's motor powers and by laboratory tests. The radiograph on this page (Fig. 206) well illustrates the size and



Fig. 206.—Radiograph of a dilated and displaced stomach. Cf. Fig. 205a. (Plate by Dr. W. F. Manges.)

site of a dilated and displaced stomach. The striking double sacculatation of the *hour-glass stomach* may be made visible by inflation, and in this rare deformity it is possible to trace the outline of the deeply notched lower gastric border where a cicatricial contraction divides the stomach into two separate compartments, one pyloric and the other cardiac, which communicate by a narrow opening (Fig. 207). An hour-glass stomach usually yields by siphonage less fluid than has been poured in through the stomach-tube, and, though apparently drained dry, may afford a sudden commingling of splashing sounds and other signs indicating the reappearance of fluid in the empty compartment.

X-ray examination of the stomach is most useful in determining the size, contour, position, and peristaltic action of the organ, and, with less certainty, the existence of neoplasms. The best results, both from radiography and from radioscopy, are obtained by using the rays after the stomach has been rendered opaque by the admin-

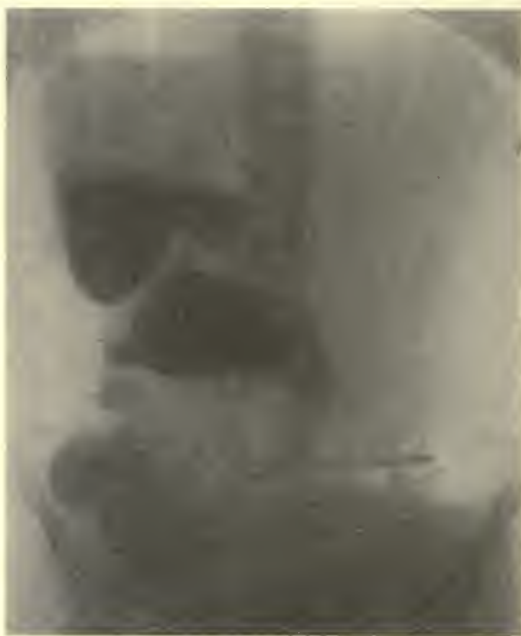

Fig. 207.—Radiograph of an hour-glass stomach. Cf. Fig. 205*a*. (Plate by Dr. W. F. Manges.)

istration of 1 pint (480 cc.) of kefir, of mucilage of acacia, or of thin gruel containing about 1 ounce (31 gm.) of bismuth sulphate.

Bismuth subnitrate, owing to its potential toxicity from nitrite-poisoning, has been generally abandoned in favor of the sulphate, carbonate, or oxid, all of which are harmless.¹ Within from four

¹ For radiographic examination of the alimentary canal the Royal Society of Medicine recommends standard test-meals of porridge and of bread and milk, each to be incorporated with 2 ounces (62 gm.) of barium sulphate or of bismuth oxychlorid. The porridge meal is prepared by adding to 7 ounces (247 gm.) of fine oatmeal sufficient milk to make the total bulk 10 ounces (310 cc.), sweetening the mixture with brown sugar. The bread and milk is made by mixing 2 ounces (62 gm.) of soft white bread with 8 ounces (240 cc.) of whole or malted milk, sugar being added to taste. With each of these test-meals, to be given on an empty stomach, the proper quantity of bismuth or barium is mixed just before use.

to six hours after the ingestion of this bismuth test-meal the normal stomach shows no vestige of the salt, which passes through the ileocecal valve into the colon within from eight to ten hours and through the descending colon and rectum within twenty-four hours. Serial radiographs taken immediately after the patient swallows the bismuth meal and twenty-four hours thereafter, with exposures made at two-hour intervals during the first twelve hours, provide accurate and correlated data of the condition of the entire gastro-intestinal canal. Especially is this true of such a series supplemented by one or two radiographs of the colon taken after the injection of a suitable clyster. (See p. 535.)

By combined radiography and fluoroscopy many cases of cancer and ulcer of the stomach are differentiated at an early period of their development chiefly by criteria such as test-meal residue, pyloric patency, and irregularities of contour

In *gastric cancer* this complex is sought for: antiperistalsis; unnatural patency or actual obstruction of the pylorus; large residue of the test-meal after six hours; fixation of the stomach as a whole; and irregularities of contour due to neoplastic deformity. In *gastric ulcer* it may be possible to identify the projecting shadow of the ulcerative mass, and also the extragastric cavity caused by the extension of a perforative process into neighboring tissues, hepatic or pancreatic. Other radiographic signs include indentation of the gastric wall opposite to the site of the ulcer, an appreciable six-hour residue of bismuth, and suggestive defects of shape and motility, such as antiperistalsis, delayed pyloric patency, hour-glass constriction, and a "fish-hook" contour of the entire stomach.

Gastrodiaphany, or transillumination of the stomach, requires the introduction into the stomach of a gastrodiaphane, or a soft rubber tube, to the lower end of which is attached a small incandescent lamp, which when illuminated renders the gastric outline luminous when the examination is made in a dark room. The most satisfactory results from gastrodiaphany have been secured in cases of dilatation and prolapse, but, on the whole, the method is less dependable than examination after inflation of the stomach or by means of the *x-ray*.

Palpation.—Palpation of the stomach corroborates the findings of inspection, and in addition reveals and localizes gastric pain and tenderness, tumors and thickening of the anterior wall, and succussion waves within the organ; exceptionally, the friction fremitus of a perigastritis can also be felt. In studying *gastric pain* it is help-

ful to recall Riedel's law, that left-sided pain generally is due to disease of the stomach itself, while right-sided pain is more often a reflex sign referable to lesions of other abdominal viscera, the principal exceptions to this general rule being in lesions of the pancreas and of the pylorus.

The pain of *gastritis* is more or less diffusely distributed, is usually increased by pressure and by taking food, and intermits without obvious reason. In uncomplicated *gastralgia* the pain occurs in neuralgic paroxysms which commonly radiate peripherally from a point low down in the epigastrium and are relieved both by pressure and by the taking of food. The pain of *gastric ulcer* is likely to be boring and scalding in character, sharply circumscribed to the situation of the lesion, greatly aggravated by taking food and by pressure and relieved by vomiting; a tender point to the left of the spine, between the tenth and twelfth thoracic vertebræ, is of considerable diagnostic importance (Fig. 68, p. 119). In *gastric cancer* there is usually a dull, gnawing area of pain localized at the site of the growth, reflected toward the loins and the back, and accompanied by tenderness along the six lower thoracic vertebræ; the pain of cancer is subject to frequent periods of quiescence and to paroxysmal exacerbations of a gastralgic form. Other important gastric factors of pain in the region of the stomach include simple irritation of the organ, atonic dyspepsia, hyperchlorhydria, gastrectasis, and gastroptosis. It is also to be noted that pain of gastric origin may be simulated by pneumonia, pleurisy, pericarditis, spinal caries, Addison's disease, locomotor ataxia, and inflammatory lesions of neighboring abdominal organs.

Tumors of the stomach are most frequently found at the pylorus, either at its normal site or lower down, owing to the associated changes in the size and position of the organ. Such tumors are generally carcinomatous, the pylorus being the favorite seat of this type of neoplasm, and may be either freely movable or firmly anchored, depending upon the extent to which they are bound down by adhesions. Neoplasms of the greater curvature may be palpable in the hypogastrium or in either hypochondrium; growths of the anterior wall are made more prominent and those of the posterior wall are obscured when the stomach is distended. Riegel emphasizes the importance of distinguishing a tumor of the lesser curvature from the pancreas, which in the subject with a thin, relaxed abdominal wall occasionally is palpable through the empty stomach, or above it, if the organ be displaced. Inflation, however, will settle such a doubt by hiding the pancreas and by clearly localizing a gastric tumor. Ewald points

out that in various forms of gastritis the inflammatory swelling of a gastric lymph-node forms a small movable tumor at the middle of the greater curvature. Hypertrophic fibrosis of the pylorus, local thickening of the anterior wall, nephroptosis, fecal masses, and small epigastric hernias are other abdominal swellings which are to be distinguished from tumors of the stomach itself.

Succussion sounds, which simply mean that the stomach contains air and fluid, are elicited bimanually, with one hand supporting the subject's flank or back and the other sharply pushing or tapping the abdomen over the lower gastric area. Since identical sounds are also produced in the colon, it may be necessary, in the doubtful case, to empty either the stomach or the gut as a differential procedure. Gastric splashing is physiologic when detected within the normal boundaries of the stomach and at the time this viscus should contain food. It is pathologic when elicited at the time the stomach should be empty, or when it occurs well beyond the normal gastric borders. The demonstration of succussion splashing three or four hours after the patient has eaten suggests gastric atony or motor inadequacy; and the presence of this sign outside the normal limits of the stomach (especially below the navel) is strongly indicative of the organ's enlargement or dislocation.

Here may be mentioned *Stiller's sign*—undue mobility of the tenth rib—which is a frequent accompaniment of gastro-enteroptosis, with or without gastric atony and nervous dyspepsia.

The Use of the Stomach-tube.—This instrument is employed in securing the gastric contents for analysis; in the process of therapeutic lavage; in rapidly emptying and cleansing the stomach and introducing antidotes in poison cases; and as a substitute for the esophageal bougie in exploring the gullet. Under the first-named circumstance the gastric contents should be withdrawn by passing the tube upon the expiration of a definite interval after the patient has eaten a standard test-meal—one hour after the “roll and tea breakfast”¹ of Ewald-Boas, or four hours after the test-meal of Riegel.² The specimen withdrawn at this time is measured, inspected for naked-eye changes, tested chemically, and examined microscopically. The technic of these procedures, which is not germane to the plan of this work, may be found in text-books on Clinical Laboratory Methods.

¹ One dry roll (40 gm.) and a cup (400 cc.) of clear tea.

² One dry roll (40 gm.), boiled lean meat (200 gm.), one plate of gruel soup (400 cc.), and one glass of water (200 cc.).

The stomach-tube, made of soft rubber, measures about 3 feet (90 cm.) in length and $\frac{1}{8}$ inch (8 mm.) in diameter, having at the lower extremity a double fenestration and at the upper a funneled expansion; a circle of white rubber inlaid at a point 22 inches (55 cm.) from the gastric end of the tube should be flush with the subject's incisor teeth when the instrument is introduced far enough to reach the stomach. Before using it is well to warm the tube by placing it in hot water, and to lubricate its tip by smearing it with a few drops of glycerin. When there is reason to anticipate obstinate choking or other interference with the introduction of the tube, preliminary spraying of the posterior pharynx with a 2 per cent. eucain solution is a useful preventive step. The patient, seated with the head bent forward, the mouth open, and the tongue unprotruded, is instructed to breathe deeply and regularly, whereupon the tube is quickly slipped backward along the posterior pharynx and down into the esophagus, at the entrance to which a muscular contraction usually arrests the instrument. This obstruction is but temporary, however, and may be overcome without much difficulty by making the patient swallow and take very deep breaths; when freed, the tube is quickly pushed down until it has entered the stomach. The patient now bends forward and strains as in defecation or retches as in vomiting, with the result that the stomach contents begin to trickle from the funnel end of the tube, which should drain into a perfectly clean receptacle. A sluggish flow may be overcome by "milking" the tube or, preferably, by aspirating into a Potain vacuum bottle. Tubes equipped with a bulb should not be used, for sanitary reasons. After the stomach has been thus emptied lavage is to be given, by pouring in and siphoning out sterile water, until the washings return clear.

Having finished the above procedures, the tube is removed by a continuous sweep of the examiner's arm, the head of the patient meanwhile being turned slightly in the opposite direction.

The use of the stomach-tube is absolutely interdicted in angina pectoris, thoracic aneurism, advanced cardiovascular disease, and recent hemorrhage from any source, since in any of these conditions the stress of the operation may be perilous; it is to be used most cautiously, if at all, in the pregnant woman, in markedly cachectic and enfeebled persons, and in those suffering from active bronchopulmonary lesions. A suspicion of esophageal diverticulum or of ulcer or cancer of the gullet or stomach calls for great care in tubing the patient, for fear of mechanically injuring the parts.

Percussion.—To map out by percussion the tympanitic area of an empty normal stomach is out of the question, since in this state the organ recedes beneath the left dome of the diaphragm. This being the case, the zone of tympany directly below the liver must be due to the transverse colon, which rises into the space created beneath the anterior abdominal wall by the recession of the contracted stomach.

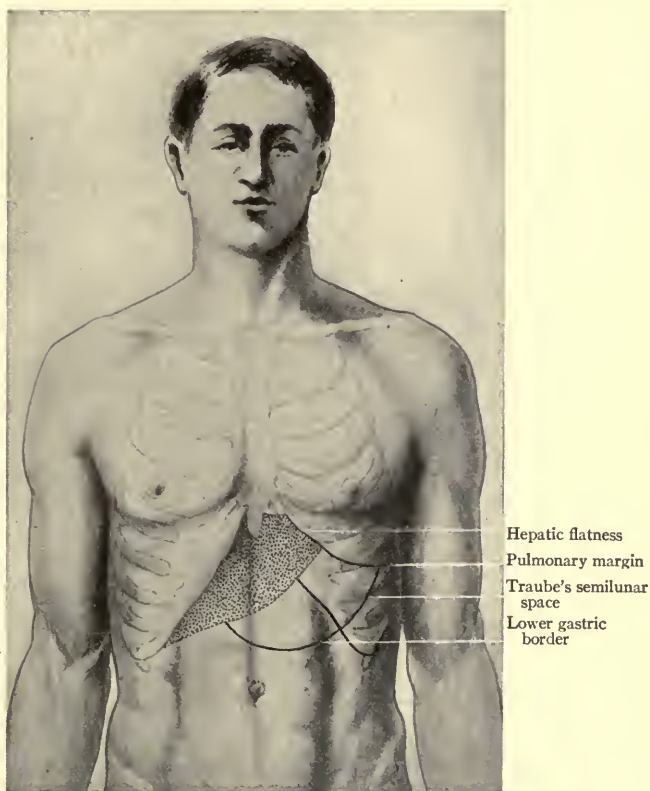


Fig. 208.—Percussion area of gastric tympany.

Nor can the lower border of the undistended stomach be accurately delimited by percussion, owing to its curving backward away from the abdominal parietes.

In the moderately distended stomach, however, a fairly accurate region of pure gastric tympany can be plotted out by the trained examiner. The following boundaries refer to the tympanitic region

delimited with the subject in the dorsal decubitus: *upper border*, fifth interspace in the left parasternal and midclavicular lines; *lower border*, 2 or 3 inches (5 to 7.5 cm.) above the umbilicus in the median line and ninth costal cartilage at the left costal margin; *right border*, 2 inches (5 cm.) to the right of the median line; and *left border*, seventh interspace in the left anterior axillary line. These boundaries are necessarily only approximate, owing to the wide variations in the size, mobility, and distensibility of the stomach in different individuals.

Traube's semilunar space, normally affording pure gastric tympany, corresponds to that part of the anterior wall of the stomach lying directly beneath the costal parietes (Fig. 208). It is bounded above by the left lobe of the liver and the lower border of the left lung; below and internally, by the left costal margin; and externally, by the anterior border of the spleen. The tympany of this area is encroached upon by flatness from above in left pleural effusion, massive pericardial effusion, and great enlargement of the heart, and the right and left lateral boundaries are similarly affected by enlargement of the liver and of the spleen. Extensive left basal pneumonia impairs, and left pneumothorax apparently extends, the upper (pulmonary) limit of Traube's space.

In delimiting the upper border percussion should be continued from below upward until alterations in the tympany indicate the margins of the lung, the liver, and the spleen; the deep-seated fundus of the stomach may yield a muffled tympany, but only exceptionally is it recognizable by ordinary percussion methods. To facilitate mapping out the lower border, the patient, standing erect, is instructed to swallow, in several tumblerful draughts, about a quart of water, with the result that a flat zone, corresponding to the lowest part of the organ, will be produced by the ingested fluid. This flatness increases vertically as the subject swallows additional fluid, it decreases after the stomach is emptied with the stomach-tube, and it shifts or disappears as the patient changes posture. This hydrostatic test is essential in distinguishing gastric and intestinal tympany when each viscus contains air, for unless their contents differ (*i. e.*, unless one contains air and the other liquid or solid matter) their percussion notes are so similar as to defy differentiation.

In practising *auscultatory percussion* of the stomach the chest-piece of a binaural stethoscope is placed at or near the site of the pylorus, and light percussion begun at several points well beyond the limits

of the stomach and continued toward the viscus, which when reached is betrayed by a higher pitched, more intense, and purer note. A line connecting the points at which these changes of note occur obviously corresponds to the outline of the organ. The auscultatory percussion tone over a tumor of the anterior wall of the stomach sounds much less resonant and less intense than the note elicited over the healthy part of the organ.

Stroke auscultation, which substitutes a gentle stroking of the surface with the finger tips for actual percussion, is employed for the same purposes as auscultatory percussion, to which it is decidedly inferior as a method of research.

Increase of Gastric Tympany.—Enlargement of the area of gastric tympany may be symptomatic of gaseous distention, pathologic dilatation, or dislocation of the stomach, and in all of these conditions the increase is chiefly in a downward direction. A horizontal extension of tympany, especially of the right border, means dilatation of the pyloric region with deficient motor power (Michaelis). Several extrinsic factors of increased gastric tympany are also to be recalled—wasting of the anterior abdominal parietes, contraction of the left lobe of the liver, retraction and emphysema of the left lung, left pneumothorax, and perigastric adhesions, causing downward and forward traction of the stomach.

Decrease of Gastric Tympany.—The area of epigastric tympany is symmetrically contracted when actual atrophy of the stomach exists, as in cirrhosis ventriculi and in cancer or other stenotic lesions of the cardia. The restriction tympany in Traube's semilunar space has been alluded to in a preceding paragraph.

Auscultation.—The *deglutition murmur* is the most important single finding afforded by this seldom-used method of examining the stomach. It is audible over the cardia, usually as a double sound, and is elicited by auscultating while the patient swallows a mouthful of water. Normally, the primary murmur (esophageal) is heard about six seconds after the act of deglutition, and the secondary (gastric) sound, some four or five seconds later. The absence of these two murmurs has been noted in stenosis of the gullet and in enfeeblement of the muscularis of this tube. Brenner describes a *metallic rub* audible in the region of the diaphragm in cases of perforation of the stomach.

Other sounds audible over the gastric area include *succussion sounds* (described above), *gurgling* arising within a dilated or displaced stomach, *effervescence* of fermenting gastric contents, *reso-*

nant echoes of the heart sounds and of bronchopulmonary *râles*, and *breath sounds* transmitted and amplified by a tensely distended stomach.

EXAMINATION OF THE INTESTINES

Clinical Anatomy.—The intestinal canal consists of two principal divisions, small and large, the former being a highly convoluted and compact central mass of gut, and the latter a stretch of larger caliber and of less twisted contour. The greater part of the intestines is covered by the great omentum which hangs, curtain-like, from the lower gastric curvature to the lower part of the hypogastric region.

The *small intestine*, some 22 to 24 feet (6.6 to 7 m.) long, occupies chiefly the umbilical, lumbar, and hypogastric regions, and stretches from the pyloric end of the stomach to the ileocecal valve, its lumen gradually diminishing from 2 inches (5 cm.) in diameter at the first point to 1 inch (2.5 cm.) at the second. The *duodenum*, or the first 10 inches (25 cm.) of the small gut, runs a C-shaped course from the pylorus to the jejunum, and lies almost entirely to the right of the median line of the belly, occupying the lower epigastrium and the upper umbilical region. The first (upper) part of the duodenum is behind the eighth right costal cartilage just to the left of the gall-bladder; the second (descending) part courses vertically from the gall-bladder along the downward projection of the right midclavicular line, in front of the right kidney, to the level of the third or fourth lumbar vertebra; the third (lower) part runs obliquely upward from this point to the left of the second or third lumbar vertebra, where it twists forward to form the *duodenojejunal flexure* whose surface marking corresponds to a point 1 inch (2.5 cm.) to the left of the linea alba in the transpyloric line. Clinically, it is important to know that the duodenum encircles the head of the pancreas; that it lies in close relation posteriorly with the portal vein, common bile-duct, right kidney, and inferior vena cava, and anteriorly with the liver, gall-bladder, and transverse colon; that it is comparatively immobile, being securely anchored to the posterior abdominal wall. The *jejunum*, which includes the next 8 feet (2.15 m.) of the small gut, lies chiefly in the upper umbilical area and in the neighboring regions to the left, while the *ileum*, forming the terminal 12 feet (3.6 m.) of the tube, lies below and to the right. On their course toward the pelvis the coils of the small intestine cover the ascending and descending colon and occupy the greater portion of the umbilical, lumbar, and hypogastric areas.

The small gut is so exceedingly mobile that the above regional arrangement must necessarily be only approximate.

The *large intestine*, which is approximately 5 feet (1.8 m.) in length, bounds the small gut and extends from the ileocecal valve to the anus, its three main divisions being the cecum, the colon, and the rectum. The *cecum*, a superficial wide cul-de-sac of the large gut, is in the right iliac fossa below the *ileocecal valve*, whose

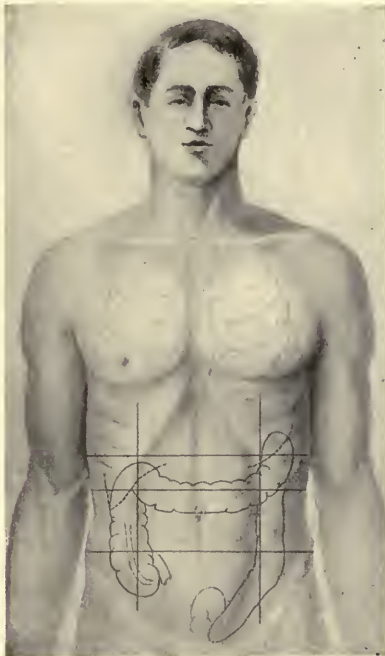


Fig. 209.—Surface topography of the large intestine.

location corresponds to a point on the anterior abdominal wall 1 inch (2.5 cm.) below the middle of a line from the anterior superior iliac spine to the navel. The *vermiform appendix* springs from the posterolateral surface of the cecum, and may stretch some 3 or 4 inches (7.5 to 10 cm.) in length behind the ileum, toward the pelvic brim, or back of the ascending colon (Fig. 209a). The orifice of the appendix (at Clado's point) lies about 1 inch (2.5 cm.) below the ileocecal valve. (Cf. p. 519.)

Of the three parts of the *colon*, the first or *ascending* passes upward from the cecum to the under surface of the right costal arch, where below the liver it bends sharply to the left to form the *hepatic flexure*. From this point the *transverse* portion, more or less in the form of a U-shaped tube, loops across the umbilical region to the left costal arch beneath which it twists upward, backward, and to the



Fig. 209a.—Radiograph of the vermiform appendix and part of the large intestine. (Plate by Dr. W. F. Manges.)

left as the *splenic flexure*, below the spleen and behind the stomach, and at a higher level than that of the hepatic flexure. The *descending* portion of the colon runs down the left side of the abdomen from the splenic flexure to the iliac crest, where, as the *sigmoid flexure* (or iliac and pelvic colon), the gut extends through the pelvis to the *rectum*, which it joins opposite the third segment of the sacrum.

Inspection and Palpation.—The technic and general results of these methods have been dealt with under Examination of the Abdomen. (See pp. 500, 501.) Applied to lesions of the bowel, combined inspection and palpation is the most satisfactory means of detecting obstruction, dislocation, and circumscribed dilatation of the intestines, and tumors, malignant, inflammatory, or fecal.

X-ray examination of the large intestine gives additional information of value, and defines with great clearness the patency

of the ileocecal valve and the state of the colon and the lower portions of the large bowel. In connection with serial radiography following the ingestion of a bismuth meal (see p. 524), one or two plates are exposed after the rectal injection of a barium clyster. Cole recommends for this purpose 3 ounces (85 gm.) of barium sulphate dissolved in 50 ounces ($1\frac{1}{2}$ liters) of warm water; or about 34 ounces (1 liter) of warm water containing 5 parts of barium sulphate and 12 parts of mucilage of acacia may be used. The enema is instilled slowly by gravity through a rectal tube, and

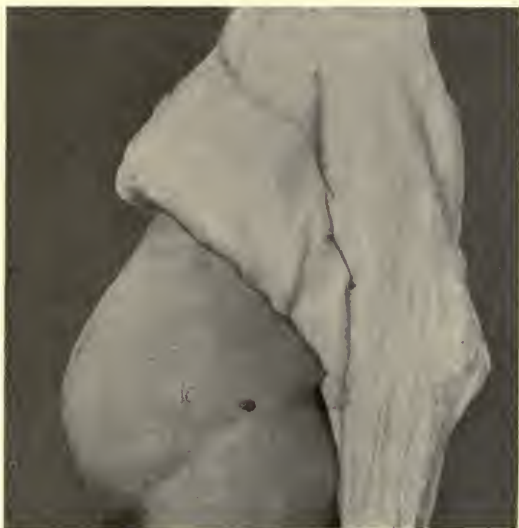

Fig. 210.—Abdominal distention due to dilatation of the small intestine (Jefferson Hospital).

should be retained by the patient until the plates have been exposed.

Intestinal obstruction, leading to meteorism of the gut above the site of the stricture, causes distention of the abdomen varying in appearance according to the part of the bowel implicated. The general statement holds true, that the more remote from the duodenum the seat of the obstruction the greater the degree of distention. In stenosis near the *ileocecal valve* (the favorite site of intussusception) the brunt of the distention falls upon the small intestine whose coils balloon the central part of the abdomen (Fig. 210), where, in the thin-bellied subject, they are visible as a series of transverse parallel ridges showing exaggerated peristalsis and paroxysms of

tetanic contraction—the so-called “organ pipe” arrangement of the intestinal loops. To the touch the latter feel stiff and rigid one

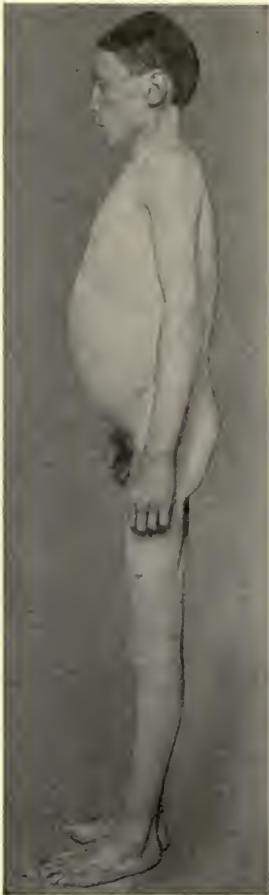

Fig. 211.—Abdominal distention due to dilatation of the colon (Jefferson Hospital).

moment, but gaseous, fluctuating, or pultaceous the next, when the spasm temporarily ceases, with a gurgling sound as the tension lessens. At the site of the stricture, in the right iliac fossa, an elongated cylindrical tumor sometimes may be felt. In stenosis near the *sigmoid* (where volvulus is so prone to occur) this portion of the large intestine and the descending colon become distended to an extraordinary degree, usually first bulging the left iliac and hypogastric regions, but eventually distending the greater part of the abdomen, the tympanitic gut often taking the form of a huge inflated crescent, with its convexity toward the right loin and its concavity encircling the navel. Distention of other portions of the colon is recognized by the presence of a cylindrical swelling corresponding to the superficial course of this part of the intestinal tract. In localizing the seat of a stenosis of the colon, percussion (*q. v.*) may be of assistance. Inflation of the intestines with air and their distention with water also are of value as a means of determining the site of an intestinal obstruction. If 6 quarts of water can be introduced with a fountain syringe, there is no obstruction in the large intestine; if less than

4 quarts can be injected, there is probably obstruction in the large intestine (J. Chalmers Da Costa).

So-called *idiopathic dilatation of the colon* leads to enormous distention of the large bowel, especially near the sigmoid flexure, whence the dilatation tends to spread upward. In such instances there is remarkable abdominal enlargement with universal tympany extend-

ing so high as to obscure the areas of hepatic and splenic dulness (Fig. 211).

Coloptosis, or downward displacement of the colon, implicates chiefly the transverse portion, the abnormal outlines of which are readily seen after the gut has been inflated with air. Commonly a dislocated colon sags downward as a V-shaped tube, whose convexity lies well below the navel; sometimes, by traction on the splenic and hepatic flexures, it causes stenosis at these points, and consequently may lead to obstruction of the large bowel. Coloptosis rarely exists without gastropnoxis and is often a part of the universal dislocation of the abdominal viscera in Glénard's disease. Ptosis of the *small intestine* doubtless can take place, though it is not evidenced by any distinctive physical signs.

Fecal impaction, which is frequently found in the colon, forms an elongated and freely movable gut-shaped tumor, either of stony hardness or of mushy consistence, more commonly the former. Such a mass, should it persist after free purgation, must be differentiated from malignant disease of the intestine by a detailed physical examination and by a critical analysis of the accompanying symptoms. During the course of *enteric fever* a soft sausage-shaped mass in the right iliac fossa may betray intestinal hemorrhage, concealed by reason of a parietic ileum; gurgling in this situation is in nowise distinctive of typhoid—it simply means fluid and gas within the gut. *Appendical thickening* or *abscess* may account for a more or less well-defined tender mass near McBurney's point, provided that palpation is not interfered with by the board-like muscular rigidity of an associated peritonitis.

In *chronic appendicitis* Bassler's method of pinching the appendix at a point midway between the umbilicus and the right anterior superior iliac spine causes acute tenderness. It is performed by passing the tip of the thumb, held vertically and pointing toward the ensiform, into the abdominal wall at the point indicated, and then swinging it to the right so as to pinch the appendix against the iliacus muscle and thus to produce sharp pain. Exquisite tenderness and pain is produced at McBurney's point in chronic appendicitis by distending the colon with air by means of a rectal tube and pump (*Bastedo's sign*).

Pericolitis sinistra, an inflammation of the lower part of the descending colon, surrounding connective tissue, and peritoneum, is comparable clinically to appendicitis, except for its situation in the lower left abdomen. In typical cases palpation reveals tenderness, great muscular rigidity, and an elongated tumor in the sigmoid region, the associated symptoms pointing to local peritonitis, circumscribed

abscess, or general peritonitis. Obstinate constipation and acquired diverticula of the colon are the two most common underlying causes of this type of colonic inflammation.

Malignant disease is especially prone to implicate the rectum, the large bowel at or near the sigmoid, hepatic, or splenic flexures, and the duodenum. When it invades a portion within reach of palpation a roughly spherical or ovoid tumor is felt, whose consistence is generally hard and resistant, and whose shape is unalterable by manipulation, differing in this particular from a fecal tumor, which sometimes can be pitted, dented, and otherwise molded by firmly pressing it between the fingers. The mobility of the tumor depends upon its situation and upon the firmness with which it is anchored by inflammatory adhesions. Speaking broadly, cancer of the sigmoid and of the cecum are fixed, while cancer of the small intestine is relatively movable. When obstruction exists above the growth, as eventually is the case sooner or later, a circumscribed dilatation of the gut occurs directly above the stricture; this pocket, alternately distending with feces and collapsing when its contents are expelled, is responsible for puzzling changes in the size and the shape of the tumor, which even may quite disappear for days at a time. In cancer of the rectum visual examination with the proctoscope plus digital exploration may explain the reason for the unbearable sacral pain and acute tenesmus from which the patient suffers.

Aside from the presence of a circumscribed tumor, most cases of malignant disease of the bowel are attended by symptoms of obstruction and by emaciation and cachexia. In perhaps the majority of instances enlargement of the mesenteric glands and of the superficial lymphatics corroborates the other findings.

Percussion.—Percussion of the intestines is useful chiefly in confirming the findings of palpation, in conditions such as those just mentioned.

Percussion over the empty *colon* elicits a tympanitic note of higher pitch, somewhat less volume, and shorter duration than is found over the stomach. The note over the *small intestine* is also tympanitic, and of still higher pitch, less volume, and less drum-like quality. By ordinary percussion these acoustic differences are not sufficiently marked to serve as reliable criteria in mapping out the different parts of the gastro-intestinal tract, but they are appreciable by auscultatory percussion or, perhaps better, by ordinary percussion after distention of the colon with air. This is accomplished by rectal inflation with a Davidson syringe, after having emptied the large bowel by an enema. Ziemssen's method of ballooning the colon with carbonic acid gas is scarcely to be advised as a routine procedure. The presence

of feces within the intestines, of course, modifies the above findings; especially in the right iliac region and left flank is the sound likely to be dull, since it is in the cecum and sigmoid that fecal matter tends to accumulate. Impacted feces in the hepatic and splenic flexures may account for undue extension of the hepatic, splenic, and renal areas of flatness.

In *intestinal obstruction* percussion of the upper lumbar regions is of service in localizing the seat of the stenosis. A loud, deep percussion sound (dull tympany) is found here on both sides of the spine in stenosis of the descending colon and sigmoid, and on the right side only in stenosis of the transverse colon and splenic flexure (Nothnagel).

Auscultation.—Auscultation of the intestines is seldom employed, except in connection with percussion, to delimit different segments of the intestinal canal and to detect solid tumors thereof. Like the stomach, the intestines afford various splashing, gurgling, and hissing sounds generated by the movements of fluid and gas, and, according to Sahli, a somewhat distinctive sizzling or whistling noise is occasionally heard over an intestinal stricture through which gas and fluid may be forced by peristalsis, so as to give rise to audible and perhaps to palpable vibrations. The presence of a distinct splashing sound just above the point of obstruction is significant of ileus.

EXAMINATION OF THE LIVER AND GALL-BLADDER

Clinical Anatomy.—Topographically, the liver is comparable to a wedge driven from right to left across the upper zone of the abdomen directly beneath the diaphragm, quite three-fourths of the organ's bulk lying to the right of the median line of the trunk. In the adult the base of the hepatic wedge occupies the right hypochondrium, the middle portion fills the upper epigastrium, and the sharp convexity tapers off into the left hypochondrium and projects some 2 or $2\frac{1}{2}$ inches (5 to 6.25 cm.) beyond the left sternal border in the fifth intercostal space. In the young child the liver, being disproportionately large, extends well beyond the limits of the right hypochondrium, and encroaches to the left almost as far as the spleen. The *falciform ligament* and the *longitudinal fissure* together divide the liver into two principal lobes, right and left, whose point of divergence at the inferior parietal aspect of the organ anteriorly is indicated by the *umbilical notch*. This interlobar indentation is situated in the epigastric region about 1 inch (2.5 cm.) to the right of the median line, at the level of the ninth rib. Just below and external to this point lies the *gall-bladder*,

whose surface marking corresponds to the angle between the ninth costal cartilage and the external border of the right rectus abdominis muscle. This pear-shaped structure, approximately 3 inches (7.5 cm.) in length, usually reaches to, if not beyond, the lower border of the liver, but its exact situation is subject to considerable variation, especially in a horizontal direction, owing to individual peculiarities and to the mobility of the liver, with which it must move. The *upper convex surface* of the liver lies beneath the vault of the diaphragm, and is anchored to this muscle and to the anterior abdominal wall by the falciform ligament, a peritoneal reflection springing from the upper hepatic border. The *lower concave surface*, grooved antero-posteriorly by the longitudinal fissure, is in relation with the stomach,

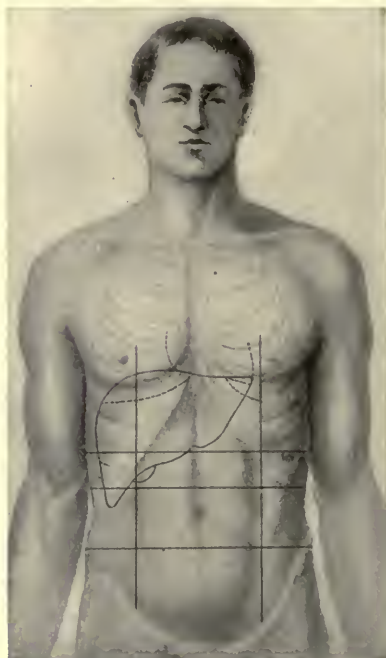


Fig. 212.—Surface topography of the liver and gall-bladder.

the hepatic flexure of the colon, and the right kidney. The *anterior surface*, thinning out into a sharp edge behind the right costal margin, and indented at its lower border by the umbilical notch, lies in contact with the anterior abdominal wall for a distance of 2 or 3 inches (5 to 7.5 cm.) below the base of the ensiform cartilage. The right *lateral* and *posterior surfaces* are in relation with the abdominal wall and the diaphragm, which separates the liver from the inner costal surfaces and the lower pulmonary edges, while behind the surface bears the impress of three intimately related structures: an esophageal groove, a vena caval fossa, and a right suprarenal impression.

The *surface topography* of the liver is represented upon the anterior and posterior walls of the thorax by a wedge-shaped area, having its apex in the left midhypochondrium and its base directed toward the right; laterally, the outline of the organ is irregularly ovoid. (Fig. 212; also Fig. 73, p. 125.) The *upper border*

is indicated by a line beginning at the upper part of the fifth left intercostal space, somewhat internal to the midclavicular line, and thence encircling the right half of the chest at the following levels: sixth chondrosternal articulation at the sternum, fourth interspace in the midclavicular line, seventh interspace in the midaxillary line, eighth rib or interspace in the scapular line, and eighth thoracic vertebra at the spine. The *lower border* passes obliquely downward and toward the right from the left extremity of the upper level, crosses the left costal margin at the eighth costal cartilage, cuts the median line about midway between the xiphisternal joint and the navel (in the transpyloric line), and reaches the right costal margin in the right Poupart (midclavicular) line; thence the lower level dips below the tip of the tenth costal cartilage, and passes backward to bridge the tenth interspace in the midaxillary line and to terminate alongside the spine at the level of the eleventh thoracic vertebra. The

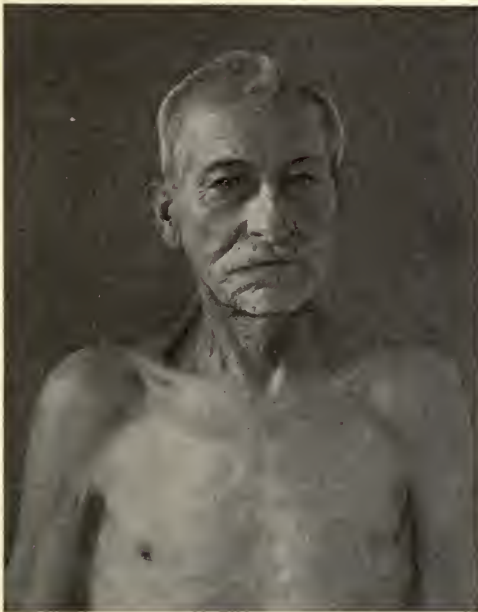


Fig. 213.—The hepatic facies (Jefferson Hospital).

upper part of the external surface of the liver is covered by the inferior edge of the right lung as far down as the sixth rib in the midclavicular line, the eighth rib in the midaxillary line, and the tenth rib in the scapular line.

Inspection.—In examining the liver, inspection is of secondary importance to palpation and percussion. A greatly enlarged liver may be shown by bulging of the lower ribs in the right hypochondrium and by fulness in the epigastrium below the right costal margin, but only exceptionally are local tumors of the organ recognizable by inspection. The transmitted impact of a hypertrophied heart may be forcible enough to jar the liver visibly, and, rarely, pulsations of the liver and of enlarged superficial veins are seen in conditions of marked venous stasis. Here also may be noted the peculiar right-sided sagging of the trunk of the patient ill of hypertrophic cirrhosis.

The *hepatic facies* (Fig. 213) of the subject of chronic affections of the liver is characterized by a muddy, sallow complexion with more or less anemic pallor, or perhaps by the typical saffron discoloration of jaundice. The conjunctivæ are similarly tinged, the eyes are watery and glistening, and beneath the skin, which is commonly wrinkled and dry, numerous distended venules may be visible, especially about the nose.

Radiographs may reveal the presence of gall-stones if the calculi are composed largely of calcium, but cholesterin stones, which but feebly absorb Röntgen rays, seldom show upon the plate.

Palpation.—Tactile sense decides the questions of hepatic tenderness, pulsation, friction, and thrills, detects extension downward of the lower border of the liver, and determines the consistence and the contour of its anterior and lower surfaces.

Tenderness and often spontaneous pain in the hepatic region are common symptoms of hepatic congestion and of various inflammatory processes, such as, for example, perihepatitis, diffuse hepatitis, acute yellow atrophy, and Hanot's cirrhosis. Or the tenderness may be due to abscess, cancer, obstructive jaundice, or fatty degeneration. Hepatic pain, it is to be remembered, is not always localized, but may be reflected upward to the right shoulder and back (Fig. 68, p. 119). Gall-bladder tenderness is commonly referred to Robson's point (*q. v. s.*). In many inflammatory conditions of the liver and the gall-bladder Bookman's maneuver is useful in eliciting acute pain in the hepatic area. This consists of forcing the umbilicus downward toward the pubis with the crooked index-finger, so as to stretch the round ligament and consequently to exert traction upon the liver and moderate downward and forward rotation of the organ.

Pulsations of the liver caused by the thrust of a hypertrophied heart are to be distinguished from those due to congestion of the hepatic venous channels. In the former the "jogging" character of the impulse, the physical signs of right ventricular hypertrophy, and the absence of tricuspid leakage are the cardinal diagnostic points;

in the latter the expansile, resilient impulse, the murmur of tricuspid insufficiency, and pulsation of the jugulars form a characteristic trinity of signs. Dynamic throbbing of the abdominal aorta also is to be differentiated from hepatic pulsation. The *friction-rub* of perihepatitis and the *thrill* elicited by palpatory percussion over a hydatid cyst have been described elsewhere. (See pp. 135 and 516.)

With complete abdominal relaxation, *enlargement* and *descent* of the liver are readily determined by palpating the upper abdominal zone, with the finger-tips pointing upward toward the hepatic area; or the bimanual method may be more satisfactory (Fig. 214). Except in the young child and in the wasted adult, it is not



Fig. 214.—Bimanual palpation of the liver.

always possible to feel the sharp lower border of the normal liver below the right costal arch and in the epigastrium, owing to the resistance offered by the abdominal musculature and fat. With deep inspiration an enlarged or a depressed liver is felt to descend and with expiration to ascend, this respiratory movement being a valuable point of distinction between hepatic enlargements and intra-abdominal tumors not connected with the liver, and hence fixed during respiration. A rigid right rectus muscle must always be considered as a possible counterfeit of a neoplasm of the right lobe of the liver. In enlargements of the liver it is important to find the umbilical notch, on either side of which lie the right and the left lobes (see p. 539).

In the presence of ascites or of meteorism it may be impossible to feel the lower edge of the liver, although it extends far below

the margin of the ribs. In the former condition "dipping" (p. 501) should be tried or aspiration may be necessary to drain off the interposed fluid; in the latter the liver may sometimes be felt by Glénard's method—strong pressure with the fingers of the left hand upon the right lumbar region and palpation with the left thumb below the right costal margin, meanwhile exerting deep rotary pressure with the right hand across the upper abdomen, the lumbar pressure forcing the liver down and the abdominal pressure pushing the intestine away from the belly wall and up beneath the liver, so that it may be felt by the examiner's thumb (Fig. 215).

The *consistence* and the *contour* of the liver, which vary greatly in

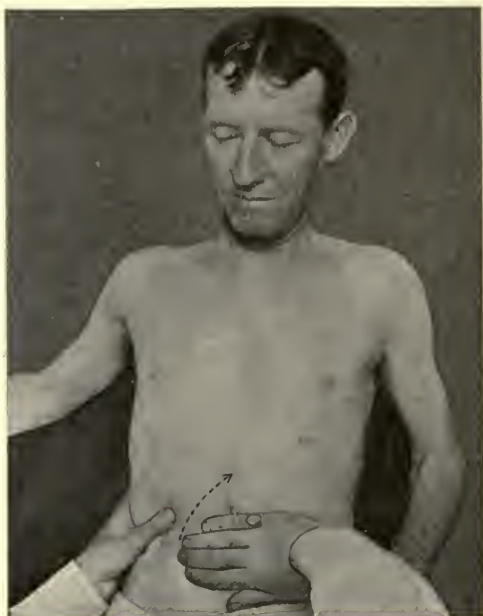

Fig. 215.—Glénard's method of palpating the liver.

different pathologic conditions, are sometimes characteristic of certain lesions causing hepatic enlargement. The consistence of the liver may be dense, yielding, or fluctuating; its surface, smooth, rough, or nodular; and its contour, furrowed, notched, or lobulated.

In amyloid disease the texture of the liver feels dense and unyielding, its surface is uniformly smooth and even, and its lower border is blunt and rounded. Increased hardness of the liver may also result from cirrhosis, cancer, syphilitic hepatitis or capsulitis, and leukemic

infiltration. A local resilient, perhaps fluctuating, area elevated above the surface of the organ, suggests circumscribed abscess, hydatid cyst, or gumma.

The contour is regular and the surface unroughened in the amyloid, fatty, cyanotic, and leukemic livers; in diffuse non-purulent hepatitis and in generalized abscess; and in the enlargements associated with febrile states, biliary obstruction, pseudoleukemic anemia, Banti's disease, and other primary anemias. In Hanot's cirrhosis the surface of the liver is generally smooth or but little roughened. It is rough, nodular, or lobulated in atrophic and syphilitic cirrhotoses, in cancer, and in deformity due to local constriction. In so-called *corset-liver* there may be a more or less oval projection of the right lobe extending downward several inches below the infracostal line, or in the extreme instance, as far as the level of the umbilicus. A slender tongue-like extension of the liver below the right costal border (*Riedel's lobe*) is occasionally appreciable in cholelithiasis attended by great enlargement of the gall-bladder.

A normal *gall-bladder*, unless distended with bile, is not palpable, but when enlarged it may produce a circumscribed globular bulging just below the right costal margin, or lower, if the distention be sufficient greatly to elongate the organ, the dimensions of which occasionally are most extraordinary. Exceptionally, the gall-bladder enlarges in an upward direction and is, therefore, impalpable. When filled with calculi, a crunching gall-stone crepitus can sometimes be felt.

Percussion.—By percussion one is able to decide, by mapping out the boundaries of the hepatic area, whether the size of the liver is normal, increased, or diminished, and whether the organ is displaced either upward or downward. Both ordinary and auscultatory percussion are useful in the examination of the liver, the latter method being especially adapted to the localization of solid tumors.

The vertical surface measurement of the hepatic area is about 4 inches (10 cm.) in the median and midclavicular lines, 6 inches (15 cm.) in the midaxillary line, and 3 inches (7.5 cm.) in the scapular line. These figures, which refer to the average healthy adult, are somewhat less in extreme old age and in the deep-chested subject; in the young child the surface area of the liver is relatively more extensive than in the adult.

The Areas of Hepatic Dulness and Flatness.—The liver, like the heart, presents two different percussion zones, which may be conveniently designated as hepatic dulness and as hepatic flatness (Fig. 216). The area of hepatic dulness, corresponding to that part of the upper right lobe separated from the chest wall by

the lower pulmonary margin, affords, on forcible percussion, a dulness tempered by the resonant quality of the intervening vesicular structure. The area of hepatic flatness, situated below the preceding and overlying that part of the organ directly in contact with the inner costal wall, is elicited by percussion of moderate force, and yields no trace of pulmonary resonance, the sound thereover being unqualifiedly flat and high pitched.

To determine the upper limit of *hepatic dulness*, the right side of

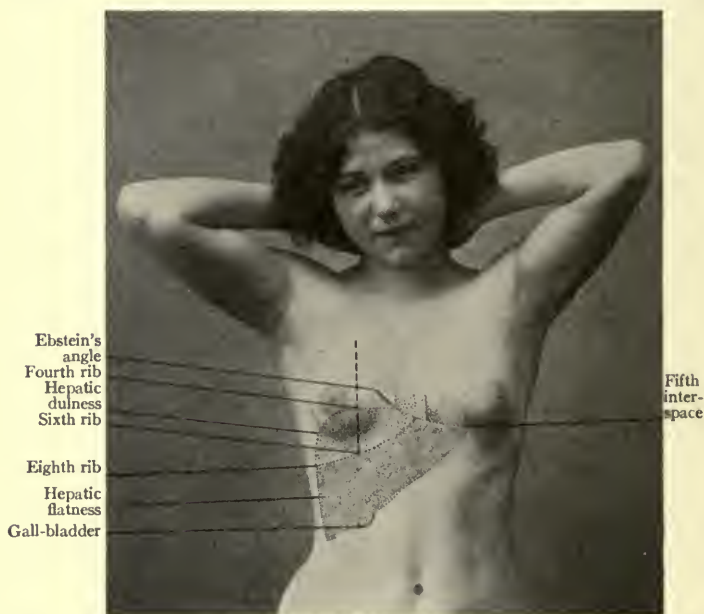


Fig. 216.—Percussion areas of hepatic dulness and flatness.

the chest is percussed from above downward, beginning at a level sufficiently high to demonstrate, for the sake of comparison, pure vesicular resonance. Carrying the percussion lines vertically downward from the second or third interspace, in the right midclavicular line the pulmonary resonance becomes modified and obviously impaired as the fourth interspace is crossed; in the midaxillary line this change is noted at the seventh interspace, and in the scapular line, at the eighth interspace. Having thus delimited the upper border of the hepatic area, percussion is continued downward along the three lines just indicated, until the level of hepatic flatness is reached at the sixth, eighth, and tenth ribs in the midclavicular,

midaxillary, and scapular lines, respectively. The dull region bounded by the horizontal limits thus mapped out represents the area of hepatic dulness. The area of *hepatic flatness* extends downward in the midclavicular line to the right costal margin, in the midaxillary line to the tenth intercostal space, and in the scapular line it cannot be distinguished from the flatness of the right kidney with which it is continuous. In the epigastrium hepatic flatness extends downward in the median line for a distance of about 3 inches (7.5 cm.) below the xiphoid. As already pointed out, it is impracticable to delimit the hepatic and cardiac flatness at their junction near the sixth left chondrosternal articulation. In mapping out the lower border of the liver anterolaterally, two fallacies must be avoided: the predominant tympany of the gut and stomach, and the dull overtone arising from the abdominal musculature. To minimize these two sources of error, the thin lower margin of the liver should be percussed very gently, so that the flat hepatic sound may not be masked by loud tympany on the one hand, or be blended with muscle dulness on the other.

A normal gall-bladder lies beyond the reach of percussion, but when enlarged it affords flatness continuous with that of the liver, unless, as sometimes happens, a coil of gut has become pushed in between the two, so as to separate them by a transverse band of tympany.

Enlargement of the liver is indicated by lengthening of the vertical lines of the hepatic area with a palpable tumor below the right costal margin, a general increase in the hepatic volume being met with in circulatory disturbances and in structural lesions of the organ, in biliary obstruction, in certain of the primary anemias, and in various diseases of the blood. Thus, the liver is unnaturally enlarged in active and passive congestion, acute hepatitis, Hanot's cirrhosis, syphilis, fatty infiltration, amyloid disease, abscess, solid tumors, and cysts; in obstruction of the bile-ducts and in Weil's disease; and in leukemia, Banti's disease, kala-azar, trypanosomiasis, malarial fever, enteric fever, and relapsing fever. A fictitious enlargement of the liver may be produced by the basal dulness of right pleural effusion or of extensive croupous pneumonia. Subphrenic abscess may have the same effect, and, should an anterior intraperitoneal abscess form, there may be, in addition to increase in the hepatic area vertically, a triangular bulging, fluctuating, flat area lying, base downward, between the median line, the lower border of the liver, and the left costal arch.

Decrease in the size of the liver accompanies acute yellow atrophy, as well as advanced Laennec's cirrhosis, in which conditions the recession of the organ from the parietes leaves a space filled with coils of gut whose loud tympany may entirely obliterate

ate every vestige of hepatic flatness. True hepatic atrophy must be carefully distinguished from simulated decrease in the size of the liver due to certain intrathoracic and intra-abdominal factors: the upper zone of the hepatic surface area may be decidedly encroached upon by the downward extension of hyperresonance in emphysema of the right lung, or by the impingement of a pneumothoracic right pleural sac; and the lower zone may be similarly affected by a mass of tympanitic intestine crowded upward between the anterior surface of the liver and the costal parietes, or by the ascent of free gas within the peritoneal cavity.

Enlargement of the gall-bladder may be symptomatic of local hydrops, empyema, calculi, or malignant disease, and also of biliary obstruction incident to simple catarrhal inflammation, intestinal parasites, and the pressure of enlarged glands or neoplasms, as in cancer of the head of the pancreas or of the pylorus. In this connection one should recall the practical application of *Courvoisier's law*, that enlargement of the gall-bladder plus jaundice suggests biliary obstruction from malignant disease rather than from cholelithiasis of other causes.

Displacement of the liver is betrayed by unnatural elevation or depression of the horizontal hepatic levels, unattended in simple displacement by deviation from the normal vertical measurements of the hepatic area. *Upward displacement* is referable chiefly to extrahepatic factors, such as excessive subphrenic pressure, intrathoracic traction and pulmonary collapse, and paralysis of the diaphragm. Thus, the liver may be crowded far upward by the pressure of ascites, meteorism, or abdominal tumor; pulled upward by a cirrhotic, atelectatic right lung; or pushed to an unusually high level when a paralyzed diaphragm is forced upward by the unopposed action of the abdominal muscles. *Downward displacement*, which is much the commoner, is generally traceable to lesions of the thorax, the heart, or the subphrenic space; less commonly to diseases of the liver itself. An emphysematous lung, a right-sided intrapleural neoplasm or effusion of air or of fluid may exert sufficient downward pressure upon the diaphragm to depress the liver below the costal margin; and, in extreme cases, a cardiac enlargement can have the same effect. The liver may also be depressed by the weight of a pus accumulation beneath the diaphragm—subphrenic abscess. *Hepatoptosis*, or prolapse of the liver, which also drags down the hepatic surface area, may exist alone or in association with ptoses of other organs, as, for example, of the stomach (gastroptosis), of the intestines (enteroptosis), of the spleen (splenoptosis), and of the kidneys (nephroptosis). A prolapsed liver forms

a rounded, notched mass having a smooth surface in the upper abdominal region, the tumor being easily removed by bimanual manipulation, and showing a restricted respiratory rise and fall. Above the tumor, in the lower right hypochondrium, the normal area of hepatic flatness is replaced by intestinal tympany.

Auscultation.—As applied to examination of the liver and gall-bladder, auscultation is resorted to only in exceptional instances, and then in confirmation of signs otherwise obtained. For example, a soft rustling *perihepatic friction-sound* provoked by respiration is sometimes demonstrable over the right hypochondrium when the peritoneal capsule of the liver is the seat of fibrinous roughening. *Gall-bladder friction-sounds* and *gall-stone crepitations* are auscultatory findings occasionally met with in cholelithiasis, and in gall-bladder distention and displacement C. M. Cooper has noted a *sys-tolic souffle* attributable to pressure upon the epigastric artery. Caval compression may account for a *venous bruit* audible over the hepatic area, while cirrhosis of the liver is sometimes attended by *venous murmurs* heard most distinctly just below the ensiform, and due to differences in pressure within the epigastric veins and tributaries (Catti).

EXAMINATION OF THE PANCREAS

Clinical Anatomy.—The pancreas is an elongated structure about 6 inches (15 cm.) in length, shaped somewhat like a blunt hook, and lying chiefly in the epigastrium, about midway between the umbilicus and the tip of the xiphoid. The organ stretches transversely between the duodenum on the right and the spleen on the left, and corresponds anatomically to the level of the first and second lumbar vertebræ (Fig. 217). The *head* of the pancreas is enclosed by the concavity of the duodenum, and lies opposite the second lumbar vertebra; the *neck* coincides with the junction of the median line of the abdomen with the transpyloric line, just above and to the left of which lies the *body*; the *tail* extends into the left hypochondrium as far as the hilus of the spleen. Anteriorly the pancreas is covered by the stomach, transverse colon, and small intestine; posteriorly it is in relation with the common bile-duct, portal vein, inferior vena cava, aorta, left kidney, and spleen.

Physical Examination.—The normal pancreas, being so deeply seated, cannot be reached through the abdominal wall, except perhaps in the old, emaciated subject and in one whose stomach lies abnormally low; in such cases the organ occasionally is palpable as a resistant mass horizontally crossing the epigastrium. An area of increased resistance, less commonly an immobile tumor, in the

central or the right epigastric region may be felt in the event of a pancreatic enlargement, due, for example, to acute hemorrhage and inflammation, to sclerosis, or to a new growth. But only when these signs are accompanied by such symptoms as violent abdominal pain, jaundice, edema, and mydriasis after the instillation of adrenalin,

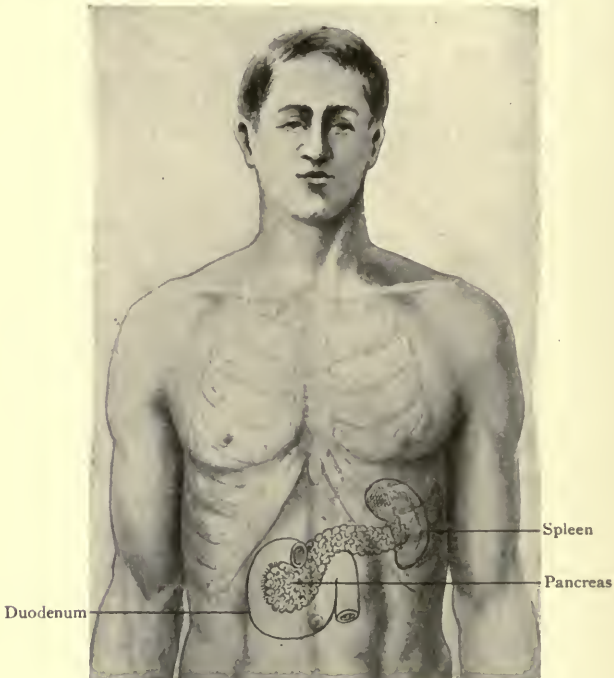


Fig. 217.—Surface topography of the pancreas.

and by such laboratory findings as fatty stools and glycosuria, is the diagnosis of a lesion of the pancreas justifiable.

EXAMINATION OF THE SPLEEN

Clinical Anatomy.—The spleen is a viscus of ovoid shape, situated in the left hypochondrium, with its long axis running obliquely downward and forward from a point $1\frac{1}{2}$ inches (3.75 cm.) from the left of the tenth thoracic spine to the tenth rib in the midaxilla (Fig. 218). The *diaphragmatic surface* is convex, and lies directly beneath the inferior surface of the diaphragm; the *gastric surface*, which is concave,

borders upon the fundus of the stomach; the *renal surface*, or the tapered upper and posterior extremity, lies in close contact with the left kidney, the percussion areas of the two organs merging; and the *intestinal surface*, notched and lying anteriorly, is in relation with the splenic flexure of the colon. The upper one-third of the spleen, being covered by the lung, pleura, and diaphragm, is beyond the reach of physical examination, but its lower two-thirds, lying immediately against the chest wall, is accessible.

Inspection.—Save in examples of extreme splenomegaly, causing conspicuous distention of the splenic area, visual examination of the spleen is of no service.

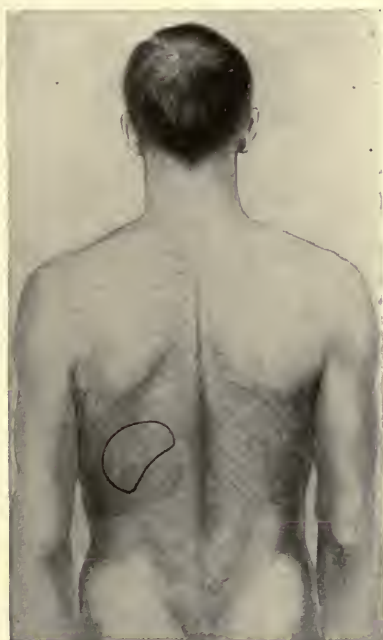

Fig. 218.—Surface topography of the spleen.

Palpation.—This, by far the most useful method of exploring the spleen, determines the important questions of tenderness and of enlargement. The patient should lie in dorsal decubitus with the abdomen relaxed, while the examiner, standing at the right of the bedside, applies the palm of his right hand to the belly wall and forcibly pushes upward with the finger-tips beneath the left costal margin, the left hand meanwhile firmly raising the patient's left loin, so as to elevate the spleen (Fig. 219). The spleen of normal

size cannot be felt beneath the costal border, but if it be even moderately enlarged, its impingement against the finger-tips with each inspiration of the patient and its recession from them with each expi-

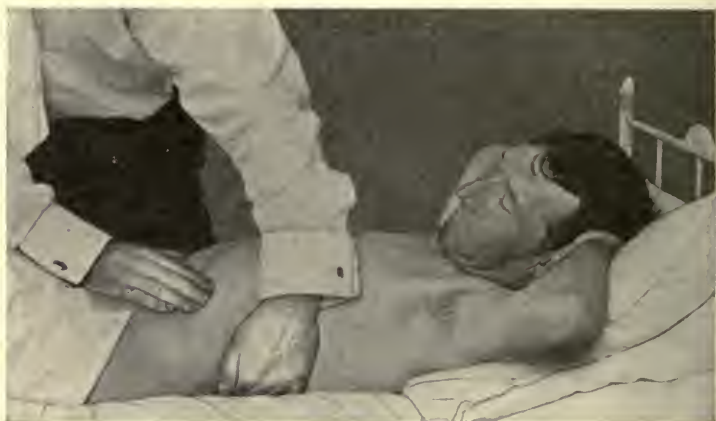

Fig. 219.—Bimanual palpation of the spleen.

ration is clearly appreciable; if decidedly enlarged, the organ is recognized as a much bulkier tumor, which moves diagonally upward and

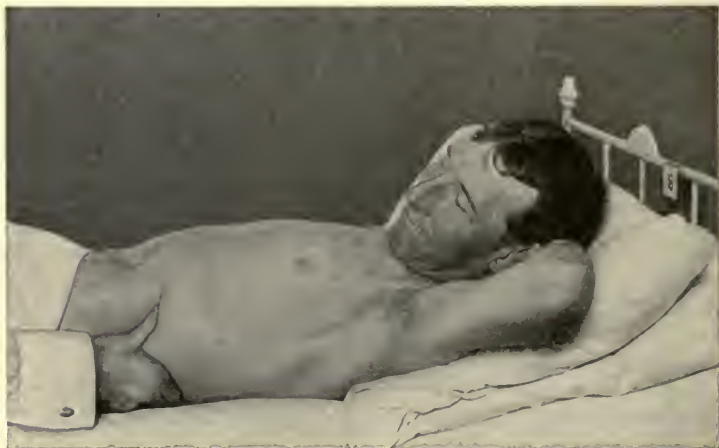

Fig. 220.—Compression-palpation of the spleen.

downward with respiration. Grasping the patient's left flank with forcible compression while the thumb feels for the organ, also is an excellent method of detecting a splenic enlargement (Fig. 220).

Tenderness and *pain* in the region of the spleen are met with in perisplenitis, and in infarction, abscess, acute congestion, and other forms of enlargement of the organ. Signorelli's *spleen point*, to which cutaneous pain is referred in inflammatory lesions of the spleen, is situated at or near the intersection of the left fifth interspace and the midclavicular line. *Pulsation* of the spleen has been described as a rare finding in Corrigan's disease.

Enlargement of the spleen, of rapid development and moderate extent, is a pertinent physical sign in various acute specific infections, of which the following are typical examples: malarial fever, relapsing fever, sepsis, typhoid fever, typhus fever, acute miliary tuberculosis, tuberculous peritonitis, erysipelas, diphtheria, variola, scarlatina, pneumonia, epidemic cerebrospinal fever, acute yellow atrophy of the liver, and Weil's disease. In trypanosomiasis and in kala-azar the organ enlarges progressively and sometimes to an extraordinary dimension. Of most of the primary anemias this is also true—myelogenous and lymphatic leukemia, Banti's disease, von Jaksch's anemia, and pernicious anemia. Amyloid disease, Hanot's cirrhosis, syphilis, rickets, acromegaly, Pick's disease, and pancreatic cirrhosis serve to illustrate chronic diseases of which moderate splenic enlargement is symptomatic, and to these may be added certain lesions inducing venous congestion, such as chronic cardiac disease, hepatic cirrhosis, and tumors causing pressure. In tumors of the spleen, such as hydatid, cancer, or lymphadenoma, and in abscess various grades of enlargement, generally of irregular contour, are encountered.

Downward displacement of the normal spleen, simulating actual enlargement, may be the result of lesions of the left thorax that exert pressure upon the upper surface of the organ, as in emphysema, pleural effusion, pneumothorax, and extensive neoplasm. *Upward displacement* of the organ is a change secondary to meteorism and ascites, and to a contracted left lung or pleura. The differentiation

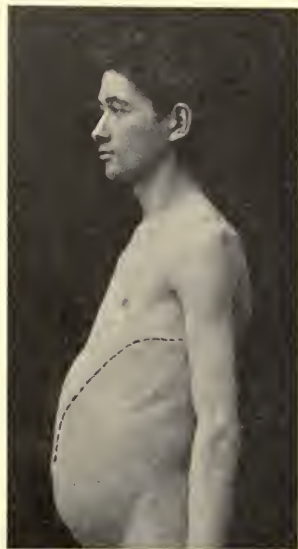

Fig. 221.—Leukemic enlargement of the spleen (Jefferson Hospital).

of splenic displacement and enlargement is based partly upon the detection of one of the above-named factors of ptosis and partly upon the delimitation of the organ's upper border by percussion.

In *splenoptosis* the spleen may sag downward as far as the umbilicus or even into the pelvis, while in the axillary region of normal splenic dulness the note is tympanitic. The dislocated organ, provided that its migration has not been complicated by inflammatory adhesions,



Fig. 222.—The area of splenic dulness.

is readily palpable as a freely movable mass, of smooth lieniform contour, of which the oval shape and notched border are the identifying marks.

Percussion.—The patient should either stand erect or lie partly upon the right side (right diagonal decubitus), with the left arm thrown across the thorax or above the head. Percussion over the anterior and inferior borders of the spleen must be very gentle, in

order to avoid the production of a dominant tympanitic tone due to the proximity of the stomach and colon. Clinically, the *splenic percussion area* corresponds to an oblong patch of dulness lying between the middle and posterior axillary lines and beneath the tenth rib, tenth interspace, and eleventh rib. This superficial surface of the spleen, unlike the corresponding cardiac and hepatic regions, affords dulness rather than true flatness, owing to its anatomic peculiarities. In defining this area, percussion is commenced in the upper left axilla and carried downward along the posterior axillary line until the pulmonary resonance changes to dulness, at the tenth rib, this point being the clinical *upper border* of the spleen. Continuing to percuss vertically downward, this dulness is replaced by tympany at the lower margin of the eleventh rib, to which level the *lower border* reaches. To find the *anterior border*, percussion is carried along the tenth rib from Traube's area toward the horizontal zone of dulness just delimited, until the note of gastric tympany changes to dulness, in the midaxillary line. The *posterior border*, which cannot be mapped out successfully, lies about $1\frac{1}{2}$ inches (3.75 cm.) to the left of the midspinal line, the upper border being at the level of the tenth thoracic vertebra and the lower margin lying next to the left kidney.

Aside from the technical difficulties inseparable from percussion of the spleen, the method must needs be more or less uncertain owing to the many extrinsic factors that may decidedly alter the size of the splenic area. The latter is *decreased* in extent by left-sided emphysema or pneumothorax, as well as by gaseous distention of the stomach or colon; and it may be *increased* in size by a long list of extrinsic causes, of which the most important are fluid or solid matter within the stomach or within the splenic flexure of the colon, consolidation or retraction of the base of the left lung, effusion within or great thickening of the left pleura, left-sided intrathoracic neoplasm, gastric cancer, and enlargement of the left kidney or of the left hepatic lobe.

In distinguishing a *splenic* from a *renal tumor*, percussion determines in the former a lieniform mass freely movable with respiration and uniformly dull from well below the left costal edge to above the upper limit of normal splenic dulness in the left axillary region; in the latter there is a subcostal reniform mass of limited motility, vertically traversed by a zone of tympany corresponding to the course of the colon, beneath which a tumor of the kidney is situated (Fig. 223). A tumor of the *fundus of the stomach*, which may be mistaken for an enlarged spleen, is localized beneath the costal arch and

fails to show the notched border, the sharp edge, and the distinctive contour of a splenic tumor. In enlarged spleen versus tumor of the *left lobe of the liver*, the latter is suggested by finding a mass continuous with hepatic dulness to the right, and one which shows neither the lieniform shape nor the ready mobility (on bimanual manipulation) of a splenic tumor; moreover, the respiratory displacement of an hepatic tumor is vertical, while that of a splenic enlargement is diagonal.



Splenic tumor.

Renal tumor.

Fig. 223.—Percussion findings in splenic and in renal tumor.

Auscultation.—A *friction-sound* over the splenic area may be symptomatic of either perisplenitis or pleurisy, for the differentiation of which other physical signs relating to the spleen and pleura are to be considered. In conditions of splenic enlargement, especially when associated with ptosis of the organ, there may be a *systolic bruit* over the spleen, due to torsion stenosis of the splenic artery (Testi). Exceptionally, a splenic systolic murmur is also audible in aortic regurgitation.

EXAMINATION OF THE KIDNEYS

Clinical Anatomy.—The kidneys, each of which measures approximately $4\frac{1}{2}$ inches (11.25 cm.) long by $2\frac{1}{2}$ inches (6.25 cm.) broad, occupy the loin on either side of the spinal column, and lie deep beneath the thick muscles of the lumbar region (Fig. 224). Topographically, the right kidney differs from the left in lying at a somewhat lower level and farther from the spine, these differences amounting to about $\frac{1}{2}$ inch (1.25 cm.). Anteriorly the kidneys lie beneath the costal borders, and extend vertically from

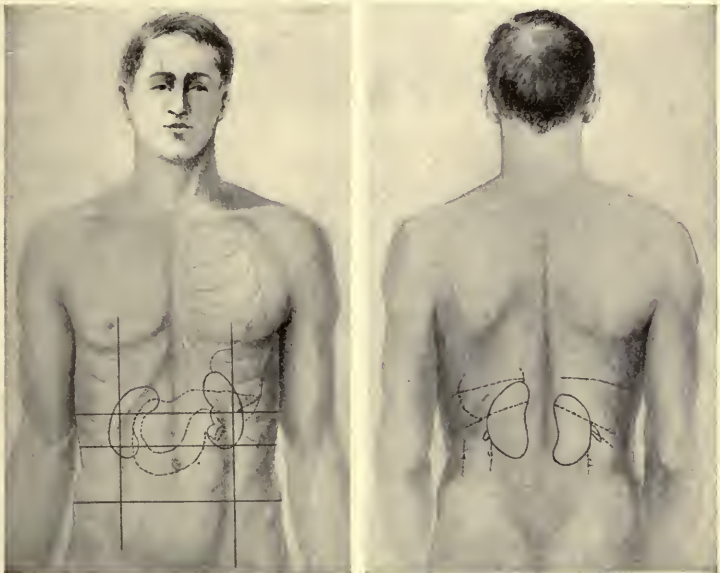


Fig. 224.—Surface topography of the kidneys.

the level of the seventh, to somewhat below that of the tenth, costal cartilage, the inner border of the right kidney being 2 inches (5 cm.), and that of the left, $1\frac{1}{2}$ inches (3.75 cm.) external to the median line. The infracostal line virtually coincides with the lower border of the left kidney, but lies well above this part of the right kidney, and the greater part of both organs is internal to Poupart's vertical lines. Posteriorly, the kidneys rest upon a dense muscular bed composed of the psoas, quadratus, transversalis, and diaphragm; they extend vertically from the eleventh thoracic to the third

lumbar vertebral spine, the lower borders being $1\frac{1}{2}$ to 2 inches (3.75–5 cm.) above the iliac crest, and the external borders lying 4 inches (10 cm.) from the midspinal line. The right kidney is in relation with the liver, the hepatic flexure of the colon, and the duodenum, and the left is adjacent to the fundus of the stomach, pancreas, spleen, jejunum, and splenic flexure of the descending colon.

Inspection.—A large renal tumor causes visible bulging of one of the lateral regions of the abdomen, the deformity being especi-

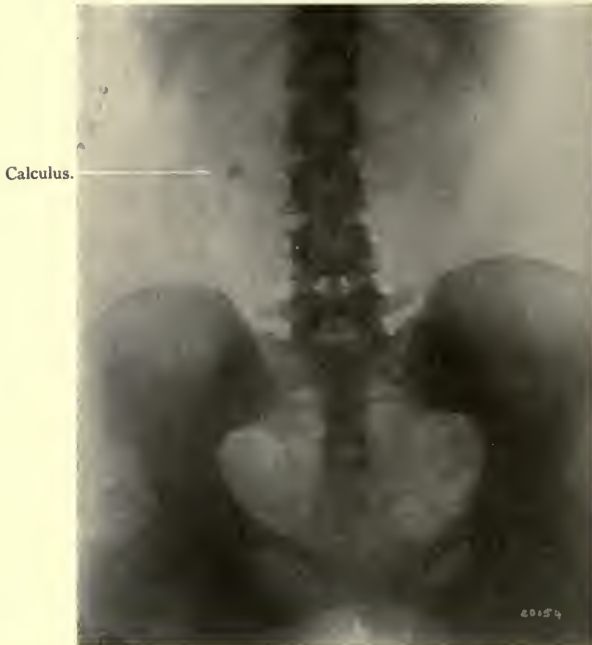

Fig. 224a.—Radiograph of a renal calculus. (Plate by Dr. W. F. Manges.)

ally marked when the patient stands with the body bent forward so as to relax the belly wall and to favor descent of the mass. A tumor first appearing in the lower hypochondrium suggests primary implication of the upper part of the kidney, but a swelling first noticed in the lumbar or iliac area points to an initial invasion of the lower renal surface; in either case the enlargement may ultimately become enormous and distend any part, if not the whole, of the abdomen. Save in abscess, which frequently causes a posterior swelling in the loin, renal tumors tend to enlarge anteriorly, owing to the firm resist-

ance offered by the muscular and osseous structures of the back. Secondary pressure-changes associated with renal growths include compression of the right lung and upward displacement of the liver by right-sided tumors, and the encroachment of left-sided neoplasms upon the heart, the left lung, the spleen, and the stomach.

As factors of renal enlargement hydronephrosis, pyonephrosis, perinephric abscess, and cystic degeneration play conspicuous, and sarcoma and echinococcus disease less prominent, rôles.

Palpation.—The patient may lie in the dorsal position or stand with the trunk inclined forward, and should breathe as deeply as possible, so as to favor vertical displacement of the kidneys by the action of the diaphragm. Either bimanual palpation, with one hand supporting the loin and the other exploring below the costal arch, or the method employed in examining the spleen (gripping the flank with one hand) is satisfactory in palpating the kidneys.

The *renal reflex* (lumbar muscle spasm) is a sign of kidney inflammation, due to acute nephritis, calculus, tuberculosis, and similar processes. To elicit it the patient sits erect, with the lumbar muscles relaxed, and the examiner palpates the lumbar region with a view to determining increased muscular firmness and density on the affected side (Pottenger).

A normal kidney is sometimes palpable in the emaciated subject and in one whose abdominal parietes offer little or no resistance. A renal tumor rises and falls with respiration to a limited degree; it is generally of roughly spherical shape, unless the growth happens to enlarge the organ symmetrically, in which event a reniform outline may be retained; and its consistence varies with the nature of the exciting lesion—it is firm and resistant in sarcoma, boggy in hydronephrosis and in cystic degeneration, and fluctuating in abscess and in hydatid disease.

Aside from renal enlargements, the condition of *nephroptosis* is the chief abnormality of the kidneys discoverable by tactile sense. Nephroptosis, or renal prolapse, exists when the mobility of one or of both kidneys exceeds the normal range, which is approximately $\frac{1}{2}$ inch (1.25 cm.). Although there are precise technical differences between a movable and a floating kidney (the latter having a mesonephron and the former none), the clinical criteria afforded by physical examination relate to the range of renal mobility and accessibility. Thus, three clinical types of renal ptosis are recognized: *palpable kidney*, palpable but not movable below the costal margin; *movable kidney*, whose entire anterior surface is easily palpable and which can be displaced toward or to the level of the

navel; and *floating kidney*, which can be readily pushed over to or beyond the median line and also depressed well below the umbilical level. Prolapse of the kidney, which is more often right- than left-sided, is recognized by palpating an abdominal reniform mass which may be replaced to the normal site of the kidney and readily pushed from place to place with the hand. Such a tumor may or may not be larger than the healthy kidney, is usually sensitive when squeezed, and occasionally shows the outline of the hilus and perhaps the throb of the renal artery; it is especially well defined when the patient ceases to breathe at the end of a forced inspiration, and may tilt forward when the subject takes the knee-chest position and drop backward when dorsal decubitus is assumed. As corroborative signs of renal displacement the so-called "lumbar recess" and a tympanitic percussion note over the renal area in the back are of importance.

An *enlarged kidney* must be distinguished from tumors of the liver and of the spleen; a displaced kidney, from an enlarged gall-bladder and from tumors of the ovary, the stomach, and the intestines. A tumor of the *liver* lengthens the vertical extent of the hepatic area, tends to invade the thorax above and to bulge it below, and to produce a subcostal mass corresponding to the contour of the liver and moving freely with respiration. A tumor of the *spleen* is recognized by its characteristic shape, oblique position, free respiratory excursion, uniform dulness on percussion, and encroachment upon the left thorax (*v. s.*). A distended *gall-bladder*, though to some extent displaceable, does not remain so, but returns of itself to the edge of the liver when the restraining pressure is removed after it has been pushed downward; nor can the gall-bladder be pushed upward out of reach. The respiratory mobility of the mass is considerable and its dulness is generally continuous with that of the liver. In the case of an *ovarian tumor* the mobility of the mass is restricted, usually to a level not much higher than that of the pelvis; the relation of the tumor to the uterus can be established by vaginal palpation; and its close proximity to the anterior abdominal wall can be proved by mapping out by percussion an area of dulness surrounded by a zone of intestinal tympany. *Gastric* and *intestinal* tumors lack the characteristic mobility of a floating kidney, they do not alter renal dulness in the loin, and they can be traced to their source by inflation of the stomach or of the gut, as circumstances indicate.

Percussion.—In attempting percussion of the kidneys the diagonal decubitus is perhaps the most satisfactory posture for the patient to assume, in order to relax the tense lumbar muscles; but even in this position it is impossible to reach the normal kidneys by percus-

sion, owing to their deep situation. The chief value of percussion of the kidneys relates to determining the presence or absence of colon tympany over a mass below the left costal arch, which may be a tumor either of the left kidney or of the spleen. (See Fig. 223.) A kidney large enough to extend, or so greatly displaced as to diminish, the renal area, can be detected by palpation. Posteriorly, renal dullness is inseparable from that of the overlying lumbar muscles, the intervening spinal column, and the adjacent spleen and liver (Fig. 225). A

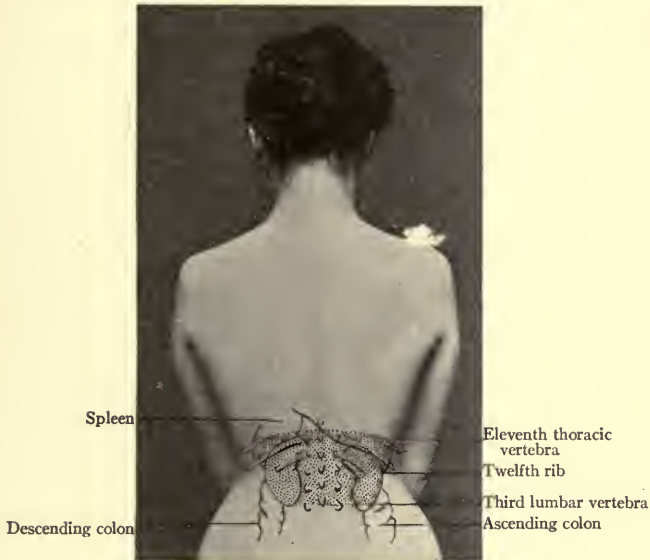


Fig. 225.—The renal area posteriorly, showing rectangle of percussion dullness between the eleventh thoracic and third lumbar vertebrae.

dull zone, extending vertically from the eleventh thoracic to the third lumbar spine and horizontally for a distance of about 3 inches (7.5 cm.) on either side of the spine, overlies the kidneys, whose outer and lower borders occasionally can be delimited from colon tympany by percussing from the level of the twelfth rib outward toward the flanks and downward toward the iliac crests. Dullness in the scapular line below a point $1\frac{1}{2}$ inches (3.75 cm.) above the iliac crest may mean an enlarged kidney—or a colon packed with feces. Loss of dullness in the renal area has been found in nephrop-tosis.

INDEX

- ABDOMEN**, areas of, 498
ascitic, 506
auscultation of, 503
clinical anatomy, 495
 types, 503
cutaneous flexion-folds of, 497
dipping of, 501
edema of, 513
enlarged and tortuous veins over, 514
enlargements of, 509
 above pubes, 511
 below left costal arch, 511
 right costal arch, 510
 from cancer of intestine, 512
 of peritoneum, 512
 from distended bladder, 512
 from gravid uterus, 512
 from leukemic spleen, 512
 from ovarian cyst, 512
 from tumors, 511
 in flank, 511
 in umbilical region, 511
enteroptotic, 508
examination of, 495
 in dorsal position, 500
 in erect position, 500
 in knee-chest position, 500
 in lateral position, 500
 methods, 500
fat necrosis of, 514
fluctuation of, 515
gaseous, 507
gastroptotic, 508
inspection of, 500
mensuration of, 502
movements of, 512
muscular rigidity of, 515
obese, 504
of pregnancy, 505
pain in, 516
palpation of, 501
 bimanual, 502
percussion of, 502
puncture of, 55
scaphoid, 504
skin of, 513. See also *Skin of abdomen*.
- Abdomen**, subcutaneous nodules of, 514
 tissue of, 513
 tactile friction of, 516
 topographic lines and areas, 498
Abdominal aorta, aneurism of, 493
 diagnosis, 493
 physical signs, 493
 pulse in, 493
 clinical anatomy, 497
 fluid, examination of, 58
 friction, 503
 respiration, 93, 95
 thrills, 516
 viscera, examination of, 495
 topographic lines and areas, 498
Abscess, myocardial, 417
 of lung, 255
 after croupous pneumonia, 203
 clinical pathology, 255
 diagnosis, 257
 physical signs, 256
 pericardial, 401
 subphrenic, 294
Absence of septa between auricles and ventricles, 474
Absent respiration, 158
Acromion auscultation, 28
Actinomycosis, pulmonary, 264
 physical signs, 264
Adenitis, 493
 tracheobronchial, 299
Adherent pericardium, 402
Adhesive pericarditis, chronic, 402
 Broadbent's sign in, 404
 clinical pathology, 402
 diagnosis, 405
 Friedreich's sign in, 404
 Kussmaul's sign in, 404
 physical signs, 404
 Sander's sign in, 404
 pleurisy, chronic, 283
 clinical pathology, 283
 diagnosis, 285
 physical signs, 284
Adventitious sounds, 160
Air-hunger, Kussmaul's, 102

- Air-passages, upper, stenosis of, as
 cause of dyspnea, 102
- Alar scapulae, 78
 thorax, 78
- Albinism, pulmonary, 237
- Alimentary canal, test-meals for x-ray
 examination of, 524
- Allorhythmia, 364
- Allorhythmic pulse, 338
- Alternating pulse, 370
- Alternation arrhythmia, 370
- Amphoric resonance, 146
 respiration, 154
- Amphoriloquy, 160
- Anacrotism in aortic stenosis, 460
- Anemic dyspnea, 101
 murmur, diastolic, 385
- Aneurism, arteriovenous, 478
 of abdominal aorta, 493
 diagnosis, 493
 physical signs, 493
 pulse in, 493
 of aorta, 476
 of common carotid artery, 490
 of innominate artery, 490
 of physical signs, 489
 of pulmonary artery, 490
 of subclavian artery, 490
 of superior vena cava, 490
 of symptoms, 489
 of thoracic aorta, 476
 ascending arch, 480
 buccal souffle in, 488
 clinical pathology, 476
 descending, 480, 481
 arch, 480, 481
 diagnosis, 489
 dissecting, 478
 Drummond's sign in, 488
 false, 478
 fusiform, 477
 Glasgow's sign in, 488
 Oliver's sign in, 486
 physical signs, 481
 pulse in, 486
 saccular, 477
 Sansom's sign in, 488
 tracheal elevation in, 486
 tugging in, 486
 transverse arch, 480, 481
 true, 478
- Rasmussen's, in chronic ulcerative
 tuberculosis, 222
 varicose, 479
- Aneurismal phthisis, 492
 varix, 478
- Angle, cardiohepatic, 352
 dulness of, 143
- Angle, epigastric, 73
 Louis', 71
 pulsations in, 323
 subcostal, 73
 respiratory alterations of, 94
- Angulus Ludovici, 71
- Anthracosis, 252
- Aorta, abdominal, aneurism of, 493
 diagnosis, 493
 physical signs, 493
 pulse in, 493
 clinical anatomy, 497
 aneurism of, 476
 ascending, clinical anatomy, 311
 dilatation of, 460
 double, 478
 thoracic, aneurism of, 476. See
 also *Aneurism of thoracic aorta.*
 transposition of, 470
- Aortic arch, dynamic dilatation of, 451
 area, 356
 incompetence, relative, 451
 murmurs, 378, 383
 diastolic, 384
 systolic, 384
 regurgitation, 449
 capillary pulse in, 453
 clinical pathology, 449
 Corrigan's pulse in, 454
 diagnosis, 457
 difference in arm and leg blood-
 pressure in, 455
 Duroziez's sign in, 457
 locomotive pulse in, 453
 movable pulse in, 453
 Musset's sign in, 452
 physical signs, 452
 pulse in, 454
 see-saw murmur in, 456
 systolic blood-pressure in, 455
 Traube's sign in, 457
 venous pulse in, 453
 roughening, 384
 sound, second, enfeeblement of, 361
 stenosis, 457
 anacrotism in, 460
 clinical pathology, 457
 diagnosis, 461
 physical signs, 460
 pulse in, 460
 pulsus bisferiens in, 460
 tardus in, 460
 relative, 460
 valve, clinical anatomy, 310
- Apex pneumonia, 199
- Apex-beat, 317
 absent, 319
 cardiogram of, 320

- Apex-beat, character of, 319
 diastolic rise of, 320
 displacement of, 318
 downward, 318
 left lateral, 318
 right lateral, 318
 upward, 318
 downstroke of, 320
 enfeebled, 319
 exaggeration of, 319
 upstroke of, 320
 Apical systolic murmur, 378
 Apneumotosis, 248, 249
 Apoplexy of lung, 188
 pulmonary, 190
 Appendicitis, chronic, Bassler's sign
 in, 537
 Bastedo's sign in, 537
 Appendix, vermiform, clinical anat-
 omy, 533
 Arachnoid pulse, 344
 Arrhythmia, 363
 alternation, 370
 extrasystolic, 364
 fibrillation, 369
 heart-block, 367
 complete, 368
 incomplete, 368
 hemisystolic, 370
 intermittent, 364, 366
 respiratory, 97, 364
 sinus, 364
 youthful type, 364
 Arm, upper, enlargement of veins, 105
 Arnold's phonophore, 26
 Arterial blood-pressure, instrumental
 estimation, 31
 murmurs, 392
 diastolic, 393
 systolic, 392
 pulse, 328
 sphygmogram, 40
 tension, 314, 329
 wall, caliber, changes in, 331
 changes in, 331
 Arteriosclerosis, 331
 Arteriovenous aneurism, 478
 Artery, carotid, common, aneurism
 of, 490
 epigastric, deep, clinical anatomy,
 497
 iliac, common, 497
 innominate, aneurism of, 490
 clinical anatomy, 311
 pulmonary, aneurism of, 490
 clinical anatomy, 311
 transposition of, 475
 subclavian, aneurism of, 490
 Arthritis in croupous pneumonia, 203
 Aschner's oculocardiac reflex, 337
 Aschoff's nodules, 419
 Ascitic abdomen, 506
 Aspiration pneumonia, 195
 Aspirator, Potain's, 49
 Asthma, bronchial, 177. See also
 Bronchial asthma.
 cardiac, 104
 catarrhal, 177
 essential, 177
 grinder's, 252
 idiopathic, 177
 renal, 102
 spasmodic, 177
 Atelectasis, 248
 acquired, 248
 compression, 249
 congenital, 249
 diagnosis, 252
 lobar, 252
 obstruction, 249
 obturation, 183
 physical signs, 251
 Atelectatic crepitation, 164
 subcrepitations, 165
 Athlete's heart, 450
 Atrophic emphysema of lungs, 240, 246
 thorax of, 80
 Atrophy of heart, 475
 progressive muscular, thorax of, 86
 senile, of lungs, 246
 Atropin reaction in cardiac com-
 petency, 333
 Auenbrugger's sign, 399
 Auricles of heart, clinical anatomy, 309
 Auricular diastole, 314
 extrasystole, 366
 fibrillation, 369
 flutter, 334
 systole, 313
 tachycardia, 334
 Auriculoventricular bundle of His, 313
 extrasystole, 366
 groove, clinical anatomy, 310
 node, 313
 Auscultation, 22
 acromion, 28
 immediate, 23, 28
 mediate, 23, 27
 of abdomen, 503
 of cardiovascular system, 355
 of heart, 355
 of liver, 549
 of lungs, 151
 of spleen, 556
 of stomach, 531
 rod, 16

- Auscultation, stroke, 16
 of stomach, 531
 technic, 27
 transmanual, 28
 tuning-fork, 28
- Auscultatory areas, 356
 percussion, 15
 of stomach, 530
 sphygmomanometry, 33
- Autophonometry, 29
- Axilla, dullness in, 143
- Axillary glands, enlargement, 113
 line, anterior, 74
 posterior, 74
 region, 77
- Axis, celiac, 497
- BAAS' theory of vesicular breathing, 153
- Baccelli's sign, 160
 in serofibrinous pleurisy, 275
- Back, percussion of, 135
- Band-box resonance in hypertrophic emphysema of lungs, 244
- Barnard-Hill sphygmomanometer, 34
- Barrel-chest, 78, 79
- Bassler's sign, 537
- Bastedo's sign, 537
- Bathycardia, 317
- Beaded excrescences of valves, 423
- Bell tympany, 150
- Biermer's sign, 150
- Biot's respiration, 99
- Black phthisis, 252
- Blocked pleurisy, 51
- Blood-pressure, 314
 arm-leg, in aortic regurgitation, 455
 arterial, instrumental estimation, 31
 venous, instrumental estimation, 36
 Oliver's method of estimating, 36
- Boat-shaped thorax, 86
- Body, position of, influence on cardiac physical signs, 316
- Bookman's maneuver in eliciting pain in hepatic area, 542
- Bowles' stethoscope, 24
- Bradycardia, 336
 Stokes-Adams', 368
- Breast, chicken-, 82
 funnel-, 83
 keel, 82
 pain in, 118, 119
 pigeon-, 82
- Breathing, 92. See also *Respiration*.
- Brenner's metallic rub in perforation of stomach, 531
- Broadbent's sign, 324, 404
- Bronchi, clinical anatomy, 126
 stenosis of, 183
- Bronchial asthma, 177
 clinical pathology, 177
 Curschmann's spirals in, 178
 diagnosis, 179
 Laennec's perles in, 178
 physical signs, 177
- catarrh, acute, 171
 chronic, 174
 dilatation, 179
 glands, tuberculosis of, 299
 râles, 162
 respiration, 153
- Bronchiarctia, 183
- Bronchiectasis, 179
 clinical pathology, 179
 cylindrical, 179
 diagnosis, 182
 fusiform, 179
 globular, 179
 physical signs, 181
 saccular, 179
 universalis, 179
- Bronchiectatic cavities, tympany in, 145
- Bronchiloquy, 160
- Bronchiolectasis, 179
- Bronchitis, catarrhal, acute, 171. See also *Catarrhal bronchitis, acute*.
 chronic, 174. See also *Catarrhal bronchitis, chronic*.
 fetid, 175
 Dittrich's plugs in, 175
 fibrinous, 175. See also *Fibrinous bronchitis*.
 plastic, 175
 putrid, 175
- Bronchocavernous respiration, 154
- Bronchophony, 159
- Bronchopneumonia, 192
 confluent, 197
- Bronchopneumonic phthisis, acute, 217. See also *Phthisis, acute bronchopneumonic*.
- Bronchopulmonary system, diseases, 171
 examination, 122
- Bronchorrhea, 175
- Bronchostenosis, 183
 clinical pathology, 183
 diagnosis, 184
 physical signs, 184
- Bronchovesicular respiration, 152, 155
- Brown induration of lungs, 186
- Bruit. See also *Murmur*.
 buccal, in aneurism of thoracic aorta, 488

- Bruit d'airain, 150, 292
 de cuir neuf, 398
 de diable, 394
 de drapeau, 163
 in fibrinous bronchitis, 176
 de galop, 362
 de moulin, 392
 in pneumopericardium, 407
 de pot fêlé, 147
 de rappel, 362
 de tabourka, 491
 systolic, over gall-bladder, 549
 over spleen, 556
 venous, over hepatic area, 549
 viole, 155
 Bryson's sign, 96
 Buccal râles, 162
 souffle in aneurism of thoracic
 aorta, 488
 Bulging, unilateral, of thorax, 86
 Buth's method of paracentesis abdomi-
 nis, 58
 Button-hole mitral defect in mitral
 regurgitation, 440

 CALMETTE'S ophthalmoreaction, 68
 Cambridge electrocardiographic outfit,
 44
 Canter rythm, 362
 Capillary pulse, 345
 in aortic regurgitation, 453
 Caprizant pulse, 343
 Caput medusæ, 514
 Carcinoma cells in pleural fluid, 54
 of lungs, 260
 physical signs, 262
 of pleura, 305
 of stomach, pain in, 526
 x-ray examination in, 525
 Cardia, clinical anatomy, 519
 Cardiac. *See Heart.*
 Cardiogram, 41
 of apex-beat, 320
 Cardiography, 37
 Cardiohepatic angle, 352
 dulness of, 143
 Cardiopneumatic râles, 166
 Cardiorespiratory murmurs, 391
 Cardiovascular system, auscultation
 of, 355
 auscultatory areas of, 356
 clinical anatomy, 308
 diseases of, 396
 examination of, 308
 inspection of, 315
 palpation of, 315
 percussion of, 350

 Cardiovascular system, percussion of,
 methods and technic, 352
 valve areas of, 356
 Carditis, 417, 423
 Carnification, pulmonary, 250
 Carotid artery, common, aneurism
 of, 490
 pulsations, 322
 wave, 42
 Catarrh, bronchial, acute, 171
 chronic, 174
 dry, 175
 mucous, 175
 suffocative, 192, 195
 Catarrhal asthma, 177
 bronchitis, acute, 171
 clinical pathology, 171
 diagnosis, 173
 physical signs, 172
 chronic, 174
 clinical pathology, 174
 diagnosis, 175
 physical signs, 174
 in croupous pneumonia, 203
 pneumonia, 192
 clinical pathology, 192
 diagnosis, 196
 physical signs, 195
 Catarrhe pituiteux, 175
 sec, 175
 Caverniloquy, 160
 Cecum, clinical anatomy, 533
 Celiac axis, 497
 Cells, cancer, in pleural fluid, 54
 heart disease, 187
 Cerebrospinal fluid, 62
 bacteriologic examination, 63
 chemic composition, 62
 cytodiagnosis of, 63
 potassium content of, 63
 volume, 62
 Wassermann reaction in, 64
 Cervical glands, enlargement, 109
 rib, pressure of, on subclavian artery,
 492
 veins, respiratory turgescence, 129
 Chalicosis, 252
 Chest, examination of, 70. *See also*
 Thorax.
 Cheyne-Stokes respiration, 97
 Chicken-breast, 82
 Chyliform pleurisy, 269
 Chylopericardium, 406
 Chylothorax, 287
 Cicatrices fistuleuses in fibroid phthisis,
 235
 of thorax, 121
 Circulation, greater, 314

- Circulation, lesser, 314
 mechanism of, 311
 pulmonary, 314
 systemic, 314
 Cirrhosis of lung, 213
 after croupous pneumonia, 203
 Clado's point, 519
 Clavicles as landmarks of thorax, 71
 Clavicular line, 74
 Click, mucous, 164
 Clubbed fingers, 121
 Coal-miner's lung, 252
 Coccygeal region, pain in, 121
 Cog-wheel respiration, 158
 Collapse, diastolic, of jugular veins,
 323
 pulmonary, 248
 Collapsing pulse in aortic regurgitation,
 454
 Colon, clinical anatomy, 534
 idiopathic dilatation, 536
 percussion of, 538
 Coloptosis, 537
 Color changes in skin of abdomen,
 514
 Compensation of heart, 430
 ruptured, 431
 Complementary pleural sac, 127
 Compression atelectasis, 249
 Confluent bronchopneumonia, 197
 Congestion, pulmonary, 185. See also
 Lungs, congestion of.
 Contraction, unilateral, of thorax,
 88
 Contusion pneumonia, 210
 Copenhagen heart, 438
 Cor bovinum, 408
 hirsutum, 397
 villosum, 397
 Core pneumonia, 199
 Corrigan's button-hole mitral defect
 in mitral stenosis, 440
 pulse in aortic regurgitation, 454
 Corset-liver, 545
 Costal arch, 496
 enlargement of veins of, 106
 line of, 76
 pain in, 118
 line, third, 74
 sixth, 76
 respiration, 93, 95
 Cough phenomenon, 227
 winter, 174
 Courvoisier's law, 548
 Cracked-pot resonance, 147
 Crepitant râles, 163
 Crepitations, gall-bladder, 549
 subpleural, 168
 Crepitations, xiphoid, 516
 Crepitus, 162. See also *Râles.*
 Cricoclavicular line, 74
 Crossed pneumonia, 199
 Croupous pneumonia, 198
 abscess of lung after, 203
 arthritis in, 203
 cardiac sounds in, 207
 catarrhal bronchitis in, 203
 cirrhosis of lung after, 203
 clinical pathology, 198
 consonating râles in, 207
 crepitus redux in, 206
 diagnosis, 207
 endocarditis in, 203
 fibrinous pleurisy in, 203
 gangrene of lung after, 203
 myocarditis in, 203
 pericarditis in, 203
 phthisis after, 203
 physical signs, 204
 pulse in, 205
 sputum in, 204
 stage of congestion, 200
 of delayed resolution, 202
 of gray hepatization, 200
 of purulent infiltration, 202
 of red hepatization, 200
 x-ray examination in, 205
 Curschmann's spirals in bronchial
 asthma, 178
 Cyanosis, 104
 Cycle, cardiac, 311
 respiratory, 92
 Crytometry, 30
 Cysts, echinococcus, examination of
 fluid from, 59
 of lung, 265
 hydronephrotic, examination of fluid
 from, 59
 of pancreas, examination of fluid
 from, 59
 ovarian, examination of fluid from,
 59
 Cytodiagnosis, 50
 of cerebrospinal fluid, 63
 of pleural fluid, 53

 DEATH-RATTLE, 165
 Decubitus, influence of, on vocal frem-
 itus, 132
 Decurtate pulse, 344
 Degeneration, myocardial, granular,
 417
 Deglutition murmur of stomach, 531
 pneumonia, 195
 Delirium cordis, 364

- d'Espine's sign, 300
 Dextrocardia, 474
 Diabetic dyspnea, 102
 Diaphragm phenomenon, 93
 Diaphragmatic pleurisy, 281
 respiration, 93
 Diastole, auricular, 314
 prolongation of, 371
 ventricular, 314
 Diastolic anemic murmur, 385
 collapse of jugular veins, 323
 murmurs, 375
 aortic, 384
 arterial, 393
 pulmonic, 388
 rise of apex-beat, 320
 Dilatation, bronchial, 179
 cardiac, 414
 auricular, 417
 clinical pathology, 414
 diagnosis, 417
 physical signs, 415
 ventricular, left, 415
 right, 416
 with hypertrophy, 414
 with thinning, 414
 dynamic, of aortic arch, 451
 idiopathic, of colon, 536
 of aorta, 460
 of lungs, acute, 247
 Dipping of abdomen, 501
 Dissecting aneurism of thoracic aorta, 478
 Dittrich's plugs in fetid bronchitis, 175
 Double aorta, 478
 murmur, Duroziez's, 393
 pneumonia, 199
 shock sound, Sansom's, 445
 Dropsy of lungs, 188
 pericardial, 406
 pleural, 285
 Drummond's sign in aneurism of thoracic aorta, 488
 Drumstick fingers, 121
 Dry catarrh, 175
 râles, 162
 Ductus arteriosus, patency of, 473, 475
 Dudgeon's sphygmograph, 40
 Dulness, 13, 19
 cardiac, area of, 351
 decrease in, 354
 increase in, 353
 from impairment in interscapular area, 143
 hepatic, 545, 546
 in axilla, 143
 of cardiohepatic angle, 143
 Dulness of lung, 141
 apical, 143
 at base, 143
 parasternal, 143
 paravertebral, 143
 sternal, 143
 unilateral, 144
 of normal tympany in Traube's space, 143
 parasternal, 143
 paravertebral, 143
 pulmonary, 141. See also *Dulness of lung*.
 relative, 19
 sternal, 143
 thymus, 492
 vascular, area of, 352
 Duodenojejunal flexure, clinical anatomy, 532
 Duodenum, clinical anatomy, 532
 Duroziez's double murmur, 393
 sign, 394
 in aortic regurgitation, 457
 Dyspnea, 100
 anemic, 101
 cardiac, 103
 constant, 100
 diabetic, 102
 expiratory, 100
 functional, 101
 in fevers, 101
 inspiratory, 100
 mechanical, 102
 mixed, 100
 objective, 100
 obstructive, 102
 paroxysmal, 100
 pulmonary, 103
 stenotic, 102
 subjective, 100
 toxemic, 101
 types, 100
 uremic, 101
 ECHINOCOCCUS cysts, examination of
 fluid from, 59
 of lung, 265
 Eclat clangoreaux diastolique, 398
 Ectasia, alveolar, of lungs, 241
 Ectopia cordis, 474
 Edema of abdomen, 513
 of lungs, 188
 acute fulminating, 189
 clinical pathology, 188
 collateral, 189
 congestive, 189
 diagnosis, 190

- Edema of lungs, focal, 189
 Huchard's paradoxical percussion sound in, 190
 inflammatory, 189
 physical signs, 189
 pulse in, 189
 of thorax, 106
 general, 109
 local, 106
- Effervescence of gastric contents, 531
- Effusion, pericardial, serous, 398
- Egophony, 160
- Electrocardiogram, 43
- Electrocardiograph outfit, 44
- Electrocardiography, 43
- Ellis' line in serofibrinous pleurisy, 273
- Embolic pneumonia, 190
- Embryocardia, 371, 416
- Emphysema, atrophic, thorax of, 80
 compensatory, hyperresonance in, 144
 glass-blowers', 241
 large-lunged, 240, 241
 pulmonary, 240
 acute, 240, 247
 atrophic, 240, 246
 collateral, 246
 compensatory, 240, 246
 complementary, 246
 hypertrophic, 240, 241
 band-box resonance in, 244
 clinical pathology, 241
 diagnosis, 245
 hyperresonance in, 144
 idiopathic, 240
 interlobular, 248
 interstitial, 240, 248
 intervesselicular, 248
 local, 246
 physical signs, 243
 pseudohypertrophic, 241
 substantive, 241
 true, 241
 vesiculotympany in, 244
 vicarious, 246
 small-lunged, 240, 246
- Emphysematous crackling, 163
 thorax, 78
- Empyema necessitatis, 120, 279
 of pericardium, 401
 of thorax, 278
 clinical pathology, 278
 physical signs, 280
 pulsating, 279
- Endocardial murmurs, 372
- Endocarditis, acute, 421
 diagnosis, 426
- Endocarditis, acute, mural, 421
 physical signs, 425
 chronic, 427
 clinical pathology, 427
 interstitial, 427
 primary effects, 430
 secondary effects, 432
 types and relative incidence, 428
 in croupous pneumonia, 203
 malignant, 423
 diagnosis, 426
 ulcerative, 423
- Endotheliocytosis in pleural fluid, 54
- Energy index, 36
- Enlargement of lateral thoracic glands, 114
 of thymus gland, 492
- Enteroptosis, 508
- Enteroptotic abdomen, 508
- Epigastric angle, 73
 artery, deep, clinical anatomy, 497
 region, 499
- Epigastrium, enlargement of, 510
 pain in, 518
 palpable thrill in, 516
 pulsations in, 324
- Episternal notch, pulsations in, 323
- Erni's sign, 231
- Erythroblastosis, fetal, 109
- Essential asthma, 177
- Ether pneumonia, 195
- Ewart's paravertebral area, 22
 sign, 399
- Excrescences, beaded, of valves, 423
 verrucose, of valves, 423
- Exercise, effect of, on heart, 355
- Exocardial murmurs, 389
- Extrasystole, 366
 auricular, 366
 auriculoventricular, 366
 ventricular, 365
- Exudate in pleural fluid, 53
- FACIES, hepatic, 542
- Falciform ligament, 539
- Falling-drop sound, 170
- False aneurism of thoracic aorta, 478
- Fat necrosis of abdomen, 514
- Fecal impaction, 537
- Fetal erythroblastosis, 109
- Fetid bronchitis, 175
 Dittrich's plugs in, 175
- Fetus, white pneumonia of, 238
- Fibrillation arrhythmia, 369
 auricular, 369
 ventricular, 370
- Fibrinous bronchitis, 175

- Fibrinous bronchitis, auscultation in, 176
 bruit de drapeau in, 176
 clinical pathology, 175
 diagnosis, 176
 physical signs, 176
 pericarditis, acute, 396
 pleurisy, 283
 acute, 267
 clinical pathology, 267
 diagnosis, 268
 physical signs, 267
 in croupous pneumonia, 203
 pneumonia, 198
 Fibroid induration of lung, 213
 lung, 213
 phthisis, 234
 cicatrices fistuleuses in, 235
 clinical pathology, 234
 diagnosis, 237
 physical signs, 235
 pneumonia, 213
 clinical pathology, 213
 circumscribed, 215
 diagnosis, 216
 diffuse, 213
 physical signs, 215
 Fibrosis, myocardial, 417
 of lung, 237
 Fibrotuberculosis of lung, 234
 Finger, clubbed, 121
 drumstick, 121
 percussion, 13
 Fistula sound, pulmonary, 165
 Flack and Keith's node, 313
 Flanks, clinical anatomy, 497
 Flat thorax, 84
 Flatness, 13, 19
 cardiac, area of, 350
 hepatic, 547
 pulmonary, 141, 144
 Flexion-folds, cutaneous, of abdomen, 497
 Flint murmur, 382
 Floating kidney, 560
 Fluctuation, abdominal, 515
 in diseases of pleura and lungs, 134
 Fluid veins, 373
 Fluoroscopy, 65
 Flutter, auricular, 334
 Foramen ovale, patent, 474, 476
 Fossa, Mohrenheim's, 71
 Fourmentin's thoracic index, 70
 Frémissement cataire, 327, 443
 Fremitus, friction, 134, 328
 hydatid, 135, 516
 muscular, 135
 rhonchal, 134
 succussion, 134
 tussile, 134
 vocal, 131
 decreased, 133
 increased, 133
 Frictio indurax, 276
 redux, 167
 Friction, abdominal, 503
 fremitus, 134, 328
 intercostal, 168
 pericardial, 328
 peritoneal, 503
 in peritonitis, 516
 pleural, 166
 pleuropericardial, 168, 328
 shoulder-blade, 168
 shoulder-joint, 168
 tactile, of abdomen, 516
 tubercle, 503
 in tuberculous peritonitis, 516
 Friction-sounds, gall-bladder, 549
 perihepatic, 549
 splenic, 556
 Friedländer pneumonia, 198
 Friedreich's sign, 149, 323, 404
 Functional murmurs, 377
 Funnel-breast, 83
 Funnel-shaped stenosis, mitral, 440
 Furrow, Harrison's, 83
 Sibson's, 73

 GAIRDNER'S coin-test, 150
 Gall-bladder, clinical anatomy, 539
 crepitations, 549
 enlargement of, 548
 examination of, 539
 friction-sounds, 549
 inspection of, 542
 palpation of, 545
 systolic souffle over, 549
 Gallop rhythm, 362
 Galloping consumption, 216
 Gall-stone crepitus, 503
 x-ray examination in, 542
 Galvanometer, string, Lewis' diagram of, 45
 Gangrene, pulmonary, 257
 after croupous pneumonia, 203
 circumscribed, 258
 clinical pathology, 257
 diagnosis, 259
 diffuse, 259
 physical signs, 259
 Gaseous abdomen, 507
 pulse, 339
 Gastralgia, pain of, 526
 Gastrectasis, 522

- Gastritis, pain of, 526
 Gastrodiaphany, 525
 Gastroptosis, 522
 Gastroptotic abdomen, 508
 Gerhardt's sign, 150
 Gibson's rule in pneumonia, 205
 Glands, lateral, thoracic, enlargement of, 114
 Glandular enlargements about thorax, 109
 Glasgow's sign in aneurism of thoracic aorta, 488
 Glass-blowers' emphysema, 241
 Glénard's disease, 508
 method of palpating liver, 544
 Goat-leap pulse, 343
 Goldscheider's method of threshold percussion, 14
 Graham Steelle murmur, 473
 Granular myocardial degeneration, 417
 Gray induration of lung, 214
 Grinder's asthma, 252
 rot, 252
 Grocco's sign, 143
 in abdominal cyst, 275
 in ascites, 275
 in lumbar abscess, 275
 in pregnancy, 275
 in serofibrinous pleurisy, 273
 in subphrenic abscess, 275
 Groin, enlarged glands in, 514
 Gurgle, metallic, 392
 Gurgling in stomach, 531
 metallic, in pneumopericardium, 407
 râles, 165
 Gutta cadens, 170
 in pneumothorax, 292
 Gutter-chest, 86
- H**AIR crepitus, 161
 Hairy heart, 397
 Harrison's furrow, 83
 Hawksley's stethoscope, 26
HEART, anomalies of size, 475
 apex of, thrill at, 327
 area, displacement of, 355
 athlete's, 450
 atrophy of, 475
 auricles of, clinical anatomy, 309
 auscultation of, 355
 base of, 309
 pulsations at or near, 323
 thrill at, 327
 borders, postural influences on, 352
 clinical anatomy, 310
 compensatory hypertrophy of, 430
 Copenhagen, 438
 Heart cycle, 311
 dilatation of, 414. See also *Dilatation, cardiac.*
 disease, congenital, 473
 clinical pathology, 473
 physical signs, 475
 dulness, area of, 351
 decrease in, 354
 increase in, 353
 dyspnea, 103
 effect of exercise on, 355
 flatness, area of, 350
 hairy, 397
 hypertrophy of, 407, 475. See also *Hypertrophy, cardiac.*
 in gastric cancer, 354
 jinrikisha, 450
 malpositions of, congenital, 474
 movements, 312
 orifices of, 310
 ruptured compensation of, 431
 valves of, 310
 Heart-beat, 311
 myogenic theory, 312
 neurogenic, 312
 Heart-block, 368
 arrhythmia, 367
 Heart-disease cells, 187
 Heart-sounds, 356
 adventitious, 372
 first, 357
 at apex, accentuation of, 359
 enfeeblement of, 360
 reduplication of, 362
 in croupous pneumonia, 207
 intensity of, changes in, 358
 psychic, 378
 quality of, changes in, 359
 reduplication of, 362
 second, 358
 at base, accentuation of, 360
 enfeeblement of, 361
 reduplication of, 363
 third, 357
 Hemisystolic arrhythmia, 370
 Hemopericardium, 406
 Hemopneumopericardium, 406
 Hemopneumothorax, 287
 Hemorrhage, concealed, of phthisis, 222
 pericardial, 406
 pleural, 286
 Hemorrhagic infarction of lungs, 190
 clinical pathology, 190
 diagnosis, 192
 physical signs, 192
 pleurisy, 269
 Hemothorax, 286
 Hen-cluck stertor, 99

- Intestines, clinical anatomy, 532
 examination of, 532
 inspection of, 534
 large, clinical anatomy, 533
 x-ray examination of, 534
 malignant disease, 538
 palpation of, 534
 percussion of, 538
 peristalsis of, 512
 small, clinical anatomy, 532
 percussion of, 538
 ptosis of, 537
- JAQUET'S sphygmocardiograph, 38
 Jejunum, clinical anatomy, 532
 Jinrikisha heart, 450
 Joint, xiphisternal, 71
 Jug sound, 147
 Jugular veins, diastolic collapse, 323
 engorgement, 326
 pulsations, 322
 Jürgensen's sign in acute broncho-
 pneumonic phthisis, 219
- KAOLINOSIS, 253
 Katzenschürren, 327
 Keel breast, 82
 Keith and Flack's node, 313
 Kent's node, 313
 Kidneys, clinical anatomy, 557
 enlarged, 560
 examination of, 557
 floating, 560
 inspection of, 558
 movable, 559
 palpable, 559
 palpation of, 559
 percussion of, 560
 puncture of, 64
 Knife-grinder's phthisis, 252
 Koch's tuberculin test, 67
 Korányi's method of percussion, 17
 spinal zones, 21
 Kussmaul's air-hunger, 102
 sign, 326, 404
 Kyphosis, 82
- LAENNEC'S catarrhe piteux, 175
 sec, 175
 perles in bronchial asthma, 178
 theory of vesicular breathing, 153
 Laryngeal crepitus in phthisis, 233
 paralysis in mitral stenosis, 442
 râles, 162
 Larynx, displacement of, 129
- Law, Courvoisier's, 548
 Leaden overcast, 316
 Leopard's growl, 100
 Lewis' diagram of string galvano-
 meter, 45
 Lian's point, 56
 Ligament, falciform, 539
 Ligaments, Poupart's, 496
 Ligne blanche abdominalale, 514
 Line, axillary, anterior, 74
 posterior, 74
 clavicular, 74
 costal, third, 74
 sixth, 76
 cricoclavicular, 74
 Ellis', in serofibrinous pleurisy, 273
 infracostal, 76, 498
 infrascapular, 77
 interspinal, 498
 mammillary, 74
 midaxillary, 74
 midclavicular, 74
 midsternal, 74
 of costal arch, 76
 of transmission of murmurs, 375
 of twelfth thoracic vertebra, 77
 parasternal, 74
 Poupart's, 498
 scapular, 74
 spinal, 77
 sternal, 74
 Linea alba, 497
 albicantes, 514
 gravidarum, 514
 nigra, 497
 Lineæ semilunares, 497
 transversæ, 497
 Lithosis, 252
 Litten's sign, 93
 Liver, areas of dulness and flatness, 545
 auscultation of, 549
 clinical anatomy, 539
 consistence of, 544
 contour of, 544
 corset-, 545
 decrease in size of, 547
 descent of, 543
 displacement of, 548
 enlargement of, 543, 547
 examination of, 539
 inspection of, 542
 pain in region of, 542
 palpation of, Glénard's method, 544
 percussion of, 545
 prolapse of, 548
 pulsations of, 324, 542
 puncture of, 64
 surface topography, 540

- Liver, tenderness in region of, 542
 venous bruit over, 549
 murmur over, 549
- Lobar atelectasis, 252
 pneumonia, 198
- Lobular pneumonia, 192
- Locomotive pulse in aortic regurgitation, 453
- Loin, clinical anatomy, 497
 pain in, 519
- Lombardi's sign of apical phthisis, 226
- Lordosis, 82
- Lorenz's sign in chronic ulcerative phthisis, 224
- Louis' angle, 71
 pulsations in, 323
- Lumbar muscle spasm, 559
 puncture, 60
 region, 499
 pain in, 120
- Lungs, abscess of, 255. See also *Abscess of lung*.
 actinomycosis of, 264
 physical signs, 264
 albinism of, 237
 alveolar ectasia, 241
 anterior borders, 123, 124
 apices of, 123
 pain at, 117
 percussion of, 136
 apoplexy of, 188, 190
 atrophy of, senile, 246
 auscultation of, 151
 borders of, changes in mobility and position, 139
 normal limits, 139
 upper, 139
 brown induration, 186
 carcinoma of, 260
 physical signs, 262
 carnification of, 250
 catarrhal pneumonia, 192
 cavities of, tympany in, 145
 circulation of, 314
 cirrhosis of, 213
 after croupous pneumonia, 203
 clinical anatomy, 122
 coal-miner's, 252
 collapse of, 248
 congestion of, 185
 acute, 185, 187
 chronic, 186, 187
 clinical pathology, 185
 collateral, 186
 diagnosis, 188
 hypostatic, 186, 188
 mechanical, 186
 passive, 186
- Lungs, congestion of, physical signs, 187
 costal surfaces, 122
 croupous pneumonia, 198
 dilatation of, acute, 247
 dropsy of, 188
 dulness of, 141. See also *Dulness of lung*.
 dyspnea of, 103
 echinococcus cyst, 265
 edema of, 188. See also *Edema of lungs*.
 emphysema of, 240. See also *Emphysema, pulmonary*.
 fever, 198
 fibroid, 213
 induration, 213
 fibrosis, of 237
 fissures of, 125
 fistula sound, 165
 flatness of, 141
 gangrene of, 257. See also *Gangrene, pulmonary*.
 gray induration, 214
 hemorrhagic infarction, 190. See also *Hemorrhagic infarction of lungs*.
 hilus of, 123
 hyperemia of, 185
 inspection of, 128
 lobes of, 125
 limits, 126
 lower borders, 124
 mediastinal surfaces, 122
 mobility of, gaging, by pulmonary borders, 139
 palpation of, 130
 percussion of, 135
 comparative, 136
 potter's, 253
 puncture of, 64
 reflex, 151
 root of, 123
 sarcoma of, 263
 sclerosis of, 213
 senile atrophy, 246
 serous infiltration, 188
 syphilis of, 237. See also *Syphilis, pulmonary*.
 tuberculofibrosis of, 234
 tumors of, 260
 tympany of, 144
 white hepatization, 237
- Lymphadenitis, mediastinal, 298
 physical signs, 299
 Smith's murmur in, 300
 suppurative, 299
- Lymphocytosis in pleural fluid, 53

- MALIGNANT** endocarditis, 423
 diagnosis, 426
- Mammary** region, 77
 veins, enlarged, 105
- Mammillary** line, 74
- McBurney's** point, 519
- Mediastinal lymphadenitis**, 298
 physical signs, 299
 Smith's murmur in, 300
 suppurative, 299
 pleurisy, 283
- Mediastinitis**, 296
 acute, 296
 chronic, 296
 suppurative, 297
- Mediastinopericarditis**, 402
 indurative, 296
- Mediastinum**, anterior, 128
 clinical anatomy, 127
 diseases of, 171
 middle, 128
 posterior, 128
 superior, 128
 tumors of, 300. See also *Tumors of mediastinum*.
- Meningeal** respiration, 99
- Mensuration** of abdomen, 502
 of thorax, 29
- Mesocardia**, 474
- Metallic** gurgle, 392
 in pneumopericardium, 407
 tinkling, 170
- Micrococcus Pasteuri**, 198
- Midaxillary** line, 74
- Midclavicular** line, 74
- Midspinal** line, 74
- Midsternal** line, 74
- Milk-spots** in serofibrinous pericarditis, 398
- Mirror-image** of precordial region, 318
- Mitral** area, 356
 murmurs, 381
 presystolic, 382
 systolic, 383
 regurgitation, 434
 clinical pathology, 434
 diagnosis, 438
 muscular type, 435
 organic type, 434
 physical signs, 436
 pulmonary pulse in, 437
 radial pulse in, 437
 stenosis, 439
 clinical pathology, 439
 Corrigan's button-hole mitral defect in, 440
 diagnosis, 448
 first stage of, 444
- Mitral** stenosis, *frémissement cataire* in, 443
 funnel-shaped, 440
 physical signs, 443
 pulse in, 444
 recurrent laryngeal nerve paralysis in, 442
 relative, 441
 Samson's double shock sound in, 445
 second stage of, 446
 soft-valve, 441
 third stage of, 447
 valve, clinical anatomy, 310
- Mohrenheim's** fossa, 71
- Moist** râles, 163
- Money-chink** resonance, 147
- Moro's** reaction, 69
- Morris' point**, pain at, 518
- Mortification**, pulmonary, 257
- Mouneret's** pulse, 339
- Mountain** sickness, 101
- Mouse-tail** pulse, 344
- Movable** kidney, 559
 pulse in aortic regurgitation, 453
- Mucous** catarrh, 175
 click, 164
 râles, 165
- Multiple** murmurs, 388
- Munro's** point, 56
- Murmurs**. See also *Bruit*.
 analysis of, 380
 anemic, 385
 diastolic, 385
 aortic, 378, 383
 diastolic, 384
 systolic, 384
 arterial, 392
 diastolic, 393
 systolic, 392
 cardiorespiratory, 391
 clinical attributes, 374
 deglutition, of stomach, 531
 diastolic, 375
 Duroziez's, 393
 endocardial, 372
 exocardial, 389
 Flint, 382
 functional, 377
 Graham Steelle, 473
 humming-top, 394
 intensity and quality, 375
 line of transmission, 375
 mid-diastolic, 375
 mitral, 381
 presystolic, 382
 systolic, 383
 multiple, 388

- Murmurs of high pressure in pulmonary artery, 473
 organic, 372
 pericardial, 389
 intensity and quality, 390
 rhythm of, 390
 pericarditic, presystolic, 383
 point of maximum intensity, 375
 post-systolic, 375
 protodiastolic, 375
 psychic heart, 378
 pulmonic, diastolic, 388
 systolic, 387
 rhythm of, 374
 Rogers', 475
 safety-valve, 378
 see-saw, in aortic regurgitation, 456
 Smith's, in mediastinal lymphadenitis, 300
 systolic, 374
 apical, 378
 pulmonic, 378
 tricuspid, 378
 transmission of, 375
 tricuspid, 385
 presystolic, 385
 systolic, 385
 vascular, 392
 venous, 394
 over hepatic area, 549
- Muscle sounds, 161
 spasm, lumbar, 559
- Muscular atrophy, progressive, thorax of, 86
 fremitus, 135
 rigidity of abdomen, 515
- Musset's sign in aortic regurgitation, 452
- Mute pneumothorax, 293
- Myocardial abscess, 417
 degeneration, granular, 417
 fibrosis, 417
- Myocarditis, 417
 acute, 417
 interstitial, 418
 parenchymatous, 417
 suppurative, 418
 chronic, 418
 clinical pathology, 417
 diagnosis, 420
 in croupous pneumonia, 203
 physical signs, 420
- Myoidema in phthisis, 231
- NAUNYN'S sign, 518
- Navel, 497
 condition of, 514
- Neck, pulsations in, 322
 venous suffusion, 129
- Necropneumonia, 257
- Necrosis, fat, of abdomen, 514
- Nephroptosis, 559
- Neuroses, functional, as cause of functional dyspnea, 101
- Nicholson's sphygmomanometer, 31
- Nipple as landmark of thorax, 73
- Nodal rhythm, 366, 369
- Node, auriculoventricular, 313
 Keith and Flack's, 313
 Kent's, 313
 sino-auricular, 313
 Tawara's, 313
- Nodules, Aschoff's, 419
 subcutaneous, of abdomen, 514
- Noise, water-whistle, 165
 in pneumothorax, 292
- OBESE abdomen, 504
- Obturation atelectasis, 183
- Occipital glands, enlargement, 110
- Oculocardiac reflex, 337
- Oligopnea, 97
- Oliver's method of estimating venous pressure, 36
 sign, 328
- Ophthalmoreaction, Calmette's, 68
- Organ-pipe arrangement of intestinal loops, 536
- Organic murmurs, 372
- Orthopnea, 100
- Osteal resonance, 19
- Ovarian cysts, examination of fluid from, 59
- Ox-heart hypertrophy, 408
- PAIN at apex of lung, 117
 at Morris' point, 518
 at Robson's point, 518
 gastric, 526
 in abdomen, 516
 in breast, 117
 in cancer of stomach, 526
 in coccygeal region, 121
 in costal arch, 118
 in epigastrium, 518
 in hepatic region, 542
 in hypochondriac regions, 519
 in hypogastric region, 518
 in ileolumbar region, 519
 in lateral wall of thorax, 119
 in left hypochondrium, 117
 shoulder, 117
 in loins, 519

- Pain in lumbar region, 120
 in posterior wall of thorax, 119
 in precordia, 117
 in right hypochondrium, 117
 shoulder, 117
 in sacral region, 220
 in sacrum, 519
 in splenic region, 553
 in thorax, 117
 in tumors of stomach, 526
 in umbilical region, 518
 of gastralgia, 526
 of gastric ulcer, 526
 of gastritis, 526
 sternal, 117
- Palpable kidney, 559
- Palpation, 11
 of abdomen, 501
 of cardiovascular system, 315
 of gall-bladder, 545
 of intestines, 534
 of kidneys, 559
 of liver, Glénard's method, 544
 of lungs, 130
 of spleen, 551
 of stomach, 525
- Palpatory percussion, 15
- Pancarditis, 423
- Pancreas, clinical anatomy, 549
 cysts of, examination of fluid from, 59
 physical examination, 549
- Parabronchial consolidations, tympany from, 146
- Paracentesis, 47
 abdominis, 55
 Buth's method, 58
 diagnostic, 55
 therapeutic, 56
 Herrick's method of, in diagnosis of pneumoperitoneum, 56
 lumbar, 60
 of kidney, 64
 of liver, 64
 of lung, 64
 of pericardial sac, 54
 of pleural cavity, 50
 of spleen, 64
 technic, 47
 visceral, 64
- Paralytic thorax, 78
- Parasternal dulness, 143
 line, 74
- Paravertebral dulness, 143
- Parietal pleura, 126
- Parotid gland, enlargement, 113
- Paroxysmal dyspnea, 100
 tachycardia, 336
- Patency of ductus arteriosus, 473, 475
- Patent foramen ovale, 474, 476
- Pectoriloquy, 159
 whispering, 159
- Pectus carinatum, 82
 excavatum, 83
- Pendulum rhythm, 371
- Percussion, 12
 auscultatory, 15
 of stomach, 530
 finger, 13
 immediate, 13, 14
 in intestinal obstruction, 539
 instrumental, 13
 Korányi's method, 17
 mediate, 13
 of abdomen, 502
 of anterior chest-wall, 135
 of apices of lungs, 136
 of back, 135
 of cardiovascular system, 350
 methods and technic, 352
 of colon, 538
 of intestines, 538
 of kidneys, 560
 of lateral regions of thorax, 136
 of liver, 545
 of lungs, 135
 comparative, 136
 of small intestine, 538
 of spleen, 554
 of stomach, 529
 palpatory, 15
 respiratory, 136
 sense of resistance, 17, 18
 spinal, 20
 technic, 13
 threshold, Goldscheider's method, 14
 zones, spinal, 21
- Percussion-sound, attributes, 17
 duration, 18
 Huchard's, 190
 hyperresonant, 13, 19
 intensity, 18
 pitch, 17
 quality, 17
 resonant, 13, 18
 special tonal changes of, 147
 tonal properties, 18
 tympanic, 13, 19
- Perez's sign, 168
- Perforation of stomach, metallic rub in, 531
- Peribronchial pneumonia, 192
- Pericardial abscess, 401
 dropsy, 406
 effusion, serous, 398
 fluid, examination, 55

- Pericardial friction, 328, 389
 intensity and quality, 390
 rhythm of, 390
 hemorrhage, 406
 sac, puncture of, 54
 succussion sounds, 392
- Pericardicentesis, 54
- Pericarditic presystolic rumble, 383
 pseudocirrhosis, 297
- Pericarditis, 396
 adhesive, chronic, 402. See also
Adhesive pericarditis, chronic.
 external, 297
 fibrinous, acute, 396
 clinical pathology, 396
 diagnosis, 398
 physical signs, 397
 in croupous pneumonia, 203
 internal, 297
 plastic, acute, 396
 purulent, 401
 clinical pathology, 401
 physical signs, 402
 serofibrinous, 398
 Auenbrugger's sign in, 399
 clinical pathology, 398
 diagnosis, 401
 Ewart's sign in, 399
 milk-spots in, 398
 physical signs, 399
 Rotch's sign in, 400
- Pericardium, adherent, 402
 empyema of, 401
- Pericolitis sinistra, 537
- Perihepatic friction-sound, 549
- Peristalsis of stomach and intestine, 512
- Peristaltic unrest, 513
- Peritoneal friction, 503
 in peritonitis, 516
- Phonometry, 28
- Phthisical thorax, 78
- Phthisis, acute bronchopneumonic, 217
 Jürgensen's sign in, 219
 physical signs, 218
 pneumonic, 216
 clinical pathology, 216
 diagnosis, 219
 physical signs, 218
 after croupous pneumonia, 203
 aneurismal, 492
 apical, Lombardi's sign, 226
 black, 252
 chronic ulcerative, 220
 chloasma phthisicorum in, 226
 clinical pathology, 220
 concealed hemorrhage of, 222
 diagnosis 233
- Phthisis, chronic ulcerative, laryngeal
 crepitus in, 233
 Lorenz's sign in, 224
 myoidema in, 231
 periods of, 224
 physical signs, 224
 Rothschild's sign in, 224
 signe du tapotage in, 231
 striæ vasculares in, 226
 valvular heart disease in, 222
 Williams' sign in, 227
- fibroid, 234. See also *Fibroid phthisis.*
- florida, 216
 galloping, 216
 knife-grinder's, 252
 Sabourin's sign, 226
 slow, 220
 stone-cutter's, 252
- Physical diagnosis, methods and technic, 11
- Physiologic venous pulse, 42
- Pick's disease, 297
- Pigeon-breast, 82
- Pirquet's tuberculin test, 67
- Pistol pulse in aortic regurgitation, 454
- Pitch of sound, 17
- Pitres' signe du sou, 151
- Plastic bronchitis, 175
 pericarditis, acute, 396
 pleurisy, 267
 chronic, 283
- Pleura, carcinoma of, 295
 clinical anatomy, 126
 parietal, 126
 sarcoma of, 296
 tumors of, 295
 visceral, 127
- Pleural cavity, puncture, 50
 dropsy, 285
 fluid, cancer cells in, 54
 cytodiagnosis, 53
 endotheliocytosis in, 54
 examination, 53
 exudate in, 53
 inoscopy of, 54
 lymphocytosis in, 53
 polynucleosis in, 54
 transudate in, 53
- friction, 166
 hemorrhage, 286
 space, complementary, 127
- Pleurésie bloquée, 51
- Pleurisy, 266
 acute dry, 267
 adhesive, chronic, 283. See also
 Adhesive pleurisy, chronic.
 blocked, 51

- Pleurisy, chyliform, 269
 circumscribed, 281
 diaphragmatic, 281
 encapsulated, 282
 encysted, 282
 fibrinous, 283
 acute, 267. See also *Fibrinous pleurisy, acute.*
 in croupous pneumonia, 203
 hemorrhagic, 269
 interlobar, 282
 mediastinal, 283
 plastic, 267
 chronic, 283
 pulsating, 279
 purulent, 278. See also *Empyema.*
 serofibrinous, 268. See also *Sero-fibrinous pleurisy.*
 with effusion, 268
- Pleuritis, 266
 sicca, 267
- Pleurocentesis, 50
- Pleuropericardial friction, 168, 328
- Pleuropneumonia, 203
- Pneumochysis, 188
- Pneumonia, apex, 199
 aspiration, 195
 catarrhal, 192. See also *Catarrhal pneumonia.*
 central, 199
 contusion, 210
 core, 199
 crossed, 199
 croupous, 198. See also *Croupous pneumonia.*
 deglutition, 195
 disseminated, 192
 double, 199
 embolic, 190
 errans, 199
 ether, 195
 fibrinous, 198
 fibroid, 213. See also *Fibroid pneumonia.*
 Friedländer, 198
 Gibson's rule in, 205
 hypostatic, 187
 interstitial, chronic, 213. See also *Fibroid pneumonia.*
 lobar, 198
 lobular, 192
 massive, 199
 migrans, 199
 peribronchial, 192
 purulent, 255
 stripe, 199
 superficial, 199
 syphilitic, 237
- Pneumonia, toxic, 208
 traumatic, 210
 typhoid, 208
 wandering, 199
 white, 237
 of fetus, 238
- Pneumonic phthisis, acute. See also *Phthisis, acute pneumonic.*
- Pneumonitis, 198
- Pneumonoconiosis, 252
 clinical pathology, 252
 diagnosis, 255
 physical signs, 255
- Pneumopericardium, 406
 bruit de moulin in, 407
 metallic gurgling in, 407
 physical signs, 407
- Pneumoperitoneum, 508
 diagnosis of, Herrick's method of
 paracentesis in, 56
- Pneumorrhagia, 190
- Pneumothorax, 287
 artificial, 52
 bilateral, 289
 bruit d'airain in, 292
 circumscribed or limited, 289
 clinical pathology, 287
 closed, 289
 diagnosis, 292
 general or complete, 289
 gutta cadens in, 292
 mute, 293
 open, 289
 physical signs, 290
 succussio Hippocratis in, 292
 tympany in, 146
 valvular, 289
 ventilated, 289
 water-whistle noise in, 292
- Pneumotyphus, 208
- Point, Clado's, 519
 Lian's, 56
 McBurney's, 519
 Morris', 518
 Munro's, 56
 Robson's, 518
 spleen, 553
 Voillemier's, 519
- Polynucleosis in pleural fluid, 54
- Polypnea, 97
- Polypous lesions of valves, 423
- Posture, influence, on cardiac signs, 316
 on percussion sound, 139
 on præcordial borders, 352
 on vocal fremitus, 132
- Potain's aspirator, 49
- Potassium content of cerebrospinal fluid, 63

- Potter's lung, 253
- Poupart's ligaments, 496
lines, 498
- Precordia, bulging of, 316
clinical anatomy, 309
flattening or depression of, 317
pain in, 117
- Precordial area, pulsations in, 323
contour, 316
- Pregnancy, abdomen of, 505
- Progressive muscular atrophy, thorax of, 86
- Prolapse of liver, 548
- Pseudocirrhosis, pericarditic, 297
- Pseudolipoma, Verneuil's, 90
- Psychic heart murmur, 378
- Pterygoid thorax, 78
- Ptosis of small intestine, 537
- Pubic region, 499
spines, 496
symphysis, 496
- Puff, veiled, Laennec's, 155
- Pulmonary artery, aneurism of, 490
clinical anatomy, 311
transposition of, 475
edema, 188
pulse in mitral regurgitation, 437
regurgitation, 471. See also *Regurgitation, pulmonary*.
resonance, 137. See also *Resonance, pulmonary*.
splenization, 187
stenosis, 467. See also *Stenosis, pulmonary*.
tympanites, 145
- Pulmonic area, 356
murmurs, diastolic, 388
systolic, 378, 387
sound, second, accentuation of, 361
weakening of, 362
valve, clinical anatomy, 310
- Pulsating empyema, 279
pleurisy, 279
- Pulsations, abnormal areas of, 321
at Louis' angle, 323
at or near base of heart, 323
carotid, 322
circumscribed areas of, in diseases of lungs and pleura, 129
in epigastrium, 324
postsystolic, 324
systolic, 324
in episternal notch, 323
in intercostal spaces, 323
in neck, 322
in precordial area, 323
of jugular veins, 322
of liver, 324, 542
- Pulsations of spleen, 553
- Pulse, allorhythmic, 338
alternating, 338, 370
arachnoid, 344
arterial, 328
asymmetry, of 345
capillary, 345, 453
caprizant, 343
collapsing, 454
Corrigan's, 454
decurtate, 344
feeling, technic of, 329
gaseous, 339
goat-leap, 343
hyperdirotic, 342
hypertension of, 339, 342
hypotension of, 339, 343
in aneurism of abdominal aorta, 493
of thoracic aorta, 486
in aortic regurgitation, 454
stenosis, 460
in croupous pneumonia, 205
in edema of lungs, 189
in mitral stenosis, 444
in pulmonary regurgitation, 472
stenosis, 468
in tricuspid regurgitation, 464
stenosis, 466
intermission of, 337
irregularity of, 337
locomotive, 453
Mouneret's, 339
mouse-tail, 344
movable, 453
pistol, 454
pressure, 33
pulmonary, 437
receding, 454
rhythm of, 329
tension of, variations in, 338
velocity of, variations in, 344
venous, 346. See also *Venous pulse*.
volume of, 330
variations, 343
water-hammer, 454
- Pulse-rate, 329
disturbances of, 332
- Pulsus alternans, 338, 370
sphygmomanometer in study of, 36
altus et celer in aortic regurgitation, 454
anacrotic, 342
bigeminus, 338
bisferiens, 342
in aortic stenosis, 460
celer, 344
celerity of, variations in, 344

- Pulsus celerrimus, 344
 in aortic regurgitation, 454
 deficiens, 338
 dicroticus, 342
 durus, 339
 equalis, 343
 frequens, 333
 inequalis, 343
 periodicus, 338
 intercicens, 338
 intermittens, 337
 irregularis perpetuus, 369
 magnus, 343
 mollis, 339
 paradoxus, 338
 parvus, 343
 plenus, 343
 rarus, 336
 subungualis, 345
 tardus, 344
 in aortic stenosis, 460
 trigeminus, 338
 vacuus, 344
 Punctum maximum of murmurs, 375
 Puncture, 47. See also *Paracentesis*.
 Pupils, inequality, in diseases of lungs
 and pleura, 130
 Purulent pericarditis, 401
 pleurisy, 278. See also *Empyema*.
 pneumonia, 255
 Putrid bronchitis, 175
 Pylorus, clinical anatomy, 519
 Pyopericardium, 401
 Pyopneumopericardium, 406
 Pyopneumothorax, 287
 subphrenic, 294
 Pyothorax, 278

 RACHITIC rosary, 82
 thorax, 81
 Radial sphygmogram, 330
 Radiography, 65
 Râles, 162
 atelectatic, 164
 bronchial, 162
 buccal, 162
 cardiopneumatic, 166
 cavernous, 162
 consonating, 207
 crepitant, 163
 dry, 162
 emphysematous, 163
 gurgling, 165
 hair, 161
 indux, 164
 laryngeal, 162
 in phthisis, 233
 moist, 163
 mucous, 165
 redux, 164
 in croupous pneumonia, 206
 sibilant, 162
 sonorous, 162
 subcrepitant, 164
 subpleural, 168
 tracheal, 162
 vesicular, 162
 Rasmussen's aneurism in chronic ul-
 cerative tuberculosis, 222
 Reaction, atropin, in cardiac compe-
 tency, 333
 Moro's, 69
 tuberculin, 67
 Receding pulse in aortic regurgitation,
 454
 Rectum, clinical anatomy, 534
 Recurrent laryngeal nerve paralysis in
 mitral stenosis, 442
 Reflex, lung, 151
 oculocardiac, 337
 renal, 559
 Reflexes, vertebral, 22
 Regurgitation, aortic, 449. See also
 Aortic regurgitation.
 mitral, 434. See also *Mitral regur-*
 gitation.
 pulmonary, 471
 clinical pathology, 471
 diagnosis, 473
 organic, 471
 physical signs, 472
 pulse in, 472
 relative, 472
 safety-valve, 435, 463
 tricuspid, 462. See also *Tricuspid*
 regurgitation.
 Renal asthma, 102
 reflex, 559
 Resistance, increased, in diseases of
 lungs and pleura, 134
 Resonance, amphoric, 146
 band-box, in hypertrophic emphy-
 sema of lungs, 244
 cracked-pot, 147
 hydatid, 19
 impaired, 19
 jug, 147
 money-chink, 147
 osteal, 19
 pulmonary, 137
 anteriorly, 138
 exaggeration of, 144. See also
 Hyperresonance, pulmonary.
 extent of, 140
 laterally, 138

- Resonance, pulmonary, posteriorly, 138
 regional differences in, 137
 Skodaic, 145
 vesicular, 137. See also *Resonance, pulmonary*.
 vesiculotympanic, 144
 vocal, 159
 Resonant percussion-sounds, 13, 18
 Respiration, 92, 152
 abdominal, 93, 94
 absent, 158
 amphoric, 154
 anomalies of, 95
 Biot's, 99
 bronchial, 153
 bronchocavernous, 154
 bronchovesicular, 152, 155
 cavernous, 154
 Cheyne-Stokes, 97
 cog-wheel, 158
 costal, 93, 95
 diaphragmatic, 93
 difficult, 100. See also *Dyspnea*.
 exaggerated, 156
 feeble, 157
 frequency, alterations in, 97
 harsh, 156
 prolonged, 156
 interrupted, 158
 irregularity, 97
 jerky, 97
 meningeal, 99
 normal, 92
 puerile, 156
 rapid, 97
 Seitz's metamorphosing, 155
 senile, 157
 slow, 97
 sternomastoid, 95
 stertorous, 99
 stridulous, 99
 thoracic, 93
 type, 93
 reversal of, 95
 vesicular, 152
 vesiculocavernous, 154
 Respiratory alterations of subcostal angle, 94
 arhythmia, 97, 364
 cycle, 92
 movements of thorax, 92. See also *Respiration*.
 percussion, 136
 sounds, 152
 turgescence of cervical veins, 129
 Retraction, abnormal areas of, 324
 Rhonchal fremitus, 134
 Rhonchus, 162
 Rhythm, canter, 362
 gallop, 362
 nodal, 366, 369
 pendulum, 371
 Rib, cervical, pressure of, on subclavian artery, 492
 Ribs as landmarks of chest, 72, 73
 Riedel's lobe, 545
 Robson's point, pain at, 518
 Rod auscultation, 16
 Rogers' murmur, 475
 Röntgen rays, examination by means of, 65
 in aneurism, 484
 in chronic interstitial pneumonia, 216
 in croupous pneumonia, 205
 in gall-stones, 542
 in gastric cancer, 525
 diseases, 524
 ulcer, 525
 in mediastinal lymphadenitis, 301
 neoplasm, 307
 in phthisis, 228
 in pleural effusion, 271
 in pneumothorax, 290
 of large intestine, 534
 Rosary, rachitic, 82
 Rotch's sign, 400
 Rothschild's sign in phthisis, 224
 Ruptured compensation of heart, 431

 SABOURIN'S sign of apical phthisis, 226
 Saccular aneurism of thoracic aorta, 477
 Sacral region, pain in, 120
 triangle, 497
 Sacrum, pain in, 519
 Safety-valve murmur, 378
 regurgitation, 435, 463
 Sahli's theory of vesicular breathing, 153
 Sander's sign, 404
 Sansom's double shock sound, 445
 leaden overcast, 316
 sign in aneurism of thoracic aorta, 488
 stethoscope, 25
 Sarcoma of lungs, 263
 of pleura, 296
 Scaphoid abdomen, 504
 scapula, 73
 Scapula, alar, 78
 scaphoid, 73
 winged, 78

- Scapular line, 74
 spinal, 77
 region, 77
- Scars of thorax, 121
 on skin of abdomen, 514
- Schusterbrust, 84
- Sclerosis of lung, 213
- Scoliosis, 82
- Scorbiculus cordis, 71, 496
- See-saw murmur in aortic regurgitation, 456
- Seitz's metamorphosing respiration, 155
- Semilunar space, Traube's, 530
- Senile atrophy of lungs, 246
 respiration, 157
- Septum, absence of, between auricles and ventricles, 474
 interventricular, defects of, 473, 475
- Serofibrinous pericarditis, 398. See also *Pericarditis, serofibrinous*.
 pleurisy, 268
 Bacelli's sign in, 275
 clinical pathology, 268
 diagnosis, 276
 Ellis' line in, 273
 Grococo's sign in, 273
 physical signs, 270
- Serum illness, 52
- Shoulder, pain in, 117
- Shoulder-blade friction, 168
- Shoulder-joint friction, 168
- Shulman's sign, 511
- Sibilant râles, 162
- Sibson's furrow, 73
 notch, 400
- Siderosis, 252
- Sigmoid flexure, clinical anatomy, 534
- Sign, Auenbrugger's, 399
 Bacelli's, 160, 275
 Bassler's, 537
 Bastedo's, 537
 Biermer's, 150
 Broadbent's, 324, 404
 Bryson's, 96
 Drummond's, 488
 Duroziez's, 394, 457
 Erni's, 231
 d'Espine's, 300
 Ewart's, 399
 Friedreich's, 147, 323, 404
 Gerhardt's, 150
 Glasgow's, 488
 Grococo's, 143, 273
 Jürgensen's, 219
 Kussmaul's, 326, 404
 Litten's, 93
- Sign, Lombardi's, 226
 Lorenz's, 224
 Musset's, 452
 Naunyn's, 518
 Oliver's, 328
 Perez's, 168
 Rotch's, 400
 Rothschild's, 224
 Sabourin's, 226
 Sander's, 404
 Sansom's, 488
 Shulman's, 511
 Skoda's, 145
 Stillier's, 527
 Traube's, 457
 Turretini's, 398
 Williams', 227
 Wintrich's, 148
- Signe du sou, 151
 du tapotage, 231
- Sino-auricular node of Keith and Flack, 313
- Sinus arrhythmia, 364
- Situs viscerum inversus, 474
- Skin of abdomen, 513
- Skodaic resonance, 145
- Slow consumption, 220
- Smith's murmur in mediastinal lymphadenitis, 301
- Snoring, 99
- Soft-valve mitral stenosis, 441
- Sonorous râles, 162
- Souffle. See *Bruit*.
- Sounds, adventitious, 160
 cardiac, 356. See also *Heart-sounds*.
 extraneous, 161
 falling-drop, 170
 Huchard's percussion, 190
 intestinal, 503
 metallic, 170
 muscle, 161
 pulmonary fistula, 165
 respiratory, 152
 splashing, 160
 stomach, 503
 succussion, 169
 Hippocratic, 170
 of stomach, 527
- Spasm, lumbar muscle, 559
- Spasmodic asthma, 177
- Spens' syndrome, 368
- Sphacelation, pulmonary, 257
- Sphygmocardiogram, interpretation of, 40
- Sphygmocardiograph, Jacquet's, 38
- Sphygmocardiography, clinical value of, 42
 technic of, 37

- Sphygmogram, arterial, 40, 330
 clinical significance, 330
 radial, 330
 venous, 42
- Sphygmograph, Dudgeon's, 39
- Sphygmography, 37
- Sphygmomanometer, Hill-Barnard, 34
 in study of pulsus alternans, 36
 Nicholson's, 31
 Rogers', 33
- Sphygmomanometry, 31
 auscultatory method, 33
 technic, 31
- Spinal percussion, 20
 scapular line, 77
 zones, Korányi's, 21
- Spine, iliac, anterior superior, 496
 pubic, 496
- Splashing sounds, 169
- Spleen, auscultation of, 556
 clinical anatomy, 550
 displacement of, 553
 enlargements of, 553
 examination of, 550
 inspection of, 551
 pain in region of, 553
 palpation of, 551
 percussion of, 554
 point, 553
 pulsations of, 553
 puncture of, exploratory, 64
 tenderness in region of, 553
- Splenic flexure, clinical anatomy, 534
 friction-sound, 556
 systolic bruit, 556
- Splenization, pulmonary, 187
- Splenoptosis, 554
- Sputum in croupous pneumonia, 204
- Stenosis, aortic, 457. See also *Aortic stenosis*.
 funnel-shaped, mitral, 440
 mitral, 439. See also *Mitral stenosis*.
 of bronchi, 183
 of upper air-passages as cause of
 dyspnea, 102
 pulmonary, 467
 congenital, 473
 clinical pathology, 467
 diagnosis of, 469
 physical signs, 468
 pulse in, 468
 relative, 468
 soft-valve, mitral, 441
 subaortic, 459
 tricuspid, 465. See also *Tricuspid stenosis*.
- Sternal dullness, 143
 line, 74
- Sternal pain, 117
 region, 77
 thrill over, 328
- Sternomastoid breathing, 95
- Sternum as landmark of thorax, 71
 enlargement of veins about, 105
- Stertorous respiration, 99
- Stethoscope, Arnold's, 26
 binaural, 24
 Bowles', 24
 choice, 23
 differential, 26
 double, 24
 Hawksley's, 26
 monaural, 24
 Sansom's, 25
 single, 24
- Stillier's sign, 527
- Stokes-Adams' bradycardia, 369
- Stone-cutter's phthisis, 252
- Stomach, auscultation of, 531
 auscultatory percussion of, 530
 body of, clinical anatomy, 520
 canal of, clinical anatomy, 520
 cancer of, pain in, 526
 x-ray examination in, 525
 clinical anatomy, 519
 contents, effervescence of, 531
 deglutition murmur of, 531
 examination of, 519
 fundus of, clinical anatomy, 520
 greater curvature of, clinical anat-
 omy, 521
 gurgling in, 531
 hour-glass, 523
 incisura angularis of, clinical anat-
 omy, 521
 inspection of, 521
 lesser curvature of, clinical anat-
 omy, 520
 mechanical inflation, 522
 pain in, 526
 palpation of, 525
 percussion of, 529
 perforation of, metallic rub in, 531
 peristalsis of, 512
 sounds, 503
 stroke auscultation of, 531
 succussion sounds of, 527
 transillumination of, 525
 tumors of, pain in, 526
 tympany of, decrease, 531
 increase, 531
 ulcer of, pain of, 526
 x-ray examination in, 525
 vestibule of, clinical anatomy, 520
 x-ray examination, 524
- Stomach-tube, use of, 527

- Striæ vasculares in chronic ulcerative phthisis, 226
 Stridor serraticus, 100
 Stridulous respiration, 99
 String galvanometer, Lewis' diagram of, 45
 Stripe pneumonia, 199
 Stroke auscultation, 16
 of stomach, 531
 Subaortic stenosis, 459
 Subclavian artery, aneurism of, 490
 pressure of cervical rib on, 492
 Subcostal angle, 73
 respiratory alterations of, 94
 Subcrepitant râles, 164
 Subcrepitations, atelectatic, 165
 Subcutaneous nodules of abdomen, 514
 tissue of abdomen, 513
 Submaxillary glands, enlargement, 110
 Subphrenic pyopneumothorax, 294
 Subpleural crepitation, 168
 Succussio Hippocratis in pneumothorax, 292
 Succussion fremitus, 134
 sounds, 169
 Hippocratic, 170
 of stomach, 527
 pericardial, 392
 Suffocative catarrh, 192, 195
 Suffusion, venous, of neck, 129
 Sulcus, Harrison's, 83
 Suppurative mediastinal lymphadenitis, 298
 mediastinitis, 297
 Supracardiac vascular area, clinical anatomy, 310
 Supraclavicular region, 77
 Suprascapular region, 77
 Symphysis pleuræ, 283
 pubis, 496
 Syndrome, Spens', 368
 Stokes-Adams', 368
 Syphilis, pulmonary, 237
 acquired, 238
 clinical pathology, 237
 congenital, 238
 diagnosis, 239
 physical signs, 239
 Syphilitic pneumonia, 237
 Systole, auricular, 313
 ventricular, 314
 Systolic bruit over spleen, 556
 epigastric throbbing, 324
 murmurs, 374
 aortic, 383
 apical, 378
 arterial, 392
 mitral, 383
 Systolic murmurs, pulmonic, 378, 387
 tricuspid, 378, 385
 plateau, 42, 320
 souffle over gall-bladder, 549
 venous pulse, 348
- TACHYCARDIA**, 333
 auricular, 334
 paroxysmal, 336
 Tactile friction of abdomen, 516
 Tawara's node, 313
 Test, Calmette's, 68
 Gairdner's, 147
 Koch's tuberculin, 67
 von Pirquet's, 67
 Thoracic aorta, aneurism of, 476. See also *Aneurism of thoracic aorta.*
 glands, lateral, enlargement of, 114
 index, Fourmentin's, 70
 respiration, 93
 vertebra, twelfth line of, 77
 Thoracometry, 29
 Thorax, alar, 78
 anterior, percussion of, 135
 asymmetry of, 86
 barrel-, 78, 79
 boat-shaped, 86
 clavicles as landmarks of, 72
 clinical anatomy, 70
 depressions of, local, 90
 edema of, 106
 emphysematous, 78
 en bateau, 86
 en gouttière, 86
 examination of, 70
 expansion of, alterations in degree, 95
 deficiency in, 95
 Bryson's sign, 96
 circumscribed, 96
 increase in, 96
 unsymmetric, 96
 wavy and uneven, 96
 expiratory form, 78
 flat, 84
 fusiform, 85
 glandular enlargements, 109
 gutter-, 86
 inflated, 78
 inspiratory form, 80
 intercostal spaces as landmarks of, 72
 lateral regions, percussion of, 136
 wall, pain in, 119
 lower, enlargement of veins of, 106
 mensuration of, 29
 movements of, mechanical restriction, as cause of dyspnea, 103

- Thorax, nipple as landmark of, 73
 normal landmarks, 71
 of atrophic emphysema, 80
 of progressive muscular atrophy, 86
 pain in, 117
 paralytic, 78
 pathologic types, 77
 phtisical, 78
 posterior wall, pain in, 119
 prominences of, circumscribed, 89
 pterygoid, 78
 rachitic, 81
 respiratory movements, 92. See also
 Respiration.
 ribs as landmarks of, 72, 73
 scars of, 121
 sternum as landmark, 71
 topographic lines and areas, 74
 unilateral bulging, 86
 contraction, 88
 upper, ramification of small venules
 over, 105
 venous enlargement and tortuosity
 over, 104
 vertical measurement, 70
 Threshold percussion, Goldscheider's
 method, 14
 Thrill, 327
 abdominal, 516
 at apex of heart, 327
 at base of heart, 327
 at intercostal spaces, 327
 hydatid, 516
 over sternal region, 328
 over xiphoid region, 328
 palpable, in epigastrium, 516
 Thymus gland, movable dulness of, 492
 Thyroid gland, enlargement, 116
 Tinkling, metallic, 170
 Tortuous and enlarged veins over
 abdomen, 514
 Toxemic dyspnea, 101
 Toxic pneumonia, 208
 Trachea, clinical anatomy, 126
 râles, 162
 tone, Williams', 149
 tugging, 328
 Tracheobronchitis, acute, 171
 Transudate in pleural fluid, 53
 Traube's plugs in fetid bronchitis, 175
 semilunar space, 530
 sign in aortic regurgitation, 457
 space, dulness of normal tympany
 in, 143
 Traumatic pneumonia, 210
 Triangle, sacral, 497
 Trichertbrust, 83
 Tricuspid area, 356
 Tricuspid murmurs, 385
 presystolic, 385
 systolic, 378, 385
 regurgitation, 462
 clinical pathology, 462
 diagnosis, 465
 organic, 462
 physical signs, 463
 pulse in, 464
 relative, 463
 stenosis, 465
 clinical pathology, 465
 diagnosis, 467
 physical signs, 466
 pulse in, 466
 valve, clinical anatomy, 310
 True aneurism of thoracic aorta, 478
 Trypanosome gambiense in cerebro-
 spinal fluid, 64
 Tubercle friction, 503
 in tuberculous peritonitis, 516
 Tuberculin reaction, 67
 test, Calmette's, 68
 Koch's, 67
 von Pirquet's, 67
 Tuberculofibrosis of lungs, 234
 Tuberculosis, chronic ulcerative, Ras-
 mussen's aneurism in, 222
 of bronchial glands, 299
 Tugging, tracheal, 328
 Tumors of mediastinum, 301
 clinical pathology, 301
 diagnosis, 307
 physical signs, 302
 of pleura, 295
 of stomach, pain in, 526
 pulmonary, 260
 Tuning-fork auscultation, 28
 Turrettini's sign, 398
 Tussile fremitus, 134
 Tympanic percussion-sounds, 13, 19
 Tympanites, pulmonary, 145
 Tympany, bell, 150
 from parabronchial consolidations,
 146
 gastric, decrease of, 531
 increase of, 531
 in bronchiectatic cavities, 145
 in pneumothorax, 146
 in pulmonary cavities, 145
 pulmonary, 144
 acute, 145
 Typhoid pneumonia, 208

 ULCER, gastric, pain of, 526
 x-ray examination in, 525
 Ulcerative endocarditis, 423

- Ulcerative phthisis, chronic, 220. See also *Phthisis, chronic ulcerative*.
- Ulceres du poumon, 255
- Umbilical changes, 514
notch, 539
region, 499
pain in, 518
- Umbilicus, 497
- Uremic dyspnea, 101
- VALVES, aortic, 310**
areas, 310
of heart, 356
beaded excrescences of, 423
ileocecal, 533
mitral, 310
of heart, 310
polypous lesions of, 423
pulmonic, 310
tricuspid, 310
verrucose excrescences of, 423
villous lesions of, 423
- Valvular disease, chronic, 427
- Valvulitis, 421
- Varicose aneurism, 479
- Varix, aneurismal, 478
- Vascular dulness, area of, 352
murmurs, 392
- Veiled puff, Laennec's, 155
- Veines fluides, 373
- Veins, cervical, respiratory, turgescence, 129
engorgement of, 326
enlarged and tortuous, over abdomen, 514
enlargement of, about sternum, 105
of costal arch, 106
of lower thorax, 106
of upper arm, 105
over thorax, 104
fluid, 373
innominate, clinical anatomy, 311
jugular, diastolic collapse, 323
engorgement of, 326
pulsations of, 322
mammary, enlarged, 105
ramification of, over upper chest, 105
tortuosity of, over thorax, 104
- Vena cava, inferior, clinical anatomy, 497
superior aneurism of, 490
clinical anatomy, 311
- Venous blood-pressure, instrumental estimation, 36
Oliver's method of estimating, 36
bruit, hepatic, 549
engorgement, 325
- Venous flow, direction of, 105
hum, 394
pulse, 346
auricular, 347
in aortic regurgitation, 435
penetrating, 349
physiologic, 42
ventricular, 348
sphygmogram, 42
suffusion of neck, 129
- Ventricular diastole, 314
extrasystoles, 365
fibrillation, 370
systole, 314
- Vermiform appendix, clinical anatomy, 533
- Verneuil's pseudolipoma, 90
- Verrucose excrescences of valves, 423
- Vertebra, twelfth thoracic, line of, 77
- Vertebral reflexes, 22
- Vesicular emphysema, 240. See also *Emphysema, pulmonary*.
râles, 162
resonance, 137. See also *Resonance, pulmonary*.
respiration, 152
- Vesiculocavernous respiration, 154
- Vesiculotympanic resonance, 144
- Vesiculotympany in hypertrophic emphysema of lungs, 244
- Vicarious emphysema of lungs, 246
- Villous lesions of valves, 423
- Viscera, abdominal, examination of, 495
topographic lines and areas, 498
- Visceral paracentesis, 64
pleura, 127
- Vocal fremitus, 131
resonance, 159
- Voice fremitus, influence of decubitus on, 132
- Voillemier's point, 519
- von Pirquet's tuberculin test, 67
- WAIST, wasp, 86**
- Wandering pneumonia, 199
- Wassermann reaction in cerebrospinal fluid, 64
- Water-hammer pulse in aortic regurgitation, 454
- Water-whistle noise, 165
in pneumothorax, 292
- Whispering pectoriloquy, 159
- White hepatization of lung, 237
pneumonia, 237
of fetus, 237

- Williams' sign in phthisis, 227
tracheal tone, 149
Winged scapulæ, 78
Winter cough, 146
Wintrich's interrupted change of note,
148
sign, 148
Woillez's disease, 186
- XIPHISTERNAL crunching, 358
joint, 71
Xiphoid crepitation, 516
region, thrill over, 328
X-rays. See *Röntgen rays*.
- ZAGOUMENNY'S rule, 53
Zones, spinal percussion, 21

SAUNDERS' BOOKS

on

**Skin, Genito-Urinary,
Chemistry, Eye, Ear, Nose,
and Throat, and Dental**

W. B. SAUNDERS COMPANY

WEST WASHINGTON SQUARE PHILADELPHIA

9, HENRIETTA STREET, COVENT GARDEN, LONDON

Davis' Accessory Sinuses

Development and Anatomy of the Nasal Accessory Sinuses in Man. By WARREN B. DAVIS, M. D., Corinna Borden Keen Research Fellow of the Jefferson Medical College, Philadelphia. Octavo of 172 pages, with 57 original illustrations. Cloth, \$3.50 net.

ORIGINAL DISSECTIONS

This book is based on the study of two hundred and ninety lateral nasal walls, presenting the anatomy and physiology of the nasal accessory sinuses from the *sixtieth day of fetal life to advanced maturity*. It represents the *original research work* and personal dissections of Dr. Davis at the Daniel Baugh Institute of Anatomy of Philadelphia and at the Friedrichshain Krankenhaus of Berlin. It was necessary for Dr. Davis to develop a *new technic* by which the accessory sinus areas could be removed *en masse* at the time of postmortem examinations, and still permit of reconstruction of the face without marked disfigurement. Ninety-six cases in this series were thus obtained. The *tables of averages*, giving you the age, size of ostia, origin, thickness of septum, and anterior and posterior walls, vertical, lateral, and posterior diameters, and relation to the nasal floor, form an extremely valuable feature.

Stelwagon's Diseases of the Skin

A Treatise on Diseases of the Skin. By HENRY W. STELWAGON, M. D., PH. D., Professor of Dermatology in the Jefferson Medical College, Philadelphia. Octavo of 1250 pages, with 331 text-cuts and 33 plates. Cloth, \$6.00 net; Half Morocco, \$7.50 net.

THE NEW (7th) EDITION

There are two features in Dr. Stelwagon's work that stand out above all the others: The special emphasis given the two practical phases of the subject—*diagnosis* and *treatment*; and the *wealth of illustrations*. These latter are of real value. They teach you diagnosis as no description can. Many of these illustrations are *in colors*.

Over 75 pages of the work are devoted to *syphilis*, giving you the Wassermann test, the salvarsan ("606") treatment, and all the newest advances. *Pellagra*, tropical affections, *hookworm disease*, Oriental sore, ringworm, impetigo contagiosa—all those diseases being so widely discussed to-day.

George T. Elliot, M. D., *Professor of Dermatology, Cornell University.*

"It is a book that I recommend to my class at Cornell, because for conservative judgment, for accurate observation, and for a thorough appreciation of the essential position of dermatology, I think it holds first place."

Schamberg's Diseases of the Skin and Eruptive Fevers

Diseases of the Skin and the Eruptive Fevers. By JAY F. SCHAMBERG, M. D., Professor of Dermatology and the Infectious Eruptive Diseases, Philadelphia Polyclinic. Octavo of 573 pages, illustrated. Cloth, \$3.00 net.

THE NEW (2d) EDITION

"The acute eruptive fevers constitute a valuable contribution, the statements made emanating from one who has studied these diseases in a practical and thorough manner from the standpoint of cutaneous medicine. . . . The views expressed on all topics are conservative, safe to follow, and practical, and are well abreast of the knowledge of the present time, both as to general and special pathology, etiology, and treatment."—*American Journal of Medical Sciences.*

Norris'

Gonorrhoea in Women

Gonorrhoea in Women. By CHARLES C. NORRIS, M. D., Instructor in Gynecology, University of Pennsylvania, with an Introduction by JOHN G. CLARK, M. D., Professor of Gynecology, University of Pennsylvania. Large octavo of 520 pages, illustrated. Cloth, \$6.00 net.

A CLASSIC

Dr. Norris here presents a work that is destined to take high place among publications on this subject. He has done his work thoroughly. He has searched the important literature very carefully, over 2300 references being utilized. This, coupled with Dr. Norris' long experience, gives his work the stamp of authority. The chapter on serum and vaccine therapy and organotherapy is particularly valuable because it expresses the newest advances. Every phase of the subject is considered.

Pennsylvania Medical Journal

"Dr. Norris has succeeded in presenting most comprehensively the present knowledge of gonorrhoea in women in its many phases. The present status of serum and vaccine therapy is given in detail."

Sharp's

Ophthalmology for Veterinarians

Ophthalmology for Veterinarians. By WALTER N. SHARP, M. D., Professor of Ophthalmology in the Indiana Veterinary College. 12mo of 210 pages, illustrated. Cloth, \$2.00 net.

ILLUSTRATED

This new work covers a much neglected but important field of veterinary practice. Dr. Sharp has presented his subject in a concise, crisp way, so that you can pick up this book and get to "the point" quickly. He first gives you the anatomy of the eye, then examination, followed by the various diseases, including injuries, parasites, errors of refraction, and medicines.

Dr. George H. Glover, *Agricultural Experiment Station, Fort Collins.*

"The best book on the subject on the market."

Barnhill and Wales' Modern Otology

A Text-Book of Modern Otology. By JOHN F. BARNHILL, M. D., Professor of Otology, Laryngology, and Rhinology, and EARNEST DE W. WALES, M. D., Associate Professor of Otology, Laryngology, and Rhinology, Indiana University School of Medicine, Indianapolis. Octavo of 598 pages, with 314 original illustrations. Cloth, \$5.50 net; Half Morocco, \$7.00 net.

THE NEW (2d) EDITION

The authors, in writing this work, kept ever in mind the needs of the physician engaged in general practice. It represents the results of personal experience as practitioners and teachers, influenced by the instruction given by such authorities as Sheppard, Dundas Grant, Percy Jakins, Jansen, and Alt. Much space is devoted to prophylaxis, diagnosis, and treatment, both *medical and surgical*. There is a special chapter on *the bacteriology of ear affections*—a feature not to be found in any other work on otology. Great pains have been taken with the illustrations, in order to have them as practical and as helpful as possible, and at the same time highly artistic. A large number represent the best work of Mr. H. F. Aitken.

PERSONAL AND PRESS OPINIONS

Frank Allport, M. D.

Professor of Otology, Northwestern University, Chicago.

"I regard it as one of the best books in the English language on this subject. The pictures are especially good, particularly as they are practically all original and not the old reproduced pictures so frequently seen."

C. C. Stephenson, M. D.

Professor of Ophthalmology and Otology, College of Physicians and Surgeons, Little Rock, Arkansas.

"To my mind there is no work on modern otology that can for a moment compare with 'Barnhill and Wales.'"

Journal American Medical Association

"Its teaching is sound throughout and up to date. The strongest chapters are those on suppuration of the middle ear and the mastoid cells, and the intracranial complications of ear disease."

DeSchweinitz's Diseases of the Eye

Seventh Edition

Diseases of the Eye: A HANDBOOK OF OPHTHALMIC PRACTICE.
By G. E. DESCHWEINITZ, M.D., Professor of Ophthalmology in the University of Pennsylvania, Philadelphia, etc. Handsome octavo of 979 pages, 360 text-illustrations, and 7 chromo-lithographic plates. Cloth, \$5.00 net; Sheep or Half Morocco, \$6.50 net.

WITH 360 TEXT-ILLUSTRATIONS AND 7 COLORED PLATES

THE STANDARD AUTHORITY

Dr. deSchweinitz's book has long been recognized as a standard authority upon eye diseases, the reputation of its author for accuracy of statement placing it far in the front of works on this subject. For this edition Dr. deSchweinitz has subjected his book to a most thorough revision. Many new subjects have been added, a number in the former edition have been rewritten, and throughout the book reference has been made to vaccine and serum therapy, to the relation of tuberculosis to ocular disease, and to the value of tuberculin as a diagnostic and therapeutic agent.

The text is fully illustrated with black and white cuts and colored plates, and in every way the book maintains its reputation as an authority upon the eye.

PERSONAL AND PRESS OPINIONS

Samuel Theobald, M.D.,

Clinical Professor of Ophthalmology, Johns Hopkins University, Baltimore.

"It is a work that I have held in high esteem, and is one of the two or three books upon the eye which I have been in the habit of recommending to my students in the Johns Hopkins Medical School."

University of Pennsylvania Medical Bulletin

"Upon reading through the contents of this book we are impressed by the remarkable fulness with which it reflects the notable contributions recently made to ophthalmic literature. No important subject within its province has been neglected."

Johns Hopkins Hospital Bulletin

"No single chapter can be selected as the best. They are all the product of a finished authorship and the work of an exceptional ophthalmologist. The work is certainly one of the best on ophthalmology extant, and probably the best by an American author."

GET
THE BEST

American Illustrated Dictionary

THE NEW
STANDARD

New (7th) Edition—5000 Sold in Two Months

The American Illustrated Medical Dictionary. A new and complete dictionary of the terms used in Medicine, Surgery, Dentistry, Pharmacy, Chemistry, Veterinary Science, Nursing, and kindred branches; with over 100 new and elaborate tables and many illustrations. By W. A. NEWMAN DORLAND, M.D., Editor of "The American Pocket Medical Dictionary." Large octavo, with 1107 pages, bound in full flexible leather. Price, \$4.50 net; with thumb index, \$5.00 net.

KEY TO CAPITALIZATION AND PRONUNCIATION—ALL THE NEW WORDS

This dictionary is the "new standard." It defines hundreds of the newest terms not defined in any other dictionary—bar none. These terms are live, active words, taken right from modern medical literature.

Howard A. Kelly, M. D.,

Professor of Gynecologic Surgery, Johns Hopkins University, Baltimore

"Dr. Dorland's Dictionary is admirable. It is so well gotten up and of such convenient size. No errors have been found in my use of it."

Theobald's Prevalent Eye Diseases

Prevalent Diseases of the Eye. By SAMUEL THEOBALD, M. D., Clinical Professor of Ophthalmology and Otolaryngology, Johns Hopkins University. Octavo of 550 pages, with 219 text-cuts and several colored plates. Cloth, \$4.50 net; Half Morocco, \$6.00 net.

THE PRACTITIONER'S OPHTHALMOLOGY

With few exceptions all the works on diseases of the eye, although written ostensibly for the general practitioner, are in reality adapted only to the specialist; but Dr. Theobald in his book has described very clearly and in detail those conditions, the diagnosis and treatment of which come within the province of the general practitioner. The therapeutic suggestions are concise, unequivocal, and specific. It is the one work on the Eye written particularly for the general practitioner.

Charles A. Oliver, M.D.,

Clinical Professor of Ophthalmology, Woman's Medical College of Pennsylvania.

"I feel I can conscientiously recommend it, not only to the general physician and medical student, for whom it is primarily written, but also to the experienced ophthalmologist. Most surely Dr. Theobald has accomplished his purpose."

Haab and DeSchweinitz's External Diseases of the Eye

Atlas and Epitome of External Diseases of the Eye. By DR. O. HAAB, of Zürich. Edited, with additions, by G. E. DESCHWEINITZ, M. D., Professor of Ophthalmology, University of Pennsylvania. With 101 colored illustrations on 46 lithographic plates and 244 pages of text. Cloth, \$3.00 net. *In Saunders' Hand-Atlas Series.*

THE NEW (3d) EDITION

Conditions attending diseases of the external eye, which are often so complicated, have probably never been more clearly and comprehensively expounded than in the foregoing work, in which the pictorial most happily supplements the verbal description. The price of the book is remarkably low.

The Medical Record, New York

"The work is excellently suited to the student of ophthalmology and to the practising physician. It cannot fail to attain a well-deserved popularity."

Haab and DeSchweinitz's Ophthalmoscopy

Atlas and Epitome of Ophthalmoscopy and Ophthalmoscopic Diagnosis. By Dr. O. HAAB, of Zürich. Edited, with additions, by G. E. DESCHWEINITZ, M. D., Professor of Ophthalmology, University of Pennsylvania. With 152 colored lithographic illustrations and 92 pages of text. Cloth, \$3.00 net. *In Saunders' Hand-Atlas Series.*

THE NEW (2d) EDITION

The great value of Prof. Haab's Atlas of Ophthalmoscopy and Ophthalmoscopic Diagnosis has been fully established and entirely justified an English translation. Not only is the student made acquainted with carefully prepared ophthalmoscopic drawings done into well-executed lithographs of the most important fundus changes, but, in many instances, plates of the microscopic lesions are added. The whole furnishes a manual of the greatest possible service.

The Lancet, London

"We recommend it as a work that should be in the ophthalmic wards or in the library of every hospital into which ophthalmic cases are received."

Gradle's Nose, Pharynx, and Ear

Diseases of the Nose, Pharynx, and Ear. By HENRY GRADLE, M.D., late Professor of Ophthalmology and Otology, Northwestern University Medical School, Chicago. Octavo of 547 pages, illustrated, including two full-page plates in colors. Cloth, \$3.50 net.

INCLUDING TOPOGRAPHIC ANATOMY

This volume presents diseases of the Nose, Pharynx, and Ear as the author has seen them during an experience of nearly twenty-five years. In it are answered in detail those questions regarding the course and outcome of diseases which cause the less experienced observer the most anxiety in an individual case. Topographic anatomy has been accorded liberal space.

Pennsylvania Medical Journal

"This is the most practical volume on the nose, pharynx, and ear that has appeared recently. . . . It is exactly what the less experienced observer needs, as it avoids the confusion incident to a categorical statement of everybody's opinion."

Kyle's Diseases of Nose and Throat

Diseases of the Nose and Throat. By D. BRADEN KYLE, M. D., Professor of Laryngology in the Jefferson Medical College, Philadelphia. Octavo, 825 pages; with 258 illustrations, 28 in colors. Cloth, \$4.50 net; Half Morocco, \$6.00 net.

JUST OUT—THE NEW (5th) EDITION

The *new (5th) edition* of Dr. Kyle's work shows an *increase of 100 pages* and some *40 new illustrations*. The following *new articles* have been added: vaccine therapy; lactic bacteriotherapy; salvarsan in the treatment of syphilis of the upper respiratory tract; sphenopalatine ganglia neuralgia; negative air-pressure in accessory sinus disease; chronic hyperplastic ethmoiditis; and congenital insufficiency of the palate. The *tables of differential diagnosis* and the *prescriptions* are striking points of Dr. Kyle's book.

Pennsylvania Medical Journal

"Dr. Kyle's crisp, terse diction has enabled the inclusion of all needful nose and throat knowledge in this book."

Ogden on the Urine

Clinical Examination of Urine and Urinary Diagnosis. A Clinical Guide for the Use of Practitioners and Students of Medicine and Surgery. By J. BERGEN OGDEN, M. D., Medical Chemist to the Metropolitan Life Insurance Company, New York. Octavo, 418 pages, 54 text illustrations, and a number of colored plates. Cloth, \$3.00 net.

THE NEW (3d) EDITION

In this edition the work has been brought absolutely down to the present day. Urinary examinations for purposes of life insurance have been incorporated, because a large number of practitioners are often called upon to make such analyses. Special attention has been paid to diagnosis by the character of the urine, the diagnosis of diseases of the kidneys and urinary passages; an enumeration of the prominent clinical symptoms of each disease; and the peculiarities of the urine in certain general diseases.

The Lancet, London

"We consider this manual to have been well compiled; and the author's own experience, so clearly stated, renders the volume a useful one both for study and reference."

Pilcher's Practical Cystoscopy

Practical Cystoscopy. By PAUL M. PILCHER, M. D., Consulting Surgeon to the Eastern Long Island Hospital. Octavo of 398 pages, with 233 illustrations, 29 in colors. Cloth, \$5.50 net.

DIAGNOSIS AND TREATMENT

Cystoscopy is to-day the most practical manner of diagnosing and treating diseases of the bladder, ureters, kidneys, and prostate. To be properly equipped, therefore, you must have at your instant command the information this book gives you. It explains away all difficulty, telling you *why* you do not see something when something *is* there to see, and telling you *how* to see it. All theory has been uncompromisingly eliminated, devoting every line to practical, needed-every-day facts, telling you how and when to use the cystoscope and catheter—telling you in a way to make you *know*. The work is complete in every detail.

Bransford Lewis, M. D., *St. Louis University.*

"I am very much pleased with Dr. Pilcher's 'Practical Cystoscopy.' I think it is the best in the English language now."—*April 27, 1911.*

Goepp's Dental State Boards

Dental State Board Questions and Answers.—By R. MAX GOEPP, M. D., author "Medical State Board Questions and Answers." Octavo of 428 pages. Cloth, \$2.75 net.

COMPLETE AND ACCURATE

This new work is along the same practical lines as Dr. Goepp's successful work on Medical State Boards. The questions included have been gathered from reliable sources, and embrace all those likely to be asked in any State Board examination in any State. They have been arranged and classified in a way that makes for a rapid résumé of every branch of dental practice, and the answers are couched in language unusually explicit—concise, definite, accurate.

The practicing dentist, also, will find here a work of great value—a work covering the entire range of dentistry and extremely well adapted for quick reference.

Haab and deSchweinitz's Operative Ophthalmology

Atlas and Epitome of Operative Ophthalmology. By DR. O. HAAB, of Zurich. Edited, with additions, by G. E. DESCHWEINITZ, M. D., Professor of Ophthalmology in the University of Pennsylvania. With 30 colored lithographic plates, 154 text-cuts, and 375 pages of text. *In Saunders' Hand-Atlas Series.* Cloth, \$3.50 net.

Dr. Haab's Atlas of Operative Ophthalmology will be found as beautiful and as practical as his two former atlases. The work represents the author's thirty years' experience in eye work. The various operative interventions are described with all the precision and clearness that such an experience brings. Recognizing the fact that mere verbal descriptions are frequently insufficient to give a clear idea of operative procedures, Dr. Haab has taken particular care to illustrate plainly the different parts of the operations.

Johns Hopkins Hospital Bulletin

"The descriptions of the various operations are so clear and full that the volume can well hold place with more pretentious text-books."

Greene and Brooks' Genito-Urinary Diseases

Diseases of the Genito-Urinary Organs and the Kidney. By ROBERT H. GREENE, M. D., Professor of Genito-Urinary Surgery at Fordham University; and HARLOW BROOKS, M. D., Assistant Professor of Clinical Medicine, University and Bellevue Hospital Medical School. Octavo of 639 pages, illustrated. Cloth, \$5.00 net; Half Morocco, \$6.50 net.

THE NEW (3d) EDITION

This new work presents *both the medical and surgical sides*. Designed as a work of quick reference, it has been written in a clear, condensed style, so that the information can be readily grasped and retained. *Kidney diseases* are very elaborately detailed.

New York Medical Journal

"As a whole the book is one of the most satisfactory and useful works on genito-urinary diseases now extant, and will undoubtedly be popular among practitioners and students."

Gleason on Nose, Throat, and Ear

A Manual of Diseases of the Nose, Throat, and Ear. By E. BALDWIN GLEASON, M. D., LL. D., Professor of Otology, Medico-Chirurgical College, Philadelphia. 12mo of 590 pages, profusely illustrated. Cloth, \$2.50 net.

JUST OUT—THE NEW (3d) EDITION

Methods of treatment have been simplified as much as possible, so that in most instances only those methods, drugs, and operations have been advised which have proved beneficial. A valuable feature consists of the collection of formulas.

American Journal of the Medical Sciences

"For the practitioner who wishes a reliable guide in laryngology and otology there are few books which can be more heartily commended."

American Text-Book of Genito-Urinary Diseases, Syphilis, and Diseases of the Skin. Edited by L. BOLTON BANGS, M. D., and W. A. HARDAWAY, M. D. Octavo, 1229 pages, 300 engravings, 20 colored plates. Cloth, \$7.00 net.

Holland's Medical Chemistry and Toxicology

A Text-Book of Medical Chemistry and Toxicology. By JAMES W. HOLLAND, M.D., Professor of Medical Chemistry and Toxicology, and Dean, Jefferson Medical College, Philadelphia. Octavo of 675 pages, fully illustrated. Cloth, \$3.00 net.

THE NEW (3d) EDITION

Dr. Holland's work is an entirely new one, and is based on his forty years' practical experience in teaching chemistry and medicine. It has been subjected to a thorough revision, and enlarged to the extent of some sixty pages. The additions to be specially noted are those relating to the electronic theory, chemical equilibrium, Kjeldahl's method for determining nitrogen, chemistry of foods and their changes in the body, synthesis of proteins, and the latest improvements in urinary tests. More space is given to toxicology than in any other text-book on chemistry.

American Medicine

"Its statements are clear and terse; its illustrations well chosen; its development logical, systematic, and comparatively easy to follow. . . . We heartily commend the work."

Ivy's Applied Anatomy and Oral Surgery for Dental Students

Applied Anatomy and Oral Surgery for Dental Students. By ROBERT H. IVY, M.D., D.D.S., Assistant Oral Surgeon to the Philadelphia General Hospital. 12mo of 280 pages, illustrated. Cloth, \$1.50 net.

FOR DENTAL STUDENTS

This work is just what dental students have long wanted—a concise, practical work on applied anatomy and oral surgery, written with their needs solely in mind. No one could be better fitted for this task than Dr. Ivy, who is a graduate in both dentistry and medicine. Having gone through the dental school, he knows precisely the dental student's needs and just how to meet them. His medical training assures you that his anatomy is accurate and his technic modern. The text is well illustrated with pictures that you will find extremely helpful.

H. P. Kuhn, M.D., *Western Dental College, Kansas City.*

"I am delighted with this compact little treatise. It seems to me just to fill the bill."

American Pocket Dictionary

New (8th) Edition

THE AMERICAN POCKET MEDICAL DICTIONARY. Edited by W. A. NEWMAN DORLAND, M. D., Editor "American Illustrated Medical Dictionary." Containing the pronunciation and definition of the principal words used in medicine and kindred sciences. 677 pages. Flexible leather, with gold edges, \$1.00 net; with thumb index, \$1.25 net.

James W. Holland, M. D.,

Professor of Medical Chemistry and Toxicology, and Dean, Jefferson Medical College, Philadelphia.

"I am struck at once with admiration at the compact size and attractive exterior. I can recommend it to our students without reserve."

Stelwagon's Essentials of Skin

7th Edition

ESSENTIALS OF DISEASES OF THE SKIN. By HENRY W. STELWAGON, M. D., PH. D., Professor of Dermatology in the Jefferson Medical College, Philadelphia. Post-octavo of 291 pages, with 72 text-illustrations and 8 plates. Cloth, \$1.00 net. *In Saunders' Question-Compend Series.*

The Medical News

"In line with our present knowledge of diseases of the skin. . . . Continues to maintain the high standard of excellence for which these question compends have been noted."

Wolff's Medical Chemistry

New (7th) Edition

ESSENTIALS OF MEDICAL CHEMISTRY, ORGANIC AND INORGANIC. Containing also Questions on Medical Physics, Chemical Physiology, Analytical Processes, Urinalysis, and Toxicology. By LAWRENCE WOLFF, M. D., Late Demonstrator of Chemistry, Jefferson Medical College. Revised by A. FERREE WITMER, PH. G., M. D., Formerly Assistant Demonstrator of Physiology, University of Pennsylvania. Post-octavo of 222 pages. Cloth, \$1.00 net. *In Saunders' Question-Compend Series.*

Bliss' Qualitative Chemical Analysis

QUALITATIVE CHEMICAL ANALYSIS. By A. R. BLISS, JR., PH. G., M. D., Professor of Chemistry and Pharmacy, Birmingham Medical College, Alabama. Octavo of 250 pages. Cloth, \$2.00 net.

Vecki's Sexual Impotence

New (4th) Edition

SEXUAL IMPOTENCE. By VICTOR G. VECKI, M. D., Consulting Genito-Urinary Surgeon to Mt. Zion Hospital, San Francisco. 12mo of 400 pages. Cloth, \$2.25 net.

Johns Hopkins Hospital Bulletin

"A scientific treatise upon an important and much neglected subject. . . . The treatment of impotence in general and of sexual neurasthenia is discriminating and judicious."

Wells' Chemical Pathology Second Edition

Chemical Pathology. Being a discussion of General Pathology from the Standpoint of the Chemical Processes Involved. By H. GIDEON WELLS, PH. D., M. D., Assistant Professor of Pathology in the University of Chicago. Octavo of 616 pages. Cloth, \$3.25 net.

Wm. H. Welch, M. D., *Professor of Pathology, Johns Hopkins University.*

"The work fills a real need in the English literature of a very important subject, and I shall be glad to recommend it to my students."

Saxe's Urinalysis The New (2d) Edition

Examination of the Urine. By G. A. DE SANTOS SAXE, M. D., formerly Instructor in Genito-Urinary Surgery, New York Post-graduate Medical School and Hospital. 12mo of 448 pages, fully illustrated. Cloth, \$1.75 net.

Francis Carter Wood, M. D., *Adjunct Professor of Clinical Pathology, Columbia University.*

"It seems to me to be one of the best of the smaller works on this subject; it is, indeed, better than a good many of the larger ones."

deSchweinitz and Randall on the Eye, Ear, Nose, and Throat

American Text-Book of Diseases of the Eye, Ear, Nose, and Throat. Edited by G. E. DE SCHWEINITZ, M.D., and B. ALEXANDER RANDALL, M.D. Imperial octavo, 1251 pages, with 766 illustrations, 59 of them in colors. Cloth, \$7.00 net; Half Morocco, \$8.50 net.

Grünwald and Grayson on the Larynx

Atlas and Epitome of Diseases of the Larynx. By Dr. L. GRÜNWALD, of Munich. Edited, with additions, by CHARLES P. GRAYSON, M.D., University of Pennsylvania. With 107 colored figures on 44 plates, 25 text-cuts, and 103 pages of text. Cloth, \$2.50 net. *In Saunders' Hand-Atlas Series.*

Mracek and Stelwagon's Atlas of Skin Second Edition

Atlas and Epitome of Diseases of the Skin. By PROF. DR. FRANZ MRACEK, of Vienna. Edited, with additions, by HENRY W. STELWAGON, M.D., Jefferson Medical College. With 77 colored plates, 50 half-tone illustrations, and 280 pages of text. *In Saunders' Hand-Atlas Series.* Cloth, \$4.00 net.

de Schweinitz and Holloway on Pulsating Exophthalmos

PULSATING EXOPHTHALMOS. An analysis of sixty-nine cases not previously analyzed. By GEORGE E. DESCHWEINITZ, M. D., and THOMAS B. HOLLOWAY, M. D. Octavo of 125 pages. Cloth, \$2.00 net.

This monograph consists of an analysis of sixty-nine cases of this affection not previously analyzed. The therapeutic measures, surgical and otherwise, which have been employed are compared, and an endeavor has been made to determine from these analyses which procedures seem likely to prove of the greatest value. It is the most valuable contribution to ophthalmic literature within recent years.

British Medical Journal

"The book deals very thoroughly with the whole subject and in it the most complete account of the disease will be found."

Jackson on the Eye

The New (2d) Edition

A MANUAL OF THE DIAGNOSIS AND TREATMENT OF DISEASES OF THE EYE. By EDWARD JACKSON, A. M., M. D., Professor of Ophthalmology, University of Colorado. 12mo volume of 615 pages, with 184 beautiful illustrations. Cloth, \$2.50 net.

The Medical Record, New York

"It is truly an admirable work. . . . Written in a clear, concise manner, it bears evidence of the author's comprehensive grasp of the subject. The term 'multum in parvo' is an appropriate one to apply to this work."

Grant on Face, Mouth, and Jaws

A TEXT-BOOK OF THE SURGICAL PRINCIPLES AND SURGICAL DISEASES OF THE FACE, MOUTH, AND JAWS. For Dental Students. By H. HORACE GRANT, A. M., M. D., Professor of Surgery and of Clinical Surgery, Hospital College of Medicine, Louisville. Octavo of 231 pages, with 68 illustrations. Cloth, \$2.50 net.

Preiswerk and Warren's Dentistry

ATLAS AND EPITOME OF DENTISTRY. By PROF. G. PREISWERK, of Basil. Edited, with additions, by GEORGE W. WARREN, D.D.S., Professor of Operative Dentistry, Pennsylvania College of Dental Surgery, Philadelphia. With 44 lithographic plates, 152 text-cuts, and 343 pages of text. Cloth, \$3.50 net. *In Saunders' Atlas Series.*

Asher's Chemistry and Toxicology

CHEMISTRY AND TOXICOLOGY FOR NURSES. By PHILIP ASHER, PH.G., M. D., Dean and Professor of Chemistry, New Orleans College of Pharmacy. 12mo of 190 pages. Cloth, \$1.25 net.

Wolf's Examination of Urine

A LABORATORY HANDBOOK OF PHYSIOLOGIC CHEMISTRY AND URINE-EXAMINATION. By CHARLES G. L. WOLF, M. D., Instructor in Physiologic Chemistry, Cornell University Medical College, New York. 12mo volume of 204 pages, fully illustrated. Cloth, \$1.25 net.

British Medical Journal

"The methods of examining the urine are very fully described, and there are at the end of the book some extensive tables drawn up to assist in urinary diagnosis."

Jackson's Essentials of Eye

Third Revised Edition

ESSENTIALS OF REFRACTION AND OF DISEASES OF THE EYE. By EDWARD JACKSON, A. M., M. D., Emeritus Professor of Diseases of the Eye, Philadelphia Polyclinic. Post-octavo of 261 pages, 82 illustrations. Cloth, \$1.00 net. *In Saunders' Question-Compend Series.*

Johns Hopkins Hospital Bulletin

"The entire ground is covered, and the points that most need careful elucidation are made clear and easy."

Gleason's Nose and Throat

Fourth Edition, Revised

ESSENTIALS OF DISEASES OF THE NOSE AND THROAT. By E. B. GLEASON, S. B., M. D., Clinical Professor of Otolaryngology, Medico-Chirurgical College, Philadelphia, etc. Post-octavo, 241 pages, 112 illustrations. Cloth, \$1.00 net. *In Saunders' Question-Compend Series.*

The Lancet, London

"The careful description which is given of the various procedures would be sufficient to enable most people of average intelligence and of slight anatomical knowledge to make a very good attempt at laryngoscopy."

Gleason's Diseases of the Ear

Third Edition, Revised

ESSENTIALS OF DISEASES OF THE EAR. By E. B. GLEASON, S. B., M. D., Clinical Professor of Otolaryngology, Medico-Chirurgical College, Phila., etc. Post-octavo volume of 214 pages, with 114 illustrations. Cloth, \$1.00 net. *In Saunders' Question-Compend Series.*

Bristol Medico-Chirurgical Journal

"We know of no other small work on ear diseases to compare with this, either in freshness of style or completeness of information."

Wilcox on Genito-Urinary and Venereal Diseases

The New (2d) Edition

ESSENTIALS OF GENITO-URINARY AND VENEREAL DISEASES. By STARLING S. WILCOX, M. D., Lecturer on Genito-Urinary Diseases and Syphilology, Starling-Ohio Medical College, Columbus. 12mo of 321 pages, illustrated. Cloth, \$1.00 net. *Saunders' Compend Series.*

Stevenson's Photocopy

PHOTOCOPY (Skiascopy or Retinoscopy). By MARK D. STEVENSON, M. D., Ophthalmic Surgeon to the Akron City Hospital. 12mo of 126 pages, illustrated. Cloth, \$1.25 net.

Edward Jackson, M. D., University of Colorado.

"It is well written and will prove a valuable help. Your treatment of the emergent pencil of rays, and the part falling on the examiner's eye, is decidedly better than any previous account."

University of California
SOUTHERN REGIONAL LIBRARY FACILITY
405 Hilgard Avenue, Los Angeles, CA 90024-1388
Return this material to the library
from which it was borrowed.

0LL

2 WKS FROM RECEIPT

UCSD

MAR 09 1992

NON-RENEWABLE

RECEIVED

MAR 30 1992

THE LIBRARY
UNIVERSITY OF CALIFORNIA
LOS ANGELES

200 Physical diagno-
D118p sis.
1915

Biomedical
Library


3 1 000 345 788 4

Biomedical
Library
WB
200
D118p
1915

UC SOUTHERN REGIONAL LIBRARY FACILITY

A 000 345 788 4

