

UC-NRLF



B 4 096 690


QUAIN'S ANATOMY

E. A. SCHÄFER & G. D. THANE

VOLUME II.
THE NERVES

G. D. THANE

MEDICAL SCHOOL
LIBRARY



John Marshall Williamson
Memorial



QUAIN'S
ELEMENTS OF ANATOMY

EDITED BY

EDWARD ALBERT SCHÄFER, F.R.S.

PROFESSOR OF PHYSIOLOGY AND HISTOLOGY IN UNIVERSITY COLLEGE, LONDON,

AND

GEORGE DANCER THANE,

PROFESSOR OF ANATOMY IN UNIVERSITY COLLEGE, LONDON.

IN THREE VOLUMES.

VOL. III.—PART II.

THE NERVES.

BY PROFESSOR THANE.

ILLUSTRATED BY 102 ENGRAVINGS.

Tenth Edition.

LONDON:
LONGMANS, GREEN, AND CO.
AND NEW YORK.

1895.

[All rights reserved.]

UNIV OF CALIF

LONDON:
BRADBURY, AGNEW, & CO. LD., PRINTERS, WHITEFRIARS.

Q M 23
 Q 25
 v. 312
 1895

CONTENTS OF PART II.

THE NERVES.

	PAGE		PAGE
THE CEREBRO-SPINAL NERVES	221	SPINAL NERVES— <i>continued.</i>	
CRANIAL NERVES	221	Brachial Plexus—	
Connection with Cerebro-Spinal Axis	222	Small Internal Cutaneous Nerve	296
Mode of Exit from the Cranium	223	Musculo-Cutaneous Nerve	297
General Distribution	225	Ulnar Nerve	299
I. Olfactory Nerves	227	Median Nerve	301
II. Optic Nerve	227	Musculo-Spiral Nerve	303
III. Oculomotor Nerve	228	Radial Nerve	304
Position of Nerves at the Caver- nous Sinus and as they enter the Orbit	231	Posterior Interosseous Nerve	306
IV. Trochlear Nerve	231	Dorsal Nerves	307
V. Trifacial Nerve	233	First Dorsal Nerve	307
Ophthalmic Nerve	235	Upper or Pectoral Intercostal Nerves	308
Ciliary Ganglion	237	Lower or Abdominal Intercostal Nerves	310
Superior Maxillary Nerve	238	Last Dorsal Nerve	311
Spheno-Palatine Ganglion	241	Lumbar Nerves	311
Inferior Maxillary Nerve	243	Lumbar Plexus	312
Submaxillary Ganglion	248	Ilio-Hypogastric and Ilio-Inguinal Nerves	314
Otic Ganglion	248	Genito-Crural Nerve	315
VI. Abducent Nerve	250	External Cutaneous Nerve	317
VII. Facial Nerve	251	Obturator Nerve	317
VIII. Auditory Nerve	256	Anterior Crural Nerve	319
IX. Glosso-Pharyngeal Nerve	258	Fifth Lumbar Nerve	322
X. Pncumo-Gastric Nerve	261	Sacral and Coccygeal Nerves	322
XI. Spinal Accessory Nerve	269	Fourth Sacral Nerve	323
XII. Hypoglossal Nerve	271	Fifth Sacral Nerve	323
SPINAL NERVES	274	Coccygeal Nerve	323
The Roots of the Spinal Nerves	275	Sacral Plexus	323
Posterior Primary Divisions of the Spinal Nerves	278	Collateral Branches	325
Suboccipital Nerve	278	Small Muscular Branches	325
Cervical Nerves	280	Superior Gluteal Nerve	325
Dorsal Nerves	280	Inferior Gluteal Nerve	326
Lumbar Nerves	281	Small Sciatic Nerve	326
Sacral Nerves	281	Perforating Cutaneous Nerve	328
Coccygeal Nerve	283	Terminal Branches	328
Anterior Primary Divisions of the Spinal Nerves	283	Pudic Nerve	328
Cervical Nerves	283	Great Sciatic Nerve	330
Suboccipital Nerve	283	Internal Popliteal Nerve	331
Second Cervical Nerve	284	Posterior Tibial Nerve	332
Cervical Plexus	285	Internal Plantar Nerve	333
Superficial Ascending Branches	286	External Plantar Nerve	334
Superficial Descending Branches	287	External Popliteal Nerve	335
Deep Branches : Internal Series	287	Musculo-Cutaneous Nerve	336
Deep Branches : External Series	288	Anterior Tibial Nerve	337
Brachial Plexus	289	SYNOPSIS OF THE SENSORY DISTRIBUTION OF THE CEREBRO-SPINAL NERVES	338
Branches above the Clavicle	291	Cutaneous Distribution of the Spinal Nerves to the Trunk and Limbs	344
Branches below the Clavicle	294	Sensory Distribution of the Spinal Nerves to the Viscera	350
Anterior Thoracic Nerves	294	Literature of the Distribution of Sensory Nerves	351
Subscapular Nerves	294		
Circumflex Nerve	294		
Internal Cutaneous Nerve	295		

	PAGE		PAGE
SYNOPSIS OF THE MUSCULAR DISTRIBUTION OF THE CEREBRO-SPINAL NERVES	351	Cardiac Plexus	372
Muscular Distribution of the Spinal Nerves	354	Solar or Epigastric Plexus	373
Literature of the Muscular Distribution of Spinal Nerves	356	Hypogastric Plexus	377
SYMPATHETIC NERVES	357	Pelvic Plexus	377
Gangliated Cords	358	Recent Literature of the Sympathetic	379
Rami Communicantes	358	MORPHOLOGY OF THE PERIPHERAL NERVES	381
Rami Efferentes	360	SPINAL NERVES	381
Prevertebral Plexuses	361	Segmentation	381
Cervical Part of the Gangliated Cord	361	Mode of Division	381
Upper Cervical Ganglion	361	Posterior Primary Divisions	381
Ascending Branch and Cranial Plexuses	362	Anterior Primary Divisions	381
Pharyngeal Nerves and Plexus	363	Nerves of the Limbs	382
Upper Cardiac Nerve	363	Meningeal Divisions	384
Branches to Blood-Vessels	364	Visceral Divisions	384
Middle Cervical Ganglion	365	Ganglia	384
Lower Cervical Ganglion	365	Constitution of a Segmental Nerve	384
Thoracic Part of the Gangliated Cord	367	CRANIAL NERVES	385
Lumbar Part of the Gangliated Cord	370	Constitution of the Cranial Nerves	385
Sacral Part of the Gangliated Cord	370	Ganglia	387
The Great Plexuses of the Sympathetic	372	Segmentation	388
		Course and Distribution	390
		Literature of the Morphology of the Peripheral Nerves	390
		INDEX	393

THE NERVES.

By G. D. THANE.

IN this section is comprised the descriptive anatomy of the cerebro-spinal and sympathetic nerves, and their ganglia. Together with these the peripheral division of the nervous system also includes the organs of the external senses, which will be described in the following section. The minute structure of the nerves and their mode of ending in the several tissues and organs of the body are discussed in the sections General Anatomy and Splanchnology.

The separation of the sympathetic from the cerebro-spinal nerves is convenient for purposes of description, but does not indicate a difference of origin or an anatomical independence of the two systems, since the fibres composing the sympathetic are connected centrally, either directly or indirectly, with the cerebro-spinal axis, which they leave as constituents of the roots of certain of the cerebro-spinal nerves. Moreover, the division cannot in all cases be strictly maintained, for some of the ganglia (ciliary, spheno-palatine, otic, and submaxillary), which are described in connection with the cranial nerves to which they are attached, have a close affinity with those of the sympathetic system, while on the other hand many of the terminal plexuses distributed to the viscera, and generally regarded as parts of the sympathetic system, are composed in large part of fibres which pass into them directly from cerebro-spinal nerves without traversing the cord of the sympathetic.

THE CEREBRO-SPINAL NERVES.

The nerves springing directly from the great cerebro-spinal centre constitute a series of symmetrical pairs, of which twelve issue from the cranium through different apertures in its base, and are thence named *cranial*. The next following nerve passes out between the occipital bone and the atlas, and the remaining thirty nerves all issue below the successive segments of the vertebral column. The first is sometimes distinguished by the name of *suboccipital*, but to the whole series of thirty-one nerves the name of *spinal* will be here given.

CRANIAL NERVES.

The cranial nerves (*nervi cerebrales*), besides being distinguished by numbers in the order of their passage through the dura mater lining the cranium, have likewise received other names, according to the place or mode of their distribution, or their functions.

The number of the cranial nerves is now universally stated as twelve, following the enumeration which was proposed by Sæmmering in 1778, but has only recently been adopted in this country. Previously they were reckoned as nine pairs, in accordance with the classification of Willis (1664), in which the facial and auditory together compose the seventh pair, while the glosso-pharyngeal, pneumo-gastric, and spinal accessory are included in the eighth. Willis also looked upon the suboccipital as a cranial nerve, and thus counted ten

pairs. The two arrangements, as well as the special designations of the several nerves, are shown in the following table:—

WILLIS.	SEMMEERING.	OTHER NAMES.
First pair of nerves . . .	First pair of nerves . . .	Olfactory nerves.
Second " . . .	Second " . . .	Optic.
Third " . . .	Third " . . .	Common oculomotor.
Fourth " . . .	Fourth " . . .	Pathetic or trochlear.
Fifth " . . .	Fifth " . . .	Trifacial or trigeminal.
Sixth " . . .	Sixth " . . .	Abducent ocular.
Seventh " { portio dura . . .	Seventh " . . .	Facial motor.
" { portio mollis . . .	Eighth " . . .	Auditory.
Eighth " { n. vagus . . .	{ Ninth " . . .	Glosso-pharyngeal.
" { n. accessorius . . .	{ Tenth " . . .	Pneumo-gastric or vagus.
Ninth " . . .	Eleventh " . . .	Spinal accessory,
Tenth " . . .	Twelfth " . . .	Hypoglossal or lingual motor.
	First cervical . . .	Suboccipital.

Connection with the cerebro-spinal axis.—The place at which a cranial nerve is attached to the surface of the cerebro-spinal axis is usually termed the

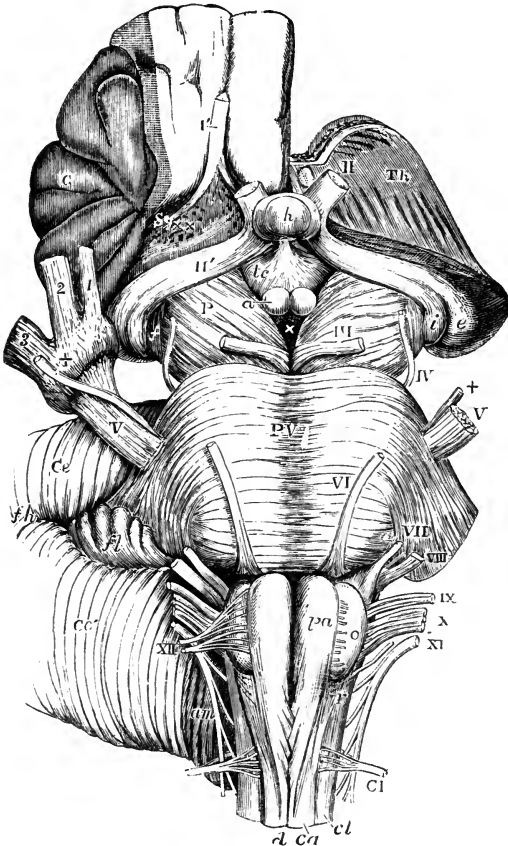


Fig. 140.—VENTRAL ASPECT OF THE BRAIN-STEM, SHOWING THE ATTACHMENTS OF THE PRINCIPAL CRANIAL NERVES. (Allen Thomson.)

The full description of this figure will be found at p. 41. The following references apply to the roots of the nerves: I', right olfactory tract, divided near its middle; II, left optic nerve, springing from the commissure, which is concealed by the pituitary body; II', right optic tract; the left tract is seen passing back into *i* and *e*, the internal and external corpora geniculata; III, left oculomotor nerve; IV, trochlear; V, V, large roots of the trifacial nerves; + +, small roots, the + of the right side is placed on the Gasserian ganglion; 1, ophthalmic, 2, superior maxillary, and 3, inferior maxillary nerves; VI, left abducent nerve; VII, facial; VIII, auditory; IX, glosso-pharyngeal; X, pneumo-gastric; XI, spinal accessory; XII, left hypoglossal nerve; at *o*, on the right side, the rootlets are seen cut short; C I, suboccipital or first cervical nerve.

superficial origin of the nerve. From this apparent origin the nerve-roots can be traced for a variable depth within the substance of the axis to certain collections of nerve-cells or *nuclei*, the connection with which is said to constitute the *deep origin* of the nerve. It is evident, however, that these terms are pro-

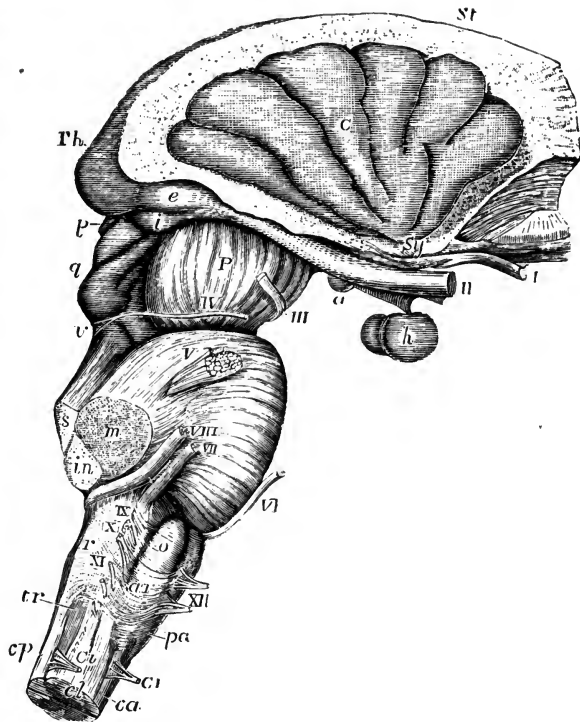
perly applicable only to the central connections of the motor or efferent nerves, the fibres of which are outgrowths of nerve-cells contained in the respective nuclei, whereas the sensory or afferent fibres originate generally in the cells of the ganglia found upon the nerve-trunks in the immediate neighbourhood of the axis, and grow

inwards to their so-called nuclei, in which they end without forming, so far as is known, any direct connection with the nerve-cells.

The superficial attachments of the cranial nerves are quite obvious: the filaments of the first pair spring from the olfactory lobes of the cerebral hemispheres; the second pair arise from the optic thalami and the dorsal part of the mesencephalon; the third are attached to the crura cerebri or ventral part of the mesencephalon; the fourth to the valve of Vieussens; the fifth to the pons; and the remainder to the medulla oblongata, with the exception of the greater part of the eleventh pair, which arise from the cervical portion of the spinal cord. The course of the fibres within the cerebro-spinal axis, and their connection

Fig. 141.—LATERAL VIEW OF THE BRAIN-STEM, SHOWING THE ATTACHMENTS OF THE CRANIAL NERVES. (Allen Thomson.)

The full description of this figure will be found at p. 42. The following references apply to the roots of the nerves; I, right olfactory tract, cut near its middle; II, the optic nerves immediately in front of the commissure; the right optic tract is seen passing back to the thalamus (*Th*), corpora geniculata (*i*, *e*), and corpora quadrigemina (*q*); III, oculomotor nerve; IV, trochlear nerve arising at *v*, from the valve of Vieussens; V, trifacial nerve; VI, abducent ocular; VII, VIII, facial and auditory nerves; between them the pars intermedia; IX, glosso-pharyngeal; X, pneumogastric; XI, spinal accessory; XII, hypoglossal; C I, the separate anterior and posterior roots of the sub-occipital or first cervical nerve.



with the nerve-nuclei are more difficult to follow, and in many respects are as yet but imperfectly understood. They have been fully discussed in the accounts of the parts of the spinal cord and brain in which they occur, and to these reference may be made for farther details than are given in the following descriptions.

Mode of exit from the cranium.—Each of the cranial nerves, after traversing the subarachnoid space and piercing the arachnoid, from which it receives a sheath generally of very short extent (see p. 188), enters an aperture in the dura mater (in the case of the third, fourth, fifth and sixth nerves at some distance from the osseous foramina by which they emerge), and carries with it in its passage from the cranial cavity a tubular prolongation of that membrane. Some of these nerves, or their main divisions, are contained in distinct foramina of the cranium, others are grouped together in one foramen. The numerous small olfactory nerves descend into the nose through the cribriform plate of the ethmoid bone; the optic nerve pierces the base of the small wing of the sphenoid bone; the third, fourth, and sixth nerves, with the ophthalmic division of the fifth, pass through the sphenoidal fissure; the superior maxillary and inferior maxillary divisions of the fifth pass respectively through the foramen rotundum and foramen ovale of the great wing of the

sphenoid ; the facial and auditory nerves enter the internal auditory meatus of the petrous bone ; the glosso-pharyngeal, pneumo-gastric, and spinal accessory nerves descend through the middle compartment of the jugular foramen between the petrous and occipital bones ; and the hypoglossal nerve passes through the anterior condylar foramen of the occipital bone.

A

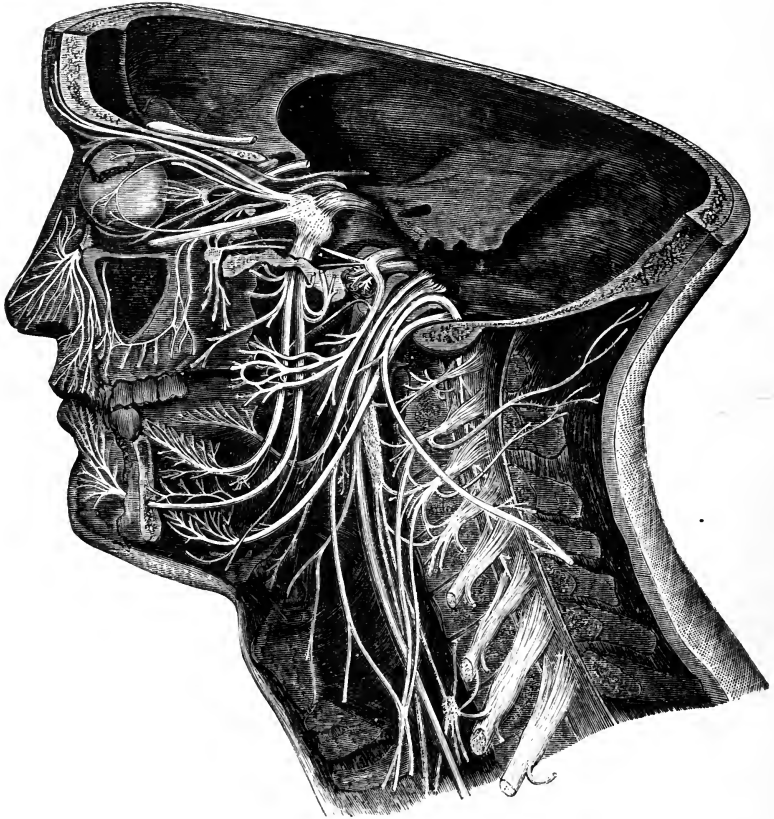
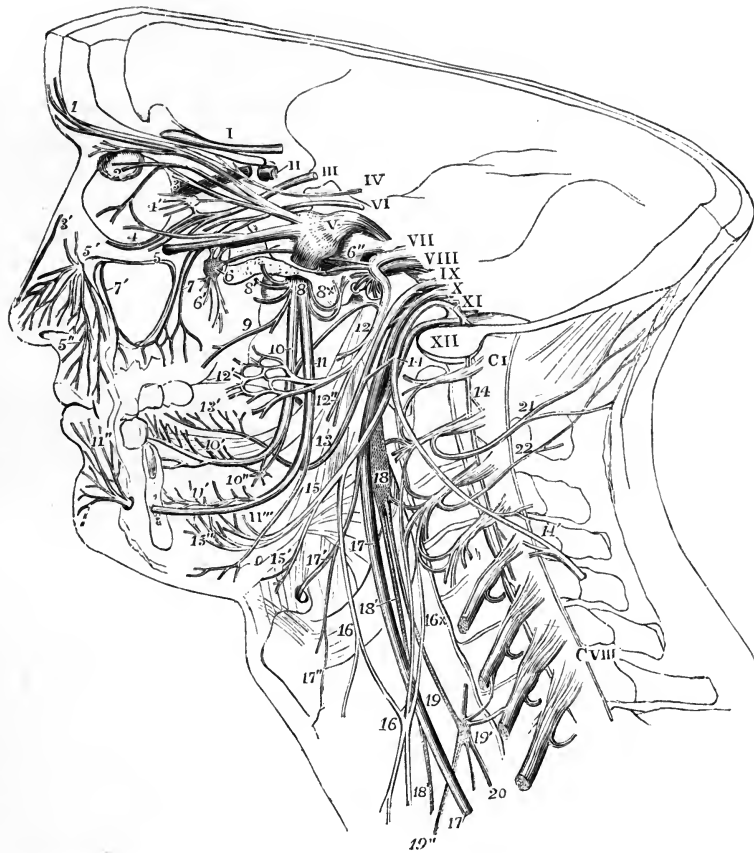

Fig. 142.—A.—SEMIDIAGRAMMATIC VIEW OF A DEEP DISSECTION OF THE CRANIAL NERVES ON THE LEFT SIDE OF THE HEAD. B.—EXPLANATORY OUTLINE OF THE SAME. (Allen Thomson.) $\frac{1}{2}$

The Roman numerals from I to XII indicate the roots of the several cranial nerves as they lie in or near their foramina of exit ; V, is upon the large root of the fifth with the Gasserian ganglion in front ; C I, the suboccipital or first cervical nerve ; C VIII, the eighth. The branches of the nerves are marked as follows, viz. :—1, supraorbital branch of the fifth ; 2, lachrymal passing into the gland ; 3, nasal passing towards the anterior internal orbital canal, and giving the long root to the ciliary ganglion, 4' ; 3', termination of the nasal nerve ; 4, lower branch of the third nerve ; 5, superior maxillary division of the fifth passing into the infraorbital canal ; 5', the same issuing at the infraorbital foramen and being distributed as inferior palpebral, lateral nasal, and superior labial nerves, 5'' ; 6, ganglion of Meckel and Vidian nerve passing back from it ; 6', palatine and other nerves descending from it ; 6'', large superficial petrosal nerve ; 7, posterior dental nerves ; 7', placed in the antrum, which has been opened, points to the anterior dental nerve ; 8, inferior maxillary division of the fifth immediately below the foramen ovale ; 8', some of the muscular branches coming from it ; 8 x, the auriculo-temporal branch cut short, and above it the small superficial petrosal nerve connected with the facial ; 9, buccal and external pterygoid ; 10, lingual nerve ; 10', its distribution to the side and front of the tongue and to the sublingual gland ; 10'', submaxillary ganglion ; below 10, the chorda tympani passing forwards from the facial above 12, to join the lingual nerve ; 11, inferior dental nerve ; 11', the same nerve and part of its dental distribution exposed by removal of the jaw ; 11'', its termination as the mental nerve ; 11''', its mylo-hyoid branch ; 12, twigs of the facial nerve immediately after its exit from the stylo-mastoid foramen to the posterior belly of the digastric and to the stylo-hyoid muscle ; 12', temporo-facial division of the facial ; 12'', cervico-facial division ; 13, trunk

General distribution.—The greater number of the cranial nerves are entirely confined in their distribution within the limits of the head, as in the case of the first six pairs, the auditory, glosso-pharyngeal, and hypoglossal nerves. Of these, the olfactory, optic, and auditory are restricted to their respective organs of sense ; while the third, fourth, and sixth are exclusively motor nerves in connection with

B



of the glosso-pharyngeal passing round the stylo-pharyngeus muscle after giving pharyngeal and muscular branches ; 13', its distribution on the side and back part of the tongue ; 14, spinal accessory nerve ; 14', the same after having passed through the sterno-mastoid muscle uniting with branches from the cervical nerves ; 15, hypoglossal nerve ; 15', its twig to the thyro-hyoid muscle ; 15'', its distribution to the muscles of the tongue ; 16, the descending cervical nerve giving a direct offset to the anterior belly of the omo-hyoid muscle, and receiving the communicating branches 16 ×, from the cervical nerves ; 17, pneumo-gastric nerve ; 17', its superior laryngeal branch ; 17'', external laryngeal twig ; 18, superior cervical ganglion of the sympathetic, uniting with the upper cervical nerves, and giving at 18' the superficial cardiac nerve ; 19, the trunk of the sympathetic ; 19', the middle cervical ganglion, uniting with some of the cervical nerves, and giving 19'', the large or middle cardiac nerve ; 20, continuation of the sympathetic down the neck ; 21, great occipital nerve ; 22, third occipital.

the muscles of the eyeball and the elevator of the upper eyelid. In the fifth or trifacial nerve all the fibres derived from the large root, and connected with the Gasserian ganglion, are entirely sensory in their function, and constitute the whole of the first and second and the greater part of the third division of the nerve ; but the last of these divisions has associated with it the fibres of the small or motor root, so as to become in some degree a compound nerve. As a nerve of sensation

the trifacial occupies in its distribution the greater part of the head superficially and deeply, excepting that part of the scalp which is situated behind a perpendicular line passing through the external auditory meatus. The muscular distribution of the inferior division of the fifth nerve is chiefly to the muscles of mastication. The glosso-pharyngeal is also a mixed nerve, and is distributed to the tongue, pharynx, and part of the ear-passages; while the hypoglossal is purely a motor nerve, destined for the muscles of the tongue, its so-called "descending" and other branches, which supply in part the muscles connected with the hyoid bone, being composed of fibres derived from the upper spinal nerves.

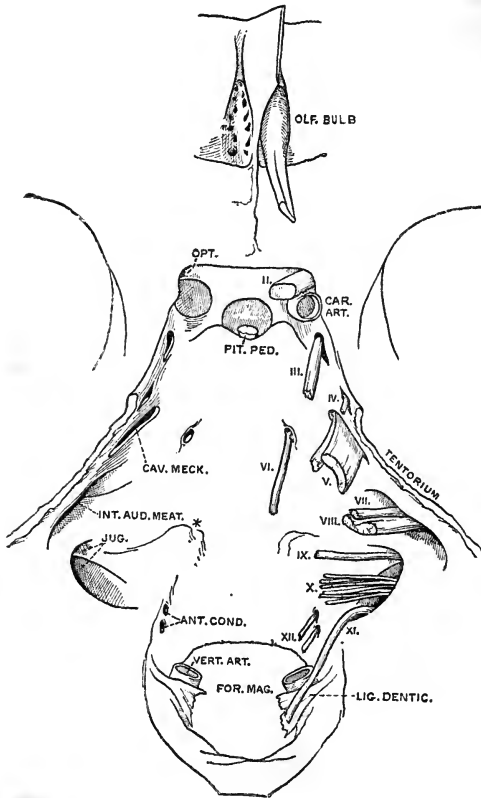


Fig. 143. —SKETCH OF THE MIDDLE PORTION OF THE BASE OF THE SKULL, SHOWING THE ENTRANCE OF THE CRANIAL NERVES INTO THE DURA MATER. (Drawn by T. W. P. Lawrence.)

The tentorium has been divided close to its attachment to the upper border of the petrous. On the right side the nerves are in place; on the left side they have been removed, and the apertures in the dura mater are seen.

Of the remaining nerves, one, the facial, mainly if not exclusively motor in function,¹ is almost entirely cephalic in its distribution, giving fibres to all the superficial and a few of the deeper muscles of the head; but one branch passes downwards in the neck to the platysma myoides.

Lastly, the tenth or pneumogastric and the eleventh or spinal accessory nerves differ from the foregoing in having only a very limited distribution in the head, and in furnishing nerves in much greater proportion to organs situated in the neck and trunk. The first of these, after giving a small branch to the external ear, and supplying nerves to the pharynx and larynx, the trachea, gullet, lungs and heart, extends into the abdominal cavity as the principal nerve of the stomach. The other, the spinal accessory, which is classed with the cranial nerves in consequence of its passing out through one of the foramina of the skull, is entirely a motor nerve; it is partially united with the pneumogastric near its origin, and thus furnishes some of the motor fibres of that nerve, but it is mainly distributed in the sterno-mastoid and trapezius muscles.

external ear, and supplying nerves to the pharynx and larynx, the trachea, gullet, lungs and heart, extends into the abdominal cavity as the principal nerve of the stomach. The other, the spinal accessory, which is classed with the cranial nerves in consequence of its passing out through one of the foramina of the skull, is entirely a motor nerve; it is partially united with the pneumogastric near its origin, and thus furnishes some of the motor fibres of that nerve, but it is mainly distributed in the sterno-mastoid and trapezius muscles.

¹ On pages 224 and 225, fig. 142 is introduced in illustration of the general view of the distribution above given. In this figure the cranium and orbit have been opened up to the depth of the several foramina through which the nerves pass. The greater part of the lower jaw has also been removed on the left side, and the tongue, pharynx, and larynx are

¹ It is possible that the chorda tympani branch of the facial may convey sensory (taste) fibres from the tongue.

partially in view. The occipital bone has been divided by an incision passing down from the occipital protuberance and through the condyle to the left of the foramen magnum. The cervical vertebrae have been divided to the left of the middle, and the sheath of the spinal cord opened so as to expose the roots of the cervical nerves.

I.—OLFACTORY NERVES.

The olfactory nerves are slender filaments, about twenty in number, which spring from the under surface of the olfactory bulb, and descend to the nose through the foramina in the cribriform plate of the ethmoid bone, each being invested by tubular prolongations of the membranes of the brain. They form an *inner group*, which are lodged for a short distance in grooves on the surface of the vertical plate of the ethmoid, and then break up into tufts of branches before being distributed to the mucous membrane over the upper part (1 to 1.5 cm.) of that bone, and an *outer*

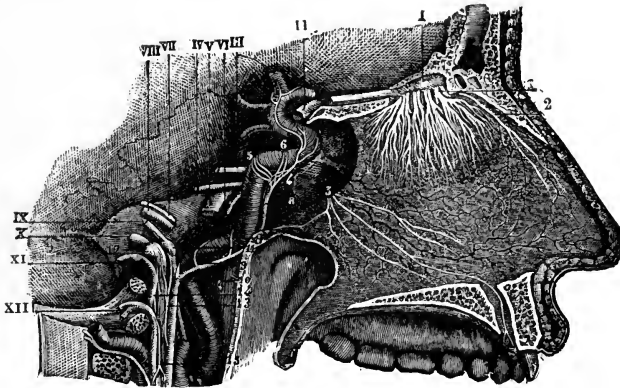


Fig. 144.—DISTRIBUTION OF THE OLFACTORY NERVES ON THE SEPTUM OF THE NOSE.
(From Sappey, after Hirschfeld and Leveillé.) 3

The septum is exposed and the anterior palatine canal opened on the right side. I, points to the olfactory bulb, and the remaining Roman numbers to the several cranial nerves; 1, the olfactory nerves as they pass through the cribriform plate; 2, internal twig of the nasal branch of the ophthalmic nerve; 3, naso-palatine nerve. The area of distribution of the olfactory nerves is represented too large.

group which ramify over the mesial surface of the lateral mass of the ethmoid, for a similar extent. The olfactory fibres do not reach the lower edge of the superior, or any part of the middle and lower turbinate bones.¹ The olfactory nerves are composed exclusively of non-medullated fibres, and their branches communicate freely with each other as they descend, thus giving rise to a narrow meshed plexus beneath the mucous membrane, especially on the outer wall of the fossa. (See also the anatomy of the nose.)

II.—OPTIC NERVE.

The second pair or optic nerves of the two sides meet each other at the optic commissure where they partially decussate. From this point they may be traced backwards round the crura cerebri, under the name of the optic tracts.

The **optic tract** arises from the pulvinar of the optic thalamus, the geniculate bodies, and the superior quadrigeminal body. As it leaves the under part of the thalamus it makes a sudden bend forwards, and then runs, in the form of a flattened band, obliquely inwards across the upper part of the anterior surface of

¹ A. v. Brunn. "Beiträge zur mikroskopischen Anatomie der menschlichen Nasenhöhle." Arch. f. mikroskop. Anat. xxxix, 1892.

the cerebral peduncle, to which it is closely attached; after this, becoming more nearly cylindrical, it is continued between the tuber cinereum and the anterior perforated space, adhering to the basal grey matter of the cerebrum, and thus reaches the optic commissure.

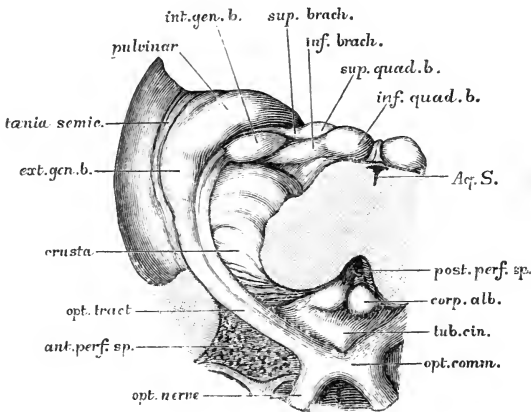


Fig. 145.—ORIGIN AND RELATIONS OF THE OPTIC TRACT. (G. D. T.)

The mid-brain has been divided immediately above the pons, and the part is viewed from below.

The **optic commissure** or **chiasma** is of an oblong form, the longer diameter (10—12 mm.) being directed transversely. It rests upon the olivary eminence of the sphenoid bone, and the internal carotid artery, ascending to the brain, is close to it on each side. A large number

of the fibres of the two nerves decussate in the commissure, but some are continued from the tract to the nerve of the same side, while those fibres of the tract which come from the internal geniculate body do not pass into either optic nerve, but cross in the hinder part of the chiasma to the opposite tract, constituting the *inferior commissure* of Gudden (see p. 118).

The **optic nerve** proper runs from the commissure forwards and outwards through the optic foramen, having the ophthalmic artery to its lower and outer side. As it enters the foramen it receives a strong sheath from the dura mater, and a slender one from the arachnoid, both of which are prolonged as far as the eyeball. Appearing in the orbit between the origins of the recti muscles, it continues its oblique course, inclining at the same time somewhat downwards, to the eyeball, which it enters on its posterior aspect about 3 mm. internal to its centre. Here the nerve perforates the sclerotic and choroid coats, and terminates by expanding in the retina (see the anatomy of the eye). The nerve has a diameter of 3—4 mm., and is from 30 to 40 mm. long. Its intraorbital part measures from 20 to 30 mm., and has a slightly flexuous course, its length exceeding the distance in a straight line from the optic foramen to the eyeball by about 5 mm., so as to allow of the movements of the latter. It is surrounded by the ciliary vessels and nerves, and is pierced about 10 mm. behind its termination by the central artery of the retina, which, with a companion vein, runs in the axis of the nerve to the eyeball.

The number of fibres in the optic nerve is estimated at somewhat less than half a million (Salzer); they are mostly of small size.

Varieties.—In a few rare instances absence of the optic commissure has been met with, each optic tract being continued directly into the optic nerve, and passing to the eyeball, of the same side. In some cases it would appear that the decussation of the fibres in the commissure is complete (see p. 118).

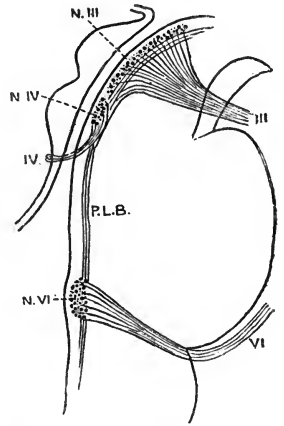
III.—OCULOMOTOR NERVE.

The third nerve, the common motor nerve of the eyeball (motor oculi), gives branches to all the muscles of the orbit, with the exception of the superior oblique and external rectus. It also supplies, through its connection with the ciliary ganglion, the sphincter muscle of the iris and the ciliary muscle of the eyeball.

The fibres of the nerve spring mainly from the oculomotor nucleus in the grey matter of the floor of the aqueduct of Sylvius opposite the superior quadrigeminal

Fig. 146.—PLAN OF THE ORIGINS OF THE THIRD, FOURTH AND SIXTH NERVES. (Modified from Gowers.)

The nerves and their nuclei are projected into the outline of a median section of the midbrain and pons: III, third nerve; N.III, its nucleus; IV, fourth nerve; N.IV, its nucleus; P.L.B., posterior longitudinal bundle; VI, sixth nerve; N.VI, its nucleus.



body (figs. 146 and 151); to these are added others which ascend in the posterior longitudinal bundle from the nucleus of the sixth nerve of the opposite side. They pass ventrally through the tegmentum, and emerge in ten to fifteen bundles from the inner side of the crus cerebri, commencing close to the upper border of the pons, and extending upwards and outwards along the line of the oculomotor groove. One of these bundles is frequently separated from the rest, and issues more externally from the anterior surface of the crus.

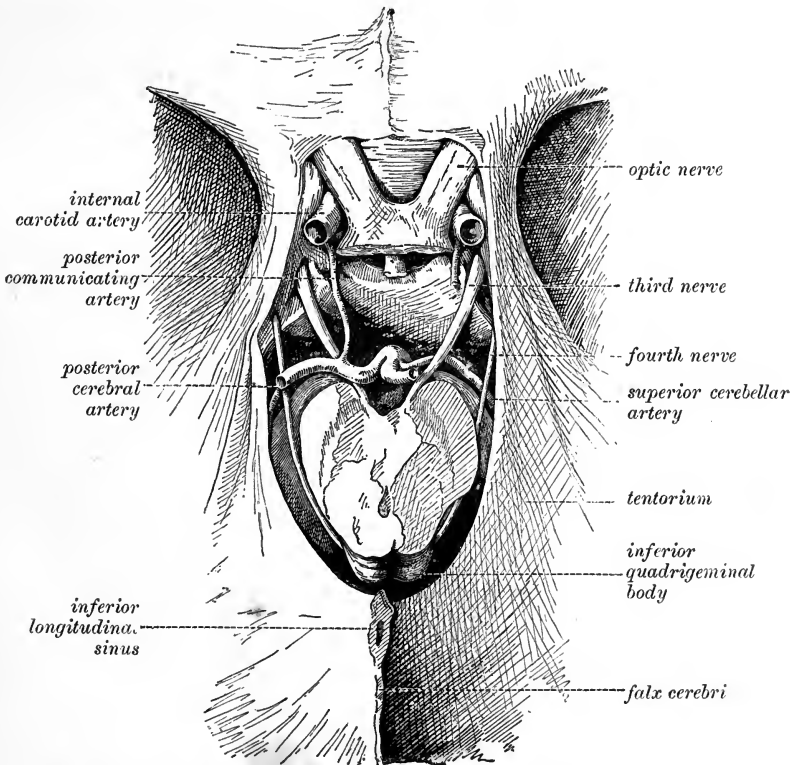


Fig. 147.—THE THIRD AND FOURTH NERVES IN THEIR INTRACRANIAL COURSE. (Drawn by T. W. P. Lawrence.)

The mid-brain is divided in the aperture of the tentorium, and the cerebrum removed. On the right side the posterior cerebral and posterior communicating arteries are cut short in order to expose the origin of the third nerve. On the left side the tentorium and crus cerebri are slightly separated so as to show the fourth nerve more fully.

Speedily becoming firm and round, the nerve is directed from the interpeduncular space forwards, as well as somewhat outwards, between the posterior cerebral and superior cerebellar arteries to the outer side of the posterior clinoid process, a little anterior to which it penetrates the layer of dura mater forming the outer boundary of the cavernous sinus. Contained within this membrane, it continues its course

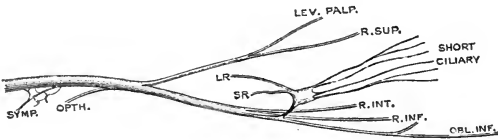


Fig. 148.—PLAN OF THE THIRD NERVE, WITH THE CILIARY GANGLION. (G. D. T.)

The ganglion is seen to be attached by its short root to the nerve of the inferior oblique muscle; LR, its long, and SR, its sympathetic root.

forwards to the inner end of the sphenoidal fissure, and there divides into two parts, upper and lower, which enter the orbit between the heads of the external rectus muscle, and are separated from each other by the nasal branch of the ophthalmic nerve. As the third nerve lies in the outer wall of the cavernous sinus, it is connected by slender filaments with the cavernous plexus of the sympathetic, and it receives also a small branch from the ophthalmic division of the fifth nerve.

The *upper*, the smaller part, is directed inwards over the optic nerve to the

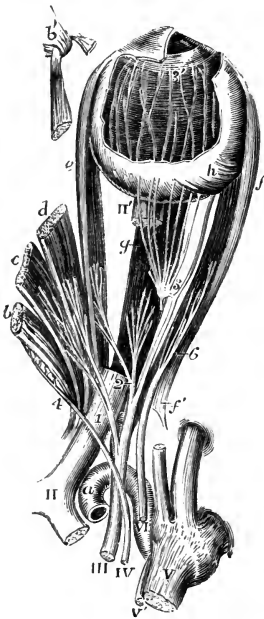


Fig. 149.—VIEW FROM ABOVE OF THE MOTOR NERVES OF THE EYEBALL AND ITS MUSCLES (after Hirschfeld and Leveillé, altered). (Allen Thomson.)

The ophthalmic division of the fifth pair has been cut short; the attachment of the muscles round the optic nerve has been opened up, and the three upper muscles turned towards the inner side, their anterior parts being removed; a part of the optic nerve is cut away to show the inferior rectus; and a part of the sclerotic coat and cornea is dissected off showing the iris, ciliary muscle, and choroid coat, with the ciliary nerves.

a, upper part of the internal carotid artery emerging from the cavernous sinus; *b*, superior oblique muscle; *b'*, its anterior part passing through the pulley; *c*, levator palpebræ superioris; *d*, superior rectus; *e*, internal rectus; *f*, external rectus; *f'*, its upper tendon turned down; *g*, inferior rectus; *h*, insertion of inferior oblique muscle.

II, optic commissure; II', part of the optic nerve entering the eyeball; III, common oculomotor; IV, trochlear nerve; V, large root of fifth; V', small or motor root; VI, abducent nerve; 1, upper division of third nerve, giving twigs to the levator palpebræ and superior rectus; 2, branches of lower division supplying the internal and inferior recti muscles; 3, the long branch of the same nerve proceeding forwards to the inferior oblique muscle, and close to the number 3, the short root of the ciliary ganglion: this ganglion is also shown, receiving from behind its long root, which has been cut short, and giving forward some of its ciliary nerves, which pierce the sclerotic coat; 3', marks the termination of some of these nerves in the ciliary muscle and iris after having passed between the sclerotic and choroid coats; 4, the trochlear nerve entering the upper surface of the superior oblique muscle; 6, the abducent nerve passing into the external rectus.

superior rectus muscle of the eye and the elevator of the eyelid, to both of which muscles it furnishes branches.

The *lower* and larger portion of the nerve divides into three branches; of these one reaches the inner rectus; another the lower rectus; and the third, the longest of the three, runs onwards between the lower and the outer rectus, and terminates below the ball of the eye in the inferior oblique muscle. The last-mentioned branch is connected with the lower part of the ciliary ganglion by a short thick offset (*short root of the ganglion*), and gives one or two filaments to the lower rectus muscle.

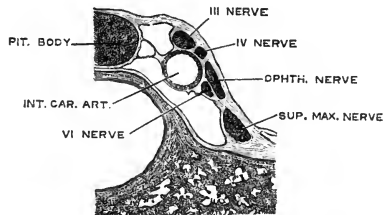
The several branches of the third nerve enter the muscles to which they are distributed on the surface which in each is turned towards the eyeball, with the exception of that to the inferior oblique, which penetrates the hinder border of its muscle.

The fibres of the third nerve, about 15,000 in number, are generally large; but there are some small ones, most of which pass into the ciliary ganglion. In the rootlets of the nerve Thomsen and Gaskell have described a peculiar structure which is regarded by them as the remains of a degenerated ganglion (Virchow's Archiv, cix, 1887; Journ. Phys., x, 1889, p. 167).

Varieties.—A communication between the third and sixth nerves as they pass the cavernous sinus has been described, but its existence is denied by most recent observers. The upper division of the third nerve may have a communication with the nasal (Svitzer, Sömmering, Testut). The third nerve has been seen in a few cases giving a branch to the external rectus (Cruveilhier, Fäsebeck, C. Krause), and in one instance a branch of the third supplied the place of the sixth nerve which was wanting (Generali). A filament to the superior oblique muscle is noticed by Volkmann. The branch to the inferior oblique muscle was seen by Arnold to pass through the lower part of the lenticular ganglion, and by Henle to pierce the inferior rectus.

POSITION OF CERTAIN NERVES AT THE CAVERNOUS SINUS, AND AS THEY ENTER THE ORBIT.—There are several nerves, besides the third, placed close together at the

Fig. 150.—THE NERVES IN THE OUTER WALL OF THE CAVERNOUS SINUS, SEEN IN TRANSVERSE SECTION. (Langer.)



cavernous sinus, and entering the orbit through the sphenoidal fissure. To avoid repetition hereafter, the relative positions of these nerves may now be described. The nerves thus associated are the third, the fourth, the ophthalmic division of the fifth, and the sixth.

At the cavernous sinus.—In the dura mater which bounds the cavernous sinus on the outer side, the third and fourth nerves and the ophthalmic division of the fifth are placed, as regards one another, in their numerical order both from above downwards and from within outwards. The sixth nerve is placed separately from the others close to the carotid artery in the cavity of the sinus, and internally to the ophthalmic nerve. Near the sphenoidal fissure, through which they enter the orbit, the relative position of the nerves is changed, the sixth nerve being here close to the rest, and their number is augmented by the division of the third and the ophthalmic nerves—the former into two, the latter into three parts.

In the sphenoidal fissure.—The fourth and the frontal and lachrymal branches of the fifth, which are here higher than the rest, lie on the same level, the fourth being the nearest to the inner side, and enter the orbit above the muscles. The remaining nerves pass between the heads of the external rectus muscle, in the following order from above downwards; the upper division of the third, the nasal branch of the fifth, the lower division of the third, and, lowest of all, the sixth.

IV.—TROCHLEAR NERVE.

The fourth, trochlear, or pathetic nerve is the smallest of the cranial nerves, and has the longest course within the cranial cavity. It is distributed solely to the superior oblique muscle of the eye.

The nucleus of the fourth nerve continues downwards the column of cells giving origin to the third nerve, being placed in the ventral grey matter of the aqueduct of

Sylvius opposite the upper part of the inferior quadrigeminal body (fig. 146). From the nucleus the fibres are directed at first downwards for a short distance, and then backwards and inwards, arching round the lower part of the aqueduct, to enter

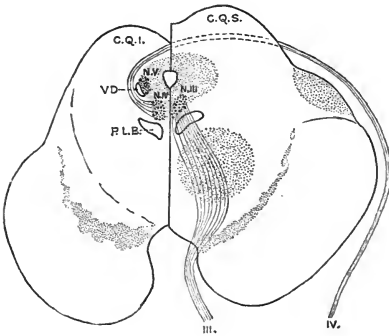


Fig. 151.—PLAN OF THE ORIGINS OF THE THIRD AND FOURTH NERVES. (G. D. T.)

The midbrain is supposed to be divided at different levels on the two sides, the section on the right side of the figure passing through the superior, and on the left side through the inferior quadrigeminal body: III, third nerve; N.III, its nucleus; IV, fourth nerve; N.IV, its nucleus; V.D, descending or mesencephalic root of the fifth nerve; N.V, its nucleus; C.Q.S, superior, and C.Q.I, inferior quadrigeminal body; P.L.B., posterior longitudinal bundle.

the superior medullary velum, where they cross to the opposite side, the two nerves thus forming a complete decussation.

Emerging from the upper end of the superior medullary velum close to the frenulum, and immediately below the inferior quadrigeminal body, the fourth nerve is directed at first outwards across the superior peduncle of the cerebellum, and then turns forwards round the outer side of the crus cerebri (figs. 141, 147), lying parallel to and between the posterior cerebral and superior cerebellar arteries. It enters an

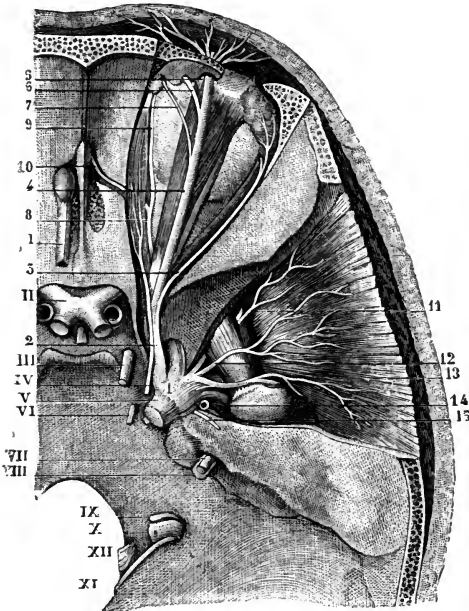


Fig. 152.—VIEW FROM ABOVE OF THE UPPERMOST NERVES OF THE ORBIT, THE GASSERIAN GANGLION, &C. (From Sappey, after Hirschfeld and Leveillé.)

I, olfactory tract, passing forwards into the bulb; II, optic commissure; III, oculomotor; IV, trochlear nerve; V, large root of the fifth nerve, a small portion of the lesser root is seen below it; VI, sixth nerve; VII, facial; VIII, auditory; IX, glosso-pharyngeal; X, pneumo-gastric; XI, spinal accessory; XII, hypoglossal: 1, Gasserian ganglion; 2, ophthalmic nerve; 3, lachrymal nerve; 4, frontal; 5, external, 6, internal branch of the supraorbital nerve; 7, supratrochlear nerve; 8, nasal nerve; 9, its infratrochlear branch; 10, nasal nerve, passing through the anterior internal orbital canal; 11, anterior deep temporal proceeding from the buccal nerve; 12, middle deep temporal; 13, posterior deep temporal arising from the masseteric; 14, origin of the auriculo-temporal; 15, great superficial petrosal nerve.

aperture in the dura mater immediately beneath the free margin of the tentorium, a little behind the posterior clinoid process, and runs forwards in the outer wall of the cavernous sinus, resting against the upper margin of the ophthalmic nerve, and crossing the third obliquely on its outer side from below upwards, to the inner end of the sphenoidal fissure. Passing into the orbit above the external rectus muscle, it inclines inwards over the levator palpebræ and superior rectus, and finally enters the superior oblique muscle on its upper surface, and close to its outer border.

While lodged in the outer wall of the sinus, the fourth nerve is connected with the sympathetic on the carotid artery, and is also joined by a filament from the ophthalmic nerve.

The fourth nerve consists of about 1,200 fibres, mostly of large size. It also shows close to its origin the vestiges of a degenerated ganglion (Gaskell).

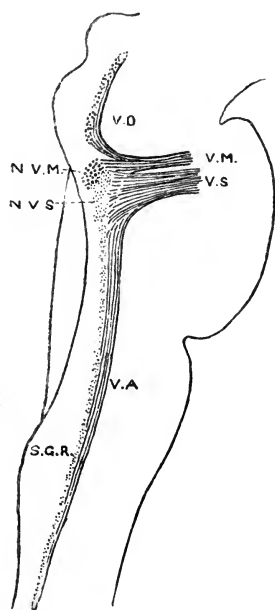
Varieties.—In one case the fourth nerve pierced the levator palpebræ superioris on its way to the superior oblique (G. D. T.). The nerve has been observed in several cases sending a branch forwards to the orbicularis palpebrarum muscle, or to join the supratrochlear, the infratrochlear, or the nasal nerve. A communication with the frontal nerve is recorded by Berté.

V.—TRIFACIAL NERVE.

The fifth, trifacial, or trigeminal nerve is the largest of the cranial nerves, and resembles a spinal nerve in the circumstance that it arises by separate sensory and

Fig. 153.—PLAN OF THE ORIGIN OF THE FIFTH NERVE.

The outline represents the contour of the medulla oblongata, pons, and a part of the midbrain, which are supposed to be transparent: V.M., motor portion of the fifth nerve; N.V.M., the motor nucleus; V.D., descending or mesencephalic root; V.S., sensory portion of the fifth nerve; N.V.S., the upper sensory nucleus; V.A., ascending or bulbar root; S.G.R., gelatinous substance of Rolando, or lower sensory nucleus.



motor roots, and also that the sensory fibres pass through a ganglion while the motor do not. Its sensory division, which is much the larger, imparts common sensibility to the face and the fore part of the head, as well as to the eye, the nose, the external ear, and the mouth, including the greater portion of the tongue; it may possibly also confer the power of taste upon the fore part of the latter organ. The motor root supplies chiefly the muscles of mastication.

The two roots of the nerve appear at the side of the pons Varolii, where the transverse fibres of the latter are prolonged into the middle peduncle of the cerebellum, and much nearer its upper than its lower border. The small root issues above the large one, and the two are separated from one another by a small band of the cross fibres of the pons. The fibres of the small root arise in part from the motor nucleus of the fifth nerve beneath the floor of the upper portion of the fourth ventricle; they are joined by the bundle known as the descending root of the fifth nerve, which springs from a collection of large nerve-cells in the grey matter at the side of the aqueduct of Sylvius. The fibres of the large root pass backwards into the pons, and some reach the upper sensory nucleus of the fifth nerve, placed to the outer side of and somewhat deeper than the motor nucleus; but the greater number turn downwards and are continued through the substance of the pons into the medulla oblongata, forming the so-called ascending or bulbar root of the fifth nerve: their mode of termination is uncertain, but they may break up among the cells of the gelatinous substance of Rolando (lower sensory nucleus of the fifth nerve).

The small root consists mainly of large fibres, and contains a vestigial ganglion (Gaskell). The large root is mostly composed of fine fibres.

From the pons, the two roots are directed forwards beneath the anterior extremity of the tentorium to the middle fossa of the base of the skull, and enter a recess in the dura mater (*cavum Meckelii*) over the summit of the petrous part of the temporal bone. Here the large root becomes expanded, and its funiculi divide and unite so as to form a plexiform network which is continued into the Gasserian ganglion. The small root inclines downwards on the inner side of the large root, and then passes outwards beneath the ganglion, without its fibres being incorporated in any way with the latter, to join below the foramen ovale the lowest of the three trunks issuing from the ganglion.

The **ganglion of the fifth nerve** or **Gasserian ganglion** (*ganglion semilunare*) occupies a depression on the upper surface of the petrous portion of the temporal bone, near the apex, and is somewhat crescentic in form, the convexity being turned forwards. It is flattened, and striated on the surface. Its internal part

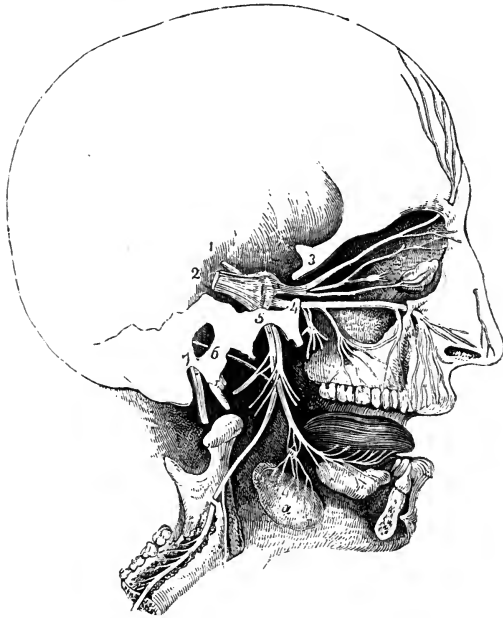


Fig. 154.—GENERAL PLAN OF THE BRANCHES OF THE FIFTH PAIR. (After a sketch by Charles Bell.) $\frac{1}{3}$

1, small root of the fifth nerve ; 2, large root, passing forwards into the Gasserian ganglion ; 3, placed on the bone above the ophthalmic nerve, which is dividing into the frontal, lachrymal, and nasal branches, the latter connected with the ciliary ganglion ; 4, placed on the bone close to the foramen rotundum, marks the superior maxillary division, which is connected below with the spheno-palatine ganglion, and passes forwards to the infraorbital foramen ; 5, placed on the bone over the foramen ovale, marks the inferior maxillary nerve, giving off the auriculo-temporal and muscular branches, and continued by the inferior dental to the lower jaw, and by the lingual to the tongue ; a, submaxillary gland, the submaxillary ganglion placed above it in connection with the lingual nerve ; 6, chorda tympani ; 7, facial nerve, issuing from the stylomastoid foramen.

comes into close relation with the posterior extremity of the cavernous sinus and the internal carotid artery. On its inner side the ganglion is joined by filaments from the carotid plexus of the sympathetic nerve ; and, according to some anatomists, it furnishes from its back part filaments to the dura mater. The cells of this ganglion are similar to those found on the posterior roots of the spinal nerves.

From the convex border of the Gasserian ganglion proceed the three large divisions of the nerve. The highest (*first or ophthalmic trunk*) enters the orbit ; the second, the *superior maxillary nerve*, is continued forwards to the face between the orbit and mouth ; and the third, the *inferior maxillary nerve*, is distributed chiefly to the external ear, the tongue, the lower teeth, the face below the mouth, and the muscles of mastication. The first two trunks proceed exclusively from the ganglion and are entirely sensory, while the third or inferior maxillary trunk, derived principally from the ganglion, has associated with it also the whole of the fibres of the motor root, and thus distributes both motor and sensory branches.

I.—OPHTHALMIC NERVE.

The ophthalmic nerve, or first division of the fifth, the smallest of the three offsets from the Gasserian ganglion, is flattened from side to side, and measures about an inch in length. It is directed forwards and upwards in the outer wall of the cavernous sinus, in company with the third and fourth nerves, towards the sphenoidal fissure, where it ends in branches which pass through the orbit to the surface of the head and to the nasal fossa. In its course forwards, the ophthalmic nerve is joined by filaments from the cavernous plexus of the sympathetic.

BRANCHES.—A small *recurrent branch (nervus tentorii)* arises from the ophthalmic trunk near the Gasserian ganglion, and, running backwards across the fourth nerve, to which it generally adheres closely for some distance, ramifies between the layers of the tentorium.

Farther forwards the ophthalmic nerve gives off three slender offsets which join respectively the third, fourth, and sixth nerves as they enter the orbit.

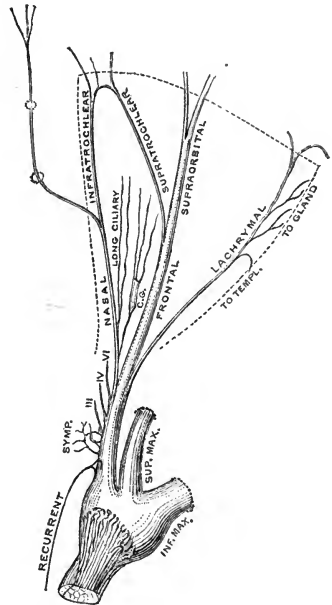
The terminal branches resulting from the division of the ophthalmic nerve close to the orbit are the nasal, which is usually the first to arise and springs from the inner and lower part of the trunk, the frontal and the lachrymal. These branches

Fig. 155.—PLAN OF THE OPHTHALMIC NERVE. (G. D. T.)

The dotted line represents the limit of the orbit. c g, ciliary ganglion, joined behind by the long root, and giving off in front the short ciliary nerves.

are transmitted separately through the sphenoidal fissure, and are continued through the orbit (after supplying some filaments to the eyeball and the lachrymal gland) to their final distribution in the nose, the eyelids and the integument of the forehead.

Lachrymal nerve.—The lachrymal nerve (fig. 152, 3) is external to the frontal at its origin, and is contained in a separate sheath of dura mater. In the orbit it passes along the outer part, above the external rectus muscle, to the outer and upper angle of the cavity. Near the lachrymal gland, the nerve has a connecting filament with the temporal branch of the superior maxillary nerve; and when in close apposition with the gland, it gives many filaments to that body and to the conjunctiva. Finally, the lachrymal nerve penetrates the palpebral fascia externally, and ends in the upper eyelid, and the skin in the neighbourhood of the external angular process of the frontal bone, the terminal ramifications being joined by twigs from the facial nerve.



Varieties.—The lachrymal nerve is occasionally smaller than usual, being reinforced by a twig from the temporal branch of the superior maxillary, and it has been seen replaced entirely by an offset of the latter nerve (Turner, Hyrtl). On the other hand, the lachrymal nerve has been found sending an offset through the malar bone in the place of the temporal branch of the superior maxillary nerve, which was absent (G. D. T.).

The lachrymal branch sometimes appears to be derived in part from the fourth nerve, but in such cases the additional root is probably composed of fibres that have passed over from the ophthalmic to the fourth, while these nerves are contained in the outer wall of the cavernous sinus.

Frontal nerve.—The frontal nerve (fig. 152, 4), the largest division of the ophthalmic, also enters the orbit above the muscles, and runs forwards between the elevator of the upper eyelid and the periosteum. About the middle of the orbit it divides into two branches, supratrochlear and supraorbital.

(a) The *supratrochlear nerve*, much the smaller of the two branches, inclines inwards towards the pulley of the superior oblique muscle, close to which it sends a filament downwards to communicate in a loop with the infratrochlear branch of the nasal nerve, and then leaves the orbit between the orbicularis palpebrarum muscle and the bone. In this position the nerve gives twigs to the skin and conjunctiva of the upper eyelid, and finally it turns upwards, dividing into branches which perforate the orbicularis and frontalis muscles, and are distributed to the integument of the lower and mesial part of the forehead.

(b) The *supraorbital nerve* is the continuation of the frontal nerve, and leaves the orbit by the supraorbital notch or foramen. It divides into two branches, inner and outer, which ascend on the forehead beneath the frontalis muscle, and are distributed by numerous slender ramifications to the skin of the fore and upper parts of the scalp. The outer branch is the larger, and extends backwards nearly to the lambdoid suture; the inner branch reaches but a little way over the parietal bone. In the supraorbital notch a slender filament of the nerve enters an aperture in the frontal bone, where it is said to be distributed to the diploe and the mucous lining of the frontal sinus; as the nerve emerges from the orbit, twigs are sent downwards to the upper eyelid; and from its terminal divisions small branches pass to the pericranium.

The primary division of the supraorbital nerve often takes place before it issues from the orbit, and in that case only the larger branch passes through the supraorbital notch, the smaller one being placed more internally, and not unfrequently traversing a second slighter notch (*frontal notch*, Henle) in the orbital margin (fig. 152, 5, 6).

The branches of the supraorbital nerve, and the same is the case with all the cutaneous offsets of the fifth, form communications with the adjacent ramifications of the facial nerve; in this way sensory fibres derived from the fifth nerve may be conveyed to the surrounding muscles.

Nasal nerve.—The nasal nerve (*oculo-nasal* or *naso-ciliary*) enters the orbit between the heads of the external rectus muscle, and between the two divisions of the third nerve. It then inclines inwards over the optic nerve, passing beneath the superior rectus and superior oblique muscles, to the inner side of the orbit, and leaves that cavity by the anterior internal orbital canal. In this part of its course it furnishes a slender branch to the ciliary ganglion, one or two filaments (long ciliary) directly to the eyeball, and a considerable infratrochlear branch, which arises just before the nerve enters its canal on the inner side of the orbit.

Arrived in the cranial cavity, the nerve is directed forwards in a groove at the outer edge of the cribriform plate of the ethmoid bone to a small canal between the fore part of the plate and the frontal bone, through which it descends to the nasal fossa. Here it gives off internal or septal and external branches to the mucous membrane of the fore part of the nasal fossa, and is then continued downwards in the groove on the back of the nasal bone, to terminate as the anterior or superficial branch in the integument of the lower part of the nose.

(a) The *branch to the ciliary ganglion*, very slender, and from a quarter to half an inch in length, arises generally between the heads of the external rectus. It lies on the outer side of the optic nerve, and enters the upper and back part of the ganglion, constituting its *long root*.

(b) The *long ciliary nerves* are situated on the inner side of the optic nerve;

they join one or more of the short ciliary branches from the ciliary ganglion, and, after perforating the sclerotic coat of the eye, are distributed in the same manner as those nerves.

(c) The *infratrochlear nerve* runs forwards along the inner side of the orbit, below the superior oblique muscle, and parallel to the supratrochlear nerve, from which it receives, near the pulley of the oblique muscle, a filament of connection. The nerve is then continued below the pulley to the inner angle of the eye, and ends, in filaments which supply the conjunctiva, the caruncle, and the lachrymal sac, as well as the integument of the upper eyelid and root of the nose (fig. 171, 22).

(d) The *internal or septal branch* (fig. 144, 2) supplies the pituitary membrane over the fore part of the septum, extending downwards nearly as far as the opening of the nostril.

(e) The *external branch* (fig. 160, 2), often represented by two or three filaments, is distributed to the mucous membrane of the fore part of the outer wall of the nasal fossa, including the anterior ends of the middle and lower turbinate bones.

(f) The *anterior or superficial branch* (fig. 171, 24) issues between the nasal bone and the upper lateral cartilage of the nose, and runs downwards under cover of the compressor naris muscle to the tip of the nose, supplying the skin of the lower part of the organ.

Varieties.—The nasal nerve occasionally (frequently, Krause) gives filaments to the superior and internal recti muscles. A branch to the levator palpebræ superioris has also been met with (Fäsebeck). In one case filaments of communication passed from a small ganglion connected with the nasal nerve to the third and sixth nerves (Svitzer). In two instances Testut observed absence of the infratrochlear branch, its place being supplied by the supratrochlear nerve. Offsets from the nasal nerve, as it traverses the anterior internal orbital canal, to the frontal sinus and ethmoidal cells are described by Meckel and Langenbeck; and a *spheno-ethmoidal* (Luschka) or *posterior ethmoidal* (Krause) branch is said to pass through the posterior internal orbital canal to the mucous membrane of the sphenoidal sinus and posterior ethmoidal cells.

SUMMARY.—The first division of the fifth nerve is altogether sensory in function. It furnishes branches to the dura mater; to the eyeball and the lachrymal gland; to the mucous membrane of the nose and eyelids; to the integument of the nose, the upper eyelid, the forehead, and the upper part of the hairy scalp. It has communications with the third, fourth, and sixth nerves, with numerous branches of the facial, and with the sympathetic.

Ciliary Ganglion.

There are four small ganglia connected with the divisions of the fifth nerve: the ciliary ganglion with the first, the spheno-palatine ganglion with the second, and the otic and submaxillary ganglia with the third. These ganglia, besides receiving branches from the sensory part of the fifth, are each connected with a motor nerve from the third, the fifth, or the facial, and with twigs from the sympathetic; and the nerves thus joining the ganglia are named their roots.

The **ciliary, ophthalmic, or lenticular ganglion** serves as a centre for the supply of nerves—motor, sensory, and sympathetic—to the eyeball. It is a small reddish body, compressed laterally and somewhat four-sided, and measures about 2 mm. from before back. It is situated at the back of the orbit, between the outer rectus muscle and the optic nerve, and generally in contact with the ophthalmic artery; it is joined behind by branches from the fifth, the third, and the sympathetic nerves; while from its fore part proceed the short ciliary nerves to the eyeball. The cells of the ganglion are of the multipolar variety.

UNION OF THE GANGLION WITH NERVES : ITS ROOTS.—The posterior border of the ganglion receives three nerves. One of these, the *long* or *sensory root*, a slender filament from the nasal branch of the ophthalmic trunk, joins the upper part of this border. Another branch, the *short* or *motor root*, much thicker and shorter than the preceding, and sometimes divided into two parts, is derived from the branch of the third nerve to the inferior oblique muscle, and is connected with the lower part of the ganglion. The *middle* or *sympathetic root* is a very small nerve which emanates from the cavernous plexus of the sympathetic, and reaches the ganglion close to the long upper root : these two nerves are frequently conjoined before reaching the ganglion. The ganglion is sometimes very small, probably from the nerve-cells being distributed along the nerves which are connected with it.

BRANCHES OF THE GANGLION.—From the fore part of the ganglion arise six or eight *short ciliary nerves*, which undergo division as they pass forwards, so that they form from twelve to twenty fine filaments as they reach the eyeball. They are dis-

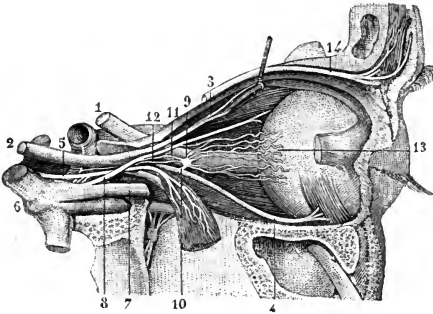


Fig. 156.—NERVES OF THE ORBIT FROM THE OUTER SIDE. (From Sappey, after Hirschfeld and Leveillé.) $\frac{3}{4}$

The external rectus muscle has been divided and turned down : 1, optic nerve ; 2, trunk of the third nerve ; 3, its upper division passing into the levator palpebrae and superior rectus ; 4, its long lower branch to the inferior oblique muscle ; 5, the sixth nerve joined by twigs from the sympathetic ; 6, Gasserian ganglion ; 7, ophthalmic nerve ; 8, its nasal branch ; 9, ciliary ganglion ; 10, its short, 11, its long, and 12, its sympathetic root ; 13, short ciliary nerves ; 14, supraorbital nerve.

posed in two bundles, springing from the upper and lower angles of the ganglion, and being placed, the one set above, the other below the optic nerve. The lower set is the more numerous, and is accompanied by the long ciliary nerves (from the nasal), with which one or more of these branches are joined. Having entered the eyeball by apertures in the back part of the sclerotic coat, the nerves are lodged in grooves on its inner surface, and are finally distributed to the ciliary muscle, the iris and the cornea (see the anatomy of the eye).

Varieties.—Additional roots to the ciliary ganglion have been observed by many anatomists, derived from the upper division of the third nerve, from the fourth nerve, from the lachrymal nerve, from the spheno-palatine ganglion, or from the sixth nerve.

Absence of the long root is recorded : in this case it is probable that the corresponding fibres pass directly from the nasal by the long ciliary nerves to the eyeball.

The sympathetic root may be represented by several fine filaments proceeding from the cavernous plexus : according to Reichart this is the normal arrangement, the majority of the filaments accompanying the third nerve.

II.—SUPERIOR MAXILLARY NERVE.

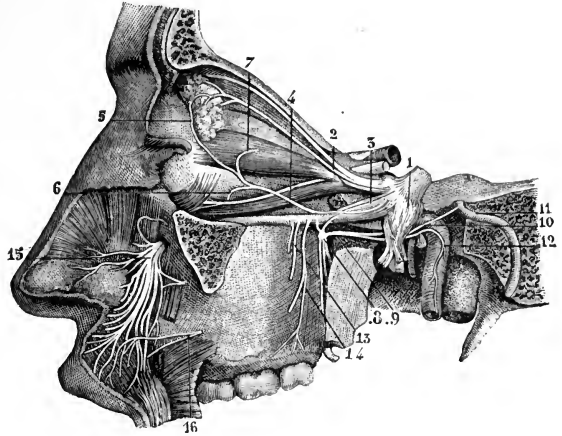
The superior maxillary nerve, or second division of the fifth (*n. maxillaris*), is intermediate in size between the ophthalmic and the inferior maxillary trunks.

It commences at the middle of the Gasserian ganglion, and, passing horizontally forwards, soon leaves the skull by the foramen rotundum of the sphenoid bone. The nerve then crosses the spheno-maxillary fossa, and, taking the name of *infraorbital*, enters the infraorbital canal of the upper maxilla, by which it is conducted to the face. After emerging from the infraorbital foramen, it terminates beneath the elevator of the upper lip in branches, which spread out to the side of the nose, the lower eyelid, and the upper lip.

BRANCHES.—Near its origin a fine *recurrent branch* (*n. meningeus medius*) passes to the dura mater and middle meningeal artery. In the spheno-maxillary fossa an orbital or temporo-malar branch ascends from the superior maxillary nerve to the

Fig. 157. — SUPERIOR MAXILLARY NERVE AND SOME OF THE ORBITAL NERVES. (From Sappey, after Hirschfeld and Leveillé.)

1, Gasserian ganglion; 2, lachrymal nerve; 3, trunk of the superior maxillary nerve; 4, its orbital branch; 6, origin of its malar twig; 7, its temporal twig, joined by 5, the communicating branch from the lachrymal nerve; 8, spheno-palatine ganglion; 9, Vidian nerve; 10, its upper branch or great superficial petrosal nerve proceeding to join 11, the facial nerve; 12, its lower branch or great deep petrosal nerve joining the sympathetic; 13, 14, posterior dental nerves; 15, terminal branches of the infra-orbital nerve in the face; 16, a branch of the facial uniting with some of the twigs of the infraorbital.



orbit, and two spheno-palatine branches descend to join Meckel's ganglion; while the nerve is in contact with the upper maxilla, it furnishes the superior dental or alveolar branches; and on the face are the terminal branches already indicated.

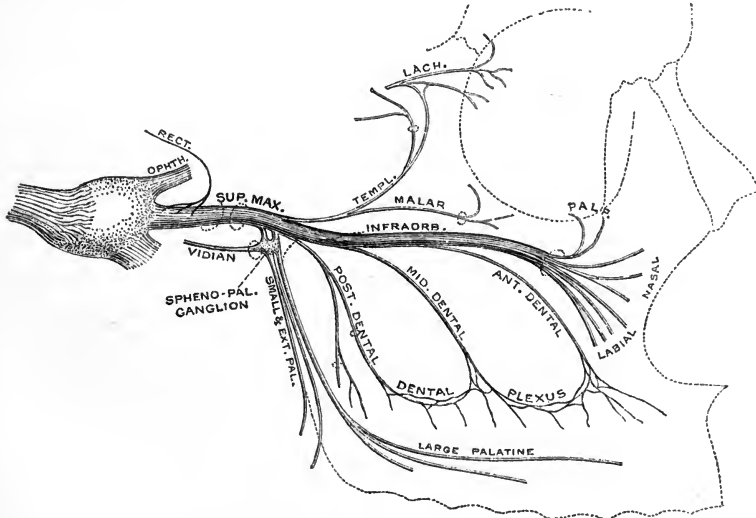


Fig. 158.—PLAN OF THE SUPERIOR MAXILLARY NERVE. (G. D. T.)

Orbital branch.—The orbital or temporo-malar branch (*n. zygomaticus*), a small cutaneous nerve, enters the orbit by the spheno-maxillary fissure, and immediately divides into two branches (temporal and malar), which pierce the malar bone, and are distributed to the temple and the prominent part of the cheek.

(a) The *temporal branch* (*n. zygomaticotemporalis*) is directed upwards in a groove on the outer wall of the orbit, and leaves this cavity by the temporal canal

in the malar bone. While still in the orbit, it is joined by a communicating filament (in some cases by two filaments) from the lachrymal nerve. The nerve is then inclined upwards in the temporal fossa between the bone and the temporal muscle, and perforating the aponeurosis over the muscle nearly an inch above the zygoma, ends in cutaneous filaments over the fore part of the temporal region. The cutaneous ramifications are united with the facial nerve, and sometimes with the auriculo-temporal branch of the third division of the fifth.

(b) The *malar branch* (*v. zygomaticofacialis*) lies at first in the loose fat in the lower angle of the orbit, and is continued to the face through the malar canal of the malar bone, where it is frequently divided into two filaments. It is distributed to the skin over the malar bone, after forming a communication with the facial nerve.

Varieties.—The temporo-malar nerve is subject to frequent deviations from the arrangement above described. Thus, either branch may be smaller than usual, or even absent, in which case the other division of the nerve may be distributed over a larger area, or the temporal branch may be reinforced or replaced by the lachrymal nerve, the malar branch by the infraorbital nerve. The temporal branch, instead of perforating the malar bone frequently passes into the temporal fossa through the anterior end of the spheno-maxillary fissure.

The **superior dental or alveolar nerves** are, as a rule, three in number, anterior, middle, and posterior, but the middle is sometimes conjoined with the anterior, while the posterior is frequently represented by two separate offsets.

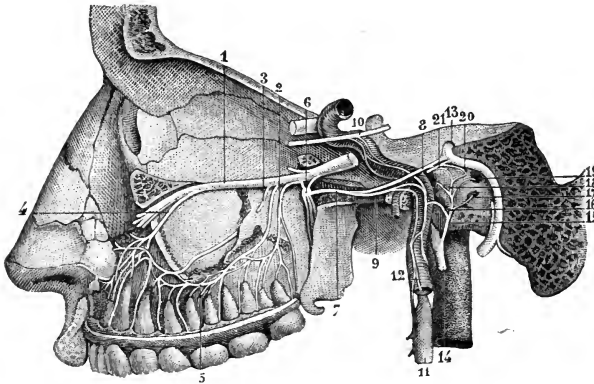


Fig. 159.—DEEP VIEW OF THE SUPERIOR MAXILLARY NERVE AND THE SPHENO-PALATINE GANGLION, &c. (From Sappey, after Hirschfeld and Leveillé.)

1, superior maxillary nerve; 2, posterior superior dental; 3, middle superior dental; 4, anterior superior dental; 5, superior dental plexus; 6, spheno-palatine ganglion; 7, Vidian nerve; 8, its great superficial petrosal branch; 9, its great deep petrosal branch; 10, a part of the sixth nerve, receiving twigs from the carotid plexus

of the sympathetic; 11, superior cervical sympathetic ganglion; 12, its ascending branch; 13, facial nerve; 14, glosso-pharyngeal nerve; 15, its tympanic branch; 16, carotico-tympanic twig joining the sympathetic; 17, filament to the fenestra rotunda; 18, filament to the Eustachian tube; 19, filament to the fenestra ovalis; 20, small superficial petrosal nerve.

The *posterior superior dental nerve* arises from the superior maxillary trunk before it enters the infraorbital groove, and immediately divides into two branches (often separate at their origin), which descend with the posterior dental artery on the zygomatic surface of the upper jaw. They send small external filaments to the gum and the adjacent part of the mucous membrane of the cheek, and then enter the posterior dental canals to terminate in offsets to the molar teeth and the lining membrane of the antrum.

Variety.—The posterior dental nerve has been seen in a few instances of large size, and replacing the buccal nerve, which was absent as a branch of the inferior maxillary, in the supply of the cheek.

The *middle superior dental nerve* leaves the superior maxillary in the hinder part of the infraorbital canal, and is directed downwards and forwards in a special canal in the outer wall of the antrum to the bicuspid teeth.

The *anterior superior dental nerve* is the largest of the three. Arising near the infraorbital foramen, it descends in its canal in the front wall of the antrum, and divides into *dental branches* for the incisor and canine teeth, and a *nasal branch*, which supplies the pituitary membrane in the fore part of the inferior meatus and the adjoining part of the floor of the nasal fossa.

The three dental nerves communicate so as to form loops with one another while they are contained in their bony canals, and from these loops other branches spring, which join again and give rise to a plexus (*superior dental plexus*) from which the minute terminal filaments proceed to the teeth and gum.

Facial branches.—The facial branches are divisible into palpebral, nasal, and labial sets.

The *inferior palpebral branches*, generally an inner and an outer, ascend from the termination of the infraorbital nerve to supply the skin and conjunctiva of the lower eyelid in its whole breadth.

The *lateral nasal branches*, two or three in number, are directed inwards between the fibres of the levator labii superioris *alæque nasi* muscle to the skin of the side of the nose.

The *superior labial branches*, the largest of the terminal offsets of the superior maxillary nerve, and three or four in number, pass downwards between the elevator muscles of the upper lip and of the angle of the mouth. Ramifying as they descend, and giving off branches to supply the integument of the fore part of the cheek, they end in the skin and mucous membrane of the upper lip.

Below the orbit, the terminal branches of the superior maxillary nerve are joined by considerable branches of the facial nerve, the union between the two being named the *infraorbital plexus*.

Spheno-Palatine Ganglion.

The spheno-palatine ganglion, also named *Meckel's* or the *nasal ganglion*, is deeply placed in the spheno-maxillary fossa, close to the spheno-palatine foramen. It receives the two spheno-palatine branches which descend together from the superior maxillary nerve as it crosses the top of the fossa. It is of a reddish-grey colour, triangular in form, and convex on the outer surface, and measures from before back about 5 mm. The grey or ganglionic substance contains multipolar nerve-cells, and does not involve all the fibres of the spheno-palatine branches of the upper maxillary nerve, but is placed at the back part, at the point of junction of the Vidian nerve, so that many of the fibres of the spheno-palatine nerves proceeding to the nose and palate pass to their destination without being incorporated with the ganglionic mass.

Branches proceed from the ganglion upwards to the orbit, downwards to the palate, inwards to the nose, and backwards through the Vidian and pterygo-palatine canals.

ASCENDING BRANCHES.—These are two or three very small twigs, which reach the orbit by the spheno-maxillary fissure, and are distributed to the periosteum and, according to Luschka, to the mucous membrane of the posterior ethmoidal and sphenoidal sinuses.

Bock and Valentin describe a branch ascending from the ganglion to the sixth nerve; Tiedemann, one to the lower angle of the ciliary ganglion. Hirzel and Arnold traced filaments to the optic nerve or its sheath.

DESCENDING BRANCHES.—These are three in number—the large, the small, and the external palatine nerves, and are in great part continued directly from the spheno-palatine branches of the superior maxillary.

(a) The *large* or *anterior palatine nerve* descends in the palato-maxillary canal, and divides in the roof of the mouth into branches which are received into grooves in the hard palate, and extend forwards nearly to the incisor teeth. In the mouth it supplies the inner side of the gum, the glands, and the mucous membrane of the hard palate, and joins in front with the naso-palatine nerve. While in its canal, the large palatine nerve gives off one or two *inferior nasal* branches, which supply the mucous membrane over the greater part of the inferior turbinate bone, together with the adjoining middle and inferior meatuses of the nose.

(b) The *small* or *posterior palatine nerve* enters the lesser palatine canal, and is conducted to the soft palate, the tonsil, and the uvula. It has been thought to convey motor fibres from the facial nerve to the levator palati and azygos uvulæ muscles.

(c) The *external palatine nerve*, the smallest of the series, courses through the external palatine canal between the maxilla and the tuberosity of the palate bone,

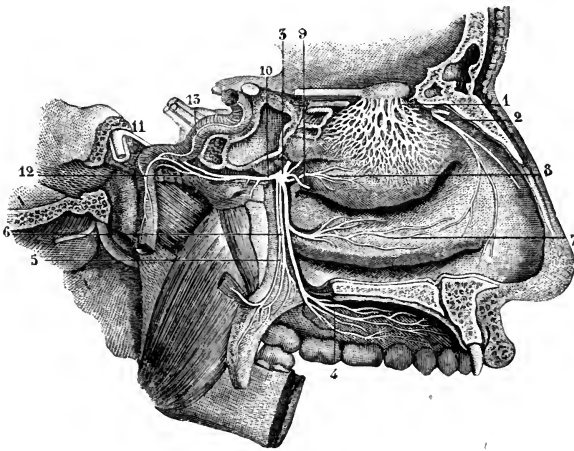


Fig. 160.—NERVES OF THE NOSE AND THE SPHENO-PALATINE GANGLION FROM THE INNER SIDE. (From Sappey, after Hirschfeld and Leveillé.) $\frac{3}{4}$

1, network of the external branches of the olfactory nerve: the area of distribution is represented somewhat too large; 2, nasal nerve, giving its external branch to the outer wall of the nose; the septal branch is cut short; 3, spheno-palatine ganglion; 4, ramification of the large palatine nerve; 5, small, and 6, external palatine nerve; 7, inferior nasal branch; 8, superior nasal branch; 9, naso-palatine nerve cut short; 10, Vidian nerve; 11, great superficial petrosal nerve; 12, great deep petrosal nerve; 13, the sympathetic nerves ascending on the internal carotid artery.

to be distributed to the tonsil and the outer part of the soft palate. This nerve is occasionally wanting.

INTERNAL BRANCHES.—These consist of the naso-palatine, and the upper nasal branches, which ramify in the lining membrane of the nasal fossæ and adjoining sinuses.

The *upper nasal* are very small branches, and enter the back part of the nasal fossa by the spheno-palatine foramen. Some are prolonged to the upper and posterior part of the septum, and the remainder ramify in the membrane covering the upper two spongy bones, and in that lining the posterior ethmoidal cells.

The *naso-palatine nerve* (fig. 144, 3), long and slender, leaves the inner side of the ganglion with the preceding branches, and after crossing the roof of the nasal fossa is directed downwards and forwards, in a slight groove on the vomer, towards the anterior palatine canal. The nerves of opposite sides descend to the palate through the median subdivisions of the canal, called the foramina of Scarpa, the nerve of the right side usually behind that of the left (see Osteology, p. 53). In the lower common foramen the two naso-palatine nerves are connected with each other in a fine plexus; and they end in several filaments, which are distributed to

the mucous membrane behind the incisor teeth, and communicate with the great palatine nerve. In its course along the septum, small filaments are furnished from the naso-palatine nerve to the pituitary membrane.

POSTERIOR BRANCHES.—The branches directed backwards from the sphenopalatine ganglion are the Vidian and pharyngeal nerves.

The *Vidian nerve*, arising from the back part of the ganglion, which seems to be prolonged into it, passes backwards through the Vidian canal to the foramen lacerum, where it divides into the *great superficial* and the *great deep petrosal nerves*. While in its canal, the Vidian nerve gives some small *nasal branches*, which supply the membrane of the back part of the roof of the nose and septum, as well as the membrane covering the end of the Eustachian tube; and it is joined by the sphenoidal filament from the otic ganglion (p. 249).

The *large superficial petrosal nerve* (fig. 159, 8), entering the cranium on the outer side of the carotid artery and beneath the Gasserian ganglion, is directed backwards in a groove on the petrous portion of the temporal bone to the hiatus Fallopii, and is thus conducted to the aqueductus Fallopii, where it joins the geniculate ganglion of the facial nerve.

The *large deep petrosal nerve* (fig. 159, 9), shorter than the other, is of a reddish colour and softer texture: it is directed backwards, and on the outer side of the carotid artery ends in the filaments of the sympathetic surrounding that vessel.

In accordance with the view taken of the ganglia connected with the fifth nerve (p. 237), the superficial and deep petrosal parts of the Vidian nerve may be regarded as the *motor* and *sympathetic roots* respectively of the sphenopalatine ganglion, the sphenopalatine nerves constituting its *sensory root*. The ganglion may also receive fibres from the glosso-pharyngeal nerve, conveyed to it through the small and large deep petrosal nerves (p. 260, and fig. 170): this connection is sometimes described as a second sensory root.

The *pharyngeal nerve* is small, and springs from the back of the ganglion, often in common with the Vidian nerve. It enters the pterygo-palatine canal with an artery, and is lost in the lining membrane of the pharynx behind the Eustachian tube.

SUMMARY.—The superior maxillary nerve, with Meckel's ganglion, supplies the integument of the cheek and the fore part of the temple, the lower eyelid, the side of the nose, and the upper lip; the upper teeth; the lining membrane of the nose; the mucous membrane of the upper part of the pharynx, of the antrum of Highmore, and of the posterior ethmoidal cells; the soft palate, tonsil, and uvula, and the glandular and mucous structures of the roof of the mouth.

III.—INFERIOR MAXILLARY NERVE.

The lower maxillary nerve (*n. mandibularis*), the third and largest division of the fifth, is made up of two portions of unequal size, the larger being derived from the Gasserian ganglion, and the smaller being the slender motor root of the fifth nerve. These two parts leave the skull by the foramen ovale in the sphenoid bone, and unite immediately after their exit. Three or four mm. below the base of the skull, and under cover of the external pterygoid muscle, the nerve separates into two primary divisions, one of which is higher in position and smaller than the other.

The *small, anterior, or upper portion* (*n. masticatorius*) receives the greater part of the fibres of the motor root, and breaks up into temporal, masseteric, external pterygoid, and buccal branches, of which the last alone is a sensory nerve. The *large, posterior, or lower portion* is chiefly sensory, and divides into auriculo-temporal, lingual, and inferior dental nerves; it likewise supplies through the last-

mentioned branch the mylo-hyoid muscle and the anterior belly of the digastric. The branch to the internal pterygoid muscle, with which also are connected those proceeding through the otic ganglion to the tensors of the palate and tympanum, is sometimes counted as a part of the larger division, but is more correctly regarded as arising from the undivided trunk.

The short trunk of the nerve also gives off, as it issues from the foramen ovale, a slender *recurrent branch* (*n. spinosus*), which passes backwards into the skull through the foramen spinosum with the middle meningeal artery, and divides like that vessel into two branches. The anterior of these sends its filaments into the

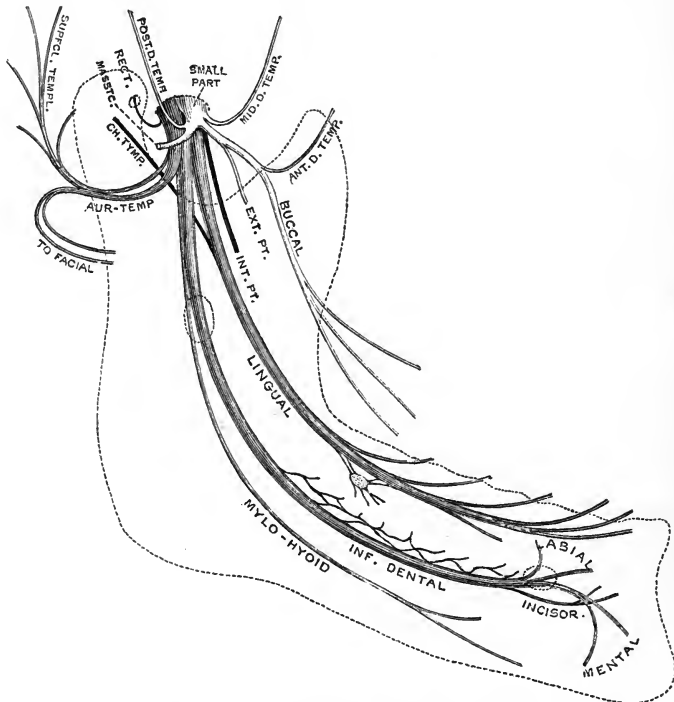


Fig. 161.—PLAN OF THE INFERIOR MAXILLARY NERVE. (G. D. T.)

great wing of the sphenoid bone, while the posterior traverses the petro-squamous fissure, and is distributed to the mucous lining of the mastoid cells (Luschka).

From the sheath which the inferior maxillary nerve receives from the dura mater in its passage through the foramen ovale tubular prolongations are continued on the several offsets of the trunk. Those containing the masseteric and auriculo-temporal nerves are of considerable strength, and become blended with the capsule of the temporo-maxillary articulation in front and on the inner side respectively, so that they are exposed to a certain degree of traction during the movements of the lower jaw. (E. Fawcett, *Journ. Anat.*, xxvii, 1893, p. 179.)

Varieties.—One or more of the branches of the superior division of the nerve may arise separately from the main trunk.

There is not unfrequently a small fibrous band (*pterygo-sphenoidal ligament*) extending from the root of the external pterygoid plate to a spot on the great wing of the sphenoid a little in front of the foramen spinosum, and lying in the angle between the two divisions of the inferior maxillary nerve. In rare cases this band is replaced by bone, so that the small part of the nerve passes out through a special foramen on the under side of the great wing of the sphenoid, just external to the foramen ovale. (Hyrtl, "Ueb. d. Porus crotaphitico-buccinatorius," *Wiener Sitzungsber.*, 1862; A. v. Brunn, "Das Foramen pterygo-spinosum

und d. Porus crotaphitico-buccinatorius," *Anat. Anz.*, vi, 1891 ; U. Grosse, "Ueb. d. Foramen pterygo-spinosum u. d. Foramen crotaphitico-buccinatorium," *Anat. Anz.*, viii, 1893 ; J. Yule Mackay, in Report of Committee of Collective Investigation of *Anat. Soc.*, *Journ. Anat.*, xxviii, 1893, p. 67.)

The **deep temporal nerves** (figs. 152 and 162) are usually three in number, but are subject to considerable variety in their arrangement. The *anterior* is given off by the buccal nerve after it has perforated the external pterygoid, and ascends

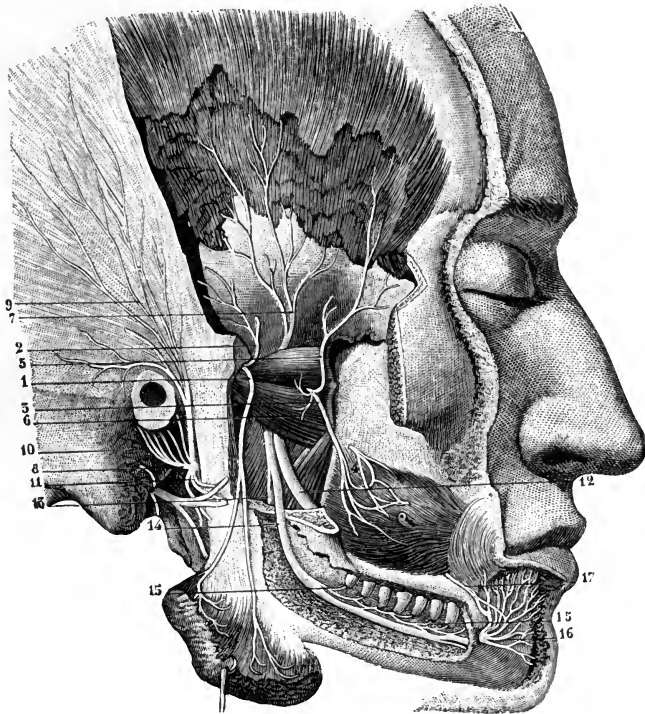


Fig. 162.—VIEW OF THE BRANCHES OF THE INFERIOR MAXILLARY NERVE FROM THE OUTER SIDE.
(From Sappey, after Hirschfeld and Leveillé.)

The zygoma and part of the ramus of the lower jaw have been removed ; the dental canal has been opened up ; the lower part of the temporal muscle has been taken away, and the masseter muscle turned down : 1, masseteric nerve ; 2, posterior deep temporal nerve ; 3, buccal nerve ; 4, branch of the facial ; 5, anterior deep temporal nerve ; 6, filaments given by the buccal to the external pterygoid muscle ; 7, middle deep temporal nerve ; 8, auriculo-temporal nerve ; 9, its temporal branches ; 10, its branches to the meatus and auricle ; 11, its union with the facial ; 12, lingual nerve ; 13, mylo-hyoid nerve ; 14, inferior dental nerve ; 15, its twigs to the teeth ; 16, mental branch ; 17, branch of the facial uniting with the mental.

to supply the foremost part of the temporal muscle. The *middle* passes outwards above the external pterygoid and turns upwards close to the bone to enter the deep surface of the muscle. The *posterior* is generally conjoined with the masseteric nerve, and, taking a course similar to the middle branch, ramifies in the hinder part of the muscle. The number of these nerves is frequently reduced by the union of the middle with either of the other branches.

The **masseteric nerve** likewise passes above the external pterygoid, and is directed nearly horizontally outwards at the posterior border of the temporal muscle, and through the sigmoid notch of the lower jaw, to the masseter, which it

enters at the hinder part of its deep surface. It also gives a filament or two to the articulation of the jaw.

The **external pterygoid nerve** generally arises in common with the buccal branch, and penetrates the inner surface of its muscle.

The **buccal nerve**, which differs from the foregoing branches in being entirely a sensory nerve, is usually conjoined at its origin with the anterior deep temporal and the external pterygoid nerves. It passes forwards between the heads of the external pterygoid, and then descends in close contact with the inner side (occasionally perforating some of the fibres) of the temporal muscle at its insertion, to the surface of the buccinator muscle. Here it divides into several branches which join in a plexus round the facial vein with the buccal branches of the facial nerve, and are finally distributed to the skin and mucous membrane of the cheek, extending as far forwards as the angle of the mouth.

Varieties.—The buccal nerve is occasionally replaced by a branch of the superior maxillary (p. 240). It has been seen by Turner arising from the inferior dental nerve in the dental canal, and issuing by a small foramen in the alveolar border of the lower jaw, close to the ramus. Gaillet describes it in one case as arising directly from the Gasserian ganglion, and passing from the cranium through a special aperture between the round and oval foramina.

The **internal pterygoid nerve** (fig. 164, 13) is closely connected at its origin with the otic ganglion, and descends to the inner or deep surface of its muscle, being separated from the lingual and inferior dental nerves by the pterygo-spinous ligament when that band is present (see Osteology, p. 47). From this nerve mainly, as it passes the otic ganglion, arise the small branches to the tensor palati and tensor tympani muscles.

Auriculo-temporal nerve.—The auriculo-temporal nerve takes its origin close to the foramen ovale, usually by two roots which embrace the middle meningeal artery. It is directed at first backwards, beneath the external pterygoid muscle, to the inner side of the neck of the lower jaw; then changing its course, it turns upwards between the ear and the temporo-maxillary articulation, under cover of the upper end of the parotid gland; and finally, emerging from beneath the latter, it ascends over the base of the zygoma in company with the superficial temporal artery, behind which it is placed, to terminate on the side of the head as the superficial temporal nerve.

Branches.—(a) *Communicating branches.*—The roots of the auriculo-temporal nerve are joined, close to their origin, by slender filaments from the otic ganglion; and from the trunk of the nerve, as it turns upwards, one or two considerable branches are sent forwards round the commencement of the superficial temporal artery to the temporo-facial division of the facial nerve.

(b) The *articular branches* are one or two fine twigs to the hinder part of the temporo-maxillary articulation.

(c) The *nerves of the external auditory meatus* are two in number, upper and lower, and enter the canal between the osseous and cartilaginous parts of its wall. They supply the skin of the meatus, and the upper one sends a filament to the membrana tympani.

(d) *Parotid branches* pass from the nerve, or from its connecting branches with the facial, to the gland.

(e) The *anterior auricular nerves* are usually two in number, and supply the skin of the tragus and of the upper and fore part of the pinna.

(f) The *superficial temporal nerve* divides into slender branches which supply the skin over the greater part of the temporal region, the anterior ones forming communications with the temporal branches of the facial nerve (fig. 171, 18).

Inferior dental nerve.—The inferior dental or mandibular nerve (*n. alveolaris inferior*) is the largest of the branches of the lower maxillary nerve. It descends under cover of the external pterygoid muscle, behind and to the outer side of the lingual nerve, and, passing between the ramus of the jaw and the internal lateral ligament of the temporo-maxillary articulation, enters the inferior dental canal. In company with the dental artery, it proceeds along this canal, and supplies branches to the teeth. At the mental foramen it bifurcates; one part, the incisor branch, being continued onwards within the bone towards the middle line, while the other, the much larger mental branch, escapes by the foramen to the face.

When about to enter the foramen on the inner surface of the ramus of the jaw, the inferior dental nerve gives off the slender mylo-hyoid branch.

Branches.—(a) The *mylo-hyoid branch* descends in the groove on the inner side of the ramus of the lower jaw to the under surface of the mylo-hyoid muscle, to which and to the anterior belly of the digastric it is distributed. The fibres of this nerve may be traced back within the sheath of the inferior dental to the motor root of the inferior maxillary nerve.

(b) The *dental branches* supply the molar and bicuspid teeth, together with the adjoining part of the gum. They form by their communications a fine *inferior dental plexus*, resembling that formed by the corresponding nerves in the upper jaw.

(c) The *incisor branch* continues the direction of the trunk of the nerve, and supplies filaments to the canine and incisor teeth.

(d) The *mental* or *labial nerve*, emerging from the bone by the mental foramen, divides beneath the depressor anguli oris into three parts, an inferior, which descends to the integument of the chin, and two superior, which ascend to the skin and mucous membrane of the lower lip. All three communicate freely with the mandibular branch of the facial nerve.

Varieties.—The inferior dental and lingual nerves have been observed to form a single trunk as far as the dental foramen. On the other hand, they are often separated by an accessory ligament stretched between the external pterygoid plate and the spine of the sphenoid, to the outer side of the pterygo-spinous ligament (see v. Brunn, *op. cit.* p. 244). The inferior dental nerve is occasionally perforated by the internal maxillary artery. It sometimes has one or two accessory roots from other divisions of the inferior maxillary. The most common of these is one which arises from the Gasserian ganglion and remains separate until after it enters the dental canal (*lesser inferior dental nerve*, Sapolini).

The mylo-hyoid nerve frequently (constantly, Sappey) gives off a small branch, which pierces the mylo-hyoid muscle and joins the lingual nerve. Branches are also described as passing from the mylo-hyoid nerve to the depressor anguli oris and platysma myoides muscles (Henle), to the integument below the chin (Krause, Schwalbe, and others), and to the sub-maxillary gland (Meckel, Henle, Curnow).

Lingual nerve.—The lingual branch descends under cover of the external pterygoid muscle, lying to the inner side and in front of the dental nerve, and generally united to that by a cord which may cross over the internal maxillary artery. Near its origin, it is joined at an acute angle by the *chorda tympani*, a small branch which is given off by the facial nerve, and descends from the inner end of the Glaserian fissure. It then passes between the internal pterygoid muscle and the ramus of the lower jaw, and is inclined obliquely inwards to the side of the tongue, over the upper constrictor of the pharynx (where this muscle is attached to the jaw), and above the deep portion of the submaxillary gland. Lastly, the nerve crosses below Wharton's duct, and is continued along the side of the tongue to the apex, lying immediately beneath the mucous membrane.

Branches.—(a) *Communicating branches.*—In addition to the cord above mentioned passing from the inferior dental to the lingual nerve, and the connection with the facial nerve through the chorda tympani, the lingual nerve gives off branches to

the submaxillary ganglion at the place where it is in contact with the submaxillary gland, and a little farther forwards one or two filaments descend over the fore part of the hypo-glossus muscle to join in loops with similar branches of the hypoglossal nerve.

(b) *Branches to the mucous membrane* of the mouth are given from the nerve at the side of the tongue, and supply also the gum. Some delicate filaments are likewise distributed to the sublingual gland.

(c) The *lingual or terminal branches* perforate the muscular structure of the tongue, and divide into filaments which are directed upwards to the mucous membrane of the anterior two-thirds of the organ, where they terminate mainly in the conical and fungiform papillæ. Microscopic ganglia are found in their ultimate ramifications.

Submaxillary Ganglion.

The submaxillary or lingual ganglion (fig. 181, 7) is placed above the deep portion of the submaxillary gland, and is connected by anterior and posterior filaments with the lingual nerve, from which it thus appears to be suspended by a loop. It is somewhat larger than the ciliary ganglion, and triangular or fusiform in shape. The cells of the ganglion are multipolar. Its hinder part receives branches

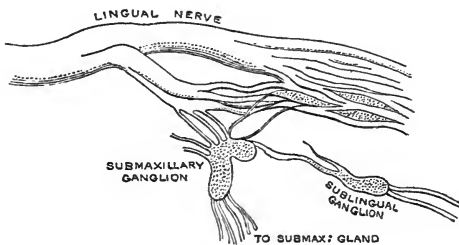


Fig. 163.—SUBMAXILLARY AND SUBLINGUAL GANGLIA OF AN INFANT. (Raubert.) $\frac{1}{2}$

from nerves which may be regarded as its roots, while from its fore and lower parts proceed the branches for distribution.

ROOTS OF THE GANGLION.—The posterior connecting branch from the lingual nerve, often broken up into two or three filaments, conveys to the ganglion fibres from the chorda tympani and the inferior maxillary nerve, and thus represents the *motor* and *sensory* roots of the ganglion. The *sympathetic* root is formed by slender twigs from the plexus on the facial artery.

BRANCHES.—Five or six small nerves descend from the ganglion to the submaxillary gland, and others run forwards to the mucous membrane of the mouth and Wharton's duct. The anterior branch of communication with the lingual nerve is probably composed of fibres which pass from the ganglion and are distributed with the offsets of that nerve. There is also occasionally a small branch or two passing to the hypoglossal nerve (Meckel, Bose).

A minute *sublingual ganglion* is described by some anatomists on the filaments passing from the lingual nerve to the sublingual gland (fig. 163; 181, 8); and small groups of nerve-cells are also found in the adjoining part of the lingual trunk (Raubert).

Otic Ganglion.

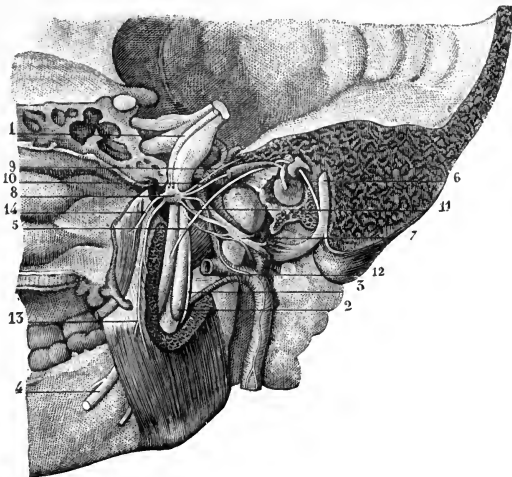
The otic ganglion, or ganglion of Arnold, of a reddish-grey colour, is oval in shape, flattened from within out, and measures about 4 mm. in its longest (antero-posterior) diameter. It is situated immediately below the foramen ovale, on the deep surface of the inferior maxillary nerve, covering, and not unfrequently surrounding, the origin of the internal pterygoid branch. Its inner surface is close to the cartilaginous part of the Eustachian tube and the tensor palati muscle;

behind it is the middle meningeal artery. Its cells also belong to the multipolar variety.

Roots.—The ganglion receives, through its connection with the nerve to the

Fig. 164.—THE OTIC GANGLION AND ITS CONNECTIONS FROM THE INNER SIDE. (From Sappey, after Arnold.) $\frac{3}{4}$

The temporal bone is divided so as to show the inner surface of the membrana tympani and the canal of the facial nerve; the foramen ovale is opened on the inner side: 1, small root of the fifth nerve, passing down on the inner side of the Gasserian ganglion to unite with the inferior maxillary division; 2, inferior dental nerve; 3, mylo-hyoid branch, seen also farther down emerging in front of the internal pterygoid muscle; 4, lingual; 5, chorda tympani; 6, facial nerve in its canal; 7, auriculo-temporal nerve, enclosing in its loop of origin the middle meningeal artery; 8, otic ganglion; 9, small superficial petrosal nerve; 10, branch to the tensor tympani muscle; 11, twig connecting the ganglion with the auriculo-temporal nerve; 12, twig to the ganglion from the sympathetic on the meningeal artery; 13, nerve to the internal pterygoid muscle; 14, branch to the tensor palati muscle.



internal pterygoid, fibres from the inferior maxillary nerve, and these may be regarded as constituting its *motor* and *sensory roots* (*short root* of Arnold); the

Fig. 165.—THE OTIC GANGLION, WITH ITS ROOTS AND BRANCHES. (Raubert.) $\frac{1}{2}$

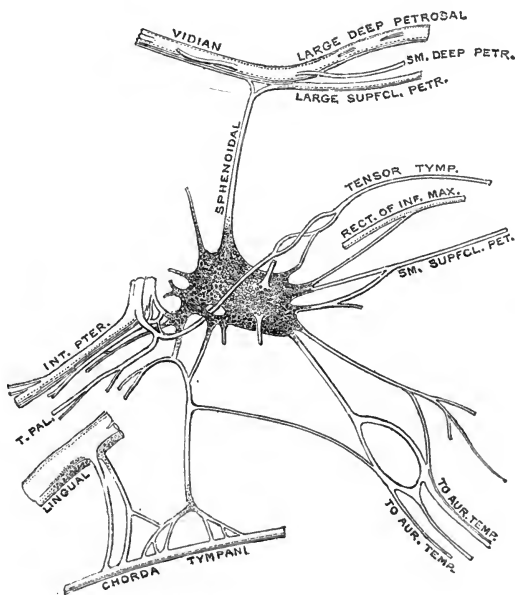
sympathetic root is a filament (or two) passing forwards from the plexus on the middle meningeal artery. The ganglion is also joined posteriorly by the *small superficial petrosal nerve* (*long root*, Arnold), which connects it with, and probably conveys to it fibres from, the facial and glosso-pharyngeal nerves (p. 260); and a slender *sphenoidal* filament ascends from it to the Vidian nerve.

BRANCHES.—(a) Two or more pale branches pass backwards to the roots of the auriculo-temporal nerve, and convey secretory fibres from the glosso-pharyngeal nerve to the parotid gland.

(b) A communicating twig descends to the chorda tympani.

(c, d and e) Slender filaments pass from the ganglion to the nerves supplying the internal pterygoid, tensor palati and tensor tympani muscles.

(f) A filament joins the buccal nerve (Raubert).



SUMMARY.—Cutaneous filaments of the inferior maxillary nerve ramify on the side of the head and the external ear, in the external auditory canal, the lower lip, and the lower part of the face; sensory branches are supplied by it to the greater part of the tongue; and branches are furnished to the mucous membrane of the mouth, the lower teeth and gums, the salivary glands, the articulation of the lower jaw, the dura mater and skull, and the mucous lining of the mastoid cells.

This nerve supplies the muscles of mastication, viz., the masseter, temporal, and two pterygoids; also the mylo-hyoid, the anterior belly of the digastric, the tensor palati and tensor tympani muscles.

VI.—ABDUCENT NERVE.

The sixth nerve (abducent nerve of the eyeball, external oculomotor) is distributed solely to the external rectus muscle of the eye. Its fibres arise from a nucleus placed close to the floor of the fourth ventricle immediately above the striæ acusticæ, beneath the eminentia teres. Leaving the inner side of the nucleus, they pass forwards and somewhat downwards through the lower part of the pons, and form a

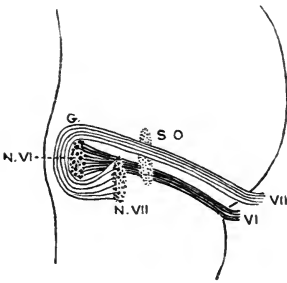


Fig. 166.—PLAN OF THE ORIGIN AND COURSE WITHIN THE PONS OF THE SIXTH AND SEVENTH NERVES.

The nerves and their nuclei are projected on to a sagittal section of the pons near the median plane: VI, sixth nerve; N. VI, its nucleus; VII, facial nerve; G, its inner genu; N. VII, its nucleus; S. O., superior olive.

flattened band, which emerges in the depression at the lower edge of that body immediately external to the pyramid. One or two of the innermost bundles frequently issue between the fibres of the pyramid, or from the lower edge of the pons.

The nerve speedily becomes rounded, and is directed upwards and forwards, lying for a distance of about 15 mm. between the anterior surface of the pons and the occipital bone. It then enters an aperture in the dura mater to the inner side of and slightly below that of the fifth nerve (see Vol. II, fig. 182), and passing on the outer side of the inferior petrosal sinus, it crosses over the apex of the petrous bone, and beneath the petro-sphenoidal ligament (see Osteology, p. 43), to enter the cavernous sinus. In that cavity the nerve is directed forwards along the outer side of the internal carotid artery, and reaching the outer wall of the space anteriorly, it then passes into the orbit through the sphenoidal fissure, and between the heads of the external rectus, to which muscle it is distributed on its ocular surface (fig. 149, 6; 156, 5). As the nerve enters the orbit, it is placed below the other nerves passing through the sphenoidal fissure, but above the ophthalmic veins.

While contained in the cavernous sinus, the sixth nerve is joined by filaments from the carotid plexus of the sympathetic, and as it enters the orbit it receives a small filament from the ophthalmic nerve.

The number of fibres in the sixth nerve has been estimated at 2,000 to 2,500 by Rosenthal, 3,600 by Tergast. They are mostly large, but there are some of medium size; fine fibres are scanty.

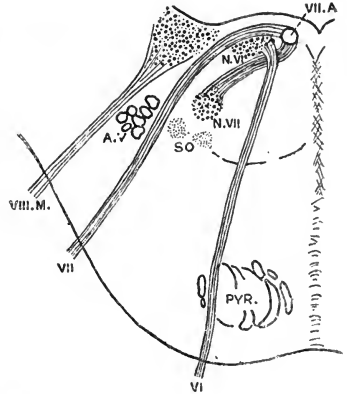
Variety.—Absence of the sixth nerve upon one side is recorded, its place being supplied by a branch of the third nerve (Generali).

VII.—FACIAL NERVE.

The nucleus of the seventh or facial nerve is situated in the formatio reticularis of the lower part of the pons, about on the same level as the nucleus of the sixth nerve, but farther from the floor of the fourth ventricle. The fibres leave the back of the nucleus, and are directed at first dorso-mesially towards the lower end of the

Fig. 167.—PLAN OF THE ORIGINS OF THE SIXTH AND SEVENTH CRANIAL NERVES. (Adapted from Schwalbe.)

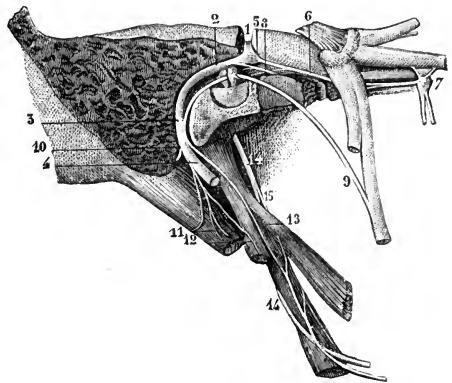
The outline represents a transverse section of the lower part of the pons, on to which the course of the facial nerve is projected: VI, sixth nerve; N.VI, its nucleus; VII, facial nerve; VII.A, the ascending portion of its root, supposed to be seen in optical section; N.VII, its nucleus; SO, superior olive; A.V, ascending or bulbar root of fifth nerve; VIII.M, mesial root of auditory nerve.



abducent nucleus. Here they are collected into a well-marked bundle, which ascends for a short distance close beneath the floor of the ventricle, then bends sharply downwards and outwards over the upper end of the abducent nucleus (*inner genu of the facial nerve*), and finally runs forwards and outwards through the lower part of the pons, to emerge at the upper end of the medulla oblongata in the depression between the olivary and restiform bodies. Those fibres of the nerve, however, which supply the frontalis, orbicularis palpebrarum and corrugator supercilii muscles (ocular facial) probably arise from the oculomotor nucleus, and descend by the posterior

Fig. 168.—THE FACIAL NERVE IN ITS CANAL, WITH ITS CONNECTING BRANCHES, &c. (From Sappey, after Hirschfeld and Leveillé.) $\frac{3}{4}$

The mastoid and a part of the petrous bone have been divided nearly vertically, and the canal of the facial nerve opened in its whole extent from the internal meatus to the stylo-mastoid foramen; the Vidian canal has also been opened from the outer side: 1, facial nerve in the first horizontal part of its course; 2, its second part turning backwards; 3, its vertical portion; 4, the nerve at its exit from the stylo-mastoid foramen; 5, geniculate ganglion; 6, large superficial petrosal nerve; 7, sphenopalatine ganglion; 8, small superficial petrosal nerve; 9, chorda tympani; 10, posterior auricular branch cut short; 11, branch to the digastric muscle; 12, branch to the stylo-hyoid muscle; 13, twig uniting with the glosso-pharyngeal nerve (14 and 15).



longitudinal bundle to join the issuing portion of the root; and it is possible that the fibres for the orbicularis oris are derived from the hypoglossal nucleus.

At its superficial origin the facial nerve rests against, and commonly adheres for a short distance to, the lower border of the pons just where the latter is passing into the middle peduncle of the cerebellum, and immediately below the fifth nerve. To its outer side is the auditory nerve, and between the two is a slender fasciculus (fig. 140, between VII and VIII) known as the **pars** or **portio intermedia** of **Wrisberg** (*n. intermedius*), which joins the facial nerve in the auditory canal.

The fibres of this part have been traced centrally to the upper end of the glosso-pharyngeal nucleus (Duval). It is frequently connected more or less closely at its emergence with one or both of the nerves between which it lies, and in many cases a few of its fibres pass distally into the auditory nerve.

The fibres of the facial nerve are mostly of medium size, but the portio intermedia consists almost wholly of very small fibres. Indications of a degenerated ganglion are found in the facial nerve close to its exit from the bulb (Thomsen, Gaskell).

From its superficial origin, the facial nerve is directed outwards in company with the auditory nerve to the internal auditory meatus. Here the facial lies in a groove along the upper and fore part of the auditory nerve, and the portio intermedia is placed between the two. At the bottom of the meatus the facial nerve enters the

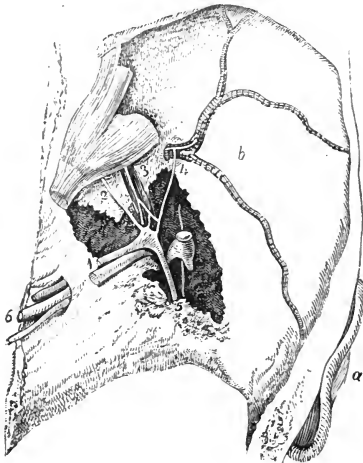


Fig. 169.—GENICULATE GANGLION OF THE FACIAL NERVE AND ITS CONNECTIONS FROM ABOVE. (Bidder.)

The dissection is made in the middle fossa of the skull on the right side, part of the temporal bone being removed so as to open the internal auditory meatus, hiatus Fallopii, and a part of the canal of the facial nerve, together with the cavity of the tympanum; *a*, auricle; *b*, middle fossa of the skull with the meningeal artery ramifying in it; 1, facial and auditory nerves in the internal auditory meatus; 2, large superficial petrosal nerve; 3, small superficial petrosal nerve lying over the tensor tympani muscle; 4, external superficial petrosal nerve joining sympathetic twig on the meningeal artery; 5, facial and chorda tympani; 6, nerves entering the jugular foramen.

aqueduct of Fallopius, and follows the windings of that canal through the temporal bone to the lower surface of the skull. It passes at first horizontally outwards for a short distance, between the cochlea and vestibule,

to the inner wall of the tympanum, where it bends sharply backwards above the fenestra ovalis, and then arches downwards behind the pyramid and the tympanic cavity to issue by the stylo-mastoid foramen. At the place where it turns backwards (*outer genu*; *genicul.-m. n. facialis*), the nerve presents on its fore part a reddish enlargement which contains unipolar nerve-cells, and is named the **geniculate ganglion** (*ganglion geniculi*). This ganglion is mainly connected with the portio intermedia, and the fibres which proceed from its cells (both proximally and distally) are probably afferent. Below the skull, the facial trunk is continued downwards and forwards through the substance of the parotid gland; and a little behind the ramus of the lower jaw it terminates by dividing into two parts, *temporo-facial* and *cervico-facial*, from which numerous branches spread over the side of the head, the face, and the upper part of the neck, communicating freely with one another, and thus forming a radiating plexus to which the name of *pes anserinus* or *plexus parotidæus* has been given.

BRANCHES.—A. *Arising from the facial nerve during its course through the temporal bone.*

Communicating filaments with the auditory nerve.—These are one or two slender twigs passing between the geniculate ganglion and the upper division of the eighth nerve at the bottom of the internal auditory meatus, and probably conveying to the facial nerve fibres derived from the portio intermedia.

The **large superficial petrosal nerve** is directed forwards from the geniculate ganglion, and issues by the hiatus Fallopii on the upper surface of the petrous

portion of the temporal bone. Inclining downwards beneath the Gasserian ganglion, the nerve enters the foramen lacerum, and is continued across the outer side of the internal carotid artery to the posterior opening of the Vidian canal, where it unites with the large deep petrosal nerve (derived from the sympathetic on the carotid artery) to form the Vidian nerve joining the back of the sphenopalatine ganglion (p. 243).

In addition to conveying fibres from the facial nerve (or portio intermedia) to the sphenopalatine ganglion, the large superficial petrosal nerve contains others, derived presumably from the fifth nerve, which run distally in the facial trunk. (See R. Penzo, "Ueb. d. Ganglion geniculi u. d. mit demselben zusammenhängenden Nerven," *Anatom. Anzeiger*, viii, 1893, 738 : M. v. Lenhossék, "Das Ganglion geniculi N. facialis u. seine Verbindungen," in "Beiträge zur Histologie des Nervensystems," &c., 1894.)

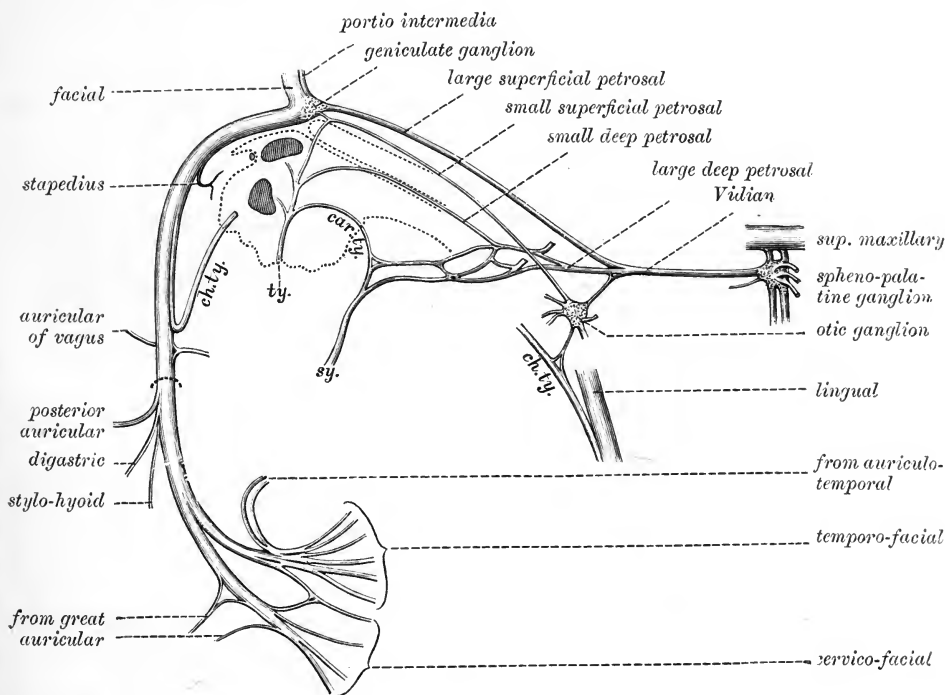


Fig. 170.—PLAN OF THE FACIAL NERVE, WITH SOME OF ITS COMMUNICATIONS. (G. D. T.)

ch.ty., chorda tympani; its middle part is removed; *ty.*, tympanic branch of the glosso-pharyngeal; *sy.*, sympathetic on the internal carotid artery; *car.ty.*, carotico-tympanic nerve, passing between the tympanic nerve and the sympathetic in the carotid canal.

Communication with the small superficial petrosal nerve.—A minute branch connects the geniculate ganglion with the small superficial petrosal nerve passing from the tympanic plexus to the otic ganglion (p. 260).

The **external superficial petrosal nerve** (Bidder) unites the geniculate ganglion with the sympathetic filaments on the middle meningeal artery. This nerve is not always present (Raubert).

A **branch to the stapedius muscle** is given off by the facial nerve as it descends behind the pyramid.

Chorda tympani.—This branch, which according to many observers—is in large

part at least continuous with the portio intermedia, leaves the facial nerve at the lower end of the aqueduct of Fallopius, and is directed upwards and forwards through a small canal (*iter chordæ posterius*) which opens on the posterior wall of the tympanum, close to the attachment of the tympanic membrane. It then arches forwards, being invested by the mucous lining of the cavity, across the upper part of the membrane and over the inner side of the handle of the malleus, above the insertion of the tensor tympani muscle. Finally, leaving the cavity by an aperture (*iter chordæ anterior*) at the inner end of the Glaserian fissure, the nerve inclines downwards on the mesial side of the internal lateral ligament of the jaw, and unites at an acute angle with the lingual nerve, in which its fibres are continued to the submaxillary ganglion and the tongue. Before joining the lingual nerve, the chorda receives a communicating filament from the otic ganglion.

A **communication with the auricular branch of the pneumo-gastric nerve** is generally present, in the form of a twig leaving the facial nerve close above the stylo-mastoid foramen (see p. 265).

B. *Arising from the facial nerve below the base of the skull.*

The **posterior auricular nerve** arises close to the stylo-mastoid foramen, and turns upwards between the ear and the mastoid process, where it divides into auricular and occipital branches.

The *auricular branch* ascends behind the ear and is distributed to the retrahens auriculam and the small muscles on the cranial surface of the pinna. A twig is sometimes continued upwards to the attollens muscle.

The *occipital branch* is directed backwards close to the bone, and supplies the posterior part of the occipito-frontalis muscle.

The posterior auricular nerve receives communications from the great auricular and small occipital nerves of the cervical plexus, as well as from the auricular branch of the pneumo-gastric, and certain filaments which may sometimes be followed from its branches to the skin are probably composed of fibres derived from these nerves.

The **digastric branch** arises close below the preceding nerve, and divides into two or three filaments which enter the posterior belly of the digastric muscle; one of these sometimes passes through or above the digastric, and joins the glosso-pharyngeal nerve near the base of the skull.

The **stylo-hyoid branch**, long and slender, arises in common with the digastric branch, and inclines forwards to enter the stylo-hyoid muscle on its posterior aspect.

TEMPORO-FACIAL DIVISION.—The temporo-facial, the larger of the two primary divisions of the facial nerve, is directed forwards through the upper part of the parotid gland, crossing over the external carotid artery and the temporo-maxillary vein. It receives one or two considerable offsets from the auriculo-temporal nerve (p. 246), and speedily divides into a number of branches which form, by their communications with one another and with branches of the fifth nerve, a network over the side of the face, extending as high as the temple and as low as the mouth. Its ramifications are arranged in temporal, malar, and infraorbital sets.

The **temporal branches** ascend over the zygoma and supply the attrahens and attollens auriculam muscles, the frontalis, the upper part of the orbicularis palpebrarum, and the corrugator supercillii. One or two filaments pass to the auricle, and are distributed to the small muscles on its outer surface. These branches form communications with the auriculo-temporal nerve, the temporal branch of the superior maxillary, and the supraorbital and lachrymal branches of the ophthalmic nerve.

The **malar branches** cross the malar bone to reach the outer side of the orbit and supply the orbicular muscle. Some filaments are distributed to both the upper

and lower eyelids: those in the upper lid join filaments from the lachrymal and supraorbital nerves, and those in the lower lid are connected with filaments from the superior maxillary nerve. Filaments from this part of the facial also communicate with the malar branch of the upper maxillary nerve.

The **infraorbital branches** (superior bucco-labial), of larger size than the

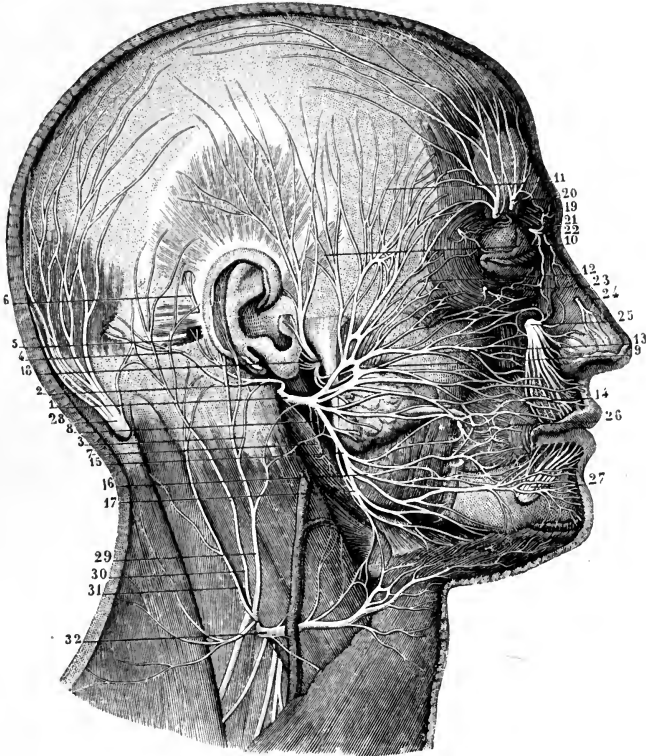


Fig. 171.—SUPERFICIAL DISTRIBUTION OF THE FACIAL, TRIGEMINAL, AND OTHER NERVES OF THE HEAD. (From Sappey, after Hirschfeld and Leveillé.)

a, Facial Nerve.—1, trunk of the facial nerve after its exit from the stylo-mastoid foramen; 2, posterior auricular branch; 3, filament of the great auricular nerve uniting with the foregoing; 4, occipital branch; 5, auricular branch; 6, twig to the superior auricular muscle; 7, nerve to the digastric; 8, that to the stylo-hyoid muscle; 9, superior or temporo-facial division of the nerve; 10, 11, temporal branches; 12, malar; 13, 14, infraorbital; 15, inferior or cervico-facial division of the nerve; 16, mandibular, and above this the buccal branches; 17, cervical branch.

b, Fifth Nerve.—18, auriculo-temporal uniting with the facial, giving anterior auricular and parotid branches, and ascending to the temporal region; 19, 20, supraorbital; 21, lachrymal; 22, infra-trochlear; 23, malar twig of the temporo-malar; 24, superficial branch of the nasal; 25, infraorbital; 26, buccal, uniting with branches of the facial; 27, mental.

c, Cervical Nerves.—28, great occipital; 29, great auricular; 30, 31, small occipital; 32, superficial cervical.

others, are almost horizontal in direction, and are distributed between the orbit and mouth. They supply the buccinator and orbicularis oris muscles, the zygomatici, the elevators of the upper lip and angle of the mouth, and the muscles of the nose. Beneath the elevator of the upper lip these nerves are united in a plexus with the terminal branches of the superior maxillary nerve; on the side of the nose they communicate with the nasal, and at the inner angle of the orbit with the infra-trochlear nerve. The lower branches of this set are connected with those of the cervico-facial division.

CERVICO-FACIAL DIVISION.—This division of the facial nerve is directed obliquely through the parotid gland towards the angle of the lower jaw, and gives branches to the face below those of the preceding division, and to the upper part of the neck. The branches are named buccal, mandibular, and cervical. In the gland, this division of the facial nerve is joined by filaments of the great auricular nerve of the cervical plexus, and offsets from it penetrate the substance of the gland.

The **buccal branches** (inferior bucco-labial) are directed across the masseter muscle to the angle of the mouth; supplying the buccinator and sphincter muscles, they communicate with the temporo-facial division, and on the buccinator muscle join with filaments of the buccal branch of the inferior maxillary nerve.

The **mandibular branch** (supramaxillary), sometimes double, runs forwards beneath the depressor anguli oris, and, after communicating with the mental branch of the inferior dental nerve, supplies the muscles of the lower lip. One superficial branch is continued along the margin of the lower jaw to the chin.

The **cervical branch** (inframaxillary) perforates the deep cervical fascia and divides into slender offsets, which form arches beneath the platysma as low as the hyoid bone. They supply the platysma, and form one or two loops of communication with the upper division of the superficial cervical nerve.

SUMMARY.—The facial nerve is the principal motor nerve of the head, supplying all the superficial, and some of the deep muscles. Its superficial offsets are distributed to the muscles of the scalp, the muscles of the external ear, nose, mouth, and eyelids (with the exception of the levator palpebræ superioris), and to the cutaneous muscle of the neck (platysma). Of the deep muscles, it supplies the stapedius, stylohyoid, and posterior belly of the digastric (according to some also the levator palati and azygos uvulæ muscles through the large superficial petrosal nerve). It also furnishes, through the chorda tympani, secretory and vaso-dilator fibres for the submaxillary and sublingual glands; and the same nerve would appear to contain the taste-fibres from the fore part of the tongue.

The facial nerve is freely connected with the three divisions of the fifth nerve; and it also has communications with the sphenopalatine, submaxillary and otic ganglia, with the auditory, glosso-pharyngeal and pneumo-gastric nerves (through the auricular branch of the latter), and with parts of the sympathetic and spinal nerves.

Filaments which may be traced from the branches of the facial nerve to the skin of the face and neck are doubtless derived from the communications with sensory nerves, especially the auriculo-temporal, great auricular and superficial cervical.

VIII.—AUDITORY NERVE.

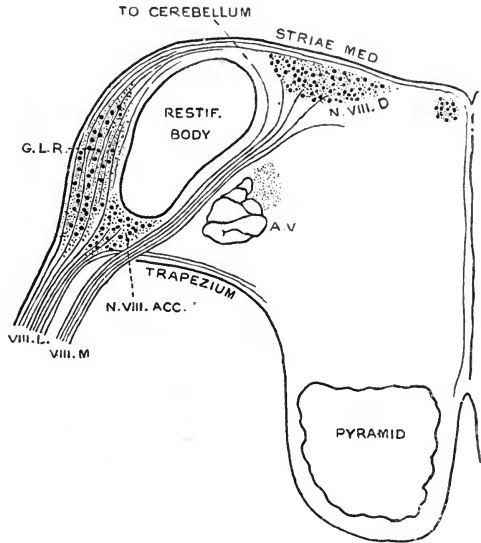
The eighth or auditory nerve (*n. acusticus*) makes its appearance on the outer side of the facial nerve, and is closely adherent for a short distance to the lower border of the middle peduncle of the cerebellum. It begins by two roots, the one of which, the *mesial* or *anterior* (*radix vestibularis*), passes obliquely backwards on the inner side of the restiform body to the dorsal auditory nucleus in the floor of the fourth ventricle, while the other, the *lateral* or *posterior* (*radix cochlearis*), passes round the outer side of the restiform body, where it is somewhat enlarged and contains numerous nerve-cells (*ganglion of the lateral root, ganglion radialis cochlearis*), and appears to be continued into the striæ medullares.

The fibres of the auditory nerve, both central and peripheral, have their origin in the cells of the several portions of the acoustic ganglion (vestibular ganglion, spiral ganglion of the cochlea, and perhaps also the ganglion of the lateral root), which is the equivalent of an intervertebral ganglion; and the auditory nerve in the meatus corresponds therefore to the posterior root of a spinal nerve. The

fibres of the mesial root pass mainly to the dorsal auditory nucleus, but some turn inwards to the raphé of the bulb, and others may ascend to the cerebellum either directly or with the intervention of a special nucleus (Bechterew). The fibres of the lateral root end in large part in the accessory or ventral auditory nucleus, which is placed between the two roots in front of the restiform body, and in the ganglion

Fig. 172.—PLAN OF THE ROOTS OF THE AUDITORY NERVE. (G. D. T.)

The outline represents a section at the junction of the bulb with the pons: VIII.M., mesial root, VIII.L., lateral root of the auditory nerve; N.VIII.ACC., accessory nucleus; G.L.R., ganglion of lateral root; N.VIII.D., dorsal nucleus of the auditory nerve; A.V., ascending or bulbar root of the fifth nerve.



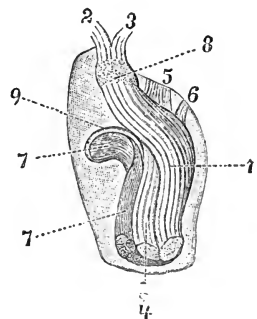
of the lateral root; but a smaller number are continued into the medullary striæ and trapezium.¹

The two roots unite as they leave the medulla oblongata, and the nerve is directed outwards to the internal auditory meatus, in company with the facial nerve, which rests in a groove along its upper and fore part, and the auditory artery, which, together with the portio intermedia of the facial nerve, is placed between

the two trunks. In the meatus, the nerve divides into an upper smaller and a lower larger part, the fibres of which are continuous with the mesial and lateral roots respectively. The *upper* or *vestibular portion* (*n. vestibuli*), passing above the crista falciformis, divides again into three branches, which are distributed to the utricle and

Fig. 173.—THE AUDITORY NERVE OF THE RIGHT SIDE IN THE INTERNAL AUDITORY MEATUS, SEEN FROM ABOVE. (Schwalbe.) $\frac{2}{3}$

The meatus has been opened from above, and the facial nerve removed together with the portio intermedia. The left side of the figure corresponds to the anterior wall of the meatus. 1, superior division; 2, utricular nerve; 3, common stem of the superior and external ampullary nerves; 4, posterior branch of the lower division; 5, saccular nerve; 6, posterior ampullary nerve; 7, cochlear nerve; 8, gangliform enlargement of superior division; 9, crista falciformis.



the ampullæ of the superior and external semicircular canals. The *lower portion* gives off a small *posterior branch* (middle branch of Schwalbe), which furnishes the nerves of the saccule and posterior semicircular canal, and is then continued as the *cochlear nerve*, the subdivisions of which enter the apertures in the fossa below the fore part of the crista falciformis. On the vestibular division of the nerve, in the superior fossa at the bottom of the auditory meatus, is a ganglionic enlargement (*intumescencia gangliiformis Scarpa, vestibular ganglion*), which is continued below into the saccular nerve; and there are said to be two small swellings on the posterior ampullary nerve in its canal (Corti). The corresponding ganglion of the cochlear nerve is contained

¹ See H. Held, "Die centrale Gehörleitung," Archiv f. Anat., 1893.

in the bony wall of the cochlea, and is called the *spiral ganglion*. The cells in these ganglia are bipolar. (See the anatomy of the ear.)

The auditory nerve often receives some of the fibres of the portio intermedia, and its upper division is connected at the bottom of the internal auditory meatus with the geniculate ganglion of the facial nerve (see p. 252).

The branches of the auditory nerve, together with the apertures by which they leave the meatus, are shown in the following table:—

Superior division or vestibular nerve	}	Utricular nerve	}	Area cribrosa superior.	
		Superior ampullary nerve			
		External ampullary nerve			
Inferior division	} Posterior branch	Saccular nerve	}	Area cribrosa media.	
		Posterior ampullary nerve			Foramen singulare.
		Cochlear nerve	}	Tractus spiralis foraminulenus and foramen centrale cochleæ.	

IX.—GLOSSO-PHARYNGEAL NERVE.

The ninth or glosso-pharyngeal nerve emerges from the upper part of the medulla oblongata, in the groove between the olivary and restiform bodies, by five

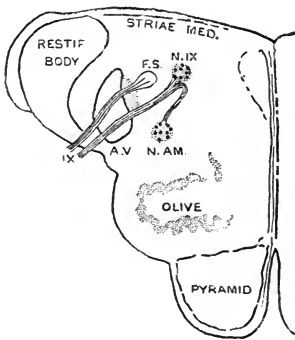


Fig. 174.—PLAN OF THE ORIGIN OF THE GLOSSO-PHARYNGEAL NERVE. (After Obersteiner.)

The outline represents a transverse section of the upper end of the bulb: IX, roots of the glosso-pharyngeal nerve; F.S., funiculus solitarius; N.IX, glosso-pharyngeal nucleus; N.AM., nucleus ambiguus; A.V, ascending or bulbar root of the fifth nerve.

or six filaments arranged in a vertical line commencing immediately below the facial nerve.

From this spot the rootlets of the nerve pass backwards and inwards through the bulb to the special nucleus beneath the inferior fovea in the floor of the fourth ventricle; some of the fibres turn downwards into the funiculus solitarius, and others, probably efferent, bend forwards to the upper prolongation of the accessory vagal nucleus (nucleus ambiguus).

The glosso-pharyngeal is composed almost entirely of very fine fibres, but mixed with these there are a few of medium size.

From its superficial origin, the glosso-pharyngeal nerve is directed outwards in front of the flocculus to the middle compartment of the jugular foramen, through which it passes in company with the pneumo-gastric and spinal accessory nerves, but in a separate tube of dura mater. In the foramen, where it is placed external to and somewhat in front of the other nerves, it is lodged in a groove, occasionally a canal, in the lower border of the petrous portion of the temporal bone, and it presents, successively, two ganglionic enlargements—the *jugular ganglion* and the *petrosal ganglion*, containing unipolar nerve-cells, like those of the spinal ganglia.

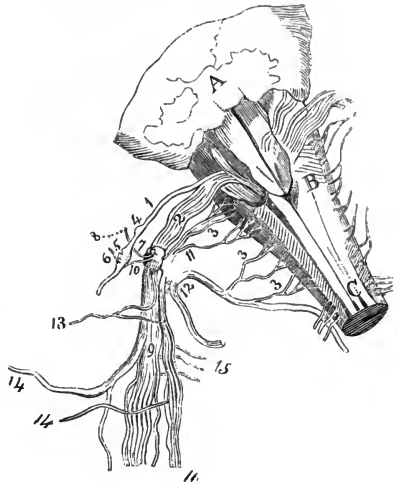
After leaving the skull, the glosso-pharyngeal nerve appears between the internal carotid artery and the jugular vein, and is directed downwards over the carotid artery and beneath the styloid process and the muscles connected with it, to the hinder border of the stylo-pharyngeus; then curving gradually forwards, it crosses

over the outer surface of the latter muscle, and passes beneath the hyo-glossus to end in branches for the hinder part of the tongue (fig. 179, 16).

The **jugular ganglion** (*g. superius*) is situated at the upper part of the osseous groove in which the nerve lies during its passage through the jugular foramen. It is

Fig. 175.—DIAGRAMMATIC SKETCH FROM BEHIND OF THE ROOTS OF THE NINTH, TENTH, AND ELEVENTH NERVES, WITH THEIR GANGLIA AND COMMUNICATIONS. (Bendz.)

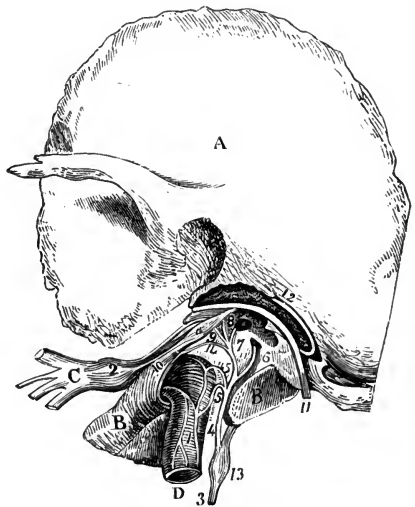
A, part of the cerebellum above the fourth ventricle; B, medulla oblongata; C, spinal cord; 1, glosso-pharyngeal nerve; 2, pneumo-gastric; 3, 3, 3, spinal accessory; 4, jugular ganglion of the glosso-pharyngeal; 5, petrosal ganglion; 6, tympanic branch; 7, ganglion of the root of the pneumo-gastric; 8, auricular branch; 9, ganglion of the trunk of the pneumo-gastric; 10, branch from the upper ganglion to the petrosal ganglion of the glosso-pharyngeal; 11, inner portion of the spinal accessory; 12, outer portion; 13, pharyngeal branch of the pneumo-gastric; 14, 14, superior laryngeal branch; 15, twigs connected with the sympathetic; 16, internal part of the spinal accessory prolonged with the pneumo-gastric.



from 1 to 2 mm. in length, and it includes only the lower filaments of the nerve, the upper ones forming a separate fasciculus which passes over the ganglion, and joins the trunk of the nerve below it. This ganglion is not always to be distinguished, and it is regarded by Henle and others as

Fig. 176.—THE TYMPANIC BRANCH OF THE GLOSSO-PHARYNGEAL NERVE, AND ITS CONNECTIONS. (Breschet.)

A, squamous part of the left temporal bone; B, petrous part; C, inferior maxillary nerve; D, internal carotid artery; a, tensor tympani muscle; 1, sympathetic plexus; 2, otic ganglion; 3, glosso-pharyngeal nerve; 4, tympanic nerve; 5, 5, carotico-tympanic twigs; 6, twig to fenestra rotunda; 7, twig to fenestra ovalis; 8, junction with the facial nerve; 9, small superficial petrosal nerve; 10, twig from the otic ganglion to the tensor tympani muscle; 11, facial nerve; 12, chorda tympani; 13, petrosal ganglion of the glosso-pharyngeal; 14, small deep petrosal nerve.



resulting, when present, from the more or less complete separation of a part of the petrosal ganglion.

The **petrosal ganglion** is contained in a small depression at the lower end of the groove in the petrous part of the temporal bone, and measures from 4 to 5 mm. in length. From it arise the small branches by which the glosso-pharyngeal is connected with other nerves at the base of the skull; these are the tympanic nerve, and the branches of communication with the pneumo-gastric and sympathetic.

BRANCHES.—A. *Connecting branches and tympanic branch.*

One filament unites the petrosal ganglion of the glosso-pharyngeal with the upper cervical ganglion of the sympathetic; a second passes to the auricular

branch of the pneumo-gastric; and a third, which however is not constant, joins the ganglion of the root of the pneumo-gastric nerve.

The glosso-pharyngeal nerve is also joined below the petrosal ganglion, in many cases, by a communicating branch from the facial nerve (p. 254).

The **tympanic branch** (nerve of Jacobson) ascends from the petrosal ganglion, in company with the tympanic branch of the ascending pharyngeal artery, through a small canal, the orifice of which is seen on the ridge of bone between the jugular fossa and the carotid foramen. Having gained the inner wall of the tympanum, the nerve runs upwards and forwards in a groove on the surface of the promontory, and, after giving (or receiving) several branches, leaves the cavity at its upper and fore part, where it becomes the *small superficial petrosal nerve*. The latter traverses a small canal, which crosses beneath the upper end of the canal of the tensor tympani muscle, and emerges on the upper surface of the petrous portion of the temporal bone, immediately external to the hiatus Fallopii. Then inclining downwards, the

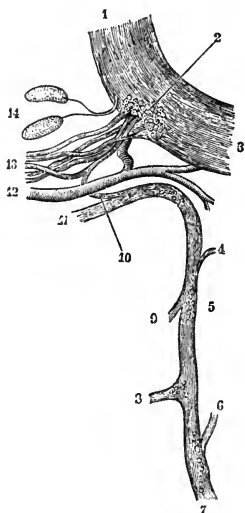


Fig. 177.—THE TYMPANIC NERVE OF THE LEFT SIDE IN ITS CONNECTION WITH THE FACIAL. (Krause.) $\frac{1}{2}$

1, facial nerve, proximal end; 2, geniculate ganglion; 3, facial nerve, distal end; 4, nerve to fenestra ovalis; 5, ganglion-cells in tympanic nerve; 6, nerve of fenestra rotunda; 7, tympanic nerve from glosso-pharyngeal; 8, small deep petrosal nerve; 9, nerve to Eustachian tube; 10, filament to geniculate ganglion; 11, small superficial petrosal nerve; 12, petrosal branch of middle meningeal artery; 13, large superficial petrosal nerve; 14, Pacinian corpuscles in the dura mater.

nerve passes from the skull through the fissure between the petrous and the great wing of the sphenoid, or occasionally through a small aperture in the latter bone, and terminates in the otic ganglion. As it lies in its canal, the small superficial petrosal nerve is joined by a filament of communication from the geniculate ganglion of the facial nerve, or from the large superficial petrosal nerve close to that ganglion.

The branches of the tympanic nerve are partly distributed to the mucous lining of the middle ear, and partly form communications with other nerves, giving rise to what is called the *tympanic plexus*. Of the former set, the principal branches are—one directed forwards to the Eustachian tube, and two backwards to the neighbourhood of the fenestra rotunda and fenestra ovalis, and to the mastoid cells. The communicating branches are, in addition to the small superficial petrosal nerve with its filament of union with the facial, one or two twigs (*carotico-tympanic*) which pass downwards and forwards through the anterior wall of the tympanum to the carotid canal and join the sympathetic on the carotid artery, and the *small deep petrosal nerve* which runs forwards in a minute canal in the substance of the processus cochleariformis and enters the foramen lacerum, where it joins the carotid plexus of the sympathetic, or sometimes one of the large petrosal nerves (figs. 165, 170).

The tympanic nerve while in its canal is surrounded by a small fusiform mass of soft vascular tissue which has been called the *tympanic gland* (Krause); and as it lies in the tympanum it contains numerous nerve-cells in irregular groups.

B. Branches distributed in the neck.

Pharyngeal branches.—The largest of these (carotid branch, pharyngeal division of the glosso-pharyngeal nerve—Henle) descends along the internal carotid

artery and unites with the pharyngeal branch of the vagus to form the pharyngeal plexus (p. 265); this branch is sometimes divided into two or even three parts. One or two smaller twigs pass inwards through the superior constrictor muscle, and supply the mucous membrane of the upper part of the pharynx.

A **muscular branch** is furnished to the stylo-pharyngeus, and sends also filaments through the muscle to the mucous membrane of the pharynx.

Tonsillitic branches.—Slender filaments pass from the glosso-pharyngeal nerve, as it approaches the base of the tongue, to the tonsil, over which they form a sort of plexus (*circulus tonsillaris*), to the soft palate, and to the pillars of the fauces.

Lingual branches.—The glosso-pharyngeal nerve divides as it passes beneath the *hyo-glossus* muscle into two parts. One turns to the upper surface of the tongue and subdivides into many branches, which supply the circumvallate papillæ and the mucous membrane over the posterior third of the organ, the hindmost filaments reaching the anterior surface of the epiglottis. The other is smaller, and is distributed to the mucous membrane of the side of the tongue, extending to about the middle of its length, where it forms a communication with the lingual nerve. Beneath the mucous membrane the terminal filaments are united in a plexus which contains microscopic ganglia.

Variety.—In one case a branch from the glosso-pharyngeal supplied the *mylo-hyoid* muscle and the anterior belly of the *digastric*, the normal *mylo-hyoid* nerve being wanting (*Guy's Hosp. Reports*, vol. xiv, p. 453).

SUMMARY.—The glosso-pharyngeal nerve distributes branches to the mucous membrane of the tongue, pharynx and middle ear, as well as to the stylo-pharyngeus muscle, and possibly also to the middle constrictor of the pharynx. By its small superficial petrosal branch it furnishes secretory and vaso-dilator fibres (through the otic ganglion and the auriculo-temporal nerve) to the parotid gland. It is connected with the following nerves, viz., the inferior maxillary division of the fifth (through the otic ganglion), the facial, the pneumo-gastric (its trunk and branches), and the sympathetic.

X.—PNEUMO-GASTRIC NERVE.

The tenth or pneumo-gastric nerve (*nervus vagus, par vagum*) is much larger than the glosso-pharyngeal, and has the longest course of all the cranial nerves, extending through the neck and thorax to the upper part of the abdomen. It arises from the medulla oblongata immediately in front of the restiform body, by twelve or fifteen filaments beginning close below, and continuing the line of, the roots of the glosso-pharyngeal nerve. Its central connections are similar to those of the glosso-pharyngeal, the roots passing backwards towards the floor of the fourth ventricle, where the greater part of the fibres enter the vagal nucleus beneath the *ala cinerea*, while a smaller number pass into the *funiculus solitarius*, and a third set, believed to be efferent, spring from the accessory vagal nucleus.

The fibres of the vagal roots are mostly small. In the trunk of the nerve there are also numerous fibres of medium size, but these are probably derived in large part from the bulbar portion of the spinal accessory nerve, which joins the vagus close below the skull. Many of the larger fibres are continued into the pharyngeal and inferior laryngeal branches, which are in great measure distributed to striped muscles.

The roots of the vagus form at first a flat band, which is directed outwards below the *flocculus* to the middle compartment of the jugular foramen. Here the nerve is contained in the same sheath of *dura mater* and *arachnoid* as the spinal

accessory nerve, and its filaments unite in a small ganglionic enlargement which is known as the *ganglion of the root* of the pneumo-gastric. After its passage through the foramen, it is joined by the accessory part of the spinal accessory nerve, and a second ganglion is formed upon it, the *ganglion of the trunk* of the nerve. Several communications are at the same time established with surrounding nerves.

The **upper ganglion** or **ganglion of the root** of the pneumo-gastric nerve (*ganglion jugulare*), situated in the jugular foramen, is of a greyish colour, nearly spherical, and about 4 mm. in diameter. It has filaments connecting it with other nerves, viz., with the facial, the petrosal ganglion of the glosso-pharyngeal, the spinal accessory, and the sympathetic.

The **lower ganglion** or **ganglion of the trunk** of the pneumo-gastric nerve (cervical ganglion, *ganglion nodosum*) is placed below the base of the skull, about 1 cm. beyond the upper ganglion. It is of a flattened cylindrical form and reddish colour, and measures from 15 to 20 mm. in length and 4 in breadth. The

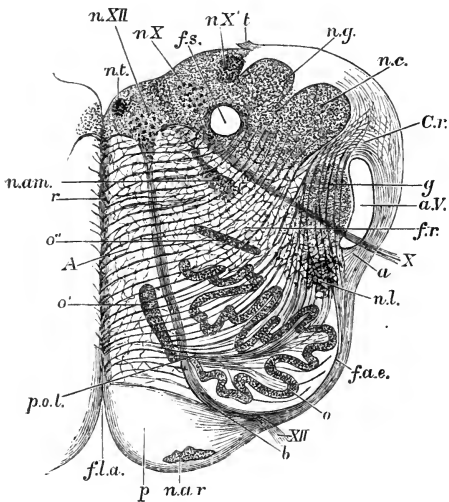


Fig. 178.—SECTION OF THE BULB AT ABOUT THE MIDDLE OF THE OLIVE. (Schwalbe.)

The full description of this figure will be found at p. 54 of part I. The following numbers refer to the vagus and hypoglossal nerves and their connections: *n. X*, *n. X'*, two parts of the vagal nucleus; *f.s.*, funiculus solitarius; *n. am.*, nucleus ambiguus or accessory vagal nucleus; *X*, bundle of vagus emerging between the restiform body and the olive; *n. XII*, hypoglossal nucleus; *XII*, bundle of hypoglossal nerve emerging between the olive and the pyramid.

accessory part of the spinal accessory nerve runs over the surface of the ganglion, and is in part continued directly into the pharyngeal and superior laryngeal branches of the vagus; some of the accessory fibres, however, become incorporated with the main trunk, and enter the inferior laryngeal and cardiac branches. The

lower ganglion communicates with the hypoglossal, the spinal, and the sympathetic nerves.

The nerve-cells in both ganglia of the vagus belong to the unipolar or spinal type.

The pneumo-gastric nerve descends in the neck between, and concealed by, the internal jugular vein and the internal carotid artery, and afterwards similarly between the vein and the common carotid artery, being enclosed along with them in the sheath of the vessels. In their passage into and through the thorax, the nerves are disposed differently on the right and left sides.

On the right side the nerve crosses over the first part of the right subclavian artery at the root of the neck, and its recurrent laryngeal branch turns backwards and upwards round that vessel. The nerve then enters the thorax behind the right innominate vein, and descends on the side of the trachea to the back of the root of the lung, where it spreads out in the posterior pulmonary plexus. It emerges from this plexus in the form of two cords, which are directed to the œsophagus, and by their union and subdivision on it form, with similar branches of the left nerve, the œsophageal plexus. Near the lower part of the thorax, the branches of the nerve, which have thus interchanged fibres with the nerve of the left side, are gathered

again into a single trunk, which, descending through the diaphragm along the back of the œsophagus, is finally divided between the posterior surface of the stomach and the solar plexus.

On the left side the pneumo-gastric nerve, entering the thorax between the left carotid and subclavian arteries and behind the left innominate vein, crosses over the

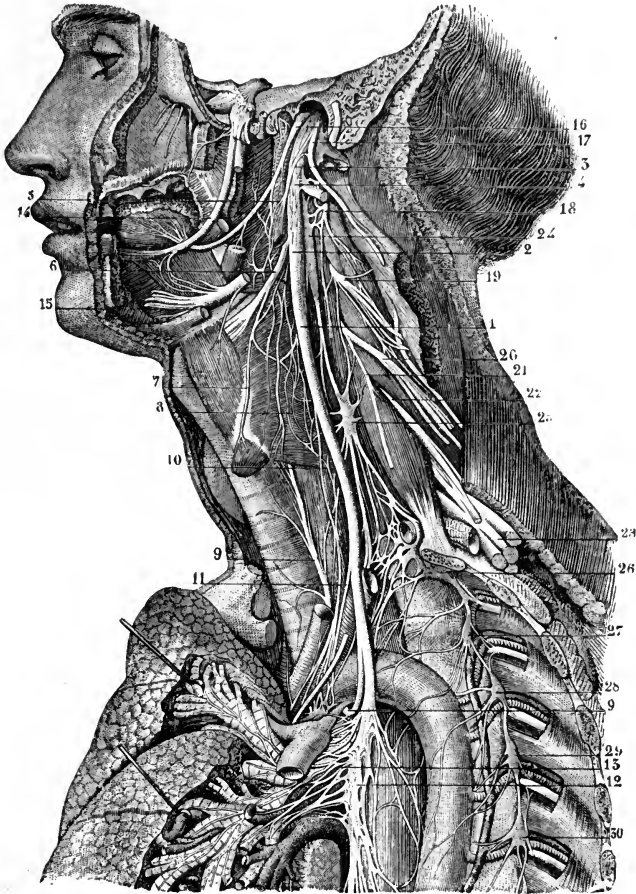


Fig. 179. — THE DISTRIBUTION AND CONNECTIONS OF THE PNEUMO-GASTRIC NERVE ON THE LEFT SIDE IN THE NECK AND UPPER PART OF THE THORAX. (From Sappey, after Hirschfeld and Leveillé.) $\frac{1}{3}$

1, pneumo-gastric nerve; 2, ganglion of its trunk; 3, accessory part of the spinal accessory; 4, union of the pneumo-gastric with the hypoglossal; 5, pharyngeal branch of the pneumo-gastric; 6, superior laryngeal nerve; 7, external laryngeal; 8, communication of the external laryngeal nerve with the superior cardiac branch of the sympathetic; 9, inferior or recurrent laryngeal; 10, superior, and 11, inferior cervical cardiac branches; 12, 13, posterior pulmonary plexus; 14, lingual branch of the inferior maxillary nerve; 15, distal part of the hypoglossal nerve; 16, glosso-pharyngeal nerve; 17, spinal accessory nerve, uniting by its inner branch with the pneumo-gastric, and by its outer passing into the sterno-mastoid muscle; 18, second cervical nerve; 19, third; 20, fourth; 21, origin of the phrenic nerve; 22, 23, fifth, sixth, seventh, and eighth cervical nerves, forming with the first dorsal the brachial plexus; 24, superior cervical ganglion of the sympathetic; 25, middle cervical ganglion; 26, inferior cervical ganglion united with the first dorsal ganglion; 27, 28, 29, 30, second, third, fourth, and fifth dorsal ganglia.

arch of the aorta, below which its recurrent laryngeal branch turns inwards and upwards. It then passes behind the root of the left lung, forming, like its fellow, a

posterior pulmonary plexus, whence it descends along the œsophagus, and takes part in the formation of the œsophageal plexus. Inferiorly, it forms a single trunk in front of the œsophagus, and is spread out on the anterior surface of the stomach.

There are various circumstances in the distribution of the pneumo-gastric nerves which at first sight appear anomalous, but which are explained by reference to the process of development. The recurrent direction of the inferior laryngeal branches arises from the extreme shortness or rather absence of the neck in the embryo at first, and from the primitive arterial arches having originally occupied a position at a higher level than the parts in which those branches are ultimately distributed, and having dragged them down as it were in the descent of the heart from the neck to the thorax. The recurrent direction may therefore be accepted as evidence of the development of those nerves before the occurrence of that descent. The passage of one recurrent laryngeal nerve round the subclavian artery, and of the other round the aorta, arises from the originally symmetrical disposition in which the innominate and subclavian arteries on the right side, and the arch of the aorta on the left, are derived from corresponding arches. The supply of the back of the stomach by the right pneumo-gastric nerve, and of the front by the left nerve, is connected with the originally symmetrical condition of the alimentary canal, and the turning over of the stomach on its right side in its subsequent growth.

BRANCHES.—Some of the branches of the pneumo-gastric serve to connect this with other nerves, but the larger number are distributed to various parts of the cir-

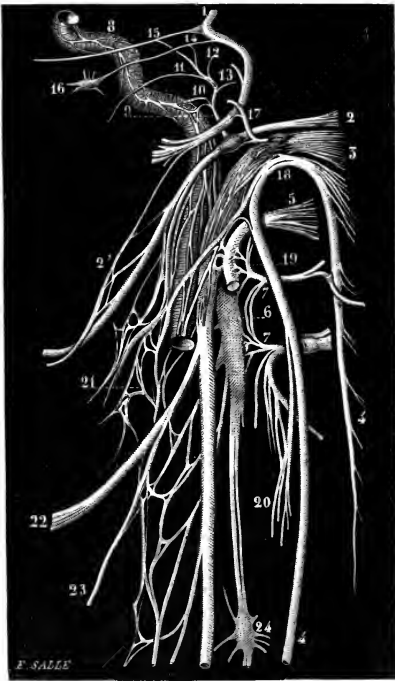


Fig. 180.—DIAGRAM OF THE ROOTS AND COMMUNICATING BRANCHES OF THE PNEUMO-GASTRIC AND NEIGHBOURING NERVES. (From Sappey, after Hirschfeld and Leveillé.)

1, facial nerve; 2, glosso-pharyngeal with the petrosal ganglion; 2', connection of the digastric branch of the facial nerve with the glosso-pharyngeal nerve; 3, pneumo-gastric, with its two ganglia; 4, spinal accessory; 5, hypoglossal; 6, superior cervical ganglion of sympathetic; 7, 7, loop of union between the first two cervical nerves; 8, carotid branch of sympathetic; 9, nerve of Jacobson (tympanic), given off from the petrosal ganglion; 10, its carotico-tympanic filaments; 11, twig to Eustachian tube; 12, twig to fenestra ovalis; 13, twig to fenestra rotunda; 14, small superficial petrosal nerve; 15, large superficial petrosal nerve; 16, otic ganglion; 17, auricular branch of pneumo-gastric; 18, connection of spinal accessory with pneumo-gastric; 19, union of hypoglossal with first cervical nerve; 20, union between the sterno-mastoid branch of the spinal accessory and that of the second cervical nerve; 21, pharyngeal plexus; 22, superior laryngeal nerve; 23, external laryngeal; 24, middle cervical ganglion of sympathetic.

culatory, respiratory and digestive systems. The special connecting branches arise from the two ganglia of the nerve. The branches of distribution arise from the nerve in the several stages of its course as follows:—In the jugular foramen, one small branch is given to the dura mater, and another to the ear; in the neck, branches are furnished successively to the pharynx, the larynx, and the heart; in the thorax, additional branches are supplied to the heart, as well as offsets to the pericardium, lungs and œsophagus; and in the abdomen, its terminal branches are distributed to the stomach, liver, and other organs.

A. Branches of communication.

The **upper ganglion** of the pneumo-gastric nerve receives a twig from the superior cervical ganglion of the sympathetic; one or two filaments pass between it

and the spinal accessory nerve; and there is sometimes a filament connecting it with the petrosal ganglion of the glosso-pharyngeal.

The **lower ganglion** of the pneumo-gastric forms connections with the hypoglossal nerve, with the superior cervical ganglion of the sympathetic, and with the loop between the first two cervical nerves.

B. Branches of distribution.

The **recurrent** or **meningeal branch** arises from the upper ganglion of the pneumo-gastric, and passes backwards through the jugular foramen to be distributed to the dura mater in the posterior fossa of the base of the skull.

The **auricular branch** (nerve of Arnold) is given off from the ganglion of the root, and, after receiving a filament from the petrosal ganglion of the glosso-pharyngeal nerve, runs backwards along the outer boundary of the jugular foramen to an opening near the root of the styloid process. It then traverses the substance of the temporal bone, crosses the aqueduct of Fallopius on its inner side about 4 mm. from the lower end, forming here a communication with the facial nerve, and finally emerges between the external auditory meatus and the mastoid process, where it divides into two parts, the one of which joins the posterior auricular nerve, while the other is distributed to the skin of the back of the pinna, and the lower and back part of the auditory canal.

Varieties.—In rare instances, absence of the auricular branch has been observed, or of the communication with the facial nerve. The auricular branch occasionally passes entirely into the facial trunk, and in that case its fibres are probably conveyed to the external ear through the posterior auricular nerve.

The **pharyngeal branch**, often represented by two or even more offsets, and composed mainly of fibres prolonged from the accessory part of the spinal accessory nerve, leaves the upper part of the ganglion of the trunk of the vagus. It courses inwards over the internal carotid artery, and divides into branches which, conjointly with those derived from the glosso-pharyngeal and the sympathetic, form the **pharyngeal plexus**. This plexus often contains one or more small ganglia, and from it filaments pass to the muscles and mucous membrane of the pharynx. The motor fibres are conveyed to the plexus by the pharyngeal branch of the vagus, but they are probably derived from the bulbar part of the spinal accessory nerve (see p. 270); the levator palati and azygos uvulæ muscles are also supplied by a branch from this source.¹ One slender branch (*lingual branch of the vagus*—Luschka) descends from the pharyngeal plexus, receiving its fibres from the pharyngeal branches of both the glosso-pharyngeal and pneumo-gastric nerves, and joins the hypoglossal nerve as that turns round the occipital artery.

Superior laryngeal nerve.—This branch springs from the middle of the ganglion of the trunk of the vagus, and inclines forwards on the inner side of the internal carotid artery towards the larynx. It is joined by filaments from the upper cervical ganglion of the sympathetic and from the pharyngeal plexus, and speedily divides into two branches which are distinguished as external and internal laryngeal.

The *external laryngeal branch*, the smaller of the two, runs downwards and forwards beneath the depressor muscles of the hyoid bone to the crico-thyroid muscle in which it ends. It receives a filament from the upper cervical ganglion of the sympathetic, and it gives off twigs to the inferior constrictor muscle of the pharynx, as well as generally a cardiac branch which joins the superior cardiac branch of the sympathetic.

The *internal laryngeal branch* is continued to the interval between the hyoid

¹ The middle constrictor of the pharynx would appear in the monkey to be partly supplied by glosso-pharyngeal fibres (Beever & Horsley, *op. cit.* on p. 270).

bone and the thyroid cartilage, where it perforates the thyro-hyoid membrane with the laryngeal branch of the superior thyroid artery, and breaks up into numerous diverging branches which supply the mucous membrane of the greater part of the larynx. Some of these ascend in the ary-epiglottic fold to the base of the tongue and the epiglottis; while others pass downwards to the false vocal cord, and also to the part of the pharyngeal mucous membrane covering the back of the larynx. One long branch descends beneath the ala of the thyroid cartilage, and joins at the lower part of the larynx a similar offset ascending from the recurrent laryngeal nerve.

Varieties.—The *superior laryngeal nerve* may pass on the outer side of the internal carotid artery. The *external laryngeal branch* often arises separately from the main trunk. Offsets of the external laryngeal nerve have been described by different anatomists as passing to the pharyngeal plexus, to the thyroid body, to the sterno-hyoid, sterno-thyroid, and thyro-hyoid muscles, to the lateral crico-arytenoid muscle, and to the mucous membrane of the true vocal cord and lower part of the larynx. The *internal laryngeal branch* has been seen piercing the thyroid cartilage.

A *middle laryngeal nerve* is described by S. Exner as a slender offset from the pharyngeal plexus (in the rabbit and dog directly from the pharyngeal branch of the vagus), which is distributed to the crico-thyroid muscle, and to the mucous membrane of the lower part of the larynx by means of twigs which perforate the crico-thyroid membrane. ("Die Innervation des Kehlkopfes," Wiener Sitzungsber., 1884.)

Inferior laryngeal nerve.—The inferior or recurrent laryngeal nerve of the right side arises at the root of the neck, and turns backwards below the subclavian

Fig. 181.—VIEW OF THE DISTRIBUTION AND CONNECTIONS OF THE PNEUMO-GASTRIC AND SYMPATHETIC NERVES ON THE RIGHT SIDE. (Hirschfeld and Leveillé.)

a, lachrymal gland; *b*, sublingual gland; *c*, submaxillary gland and facial artery; *d*, thyroid body; *e*, trachea, below which is the right bronchus cut across; *f*, œsophagus; *g*, stomach, divided near the pylorus; *i*, transverse colon; *r*, the diaphragm.

A, heart; B, aorta, drawn forwards to show the cardiac plexus; C, innominate artery; D, subclavian; E, inferior thyroid; F, a detached part of the external carotid, upon which runs a nervous plexus; G, internal carotid emerging from its canal superiorly; H, descending thoracic aorta; K, intercostal vein; L, pulmonary artery; M, superior vena cava; O, intercostal artery.

1, ciliary nerves; 2, branch of third nerve to inferior oblique muscle; 3, 3, 3, the three divisions of the fifth nerve; 4, ciliary ganglion; 5, sphenopalatine; 6, otic; 7, submaxillary; 8, sublingual; 9, sixth nerve; 10, facial in its canal, uniting with the sphenopalatine and otic ganglia; 11, glosso-pharyngeal; 12, right pneumo-gastric; 13, left pneumo-gastric spreading on the anterior surface of the stomach; 14, spinal accessory; 15, hypoglossal; 16, 16, nerves of cervical plexus; 17, middle trunk of brachial plexus; 18, intercostal nerve; 19, lumbar nerve; 21, superior cervical ganglion; 22, tympanic nerve; 23, large superficial petrosal nerve; 24, cavernous plexus; 25, sympathetic root of ciliary ganglion; 26, filament to pituitary body; 27, union of sympathetic with upper cervical nerves; 28, pneumo-gastric nerve; 29, superior laryngeal nerve; 30, pharyngeal plexus; 31, cord of sympathetic; 32, superior cardiac nerve; 33, middle cervical ganglion; 34, twig connecting the ganglion with, 35, the recurrent; 36, middle cardiac nerve; 37, cord of sympathetic; 38, inferior cervical ganglion; 39, the line from this number crosses the nerves proceeding from the brachial plexus; 40, sympathetic twigs surrounding the axillary artery; 41, branch of union with the first intercostal nerve; the line from the letter *e*, pointing to the trachea, crosses the superior, middle, and inferior cardiac nerves; 42, cardiac plexus; 43, 44, right and left coronary plexuses; 45, 46, thoracic portion of the sympathetic cord; 47, great splanchnic nerve; 48, semilunar ganglion; 49, lesser splanchnic; 50, solar plexus; 51, union with the pneumo-gastric nerve; 52, diaphragmatic plexus; 53, gastric plexus; 54, hepatic; 55, splenic; 56, superior mesenteric; 57, renal plexus; 58, first lumbar sympathetic ganglion.

artery; the nerve of the left side arises in the upper part of the thorax, and is reflected round the arch of the aorta immediately beyond the attachment of the ligamentum arteriosum. Each nerve ascends in the neck behind the common carotid artery, crossing either in front of or behind the inferior thyroid artery (see Vol. II, p. 424), and lying in the groove between the trachea and œsophagus, to the lower border of the cricoid cartilage, where it enters the larynx beneath the inferior constrictor muscle. Under cover of the ala of the thyroid cartilage, the nerve divides into branches which supply all the intrinsic muscles of the larynx, with the exception of the crico-thyroid. It likewise gives a few offsets to the mucous membrane below

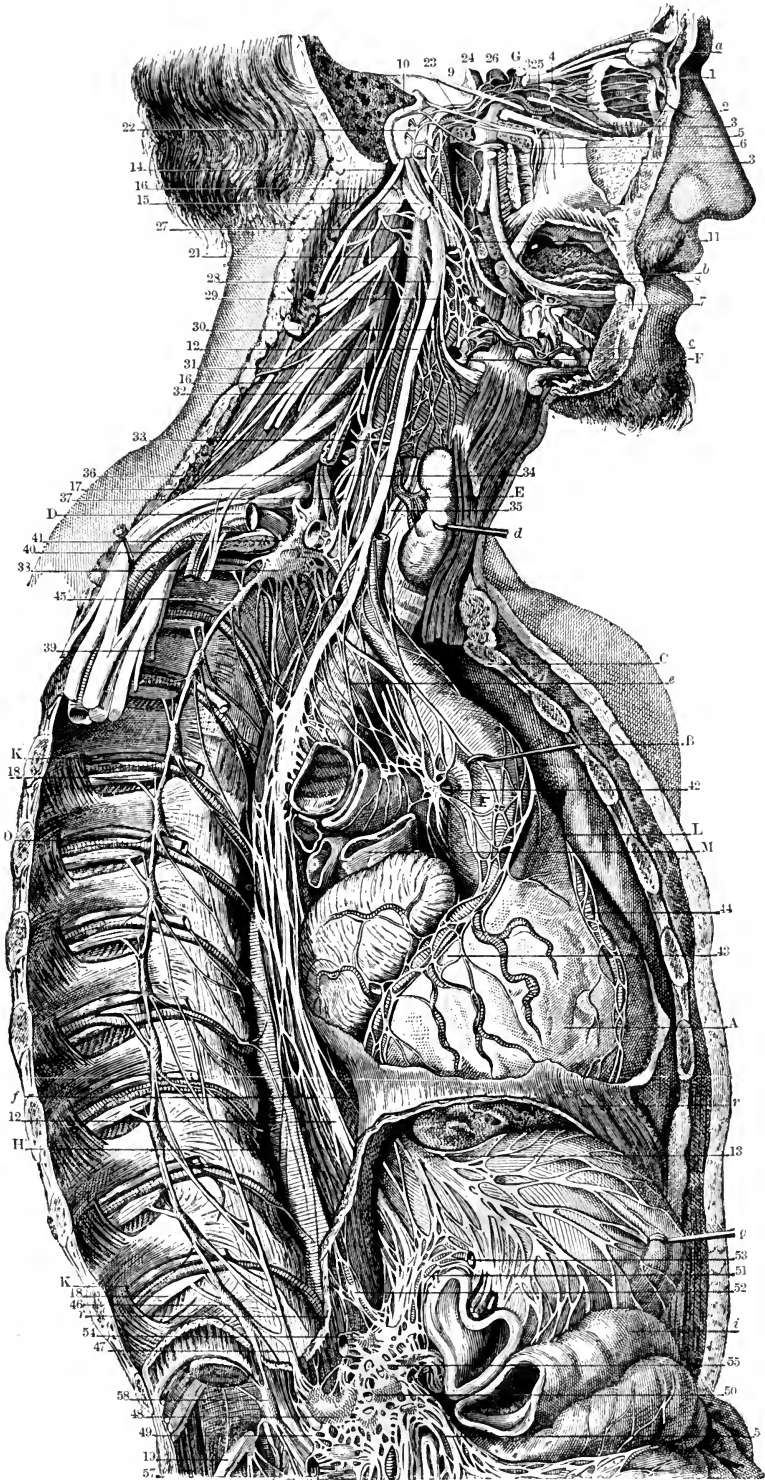


Fig. 181

the rima glottidis, and a connecting filament which joins the long branch of the upper laryngeal nerve beneath the hinder part of the thyroid cartilage : through this communication sensory fibres are probably conveyed to the inferior laryngeal nerve.¹

The recurrent nerve also furnishes branches to the cardiac plexus, and twigs of communication with the inferior cervical ganglion of the sympathetic, as it turns round the large artery ; tracheal and œsophageal branches as it ascends in the neck ; and lastly, offsets to the inferior constrictor of the pharynx as it passes beneath that muscle.

Varieties.—In cases of dorsal origin of the right subclavian artery the inferior laryngeal nerve does not turn round that vessel, but passes inwards more directly to the larynx (see Vol. II, p. 386). This nerve has been seen furnishing twigs to the crico-thyroid muscle.

Cardiac branches.—Branches to the heart are given off by the pneumo-gastric nerve both in the neck and in the thorax.

The *cervical cardiac* branches arise at both the upper and the lower part of the neck. The *upper branches*, one or two, are small, and join the cardiac nerves of the sympathetic. The *lower*, a single branch, arises as the pneumo-gastric nerve is about to enter the chest. On the right side this branch lies by the side of the innominate artery, and joins one of the cardiac nerves destined for the deep cardiac plexus ; it gives some filaments to the coats of the aorta. The branch of the left side crosses the arch of the aorta, and ends in the superficial cardiac plexus.

The *thoracic cardiac* branches of the right side leave the trunk of the pneumo-gastric as this nerve lies by the side of the trachea, and some are also derived from the first part of the recurrent branch ; they pass inwards on the air-tube, and end in the deep cardiac plexus. The corresponding branches of the left side usually come entirely from the recurrent laryngeal nerve.

The *depressor nerve* of the rabbit would appear to be represented in man in many cases by a slender branch which arises from the vagus in common with or just below the superior laryngeal nerve, or perhaps has a double origin, and either descends to the cardiac plexus in conjunction with the superior cardiac nerve of the sympathetic (seldom independently), or rejoins the vagus trunk from 1 to 3 cm. below its origin. In cases where this branch is not to be recognised the fibres are probably contained in the vagus trunk as far as the lower part of the neck. It is thought by Finkelstein and Alpiger that depressor fibres run in the cardiac offset of the external laryngeal nerve. (A. Kreidmann, "Anatomische Untersuchungen über den Nervus depressor beim Menschen und Hunde," Arch. f. Anat., 1878; A. Finkelstein, "Der Nervus depressor beim Menschen, Kaninchen, Hunde," &c., Arch. f. Anat., 1880; A. Viti, "Recherches de morphologie sur le nerf depresseur chez l'homme et chez les autres mammifères," Arch. ital. de Biol., v, 1884; G. Békésy, "Beiträge zur Anatomie der Herznerven," 1888; M. Alpiger, "Anatomische Studie über das gegenseitige Verhalten der Vagus- und Sympathicusäste im Gebiete des Kehlkopfes," Langenbeck's Archiv, xl, 1890.)

Pulmonary branches.—Two sets of pulmonary branches are distributed from the pneumo-gastric nerve to the lung ; and they reach the root of the lung, one on its fore part, the other on its posterior aspect. The *anterior pulmonary nerves*, two or three in number, are of small size. They join with filaments of the sympathetic ramifying on the pulmonary artery, and with these nerves constitute the **anterior pulmonary plexus**. Behind the root of the lung the pneumo-gastric nerve becomes flattened, and gives several branches of much larger size than the anterior branches, which, with filaments derived from the second, third, and fourth thoracic ganglia of the sympathetic, form the **posterior pulmonary plexus**. Offsets from this plexus

¹ Howell and Huber, "Physiology of the communicating branch between the superior and the inferior laryngeal nerves," Journ. of Physiology, xii, 1891.

extend along the ramifications of the air-tube through the substance of the lung, where they are beset with minute ganglia.

The anterior and posterior pulmonary plexuses of the two sides communicate with one another in an open network across the front and back respectively of the lower end of the trachea, and through these networks fibres are conveyed from both pneumo-gastric nerves into each lung.

Œsophageal branches.—The œsophagus within the thorax receives branches from the pneumo-gastric nerves, both above and below the pulmonary branches. The lower branches are the larger, and are derived from the **œsophageal plexus**, formed by connecting cords between the nerves of the right and left sides, while they lie in contact with the œsophagus.

Pericardial branches.—Either vagus may furnish a filament to the upper and fore part of the pericardium. Other twigs pass regularly to the back of the pericardium from the œsophageal plexus, and often from the posterior pulmonary plexuses (Zuckerkanndl).

Gastric branches.—The branches distributed to the stomach (*gastric nerves*) are terminal branches of both pneumo-gastric nerves. The nerve of the left side, on arriving in front of the œsophagus, opposite the cardiac orifice of the stomach, divides into many branches: the largest of these extend over the fore part of the stomach; others lie along its small curvature, and unite with branches of the right nerve and the gastric plexus of the sympathetic; and some filaments are continued between the layers of the small omentum to the hepatic plexus. The right pneumo-gastric nerve descends on the back of the gullet to the stomach, and distributes branches to the posterior surface of the organ: a large portion of this nerve passes to the solar, splenic and left renal plexuses of the sympathetic.

SUMMARY.—The pneumo-gastric nerves convey motor fibres to the voluntary muscles of the soft palate (with the exception of the tensor palati), pharynx and larynx, these being in part at least derived originally from the spinal accessory, to the unstriped muscle of the alimentary canal—œsophagus, stomach and intestine (with the exception of the rectum), and of the air-passages—trachea, bronchi, and their divisions in the lungs. Sensory fibres are furnished to the pharynx, œsophagus and stomach, to the larynx, trachea and bronchial ramifications, as well as to the dura mater, the external ear, and the pericardium. The vagi also supply nerves to the heart, both efferent (inhibitory—also received from the spinal accessory) and afferent (depressor), and possibly inhibitory dilator fibres to the vessels of the intestine. Lastly, pneumo-gastric fibres pass, either directly or through the solar plexus and its offsets, to the liver, pancreas, spleen, kidneys and suprarenal bodies. Each pneumo-gastric nerve is connected with the following cranial nerves—the spinal accessory, glosso-pharyngeal, facial, and hypoglossal; also with some spinal nerves; and with the sympathetic in the neck, thorax and abdomen.

XI.—SPINAL ACCESSORY NERVE.

The eleventh or spinal accessory nerve (spinal nerve accessory to the vagus) consists of two parts, the one of which (bulbar or accessory) joins the trunk of the pneumo-gastric, while the other (spinal) is distributed to the sterno-mastoid and trapezius muscles. Its fibres spring from a continuous column of cells extending from the level of the lower third of the olive to the fifth cervical nerve, in the bulb placed dorso-laterally to the hypoglossal nucleus, and in the spinal cord forming a part of the ventro-lateral group of the anterior horn. From this nucleus the fibres are directed at first dorsally for a short distance, and then turn outwards through the lateral region of the bulb or cord to emerge in a series of filaments from the side of the

medulla oblongata below the pneumo-gastric nerve, and from the lateral column of the spinal cord as low down as the fifth or sixth cervical nerve. The filaments arising from the medulla oblongata form the small bulbar portion of the nerve. The lowest spinal filaments are attached to the middle of the lateral column; the highest ones arise close to the posterior nerve-roots, with the upper one or two of which they are frequently connected.

According to Holl the association of the dorsal root of the first cervical nerve with the spinal accessory is only apparent, the two being merely bound together by connective tissue, and not interchanging any fibres. Kazzander found, however, in many cases a common origin of rootlets of the accessory and first cervical nerves, or a passage of filaments between the two, and less frequently a communication with the second cervical nerve. In one case also there was a small ganglion on the highest root of the bulbar portion of the spinal accessory nerve. (M. Holl, "Ueb. d. Nerv. accessorius Willisii." Arch. f. Anat., 1878; J. Kazzander, "Ueb. d. N. accessorius Willisii u. seine Beziehungen zu d. oberen Cervicalnerven," &c., Arch. f. Anat., 1891.)

In the bulbar portion of the eleventh nerve fine fibres predominate, although there are some of medium and large size. The spinal portion of the nerve consists almost wholly of large fibres, and fine fibres are absent.

The bulbar portion is directed outwards with the pneumo-gastric nerve: the spinal part ascends between the ligamentum denticulatum and the posterior

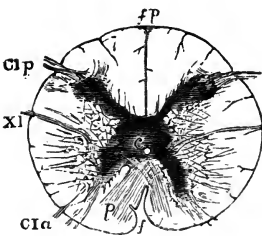


Fig. 182.—SECTION OF UPPER END OF SPINAL CORD, SHOWING ORIGIN OF SPINAL ACCESSORY NERVE. (After Lockhart Clarke.)

f, anterior, *fp*, posterior median fissure; *p*, end of decussation of pyramids; *Cl**a*, *Cl**p*, anterior and posterior roots of first cervical nerve; *XI*, root of spinal accessory nerve; *c*, central canal.

roots of the cervical nerves, passes into the skull through the foramen magnum, and immediately bends outwards to enter the middle compartment of the jugular foramen, where the nerve is contained in the same sheath of dura mater as the vagus (see Vol. II, fig. 182). In the foramen, the two parts of the nerve interchange fibres, and they are sometimes intimately united so as to form a single trunk for a short distance. The accessory part is also connected by one or two filaments with the ganglion of the root of the pneumo-gastric.

Below the skull, the **internal, bulbar, accessory or vagal portion** passes over the surface of the lower ganglion of the vagus, and sends its fibres into the pharyngeal and superior laryngeal branches, and into the trunk of that nerve below the ganglion in the manner already described.

The bulbar portion of the spinal accessory nerve contains the inhibitory fibres which pass by the vagus to the heart, and, as has been shown for the monkey by the experiments of Beevor and Horsley and of Réthi, the motor fibres of the levator palati and azygos uvulae, as well as, in part at least, of the constrictor muscles of the pharynx. It is generally stated also that the motor fibres of the laryngeal muscles are derived from the same source, but this view is not confirmed by recent observations of Grossmann, Grabower and Navratil. (Beevor and Horsley, "Note on some of the Motor Functions of certain Cranial Nerves (V., VII., IX., X., XI., XII.), and of the three first Cervical Nerves, in the Monkey," Proc. Roy. Soc., 1888; L. Réthi, "Die Nervenwurzeln der Rachen- und Gaumenmuskeln," and "Der periphere Verlauf der motorischen Rachen- und Gaumennerven," Wiener Sitzungsber., 1892 and 1893; M. Grossmann, "Ueber die Athembewegungen des Kehlkopfes, II. Die Wurzelfasern der Kehlkopfnerven," Wiener Sitzungsber., 1889; Grabower, "Das Wurzelgebiet der motorischen Kehlkopfnerven," Centralbl. f. Physiol., iii, 1890; E. v. Navratil, "Thierversuche über die Kehlkopfnnervation und über den N. accessorius Willisii," Ungar. Arch. f. Med., ii, 1894.)

The **external** or **spinal portion** (fig. 183, 5), after issuing from the jugular foramen, is directed backwards either across the front of or behind the internal jugular vein, and perforates the sterno-mastoid muscle, supplying this with branches, and joining amongst the fleshy fibres with the nerve furnished to the muscle from the cervical plexus. Descending in the next place obliquely across the posterior triangular space of the neck behind the sterno-mastoid, the nerve passes beneath the trapezius muscle. Here it forms a kind of plexus with branches of the third and fourth cervical nerves, and distributes filaments to the trapezius, which extend nearly to the lower border of the muscle.

Varieties.—The lower limit of the origin of the spinal part of the nerve was found by Holl to range from the third to the seventh cervical nerve, but in the greater number of cases it corresponded to the fifth or sixth nerve. It was seen by Sömmering opposite the first dorsal nerve. The spinal part of the nerve in one case pierced the dura mater below the first cervical nerve, and re-entered the spinal theca higher up (Holl). The external portion of the spinal accessory nerve sometimes passes beneath the sterno-mastoid without piercing the muscle. In one instance this nerve has been seen terminating in the sterno-mastoid muscle, the trapezius being supplied entirely by the third and fourth cervical nerves (Curnow). In rare cases it has been observed sending a branch to join the descending cervical nerve.

XII.—HYPOGLOSSAL NERVE.

The hypoglossal or twelfth cranial nerve arises from a nucleus placed ventrolaterally to the central canal in the lower part of the medulla oblongata, and extending upwards beneath the trigonum hypoglossi of the fourth ventricle (fig. 178, *n.* XII). Thence the fibres pass obliquely forwards and outwards, between the anterior and lateral areas of the bulb, and form a series of from ten to fifteen fine roots which emerge along the groove separating the pyramid from the olivary body. The filaments are directed outwards above (or behind) the vertebral artery, and are usually collected into two bundles which perforate the dura mater separately opposite the anterior condylar foramen, and are united into a single trunk as they pass through that opening.

As it leaves the anterior condylar foramen the nerve is very deeply placed on the inner side of the deep cervical vessels and the pneumo-gastric nerve. Winding round the lower ganglion of the last, to which it is closely bound by connective tissue, the hypoglossal nerve descends, inclining at the same time gradually forwards between the internal carotid artery and jugular vein, to the lower border of the digastric muscle. At this level it curves forwards round the commencement of the occipital artery, the sterno-mastoid branch of which turns downwards over the nerve, and is thence directed forwards above the hyoid bone to the under part of the tongue. In the latter part of its course, it passes beneath the tendon of the digastric, the lower end of the stylo-hyoid, and the mylo-hyoid muscles; it crosses the external carotid and the lingual arteries; and it rests upon the hyo-glossus muscle, being accompanied by the ranine vein of the tongue. At the anterior border of the hyo-glossus it is connected with the lingual branch of the fifth nerve, and then penetrates the fibres of the genio-glossus muscle, dividing into branches which are distributed to the muscular substance of the tongue.

BRANCHES.—While passing through the anterior condylar foramen, the hypoglossal nerve gives off one or two minute *recurrent* twigs which ramify in the dura mater around the foramen magnum, and in the diploe of the occipital bone. They were thought by Luschka to be formed by recurrent fibres derived from the lingual nerve, but it is possible that they consist of fibres which ascend from the communication with the first cervical nerve, or from the sympathetic (Rüdinger). The branches arising from the nerve in the neck are partly filaments of communication with other

nerves, but mainly offsets of distribution to muscles connected with the hyoid bone and larynx, and to the muscles of the tongue.

A. Branches of communication.

Close below the skull the hypoglossal nerve is united by a filament with the superior cervical ganglion of the sympathetic, by one or more twigs with the loop between the first and second cervical nerves, and with the ganglion of the trunk of the vagus by fibres which pass between the two nerves where they are in close connection with one another.

As the nerve turns round the occipital artery, it is joined by the small lingual branch of the vagus (p. 265); and in the submaxillary region, it is connected with

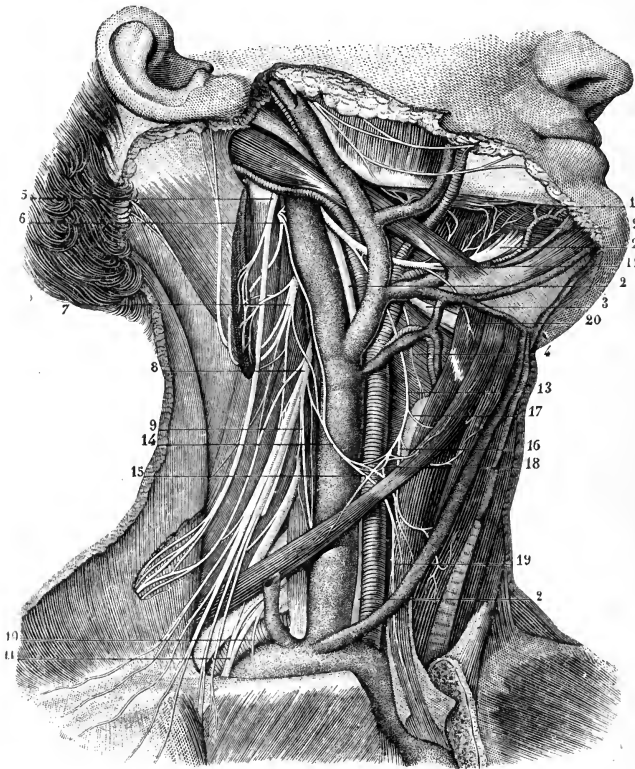


Fig. 183.—VIEW OF THE DISTRIBUTION OF THE SPINAL ACCESSORY AND HYPOGLOSSAL NERVES. (From Sappey, after Hirschfeld and Leveillé.) $\frac{1}{2}$

1, lingual nerve; 2, pneumo-gastric nerve; 3, superior laryngeal (represented too large); 4, external laryngeal branch; 5, spinal accessory; 6, second cervical; 7, third; 8, fourth; 9, origin of phrenic nerve; 10, nerve to subclavius; 11, external anterior thoracic nerve; 12, hypoglossal nerve; 13, descending cervical nerve; 14, communicating cervical nerve; 15, 16, 18, 19, branches from the plexiform union of these nerves to the sterno-hyoid, sterno-thyroid and omo-hyoid muscles; 17, branch to the anterior belly of the omo-hyoid muscle; 20, branch to the thyro-hyoid muscle; 21, communicating twigs from the hypoglossal to the lingual nerve; 22, terminal branches of the hypoglossal nerve.

the lingual branch of the fifth nerve by one or two slender loops over the fore part of the *hyo-glossus* muscle.

B. Branches of distribution.

Vascular branches.—These are one or two slender twigs which leave the hypoglossal nerve close below the skull and pass to the mesial aspect of the internal

jugular vein, where they are often joined by filaments from the superior cervical ganglion of the sympathetic (Luschka).

The **descending cervical nerve** (*r. descendens hypoglossi*) consists mainly of fibres which pass to the hypoglossal from the first and second cervical nerves in the communication below the skull. Leaving the trunk as it turns round the occipital artery, or a little higher up, the descending nerve runs downwards on the surface of the common carotid artery, inclining gradually from the outer to the inner side, and

Fig. 184.—PLAN OF THE CONNECTIONS OF THE HYPOGLOSSAL WITH THE CERVICAL NERVES, AND THE FORMATION OF THE ANSA CERVICALIS. (After Holl.)

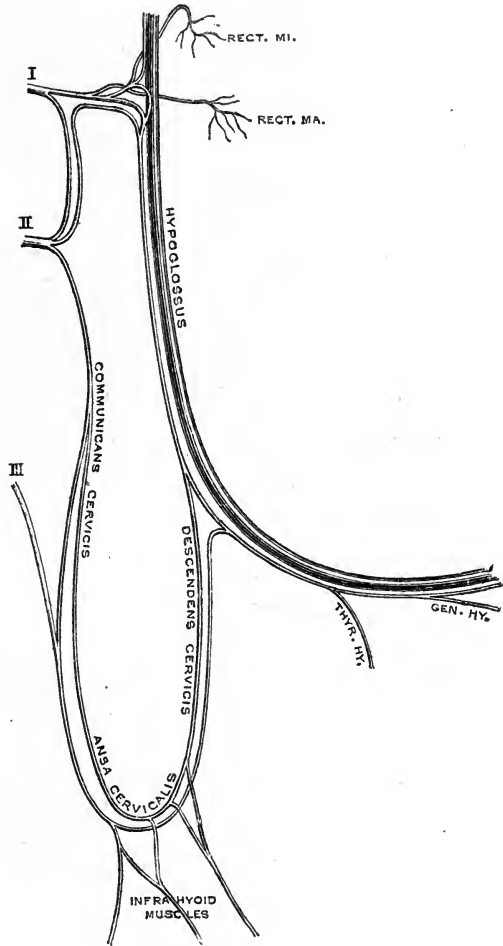
being placed generally within, but sometimes on the front of, the carotid sheath. After having given off a branch to the anterior belly of the omo-hyoid muscle, it joins about the middle of the neck in a loop (*ansa cervicalis*) with the *communicating cervical branches* from the second and third cervical nerves. The concavity of the loop is turned upwards, and the connection between the nerves is frequently effected by two or more interlacing filaments which form a small plexus. From this interlacement of the nerves, offsets are continued backwards to the posterior belly of the omo-hyoid, and downwards to the sterno-hyoid and sterno-thyroid muscles.

Muscular branches.—

The branch to the thyro-hyoid muscle is a separate twig also composed of fibres proceeding from the cervical nerves, and leaving the hypoglossal trunk as it approaches the hyoid bone.

As it lies beneath the mylo-hyoid, the nerve gives offsets to the styloglossus, hyoglossus and genio-hyoid muscles, and the terminal branches, penetrating the genio-glossus, supply that muscle and the intrinsic muscles of the tongue. According to Holl the nerve to the genio-hyoid is of cervical origin.

The fibres proceeding from the first and second cervical nerves do not become mingled with those of the hypoglossal trunk, but for the most part form a small cord which can be separated from the latter by removing the common sheath, and followed down into the descending cervical nerve. A minute funiculus runs proximally with the hypoglossal nerve, and others pass on the deep aspect of the trunk to the recti antici. The descending cervical nerve



also contains fibres which pass upwards from the communicating branches and run peripherally to enter the nerves of the thyro-hyoid and genio-hyoid muscles. (See M. Holl, "Beobachtungen über die Anastomosen des Nervus hypoglossus," *Zeitschr. f. Anat. u. Entw.*, 1876.)

The spinal origin of the nerves of the infrahyoid muscles has also been demonstrated experimentally in the monkey by Beevor and Horsley, who found that stimulation of the hypoglossal roots within the skull produced no effect on these muscles, while they were called into action by stimulating the first and second cervical nerves. The sterno-hyoid and sterno-thyroid were supplied mainly from the first nerve, and the omo-hyoid from the second (*op. cit.* on p. 270).

The fibres of the hypoglossal nerve are of medium size, resembling in this respect those of the facial nerve, and being smaller than those of most of the motor nerves passing to voluntary muscles (Gaskell).

Varieties.—In one instance, recorded by Rüdinger, the hypoglossal nerve was found taking its superficial origin from the posterior surface of the medulla oblongata. The vertebral artery is not unfrequently found passing forwards between, very rarely above, the roots of the nerve. The right and left nerves are occasionally united by a cross branch or loop in the substance of the genio-hyoid, or between that and the genio-glossus muscle. In rare cases, the twelfth nerve gives filaments to the mylo-hyoid, to the digastric, or to the stylo-hyoid muscle.

The descending cervical nerve sometimes appears to be derived either altogether from the pneumo-gastric or from both the pneumo-gastric and hypoglossal nerves, but it can always be shown by dissection that these varieties of origin are only apparent, resulting from the temporary adhesion of the filaments of this branch to those of the pneumo-gastric. A filament is occasionally continued from the descending cervical nerve into the thorax, where it joins the phrenic or the cardiac nerves; in the latter case it is probably composed of fibres from the vagus or the sympathetic, which have joined the hypoglossal or the descending nerve. This nerve has also been seen sending a branch to the sterno-mastoid muscle.

In some animals the twelfth nerve possesses a posterior root furnished with a ganglion, like a spinal nerve. A similar condition has been met with in a few instances in man.

SUMMARY.—The hypoglossal nerve proper supplies only the muscles of the tongue, with the exception of the palato-glossus and the pharyngeo-glossus. Fibres derived from the first three cervical nerves, which are associated with the hypoglossal for a part of their course are distributed to the infrahyoid muscles and the genio-hyoid. Others of uncertain origin pass to the skull and dura mater, and to the internal jugular vein. The hypoglossal forms connections with the pneumo-gastric, lingual, upper three cervical nerves, and sympathetic.

SPINAL NERVES.

The spinal nerves are characterised by their origin from the spinal cord, and their direct transmission outwards from the spinal canal in the intervals between the vertebræ. There are, in all, thirty-one pairs of these nerves, and, according to the region in which they issue from the spinal canal, they are named cervical, dorsal or thoracic, lumbar, sacral, and coccygeal.

By universal usage each pair of nerves in the dorsal, lumbar and sacral regions is named in correspondence with the vertebra below which it emerges. Of the eight pairs of nerves between the cranium and the first dorsal nerve, the uppermost is placed above the atlas, and the second and following nerves below the seven cervical vertebræ in succession. These eight pairs are usually reckoned as eight cervical nerves, but the first is also distinguished by the name of suboccipital nerve. The nerves of the thirty-first pair emerge from the lower end of the sacral canal, pass below the first vertebra of the coccyx, and are named coccygeal.

Varieties.—The spinal nerves necessarily vary in number with any deviation from the usual number of the segments of the vertebral column. Sometimes an additional coccygeal nerve exists. Among seven cases which were examined by Schlemm two coccygeal nerves were found on each side in one instance, and on one side in another case. According to Rauber vestiges of these, and also of a third pair of coccygeal nerves, are normally present in the bundles of medullated fibres contained in the filum terminale (see Part I, p. 6). On the other hand, the coccygeal nerve often appears to be wanting, being united to the filum terminale (Rauber, Kadyi).

THE ROOTS OF THE SPINAL NERVES.

Each spinal nerve springs from the spinal cord by two roots which approach one another as they quit the spinal canal, and join in the corresponding intervertebral

Fig. 185.—DIAGRAMMATIC OUTLINE OF THE ROOTS AND FIRST PART OF THE SPINAL NERVES, TOGETHER WITH THE SYMPATHETIC TRUNK OF ONE SIDE. (Allen Thomson.) $\frac{1}{2}$

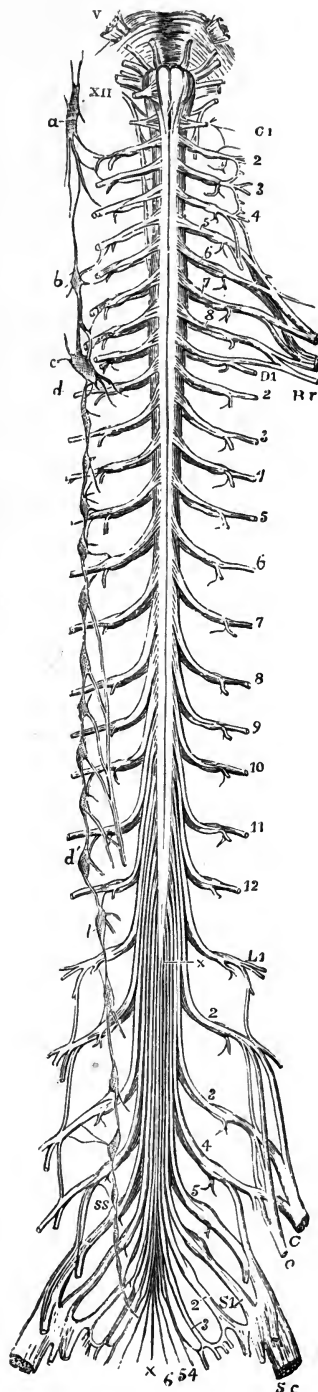
The view is taken from before. In the upper part of the figure the pons Varolii and medulla oblongata are represented, and from V to XII, the roots of the several cranial nerves from the trifacial to the hypoglossal are indicated. On the left side C 1, is placed opposite the first cervical nerve; and the numbers 2 to 8, following below indicate the corresponding cervical nerves; Br, brachial plexus; D 1, is placed opposite the intercostal part of the first dorsal nerve, and the numbers 2, to 12, following mark the corresponding dorsal nerves; L 1, the first lumbar nerve, and the numbers 2, to 5, following the remaining lumbar nerves; Cr, the anterior crural, and o, the obturator nerve; S 1, the first sacral, and the following numbers 2, to 5, the remaining sacral nerves; 6, the coccygeal nerve; Sc, great sciatic nerve; x x, the filum terminale of the cord.

On the left side of the figure the following letters indicate parts of the sympathetic nerve, viz., a, the superior cervical ganglion communicating with the upper cervical spinal nerves and continued below into the sympathetic cord; b, the middle cervical ganglion; c, d, the lower cervical ganglion united with the first dorsal; e, the eleventh dorsal ganglion; from the sixth to the ninth dorsal ganglion the origins of the great splanchnic nerve are shown; l, the highest lumbar ganglion; s s, the upper sacral ganglion. In the whole extent of the sympathetic cord, the twigs of union with the spinal nerves are shown.

foramen into a single cord; and each cord so formed separates immediately into two divisions, one of which is destined for parts in front of the spine, the other for parts behind it.

General arrangement.—The roots of the nerves arise on each side of the spinal cord by two nearly continuous series of filaments (*fila radicularia*), the anterior of which emerge from the antero-lateral column opposite the anterior cornu of the grey matter, while the posterior are attached in a narrower line along the postero-lateral sulcus of the cord. The filaments composing a single nerve-root vary in number from five to ten, and converge from above downwards as they pass from the cord to the dura mater, where each enters a special aperture.

The *posterior roots* of the nerves are distinguished from the anterior roots by their greater size, which is due to their constituent filaments being both more numerous and individually larger than those of the anterior roots. Each posterior root is farther marked by a ganglion (*intervertebral or spinal*), of a size proportionate to that of the nerve on which it is formed. The cells of these ganglia are unipolar, and give origin to the afferent fibres of the spinal nerves, both central and peripheral.



The ganglia are in general placed in the intervertebral foramina, immediately beyond the spots at which the roots perforate the dura mater lining the spinal canal. The first and second cervical nerves, however, which do not pass through intervertebral foramina, have their ganglia in the corresponding position as they lie over the neural arches of the vertebræ. The ganglia of the sacral nerves are contained in the spinal canal, that of the last nerve being occasionally at some distance from the point at which the nerve issues. The ganglion of the coccygeal nerve is placed in the canal within the sac of the dura mater, and at a variable distance from the origin of the nerve.

The filaments of the posterior root of the nerve are collected into two bundles as they approach the ganglion, and the inner extremity of the oval-shaped ganglion is usually bilobate, the lobes corresponding to the two bundles of filaments.

The *anterior roots* of the spinal nerves are smaller than the posterior, and are devoid of ganglia, their fibres arising from the cells of the grey matter of the spinal

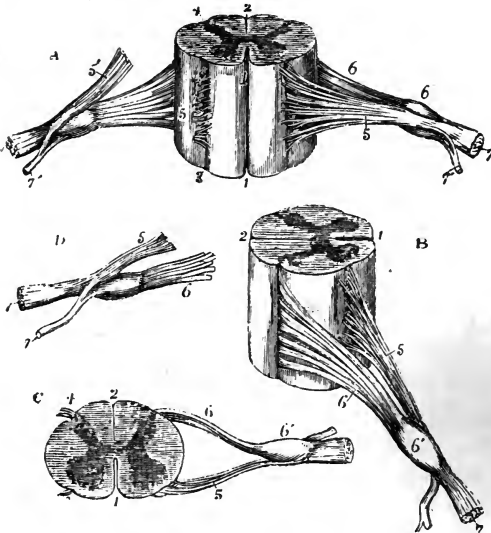


Fig. 186.—DIFFERENT VIEWS OF A PORTION OF THE SPINAL CORD FROM THE CERVICAL REGION WITH THE ROOTS OF THE NERVES. Slightly enlarged. (Allen Thomson.)

In A, the anterior surface of the specimen is shown, the anterior nerve-root of the right side being divided; in B, a view of the right side is given; in C, the upper surface is shown; in D, the nerve-roots and ganglion are shown from below: 1, anterior median fissure; 2, posterior median furrow and septum; 3, origin of the anterior nerve-roots; 4, posterolateral groove, into which the filaments of the posterior root are seen to sink; 5, anterior root passing over the ganglion; 5', in A, the anterior root divided; 6, posterior root, the fibres of which enter 6', the ganglion; 7, the anterior, and 7', the posterior primary division of the nerve, each of which is seen in A and D to be derived in part from the anterior and in part from the posterior root.

cord, and mainly from those of the anterior cornu. Their filaments also tend to be collected into two bundles near the intervertebral foramen.

Both anterior and posterior roots of all the spinal nerves contain fibres of very various sizes—large, medium ($10\ \mu$ to $5\ \mu$), and fine, but the proportion in which the different groups occur is not the same throughout. The anterior roots of the cervical, lumbar, and sacral nerves consist mainly of large and medium-sized fibres, fine fibres being present only in small number, generally not exceeding one-sixth of the whole. Those of the dorsal nerves, however, as well as the coccygeal, show a preponderance of fine fibres, which are about three times as numerous as the larger ones. The finest fibres ($2.6\ \mu$ and less) are abundant in the anterior roots of the dorsal nerves, but rare in the other regions, except in the last two sacral and the coccygeal nerves. In the posterior roots the small fibres are about equal in number to the medium-sized and large fibres together; and fibres of the largest size (above $20\ \mu$), which are frequent in the anterior roots, are here scanty. (E. Siemerling, *Neurol. Centralbl.*, 1886, and "Anatomische Untersuchungen über die menschlichen Rückenmarkswurzeln," Berlin, 1887.)

Varieties.—The posterior root of the first cervical nerve is sometimes wanting (8 per cent., Kazzander); or it may arise partly or wholly from, or in common with, the spinal accessory nerve (see p. 270). A defect in the roots of the thoracic nerves is said to be very common by Adamkiewicz, who found in sixteen spinal cords only three with the full number of thoracic roots; in three there was absence of both anterior and posterior roots of one nerve, in three absence of a posterior root only, and in seven absence of one anterior root (*Virchow's Archiv*, lxxxviii, 1882). Communications between the root-filaments (especially the posterior) of adjoining nerves are frequently met with. Small detached portions of the intervertebral

ganglia (*ganglia aberrantia* of Hyrtl) are sometimes found on the posterior roots of the upper cervical nerves. The ganglia of the lumbar and upper sacral nerves are often double, there being a distinct swelling on each of the bundles of the posterior root. The ganglion of the suboccipital nerve may be situated within the dural sheath, or be wanting (9 per cent., Kazzander), but in such cases there are probably nerve-cells interspersed in the posterior root. According to Rattone there are regularly scattered nerve-cells along the posterior roots of all the spinal nerves (Internat. Monatschr. f. Anat. u. Hist., i, 1884).

Size.—The roots of the upper *cervical nerves* are smaller than those of the lower nerves, the first being much the smallest, and the sixth the largest. The posterior roots of these nerves, with the exception of the first in which the anterior root is larger than the posterior, exceed the anterior in size more than in the other spinal nerves, and they are likewise composed of filaments which are considerably larger than those of the anterior roots.

The roots of the *dorsal nerves*, exception being made of the first, which resembles the lowest cervical nerves and is associated with them in a part of its distribution, are of small size, and vary but slightly, or not at all, from the second to the last. The filaments of both roots are thinly strewed over the spinal cord, and are slender, those of the posterior exceeding, in thickness those of the anterior root in only a small degree.

The roots of the lower *lumbar*, and of the upper *sacral nerves*, are the largest of all the spinal nerves; those of the lowest sacral and of the coccygeal nerve are, on the other hand, the smallest. All these nerves are crowded together upon the lower end of the cord. Of these nerves the anterior roots are the smaller, but the disproportion between the anterior and posterior roots is not so great as in the cervical nerves.

Length.—The place at which the roots of the upper cervical nerves are connected with the spinal cord being nearly opposite the foramina by which they respectively leave the canal, these roots are comparatively short. But the distance between the two points referred to is gradually augmented from nerve to nerve downwards, so that the place of origin of the lower cervical nerves is the depth of at least one vertebra, and that of the lower dorsal nerves about the depth of three vertebrae, above the foramina by which they respectively emerge from the canal. Moreover, as the spinal cord extends no farther than the first lumbar vertebra, the length of the roots of the lumbar, sacral and coccygeal nerves increases rapidly from nerve to nerve, and in each case may be estimated by the distance of the foramen of exit from the extremity of the cord. Owing to their length, and the appearance they present in connection with the spinal cord, the aggregation of the roots of the nerves last referred to has been named the *cauda equina*.

A diagram showing the level at which the several roots arise from the cord in relation to the spines of the vertebrae, as determined by R. W. Reid, is given on p. 4 of Part I. of this volume. The absolute length of certain of the nerve-roots in a subject of 18 years of age, whose spinal cord was 41 cm. long, is shown in the following table, taken from Testut:—

	RIGHT SIDE.	LEFT SIDE.
3rd cervical nerve	18 mm.	17 mm.
5th " "	25 "	25 "
1st dorsal nerve	33 "	32 "
5th " "	47 "	47 "
10th " "	68 "	68 "
12th " "	111 "	110 "
1st lumbar nerve	114 "	114 "
2nd " "	138 "	134 "
3rd " "	151 "	151 "
4th " "	163 "	164 "
5th " "	181 "	180 "
1st sacral nerve	188 "	188 "
5th " "	280 "	280 "

Direction.—The first cervical nerve is directed horizontally outwards. The roots of the lower cervical and dorsal nerves at first descend over the spinal cord, held in contact with it by the arachnoid, till they arrive opposite the several intervertebral foramina, where they are directed horizontally outwards. The nerves of the cauda equina run in the direction of the spinal canal.

Division of the nerves.—The two roots of each of the spinal nerves unite immediately beyond the ganglion, and the trunk thus formed separates, as already mentioned, into two divisions, an anterior or ventral and a posterior or dorsal, which are called primary branches or divisions, and each of which contains fibres proceeding from both the anterior and posterior roots.

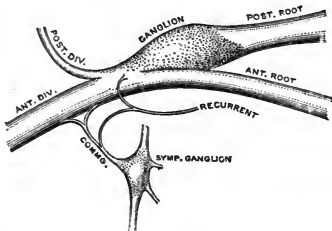


Fig. 187.—PLAN OF THE MODE OF BRANCHING OF A SPINAL NERVE.

Before dividing in the manner above described each spinal nerve gives off a small *recurrent* or *meningeal branch*, which is joined by a filament from the communicating cord between the anterior division of the nerve and the sympathetic, and then runs inwards through the intervertebral foramen to the spinal canal, where it is distributed to the vertebræ and ligaments, to the blood-vessels of the canal, and to the dura mater (Luschka, Rüdinger).

POSTERIOR PRIMARY DIVISIONS OF THE SPINAL NERVES.

The posterior divisions of the spinal nerves are, with few exceptions, smaller than those given to the fore part of the body. Springing from the trunk which results from the union of the roots of the nerve in the intervertebral foramen, or frequently by separate fasciculi from the two roots, each turns backwards at once, and soon divides into two parts, distinguished as *external* and *internal*, distributed to the muscles and the integument behind the spine. The first cervical, the fourth and fifth sacral, and the coccygeal are the only nerves the posterior divisions of which do not separate into external and internal branches.

SUBOCCIPITAL NERVE.—The posterior division of the first cervical or suboccipital nerve, slightly larger than the anterior, emerges over the arch of the atlas, between this and the vertebral artery, and enters the space bounded by the larger rectus and the two oblique muscles, where it divides into branches for the surrounding muscles.

(a) One branch descends to the inferior oblique, and gives a filament, through or over the fibres of that muscle, to join the second cervical nerve.

(b) Another ascends over the rectus posticus major muscle, supplying it and the smaller rectus.

(c) A third enters the superior oblique muscle.

(d) A fourth sinks into the complexus, where that muscle covers the nerve and its branches.

Variety.—A *cutaneous branch* is occasionally given to the back of the head: it accompanies the occipital artery, and is connected beneath the integument with the great and small occipital nerves.

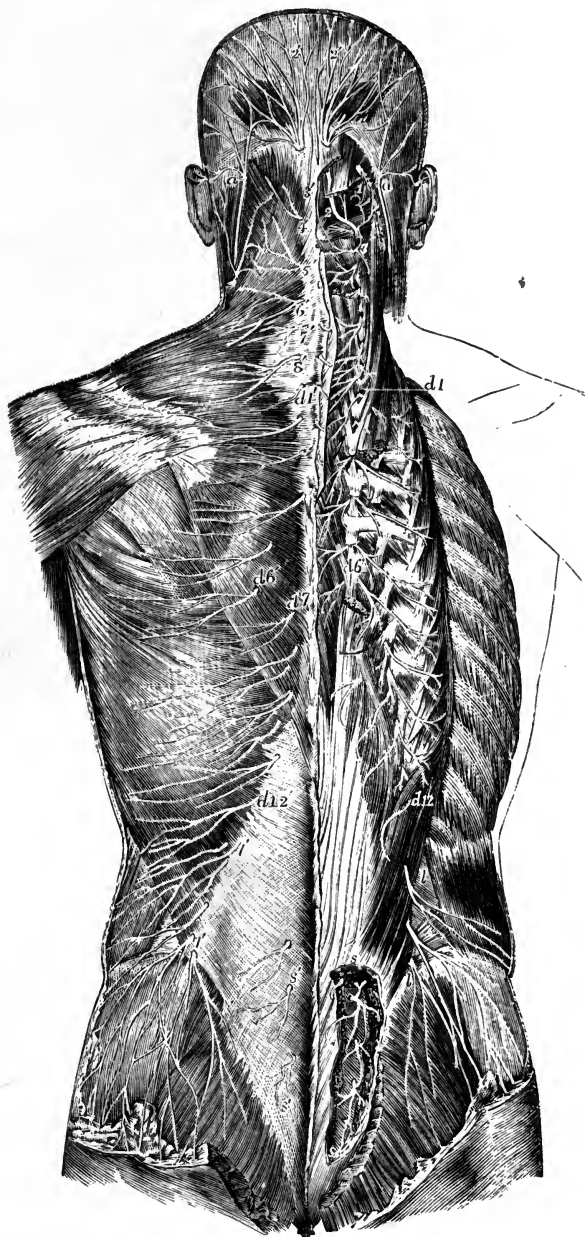


Fig. 188.—SUPERFICIAL AND DEEP DISTRIBUTION OF THE POSTERIOR PRIMARY DIVISIONS OF THE SPINAL NERVES. (After Hirschfeld and Leveillé.) †

On the left side the cutaneous branches are shown lying upon the superficial muscles; on the right side, these muscles having been removed, the splenius and complexus have been divided in the neck, and the erector spinae separated and partially removed in the back, so as to expose the deep portions of the nerves.

a, *a*, small occipital nerve from the cervical plexus; 1, muscular branches of the first cervical nerve and union by a loop with the second; 2, placed on the rectus capitis posticus major, marks the great occipital nerve passing round the inferior oblique muscle and piercing the complexus; the external branch is seen to the outside; 2', cranial distribution of the great occipital; 3, external branch of the posterior primary division of the third nerve; 3', its internal branch, or third occipital nerve; 4', 5', 6', 7', 8', cutaneous offsets from the internal branches of the cervical nerves on the left side; the external branches of these nerves proceeding to muscles are displayed on the right side; *d* 1 to *d* 6, and thence

to *d* 12, external muscular branches of the posterior primary divisions of the twelve dorsal nerves on the right side; *d* 1', to *d* 6', the internal cutaneous branches of the six upper dorsal nerves on the left side; *d* 7' to *d* 12', cutaneous branches of the six lower dorsal nerves from the external branches; *l*, *l*', external branches of the posterior primary divisions of several lumbar nerves on the right side piercing the muscles, the lower descending over the gluteal region; *l*', *l*', the same more superficially on the left side (the cutaneous branches of the lower dorsal and upper lumbar nerves are represented as piercing the latissimus too high); *s*, *s*, on the right side, the issue and union by loops of the posterior primary divisions of four sacral nerves; *s*', *s*', on the left side, cutaneous filaments from the internal branches of the lower lumbar and upper sacral nerves.

CERVICAL NERVES (*excepting the suboccipital*).—The **external branches** give only muscular offsets, and are distributed to the splenius and the slender muscles prolonged to the neck from the erector spinæ, viz., the cervicalis ascendens, and the transversalis cervicis with the trachelo-mastoid. That of the second nerve is the largest of the series of external branches of the cervical nerves, and is often united to the corresponding branch of the third.

The **internal branches**, larger than the external, are differently disposed at the upper and the lower parts of the neck. That of the second cervical nerve is named, from its size and destination, the *great occipital*, and requires separate notice. The rest are directed inwards to the spinous processes of the vertebræ. Those derived from the third, fourth, and fifth nerves pass over the semispinalis and beneath the complexus, giving offsets to those muscles and to the multifidus, and, having reached the spines of the vertebræ, pierce the splenius and trapezius, to be distributed in the integument over the latter muscle. From the cutaneous branch of the third nerve an offset passes upwards to the integument on the lower part of the occiput, lying at the inner side of the great occipital nerve; this is sometimes called the *third occipital nerve*.

Between the inner branches of the first three or four cervical nerves, beneath the complexus, there are frequently communicating loops; this communication has been designated by Cruveilhier the *posterior cervical plexus*.

The internal branches from the lowest three cervical nerves are placed beneath the semispinalis muscle, and end in the muscular structure, without furnishing any offset to the skin. These three nerves are the smallest of the series.

The *great occipital nerve* is directed upwards across the inferior oblique muscle, and is transmitted to the surface through the complexus and trapezius muscles, giving twigs to the complexus. Ascending with the occipital artery, it divides into branches which radiate over the back of the head, the most external communicating with the small occipital nerve.

Varieties.—The great occipital nerve occasionally sends a branch to the auricle, or replaces, to a greater or less extent, the small occipital nerve (p. 286). The external division of the second nerve is said to give off a cutaneous branch sometimes, or a twig to the superior oblique. Either the sixth or the eighth cervical nerve may furnish a cutaneous branch. On the other hand, the cutaneous branch of the fifth is sometimes wanting.

DORSAL NERVES.—The **external branches** increase in size from above downwards. They are directed through or beneath the longissimus dorsi to the space between that muscle and the ilio-costalis or accessorius, and supply the several divisions of the erector spinæ. The lower five or six nerves give cutaneous twigs, which are transmitted to the integument in a line with the angles of the ribs.

The **internal branches** of the upper six or seven dorsal nerves pass backwards in the interval between the multifidus spinæ and the semispinalis muscle; they supply the transverso-spinales muscles, and become cutaneous by the side of the spinous processes of the vertebræ. The cutaneous branch of the second nerve, and sometimes others, extend outwards over the scapula. The internal branches of the

lower dorsal nerves are placed between the multifidus spinæ and longissimus dorsi, and end in the multifidus without giving branches to the integument. Where cutaneous nerves are supplied by the internal branches, there are generally none from the external branches of the same nerves, and *vice versâ*.

The cutaneous offsets of the dorsal nerves run obliquely downwards in their passage between and through the muscles, so that they become superficial and are distributed to the skin at a level below that of the vertebræ to which they correspond (see fig. 189). This descent is but slight in the case of the upper branches, which are derived from the internal divisions of the nerves, and which in their subcutaneous course are directed nearly horizontally outwards, but it becomes progressively greater in the lower branches, proceeding from the outer divisions, and the offset of the twelfth dorsal only makes its appearance a little distance above the iliac crest. There is considerable variety in the size and in the extent of distribution of the several nerves, which often differ on the two sides of the body; and twigs from one or two of the lowest dorsal nerves frequently pass over the iliac crest to the skin of the buttock. (See Wardrop Griffith and Oliver, "On the Distribution of the Cutaneous Nerves of the Trunk," Proc. Anatom. Soc., 1890, in Journ. Anat., xxiv.)

Varieties.—The cutaneous offset of the first dorsal nerve is sometimes absent. There are not unfrequently cutaneous branches from both divisions of the middle (sixth, seventh, and eighth) dorsal nerves.

LUMBAR NERVES.—The **external branches** enter the erector spinæ, and give branches to that muscle. From the upper three, cutaneous nerves are supplied; and from the last, a filament descends to the corresponding branch of the first sacral nerve. The *cutaneous nerves* given from the external branches of the first three lumbar nerves (*nn. clunium superiores*) pierce the fleshy part of the iliocostalis and the aponeurosis of the latissimus dorsi: they cross the iliac crest near the edge of the erector spinæ, and terminate in the integument of the gluteal region. One or more of the filaments may be traced as far as the great trochanter of the femur.

The **internal branches** wind backwards in grooves close below the mamillary processes of the vertebræ, and sink into the multifidus spinæ muscle.

SACRAL NERVES.—The posterior divisions of these nerves, except the last, issue from the sacrum through its posterior foramina. The first three are covered at their exit from the bone by the multifidus spinæ muscle, and bifurcate like the posterior trunks of the other spinal nerves; but the remaining two, which continue below that muscle, are not thus divided.

The **internal branches** of the first three sacral nerves are small, and are lost in the multifidus spinæ muscle.

The **external branches** of the same nerves are united with one another, and with the last lumbar and fourth sacral nerves, so as to form a series of anastomotic loops on the upper part of the sacrum. From these, branches are then directed outwards to the cutaneous or posterior surface of the great sacro-sciatic ligament, where, covered by the gluteus maximus muscle, they form a second series of loops, and end as cutaneous nerves (*nn. clunium mediæ*). The latter pierce the great gluteus muscle in a line drawn from the posterior superior iliac spine to the tip of the coccyx. They are commonly two in number—one is near the lower part of the sacrum, the other by the side of the coccyx. All are directed outwards over the great gluteal muscle.

In six dissections by Ellis the above arrangement was found to be the most frequent. The variations to which it is liable are these:—the first nerve may not take part in the formation of the second series of loops, and the fourth may be associated with them. From the first three sacral nerves filaments are given to the sacro-iliac articulation (Luschka, Rüdinger). Small cutaneous twigs from the internal branches of the lower lumbar and upper sacral nerves are described by many anatomists (fig. 188, *s's'*).

The posterior divisions of the *last two sacral nerves* are smaller than those above them, and are not divided into external and internal branches. They are connected

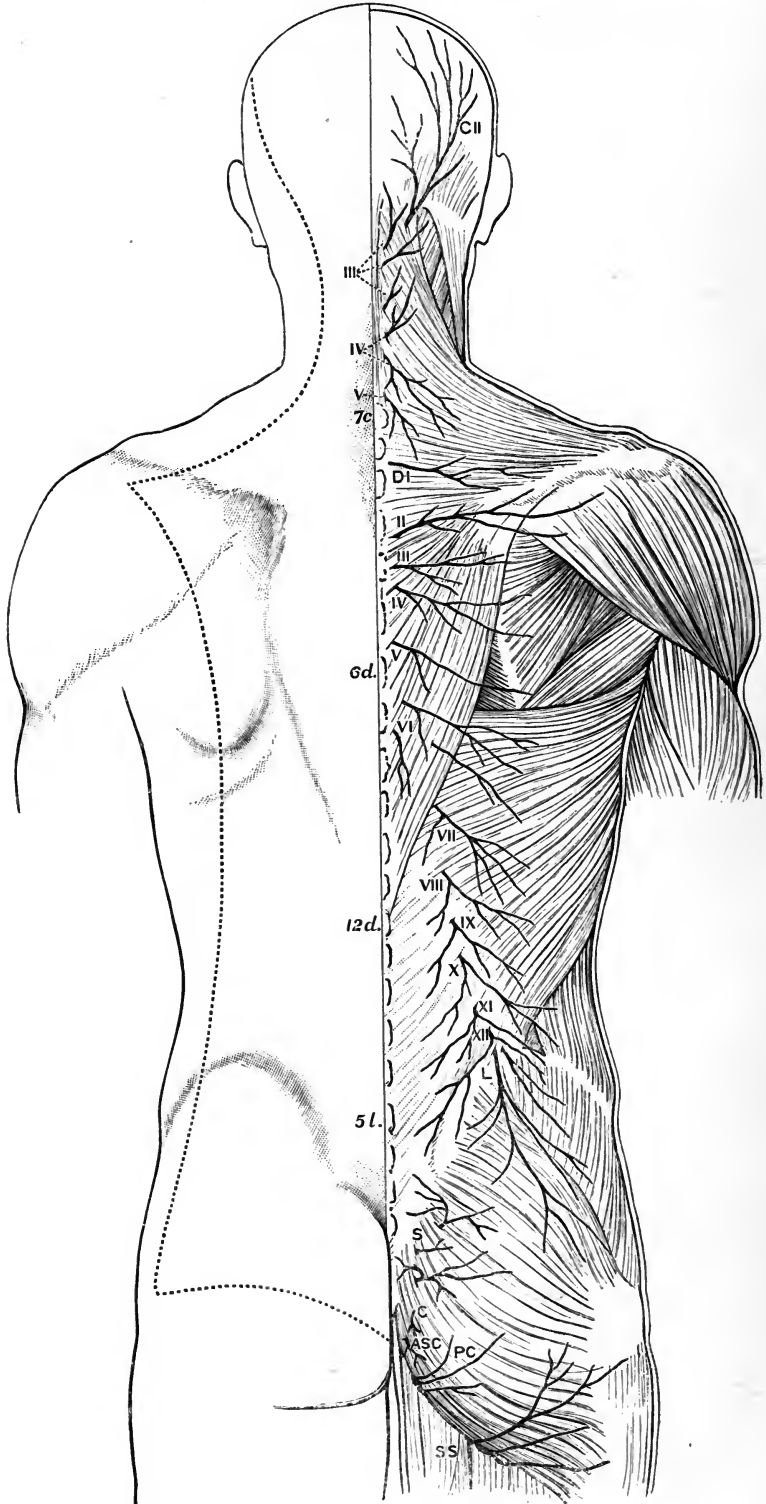


Fig. 189.

with each other by a loop on the back of the sacrum, and the lowest is joined in a similar manner with the coccygeal nerve; one or two filaments from these sacral nerves are distributed in the neighbourhood of the coccyx.

COCYGEAL NERVE.—The posterior division of the coccygeal nerve is very small, and separates from the anterior primary portion of the nerve in the sacral canal. It is joined by a communicating filament from the last sacral nerve, and ends in the integument over the posterior surface of the coccyx.

ANTERIOR PRIMARY DIVISIONS OF THE SPINAL NERVES.

The anterior primary divisions of the spinal nerves are distributed to the parts of the body situated in front of the vertebral column, including the limbs. They are, for the most part, considerably larger than the posterior divisions, and each is connected by one or two slender filaments with the sympathetic. Those of the cervical, lumbar, and sacral nerves form plexuses of various forms; but those of the dorsal nerves remain for the most part separate from one another.

CERVICAL NERVES.

The anterior divisions of the upper four cervical nerves form the cervical plexus. The first emerges between the rectus lateralis and rectus anticus minor muscles; and the others, having passed behind the vertebral artery and between the two intertransverse muscles, appear at the side of the neck between the scalenus medius and rectus anticus major muscles. They are each united by a communicating filament

Fig. 189.—CUTANEOUS DISTRIBUTION OF THE POSTERIOR PRIMARY BRANCHES OF THE SPINAL NERVES. (G. D. T.)

On the right side the nerves are shown lying on the superficial muscles; on the left side the limit of the skin-area supplied by these nerves is indicated by the dotted line. 7 c, seventh cervical spine; 6 d, sixth dorsal; 12 d, twelfth dorsal; 5 l, fifth lumbar.

The nerves are indicated as follows:—C II, great occipital, from second cervical; III to V, third to fifth cervical; D I, first dorsal; II to XII, second to twelfth dorsal; three cutaneous branches are given by the sixth dorsal, two from the internal, and one from the external division; L, lumbar; S, upper sacral; C, lower sacral and coccygeal; A S C, anterior divisions of the last sacral and coccygeal; P C, perforating cutaneous; S S, small sciatic

to the first cervical ganglion of the sympathetic nerve, or to the cord connecting that ganglion with the second.

The anterior divisions of the lower four cervical nerves, larger than the upper four, appear between the anterior and middle scaleni muscles, and, together with the larger part of the first dorsal, go to form the brachial plexus. They are each connected by a filament with one of the two lower cervical ganglia of the sympathetic, and with the plexus on the vertebral artery.

The anterior divisions of the first and second nerves require a notice separately from the description of the nerves of the cervical plexus.

SUBOCCIPITAL NERVE.

The anterior primary division of the first nerve runs forwards in a groove on the outer side of the upper articular process of the atlas, and bends downwards in front of the transverse process of that vertebra to join the second nerve. In this course forwards it lies beneath the vertebral artery, and on the inner side of the rectus lateralis muscle, to which it gives a branch. As it crosses the inner side of the foramen in the transverse process of the atlas, the nerve is joined by a filament from the sympathetic on the vertebral artery. From the loop which it makes in front of the transverse process, twigs are supplied to the two anterior recti muscles, and one or two larger branches pass to the hypoglossal trunk, in connection with which most of the fibres pass down into the descending cervical nerve (p. 273).

The loop is also united by short filaments to the superior cervical ganglion of the sympathetic and to the trunk-ganglion of the vagus.

Filaments of this nerve are distributed to the articulation of the occipital bone with the atlas, and, according to Valentin, also to the mastoid process of the temporal bone.

SECOND CERVICAL NERVE

The anterior division of the second cervical nerve, beginning between the arches of the first two vertebræ, is directed forwards between their transverse processes,

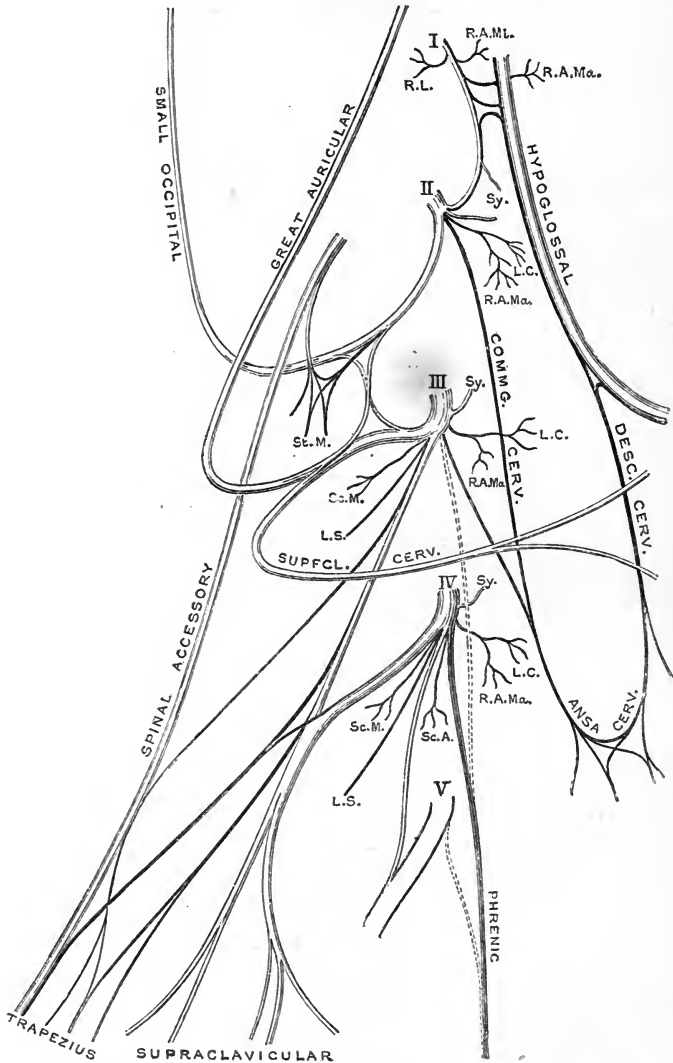


Fig. 190.—PLAN OF THE CERVICAL PLEXUS AND ITS CONNECTIONS. (G. D. T.)

I to V, anterior divisions of the first to fifth cervical nerves; Sy, communicating branches to the upper cervical ganglion of the sympathetic; branches to muscles are indicated as follows:—R. L., rectus lateralis; R.A.Mi., rectus anticus minor; R.A.Ma., rectus anticus major; L.C., longus colli; St.M., sterno-mastoid; Sc.A., scalenus anticus; Sc.M., scalenus medius; L.S., levator scapulæ.

passing round the outer side of the vertebral artery, and beneath the posterior intertransverse and other muscles fixed to those processes. In front of the

intertransverse muscles, the nerve divides into an ascending part, which joins the first cervical nerve, and a descending part to the third.

CERVICAL PLEXUS.

The cervical plexus is formed by the anterior divisions of the upper four cervical nerves, and distributes branches to some of the muscles of the neck, and to a

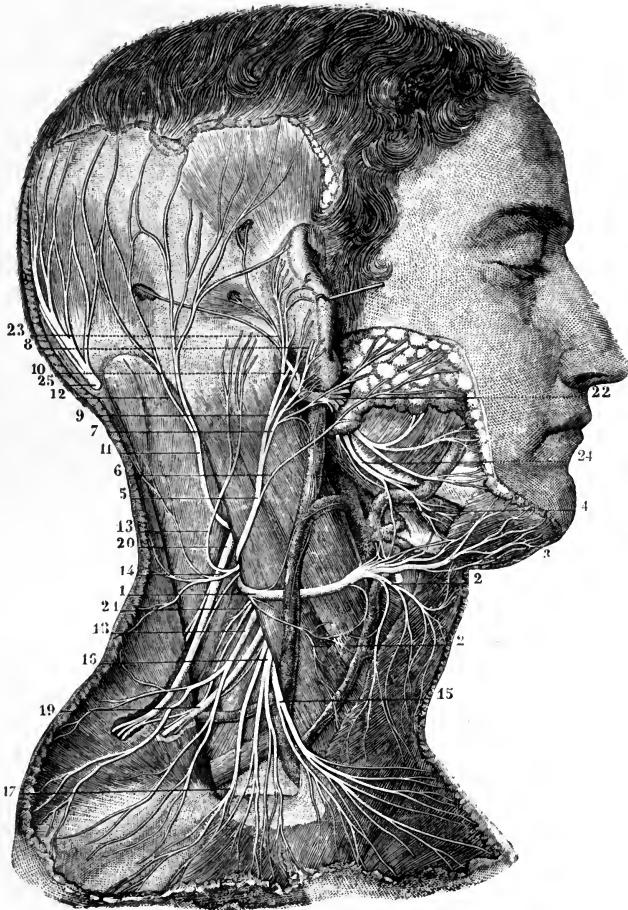


Fig. 191.—THE SUPERFICIAL BRANCHES OF THE CERVICAL PLEXUS. (From Sappey, after Hirschfeld and Leveillé.)

1, superficial cervical nerve (represented too large); 2, its inferior branch; 3, its superior branch; 4, its union with the facial; 5, great auricular nerve; 6, one of its facial branches; 7, its branch to the lobule; 8, twig which pierces the auricle to pass to its outer surface; 9, branch to the deep surface of the pinna; 10, its union with the posterior auricular of the facial nerve; 11, small occipital nerve; 12, its branch which unites with the great occipital nerve; 13, a mastoid branch arising separately from the plexus; 14, twigs from this to the back of the neck; 15, inner, 16, 17, middle, 18, outer branches of the supraclavicular nerves; 19, branch of the cervical nerves passing into the trapezius muscle; 20, spinal accessory distributed to the same and receiving a uniting branch from the cervical nerves; 21, branch to the levator scapulae; 22, trunk of the facial nerve; 23, its posterior auricular branch passing into the occipital and posterior and superior auricular muscles; 24, its cervical branch; 25, great occipital nerve.

portion of the integument of the head, neck, and chest. It is placed opposite the first four vertebræ, beneath the sterno-mastoid muscle, and rests against the middle scalenus muscle and the levator anguli scapulae. The disposition

of the nerves in the plexus is as follows :—Each nerve, except the first, divides into an ascending and a descending part ; and these are united in communicating loops with the contiguous nerves. From the union of the second and third nerves, superficial branches are supplied to the head and neck ; and from the junction of the third with the fourth, arise some of the cutaneous nerves of the shoulder and chest. Muscular and communicating branches spring from the same nerves.

The BRANCHES of the plexus may be divided into two sets—a superficial and deep ; the superficial consisting of those which perforate the cervical fascia and supply the integument ; the deep comprising branches which are distributed for the most part to the muscles. The superficial nerves may be subdivided into ascending and descending ; the deep nerves into an internal and an external series.

SUPERFICIAL ASCENDING BRANCHES.

Small occipital nerve.—The small occipital nerve varies in size, and is occasionally double. It springs from the second and third (sometimes only the second) cervical nerves, and is directed almost vertically to the head along the posterior border of the sterno-mastoid muscle, giving off in its course twigs to the skin over the upper portion of the posterior triangular space. Having perforated the deep fascia near the cranium, the small occipital nerve ascends to the scalp between the ear and the great occipital nerve, and ends in cutaneous filaments which extend upwards to somewhat above the level of the ear. It communicates with branches from the great occipital, great auricular and posterior auricular nerves, and it supplies an *auricular branch* which is distributed to the upper part of the ear on its inner aspect.

Varieties.—The small occipital nerve is sometimes directed backwards across the posterior triangle of the neck, and perforates the trapezius muscle close to its upper border, before ascending to the head. The auricular branch is occasionally derived from the great occipital nerve. The small occipital is sometimes much reduced in size and distributed solely to the skin of the neck, its place on the head being taken by branches of the great occipital nerve.

Great auricular nerve.—Arising from the second and third cervical nerves, this, the largest of the ascending branches of the plexus, winds round the hinder border of the sterno-mastoid, and is directed obliquely upwards between the platysma myoides muscle and the deep fascia of the neck towards the lobule of the ear. A little below the latter the nerve gives a few small offsets to the face, and then ends in auricular and mastoid branches.

(a) The *auricular branches* are directed to the back of the auricle, on which they ramify, and are connected with twigs derived from the posterior auricular branch of the facial nerve. One offset reaches the outer surface of the ear by a fissure between the antihelix and the concha. A few filaments are supplied likewise to the outer part of the lobule.

(b) The *mastoid branch* ramifies in the integument over the upper end of the sterno-mastoid muscle and the mastoid process, and communicates with the posterior auricular and small occipital nerves.

(c) The *facial branches* are distributed to the integument of the face over the parotid gland. Some slender filaments penetrate into the substance of the gland, and communicate with the lower division of the facial nerve.

Varieties.—The great auricular nerve may arise solely from the third, or from the third and fourth cervical nerves (Henle). The mastoid branch is often a separate offset of the plexus, ascending between the great auricular and small occipital nerves (fig. 191, 13).

Superficial cervical nerve (*n. subcutaneus colli*).—This nerve takes origin, usually in common with the great auricular, from the second and third cervical

nerves, turns forwards over the sterno-mastoid muscle about the middle, and after perforating the cervical fascia, divides beneath the platysma myoides into two branches, which are distributed to the anterior part of the neck.

(a) The *upper branch* is the larger, and gives an ascending twig which accompanies the external jugular vein, and communicates freely with the cervical branch of the facial nerve; it is then transmitted through the platysma to the surface, and ramifies in the integument of the upper half of the front of the neck, filaments reaching as high as the lower maxilla.

(b) The *lower branch*, sometimes represented by two or three smaller offsets, likewise pierces the platysma and is distributed below the preceding, its filaments extending in front as low as the sternum.

Varieties.—The superficial cervical nerve also may arise from the third only, or from the third and fourth cervical nerves. It is sometimes represented by two or more branches arising separately from the plexus.

SUPERFICIAL DESCENDING BRANCHES.

Supraclavicular nerves.—The descending series of the superficial nerves are thus named. They arise together from the third and fourth cervical nerves, and descend in the interval between the sterno-mastoid and the trapezius muscles. As they approach the clavicle, they are three or more in number, and are recognized as internal, middle, and external.

(a) The *internal branch* (suprasternal), which is much smaller than the rest, ramifies over and below the inner third of the clavicle, and terminates near the sternum. From it one or two filaments are furnished to the sterno-clavicular articulation (Rüdinger, Hepburn).

(b) The *middle branch*, generally divided into two or three parts, and crossing the clavicle in the interval between the sterno-mastoid and trapezius muscles, distributes some twigs over the fore part of the deltoid, and others over the pectoral muscle as low as the third rib. The latter join the small anterior cutaneous branches of some of the upper intercostal nerves.

(c) The *external or posterior branch* (supra-acromial) is directed outwards across the clavicular attachment of the trapezius muscle, and ramifies over the acromion and in the integument of the outer and back part of the shoulder.

Filaments from these nerves supply the skin over the lower part of the posterior triangular space, and one or two twigs pass backwards over the trapezius to the integument above the spine of the scapula.

Variety.—One of the middle branches of the supraclavicular nerves occasionally perforates the clavicle on its way downwards.

DEEP BRANCHES : INTERNAL SERIES.

Connecting branches.—The cervical plexus is connected near the base of the skull with the pneumo-gastric, hypoglossal, and sympathetic nerves, by means of filaments intervening between those nerves and the loop formed by the first two cervical nerves in front of the atlas (p. 283).

Muscular branches.—Branches to the prevertebral muscles proceed from the cervical nerves close to the vertebræ, including the loop between the first two of these nerves; and from the fourth nerve a twig is frequently given to the upper part of the scalenus anticus.

Two **communicating cervical branches**, one from the second, the other from the third cervical nerve, descend over or under the internal jugular vein to join the descending cervical nerve in the ansa cervicalis, from which the infrahyoid muscles are supplied (p. 273).

Variety.—In some cases there is also a communicating branch from the fourth nerve (fig. 183).

Phrenic nerve.—The diaphragmatic or phrenic nerve (fig. 183, 2; 193, 3) passes down through the lower part of the neck and the thorax to its destination. It arises mainly from the fourth cervical nerve, but it also receives, in the majority of instances, an additional root from either the third or the fifth nerve. While descending in the neck, the nerve inclines inwards over the anterior scalenus muscle; and near the chest it is joined by a filament from the middle or lower cervical ganglion of the sympathetic.

At the root of the neck each phrenic nerve is placed between the subclavian artery and vein, and crosses over the internal mammary artery from without inwards and backwards. It then takes a nearly vertical course, in front of the root of the lung on each side, and along the side of the pericardium—between this and the mediastinal part of the pleura. Near the diaphragm it divides into branches, which pass separately through the muscle, and then diverging from each other, are distributed on the under surface.

The *right nerve* has a more direct course than the left, and lies at first along the outer side of the right innominate vein and the superior vena cava.

The *left nerve* is somewhat longer than the right, in consequence of the oblique position of the heart and pericardium round which it winds, and also because the diaphragm is lower on this than on the opposite side. It passes into the thorax between the left innominate vein and subclavian artery, and then crosses in front of the left vagus and over the left side of the arch of the aorta before reaching the pericardium.

Besides the terminal branches supplied to the diaphragm, each phrenic nerve gives on its way through the thorax filaments to the pleura and pericardium. Luschka describes also twigs from the lower part of the nerve to the peritoneum, and on the right side to the inferior cava and the right auricle of the heart.

One or two filaments of the nerve of the right side join in a small ganglion with branches to the diaphragm which are derived from the solar plexus of the sympathetic; and from the ganglion twigs are given to the suprarenal capsule, the hepatic plexus, and the lower vena cava. On the left side there is a junction between the phrenic and the sympathetic nerves near the œsophageal and aortic openings in the diaphragm, but without the appearance of a ganglion.

According to the observations of Pansini in animals (Arch. ital. de Biologie, x, 1888) the terminal ramifications of the phrenic nerves form in the diaphragm a complicated plexus, in which the three last intercostal nerves also take part, and which contains microscopic ganglia. On sensory fibres in the phrenic nerve, see J. Ferguson, in "Brain," 1891.

Varieties.—The phrenic may receive an accessory root from the second or the sixth cervical nerve (rarely), from the descendens cervicis or the ansa cervicalis, or from the nerve to the subclavius (frequently). The last may be of considerable size; and in some instances the whole nerve has been found arising in this way and descending in front of the third part of the subclavian artery and the subclavian vein to the thorax. The *accessory phrenic nerve* is a filament arising from the fifth, or more rarely the fifth and sixth cervical nerves, and passing either in front of or behind the subclavian vein to join the trunk at the root of the neck or at a variable level in the thorax. The phrenic nerve, having a normal origin, has been observed in different cases lying along the outer border of, or piercing, the scalenus anticus, crossing in front of the subclavian vein, and passing through a ring formed by that vessel. It occasionally gives a branch to the scalenus anticus.

DEEP BRANCHES: EXTERNAL SERIES.

Muscular branches.—The sterno-mastoid receives a branch from the second cervical nerve. Two branches proceed from the third and fourth nerves to the levator anguli scapulæ; and from the same nerves, as they leave the spinal canal,

branches are given to the middle scalenus muscle. Farther, the trapezius receives one or more considerable branches which arise from the third and fourth cervical trunks in common with the supraclavicular nerves.

Communications with the spinal accessory nerve.—In the substance of the sterno-mastoid muscle, this nerve is connected with the branch of the cervical plexus furnished to that muscle. It is also connected with the branches distributed to the trapezius—the union between the nerves being beneath the muscle, and having the appearance of a plexus; and with another branch of the cervical plexus in the interval between the two muscles.

SUMMARY OF THE CERVICAL PLEXUS.—From the cervical plexus cutaneous nerves are distributed to the side of the head, to part of the ear and face, to the anterior two-thirds or more of the neck, and to the upper part of the chest and shoulder. The muscles supplied with nerves from the plexus are the sterno-mastoid, the trapezius, and the infrahyoid muscles, the anterior and lateral recti capitis, the longus colli, the levator anguli scapulæ, the scalenus medius and anticus in part, and the diaphragm. By means of its branches the plexus communicates with the pneumo-gastric, spinal accessory, hypoglossal, and sympathetic nerves.

BRACHIAL PLEXUS.

This large plexus, from which the nerves of the upper limb are supplied, is formed by the union of the anterior trunks of the four lower cervical and the greater part of the first dorsal nerves. It also receives in many cases a fasciculus from the lowest of the nerves (fourth) which go to form the cervical plexus, or a filament from the second dorsal nerve: these two roots may co-exist. The plexus extends from the lower part of the neck to the axillary space, and terminates opposite the coracoid process of the scapula in large nerves for the supply of the limb.

The *cervical* or *supraclavicular portion* of the plexus, emerging from the cleft between the scalenus anticus and medius, lies in the lower part of the posterior triangular space, above and behind the third part of the subclavian artery: it is crossed by the posterior belly of the omo-hyoid muscle, and is often pierced by the transverse cervical or posterior scapular artery. After passing behind the clavicle, the *axillary* or *infraclavicular portion* of the plexus is placed to the acromial side of the axillary vessels, being enclosed in the axillary sheath, and covered by the pectoralis major and subclavius muscles; and at its termination it lies between the pectoralis minor and subscapularis muscles.

The manner in which the nerves are disposed in the plexus is liable to some variation, but the following may be regarded as the typical arrangement, from which the different forms met with may in most cases be readily derived. The fifth and sixth cervical join together at the outer border of the scalenus medius to form an *upper trunk*; similarly the eighth cervical and first dorsal unite together between the scaleni muscles to form a *lower trunk*; while the seventh cervical remains single, forming a *middle trunk*.

Soon after passing the outer border of the scaleni muscles, each primary trunk divides into an *anterior* and a *posterior branch*. The posterior branch of the lower trunk, however, is much smaller than the others, and in most instances is derived solely from the eighth cervical nerve. The anterior branches of the upper and middle trunks unite together to form what is called the *upper* or *outer cord* of the plexus; the large anterior branch of the lower trunk forms by itself the *lower* or *inner cord* of the plexus; and the posterior branches of all three trunks unite together to form the *middle* or *posterior cord*. The cords thus formed lie at first in a single bundle on the outer side of the first part of the axillary artery, but lower

down they are placed, the first on the outer side, the second on the inner side, and the third behind that vessel in its second part, whence they are continued into the principal nerves for the arm.

Varieties.—Deviations from the arrangement above described, depending upon alterations in the level at which the several portions of the plexus separate and unite, are often met with. The seventh cervical nerve is sometimes divided into three branches, one passing to each of the three cords of the plexus. The posterior cord has been observed arising from the sixth, seventh, and eighth, and in one case only from the seventh and eighth cervical nerves (Turner). Cases are recorded in which the plexus consisted of only two cords, the larger one representing either the inner and outer, or the posterior and inner cords of the normal arrangement.

The fifth cervical nerve is not unfrequently, the sixth more rarely, directed outwards through the fibres of the scalenus anticus; the fifth nerve may even pass altogether in front of that muscle.

BRANCHES.—The nerves proceeding from the brachial plexus are usually divided into two classes, viz., A, those that are given off from its supraclavicular part, and

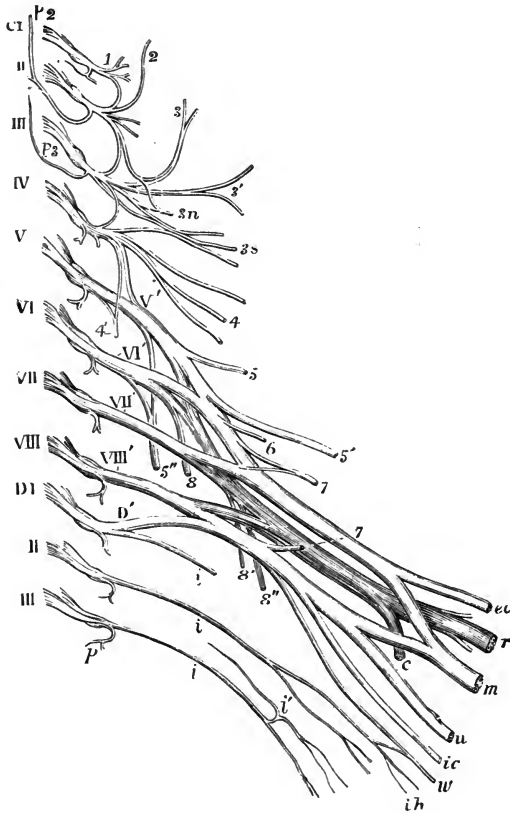


Fig. 192.—PLAN OF THE CERVICAL AND BRACHIAL PLEXUSES. (Allen Thomson). $\frac{1}{3}$

The nerves are separated from the spinal cord at their origin and are supposed to be viewed from before: C1, the first cervical or suboccipital nerve, and the Roman numbers in succession from II, to VIII, the corresponding cervical nerves; D1, the first, and II, and III, the second and third dorsal nerves; the origin of the posterior primary branch is shown in all the nerves; of these *p* 2, indicates the great occipital from the second, and *p* 3, the smallest occipital nerve from the third. *Cervical plexus*: 1, anterior primary branch of the first cervical nerve and loop of union with the second nerve; 2, small occipital nerve; 3, great auricular nerve; 3', superficial cervical nerve: 3 *n*, communicating branches to the ansa cervicalis from the second and third; 3 *s*, communicating to the spinal accessory from the third and fourth nerves; 4, supraclavicular nerves; 4', phrenic nerve. *Brachial plexus*: V', to VIII', and D', the five roots of the brachial plexus; 5, the rhomboid nerve; 5', suprascapular; 5'', posterior thoracic; 6, nerve to the subclavius muscle; 7, 7', inner and outer anterior thoracic nerves; 8, 8', 8'', subscapular nerves. In the larger nerves proceeding to the shoulder and arm from the plexus, those of the anterior divisions are represented of a lighter shade, those belonging to the posterior division darker; *cc*, external cutaneous or musculo-cutaneous; *m*, median; *u*, ulnar; *ic*, internal cutaneous; *w*, nerve of Wrisberg; *r*,

musculo-spiral; *c*, circumflex; *i, i*, intercostal nerves; *i'*, lateral branch of the same; *ih*, intercosto-humeral nerve.

so arise before the formation of the three cords of the plexus; and B, those arising below the clavicle from the outer, inner, and posterior cords.

To the former (supraclavicular) group belong some small muscular nerves to the scaleni and longus colli muscles the nerve to the rhomboid muscles, the posterior

thoracic nerve for the serratus magnus muscle, the suprascapular nerve, the nerve to the subclavius, and sometimes a branch to join the phrenic nerve.

The nerves given off below the clavicle are derived from the three great cords of the plexus in the following manner :—

From the upper or outer cord,—the external of the two anterior thoracic nerves, the nerve to the coraco-brachialis, the musculo-cutaneous, and the outer head of the median.

From the lower or inner cord,—the inner of the two anterior thoracic nerves, the nerve of Wrisberg or small internal cutaneous, the internal cutaneous, the ulnar, and the inner head of the median.

From the posterior cord,—the three subscapular nerves, the circumflex, and the musculo-spiral.

The following table shows the spinal nerves from which the several offsets of the plexus are commonly derived.¹ + signifies that the branch in question receives fibres from the spinal nerve in whose column the sign is placed ; +? signifies that there is most frequently a root from that spinal nerve, but it may be wanting ; ? signifies that the corresponding root is not unfrequently present, although exceptional. The rarer forms of variation are not taken into account :—

	C. V.	C. VI.	C. VII.	C. VIII.	D. I.
A. SUPRACLAVICULAR BRANCHES.					
<i>a.</i> To trunk-muscles.					
To longus colli	+?	+?	+?	+?	
To scaleni	+	+	?		
To phrenic nerve	?				
<i>b.</i> To limb-muscles.					
To rhomboidei	+				
Posterior thoracic	+		+?		
Suprascapular	+	+?			
To subclavius	+	?			
B. INFRACLAVICULAR BRANCHES.					
<i>a.</i> From outer cord.					
External anterior thoracic	+?	+	+		
To coraco-brachialis			+		
Musculo-cutaneous	+	+			
Outer head of median		+	+		
<i>b.</i> From inner cord.					
Internal anterior thoracic				+	+
Nerve of Wrisberg					+
Internal cutaneous				+	+
Ulnar			?	+	+
Inner head of median			?	+	+
<i>c.</i> From posterior cord.					
Upper subscapular	+	+			
Middle or long subscapular		?	+	?	
Lower subscapular	+?	+	?		
Circumflex	+	+?			
Musculo-spiral	?	+	+	+	

A.—BRANCHES ABOVE THE CLAVICLE.

Small muscular branches.—The branches for the *scaleni* and *longus colli* muscles spring in an irregular manner from the lower cervical nerves close to their place of emergence from the intervertebral foramina.

Branch to the phrenic nerve.—This small branch is, when present, an offset from the fifth cervical nerve ; it usually joins the phrenic nerve on the anterior scalenus muscle.

¹ See W. P. Herringham, "The Minute Anatomy of the Brachial Plexus," Proc. Roy. Soc., xli, 1886.

Varieties.—The communicating branch to the phrenic nerve has been seen to pass down into the thorax over the subclavian artery, and even over the vein, before joining with the trunk. A second filament to the phrenic, from the sixth nerve, is rarely met with.

The **branch for the rhomboid muscles** (*n. dorsalis scapulæ*) arises in common with the highest root of the posterior thoracic nerve from the fifth nerve

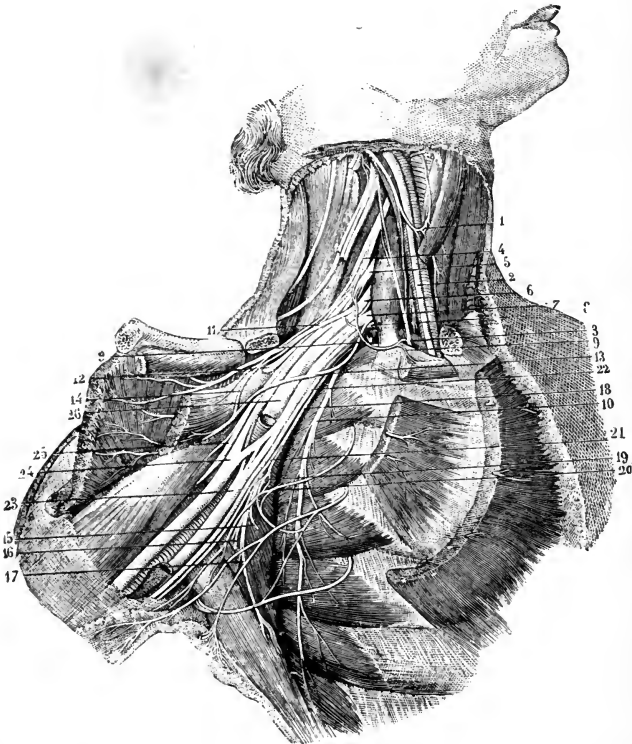


Fig. 193.—DEEP DISSECTION OF THE AXILLA, SHOWING THE BRACHIAL PLEXUS AND NEIGHBOURING NERVES. (From Sappey, after Hirschfeld and Leveillé.) $\frac{1}{2}$.

The clavicle has been sawn through near its sternal end, and is turned aside with the muscles attached to it; the subclavius and the greater and lesser pectoral muscles have been removed from the front of the axilla. 1, ansa cervicalis; 2, pneumo-gastric; 3, phrenic, passing down to the inner side of the scalenus anticus muscle; 4, anterior primary division of the fifth cervical nerve; 5, 6, 7, the same of the sixth, seventh, and eighth cervical nerves; 8, the same of the first dorsal nerve; 9, 9, nerve to the subclavius muscle, communicating with the phrenic nerve; 10, posterior thoracic nerve distributed to the serratus magnus; 11, external anterior thoracic nerve, passing into the great pectoral muscle; 13, internal anterior thoracic, distributed to the lesser pectoral; 14, twig of communication between these two nerves; 12, suprascapular nerve, passing through the suprascapular notch; 15, upper subscapular nerve; 16, lower subscapular nerve; 17, long subscapular nerve; 18, 21, small internal cutaneous nerve; 19, union of this with the second and third intercostal nerves; 20, lateral branch of the second intercostal; 22, internal cutaneous nerve; 23, ulnar nerve to the inside of the axillary artery, passing behind the vein, and having, in this case, a root from the outer cord of the plexus; 24, median nerve immediately below the place where its two roots embrace the artery, which is divided above this place; 25, musculo-cutaneous nerve, passing into the coraco-brachialis muscle, to which it is giving a branch; 26, musculo-spiral nerve, passing behind the divided axillary artery.

close to the vertebræ, and is directed backwards to the base of the scapula through the fibres of the middle scalenus, and beneath the levator anguli scapulæ, to the deep surface of the rhomboid muscles, in which it terminates. It gives one or two branches to the levator scapulæ, and sometimes a twig to the highest digitation of the serratus posticus superior (Rieländer).

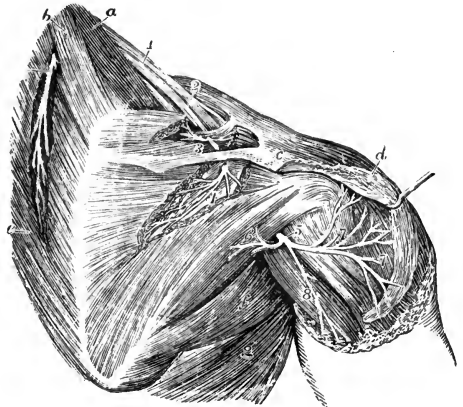
The **posterior thoracic nerve** (*n. thoracalis longus*) usually arises by three roots from the fifth, sixth, and seventh cervical nerves. The upper and middle roots perforate the scalenus medius and join either in the substance or on the surface of that muscle; the lower root passes in front of the scalenus medius and joins the trunk opposite or below the first rib. The nerve descends behind the brachial plexus and the first part of the axillary artery, on the outer surface of the serratus magnus, nearly to the lower border of that muscle, supplying it with numerous branches. The fibres derived from the several roots are distributed to the slips of the muscle in order from above downwards.

Varieties.—The root from the seventh nerve is sometimes wanting. In three instances the nerve was found by Lucas receiving a fourth root from the eighth cervical nerve. The root from the fifth nerve sometimes remains separate, being distributed only to the upper division of the muscle.

The **suprascapular nerve** arises from the trunk formed by the union of the fifth and sixth cervical nerves, but its fibres are derived mainly from the fifth nerve. It passes outwards and backwards beneath the trapezius and omo-hyoid muscles to

Fig. 194.—DISTRIBUTION OF THE SUPRASCAPULAR AND CIRCUMFLEX NERVES. (Hirschfeld and Leveillé.) $\frac{1}{3}$

a, scalenus medius and posticus muscles; *b*, levator anguli scapulae; *c*, acromion; *d*, deltoid muscle, of which the back part has been removed; *e*, rhomboid muscles; *f*, teres major; *g*, latissimus dorsi; 1, the brachial plexus, seen from behind; 1', nerve to the rhomboid muscles; 2, placed on the clavicle, the suprascapular nerve; 3, its branches to the supraspinatus muscle; 4, branch to the infraspinatus; 5, the circumflex nerve, passing out of the quadrangular interval; 6, its branch to the teres minor muscle; 7, branches to the deltoid; 8, cutaneous branch.



the upper border of the scapula, where it enters the supraspinous fossa through the suprascapular notch, below the ligament of the same name. In the supraspinous fossa, the nerve supplies branches to the supraspinatus muscle, and a slender *articular* filament to the shoulder-joint; and it then descends through the great scapular notch to the lower fossa, where it ends in the infraspinatus muscle, furnishing sometimes a second twig to the articulation of the shoulder.

Varieties.—The suprascapular nerve is sometimes derived solely from the fifth nerve; or it may receive a few fibres from the fourth nerve. It has been seen dividing into two parts, the one of which passes through the suprascapular notch, while the other pierces the bone just below the notch. Very rarely a branch is given to the upper part of the subscapularis muscle, or to the teres minor. Filaments to the acromio-clavicular articulation have been noticed by Rüdinger, and to the periosteum and substance of the scapula by Swan and Ellis.

The **nerve of the subclavius muscle**, a slender branch given off from the front of the upper trunk of the plexus, is also derived mainly or wholly from the fifth cervical nerve. It descends over the third part of the subclavian artery and behind the clavicle to the posterior surface of its muscle.

Varieties.—The nerve to the subclavius often sends a branch inwards to join the phrenic nerve either at the root of the neck (fig. 193) or, less frequently, in the thorax. A communicating twig to the external anterior thoracic nerve, and a branch to the clavicular head of the sterno-mastoid have also been observed (Turner).

B.—BRANCHES BELOW THE CLAVICLE.

Anterior thoracic nerves.—The anterior thoracic nerves, two in number, supply the pectoral muscles.

The *external*, or more superficial branch, arising from the outer cord under cover of the clavicle, is derived from the sixth and seventh nerves, very frequently also the fifth. It crosses inwards over the axillary artery, and, after giving off a branch to join the inner nerve, terminates in the great pectoral muscle.

The *internal*, or deeper branch, springing from the inner cord, mostly receives fibres from both the last cervical and first dorsal nerves. It comes forwards between the axillary artery and vein, and is joined by the communicating branch from the external nerve, with which it forms a plexiform loop embracing the axillary artery. From this loop offsets proceed to the small and to the lower part of the large pectoral muscles.

Varieties.—The internal branch occasionally has no fibres from the first dorsal nerve. Cutaneous filaments from the anterior thoracic nerves to the mammary region and to the arm have been described by various observers. The external branch is said to supply twigs sometimes to the clavicular part of the deltoid; and, according to Bock and Valentin, a filament is given to the acromio-clavicular articulation.

Subscapular nerves.—The subscapular nerves are usually three in number, and supply the muscles forming the posterior wall of the axilla.

The *upper nerve*, the smallest of the three, is derived from the fifth and sixth cervical nerves, and penetrates the upper part of the subscapularis muscle. This branch is often double.

The *middle* or *long subscapular nerve* (*n. thoracodorsalis*) is the largest of the three, and obtains its fibres mainly from the seventh, to a less extent in many cases also from the sixth or eighth cervical nerves. It descends in company with the subscapular artery to enter the deep surface of the latissimus dorsi muscle.

The *lower subscapular nerve* is derived from the fifth and sixth, or less frequently the sixth and seventh cervical nerves. It gives one or two branches to the lower part of the subscapularis, and ends in the teres major muscle.

Varieties.—The *upper nerve* occasionally proceeds from the fifth or sixth cervical nerve alone. The most frequent origin of the *long subscapular nerve* is from the seventh alone, or from the seventh and eighth nerves; it rarely receives fibres from the fifth. The *lower nerve* seldom proceeds from the fifth or sixth nerve alone, or from the fifth, sixth, and seventh nerves. The branches to the lower part of the subscapularis and the teres major muscles are sometimes independent offsets of the brachial plexus. The nerve to the teres major is occasionally given off by the commencement of the circumflex nerve.

Circumflex nerve.—The circumflex nerve (*n. axillaris*), one of the terminal branches of the posterior cord of the plexus, obtains its fibres from the fifth and sixth cervical nerves. It is placed at first behind the axillary artery, resting on the subscapularis muscle, at the lower border of which it turns backwards with the posterior circumflex vessels. It then appears at the back of the shoulder in the quadrilateral space between the two teres muscles (fig. 194), external to the long head of the triceps, and divides into branches, which are distributed to the deltoid and teres minor muscles, the integument of the shoulder, and the shoulder-joint.

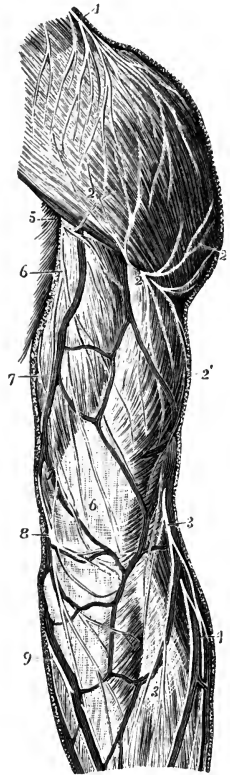
(a) The *upper branch* winds round the upper part of the shaft of the humerus, extending nearly as far as the anterior border of the deltoid muscle, to which it is distributed. One or two *cutaneous filaments* penetrate between the muscular fibres, and are bent downwards to supply the integument over the lower part of the muscle.

(b) The *lower branch* supplies offsets to the back part of the deltoid, and

furnishes the nerve to the teres minor, on which there is often a small reddish enlargement. It then turns round the posterior border of the deltoid below the

Fig. 195.—DISTRIBUTION OF THE POSTERIOR CUTANEOUS NERVES OF THE SHOULDER AND ARM (Hirschfeld and Leveillé.) $\frac{1}{2}$

1, supra-acromial branches of the cervical plexus descending on the deltoid muscle; 2, ascending and 2', descending cutaneous branches of the circumflex nerve; 3, inferior external cutaneous of the musculo-spiral nerve; 4, posterior cutaneous branches of the musculo-cutaneous nerve to the forearm; 5, 6, internal cutaneous of the musculo-spiral; 7, nerve of Wrisberg; 8, 9, posterior branches of the internal cutaneous nerve.



middle, and ramifies in the integument over the lower two-thirds of that muscle, and over the adjacent part of the triceps (*n. cutaneus brachii lateralis*).

(c) One or two *articular filaments* for the shoulder-joint arise near the commencement of the nerve, and enter the capsular ligament below the subscapular muscle.

Rauber describes a filament of the upper branch as ascending in the bicipital groove to be distributed to the upper extremity of the humerus and the capsule of the shoulder-joint.

Varieties.—The circumflex nerve is occasionally derived wholly from the fifth cervical; and the contribution from the sixth nerve is often very small. It has been seen to perforate the lower part of the subscapularis muscle (Macalister, Bubenik), to which it often furnishes a branch. Branches to the long head of the triceps and to the infraspinatus are also mentioned.

Internal cutaneous nerve.—The internal cutaneous nerve (*n. cutaneus antibrachii medialis*) is composed of fibres proceeding from the first dorsal, and usually also from the eighth cervical nerve. After leaving the inner cord of the plexus, it is placed at first to the inner side of the axillary artery, and then descends superficially between the brachial artery and the basilic vein to rather below the middle of the arm, where it becomes subcutaneous. As it pierces the fascia it is divided into two parts, one destined for the anterior, the other for the posterior surface of the forearm.

(a) The *anterior division* crosses at the bend of the elbow behind (less frequently over) the median-basilic vein, and distributes filaments in front of the forearm, as far as the wrist; one of these may be joined with a cutaneous branch of the ulnar nerve (fig. 197, 14).

(b) The *posterior division*, smaller than the anterior, inclines to the inner side of the basilic vein, and sends its branches obliquely backwards round the inner margin of the forearm to supply the skin about as far as the subcutaneous border of the ulna. Above the elbow this division is connected with the small internal cutaneous nerve; in the forearm it communicates with the anterior part of the internal cutaneous, and near the wrist sometimes with the dorsal branch of the ulnar nerve.

(c) One or more *branches to the integument of the arm* pierce the fascia near the axilla, and reach to the elbow, or nearly so, distributing filaments outwards over the biceps muscle.

Varieties.—The posterior division of the internal cutaneous nerve has been seen arising separately from the posterior branch of the lower trunk of the brachial plexus (G. Elliot Smith, Journ. Anat., xxix, 85). Cases are recorded in which the posterior division is joined,

or replaced to a greater or less extent, by a branch of the ulnar nerve. In one instance the posterior branch was large and extended to the hand, taking the place of the absent dorsal branch of the ulnar nerve (G. D. T.).

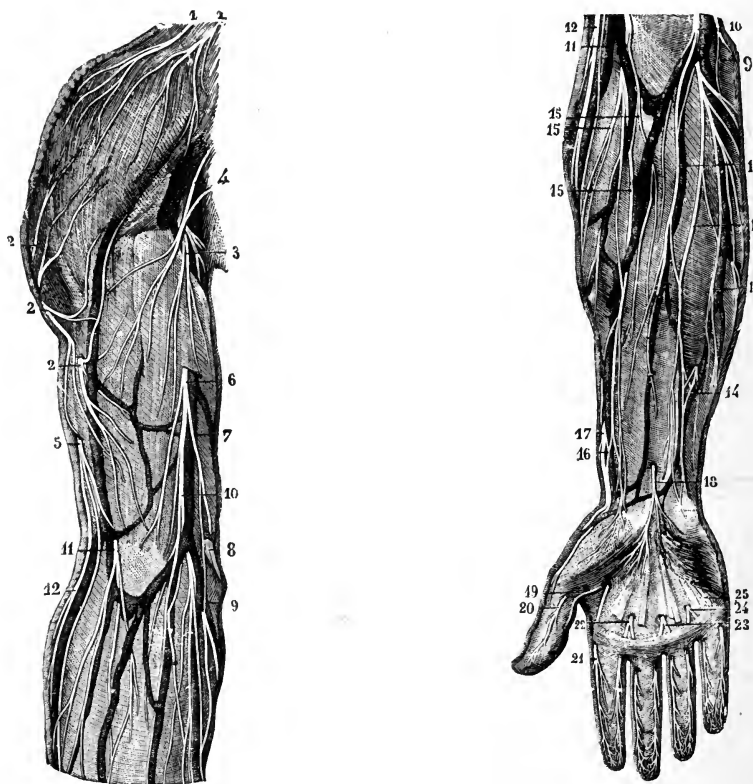


Fig. 196.—ANTERIOR CUTANEOUS NERVES OF THE SHOULDER AND ARM. (From Sappey, after Hirschfeld and Leveillé.) $\frac{1}{3}$

1, 1, supraclavicular nerves from the cervical plexus; 2, 2, 2, cutaneous branches of the circumflex nerve; 3, 4, upper branches of the internal cutaneous nerve; 5, upper external cutaneous branch of the musculospiral; 6, internal cutaneous nerve piercing the deep fascia; 7, its posterior branch; 8, communicating twig with one of the anterior branches; 9, 10, anterior branches of this nerve, some turning round the median basilic and ulnar veins; 11, musculocutaneous nerve descending (exceptionally) over the median-cephalic vein; 12, lower external cutaneous branch of the musculospiral nerve.

Fig. 197.—ANTERIOR CUTANEOUS NERVES OF THE FOREARM AND HAND. (From Sappey, after Hirschfeld and Leveillé.) $\frac{1}{3}$

9, 10, 13, distribution of the anterior division of the internal cutaneous nerve; 14, union of one of these with a twig of the ulnar nerve; 12, lower external cutaneous branch of the musculospiral nerve; 11, 15, distribution of the external cutaneous nerve; 16, union of one of its branches with 17, the radial nerve; 18, palmar cutaneous branch of the median nerve; 19, 20, internal and external digital branches to the thumb from the median nerve; 21, external digital to the index finger; 22, 23, digital branches to the index, middle, and ring fingers; 24, 25, digital branches from the ulnar nerve to the ring and little fingers.

Small internal cutaneous nerve.—The small internal cutaneous nerve or nerve of Wrisberg (*n. cutaneus brachii medialis*), derived from the first dorsal nerve, commonly arises from the inner cord of the brachial plexus in union with the large internal cutaneous nerve. In the axilla it lies at first behind the axillary vein, but it soon appears on the inner side of that vessel, and communicates with the intercosto-humeral nerve. It then descends along the inner side of the basilic vein

to about the middle of the arm, where it pierces the fascia, and its filaments are thence continued to the interval between the internal condyle of the humerus and the olecranon.

Varieties.—The small internal cutaneous may receive fibres from the eighth cervical (rarely) or the second dorsal nerve. The *connection with the intercosto-humeral nerve* presents much variety in different cases :—in some, there are two or more intercommunications, forming a kind of plexus on the posterior boundary of the axillary space ; in others the intercosto-humeral nerve is of larger size than usual, and takes the place of the nerve of Wrisberg, only receiving in the axilla a small filament from the brachial plexus, and this small communicating filament represents in such cases the nerve of Wrisberg. It sometimes communicates also with the lateral cutaneous branch of the third intercostal nerve. Absence of the nerve of Wrisberg is noted.

The **nerve to the coraco-brachialis** is a small branch formed by fibres derived from the seventh cervical nerve. In the infant it is a separate offset from the outer cord of the plexus, but in the adult it is commonly more or less closely united to the trunk of the musculo-cutaneous nerve, from which it separates before that nerve enters the muscle (Herringham). It is often represented by two filaments.

Musculo-cutaneous nerve.—The musculo-cutaneous or external cutaneous nerve, derived from the fifth and sixth cervical nerves, is deeply placed between the muscles as far as the elbow, and below that point is immediately under the integument. Arising from the outer cord of the brachial plexus opposite the small pectoral muscle, it perforates the coraco-brachialis, and, passing obliquely across the arm between the biceps and brachialis anticus muscles, reaches the outer side of the biceps a little above the elbow. Here it perforates the fascia, and, passing behind the median-cephalic vein, divides into two branches which supply the integument on the outer side of the forearm, one on the anterior, the other on the posterior aspect.

A. *Branches in the arm.*

In addition to the one or two twigs to the coraco-brachialis which may be given off from this nerve near its origin (see above), the musculo-cutaneous furnishes the following offsets in the deep part of its course :—

(a) *Branches to the biceps and brachialis anticus* muscles, which arise after the nerve has pierced the coraco-brachialis.

(b) A slender *branch to the humerus*, entering the bone with the medullary artery.

(c) An *articular filament* to the elbow-joint.

The nerve to the humerus is described by Rauber and others as arising from the nerve before it enters the coraco-brachialis, and descending along the brachial artery, to which it supplies filaments ; but Testut states that in all the cases in which he found this branch it was given off by the nerve to the brachialis anticus. An articular filament may proceed from the nerve to the biceps (Cruveilhier) or from that to the brachialis anticus (Rüdinger) ; Testut traced a twig from the latter source to the periosteum about the coronoid fossa. A *vascular branch* to the lower part of the brachial artery from the nerve of the brachialis anticus is described by Swan and Testut.

B. *Branches in the forearm.*

(a) The *anterior branch* descends near the radial border of the forearm. It is placed in front of the radial artery near the wrist, and distributes its terminal offsets over the thenar eminence. One or two filaments pierce the fascia and run on the artery to the articulations of the wrist. This part of the nerve is connected above the wrist with a branch of the radial nerve.

(b) The *posterior branch* is directed outwards to the back of the forearm, and

ramifies in the integument of the lower two-thirds, extending as far as or somewhat beyond the wrist. It communicates with a branch of the radial nerve, and with the lower external cutaneous branch of the musculo-spiral nerve.

Varieties.—The musculo-cutaneous nerve proper occasionally receives fibres from the seventh cervical nerve.

In some cases the constituent fibres of the nerve remain adherent to the outer head and

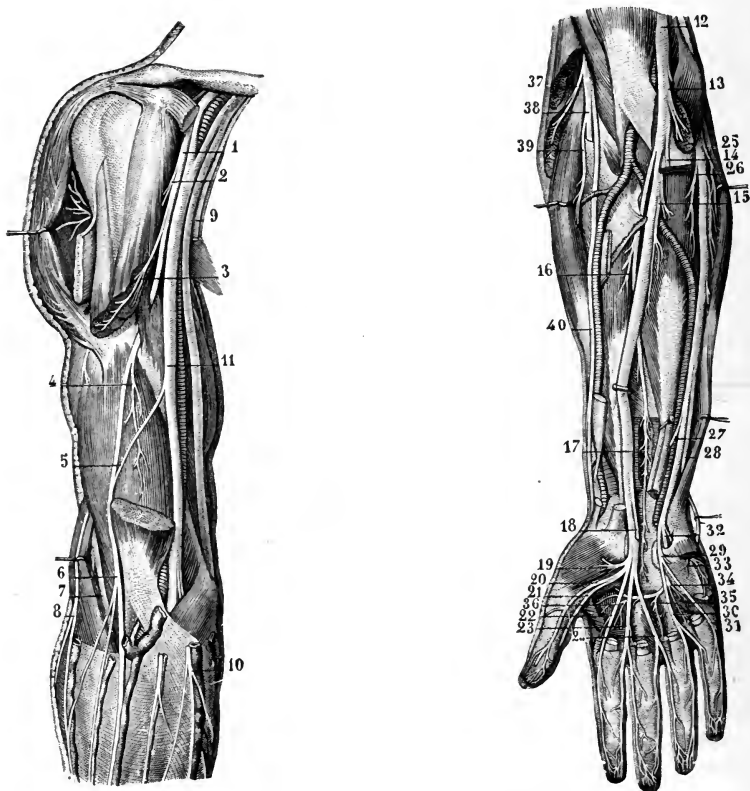


Fig. 198.—DEEP VIEW OF THE ANTERIOR NERVES OF THE SHOULDER AND ARM. (From Sappey, after Hirschfeld and Leveillé.) $\frac{1}{2}$

1, musculo-cutaneous nerve, giving off 2, the branch to the coraco-brachialis muscle; 3, branch to the biceps, represented incorrectly as given off before the nerve pierces the coraco-brachialis; 4, branch to brachialis anticus; 5, communicating branch from the median to the musculo-cutaneous nerve (an infrequent variety); 6, continuation of the nerve to its cutaneous distribution; 7, musculo-spiral nerve in the interval between the brachialis anticus and supinator longus muscles; 8, inferior external cutaneous branch of the musculo-spiral; 9, the large and small internal cutaneous nerves divided; 10, anterior branch of the internal cutaneous; 11, median nerve; to the inner side of this the ulnar nerve is crossed by the line from 11.

Fig. 199.—DEEP VIEW OF THE ANTERIOR NERVES OF THE FOREARM AND HAND. (From Sappey, after Hirschfeld and Leveillé.) $\frac{1}{2}$

12, median nerve; 13, its branch to the pronator teres; 14, branch to the superficial flexor muscles, which have been removed; 15, branch to the flexor profundus digitorum; 16, branch to the flexor longus pollicis; 17, anterior interosseous nerve; 18, palmar cutaneous branch cut short; 19, branch to short muscles of thumb; 20, 21, digital branches to thumb; 22, 23, 24, third, fourth, and fifth digital branches; 25, branch given by ulnar nerve to flexor carpi ulnaris; 26, branch to flexor profundus digitorum; 27, cutaneous twig; 28, dorsal branch of ulnar; 29, superficial palmar portion; 30, 31, digital branches to ring and little fingers; 32, deep palmar branch; 33, its branch to short muscles of little finger; 34, 35, 36, twigs given by deep branch of ulnar to third and fourth lumbricals, all the interosseous muscles, and the adductors of the thumb.

trunk of the median for a variable distance in the upper part of the arm, the musculo-cutaneous or its several branches then being given off from the median trunk, and passing outwards to the interval between the biceps and brachialis anticus muscles: this is a common arrangement in lower mammals. In other cases (2 per cent., Testut; 8 per cent., Villar) only a part of the fibres take this course, so that a communicating branch runs from the median to the musculo-cutaneous (fig. 198, 5); or the muscular part of the nerve perforates the coraco-brachialis and the cutaneous part is given off from the median (Schwalbe); or the median furnishes only the muscular branches (Villar). Much more frequently (36 per cent., Testut) some of the median fibres are associated with the musculo-cutaneous in its passage through the coraco-brachialis, a communicating branch then passing from the latter nerve to the median. Very rarely the whole outer cord of the plexus pierces the coraco-brachialis, and then divides into musculo-cutaneous and outer head of the median. (Testut, "Recherches anatomiques sur l'anastomose du nerf musculo-cutané avec le nerf median," Journ. de l'Anat., 1883; and "Mémoire sur la portion brachiale du nerf musculo-cutané," Internat. Monatschr. f. Anat., 1884; F. Villar, "Quelques recherches sur les anastomoses des nerfs du membre supérieur." Bull. Soc. Anat. de Paris, 1888.)

Sometimes the musculo-cutaneous nerve does not perforate the coraco-brachialis, in which case it may pass either behind that muscle, or between the coraco-brachialis and the short head of the biceps. The nerve has also been seen perforating the short head of the biceps, or the brachialis anticus, as well as the coraco-brachialis.

In rare cases a branch is given to the pronator teres muscle. The terminal portion of the nerve is not unfrequently continued on the back of the hand to the skin over the first metacarpal bone and the adjoining interosseous space. Hepburn found the musculo-cutaneous supplying the back of the thumb in a case in which the radial nerve was wanting; and H. Virchow and Th. Kölliker describe a case in which it gave the dorsal digital nerves to both sides of the ring and the radial side of the little fingers.

SUMMARY.—The musculo-cutaneous nerve supplies the biceps and brachialis anticus muscles, the integument on the outer side of the forearm, the humerus, and the elbow and wrist-joints. Communications are established between it and the radial and the lower external cutaneous branch of the musculo-spiral.

Ulnar nerve.—The ulnar nerve, the largest branch of the inner cord of the brachial plexus, receives its fibres from the last cervical and first dorsal nerves. From its origin, where it is placed between the axillary artery and vein, it descends on the inner side of the main artery of the limb as far as the middle of the arm, and thence with the inferior profunda artery along the back of the internal intermuscular septum, being often lodged in a groove in the substance of the inner head of the triceps muscle, to the interval between the olecranon and the inner condyle of the humerus. In the arm it is covered only by the fascia, and it may be felt through the integument a little above the elbow. It next passes between the two heads of the flexor carpi ulnaris muscle, under cover of which it is continued with a straight course as far as the wrist, resting on the flexor profundus digitorum. The nerve meets the ulnar vessels somewhat above the middle of the forearm, and from this point it remains in contact with them on their inner side. Above the wrist it gives off a large dorsal branch to the hand, and the trunk then runs over the front of the annular ligament, being placed between the ulnar artery and the pisiform bone, to terminate as it enters the palm by dividing into superficial and deep parts.

The ulnar nerve usually gives off no branches in the upper arm.

A. *Branches in the forearm.*

(a) *Articular filaments* are given to the elbow-joint as the nerve passes behind it.

(b) *Muscular branches* (8 c, 1 d) arise from the nerve near the elbow, and pass to the flexor carpi ulnaris and the inner half of the flexor profundus digitorum muscles.

(c) *Cutaneous branches.*—These two small nerves arise about the middle of the forearm by a common trunk. One pierces the fascia, and turning downwards, joins a branch of the internal cutaneous nerve: this branch is often absent. The second, a *palmar branch*, lies on the ulnar artery, which it accompanies to the hand. This little nerve gives filaments around the vessel, and ramifies in the integument of the

inner part of the palm, joining in some cases with other cutaneous offsets of the ulnar or median nerve.

(d) *Dorsal branch to the hand.*—This large offset (8 c), leaving the trunk of the ulnar nerve two or three inches above the wrist, winds backwards beneath the flexor carpi ulnaris, gives a twig over the back of the wrist which usually joins in a loop with an offset of the radial nerve, and then divides into branches: one of these ramifies on the inner side of the little finger; another divides to supply the contiguous sides of that finger and the ring finger; a third supplies in part the contiguous sides of the ring and middle fingers, and usually communicates with the branch of the radial passing to the same interspace; while a fourth is distributed to the skin of the metacarpal region of the hand, often extending to the base of the index finger (fig. 201 A). The dorsal digital branches on the little finger reach as far as the nail; on the ring finger they do not usually reach beyond the second phalanx. On the sides of the fingers they form communications with the corresponding volar digital nerves.

B. *Branches in the palm.*

(a) The *superficial part* of the ulnar nerve (1 d, or 8 c, 1 d) supplies filaments to the palmaris brevis muscle and the integument of the hypothenar eminence, and divides into two *digital branches*. One of these passes to the ulnar side of the little finger; the other is connected in the palm of the hand with the innermost digital branch of the median nerve, and at the cleft between the little and ring fingers, divides into the collateral nerves for these fingers. From the communicating branch with the median nerve filaments are sent to the skin and vessels of the palm. The terminal disposition of the digital branches on the fingers is the same as that of the median nerve, to be presently described.

(b) The *deep part* (8 c) sinks backwards with the deep branch of the ulnar artery between the abductor and flexor brevis minimi digiti muscles, and passing to the inner side of and below the hook of the unciform bone (which it sometimes grooves¹), through the cleft in the opponens minimi digiti muscle (Vol. II, p. 238), follows the course of the deep palmar arch across the hand. It supplies the short muscles of the little finger as it passes between them; as it lies over the metacarpal bones it distributes branches to the interosseous muscles and the inner two lumbricales; and at the outer side of the palm it terminates in offsets to the adductores pollicis and the abductor indicis muscles. *Articular filaments* pass upwards to the wrist, and others descend to the metacarpo-phalangeal articulations (Rüdinger). Rauber also describes small *perforating branches*, which accompany the superior perforating arteries in the interosseous spaces, and join the terminal filaments of the posterior interosseous nerve.

Varieties.—The ulnar nerve not unfrequently has an additional root from the seventh cervical nerve. It is rarely derived wholly from the eighth nerve, or from the seventh and eighth cervical. In a few instances the nerve has been seen descending in front of the inner condyle instead of behind. Cases are also recorded in which the ulnar nerve slipped forwards over the internal condyle when the elbow was bent. A branch may pass from the ulnar nerve in the arm to reinforce the internal cutaneous (p. 295). A communication between the ulnar and median nerves in the arm was seen by Villar, and also a communication with the musculo-spiral (Bull. Soc. Anat. Paris, 1888, 613). A branch from the median to join the ulnar in the forearm is of frequent occurrence (p. 302). When the occasional epitrochleo-anconeus muscle (Vol. II, p. 225) is present, it receives a branch from the ulnar nerve. Filaments of the ulnar nerve have been found passing to the inner part of the triceps, or to the flexor sublimis digitorum, and from the deep part to the second (H. St. John Brooks, Testut), or to the first lumbricalis (J. T. Wilson), or to the outer head of the flexor brevis pollicis (normal according to Swan and Brooks). The dorsal branch may be smaller than

¹ W. Anderson, "A Note on the Course and Relations of the Deep Branch of the Ulnar Nerve," Proc. Anat. Soc., Feb. 6, 1894.

usual, or even absent, in which case the deficiency is generally compensated by the radial nerve (p. 306), in rare cases by the lower external cutaneous of the musculo-spiral (p. 304), or by the internal cutaneous (p. 296). Its area of digital distribution is seldom increased, but it was found by Hepburn supplying all four fingers in a case of absence of the radial nerve. Its filaments often reach to the radial side of the second metacarpal bone, and in one instance they were followed by Zander to the back of the first phalanx of the thumb.

SUMMARY.—The ulnar nerve gives cutaneous filaments to the lower part of the forearm (to a small extent), and to the inner part of the hand on its palmar and dorsal aspects. It supplies the following muscles, viz., the ulnar flexor of the carpus, the deep flexor of the fingers (its inner half), the short muscles of the little finger with the palmaris brevis, the interosseous muscles of the hand, the inner two lumbricales, and the adductores pollicis. Lastly, it contributes to the nervous supply of the joints of the elbow, wrist, and hand.

Median nerve.—The median nerve, composed of fibres proceeding from the lower three cervical and the first dorsal nerves, arises by two roots or heads, one from the outer, the other from the inner cord of the brachial plexus. Commencing by the union of these roots in front or on the outer side of the axillary artery, the nerve descends in contact with the brachial artery, lying on its antero-lateral aspect as far as the middle of the arm, then gradually passes inwards over it, and near the elbow gains the inner side of the vessel. Sinking into the hollow at the bend of the elbow, the nerve passes beneath the superficial portion of the pronator teres, but over the deep slip of that muscle, by which it is separated from the ulnar artery, and continues straight down the front of the forearm between the flexor sublimis and flexor profundus digitorum muscles. Arrived near the wrist it lies beneath the fascia, between the tendons of the flexor sublimis and palmaris longus internally and that of the flexor carpi radialis externally. It then enters the palm behind the annular ligament, and rests on the flexor tendons. Somewhat enlarged, and of a slightly reddish colour, it here separates into two parts of nearly equal size. One of these (the external) supplies some of the short muscles of the thumb, and gives digital branches to the thumb and the index finger; the second portion supplies the middle finger, and in part the index and ring fingers.

The median nerve usually gives no branch in the upper arm.

A. *Branches in the forearm.*

(a) *Articular branches.*—These are one or two filaments to the front of the elbow-joint (Rüdinger).

(b) *Muscular branches* arise either together or separately in the neighbourhood of the elbow and pass to the pronator teres (6 c), flexor carpi radialis (6 c), palmaris longus and the condylo-ulnar head of the flexor sublimis digitorum (7, 8 c, 1 d). A separate offset enters the radial head of the flexor sublimis, and a third branch supplying the index finger belly of the same muscle is given off by the trunk at a lower level in the forearm.

(c) *Anterior interosseous nerve* (7, 8 c, 1 d or 8 c, 1 d).—This is the longest branch of the median nerve, and it supplies the deeper muscles of the front of the forearm. Leaving the main trunk a little below the elbow, it runs downwards with the artery of the same name on the interosseous membrane to the deep surface of the pronator quadratus muscle, in which it ends. It distributes branches to the flexor longus pollicis and the outer half of the flexor profundus digitorum, between which it lies; a slender branch is given off to the interosseous membrane, along or in which it descends, dividing into two, and supplying filaments to the membrane, to the anterior interosseous vessels, to the shafts of the radius and ulna with the medullary arteries, and to the periosteum; and from the lower end of the nerve a twig is continued to the front of the wrist-joint. Small Pacinian bodies are found on the branches passing to the bone and periosteum (Raubert).

(d) The *palmar cutaneous branch* arises a variable distance above the wrist, and pierces the fascia of the forearm between the tendons of the flexor carpi radialis and palmaris longus, close to the annular ligament, to terminate in the integument of the palm, where it communicates with the palmar cutaneous branch of the ulnar nerve. Some filaments are distributed over the thenar eminence, and form communications with twigs of the radial or external cutaneous nerve.

B. *Branches in the hand.*

(a) *Branch to muscles of the thumb.*—This short nerve (6 c), arching outwards immediately below the annular ligament, subdivides into branches for the abductor, the opponens, and the outer head of the flexor brevis pollicis muscles.

(b) *Digital nerves.*—These are five in number, and belong to the thumb, and the fingers as far as the outer side of the ring-finger. They lie at first beneath the superficial palmar arch and its digital branches, but as they approach the clefts between the fingers, they are close to the integument in the intervals between the longitudinal divisions of the palmar fascia, and on the fingers the nerves lie in front of the vessels.

The *first* and *second nerves* lie along the sides of the thumb; and the former (the outer one) is connected with the radial nerve over the border of the thumb.

The *third*, destined for the radial side of the index finger, gives a branch to the first or most external lumbricalis muscle.

The *fourth* supplies the second lumbricalis, and divides into collateral branches for the adjacent sides of the index and middle fingers.

The *fifth*, the most internal of the digital nerves, is connected by a cross branch with the ulnar nerve, and divides to supply the adjacent sides of the ring and middle fingers. It often gives a branch to the third lumbricalis, which then has a double supply.

Each digital nerve divides at the end of the finger into two branches, one of which supplies the ball on the fore part of the finger, while the other ramifies in the pulp beneath the nail. Branches pass from each nerve forwards and backwards to the integument of the finger; those passing backwards join the dorsal collateral nerve, and supply mainly the integument over the second and third phalanges of the middle three digits. Filaments are also furnished to the articulations of the fingers. The volar digital branches of the median and ulnar nerves are beset with numerous Pacinian corpuscles both in the palm and on the fingers: the number of these bodies varies from 60 to 100 in each digit.

Varieties.—Occasionally the median nerve does not receive any fibres from the first dorsal nerve.

Either of the heads of the nerve may be double. The level at which the two heads join is very variable: they have been found separate to the middle of the arm, and in one case nearly as far as the elbow (Testut). Calori saw the two heads embracing the axillary vein as well as the artery. The inner head may cross behind, instead of in front of, the axillary artery. The whole nerve is often found passing behind the brachial artery (Vol. II, p. 441). The outer head has been seen by Turner passing behind the axillary artery, so that the trunk of the nerve lay altogether to the inner side of the brachial artery; and in another case recorded by the same anatomist the outer head separated from the musculo-cutaneous in the middle of the arm and crossed behind the brachial artery to join the inner head. Gruber and Walsh have described cases in which the nerve entered the forearm over the pronator teres muscle. It has also been seen running down the forearm superficial to the flexor sublimis digitorum (G. D. T.). The nerve has been found split for a certain distance in the forearm, the cleft giving passage to the ulnar artery (Testut) or a branch of that vessel (Mauclaire), or to the superficial long head of the flexor longus pollicis (Davies-Colley, Taylor and Dalton, J. W. Williams), or to a supernumerary long palmar muscle (Reid and Taylor).

The frequent communication between the median and musculo-cutaneous nerves in the arm has already been referred to (p. 299). One instance is recorded of a connection between the median and ulnar nerves in the arm (p. 300). A communication between these nerves in the upper part of the forearm is present in the proportion of one in four or five limbs, usually

in the form of a branch leaving the median in common either with the muscular offsets at the elbow or with the anterior interosseous nerve, and passing with or near the ulnar artery to join the ulnar nerve about the middle of the forearm: less frequently the connection is by means of a loop or small plexus, from which twigs are given off to the flexor profundus digitorum muscle: this communication between the median and ulnar nerves in the upper part of the forearm is normal in most apes (Hepburn, Höfer), and in lower mammals (Bardeleben). A communication in the lower part of the forearm is rare. In two cases a branch was seen passing from the median nerve at the elbow, over the superficial muscles, to join the ulnar (T. J. Jeans). Very seldom a branch runs from the ulnar to the median trunk or to its anterior interosseous branch. The communicating branch between the median and ulnar nerves in the palm is commonly directed from the ulnar to the median, but it may run in the opposite direction, or the communication may be looped or plexiform in arrangement. Absence of the communication has been noted. In two cases described by Klint the anterior interosseous nerve received a branch from the musculo-spiral (posterior interosseous?) through the interosseous membrane. A communication between the anterior and posterior interosseous nerves at the lower end of the interosseous space is noticed by Martin and Rauber. (F. Curtis, "Recherches anatomiques sur l'anastomose du Médian et du Cubital à l'avant-bras," Internat. Monatschr. f. Anat. u. Hist., iii, 1886; Third Annual Report of Committee of Collective Investigation of the Anat. Soc., by Arthur Thomson, Journ. Anat., xxvii, 1892.)

The digital nerves in the palm are often pierced by the corresponding arteries. Four cases are recorded by Gruber in which the nerve supplying the adjacent sides of the middle and ring fingers arose from the trunk in the forearm. A branch from the median nerve to the abductor indicis muscle was observed by Brooks.

SUMMARY.—The median nerve gives cutaneous branches to the palm, and to three and a half fingers. It supplies the pronator muscles, the flexors of the carpus and the long flexors of the fingers (except the ulnar flexor of the carpus, and part of the deep flexor of the fingers), likewise the outer set of the short muscles of the thumb, and two lumbricales. Articular filaments are also given to the joints of the elbow, wrist, and fingers.

A great similarity will be observed in the distribution of the median and ulnar nerves. Neither gives any offset in the arm. Together they supply all the muscles of the front of the forearm and in the hand, and together they supply the skin of the palmar surface of the hand, and impart tactile sensibility to all the fingers.

Musculo-spiral nerve.—The musculo-spiral nerve (*n. radialis* of French and German writers), the largest offset from the brachial plexus, is derived from the sixth, seventh, and eighth cervical nerves, in some cases also from the fifth. It occupies chiefly the back part of the limb, and supplies nerves to the extensor muscles, as well as to the skin.

Arising behind the axillary vessels from the posterior cord of the brachial plexus, of which it is the principal continuation and the only branch prolonged into the arm, it soon turns backwards with the superior profunda artery between the long and internal heads of the triceps, and runs beneath the external head of that muscle, in the hinder part of the spiral groove of the humerus, to the outer side of the arm. It then pierces the external intermuscular septum, and descends in the interval between the supinator longus and brachialis anticus muscles nearly to the level of the outer condyle of the humerus, where it ends by dividing into the *radial* and *posterior interosseous nerves*. Of these, the radial is altogether a cutaneous nerve, while the posterior interosseous is the muscular nerve of the back of the forearm.

The branches of the musculo-spiral nerve may be classified according as they arise from the inner side of the humerus, behind that bone, or on the outer side.

A. Internal branches.

(a) *Muscular branches* for the long and inner heads of the triceps (7, 8 c). That for the inner head gives two or three filaments to the upper part of the muscle, and then descends by the side of the ulnar nerve, to which it is often closely adherent for a part of its course, and enters the lower short fibres of the head. This long filament is named by Krause the *ulnar collateral branch*.

(b) The *internal cutaneous branch* of the musculo-spiral nerve (*n. cutaneus brachii posterior*) (8 c), often united in origin with the preceding, winds backwards beneath the intercosto-humeral nerve, and extends, supplying filaments to the skin over the long head of the triceps, nearly as far as the olecranon. This nerve is accompanied by a small cutaneous artery.

B. *Posterior branches.*

These consist of a fasciculus of *muscular branches* (7, 8 c) which supply the outer and inner heads of the triceps muscle and the anconeus. The *branch of the anconeus* is slender, and remarkable for its length; it descends in the substance of the inner head of the triceps to reach its destination.

C. *External branches.*

(a) The *external cutaneous branches*, two in number, arise before the nerve pierces the external intermuscular septum, and become superficial just below the middle of the arm, between the outer head of the triceps and the brachialis anticus muscles.

The *upper branch* (6 c), the smaller of the two, is directed downwards to the fore part of the elbow, along the cephalic vein, and distributes filaments to the lower half of the arm on its outer and anterior aspect. The *lower branch* (*n. cutaneus antibrachii dorsalis*) (6 c, or 6, 7 c, or 7 c, or 7, 8 c) descends in the interval between the external condyle and the olecranon, and reaches as far as the wrist, distributing its offsets to the lower half of the arm, and to the forearm, on their posterior aspect. It is connected near the wrist with a branch of the external cutaneous nerve, and often with the dorsal branch of the ulnar nerve. In some cases this branch is prolonged to the back of the hand (fig. 201, A).

(b) *Muscular branches* are furnished to the supinator longus (6 c), extensor carpi radialis longior (6, 7 c) (the extensor carpi radialis brevior usually receiving its nerve from the posterior interosseous), and frequently a small twig to the outer part of the brachialis anticus (6 c), as the nerve lies between those muscles. Together with these branches *articular filaments* are given to the outer part of the elbow-joint.

According to Rauber a branch of the musculo-spiral nerve is given regularly to the periosteum on the back of the humerus; and in some cases it also furnishes the nerve to the shaft of that bone, when the principal medullary artery is derived from the superior profunda. Filaments are described as passing to the elbow-joint also from the ulnar collateral nerve, and from the branch to the anconeus.

Varieties.—The musculo-spiral nerve has been seen passing backwards through the quadrilateral space between the teres muscles with the circumflex nerve (Guy's Hosp. Rep., xlv). A communication with the ulnar nerve in the arm is recorded by Villar (p. 300). The lower external cutaneous branch was traced by Brooks in one case to the first phalanx of the ring and the second phalanx of the little fingers; and it has been observed furnishing the dorsal digital nerves of the little and the ulnar half of the ring fingers in the place of the ulnar nerve (Gruber, Gegenbaur).

Radial nerve.—The radial nerve (*ramus superficialis n. radialis*) receives its fibres from the sixth cervical nerve, sometimes also the fifth or seventh. Continuing straight down from the musculo-spiral nerve, it lies a little to the outer side of the radial artery along the anterior border of the extensor radialis brevior, under cover of the supinator longus, and resting on the supinator brevis, the insertion of the pronator teres, and the radius. About three inches above the wrist the nerve turns backwards beneath the tendon of the supinator longus and becomes subcutaneous. It then divides into two branches, which ramify on the back of the hand in the following manner:—

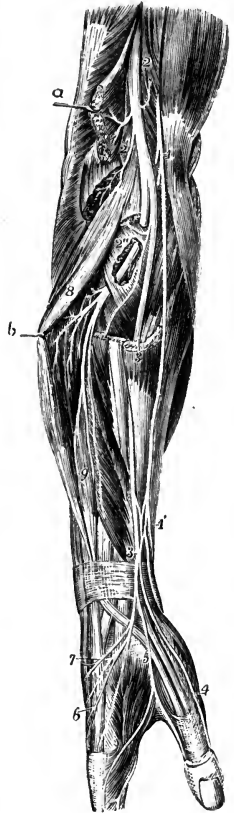
(a) The external portion passes to the radial side of the thumb, and is joined by an offset of the external cutaneous nerve. It distributes filaments over the thenar eminence.

(b) The internal portion communicates with the posterior branch of the musculo-cutaneous nerve in the forearm, sends an offset to the back of the wrist, which usually joins in an arch with the dorsal branch of the ulnar nerve, and then divides into four branches for the thumb and the outer two fingers. One

Fig. 290.—VIEW OF THE RADIAL SIDE OF THE FOREARM, SHOWING THE FINAL DISTRIBUTION OF THE MUSCULO-SPIRAL NERVE. (Hirschfeld and Leveillé.) †

The supinator longus and the radial extensors have been divided, and their upper parts removed; the extensor communis digitorum is pulled backwards, and the supinator brevis has been partially dissected to show the posterior interosseous nerve passing through it.

1, on the tendon of the biceps muscle, the musculo-cutaneous nerve; 1', near the wrist, the lower part of this nerve and its plexus of union with the radial nerve; 2, trunk of the musculo-spiral nerve in the interval between the brachialis anticus, on which the number is placed, and the supinator longus muscles; 2', its muscular twigs to the long supinator and long radial extensor; 2'', the posterior interosseous nerve passing through the substance of the supinator brevis; 3, placed upon the cut lower portion of the supinator longus, and lower down, the radial nerve; 4, the external digital nerve of the thumb; 5, digital nerves of the forefinger and thumb arising in common; 6, the same of the fore and middle fingers; 7, twig of union with the dorsal branch of the ulnar nerve; 8, placed upon the common extensor of the fingers, the muscular branches of the posterior interosseous nerve to the long extensor muscles; 9, upon the extensor longus pollicis, the branches to the short extensor muscles.



of these supplies the ulnar side of the thumb, the second passes to the radial side of the index finger, the third divides for the adjacent sides of the index and middle fingers, and the fourth is directed to the interspace between the middle and ring fingers. In their course these branches supply twigs to the skin of the outer part of the back of the hand; and the innermost one crosses, and usually communicates with the outer branches of the dorsal ulnar nerve.

The distance to which the branches of the radial nerve extend varies in the several digits. On the thumb they reach to the nail, on the index finger to the second phalanx, and on the middle finger only to the first phalanx, while from the innermost branch filaments pass to the root of the ring finger.

From the dorsal digital nerves twigs are said to be given to the carpo-metacarpal, metacarpophalangeal, and first interphalangeal articulations; and according to Hédon filaments pass forwards through the interosseous spaces to the skin of the palm. Lejars describes an offset from the outer division of the radial nerve to the abductor pollicis muscle (Bull. Soc. Anat. Paris, 1890, 433)

Varieties.—The area of distribution of the radial and ulnar nerves, and the degree to which they overlap on the back of the hand, as well as the extent of the dorsal nerves on the three middle fingers, are subject to much variability. From observations in man and mammals Hédon and Zander conclude that the primitive arrangement is that in which the radial nerve supplies three and a half digits and the ulnar one and a half, all the digital branches extending to the nail. The reduction of the dorsal nerves on the three middle fingers appears to be an arrangement peculiar to man, in whom however the nerves are not unfrequently continued to the nail in the index and ring fingers, but very rarely in the middle finger. (H. St. John Brooks, "On the distribution of the cutaneous nerves on the dorsum of the human hand." Internat. Monatschr. f. Anat. u. Phys., v, 1888; E. Hédon, "Étude critique sur l'innervation de la face dorsale de la main." Internat. Monatschr. f. Anat. u. Phys., vi, 1889; R. Zander, "Ueber die sensibeln Nerven auf der Rückenfläche der Hand bei Säugetieren und beim Menschen," Anat. Anz., iv, 1889.)

Occasionally the radial nerve supplies the whole of the back of the hand and fingers. Its outer division often gives a branch to the palm. Absence of the radial nerve was met with by Heppburn, the musculo-cutaneous supplying the thumb, and the ulnar nerve all the four fingers (Journ. Anat., xxi, 511).

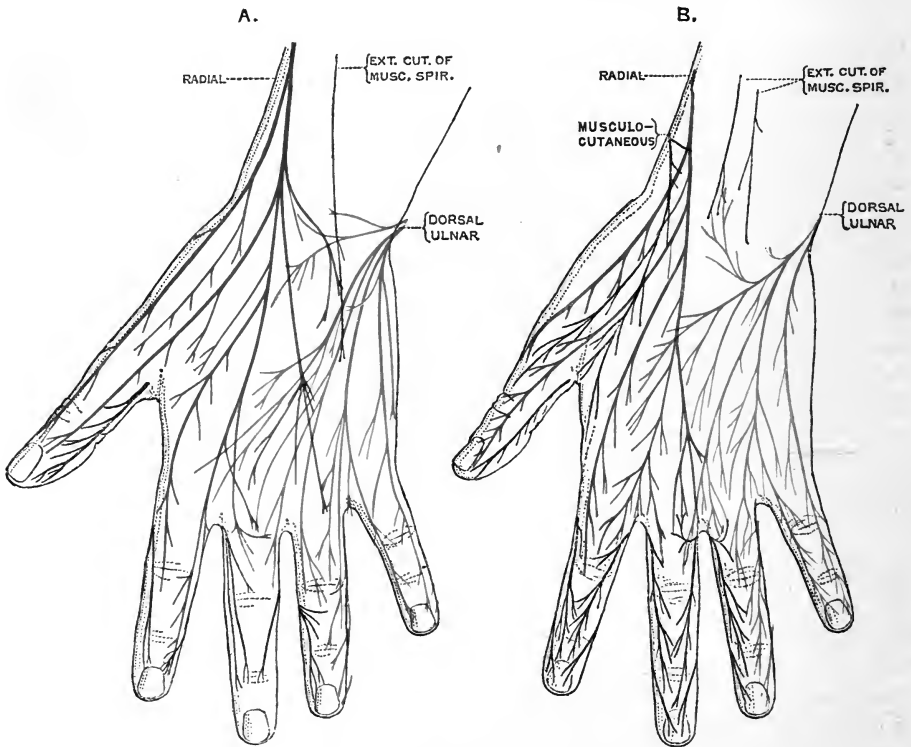


Fig. 201.—DORSAL CUTANEOUS NERVES OF THE HAND. (A, after Brooks ; B, after Hédon.)

The radial nerve is shown in blue, the branches of the ulnar in red, offsets of the musculo-cutaneous, musculo-spiral and median in black. The two figures illustrate variations in the cutaneous supply. In A, the radial and ulnar nerves overlap to a considerable extent, and the lower external cutaneous of the musculo-spiral extends to the back of the hand. In B, the overlapping of the radial and ulnar nerves is slight, and the musculo-cutaneous is prolonged independently to the hand.

Posterior interosseous nerve.—This nerve (*r. profundus n. radialis*), the larger of the two divisions of the musculo-spiral, is composed of fibres derived from the sixth and seventh, sometimes also the eighth, cervical nerves. It winds to the back of the forearm round the outer side of the radius, traversing the cleft in the supinator brevis muscle, and is prolonged between the deep and superficial layers of the extensor muscles to somewhat below the middle of the forearm, where it sinks beneath the long extensor of the thumb, and reaches the lower part of the interosseous membrane.

Much diminished in size by the separation of numerous branches for the muscles, the nerve lies at the back of the wrist beneath the tendons of the extensor indicis and the common extensor of the fingers, and forms here a small enlargement, from which filaments are given to the adjoining ligaments and articulations.

Branches.—(a) *Muscular branches.*—Before the nerve passes to the back of the forearm it gives offsets to the extensor carpi radialis brevis (6, 7 c) and the supinator brevis (6 c) muscles. After perforating the supinator brevis, it supplies branches (7 c)

to the extensor communis digitorum, extensor minimi digiti, extensor carpi ulnaris, the three extensors of the thumb, and the extensor indicis.

(b) *Articular branches*.—From the terminal enlargement of the nerve fine twigs proceed to the articulations of the wrist, and, according to Rüdinger and Rauber, other filaments descend on the back of the hand to the metacarpo-phalangeal articulations.

Varieties.—The posterior interosseous nerve may pass over, instead of perforating, the supinator brevis muscle (Luschka, Krause). A branch to the anconeus muscle is described by the same anatomists. There may be a communication between the anterior and posterior interosseous nerves at the lower part of the interosseous space (p. 303). In two cases, recorded by Turner and Schwalbe, the posterior interosseous nerve passed down to supply the adjacent sides of the index and middle fingers; a similar condition has been found in the chimpanzee, orang and gibbon (Westling, Hepburn, Höfer).

SUMMARY.—The musculo-spiral nerve supplies the extensor muscles of the elbow-joint, and frequently sends a filament to the brachialis anticus, which, however, receives its principal supply from another source. Before separating into its two large divisions, the nerve gives branches to two muscles of the forearm, viz., the long supinator, and the long radial extensor of the carpus. The posterior interosseous division distributes nerves to the remaining muscles on the outer and back part of the forearm, except the anconeus (previously supplied), viz., to the short supinator and the extensors.

Cutaneous nerves are distributed, from the trunk of the nerve and its radial division, to the upper arm, to the forearm, and to the hand—on the posterior and outer aspect of each. Articular branches are furnished to the elbow, wrist, metacarpo-phalangeal, and first interphalangeal joints.

DORSAL NERVES.

The anterior divisions of the twelve dorsal or thoracic nerves are distributed almost entirely to the walls of the thorax and abdomen. The exceptions are the first, the greater part of which joins the brachial plexus, and the second and twelfth, which send cutaneous offsets to the arm and hip respectively. Close to the intervertebral foramina, these nerves are connected to the gangliated cord of the sympathetic by very short communicating branches; they are then directed transversely outwards to their destination without forming any plexus, and in this respect they differ from the anterior primary divisions of the other spinal nerves. The smaller part of the first, and the trunks of the succeeding ten nerves pass forwards in the intercostal spaces, and are thence termed *intercostal nerves*. Of these, the upper six are confined to the parietes of the thorax, while the lower five are continued anteriorly from the intercostal spaces into the wall of the abdomen. The twelfth nerve, sometimes distinguished as the *subcostal nerve*, is placed below the last rib, and is therefore contained altogether in the abdominal wall.

FIRST DORSAL NERVE.

The anterior division of the first dorsal nerve divides into two parts, the larger of which ascends over the neck of the first rib to enter into the brachial plexus. The remaining portion of the nerve is continued as the *first intercostal*, a small branch which lies at first under cover of the first rib, and then courses along the first intercostal space, in the manner of the other intercostal nerves, but has usually no lateral cutaneous branch, and may also want the anterior cutaneous.

Variety.—The first dorsal nerve frequently receives a connecting twig which passes upwards in front of the neck of the second rib from the second nerve. This branch was found by Cunningham in twenty-seven out of thirty-seven dissections; it was of variable size, but

generally very small, and it sometimes joined only one, in other cases both, of the divisions of the first nerve (Journ. Anat., xi, 539).

UPPER OR PECTORAL INTERCOSTAL NERVES.

In their course to the fore part of the chest, these nerves accompany the intercostal blood-vessels. From the intervertebral foramina they are directed outwards in front of the superior costo-transverse ligaments, the levatores costarum and the external intercostal muscles, being covered anteriorly, as far as the angles of the ribs, only by the pleura and the thin layer of connective tissue known as the endothoracic fascia. Gaining the upper part of the corresponding intercostal spaces, where they are placed below the intercostal vessels, the nerves next run between the external and internal intercostal muscles, and soon give off the large lateral cutaneous branches,

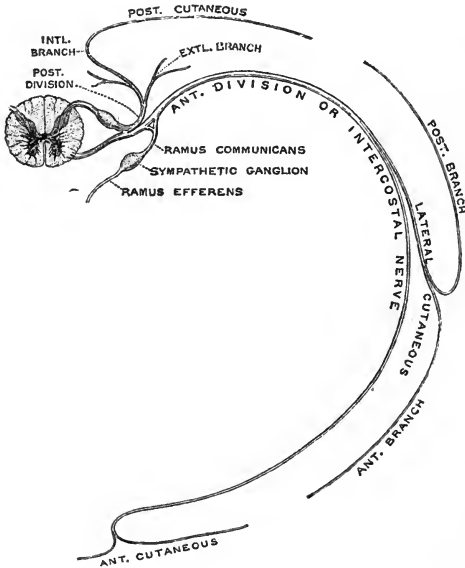


Fig. 202.—PLAN OF AN UPPER DORSAL NERVE.
(G. D. T.)

which accompany the prolongations of the trunks for a short distance, and then bend outwards through the external intercostal muscles about midway between the spine and the sternum. The nerves themselves, much reduced in size, are now continued forwards amid the fibres of the internal intercostal muscles as far as the costal cartilages, where they again come into close relation with the pleura. In approaching the sternum they cross in front of the internal mammary vessels and the triangularis sterni; and finally they pierce the internal intercostal muscles and the greater pectoral, to end in the integument of the breast, receiving the name of the *anterior cutaneous nerves of the thorax*.

BRANCHES.—**Muscular branches** are furnished by the intercostal nerves in the first part of their course to the levatores costarum, and, from the upper four nerves, to the serratus posticus superior. Several twigs enter the intercostal muscles with which the nerves are in relation. At the fore part of the chest the triangularis sterni is supplied by offsets of these nerves from the second or third to the sixth; and from the fifth and sixth nerves branches pass to the upper end of the rectus abdominis.

Minute **subcostal branches** perforate the internal intercostal muscles to reach the inner surface of the ribs, where they are distributed to the periosteum and bone, as well as probably to the costal pleura (Testut); and, according to Luschka, fine **sternal twigs** are given off at the anterior ends of the intercostal spaces to the back of the sternum.

The **lateral cutaneous nerves of the thorax** pierce the external intercostal and serratus magnus muscles, in a line a little behind the pectoral border of the axilla. The first intercostal usually gives no lateral branch, or only a slender twig to the axilla, but when that of the second nerve is unusually small, it may be supplemented by a branch of the first. The branch from the second intercostal is named *intercosto-humeral*, and requires separate description. Each of the remaining latera

cutaneous nerves divides into two branches, which reach the integument at a short distance from each other, and are named *anterior* and *posterior*.

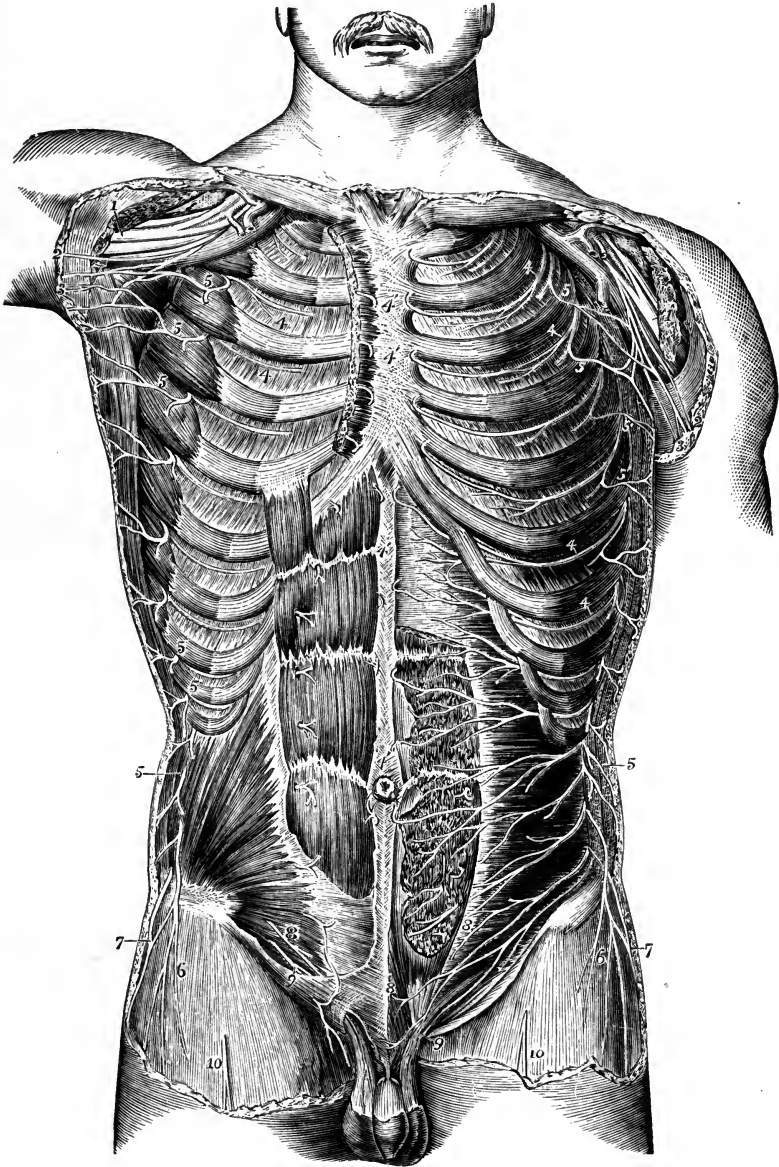


Fig. 203.—VIEW OF THE ANTERIOR DIVISIONS OF THE DORSAL AND SOME OF THE OTHER SPINAL NERVES FROM BEFORE. (Hirschfeld and Leveillé.) $\frac{1}{4}$

The pectoralis major and minor muscles have been removed; on the right side the rectus abdominis and internal oblique muscles are shown; on the left side the anterior part of the rectus is cut away, and the transversalis is exposed.

1, median and other nerves of the brachial plexus; 2, nerve of Wrisberg; 3, intercosto-humeral; 4, intercostal nerves continued forwards to 4', their anterior cutaneous twigs; 5, lateral cutaneous branches of these nerves; 6, lateral cutaneous branch of the last dorsal nerve; 7, iliac branch of the ilio-hypogastric nerve; 8, hypogastric branch of the same; 9, ilio-inguinal; 10, middle cutaneous of the thigh.

The *anterior branches* are continued forwards over the border of the great pectoral muscle. In the female their terminal ramifications supply the skin over the mamma, and some filaments enter the substance of the gland. From the lowest two nerves twigs are supplied to the upper digitations of the external oblique muscle of the abdomen.

The *posterior branches* turn backwards to the integument over the scapula and the latissimus dorsi muscle. The branch from the third nerve ramifies in the axilla, and a few filaments often reach the arm.

The *intercosto-humeral nerve* (*n. intercosto-brachialis*), the lateral cutaneous branch of the second intercostal nerve, corresponds with the posterior of the two divisions of the succeeding lateral cutaneous branches, the anterior being commonly wanting. It crosses the axillary space to reach the arm, and is connected in the axilla with an offset of the nerve of Wrisberg (p. 296). Penetrating the fascia, it becomes subcutaneous, and ramifies in the integument of the upper half of the arm on the inner and posterior aspect; a few filaments reach the integument over the scapula. The branches of this nerve cross over the internal cutaneous offset of the musculo-spiral, and a communication is established between the two nerves. The size of the intercosto-humeral nerve, and the extent of its distribution, are in inverse proportion to the size of the other cutaneous nerves of the upper arm, especially the nerve of Wrisberg.

The **anterior cutaneous nerves of the thorax**, which are the terminal twigs of the intercostal nerves, are reflected outwards in the integument over the great pectoral muscle. One or two of the upper branches may be connected with the supraclavicular nerves. In the female, those from the second, third, and fourth nerves are distributed over the mammary gland.

Varieties.—At the hinder part or side of the chest some of the adjacent intercostal nerves are occasionally connected by filaments which cross the inner surfaces of the ribs, passing from one intercostal space to join the nerve in the interval next below. A twig from the second intercostal nerve to the pectoralis major has been described by Swan and M. Flesch; one to the pectoralis minor by Brooks.

LOWER OR ABDOMINAL INTERCOSTAL NERVES.

The lower intercostal nerves in the first part of their course have relations like those of the upper nerves already described. Lying between the external and internal intercostal muscles, they give off the lateral cutaneous branches, and at the fore part of the intercostal spaces they penetrate the internal intercostal muscles. They then pass between the slips of origin of the diaphragm, the seventh, eighth, and ninth nerves each crossing behind the cartilage of the rib below, and enter the abdominal wall. Here they are continued between the internal oblique and transversalis muscles as far as the outer edge of the rectus, diverging from one another as they pass inwards, in consequence of the increasing obliquity of the lower nerves. Finally, perforating the posterior layer of the sheath of the rectus, they turn forwards through the substance of that muscle and the anterior layer of its sheath to end in small cutaneous branches (*anterior cutaneous nerves*). While between the abdominal muscles the lower three or four nerves are united by loops of communication, and sometimes form a small plexus.

BRANCHES.—**Muscular branches** are given to the levatores costarum, to the serratus posticus inferior (from the ninth, tenth, and eleventh nerves), to the subcostal and intercostal muscles, and to the abdominal muscles with which the nerves are in contact. Filaments are also described as passing from these nerves to the costal portion of the diaphragm (Baur, Swan, Luschka).

The **lateral cutaneous nerves of the abdomen** pass to the integument through the external intercostal and external oblique muscles, in a line with the corresponding

nerves on the thorax, and divide in the same manner into anterior and posterior branches.

The *anterior branches* are the larger. They supply the digitations of the external oblique muscle, and are then directed inwards, the lower nerves also inclining downwards, in the superficial fascia, with small cutaneous arteries, nearly to the edge of the rectus muscle.

The *posterior branches* bend backwards over the latissimus dorsi.

The **anterior cutaneous nerves of the abdomen** are uncertain in number and position. There are generally two or three twigs from each nerve, and some of them perforate the rectus near its outer border, but the greater number issue near the linea alba. The branches of the seventh nerve emerge near the lower end of the ensiform process, and those of the tenth usually supply the skin about the umbilicus.

LAST DORSAL NERVE.

The anterior primary division of the last dorsal nerve is directed outwards in company with the abdominal branch of the first lumbar artery along the lower border of the twelfth rib. It passes beneath the external arched ligament of the diaphragm, across the front of the quadratus lumborum, and at the outer border of the latter muscle it perforates the posterior aponeurosis of the transversalis (middle layer of the lumbar fascia), to follow a course similar to that of the lower intercostal nerves in the abdominal wall. It is usually connected near its origin with the first lumbar nerve by means of a small cord, which descends on or through the substance of the quadratus lumborum muscle. It supplies branches to the quadratus lumborum (frequently), internal oblique, transversalis, rectus, and pyramidalis muscles, as well as lateral and anterior cutaneous branches; and it sometimes communicates in the abdominal wall with the ilio-hypogastric nerve. Its anterior cutaneous twigs are distributed below a point midway between the umbilicus and pubis.

The **lateral cutaneous branch** of the last dorsal nerve is usually of considerable size. It pierces the internal oblique muscle, gives a branch to the lowest slip of the external oblique, and then emerging through the latter muscle a variable distance (from one to three inches) above the iliac crest, is directed downwards to the integument of the fore part of the gluteal region, some filaments reaching as far as the great trochanter.

Varieties.—In some cases the lateral cutaneous branch of the last dorsal nerve is small, and is distributed entirely to the skin above the iliac crest, its place over the hip being taken by the iliac branch of the ilio-hypogastric nerve. Complete absence of this branch was observed by M. Griffin four times in fifty cases ("Some Varieties of the Last Dorsal and First Lumbar Nerves," *Journ. Anat.*, xxvi, 1891).

LUMBAR NERVES.

The anterior divisions of the lumbar nerves increase in size from the first to the fifth. The upper three and the greater part of the fourth enter the lumbar plexus; the smaller part of the fourth and the fifth pass down to the sacral plexus. On leaving the intervertebral foramina, the nerves are connected by filaments with the cord of the sympathetic, these filaments being longer than those connected with other spinal nerves, in consequence of the position of the lumbar sympathetic ganglia on the fore part of the bodies of the vertebræ. In the same situation small twigs are furnished to the quadratus lumborum muscle from the first and, sometimes, the second nerve, and to the psoas from the second and third nerves.

LUMBAR PLEXUS.

The lumbar plexus is formed by the anterior primary divisions of the upper four lumbar nerves. It is placed in the substance of the psoas muscle, in front of the transverse processes of the corresponding vertebrae. Above, the plexus is narrow, and is usually connected with the last dorsal nerve by a small offset from that nerve,

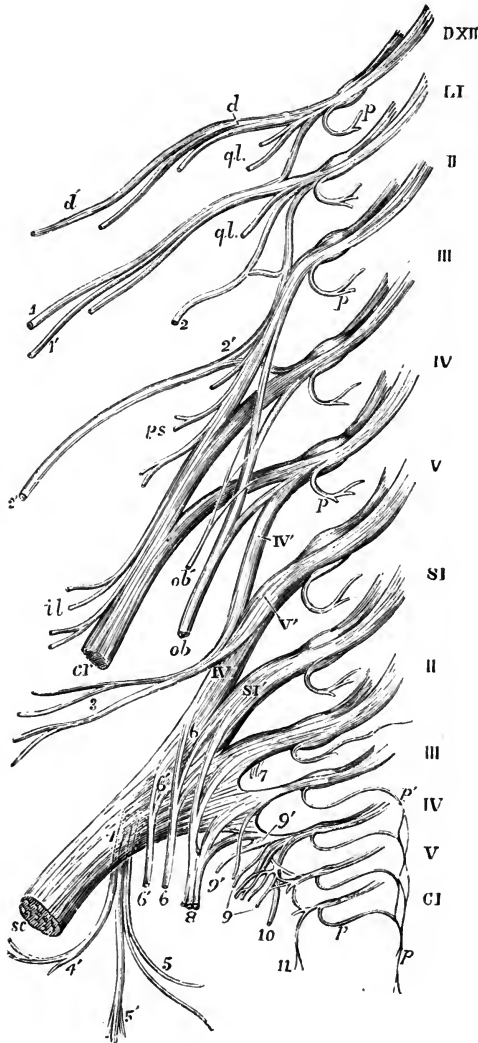


Fig. 204.—DIAGRAM OF THE LUMBAR AND SACRAL PLEXUSES WITH THE PRINCIPAL NERVES ARISING FROM THEM. (Allen Thomson.) $\frac{1}{2}$

DXII, the divided roots of the last dorsal nerve; LI, to V, the roots of the five lumbar nerves; the loops uniting the anterior primary divisions of these nerves together, and the first with the twelfth dorsal, are shown; SI, to V, and CI, the sacral and coccygeal nerves; *p*, placed on some of the nerves, marks the posterior primary divisions cut short; *p*, *p'*, the plexus formed by the union of the posterior branches of the third, fourth, and fifth sacral and the coccygeal nerves; *d*, anterior division of the last dorsal nerve, from which *d'* the lateral cutaneous branch arises; 1, 1', ilio-hypogastric nerve, dividing into its two branches; the ilio-inguinal nerve is seen below these, without a number; 2, genitocrural; 2', external cutaneous of the thigh; *ql*, branches to quadratus lumborum; *ps*, branches to the psoas muscle; *cr*, anterior crural nerve; *il*, branches to the iliacus; *ob*, obturator nerve; *ob'*, accessory obturator; IV', V', loop from the fourth and fifth lumbar, forming the lumbo-sacral cord; 3, superior gluteal nerve; *sc*, great sciatic nerve, continued from the sacral plexus; 4, small sciatic nerve rising from the plexus posteriorly; 4', inferior gluteal nerve; 5, inferior pudendal; 5', posterior cutaneous of the thigh and leg; 6, 6, branch to the obturator internus and gemellus superior; 6', 6', branch to the gemellus inferior, quadratus femoris and hip-joint; 7, twigs to the pyriformis; 8, pudic nerve; 9, visceral branches; 9', twig to the levator ani; 10, perforating cutaneous nerve; 11, coccygeal branches.

named *dorso-lumbar*; below, it is wider, and is joined to the sacral plexus by means of a branch passing from the fourth lumbar nerve to the fifth.

The nerves entering the lumbar plexus do not form an interlacement, as in the brachial plexus, but the several nerves of distribution proceeding from the plexus for the most part arise by two or more roots from a corresponding number of spinal nerves, so as to produce the appearance of a series of loops. The usual arrangement may be thus stated:—The first lumbar nerve, having been joined by the branch from the last dorsal, gives off the ilio-hypogastric and ilio-inguinal nerves, and sends downwards a communicating branch to the second nerve. The fibres of the dorso-lumbar cord enter chiefly the ilio-hypogastric nerve, but some may pass also to the ilio-inguinal. The

descending branch of the first nerve contributes to the genito-crural, often to the anterior crural, and occasionally to the obturator nerve. The second lumbar nerve furnishes the greater part of the genito-crural and external cutaneous nerves, and gives a connecting branch to the third, from which some of the fibres of the anterior crural and obturator nerves are derived. From the third nerve three branches proceed; the largest part enters the anterior crural nerve; a small branch, dorsally placed, joins the external cutaneous; and the third, arising from the ventral aspect of the trunk, passes to the obturator nerve. The fourth nerve also gives three branches, of which the anterior and posterior serve to complete the obturator and anterior crural nerves respectively, while the third, placed below the others, descends to join the fifth lumbar nerve, thus forming the *lumbo-sacral cord*, which enters into the sacral plexus.

The BRANCHES of the lumbar plexus form two sets, which are distributed, one to the lower part of the wall of the abdomen, the other to the fore part and inner side of the lower limb. In the former set are the ilio-hypogastric and ilio-inguinal nerves, and part of the genito-crural; and to the latter belong the remaining part of the genito-crural nerve, the external cutaneous, the obturator, and the anterior crural nerves.

Varieties of the lumbar plexus.—In the normal condition, the first three lumbar nerves enter wholly into the lumbar plexus, and the fifth lumbar nerve into the sacral plexus, while the fourth—the *nervus furcalis* of v. Jhering—is divided between the two plexuses. The proportion of the fourth nerve, which descends to the sacral plexus, is normally less than one-half, but it varies in different cases from one-twentieth to nine-tenths (Eisler). When the sacral division of this nerve is very large it may be joined by a branch from the third lumbar nerve; and conversely, when the sacral division of the fourth nerve is very small, the fifth lumbar nerve may send an offset to the lumbar plexus, where it contributes to the formation of the anterior crural and obturator nerves, or, perhaps, only to the former. In these cases there are, therefore, two furcal nerves, viz., 3 *l* and 4 *l*, or 4 *l* and 5 *l* respectively. Farther, the sacral branch of the fourth lumbar nerve may be wanting, and then the fifth lumbar is the sole furcal nerve. A series may thus be traced in which the furcal nerves are progressively, from above downwards, 3 and 4 *l*, 4 *l*, 4 and 5 *l*, and 5 *l*. At the same time, the nerves given off to the limb from the lumbar and sacral plexuses are found to vary in their origin to some extent, having a tendency to arise higher or lower, according to the position of the furcal nerve or nerves. In the slighter degrees of variation this is shown by a difference in the size of the contributing roots, so that a given trunk will derive a larger share of its fibres from an upper, and a smaller share from a lower spinal nerve, or *vice versa*; but in the more marked degrees the origin may be shifted upwards or downwards to the extent of one spinal nerve. There are thus to be distinguished two extreme forms of plexus (fig. 205), which may be called *high* and *low* (the “anterior” and “posterior” forms of Langley, “prefixed” and “postfixed types” of Sherrington), and between which the normal or average plexus is placed, as is shown, for the lumbar plexus only, in the following table, wherein the order of the nerves in each case indicates the size of the roots in descending series, and the roots enclosed in parentheses are inconstant :—

	High form.	Normal form.	Low form.
External cutaneous ...	2, (1) <i>l</i>	2, 3 <i>l</i>	3, 2 <i>l</i>
Obturator.....	3, 2, 4, 1 <i>l</i> (very rarely 3, 2, 1 <i>l</i>)	3, 4, 2 <i>l</i>	4, 3, 5, 2 <i>l</i>
Anterior crural	3, 2, 4, 1 <i>l</i> , (12 <i>d</i>)	4, 3, 2, 1 <i>l</i>	4, 3, 5, 2 <i>l</i>
Furcal nerves	3 and 4 <i>l</i> (or 4 <i>l</i> with large sacral division)	4 <i>l</i>	4 and 5 <i>l</i> , or 5 <i>l</i>

Forms intermediate to these also occur: and the relations of the several offsets of the plexus to one another sometimes vary to a limited extent: that is, one nerve may have a high origin, while the others belong to the normal form, or *vice versa*. Variations are more frequent and extensive in the downward direction than the opposite. In some instances the extreme forms are associated with irregularities of the vertebral column (see Vol. II, p. 12),

the low form of plexus with an additional moveable vertebra, and the high form with assimilation of the fifth lumbar vertebra to the sacrum, but this is not always the case. The upper three offsets of the lumbar plexus, not being true limb-nerves, do not vary so much in their

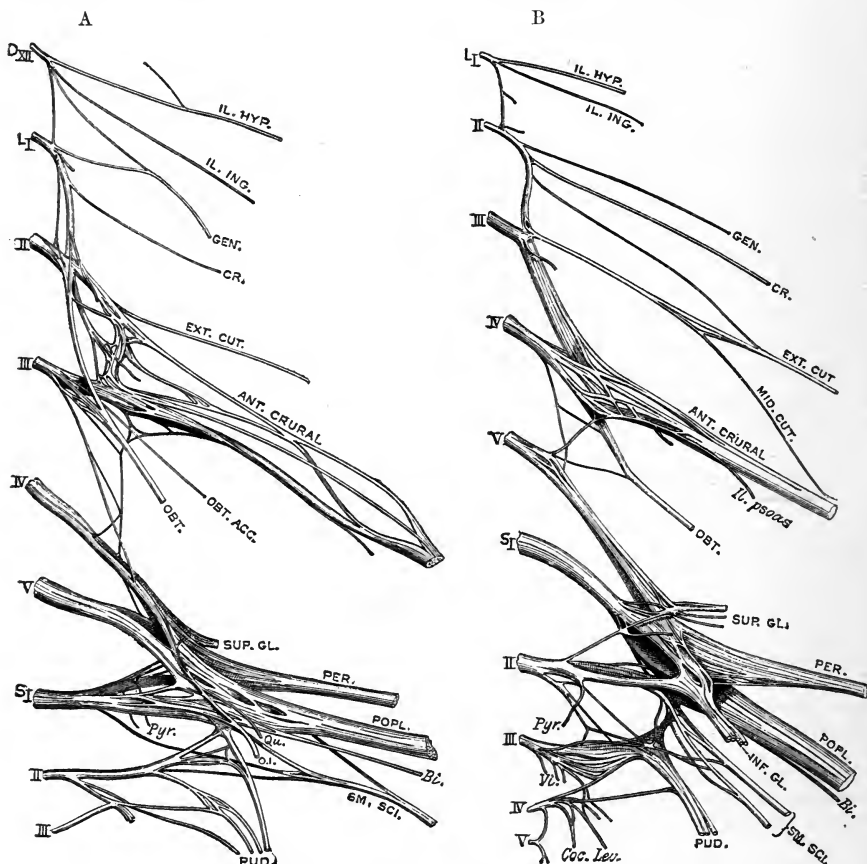


Fig. 205.—EXTREME FORMS OF LUMBAR AND SACRAL PLEXUSES. (From Eisler.)

A. High form of plexus: ventral aspect. From a subject in which the fifth lumbar vertebra was assimilated to the sacrum, and articulated on both sides with the ilium.

B. Low form of plexus: dorsal aspect. From a subject in which there were thirteen dorsal and five lumbar vertebrae.

origin, although they also are affected at times by the general form of the plexus; on the other hand, it may happen with a low form of plexus that the ilio-hypogastric and ilio-inguinal nerves receive an additional root from the twelfth dorsal (Paterson). (J. N. Langley (lumbar plexus of cat), *Journ. Phys.*, xii, 349, xv, 210, and xvii, 296; C. S. Sherrington (cat and monkey), *Journ. Phys.*, xiii, 639; P. Eisler, "Der Plexus lumbosacralis des Menschen," Halle, 1892; A. M. Paterson, "The Origin and Distribution of the Nerves to the Lower Limb," *Journ. Anat.*, xxviii, 84).

Ilio-hypogastric and ilio-inguinal nerves.—These nerves are the upper two branches of the lumbar plexus. They are both derived mainly from the first lumbar nerve, and have a nearly similar course and distribution, corresponding together to the anterior (intercostal) division of a dorsal nerve. They pass forwards between and through the broad muscles of the abdomen, furnish a lateral cutaneous branch to the integument of the hip, and becoming subcutaneous anteriorly, end in the integument of the lowest part of the abdomen and scrotum in the male, or labium pudendi in the female, as well as the adjacent part of the

thigh. The extent of distribution of the one is inversely proportional to that of the other.

The **ilio-hypogastric nerve**, the highest and largest of the branches proceeding from the first lumbar nerve, usually receives fibres also from the last dorsal nerve through the dorso-lumbar cord. Issuing from the upper part of the psoas muscle at the outer border, it runs obliquely over the quadratus lumborum to the iliac crest, and there perforating the transverse muscle of the abdomen, gets between that muscle and the internal oblique, and divides into an iliac and a hypogastric branch.

(a) The *iliac branch (ramus cutaneus lateralis)* pierces the internal oblique muscle, and then emerges through the external oblique close to the iliac crest about the junction of its middle and anterior thirds, to be distributed to the integument over the gluteus medius and tensor vaginæ femoris muscles.

(b) The *hypogastric or abdominal branch* passes on between the transversalis and internal oblique muscles, to both of which it supplies twigs, and is connected with the ilio-inguinal nerve near the iliac crest. It then perforates the internal oblique muscle, and, piercing the aponeurosis of the external oblique a little above the external abdominal ring, is distributed to the skin of the abdomen above the pubis (*r. cutaneus anterior*).

Varieties.—The ilio-hypogastric nerve is occasionally derived from the last dorsal, and it may even receive a root from the eleventh dorsal nerve (fig. 205, A). The iliac branch varies in size inversely with the lateral cutaneous of the twelfth dorsal, and it is sometimes altogether wanting. The hypogastric branch is not unfrequently joined with the last dorsal nerve between the muscles. In some cases this branch supplies the pyramidalis muscle.

The **ilio-inguinal nerve**, smaller than the preceding, is also derived from the first lumbar nerve, and sometimes receives an accession from the dorso-lumbar cord. Appearing from beneath the outer border of the psoas muscle below the ilio-hypogastric nerve, it is directed obliquely downwards and outwards over the quadratus lumborum and iliacus to the fore part of the iliac crest, where it perforates the transversalis, and communicates with the ilio-hypogastric nerve between the muscles. Then piercing the internal oblique muscle, it descends in the inguinal canal, and emerging at the external abdominal ring on the outer side of the spermatic cord, divides into branches which are distributed to the skin of the pubic region and root of the penis and scrotum in the male, or labium pudendi in the female (*nn. scrotales s. labiales anteriores*), and of the adjacent upper and inner part of the thigh. In its progress this nerve may furnish branches to the internal oblique and transversalis muscles.

Varieties.—The ilio-hypogastric and ilio-inguinal nerves often arise by a common trunk, which divides after perforating the transversalis muscle. The ilio-inguinal nerve is occasionally derived from the last dorsal nerve (fig. 205, A). On the other hand, it may spring from the loop between the first and second lumbar nerves, or even entirely from the latter nerve. It is sometimes small, and ends near the iliac crest by joining the ilio-hypogastric nerve, which in that case gives off an inguinal branch having a similar course and distribution to the ilio-inguinal nerve. The ilio-inguinal nerve may be absent, its place being taken by the genital, rarely by the crural, branch of the genito-crural. In some cases the nerve has an iliac or lateral branch, which is distributed to the skin in the neighbourhood of the anterior superior iliac spine. The ilio-inguinal nerve may also replace to a greater or less extent the genital branch of the genito-crural, or (very rarely) the external cutaneous nerve (M. Griffin).

Genito-crural nerve.—The genito-crural nerve (*n. genitofemoralis*) belongs partly to the external genital organs and partly to the thigh. It is derived chiefly from the second lumbar nerve, but receives also a few fibres from the connecting cord between that and the first nerve. The nerve descends obliquely through the psoas muscle, from which it emerges near the inner border, about on a level with

the disc between the third and fourth lumbar vertebræ, and then lying on the fascia covering the anterior surface of that muscle divides at a variable height into an internal or genital, and an external or crural branch. It often bifurcates close to

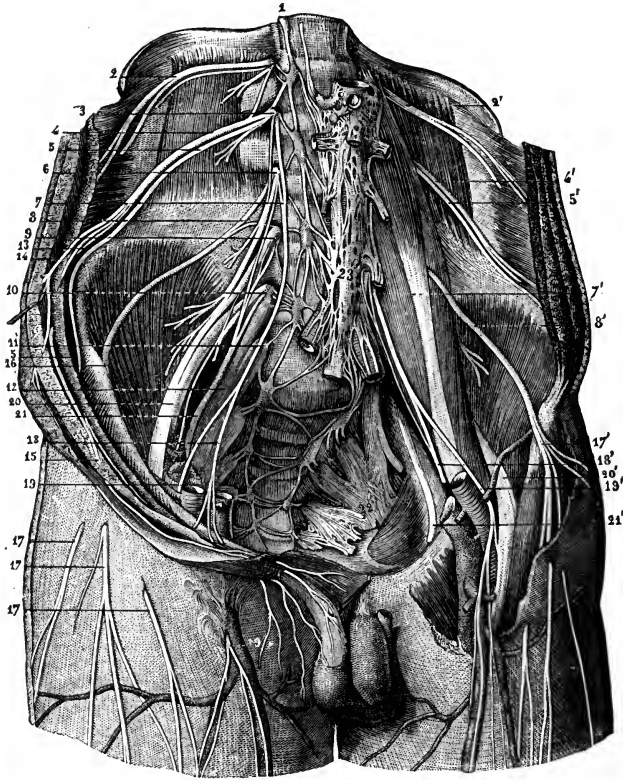


Fig. 206.—VIEW FROM BEFORE OF THE ANTERIOR BRANCHES OF THE LUMBAR AND SACRAL NERVES WITH THE PLEXUSES. (From Sappey, after Hirschfeld and Leveillé.) †

1, lumbar part of the sympathetic cord; 2, 2', anterior primary division of the twelfth dorsal nerve; 3, first lumbar; 4, 4', ilio-hypogastric branch of this nerve; 5, 5', ilio-inguinal branch; 6, second lumbar nerve; 7, 7', genito-crural nerve; 8, 8', external cutaneous nerve of the thigh; 9, third lumbar nerve; 10, fourth; 11, fifth; 12, lumbo-sacral cord; 13, iliac branch of the ilio-hypogastric; 14, its abdominal branch; 15, ilio-inguinal nerve; 16, external cutaneous nerve of the right side passing out of the abdomen under Poupart's ligament; 17, 17', cutaneous ramifications of this nerve; 17', the same nerve exposed on the left side; 18, 18', genital branch of the genito-crural; 19, 19', its crural branch on the right side; 19', the same on the left side exposed as it descends in front of the femoral artery; 20, 20', anterior crural nerve; 21, 21', obturator nerve; 22, left sacral plexus; 23, aortic plexus of the sympathetic, connected with the other preaortic plexuses and the lumbar ganglia.

its origin from the plexus, in which case its two branches perforate the psoas muscle in different places.

(a) The *genital branch* (*n. spermaticus externus*) lies upon or near the external iliac artery, and sends a filament along that vessel; then perforating the transversalis fascia (or passing through the deep abdominal ring) it traverses the inguinal canal with the spermatic cord, supplies the cremaster muscle, and sends filaments to the skin of the scrotum and adjoining corner of the thigh. In the female it accompanies the round ligament of the uterus to the skin of the groin.

(b) The *crural branch* (*n. lumboinguinalis*) descends upon the psoas muscle beneath Poupart's ligament into the thigh. Immediately below that ligament, and

at the outer side of the femoral artery, it pierces the fascia lata, and supplies the skin on the upper part of the thigh, communicating with the middle cutaneous branch of the anterior crural nerve. While it is passing beneath Poupart's ligament, some filaments are prolonged from this nerve on the femoral artery.

Varieties.—The two divisions of the genito-crural nerve often arise independently from the lumbar plexus (fig. 205). The genital branch is occasionally derived from the last dorsal and first lumbar nerves (fig. 205, A). Either branch may proceed wholly from the first or the second lumbar nerve (fig. 205, B). Absence of either division, or more rarely of the whole nerve, may occur: in such cases the fibres usually forming the genital branch are associated with the ilio-inguinal nerve, and those belonging to the crural division with the external cutaneous or anterior crural nerve. Conversely, the genital branch may reinforce or replace the ilio-inguinal nerve, and the crural branch the external or middle cutaneous. The genital branch often gives filaments to the lower fibres of the internal oblique and transversalis muscles.

External cutaneous nerve.—This nerve (*n. cutaneus femoris lateralis*), arising from the second and third lumbar nerves, emerges from the outer border of the psoas muscle, and crosses the iliacus below the ilio-inguinal nerve, where it is placed beneath the iliac fascia. It passes under Poupart's ligament, and enters the thigh immediately below the anterior superior iliac spine, where it divides into an anterior and a posterior branch distributed to the integument of the outer side of the hip and thigh (fig. 208, 1).

(a) The *posterior branch* perforates the fascia lata and subdivides into two or three others, which turn backwards and supply the skin upon the outer surface of the limb, from the upper border of the hip-bone nearly to the middle of the thigh. The highest among them are crossed by the cutaneous branches from the last dorsal nerve.

(b) The *anterior branch*, the continuation of the nerve, is at first contained in a canal formed in the substance of the fascia lata; but, about four inches below Poupart's ligament, it enters the subcutaneous fatty tissue, and is distributed along the outer part of the front of the thigh, ending near the knee. The principal offsets spring from its outer side. In some cases, this branch reaches quite down to the knee, and takes part there in the formation of the patellar plexus.

Varieties.—In the normal form of lumbar plexus the external cutaneous nerve is derived mainly from the second lumbar nerve, and receives only a small root from the third. In the high form of plexus it arises entirely from the second lumbar nerve, or from the second and first; while in the low form its chief root is furnished by the third nerve. The external cutaneous nerve often accompanies, or is united with, the anterior crural trunk to below Poupart's ligament. The posterior branch is sometimes replaced by an offset of the genito-crural nerve. In one instance the place of the external cutaneous nerve was taken by a branch of the ilio-inguinal (M. Griffin).

Obturator nerve.—The obturator nerve arises from the lumbar plexus generally by three roots, which proceed from the second, third and fourth lumbar nerves, and of which that from the third is the largest, while the root from the second nerve is often very small. Having emerged from the inner border of the psoas muscle, opposite to the brim of the pelvis, it runs along the side of the pelvic cavity, above the obturator vessels, as far as the opening in the upper part of the thyroid foramen, through which it escapes from the pelvis into the thigh. In the foramen, it divides into an anterior and a posterior branch, which are separated from one another by some fibres of the obturator externus, and lower down by the short adductor muscle.

A. The *anterior or superficial portion* communicates with the accessory obturator nerve, when this is present, and descends over the upper border of the obturator

externus and in front of the adductor brevis, but behind the pectineus and adductor longus muscles. It gives branches as follows:—

(a) An *articular branch* to the hip-joint arises in the thyroid foramen.

(b) *Muscular branches* are given to the gracilis and adductor longus muscles, and generally also to the adductor brevis.

(c) The *terminal twig* turns outwards upon the femoral artery, and surrounds that vessel with small filaments.

(d) An offset at the lower border of the adductor longus communicates beneath the sartorius with the internal cutaneous branch of the anterior crural nerve, and with a branch of the internal saphenous nerve, forming a sort of plexus.

B. The *posterior* or *deep part* of the obturator nerve, having perforated the upper

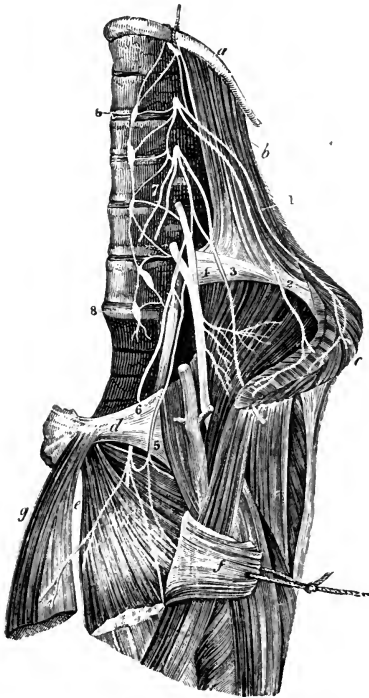


Fig. 207.—THE LUMBAR PLEXUS FROM BEFORE, WITH THE DISTRIBUTION OF SOME OF ITS NERVES. (Slightly altered from Schmidt.) $\frac{1}{2}$

a, last rib; *b*, quadratus lumborum muscle; *c*, oblique and transverse muscles, cut near the crest of the ilium and turned down; *d*, pubis; *e*, adductor brevis muscle; *f*, pectineus divided and turned outwards; *g*, adductor longus; 1, ilio-hypogastric nerve; 2, ilio-inguinal; 3, external cutaneous; 4, anterior crural; 5, accessory obturator; 6, obturator, united with the accessory by a loop round the pubis; 7, genito-crural in two branches cut short near their origin; 8, 8, lumbar portion of the gangliated sympathetic cord.

fibres of the obturator externus muscle, crosses behind the short adductor to the fore part of the adductor magnus, where it divides into several branches, all of which end in those muscles, excepting one which is prolonged downwards to the knee-joint.

(a) The *muscular branches* supply the external obturator and the great adductor muscle, with the short adductor also when this muscle receives no branch from the anterior division of the nerve.

(b) The *articular branch* for the knee rests at first on the adductor magnus, but perforates the lower fibres of that muscle, and thus reaches the upper part of the

popliteal space. Supported by the popliteal artery, and sending filaments around that vessel, the nerve then descends to the back of the knee-joint, and enters the articulation through the posterior ligament. This branch is often wanting.

Varieties.—The obturator nerve sometimes has an additional root from the first or the fifth lumbar nerve. In extreme cases of the high form of the plexus it may arise from the upper three lumbar nerves. The root from the second nerve is rarely wanting (Eisler). It occasionally gives a branch to the pectineus muscle. A branch to the obturator internus is described by Krause. Eisler traced filaments to the obturator artery and the periosteum on the back of the pubis.

Occasional cutaneous nerve.—In some instances the communicating branch described above is larger than usual, and descends along the posterior border of the sartorius to the inner side of the knee, where it perforates the fascia, communicates with the internal saphenous nerve, and extends down the inner side of the limb, supplying the skin as low as the middle of the leg.

When this cutaneous branch of the obturator nerve is present, the internal cutaneous branch of the anterior crural nerve is small, the size of the two nerves bearing an inverse proportion to each other.

Accessory obturator nerve.—This slender nerve is present in one out of every three or four bodies (29 per cent., Eisler). It arises from the third and fourth lumbar nerves (rarely also from the fifth, sometimes only from the third), between the roots of the obturator and anterior crural nerves, being associated at its origin more closely with the latter, but it is often bound up for a short distance with the obturator nerve, of which it then appears to be a branch. It descends beneath the iliac fascia along the inner border of the psoas muscle, crosses over the superior ramus of the pubis, and passing behind the pectineus muscle, ends by dividing into branches. Of these, one joins the superficial part of the obturator nerve; another enters the pectineus on its under surface; and a third passes to the hip-joint. Through the communication with the obturator nerve fibres may also pass to the adductor longus, gracilis, and adductor brevis muscles, rarely to the skin of the inner side of the thigh. The accessory nerve is sometimes very small, and ends in filaments which perforate the capsule of the joint. (See A. M. Paterson, "The pectineus muscle and its nerve-supply," Journ. Anat., xxvi, 1891, and *op. cit. s.*, Journ. Anat., xxviii, 95; P. Eisler, "Der Plexus lumbosacralis," 1892).

SUMMARY.—The obturator nerve and accessory obturator supply the three adductor muscles of the thigh, with the gracilis and obturator externus, and in some cases, the pectineus. They also give branches to the hip and knee-joints; and occasionally a cutaneous branch descends to the inner side of the thigh, and to the inner and upper part of the leg.

Anterior crural or femoral nerve.—This, the largest nerve arising from the lumbar plexus, is derived principally from the third and fourth lumbar nerves, but in part also from the second and first. Emerging from the outer border of the psoas muscle near its lower part, it descends into the thigh in the groove between that muscle and the iliacus, and therefore to the outer side of the femoral blood-vessels. Below Poupart's ligament, the nerve becomes flattened out and divides into two parts, one of which is mainly cutaneous, while the other is distributed for the most part to muscles.

A. *Branches in the trunk.*—The branches given from the anterior crural nerve within the abdomen are few and of small size.

(a) The *iliacus* receives three or four small branches (2, 3/1), which are directed outwards from the nerve to the muscle.

(b) The *nerve of the femoral artery* is a small branch which divides into numerous filaments upon the upper part of that vessel. It sometimes arises lower down than usual, in the thigh. It may, on the other hand, be found to take origin above the ordinary position from the third lumbar nerve. Beck and Rauber describe filament passing from this nerve, in company with the medullary artery, to the femur.

B. *Terminal branches.*—From the principal or terminal divisions of the nerve the remaining branches take their rise as follows.

From the *superficial or anterior division* cutaneous branches are given to the fore part of the thigh, and to the inner side of the leg; they are the middle and internal cutaneous nerves. Two muscles, the sartorius and the pectineus, receive their nerves from this group.

From the *deep or posterior division* branches proceed to supply the extensor muscle of the knee, and also one cutaneous nerve, the internal saphenous.

(a) *Middle cutaneous nerve.*—The middle cutaneous nerve (2, 3/1) either pierces the fascia lata in two parts about four inches below Poupart's ligament, or as one trunk which soon divides into two branches. These branches descend on the fore part of the thigh to the front and inner side of the patella. After or before the nerve has become subcutaneous, it communicates with the crural branch of the genito-crural nerve, and also with the internal cutaneous.

This nerve, or the outermost of its branches, frequently pierces the upper part of the sartorius muscle.

(b) *Internal cutaneous nerve.*—The internal cutaneous nerve (2, 3/1) gives branches

to the skin on the inner side of the thigh, and the upper part of the leg; but the extent to which it reaches varies with the presence or absence of the "occasional cutaneous" branch of the obturator nerve.

Lying beneath the fascia lata, this nerve descends obliquely over the upper part of the femoral artery. It divides either in front of that vessel, or at the inner side, into two branches (one anterior, the other posterior), which pierce the fascia separately. Before dividing, this nerve gives off two or three cutaneous twigs, which accompany the upper part of the long saphenous vein. The highest of these perforates the fascia near the saphenous opening, and reaches down to the middle of

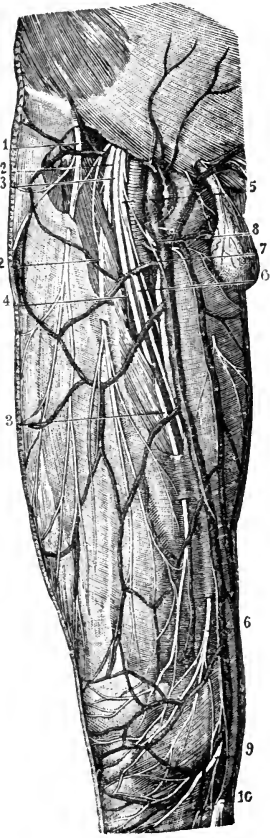


Fig. 208.—CUTANEOUS NERVES OF THE ANTERIOR AND INNER PART OF THE THIGH. (From Sappey, after Hirschfeld and Leveillé.) $\frac{1}{2}$

1, external cutaneous nerve; 2, 3, middle cutaneous, the outer one passing through the sartorius muscle; 4, filament to the sartorius; 5, internal cutaneous nerve; 6, its anterior division; 7, one of its upper branches; 8, a cutaneous twig from the nerve to the pectineus; 9, patellar branch of the internal saphenous nerve; 10, continuation of the saphenous to the leg.

the thigh. Another, larger than the rest, passes through the fascia about the middle of the thigh, and extends to the knee. In some instances, these small branches spring directly from the anterior crural nerve; and one branch is frequently given off from the nerve to the pectineus, joining in a loop on the inner side of the femoral artery with a branch passing in front of that vessel (fig. 208, 8; 209, 7).

The *anterior branch*, descending in a straight line to the knee, perforates the fascia lata in the lower part of the thigh; it afterwards runs down near the tendon of the adductor magnus, giving off filaments on each side to the skin, and is finally directed over the patella to the outer side of the knee. It communicates above the joint with a branch of the long saphenous nerve; and sometimes it takes the place of the branch usually given by the latter to the integument over the patella.

The *posterior or inner branch* of the internal cutaneous nerve, descending along the posterior border of the sartorius muscle, perforates the fascia lata at the inner side of the knee, and communicates by a small branch with the internal saphenous nerve, which here descends in front of it. It gives some cutaneous filaments to the lower part of the thigh on the inner side, and is distributed to the skin upon the inner side of the calf. While beneath the fascia, this branch of the internal cutaneous nerve joins in an interlacement with offsets of the obturator and internal saphenous nerves below the middle of the thigh; and in the leg it communicates again with branches of the saphenous nerve.

(c) The *branch to the pectineus* (2, 3l) is usually associated at its origin with the internal cutaneous nerve. It crosses inwards behind the femoral vessels, and enters the muscle on its anterior aspect: this branch is occasionally double.

(d) The *sartorius* muscle receives two or three twigs (2, 3l) which arise in common with the middle cutaneous nerve, and enter the upper part of the muscle.

(e) The *branch to the rectus femoris* (3, 4 l) enters the posterior surface of its muscle: from this nerve, and from some of the other muscular branches, twigs are sent, in company with a branch of the external circumflex artery, to the hip-joint.

(f) The *nerve to the vastus externus* (3, 4 l), of considerable size, descends with a large branch of the external circumflex artery along the anterior border of the muscle, and sends a filament to the knee-joint.

(g) Two or three branches (3, 4 l) penetrate the *crureus* muscle on its anterior surface, and from the most internal of these a filament can be traced, under cover of the anterior border of the vastus internus muscle, to the subcrureus, the periosteum of the lower end of the femur, and the synovial membrane of the knee-joint.

Fig. 209.—DEEP NERVES OF THE ANTERIOR AND INNER PART OF THE THIGH. (From Sappey, after Hirschfeld and Leveillé.) $\frac{1}{2}$

1, anterior crural nerve; 2, branches to the iliacus muscle; 3, branch to the lower part of the psoas; 4, internal and middle cutaneous nerves, divided to show the deeper branches; 5, 6, nerves to the pectineus; 7, cutaneous filament from the last; 8, posterior branch of the internal cutaneous nerve; 9, branch to the rectus; 10, branch to the vastus externus; 11, branch to the vastus internus; 12, internal saphenous nerve; 13, its patellar branch; 14, its continuation to the leg; 15, obturator nerve; 16, branch to the adductor longus; 17, branch to the adductor brevis; 18, branch to the gracilis; from this a filament is prolonged downwards, to unite with the plexus formed by the union of branches from the internal cutaneous and internal saphenous nerves; 19, deep branch of the obturator nerve to the adductor magnus; 20, lumbo-sacral cord; 21, its union with the first sacral nerve; 22, 22, lumbar and sacral parts of the sympathetic nerve; 23, external cutaneous nerve.

(h) The *nerve of the vastus internus* (3, 4 l) runs downwards with the internal saphenous nerve beneath the aponeurosis covering the femoral vessels, giving several branches to the upper part of its muscle; it enters the latter about the middle of the thigh, and from its lower end a considerable twig is continued to the knee-joint, in company with the deep branch of the anastomotic artery.

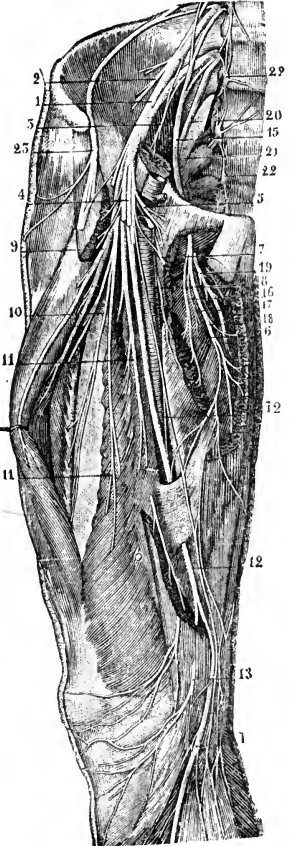
(i) *Internal saphenous nerve.*—The internal or long saphenous (3, 4 l) is the largest of the branches of the anterior crural nerve. It is deeply placed as far as the knee, but is subcutaneous in the rest of its extent.

In the thigh, it accompanies the femoral vessels, lying at first to their outer side, but lower down gradually crossing over the artery, and passing beneath the same aponeurosis. When the vessels pass through the opening in the adductor magnus muscle into the popliteal space, the saphenous nerve separates from them, and is continued beneath the sartorius muscle to the inner side of the knee; here, having first given off, as it lies near the inner condyle of the femur, a branch which is distributed over the front of the patella, it becomes subcutaneous by piercing the fascia at the lower border of the sartorius.

The nerve then accompanies the saphenous vein along the inner side of the leg, and, passing in front of the inner ankle, terminates on the inner side of the metatarsal region of the foot. In the leg it is connected with the posterior branch of the internal cutaneous nerve.

The distribution of its branches is as follows:—

A *communicating branch* is given off about the middle of the thigh to join in the



interlacement formed beneath the sartorius by this nerve and branches of the obturator and internal cutaneous nerves.

The *patellar branch* perforates the sartorius muscle and the fascia lata, and spreads out over the front of the knee, where it forms, by uniting with branches of the internal and middle (sometimes also the external) cutaneous nerves, a plexus named the *patellar plexus*.

Numerous branches are given off from the nerve to the skin of the leg, and the larger of these turn forwards over the anterior border of the tibia. Its terminal offsets on the inner side of the foot communicate with branches of the musculo-cutaneous nerve.

Varieties.—In the high form of plexus the anterior crural may receive fibres from the last dorsal nerve, in the low form from the fifth lumbar, the root at the opposite end of the plexus being correspondingly reduced. The nerve has been seen entering the thigh between the femoral artery and vein (Dubruel). The several branches of the middle, or of the internal, cutaneous nerve frequently arise independently from the anterior crural. The middle or internal cutaneous nerve sometimes leaves the trunk of the anterior crural at a higher level than usual, within the abdomen. The posterior branch of the internal cutaneous is sometimes very small or absent, its place being supplied by the obturator or the internal saphenous nerve. The anterior crural occasionally gives off the external cutaneous nerve of the thigh. The internal saphenous nerve has been seen ending at the knee, its place in the leg being taken by a branch of the internal popliteal nerve (G. H. Meyer). The patellar branch has been observed arising from the nerve to the vastus internus (Guy's Hosp. Reports, 3rd ser., xvi, 161). The internal saphenous rarely furnishes the internal dorsal digital nerve of the great toe. Branches of the anterior crural nerve to the tensor vaginæ femoris and adductor longus are described by several anatomists. Arthur Thomson found a branch passing behind the femoral vessels to join the accessory obturator nerve and supply in part the latter muscle (Journ. Anat., xix, 331).

SUMMARY.—The anterior crural nerve is distributed to the skin upon the fore part and inner side of the thigh, commencing below the termination of the ilio-inguinal and genito-crural nerves. It furnishes also a cutaneous nerve to the inner side of the leg and foot. All the muscles on the front of the thigh receive their nerves from the anterior crural, and the iliacus and pectineus are also supplied by this nerve. Lastly, branches are given from the anterior crural nerve to the femoral artery, to the thigh-bone, and to the hip and knee-joints.

FIFTH LUMBAR NERVE.

The anterior branch of the fifth lumbar nerve, having received a fasciculus from the nerve next above it, descends to join the first sacral nerve, and forms part of the sacral plexus. The trunk resulting from the union of the fifth with a part of the fourth nerve is named the *lumbo-sacral cord*, and gives origin to the greater part of the superior gluteal nerve.

SACRAL AND COCCYGEAL NERVES.

The anterior divisions of the first four sacral nerves emerge from the spinal canal by the anterior sacral foramina, and the fifth passes forwards between the sacrum and coccyx.

The first two sacral nerves are large, and of nearly equal size; the others diminish rapidly, and the fifth is exceedingly slender. Like the anterior divisions of the other spinal nerves, those of the sacral nerves communicate with the sympathetic: the communicating cords are very short, as the sympathetic ganglia are close to the inner margin of the foramina of the sacrum.

The first three nerves and part of the fourth contribute to form the sacral plexus. The fifth has no share in the plexus,—it ends on the back of the coccyx. As the description of the fourth and fifth sacral nerves and of the coccygeal will occupy

only a short space, these three nerves may be noticed first, before the other nerves and the numerous branches to which they give rise are described.

FOURTH SACRAL NERVE.

Only one part of the anterior division of this nerve joins the sacral plexus; the remainder, which is more than half the nerve, supplies branches to the viscera and muscles of the pelvis, and sends downwards a connecting filament to the fifth nerve.

(a) The *visceral branches* of the fourth sacral nerve are directed forwards to the lower part of the bladder, and communicate freely with branches from the sympathetic nerve. Offsets are distributed to the neighbouring viscera, according to the sex (*nn. hæmorrhoidales medii; nn. vesicales inferiores; nn. vaginales*). They will be described with the pelvic portion of the sympathetic nerve. These branches are associated with others proceeding from the third sacral nerve, and they are sometimes derived mainly from the latter nerve. Sometimes filaments are added from the second sacral nerve.

(b) Of the *muscular branches*, one supplies the *levator ani*, piercing that muscle on its pelvic surface; another enters the *coccygeus*; while a third (*hæmorrhoidal or perineal branch*) ends in the *external sphincter* muscle of the anus. The last branch, after passing either through the coccygeus, or between it and the levator ani, reaches the perineum, and gives filaments also to the integument between the anus and the coccyx.

According to Eisler the nerve to the levator ani is derived from the third and fourth sacral nerves, in some cases even from the second and third.

FIFTH SACRAL NERVE.

The anterior branch of this, the lowest sacral nerve, comes forwards through the coccygeus muscle opposite the junction of the sacrum with the first coccygeal vertebra: it then descends upon the coccygeus nearly to the tip of the coccyx, where it turns backwards through the fibres of that muscle, and ends in the integument upon the posterior and lateral aspect of the bone (*nn. ano-coccygei*).

As soon as this nerve appears in front of the coccygeus muscle (in the pelvis) it is joined by the descending filament from the fourth nerve, and lower down by the small anterior division of the coccygeal nerve. It supplies filaments to the coccygeus muscle.

COCYGEAL NERVE.

The anterior branch of the coccygeal, or, as it is sometimes named, the sixth sacral nerve, is a very small filament. It escapes from the spinal canal by the terminal opening, pierces the sacro-sciatic ligaments and the coccygeus muscle, and, being joined upon the side of the coccyx with the fifth sacral nerve, partakes in the distribution of that nerve. The connection between the fourth and fifth sacral and the coccygeal nerves is sometimes described as the *coccygeal plexus*.

SACRAL PLEXUS.

The lumbo-sacral cord (resulting as, before described from the junction of the fifth and part of the fourth lumbar nerves), the anterior divisions of the first three sacral nerves, and part of the fourth unite to form this plexus. Its construction is simpler than that of the spinal nerve-plexuses already described, as the several nerves unite without much interlacement into an upper large, and a lower small, cord or band. The upper band is formed by the union of the lumbo-sacral cord with the first and second, and the greater part of the third, sacral nerves, and is continued

into the great sciatic nerve: the lower band, which has a more plexiform arrangement, results mainly from the junction of the smaller part of the third sacral nerve with the portion of the fourth nerve belonging to the plexus, and is prolonged into

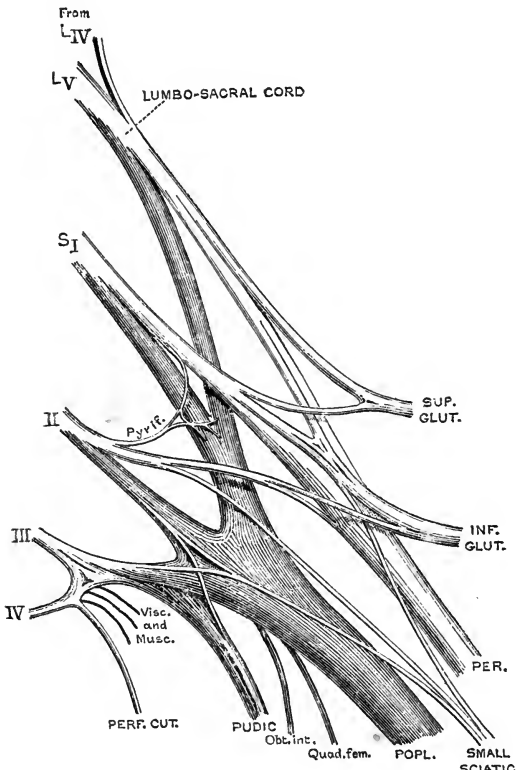


Fig. 210.—THE SACRAL PLEXUS OF THE RIGHT SIDE, FROM BEHIND. (G. D. T.)

The peroneal and popliteal divisions of the great sciatic nerve are separated up to their origin. The dorsal offsets of the plexus are represented light, and the ventral offsets dark.

the pudic nerve. The lower band is, however, joined by a small fasciculus from the second sacral nerve, and according to Bisler it receives fibres also from the first sacral nerve. To the place of union the nerves proceed in different directions, that of the upper ones being obliquely downwards, while that of the lower is nearly horizontal; and, as a consequence of this difference, they diminish in length from the first to the last. The sacral plexus rests on the anterior surface of the pyriformis muscle, opposite the side of the sacrum, and escaping through the great sacro-sciatic foramen, ends at the lower border of the pyriformis in the great sciatic and pudic nerves.

BRANCHES.—In addition to the terminal offsets, viz., the great sciatic and pudic nerves, the sacral plexus gives origin to a number of collateral branches of smaller size. These are the superior gluteal, inferior gluteal, small sciatic, and perforating cutaneous nerves, and branches to the pyriformis, obturator internus, gemelli, and quadratus femoris muscles.

In the description of the sacral plexus a division is sometimes made into two subordinate plexuses. The larger upper part, which ends in the great sciatic nerve and gives off the other branches to the limb, is distinguished as the *sciatic plexus* (*plexus ischiadicus*), while the smaller lower part, including the pudic nerve together with the visceral and muscular branches of the third and fourth sacral nerves, is designated the *pudic plexus* (*plexus pudendus*).

In the usual condition the greater part of the sacral plexus is prolonged, as already stated, into the great sciatic trunk, which divides at a variable level in the thigh into the internal popliteal and external popliteal (or peroneal) nerves. But in many cases (1 in 5 or 6) these nerves spring independently from the plexus, and the external popliteal division passes backwards through a cleft in the pyriformis muscle, the lower part of which is interposed between the two nerves. In the normal arrangement also the two nerves can be readily separated up to the pelvis by dissecting off the sheath of the great sciatic trunk, and it is then found that the plexus and the nerves entering it are divided into ventral and dorsal portions, the internal popliteal nerve being formed by the union of the ventral divisions of the lumbo-sacral cord and the first three sacral nerves, while the external popliteal receives the dorsal divisions of the lumbo-sacral cord and the first two sacral nerves. The collateral branches of the plexus may also be divided in a corresponding manner according as they arise from the anterior or

posterior divisions of the nerves, and thus the offsets of the plexus passing to the limb may be grouped as follows :—

Anterior or ventral nerves.

Nerve to quadratus femoris.
Nerve to obturator internus.
Internal popliteal.
Small sciatic (perineal branch and inner part of femoral division).

Posterior or dorsal nerves.

Superior gluteal.
Inferior gluteal.
Nerves to pyriformis.
External popliteal.
Small sciatic (gluteal branches and outer part of femoral division).
Perforating cutaneous.

Varieties of the sacral plexus.—The nerves proceeding from the sacral plexus vary in their origin, like the offsets of the lumbar plexus, in accordance with the position of the *nervus furcalis* (see p. 313). The range of variation is shown in the following table, mainly after Eisler :—

	High form of plexus.	Normal form.	Low form.
Furcal nerves... ..	$\left\{ \begin{array}{l} 3l \text{ and } 4l \text{ (or } 4l) \\ \text{with large sacral} \\ \text{division} \end{array} \right\}$	4l	4l and 5l, or 5l
N. to quad. fem.		4, 5l, 1s	1s, 5l
N. to obt. int.	1s, 5, 4l, 2s	5l, 1, 2s	2, 1, 3s
Internal popliteal	1s, 5, 4l, 2s, (3l)	1s, 5l, 2s, 4l, 3s	2, 1s, 5l, 3s, (4s)
Superior gluteal	5, 4l, 1s	5l, 1s, 4l, (2s)	5l, 1, 2s
Inferior gluteal	5l, 1s, 4l	1s, 5l, 2s	1, 2s, 5l
N. to pyriformis	(5l), 1, 2s	1, 2s	2, 1, (3)s
External popliteal	5, 4l, 1s, (3l)	5l, 1s, 4l, 2s	1, 2s, 5l, (3s)
Small sciatic	1, 2s, 5l	2, 3, 1s	2, 3, 4s
Pudic... ..	2, 3, 1s, 5l	3, 4, 2, 1s	3, 4, 2, 1s

(The relative size of the several roots is indicated by the order of the nerves, and those included in parentheses are inconstant.)

A.—COLLATERAL BRANCHES.

Small muscular branches.—The *pyriformis muscle* is supplied by twigs arising from the back of the first and second sacral nerves.

The *nerve of the quadratus femoris muscle* arises from the front of the upper part of the plexus, receiving its fibres from the lumbo-sacral cord and first sacral nerve. Concealed at first by the great sciatic nerve, it passes beneath the gemelli and the tendon of the obturator internus—between those muscles and the capsule of the hip-joint,—and reaches the deep (anterior) surface of the quadratus. It gives off a branch to the inferior gemellus muscle, and another to the back part of the hip-joint. A second filament frequently passes directly from the sacral plexus to the articulation.

The *nerve of the obturator internus muscle*, derived from the fifth lumbar and upper two sacral nerves, springs from the front of the plexus immediately below the foregoing, with which it is usually connected at its origin. Appearing at the lower border of the pyriformis to the inner side of the great sciatic nerve, it then turns over the ischial spine on the outer side of the pudic vessels, and is directed forwards through the small sacro-sciatic foramen to reach the inner surface of the obturator muscle. This nerve furnishes a small offset to the superior gemellus.

Varieties.—Occasionally the branch to the superior gemellus is also given off by the nerve to the quadratus; or that muscle may be supplied from both sources. In one instance J. T. Wilson found the nerve to the quadratus continued to the upper part of the adductor magnus (Journ. Anat., xxiii, 354).

Superior gluteal nerve.—The superior gluteal nerve arises from the back of the lumbo-sacral cord and first sacral nerve. It leaves the pelvis with the gluteal

vessels through the great sacro-sciatic foramen above the pyriformis muscle, and immediately divides into two branches, which run forwards between the gluteus medius and minimus, supplying those muscles and the tensor vaginae femoris.

(a) The *upper branch* is the smaller and more superficial; it sends its offsets solely to the gluteus medius.

(b) The *lower branch* crosses the middle of the gluteus minimus muscle with the lower branch of the gluteal artery; it sends branches to both the gluteus medius and minimus, and generally perforates the fore part of the latter muscle to reach the deep surface of the tensor vaginae femoris, in which it ends.

Varieties.—The superior gluteal sometimes receives fibres also from the second sacral nerve. A branch to the pyriformis muscle may be given off from the lowest root of this nerve.

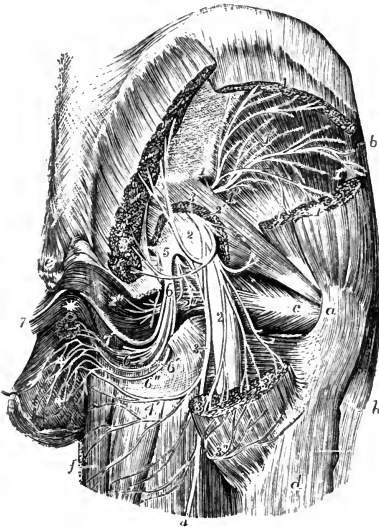


Fig. 211.—BRANCHES OF THE SACRAL PLEXUS IN THE BUTTOCK. (Hirschfeld and Leveillé.) †

a, great trochanter; *b*, tensor vaginae femoris muscle; *c*, tendon of the obturator internus muscle; *d*, upper part of the vastus externus; *e*, coccyx; *f*, gracilis muscle; between *f* and *d*, the adductor magnus, semitendinosus, and biceps muscles, with the lower end of the gluteus maximus; 1, 1, upper branch of the superior gluteal nerve; 1', 1', inferior branch of the same nerve; 1'', branch of the nerve to the tensor vaginae femoris; 2, 2, sacral plexus and great sciatic nerve; 2', muscular twig from the plexus to the pyriformis; 2'', branch to the gemellus superior and obturator internus; 3, small sciatic nerve, 3', 3', placed on the upper and lower parts of the divided gluteus maximus, the branches of the inferior gluteal nerve; 3'', the gluteal cutaneous branches of the small sciatic nerve winding round the lower border of the gluteus maximus; 4, the continuation of the small sciatic nerve as posterior cutaneous nerve of the thigh; 4', inferior pudendal branch of the small sciatic; 5, placed on the lower part of the sacral plexus points to the origin of the pudic nerve; 6, its perineal division with its muscular branches; 6', internal superficial perineal branch; 6'', external superficial perineal; + +, distribution of these nerves and the inferior pudendal on the scrotum; 7, dorsal nerve of the penis.

Inferior gluteal nerve.—The inferior gluteal nerve arises from the back of the plexus, being formed of fibres which are derived from the lumbo-sacral cord, the first and second sacral nerves. It usually sends a branch downwards to join the commencement of the small sciatic nerve, and sometimes the two nerves are more closely connected at their origins. The inferior gluteal nerve turns backwards at the lower border of the pyriformis muscle, and immediately divides into a number of branches which, diverging upwards and downwards, enter the deep surface of the gluteus maximus muscle about midway between its origin and insertion.

Small sciatic nerve.—The small sciatic nerve (*nervus cutaneus femoris posterior*) is entirely a sensory nerve, supplying the integument of the lower part of the buttock, the back of the thigh, and the upper part of the back of the leg; it also furnishes one branch to the perineum—the inferior pudendal nerve.

The nerve takes its origin usually from the back of the upper three sacral nerves by as many roots, the highest of which arises in common with a part of the inferior gluteal nerve. Emerging below the pyriformis muscle, it descends beneath the gluteus maximus muscle, resting on the great sciatic nerve, and then along the back of the thigh under cover of the fascia lata to a little beyond the knee. Here it becomes subcutaneous, and its terminal ramifications are distributed to the skin of

the calf, one branch accompanying the short saphenous vein and forming a communication with the external saphenous nerve.

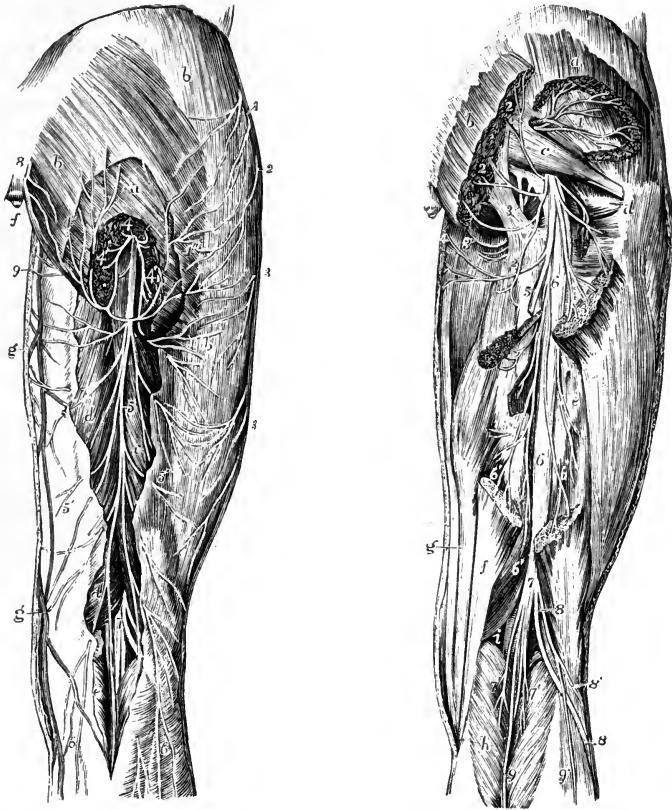


Fig. 212.—POSTERIOR CUTANEOUS NERVES OF THE HIP AND THIGH. (Hirschfeld and Leveillé.) $\frac{1}{2}$

a, gluteus maximus muscle, divided at its inferior part to show the small sciatic nerve; *b, b*, fascia lata; *c, d*, part of the semitendinosus, biceps, and semimembranosus muscles exposed by the removal of the fascia; *e*, gastrocnemius; *f*, coccyx; *g*, internal saphenous vein; 1, 2, 3, 3, posterior twigs of the external cutaneous nerve of the thigh; 4, small sciatic nerve; 4', 4'', its gluteal cutaneous branches; 5, continuation of the small sciatic; 5', 5'', its inner and outer femoral cutaneous branches spreading on the fascia of the thigh; 6, 6, its terminal branches descending on the calf of the leg; 7, internal and external popliteal nerves, separating in the popliteal space; 8, posterior divisions of the lower sacral and coccygeal nerves; 9, inferior pudendal nerve.

Fig. 213.—DEEP POSTERIOR NERVES OF THE HIP AND THIGH. (Hirschfeld and Leveillé.) $\frac{1}{2}$

a, gluteus medius muscle; *b*, gluteus maximus; *c*, pyramidalis; *d*, placed on the great trochanter, points to the tendon of the obturator internus; *e*, upper part of the femoral head of the biceps; *f*, semitendinosus; *g*, semimembranosus; *h*, gastrocnemius; *i*, popliteal artery; 1, placed on the gluteus minimus muscle, points to the superior gluteal nerve; 2, 2, 2, ramifications of the inferior gluteal nerve; 3, placed on the great sacro-sciatic ligament, points to the pudic nerve; 3', its farther course; 4, inferior pudendal; 5, placed on the upper divided part of the semitendinosus and biceps, points to the divided small sciatic or posterior cutaneous nerve of the thigh; 6, great sciatic nerve; 6', 6', some of its muscular branches to the hamstrings; 7, internal popliteal nerve; 7', its muscular or sural branches; 8, external popliteal nerve; 8', its external cutaneous branch; 9, communicating tibial; 9', communicating peroneal branch to the external saphenous nerve.

Branches.—(*a*) The *gluteal cutaneous branches* (*nn. clunium inferiores*) are two or three in number, and bend upwards over the lower border of the gluteus maximus muscle, to be distributed to the skin of the lower and outer part of the gluteal region.

(b) The *inferior pudendal nerve* (*rr. perineales*) turns inwards below the ischial tuberosity, giving offsets (sometimes separate branches of the nerve) to the skin of the upper and inner part of the thigh, and is continued forwards to the outer part of the scrotum (or external labium pudendi), where its terminal filaments are distributed, after forming communications with the external superficial perineal branch of the pudic nerve.

(c) The *femoral cutaneous branches* are numerous, and arise from both sides of the nerve while it lies beneath the fascia: they supply the skin of the back of the thigh, the larger number passing to the inner side.

Varieties.—In cases of separate origin of the internal and external popliteal nerves (p. 324), the small sciatic nerve also arises from the sacral plexus in two parts. The ventral portion descends with the internal popliteal nerve below the pyriformis, and gives off the inferior pudendal and inner femoral branches, while the dorsal portion passes through that muscle with the external popliteal nerve, and furnishes the gluteal and outer femoral branches. The inferior pudendal nerve sometimes pierces the great sacro-sciatic ligament. The small sciatic may be joined on the back of the thigh by a branch of the great sciatic nerve (p. 331). In some cases the small sciatic nerve ends behind the knee, its place in the leg being then taken by a branch of the external popliteal (p. 336).

The **perforating cutaneous nerve** (fig. 215, 10) is a slender branch which arises most frequently from the second and third sacral nerves, and passes backwards through the great sacro-sciatic ligament: it then turns upwards round the lower border of the gluteus maximus, and is distributed to the skin over the inner and lower part of that muscle.

Varieties.—A perforating cutaneous nerve arising as above stated was found by Eisler 22 times in 34 plexuses: in three of these it was conjoined at its origin with the pudic nerve. Instead of piercing the great sacro-sciatic ligament it may run with the pudic nerve between the great and small ligaments, or it may pass between the great ligament and the gluteus maximus muscle. In other cases a nerve having a similar distribution (*n. perforans coccygeus major*, Eisler) arises from the third and fourth (fig. 210), or fourth and fifth nerves (fig. 204, 10), and pierces the coccygeus muscle on its way backwards. Its place may also be supplied by a branch of the small sciatic.

B.—TERMINAL BRANCHES.

Pudic nerve.—The pudic nerve (*n. pudendus*) is a short plexiform trunk, which is given off from the lower part of the sacral plexus, and distributes branches to the perineum and external organs of generation. Its chief root is usually derived from the third sacral nerve. To this are added others from the fourth and second nerves; and according to Eisler it also receives fibres from the first sacral nerve. The upper roots spring from the front of the ventral divisions of the corresponding sacral nerves. Passing out of the pelvis between the pyriformis and coccygeus muscles, it turns forwards over the attachment of the small sacro-sciatic ligament to the ischial spine, where it is placed on the inner side of the pudic vessels, to the small sacro-sciatic foramen. Having thus arrived at the hinder part of the ischio-rectal fossa, the trunk ends by dividing into the following three branches, viz., the inferior hæmorrhoidal nerve, the perineal nerve, and the dorsal nerve of the penis, or clitoris, according to the sex.

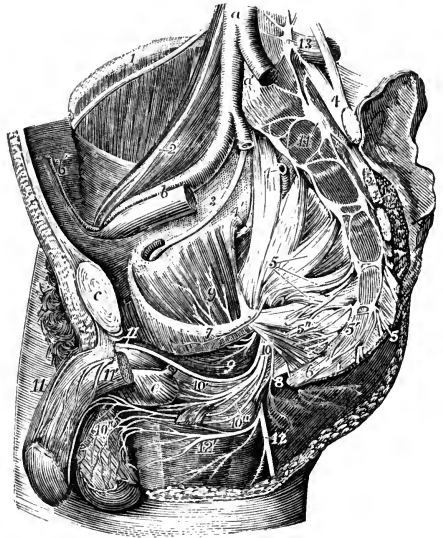
(a) The *inferior hæmorrhoidal nerve* (4, 3, (2) s) is sometimes derived separately from the sacral plexus; it inclines inwards towards the anus and divides into numerous branches which supply the skin of the hinder part of the perineal space and the external sphincter muscle. The most anterior branches form communications with the inferior pudendal and superficial perineal nerves.

(b) The *perineal nerve* (3, 2, 4 s) is the largest of the three divisions of the pudic nerve. It runs forwards along the outer wall of the ischio-rectal fossa, being con-

tained in a special sheath of the obturator fascia below the pudic vessels, and breaks up into superficial and deep branches.

The *superficial perineal nerves* are two in number, external and internal. The *external* or *posterior*, which is the first to leave the perineal trunk, runs forwards along the outer side of the perineal space to the scrotum, and sometimes gives a branch to the adjacent part of the thigh. The *internal* or *anterior* branch is larger, and runs forwards nearer the middle line, dividing into long slender offsets which are distributed to the integument of the scrotum. The two branches communicate freely together, and the external generally receives the connecting filaments from the inferior pudendal and inferior hæmorrhoidal nerves. The superficial perineal and

Fig. 214.—RIGHT SIDE OF THE INTERIOR OF THE MALE PELVIS, WITH THE PRINCIPAL NERVES DISPLAYED. (Hirschfeld and Leveillé.) $\frac{1}{4}$



The left wall has been removed as far as the sacrum behind and the symphysis pubis in front; the viscera and the lower part of the right levator ani have been removed; *a*, lower end of the aorta; *a'*, placed on the fifth lumbar vertebra, between the two common iliac arteries, of which the left is cut short; *b*, right external iliac vessels; *c*, symphysis pubis; *d*, the divided pyriformis muscle, close to the left auricular surface of the sacrum; *e*, bulb of the urethra covered by the bulbo-cavernosus muscle; the membranous part of the urethra cut short is seen passing into it; 1, on the crest of the ilium, the external cutaneous nerve of the thigh passing over the iliacus muscle; 2, on the psoas muscle, the genito-crural nerve; 3, obturator nerve; 4, 4, on the lumbo-sacral cords; that of the right side points to the gluteal artery cut short; 4', superior gluteal nerve; 5, on the right sacral plexus, points by four lines to the anterior divisions of the four upper sacral nerves, which, with the lumbo-sacral cord, form the plexus; 5', placed on the fifth piece of the sacrum, points to the fifth sacral nerve; 5'', visceral branches from the third and fourth sacral nerves; 6, placed on the lower part of the coccyx, below the coccygeal nerves; 7, the nerve of the levator ani muscle; 8, inferior hæmorrhoidal nerve; 9, nerve of the obturator internus; 10, pudic nerve; 10', muscular branches of the perineal nerve; 10'', superficial perineal nerves, and on the scrotum the distribution of these nerves and the inferior pudendal nerve; 11, right dorsal nerve of the penis; 11', the nerve on the left crus penis which is cut short; 12, small sciatic nerve; 12', its inferior pudendal branch; 13, on the transverse process of the fifth lumbar vertebra, the lowest lumbar sympathetic ganglion; 14, on the first piece of the sacrum, the upper sacral sympathetic ganglia; between 14 and 6, are seen the remaining ganglia and sympathetic nervous cords, as well as their union with the sacral and coccygeal nerves, and at 6, the lowest ganglion or ganglion impar.

inferior pudendal nerves are sometimes named from their distribution *long scrotal nerves* (*nn. scrotales posteriores*).

In the female, both the superficial perineal branches terminate in the external labium pudendi (*nn. labiales posteriores*).

The *deep branches* generally arise by a single trunk, and are distributed mainly to the muscles of the perineum. They supply the fore part of the external sphincter and levator ani muscles, the transversus perinei, ischio-cavernosus and bulbo-cavernosus. One branch passes inwards through the bulbo-cavernosus muscle, and divides into slender filaments which penetrate the corpus spongiosum and reach the mucous membrane of the urethra.

(*c*) The *dorsal nerve of the penis* (2, 3, (1) *s*) is the deepest branch of the pudic nerve, and accompanies the pudic artery in its course through the deep perineal fascia (Vol. II, pp. 339 and 477), and between the layers of the suspensory liga-

ment to the dorsum of the penis, along which it passes as far as the glans, where it divides into filaments for the supply of that part. While passing through the deep perineal fascia, it gives fine twigs for the supply of the constrictor urethræ muscle ; and on the dorsum of the penis, it is joined by branches of the sympathetic system, and sends outwards numerous offsets to the integument on the upper surface and sides of that organ. Some filaments also penetrate the corpus cavernosum.

In the female the *dorsal nerve of the clitoris* is much smaller than the corresponding branch in the male ; it is similarly distributed.

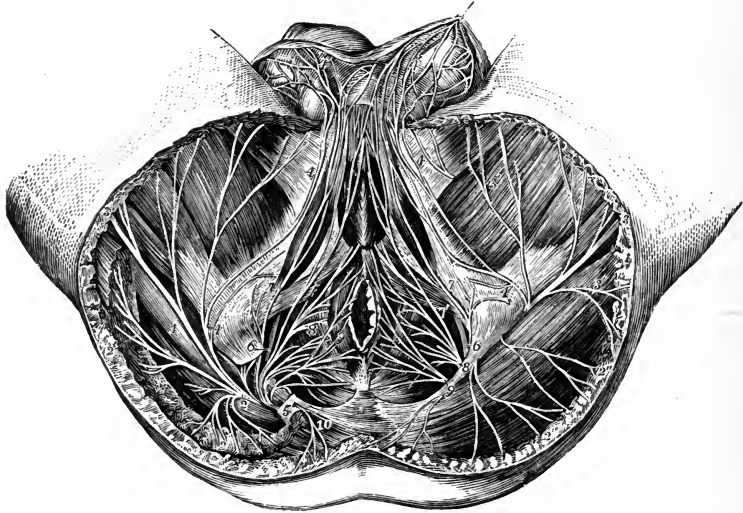


Fig. 215.—DISSECTION OF THE PERINEUM OF THE MALE TO SHOW THE DISTRIBUTION OF THE PUDIC AND OTHER NERVES. (Hirschfeld and Leveillé.) $\frac{1}{4}$

On the right side a part of the gluteus maximus muscle and the great sacro-sciatic ligament have been removed : 1, great sciatic nerve of the right side ; 2, 2', on the right side, inferior gluteal nerve ; 2'', on the left side, gluteal cutaneous branches of the small sciatic ; 3, small sciatic nerve in the thigh ; 4, 4, inferior pudendal nerve ; 4', network of this and the superficial perineal nerves in the scrotum ; 5, right pudic nerve ; 6, superior branch or dorsal nerve to the penis ; 7, external superficial perineal branch ; 7', internal superficial perineal branch ; 8, deep or musculo-bulbal branches ; 9, inferior hæmorrhoidal nerve ; 10, perforating cutaneous nerve.

Varieties.—In the high form of plexus the pudic nerve may receive fibres from the fifth lumbar (Eisler). Henle describes and figures a root to the pudic from the fifth sacral nerve, but this was never met with by Eisler or Paterson. The inferior hæmorrhoidal nerve often pierces the great or the small sacro-sciatic ligament on its way to the perineum (Eisler). The external superficial perineal nerve may also pierce the great sacro-sciatic ligament.

SUMMARY.—The pudic nerve supplies the skin and muscles of the perineum, the penis, and part of the scrotum in the male ; and the clitoris, labia, and other corresponding parts in the female. It communicates with the inferior pudendal branch of the small sciatic nerve.

Great sciatic nerve.—The great sciatic nerve (*nervus ischiadicus*), the largest nerve in the body, supplies the muscles at the back of the thigh, and by the branches continued from it gives nerves to all the muscles below the knee and to the greater part of the integument of the leg and foot. The several joints of the lower limb receive filaments from it and its branches.

This large nerve is the continuation of the main part of the sacral plexus. It extends from the lower border of the pyriformis muscle to somewhat below the middle of the thigh, where it separates into two large divisions, named the *internal* and *external popliteal nerves*. At first it lies in the hollow between the great

trochanter and the ischial tuberosity, covered by the gluteus maximus and resting on the gemelli, obturator internus, and quadratus femoris muscles, in company with the small sciatic nerve and the sciatic artery, and receiving from that artery a branch which runs for some distance in its substance. Lower down it rests on the adductor magnus, and is covered behind by the long head of the biceps muscle.

Branches.—In its course downwards, the great sciatic nerve supplies offsets to the hamstring muscles, viz., the semitendinosus, two heads of the biceps, and semimembranosus. A branch is likewise given to the inner part of the adductor magnus.

The branches of the great sciatic nerve to the muscles arising from the ischial tuberosity are associated with its internal popliteal division, from which, however, they may be separated up to their origin from the sacral plexus. They are then found to arise in the following order from above downwards:—the nerves to the adductor magnus (from 4 and 5 l) and semimembranosus (4, 5 l and 1 s), these being commonly united in one cord; two branches for the semitendinosus (from 5 l, 1 and 2 s), one supplying the part of the muscle above, and the other the part below the tendinous inscription; and the nerve of the long head of the biceps (from 1, 2 and 3 s). The nerve of the short head of the biceps is united with the external popliteal division, and according to Paterson may be followed up to 5 l, 1 and 2 s.

Varieties.—The bifurcation of the great sciatic nerve may take place at any point intermediate between the sacral plexus and the lower part of the thigh; and in some cases the two popliteal nerves arise separately from the sacral plexus (see p. 324). Very rarely the division takes place below the popliteal space (Henle). A branch of the great sciatic to join the small sciatic on the back of the thigh is said to be normal by Krause, of frequent occurrence by Henle. In one instance a nerve to the short head of the biceps arose directly from the sacral plexus in union with the inferior gluteal nerve (G. D. T.).

Internal popliteal nerve.—The internal popliteal (*n. tibialis*), the larger of the two divisions of the great sciatic nerve, following the same direction as the parent trunk, continues along the middle of the popliteal space to the lower border of the popliteus muscle, beyond which point the continuation of the trunk receives the name of *posterior tibial*. The internal popliteal nerve lies at first at a considerable distance from the popliteal artery, at the outer side and nearer to the surface; but, from the knee-joint downwards, the nerve, continuing a straight course, is close behind the artery, and then crosses it rather to the inner side.

Branches.—The internal popliteal nerve supplies branches to the knee-joint and to the muscles of the calf of the leg, and also part of a cutaneous branch, the external or short saphenous nerve.

(a) The *articular branches* are given off from the upper part of the popliteal trunk, and are generally three in number; two of them accompany the upper and lower articular arteries of the inner side of the knee-joint, the third follows the middle or azygos artery. These nerves pierce the ligamentous tissue of the joint. The upper one is often wanting.

(b) The *muscular branches* arise from the nerve while it is contained in the popliteal space. They include two nerves to the gastrocnemius (1, 2 s)—one to each head of the muscle; a small nerve to the plantaris (4, 5 l, 1 s), derived either from the branch to the outer head of the gastrocnemius, or directly from the main trunk; a considerable branch to the soleus (5 l, 1, 2 s), which enters the muscle on its posterior aspect, close to the upper border; and a nerve to the popliteus (4, 5 l, 1 s). The last branch arises somewhat lower down, and is more deeply placed, than the others; it descends on the outer side of the popliteal vessels, gives off filaments to the superior tibio-fibular articulation, to the tibia, and to the interosseous membrane, and then turns beneath the lower border of its muscle, which it penetrates on the deep or anterior surface. The branch to the tibia enters the shaft of the bone with the medullary artery: that to the interosseous membrane is a long slender twig

which, after supplying filaments to the anterior and posterior tibial arteries, is continued downwards in the membrane to end in the inferior tibio-fibular articulation, and the periosteum of the lower part of the tibia; small Pacinian corpuscles occur on the filaments passing to the bone and ligaments.

(c) The *cutaneous branch*.—*External* or *short saphenous nerve (n. suralis)*.—The cutaneous branch of the internal popliteal nerve (*tibial communicating nerve; n. cutaneus surae medialis*) (1, 2 s) descends along the leg, in the furrow between the heads of the

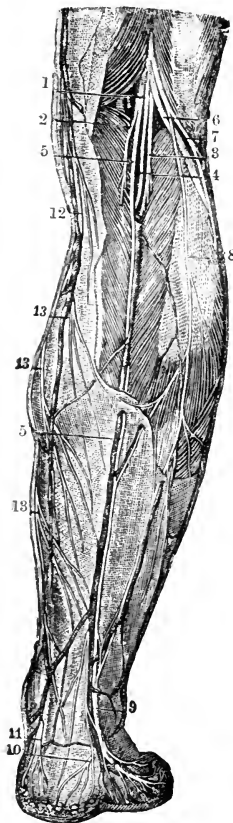


Fig. 216.—POSTERIOR CUTANEOUS NERVES OF THE LEG. (From Sappey, after Hirschfeld and Leveillé.)

1, internal popliteal nerve; 2, branch to the inner head of the gastrocnemius muscle; 3, 4, branches to the outer head and plantaris; 5, tibial communicating nerve; 6, external popliteal nerve; 7, lateral cutaneous branch of the leg; 8, peroneal communicating branch, descending to unite with the tibial communicating in 9, the external saphenous nerve; 10, calcaneal branch from this nerve; 11, calcaneal and plantar cutaneous branches from the posterior tibial nerve; 12, internal saphenous nerve; 13, posterior branches of this nerve.

gastrocnemius muscle, to about midway between the knee and the foot. Here it perforates the fascia, and a little lower down is usually joined by a branch from the external popliteal nerve (*peroneal communicating*). After receiving this communicating branch, the external saphenous nerve descends beneath the integument near the outer side of the tendo Achillis in company with the short saphenous vein, and turns forwards below the external malleolus to end in the skin on the outer side of the little toe, forming also a communication on the dorsum of the foot with the outer division of the musculocutaneous nerve. While turning round the external malleolus, the external saphenous nerve gives off *external calcaneal branches* to the skin on the outer side of the heel; and other filaments pass to the ankle-joint and the astragalo-calcaneal articulation (Rüdinger).

Varieties.—The union between the tibial communicating nerve and the branch of the external popliteal nerve occurs in some cases higher than usual, occasionally even at or close to the popliteal space. It sometimes happens that the communication between the nerves is altogether wanting; in which case the cutaneous nerve to the foot is generally continued from the branch of the internal popliteal nerve. The area of distribution of the external saphenous nerve in the foot is often increased, so that it supplies in part or wholly the outer one and a half, or even two and a half toes on their dorsal aspect: in these cases the peroneal communicating branch is said to be of larger size than usual. Occasionally the external saphenous nerve ends on the outer border of the foot, without reaching the toes.

Posterior tibial nerve.—The internal popliteal nerve receives the name of posterior tibial at the lower margin of the popliteus muscle. It passes down the leg with the posterior tibial artery, lying for a short distance on the inner side of the vessel and afterwards on the outer side, the artery inclining inwards from its origin while the nerve takes a straighter course. In the interval between the inner malleolus and the heel, it divides into the two *plantar nerves (internal and external)*. The posterior tibial nerve, like the accompanying vessels, is covered at first by the muscles of the calf of the leg, afterwards only by the integument and fascia, and it rests upon the deep-seated muscles.

Branches.—The deep muscles on the back of the leg, the fibula, the integument of the sole of the foot, and the ankle-joint receive branches from the posterior tibial nerve in its course along the leg.

(a) The *muscular branches* (5 l, 1, 2 s) emanate from the upper part of the nerve either separately or by a common trunk; one is distributed to each of the deep muscles, viz., the tibialis posticus, the flexor longus digitorum, and the flexor longus hallucis; and a second nerve is furnished to the soleus, piercing the deep surface of the muscle.

(b) The *fibular branch* is a long slender offset which arises in common with the nerves to the deep muscles, and descends, beset with numerous Pacinian corpuscles, in the canal of the peroneal vessels as far as the ankle. It gives off filaments to the vessels which it accompanies, to the shaft of the fibula with the medullary artery, and to the periosteum covering that bone (Raubert).

(c) The *calcaneo-plantar nerve* (1, 2 s) is given off by the posterior tibial in the lower part of the leg, and becomes superficial by piercing the internal annular ligament. It divides into *internal calcaneal branches* which ramify in the integument on the inner side of the heel, and *plantar cutaneous branches* which supply the skin of the inner and hinder part of the sole.

(d) One or two *articular filaments* pass from the posterior tibial nerve close above its division to the inner side of the ankle-joint (Rüdinger).

Internal plantar nerve.—The internal plantar (4, 5 l, 1 s), slightly the larger of the two nerves to the sole of the foot into which the posterior tibial divides, accompanies the internal or smaller plantar artery, and supplies nerves to both sides of the inner three toes, and to one side of the fourth. From the point at which it separates from the posterior tibial nerve, it is directed forwards under cover of the first part of the abductor of the great toe; then passing between that muscle and the short flexor of the toes, it gives off the internal collateral branch for the great toe, and divides about the middle of the foot into three digital branches. The outermost of these branches communicates with the external plantar nerve. The distribution of this nerve in the foot closely resembles that of the median nerve in the hand.

Branches.—(a) *Muscular branches* are supplied to the abductor hallucis and flexor brevis digitorum.

(b) An *articular filament* passes deeply between the abductor hallucis and the tendons of the long flexors of the toes to supply the joints between the astragalus, the navicular, and the inner two cuneiform bones (Rüdinger).

(c) Small *plantar cutaneous branches* perforate the plantar fascia to ramify in the integument of the sole of the foot.

(d) The *digital branches* are named numerically from within outwards: the outer three pass from under cover of the plantar fascia near the clefts between the toes. The first or innermost branch continues single, but the other three bifurcate to supply the adjacent sides of two toes. They are distributed as follows:—

The *first* digital branch is destined for the inner side of the great toe; it becomes subcutaneous farther back than the others, and sends off a branch to the flexor brevis hallucis muscle.

The *second* branch, having reached the interval between the first and second metatarsal bones, furnishes a small twig to the first lumbricalis muscle, and bifurcates behind the cleft between the great toe and the second to supply their contiguous sides.

The *third* digital branch, corresponding with the second interosseous space, divides in a manner similar to that of the second branch into two offsets for the sides of the second and third toes.

The *fourth* digital branch, distributed to the adjacent sides of the third and fourth toes, usually has a communication with the external plantar nerve.

Along the sides of the toes, cutaneous and articular filaments are given from these digital nerves; and, opposite the ungual phalanx, each sends a dorsal branch to the pulp beneath the nail, and then runs on to the ball of the toe, where it is distributed like the nerves of the fingers. Pacinian corpuscles are attached at intervals to these nerves.

External plantar nerve.—The external plantar nerve (1, 2 s) completes the supply of digital nerves to the toes, furnishing branches to the little toe and half the fourth; it also gives a deep branch of considerable size, which is distributed to several of the short muscles in the sole of the foot. There is thus a great resemblance between the distribution of this nerve in the foot and that of the ulnar nerve in the hand.

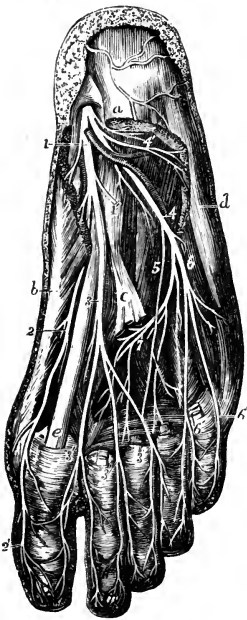


Fig. 217.—SUPERFICIAL AND DEEP DISTRIBUTION OF THE PLANTAR NERVES. (After Hirschfeld and Leveillé, slightly modified.) (Allen Thomson.) $\frac{1}{3}$

Parts of the flexor brevis digitorum, abductor hallucis, abductor minimi digiti, and the tendons of the flexor longus digitorum, together with the lumbricales muscles, have been removed so as to bring into view the adductor transversus and interosseous muscles in the middle of the foot.

a, upon the posterior extremity of the flexor brevis digitorum, near which, descending over the heel, are seen ramifications of the calcaneal branch of the posterior tibial nerve; *b*, abductor hallucis; *c*, tendon of the flexor longus digitorum, divided close to the place where it is joined by the flexor accessorius; *d*, abductor minimi digiti; *e*, tendon of the flexor longus hallucis between the two portions of the flexor brevis hallucis; 1, internal plantar nerve giving twigs to the abductor hallucis, and 1', a branch to the flexor brevis digitorum, cut short; 2, inner branch of the internal plantar nerve, giving branches to the flexor brevis hallucis, and forming 2', the internal collateral nerve of the great toe; 3, continuation of the internal plantar nerve, dividing into three branches, which form, 3', 3', 3', the plantar digital nerves of the first and second, second and third, and third and fourth toes; 4, external plantar nerve; 4', its branch to the abductor minimi digiti; 5, twig of union between the plantar nerves; 6, superficial branch of the external plantar nerve, dividing into 6', 6', the collateral digital nerves of the fourth and fifth toes and the external nerve of the fifth; 7, deep branch of the external plantar nerve.

The external plantar nerve runs obliquely forwards towards the outer side of the foot, along with the external plantar artery, between the flexor brevis digitorum and the flexor accessorius, as far as the interval between the former muscle and the abductor of the little toe. Here it divides into a superficial and a deep branch, having previously furnished offsets to the abductor minimi digiti and the flexor accessorius, as well as a filament through the last muscle to the calcaneo-cuboid articulation (Rüdinger).

(*a*) The *superficial portion* separates into two *digital branches*, which have the same general arrangement as the digital branches of the internal plantar nerve. The outermost of these is undivided, and runs along the outer side of the little toe: it is smaller than the other, and pierces the plantar fascia farther back. The short flexor muscle of the little toe, and sometimes one or both of the interosseous muscles of the fourth space, receive branches from this nerve.

The larger digital branch usually communicates with the internal plantar nerve, and bifurcates near the cleft between the fourth and fifth toes to supply one side of each.

(*b*) The *deep or muscular part* of the external plantar nerve dips into the sole of the foot with the external plantar artery, under cover of the tendons of the flexor

muscles and the accessorius, and terminates in numerous branches for the following muscles:—all the interosseous (dorsal and plantar) except occasionally one or both of those in the fourth space, the outer three lumbricales, the adductor transversus and adductor obliquus hallucis. This part of the nerve also furnishes *articular filaments* to the tarso-metatarsal, and frequently to the metatarso-phalangeal joints, as well as minute *perforating branches*, which pass upwards through the posterior ends of the intermetatarsal spaces to join the interosseous branches of the anterior tibial nerve (Rüdinger).

Out of ten dissections by Brooks, the lumbricales were supplied as stated above in nine. In the tenth case the first and second lumbricales received branches from both the internal and

Fig. 218.—CUTANEOUS NERVES OF OUTER SIDE OF THE LEG AND FOOT. (From Sappey, after Hirschfeld and Leveillé.) $\frac{3}{4}$

1, external popliteal nerve; 2, its lateral cutaneous branch; 3, peroneal communicating branch which unites with 4, the tibial communicating, in 5, the external saphenous nerve; 6, calcaneal branch of the external saphenous; 7, external dorsal digital branch of the fifth toe; 8, dorsal digital branch of the fourth and fifth toes; 9, 9, musculo-cutaneous nerve; 10, 10, its two divisions; 11, union with the external saphenous; 12, communication between its outer and inner branches; 13, anterior tibial nerve, shown by the removal of a part of the muscles; 14, its inner terminal branch, emerging in the space between the first and second toes, where it gives the collateral dorsal digital branches to their adjacent sides; 15, recurrent articular nerve.

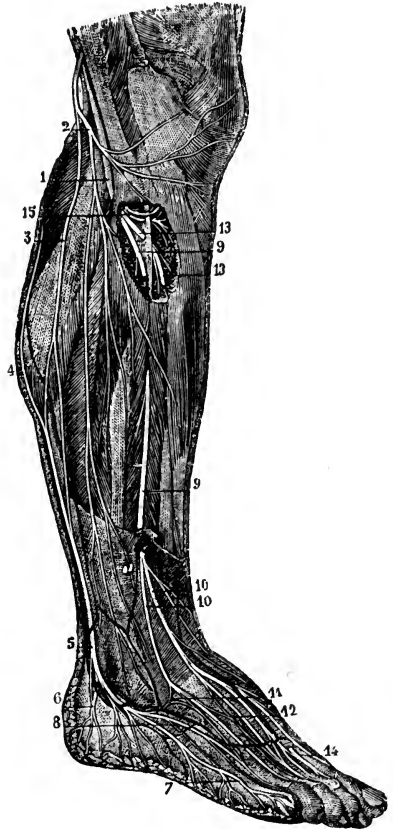
external plantar nerves (Journ. Anat., xxi, 575). The branch of the external plantar nerve to the second lumbricalis runs forwards beneath the adductor transversus hallucis, and then turns backwards over that muscle to reach its destination. Cruveilhier describes the branch to the third lumbricalis as piercing the adductor transversus hallucis. The deep part of the external plantar nerve rarely gives a branch to the outer head of the flexor brevis hallucis (normal according to Henle and Schwalbe).

SUMMARY OF THE INTERNAL POPLITEAL NERVE.—This nerve supplies all the muscles of the back of the leg and sole of the foot, the articulations of the knee, ankle and foot, the bones and vessels of the leg, and the integument of the plantar aspect of the toes, the sole of the foot, and in part that of the lower half of the back of the leg.

External popliteal or peroneal nerve (*n. peronæus communis*).—This nerve descends obliquely along the outer side of the popliteal space, lying close to the biceps muscle. Continuing downwards over the outer part of the gastrocnemius muscle (between it and the biceps) and below the head of the fibula, the nerve turns round that bone and, passing between it and the peroneus longus muscle, divides into the *anterior tibial* and the *musculo-cutaneous nerves*.

BRANCHES.—Some articular and cutaneous branches are derived from the external popliteal nerve before its final division.

(a) The *articular branches* are conducted to the outer side of the capsular ligament of the knee-joint by the upper and lower articular arteries of that side. They



sometimes arise together, and the upper one occasionally springs from the great sciatic nerve before the bifurcation. From the lower branch a filament is given to the superior tibio-fibular articulation (Rüdinger).

From the place of division of the external popliteal nerve, a branch (often double) called the *recurrent articular nerve* ascends through the tibialis anticus with the anterior tibial recurrent artery; its fibres terminate mainly in that muscle, but filaments may be traced to the superior tibio-fibular articulation, the periosteum over the outer tuberosity of the tibia, and the fore part of the knee-joint.

(b) The *cutaneous branches* (5 l, 1, 2 s), generally two in number, supply the skin on the back part and outer side of the leg.

The *peroneal* or *fibular communicating branch*, which usually joins the short saphenous nerve below the middle of the back of the leg, is the largest of these nerves. In some instances, it continues as a separate branch, and its cutaneous filaments reach down to the heel or on to the outer side of the foot.

The *lateral cutaneous branch of the leg* (*n. cutaneus suræ lateralis*), often arising in conjunction with the foregoing, extends along the outer side of the leg to the middle or lower part, sending offsets both backwards and forwards.

In some cases there is another cutaneous branch which arises from the upper part of the external popliteal nerve, and ramifies over the back of the calf, taking the place of the small sciatic nerve below the knee.

Musculo-cutaneous nerve.—The musculo-cutaneous nerve (*n. peronæus superficialis*) (4, 5 l, 1 s) descends between the peronei muscles and the long extensor of the toes, and reaches the surface by perforating the fascia in the lower part of the leg on the anterior aspect. It then divides into two branches, distinguished as external and internal, which proceed to the toes. The two branches sometimes perforate the fascia at different spots.

Branches.—(a) *Muscular branches* are given to the peroneus longus and peroneus brevis.

(b) *Cutaneous branches* given off near the primary division are distributed to the lower part of the leg.

(c) The *internal branch* of the musculo-cutaneous nerve, passing forwards along the dorsum of the foot, furnishes one branch to the inner side of the great toe, and another to the contiguous sides of the second and third toes. It also gives offsets which extend over the inner ankle and side of the foot. This nerve communicates with the long saphenous nerve on the inner side of the foot, and with the anterior tibial nerve between the first and second toes.

(d) The *external branch*, smaller than the internal, descends over the foot towards the fourth toe, which, together with the contiguous borders of the third and fifth toes, it supplies with branches. Cutaneous nerves, derived from this branch, spread over the outer ankle and the outer side of the foot, where they are connected with the short saphenous nerve.

The dorsal digital nerves are continued on to the last phalanges of the toes.

The number of toes supplied by each of the two divisions of the musculo-cutaneous nerve is liable to vary; together, these nerves commonly supply all the toes on the dorsal aspect, excepting the outer side of the little toe, which receives a branch from the short saphenous nerve, and the adjacent sides of the great toe and the second toe, to which the anterior tibial nerve is distributed: with this latter branch, however, it generally communicates.

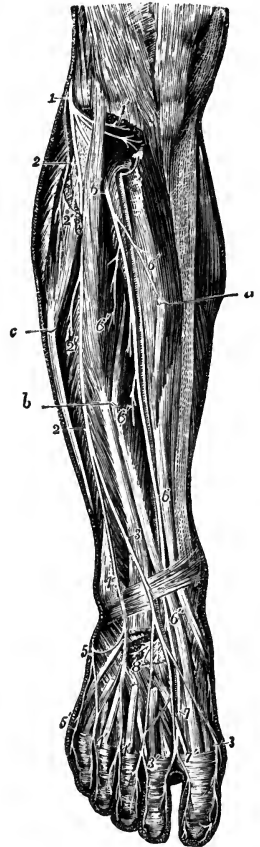
Varieties.—The external division of the musculo-cutaneous nerve is often reduced in size, the deficiency being supplied by the external saphenous nerve. Less frequently the internal branch is replaced to a greater or less extent on the toes by the anterior tibial nerve. The

number of toes supplied by the musculo-cutaneous nerve is seldom increased. (On variations in the nerves of the dorsum of the foot, and their relative frequency, see the Second Annual Report of the Committee of Collective Investigation of the Anat. Soc., by Arthur Thomson, Journ. Anat., xxvi, 1891.)

Anterior tibial nerve.—The anterior tibial nerve (*n. peronæus profundus*) (4, 5 l, 1 s), commencing between the fibula and the peroneus longus, inclines obliquely beneath the long extensor of the toes to the fore part of the interosseous membrane, and there comes into contact with the anterior tibial vessels; with these vessels it descends to the front of the ankle-joint, where it divides into an external and an internal branch. The nerve reaches the anterior tibial artery about

Fig. 219.—DISTRIBUTION OF THE BRANCHES OF THE EXTERNAL POPLITEAL NERVE ON THE FRONT OF THE LEG AND DORSUM OF THE FOOT. (After Hirschfeld and Leveillé.) $\frac{1}{2}$

The upper part of the peroneus longus muscle has been removed, the tibialis anticus, the long extensor of the great toe and the peroneus longus are drawn apart in the leg by hooks marked *a*, *b*, and *c*, and the tendons of the extensor muscles have been removed on the dorsum of the foot; 1, external popliteal or peroneal nerve, winding round the outer part of the fibula; 1', its recurrent articular branches exposed by the dissection of the upper part of the tibialis anticus muscle; 2, 2, musculo-cutaneous nerve; 2' 2', twigs to the long and short peroneal muscles; 3, 3', internal branch of the musculo-cutaneous nerve; 4, 4', 4', its external branch; 5, external saphenous nerve, uniting at two places with the outer branch of the musculo-cutaneous; 5', its branch to the outer side of the fifth toe; 6, placed on the upper part of the extensor longus digitorum, marks the anterior tibial nerve passing beneath the muscle; 6, placed farther down on the tendon of the tibialis anticus, points to the nerve as it lies in front of the anterior tibial artery; 6', 6', its muscular branches in the leg; 6'', on the tendon of the extensor longus hallucis, points to the anterior tibial nerve after it has passed into the foot behind that tendon; 7, its inner branch, uniting with a twig of the musculo-cutaneous, and giving the dorsal digital nerves to the adjacent sides of the first and second toes; 8, distribution of its outer branch to the extensor brevis digitorum and tarsal articulations.



the junction of the upper with the second fourth of the leg, and is thence placed in front of the vessels as far as the ankle, at which spot it is usually on their outer side.

Branches.—(*a*) *Muscular branches.*—In its course along the leg, the anterior tibial nerve gives offsets to the adjacent muscles, namely, the tibialis anticus, the extensor longus digitorum, the extensor proprius hallucis, and the peroneus tertius.

(*b*) An *articular filament* for the ankle-joint arises from the lower part of the nerve.

(*c*) The *external branch* of the anterior tibial nerve turns outwards over the tarsus beneath the short extensor of the toes; and, having become enlarged (like the posterior interosseous nerve on the wrist) breaks up into branches which supply the short extensor muscle, and the articulations of the foot.

(*d*) The *internal branch*, continuing onwards in the direction of the anterior tibial nerve, accompanies the dorsal artery of the foot to the first interosseous space, and ends in two branches, which supply the integument on the neighbouring sides of the great toe and the second toe on their dorsal aspect. It communicates with the internal division of the musculo-cutaneous nerve.

From the internal branch one, and from the external two or three slender *interosseous branches* are sent forwards to the intermetatarsal spaces, where they are joined by the perforating twigs of the external plantar nerve (p. 335). They supply

filaments to the tarso-metatarsal articulations and the periosteum of the metatarsal bones, and terminate in the metatarso-phalangeal joints. The second and sometimes the first of these nerves give twigs also to the dorsal interosseous muscles upon which they lie (Rüdinger, Cunningham).

Varieties.—Occasionally the anterior tibial nerve supplies also the inner side of the great toe, or the adjacent sides of the second and third toes. In one case the anterior tibial nerve sent branches to the outer three and a half toes, the great toe and the inner half of the second being supplied by the musculo-cutaneous (F. T. Roberts, Liverpool Med. and Surg. Reports, vi, 1867). Very rarely the digital branches are altogether wanting.

SUMMARY OF THE EXTERNAL POPLITEAL NERVE.—This nerve supplies, besides articular branches to the knee, ankle, and foot, the muscles and integument of the outer side and front of the leg and dorsum of the foot. It gives the peroneal communicating branch to the short saphenous nerve, and communicates with the long saphenous nerve.

SYNOPSIS OF THE SENSORY DISTRIBUTION OF THE CEREBRO-SPINAL NERVES.

1. **In the head.**—The *face and head in front of the ear* are supplied with sensory nerves from the fifth cranial nerve. The ophthalmic division supplies branches to the forehead, upper eyelid, and dorsum of the nose. The superior maxillary division supplies the greater part of the cheek, the side of the nose, upper lip, lower eyelid, and the region behind the eye over the fore part of the temporal fascia. The inferior maxillary division supplies the chin and lower lip, the hinder part of the cheek, the fore and upper parts of the pinna of the ear on its outer side, and the integument in front of the ear and upwards on the side of the head.

The *head behind the ear* is mainly supplied by the great occipital branch of the posterior division of the second spinal nerve, but above the occipital protuberance there is also distributed the branch from the posterior division of the third spinal nerve; and in front of the area of the great occipital nerve is a space supplied by anterior divisions of spinal nerves, viz., the back of the pinna of the ear, and the lower part of its outer surface, together with the integument behind, and that in front over the parotid gland, which are supplied by the great auricular nerve (2, 3 c); while between the area of this nerve and the great occipital the small occipital nerve (2, 3 c) reaches the scalp, and sends a branch to the upper part of the pinna. The auricular branch of the pneumo-gastric nerve also is distributed on the back of the ear.

Cavities of the head.—The mucous membrane of the *nasal fossa* is supplied by the olfactory nerves and the first and second divisions of the fifth nerve. The ramifications of the olfactory nerves are restricted to the small olfactory region at the highest part of the cavity; the nasal branch of the ophthalmic division of the fifth nerve supplies the anterior portion of the lining membrane; and the superior maxillary serves all the remainder. The *frontal sinus* is supplied by the nasal nerve, the *ethmoidal cells* and *sphenoidal sinus* by the nasal and superior maxillary, and the *maxillary antrum* by the superior maxillary nerve.

In the *mouth*, the upper lip, the teeth of the upper jaw with the gum, and the mucous membrane of the hard palate, are supplied by the superior maxillary nerve. The lower lip and the inner surface of the cheek, the lower teeth and the gum, and the greater part of the tongue in front of the anterior pillars of the fauces, together with the mucous membrane of the alveolo-lingual sulcus, are supplied by the inferior maxillary nerve. The taste-fibres of the fore part of the tongue probably run in the chorda tympani; and the root of the tongue is supplied by the glosso-pharyngeal

nerve. The *soft palate* receives branches from the superior maxillary and glosso-pharyngeal nerves. The mucous membrane of the *pharynx* in its upper part, including the mouth of the Eustachian tube, receives twigs of the superior maxillary

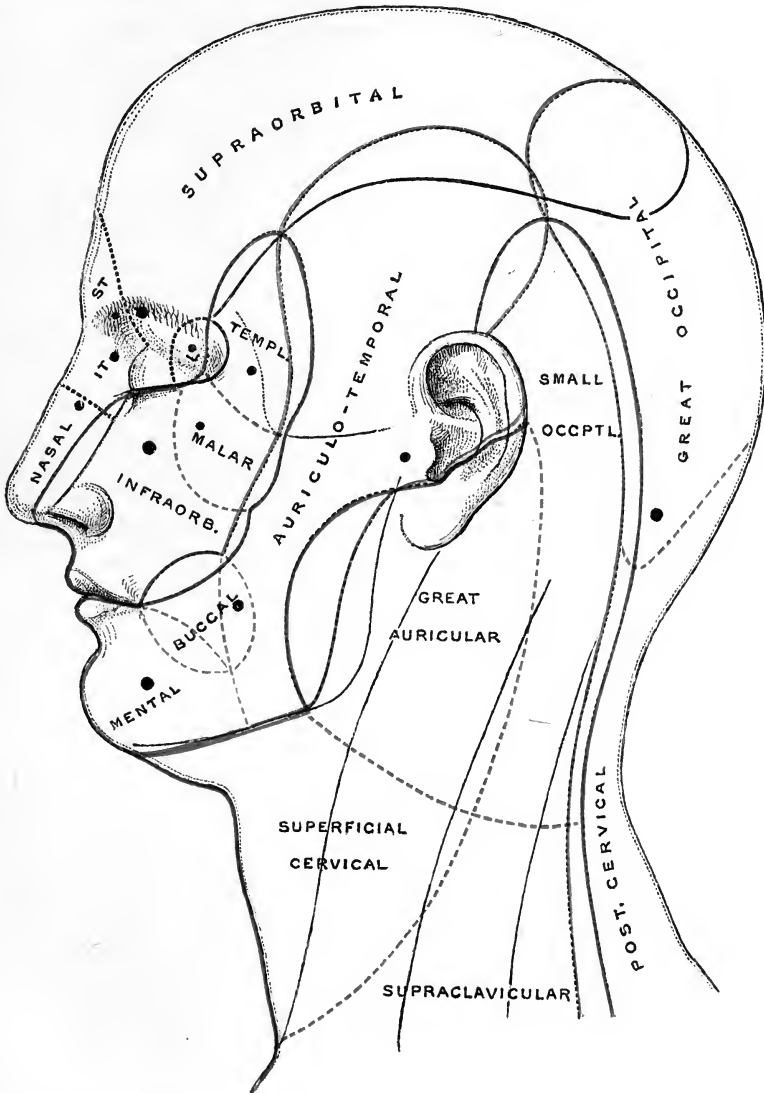


Fig. 220.—CUTANEOUS AREAS OF THE NERVES OF THE HEAD AND NECK. (G.D.T.)

The areas supplied by the branches of the first division of the fifth are enclosed by black lines; those supplied by the second division of the fifth and by branches of the cervical plexus by red lines; and those supplied by the third division of the fifth and by the posterior primary divisions of the cervical nerves by blue lines. ST, supratrochlear, IT, infratrochlear, and L, lacrimal branches of the first division of the fifth. The hinder part of the cheek, on which the word "auriculo" is placed, receives fibres of the auriculo-temporal nerve through the communication with the facial. The black spots denote the points at which the respective nerves become superficial.

In this and similar figures the overlapping of adjacent nerves is indicated, so that along the boundary of each area there is a region which is supplied by the two nerves. It is, however, to be remarked that, owing to the difficulty of determining anatomically the precise extent of skin supplied by a branch of nerve, and the great degree of individual variability in this respect, neither the extent of the several areas nor the degree of overlapping are to be regarded otherwise than as approximate representations of what appears to be the average condition.

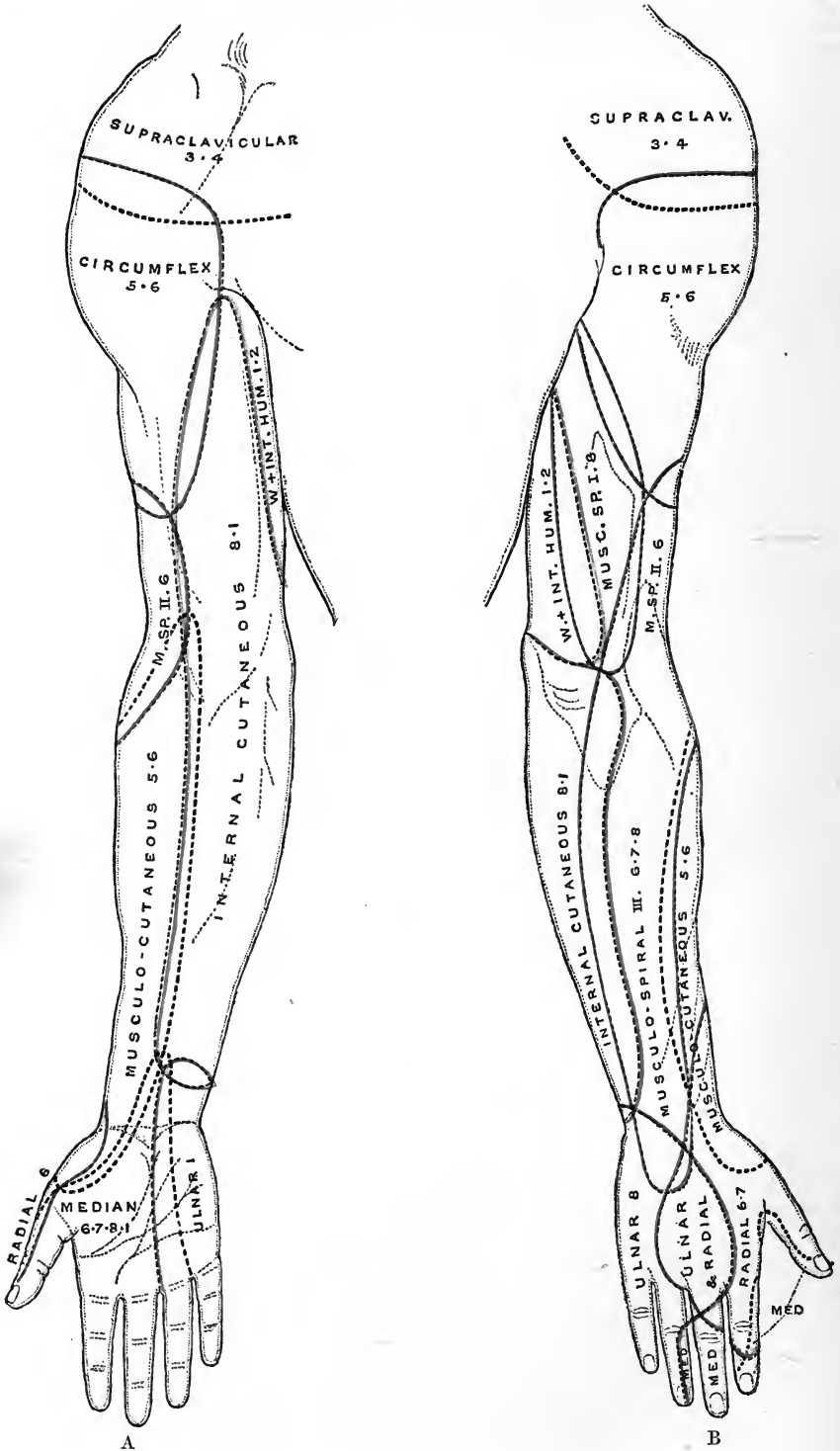


Fig. 221.

nerve; in the rest of its extent it is supplied by the glosso-pharyngeal and pneumo-gastric nerves, mainly through the pharyngeal plexus, but in the neighbourhood of the superior aperture of the larynx it receives filaments of the superior laryngeal nerve. The *larynx* is supplied mostly by the superior laryngeal nerve, but in its lowest part it receives fibres from the inferior laryngeal, which also supplies the *trachea*. The sensory nerves of the *oesophagus* are probably derived from the pneumo-gastric.

The mucous lining of the *tympanic cavity* and *Eustachian tube* are supplied by the glosso-pharyngeal nerve, while to the *mastoid cells* filaments pass from the same source, as well as from the inferior maxillary nerve (Luschka). The outer surface of the *tympanic membrane*, like the skin of the external auditory meatus generally, is supplied by the auriculo-temporal of the fifth and the auricular branch of the pneumo-gastric nerves.

In the *cranial cavity* the *dura mater* receives branches from the three divisions of the fifth, the pneumo-gastric, and the hypoglossal nerves.

2. **In the trunk.**—The *posterior divisions of the spinal nerves* supply an area extending on the back from the vertex of the skull to the buttock. This area is narrow in the neck; it is expanded in the upper dorsal region, extending over the back of the scapula; in the lower dorsal and lumbar regions its extent may be marked by a line drawn from the lower angle of the scapula (the arm hanging against the side) to the middle of the iliac crest; and in the buttock its lower limit is indicated by a line from the tip of the coccyx to the great trochanter (see fig. 189, p. 282). The series of cutaneous branches is not continuous, there being gaps in the lower cervical and lower lumbar regions, corresponding to the middle parts of the brachial and lumbo-sacral plexuses; that is, those spinal nerves which contribute most largely to the supply of the limbs do not furnish dorsal cutaneous offsets.

The *area supplied by the cervical plexus*, besides extending upwards, as already mentioned, on the lateral part of the skull, stretches over the front and sides of the neck, and the upper part of the shoulder and breast.

The *area of the anterior divisions of the dorsal and first lumbar nerves* meets superiorly with that of the cervical plexus, and posteriorly with that of the posterior divisions of the dorsal and lumbar nerves. It passes down over the haunch and along by the outer part of Poupart's ligament, and includes part of the penis and scrotum, and a small portion of the integument of the thigh internal to the saphenous opening. This extensive area may be subdivided by a line passing through the nipple downwards to the centre of Poupart's ligament into a mesial region supplied by the anterior cutaneous branches of the nerves, and a larger lateral region supplied by the lateral cutaneous branches. In the former region the skin over the ensiform process is supplied by the sixth and seventh dorsal nerves, and that around the umbilicus usually by the tenth dorsal nerve.

The *root of the penis* on its dorsal aspect and a part of the *scrotum* anteriorly are

Fig. 221.—CUTANEOUS AREAS OF THE NERVES OF THE UPPER LIMB. (G.D.T.)

A, anterior view; B, posterior view.

The areas supplied by the circumflex and musculo-spiral nerves, derived from the posterior cord of the brachial plexus, are circumscribed by red outlines; those of the ulnar, internal cutaneous, and nerve of Wrisberg (W), from the inner cord of the plexus, together with the intercosto-humeral nerve, by blue lines; and those of the musculo-cutaneous from the outer cord of the plexus, with the median derived from both outer and inner cords, by interrupted black lines. The lower limit of the supra-clavicular nerves over the shoulder is also shown by a broken black line. The numerals following the names of the nerves indicate the spinal nerves from which the latter arise; 3, 4, 5, 6, 7, 8, the corresponding cervical nerves; 1, 2, the first and second dorsal nerves. The cutaneous branches of the musculo-spiral are distinguished as follows:—I, internal cutaneous; II, upper, and III, lower external cutaneous.

supplied by the ilio-inguinal and genito-crural nerves (1 *l*). The greater part of the *penis*, the lower and hinder parts of the *scrotum*, and the *perineum* are supplied by the pudic nerve (2, 3, 4 *s*), the scrotum also receiving branches from the inferior pudendal of the small sciatic (2, 3 *s*). The branches to the penis are derived mainly from the second sacral nerve, to a less extent from the third; those to the scrotum and fore part of the perineum chiefly from the third nerve, but in part also from the second; and those to the hinder part of the perineum from the fourth and third sacral nerves (Paterson).

3. **In the upper limb.**—The *shoulder*, supplied superiorly by the descending branches of the cervical plexus (3, 4 *c*), receives its cutaneous nerves inferiorly from the circumflex nerve (5, 6 *c*).

The *arm* internally is supplied by the intercosto-humeral nerve (2 *d*) and the nerve of Wrisberg (1 *d*). The inner and anterior part is supplied by the

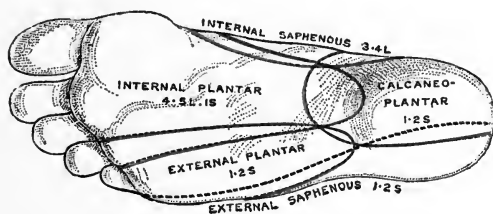


Fig. 223.—NERVE-SUPPLY OF THE SKIN OF THE SOLE. (G.D.T.)

The areas enclosed by red lines are those supplied by the external cutaneous nerve, the middle and internal saphenous branches of the anterior crural nerve, the perforating cutaneous nerve, and the lateral cutaneous, musculo-cutaneous, and anterior tibial branches of the peroneal nerve, *i.e.*, the dorsal offsets of the limb-plexus. Those enclosed in blue lines are supplied by branches derived from the ventral offsets of the limb-plexus, *viz.*, the calcaneo-plantar branch of the posterior tibial and the plantar nerves. The area of the small sciatic is enclosed internally by a blue and externally by a red line, corresponding to the double nature of the nerve (see p. 325). The area of the inner side of the leg supplied by the obturator and internal cutaneous in common, and that supplied by the external saphenous, are enclosed in interrupted black lines, the nerves concerned being derived partly from dorsal and partly from ventral divisions.

internal cutaneous nerve (8 *c*, 1 *d*) and the posterior and outer parts by the circumflex (5, 6 *c*), and by the internal and external branches of the musculo-spiral nerve (6, 7, 8 *c*).

The *forearm*, anteriorly and on the outer side, is supplied by the musculo-cutaneous (5, 6 *c*); on its outer and posterior aspect by the lower external cutaneous branch of the musculo-spiral (6, 7, 8 *c*), and inferiorly by the radial branch (6, 7 *c*) of the same nerve. On the inner side, both in front and behind, is the internal cutaneous nerve (8 *c*, 1 *d*), and inferiorly are branches of the ulnar (8 *c*, 1 *d*).

On the *back of the hand* are the radial and ulnar nerves, the radial (6, 7 *c*) supplying about three fingers and a half or less, and the ulnar (8 *c*) one and a half or more.

On the *front of the hand*, the median nerve (6, 7, 8 *c*, 1 *d*) supplies three fingers and a half, and the ulnar (1 *d*, or 8 *c*, 1 *d*) one and a half. In the *palm* is a branch of the median, and also a branch of the ulnar, given off above the wrist. On the *thenar eminence* are branches of the musculo-cutaneous, median, and radial nerves.

4. **In the lower limb.**—The *buttock* is supplied from above by the cutaneous branches of the posterior divisions of the lumbar nerves, with the ilio-hypogastric (1 *l*)

and lateral branch of the last dorsal nerves; internally by the posterior divisions of the sacral nerves; externally by the posterior branch of the external cutaneous nerve (2, 3 l) proceeding from the front; and inferiorly by the perforating cutaneous nerve (2, 3 s) and branches of the small sciatic nerve (1, 2, 3 s) proceeding from below.

The *thigh* is supplied externally by the external cutaneous nerve (2, 3 l) from the lumbar plexus; posteriorly, and in the upper half of its inner aspect, by the small sciatic (1, 2, 3 s); anteriorly, and in the lower half of the inner aspect, by the middle and internal cutaneous (2, 3 l) of the anterior crural, the latter being frequently assisted by the obturator nerve (2, 3, 4 l).

The *leg* is supplied posteriorly by the small sciatic (1, 2, 3 s) and short saphenous (1, 2 s) nerves; internally by the long saphenous (3, 4 l) and branches of the internal cutaneous of the thigh (2, 3 l) (or obturator); and outside and in front by cutaneous branches of the external popliteal nerve (5 l, 1, 2 s) and by its musculo-cutaneous branch (4, 5 l, 1 s).

On the *dorsum of the foot* are the branches of the musculo-cutaneous (4, 5 l, 1 s), supplying all the toes with the exception of the adjacent sides of the first and second, which are supplied by the anterior tibial (4, 5 l, 1 s), and the outer side of the little toe, which, with the outer margin of the foot, is supplied by the short saphenous nerve (1, 2 s). The long saphenous (3, 4 l) is the cutaneous nerve of the inner side of the foot.

The *sole of the foot* is supplied in its posterior part, together with the inner side of the heel, by the calcaneo-plantar branch of the posterior tibial nerve (1, 2 s). In front of this, the inner and larger part is supplied by the internal plantar nerve (4, 5 l, 1 s), which extends to the inner three toes and a half, while the outer part, with the remaining one toe and a half, is supplied by the external plantar nerve (1, 2 s). Over the outer side of the heel, and along the outer margin of the sole, are branches of the external saphenous nerve (1, 2 s).

CUTANEOUS DISTRIBUTION OF THE SPINAL NERVES TO THE TRUNK AND LIMBS.

The manner in which the several spinal nerves are distributed to the skin has been greatly elucidated by the experimental investigations of Sherrington, the dissections of Herringham and Paterson, and the clinical and pathological observations of Ross, Thorburn, Head, and others. From these it would appear that in the trunk the branches of each dorsal (segmental) nerve are generally distributed to a continuous area of skin, which has the form of a zone extending horizontally or obliquely from the dorsal to the ventral median line (see fig. 225, A, B, C). According to the observations of Head, the upper dorsal nerves form exceptions to this statement, their zones being interrupted laterally by the interposition of the upper limb, into which the middle portions of the first and second nerves (corresponding to their lateral cutaneous offsets) are prolonged; but Sherrington found in the monkey that there was complete continuity between the trunk and limb portions of the areas of these nerves. Inferiorly, the zone of the last dorsal nerve is produced downwards over the hip; and the first lumbar nerve, which resembles a dorsal nerve in its distribution, also supplies a zone which is similarly extended laterally over the hip, as well as ventrally to the penis, scrotum, and upper part of the thigh; while with the second lumbar nerve the series of limb-nerves proper commences. These zones, moreover, overlap to a considerable extent, owing partly to the communications established between the several trunks, as is especially the case with the lower intercostal nerves (see p. 310), and partly to the crossing of

their terminal filaments, so that there is probably no spot of the skin which is supplied only by one spinal nerve (Sherrington).

In the limbs, although the nerves have been mingled in the plexuses, there is a similar principle to be recognized in their ultimate distribution, the fibres derived from the several spinal nerves being supplied to definite continuous areas in positions which are readily explained by reference to the mode of development of the limb. Thus, the upper nerves are distributed along the preaxial side of the limb, and the lower nerves along the postaxial side, while the intermediate nerves descend along the centre of the limb, and supply only the more distal parts. The skin at the root of the limb is not supplied by offsets of the limb-plexus, but by branches of nerves which have been drawn out, as it were, with the skin of the adjoining part of the trunk during the development of the limb.

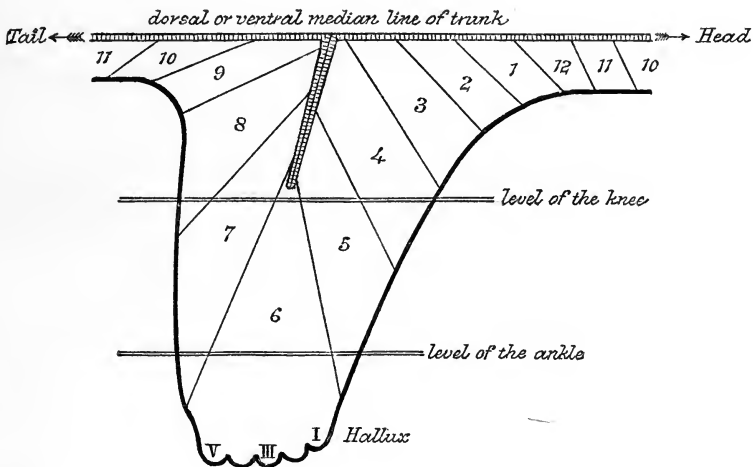


Fig. 224.—SCHEME OF THE SENSORY SPINAL SKIN-FIELDS OF THE HIND LIMB OF MONKEY (*Macacus rhesus*). (Sherrington.)

10, 11, 12, areas of lower dorsal nerves; 1—7, areas of lumbar nerves; 8—11, areas of sacral and caudal nerves. Of the seven lumbar nerves in this monkey, the second and seventh correspond respectively to the first lumbar and first sacral nerves of man. The overlapping of the skin-fields is not indicated. The arrangement is the same on the dorsal and ventral aspects.

The following rules have accordingly been formulated by Herringham from his observations on the nerves of the upper limb, and have been confirmed by Paterson for the lower limb:—

A. *Of two spots on the skin, that which is nearer the preaxial border tends to be supplied by the higher nerve.*

B. *Of two spots in the preaxial area, the lower tends to be supplied by the lower*

Fig. 225.—SEGMENTAL CUTANEOUS AREAS FROM THE FIRST DORSAL TO THE FOURTH SACRAL, AS DETERMINED BY CLINICAL AND PATHOLOGICAL OBSERVATIONS IN MAN. (Head.)

On the right side of the figures the areas are marked by different colours and modes of shading; on the left side the "maximum spots" (seat of most marked tenderness and pain) of the areas are shown. The several dorsal, lumbar and sacral areas are indicated each by the initial letter followed by a number. In C, C 7 is the seventh cervical spine, 3 to 12 are the corresponding dorsal spines, and L 1 to 4 are lumbar spines.

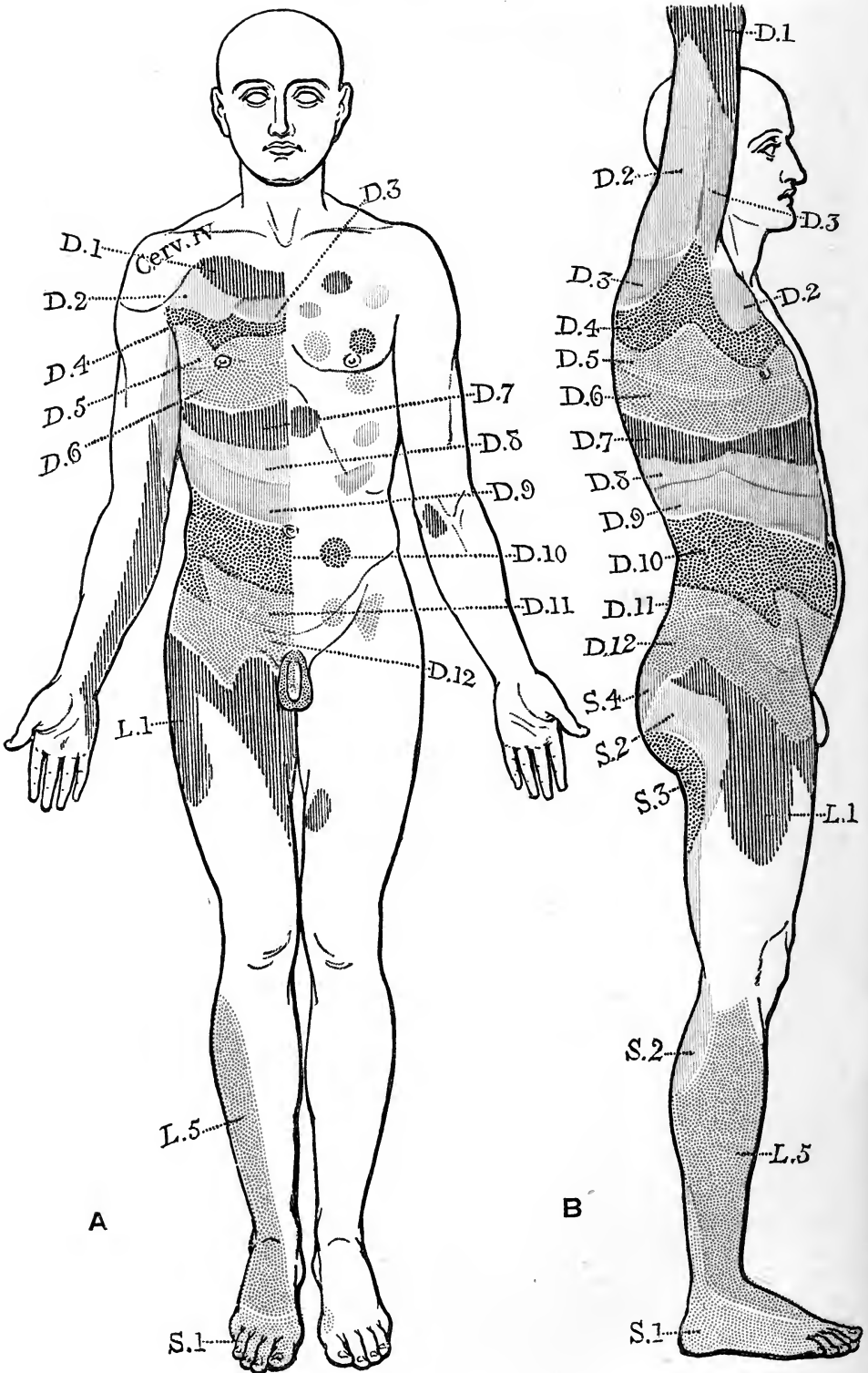


Fig. 225.

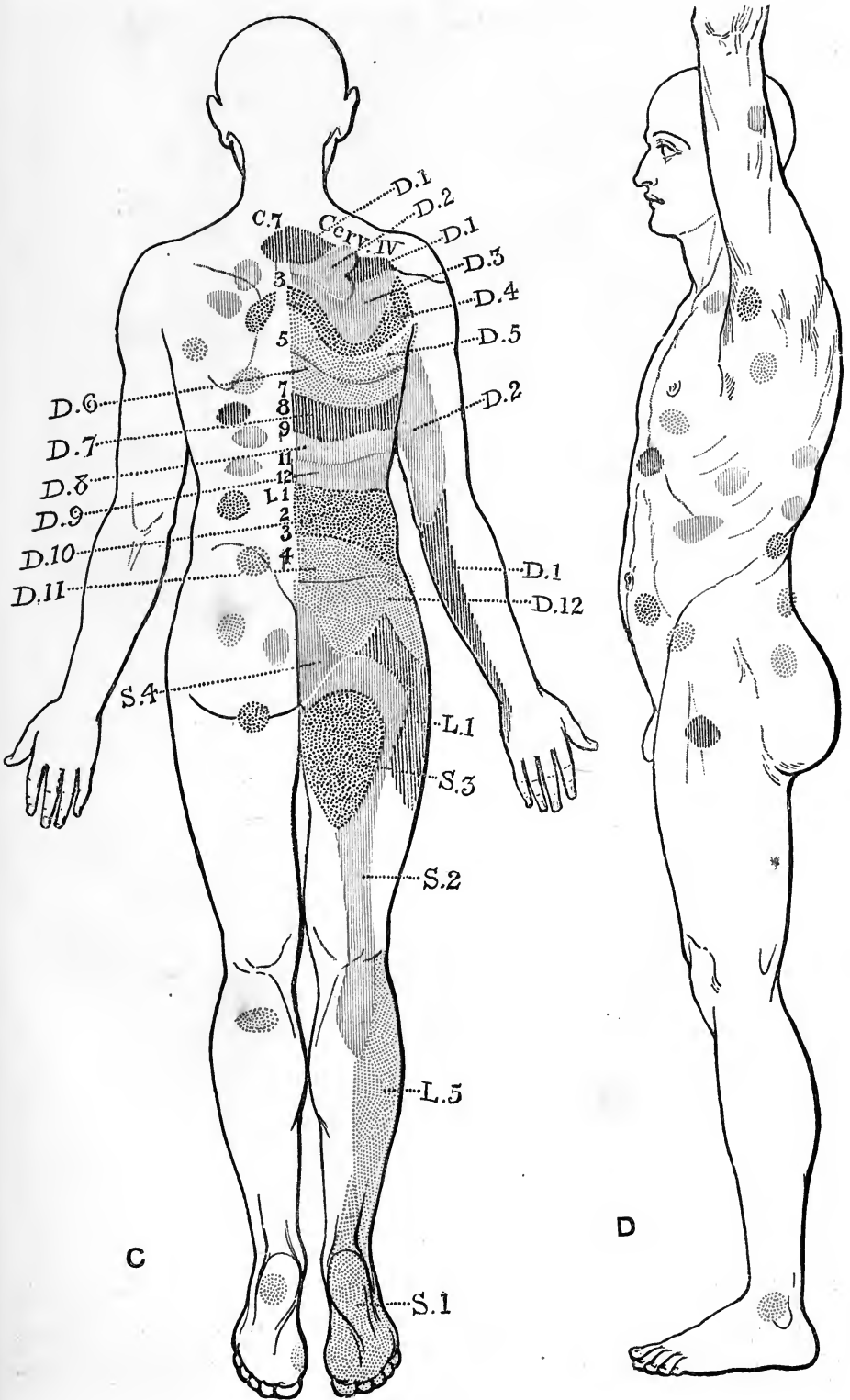


Fig. 225.

nerve, and of two spots in the postaxial area, the lower tends to be supplied by the higher nerve.

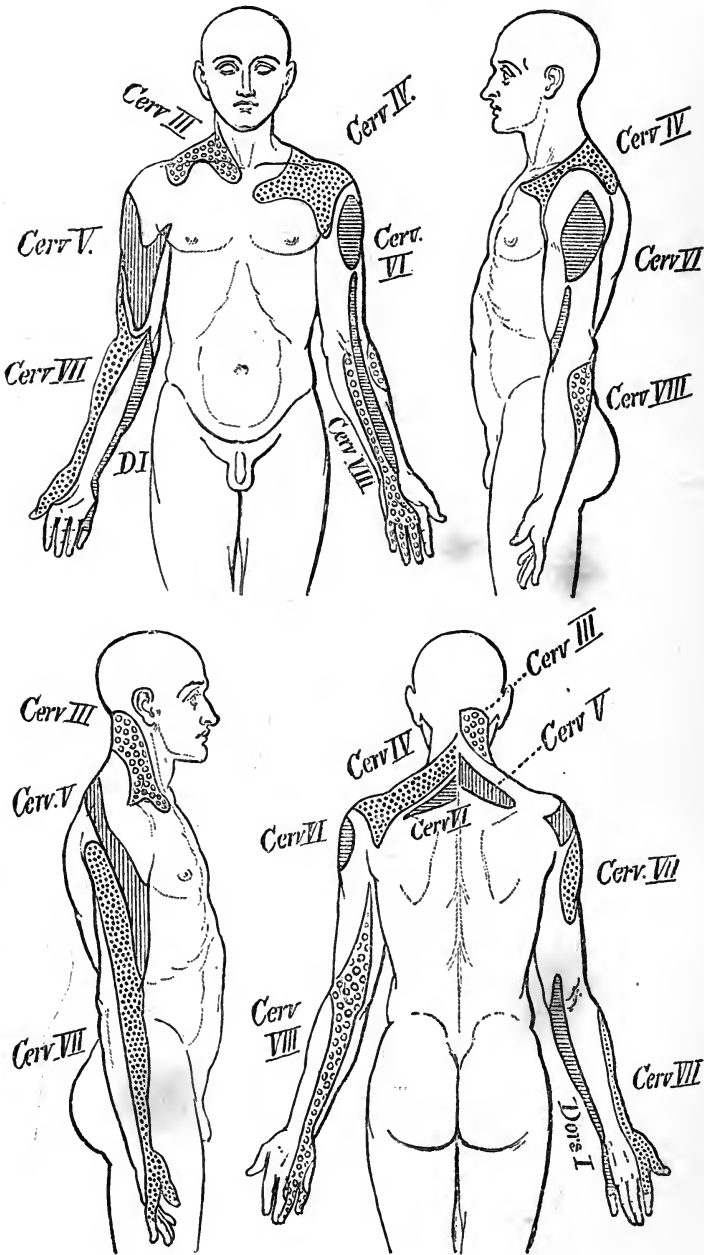


Fig. 226.—THE SEGMENTAL CUTANEOUS AREAS FROM THE THIRD CERVICAL TO THE FIRST DORSAL. (Head.)

In the upper limb, as is shown in fig. 221, the shoulder is supplied by offsets of the cervical plexus, proceeding from the third and fourth cervical nerves; the preaxial side of the limb, extending from the outer side of the shoulder to the

thumb, is supplied by the fifth and sixth cervical nerves; and the postaxial side, from the little finger to the axilla, by the eighth cervical and first and second dorsal nerves. The seventh cervical nerve does not become superficial on the ventral aspect until the hand is reached, although on the dorsal aspect it appears earlier in the lower external cutaneous branch of the musculo-spiral, but here it is probably distributed to the lower part of the area of that nerve. The digits are supplied by the sixth, seventh, and eighth cervical, and first dorsal nerves, in this order, from the radial (preaxial) to the ulnar (postaxial) side.

In the lower limb (figs. 222 and 223) the skin of the hip receives its nerves from the lateral cutaneous offsets of the last dorsal and first lumbar nerves, and from the posterior primary divisions of the lumbar and sacral nerves, while the anterior division of the first lumbar nerve reaches the upper part of the thigh in front. The nerves of the preaxial and postaxial borders of the limb are not so readily traced as in the case of the upper limb, owing to the displacement which has taken place with the marked rotation of the lower limb during development, and the great extension

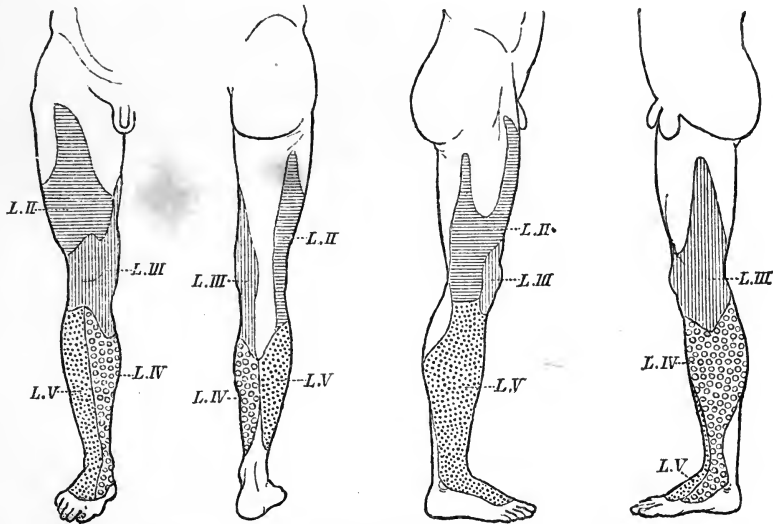


Fig. 227.—THE SEGMENTAL CUTANEOUS AREAS FROM THE SECOND TO THE FIFTH LUMBAR. (Head.)

The second lumbar area is marked in cross lines, the third in vertical lines, the fourth with circles, and the fifth with dots.

of the area supplied by dorsal branches of the limb-nerves, with a corresponding reduction of the ventral area. The preaxial border may be represented by a line following the course of the internal saphenous vein from the groin along the inner border of the sartorius to the knee, and thence along the inner border of the tibia to the ankle and inner border of the foot; and the postaxial border by a line running from the coccyx along the lower border of the gluteus maximus, thence down the postero-lateral aspect of the thigh to the back of the head of the fibula, and descending along the leg over the external malleolus to the outer border of the foot (Paterson). Along the preaxial border, as thus defined, are the second, third, and fourth lumbar nerves, while along the postaxial border are found the first, second, and third sacral. It will be observed that both of the lines are overstepped to some extent by nerves of dorsal origin, and that the area supplied by ventral nerves is reduced to a strip along the postero-internal part of the thigh, over but not completely covering the hamstring and adductor muscles, and along the back of the leg, but spreading out

in the foot to the whole breadth of the sole. The fifth lumbar nerve does not become cutaneous on the ventral aspect until the sole is reached, but in the dorsal nerves it appears earlier in the lateral cutaneous branch of the peroneal. The toes are supplied by the fourth and fifth lumbar, and the first and second sacral nerves, in this order, from the preaxial to the postaxial side.

The disposition of the cutaneous areas of the segmental nerves in the limb, as determined by Sherrington for the pelvic limb of the monkey, is shown diagrammatically in fig. 224. The several fields are seen to be arranged in regular order along a line continued outwards from the dorsal or ventral median line of the trunk, over the corresponding surface of the limb, and forming a kind of secondary axial line for the latter. The fields of the preaxial nerves constitute a descending series along this line, the sixth lumbar field spreads from the end of the axial line to the extremity of the limb, and the fields of the postaxial nerves, less numerous than the preaxial, form an ascending series. The arrangement of the cutaneous nerves does not agree with that of the motor nerves of the limb, which supply each a continuous band running parallel to the limb-axis from the trunk to the free border of the limb. The muscles of a given part of the limb and the overlying integument are, therefore, not necessarily supplied by the same segmental nerves (Sherrington).

Figures 225, 226 and 227 represent the "segmental areas" of the skin over the trunk and limbs as determined by Head from clinical observations. These areas are, however, not the regions supplied by the respective posterior spinal nerve-roots, but represent rather the parts of the skin in connection with the segments of the grey matter of the spinal cord by means of fibres subserving the sensations of pain, heat, and cold, but not touch. They differ strikingly from the areas of the posterior nerve-roots in not overlapping, except to a small extent in the neck and upper limbs, whereas the root-areas overlap so much that there is no loss of tactile sensation after division of a single posterior root (Sherrington, Head). It may also be pointed out that the areas as designated by Head do not always agree with the distribution of the corresponding nerves as determined anatomically. Thus, the area marked D 3 on the inner side of the arm corresponds rather to the brachial distribution of the second dorsal nerve through its intercosto-humeral branch and the communication with the nerve of Wrisberg, while the third dorsal nerve does not usually contribute largely to the supply of the arm. Similarly, the areas marked D 11, D 12, and L 1, would seem on anatomical-grounds, as well as from observations in cases of injury, as shown by Thorburn, to correspond more nearly to the twelfth dorsal and first and second lumbar nerves. It is therefore possible that, while the general arrangement and distribution of the segmental areas, as well as their visceral associations, have been in principle correctly recognized by Head, some modifications in the details of limitation and enumeration of these areas may be rendered necessary by more extended observations.

SENSORY DISTRIBUTION OF THE SPINAL NERVES TO THE VISCERA.

There is strong reason for believing that the thoracic and abdominal viscera are supplied with sensory fibres derived from the spinal nerves, and passing through the sympathetic. In the dog Edgeworth has traced medullated fibres of medium size, which he regards as sensory, from the posterior roots of the spinal nerves into the sympathetic, and thence to the several viscera; and his results are generally in close agreement with the inferences drawn from clinical observations in man (Head), although their accuracy in some particulars is disputed by Langley. Kölliker also recognizes medullated sensory nerve-fibres passing without interruption from the posterior roots of spinal nerves through the sympathetic to the viscera. Indirect evidence as to the source of these fibres is furnished by the seat of "referred pain" in affections of the several organs. According to the hypothesis of Ross, the pain is referred in such cases to parts supplied by somatic sensory fibres having their origin from the nerves in which the sensory fibres of the affected viscera are contained, owing to diffusion of the irritation conveyed by the latter fibres in the corresponding segment of the grey matter of the spinal cord. The following table, taken from Head, shows the probable origin of the sensory fibres of the different organs:—

Heart.—1, 2, 3 dorsal.

Lungs.—1, 2, 3, 4, 5 dorsal.

Stomach.—6, 7, 8, 9 dorsal. Cardiac end from 6, 7. Pyloric end from 9.

Intestines.—(a) Down to upper part of rectum, 9, 10, 11, 12 dorsal. (b) Rectum, 2, 3, 4 sacral.

Liver and Gall-Bladder.—(6 ?), 7, 8, 9, 10 dorsal.

Kidney and Ureter.—10, 11, 12 dorsal. Upper part of ureter, 10 dorsal. At lower end of ureter, 1 lumbar tends to appear.

Bladder.—(a) Mucous membrane and neck of bladder, (1), 2, 3, 4 sacral. (b) Over-distension and ineffectual contraction, 11, 12 dorsal, and 1 lumbar.

Prostate.—10, 11, (12) dorsal.

1, 2, 3 sacral, and 5 lumbar.

Epididymis.—11, 12 dorsal, and 1 lumbar.

Testis.—10 dorsal.

Ovary.—10 dorsal.

Appendages, &c.—11 and 12 dorsal, 1 lumbar.

Uterus.—(a) In contraction, 10, 11, 12 dorsal, and 1 lumbar. (b) Os uteri, (1), 2, 3, 4 sacral (5 lumbar very rarely).

LITERATURE OF THE DISTRIBUTION OF SENSORY NERVES.

Edgeworth, F. H., *On a large-fibred Sensory Supply of the Thoracic and Abdominal Viscera*, Journ. of Physgy., xiii, 1892.

Head, H., *On Disturbances of Sensation, with especial reference to the Pain of Visceral Disease*, Brain, parts lxi and lxii, 1893, and lxvii, 1894.

Herringham, W. P., *The Minute Anatomy of the Brachial Plexus*, Proc. Roy. Soc., xli, 1886.

Langley, J. N., *On the larger Medullated Fibres of the Sympathetic System*, Journ. of Physgy., xiii, 1892.

Mackenzie, J., *Some Points bearing on the Association of Sensory Disorders and Visceral Disease*, Brain, part lxiii, 1893.

Paterson, A. M., *The Origin and Distribution of the Nerves to the Lower Limb*, Journ. of Anat., xviii, 1893—4.

Ross, J., *On the Segmental Distribution of Sensory Disorders*, Brain, 1888, and in "Studies in Anatomy," the Owens College, 1891.

Sherrington, C. S., *Experiments in Examination of the Peripheral Distribution of the Fibres of the Posterior Roots of some Spinal Nerves*, Proc. Roy. Soc., lii, 1892, and Phil. Trans., 1893.

Starr, M. Allen, American Journ. Med. Sci., May, 1888; *Local Anæsthesia as a guide to the Diagnosis of Lesions of the Lower Spinal Cord*, Internat. Journ. of Med. Science, 1892; *Local Anæsthesia as a guide in the Diagnosis of Lesions of the Upper Portion of the Spinal Cord*, Brain, part lxvii, 1894.

Thorburn, W., *A Contribution to the Surgery of the Spinal Cord*, 1889; *The Sensory Distribution of Spinal Nerves*, Brain, part lxiii, 1893.

Voigt, C. A., *Beiträge zur Dermato-Neurologie, nebst der Beschreibung eines Systems neu entdeckter Linien an der Oberfläche des menschlichen Körpers*, Wiener Denkschriften, 1862.

SYNOPSIS OF THE MUSCULAR DISTRIBUTION OF THE CEREBRO-SPINAL NERVES.

1. To muscles of the head and fore part of the neck.—The muscles of the orbit are mostly supplied by the third cranial nerve—the superior division of that nerve being distributed to the levator palpebræ and the superior rectus muscles, and the inferior division to the inferior and internal recti and the inferior oblique. The superior oblique muscle is supplied by the fourth nerve, and the external rectus by the sixth; while the tensor tarsi has no special nerve apart from those of the orbicularis palpebrarum, which are derived from the facial.

The superficial muscles of the face and scalp, which are associated in their action as a group of muscles of expression, together with the buccinator muscle, are supplied by the seventh cranial nerve, the retrahens auriculam and occipitalis muscles being supplied by its posterior auricular branch.

The deep muscles of the face employed in mastication, viz., the temporal, masseter, and two pterygoid muscles, are supplied by the inferior maxillary division of the fifth cranial nerve.

Muscles above the hyoid bone.—The mylo-hyoid muscle and anterior belly of the digastric are supplied by a branch of the inferior maxillary division of the fifth cranial nerve; the posterior belly of the digastric muscle and the stylo-hyoid (together with the stapedius muscle) are supplied by branches of the facial. The muscles of the tongue receive their nervous supply from the hypoglossal nerve; and the genio-hyoid muscle is supplied (like the infrahyoid muscles) by the upper cervical nerves.

The muscles ascending to the hyoid bone and larynx, viz., the sterno-hyoid, omohyoid, and sterno-thyro-hyoid, are supplied from the upper cervical nerves through their communications with the hypoglossal nerve and the ansa cervicalis.

The *larynx, pharynx, and soft palate*.—The crico-thyroid muscle is supplied by the external laryngeal branch of the pneumo-gastric nerve, and the other intrinsic muscles of the larynx by the recurrent laryngeal. The constrictors of the pharynx are supplied mainly by the bulbar part of the spinal accessory nerve through the pharyngeal branch of the vagus and the pharyngeal plexus; and the levator palati, azygos uvulæ, palato-pharyngeus, and palato-glossus are innervated from the same source. The stylo-pharyngeus, and possibly the middle constrictor in part, are supplied by the glosso-pharyngeal. The tensor palati is supplied through the otic ganglion by the inferior maxillary division of the fifth nerve (and the tensor tympani is supplied in the same way).

2. To muscles belonging exclusively to the trunk, and muscles ascending to the skull.—All those *muscles of the back* which act upon the spine and head, viz., the splenius, complexus, erector spinæ, and the muscles more deeply placed, receive their supply from the posterior divisions of the spinal nerves.

The *sterno-mastoid* is supplied by the spinal accessory nerve and a twig of the cervical plexus coming from the second cervical nerve.

The *rectus capitis anticus minor* and *rectus capitis lateralis* are supplied by the first cervical nerve, the *rectus capitis anticus major* by the upper four cervical nerves; the *longus colli* and *scaleni* receive twigs from nearly all the cervical nerves.

The *muscles of the chest-wall*, viz., the intercostals, subcostals, levatores costarum, serrati postici, and triangularis sterni, are supplied by the intercostal nerves.

The *obliqui, transversalis*, and *rectus* of the abdomen are supplied by the lower six to eight intercostal nerves; and the internal oblique and transverse muscles also get branches from the first lumbar nerve. The *cremaster* muscle is supplied by the genital branch of the genito-crural nerve (1, 2 *l*).

The *quadratus lumborum* receives small branches from the last dorsal and upper one or two lumbar nerves.

The *diaphragm* receives the phrenic nerves from the fourth and fifth cervical nerves, branches from the lower intercostal nerves, and likewise sympathetic filaments from the plexuses round the phrenic arteries.

The *muscles of the urethra and penis* are supplied by the pudic nerve (2, 3, 4 *s*), the *levator and sphincter ani* by the pudic and the fourth sacral nerves; and the *coccygeus* muscle by the fourth and fifth sacral nerves.

3. To muscles attaching the upper limb to the trunk.—The *trapezius* and the *cleido-mastoid* receive the distribution of the spinal accessory nerve, and, in union with it, offsets from the cervical plexus.

The *latissimus dorsi* receives the long subscapular nerve (7, 8 *c*).

The *rhomboidei* are supplied by a branch from the fifth cervical nerve.

The *levator anguli scapulae* is supplied by branches from the third and fourth cervical nerves, and partly also by the branch to the rhomboid muscles.

The *serratus magnus* has a special nerve, the posterior thoracic, derived from the fifth, sixth, and usually the seventh cervical nerves.

The *subclavius* receives a branch from the place of union of the fifth and sixth cervical nerves.

The *pectorales* are supplied by the anterior thoracic branches of the brachial plexus, the larger muscle usually receiving fibres from the lower four cervical and first dorsal nerves, and the smaller from the last two cervical and first dorsal.

4. To muscles of the upper limb.—*Muscles of the shoulder.*—The supraspinatus and infraspinatus are supplied by the suprascapular nerve (5, 6 *c*); the subscapularis by the upper and lower subscapular nerves (5, 6 *c*); the teres major by the lower subscapular (5, 6 *c*); and the deltoid and teres minor by the circumflex nerve (5, 6 *c*).

Posterior muscles of the arm and forearm.—The triceps (7, 8 c), anconeus (7, 8 c), supinator longus (6 c), and extensor carpi radialis longior (6, 7 c) are supplied by direct branches of the musculo-spiral nerve; while the extensor carpi radialis brevis (6, 7 c), the supinator brevis (6 c), and the other extensor muscles in the forearm (7 c) receive their branches from the posterior interosseous division of that nerve.

Anterior muscles of the arm and forearm.—The coraco-brachialis is supplied by the seventh cervical nerve, and the biceps and brachialis anticus by the fifth and sixth cervical nerves through the musculo-cutaneous trunk; the brachialis anticus likewise receives a twig frequently from the musculo-spiral nerve (6 c). The muscles of the front of the forearm are supplied by the median nerve, with the exception of the flexor carpi ulnaris and the inner half of the flexor profundus digitorum, which are supplied by the ulnar nerve. The offsets to the pronator teres and flexor carpi radialis are derived from the sixth cervical nerve, those to the flexor sublimis digitorum from the seventh and eighth cervical and first dorsal nerves, and those to the flexor carpi ulnaris, flexor longus pollicis, flexor profundus digitorum and pronator quadratus from the eighth cervical and first dorsal nerves.

Muscles of the hand.—The abductor, opponens, and outer head of the flexor brevis pollicis are supplied by a branch of the median nerve (6, or 6 and 7 c). The lumbricales (7, 8 c, 1 d) receive their branches, the outer two from the median, and the inner two from the ulnar nerve. All the other muscles are innervated through the ulnar from the eighth cervical nerve.

5. **To muscles of the lower limb.**—*Muscles of the hip.*—The ilio-psoas is supplied by the second and third lumbar nerves, the branches to the iliacus being given off from the anterior crural. The gluteus medius and minimus and the tensor vaginæ femoris are innervated by the superior gluteal (4, 5 l, 1 s), and the gluteus maximus by the inferior gluteal (5 l, 1, 2 s). The pyriformis (1, 2 s), quadratus femoris and inferior gemellus (4, 5 l, 1 s), and obturator internus with the superior gemellus (5 l, 1, 2 s), receive special branches from the sacral plexus. The obturator externus is supplied by the obturator nerve (3, 4 l).

Muscles of the thigh.—The sartorius (2, 3 l), pectineus (2, 3 l), and quadriceps extensor cruris (3, 4 l) are supplied by the anterior crural nerve. The adductor longus (2, 3 l), gracilis (2, 3, 4 l), adductor brevis (2, 3, 4 l), and adductor magnus (3, 4 l) are supplied by the obturator nerve, but the adductor magnus likewise receives a branch (4, 5 l) from the internal popliteal division of the great sciatic nerve. The hamstring muscles are supplied by branches of the great sciatic nerve, the semimembranosus (4, 5 l, 1 s), semitendinosus (5 l, 1, 2 s), and long head of the biceps (1, 2, 3 s), receiving their branches from its internal popliteal division, and the short head of the biceps (5 l, 1, 2 s) from its external popliteal division.

Anterior muscles of the leg and foot.—The muscles in front of the leg, together with the extensor brevis digitorum, are supplied by the anterior tibial nerve (4, 5 l, 1 s).

The *peroneus longus* and *brevis* are supplied by the musculo-cutaneous nerve (4, 5 l, 1 s).

Posterior muscles of the leg.—The gastrocnemius (1, 2 s), plantaris (4, 5 l, 1 s), popliteus (4, 5 l, 1 s), and soleus (5 l, 1, 2 s) are supplied by the internal popliteal nerve, the last muscle receiving also a second branch (1, 2 s) from the posterior tibial nerve. The flexor longus digitorum (5 l, 1 s), tibialis posticus (5 l, 1 s), and flexor longus hallucis (5 l, 1, 2 s) derive their nerves from the posterior tibial.

Plantar muscles.—The flexor brevis digitorum, the abductor and flexor brevis hallucis, and the innermost lumbricalis are supplied by the internal plantar nerve (5 l, 1 s); all the others, including the flexor accessorius and interosseous muscles, are supplied by the external plantar nerve (1, 2 s).

MUSCULAR DISTRIBUTION OF THE SPINAL NERVES.

The statements made in the foregoing synopsis, and in the following lists of the muscles supplied by each spinal nerve, are based mainly upon dissections and pathological observations in man, but in part also upon physiological experiments in the monkey. Owing to the difficulties of these investigations, and the limited number of observations that have as yet been made, there is still some uncertainty as to the exact supply of some of the muscles of the limbs, where the nerves are mingled in plexuses before passing to their distribution, and especially as to the range of individual variations.

In the case of the short trunk-muscles, which are derived from a single myomere, the nervous supply is single, coming from the nerve of that segment. In more extended muscles, which are formed by the fusion of portions of several segments, the nervous supply is correspondingly multiple, although there is at times a reduction in the number of nerves in comparison with the segments from which the muscle appears to have been derived, *e.g.*, in the quadratus lumborum and complexus. In the limbs the segmental arrangement of the muscles and nerves is obscured; but with regard to the general disposition it may be stated that most if not all of the muscles are supplied from more than one spinal nerve, and that the muscles on the preaxial side of the limb tend to be supplied by higher nerves than those on the postaxial side.

From the lists it will be seen that muscles of different action are often supplied from the same nerve-roots. Ferrier and Yeo concluded from their experiments in the monkey that the muscles called into action by the stimulation of a single nerve-root entering into the brachial or crural plexus form a group executing some definite co-ordinated movement of the limb, but Sherrington, in numerous observations on the same animal, failed to find evidence of such an association. Risien Russell, while supporting Ferrier and Yeo as to the co-ordination, also points out that (in the dog) when antagonistic muscles are represented in the same nerve-roots, one group predominates in one root and the opposite group in another root. Similarly, in man, at least for the larger joints of the limbs, the muscles producing the chief movements in opposite directions are mainly represented at different levels. Thus, the abductors of the shoulder are innervated mainly by the fifth cervical root, and the adductors by the sixth and seventh; the flexors of the elbow are supplied mainly through the fifth and sixth cervical nerves, and the extensors through the seventh and eighth; the extensors of the wrist predominate in the seventh, and the flexors in the eighth cervical and first dorsal nerves. So also in the lower limb, the flexors of the hip are represented mainly in the second and third lumbar nerves, and the extensors in the fifth lumbar and first and second sacral; the adductors in the third and fourth lumbar, and the abductors in the fifth lumbar and first sacral nerves; the flexors of the knee in the fifth lumbar and first and second sacral nerves, and the extensors in the third and fourth lumbar.

TABLE OF THE MUSCLES SUPPLIED BY THE SEVERAL SPINAL NERVES.

NERVE.	ANTERIOR DIVISION.	POSTERIOR DIVISION.
1st cervical . . .	Rectus lateralis, Rectus anticus minor and major, Genio-hyoid, Infrahyoid muscles.	Rectus posticus major and minor, Obliquus superior and inferior, Complexus.
2nd cervical . . .	Rectus anticus major, Longus colli, Sterno-cleido-mastoid, Genio-hyoid, Infrahyoid muscles.	Obliquus inferior, Complexus, Splenius, Trachelo-mastoid.

NERVE.	ANTERIOR DIVISION.	POSTERIOR DIVISION.	
3rd cervical . . .	Rectus anticus major, Longus colli, Infrahyoid muscles, Scalenus medius, Levator scapulæ, (Sterno-cleido-mastoid), ¹ Trapezius, (Diaphragm).	Complexus, Transverso-spinales, Splenius, Erector spinæ.	
4th cervical . . .	Rectus anticus major, Longus colli, Scalenus medius (and anticus), Diaphragm, Levator scapulæ, Trapezius.		
5th cervical . . .	Longus colli, Scalenii, (Diaphragm), Levator scapulæ, Rhomboidei, Serratus magnus, Subclavius, Supraspinatus, Infraspinatus, Teres minor, Subscapularis, (Teres major), Deltoid, (Pectoralis major), Biceps, Brachialis anticus.		
6th cervical . . .	Longus colli, Scalenii, (Subclavius), Serratus magnus, (Supraspinatus, Infraspinatus, Teres minor), Subscapularis, Teres major, Deltoid, Pectoralis major, Biceps, Brachialis anticus, Pronator teres, Flexor carpi radialis, Supinator longus and brevis, Extensores carpi radiales, Abductor, Opponens and Flexor brevis pollicis.		
7th cervical . . .	Longus colli, Scalenus medius, (Serratus magnus), Pectoralis major and minor, Latissimus dorsi, (Teres major), Coraco-brachialis, Triceps brachii, Anconeus, Flexor sublimis digitorum, (Flexor profundus digitorum, Flexor longus pollicis, Pronator quadratus), Extensores radiales, Extensors of digits, Extensor carpi ulnaris, (Abductor, Opponens and Flexor brevis pollicis).		
8th cervical . . .	Longus colli, Pectoralis major and minor, Latissimus dorsi, Triceps brachii, Anconeus, Flexors of digits, Flexor carpi ulnaris, Pronator quadratus, Adductores pollicis, Interossei, Abductor, Flexor brevis and Opponens minimi digiti.		
1st dorsal . . .	Pectoralis major and minor, Flexors of digits, Flexor carpi ulnaris, Pronator quadratus, Intercostales, Levator costæ, Serratus posticus superior.		Transverso-spinales, Erector spinæ.
2nd dorsal . . .	Intercostales, Levator costæ, Serratus posticus superior, (Triangularis sterni).		
3rd dorsal . . .	} Intercostales, Levatores costarum, Serratus posticus superior, Triangularis sterni.		
4th dorsal . . .			
5th dorsal . . .	} Intercostales, Levatores costarum, Triangularis sterni, Obliquus externus, Rectus abdominis.		
6th dorsal . . .			
7th dorsal . . .	} Intercostales, Levatores costarum, Subcostales, Obliquus externus, Obliquus internus, Transversalis abdominis, Rectus abdominis.		
8th dorsal . . .			
9th dorsal . . .	} Intercostales, Levatores costarum, Subcostales, Serratus posticus inferior, Obliquus externus, Obliquus internus, Transversalis abdominis, Rectus abdominis.		
10th dorsal . . .			
11th dorsal . . .			
12th dorsal . . .	(Quadratus lumborum), Obliquus externus, Obliquus internus, Transversalis abdominis, Rectus abdominis, Pyramidalis.		
1st lumbar . . .	Quadratus lumborum, (Obliquus internus, Transversalis abdominis), Cremaster.		
2nd lumbar . . .	(Quadratus lumborum), Cremaster, Psoas magnus, (Psoas parvus), Iliacus, Pectineus, Adductor longus, Adductor brevis, Gracilis, Sartorius.		

¹ Names enclosed in parentheses indicate that the muscles are not always supplied from the nerve-root in question.

NERVE.	ANTERIOR DIVISION.	POSTERIOR DIVISION.
3rd lumbar . . .	Psoas magnus, Iliacus, Pectineus, Adductor longus, Adductor brevis, Adductor magnus, Gracilis, Obturator externus, Sartorius, Quadriceps.	} Multifidus spinæ, Erector spinæ.
4th lumbar . . .	(Psoas magnus), Adductor brevis, Adductor magnus, Gracilis, Obturator externus, Quadriceps, Gluteus medius and minimus, Tensor vaginæ femoris, (Gluteus maximus, Obturator internus), Quadratus femoris, Semimembranosus, (Deep muscles of back of leg), Muscles of front and outer side of leg, Extensor brevis digitorum.	
5th lumbar . . .	(Quadriceps), Adductor magnus, Gluteus maximus, medius and minimus, Tensor vaginæ femoris, (Pyriformis), Quadratus femoris, Obturator internus, Hamstrings, Muscles of leg (except gastrocnemius), Extensor brevis digitorum, Inner muscles of sole.	
1st sacral . . .	Gluteus maximus, medius and minimus, Tensor vaginæ femoris, Pyriformis, Obturator internus, Quadratus femoris, (Adductor magnus), Hamstrings, Muscles of leg and foot.	
2nd sacral . . .	Gluteus maximus, (Gluteus medius and minimus, Tensor vaginæ femoris), Pyriformis, Obturator internus, Semitendinosus, Biceps, (Muscles of front of leg, Peronei), Gastrocnemius, Soleus, Flexor longus hallucis, (Flexor longus digitorum, Tibialis posticus), Outer muscles of sole, Perineal muscles.	
3rd sacral . . .	(Pyriformis), Biceps, long head, (Gastrocnemius, Soleus, Muscles of sole), (Levator ani, Coccygeus), Perineal muscles.	
4th sacral . . .	Levator ani, Coccygeus, Perineal muscles.	
5th sacral . . .	(Coccygeus).	

The unstriped muscles of the viscera and other parts are also under the influence of fibres derived from the cerebro-spinal nerves. These will be referred to in the description of the sympathetic.

LITERATURE OF THE MUSCULAR DISTRIBUTION OF SPINAL NERVES.

- Beevor, C. E., and Horsley, V.,** *Note on some of the Motor Functions of certain Cranial Nerves, and of the three first Cervical Nerves, in the Monkey*, Proc. Roy. Soc., 1888.
- Bolk, L.,** *Beziehungen zwischen Skelet, Muskulatur und Nerven der Extremitäten, dargestellt am Beckengürtel, an dessen Muskulatur, sowie am Plexus lombo-sacralis*, Morphol. Jahrb., xxi, 1894.
- Eisler, P.,** *Der Plexus lumbosacralis des Menschen*, 1892.
- Ferrier, D., and Yeo, G. F.,** *The Functional Relations of the Motor Roots of the Brachial and Lumbo-sacral Plexuses*, Proc. Roy. Soc., 1881.
- Forgue et Lannegrace,** *Distribution des racines motrices dans les muscles des membres, and Distribution spéciale des racines motrices du plexus lombo-sacré*, Comptes rendus, 1884.
- Gowers, W. R.,** *Diseases of the Nervous System*.
- Herringham, W. P.,** *The Minute Anatomy of the Brachial Plexus*, Proc. Roy. Soc., 1886.
- Paterson, A. M.,** *The Origin and Distribution of the Nerves to the Lower Limb*, Journ. of Anat., xxviii, 1893-4.
- Ruge, G.,** *Zeugnisse für die metamere Verkürzung des Rumpfes bei Säugethieren. Der Musculus rectus thoraco-abdominalis der Primaten*, Morphol. Jahrb., xix, 1892; *Verschiebungen in den Endgebiäten der Nerven des Plexus lumbalis der Primaten*, Morphol. Jahrb., xx, 1893 (Nerves to abdominal muscles).
- Russell, J. S. Risien.** *An Experimental Investigation of the Nerve-roots which enter into the Formation of the Brachial Plexus of the Dog*, Phil. Trans., 1892.
- Sherrington, C. S.,** *Notes on the Arrangement of some Motor Fibres in the Lumbo-sacral Plexus*, Journ. of Physg., xiii, 1892.
- Simon, A.,** *Ueber die Beziehungen bestimmter Muskeln zu bestimmten Abschnitten der grauen Substanz des Rückenmarks*, In. Diss., Strassburg, 1892.
- Starr, M. Allen,** *American Journal of the Medical Sciences*, May, 1888.
- Thorburn, W.** *A Contribution to the Surgery of the Spinal Cord*, 1889.

THE SYMPATHETIC NERVES.

The nerves of the sympathetic system are distributed to the internal viscera, together with other glandular organs of the body, to the heart and blood-vessels.

Fig. 228.—DIAGRAMMATIC OUTLINE OF THE SYMPATHETIC CORD OF ONE SIDE IN CONNECTION WITH THE SPINAL NERVES. (Allen Thomson.)

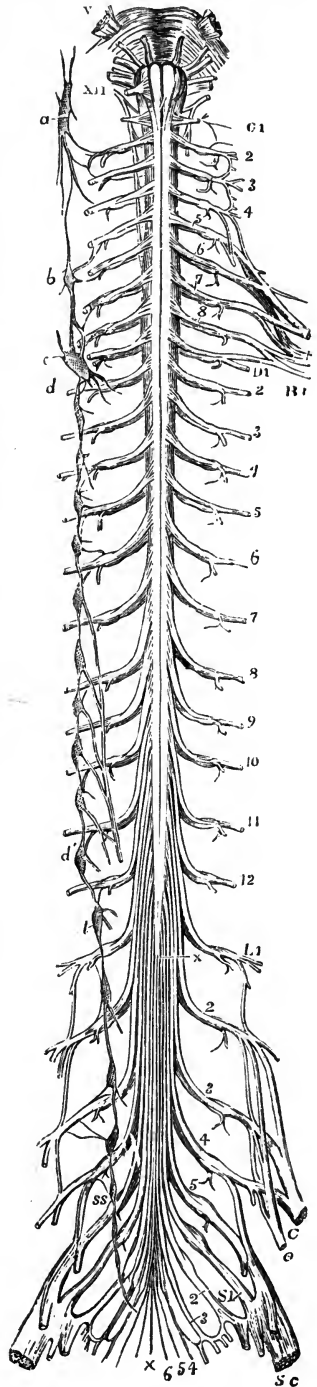
The full description of this figure will be found at p. 275.

On the right side the following letters indicate parts of the sympathetic nerves, viz.,—*a*, superior cervical ganglion, communicating with the upper cervical spinal nerves, and continued below into the great sympathetic cord; *b*, middle cervical ganglion; *c, d*, lower cervical ganglion united with the first dorsal; *d'*, eleventh dorsal ganglion; from the sixth to the ninth dorsal ganglia the origins of the great splanchnic nerve are shown, and from the tenth that of the small splanchnic nerve; *l*, first lumbar ganglion; *ss*, first sacral ganglion. In the whole extent of the sympathetic cord the twigs of union with the spinal nerves are shown.

and to the unstriped muscles of the body generally. Some organs, however, receive nerves also from the cerebro-spinal system directly, as the lungs, the heart, and the upper and lower parts of the alimentary canal; and those viscera which are not supplied directly in this way receive fibres derived originally from cerebro-spinal nerves through their sympathetic plexuses.

This division of the nervous system consists of a somewhat complicated collection of ganglia, cords and plexuses, the parts of which may, for convenience, be classified in two groups, viz., the principal gangliated cords, and the great prevertebral plexuses, with the nerves proceeding from them. The ganglia of union with cranial nerves, viz., the ciliary, sphenopalatine, otic, and submaxillary ganglia, which agree in their connections and structure with the ganglia of the sympathetic system, have already been described in connection with the fifth nerve.

The foundation of the sympathetic is constituted by medullated fibres, for the most part of very small size (2.6μ and less), which pass by means of the *white rami communicantes* from certain of the cerebro-spinal nerves into the cords and ganglia of the sympathetic. Here some of the fibres terminate in arborisations around the cells of the ganglia of the great sympathetic cord (*vertebral* or *lateral ganglia* of Gaskell), while others, which frequently run for a variable distance either upwards or downwards in the cord, pass by the *rami efferentes* to the prevertebral plexuses, where they may end similarly in the ganglia of those plexuses (*prevertebral* or *collateral ganglia*, Gaskell), or they may be continued on to the secondary plexuses, to break up in the ganglia close to or in the organs supplied (*terminal ganglia*, Gaskell). Some of the medullated fibres also pass through the several plexuses to the viscera or other parts without being



interrupted in any of the ganglia above mentioned. From the cells of the ganglia other fibres, in great part if not entirely non-medullated, arise. These are the proper *sympathetic fibres*. They run partly in the *grey rami communicantes* to the spinal nerves, partly in the rami efferentes and the offsets of the collateral and terminal ganglia to their ultimate distribution.

The **great gangliated cords** (*trunci sympathici*) are two in number, and each consists of a series of ganglia (*ganglia trunci sympathici*), united by short intervening cords, sometimes double. These gangliated cords are placed symmetrically, partly in front, and partly on the side, of the vertebral column, extending from the base of the skull to the coccyx. Superiorly they are connected with

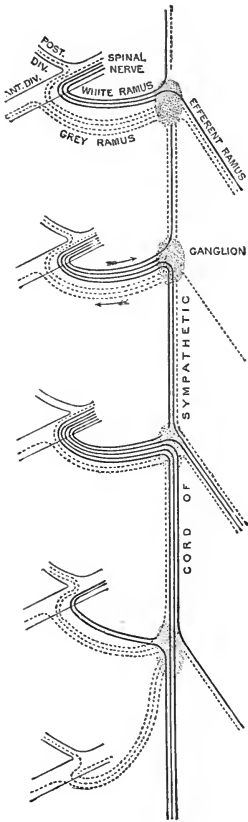


Fig. 229.—SCHEME OF THE SYMPATHETIC CORD AND ITS CONNECTIONS WITH THE SPINAL NERVES. (G. D. T.)

Medullated fibres passing into and through the sympathetic cord are represented by continuous lines, pale fibres arising from the sympathetic ganglia by dotted lines.

plexuses which enter the cranial cavity, while inferiorly they converge on the sacrum, and terminate in a loop on the coccyx. The several portions of the cords are distinguished as cervical, dorsal or thoracic, lumbar, and sacral, and in each of these parts the ganglia are equal in number, or nearly so, to the vertebrae against which they lie, except in the neck, where there are only three.

Connection of the gangliated cords with the cerebro-spinal system.—The ganglia are severally connected with the anterior primary divisions of the spinal nerves in their neighbourhood by short filaments called *rami communicantes*, which are of two kinds, white and grey, the former consisting mainly of medullated fibres, and the latter of pale fibres. In some cases these are separate branches; in others they are united in one cord, which then consists of a white and a grey part. As a rule, the communicating branches join the ganglia of the sympathetic trunk, but sometimes they unite with the part of the cord connecting adjacent ganglia.

White rami communicantes are composed, as stated above, mainly of very fine medullated fibres passing from the spinal nerves to the sympathetic cord. The fibres proceed from both roots of the spinal nerves, but to a greater extent from the anterior. It is probable that the fibres derived from the posterior roots are for the most part afferent, but it has been shown by v. Lenhossék and others in the chick that the posterior roots also contain fibres which spring from cells of the spinal cord, and are believed to enter the sympathetic (Kölliker). These fibres have, however, as yet not been observed in mammals, and Sherrington in the cat and monkey failed to find evidence of any fibres in the posterior roots arising from cells of the spinal cord. Some of the medullated fibres are continued over the ganglia of the cord to enter the efferent branches; others end in the ganglia, often ascending or descending for a considerable distance in the cord to reach ganglia at a higher or lower level than that of the communicating branch by which they pass to the sympathetic. The individual fibres also which terminate in the cord are not necessarily confined to one ganglion. According to Langley and Anderson, a single fibre may send

branches to several (about four) ganglia. In this way the fibres contained in one communicating branch may have a wide distribution in the sympathetic.

White rami communicantes are not furnished by all the spinal nerves. According to Gaskell, by whose investigations the fundamental constitution of the sympathetic and its relations to the cerebro-spinal nerves were first made clear, they are found in the dog from the second dorsal to the second lumbar nerve inclusive; but Langley has shown that in the dog and cat white rami communicantes are given off by the spinal nerves from the first dorsal to the fourth lumbar, and in the rabbit from the first dorsal to the fifth lumbar inclusive. In man it is most probable that they exist from the first dorsal to the first or second lumbar nerves, perhaps also the third in some cases. The visceral branches of the second, third, and fourth sacral nerves (*pelvic splanchnics* of Gaskell) correspond to white rami communicantes, although they do not join the sympathetic cord, but pass directly to the prevertebral plexuses; and in this group also are to be included the visceral branches of the spinal accessory, vagus, glosso-pharyngeal, and facial nerves (*cervico-cranial rami viscerales*, Gaskell), as well as the short root of the ciliary ganglion from the third nerve.

The medullated fibres passing into the sympathetic system are classified by Kölliker as follows:—

- (a) **Sensory fibres** which, when derived from spinal nerves, run in the posterior roots.
- (b) **Vaso- and viscer-constrictors**, proceeding from certain cranial (IX, X, XI) and spinal nerves, mainly from the anterior roots of the latter, but possibly also from the posterior roots. These fibres all end in ganglia of the sympathetic, and their action is transmitted through pale fibres springing from the cells of the ganglia.¹
- (c) **Vaso-dilators and viscer-inhibitory nerves**, given off from the above-mentioned cranial nerves, and the anterior roots of spinal nerves. They are continued as medullated fibres, not forming any connection with nerve-cells, to their respective organs.

The existence of special trophic and secretory fibres in the sympathetic is as yet uncertain.

Grey rami communicantes are found passing between the sympathetic cord and all the spinal nerves. Their pale fibres arise wholly from the nerve-cells of the ganglia of the sympathetic cord, and for the most part from the cells of the ganglion with which the branch is connected. Pale fibres arising from the cells of one ganglion, and running along the cord to leave by the grey ramus of the next ganglion, only occur exceptionally (Langley). On entering the anterior primary division of a spinal nerve, the fibres of the grey ramus are directed both peripherally and centrally. Of those passing centrally, some go off in the posterior primary division of the nerve, others enter the sheath of the nerve, the surrounding tissue in the intervertebral foramen, and the dura mater, running up to the latter in the posterior root. In the whole of the anterior root, and in the intradural portion of the posterior root, there are no pale fibres (Gaskell). The fibres passing distally in the anterior and posterior primary divisions of the spinal nerves have been shown, by experiments on animals, to supply vaso-motor nerves to the arteries of the body-wall and limbs, pilo-motor fibres to the muscles of the hairs, and secretory fibres to the sweat-glands.

Intermixed with the pale fibres in the grey rami communicantes there are also a

¹ To this group must also be added the pilo-motor nerves, which have been shown by Langley and Sherrington to have a similar arrangement, as well as probably the motor nerves of the sphincter muscle of the iris, which pass from the third nerve through the ciliary ganglion. The last, however, present the peculiarity that the fibres of the short ciliary nerves arising from the cells of the ciliary ganglion are medullated.

It may also be observed here that doubt is thrown by Langley upon the universal validity of the rule that fibres passing from the cerebro-spinal nerves to the sympathetic are medullated until they reach the ganglion in which they end, while the fibres arising from the ganglion-cells are always non-medullated. He thinks that spinal fibres sometimes lose their medulla some distance before reaching the cells amongst which they end, and on the other hand that fibres proceeding from sympathetic ganglion-cells may in some cases be medullated, like the short ciliary nerves. He also considers it probable that a given fibre in the sympathetic is interrupted by a nerve-cell in one ganglion only.

few medullated fibres of varying size, even in regions where distinct white rami do not exist (Langley).

From each grey ramus a filament is given off to join the recurrent branch of

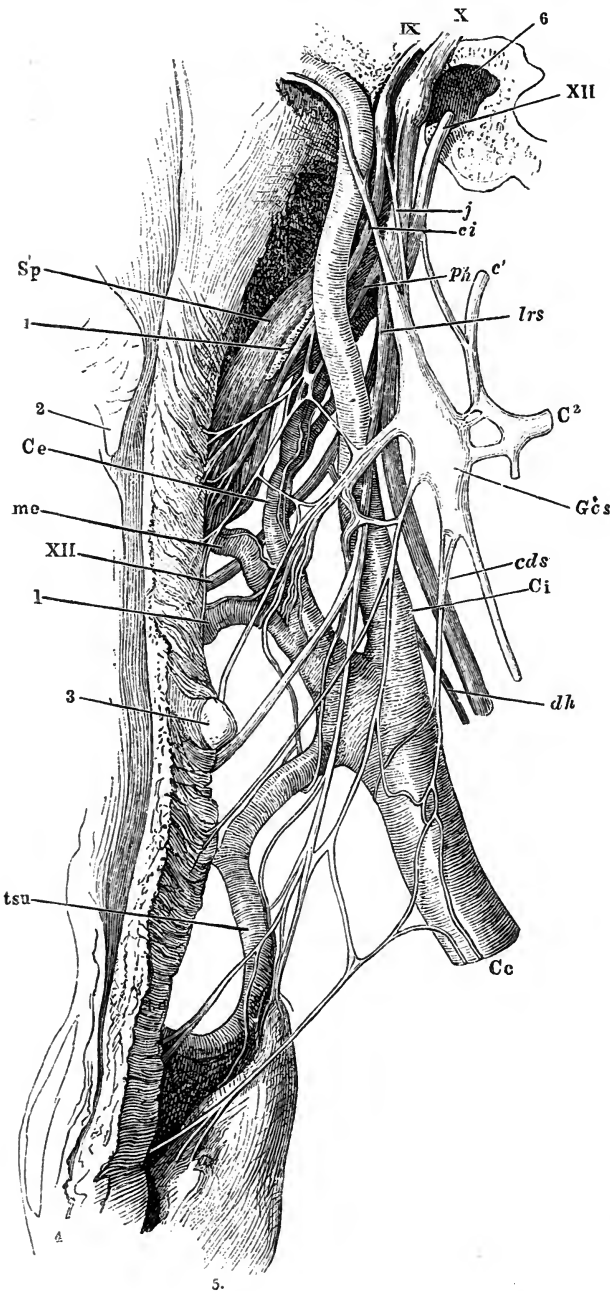


Fig. 230.—THE SUPERIOR CERVICAL GANGLION OF THE SYMPATHETIC, WITH ITS BRANCHES AND CONNECTIONS. (Henle.)

1, styloid process; 2, uvula; 3, great cornu of hyoid bone, pushing up the posterior wall of the pharynx; 4, oesophagus; 5, thyroid body; Sp, stylo-pharyngeus muscle.

Cc, common carotid artery; Ci, internal carotid; Ce, external carotid; t su, superior thyroid; l, lingual; m e, facial.

IX, glosso-pharyngeal nerve; X, vagus; XII, hypoglossal; c¹, first cervical; c², second cervical; ph, pharyngeal branch of vagus; lrs, superior laryngeal; dh, descending cervical nerve; Gcs, superior cervical ganglion of sympathetic; ci, ascending branch; j, jugular branch; cds, superior cardiac nerve.

the corresponding spinal nerve, which is distributed in the interior of the spinal canal (p. 278). Other filaments pass over the bodies of the vertebrae, supplying the intercostal and lumbar arteries, the ligaments, and the bones.

The portions of the sympathetic cord intervening between the ganglia are composed of a white and a grey part, the former, which is usually the larger, consisting of medullated fibres continued from the white rami communicantes, and the latter of pale fibres, which arise in the

ganglia and run along the cord before entering the efferent branches.

The **rami efferentes** are the branches proceeding from the gangliated cord to the prevertebral plexuses, and likewise composed of medullated fibres of spinal origin and pale fibres springing from the ganglia.

The **great prevertebral plexuses** comprise three large aggregations of nerves, or nerves and ganglia, situated in front of the spine, and occupying respectively the thorax, the abdomen, and the pelvis. They are single and median, and are named respectively the cardiac, the solar, and the hypogastric plexus. These plexuses receive branches from the cerebro-spinal nerves, as well as from both the gangliated cords above noticed, and they constitute centres from which the viscera are supplied with nerves.

CERVICAL PART OF THE GANGLIATED CORD.

In the neck, the gangliated cord is deeply placed behind the great cervical blood-vessels, being embedded in the fascia forming the back of the carotid sheath, and resting on the muscles which immediately cover the fore part of the vertebral column. It comprises three ganglia, the first of which is placed near the base of the skull, the second in the lower part of the neck, and the third close to the head of the first rib.

UPPER CERVICAL GANGLION.

This is the largest ganglion of the great sympathetic cord, 20 mm. or more long and 4—6 mm. wide. It is continued superiorly into an ascending branch, and tapers below into the connecting cord, so as to present usually a fusiform shape; but there is considerable variety in this respect in different cases, the ganglion being occasionally shorter and broader than usual, and sometimes constricted at intervals. It has the reddish-grey colour characteristic of the ganglia of the sympathetic system. It is placed on the rectus anticus major muscle opposite the second and third cervical vertebræ, lying behind the internal carotid artery, and to the inner side of the vagus nerve.

Connection with spinal nerves.—At its outer side, the superior cervical ganglion is connected with the first four spinal nerves by means of slender cords, which belong to the group of grey rami communicantes. The branches to the third and fourth nerves often pierce the rectus anticus major muscle; and they may be given off from the upper part of the cord, instead of directly from the ganglion.

The circumstance of this ganglion being connected with so many as four spinal nerves, together with its occasionally constricted appearance, is favourable to the view that it may be regarded as consisting of several ganglia which have coalesced.

The superior cervical ganglion is considered by Gaskell to be a distal or collateral ganglion. It receives its cerebro-spinal fibres, which constitute the *cervical splanchnics* of Gaskell, from the upper dorsal nerves, through the cervical part of the sympathetic cord.

Connection with cranial nerves.—Small twigs connect the ganglion or its cranial cord with the lower ganglion of the pneumo-gastric, and with the twelfth cranial nerve, near the base of the skull; and another branch (*n. jugularis*), which is directed upwards from the ganglion, divides at the base of the skull into two filaments, one of which ends in the petrosal ganglion of the glosso-pharyngeal nerve; while the other, entering the jugular foramen, joins the ganglion of the root of the pneumo-gastric.

From the lower part of the ganglion a filament sometimes runs forwards and downwards to join the external laryngeal nerve. This branch is described as normal by many anatomists, but according to Drobnik it is only exceptionally present.

Besides the branches connecting it with cranial and spinal nerves, the first cervical ganglion gives off also the ascending branch, pharyngeal branches, the upper cardiac nerve, and branches to blood-vessels, as well as two or three filaments which pierce the prevertebral muscles to supply the upper cervical vertebræ and their ligaments.

1. ASCENDING BRANCH AND CRANIAL PLEXUSES.—The **ascending** or **carotid branch** of the first cervical ganglion (*n. caroticus internus*) is soft in texture and of a reddish-grey tint, seeming to be in some degree a prolongation of the ganglion itself. In its course to the skull, it is concealed by the internal carotid artery, with which it enters the carotid canal in the temporal bone, and it is then divided into two parts, which are placed one on the outer, the other on the inner side of the vessel.

The *external division* distributes filaments to the internal carotid artery, receives one or two carotico-tympanic twigs from the tympanic branch of the glossopharyngeal (p. 260), and, after communicating by means of other filaments with the internal division of the cord, forms the *carotid plexus*.

The *internal division*, rather the smaller of the two, supplies filaments to the carotid artery, and goes to form the *cavernous plexus*. The terminal parts of these divisions of the cranial cord are prolonged on the trunk of the internal carotid, and extend to the cerebral and ophthalmic arteries, around which they form secondary plexuses, those on the cerebral arteries ascending to the pia mater. One minute plexus enters the eye-ball with the central artery of the retina.

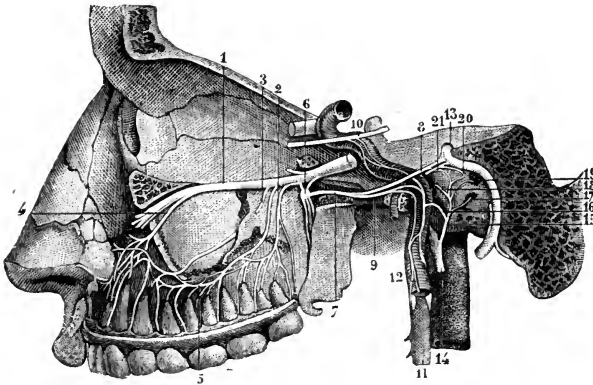


Fig. 231. — CONNECTIONS OF THE SYMPATHETIC NERVE THROUGH ITS CAROTID BRANCH WITH SOME OF THE CRANIAL NERVES. (From Sappey, after Hirschfeld and Leveillé.)

The full description of this figure will be found at p. 240. The following numbers refer to sympathetic nerves and their connections: 6, sphenopalatine ganglion; 7, Vidian nerve; 9, large deep petrosal nerve; 10, a part of the sixth nerve, receiving twigs from the carotid plexus of the sympathetic; 11, superior cervical sympathetic ganglion; 12, its prolongation

in the carotid branch; 15, tympanic nerve; 16, twig uniting it to the sympathetic.

Carotid plexus.—The carotid plexus (*plexus caroticus internus*), situated on the outer side of the internal carotid artery at its second bend (reckoning from below), or between the second and third bends, joins the fifth and sixth cranial nerves, and gives many filaments to the vessel on which it lies.

Branches.—(a) The connection with the *sixth nerve* is established by means of one or two filaments of considerable size, which are supplied to that nerve where it lies by the side of the internal carotid artery.

(b) The filaments connected with the *Gasserian ganglion* of the fifth nerve proceed generally from the carotid plexus, but sometimes from the cavernous.

(c) The *large deep petrosal nerve* passes forwards from the outer side of the artery to the posterior aperture of the Vidian canal, where it joins the large superficial petrosal from the facial to form the Vidian nerve, which is continued to the sphenopalatine ganglion (p. 243).

(d) The *small deep petrosal nerve* passes between the carotid plexus and the tympanic plexus (p. 260).

Cavernous plexus.—The cavernous plexus, named from its position in the sinus of the same name, is placed below and rather to the inner side of the highest turn of the internal carotid artery. Besides giving branches on the artery, it

communicates with the third, the fourth, and the ophthalmic division of the fifth cranial nerves.

BRANCHES.—(a) The filament which joins the *third nerve* comes into connection with it close to the point of division of that nerve.

(b) The branch to the *fourth nerve*, which may be derived from either the cavernous or the carotid plexus, joins the nerve where it lies in the wall of the cavernous sinus.

(c) The filaments connected with the *ophthalmic trunk of the fifth nerve* are supplied to its inner surface.

(d) The *sympathetic root of the ciliary ganglion* passes from the cavernous plexus into the orbit, either separately, or in connection with the nasal nerve, or, according to Reichart, with the third nerve (p. 238).

(e) Minute filaments are furnished to the pituitary body.

2. PHARYNGEAL NERVES AND PLEXUS.—These nerves arise from the fore part of the ganglion, and are directed obliquely inwards to the side of the pharynx. Opposite the middle constrictor muscle they unite with branches of the pneumogastric and glosso-pharyngeal nerves; and by their union with these nerves the **pharyngeal plexus** is formed. Branches emanating from the plexus are distributed to the muscles and mucous membrane of the pharynx (p. 265). One or two filaments pass from these branches to the superior and external laryngeal nerves (fig. 228).

3. UPPER CARDIAC NERVE.—Each of the cervical ganglia of the sympathetic usually furnishes a cardiac branch, the three being named respectively the upper, middle, and lower cardiac nerves.

These branches are continued singly, or in connection, to the large prevertebral centre (cardiac plexus) of the thorax. Their size varies considerably, and where one branch is smaller than common, another will be found to be increased in size, as if to compensate for the defect. There are some differences in the disposition of the nerves of the right and left sides.

The **upper or superficial cardiac nerve** of the *right side* proceeds generally from two or more branches of the ganglion, with, in some instances, an offset from the cord connecting the first two ganglia. In its course down the neck the nerve lies in the back of the carotid sheath, along the front of the longus colli muscle; it crosses either in front of or, less frequently, behind the inferior thyroid artery, and is placed in front of the recurrent laryngeal nerve. Entering the thorax, it passes in some cases before, in others behind, the subclavian artery, and is directed along the innominate artery to the back part of the arch of the aorta, where it ends in the deep cardiac plexus, a few small filaments continuing also to the front of the great vessel. Some branches accompany the inferior thyroid artery to be distributed to the thyroid body.

In its course downwards this cardiac nerve is repeatedly connected with other branches of the sympathetic, and with the pneumogastric nerve. Thus, about the middle of the neck it is joined by one or more filaments from the external laryngeal nerve; and, rather lower down, by one or two filaments from the trunk of the pneumogastric nerve (upper cervical cardiac branches); lastly, on entering the chest, it joins with the recurrent laryngeal.

The **upper cardiac nerve** of the *left side* has, while in the neck, the same course and relations as that of the right side. Within the chest it follows the left carotid artery to the arch of the aorta, and usually crosses over that vessel to enter the superficial cardiac plexus. In some cases, however, this nerve ends, either wholly or in part, in the deep cardiac plexus, and it then descends behind the arch of the aorta.

Varieties.—The cardiac nerves vary greatly in their disposition, and in many cases it is difficult, if not impossible, to recognize the arrangement which is described as typical. The superior cardiac nerve of the right side, instead of passing to the thorax in the manner stated above, may join the cardiac branch furnished from one of the other cervical ganglia. This nerve is sometimes wanting, especially on the right side; in such cases it appears to be

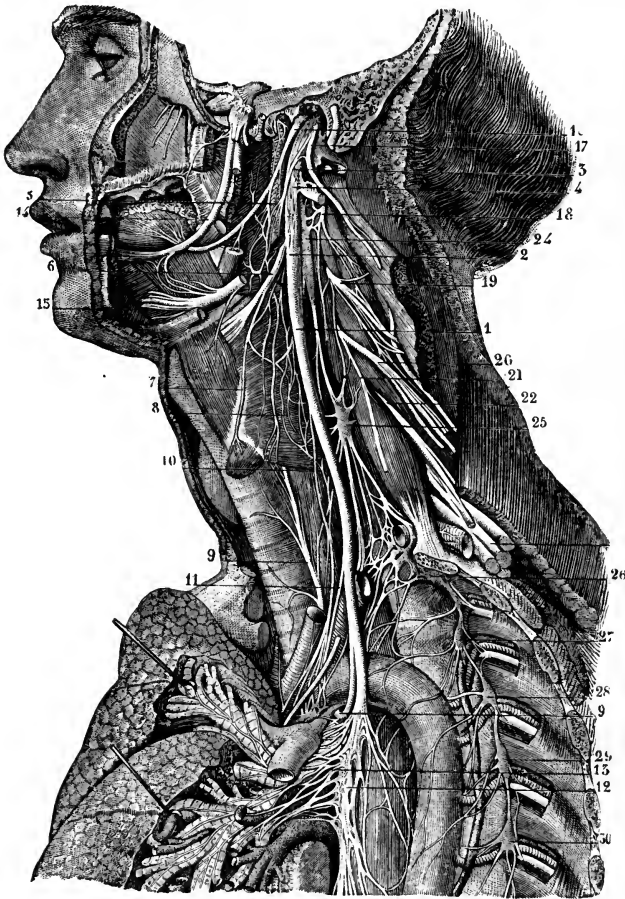


Fig. 232.—CONNECTIONS OF THE CERVICAL AND UPPER THORACIC SYMPATHETIC GANGLIA AND NERVES ON THE LEFT SIDE. (From Sappey, after Hirschfeld and Leveillé.)

The full description of this figure will be found at p. 263. The following numbers refer to the sympathetic ganglia and nerves, and those immediately connected with them: 5, pharyngeal plexus; 12, 13, posterior pulmonary plexus; and to the reader's left, above the pulmonary artery, the superficial cardiac plexus; 24, superior cervical ganglion of the sympathetic; 25, middle cervical ganglion; 26, conjoined inferior cervical and first thoracic ganglia; 27, 28, 29, 30, second, third, fourth, and fifth thoracic ganglia.

replaced by a larger superior cardiac offset from the vagus or its external laryngeal branch (M. Alpiger).

Drobnik describes a special *pretracheal branch* which is given off from the communication between the superior cardiac nerve and the recurrent laryngeal; it descends on the trachea, and terminates partly in the pericardium, partly in the anterior pulmonary plexus.

4. BRANCHES TO BLOOD-VESSELS.—The nerves which ramify on the arteries (*nn. carotici externi*) spring from the front of the ganglion, and twine round the trunk of the external carotid artery (*plexus caroticus externus*). They are also prolonged on the branches of the artery, forming upon them slender plexuses which are named like the arteries they accompany. From the plexus on the facial artery

is derived the filament which forms the sympathetic root of the submaxillary ganglion; and from that on the middle meningeal artery twigs are described as extending to the otic ganglion, as well as to the geniculate ganglion of the facial nerve (*external superficial petrosal nerve*, p. 253). One filament descends from these nerves to the carotid gland.

Microscopic ganglia are frequently met with in the vascular plexuses, and several larger ones of more constant occurrence have been described. The most important of these is the *temporal ganglion*, about 2 mm. in length, situated on the external carotid artery at the place of origin of the posterior auricular branch; it is said to receive a filament from the stylo-hyoid branch of the facial nerve.

MIDDLE CERVICAL GANGLION.

The middle ganglion, much the smallest of the cervical ganglia, is placed on the sympathetic cord at or near the spot where it crosses the inferior thyroid artery, about opposite the sixth or seventh cervical vertebra. It is usually connected by grey branches with the fifth and sixth spinal nerves, but in a somewhat variable manner. It gives off thyroid branches and the middle cardiac nerve.

Thyroid branches.—From the inner side of the ganglion some twigs proceed along the inferior thyroid artery to the thyroid body, where they join the recurrent laryngeal and the external laryngeal nerves. While on the artery, these branches communicate with the upper cardiac nerve.

The **middle cardiac nerve** (deep or great cardiac nerve) of the *right side* is prolonged to the chest either in front of or behind the subclavian artery. In the chest it lies on the trachea, where it is joined by filaments of the recurrent laryngeal nerve, and it ends in the right side of the deep cardiac plexus. While in the neck, this nerve communicates with the upper cardiac nerve and the recurrent branch of the pneumo-gastric.

On the *left side*, the middle cardiac nerve enters the chest between the left carotid and subclavian arteries, and joins the left side of the deep cardiac plexus.

Varieties.—The middle cervical ganglion is often absent, and in that case the middle cardiac nerve is given off by the interganglionic cord. On the other hand, it is sometimes double (fig. 233). The smaller upper portion (A) is the middle cervical ganglion of Arnold and Luschka, the thyroid ganglion of Krause; while the larger lower portion (B) is the middle cervical ganglion of Swan and Krause, the inferior cervical ganglion of Arnold, Luschka, and Rüdinger. The single ganglion is more frequently in the latter situation.

This part of the cord is sometimes placed behind the inferior thyroid artery, or it may be divided so that the artery is enclosed in a loop of the nerve.

LOWER CERVICAL GANGLION.

The lower cervical ganglion is irregular in shape, usually somewhat flattened and round, or semilunar, and is frequently united to the first thoracic ganglion, the common mass being described as the first thoracic ganglion by many authors. It lies over the first costo-central articulation, in the lateral angle between the subclavian and vertebral arteries. The connecting cord between the middle and lower cervical ganglia usually passes behind the vertebral artery, but in some cases, especially on the left side, the interganglionic cord forms a ring around the vessel. The two ganglia are also united by the *ansa subclavia* (see below).

The inferior cervical ganglion is connected to the lowest two cervical nerves by grey communicating branches, and it gives off the lower cardiac nerve and offsets to blood-vessels.

The **lower cardiac nerve**, issuing from the inferior cervical ganglion, or from the first thoracic, inclines inward on the *right side*, behind the subclavian artery and terminates in the cardiac plexus behind the arch of the aorta. It communicates

with the middle cardiac and recurrent laryngeal nerves behind the subclavian artery.

On the *left side*, the lower cardiac often becomes blended with the middle cardiac nerve, and the cord resulting from their union terminates in the deep cardiac plexus.

Branches to blood-vessels.—From the lowest cervical and first dorsal ganglia slender grey branches ascend along the vertebral artery in its canal, forming a plexus (*plexus vertebralis*) round the vessel by their intercommunications, and supplying it with offsets. This plexus is connected with the cervical spinal nerves as they cross the vertebral artery, and its ultimate ramifications are continued on the intracranial branches of the vertebral and basilar arteries.

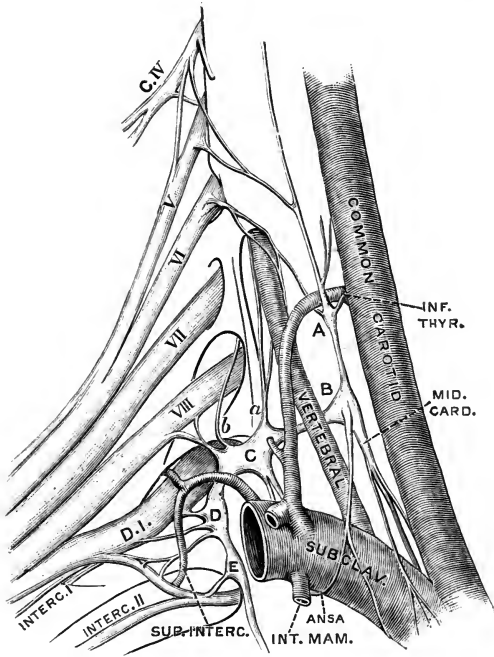


Fig. 233.—THE SYMPATHETIC AT THE LOWER PART OF THE NECK. (G. D. T.)

A, B, middle cervical ganglion in two pieces; C, inferior cervical ganglion; D and E, first and second thoracic ganglia.

a, vertebral offset of inferior cervical ganglion; *b*, branch which ascends through the foramen in the transverse process of the last cervical vertebra to join the seventh nerve.

Below C are the origin of the inferior cardiac nerve, and the termination of the ansa subclavia. The arteries have been drawn downwards and inwards in order to display the nerves. The middle cervical ganglion is, therefore, in a lower position than natural; and the communication between the middle and lower ganglia is directed more transversely than would be the case if the parts were in their natural place.

Ansa subclavia (*Viousseni*).—

This name is given to a small cord, often double, which passes between the middle cervical and the lower cervical, or first dorsal, ganglia, in front of the subclavian artery, forming a loop

around that vessel, and supplying it with small offsets (*plexus subclavius*). From the latter, filaments pass to the internal mammary artery, and in some cases form a communication with the phrenic nerve.

A direct twig of communication to the phrenic nerve is often given off from the inferior cervical ganglion, less frequently from the middle cervical ganglion.

The **stellate ganglion** of the dog and cat corresponds to the united lower cervical and upper three or four thoracic ganglia of man. In the rabbit the name *ganglion stellatum* was used for the lower cervical ganglion, corresponding to the middle cervical ganglion of man, by Ludwig and Thiry, whereas Cyon applied it to the first thoracic ganglion, which corresponds to the lower cervical ganglion in man (Krause).

CONSTITUTION OF THE CERVICAL SYMPATHETIC.

The sets of fibres which have been recognized in the cervical sympathetic, and their probable origin, are as follows:—

(*a*) **Pupillo-dilator fibres**, arising from the first, second, and third dorsal nerves. They pass upwards in the ascending branch of the superior cervical ganglion, and thence to the Gasserian ganglion, reaching the eyeball through the first division of the fifth and the long ciliary nerves. (It is stated by many observers that pupillo-dilator fibres are contained also in the seventh and eighth cervical nerves.)

(b) **Motor fibres to the involuntary muscle of the orbit and eyelids**, from the highest four or five dorsal nerves (Langley).

(c) **Vaso-motor fibres of the head.** *Vaso-constrictor fibres* are given off in the dog and cat chiefly by the second, third, and fourth dorsal nerves, in the rabbit by the dorsal nerves from the second to the eighth (Langley). There is also some evidence as to the existence of *vaso-dilator fibres*. but the origin of these has not been fully ascertained.

(d) **Secretory fibres of the submaxillary gland**, mainly from the second and third dorsal nerves.

(e) **Pilo-motor fibres of the face and neck**, in the monkey arising from the second, third, fourth, and fifth dorsal nerves (Sherrington).

In all the foregoing groups the fibres of spinal origin terminate, and fibres of sympathetic origin arise, in the superior cervical ganglion.

(f) **Accelerator fibres of heart**, derived from the upper four or five dorsal nerves, but chiefly from the second and third. The spinal fibres end and sympathetic fibres begin in the middle and lower cervical (perhaps also the first thoracic) ganglia.

THORACIC PART OF THE GANGLIATED CORD.

In the thorax the gangliated cord is placed at the side of the spinal column, along a line passing over the costo-central articulations. It is covered by the pleura, and crosses the intercostal blood-vessels.

The ganglia are commonly eleven in number, seldom twelve. The first, when distinct, is larger than the rest, and lies at the vertebral extremity of the first intercostal space; but it is often blended with the lower cervical ganglion. The succeeding ganglia are small, oval or triangular in form, and correspond generally to the heads of the ribs from the third to the eleventh; while the last is placed a little in front of the head of the twelfth rib, about the upper border of the last dorsal vertebra.

Connection with spinal nerves.—The branches of connection between the dorsal nerves and the ganglia of the sympathetic are usually two in number for each ganglion, one of these being white and the other grey (p. 358).

BRANCHES OF THE GANGLIA.

The branches furnished by the *upper four or five ganglia* are small, and are distributed in great measure to the vertebræ and ligaments, and to the descending thoracic aorta (fig. 232), on which they form, together with filaments proceeding lower down from the great splanchnic nerve, a slender network (*plexus aorticus thoracalis*). From the second, third, and fourth ganglia offsets pass also to the posterior pulmonary plexus (p. 268).

The branches furnished by the *lower six or seven ganglia* unite into three cords on each side, which pass down to join plexuses in the abdomen, and are distinguished as the great, the small, and the smallest splanchnic nerves (*abdominal splanchnics* of Gaskell).

The **great splanchnic nerve** is formed by the union of roots which are given off by the thoracic ganglia from the fifth or sixth to the ninth or tenth inclusive. The trunk thus constituted descends obliquely forwards over the bodies of the dorsal vertebræ, and after perforating the crus of the diaphragm terminates in the upper part of the semilunar ganglion: some of the fibres may occasionally be followed to the suprarenal body and the renal plexus. This nerve is remarkable from its white colour and firmness, due to its consisting in large part (four-fifths according to Rüdinger) of medullated fibres, which are continued directly from the spinal nerves; from the highest root they may be traced upwards along the sympathetic cord as far as the third thoracic ganglion and nerve, or even higher.

In the chest the great splanchnic nerve is not unfrequently divided into parts, and forms a plexus with the small splanchnic nerve. In many cases also a small

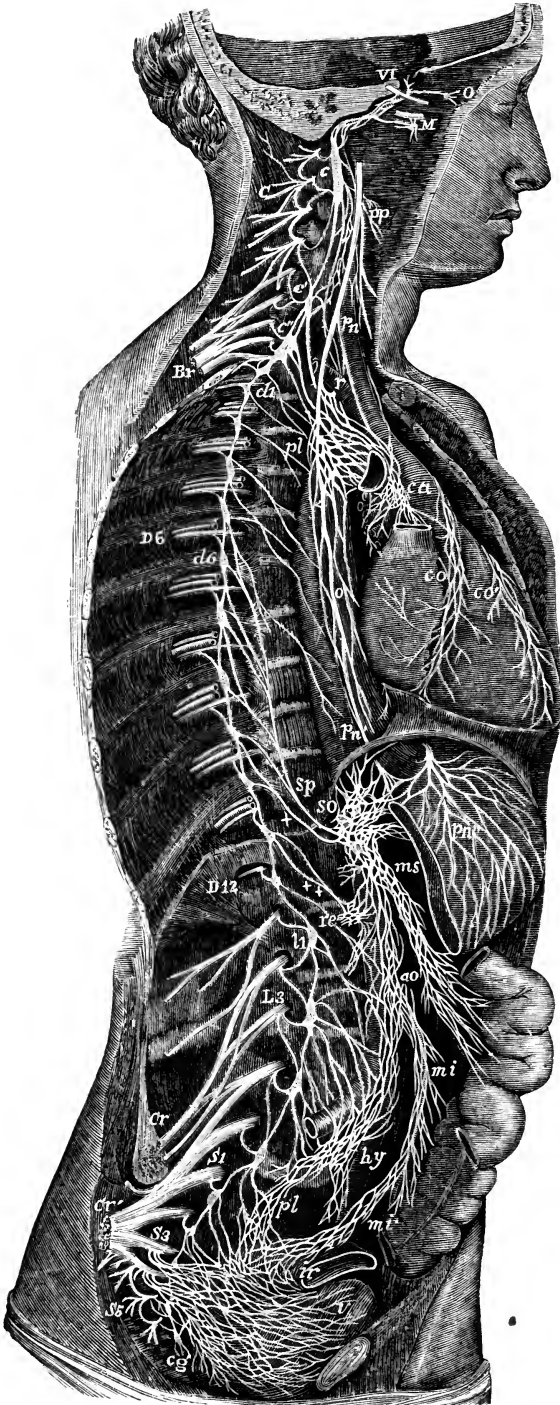


Fig. 234.—DIAGRAMMATIC VIEW OF THE SYMPATHETIC CORD OF THE RIGHT SIDE, SHOWING ITS CONNECTIONS WITH THE PRINCIPAL CEREBRO-SPINAL NERVES AND THE MAIN PNEAORTIC PLEXUSES. †

Cerebro-spinal Nerves.—VI, a portion of the sixth cranial nerve as it passes through the cavernous sinus, receiving two twigs from the carotid plexus of the sympathetic nerve; O, ciliary ganglion, connected by a twig with the cavernous plexus; M, connection of the sphenopalatine ganglion by the large deep petrosal nerve with the carotid plexus; C, cervical plexus; Br, brachial plexus; D 6, sixth dorsal nerve; D 12, twelfth; L 3, third lumbar nerve; S 1, first sacral nerve; S 3, third; S 5, fifth; Cr, anterior crural nerve; Cr', great sciatic; pm, pneumo-gastric nerve in the lower part of the neck; r, recurrent nerve, winding round the subclavian artery.

Sympathetic Cord.—c, superior cervical ganglion; c', middle; c'', inferior; from each of these ganglia cardiac nerves (all deep on this side) are seen descending to the cardiac plexus; d 1, placed immediately below the first dorsal sympathetic ganglion; d 6, is opposite the sixth; l 1, first lumbar ganglion; cg, the terminal or coccygeal ganglion.

Pneurotic and Visceral Plexuses.—pp, pharyngeal plexus; pl, posterior pulmonary plexus, spreading from the pneumo-gastric on the back of the right bronchus; ca, on the aorta, the cardiac plexus, towards which, in addition to the cardiac nerves from the three cervical sympathetic ganglia, other branches are seen descending from the pneumo-gastric and recurrent nerves; co, right or posterior, and co', left or anterior coronary plexus; o, oesophageal plexus in long meshes on the gullet; sp, great splanchnic nerve; +, small splanchnic; ++, smallest splanchnic; the first and second of these are shown joining so, the solar plexus; the third descending to re, the renal plexus; connecting branches between the solar plexus and the pneumo-gastric nerves are also represented; pn', above the place where the right pneumo-gastric passes to the posterior surface of the stomach; pn'', the left, distributed on the anterior surface of the cardiac portion of the organ; from the solar plexus large branches are seen surrounding the arteries of the cœliac axis, and descending to ms, the superior mesenteric plexus; opposite to this is an indication of the suprarenal plexus; below re (the renal plexus), the spermatic plexus is also indicated; av, on the front of the aorta, marks the aortic plexus, formed by nerves descending from the solar and superior mesenteric plexuses and from the lumbar ganglia; mi, the inferior mesenteric plexus, surrounding the corresponding artery; hy, hypogastric plexus, placed between the common iliac arteries, connected above with the aortic plexus, receiving nerves from the lower lumbar ganglia, and dividing below into the right and left pelvic or inferior hypogastric plexuses; pl, right pelvic plexus; from this the nerves descending are joined by those from the plexus on the superior hæmorrhoidal

vessels m', by sympathetic nerves from the sacral ganglia, and by numerous visceral nerves from the third and fourth sacral spinal nerves, and there are thus formed the rectal, vesical, and other plexuses, which ramify upon the viscera from behind forwards, and from below upwards, as towards ir, and v, the rectum and bladder.

ganglion (*splanchnic ganglion*) is formed on it, usually confined to the inner part of the nerve, over the last dorsal vertebra, or the last but one; and when it presents a plexiform arrangement, several small ganglia have been observed on its divisions. According to Cunningham, the splanchnic ganglion is always present on the right side.

From the great splanchnic nerve and the splanchnic ganglion filaments are given to the front of the vertebræ and the aorta.

In eight instances out of a large number of bodies, Wrisberg observed a fourth splanchnic nerve (*nervus splanchnicus supremus*). It is described as formed by offsets from the cardiac nerves, and from the lower cervical as well as some of the upper thoracic ganglia.

The **small splanchnic nerve** springs from the ninth and tenth (sometimes the tenth and eleventh) thoracic ganglia, or from the neighbouring part of the cord. It passes along with the preceding nerve, or separately, through the diaphragm, and ends in the lower part of the semilunar (or aortico-renal) ganglion. In the chest, this nerve often communicates with the great splanchnic nerve; and in some instances it furnishes a branch to the renal plexus, especially if the lowest splanchnic nerve is very small or wanting.

The **smallest splanchnic nerve** (*nervus renalis posterior*, Walter) arises from the last thoracic ganglion, and communicates sometimes with the nerve last described. After passing the diaphragm with the cord of the sympathetic, it ends in the renal plexus. Its place is frequently supplied by a branch of the small splanchnic nerve.

CONSTITUTION OF THE THORACIC PART OF THE SYMPATHETIC.

The thoracic portion of the gangliated cord receives most of the spinal fibres entering the sympathetic system (*cf.* p. 359). Only a small part of these end in the thoracic ganglia; the greater number pass either upwards into the neck or downwards into the abdomen. The fibres ascending to the neck arise from the upper dorsal nerves; they include the pupillo-dilator fibres, secretory fibres of the submaxillary gland, vaso-motor fibres of the head and neck, accelerator fibres of the heart, and others, all of which have been referred to in connection with the cervical sympathetic (p. 366). In addition to these, the following groups have been demonstrated experimentally in the lower animals:—

(a) **Vaso-constrictor fibres of the pulmonary vessels** have been shown by Bradford and Dean, in the dog, to pass out of the spinal cord by the thoracic nerves from the second to the seventh (mainly, however, through the third, fourth, and fifth nerves), and to end in the ganglion stellatum.

(b) **Vaso-constrictor fibres of the limbs** are connected with the vertebral ganglia. Those of the fore limb are given off by the dorsal nerves, in the dog from the third to the eleventh (Bayliss and Bradford), in the cat from the fourth to the ninth (Langley). Those of the hind limb are furnished, according to the same investigators, in the dog by the last three (11, 12, 13) dorsal and first three lumbar nerves, and in the cat by the last two or three dorsal and the first three or four lumbar nerves.

(c) **Secretory fibres to the sweat-glands** of the fore foot leave the dorsal nerves from the third or fourth to the ninth, and pass to the ganglion stellatum; while those of the hind limb emerge by the last two dorsal and upper three lumbar nerves, and descend in the cord to the lower lumbar and upper sacral ganglia—in the cat (Langley).

(d) **Pilo-motor fibres** in the cat pass from the lower nine or ten dorsal nerves, as well as the upper three or four lumbar, to the vertebral ganglia (Langley).

The splanchnic nerves contain:—

(e) **Viscero-inhibitory fibres of the stomach and intestine**.—According to Langley and Dickinson they end in the ganglia of the solar plexus.

(f) **Vaso-motor nerves of the abdominal blood-vessels**.—The existence of vaso-constrictor fibres for the arteries of the alimentary canal in the splanchnic nerves is well established; and, according to Langley and Dickinson, these nerves also contain the vaso-dilator fibres of the same vessels: both sets of fibres end in the ganglia of the solar plexus. Vaso-constrictor fibres of the portal vein and its tributaries were originally demonstrated by Mall; according to Bayliss and Starling, in the dog, they are given off by the dorsal nerves from the third to the eleventh, but mainly from the fifth to the ninth. The nerves of the renal blood-vessels, both constrictor and dilator, are derived in the dog from the dorsal nerves from the sixth downwards, as well as (constrictors only) from the upper two lumbar nerves

(Bradford): the renal vaso-motor fibres probably end in the ganglia of the renal plexus (Langley and Dickinson).

(g) **Afferent fibres from the abdominal viscera.**

The lowest part of the cord also contains:—

(h) Some of the **motor fibres of the circular muscle of the rectum**, proceeding from the lower dorsal nerves. Together with fibres from the upper one or two lumbar nerves, they pass by the aortic plexus to the inferior mesenteric ganglion. Associated with these are the inhibitory fibres of the longitudinal muscle of the rectum (Fellner).

LUMBAR PART OF THE GANGLIATED CORD.

In the lumbar region, the two gangliated cords approach one another more nearly than in the thorax. They are placed on the front of the bodies of the vertebræ, each lying along the inner margin of the psoas muscle; and that of the right side is partly covered by the vena cava, that of the left by the aorta.

The ganglia are small, and of an oval shape. They are commonly four in number, but occasionally their number is diminished, and they are then of larger size.

Connection with spinal nerves.—In consequence of the greater distance at which the lumbar ganglia are placed from the intervertebral foramina, the branches of connection with the spinal nerves are longer than in other parts of the gangliated cord. There are generally two connecting branches for each ganglion, but the number is not so uniform as it is in the chest; nor are those belonging to any one ganglion connected always with the same spinal nerve. The connecting branches accompany the lumbar arteries, and, as they cross the bodies of the vertebræ, are covered by the fibrous bands which give origin to the muscular fibres of the psoas.

BRANCHES.—The branches of these ganglia are uncertain in their number. Some join the plexus on the aorta; others descending go to form the hypogastric plexus. Several filaments are distributed to the vertebræ and the ligaments connecting them.

CONSTITUTION OF THE LUMBAR PORTION OF THE SYMPATHETIC.

Spinal fibres pass into the sympathetic from the upper one or two lumbar nerves, and others descend in the cord from the lower dorsal nerves. For the most part they form a continuation of groups of fibres which have been noticed in the account of the thoracic sympathetic (p. 369), including vaso-constrictor and secretory nerves of the hind limb, pilo-motor fibres, vaso-constrictor fibres of the abdominal vessels, and motor fibres of the circular muscle, with inhibitory fibres of the longitudinal muscle of the rectum.

Arising from the lumbar nerves only are the following:—

(a) **Vaso-motor nerves of the penis.**—The *vaso-constrictor fibres* probably pass from the upper lumbar nerves into the sympathetic cord, whence they are mainly continued by pale fibres through grey rami communicantes to the pudic nerve; but it is stated by François-Franck that some constrictor fibres run through the inferior mesenteric ganglion to the hypogastric plexus, and that these are accompanied by a part of the *vaso-dilator fibres* of the penis.

(b) **Motor fibres to the bladder**, passing by the aortic plexus to the inferior mesenteric ganglion, and thence through the hypogastric and pelvic plexuses, to supply the circular muscle, including the sphincter. Associated with these there are probably inhibitory fibres of the longitudinal muscle.

(c) **Motor fibres to the uterus**, taking a similar course to the foregoing.

(Motor fibres to the vas deferens in the male, or to the round ligament of the uterus in the female, were found by Sherrington in the monkey leaving the cord by the anterior roots of the second and third lumbar nerves (corresponding to the first and second lumbar of man), and passing to their destination through the genital branch of the genito-crural nerve.)

SACRAL PART OF THE GANGLIATED CORD.

Over the sacrum, the gangliated cord of the sympathetic nerve is much diminished in size, and gives but few branches to the viscera. Its position on the front of the sacrum is along the inner side of the anterior sacral foramina; and like the two

series of those foramina, the right and left cords approach one another in their progress downwards. The upper end of each is united to the last lumbar ganglion by a single or a double interganglionic cord; and at the lower end they are connected by means of a loop, in which a single median ganglion, *ganglion impar* or *coccygeal ganglion*, placed on the fore part of the coccyx, is often found. The sacral ganglia are usually four in number; but the variation both in size and number is more marked in these than in the thoracic or lumbar ganglia.

Variety.—In one instance the cord was found terminating at the second sacral nerve (E. Fawcett, Journ. Anat., xxix, 329).

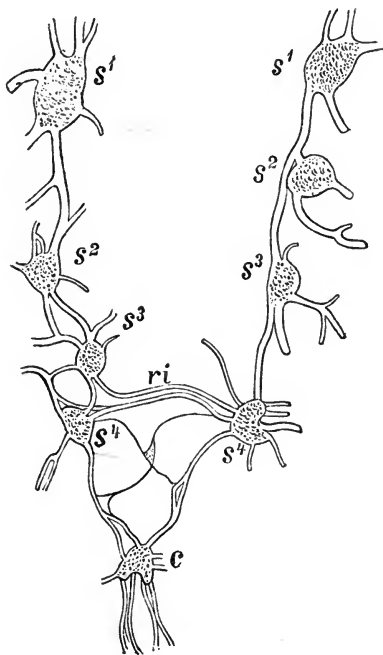
Connection with spinal nerves.—From the proximity of the sacral ganglia to the spinal nerves at their emergence from the foramina, the communicating

Fig. 235.—SACRAL PORTION OF THE SYMPATHETIC CORDS OF AN INFANT, SLIGHTLY ENLARGED. (Raubert.)

s 1—s 4, sacral ganglia; c, coccygeal ganglion, showing indications of its origin by the fusion of two ganglia, and sending downwards branches which run with the middle sacral artery; ri, interfunicular branches uniting the ganglia of the two sides; below these is seen a small interfunicular ganglion.

branches are very short: there are often two for one ganglion, and these are in some cases connected with different sacral nerves. The coccygeal nerve communicates with the last sacral, or the coccygeal ganglion.

BRANCHES.—The branches proceeding from the sacral ganglia are much smaller than those from other ganglia of the cord. They are for the most part expended on the front of the sacrum, and join the corresponding branches from the opposite side. Some filaments from one or two of the upper ganglia enter the pelvic plexus, while others go to form a plexus on the middle sacral artery. From the loop connecting the two cords, filaments are given to the coccyx and to the ligaments about it, and to the coccygeal gland.



CONSTITUTION OF THE SACRAL SYMPATHETIC.

There are no spinal fibres passing from the sacral nerves to the sympathetic cord, but the latter contains medullated fibres which descend from the lumbar region and terminate in the sacral ganglia. These fibres include vaso-constrictor and secretory fibres of the hind limb, and the pilo-motor fibres of the hindmost part of the body and the tail in the cat (Langley).

The visceral branches of the sacral nerves (*pelvic splanchnics*, Gaskell) are equivalent to white rami communicantes (p. 359), but they pass directly into the pelvic plexuses, where a few of the fibres may turn upwards to the inferior mesenteric ganglion,¹ while the larger number enter the plexuses of the pelvic viscera. They comprise:—

(a) Motor fibres to the longitudinal muscle, and inhibitory fibres to the circular muscle of the rectum.

¹ Fibres ascending to the inferior mesenteric ganglion are described by Gaskell in the dog, but they were not found by Langley in the cat.

(b) The chief motor fibres of the bladder, distributed probably to the longitudinal muscle.

(c) Motor fibres of the uterus.

(d) Vaso-dilator fibres of the penis (*nerri erigentes*).

(e) Secretory fibres of the prostate gland.

THE GREAT PLEXUSES OF THE SYMPATHETIC.

Under this head are included certain large plexuses of nerves placed farther forwards in the visceral cavity than the gangliated cords, and furnishing branches to the viscera. The principal of these plexuses are the cardiac, the solar, and the hypogastric with the pelvic plexuses prolonged from it. They are composed of assemblages of nerves, or of nerves and ganglia, and from them smaller plexuses are derived.

CARDIAC PLEXUS.

This plexus receives the cardiac branches of the cervical ganglia and those of the pneumo-gastric nerves, and from it proceed the nerves which supply the heart, besides some offsets which contribute to the nervous supply of the lungs. It lies against the aorta and pulmonary artery, where these vessels are in contact, and in its network are distinguished two parts, the superficial and the deep cardiac plexuses, the deep plexus being seen behind the vessels, and the superficial more in front, but both being closely connected. The branches pass from these plexuses chiefly forwards in two bundles, accompanying the coronary arteries.

Superficial cardiac plexus.—The superficial cardiac plexus (fig. 232) lies in the concavity of the arch of the aorta, between the ligament of the ductus arteriosus and the right branch of the pulmonary artery. In it the superficial or upper cardiac nerve of the sympathetic of the left side terminates, either wholly or in part, together with the lower cervical cardiac branch of the left pneumo-gastric nerve. In the superficial plexus a small ganglion, the *ganglion of Wrisberg*, is frequently found at the point of union of the nerves. Besides ending in the right coronary plexus, the superficial cardiac plexus furnishes laterally filaments along the pulmonary artery to the anterior pulmonary plexus of the left side.

Deep cardiac plexus.—The deep cardiac plexus, much larger than the superficial one, is placed behind the arch of the aorta, between it and the end of the trachea, and above the bifurcation of the pulmonary artery.

This plexus receives all the cardiac branches of the cervical ganglia of the sympathetic nerve, except the upper cardiac nerve of the left side. It likewise receives the cardiac nerves furnished by the vagus and by the recurrent laryngeal branch of that nerve, with the exception of the left cervical cardiac nerves.

Of the branches from the *right side* of the plexus, the greater number descend in front of the right pulmonary artery, and join branches from the superficial part in the formation of the right coronary plexus; others, passing behind the right pulmonary artery, are distributed to the right auricle of the heart, and a few filaments are continued into the left coronary plexus.

On the *left side*, a few branches pass forwards by the side of the ductus arteriosus to join the superficial cardiac plexus, and others descend to the left auricle; but the great majority end in the left coronary plexus.

The deep cardiac plexus sends filaments to the anterior pulmonary plexus on each side.

Coronary plexuses.—The *right* or *posterior coronary plexus* is derived from both the superficial and deep cardiac plexuses, the filaments by which it arises embracing the root of the aorta. It accompanies the right coronary artery on the heart, sending its branches upwards and downwards to the auricle and ventricle.

The *left or anterior coronary plexus* is larger than the right, and is derived mainly from the left half of the deep cardiac plexus. Being directed forwards between the pulmonary artery and the left auricular appendage, it reaches the left coronary artery, and subdivides into two principal portions which accompany the primary divisions of that vessel.

Nervous filaments ramify in great number under the epicardium, especially on the ventricular portion of the heart. They are not so easily distinguished in man as in some animals. In the heart of the calf or the lamb they are distinctly seen without dissection, running in lines which cross obliquely the muscular fibres. Microscopic ganglia occur on the nerves of the auricles, and in the course of the coronary plexuses, but they are absent from the offsets to the ventricular wall (see Vol. II, p. 372).

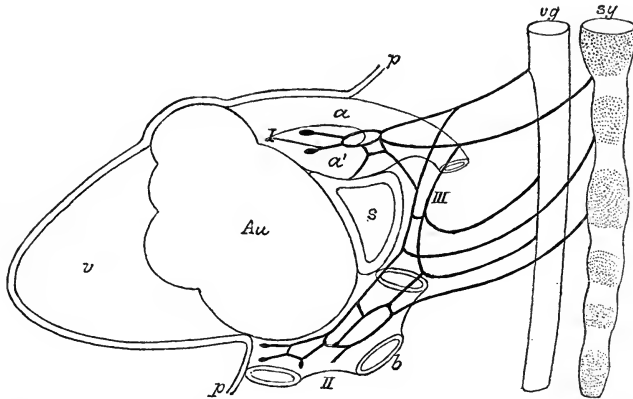


Fig. 236.—DIAGRAMMATIC REPRESENTATION OF THE CARDIAC PLEXUS OF THE HUMAN EMBRYO.
(W. His, jun.)

a, aorta; *a'*, pulmonary artery; *b*, atrium, with the orifices of the veins; *Au*, auricle proper; *v*, ventricle; *vg*, vagus; *sy*, cord of sympathetic; *p*, pericardium; *s*, transverse sinus of pericardium; *I*, bulbar plexus; *II*, atrial plexus; *III*, intermediate plexus.

From the embryological investigations of W. His, jun., it appears that the ascending aorta, the pulmonary trunk, and the ventricles of the heart are supplied by the upper cardiac nerves, while the auricles receive branches arising at a lower level. The earliest of the cardiac nerves to be developed are branches from both vagus and sympathetic of each side to the arterial bulb, which appear about the end of the fourth or the beginning of the fifth week of foetal life, and make their way between the aorta and the pulmonary trunk, where they form the *bulbar plexus*. In the seventh week other nerves are found passing from the vagi lower down to the back of the auricles, and forming there the *atrial plexus*, which also receives sympathetic branches through the following plexus. The bulbar and atrial plexuses are connected by branches which descend from the former behind the transverse sinus of the pericardium, and are joined by offsets of both vagi, the left recurrent nerve, and the sympathetic cords, the whole constituting the *intermediate plexus*. All of these branches contain numerous ganglion-cells of sympathetic nature, which travel downwards with the growth of the nerves. In the course of the third month the coronary nerves are developed from the bulbar plexus, and offsets of the atrial plexus spread over the auricles. In the definitive state therefore the bulbar plexus is represented by the superficial cardiac plexus and a part of the deep cardiac plexus, with their coronary offsets, the intermediate plexus by the remainder of the deep cardiac plexus, and the atrial plexus by the network on the auricles. The distribution of the ganglia in the adult heart corresponds to the extent of these plexuses.

SOLAR OR EPIGASTRIC PLEXUS.

The solar or epigastric plexus (*plexus cœliacus*), the largest of the prevertebral centres, is placed at the upper part of the abdomen, behind the stomach, and in

front of the aorta and the pillars of the diaphragm. Surrounding the origin of the celiac axis and the superior mesenteric artery, it occupies the interval between the suprarenal bodies, and extends downwards as far as the pancreas. The plexus

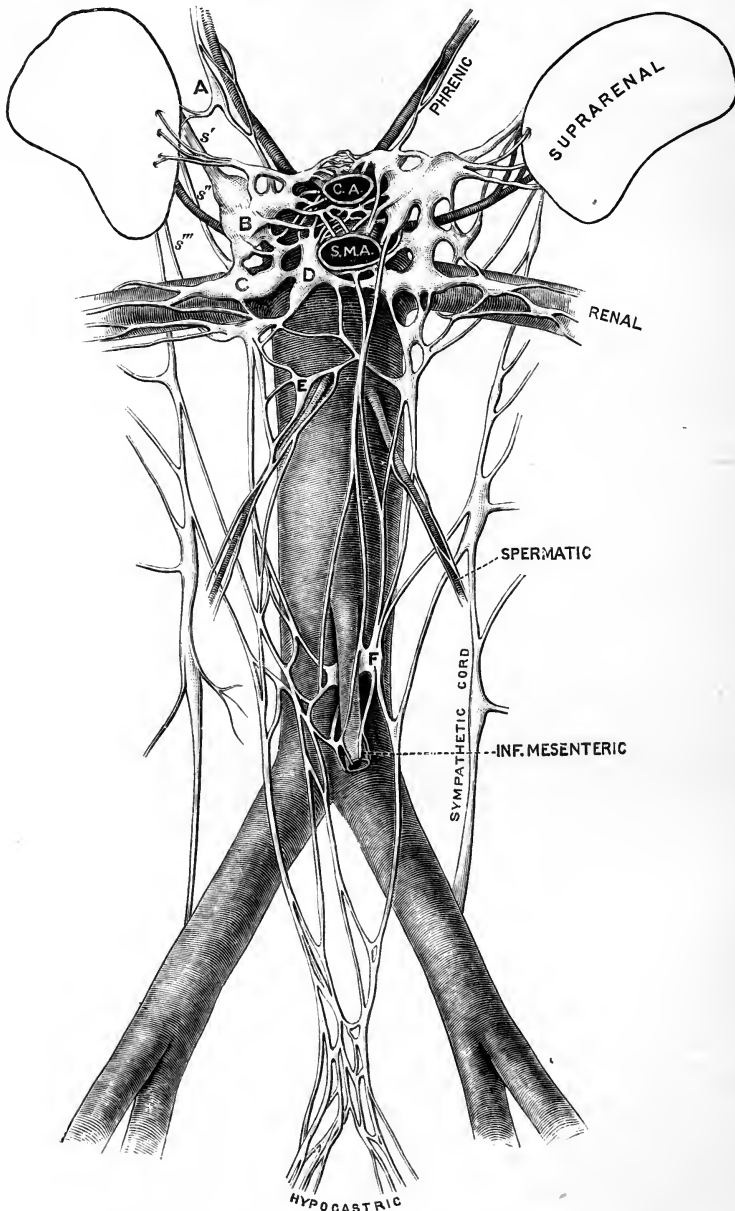


Fig. 237.—SOLAR AND AORTIC PLEXUSES, WITH THE LUMBAR PORTION OF THE SYMPATHETIC CORDS, IN THEIR RELATIONS TO THE AORTA, &c. (G. D. T.)

C.A., celiac axis, and S.M.A., superior mesenteric artery, both cut close to their origin; surrounding them is the solar plexus; on the aorta below the renal arteries is the aortic plexus; *s'*, great, *s''*, small, and *s'''*, smallest splanchnic nerves; A, phrenic ganglion; B, semilunar ganglion; C, aortico-renal ganglion; D, superior mesenteric ganglion; E, spermatic ganglion; F, inferior mesenteric ganglion.

consists of nervous cords, with several ganglia of various sizes connected with them. The large and small splanchnic nerves on both sides, and some branches of the pneumo-gastric, terminate in it. The branches given off from it are very numerous, and accompany the arteries to the principal viscera of the abdomen, constituting so many secondary plexuses on the vessels. Thus, diaphragmatic, celiac, mesenteric, and other plexuses are recognised, which follow the corresponding arteries.

Semilunar ganglia.—The solar plexus contains, as already mentioned, several ganglia (*ganglia celiaca*); and by the size of these bodies it is distinguished from the other prevertebral plexuses. The two principal ganglionic masses, named *semilunar*, though they have often little of the form the name implies, occupy the upper and outer part of the plexus, one on each side, and are placed close to the suprarenal bodies, by the side of the celiac and the superior mesenteric arteries. At the upper end, which is expanded, each ganglion receives the great splanchnic nerve. The lower part of the ganglionic mass, lying over the root of the renal artery, is commonly more or less detached from the rest, and is distinguished as the *aortico-renal ganglion*; it is joined by the small splanchnic nerve, and gives origin to the greater part of the renal plexus. Another part, lying below and to the right of the origin of the superior mesenteric artery, is named the *superior mesenteric ganglion*.

Diaphragmatic or phrenic plexus.—The nerves composing this plexus are derived from the upper part of the semilunar ganglion, and are larger on the right than on the left side. Accompanying the arteries along the lower surface of the diaphragm, the nerves sink into the substance of the muscle. They furnish some filaments to the suprarenal body, and join with the spinal phrenic nerves.

At the right side, on the under surface of the diaphragm, and near the suprarenal body, there is a small ganglion (*diaphragmatic* or *phrenic ganglion*), which marks the junction between the phrenic nerves of the spinal and sympathetic systems. From this small ganglion filaments are distributed to the vena cava, the suprarenal body, and the hepatic plexus. On the left side the ganglion is wanting.

Suprarenal plexus.—The suprarenal nerves issue from the solar plexus and the outer part of the semilunar ganglion, some filaments being added from the diaphragmatic plexus and one of the splanchnic nerves. They are short, but numerous in comparison with the size of the suprarenal body, which they enter on its inner and posterior part. These nerves consist in great part of white fibres, and are beset with minute ganglia.

Renal plexus.—The nerves forming the renal plexus emanate for the most part from the aortico-renal ganglion, but some are added from the solar and aortic plexuses. The renal plexus also receives the termination of the smallest, and sometimes filaments from the small splanchnic nerve, as well as a branch from the first lumbar ganglion. The nerves of the plexus are mostly grey, and in their course along the renal artery ganglia of different sizes (*renal ganglia*) are formed on them. Lastly, dividing with the branching of the vessel, the nerves follow the renal arteries into the substance of the kidney. On the right side some filaments are furnished to the vena cava, behind which the plexus passes with the renal artery; and on both sides offsets pass to the spermatic plexus, and a filament to the ureter.

Spermatic plexus.—This small plexus commences in the renal, but receives in its course along the spermatic artery an accession from the aortic plexus, in which a small *spermatic ganglion* is often formed at the place where these branches arise. Continuing downwards to the testis, the spermatic nerves are connected with others which accompany the vas deferens and its artery from the pelvis.

In the female, the plexus, like the artery, is distributed to the ovary and the uterus.

Cœliac plexus.—This plexus is of large size, and is derived from the fore part of the great epigastric plexus. It surrounds the cœliac axis in a kind of fenestrated sheath, and subdivides, with the artery, into coronary, hepatic, and splenic plexuses, the branches of which form communications corresponding with the arches of the arterial anastomosis. The plexus receives on the left side a considerable offset from the right pneumo-gastric nerve.

The *coronary plexus* is placed with its artery along the small curvature of the stomach, and unites with the nerves which accompany the pyloric artery, as well as with branches of the pneumo-gastric nerves. The nerves of this plexus enter the coats of the stomach, after running a short distance beneath the peritoneum.

The *hepatic plexus*, the largest of the three divisions of the cœliac plexus, ascends with the hepatic vessels and the bile duct, and, entering the substance of the liver, ramifies on the branches of the portal vein and the hepatic artery. Offsets from the left pneumo-gastric nerve join the hepatic plexus at the left side of the vessels. From this plexus filaments pass to the right suprarenal plexus, as well as other secondary plexuses which follow the branches of the hepatic artery. Thus there is a *cystic plexus* to the gall-bladder; and there are *pyloric*, *gastro-epiploic*, and *pancreatico-duodenal plexuses*, which unite with coronary, splenic, and mesenteric nerves.

The *splenic plexus* (*plexus linealis*), continued on the splenic artery and its branches into the substance of the spleen, is reinforced at its beginning by branches from the left semilunar ganglion, and by filaments from the right vagus nerve. It furnishes the *left gastro-epiploic* and *pancreatic plexuses*, which course along the corresponding branches of the splenic artery, and, like the vessels, are distributed to the stomach and pancreas.

Superior mesenteric plexus.—The plexus accompanying the superior mesenteric artery, whiter in colour and firmer than any of the preceding offsets, is mainly given off from the lower part of the solar plexus and the superior mesenteric ganglion, but it also receives fibres from the right pneumo-gastric nerve at its junction with the cœliac plexus. Surrounding the trunk of the superior mesenteric artery, it divides into secondary plexuses which agree in name and distribution with the branches of that vessel. In their progress to the intestine some of the nerves quit the arteries which first supported them, and are directed forwards in the intervals between the vessels. As they proceed they divide, and unite with lateral branches, like the arteries, but without the same regularity; they finally pass upon the intestine along the line of attachment of the mesentery.

Aortic plexus.—The aortic or intermesenteric plexus (*plexus aorticus abdominalis*), placed along the abdominal aorta, occupies the interval between the origins of the superior and inferior mesenteric arteries. It consists, for the most part, of two lateral cords, which are connected above with the semilunar ganglia and renal plexuses, and extend downwards on the sides of the aorta, meeting in several communicating branches over the front of that vessel. The cords receive branches from some of the lumbar ganglia, and at the spots where these join there are often small ganglionic enlargements, which are more distinct in the infant. Several filaments pass to the root of the inferior mesenteric artery to form the plexus on that vessel, and in connection with these is the *inferior mesenteric ganglion*, placed below the origin of the artery.

The aortic plexus furnishes the inferior mesenteric plexus and part of the spermatic, gives some filaments to the lower vena cava, and ends below in the hypogastric plexus.

Inferior mesenteric plexus.—This plexus is derived principally from the left lateral part of the aortic plexus, and closely surrounds with a network the inferior mesenteric artery. It distributes nerves to the left or descending and the sigmoid

colon, and assists in supplying the rectum. The nerves of this plexus, like those of the superior mesenteric plexus, are firm in texture and of a whitish colour.

The highest branches (those on the left colic artery) are connected with the last branches (middle colic) of the superior mesenteric plexus, while others in the pelvis unite with offsets derived from the pelvic plexus.

On the branches of the cœliac and mesenteric plexuses Pacinian corpuscles are often present. They are very variable in number, and are not so numerous or regular in man as in the cat. Their most frequent seat is in the loose tissue behind the pancreas.

HYPOGASTRIC PLEXUS.

The hypogastric plexus, the assemblage of nerves destined for the supply of the viscera of the pelvis, lies, invested in a sheath of dense connective tissue, in the interval between the two common iliac arteries. It is formed by the prolongations of the aortic plexus on each side, which receive considerable branches from the lumbar ganglia, and, after crossing the common iliac artery, interlace in the form of a flat plexiform mass placed in front of the lowest lumbar vertebra. The plexus contains no distinct ganglia. At the lower end it divides into two parts, which are directed downwards, one to each side of the pelvic viscera, and form the pelvic plexuses.

PELVIC PLEXUS.

The pelvic or inferior hypogastric plexuses (fig. 234, *pl*), one on each side, are placed in the lower part of the pelvic cavity by the side of the rectum, and of the vagina in the female. The nerves, continued from the hypogastric plexus, enter into repeated communications as they descend, and form at the points of connection small knots, which contain a little ganglionic matter. After descending some way, they become united with branches of the spinal nerves, as well as with a few offsets of the sacral ganglia, and the union of all constitutes the pelvic plexus. The spinal branches which enter into the plexus are furnished from the third and fourth sacral nerves, sometimes also the second. Small ganglia are formed at the places of union of the spinal nerves, as well as elsewhere in the plexus.

From the plexus so constituted, numerous nerves are distributed to the pelvic viscera. They correspond in great measure with the branches of the internal iliac artery, and vary with the sex; thus, besides hæmorrhoidal and vesical nerves, which are common to both sexes, there are nerves special to each:—namely, in the male for the prostate, vesicula seminalis, and vas deferens; in the female, for the vagina, uterus, ovary, and Fallopian tube.

The nerves distributed to the urinary bladder and the vagina contain a larger proportion of spinal fibres than those furnished to the other pelvic viscera.

Hæmorrhoidal plexus.—These slender nerves proceed from the upper part of the pelvic plexus. They join with the nerves (superior hæmorrhoidal) which descend with the inferior mesenteric artery, and penetrate the coats of the rectum.

Vesical plexus.—The nerves of the urinary bladder are very numerous. They are directed from the lower part of the pelvic plexus to the side and lower part of the bladder. At first these nerves accompany the vesical blood-vessels, but afterwards they leave the vessels, and subdivide into minute branches before perforating the muscular coat of the organ. The lower part of the ureter is also supplied by these nerves; and secondary plexuses are given in the male to the vas deferens and the vesicula seminalis.

The nerves of the vas deferens ramify round that tube, and communicate in the spermatic cord with the nerves of the spermatic plexus. Those furnished to the vesicula seminalis form an interlacement on the vesicula, and some branches

penetrate its substance. Other filaments from the prostatic nerves reach the same structure.

Prostatic plexus.—The nerves of this plexus are of considerable size, and pass between the prostate gland and the levator ani. Some are furnished to the prostate and to the vesicula seminalis; and the plexus is then continued forwards to supply the erectile substance of the penis, where its nerves are named *cavernous*.

Cavernous nerves of the penis.—These are very slender, and difficult to dissect. Continuing from the prostatic plexus, they pass onwards beneath the subpubic arch and through the muscular structure connected with the membranous part of the urethra, to the dorsum of the penis. At the root of the latter, the cavernous nerves are joined by some short filaments from the pudic nerve. Having distributed twigs to the fore part of the prostate and the membranous part of the urethra, these nerves divide into branches for the erectile substance of the penis, as follows:—

The *small cavernous nerves* perforate the fibrous covering of the corpus cavernosum near the root of the penis, and end in the erectile substance.

The *large cavernous nerve* extends forwards on the dorsum of the penis, and dividing, gives filaments which penetrate the corpus cavernosum, and pass with or near the cavernous artery. As it continues onwards, this nerve joins with the dorsal branch of the pudic nerve about the middle of the penis, and is distributed to the corpus cavernosum. Branches from the foregoing nerves reach the corpus spongiosum urethræ. The cavernous nerves are composed mainly of pale fibres.

Vaginal nerves.—The nerves furnished to the vagina leave the lower part of the pelvic plexus—that part with which the spinal nerves are more particularly combined. They are distributed to the vagina without previously entering into a plexiform arrangement; and they end in the erectile tissue on the lower and anterior part, and in the mucous membrane.

Nerves of the uterus.—These nerves are derived mainly from the lateral fasciculus prolonged to the pelvic plexus from the hypogastric plexus, but some filaments are also added from the third and fourth sacral nerves. They are directed upwards with the blood-vessels, between the layers of the broad ligament, along the side of the organ, and some slender filaments accompany the branches of the uterine artery, but the larger number of the nerves sink directly into the substance of the uterus, penetrating for the most part its neck and the lower portion of its body. They form connections in the broad ligament with the ovarian nerves, and the fundus of the uterus also receives an offset from that plexus. Numerous small ganglia are contained in the plexus by the side of the neck of the uterus, and a cluster of these constitutes the *ganglion cervicale* of Frankenhäuser. They appear to be absent in the muscular substance of the organ. One branch continued directly from the common hypogastric¹ plexus, reaches the hinder surface of the body of the uterus above the rest; and a nerve from the same source ascends to the Fallopian tube.

The *nerves of the gravid uterus* have been frequently investigated, with a view to discover if they become enlarged along with the increase in size of the organ. It is ascertained that the increase which takes place is confined, for the most part, to the thickening of the fibrous envelopes of the nerves; but it is stated also that fibres furnished with a medullary sheath, which in the unimpregnated state of the uterus lose that sheath as they proceed to their distribution, in the impregnated condition of the uterus continue to be surrounded with it as they run between the muscular fibres (Kilian).

RECENT LITERATURE OF THE SYMPATHETIC.

Alpiger, M., *Anatomische Studie über das gegenseitige Verhalten der Vagus- und Sympathicusäste im Gebiete des Kehlkopfes*, Langenbeck's Archiv, xl, 1890.

Bayliss, W. M., and Bradford, J. R., *The Innervation of the Vessels of the Limbs*, Journ. Physiol., xvi, 1894.

Bayliss, W. M., and Starling, E. H., *On the Origin from the Spinal Cord of the Vaso-constrictor Nerves of the Portal Vein*, Journ. Physiol., xvii, 1894.

Bechterew, W., u. Misowski, N., *Ueber centrale und periphere Darminnervation*, Arch. f. Physiol., Suppl. Bd., 1889; *Zur Frage über die Innervation des Magens*, Neurolog. Centralbl., 1890.

Bonuzzi, P., *Ueber Vasodilatatoren in den hinteren Rückenmarkswurzeln*, Wiener Jahrbücher, 1885.

Bradford, J. R., *The Innervation of the Renal Blood-Vessels*, Journ. Physiol., x, 1889.

Bradford, J. R., and Dean, H. P., *The Pulmonary Circulation*, Journ. Physiol., xvi, 1894.

Braunstein, E. P., *Zur Lehre von der Innervation der Pupillenbewegung*, Wiesbaden, 1894.

Cavazzani, A., *L'innervazione vaso-motrice dei polmoni*, Rivista veneta d. sc. med., 1891, and Arch. ital. de biol., xvi, 1891.

Dastre, R., et Morat, J. P., *Le système grand sympathique*, Bull. scient. du départ. du Nord, 1880; *Sur l'expérience du grand sympathique cervical*, & *Sur les nerfs vaso-dilatateurs des parois de la bouche*, Comptes rendus, xci, 1880; *Sur la fonction vaso-dilatatrice du nerf grand-sympathique*, Arch. de physiol. norm. et pathol., 1882; *Les nerfs vaso-dilatateurs de l'oreille externe*, Arch. de physiol. norm. et pathol., 1882; *Sur les nerfs vaso-dilatateurs du membre inférieur*, Arch. de physiol. norm. et pathol., 1883; *Du rôle tonique et inhibitoire des ganglions sympathiques, et de leur rapport avec les nerfs vaso-moteurs*, Comptes rendus, xcvi, 1883; *Contribution à l'étude des ganglions sympathiques; leur rôle tonique et inhibitoire; leur rapport avec les nerfs vaso-moteurs*, C. r. hebdom. d. l. Soc. d. biol., 1883; *Recherches expérimentales sur le système nerveux vaso-moteur*, Paris, 1884.

Doyon, M., *Recherches sur les nerfs vasomoteurs de la rétine*, Arch. de physiol. norm. et pathol., 1890 and 1891.

Drobnik, T., *Topographisch-anatomische Studien über den Halssympathicus*, Arch. f. Anat., 1887.

Edgeworth, F. H., *On a large-fibred Sensory Supply of the Thoracic and Abdominal Viscera*, Journ. Physiol., xiii, 1892.

Ehrmann, S., *Ueber die Innervation des Dünndarms*, Wiener Jahrbücher, 1885.

Eisenlohr, L., *Ueber die Nerven- und Ganglienzellen des menschlichen Herzens, nebst Bemerkungen zur pathologischen Anatomie derselben*, Inaug. Diss., München, 1887.

Fellner, L., *Die Bewegungs- und Hemmungsnerven des Rectums*, Wiener Jahrbücher, 1883; *Weitere Mittheilungen ueber die Bewegungs- und Hemmungsnerven des Rectums*, Arch. f. d. gesammte Physiologie, lvi, 1894.

François-Franck, *Recherches sur l'innervation vaso-motrice du pénis*, Arch. de Physiol. norm. et pathol., 1895.

Gaskell, W. H., "On the Structure, Distribution and Function of the Nerves which innervate the Visceral and Vascular Systems," Journ. Physiol., vii, 1886; *Do the Nervi Erigentes leave the Spinal Cord in Anterior or Posterior Roots?* Proc. Physiol. Soc., Jan. 15, 1887, Journ. Physiol., viii.

Gaule, J., *Versuch eines Schemas der Innervation der Blase, insbesondere der localen Reflexbahnen*, Arch. f. Physiol., Suppl. Bd., 1892.

Gehuuchten, A. v., *Les éléments nerveux moteurs des racines postérieures*, Anatom. Anzeiger, viii, 1893.

Guépin, A., *Sur l'innervation vésicale*, Journ. de l'Anat. et de la Physiol., 1892.

His, W., *Histogenese und Zusammenhang der Nervenelemente*, Verhandlg. d. x. Internat. Med. Congresses. Berlin, 1890, and Arch. f. Anat., Suppl. Bd., 1890. (Development of Sympathetic.)

His, W., junr., *Die Entwicklung des Herznervensystems bei Wirbelthieren*, Abhandlg. d. königl. sächsisch. Gesellsch. d. Wissensch., 1891.

Jastreboff, N. W., *On the Normal and Pathological Anatomy of the Ganglion Cervicale Uteri*, Trans. Obstetr. Soc., London, xxiii, 1881.

Jegorow, J., *Ueber den Einfluss der langen Ciliarnerven auf die Erweiterung der Pupille*, Arch. f. Physiol., 1886; *Zur Lehre von der Innervation der Blutgefäße*, Arch. f. Physiol., Suppl. Bd., 1892.

Kasem-Beck, A., *Zur Kenntniss der Herznerven*, Arch. f. mikrosk. Anat., xxiv, 1884; *Ueber das Vorkommen von Ganglien und einzelnen Nervenzellen auf den Herzventrikeln der Menschen, der Säugethiere und der Vögel*, Centralbl. f. d. med. Wissensch., 1887.

Keng, Lim Boon, *On the Nervous Supply of the Dog's Heart*, Journ. Physiol., xiv, 1893.

Kölliker, A. v., *Der feinere Bau und die Functionen des sympathischen Nervensystems*, Würzburger Sitzungsberichte, 1894; *Ueber die feinere Anatomie und die physiologische Bedeutung des sympathischen Nervensystems*, Verhdlgn. d. Ges. d. deutschen Naturf. u. Aerzte, 1894.

Kühlwetter, E., *Zur Lehre von der Lagerung der Gefässnerven in den Wurzeln der Rückenmarksnerven*, Eckhard's Beiträge z. Anatom. u. Physiol., xi, 1885.

Langendorff, O., *Die Beziehungen der Nervenfasern des Halssympathicus zu den Ganglienzellen des oberen Halsknotens*, Centralbl. f. Physiologie, v, 1891.

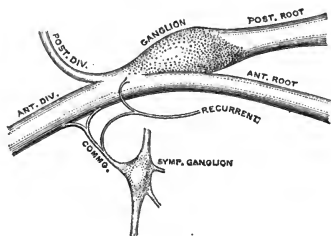
- Langley, J. N.**, *The Innervation of the Pelvic Viscera*, Proc. Physiol. Soc., Dec. 13, 1890, Journ. Physiol., xii; *On the Course and Connections of the Secretory Fibres supplying the Sweat-Glands of the Feet of the Cat*, Journ. Physiol., xii, 1891; *On the Origin from the Spinal Cord of the Cervical and upper Thoracic Sympathetic Fibres, with some Observations on White and Grey Rami Communicantes*, Phil. Trans., 1892; *On the Larger Medullated Fibres of the Sympathetic System*, Journ. Physiol., xiii, 1892; *On an "Accessory" Cervical Ganglion in the Cat and Notes on the Rami of the Superior Cervical Ganglion; also Notes on the Cervical Sympathetic, and chiefly on its Vaso-motor Fibres*, Proc. Physiol. Soc., Jan. 21, 1893, Journ. Physiol., xiv; *The Arrangement of the Sympathetic Nervous System, based chiefly on Observations upon Pilo-motor Nerves*, Journ. Physiol., xv, 1893; *Further Observations on the Secretory and Vaso-motor Fibres of the Foot of the Cat, with Notes on other Sympathetic Nerve Fibres*, Journ. Physiol., xvii, 1894.
- Langley, J. N., and Anderson, H. K.**, *On Reflex Action from Sympathetic Ganglia*, Journ. Physiol., xvi, 1894; *The Constituents of the Hypogastric Nerves (cat)*, Journ. Physiol., xvii, 1894.
- Langley, J. N., and Dickinson, W.**, *On the Local Paralysis of Peripheral Ganglia, and on the Connexion of different Classes of Nerve Fibres with them*, Proc. Roy. Soc., xlvii, 1889.
- Langley, J. N., and Sherrington, C. S.**, *On Pilo-motor Nerves*, Journ. Physiol., xii, 1891.
- Lenhossék, M. v.**, *Ueber Nervenfasern in den hinteren Wurzeln, welche aus dem Vorderhorn entspringen*, Anatom. Anzeiger, v, 1890.
- Mall, F.**, *Die motorischen Nerven der Portalvene*, Arch. f. Physiol., Suppl. Bd., 1890; *Der Einfluss des Systems der Venæ Portæ auf die Vertheilung des Blutes*, Arch. f. Physiol., 1892.
- Morat, J. P.**, *Recherches sur les vaso-moteurs de la tête*, Arch. de physiol. norm. et pathol., 1889; *Les nerfs vaso-dilatateurs et la loi de Magendie*, Arch. de physiol. norm. et pathol., 1890; *Recherches sur les nerfs vaso-moteurs de la tête. Trajet intra-crânien des vaso-moteurs auriculaires*, Arch. de physiol. norm. et pathol., 1891; *Origines et centres trophiques des nerfs vaso-dilatateurs*, Comptes rendus, cxiv, 1892; *Les fonctions vaso-motrices des racines postérieures*, Arch. de physiol. norm. et pathol., 1892; *Sur quelques particularités de l'innervation motrice de l'estomac et de l'intestin*, Arch. de physiol. norm. et pathol., 1893.
- Morat, J. P., et Doyon, M.**, *Le grand sympathique, nerf de l'accommodation pour la vision des objets éloignés*, Comptes rendus, cxii, and Arch. de physiol. norm. et pathol., 1891.
- Nawrocki, P., und Przybylski**, *Die pupillenerweiternden Nerven der Katze*, Arch. f. d. gesammte Physiol., I, 1891.
- Nawrocki, P., und Skabitschewsky, B.**, *Ueber die motorischen Nerven der Blase*, Arch. f. d. gesammte Physiol., xlviii, 1891; *Ueber die sensiblen Nerven deren Reizung Contraction der Blase hervorruft*, Arch. f. d. gesammte Physiol., xlix, 1891.
- Onodi, A. D.**, *Ueber das Verhältniss der cerebrospinalen Faserbündel zum sympathischen Grenzstrange*, Med. Centralbl., 1883, and Arch. f. Anat., 1884; *Ueber die Entwicklung der Spinalganglien und der Nervenwurzeln*, Internat. Monatsschr. f. Anat. u. Histol., 1884; *Ueber die Entwicklung des sympathischen Nervensystems*, Arch. f. mikroskop. Anat., xxvi, 1885.
- Oser, L.**, *Ueber die Innervation des Pylorus*, Wiener Jahrbücher, 1884; *Experimentelle Beiträge zur Innervation des Magens*, Zeitschr. f. Klin. Med., xx, 1892.
- Pal, J.**, *Ueber die Hemmungsnerven des Darmes*, Wiener klin. Wochenschrift, 1893.
- Paterson, A. M.**, *The Development of the Sympathetic Nervous System in Mammals*, Proc. Roy. Soc., xlviii, 1890, and Phil. Trans., 1890.
- Przybylski**, *Sur les nerfs dilatateurs de la pupille chez le chat*, Arch. slaves de Biologie, ii, 1887.
- Rein, G.**, *Beitrag zur Lehre von der Innervation des Uterus*, Arch. f. d. gesammte Physiol., xiii, 1880; *Note sur le plexus nerveux fondamental de l'uterus*, C. R. Soc. de Biol., 1882.
- Remy, Ch.**, *Nerfs ejaculateurs*, Journ. de l'anat. et de la physiol., 1886.
- Romberg, E.**, *Zur Frage der Herzganglien*, Centralbl. f. Physiol., iv, 1891.
- Sherrington, C. S.**, Journ. Physiol., xiii, 1892 (p. 702, Pupillo-dilator fibres in monkey; p. 676, Nerves of bladder): *ib.*, xvii, 1894 (p. 217, Efferent fibres in posterior roots of spinal nerves); see also Langley and Sherrington.
- Sperino, G.**, *Sulla presenza di cellule ganglionari sul decorso delle fiore che compongono i nervi splanchnici major ed minor*, Gazz. Osp., 1886.
- Steil, A.**, *Ueber den spinalen Ursprung des Hals-sympathicus*, Arch. f. d. gesammte Physiol., lviii, 1894.
- Steinach, E.**, *Die motorische Innervation des Darmtractus durch die hinteren Spinalnervenwurzeln*, Lotos, xiv, 1893.
- Thompson, W. H.**, *Ueber die Abhängigkeit der Gliederven von motorischen Nerven*, Arch. f. Physiol., 1893.
- Varoglia, S., e Conti, A.**, *Alcune particolarità macro- e microscopiche dei nervi cardiaci nell' uomo*, Atti della R. Accad. d. Sc. di Torino, xxii, 1887; *Sur la présence de cellules nerveuses le long des nerfs cardiaques et dans quelques autres nerfs de l'homme*, Arch. ital. de biologie, ix, 1887.
- Vás, F.**, *Ueber die Bedeutung der grossen Ganglien im sympathischen Grenzstrange*, Allgem. Wiener med. Zeitung, 1891.
- White, W. Hale**, *On the Histology and Function of the Mammalian Superior Cervical Ganglion*, Journ. Physiol., viii, 1887; *Further Observations on the Histology and Function of the Mammalian Sympathetic Ganglia*, Journ. Physiol., x, 1889.
- Zeglinsky, N.**, *Experimentelle Untersuchung über die Irisbewegung*, Arch. f. Physiol., 1885.
- Zeissl, M. v.**, *Ueber die Innervation der Blase*, Arch. f. d. gesammte Physiol., liii, 1893, and Iv, 1894.

MORPHOLOGY OF THE PERIPHERAL NERVES.

SPINAL NERVES.—Segmentation.—The spinal nerves in their arrangement as they leave the vertebral column exhibit in a marked degree the character of segmentation. This is not the case however at their attachment to the spinal cord, where the filaments of both the anterior and posterior roots form each a nearly continuous series along the whole length of the cord. In their connection with the grey matter of the spinal cord there is again evidence of a segmental arrangement, which appears not to correspond exactly to the segmentation seen in the nerve-trunks, for it seems probable that the fibres composing one posterior root, for example, may be connected with more than one segment of the spinal cord (cf. p. 350).

Mode of division.—A typical segmental nerve, on leaving the vertebral canal, divides at once into two parts, which are known as the *anterior* or *ventral*, and the *posterior* or *dorsal*

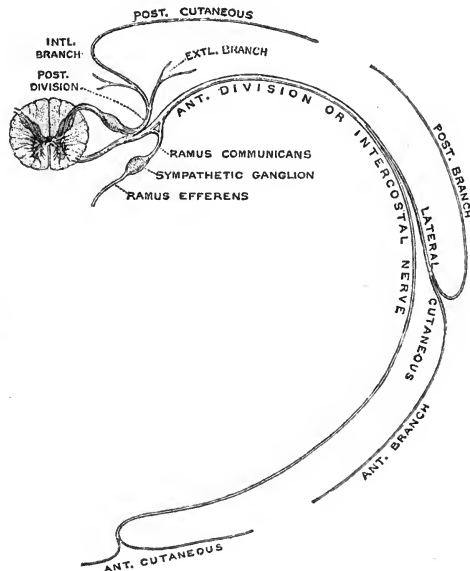
Fig. 238.—PLAN OF THE MODE OF BRANCHING OF A SEGMENTAL NERVE.



primary divisions. In addition to these, the trunk also gives off a small *recurrent* or *meningeal branch* to the interior of the spinal canal, and the anterior division furnishes a *branch to the sympathetic*. The primary branching of the nerve may thus be looked upon as a separation into four parts, of which the anterior, posterior, and recurrent divisions are said to be *somatic*, while the offset to the sympathetic is usually called *visceral* or *splanchnic* (*ramus visceratis*). The latter term, although often convenient, is, however not strictly accurate, since the sympathetic division contains, in addition to visceral fibres, other fibres which influence the unstriated muscles of the vessels and skin of the trunk and limbs, parts which are of somatic origin.

Posterior primary divisions.—These supply the dorso-lateral muscle (see Vol. II, p. 347) and the overlying integument. As a rule, each is divided into internal and external branches

Fig. 239.—PLAN OF AN UPPER DORSAL NERVE, SHOWING THE TYPICAL MANNER OF BRANCHING OF THE ANTERIOR AND POSTERIOR PRIMARY DIVISIONS OF A SEGMENTAL NERVE. (G. D. T.)



corresponding to the cleavage of the dorso-lateral muscle, and from one only of these an offset passes to the skin. The first cervical nerve has no external branch or cutaneous offset; while the last two sacral and the coccygeal nerves give off no muscular branches, as the dorso-lateral muscle terminates at the fourth sacral vertebra, and therefore they do not divide into the usual two branches. As has been previously pointed out (p. 341), cutaneous branches are not usually furnished by those nerves, the anterior divisions of which occupy a central position in the limb-plexuses (lower cervical and lower lumbar nerves).

Anterior primary divisions.—In the primitive condition the anterior primary division of a segmental nerve supplies the ventro-lateral muscle of the segment and a corresponding zone of skin. The *cutaneous* or *perforating branches* are two in number, a *lateral*, which again divides into anterior and posterior branches, and an *anterior*. This arrangement is however retained only in the nerves from the second dorsal to the first lumbar inclusive. Above and below the region thus indicated the primitive condition is much modified by the union of the nerves in plexuses, in great part for the supply of the limbs. But the cutaneous distribution of each of these nerves, as has already been shown (p. 345), is to a definite continuous area of skin, altered in shape and position in consequence of growth-changes, and in the case of the central limb-nerves shifted so much that all connection with the trunk is lost.

Nerves of the limbs.—As to the morphological nature of the limb-nerves, it is held by Paterson, Eisler, and others that they represent the whole of the anterior primary divisions of segmental nerves, but it seems probable that the view enunciated by Goodsir, namely, that the limb-nerves are greatly developed lateral perforating branches of segmental nerves, is the better founded. At the same time it is to be noticed that the increase of the lateral branch for the supply of the limb is accompanied by a reduction of the other portions of the segmental nerve, which proceeds so far that the anterior and posterior cutaneous offsets, as well as the visceral branch, are all wanting in the case of the central nerves of the limb-plexuses.

The transition from the typical segmental nerves to the modified form met with in the limbs takes place gradually, and may be thus traced. The third dorsal nerve has the typical character; the second differs but little, its posterior cutaneous branch is drawn out over the scapula, and its lateral perforating branch becomes enlarged and extends down the arm, forming a connection with the brachial plexus, while some of the fibres belonging to this division often begin to take a shorter course to the plexus through the communication with the first dorsal nerve (p. 307). In the first dorsal nerve the lateral branch, greatly enlarged, passes directly into the brachial plexus, the anterior and posterior cutaneous offsets are small, and sometimes wanting, and its contribution to the sympathetic is less than that of the second. The eighth, seventh and sixth cervical nerves consist almost wholly of large lateral offsets, the anterior and posterior perforating, and the visceral branches are suppressed, and the supply from the anterior primary division to trunk-muscles is represented only by the twigs to the scaleni and longus colli. With the fifth cervical nerve the posterior cutaneous branch reappears; and in the fourth, third, and second nerves the lateral offsets are freed from the limb-plexus (except the fourth to a slight extent in some cases), and furnish the superficial branches of the cervical plexus, the lower of which are however drawn out over the root of the limb, while anterior perforating branches are wanting.

At the lower part of the trunk, the twelfth dorsal and first lumbar nerves have the characteristic segmental disposition, but their posterior and lateral perforating branches are drawn down over the root of the limb, as is the case also to a slight extent with a part of the anterior perforating branch of the first lumbar (ilio-inguinal nerve), while a small part of the fibres of this nerve often passes into the limb-plexus. The second lumbar nerve is distinctly intermediate in character, since it possesses all the branches of a segmental nerve, although its larger part passes into the limb-plexus. Its anterior perforating branch is represented by the genital division of the genito-crural, and its lateral cutaneous offset by the fibres passing to the crural division of the genito-crural and to the external cutaneous nerve. The third lumbar nerve has a posterior perforating offset, but it consists mainly of a large lateral division passing into the plexus; an anterior perforating branch is wanting, and the contribution to the sympathetic is very small or absent. The fourth lumbar is purely a limb-nerve, the posterior and anterior cutaneous and the visceral offsets being suppressed. The fifth lumbar is like the fourth, except that it may have a small posterior cutaneous offset; and this branch is regularly present in the succeeding nerves. With the second sacral nerve the contribution to the limb-plexus diminishes, the visceral branch reappears, the lateral cutaneous branch begins to be more independent in the small sciatic and perforating cutaneous nerves, and the continuation of the trunk to form an anterior perforating offset is to be recognized in the pudic nerve. The third sacral furnishes only a small contribution to the limb-plexus, and both it and the fourth sacral have the usual constitution of segmental nerves, but their anterior primary divisions are more or less closely united in the pudic nerve. Of the branches of the latter, the inferior hæmorrhoidal probably corresponds to a lateral perforating offset, while the perineal division and the dorsal nerve of the penis represent anterior perforating offsets.

In the foregoing sketch it has been shown that the lateral divisions of the nerves are enlarged and carried outwards to supply the integument of the limbs. The cutaneous offsets of some of the posterior primary divisions are also drawn out to a slight extent over the roots of the limbs (especially the lower), but they do not enter into the plexuses. The anterior perforating branches however are not extended to the limbs, except the first lumbar to a slight degree where the lower limb impinges upon the area of these nerves. The supply of the muscles of the limbs by lateral divisions of spinal nerves offers no difficulty, since these muscles are derived from the superficial layer of the great ventro-lateral muscle (see Vol. II, p. 274), and the obliquus externus, the sole trunk-muscle of this layer (the pectorales, serratus magnus, latissimus dorsi, &c., being limb-muscles, and deriving their nerves from the limb-plexus), is supplied by the lateral cutaneous branches of intercostal nerves.

The number of nerves entering the limb-plexus is subject to some variation, not only in different animals, but also in different individuals of the same species. In man, the *brachial plexus* is formed mainly by the lower four cervical and first dorsal nerves, but contributions are often furnished by either or both of the fourth cervical and second dorsal: the number varies therefore from five to seven. The lower limb-plexus comprises the greater part, but

not the whole, of both the lumbar and sacral plexuses, and the name *crural plexus* may be used for the sum of the nerves constituting the proper limb-plexus. Into this enter usually seven nerves, viz., the lower four lumbar and the upper three sacral, but the first lumbar nerve in some cases also furnishes a branch, in rare instances even the last dorsal nerve; while at the opposite end the offset from the third sacral may be wanting, or in extreme cases of low form of plexus the fourth sacral may be drawn in (cf. pp. 313 and 325).

In the case of the brachial plexus all the nerves have the same relation to the shoulder-girdle, passing behind the clavicle. With the crural plexus the arrangement is different: in association with the greater development of the ventral portion of the limb-girdle the nerves are separated as they enter the limb, one set, the external cutaneous and anterior crural, passing in front of the pubic portion of the girdle, a second, the obturator, passing between the pubic and ischial portions of the girdle, and a third, the largest, the gluteal, sciatic, &c., passing behind the ischial portion of the girdle—the *prezonal, diazonal, and metazonal nerves* of Fürbringer. Thus there is brought about the separation of the lumbar and sacral plexuses of descriptive anatomy; and the *nervus furcalis* is only the nerve (entering into loops like the others) which lies at the boundary between the pre- and diazonal nerves on the one hand and the metazonal nerves on the other.

As to the significance of the plexuses, it may be remarked in the first place that the term "plexus" is somewhat misleading. Except in the case of the brachial plexus, the so-called "plexuses" are not interlacings of the spinal nerves, but result from the multiple origin of the nerves of distribution, so that most of the offsets of the plexus contain fibres derived from two or more segmental nerves. This multiple origin is intimately related to the fusion of the myomeres from which the muscles of the limbs are derived, and in association with this is the multiple innervation of individual muscles (see p. 354). A similar condition is seen in the lower intercostal nerves (p. 310) before supplying the broad muscles of the abdomen, in which the constituent myomeric elements are fused, so that these muscles are *polymeric* and *polynerval*; whereas such communications are much less frequent between the upper intercostal nerves, which are distributed to the *monomeric* and *mononeural* intercostal muscles, &c. Similarly also with the cutaneous offsets, the plexuses afford the means by which the fibres of two or more segmental nerves become mingled in order that they may supply in common a given area of skin. Gegenbaur and Fürbringer look upon the plexuses of the limbs as the result of the shifting of the latter along the vertebral column in the course of phylogenetic development, but it is extremely doubtful whether this shifting of the limbs has taken place to the extent supposed by them, and it is difficult to explain in this way the presence of the communications between the lower intercostal nerves while they are absent between the upper nerves, or the formation of the pudendal plexus. It does not appear that the plexuses have a physiological significance, so far at least as the muscles are concerned, beyond the provision of the multiple supply, that is, the mingling of the nerves in the plexuses does not seem to be necessarily related to any functional grouping of the muscles supplied.

The nerves entering the limb-plexuses show a remarkable division, the significance of which was first pointed out by Paterson, into *anterior* or *ventral* and *posterior* or *dorsal portions*, corresponding to the primary subdivisions of the limb-musculature (Vol. II, pp. 274, 275). The dorsal and ventral divisions of a nerve entering the limb are regarded by Paterson and others, who consider that the limb-nerve represents the whole anterior primary division of a spinal nerve, as corresponding respectively to the lateral offset and the anterior portion of a segmental nerve. The ventral divisions of the brachial nerves form the inner and outer cords of the plexus, and the dorsal divisions the posterior cord of the plexus. The ventral divisions of the crural nerves include the obturator, internal popliteal, and some smaller branches, while the dorsal divisions furnish the external cutaneous, anterior crural, external popliteal, gluteal, and some other nerves (p. 325). In their cutaneous distribution, while as a general rule the skin overlying ventral muscles is supplied by nerves of ventral origin, and that over dorsal muscles by the dorsal divisions of the nerves, the limits are not strictly kept, and the territory of the one group is often greatly extended at the expense of the other (cf. figs. 221, 222, and 223). In the following table the nerves of each group are shown, together with the probable homologies of the nerves of the two limbs, so far as they can be traced:—

CLASSIFIED TABLE OF THE NERVES OF THE LIMBS, WITH THEIR PROBABLE HOMOLOGIES.

UPPER LIMB.	LOWER LIMB.
<i>Dorsal nerves.</i>	<i>Dorsal nerves.</i>
N. to rhomboidei.	
Posterior thoracic.	
Suprascapular	Branches of anterior crural to iliacus.
Subscapular (3)	{ Superior gluteal.
Circumflex: muscular part	{ N. to pyriformis.
	{ Inferior gluteal.

CLASSIFIED TABLE OF THE NERVES OF THE LIMBS, WITH THEIR PROBABLE HOMOLOGIES—*continued.*

UPPER LIMB.				LOWER LIMB.			
<i>Dorsal nerves.</i>				<i>Dorsal nerves.</i>			
Circumflex : cutaneous part	Small sciatic : gluteal branches and outer part of femoral division.	Perforating cutaneous.		
Musculo-spiral.							
Branches in arm	} External cutaneous.	} Anterior crural. ¹		
Rest of trunk			External popliteal.	
Radial	Musculo-cutaneous.			
Posterior interosseous	Anterior tibial.			
<i>Ventral nerves.</i>				<i>Ventral nerves.</i>			
N. to subclavius	} Obturator.	} N. to quadratus femoris.		
Anterior thoracics			} N. to obturator internus.	
N. to coraco-brachialis				
Musculo-cutaneous.							
Muscular part	Branches of internal popliteal in thigh.			
Cutaneous part	Cutaneous of obturator.			
Median	} Internal popliteal }	} Internal plantar.		
Ulnar			} and posterior tibial }	} External plantar.
Internal cutaneous				
N. of Wrisberg	} Small sciatic : inner part of femoral division.			
Intercosto-humeral				

Recurrent or meningeal divisions.—These are presumably afferent nerves, and are said to be furnished by all the spinal nerves (p. 278).

Visceral or sympathetic divisions.—These are the white rami communicantes of the sympathetic system, in connection with which their arrangement has been described (p. 358). They are absent in the cervical region, as well as from the lower two or three lumbar, first sacral, last sacral, and coccygeal nerves. The grey rami communicantes, as has already been explained, are not branches of the spinal nerves, but are given off by the sympathetic to the latter.

Ganglia.—The ganglia found in connection with the peripheral nerves fall into two groups, which differ in their structure and position. To the first group belong the *spinal ganglia* on the posterior roots of the spinal nerves, which contain unipolar nerve-cells. The other group includes the various *sympathetic ganglia*, the cells of which are multipolar. Both groups have a common origin, their nerve-cells being derived from the neural crest of the embryo (see Embryology, pp. 73 and 81). The spinal ganglia undergo but little change in position in the course of development, and are always placed on the posterior roots of the nerves at or near their aperture of exit from the spinal canal, whence they have been named *stationary ganglia* by Gaskell. The neuroblasts which form the nerve-cells of the sympathetic ganglia, however, make their way from the primitive ganglion-rudiments along the spinal nerves and their visceral offsets into the ventral portion of the body, and there become collected into groups which give rise to the various sympathetic ganglia—the *splanchnic* or *vagrant ganglia* of Gaskell. It is probable that all the ganglia of the sympathetic arise in this way, but they have as yet been fully traced only in the case of the heart. The mode of development especially of the ganglia in the myenteric plexuses of the alimentary canal has not been observed.

Constitution of a segmental nerve.—A typical segmental nerve comprises—(1) *somatic efferent fibres* distributed to skeletal muscles; (2) *splanchnic efferent* or *sympathetic fibres* passing through the sympathetic system, where many if not all are interrupted by the nerve-cells of the ganglia, to the visceral muscles and other unstriped muscles of the body, as well as to the glandular organs; (3) *somatic afferent fibres* supplying the skin and other parts of the body-wall with sensory nerves; and (4) *splanchnic afferent fibres* furnished to the viscera. The somatic efferent fibres and the greater part, if not the whole, of the splanchnic efferent fibres constitute the anterior root of the nerve, while the somatic afferent fibres run in the posterior root, being connected with the cells of its ganglion, and the same is probably the case with the splanchnic afferent fibres. In the cervical region, in addition to the two roots of

¹ According to Eisler the anterior crural nerve is not exclusively dorsal, but contains both ventral and dorsal elements. The ventral part comprises the internal cutaneous nerve, the branch to the pectineus, and the internal saphenous nerve. Instead of occupying a ventral position at their origin, however, these branches are placed on the mesial side of the trunk, in consequence of a torsion, amounting to about 90°, which is to be recognized in the bundles of the nerve between the lumbar plexus and Poupart's ligament, and which is probably associated with the inward rotation of the limb during development.

the cervical segmental nerves, there is also, arising separately from the cord, the spinal accessory nerve, which, although reckoned with the cranial nerves, is in greatest part of spinal origin. This belongs to a group, more developed amongst the cranial nerves, which is designated by Gaskell *splanchnic non-ganglionated efferent*, but as it is distributed to skeletal muscles, it is better termed *lateral somatic efferent*. The somatic efferent fibres in this region are therefore again divided into a *mesial set*, which arise from the cells of the fore part and inner side of the anterior horn of the grey matter of the cord, and a *lateral set* derived from cells placed at the outer part of the anterior horn. It is uncertain whether the latter fibres are represented in the lower parts of the cord, but Gaskell places the phrenic nerve and the branches supplying the transversalis abdominis muscle in this group; if present, they also run in the anterior roots of the spinal nerves.

CRANIAL NERVES.—The attempt to determine the morphological position of the cranial nerves is beset with difficulties, and any classification that is based on the facts at present known with regard to their development, connections, and functions can only be regarded as tentative. Assuming that they include the representatives of a series of segmental nerves, the arrangement is profoundly modified, on the one hand by the separation of the constituent portions of some of these nerves so as to form independent trunks, and on the other by the coalescence of elements belonging to different segments in a single stem. In many cases also parts of the typical segmental nerves are suppressed, either not being formed in the embryo, or disappearing more or less completely in the course of development. So great indeed is the

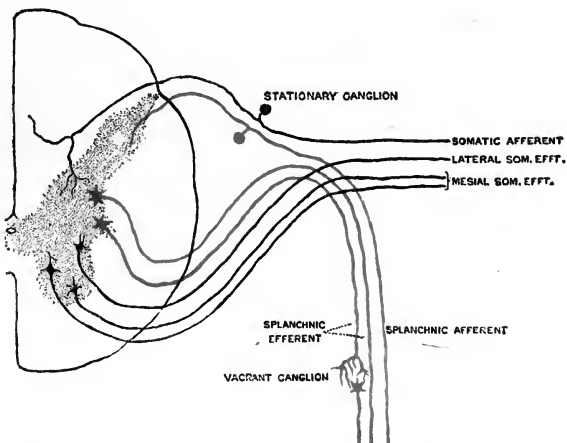


Fig. 240.—SCHEME OF THE HYPOTHETICAL CONSTRUCTION OF A SEGMENTAL NERVE, BASED MAINLY ON GASKELL'S CLASSIFICATION OF THE CONSTITUENT FIBRES. (G. D. T.)

change that it may be affirmed that no cranial nerve, according to the usual enumeration, corresponds exactly to a single complete segmental nerve, such as is met with in the dorsal region for example.

In considering the cranial nerves from this point of view the first two pairs are generally set aside as occupying an exceptional position, but evidence is not wanting that these have in some respects a similar origin to other sensory nerves. According to van Wijhe and Hoffmann the olfactory nerves are developed at the anterior margin of the neuropore, at a spot where the floor of the neural groove or canal passes into the epidermis. This would correspond to the foremost part of the ganglion-groove of His, the forerunner of the neural or ganglion crest, at the place where it passes from one side to the other, following the margin of the medullary plate, and is not irreconcilable with the statement of Milnes Marshall that the olfactory nerves are derived from the foremost part of the neural crest. The optic nerve, including the retina, is developed as a hollow outgrowth of the neural tube, and Hoffmann states that in the elasmobranch the dorsal portions of the other cranial nerves are formed in the same way, their ganglion-rudiments at first enclosing a cavity which is continuous with the medullary canal, so that the retina would correspond to a specially developed root-ganglion, and the optic nerve to a dorsal root. The relations of these nerves to the head segments, however, have not been ascertained, and at all events for the present they cannot be grouped amongst the segmental nerves. In the following observations therefore only the ten nerves from the third to the twelfth inclusive are dealt with.

Constitution of the cranial nerves.—Four of these nerves, namely, the twelfth, the sixth, the fourth, and the third, arise from large-celled nuclei forming a group which appears

to be in series with the anterior and internal cell-columns of the anterior cornu of the spinal cord. These nerves also, with the exception of the fourth, emerge from the axis in a line which forms a continuation of that of the anterior roots of the spinal nerves, and like those they consist mainly of large fibres (not so large in the hypoglossal however as in the others), which are distributed to voluntary muscles. In this group therefore are comprised the *mesial somatic efferent fibres* of the cranial nerves.¹

It has already been seen that in the upper cervical region the *lateral somatic efferent fibres* are separated from the anterior roots, and form the spinal accessory nerve, which arises from the outer group of cells of the anterior horn. Proceeding upwards in the brain-stem, the following nuclei form a lateral series from which the fibres of this group arise—the bulbar portion of the accessory nucleus in part, the accessory vago-glosso-pharyngeal nucleus (nucleus ambiguus), the facial nucleus, and the nuclei of the motor root of the fifth nerve, ventricular and mesencephalic. The cells of the facial and accessory vago-glosso-pharyngeal nuclei are of moderate size, but they are larger in the motor nuclei of the fifth nerve and in the nucleus of the spinal accessory nerve. The fibres of the nerves arising from these nuclei are mostly of medium size, but the spinal part of the spinal accessory consists of large fibres.

Splanchnic efferent fibres, characterized by their small size, are present in the bulbar portion of the spinal accessory nerve, in the vagus nerve of which they form a large part, in

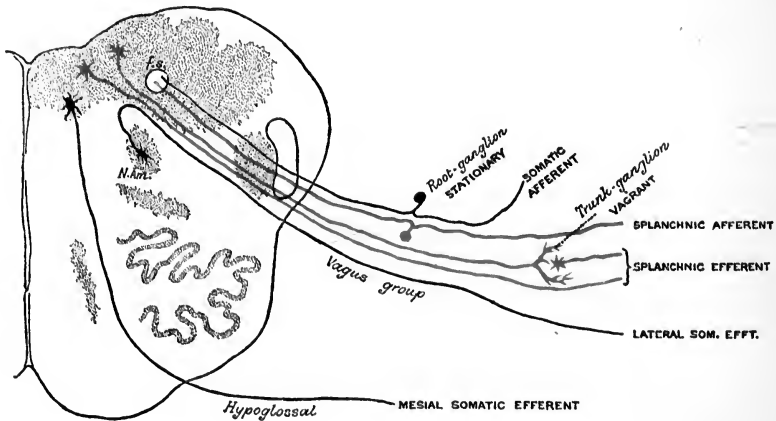


Fig. 241.—PLAN OF THE ARRANGEMENT OF THE CONSTITUENT FIBRES OF THE CRANIAL NERVES IN THE BULB. (Based on Gaskell, with modifications.) (G. D. T.)

the glosso-pharyngeal nerve (small superficial petrosal branch), in the facial nerve (large superficial petrosal branch and the efferent part of the chorda tympani), and in the third nerve (ciliary portion). The origin of the splanchnic efferent fibres in the spinal cord has not been determined, but in the brain-stem there are special nuclei from which the fibres of this group arise. These are the bulbar portion of the accessory nucleus (in part), the small-celled vago-glosso-pharyngeal nucleus, from which not only the splanchnic efferent fibres of the vagus and glosso-pharyngeal proceed, but according to Duval also those of the facial—through the portio intermedia, and the groups of smaller cells at the upper end of the oculomotor nucleus (see Part I of this Volume, p. 99).

Somatic afferent fibres constitute the greater part of the large root of the fifth nerve and the auditory nerve; and a small group of these fibres occurs also in the vagus, composing its auricular branch. *Splanchnic afferent fibres* are contained in the facial (afferent part of the chorda tympani), glosso-pharyngeal and vagus nerves, probably also in the sensory part of the fifth nerve. With regard to the central connections of these fibres it is to be remarked that many of them descend in the bulb and upper part of the spinal cord, forming the so-called "ascending roots"—the funiculus solitarius for the vagus and glosso-pharyngeal, perhaps also for the portio intermedia, and the bulbar root of the fifth nerve. A great number of the fibres enter the auditory nuclei, the sensory nucleus of the fifth nerve and the substantia gelatinosa, which may be looked upon as derivatives of the posterior horn of the grey substance of the cord, just as the nerves at their attachment to the brain-stem form a series continuing the

¹ According to Hatschek there are also ventral roots to the glosso-pharyngeal and vagus nerves in *Ammocetes*, and the same have been described in the embryo of man and the rabbit by Zimmermann.

line of the posterior roots. The afferent fibres, both somatic and splanchnic, are offsets of the cells of stationary ganglia (see below) and grow thence into the cerebro-spinal axis. The constituent fibres of the several cranial nerves are shown in the following table:—

TABLE SHOWING THE CONSTITUTION OF THE CRANIAL NERVES FROM THE THIRD TO THE TWELFTH.

CRANIAL NERVE.	Mesial somatic efferent.	Lateral somatic efferent.	Splanchnic efferent.	Splanchnic afferent.	Somatic afferent.
THIRD	To orbital muscles.	—	Ciliary.	—	—
FOURTH	To obliquus superior.	—	—	—	—
FIFTH	—	Motor root.	?	Sensory	root.
SIXTH	To rectus externus.	—	—	—	—
SEVENTH	—	Facial, main part.	Large superficial petrosal nerve; chorda tympani, fibres to submaxillary ganglion.	Chorda tympani, taste-fibres.	—
EIGHTH	—	—	—	—	Auditory.
NINTH	—	To stylo-pharyngeus.	Small superficial petrosal, to otic ganglion.	Lingual, including taste-fibres.	—
TENTH	—	To laryngeal muscles?	To unstriped muscle of alimentary canal, air-passages, &c.	From alimentary canal, air-passages, &c.; cardiac depressor fibres.	Auricular.
ELEVENTH	—	To sterno-mastoid and trapezius; to laryngeal muscles?	To palatine and pharyngeal muscles; cardiac inhibitory fibres.	—	—
TWELFTH	To tongue-muscles.	—	—	—	—

Ganglia.—The ganglia in connection with cranial nerves also fall into the two groups, stationary and vagrant, which have been characterized in dealing with the spinal nerves (p. 384).

Stationary ganglia necessarily occur only on those nerves which contain afferent fibres. They are the Gasserian ganglion on the large root of the fifth nerve, the geniculate ganglion on the portio intermedia, the acoustic ganglion on the auditory nerve (see p. 256), the jugular and petrosal ganglia of the glosso-pharyngeal nerve, and the upper ganglion (possibly also the lower) of the pneumo-gastric nerve. The nerve-cells are unipolar, like those of the spinal ganglia, in all of these except the acoustic ganglion, in which the cells retain their primitive bipolar form. There are also found upon the roots of the third, fourth, motor part of the fifth, and seventh nerves traces of ganglionic structure which are regarded by Gaskell as indications of the former existence of stationary ganglia and afferent fibres belonging to those nerves. In some animals, and in rare cases in man, there is moreover a gangliated posterior root to the hypoglossal nerve.

The *vagrant ganglia* in connection with the cranial nerves include four ganglia usually associated with the fifth nerve, namely, the ciliary, sphenopalatine, submaxillary, and otic, all of which are of sympathetic type, containing multipolar nerve-cells, and according to Gaskell also the lower ganglion of the vagus, the cells of which are, however, of the spinal type. The ciliary, sphenopalatine and otic ganglia are known to be developed as offsets of the Gasserian ganglion, and the same is probably the case with the submaxillary ganglion, but they receive splanchnic efferent fibres, with which they form physiological connections, from other sources—the ciliary ganglion from the third nerve, the sphenopalatine ganglion from the facial nerve (portio intermedia?), the submaxillary ganglion from the portio intermedia through the chorda tympani, and the otic ganglion from the glosso-pharyngeal. The condition in the last three cases resembles that in the sympathetic, where a given ganglion of the cord, presumably derived from the spinal ganglion of the same segment, receives efferent fibres from spinal nerves at different levels.

Segmentation.—It has been shown in some of the lower vertebrates, especially elasmobranchs, that at least nine segments are included in the constitution of the head (see Embryology, p. 161), and it is probable that the number is not less in the higher vertebrates, although it may be that the segments have not the same morphological value in all cases, since there is reason for believing that only six of these belonged primitively to the head, while three or more, originally spinal, have also become incorporated in the head in later stages of phylogenetic development. Assuming provisionally, however, that the nerves of nine segments are represented more or less completely in the ten cranial nerves, there is still much uncertainty as to the manner in which some of these nerves are to be allotted to the several segments. It is also to be observed that, as in the case of the spinal nerves, the segmentation which is to be recognized in the central grey matter does not always correspond to the segmentation represented in the nerve-trunks, since fibres which arise from what appears to be a single segmental nucleus may pass out in nerves at different levels, and conversely, a single nerve may contain fibres derived from the nuclei of more than one segment.

The third nerve belongs to the first head-segment. It includes a large-fibred mesial somatic efferent part, distributed to the orbital muscles developed from the first somite, and a small-fibred splanchnic efferent part passing to the ciliary ganglion. The lateral somatic efferent fibres of this segment are perhaps represented, as suggested by Gaskell, by the ocular facial, which arises from the oculomotor nucleus (p. 251). The ophthalmic division of the fifth appears to be the afferent nerve of this segment. In the elasmobranch Hoffmann finds that the "ramus ophthalmicus profundus," which corresponds to the nasal nerve of man (Ewart), is developed independently of the rest of the fifth nerve, and in close relation to the first somite. Gaskell considers, however, that the afferent fibres of the first segmental nerve, with their stationary ganglion, have undergone degeneration, and are now represented only by the vestigial structure in the roots of the third nerve; and his view receives support from the observation of Martin that in the early embryo of the cat the third nerve is provided with a dorsal root, which subsequently disappears.¹

The fourth nerve, supplying the superior oblique muscle formed from the second somite, is the mesial somatic part of the second segmental nerve. The fifth nerve, excluding the ophthalmic division, also belongs to this segment (Hoffmann), of which the small root of the fifth will therefore form the lateral somatic efferent nerve, while the superior and inferior maxillary portions of the large root will be the afferent nerve. The existence of splanchnic efferent fibres is uncertain, since it is not known whether any efferent fibres are furnished by the fifth nerve to the sphenopalatine, submaxillary, and otic ganglia, all of which must be referred to this segment if, as is most probable, they are derived from the Gasserian ganglion, although they receive efferent fibres from other segmental nerves (*cf. supra*).

The third segmental nerve includes the sixth, seventh, and eighth cranial nerves. The sixth is the mesial, and the facial proper the lateral somatic efferent portion together with, in the large superficial petrosal branch, a part of the splanchnic efferent. In the portio intermedia are comprised also splanchnic efferent fibres to the submaxillary ganglion and splanchnic afferent fibres which are connected with the geniculate ganglion. The somatic afferent part is the auditory, with the acoustic ganglion, the resemblance of which to the posterior root of a spinal nerve has already been pointed out (p. 256).

The fourth segmental nerve, according to Hoffmann, is suppressed. A rudiment is present in the early embryo of the elasmobranch, but it afterwards aborts. It would seem possible that the portio intermedia, in view of its central connection and partially independent course, might belong to this segment.

The nerve of the fifth segment is the glosso-pharyngeal. In this, mesial efferent, and afferent somatic fibres are altogether wanting. Lateral somatic efferent fibres are present in the branch to the stylo-pharyngeus, and probably arise from the accessory vago-glosso-pharyngeal nucleus. Splanchnic efferent fibres run in the small superficial petrosal nerve to the otic ganglion. The chief part of the nerve however is composed of splanchnic afferent fibres, which enter the funiculus solitarius.

The sixth and seventh segmental nerves are united in the vagus (Hoffmann), which contains fibres of all groups except mesial somatic efferent (see p. 386). The latter fibres of the seventh segment may be included in the hypoglossal nerve, which is composed of the mesial somatic efferent parts of the last three or more cephalic (originally first spinal) segmental nerves. Otherwise, these segmental nerves are only represented (doubtfully) by the oral fibres of the facial which are said to arise from the hypoglossal nucleus (lateral somatic efferent), and by the bulbar part of the spinal accessory (lateral somatic efferent and splanchnic efferent), except in those cases in which the hypoglossal nerve is provided with a gangliated dorsal root.

The arrangement sketched out above is summed up in the annexed table.

¹ What appears to be a gangliated dorsal root to the oculomotor nerve has also been described by Kupffer in *Ammocetes*, and by Froriep in *Torpedo*.

TABLE OF THE SEGMENTAL NERVES OF THE HEAD.

SEGMENTAL NERVE.	Mesial somatic efferent.	Lateral somatic efferent.	Splanchnic efferent.	Vagrant ganglia.	Splanchnic afferent.	Somatic afferent.	Stationary ganglia.
FIRST	Oculomotor.	Ocular facial?	Ciliary.	Ciliary.	Ophthalmic.	Gasserian.	Gasserian.
SECOND	Trochlear.	Fifth, small root.	—	Spheno-palatine. Otic. Submaxillary?	Superior and inferior maxillary.		
THIRD	Abducens.	Facial.	Large superficial petrosal. Portio intermedia, efferent part.	—	Portio intermedia, afferent part.	Auditory.	Acoustic and geniculate.
FOURTH	—	—	—	—	—	—	—
FIFTH	—	Glosso-pharyngeal, fibres from nucleus ambiguus.	Small superficial petrosal.	—	Glosso-pharyngeal, fibres to funiculus solitarius.	—	Jugular and petrosal.
SIXTH	—	Vagus, fibres from nucleus ambiguus.	Vagus, fibres from small-celled nucleus.	Trunk-ganglion.	Vagus, fibres to funiculus solitarius.	Auricular.	Root-ganglion.
SEVENTH	—	Oral facial? Bulbar part of accessory.	Bulbar part of accessory.	—	—	—	—
EIGHTH	Hypoglossal.	—	—	—	—	—	—
NINTH	—	—	—	—	—	—	—

with hypoglossal, ganglion.

Course and distribution.—While it is obvious that in the distribution of the cranial nerves the segmental arrangement, if it ever existed, has been in many cases greatly modified, there are certain striking relations between the course and distribution of some of these nerves and the developmental subdivisions of the head.

The distribution of the third, fourth, and sixth nerves to the muscles of the first three somites has already been pointed out. The nasal branch of the ophthalmic division of the fifth is the nerve of the fronto-nasal process. The inferior maxillary is the nerve of the mandibular arch, its motor root supplying the muscles of that arch (Vol. II, p. 349), and its sensory part extending by its splanchnic lingual branch into the part of the tongue which is formed from the tuberculum impar in the concavity of the arch. The superior maxillary nerve is the offset furnished by the more primitive mandibular nerve to the maxillary process. The three divisions of the fifth supply the skin externally, and the mucous membrane internally, of their respective portions of the face; and they send dorsal branches—supraorbital and supratrochlear, temporo-malar, and auriculo-temporal—to ramify over the neural cavity in the same way as the posterior divisions of the spinal nerves, the cutaneous area of which they continue anteriorly.

The facial is the nerve of the hyoid arch, supplying the muscles of that arch—stapedius, posterior belly of digastric, and stylo-hyoid—and the system of cutaneous muscles which according to Rabl take their origin in that arch (Vol. II, p. 349).

The glosso-pharyngeal is the nerve of the third cephalic visceral (first branchial) arch, in which it runs to the root of the tongue, but its lingual distribution extends considerably beyond the part which is formed from that arch. It also supplies the muscle of the third arch—the stylo-pharyngeus.


The vagus is a complex nerve. Its auricular branch, somatic in nature, is the diminished representative of a largely developed somatic portion in fishes, known as the "lateral branch." The superior laryngeal is the nerve of the fourth visceral (second branchial) arch, and the inferior laryngeal of the fifth (third branchial) arch, the latter being drawn down so as to acquire its recurrent character by the shifting of the arteries during development. The remaining portion of the vagus extends far beyond the limits of the head, and supplies nearly the whole of the alimentary canal with its derivatives, and other abdominal organs, the greater part of which, it is to be noted, are developed from the foregut or cephalic segment of the enteric cavity. The accessory part of the spinal accessory in its distribution cannot be separated from the vagus; and the spinal portion of the same nerve is not morphologically cranial, but entirely spinal both in origin and distribution.

Lastly, the hypoglossal nerve, also spinal originally, is distributed to tongue-muscles, which are also foreign to the head, being probably derived from the longitudinal system of the ventral muscles of the trunk (Vol. II, p. 348). It is thus in series with the upper cervical nerves supplying the muscles of the front of the neck, and the connection that is formed between the hypoglossal and these nerves, giving rise to the ansa cervicalis, &c., may be regarded as representing a prolongation of the cervical plexus.

LITERATURE OF THE MORPHOLOGY OF THE PERIPHERAL NERVES.

- Adolphi, H.**, *Ueber Variationen der Spinalnerven und der Wirbelsäule anurer Amphibien*, Morphol. Jahrb., xix, 1892.
- Beard, J.**, *The Ciliary or Motoroculi Ganglion and the Ganglion of the ophthalmicus profundus in Sharks*, Anatom. Anzeiger, ii, 1887.
- Bolk, L.**, *Beziehungen zwischen Skelet, Musculatur und Nerven der Extremitäten, dargelegt am Beckengürtel, an dessen Musculatur, sowie am Plexus lumbo-sacralis*, Morphol. Jahrb., xxi, 1894.
- Davidoff, M.**, *Ueber die Varietäten des Plexus lumbo-sacralis von Salamandra maculosa*, Morphol. Jahrb., ix, 1884.
- Eisler, P.**, *Der Plexus lumbo-sacralis des Menschen*, Abhandlg. d. Naturforsch. Gesellsch. zu Halle, 1892.
- Ewart, J. C.**, *On the Cranial Nerves of Elasmobranch Fishes*, Proc. Roy. Soc., xlv, 1889; *On the Development of the Ciliary or Motor Oculi Ganglion, and The Cranial Nerves of the Torpedo*, Proc. Roy. Soc., xlvii, 1890.
- Froriep, A.**, *Ueber ein Ganglion des Hypoglossus und Wirbelanlagen in der Occipitalregion*, Arch. f. Anat., 1882; *Ueber Anlagen von Sinnesorganen am Facialis, Glosso-pharyngeus und Vagus, über die genetische Stellung des Vagus zum Hypoglossus, und über die Herkunft der Zungenmusculatur*, Arch. f. Anat., 1885; *Ueber das Homologon der Chorda tympani bei niederen Wirbeltieren*, Anatom. Anzeiger, ii, 1887; *Zur Frage der sogenannten Neuromerie*, Verhandlg. d. anatom. Gesellsch., 1892.
- Fürbringer, M.**, *Zur Lehre von den Umbildungen der Nervenplexus*, Morphol. Jahrb., v, 1879.
- Gaskell, W. H.**, *On the Structure, Distribution, and Function of the Nerves which innervate the Visceral and Vascular Systems*, Journ. Physiol., vii, 1886; *On the Relation between the Structure, Function and Distribution of the Cranial Nerves*, Preliminary Communication, Proc. Roy. Soc., xliii, 1888; *On the Relation between the Structure, Function, Distribution and Origin of the Cranial Nerves; together with a Theory of the Origin of the Nervous System of Vertebrata*, Journ. Physiol., x, 1889.

- Gegenbaur, C.**, *Die Metamerie des Kopfes und die Wirbeltheorie des Kopfskeletes*, Morphol. Jahrb., xiii, 1887.
- Hatschek, B.**, *Die Metamerie des Amphioxus und des Ammocetes*, Verhandlg. d. Anatom. Gesellsch., 1892.
- Hill, A.**, *The Plan of the Central Nervous System*, Cambridge, 1885; *The Grouping of the Cranial Nerves*, Brain, 1888.
- His, W.**, *Ueber die Anfänge des peripherischen Nervensystems*, Arch. f. Anat., 1879; *Ueber das Auftreten der weissen Substanz und der Wurzelfasern am Rückenmark menschlicher Embryonen*, Arch. f. Anat., 1883; *Zur Geschichte des menschlichen Rückenmarkes und der Nervenwurzeln*, Abhandlg. d. Kgl. Sächs. Gesellsch., 1886; *Zur Geschichte des Gehirns, sowie der centralen und peripherischen Nervenbahnen beim menschlichen Embryo*, Abhandlg. d. Kgl. Sächs. Gesellsch., 1888; *Die Entwicklung der ersten Nervenbahnen beim menschlichen Embryo, Uebersichtliche Darstellung*, Arch. f. Anat., 1887; *Die morphologische Betrachtung der Kopfnerven*, Arch. f. Anat., 1887; *Histogenese und Zusammenhang der Nervenelemente*, Verhandlg. d. x internat. med. Congresses, Berlin, 1890, and Arch. f. Anat., Suppl. Bd., 1890.
- His, W., jun.**, *Zur Entwicklungsgeschichte des Acustico-facialis Gebietes beim Menschen*, Arch. f. Anat., Suppl. Bd., 1889; *Die Entwicklung des Herznervensystems bei Wirbeltieren*, Abhandlg. d. Kgl. Sächs. Gesellsch., 1891.
- Hoffmann, C. K.**, *Zur Entwicklungsgeschichte des Selachierkopfes*, Anatom. Anzeiger, ix, 1894.
- Holl, M.**, *Ueber die Lendennerven*, Wiener Jahrbücher, 1880.
- Jhering, H. v.**, *Das peripherische Nervensystem der Wirbeltiere als Grundlage für die Kenntniss der Regionenbildung der Wirbelsäule*, Leipzig, 1878.
- Kupffer, C. v.**, *Die Entwicklung der Kopfnerven der Vertebraten*, Verhandlg. d. anatom. Gesellsch., 1891.
- Marshall, A. Milnes**, *The Segmental Value of the Cranial Nerves*, Journ. Anat., xvi, 1882.
- Martin, P.**, *Die Entwicklung des neunten bis zwölften Kopfnerven bei der Katze*, Anatom. Anzeiger, vi, 1891.
- Paterson, A. M.**, *The Morphology of the Sacral Plexus in Man*, Journ. Anat., xxi, 1887; *The Limb-Plexuses of Mammals*, Journ. Anat., xxi, 1887; *On the Fate of the Muscle-Plate, and the Development of the Spinal Nerves and Limb-Plexuses in Birds and Mammals*, Quarterly Journ. Microscop. Sci., xxviii, 1887; *The Position of the Mammalian Limb, regarded in the light of its Innervation and Development*, Journ. Anat., xxiii, 1889; *The Origin and Distribution of the Nerves to the Lower Limb*, Journ. Anat., xxviii, 1894.
- Rabl, K.**, *Zur Bildungsgeschichte des Halses*, Prager med. Wochenschr., 1886; *Ueber das Gebiet des N. facialis*, Anatom. Anzeiger, ii, 1887; *Ueber die Metamerie des Wirbeltierkopfes*, Verhandlg. d. anatom. Gesellsch., 1892.
- Ruge, G.**, *Der Verkürzungsprocess am Rumpfe von Halbaffen*, Morphol. Jahrb., xviii, 1892; *Zeugnisse für die metamere Verkürzung des Rumpfes bei Säugethieren. Der Musculus rectus thoraco-abdominalis bei Primaten*, Morphol. Jahrb., xix, 1892; *Verschiebungen in den Endgebieten der Nerven des Plexus lumbalis der Primaten, Zeugnisse für die metamere Verkürzung des Rumpfes bei Säugethieren*, Morphol. Jahrb., xx, 1893.
- Schwalbe, G.**, *Das Ganglion oculomotorii*, Jenaische Zeitschr. f. Naturwiss., xiii, 1879.
- Sherrington, C. S.**, *Notes on the Arrangement of some Motor Fibres in the Lumbo-sacral Plexus*, Journ. Physiol., xiii, 1892 (p. 708, Significance of limb-plexus).
- Shore, T. W.**, *The Morphology of the Vagus Nerve*, Journ. Anat., xxii, 1888; *On the Minute Anatomy of the Vagus Nerve in Selachians, with remarks on the Segmental Value of the Cranial Nerves*, Journ. Anat., xxiii, 1889.
- Utschneider, A.**, *Die Lendennerven der Affen und des Menschen*, Münchener medicinische Abhandlungen, 1892.
- v. Wijhe, J. W.**, *Ueber die Mesodermsegmente und die Entwicklung der Nerven des Selachierkopfes*, Naturk. Verh. der Koninkl. Akad., Amsterdam, 1882; *Ueber Smiten und Nerven im Kopfe von Vögel und Reptilienembryonen*, Zoolog. Anzeiger, 1886.
- Zimmermann, W.**, *Ueber die Metamerie des Wirbeltierkopfes*, Verhandlg. d. anatom. Gesellsch., 1891.



INDEX AND GLOSSARY TO VOL. III., PT. II.

- ABDOMEN**, nerves to muscles of, 352
Abdominal branch of ilio-hypogastric, 315
 intercostal nerves, 310
 splanchnics, 367
 viscera, afferent nerves of, 370
Abducent nerve. *See* NERVE.
Accelerator fibres of heart, 367, 369
Accessory nerve. *See* NERVE.
Acoustic ganglion, 256, 387, 388
Acromio-clavicular joint, nerves of, 293, 294
Afferent nerves. *See* NERVES.
Alveolar nerves, 239, 240, 247
Ampullary nerves, 257, 258
Ankle-joint, nerves of, 332, 333, 335, 337, 338
Ansa (loop) cervicalis, 273, 287, 288, 390
 subclavia, 365, 366
Anterior crural nerve. *See* NERVE.
 cutaneous nerves of abdomen, 310, 311, 381
 thorax, 307, 308, 310, 381
 interosseous artery, nerves of, 301
 roots of spinal nerves, 276, 358, 359, 381, 384
 thoracic nerves. *See* NERVES.
 tibial nerve, 335, 336, 337, 384
Antrum, maxillary, nerves of, 338
Anus, nerves to muscles of, 352
Aortic plexus, 370, 375, 376, 377
Aortico-renal ganglion, 369, 375
Arm, cutaneous nerves of, 343
 nerves to muscles of, 353
Arnold, ganglion of. *See* GANGLION, OTIC.
 nerve of, 265
Arteries, nerves of, anterior interosseous, 301
 brachial, 297
 carotid, external, 364
 internal, 362
 central of retina, 362
 cerebral, 362
 femoral, 319
 internal mammary, 366
 ophthalmic, 362
 palmar, 300
 peroneal, 333
 subclavian, 366
 tibial, anterior, 332
 posterior, 332
 ulnar, 299
 vertebral, 366
Articular nerves. *See* the several joints.
Ascending branch of upper cervical ganglion,
 361, 362, 366
 branches of cervical plexus, 286
 root of fifth nerve, 233
Astragalo-calcaneal joint, nerve of, 332
Astragalo-navicular joint, nerve of, 333
Atrial plexus, 373
Auditory meatus, external, nerves of, 246
 nerve. *See* NERVE.
Auricular nerves. *See* NERVES.
Auriculo-temporal nerve. *See* NERVE.
- BACK**, cutaneous nerves of, 341
 motor nerves of, 352
Bladder, inhibitory nerves of, 370
 motor nerves of, 370, 372
 sensory nerves of, 350
Brachial artery, nerves of, 297
 plexus, 283, 289, 307, 382, 383
Buccal nerves. *See* NERVES.
Bulbar plexus of heart, 373
 portion of spinal accessory nerve, 269, 270, 386, 388
 root of fifth nerve, 233
Buttock, cutaneous nerves of, 344
- CALCANEAL** branches, 332, 333
Calcaneo-cuboid joint, nerve of, 334
Calcaneo-plantar nerve, 333
Cardiac nerves. *See* NERVES.
 plexus. *See* PLEXUS.
Carotico-tympanic nerve, 260, 262
Carotid artery, external, nerves of, 364
 internal, nerves of, 362
 branch of ninth nerve, 260
 upper cervical ganglion, 362
 plexus, 234, 243, 250, 260, 362
Carpo-metacarpal joints, nerves of, 305
Cauda equina (horse's tail), 277
Cavernous nerves of penis, 378
 plexus, 230, 233, 235, 238, 362
 sinus, nerves in relation to, 231
Cavities of head, nerves of, 338
Cavum (a hollow) Meckelii, 234
Central artery of retina, nerves of, 362
Cerebral arteries, nerves of, 362
Cerebro-spinal nerves, 221
 muscular distribution of, 351
 sensory distribution of, 338
Cervical branch of facial nerve, 256, 287
 gangliated cord, 361
 ganglion. *See* GANGLION.
 nerves. *See* NERVES.
 plexus, 283, 285
 cutaneous area of, 341
 posterior, 280
 splanchnic nerves, 361
 sympathetic, 361
 constitution of, 366

- Cervico-cranial rami viscerales, 359
 Cervico-facial division of facial nerve, 252, 255
 Chest-wall, nerves to muscles of, 352
 Chiasma. *See* COMMISSURE.
 Chorda tympani, 226, 247, 248, 249, 253, 256, 386, 387
 Ciliary ganglion. *See* GANGLION. nerves. *See* NERVES.
 Circulus tonsillaris, 261
 Circumflex nerve, 291, 294, 383, 384
 Clitoris, dorsal nerve of, 328, 330
 Coccygeal ganglion, 371 nerves. *See* NERVES. plexus, 323
 Cochlea, spiral ganglion of, 256
 Cochlear nerve, 257, 258
 Cœliac plexus, 376
 Collateral digital nerves, 300, 302, 305, 333 ganglia, 357, 361 nerve, ulnar, 303, 304
 Commissure, optic, 227, 228
 Communicating nerve, fibular, 336 peroneal, 332, 336 tibial, 332
 Cord, dorso-lumbar, 312, 315 gangliated. *See* SYMPATHETIC. lumbo-sacral, 313, 322, 323
 Cords of brachial plexus, 289, 291, 383
 Coronary nerves, 372, 373 plexus of heart, 372 of stomach, 376
 Cranial cavity, sensory nerves of, 341 nerves. *See* NERVES. plexuses of sympathetic, 362
 Crural nerve, anterior, 313, 317, 319, 383, 384 plexus, 383
 Cutaneous area of cervical plexus, 341 of dorsal and first lumbar nerves, 341 distribution of nerves to trunk and limbs, 344 innervation of limb, rules of, 345 nerves. *See* NERVES. or perforating branches of segmental nerves, 381, 382
 Cystic plexus, 376
- DENTAL nerves. *See* NERVES. plexus, inferior, 247 superior, 241
 Depressor nerve, 268
 Descending cervical nerve, 271, 273, 274, 283, 287, 288 root of fifth nerve, 233
 Diaphragmatic ganglion, 375 nerve, 288 plexus, 375
 Diazonal (*δία*, through; *ζώνη*, girdle) nerves, 383
 Digastric branch of facial nerve, 254, 390
 Digital nerves. *See* NERVES.
 Distribution of cranial nerves, 225, 338, 351 cutaneous, of nerves to trunk and limbs, 344 muscular, of cerebro-spinal nerves, 351 of spinal nerves, 354 sensory, of cerebro-spinal nerves, 338 visceral, of sensory spinal nerves, 350
 Divisions, of nerves of limb-plexuses, 383 primary, of spinal nerves, anterior, or ventral, 283, 341, 381, 382 posterior, or dorsal, 278, 341, 381
 Dorsal nerve of clitoris, 328, 330
 Dorsal nerve of penis, 328, 329, 382 nerves. *See* NERVES.
 Dorso-lumbar cord or nerve, 312, 315
 Dura mater, nerves of, 341
- EFFERENT nerves. *See* NERVES.
 Eighth pair of cranial nerves. *See* NERVES.
 Elbow-joint, nerves of, 297, 299, 301, 303, 304, 307
 Eleventh pair of cranial nerves. *See* NERVES.
 Eyelid, nerves of involuntary muscle of, 367 sensory nerves of, 338
 Epididymis, sensory nerves of, 351
 Epigastric or solar plexus, 373
 Ethmoidal cells, nerves of, 338 nerve, posterior, 237
 Eustachian tube, nerves of, 341
 Exit of nerves from cranium, 223
- FACE, motor nerves of, 351 pilo-motor nerves of, 367 sensory nerves of, 338
 Facial nerve. *See* NERVE.
 Femoral artery, nerve of, 319 cutaneous branches of small sciatic, 328 nerve, 319
 Femur, nerves of, 319, 321, 322
 Fibres, sympathetic, 357, 358
 Fibular branch of posterior tibial, 333
 Fibular communicating nerve, 336
 Fifth pair of cranial nerves. *See* NERVES.
 Fila radicularia, 275
 Fingers, cutaneous nerves of, 343
 First pair of cranial nerves. *See* NERVES.
 Foot, motor nerves of, 353 sensory nerves of, 344
 Forearm, motor nerves of, 353 sensory nerves of, 343
 Fossa, nasal, nerves of, 338
 Fourth pair of cranial nerves. *See* NERVES.
 Frontal nerve, 231, 233, 235, 236 sinus, nerves of, 338
 Funiculus solitarius, 258, 261, 386
 Furcal (*furca*, fork) nerves, 313, 325, 383
- GANGLIATED cord. *See* SYMPATHETIC.
 GANGLION OF GANGLIA, aberrantia, 277 acoustic, 256, 387, 388 aortico-renal, 369, 375 of Arnold. *See* GANGLION, OTIC. cardiac, 373 cervical sympathetic, lower, 268, 283, 288, 365 middle, 283, 288, 365, 366 upper, 259, 264, 265, 272, 273, 283, 284, 361, 366, 367 cervicale uteri, 378 ciliary, 221, 228, 230, 236, 237, 241, 357, 359, 363, 387 coccygeal, 371 cœliac, 375 collateral, 357, 361 connected with cranial nerves, 387 diaphragmatic, 375 Gasserian, 225, 234, 246, 247, 362, 387 geniculate, 243, 252, 253, 258, 260, 365, 387, 388 geniculi, 252 of hypoglossal nerve, 274

Ganglion or ganglia—*continued.*

impar, 371
 intervertebral, 275, 276, 277
 jugular, 258, 259, 387
 jugulare, 262
 lateral, 357
 of lateral root of auditory nerve, 256, 257
 lenticular. *See* GANGLION, CILIARY.
 lingual. *See* GANGLION, SUBMAXILLARY.
 of lingual branches of ninth nerve, 261
 of lingual nerve, 248
 of Meckel. *See* GANGLION, SPHENO-PALATINE.
 mesenteric, inferior, 370, 371, 376
 superior, 375, 376
 lumbar sympathetic, 370
 nasal. *See* GANGLION, SPHENO-PALATINE.
 of nasal nerve, 237
 nodosum, 262
 ophthalmic. *See* GANGLION, CILIARY.
 otic, 221, 237, 244, 246, 248, 260, 357, 387, 388
 petrosal, 258, 259, 387
 of pharyngeal plexus, 265
 phrenic, 288, 375
 of posterior pulmonary plexus, 269
 prevertebral, 357
 radicis cochlearis, 256
 renal, 375
 of root of tenth nerve, 262, 264, 270, 361, 387
 sacral, sympathetic, 371, 377
 semilunar, 367, 369, 375
 semilunare, 234
 spermatic, 375
 spheno-palatine, 221, 237, 238, 239, 241, 357, 387, 388
 spinal, 275, 276, 277, 384
 of spinal-accessory nerve, 270
 spiral of cochlea, 256, 258
 splanchnic, 369
 splanchnic or vagrant, 384, 387
 stationary, 384, 387
 stellate, 366, 369
 sublingual, 248
 submaxillary, 221, 237, 248, 357, 387, 388
 superius of ninth nerve, 259
 of suprarenal nerves, 375
 sympathetic, 259, 264, 265, 268, 384, 387
 temporal, 365
 of tenth nerve, lower, 262, 264, 265, 272, 284, 361, 387
 upper, 262, 264, 265, 270, 387
 terminal, 357
 of terminal branches of phrenic nerve, 288
 thoracic, sympathetic, 365, 367
 thyroid, 365
 trunci sympathici, 358
 of trunk of tenth nerve, 262, 264, 265, 272, 284, 361, 387
 vertebral, 357
 vestibular, 256, 257
 vestigial, of facial nerve, 252, 387
 of fifth nerve, 233, 387
 of fourth nerve, 233, 387
 of third nerve, 231, 387, 388
 of Wrisberg, 372

Gasserian ganglion, 225, 234, 246, 247, 362, 387
 Gastric nerves, 226, 263, 264, 269.
 plexus, 269
 Gastro-epiploic plexus, 376
 Geniculate ganglion. *See* GANGLION.
 Geniculum nervi facialis, 252
 Genito-crural nerve, 313, 315, 370, 382
 Genu (knee) inner, of facial nerve, 251
 outer, of facial nerve, 252
 Gland, tympanic, 260
 Glosso-pharyngeal nerve. *See* NERVE.
 Gluteal nerves. *See* NERVES.
 Grey rami communicantes, 358, 359, 361, 365, 367, 384
 Gudden, inferior commissure of, 228

HÆMORRHOIDAL NERVES. *See* NERVES.
plexus, 377

Hand, cutaneous nerves of, 343
 muscular nerves of, 353
 joints of, nerves of, 301
 Head, nerves to muscles of, 351
 sensory nerves of, 338
 vaso-motor nerves of, 367, 369
 Heart, accelerator nerves of, 367, 369
 inhibitory nerves of, 269, 270
 sensory nerves of, 350
 Hepatic plexus, 269, 288, 375, 376
 Hip, nerves of muscles of, 353
 Hip-joint, nerves of, 318, 319, 321, 322, 325
 Homologies of limb nerves, 383
 Humerus, nerves of, 297, 304
 Hypogastric plexus, 361, 370, 372, 376, 377, 378
 inferior, 377
 Hypoglossal nerve. *See* NERVE.

ILIO-HYPOGASTRIC nerve, 311, 312, 313, 314, 315
 Ilio-inguinal nerve, 312, 313, 314, 315, 382
 Incisor branches, 241, 247
 Inferior maxillary nerve, 223, 234, 243, 248, 249
 Infraclavicular branches of brachial plexus, 290, 291, 294
 Infrahyoid muscles, nerves of, 351
 Inframaxillary nerve, 256
 Infraorbital branches of facial nerve, 255
 nerve, 238, 240
 plexus, 241
 Infratrochlear nerve, 233, 236, 237, 255
 Inguinal branch of ilio-hypogastric, 315
 Inhibitory nerves of bladder, 370
 of rectum, 370
 Innervation, cutaneous, of limbs, rules of, 345
 Intercoastal nerves, 288, 307, 308, 310, 345, 382, 383
 Intercosto-humeral nerve, 296, 297, 308, 310, 384.
 Intermediate plexus, 373
 Intermesenteric plexus, 376
 Internal cutaneous nerve of arm, 291, 295, 299, 301, 384
 small, 291, 295, 296
 of thigh, 318, 319, 321, 322, 384
 mammary artery, nerves of, 366
 saphenous nerve, 318, 319, 320, 321, 384
 Interosseous nerve, anterior, 301, 303, 307
 posterior, 300, 303, 306, 384
 Interphalangeal joints, nerves of, 302, 303, 305, 307, 334
 Intervertebral ganglia, 275, 276, 277

- Intestines, sensory nerves of, 350
viscero-inhibitory nerves of, 369
- Intumescencia gangliiformis Scarpæ, 257
- Iter chordæ anterioris, 254
posterioris, 254
- JACOBSON, nerve of, 260
- Jugular ganglion, 258, 259, 387
- KIDNEY, sensory nerves of, 350
vaso-motor nerves of, 370
- Knee-joint, nerves of, 318, 319, 321, 322, 331,
335, 336, 338
- LABIAL nerves, 241, 247
- Lachrymal nerve, 231, 235, 238, 240, 254, 255
- Laryngeal nerves. *See* NERVES.
- Larynx, motor nerves of, 352
sensory nerves of, 341
- Last dorsal nerve. *See* TWELFTH DORSAL NERVE.
- Lateral cutaneous nerves. *See* NERVES.
- Lateral ganglia, 357
- Leg, cutaneous nerves of, 344
muscular nerves of, 353
- Lenticular ganglion. *See* GANGLION, CILIARY.
- Ligament, round of uterus, motor nerves of, 370
- Limb, cutaneous innervation of, rules of, 345
lower, cutaneous nerves of, 344, 349, 382
muscular nerves of, 353, 354, 382
upper, cutaneous nerves of, 343, 344, 348,
382
muscular nerves of, 352, 354, 382
- Limb-nerves, morphology of, 382
homologies of, 383
- Limb-plexuses, divisions of nerves of, 383
- Lingual branches of ninth nerve, 261
branch of vagus, 265, 272
ganglion. *See* GANGLION, SUBMAXILLARY.
nerve, 243, 247, 261, 271, 272, 390
- Lips, nerves of, 238, 241, 247, 338
- Liver, sensory nerves of, 350
- Long scrotal nerves, 329
- Lower limb, cutaneous nerves of, 344, 349
muscular nerves of, 353, 354
- Lumbar gangliated cord, 370
- Lumbar nerves, 274, 281, 311, 355, 382
fifth, 322
plexus, 283, 311, 312, 383
sympathetic, constitution of, 370
ganglia, 370, 375, 377
- Lumbo-sacral cord, 313, 322, 323
- Lungs, sensory nerves of, 350
- MALAR branches of facial nerve, 254
nerve, 239, 240, 255
- Mandibular branch of facial nerve, 256
nerve, 247, 390
- Masseteric nerve, 243, 244, 245
- Mastoid branch of great auricular, 286
cells, nerves of, 341
- Maxillary antrum, nerves of, 341
nerves. *See* NERVES.
- Meatus, external auditory, nerves of, 246
- Meckel's ganglion. *See* GANGLION, SPHENO-PALATINE.
- Median nerve, 291, 299, 300, 301, 384
- Meningeal branch of vagus, 265
or recurrent branches of spinal nerves, 278,
360, 381, 384
- Mesenteric ganglia. *See* GANGLIA.
plexus. *See* PLEXUS.
- Metacarpo-phalangeal joints, nerves of, 300, 302,
303, 305, 307
- Metatarsal bones, nerves of, 338
- Metatarso-phalangeal joints, nerves of, 335, 338
- Metazonal (*μετά*, behind; (*ζώνη*, girdle) nerves,
383
- Middle cutaneous nerve of thigh, 317, 319, 320,
322
- Mononeural (*μόνος*, single; *νεῦρον*) muscles, 383
- Morphology of cranial nerves, 385
of limb-nerves, 382
of peripheral nerves, 381
- Motor nerves of bladder, 370, 372
of rectum, 370, 371
of round ligament of uterus, 370
of uterus, 370, 372
of vas deferens, 370
nuclei, 222, 386
root of ganglia, 237, 386
- Mouth, sensory nerves of, 338
- Muscular distribution of cerebro-spinal nerves,
351
of spinal nerves, 354
- Musculo-cutaneous nerve of lower limb, 332,
335, 336, 384
of upper limb, 291, 297, 306
- Musculo-spiral nerve, 291, 300, 303, 384
- Mylo-hyoid nerve, 244, 247, 261
- NASAL branch of superior maxillary nerve, 241
of spheno-palatine ganglion, 242
of vidian nerve, 243
fossa, nerves of, 338
ganglion. *See* GANGLION, SPHENO-PALATINE.
nerve, 231, 233, 235, 236, 238, 255, 388,
390
- Naso-ciliary nerve, 236
- Naso-palatine nerve, 242
- Naviculo-cuneiform joint, nerve of, 333
- Neck, muscular nerves of, 351, 352
- NERVE or NERVES (*νεῦρον*, originally sinew,
tendon), 221
abdominal vaso-motor, 369, 370
abducent, 222, 223, 225, 231, 235, 238,
241, 250, 386, 388, 390
accelerator, of heart, 367, 369
afferent, of abdominal viscera, 370
alveolar, superior, 239, 240
inferior, 247
ampullary, 257, 258
of anconeus, 304, 307
anterior crural, 313, 317, 319, 383, 384
thoracic, external, 291, 293, 294, 384
internal, 291, 294, 384
of antrum, maxillary, 338
of Arnold, 265
articular. *See* the several joints.
auditory, 222, 223, 224, 225, 252, 256, 286,
388
auricular, anterior, 246
great, 254, 256, 286
of great occipital, 280
posterior, 254, 265, 286
of small occipital, 286

Nerve or nerves—*continued.*

- auricular, of vagus, 265, 386, 390
 auriculo-temporal, 240, 243, 244, 246, 390
 of bladder, inhibitory, 370
 motor, 370, 372
 sensory, 350
 of brachial artery, 297
 buccal, 240, 243, 246, 249, 256
 of facial, 256
 bucco-labial, inferior, 256
 superior, 255
 cardiac, deep, 365
 of descending cervical nerve, 274
 of external laryngeal, 265
 great, 365
 lower, 363, 365, 372
 middle, 363, 365, 366, 372
 of recurrent laryngeal, 268
 upper or superficial, 268, 361, 363, 365, 372, 373
 of vagus, 262, 265, 268, 372
 calcaneo-plantar, 333
 carotico-tympanic, 260, 362
 cavernous, 378
 cerebro-spinal, 221
 muscular distribution of, 351
 sensory distribution of, 338
 cervical, 274, 276, 277, 280, 283, 354, 382
 descending, 271, 273
 first, 222, 278, 283
 superficial, 256, 286
 splanchnic, 361
 chorda tympani, 226, 247, 248, 249, 253, 256, 386
 ciliary, long, 236, 238, 366
 short, 237, 238, 359
 circumflex, 291, 294, 383, 384
 coccygeal, 278, 283, 322, 371, 381
 cochlear, 257, 258
 of coraco-brachialis muscle, 297, 384
 coronary, 372, 373
 cranial, 221
 constitution of, 385
 distribution of, 225, 390
 eighth pair. *See* Auditory.
 eleventh pair. *See* Spinal Accessory.
 exit of, from cranium, 223
 fifth pair. *See* Trifacial.
 first pair. *See* Olfactory.
 fourth pair. *See* Trochlear.
 morphology of, 385
 ninth pair. *See* Glosso-pharyngeal.
 nuclei of, 222
 number of, 221
 origin of, deep, 222
 superficial, 222.
 second pair. *See* Optic.
 seventh pair. *See* Facial.
 sixth pair. *See* Abducent.
 segmentation of, 388
 Semmering's enumeration, 221
 tenth pair. *See* Pneumo-gastric.
 twelfth pair. *See* Hypoglossal.
 third pair. *See* Oculomotor.
 Willis's enumeration, 221
 cutaneous, anterior, of abdomen, 310, 311
 of thorax, 307, 308, 310
 external, of upper limb, 297, 304

Nerve or nerves—*continued.*

- cutaneous, external, of lower limb, 313, 317, 382, 383, 384
 of head, 338
 internal, of anterior crural, 318, 319, 384
 of musculo-spiral, 304, 310
 small, 291, 295, 296, 384
 of brachial plexus, 291, 295, 384
 lateral, of abdomen, 310, 314, 381
 of leg, 336
 of thorax, 307, 308, 344, 381, 382
 of lower limb, 344, 349, 382
 middle, 317, 319
 occasional, of obturator, 318, 320
 perforating, 324, 325, 328, 382, 384
 plantar, of posterior tibial, 333
 of perineum, 343
 of trunk, 341, 344, 350
 of upper limb, 343, 344, 348, 382
 cutaneous or perforating, of segmental nerves, 381, 382
 dental, inferior, 243, 246, 247
 lesser, 247
 superior, 239, 240
 depressor, 268
 diaphragmatic, 288
 diazonal, 383
 digital of foot, 322, 332, 333, 334, 336, 337
 of hand, 300, 302, 303, 304, 305
 dorsal, 274, 276, 277, 280, 283, 307, 344, 355, 361, 366
 of clitoris, 328, 330
 first, 307
 of penis, 328, 329
 twelfth, 307, 311, 314, 315, 317, 322, 344, 382
 of dorso-lateral muscle, 381
 dorso-lumbar, 312
 of epididymis, sensory, 351
 of ethmoidal cells, 338
 ethmoidal, posterior, 237
 of external auditory meatus, 246
 facial, 222, 224, 226, 236, 251, 262, 359, 386, 387, 388, 390
 genu of, inner, 251
 outer, 252
 femoral, 319
 fibular communicating, 336
 frontal, 231, 233, 235, 236
 of frontal sinus, 338
 furcal, 313, 325, 383
 gastric, 269
 genito-crural, 313, 315, 370, 382
 gluteal, inferior, 324, 325, 326, 331, 383, 384
 superior, 322, 324, 325, 383, 384
 glosso-pharyngeal, 222, 223, 224, 225, 226, 254, 258, 359, 386, 387, 388, 390
 hæmorrhoidal, inferior, 328, 329, 330, 382
 superior, 377
 of heart, 268, 269, 270, 350, 363, 365, 367, 369, 372
 hypoglossal, 222, 223, 224, 225, 226, 248, 265, 271, 385, 387, 388, 390
 ilio-hypogastric, 311, 312, 313, 314, 315
 ilio-inguinal, 312, 313, 314, 315, 317, 382
 inframaxillary, 256
 infraorbital, 238, 240
 infratrochlear, 233, 236, 237, 255, 390

Nerve or nerves—*continued.*

- inhibitory of heart, 269, 270
- intercostal, 288, 307, 308, 382, 383
 - first, 307
 - lower or abdominal, 310
 - upper or pectoral, 308
- intercosto-humeral, 296, 297, 308, 310, 384
- interosseous, anterior, 301, 303, 307
 - posterior, 300, 303, 306, 384
- of intestines, inhibitory, 369
 - motor, 269
 - sensory, 350
- of Jacobson, 260
- of joints. *See* the several joints.
- of kidney, sensory, 350
 - vaso-motor, 370
- labial, 241, 247, 338
- lachrymal, 231, 235, 238
- laryngeal, external, 265, 268, 361, 363, 364, 365
 - inferior or recurrent, 264, 266, 268, 363, 365, 366, 390
 - internal, 265
 - middle, 266
 - superior, 262, 265, 268, 270, 363, 390
- of levator ani, 323, 329
- of limbs, homologues of, 383
 - morphology of, 382
- of limb-plexuses, divisions of, 383
- lingual, of fifth nerve, 243, 247, 261, 271, 272, 390
 - of glosso-pharyngeal, 261
 - of vagus, 265
- of lips, 241, 247, 338
- of liver, sensory, 350
- long scrotal, 329
- lumbar, 274, 281, 311, 344, 355, 382
 - fifth, 322
- of lungs, sensory, 350
- malar, 239, 240, 255
- mandibular, 247, 390
- masseteric, 243, 244, 245
- maxillary, inferior, 223, 234, 243, 388, 390
 - superior, 223, 234, 238, 388, 390
- median, 291, 299, 300, 301, 384
- mental, 247, 256
- metazonal, 383
- morphology of, 381
- of muscles of head, 351, 390
 - of lower limb, 353, 354, 382
 - of neck, 351, 352, 390
 - of trunk, 352, 354
 - of upper limb, 352, 354, 382
- musculo-cutaneous of arm, 291, 297, 302, 384
 - of leg, 322, 332, 335, 336, 338, 384
- musculo-spiral, 291, 300, 303
- mylo-hyoid, 244, 247, 261
- nasal, 231, 233, 235, 236, 238, 255, 388
- of nasal fossa, 338
- naso-ciliary, 236
- naso-palatine, 242
- obturator, 313, 317, 320, 321, 383, 384
 - accessory, 317, 319, 322
- of obturator internus, 324, 325, 384
- occipital, great, 280, 286
 - small, 254, 280, 286
 - third, 280
- oculomotor, 222, 223, 225, 228, 238, 359, 386, 387, 390
 - external. *See* Abducent.
- oculo-nasal, 236

Nerve or nerves—*continued.*

- olfactory, 222, 223, 225, 227, 385
- ophthalmic, 223, 230, 231, 233, 234, 235, 250, 388
- optic, 222, 223, 225, 227, 241, 385
- orbital, 239
- of ovary, 351, 375, 378
- palatine, external, 242
 - large or anterior, 242, 243
 - small or posterior, 242
- parotid, 246, 249, 256, 261, 286
- pathetic. *See* Trochlear.
- of pectineus muscle, 320, 384
- pelvic splanchnic, 359, 371
- of penis, 341, 343
 - vaso-constrictor, 370
 - vaso-dilator, 370, 372
- perineal, 328
 - deep, 329
 - superficial, 328, 329, 330
- peroneal. *See* Popliteal, external.
 - communicating, 332, 336
- petrosal, external superficial, 253
 - large deep, 243, 253, 262
 - superficial, 243, 252, 256, 260, 362, 386
 - small deep, 260, 362
 - small superficial, 249, 253, 260, 261, 386, 388
- pharyngeal, of glosso-pharyngeal, 260
 - of sympathetic, 363
 - of vagus, 265
- phrenic, 274, 288, 385
 - accessory, 288
- pilo-motor, 359, 367, 369, 370, 371
- plantar, external, 332, 334, 337, 384
 - internal, 332, 333, 331, 384
- pneumo-gastric, 222, 223, 224, 226, 254, 259, 261, 270, 274, 359, 364, 386, 388, 390
- popliteal, external, 324, 325, 328, 330, 332, 335, 383, 384
 - internal, 322, 324, 325, 328, 330, 331, 383, 384
- postaxial of limb-borders, 349
- posterior thoracic, 291, 293, 383
- preaxial of limb-borders, 348, 349
- pretracheal, 364
- prezonal, 383
- of prostate, secretory, 372
 - sensory, 351
- pterygoid, external, 243, 246
 - internal, 244, 246, 248, 249
- pubental, inferior, 326, 328, 329, 330
- pubic, 324, 325, 328, 370, 378, 382
- pulmonary, anterior, 268
- pupillo-dilator, 366, 369
- of pyriformis, 324, 325, 326, 383
- of quadratus femoris, 324, 325, 384
- radial, 297, 298, 300, 302, 303, 304, 384
- of rectum, inhibitory, 370
 - motor, 370, 371
 - sensory, 350
- recurrent articular, 336
 - of hypoglossal, 271
- laryngeal. *See* Laryngeal, inferior.
- of maxillary, inferior, 244
 - superior, 239
- of ophthalmic, 235
- of spinal nerves, 278, 360, 381, 384
- of vagus, 265
- of rhomboid muscles, 292, 383

Nerve or nerves—*continued.*

- of round ligament of uterus, motor, 370
- saccular, 257, 258
- sacral, 274, 276, 277, 278, 281, 322, 356, 381
 - fifth, 323, 381
 - fourth, 323, 381
 - sixth, 323
- saphenous, external or short, 327, 331, 332, 336, 338
 - internal or long, 318, 319, 320, 321, 322, 336, 338, 384
- sciatic, great, 324, 328, 330, 383
 - small, 324, 325, 326, 331, 336, 382, 383, 384
- of scrotum, 341, 343
- segmental, 344, 350, 354, 381, 382, 384, 385, 388
- sensory, of cavities of head, 338
 - distribution of, 338
 - of head, 338
 - of viscera, 350
- somatic afferent, 384, 388
 - efferent, mesial, 384, 385, 386, 388
 - lateral, 385, 386, 388
- spheno-ethmoidal, 237
- sphenoidal, 243, 249
- of sphenoidal sinus, 338
- spheno-palatine, 239, 241, 242, 243
- spinal, 221, 274
 - connection of, with sympathetic cords, 283, 357, 358, 359, 361
 - cutaneous distribution of, to trunk and limbs, 344
 - muscular distribution of, 354
 - roots of, 256
 - segmentation of, 381
 - sensory distribution of, to viscera, 350
- spinal accessory, 222, 223, 224, 226, 262, 265, 269, 359, 385, 386, 388, 390
- splanchnic afferent, 384, 388
 - efferent, 384, 386, 388
 - non-gangliated, 385
 - great, 367, 369, 375
 - small, 367, 369, 375
 - smallest, 367, 369, 375
- of stomach and intestines, motor, 269
 - sensory, 350
 - viscero-inhibitory, 369
- subcostal, 307
- of submaxillary gland, secretory, 367, 369
- suboccipital, 221, 222, 274, 277, 278, 283
- subscapular, 291, 294, 383
 - long, 294
- supraclavicular, 287, 310
- supramaxillary, 256
- supraorbital, 236, 254, 255, 390
- suprascapular, 291, 293, 383
- supratrochlear, 233, 236, 237
- of sweat-glands, secretory, 369, 370
- sympathetic, 221, 357, 372, 384
- temporal, 235, 239, 254
 - deep, 243, 245, 246
 - superficial, 246
- temporo-malar, 239, 390
- thoracic. *See also* Dorsal.
 - anterior internal, 291, 294, 384
 - external, 291, 293, 294, 384
- of testis, sensory, 351
- tibial, anterior, 335, 336, 337, 384
 - communicating, 332
 - posterior, 331, 332, 384

Nerve or nerves—*continued.*

- of tongue, sensory, 248, 256, 261, 338
 - muscular, 351, 390
 - trifacial, or trigeminal, 222, 223, 225, 233, 386, 387, 388
 - trochlear, 222, 223, 225, 231, 235, 238, 386, 387, 388, 390
 - of trunk and limbs, cutaneous distribution of, 344
 - tympanic, 259, 260, 362
 - ulnar, 291, 295, 296, 299, 302, 303, 306, 384
 - collateral, 303, 304
 - of ureter, sensory, 350
 - of uterus, 351, 370, 372, 375, 378
 - motor, 370, 372
 - and appendages, sensory, 351
 - utricular, 257, 258
 - vaginal, 378
 - of vas deferens, 370, 377
 - vaso-constrictor, 359
 - of limbs, 369, 370, 371
 - pulmonary, 369
 - vaso-dilator, 359
 - vaso-motor, 359, 367, 369
 - of ventro-lateral muscle, 381
 - of vesicula seminalis, 377
 - vestibular, 257, 258
 - vidian, 243, 249, 253, 362
 - viscero-constrictor, 359
 - viscero-inhibitory, 359
 - of Wrisberg, 291, 296, 384
- Nerve-plexuses. *See* PLEXUS.
- Nerve-roots. *See* ROOTS.
- NERVUS vel NERVI, acusticus, 256
- alveolaris, inferior, 247
 - ano-coecygei, 323
 - axillaris, 294
 - carotici externi, 364
 - carotici internus, 362
 - cerebrales, 221
 - clunium inferiores, 327
 - medii, 281
 - superiores, 281
 - cutaneus antibrachii dorsalis, 304
 - medialis, 295
 - brachii medialis, 296
 - lateralis, 295
 - posterior, 304
 - femoris lateralis, 317
 - posterior, 326
 - suræ lateralis, 336
 - medialis, 332
 - dorsalis scapulae, 292
 - erigentes, 372
 - furealis, 313, 325, 383
 - genito-femoralis, 315
 - hæmorrhoidales medii, 323
 - intercosto-brachialis, 310
 - intermedius, 251
 - ischiadicus, 330
 - jugularis, 361
 - labiales posteriores, 329
 - lumbo-inguinalis, 316
 - mandibularis, 243
 - masticatorius, 243
 - maxillaris, 238
 - meningeus medius, 239
 - perforans coccygeus major, 328
 - peronæus communis, 335
 - profundus, 337
 - superficialis, 336

- Nervus vel nervi—*continued*.
 pudendus, 328
 radialis, 303
 renalis posterior, 369
 scrotales posteriores, 329
 spermaticus externus, 316
 spinosus, 244
 splanchnicus supremus, 369
 subcutaneus colli, 286
 suralis, 332
 tentorii, 235
 thoracalis longus, 293
 thoraco-dorsalis, 294
 tibialis, 331
 vaginales, 323
 vagus, 261
 vesicales inferiores, 323
 vestibuli, 257
 zygomaticus, 239
- Ninth pair of cranial nerves. *See* NERVES.
- Nuclei of nerves, motor, 222, 386
 sensory, 222, 386
- OBTURATOR NERVE, 313, 317, 320, 322, 383, 384
 accessory, 317, 319, 322
- Occasional cutaneous branch of obturator, 318, 320
- Occipital nerve, great, 280, 286
 of posterior auricular, 254
 small, 254, 280, 286
 third, 280
- Occipito-atlantal joint, nerve of, 284
- Oculomotor nerve. *See* NERVE.
- Oculo-nasal nerve, 236
- Esophageal branches, 268, 269
 plexus, 262, 264, 269
- Esophagus, motor nerves of, 269
 sensory nerves of, 341
- Olfactory nerves, 222, 223, 225, 227, 385
- Ophthalmic artery, nerves of, 362
- Ophthalmic ganglion. *See* GANGLION, CILIARY.
- Ophthalmic nerve, 223, 230, 231, 233, 234, 235,
 250, 388
- Optic commissure, 227, 228
 nerves, 222, 223, 225, 227, 241, 385
 tracts, 227
- Orbit, nerves to muscles of, 351
- Orbital nerve, 239
- Origin, deep, of cranial nerves, 222
 superficial, of cranial nerves, 222
- Os uteri, sensory nerves of, 351
- Otic ganglion. *See* GANGLION.
- Ovary, nerves of, 351, 375, 378
- PACINIAN bodies, 301, 302, 332, 333, 334, 377
- Palate, soft, motor nerves of, 352
 sensory nerves of, 339
- Palatine nerves. *See* NERVES.
- Palm, cutaneous nerves of, 343
- Palmar arteries, nerves of, 300
 branch of ulnar nerve, deep, 300
 superficial, 300
 cutaneous branch of median nerve, 302
 ulnar nerve, 299, 302
- Palpebral nerves, 235, 236, 237, 241, 255
- Pancreatic plexus, 376
- Pancreatico-duodenal plexus, 376
- Par (pair) vagum (wandering), 261
- Parotid nerves, 246, 249, 256, 261, 286
- Pars intermedia of Wisberg, 251, 252, 254, 258,
 386, 388
- Patellar branch of internal saphenous, 322
 plexus, 317, 322
- Pathetic nerve. *See* NERVE, TROCHLEAR.
- Pectoral intercostal nerves, 308
- Pelvic plexus, 370, 371, 372, 377
 splanchnic nerves, 359, 371
- Penis, nerves of, 341, 343
 cavernous, 378
 dorsal, 328, 329
 motor, 352
 vaso-dilator, 370, 372
 vaso-constrictor, 370
- Perforating branches of external plantar nerve,
 335
 cutaneous nerve, 324, 325, 328, 382, 384
 or cutaneous branches of segmental nerves,
 381, 382
- Pericardial branches of vagus, 269
- Perineal branch of fourth sacral, 323, 382
 nerve, 328
 deep, 329
 superficial, 328, 329, 330
- Perineum, cutaneous nerves of, 343
- Peripheral nerves, morphology of, 381
- Peroneal artery, nerves of, 333
 nerve, 324, 325
 communicating, 332, 336
- Pes anserinus (goose's foot), 252
- Petrosal ganglion, 258, 259, 260, 262, 265, 361,
 387
 nerves. *See* NERVES.
- Pharyngeal branches of upper cervical ganglion,
 361, 363
 of vagus, 261, 265, 270
 division of ninth nerve, 260
 nerves, 243, 260, 261, 262, 266, 268
 plexus, 261, 265, 266, 363
- Pharynx, motor nerves of, 352
 sensory nerves of, 339
- Phrenic ganglion, 288, 375
 nerve, 274, 288, 291, 293, 366, 375, 385
 accessory, 288
 plexus, 375
- Pilo-motor nerves, 359, 367, 369, 370, 371
- Pituitary body, nerves of, 363
- Plantar nerves. *See* NERVES.
- PLEXUS (plaiting, twining) or PLEXUSES, nervous
 221, 383
 aortic, 370, 375, 376, 377
 aortic abdominalis, 376
 thoracalis, 367
 atrial, 373
 beneath sartorius muscle, 318, 322
 brachial, 283, 289, 307, 382, 383
 bulbar, 373
 cardiac, deep, 268, 363, 365, 366, 372, 373
 superficial, 268, 363, 372, 373
 caroticus externus, 364
 internus, 362
 carotid, 234, 243, 250, 260, 362
 cavernous, 230, 233, 235, 238, 362
 cervical, 283, 285
 cutaneous area of, 341
 posterior, 280
 coccygeal, 323
 cœliac, 376
 cœliacus, 373
 coronary of heart, 372
 of stomach, 376
 cranial, 362
 cystic, 376
 dental, inferior, 247

- Plexus or plexuses—*continued*.
 dental, superior, 241
 diaphragmatic, 375
 epigastric, 373
 facial, 248
 gastric, 269
 gastro-epiploic, 376
 great, of sympathetic, 372
 hepatic, 269, 288, 375, 376
 hæmorrhoidal, 377
 hypogastric, 361, 370, 372, 376, 377, 378
 inferior, 377
 infraorbital, 241
 of intercostal nerves, 310, 383
 intermediate, 373
 intermesenteric, 376
 ischiadicus, 324
 linealis, 376
 lumbar, 283, 311, 312, 317, 318, 383
 mesenteric, inferior, 376
 superior, 376, 377
 middle meningeal, 249, 253
 œsophageal, 262, 264, 269
 pancreatic, 376
 pancreatico-duodenal, 376
 parotideus, 252
 patellar, 317, 322
 pelvic, 370, 371, 372, 377
 pharyngeal, 261, 265, 266, 363
 phrenic, 375
 prevertebral, 357, 359, 360, 361
 prostatic, 378
 pudendus, 324
 pudic, 324
 pulmonary, anterior, 268, 269, 364, 372
 posterior, 262, 264, 268, 269, 367
 pyloric, 376
 renal, 269, 367, 369, 370, 375
 sacral, 283, 311, 312, 313, 322, 323, 330, 383
 sciatic, 324
 solar, 263, 269, 288, 361, 369, 372, 373
 spermatic, 375, 376, 377
 splenic, 269, 376
 subclavius, 366
 suprarenal, 375
 tympanic, 260, 362
 vertebralis, 366
 vesical, 377
- Pneumo-gastric nerve. *See* NERVE.
 Polyneurial (πολύς, many; νεῦρον) muscles, 383
 Popliteal nerves. *See* NERVES.
 Portio dura (hard, tough), 222
 intermedia, of Wisberg, 251, 252, 254,
 258, 386, 388
 mollis (soft), 222
 Postaxial limb-borders, nerves of, 349
 Posterior auricular nerve, 254, 265, 286
 interosseous nerve, 300, 306, 384
 roots of auditory nerve, 256
 of spinal nerves, 275, 276, 358, 359,
 381, 384
 thoracic nerve, 291, 293, 383
 tibial nerve, 331, 332, 384
 Postfixed type of lumbar plexus, 313
 Preaxial limb-borders, nerves of, 348, 349
 Prefixed type of lumbar plexus, 313
 Pretracheal nerve, 364
 Prevertebral ganglia, 357
 plexuses, 357, 359, 360, 361
 Prezonal nerves, 383
 Primary divisions of spinal nerves, posterior or
 dorsal, 275, 278, 341, 381
- Primary divisions of spinal nerves, anterior or
 ventral, 275, 278, 283, 341, 381, 382
 Prostate, secretory nerves of, 372
 sensory nerves of, 351
 Prostatic plexus, 378
 Pterygoid nerve. *See* NERVE.
 Pterygo-sphenoidal ligament, 244
 accessory, 247
 Pudendal nerve, inferior, 326, 328, 329, 330
 Pudic nerve, 324, 325, 328, 370, 378, 382
 Pulmonary nerves, anterior, 268
 plexus. *See* PLEXUS.
 Pupillo-dilator fibres, 366, 369
 Pyloric plexus, 376
- QUADRATUS femoris muscle, nerve of, 324, 325,
 384
- RADIAL nerve, 297, 298, 300, 302, 303, 304, 384
 Radius, nerve of, 301
 Radix cochlearis, 256
 vestibularis, 256
 Ramus vel Rami, communicantes, grey, 358,
 359, 361, 365, 367, 384
 white, 357, 358, 367, 371, 384
 cutaneous anterior, 315
 lateralis, 315
 descendens hypoglossi, 273
 efferentes, 357, 358, 360
 ophthalmicus profundus, 388
 perineales, 328
 profundus nervi radialis, 306
 superficialis nervi radialis, 304
 viscerales, cervico-cranial, 359
 visceralis, 381
 zygomaticofacialis, 240
 zygomaticotemporalis, 239
- Rectum, inhibitory nerves of, 370
 motor nerves of, 370, 371
 sensory nerves of, 350
 Recurrent nerves. *See* NERVES.
 Renal ganglia, 375
 plexus, 269, 367, 369, 370, 375
 Rhomboid muscles, nerve of, 292, 383
 Ribs, nerves of, 308
 Root or Roots, ascending or bulbar of fifth
 nerve, 233
 of auditory nerve, 256, 257
 of ciliary ganglion, 230, 236, 237, 238, 359,
 363
 descending or mesencephalic, of fifth nerve,
 233
 of ganglia, 237
 of hypoglossal nerve, 271, 274
 motor of fifth nerve, 225, 233, 243, 247
 of otic ganglion, 249
 sensory, of fifth nerve, 225
 of spinal nerves, anterior, 275, 276, 354,
 358, 359, 384
 posterior, 256, 275, 358, 359, 381, 384
 of spheno-palatine ganglion, 243
 of submaxillary ganglion, 248, 365
 of tenth nerve, 261
- Round ligament of uterus, motor nerves of, 370
 Rules of cutaneous nerve-supply of limbs, 345
- SACCULAR nerve, 257, 258
 Sacral nerves, 274, 276, 277, 278, 281, 322, 356, 381
 fifth, 323, 381

- Sacral nerves—*continued*.
 fourth, 323, 381
 sixth, 323
 gangliated cord, 370
 plexus, 283, 311, 312, 313, 322, 323, 330, 383
 sympathetic, constitution of, 371
- Sacro-iliac joint, nerves of, 281
- Saphenous nerves. *See* NERVES.
- Scapula, nerves of, 293
- Sciatic nerves. *See* NERVES.
 plexus, 324
- Scrotal nerves, long, 329
- Scrotum, nerves of, 341, 343
- Second pair of cranial nerves. *See* NERVES.
- Secretory nerves of prostate, 372
 of submaxillary gland, 367, 369
 of sweat-glands, 369, 370
- Segmental nerves, 344, 350, 354, 381, 382, 384, 385
- Segmentation of cranial nerves, 388
 of spinal nerves, 381
- Semilunar ganglion, 367, 369, 375
- Sensory distribution of cerebro-spinal nerves, 344
 of spinal nerves to viscera, 350
 fibres, spinal, to sympathetic system, 359
 nerves. *See* NERVES.
 nuclei, 222
 root of ciliary ganglion, 236, 237, 238
 of fifth nerve, 225, 233
 of ganglia, 237
 of otic ganglion, 249
 of sphenomaxillary ganglion, 243
 of submaxillary ganglion, 248
 zones of trunk and limbs, 344
- Septal branch of nasal nerve, 237
- Seventh pair of cranial nerves. *See* NERVES.
- Shoulder, cutaneous nerves of, 343
 motor nerves of, 352
- Shoulder-joint, nerves of, 293, 294, 295
- Sinus, frontal, nerves of, 338
 sphenoidal, nerves of, 338
- Sixth pair of cranial nerves. *See* NERVE.
- Sixth sacral nerve, 323, 381
- Stemmering's classification of nerves, 221
- Soft palate, motor nerves of, 352
 sensory nerves of, 339
- Solar plexus, 263, 269, 288, 361, 369, 372, 373
- Sole, cutaneous nerves of, 344
- Somatic (*σώμα*, body) afferent nerves, 384, 388
 division of spinal nerves, 381
 efferent, mesial, 384, 385, 386, 388
 lateral, 385, 386, 388
- Spermatic ganglion, 375
 plexus, 375, 376, 377
- Spheno-ethmoidal nerve, 237
- Sphenoidal nerve, 243, 249
- Sphenoidal sinus, nerves of, 338
- Spheno-palatine ganglion, 221, 237, 238, 239, 241, 253, 256, 357, 387, 388
 nerve, 239, 241, 242, 243
- Spinal accessory nerve. *See* NERVE.
 cord, 223, 274, 275
 ganglia, 275, 276, 277, 384
 nerves, 221, 274
 connection with sympathetic cords, 357, 358, 359, 361, 365, 367, 370, 371
 cutaneous distribution of to trunk and limbs, 344
 morphology of, 381
 muscular distribution of, 354
- Spinal nerves, primary division of, anterior, 275, 278, 283, 341, 381, 382
 primary division of, posterior, 275, 278, 341, 381
 roots of, 256, 275, 351, 359, 381
 segmentation of, 381
 sensory distribution, to viscera, 350
 portion of spinal accessory nerve, 269, 270, 271, 385, 386, 390
- Spiral ganglion of cochlea, 256, 258
- Splanchnic ganglion, 369
 nerves. *See* NERVES.
- Splanchnic (*σπλάγχνα*, viscera), or vagrant ganglia, 384
 or visceral divisions of spinal nerves, 381
- Splanchnics, abdominal, 367
 cervical, 361
 pelvic, 359, 371
- Splenic plexus, 269, 376
- Stapedius branch of facial, 253, 390
- Stationary ganglia, 384, 387
- Stellate ganglion, 366, 369
- Sternal branches of intercostal nerves, 308
- Sterno-clavicular joint, nerves of, 287
- Sternum, nerves of, 308
- Stomach, motor nerves of, 269
 sensory nerves of, 350
 visceroinhibitory nerves of, 369
- Stria medullares, 256, 257
- Stylo-hyoid branch of facial, 254, 365, 390
- Stylo-pharyngeus, nerve to, 261, 390
- Subclavian artery, nerves of, 366
- Subclavius muscle, nerve of, 288, 291, 293, 384
- Subcostal nerve, 307
 branches of intercostal nerves, 308
- Sublingual ganglion, 248
- Submaxillary ganglion, 221, 237, 248, 254, 256, 357, 365, 387, 388
 gland, secretory nerves of, 367, 369
- Suboccipital nerve, 221, 222, 274, 277, 278, 283
- Subscapular nerves, 291, 294, 383
- Superficial cardiac nerve, 268, 361, 363, 365, 372, 373
 cervical nerve, 256, 286
- Superior maxillary nerve, 223, 234, 238, 388, 390
- Supra-acromial branch of cervical plexus, 287
- Supraclavicular nerves, 287, 310
- Suprahyoid muscles, nerves of, 351
- Supramaxillary nerve, 256
- Supraorbital nerve, 236, 254, 255
- Suprarenal plexus, 375
- Suprascapular nerve, 291, 293, 383
- Suprasternal branches of cervical plexus, 287
- Supratrochlear nerve, 233, 236, 237
- Sweat-glands, secretory nerves of, 369, 370
- Sympathetic branch of spinal nerves, 381, 384
- Sympathetic, cervical, constitution of, 366
 fibres, 358
 ganglia. *See* GANGLIA.
 lumbar, constitution of, 370
 nerves, 221, 357, 372, 384
 plexuses, great, 372
 roots of ganglia, 237, 238, 243, 248, 249, 363, 365
 sacral, constitution of, 371
 thoracic, constitution of, 369
- Synopsis of muscular distribution of nerves, 351
 of sensory distribution of nerves, 338
- TABLE of homologies of limb-nerves, 383
 of muscular distribution of spinal nerves, 354

- Table of origins of branches of brachial plexus, 291
of segmental nerves of head, 389
- Tarsal joints, nerves of, 337
- Tarso-metatarsal joints, nerves of, 335, 338
- Temporal branches of facial, 254
ganglion, 365
nerve, 235, 239, 254
deep, 243, 245, 246
superficial, 246
- Temporo-facial division of facial, 252, 254, 256
- Temporo-malar nerve, 239
- Temporo-maxillary joint, nerves of, 246
- Tenth pair of cranial nerves. *See* NERVES.
- Terminal ganglia, 357
- Testis, sensory nerves of, 351
- Thenar eminence, cutaneous nerves of, 344
- Thigh, nerves of, cutaneous, 344
muscular, 353
- Third occipital nerve, 280
- Third pair of cranial nerves. *See* NERVE.
- Thoracic ganglia, sympathetic, 365, 367
gangliated cord, 367
nerves. *See* NERVES.
spinal, 274, 307
sympathetic, constitution of, 369
- Thumb-muscles, nerves of, 302
- Thyroid branches of middle cervical ganglion, 365
ganglion, 365
- Tibia, nerves of, 331, 332, 336
- Tibial artery, anterior, nerves of, 332
posterior, nerves of, 332
- Tibial nerve. *See* NERVE.
- Tibial communicating nerve, 322
- Tibio-fibular joints, nerves of, 331, 332, 336
- Toes, articular nerves of, 334
cutaneous nerves of, 344
- Tongue, muscular nerves of, 351, 390
sensory nerves of, 248, 256, 261, 338
- Tonsillitic branches of ninth nerve, 261
- Trachea, sensory nerves of, 341
- Tracts, optic, 227
- Trifacial or Trigeminal nerve. *See* NERVE.
- Trochlear nerve. *See* NERVE.
- Trunci sympathici, 358
- Trunk, cutaneous nerves of, 341, 344, 350
muscular nerves of, 352, 354
- Trunk-ganglion of vagus, 262, 264, 265, 272, 284, 361
- Trunks of brachial plexus, 289
- Tube, Eustachian, nerves of, 341
- Twelfth dorsal nerve, 307, 311, 314, 315, 317, 322, 344, 382
- Twelfth pair of cranial nerves. *See* NERVES.
- Tympanic branches, 246, 260
cavity, sensory nerves of, 341
gland, 260
membrane, nerves of, 341
nerve, 259, 260, 362
plexus, 260, 362
- Types of lumbar plexus, 313
- ULNA, nerve of, 301
- Ulnar artery, nerves of, 299
nerve, 291, 295, 296, 299, 302, 303, 306, 384
collateral, 303, 304
- Ureter, sensory nerves of, 350
- Urethra, muscular nerves of, 352
- Uterine appendages, sensory nerves of, 351
- Uterus, nerves of, 351, 370, 372, 375, 378
- Utriclar nerve, 257, 258
- VAGAL portion of spinal accessory nerve, 270
- Vaginal nerves, 378
- Vagrant ganglia, 384, 387
- Vagus nerve. *See* NERVE, PNEUMO-GASTRIC.
- Vas deferens, nerves of, 370, 377
- Vascular branches of hypoglossal nerve, 272
of musculo-cutaneous nerve, 297
- Vaso-constrictor nerves, cerebro-spinal, to sympathetic system, 359
of limbs, 369, 370, 371
of penis, 370
pulmonary, 369
- Vaso-dilator nerves, cerebro-spinal, to sympathetic system, 359
of penis, 370, 372
- Vaso-motor nerves, 359
abdominal, 369, 370
of head, 367, 369
of kidney, 370
- Ventral or anterior primary divisions of spinal nerves, 283, 341, 381, 384
- Vertebral artery, nerve of, 366
- Vertebral ganglia, 357
- Vesical plexus, 377
- Vesicula seminalis, nerves of, 377
- Vestibular ganglion, 256, 257
nerve, 257, 258
- Vestigial ganglia of cranial nerves, 231, 233, 252, 387, 388
- Vidian nerve, 243, 249, 253, 362
- Viscera, abdominal, afferent nerves of, 370
sensory distribution of spinal nerves to, 350
- Visceral branches of fourth sacral nerve, 323
of sacral nerves, 371
or splanchnic division of spinal nerves, 381, 384
- Viscero-constrictor nerves, cerebro-spinal, to sympathetic system, 359
- Viscero-inhibitory nerves, cerebro-spinal, to sympathetic system, 359
of stomach and intestine, 369
- WHITE rami communicantes, 357, 358, 367, 371, 384
- Willis's classification of cranial nerves, 221
- Wrisberg, ganglion of, 372
nerve of, 291, 296, 384
pars intermedia of, 251, 252, 254, 258
- Wrist-joint, nerves of, 300, 301, 303, 307
- ZONES, sensory, of trunk and limbs, 344

END OF PART II.



A LIST OF WORKS ON
MEDICINE, SURGERY
AND
GENERAL SCIENCE,

PUBLISHED BY

LONGMANS, GREEN & CO.,

39, PATERNOSTER ROW, LONDON.

15, EAST 16th ST., NEW YORK.

Medical and Surgical Works.

ASHBY. NOTES ON PHYSIOLOGY FOR THE USE OF STUDENTS PREPARING FOR EXAMINATION. By HENRY ASHBY, M.D. Lond., F.R.C.P., Physician to the General Hospital for Sick Children, Manchester; formerly Demonstrator of Physiology, Liverpool School of Medicine. Sixth Edition, thoroughly revised. With 141 Illustrations. Fcap. 8vo, price 5s.

ASHBY AND WRIGHT. THE DISEASES OF CHILDREN, MEDICAL AND SURGICAL. By HENRY ASHBY, M.D. Lond., F.R.C.P., Physician to the General Hospital for Sick Children, Manchester; Lecturer and Examiner in Diseases of Children in the Victoria University; and G. A. WRIGHT, B.A., M.B. Oxon., F.R.C.S. Eng., Assistant Surgeon to the Manchester Royal Infirmary and Surgeon to the Children's Hospital; Examiner in Surgery in the University of Oxford. Enlarged and Improved Edition. With 178 Illustrations. 8vo, price 24s.

BENNETT.—*WORKS* by WILLIAM H. BENNETT, F.R.C.S.. Surgeon to St. George's Hospital; Member of the Board of Examiners, Royal College of Surgeons of England.

CLINICAL LECTURES ON VARICOSE VEINS OF THE LOWER EXTREMITIES. With 3 Plates. 8vo. 6s.

ON VARICOCELE: A PRACTICAL TREATISE. With 4 Tables and a Diagram. 8vo. 5s.

CLINICAL LECTURES ON ABDOMINAL HERNIA: chiefly in relation to Treatment, including the Radical Cure. With 12 Diagrams in the Text. 8vo. 8s. 6d.

BENTLEY. A TEXT-BOOK OF ORGANIC MATERIA MEDICA.

Comprising a Description of the Vegetable and Animal Drugs of the British Pharmacopœia, with some others in common use. Arranged Systematically and Especially Designed for Students. By ROBERT BENTLEY, M.R.C.S. Eng., F.L.S. With 62 Illustrations on Wood. Crown 8vo, price 7s. 6d.

CLEWOW. THE CHOLERA EPIDEMIC OF 1892 IN THE RUSSIAN EMPIRE. With Notes upon Treatment and Methods of Disinfection in Cholera, and a short account of the Conference on Cholera held in St. Petersburg in December, 1892. By FRANK CLEWOW, M.D. Edin., Member of the Epidemiological Society of London, &c. Royal 8vo, 5s.

COATS. A MANUAL OF PATHOLOGY. By JOSEPH COATS, M.D., Pathologist to the Western Infirmary and the Sick Children's Hospital, Glasgow; Lecturer on Pathology in the Western Infirmary; Examiner in Pathology in the University of Glasgow. Second Edition. Revised and mostly Re-written. With 364 Illustrations. 8vo, price 31s. 6d.

COOKE — *WORKS* by THOMAS COOKE, F.R.C.S. Eng., B.A., B.Sc., M.D. Paris, Senior Assistant Surgeon to the Westminster Hospital.

TABLETS OF ANATOMY. Being a Synopsis of Demonstrations given in the Westminster Hospital Medical School in the years 1871-75. Tenth Thousand, being a selection of the Tablets believed to be most useful to Students generally. Post 4to, price 10s. 6d.

APHORISMS IN APPLIED ANATOMY AND OPERATIVE SURGERY. Including 100 Typical *vivâ voce* Questions on Surface Marking, &c. Crown 8vo, 3s. 6d.

DISSECTION GUIDES. Aiming at Extending and Facilitating such Practical Work in Anatomy as will be specially useful in connection with an ordinary Hospital Curriculum. 8vo, 10s. 6d.

DICKINSON. — *WORKS* by W. HOWSHIP DICKINSON, M.D. Cantab., F.R.C.P., Physician to, and Lecturer on Medicine at, St. George's Hospital; Consulting Physician to the Hospital for Sick Children.

ON RENAL AND URINARY AFFECTIONS. Complete in Three Parts, 8vo, with 12 Plates and 122 Woodcuts. Price £3 4s. 6d. cloth.

* * The Parts can also be had separately, each complete in itself, as follows :—

PART I.—*Diabetes*, price 10s. 6d. sewed, 12s. cloth.

„ II.—*Albuminuria*, price £1 sewed, £1 1s. cloth.

„ III.—*Miscellaneous Affections of the Kidneys and Urine*, price £1 10s. sewed, £1 11s. 6d. cloth.

THE TONGUE AS AN INDICATION OF DISEASE; being the Lumleian Lectures delivered at the Royal College of Physicians in March, 1888. 8vo, price 7s. 6d.

THE HARVEIAN ORATION ON HARVEY IN ANCIENT AND MODERN MEDICINE. Crown 8vo, 2s. 6d.

DUANE. THE STUDENT'S DICTIONARY OF MEDICINE AND THE ALLIED SCIENCES. Comprising the Pronunciation, Derivation, and Full Explanation of Medical Terms, together with much Collateral Descriptive Matter, numerous Tables, &c. By ALEXANDER DUANE, M.D., Assistant-Surgeon to the New York Ophthalmic and Aural Institute, Reviser of Medical Terms for "Webster's International Dictionary." 8vo, 21s.

ERICHSEN.—*WORKS by Sir JOHN ERIC ERICHSEN, Bart., F.R.S., LL.D. (Edin.), Hon. M. Ch. and F.R.C.S. (Ireland), Surgeon Extraordinary to H.M. the Queen; President of University College, London; Fellow and Ex-President of the Royal College of Surgeons of England; Emeritus Professor of Surgery in University College; Consulting-Surgeon to University College Hospital, and to many other Medical Charities.*

THE SCIENCE AND ART OF SURGERY; A TREATISE ON SURGICAL INJURIES, DISEASES, AND OPERATIONS. Tenth Edition. Revised by the late MARCUS BECK, M.S. & M.B. (Lond.), F.R.C.S., Surgeon to University College Hospital, and Professor of Surgery in University College, London; and by RAYMOND JOHNSON, M.B. & B.S. (Lond.), F.R.C.S., Assistant Surgeon to University College Hospital, &c. Illustrated by nearly 1,000 Engravings on Wood. 2 Vols. royal 8vo, 48s.

ON CONCUSSION OF THE SPINE, NERVOUS SHOCKS, and other Obscure Injuries of the Nervous System in their Clinical and Medico-Legal Aspects. Crown 8vo, 10s. 6d.

FRANKLAND. MICRO-ORGANISMS IN WATER, THEIR SIGNIFICANCE, IDENTIFICATION, AND REMOVAL. Together with an Account of the Bacteriological Methods Involved in their Investigation. Specially Designed for the Use of those connected with the Sanitary Aspects of Water Supply. By Professor PERCY FRANKLAND, Ph.D., B.Sc. (Lond.), F.R.S., Fellow of the Chemical Society; and Mrs. PERCY FRANKLAND, Joint Author of "Studies on Some New Micro-Organisms Obtained from Air." With 2 Plates and numerous Diagrams. 8vo. 16s. net.

GAIRDNER AND COATS. ON THE DISEASES CLASSIFIED by the REGISTRAR-GENERAL as TABES MESENTERICA. LECTURES TO PRACTITIONERS. By W. T. GAIRDNER, M.D., LL.D. On the PATHOLOGY of PHTHISIS PULMONALIS. By JOSEPH COATS, M.D. With 28 Illustrations. 8vo, price 12s. 6d.

GARROD.—*WORKS* by Sir ALFRED BARING GARROD, M.D., F.R.S., &c.; Physician Extraordinary to H.M. the Queen; Consulting Physician to King's College Hospital; late Vice-President of the Royal College of Physicians.

A TREATISE ON GOUT AND RHEUMATIC GOUT (RHEUMATOID ARTHRITIS). Third Edition, thoroughly revised and enlarged; with 6 Plates, comprising 21 Figures (14 Coloured), and 27 Illustrations engraved on Wood. 8vo, price 21s.

THE ESSENTIALS OF MATERIA MEDICA AND THERAPEUTICS. The Thirteenth Edition, revised and edited, under the supervision of the Author, by NESTOR TIRARD, M.D. Lond., F.R.C.P., Professor of Materia Medica and Therapeutics in King's College, London, &c. Crown 8vo, price 12s. 6d.

GRAY. ANATOMY, DESCRIPTIVE AND SURGICAL. By HENRY GRAY, F.R.S., late Lecturer on Anatomy at St. George's Hospital. The Thirteenth Edition, re-edited by T. PICKERING PICK, Surgeon to St. George's Hospital; Member of the Court of Examiners, Royal College of Surgeons of England. With 636 large Woodcut Illustrations, a large proportion of which are Coloured, the Arteries being coloured red, the Veins blue, and the Nerves yellow. The attachments of the muscles to the bones, in the section on Osteology, are also shown in coloured outline. Royal 8vo, price 36s.

HALLIBURTON.—*WORKS* by W. D. HALLIBURTON, M.D., B.Sc., M.R.C.P., Professor of Physiology at King's College, London; Lecturer on Physiology at the London School of Medicine for Women; late Assistant Professor of Physiology at University College, London.

A TEXT-BOOK OF CHEMICAL PHYSIOLOGY AND PATHOLOGY. With 104 Illustrations. 8vo, 28s.

ESSENTIALS OF CHEMICAL PHYSIOLOGY. 8vo, 5s.

* * This is a book suitable for medical students. It treats of the subject in the same way as Prof. SCHÄFER's "Essentials" treats of Histology. It contains a number of elementary and advanced practical lessons, followed in each case by a brief descriptive account of the facts related to the exercises which are intended to be performed by each member of the class.

LANGTON. ABDOMINAL HERNIA. By JOHN LANGTON, F.R.C.S., Surgeon to St. Bartholomew's Hospital, Senior Surgeon to the City of London Truss Society, Member of the Council and Court of Examiners of the Royal College of Surgeons of England. With numerous Illustrations. [*In the press.*]

LIVEING.—*WORKS* by ROBERT LIVEING, M.A. & M.D. Cantab., F.R.C.P. Lond., &c., Physician to the Department for Diseases of the Skin at the Middlesex Hospital, &c.

HANDBOOK ON DISEASES OF THE SKIN. With especial reference to Diagnosis and Treatment. Fifth Edition, revised and enlarged. Fcap. 8vo, price 5s.

ELEPHANTIASIS GRÆCORUM, OR TRUE LEPROSY ;
Being the Goulstonian Lectures for 1873. Cr. 8vo, 4s. 6d.

LONGMORE.—*WORKS* by Surgeon-General Sir T. LONGMORE (Retired), C.B., F.R.C.S., late Professor of Military Surgery in the Army Medical School; Officer of the Legion of Honour.

THE ILLUSTRATED OPTICAL MANUAL ; OR, HANDBOOK OF INSTRUCTIONS FOR THE GUIDANCE OF SURGEONS IN TESTING QUALITY AND RANGE OF VISION, AND IN DISTINGUISHING AND DEALING WITH OPTICAL DEFECTS IN GENERAL. Illustrated by 74 Drawings and Diagrams by Inspector-General Dr. MACDONALD, R.N., F.R.S., C.B. Fourth Edition. 8vo, price 14s.

GUNSHOT INJURIES. Their History, Characteristic Features, Complications, and General Treatment ; with Statistics concerning them as they have been met with in Warfare. With 78 Illustrations. 8vo, price 31s. 6d.

LUFF. TEXT-BOOK OF FORENSIC MEDICINE AND TOXICOLOGY. By ARTHUR P. LUFF, M.D., B.Sc. (Lond.), Physician in Charge of Out-Patients and Lecturer on Medical Jurisprudence and Toxicology in St. Mary's Hospital ; Examiner in Forensic Medicine in the University of London ; External Examiner in Forensic Medicine in the Victoria University ; Official Analyst to the Home Office. With numerous Illustrations. 2 vols., crown 8vo, 24s.

NEWMAN. ON THE DISEASES OF THE KIDNEY AMENABLE TO SURGICAL TREATMENT. Lectures to Practitioners. By DAVID NEWMAN, M.D., Surgeon to the Western Infirmary Out-Door Department; Pathologist and Lecturer on Pathology at the Glasgow Royal Infirmary; Examiner in Pathology in the University of Glasgow; Vice-President Glasgow Pathological and Clinical Society. 8vo, price 16s.

OWEN. A MANUAL OF ANATOMY FOR SENIOR STUDENTS. By EDMUND OWEN, M.B., F.R.S.C., Senior Surgeon to the Hospital for Sick Children, Great Ormond Street, Surgeon to St. Mary's Hospital, London, and co-Lecturer on Surgery, late Lecturer on Anatomy in its Medical School. With 210 Illustrations. Crown 8vo, price 12s. 6d.

PAGET. LECTURES ON SURGICAL PATHOLOGY, Delivered at the Royal College of Surgeons of England. By Sir JAMES PAGET, Bart., F.R.S., D.C.L. Oxon., LL.D. Cantab., &c., Sergeant-Surgeon to the Queen, Surgeon to the Prince of Wales, Consulting Surgeon to St. Bartholomew's Hospital. Fourth Edition, re-edited by the AUTHOR and W. TURNER, M.B. 8vo, with 131 Woodcuts, price 21s.

POOLE. COOKERY FOR THE DIABETIC. By W. H. and Mrs. POOLE. With Preface by Dr. PAVY. Fcap. 8vo. 2s. 6d.

POORE. ESSAYS ON RURAL HYGIENE. By GEORGE VIVIAN POORE, M.D., F.R.C.P. Crown 8vo, 6s. 6d.

QUAIN. A DICTIONARY OF MEDICINE; Including General Pathology, General Therapeutics, Hygiene, and the Diseases of Women and Children. By Various Writers. Edited by RICHARD QUAIN, Bart., M.D. Lond., LL.D. Edin. (Hon.) F.R.S., Physician Extraordinary to H.M. the Queen, President of the General Medical Council, Member of the Senate of the University of London, &c. Assisted by FREDERICK THOMAS ROBERTS, M.D. Lond., B.Sc., Fellow of the Royal College of Physicians, Fellow of University College, Professor of Materia Medica and Therapeutics, University College, &c.; and J. MITCHELL BRUCE, M.A. Abdn., M.D. Lond., Fellow of the Royal College of Physicians of London, Physician and Lecturer on the Principles and Practice of Medicine, Charing Cross Hospital, &c. New Edition, Revised throughout and Enlarged. In 2 Vols. medium 8vo. cloth, red edges, price 40s. net.

QUAIN. QUAIN'S (JONES) ELEMENTS OF ANATOMY.

The Tenth Edition. Edited by EDWARD ALBERT SCHÄFER, F.R.S., Professor of Physiology and Histology in University College, London; and GEORGE DANCER THANE, Professor of Anatomy in University College, London. (In three volumes.)

VOL. I., PART I. EMBRYOLOGY. By Professor SCHÄFER. Illustrated by 200 Engravings, many of which are coloured. Royal 8vo, 9s. [Ready. ✓]

VOL. I., PART II. GENERAL ANATOMY OR HISTOLOGY. By Professor SCHÄFER. Illustrated by nearly 500 Engravings, many of which are coloured. Royal 8vo, 12s. 6d. [Ready. ✓]

VOL. II., PART I. OSTEOLOGY. By Professor THANE. Illustrated by 168 Engravings. Royal 8vo, 9s. [Ready. ✓]

VOL. II., PART II. ARTHROLOGY, MYOLOGY, ANGEIOLOGY. By Professor THANE. Illustrated by 255 Engravings, many of which are Coloured. Royal 8vo, 18s. [Ready. ✓]

VOL. III., PART I. SPINAL CORD AND BRAIN. By Professor SCHÄFER. Illustrated by 139 Engravings. Royal 8vo, 12s. 6d. [Ready. ✓]

VOL. III., PART II. THE NERVES. By Professor THANE. Illustrated by 102 Engravings, many of which are Coloured. Royal 8vo, 9s. [Ready. ✓]

VOL. III., PART III. ORGANS OF THE SENSES. By Professor SCHÄFER. Illustrated by 178 Engravings. Royal 8vo, 9s. [Ready. ✓]

VOL. III., PART IV. VISCERAL ANATOMY. [In preparation.]

RICHARDSON. THE ASCLEPIAD. A Book of Original Research in the Science, Art, and Literature of Medicine. By BENJAMIN WARD RICHARDSON, M.D., F.R.S. Published Quarterly, price 2s. 6d. Volumes for 1884, 1885, 1886, 1887, 1888, 1889, 1890, 1891, 1892, 1893, & 1894. 8vo, price 12s. 6d. each.

SCHÄFER. THE ESSENTIALS OF HISTOLOGY: Descriptive and Practical. For the Use of Students. By E. A. SCHÄFER, F.R.S., Jodrell Professor of Physiology in University College, London; Editor of the Histological Portion of Quain's "Anatomy." Illustrated by more than 300 Figures, many of which are new. Third Edition, Revised and Enlarged. 8vo, 7s. 6d. (Interleaved, 10s.)

SCHENK. MANUAL OF BACTERIOLOGY. For Practitioners and Students. With especial reference to Practical Methods. By Dr. S. L. SCHENK, Professor (Extraordinary) in the University of Vienna. Translated from the German, with an Appendix, by W. R. DAWSON, B.A., M.D., Univ. Dub.; late University Travelling Prizeman in Medicine. With 100 Illustrations, some of which are coloured. 8vo. 10s. net.

SMALE AND COLYER. DISEASES AND INJURIES OF

THE TEETH, including Pathology and Treatment : a Manual of Practical Dentistry for Students and Practitioners. By MORTON SMALE, M.R.C.S., L.S.A., L.D.S., Dental Surgeon to St. Mary's Hospital, Dean of the School, Dental Hospital of London, &c. ; and J. F. COLYER, L.R.C.P., M.R.C.S., L.D.S., Assistant Dental Surgeon to Charing Cross Hospital, and Assistant Dental Surgeon to the Dental Hospital of London. With 334 Illustrations. Large Crown 8vo, 15s.

SMITH (H. F.). THE HANDBOOK FOR MIDWIVES. By HENRY FLY SMITH, B.A., M.B. Oxon., M.R.C.S. Second Edition. With 41 Woodcuts. Crown 8vo, price 5s.

STEEL.—*WORKS by JOHN HENRY STEEL, F.R.C.V.S., F.Z.S., A.V.D., late Professor of Veterinary Science and Principal of Bombay Veterinary College.*

A TREATISE ON THE DISEASES OF THE DOG ; being a Manual of Canine Pathology. Especially adapted for the use of Veterinary Practitioners and Students. 88 Illustrations. 8vo, 10s. 6d.

A TREATISE ON THE DISEASES OF THE OX ; being a Manual of Bovine Pathology specially adapted for the use of Veterinary Practitioners and Students. 2 Plates and 117 Woodcuts. 8vo, 15s.

A TREATISE ON THE DISEASES OF THE SHEEP ; being a Manual of Ovine Pathology for the use of Veterinary Practitioners and Students. With Coloured Plate, and 99 Woodcuts. 8vo, 12s.

OUTLINES OF EQUINE ANATOMY ; a Manual for the use of Veterinary Students in the Dissecting Room. Crown 8vo, 7s. 6d.

"STONEHENGE." THE DOG IN HEALTH AND DISEASE. By "STONEHENGE." With 84 Wood Engravings. Square crown 8vo, 7s. 6d.

THORNTON. HUMAN PHYSIOLOGY. By JOHN THORNTON, M.A., Author of "Elementary Physiography," "Advanced Physiography," &c. With 267 Illustrations, some of which are Coloured. Crown 8vo, 6s.

WALLER. AN INTRODUCTION TO HUMAN PHYSIOLOGY.

By AUGUSTUS D. WALLER, M.D., Lecturer on Physiology at St. Mary's Hospital Medical School, London; late External Examiner at the Victorian University. Second Edition, Revised. With 305 Illustrations. 8vo, 18s.

WEICHSELBAUM. THE ELEMENTS OF PATHOLOGICAL HISTOLOGY, With Special Reference to Practical Methods.

By Dr. ANTON WEICHSELBAUM, Professor of Pathology in the University of Vienna. Translated by W. R. DAWSON, M.D. (Dub.), Demonstrator of Pathology in the Royal College of Surgeons, Ireland, late Medical Travelling Prizeman of Dublin University, &c. With 221 Figures, partly in Colours, a Chromo-lithographic Plate, and 7 Photographic Plates. Royal 8vo, 21s. net.

WILKS AND MOXON. LECTURES ON PATHOLOGICAL ANATOMY.

By SAMUEL WILKS, M.D., F.R.S., Consulting Physician to, and formerly Lecturer on Medicine and Pathology at, Guy's Hospital, and the late WALTER MOXON, M.D., F.R.C.P., Physician to, and some time Lecturer on Pathology at, Guy's Hospital. Third Edition, thoroughly Revised. By SAMUEL WILKS, M.D., LL.D., F.R.S. 8vo, 18s.

YOUATT.—*WORKS* by WILLIAM YOUATT.

THE HORSE. Revised and Enlarged by W. WATSON, M.R.C.V.S. Woodcuts. 8vo, 7s. 6d.

THE DOG. Revised and Enlarged. Woodcuts. 8vo, 6s.

General Scientific Works.

ARNOTT. THE ELEMENTS OF PHYSICS OR NATURAL PHILOSOPHY. By NEIL ARNOTT, M.D. Edited by A. BAIN, LL.D. and A. S. TAYLOR, M.D., F.R.S. Woodcuts. Crown 8vo, 12s. 6d.

BENNETT AND MURRAY. A HANDBOOK OF CRYPTOGAMIC BOTANY. By A. W. BENNETT, M.A., B.Sc., F.L.S., and GEORGE R. MILNE MURRAY, F.L.S. With 378 Illustrations. 8vo, 16s.

CARNEGIE. LAW AND THEORY IN CHEMISTRY: A COMPANION Book for Students. By DOUGLAS CARNEGIE, sometime Scholar and Demonstrator in Chemistry of Gonville and Caius, Cambridge. Crown 8vo, 6s.

CLERKE. THE SYSTEM OF THE STARS. By AGNES M. CLERKE, Author of "A History of Astronomy during the Nineteenth Century." With 6 Plates and Numerous Illustrations. 8vo, 21s.

CLODD.—*WORKS* by EDWARD CLODD, Author of "*The Childhood of the World*," &c.

THE STORY OF CREATION. A Plain Account of Evolution. With 77 Illustrations. Crown 8vo, 3s. 6d.

A PRIMER OF EVOLUTION: being a Popular Abridged Edition of "The Story of Creation." With Illustrations. Fcp. 8vo, 1s. 6d.

CROOKES. SELECT METHODS IN CHEMICAL ANALYSIS (chiefly Inorganic). By W. CROOKES, F.R.S., V.P.C.S., Editor of "The Chemical News." Third Edition, re-written and enlarged. Illustrated with 67 Woodcuts. 8vo, 21s. net.

CULLEY. A HANDBOOK OF PRACTICAL TELEGRAPHY. By R. S. CULLEY, M.I.C.E., late Engineer-in-Chief of Telegraphs to the Post Office. With 135 Woodcuts and 17 Plates, 8vo, 16s.

GANOT. ELEMENTARY TREATISE ON PHYSICS; Experimental and Applied, for the use of Colleges and Schools. Translated and edited from GANOT's *Éléments de Physique* (with the Author's sanction) by E. ATKINSON, Ph.D., F.C.S., formerly Professor of Experimental Science, Staff College, Sandhurst. Fourteenth Edition, revised and enlarged, with 9 Coloured Plates and 1,028 Woodcuts. Large crown 8vo, 15s.

NATURAL PHILOSOPHY FOR GENERAL READERS AND YOUNG PERSONS; Being a Course of Physics divested of Mathematical Formulæ, and expressed in the language of daily life. Translated from GANOT's *Cours de Physique* (with the Author's sanction) by E. ATKINSON, Ph.D., F.C.S. Seventh Edition, carefully revised; with 37 pages of New Matter, 7 Plates, 569 Woodcuts, and an Appendix of Questions. Crown 8vo, 7s. 6d.

GOODEVE.—*WORKS* by *T. M. GOODEVE, M.A., Barrister-at-Law; Professor of Mechanics at the Normal School of Science and the Royal School of Mines.*

PRINCIPLES OF MECHANICS. New Edition, re-written and enlarged. With 253 Woodcuts and numerous Examples. Crown 8vo, 6s.

THE ELEMENTS OF MECHANISM. New Edition, re-written and enlarged. With 342 Woodcuts. Crown 8vo, 6s.

A MANUAL OF MECHANICS: an Elementary Text-Book for Students of Applied Mechanics. With 138 Illustrations and Diagrams, and 141 Examples taken from the Science Department Examination Papers, with Answers. Fcp. 8vo, 2s. 6d.

HELMHOLTZ.—*WORKS* by *HERMANN L. F. HELMHOLTZ, M.D., Professor of Physics in the University of Berlin.*

ON THE SENSATIONS OF TONE AS A PHYSIOLOGICAL BASIS FOR THE THEORY OF MUSIC. Second English Edition; with numerous additional Notes, and a new Additional Appendix, bringing down information to 1885, and specially adapted to the use of Musical Students. By *ALEXANDER J. ELLIS, B.A., F.R.S., F.S.A., &c.,* formerly Scholar of Trinity College, Cambridge. With 68 Figures engraved on Wood, and 42 Passages in Musical Notes. Royal 8vo, 28s.

POPULAR LECTURES ON SCIENTIFIC SUBJECTS. With 68 Woodcuts. 2 Vols. crown 8vo, 3s. 6d. each.

HERSCHEL. **OUTLINES OF ASTRONOMY.** By Sir *JOHN F. W. HERSCHEL, Bart., K.H., &c.,* Member of the Institute of France. Twelfth Edition, with 9 Plates, and numerous Diagrams. 8vo, 12s.

HUDSON AND GOSSE. **THE ROTIFERA OR 'WHEEL ANIMALCULES.'** By *C. T. HUDSON, LL.D.,* and *P. H. GOSSE, F.R.S.* With 30 Coloured and 4 Uncoloured Plates. In 6 Parts. 4to, price 10s. 6d. each; Supplement, 12s. 6d. Complete in Two Volumes, with Supplement, 4to, £4 4s.

* * The Plates in the Supplement contain figures of almost all the Foreign Species, as well as of the British Species, that have been discovered since the original publication of Vols. I. and II.

KOLBE. **A SHORT TEXT-BOOK OF INORGANIC CHEMISTRY.** By *DR. HERMANN KOLBE,* late Professor of Chemistry in the University of Leipzig. Translated and Edited by *T. S. HUMPIDGE, Ph.D., B.Sc. (Lond.),* late Professor of Chemistry and Physics in the University College of Wales, Aberystwyth. New Edition. Revised by *H. LLOYD-SNAPE, Ph.D., D.Sc. (Lond.),* Professor of Chemistry in the University College of Wales, Aberystwyth. With a Coloured Table of Spectra and 66 Woodcuts. Crown 8vo, 8s. 6d.

LADD.—*WORKS* by *GEORGE T. LADD*, Professor of Philosophy in Yale University.

ELEMENTS OF PHYSIOLOGICAL PSYCHOLOGY: A TREATISE OF THE ACTIVITIES AND NATURE OF THE MIND FROM THE PHYSICAL AND EXPERIMENTAL POINT OF VIEW. With 113 Illustrations. 8vo, price 21s.

PSYCHOLOGY, DESCRIPTIVE AND EXPLANATORY: A Treatise of the Phenomena, Laws, and Development of Human Mental Life. 8vo. 21s.

OUTLINES OF PHYSIOLOGICAL PSYCHOLOGY. With numerous Illustrations. 8vo. 12s.

PHILOSOPHY OF MIND: an Essay on the Metaphysics of Psychology. 8vo, 16s.

LARDEN. **ELECTRICITY FOR PUBLIC SCHOOLS AND COLLEGES.** With numerous Questions and Examples with Answers, and 214 Illustrations and Diagrams. By *W. LARDEN*, M.A. Crown 8vo, 6s.

LINDLEY AND MOORE. **THE TREASURY OF BOTANY, OR POPULAR DICTIONARY OF THE VEGETABLE KINGDOM:** with which is incorporated a Glossary of Botanical Terms. Edited by *J. LINDLEY*, M.D., F.R.S., and *T. MOORE*, F.L.S. With 20 Steel Plates, and numerous Woodcuts. 2 Parts, fcp. 8vo, price 12s.

LOUDON. **AN ENCYCLOPÆDIA OF PLANTS.** By *J. C. LOUDON*. Comprising the Specific Character, Description, Culture, History, Application in the Arts, and every other desirable particular respecting all the plants indigenous to, cultivated in, or introduced into, Britain. Corrected by *Mrs. LOUDON*. 8vo, with above 12,000 Woodcuts, price 42s.

MARTIN. **NAVIGATION AND NAUTICAL ASTRONOMY.** Compiled by Staff-Commander *W. R. MARTIN*, R.N., Instructor in Surveying, Navigation, and Compass Adjustment; Lecturer on Meteorology at the Royal Naval College, Greenwich. Sanctioned for use in the Royal Navy by the Lords Commissioners of the Admiralty. Royal 8vo, 18s.

MENDELÉEFF. **THE PRINCIPLES OF CHEMISTRY.** By *D. MENDELÉEFF*, Professor of Chemistry in the University of St. Petersburg. Translated by *GEORGE KAMENSKY*, A.R.S.M. of the Imperial Mint, St. Petersburg, and Edited by *A. J. GREENAWAY*, F.I.C., Sub-Editor of the Journal of the Chemical Society. With 97 Illustrations. 2 Vols. 8vo, 36s.

MEYER. **OUTLINES OF THEORETICAL CHEMISTRY.** By *LOTHAR MEYER*, Professor of Chemistry in the University of Tübingen. Translated by Professors *P. PHILLIPS BEDSON*, D.Sc., and *W. CARLETON WILLIAMS*, B.Sc. 8vo, 9s.

MILLER.—*WORKS* by **WILLIAM ALLEN MILLER, M.D., D.C.L., LL.D.**, late Professor of Chemistry in King's College, London.

THE ELEMENTS OF CHEMISTRY, Theoretical and Practical.

PART II. INORGANIC CHEMISTRY. Sixth Edition, revised throughout, with Additions by C. E. GROVES, Fellow of the Chemical Societies of London, Paris, and Berlin. With 376 Woodcuts. 8vo, price 24s.

PART III. ORGANIC CHEMISTRY, or the Chemistry of Carbon Compounds. *Hydrocarbons, Alcohols, Ethers, Aldehydes and Paraffinoid Acids.* Fifth Edition, revised and in great part re-written, by H. E. ARMSTRONG, F.R.S., and C. E. GROVES, F.C.S. 8vo, price 31s. 6d.

MITCHELL. MANUAL OF PRACTICAL ASSAYING. By JOHN MITCHELL, F.C.S. Sixth Edition. Edited by W. CROOKES, F.R.S. With 201 Woodcuts. 8vo, 31s. 6d.

MORGAN. ANIMAL BIOLOGY. An Elementary Text Book. By C. LLOYD MORGAN, Principal of University College, Bristol. With numerous Illustrations. Crown 8vo, 8s. 6d.

MUIR. THE ALCHEMICAL ESSENCE AND THE CHEMICAL ELEMENT: an Episode in the Quest of the Unchanging. By M. M. PATTISON MUIR, Fellow of Gonville and Caius College, Cambridge. 8vo. 4s. 6d.

ODLING. A COURSE OF PRACTICAL CHEMISTRY, Arranged for the use of Medical Students, with express reference to the Three Months' Summer Practice. By WILLIAM ODLING, M.A., F.R.S. With 71 Woodcuts. Crown 8vo, 6s.

OSTWALD. SOLUTIONS. By W. OSTWALD, Professor of Chemistry in the University of Leipzig. Being the Fourth Book, with some additions, of the Second Edition of Ostwald's "Lehrbuch der Allgemeinen Chemie." Translated by M. M. PATTISON MUIR, Professor of Gonville and Caius College, Cambridge. 8vo, 10s. 6d.

PAYEN. INDUSTRIAL CHEMISTRY; A Manual for use in Technical Colleges or Schools, also for Manufacturers and others, based on a Translation of Stohmann and Engler's German Edition of PAYEN's *Précis de Chimie Industrielle*. Edited and supplemented with Chapters on the Chemistry of the Metals, &c., by B. H. PAUL, Ph.D. With 698 Woodcuts. 8vo, 42s.

REYNOLDS. EXPERIMENTAL CHEMISTRY for Junior Students. By J. EMERSON REYNOLDS, M.D., F.R.S., Professor of Chemistry, Univ. of Dublin. Fcp. 8vo, with numerous Woodcuts.

PART I.—*Introductory*, 1s. 6d. **PART III.**—*Metals and Allied Bodies*, 3s. 6d.

PART II.—*Non-Metals*, 2s. 6d. **PART IV.**—*Chemistry of Carbon Compounds*, 4s.

PROCTOR.—*WORKS* by RICHARD A. PROCTOR.

- OLD AND NEW ASTRO-
NOMY. By RICHARD A.
PROCTOR and A. COWPER
RANYARD. With 31 Plates and
472 Illustrations. Text. 4to, 21s.
- LIGHT SCIENCE FOR
LEISURE HOURS; Familiar
Essays on Scientific Subjects,
Natural Phenomena, &c. 3 Vols.
crown 8vo, 5s. each.
- THE ORBS AROUND US; a
Series of Essays on the Moon and
Planets, Meteors, and Comets.
With Chart and Diagrams, crown
8vo, 5s. Cheap Edition, crown
8vo, 3s. 6d.
- OTHER WORLDS THAN
OURS; The Plurality of Worlds
Studied under the Light of Recent
Scientific Researches. With 14
Illustrations, crown 8vo, 5s.
Cheap Edition, crown 8vo, 3s. 6d.
- THE MOON; her Motions, As-
pects, Scenery, and Physical
Condition. With Plates, Charts,
Woodcuts, and Lunar Photo-
graphs, crown 8vo, 5s.
- UNIVERSE OF STARS; Pre-
sented Researches into and New
Views respecting the Constitution
of the Heavens. With 22 Charts
and 22 Diagrams, 8vo. 10s. 6d.
- LARGER STAR ATLAS for
the Library, in 12 Circular Maps,
with Introduction and 2 Index
Pages. Folio, 15s., or Maps
only, 12s. 6d.
- NEW STAR ATLAS for the
Library, the School, and the Ob-
servatory, in 12 Circular Maps
(with 2 Index Plates). Crown
8vo, 5s.
- THE STUDENT'S ATLAS.
In 12 Circular Maps on a Uni-
form Projection and 1 Scale,
with 2 Index Maps. Intended as
a *vade-mecum* for the Student
of History, Travel, Geography,
Geology, and Political Economy.
With a letter-press Introduction
illustrated by several cuts. 5s.
- ELEMENTARY PHYSICAL
GEOGRAPHY. With 33 Maps
and Woodcuts. Fcp. 8vo, 1s. 6d.
- LESSONS IN ELEMENTARY
ASTRONOMY; with Hints for
Young Telescopists. With 47
Woodcuts. Fcp. 8vo, 1s. 6d.
- FIRST STEPS IN GEOME-
TRY: a Series of Hints for the
Solution of Geometrical Pro-
blems; with Notes on Euclid,
useful Working Propositions, and
many Examples. Fcp. 8vo, 3s. 6d.
- EASY LESSONS IN THE
DIFFERENTIAL CALCU-
LUS: indicating from the Outset
the Utility of the Processes called
Differentiation and Integration.
Fcp. 8vo, 2s. 6d.
- THE STARS IN THEIR SEA-
SONS. An Easy Guide to a
Knowledge of the Star Groups, in
12 Large Maps. Imperial 8vo, 5s.
- STAR PRIMER. Showing the
Starry Sky Week by Week, in 24
Hourly Maps. Crown 4to, 2s. 6d.
- ROUGH WAYS MADE
SMOOTH. Familiar Essays
on Scientific Subjects. Crown,
3s. 6d.
- HOW TO PLAY WHIST:
WITH THE LAWS AND ETI-
QUETTE OF WHIST. Crown
8vo, 3s. 6d.
- HOME WHIST: an Easy Guide
to-Correct Play. 16mo, 1s.
- OUR PLACE AMONG INFI-
NITIES. A Series of Essays
contrasting our Little Abode in
Space and Time with the Infini-
ties around us. Crown 8vo, 5s.
- STRENGTH AND HAPPI-
NESS. Crown 8vo, 5s.

[Continued.]

PROCTOR.—*WORKS* by **RICHARD A. PROCTOR**—*continued.*

STRENGTH : How to get Strong and keep Strong, with Chapters on Rowing and Swimming, Fat, Age, and the Waist. With 9 Illustrations. Crown 8vo, 2s.

THE EXPANSE OF HEAVEN. Essays on the Wonders of the Firmament. Crown 8vo, 5s. Cheap Edition, crown 8vo, 3s. 6d.

THE GREAT PYRAMID, OBSERVATORY, TOMB, AND TEMPLE. With Illustrations. Crown 8vo, 5s.

PLEASANT WAYS IN SCIENCE. Crown 8vo, 5s. Cheap Edition, crown 8vo, 3s. 6d.

MYTHS AND MARVELS OF ASTRONOMY. Crown 8vo, 5s. Cheap Edition, crown 8vo, 3s. 6d.

CHANCE AND LUCK ; a Discussion of the Laws of Luck, Coincidences, Wagers, Lotteries, and the Fallacies of Gambling, &c. Crown 8vo, 2s. boards, 2s. 6d. cloth.

NATURE STUDIES. By GRANT ALLEN, A. WILSON, T. FOSTER, E. CLODD, and R. A. PROCTOR. Crown 8vo, 5s. Cheap Edition, crown 8vo, 3s. 6d.

LEISURE READINGS. By E. CLODD, A. WILSON, T. FOSTER, A. C. RUNYARD, and R. A. PROCTOR. Crown 8vo, 5s.

SLINGO AND BROOKER. **ELECTRICAL ENGINEERING FOR ELECTRIC LIGHT ARTISANS AND STUDENTS.** (Embracing those branches prescribed in the Syllabus issued by the City and Guilds Technical Institute.) By W. SLINGO and A. BROOKER. With 346 Illustrations. Crown 8vo, 12s.

SMITH. **GRAPHICS ; OR, THE ART OF CALCULATION BY DRAWING LINES,** applied to Mathematics, Theoretical Mechanics and Engineering, including the Kinetics and Dynamics of Machinery, and the Statics of Machines, Bridges, Roofs, and other Engineering Structures. By ROBERT H. SMITH, Professor of Civil and Mechanical Engineering, Mason Science College, Birmingham.

PART I. Text, with separate Atlas of Plates—Arithmetic, Algebra, Trigonometry, Vector, and Locor Addition, Machine Kinematics, and Statics of Flat and Solid Structures. 8vo, 15s.

SORAUER. **A POPULAR TREATISE ON THE PHYSIOLOGY OF PLANTS.** For the Use of Gardeners, or for Students of Horticulture and of Agriculture. By Dr. PAUL SORAUER, Director of the Experimental Station at the Royal Pomological Institute in Proskau (Silesia). Translated by F. E. WEISS, B.Sc., F.L.S., Professor of Botany at the Owens College, Manchester. With 33 Illustrations. 8vo, 9s. net.

THORPE. **A DICTIONARY OF APPLIED CHEMISTRY.** By T. E. THORPE, B.Sc. (Vict.), Ph.D., F.R.S., Treas. C.S., Professor of Chemistry in the Royal College of Science, London. Assisted by Eminent Contributors. To be published in 3 vols. 8vo. Vols. I. and II. £2 2s. each, Vol. III. £3 3s.

TYNDALL.—*WORKS* by JOHN TYNDALL, F.R.S., &c.

FRAGMENTS OF SCIENCE. 2 Vols. Crown 8vo, 16s.

NEW FRAGMENTS. Crown 8vo, 10s. 6d.

HEAT A MODE OF MOTION. Crown 8vo, 12s.

SOUND. With 204 Woodcuts. Crown 8vo, 10s. 6d.

RESEARCHES ON DIAMAGNETISM AND MAGNE-CRYSTALLIC ACTION, including the question of Diamagnetic Polarity. Crown 8vo, 12s.

ESSAYS ON THE FLOATING-MATTER OF THE AIR in relation to Putrefaction and Infection. With 24 Woodcuts. Crown 8vo, 7s. 6d.

LECTURES ON LIGHT, delivered in America in 1872 and 1873. With 57 Diagrams. Crown 8vo, 5s.

LESSONS IN ELECTRICITY AT THE ROYAL INSTITUTION, 1875-76. With 58 Woodcuts. Crown 8vo, 2s. 6d.

NOTES OF A COURSE OF SEVEN LECTURES ON ELECTRICAL PHENOMENA AND THEORIES, delivered at the Royal Institution. Crown 8vo, 1s. 6d.

NOTES OF A COURSE OF NINE LECTURES ON LIGHT, delivered at the Royal Institution. Crown 8vo, 1s. 6d.

FARADAY AS A DISCOVERER. Crown 8vo, 3s. 6d.

WATTS' DICTIONARY OF CHEMISTRY. Revised and entirely Re-written by H. FORSTER MORLEY, M.A., D.Sc., Fellow of, and lately Assistant-Professor of Chemistry in, University College, London; and M. M. PATTISON MUIR, M.A., F.R.S.E., Fellow, and Prælector in Chemistry, of Gonville and Caius College, Cambridge. Assisted by Eminent Contributors. To be Published in 4 Vols. 8vo. Vols. I. II. 42s. each. Vol. III. 50s. Vol. IV. 63s.

WEBB. CELESTIAL OBJECTS FOR COMMON TELESCOPES.

By the Rev. T. W. WEBB, M.A., F.R.A.S., Vicar of Hardwick, Herefordshire. Fifth Edition, Revised and greatly Enlarged by the Rev. T. E. ESPIN, M.A., F.R.A.S. (Two Volumes.)

VOL. I. With Portrait and a Reminiscence of the Author, 2 Plates, and numerous Illustrations. Crown 8vo, 6s.

VOL. II. With Illustrations and Map of Star Spectra. Crown 8vo, 6s. 6d.

WRIGHT. OPTICAL PROJECTION: A Treatise on the Use of the Lantern in Exhibition and Scientific Demonstration. By LEWIS WRIGHT, Author of "Light: a Course of Experimental Optics." With 232 Illustrations. Crown 8vo, 6s.

DATE DUE SLIP

UNIVERSITY OF CALIFORNIA MEDICAL SCHOOL LIBRARY

**THIS BOOK IS DUE ON THE LAST DATE
STAMPED BELOW**

2m-5,'81

Q125 Quain, J. 580MF
Q2s Quain's elements of anat-
v.5:2 my, ed. by E.A.Schäfer and
1895 G.D.Thane. 10th ed.

