

3 1761 05890844 3

616.8

S385



Library  
of the  
Academy of Medicine,  
Toronto.

11699

Presented by

Mrs G. A. Ingle

1921





Digitized by the Internet Archive  
in 2008 with funding from  
Microsoft Corporation



ROENTGEN DIAGNOSIS OF  
DISEASES OF THE HEAD



# ROENTGEN DIAGNOSIS OF DISEASES OF THE HEAD

BY

DR. ARTHUR SCHÜLLER

HEAD OF THE CLINIC FOR NERVOUS DISEASES AT THE  
FRANZ-JOSEPH AMBULATORIUM, VIENNA

AUTHORIZED TRANSLATION BY

FRED F. STOCKING, M.D., M.R.C.

WITH A FOREWORD BY ERNEST SACHS, M.D.

ASSOCIATE PROFESSOR OF SURGERY IN WASHINGTON UNIVERSITY.

Approved for Publication by the Surgeon General  
of the United States Army

ST. LOUIS

C. V. MOSBY COMPANY

1918



COPYRIGHT, 1918, BY C. V. MOSBY COMPANY



Press of  
C. V. Mosby Company  
St. Louis



## PREFACE

This work was translated by the editor when it first appeared in German. He was at that time a student of Doctor Schüller's, and, while reading the book, thought it worth while to make a written copy of the translation.

No apology is made for its late appearance in print, for, at the time of its publication, there was not a great deal of interest in the subject and relatively few physicians were acquainted with roentgen laboratories that were well enough equipped to make a careful study of the head cases met with so often in general practice. Even yet it is doubtful if sufficient attention has been given to the skull in its etiologic connection with certain definite symptoms frequently left unexplained in the mind of the clinician. However, almost every physician now has access to a well-equipped x-ray laboratory where he can take or send cases for examination, and this procedure can not be too strongly encouraged.

One thing the editor wishes to emphasize in connection with this book is that it is intended to help out in the matter of diagnosis of cranial conditions and makes no attempt at treatment. It may seem that the results of the treatment, when mentioned, have been disappointing and discouraging; but the operations and the frequently following necropsies have been used only as a confirmation of the x-ray diagnosis and should be considered as such.

In all medical and surgical work, it has been true that the technical features of the treatment have been acquired through a more or less rapid evolution, following definite methods of diagnosis, and it is to be hoped that here, as well as elsewhere, early diagnosis will enable earlier interference to be instituted, with its usual attendant assurance of a relatively more certain successful outcome. As we become more familiar with the pathology, its etiology, and its symptoms, we will become more competent to deal with them medically and surgically, and noteworthy results will become more numerous.

The surgical treatment of head conditions is, or, perhaps better said, should be, limited to the specialist or to men of special surgical ability, but the diagnostic knowledge may be and should be the common property of the general practitioner. For that reason this book should be of special interest.

In writing the translation, effort has been made to keep it as literal as possible. To that end everything has been done to convey the intention of the author in as nearly identical wording as was within the editor's power. Where there is a possibility of confusion, footnotes have been made use of, but this has not often been necessary. The illustrations are those that were in the original work, with the addition of a few others that seemed to be advisable.

In concluding, the editor wishes to make a suggestion that has undoubtedly occurred to those engaged in the interpretation of plates. Whenever possible, x-ray pictures of the skull should be made and studied stereoscopically. This is much simpler than it sounds to the uninitiated, and the advantage gained by such a method of procedure can only be appreciated fully when it has been consistently followed. The perspective obtained in examining such pictures is almost invaluable at times in locating new growths, and, in addition, it gives to the individual, unaccustomed to x-ray diagnosis, such assistance as is afforded by no other means.

FRED F. STOCKING.

## FOREWORD

The problems associated with intracranial lesions have increased in number so greatly in the last few years that it seems very desirable that this admirable book should be more generally known. Since the roentgenologic technic has made such rapid strides in the past few years, it has become necessary to make a roentgenologic study of every case that may possibly have an intracranial lesion. The first necessary step was to determine what the normal variations of the skull might be, so that normal shadows might not be interpreted as pathologic lesions. When this had once been done, the recognition of pathologic lesions became very much simpler. This work of Schüller's constitutes the first comprehensive study devoted to roentgenology of the head. The beautiful illustrations and diagrams bring out the various points described in the text most clearly. One of the most helpful points in the recognition of intracranial lesions has been the use of the stereoscopic plates. By the study of these, many shadows that seem difficult to explain are readily interpreted. The studies of normal conditions are excellently described and illustrated and make it possible for any careful observer to distinguish normal variations from pathologic lesions. It is very fortunate that through Dr. Stocking's careful translation of this book, it has been made generally available for students in this country.

ERNEST SACHS.

Washington University Medical School,  
St. Louis, Mo.



## INTRODUCTION

Roentgenology of the skull represents a limited sphere of knowledge, the significance of which, for the diagnosis of internal diseases, is not yet sufficiently appreciated. The number of monographs that deal with roentgen diagnosis of diseases of the head which come under the observation of the internist, is relatively small. This is especially true if one disregards those publications the authors of which had entered upon the work of this difficult sphere without sufficient experience. To that must be added the fact that the knowledge already obtained has by no means become the common property of the physicians, and that even a great portion of roentgenologists are not proficient in x-ray of the skull.

Owing to the circumstance that the obtaining of roentgenograms of the head met with serious difficulties in the beginning of the x-ray era, because of the massiveness of this portion of the body, and also because the interpretation, even of technically successful shadow pictures, was not easy, it can be readily understood that the literature relating to pictures of the head during those first years reports nothing essential for the purposes of the internist. During that time the surgeons made use of roentgenograms of the head almost exclusively for the purpose of determining the presence and localization of projectiles. In the second place the rhinologists turned their attention to the study of the shadow pictures of the facial portion of the skull in order to obtain evidence from them for the diagnosis of pathologic changes in the accessory sinuses.

Only later was the interest of the internist, especially the neurologist, aroused for the roentgen presentation of anomalies in the intracranial pictures. Unfortunately they at once turned their attention to an unattainable problem. They sought to distinguish, directly on the roentgen picture, soft tissue structures and their pathologic changes such as hemorrhages and accumulations of pus in the brain and meninges. It was quickly apparent that those authors who had been able to ob-

tain such pictures had been deceived by phantoms, so that their observations have delayed rather than hastened the progress of knowledge in this sphere. I was the first to call attention to the fact that the pineal gland is the only soft tissue structure that can be identified on the x-ray plate, and that occurs only when there has been a calcium deposit in it. Only the authors who entered upon the work of roentgen diagnosis equipped with sufficient technical and anatomic knowledge were able to produce the evidence that only exceptionally could one succeed in the direct proof of pathologic changes in the intracranial soft tissue structures, and that one must always be satisfied to detect intracranial abnormalities by means of secondary changes in the skull bones as shown by x-ray plates. As a result of this, it occurred to me that a study of the pathologic changes in the bones of the skull was of much more importance than it had been considered heretofore by clinicians. Although generally conceded that pathologic changes in the skull affected its organic contents and that diseases of the brain and sense organs effected changes in the bones of the skull, the interest of clinicians was not sufficiently attracted to these associated changes before the roentgen era, because the methods of examination were extremely inadequate. The inspection of the skull, palpation, auscultation, and percussion, all permit us to determine only the relatively gross changes.

The inspection of the skull, to be sure, informs us quickly as to the size and shape of the vault and the face, but it gives us no conclusion concerning the base. It permits us, indeed, to recognize prominences of the skull, but does not permit us to determine whether the prominences are due to a thickening or a bulging of the wall. Inspection proves the existence of pulsating areas on the skull, without, however, permitting a positive decision concerning the cause of the pulsation, as, for example, when it is a question of the differentiation between pulsating tumors of the skull wall and the pulsation of the normal skull content through a skull defect. Even the changes in color of the soft skull coverings do not always permit a sure conclusion, significant as is the discovery of a suffusion of the scalp for the assumption of skull fracture, and a green color

for the diagnosis of a chloroma. The blue marking of the skin in consequence of dilated veins is found in general disturbances of circulation, in tumors of the scalp or the vault, and in increased intracranial pressure.

The palpation of the skull may furnish proof of changes in the structure of the latter through the discovery of unevennesses of the outer surface without permitting the determination of how wide and how deep the change in the skull wall extends. In other words, palpation does not furnish us positive evidence as to whether the irregularity in the surface is due to a superficial exostosis or a deeper seated osteoma, nor, in the case of an indentation, does it permit us to decide whether the latter is due to a defect in the skull wall or merely a depression due to trauma. Even the proof of fluctuation and pulsation may not always aid in the differentiation of the last named changes in structure. Fluctuation is found, for example, over skull defects (in brain hernias), over superficial erosions (gummata, abscesses) in hematomata of the scalp after skull fracture, and in sinus pericranii, while pulsation occurs in a very marked dilatation of the mastoid emissary vein.<sup>1</sup> On the other hand, in spite of a large defect in the skull, pulsation may be absent if a dense scar in the dura covers the bone defect.

Even the symptom of abnormal compressibility of the skull wall is of little practical utility. It is found usually only in cases of far advanced skull change, in severe halisteresis in consequence of rickets or tumor infiltration, in pressure atrophy, in comminuted fractures, and finally in the formation of thin bony scales over hematomata. The compressibility of the skull wall, determined by palpation, is at best a sign of relatively little value.

Just as uncertain are the results of percussion which are the sensitiveness to percussion and the difference in sound with variations in thickness and density of the skull wall. The testing of the tone conductivity of the skull gives, only in rare cases, information relative to pathologic changes in the skull wall and its inner surface.

Also, only exceptionally does auscultation furnish positive

---

<sup>1</sup>Merkel and the author saw this in narrowing of the jugular foramen. The emissary, the size of the little finger, showed a systolic (arterial from the brain) and a diastolic (from the extracranial venous circulation) pulsation.

diagnostic evidence. Pulsating noises occur in intracranial aneurysms, in narrowing of intracranial vessels, in hydrocephalus, in brain and skull tumors (Beadles, v. Frankl-Hochwart).

We have reviewed the various methods of physical examination in order to show that they, when used individually or collectively, offer very little proof of the pathologic changes in the head. On the other hand, we wish to emphasize that these methods should not only always be called upon to supplement the roentgenologic examination, but that special attention must just at present be paid to evidence thus obtained since the roentgen examination in most cases permits a definite explanation of these findings.

In the following pages the importance of accurate knowledge of skull pathology for roentgen diagnosis of diseases of the head will be taken into account in fullest measure. In Chapter I there is given a review of the normal relations as to size, shape, and structure of the skull at the various ages, as well as the different varieties of skulls.

Chapter II treats of the irregularities in the development of the skull—the anomalies of size and shape in consequence of disturbances in the growth of the skeleton, the changes in the structure of the bone (in consequence of inflammation and new growth), and injuries to the skull.

Chapter III, in addition to pathologic changes in the brain which can be directly exhibited roentgenologically, takes up the changes in the skull produced by intracranial affections, such as processes causing increased intracranial pressure, brain tumors, epilepsy, migraine, and psychoses.

In the appendix are discussed the changes which can be roentgenologically determined in the nose, ear, eye, and teeth so far as they come under the consideration of the internist.

In each chapter, at the beginning of the individual sections, will be given a review of those anatomic and clinical details of the skull, which, scattered through the manuals, monographs and periodicals relating to normal and pathologic anatomy, to anthropology and craniology, to internal medicine and neurology, to surgery and syphilology, to rhinology,



ophthalmology, otology and dental therapeutics, to pediatrics and forensic medicine, are necessary for the understanding of the results to be achieved by the roentgen examination. The works utilized are in part quoted in the text and in part cited in the catalogue of the literature.

The technical difficulties, the possibility of injury to the patient by frequent exposures, and lastly, the cost, make it necessary before every skull examination, to arrange a plan for the pictures, which determines the number of them, the position of the head, and the region to be roentgenographed. In most cases it is advisable to make pictures of the whole head in two directions, frontal and sagittal. Depending on special conditions, also pictures of the whole head in the oblique diameters of the skull, and regional pictures (for presentation of smaller skull areas) in the directions just enumerated, are necessary.

We have left out the detailed discussion of the technic of roentgen pictures of the head. For this, we refer to our former monographs.<sup>2</sup> We have illustrated the importance of the roentgen finding for the explanation or supplementing of the clinical diagnosis, by means of numerous personal observations. We have also inserted in their respective places those results of skull roentgenology which lay claim to less diagnostic than scientific or heuristic value. The monographs concerning skull roentgenology found in the literature were reviewed as completely as possible and critically considered.

The material upon which our work is founded is derived from two sources, roentgen pictures of normal and pathologic skulls, and from clinical cases. For the skeletal material we are indebted to the kindness of the directors of the anatomic, the pathologic and the medicolegal museums in Vienna. The clinical cases were derived for the most part (over 5,000 pictures) from the wards of the General Hospital in Vienna, and

---

<sup>2</sup>The technical rules which we have given in our earlier monographs (see *Die Schädelbasis im Röntgen-Bilde* and also the collection of the literature in the *Zentralblatt für die Grenzgebiete der Medizin und Chirurgie*) have up to the present not become generally known to roentgenologists; otherwise it could not happen that they are constantly ignored, or in other cases newly discovered. In the usual compendiums, school books and manuals of Roentgen information (Gocht, Grashey, Groedel, Des-sauer-Wiesner, etc.) the roentgenology of the skull is treated in a very niggardly manner.

for the lesser part (about 500 pictures) from our private patients.

The professors of the institutes and clinics have, through their kindness in furnishing suitable material, placed us under great obligations to them. I express my most humble thanks to v. Wagner for his ever helpful interest in my roentgenologic examinations of the skull. I thank Holzknrecht not only for my initiation into roentgen knowledge, but also for his untiring assistance in my researches, carried on for ten years in his institution.

---

<sup>3</sup>The abundance of our material we believe can be sufficiently appreciated when we say that we had occasion to examine 67 cases of turriccephaly and 90 cases of hypophyseal tumor.

# CONTENTS

	PAGE
INTRODUCTION . . . . .	8
History of Roentgenology of the Skull . . . . .	8
Clinical Methods of Examining the Skull . . . . .	9
Technic of Roentgen Pictures of the Skull . . . . .	12

## CHAPTER I.

SIZE, SHAPE, AND THICKNESS OF THE NORMAL SKULL . . . . .	21
Influence of Birth, Trade, Position, and Race upon the Shape of the Head . . . . .	22
Roentgenographic Determination of Shape and Size . . . . .	26
Anthropologic Skull Measurements . . . . .	27
Variations in Skull (Sexual, Racial, Individual) . . . . .	30

## CHAPTER II.

DISEASES OF THE SKULL . . . . .	34
A. Anomalies in the Shape and Size of the Skull in Consequence of Disturbances in Development . . . . .	34
1. Malformation of the Skull . . . . .	36
2. Disturbances in the Growth of the Skull Due to Anomalies in Contents . . . . .	41
a. Microcephaly (pseudo, partial) . . . . .	42
b. Megalocephaly (Cephalonia, Hydrocephalus) . . . . .	45
3. Skull Deformities in Consequence of Premature Suture Synostosis . . . . .	56
a. Dolichocephaly (Long Head) . . . . .	60
b. Brachycephaly (Short Head) . . . . .	61
c. Turricephaly (Turret Head) . . . . .	62
d. Scaphocephaly (Scaphoid Head) . . . . .	72
e. Plagiocephaly (Slanting Head) . . . . .	77
f. Secondary Premature Suture Obliteration . . . . .	80
4. Changes in the Shape of the Skull in Consequence of Ex- ternal Influences . . . . .	82
a. Skull Deformity in Consequence of Habitual Attitudes of the Head (Caput Scolioticum, Obstipum, Kyphoticum, Progenium) . . . . .	82
b. Disturbance in Growth Resulting from Anomalies in the Soft Tissues of the Skull . . . . .	85
c. Artificial Deformities of the Skull . . . . .	86

	PAGE
DISEASES OF THE SKULL - CONT'D.	
5. Deformities of the Skull in Systemic Diseases of the Skeleton	89
a. Cretinism . . . . .	90
b. Mongolian Idiot . . . . .	93
c. Chondrodystrophy, Dysplasia Periostalis . . . . .	94
d. Dysostosis Cleidocranialis . . . . .	96
e. Rachitis . . . . .	98
f. Dwarf Growths . . . . .	101
g. Giant Growths . . . . .	102
B. Anomalies in the Structure of the Skull . . . . .	105
1. Inflammations of the Skull bone . . . . .	107
a. Acute Osteomyelitis . . . . .	107
b. Syphilis . . . . .	108
c. Tuberculosis . . . . .	112
d. Actinomycosis . . . . .	113
e. Necrosis from Phosphorus . . . . .	113
2. Atrophic and Hyperostotic Changes in the Skull . . . . .	113
a. Senile Atrophy . . . . .	114
b. Osteomalacia . . . . .	115
c. Neurotic Atrophy . . . . .	117
d. Basilar Invagination . . . . .	118
e. Acromegaly . . . . .	124
f. Hyperplastic Osteitis . . . . .	127
g. Osteitis Deformans . . . . .	128
h. Hyperostoses (Diffuse, Tumor-like) . . . . .	132
3. Tumors of the Skull . . . . .	138
a. Bone . . . . .	139
b. Soft Tissues . . . . .	144
C. Injuries of the Skull . . . . .	147

## CHAPTER III.

ROENTGEN DIAGNOSIS OF INTRACRANIAL DISEASES . . . . .	155
A. Details of Intracranial Contents Directly Discernible on a Roentgen Picture . . . . .	155
B. Changes in the Skull in Consequence of Intracranial diseases . . . . .	159
I. Local Destruction of the Skull in Intracranial Tumors . . . . .	162
1. Tumors of the hypophysis . . . . .	162
a. In Acromegaly . . . . .	178
With Slight Widening of the Sella . . . . .	178
With Moderate Widening of the Sella . . . . .	181
Total Destruction of the Body of the Sphenoid . . . . .	187
b. In Dystrophia Adiposogenitalis (Fröhlich Type) . . . . .	188
Slight Widening of the Sella . . . . .	189

	PAGE
ROENTGEN DIAGNOSIS OF INTRACRANIAL DISEASES—CONT'D.	
Moderate Widening of the Sella . . . . .	190
Total Destruction of the Sella . . . . .	191
c. Without Symptoms of Trophic Disturbance . . . . .	193
Slight Widening of the Sella . . . . .	193
Moderate Widening of the Sella . . . . .	195
Total Destruction of the Sphenoid Body . . . . .	200
2. Acusticus Tumors . . . . .	201
a. With Pathognomonic Changes in the Dorsum Sellae . . . . .	204
b. With Erosion of the Sella . . . . .	206
c. Generalized Pressure Atrophy of the Inner Surface of the Skull . . . . .	207
3. Intracranial Tumors in Other Localities . . . . .	209
a. Of the Base of the Brain . . . . .	209
b. Of the Convexity of the Brain . . . . .	213
II. Changes in the Skull in Consequence of Chronic Excessive Intracranial Pressure . . . . .	215
1. Generalized Erosion of the Inner Surface . . . . .	215
2. Changes in the Shape of the Skull . . . . .	224
3. Changes in the Sutures . . . . .	226
4. Widening of the Venous Canals . . . . .	229
5. Thickening of the Skull . . . . .	236
C. Roentgen Findings in Epilepsy, Cerebral Infantile Paralysis, Idiocy, Psychosis, and Migraine . . . . .	238
D. General Remarks Concerning the Technic of Roentgen Exami- nations in Intracranial Diseases . . . . .	252

## CHAPTER IV.

APPENDIX . . . . .	254
Rhinology . . . . .	254
Otology . . . . .	259
Ophthalmology . . . . .	260
Odontology . . . . .	263
BIBLIOGRAPHY . . . . .	265

## ILLUSTRATIONS

FIG.	PAGE
1-3. Three cuts illustrating the relationship between basal angle and the prominence of the jaw . . . . .	28
4. A portion of a Lückenschädel . . . . .	41
5. A sketch from an x-ray of Case 5, showing erosion of the sella in hydrocephalus . . . . .	52
6. A sinistrodextral x-ray plate of a hydrocephalic skull . . . . .	53
7. A line drawing of the prominent features found in Fig. 6 . . . . .	53
8. A sinistrodextral exposure of a hydrocephalic head . . . . .	54
9. A sketch of the salient features to be seen in Fig. 8 . . . . .	54
10. Photograph taken after palliative trephination had been done . . . . .	71
11. The sinistrodextral roentgen picture of a 14-year-old boy with a turriccephalus . . . . .	73
12. Sketch of Fig. 11 . . . . .	73
13. Roentgen gram of case of scaphocephalus . . . . .	78
14. A sketch of Fig. 13 . . . . .	78
15. A child with scaphocephaly . . . . .	79
16. A combination of plagiocephalus and caput obstipum . . . . .	88
17. Picture of an adult cretin showing the characteristic shape of the head . . . . .	93
18. A drawing of the sella turcica as seen in Fig. 17 . . . . .	93
19. Roentgenogram of case of syphilitic osteoporosis . . . . .	111
20. A drawing of the plate in Fig. 19 . . . . .	111
21. Roentgenogram of case of basilar invagination . . . . .	122
22. A drawing of Fig. 21 . . . . .	122
23. A drawing illustrating what one should see in an anteroposterior picture of the base of the skull and the vertebrae . . . . .	123
24. Sketch from an anteroposterior picture of a basilar invagination . . . . .	124
25. Roentgenogram of diffuse hyperostosis of the skull . . . . .	135
26. Sketch of picture in Fig. 25 . . . . .	135
27. Picture of a tumor-like hyperostosis of the vault and base of the skull . . . . .	137
28. Sketch of Fig. 27 . . . . .	137
29. Roentgenogram of a case of sarcomatous infiltration of the skull . . . . .	143
30. Sketch of Fig. 29 . . . . .	143
31. Picture of a skull in which there are two fissures on the left side . . . . .	152
32. Sketch of Fig. 31 . . . . .	152
33. Sketch of profile roentgenogram of a normal sella in an adult . . . . .	163
34. Another type of normal sella as found in the dolicocephalic . . . . .	164
35. A type of normal sella seen in individuals with short skulls . . . . .	164
36. A type of normal sella with a very plump dorsum . . . . .	165

FIG.	PAGE
37. Sketch of a sella that is otherwise normal except for a connecting bone between anterior and posterior clinoid processes . . .	165
38. Sella of a two-year-old child . . . . .	166
39. Sella of a child five years old . . . . .	166
40. Sella of a child nine years old . . . . .	166
41. Sella of a child twelve years old . . . . .	167
42. Widening of the sella produced by a small intrasellar tumor . .	167
43. An asymmetrical widening of the sella . . . . .	167
44. Moderately wide sella present in a case with a tumor of the hypophysis . . . . .	168
45. Total destruction of the sella caused by a large intrasellar tumor of the hypophysis . . . . .	168
46. Widening of sella produced by a small tumor in the entrance to the sella . . . . .	169
47. Widening of sella produced by moderate sized tumor in the entrance . . . . .	170
48. Total destruction of the sella produced by a large tumor in the entrance . . . . .	170
49. Roentgenogram of a case of acromegaly . . . . .	179
50. A sketch of Fig. 49 . . . . .	179
51. Sketch of the sella of a patient with acromegaly . . . . .	180
52. A sella of a patient with acromegaly . . . . .	180
53. A sella of a patient with acromegaly . . . . .	180
54. A sketch of a sella of a patient with acromegaly . . . . .	181
55. Roentgenogram of a sella containing a tumor of the hypophysis in a patient with acromegaly . . . . .	182
56. A sketch of the picture in Fig. 55 . . . . .	182
57. Sketch of a sella that is slightly larger than normal . . . . .	183
58. Sketch showing slight deepening and widening of the sella . .	183
59. Sketch of a very deep sella . . . . .	183
60. Roentgenogram of sella erosion in a patient with a tumor of the hypophysis associated with acromegaly . . . . .	184
61. A sketch of Fig. 60 . . . . .	184
62. Roentgenogram showing excessive enlargement of the frontal sinus	185
63. Roentgenogram showing marked hemispherical widening of the hypophyseal fossa . . . . .	186
64. Sketch of very wide and deep sella. The dorsum is asymmetrically eroded . . . . .	187
65. Sketch of sella showing the body of the sphenoid almost completely destroyed . . . . .	187
66. Sketch of sella showing outline of mastoid cells . . . . .	188
67. Roentgenogram showing almost complete destruction of body of the sphenoid . . . . .	189
68. Sketch of Fig. 67 . . . . .	189
69. Sketch of sella showing entrance wider than normal . . . . .	190
70. Sketch of sella showing floor eroded in such a manner that one side of dorsum must also be gone . . . . .	190

FIG.	PAGE
71. Sketch showing body of sphenoid, dorsum sella, and anterior clinoid process to be destroyed . . . . .	191
72. Roentgenogram showing the dorsum sella almost entirely gone . . . . .	192
73. Sketch of Fig. 72 . . . . .	194
74. Roentgenogram showing the destruction of the sella, and eroded venous channels . . . . .	196
75. Sketch of Fig. 74 . . . . .	196
76. Roentgenogram showing the skull vault to be of normal contour, hypophysis shallow and widened, dorsum completely gone, except for two short points, and anterior clinoid processes not changed except for shortening . . . . .	199
77. Sketch of x-ray showing asymmetrical erosion in that a double contour is present . . . . .	199
78. Sketch of x-ray showing dorsum to be thinner than normal and pushed forward . . . . .	204
79. Roentgenogram showing dorsum sellæ thinner than normal and pushed forward . . . . .	205
80. Sketch of Fig. 79 . . . . .	205
81. Sketch showing sella slightly widened and dorsum entirely eroded . . . . .	206
82. Sketch showing symmetrical erosion of the sella. Dorsum is thin and bent forward . . . . .	208
83. Sketch of a sella showing appearance of calcified plates as they sometimes appear in the wall of some hypophyseal tumors . . . . .	210
84. X-ray picture of a tumor in the temporal region . . . . .	214
85. Sketch of Fig. 84 . . . . .	214
86. Roentgenogram showing pressure erosions and spreading of the sutures . . . . .	228
87. Sketch of Fig. 86 . . . . .	228
88. X-ray picture of a calvarium with a bilateral erosion . . . . .	231
89. Sketch of the x-ray of the calvarium in which there was a phenomenal enlargement of the diploic veins . . . . .	233
90. Picture showing extreme enlargement and an increase in the number of diploic veins . . . . .	235
91. Sketch of Fig. 90 . . . . .	235
92. Roentgenogram showing a half-moon-shaped area of calcification within the left frontal lobe . . . . .	245
93. Sketch of Fig. 92 . . . . .	245
94. A microcephalic type of turriccephalus . . . . .	248
95. Roentgenogram showing outline of the sella quite indistinct due to carcinomatous growth . . . . .	257
96. Sketch of Fig. 95 . . . . .	257
97. Deformity of the head . . . . .	262



# ROENTGEN DIAGNOSIS OF DISEASES OF THE HEAD

## CHAPTER I

### SIZE, THICKNESS, AND SHAPE OF THE NORMAL SKULL

Even normally, the dimensions of the skull are very variable. In the first place, the size of the skull is dependent upon the size of the brain. The volume of the brain and the capacity of the skull bear a constant relation to each other, in that, as Reichardt determined, the volume of the brain is about 10 per cent less than that of the skull capacity. The weight of the brain, varying normally within considerable limits, explains, therefore, the essential differences in the skull capacity. Vierordt's table gives 1000 to 1800 grams as the weight of the brain in adults. Hence one may consider 1400 grams as an average brain weight, and 1540 cubic centimeters as an average skull capacity. The size of the brain and of the skull is on the average greater in men than in women. It increases in general with the length of the body, but small persons have relatively larger skulls than the tall ones. Also the race of the individual shows itself in a certain measure in the size of the skull.

For clinical purposes the determination of the skull capacity is important, as the researches in the Rieger School, Würzburg, have recently demonstrated. Up to the present the largest horizontal circumference of the head, determined by the tape measure, has usually served as a measure of the skull capacity. (Eyerich, Löwenfeld, Beck, and Froriep.<sup>1</sup>)

---

<sup>1</sup>Froriep gives a review of the new researches concerning the determination of the skull capacity, especially those of Beddoe, and he proposes a new method of reckoning which takes into consideration the three diameters of the skull ellipsoid. However, he has taken the external measurements, and by doing so has not taken into consideration the thickness of the walls. He suggests, however, a picture of the skull thickness as a regular procedure in the measurement of the skull in the future.

With the help of empirically arranged tables, the calculation of the skull capacity is determined from the circumference. Always in this case the uncertainty, as to the thickness of the soft tissues outside the skull, and the uncertainty, as to the thickness of the skull, become troublesome sources of error. The latter varies greatly. Apart from the variations in the thickness of separate skull regions, the average thickness of the skulls of different adults varies between 3 and 8 millimeters. The age of the individual, the sex, the general bone construction, as well as race, appear to influence its thickness.

The roentgen picture permits the thickness of the soft tissues as well as the thickness of the cranial wall to be determined, and offers accordingly the possibility for correcting the capacity of the skull obtained by cephalometric methods.

The shape of the normal skull is, as we have said, influenced by inherited factors, namely, the characteristics of the race and family of the individual, and in addition it is affected by external influences. The racial factors manifest themselves in such a characteristic manner in the shape of the skull, that this is utilized as one of the most important anthropologic points for the differentiation of race. Family characteristics also find their expression in the shape of the skull. Indeed the similarity in the physiognomy of families depends in a large part upon unanimity in the shape of the cranial skeletons. Among the external influences upon which the shape of the skull depends, those occurring intrauterine and during labor play an important part. Also the habitual position of both the head and the body, especially during the first years of life, plays a part.

Repeated assertions are found in the literature concerning the reciprocal dependence of trade and the size and shape of the skull. Beyond doubt the shape is influenced by the position peculiar to certain trades, and the large brains characteristic of greater intelligence seem to occasion the large skulls of those belonging to higher callings. Ranke found in measurements of cranial capacity that it was greater in the city population than among the country people. According to Lomer, the day laborer shows the smallest skull measurement, while

the skull measurements of peasants are strikingly large, larger in fact than those of handworkers, merchants and officials.

Bayertal undertook investigations concerning the relation between cranial circumference and intelligence at the school age, and found that children with large skulls were more intelligent than those with small ones. MacDonald found that the boys in school were for the most part broad-headed, only 11 per cent had long heads, and also that the untalented boys showed the greatest percentage of long heads.

Of general interest and of practical significance is the relation between the shape of the head of the adult and that of the newborn. The fundamental form of the skull with its inherited peculiarities is demonstrable *in utero*, as A. Mueller has worked out in detail. Under certain conditions a change of the skull shape is brought about *in utero* through the pressure of the uterine wall resulting from scanty amniotic fluid, and through the long-continued resting of the head upon the pelvic inlet. A further remodeling of the fetal head is produced by the process of labor. It is known that a characteristic molding of the skull belongs to every fetal position. For instance, the skull born with the occipital or face presentation is a long skull; that born with frontal presentation a high skull; that born with vertex presentation a short skull. Hence one can draw a conclusion from the shape of the head of the newborn as to the mechanism of exit. It seems that the varieties of skull shapes just named not only arise through the act of labor itself, but that they have already existed, although in less pronounced degree, before birth, and on their part have decisively influenced the position of the head in its passage through the pelvis. To what extent the deformity caused by the process of labor is preserved in later life is not known, as positive observations are wanting. Walcher was able to prove that the position of the head in the first weeks after birth is of influence upon the permanent shape. In a case of twins with similarly shaped heads after birth, the one which was compelled to lie on a hard surface was made a long-headed child, and the other one, whose head rested on a soft surface, was made a short-headed one.

In investigations concerning the dependence of the shape of

the head of the newborn upon the shape of the head of its parents, Stern has found that fixed relations exist only between the size and shape of the head of the newborn and the head of the mother. The same author found a relationship between small and short heads on one hand and a narrow pelvis on the other. Further, it appeared remarkable to him that the very short-headed women produce a far greater percentage of female children than the very long-headed ones.

Swartz gives a review of measures, circumferences, and indices in children of both sexes, together with a good bibliography.

Neumayer finds that at birth the postauricular part of the cranium is longer than the preauricular portion. The postauricular part continues to grow up to the ninth or tenth year, the preauricular portion up to the middle of the third decade. The exact determination of the size of the fetal skull *in utero* by means of the roentgen ray would be of great practical importance.<sup>2</sup> Also of interest would be a positive roentgenographic observation of the relations of the shape and size of the skull in the course of later development and in old age.<sup>3</sup>

The race peculiarities of the skull appear, as already mentioned, in a characteristic way with reference to shape. In general the long- and short-headed races are differentiated upon the basis of the mutual relation between the length and breadth of the skull. In addition to this, the structure of single parts of the cranial and facial skeleton permit the determination of characteristic differences, not only between the five chief races, Australian, Indian, Mongolian, Ethiopian, and Caucasian, but also the determination of territorial differences within the races themselves. For instance, the yellow race is short-headed in contrast to the American, while within the white race the inhabitants of the Alps and the Slavs have characteristically short heads. The skull of the Kalmuck is strikingly large and broad. The Eskimo has a long skull which becomes narrowed in the parietal region, canoe-shaped, while the flattest forms are found in Australia. In Europe, the Scandinavians, Germans, English, Irish, and French, and in Asia the

<sup>2</sup>Concerning roentgen pictures of the fetus *in utero*, see the researches of Edling.

<sup>3</sup>Bade describes the skull development for the most part from the roentgenologic standpoint. Concerning the determination of age of the skull see the *Manual of Medical Jurisprudence*, by Hofmann-Kolisko.

Hindus and Georgians belong to the orthognathic dolichocephalies. The Japanese and Chinese are prognathic dolichocephalies. In Europe, the Slavs, Russians, Poles, Finlanders, Laplanders, Hungarians, and in Asia the Turks, belong to the orthognathic brachycephalies with slightly prominent jaw framework.

Torok designated the Negroes, Eskimos, Weddas, Singhalese, Tamils, Australians and Swedes as manifestly dolichocephalic races. His researches enabled him to say that adult human skulls varied considerably in their three general dimensions. Between the two extremes, the difference amounted to 82 mm. in length, 67 mm. in breadth, and 56 mm. in height. The so-called dolichocephalic skulls are not always truly long, but are, for the most part, narrow. We do not know why certain races are dolichocephalic and others brachycephalic. In regard to that, the fact has been mentioned that every race, with the progress of culture, has the tendency to become brachycephalic. This process of development from dolichocephalic to brachycephalic is also demonstrable in the evolution of the race (Neumayer). The shape of certain bones, especially occipital and frontal bones, has been made responsible for the origin of the shape of the head. However, one can show in brachycephalic skulls that the single segments of similarly shaped skulls participate in an extremely variable degree in the development of the length of the skulls. The original shape of the skull base, which can be first well differentiated embryologically, appears to be more important as the cause of the ultimate shape of the head.

Reuter sought to convey the thought that there is some relation between growth and cortical areas so that people with long limbs have long heads, and those with long bodies have short heads.

The consideration of the shape of the skull is of practical importance with regard to craniocerebral topography. Froriep shows that there exist definite relations between the length and height of the skull on the one hand, and the site of the cerebral fissures on the other. The occipitopetal type of brain corresponds to the long flat skull, which means that the fissure of Rolando lies here oblique and quite posterior. In the short

high skulls the frontopetal type of brain is present, meaning that the fissure of Rolando lies quite far forward and more nearly approaches the perpendicular.

Roentgenography is of special value for locating on the skull the approximate position of the brain fissures, the importance of which grows daily owing to the increase in frequency of operative interference. The roentgen picture of the skull facilitates the discovery of such points which serve as landmarks in craniocerebral topography. Braun (*Manual by Lewandovsky*, vol. i, p. 1152) refers to the fact that the relations given by Froriep can be directly demonstrated with the help of a sagittal roentgen picture of the skull. We add that the roentgen picture permits the certain course of the artery furrows and venous canals to be determined, and in this way renders it possible to avoid their injury in operative interference.

Roentgen pictures would also be very instructive for the presentation of the topographic relations of the interior of the brain to the skull, as pictured in Hermann's *Atlas*. Since the skull represents that part of the skeleton, which from an anthropologic standpoint, deserves the greatest dignity, it is thus readily understood that exact methods of measurement of it exist in very great numbers. While at first one was satisfied to draw the outlines of the skull as they appeared in the view from in front (*norma frontalis*) from behind (*norma occipitalis*), from the side (*norma temporalis*), and from above (*norma verticalis*), following the example of Blumenbach, the father of anthropology, later on one went farther to reach a detailed geometric representation of the size and shape of the skull; first, by means of accurate measurements, and, second, by means of complicated graphic methods. Unfortunately in the choice of the system of measurement they did not proceed uniformly. Broca's French School especially based its measurements on other lines of orientation than the German anthropologists. He who wants definite information concerning these methods of measurement finds abundant material in the old works of Huschke, Lucae, Aeby, Virchow, von Baer, Welcker, Petzius, Topinard, Benedikt, Ranke and others. Most recently, the method worked out in accordance with the suggestions of Lissauer has been quite universally adopted.

(P. and F. Sarasin, 1892-1893, Klaatsch, Martin, Schlaginhausen). This method consists in the exact graphic representation of a large number of outlines of the skull corresponding to sagittal, horizontal, and frontal planes of section which stand perpendicular to one another; one constructs four horizontal, three sagittal, and three transverse curves.

As points of measurement are chosen certain marks for orientation always easily located on the skull, as for instance, the root of the nose, the highest point of the external auditory meatus (ear point) the most prominent points of the skull vault, and so on corresponding to the directions of the Frankfort craniologic agreement (*Archiv für Anthropologie*, 1884, vol. xv). To this agreement corresponds also the selection of the joining line between ear point and lower orbital margin known as the "German horizontal."<sup>4</sup> The measurements most important for practical purposes are included in these. In the first place one determines a series of linear measurements; viz., the greatest length of the skull as the distance from the most remote point of the occiput to the forehead (about 180 mm.), the greatest breadth as the distance between the opposite points of the temporal region most distant from one another (146 mm.), the greatest height as the distance from the anterior edge of the foramen magnum to the highest point of the vertex (135 mm.). Besides these diameters above mentioned, one determines a number of radii and chords of the skull vault, for instance the communicating line from the root of the nose to the most anterior edge of the foramen magnum (length of skull base, 100 mm.). In addition one obtains several arc measurements, the most important of which are the greatest horizontal circumference (520 mm.) and the arc of the vault between the external auditory meati (315 mm.).

According to the suggestion of Retzius, one usually determines the arithmetrical relation between the linear diameters, in order, in this way, to learn a uniform numerical expression for the fundamental shape of the skull. Most often the "Linear Index" is given, which means the relation between the length and the breadth and is obtained from the formula  $I = \frac{B}{L} \cdot 100$ .

<sup>4</sup>Reid's base line is drawn from the lower orbital margin through the center of the external auditory meatus.—EDITOR.

A skull in which this index lies between 70 and 80 is designated as mesocephalic, a skull under 70 as dolichocephalic, and one over 80 as brachycephalic.

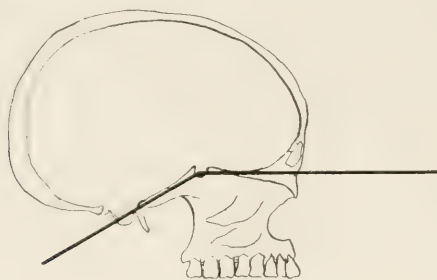


Fig. 1.

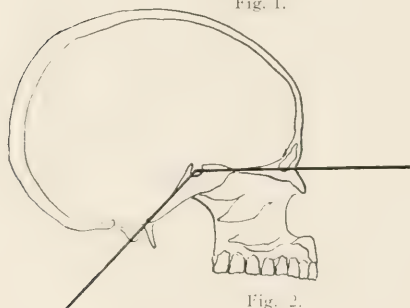


Fig. 2.

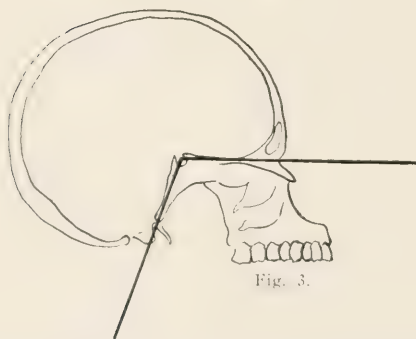


Fig. 3.

Figs. 1, 2, and 3.—These three cuts have been inserted by the editor for the purpose of illustrating the author's idea of the relationship between the basal angle and the prominence of the jaw. Fig. 2 has a normal basal angle of  $134^{\circ}$  while in Fig. 1 the basal angle is greater and represents a platybasia and in Fig. 3 it is more acute and illustrates the appearance of a basal kyphosis, with the corresponding retraction and prominence of the upper jaw that goes with the two conditions.

The measurement of the angles form an important supplement to the linear measurements. One usually determines the facial angle, one leg of which is obtained by the line from the



root of the nose to the middle point of the alveolar process of the upper jaw, and the other leg by the line from the last named point to the anterior edge of the foramen magnum (according to Weisbach the normal is  $73^\circ$ ). A skull with a smaller facial angle is designated as prognathic in contradistinction to a normal (orthognathic) skull. The angle between the line from the foremost point of the foramen magnum to the center of the sella turcica and from this point to the root of the nose is called the sphenoid angle ( $134^\circ$ , Weleker). Its size is a criterion for the fundamental shape of the skull base. In abnormal obtuseness of the sphenoid angle there exists a flattening of the basal angularity (platybasia), in abnormal smallness of the angle there is present a pathologic kyphosis of the skull base. (See Figs. 1, 2, and 3.)

The methods of measurement which we have cited in the foregoing refer to the cranial skeleton and are for the most part feasible only upon this. In the living only a few of the mentioned measurements can be determined by means of the tape measure, lead wire, calipers, and goniometer, and in these the soft skull coverings cause trouble. On the other hand, as has already been explained in the author's *Atlas of the Base of the Skull* (*Atlas der Schädelbasis*), the roentgen method alone furnishes the opportunity to calculate in the living all the important measurements which would otherwise be obtained only on the skeleton. Indeed the basal parts which are indispensable for the complete examination of the skull and the contour of the inner surface corresponding to the norma frontalis, norma temporalis, and norma occipitalis, can be produced with complete distinctness in the roentgenogram. The measurements necessary for craniologic purposes can be gathered from the roentgenogram of the skull, and, with the help of rules which are valuable for the linear projection of bodies upon a surface, can be ascertained numerically. It is to be hoped that in the near future the roentgenologic method, which up to the present has been used in only a limited way for anthropologic purposes<sup>5</sup> will enjoy general consideration. For practical purposes it is

<sup>5</sup>Tandler (*Mitteilungen der Anthropologischen Gesellschaft in Wien*, 1909) determined the reciprocal relations between the cranial skeleton and the soft tissue covering it. He superimposed upon one another, the roentgenogram of a skull and the photograph provided with soft parts or the facial mask of the same individual, and used this procedure in a clever way for establishing the similarity between the death mask of an individual and his skull.

likely to form a welcome supplement to the photographic methods of measurement devised by Bertillion and further developed by Chervin. In connection with the study of the roentgenographic method of measurement, one may think of the possibility of using the roentgen examination for the presentation of the variations in the skull, especially the variations of the external and internal surfaces.

We will let the discussion of the variations in the skull, for the detailed presentation of which we thank Le Double, follow in those chapters where the relations of pathologic conditions to variations are discussed. The knowledge of the variations in the normal skull is indispensable to an understanding of the pathology. Mention will be made here of variations of sex, race and individuals in general only.

So far as the sexual differences of the skull are concerned, they are found compiled in the extensive reports of Rebentisch, Bartels, Möbius, and others. The more marked prominence of the bone ledges and projections on the external surface of the male skull may be mentioned in distinction to the smooth surface of the female skull. The marked prominence of the eminences, the absence of the glabella and of the projecting superciliary ridge are peculiarities of the female skull, as well as the flat appearance of the maxillary articulation. This latter is probably the explanation for the predisposition to posterior luxation of the head of the jaw. Welcker has referred to the tendency of the female skull to orthognathia. That the female skull has in general a smaller cranial capacity has been already mentioned.

As for the variations to be considered as racial features, we refer to the research of Bartels.<sup>6</sup>

<sup>6</sup>Radical differences of race on the basis of variations do not exist in the skull, as Bartels emphasized. That corresponds to the view of the original unity of mankind before the formation of races and before the influence of mixtures. Bartels mentions in particular among racial peculiarities the order of succession in the ossification of sutures. Gradiotet has determined that sutures are ossified according to a different order in the higher human races than in the lower. In the latter the process begins, as in apes, in front, and advances from here toward the back. The result is a premature limitation of anterior lobes of the brain. In higher races the frontoparietal suture ossifies only after the disappearance of the parietooccipital suture.

Metopism (persistence of the frontal suture) is considered by some authors a regressive feature and by others a progressive one. It is also taken for a sign of degeneration. A supernumerary bone in the large fontanelle, os bregmaticum, or os antiepilepticum, is very rare. The os inca, a part separated from the squama occipitalis, is found in Peruvian skulls, and was considered to have some connection with its artificial deformity. Torus occipitalis is said to be especially frequent among the Papuas, while katarrhinia is the frequent form of diminutiveness of the nose among the Malays with underdevelopment of the nasal bones.

The consideration of race peculiarities is not unimportant from a practical medical standpoint. Sometimes the differentiation of racial peculiarities and artificial deformities from pathologic changes is difficult. Further, abnormal sutures should be thought of, as they occur in a divided squama occipitalis (os inea) or in a divided zygomatic bone (os japonicum) or in a divided frontal bone (metopistic suture). Such abnormal sutures can be confused with fractures.

Barret discusses the application of craniology to clinical medicine. The connection between pathology and race peculiarities of the skull seems, according to some authors, to consist in the fact that the peculiarities of race can be traced back to morbid changes.

So far as concerns the individual variations in skull outline induced by cerebral peculiarities, it should be remembered that the inner surface of the skull, especially the base, often presents a very plain impression of the brain surface; so that a cast of the inner surface of the skull permits us to make a partial reconstruction of the brain surface (Landau). G. Schwalbe could even, from the irregularities of the inner surface of the skull in old even prehistoric skulls, not only determine the position of the principle convolutions, but could also determine, in a measure, the size of the lobes of the brain. Schwalbe, and after him F. W. Miller, asserts further that the outline of the convolutions of the brain shows itself upon the outer surface also, especially in the temporal region. This fact is of interest because it furnishes a new confirmation of the fundamental idea of Gall's system of phrenology. It is known that at a time when there was not yet any talk of the localization of the higher functions in the cortex of the brain Gall believed the cortex of the brain to be the bearer of the psychic life, and to him every part of the brain cortex was the site of a special psychic function. He divided the surface of the brain accordingly into a great number of fields, each one of which represented a definite sense, as for instance the figure sense, sense of patriotism, friendship sense, and so forth. Gall assumed further that every pronounced prominence of one of these mental peculiarities was united with an especially conspicuous anatomic development of the center in question, and that this also could be recognized

in a circumscribed bulging of the cranial skeleton. Gall's doctrine, which for a long time was scoffed at or unnoticed, has only in the last decade found appreciation, particularly in the sense that the localization of the functions in the brain cortex, nowadays generally acknowledged, in a measure reminds one of Gall's ideas. More recent authors have recognized some points in Gall's craniologic conclusions as having a sound basis. Moebius especially defended the fundamental idea of Gall in a series of researches, drawing attention, for example, to the fact that marked projection of the external supraorbital region is associated with mathematical capacity (Gall localized the sense of numbers as one of the twenty-seven primitive mental forces in the third frontal convolution on the left side). He also pointed out that the bulging of the temporal region is associated with musical tendencies, and that the bulging of the squama occipitalis is associated with a predominance of the sexual tendencies. Also the differences of sex on the outside of the skull, determined by Gall, were admitted by Moebius and Schultz. It is obvious that in such investigations on the living, the decision of the question is of importance as to whether the bulging of the skull corresponds actually to a more marked bulging of the brain. For deciding this, the roentgenogram could be utilized.

A further rehabilitation of Gall's ideas has come from the criminal anthropologists (Lombroso, Benedikt), since these start out with the idea that the criminal deeds are due to a peculiar predisposition of the brain. They examined the morphologic peculiarities of the brains and skulls of criminals. Lombroso ("Anomalies de Cranes prehistoriques," *Arch. de Psych.*, 1907) maintains that the prehistoric skull is the skull of the born criminal. He finds extreme prognathia and other abnormalities with striking frequency in criminals. Ottolenghi sought to describe more exactly a facial skull type which occurs in criminals, the same one found by Ascarelli in 300 individuals. (Concerning marks of degeneration and skull anomalies of criminals see Fritsch in *Manual of Medical Jurisprudence* by Hofman Kolisko). But up to the present Gall's craniologic idea has by no means achieved general acceptance, and it is especially

not permissible for practical forensic purposes to determine specific predispositions on the basis of craniologic investigations.

Furthermore, the refinement of skull diagnosis afforded by the roentgenographic method is not likely to make any alterations in regard to this fact.

The individual details of the inner skull surface can be obtained in the living with the help of roentgen photography. The same applies to the details of the external skull surface.

## CHAPTER II

### THE DISEASES OF THE SKULL

#### **ANOMALIES IN THE SHAPE AND SIZE OF THE SKULL IN CONSEQUENCE OF DISTURBANCES IN ITS DEVELOPMENT**

The various kinds of skull anomalies comprising this group, show, as a common characteristic, variations from the normal in size and shape. In this group abnormalities of skull structure play an insignificant part. The skull is too small or too large, asymmetric, disproportionate, or completely deformed. These deformities occur through disturbances in the normal development of the skull. For the understanding of skull deformities it is indispensable to know the normal development of the skull and the efficiency of the factors influencing its shape and size under both normal and pathologic conditions. The skull, during embryonic development, exhibits, in part, a cartilaginous and, in part, a primitive membranaceous shell. The skull base and the facial skeleton are originally cartilaginous and the cranium membranaceous. Later, a great number of bone areas appear in the cartilaginous part as well as in the connective tissue portion, namely, several points of ossification for each piece of the skull. With the growth of these areas of bone the cartilaginous and the connective tissue ground substances disappear more and more, so that finally only narrow bands of cartilage and connective tissue are left between the pieces of bone. These correspond to the so-called sutures of the skull. Certain basal sutures are already closed in the newborn, and the remainder of them ossify during the first months or in the first years of extrauterine life. The sutures of the vault, on the other hand, remain open for a long time. Normally they do not disappear for years after the conclusion of the period of growth of the rest of the body.<sup>1</sup> The purpose

---

<sup>1</sup>Perchappe maintains that the skull grows up to the sixtieth year. See also Exner, *Osterreichische Rundschau*, 1910.

of this arrangement is apparently to allow a latitude, although slight, for changes in the volume of the brain. During the period of growth the sutures represent that portion of the skull within which growth for the most part occurs.<sup>2</sup>

Disturbances of skull development result from the fact that the growth may be abnormally slow or abnormally rapid, that it terminates before or after the normal time, and that ossification of the cartilaginous and connective tissue skull shell and the sutures occurs prematurely or is delayed.

The peculiarity of the origin of the skeleton of the head from two different kinds of tissue, connective tissue and cartilage, permits it to be understood that disturbances of growth and of ossification do not always affect the entire skull, but sometimes the dome alone, and in other cases, only the base. Furthermore, one sees why, in the same disease, the separate sections of the skull show dissimilar disturbances, as, for instance, the skull base and the facial skeleton, so far as anomalies of their development are concerned, show features analogous to the originally cartilaginous parts of the rest of the skeleton, while the changes in the vault practically appear analogous only to those in the collar bone, for example.

The causes of disturbances in development are diverse in kind. Just as the normal development of the shape and size is dependent on various factors, so the diversity of the factors influencing development assert themselves also under pathologic conditions. In general, from an etiologic standpoint, two great groups of anomalies in the shape and size of the skull can be differentiated. In the one group there are abnormalities of skull content, of the brain and its covering, of the organs of sense and the external coverings of the skull which modify the size and shape of the latter. In the other group it is a question of primary disturbances of growth of the bony skull which lead to anomalies in the shape and size of it. Comprehensively the etiologic factors lying at the foundation of both groups may also combine with one another.

Accordingly deformities of the skull may be divided in the

---

<sup>2</sup>Gudden asserted, to be sure, that the skull increased in size exclusively through the interstitial growth of already completely formed bone; however, very fundamental investigations by Thoma have more recently reduced the meaning of interstitial growth to its occurrence in changes in the shape of the skull.

following way: 1. The malformations of the skull. 2. The skull anomalies produced through changes of skull content, microcephalic, megalcephalic, hydrocephalic. 3. The skull deformities produced by premature suture synostosis (cranio-stenosis). 4. Those produced by external factors. In this latter class come abnormal conditions of pressure and traction such as anomalies of shape resulting from the action of associated soft tissues, as in the scoliotic or kyphotic skull, the *caput obstipum* in *colli obstipum*, the deformities from shrinking of scars, the disturbances of growth of the skull through central and peripheral paralyses in the region of the head and neck, and finally the deformities in consequence of artificial influences. 5. The anomalies of size and shape produced by systemic diseases of the skeleton such as the characteristic skull shapes in *micromelia* and *dysostosis cleidocranialis*, in *myxedema* and *mongolism*, in *ricketts*, in *dwarfs* and *giants*. The changes in size and shape brought about by anomalies of structure of the cranial bones will be spoken of in a later chapter.

The roentgenographic presentation of the deformities of the skull serves, as has been said, as a valuable supplement to the older methods of measurement in so far as it brings out in a clear way the skull outlines covered by soft parts; but, in addition to this, it is of value because it demonstrates the shape and size of the skull in a way not otherwise demonstrable, because it permits a view of the appearance of the internal surface of the skull, as well as sutures, so important for the understanding of these anomalies of the skull, and finally because it permits the progress of abnormal development to be followed.

### Malformation of the Skull

(Literature—Anton, E. Schwalbe, Ernst.)

Among the malformations of the skull should be mentioned congenital defects, the cleft formations, the fusion formations, and the double malformations. So far as concerns the double malformations, which arise through the growing together of two individuals with reciprocal restraint of development, one differentiates the two forms, *duplicatus anterior* and *duplicatus*



posterior according to whether a duplication of the upper or lower portions of the body is present. In the former there are two completely separated heads (dicephalus) or there is only a double face (diprosopus). In duplicatus posterior there are either two completely developed individuals which are grown together at the head (craniopagus) or there has occurred such a coalescence of the heads that, of the two faces which look away from each other, the half of each one belongs to the second individual (syncephalus). The epignathus presents a rare, peculiar double malformation, in which a rudimentary but perfect fetus, the so-called parasite, hangs out from the mouth of the other, the autosite. The site of union of the two fetuses is either on the palate or base of the skull of the autosite. This peculiar position results from the origin of the parasite which appears to be a teratoma formation arising from the hypophysis.

The most frequent single malformations observed are the malformations per defectum. It is a matter of either cleft or fusion malformations. So far as the latter is concerned, there takes place in this type a fusion in the ventral median line of the body, of the paired parts lying next to each other. The anomaly designated as cyclopia represents the highest grade of this malformation. It is characterized in a striking way externally through the presence of a single eye in the middle of the face, and the absence of the nose. Less marked forms of this anomaly are called arhinencephaly by Kundrat, since in these cases there appears to be a deficiently developed olfactory mechanism. The slightest grade of this anomaly is trigonocephaly.

The nature of the skull anomaly designated as trigonocephaly consists in a premature synostosis of the two halves of the frontal bone, and the approximation of the two orbital roofs. Trigonocephaly suggests itself at a glance by the peculiar appearance of the forehead, in the median line of which is a keel-like projecting ridge toward which the two halves of the forehead converge at an obtuse angle. The base of the skull shows a narrowing of the anterior groove through rudimentary development of the ethmoid bone. Since, because of the premature closure of the frontal bone, the development of breadth of the

anterior half of the skull is impaired, there occurs in most cases a compensatory extension of the skull in length and height. In case of insufficient compensation, pressure erosions may occur on the inner surface of the skull, just as in the craniostenotic skulls to be discussed later. Quite apart from the deformity produced by the configuration of the forehead, trigonocephaly may manifest itself clinically through disturbances of smell, through symptoms of increased brain pressure, disturbance of sight, and psychic phenomena. Indeed one should say that it may at birth manifest its presence clinically by prolonging labor.

Weleker noted occasionally in the description of a trigonocephalus that the optic nerve is perceptibly smaller than normal. Küstner described eye changes in trigonocephaly. Berkhan has recently described two cases of trigonocephaly, one an adult, and the other a boy. In the case of the latter, in addition to the characteristic shape of the head, blindness had been observed since the first year.

In malformations of the skull arising through defects, one differentiates the higher grades from the lower. The former, because of the usually kyphotic skull base, affect the whole skull vault (acrania) or a great part of the same (meroacrania) and show only a limited capacity of life for hours or days; and the latter, of much less degree (cranioschisis), do not interfere with vitality. There occur here all the intervening grades from the greatest skull defects to a small hole in a single bone.

The defects of the skull vault and the skull base often afford portals of exit for portions of the skull content (hernia cerebri). The site of brain hernias is extremely variable. By means of the terms hernia occipitalis, sincipitalis, orbitalis, nasalis, pharyngeus, the place of exit and the site of the hernia are sufficiently described as being in the median line of the occipital bone,<sup>3</sup> at the root of the nose, inner canthus of the orbit, nasal cavity, and mouth.

The skull defects in cases of brain hernia have a round or oval shape with a sharp edge and a regular contour, and are of

<sup>3</sup>One designates as iniencephaly an occipital hernia combined with a defect of the spinal column (Hunziker).

considerable width. The shape and size of the skull depends upon the quantity of skull content going out through the hernia. It is in most cases smaller and saddle-shaped in the middle, but it can be considerably enlarged and deformed by collections of fluid. Occasionally premature synostoses are found in such skulls.

In addition to the defects mentioned, there is yet a series of other congenital gaps in the skull, knowledge of which is of practical value,<sup>4</sup> for the sake of differentiation from the defects arising from trauma or through inflammation, tumor, senile atrophy, cranial pressure, or rickets. The defects under discussion are due either to embryonal pressure atrophy (in consequence of amniotic adhesions)<sup>5</sup> or widened emissary vessels, in which latter case it is in most instances a matter of widely dilated emissaria parietalia or the place of exit of a so-called sinusele. Almost all of these skull defects have a circular, sharp margin.

In this connection may be mentioned also a skull deformity which is not seldom combined with spina bifida; namely, the so-called "Lückenschädel" (Engstler).<sup>6</sup> By that term is understood a skull anomaly demonstrable even in the newborn, in which the ossification of the cranial vault is far below the normal. In place of the starlike bone platelet to be seen in the center of each piece, one finds only an ossification extending throughout the skull wall in the shape of narrow ribs. Between these ribs the vault remains membranaceous. The anomalies of ossification appear most striking in their appearance on the inner surface where the bone ribs stand out prominently, while the membranaceous areas between appear

---

<sup>4</sup>See *Manual of Medical Jurisprudence*, of Hoffmann-Kolisko.

<sup>5</sup>Kehrer described 32 cases of congenital skull defect in the literature. Between the sagittal suture and the parietal eminences, upon the top of the vertex on symmetrical points are found deep irregular defects which may extend through the skin, the galea, periosteum, and bone, down to the meninges.

<sup>6</sup>Engstler describes the "Lückenschädel" of a four-day-old infant with spina bifida. It could be pressed in as if it were a plastic mass. In eight cases of spina bifida Engstler found the same change in six. Wieland, who accumulated the literature of congenital defects in the skull (foramina parietale, abnormal fontanels, etc.), describes localized bulging of the bone in the Engstler skull. Heubner had already earlier described this peculiarity in a case of his. Such soft places are found in over 18 per cent of newborn skulls, mostly situated on the vertex ("soft skull"). These are not premature fetuses because premature fetuses always have quite hard skull bone. Wieland considered the "soft skull" as a definite phase of development which accompanies especially rapid expansion of the skull vault. He quoted Schäffer who has proved by statistics the preponderating growth of the parietal region. Kossowitz called the Wieland "soft skull" rachitic.

deeply sunken. Through this deficiency of ossification the skull vault becomes less resistant to intracranial pressure, and later hydrocephalic skull enlargement usually takes place.

The peculiar case described by Carpenter, of acrocephaly, with a cranium pointed at the vertex like a pyramid, and with oddly shaped orbits, belongs probably in the category of the "Lückenschädel." This is also possibly true in the case reported by Almond of a two-year-old boy with congenital oxycephaly, wide open fontanels, encephalocele, and enormous exophthalmus.

Apert describes, as acrocephalosyndactylia, a combination of a peculiar malformation of the skull (acrocephaly) with syndactylia in all extremities. This condition was observed in nine cases in the literature.

The single, or double-sided fissure of the jaw and gums (gnathouranoschisis) is the most frequent fissure formation in the region of the face. It is not seldom combined with arhinencephaly. There have been observed aprosopy (a deficiency of the whole face), agnathly (absence of the under jaw with approximation and union of the two ears, synotia) and micrognathly (abnormal smallness of the upper or lower jaw). Micrognathly of the lower jaw is usually combined with ankylosis of the jaw. In the malformations of the face mentioned the remainder of the skull is also almost always deformed, especially at the base. There occur also combinations of cyclopia with encephalocele or with microcephaly.

The roentgen examination of the malformations of the skull serves occasionally as a useful supplement to other methods of examination in obtaining a view of the basal parts, the inner surface, and the condition of the sutures (in trigonocephaly and "Lückenschädel"). In cases of brain hernia the roentgen picture permits the location of the port of exit, permits a conclusion as to the contents of the hernia, and renders possible the differential diagnosis from other tumors on the skull. Preliminary to operative interference in skull deformities, roentgenograms are valuable. Roentgen pictures of skull deformities have been published by Simmonds, Beck, E. Schwalbe, and di Gaspero. These pictures have been for the most part taken from anatomic specimens.

Among the cases of malformation that we have been able to examine roentgenologically may be mentioned a case of "Lückenschädel" in a fourteen-day-old child. The roentgen picture showed normal size and shape of the head, but there was a decided thinness of the cranium, on the inner surface of which the characteristic ridges of the bone projected. The sites of the sutures and fontanels showed extensive bone defects.

We had in addition the opportunity to examine roentgenographically two cases of hernia cerebri. Both hernias lay above the root of the nose. The description of one of these cases is found in the author's *Atlas der Schädelbasis*, page 35.

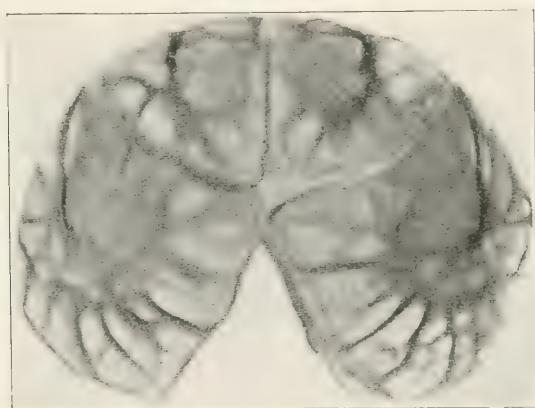


Fig. 4.—A portion of a "Lückenschädel." Note the thin ribs and islands of bone and the relatively large intervening areas of membranaceous tissue and cartilage. (The specimen is in the Pathological Institute of Weichselbaum.)

In the same place are also described roentgen pictures of the skulls of cases of trigonocephaly and skull defects contained in our collection. Fig. 4 shows the roentgen picture of a part of the skull vault of an Engstler "Lückenschädel."

### **Disturbances in the Growth of the Skull Due to Anomalies in Contents**

We have already mentioned in the first chapter that the growth of the skull and its final size depend in the first place upon the size of its contents. If the brain is backward in its development, the skull is in most cases smaller. An abnormal

enlargement of the contents of the skull causes always an excessive dilatation of the latter, provided that the former takes place at a time when the skull can still change its size. The cranial capacity of the normal adult varies between 1200 and 1750 c.c., which amounts to an average of 1500 c.c. A skull which holds under 1200 c.c. is designated as microcephalic and one that holds more than 1700 c.c. is called megalcephalic.

### MICROCEPHALY

(Literature: Anton, E. Schwalbe, Zappert.)

If we disregard dwarfs<sup>7</sup> and consider the size of the skull in comparison with the rest of the body, abnormally small skulls are found in those with congenitally underdeveloped brains (microcephaly, porencephaly, microgyria). This condition is known as "microcephalus vera." People whose brains are small through arrest of development following disease of the brain also have small skulls. These bear the name of "pseudo-microcephalus." In instances where the skull growth is back-

#### CIRCUMFERENCE OF THE SKULL

In a normal child (according to Bendix)	In cases of Microcephaly (according to Pfeleger and Pilez)
End of 1st month, 35.4 cm.	14 days old, 22.0 cm.
" " 3rd " 40.9 "	9½ months, 28.0 "
" " 6th " 42.7 "	15 months, 30.5 "
" " 9th " 45.3 "	
" " 12th " 45.6 "	
" " 15th " 46.2 "	
" " 18th " 46.6 "	
" " 21st " 46.8 "	
" " 2nd year, 48.0 "	2 years old, 40.0 cm.
" " 3rd " 48.5 "	4 " " 40.0 "
" " 4th " 50.0 "	4 " " 43.0 "
" " 5th " 50.0 "	4 " " 41.0 "
" " 6th " 50.9 "	6 " " 41.0 "
" " 7th " 51.0 "	7 " " 47.0 "
" " 8th " 51.3 "	9 " " 44.0 "
" " 9th " 51.7 "	
" " 10th " 51.8 "	

<sup>7</sup>Abnormally large skulls occur very frequently in dwarfs (see Micromelia, Dysostosis, Kallmann).

ward in consequence of deficient brain development,<sup>8</sup> small skulls result through premature suture synostosis.

Clinically idiocy, epilepsy, and cerebral infantile paralysis, may be accompanied by microcephaly.

The preceding figures serve, according to Weleker, as a normal average size for the cranial capacity of the growing skull: 400 c.c. at birth, 540 c.c. at two months, 900 c.c. at one year, 1080 c.c. at five years, 1360 c.c. at ten years. In practice one must be satisfied to consider the horizontal circumference as a measurement for the cranial capacity, and the preceding table gives the circumference of the average normal head at various ages along with the circumference of a few microcephalics.

In addition to its smallness, the microcephalic skull has an abnormal shape. The cranium is of brachycephalic type, the forehead is in most cases sloping and flat, the occiput faintly prominent. On the other hand the skull base, as well as the facial bones, are usually well developed. The contrast between the size of the cranium and the face is strikingly noticeable because of the prominence of the face ("birdface," Aztec skulls).

Since the little skull is often too large for the little brain the cranial cavity may be filled up in part with liquid, or instead of the brain a cyst filled with liquid may be present (hydromicrocephaly according to Zappert-Hitschmann) or the bones of the cranial vault may overlap at the sutures. It is probable that the thickness of the skull in these cases may be attributed to this disproportion between the brain and the skull. This thickening is sometimes very considerable, especially at the base. Only rarely is the wall of the skull thinner than normal. As the result of prolonged lying on the occiput, this region becomes markedly flattened in paralyzed children. The sutures usually appear normal, but occasionally there exists a premature or delayed synostosis. There may be a persistence of the frontal suture, or the sutures may not be as irregular as is normally the case.

In pseudomicrocephaly there is more often a premature synos-

---

<sup>8</sup>Deficient development of the brain as a whole or in part may also be attended by a considerable collection of fluid, and hence be associated with enlargement of the skull.

tosis of the sutures because of the cessation in the growth of the brain. If later the brain grows, deep impressions are sometimes formed on the inner surface of the skull.

Through deficient development of portions of the brain, there occurs a partial microcephaly. Tamburini and Luciani noted occipital brachycephaly in cases with deficient sensory functions. Benedikt asserted that the craniologic peculiarities of the congenitally blind result from aplasia of the occipital lobes.

The cases of partial microcephaly of the cerebellum are very rare. In such cases there is a small posterior cranial fossa,<sup>9</sup> even though the rest of the skull may appear normal. Microcephaly, in cases of brain hernia, and arhinencephaly have already been discussed.

In addition to revealing the shape, the roentgen picture of the microcephalic skull enables one to learn the thickness of the bone and the condition of its inner surface as well as the condition of the sutures. It permits one to be able to make an accurate statement regarding the size of the cranial cavity, and whether or not there is any likelihood of further growth in the size of the head.

The differentiation between microcephalus vera and pseudomicrocephalus is not always possible on the skull. In most cases one must make use of the clinical examination of the rest of the body and of the history for differentiation. Sometimes a diagnosis can only be arrived at through an anatomic examination of the brain. Certain factors, as for instance an asymmetrical shape of the skull, speak for pseudomicrocephaly. It is possible to call the abnormally thick skulls and those covered with depressions pseudomicrocephalic. Although not fundamentally such, they have become microcephalic postpartem in consequence of previous intrauterine disturbance of development or through diseases.

In conclusion then, we may say that the roentgen examinations enable one to make the differentiation between microcephaly and craniostenosis. For roentgen findings in the cases of microcephaly examined by us, we refer you to the author's

---

<sup>9</sup>See cases of Otto, Anton. Anton mentioned compensatory thickening of the wall of the posterior cranial fossa as occurring in cerebellar atrophy with hypertrophy of the cerebrum and a thinning of the remainder of the skull. He was able to make the diagnosis in life with the aid of roentgenograms.



*Atlas of the Base of the Skull*, page 39. See also the section on craniostenosis, epilepsy and cerebral infantile paralysis in this book.

### MEGALOCEPHALY (CEPHALONIA, HYDROCEPHALUS)

The predominating majority of all abnormally large skulls are hydrocephalic. This means they are produced by an accumulation of abnormal quantities of cerebrospinal fluid (hydrocephalus). Virchow classified large skulls as cephalonic or hydrocephalic, meaning by the former those abnormally large skulls produced by the size of the brain alone. In such cases the brain is only rarely normal in structure and function,<sup>10</sup> and in most cases the hypertrophic brain is pathologic. Hence Virchow differentiated normal and pathologic cephalonia. The latter should have a shortened skull base as in the case of hydrocephalus, while in the normal cephalonia the skull base grows along uniformly with the brain. The appearance of the inner surface of the skull of the cephalonian varies. Sometimes the skull is of normal thickness, its inner surface smooth, while at other times it is thinned by convolutional atrophy, and ridges and points project upon the inner surface. Cerebral symptoms, such as epileptoid conditions, and psychic disturbances, are often present in these individuals. (See Voland concerning hypertrophia cerebri.)

In Virchow's first case, 3½ years old, who died with the symptoms of hydrocephalia, the skull bones were very much thinned. This was also true in the second case, while the third case showed a thick skull with a strong inner table. Anton's case, which was combined with slight hydrocephalus had a very large, very thin-walled skull with a shortened base. A thin-walled skull was also mentioned by Höstermann as well as by Hansemann. Hitzig calls attention to the fact that with the appearance of enlargement of the skull there may occur a general or partial pressure atrophy of the bone with consequent transparent areas and roughness of the inner surface. He refers to the fact that this atrophy of the bone was present in Tuke's case of one sided hypertrophy.

<sup>10</sup>Cuvier's brain, for instance, weighed 1800 grams.

Volland, from whom the preceding cases are taken, describes in his case, marked depressions and ridges. According to Regnault, large heads differentiate themselves from hydrocephalic heads, in childhood, through the reciprocal relations of their diameters. While the diameters in normal skulls retain their relations, the development of the hydrocephalic head resembles a progressive brachycephalus. According to D'Astros, the head, in cerebral hypertrophy, does not have a tendency to assume a spherical shape, and an increase in size is often first discovered in the occiput. If the forehead becomes prominent, the eyes remain sunken in the orbits and the large fontanel is depressed instead of bulging and stretched.

Cerebral hypertrophy represents in most cases a congenital affection which is frequently associated with aplasia of the suprarenals and with persistence of the thymus (Anton, Ehrlich). In one case observed by us, a seventeen-year-old boy with brain hypertrophy (1539 grams), there was extreme convolitional atrophy, and the sutures were in part in process of obliteration. In this case, there was advanced suprarenal tuberculosis. Abnormal size of the head is found also as a local manifestation of excessive body growth in precociousness. On the other hand in gigantism, in cases not combined with acromegaly, it is usual for the size of the skull to remain proportionately below the dimensions of the rest of the skeleton, especially in infantile gigantism (eunuchism).

The roentgen examination, by ascertaining the skull thickness, the appearance of the inner surface, and the configuration of the base, is likely to make the differentiation easier between skull growth and hydrocephalus. However, up to the present, no one has discussed the differentiation.

The enlargements of the skull produced by skull thickening, (Paget's disease, acromegaly) as well as those arising from abnormal elasticity (rachitis, osteomalacia, dysostosis, micro-melia, osteogenesis imperfecta, tumor infiltration) are treated in detail in the sections relating to them.

The most frequent form and the one leading to the highest grades of skull enlargement is the one caused by hydrocephalus. (See D'Astros: *Les hydrocephalies*, Paris, 1898; Schultze's Manual, vol. ix, 3; Anton; Zappert.) The characteristic peculiarity

of hydrocephalia consists not only in the abnormal size of the skull, for the shape is very striking since the head approximates the dimensions of a sphere. The more solid base furnishes greater resistance to change than the yielding vault, and shows on that account less alteration. However, the orbital roofs, being the most yielding portion of the base, are flattened, even concave, and the sella turcica is frequently widened out flat. The latter is seldom deepened. The posterior fossa of the skull shows occasionally a marked basal outward bulging, and the foramen magnum may be considerably enlarged. The facial part of the skull is apparently left out of the change, and, being overshadowed by the vault, appears to recede.

So long as the cause of the hydrocephalic process of enlargement lasts, the skull is in most cases thinner than normal, the sutures are widened, and their edges are yielding. Ossification defects may also be present within the bone. The author had the opportunity of demonstrating a three-year-old child with left-sided cerebral infantile paralysis following encephalitis. In this case there were extensive bone defects in the anterior part of the right parietal bone. The cause of this latter condition was likely both rickets and hydrocephalus, the latter occurring in consequence of the encephalitis.

The inner surface of the hydrocephalic skull remains smooth in most cases. However, there may be convolitional impressions. In these cases enlargement of the skull has been unable to keep pace with the increase in the contents. Sometimes there may be a cessation in the accumulation of the hydrocephalic fluid, a synostosis of the sutures may take place, and then the skull is thus prevented from stretching when there is a renewed increase in the hydrocephalus.

The hydrocephalic accumulation of liquid which takes place after the conclusion of skull growth as in local diseases (tumors) of the brain or in meningeal diseases, causes no enlargement of the skull whatever, but instead only a thinning of the latter.

If for any reason the balance is restored between internal and external meningeal fluid, the bone changes that occur are ossification of the membranaceous bone edges and the fontanels

and the thickening of the cranial wall. Bone islands frequently form within these membranaceous areas, and ossification develops from these. If these bone islands maintain their individuality, they become the so-called supernumerary, or Wormian, bones.<sup>11</sup> The point of predilection of this kind of accessory bone formation is the lambda suture, where accessory bones occur normally.

A skull deformity occurring through excessive accessory bone formation in the lambda suture is designated as bathrocephaly (Merkel). The bathrocephalic skulls present a marked projection of the squama occipitalis which appears in the lambda suture as a step-like transition to the parietal bones. It is quite doubtful that bathrocephaly is caused by a localized hydrocephalic bulging of the posterior horns of the ventricles. Of interest is the circumstance that we have been able to determine the presence of bathrocephaly occasionally in cases of true migraine.

According to G. Schwalbe, a division of the parietal bone is sometimes found in hydrocephalus. In most cases the sutures arising in this condition run horizontal, but they may be oblique or vertical. Sometimes also the bone is divided into more than two parts. According to Gaupp, most of the bones of the skull develop from several bone centers (bone nuclei) which coalesce with one another. Sometimes, however, they remain apart for a time. It is improbable that supernumerary bones are a sign of atavism. Rather it seems to be an evidence of higher development, if a center of ossification that is normally independent only in its origin and later coalesces with the others retains its independence in exceptional cases.

The size, the form, and the appearance of the wall of hydrocephalic skulls varies according to the etiology. The congenital hydrocephalus usually assumes the greatest dimensions. Among the cases of acquired hydrocephalus, those appearing

---

<sup>11</sup>Supernumerary bones are also found in other types of skulls of abnormal size which also remain membranaceous an abnormally long time, as, for instance, in dysostosis cleidocranialis. The Wormian bones, in addition to this, attain to anthropologic interest because they appear in certain animals and are apparently also met with regularly in certain human races. These Wormian bones are found not only in the lambda suture, but also in various other places, for instance, in the orbital roof or on the tegmen tympani. For literature concerning supernumerary bones, see Ficalli in *Monitore Zoolog. ital.*, 1890, No. 70, and Hyrtl, in *Sitzungsberichte der Akademie der Wissenschaften*, Wien, 1860. Concerning accessory bones in the skull, see Spee's article in *Banckeler's Handbuch der Anatomie*, page 325.

after cerebrospinal meningitis or meningitis serosa as well as those cases accompanying a local disease of the brain (encephalitis, brain tumor), have the largest circumference. The skull fossæ are longer and less concave. In contrast to this, syphilitic hydrocephalus is characterized by slight increase in circumference, and because of the shortening of the skull base, one is able to differentiate it externally in most cases, since this anatomic feature produces the well-known saddle-nose. The rachitic hydrocephalus has a quadrangular shape on account of the laying down of additional bone over the four eminences. Its base shows in most cases the condition designated as kyphosis.

Hydrocephalus is not always symmetrical. Sometimes only one-half of the skull is enlarged, or a segment of the skull may be strikingly prominent.

Speaking in general, the shape and size of the hydrocephalus depends on its time of origin. The earlier it appears the greater is the circumference usually.

The clinical pictures, which come under observation associated with hydrocephalic enlargement of the skull, are epilepsy, idiocy, psychoses, cerebral infantile paralysis, cephalonia, and abnormal conditions of growth (dysgenitalism, obesity). There may also be associated with it the symptom picture of brain tumor or progressive infantile paralysis.

The roentgenographic examination of the hydrocephalic skull permits: First. An instructive presentation of the size and shape of the cranial skeleton, and if repeated pictures are taken, one is able to note the changes that take place.

Second. A definite conception of the general shape and the delicate but important details of the skull base, especially the appearance of the sella turcica. The features of the latter bear a close relationship to some of the clinical symptoms that may be present, as, for example, obesity. The sella is frequently larger than it should be, and this may appear as a uniform enlargement of all its diameters or as a flat, dish-shaped widening of its entrance.

Third. The obtaining of positive information relative to the appearance of the sutures (obliteration, widening, presence of supernumerary bones).

Fourth. The determination of the thickness and density of the bone in general, and the variation, if present, of the two halves of the skull.

Fifth. The diagnosis of the condition of the inner surface of the skull as to the presence or absence of convolutional pressure atrophy.

Upon the basis of facts thus deduced, we are able to obtain from the roentgenogram clues as to the etiology of hydrocephalus. We should be able to decide whether the hydrocephalus in individual cases is due to syphilis, rickets, or meningeal or cerebral diseases, either congenital or acquired.<sup>12</sup> Furthermore we should be able to make the differential diagnosis between skull enlargement due to thickening of the bone and that due to hydrocephalus. And finally we are able to obtain a knowledge concerning those details which are important for the surgeon in deciding upon the site for operative interference. Perhaps it may be possible in the near future, with the aid of the x-ray, to make a diagnosis of fetal hydrocephalus *in utero*.

The hydrocephalic enlargements of the skull examined roentgenologically by us (about forty in number) were cases of congenital hydrencephalus or those of inflammatory origin, cases with brain tumor or tuberculosis, and cases with congenital luetic, or rachitic hydrocephalus. The etiology of the hydrocephalic enlargement was determined in some cases from the x-ray picture alone, and in others we were assisted by the other clinical findings and the diagnosis as to etiology was repeatedly verified by operation or dissection.

Among the clinical symptoms which in our cases were the cause of the roentgen examination we mention as the most frequent hemiplegia and other forms of cerebral infantile paralysis, epilepsy, disturbances of sight, psychoses, progressive paralysis, obesity. As diagnostic signs and as indication for or against surgical interference, we have always made use of the

---

<sup>12</sup>As we will see under the discussion of brain tumor, even a quickly developing increase in skull content during early childhood is usually associated with hydrocephalic bulging without erosion of inner surface. In later childhood (from the fourth to the fifth year on) the characteristic picture of erosion is produced on the inner surface of the skull. However, there occurs often enough, even in later childhood, a simple hydrocephalic dilatation. Only after the termination of the growth of the skull is it usual for pressure erosion, without changes in shape, to occur, and it is associated with the symptoms of increased brain pressure.

existence or absence of convolutional atrophy, marked spreading of the sutures, widening of the sella, the asymmetrical character of the hydrocephalic bulging, as well as widened veins and emissaries. Naturally the prevailing majority of our observations were in children and youths.

A part of the cases of hydrocephalus examined by us will be discussed in later sections (brain tumor, epilepsy). Here we will cite the following as examples of simple hydrocephalic enlargement of the skull without pressure erosion on the inner surface.

CASE 1.—M. V., four-year-old boy. Clinical symptoms: headache, vomiting, choked disc, paresis of legs, gradual enlargement of head. The roentgenogram showed that despite the extensive hydrocephalic stretching of the cranial vault, the thickness of which amounted to  $1\frac{1}{2}$  mm., the sutures were not spread. Base configuration normal.

CASE 2.—Z. R., six-year-old boy with pontine symptom-complex and rapid development of enlarged head. The roentgenogram showed that the thickness of the cranium amounted to 2 mm. There were deep vein furrows in the forehead region, sutures were not separated, base was normal. The section showed the existence of a tubercle in the pons.

Pressure erosions were absent in both cases, which is probably due in part to the elasticity of the skull in consequence of the youth of the individual and in part to the nature of the process leading to the hydrocephalus, namely, a tubercle.

The following cases show the various differences in erosion on the inner surface and base of the skull in hydrocephalus.

CASE 3.—B. L., eight-year-old girl. The disease began a year previously with disturbance of sight, occasional headache associated with vomiting and dizziness. After a short time there occurred a disturbance of gait in consequence of spastic paresis of lower extremities with ataxia. There was incontinence, obesity, and atrophy of the optic nerve. The latter had followed a papillitis. The circumference of the skull had increased about 6 cm. in six months.

The roentgenogram of the skull showed, besides the hydrocephalic enlargement, a thinning of the vault, convolutional in character, and a separation of the coronal suture. As a partial manifestation of the general pressure atrophy, there was found a flat widening of the sella tureica with shortening of the dorsum sellæ.

The operation undertaken in the clinic of von Eiselsberg and the post-mortem which followed, established the existence of a tumor in the region of the pineal gland, and enabled us to verify the roentgen findings. (See Leischner, *Chirurgische Behandlung von Hirntumoren*, Case 21.)

CASE 4.—W. R., twelve-year-old boy. Clinical symptoms: double vision

for six months, disturbance of gait, pain in the neck and sacrum, skull sensitive to tapping, nystagmus, paresis of eye muscles, slight ataxia, choked disc.

In the x-ray picture, one could make out hydrocephalic enlargement of the skull with convolutional pressure atrophy, deepening of the sella, marked prominence of the sutures.

At the section a tumor was found in the right half of the cerebellum.

CASE 5.—R. K., sixteen-year-old boy. For several years amaurosis and attacks of unconsciousness, increasing paresis of the legs, gradual growth of skull circumference. At time of examination he had a very large head.

The roentgenogram showed a skull thickness of 4 mm., open sutures, widened vein fissures, a smooth inner surface to the skull. The sella was greatly widened and deepened, and the dorsum was eroded. (See Fig. 5.) While preparing for palliative trephination of the skull, the boy died.

The section proved the existence of a marked hydrocephalus interna resulting from a cyst in the worm of the cerebellum. The pituitary body was

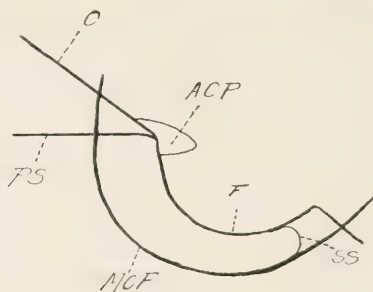


Fig. 5.—A sketch<sup>23</sup> from an x-ray of Case 5, this page, showing erosion of the sella in hydrocephalus. *O*, Roof of orbit. *PS*, Planum sphenoidale. *ACP*, Anterior clinoid processes. *MCF*, Outline of middle cranial fossa. *SS*, Posterior wall of sphenoidal sinus. *F*, Floor of sella.

3 mm. in thickness, and pressed back into the posterior portion of the sella, and the floor of the third ventricle, forced very much forward, lay as a gauze-like lamella on the bottom of the greatly widened sella.

CASE 6.—L., Twenty-two-year-old man. Symptoms: tremor and uncertain gait since early childhood, hydrocephalic skull, and infantile habitus.

The roentgenogram showed that the widened skull was 4 mm. thick and its inner surface was smooth. The hypophyseal groove was uniformly widened in all its diameters, the dorsum sellæ was still present. (See Figs. 6 and 7.)

<sup>23</sup>The above sketch, as well as all the other sketches, is a faithful drawing of the size and shape of the sella.

*F*, Floor of sella turcica.  
*M.C.*, Mastoid cells.  
*C.S.*, Chiasmatic sulcus.  
*P.S.*, Planum sphenoidale.  
*R.*, Interconvolutional spines and ridges.  
*S.S.*, Sphenoid antrum.  
*D.*, Dorsum sellæ.

*O*, Orbital roof.  
*A.C.P.*, Processus clinoides anterior.  
*P.C.P.*, Processus clinoides posterior.  
*M.C.F.*, Floor of middle cranial fossa.  
*S.*, Sphenooccipital synchondrosis.  
*T.*, Tuberculum sellæ.  
*A.M.*, Root of ala minor.



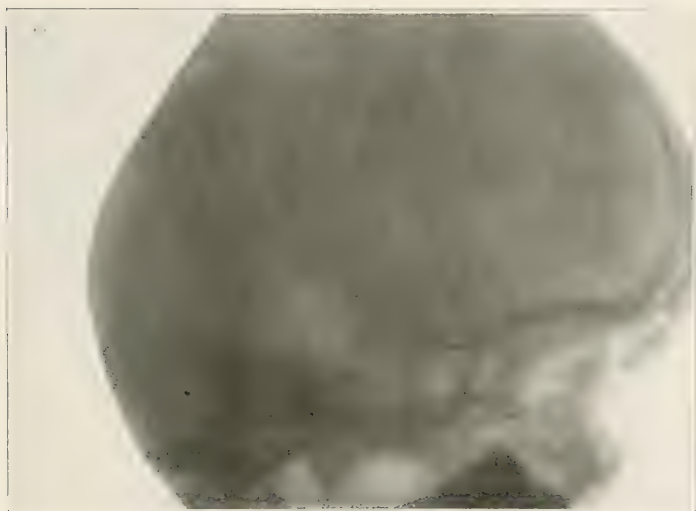


Fig. 6.—A sinistrodextral x-ray plate of a hydrocephalic skull, showing a widening of the sella. The plate is the picture of L., Case 6. One notices also a certain amount of mottling due to erosion from pressure.

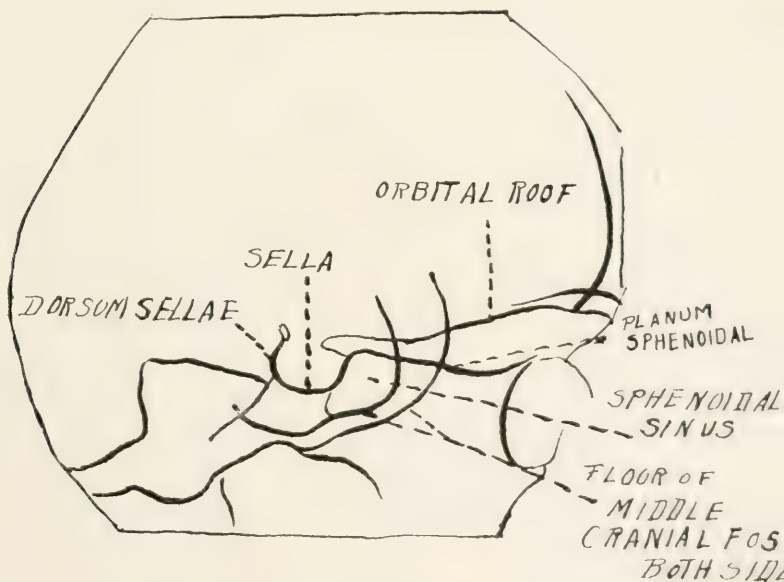


Fig. 7.—This is a line drawing of the prominent features found in Fig. 6, and intended as an aid in reading the details of the plate.




Fig. 8.—A sinistrodextral exposure of a hydrocephalic head. The mottling due to pressure atrophy is very noticeable in this instance. It is the picture of the head of Case 7.

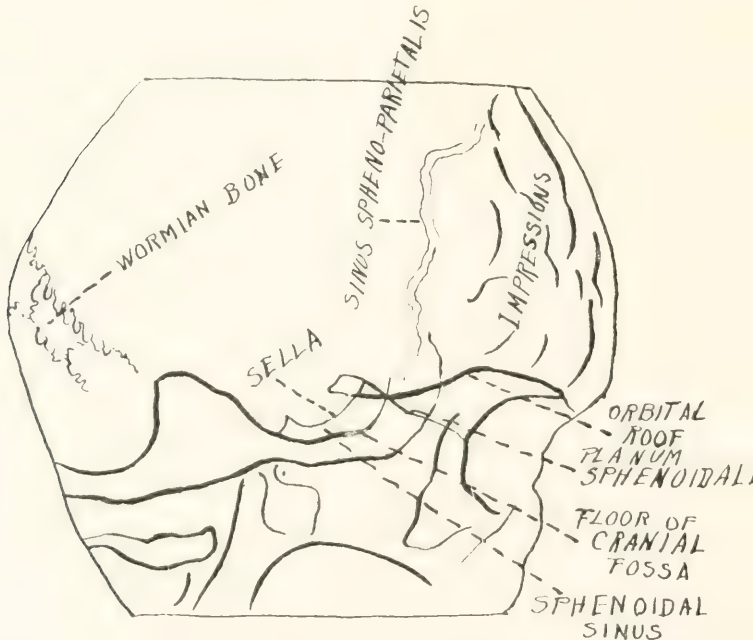


Fig. 9.—A sketch of the salient features to be seen in Fig. 8. Note the erosion of the sella with the complete destruction of the dorsum. There is a Wormian bone in the lambda suture.

CASE 7.—Nineteen-year-old girl. Symptoms: headache for years, blindness; for several months there has been trickling of liquid from the nose and during this time there has been relief from the headaches.

The roentgenogram showed extensive erosion and thinning of the skull ( $\frac{1}{2}$  to 3 mm.). The sella was greatly widened and deepened, and its dorsum was destroyed. (See Figs. 8 and 9.)

The five cases (Nos. 3 to 7) cited show, in part, only erosion of the vault, and, in part, also erosions of the base, especially of the sella turcica. The proof of such an erosion of the sella in our cases was not only of significance with relation to the choice of the method of operation (Case No. 5 was suitable for palliative trephination of the sella), but also of interest on account of several clinical symptoms pointing to changes in the hypophysis.

The following case shows an asymmetrical appearance of the pressure erosions:

CASE 8.—A., seven-year-old girl. Clinically, epilepsy existed as alleged convulsive movements in left upper arm. Patient had a large head. The roentgenogram showed the right half of the skull more markedly distended. This side also showed more pronounced pressure erosions. All sutures were widely separated.

Examples of hydrocephalus of rachitic and hereditary syphilitic origin with their typical appearance in roentgen pictures are described in the author's *Atlas der Schädelbasis*. To the two cases of hydrocephalus of luetic origin described there, we can add yet one more observed since that time.

CASE 9.—C., nine-year-old girl with epilepsy.

The roentgen examination showed a moderate hydrocephalus and a skull 4 mm. thick, with a strikingly short base. Our tentative diagnosis "Hydrocephalus e lue hereditaria" made on the strength of the latter finding was strengthened through the proof of tabetic disease in the father.

Finally it may be mentioned that we possess the pictures of two hydrocephalic skulls of unusual size in our collection of roentgenograms of the head. In both cases it is a matter of a healed hydrocephalus in grown individuals. One shows a noticeable thickening of the vault and a normal hypophyscal fossa, and the other, a marked widening of the sella.

## Skull Deformities in Consequence of Premature Suture Synostosis

There is a definite time for the beginning of the obliteration of the sutures of the vault and the cartilaginous fissures of the base. So far as concerns the fissures of the base, the majority of them become ossified during the first months after birth. Only the sphenooccipital fissure remains open until the thirteenth year. It becomes obliterated at any time from then on until the conclusion of general bone growth. The sutures of the face remain open until old age. Also the sutures of the vault are open far beyond the time for the termination of general growth,<sup>14</sup> if we disregard the frontal suture in which synostosis occurs in most cases toward the end of the second year.

According to Savage, there is not a suture of the skull ossified before the thirty-fifth year when conditions are normal. At the fortieth year, the ossification of the posterior portion of the sagittal suture begins, and with the fiftieth year the union of the coronal suture starts from the bregma. The temporal suture does not ossify until the seventieth year.<sup>15</sup>

Frederic asserts that in the sutures of the vault, as well as in those of the face, the tendency to obliteration is less, and the course is slower in females as compared with males. Luschka found all the sutures, including a frontal suture, open, in a woman one hundred years old. The synostosis of the facial sutures begins in the majority of males between the thirty-first and fortieth years, most frequently, probably, at the posterior end of the median palatine suture.

---

<sup>14</sup>The frontal or metopiotic suture not so seldom remains open longer, and when it does it is likely to remain so even longer than the other sutures. The skulls with retained frontal sutures have typical peculiarities. They have broad flat foreheads, widely separated tubera frontalia, are broader between the eyes and have short noses. The sinus frontalis may be absent or be developed on one side only. The skull base is shorter and the sphenoid and ethmoid bones are broad (brachycephalus frontalis, Welcker). According to Hyrtl, those people with frontal sutures appear to be especially intelligent. By no means can one consider the persistence of the frontal suture as a peculiarity of race, still less as a sign of race inferiority. Sometimes the metopia appears to be present for the purpose of compensatory growth when other sutures have become obliterated. G. Schwalbe describes a metopic fontanel lying above the root of the nose and resembling a separation of the frontal suture. Abnormal fissures and clefts may extend from this place, or a supernumerary bone may lie there. Tumors may also take their origin there.

<sup>15</sup>As mentioned before, a few authors have found differences in suture obliteration in different races. In Negroes and Hindus the portion of the coronal suture lying in the temporal region is supposed to obliterate first. In addition, in the Hindu, more often the suture between the great wing of the sphenoid and the parietal and frontal bones is obliterated. In Kant, all the sutures were open until his death.

The premature synostosis of sutures means that one or more sutures or fissures of the skull ossify before their usual normal time. Synostosis may be present at the time of birth, but usually it makes its appearance at a later period.

The cause of premature synostosis is unknown. It has been assumed that it could be the result of the pressure of the edges of the bones against each other, occurring *in utero* or during labor. Premature synostosis as a race peculiarity has also been referred to. These ideas seem, however, to be without foundation, as well as the assumption that every suture synostosis is due to a constitutional skeletal disease (rachitis, syphilis), or to an affection of the meningeal membranes which has involved the bone. Our idea is that we have to deal here with a disturbance in development which manifests itself undoubtedly in most cases as an ossification anomaly of the skull, while in the rest of the skeleton no disturbances of growth can be positively determined. Nevertheless, the interesting observation may here be mentioned that in the case of a brother and a sister the one showed a synostosis with the formation of a turricephalus, while the other suffered from chondrodystrophy. The latter is known as an affection for which a premature obliteration of the epiphyseal cartilage of the general skeleton is characteristic. Grübner mentioned three cases of turricephalus in which chondrodystrophy existed at the same time. Its hereditary appearance has been observed not so seldom. Manchot found turricephalus in four members of one family (in the patient, in his mother, as well as in her mother and sister). Finally the combination of suture synostosis and malformations elsewhere (for instance, atresia of the ear), observed occasionally, speaks also for the assumption of a disturbance in development. The irregularity in growth produced by premature synostosis appears as a result of the fact that the skull is not able to increase in size in the direction perpendicular to the course of the obliterated suture. In most cases this limitation of growth is compensated for by the fact that the skull develops more than normally in the other directions. If the compensation occurs with sufficient rapidity and in proper extent, there results only a striking anomaly in the shape of the skull. Sometimes the compensation is not sufficient however.

The skull growth does not keep pace with the brain, increasing normally in size, and there results a disproportion between the volume of the skull content and the cranial capacity. In consideration of the fact that the skull is too small for its contents, one speaks of craniostenosis. The disproportion between brain and skull is expressed anatomically by the fact that the inner surface of the skull is eroded at points corresponding to the tops of the convolutions of the brain, which means that the convolutional outlines are very plain and the ridges between are high and pointed.

The obliterated suture may stand out on the outer surface of the skull as a ridge. In most cases, however, the suture obliteration can not be determined in the living by inspection or by palpation of the surface of the skull. Often the endeavor of the cranial contents to distend the skull makes itself manifest very conspicuously by the fact that the more yielding parts of the bone, as, for instance, the large fontanel or the thin temporal shell, appear greatly bulged, so that in the living it may produce the appearance of a circumscribed tumor of the bone. The pressure of the brain on the parts of the skull pushed out may even lead to a rupture in the continuity of the bone. The average thickness of the craniostenotic skull is in most cases less than normal. Nevertheless, in isolated localities there may be a strikingly thick wall.

The skulls, deformed through premature suture synostosis (the appearance of which Virchow first described in a systematic way after he had discovered the law for their origin) have always aroused interest because of their bizarre shape. However, their clinical significance has not been sufficiently appreciated. Clinicians have been much more inclined to look upon craniostenosis itself as meaningless and to consider the clinical symptoms possibly connected with it as an expression of that kind of cerebral and meningeal disease which one felt compelled to assume as the cause of the premature synostosis. Only recently have the reported cases so increased in number as to permit no doubt to arise over the fact that the effect of the skull narrowing in itself furnishes a frequent and wholly sufficient etiology for the severe cerebral symptoms.

The change in shape and the narrowing of the cranial cavity produced by the premature synostosis is quite variable, and on that account the intensity of the clinical symptoms and the point of time of their appearance are also somewhat irregular. In most cases the deformity is recognizable at birth, and becomes yet plainer with the progress of growth. Not rarely is the deformity so slight that it escapes the notice of unpracticed observers completely.

The cerebral symptoms of craniostenosis consist in headache occurring periodically, epileptic attacks, psychic anomalies, irregularities in growth (probably as a manifestation of a hypophyseal affection, Goldstein), and manifestations of deficiency in the organs of sense, especially the eyes.

The fact can not be sufficiently emphasized that often the symptoms just mentioned may be caused by craniostenosis without the characteristic anomaly in the shape of the head being so prominent that at the external examination it would lead to the correct diagnosis at once. Furthermore, the knowledge of the meaning of craniostenosis has for a long time not been sufficiently known among medical men, so that even such cases were not recognized where the correct diagnosis would have forced itself upon the skillful person, upon a superficial observation of the configuration of the skull.

Most frequently, the cerebral symptoms make their appearance in early childhood. According to Merkel the skull enlarges normally under the influence of the growth of the brain up to the seventh year. During this time, if there is a limitation in the growth of the skull the disproportion in size must appear most plainly. In the time from the seventh year to puberty there is usually a cessation in the growth of the brain. Corresponding to this, it is usual for brain pressure symptoms to be absent at this time, and only at the time of puberty, if growth progresses anew, do symptoms of craniostenosis become manifest. However, occasionally only after the termination of growth may the first morbid manifestations make their appearance. In addition the fact should be mentioned that the deformity of the skull, existing already *in utero*, may be the cause of abnormal fetal positions and of complications during labor.

Roentgen investigation has contributed essentially to the elaboration of the ideas concerning craniostenosis which have been established anew in recent years. It is very often indispensable for the determination of the diagnosis and the prognosis, since it allows the establishing of the facts concerning the shape and size of the vault, as well as the basal portions, configuration of which, as Bertolotti was the first to point out, is of greater significance with reference to the origin of the clinical symptoms. Especially is this true since the basal portion may be abnormal in cases in which no definite deformity is to be distinguished on the vault. The roentgen picture furnishes the information as to whether a premature synostosis of the sutures exists and which sutures are affected. It shows the increased prominence of the ridges and the deepening of the convolutional impressions, as an expression of the disproportion between skull and brain. The roentgenogram alone permits in many cases the positive differentiation of craniostenosis from other processes leading to increased intracranial pressure (brain tumor, hydrocephalus) as well as from microcephaly which has been caused through the smallness of the brain. The result of the roentgen examination is therefore also of decisive significance concerning the question of treatment. Through operative measures (palliative trephination, puncture of the corpus callosum) it is possible to reduce the disproportion between the skull and its contents and cause a decline of the clinical symptoms in contradistinction to microcephaly, in which case the opening of the skull is valueless, and, on that account, long since discontinued.

As Virchow has shown, the following types are differentiated upon the basis of the direction of the course of the sutures and the number of sutures which are prematurely obliterated, and also upon the basis of the compensatory bulging of the other dimensions.

#### *Dolichocephaly (Long Head)*

Simple dolichocephaly resulting from synostosis of the sagittal suture; sphenoccephaly (sphenoid head) occurring from synostosis of the sagittal suture and compensatory stretching of the area of the great fontanel; leptoccephaly (narrow head)



resulting from synostosis of the suture between the frontal bone and the wing of the sphenoid; clinoccephaly (saddle-head) occurring from synostosis of the parietosphenoidal or parieto-temporal sutures.

*Brachycephaly (Short Head)*

Pachycephaly (thick head) occurring from synostosis of the parietal bone with the squama occipitalis; oxycephaly (pointed head) occurring from synostosis of the parietal bone with the squama occipitalis and the temporal bone, together with compensatory bulging of the larger fontanel region; platycephaly (flat head) occurring from extensive synostosis of the frontal and parietal bones; trochocephaly (round head) resulting from partial synostosis of the frontal and parietal bones in the middle of the coronal suture; plagiocephaly (slanting head) occurring from unilateral union of the frontal and parietal bones; simple brachycephaly occurring from premature union of the occipital and sphenoid bones.

From a clinical standpoint, one differentiates at present, in most cases, only the three following fundamental types of skull deformity in consequence of premature synostosis.

1. Turricephaly (turret head),<sup>16</sup> which is the short, broad and abnormally high skull.
2. Scaphocephaly (scaphoid head) which is the name of the abnormally long and narrow skull.

<sup>16</sup>[There seems to be some confusion in the terminology used for the various shapes of heads. This is perhaps due chiefly to two causes, the first one of which is undoubtedly the fact that anthropologic interest seems to have been the most common reason for research and classification up to the present. Whereas it appears to us as being more important to physicians that what there is of clinical significance attached to the different shapes of skulls, both as to etiology and symptoms, should be the feature kept uppermost in mind.

The second cause for confusion seems to be that too many minor details have crept into the differentiation, and the gross general distinctions have been more or less lost sight of amid the plethora of technical terms.

It is not difficult to illustrate the confusion of terms in the various classifications by referring to the literature. In German works on the subject, "Turmschädel" has been generally used to describe a particular kind of head, for which authors in other languages have used terms less descriptive. "Oxycephalus" is one of these. This word means a pointed head, which is by no means the commonest type of Turmschädel. Others have used the word "acrocephalus," the first portion of which is derived from the Greek word "akron," meaning top or extremity, and which we make use of in the word "acromegaly" in reference to enlargement of the distal portions of the body. Still others have used the term "hyperbrachycephalus," which yet does not describe the condition as acceptably as the word "Turmschädel."

The author has made use of the word "turriccephalus" as synonymous with "turmschädel" and for that reason we have used it wherever the latter word appears in the original work.—EDITOR.]

3. Plagiocephaly (slanting head) which is the name given the skulls with asymmetrical synostosis.

The literature concerning craniostenosis has in recent years been greatly increased. Clinical and anatomic observations, theoretical considerations, as well as therapeutic proposals, have been published in great number by oculists, neurologists, roentgenologists and surgeons.

Nevertheless it can not be denied that the theory of the premature union of sutures is not yet finished satisfactorily in all details. Great differences in meaning prevail with relation to etiology. The explanations of authors concerning the origin of single symptoms differ from one another. Combined pathologic and anatomic investigations have not yet been made in sufficient number, and hence one can not wonder at the small number of therapeutic results reported. Only with reference to the diagnosis have we had much success, and we must thank roentgenology to a great extent for this.

We want now to speak in detail concerning the individual types of craniostenosis upon the basis of the literature and our own experience with some eighty cases.

### TURRICEPHALY (TURRET HEAD)

Turriccephaly is the most frequent manifestation of craniostenosis. The predominance of turriccephaly as contrasted with the other types of synostosis is proved at once upon the examination of every large collection of the pathologic skull shapes in the anatomic museums. Among the patients with diseases in the region of the head (about 5000 in number) which have been examined roentgenologically by the author, the diagnosis of a turriccephaly could be made sixty-seven times as contrasted with about ten cases of scaphocephaly, plagiocephaly, and others. The fact that the literature of the last few years bearing on the subject contains references to turriccephaly almost exclusively, is likely due, not so much to its frequency, as to the fact that turriccephaly more often than the other forms of craniostenosis, is associated with severe clinical symptoms.

The term "turriccephaly" is the customary class name used almost everywhere for that premature synostosed skull, the abnormal height of which strikes the eye, especially as con-

tracted with its development anteroposteriorly. The abnormal development in height occurs through the fact that the skull, prevented from growth in the sagittal direction in consequence of the premature obliteration of the transverse sutures and fissures, is compelled, with the help of the sutures running sagittally, to stretch out excessively upward, and, in most cases, also in breadth.<sup>17</sup>

We observed the highest grade of a high head, in the Pathologicoanatomic Museum, Vienna. In this case there was obliteration of the sagittal suture only!

Since in most cases the compensatory growth in the open sutures<sup>18</sup> is not sufficient, the growing brain endeavors to create room in such a way that it forces outward the less resistant and thinner parts of the skull in a circumscribed manner. On the vault one usually finds a projection of the bregma in the region of the large fontanel, as well as a marked bulging of the temporal region at the site of the thin unresisting squama temporalis. Besides this, the basal fossæ are protruded considerably downward, and there appears to be a thinning of the whole inner surface manifested by deepened convolitional impressions, especially in the region of the forehead and the anterior and middle basal fossæ. Since the skull is *in toto* thin in most cases, the deepened depressions can lead to a simple perforation of the skull wall here and there. Also the shape of the convolutions may be discernible on the exterior of the skull, particularly in the temporal region. The Pacchionian grooves and the vessel furrows on the inner surface of the

<sup>17</sup>A form of skull similar to a turricephalus occurs also as a peculiarity of race without premature synostosis of sutures being the cause. We mean the hyperbrachycephalic skull. Toldt describes hyperbrachycephaly as a frequent occurrence in inhabitants of the Alps and in the southern Slavs. Also we have seen it in Turks and Jews; and Luschan saw it in Armenians.

Toldt considers a primary shortening and broadening of the skull base, resting upon heredity, as a possible cause of hyperbrachycephaly, especially because the peculiarity is very plain in the children's skulls, notwithstanding the fact that there does not exist a synchondrosis of the basal fissures. In certain hyperbrachycephalic skulls, which, thanks to the kindness of Toldt, we had the opportunity to examine, we were struck by the prominence of the impressions and ridges. We saw in that the expression of a long lasting disproportion between the skulls and brains in these races, and would like to express the opinion that hyperbrachycephaly, without suture obliterations, and appearing as a mark of race could be a predisposing factor for the development of cerebral symptoms (migraine, epilepsy, psychosis). We consider as a confirmation of this conjecture, a remark by Smith which concerned the presence of deepened Pacchionian grooves in the people of the Balkan lands. (See section on Brain Pressure.)

<sup>18</sup>It occurred to me as striking that in craniostenosis the open sutures never appear sprung apart in spite of the very marked erosion elsewhere. The reason for that is probably the very gradual increase of brain pressure that takes place.

skull, are sometimes deepened. Only seldom, and that only in adult individuals, does the vault have a thick wall, and, then, it stands to reason that the expansibility of the skull is reduced to a minimum.

As is readily understood from what has been said, the external examination permits the differentiation of several varieties of the deformity designated as turriccephaly. The previously enumerated types given by Virchow do not exhaust the diversity of the forms observed. The most frequent type is that one in which the cranium shows a horizontal circumference approaching the shape of a circle. The forehead is in this case high, and rises precipitously upward. The vertex is broad, or, more seldom, pointed (oxycephalic). The second type of turriccephaly is similar to the microcephalic skull. The cranium has a round form approaching uniform dimensions in all its diameters, and on account of the receding forehead, its resemblance to microcephaly is even more increased. The third type is characterized by the fact that in connection with an especially slight degree of extension anteroposteriorly, the development of the height and particularly the development of the breadth of the skull vault are striking. In such a case the temporal regions may bulge outward to such an extent that a horizontal section of the skull assumes the shape of a heart with the point turned toward the rear.

It remains yet to be investigated whether and to what extent the differences in shape cited are connected with the position of the head at birth, as Backman has asserted for scaphocephaly.

A characteristic detail of those with turriccephaly is the prominence of their eyes. This results from the expansion of the middle skull fossa, especially its anterior flexible wall, formed by the greater wing of the sphenoid bone. In this way, the posterior wall of the orbit becomes bulged forward, and hence the orbit is shortened. Add to that the fact that the premature synostosis appearing in the vault and base may, as I was able to convince myself in anatomic preparations, also involve the bones of the face, a condition arises which is likely to contribute to a narrowing of the orbit. Finally, it occurred to me that the suture which is normally present in the zygo-

matic bone may be prematurely obliterated. By this the zygomatic bridge becomes shortened, and affects, to a certain extent, a lateral rotation of the edge of the external orbital, whereby we have another contributory factor for the shortening of the orbit.

The nasal framework also sometimes shows a peculiar appearance. A deviation of the nasal septum, found frequently, appears especially worthy of mention. It can be explained by the fact that the two points of attachment of the septum, the under one formed by the decidedly arched palate, and the upper one by the skull base which is protruded downward, are brought abnormally near to each other. I have often observed very prominent noses in people with turriccephaly. The configuration of the nasal structure in turriccephaly appears, according to our observations, to create a predisposition to diseases of the accessory sinuses. Also the shape and position of the jaw and teeth are often irregular.

Yet other important details must be considered in the region of the skull base. It also participates in the deficient linear extension of the vault. Especially noticeable is the shortening and deepening of the anterior fossa. The lesser wings of the sphenoid which normally run lateral from the median line outward in the plane of the planum sphenoidale (that is, in a horizontal direction) show a steep rise directed upward laterally. Corresponding to that, the position and direction of the canalis opticus and the fissura orbitalis superior, are in most cases also abnormal. Due to the fact that the course of the lesser sphenoid wing is also directed upward, a kinking or a narrowing of the lumen of the canalis opticus may result, since the latter lies between the two parts of the former. The fissura orbitalis superior is in most cases narrow and short. The configuration of the sella turcica may be normal, but the floor of the sella very often appears widened and deepened from the erosion which stands out in most cases especially plain on the skull base.

Marchand had the opportunity to make an anatomic examination of a skull and brain in hypsocephaly associated with premature synostosis of sutures. Owing to the fact that such an exact

anatomic description of turriccephaly and the accompanying brain occurs only rarely in literature, the communication of Marchand should be cited here in brief.

In a man thirty years old and 167 cm. in height, the head had a high cranial vault; the face was long and narrow; and the forehead slanted backwards. The sutures were for the greater part obliterated, only slight traces of the coronary and sagittal sutures were to be found. Somewhat more could be seen of the lateral portions of the lambda suture. The temporal suture, with the exception of the posterior portion, had completely disappeared. On the inner surface of the skull there were abnormally prominent ridges, and between them deep depressions, so that the inner surface showed a very accurate impression of the outer surface of the brain. The most remarkable thing was the peculiar configuration of the base. There was a deep impression corresponding to the middle of the anterior cranial fossa, and the median portion of the two frontal lobes was pressed into this depression in the shape of a beak. The deep depression involved only the ethmoid bone, and was bounded posteriorly by a sharp ledge of bone by which the tractus olfactorius appeared directly pinched off, and in addition there was visible a deep transverse furrow on the brain at this place.

Vorschütz also describes an interesting case of turriccephaly. Among its peculiarities may be mentioned discharge from the nose (which probably must be interpreted as meningeal fluid), marked dilatation of the third ventricle with widening of the sella, and pressure upon the optic nerve. In addition, there was deep excavation of the posterior cranial fossa, so that the epistropheus projected into it and pressed upon the medulla oblongata.

The above described osteologic peculiarities of turriccephaly are sufficient to explain the clinical symptoms observed in this deformity. The person with such a head may be free from complaints during his whole life. Often, however, clinical symptoms of various kinds, chiefly cerebral and ocular, appear. The latter, if we disregard the exophthalmus, consist mostly in changes in the optic nerve (Enslin). The disturbance of the optic nerve may occur in earliest childhood, and during youth cause complete blindness. It may, however, set in

only in later life.<sup>19</sup> The disturbances of the optic nerve are explained in part by the osteologic peculiarities of the skull base, which, on account of the unfavorable course of the optic nerve, kink or compress the latter. In part they are explained by the increased brain pressure caused by the craniostenosis. Sometimes the ocular symptoms are definite only on one side, apparently associated with asymmetrical configuration of the base. Besides the optic nerve, other parts of the eye are often diseased. Occasionally have we observed choroidal changes and cataract.

Only rarely are disturbances demonstrable on the part of the other organs of sense. In one of the cases observed by us there existed diminished acuteness of hearing. Frey was able to prove that a membranaceous atresia of the external ear was the cause of that. The case cited above by Marchand serves as an example of the fact that disturbances of the olfactory nerve may be present in some cases.

Next to the ocular symptoms, headaches play the most important part in the clinical picture of turriccephaly. The latter occur in most cases periodically, and frequently have, as I was first to emphasize, a pronounced migraine character. They appear also in earliest childhood, so that one must always think first of the possibility of craniostenosis, on account of the infrequency of other etiology for the migraine.

Besides the foregoing symptoms, there are observed, as Benedikt has first shown, epileptic and epileptiform attacks. These occur in the very earliest childhood. The intermittent manifestations of the cerebral symptoms is characteristic of the limitation of the brain in turriccephaly. It is probably not necessary to trace back the attacks to meningitis or hydrocephalus as was done by several authors (Vorschütz, Kopeynaki). Naturally the disproportion between the skull and the brain may produce a pressure of the cerebellum against the spinal canal and in this manner induce hydrocephalus. [By closing the foramen of Majendie.—EDITOR.]

The individuals suffering from turriccephaly are intelligent

<sup>19</sup>Vorschütz asserted that the children with turriccephaly, in most cases, become blind during the third year of life. He explained this observation by the fact that the closure of the fontanel in rickets takes place at three years of age, and he ranked rickets high as an etiological factor in addition to inflammatory intracranial processes.

as compared to the microcephalics. Not so seldom, however, they suffer from psychic disturbances.

The pathology of turriccephaly has been repeatedly and exhaustively discussed in recent monographs, reviews, and individual researches. We refer to the researches of Enslin, Hauotte, Patry, Vorschütz (literature up to 1909), Meltzer, Dorfmann.

The roentgen examination has, as already mentioned, furnished an essential contribution to the explanation of the views concerning the pathogenesis of the deformity designated as turriccephaly, as well as to a broadening of our knowledge concerning the clinical status of this anomaly. In individual cases, the roentgen examination permits the characteristic details of shape to be revealed, and the obliteration of the sutures as well as the erosions on the inner surface of the skull to be proved. In this way it permits the differentiation of craniostenosis, from: First, microcephaly, in which, to be sure, a small head also exists, but the sutures are in most cases open and the inner surface of the skull appears thickened rather than eroded. Second, it permits the differentiation from increased intracranial pressure resulting from brain tumor or hydrocephalus, in which case the sutures are not only not obliterated, but in most instances they are separated. Third, one is able by this means to eliminate pseudoturriccephaly, which may simulate a craniostenotic turriccephalus, by demonstrating a hyperostosis of the cranium. The roentgen picture occasionally proves the craniostenotic appearance of the skull base (by the shortening and deepening of the fossa, the steep course of the ala minor, shortening of the superior orbital fissure) even in those cases where the characteristic peculiarities of the deformity of the cranium are not clearly manifest externally. Especially has it been shown possible, as Bertolotti suggested, in cases of disturbances of sight of unknown etiology, to prove, with the help of the roentgen examination, contour changes in the skull base referable to suture obliteration in that region.

The result of the roentgen examination is, finally, also of importance with reference to the question of therapy. Palliative trephination, practiced lately with success in turriccephaly, should be done only in cases where the roentgen picture yields



sufficient evidence of the existence of a disproportion between the brain and skull, since every operative procedure in case of small heads resulting from insufficient development of the brain is useless, even the circular removal of the skull vault recommended by Lannelongue. Also the point where the palliative trephination should be attempted, may be determined by the help of the roentgenogram. Especially is it important to determine whether the temporal region, the typical place for palliative trephination or the base (palliative trephination of the sella, Schüller), because of extreme bulging and thinning, appears more suitable for the operation.<sup>20</sup> The roentgen examination, however, produces as little evidence as the other clinical methods for determining whether the craniostenosis is combined with hydrocephalus interna. For the latter condition puncture of the corpus callosum is to be considered.<sup>21</sup>

I published a print of a roentgenogram of a craniostenotic skull specimen in my *Atlas der Schädelbasis*, and the more recent publications concerning turriccephaly contain roentgen pictures and descriptions of pictures.

The clinical turriccephaly material which was assigned to us for roentgen examination comprises sixty-seven cases. By far the majority were young individuals (under fourteen years), mostly of the male sex. The pure hypsocephalic type predominated among the different forms, the oxycephalic and microcephalic being in the minority. In most cases the lambda and temporal sutures had remained open. The thickness of the skull was in the majority of cases diminished. In some cases it was very greatly diminished, being in places, especially in the region of the frontal bone, only 12 to 15 mm. thick.

The clinical symptoms, on account of which the patients came for roentgen examination, consisted most frequently of ocular disturbances, especially progressive blindness in consequence of optic nerve atrophy following a neuritis. Further

---

<sup>20</sup>Beaumont advises against trephination for disturbance of sight in oxycephaly, and bases his view upon the description of the symptomatology given by Mackenzie. However, Beaumont likely had in mind cases in which the signs of general cerebral pressure are wanting. He surmises that the so-called idiopathic optic atrophy may be attributed to oxycephaly running a latent course.

<sup>21</sup>The effectiveness of puncture of the corpus callosum in craniostenosis (Anton, Lossen) should probably be attributed less to the removal of the hydrocephalus interna, which is perhaps only rarely present, than to the production of a vent in the skull, and the relief of the extracranial collateral circulation, to which, by the way, Anton himself referred in his discussion of his case of turriccephaly operated on by puncturing the corpus callosum.

there were found chorioretinitis, cataract, congenital nystagmus, etc. They came not seldom also on account of general intracranial pressure symptoms, cephalalgia, epilepsy, migraine, psychosis (delirium tremens, melancholy, dementia precox). Their coming was not rarely in consequence to accessory sinus affections.

Of the cases under our observation, three were operated upon. One, who is cited as Case No. 1 below, was the case of turriccephaly in which palliative trephination was performed for the first time on the basis of our roentgenologically determined indication sign, and was accompanied by success.

CASE 1.—R. L., four-year-old girl. Skull deformed since birth. Difficulty in breathing since two years old, which was not benefited by an operation for nasal polypi. Severe nightly headaches. The physical features were high turriccephalic, narrow perpendicular forehead without frontal eminences, a low ridge along the sagittal suture, temporal and zygomatic regions very broad, hard palate strikingly high, nasal septum deviated, vision greatly reduced.

The roentgenogram showed a typical turriccephalus with extreme thinning of the skull vault. The impressions of the convolutions were everywhere very plainly visible. The middle fossa was deep. The anterior fossa and the orbits were short.

On November 26th, 1907, a temporal palliative trephination was performed by von Eiselsberg. Three weeks later, examination of vision showed almost a double acuteness.

The case is described and illustrated in detail in an article by Dorfmann (*Gräfe's Archiv für Ophthalmologie*, 1908, vol. lxxviii, No. 3). There, also, are reproduced the roentgenograms, made by us, of two other cases of turriccephaly which permitted quite readily the recognition of the peculiar malformation and thinning of the skull.

CASE 2.—R., ten year old boy. He had a hypsocephalic skull and extreme disturbance of vision. The admission of the boy into an institution for the blind was made impossible by the fact that he wet the bed nightly.

The roentgenogram showed striking convolutional impressions, shortening of the anterior and middle fossæ, obliteration of the sutures.

Palliative trephination undertaken in the clinic of von Eiselsberg had the desired result of the immediate cessation of the nocturnal enuresis, the epileptiform significance of which was already surmised from the associated symptoms, and was made more probable by the favorable effect produced by the operative interference. The accompanying picture (Fig. 10) gives a view of the skull deformity and the trephination scar.

CASE 3.—Dr. A. R., twenty-eight years old. Turriccephaly of microcephalic form. For five years had suffered from severe headaches and epileptic attacks. He had a disturbance in vision in consequence of beginning optic nerve atrophy.

The roentgenogram showed variable thickness of the skull, which, near the median line, was 8 mm. thick, and in the temporal regions was thin as paper. The convolitional impressions were well marked.

The palliative temporal trephination undertaken in von Eiselsberg's clinic had a favorable result in that the disturbance of vision progressed no further during the following months.



Fig. 10.—The photograph of R., Case 2, page 70, taken after palliative trephination had been done. This is a good illustration of a turriccephalus. There is also present in this case a certain amount of exophthalmus, which, according to Schüller, is one of the features of turriccephalus.

As is seen, disturbance of vision and epileptic attacks were considered as indications for operative interference in our cases. Temporal trephination was very easy on account of the thinness of the bone.

A great number of cases under our observation have demonstrated to us that also the palliative sellar trephination (the authorization for which we believe to have been theoretically sufficiently confirmed by the basal disturbances in turriccephaly) may meet with favorable anatomic conditions. In these cases the sella turcica appeared very much deepened, its floor thinned,

the sphenoid cavity roomy, the distance from the hypophysal fossa to the nasal opening not great.

The late appearance of disturbances due to turriccephaly occurred in three cases observed by us. Two of these should be cited here, and the third one is given in the section on Intra-cranial Pressure (page 226, Case 2).

CASE 4.—Man, forty-five years old. Rapidly increasing disturbance of sight recently. Beginning optic nerve atrophy. The skull was small and the forehead receding.

On the roentgenogram one saw that the skull was considerably thinned, that the temporal region was bulged outward, and was 5 mm. in thickness. Everywhere there were very much deepened impressions, and the sella was slightly widened. On account of the absence of every other etiology, the typical turriccephalic finding must be looked upon as the cause of this visual disturbance.

CASE 5.—N., woman, thirty-five years old. Patient had suffered for several weeks from a rapidly increasing disturbance of vision in the right eye. Negative ophthalmoscopic findings. The roentgen examination was desired because of the suspicion of accessory sinus disease.

The roentgen picture proved that the accessory sinuses were roomy and contained air. The skull was hypsocephalic. The thickness of the frontal bone was 6 mm. and in other places the skull was as thin as 4 mm. The convolutional impressions were deeper than normal. The family history, taken at this time, furnished an important supplement to the findings. Among eight brothers and sisters the first one was microcephalic, with bilateral cerebral infantile paralysis. Of the others, some had large broad heads and others had short high ones, the possessors of which, among them the patient, were often teased during their youth because of the shape of their heads.

The roentgenogram, reproduced in Figs. 11 and 12 of a turriccephalus in a fourteen-year-old boy, shows the various morphologic peculiarities of turriccephaly; viz., the deformity of the base, the deepening of the venous sulci, as well as the convolutional impressions.

### SCAPHOCEPHALY (SCAPHOID HEAD)

The scaphocephalic or canoe-shaped skulls are characterized by their excessive development of length in connection with diminished development of breadth. Most frequently this deformity occurs through premature obliteration of the sagittal suture. The site of the latter usually projects upward in such a way that the similarity of the shape of the skull to that of a canoe<sup>22</sup> is quite apparent. The frontal and occipital regions are

<sup>22</sup>The anthropologic significance of the local formations of the skull was discussed by Matiegka.



Fig. 11.—The sinistrolateral roentgen picture of a 14-year-old boy with a turricephalus, mentioned on page 72. Attention is called to the generalized erosion over the inner surface of the skull and the visible impression made by the transverse sinus. The lighter area in the region of the bregma is probably due to erosion caused by the pressure of Pacchionian bodies.

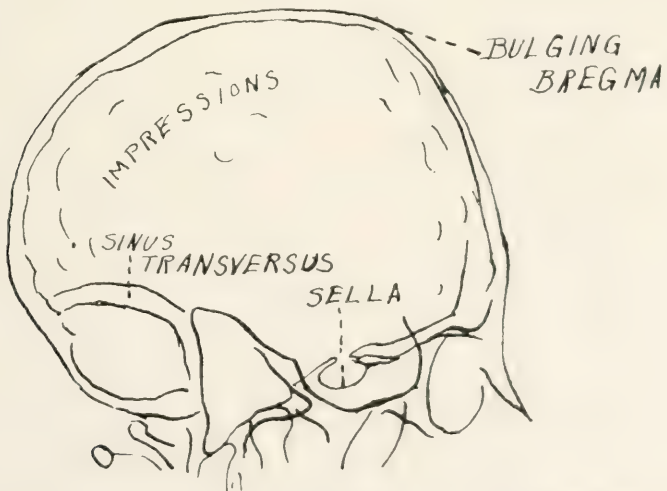


Fig. 12.—Sketch of Fig. 11. There is some concentric dilatation of the sella. Note the characteristic turricephalic contour of the head.

in most cases prominent and the area of the large fontanel may be forced outward as a protuberance. The development of breadth is still more inhibited if, in addition to the sagittal suture, there is also an obliteration of another suture running in a sagittal direction, the parietotemporal suture, and its anterior continuation, the sphenoparietal and sphenofrontal sutures. Such a skull is called *leptocephalic* (narrow head) or *clinocephalic* (saddle-head).

In the skull base the narrowness and great length of the fossae as well as the diminution of the angle formed by the two pyramids, are very striking. The facial skeleton shows occasionally a more prominent and narrower upper jaw, so that there occur anomalies in the position of the teeth.

The frequency of scaphocephaly is less than that of turri-*cephaly*, and since apparently there can occur a sufficient compensation in the sutures remaining open, the signs of a disproportion between brain and skull are usually much less marked, corresponding to which the clinical symptoms in such cases are usually minor in character. Often they complain of headache occurring periodically. Von Baer asserted that there was a tendency to premature death among scaphocephalics. An argument that craniostenosis is not so great in the deformity under discussion is to be seen in the fact that convolutional impressions are present only here and there on the inner surface of the skull.

Thoma has studied the histologic details of the bone structure in scaphocephalic skulls, and has produced the evidence that the change in the curvature relations of the skull bones, taking place normally during growth but hindered by suture obliteration, is here made possible by interstitial bone growth. The same author pointed out that in scaphocephalics the large fontanel approximated a triangle, running toward a point in front, and that sometimes the anterior end of the obliterated sagittal suture projects into the anterior fontanel in the manner of a beak. He drew attention to the fact that since the curve in the frontal plane as well as that in the sagittal plane is fixed through the obliteration of the sagittal suture, there is usually present a steplike elevation of the cranial curvature in

front of and behind the sagittal suture. This steplike projection of the squama occipitalis forms, as Virchow has shown, a valuable sign of obliteration of the sagittal suture.

Backman defined this as, "The elongated dolichocephalic form of the cranium in which the parietal bones form an angle at the site of the sagittal suture. To these signs could be added further the sagittal ridge, the projection of the frontal bone, the pouching out of the occiput, the obliteration of the parietal protuberances, and the synostosis of the sagittal suture." Weleker assumed a relationship to exist between parietal deficiencies and sagittal suture synostosis. The sagittal keel occurs among the Eskimos and Australians, as well as in cases in which there are separate centers of ossification in the two parietal bones. Thurmann asserted that the Africans, among all people, are the ones who most often show a purely natural scaphocephaly. According to Mathouillet, scaphocephaly is found especially among dolichocephalic peoples. Agostini is the only one who has described the brain of an extremely scaphocephalic skull. It looked quite normal except for minor variations. The left side was more developed than the right. The occipital lobes were small, the frontal lobes very large. There existed abnormalities of arrangement and form in the convolutions, fissures, and lobes, but no defects, and there were many supernumerary sagittally running convolutions and fissures. The persistence of the frontal suture occurs, according to Backman, in 1 to 2 per cent of the cases. The premature synostosis of the sagittal suture does not necessarily produce scaphocephaly, while on the other hand, scaphocephaly occurs without premature suture obliteration. Sometimes in scaphocephaly the coronary and occipitotemporal sutures are obliterated or all sutures are closed. In 79 per cent of the cases the sagittal suture in its entire extent was closed, while in only 4 per cent was it open in its entirety. The average age of death, in 65 observations, was 33 years. The process of synostosis seems to begin in later fetal life and extends over the first ten years after birth. Parietal foramina are absent in 60 per cent. The other foramina and the emissaries appear to be enlarged. Bathrocephaly occurs frequently in combination with scaphocephaly. The cranial capacity varies. In most

cases, however, it goes 150 c.c. over the normal. The face is usually small, narrow, and receding. The deformity is always present at birth, and decreases rapidly. Among the Eskimos it appears first at ten years of age. The face of the Eskimo is broad.

So far as relates to the cause of scaphocephaly, it can not rest on race attributes, since it has been described at all times and in all lands. The atavistic hypothesis based on the skulls of beasts of prey must be rejected. The radiation of the parietal region shows the parietal bone to be formed from one center region. Backman does not consider the premature synostosis as an etiologic factor. He assumes pathologic bone changes which manifest themselves in thickening of the bone edges, ivorylike exostoses, mosslike hyperostoses. As cause of these, rickets or syphilis may be considered. The inner surface is in most cases smooth. The deformity becomes yet more increased by labor. Backman differentiated four types of deformity in scaphocephaly, which develop during labor, and may persist throughout life: scaphoid heads, helmet-heads, cockscorn-heads, peak-heads. The frequency of scaphocephaly is one in a thousand (in recruits). It is found in boys twice as often as in girls. Heredity is occasionally observed. Assertions concerning clinical symptoms (epilepsy, idiocy) were found in fifty-five cases out of seventy-two in the literature. These are not more frequent than in other skull deformities.

The roentgen pictures of scaphocephalic skulls enable the existence of premature suture synostosis to be determined, and from the appearance of the inner surface one can arrive at a conclusion relative to the presence of skull narrowing, or decide whether the clinical symptoms present may be explained on the assumption of craniostenosis.

We had occasion to examine seven cases of scaphocephaly. A few of these may be cited here briefly.

CASE I.—N. G., male, thirty-two years old, suffered for years from neurosthenic complaints and periodic attacks of headache. Skull extremely dolichocephalic.

The roentgen picture showed a skull vault 10 mm. thick in front and behind. It was thinned to between 1 and 2 mm. in the middle of the vertex and in the temporal regions. There were broad and deep Paechionian



grooves at the vertex and distinct convolutional impressions on the basal part of the skull wall.

On account of the intense headaches the patient decided upon operation. Removal of a dollar-sized piece of bone in the right temporal region showed dura to be thinned and stretched. Brain bulged prominently into the wound. However, it could be readily pressed back with the finger. In doing so, one experienced the sensation as of forcing a large quantity of fluid from the lateral ventricle. Nevertheless puncture of the ventricle was not done. The palliative operation had only transitory therapeutic effect.

CASE 2.—K., female, forty years old. Atrophy of optic nerve, of unknown origin. Scaphocephaly.

Roentgen picture revealed the skull to be 10 mm. thick and traversed by many diploic venous canals. There was a large mastoid emissary, the sutures were not demonstrable, impressions were somewhat noticeable.

CASE 3.—D., male, twenty-one years old. Subjectively there had existed for several months diminished acuteness of vision, although it was determined numerically to be 6/6. Optic nerve atrophic. The skull showed dolichocephaly with a helmetlike elevation of the vertex. Greatest breadth of head, 14 cm.; greatest length, 18.7 cm., hence index was 70. The horizontal circumference was 54 cm.

The roentgenogram showed a thickness of the skull wall of 3.7 mm. The lambda suture was the only one open. The impressions were plain, the sella was slightly wider than normal, and the sulcus chiasmatis was deepened. (See Figs. 13 and 14.)

CASE 4.—W. F., male, seventeen years old. Had a headache one day every week. Roentgen picture showed skull wall 9 mm. thick, smooth.

As a review of our cases proves, the roentgenogram in case of scaphocephaly with clinical symptoms (headache, disturbance of vision), often revealed the characteristic signs of craniostenosis. There is sometimes here also indication for palliative trephination.

The accompanying photograph (Fig. 15) shows the profile of a few-months-old baby with scaphocephaly.

#### PLAGIOCEPHALY (SLANTING SKULL)

Premature synostosis may be limited to the sutures of one-half of the skull, in consequence of which there is an asymmetrical development of the latter. Upon the side of the suture obliteration the growth is retarded, while upon the other side there occurs a compensatory expansion of the skull. Be-

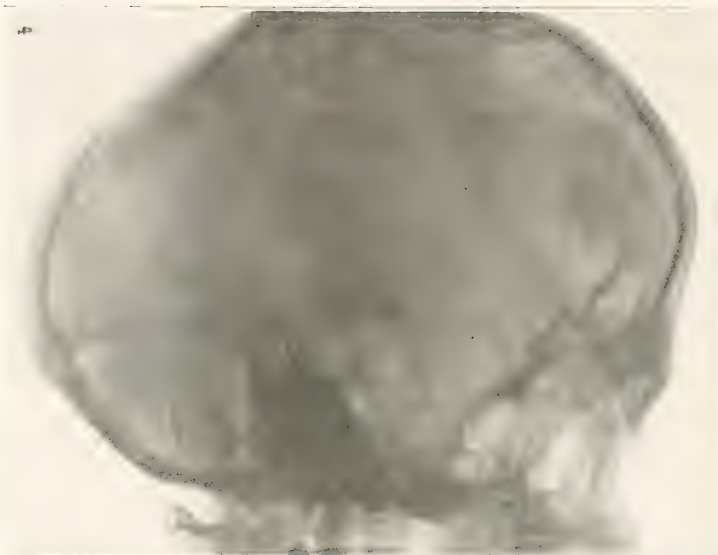

Fig. 13.—A structural exposure of the head of D., Case 3, page 77. This is a case of scaphocephalus resulting from suture ossification and is associated with erosion of the inner surface of the skull and deepening of the vein furrows. By comparing this picture with Fig. 11 one obtains a very clear idea of the difference in the shape of turricephaly and scaphocephaly.

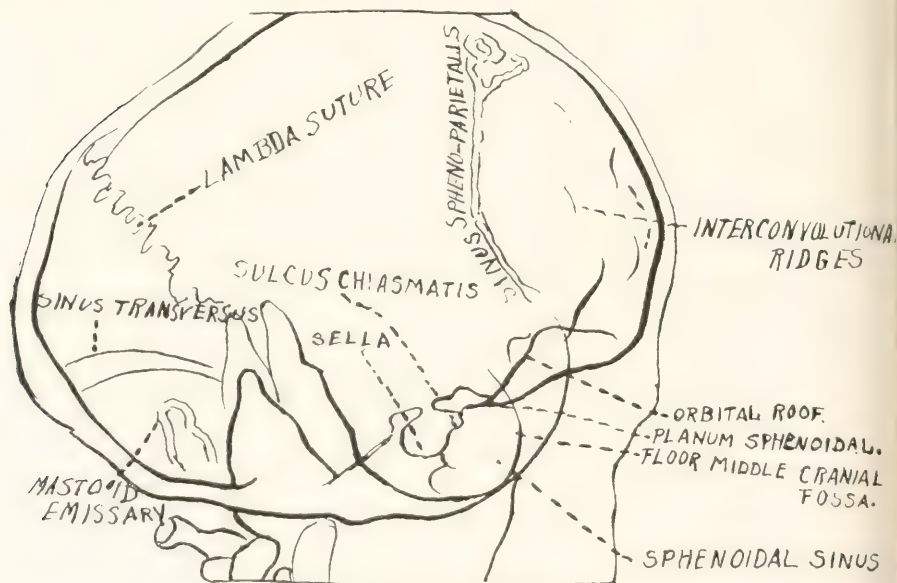


Fig. 14.—A sketch of Fig. 13. Still other features, connected with the pathology of this case, beside those in the above sketch, may be interpreted from Fig. 13. They were not put in this sketch for fear of making it confusing. There is a concentric enlargement of the sella with no erosion of the dorsum or of the anterior clinoid processes.

sides that, slight grades of asymmetry exist very often in synostotic skulls of all kinds. Most frequently there takes place a one-sided synostosis of the frontoparietal suture<sup>23</sup>; but sometimes only a part of this is obliterated. The compensatory expansion takes place either in the longitudinal direction (long plagiocephalic skull) or in height (high plagiocephalic skull). Clinically, plagiocephaly, caused by suture synostosis, attracts attention through symptoms of craniostenosis, especially attacks of headache.

The roentgenogram, by proving suture synostosis, permits the clearing up of the origin of the plagiocephalic malformation with its differentiation from other forms of skull asymmetry. In most cases it shows an obvious asymmetry of the

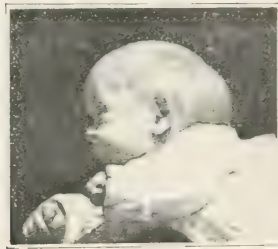

Fig. 15. A child with scaphocephaly. Attention is called to the prominence of the forehead and the occiput. There is a decided notch in the contour at the junction of the squama occipitalis with the parietal bones.

basal portion and the presence of convolitional impressions as a manifestation of craniostenosis.

Asymmetry is also found in microcephaly and hydrocephalus, in scoliosis of the skull and in hemiatrophy and hemihypertrophy. Premature suture obliteration is only one cause, and that a rare one, of asymmetry. According to Zuckerkandl, synostotic plagiocephaly is found six times in one thousand skulls, while asymmetry from other causes is found in 17 per cent of them. According to him, the most frequent cause of asymmetry is brought about through the squeezing of the skull during birth. The part lying posterior is shoved against the anterior portion lying fixed against the pelvis (rhombcephaly). Since the first position (left occipitoanterior) of the fetal head occurs from two to two and one-half times as

<sup>23</sup>Cevidalli described a plagiocephalic skull in consequence of the obliteration of the frontoparietal suture.

often as the second (right occipitoanterior), it can be readily understood that a similar predominance of left-sided asymmetry is found. Among 969 craniums, 121 showed a left-sided, and 48, a right-sided asymmetry. We had the opportunity to examine the following cases of plagiocephaly:

CASE 1.—K. P., boy, eight years old. Severe headaches appearing periodically. Skull extremely dolichocephalic. Right side of forehead was more prominent than the left.

The roentgenogram showed a skull thickness of 4 mm., impressions deepened. Sella slightly widened.

CASE 2.—P., boy, seven and one-half years old. Cranium hypsocephalic and asymmetric. The left side was less distended.

Roentgen picture showed skull thickness 3 mm. Impressions deepened, especially on left side.

### SECONDARY PREMATURE SUTURE OBLITERATION

Besides the synostosis previously described, which must be looked upon as a primary disturbance in the growth of the skeleton, there is a secondary premature synostosis which may appear in sequence to diseases of the brain itself, the meninges, as well as the skull bone. An instance of the latter is rickets.

As was already mentioned in the description of pseudomicrocephaly, brain hypertrophy, and hydrocephalus, and, as will be brought out later in the section on rickets, the sutures usually remain open in these affections. Exceptionally, however, at the time when the brain growth or the progress of a hydrocephalus has stopped, a premature obliteration of one or more sutures, even a thickening of the skull wall, may take place. If then at a later time there occurs a renewed increase in the skull content, the skull no longer yields sufficiently to this impulse and a disproportion between brain and skull appears. The disproportion shows itself anatomically or roentgenographically by deepened convolutional impressions, and clinically, by the appearance of headaches, epileptic attacks, psychic anomalies or disturbances of sight. Such individuals, who sometimes suffer from cerebral infantile paralysis and whose skulls on mere inspection appear either of normal shape or deformed, may occasionally, especially at the time of puberty under the influence of an insignificant cause of increased cerebral pressure (corporal punishment or reprimand),

suddenly show severe cerebral symptoms, which may even be followed by sudden death. Kolisko has written a paper (in the *Handbuch der ärztlichen Sachverständigen-Tätigkeit*, Chapter on "Plötzlicher Tod") concerning a great series of such findings disclosed at coroner's postmortems.

Having in mind such experiences, it is advisable, in cases of healed brain or meningeal disease or rickets, to learn the facts with the help of the roentgenogram, concerning the possible existence of suture obliteration and skull erosion as soon as signs of cerebral pressure, headache, epileptic attacks, etc., make themselves noticeable. By means of a palliative trephination or puncture of the corpus callosum one can certainly protect such individuals from dangerous complications.

We consider the following cases, coming under our observation, as belonging to the group of skulls with secondary premature obliteration of the sutures.

CASE 1.—A. M., girl, ten years old. At six months was sick, had fever accompanied with epileptic attack. Since then there has been a right-sided hemiplegia and epileptic attacks of Jacksonian type.

The roentgenogram showed thinning of the cranium and deepened convolutional impressions corresponding to the left side of skull.

Postmortem permitted the proof of the existence of a hydrocephalus interna of the left hemisphere. The coronary suture of the left side was here and there obliterated, the inner surface of the vault was rough on the left side.

CASE 2.—A. H., boy, three years old. Skull hydrocephalic in type, strikingly high, bregma pushed outward.

The roentgenogram showed a skull thickness of 2 mm., obliteration of the sutures, and deepened impressions.

CASE 3.—K., boy, thirteen years old. Severe rachitis in childhood. Epileptic attacks for the last year.

The roentgen picture showed rachitic hyperostoses of the vault and absence of the coronary suture.

The three cases cited are representative of various skull types occurring through secondary suture obliteration. In the first case, the skull was apparently normal externally, but nevertheless the synostotic half of the skull was eroded on the inner surface through hydrocephalus of that half of the brain. In the second case, the skull was seen, on external examination, to be enlarged, as if by hydrocephalus. In addi-

tion to that, however, it was eroded on the inside, since apparently a premature synostosis had not permitted a further giving away of the skull wall as the progressive hydrocephalus advanced. Finally the third case showed obliteration of the sutures in a healed rachitis.

### **Changes in the Shape of the Skull in Consequence of External Influences**

We will consider here the skull deformities which appear in connection with anomalies in the position of the head in consequence of kyphosis and scoliosis of the vertebral column, as well as in consequence of collum obstipum. And in addition to that we will include the deformities resulting from the shrinking of scars or the presence of tumors (hemangioma) of the soft tissues of the head, which appear early in life, as well as the deformities resulting from paralysis of muscles attached to the head. Under this section come also the changes in the shape of the skull brought about by artificial measures.

The mechanism which leads to the origin of these deformities can be explained by the fact that the traction and pressure, which act upon the skull externally, are exerted with an abnormal distribution or with abnormal intensity. The age at which it appears is of most importance, with relation to the degree of disturbance produced. The earlier it sets in, the more effect it produces in most cases.

A predisposing factor for the development of the deformity under discussion is afforded by diseases of the cranial bones, especially rachitis, which lead to changes in their structure.

The clinical significance of the deformities, here arranged together, is slight. It lies chiefly in the disfiguration brought about by them; viz., cranial deformity, narrowing of the nasal passages, asymmetry of the jaws. On account of their similarity to the deformities taken up previously, which are associated with cerebral symptoms, they must be given due attention for purposes of differential diagnosis.

### **SKULL DEFORMITIES IN CONSEQUENCE OF HABITUAL ANOMALIES IN THE POSITION OF THE HEAD**

As already mentioned earlier, the position in which the head is held has an essential influence upon its configuration. Just

as certain trades, through the enforced position of the body and head, modify the shape of the head, so pathologic positions of the spinal column, in consequence of which the skull is exposed to an abnormally distributed pressure and traction of the musculature attached to its external surface, leads to deformities of the skull. Especially is this true, since, in most cases, the abnormal pressure and traction act upon a skull which is particularly yielding owing to rickets. The character of the skull deformity depends upon the deformity of the spinal column. Hence one differentiates the scoliotic skull, arising with the scoliosis of the spinal column, from the kyphotic skull, to be observed in kyphosis of the spinal column.

The scoliotic skull is an asymmetrical one of such a nature that the two halves are displaced with regard to each other, in the sagittal direction. That is, the portion of the skull that is on the side opposite to the dorsal convexity of the vertebrae is held further posterior. It broadens out in the parietal region, while the frontal protuberance of this side is less prominent than that of the other side. Since in most cases the scoliosis is a right-sided one, it is usual for the left side of the skull to be the one that is the more posterior. Meyer considers the asymmetrical action of the muscles of the neck as the cause for this deformity, lighter grades of which are seen in blacksmiths, cabinetmakers, and baggage porters, and in general in workmen carrying their shoulders at an unequal elevation. Upon the side where the musculature has developed less strength, the skull bulges out, while on the side of the greater muscular development the skull wall is less prominent, and is considerably thinner.<sup>24</sup>

The *caput obstipum congenitum*, which at the present time is probably generally considered as a deformity produced within the uterus (Völeker), is an asymmetrical shape of the head with a disturbance of growth of that side which corresponds

---

<sup>24</sup>L. Meyer, who studied with special care the influence of the position of the body and muscular tone upon the shape of the head, attributed the brachycephaly of the alpine inhabitants to their custom of carrying loads up hill. Because, in that way, there occurred a very powerful development of the neck muscles, and a consecutive depression of the occipital region. G. Schwalbe found that the places of the skull upon which muscles lie, are thinned but not flattened out. (By the way, Stern, *Müller's Archiv*, 1834, had already described the scoliotic skull before L. Meyer.) Peter Camper also observed that the face was changed by crooked habitual attitudes of the body.

to the short side of the neck. The cause of this inhibition in growth is, in part, to be sought in the compression of the blood vessels which run to the side of the head affected and, in part, to the pressure to which the head, lying upon the shoulder, is subjected *in utero*. Caput obstipum shows definite asymmetry in the two halves of the face. The median line of the face is bent in the shape of a bow, the concavity corresponding to the short side of the neck. The vault of this side of the head shows a flattening of the forehead, but a prominent bulging of the occiput (Infeld). Lesser grades attain the asymmetry of those forms of caput obstipum which arise only during labor, or later, in consequence of muscle contraction, the shrinking of scars, or disease of the vertebræ. In a nine-year-old boy observed by us, there existed a caput obstipum of the left side in consequence of the stronger development of the musculature on the left side than on the right. The muscles on the right were atrophic on account of a right-sided paralysis of the accessory nerve acquired in the second year. In caput obstipum, severe neuralgia of the sound side is sometimes observed. Not rarely is caput obstipum combined with a paralysis of the arm acquired during labor. Armstrong mentioned the origin of a skull asymmetry in infants in consequence of prolonged lying at the mother's breast.

The kyphotic skull which develops in kyphosis of the spinal column is characterized by a prominence of the occiput (perpendicular occiput according to L. Meyer). It occurs also in rachitis without kyphosis. "Basal kyphosis" is increased by the steep position of the clivus, this has for consequences the marked sinking in of the root of the nose and pronounced prognathia of the under jaw.

In this respect the kyphotic skull resembles the anomaly called caput progenum by L. Meyer. In that type the anterior half of the cranium is strikingly prominent and projects over laterally; the upper jaw recedes and the under jaw projects; the occiput is deficiently developed, its shell shows an angular kinking between the horizontal and the perpendicular part, its surface presents a prominent ledge for the powerful ligamentum nuchæ, and the point of the occipital bone is wedged in under the parietal bones. Meyer found caput pro-



geneum eleven times among two hundred cases of mental disease, and twice in a collection of forty skulls.<sup>25</sup>

The prognathia of the under jaw, which forms the most noticeable feature of caput progeum, occurs also in various other affections of the skull. We may mention the prognathia in chondrodystrophy and "dysostosis cleidocranialis" in rachitis, in senile atrophy, and in shrinking of the upper jaw from various causes. The roentgenogram gives information concerning the configuration of the skull base, responsible for the position of the jaw, as well as the structure of the bone. (See section on Odontology.)

#### DISTURBANCE IN THE GROWTH OF THE SKULL IN CONSEQUENCE OF ANOMALIES IN THE SOFT TISSUES

In this group we place the anomalies in the shape of the skull that occur in paralysis of muscles inserted on the head, and in extensive scars, tumors, or defects of the soft tissues acquired early.

So far as the paralyzes are concerned, those of central as well as of peripheral origin may cause deformities of the skull. Hence one observes skull asymmetry in hemiplegia associated with cerebral infantile paralysis. In such a case, the portion of the face, corresponding to the paralyzed side, is smaller, while the side of the skull corresponding to the affected hemisphere is sometimes smaller and sometimes larger than that of the other side. The asymmetry may affect also, only, or chiefly, the skull base (Paul-Boneour). The cause of the asymmetry is to be found, first, in the dissimilar development of the hemispheres of the brain; second, in the deficient traction of the muscles of the paralyzed side,<sup>26</sup> and third, in a disturbance in

<sup>25</sup>Progeum is one of the ugliest anomalies of jaw position. It produces an obstacle to proper mastication, and on that account should be put under dental treatment. In a caput progeum the incisors of the under jaw meet those of the upper jaw on their anterior surface. The characteristics of the condition are abnormal length of the under jaw or shortness of the upper one, narrowness of the skull base and of the face, especially of the alveolar portion, and a long bitemporal diameter (infantile skull form, according to Meyer). Disease of the skull base in earliest childhood appears to lie at the bottom of this abnormality. Meyer thought that the occiput, in consequence of traumatism during labor, suffers from disturbances in development, and that, as the result, the brain is compelled to grow downwards and forwards, and that the increased pressure of the growing brain, acting in this direction, causes the progenic shape of the skull.

<sup>26</sup>Exceptionally one sees a hypertonic condition of the muscles inserted on the hemiplegic side of the skull, especially in hemiathetosis. Neurath described in detail the part taken by the muscles of the head, in hemiplegia (*Wiener medizinische Presse*, 1907, No. 16).

the growth of the hemiplegic side referable to nerve influence.

In peripheral paralysis of the muscles inserted upon the head, asymmetry of the skull appears in consequence of dissimilar growth. In the peripheral facial paralysis which may be congenital or may arise in earliest childhood, there appears to occur a trophic disturbance manifested by a backwardness in the development of the bone on the paralyzed side of the face. Through the lack of a corresponding pressure exerted by the cheeks, there results a change in the position of the teeth upon the side of the paralysis.

Occasionally a disturbance of growth or atrophy (the atrophy of inactivity) of the bone may appear in muscular dystrophy.<sup>27</sup> (Compare Lorenz, "Muskelkrankheiten." *Handbuch*, vol. xi, p. 629). This is also a sequence to a paralysis of the cranial nerves due to poliomyelitis.

Atypical disturbances in the growth of the skull take place through the effect of extensive scars in the soft issues, as in the case of the large burns. That after early removal of an eye the skeleton of the orbit is backward in growth has not only been learned from clinical experience, but also determined as a fact through the experimental investigations of Guddens.

Peculiar forms of asymmetry arise through destruction of the mandibular joint in early youth.<sup>28</sup>

#### ARTIFICIAL DEFORMITIES OF THE SKULL

In conclusion, the artificial deformities of the skull may be mentioned here. Even now, in civilized lands, as in ancient Peru (Aztec skulls), heads are arbitrarily altered. According to the reports of French investigators (as Foville and Gosse) the artificial alteration of the shape of the head is practiced in northern and northwestern France, especially in Normandy, Bretagne, Gascony, Limousin, and Toulouse.

<sup>27</sup>Marie and Onanoff have described abnormal skull shapes (length 1.6 mm., breadth 168 mm.) in people with progressive muscular atrophy of hereditary type. They believe that osteomalacia of the occiput is to blame for this, and trace it back to the extreme atrophy of the neck musculature.

Anthony made experiments in an effort to determine the change occasioned in the surface and thickness of the skulls of dogs by the removal of the temporal muscles.

<sup>28</sup>Clair gave an accurate description of the asymmetry of the skull vault, the base, and the face resulting from the destruction of the right mandibular joint. The bones of the skull appeared twisted, the median plane formed a spiral. The sagittal suture was curved in the shape of an "S" (in front the convexity was directed toward the left, and in the posterior half to the right). The skull shapes in congenital or acquired jaw ankylosis of one or both sides will be discussed in the section devoted to Odontology.

One differentiates (according to Lenhossék) two types of artificial deformity of the skull: 1. The flattening of the skull dome (deformation couchée). 2. The elevation of the skull dome (deformation relevée). The first, which is practiced in France, is accomplished through the laying of a cap over the large fontanel, and this is held in position by bandages tied under the jaw or the occiput. These bandages are left on from birth until the eighth year, in the case of boys, and until marriage in the case of the girls. The second shape is produced by a circular bandage or by compression of both sides or by pressure applied in the direction of the antero-posterior diameter.

Walcher has shown that the shape of the skull may be influenced permanently by the laying of the newborn on hard or soft cushions.

The object of artificial alteration of the skull seems to be based solely on a barbaric custom. It was made use of to make the head suitable for the easier fitting of a special headdress, or as a means of differentiation of those belonging to one tribe or for the production of an appearance such as would frighten the enemy. It is conceivable that the forcible artificial alteration of the skull very often has injurious, even fatal, consequences for the possessor of it.

The differentiation of artificial deformities of the skull from pathologic ones is often enabled through the fact that the sutures are open in the artificially deformed skulls, while in the pathologically deformed skulls of similar shape they are in most cases prematurely obliterated.

The roentgenograms of those skull anomalies placed in the group of skull deformities in consequence of external influences, offer a desirable supplement to the other methods of examination. The accurate reproduction of the base, the sutures, and the appearance of the inner surface of the skull, is rendered possible by the x-ray, and especially is the differentiation made easier between the asymmetrical skulls belonging in this group and those asymmetrical on account of intracranial diseases or primary disturbances of skull growth. To be sure, the exact proof of asymmetry, especially of the skull

base, often furnishes technical difficulties for the roentgen examination.

Among the cases belonging to this group which have come under our observation, two should be mentioned here.

CASE 1.—G., male, thirty-nine years old. Weak-minded since childhood. Left-handed because of a slight cerebral infantile paralysis of the right side. Epilepsy for several years. Skull very asymmetrical; namely, the left half of the skull was considerably smaller than the right, while the face from the forehead down was plainly smaller on the right side. The middle line of the face bent noticeably to the right in its lower half.

The roentgenogram showed an asymmetry of the base of the skull. The left half was smaller.

The case was published in detail by Infeld. ("Klinischer Beitrag zur Hemisphärenatrophie," *Weiner Klinische Rundschau*, 1904).



Fig. 16. A combination of plagiocephalus and caput obstipum. The illustration is a picture of W., Case 2, page 88, where a complete description of the features to be found in the picture is given.

CASE 2.—W., boy, seven years old. Paresis of the right side of the body in consequence of cerebral infantile paralysis, right-sided collum obstipum musculare congenitum. Skull extremely asymmetrical, the right side of the face was shorter and broader. The cranium showed marked bulging of the right temporal and parietal regions in contrast to the marked flattening of the corresponding regions on the other side. The latter viewed from above, appeared like an appendix to the right half. The dissimilarity between the two halves of the skull was, however, partially compensated for through the difference in the two halves of the forehead, the left portion of which was more prominent than the right. The latter was separated from the prominently bulging vertex by a saddle-shaped indentation and receded strikingly. (See Fig. 16.)

The roentgenogram showed that only the right leg of the lambda suture was open. One could also discern that the sagittal suture was to the right of what was considered the middle line on external examination. By this

fact, it was proved that the two halves of the skull were less different in respect to their size than one would be inclined to assume from the difference in their relative prominence.

The first case represents a skull asymmetry produced by a unilateral atrophy of the hemisphere (diminution of the same side of the skull and the opposite side of the face). The second case is the rare combination of an asymmetry of the face produced through *collum obstipum* and a *plagiocephaly* resulting from an atrophy of a hemisphere.

### Deformities of the Skull in Systemic Diseases of the Skeleton

We will place in this group those anomalies of shape and size, arising during the period of growth, which are the local manifestations of a general disease of the skeleton (*cretinism*, *mongolian idiocy*, *chondrodystrophy*, *dysostosis cleidocranialis*, *rachitis*, *dwarfs*, and *giants*).

The common morphologic peculiarity of the affections under discussion lies in the fact that the entire skeletal system shows a change in the time of cessation of growth and of ossification. The consequent anomalies of shape and size appear in general on the skeleton, and especially in the skull. In most cases the growth is delayed and the ossification prolonged. More seldom one finds the contrary. As a result, in the majority of systemic diseases enumerated, the entire skeleton remains dwarfed, while on the other hand the skull usually attains abnormally large dimensions. In the trunk and the extremities the line of epiphyseal cartilage shows a limited proliferation or becomes obliterated prematurely, and in that way affects a prolongation of the time of growth and a diminution in the length of the bones. The disturbance in the growth of the skull manifests itself in an analogous way only in the base, which appears actually shorter than normal. In the vault, on the other hand, the variation in growth is manifested by a deficient ossification. The cranium remains here and there membranaceous, possesses in consequence less resistance against the intracranial pressure, and suffers abnormal dilatation. Besides the latter, external pressure and traction take part in the alteration of the yielding skull.

Abnormalities of structure play a most unimportant part in this group of skull deformities.

The similarity of the anomalies of ossification lying at the foundation of the various affections, and their early appearance, produce certain analogies in the clinical pictures, so that sometimes they cause difficulty in differential diagnosis.

Etiologically, according to the results of the latest investigators, there exists a similarity between the types of this group, in so far as it is likely that they are caused by diseases of glands with internal secretions.

The roentgen examination has already produced important results for the clarification of the disturbances in development in this group. On account of the rarity of suitable anatomic material, the roentgenographic representation of the skeleton gives us a very much desired supplement to our knowledge concerning the disturbances of development in the skeleton. In addition to this, the x-ray has the advantage over the anatomic methods of examination, by offering a valuable insight into the course of the growth irregularities, through repetition of the examination of the same individual.

#### CRETINISM<sup>29</sup>

As Dieterle, Hofmeister, Kassowitz, Langhans, Nièpee, von Wagner, von Wyss, and others have pointed out, the characteristic skeletal anomaly of the cretin consists in a retardation of development leading to greater or less degrees of dwarf growths. In which case the time of ossification of the skeleton comes abnormally late, and proceeds with abnormal slowness, so that the cartilaginous fissures remain open and capable of development longer than the time of normal growth.<sup>30</sup>

In the skull, this peculiarity manifests itself in the fact that

<sup>29</sup>Following the customary usage at the present time, we consider under the designation "Cretinism" only the irregularities of development resulting from degeneration of the thyroid gland. In former times, almost every form of idiocy was considered as cretinism. On that account, one often finds all kinds of synostotic, microcephalic, chondrodystrophic, and other skulls in anatomic museums bearing the title "cretin skulls."

<sup>30</sup>In close relation to cretinism appear to be those rare cases in which the epiphyseal fissures remain open throughout life, "true dwarfs" (according to Poltauf) in contrast to nanosomia in which growth terminates at the right time.

the skull base remains too short.<sup>31</sup> On that account the root of the nose appears deeply drawn in (cretin saddle-nose) and that, apparently as a compensatory feature, a more marked development of the breadth of the skull results.<sup>32</sup>

The deformity of the skull base is also in most cases the cause of the peculiar shape of the face. The characteristic cretinoid facial expression is not caused through changes in soft parts alone, but, above all, by the configuration of the bones. The most striking features are the sinking in of the root of the nose, the broad flat nasal skeleton, the prominent cheek bones and the prognathia of the upper jaw. The deformity of the jaw is caused also by the enlargement of the tongue and the delay in cutting the teeth.

The skull vault is in most cases very roomy, broadened, brachycephalic. The circumstance that the cranial capsule contains membranaceous places for many months, and that such children lie for a long period of time on their backs is likely to contribute to the shortening of the skull. So far as the sutures are concerned, they are often less<sup>33</sup> serrated. Occasionally the persistence of the frontal suture is observed. Sometimes the site of the sutures is depressed, and the neighboring areas are elevated as in rachitis. Besides this, in rare cases, there appears to occur also a combination of myxedema and rachitis (von Kutschera).

The thickness of the skull of the adult cretin is in most cases very great.

The descriptions of the skull bones of cretins contained in the literature are in part not available, because they have to do also with skull deformities having a different origin. This

---

<sup>31</sup>As is known, Virchow, in his time considered the premature synostosis of the basal fissure (tribasilar synostosis) as characteristic of the skulls of cretins. He attributed the deficiency in the length of the skull base to this factor which we know is characteristic of chondrodystrophy, and saw in that the cause for the deficient brain development and idiocy in cretins.

<sup>32</sup>The brachycephaly, frequently observed in the skulls of cretins, has given occasion for the conjecture that also in most cases the brachycephalic skull formation in the races designated as "Homo Alpinus," is probably an expression of cretinoid irregularity in growth.

<sup>33</sup>The simplifying of the suture serrations is a sign of rudimentary development. In early childhood the sutures appear as stripes of connective tissue running in straight lines. Later the edges of the bone approach each other, almost to complete approximation, so that only a thin line of suture substance remains between. Then there are formed little projections from the edges of the bone (projections of the first class), and as these jagged edges interlock they send out the second series of projections, and, finally, from these, still a third series is given off. The less serrated condition of the sutures, therefore, corresponds to an early stage in development.

applies even to Virchow's fundamental investigation. In recent time Lombroso, Paul-Boncour, Mingazzini, Jentsch, Scholz, von Kutschera, and others, have studied the craniology of cretins.

Jentsch, who has examined thirteen cretin skulls, described them in the following manner: "In most cases are they light skulls. Their index amounts to 80 to 90, circumference and capacity are almost all below normal and frequently asymmetry exists. The sutures are usually tolerably simple and in some cases, firmly grown together. Sometimes, on the other hand, they are separated with the edges of the bone shoved over one another. Often the frontal suture is retained, and frequently Wormian bones are found."

Scholz, who described the collection at Graz, among which also some skulls not cretin are found, considers the following changes as characteristic of cretin skulls.

1. Irregular shape, thickness, and weight of the bone.
2. Persistence of the sutures, often also a frontal suture.
3. Prognathism.
4. Steepness of the clivus, often widened hypophysis.

According to von Kutschera, the cretin shapes of skulls are extremely variable, so that a real type can hardly be fixed upon. One sees very often microcephaly, hydrocephalus, plagiocephaly, turriccephaly, and other irregularities in skull formation.

The physical signs of degeneration, as well as the psychic disturbances (imbecility, deafness, disturbance of speech) appear in the clinical picture of cretinism in varying degrees. The skull deformity in like manner shows considerable difference in degree. One finds skull changes in endemic, as well as sporadic cretinism, but in the acquired cretinism they are present only when the onset occurs during the period of growth.

The roentgenologic study of cretin skulls has added some new details to the knowledge of the structure. I was the first to call attention to the characteristic deformity in a living cretin. Upon the basis of his investigations which were worked out on a yet greater cretin material, Bircher has been able to con-



firm and supplement my results. With the help of the roentgenogram one can determine, in the first place, the thickness of the skull, and the condition of the sutures and basal cartilaginous fissures. The roentgenogram shows the outline of the os tribasilaris. According to Bircher, the saddle angle is considerably diminished (in most cases more than  $20^\circ$ ) as compared to the normal ( $134^\circ$ ), and must be considered as a marked basal kyphosis. It also permits the shortening of the



Fig. 17.—The picture of an adult cretin showing the characteristic shape of the head.

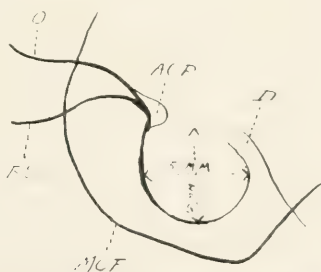


Fig. 18.—A drawing of the sella turcica as seen in the x-ray plate of the head of an adult cretin. The dimensions as given show it to be concentrically enlarged.

skull base and the flatness of the skull fossæ to be established. Finally, one recognizes very plainly in the roentgenogram the prognathia of the upper jaw and the position of the nose. One is convinced that the root of the nose is not only drawn down, but also is forced down abnormally low, a detail which is apt to add to the stupid facial expression of the cretin. The angle which the forehead forms with the nasal bones is diminished (often only  $110^\circ$  to  $100^\circ$  in contrast to  $140^\circ$ ).

From the shape of the sella obtained from the roentgeno-

gram, one can also draw a conclusion as to the size of the hypophysis.<sup>1</sup>

We had occasion to examine thirteen cases of cretinism. Five of them are found briefly described in our *Atlas der Schädelbasis*. One will find there also an illustration of the cretin skull.

The accompanying photograph (Fig. 17) shows the typical head of an adult cretin observed by us for several years in succession. The roentgenogram of the patient permitted the recognition of an unusually large sella (length 15 mm., depth 12 mm.). (See Fig. 18.)

### MONGOLIAN IDIOT<sup>25</sup>

Mongolian idiocy, frequently brought into association with cretinism, but most probably arising from another (to be sure, unknown) etiology, expresses itself in the skeleton through insufficient development, especially of the distal parts, so that one, in apposition to acromegaly, could speak of acromieria.

As a sign of this, the jaw and the nose are abnormally small. In this way is produced the extremely characteristic facial expression; viz., the slanting palpebral fissure. The short, round skull vault remains membranaceous at the sutures and fontanelles for an abnormally long time (until the third to fifth year). There are frequently round defects in the line of the sutures. Clinically, a good natured imbecility is usually found in mongolian idiots.

Roentgen pictures of the skull of mongolian idiots are found in the author's *Atlas der Schädelbasis*.

### CHONDRODYSTROPHY (MICROMELIA, ACHONDROPLASIA)

The nature of this anomaly of the skeleton, described in a classic way by Porak and Kaufmann, consists in a congenital irregularity in the linear growth of the cartilage along with a

<sup>1</sup>It is to be noted that the hypophysis may act vicariously for the thyroid gland. In cases where the cretinism showed itself in slighter degree, we could determine a strikingly large hypophyseal fossa.

<sup>25</sup>The term "mongolian idiot" and its description as an independent disease, was the work of Langdon Down. Several times recently mixed forms of myxedema and mongolism have been described. Boarneville found a fibroma of the dura in the parietal region, in one case that came to section.

premature obliteration of the epiphyseal cartilages.<sup>36</sup> This anomaly makes itself noticeable in a most striking way in the head and in the extremities. The latter remain short. The cartilaginous fissures of the skull base are obliterated *in utero*.<sup>37</sup> Because of this, there results a deficient linear development of the base, a marked drawing in of the root of the nose, and increase in the kyphosis of the skull base. These factors produce a diminution of the saddle angle, and a diminution in the size of the foramen magnum. In the face, the receding of the upper jaw and the prognathic appearance of the lower one are striking. This is also a result of the basal kyphosis. The cranial vault, in contrast to the base, shows a delay of the suture union. Because the fontanel and sites of the sutures remain membranaceous for an abnormally long time, the opportunity is given for excessive expansion of the vault through intracranial pressure. If ossification of the skull vault occurs later, numerous supernumerary bones are usually formed. Micromelia exhibits no pathologic manifestations apart from the dwarfed condition.

There are descriptions of micromelia by Breus-Kolisko, Glässner, Katolicky, Regnault, Porak and Durante, Simmonds, and Weygandt.

All the described characteristic peculiarities of the micromelic skull admit of instructive delineation in the roentgen picture. Some of the publications just cited contain descriptions and reproductions of skull roentgenograms.

We have in our collection the roentgenograms of the skulls of four individuals with micromelia in addition to the picture which is reproduced in the *Atlas der Schädelbasis*.

In connection with chondrodystrophy, a disease may be briefly mentioned which, so to speak, represents the counterpart of achondroplasia, namely, the skeleton anomaly, called by Vrolik, "osteogenesis imperfecta." This irregularity of development, named by the French authors (Porak and Durante) "dysplasia periostalis," affects the diaphysis of the long bones, the ribs and the skull vault. Anatomically, it is char-

<sup>36</sup>Wiesermann considered the cause for this variation in development an abnormal pressure of the wall of the uterus upon the fetus, thereby causing a compression of the cartilaginous fissures. On account of its frequent occurrence in families, micromelia has been repeatedly considered as peculiar to a certain race of dwarfs.

<sup>37</sup>The skull of the newborn in which Virchow found the sphenoccipital synchondrosis already ossified (tribasilar synostosis) belonged to one with chondrodystrophy, and not, as Virchow intimated, to a cretin.

acterized by lack of compact bone, clinically, by fragility of the bone. Absence of premature ossification of the cartilaginous fissures on the base and deficient ossification of the vault, are, in the head, the characteristic peculiarities of the affection mentioned. The skull resembles a membranaceous sack in which are present isolated single bone plates, and the latter are fragmented.

The affection termed "idiopathic osteopsathyrosis" by Lobstein, is called "osteogenesis imperfecta tarda" by Losser.

### DYSOSTOSIS CLEIDOCRANIALIS

This rare affection, first accurately described by Scheuthauer, then discovered anew by Marie and Sainton, and recently treated in detail in monographs by Hultkrantz and by Fitzwilliams, is to be considered as a congenital, sometimes a familial malformation of the skeleton. This consists chiefly in a limitation of the ossification of the portions of the skeleton coming from a membranaceous foundation; viz., the cranium and collar bones. The sufferers from this affection<sup>35</sup> are mostly small, gracefully built individuals. The most striking thing is in the shape of their heads. Since the cranium remains membranaceous an abnormally long time, its yielding walls suffer a typical alteration from the effect of the intracranial pressure on the one hand, and, on the other hand, from the influence of the external pressure and traction, and especially from the upward pressure by the spinal column when in the upright position. The cranial vault suffers from hydrocephalic distention, the sites of the sutures and the fontanels are to a great extent membranaceous and often remain so until advanced age. Extensive areas of the bony skull wall appear composed of a great number of pieces similar to Wormian bones. The base is narrow and forced upwards towards the interior of the skull ("basilar invagination"). The facial skeleton is small, nasal, lacrimal and zygomatic bones are imperfectly developed, the superior maxilla is drawn in, the mandible is very prognathic and the teeth are irregular. A further peculiarity of such a skull is

<sup>35</sup>According to Hultkrantz ninety cases have been reported up to the present, 1912.

the absence or diminutiveness of the accessory sinuses. The intact condition of the brain is recognized clinically by the intelligence of the individuals in most cases. Rarely was idiocy observed.

In the roentgenogram one distinguishes the deficient ossification of the vault and the fragmental pieces of the skull wall,<sup>39</sup> the invagination of the base the absence of the accessory sinuses and the defects of the facial bones.

We had opportunity to examine roentgenographically the original skull described in Scheuthauer's publication. It is preserved in the pathologic-anatomic museum in Vienna. In addition we made a similar examination in life of a case, observed and published by our colleague, A. Fuchs. A postmortem was recently held on the last mentioned case. I take the following from the postmortem findings: The skull vault was composed of about 150 pieces, its inner surface grossly uneven, the base pressed inward. In spite of the size of the skull, there was no hydrocephalic fluid found. The cranial capacity of the skull was decidedly diminished through the invagination of its base, so that the enlargement of its capacity was only apparent. In the face, the defect of the nasal bones and the diminutiveness of the maxillary bones were striking. On account of the smallness of the jaws, a portion of the teeth remained unerupted in the structure of the latter.

Bergmeister described a peculiar case, interpreted on the basis of the roentgenogram, as a latent form of dysostosis cleidocranialis. It occurred in a twelve-year-old girl who showed the combination of micrognathia of the inferior maxilla with bilateral congenital cataracts and ossification defects in the region of the lambda and sagittal sutures. Bergmeister was able to find an analogous case in a publication by Aubry under the title "Alopécie sutural" (*Annales de Dermatologie et Syphil.*, 1893). Here, as in Bergmeister's case, there was baldness over the suture areas mentioned.<sup>40</sup>

<sup>39</sup>Voisin and his associates have wrongly considered as the picture of the brain convolutions (visible according to them through the membranaceous skull) the markings seen in the roentgenogram, since these are produced by the supernumerary bones and their membranaceous edges.

<sup>40</sup>We described recently, as an accidental finding in a 68 year old man, a circumscribed alopecia corresponding to a shallow depression of the left parietal bone, in consequence of senile atrophy.

## RACHITIS

The skull seems to be the portion of the skeleton most often affected by rickets. The features in the bone are resorption of the already completely formed bone and only slight additional formation of new bone, as an "osteoid" tissue, poor in lime salt. In the skull the vault is the most involved by the affection. The edges of the flat skull bones do not ossify. On that account, the sites of the sutures and the fontanels are abnormally wide.<sup>41</sup> In addition, the already ossified portions of the skull wall show slight calcium content, and there exists an abnormal lack of resistance in the latter. The cranium is stretched by the action of internal pressure, and it assumes a hydrocephalic shape. Also any external pressure adds to the deformity of the skull. So long as children lie in bed, the occiput is flattened out by the pressure of the head against the underlying surface, and the portions of the skull wall exposed to pressure lose their calcium content (Elsässer's *craniotabes* of the occiput). If, then, the children begin to sit up and to stand, the base of the skull becomes deformed through the pressure of the large head upon the spinal column, the curvature of the posterior fossa becomes flattened out and the clivus lies more nearly horizontal (Regnault's *platybasia*). As a consequence of rachitic bone softening, there seems to occur the "basilar invagination" to be mentioned later. The scoliotic and kyphotic skulls, as well as the skulls with a perpendicular occiput, without kyphosis of the vertebræ, also occur in rachitis.

A further characteristic detail of the rachitic skull is caused by thick deposits of osteoid tissue on its outer surface. Since for the most part these deposits occur in the region of the parietal and temporal eminences, the head assumes a cubical shape (*caput quadratum*). The bone is unusually thickened through osteoid deposit in the neighborhood of the widened sutures corresponding to the zone of growth of the flat bones, so that the site of the sutures themselves appears to be sunken in (*caput natiforme*).

The facial skeleton is in most cases diminutive. Since the

---

<sup>41</sup>In children free from rickets the fontanels constantly diminish in size from birth on, and are often closed toward the end of the first six months. This fact is sometimes ignored, and an early closure of the fontanels carelessly diagnosed as the cause of cerebral disturbance.

rupture of the teeth is delayed, the bend of the jaw is narrowed. Marfan pointed out, as characteristic of the rachitic facial skeleton, the narrow beak-shaped maxilla, the sharply bent palate combined with narrowing of the bony nasal passages, bending of the septum, and deformity of the side walls of the nose. Later the under jaw becomes thick and angular on account of additions in bone substance, and its thickened lower edge turns outward.

The rachitic changes are most prominent in the first and second years of life. No general harmony prevails among the pediatricians and pathologists relative to the time of origin of rachitic bone changes. Formerly all skeleton anomalies, seen in the newborn, were grouped under the name "fetal rachitis," especially chondrodystrophy, dysostosis, and dysplasia. With the removal of these affections from the group of rachitic disorders there remains only the "soft skull" of the newborn. Upon the basis of histologic examination, Kassowitz interpreted the softness of the skull (evidence of which was deduced clinically through the abnormal malleability of the edges of the sagittal suture), as a sure sign of rachitis, and founded his idea of the congenital origin of rickets upon this symptom. In apposition to Kassowitz, Wieland advocated the view that the congenitally soft skull is not of rachitic origin: that, while the rachitic softness of the head localizes itself in the occiput, the softening of the top of the head in the region of the vertex is characteristic of congenital soft skull. He said that rachitic changes develop only during the first year of life, that congenital soft skull represents a developmental anomaly which is likely to occur through the fact that the brain growing rapidly toward the end of fetal life stretches and erodes the more slowly growing skull capsule.

If one at present inclines more toward the view of Kassowitz that rachitis develops *in utero*, then he can hardly deny the existence of congenital soft-headedness not of rachitic origin. This is authenticated in a most striking manner in the case of the so-called "lacuna skull" (Engstler), which we have mentioned in the description of malformations (page ???). This thinning of the skull, occurring in most cases in combination with spina bifida and brain hernias, is to be considered as analogous to

the erosion of the skull wall occurring in processes producing increased intracranial pressure. The thinned places in the skull wall correspond to the tops of the convolutions and the intervening ridges to the brain fissures. Histologic investigation of the thin places reveals no signs of rickets, as I am in a position to report on the authority of Kassowitz. According to that, one questions the assertion of Marfan that, in case of the premature onset of rachitis, the inner surface of the skull is buckled in by the brain convolutions. Rachitic changes may, however, occasionally, extend over a longer period than the first two years, and in rare cases may be apparent only at the time of the normal termination of bone growth, such a condition is known as "rachitis tarda." Zybelle asserted that the skull shows no change in rachitis tarda. In most cases there is a termination of the rachitic skull change in the second or third year. The sutures and fontanels close, whereupon accessory bone formation usually appears. The osteoid tissue is calcified, and in this way an abnormal thickness and density of the skull results (rachitic hyperostosis). A premature suture synostosis may occasionally also occur in connection with this hyperostosis.

Naturally the deformity of the facial skeleton may be the cause for the narrowness in the anomalies of the nose and teeth.

In a case of extreme rachitic skeletal changes observed by us in a seventeen-year-old boy, we decided that the occipital neuralgia, from which he had suffered for months, was due to the pressure or the tearing of the nerve by the perpendicular occiput.

The brain development is not disturbed in most cases by the rachitis of the skull. Quite the contrary, it is asserted that, through the elasticity of the skull wall, favorable opportunity is afforded for the development of the brain. In connection with this, however, the fact must not be overlooked that the large skull is filled up not alone by brain mass, but also, in most cases, by a collection of hydrocephalic fluid. It is generally accepted that the intelligence of those with rickets is normal or especially good.

That rachitis leads to idiocy is without proof, as well as is



the assertion that rachitis of the skull is a direct etiologic factor in the origin of tetany, spasmophilia or spasmus nutans. At present, these symptoms often combined with rachitis, are considered as more probably manifestations of the same injurious agent; namely, disease or injury of the epithelial bodies, the so-called accessory thyroids (Erdheim). Only premature suture synostosis can give rise to craniostenosis and its clinical sequela.

The roentgenologic examination only will permit one to arrive at a definite conclusion relative to the outline of the base, the state of ossification, the thickness and density of the skull wall, as well as the appearance of the inner surface and the sutures.

Description of two cases of rachitic hydrocephalus are to be found in the author's *Atlas der Schädelbasis*. See also the section on Epilepsy.

#### DWARF GROWTHS

Besides the previously described skeletal diseases, which are associated with abnormal smallness of the body, there are yet the dwarfs in whom the skull is not malformed as in the affections mentioned, but is only abnormally small as a part of the general dwarfed condition. Etiologically, various factors come under consideration here. In the first place, there is a hereditary tendency to a dwarfed condition in the sense of belonging to a race of dwarfs. Constitutional anomalies, as congenital syphilis, heart disease, etc., can likewise give occasion to limitation of growth. According to the experimental and clinical experience of Aschner, a special kind of dwarf growth seems to depend on dystrophy of the hypophysis.

It will probably necessitate prolonged investigations before anyone succeeds in establishing, in a conclusive way, the classification of nanosomus outlined here in brief. With the rarity of material for examination, on the one hand, and with the similarity to the other kinds of dwarfed growths, on the other hand (especially cretinism), it should occasion no wonder if up to the present only very few positive results exist. Roentgenography is likely to be appealed to in the future to give information through a systematic skeleton examination. At

the same time, an examination of the shape of the skull and the size of the hypophyseal fossa is especially not to be forgotten.

#### GIANT GROWTHS

While the giant growths were formerly considered as a variation in the structure of the skeleton, occurring as a race or family characteristic, it is now known that besides the "normal" giants such as are found as members of some tribes (southern Slav or African), there also exist various groups of "pathologic" giants. A classic presentation of the pathology of giants is given by Launois and Roy.

At present, one usually differentiates two kinds of pathologic giant growth, the acromegalic and the eunuchoid. Certain diseases of the hypophysis and the generative glands in youths exercise a peculiar influence upon the bone system. The epiphyseal cartilage grows more rapidly and continues to develop after the time of termination of the usual growth, so that there results an excessive length of the body.

The skull presents in "normal" giant growth a size corresponding to the proportions of the rest of the skeleton. The skull changes in the acromegalic giant growth are found described in the section on acromegaly. In the eunuchoid giant (Tandler and Gross) the skull is disproportionately small, and the jaw apparatus powerfully developed. The hypophyseal fossa may be widened in consequence of an enlargement of the hypophysis, secondary to the affection of the generative glands.

Besides the general giant growth, there is also a partial giant growth. This affects in most cases one side of the body, and represents a congenital anomaly. The skull may suffer from hemihyperplasia not only in onesided giant growth of the body, but also in symmetrical gigantism of the rest of the body or in combination with a normal appearance of the rest of the skeleton. Besides this, there is a hemihypertrophia facialis progressiva, in which, in contrast to hemiatrophy, there appears an excessive development of the bones, soft tissues, and hair of half of the face. This begins usually in early youth, with or without enlargement of the other parts of the body.

Among researches concerning partial and, especially, uni-

lateral giant growth, we mention those of Böhagen and Brüning.

While in unilateral gigantism, as a rule, the skull and body on the same side are enlarged, Reissmann described a contralateral hyperplasia of the skull and body.

Sabrazès and Cabanne collected in the literature seventeen cases of congenital and five cases of acquired unilateral facial hypertrophy. The case reported by these authors was a three-year-old child who showed the beginning of dentition earlier on the right side than on the left, and further exhibited an asymmetry of the skull in consequence of hypertrophy of the right half of the face.

Hoffmann considered hemihypertrophia facialis progressiva as a disturbance of nervous origin, and cited the observation of Schiff in support of his view, who, "after section of the mandibular nerve in young dogs witnessed the development of a hypertrophy of the jaw of the same side."

Stier described three cases of hemihypertrophia facialis progressiva affecting, respectively, a twelve-year-old child, a four-year-old child, and a four and one-half-months-old baby. He considered disease of the cerebral cortex as the cause, and demonstrated a preponderance of right-sided hemihypertrophy as compared to the left-sided hemiatrophy.

The roentgenogram, by exhibiting the shape and structure details of the skull and, especially, the size of the hypophyseal fossa, facilitates the differentiation of normal from pathologic giant growths and the identification of the various kinds of pathologic gigantism. In consideration of the fact that giants who have been apparently normal during the first decade of life later develop symptoms of acromegaly, repeated roentgenograms of the skull are indispensable. The roentgen examination permits the determination of the extent to which the skull participates in the different forms of partial giant growth, and its differential diagnosis from other varieties of skull asymmetry.

We had occasion to examine roentgenologically three cases of general giant growth.

CASE I.—A eunuchoid giant whose clinical and roentgenologic descrip-

tion is found in a publication by Redlich ("Ein Fall von Gigantismus infantilis," *Wiener klinische Rundschau*, 1906).

CASE 2.—S., male, thirty-six years old, a Moravian. Height 205 cm., from the waist down, 113 cm. When only fourteen years of age he was strikingly tall, even compared to his tall brothers and sisters. He grew no more after his twentieth year. Complained of impotence. Testicles very small, penis normal. Was well covered with hair of male type; epiphyseal cartilages were ossified. Skull was large. The under jaw was very large; the teeth were closely set.

The roentgenogram showed a sella of relatively small dimensions. The accessory sinuses were very large.

CASE 3.—A., male, thirty years old, a Bosnian. Height 210 cm. Mother was very tall. Patient had not grown since his twenty-first year. Complained of a discharge of pus from his nose. Skull very powerfully constructed, but not out of proportion.

The roentgenogram revealed a very large but not pathologically changed sella, and very large accessory sinuses.

The two last mentioned cases were at the time of the examination designated as "normal" giants.

In concluding the discussion of giant growth, precociousness should be mentioned. Precocious children appear, with relation to their body size and sexual development, several years in advance of children of the same age. Neurath, to whom we are indebted for a comprehensive presentation of the phenomena of premature body development, cited, as a cause of this, affections of the generative glands, the adrenals, and the pineal gland. Of importance also is the behavior of the other glands with internal secretion. (*Ergebnisse der inneren Medizin und Kinderheilkunde*, vol. iv.)

The roentgen examination of the heads of precocious children permits the demonstration of the configuration of the sella turcica, authoritative for the estimation of the size of the hypophysis. It also enables one to determine the presence or absence of signs of a pineal tumor.

CASE 4.—K., six-year-old boy. (At the age of four years he was studied by Knöpfelmacher who published his observations.) Had the appearance, the voice, and the size of a fourteen-year-old child. Skull circumference 52 cm., shape regular.

The roentgenogram showed a far advanced development of the accessory sinuses, and a large but normally formed sella. No evidence of pineal tumor.

A second case under our observation was a three-year-old boy who showed similar findings.

### **ANOMALIES IN THE STRUCTURE OF SKULL**

In this large group of pathologic changes in the skull, we include the anomalies arising through inflammatory processes, as well as the atrophies, the hypertrophies, and the true tumors. Before we discuss these conditions individually, we should make a few general remarks concerning the normal structure of the skull and its roentgenologic portrayal.

The skull bones belong to the type of so-called flat bones. This means that they possess in no place a large marrow cavity, but rather diploë filled with medullary tissue lying between an external and an internal shell of compact bone. The thickness of these three layers is quite variable. The external compacta is in most cases 1.5 mm. thick, and the internal, 0.5 mm. The entire thickness of the skull on the average amounts to 5 mm. In the thinnest places of the skull wall, for instance, in the middle of the squama temporalis, in the orbital portion of the frontal bone, and in the mandibular fossa, the spongiosa is completely absent, while in the thickest portions, for example in the eminentia cruciata of the occipital bone, which is not rarely 15 mm. thick, it is abundantly developed. The individual variations of the thickness and density of the skull are likewise very considerable. They depend upon the general constitution, the race and family characteristics, and, naturally, also upon the age. True diploë do not develop before puberty. In general the individual differences in thickness of the bones of the vault usually show a harmonious relation. In contrast, the thickness of the base in most cases shows no conformity to that of the vault.

A special peculiarity of the skull bones consists in the fact that a large number of the latter contain cavities which communicate with the exterior. The size and shape of the cavities is subject to large individual variations. In diseases of the skull, they become involved even as, on the other hand, they themselves often form the site of origin for diseases of the skull.

The external surface of the skull vault is, as a rule, entirely

smooth. Only the suture irregularities produce a slight irregularity of the superficial contour.

In rare cases one observes a peculiar "worm-eaten" unevenness of the outer skull surface (porosity).<sup>42</sup> The inner surface of the skull is uneven, showing depressions made by the convolutions of the brain, and excavations containing the Pacchionian bodies.

As for the Pacchionian fossæ, they are entirely wanting in children up to the eighth year. In old age and under pathologic influences, they assume a very considerable size.<sup>43</sup>

The skull wall is penetrated by a large number of canals carrying vessels and nerves. The position, shape, and size of the openings serving for the passage of the nerves, all of which lie on the base, appear more constant than those of the vascular canals. There always exist individual variations which possibly have some relation to the predisposition to affections of the cranial nerves. The occurrence of periodic paralyses and periodic neuralgia of the cranial nerves, may perhaps be explained occasionally by the abnormal position or size of the nerve canals.

The blood vessel furrows and canals are of five kinds.<sup>44</sup>

1. Furrows for the branches of the middle meningeal artery, which run on the inner surface of the cranial cavity proceeding from the middle cranial fossa. They show dichotomous branching and a uniform decrease in caliber in their course directed toward the parietal region. 2. The half-canals for the sinuses of the dura mater on the inner surface of the vault and base—*sinus longitudinalis*, *sinus sphenoparietalis*, *sinus transversus*, *sinus sigmoides* (these last two are deeper and broader on the right side than on the left) and the sinus caroticus and sinus petrosus. 3. Emissaria Santorini, short canals, which run from the inner surface, that is, from a sulcus venosus<sup>45</sup> to the outer

<sup>42</sup>According to Adachi, porosity of the outer surface, in the form of deep grooves which do not extend into the inner surface, is found in other than European skulls, especially Peruvians, on the parietal and occipital bones. Toldt has described porosity of the *cribra orbitalia*.

<sup>43</sup>Brême described in detail the relations of the Pacchionian fossæ. They have their origin in the arachnoidal villi. They are most commonly located on the bregma and in the middle cranial fossæ.

<sup>44</sup>The sinuses and emissaries distinguishable in the roentgenogram are in italics.

<sup>45</sup>Schultze described as *sulci venosi*, small, shallow furrows, coursing on both sides of the middle line, perpendicular to the course of the *sinus longitudinalis*, apparently exposed diploic veins.

surface of the skull (parietal, *mastoid*, occipital, and condyloid emissaries). 4. Shallow furrows on the outer surface for larger veins of the skin mostly in the frontal region. 5. The canals of the diploic veins which appear as a network of branching channels of an extremely variable venous system, which, coursing within the diploë, appear most plainly in the region of the eminences. Their caliber shows great variations (from 2 to 5 mm.) and not rarely is there a sudden increase or decrease in their caliber.

All the details of structure mentioned show characteristic changes in the diseases of the skull to be discussed in this section. These can be shown by no better method than by the help of roentgen procedures. The roentgenogram permits the determination of the thickness and density of the skull, the shape and size and contents of the accessory sinuses, as well as the course, the number and the size of the vessel furrows. In what manner the various anomalies in the structure of the skull are recognized in the roentgenogram will be discussed more in detail in the following pages.

### Inflammations of the Skull Bone

The inflammations of the skull bone may be divided into acute and chronic.

#### ACUTE OSTEOMYELITIS

Acute osteomyelitis is only rarely localized as an independent affection in the region of the skull. More often there are metastatic inflammations of the skull in purulent conditions on other parts of the body as in smallpox, typhoid, or influenza. In the last mentioned disease, there are observed areas of serous or productive osteitis or periostitis in the form of a flat nodular swelling. Purulent inflammations of the bone appear most frequently in consequence of wound infection or through extension of infections from the accessory sinuses. Acute osteomyelitis is found in most cases in the frontal, parietal, and temporal bones; only exceptionally in the base.

Osteomyelitis of the flat and short bones was described in monographic form by Fröhner. Primary osteomyelitis in the

squama temporalis and in the parietal bone was observed by von Bergmann, Terillon, and Fischer (cited by Stroebe). Eichel's case was an osteomyelitis of the skull base, and the upper portion of the cervical spine. Goris described a peculiar bone affection which began on the processus mastoideus and spread from there despite repeated operations. Anatomically there was a sclerosis of the bone.

In doubtful cases the roentgenogram will enable one to decide whether and to what extent the skull bone participates in the inflammation of the skull coverings. The roentgen examination will also, in certain cases, explain the origin of the inflammation, with the help of the proof of an injury to the bone or of a disease of the accessory sinuses.

### CHRONIC INFLAMMATION

Among the chronic inflammations of the skull, there come under observation, in order of frequency, the luetic, then the tuberculous, the actinomycotic, and finally those caused by phosphorus.

#### *Syphilis of the Skull*

The skull is a frequent site for luetic manifestations. They make their appearance there, most often, in the region of the face and the vault, more rarely on the base. When it does occur on the base, it is found chiefly in the sphenoid bone. The formation of syphilitic granulation tissue has its origin in the periosteum, in the dura, in the mucous membrane, or in the bone marrow.

The skull may become affected in all stages of lues. (See Neumann's *Handbuch*, vol. xxiii, and Finger, *Die Geschlechtskrankheiten*, 1908). Even in the early stages of the disease there have been observed flat swellings (tophi), consisting of granulation tissue between bone and periosteum on the outer surface of the frontal, the temporal, or the parietal bone. The bone lying underneath appears osteoporotic, and the external table, especially, is perforated by numerous canals here and there, covered by periosteal deposits. The medullary spaces of the diploë are widened (rarefying osteitis). In most instances these tophi heal. In such a case extensive osteophyte production takes place in the bone, which at an earlier stage was



porotic. So that a sclerosis of the bone and a thickening or exostosis of the surface develops (ossifying osteitis).

In the later stages of lues gummatous changes of the bone are most usual, chiefly on the frontal, temporal, and parietal bones, but even on the occiput. Gummata may be localized in one or more places, or may extend superficially over a large area. If there are one or more gummata the picture shows one or more holes with sharply defined edges. If a gumma extends superficially over a large area, the bone appears gnawed and osteoporotic over a wide extent. Sometimes large portions of the bony tables become separated as necrotic sequestra. In the later stage of lues there are almost always found, besides the destructive changes, reparatory processes which lead to the formation of osteophytes, there is a sclerotic increase in density, and the bone becomes thick in the neighborhood of the rarefied places. In such a late stage the development of syphilitic granulation tissue is sometimes less noticeable, and the signs of resorption or new formation predominate in the picture. When the destructive process predominates, there may exist an osteoporosis and a fragility extending over a large area of the skull. Later through increasing periosteal and endosteal new bone formation, there is formed a sclerosis of the diploë progressing in places even to a condition of eburnation along with massive thickening of the bone.

Hereditary syphilis manifests itself on the skull in three ways, first, by ulcerative processes, similar to the acquired, second, through disturbance of growth in the sutures and fissures (syphilitic saddle-nose!), and, third, through hydrocephalic enlargement (Hochsinger).

Fournier enumerated the following as dystrophic stigmata of hereditary lues on the skull: infantile vault, anomalies in ossification, broad nasal root, high palate, teeth anomalies.

Shuttleworth referred to the fact that hereditary syphilis is frequently the cause of abnormal mental development. The development of the brain is limited through an osteitis of the vault.

Clinically, syphilis of the skull expresses itself by the typical nocturnal pain, phenomena of paralysis and irritation of the cranial nerves and circulatory disturbance in the vessels, by

symptoms of basal meningitis, and by the occurrence of epilepsy, apoplexy, and brain tumors (gummata).

One can succeed in bringing out on the roentgenogram, the anatomic details of the various stages just described. The topi are shown by changes in the lamina externa, the surface of which appears uneven and its structure rarefied, while on the border are distinguishable the prominences corresponding to the topi. In the stage of healing one recognizes the prominence of the skull wall corresponding to the tophus and the increase in density in the bone structure.

Circumscribed gummata appear as defects with sharp, crescentic, or kidney-shaped, edges. The superficial syphilitic osteitis appears as a mottling on the roentgenogram with light areas in the bone shadow between the islands of normal or sclerotically dense or thickened bone. The diffuse osteoporosis and luetic hyperostosis are also distinguishable on the roentgen plate. One can follow the changes which take place in the spreading or healing of luetic disease on the skull, with the help of roentgen pictures.

In addition to the cases with congenital luetic hydrocephalus and those with luetic destruction of the facial bones spreading from the nasal cavity, we have repeatedly been able to point out positive roentgen findings on the cranium of syphilitics. Among them are found cases with topi in the frontal region, a gumma of the parietal bone, four cases of superficial syphilitic osteoporosis, and a case of enostosis of the frontal bone. A few of these cases may be briefly mentioned here (see also the sections on Hyperostosis and Epilepsy).

CASE 1.—Female, forty years old, with attacks of dizziness and with headache over a circumscribed place on the parietal bone.

The roentgenogram showed, on that place where superficially there was a little soft tumor, a defect with sharp edges, 2 cm. in diameter. In its further course we observed the rupture of the gumma through the skin.

CASE 2.—P., male, forty years old, with severe headache, psychic disturbances, and swelling of the skin on the right side of the forehead.

The roentgenogram showed extensive osteoporosis of the right frontal and parietal bones. (Figs. 19 and 20.)

CASE 3.—K.,<sup>46</sup> male, thirty-three years old with history of repeatedly occurring symptoms of cerebral lues (aphasia, right-sided hemiparesis, epileptic attacks). The cranium had a smooth surface, was tender on pressure

<sup>46</sup>The case was published by Rothlich and Schuller, Case 7, with Fig. 2, Plate XVIII, in *Fortschritte auf dem Gebiete der Roentgenstrahlen*, vol. xvii.



Fig. 17.—A posteroanterior plate of the head of P., Case 2, a man forty years old with a syphilitic osteoporosis chiefly limited to the right parietal region.

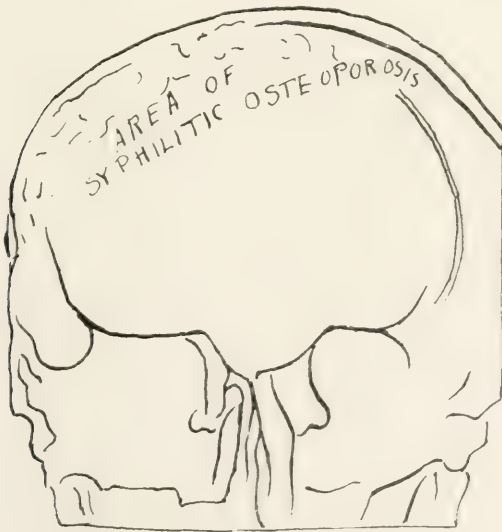


Fig. 20.—A drawing of the plate in Fig. 19.

and percussion at various places, and there was a history of the frequent appearance of painful swellings in the region of the skull vault.

The roentgenogram of the skull showed extensive osteoporosis over a great part of the vertex which corresponded to the typical picture of a syphilitic osteitis. At section the roentgen finding was verified.

### *Tuberculosis of the Skull*

In contrast to syphilis, tuberculosis shows slight tendency to attack the skull. When present, the most common site is in those bones which have air chambers (temporal and ethmoid bones). In these cases the bone always becomes affected through extension of the inflammation from a tuberculous mucous membrane. Tuberculosis is also found on the base of the skull in connection with tuberculosis of the upper cervical vertebrae. From the petrous portion of the temporal bone, the ethmoid bone and the occipital bone, the disease spreads wider on the skull base. Tuberculosis comes under observation only rarely as a primary affection in the other bones.

Tuberculous change consists in most cases in a superficial or deep erosion of the bone. The defect has an indistinct contour, as if gnawed, and there is no tendency to osteophyte formation. One differentiates two forms, the perforating or sequestering form and the progressive infiltrating form. The former is the more frequent.

Clinically, tuberculosis of the skull attracts attention through symptoms arising from the cranial nerves and the organs of sense, as well as the symptom-complex peculiar to brain tumor (solitary follicle), and tuberculous meningoencephalitis.

In the roentgenogram one has occasion quite frequently to observe changes in the skull base, especially the destruction of the occipital condyle associated with destruction and change in the position of the uppermost cervical vertebrae.

The cases examined roentgenologically by us were affected with carious destruction in the region of the skull vault and the face, tuberculosis of the atlantooccipital joint, and we had one case with tuberculosis of the hypophyseal fossa. A part of these cases are found described in the author's *Atlas der Schädelbasis*. The last mentioned case may be cited here in brief.

M., girl, fourteen years old. Symptoms of a tumor of the pons. The roentgenogram showed the sella widened to a moderate extent, the contour of its floor was irregular, the dorsum sellæ was gone, the anterior clinoid processes were more pointed than normal. Postmortem showed that a tuberculous caries, originating from the floor of the sella, had spread out over the base of the brain.

### *Actinomycosis of the Skull*

The bones of the skull are a point of predilection for actinomycosis which, as is known, spreads from a decayed tooth into the jaws, into the face, and on to the base of the skull, producing carious destruction as it travels.

### *Phosphorus Necrosis of the Skull*

The inflammation of the bone produced by phosphorus also always takes its origin from the teeth, and leads to a necrosis of the jaw, the bones of the face and the base of the skull.

### **Atrophic and Hyperostotic Changes in the Skull**

We place in this group those changes in the structure of the skull which are a local manifestation of the so-called systemic diseases, senile and marantic atrophy, osteomalacia, acromegaly, Paget's disease, and hyperplastic osteitis.

We classify here also those atrophic and hyperostotic changes of the skull which are to be considered as an expression of a local disturbance. These are such conditions as basilar invagination, neurotic atrophy, hemiatrophia faciei progressiva, hemihypertrophy, basal hyperostosis, and diffuse and tumor-like hyperostosis.

The affections mentioned (individual cases of which are yet as little understood in regard to their etiology as with relation to the pathologic and anatomic details of their change in structure) offer welcome objects for roentgen examination, especially since, on account of the rareness of some of the anomalies under discussion, only a small number of postmortem findings are at our service.

In the classification and description of the various forms we confine ourselves to the ideas of M. Sternberg, Breus-Kolisko, and Kaufmann.

## SENILE ATROPHY

Senile atrophy appears in the skull bones, usually as a wasting of the bone substance, an external and internal atrophy of high degree. The skull becomes thereby thinned only in places, or as a whole. In most cases it is osteoporotic and, therefore, abnormally fragile.<sup>47</sup> More rarely the bone becomes sclerotic and, as a result, less elastic.

Most striking is the thinning usually found in the parietal region,<sup>48</sup> the outer surface of which is sunken in in the manner of a trough. The atrophy begins in the lamina externa, whereby the spongy bone is laid bare. This also then disappears so that the inner table lies bare. The latter finally is absorbed here and there. The atrophy makes itself especially noticeable in the jaws. In the region of the skull base, erosions of the inner surface may appear which bear a similarity to those which are peculiar to pressure atrophy so that even a widening of the sella turcica may be present.

In senile atrophy some of the air chambers usually diminish in size (especially the antrum of Highmore) while others increase in extent (frontal and sphenoidal sinuses).

The enlargement of the accessory sinuses occurs through the fact that the wasting of the diploë in their neighborhood facilitates the inclusion of these cavities by the accessory sinuses. Besides, through senile atrophy of the brain, there is brought about a diminution of the pressure upon the inner surface of the skull and on account of this the delicate walls of the accessory sinuses tend to curve inward toward the cranial cavity. The latter mentioned factor of diminished pressure from cerebral atrophy appears also to affect the hyperostosis occurring occasionally in the skulls of the aged, especially on the frontal bone. (See section on Hyperostosis.)

The emissaries and diploic veins may be widened in the

---

<sup>47</sup>Higher grades of fragility of the bone are designated as "osteopsathyrosis." The latter is a manifestation not only of senile and marantic osteoporosis, but also of rachitis, osteomalacia, diffuse carcinomatosis, as well as neurotic atrophy (tabes, syringomyelia). Concerning idiopathic osteopsathyrosis see the section on Chondrodystrophy.

<sup>48</sup>That the atrophy makes itself noticeable in such a considerable degree just on the parietal bone has been sought to be explained from a decreased ossification process in this part of the skull. As analogies are cited the occurrence of defects in ossification more frequently observed in this part of the skull as, for instance, abnormally large parietal foramina, false fontanels.

skulls of the aged. The diploic veins empty into a canal running sagittally through the parietal bone to the mastoid emissary.

The change in the shape of the skull of the aged will be mentioned in the discussion of senile osteomalacia.

From a clinical standpoint no great significance can be attributed to senile atrophy. It is limited to the increase in the fragility of the bone. Whether the severe trigeminal neuralgias of the aged have some connection with the senile atrophic changes of the skull is not decided.

The roentgenogram of senile atrophy of the skull permits the recognition of the thinning and the osteoporosis of the skull wall, the symmetrical trough-like excavation of the parietal region, the erosion of the delicate bone in the neighborhood of the sella turcica, the enlargement of the air chambers, and the widening of the emissaries and diploic veins.

The consideration of the details mentioned is diagnostically important, since the latter in great measure occur also in case of increased intracranial pressure. Occasionally senile and pressure atrophy are found combined in the same case as the following observation shows.

CASE P., female, sixty-three years old. On account of hemiplegia and optic neuritis, the probable diagnosis of cerebral hemorrhage was made.

The roentgenogram showed typical trough-like excavation of the outer surface of the parietal bones, while, on the inner surface, there existed an erosion of the delicate portions of the sella turcica. Since, at the same time, deepened impressions were noticeable we assumed that an increased intracranial pressure was present along with the senile atrophy. Post-mortem showed that there was indeed a tumor of the frontal lobe.

### OSTEOMALACIA

The nature of this general disease of the skeleton consists in a progressive decrease in calcium (calisteresis) and a resorption of the bone tissue with substitution of a newly formed osteoid structure for the latter. As a result the skeleton loses its firmness and becomes soft and pliable, or fragile and brittle. The skull does not usually participate in the most frequent, the puerperal, form of osteomalacia. It does participate, not rarely, however, in the nonpuerperal, in the juvenile, and senile forms. Sometimes it is the first portion of

the skeleton affected. Severe osteoporosis or osteomalacia may occur also in younger individuals who become marantic in sequence to chronic diseases (marantic atrophy).

The skull, suffering from osteomalacia, may be very light, porous or pliable and is hence likely to be deformed. By lying in bed, flattening and asymmetry of the skull appear, whereby the kyphosis of the skull base becomes increased. Another change in the shape of the skull base is produced in the upright position by the pressure of the head against the vertebral column. In this way the base becomes elevated (basilar invagination).

We have been able repeatedly to observe this change in basal contour in senile skulls. According to our opinion the peculiar position of the jaw in skulls of aged persons (retracted upper jaw, prognathic lower jaw) is brought about by the kinking of the base.

Recklinghausen also described changes in the occiput and base, in children with distorted extremities, due to osteomalacia. (See section on Osteitis Deformans.) The same author advocated the identity of rachitic and osteomalacic changes in the bone. Taking into consideration the difference in the time of their appearance, it is better that the two diseases be treated separately from a craniologic standpoint. Rickets, since it affects the growing skull, usually produces disturbances in growth, while osteomalacia produces changes in structure.

From the publication of Recklinghausen relative to osteitis deformans, which has many things in common with osteomalacia, we mention the following case of puerperal osteomalacia. Chips could be cut from the skull with a knife. The edge of the foramen magnum projected upward like a wall. The elivus was not shoved up but was sharply bent. There were deep convolutional impressions and between these were prominent interconvolutional ridges.

Anschütz described the head of an eighteen-year-old youth with osteomalacia. The head was large and well developed with relation to the rest of the body and the sutures were everywhere plainly palpable as hard ridges. Through the meeting of these ridges little elevated planes arose on the site of the fontanels.



In the severest cases of osteomalacia there is no longer any bone substance present so that the skull is elastic and can be pressed in like an india rubber globe (caoutchouc head).<sup>49</sup>

We could find only isolated reports in the literature, relative to the clinical symptoms of osteomalacia of the skull. Hahn mentioned that, in a few cases of osteomalacia virilis, a disturbance of the mind developed. This was considered the result of the softening and deformity of the skull bone. It might have been partly due to the diminution of the cavity of the skull produced by the deformity.

The roentgenogram permits the determination of the changes in the structure of skulls suffering from osteomalacia and the change in shape of the base.

In our collection there is a roentgenogram of a skull with "osteoporosis in consequence of osteomalacia" belonging to the Pathologicoanatomic Museum in Vienna. The case, which we have described more accurately in our *Atlas* (page 51) was that of a forty-four-year-old day laborer. The skull showed atrophy of high grade and consisted of a porous pumicestone-like, easily crumbled mass. The cerebellar fossa appeared abnormally deep and narrow in consequence of basilar deformity.

In connection with the various atrophic changes of the skull mentioned in the preceding paragraphs (which are local manifestations of a general disease of the skeleton), mention should be made of the atrophies which appear as local processes. We enumerate here pressure atrophy, neurotic atrophy, and basal invagination as belonging to this group.

The pressure atrophy of the skull, which arises in consequence of pressure by gradually growing tumors in the soft tissues outside or in the intracranial contents, is treated in the section relating to that.

### NEUROTIC ATROPHY

One designates as neurotic atrophy the changes in the skeleton occurring in diseases of the nervous system and depending upon a disturbance of the trophic function of the latter. It

<sup>49</sup>We had the opportunity to be present at the section of a case of osteomalacia of the whole skeleton in a fifteen-year-old girl. Erdheim found in this case a tumor of a parathyroid whereby a new clue is given for the etiologic significance of affections of the epithelial bodies with regard to general diseases of the skeleton, such as osteomalacia and rickets.

appears as a concentric atrophy or as osteoporosis with abnormal fragility or elasticity of the bones.

Neurotic atrophy in the skull rarely comes under observation. One must consider, as belonging here, progressive facial hemiatrophy and the atrophy in tabes and syringomyelia.

In the former the soft parts of one-half of the face are usually involved. In later stages, however, also the bones of the face, especially the upper jaw and sometimes the anterior portion of the skull vault, become affected (Möbius, *Handbuch*, vol. xi).

In tabes there appears not so rarely an atrophy of the jaw with a rapid loss of the teeth. Infeld reported arthropathy of the mandibular joint.

The roentgen examination of the forms of atrophy just mentioned has brought out no essential new ideas up to the present. Nevertheless it permits one to see the involvement of the skeleton in trophic disturbances, as one may judge from the few reports contained in the literature (see Fürnrohr).

In a given case it could be depended upon to make a definite diagnosis of progressive facial hemiatrophy from other varieties of asymmetry, such as unilateral over- or underdevelopments (hemihyperplasia and hemihypoplasia), from caput obstipum, and hemiatrophy of the skull in cerebral infantile paralysis.

Up to the present there has been no description of the skull in the affection designated as "acute bone atrophy." This disease was first reported by Sudeek and was thought to be trophoneurotic in origin. It appears in connection with inflammations and traumas of the joints and soft tissues and consists in a decalcification which is demonstrable by the roentgen picture.

#### BASILAR INVAGINATION

One designates as basilar invagination a peculiar change in the shape of the skull base, the most striking feature of which is the upward bulging of the floor of the posterior cranial fossa around the foramen magnum. Looked at from inside the cranial cavity, the base of the skull shows in typical cases, an elevation of the edge of the foramen magnum lying between the pyramids of the temporal bones. The broad surface of the

clivus which with the pars basilaris and the condyloid portion of the os occipitale, run down normally with a concave curvature to the squama occipitalis, forms, in basilar invagination, a convex bend, the vertex of which comes to lie at the level of the floor of the sella turcica, so that the so-called basal angle which is formed by the plane of the clivus with the planum sphenoidale (normally amounting to 115°-140°) approaches a straight angle. Looked at from the under surface of the skull base, the condyloid processes do not extend as normally to the level of the mastoid processes. More often they are hidden in the bottom of a deep trough, the floor of which is formed by the pars basilaris and the condyloid processes and which is surrounded by the pyramids of the temporal bones along with the body of the sphenoid.

Along with the change in shape, the wall of the posterior cranial fossa shows also a very considerable anomaly in structure. The elevated portions of the occiput are very greatly thinned so that the pars basilaris and the condyloid areas may be reduced to the thinness of paper and the condyloid processes to little flat buttons.

The uppermost portion of the cervical vertebræ also shows essential changes, a description which we base on skull No. 5082 from the Weichselbaum Institute. The atlas appears more like a poor rudiment in the form of a thin bracelet which suggests the anterior arch of the atlas with a little bone remaining from the lateral portion and the transverse processes. The rudimentary atlas is grown to the lower surface of the occipital bone and has three joint surfaces for articulation with the epistropheus. This is likewise deformed. Its spinous process is detached from the arch and is grown to the spine of the third vertebra.

This anomaly of the skull develops gradually without pain and without essential limitation in movement and therefore is not noticed for a long time in young individuals. When it is fully developed the individuals affected by it appear remarkable at first glance, because the peculiar position of the head is such as one sees in people with a gibbus after a healed tuberculosis of the upper portion of the vertebral column. The occiput lies upon the back of the neck, the neck is short

and the head is, as it were, stuck in between the shoulders.

In later stages of the affection there usually appear symptoms arising from the nervous system. One can arrange these symptoms in three groups.

1. Paralyzes and symptoms of irritation of the nerves arising in the posterior cranial fossa; as well as also the uppermost spinal nerves. These nerves become forced into an abnormal course and pulled and compressed by the basilar invagination.

2. Symptoms resulting from a process which diminishes the capacity of the posterior cranial fossa. Through the elevation of the floor of the latter the cerebellum becomes pressed against the tentorium and in this way obstructs the aqueduct of Sylvius.

3. Symptoms of compression of the medulla oblongata which undergoes an angular kink at the level of the anterior edge of the foramen magnum and is pressed upon by the odontoid process of the epistropheus.

From what has been said it is readily understood that the course of the affection under discussion may be, for a long time, a benign one, bearing in itself no particular hardships for the sufferer. However, the malady may lead to death with severe cerebrospinal manifestations.

We are forced to consider the mechanism of the origin of basilar invagination as being the following: The edges of the foramen magnum represent that part of the skull base which has to bear the direct weight of the head. If there exists a diminution in the firmness of the edges or the weight of the head is disproportionately great, there is produced, through the counterpressure of the cervical vertebrae, a flattening out of the normal curvature of the floor of the posterior cranial fossa and, in its later course, a bulging of the floor toward the interior of the cranium. The vertebral column no longer rests on the condyles, but rests anteriorly on the base of the body of the sphenoid bone and posteriorly on the squama occipitalis. The elevated portions of the skull base, relieved of weight but exposed to brain pressure, atrophy so that they assume the paper-thin appearance described above. The atlas, which no longer rests on the skull base with the strong lateral masses,

but with the anterior and posterior arches also undergoes an extensive atrophy of the parts relieved of pressure and an erosion of the now burdened parts, the structure of which is not suitable for such a pressure. If the epistropheus finally comes into direct contact with the skull base its arch may also undergo pressure erosion.

The nature of the condition resulting in basilar invagination is by no means clear with regard to its etiology. The authors who have studied the matter (Virchow, Grawitz) have assumed different causes for the abnormal lack of resistance of the skull base. In the first place, rachitis, osteomalacia and hydrocephalic atrophy have been thought of. Apparently there are yet other etiologic factors, the most important one of which is a congenital anomaly in the formation of the skeleton. We mean the so-called atlas ankylosis. The atlas is not rarely developed as a rudimentary structure, that is, the posterior arch is entirely or partially absent, and also even the parts present may be extremely reduced and grown together with the under surface of the base of the skull. Occasionally the anomaly is developed only on one side (Langerhans, Mouchotte). Although this variety remains in most cases throughout life without progression and without clinical significance, it could furnish a *locus minoris resistentiae* and be followed by a progressive change in structure under the influence of an increase in head weight, as in the case of people who from their youth must carry heavy loads on their head.

There exist, furthermore, very gradual transitions between the typical basilar invagination and the elevation of the skull base to be observed in the various skeletal diseases, as puerperal and senile osteomalacia, osteitis deformans (Paget), and dysostosis eleidocranialis which bring about a kind of basilar invagination along with their other changes in shape and structure. Some cases in the literature considered as tuberculous caries, or described under other names, are probably to be classed here also (Homén).

The examination of the skull base with the x-ray is indispensable for the diagnosis of basilar invagination. The roentgenogram permits the determination of the change in the curvature of the posterior cranial fossa, as well as the rudimentary

formation of the atlas and epistropheus. The roentgenogram will also permit the discovery of erosions of the inner surface of the skull, the origin of which is to be attributed to an in-

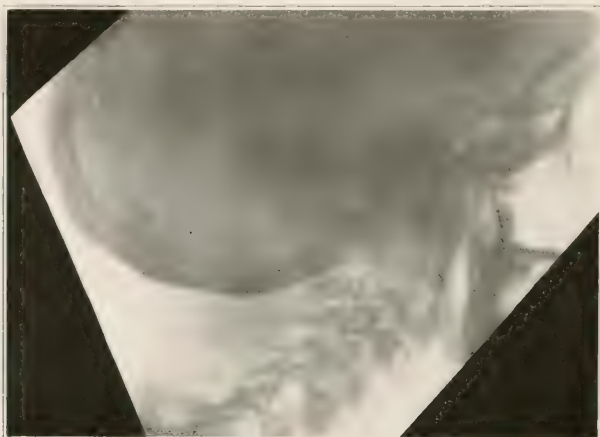


Fig. 21.—A print from an x-ray plate of Case 1, a woman, forty-one years old, with basilar invagination. The picture brings out quite clearly the almost pathognomonic position of the head. One gets also a very clear picture of the nearly flat skull base due to a shoving up of the posterior cranial fossa by the cervical vertebrae.

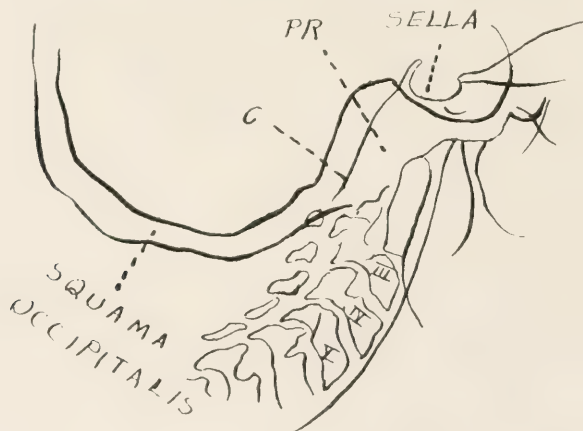


Fig. 22.—A drawing of Fig. 21. *C* is clivus, *PR* is the pyramid on the right side, since it is a sinistrodextral picture. Only a rudiment of the first vertebra is to be seen in the picture.

crease in intracranial pressure caused by pronounced diminution in the size of the posterior cranial fossa.

We had occasion to examine two cases of invagination of the skull base.

CASE 1.—Female, forty-one years old. Several weeks previously there had appeared immobility of the head with severe pain in the occiput. The pain soon abated and in its stead there appeared difficulty in speaking and swallowing. The examination revealed a characteristic position of the head said to have been observed for several years by the patient and her relatives. The head was inclined backward so that the occiput lay almost on the back of the neck. The active and passive movement of the head was limited but not painful. There existed right-sided paralysis of the tongue with atrophy. The examination of the spinal column undertaken in a surgical clinic yielded a negative result.

In contrast to that, the sinistrodextral roentgenogram of the skull base made by us, a reproduction of which is to be seen in Figs. 21 and 22,

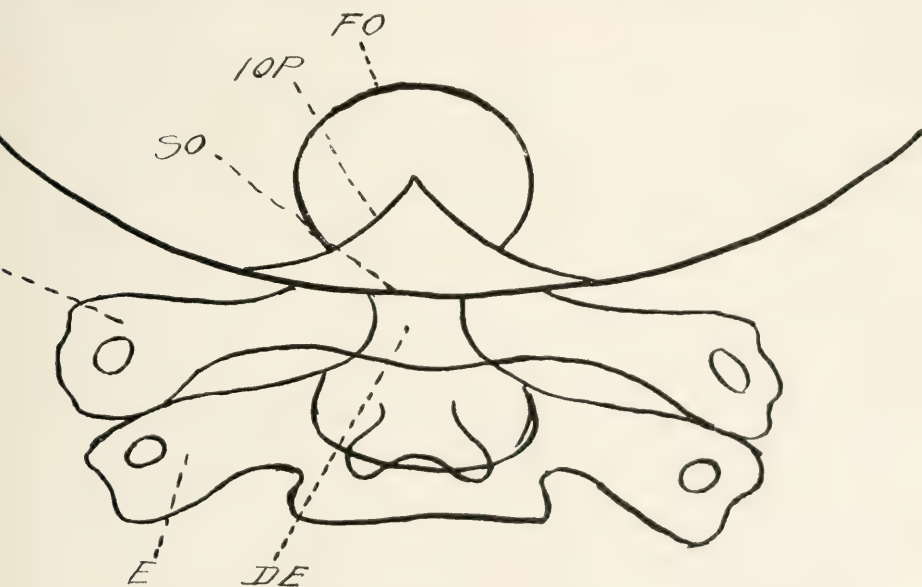


Fig. 23.—A drawing serving to illustrate what one should see in an anteroposterior picture of the base of the skull and the vertebrae. *FO*. Foramen ovale. *IOP*. Internal occipital protuberance. *SO*. Squama occipitalis. *A*. Atlas. *E*. Epistropheus. *DE*. Dens epistropheus.

permitted one to see plainly that the posterior cranial fossa was elevated, that the uppermost cervical vertebrae were shoved forward, and that the invaginated occiput rested on the posterior surface of the bodies of the uppermost cervical vertebrae in such a way that one must assume there were extensive defects in their transverse and spinous processes. So far as we know, this case was the first one in which the anomaly was diagnosed in life. (See *Atlas der Schädelbasis*, page 55.)

CASE 2.—Sixteen-year-old apprentice. Symptoms of a spastic paresis of both extremities. Since simultaneous, unassociated disturbances of sensation existed, the diagnosis of syringomyelia was made.

The roentgen examination proved the presence of destructive changes in the region of the skull base and the cervical vertebrae, the interpretation of which as Pott's disease did not coincide with the history and the other clinical findings. The postmortem confirmed the existence of destructive changes discernable in the roentgen picture; viz., elevation of the skull base, absence of the atlas with the exception of little rudiments of the transverse processes, asymmetrical position of the cervical vertebrae with

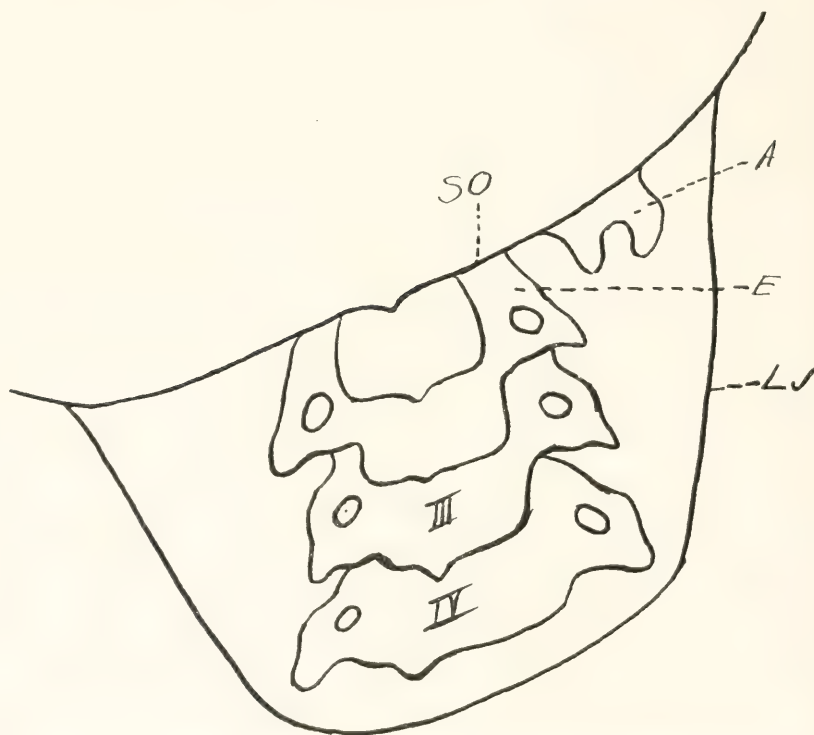


Fig. 24. Sketch made from an anteroposterior picture of a basilar invagination. *SO*, Squama occipitalis. *A*, Rudiment of the atlas. *E*, Epistropheus. *LJ*, Lower jaw.

regard to the skull base. No signs of a tuberculous disease were found, but rather the details characteristic of basilar invagination. Figs. 23 and 24 show in outline the difference between the normal and the pathologic conditions shown in the x-ray plate of this case.

#### ACROMEGALY

The characteristic bone enlargement in acromegaly affects the whole skeleton, but to the greatest degree the peripheral



portions of the extremities and the skull. The skull change in acromegaly, if we overlook the usual destruction of the sella turcica produced by a hypophyseal tumor, consists in a gradually developing enlargement of the skull of individuals between thirty and fifty years of age. The enlargement is usually to be seen most plainly in the face, especially in the framework of the nose and in the under jaw. The latter is thickened and lengthened, the angle of the jaw increased, the alveolar edge is bent outward, and the teeth are separated from each other. Not rarely there exists alveolar prognathia, probably as a result of pressure from an enlarged tongue. In the region of the skull vault one is struck in most cases by the prominence of the supraorbital ridges as well as the prominence of the points of insertion of muscles and ligaments. Sometimes the whole skull appears enlarged through hyperostosis. Its structure is changed in such a way that, in the beginning, sclerosis of the skull bones takes place and in a later stage they become porous. With the increase in size, the accessory sinuses also always become very much larger. The projections and ledges on the inner surface of the base usually assume a plump shape. Very seldom there appears a unilateral enlargement of the face (hemihypertrophy of the face). Occasionally one observes exostoses on both the outer and inner surfaces. If a marked increase in intracranial pressure occurs, as a result of a large hypophyseal tumor, the interconvolutional ridges and points on the bone may stand out prominently as large protuberances in combination with deepened impressions. The sutures may undergo premature synostosis.

Keith gives a description of the enlargement of a skull suffering from acromegaly and also an explanation of its formation along with many sketches of enlargement of single parts. He found a similarity to the Neandertal type which, according to his view, apparently also depends upon excessive pituitary activity.

Apart from the destructive changes produced through hypophysis tumor, to be later described, the roentgenogram shows the enlargement and thickening of this variation in skull structure, the sclerosis or rarefaction of its wall, the formation of

bony projections, and the enlargement of the accessory sinuses.<sup>50</sup>

The demonstration of the described skull changes is of significance diagnostically, especially in those cases where an enlargement of the hypophyseal fossa is not discernible. There are rare cases of acromegaly in which the sella turcica contains no hypophyseal tumor, in which rather there is present a tumor in the sphenoid sinus or in the roof of the pharynx, coming from a hypophyseal rest, which may be the cause of the acromegaly. In these cases one finds only the hyperplastic skull changes. These are so characteristic and so constant that upon the basis of their presence the differentiation can be made between acromegaly and the other hyperplasias and enlargements of the skull such as cephalonia, giant growths and tumor-like hyperostoses.<sup>51</sup>

A special interest attaches itself to the roentgenographic determination of changes which, as Hoehenegg first pointed out, appear on the acromegalic skull as manifestations of an attempt at healing after successful operations for removal of hypophyseal tumors.

Descriptions and reproductions of roentgenograms are found in large number in the literature of recent years.

Our own observations are presented in the section on Hypophyseal Tumors. (See also the author's *Atlas der Schädelbasis*, page 56.) Here may be mentioned a case of acromegaly without enlargement of the sella.

CASE K., male, 50 years old. Typical acromegaly. The roentgenogram showed the skull changes peculiar to acromegaly but no widening of the hypophyseal fossa. At the postmortem there was found no enlargement of the sella turcica. Nevertheless, there was a hypophyseal tumor in the body of the sphenoid (Erdheim).

<sup>50</sup>We doubt whether one can also determine roentgenographically the persistence of the canalis craniopharyngeus. We also doubt the frequency and significance of this finding as obtained by Levi in the skulls of those with acromegaly.

<sup>51</sup>There are peculiar enlargements suggestive of acromegaly in the extremities, as cause of which one can demonstrate local hyperostoses. In these the skull does not show the characteristic changes of acromegaly even if, as is occasionally observed, the skeleton in general shows gigantism. Mossé (*Nouvelle Iconographie de la Salpêtr.*, 1911, No. 2) has recently sought to characterize such cases as an independent type. We refer to the demonstration of a case from the Hoehenegg Clinic, belonging in this group (*Gesellschaft der Aerzte Wiens*, May, 1911). We ourselves had occasion to examine two such cases, the one from Neusser's clinic and the other one from Strümpell's. In both cases was the hypophyseal fossa on the roentgenogram roomy, but not pathologically changed. Meige (*Rev. Neurologique*, 1911, page 646) objects that one should consider such cases as latent forms of acromegaly.

## HYPERPLASTIC OSTEITIS

One places under this heading various processes scattered over the whole skeleton but not affecting the soft tissues. First among those to be mentioned here is hypertrophic pulmonary arthropathy (Marie-Bamberger's disease) which develops in chronic heart and lung diseases. Also there belongs in this class the hyperostosis occurring in consequence of syphilis, and the hyperostosis occurring in icterus (Obermeyer). And, finally, one must consider, as being in this class, the ossifying osteitis occurring in leukemia, malignant tumors, chronic arsenic and phosphorus poisoning, chronic alcoholism, as well as in pregnancy and osteomalacia. Since in most cases these latter diseases have a toxic etiology, M. Sternberg proposes the name "toxic osteoperiostitis ossificans."

There is not much known concerning the participation of the skull in the affections mentioned if we make an exception of syphilitic osteitis. It appears to be wanting in cases of Marie-Bamberger's disease, but, on the other hand, to be present in the other affections in this group.

Wegner describes such a case of slight general hyperostosis of the skull and slight ossifying periostitis of the alveolar processes of both jaws in an eighteen-year-old male who had worked for years in a phosphorus factory. Schlagenhauer, who collected the literature relative to the periostitis under discussion, described the case of a young lady twenty-one years old in whom there occurred a diffuse ossifying periostitis of the whole skeleton in connection with a carcinoma of the pharynx. The vault of the skull was symmetrically dolichocephalic and the sutures were all open. On the outer surface of the frontal bone there were two, on the parietal wall four, and on the temporal bone two gray-white areas which proved to be fine osteophytic deposits. On the inner surface there were fine porous bone deposits on the parietal bones as well as on the frontal bone which covered almost the whole surface. Schlagenhauer expressed the conjecture that a long continued arsenic therapy had caused the bone thickening in these cases.

In leukemia there rarely occur hypertrophic changes of the skeleton, in which apparently the skull may also take part.

The bone is not changed with relation to its size, however, there exists a sclerosis of its marrow substance (Schwarz, K. Sternberg).

There is very often observed a hyperostosis during pregnancy. While, as was mentioned, the skull in most cases of puerperal osteomalacia does not participate in the disease, there appears very often in healthy pregnant women, from the third month on, a delicate velvety deposit along the sagittal sinus and in the region of the middle meningeal artery which consists of osteoid tissue that later changes into bone (puerperal osteophytes). According to Hanau, this osteophytic condition is connected with processes resembling osteomalacia in otherwise healthy pregnant women. On the other hand, the conjecture is obvious that this hyperostosis may have a bearing on the hypertrophy of the hypophysis in pregnant women. Puerperal osteophyte formation occurs in addition also on the outer surface of the skull vault and on individual bones of the face (bones of the nose, upper jaw, Virchow). The puerperal skull osteophytes seem to have no clinical significance, although they have been considered by some authors to have an etiologic bearing on puerperal epilepsy.

The roentgen examination serves the purpose of facilitating the differential diagnosis of skull changes found in hyperplastic osteitis from those of similar affections as, for example, acromegaly. Since the hyperostosis of the skull is only very slight it is not always detected. Especially does this apply to osteophytes in pregnancy which were falsely asserted by Benedict (*Naturforscher-Versammlung*, Salzberg, 1909) to be visible in the roentgen picture of the skull. Just as negative a result is given in cases belonging here, relative to changes in the sella turcica.

#### OSTEITIS DEFORMANS, PAGET'S DISEASE, OR OSTEITIS FIBROSA (RECKLINGHAUSEN)

Osteitis deformans is a disease of old age. It appears in various parts of the skeleton and almost always in the skull. The characteristic change of the skull consists in an eccentric thickening of the whole vault or only single portions (frontal

bone, squama occipitalis, isolated regions of the parietal bone). The bones of the base may also be involved while those of the face usually remain free.

The thickening of the skull develops gradually, in individuals usually over forty years of age, sometimes with headache of migraine character, psychic anomalies, or disturbances on the part of the organs of sense. The circumference of the head increases gradually and the shape becomes deformed.

The outer surface is uneven, even rough. The inner surface shows, in most cases, no essential changes, so that the furrows of the vessels and the nerve foramina show no change in caliber. The thickening of the bone results both by addition from the periosteum and also through new bone formation from the marrow. On account of this there occurs a reconstruction of the bone. The skull wall exhibits no longer the normal line of demarcation between the compact and the spongy bone, but, instead, it consists of a sclerotic bone tissue, soft in places and hard in others. Occasionally there are cystlike formations in the bone.

Besides the change in shape and size of the skull produced by the thickening, there is sometimes also a change in the outline of the base to be observed, since if the basal portions of the skull consist of soft osteoid tissue, they are flexible and a basilar invagination may arise from the pressure of the heavy head.

The etiology of Paget's disease is unknown. It is possible that it is a question of disturbances of the bone system of nervous or hypophyseal origin. Trauma appears to play an important part.

V. Kutschka, who described a case of asymmetrical Paget-like thickening of the skull in a forty-six-year-old patient from the clinic of von Eiselsberg (*Wiener klinische Wochenschrift*, 1909, p. 109), emphasized the parallelism in the Paget-Recklinghausen view of osteitis deformans (the bone changes of which result from a disturbance in circulation consisting of an active hyperemia and a passive venous congestion aided by the usually atheromatous vessel walls) and the endeavors of Bier to stimulate callus formation by means of passive congestion or

through injection of blood between the fragments of bone to hasten a slowly forming callus.

In certain cases of Paget's disease the hyperostosis seems to develop, in its later course, very much like a sarcoma. In that way there is a transition to the osteoplastic form of diffuse sarcomatosis of the skeleton. Auvray described a case of sarcoma of the skull with increase of cranial circumference. P. Marie considered this case as Paget's disease with later sarcoma formation.

Of interest is the occurrence of Paget's disease in families. Oettinger and his coworkers emphasized this fact and referred also to the connection of the disease with trades (laundry workers and workers in mineral stuffs).

Here may be cited briefly a few cases from the original publication of Recklinghausen:

Case 1.—Skull circumference 640 mm. thickness from 8 to 20 mm. distinct elevation of the skull base.

Case 2.—Circumference of the skull 615 mm., hyperbrachycephalus, marked elevation of the base. Thickness of the vault 17 to 25 mm.

Case 4.—Female, 43 years old. The entire frontal bone was thickened up to 12 mm., could be cut with a knife. There was elevation of the skull base.

These cases are typical examples of osteitis deformans in the skull. One more case in the same publication suffered from a partial disease of the skull.

Case 5.—Female, sixty-six years old, showed general hyperostosis of the skeleton with cyst formation. Skull was brachycephalic, all the sutures closed, skull wall thin, except for the right half of the occipital bone which was 10 mm. thick toward the lower portion. Upon section it was revealed that the bone was hollow on the inside, but in such a way that these cavities were closed both externally and toward the side of the cranial cavity by a compact dense hard bone wall the thickness of which only amounted to 2 to 3 mm. There was an elevation of the skull base.

Kaufmann examined two skulls, one of which was 2.8 cm. thick and the other 4 cm. He described the structure of the

dried-out skulls as "white and fragile as frosting, being broken by handling."

As Recklinghausen mentioned, a picture similar to osteitis deformans may arise in some cases of rachitis. As we mentioned earlier, rachitis, if it is cured almost always produces in the skull a limited amount of thickening and increase in density. In very rare cases in children one finds extreme thickening of all parts of the skull, especially the vault in which the bone is soft and flexible and consequently subject to changes in shape. The sutures become obliterated to a great extent. Virchow, and later von Hansemann, spoke of a rachitic proliferative periostitis.

In Basel, Kaufmann saw many such preparations with pumicestone-like thickening up to 15 mm., chiefly in the frontal portion of the skull. In one case, a two-year-old boy, there was here and there a suggestion of the frontal and coronal sutures, but the sagittal was obliterated. Besides that, the posterior portion of the skull was, in places, in the region of the deep impressions, so thin as to be transparent, and the large fontanel was wide open.

The roentgenogram in osteitis deformans permits the demonstration of the thickening of the skull wall, the change of the bone structure, the change in the sclerotic and porotic places, the stratification of the bone, the unevenness of the surface, as well as the change in the outline of the base. Other processes which cause skull enlargement (soft tissue tumors, tumor-like skull hyperostoses, hydrocephalus) can be differentiated in this manner from Paget's disease.

The literature on osteitis deformans was collected by Schirmer and Glaessner. After that Fitz (*American Journal of Medical Sciences*, November, 1902) published the first roentgenograms of the skull in a case of Paget's disease.

We had occasion to examine a typical case of Paget's disease. This case, which Glaessner described and illustrated in detail, was that of a man fifty-two years old, the circumference of whose skull had been observed to be increasing gradually for six years. The largest circumference amounted to 63.5 cm.

The roentgen examination showed the skull vault to be 3 cm. thick with several layers of various densities. The outer layer

was spongy, of slight density, slightly uneven on the outer surface. The internal layers showed in some places lentil-sized sclerotic areas and elsewhere similarly large porotic spots. The inner surface appeared even. The base was frail and of normal configuration.

In the hyperostoses of the skull, occurring in the literature up to the present, the skull affection formed the local manifestation of a disease of the whole skeleton. Hyperostosis, however, is observed also as an affection limited to the skull, and occurs both as a diffuse and a tumor-like hyperostosis. The thickening of the inner surface in endocranial disease and the hyperostosis of the outer surface in affections of the soft tissues will be discussed in later sections.

#### DIFFUSE AND TUMOR-LIKE HYPEROSTOSES

The cases of skull thickening belonging in this group are found described and pictured in detail in a monograph by Sternberg (his textbook, vol. vii, p. 2). In the highest degrees of the hyperostosis under discussion, which have been described as leontiasis ossea (Virchow), cephalomegaly or megaloccephalus, the skull is a colossal deformed bone mass of several kilograms weight. Its outer surface shows low nodular ridges, in connection with which the hollow spaces on the inner surface are filled in with bone proliferation. In less severe cases of diffuse hyperostosis there is extensive flat proliferation and sclerosis of the cranium along with a hyperplasia of the facial bones. In the tumor-like hyperostosis, isolated, more or less sharply limited, bony tumors with a spongy structure stand out upon a base of a usually insignificant, diffuse hyperostosis.

The addition of bone may take place on the inside as well as on the outside and runs a slowly progressive course. Cystic cavities occasionally occur within the areas of hyperostosis. The accessory sinuses in the region of the hyperostosis may even be enlarged.

The sufferers from the hyperostosis under discussion are in most cases not only disfigured to a considerable degree but they also suffer by reason of the diminution of their cranial cavity and their orbits and the nasal, nasopharyngeal, and oral cavities, as well also from the severe disturbances caused by



the stopping of the neural canals. This last change manifests itself by pain along the course of the cranial nerves, by psychic anomalies and by disturbances of sight, hearing, and smell. Sometimes there is a local hyperostosis combined with a general gigantism.

The hyperostosis very often remains limited to certain portions of the skull. Accordingly one can differentiate various types. There is a unilateral hyperostosis of the skull (hemisiderosis according to Brissaud and Lereboullet). Further there is a hyperostosis limited to the jaws, especially the upper jaw, of one or both sides. There is a thickening of the bone in the parietal region either symmetrical or asymmetrical (helmet-head), a hyperostosis of one squama temporalis.<sup>52</sup> or of one-half of the sphenoid bone, etc.

The cases of hyperostosis mentioned are to be considered, in part, as products of inflammatory irritation and, partly, as new formations. They arise in consequence of frequently recurring erysipelas of the head, in infectious diseases (influenza), lues, or after trauma.<sup>53</sup> There was observed, for instance, a periosteal addition of bone after a prolonged constriction of the skull by means of a rubber band. Also in the case of wood splitters, who carry and shift heavy boards upon the top of their heads, the chronic irritation is supposed to form a considerable hyperostosis of the vertex. The skull hyperostoses coming under observation as early as in childhood are to be considered as a congenital anomaly of formation or as the result of trauma during labor. As evidence that the latter are of congenital origin there is the often suggestive segmentation of the hyperostosis corresponding to the certain bones of the skull, also there is the observation that the progress of the thickening stops with the termination of normal bone growth (Schiller). Close relationship exists between this and osteitis deformans. Some cases may even suggest an osteoplastic sarcomatosis, especially since the transition of a previously benign

---

<sup>52</sup>Rinne described partial hyperostosis of the right frontotemporal region, developing in a young man subsequent to a trauma.

<sup>53</sup>The fact that hyperostoses of the skull appear in connection with trauma of the skull, for instance a kick on the head, makes the thought obvious that injuries could be the cause in Paget's disease (analogous to the etiologic significance of hypophyseal tumors in the matter of skeleton changes in acromegaly) and that a systematic investigation of the conditions resulting from basal skull injury could occasionally bring to light hypertrophic changes. Researches made by Leischner relative to this gave a negative result.

hyperostosis into an osteosarcoma can be established with certainty. In such cases also the simultaneous presence of a soft tissue tumor (endothelioma) of the dura may offer a hint as to the tumor-like character of the hyperostosis. (See section on Brain Tumors).

The pathogenesis of the affections under discussion is by no means clear, judging from what has been said. Owing to the rareness of its occurrence it is not to be wondered at that certain cases are judged differently and classified according to the ideas of the observer, especially since the nomenclature is not at all uniform.

The roentgen examination is an indispensable help in the determination of the existence, the extent, and the structure of the varieties of hyperostosis of the skull mentioned. It enables one to differentiate the deformities caused by hyperostosis from the more definite anomalies such as hydrocephalus, turri-cephalus, etc. In cases with indefinite symptoms, especially epilepsy, cranial nerve paralysis, psychoses, intracranial pressure, disturbances of sight or hearing, it may locate the cause as a concentric hyperostosis or a partial thickening of the base or as a thickening of some other part of the inner surface. This may be true even when, on the basis of the external examination, there has not been a suspicion of the existence of a hyperostosis. The finding on the roentgenogram naturally enables one to decide whether there is an indication for surgical interference.

The literature concerning hyperostosis of the skull is collected in Sternberg's monograph and the researches printed in recent years contain roentgenologic pictures (Boekenheimer, v. Eiselsberg, Sanger, Schiller).

Boekenheimer cited twenty-five cases, observed clinically, and included five cases examined by himself in 400,000 patients. He mentioned the fact that they sometimes get worse after operation.

Sanger's case was a woman, fifty-two years old, with headache, attacks of dizziness, humming in the ears, and nausea. The circumference of her head amounted to 63 cm.

The roentgenogram showed extraordinary thickening of the bone.

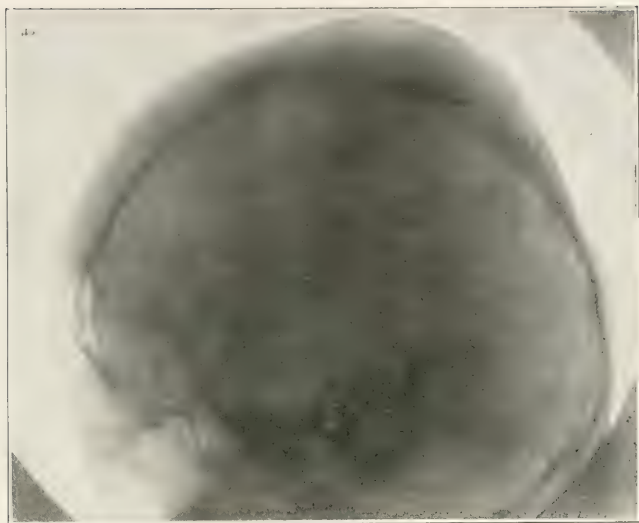

Fig. 25.—Diffuse hyperostosis of the skull in the patient discussed in Case 4.

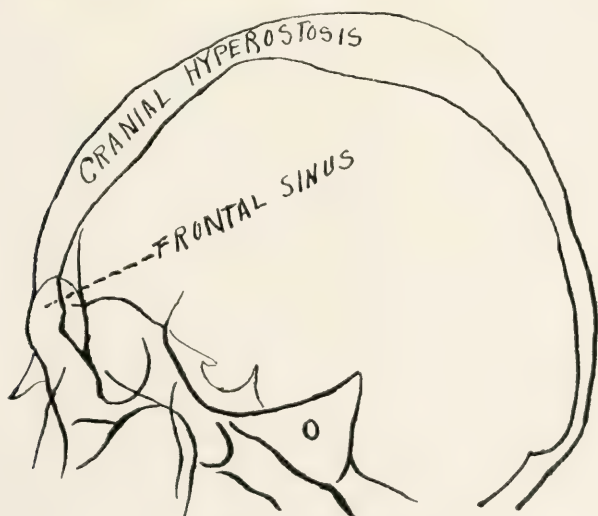


Fig. 26.—Sketch of picture in Fig. 25.

V. Eiselsberg described some interesting cases of hyperostosis, the roentgenograms of which we had occasion to take, and they are discussed below.

In our collection there are roentgenograms of several cases

of diffuse or tumor-like hyperostosis. Several of these may be cited here briefly:

CASE 1.—Boy, five years old. Imbecile. The skull appeared enlarged, hydrocephalic in shape, and asymmetrical. At the root of the nose there was a hemispherical prominence.

The roentgen picture showed, as the cause of the enlargement of the skull, a thickening of the bone, spongy in character and chiefly in the region of the frontal bone, and on the right side more than the left. The hyperostosis affected the outer surface of the skull and the root of the nose and amounted to 4 cm. in thickness.

CASE 2.—Boy, seven years old. Cerebral hemiplegia of the left side. The skull showed externally a deformity, in that there was a prominence of the right frontoparietal region.

The roentgenogram permitted the determination of a tumor-like hyperostosis, with a spongy structure, in the region of the right frontal and parietal bones. In places this was 5 cm. thick. Since the thickening projected markedly on the inner surface there was pressure on the cerebral centers which accounted for the cerebral infantile paralysis.

CASE 3.—B, male, fifty-four years old. An examination of the peculiarly formed high skull was desired because of hemiplegic attacks within recent months. The skull vault, on the roentgenogram, was 22 mm. thick, decreasing gradually in thickness toward the base. The bone was spongy in character. The base was normal. The thickening caused no decrease in size of the cranial cavity.

CASE 4.—Male, twenty-one years old, with hysteria and a strikingly high skull. In the roentgenogram the frontal and parietal bones were 20 mm. thick, the temporal and occipital portions of the vault were 4 mm. thick. The hyperostosis showed the normal spongy structure. The cranial cavity was not diminished in size. (See Figs. 25 and 26.)

CASE 5.—Female, twenty years old. Since earliest childhood a colossal enlargement, by gradual growth, had taken place in the perpendicular diameter of the head. In the last two years there had appeared a prominence over the left supraorbital region, accompanied by a protrusion of the left eye. Quite recently there had occurred a diminution in vision.

The roentgenogram showed a mass of bone of spongy character 80 mm. high, 165 mm. long, and 135 mm. broad, located on the vertex, and tapering off toward the thickened bone of the lateral portions of the head. Besides this there was a hemispherical mass of bone, 30 mm. long, lying sagittally on the skull base, in the region of the left half of the planum sphenoidale. This latter mass of bone caused an increase in intracranial pressure, signs of which were discernible in the deepened impressions on the inner surface of the skull. It also caused the protrusion of the left eye with compression of the ocular nerves. (See Figs. 27 and 28.) Repeated operations and finally the postmortem verified the roentgen finding. This case is described in detail in the author's *Atlas der Schädelbasis*, p. 58. It was later discussed by von Eiselsberg.

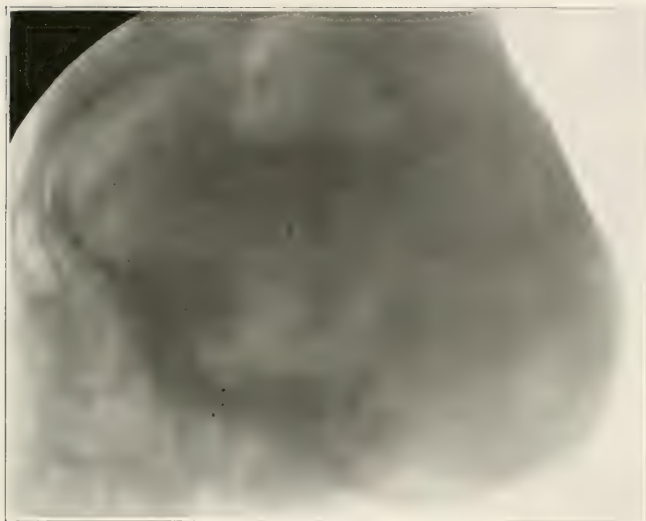

Fig. 27.—Dextrosinistral picture of a tumor-like hyperostosis of the vault and base of the skull of the patient discussed in Case 5. All of the hyperostosis of the vault does not appear on the plate.

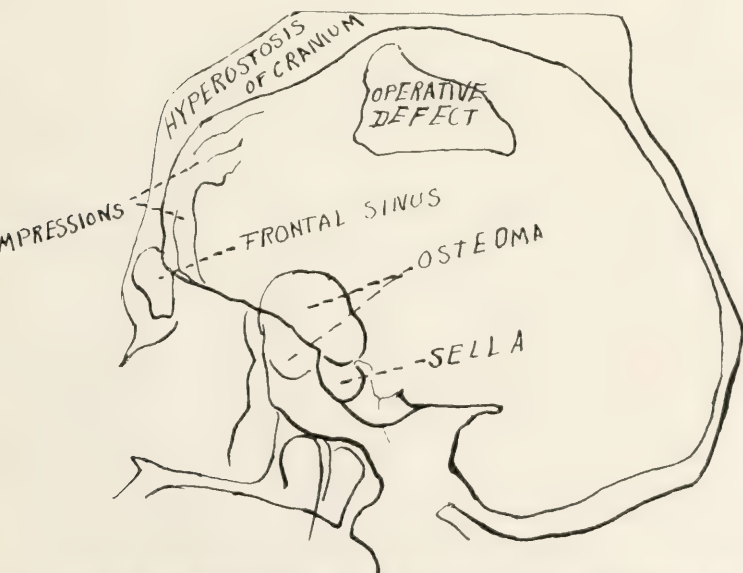


Fig. 28.—The sketch of Fig. 27. By studying the two in conjunction, the details of Fig. 27 come out more clearly.

All five cases mentioned show superficially developed spongy hyperostosis of the exterior of the skull in the vertex region. The hyperostosis produced, clinically, a deformity of the skull which, however, was without cerebral symptoms in Cases 1, 3, 4 and 5. At least, we do not venture to establish a relationship between the nervous disturbances (imbecility, hemiplegia, hysteria) in these four cases and the excentric thickening of the skull. In Case 5 the basal bone growth was the cause of the eye symptoms. Only in Case 2, where the hyperostosis of the parietal region extended toward the interior, do we consider it the cause of the contralateral hemiplegia.

We will discuss partial hyperostosis of the base of the skull and of the face in the sections on Eye, Ear, and Nose Diseases.

### **Tumors of the Skull**

Under this heading we will discuss those anomalies of the skull which are caused, on the one hand, through primary and metastatic tumors of the skull bones and, on the other hand, by tumors of the soft tissues covering the skull. Although the tumors of the skull are of primary interest to the surgeon, they also must be passed upon very often by the internist, on account of symptoms arising intracranially (intracranial pressure, epilepsy, paralysis of the cranial nerves, neuralgia), or it may be on account of their relation to a general disease of the individual (leucemia, tumor metastases). The tumors of the skull may be associated with either a new formation of bone or with destructive processes and changes in the shape of the skull.

With the help of roentgen procedures one may succeed in determining the character of the new bone formation associated with the tumor, and also the character of the destructive changes and alterations in the shape of the skull. By this means one may succeed in determining the point of origin, as well as the extent, and therefore be enabled to decide as to the operability of the tumor.

We will discuss first the primary tumors of the skull bone; namely, osteoma, sarcoma, osteosarcoma, myeloma, chloroma, chondroma, the parasitic tumors of the skull. And then we will discuss the metastatic tumors, sarcoma and car-

cinoma. Finally we will take up the tumors arising in attached soft tissues as, angioma, fibroma, lipoma, etc. The tumors arising from the intracranial structures, which grow through the bone, must also be mentioned here briefly (hydatid cysts, fungus dura matris). There is an excellent paper on skull tumors written by Auvray.

#### TUMORS OF THE SKULL BONES

Osteomata appear as circumscribed excrescences of the outer or inner surface (exostoses, enostoses), or in the wall of the skull. Consequently they may project internally as well as externally or they may extend from the accessory sinuses (so-called cavity osteomata, see in section on Nasal Diseases).

Their structure may be spongy, often with a radial arrangement of bone columns, or they may be as hard as ivory. Their external surface is smooth, nodular or jagged. They are sometimes multiple. Occasionally one finds an osteoma simplex in the process of transition into sarcoma at several points. There are also processes that are intermediate between osteoma and diffuse hyperostosis.

Rolleston described a calcified tumor the size of an orange, which had its point of origin at the junction of the occipital bone with the sphenoid, possibly in the sphenoccipital cartilage. The latter was already ossified in a fourteen-year-old boy, when normally it usually ossifies in the twenty-first year. There is a description of osteoma of the face and skull by Cornil-Coudray. The most recent review of the literature is by Sippel.

It is worth while to mention that in multiple cartilaginous exostosis the skull almost always remains uninvaded. On the other hand we find osteoma formation in the muscles of the head (especially in the jaw muscles) as a local manifestation of polymyositis ossificans. Such ossification may occur without other manifestation.

The most frequent form of sarcoma is the osteosarcoma. It may have its origin from the outer surface (periosteal sarcoma) or from the marrow of the diploë (myelogenous sarcoma), or from the dura. The favorite sites are the jaw and the wall of the nasal cavity. Osteosarcoma is in most cases a soft tissue tumor eroding the bone or substituting for it a bony

framework which is developed as a network or as nodes or only as bony scales.

Sometimes an osteosarcoma has such a similarity to the earlier described tumor-like or diffuse hyperostosis that even in an anatomic preparation it is not possible to determine the difference macroscopically.

Myeloma and lymphosarcoma belong to the rare types of primary sarcoma of the skull. In both, as a usual thing, the sarcomatous affection is but a local manifestation of a general disease of the skeleton. As elsewhere in the skeleton, myeloma makes its appearance in the shape of numerous areas which rarefy the skull vault, excavate small cavities, or perforate the bone. Lymphosarcoma, which with predilection occurs as a primary affection in the skull during early childhood, forms diffuse superficial proliferations which, on the one hand give rise to a rarefication of the bone whereby the latter becomes flexible and undergoes changes in shape, and on the other hand, leads to a formation of new bone causing the skull to appear enlarged. The most frequent form of lymphosarcoma is the chloroma, whose extension on the skull base, especially in the neighborhood of the orbit, in most cases leads to symptoms referable to the organs of sense and the cranial nerves. The discoloration and hemorrhagic suffusion of the skin which is brought about by this tumor may simulate Barlow's disease.

Among the metastatic tumors of the skull, coming under observation, the most common are carcinoma and sarcoma originating in the thyroid, prostate, mamma, or suprarenal gland. The metastases manifest themselves either in the form of circumscribed areas of destruction or rarefication of the skull wall, or they infiltrate it diffusely without essentially changing its shape. In the latter case there results either a rarefication or sclerosis of the bone, the osteoclastic and osteoplastic form of carcinoma or sarcoma.

Cholesteatoma is a variety of tumor peculiar to the skull. It may produce an extensive destruction of the bone, especially the temporal bone.

Hydatid cysts of the skull are very rare. They take their origin either from the outer surface of the dura or from the



sinuses of the base (Antoniu). The bone becomes pressed outward, thinned, and even perforated by the cyst.

Rare new growths, are the periosteal lipomata which erode the bone (Auvray). Enchondroma and chordoma are also rare. The latter is found in the region of the basilar synchondrosis in the middle of the clivus and is usually small (the size of millet to lentil seed) but in rare cases larger ones have been described (chestnut in size, Sieffer). Exceptionally, the tumor is found in the sella turcica (Spiess). It is derived from rests of the chorda dorsalis. Fischer described a malignant chordoma. Enchondroma is found only in the cartilage of the jaws prior to the ossification. This is also the case with enchondrosis ossificans which appears usually multiple, but does not attack the skull vault.

The roentgen examination gives indispensable assistance for the diagnosis of bony tumors of the skull. It discloses the existence of osteomata and osteosarcomata which are absolutely not discernible externally, such as those on the base, the inner surface, or in the air chambers. It demonstrates the extension toward the cranial cavity of bone growths visible externally. It permits a view of the structure of the tumor and enables a determination of its character, whether it is a question of a simple osteoma (spongy or eburnated) or of an osteosarcoma. And finally it reveals definitely that there is a bony tumor present and not simply a distention of the bone, or an inflammatory swelling (gumma), or a tumor of the soft tissues.

The roentgen examination permits also the proof of the halisteresis, osteoporosis, and defect formations of the bone caused by tumors of the skull which contain no bone, even in those localities where examination is impossible from the outside. From the character and extent of the destruction one obtains a clue for determining the nature of the tumor and for its differentiation from the destructive effects of lues, tuberculosis, etc., as well as for making a decision as to the possibility of operative interference.

Apart from tumors of the bones of the face which are mentioned in later sections, roentgenographic pictures of tumors of the bones of the skull are quite rare.

We had occasion to examine, among others, the following cases:

CASE 1.—P., female, twenty-eight years old, with hysterical attacks for years. Gradually, during the course of these attacks, a hemispherical swelling had appeared on the forehead which had been falsely diagnosed as luetic in character.

The roentgenogram showed that the visible bulging was caused by an osteoma which had projected 4 mm. into the cranial cavity and which was probably without clinical significance.

CASE 2.—S., female, thirty years old. Patient had suffered for two years from neuralgia of the left upper branch of the trigeminal nerve, and in the last few months there had been an exophthalmus of the left eye.

As a cause of these disturbances, which were associated with a nasal accessory sinus affection, the roentgenogram established the presence of an olive-sized osteoma of the roof of the left orbit.

CASE 3.—B., male, twenty-five years old. Had neurasthenic complaints which even reached the grade of attacks of melancholia.

The roentgen examination showed a flat, sharply marked, enostosis the size of a bean in the region of the bregma near the middle line. Of interest, is the fact that after extirpation of this enostosis the psychic features disappeared so that the patient was able to resume his trade.

CASE 4.—Female, forty years old. For years the patient had complained of symptoms referable to the cranial nerves on the left side. During this time there had been a tumor of bony hardness projecting 1.5 cm. above the level of the skull in the region of the frontal eminence.

The roentgen picture showed that the visible tumor represented an osteoma which projected deep into the cranial cavity to the region of the middle cranial fossa. The case was operated and was published.<sup>54</sup>

The four cases cited represent circumscribed osteomata which, according to their site, have a course free from symptoms or are associated with severe cerebral, nervous, or ocular disturbances.

The two cases following illustrate the significance of the roentgen examination for the diagnosis of metastatic tumors of the skull bone:

CASE 5.—Male, fifty-six years old. Was suffering from diffuse pain, especially in the region of the vertebral column.

The roentgenogram made and demonstrated to us by our colleague Hauddeck showed thickening (up to 10 mm.) and island-like osteoporosis of the cranium which could be interpreted as a local manifestation of a general sarcomatosis of the skeleton.

<sup>54</sup>A roentgenogram of this case is found in my monograph in the *Handbuch der Neurologie* by Lewandowsky, vol. i, Plate XI, Fig. 1.

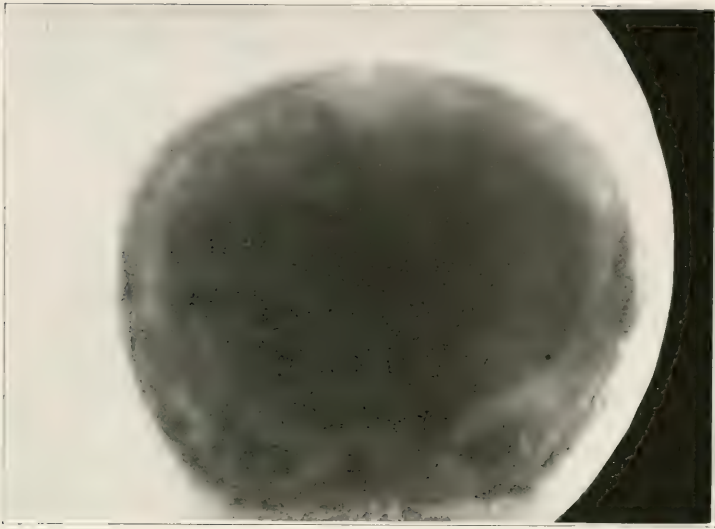


Fig. 29.—An anteroposterior picture of a case of sarcomatous infiltration of the skull. Note the osteoporosis appearing in the vault. At one point the vault appears to be perforated.

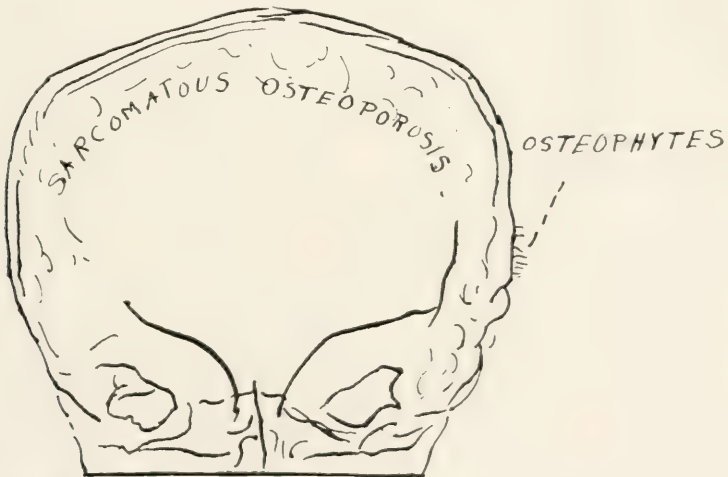


Fig. 30.—Sketch of Fig. 29. Attention is called to the formation of osteophytes on the surface.

CASE 6.—G., female, fifty-five years old. Pulsating tumor of the skull.

The roentgenogram showed, corresponding to this place, an extensive, indistinct, irregularly outlined defect of the bone. The neighboring tissue was osteoporotic (metastasis from a carcinoma of the thyroid gland).

We will add here a peculiar case of sarcoma of the whole skull.

CASE 7.—D., child, three years old. Showed a broadened head, swelling of the soft tissues, and a bluish discoloration of the skin.

The roentgenogram revealed extensive osteoporosis of the whole skull vault, on the outer surface of which were needle-like osteophytes 2-3 mm. long arranged in the manner of a halo. (See Figs. 29 and 30.) Section showed sarcoma of the skull.

Cases of osteoma and sarcoma of the base of the skull and the bones of the face are cited in the discussion of eye, nose, and ear diseases.

#### TUMORS OF THE SOFT TISSUES OF THE CRANIUM

The tumors which arise from the soft tissues of the head, may either infiltrate the bone in a similar manner to those tumors arising in the bone itself or they may simply cause atrophy of the bone by pressure. They may produce extensive deformities of the skull bone and, not rarely, are in communication with the intracranial contents through holes. They rarely produce a formation of new bone.

Sarcomata and carcinomata, arising from the skin of the head or from the mucous membrane of the accessory sinuses and cavities, belong to the category of tumors infiltrating the bone. Their differentiation from the tumors of the cranial vault is often not possible. Angioma, fibroma, dermoid, and lipoma belong to the group of tumors causing pressure atrophy of the bone.

The angiomata arising from the soft tissues of the head are diverse in kind. We mention first hemangioma venosum, simple and cavernous, of the soft skull covering. The veins of these are sometimes in communication with the veins of the diploë or with the intracranial veins. This is shown on the x-ray picture through the presence of numerous openings. The vessel tumor is usually surrounded at the edge by a wall of bone and, at the base of the tumor, the surface of the bone may appear uneven. Changes in the shape of the skull may be produced by the presence of these tumors. Wolf describes enlargements of the jaw with anomalies in curvature of the latter caused by flat angiomata.

The fact that the angiomata of the outer surface of the skull,

which occur most frequently on the face, more seldom on the forehead, in the region of the little fontanel, and external occipital protuberance, sometimes communicate with the interior of the skull makes it readily understood that cerebral symptoms are observed in sufferers from such angiomata.

The "sinuscele" manifests a similar behavior to that of the angioma communicating with the intracranial circulation. One designates as a "sinuscele" (*varix spurius venae diploeticæ*) an accumulation of venous blood in a cavity in the soft tissues on the outer surface of the vault, arising through erosion of the skull wall over diploic veins, Pacchionian granulations, or venous sinuses. The cavity of the sinuscele is, in consequence, in communication with the diploic and intracranial venous systems through a hole in the skull. The compressibility and the change in the shape of the tumor produced by a change in the position of the head are characteristic. The sinuscele may be of congenital or of traumatic origin. (Cases of Krause, Borchardt, Wieting, von Eiselsberg, *Wiener klinische Wochenschrift*, 1905, p. 149). Concerning blood tumors (cephalhematoma), produced by trauma, see Injuries of the Skull.

Cirroid aneurysm is a variety of tumor which, consisting of widened and manifoldly twisted arterial vessels, localizes by preference in the region of the skin of the head. It produces usually a rarefying osteitis of the skull wall lying under it and may lead to perforation of the latter. Simultaneously with the external cirroid aneurysm or independent of it, a similar picture may appear on the inner side of the skull wall, in which case the furrows of the middle meningeal artery are deepened and increased in number. In addition to this the simple aneurysm, which may take its origin from the arteries of the soft external tissues, the intracranial arteries, the meningeal arteries, or the carotid, leads sometimes to erosion of the skull wall.

Dermoid cysts, which, as is known, come under observation quite often, usually cause erosion of the skull bone. They may even communicate with the interior (Vincent, *Jahresbericht für Chirurgie*, 1905, p. 344).

Fibromata, which occur in the soft tissues attached to the skull, appear often in diffuse form. They permit differentiation into neurofibromata and lymphofibromata according to their

location on the nerves or lymph vessels (Helmholtz and Cushing, *American Journal of Medical Sciences*, 1906). In most cases the presence of these tumors produces significant changes in the bone of the skull. One observes either hyperostosis of the skull wall or atrophy of the latter, which may continue even to perforation, so that this tumor may communicate with the interior of the cranium. In such a case it will pulsate (Billroth). In an appropriate way the appearance of a neurofibroma has been compared to that of an empty mamma and the appearance of a lymphangioma to loops of intestine.

Among the lipomata of the skull covering, the so-called osteoperiosteal (Schwartz and Chevrier, *Revue de Chir.*, 1906) deserve special notice. They erode the skull and form a bony ring at their base. If they are located on the outer surface of the skull base they may press forward and deform the bones of the face.

See the section on Rhinology in regard to the air-containing tumors of the skull (pneumatocele).

The roentgen examination permits one to arrive at important conclusions relative to the changes in the skull occurring in connection with tumors which arise from the soft tissues. It reveals destruction and infiltration of the bone in consequence of malignant tumors of the soft tissues. It also, however, enables us to demonstrate the pressure atrophy in the skull from benign tumors developing in the course of years, as well as the occasional hyperostosis. It facilitates the differential diagnosis of the tumors under discussion from inflammatory changes or congenital malformations (brain hernias). Occasionally the roentgenogram shows changes of the skull wall which point to the fact that the tumor, visible externally, invades the bone and even may project into the cranial cavity.

Clairmont described the roentgenogram of a man with angioma racemosum of the arteries of the head. One could see the furrows of the middle meningeal artery were broadened and tortuous, and the small branches were readily discernible. Clinically there existed headache and epileptoid attacks.

Flesch demonstrated a case of plexiform angioma of the soft tissues with extensive erosion and osteophyte formation

of the outer surface of the skull, which was readily discernible in the roentgenogram.

Wolf published some pictures of the previously mentioned changes in the jaw with nevus of the skin of the face.

We had the opportunity, in several cases of soft tissue tumors of the skull, to make the differentiation, with the help of the roentgen examination, as to whether a visible and palpable tumor of the soft tissues had invaded the skull or even the interior of the cranium.

One of these cases may be mentioned here:

CASE 1.—D., male, sixty years old. During the course of several years, a flat tumor the size of the palm of the hand had developed on the left parietal region of the patient, while, simultaneously, a gradually progressive hemiplegia of the right side with aphasia had developed. The tumor which felt as hard as bone had been considered as the cause of the cerebral symptoms, since it was assumed that the tumor had grown into the intracranial cavity.

The roentgenogram showed that the tumor was confined to the outer surface of the skull and was not ossified.

Further we examined two cases of hemangioma venosum and one lymphangioma of the skin of the face. The latter case is described in the section on Eye Diseases. The other two cases may be cited here briefly:

CASE 2.—Girl, seventeen years old. Since her birth she had had a soft fluctuating collapsible tumor of the vertex.

The roentgenogram showed no change in the skull wall. The case was demonstrated and afterwards operated by von Eiselsberg as a sinusecele or a pericranial hematoma.

CASE 3.—Male, twenty-two years old. Since he was six years old patient had had a tumor of the right cheek and temporal region which became distended when the patient lay down.

The roentgenogram showed thinning of the skull in the temporal region and the floor of the middle cranial fossa. The case was demonstrated by my colleague Tauber. (*Wiener klinische Wochenschrift*, 1905, p. 294.)

## INJURIES OF THE SKULL

Although the wounds of the skull are of primary interest to the surgeon, the internist is also frequently in a position to observe the results of trauma of the skull, especially when on account of the wound an injury of the intracranial contents has been produced.

The pathologic changes caused by a wound of the head may be divided into injuries of the soft tissues on the outside, injuries of the bone and injuries of the contents.

Among the injuries to the soft tissues the consequences of which bring changes in the skull, cephalhematoma and aneurysm come under consideration. A cephalhematoma arises in the newborn through a collection of large quantities of blood between the outer surface of the skull and the pericranium. It is found in about  $\frac{5}{10}$  of 1 per cent of births. It is located usually over the upper posterior angle of the right parietal bone, seldom over both parietal bones. The elevated periosteum almost always forms a bony wall around the base of the blood tumor. Only extremely seldom does the bone formation extend over the entire surface of the hematoma as a thin scale.<sup>55</sup>

The arterial aneurysm arising from injury as well as the earlier described aneurysms not of traumatic origin may produce pressure atrophy of the skull.

So far as the wounds of the cranial skeleton are concerned they occur, almost without exception, as a solution of continuity, the character of which is influenced, on the one hand, by the character of the violence and, on the other hand, by the structure of the part affected. The stab wounds, sword wounds, and gashes, produced by sharp instruments, affect chiefly the vault and show often a dislocation of the fragments (depressed fractures), while the solution of continuity caused by a blunt force affects, by preference, the delicate portions of the base and results in simple fissures or separated sutures. A combination of both mechanisms of skull injury is found in gunshot wounds.

Under conditions otherwise similar, the character of the injury depends upon the structure of the skull. The elastic skull bone of the young and the compact bone of the healthy adult permit of a solution of continuity much less readily than the thin senile skull or the skull that has become fragile through processes of disease.

The conditions resulting from injuries to the skull bone should be divided into two groups; viz., the processes capable of being repaired and those that can not be repaired. No in-

<sup>55</sup>As mentioned previously we can not say whether the tumor like hyperostosis some times occurring in children, is not also dependent upon a traumatic injury during birth.



injuries to the bone manifest that activity at repair in the skull that is common to the other parts of the skeleton. Indeed, it not seldom happens that a traumatic solution of continuity in the skull will not undergo bony healing. Losses of bone tissue which arise in childhood through trauma, as a usual thing, even become greatly enlarged with the growth of the skull, so that the soft intracranial tissues lying under the hole are usually pathologically changed as is the case in porencephalia traumatica or meningocele traumatica spuria. The enlargement of fissures and holes results through the growth of the brain.<sup>56</sup>

Of interest is that observation that there may develop gradually a depression of the skull wall at the site of a dull blow. More seldom there occurs an excessive formation of bone on the site of the fracture and then one sees a thick deposit of osteophytes corresponding to the location of the fracture. We have already mentioned that an extensive diffuse hyperostosis of the bone may occur in connection with skull trauma.

The injuries of the cranial content produced by trauma manifest themselves, as is known, either as a cerebral concussion, in which no macroscopic changes exist, or as contusions or lacerations of the brain, its membranes, and vessels. The site of the brain injury lies in close relation to the site of the skull injury. This is readily understood in penetrating wounds made by sharp instruments. In the injury produced by a dull blow the portions of the brain opposite the site of injury show contusions (*contrecoup*). In addition to inflammatory changes (meningitis, brain abscess), the occasional calcification of softened areas, the formation of arterial aneurysms, and the development of brain tumor,<sup>57</sup> should be mentioned as sequelae following injuries of the cranial contents.

---

<sup>56</sup>H. Chiari has given an accurate anatomic description of a peculiar case of this character. The portion of the skull affected was enlarged and perforated by numerous large holes. A cavity filled with liquid was found in the brain.

A similar case was recently described by E. Winkler. He, also, reviewed the literature concerning the condition.

Beitzke demonstrated a case in which the clinical diagnosis was a brain tumor. The anatomical examination showed an apparent duplication of the squama occipitalis and, between the two lamellae, there was a narrow cavity filled with liquid which communicated with the posterior horn of the left ventricle. Simultaneously there existed a hydrocephalus interna "most probably of traumatic origin" and on that account it is mentioned here.

<sup>57</sup>Cerebral symptoms were found in a male patient from the Wagner clinic which could be traced back to a severe trauma of the skull, suffered several years previously. As a residuum of this trauma there were deep depressions on the parietal bone and at the postmortem a tumor of the brain was found.

The roentgenologic examination is an indispensable supplement to the other methods of examination for the diagnosis of skull injuries. In the very beginning of the roentgen era, the x-ray examination of gunshot wounds was utilized everywhere successfully. With the help of the fluoroscope and the roentgenogram it is possible, not only to determine the presence of a projectile, but also to locate its position accurately and even possibly determine the route which it has traveled to reach the site where the roentgenogram shows it to be. The roentgenologic discovery of a projectile or other foreign body is sometimes a surprising occurrence, clearing up the state of affairs at one stroke. Of importance is the circumstance that with the help of the roentgenogram it is possible to make a quick and trustworthy focal diagnosis which is of equal value to the one made on the basis of the neurologic symptoms.

The second group of traumatic changes which come under consideration for roentgenologic investigation is composed of the fractures and the changes in the shape and structure of the skull wall. So far as the changes in structure are concerned there have been, up to the present, no observations made proving the possibility of their being exhibited roentgenographically.<sup>58</sup> It has not been decided up to the present whether Sudeck's bone atrophy, which occurs in connection with injuries to the skeleton of the extremities, also occurs in the skull. However, the roentgenogram enables one to ascertain the thickness and density of the skull and hence arrive at a conclusion as to its predisposition to fracture. For the determination of changes in shape (depressions) of the skull wall in consequence of injuries, the roentgen examination is particularly indispensable if the other methods of examination are prevented on account of swelling from the accumulation of pus, blood (*varix spurius traumaticus*), or fluid (*traumatic meningocoele*), or on account of painfulness to the touch. But even if neither the swelling nor the painfulness make the examination difficult, it is not always possible, by means of palpation, to make the differentiation between depression and defect in the skull bone. A defect may, for instance, be bridged over by such firm connec-

<sup>58</sup>Benedikt's assertion that one could observe differences in shadows which are to be accounted for by hemorrhagic suffusion of the skull wall does not correspond to the facts in the case

tive tissue that for the palpating finger there is the feeling of a bonelike resistance.

Of special importance is, finally, the use of the x-ray in those instances where the external examination gives no evidence or no certain clues as to the existence and location of a solution of continuity, as is very often the case in fractures of the base of the skull. In such cases the roentgenogram permits one to determine the existence of fissures or separated sutures and their course with relation to the vessel furrows. Occasionally, roentgenologic proof of darkening of the accessory sinuses, in consequence of a collection of blood, may offer a hint as to the existence of the basal fracture. Upon the basis of a definite knowledge of the place and the course of a basal solution of continuity one may often, not only obtain a suggestion as to the mechanism of the injury, but also be enabled to decide whether there are likely to be injuries to the brain and where they will probably be.

Finally, so far as concerns the injuries of the intracranial structures, their direct exhibition, only very rarely, forms the object of the roentgenogram. As mentioned above, collections of blood and pus do not show on an x-ray plate. Consequently it occurs only exceptionally that the roentgenogram offers any valuable assistance in these cases except when calcification of a traumatic area of softening occurs,<sup>59</sup> or when, in connection with the trauma, processes causing increased intracranial pressure are set up, as, for example, hydrocephalus, meningitis serosa circumscripta, tumor cerebri.

The numerous old researches, relative to the roentgen diagnosis of head injuries, are cited by Fürnrohr. We should mention also the more recent reports of Schwartz who studied the healing of skull fractures roentgenologically: of Denks, who emphasized the frequency of demonstrable fissures in apparently harmless hematmata in children, and of Markovic, who collected the cases of basal fracture from our material.

The cases which we had opportunity to examine were those of fissures, depressed fractures, gunshot wounds, defects, and others. Several of these may be cited in brief:

---

<sup>59</sup>According to our experience, such an occurrence seems to be able to take place within a few months after the trauma.

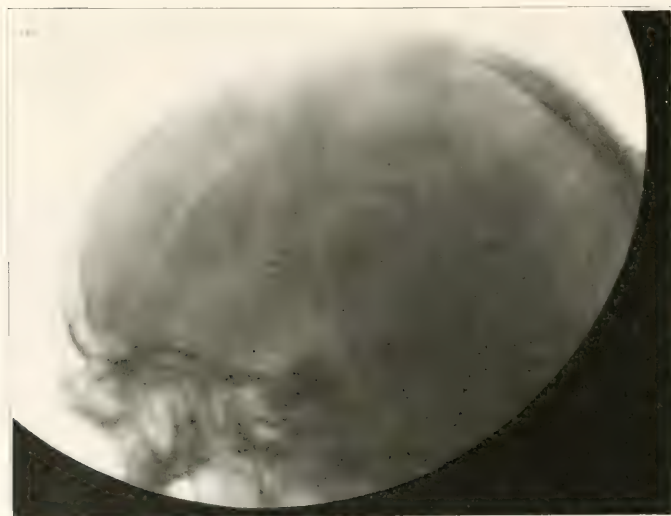


Fig. 31.—A dextrosinistral picture of a skull in which there are two fissures, one in the frontal bone and the other in the temporal bone, on the left side.

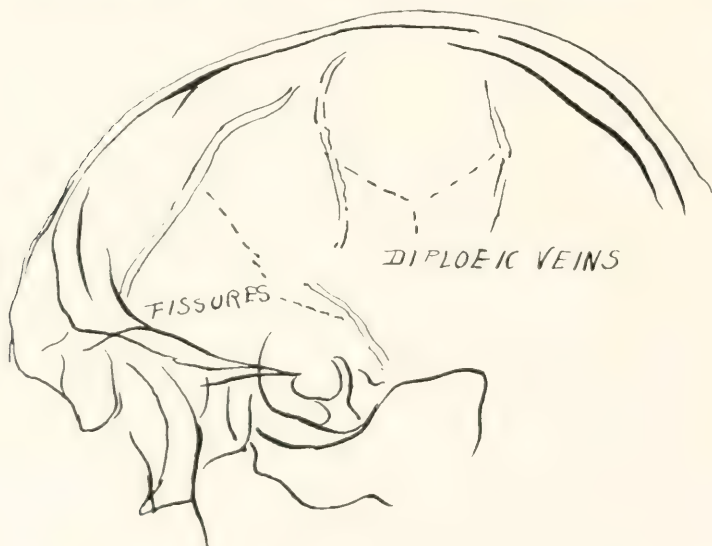


Fig. 32.—Sketch of Fig. 31 in which the main features are emphasized.

CASE 1. Sch., male, thirty four years old. Severe skull injury from an automobile accident. Hematoma of the left eye and temporal region. Cranial nerve paralysis on the left side.

The roentgenogram showed a slightly gaping fissure of the left half of

the skull extending from the vertex forward and downward. Besides this there was a delicate fissure, 3 cm. long, on the skull base in the region of the middle cranial fossa. (See Figs. 31 and 32.)

CASE 2.—G., girl, sixteen years old. Showed symptoms of concussion of the brain after a fall from a ladder. Was examined roentgenologically on account of continued disturbances (headache, dizziness) after several months. By means of an x-ray picture, one was able to see that there were several changes in the skull; namely, a fissure in the squama occipitalis, a round area of calcification corresponding the center of the left occipital lobe and an increase in the depth of the convolutional impressions.

CASE 3.—A. M., male, thirty years old. In 1906 suffered a trauma of the head, asserted to have been in region of occiput. Jacksonian epilepsy in facial region at time of examination.

In the roentgenogram was found a linear fissure 2 cm. long on the left side of the frontal bone and two fingerbreadths above the orbital margin.

CASE 4.—Male, thirty-six years old. Following a blow with a club on the left temporal region, motor aphasia and Jacksonian epilepsy of the right extremity appeared within two days. Roentgen examination was desired on account of the suspicion of a rupture of the meningeal artery.

The picture revealed the existence of an angular fissure of the frontal bone above the outer orbital edge and a separation of the coronal suture at the bregma. The furrow of the middle meningeal artery appeared distinct and was not affected by a solution of continuity, and on that account it was decided not to operate. Complete healing after two weeks.<sup>60</sup>

All four cases are of diagnostic interest. In the first case there were no clinical symptoms that would cause one to think of the presence of the long fissure in the vault. In the second case there existed symptoms which were interpreted as a manifestation of a traumatic neurosis until the roentgenogram proved changes in both the bone and the brain. In the third case, the history revealed no clue for the fissure visible roentgenographically. Proof of its presence on the other hand, explained the clinical finding. The fourth case, without the roentgenogram, would certainly have suffered the operative exposure of the middle meningeal artery.

Further, four of our cases were individuals who showed large defects in the skull wall along with signs of porencephaly or traumatic meningocele after severe injuries to the head in childhood and youth. All four patients suffered from epilepsy, but two of them presented still other interesting symptoms, so that

<sup>60</sup>See Fig. 5, Plate VII in my monograph on the *Head* (by G. Leonard Dawley, vol. 1.

they may be mentioned here briefly. The other two cases are to be found in the section on Epilepsy.

CASE 5.—K., female, twenty-eight years old. Suffered a fall upon the occiput at two years of age. At the time of examination, patient complained of attacks of epilepsy, and blindness in the right upper quadrant of field of vision. On the occiput, to the left of the middle, there was a depression on the skull with palpable pulsation and, over it, a fluctuating soft tissue tumor.

The roentgenogram showed an oval defect in the occiput (7x4 cm.) with wall-like projecting edges.<sup>61</sup> The operation, performed in the clinic of von Eiselsberg, exposed a cyst of the occipital lobe.

CASE 6.—St. K., male, twenty-six years old. Trauma of the right temporal region four years previously. Some time after the trauma there appeared a tumor in the right temporal and frontal regions. Epileptic attacks. Following ligation of the carotid, both the tumor and the epileptic attacks disappeared for a long time. Recently the tumor reappeared following an epileptic attack.

The roentgenogram revealed the skull vault as being thin, (3 mm.) *in toto* and in the temporal region it was only 1 to 2 mm. thick. The frontal sinus was the size of a pea. There was a defect in the lateral portion of the right orbital rim, the roof, and the median wall. There was a widening of the sella and erosion of the temporal wall with bone proliferation at the edges of the defect. The operation verified these findings, as the cause of which, there was found an extra and intracranial collection of fluid containing masses of fibrin.<sup>62</sup>

<sup>61</sup>See Glaser, *Demonstration in the Verein für Neurologie und Psychiatric in Wien*, March 14, 1911.

<sup>62</sup>See Winkler, "Beitrag zur Kasuistik der Meningocele traumatica, spuria," *Wiener klinische Wochenschrift*, 1911, No. 36.

## CHAPTER III

### ROENTGEN DIAGNOSIS OF INTRACRANIAL DISEASES

In this chapter must be discussed the affections of the skull contents namely, the brain, the meninges, cranial nerves, and cranial vessels as well as the accessory glands of the brain, which are to be considered in roentgen diagnosis. We will begin with the discussion of the features of both normal and pathologically changed intracranial contents which can be photographed. We will then discuss in detail the skull changes which enter into the roentgenologic diagnosis of tumors of the brain, as well as the diagnosis of the increase in intracranial pressure which is intimately connected with them. Finally we will give a number of roentgen findings that were present in several cases with cerebral symptoms, especially epilepsy, migraine, psychoses and cerebral infantile paralysis.

#### **DETAILS OF INTRACRANIAL CONTENTS DIRECTLY DISCERNIBLE IN A ROENTGEN PICTURE**

As was previously mentioned, there exists such a close relationship between the inner surface of the skull and the outer surface of the brain that details of the external surface of the brain may be derived from an examination of the inner surface of the skull. Especially does the surface of the base of the skull show a true copy of the base of the brain, so that not only the boundaries of single lobes of the brain, the position of the brain stem and the shape of the hypophysis may be determined but also the outline of the convolutions can be distinguished here and there. The position of the sinus longitudinalis and the sinus transversus, as well as the Pacchionian grooves are also very plainly marked.

On the roentgenogram one can recognize in the living the details of the inner surface of the skull that have been mentioned and from them obtain such evidence as will enable one to

decide on the position, shape, size, and appearance of the corresponding intracranial structures. For instance, one can determine immediately the size of the hypophysis from the size of the hypophyseal fossa. On the other hand, it can not be sufficiently emphasized that one is not in a position to recognize directly on the roentgen picture anything from the brain tissue and its membranes, with the single exception that the pineal gland, when calcified, may be seen as a round or lentil-sized shadow lying in the middle line 4.5 to 5 cm. above a line joining the external auditory meatus and the lower border of the orbit, and 1 cm. posterior to the vertical plane through the external auditory meati.

The fact that one can often identify, in the roentgenograph of the skull, a structure lying intracranially at the typical place<sup>1</sup> is of practical value, as the existence of a normal pineal shadow may enable one, in doubtful cases, to decide against the presence of a pineal tumor.<sup>2</sup> One can also, for example, in case of a displacement of the shadow of a pineal gland to the right or left of the median line, in symmetrically formed skulls, conclude the cause of its displacement to be pressure on the part of a tumor or traction on the part of a brain scar, as the following case shows:

R. F., male, thirty-six years old. Trauma to the skull two years previously. At the time of examination he was suffering from hemiplegia of the right side following an apopleptic stroke. Internal organs normal. Wassermann negative. Suspicion of cerebral tumor.

The roentgenogram showed that the pineal gland, the shadow of which was plainly recognizable, was displaced several millimeters to the left from the middle line, from which fact one was able to draw the conclusion that no large tumor of the left hemisphere could be the cause of the hemiplegia, but, rather, that there was probably a contraction present, perhaps in consequence of an area of softening.

Pathologic changes in the intracranial contents permit of direct recognition on the roentgenogram to no greater extent than the normal contents, with exception of the calcified pineal gland just mentioned. Only two groups of cases, occurring, by the way, relatively seldom, form an exception to this rule.

<sup>1</sup>The pineal gland very often shows a calcium deposit in young individuals from about the third decade on, and occasionally even in children.

<sup>2</sup>Perhaps in the near future it will be possible, with the aid of a roentgen-kinematograph of the skull, to recognize the movement of the intracranial contents by the changes in the position of a calcified pineal gland or other shadow pictures (projectiles, calcified tumors).



The first group is composed of those destructive processes (intracranial pressure, tumors) which erode the accessory sinuses (frontal, sphenoid, mastoid process) so that then the shadow of the soft tissue (brain, meninges, tumor) forced into the accessory sinus stands out noticeably against the light area corresponding to the air chamber.

The second group of intracranial formations, directly recognizable roentgenologically, are relatively large areas of calcification or bone formation on the inside of the skull. These areas of calcification may be of variable origin, as calcified tubercles and Cysticercus cysts, calcified or ossified tumors (sarcoma and osteoma of the brain, hypophysis tumors, tumors of the pineal gland), calcified brain scars following encephalitis and contusions, calcium plates in the wall of cysts or aneurysms of the carotid.<sup>3</sup>

Areas of calcification in the brain have been seen in roentgenograms by Lichtheim, Fittig, Grummach, Robinsohn, Algyogyi, Sterz, Stieh, and others.

The case of Algyogyi was one of a basal tumor which suggested its presence in the roentgenogram, partly, by pressure atrophy of the sella turcica and, partly, by extensive calcification.

We had the opportunity of determining areas of calcification in the brain in five cases. Besides the three cases cited in the sections on Injuries and Epilepsy the other two may be mentioned here:

CASE 1.—K., female, thirty years old. Hemiathetosis since youth with contralateral oculomotor paralysis (Syndrome de Benedikt).

In the roentgenogram was seen one area of calcification, scalelike in appearance, lying in the vertical plane, through the external auditory meati, 3.5 cm. above the "German horizontal," and 0.5 cm. from the median line.

<sup>3</sup>On the other hand, it is not possible to take a picture that shows a slight calcification of the choroid plexus, the brain substance, or the basal arteries. It is also impossible to show the little bone platelets that occur in the falx.

Oppenheim cited a number of calcified tumors in the literature. They were a partially ossified tumor of the cerebral hemisphere, bone in a glioma, and calcified tumors of the choroid plexus and of the hypophysis. He spoke also of the fact that osteomata and osteofibromata were frequently supposed to take their origin from encephalitic scars. Arnold described an apple-sized psammoma of the choroid plexus in the third ventricle. Rheindorf (*Charité-Annalen*, vol. xxxii, 1908) described a papillary epithelioma of the fourth ventricle with lime concretions.

Marie and Levi found, at postmortem, a calcified area 1 c.c. in size (most probably a tubercle) in the lower portion of the cerebral peduncle.

Astwazaturow, in speaking of cavernous tumors of the brain, emphasized the possibility of recognizing them in roentgenograms on account of the frequent presence of a calcium content.

CASE 2.—S., male, thirty years old. Clinical findings the same as in the case above.

The roentgenogram showed a bean-shaped area of calcification having a localization similar to the one in the case above.

The two cases mentioned, which were demonstrated by my colleague Gross in the Verein für Psychiatrie und Neurologie, 1911, are of special interest because in this instance the diagnosis of their location in the region of the red nucleus could in this way be verified during life.

Apart from the exceptional cases discussed in the previous chapter, pathologic changes of the intracranial organs, such as abscesses, exudates, cysts, hematomata, and soft tissue tumors, do not permit of direct exhibition on the roentgen plate.

In the beginning of the roentgen era great pains were taken to present directly the structures mentioned, especially soft tissue tumors (which, as is known, form the majority of all brain tumors) which means they endeavored to find a shadow on the roentgen plate corresponding to the tumor, abscess, etc. They sought first to convince themselves whether brain tumors, which were actually present in dead people or had been laid in the brain expressly for that purpose, were visible on the roentgen plate (Obici-Bollici, Oppenheim, cited by Fürnrohr). Such experiments permitted it to be quickly learned that it was wasted effort to endeavor to recognize soft tissue tumors, the density of which coincided exactly with the density of the rest of the brain and was much less than the density of the bony capsule of the skull surrounding the tumor on all sides. As final as these conclusions were (which were formulated by Holzknrecht in a most clear way), and as fruitless as were the experiments on the dead just mentioned, there were yet a great number of authors who were able to report concerning successful roentgenographic pictures of abscesses, soft tissue tumors of the brain, etc. (Church, Durante, Londe, Straeter, Mills-Pfahler, Benedikt.)

The reason why shadows of soft tissue tumors are found by observers, with limited experience, lies in the fact that a light area can be seen at the place where the skull lies upon the plate. Its presence is explained in the following way: On account of the nearly round shape of the head, a direct contact

of the latter upon the roentgen plate takes place always only upon a small portion of the surface of the skull. Around this point of contact between the surface of the skull and the plate there is present a layer of air within which secondary rays arise that darken the plate. The bright spot which corresponds to the point of contact between the head and the plate is, therefore, to be looked upon as due to absence of secondary rays. The authors who believed they had the shadow of a tumor before them could so much easier fall a victim to the deception since, taking into consideration the clinical finding, they had laid the plate under the region in which the tumor most probably had its location. If then, the result of the postmortem verified the clinical finding, it appeared unquestionable that the shadow seen upon the plate was the picture of the brain tumor found. Although those cases, in which the section determined a localization different from the one conjectured (cases of Rutkofsky), permit us to consider the much-mentioned shadow as a phantom, Robinsohn explained perfectly the true nature of the shadow picture by discovering a simple means for preventing it: namely, by using two plates. The secondary rays were intercepted by the plate lying next to the skull to such an extent that they appeared almost without effect on the second one.

Nowadays the knowledge of the fact that the great majority of brain tumors do not make themselves directly distinguishable as shadows upon the roentgen plate has been generally accepted. But an extremely small minority of authors continue to cling to the possibility of this direct presentation. The bad result of the impossibility of making pictures of tumor is the erroneous view which prevails, that, because of this, we can not use the x-ray at all in making the diagnosis of brain tumors. We find this standpoint expressed even in books of recent date.

## **SKULL CHANGES IN CONSEQUENCE OF INTRACRANIAL DISEASES**

As follows from the foregoing statements, the great majority of all brain tumors and other intracranial processes would undoubtedly present unfavorable objects for roentgen diagnosis

if one would limit himself to those intracranial anomalies which are directly visible as shadows on the plate. Fortunately another way was early discovered; namely, the disclosure of intracranial anomalies by discovering changes which were produced in the skull bone by the pathologic intracranial processes.

Oppenheim was the first one who saw a widening of the sella turcica in the roentgenogram of a case of acromegaly and from this change made the diagnosis of the existence of a hypophyseal tumor. About the same time Albers-Schönberg observed a thinning of the skull vault produced by a brain tumor. With these observations it became evident that one must use this and similar evidence in order to obtain utilizable results in the x-ray diagnosis of intracranial processes. Later the positive roentgen findings, relative to the destruction of the sella turcica in consequence of hypophyseal tumors, multiplied (Beclère, Holzknrecht-Fuchs, Josefson, and many others). Investigations by Erdheim taught the differentiation between destruction of the sella turcica which was produced by tumors arising intrasellar and that which took place on account of extrasellar hypophyseal tumors, as well as that arising from tumors located elsewhere. That this differentiation was possible with the help of the roentgenogram, we were able to show first on anatomic skull preparations and later in the living.

As the result of our further investigations we have made progress, in the way indicated, in determining the existence of intracranial diseases from the secondary changes in the skull that were visible on the roentgen plate. For that purpose it was necessary above all to know those pathologic changes in the skull bone which were produced by intracranial disorders. Fitted with this preliminary knowledge, we were able to convince ourselves that two main groups of intracranial diseases could be diagnosed from the skull changes as shown in the roentgenogram. The two groups consisted of, first, those which produced local destruction of the inner surface of the skull and, second, those which brought about chronic increased intracranial pressure. These diseases are for the most part represented by tumors and tumor-like affections (cysts, tubercles, syphilomata, aneurysms) of the brain, its membranes and glands, as well as by hydrocephalus.

As regards the kind of alteration in the skull, it is most often a matter of destructive changes on the inner surface. This destruction is either local or is spread over the whole inner surface. The first arises usually through direct pressure (pressure atrophy) on the part of the disease of the soft tissues located at that point, more rarely does the destruction result from carious or infiltrative destruction.

The second form of destruction, namely, the erosion spread over the whole inner surface of the skull, is an expression of the increase in intracranial pressure. The erosion does not appear however, at all points on the skull simultaneously or in similar degree. Usually the delicate portions of the base in the neighborhood of the sella turcica, as well as the frail floor of the anterior and middle fossæ, suffer first. The bony ledges become sharpened, the convolutional impressions become deepened, the interconvolutional ridges become pointed, and little basin-shaped cavities, containing little brain hernias, appear. Also in the region of the vault, and that first in the frontal portion, are formed irregular excavations of the inner surface which correspond to deepened convolutional impressions between which points of bone sharply project.

Further, anatomic changes in the skull, in consequence of the increased intracranial pressure, affect the venous vessels. There follows a deepening of the venous sinuses and Pacchionian fossæ, as well as a widening of the emissaries and the diploic veins.

Of importance also is the behavior of the sutures of the cranium in cases with elevated intracranial pressure. They become widened, the suture serrations become thinned, and, in the end, the sutures may undergo a complete separation.

The shape of the skull sometimes undergoes changes also, that is, through the effect of the increased pressure in skull-capable of growing, the whole cranium becomes enlarged. Only in rare cases does one observe a local bulging of the skull wall corresponding to the site of the affection.

Finally, there comes under consideration a thickening of the wall of the skull, a change not sufficiently studied up to the present. It appears in the form of circumscribed protuberances or diffuse hyperostoses on the inner surface.

All the changes mentioned, which earlier were almost entirely of pathologic or anatomic interest alone, can be presented clearly in the roentgenogram and gain thereby great clinical significance. We will discuss the above enumerated kinds of skeletal changes in the skull in their order and demonstrate their practical usefulness by means of characteristic cases that have come under our observation.

### Local Destruction of the Skull in Intracranial Tumors

Local disintegration, in the form of pressure atrophy or carious or infiltrative destruction, may arise through disease processes on any point of the inner surface of the skull. One can draw a conclusion as to their cause from the position and outline of the local pathologic change. Such as come under consideration are tumors (cysts) of the meninges, the cranial nerves, the hypophysis, and the surface of the brain, tuberculous and syphilitic disease of the interior of the skull which take their origin from the meninges or the surface of brain, and, finally aneurysms of the basal intracranial arteries.

We will begin with the discussion of the erosions on the skull base.

The most frequent forms of local destruction of the base, coming under observation, are those caused by the following:

#### TUMORS OF THE HYPOPHYSIS

From a pathologic and anatomic standpoint (Erdheim) one differentiates, at present, two groups of hypophysis tumors.

1. The tumors arising from the hypophysis itself and developing within the sella turcica.

2. Those arising in the entrance to the hypophyseal fossa, that is, tumors growing above the sella turcica.

The tumors of the first group appear, in most cases, under the clinical picture of acromegaly, those of the second appear often as dystrophia adiposogenitalis (Fröhlich type).

Both kinds of hypophyseal tumors cause characteristic pathologic changes in the region of the sella. As Erdheim has shown, the hypophyseal fossa becomes evenly enlarged in all diameters by the true hypophyseal tumors developing within the sella,

while those tumors of the second group, developing above the sella, widen only the entrance to the fossa. As simple as this differentiation is, still manifold variations in detail result from the nature, the size, and the direction of the growth of the tumor. For the explanation of these, the numerous roentgen examinations of the last few years have furnished valuable material. Before we discuss this in detail we will speak of the normal sella as it appears in the roentgenogram.<sup>4</sup>

The following somewhat schematic figures are drawn according to the roentgenograms taken with the head in a transverse position, that is, the head is laid on the plate so that the median plane is parallel to it and the tube is focused over the middle point between the external orbital margin and the external auditory meatus.<sup>5</sup>

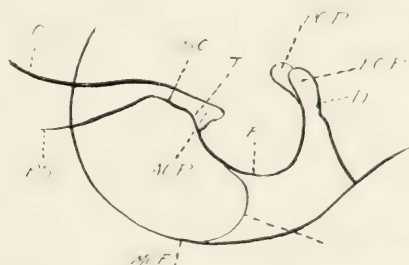


Fig. 33.—Sketch of a profile roentgenogram of a normal sella in an adult. *O*. Roof of orbit. *PS*. Planum sphenoidale. *SC*. Sulcus chiasmaticus. *T*. Tuberculum sellae. *AC.P.* Anterior clinoid processes. *MCF*. Outline of middle cranial fossa. *SS*. Posterior wall of the sphenoidal sinus. *F*. Floor of the sella. *PCP*. Posterior clinoid processes. *D*. Dorsum sellae.

Fig. 33 is a drawing of the roentgenogram of the normal sella turcica of a twenty-four-year-old man. The floor of the sella (*F*) forms a semicircle 13 mm. in diameter and is 1 mm. thick. The dorsum sellae (*D*) is 7 mm. high and 2 mm. thick. The tuberculum sellae (*T*) stands out bluntly and passes over with a slight bend representing the sulcus chiasmaticus (*SC*) into the straight line (*PS*) representing the projection of the planum sphenoidale. The contour of the anterior clinoid processes (*AC.P.*) stands out as a pointed arch. The distance

<sup>4</sup>According to Fitzgerald the length of the skull base is a criterion for the position and the size of the hypophyseal fossa. The length of the latter amounts to 10 to 14.5 mm., the breadth, 14 to 17 mm., the depth 7 mm.

<sup>5</sup>[The picture is called dextrorsinistral or sinistrodextral, depending on which side of the head lies next to the plate. The side mentioned last in the compound word is the side lying next to the plate.—EDITOR.]

from the floor of the sella to the floor of the middle cranial fossa (*M.C.F.*) amounts to 1.5 cm. The anterior half of the hypophyseal fossa is adjacent to the sphenoidal sinus (*S. S.*) and the posterior portion lies on the spongy sphenoid bone. The shape

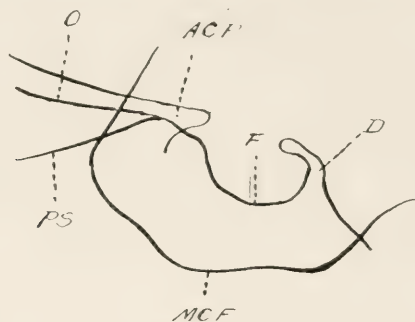


Fig. 34.—Another type of normal sella as found in the dolichocephalic. *O.* Orbital roof. *PS.* Planum sphenoidale. *ACP.* Anterior clinoid processes. *F.* Floor of sella. *D.* Dorsum sellæ. *MCF.* Outline of the middle cranial fossa.

above described is the most frequent in the adult mesocephalic skull.

In another variety of the normal sella turcica (Fig. 34), the floor is smooth and at the same time shallow. One meets with

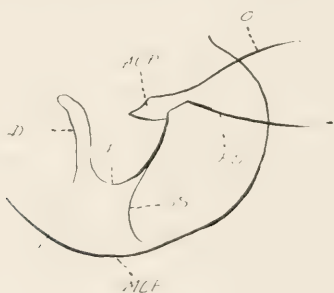


Fig. 35.—A type of normal sella seen in the individuals with short skulls. *D.* Dorsum sellæ. *F.* Floor of sella. *ACP.* Anterior clinoid processes. *SS.* Posterior wall of the sphenoidal sinus. *MCF.* Outline of the middle cranial fossa. *PS.* Planum sphenoidale. *O.* Roof of orbit.

such shapes in dolichocephalic skulls and in cases with sphenoidal sinuses of large size.

Another type of sella configuration occurring in short skulls is represented by Fig. 35. The anteroposterior diameter is short, the hypophyseal fossa is deeply excavated and the en-



trance to the sella is narrow. This type frequently appears in childhood also.

Among the other variations may be mentioned the abnormally plump appearance of the dorsum sellæ (Fig. 36), the

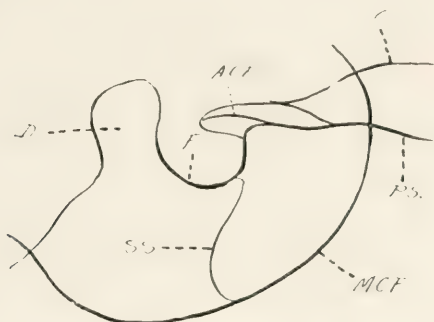


Fig. 36.—A type of normal sella with a very plump dorsum. *D*, Dorsum. *F*, Floor of sella. *SS*, Posterior wall of the sphenoidal sinus. *ACP*, Anterior clinoid processes. *MCF*, Outline of the middle cranial fossa. *PS*, Planum sphenoidale. *O*, Roof of orbit.

occurrence of a bridge connecting the anterior clinoid processes with the posterior (Fig. 37), possibly also with the middle clinoid processes, the occurrence of a double line representing the floor of the hypophyseal fossa in asymmetrical skulls, and,

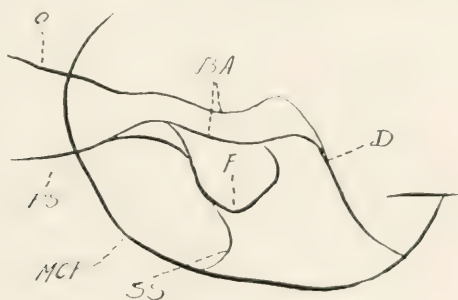

Fig. 37.—A sketch of a sella that is otherwise normal except for a connecting bridge of bone between anterior and posterior clinoid processes. *O*, Roof of orbit. *BA*, Bony arch across from anterior to posterior clinoid processes. *F*, Floor of sella. *D*, Dorsum sella. *PS*, Planum sphenoidale. *MCF*, Outline of middle cranial fossa. *SS*, Posterior wall of the sphenoidal sinus.

finally, the occurrence of bone ledges on the posterior surface of the dorsum sellæ at the site of the attachment of the tentorium.

The shape and size of the sella in children is represented

by Figs. 38, 39, 40 and 41, corresponding to the ages two, five, nine and twelve years respectively.

There is no doubt that in addition to the length and depth of the hypophyseal fossa, discernible in a transverse roentgenogram, the breadth of the fossa could be of importance in deciding as to the shape and size of the latter. One can not

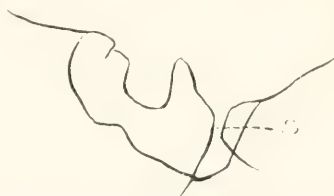

Fig. 38. Sella of a two-year-old child. *S* is the sphenooipital fissure.

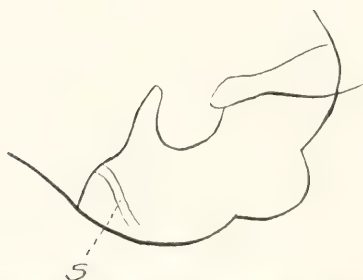


Fig. 39. Sella of a child five years old. *S* is the sphenooipital fissure.

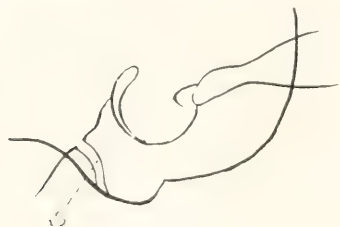

Fig. 40.—Sella of a child nine years old. *S* is the sphenooipital fissure.

succeed in obtaining this by a sagittal picture. Nevertheless, experience teaches that one obtains enough evidence for the determination of the size of the hypophyseal fossa from the details of the transverse picture alone, especially since no significant variations in size of the sella occur normally as a rule.

Only considerable degrees of hypophyseal enlargement make

themselves noticeable in the roentgenogram of the sella. For example, it is not possible to determine roentgenographically the swelling of the hypophysis during pregnancy, which latter

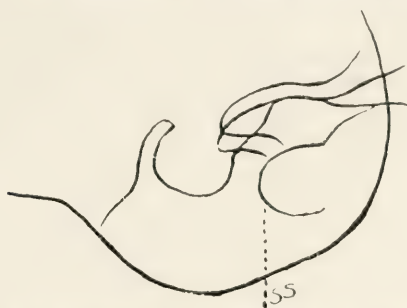


Fig. 41. Sella of a child twelve years old. *SS* is the posterior wall of the sphenoidal sinus.

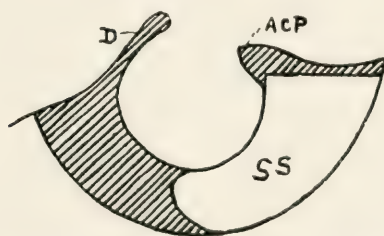


Fig. 42. Widening of the sella produced by a small intrasellar tumor. *D*, Dorsum sellae. *ACP*, Anterior clinoid processes. *SS*, Sphenoidal sinus.

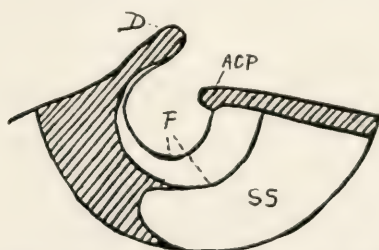


Fig. 43. An asymmetrical widening of the sella which was the result of a tumor of the hypophysis that developed asymmetrally. *F*, Double outline of the floor of the sella. *D*, Dorsum sellae. *ACP*, Anterior clinoid processes. *SS*, Sphenoidal sinus.

is chiefly discernible at the postmortem by its growth upward from the hypophyseal fossa without erosion of the sella." Just as uncertain also is the evidence of a diminution of the hypophi-

\*Mohr asserts that he has seen the enlargement of the sella in the roentgenogram of pregnant women.

ysis, as obtained in a roentgenogram, except in the cases in which the size of the fossa is considerably under the normal. The more valuable then are the even insignificant variations from the normal details of shape cited, for the diagnosis of anomalies of the hypophysis.

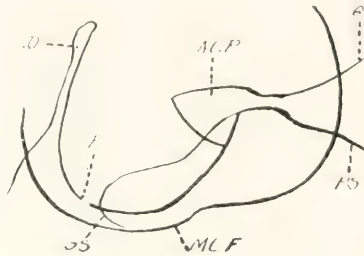


Fig. 44. Moderately wide sella present in a case with a tumor of the hypophysis. *D*, Dorsum sellae. *F*, Floor of the sella. *ACP*, Anterior clinoid processes. *O*, Roof of the orbit. *PS*, Planum sphenoidale. *MCF*, Middle cranial fossa. *SS*, Posterior wall of the sphenoidal sinus.

Apparently there has been an unequal erosion of the sella in this case as a portion of the sphenoidal sinus can be seen within the outlines of the sella.

We will now describe the varieties of sella destruction resulting from intrasellar hypophyseal tumors.

Fig. 42 shows the roentgenogram of a widened sella resulting from the presence of a small intrasellar hypophyseal tumor. The floor of the sella turcica appeared thinned and forced uniformly forward, downward, and posteriorly, thereby was

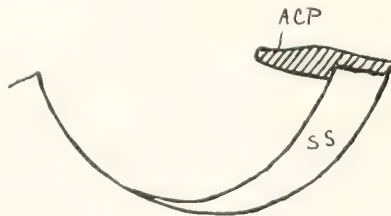


Fig. 45. Total destruction of the sella caused by a large intrasellar tumor of the hypophysis. *ACP*, Anterior clinoid processes. *SS*, Sphenoidal sinus.

the distance from the level of its floor to that of the middle cranial fossa diminished and the dorsum of the sella was thinned and lengthened.

Fig. 43 represents a variation of this picture. Here one discerns the existence of a double contour of the floor of the sella

resulting from a unilateral deepening of the latter in an asymmetrical tumor of the hypophysis.

Fig. 44 represents a further progress of the destruction caused by an intrasellar hypophyseal tumor. One recognizes the extreme universal deepening of the floor of the sella, the difference in level between it and the floor of the middle cranial fossa is reduced to a few millimeters. The dorsum sella appears greatly thinned, elongated, displaced and bent backward. Sometimes the anterior clinoid processes in such cases show the plump appearance indicated in the illustration. It is a local manifestation of the acromegaly.

Fig. 45 demonstrates the degree of sella destruction to be observed in very large tumors of the hypophysis. The body

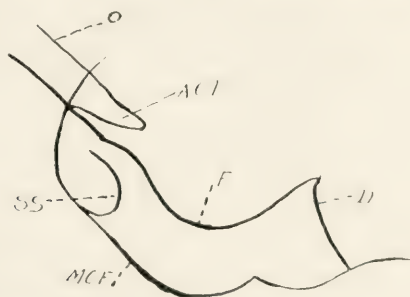


Fig. 46. Widening of the sella produced by a small tumor in the entrance to the sella. *O*, Roof of orbit. *ACP*, Anterior clinoid processes. *SS*, Posterior wall of sphenoidal sinus. *F*, Floor of sella. *D*, Dorsum sella. *MCF*, Outline of the middle cranial fossa.

of the sphenoid bone is completely destroyed and the dorsum sellæ is gone. One sees only the contour of the base of the middle cranial fossa and the anterior clinoid processes.

The types of sella destruction described above can sometimes be made out in the order given, in one and the same case, during a period of observation extending over months or years.

The pathologic changes of the sella produced by tumors of the hypophyseal entrance are illustrated in Figs. 46 to 48.

Fig. 46 shows the change in the sella corresponding to the beginning of the growth of such a suprahypophyseal tumor. The floor of the sella is thinned but not deepened. Its distance from the floor of the middle cranial fossa corresponds to the

normal. The dorsum is thinned and shortened, the anterior clinoid processes appear sharpened, the dorsum sellæ is flattened out.

With the further progress of the enlargement of the tumor, there occurs the change in the shape of the sella represented by Fig. 47. The dorsum is completely destroyed and the floor of the sella is eroded in the shape of a shallow bowl so that its distance from the floor of the middle cranial fossa is short-

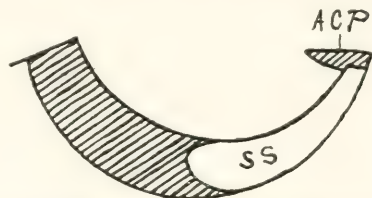


Fig. 47. Widening of the sella produced by a moderate sized tumor in the entrance. *ACP*, Anterior clinoid processes. *SS*, Sphenoidal sinus.

ened. The difference between this dishlike depression of the sella and the deeper one in Fig. 44 is obvious.

In the highest grades of destruction of the sella resulting from tumors in the entrance to the hypophysis (Fig. 48), we meet with the same picture as is found in the maximum de-



Fig. 48. Total destruction of the sella produced by a large tumor in the entrance. *ACP*, Anterior clinoid processes.

struction of true tumors of the hypophysis (Fig. 45). There exists only in most cases, a difference relative to the anterior clinoid processes which are preserved in Fig. 45 but are decidedly shortened and sharp in Fig. 48.

Besides the above cited characteristic differences in the appearance of the sella turcica the roentgenogram shows also distinctive features on the rest of the skull, in the two types of hypophyseal tumors. In the true hypophyseal tumors there

is found the well-known acromegalic enlargement and thickening of the skull as well as the noticeable enlargement of the accessory sinuses, but it is interesting to note that, not always, by any means, does there need to exist a relation between the extent of the destruction of the sella (that is the size of the tumor) and the manifestations of the acromegaly. We have seen cases where, despite complete destruction of the sphenoidal sinus, the symptoms of acromegaly were quite insignificant, while, on the other hand, in other cases of very marked acromegaly the slight amount of widening of the sella was striking. In the tumors of the hypophyseal entrance, the skull is not only thickened, but frequently it shows the erosions of the whole inner surface, suggestive of an increase in intracranial pressure.

On the basis of these introductory remarks we can lay down the following principles relative to the roentgenologic representation of the changes in the skull produced by tumors of the hypophysis.

Hypophyseal tumors arising intrasellar widen and deepen the sella in such a way that its floor is thinned and brought closer to the floor of the middle cranial fossa, that the dorsum sellæ appears thinned, pushed posteriorly, tipped backward, and elongated. The angle formed by the projection of the dorsum sellæ and the planum sphenoidale becomes more acute. The anterior clinoid processes seem normal or pushed upward and their under surface hollowed out or strikingly plump. Acromegalic changes are frequently found in the rest of the skull, as shown by thickening of the wall and the bony ledges, and enlargement of the accessory sinuses.

Hypophyseal tumors arising extrasellar produce a flat, saucer-like widening of the sella in which the dorsum becomes thinned, shortened, the anterior clinoid processes are pointed and shortened. The floor of the sella is not pushed much closer to the floor of the middle cranial fossa, and forms an obtuse angle with the planum sphenoidale. In the rest of the skull are found no acromegalic changes but rather a thinning of the wall in consequence of increased intracranial pressure.

Very large tumors of the hypophysis bring about a total destruction of the body of the sphenoid. In this stage the

differentiation between tumors of extrasellar and intrasellar origin is no longer possible. Under favorable circumstances the appearance of the anterior clinoid processes, in connection with the details of the other skull changes, may suggest the correct diagnosis.

This classification, serving for the majority of all hypophyseal tumors, must be supplemented by the following considerations before their utility in diagnosis can be discussed. The changes in the sella, which are produced by hypophyseal tumors, have a great similarity to those caused by other processes of disease at the base of the brain, as well as those which are a local manifestation of the erosion of the inner surface of the skull as produced by a general increase in intracranial pressure.

The following pathologic processes leading to erosion of the sella come under consideration in particular.

1. Intracranial diseases which have induced a chronic increase in intracranial pressure (brain tumors in any locality, and chronic hydrocephalus). The erosion of the sella, brought about by these processes, has in most cases great similarity to those characteristic of an extrasellar hypophyseal tumor. Much more seldom does it resemble the erosion caused by an intrasellar tumor.

The factors which render the differentiation possible are furnished by the signs of chronic abnormal intracranial pressure found in the rest of the skull (hydrocephalic shape and size of the skull, erosion of the inner surface of the vault, separation of sutures, widening of the venous canals), changes which usually develop in case of hypophyseal tumors only in connection with extensive erosion of the sella. In the processes causing increased intracranial pressure these changes are simultaneous with the erosion of the sella.

2. Primary diseases of the body of the sphenoid bone. The changes of the sella which are produced by diseases of the skull base (carcinoma of the sphenoid sinus, other malignant tumors, tuberculosis of the body of the sphenoid) have a characteristic appearance, in that the diseases mentioned infiltrate the sphenoid bone. They cause a diminution in the density of its shadow and hence the sharpness of its upper contour, the



sella turcica, without essentially changing the shape of the latter. In contrast to the change in the shape of the sella resulting from pressure atrophy, in hypophysal tumors and other intracranial processes, the reduction in the density of the shadow of the sphenoid bone brought about by the osteoporosis, and the indistinct contour of the sella (yet retaining its general shape) form a sure index to a primary disease of the skull base (see page 256, Case 3).

3. Basal tumors of the brain. The tumors and tumor-like processes<sup>7</sup> developing on the base of the brain produce pressure atrophy of the sella which may have so great a similarity to that caused by extrasellar hypophysal tumors that a differentiation is in most cases impossible. Occasionally, however, individual distinctive features can be found, such as an asymmetrical appearance to the erosion of the two clinoid processes resulting from the pressure of a tumor of the base lying outside the median line, the erosion of the dorsum sellae characteristic for fibroma of the acousticus, and finally the lime platelets (in the form of a bow-shaped outline over the widened sella, see Fig. 83) sometimes observed in the wall of aneurysms.

4. The pathologic changes produced by a tumor of the hypophysis and those produced by a tumor or a process, causing increased pressure, located elsewhere may be combined in the same individual.

By the use of the empirical laws discussed in the preceding paragraphs, which serve as a guide in the interpretation of the x-ray pictures of erosions produced by hypophysis tumors and, by having regard for the limitations to which these criteria are subjected, the utility of the roentgen examination for the diagnosis of tumors of the hypophysis may be formulated as follows:

In cases of typical acromegaly or dystrophia adiposogenitalis (Frölich type), in which the clinical diagnosis "hypophysal tumor" can be made as being very probable, the proof of the characteristic erosion of the sella serves as an obvious ratification or confirmation of the diagnosis. The absence of ero-

<sup>7</sup>Such as endothelioma of the tissues covering the base, meningioma and glioma of the basal portion of the frontal and temporal lobes, fibromata and sarcomata of the cranial nerves on the base (especially the acousticus), tumors, cysts and hydrocephalic dilations of the third ventricle, cystic collections of fluid in the cisterna chiasmatis, aneurysms of the basal arteries.

sion of the sella in such cases is very rare and is the result of tumor formation in a hypophyseal tissue rest lying in an atypical location (body of sphenoid, sphenoid sinus, roof of pharynx).

In cases with incomplete symptoms (*formes frustes*) of acromegaly and *dystrophia adiposogenitalis* or with isolated local symptoms of a hypophysis tumor, even if characteristic, the roentgenogram renders possible a positive diagnosis. A picture which shows an erosion of the sella speaks for the existence of a hypophyseal tumor, while the absence of such erosion may be considered as being very much against the diagnosis of hypophyseal tumor and should cause one to seek another explanation for the clinical symptoms. An enlargement of the skeleton, suggesting acromegaly, may be produced or simulated by a physiologic giant growth or hyperplastic osteitis. A thickening of the soft tissues similar to *dystrophia adiposogenitalis* may be caused by affections of other glands with internal secretion (generative glands, pineal gland, suprarenal, thyroid) or by hydrocephalus. Bitemporal hemianopia occurs not at all seldom as a symptom of a brain tumor localized elsewhere. It may appear as a symptom of a primary disease of the optic nerve or as a local manifestation of cerebral lues or as a symptom of tabes.<sup>8</sup>

In cases where the clinical examination brings to light an indistinct or uncharacteristic group of symptoms, the roentgenologic proof of a typical sella erosion alone makes possible the early determination of the diagnosis. Such symptoms are: disturbance of vision, headache of migraine character, epileptic attacks, psychic anomalies, and trophic disturbances such as obesity, infantilism, disturbance of menstruation, impotence, giant or dwarf growths.

The roentgenologic proof of the existence, and the character and amount of erosion of the sella is indispensable as an index to the operative treatment of hypophyseal tumors. In particular,

---

<sup>8</sup>We had the opportunity to examine nine cases with bitemporal hemianopia in whom the roentgen picture did not permit the recognition of any enlargement of the sella. Further clinical examination proved the presence of lues cerebri in four of the cases, tumor in the frontal lobe (?) of one, tabes in two, and in the remaining two no cause was found, despite repeated roentgen examinations and several years of observation, during which time no essential progress of the symptoms occurred. Curiously both of these cases were physicians as were also one of the cases of the luetic and one of the tabetic hemianopia.

the examination of the roentgenogram gives the surgeon information relative to the choice of approach to the hypophysis because it gives him information concerning the degree of bulging of the hypophyseal fossa, the thickness of the floor of the sella, its distance from the spina nasalis anterior, from the root of the nose, and from the nasopharynx. One is also enabled to decide the question relative to the progress of the tumor growth, so important for the chances of successful surgical interference. On the other hand the roentgen picture permits only uncertain conclusions relative to the extension of the tumor upwards and laterally towards the brain. The more the upper contour of the sella is widened out and the more extensive the erosions found in the rest of the skull, the more positively may an extension of the tumor beyond the limits of the sella be assumed. Marked widening of the sphenoparietal sinus of one or both sides speaks for a compression of the sinus cavernosus resulting from lateral proliferation of the tumor. The roentgen picture permits of no conclusion concerning the nature of the tumor, if we overlook the occasional proof of an area of calcification within the widened sella.<sup>9</sup>

The advances of roentgen diagnosis in suggesting and perfecting the methods of the nasal operation for hypophyseal tumors, practiced with such success in recent years, have a considerable, though not always a sufficiently appreciated, place in the literature.

Horsley operated on the hypophyseal tumors through the temporal region. Partels was the first to make the suggestion to puncture the hypophyseal fossa from the nose or from the roof of the nasopharynx, in cases in which the roentgen picture permitted the determination of a sufficient excavation of the sella. This proposition formed the forerunner of the per-nasal method of operation proposed, and repeatedly performed

<sup>9</sup>The objection of Barrels and Schützler, that the calcification of hypophyseal tumors obscures the roentgen picture, is as invalid as the assumption of Schnitzler that the erosion was produced by calcitrating solutions. On the contrary the great amount of calcification combined with destruction of the sella permits the diagnosis of a hypophyseal tumor to be made almost with certainty. (Algebra, Kirchheim.)

The assertion of Schnitzler that the roentgenologic finding of sella erosion shows imperfect conformity with the anatomic finding is to be refuted on the ground that, in case of insufficient experience, parts of the skull not belonging to the sella are sometimes considered as belonging to it, as, for instance, the interconvolutional spines and ridges of the base (Fig. 71) of the skull, or mastoid cells in the squama temporalis (Fig. 66).

with success by Schloffer, and of its modifications, especially the excellent endonasal method of Hirsch, and the method of Marschik, also performed successfully, as well as several other theoretic proposals not yet practiced (Fein, Lowe, and others).

Faulty diagnoses made from roentgen pictures are rare,<sup>10</sup> if a person has sufficient experience. The practical consequences of such faults in diagnosis are almost without significance, since we have learned that the methods of operation serving for hypophyseal tumors may be used for other intracranial processes which cause a similar sella erosion. Especially is this true of hydrocephalus of the third ventricle and cystic accumulation of fluid inside of the cysterna chiasmatis.

Abnormal size of the hypophyseal fossa is found sometimes in cretins and eunuchs, as already mentioned earlier (see page 94, Fig. 18). This form of enlargement is easy to differentiate from an erosion of the sella, since in this case neither the floor nor the dorsum of the sella is thinned. Hypophyseal tumors may be combined with myxedema. Case No. 4, page 191, observed by us, is an example. (See Sainton and Rothery, *Bull. et mem. de la Soc. md. des hôpit. de Paris*, May 8, 1908.)

We have also mentioned the occurrence of erosion of the sella as a local manifestation of senile atrophy of the skull (page 115).

Observations by Beadles, Weigert, Kuss, and others show that destruction of the sella may be produced by syphilis of the hypophysis.

As for the literature on tumors of the hypophysis, it has appeared in recent years in such quantity as to be beyond possibility of review. A large number of researches are devoted to the description of the normal and pathologic anatomy of the hypophysis. Among these researches, which verify important facts, indispensable to the clinician, we mention the publications of Benda, Erdheim, Biedl, and Fraenkel. The clinical researches concerning tumors of the hypophysis relate, on the one

---

<sup>10</sup>Our faulty diagnoses, proved so by operation or postmortem, have to do with four cases, in all. In three of the cases we diagnosed tumor of the hypophysis, whereas the postmortem proved the widening of the sella to be due, in one case, to a hydrocephalus interna; in a second case, to a brain tumor of the parietal region (in combination, to be sure, with an adenoma of the hypophysis) and, in the third case, to a hydrocephalus (meningitis serosa circumscripta) of the cysterna chiasmatis. In a fourth case we diagnosed an enlargement of the sella, due to a hypophysis tumor, as resulting from a tumor located elsewhere.

hand, to their symptomatology and diagnosis (Fröhlich, von Frankl-Hochwart, Bartels, A. Fuchs), and, on the other hand, to the therapeutic effect of surgical treatment especially (Schlosser, von Eiselsberg, Hoehenegg, Hirsch, Chiari). The x-ray literature relative to hypophyseal tumors has assumed great dimensions (review of the literature by Melchior).

We had occasion to examine ninety cases of hypophyseal tumors, of whom twenty-eight were operated upon.

The large number of observations of a disease, considered as rare, within a period of barely ten years, is not to be explained by a special predisposition to it by our Vienna patients. We believe, rather, that the arrangement of a central roentgen laboratory, like the Roentgen Institute in the Vienna General Hospital, makes possible the concentration of all the cases coming to Vienna. Also the zealously prosecuted investigations and work in the sphere of hypophyseal diseases, by a large number of Vienna clinicians and pathologists for many years, must favor the gathering of many patients from the nearer environs and even from farther away.

Among the cases examined by us, those are of special interest which could be verified by operation or postmortem. The greater portion of these cases already appear in publications by Chiari, Erdheim, von Eiselsberg, Exner, von Frankl-Hochwart, Hirsch, Hoehenegg, Leischner, Sträussler, or are awaiting publication. We will refer to those articles where the roentgen finding obtained by us is quoted, and be satisfied here to sketch quite superficially the clinical course of these and several others examined by us, describe the roentgen picture, and possibly add a photographic or schematic representation of the sella.

As to the principle of classification which we have followed in the presentation of the cases, we have in some instances paid attention to the clinical symptoms, and in others have sought to take into account the practical necessity of the operator. We have, therefore, formed three groups upon the basis of the clinical symptoms; namely, the "acromegaly group," the "Fröhlich type," and the group of "cases with, for the most part, local symptoms without general trophic changes." In each of these three groups we differentiate cases with slight,

medium, and extensive sella destruction. This differentiation is authorized from the surgical standpoint, yet attention may be called once more to the fact that a direct proportion does not always exist between the size of the sella erosion and the intensity of the clinical symptoms.

### Group 1. Hypophyseal Tumors in Acromegaly

The most of the cases cited in this group permit the recognition of the characteristic signs of acromegaly even in the clinical examination and allow the conjecture of the existence of a hypophyseal tumor. The roentgen picture makes the diagnosis certain and permits the determination of the details of sella destruction, especially the size of the sella, which are important from the standpoint of the surgeon.

#### *Cases with Slight Erosion of the Sella*

CASE 1.—M., female, thirty years old. For two years patient had suffered from headache, pain in the bones, and diabetes. At the time of examination there existed the typical habitus of acromegaly.

The roentgenogram showed an insignificant but distinct widening of the sella turcica. The dorsum sellæ was slightly thinned. (See Figs. 49 and 50.)

CASE 2.—A. P., female, twenty-nine years old. Typical acromegalic habitus.

The roentgenogram showed enlargement of the accessory sinuses. The sella turcica was slightly widened, its floor slightly deepened and showing a double contour. The dorsum sellæ was tipped backward and slightly thinned. The anterior clinoid processes were plump (see Fig. 51).

CASE 3.—U., acromegaly.

In the roentgenogram, the skull was 6 mm. thick, spongy. The sella was slightly deepened, the dorsum was shortened (similar to the drawing of Case 2).

CASE 4.—B. M., female, forty years old. Enlargement of fingers and face in recent years.

The roentgenogram showed a strikingly thick cranium. The sella was slightly wider and the dorsum somewhat thinner than normal. (See Fig. 52.)

CASE 5.—J. K., male, forty-two years old. For several months patient had manifested psychic changes resembling paralytic dementia. Wassermann reaction positive. Acromegalic habitus.

The roentgenogram showed the sella turcica enlarged to a slight degree, clearly deepened in the region of the dorsum sellæ. (See Fig. 53.) The

accessory sinuses were decidedly enlarged. The postmortem finding, obtained a few weeks later, confirmed the existence of an adenoma of the hypophysis combined with an atrophy of the brain characteristic for paralysis.

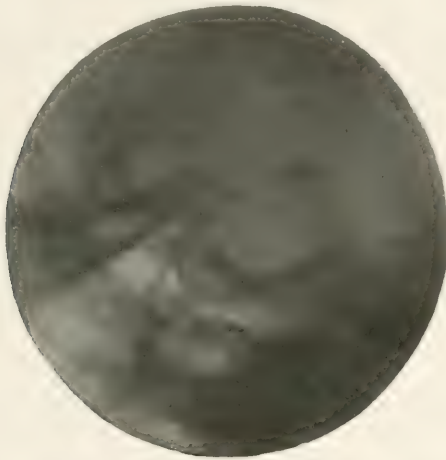

Fig. 49. A dextrosinistral picture of a case of acromegaly having a slight amount of erosion of the sella as it appears in profile. There was a tumor of the hypophysis.

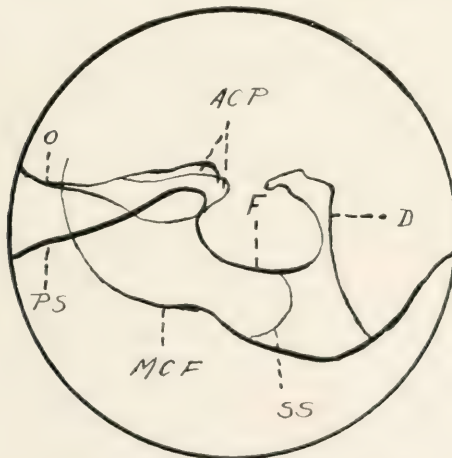


Fig. 50.—A sketch of Fig. 49.—O, Roof of orbit. ACP, Anterior clinoid processes. D, Dorsum sellae. F, Floor of sella. PS, Planum sphenoidale. SS, Posterior wall of the sphenoidal sinus. MCF, Outline of the middle cranial fossa.

#### CASE 6.—B., acromegaly.

Roentgenogram showed that sella was widened slightly in all its dimensions. Dorsum was thinned and pushed backward. The anterior clinoid processes were preserved. (See Fig. 54.)

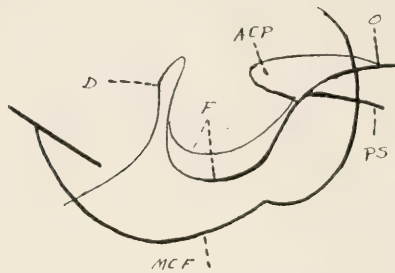


Fig. 51.—Sketch of the sella of a patient with acromegaly. It was somewhat larger than normal with a double contour to the floor. The dorsum was pushed back and somewhat thinner than it should be. The anterior clinoid processes were quite plump. *D*, Dorsum sellæ. *F*, Double line of the floor. *ACP*, Anterior clinoid processes. *O*, Roof of orbit. *PS*, Planum sphenoidale. *MCF*, Middle cranial fossa.

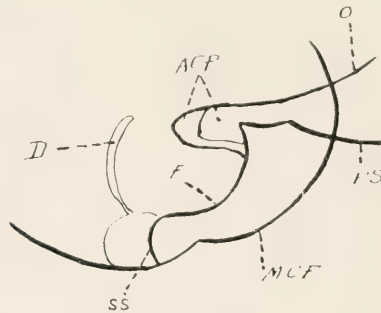


Fig. 52.—A sella of a patient with acromegaly. The sella was slightly enlarged only. The dorsum was tipped backward and thinned. *D*, Dorsum sellæ. *F*, Floor of sella. *ACP*, Anterior clinoid processes. *O*, Roof of orbit. *PS*, Planum sphenoidale. *MCF*, Outline of the middle cranial fossa. *SS*, Posterior wall of the sphenoidal sinus.

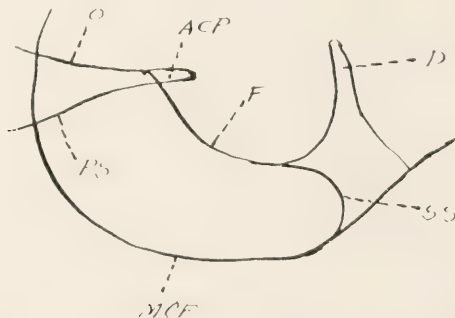


Fig. 53.—Sella of a patient with acromegaly. The sella is slightly larger than normal. The dorsum is pushed backward. The anterior clinoid processes are sharper than is usual in acromegaly with this degree of sella enlargement. *O*, Roof of orbit. *ACP*, Anterior clinoid processes. *F*, Floor of sella. *D*, Dorsum sellæ. *SS*, Posterior wall of sphenoidal sinus. *PS*, Planum sphenoidale.



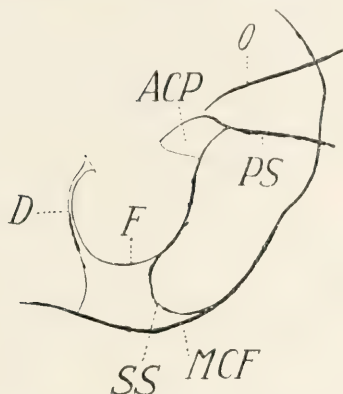


Fig. 54.—Sketch of a sella of a patient with acromegaly. It is slightly larger than normal, the dorsum is pushed backward and hollowed out. *D.* Dorsum sellae. *F.* Floor of sella. *ACP.* Anterior clinoid processes. *O.* Roof of orbit. *PS.* Planum sphenoidale. *SS.* Posterior wall of the sphenoidal sinus. *MCF.* Outline of the middle cranial fossa.

### Cases with Moderate Widening of the Sella

CASE 1.—M. K., female, thirty years old. Acromegalic changes had occurred during last several months. The roentgenogram showed a very considerable widening of the sella turcica with thinning and elongation of the dorsum. The patient was operated on in the Hochenegg Clinic in accordance with the Schloffer method and the acromegalic changes disappeared in a few weeks.<sup>11</sup>

CASE 2.—E. F., female, twenty-nine years old. Typical acromegaly with excessive headache. The roentgenogram showed the sella to be considerably widened in all its dimensions and the dorsum thinned and tipped backward. The distance from the floor of the sella to the spina nasalis anterior was 8.4 cm. (see Figs. 55 and 56). The operation confirmed the x-ray finding. (See Hirsch, *Wiener klinische Wochenschrift*, 1911, p. 109.)

CASE 3.—Dr. B., male, thirty-five years old. Typical acromegaly.

The roentgen picture showed extensive destruction of the sella. The dorsum however was still present, was elongated and somewhat plump. The patient was operated upon by Hirsch. (See Hirsch, *Wiener klinische Wochenschrift*, 1911, p. 923.)

CASE 4.—S., female, thirty-one years old. For six months patient had shown a bitemporal hemianopia and symptoms of acromegaly.

The x-ray picture showed the sella to be considerably widened and deepened. The dorsum was almost gone and the floor of the sella was extremely thin. The patient was operated in the Chiari clinic.

<sup>11</sup>See Hochenegg, *Wiener klinische Wochenschrift*, 1908, pp. 409 and 891; 1909, p. 323; and Exner, *Mitteilungen aus den Grenzgebieten der Medizin und Chirurgie*, October, 1909.

CASE 5.—K., female, fifty-seven years old. Patient had attacks of dizziness with a decrease in vision and slight acromegalic changes.

The roentgenogram, taken May 14, 1906, showed the sella turcica to be widened to a considerable degree. Its floor had a double contour. The

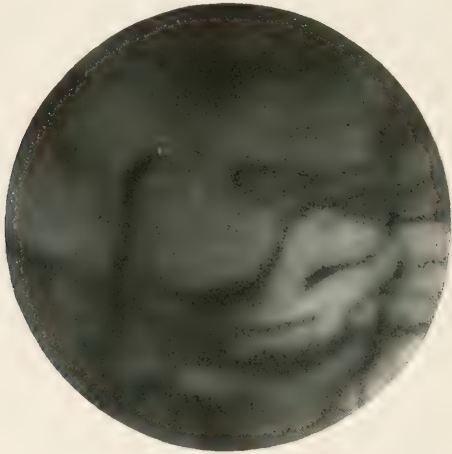


Fig. 55.—A sinistrodextral picture of a sella containing a tumor of the hypophysis in a patient with acromegaly. The dorsum is pushed backward and is thinner than normal.

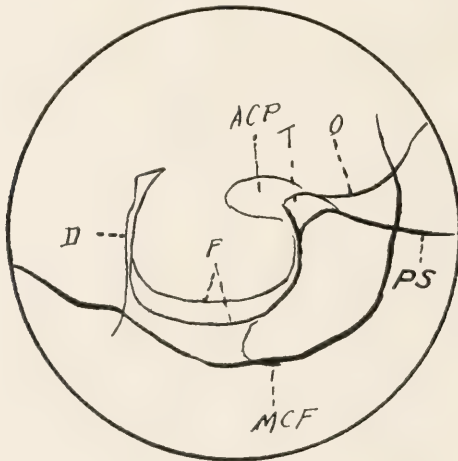


Fig. 56.—A sketch of the picture in Fig. 55. *D.* Dorsum sellae. *F.* Floor of sella. *ACP.* Anterior clinoid processes. *T.* Tuberculum sellae. *O.* Roof of orbit. *PS.* Planum sphenoidale. *MCF.* Outline of the middle cranial fossa.

dorsum and the anterior clinoid processes were unchanged. (See Fig. 57.) The roentgenogram, taken September, 1910, showed a considerable increase in the sella erosion. At the operation, performed by Hirsch, a cyst of the

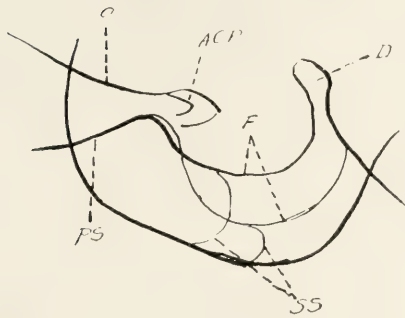


Fig. 57.—Sketch of a sella that is slightly larger than normal. There is a double contour to the floor, significant of unequal erosion. O. Orbital roof. PS. Planum sphenoidale. ACP. Anterior clinoid processes. F. Floor of sella. D. Dorsum sellæ. SS. Double outline of the posterior wall of the sphenoidal sinus.

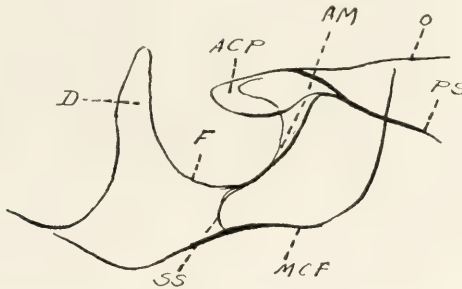


Fig. 58.—Sella showing slight deepening and widening of the sella. The dorsum is pushed backward but it is plump as are also the anterior clinoid processes. D. Dorsum sellæ. F. Floor of the sella. ACP. Anterior clinoid processes. AM. Ala minor of the sphenoid. O. Roof of the orbit. PS. Planum sphenoidale. SS. Posterior wall of the sphenoidal sinus. MCF. Outline of the middle cranial fossa.

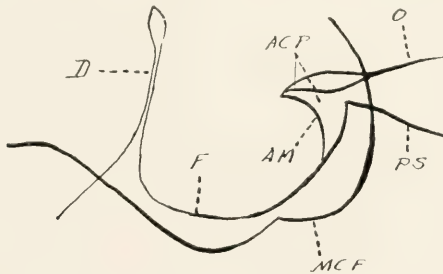


Fig. 59.—Sketch of a very deep sella. The dorsum is extremely thin and is somewhat pushed backward. The floor of the sella closely approximates the outline of the floor of the middle cranial fossa. D. Dorsum sellæ. F. Floor of the sella. AM. Ala minor of the sphenoid. ACP. Anterior clinoid processes. O. Roof of the orbit. PS. Planum sphenoidale. MCF. Outline of the middle cranial fossa.

hypophysis was found. (Hirsch, *Wiener klinische Wochenschrift*, 1911, p. 109.)

CASE 6.—F., female, thirty-eight years old. Typical acromegaly.

On the roentgenogram the sella was widened and deepened to a considerable degree. The dorsum was thinned, elongated, and tipped backward.

CASE 7.—D., female, thirty-five years old. Typical acromegaly. (Teleky, *Wiener klinische Wochenschrift*, 1911, p. 924.)

On the roentgenogram the sella was evenly widened in moderate degree and the dorsum was thin.




Fig. 60.—A sinistrodextral picture of sella erosion in a patient with a tumor of the hypophysis associated with acromegaly. The sella is wide and deep, the dorsum is pushed backward and the anterior clinoid processes are plump.

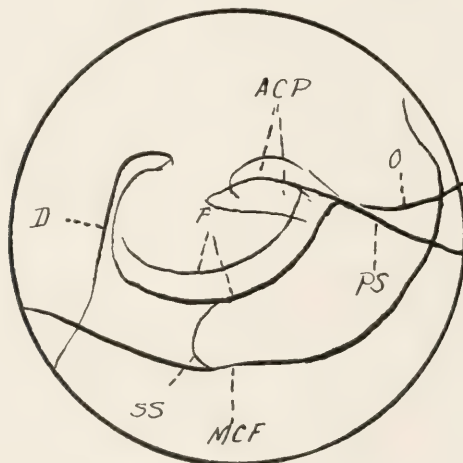


Fig. 61.—A sketch of Fig. 60 showing the important features of the sella. *D.* Dorsum sellae. *F.* Floor of the sella. *ACP.* Anterior clinoid processes. *O.* Roof of the orbit nearest to the plate. *P.* Planum sphenoidale. *MCF.* Outline of the middle cranial fossa. *SS.* Posterior wall of the sphenoidal sinus.

CASE 8.—K. K., male, forty-eight years old. Hands and feet were plump. Lower jaw was larger than normal. Cirrhosis hepatis.

The roentgenogram showed a moderate deepening and a considerable

widening of the sella (anteroposterior diameter 17 mm.). The dorsum sellæ was plump and tipped backward. There was a striking plumpness of the anterior clinoid processes. (See Fig. 58.)

CASE 9.—B., male, thirty-six years old. Enlargement of the hands for the last fourteen years. Typical acromegaly.

The roentgenogram showed extreme deepening of the sella and an extremely long and thin dorsum. (See Fig. 59.)

CASE 10.—A. S., female, forty-four years old. In connection with pregnancy, twelve years previously, marked signs of acromegaly had appeared.

The roentgenogram showed a thickened skull. The sella was wide and its floor deep. The latter had a double contour. The dorsum was thick, elongated, and pushed backward. The clinoid processes were plump. (See Figs. 60 and 61.)

CASE 11.—F. T., male, forty-three years old. Typical acromegalic habitus.

The roentgenogram showed excessive enlargement of the frontal sinus in all its dimensions. The sella was somewhat wider and deeper than nor-



Fig. 62.—Sketch of the sella in Case 11. The sella is moderately wide and deep. The dorsum is pushed backward and thinned. *O*. Roof of orbit. *F*. Floor of sella. *D*. Dorsum sellæ. *SS*. Posterior wall of the sphenoidal sinus. *MCF*. Outline of the middle cranial fossa.

mal. The dorsum was pushed posteriorly, tipped backward and thinned. (See Fig. 62.)

CASE 12.—K. B., male, sixty-one years old. Acromegaly.

The roentgenogram showed marked hemispherical widening of the hypophyseal fossa. The dorsum was represented by a long thin line, pushed backward and slightly tipped back. The anterior clinoid processes were sharpened and pushed upward. (See Fig. 63.)

CASE 13.—F. F., male, twenty-four years old. Typical acromegalic habitus.

On the roentgenogram the sella was widened spherically (18 mm.) and the dorsum was very much thinned and elongated. Large accessory sinuses.

CASE 14.—F. K., male, thirty-two years old. Typical acromegaly.

The roentgenogram showed an extraordinary thickening of the skull.

The sella was considerably widened and deepened and the dorsum was reduced to a very thin line. The anterior clinoid processes were thickened.

CASE 15.—W., female, sixty-seven years old. Patient complained of disturbance of sight with extreme limitation of vision, chiefly in the temporal region. The face was said to have always had the striking prognathia alveolaris, found present at the time of examination.

The roentgenogram showed that the vault was thicker than normal, especially the frontal bone. The thickness approximated 20 mm. The inner surface of the hyperostosis was uneven and nodular. The sella turcica was enlarged in all diameters, its floor was very thin. The dorsum was almost completely destroyed.

The thickening of the skull that occurs in connection with intrasellar hypophyseal tumors should probably be considered of acromegalic nature. In connection, however, it should be

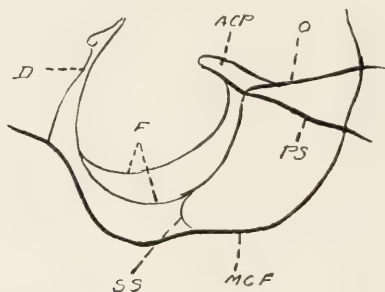


Fig. 63.—Sketch of the sella in Case 12, page 185. It is hemispherically enlarged to a marked degree, the dorsum is slightly pushed backward and is somewhat thinner than normal. *D.* Dorsum sellæ. *F.* Double contour of the floor. *ACP.* Anterior clinoid processes. *O.* Roof of the nearer orbit. *PS.* Planum sphenoidale. *MCF.* Outline of the middle cranial fossa. *SS.* Posterior wall of the sphenoidal sinus.

noted that in older people there occurs, not rarely, a hyperostosis of the skull associated with a bone atrophy. (See section on Senile Atrophy.)

CASE 16.—Dr. K., male, sixty-three years old. Had suffered from epileptic attacks for years. Strikingly pale. Had complained of disturbance of sight for the last six months. Cranium was very large, horizontal circumference 61 cm. Face hairless. Of acromegalic habitus.

In the roentgenogram the sella was markedly widened and deepened and the dorsum was shortened.

CASE 17.—A., male, forty-four years old. There had been enlargement of the hands and head for several years. Typical acromegaly combined with tabetic symptoms and diabetes.

The roentgenogram showed extreme thickening of the skull, considerable widening of the sella, and thinning and shortening of the dorsum.

CASE 18.—X., female, 50 years old. Bitemporal hemianopia.

The roentgenogram showed the sella to be widened to a considerable degree and its floor was thinner than normal.

CASE 19.—F. G., male, thirty-nine years old. For the last three years there had been a noticeable enlargement of the prominent portions of the face. There was no disturbance of sight present.

On the roentgenogram the skull appeared of normal size and shape, thickness 4 mm., inner surface smooth. Sella was much widened and

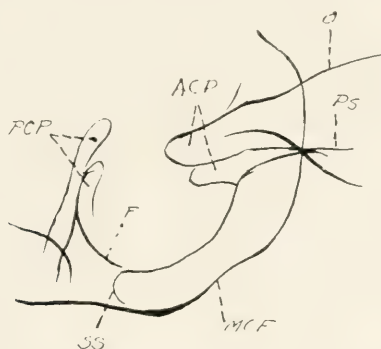


Fig. 64.—Sketch of the sella of Case 19. The sella is very wide and deep and the dorsum is asymmetrically eroded, appearing as a double shadow. *PCP*. Posterior clinoid processes. *F*. Floor of sella. *ACP*. Anterior clinoid processes. *O*. Roof of orbit nearest to the plate. *PS*. Planum sphenoidale. *MCF*. Outline of the middle cranial fossa. *SS*. Posterior wall of the sphenoidal sinus.

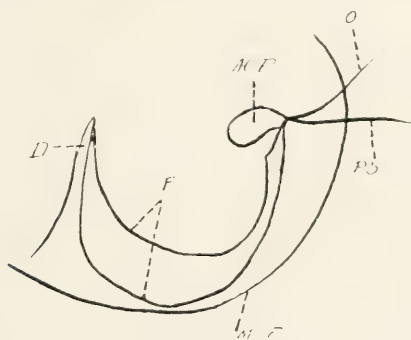


Fig. 65.—Sketch of the sella of Case 1, page 187. The body of the sphenoid is almost completely destroyed. The erosion has been asymmetrical in that the floor shows a double outline. *D*. Dorsum sellæ. *F*. Floor of the sella. *ACP*. Anterior clinoid processes. *O*. Roof of orbit. *PS*. Planum sphenoidale. *MCF*. Outline of the middle cranial fossa.

deepened, dorsum asymmetrically eroded. Anterior clinoid processes were intact. (See Fig. 64.)

#### *Cases with Total Destruction of the Body of the Sphenoid*

CASE 1.—Ch. T., female, thirty-three years old. Typical acromegaly. Amaurosis right side, hemianopia left side.

The roentgenogram disclosed atrophy of the skull and a decided enlargement of the accessory sinuses. The sella was almost completely destroyed. At the location for the dorsum sellæ, one could see three thin leaves of bone, lying one behind the other. (See Fig. 65.) A postmortem performed several months later showed the presence of a tumor of the hypophysis, the size of a child's fist, which had destroyed the body of the sphenoid and in places the floor of the middle cranial fossa.

CASE 2.—A. K., female, thirty-three years old. Enlargement of the hands had been noticed for the last year. Disturbance of vision.

The x-ray picture showed thickening of the skull vault and very much enlarged accessory sinuses. Sella was very much dilated. The air cells of the mastoid were projected over the dorsum sellæ. (See Fig. 66.)

The patient was operated upon in Hoehenegg's Clinic according to the Schloffer method. The postmortem showed the existence of a large cystic tumor of the hypophysis.

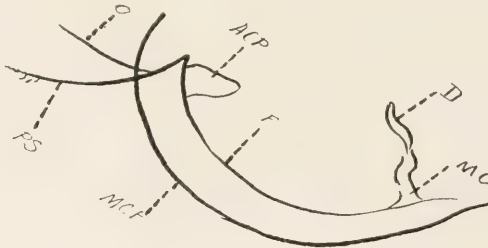


Fig. 66.—Sketch of the sella in Case 2. *MC*. Outline of mastoid cells. They make the dorsum appear irregular in detail.

CASE 3.—M., female, twenty-nine years old. Typical acromegaly. Atrophy of the optic nerves of both eyes.

On the x-ray picture, the body of the sphenoid was destroyed, the dorsum was not to be seen, and the anterior clinoid processes were thinned and turned upward. The air cells in the mastoid extended far forward into the squama temporalis so that their contour was to be seen at that point where the dorsum sellæ is usually found.

CASE 4.—R., male, thirty-two years old. There existed an acromegalic habitus along with congenital anomalies (nystagmus, imbecility).

The roentgenogram showed almost complete destruction of the body of the sphenoid. Only at the place corresponding to the site of the dorsum sellæ was seen a thin leaf of bone which was bent in the shape of a hook at its upper end. (See Figs. 67 and 68.)

## Group II. Hypophyseal Tumors in Dystrophia Adiposogenitalis (Fröhlich Type)

In this group are placed those cases in which the symptoms of infantilism and obesity stood out strikingly in the clinical picture.



*Cases with Slight Sellar Erosion*

CASE 1.—B. I., female, thirty-two years old. Menopause and headache during the last year. Began to get fatter a short time previous to the examination. Some disturbance in sight.



Fig. 67.—X-ray picture of the sella of Case 4, page 188.

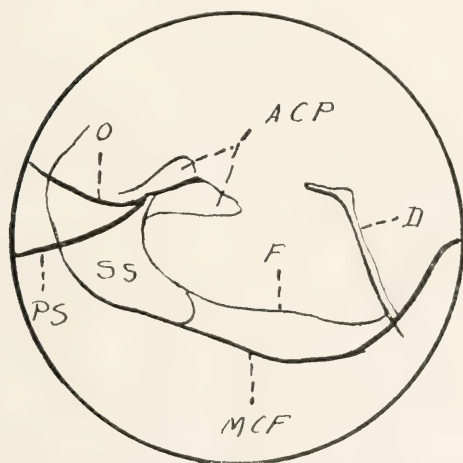


Fig. 68.—Sketch of Fig. 67. *O*. Orbital roof. *ACP*. Anterior clinoid processes. *SS*. Sphenoidal sinus. *F*. Floor of sella. *D*. Dorsum sellae. *MCF*. Outline of the middle cranial fossa. *PS*. Planum sphenoidale.

On the roentgenogram the sella appeared shallow, owing to the entrance being wider than normal. The floor of the sella was thin, the dorsum gone, the anterior clinoid processes were pointed. (See Fig. 69.)

Several months after this examination a postmortem was held on this case. There was found a cyst above the hypophysis.

CASE 2.—H. S., female, thirty-six years old. For the three years previous to examination she had suffered from amenorrhea, obesity, and disturbances in sight.

The roentgenogram revealed a shallow widening of the sella, a sharpened short dorsum and anterior clinoid processes. The operation, undertaken in the von Eiselsberg Clinic, determined the existence of a sarcoma of the hypophysis.

### *Cases with Moderate Erosion of the Sella*

CASE 1.—M., male, thirty-six years old. The symptoms present were headache, facial paresis, optic atrophy, loss of sexual desire and potency. He was pale, and suffered from a slight degree of obesity.



Fig. 69.—Sketch of the sella of Case 1, page 189. The lettering is the same as in other sketches.

The roentgenogram showed the sella to be widened and deepened. Its floor had a double contour, the dorsum was gone except for an insignificant portion, and the anterior clinoid processes were sharpened. (See Fig. 70.)

At the operation, performed according to the Schloffer method, in the von Eiselsberg Clinic, small portions of a soft tumor were removed. The size of the hands and the adipose tissues in general decreased soon after the operation. (*Wiener klinische Wochenschrift*, 1909, pp. 287 and 1771.)

CASE 2.—P., male, thirty-six years old. Infantile habitus.

The roentgenogram revealed a shallow erosion of the sella turcica. The dorsum and the anterior clinoid processes were gone.

CASE 3.—Pr., male, thirty-four years old. Infantilism. Optic nerve atrophy.

The roentgenogram showed a shallow widened sella. Its dorsum was

shoved posteriorly and was much thinner than normal. Anterior clinoid processes were pointed.

CASE 4.—F., female, thirty-seven years of age. Had never menstruated. Myxedematous habitus. Bitemporal hemianopia. Attacks of epilepsy.

On the roentgenogram the sella was enlarged in all its diameters and its dorsum was thinner and shorter than normal. (*Wiener klinische Wochenschrift*, 1911, p. 1174.)

### Cases with Total Destruction of the Sella

CASE 1.—R. D., male, nineteen years of age. For the last eight years had suffered from headache, disturbance of sight, and increasing obesity.

On the roentgenogram one could readily see that there had been a total destruction of the dorsum sellæ and the body of the sphenoid. The anterior clinoid processes were present only in part.

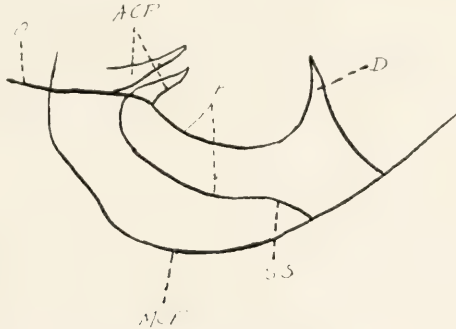


Fig. 70.—Sketch of the sella in Case 1, page 190. The floor is eroded in such a manner that one side of the dorsum must also be gone. O. Roof of orbit. F. Floor of the sella. D. Dorsum sellæ. ACP. Anterior clinoid processes. MCF. Outline of the middle cranial fossa. SS. Posterior wall of the sphenoidal sinus.

At the operation, done in the von Eiselsberg Clinic by the Schloffer method, there was found a liquefying new-growth on the hypophyseal site. Microscopic examination showed the tumor to be a carcinoma. (See *Wiener klinische Wochenschrift*, 1907, p. 1341.)

CASE 2.—K. W., male, twenty-seven years old. Amblyopia and dystrophia adiposogenitalis.

The roentgenogram showed the body of the sphenoid, the dorsum sellæ, and the anterior clinoid processes to be destroyed. (See Fig. 71.)

The patient was operated.

CASE 3.—Dr. C., male, thirty-six years old. Patient had been sick for the last seven years. Disturbance of vision. Dystrophia adiposogenitalis.

The roentgenogram revealed almost total destruction of the body of the sphenoid.

The operation and the postmortem held eight days later verified the existence of a hypophyseal tumor. It was the size of an egg and had

burrowed deeply into the base of the brain. (*Wiener klinische Wochenschrift*, 1911, p. 109.)

CASE 4.—Z., male, twenty-three years of age. Obesity, blindness, and progressively increasing dementia.

On the roentgenogram one could see that the body of the sphenoid and the dorsum sellæ had undergone complete destruction. The postmortem revealed a tumor the size of a child's fist in the sella with extension toward the base of the brain and invasion of the right trigeminal nerve. The skull base in the region of the sphenoid bone, the clivus, and the petrosal ridges was eroded. A connection extended from the tumor in the hypophysis to a yet greater tumor in the right frontal lobe.

CASE 5.—B. H., male, thirty-two years of age. Disturbance of vision. Obesity.

The roentgenogram showed total destruction of the body of the sphenoid bone and the dorsum sellæ with thinning of the anterior clinoid processes.

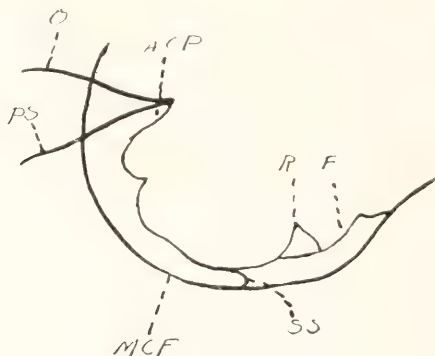


Fig. 71.—Sketch of the sella in Case 2, page 191. The dorsum is entirely gone. The sharp points that appear on the floor of the sella are in reality the outline of ridges or spines on the floor of the middle cranial fossa. *R*. Ridge on floor of the middle cranial fossa. *F*. Floor of sella. *SS*. Posterior wall of the sphenoidal sinus. *MCF*. Middle cranial fossa. *PS*. Planum sphenoidale. *O*. Roof of orbit. *ACP*. Anterior clinoid process.

In the roentgenogram made a year previously there had been considerably less erosion. (*Wiener klinische Wochenschrift*, 1903 and 1905, articles by A. Fuchs.)

CASE 6.—L., male, twenty-eight years of age. Extreme obesity for many years. Occasional headaches and epileptic attacks. Impotence.

The roentgenogram disclosed a total destruction of the body of the sphenoid bone. (See Redlich and Schüller, Case 27.)

CASE 7.—F. A., male, forty years old. The patient had the general appearance of a eunuch.

In the roentgenogram the sella was extremely widened and deepened and the dorsum thinned and pushed backward. The anterior clinoid processes were thinner than normal and were pushed upward.

CASE 8.—G., male, sixty-six years of age. Feminine habitus. Obesity.

On the roentgenogram the sella turcica was almost completely destroyed. The anterior clinoid processes were gone. (Bondi, *Wiener klinische Wochenschrift*, 1911, p. 1684.)

### Group III. Tumors of the Hypophysis without Symptoms of Tropic Disturbance

In this group are placed those cases in which are found neither the characteristic symptoms of acromegaly nor those of dystrophia adiposogenitalis. Besides the local symptoms caused by the hypophyseal tumor, especially disturbance of sight which become noticeable frequently as a bitemporal hemianopia, there exist in most cases uncharacteristic general brain symptoms such as headache, psychoses, and epilepsy. Not rarely was a premature cessation of menstruation observed in women.

#### *Cases with Slight Erosion*

CASE 1.—K. M., male, forty-two years old. For the last six months there had been attacks of right-sided headaches resembling migraine. Normal eye findings.

The roentgen examination showed a distinct enlargement of the hypophyseal fossa in all diameters, so that even at this early stage the diagnosis of a hypophyseal tumor could be made.

CASE 2.—M. R., female, thirty-eight years of age. Bitemporal hemianopia, headaches, and optic nerve atrophy were present.

The roentgenogram revealed deepened convolutional impressions. The sella was enlarged in all diameters. The operation performed in the von Eiselsberg Clinic, as well as the later postmortem, determined the existence of a hypophysis tumor. There was found a walnut-sized tumor, the larger portion of which projected from the sella. The skull was 4 mm. thick, spongy, and its inner surface showed deep Pacchionian grooves on both sides of the middle line in the vertex and on the frontal bone.

CASE 3.—L. G., male, thirty years old. Right temporal hemianopia.

The roentgenogram showed the sella to be widened at the top, the floor thin, and the dorsum gone except for an insignificant shadow. The anterior clinoid processes were greatly thinned. (See Figs. 72 and 73.)

CASE 4.—G. C., male, fifty years of age. During the last three years there had been rapid loss of sight in the left eye. At the time of examination there was amaurosis of the left eye and the disc of the right was paler than normal.

The roentgen examination revealed a slight widening of the sella with

thinning and tipping backward of the dorsum. (See Schüller, Manual of Lewandowsky, Plate IX, Fig. 2.)

CASE 5.—O. K., girl, eighteen years old. Diplopia. Recently amenorrhea. Bilateral choked disc.




Fig. 72. —Roentgenogram of Case 3, page 193. The dorsum sellæ is almost entirely gone.

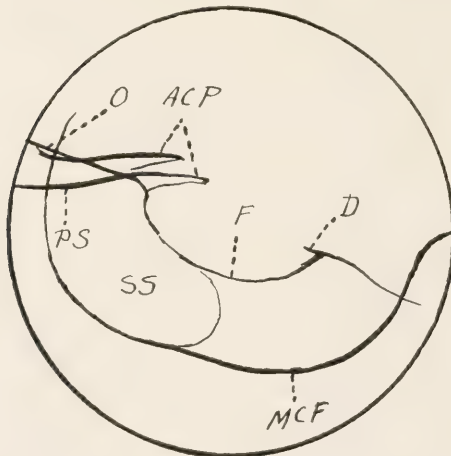


Fig. 73.—Sketch of Fig. 72. *O.* Roof of orbit. *ACP.* Anterior clinoid processes. *F.* Floor of sella. *D.* Dorsum sellæ. *SS.* The sphenoidal sinus. *MCF.* Outline of the middle cranial fossa. *PS.* Planum sphenoidale.

On the roentgenogram the hypophyseal fossa was slightly deepened, its floor thinned, dorsum destroyed, and the anterior clinoid processes hollowed out on their under surface. Inner surface of the skull elsewhere was completely smooth. Diagnosis, basal tumor, probably hypophyseal.

CASE 6.—H., female, seventy-six years old. Bitemporal hemianopia.

On the roentgenogram, the sella was slightly widened and deepened, the dorsum was thinned and shortened. The anterior clinoid processes were sharp pointed.

CASE 7.—F. T., male, thirty-seven years of age. Bitemporal hemianopia.

The roentgenogram showed the sella turcica to be slightly enlarged and the dorsum very much shortened and shoved posteriorly.

CASE 8.—Qu., female, forty-two years old. Temporal hemianopia.

Roentgenogram showed the sella deepened and the dorsum shortened.

### *Cases with a Moderate Degree of Sella Erosion*

CASE 1.—B., female, forty-six years of age. Headaches for years. Of late there had been disturbance of sight with loss of both temporal fields of vision.

On the roentgenogram the skull appeared thick and porous. Its inner surface was smooth. The sella was evenly widened and its floor moderately thick. The anterior clinoid processes were still present, though the dorsum was for the most part destroyed. (See Figs. 74 and 75.) The patient was operated upon, but, because of deterioration of sight, it was necessary to repeat the operation nine months later. At that time the patient died. The postmortem disclosed the fact that the tumor, originating from the hypophysis, had grown toward the third ventricle. The skull was found to be thickened and smooth and supplied with only small, but very much deepened, Paechionian grooves, from which very much eroded vein furrows extended on both sides toward the base.

CASE 2.—E., female, forty-five years old. Disturbance of sight, especially in the right eye.

The roentgenogram showed a very much deepened sella with thinning and tipping back of the dorsum. The anterior clinoid processes were still present. The operation was performed in the von Eiselsberg Clinic.

CASE 3.—W. J., female, thirty-eight years of age. Disturbance of sight.

Roentgen finding: Sella hemispherically widened, 22 mm. across. Its floor was quite thick, the dorsum was drawn out to a thin point and the anterior clinoid processes were intact. The patient was operated upon. (Hirsch, *Wiener klinische Wochenschrift*, 1911, p. 1579.)

CASE 4.—M., female, twenty-three years of age. Amenorrhœa, headache and disturbance of vision.

On the roentgenogram the skull was of normal size and shape, 3 to 4 mm. thick, porous, smooth on the inner surface. Sella was enlarged in all diameters, the anteroposterior diameter amounting to 22 mm. Corresponding to the normal location for the floor of the sella, there were two parallel contours to be seen. These were thin and separated 5 mm. from each other. The dorsum sellæ was somewhat thinned and shoved backward. The anterior clinoid processes were normal. The distance from the tuberculum sellæ to the spina nasalis anterior was 8.5 cm. The opera-

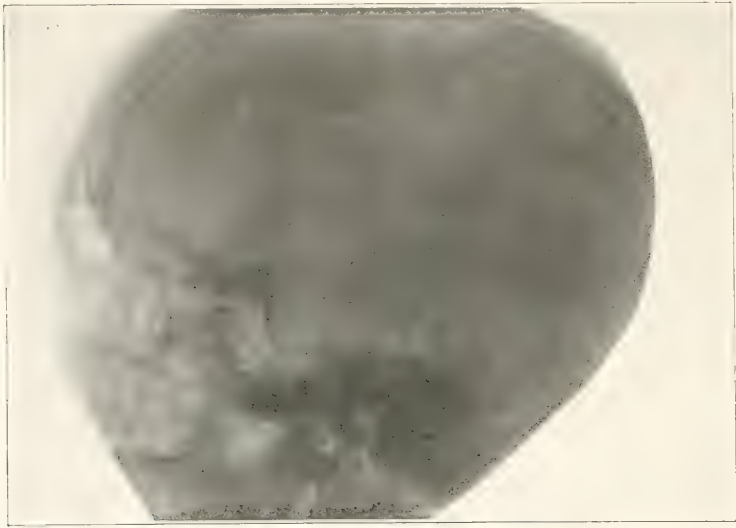

Fig. 74.—Portion of the x-ray picture of the head of Case 1, page 195. In addition to the destruction of the sella that is readily apparent one can distinguish the outlines of eroded venous channels.

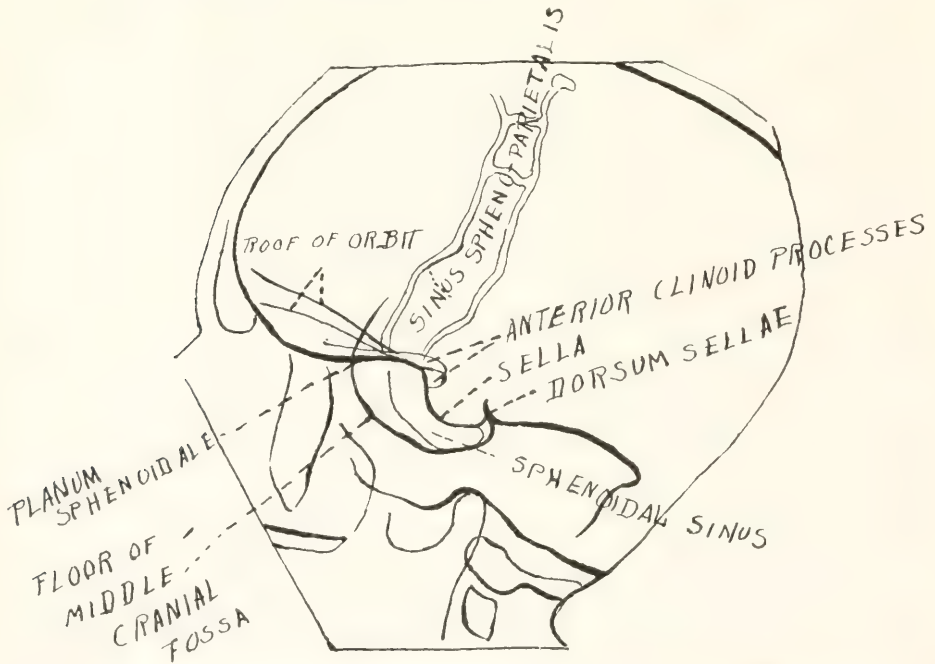


Fig. 75.—Sketch intended to bring out the important features to be seen in Fig. 74.



tion verified this measurement and the thinness of the floor of the sella. However, the bone was sclerotic. A repetition of the roentgenogram after a year revealed no essential changes.

CASE 5.—J. N., man, fifty-four years old. Disturbance of sight with limitation of temporal field of vision.

The roentgenogram showed the skull vault to be of normal size and contour, averaging 5 mm. in thickness. It was spongy. The inner surface showed slightly deepened impressions. The sutures were quite plain. The sella was symmetrically widened, the dorsum completely destroyed, the anterior clinoid processes were somewhat pointed. The sphenoid sinus contained air. The patient was operated upon.

CASE 6.—R., male, sixty-nine years old. Disturbance of sight for the last nine months, amaurosis of left eye, hemianopia of right eye.

Roentgen finding showed the floor of the sella very much deeper and wider than normal. Its distance from the anterior nasal spine was 8.7 cm. The dorsum sellæ was destroyed. The anterior clinoid processes were intact. The patient was operated.

CASE 7.—B., female, thirty-six years old. Disturbance of sight for the last six years. Left eye blind, right amblyopic. Amenorrhæa.

The x-ray showed the sella to be widened and deepened (20 mm. in anteroposterior diameter and 17 mm. deep), and its floor to be 7.8 cm. distant from the spina nasalis anterior. Slightly deepened convolutional impressions. The sinus sphenoparietalis was very prominent. The patient was operated.

CASE 8.—B., female, forty-one years of age. Headaches, amenorrhæa, disturbance of sight had been present for the last seven years. At the time of examination there was a temporal hemianopia of right eye.

The roentgen examination showed a considerable degree of widening and deepening of the sella (22 mm. long by 16 mm. deep) and the dorsum was almost gone. The distance from the floor of the sella to the spina nasalis anterior was 8.6 cm. The operation performed by Hirsch verified the diagnosis of a hypophyseal tumor.

CASE 9.—R., male, forty years old. Bitemporal hemianopia.

The roentgenogram showed the skull to be 6 mm. thick, spongy. It revealed also the presence of deep Pacchionian erosion. The sella was very much widened and deepened, and its floor showed a double contour. The sphenoid sinus was 5 mm. across and contained air. The patient was operated in the Chiari clinic. (See Chiari, *Wiener klinische Wochenschrift*, 1911, p. 924.)

CASE 10.—P. B., male, forty-eight years of age. For years the patient had complained of disturbance of sight with temporal limitation of the visual field.

The roentgenogram showed the sella to be considerably deepened, its floor thinned and showing a double contour, dorsum gone, and the anterior clinoid processes intact.

CASE 11.—G., female, thirty-five years old. There had been a disturbance of sight nine years previously, which disappeared after some sort of treatment with iodine. Shortly before the examination this visual disturbance had again become worse. Bitemporal hemianopia present.

The roentgenogram showed the sella turcica to be considerably wider and deeper than normal. The dorsum sellæ was reduced to a thin leaf which was sharply turned backward. Slight pressure erosion was found on the rest of the skull.

Following the taking of thyroid gland the patient's condition improved.

CASE 12.—N. D., male, fifty-two years old. The patient had a strikingly large and strong body framework. There was present an amaurosis of the right eye and a temporal hemianopia of the left with very slight amount of vision.

The roentgen examination showed a hemispherical widening of the sella turcica (23 mm. in anteroposterior diameter) combined with a persistent dorsum sellæ that appeared thinned and elongated.

CASE 13.—F. F., female, thirty-five years of age. For ten years previous to examination, patient had complained of headache about once a month. Mother and sister of patient suffered from migraine. For a year there has been a noticeable increase in the severity of the headache. There has also been a deterioration in sight. Six months previous to the present examination there was a left-sided nasal hemianopia. At that time there was a temporary improvement in the power of vision, which seemed to follow a nasal operation (removal of turbinate), and which made itself evident objectively in an increase in vision in the lower sector of the field. Shortly previous to the present examination, an atrophy of the left optic nerve had begun. The sight of the right eye was poor. Patient had not menstruated since sixteen years of age.

The roentgen examination revealed a considerable enlargement of the sella, with deepening of the floor and destruction of the dorsum. The anterior clinoid processes were normal.

CASE 14.—W., male, forty-five years of age. Bitemporal hemianopia.

The roentgenogram showed an enlargement of the sella (anteroposterior diameter 20 mm.). The floor of the sella appeared as a double contour, the upper one of which corresponded to that of a slightly enlarged sella while the lower one was some 7 mm. deeper. The dorsum sella was persistent but pushed backward.

CASE 15.—R. E., female, thirty-eight years of age. Bitemporal hemianopia. Optic atrophy.

The x-ray picture showed a considerable deepening of the hypophyseal fossa. The dorsum was tipped backward, being very markedly convex on the posterior side.

CASE 16.—Z. S., male, fifty-three years old. Disturbance of sight.

The roentgenogram showed the skull vault to be of normal contour, 5 mm. thick. The hypophysis was shallow and widened at the top. The dorsum

was completely gone, except for two short points. The anterior clinoid processes showed no change except shortening. (See Fig. 76.)

CASE 17.—Female, fifty-five years old. Bitemporal hemianopia and headache.

The roentgenogram showed a considerable widening of the sella.

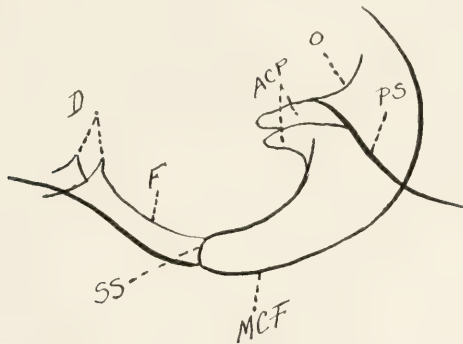


Fig. 76.—Sketch of the sella of Case 16, page 198. *D*, Dorsum sellae (appearing as two points). *F*, Floor of sella. *ACP*, Anterior clinoid processes. *O*, Roof of orbit. *PS*, Planum sphenoidale. *MCF*, Outline of middle cranial fossa. *SS*, Posterior wall of the sphenoidal sinus.

CASE 18.—B. H., female, forty-four years of age. Cessation of menstruation two years previously. Headache and disturbance of vision. The right papilla was paler than normal.

The roentgenogram showed the sella to be much deepened, its floor thinned, and the dorsum gone. The floor had a double contour. The an-

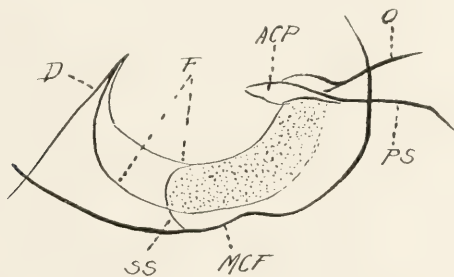


Fig. 77.—Sketch of the x-ray picture of Case 19, page 200. The floor of the sella shows asymmetrical erosion in that a double contour is present. *D*, Dorsum. *F*, Double contour lines of the floor. *ACP*, Anterior clinoid processes. *O*, Roof of orbit. *PS*, Planum sphenoidale. *SS*, Posterior wall of the sphenoidal sinus. *MCF*, Outline of the middle cranial fossa.

terior clinoid processes were somewhat pointed. There were broad furrows at the site of Merkel's veins. The patient was operated upon by Hirsch. (See *Wiener klinische Wochenschrift*, 1911, p. 1579.)

CASE 19.—J. A., male, thirty-one years of age. Blindness of the right eye. Acuteness of vision was preserved in the left eye in the nasal half of the field but was not sharp in the temporal half.

In the roentgenogram the sella was enlarged in all dimensions. The dorsum was thinned. The anterior clinoid processes were pointed. The floor of the sella showed a double contour. The distance between the two contours amounted to more than one centimeter. The lower contour bulged far downward and forward into the sphenoid sinus and in places it lacked the shadow density of a bony wall. (See Fig. 77.) It was possible to verify this finding at the operation performed by Hirsch.

CASE 20.—Woman, twenty-seven years old. For the past two years suffered from amenorrhœa, headache, increase in weight, disturbance of sight. The latter was worse in the left eye than in the right.

On the roentgenogram the sella was widened and deepened. The dorsum was elongated, thin, and tipped backward. The anterior clinoid processes were intact. The patient was operated upon in the Clinic of von Eiselsberg. (See Ranzi, *Wiener klinische Wochenschrift*, 1910, p. 831.)

### *Cases with Total Destruction of the Sphenoid Body*

CASE 1.—D., female, thirty-five years old. Epileptic attacks for the last seven years. Cessation of menstruation four years before examination. Later, headache appeared, and finally also disturbance of power of vision with total blindness of left eye and extreme amblyopia in the right.

The roentgen examination revealed an almost complete destruction of the sella turcica with erosion of the dorsum and of the anterior clinoid processes. The operation was performed by Hirsch (see Hirsch, *Endonasale operationen*, etc., Case 1 with Fig. 3, Plate II) and revealed the existence of a cyst. The postmortem performed a year and a half later showed a rest from a hypophyseal tumor the size of a walnut.

CASE 2.—S., male, forty-eight years old. Strikingly pale. Bilateral optic atrophy.

The roentgenogram showed destruction of the body of the sphenoid bone and the dorsum sellæ. The anterior clinoid processes were intact. The operation performed in the Hoehenegg Clinic and the later postmortem verified the existence of a large tumor of the hypophysis. (See Exner, *Mitteilungen aus den Grenzgebieten*.)

CASE 3.—G. W., male, twenty-seven years old. During the four years previous, patient had suffered from repeated attacks of extreme decrease in the power of vision which would suddenly improve, so much that patient would enjoy normal sharpness of vision. At time of examination optic atrophy of left eye.

The roentgenogram showed complete destruction of the corpus sphenoidalis along with the dorsum sellæ. The anterior clinoid processes were pointed. In this case it was possibly a matter of a repeatedly bursting cystic tumor.

CASE 4.—E. K., female, sixty-nine years old. Disturbance of sight for

several years. An examination eight years previously permitted the diagnosis of bitemporal hemianopia.

The roentgen examination that was made did not permit the diagnosis of enlargement of the sella turcica. (See, *Demonstration by Redlich, ophthalmologische Gesellschaft in Wien, 1903.*)

A year later we were able to observe in another roentgenogram of this case a considerable destruction of the sella turcica. At the time of the last examination the body of the sphenoid was completely destroyed. Nevertheless the clinical symptoms had practically not changed at all. Besides the hemianopia there existed only the striking size of the tongue. Of interest is the fact that the examination of the nose had revealed an abundant growth of polypi in the sphenoid sinus. The cleaning out of the sphenoid cavity, which Hajek did, was of only transitory success, for the cavity became filled up with new polypi at once. We have grounds for thinking that the polypi of the sphenoid cavity were only a part of a hypophyseal tumor which had grown through the base of the skull and that the benign course of the case was due to the fact that the tumor was not prevented from growing downward.

CASE 5.—Ph. P., girl, sixteen years old. No menstruation for the last eight months. Amaurosis right side, temporal hemianopia on left side.

The roentgenogram showed marked enlargement of the sella turcica, dorsum merely a stump. The anterior clinoid processes were intact. The floor of the sella was in places completely destroyed so that only the contour of a soft tissue shadow stood out in contrast to the air in the sphenoid sinus. (See *Demonstration Fuchs, Schüller.*)

The second form of local destruction on the base of the skull is that which is caused by tumors of the cerebellar-pontine angle, the so-called acoustic tumors.

### ACUSTICUS TUMORS

The erosion of the skull base, characteristic for tumors on this site, consists in the fact that the dorsum sellæ becomes thinned by pressure atrophy of its posterior surface. It later becomes bent forward.

As characteristic as this form of destruction is,<sup>12</sup> and as easy as it is to diagnose on the roentgenogram when present, it is by no means observed in all cases of acoustic tumor. Its typical appearance depends rather upon the site and the size of the tumor. Upon the basis of our experience up to the present time, it appears to be determined that this typical erosion is likely to be caused only by those tumors which grow from their

<sup>12</sup>This was first recognized in the roentgenograms by me, then verified at post-mortem, and published by me in the year 1909 on the occasion of the triennial meeting of the Society of German Neurologists in Vienna.

site of origin, the cerebellar-pontine angle, anteriorly along the posterior surface of the petrous portion of the temporal bone, and hence have not yet reached any significant extension.

A change, analagous to the one just described, could also exceptionally be caused by another kind of tumor similarly located, as, for instance, tumors in the pons, cholesteatoma and endothelioma of the posterior cranial fossa, chordoma (which arises at that point in the clivus where the synchondrosis sphenooccipitalis divides it) and, finally, aneurysm lying in the cerebellar pontine angle.

A second variety of local erosion in acusticus tumors is the widening of the internal auditory meatus described by Henschen (*Hygiea*, 1910).

The roentgenologic determination of this detail, in which we have been as unsuccessful as Josefson in the few cases examined in this manner up to the present, is likely to be possible by the comparison of two profile pictures of the head, made in the same position.

Apart from the erosions previously mentioned as pathognomonic for acusticus tumors, there are developed numerous other kinds of skull changes in consequence of the presence of a tumor of the cerebellar-pontine angle. Most frequently there are signs of a general increase in intracranial pressure, similar to the tumors of the cerebellum which produce internal hydrocephalus by compression of the aqueduct of Sylvius, or there are erosions of the delicate portions of the entrance to the sella tureica similar to that which usually occurs in tumors of the base of the brain. Finally, it may be mentioned that there may be made out a combination of the characteristic local destruction with general erosion of the skull. However, there may be an absence of every skull change.

The diagnostic utility of the skull changes in acusticus tumors, recognizable on the roentgenogram, may be formulated in the following manner:

1. The pathognomonic change (the thinning and the forward bending of the dorsum sellæ) is a valuable sign, making certain the diagnosis of acusticus tumor. In a well-marked case of the latter one may assume with the greatest probability that the tumor extends from the cerebellar-pontine angle anteriorly.

2. The proof of a general erosion of the inner surface of the skull points to the fact that either the tumor has reached a considerable size, or, by its position, has rendered the exit of the cerebrospinal fluid difficult, or that it is combined with other processes causing an increase in intracranial pressure (multiple tumors).

3. The result of the roentgen examination is of value for determining whether or not surgical interference is indicated.

The roentgenogram affords exact information relative to the appearance (thickness, density, vessel furrows) of the portions of the skull wall coming under consideration for trephination and it enables one to decide as to the necessity of a palliative operation for removal of pressure before the radical operation.

4. It may be of no value in diagnosis. If there are no pressure erosions discernible on the roentgenogram of the skull or only the changes significant of a general intracranial pressure, then the roentgenologic examination offers no evidence for a correct diagnosis.

The literature of recent years contains a large number of clinical and surgical publications concerning acoustic tumors. We mention the researches of Sternberg, von Monakow, F. Hartmann, Henneberg and Koch, Henschen, Josefson, Alquier and Klarfeld, Krause and Leischner.

We had occasion to examine fifteen cases of acoustic tumors. They occurred in five men and ten women at ages between twenty and fifty-nine years. A large number of our cases are verified by operation (eight), or postmortem (nine), or both. These cases have almost all been described in the literature by Leischner so that we can be very brief in the following review of them.

We group the cases, examined roentgenologically by us and reported below, according to the kind of skull erosion.

### **Group 1.—Acoustic Tumor with Pathognomonic Change of the Dorsum Sellæ**

CASE 1.—A. Z., female, thirty-eight years old. For past two years disturbance in hearing, headache, dizziness, vomiting. For past two months marked decrease in power of vision. "Puffy" feeling of the right side of face. Deafness right side, vestibule of right side could not be stimu-

lated. Hypalgnesia of the second and third branches of the right trigeminal nerve. Choked disc. Diagnosis was acoustic tumor of right side.

The roentgenogram showed a normal appearance of the inner surface of the skull and all portions of the sella, except the dorsum, which was thinned and pushed forward. (See Fig. 78.) Operation and postmortem verified the finding (see Leischner, Case 1).

CASE 2.—K. M., female, fifty-nine years old. For eight months patient had suffered from a posterior headache, dizziness, and vomiting. There was weakness of the left leg and left hand and a staggering gait. Decrease in power of sight and hearing. Dementia. The examination revealed choked disc, nystagmus, slight affection of the right trigeminal nerve, deafness in right ear, slight spastic paresis of the left extremity. Clinical diagnosis: acoustic tumor on right side.

Roentgen finding: Inner surface of skull was smooth, frontal bone thickened. The sella plainly, though slightly, widened and deepened, dor-

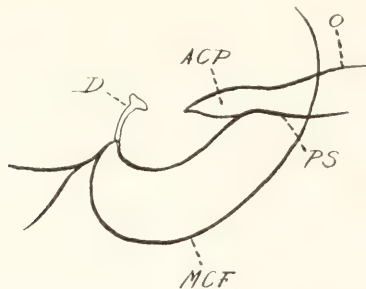


Fig. 78.—Sketch of the x-ray picture of the sella in Case 1, page 204. The dorsum is thinner than normal and is pushed forward. *D*, Dorsum sellæ. *ACP*, Anterior clinoid processes. *O*, Roof of orbit. *PS*, Planum sphenoidale. *MCF*, Outline of the middle cranial fossa.

sum very much thinned and tipped somewhat forward. Diagnosis was basal tumor of the brain, most likely an acoustic tumor with hydrocephalus of the third ventricle. The postmortem verified the diagnosis as there was a plum-sized tumor of the acousticus on the right side, and a marked chronic internal hydrocephalus.

CASE 3.—J. J., female, fifty years old. Choked disc both sides. On the left side there was absence of reflex in the fifth nerve, paresis of the third, slight paresis of the seventh, the eighth paralyzed. Slight ataxia of the upper extremities. Romberg positive. Clinical diagnosis: tumor of acousticus on the left side.

The roentgenogram showed the skull to be 6 mm. thick, inner surface smooth. Sella was of normal size, dorsum much thinned and tipped forward. (See Figs. 79 and 80.) The operation performed in the clinic of von Eiselsberg and the postmortem, later, verified the clinical finding. There was found a gliofibroma of the acousticus. The inner surface of the skull was smooth, the dorsum sellæ thin as paper and bent forward. (See Leischner, Case 3.)



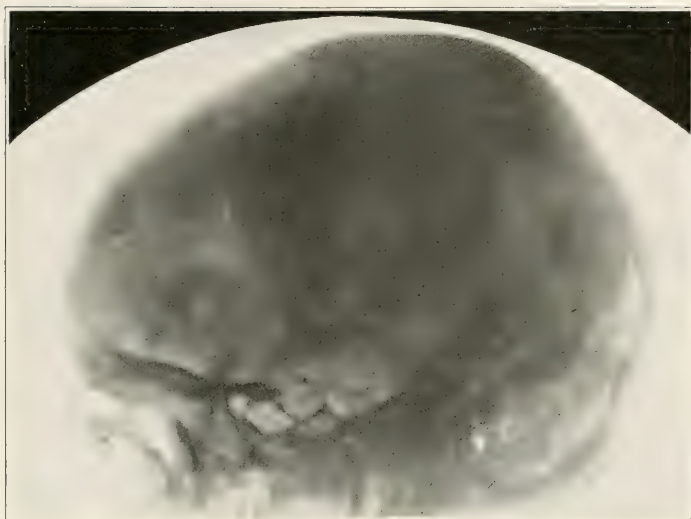


Fig. 79.—A dextrosinistral picture of the head of Case 3, page 204. In this picture there appears a definite change in the dorsum sellæ in that it is thinner than normal and is pushed over forward.

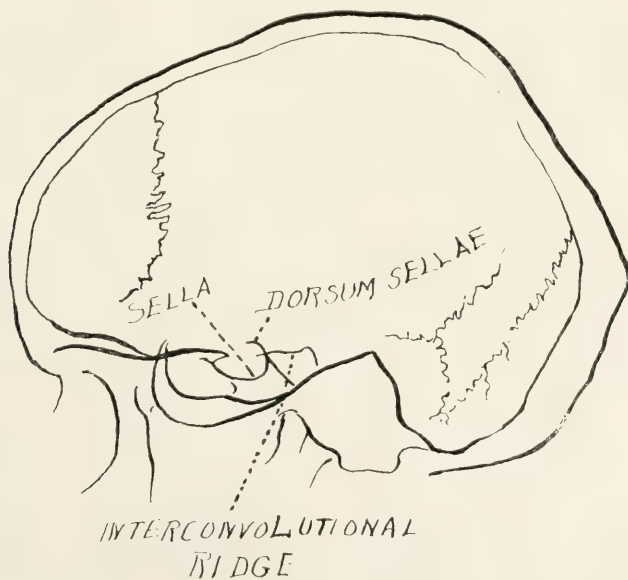


Fig. 80.—A sketch of Fig. 79.

CASE 4.—M. H., female, fifty-seven years old. Choked disc, epileptic attacks, paralysis of the fifth nerve left side, left side deafness. Diagnosis: tumor of acousticus on left side.

While the first roentgenogram yielded a negative result, several months later the inner surface of the skull was found to be smooth, sella small, its floor thin, the dorsum thin and its posterior surface eroded. The post-mortem confirmed this finding. There was found an apple-sized (crab-apple?) tumor in the left cerebellar-pontine angle, an edema of the right trigeminal nerve with a softening of the pons at the point of exit of the nerve.

CASE 5.—J. D., male, twenty-eight years old. For two years suffered successively from loss of speech, double vision, disturbance of gait, loss of hearing and loss of taste. For the last year had suffered from trembling of the left side, and headache. Examination of eyes showed slight choked disc. Clinical diagnosis: acousticus tumor.

The roentgenogram showed the dorsum sellæ changed to the extent that it appeared eroded on its posterior surface. The inner surface of the skull was smooth.

## Group 2. Acousticus Tumor with Erosion of the Sella

CASE 6.—Sch. A., female, fifty-two years old. Distinct choked disc right side, beginning choked disc on left side. Hypesthesia in the region of the left trigeminal nerve. Reflex of fifth nerve as well as movement of

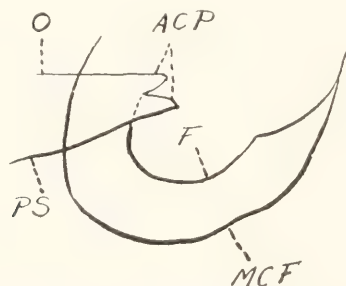


Fig. 81.—Sketch of the x-ray plate of Case 6, page 206. The sella in this case is slightly widened and the dorsum is entirely eroded. ACP. Anterior clinoid processes. O. Roof of nearest orbit. F. Floor of sella. PS. Planum sphenoidale. MCF. Outline of the middle cranial fossa.

muscles supplied by fifth on left side were weaker. Nervus facialis slightly paretic on left. Eighth nerve, left side, could not be stimulated and the twelfth was slightly paretic. Upper extremity left side plainly paretic. Bilateral ataxia of the upper extremities. Achilles reflex more marked on right side than left. Babinski reflex right side plainly positive. Diagnosis: Acousticus tumor.

Roentgenogram showed the skull to be 7 mm. thick, lamina interna 3 mm. thick, inner surface smooth. The sella showed a slight shallow widen-

ing, dorsum gone. (See Fig. 81.) The finding was confirmed by the operation (von Eiselsberg Clinic) and the postmortem (see Leischner, Case 10).

CASE 7.—T. Z., female, fifty-three years old. Deafness right side, difficulty in swallowing, paralysis of eye muscles. Diagnosis: tumor of acousticus.

The roentgenogram showed dorsum sellæ thinned with slight widening of the sella, as in basal tumors of the brain. The postmortem revealed a tumor of the right acousticus the size of a small apple.

CASE 8.—A. B., male, forty-three years old. Lues twenty-five years previously. Disturbance of hearing on left side for the last three years. Choked disc.

On the roentgenogram the sella was slightly deepened, its floor thinned, the dorsum eroded, signs of a basilar destructive process. At the postmortem there was found a tumor of the acousticus of the left side with chronic internal hydrocephalus and flattening out of the convolutions. (See Leischner, Case 5.)

### Group 3. Acousticus Tumors with General Pressure Atrophy of the Inner Surface of the Skull

CASE 9.—F. J., male, forty years old. Bilateral choked disc. Hypalgnesia of the first and second branches of the trigeminal on the left side with absence of trigeminal reflex. Unable to stimulate eighth nerve left side. Diagnosis: tumor of acousticus, left side.

The roentgen finding showed the skull vault to be diminished in thickness and porous, its inner surface uneven in consequence of deepened convolutional impressions, hypophysal fossa small, anterior clinoid processes pointed, dorsum sellæ very thin and short. We concluded, on that account, that there was a tumor of the middle or posterior cranial fossa in connection with a general increase in intracranial pressure. The operation (von Eiselsberg Clinic) revealed the existence of an acousticus tumor on the left side. The section showed in addition to this, multiple fibromata up to the size of a bean, along the falx cerebri. These had produced impressions on the inner surface of the skull. (See Leischner, Case 7.)

CASE 10.—B. P., female, thirty-two years old. Clinically there were symptoms of an acousticus tumor.

On the roentgenogram the vault appeared 8 mm. thick and there were marked convolutional impressions, and numerous visible diploic veins. There was a deepening of the sella with thinning of the dorsum. In other words, there were present the signs of a general increase in intracranial pressure.

CASE 11.—N., girl, twenty-seven years old. Headache, dizziness, disturbance of hearing.

The roentgenogram showed extremely deepened convolutional impressions over the whole inner surface of the skull, spherical widening of the sella turcica, thinning of the dorsum (Fig. 82). These were changes such

as we see in intracranial pressure of a high degree. The operation (Hochenegg Clinic) and the postmortem revealed that it was a case of acoustic tumor the size of a small apple which had extended deeply into the cerebellum.

CASE 12.—K. E., male, thirty-seven years old. Choked disc, disturbance of hearing, cerebellar ataxia.

On the roentgenogram there appeared an erosion of the dorsum sellæ, shallow widening of the hypophyseal fossa, very marked convolitional impressions, and separation of the sutures. The postmortem showed that, in addition to a cystic tumor of the acoustic the size of a small apple, causing marked compression of the cerebellum and the pons, there existed a chronic internal hydrocephalus with flattening of the convolutions. (See Leischner, Case 6.)

CASE 13.—B. M., female, thirty-nine years old. Headache and vomiting for the last year. For the last five weeks there had been diminished power

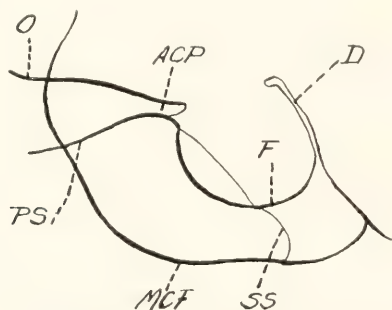


Fig. 82. Sketch of the sella of Case 11, page 207. It shows a symmetrical erosion of the sella. The dorsum is thin and is bent forward. The erosion is of such a nature that the posterior wall of the sphenoidal sinus is projected into the area of the sella. *O*. Roof of orbit. *PS*. Planum sphenoidale. *ACP*. Anterior clinoid processes. *F*. Floor of the sella. *D*. Dorsum sellæ. *SS*. Posterior wall of the sphenoidal sinus. *MCF*. Outline of the middle cranial fossa.

of vision and hearing on the left side. Papillitis. On the left side the fifth and seventh nerves were slightly affected. Deafness and vestibular symptoms. The tongue was deviated somewhat toward the left. Ataxia of the left hand. Diagnosis, acoustic tumor on the left side.

On the roentgenogram the skull appeared somewhat thick and showed slight convolitional impressions chiefly on the left side of the vault, and an enlargement of diploic veins was visible, signs of intracranial pressure, chiefly on the left side.

In connection with the detailed description of the skull changes produced by hypophyseal and acoustic tumors, there should be mentioned the local changes which are caused by:

## OTHER INTRACRANIAL TUMORS AND TUMOR-LIKE PROCESSES

*Tumors of the Base of the Brain*

The tumors (glioma, sarcoma, endothelioma, fibroma, cholesteatoma, tubercle, syphiloma, cysts) of the basal portion of the brain and meninges as well as the cranial nerves<sup>13</sup> not rarely produce changes in the bone of the skull base resembling pressure atrophy or carious destruction of the latter. The delicate portions of the skull base (sella turcica, planum sphenoidale) are those which suffer, especially, from the effect of pressure by basal tumors lying in their neighborhood. For this reason it happens that basal erosions can be made out in tumors in the anterior and middle cranial fossæ in most cases, but they are more seldom made out in tumors of the posterior cranial fossa.<sup>14</sup> In connection with the local erosion there may also occur erosions of the entire inner surface of the skull as a manifestation of a general increase in intracranial pressure, particularly in the case of tumors of the posterior cranial fossa which obstruct the foramen of Magendie.

The roentgen examination makes possible the proof of the skull changes produced by the basal tumors mentioned. Most frequently one sees that picture which we had occasion to observe in cases of extra-hypophyseal tumors: namely, changes in the fragile portions at the entrance of the sella turcica (thinning and deepening of the floor, sharpening of the anterior clinoid processes, wasting and shortening of the dorsum). The bony projections are eroded anterior or posterior or on one side, according to the position of the tumor. A further detail that can be distinguished on the roentgenogram is the unilateral or bilateral widening of the meningeal veins (sinus sphenoparietalis) which usually occurs if the cavernous sinus is compressed by the basal tumor. In addition to the local manifestations mentioned, the possible bilateral presence of general erosion of the inner surface of the skull may be ascertained roentgenographically. Along with basal tumors we should enumerate the basal aneurysms. At the occasion of a postmortem of an aneurysm of the carotid we were able to obtain the

<sup>13</sup>The tumors arising from the skull base itself will be described in the section on Rhinology (see also page 173).

<sup>14</sup>Only once did we see a bean-sized defect in the base of the cerebellar fossa in a child with a large tubercle of the cerebellum.

following finding in the cavernous sinus. The aneurysm formed a plum-sized sack which had hollowed out the sella turcica and contained calcium platelets in its wall.

In the lateral roentgenogram of the anatomic preparation of the skull base with the aneurysmal sack left in place one recognized the erosion of the sella and the domelike contour bent over the entrance to the sella. (See CP in Fig. 83.)

In accordance with what has been said, the utility of the roentgen examination for the diagnosis of basal intracranial tumors (with exclusion of hypophyseal and acoustic tumors) may be formulated in the following manner:

1. An asymmetrical erosion of the bony prominences located at the entrance to the sella, in combination with widening of the sinus sphenoparietalis of the same side, permits the very prob-

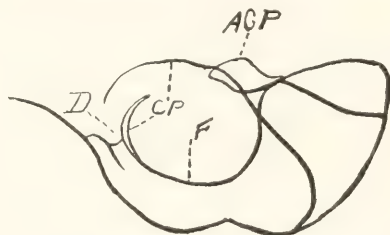


Fig. 83.—A sketch of a sella showing the appearance of calcified plates as they sometimes occur in the wall of some hypophyseal tumors. *D*, Dorsum sellæ. *CP*, Calcium plates. *ACP*, Anterior clinoid processes. *F*, Floor of the sella.

able diagnosis of an extramedian tumor located in the middle cranial fossa.

2. By taking into consideration the other clinical findings the existence of a tumor in the anterior or posterior cranial fossæ may be diagnosed with some degree of certainty from the isolated erosion of the anterior or posterior bony projections at the entrance to the sella.

3. The median basal tumors of the middle cranial fossa, in most cases, can not be differentiated from hypophyseal tumors, on the basis of the roentgenogram alone.

Among the cases observed by us the following should be mentioned here:

CASE 1.—*J.*, male, thirty years old. Attacks of epilepsy for the last several months. After the attacks there was an increase in the reflexes on the left side, with slight aphasia. Choked disc. Sensitiveness to percus-

sion over left temporal region. Tumor cerebri was diagnosed, but its site could not be definitely determined. One was led to think of a multiple tumor formation on account of the bilateral symptoms.

The roentgen examination showed the thickness of the skull to be 4 mm. The bone was spongy and its inner surface was smooth. The left half of the skull showed very much dilated venous furrows which extended from the parietal region in a curved direction posteriorly and downwards toward the temporal region. The sella was widened, its floor thinned and deepened, dorsum thinned and shortened, anterior clinoid processes thin. In consideration of this finding, the diagnosis was made of a tumor in the middle cranial fossa at the base. The operation performed in the von Eiselsberg Clinic showed the existence of an apple-sized tumor in the region of the left insula. (See Ranzi, "Demonstration in der Gesellschaft der Aertzte," *Wiener klinische Wochenschrift*, 1911, p. 995.)

CASE 2.—F. W., male, 50 years old. Patient had suffered for a year from double vision, attacks of dizziness, and headache. Patient was better after an antiluetic course of treatment, in spite of a negative Wassermann. During the last few months there had been a renewed increase in the earlier symptoms. Examination of the eyes showed neuroretinitis as in nephritis (patient had some albumin in urine). The right eye was more affected than the left. Gait not sure, with inclination of the body to the right or left. Weak memory. Sleepy. The clinical diagnosis lay between tumor of the hypophysis, tumor of the cerebellum of the left side, and cerebral disturbance from nephritis.

The roentgen examination of the skull revealed the inner surface to be smooth, the sella small, its floor not deepened. There was erosion of the anterior clinoid processes and the dorsum sellæ. Diploic veins were congested on the right side of the skull. Diagnosis, basilar tumor in the region of the middle cranial fossa.

Patient died during the two-stage operation. The postmortem showed a walnut-sized endothelioma of the dura, at the base, in the right middle cranial fossa, with compression of the posterior portion of the frontal lobe as well as the anterior pole of the right temporal lobe. There was compression of the right middle cerebral artery and flattening of the right half of the pons.

CASE 3.—K. L., female, thirty-three years old. During her fourth pregnancy eight years previously there had occurred a decrease in ability to see with the left eye. She became better after confinement. During her fifth pregnancy, a year previous to examination, she suffered from an attack of unconsciousness. Was unconscious three hours and, following this, was unable to talk. Later there was a hemiparesis on the right side. After confinement almost all the symptoms disappeared. For the last several months patient has been pregnant again. During this pregnancy patient has had headache, vomiting, disturbance of speech. At the time of examination there was ptosis and abducens paresis in the left eye, right-side hemiplegia, blindness on both sides, atrophy of left optic nerve with total ex-

cavation, old retinohoroiditis, atrophy of right optic nerve following a papillitis.

The roentgen examination showed the existence of a destructive process in the region of the sella turcica, the floor of which was deepened in varying degrees on the two sides, corresponding to the picture spoken of as having a double contour. The dorsum sellæ was destroyed with the exception of a slight trace. Since no pressure erosions were discernible in the rest of the skull, the diagnosis of a destructive process at the base of the brain was made, in consideration of the neurologic finding.

The postmortem, which was performed seven weeks later, revealed the existence of a tumor of a myxomatous nature, which lay in the left temporal lobe and projected onto the base of the latter, beside the peduncle. Pressure erosion was found over the whole inner surface of the skull, and it could be seen that the erosion had occurred very recently (probably the result of the rapidly increasing brain pressure) in contrast to the destruction of the hypophyseal fossa which apparently (from the roentgen finding) had occurred much earlier, as the local effect of pressure caused by the tumor. In addition to the smooth appearance of the inner surface of the skull at this place, the circumstance that the deepening was more marked on the left side of the sella should have been considered also as roentgenographic evidence of a tumor at this point.

CASE 4.—A. P., male, forty years old. For the last two years the patient has complained of headache, attacks of dizziness, disturbance of speech. Left side of head sensitive to percussion. Bilateral choked disc, left more than right. Sense of smell gone on left side. Right-side hemiparesis. Diagnosis, tumor of the cerebrum on the posterior basal portion of the left frontal lobe, possibly extending to the temporal lobe.

The roentgenogram showed the vault to be 6 mm. thick and smooth on its inner surface. Sella was widened at the top, but not deepened, and there was erosion of the anterior clinoid processes and the dorsum sellæ. The operation (von Eiselsberg Clinic) determined the existence of a tumor on the base of the brain in the region of the Sylvian fossa, the size of a goose egg, which could be easily shelled out. (See, demonstration von Eiselsberg, *Wiener klinische Wochenschrift*, 1910, p. 1702.)

CASE 5.—M., female, thirty-eight years old. The patient complained of disturbance of sensibility and motor paresis on the left side of the body. Choked disc. Psychic disturbances. Clinical diagnosis was tumor of the thalamus and internal capsule of the right hemisphere.

On the roentgenogram the skull was 2 to 3 mm. thick, its inner surface smooth, sella widened and deepened, dorsum thinned, anterior clinoid processes preserved. Diagnosis: basilar tumor of the brain.

The postmortem held five weeks later confirmed the existence of sellar erosion. As cause for the latter, was found a gumma of the right optic thalamus which had extended over onto the peduncle and the left thalamus. Besides this there was a cysticercus cyst in the infundibulum.



CASE 6.—C. Dementia. Slight right lateral facial paresis. Babinski positive, right side. Choked disc. Probable diagnosis was tumor of the frontal lobe or progressive paralysis.

The roentgenogram showed a roomy skull 5 mm. thick with large and numerous diploic veins, large veins of Merkel (sphenoparietal sinuses) which ran to deep Paechionian grooves. The floor of sella was much thinned, being barely distinguishable, and the dorsum was completely gone. Anterior clinoid processes were destroyed. Diagnosis: basal tumor in region of middle cranial fossa.

All six cases serve as instructive examples of the utility of the roentgen diagnosis for basilar tumor of the brain. They show how the roentgen findings supplement the result of the clinical examination relative to the question of the character of the intracranial disease as well as of the site of the same.

#### *Tumors of the Convexity of the Brain*

The signs of the local destructive processes of the cranial vault produced by intracranial tumors may be grouped, first, as a circumscribed thinning of the skull wall in consequence of pressure erosion of its inner surface (in which case the continuity of the outer surface of the skull is maintained), or, second, as a local bulging of the thinned skull wall, or, third, there occurs an infiltration of the bone by the tumor.

While the clinical examination, at best, permits a thinning or infiltration of the skull wall to be guessed at through the help of the symptom of local tenderness, and makes possible the determination of only plain bulging or perforation of the bone, the roentgenogram permits us to recognize the character of all the skull changes mentioned. From the position, the contour, and the limitation of the changed portion of the skull, one may draw conclusions as to the site, the size, and the nature of the tumor. If, in addition to the circumscribed change in the skull, there are recognizable signs of general erosion, it is probable that the tumor is of considerable size. Uniform thinning or bulging of the skull wall speaks for the presence of a benign tumor (cyst, endothelioma, fibroma) while osteoporosis of the bone speaks for infiltration through a malignant process, (sarcoma, tubercle, etc.).

Of especial diagnostic significance is, finally, the roentgenologic proof of an intracranial area of calcification in the neighborhood of changed areas in the skull wall (as signs of a cal-

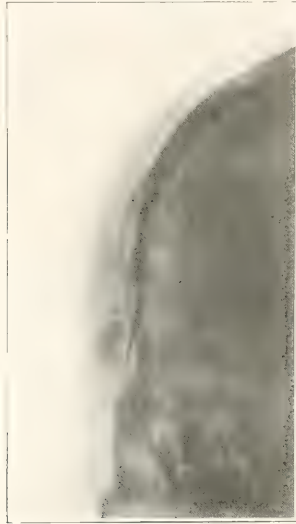


Fig. 84.—An anteroposterior x-ray picture of the temporal region in a man who had a tumor in that region. The temporal bone has been forced out and thinned in that region by the local pressure of the tumor.

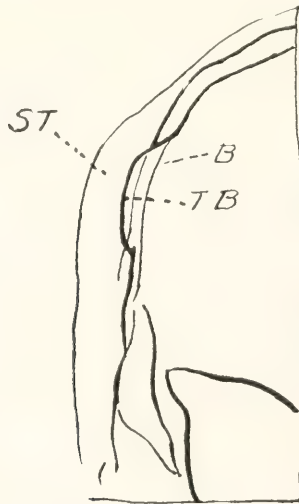


Fig. 85.—A sketch of Fig. 84. *ST*. Soft tissues. *TB*. Bulging temporal bone. *B*. The shadow of the bone posterior to the bulging area.

cium-containing tumor) or of vascular canals in the skull wall (Clairmont).

The local thickening of the skull produced through tumors of the dura will be discussed later.

Albers-Schönberg was the first who succeeded in making a diagnosis of the existence of a brain tumor from the erosion of the vault. We also had occasion several times to make out circumscribed changes in the skull wall in consequence of brain tumor, as, for instance, in the following case:

There was found a palpable bulging of the left temporal region in a man thirty-two years old. The roentgenogram showed that the skull wall was thinned and bulged out at this place like a watch crystal. (See Figs. 84 and 85.)

A circumscribed thinning of the skull wall through erosion of the inner surface, caused by a meningeal cyst in the parietal region, is found described in the section on Epilepsy (Case 11).

### **Skull Changes in Consequence of Chronic Excessive Intracranial Pressure**

#### GENERAL EROSION OF THE INNER SURFACE OF THE SKULL IN EXCESSIVE INTRACRANIAL PRESSURE

An excessive intracranial pressure lasting for a long time, such as usually appears in chronic hydrocephalus, tumors, cysts, tubercles, gummata, etc., may result in an extensive pressure erosion of the inner surface of the skull. If the increase in pressure develops to a considerable degree in a short time, the lamina interna will be consumed. In such a case the inner surface of the skull feels rough. In a case in which a very gradual development of the increased pressure occurs, or when the increase in pressure is intermittent, the inner surface remains smooth. The surface of the brain with its pulsating pressure wears off the ledges of the bone and its convolutions cause erosions, until the skull becomes thin and its interior appearance completely remodeled. The calcium salt freed by the tearing down of the inner surface may be transported into the dura or be deposited on the tips of the ridges between the convolutions.

Although the roughness of the inner surface produced by a rapidly increasing pressure can not be distinguished on the roentgenogram, the erosions resulting from chronic pressure (as I was the first to point out) appear very plainly in the roentgenogram as follows:

1. The normally almost gray shadow of the skull shows, in a chronic increase in pressure, a characteristic mottling in which there are present numerous roundish light areas which are spread over the whole surface or over isolated areas. The dark places correspond to the thin portions of the skull which are produced by the tops of the convolutions and are pathologically deepened convolutional impressions. The normal convolutional impressions will never appear as a mottling of the skull shadow in the roentgenogram.

2. The interconvolutional ridges are, under normal conditions, recognizable in the roentgenogram of the skull only in the region of the floor of the anterior and middle cranial fossæ as low projections. In case of erosion of the skull from increased pressure, however, they are distinctly seen on the inner surface of the vault, and there especially in the frontal area, where they produce pointed projections in the contour of the lamina interna and a mottling of the x-ray picture. Naturally the normally recognizable ridges of the base are sharper pointed. On the sagittal picture of the skull, the sharpening of the ridges may also be sometimes seen in the temporal region as prominent projections in the contour of the lamina interna.

3. The destruction of the bony prominences at the entrance to the hypophyseal fossa makes itself noticeable in a very striking way on the profile picture of the skull as a local manifestation of the general erosion of the inner surface of the latter. The character of this destruction corresponds perfectly with that which is produced by basal brain tumor; that is, there is a thinning and deepening of the floor of the sella, thinning and shortening of the dorsum, and a sharpening of the anterior clinoid processes.

Naturally the changes just described do not always appear with similar distinctness. This depends on the one hand, upon the nature of the increased pressure, the size, the site, and

the nature of the tumor, and, on the other hand, upon the resistance offered by the bone. Under favorable conditions the erosion of the inner surface of the skull may be proved in a roentgenogram within a few weeks after the appearance of the clinical symptoms.

In the beginning, the erosion is usually more noticeable in certain areas where normally the outlines of the brain surface are shown on the inner surface of the skull in the shape of impressions and ridges, that is, in the floor of the middle and anterior cranial fossæ and in the region of the frontal bone. With a further progress of the disease the irregular erosions are to be seen over the inner surface of the whole cranium.

In the most extreme grades of increased pressure the ridges disappear and there results a uniform thinning of the skull wall.

The plasticity of the skull of the young results in the erosions being seen earlier and with greater plainness.

If the exit of the ventricles is obstructed, especially through adhesion of the membranes or in tumors of the ventricle (cysticercus of the fourth ventricle), there is, as is known, a very early manifestation of increased intracranial pressure. Corresponding to this the skull erosion in such processes can be recognized very soon and very plainly on the roentgenogram.

The degree of the erosions depends also upon the site of the disease producing the increase in intracranial pressure, in so far as it is more prominent usually in that portion of the skull in which the disease is located. Thus we have repeatedly succeeded in proving a difference in the configuration of the contour of the lamina interna of the two halves of the skull on a roentgenogram taken in a sagittal direction. On the side upon which the condition causing the increase was located, the characteristic notches of the convolutional impressions and the prominences of the ridges were recognizable, while the other side showed the normal contour. We have sometimes found a similar difference in the outline of the inner surface of the two halves of the skull in very large tumors of one or the other hemispheres. In cases where, through the presence of the tumor, the convolutions of the affected side are flattened out completely, the ridges of the same side are also usually worn off,

while upon the opposite side the contour of the lamina interna shows the typical notches and projections.

The erosions described remain, also, for a long time after the removal of the cause. While in a recent erosion, or during the progress of an erosion, the lamina interna appears thin and somewhat indistinctly outlined, after a cessation of the pressure there follows a thickening of the lamina interna and a slight filling in of its irregularities.

The diagnostic utility of the erosion, spread out over the whole inner surface of the skull, may from a radiologic standpoint, be formulated as follows:

1. The roentgenologic proof of the erosion of the inner surface of the skull is a sure sign of an increased intracranial pressure which has existed for a long time. Such a disproportion between the skull and its content occurs in intracranial tumors, hydrocephalus, hypertrophy of the brain, and cranio-stenosis. In cases where it is a question of a differential diagnosis of one of the processes just mentioned from some other cerebral affection such as cerebral hemorrhage, brain softening, progressive paralysis, brain abscess, or from a functional symptom-complex as neurasthenia, hysteria, or from general affections (arteriosclerosis, nephritis, leucemia, diabetes) or from diseases of the organs of special sense associated with cerebral symptoms (headache, dizziness, vomiting, disturbances of hearing, disturbances in vision) an equal significance can be attributed to the demonstration of the characteristic skull erosion on an x-ray picture, as can be attributed to the discovery of a choked disc by means of an ophthalmoscopic examination of such cases. It must be emphasized that the diagnostic utility of the erosion of the skull is of no less importance than choked disc, which, as is known, is looked upon as one of the most frequent, earliest, and most sure symptoms of chronically high intracranial pressure. There are, however, cases in which the choked disc develops later than the erosion of the skull, for example, in young individuals, and there are cases in which it is difficult to determine whether the swelling of the optic nerve is a choked disc or an optic neuritis in consequence of nephritis, lues, or infection of accessory sinuses.

2. The roentgenogram sometimes gives evidence for answer-

ing the question as to the site, the nature and the extent of the process leading to increased intracranial pressure.

The finding of convolutional impressions on one side only enables one to decide in which half of the skull the disease is located. The side of the more prominent impressions is the affected one, provided the other side is not thinner as a whole. If, as is rarely the case, the latter condition is found, a large tumor on that side is the cause of the generalized atrophy.

If, in addition to the general erosion, there is demonstrable a distinct local destruction of the inner surface of the skull the site of the process causing the high pressure can with the greatest probability be located by making use of the diagnostic points contained in the preceding sections.

The decision of the question whether the chronic high intracranial pressure is caused by the abnormally large amount of the skull content or by the abnormal smallness of the skull can be decided by the appearance of the sutures. (See the next chapter.)

3. Difficulties in utilizing a general erosion of skull as a diagnostic sign arise, first, if the case is an old individual whose sutures are normally obliterated, and second, if, in the beginning of the variation in intracranial pressure one must decide whether the erosion found is to be looked upon as local erosion or a local manifestation of a general erosion.

4. A negative roentgen finding, as when there is an absence of impressions and erosions, does not speak against the existence of a brain tumor or of another affection causing increased intracranial pressure. The cases in which the clinical symptoms permit the assumption of the existence of a tumor with great probability, without the erosion appearing on the roentgenogram, may be divided into two groups. Either on account of a too short duration of the process or on account of the smallness of the tumor the characteristic skull changes have not yet appeared, or because the lamina interna is so abnormally dense and thick that it does not give way before the pressure.<sup>15</sup>

5. The roentgenogram makes possible the orientation of the surgeon relative to the details of the skull thickness, a knowledge of which is desirable before performing an operation for

<sup>15</sup>See the section on Hyperostosis in Consequence of Increase in Intracranial Pressure.

the relief of pressure (palliative trephination, puncture of the corpus callosum, brain puncture). As mentioned, the extent of the erosion of the skull does not attain the same degree on all portions of the inner surface. The roentgenogram permits the recognition of the places most eroded and in this manner shows the location where the opening of the skull would be most easily accomplished and would be most effective for relieving the pressure.<sup>16</sup>

We had occasion to examine a great number of cases in which the roentgenogram proved extensive erosions of the inner surface of the skull. The extent and location of the erosion may be illustrated by means of a few of these cases:

CASE 1.—(Already given on page 55.) Girl, nineteen years old. Several years previously, blindness had gradually occurred accompanied by severe headache. During recent months patient had not had headache, and during this time the girl had observed the periodic escape of a clear fluid from her nose (hydrorrhea nasalis). This latter statement was verified by rhinologic examination.

The roentgenogram showed extreme deepening of the convolitional impressions on the frontal bone and an almost complete destruction of the sella turcica. (See Figs. 8 and 9, page 54.) The diagnosis was hydrocephalus with automatic relief in consequence of perforation into the nasal cavity.<sup>17</sup>

CASE 2.—Girl, nineteen years old. Patient suffered from severe headache, dizziness, choked disc, ataxia, and paralysis of certain cranial nerves.

The roentgenogram revealed deepened impressions on the skull vault and extensive widening and deepening of the sella. At the operation there was found a tumor of the cerebellum.

CASE 3.—H., twenty-two-year-old female. Patient complained of disturbance of sight and amenorrhea. The conjecture that it could be a hypophysis tumor was refuted by the roentgenogram, for although the hypophyseal fossa was deepened and appeared widened and the dorsum sellæ was for the most part destroyed, there were such prominent erosions over the rest of the skull especially on the frontal bone and on the floor of the middle cranial fossa that the sellar destruction could be looked upon only as a local manifestation of general pressure.

CASE 4.—J. Sch., male, twenty-four years old. Seven years previously a skull trauma had occurred from a fall, as a result of which he was unconscious two hours. At the time of examination there was choked disc on both sides. Diagnosis, tumor cerebelli, for the most part on left side.

<sup>16</sup>We have explained this more in detail in the monograph "sellare Palliativtrephination und Punktion des dritten Ventrikels." *Wiener medizinische Wochenschrift*, 1911).

<sup>17</sup>The observation of this case caused us to propose sellar trephination for the purpose of relieving the increased intracranial pressure.



The roentgenogram showed extensive convolitional impressions over the frontal bone. The sella was widened and deepened, the dorsum was gone.

CASE 5.—K. Z., twenty-year-old girl. There had been a disturbance of sight for the last five years, and gradually increasing tumor symptoms. Recently there had occurred convulsions of the left upper extremity, which, as well as the lower extremity, was paretic. Choked disc in process of atrophy.

The roentgenogram showed deepened impressions and a considerable deepening of the sella turcica. The dorsum sellæ was for the most part eroded.

The cases cited permit the recognition of the various kinds and degrees of sella destruction which are observed as a local manifestation of general erosion of the inner surface of the skull. As is seen, all the erosions of the sella, enumerated in the discussion of local destruction, are found also here. However, in the latter case they are always combined with erosions of the rest of the skull, especially of the frontal bone. Only in isolated cases does one find an erosion of the sella exclusively, where there is a generalized pressure. In such cases mistaken diagnoses are not to be avoided as the two following cases, observed by us, show:

CASE 6.—G., male, twenty years old. He had complained of headache with vomiting for several months. There was a paralysis of the cranial nerves that are found in the posterior cranial fossa. Diagnosis: tumor of the cerebellum.

The roentgen examination revealed the skull to be of normal shape, 4 mm. thick, its inner surface smooth, sutures preserved, hypophyseal fossa deepened, dorsum sellæ thinned and shortened. Upon the basis of this roentgen finding we made the diagnosis of a tumor on the base of the brain corresponding to the locality of the middle cranial fossa, probably a hypophyseal tumor. The section did not verify this diagnosis, but instead there was found, as the cause of the sella erosion, on extreme internal hydrocephalus, in consequence of obliteration of the foramen Magendie. Subsequently it was learned that the patient had been sick with epidemic cerebrospinal meningitis a year previously.

CASE 7.—Female, forty-five years old. Menopause. Bitemporal hemianopia.

The roentgenogram showed a hemispherical widening of the sella with a thinning and elongation of its dorsum, and slight pressure erosion on the inner surface of the cranium. In consideration of the extreme widening of the sella, along with the slight amount of general erosion, the diagnosis of hypophyseal tumor was made. The case was operated endonasally by Hirsch. The postmortem verified the existence of the erosion

described. A cause for it, however, could not be found. Upon the basis of the finding at operation, one would assume, as most probable, a circumscribed hydrocephalus of the third ventricle, as the anatomic foundation for the clinical and anatomic picture. (See Hirsch, *Wiener klinische Wochenschrift*, 1911, p. 1579.)

We were able to establish a similar finding at the postmortem of a man seventy-two years old. The hypophyseal fossa was hemispherically widened and the hypophysis lay very much compressed on the floor of the sella.

The following observations illustrate the early appearance of the erosions:

CASE 8.—A. B., male, fifty-three years old. Patient had suffered incessant headache in the frontal region for the last sixteen days.

The roentgenogram revealed deepened impressions and erosion of the dorsum sellæ.

CASE 9.—H. P. For the last four weeks the patient had complained of headache and vomiting and with it, occasionally, a slowing of the pulse. No choked disc.

The roentgenogram showed distinct impressions over a great part of the vault.

A considerable number of our cases with erosion of the inner surface of the skull had to do with children in whom, even if, clinically, there were present only slight brain pressure manifestations, there were, nevertheless, usually perceptible erosions. We cite two such examples:

CASE 10.—L., boy, twelve years old. For the last month there had been a paralysis of the left oculomotor and paresis of the right extremity. Fundus was normal.

The roentgenogram showed the skull to be of normal size and shape, but there were distinct erosions of the inner surface in the region of the frontal bone. Sella was normal.

CASE 11.—A. F., girl, twelve years old. For the last two years she had complained of headache, dizziness, and frequent vomiting. On examination there was a decrease in visual power, ataxia, bilateral choked disc. The shape and size of the head were normal.

On the roentgenogram one saw very marked impressions on the vault. The sutures were retained, but not separated. Sella normal.

In several cases we could make out asymmetrical distribution of the impressions, as, for instance, in the following cases:

CASE 12.—M., female, forty years old. For the last few years the patient had been blind and during that time there had been an increasing dementia. Cerebellar ataxia.

The roentgenogram showed that the skull was thin (1 to 3 mm.), with extremely deepened impressions, much more prominent on the left than on the right. In connection with this, the thickness of the skull as a whole was less on the right side. The section revealed the presence of an endothelioma of the dura, larger than one's fist, in the right parietal region. In this case, therefore, the roentgenogram permitted the determination of the variation in the thickness of the skull and the prominence of the impressions on the two sides. The thinner portion of the skull was covered with lower ridges and corresponded to the side of the tumor, which was especially large in this case.

The following group of cases demonstrates the significance of the proof of skull erosion for the differential diagnosis between processes causing high intracranial pressure and other affections.

CASE 13.—Ch., female, twenty-nine years old. For the last several years the patient had suffered from headache, appearing periodically with vomiting. The attacks were looked upon as migraine. A sister of the patient also suffered from migraine.

The roentgen examination revealed the skull to be, on the average, 7 mm. thick with much deepened impressions and deep Pacchionian grooves on the bregma. The sella turcica was deeper than normal and the dorsum was destroyed. On the basis of the roentgen finding, the diagnosis was made of a process causing increased intracranial pressure. The patient died in an attack of headache. The postmortem revealed the existence of an extreme internal hydrocephalus resulting from a cysticercus cyst of the fourth ventricle.

CASE 14.—A., girl, sixteen years old. Intense headache, symptoms of hysteria.

The roentgenogram showed deepened convolitional impressions over the frontal bone. The anterior clinoid processes were sharp and the dorsum sellæ was thinner than normal. The probable diagnosis made on this finding was "tumor cerebri" which was verified by the course, since the patient died a few months later with severe cerebral symptoms.

CASE 15.—N., female, twenty-eight years old. Two years previously, during lactation, she became affected by a disturbance of sight. The optic neuritis was considered as a neuritis of lactation. Since that time the disturbance in vision had remained stationary. Occasionally, the patient had headache of unbearable intensity.

The roentgenogram determined the existence of extreme pressure erosion over the entire inner surface and an almost complete destruction of the sella turcica. The patient died during an attack of headache.

CASE 16.—R. D., male, thirty years old. The patient had suffered from an intense headache for a long time. Recently an optic neuritis had appeared. Both conditions were considered to be the result of an accessory sinus inflammation. Nasal treatment brought about no improvement. Since

the patient by accident had a little exostosis of the vertex he had a roentgen picture taken, which revealed the existence of pressure erosion on the inner surface of the skull vault and a shallow widening of the portio sellæ.

CASE 17.—Sch., boy, fifteen years old. He had complained of attacks of dizziness and headache for the last three months. Eye findings were normal. Diagnosis: “neurasthenia.”

The roentgenogram showed prominent impressions and a sharpening of the anterior clinoid processes combined with a shortening of the dorsum.

CASE 18.—M. I., girl, twenty years old. The patient had experienced convulsive attacks with unconsciousness and a subsequent confused condition. There was a nystagmus and an ataxia of the right upper extremity. Diagnosis: multiple sclerosis.

The roentgenogram showed marked impressions on the inner surface, numerous diploic veins, and a widened sella with a thin dorsum. This finding permitted the diagnosis of the existence of an intracranial tumor as being very probable.

Since in the preceding sections we have discussed the destructive changes produced by intracranial processes, and have explained their diagnostic utility, we will cite briefly a series of further changes which the skull undergoes through the effect of a chronic, high intracranial pressure. These are changes in the shape of the skull, changes in the sutures and venous exits, and, finally, thickening of the inner table.

#### CHANGES IN THE CONTOUR OF THE SKULL IN CONSEQUENCE OF CHRONICALLY INCREASED INTERNAL PRESSURE

The change in shape occurring most frequently in consequence of the existence of a process causing high intracranial pressure is the hydrocephalic enlargement of the skull. Naturally an enlargement of the skull becomes plainly visible only in a skull capable of growing, as in children. However, it can be absent even at this age without one being in a position to give the cause for this exception. Upon the basis of our experience we may voice the conjecture that hydrocephalus, occurring in early childhood, up to the fourth year, usually produces an enlargement of the skull, whereas, when hydrocephalus sets in later in childhood, erosion of the inner surface is the rule. Also the rapidity with which the increased intracranial pressure develops and the quality of the skull bone are

likely to be of influence upon the presence or absence of a skull enlargement.

The details<sup>48</sup> of hydrocephalic skull change, important for diagnosis, have been already discussed in the section on hydrocephalus. See also the sections on Cerebral Infantile Paralysis and Epilepsy. Localized bulging of the skull in consequence of intracranial processes has already been discussed in the sections on Hydrocephalus, Skull Asymmetry, Local Skull Erosions.

Here the changes in shape, which occur through increased intracranial pressure, in consequence of craniostenosis, might be briefly recalled. The altered shape of the skull occurring as the result of premature suture synostosis (turriccephaly, scaphocephaly, plagiocephaly, etc.), is caused only in part, by deficient growth of the portion of the skull affected. Some of the blame for the disfigurement may be ascribed to the compensatory expansion of the skull, which is brought about by the increased pressure on the part of the limited brain (since the latter continues to grow normally), or on the part of the hydrocephalus frequently associated with it. The other changes in shape, as well as the hydrocephalic enlargement, develop in most cases only during the years of skeletal growth, rarely in advanced age.

The roentgenogram supplements very essentially the picture of the change in the shape of the skull in chronic increase in intracranial pressure, which is obtained by the other methods of examination. As has often been stated, it permits the determination of the shape of the base of the skull. It further allows the differentiation between an abnormal shape caused by bulging on the part of the cranial content and that produced by the thickening of the wall. And, finally it facilitates the answering of the question as to whether the change in shape is brought about by a former increase in intracranial pressure or one existing at the time. If due to a former process, there is usually a noticeable thickening of the lamina interna and a leveling of unevenness previously present on the inner surface of the skull.

---

<sup>48</sup>These details are the appearance of the inner surface of the vault, the contour outlines of the base, especially the sella turcica, the thickness of the wall, the condition of the sutures, etc.

Special diagnostic difficulties arise if a new intracranial process is superimposed upon a pathologic condition which has existed since childhood. Two such cases may be cited here:

CASE 1.—K., male, twenty-three years old. The patient had a congenital hydrocephalus of moderate size (horizontal circumference 60.5 cm.). For the last six months there had been a disturbance in sight (choked disc) and cerebellar ataxia. The roentgenogram showed that the skull vault was thick and traversed by prominent venous furrows. The sella showed a shallow widening and a thinning of the floor, sharpened anterior clinoid processes, and a thin dorsum. In consideration of this finding, the diagnosis was made of a basilar tumor of the brain, in combination with congenital hydrocephalus. The existence of large pigmented nevi, scattered over the whole body, permitted the conjecture that the basal tumor was a neurofibroma (Recklinghausen's disease). The patient died a few months later.

CASE 2.—W. K., male, forty-five years old. Several weeks after an automobile accident there had appeared headache, irregularity of gait, and a diminution in the power of vision on both sides (optic nerve atrophy). The skull was short and high with a receding forehead (a typical turri-cephalus).

The roentgenogram revealed the skull vault to be thick (5 to 10 mm.). Its inner surface showed distinct impressions and a sharpness to the basal bone projections. The sella was roomy, its floor was of normal contour and thickness. Upon the basis of this roentgen finding, we assumed that the existing disturbances were late symptoms of a craniostenosis existing since childhood, the sudden appearance of which had been favored by the skull trauma.

The other cases under our observation which showed changes in the skull in consequence of high intracranial pressure are already cited in the sections on Hydrocephalus, Craniostenosis and Local Erosions.

#### SUTURE CHANGES IN CONSEQUENCE OF CHRONICALLY INCREASED INTRACRANIAL PRESSURE

Characteristic changes in the sutures usually take place in intracranial diseases which are associated with prolonged excessive intracranial pressure. The suture dentations become thinned and elongated and the suture fissures become widened. The younger the affected individual is, the more distinctly visible are the suture changes. If the process causing the increase in pressure becomes stationary, there sometimes occurs a

premature suture obliteration. (See section on Suture Synostosis.)

These changes in the sutures show very strikingly on the roentgen picture. In little children they appear as broad light stripes and in later life the suture fissures and the elongated suture dentations are more than normally visible.<sup>19</sup>

The sphenooccipital synchondrosis, which usually becomes ossified between the 13th and the 18th year, is, as we have often observed, visible as a broad stripe on the roentgenogram beyond the normal time, when there is present a process causing high intracranial pressure.

Diagnostically, the roentgenographic determination of suture separation is of great importance. It is a frequent and sure sign of high intracranial pressure. The proof of its existence or its absence is especially valuable in cases in which it is a matter of differentiation between craniostenosis and the other processes causing increased pressure.

From the cases under our observation, in which the separation of the sutures was strikingly noticeable on the roentgenogram, we mention the following:

CASE 1.—A., girl, nine years old. The patient showed symptoms of a rapidly growing cerebral tumor of indefinite location.

The roentgenogram showed the skull to be very roomy, thin (2 to 3 mm.). The impressions were very prominent, and all sutures were gaping. The sphenooccipital synchondrosis was visible as a broad crevice, the sella was slightly widened, and the anterior clinoid processes and dorsum sellæ were pointed (see Figs. 86 and 87). Considering the prominence of the pressure manifestations on the skull, a probable diagnosis was made of "tumor of the posterior cranial fossa." The section revealed a glioma of the cerebellum (superior worm).

CASE 2.—Boy, eighteen years old. For the last six months had complained of headache in the right temporal region associated with vomiting, decrease in power of vision, and a staggering gait. He had a choked disc, and loss of power of conjugate deviation to the right.

The roentgenogram showed a pronounced deepening of the convolutional impressions, separation of all sutures, and slight widening of the sella. Postmortem revealed a tumor of the cerebellar hemisphere.

CASE 3.—W., child, two and one-half years of age. Regressive choked disc on both sides. Dolichocephalic cranium with slight bulging of the vertex corresponding to the large fontanel.

<sup>19</sup>The anteroposterior picture gives the best view of the condition of all sutures of the vault.

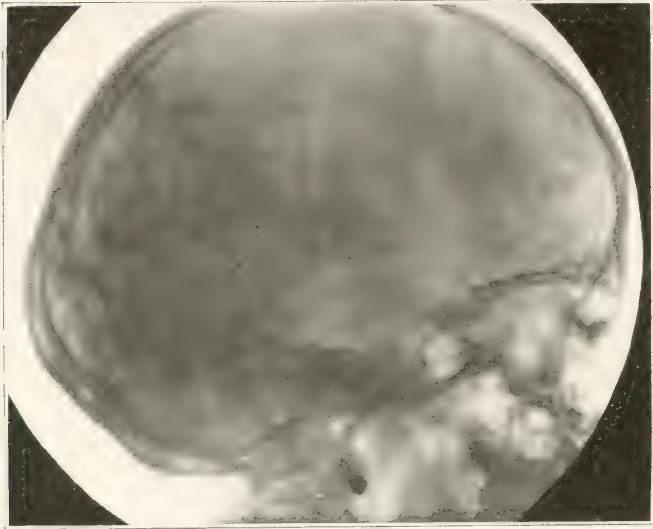


Fig. 86.—A sinistrodextral picture of Case 1, page 227. Pressure erosions and spreading of the sutures are plainly seen. The case was one of tumor of the cerebellum.

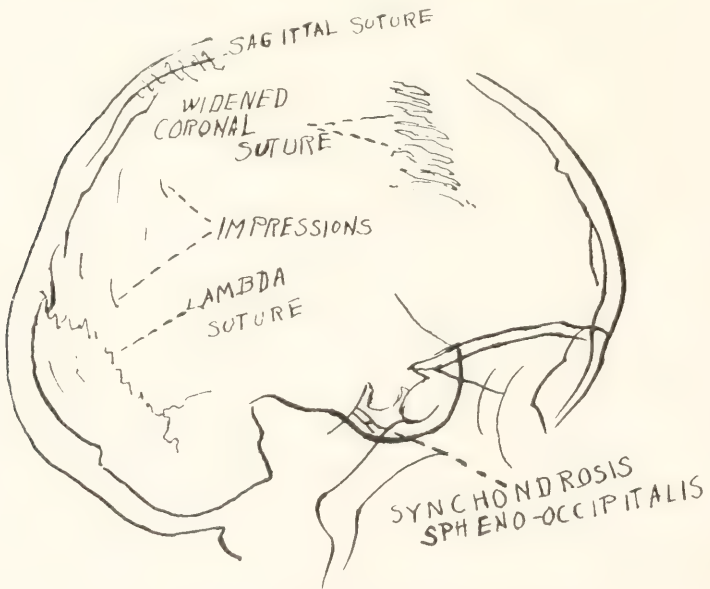


Fig. 87.—A sketch of Fig. 86.



On the roentgenogram, the vault of the skull appeared of diminished thickness. Its inner surface showed deepened impressions. All the sutures were well preserved and here and there they were gaping. There was no craniostenosis.

CASE 4.—M., girl, eight years old. For the last three months has suffered from blindness in consequence of neuritic atrophy. Facial paresis. There was disturbance of intelligence, headache, vomiting, and dizziness.

The roentgenogram showed markedly deepened impressions and gaping sutures. The coronal suture appeared as a bright stripe the width of a finger, within which the shadow lines corresponding to the suture indentations were strikingly discernible.

#### WIDENING OF THE VENOUS CANALS OF THE SKULL IN CONSEQUENCE OF INCREASE IN INTRACRANIAL PRESSURE

If there exists for a long time a continuous or a frequently repeated disproportion between the cranial cavity and the cranial content, there occurs, apparently as a consequence of the venous congestion and difficulty of exit for the blood passing out through the jugular foramina, a deepening and widening of those shallow furrows on the inner surface of the skull which are the sites of the sinuses in the dura mater. Besides that, the double venous collateral circulation (the one in the diploë of the skull wall and the one lying in the soft skull covering), becomes more developed than is the case under normal conditions. The collateral circulation in the bone is made possible by the network of Breschet's veins contained in the diploë which, in case of elevated intracranial pressure increase considerably in number and size. In case of such development their places of communication with the intracranial veins, the Pacchionian grooves, become much deepened. The venous collateral circulation of the soft tissue skull covering is distended,<sup>29</sup> thanks to the widening of the emissaries which carry the blood by a shorter way from the interior of the skull.

In case of a local hindrance to the exit of the blood in consequence of compression of a sinus in the dura mater, there may result a partial collateral circulation, beginning peripheral to the point of compression, similar to the widening of all the venous exits in a general rise in intracranial pressure.

<sup>29</sup>With the arterial pulsation the content of the intracranial veins becomes compressed, and forced out into the extracranial veins. Therefore, the intracranial veins show a negative pulse, while the extracranial and also the diploic veins show a positive pulse. This latter is likely to lead to a rapid widening of these veins.

We are indebted to Breschet for the positive knowledge of the behavior of the venous network lying in the diploë, under normal and pathologic conditions. The canals of the diploic veins are normally developed as thin passages, in most cases being only 1 to 3 mm. in diameter. Their number is subject to great variation, and their location is also a variable one.

Usually the canals are most numerous, and largest in the region of the frontal and parietal eminences. The canals show either a straight course or are twisted, and not seldom are they arranged netlike or star-shaped. Sudden change in caliber and varicose dilatations are characteristic details of these canals. The canals are richly developed in thick skulls, in the skulls of females, and in those of the aged. Formerly this venous system, which, through fine openings on the inner and outer surface of the skull communicate with the intracranial veins and the veins running in the soft tissues covering the skull, was of no clinical significance since it was not possible to discern pathologic changes in it during life. This was also usually the case with regard to the other venous exits (sinuses of the dura mater, Pacchionian grooves, emissaries.)<sup>21</sup>

The roentgenogram permits the appearance of the bone furrows and canals which carry venous blood to be exhibited with great plainness in the living. Under pathologic conditions occurring in high intracranial pressure or local compression, one distinguishes the furrows corresponding to the longitudinal, transverse, sigmoid, and sphenoparietal sinuses as broad bright stripes, whereas these furrows are barely noticeable under normal conditions, with the exception of the sinus transversus and sigmoideus. The roentgenogram permits the ready determination of the deepening, enlargement, and increase in the number of the Pacchionian fossæ lying on the vertex and forehead (more rarely elsewhere), as well as the widening of the emissary veins.

Philipp and Smith observed an unusually extensive development of the collateral circulation in the skin of the skull (through the right foramen parietale) and in the diploë, in the case of a large tumor of the right cerebral hemisphere which

---

<sup>21</sup>In one of the cases demonstrated to us by Bárány, there existed a mastoid emissary on the right side, the size of the little finger. From this a very plainly visible and palpable vein made its exit, pulsating synchronously with the systole.

had eroded the inner surface of the skull. Smith referred to the fact that, in the people of the Balkan peninsula, the retrobregmatic Pacchionian grooves are especially well developed.

Repeatedly have we been struck by the presence of venous convolutions in the region of the Pacchionian fossæ at the operation or the postmortem of cases with chronic excessive intracranial pressure or epilepsy. We must assume that such vascular changes, through tension on the dura and erosion of the bone, can cause local headache, and, by irritation of the cortex, may cause cerebral symptoms.<sup>22</sup> On the roentgenogram

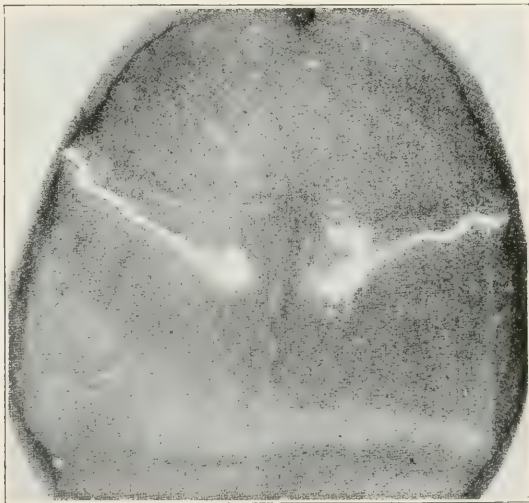


Fig. 88.—An x-ray picture of a calvarium with a bilateral erosion produced by sphenoparietal sinuses.

the erosions of the inner surface of the skull, produced by these vessels, appear as sharply outlined, bright areas lying in the parietal region near the middle line, and from these bright places run short varicose venous canals.

In conclusion one recognizes on the roentgenogram, without difficulty, the changes in the number, breadth, direction of course and the locality of the venous canals of Breschet.

The diagnostic significance of the roentgenologic proof of

<sup>22</sup>See Leischner, *Chirurgie der Hirntumoren*, Case 9, and, in addition, Ranzi *Wiener klinische Wochenschrift*, 1911, p. 995.

the changes in the venous vessels may be formulated, as I was the first to point out, in the following manner:

1. On the roentgenogram the recognizable deepening of the sulci venosi and the Pacchionian fossæ, as well as the widening of the diploic veins and emissaries, is a quite frequent sign of chronically increased intracranial pressure.

2. Asymmetrical widening of the venous vessels suggests the existence of a unilateral obstruction to the venous circulation, and in most cases the dilatation is found on the same side as the obstruction.

3. The discovery of isolated dilated venous canals facilitates the positive localization of the obstruction. The most frequent occurrence of this character is the unilateral or bilateral widening of the sinus sphenoparietalis<sup>23</sup> in tumors of the brain, which, lying in the middle cranial fossa, compress the sinus cavernosus.

The roentgenographic proof of the existence of abnormally widened venous canals and their localization, is a valuable help to the surgeon for obviating dangerous hemorrhage<sup>24</sup> in opening the skull.

There may be cited here a few of the cases coming under our observation which permitted the recognition of changes in the venous circulation in consequence of the presence of brain tumors and other intracranial affections.

CASE 1.—I. H., male, forty-three years old. Patient had become affected with a Jacksonian epilepsy of the right leg three months previously.

The roentgenogram showed in the left half of the skull an extreme widening of a diploic venous canal,<sup>25</sup> which, arising from a deepened Pacchionian fossa in the region of the coronal suture near the middle line, ran posteriorly and downwards and emptied into a radiating canal system located in the region of the parietal eminence. On the antero-posterior picture, one discerned that the venous canal occupied almost the whole thickness of the skull vault which was somewhat thick (6 mm.). In consideration of this finding and the existence of Jacksonian epilepsy in the right leg, the diagnosis could be made of a tumor in the cortical

<sup>23</sup>A wide sinus sphenoparietalis, on the site of the vena meningea, parallel to the coronary suture, is present, according to our observation, only rarely as a normal variation of the intracranial vascular arrangement on one or both sides. (See Fig. 88.) In most cases a local obstruction or a general disturbance of the venous canals is responsible for its development. The knowledge of this sinus prevents its confusion with fissures.

<sup>24</sup>In a case operated and published by von Eiselsberg, there occurred a hemorrhage from a dilated diploic vein which could not be stopped, and which killed the patient.

<sup>25</sup>See the illustrations in our monograph on diploic venous canals, *Fortschritte auf dem Gebiete der Röntgen Strahlen*, 1908.

center of the right leg. The operation, performed in the von Eiselsberg Clinic, had to be discontinued after the opening of the skull on account of hemorrhage from the widened diploic veins. The second operation, undertaken several days later, disclosed the existence of a walnut-sized glioma in the cortex in the region controlling leg movements. (See Leischner, *Chirurgie der Hirntumoren*, Case 4.) The postmortem held several months later, verified the result of the clinical examination.

The widened diploic veins had, in this case, taken over the removal

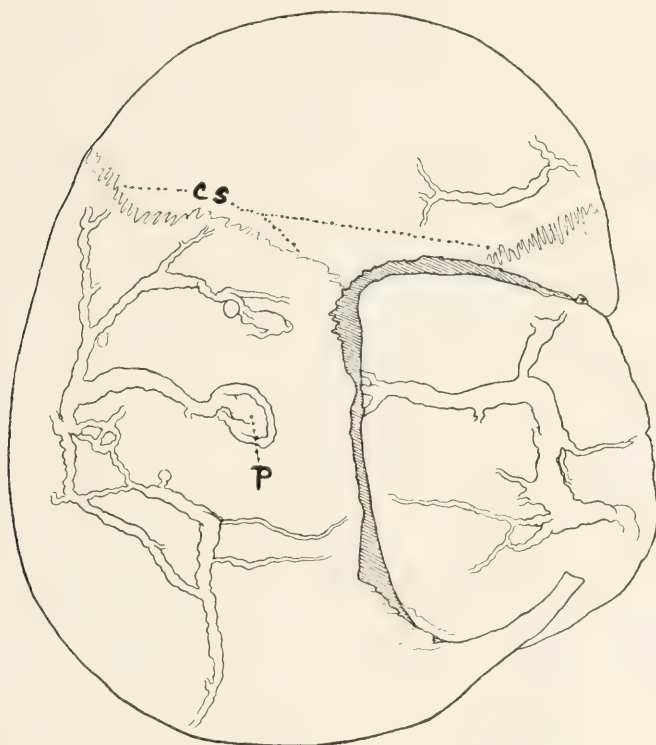


Fig. 89.—A sketch of the x-ray of the calvarium in which there was a phenomenal enlargement of the diploic veins. On the right side they approximated the size of the femoral vein. The piece of bone removed at operation is laid back in place. This is the explanation of the irregularity on the right side of the picture. *P.* Pacchionian groove. *CS.* Coronal suture.

of the blood from that area in which a compression of the longitudinal sinus had resulted on account of the tumor in the cortex.

CASE 2.—N. G., male, thirty-six years old. Jacksonian epilepsy, paresis, ataxia, and disturbance of deep sensibility in the left leg. Choked disc. Diagnosis: tumor of the right motor region (leg center).

Roentgen finding showed the skull to be permeated by numerous greatly widened diploic veins which were developed to the greatest degree in the

right parietal region. The operation, performed in the von Eiselsberg Clinic, had to be discontinued because of the extreme hemorrhage from the diploic veins. The second operation determined the existence of a large tumor (glioma) on the site diagnosed. (See Leischner, *Chirurgie der Hirntumoren*, Case 6.). The postmortem verified the clinical finding. On the roentgenogram of the head (see Fig. 89) one could distinguish the extreme dilatation of the diploic venous canals. The veins on the right side equaled in diameter the femoral vein.

CASE 3.—B. R., female, fifty-five years old. Right side hemiparesis, which, for the most part, depended upon disturbances of sensibility (stereognosis). Aphasia irregularities, for the most part, of sensory nature. Optic neuritis. Diagnosis, tumor of the cerebral hemisphere in the region of the parietal lobe.

The roentgenogram furnished a valuable confirmation for the assumption of this as the point of localization. For, at this site, one made out several very small dilated venous canals on the left side of the skull. One saw, especially, a large vein which began near the middle line above the parietal eminence and ran basalward in this same plane. There was an anastomosis with other enlarged veins. The diameter of this vein amounted to 5 mm. The sinus spenoparietalis was also very much developed. (See Figs. 90 and 91.)

CASE 4.—F. R., male, thirty years old. Symptoms of a tumor of the posterior cranial fossa.

The roentgenogram showed the existence of slight convolitional impressions and a thinning of the dorsum sellæ. Besides this, one saw widened venous furrows on the left side of the skull. The operation, in the von Eiselsberg Clinic, disclosed a tumor the size of a small apple in the left cerebellar hemisphere.

The four cases described demonstrate not only the existence of widened diploic veins in the case of brain tumors, but also their asymmetrical location, with relation to the site of the tumor. In Cases 1, 2, and 3, moreover, there clearly appeared a close relationship between the course of the widened diploic veins and the position of the tumor.

The following cases show the increase in size of the Pacchionian fossæ and the emissaries in a general increase of intercranial pressure:

CASE 5.—G., male, fifty years old. Choked disc, right more than left. Symptoms of a tumor in the left parietal lobe.

The roentgenogram showed slight pressure erosion of the inner surface of the skull in the parietal region, right side more than left. The section revealed the existence of a tumor in the left occipital lobe, although the Pacchionian fossæ were deeper on the right side.

In this case, the greater pressure erosion, as well as the greater swelling of the papilla, did not coincide with the side on which the tumor was located.

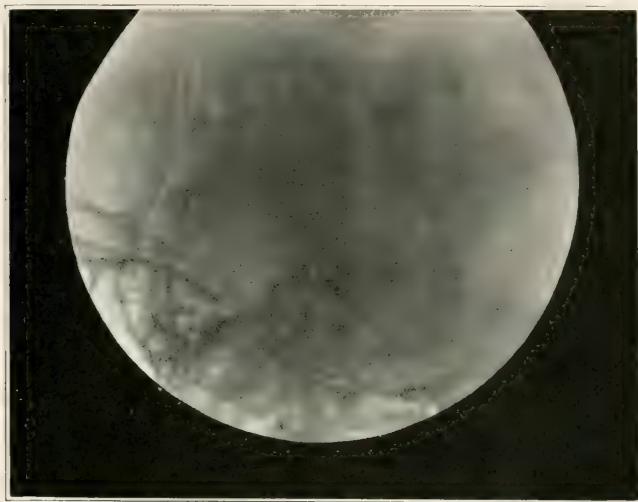


Fig. 90.—A dextrosinistral picture of the head of Case 3, page 234. It shows extreme enlargement and an increase in the number of the diploic veins.

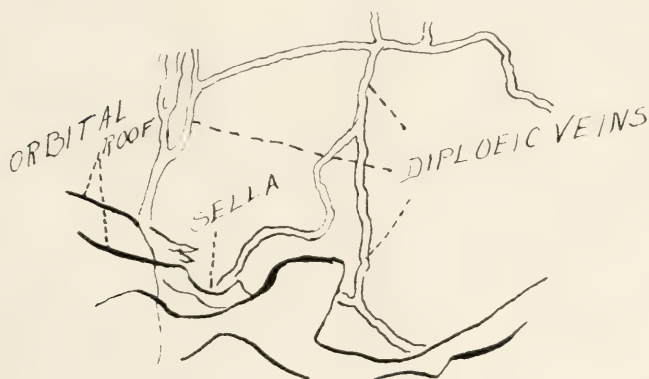


Fig. 91.—A sketch of Fig. 90 intended to bring out more clearly the outlines of the venous canals to be seen there.

CASE 6.—W. V., girl, six years old. Symptoms of a brain tumor.

On the roentgenogram the skull was 1 to 2 mm. thick, veins widened, impressions more than normally prominent, and the mastoid emissary was strikingly large.

The following case shows the existence of a widened Pacchionian fossa at the site of a circumscribed headache:

CASE 7.—K. B., male, fifty years old. Headache for twenty-seven years in a circumscribed place on the right parietal region.

The roentgenogram showed a very marked thinning of the skull wall at this point, which, from the shape, was to be considered as caused by a venous plexus (Pacchionian body).

#### SKULL THICKENING IN CONSEQUENCE OF CHRONICALLY INCREASED INTRACRANIAL PRESSURE

In the discussion of hyperostosis of the skull, mention was made of the occurrence of thickening of the inner table of the skull in intracranial diseases. Since the dura mater also acts as an inner periosteum of the skull, it is not remarkable if the bone is induced to grow in consequence of its chronically stimulated condition, as is the case in tumors of the dura or in long-continued cerebral affections leading frequently to hyperemia of the skull contents. Corresponding to that, one observes hyperostosis of the skull wall not so rarely in endothelioma of the dura mater, in tumors, and in diffuse diseases of the brain, especially those which are associated with epilepsy or psychosis. This hyperostosis may occur as a diffuse or circumscribed thickening of the inner surface of the skull or there occurs a thickening of the skull described as tumor-like hyperostosis.

The assertions in the literature, relative to hyperostosis in intracranial affections, are quite scarce. Kaufmann mentions the occurrence of diffuse thickening of the lamina interna in brain tumors. In the section on hyperostosis we have already cited the hemieraniosis described by Brissaud and Lereboullet (unilateral thickening of the skull combined with dural endotheliomas). On the occasion of his discussion of two cases of hemieraniosis with endothelioma of the dura, Spiller also mentions the observations of Parhon and Goldstein as well as those of Parhon and Nadjade. Barling described a case of brain tumor (endothelioma) associated with bone growth in the bone lying over it. Krause mentioned a case operated by him where the bone was thickened over the brain tumor as much as 21 mm. Above the frontal eminence was a projection the size of a goose egg so that here was the rare case of a



“brain tumor in a closed skull capsule, appearing also outside.” Schlesinger (“Diskussions-bemerkung,” *Wiener klinische Wochenschrift*, 1910, p. 1702) mentioned two cases of endothelioma of the dura with a bony tumor of the inner surface of the skull lying over it. Also, Ranzi observed a bean-sized enostosis over a dural endothelioma.

One must, on that account, think of the possibility of the existence of an intracranial soft tissue tumor in a case of bony tumor of the skull, and, in addition, must be on the lookout for hyperostosis in the skull wall in cases where there is in all probability a brain tumor.

We had the opportunity to be present at a trephination in the von Eiselsberg Clinic, during the course of which, after the removal of the soft tissue flap, there was found on its inner surface a flat smooth enostosis the size of a dollar projecting scarcely 5 mm. Immediately under this, lay a tumor of the brain surface, the size of one's fist, and covered by intact dura.

The hyperostosis of the skull occurring in epilepsy, psychoses, idiocy, etc., will be discussed in the next section.

The diagnostic utility of the roentgen examination, in the diffuse and circumscribed thickenings of the skull wall under discussion, may be formulated in the following manner, as I was the first one to point out:

1. In cases in which the other examination reveals no evidence of the existence of a hyperostosis of the skull, the roentgenogram alone makes possible its demonstration.

2. Also, if a prominence is distinguishable externally, the roentgenogram alone determines its bony nature, and possibly its extension toward the inner surface.

3. If the clinical examination suggests the existence of a brain tumor, the roentgenologic proof of a circumscribed hyperostosis of the skull facilitates the localization of the brain tumor.

4. The determination of a diffuse hyperostosis of the inner surface of the skull is of special value for the diagnosis of an intracranial tumor or of a process causing increased intracranial pressure (as contrasted with other etiologic factors leading to hyperostosis, as lues and alcoholism) if simultaneously erosions

of the inner surface of the skull are discernible on the base or on a circumscribed portion of the vault.

5. The determination of the shape and thickness of the hyperostosis on the roentgenogram is of importance for operative interference.

A. Fuchs reported the case of a man fifty-seven years old, with Jacksonian epilepsy of the right upper extremity. Corresponding to the left motor region there was found a flat elevation of the skull bone which had formed in connection with an injury to the head suffered twenty years previously. The roentgen examination revealed a flat bone growth with secondary resorption (areas of softening). The operation brought to light an endothelioma of the dura lying under the thickening of the bone (*Wiener klinische Wochenschrift*, p. 1701).

We have repeatedly had the opportunity of examining cases of skull hyperostosis combined with cerebral symptoms. A number of these cases have already been mentioned in the section on skull hyperostosis; namely, those in which, on the basis of the roentgenogram, no intracranial disease could be assumed as the cause of the hyperostosis. Another portion of these cases will be cited in the discussion of epilepsy.

Here only the following case will be mentioned:

W., female, twenty-nine years old. For the last three years she has suffered from headache and disturbance of sight in the right eye. At the time of examination there was right optic nerve atrophy and a beginning neuritis in the left eye. Diminution of the power of smell, especially on the left side.

On the roentgenogram was seen superficial thickening and nodular protuberances on the inner surface of the frontal bone. The sella showed double contour, its floor was thinned and deepened, its dorsum shortened. Upon the basis of this finding, we made the diagnosis of tumor of the frontal lobe.

## **ROENTGEN FINDINGS IN EPILEPSY, CEREBRAL INFANTILE PARALYSIS, IDIOCY, PSYCHOSIS, AND MIGRAINE**

Since we have discussed in the preceding pages the changes in the skull recognizable in the roentgenogram in general increase of intracranial pressure, especially in intracranial tu-

mors, we will, with due allowance for the practical needs of the clinician, place together the roentgen findings which we observed as occurring frequently in a series of cases with cerebral symptoms.

### **Epilepsy, Cerebral Infantile Paralysis, and Idiocy**

The discussion of these affections under one heading is justified by the fact that they are frequently met with simultaneously in the same individual, and moreover, by the fact that, corresponding to the similarity of their pathogenesis and pathologic anatomy, the roentgen findings show many analogies.

Since the skull changes in epilepsy (Binswanger, vol. xii, 1) and in cerebral infantile paralysis (Freud, vol. ix, 3) have been already presented in detail in this manual, from both an anatomic and a clinical standpoint, we may confine ourselves here to the mention of the important details that appear on a roentgenogram. In addition, we refer to our monograph *Ueber Roentgen-Befunde am Schädel von Epileptikern*, published in common with Redlich. There twenty-eight cases<sup>26</sup> are reported with positive roentgen findings.

The most frequent skull changes in epilepsy are those traumatically produced (ten cases among the twenty-eight mentioned). This condition is also found occasionally in cerebral infantile paralysis and idiocy. The roentgen examination makes it possible to obtain objective evidence of the traumatic etiology, through the proof of fissures, defects, depressed fractures, thinning or thickening of the skull wall, projectiles, etc. It is also of value in those cases where the external examination is without result, and it supplements this finding in a desirable way.

Among the cases observed by us, several have already been cited in the section on Injuries (Cases 3, 4, and 5). Here the following cases may be mentioned briefly:

CASE 1.—B., male, twenty years old. When six years old, he suffered an injury to the head from a fall. Attacks of epilepsy since between the ages of eleven and twelve. Over the right parietal bone one could see a shallow excavation in the external surface. At the base of this, the palpating finger felt a bony resistance. In spite of this bony resistance,

<sup>26</sup>About 100 cases of epilepsy were examined.

there was found in the x-ray picture, a bone defect the shape of which corresponded to the palpable excavation. (See Redlich and Schüller, Case 1, with Figs. 1 and 2, Plate XVII.) Through the operation and post-mortem, the roentgen finding was verified. Underneath the bone defect was found a large hole in the right parietal lobe which extended into the lateral ventricle. (See Ranzi, *Wiener klinische Wochenschrift*, 1905, No. 47, Sitzungsbericht.)

CASE 2.—Male, forty-five years old. At the age of forty-one he fell from a considerable height. Afterwards he suffered from epileptic attacks. There was a skull defect the size of a quarter in the right parietal bone.

The roentgenogram showed under the skull defect a large bone splinter which projected about 5 mm. toward the interior. (See Redlich and Schüller, Case 6, with Fig. 4, Plate XVII.)

CASE 3.—R., young man, seventeen years old. Two years previously he had suffered from a gunshot wound of the right cheek with great loss of blood, and had fainted. Since then had complained of a left-sided hemiplegia and epileptic attacks. In spite of the positive assertion made that "the projectile had fallen out of the mouth at the time of the injury," there was found, in the roentgenogram, a projectile in the right occipital lobe (!) close to the median plane.

A second group of frequent skull changes in epilepsy, cerebral infantile paralysis and idiocy, is represented by anomalies in shape and size of the skull. Malformations of the skull (holes, porocraniosis, cerebral hernia), microcephaly and pseudo-microcephaly, hydrocephalus, and craniostenosis, in consequence of premature suture synostosis, come under consideration here. They may all be associated with asymmetry of the skull, in which case the portion of the skull corresponding to the affected hemisphere is smaller and thinner. Only rarely is it more prominent.

Formerly disturbances of growth and anomalies in shape have been considered very important as the cause of epilepsy (asymmetry of the base, abnormal narrowness of the foramen magnum, ankylosis of the atlas). The anomalies of shape and size under discussion, with which the cretin and mongolian skull malformations rank, permit of ready analysis in roentgenograms, as we have explained in detail in the sections relating to them. This is especially important, because these features (configuration of the base, thickness of the wall, appearance of the inner surface and the sutures), are not accessible to the other methods of clinical examination.

In other sections (Microcephaly, Hydrocephalus, Cranioste-

nosis) we have already cited several of the cases, belonging here, which have come under our observation.

The following case is a pseudomicrocephalus with infantile cerebral paralysis and epilepsy:

CASE 4.—S., boy, nine years old. Hemiplegic on his right side since infancy (difficult labor?). He had a nocturnal convulsion at two years of age. For a year previous to examination he had had convulsions. Cranium slightly microcephalic, (circumference 48 cm.) forehead very flat, left side less prominent.

The roentgenogram showed the presence of deepened convolitional impressions on the inner surface of the skull. Taking into consideration the unilateral smallness of the skull, which was the result of the congenital brain process leading to smallness of the left hemisphere, it was necessary to make the diagnosis of pseudomicrocephaly. The existence of pressure erosions sanctioned this conjecture, and suggested a disproportion existing between the skull and brain at the time of examination. This was likely the cause of the epilepsy, following the cerebral infantile paralysis rather late.

Finally, we will cite a case of epilepsy occurring in hydrocephalus:

CASE 5.—B., girl, seven years old. At the age of seven, there appeared occasional attacks of petit mal, chiefly with left-sided localization. On rare occasions, there occurred severe attacks with loss of consciousness and general convulsions.

The roentgenogram showed the skull to be very roomy and the posterior cranial fossa was strikingly enlarged and deepened. The wall of the skull was uniformly thin, with no difference between the two sides.

As was also true in other cases of epilepsy with a unilateral localization of the attacks, we could prove the presence of hydrocephalus without asymmetry of the wall. In that way we were enabled to bring out a noteworthy argument against the assumption of a local affection as a cause and, hence, an argument against operative interference depending on this assumption.

Besides the changes in shape described, there are not rarely found in epilepsy also other changes similar to those occurring with brain tumor or to other processes causing high intracranial pressure. Such changes as general and local pressure erosions of the inner surface of the skull are an example.

Cases belonging here were cited in those sections which discussed the erosions of the skull occurring in craniostenosis

(Case 1, p. 81) in hypophyseal tumors (Case 4, p. 191, Case 6, p. 192, Case 1, p. 200, as well as tumors and processes located elsewhere, which cause high intracranial pressure. Here also belong some cases cited under the title "Widening of the venous exits noticed in observations on epileptics." (Cases 1 and 2, pages 232 and 233 respectively.)

At this time, several other cases examined by us should be cited since they are of diagnostic interest:

CASE 6.—Sch., girl, twenty-six years old. Brought to the clinic because of hysteric attacks.

The roentgenogram revealed a skull thickness of 4 mm. Its sutures were preserved. Impressions deepened. An observation covering several years left no doubt of the epileptic nature of the attacks.

CASE 7.—H., young man, eighteen years old. For several years there had been attacks of clonic convulsions of the right upper extremity, rarely, extending to the right lower extremity or spreading over the whole body. No loss of consciousness.

The roentgenogram showed the skull to be 2 to 4 mm. thick, very roomy. The inner surface, over the left hemisphere, showed very much deepened impressions. The diagnosis was a left side hydrocephalus. Further examination of the patient revealed the fact that the patient was left-handed.

On account of the practical significance, there should yet be mentioned several cases of craniostenosis (turriccephaly) with epilepsy or idiocy. Epilepsy was found eight times in our cases of turriccephaly.

CASE 8.—G., male, eighteen years old. Spasms of the glottis occurred during infancy and childhood. There had been epileptic attacks for the past several years. Turriccephaly.

The roentgenogram showed a thickening of the skull wall, in the region of the frontal bone, and extreme deepening of the convolutional impressions. All sutures were obliterated with the exception of the lambda and temporal sutures. (See Redlich and Schüller, Case 11, with Fig. 5, Plate XVII.)

CASE 9.—B., girl, twelve years old. There was a history of nightly convulsions at ten months of age. Epileptic attacks for a year previous to examination. Skull strikingly high, horizontal circumference 47 cm.

On the roentgenogram there was shortening of the skull base, especially of the anterior fossæ. There were deepened impressions, especially over the whole inner surface of the frontal bone. Diagnosis: turriccephaly. (See Redlich and Schüller, Case 12.)

In this class we can also place cases, in which, in consequence of rachitis a premature suture obliteration developed with consecutive craniostenosis, as for instance Case 3, p. 81.

The cases with diffuse thickening of the skull forms the next group of skull anomalies found in epilepsy, cerebral infantile paralysis, and idiocy. This thickening manifests itself as a concentric hyperostosis, in which case the bone may be sometimes strikingly porous, or, on the contrary, completely sclerotic. The thickening affects either the whole cranium or only a portion, especially the frontal bone. Sometimes only the skull base is involved by the thickening.<sup>27</sup>

Chiari has given special attention to the anomaly designated by him as "basal hyperostosis of the skull in idiocy." He mentioned the fact that Virehow, Rokitansky, Greisinger, Giacomini, and later Humphrey, have described basal hyperostosis of the skull in idiocy and epilepsy. According to his belief, it is an independent process which has nothing to do with rickets, inflammatory or senile thickenings, any more than it has to do with leontiasis ossea. It is limited to the inner surface of the skull base, the outer surface of which shows a normal appearance. The skull vault takes part in the thickening either not at all or in a less degree. The skull has the usual shape, it may be normal in size, or smaller or larger. The bone is, in addition, often sclerotic (ivorylike), the ridges are slightly prominent, the fissures, canals, and holes of the base are in most cases plainly smaller. Chiari also found a unilateral skull hyperostosis in unilateral sclerosis of the brain with idiocy. He considered the process a primary disturbance in the growth of the bone.

---

<sup>27</sup>There is no uniform explanation for the cause of this hyperostosis. It is either a question of compensatory filling in of the cavity in cases of abnormal or relatively small brain (compare hyperostosis of microcephaly and senile atrophy), or the thickening is the result of chronically increased intracranial pressure (analogous to the hyperostosis mentioned in the section on Brain Tumors), or it is a question of a disturbance of development coordinate with the cerebral disease and arising from the same fundamental cause. Pierret looked upon the hyperostosis as the cause of the epilepsy, since the interference with the venous return produces a disturbance of intracranial circulation.

Hyperostosis similar to that found in epilepsy and idiocy is observed not rarely in chronic psychosis. Fries describes markedly nodular exostosis of the lamina vitrea of the frontal bone in two sisters with psychosis. Zuckerkandl found hyperostosis in 24 instances in skulls of 132 insane individuals. The greater portion of them possessed a hydrocephalic shape so that the hyperostosis is looked upon as compensatory to a healed hydrocephalus or a hydrocephalus with a diminished accumulation of fluid.

The generally known and acknowledged frequency of hyperostosis in chronic psychosis is placed in doubt by Reichardt and his scholars on the basis of theoretic considerations. Meynert describes the different skull changes to be observed in psychic anomalies. A. Marie gives a review of skull anomalies associated with psychic degeneration. Ganter could not find any characteristic changes of the skull in psychosis.

We had repeated opportunities to observe circumscribed and diffuse hyperostosis on the roentgenograms in psychic diseases. We were also able to determine that cranium progenium is frequently found in the inhabitants of insane asylums, as Myer has emphasized (see page 84).

The cases of hyperostosis of the skull in epilepsy, idiocy and cerebral infantile paralysis which were examined by us are in part already mentioned in the sections on Hyperostosis, Syphilis, and Brain Tumors. Here we will cite the following additional cases:

CASE 11.—Sch., boy, thirteen years old. Hemiplegia of the left side of the body and feeble minded since two years of age. Some time later, epileptic attacks began.

On the roentgenogram the skull vault appeared capacious. The right side was 9 mm. thick, the left side 11 mm. thick, porous. In the right parietal region there was found a thinning of the skull wall which was due to a slight outward distention of the inner surface. The base was normal. In the trephination done by von Eiselsberg, the thickened porous skull appeared unusually soft. At the site of the thin place in the skull, there was found a cystic, tumor-like edema of the arachnoid. (See Redlich and Schüller, Case 19 with Fig. 6, Plate XVII.)

CASE 12.—S., male, twenty-eight years old. Had suffered from epileptic attacks for the last six years.

The roentgenogram showed a considerable hyperostosis of the skull. The operation disclosed a glioma of the brain at this place. (See Redlich and Schüller, Case 21, with Fig. 7, Plate XVIII.)

Among the rare occurrences, may be mentioned the finding of luetic changes in the skull and calcified areas within the brain.<sup>28</sup>

Robinson demonstrated the roentgenogram of an area of calcification in the brain of a case of epilepsy.

We have already cited cases of lues of the skull in epilepsy, and of calcifications in the brain in cerebral infantile paralysis, in the sections on Syphilis, Hydrocephalus, and in Chapter 3, page 157. Here several more cases may be mentioned:

CASE 13.—M., female, thirty-six years old. Epileptic attacks for the last two years. Lues ten years previously. Optic neuritis, left more marked than the right.

The roentgen examination showed on the inner surface of the frontal bone a flat enostosis projecting inward about 6 mm. It was 3 cm. broad, and was surrounded by prominent vein furrows. (See Redlich and Schüller, Case 22, with Fig. 8, Plate XVIII.)

CASE 14.—(Already mentioned on page 110.) K., male, thirty-three years old. Lues thirteen years previously. Numerous recurrences of paralysis of eye muscles, aphasia, psychic disturbances, right-sided hemi-

<sup>28</sup>Frotscher and Becker described a walnut-sized endothelioma with lime deposit in it, which was located on the ala minor near the sella. Clinically, idiocy existed.



paresis. Epileptic attacks for the last three years. Cranium 57 cm. in horizontal circumference. The surface was smooth but sensitive to pressure at various places.

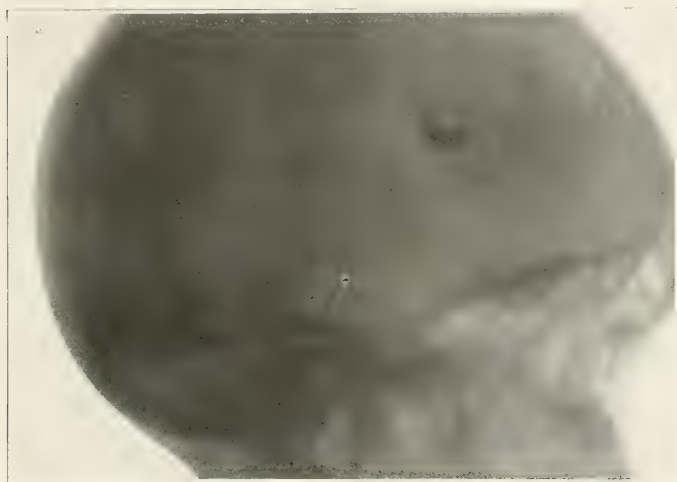

Fig. 92. —A sinistrodextral picture of the head of Case 15, page 246. The shadow of a calcareous deposit is plainly seen.

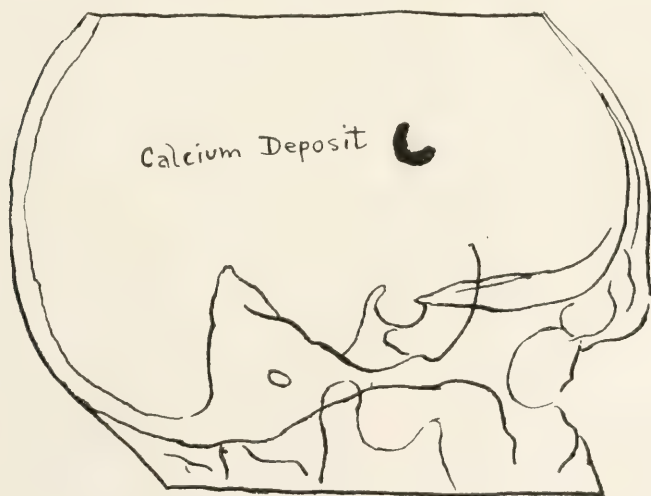


Fig. 93.—A sketch of Fig. 92.

The roentgenogram showed an insular osteoporosis scattered out over the greater portion of the cranium, similar to a typical picture of otitis syphilitica. (See Redlich and Schüller, Case 25 with Fig. 9, Plate XVIII.)

CASE 15.—L. K., male, thirty-eight years old. Occasional attacks of epilepsy for the last eight years.

Roentgenogram showed a half-moon-shaped area of calcification within the left frontal lobe. (See Figs. 92 and 93.)

CASE 16.—A. M., male, twenty-three years old. In very early childhood the patient had suffered from a bilateral purulent discharge from the ears following measles. Bilateral radical operation. Patient complained of epileptic attacks for the last two years. Cranium progenium.<sup>29</sup>

The roentgenogram showed two polyhedral areas of calcification within the right cerebral hemisphere. One was in the temporal lobe, and the other in the parietal lobe. They were probably old calcified areas of encephalitis which likely had developed in connection with the purulent otitis media. (See Redlich and Schüller, Case 26 with Fig. 10, Plate XVIII.) At the operation performed in the Eiselsberg Clinic, it was possible to find the area of calcification in the temporal lobe by sounding with an aspirating needle. The other area was not sought.

The preceding paragraphs permit the diagnostic value of the roentgen examination of the head in epileptics to be seen with probably sufficient clearness. In all cases where trauma comes into the case as an etiologic factor, the roentgenogram may furnish important evidence for a clinical diagnosis, by the proof of fissures, defects, thickenings, and foreign bodies, even if the physical examination fails to disclose such changes. The result of systematic roentgen examinations in epileptics tends to confirm the present belief that the domain of the so-called genuine epilepsy is becoming more and more limited as compared to epilepsy with anatomic findings.

The interest awakened in recent years concerning the surgical treatment of epilepsy, makes necessary its regular roentgenologic examination. This not rarely gives the most important information regarding operative interference or nonoperative treatment.

It is a very remarkable fact, both theoretically and practically, that positive roentgen findings can be obtained in the skull in about 30 per cent of all epileptics.

### Migraine, Headache, Neuralgia

Changes in the skull are observed in symptomatic migraine as well as in the so-called genuine migraine. We will first

<sup>29</sup>A typical cranium progenium in an epileptic is found pictured by Knobloch in the *Klinik und Atlas der chronischer Krankheiten des Zentralnerven Systems*.

enumerate the various groups of pathologic conditions in which migraine occurs as one of the symptoms. One usually speaks of the following varieties of symptomatic migraine.

1. Migraine in brain tumors and after meningitis.
2. Migraine in Paget's disease of the skull.
3. Migraine in the beginning stage of tabes and taboparesis.
4. As a fourth form not commonly known, one must mention, as I have pointed out, the migraine in turriccephaly and other forms of craniostenosis.

In all the forms of symptomatic migraine mentioned (with the exception of the pathologically indefinite migraine of the taboparalytics), a close relationship can be shown between skull anomalies and the symptom-complex designated as migraine.

Tumors of the brain may give rise to migraine in two different ways. In the first class are those tumors which originate at the point of exit for the cerebrospinal fluid and induce quickly an internal hydrocephalus with early erosion of the inner surface of the skull. In the other class are those tumors which, having their location on the base of the brain especially in the middle cranial fossa, produce migraine-like pain by pressure on the trigeminal nerve. In this latter class of cases one often finds, even in the beginning of the disease, a local erosion of the bone. Hypophyseal tumors are a good example of this variety.

In migraine, in connection with a healed meningitis, one makes out pressure erosions on the inner surface of the skull as the result of high intracranial pressure. Paget's disease of the skull, with its massive eccentric and concentric thickening of the bone, and craniostenosis show also striking anomalies of the skull as the cause of symptomatic migraine.

From what has been said, it follows that, with the roentgen examination of cases of symptomatic migraine, various and significant findings may be disclosed. It shows on the skull the localized and general pressure erosions produced by the above mentioned classes of brain tumors and also by other processes causing an increase in intracranial pressure.

Cases of symptomatic migraine with positive roentgen findings have been already mentioned in the sections on Cranioste-

nosis (Case 1, page 76), Brain Tumors (Case 13, page 223), and Hypophyseal Tumors (Case 1, page 193). Here may be cited the following cases:

CASE 1.—Male, twenty-two years old. Had suffered for years from migraine. His mother was also a sufferer from migraine. Patient had a short, broad and high skull vault (turricephalic). His mother was said to have exactly the same shaped head.

On the roentgenogram, one saw that the sutures were for the most part obliterated, and the convolational impressions eroded deeply.

CASE 2.—M. G., male, twenty-one years of age. For the previous two years the patient had suffered periodic attacks of headache, lasting several hours, and with this he was slightly nauseated. The headache made its appearance on one side and then became general. Patient had a typical



Fig. 94.—A microcephalic type of turricephalus. Photograph of Case 2.

turricephalus of the microcephalic type with a receding forehead. Horizontal circumference was 52 cm. Exophthalmus. Large deformed nose. (See Fig. 94.)

The roentgenogram showed the skull thickness to be variable. Toward the vertex it reached 9 mm. and in the temporal region it was very thin. There were eroded impressions.

CASE 3.—Boy, seven years old. Typical migraine. Turricephaly.

The roentgenogram showed extremely deepened impressions which, in places, had made the bone as thin as paper. (See Schüller, *Wiener klinische Wochenschrift*, 1908, p. 703.)

CASE 4.—Boy, eleven years old with typical migraine.

The roentgenogram permitted the recognition of the characteristics of a hydrocephalus, and enabled one to complete the history of aluetie etiology. (See same reference as in Case 3.)

This latter case illustrates the well-known close relationship between migraine and lues.

In genuine migraine, there are also sometimes found changes in the skull. It can be readily understood why there are only isolated observations reported in the literature when one stops to think of the infrequency of postmortem findings in typical cases of genuine migraine. Möbius cited the following finding obtained by him at the postmortem of a case of genuine migraine. On the outer surface of the right side of the frontal bone, the skull showed a superficially projecting, smooth, round proliferation the size of a penny. The sutures were ossified and their site was marked by a ridge on the bone. Throughout the rest of the skull vault, the bones were thin and full of blood. The dura was firmly adherent to the inner surface. The inner surface of the bone was particularly rough all over the frontal region as the result of the presence of numerous small bony proliferations having the shape of jagged ledges or isolated points, some of them as much as 5 mm. high. The vessel furrows were deeply eroded.

In another case mentioned by Möbius, there were also found pointed exostoses on the inner surface of the skull vault. Lallemand reported that he had found after death "*saillies épineuses à l'intérieur du crâne*" in several sick people who had suffered from obstinate headache and had always been considered as having migraine.

Relative to the significance of these findings, there is probably hardly any doubt that these were not enostoses but were the pointed ridges remaining between the deepened convolutional impressions. Consequently they were the typical pictures of pressure erosion appearing in cases with increased intracranial pressure.

On account of the infrequent opportunity of making examination at autopsy, it seemed advisable to us to make systematic roentgen examinations of the heads of all cases of typical migraine occurring in our extensive clinical material.

We were able in this way to prove the existence of deepened convolutional impressions to be the most frequent positive finding. This finding offers an essential support of the theory, already asserted by a number of authors (Spitzer, Quincke),

which assumed a high intracranial pressure as the essential thing in attacks of migraine, and suggests at the same time that a disproportion between the volume of the brain and the capacity of the skull could be the essential factor in the so-called predisposition to migraine. In this there seems to be an analogy between genuine migraine and the various forms of symptomatic migraine, the general peculiarity of which is a prolonged disproportion between the skull and its contents. In brain tumors and hydrocephalic accumulations of fluid, the content of the skull is abnormally large for the normal skull, while in Paget's disease and in craniostenosis the skull is too small for the brain of normal size.

We can not answer with certainty whether in genuine migraine the brain is too large or the skull too small. We can only assert that this disproportion in most cases is a congenital and a hereditary one and that it disappears with age.

According to Reichardt and others, there exists normally, as we have already mentioned, a difference of about 10 per cent between the skull capacity and the volume of the brain. Such a difference is apparently necessary to allow free play for the functional variations of the brain volume. In case of a diminution of the difference, which is unfavorable to the brain, there can very easily occur an acute pressure on the latter accompanied by an attack of migraine. This may occur under the influence of something producing a cerebral hyperemia, as, for instance, alcohol or psychic excitation.

As has been mentioned, the question can not be decided whether in those suffering from genuine migraine the brain is too large or the skull too small, without direct measurement of volume in those dead from migraine. However, the fact that one finds rather large heads in migraine sufferers and that also migraine occurs most often in individuals distinguished mentally (for which one<sup>30</sup> assumes the existence of a voluminous brain), seems to indicate that an abnormally large brain may be the cause of the disproportion producing the migraine. Every day experience reveals the fact that the shape and size

---

<sup>30</sup>Lombroso reported that out of twelve brains (examined by Wagner and Bischoff) of prominent people, eight had a large volume and four had a small volume. The greater proportion of geniuses possess large skulls (1600-2000 c.c. capacity). In twenty-six skulls of French geniuses, Lebon found an average capacity of 1532 c.c.

of the face are hereditary, and the same might be said concerning the cranium and its contents. Karplus has indeed pointed out that even details of arrangement and the size of the brain convolutions may be inherited.

The origin of pressure erosions and the degree of their development apparently depends not only upon the degree of the disproportion, but also upon the number of attacks and the nature of the skull. It may be readily believed that cases in which the development of the pressure erosions is made difficult by the abnormal firmness of the bone represent the most obstinate cases, while the development of the pressure erosions leads to relief from the disease. This compensation or adaptation may explain the cessation of the attacks with the advance of age.

Among the cases under our observation with the finding of pressure erosions combined with symptoms of migraine (nine in number), several may be cited here:

CASE 5.—R., boy, seventeen years old. Was under treatment in the hospital for years on account of a typical migraine.

On the roentgenogram the skull was roomy, 2 to 3 mm. thick, sutures preserved, impressions deepened.

CASE 6.—K., girl, thirteen years old. Father had syphilis. In the family of the mother there were cases of typical migraine. Patient often had attacks of headache, accompanied with vomiting, that lasted several hours.

On the roentgenogram the cranium was normally formed but contained deepened impressions on the floor.

In addition to the deepened impressions, which we found frequently, we were able to establish the presence occasionally of other anomalies. In three cases there was noted an enlarged sella, a finding which would support the theory, advanced by Deyl and Plavec, of hypophyseal swelling as the cause of migraine. In one case we proved the existence of a bathrocephalus with extreme deepening of the convolutional erosions. In another case there existed a thickening of the skull, as great as 10 mm. in places. In still another case there were found very plain diploic veins in the frontal bone.

Finally the occurrence of skull asymmetry in genuine migraine should be mentioned.<sup>31</sup> Such a case may be cited here:

<sup>31</sup>Stern found, in eight cases of migraine, underdevelopment of one-half of the face along with a peculiar disturbance of sensibility, a hyperalgesia of the hypoplastic side of the face and a contralateral hyperalgesia in the extremities. The migraine appeared on the hypoplastic side and seemed to be related to a slight infantile cerebral paralysis.

CASE 7. —L., female, forty years old. The patient had a typical migraine. The left fronto-temporal region appeared less prominent than the right on external examination.

On the roentgenogram one could distinguish that the asymmetry was especially marked in the region of the base. Here the diminished size of the left half of the skull became even more striking.

As in migraine, so also in other forms of headache and neuralgia we may occasionally obtain positive roentgen findings. These findings consist of the same changes that are associated with intracranial pressure, as well as tumors localized in the facial and cranial bones.

### GENERAL REMARKS CONCERNING THE TECHNIC OF ROENTGEN EXAMINATIONS IN INTRACRANIAL DISEASES

Since we have discussed in detail the changes which are recognizable on the roentgenograms in intracranial diseases and have emphasized their diagnostic utility, it is necessary that we explain in a few words the procedure which we make use of for the purpose of proving the skull changes mentioned.

In general, we recommend that a profile picture of the whole skull be made first.<sup>32</sup> Upon such a picture one is able to determine the size and contour of the entire skull, the thickness and structure of the vault, the appearance of the inner surface, the configuration of the three cranial fossæ, the shape and contents of the accessory sinuses, the condition of the sutures (especially the coronary and lambda sutures) and the vessel furrows. In such a picture one should look for the existence of areas of calcification within the brain.

For a second picture the sagittal one taken in the antero-posterior direction is advised. This picture serves to deter-

---

<sup>32</sup>[In designating the position in which pictures have been taken the author has made use of a simple method, which might be worth explaining for the benefit of those not accustomed to it. The information concerning the direction in which the exposure has been made is thus easily conveyed. A picture taken transversely from left to right is spoken of as being a *sinistrodextral* exposure, that taken from right to left is *dextrosinistral*, and one taken from front to back is designated as *anteroposterior*. In other words, the side last mentioned is the one nearest to the plate. In diagonal exposures, for special purposes, other terms, such as *parietotemporal* may be used, always with the main idea in view of having a systematic nomenclature. The knowledge of the direction in which an exposure has been made is very often important in making a diagnosis. The anatomic structures lying nearest to the plate are always more distinctly seen than those farther away, a fact that can be readily understood if one observes shadows cast on a wall by objects at varying distances.—EDITOR.]



mine, in addition to the first one, differences of outline in the two halves of the skull with relation to the thickness of the wall, the contour of the inner surface on the sides, the structure of the bone in this locality, and the condition of the sutures (sagittal, lambda, temporal, and possibly coronary), the Pacchionian fossæ, and the venous canals. Finally one endeavors to determine variations in the position of a calcified pineal gland.

To these two pictures, one adds in most cases one or more local pictures which aim at a clear presentation of that part in which there is reason to suspect a pathologic change in the skull, on the basis of the other two pictures or from the result of the clinical examination. Special pictures that suggest themselves are a roentgenogram of the middle cranial fossa with the sella turcica, a sagittal one made in the posteroanterior direction, one transverse with the head slightly twisted or tilted, a sagittal one of the posterior cranial fossa through the open mouth, as well as tangential pictures of individual parts of the vault.

The fluorescent screen plays a very inconsiderable role in the examination of the head.

## APPENDIX

---

In this section should be discussed the affections of interest to the internist, that involve the nose, eye, ear, and teeth with reference to roentgen diagnosis. We will not go into detail, however. For that, we refer to our collection of the literature on skull roentgenology and to the manuals, as well as special works on the subject.

### RHINOLOGY

The most frequent diseases of the accessory sinuses (frontal, ethmoid, sphenoid, maxillary antrum) are caused through inflammation of the mucous membrane which covers the cavities named. The products of this inflammation, mucus and pus, as well as the swelling and the polypoid degeneration of the mucous membrane fill completely or in part the cavity otherwise occupied by air.

The roentgen examination offers a valuable supplement to the other rhinologic methods of examination, in the diagnosis of inflammatory affections of the accessory sinuses. The roentgenogram permits the positive determination of the air content of the chambers and facilitates, even in indefinite cases, the solution of the question as to whether the clinical symptoms (headache, asthma, dizziness, disturbance of vision) can be accounted for by a disease of the accessory sinuses.

The literature relative to roentgenologic diagnosis of the inflammatory diseases of the accessory sinuses has grown to such a volume that it is hardly possible to review it. We mention especially the works of Winkler, Scheier, Wassermann, Kuttner, Caldwell, Goldman and Killian, Burger, Jansen, Peyser, Rhese, Onodi, and Joseph C. Beck.

Among the many hundreds of cases, which we had to examine because of surmised disease of the accessory sinuses, are those of special interest in which the roentgen examination could not confirm the assumption of sinus disease, but, on the

other hand, was able to assist in explaining the clinical symptoms through proof of other skull changes ( turricephaly,<sup>1</sup> tumors, etc.).

Those pictures, which permitted the determination of a complete absence of sinuses that had been considered diseased, form no real small fraction of the "negative" cases; and, on the other hand, we were able by the roentgen examination to establish the existence of an accessory sinus inflammation in several cases which were considered as negative on the basis of a rhinologic examination. Such a case may be cited here:

K. A., female, forty-seven years old. Under treatment for ozena. The patient was sent to us for neurologic examination because there had recently appeared a supraorbital neuralgia of the left side and a rapidly progressive amblyopia associated with a left side optic neuritis.

The roentgen examination determined the existence of a spacious sphenoidal sinus which, however, was completely devoid of air. In the rhinologic examination following this finding, there was revealed the existence of a tumor in the left sphenoidal sinus. Puncture disclosed the fact that the tumor was cystic.

A second group of diseases of the nose and its accessory sinuses is formed by tumors which take their origin from the walls of these cavities. These are most frequently sarcomata, carcinomata, and osteomata.

The periosteum or a cartilaginous rest forms the point of origin for these osteomata. They displace the wall of the cavity and may invade the neighboring tissues. In a case observed by Haymann, there existed simultaneously several osteomata of the face and skull, all on the right side. The so-called dead bodies of the accessory sinuses, that one meets with occasionally, are osteomata that have become separated from the wall through purulent inflammation.

Mucoceles and pneumatocoeles occur as rare forms of tumors. A mucocele is, according to Hajek, an accumulation of mucus

<sup>1</sup>As we have already mentioned in the section on turricephalus, disturbances of the sense of smell, on account of compression of the olfactory nerve, are found in this class of anomalies.

Through the deformity of the skull base there is also produced a curvature of the nasal septum. It should be mentioned here that the roentgen examination permits the exact determination of other irregularities in the contour of the skull bones which appear to be an etiologic factor in certain nasal diseases. This relationship has been repeatedly emphasized in the literature. Kaufmann, for instance, mentioned that ozena, which is caused by a metaplasia of the nasal mucous membrane, is found in wide noses on broad faces. In this connection, one should also mention the monograph of Bentzen, who showed a relationship between high palates and deviation of the septum.

in a cavity bounded by bony walls in which there is pressure because of closure of the port of exit. Dilatation and rarefaction of the cavity wall follow. Such accumulations of mucus come under observation most frequently in the frontal and ethmoidal sinuses. One designates as pneumatoceles collections of air under the periosteum of the skull. They result from an escape of air from an accessory sinus through a hole in the wall. Pneumatoceles have their origin either in the frontal region or in the region of the mastoid process. They appear spontaneously in consequence of a trauma or an inflammation. Over an accumulation of air the bone may show an irregular surface.

In many cases, only the roentgenogram discloses the existence of tumors of the accessory sinuses. It enables one also to determine their extent and structure. Reports concerning the roentgenologic proof of tumors of the accessory sinuses are found relatively infrequently in the literature. Marschik and Schüller demonstrated a large number of such tumors in roentgenograms. Several of them may be cited here.

CASE 1.—G. B., male, thirty-seven years old. For the last two years there had existed a neuralgia over the area supplied by the second branch of the trigeminal nerve on the left side. Recently there had occurred an exophthalmus on that side. On account of the suspicion of an accessory sinus inflammation, the patient was examined by a rhinologist. There was no positive finding and an x-ray picture was made.

In the region of the left half of the face there was found a large bony tumor with sharply outlined nodular edges. The center of the tumor corresponded in location to the left ethmoid bone. The tumor extended upward to the planum sphenoidale, posteriorly to the sphenoid sinus, and outward to the lateral third of the orbit. The extirpation of the osteoma of von Eiselsberg verified the x-ray finding.

CASE 2.—T., male, twenty-eight years of age. Exophthalmus on the right side. A hard tumor was palpable on the inner surface of the right orbit.

The roentgenogram showed an olive-sized bony tumor, with a broad base, on the median wall of the orbit. Since the shadow of the tumor was less dense in the center than on the edges, we made the diagnosis of a combined osteoma and mucocele. In the operation, performed in the Fuchs clinic, there was actually found a cavity covered with mucous membrane in the middle of the osteoma.

CASE 3.—S. W., female, forty-seven years old. Complete blindness. The rhinologic examination revealed the fact that a tumor, a cylindroma, was growing out from the sphenoid sinus.

On the roentgenogram one saw that the body of the sphenoid was nearly

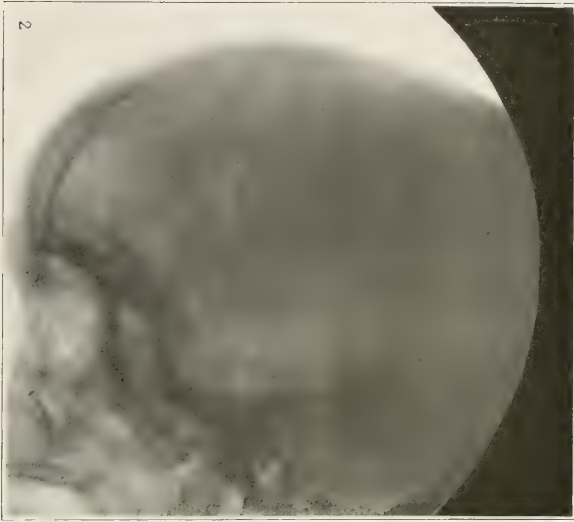


Fig. 95.—A dextrosinistral picture of the head of Case 3. The outline of the sella is quite indistinct due to the fact that it is infiltrated by a carcinomatous growth.

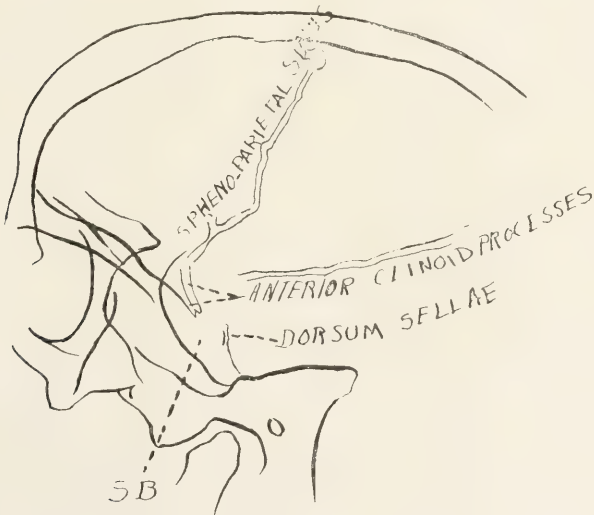


Fig. 96.—A sketch of Fig. 95. *SB* is the site at which the outlines of the sphenoid bone should be seen.

destroyed. One could see only an indistinct contour remaining from the floor of the sella. Remnants of the dorsum sellae and of the anterior clinoid processes were also to be seen. (Figs. 95 and 96.)

CASE 4.—P., female, fifty-two years old. Paralysis of several cranial nerves.

The roentgenogram showed extensive osteoporosis of the body of the sphenoid, so that the contour of the sella was only indistinctly visible and it was scarcely possible to outline the sphenoid cavity.

CASE 5.—N. N., female, forty years of age. Cranial nerve paralysis.

On the roentgenogram the sphenoid body was osteoporotic and the sphenoid cavity contained no air. The sella was of normal size and shape, but its contour was indistinct. The rhinologic examination made out the presence of a tumor in the nasopharynx.

While Cases 1 and 2 illustrate the occurrence of osteomata on the wall of nasal sinuses, Cases 3 and 4 are examples of malignant tumors of the soft tissues that have invaded the bone at the base of the skull.

Destruction, similar to that just mentioned as resulting from soft tissue tumors, occurs also in tuberculosis and syphilis. Among such cases falling under our observation, the following should be mentioned here:

CASE 6.—(Already mentioned on page 113.) M., girl, fourteen years, of age. Clinically there existed symptoms of a tumor of the pons.

The roentgenogram showed the sella to be eroded in slight degree. The contour of its floor was jagged and its dorsum was gone. The anterior clinoid processes were pointed. The postmortem disclosed the fact that a tuberculous caries, starting from the floor of the sella, had spread out toward the base of the brain.

The x-ray is a valuable aid in the diagnosis of other conditions, such as foreign bodies in the accessory sinuses, malposition of teeth, diminution of the air content of the accessory sinuses by an accumulation of blood in consequence of fracture of the skull at the base.

Finally one should be reminded that, with the help of a roentgenogram it is possible to obtain knowledge (indispensable for surgical interference) relative to the size, shape, structure, and variations<sup>2</sup> of the accessory sinuses as well as their relation to the base of the skull and the brain.

<sup>2</sup>The occurrence of a recessus supraorbitalis (Witte), belonging to either the sphenoid or the frontal sinus, forms a frequent variation. There may also be an air chamber within the nasal septum or the anterior clinoid processes. The absence of all accessory sinuses is a rare occurrence in an adult. In the newborn the sinuses are not yet developed. The first hint of a frontal sinus appears, according to Toldt, toward the end of the third year. The development of this cavity proceeds slowly so that, at six years of age, it attains a size hardly greater than a pea. The frontal sinus grows quite appreciably from the eleventh to the twelfth years of life.

The sphenoid sinus begins to develop about the time of puberty. Absence of one or both frontal sinuses is not rarely observed in an otherwise normally developed

## OTOLOGY

Among the changes in the organs of hearing, in which the roentgenogram offers a valuable supplement to the findings obtained by other methods of examination, the following may be mentioned: 1. Malformations (atresia congenita). 2. Interruption in continuity (fractures of the skull base). 3. Foreign bodies. 4. Inflammations of the accessory sinuses. 5. Destructive processes (tumors and caries). 6. Hyperostoses.

The number of monographs which deal with roentgen diagnosis in ear affections is quite small. Among those most recent, that should be mentioned, are the publications of Joseph C. Beck, G. Schwarz, Jansen, Kühne and Plagemann, Lange, Iglauer, and Leidler.

The cases which we had opportunity to examine roentgenologically, on account of changes in the organs of hearing, are found, in part, in our publication in conjunction with Leidler. Here the following cases may be given:

CASE 1.—Male, thirty years old. There had been gradually increasing difficulty in hearing in the right ear in consequence of narrowing of the bony external passage.

On the roentgenogram one saw a very marked thickening of the right posterior portion of the skull (temporal and occipital bones) amounting to 20 mm. The structure of the bone corresponded to that which is considered as characteristic for Paget's disease.

CASE 2.—Female, thirty-five years old. Diminution of acuteness of hearing in the left ear. External auditory passage completely closed.

The roentgenogram revealed the pyramid on the left side to be spongy only in its posterior portion. In the anterior portion there was found a shadow of bony density on the site of the external auditory passage. The operation performed by Frey disclosed a hemispherical osteoma that filled the auditory canal.

In addition to the above conditions, one may sometimes succeed in obtaining a positive finding by using the x-ray in nervous disturbances of hearing such as central deafness, subjective noises in the ear, and dizziness. Relative to this, we refer to cases cited in the section on Acusticus Tumors.

---

skull. It occurs in 5 per cent of all cases according to Preysing. It is possible that a frontal sinus, originally present, may disappear through fungoid development, analogous to the mastoid cells. Hultkranz found a striking smallness in the accessory sinuses in dysostosis cleidocranialis. Remarkably large accessory sinuses are found, as mentioned earlier, in acromegaly and other forms of hyperostosis of the skull, as well as in cases of senile atrophy.

Abnormally broad frontal sinuses, which according to Curella signify an atavistic reaction, were looked upon by Frotscher and Becker as associated with imbecility (!).

Finally, of interest is the circumstance that in occasional individuals with subjective noises in the head, which could also be proved objectively, changes in the skull could be determined with the help of the roentgenogram.

One of those cases was a man, forty-three years of age, who was thought to have an intracranial aneurysm because of the character and localization of the noise heard in his head. The roentgenogram permitted one to make out isolated areas of osteoporosis in various places on the cranium. The postmortem showed that multiple sarcoma metastases were the cause of this osteoporosis. (See *Wiener klinische Wochenschrift*, 1911, p. 1684).

In a patient, nine years old, we made out on the roentgenogram a strikingly thin hydrocephalic skull as the probable cause of the noise in his head, which could also be heard from the outside.

## OPHTHALMOLOGY

The affections associated with ocular disturbances, for the explanation of which the x-ray can be used with success, may be grouped in the following manner:

1. Intracranial processes such as tumors and other affections causing an increase in intracranial pressure.
2. Diseases of the accessory sinuses.
3. Injuries, as fractures of the orbital wall.
4. Foreign bodies in the eye and orbit.
5. Anomalies in contour, destruction, or hyperostosis of the orbital walls.

Since we have already discussed in a former section the affections included above under 1, 2 and 3, there are left for discussion only those changes included in 4 and 5.

As for the foreign bodies in the orbit, there come under discussion, first, the projectiles and splinters coming from the outside and, second, the calcified formations arising within the eye itself.

The roentgen examination enables one to determine the size, appearance, and position of the foreign body, and especially does it help one to decide as to whether it is inside or out-



side the bulb. (Methods of localization by Mengelberg, Holth, Hamburger, B  cl  re, and Holzkn  cht.)

Anomalies in the contour<sup>3</sup> of the orbit are in most cases a local manifestation of deformity in the skull in general. (See the section on Anomalies in the Shape and Size of the Skull.) More seldom are they produced by congenital or early acquired anomalies in the orbital content.

Atrophic and absorptive changes in the orbital wall, as well as diffuse or circumscribed hyperostosis, are produced by inflammatory processes or tumors.

The roentgenogram permits the changes in the orbital wall, as well as the size and shape of the superior orbital fissure and the foramen opticum to be plainly distinguished. It frequently assists in clearing up odd groups of symptoms associated with the eye, such combinations as disturbances of sight, combined with disturbances of movement or changes in the position of the bulb, with or without neuralgic pain. Oppenheimer appreciated the utility of the roentgen examination in tumors of the orbit. Heine and Birch-Hirschfeld have exhibited, roentgenologically, circumscribed tumors (osteoma and osteosarcoma) in the orbit. From among the cases which we had the opportunity to examine, the following may be cited here:

CASE 1. (Already mentioned on page 142.) S., female, thirty years of age. For the last two years she has suffered from neuralgia of the first branch of the trigeminal on the left side. For the last three months there had been a gradually increasing exophthalmus. Rhinologic examination negative.

The roentgenogram showed, as the cause of the clinical symptoms, an olive-sized osteoma in the posterior portion of the orbital roof. From this point it projected about 1 cm. toward both the inner surface of the skull and the orbit.

CASE 2.—B., female, forty-five years old. Gradually in the course of several years there occurred an exophthalmus of the right eye, diminution of distinctness of vision, edema of the conjunctiva, and diminution in movement of the bulb. Probable diagnosis was hyperostosis of the orbital wall on the right side.

The roentgenogram showed that there was a hyperostosis of the right

<sup>3</sup>The shape and size of the orbit, which has been repeatedly submitted to exact measurement on account of its anthropologic significance, not only determine the position of the eye but are of influence upon the refraction (Stilling).

Adachi mentioned the fact that the obliteration of the sutures of the orbit begins with the twenty-eighth year and is completed in the seventieth year. The superior orbital fissure shows a variable shape and breadth. The foramen opticum may be divided.

half of the body of the sphenoid, so that the floor of the sella was thickened and the sphenoid antrum appeared to be filled up with compact bone. There was also a thickening of the ala major and minor. The hyperostosis of both alae produced a diminution of the superior orbital fissure and consequently a compression of the ophthalmic vein and the nerves controlling the movements of the bulb. The foramen opticum was not diminished in size. (See Sachs and Schüller.)

CASE 3.—H., male, twenty-eight years of age. Trauma of the head in early youth. Deformity of the skull and face from early childhood. At the time of examination there was an exophthalmus pulsans. It was possible to push the eye back. There was bulging of the right temporal region, and thickening of the tissues of the right side of the face, resembling elephantiasis. (See Fig. 97.)




Fig. 97.—Photograph of H., Case 3, page 262.

The roentgen examination permitted one to see that the upper and posterior portions of the orbit were gone. The wall of the skull, corresponding to the right temporal region, appeared thinned, bulged outward, and rarefied by the presence of numerous vascular canals. The floor of the right middle cranial fossa was lower than the left. The sella turcica was shallow and widened at the top. Taking into consideration the change in the facial skin, a lymphangioma was assumed as the cause of the symptoms. It is probable that the circumscribed destructive changes in the orbital wall, the skull base, and the temporal region were produced by a portion of the lymphangiomatous tumor, lying intracranially. (See Lauber and Schüller.)

## ODONTOLOGY

The pathologic changes in the jaws and teeth are either a local manifestation of anomalies of the whole skull, and were on that account, mentioned in previous sections, or they represent local affections that are limited to these portions of the skull. As such, there come under consideration disturbances in the development of the jaws (micrognathia) and the teeth (retention, malposition), injuries (foreign bodies), inflammations (necrosis of the jaw, root abscess), as well as tumors of the jaws and teeth, such as osteomata, osteofibromata, cysts, granulomata, sarcomata, and carcinomata. Also worthy of mention are diseases of the mandibular joint.

The diseases, inflammations, and injuries of the mandibular joint or its surrounding tissues may lead to ankylosis of the jaw; and ankylosis of the jaw, either congenital or acquired during the period of growth, may bring about peculiar anomalies of shape and size, not only of the lower jaw, but of the whole skull (Orlow, and von Hansemann). Bilateral ankylosis of the jaw produces micrognathia, unilateral ankylosis produces asymmetry of the face, the jaw, and the position of the teeth.

The affections of the jaws and teeth, which arouse the interest of the clinician on account of their relation to general diseases or because of their associated symptoms (trigeminal neuralgia, accessory sinus affections, etc.), are in most cases easily seen in the x-ray picture.

Comprehensive reports of the use of the x-ray in dental therapeutics were made by Port, Kienböck, G. Schwarz, Robinsohn and Spitzer, Witzel, and Dieck. Also Martens, Perthes, Bakay, Breuer, Haenisch, Hauchamps, and Kunert have reported single observations belonging in this class. Herpin studied, radiographically, the position of the "eye teeth." Höck showed the changes in the mandibular joint by means of the x-ray.

Among the cases with affections of the jaws, which we had the opportunity to examine, one is reported in our *Atlas der Schädelbasis* (Case XXIV with Fig. 7, plate V). The case was that of a woman, twenty-five years old, who suffered from pain and difficulty in moving the left mandibular joint. On the

roentgenogram there was found an erosion of the head of the bone, a chronic deforming arthritis.

In one patient, thirty-five years old, who suffered from a neuralgia of the second and third branches of the trigeminal nerve on the left side, there was found, on the roentgenogram, two granulomata, one in the upper and the other in the lower jaw.

In conclusion the following cases may be mentioned:

G., male, thirty-five years old. After extraction of five teeth from the upper jaw (when between twelve and eighteen years of age), there appeared a gradual receding of the teeth of the upper jaw and at the time of the examination there existed an extreme prognathism of the lower jaw. The upper jaw had retracted until the teeth had approached each other so closely that there were seen only little holes at the locality of the extracted teeth.

As the cause of this change in facial contour, we could prove on the roentgenogram an atrophy of all the skeletal portions of the head. The skull vault was 4 mm. to 5 mm. thick, of diminished density, so that one was able to distinguish the bone columns of the spongiosum. There were greatly developed venous canals in the vault. The basal angle was small ( $110^\circ$ ). The sella turcica was of small size. The maxillary skeleton showed a striking smallness and delicateness as well as an orthognathic shape. The accessory sinuses were spacious, the nasal septum was deviated to the left, and the turbinated bones on the right side were hypertrophic. The lower jaw was large and the mandibular canal 6 mm. in diameter. The teeth were apparently of diminished density. The bones of the extremities were normal. It was impossible to decide with certainty what kind of atrophy of the skull this was. It was probably an osteomalacia.

In a similar manner, the roentgenogram could be of assistance in enabling one to understand the so-called anomalies of occlusion (Angle) and aid in the odontologic treatment of the same.

## BIBLIOGRAPHY

---

Adachi, Die Orbita und die Hauptmasse des Schädels der Japaner. Zeitschrift für Morphologie und Anthropologie. 1904, Vol. VII.

Ibid., Die Porosität des Schädeldaches. Zeitschrift für Morphologie und Anthropologie. 1904, Vol. VII.

Ahlfeld, Die Missbildungen des Menschen. 1882. (Mit Atlas.)

Albers-Schönberg, Zwei Fälle von Hypophysentumoren. Ärztlicher Verein in Hamburg. February 9, 1904.

Alessandrini, Die Anezenphalie. Monatschrift für Psychiatrie und Neurologie. 1910, XXVIII.

Alexander G., Zur Kenntnis der Missbildungen des Gehörorganes, besonders des Labyrinthes. Zeitschrift für Ohrenheilkunde. Vol. XLVI, Chap. 3.

Algyógyi, Turmschädel. Demonstration in der Gesellschaft der Ärzte Wiens, June 26, 1908. Wiener klinische Wochenschrift. 1909, No. 28.

Ibid., Verkalkter Hirntumor. Demonstration in der Gesellschaft der Ärzte Wiens. May 28, 1909. Wiener klinische Wochenschrift, 1909, p. 831.

Almond, Notes on a Case of Exophthalmic Oxycephaly. The Alienist and Neurologist. Vol. XXXI, No. 4, 487, 1910 (Ref.: Jahreshb. für Neurologie und Psychiatrie).

Alquier und Klarfeld, Tumor, der den Aquaeductus Sylvii komprimiert. Nouv. Jcon. de la Salpetr. 1911, No. 3. (Verkalktes Sarkom im Hirnstamm.)

Ibid., Diagnose der Kleinhirnbrückenwinkel-Tumoren. Gaz. d. Hôpit. 1911, No. 57, 67, 72.

Alsberg, Die Abstammung des Menschen und die Bedingungen seiner Entwicklung. 1902.

Amadei, Epileptische Schädelveränderungen. Archiv für Anthropologie und Ethnologie. 1882.

Amberger, Zwei bemerkenswerte Fälle von Gehirnchirurgie. Deutsche medizinische Wochenschrift. 1906.

Ambialet, Déformation cranio-cérébrale, troubles de l'appareil visuel. Annales d'oculistique. Nov. 1905.

Angle, Behandlung der Okklusionsanomalien der Zähne. Deutsche Übersetzung von Grünberg. 1908.

Anschütz, Über einige seltene Formen der Knochenatrophie und der Osteomalazie. Mitteilungen aus den Grenzgebieten der Medizin und Chirurgie. 1902.

Anthony und Pietkewicz, Nouvelles expériences sur le rôle du muscle crotaphyte (temporal) dans la constitution morphologique du crâne et de la face. C. r. de l'Académie des sciences (Paris), November 15, 1909.

- Anton, Hydrozephalien, Entwicklungsstörungen des Gehirns. Handbuch der pathologischen Anatomie des Nervensystems. 1903.
- Ibid., Demonstration eines Mädchens mit Kleinhirnatrophie. Ref.: Münchener medizinische Wochenschrift, 1910, p. 2444.
- Anton, Hypertrophie des Gehirns. Wiener klinische Wochenschrift. 1902, No. 50.
- Ibid., Zur Diagnose und Therapie der Hirngeschwülste im 4. Ventrikel. Verein der Ärzte in Halle a. d. S. Ref.: Münchener medizinische Wochenschrift. 1911, p. 761.
- Ibid., Agenesie des Kleinhirns. Ref.: Wiener klinische Wochenschrift. 1911, No. 44, p. 1546.
- Antoniu, Die Hydatidenzysten der Schädelknochen. Spitalul. 1905, No. 2. Münchener medizinische Wochenschrift. 1906, p. 185.
- Arena, Hypophysis pharyngea. Rif. med. 1910, No. 34.
- Armstrong, Cranial asymmetry due to postural causes. Lancet, March 4, 1907.
- Ascarelli, Il Tipo craniofaciale in 300 omicidi, Boll. d. R. Acad. med. di Roma, 1907. Archivio di Psich. 1908.
- Aschner, Über einen Fall von hypoplastischem Zwergwuchs mit Gravidität, nebst Bemerkungen über die Ätiologie des Zwergwuchses. Monatsschrift für Geburtshilfe und Gynäkologie. Vol. XXXIII, Chap. 6.
- Astwazaturow, Beitrag zur Kasuistik der kavernösen Blutgeschwülste des Gehirns. Neurologisches Zentralblatt. 1911, p. 363.
- Aubry, Alopecie sutural, variété singulière d'alopecie congénital. Annal. de Dermatol. et Syphil. 1892.
- Auerbach und Brodnitz, Neurologisch-chirurgische Beiträge. (Aneurysma des confluens sinuum.) Mitteilungen aus den Grenzgebieten der Medizin und Chirurgie. 1910, Vol. XXI, Chap. 4.
- Auvray, Maladies du crâne et de l'encéphale. Paris 1909.
- Ibid., Hypertrophie du crâne et sarcome. Soc. de chirurgie de Paris, December 14, 1910. Ref.: Sem. Med. 1910, p. 605.
- Babonneix et Paiseau, Sur quelque cas d'obésité infantile. Gaz. d. Hôp. Sept. 13, 1910.
- Backman, Über Skaphozephalie. Anatomische Hefte. 1908, Vol. XXXVII.
- Bade, Die Entwicklung des menschlichen Skelettes bis zur Geburt. Eine röntgenographische Studie. Archiv. für mikroskopische Anatomie und Entwicklungsgeschichte. 1900, Vol. LV.
- v. Baer, Crania selecta. Petersburg 1859.
- Bakay, Über die Entstehung der zentralen Epithelialgeschwülste des Unterkiefers. Berliner klinische Wochenschrift. 1909, p. 590.
- Bamberg und Huldshinsky, Osteogenesis congenita und tarda. Ref.: Deutsche medizinische Wochenschrift. 1911, p. 1498.
- Bardleben, Schädel. Eulenburgs Real-Enzyklopädie. 1899.
- Barling, Removal of a Cerebral Tumour (Endothelioma), Which Had Invaded the Overlying Cranial Bone. Lancet, August 4, 1906.
- Barrett, Application of Craniology in Clinical Medicine. Intercolon. Med. Journ. December, 1909.

- Bartels, Über Rassenunterschiede am Schädel. Leipzig 1904.
- Ibid., Über Geschlechtsunterschiede am Schädel. Inaugural-Dissertation. Berlin 1897.
- Bartels, M., Über Plattenepithelgeschwülste der Hypophysengegend. Zeitschrift für Augenheilkunde. Vol. XVI, 1906.
- Bassoe, Gigantism and leontiasis ossea with report of the case of the giant Wilkins. Journal of Nervous and Mental Diseases. 1903.
- Bauer F., Demonstration eines Endothelioms an der Hirnbasis. Verein für Psychiatrie und Neurologie in Wien, 14. März 1911. Ref.: Wiener klin. Wochenschrift.
- Bayerthal, Untersuchungen über die Beziehungen zwischen Schädelumfang und Intelligenz im schulpflichtigen Alter. Zeitschrift für experimentelle Pädagogik. V.
- Beadles, Gummatous Enlargement of the Pituitary Gland. Brit. Med. Journal, December 1896.
- Ibid., Aneurisms of the Larger Cerebral Arteries, Brain, XXX, 1907.
- Beaumont, Oxycephaly. Brit. Med. Journal. 1909, II, p. 1468.
- Beck, Eine Methode zur Bestimmung des Schädelinhaltes. Dissertation. Würzburg 1906. Zeitschrift für Morphologie und Anthropologie. Vol. X, Chap. 1.
- Beck, Joseph C., Photographic Atlas of Radiography of the Mastoid Region and of the Nasal Accessory Sinuses. St. Louis, 1911.
- Beck, Carl, Contribution to the Therapy of Encephalocele. Internat. Medie. Magaz., August, 1900.
- Béclère, Radiodiagnostique de l'acromégalie. Presse médicale. 1903, No. 298.
- Ibid., Un nouveau procédé de localisation des corps étrangers métalliques Intraoculaires. Rev. génér. d'Ophthal. 1907.
- Behr, Beiträge zur gerichtsarztlichen Diagnostik am Kopf, Schädel und Gehirn. Arbeiten aus der psychiatrischen Klinik Würzburg. Herausgegeben von Reichardt, Chap. 3.
- Behr, C., Über die Entstehung der Optikusveränderungen bei Turmschädel. Ophthalmologen-Kongress. 1910. Neurol. Zentralblatt. 1911. No. 2.
- Beitzke, Intraossäres Hygrom des Os occipitale. Deutsche Pathologische Gesellschaft. 1905.
- Belkowski, Aktinomykose de la base du crâne. Rev. de médec. 1911.
- Benda, Pathologie der Hypophyse; Handbuch der pathologischen Anatomie des Nervensystems von Flatau-Jakobsohn.
- Benedikt, Kranimetrie und Kephalometrie. Wien. 1888.
- Ibid., Schädel- und Kopfmessung. Eulenburgs Realenzyklopädie. XXI, 1899.
- Ibid., Über Röntgen-Diagnostik der Schädel-, Hirn- und Wirbelsäulenerkrankungen. II. internationaler Kongress für medizinische Elektrologie und Radiologie. Bern 1902. Ref.: Fortschritte auf dem Gebiete der Röntgen-Strahlen. Vol. VI.
- Ibid., Zur Röntgen-Diagnostik der traumatischen Neurose. Wiener medizinische Presse. 1903, No. 26.

Ibid., Ein weiterer Beitrag zur Radiologie der Kopftraumen. *Zeitschrift für Elektrotherapie und physikalische Heilmethode*. 1904, Chap. 7.

Ibid., Die Röntgenologie im Dienste der Krankheiten des Schädels und des Gehirns und der gerichtlichen Medizin. *Deutsche medizinische Wochenschrift*. 1902, No. 23, p. 405. Demonstration in der Gesellschaft der Ärzte Wiens, November 9, 1906 and February 1, 1907.

Ibid., Röntgen-Befunde bei Epilepsie. *Wiener klinische Wochenschrift*. 1908, p. 376.

Ibid., Demonstration von Pachymeningitis. *Wiener klinische Wochenschrift*. 1909, p. 179.

Bentzen, Septumdeviation und hoher Gaumen. *Archiv für Laryngologie*. 1903, Vol. XIV.

Bergmeister, Fall von doppelseitiger Katarakt mit Mikrognathie und Schädelanomalie. *Archiv für Ophthalmologie*. 1911.

Berkhan, Zwei Fälle von Skaphozephalie. *Archiv für Anthropologie*. 1907.

Ibid., Zwei Fälle von Trigonocephalie. *Archiv für Anthropologie*. 1909.

Bertillon et Chervin, *Anthropologie métrique*. Paris, 1909.

Bertolotti, Étude radiograph de la base du crâne sur certaines aveugles. *Soc. de Neurol. de Paris*, February 10, 1910. *Rev. neurolog.* 1910, No. 4.

Derselbe, Le syndrome radiologique d'oxycéphalie et des états similaires d'hypertension cérébrale. *La presse médicale*. No. 101, October 17, 1910.

Biedl, *Innere Sekretion*. 1910.

Binet, *Nouvelles recherches de céphalometrie*. *L'année psycholog.* 1902.

Ibid., La croissance du crâne et de la face chez les normaux entre 4 et 18 ans. *L'année psycholog.* 1902.

Birch-Hirschfeld, Osteome der Orbita. *Klinische Monatsblätter für Augenheilkunde*. 1907, Vol. XLV, p. 318.

Bireher, Knochentumoren im Röntgenogramm. *Fortschritte auf dem Gebiete der Röntgen-Strahlen*. Vol. XII.

Ibid., Die Entwicklung und der Bau des Kretinenskelettes im Röntgenogramm. 1909. *Ergänzungs-Bd. XXI der Fortschritte auf dem Gebiete der Röntgen-Strahlen*.

Blauel, Operation eines Hypophysentumors. *Münchener medizinische Wochenschrift*. 1911, p. 931.

Blühdorn, Die Bedeutung des Traumas für die Ätiologie von Hirntumoren. *Inaugural-Dissertation*. Breslau. 1909.

Bockenheimer, Über diffuse Hyperostose der Schädel- und Gesichtsknochen s. Ostitis deformans fibrosa. *Archiv für klinische Chirurgie*. 1908, Vol. LXXXV, Chap. 2.

Bode, Zur Frage der Operabilität der Hypophysentumoren. *Deutsche Zeitschrift für Chirurgie*. 1911, Vol. CIX.

Bölsche, *Die Abstammung des Menschen*. 1907.

Böshagen, Ein Fall von Hypertrophie der linken Kopfhälfte. *Inaugural Dissertation*. Bonn. 1903.



Bolk, Über eine sehr seltene Verknöcherungsanomalie des Hirnschädels. Petrus Camper. 1904.

Bonfiglio, Di speciali riperti in un caso di prob. sifilide cerebrale. Riv. di Fren. XXXIV, 1 and 2.

Borchardt, Operation eines Hypophysentumors. XXXVII. Kongress der Deutschen Gesellschaft für Chirurgie. 1908.

Ibid., Fall von Sinus pericranii, Hochgradigste Hydrozephalie. Freie Vereinigung der Chirurgen Berlins, June 13, 1910.

Ibid., Zystische Geschwülste (Blutgeschwülste) am Schädel. Deutsche medizinische Wochenschrift. 1910, p. 1729.

Ibid., Diagnostik und Therapie der Geschwülste in der hinteren Schädelgrube. Ergebnisse der Chirurgie und Orthopädie. Vol. II.

Bornhaupt, Ein Fall von linksseitigem Stirnhöhlenosteom. Langenbecks Archiv. 1881, Vol. XXVI.

Bouehard, Traité de Radiologie. 1904.

Bouisson, Mémoire sur la luxation traumatique de l'articulation occipitoatloldienne. Revue de therapie du midi. Montpellier. 1854.

Boyd, Tumors of the Hypophysis. Lancet, October 15, 1910.

Bregmann und Steinhaus, Zur Kenntnis der Geschwülste der Hypophysis und der Hypophysengegend. Virchows Archiv. Vol. CLXXXVIII.

Brême, Über die durch Pacchionische Granulationen verursachten Ein drücke der Schädelknochen. Zeitschrift für Morphologie und Anthropologie. 1903. Vol. V.

Breuer, Was lehrt uns das Röntgen-Bild des Kiefergelenkes? Vierteljahrschrift für Zahnheilkunde. 1910.

Breus-Kolisko, Die pathologischen Beckenformen. Wien. 1904.

Brissaud et Bruandel, Anencéphalie avec amyélie. Nouvelle Iconogr. de la Salpêtr. 1903.

Brissaud et Lereboullet, Deux cas d'hémieraniose. Revue neurologique. 1903.

Broca, Mémoires d'Anthropologie. Paris.

Brüning, Über angeborenen halbseitigen Riesenwuchs. Münchener medizinische Wochenschrift. 1904, No. 9.

Brüning's, Neue röntgenographische Darstellungsmethode der Nebenhöhlen und Schläfebeine. Verhandlungen deutscher Laryngologen. Dresden. May 11 and 12, 1910.

Brunzlow, Die Darstellung der Nasennebenhöhlen und ihrer Erkrankungen im Röntgen-Bild. Fortschritte auf dem Gebiete der Röntgen-Strahlen. 1911, Vol. XVII, Chap. 4.

Buday, Osteogenesis imperfecta. Stizungsbericht der kaiserlichen Akademie der Wissenschaften in Wien. 1895, CIV, Section III.

Buhl, Ein Riese mit Hyperostose der Gesichts- und Schädelknochen. Mitteilungen aus dem pathologischen Institut. München, 1878.

Burger, Die Bedeutung der Röntgen-Strahlen in der Rhinolarngologie. Referat auf dem I. internationalen Rhinolarngologen-Kongress. Wien. 1908 (Als Monographie erschienen unter dem Titel: Was leisten die Röntgen-Strahlen auf dem Gebiete der Rhinolarngologie? 1908.)

Busch, Neue Röntgen-Aufnahmen vom Schläfebein an Lebenden. Passows Beiträge. Vol. III, Chap. 6.

Buschan, Gehirn und Natur. Wiesbaden. 1906.

Busi and Balli, Studie über die normale deskriptive und röntgenographische Anatomie der Sella turcica. Bolletino della Società Med.-chirurg. di Modena. 1910/11. Series 13. Ref.: Fortschritte auf dem Gebiete der Röntgen-Strahlen. Vol. XVII, p. 413.

Bychowski, Zur Diagnose und Therapie der Hypophysishgeschwülste. Deutsche medizinische Wochenschrift. 1909, No. 36.

Byloff, Insuffizienz der inneren Drüsensekretion. Wiener klinische Wochenschrift. 1908.

Caldwell, Skiagraphy of the accessory sinuses of the nose. Americ. Quart. of Roentgenology, January, 1907. Ref.: Fortschritte auf dem Gebiete der Röntgen-Strahlen. Vol. XI, p. 399.

Camper, Les variétés naturelles, qui caractérisent la physiognomie. Übersetzung von Jansen. Paris. 1791.

Canestrini und v. Saar, Zur Frage der sellaren Palliativtrepanation. Beiträge zur klinischen Chirurgie. 1911, Vol. LXXXVI, Chap. 1.

Cantonnet, Sehstörungen durch einen Hypophysentumor ohne Akromegalie. Soc. d'ophthalmol. de Paris. November 6, 1910. Berliner klinische Monatsblätter für Augenheilkunde. February, 1911, XLIX, p. 219.

Carpenter, Aerocephaly with other congenital malformations. Proc. of the Royal Soc. of Med. 1909. Vol. II, Nos. 2 and 7.

Catola, Sur un cas de maladie de Paget à localisation céphalique isolée, Nouv. Jeon. de la Salp. No. 3, 1910, p. 276.

Cavidalli, Sinostosi e asimmetria cranica nel feto. Lo sperimentale. Vol. III, 1910, p. 423.

Chaillou, Les différents types humains d'après y'aspect de la tête. Clinique, 1909, IV, 97—101.

Chiari und Marschik, Nasensarkom; Differentialdiagnose mittels Röntgen-Strahlen. Annal. des malad. de l'oreille. 1907.

Chiari H., Zur Kenntnis der Spaltbildungen am Schädel nach Fraktur im Kindesalter Prager medizinische Wochenschrift. 1899.

Ibid., Über basale Schädelhyperostose und ihre Beziehungen zur Idiotie. Verhandlungen der Deutschen Pathologischen Gesellschaft in München. 1899.

Chudjakow, Angioma cavernos. cerebri. Korsakoffsches Journal für Neuropathologie und Psychologie. 1911. Referat: Zeitschrift für die gesamte Neurologie und Psychiatrie. 1911, p. 674.

Church, Pituitary tumor in its surgical relations. Journ. of the Amer. Med. Association. Vol. LIII, July 10, 1909.

Clair, Déformation profonde du crâne et de la face consecut. à la destruction de l'apophyse articulaire du maxill. infér. Bibliogr. anatomique. 1909.

Clairmont, Zur Behandlung des Angioma arteriale racemosum. Archiv. für klinische Chirurgie. 1908, Vol. LXXXV, Chap. 2.

Clark, A Case of Facial Hemiatrophy. New York Neurolog. Soc. March 1, 1904. The Journal of Nervous and Mental Dis., XXXI, p. 539.

Ibid., A Case of Enchondrome of the Sella Turcica. *Journ. of Nerv. and Ment. Dis.* 1907, p. 596.

Claude et Schäffer, Adiposité et lésions hypophysaires dans un cas de tumeur du corps calleux. *Journ. de phys. et pathol. gener.* 1911, No. 3.

La nuova Convenzione internaz. per l'unificazione delle misure craniometriche e cefalometriche. *Arch. per l'Antropol. e la etnol.* 1907, Vol. XXXVII.

Cornil et Coudray, Quelques variétés d'ostéomes et d'exostoses. *Journal de l'anat. et phys.* 1908.

Cryer, Use of the Roentgen-ray in the Studies of Normal and Pathological Anatomy of the Internal Structures of the Face. *Americ. Journal of Med. Sciences.* February, 1905.

Curschmann, Knochenveränderungen bei Akromegalie. *Fortschritte auf dem Gebiete der Röntgen-Strahlen.* IX.

Cushing, *Surgery of the Head.* Baltimore. 1908.

Czellitzer, Geschwulst in der Hypophysengegend mit ungewöhnlichen Sehstörungen. *Berliner klinische Wochenschrift.* May 17, 1909.

Davidson, X-ray in Treatment of the Eye. *Transactions of the British Med. Assn.,* 1898. *Münchener medizinische Wochenschrift.* 1898, No. 35.

Denks, Über Schädelbrüche bei Kindern im Röntgen-Bilde. *Beiträge zur klinischen Chirurgie.* Vol. LXVI.

le Dentu and Baudon, De l'hyperostose des os de la face et du crâne. *Bulletin de l'Acad. de Médec.* 1899, Series 63, No. 16.

Dessauer and Wiesner, *Leitfaden des Röntgen-Verfahrens.* 3. Aufl.

Dessloch, Über das Volumen der Schädeldächer. *Inaugural-Dissertation.* Würzburg 1908.

Destot, Röntgen-Bilder bei Sinusitis maxillaris. *Soc. de chirurgie de Lyon.* March 22, 1906.

Dieck, *Anatomie und Pathologie der Zähne und Kiefer im Röntgen-Bild* Hamburg, 1911.

Dieterle, *Athyreosis,* *Virehows Archiv,* CLXXXVI, Chap. 1.

Dietz, Weitere Beiträge zur Frage der sekundären konzentrischen Hyperostose am Schädel. *Inaugural-Dissertation.* Würzburg. 1908.

Dorfmann, Über Pathogenese und Therapie des Turmschädels. *Archiv für Ophthalmologie.* 1908, XLVIII, Chap. 3.

le Double, *Traité des variations des os du crâne de l'homme.* 1903.

Ibid., *Traité des variations de os de la face.* 1906.

Draesecke, *Gehirngewicht und Intelligenz.* *Archiv für Rassen- und Gesellschaftsbiologie.* 1906, Vol. III.

Dreyfus, Über Erkrankungen der Hypophysis. *Ärzteverein in Frankfurt a. M. Ref.:* *Münchener medizinische Wochenschrift.* 1911, p. 1328.

Driesmans, Schädelwachstum und Geschlechtsreife. *Österreichische Rundschau,* XXVI, pp. 145—147.

Edling, Über die Anwendung des Röntgen-Verfahrens bei der Diagnose der Schwangerschaft. *Münchener medizinische Wochenschrift.* 1911, p. 567. *Fortschritte auf dem Gebiete der Röntgen-Strahlen.* Vol. XVII, Chap. 6.

Ehrlich, Über einen Fall multipler Meningokelen bei Hypertrophia cerebri. Frankfurter Zeitschrift für Pathologie, Vol. III, p. 358.

Eichel, Osteomyelitis acuta des Atlas. Münchener medizinische Wochenschrift, 1900, No. 35.

Eijkmann, Un nouveau système graphique pour la craniologie. Übersetzung von Mayet. Lyon, 1905.

v. Eiselsberg, Zur Kasuistik der Tumoren der Schädelknochen. Naturforscherversammlung Meran, 1905. Archiv für klinische Chirurgie, Vol. LXXXI.

Ibid., Akromegalie Gesellschaft der Ärzte Wiens, February 29, 1907.

Ibid., Operation von Hypophysentumoren. XXXVII. Kongress der deutschen Gesellschaft für Chirurgie, 1908, also Wiener klinische Wochenschrift, 1909, p. 287, and 1911, p. 995.

v. Eiselsberg and v. Frankl-Hochwart, Über operative Behandlung der Tumoren der Hypophysengegend. Neurologisches Zentralblatt, 1907, No. 21.

Ibid., Ein neuer Fall von Hypophysisoperation bei Degeneratio adipogenitalis. Wiener klinische Wochenschrift, 1908.

Enderlein, Osteopsathyrosis. Virchows Archiv, Vol. CXXXI.

Enderlein, Hypophysentumoroperation. Ref.: Münchener medizinische Wochenschrift, 1911, p. 1747.

Engel, Untersuchungen über die Schädelform, 1851.

Engelhardt, Zur Frage der Dauerheilung nach operativer Behandlung der traumatischen Jackson-Epilepsie. Deutsche medizinische Wochenschrift, 1904, No. 3.

England, Hemihypertrophy with Multiple Neurofibroma. Montreal Med. Journal, 1902.

Engstler, Über den Lückenschädel Neugeborener. Archiv. für Kinderheilkunde, 1905, XC.

Enslin, Die Augenveränderungen beim Turmschädel. Graefes Archiv für Ophthalmologie, Vol. LVIII, No. 1.

Erdheim, Über Hypophysengangsgeschwülste und Hirncholesteatome. Sitzungsberichte der Akademie der Wissenschaften, Wien, December, 1904.

Ibid., Über einen Hypophysentumor von ungewöhnlichem Sitz. Ziegler's Beiträge, 1909, XLVI.

Ibid., Über Epithelkörperbefunde bei Osteomalazie. Sitzungsberichte der Akademie der Wissenschaften in Wien, 1907.

Ernst, Missbildungen des Nervensystems, in: Schwalbe, Die Morphologie der Missbildungen, 1909, Vol. III, Chap. 2.

Eschbach, Recherches sur la plagiocéphalie chez l'enfant. La clinique infantile, 1907, No. 16.

Ewald, Klinische Vorstellung von Hypophysistumoren nebst Bemerkungen über die biologische Bedeutung der Hypophyse. Wissenschaftliche Vereinigung Frankfurt. Münchener medizinische Wochenschrift, 1908, p. 1853.

Exner A., Über Hirnbrüche. Deutsche Zeitschrift für Chirurgie, 1909, Vol. CII.

Ibid., Beitrag zur Pathologie der Hypophyse. 81. Versammlung d. Naturforscher. Wiener medizinische Presse, October 3, 1909. Mitteilungen aus den Grenzgebieten der Medizin und Chirurgie. 1909.

Eyerich und Löwenfeld, Über die Beziehungen des Kopfumfanges zur Körperlänge und zur geistigen Entwicklung. 1905.

Fabiancke, Beiträge zur Röntgen-Diagnostik der Mund- und Kieferhöhle. Berliner klinische Wochenschrift. 1909, p. 571.

Fabre, Barcon et Trillat, Radiographie des lebenden Fötus. Archiv d'Electr. méd. No. 300.

Falta and Schüller, Turmschädel. Wiener klinische Wochenschrift. 1908, p. 208.

Fennell, Mongolian imbeciles. Journal of Mental Science. 1904.

Fischer, Über malignes Chordom der Schädelrückgrathöhle. Beiträge zur pathologischen Anatomie. 1907, XL.

Fischer und Hald, Röntgen-Untersuchung der Nasennebenhöhlen. Ref.: Zentralblatt für Ohrenheilkunde. 1908.

Fittig, Über einen röntgenographisch lokalisierten Fall von Hirntumor. Fortschritte auf dem Gebiete der Röntgen-Strahlen. Vol. VI.

Fitzgerald, The Pituitary Fossa and Certain Skull Measurements. Journ. of Anatomy and Physiology. 1910, Vol. XLIV.

Fitzwilliams, A Child with an Ossified Cephalhaematoma. West London Med. Journal. 1909, XIV, 32.

Ibid., Hereditary Cranio-Cleido-Dysostosis. The Lancet. 1910, II, p. 1466.

Fletcher, Four Cases of Oxycephaly. Proceedings of the Royal Soc. of Med. Vol. II, No. 5, March, 1909. Clin. Section, p. 113.

Forli, Hirn- und Schädelatrophie nach experimentellen Hirnläsionen. Riv. speriment. di Freniatria. April 30, 1909.

Fournier, Les Malformations crâniennes chez les heredo-syphilit. Nouv. Icon. d. la Salp. 1898. No. 4.

Fraenkel E., Über Verkalkung der Hirngefäße mit Demonstrationen von Röntgen-Bildern. Biologische Abteilung des ärztlichen Vereines in Hamburg, April 27, 1909, and Über pathologische Verkalkungen und ihren Nachweis durch Röntgen-Strahlen Fortschritte auf dem Gebiete der Röntgen-Strahlen. Vol. XIV, Chap. 2.

Ibid., Über Wirbelgeschwülste im Röntgen-Bilde. Fortschritte auf dem Gebiete der Röntgen-Strahlen. 1911. Vol. XVI, Chap. 4.

Fraenkel und Lorey, Die Rachitis im Röntgen-Bilde. Supplementary Vol. XXII der Fortschritte auf dem Gebiete der Röntgen-Strahlen.

Franchini, Atrofie ossee ed alterazioni della sella turcica nell' acromegalia. Riv. critica di clin. med. 1909.

Franchini et Giglioli, Acromégalie. Icon. de la Salp. 1908, No. 5.

Frangenheim, Chondrodystrophische Zwerge. Fortschritte auf dem Gebiete der Röntgen-Strahlen. 1911, Vol. XVII, Chap. 2.

Frank, Beitrag zur Lehre von den Schädelarkomen. Inaugural-Dissertation. Rostock. 1909.

Frankfurter, Kraniometrische Vereinbarung. Archiv für Anthropologie. 1884, Vol. XV.

v. Frankl-Hochwart, Hypophysentumor. Wiener klinische Wochenschrift. 1909, p. 146.

Ibid., Diagnostik der Hypophysistumoren ohne Akromegalie. Ref.: Neurologisches Zentralblatt. 1909, No. 18, and Wiener medizinische Wochenschrift. 1909, No. 37. Also: XVI. Internationaler medizinischer Kongress, Budapest, 1909.

Frassetto, Studi sulle forme del cranio umano (forme eurasiche). Monit. Zool. Ital. Anno XIX.

Frédéric, Untersuchungen über die normale Obliteration der Schädelnähte. Zeitschrift für Morphologie und Anthropologie. 1906, Vol. IX, II. Die Obliteration der Nähte des Gesichtsschädels. Dieselbe Zeitschrift. 1909, Vol. XII.

Frick, Ein Fall von Cholesteatom im IV. Ventrikel. Frankfurter Zeitschrift für Pathologie. 1911, Vol. VI, Chap. 2.

Fries, Knollige Exostosen an der Tabula vitrea des Stirnbeins bei zwei psychotischen Schwestern. Neurologisches Zentralblatt. 1908, p. 1101.

Fritsch, Komplizierte Schädelfraktur mit Knochensplintern, am Röntgen-Bilde sichtbar. Messerklinge im Schädel bei angeblichem Simulanten. Freie Vereinigung der Chirurgen Berlins. March 8, 1909.

Frizzi, Ein Beitrag zur Anthropologie des Homo alpinus Tirolensis. Mitteilungen der Anthropologischen Gesellschaft in Wien. 1909.

Fröhlich, Ein Fall von Tumor der Hypophysis cerebri ohne Akromegalie. Wiener klinische Rundschau. 1901, No. 47, 48.

Froriep, Die Lagebeziehungen zwischen Grosshirn und Schädeldecke. 1897.

Ibid., Über die Bestimmung der Schädelkapazität durch Messung oder Berechnung. Zeitschrift für Morphologie und Anthropologie. 1910, XIII.

Frotseher und Becker, Zur Kasuistik der Duraendotheliome. Archiv für Psychiatrie. 1910, Vol. XLVII.

Fuchs, Zur Frühdiagnose der Hypophysentumoren. Wiener klinische Wochenschrift. 1903, No. 6.

Ibid., Die Veränderungen der Dura mater. Arbeiten aus dem Institut Obersteiner. 1903.

Ibid., Hypophysentumor. Demonstration im Vereine für Psychiatrie und Neurologie. Wien. March 14, 1905. Neurologisches Zentralblatt. 1905. Wiener klinische Wochenschrift. 1906, p. 743.

Ibid., Die Diagnose des Hypophysentumors. Jahrbücher für Psychiatrie und Neurologie. Vol. XXVI.

Ibid., Ein Fall von Scheuthauers Kombination rudimentärer Schlüsselbeine etc. Wiener klinische Wochenschrift. 1907, p. 763.

Fuchs and Schüller, Tumor der Hypophysis. Gesellschaft für innere Medizin und Kinderheilkunde. February 9, 1905.

Fürnrohr, Die Röntgen-Strahlen im Dienste der Neurologie. Berlin. 1906.

Gall, Anatomie et physiologie du système nerv. Paris. 1810—19.

Ganter, Über die Beschaffenheit des Schädeldaches bei Psychosen und über einige innere Degenerationszeichen. Allgemeine Zeitschrift für Psychiatrie. LXV, 6.

di Gaspero, Zur Kenntnis der abnorm grossen Foramina parietalia. Mitteilungen des Vereines der Ärzte in Steiermark. 1911, No. 9.

Gaupp E., Die Entwicklung des Kopfskelettes. Handbuch der vergleichenden und experimentellen Entwicklungslehre der Wirbeltiere. Jena. 1906, Vol. III, Chap. 2.

Geddes, Changes in the skull in Acromegaly. Brit. Med. Journ. 1908, p. 598.

Geist, Ein Fall von halbseitiger Unterentwicklung. Neurologisches Zentralblatt. 1911, No. 3.

Giordani, Sur le diagnostic des tumeurs de l'hypophyse par la radiographie. Thèse de Paris. 1906, 189.

Giuffrida-Ruggeri, Asimmetrie endocraniche e altre particolarità morfologiche nella base del cranio. Riv. sperim. di fren. Vol. II, 1899.

Ibid., Sulla dignità morfologica dei segni detti "degenerativi." Atti della società Romana di Antropologia. Vols. II and III, 1896—1897.

Glaessner, Zur Kenntnis der Pagetschen Knochenkrankung. Wiener klinische Wochenschrift. 1908, No. 38.

Ibid., Chondrodystrophie. Wiener klinische Wochenschrift. 1909, p. 356.

Gocht, Handbuch der Röntgen-Lehre. 1911 (Literatur).

Goerke Otto, Beitrag zur funktionellen Gestaltung des Schädels bei den Anthropomorphen und Menschen durch Untersuchung mit Röntgen-Strahlen. Archiv für Anthropologie. 1904, New Series, Vol. I.

Goldmann und Killian, Über die Verwendung der X-Strahlen für die Bestimmung der nasalen Nebenhöhlen und ihrer Erkrankungen. Tübingen. 1907.

Goldstein, Fall von Turmschädel mit Insuffis. pluriglandulaire. Deutsches Archiv für klinische Medizin. 1909, Vol. XCVIII.

Goris, Ostéosclérose progr. des os crân. Bull. de l'Acad. Roy. de Médec. de Belgique. 1909, Nos. 6 and 7, p. 404.

Gosse, Essais sur les déformat. artif. du crâne. Paris. 1855.

Gottschalk, Demonstration eines Gehirntumors. Verhandlungen der Deutschen Röntgen-Gesellschaft. 1907, Vol. III.

v. Grage, Akromegalie. Demonstration im ärztlichen Vereine in Hamburg, 28. November 1905. Münchener medizinische Wochenschrift. 1905, No. 49.

Grahaud, Le syndrome hypophysaire adipo-génital, Paris. 1911.

Grashey, Über die Untersuchung der Frakturen mit Röntgen-Strahlen. Fortschritte auf dem Gebiete der Röntgen-Strahlen. 1907.

Ibid., Atlas typischer Röntgen-Bilder vom normalen Menschen. München. 1905.

Ibid., Atlas chirurgisch-pathologischer Röntgen-Bilder. München. 1909.

Graupner, Zwei bemerkenswerte Fälle von Chlorom. Berliner Otologische Gesellschaft. November 5, 1909.

Grawitz, Beitrag zur Lehre von der basilaren Impression des Schädels. Virchows Archiv. Vol. LXXX.

Grinker, Hypophysentumor. Chicago Neurological Society. Reference. Journal of Nervous and Mental Diseases. 1911, p. 295.

Groedel, Atlas und Grundriss der Röntgen-Diagnostik in der inneren Medizin. Lehmanns Atlanten. 1909.

Gross, Erwin, Drei Fälle von Akromegalie mit radiographischem Nachweis von Veränderungen der Sella turcica. Dissertation. Königsberg, July, 1911.

Grübner, Über Turmschädel. Charité-Annalen. 1910, XXXIV.

Grunmach, Diagnose eines Tumors mittels Röntgen-Strahlen. Freie Vereinigung der Chirurgen Berlins. Deutsche medizinische Wochenschrift. 1898, No. 35.

Gudden, Anomalien des menschlichen Schädels. Wachstumsbeschränkung und Verschiebung durch Druck während der Schwangerschaft. Archiv für Psychiatrie. 1870, II.

Ibid., Experimentelle Untersuchungen über das Schädelwachstum. München 1874.

v. Haberer, Zur Frage der Knochenzysten und der Ostitis fibrosa. Archiv für klinische Chirurgie. Vol. LXXXII, Chap. 3.

Haberfeld, Zur Pathologie des Canalis craniopharyngeus. Frankfurter Zeitschrift für Pathologie. 1910.

Haebelin, Zur Topographie der Hirnventrikel. Archiv für Anatomie und Physiologie, Anatomische Abteilung. 1909.

Haenel F., Osteombildung in sämtlichen Nebenhöhlen der Nase. Gesellschaft für Natur- und Heilkunde in Dresden. 20. February 1904.

Haenisch, Die isolierte Aufnahme einer Unterkieferhälfte, zugleich ein Beitrag zur Röntgen-Diagnose der Unterkiefertumoren. Fortschritte auf dem Gebiete der Röntgen-Strahlen. 1910.

Hagenbach, Physiologie und Pathologie der Hypophyse. Volkmanns Sammlung klinischer Vorträge. 1911, No. 637.

Ibid., Osteogenesis imperfecta tarda und Hypophysentumor am gleichen Individuum. Frankfurter Zeitschrift für Pathologie. 1911, Vol. VI, Chap. 3.

Hahn F., Über Osteomalazie beim Manna. Sammelreferat. Zentralblatt für die Grenzgebiete der inneren Medizin und Chirurgie. 1899.

Hahn und Deycke-Pascha, Knoockensyphilis im Röntgen-Bilde. Fortschritte auf dem Gebiete der Röntgen-Strahlen. Supplementary volume XIV.

Hajek, Pathologie und Therapie der entzündlichen Erkrankungen der Nebenhöhlen der Nase. 1909.

Hamburger, Zum Nachweis intraokulärer Fremdkörper mit Hilfe der Röntgen-Strahlen. Klin. Monatsbl. für Augenheilkunde. XLV, Vol. I.

Hanau, Über Osteomalazie. Korrespondenzblatt für Schweizer Ärzte. 1892.

Hann, A Case of Osteitis Deformans Terminating with Cerebral Symptoms. Brit. Med. Journ. January 15, 1910.

Hanotte, Anatomie pathologique de l'oxicéphalie. Paris. 1898.



- v. Hansemann, Zwei Fälle von Mikrozephalie mit Rachitis. *Bibliotheca medica*. 1899, Chap. 11c.
- Ibid., *Die Rachitis des Schädels*. Berlin. 1901.
- Ibid., Über die rachitische Veränderung des Schädels. *Zeitschrift für Ethnologie*. 1904.
- Ibid., Über einen Schädel mit doppelseitiger Kieferankylose. *Berliner klinische Wochenschrift*. 1903, No. 28.
- Ibid., Über echte Megalenzephalie. *Berliner klinische Wochenschrift*. 1908, No. 1.
- Harbitz, *Osteogenesis imperfecta*. *Zieglers Beiträge*. 1901, Vol. XXX.
- Hartmann F., Beitrag zur pathologischen Anatomie und Klinik der Geschwülste der Schädelbasis. *Journal für Psychologie und Neurologie*. 1906.
- Hartmann, Über Osteopsathyrosis. *Medizinische Gesellschaft in Leipzig*. February 21, 1911.
- Haubold, Röntgen-Aufnahmen von Knochensyphilis. *Medizinisch-naturwissenschaftliche Gesellschaft*. Jena, June 4, 1908. *Münchener medizinische Wochenschrift*. 1908, p. 1617.
- Hauchamps, *Radiographie du maxillaire et des dents*. *La Clinique*. 1906, No. 25.
- Haughton, *The Anatomy of the Skull, Stereoscopically Demonstrated by X-ray*. *The Dublin Med. Journal*, March, 1903, page 224.
- Heine, Über knöcherne Geschwülste der Orbitalhöhle und ihre Röntgen-Durchleuchtung. *Inaugural-Dissertation*. Halle. 1905.
- Heller, Röntgen-Photographie eines Falles von chronischem Hydrokephalus bei hereditärer Syphilis. *Verein für innere Medizin*, Berlin, December 6, 1897. *Münchener medizinische Wochenschrift*. 1897.
- Henle und Hinsberg, *Demonstration von Röntgen-Bildern des Schläfenbeines*. *Verhandlungen deutscher Naturforscher und Ärzte*. Breslau, 1904.
- Henrich, Über einen Fall von beginnender Akromegalie. *Die ärztliche Praxis*. 1906, Nos. 14 and 15.
- Herbst Oskar, Leukämie mit Schädelstumoren bei einem einjährigen Kinde. *Monatsschrift für Kinderheilkunde*. Vol. IX, No. 8.
- Hermann, *Gehirn und Schädel*. Jena. 1908.
- Herpin, *La dent de l'œil*. *Progr. médecine*. 1911, p. 133.
- Herschel, *Röntgenographie des Felsenbeins*. *Fortschritte auf dem Gebiete der Röntgen-Strahlen*. 1909, Vol. XIII.
- Heubner, *Demonstration von Röntgen-Bildern eines Gehirntumors*. *Gesellschaft der Charité-Ärzte*. July 28, 1898. *Münchener medizinische Wochenschrift*. 1898.
- Ibid., Über Turmschädel. *Charité-Annalen*. 1910, Vol. XXXIV.
- Ibid., *Lehrbuch der Kinderheilkunde*. 1911.
- Heyden, *Das Chlorom*. Bergmann. Wiesbaden. 1904.
- Hildebrand H., Über den diagnostischen Wert der Röntgen-Strahlen in der inneren Medizin. *Münchener medizinische Wochenschrift*. 1901, p. 1957.

Hildebrand und Hess, Ein Röntgen-Bild der Sella turcica bei Basistumor. Archiv für physikalische und medizinische Technik. 1905, Vol. 1, Part 1.

Hildebrand O., Lehrbuch der allgemeinen Chirurgie. 1909.

Hirsch O., Zur endonasalen Operation von Hypophysentumoren. Wiener medizinische Wochenschrift. 1909, No. 13, also Wiener Laryngologische Gesellschaft. December 7, 1910, Stützungsbericht in: Wiener medizinische Wochenschrift. 1911, No. 10.

Ibid., Über Methoden der operativen Behandlung von Hypophysentumoren auf endonasalem Wege. Archiv für Laryngologie. Vol. XXIV, Part 1.

Hirsch Paul, Ein Fall von Sinus pericranii. Berliner klinische Wochenschrift. 1910, p. 2318.

Hirschberg, Katarakt bei Mikrozephalie. Zentralblatt für Augenheilkunde. 1885.

Hirschberg und Grummach, Über doppelseitiges Schmelmenleiden bei Turmschädel. Berliner klinische Wochenschrift. 1909, No. 5.

Hitzig, Hypertrophie des Gehirns. Ziemssens Handbuch der speziellen Pathologie und Therapie. ed. 2.

Hoehnegg, Operation eines Hypophysentumors bei Akromegalie. Wiener klinische Wochenschrift. 1908, p. 409.

Ibid., Zur Therapie der Hypophysentumoren. Deutsche Zeitschrift für Chirurgie. Vol. 100.

Hochsinger, Studien über die hereditäre Syphilis. 1904. Vol. II,

Ibid., Die Beziehungen der hereditären Lues zur Rachitis und Hydrozephalie. Wiener Klinik. 1904, Series XXX, Part 6.

Höck, Röntgenologie des Kiefergelenkes. V. Kongress der Deutschen Röntgen-Gesellschaft. 1909.

Hoffmann A., Hemihypertrophia facialis progressiva. Deutsche Zeitschrift für Nervenheilkunde. 1903.

Holth, Zur Röntgen-Lokalisation okulärer Fremdkörper. Fortschritte auf dem Gebiete der Röntgen-Strahlen. Vols. VIII and IX, p. 211.

Holzknacht, Bemerkungen zu Winklers Aufsatz über das Röntgen-Bild des Gesichtsschädels usw. Fortschritte auf dem Gebiete der Röntgen-Strahlen. Vol. VI, p. 194.

Ibid., Das Röntgen-Licht im Dienste der Krankheiten des Schädels und Gehirns und der gerichtlichen Medizin. Deutsche medizinische Wochenschrift. 1902, No. 34.

Holzknacht, Lokalisation okulärer Fremdkörper. Zitiert bei Holth.

Homén, Zur Kenntnis der rachitischen Deformation der Schädelbasis und der basalen Schädelhyperostose. Deutsche Zeitschrift für Nervenheilkunde. 1901, XX.

Hudovernig, Étude complément sur un cas de gigantisme Précoce. Nouv. Icon. de la Salp. 1906.

Hudovernig und Popovits, Gigantisme précoce. Icon. de la Salp. 1903.

Hultkrantz, Dysostose cleidoerânienne. Icon. de la Salp. 1908.

Ibid., Über Dysostosis cleidoerânialis. Zeitschrift für Morphologie und Anthropologie. Vol. XI, Part 3.

Hunziker, Über einen Fall von Inienzephalie. Frankfurter Zeitschrift für Pathologie. 1911, Vol. VI, Part 2.

Hutchinson, Three Cases of Oxycephalus. Proc. of the Royal Soc. of Medicine of London. Vol. III, No. 3, May, 1910.

Hutter, Ein Fall von diffuser Hyperostose der beiden Oberkiefer. Wiener Laryngologische Gesellschaft. December 3, 1909.

Hyrtil, Topographische Anatomie.

Iglauer, The Clinical Value of Radiography of the Mastoid Region. Journal of the Amer. Med. Assoc. 1909. (Ref.: Fortschritte auf dem Gebiete der Röntgen-Strahlen. 1910, No. 1.)

Infeld, Klinischer Beitrag zur Hemisphärenatrophie. Wiener klinische Rundschau. 1904.

Ipsen, Zur Deutung des Entstehens der Brüche des Schädelgrundes. Vierteljahrsschrift für gerichtliche Medizin. 1910. Supplement.

Jacobius, Untersuchungen über das Hirnwindungsrelief an der Aussenseite des menschlichen Schädels. Dissertation. Leipzig. 1906.

Jansen, Was leistet das Röntgen-Verfahren auf otiatrischem und rhinologischem Gebiete für die Diagnose. Deutsche Zeitschrift für Chirurgie. 1909.

Jarriocot, La triple-équerre craniostatique et les diagrammes analyt. du crâne. Bull. Soc. d'Anthropol. de Lyon. 1909, Vol. XXVII.

Jelliffe und Larkin, Über ein malignes Chondrom mit Symptomen von seiten des Gehirns und Rückenmarkes. Zeitschrift für die gesamte Neurologie und Psychiatrie. 1911, Vol. V, Part 4.

Jendrassik, Hemiatrophia facialis. Deutsches Archiv für klinische Medizin. Vol. LIX.

Jentsch, Beitrag zur Kraniologie der Kretins. Allgemeine Zeitschrift für Psychiatrie. 1898.

Jewett, Epignathus. The New York Med. Journal. 1902, No. 12, p. 485.

Josefson, Studier öfver akromegali och hypophysis tumörer. Verhandlungen der schwedischen Ärztgesellschaft. Stockholm. 1903.

Ibid., Zwei Fälle von intrakraniellern Akustikustumor. Deutsche Zeitschrift für Nervenheilkunde. Vol. XXXIX, 1910.

Ibid., Dentition und innere Sekretion. Neurologisches Zentralblatt. 1911, p. 834.

Jumentié, Läsionen des Hirns im Laufe der Entwicklung der Tumoren des Brückenwinkels. Rev. Neurolog. 1910.

Jungherr, Die bisherigen Leistungen der Röntgen-Photographie auf dem Gebiete der Rhino-, Laryngo- und Otologie. Zeitschrift für Elektrologie und Röntgen-Kunde. Vol. IX, Parts 4—7.

Kahler, Ein überzähliger Zahn in der Nase. Wiener klinische Wochenschrift. 1905, No. 40.

Kalkhof, Zur Anthropologie der Orbita. Dissertation. Freiburg i. B. Sept., 1911.

Kassabian, Roentgenology in Neurology. Journ. Amer. Med. Assoc., 1908, VIII.

- Kassowitz, Infantiles Myxödem, Mongolismus und Mikromelie. Wiener medizinische Wochenschrift. 1902, No. 22.
- Ibid., Praktische Kinderheilkunde. 1910.
- Kaufmann, Untersuchungen über die sogenannte fötale Rachitis. Berlin 1892.
- Ibid., Lehrbuch der speziellen pathologischen anatomie. 1909, ed. 3.
- Kehrer, Über kongenitale Defekte am Schädel infolge amniotischer Verwachsungen. Monatsschrift für Geburtshilfe und Gynäkologie. Vol. XXXI.
- Keith, An Inquiry into the Nature of the Skeletal Changes in Acromegaly. Lancet. 1911, p. 993.
- Kellner, Über Porenzephalie. Monatsschrift für Psychiatrie und Neurologie. 1902.
- Kienböck, Riesenwuchs. Wiener klinische Wochenschrift. 1907, p. 1339.
- Ibid., Die Untersuchung der trophischen Störungen bei Tabes und Syringomyelie mit Röntgen-Licht. Neurologisches Zentralblatt. 1901, No. 2.
- Ibid., Über akute Knochenatrophie bei entzündlichen Prozessen an den Extremitäten und ihre Diagnose nach dem Röntgen-Bilde. Wiener medizinische Wochenschrift. 1901, No. 28 ff.
- Ibid., Über Technik und Ergebnisse der Röntgen-Untersuchung in der Zahnheilkunde. Wiener zahnärztliche Monatsschrift. 1902, No. 6.
- Ibid., Über Wachstumshemmung des Skelettes bei spinaler Kinderlähmung. Deutsche Zeitschrift für Nervenheilkunde. 1909, Vol. XXXVII.
- Killian, Die Röntgen-Photographie im Dienste der Rhinologie. I. internationaler laryngo-rhinologischer Kongress. Wien. 1908.
- Kirchoff, Osteom der Stirnhöhle. Inaugural-Dissertation. Bonn. 1907.
- Kirchoff E., Artikel: Gehirnbruch. Eulenburgs Realenzyklopädie. 1908.
- Klaatsch, Kraniomorphologie und Kraniotrigonometrie. Archiv für Anthropologie. Neue Folge. Vol. VIII.
- de Kleijn, Studien über Optikus- und Retinaleiden. II. Über die ophthalmologischen Erscheinungen bei Hypophysistumoren und ihre Variabilität. Archiv für Ophthalmologie. 1911, Vol. LXXX, No. 2.
- Klieneberger, Radioskopisch darstellbare Hirngeschwülste. XXVI. Kongress für innere Medizin. Wiesbaden. April, 1909.
- Ibid., Die Radiographie intrakranieller Prozesse in der inneren Medizin, mit besonderer Berücksichtigung der radiographisch darstellbaren Hirntumoren. Fortschritte auf dem Gebiete der Röntgen-Strahlen. Vol. XIV, Part 2.
- Klose, Die radiologische Topik der Kindertumoren im Gehirn. Archiv für Kinderheilkunde. 1908, Vol. XLVIII.
- Kloty, Osteogenesis imperfecta. Journ. of Pathol. and Bacteriol. 1909, XIII.
- Knapp, Fortschritte in der Diagnostik der Hirntumoren. Münchener medizinische Wochenschrift. 1908.
- Knoblauch, Operierter Fall von Hypophysentumor. Gesellschaft deutscher Nervenärzte. Frankfurt a. M. 1911.

Knöpfelmacher und Lehdorff, Hydrocephalus chronicus internus congenitus und Lues. Medizinische Klinik. 1908, No. 49.

Knox, Radiography as an aid to the diagnosis of diseases and injuries of the skull and brain. *Lancet*. April 10, 1909.

Koch Max, Leontiasis ossea von Virchow und die Pagetsche Ostitis deformans. Berliner medizinische Gesellschaft. July 13, 1910.

Kocher, Hirndruck usw. Nothnagels Handbuch. 1901.

Kocher, Ein Fall von Hypophysistumor. Deutsche Zeitschrift für Chirurgie Vol. C, p. 13.

Köhler, Knochenkrankungen im Röntgen-Bilde. Wiesbaden. 1901.

Ibid., Die Röntgen-Diagnose der Erkrankungen des Skelettes. Atlas von Groedel. 1909.

Ibid., Die Radiographie der Sella turcica und die Feststellung von Hypophysentumoren. *Journ. d. Radiol. Bruxelles*. 1909.

Körner, Die Exostosen und Hyperostosen im Gehörgange und die Osteome in den Operationshöhlen des Schläfebeins. Zeitschrift für Ohrenheilkunde. Vol. XLVIII, Ergänzungsheft.

Ibid., Die neueste Chlorom-Kasuistik mit Rücksicht auf die Lokalisation des Chloroms im Schläfebein und im Ohr. Zeitschrift für Ohrenheilkunde. 1903, Vol. L, p. 159.

Kohn, über die Hypophyse. Münchener medizinische Wochenschrift. 1910, No. 28.

Konietzko, Abstossung eines daumengliedgrossen Knochensequesters vom Boden der Keilbienenhöhle und der Pars basilaris ossis occipitis mit Freilegung der Dura. *Archiv für Ohrenheilkunde*. Vol. LXXXIII, Part 3—4, p. 282.

Konjetzny, Eine Struma calcuosa der Hypophysis. *Zentralblatt für allgemeine Pathologie und pathologische Anatomie*. 1911, Vol. XXII, No. 8.

Kolisko, Plötzlicher Tod aus natürlicher Ursache. *Handbuch der ärztlichen Sachverständigentätigkeit*.

Kollmann, *Plastische Anatomie*. 1886.

Kopezynski, Akute Hydrozephalie in einem Falle von Zuckerhutschädel. Gesellschaft für Neurologie und Psychiatrie in Warschau. May 21, 1910. Ref. in: *Rev. Neurol*. 1911, p. 226.

Koplik, Percussion of the skull. *Med. Record*. Vol. LXX, No. 13.

Krause F., Chirurgie des Gehirns und Rückenmarks. 1908, Vol. I. Derselbe, Die operative Behandlung der Epilepsie. *Medizinische Klinik*. 1909, No. 38.

Krause P., über Gehirntumor. Breslauer Röntgen-Vereinigung. January 8, 1907.

Krause W., *Handbuch der Anatomie des Menschen*. 1903.

Krotoschiner, Radiogramm der Nasennebenhöhlen. Breslauer chirurgische Gesellschaft. July 12, 1909. Ref.: *Berliner klinische Wochenschrift*. 1909, p. 1672.

Kühne und Plagemann, Die Röntgen-Untersuchung des Proc. mastoid. bei Otitis media. Fortschritte auf dem Gebiete der Röntgen-Strahlen. 1908.

Kümmell, Zur Kenntnis der Geschwülste der Hypophysengegend. *Münchener medizinische Wochenschrift*. 1911, p. 1293.

Küttner, Cholesteatom der Hirnbasis und Kleinhirnbrückenwinkeltumoren. Breslauer chirurgische Gesellschaft. March 14, 1910.

Ibid., Fall von erfolgreicher Exstirpation eines Hirntumors aus der Gegend des Chiasma nervi opt. Ref. in: Berliner klinische Wochenschrift. No. 33. August 15, 1910, p. 1555.

Kuhn, Der perorale Weg zur Keilbeinhöhle und zur Schädelbasis. Laryngologische Gesellschaft in Berlin. April 7, 1911. Ref.: Berliner klinische Wochenschrift. 1911, p. 914.

Kundrat, Arhinenzephalie als typische Art von Missbildung. Prag. 1882.

Kunert, Die Bedeutung der Röntgen-Strahlen für die Zahnheilkunde. Zeitschrift für Elektrotherapie. 1906, Vol. VIII.

Kuttner, Die entzündlichen Nebenhöhlenerkrankungen der Nase im Röntgen-Bilde. 1908.

Lambertz, Die Entwicklung des menschlichen Knochengerstes während des Fötallebens. Fortschritte auf dem Gebiete der Röntgen-Strahlen. 1900, Supplementary Volume I.

Landau, Das Gehirnrelief der Fossa cranii anterior. Gegenbauers Morphologisches Jahrbuch. XXXIX.

Lang, Monographie de Chloroma. Archiv général. de médecine. 1893.

Langdon Down, Mental Affections of Childhood and Youth. 1887.

Lange, X-ray Examination of the Mastoid Process. Amer. Roentgen Ray Society. 1909. Ref.: Fortschritte auf dem Gebiete der Röntgen-Strahlen. 1910, Vol. XV.

v. Langer, Über die Blutgefäße der Knochen des Schädeldaches. Sitzungsberichte der Akademie der Wissenschaften. 1877.

v. Langer-Toldt, Lehrbuch der systematischen und topographischen Anatomie. 1893.

Langerhans, Über Atlasankylose. Virchows Archiv. 1890, Vol. CXXI.

Lannelongue, De la craniectomie chez les microcephales. chez les enfants arriérés etc. Nouv. Iconogr. de la Salp. March, 1891.

Lauber und Schüller, Pulsierender Exophthalmus. Zeitschrift für Augenheilkunde. 1908, Vol. XIX, p. 172.

Lauffer, Zur Pathologie und Therapie der Osteomalazie des Weibes. Sammelreferat: Zentralblatt für die Grenzgebiete der inneren Medizin und Chirurgie. 1900.

Launois, Gigantisme et acromégalie. Nouv. Icon. de la Salp. 1903, Vol. XVI.

Launois et Cléret, Le syndrome hypophysaire adipo-génital. Gaz. des hôpitaux. 1910, Nos. 5 and 7.

Launois und Roy, Études biolog. sur les géants. Paris, 1904.

Lehndorff, Chlorom, Ergebnisse der inneren Medizin und Kinderheilkunde. 1910, Vol. VI.

Lehndorff und Schüller, Turmschädel. Gesellschaft für innere Medizin und Kinderheilkunde. March 5, 1908.

Leidler, Klinische Röntgen-Befunde an Ohrkranken. Archiv für Ohrenheilkunde. 1911, Vol. LXXXV.

Leidler und Schüller, Röntgen-Untersuchungen in der Otologie. Zentralblatt für Ohrenheilkunde. 1908, p. 549.

Leischner, Zur chirurgischen Behandlung der Hirntumoren. Archiv für klinische Chirurgie. Vol. LXXXIX.

Ibid., Zur Chirurgie der Kleinhirnbrückenwinkeltumoren. Mitteilungen aus den Grenzgebieten der Medizin und Chirurgie. 1911, Vol. XXII, Part 5.

v. Lenhossék, Die künstlichen Schädelverbildungen. Budapest, 1878.

Leonard, Roentgen Diagnosis of Hydrocephalus. Archives of X-ray, No. 127.

Leonowa, Ein Fall von Zyklopie, kombiniert mit Mikro- und Arhinenzephalie. Archiv für Psychiatrie. Vol. XXXVIII.

Léri, Radiologie. La pratique neurologique. Paris, 1911.

Lester, Roentgen Diagnosis of Hydrocephalus. Arch. of X-ray. 1911, p. 336.

Lévi, E., Contrib. a la connaissance de la microsomie essentielle hérédofamiliale. Iconogr. de la Salp. 1910.

Levy-Dorn, Radiographische Untersuchungen des Schädels. Journal de Radiologie. June, 1911.

Lewis, Tumors of the Hypophysis, Journ. of Amer. Med. Assoc. September 17, 1910.

Lichtheim, Gehirntumor. Diskussion zum Vortrag von Ludloff. Deutsche medizinische Wochenschrift. 1899, No. 40.

Lieblein, Fehlerquellen bei der Deutung von Röntgen-Befunden. Handbuch der ärztlichen Sachverständigentätigkeit. 1906, Vol. III.

Linck, Beitrag zur Kenntnis der menschlichen Chorda dorsalis und ihrer Beziehungen zur Anatomie des Nasen-Rachenraumes und zur Geschwulstbildung an der Schädelbasis. Anatomische Hefte 1911, Vol. XLII, Part 3.

Lissauer, Untersuchungen über die sagittale Krümmung des Schädels. Archiv für Anthropologie. Vol. XV.

Lohrmann, Über die sekundären Skelettveränderungen bei Caput obstipum. Inaugural-Dissertation. Greifswald. 1905.

Lombroso, Über die Entstehungsweise und Eigenart des Genies. Schmidts Jahrbücher. 1907, Part 9.

Ibid., Anomalies des crânes préhistoriques. Arch. di Psych., Neuropathol. etc. 1907, Vol. XXVIII.

Lomer, Schädelmasse und Beruf. Allgemeine Zeitschrift für Psychiatrie. Vol. LXIV.

Loos, Der anatomische Bau des Unterkiefers. Wien. 1899.

Ibid., Bau und Topographie des Alveolarfortsatzes im Oberkiefer. 1900.

Looser, Zur Klinik der Osteogenesis imperfecta congen. und tarda, sogenannte idiopathische Osteopsathyrosis. Mitteilungen aus den Grenzgebieten der Medizin und Chirurgie. 1905, Vol. XV.

Lorenz, Beiträge zur Kenntnis der Mikrognathie. Deutsche Zeitschrift für Chirurgie. Vol. LVII.

Lubarsch-Ostertag, Ergebnisse der allgemeinen Pathologie etc. 1895.

Lubosch, Über Variationen am Tuberculum articulare des Kiefergelenkes des Menschen und ihre morphologische Bedeutung. Morphologisches Jahrbuch. 1906, Vol. XXXV.

Lucae, Schädel abnormer Form. 1855.

MacDonald, Beiträge zur Entwicklung und den Entwicklungsfehlern der Kinder. Jahrbuch für Kinderheilkunde. February 1, 1910.

Mackay, On So-called Facial Hemihypertrophy. Brain. 1904.

Madelung, Über Verletzungen der Hypophysis. Archiv für klinische Chirurgie. 1904.

Magnus-Lewy, Myxödem. Zeitschrift für klinische Medizin. 1904, Vol. LII.

Manchot, Familiäres Auftreten von Turmschädel. Ärztlicher Verein zu Hamburg. May 23, 1911. Ref. in: Münchener medizinische Wochenschrift. 1911, p. 1265.

Marchand, Missbildungen. Eulenburgs Realenzyklopädie. 1897.

Ibid., Über Formveränderung des Schädels und des Gehirns infolge frühzeitiger Nahtverknöcherung. Archiv für Entwicklungsmechanik. Vol. XXVI.

Marekwald, Ein Fall von multiplem intravaskulärem Endotheliom in den gesamten Knochen des Skelettes. Virchows Archiv. 1895, Vol. CXLI.

Marcuse, Normale Sella turcica bei Akromegalie. Diskussion zu Thumims Vortrag. Berliner medizinische Gesellschaft. March 10, 1909.

Marfan, Études anatomiques sur les os rachit. Journal de Physiol. et Pathol. génér. 1909, VII, No. 4.

Marie A., Essai d'anthropologie psychiatrique. Traité international de psychologie pathologique. Paris. 1910.

Marie, Chaillou et Mac-Anliffe, Le type cérébral. Arch. de Neurol. January, 1911.

Marie P., und Lévi, Voluminöse Verkalkung in einem Hirnstiel. Soc. de neurol. de Paris. March 3, 1904. Ref. in: Neurologisches Zentralblatt. 1905, p. 496.

Marie et Onanoff, Sur la déformation du crâne constatée dans certains cas de myopathie progressive primitive. Bull. et mémoire de la soc. des hôpit. 1891, No. 6.

Markoe, An unusual malformation of the cranial bones in a new born infant. Bull. of the Lying-in Hosp. New York. 1907.

Markovič, Röntgenologische Diagnostik der Schädelbasisverletzungen. Fortschritte auf dem Gebiete der Röntgen-Strahlen. 1910, Vol. XV.

Marro, Variations crâniennes chez les criminels et les Aliénés. Turin. 1907.

Marschik, Rhinologische Operation von Hypophysentumoren. Wiener klinische Wochenschrift. 1910, p. 565.

Martens, Über einen Fall von Odontum und über Knochentumoren im Röntgen-Bilde. Zentralblatt für Chirurgie. 1902.

Martens Rob., Der Torus palatinus als Rassenmerkmal. Dissertation. Rostock, June, 1911.

Marx, Variat. crâniennes chez les criminels et les aliénés. Arch di Psych. etc. 1907.



Marx, Hermann. Die Missbildungen des Ohres. Schwalbes Morphologie der Missbildungen.

Masi, Saggi di radiographie stereoscopiche del cranio. XI Congr. della soc. fren. ital. 1902.

Masini und de Albertis, Oxyzephalie, Plagiozephalie und Trigonozephalie bei einem Verbrecher. Arch. d. Psych. 1908, Vol. XXIX.

Matiegka, Über das Hirngewicht, die Schädelkapazität und die Kopfform sowie deren Beziehungen zur psychischen Tätigkeit des Menschen. Sitzungsberichte der böhmischen Gesellschaft der Wissenschaft. Prag. 1902.

Ibid., Über die an Kammbildungen erinnernden Merkmale des menschlichen Schädels. Sitzungsberichte der Wiener Akademie der Wissenschaften. CXV.

Matthias, Demonstration von Röntgenogrammen eines Falles von Geirnerkrankung. Verein für wissenschaftliche Heilkunde. Königsberg. March 27, 1904.

Melchior, Die Hypophysis cerebri in ihrer Bedeutung für die Chirurgie. Ergebnisse der Chirurgie und Orthopädie. June, 1911, Vol. III. Berliner klinische Wochenschrift. 1911.

Meltzer, Zur Pathologie der Optikusatrophie und des sogenannten Turmschädels. Neurologisches Zentralblatt. 1908, 12.

Menetrier et Gauckler, Deux cas de maladie osseuse de Paget avec examen anatomique. Soc. méd. des hôpitaux de Paris. May 29, 1903.

Mengelberg, Zur Diagnose intraokulärer Fremdkörper. Wochenschrift für Therapie und Hygiene des Auges. 1903, No. 42.

Merkel, Handbuch der topographischen Anatomie. 1890.

Messedaglia, Études sur l'acromégalie. Padua. 1908.

Meyer, Fall von doppelseitiger Trigeminuslähmung (Karzinometastasen des Schädels). Berliner medizinische Gesellschaft May 10, 1911. Ref.: Münchener medizinische Wochenschrift. 1911, p. 1107.

Meyer G. H., Die Statik und Mechanik des menschlichen Knochen gerüstes. Leipzig 1873.

Meyer H., Zur Frage der sekundären exzentrischen Hyperostose der Schädelknochen bei Volumsabnahme des Gehirns. Inaugural-Dissertation. Würzburg 1908.

Meyer L., Über Crania progenea. Archiv für Psychiatrie. Vol. I, p. 36.

Ibid., Über Schädelverbiegungen. Archiv für Psychiatrie. Vol. IX.

Meyer L., Der skoliotische Schädel. Archiv für Psychiatrie. Vol. VIII.

Meynert, Klinische Vorlesungen über Psychiatrie. Wien 1890.

Michaud und Luthje, Akromegalie. Jahreskurse für ärztliche Fortbildung. 1911, Part 3.

Mills and Pfahler, Tumor of the Brain Localized Clinically and by the Roentgen Rays. Phil. Med. Journ. 1902.

Minor, Ein Fall von Hemihypertrophie des Gesichtes. Gesellschaft der Neuropathologen. Moskau, April 1902.

Modena, L' acromegalia. Riv. sperim. di freniatr. 1903.

Möbius, Der umschriebene Gesichtsschwund. Nothnagels Handbuch der speziellen Pathologie. 1895.

Ibid., Über Kunst und Künstler. Leipzig 1891.

Ibid., Franz Josef Gall, Ausgewählte Werke, 1905, Vol. VII. Mit einem Anhang: Über den Schädel eines Mathematikers.

Ibid., Über die Verschiedenheit männlicher und weiblicher Schädel. Archiv für Anthropologie. Vol. VI.

Ibid., Über die Anlage der Mathematik. Leipzig. 1907.

Mohr, Demonstration zur Pathologie der Drüsen mit innerer Sekretion. Münchener medizinische Wochenschrift. 1911, p. 542.

Momberg, Die Schädelbasis im Röntgen-Bilde. Ref.: Berliner klinische Wochenschrift. 1910, p. 1337.

Monakow, Missbildungen des Zentralnervensystems. Lubarsch-Ostertag, Ergebnisse. 1899.

Morax, Die Radiographie bei den Knochenaffektionen der Orbita. Soc. ophthalm. de Paris. Ref.: Presse médicale. 1911, No. 15, p. 133.

Morton-Prince, Osteitis deformans and one case of hyperostosis cranii. Amer. Journal of Medical Sciences. 1902, CXXIV, p. 796.

Mossé, Déformations Acromégaloïdes. Soc. de Neurol. Ref.: Revue de Neurologie. 1911, p. 646.

Mouchotte, Soudure congénitale de l'Atlas avec l'occipital. Gaz. hebdomad. de méd. et chir. 1899.

Mueller Artur, Über wechselseitige Beziehungen zwischen Kopfform und Geburtsmechanismus. Archiv für Gynäkologie. 1907, LXXXII.

Ibid., Die typischen Profilkurven des Schädels der Neugeborenen und ihre Beziehungen zum Geburtsverlauf und zur Kopfform der Erwachsenen. Archiv für Anthropologie. New series. 1910, Vol. IX.

Müller F. W., Über die Beziehungen des Gehirns zum Windungsverlauf an der Aussenseite der Schläfengegend. Archiv für Anatomie und Physiologie. 1908.

Müller und Siebeck, Über die Vasomotoren des Gehirns. Untersuchungen an Tieren und Menschen. Zeitschrift für experimentelle Pathologie und Therapie. 1907.

Münzer, Der Zahlensinn. Berliner klinische Wochenschrift. 1910, p. 703.

Ibid., Die Hypophysis. Berliner klinische Wochenschrift. 1910.

Ibid., Die Zirbeldrüse. Berliner klinische Wochenschrift. 1911, No. 37.

Munch, La radiographie des tumeurs intra-crâniennes. Semaine Méd. January 14, 1903.

Neumann, Syphilis. Nothnagels Spezielle Pathologie und Therapie. 1899.

Neumayer, Beitrag zur Lehre vom Längenwachstum des Hirnschädels. Mitteilungen der Anthropologischen Gesellschaft in Wien. 1908.

Nyström, Über die Formveränderungen des menschlichen Schädels und deren Ursachen. Archiv für Anthropologie. 1902.

Obici e Bollici, Applicazioni dei raggi "X," alla diagnosi dei tumori intracranici. Riv. di pathol. nerv. e ment. Vol. II, 10, and Münchener medizinische Wochenschrift. 1898, No. 7.

Öttinger et Agasse-Lafont, Maladie osseuse de Paget. Iconogr. de la Salp. 1905.

Onodi, Röntgen-Aufnahmen der Stirnhöhlen. Verhandlungen des ersten internationalen Laryngologen-Kongresses. Wien. 1909.

Ibid., Die Eröffnung der Schädelhöhle und Freilegung des Gehirns von den Nebenhöhlen der Nase aus. Zeitschrift für Laryngologie. 1911, Part I.

Oppenheim, Erl., Die Suturen des menschlichen Schädels in ihrer anthropologischen Bedeutung. Korrespondenzblatt der Deutschen Gesellschaft für Anthropologie. 1907.

Oppenheim H., Die Geschwülste des Gehirns. 2. Aufl. Nothnagels Handbuch der speziellen Pathologie. 1903.

Ibid., Diskussion zum Vortrag von Cassirer. Berliner Gesellschaft für Psychiatrie und Neurologie. November 13, 1899. Archiv für Psychiatrie. XXXIV.

Ibid., Lehrbuch der Nervenkrankheiten. 1908.

Oppenheimer, Der Wert der Radiographie bei Orbitaltumoren. Klinische Monatsblätter für Augenheilkunde. XLIV, I, p. 358.

Orlow, Ankylosis mandibulae vera. Deutsche Zeitschrift für Chirurgie. 1903, Vol. XXVI, p. 399.

Ottenberg, Froelich's Syndrome in Cases of Pituitary Tumor. New York Med. Journ. 1910, p. 1222, Vol. 92.

Otto, Ein Fall von Verkümmerng des Kleinhirns. Archiv für Psychiatrie. 1873, Vol. IV.

Ottolenghi, Polizia scientifica. Rome, 1907.

Paget, On a form of chronic inflammation of bones (Osteitis deformans). Med.-Chir. Transactions. 1877, LX and 1882, LXV.

Paltauf A., Über den Zwergwuchs und verwandte Wachstumsstörungen des menschlichen Skelettes. Wien. 1891.

Papillault, Étude morphologique de la base du crâne. Bullet. et Mémoir. de la Société d'Anthropologie. Paris, 1898.

Pappenheimer, Über Geschwülste des Corpus pineale. Virchows Archiv. 1910, Vol. CC.

Paul-Boncour, Le crâne dans les idioties, in: Bourneville, Recherches sur l'épilepsie l'hystérie et l'idiotie. Compt. rend. de Bicêtre 1901, p. 193.

Ibid., Sur la morphologie crânienne dans ses rapports avec les états patholog. du cerveau. Bullet. et Mémoir. de la Soc. d'anthropolog. de Paris. 1902.

Ibid., Mécanisme de quelques déformations crâniennes dans le myxoedème. Archives de Neurologie. 1903, VIII.

Ibid., Sur les modifications crâniennes consécutives aux atrophies cérébrales unilatérales. Archives de Neurologie. 1904, No. 103.

Paviot and Mauriquand, Du crâne osteomalacique. Soc. méd. des hôpitaux de Lyon. June 30, 1903.

Péan, Radiographie du crâne. Gaz. des Hôpitaux. 1897, No. 27.

Pearce F., Savary, Hyperostosis cranii. Cephalomegaly. Medic. fortnightly. February, 1903.

Pearce, Rankin und Ormond, Report of Twenty-eight Cases of Mongolism. Brit. Med. Journ. July, 1910.

- Peckert, Das Antrum im Röntgen-Bilde. Deutsche zahnärztliche Wochenschrift. 1907, X, No. 16.
- Peckert, Die Missbildungen des Gebisses. Schwalbes Handbuch. 1911.
- Pel, Acromégalie partielle avec infantilisme. Nouv. Icon. de la Salp. 1906, No. 1.
- Perthes, Die Erkrankungen der Kiefer. Deutsche Chirurgie. 1907.
- Ibid., Die Bedeutung der Röntgen-Strahlen für die Diagnose und Operation der Stirnhöhlenosteome. Archiv für klinische Chirurgie. Vol. LXXII, Part 4.
- Pescarolo et Bertolotti, Sur un cas d'ostéite déformante de Paget Icon. de la Salp. 1909, No. 3.
- Peters, Über Gesicht- und Schädelasymmetrie und ihr Verhältnis zum Caput obstipum. Münchener medizinische Wochenschrift. 1908, No. 34.
- Peterson and Fisher, Cranial Measurements in 20 Cases of Infantile Cerebral Hemiplegia. New York Neurolog. Society. April 6, 1889.
- Peyser, Zum Nachweis der Basisfraktur. Berliner Otologische Gesellschaft. January 14, 1908. Deutsche medizinische Wochenschrift. 1908, No. 18, p. 785.
- Ibid., Die Röntgen-Untersuchung der Nasennebenhöhlen. Archiv für Laryngologie. Vol. XXI, Part 1.
- Pfahler, Cerebral skiagraphy. Amer. Journal of Med. Sciences. December, 1904. Ref.: Fortschritte auf dem Gebiete der Röntgen-Strahlen. 1906, Vol. X.
- Ibid., Die isolierte Aufnahmen einer Oberkieferhälfte und die isolierte Aufnahmen des Processus styloideus. Fortschritte auf dem Gebiete der Röntgen-Strahlen. Vol. XVII, Part 6, p. 369.
- Pfleger und Pilez, Beiträge zur Lehre von der Mikrocephalie. Arbeiten aus dem Institute von Obersteiner. Wien. 1897.
- Philip, The X-ray in Determining the Limits of the Frontal Sinus. Journal of Amer. Med. Assoc. 1902.
- Philip and Smith, On a Remarkable Case of Venous Accommodation after Compression of the Superior Longitud. Sinus by a Glioma. Lancet. November 7, 1908.
- Phleps, Diagnostische Verwertung der Schalleitungsveränderungen des Schädels bei intra- und extrakraniellen Herderkrankungen. Archiv für Psychiatrie. Vol. XLIII.
- Pick L., Über Dystrophia adiposogenitalis bei Neubildungen im Hypophysengebiet. Deutsche medizinische Wochenschrift. 1911, Nos. 43, 44, 45.
- Pilez, Weiterer Beitrag zur Lehre von der Mikrocephalie. Jahrbuch für Psychiatrie und Neurologie. 1899.
- Plenk, Zur Kenntnis der grossen Foramina parietalia. Virchows Archiv. 1910, Vol. CCII, Part 2.
- Politzer, Lehrbuch der Ohrenheilkunde. 1908, ed. 5.
- Pollack, Über Hirnpunktion. Mitteilungen aus den Grenzgebieten der Medizin und Chirurgie. 1908.
- Pommer, Zur Kenntnis der hereditären Schädel-syphilis. Pathologische Gesellschaft. 1905, IX.

Ponfiek, Myxödem und Hypophysis. Zeitschrift für klinische Medizin. 1899.

Poppel, Haben Geisteskranke andere Schädel als nicht Geisteskranke? Dissertation. Würzburg. 1908.

Poppi, L' ipofisi cerebrale faringeae e la glandula pineale in patologia. Bologna 1911. Ref. in: Wiener klinische Wochenschrift. 1911, p. 912.

Porak, De l'achondroplasia. 1890.

Porak and Durante, Les Microméliees congénit. Icon. de la Salp. 1905, XVIII.

Port und Peckert, Über Röntgen-Photographie in der Zahnheilkunde. Deutsche Zahnheilkunde in Vorträgen. Leipzig, Part 11.

Preysing, Spongiosierung der Stirnhöhlen. Zeitschrift für Laryngologie, Rhinologie und ihre Grenzgebiete. 1910, Vol. III, Part 4.

Putnam, Hyperostosis cranii. Amer. Journal of Med. Sciences. 1897, CXII.

Ranke, Die überzähligen Hautknochen des menschlichen Schädeldaches. Abhandlungen der bayerischen Akademie der Wissenschaften. 1899.

Ranzi, Demonstration operierter Hirntumoren. Wiener klinische Wochenschrift. 1911, p. 995.

v. Recklinghausen, Die fibröse oder deformierende Ostitis, die Osteomalazie und das osteoplastische Karzinom. Festschrift der Assistenten für Virchow. Berlin. 1891.

Redard, Atlas der Radiographie. Paris. 1900.

Redlich, Ein Fall von Gigantismus infantilis. Wiener klinische Rundschau. 1906.

Redlich und Pötzl, Über Liquordruckmessungen bei Epileptikern. Zeitschrift für die gesamte Neurologie und Psychiatrie. 1910, Vol. III, Part 4.

Redlich und Schüller, Über Röntgen-Befunde an Schädeln von Epileptikern. Naturforscherversammlung Salzburg 1909, und Fortschritte auf dem Gebiete der Röntgen-Strahlen. Vol. XIV.

Redslob, Exophthalmus bei Schädeldeformitäten. Klinische Monatsblätter für Augenheilkunde. 1909.

Regnault, Crânes présentant une soudure de l'atlas due au torticollis. Le progrès méd. 1910.

Ibid., Altérations crâniennes dans le rachitisme. Paris 1888.

Ibid., Le crâne rachitique, Revue mensuelle des maladies de l'enfance. 1899, T. XVII.

Ibid., La base du crâne dans l'achondroplasia. Gaz. hebdom. de Med. 1901, II, No. 55.

Ibid., Enfoncement de la base du crâne (platybasie) chez un achondroplasia. Rev. de neurolog. 1909. Bullet. et mémoire. de la Soc. anat. de Paris. 1908.

Ibid., Cause de la brachycéph. consécut. à la myopathie. Bull. de la Soc. anat. de Paris. 1908, 3. S. T. IX, No. 9, p. 497.

Reichardt, Schädel und Gehirn. 1908.

Ibid., Über Hirnschwellung. Zeitschrift für die gesamte Neurologie und Psychiatrie. 1911, Vol. III, Part I.

Ibid., Die Methode der Kopfmessung am lebenden Menschen nach Professor Rieger. Zeitschrift für die Behandlung Schwachsinniger. 1908. Nos. 7 and 8.

Ibid., Über einige normale und krankhafte Vorgänge der Hirnsubstanz. Physikalisch-medizinische Gesellschaft in Würzburg. December 15, 1910. Ref.: Berliner klinische Wochenschrift. 1911, p. 149.

Reichmann, Über Hypophysentumoren im Röntgen-Bilde. Zentralblatt für Röntgen-Strahlen. Vol. I.

Reiner, In die Nasenhöhle aberrierter Zahn, Berliner Laryngologische Gesellschaft. May 21, 1909.

Reissmann, A Case of Complete One-sided Gigantism with Enlargement of the Opposite Side of the Brain. The Australasian Med. Gaz. 1902. Münchener medizinische Wochenschrift. 1904, No. 21.

Reuter, Kopfform und Körperbau, Archiv für Rassen- und Gesellschaftsbiologie. 1908, Vol. V.

Reynier and Glover, Radiographie Researches on the Topographical Relations of the Brain, the Frontal and Maxillary Sinuses and the Venous Sinuses of the Dura Mater to the Walls of the Skull. Lancet. 1900.

Rhese, Die Diagnostik der Erkrankungen des Siebbeinlabyrinthes und der Keillbeinhöhlen durch das Röntgen-Verfahren. Deutsche medizinische Wochenschrift 1910.

Richter, Über Porencephalie. Archiv für Psychiatrie. Vol. XXXII.

Rieger, Eine exakte Methode der Kraniographie. Jena. 1885.

Rinne, Partielle Hyperostose des Schädels. Zentralblatt für Chirurgie. 1906, p. 679.

Rivet, Recherches sur le prognathisme. L'Anthropologie. 1909, Vol. XX.

Robinson, Über einen positiven Röntgen-Befund am Schädel bei Epilepsie. Wiener klinische Wochenschrift. 1908, pp. 376 and 411.

Robinson und Spitzer, Zahnärztliche Röntgenologie. Handbuch der Zahnheilkunde von Scheff. ed. 3, 1909, Vol. I.

Röll, Bestimmung des Schädelinnenraumes Dissertation. Würzburg. 1910.

Roerig, Der Gesichtsteil des menschlichen Schädels. Archiv für Entwicklungsmechanik. Festschrift. Vol. XXX.

Rolleston, A Case of Tumour Growing from the Basilar Process of the Occipital Bone. The Lancet. 1897, I, p. 879.

Rüdinger, Über willkürliche Verunstaltung des menschlichen Körpers. Virchow-Holtzendorff, Sammlung gemeinverständlicher Vorträge. Series IX, Part 215.

Rumpel, Die Tumoren im Röntgen-Bilde Archiv und Atlas der normalen und pathologischen Anatomie im Röntgen-Bilde. Hamburg, Vol. XIX. v. Rutwoski, Ein Beitrag zum Röntgen-Verfahren im Dienste der Neurologie. Char. Ann. 1904.

Sabrazès et Cabannes, Hémihypertrophie faciale. Nouv. Icon. de la Salp. 1898, Vol. XI.

Sachs und Schüller. Exophthalmus infolge partieller Hyperostose des Keilbeins. Zeitschrift für Augenheilkunde. 1905, XIII, p. 381.

Saenger. Hypophysentumor. Ärztlicher Verein in Hamburg. June 25. 1907. Kongress im Amsterdam. 1907. Gesellschaft deutscher Nervenärzte. Dresden. 1907. Deutsche medizinische Wochenschrift. 1908, p. 1292.

Ibid., Diffuse Hyperostose des Schädels, Cephalomegalie. Ärzteverein Hamburg. January 18, 1910. Ref.: Neurologisches Zentralblatt. 1910.

Salzberger, Kasuistische Mitteilungen über einen Eunochoiden. Neurologisches Zentralblatt. 1911, p. 245.

Sauvage, l'État sénile du crâne. Paris, 1878.

Sawalischin Marie, Über Gesichts-Indizes. Archiv für Anthropologie. 1909.

Schäfer, Die Funktionen des Gehirnanhanges, Hypophysis cerebri. Bern. 1911.

Schäffer E., Zur Kasuistik der Akromegalie. Neurologisches Zentralblatt. 1903.

Schaeffer O., Untersuchungen über die normale Entwicklung der dimensionalen Verhältnisse des fötalen Menschenschädels mit besonderer Berücksichtigung des Schädelgrundes und dessen Gruben. München, Lehmann. 1892.

Ibid., Über die Entstehung der Porenzephalie und der Hydranzenzephalie auf Grund entwicklungsgeschichtlicher Studien Virchows Archiv. 1896, CXLV.

Scheib, Osteogenesis imperfecta. Beiträge zur klinischen Chirurgie. 1900, XXVI.

Scheier, Mitteilungen über die Anwendung der Röntgen-Strahlen in der Rhino- und Laryngologie. Fortschritte auf dem Gebiete der Röntgen-Strahlen. 1897/98, Vol. I.

Ibid., Applications de la radiologie à l'étude embryologique de la tête. Traité de Radiologie par Bouchard. 1904.

Ibid., Die Bedeutung der Röntgen-Strahlen für die Rhinologie. Deutsche medizinische Wochenschrift. 1908.

Ibid., Die Bedeutung der Röntgen-Strahlen für die Erkrankungen der Nasennebenhöhlen. Beiträge zur Anatomie, Physiologie, Pathologie und Therapie des Ohres, der Nase und des Halses. August 1, 1908.

Scheier, Über die Verwertung der Röntgen-Strahlen in der Rhino- und Laryngologie. Archiv für Laryngologie. Vol. VI.

Ibid., Die Diagnostik der Empyeme der Nasennebenhöhlen und das Röntgen-Verfahren. Archiv für Laryngologie und Rhinologie. 1909, Vol. XXI, Part 3.

Ibid., Zur Untersuchung der Keilbeinhöhlen mittels Röntgen-Strahlen. Berliner klinische Wochenschrift. January 2, 1911, p. 37.

Schick, Zur Kenntnis der "Hypertrophia cerebri" als Krankheitsbild im Kindesalter. Jahrbuch für Kinderheilkunde. 1903.

Schiffmacher, Senile Osteomalazie. Münchener medizinische Wochenschrift. 1904, No. 13.

Schiffner, Untersuchungen über die Anordnung der Spongiosa. Virchows Archiv. 1878, LXXIV.

Schiller, Über einen Fall von tumorartiger Hyperostose des Schädels. Münchener medizinische Wochenschrift. 1901.

Schirmer, Die Pagetsche Knochenkrankung. Sammelreferat. Zentralblatt für die Grenzgebiete der Medizin und Chirurgie. 1908, XI.

Schlagenhauser, Über diffuse ossifizierende Periostitis. Zeitschrift für Heilkunde. 1904.

Schlöffer, Erfolgreiche Operation eines Hypophysentumors auf nasalem Wege. Wiener klinische Wochenschrift. 1907, pp. 621 and 670.

Ibid., Weiterer Bericht über den Fall von operiertem Hypophysentumor. Wiener klinische Wochenschrift. 1907.

Schmidt M. B., Allgemeine Pathologie und pathologische Anatomie der Knochen. Lubarsch-Ostertag, Ergebnisse. 1897 and 1898.

Schmiegelow, Operative Behandlung der Hypophysen-Leiden. Zeitschrift für Ohrenheilkunde. Vol. LXII, Part 1.

Schnabl, Zur Diagnose der Hypophysenvergrößerung. Ophthalmologische Gesellschaft in Wien. Zeitschrift für Augenheilkunde. XIII, Part 1.

Schnitzler J. G., Zur Symptomatologie der Hypophysentumoren. Deutsche Zeitschrift für Nervenheilkunde. 1911, Vol. XLI.

Scholz, Kretinismus und Mongolismus. Ergebnisse der inneren Medizin and Kinderheilkunde. 1909.

Schönfeld, Ein Beitrag zum Mongolismus. Wiener medizinische Wochenschrift. 1911, No. 36.

Schüller, Die Schädelbasis im Röntgen-Bilde. XI. Ergänzungsband der Fortschritte auf dem Gebiete der Röntgen-Strahlen. 1905.

Ibid., Röntgenologie und Neurologie. Naturforscher-Versammlung. Breslau 1904.

Ibid., Hemi hypertrophie des Schädels. Wiener klinische Wochenschrift. 1905, p. 738.

Ibid., Bitemporale Hemianopsie. Zeitschrift für Augenheilkunde. XIV, p. 362.

Ibid., Ossifikationsdefekt des Schädels bei zerebraler Kinderlähmung. Gesellschaft für innere Medizin und Kinderheilkunde. January 18, 1906.

Ibid., Halisterese des Schädelknochens bei intrakranieller Drucksteigerung. Verein für Psychiatrie und Neurologie in Wien. February 19, 1907.

Ibid., Turmschädel. Fortschritte auf dem Gebiete der Röntgen-Strahlen. Vol. XII, p. 354.

Ibid., Röntgen-Befunde bei Epilepsie. Wiener klinische Wochenschrift. 1908, p. 411.

Schüller, Die Röntgen-Diagnostik der Schädel- und Gehirnkrankheiten. Wiener medizinische Wochenschrift. 1908.

Ibid., Die röntgenographische Darstellung der diploëtischen Venenkanäle des Schädels. Fortschritte auf dem Gebiete der Röntgen-Strahlen. 1908.

Ibid., Über genuine and symptomatische Migräne. Wiener medizinische Wochenschrift. 1909, No. 17.

Ibid., Zur Diagnostik der Gehirntumoren. Medizinische Klinik. 1909.

Ibid., Verkalkte Herde in Gehirn bei Epilepsie; verkalkte Zirbeldrüse. Wiener klinische Wochenschrift. 1909, No. 32.



Ibid., Röntgen-Diagnose der Hirntumoren. III. Versammlung der Gesellschaft deutscher Nervenärzte. Wien, 1909. Ref.: Neurologisches Zentralblatt. October 1, 1909.

Ibid., Röntgen-Bild des Schädels bei Kleinhirntumor und bei Akustikustumor. Wiener klinische Wochenschrift. 1909, p. 1580.

Ibid., Röntgen-Diagnostik. Handbuch der Neurologie von Lewandowsky. 1910, Vol. I.

Ibid., Über sellare Palliativtrepanation und Punktion des dritten Hirnventrikels. Wiener medizinische Wochenschrift. 1911, No. 3 and 47.

Schüller und Robinsohn, Die typischen Aufnahmen der Schädelbasis. Wiener klinische Rundschau. 1903.

Schultze, Über Sulci venosi meningei des Schädeldaches. Zeitschrift für Morphologie und Anthropologie. 1899, Vol. I.

Schulz, Ein neuer Fall von Akromegalie mit Sektionsbefund. Inaugural-Dissertation. Königsberg. 1905.

Schuster, Hypophysistumor mit Röntgen-Photogramm. Neurologisches Zentralblatt. 1907, No. 18.

Schwabach und Bielschowsky, Tumor des Felsenbeins mit multipler Hirnnervenlähmung. Berliner Otologische Gesellschaft. December 4, 1908.

Schwalbe E., Der Epignathus und seine Genese. Zieglers Beiträge. 1904.

Ibid., Die Morphologie der Missbildungen des Menschen und der Tiere. 1906 to 1910.

Schwalbe G., Über akzessorische Schädelknochen des Menschen und akzessorische Schädelnähte. Berliner klinische Wochenschrift. 1899. (See also Zeitschrift für Morphologie und Anthropologie. 1901 to 1904.)

Ibid., über die Fontanella metopica (medio-frontalis) und ihre Bildungen. Zeitschrift für Morphologie und Anthropologie. 1901, Vol. III.

Ibid., über die Beziehungen zwischen Innenform und Aussenform des Schädels. Deutsches Archiv für klinische Medizin. LXXVIII, 1902.

Ibid., über geteilte Scheitelbeine. Zeitschrift für Morphologie und Anthropologie. 1904, Vol. VI.

Ibid., über das Gehirnrelief der Schläfengegend des menschlichen Schädels. Zeitschrift für Anthropologie und Morphologie. 1906, X.

Schwarz E., Der Gewölbebruch des Schädels in Röntgen-Bilde. Beiträge zur klinischen Chirurgie. Vol. LXVIII.

Schwarz Franz, Untersuchungen über das Wachstum des Menschen. Archiv für Anthropologie. 1911, Vol. I.

Schwarz G., Die Röntgen-Strahlen im Dienste der Zahnheilkunde. Österreichische Ärzte-Zeitung. 1909, VI, No. 5.

Schwarz L., Die Bedeutung der Röntgen-Strahlen für die gerichtliche Medizin. Fortschritte auf dem Gebiete der Röntgen-Strahlen. 1909, Vol. XIII, No. 4.

Schwetz, Encephalocele basalis intranasalis. Zeitschrift für Ohrenheilkunde und für Krankheiten der Luftwege. 1909.

Seelert, Zur Kenntnis des Dura-Psammons. Dissertation. München. 1908.

- Seiffer, Chondrom der Schädelbasis. *Neurologisches Zentralblatt*. 1905.
- Shuttleworth, Infantile Ostitis Cranii from Hereditary lues. *Brit. Journ. of Children's Diseases*. 1908, No. 4.
- Siegert, Kretinismus etc. *Handbuch der Kinderheilkunde von Pfaundler-Schlossmann*, ed. 2.
- Ibid., Der Mongolismus. *Ergebnisse der inneren Medizin und Kinderheilkunde*. 1910.
- Ibid., Myxödem im Kindesalter. *Ergebnisse der inneren Medizin und Kinderheilkunde*. 1910.
- Simmonds, Untersuchungen von Missbildungen mit Hilfe des Röntgen-Verfahrens. Fortschritte auf dem Gebiete der Röntgen-Strahlen. 1900-1901, Vol. IV.
- Sippel, Exostosen und Osteome am Schädel. *Inaugural-Dissertation*. Würzburg. 1909.
- Sjögren, Kasuistische Beiträge zur Chirurgie des Schädels. *Deutsche medizinische Wochenschrift*. 1901, No. 18.
- Smoler, Zur Operation der Hypophysentumoren auf nasalem Weg. *Wiener klinische Wochenschrift*. 1909, No. 43.
- Sommer, Zur Kasuistik der Atlas-Synostose. *Virchows Archiv*. Vol. XCIV.
- Ibid., Atlas-Ankylose und Epilepsie. *Virchows Archiv*. Vol. CXIX, p. 362.
- Spee, Das Kopfskelett. *Handbuch der Anatomie von Bardeleben*. 1891.
- Spieß, Die Röntgen-Untersuchung der oberen Luftwege. *Atlas von Groedel*. 1909.
- Ibid., Tumor der Hypophysengegend, auf endonasalem Wege operiert, *Münchener medizinische Wochenschrift*, November 21, 1911.
- Spiller, Hemicraniosis. *The Journal of the Amer. Med. Assoc.* Vol. XLIX. December, 1907.
- Stahl, Einige klinische Studien über Schädeldeformitäten. *Zeitschrift für Psychiatrie*. 1885.
- Starck, Hypophysentumor. *Zweite Versammlung der Gesellschaft deutscher Nervenärzte in Heidelberg*. 1908.
- Stein, Akromegalie. *Ärztlicher Verein in Brünn*. June 3, 1908.
- Steinbrecher, Zur Differentialdiagnostik des Hydrocephalus internus. *Klinik für psychische und Nervenkrankheiten*. 1910, Vol. V, p. 3.
- Stern K., Besteht eine Abhängigkeit der Kopfform des Neugeborenen von der des Vaters oder der Mutter? *Inaugural-Dissertation*. Freiburg. i. B. 1908.
- Stern R., Erscheinungen bei Hemikranie. *Verein für Psychiatrie und Neurologie in Wien*, November 8, 1910. Ref.: *Neurologisches Zentralblatt*. 1911, p. 463.
- Sternberg M., Die Akromegalie. *Spezielle Pathologie und Therapie von Nothnagel*.
- Ibid., Vegetationsstörungen. und Systemerkrankungen der Knochen. *Nothnagels Spezielle Pathologie und Therapie*. 1899.

Sterz und Stieh, Stirnhirntumor. Niederrheinische Gesellschaft für Natur- und Heilkunde. May 20, 1910.

Stier, Demonstration eines Falles von Hemiatrophia faciei. Berliner Gesellschaft für Psychiatrie und Nervenkrankheiten. January 9, 1911.

Ibid., Drie Fälle von Hemihypertrophie. Neurologisches Zentralblatt. 1911, p. 760.

Stilling, Schädelbau und Kurzsichtigkeit. Wiesbaden, 1888.

Stilling H., über Ostitis deformans. Virchows Archiv. Vol. CXIX.

Ibid., Osteogenesis imperfecta. Virchows Archiv. Vol. CXV.

Stoeltzner, Rachitis. Handbuch der Kinderheilkunde von Pfaundler-Schlossmann. 1910.

Strada, Beitrag zur Kenntnis der Geschwülste der Hypophyse und der Hypophysengegend. Virchows Archiv. 1911, Vol. CCCCIII, Part 1

Straeter, Gehirnabszess im Röntgen-Bilde. Fortschritte auf dem Gebiete der Röntgen-Strahlen. Vol. VII.

Sträussler, Zur Symptomatologie und Anatomie der Hypophysenganggeschwülste. Arbeiten aus der deutschen psychiatrischen Klinik in Prag. Berlin 1908. Karger.

Stratz, Naturgeschichte des Menschen. 1904.

Stroebe, Krankhafte Veränderungen der knöchernen Kapsel und der Hüllen des Gehirns. Handbuch der pathologischen Anatomie des Nervensystems. Berlin 1903.

Stumme, Akromegalie und Hypophyse. Archiv für klinische Chirurgie. Vol. LXXXVII, Part 2.

Suchsland, Die mongoloide Idiotie. Inaugural-Dissertation. Halle a.S. 1909.

Sudeck, Akute entzündliche Knochenatrophie. Langenbecks Archiv. 1900, LXII.

Süsse, Zur Frage der exzentrischen Hyperostose der Schädelknochen. Inaugural-Dissertation. Würzburg 1908.

Tandler, Über den Schädel Haydns. Mitteilungen der Anthropologischen Gesellschaft in Wien. 1909.

Tandler und Gross, Untersuchungen an Skopzen. Wiener klinische Wochenschrift. 1908, No. 9.

Ibid., Über den Einfluss der Kastration auf den Organismus. Archiv für Entwicklungsmechanik. 1910.

Tauber, Haemangioma cavernosum venosum. Wiener klinische Wochenschrift. 1905, p. 294.

Thiemich, Sektionsbefund bei einem Falle von Mongolismus. Monatsschrift für Kinderheilkunde. 1903, Vol. II.

Thoma, Synost. sutur. sagitt. cranii. Ein Beitrag zur Histomechanik des Skelettes und zur Lehre vom interstitiellen Knochenwachstum. Virchows Archiv. Vol. CLXXXVIII.

Ibid., Zur Mechanik der Schädelbrüche. Zeitschrift für Chirurgie. 1909, XCVIII, 2 and 3.

v. Török, Neue Untersuchungen über Dolichocephalie. Zeitschrift für Morphologie und Anthropologie. 1905, Vol. VIII.

Toupet und Infroit, Radiographische Messungen der Sella turcica. Soc. de Biologie. November 4, 1909.

Trömner, Tumor der Hirnbasis. Ärztlicher Verein, Hamburg. December 15, 1908.

Tsiminakis, Zur Kenntnis der reinen Hypertrophie des Gehirns. Arbeiten aus dem neurologischen Institut Obersteiner, Wien.

Uthhoff, Wachstumsanomalien bei der temporalen Hemianopsie, beziehungsweise den Hypophysisaffektionen. Deutsche medizinische Wochenschrift. 1907, No. 38.

Underwood, An inquiry into the anatomy and pathology of the maxillary sinus. Journ. of Anat. and Physiol. 1910, Vol. XLIV.

Uyeno, Das Osteofibrom des Oberkiefers, eine typische Geschwulst. Beiträge zur klinischen Chirurgie. Vol. LXV, December 1909.

Velhagen, Über Turmschädel und Sehnervenatrophie. Münchener medizinische Wochenschrift. 1904, No. 31.

Virchow, Gesammelte Abhandlungen. 1856.

Virchow, Untersuchungen über die Entwicklung des Schädelgrundes. Berlin 1857.

Völcker, Das Caput obstipum, eine intrauterine Belastungsdiformität. Beiträge zur klinischen Chirurgie. XXXIII.

Vogel, A case of Paget's disease. Medical Record. 1911, p. 214.

Vogt, Über den mongoloiden Typus der Idiotie. Klinik für psychische und nervöse Krankheiten. 1906, Zentralblatt für Nervenheilkunde und Psychiatrie. 1906, Allgemeine Zeitschrift für Psychiatrie. 1906. Article: "Infantilismus" in Eulenburs Realenzyklopädie. 1909.

Ibid., Allgemeine Übersicht über das zentrale Nervensystem. Handbuch der Neurologie von Lewandowsky. 1910, Vol. I.

Voisin, de Lépinay et Infroit, Étude clinique et radiographique d'un cas de dysostose cléïdocrânienne. Nouv. Iconogr. de la Salp. 1907, XX.

Volland, Über Megalenzephalie. Archiv für Psychiatrie. 1910.

Vorschütz, Röntgenologisches und Klinisches zum Bilde der Akromegalie. Deutsche Zeitschrift für Chirurgie. XCIV, Parts 3 and 4.

Ibid., Zur Frage des operativen Eingriffes bei Turrizephalie. Deutsche Zeitschrift für Chirurgie. XCIX.

Ibid., Operation von Turmschädel. Allgemeiner ärztlicher Verein zu Köln. April 3, 1911. Diskussion: Lossen. Ref.: Münchener medizinische Wochenschrift. 1911, p. 1268.

Voss, Die Radiologie in der Ohrenheilkunde. XVI. Versammlung der Deutschen Otologischen Gesellschaft. Bremen 1907.

Voss, F., Das Sarkom des Keilbeins, ein typisches Krankheitsbild. St. Petersburger medizinische Wochenschrift. 1910, p. 205.

Wagemann, Beiderseitige Keratitis parench. luet. bei einer 20jährigen Patientin mit Dystrophia adiposogenitalis (Hypophysentumor). Naturwissenschaftlich-medizinische Gesellschaft in Jena. February 27, 1908.

v. Wagner, Über Myxödem und sporadischen Kretinismus. Wiener klinische Wochenschrift. 1903.

Walcher, Über künstliche Schädeldeformierung. Zentralblatt für Gynäkologie. 1904.

Derselbe, Weitere Erfahrungen in der willkürlichen Beeinflussung der Form des kindlichen Schädels. Münchener medizinische Wochenschrift. 1911, No. 3.

Walz, Über die Bedeutung der überzähligen Knochen des kindlichen Schädels. Vierteljahrsschrift für gerichtliche Medizin. 1909, Vol. XXXVII.

Wassermann, Die Bedeutung des Röntgen-Verfahrens für die Diagnose der Siebbein- und Stirnhöhleneiterungen. XVI. Versammlung der Otologischen Gesellschaft. Bremen 1907. Ärztlicher Verein. München 1907, June 12. Internationaler laryngologisch-rhinologischer Kongress in Wien. 1908.

Ibid., Die Bedeutung des Röntgen-Verfahrens auf dem Gebiete der Rhinologie und Laryngologie. Fortschritte auf dem Gebiete der Röntgen-Strahlen. 1908.

Ibid., Sammelreferat über Rhinologie. Zentralblatt für Ohrenheilkunde. 1907, p. 429.

Watson, Stereoskopische Skiagramme der Nebenhöhlen. Londoner Laryngologische Gesellschaft. January, 1907.

Weber, Die pathologischen Schädelformen. Handbuch der pathologischen Anatomie des Nervensystems. 1903.

Weber, R., De quelques altérations du tissu cerebral dues à la présence de tumeurs. Nouvelle Iconographie de la Salp. 1911, No. 2.

Weigert, Gummiknoten der Hypophysis cerebri. Virchows Archiv. Vol. LXV, p. 219.

Weil, Röntgen-Aufnahmen der Nebenhöhlen nach Injektion von schattengebenden Massen. Wiener klinische Wochenschrift. 1903, p. 1471 and 1904, No. 2, p. 61.

Ibid., Röntgen-Bild mit dem Nachweis der Kommunikation beider Stirnhöhlen. Wiener Laryngologische Gesellschaft. May 13, 1908. Ref.: Wiener klinische Wochenschrift. 1908, No. 34, p. 1893.

Weisenburg, Tumours of the Third Ventricle Brain. October, 1910.

Welcker, Untersuchungen über Wachstum und Bau des menschlichen Schädels. 1862.

Wendt, Alte und neue Gehirnprobleme. München. 1909.

Westphal, Über Akromegalie. Deutsche medizinische Wochenschrift. 1907, No. 22.

Wiedersheim, Bau des Menschen als Zeugnis für seine Vergangenheit. Tübingen. 1902.

Wiegmann, Ein Fall von Osteom des Siebbeins. Zeitschrift für Ohrenheilkunde und Krankheiten der Luftwege. Vol. LVII, Part 1.

Wieland, Der angeborene Weich- oder Lückenschädel. Virchows Archiv. Vol. CXCVII.

Ibid., Die Frage der angeborenen und hereditären Rachitis. Ergebnisse der inneren Medizin und Kinderheilkunde. 1910.

Wiesermann, Über Chondrodystrophia foetalis mit besonderer Berücksichtigung ihrer Entstehung durch mechanische Ursachen. Archiv für Entwicklungsmechanik. 1908, Vol. XXVI.

Wieting, Zur Chirurgie des Sinus perieranii. Deutsche medizinische Wochenschrift. 1911, No. 31.

Wilsner, Die Rassengliederung des Menschengeschlechtes. Politisch-anthropologische Revue. 1906.

Windle, Epignathus, Journal of Anatomy and Physiology. London 1898-1899.

Winkler, Eiterige Erkrankungen der oberen nasalen Nebenräume des Gesichtsschädels. Fortschritte auf dem Gebiete der Röntgen-Strahlen. Vol. VI, p. 79.

Ibid., Fälle von nasalen Nebenhöhlenerkrankungen. LXXIII. Naturforscherversammlung in Hamburg. 1901.

Ibid., Die Orientierung auf dem Röntgen-Bilde des Gesichtsschädels und das Studium der oberen Nasennebenhöhlen auf demselben. Fortschritte auf dem Gebiete der Röntgen-Strahlen. Vol. V, p. 147.

Ibid., In welcher Weise kann bei eiterigen Erkrankungen der oberen Nasennebenhöhlen das Röntgen-Bild des Gesichtsschädels den Operationsplan, diese Hohlräume durch äussere Eingriffe freizulegen, modifizieren? Fortschritte auf dem Gebiete der Röntgen-Strahlen. Vol. VI.

Ibid., Röntgen-Aufnahmen der Warzenfortsatzgegend XVI. Versammlung der Deutschen Otologischen Gesellschaft. Bremen. 1907.

Witt, Ausbreitung der Stirnhöhlen und Siebbeinzellen über die Orbita. Anatomische Hefte. 1908. Vol. XXXVII, Chap. 1.

Witzel, Entwicklung der Kiefer und Zähne beim Menschen. (Röntgen-Atlas.) 1907.

Wolf, Zur Kasuistik der Deformität des Gesichtsschädels bei angeborener. Angiombildung. Beitrag zur klinischen Chirurgie. 1909.

Wolf Therese, Beitrag zur Anthropologie der Orbita. Dissertation. Zürich 1906.

Wrede, Ostitis fibrosa circumscripta. Naturforscherversammlung in Köln. 1908.

v. Wyss, Beitrag zur Kenntnis der Entwicklung des Skelettes von Kretinen und Kretinoiden. Fortschritte auf dem Gebiete der Röntgen-Strahlen. III

Zappert, Organische Erkrankungen des Nervensystems. Handbuch der Kinderheilkunde von Pfaundler-Schlossmann, 1910, ed. 2.

Ziegler, Lehrbuch der pathologischen Anatomie. 1901-1902.

Ziehen, Nervensystem. Handbuch der Anatomie von Bardeleben. 1899.

Zöllner, Hypophysentumor. Unter-Elsässischer Verein in Strassburg June 26, 1909.

Zollschan, Das Rassenproblem. 1909.

Zuckermandl, Kranien der Novara-Expedition. Wien. 1875.

Ibid., Zur Anatomie und Entwicklungsgeschichte der Naso-Ethmoidal-Region. Medizinische Jahrbücher. Wien. 1878.

Zuckermann, Über ein knochenhaltiges Lipom am Tuber cinereum. Virchows Archiv. 1911, Vol. CCIII, Part 1.

Zybell, Die Entwicklung der Rachitis-Frage im letzten Jahrzehnt. Beihefte zur medizinischen Klinik, 1910, 6th Series, No. 12.

## INDEX

### A

- Abscesses, futility of trying to picture, 158  
proper method of determining presence of, 160
- Absence of impressions and erosions, 219
- Accessory sinuses, absence of, 258
- Achondroplasia, 94
- Acrania, 38
- Acrocephalosyndactylia, 40
- Acrocephalus, 61
- Acrocephaly, 40
- Aeromegalic giants, 102
- Aeromegaly, 124  
hemihypertrophy of the face in, 125  
hypophyseal tumors in, 178  
osteologic peculiarities of skull in, 125  
total destruction of the body of the sphenoid in, 187  
without a tumor of hypophysis, 126
- Actinomyces of the skull, 113
- Acusticus tumors, 201  
bone changes produced by, 202  
with erosion of the sella, 206  
with general pressure atrophy of the inner surface of the skull, 207  
with pathognomonic change of the dorsum sellæ, 203
- Agnathy, 40
- Angioma, 144  
racemosum, 146
- Angle, facial, determination of, 28  
sphenoid, 29
- Ankylosis of the jaw, 263
- Anomalies in contour of the orbit, 261  
in shape and size of the skull, relation of, to epilepsy, 240
- Anterior clinoid process, significance of plump appearance of, 169
- Anterior fossa, shortening and deepening of, in turriccephaly, 65

- Aplasia of the suprarenals, in connection with cerebral hypertrophy, 46
- Aprosopy, 40
- Arhinencephaly, 37, 40
- Arthritis of the jaws, chronic deforming, 264
- Atresia congenita, 259
- Atrophic and absorptive changes in the orbital wall, 261
- Atrophy, senile, 114

### B

- Barlow's disease, similarity of chloroma to, 140
- Basal kyphosis, 84  
osteologic peculiarities of, 84
- Basal tumors of the brain, 172
- Basilar invagination, 96, 98, 116, 118  
etiology of, 121  
mechanism of the origin of, 120  
symptoms of, 120
- Bathrocephaly, 48  
in migraine, 48
- Bilateral and unilateral widening of the meningeal veins, 209
- Bilateral erosion produced by sphenoparietal sinuses, 231
- Blood vessel furrows and canals, kinds of, 106
- Bone changes produced by acusticus tumors, 202
- Brachycephalic skull, 28
- Brachycephaly, 61
- Brain, basal tumors of the, 173  
development in rickets, 100  
relation of size of, and migraine, 250  
tumors of the base of the, 209  
tumors of the convexity of the, 213
- Brechet's veins, 229

### C

- Calcification in the brain in epilepsy, 244

- Calcification—Cont'd  
 of traumatic area of softening, 151  
 of pineal gland, 156  
 Calcified pineal gland, value of, in diagnosis, 156  
 Caoutchouc head, 117  
 Caput natiforme, 98  
   obstupum congenitum, 83  
   cause of, 84  
   progennium, characteristics of, 85  
   quadratum, 98  
 Carcinoma of the jaw, 263  
 Carcinomata of the nose, 255  
 Cavity osteomata, 139  
 Cephalhematoma, 145  
   frequency of, 148  
   usual site of, 148  
 Cephalomegaly, 132  
 Cephalonia, 45  
 Cerebral hypertrophy, 46  
   infantile paralysis, roentgen findings in, 238  
 Chloroma, 140  
 Cholesteatoma, 140  
 Chondrodystrophy, 94  
   osteologic peculiarities of, 95  
 Chordoma, 141  
 Cirroid aneurysm, 145  
 Clincephaly, 61  
 Convolutional impressions, 216  
   how produced, 215  
   on one side only, 219  
 Cranial capacity in scaphocephaly, 75  
   of growing skull, 43  
   of normal adult, 42  
 Craniocerebral topography, 26  
 Craniopagus, 37  
 Craniostenosis, 38  
 Craniostenosis, 58  
   as cause of changes in shape of skull, 225  
   cerebral symptoms of, 59  
   disproportion between skull and its contents in, 218  
   x-ray in diagnosis of, 60  
 Craniostenotic skull, thickness of the, 58  
 Cretin saddle-nose, 91  
   thickness of skull in, 91  
 Cretinism, 90  
   x-ray in diagnosis of, 93  
 Cretins, diagnosis of abnormal size of sella in, 176  
   skull vault in, 91  
 Cysts of the jaw, 263
- D
- Dead bodies of the accessory sinuses, 255  
 Death, sudden, associated with craniostenosis, 81  
 Deformities of the skull, classification of, 35  
 Dermoid, 144  
   cysts, 145  
 Diagnosis of abnormal size of sella in cretins and eunuchs, 176  
 Diagnostic utility of the skull changes in acusticus tumors, recognizable on the roentgenogram, 202  
 Dicephalus, 37  
 Diffuse and tumor-like hyperostoses, 132  
 Diploic veins, most numerous and largest, 230  
   normal, 230  
 Diseases of the mandibular joint, 263  
 Diseases of the skull, 34  
 Dolichocephalic skull, 28, 60  
 Dolichocephaly, 60  
 Dorsum sellæ, acusticus tumor with pathognomonic change of the, 203  
 Dwarf growths, 101  
 Dysostosis cleidocranialis, 96  
 Dysplasia periostalis, 95  
 Dystrophia adiposogenitalis, cases with sellar erosion, 189, 190  
   hypophysal tumors in, 188  
   total destruction of sella in, 191
- E
- Elsässer's craniotabes, 98  
 Embryonic development of the skull, 31  
 Enchondroma, 141  
 Enchondrosis ossificans, 141  
 Endothelioma of the dura mater, hyperostosis associated with, 236  
 Enostoses, 139  
 Epignathus, 37  
 Epilepsy, calcification in the brain in, 244  
   frequency of positive x-ray findings in, 246  
   occurring in hydrocephalus, 241  
   relation of the anomalies in shape and size of the skull, 240  
   roentgen findings in, 238



- Erosion due to a former process, 225  
 features determining degree of, under pressure, 217  
 of sella in acromegaly, 178  
 of the inner surface of the skull in excessive intracranial pressure, 215  
 of the sella, pathologic processes leading to, 172
- Eunuchoid giants, 102
- Eunuchs, diagnosis of abnormal size of sella in, 176
- Exophthalmus, 261  
 pulsans, 262
- Exostoses, 139
- Exostosis of the skull, multiple cartilaginous, 139
- Eye changes in turriccephaly, 67
- Eyes, prominence in turriccephaly, 64
- F
- Fibroma, 244
- Fibromata, 145
- Fissures, ossification of, 56
- Foreign bodies in the orbit, 260
- Fractures of the skull base, 259
- Frontal sinus, absence of, 259  
 development of, 258  
 frequency of large, 259
- G
- Gall's system of phrenology, 31
- German horizontal, 27
- Giant growths, 102
- Giants, acromegalic, 102  
 eunuchoid, 102
- Gigantism, contralateral, 103  
 unilateral, 103
- Gnathouranoschisis, 40
- Granulomata of the jaw, 263
- H
- Halisteresis, 115
- Headache, 246
- Hearing in turriccephaly, 67
- Helmet-head, 133
- Hemangioma venosum, 144
- Hemicraniosis, 133
- Hemihypertrophia facialis progressiva, 102, 103
- Hemihypertrophy of the face in acromegaly, 125
- Hereditary syphilis, 109
- Heredity in Paget's disease, 130
- Hernia, brain, site of, 38
- Hydatid cysts, 140
- Hydrocephalus, 45  
 disproportion between skull and its contents in, 218  
 division of the parietal bone in, 48  
 epilepsy occurring in, 241  
 signs of, 50  
 shape of skull in, 47  
 symmetry of, 49  
 syphilitic, 49
- Hydrorrhoea nasalis, 220
- Hyperbrachycephalus, 61, 63
- Hyperostoses, diffuse and tumor-like, 132
- Hyperostosis associated with endothelioma of the dura mater, 236  
 associated with icterus, 127  
 during pregnancy, 128  
 of one squama temporalis, 133  
 of one-half of the sphenoid bone, 133  
 syphilitic, 127  
 tumor-like, pathology of, 132
- Hyperplastic osteitis, 127
- Hypertrophic pulmonary arthropathy, 127
- Hypertrophy of the brain, disproportion between skull and its contents in, 218
- Hypophyseal tumors, classification of, 177  
 in acromegaly, 178  
 in dystrophia adiposogenitalis, 188  
 x-ray in diagnosis of, 174
- Hypophysis, swelling of, during pregnancy not determined by x-ray picture, 167  
 tumors of the, 162
- I
- Idiocy in rachitis, 100  
 roentgen findings in, 238
- Idiopathic osteopsathyrosis, 96
- Infantilism, 188
- Inflammations of the skull bone, 107
- Inienecephaly, 38
- Intelligence in turriccephaly, 67
- Interconvolutional ridges, 216
- Internal pressure, chronically increased, as cause of changes in the contour of the skull, 224

- Intracranial contents, directly discernible in a roentgen picture, 155  
 visibility of, on x-ray plates, 156  
 diseases, roentgen diagnosis of, 155  
 technic of roentgen examinations in, 252  
 pressure, chronically increased, as cause of skull thickening, 236  
 chronically increased, as cause of suture changes, 226  
 evidence of increased, 161  
 increased, as cause of widening of the venous canals, 229  
 structures that are recognizable on the x-ray plate, 157  
 tumors, disproportion between skull and its contents in, 218  
 local destruction of, 162  
 skull changes produced by, 160
- Invagination, basilar, 118
- K
- Kyphosis, basal, in hydrocephalus, 49  
 osteologic peculiarities of, 84  
 of the skull base, 29
- Kyphotic skull, 83, 84  
 osteologic peculiarities of, 84  
 similarity to caput progeneum, 84
- L
- Lacuna skull, 99  
 Leontiasis ossea, 132  
 Leptocephaly, 60  
 Linear index, 27  
 Lipoma, 144  
 Lissauer's method for measuring the skull, 26  
 Lückenschädel, 39, 41  
 Lymphosarcoma, favorite site of, 40
- M
- Malformation of the skull, 36  
 Malposition of the teeth, 263  
 Marantic atrophy, 116  
 Measurements of skull, 27  
 Megalocephalus, 132  
 Meningeal veins, widening of the, 209  
 Meningocele traumatica spuria, 149  
 Meroerania, 38
- Mesocephalic skull, 28  
 Metastatic tumors of the skull, 138  
 origin of, 140  
 Metopism, 30  
 Microcephalic skull, description of, 43  
 Microcephalus vera, 42  
 Microcephaly, 42, 45  
 Micrognathia, 263  
 Micrognathy, 40  
 Micromelia, 94  
 Migraine, 246  
 bathrocephaly, 48  
 causes of, in tumors of the brain, 247  
 pressure erosions in, 251  
 relation of, and size of brain, 250  
 roentgen findings in, 238  
 skull asymmetry in, 251  
 varieties of symptomatic, 247
- Mongolian idiot, 93  
 Mucoceles, 255  
 Myeloma, 140
- N
- Nanosomus, 101  
 Nasal septum, deviation of, in turriccephaly, 65  
 Necrosis of the jaw, 263  
 Neuralgia, 246  
 of the second and third branches of the trigeminal nerve on the left side, 264  
 Neurotic atrophy, 117  
 Nevus, 147  
 Noise in the head, 260  
 Norma frontalis, 26  
 occipitalis, 26  
 temporalis, 26  
 verticalis, 26  
 Normal giants, 102
- O
- Obesity, 188  
 Obliteration of the sutures of the orbit, time of beginning and completion, 261  
 Odontology, 263  
 Ophthalmology, 260  
 Orbit, anomalies in the contour of, 261  
 foreign bodies in the, 260  
 Orthognathic skull, 29  
 Os bregmaticum, 30  
 inca, 30  
 japonicum, 31  
 Ossification of fissures, 56  
 of sutures, succession in, 30

Ossifying osteitis, 109  
 Osteitis deformans, 128  
   characteristic changes of the skull in, 128  
   osteologic peculiarities of, 129  
 fibrosa, 128  
 hyperplastic, 127  
 occurring in leukemia in malignant tumors, chronic, arsenic and phosphorus poisoning, 127  
 ossifying, 109  
 rarefying, 108  
 Osteofibromata of the jaw, 263  
 Osteogenesis imperfecta, 95  
   tarda, 96  
 Osteologic peculiarities of scaphocephaly, 72  
   of turriccephaly, 62-66  
 Osteoma in the orbit, 261  
   of the face, 139  
 Osteomalacia, 115  
   puerperal, 115  
 Osteomata, 139  
   of the jaw, 263  
   of the nose, 255  
 Osteomyelitis, acute, 107  
 Osteoperiosteal lipomata, 146  
 Osteophyte formation in syphilis, 109  
 Osteophytes, puerperal, 128  
 Osteopsathyrosis, 114  
 Osteosarcoma, 139  
   in the orbit, 261  
 Otology, 259  
 Oxyccephaly, 40, 61

## P

Pacchionian fossæ, time of appearance, 106  
 Pachycephaly, 61  
 Paget's disease, 128, 259  
   etiology of, 129  
   heredity in, 130  
 Pathologic giants, 102  
 Phosphorus necrosis of the skull, 113  
 Pineal gland, calcification of, 156  
 Plagiocephaly, 61, 62, 77  
 Platybasia, 29  
 Platycephaly, 61  
 Plexiform angioma, 146  
 Pneumatoceles, 146, 255  
 Polymyositis ossificans, 139  
 Porencephalia traumatica, 149  
 Precociousness, 104  
 Pregnancy, hyperostosis during, 128

Pressure erosions in migraine, 251  
 Pseudomicrocephalus, 42  
   with infantile cerebral paralysis and epilepsy, 241  
 Pseudoturriccephaly, 68  
 Psychosis, roentgen findings in, 238  
 Prognathic skull, 29  
 Puerperal osteophytes, 128

## R

Races showing scaphocephaly, 75  
 Rachitic changes, time of, 99  
 hyperostosis, 100  
   proliferative periostitis, 131  
 Rachitis, 98  
   idiocy in, 100  
   similarity to osteitis deformans, 131  
   tarda, 100  
 Rarefying osteitis, 108  
 Recessus supraorbitalis, 258  
 Regnault's platybasia, 98  
 Relation of classes of hypophyseal tumors to clinical conditions, 162  
 Retention of the teeth, 263  
 Rhinology, 254  
 Rickets, brain development in, 100  
   premature suture synostosis in, 100  
 Roentgen diagnosis of intracranial diseases, 155  
   examination for the diagnosis of basal intracranial tumors, 210  
   examinations in intracranial diseases, 252  
   findings in epilepsy, cerebral infantile paralysis, idiocy, psychosis, and migraine, 238

## S

Sagittal suture, signs of, 75  
 Sarcoma metastases as cause of osteoporosis, 260  
   of the skull bones, favorite sites of, 139  
   origin of, 139  
 Sarcomata of the jaw, 263  
   of the nose, 255  
 Scaphocephaly, 61, 72  
   clinical symptoms, 74  
   cranial capacity in, 75  
   etiology of, 76  
   frequency of, 74  
   osteologic peculiarities of, 72

## Scaphocephaly—Cont'd

- persistence of frontal suture, 75
- races showing, 75
- synostosis of sagittal suture, 75

## Scaphoid head, 72

## Scoliotic skull, 83

## Sella:

- acoustic tumor with, 206
- asymmetrical widening of the, 167
- destruction resulting from intrasellar hypophyseal tumors, 168
- diagnosis of abnormal size of sella in cretins and eunuchs, 176
- erosion of, in acromegaly, 178
  - in hydrocephalus, 52
  - without symptoms of trophic disturbances, 193, 195
- in childhood, 166
- moderate widening of, in acromegaly, 181
- pathologic changes of, produced by tumors of the hypophyseal entrance, 169
- relation between the extent of destruction and the manifestation of acromegaly, 171
- total destruction of, in dystrophia adiposogenitalis, 191
- varieties of normal, 164

## Sellar erosion in dystrophia adiposogenitalis, 189, 190

## Senile atrophy, 114

- usual sites of, 114

## Sexual differences of the skull, 39

## Sinus sphenoparietalis, 232

## Sinusecele, 145

## Skull:

- actinomycosis of the, 113
- anomalies in the structure of, 105
- artificial alteration of, 86
- artificial deformities of the, 86
- asymmetry due to anomalies in soft tissues, 85
  - in genuine migraine, 251
- atrophic and hyperostotic changes in the, 113
- bone, inflammations of, 107
- brachycephalic, 28
- changes in consequence of chronic excessive intracranial pressure, 215
- changes in the contour of, in consequence of chronically increased internal pressure, 224

## Skull—Cont'd

- changes of, in osteitis deformans, 128
- changes produced by intracranial tumors, 160
- circumference of, 42
- defects, characteristics of, 38
- deformities of, 35
  - due to position, 82
  - due to systemic diseases of the skeleton, 89
  - in consequence of premature suture synostosis, 56
- diseases of the, 34
- disturbances of development, 35
  - causes, 35
  - in growth due to anomalies in contents, 41
  - in growth due to anomalies in the soft tissues, 85
- dolichocephalic, 28
- during embryonic development, 34
- growth, 35
- injuries of the, 147
- kyphotic, 83, 84
- length of, 27
- local destruction of, in intracranial tumors, 162
- malformation, 36
- mesocephalic, 28
- microcephalic, description of, 43
- normal structure of, 105
- orthognathic, 29
- osteologic peculiarities of, in acromegaly, 125
- phosphorus necrosis of the, 113
- prognathic, 29
- scoliotic, 83
- shape of, in hydrocephalus, 47
  - normal, 22
- size of normal, 21
- slanting, 77
- soft, 99
- syphilis of the, 108
- thickening caused by chronically increased intracranial pressure, 236
- thickness of normal, 22
- tuberculosis of the, 112
- tumors of the, 138
- vault in cretins, 91

## Slanting skull, 77

## Soft skull, 99

## Spasmophilia, association of, with rickets, 101

## Spasmus nutans, association of, with rickets, 101

- Sphenocephaly, 60
- Sphenoid:
- angle, 29
  - bone, primary diseases of the body of the, 172
  - sinus, development of, 258
  - total destruction of the body of, in acromegaly, 187
  - total destruction of, without trophic disturbance, 200
- Sphenooceipital synchondrosis, time of ossification of, 227
- Suture changes in consequence of chronically increased intracranial pressure, 226
- formation, 34
  - obliteration, premature, 227
  - serrations, development of, 91
  - synostosis, premature, in rickets, 100
- Sutures, obliteration of, in osteitis deformans, 131
- ossification of, 30
- Swelling of hypophysis during pregnancy not determined by x-ray picture, 167
- Synostosis, cause of premature, 57
- premature, 57
  - secondary premature, 80
- Synotia, 40
- Syphilis, hereditary, 109
- of the skull, 108
- Syphilitic hydrocephalus, 49
- hyperostosis, 127
- Systemic diseases of the skeleton as cause of deformities of the skull, 89
- T
- Technic of roentgen examinations in intracranial diseases, 252
- Tetany, association of, with rachitis, 101
- Topographic relations of brain to skull, 26
- Toxic osteoperiostitis ossificans, 127
- Traumatic meningocele, 150
- Tribasilar synostosis, 91, 95
- Trigonocephaly, 37
- symptoms of, 38
- Trochocephaly, 61
- Tuberculosis, forms of, 112
- of the skull, 112
- Tumor-like hyperostosis, pathology of, 132
- Tumors:
- acusticus, 201
  - basal, intracranial, roentgen examination for the diagnosis of, 210
  - futility of trying to picture, 158
  - of the base of the brain, 209
  - of the brain, causes of migraine in, 247
  - of the convexity of the brain, 213
  - of the hypophysis, 162
    - without symptoms of trophic disturbance, 193  - of the skull, 138
  - of the skull bones, 139
    - primary, 138  - of the soft tissues of the cranium, 144
  - proper method of determining presence of, 160
- Turmschädel, 61
- Turret head, 62
- Turriccephaly, 61, 62
- a deviation of the nasal septum in, 65
  - clinical symptoms, 66
  - eye changes in, 67
  - hearing in, 67
  - intelligence in, 67
  - osteologic peculiarities of, 66
  - predominance, 62
  - prominence of eyes in, 64
- U
- Unilateral and bilateral widening of the meningeal veins, 209
- V
- Varix spurius traumaticus, 150
- venae diploëticae, 145
- Venous canals of the skull, widening of, caused by increase in intracranial pressure, 229
- W
- Wormian bones, etiology of, 48
- X
- X-ray in diagnosis of craniostenosis
- 60
  - in diagnosis of cretinism, 93
  - in diagnosis of hypophyseal tumors, 174
  - in determining surgical treatment of hypophyseal tumors, 174















