

STEREOROENTGENOGRAPHY

Pulmonary Tuberculosis

BY
KENNON DUNHAM, M. D.

PART II.



THE SOUTHWORTH COMPANY
TROY, N. Y.



THE LIBRARY
OF
THE UNIVERSITY
OF CALIFORNIA
LOS ANGELES

GIFT

of

LOUIS B. ROCKLAND

Stereoroentgenography

PULMONARY TUBERCULOSIS
KENNON DUNHAM, M. D.

PART II.



PUBLISHED BY
THE SOUTHWORTH CO.
TROY, N. Y.

Biomedical
Library

WF
300
D921A
M.2

Copyrighted by
THE SOUTHWORTH COMPANY, Publishers
Troy, N. Y.

Fibroid Tuberculosis

¶ Fibroid tuberculosis deserves especial consideration because the process is slow, the prognosis is comparatively good, the roentgen findings are exact, and brilliant deductions can be made by those having only a meager knowledge of this subject. Tuberculosis is essentially a disease of fibrosis. I contend that it is the fibrosis changes which make the characteristic tuberculosis markings. Thus it is but natural that the type of tuberculosis which has the most extensive fibroid change should give the most striking picture.¹

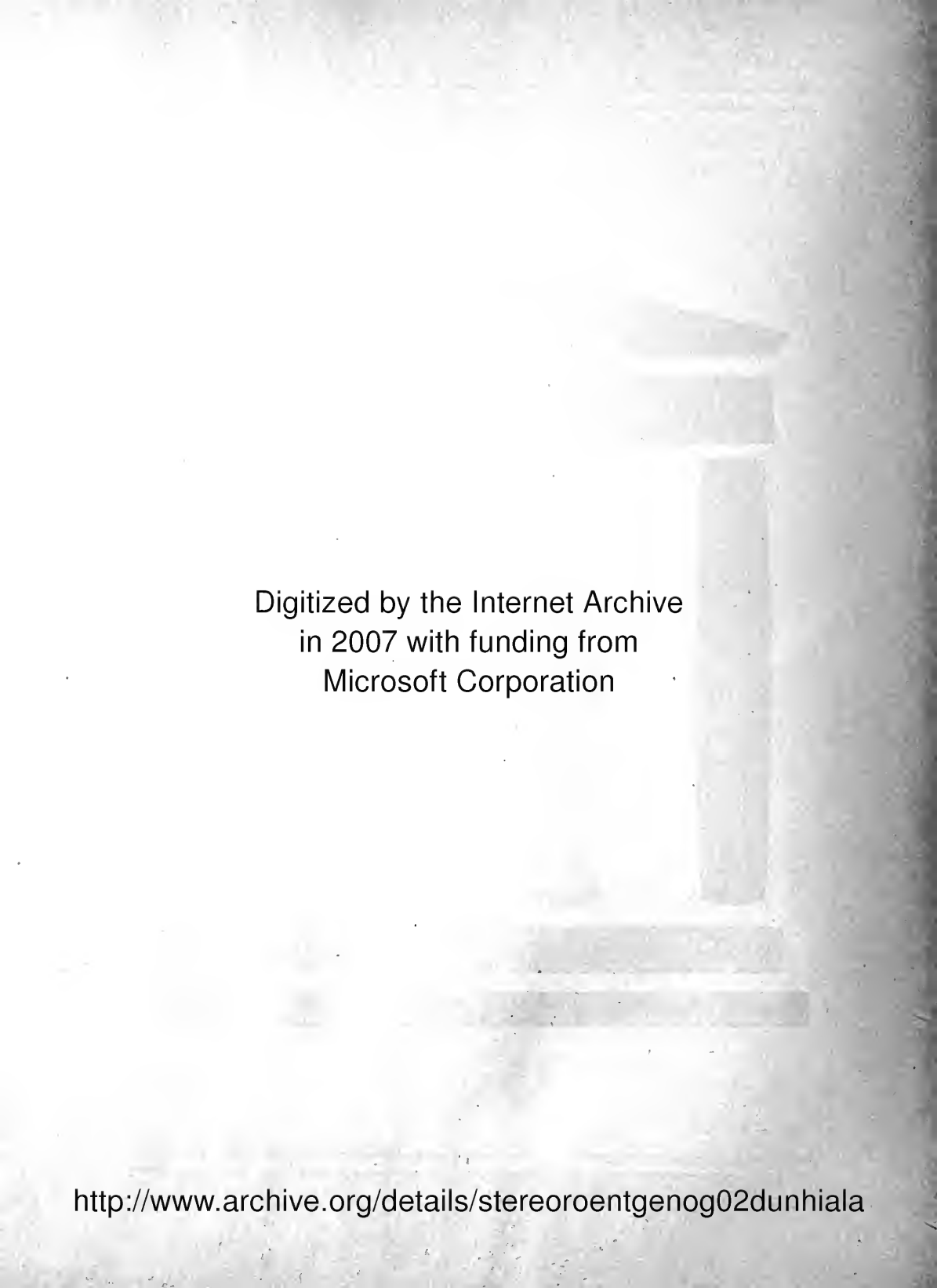
¶ No other diagnostic method can compare with these stereoroentgenograms in making the diagnosis so early, in marking so exactly the extent and character of the lesion, in suggesting the original seat of infection, or in predicting so correctly the prognosis of fibroid tuberculosis.

¶ If roentgenologic and diagnostic methods were limited to this one variety of tuberculosis, the necessary expense and laborious technique would be justified.

¶ Physical examinations suggested in Stereos 18, 19 and 20, a small heart; in Stereos 21 and 22, an unexplained heart position; in Stereo 25, a large heart. The plates cleared the diagnosis and explained the trouble, while the additional knowledge enabled me to draw better conclusions from the physical findings.

¶ It is impossible to secure sufficient post-mortems to gain an adequate understanding of how frequently and how extensively the thoracic viscera may be distorted; especially to realize that patients with such lesions may live comfortably and work for a long time.

¹ Stereos 18, 26.



Digitized by the Internet Archive
in 2007 with funding from
Microsoft Corporation

<http://www.archive.org/details/stereoroentgenog02dunhiala>

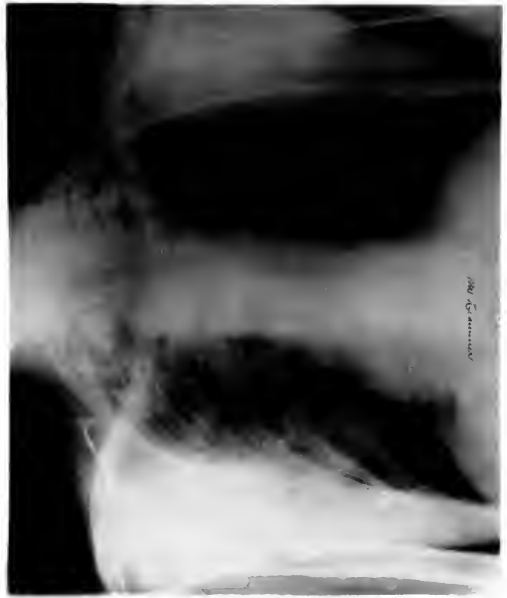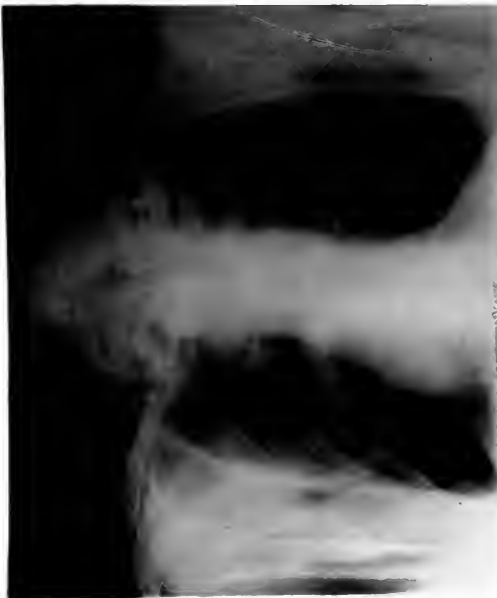¶ Further, these cases of fibroid tuberculosis where the tuberculous lesions are clear cut and vividly shown enables us to obtain, by contrast, a better understanding of the pathology of secondary infection. The latter is only catarrhal condition, has no fibrosis and shows no plate changes.



Fibroid Tuberculosis.

[Stereo 18.]

- ☐ Fibroid tuberculosis, with distortion of heart and aorta.
- ☐ Male, forty-nine years. Sputum positive. Both sides involved. The left more advanced.
- ☐ Roentgen findings confirm clinical findings.
- ☐ The interspaces are narrow and ribs drop sharply from spine, and eighth and ninth on left side are irregular. This is probably due to the contractile effect of a thickened pleura, which cannot be made out objectively, due to compensatory emphysema, especially at right base. Right diaphragm is higher than left, but they are both much flattened.
- ☐ The heart and aorta are drawn up and to the left by fibrosis in upper left. The lesions below the second rib are atypical, and if it were not for the characteristic lesions of the apices, the X-ray findings alone could not classify this case as tuberculous.

Stereo 18.**Serial N^o 1113**

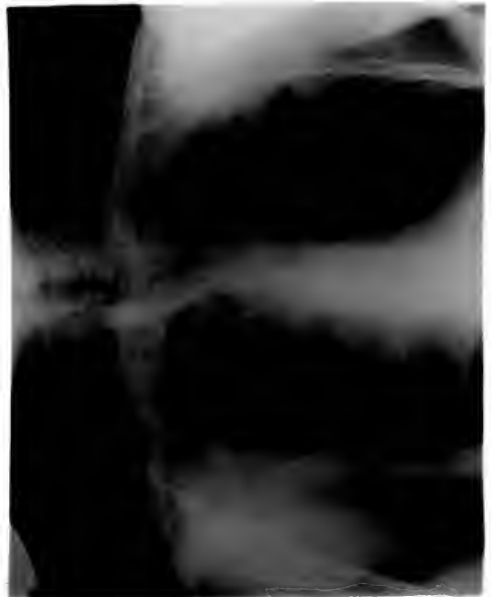
Fibroid Tuberculosis, with Lesion.

[Stereo 19.]

☐ Unusual lesion in upper left. This is the only stereo in this volume not viewed through the back—here clavicles are closest to eye.

☐ Trunks and linear markings of right upper obliterated by mass of fibroid tissue.

☐ Left upper also contains fibrous tissue, but further shows areas of increased and decreased densities which require explanation. The area of decreased density surrounding entire left apex and coming between it and mediastinum as low as top of aorta, and showing no lung markings is probably a partial pneumothorax limited by pleural adhesions. To decide the character of this area the patient swallowed some bismuth, which in the esophagus, makes increased density to left of spine.

Stereo 19.**Serial N^o 1057**



Fibroid Tuberculosis and Distortion Mediastinal Viscera [Stereo 20.]

☞ Distorted viscera. This case has a long standing tuberculous history. Outline of the heart density completely obliterated and both upper lobes destroyed. Upper right is almost homogeneous and is probably the older lesion, while in upper left the separate lesions of the vertebral, first and second interspace trunks can be seen.

☞ Lower left lobe is carrying almost entire burden of aeration.

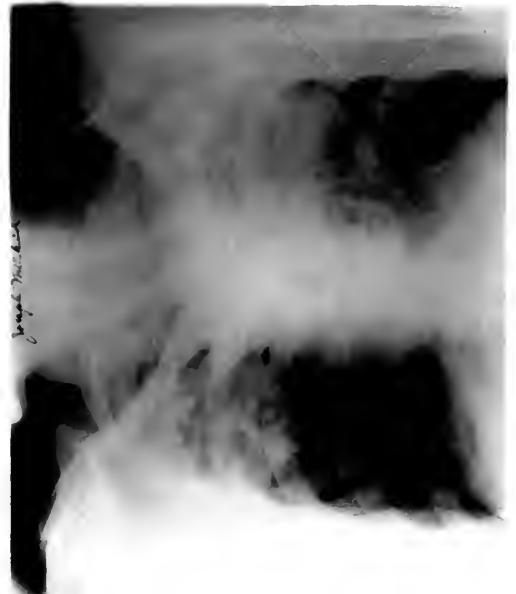
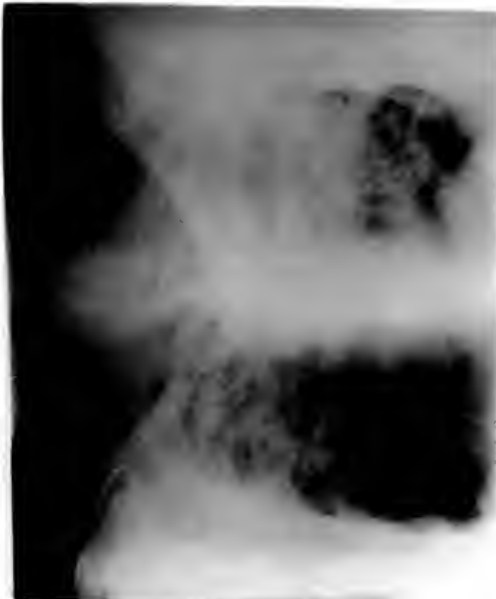☞ Great distortion of thoracic viscera, as shown in this case, is most interesting. The heart density cannot be made out. Almost entire right thorax and large part of left thorax is occupied by fibrous tissue.

☞ Auscultation in these cases is quite characteristically harsh, with rough and prolonged expiration, but seldom is such an area flat. Loss of resonance is usual, but frequently, as over the upper left, the note is distinctly hyper-resonant.

☞ The prognosis is clear. Life hangs on the ability of the lower left lobe to functionate.

Stereo 20.

Serial No. 1117





Fibroid Tuberculosis, with Distorted Viscera.

[Stereo 21.]

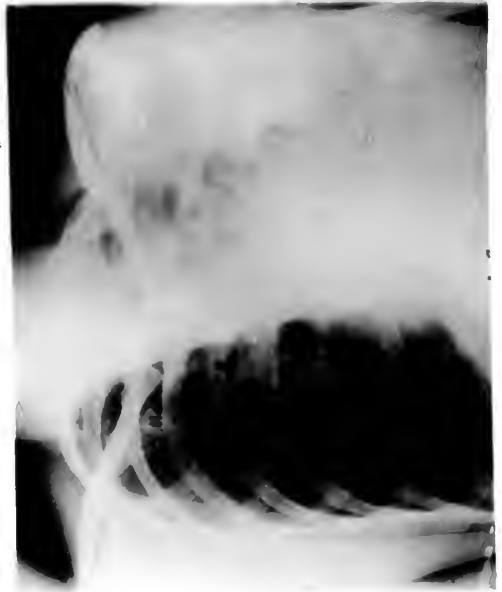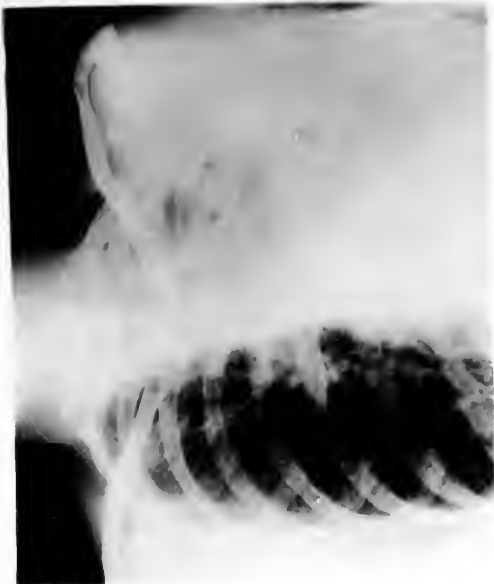☞ Age twenty-five years, admitted to hospital 1909. Left side markedly emphysematous. Right side tuberculosis. Patient did well until March, 1913, when no rales could be heard on right side, but left showed marked activity.

☞ Physical examination suggested that right side had healed, and collapse of left lung was considered. Plates show how quickly death would have followed such a procedure.

☞ Note the heart and trachea drawn to right of spine. Left diaphragm flattened. Left interspace wide with abnormally dark left thorax—these findings prove emphysema.

☞ The left vertebral and first interspace trunks are named together, but they can be clearly followed from the hilus to the periphery, and behind the first rib the markings are so studded as to suggest golden rod.

☞ Such markings are typically tuberculous.

Stereo 21.**Serial N^o 1138**

Fibroid Tuberculosis, with Distortion of Viscera.

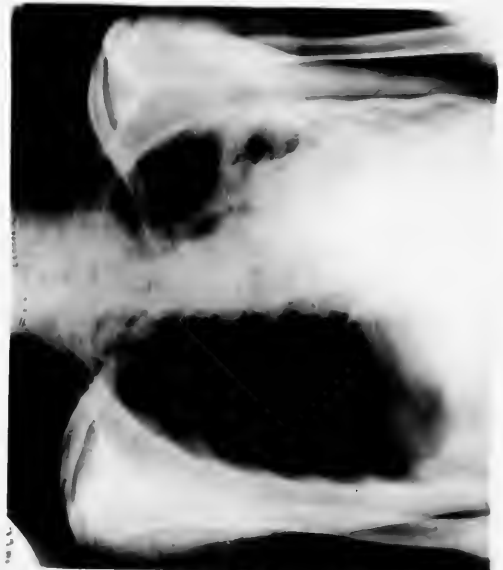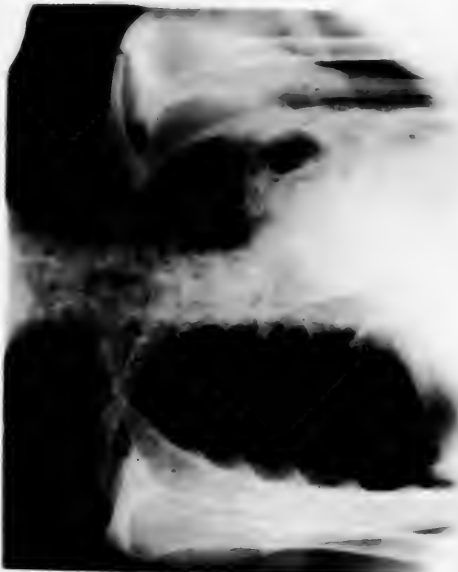[Stereo 22.]

☞ Long standing tuberculosis history. Heart is drawn to the right and lost in a mass of increased density which obliterates lower right division. Left side indicated by large gas bladder below the diaphragm. Trachea is drawn sharply across spine and far into the right thorax.

☞ In upper right there is a dark area, in which lung markings can be made out. This is either a large cavity or a partial pneumothorax, probably the latter. Patient has been under observation for two years.

☞ The entire left side is emphysematous, except at the apex, where the fibrous bands can be seen drawn to the right side. This shows how nature, through the action of fibrous tissue, will distort the thoracic viscera in her attempt to replace destroyed lung parenchyma.

☞ Thus the production of an artificial pneumothorax is only following nature's own method.

Stereo 22.**Serial N^o 1136**



Fibroid Tuberculosis. Cavities at Apices.

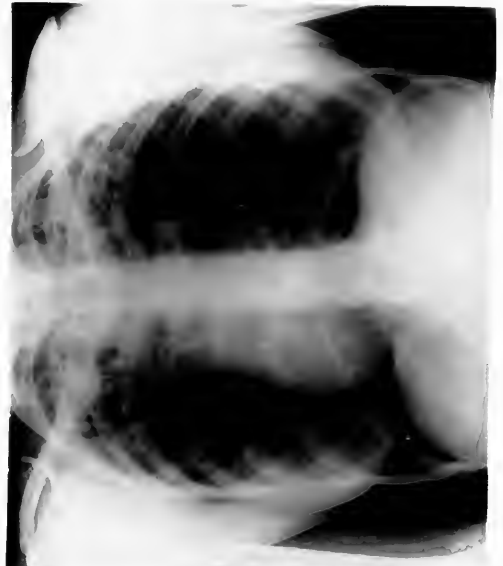
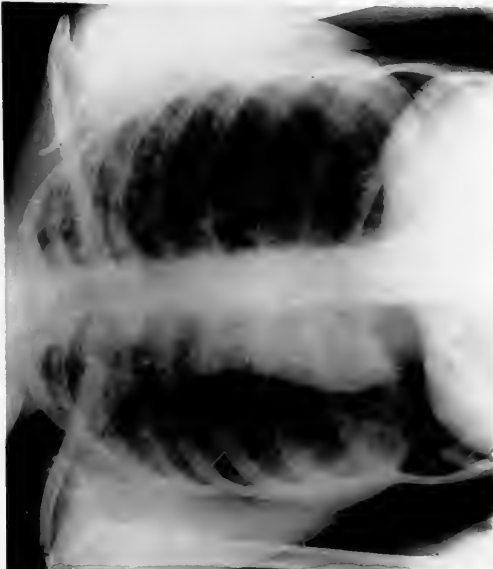[Stereo 23.]

☐ Fibroid tuberculosis—girl, twenty years old, worked in shoe factory. Physical signs and clinical symptoms, while positive, in no way suggested a lesion so extensive or so long standing.

☐ Both apices extensively involved. Cavities seen in left upper, suggested in right upper. Trunks and markings obliterated, but lesions extend from periphery to hilus. While all lobes involved, oldest and most extensive lesions are in upper lobes. Upper left probably seat of earliest infection because cavities are large and heart and aorta are drawn up and decidedly to left.


☐ Left bronchus seen passing under aortic arch between second rib and sixth interspace, which is abnormally high.

Stereo 23.

Serial N^o 1166



☞ Plates in such a case are most valuable because they indicate a grave prognosis and the necessity of very exacting treatment, neither of which are suggested by the appearance of the patient. In this case the girl's parents thought her able to marry.



Fibroid Tuberculosis and Cavities.

[Stereo 24.]

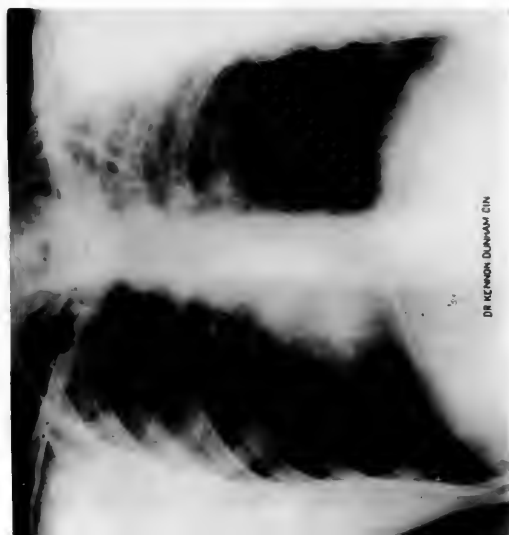☞ Male, aged twenty. Sputum positive. Physical and Roentgen examination agreed, except that through latter alone, cavity formation was discovered. All lobes involved, except lower left, which is emphysematous.

☞ The upper right lobe is entirely destroyed by cavity formations in the upper half and fibrosis of the lower half. Over cavities the percussion sound is hyper-resonant. Merged lower and middle right divisions badly involved.

☞ In upper left lobe early active tuberculous lesions are seen. Three distinct trunks are involved from periphery to hilus. The vertebral are most involved and have a heavy mottled cloud, which extends from the periphery at the apex to the top of the hilus. The first interspace trunks are involved from periphery almost to hilus, but the mottled cloud is less dense. The second interspace trunks are least

Stereo 24.

Serial No. 1115



involved in division. There is a light mottled cloud seen near periphery and connected to hilus by long, thin trunk of increased density. Such a lesion as that seen in the upper left division is pathognomonic of tuberculosis and almost certainly active.



Fibroid Tuberculosis, with Cavity Formation.

[Stereo 25.]

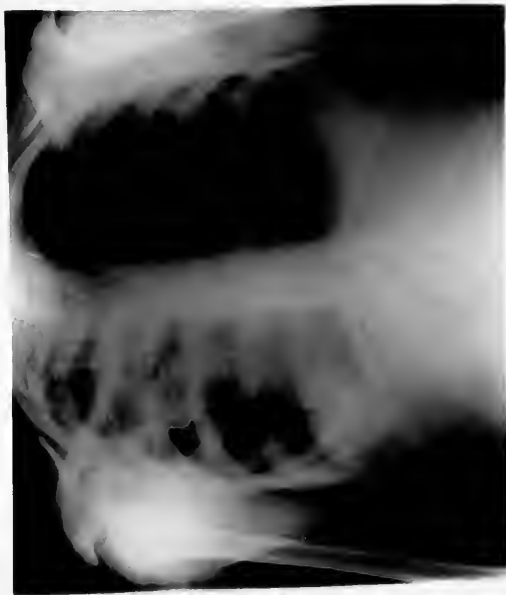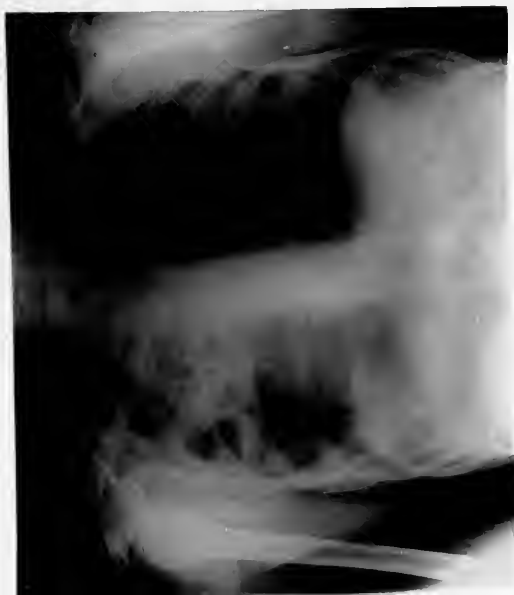
¶ Patient, eighteen years old when plates were taken. She lived two years after lung had reached this condition. Tubercle bacilli found.

¶ Physical and X-ray examinations agreed. Left diaphragm very high, heart drawn far into the left thorax and upper left lobe entirely replaced by cavities and fibrous tissue.


¶ Upper right lobe is emphysematous and least involved, but on original plates each trunk group, with its linear markings, is involved.

¶ The middle right division shows the greatest involvement of any right lobe, although its exact outline is obscured by disease, fibrosis and distortion of thoracic viscera

Stereo 25.

Serial N^o 1168

at the age of eighteen. Such cases are more common than is generally known, and are usually called hasty consumption. I believe that this girl's life was much prolonged by the care and education which she received at Saranac.



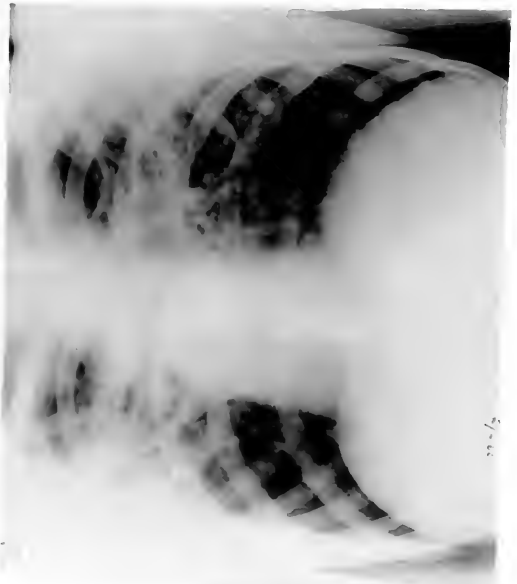
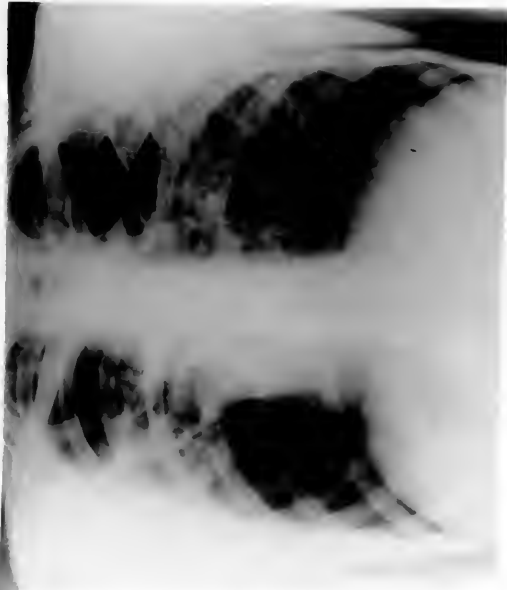
Fibroid Tuberculosis, with Cavities.

[Stereo 26.]

¶ Large cavities found at both apices. The heart density is small and apparently drawn up. The mediastinal density is so great that the trachea and aortic shadows are obscured. Both upper divisions are destroyed. Heavy bands of fibrous tissue wall off the cavities, which extend on both sides below the second rib. The lung is so completely destroyed at the upper right, as to make one think of a partial pneumothorax.

¶ The middle right division is badly involved. The lower left division is the least involved. The lesion in the lower right is extensive, but when compared with the middle right it seems slight.

¶ This case is particularly interesting because the patient, to the general observer, appears perfectly well, and because of the clear marking out of the middle right lobe.

Stereo 26.**Serial No. 1059**

Pulmonary Tuberculosis, with Hydro-Pneumothorax.

[Stereo 27.]

☞ The hydro-pneumothorax is at right base. Boney frame work normal. Right diaphragm is obscured. Heart and aorta are pushed to the left, due to the usual increased air pressure of these cases.

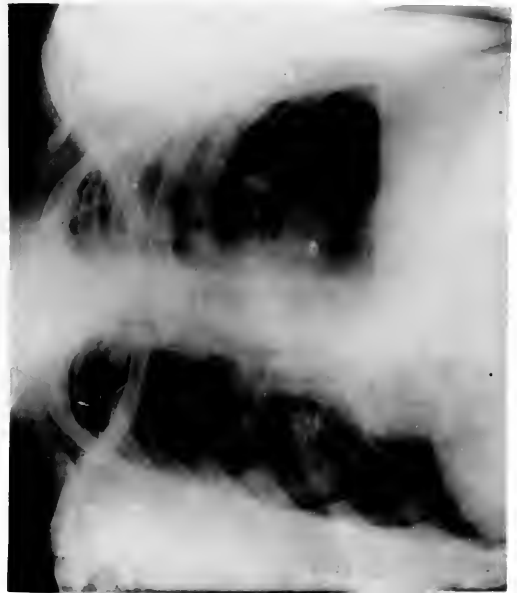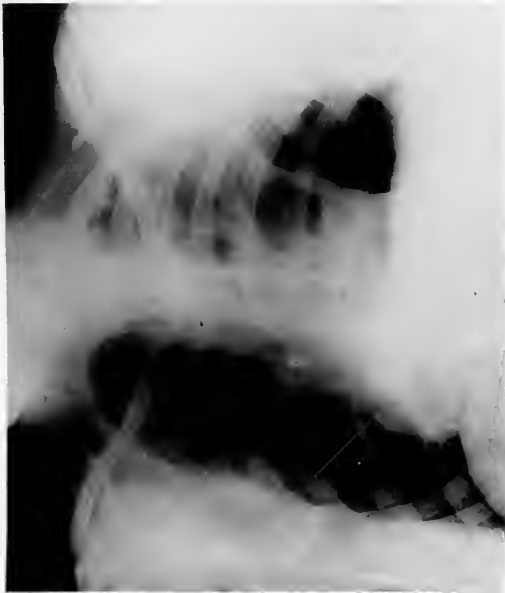
☞ The upper part of the lower right lobe and almost all of the upper right lobe are attached to the thoracic wall by adhesions.

☞ A horizontal line is seen at the right base, caused by the fluid below and the air above; this is pathognomonic of hydro-pneumothorax. A simple hydro-thorax would show the curved line typical of that condition.

☞ The entire left thorax shows the characteristic tuberculous markings. The vertebral and second interspace trunks of the upper left division are most involved.

Stereo 27.

Serial No. 1058





Therapeutic Pneumothorax, Safeguarded by Stereoroentgenograms.

¶ Artificial pneumothorax is the introduction into the intrapleural space of an innocuous, slowly absorbable gas, which will collapse the diseased lung. The treatment is repeated until the clinical symptoms warrant the gradual cessation of the injections and the consequent normal re-inflation of the lung.

¶ This collapse and forced rest or immobilizing of the lung is indicated by the proved value of rest in the treatment of all tuberculous infections. Perhaps, nature, too, has given her suggestions as to palliative measures for tuberculosis, in the restricted muscular action of the chest, by¹ the pleuritic effusion,² the hydro-pneumothorax³ and the closing of a large lesion with the drawn-over heart, often found in these cases.⁴

¶ The lack of contra-indications in properly selected cases is the best recommendation for induced pneumothorax. The operation is simple, the danger slight, the shock nil, and the effects most satisfactory.

¶ The results and effects of this therapy are positive. The principal pathologic findings after collapsing the lung are that the cavities are emptied in part or in whole according to the extent of the pleural adhesions, caseous areas have become cicatrized, and above all, an extensive overgrowth of the fibrous tissue is permitted during the enforced lung rest, which is nature's best method of healing such a condition.

¹ Stereo 14. ² Stereo 27. ³ Stereo 22. ⁴ Stereos 20, 21, 28, 29, 30, 31.



¶ The clinical effects of pneumothorax are most encouraging and are really what we have been working for, in the absence of definite proof that we might obtain a cure by this treatment.

¶ In the first place, with the introduction of the nitrogen, the lung collapses, except where held out by pleural adhesions.⁵ Any pain which follows injection is always due to the stretching of these pleural adhesions. Pleural bands have invariably been made out in close proximity to an indicated area of tenderness. The pain is always sharpest just after refilling, and gradually becomes duller. It is remarkable, but true, that a patient suffers no other pain and comparatively little inconvenience of any kind, even when a whole lung is collapsed to a mere solid mass lying close to the spinal column. With the progressive treatment, all detrimental symptoms abate. The diminished amount of retained infectious material shows the usual results of lessened toxic absorption—a fall in temperature and a reduced number of night-sweats, increased strength and appetite and final gain in weight. In addition, both the cough and the sputum are greatly lessened, and the elimination of the tubercle bacilli makes the patient a less dangerous source of infection. The value of the treatment is best seen when a restless, despondent, hectic, emaciated, dependent cripple is transformed into a live, happy, resourceful being, who sleeps and eats well, and who goes about recommending the treatment to all who will listen.

¶ We have learned from stereoscopic roentgenograms that it is almost impossible to map out accurately the extent of pneumothorax by percussion, because, in some cases the

⁵ Stereo 29.

lung is collapsed anteroposteriorly and in others from the mediastinum toward the chest wall; in others the lung is adherent to the chest wall as a streamer, collapse taking place around the various attachments, whereas, complete collapse from chest wall to mediastinum is rather the exception. It is of great interest in any of these cases to watch the cavities becoming gradually obliterated by successive injections of the gas. The position of the heart cannot always be made out by percussion or auscultation either, as it is frequently pushed from the left posteriorly, rather than altogether from the left to the right. In short, these conditions can be accurately determined only by the Roentgen rays. Perhaps the greatest value of roentgenography here lies in being able to watch the progress of disease in the uncollapsed side.

¶ Stereos 28, 29, 30, 31, illustrate one case of pulmonary tuberculosis having repeated and severe hemorrhages, which has been successfully treated on the right side by this procedure. The last injection was given to this man more than a year before writing, and since then he has worked regularly, has suffered no discomfort or hemorrhage, and to all appearance is well.

¶ Stereo 28 shows the roentgen markings before treatment, while the hemorrhages were severe. Stereo 29 shows the lung partially collapsed, the pleural adhesions preventing complete collapse. Stereo 30 illustrates the lung as completely collapsed, as was possible, while Stereo 31 was made after the lung had expanded again, at the end of the treatment.

¶ Thickening of the pleura is one of the necessary results of this treatment, and its effects upon the heart and

ribs are plainly shown. The thickened pleura itself can be easily made out at the right base.

¶ Compensatory emphysema has taken place upon the left side. By comparing Stereos 28 and 31 it is easy to see that the ribs of the latter are more horizontal, the interspaces wider, the diaphragm greater.

Class II.—Tuberculous.

Lung Before Therapeutic Pneumothorax Treatment.

[Stereo 28.]

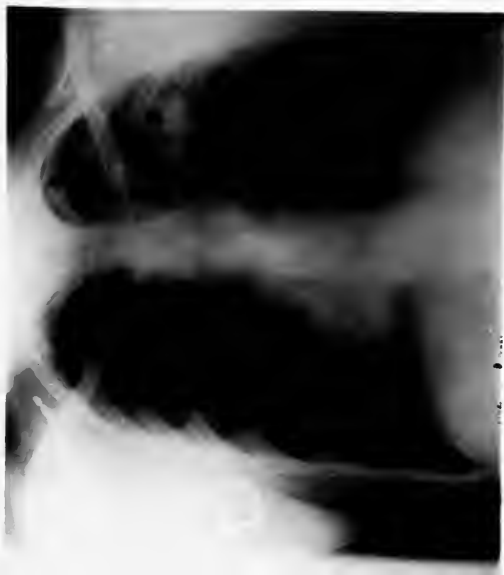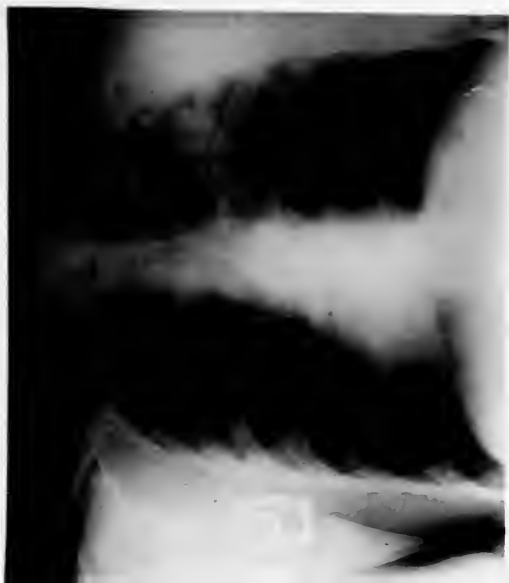☞ Bones normal, except that ribs on the left side are slightly more horizontal and more separated than on the right. The entire upper right thorax is involved, with the greatest lesion in the second interspace trunks, where a heavy mass of increased density is noted surrounding an elliptical area of decreased density. This may be the cavity from which the hemorrhage occurred.

☞ Note that densities grow progressively heavier from the vertebral through the first to the second interspace areas.

☞ The middle right lobe is extensively involved and also the lower right, especially just to the right of heart density.

Stereo 28.

Serial N^o 1136





Lesions in the left thorax have a different distribution from those on the right. The second interspace trunks are most involved, the vertebral trunks, to a much less extent, while the first interspace trunks have a comparatively slight lesion. The lower left division is diffusely but slightly involved.

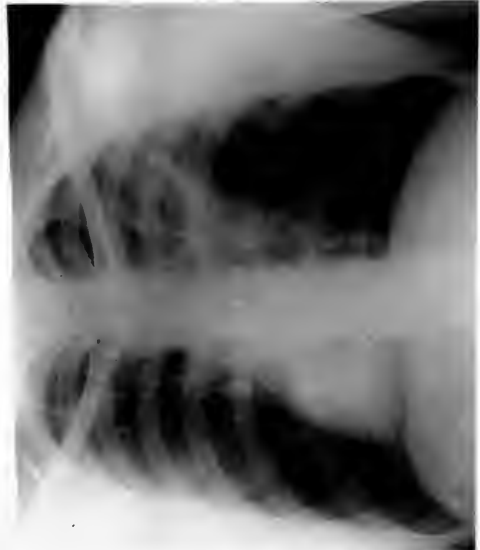
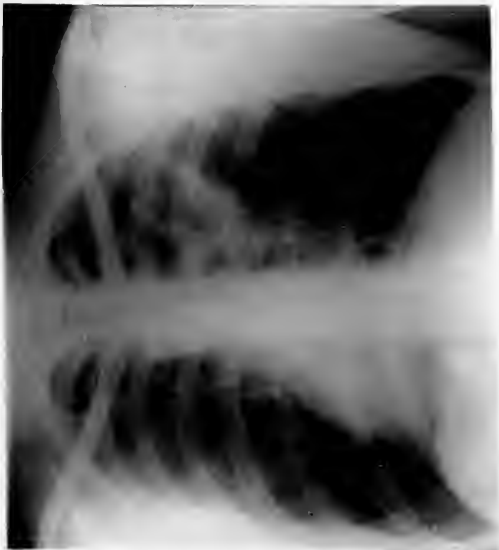
Lung Partially Collapsed.

[Stereo 29.]

¶ The right lung is partially collapsed with a marked increase of density behind the first and second interspaces. The lesion in the lower right lobe near the heart is still resisting compression. The left thorax is particularly interesting because the lesions in the vertebral and second interspace trunks show no improvement, whereas, the subsequent plates show a decided improvement.

Stereo 29.

Serial N^o 1174



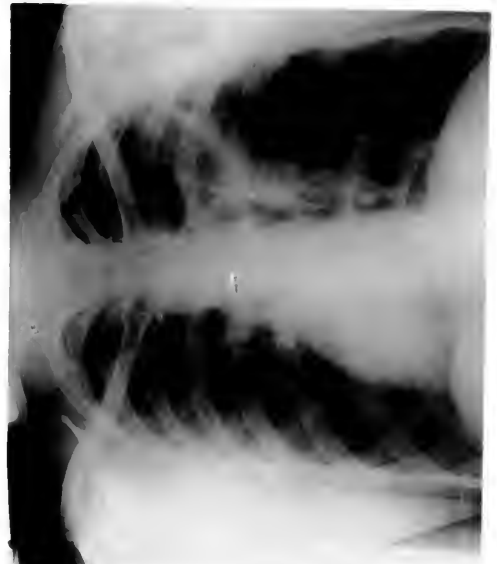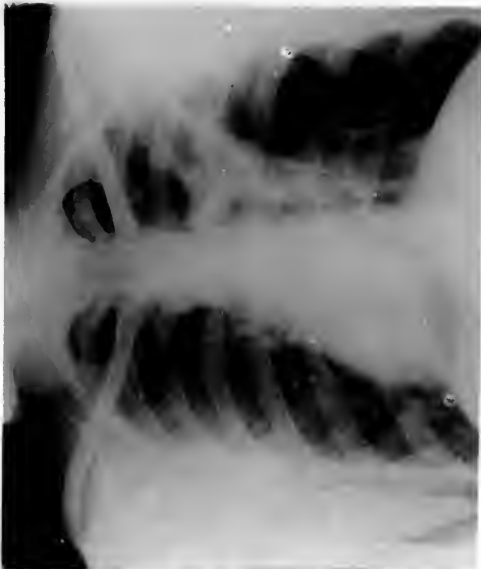Lung Completely Collapsed.

[Stereo 30.]

¶ Right lung collapsed by nitrogen gas. There is no difficulty in finding pleural cavity through the seventh interspace anterior to the axillary line.

¶ This stereo shows the greatest extent to which a lung can be collapsed. The lung is held by pleural adhesions to the lateral wall and is seen behind the second interspace and partially behind the first, also at the right base near the heart. By referring to the previous stereos, it is seen that these are regions of most extensive lesions. Fortunately the gas found its way to the apex and has thus pressed upon the cavity both from below and above.

¶ The hemorrhage was completely controlled after second injection. It should be noted that the left side has greatly improved; especially is this true of the lesion in the second interspace trunk.

Stereo 30.**Serial N^o 1056**



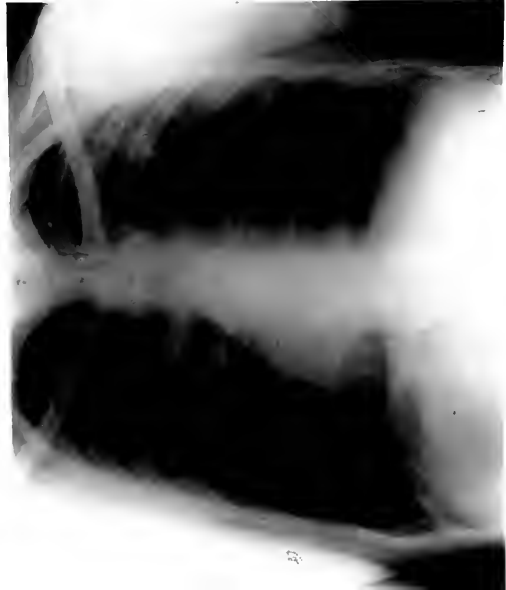
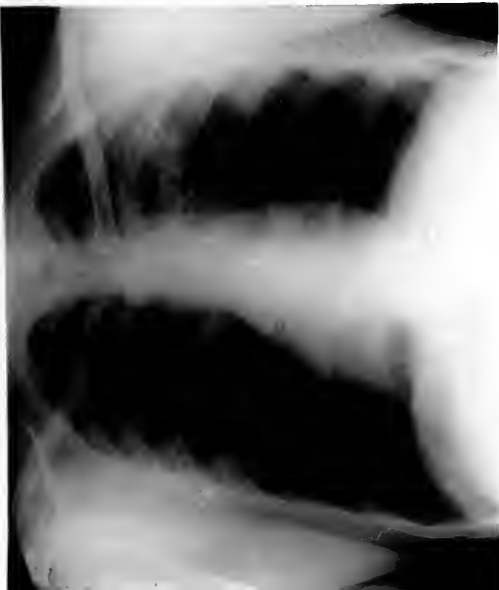Lung Expanded after Artificial Pneumothorax.

[Stereo 31.]

☐ This stereo shows thorax eight months after last injection. Ribs more horizontal and wider on right side than on left, and right base contracted. Diaphragms flat and left side suggests emphysema. Right side contracture, due to thickened pleura, which is seen on right lateral wall extending from seventh to tenth rib.

☐ Entire thoracic picture changed. Entire right lung completely expanded, and bird-shaped scar has replaced cavity originally seen near periphery of the right, second interspace trunk. Heavy densities, obscure markings of vertebral and first interspace trunks. Mottled area occupies middle right division. Trunks of lower right division heavy, studded and matted, especially near heart.

☐ Left thorax, slight lesion seen in vertebral and second interspace trunks on left side; lower left is greatly improved.

Stereo 31.**Serial N^o 1059**



Bilateral Seventh Cervical Ribs.

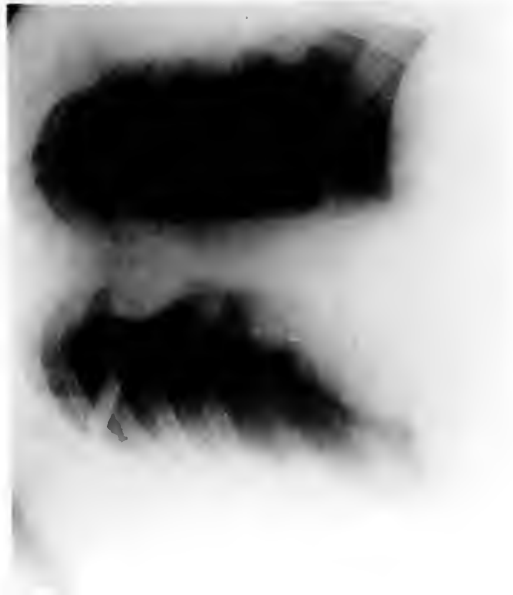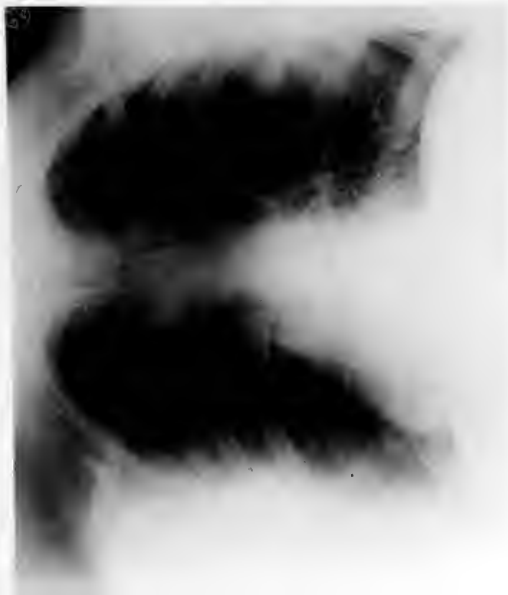[Stereo 32.]

☞ Tuberculous lesions may exist in the vertebral trunks of both upper lobes and in each base.

☞ This stereo is introduced to show the seventh cervical ribs and the relation of trachea and bronchi to the aortic arch. The aortic density is abnormally high and to the left. The left bronchus reaches the hilus between the seventh interspace and second rib and shows characteristic curve.

☞ The right bronchus reaches the hilus between the seventh rib and the first interspace. Seldom are these points so well illustrated as in this stereo.

Stereo 32.

Serial N^o 1055



Healed Tuberculosis and Syphilis.

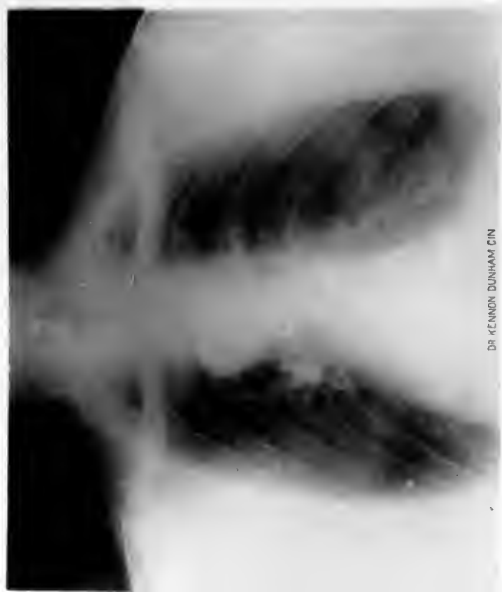[Stereo 33.]

¶ Aged sixty-three. Healed tuberculosis. Tertiary Syphilitic lesions are here shown in right clavicle and left humerus. There is also aortitis, with marked sclerosis. Note the sharp angle of ribs with spine. The narrow interspaces suggest thickened pleura. The prominent aortic density suggests sclerosis, probably from the same cause. The aorta is seen coming out of the heart density, turning backward and down. This is not an aneurism.

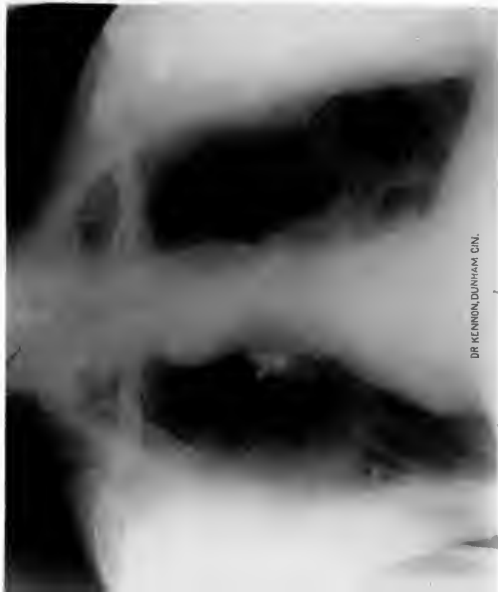¶ The trachea is pushed to the right, while the left bronchus, after passing under, is seen to its left.

¶ The left bronchus enters the hilus just below a mass of caseous material. The vertebral trunk passes from the left hilus, just above the caseous density, and extends to the periphery, within the circle of the first rib.

¶ Autopsy showed very thick pleura, passive congestion of lung, aortitis, with marked sclerosis, old, healed tuberculous lesion in both apices, with greatest fibrosis in upper left. Syphilis of liver found. Clavicles and humerus not examined.

Stereo 33.**Serial N^o 1167**

DR. KENNEDY, DUNHAM, CHN.



DR. KENNEDY, DUNHAM, CHN.



Class IV.—Diseases Differentiated from Tuberculosis.

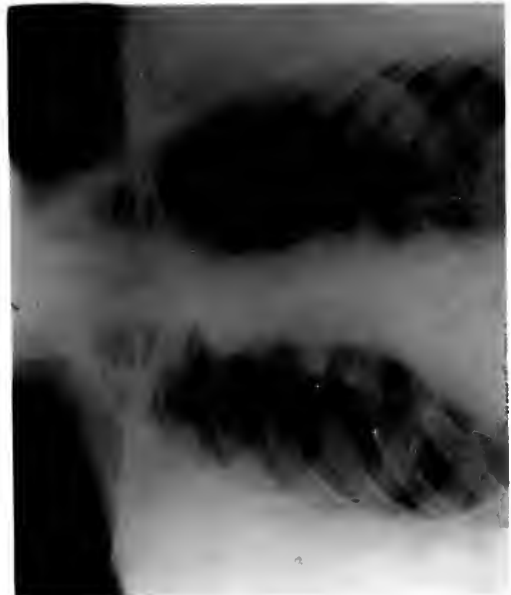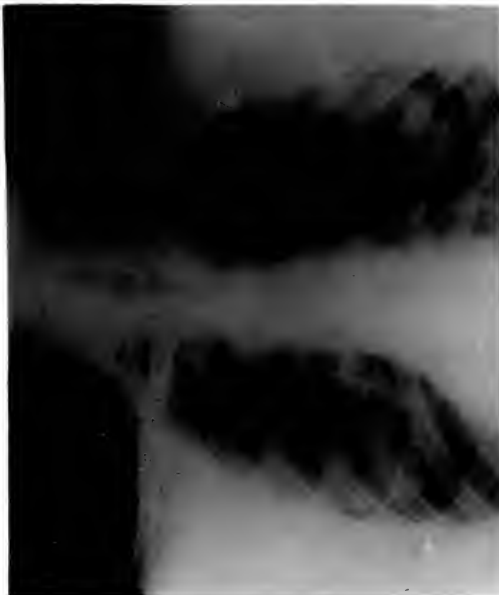Chronic Bronchitis and Emphysema.


[Stereo 34.]

¶ Note the straight line of the clavicles, with calcification of the first rib of the cartilage, heavy hilus shadows and large aortic shadow. The lung fields are abnormally clear everywhere, with the exception of trunks of the lower right lobe, which are very heavy. The patient is emaciated and shows degeneration of anterior and posterior chest muscles. Hyper-resonance is found over the entire chest, but especially in both upper lobes. The heart dullness is obliterated. Breath sounds are abnormally loud, with roughened and prolonged expiration. Large, moist rales are heard, markedly modified by coughing. No tubercle bacilli could be found in the sputum.

Stereo 34.

Serial No 1110





¶ X-ray findings. Pectoral muscles cut fourth interspace and fifth rib, and indicate emaciation; dilated aorta; heavy hilus shadows; trunks and heavy markings reach periphery, but radiate, are not interwoven, and not obliterated. These X-ray findings indicate that patient has not pulmonary tuberculosis.

¶ Clinical diagnosis in this case was arterio-sclerosis, disease of aorta, (aneurism suspected) emphysema and chronic bronchitis. Tuberculosis and aneurism were only ruled out by X-ray examination.



Arterio-Sclerosis, with Emphysema.

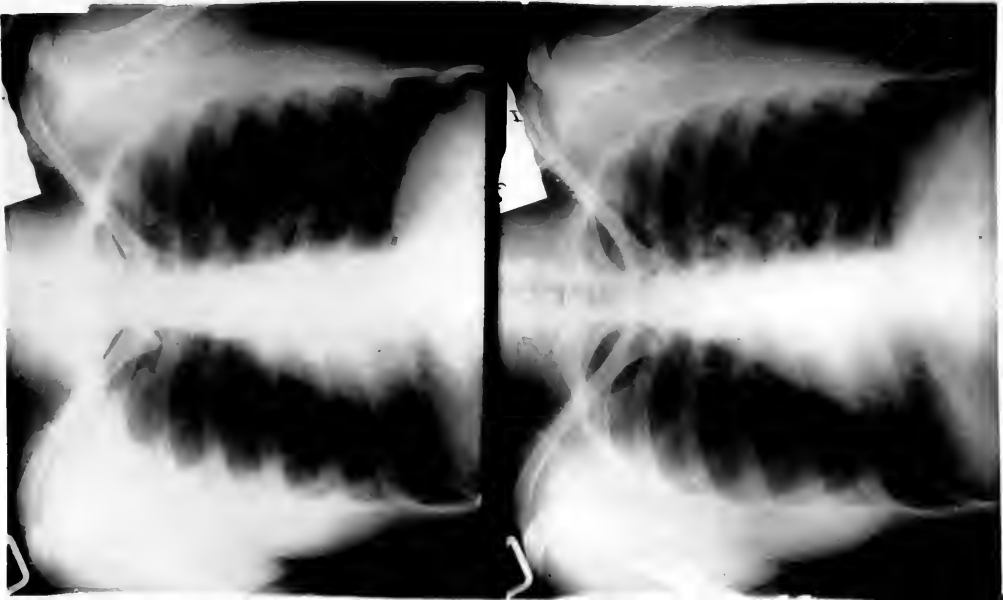
[Stereo 35.]

☞ Ribs leave spine almost at right angles. The interspaces in the back are abnormally wide. Diaphragms, especially left, are flattened. A space is seen between heart and diaphragm. These findings, with hyper-resonance, suggested emphysema.

☞ The hilus shadows are abnormally heavy; especially is this so of the right. The left trunks are heavy and studded, but markings radiate and do not reach the periphery. The right trunks are not so distinct. Interwoven mesh-work extends from the hilus to ends of linear markings, which do not reach the periphery. From apex to base, on both sides, an even change is noted throughout trunks and markings, which suggests circulatory disturbance, and enables us to differentiate from tuberculosis.

Stereo 35.

Serial No 1167



The history of the United States is a story of growth and change. From the first settlers to the present day, the nation has expanded its territory and diversified its economy. The early years were marked by struggle and hardship, but the spirit of innovation and freedom prevailed. The American dream of a better life for all has inspired generations to strive for progress and justice. The challenges of the past have been met with courage and resilience, shaping the character of the nation. Today, we stand on the shoulders of our ancestors, ready to face the future with confidence and hope.

¶ The clinician suspected tuberculosis, because of emaciation, hacking cough, winter colds, roughened inspiration and prolonged expiration over both apices, a rapid heart and small heart dullness, and in spite of hyper-resonance over the entire front and back.

¶ Patient died two years after making plate. Certificate gave Brights disease as the cause of death.

¶ Compare with Stereo 16.

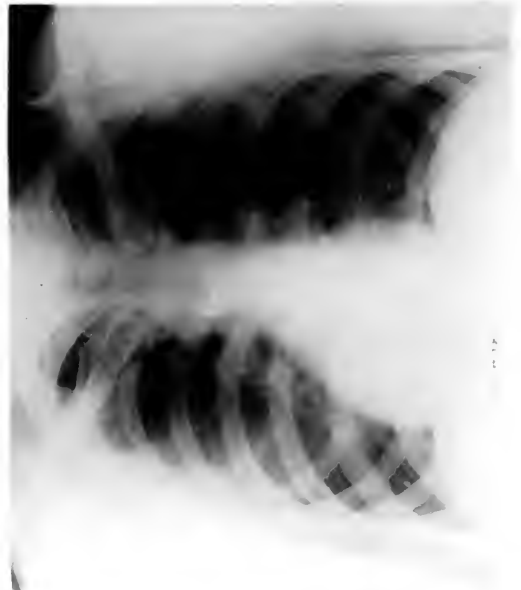
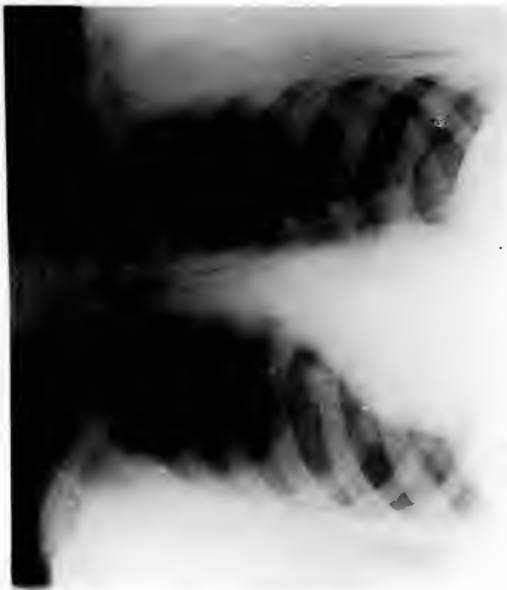Syphilis, with Appearance of Normal Chest.


[Stereo 36.]

¶ Syphilis in secondary stage. Roentgen picture of normal chest.

¶ Description of case. White, male, age twenty-four. Cough very annoying, expectoration free. Morning temperature 97, evening temperature 100. Respiration 25. Pulse 100. Appetite poor. Patient was well nourished, but undoubtedly sick. Mouth and throat clear. Skin clean, but papular eruption and mucus patches began to show second day after X-ray examination.

¶ Lung expansion good, but diminished excursion of the diaphragm is noted on the right side. Increased muscular rigidity in right neck and trapezius and pectoral muscles. Vocal fremitus is increased from apex to second right intercostal space. Impaired resonance on right side to second intercostal, otherwise percussion normal. Prolonged ex-

Stereo 36.**Serial No 1135**



piration with fine dry and subcrepitant rales from right apex to second intercostal. These physical signs could not be elicited in the upper back. Sputum negative.

¶ Roentgen examination showed the chest of a healthy man, with the exception of second interspace trunks which should be described as a possibly tuberculous lesion. But such physical findings as have been described, if a diagnosis of tuberculosis is to be maintained, must show changes in right vertebral or first interspace trunks, usually in both, which are more extensive than change found in second interspace group.

¶ Thus with extensive physical findings, limited to the areas of vertebral and first interspace trunks and very slight roentgen changes occupying a different anatomical area, tuberculosis was excluded and syphilitic lesion suggested, which was later confirmed by a positive Wasserman, and the appearance of mucus patches. Further, the physical signs completely cleared up after one injection of Salvarsan.

¶ Since the above case came under observation, we have found several more cases of syphilis of the lung which simulate tuberculosis. We are reasonably well assured that the bronchial mucus membrane in secondary syphilis is subject to some form of lesion resembling mucus patch of the mouth. These lesions produce physical signs which minutely simulate those of early tuberculosis, but since the syphilitic catarrh leaves no record upon the X-ray plate and the catarrh of tuberculosis is accompanied with fibrous changes which are so recorded, we have a certain means of differential diagnosis.

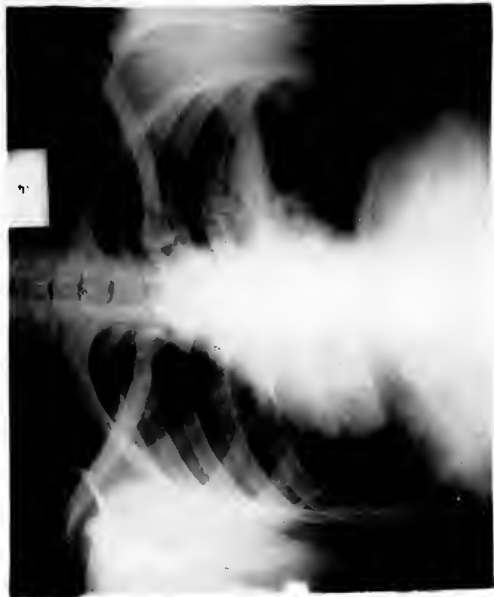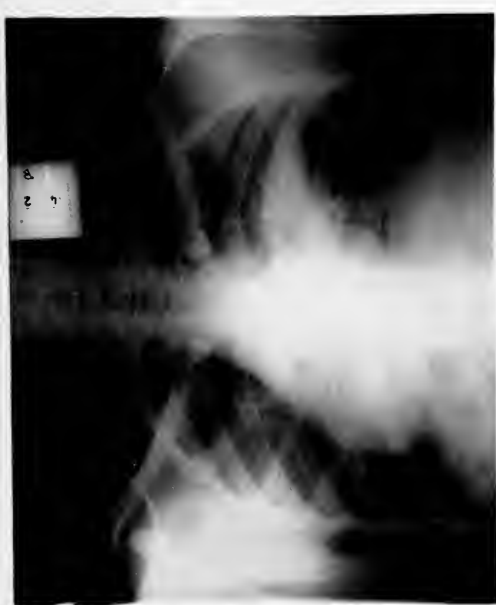Right Sided Interlobular Pleurisy.

[Stereo 37.]

¶ This case is not complicated with tuberculosis, is contrast to stereo 15, which is tuberculous. The heart is enlarged and the patient suffered from mitral insufficiency.

¶ Both vertebral trunks are heavy and somewhat studded, but the markings do not reach the periphery.

¶ The triangular density, with its base towards the mediastinum, which separates the upper from the middle lobe on the right side, is characteristic of interlobular pleurisy. An increased density of such a character, due to tuberculosis, would have its base at the periphery.

Stereo 37.**Serial N^o 1195**



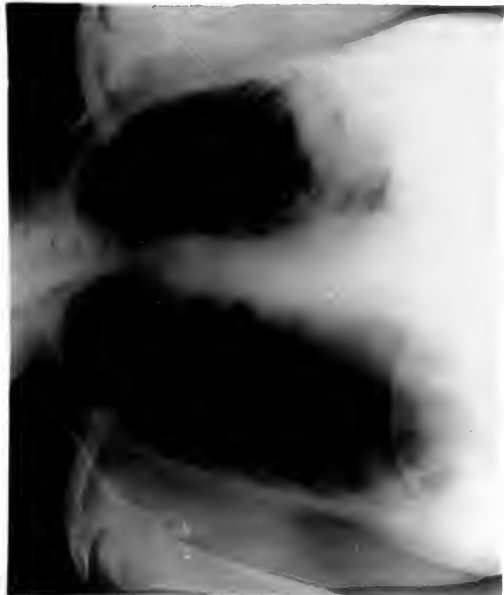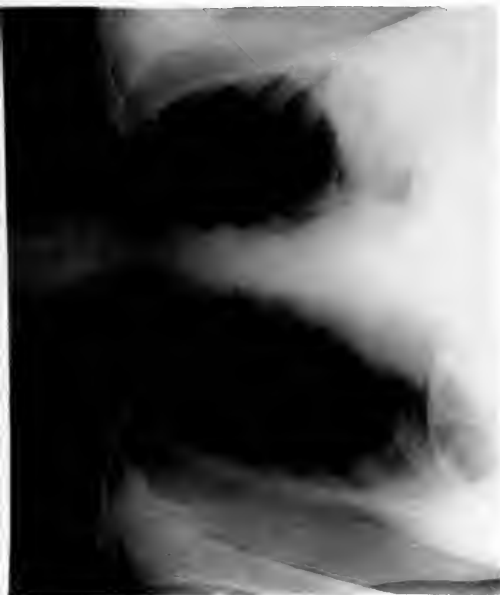Abscess of the Lung.

[Stereo 38.]

¶ Female, aged twenty. Case referred for X-ray examination to determine location of abscess and to ascertain if tuberculous.

¶ The Roentgen examination excluded tuberculosis and located an abscess at the right base with its wall attached to the pleura. Probably, therefore, the intra-pleural space near the abscess is obliterated by adhesions and the abscess may be opened and drained without infecting the pleura. The contents of the abscess can be made out by the horizontal line just above the center of the area of density. Below there is a region of greater density due to fluid, and above, a lesser density due to gas. Thus we deduce that the cavity connects with the bronchus.

¶ Roentgen examinations in such cases are necessary. The abscess as may be multiple and surgery be contra-indicated or, as in this case, single, well walled off and definitely located, and thus surgery is made easy and safe.

Stereo 38.**Serial N^o 1111**



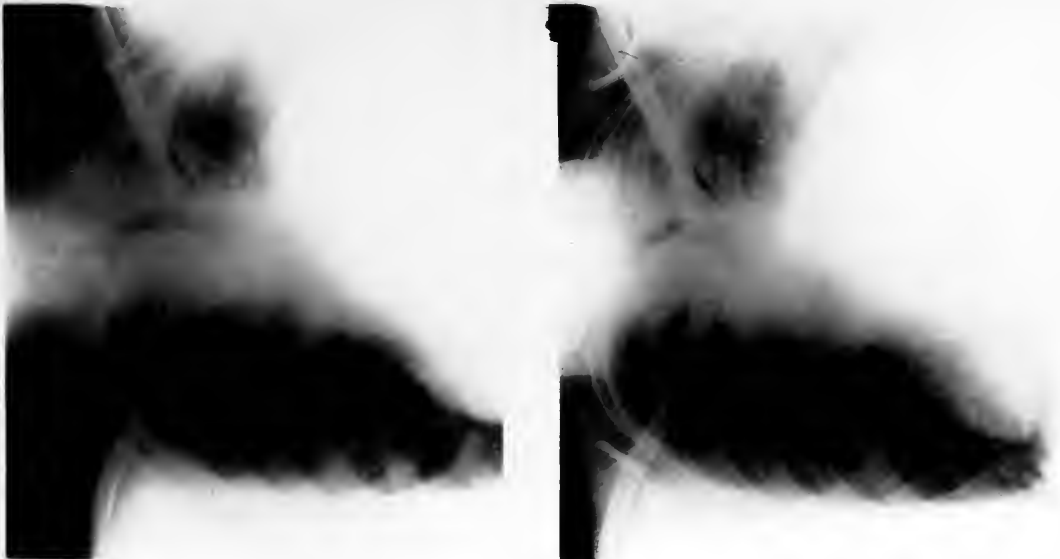
Secondary Carcinoma—Hydro-Pneumothorax on Right.

[Stereo 39.]

- ☐ Diagnosis confirmed by post-mortem.
- ☐ Mediastinum—Heart and aorta pushed to left. Trachea pushed to right by mediastinal tumor lying above the aortic arch.
- ☐ Left thorax—General mottling resembles tuberculosis, but is differentiated from it by evenness of distribution in all trunks from first interspace to base.
- ☐ Right thorax—Pyramidal-shaped tumor extending out from mediastinum and up from right diaphragm with apex near costal margin of second rib is partially collapsed lung and fluid. A characteristic hydro-pneumothorax line is obscured by the shadow thrown by the lung tumor. No lung markings are to be seen above the clavicle in front and the fifth rib in the back.

Stereo 39.

Serial No. 1168





¶ Physical examination—Patient recumbent, movable dullness reached second interspace in front, and covered entire front and only reached two finger-breadths below the angle of the scapula. Accurate diagnosis from plates alone would be difficult, but such can be made, when the fact that there is movable dullness, is also considered.



Lung Fungus.

¶ I now present three cases, Stereos 40, 41, 42, of pulmonary lesions classed by the French writers as "The Mycocos." These cases present three striking characteristics in common. First—a mould belonging either to the genus *Asperigilus*, or the genus *Mucor*, is found in the sputum, and tubercle bacilli are only found with difficulty; second—the diagnosis in each case has been pulmonary tuberculosis; and last—there is in each case a characteristic calcified studding which follows one or more of the main trunks, but usually does not quite reach the periphery. These studdings are either separated from the periphery by an area of lung density or by a cloud of increased density. Thickened pleura can be demonstrated somewhere in every case. Further, each of these cases which I have examined has, in some part of the lung, typical tuberculous markings.

¶ I am not able to say at this time that this remarkable picture of calcification is the result of the fungus. But these are the only cases in which we have demonstrated large numbers of fungi in the sputum. So far none of these cases have come to autopsy, but it is to be noted that the Roentgen plates of this series do not show the cavities, which are spoken of in the literature of fungi of the lung.



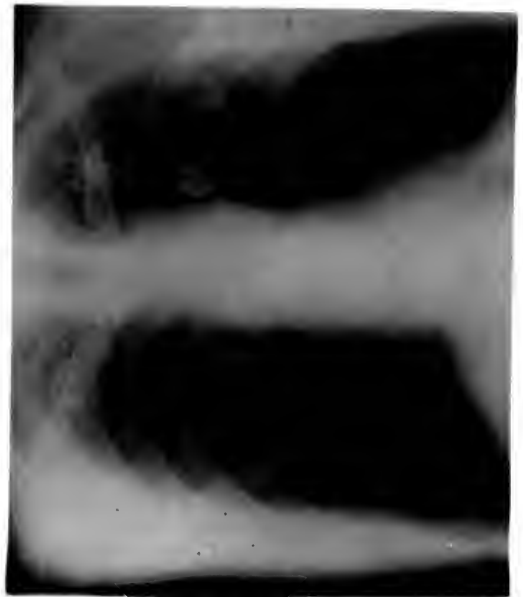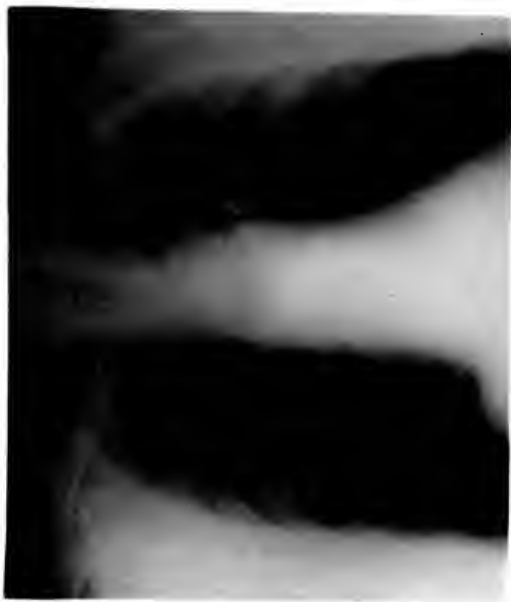Lung Fungus.—A.

[Stereo 40.]

¶ Characteristic fungus markings noted in both upper lobes. The aorta is drawn to the left and the three trunks of the upper left lobe appear abnormally low, that is, the vertebral trunk does not stay within the circle of the first rib, the first interspace trunk encroaches upon the second interspace, and the second interspace trunk lies behind the third interspace. In the right upper lobe the reverse is the case. The first interspace trunk encroaches upon the circle of the first rib, and part of the second interspace trunk is seen behind the first interspace. This is as though the apices of the two lungs had been rotated to the left.

¶ The anterior branch of the right middle division is seen as a fan-shaped cloud lying behind the fourth and fifth ribs and has the characteristic markings of tuberculosis.

¶ Thickened pleura seen at the apex. The sputum showed large numbers of fungi, and tubercle bacilli were demonstrated with difficulty.

Stereo 40.**Serial N^o 1112**

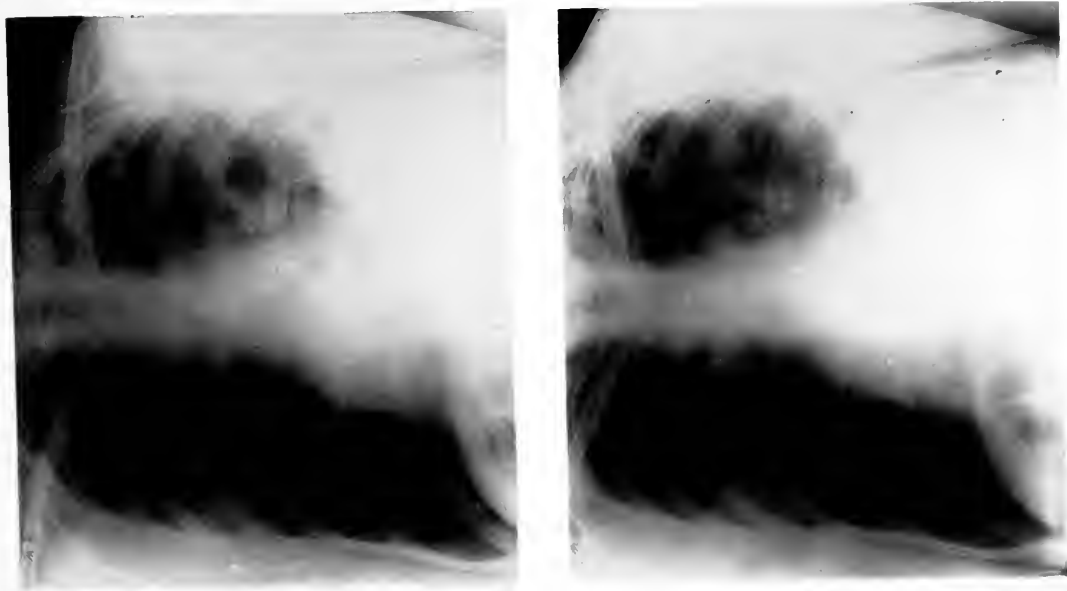


Lung Fungus.—B.

[Stereo 41.]

☞ Pulmonary tuberculosis. Large numbers of fungi are found in the sputum, while but few tubercle bacilli can be demonstrated. Pleurisy, with effusion, is seen in the right base, and compensatory emphysema at the left base.

☞ Male, aged thirty-three. Boney frame work slight, ribs contracted, interspaces narrow at right base and wide at the left base. Heart drawn to right. Right diaphragm obscured. Trachea normal. The left bronchus is seen curving under the aortic arch. Characteristic tuberculous markings are seen in the upper left lobe. Typical fungus markings show in the second interspace of the upper right lobe, separated from the periphery by a dense cloud effect. At the right base there is an increased density, the result of pleurisy, with effusion. The heart and the ribs are drawn toward one another, while usually in pleural effusion, ribs are

Stereo 41.**Serial No. 1165**



widely separated, interspaces bulging and heart and aorta pushed aside. This variation is explained by the fact that the effusion is of long standing. The pleurae are greatly thickened, especially at the apex and extremity of the second interspace trunk, are they seen to act as contractile tissue. Fluid was demonstrated by aspiration.



Lung Fungus.—C.

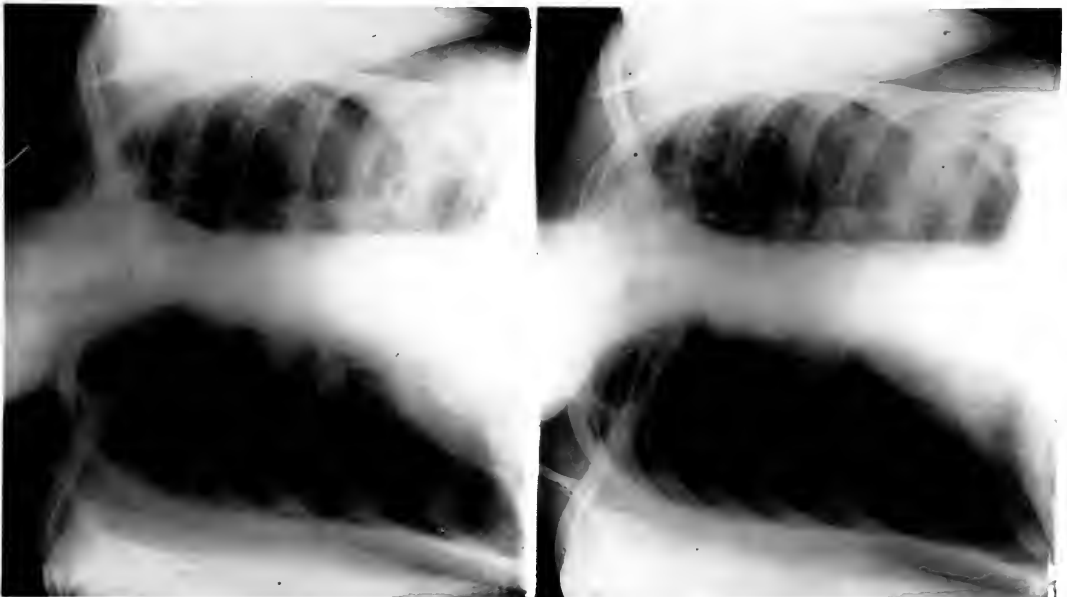
[Stereo 42.]

¶ Characteristic fungus markings are seen in the upper right lobe, and typical tuberculous markings in the vertebral trunk of the upper left lobe.

¶ The pleura is markedly thickened throughout the entire right side. The trachea is drawn sharply to the right. The ribs at the right base are contracted. Here the thickened pleura can be distinguished. It is remarkable that the heart should not be drawn toward the contracted ribs.

¶ At the right base of the stereo suggests a previous pleurisy, with effusion. This has caused a sufficient inflammatory reaction to fix the mediastinal viscera and thus prevent the heart from being drawn toward the right thoracic wall.

¶ The sputum showed great numbers of fungi and a few tubercle bacilli.

Stereo 42.**Serial N^o 1172**



Index to Stereograms

Page	Stereo	
22	1	Cadaver—Bismuth Injected through Trachea.
25	2	Injected Lung of Stereo 1 removed from Body.
26	3	Heart and Lungs Removed.
27	4	Heart Removed, Lung Inflated.
28	5	Tuberculous. Lung Removed.
29	6	Normal Chest, with Fractured Clavicle.
31	7	Marked Scoliosis.
32	8	Tuberculous Mediastinitis.
33	9	Early Tuberculosis.
35	10	Active Pulmonary Tuberculosis.
36	11	Early Tuberculosis.
37	12	Unilateral Tuberculosis.
38	13	Pulmonary Tuberculosis, Active Effusion at Left Base.
39	14	Pulmonary Tuberculosis, with Effusion.
40	15	Pulmonary Tuberculosis. Interlobular Pleurisy on Right.
41	16	Pulmonary Tuberculosis, with Emphysema and Thickened Pleura.
42	17	Pulmonary Tuberculosis, with Abscess.
45	18	Fibroid Tuberculosis.
46	19	Fibroid Tuberculosis, with Lesion.
47	20	Fibroid Tuberculosis and Distortion Mediastinal Viscera.
48	21	Fibroid Tuberculosis, with Distorted Viscera.
49	22	Fibroid Tuberculosis, with Distortion of Viscera.
50	23	Fibroid Tuberculosis—Cavities at Apices.
52	24	Fibroid Tuberculosis and Cavities.
54	25	Fibroid Tuberculosis, with Cavity Formation.
56	26	Fibroid Tuberculosis, with Cavities.
57	27	Pulmonary Tuberculosis, with Hydro-Pneumothorax.
62	28	Lung before Therapeutic Pneumothorax Treatment.
64	29	Lung Partially Collapsed.
65	30	Lung Completely Collapsed.
66	31	Lung Expanded after Artificial Pneumothorax.
67	32	Bilateral Seventh Cervical Ribs.
68	33	Healed Tuberculosis and Syphilis.
69	34	Chronic Bronchitis and Emphysema.
71	35	Arterio-Sclerosis, with Emphysema.
73	36	Syphilis, with Appearance of Normal Chest.
75	37	Right Sided Interlobular Pleurisy.
76	38	Abscess of the Lung.
77	39	Secondary Carcinoma—Hydro-Pneumothorax on Right.
80	40	Lung Fungus—A.
81	41	Lung Fungus—B.
83	42	Lung Fungus—C.

**THE LIBRARY
UNIVERSITY OF CALIFORNIA
LOS ANGELES**

