

COLUMBIA LIBRARIES OFFSITE  
HEALTH SCIENCES STANDARD



HX64085775

QM531 .T72 1901 Surgical applied ana

*Anatomy*

**RECAP**

*F. Treves, F.R.C.S.*

QM531

T72

1901

**Columbia University**  
**in the City of New York**


**College of Physicians and Surgeons**  
**Library**



No. - 125

— O. L. Chaffee —

— Chicago







# SURGICAL APPLIED ANATOMY

BY

SIR FREDERICK TREVES  
K.C.V.O., C.B., F.R.C.S.

SERGEANT SURGEON TO H.M. THE KING  
SURGEON IN ORDINARY TO H.R.H. THE DUKE OF CORNWALL AND YORK  
CONSULTING SURGEON TO THE LONDON HOSPITAL  
LATE LECTURER ON ANATOMY AT THE LONDON HOSPITAL

*NEW EDITION, REVISED BY THE AUTHOR*

WITH THE ASSISTANCE OF

ARTHUR KEITH, M.D., F.R.C.S.

LECTURER ON AND SENIOR DEMONSTRATOR OF ANATOMY AT THE  
LONDON HOSPITAL



PHILADELPHIA  
LEA BROTHERS & CO.

QM531

T72

1901



GMK  
MAY 18 1944

## PREFACE TO THE PRESENT EDITION.



IN the present edition the work has been carefully revised throughout; certain sections have been re-written, and much new matter has been added. Every effort has been made to bring each chapter of the book well up to date. Many new woodcuts have been added or have replaced the illustrations used in previous editions.

F. T.  
A. K.

*London Hospital,  
May, 1901.*

0-20-43  
M.L.A. Exchange



## PREFACE TO THE FIRST EDITION.

---

APPLIED ANATOMY has, I imagine, a twofold function. On the one hand it serves to give a precise basis to those incidents and procedures in practice that more especially involve anatomical knowledge; on the other hand it endues the dull items of that knowledge with meaning and interest by the aid of illustrations drawn from common medical and surgical experience. In this latter aspect it bears somewhat the same relation to Systematic Anatomy that a series of experiments in Physics bears to a treatise dealing with the bare data of that science.

The student of Human Anatomy has often a nebulous notion that what he is learning will sometime prove of service to him; and may be conscious also that the study is a valuable, if somewhat unexciting, mental exercise. Beyond these impressions he must regard his efforts as concerned merely in the accumulation of a number of hard unassimilable facts. It should be one object of Applied Anatomy to invest these facts with the interest derived from an association with the circumstances of daily life; it should make the dry bones live.

It must be owned also that all details in Anatomy have not the same practical value, and that the memory of many of them may fade without loss to the competency of the practitioner in medicine or surgery. It should be one other object, therefore, of a book having such a purpose as the present, to assist the student in judging of the comparative value of the matter he has learnt; and should help him, when his recollection of anatomical facts grows dim, to encourage the survival of the fittest.

In writing this manual I have endeavoured, so far as the space at my command would permit, to carry out the objects above described; and while I believe that the chief matters usually dealt with in works on Surgical Anatomy have not been neglected, I have nevertheless tried to make the principle of the book the principle that underlies Mr. Hilton's familiar lectures on "Rest and Pain."

I have assumed that the reader has some knowledge of Human Anatomy, and have not entered, except in a few instances, into any detailed anatomical descriptions. The bare accounts, for example, of the regions concerned in Hernia I have left to the systematic treatises, and have dealt only with the bearings of the anatomy of the parts upon the circumstances of practice. The limits of space have compelled me to omit all those parts of the "Surgery of the Arteries" that deal with ligature, collateral circulation, abnormalities, and the like. This omission I do not regret, since those subjects are fully treated not only in works on operative surgery but also in the manuals of general anatomy.

The book is intended mainly for the use of students preparing for their final examination in surgery. I hope, however, that it will be of use also to practitioners whose memory of their dissecting-room work is growing a little gray, and who would wish to recall such anatomical matters as have the most direct bearing upon the details of practice. Moreover, it is possible that junior students may find some interest in the volume, and may have their studies rendered more intelligent, by learning how anatomy is concerned in actual dealings with disease.

FREDERICK TREVES.

Sept., 1883.

# CONTENTS.



## PART I.—THE HEAD AND NECK.

| CHAPTER  | PAGE |
|--|------|
| I.—THE SCALP . . . . .                                 | 1    |
| II.—THE BONY VAULT OF THE CRANIUM . . . . .            | 15   |
| III.—THE CRANIAL CONTENTS . . . . .                    | 28   |
| IV.—THE ORBIT AND EYE . . . . .                        | 41   |
| V.—THE EAR . . . . .                                   | 68   |
| VI.—THE NOSE AND NASAL CAVITIES . . . . .              | 81   |
| VII.—THE FACE . . . . .                                | 95   |
| VIII.—THE MOUTH, TONGUE, PALATE, AND PHARYNX . . . . . | 117  |
| IX.—THE NECK . . . . .                                 | 135  |

---

## PART II.

|                         |     |
|-------------------------|-----|
| X.—THE THORAX . . . . . | 168 |
|-------------------------|-----|

---

## PART III.—THE UPPER EXTREMITY.

|  |     |
|--|-----|
| XI.—THE REGION OF THE SHOULDER . . . . . | 185 |
| XII.—THE ARM . . . . .                   | 223 |

| CHAPTER                                  | PAGE |
|--|------|
| XIII.—THE REGION OF THE ELBOW . . . . .  | 230  |
| XIV.—THE FORE-ARM . . . . .              | 246  |
| XV.—THE WRIST AND HAND . . . . .         | 253  |
| -----                                    |      |
| PART IV.—THE ABDOMEN AND PELVIS.         |      |
| XVI.—THE ABDOMEN . . . . .               | 282  |
| XVII.—THE ABDOMINAL VISCERA . . . . .    | 316  |
| XVIII.—THE PELVIS AND PERINEUM . . . . . | 372  |
| -----                                    |      |
| PART V.—THE LOWER EXTREMITY.             |      |
| XIX.—THE REGION OF THE HIP . . . . .     | 423  |
| XX.—THE THIGH . . . . .                  | 458  |
| XXI.—THE REGION OF THE KNEE . . . . .    | 465  |
| XXII.—THE LEG . . . . .                  | 489  |
| XXIII.—THE ANKLE AND FOOT . . . . .      | 500  |
| -----                                    |      |
| PART VI.                                 |      |
| XXIV.—THE SPINE . . . . .                | 537  |
| INDEX . . . . .                          | 557  |

# SURGICAL APPLIED ANATOMY.

---

## Part I.

### THE HEAD AND NECK.

---

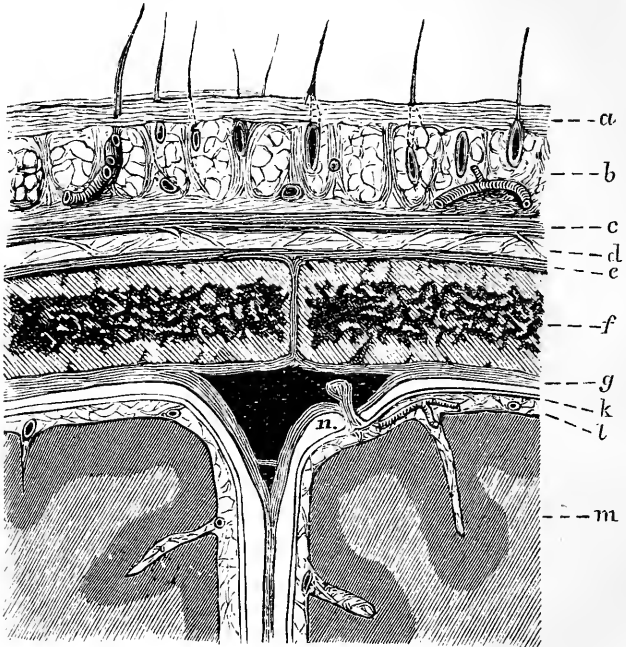
#### CHAPTER I.

##### THE SCALP.

THE **soft parts covering the vault of the skull** may be divided into five layers: (1) the skin, (2) the subcutaneous fatty tissue, (3) the occipitofrontalis muscle and its aponeurosis, (4) the subaponeurotic connective tissue, and (5) the pericranium. It is convenient to consider the term "scalp" as limited to the structure formed by the union of the first three layers above named (Fig. 1).

The skin of the scalp is thicker than it is in any other part of the body. It is in all parts intimately adherent, by means of the subcutaneous tissue, to the aponeurosis and muscle beneath it, and, from this adhesion, it follows that the skin moves in all movements of that muscle. The subcutaneous tissue is, like a similar tissue in the palm, admirably constructed to resist pressure, being composed of a multitude of fibrous bands enclosing fat lobules in more or less isolated spaces (Fig. 1, *b*). The density of the scalp is such, that in surface inflammations, such as cutaneous erysipelas, it is unable to present (except in a very slight degree) two conspicuous features of such inflammations, viz., redness and swelling. The skin is provided with a great number of sebaceous glands, which may develop

into cystic tumours or wens, such cysts being more common upon the scalp than in any other part of the body. Being skin growths, these cysts, even when large, remain, except in rare instances, entirely outside the aponeurosis, and can therefore be removed



$\frac{2}{1}$

Fig. 1.—Diagram showing the Layers of the Scalp and Membranes of the Brain in Section.

*a*, Skin; *b*, subcutaneous tissue with hair roots and vessels; *c*, epicranium; *d*, sub-aponeurotic layer; *e*, pericranium; *f*, parietal; *g*, dura mater; *k*, arachnoid; *l*, pia mater; *m*, cortex; *n*, in subdural space near a Pacchionian body projecting within the superior longitudinal sinus.

without risk of opening up the area of loose connective tissue between the aponeurosis and the pericranium.

There being no fatty tissue in any of the layers that cover the bony vault save in the subcutaneous



layer, it happens that in cases of obesity the scalp undergoes but little change, the fat in the subcutaneous tissue being limited by the dense fibrous structures that enclose it. For the same reasons fatty tumours of the scalp are very rare. The attachment of the hairs collectively to the scalp is so strong that there are many cases where the entire weight of the body has been supported by the hair of the scalp. Agnew records the case of a woman whose hair became entangled in the revolving shaft of a machine. The hair did not give way, but the entire scalp was torn off from the skull. The patient recovered. I have seen a precisely similar case in a girl aged 13. (Museum, R. Coll. Surgeons, 87 F.)

The **dangerous area of the scalp**.—Between the aponeurosis and the pericranium is an extensive layer of loose connective tissue, that may, for reasons to be presently given, be fairly called the dangerous area of the scalp (Fig. 1, *d*). The mobility of the scalp depends entirely upon the laxity of this layer of tissue. In extensive scalp wounds, when a part of the scalp is separated in the form of a large flap, a flap that may hang down and cover half the face, it is the very looseness of this tissue that permits such separation. In the Indian process of scalping, a taste that is becoming one of the past, the much-prized piece of skin is torn from the skull through this lax area of connective tissue, and, were there no such area, scalping would be an operation requiring some time and art.

The exposure of the skull in a post-mortem examination is effected by peeling off the scalp along this layer of loose tissue, and it is remarkable with what ease the skull can be exposed by this manœuvre. Sutures may be safely applied to adjust scalp wounds, provided they are not too long retained. They probably include the aponeurosis, and if long retained may act as setons and set up suppuration, which may find its way into the loose layer beneath the aponeurosis.

**Wounds of the scalp** never gape, unless the wound has involved the scalp muscle or its aponeurosis. When this structure has been divided the lax layer beyond permits of great separation of the edges of even the simplest wounds. In uncomplicated incised wounds, the amount of gaping of the cut depends upon the action of the occipito-frontalis muscle. Those wounds gape the most that are made across the muscle itself, and that are transverse to the direction of its fibres, while those show the least separation that involve the aponeurosis and are made in an antero-posterior direction. The mobility of the scalp is more marked in the young than in the old. A case recorded by Agnew serves in a strange degree to illustrate this fact in the person of an infant. A midwife attending a woman in labour mistook the scalp of the infant for the membranes, and gashed it with a pair of scissors. Labour pains came on and the head was protruded through the scalp wound, so that the whole vault of the skull was peeled like an orange. The scalp being firmly stretched over the hard cranium beneath, it follows that contused wounds often appear as cleanly cut as are those that have been made by an incision. Such wounds may be compared to the clean cut that may be made in a kid glove when it is tightly stretched over the knuckles and those parts are sharply rapped.

The scalp is extremely vascular, and presents therefore a great resistance to sloughing and gangrenous conditions. Large flaps of a lacerated scalp, even when extensively separated and almost cut off from the rest of the head, are more prone to live than to die. A like flap of skin, separated from other parts of the surface, would most probably perish; but the scalp has this advantage, that the vessels run practically in the skin itself, or are, at least, in the tissue beyond the aponeurosis (Fig. 1). Thus, when a scalp flap is torn up, it still carries with it a very copious blood supply. Bleeding from these wounds is usually very free, and often difficult to arrest. This depends not

so much upon the number of vessels in the part as upon the density of the tissue through which these vessels run, the adherence of the outer arterial wall to the scalp structure, and the inability, therefore, of the artery to properly retract when divided.

For the same reason it is almost impossible to pick up an artery divided in a scalp wound. The bleeding is checked by a hare-lip pin or by pressure.

In all parts of the body where a dense bone is covered by a comparatively thin layer of soft tissues, sloughing of those tissues is apt to be induced by long and severe pressure. The scalp, by its vascularity, is saved to a great extent from this evil, and is much less liable to slough than are the soft parts covering such bones as the condyles of the humerus or the sacrum. But such an effect is sometimes produced, as in a case I saw, where the tissues over the frontal and occipital regions sloughed from the continued application of a tight bandage put on to arrest bleeding from a frontal wound.

The **pericranium** is but slightly adherent to the bone, except at the sutures, where it is intimately united (Fig. 1, *e*). In lacerated wounds this membrane can be readily stripped from the skull, and often, in these injuries, extensive tracts of bone are laid bare. The pericranium differs somewhat in its functions from the periosteum that covers other bones. If the periosteum be removed to any extent from a bone, the part from whence it is removed will very probably perish, and necrosis from deficient blood supply result. But the pericranium may be stripped off a considerable part of the skull vault without any necrosis, save perhaps a little superficial exfoliation, following in consequence. This is explained by the fact that the cranial bones derive their blood supply mainly from the dura mater, and are therefore to a considerable extent independent of the pericranium. A like independence cannot be claimed for the periosteum covering other bones, since that membrane brings to the part it covers a very copious and essential contribution to its blood supply. This

disposition of the pericranium is also well illustrated by its action in cases of necrosis of the cranial bones. In necrosis of a long bone, the separation of the sequestrum is attended with a vigorous periosteal growth of new bone, which repairs the gap left after the removal of such sequestra. In necrosis of the vault of the skull, however, no new bone is, as a rule, formed, and the gap remains unrepaired. The general indisposition of the pericranium to form new bone in other circumstances is frequently illustrated.

**Abscess** in the scalp region may be situated (1) above the aponeurosis, (2) between the aponeurosis and the pericranium, and (3) beneath the pericranium. Abscesses in the first situation must always be small and comparatively insignificant, since the density of the scalp tissue here is such that suppuration can only extend with the greatest difficulty. Suppuration, however, in the second situation (in the loose tissue beneath the aponeurosis) may prove very serious. The laxity of this tissue offers every inducement to the abscess to extend when once pus has found its way between the aponeurosis and the pericranium. Suppuration in this area may undermine the entire scalp, which in severe and unrelieved cases may rest upon the abscess beneath as upon a kind of water-bed. As in scalp wounds the aponeurosis is often divided, and as suppuration may follow the injury, it will be seen that the chief danger of those lesions depends upon the spreading of such suppuration to the area of lax connective tissue now under notice. The significance of a small amount of bare bone in a scalp wound is not so much that evils will happen to the bone, but that the aponeurosis has been certainly divided and the dangerous area of the scalp opened up. Suppuration, when it occurs in this area, is only limited by the attachments of the occipito-frontalis muscle and its aponeurosis, and therefore the most dependent places through which pus can be evacuated are along a line drawn round the head, commencing in front, above the eyebrow, passing at the side a little above the zygoma, and ending

behind at the superior curved line of the occipital bone. The scalp, even when extensively dissected up by such abscesses, does not perish, since it carries, as above explained, its blood supply with it. The abscess is often very slow to close, since its walls are prevented from obtaining perfect rest by the frequent movement of the epicranial muscle. To mitigate this evil, and to ensure closing of the sinuses in obstinate cases, Mr. Hilton advises that the whole scalp be firmly secured by strapping, so that the movement of the muscle is arrested.

Abscess beneath the pericranium must be limited to one bone, since the dipping in of the membrane at the sutures prevents a more extensive spreading of the suppuration.

**Hæmatomata**, or **blood tumours** of the scalp region, occur in the same localities as abscess. The extravasation of blood above the aponeurosis must be of a limited character, while that beneath it may be very extensive. It fortunately happens, however, that the cellular tissue between the aponeurosis and the pericranium contains but very few vessels, and hence large extravasations in this tissue are uncommon.

Extravasations of blood beneath the pericranium are generally termed cephalhæmatomata, and are of necessity limited to one bone. They are usually congenital, are due to pressure upon the head at birth, and are thus most commonly found over one parietal bone, that bone being probably the one most exposed to pressure. Their greater frequency in male children may depend upon the larger size of the head in the male foetus. Such extravasations in early life are encouraged by the laxity of the pericranium, and by the softness and vascularity of the subjacent bone.

In the **temporal region**, or the region corresponding to the temporal muscle, the layers of soft parts between the skin and the bone are somewhat different from those that have been already described as common to the chief parts of the scalp. There is a good deal of fat in the temporal fossa, and when this

is absorbed it leads to more or less prominence of the zygoma and malar bone, and so produces the projecting "cheek bones" of the emaciated. The temporal muscle above the zygoma is covered in by a very dense fascia, the temporal fascia, which is attached above to the temporal ridge on the frontal and parietal bones, and below to the zygomatic arch. The unyielding nature of this fascia is well illustrated by a case recorded by Denonvilliers. It concerned a woman who had fallen in the street, and who was admitted into hospital with a deep wound in the temporal region. A piece of bone of several lines in length was found loose at the bottom of the wound, and was removed. After its removal the finger could be passed through an opening with an unyielding border, and came in contact with some soft substance beyond. The case was considered to be one of compound fracture of the squamous bone, with separation of a fragment and exposure of the brain. A bystander, however, noticed that the bone removed was dry and white, and a more complete examination of the wound revealed the fact that the skull was uninjured, that the supposed hole in the skull was merely a laceration of the temporal fascia, that the soft matter beyond was muscle and not brain, and that the fragment removed was simply a piece of bone which, lying on the ground, had been driven into the soft parts when the woman fell.

Abscesses in the temporal fossa are prevented by the fascia from opening anywhere above the zygoma, and are encouraged rather to spread into the pterygoid and maxillary regions and into the neck.

The pericranium in the temporal region is much more adherent to the bone than it is over the rest of the vault, and subpericranial extravasations of blood are therefore practically unknown in this part of the cranial wall.

**Trephining.**—This operation is frequently performed in the temporal region, its object being to reach extravasations of blood from the middle meningeal artery. This artery crosses the anterior inferior angle

of the parietal bone at a point  $1\frac{1}{2}$  inches behind the external angular process of the frontal bone, and  $1\frac{3}{4}$  inches above the zygoma.

In cutting down to the bone in the temporal region the following structures are met with in order : (1) The skin ; (2) branches of the superficial temporal vessels and nerves ; (3) the fascia continued down from the

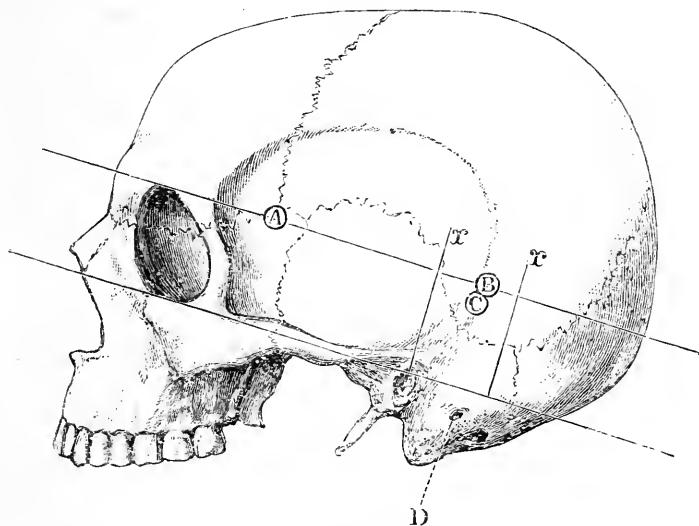


Fig. 2. - Points for Trephining.

A, B, Spots for trephining in middle meningeal hæmorrhage ; C, spot for trephining in abscess of the temporo-sphenoidal lobe ; D, mastoid foramen. (After Nancrede.)

epicranial aponeurosis ; (4) the temporal fascia ; (5) the temporal muscle ; (6) the deep temporal vessels ; and (7) the pericranium.

*Trephining for meningeal hæmorrhage.*—Unless localising symptoms give other indications, Kronlein advises that the trephine holes in cases of meningeal hæmorrhage be determined as follows :—A line is drawn around the skull at the level of the upper margin of the orbit, and is throughout parallel with Reid's base-line, Fig. 2. (See also page 35.) The trephine is first placed at a point on this line, which is from  $1\frac{1}{4}$  to  $1\frac{1}{2}$  inches

(according to age and size of head) behind the external angular process of the frontal bone (Fig. 2, A). Should no clot be revealed, a second hole is made upon the same line, just below the parietal eminence, and at a point where a vertical line carried up from the posterior border of the mastoid process bisects the line already given (Fig. 2, B). The anterior branch of the middle meningeal artery is exposed at the first point, and the posterior branch at the second.

*Trephining for intracranial abscess.*—The abscess is often due to middle-ear disease, and is then very commonly found in the temporo-sphenoidal lobe or in the cerebellum. It is estimated to be three times more common in the cerebrum than in the cerebellum.

The abscess of the temporo-sphenoidal lobe is usually found, according to Mr. Barker, between two lines drawn at right angles to Reid's base-line. These lines are about  $1\frac{1}{4}$  inches apart; one passes through the meatus, the other about  $1\frac{1}{4}$  inches behind that opening (Fig. 2, *xx*). The trephine should be introduced in the centre of the space marked out by these two lines, and at a distance of about  $1\frac{1}{4}$  inches above the base-line (Fig. 2, *c*).

In dealing with an abscess of the cerebellum, the best spot to select is, in the adult,  $1\frac{1}{2}$  inches behind the centre of the meatus and a quarter of an inch below the base-line (Fig. 3, *d*).

In some cases it is impossible to say if the abscess is situated in the temporo-sphenoidal lobe or cerebellum. In such cases Mr. Dean trephines at a point which lies  $1\frac{1}{4}$  inches behind and a quarter of an inch above the centre of the meatus. The lateral sinus is thus exposed with a part of the dura mater above the tentorium cerebelli, through which the temporo-sphenoidal lobe may be explored. By extending the trephine opening half an inch downwards the cerebellum may be examined.

*Trephining for cerebral tumour.*—The position of the opening in the skull is obviously determined by the localising symptoms. It is remarkable that little trouble from hæmorrhage has attended these operations.



In any case, after trephining, the portion or portions of bone removed may—if properly treated—be replaced in the opening, and will serve to make good the gap left by the operation.

In trephining the skull generally, the comparative thickness of the cranial wall in various parts should be borne in mind (page 28), and the large arteries of

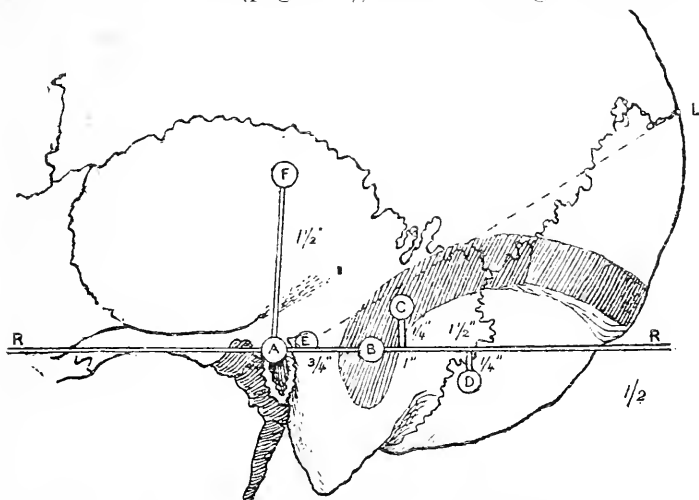


Fig. 3.—Posterior part of Skull showing Points for Trephining.  
(After Dean.)

RR, Reid's base line; A, meatal point (central point of external auditory meatus); B, over sigmoid sinus ( $\frac{1}{4}$ " behind meatal point); C, over lateral sinus ( $1\frac{1}{2}$ " behind and  $\frac{1}{4}$ " above meatal point); D, over cerebellum ( $1\frac{1}{2}$ " behind and  $\frac{1}{4}$ " below meatal point); E, supra-meatal triangle, over mastoidal antrum; F, point for tapping lateral ventricle ( $1\frac{1}{2}$ " above meatal point); A L, meato-lambda line—the second inch of this line lies over the convexity of the lateral sinus.

the scalp should be avoided if possible. In order to accommodate the instrument to the varying thickness of the skull, the pin of the trephine is not allowed to protrude more than  $\frac{1}{16}$ th of an inch. The trephine should not be applied over the frontal sinuses, which are often of large size in the aged, and should, when possible, keep clear of the sutures, owing to the frequent exit of emissary veins at or about suture lines. The bone, moreover, at certain of these lines is of unequal thickness. Between the bones forming the sutures

passes the sutural membrane. This structure blends with the dura mater, and laceration of it may conduce to meningitis. Especially must the superior longitudinal sinus be avoided, which runs backwards in the middle line, and terminates at, or slightly above, the external occipital protuberance. Lateral lacunæ of this sinus may be encountered over an inch distant from the middle line. The lateral sinus begins at the external occipital protuberance, passes forwards and slightly upwards and then bends downwards to groove the mastoid three quarters of an inch behind the external auditory meatus. In its passage forwards it rises half an inch above the level of the meatus. If a line be drawn from the meatal point to the lambda, it will be found that the second inch of this line, counting from the meatus, lies over the convexity of the lateral sinus (see Fig. 3).

The **zygoma** may be broken by direct or indirect violence. In the latter case the violence is such as tends to thrust the upper jaw or malar bone backwards. When due to direct violence, a fragment may be driven into the temporal muscle, and much pain caused in moving the jaw. In ordinary cases there is little or no displacement, since to both fragments the temporal fascia is attached above and the masseter below.

The **vessels and nerves of the scalp**.—The supraorbital artery and nerve pass vertically upwards from the supraorbital notch, which is situate at the junction of the middle with the inner third of the upper orbital margin. Nearer the middle line the frontal artery and supratrochlear nerve ascend. This artery gives life to the flap that in rhinoplasty is taken from the forehead to form a new nose. The temporal artery, with the auriculo-temporal nerve behind it, crosses the base of the zygoma just in front of the ear. The vessel divides into its two terminal branches (the anterior and posterior) 2 inches above the zygoma. The branches of this artery, especially the anterior branch, are often very tortuous in the aged, and afford early evidence of arterial degeneration: Arteriotomy is some-

times practised on the anterior branch of this vessel. The superficial temporal vessels are very liable to be the seat of cirroid aneurism, as, to a less extent, are the other scalp arteries. Cirroid aneurism is more often met with in the superficial temporal arteries than in any other artery in the body. The posterior auricular artery and nerve run in the groove between the mastoid process and the ear, and the occipital artery and great occipital nerve reach the scalp just internal to a point midway between the occipital protuberance and the mastoid process.

Certain of the **emissary veins** are of great importance in surgery. These veins pass through apertures in the cranial wall, and establish communications between the venous circulation (the sinuses) within the skull and the superficial veins external to it. The principal emissary veins are the following: 1. A vein passing through the mastoid foramen and connecting the lateral sinus with the posterior auricular vein or with an occipital vein. This is the largest and most constant of the series. The existence of this mastoid vein serves to answer the question, Why is it a common practice to apply leeches and blisters *behind the ear* in certain cerebral affections? 2. A vein connecting the superior longitudinal sinus with the veins of the scalp through the parietal foramen. 3. A vein connecting the lateral sinus with the deep veins at the back of the neck through the posterior condylar foramen (inconstant). 4. Minute veins following the twelfth nerve through its foramen, and connecting the occipital sinus with the deep veins of the neck. 5. Minute veins passing through the foramen ovale, foramen lacerum and carotid canal to connect the cavernous sinus with (respectively) the pterygoid venous plexus, the pharyngeal plexus, and the internal jugular vein.

Then, again, many minute veins connect the veins of the scalp with those of the diploe. Of the four diploic veins, two (the frontal and anterior temporal) enter into surface veins (the supraorbital and deep temporal), and two (the posterior temporal and occipital) enter into the lateral sinus.

Lastly, there is the well-known communication between the extra- and intra-cranial venous circulation effected by the commencement of the facial vein at the inner angle of the orbit. In this communication the angular and supraorbital veins unite with the superior ophthalmic vein, a tributary of the cavernous sinus.

Through these various channels, and through many probably still less conspicuous, inflammatory processes can spread from the surface to the interior of the skull. Thus we find such affections as erysipelas of the scalp, diffuse suppuration of the scalp, necrosis of the cranial bones, and the like, leading by extension to mischief within the diploe, to thrombosis of the sinuses, and to inflammation of the meninges of the brain. If there were no emissary veins, injuries and diseases of the scalp and skull would lose half their seriousness. Mischief may even spread from within outwards along an emissary vein. Erichsen reports a case where the lateral sinus was exposed in a compound fracture. The aperture was plugged. Thrombosis and suppuration within the sinus followed, and some of the pus, escaping through the mastoid vein, led to an abscess in the neck.

Certain venous tumours are met with on the skull. They consist of collections of venous blood under the pericranium that communicate, through holes in the skull, with the superior longitudinal sinus. They are median, are reducible on pressure, and receive a faint pulsation from the brain. The holes are sometimes the result of accident, others depend upon bone disease or atrophy about a Pacchionian body, and a few are due to a varicose emissary vein or to a congenital defect in the cranium.

The scalp **nerves**, especially such as are branches of the fifth pair, are often the seat of neuralgia. To relieve one form of this affection, the supraorbital nerve has been divided (neurotomy) at its point of exit from the orbit, and a portion of the nerve has been resected (neurectomy) in the same situation.

Some forms of frontal headache depend upon neuralgia of this nerve. The inner branch of the nerve reaches the middle of the parietal bone; the outer branch, the lambdoid suture.

The **lymphatics** from the occipital and posterior parietal regions of the scalp enter the occipital and mastoid glands; those from the frontal and anterior parietal regions go to the parotid glands, while some of the vessels from the frontal region join the lymphatics of the face and end in the submaxillary glands (Fig. 21).

---

## CHAPTER II.

### THE BONY VAULT OF THE CRANIUM.

**Position of the sutures.**—The bregma, or point of junction of the coronal and sagittal sutures, is in a line drawn vertically upwards from a point just in front of the external auditory meatus, the head being in normal position (Fig. 2). The lambda, or point of junction of the lambdoid and sagittal sutures, lies in the middle line, about  $2\frac{3}{4}$  inches above the occipital protuberance. The lambdoid suture is fairly represented by the upper two-thirds of a line drawn from the lambda to the apex of the mastoid process on either side. The coronal suture lies along a line drawn from the bregma to the middle of the zygomatic arch. On this line, at a spot about on a level with the external angular process of the frontal bone, and about  $1\frac{1}{2}$  inches behind that process, is the pterion, the region where four bones meet, viz. the squamous bone, the great wing of the sphenoid, the frontal and parietal bones. The summit of the squamous suture is  $1\frac{3}{4}$  inches above the zygoma.

In the normal subject all traces of the **fontanelles** and other unossified parts of the skull disappear before the age of two years. The anterior fontanelle is the last to close, while the posterior is already filled at the time of birth. It is through or about the anterior fontanelle that the ventricles are usually aspirated,

in cases of hydrocephalus. The needle is entered either at the sides of the fontanelle at a sufficient distance from the middle line to avoid the sinus, or is introduced through the coronal suture at some spot other than its middle point. It may be noted that in severe hydrocephalus the coronal and other sutures of the vault are widely opened.

The condition known as **cranio-tabes**, a condition assigned by some to rickets and by others to inherited syphilis, is usually met with in the vertical part of the occipital bone, and in the adjacent parts of the parietal bones, but especially in the posterior inferior angles of these bones. In this condition the bone is greatly thinned in spots, and its tissue so reduced that the affected district feels to the finger as if occupied by parchment, or, as some suggest, by cartridge paper. The thinning is mainly at the expense of the inner table and diploe. The pits are situated in early formed convolution impressions. It is, on the other hand, about the site of the anterior fontanelle that certain osseous deposits are met with on the surface of the skull in some cases of *hereditary syphilis* (Parrot). These deposits appear as rounded elevations of porous bone situated upon the frontal and parietal bones, where they meet in the middle line. These bosses are separated by a crucial depression represented by the frontal and sagittal sutures on the one hand and the coronal suture on the other. They have been termed "natiform" elevations by M. Parrot, from their supposed resemblance, when viewed collectively, to the nates. To the English mind they would rather suggest the outlines of a "hot-cross bun."

It is necessary to refer to the **development of the skull** in order to render intelligible certain conditions (for the most part those of congenital malformation) that are not unfrequently met with. Speaking generally, it may be said that the base of the skull is developed in cartilage, and the vault in membrane. The parts actually formed in membrane are represented in the completed skull by the frontal

and parietal bones, the squamo-zygomatic part of the temporal bone, and the greater part of the expanded portion of the occipital bone. The distinction between these two parts of the skull is often rendered very marked by disease. Thus there are, in the museum of the Royal College of Surgeons, the skulls of some young lions that were born in a menagerie, and that, in consequence of mal-nutrition, developed certain changes in their bones. A great part of each of these skulls shows considerable thickening, the bone being converted into a porous structure; and it is remarkable to note that these changes are limited to such parts of the skull as are formed in membrane, the base remaining free.

Among the more common of the gross malformations of the skull also is one that shows entire absence of all that part of the cranium that is formed in membrane, while the base, or cartilaginous part, is more or less perfectly developed.

**Meningocele** is the name given to a congenital tumour that consists of a protrusion of a part of the cerebral membranes through a gap in an imperfectly developed skull. When the protrusion contains brain, it is called an encephalocele, and when that protruded brain is distended by an accumulation of fluid within the ventricles, it is called hydrocephalocele. These protrusions are most often met with in the occipital bone, and next in frequency in the fronto-nasal suture, while in rarer cases they have been met with in the lambdoid, sagittal, and other sutures, and have projected through normal and abnormal fissures at the base of the skull into the orbit, nose, and mouth. Their frequency in the occipital bone may be in some way explained by a reference to the development of that part. This bone at birth consists of four separate parts.

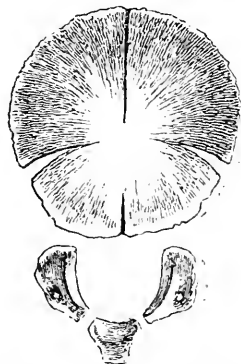


Fig. 4.—The Occipital Bone at Birth.

(see Fig. 4), a basilar, two condylar, and a tabular or expanded part. In the tabular part, about the seventh week of foetal life four nuclei appear, an upper and a lower pair. These nuclei are to some extent separated by fissures running inwards from the four angles of the bone to meet at the occipital protuberance. The gap running up in the median line from the inferior angle at the foramen magnum to the occipital protuberance

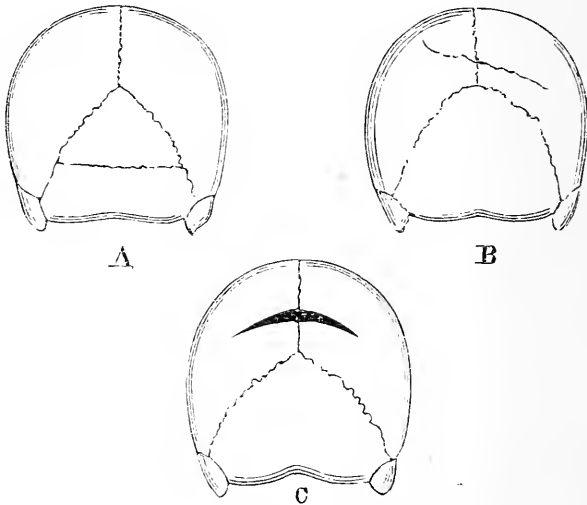


Fig. 5.—Back View of Abnormal Skulls, showing Occipital and Parietal Bones.

A, The "os épactal"; B, parietal fissures; C, the sagittal fontanelle.

is especially distinct (the temporary occipital fontanelle of Sutton). It exists from the beginning of the third to the end of the fourth month of intrauterine life. Meningocele of the occiput are always in the middle line, and the protrusion probably occurs through this gap. The gap associated with meningocele may extend through the whole vertical length of the occipital bone, and very commonly opens up the foramen magnum. The lateral or transverse fissures divide the bone into two parts. The upper part is developed from membrane,



the lower part from cartilage. The lateral fissures may persist, and may simulate fractures, for which they have, indeed, been mistaken; or they may be so complete as to entirely separate the highest part of the occipital bone from the remainder. The bone so separated is the *os épactal* of the French (Fig. 5, A), the interparietal bone of some animals.

**Parietal fissures.**—In the developing parietal bone, fibres concerned in ossification radiate towards the periphery from two nuclei about the centre of the bone. An interfibrillar space, larger than the rest, is seen about the fifth month to separate the loose osseous fibres which abut on the posterior part of the sagittal border from the stronger fibres which form the rest of this border (Pozzi). This is the *parietal fissure*. It usually closes and leaves no trace, but it may persist in part as a suture-like fissure, and be mistaken for a fracture (Fig. 5, B). If the fissure persists equally on the two sides an elongated lozenge-shaped gap is left, the *sagittal fontanelle*. It is situated about an inch in front of the lambda, and occurs in over 4 per cent. of newly born children (Lea) (Fig. 5, c). The parietal foramina are remains of this interval.

**Wormian bones.**—These irregular bones may be mistaken for fragments produced by fracture. They are most usually met with in the lambdoid suture. One Wormian bone deserves special notice, as it may be met with in trephining over the middle meningeal artery. It exists between the anterior inferior angle of the parietal bone and the great wing of the sphenoid. It is scale-like, and gives the impression that the tip of the great wing had been separated. It is known as the epipterice bone.

**Necrosis** is fairly common on the vault of the skull, and most often attacks the frontal and parietal bones, while, for reasons that are not very obvious, it is rare in the occipital bone. The external table is frequently necrosed alone, it being more exposed to injury and less amply supplied with blood than is the internal table. From the converse of these reasons it happens that

necrosis of the internal table alone is but rarely met with. Necrosis involving the entire thickness of the bone may prove very extensive, and in a case reported by Saviard, practically the whole of the cranial vault necrosed and came away. The patient was a woman, and the primary cause of the mischief was a fall upon the head when drunk. (See page 5.)

Necrosis of the skull, as well as caries of the part, is attended by certain special dangers that depend upon the anatomical relations of the cranial bones.

Thus, when the whole thickness of the skull is involved by disease, or when the inner table is especially attacked, a collection of pus may form between the dura mater and the affected bone, and may produce compression of the brain. When the diploic tissue is implicated, the veins of that part may become thrombosed, or may be the seat of a suppurative phlebitis. The mischief thus commenced may spread, the great intracranial sinuses may be closed by thrombus, or septic matter may be conveyed into the general circulation and lead to the development of pyæmia.

Mere local extension may also cause meningitis.

In cases of necrosis of the external table the growth of granulation tissue from the exposed and vascular diploe plays a very important part in aiding the exfoliation of the lamella of dead bone.

When bone disease leads to perforation of the skull, the pulsations of the brain may be visible through the abnormal opening.

**Fractures of the skull.**—It is not easy to actually fracture the skull of a young infant. The skull as a whole at this age is imperfectly ossified, the sutures are wide, and between the bones there is much cartilage and membrane. Moreover, the bones themselves in early life are elastic, and comparatively soft and yielding. If a blow be inflicted upon the vault in a young child the most probable effect, so far as the bone itself is concerned, is an indenting or bulging in of that bone unassociated with a fracture in the ordinary sense. In this particular relation, the

skull of an infant is to that of an old man as a cranium of thin tin would be to a cranium of strong earthenware. The yielding character of the young child's skull is well illustrated by the gross deformity of the head that certain Indian tribes produce in their offspring by applying tight bandages to the part in infancy. In the Royal College of Surgeons museum are many skulls of "flat-headed" Indians, that show to what an extreme this artificial deformity may be carried. Guéniot also asserts that much deformity of the head may be produced in infants by the practice of allowing them to always lie upon one side of the body. Here the deforming agent is simply the weight of the brain.

Even in adults the skull is much less brittle than is commonly supposed, and notions as to the breaking ability of the cranial bones derived from the study of the dried specimens are apt to be erroneous. During life, a sharp knife properly directed may be driven through the cranial vault so as to cause only a simple perforating wound without splintering, and without fracture of the bone beyond the puncture. Such a wound may be as cleanly cut as a wound through thick leather, and a specimen in the London Hospital museum serves well to illustrate this. A case reported in the *Lancet* for 1881 affords a strange instance of a knife penetrating the skull without apparently splintering the bone. A man wishing to commit suicide placed the point of a dagger against the skull in the upper frontal region, and then drove it well into the brain by a blow from a mallet. He expected to fall dead, and was disappointed to find that no phenomena of interest developed. He then drove the dagger farther in by some dozen blows with the mallet, until the blade, which was four inches long, was brought to a standstill. The dagger was removed with great difficulty, the patient never lost consciousness, and recovered without a symptom.

The following anatomical conditions tend to *minimise the effects of violence* as applied to the skull: The density of the scalp and its great mobility; the dome-like

arrangement of the vault; the number of the bones that compose the head, and the tendency of the violence to be broken up amongst the many segments; the sutures which interrupt the continuity of any given force, and the sutural membrane, which acts as a kind of linear buffer; the mobility of the head upon the spine; and the elasticity of the cranial bones themselves.

The skull is further strengthened by the presence of six buttresses or pillars at the junction of the vault and base. Two of these are lateral, the orbito-sphenoid anteriorly and the petro-mastoid posteriorly, while the fronto-nasal and occipital strengthen the anterior and posterior ends of the skull.

In children the membranous layer between the sutures is of considerable thickness, but, as age advances, this membrane disappears, and the bones tend to fuse together (synostosis). *The sutures begin to be obliterated* about the age of forty, the change commencing on the inner aspect of the suture, and appearing first in the sagittal suture, then in the coronal and lambdoid, and last in the squamous. The synostosis may be complete by the age of eighty (Tillaux), and its onset is said to be coincident with the cessation of increase in the weight of the brain. This latter assertion is supported by the fact that it appears earlier in the lower races of mankind. As age advances, moreover, the skull bones become less porous, and lose much of their elasticity. They are, therefore, more readily fractured in the aged than in the young.

As a rule, in fracture, the entire thickness of the bone is involved; but the external table alone may be broken, and may even be alone depressed, being driven into the diploe, or, in the case of the lower frontal region, into the frontal sinus. The internal table may be broken without a corresponding fracture in the outer plate; and in nearly all cases of complete fracture, especially in such as are attended with depression, the internal table shows more extensive splintering than does the external. There are many reasons for this. The in-

ternal plate is not only thinner than the external, but is so much more brittle as to receive the name of the "vitreous table." A force applied to the external table may be extremely limited, and produce, as in a sabre cut, but a limited lesion. As the force, however, travels

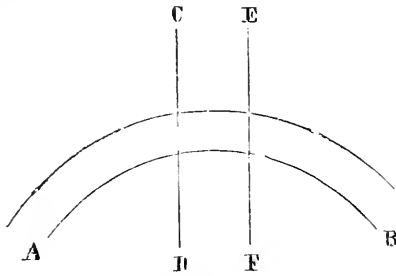


Fig. 6.

through the diploe it becomes broken up, and reaches the inner plate as a much more diffused form of violence. This is especially the case when parts of the outer table are driven in. Then, again, the internal plate is a part of a smaller curve than is the external plate; and,

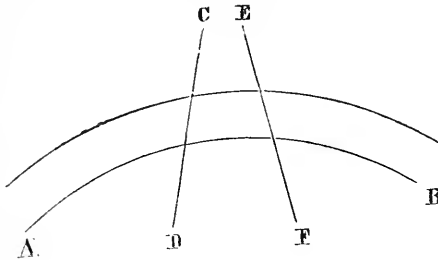


Fig. 7.

lastly, Agnew assigns a reason for the greater vulnerability of the inner plate that has reference to the general yielding of the bone. In Fig. 6 A B represents a section of a part of the vault through both tables, and C D and E F two vertical and parallel lines. Now, if force be applied to the vault between these parallel lines, the ends of the arch, A B, will tend to become separated,

and the whole arch, yielding, will tend to assume the curve shown in Fig. 7. In such case, the lines *CD* and *EF* will converge above and diverge below (Fig. 7), so that the violence would tend to force the bone particles together at the outer table and asunder at the inner table.

**Fractures of the vault** are due to direct violence. The construction of the skull is such that the fracturing force is resisted in many ways. (1) When a blow is received on the vertex in the *parietal* region, the force tends to drive the upper borders of the two parietal bones inwards. Such driving in of these borders must be associated with a corresponding outward movement of the inferior borders. This latter movement is forcibly resisted by the squamous bone and the great wing of the sphenoid, which overlap the lower edge of the parietal bone. Moreover, the force transmitted to the squamous bone is passed on to the zygomatic arch, which takes its support from the superior maxillary and frontal bone. This arch then acts as a second resisting buttress, and this transmission of force from the vertex to the facial bones is said to be illustrated by the pain often felt in the face after blows upon the top of the head. (2) If the upper part of the *frontal* bone be struck, the force is at once transmitted to the parietal bones, because the upper part of the frontal bone (owing to the manner in which its border is bevelled) actually rests upon the two parietal bones, so the same resistance is again called into action. If there be any tendency for the inferior parts of the bone to move outwards, as would certainly be the case while the mid-frontal suture existed, such movement would be resisted by the great wings of the sphenoid and by the anterior inferior angles of the parietal bones which embrace or overlap these parts of the frontal. Thus it will be seen that much depends upon the manner in which the corresponding edges of the frontal and parietal bones are bevelled. (3) Blows upon the *occiput* are less distinctly provided for, and it must be owned that a by no means heavy fall is sufficient to break this bone.

It must receive, however, much protection from its connections with the two parietal and temporal bones, and from its articulation with the elastic vertebral column.

**Fractures of the base of the skull** may be due to (1) direct or to (2) indirect violence, and, most commonly of all, to (3) extension of a fracture from the vault. (1) The base has been fractured by direct violence by foreign bodies thrust through the nasal roof, through the orbital roof, and through the base as it presents in the pharynx. The posterior fossa can also be fractured by violence applied to the nape of the neck. (2) Of fractures by indirect violence the following examples may be given: Blows applied to the lower part of the frontal bone have been associated with no lesion other than a fracture of the cribriform plate or of the orbital part of the frontal, these parts being much disposed to fracture on account of their extreme tenuity. In falls upon the chin, the condyle of the lower jaw has been so violently driven against the glenoid cavity as to fracture the middle fossa of the skull. Chassaignac gives a case where the condyle was actually thrust into the cranial cavity, and produced an abscess in the superimposed part of the brain. When the body in falling has alighted upon the feet, knees, or buttocks, the force has been transmitted along the vertebral column, and has led to fracture of the base in the occipital region. Such accidents are most apt to occur when the spine is kept rigid by muscular action, and the mechanism involved is precisely similar to that whereby the head of a broom is driven more firmly on to the broom-handle by striking the extreme end of the stick against the ground. The theory that the base is often broken by *contre-coup* is pretty generally abandoned, although there are a few cases that appear to support the suggestion. Such a case was recorded by Mr. Hutchinson, and in it a fracture of the occipital bone was associated with a like lesion in the cribriform plate, the intervening part of the skull being uninjured. (3) Fractures of the vault, and especially linear fractures due to such diffused

violence as obtains in a fall upon the head, are very apt to spread to the base. In so spreading they reach the base by the shortest possible route, and without any regard to the sutures encountered or to the density of the bones involved. Thus, fractures of the frontal region of the vault spread to the anterior fossa of the base, those of the parietal region to the middle fossa, and those of the occipital region to the posterior fossa. To this rule there are but few exceptions. To indicate more precisely the exact bones involved in these three districts, P. Hewett has divided the skull into three zones. The anterior zone included the frontal, the upper part of the ethmoid, and the fronto-sphenoid; the middle, the parietals, the squamous, the anterior part of the petrous portion, and the greater part of the basi-sphenoid; and the posterior, the occipital, the mastoid, the posterior part of the petrous bone, with a small part of the body of the sphenoid.

In all fractures of the base there is usually a discharge of blood and of cerebro-spinal fluid externally. (1) In fractures of the anterior fossa the blood usually escapes from the nose, and is derived from the meningeal vessels, or in greater degree probably from the torn mucous lining of the nasal roof. To allow of the escape of cerebro-spinal fluid from the nose, there must be, in addition to the fracture in the nasal roof, a laceration of the mucous membrane below that fracture, and of the dura mater and arachnoid above it. In many cases of fracture in this part the blood finds its way into the orbit, and appears beneath the conjunctiva. (2) When the middle fossa is involved, the blood escapes from the external auditory meatus, through a rupture in the tympanic membrane, and is derived from the vessels of the tympanum and its membrane, or from an intracranial extravasation, and in some cases from a rupture of one of the sinuses about the petrous bone. The blood may follow the Eustachian tube, and may escape from the nose or mouth, or be swallowed and subsequently vomited. To allow of the escape of cerebro-spinal fluid by the ear ("the serous



discharge"), (a) the fracture must have passed across the internal auditory meatus; (b) the tubular prolongation of the membranes in that meatus must have been torn; (c) there must be a communication between the internal ear and the tympanum; and (d) the membrana tympani must have been lacerated. (3) In fractures of the posterior fossa an extravasation of blood may appear about the mastoid process or at the nape of the neck, or may even extend into the cervical region.

It may be added that in compound fractures of the *vault* associated with tearing of the dura mater and arachnoid, an escape of cerebro-spinal fluid has in a few rare instances been noted. After simple fracture of the vault in children a swelling may form at the injured part, which fluctuates, becomes tenser when the patient cries, and may possibly pulsate synchronously with the brain. Such swellings are due to a collection of cerebro-spinal fluid beneath the scalp, and indicate a coincident rupture of the brain membranes. In cases of free serous discharge from the ear after injury to the head, but without fracture, the fluid is derived from the mastoid cells, and escapes through a rupture in the tympanic membrane. In a few instances it may possibly be blood serum, or depend upon mild catarrh of the meatus. Some authors assert that it may be due to the escape of the liquor Cotunnii, but the very minute quantity of that fluid in the ear renders the suggestion improbable.

**Separation of sutures.**—This condition, as the result of injury, is practically restricted to the young skull. In later life, force applied at the site of an obliterated suture may cause a fracture, which accurately follows the old suture line. Separation of the sutures, independent of fracture, is very rare in the adult skull. In the few instances of such a condition the temporal bone has usually been the one displaced and the separation noted at the squamous suture. When associated with fracture, the coronal and sagittal sutures are those most frequently separated, and next in frequency the lambdoid.

The **thickness of the skull cap** varies greatly, not only in different parts of the same skull, but also in corresponding parts in different individuals. The average thickness is one fifth of an inch. The thickest parts are at the occipital protuberance (where the section may measure half an inch), the mastoid process, and the lower part of the frontal bone. The bone over the inferior occipital fossæ is very thin, while it is thinnest over the squamous bone. Here the bone may be no thicker in parts than a visiting card. The skull is also thinned over the sinuses and grooves for the meningeal vessels. It is especially thin over the anterior inferior angle of the parietal bone. It is important to remember in trephining that the inner table is not always parallel with the outer.

**Craniectomy.**—This operation is carried out in cases of microcephaly in infants and children. It consists in the removal of a strip of bone from the vertex of the skull so as to give to the brain, as an American author expresses it, “more elbow room.”

---

## CHAPTER III,

### THE CRANIAL CONTENTS.

**THE membranes of the brain.**—The *dura mater*, from its toughness, forms an excellent protection to the brain. It is very intimately adherent to the bone over the whole of the base of the skull, and consequently in this situation extravasations between the membrane and the bone are scarcely possible. Over the vault its attachments are comparatively loose, although it is more closely adherent along the lines of the sutures. This lax attachment allows large hæmorrhagic and purulent extravasations to collect between the *dura mater* and the bone. Such extravasations usually lead to compression of the brain, and it may be noted that in the great majority of all cases of compression the compressing force is outside the *dura mater*. Thus, in uncomplicated cases

when symptoms of compression come on at the time of an accident, the cause is probably depressed bone ; when they appear after a short interval, the cause is probably extravasated blood between the membrane and the bone ; and when a long interval (days or weeks) has elapsed after the accident, the cause is probably a collection of pus in the same situation.

Sir C. Bell pointed out that the dura mater of the vault may be separated from the bone by the vibration produced by a blow. "Strike the skull of a subject with a heavy mallet ; on dissecting you find the dura mater to be shaken from the skull at the point struck. Repeat the experiment on another subject, and inject the head minutely with size injection, and you will find a clot of injection lying betwixt the skull and dura mater at the part struck, and having an exact resemblance to the coagulum found after violent blows on the head." Tillaux has demonstrated that the adhesions between the dura mater and the bone are particularly weak in the temporal fossæ, the most usual site of meningeal hæmorrhage.

When blood is poured out between the dura mater and the bone in cases of fracture, the vessel that as a rule gives way is the **middle meningeal artery**. In thirty-one cases of such hæmorrhage, this vessel was the source of the bleeding in twenty-seven instances (P. Hewett). The vessel, having passed through the foramen spinosum, divides into two branches ; the anterior, the larger, runs upwards across the anterior inferior angle of the parietal bone and ascends the vault some distance behind the coronal suture ; the posterior runs backwards, with a horizontal sweep across the squamous bone, and takes the course of the second temporal convolution. (*See page 9.*)

Mr. Jacobson has shown that the branches of the artery are more frequently ruptured than the trunk. The vessel is very frequently torn as it crosses the anterior angle of the parietal bone. There are many reasons for this : the bone where grooved by the artery is very thin ; the artery is often so embedded in the

bone that fracture without laceration of the vessel would hardly be possible; and lastly, the particular region of the artery is a part of the skull peculiarly liable to be fractured. Mr. Jacobson shows that the artery may be ruptured by a force that does not fracture the skull, but merely leads to detachment of the dura mater. (See page 29.) Failing this vessel, the most frequent source of extra-meningeal hæmorrhage is the lateral sinus, for reasons that will be obvious.

With regard to the blood sinuses formed by the dura mater, nothing remains to be added to what has been already said (page 12), except, perhaps, to observe that the relations between the internal carotid artery and cavernous sinus are so intimate that arterio-venous aneurism has followed injury involving these parts. It will be seen also with what ease this sinus could become thrombosed in cases of inflammation within the orbit by the extension of the mischief along its great tributaries, the two ophthalmic veins.

Sarcomatous growths, springing from the dura mater or other of the meninges, may make their way through the cranial bones, and project as pulsating tumours beneath the scalp. Such growths are included under the title of "fungus of the dura mater."

Between the dura mater and the arachnoid is the **subdural space**, formerly known as the "cavity of arachnoid" (Fig. 1, p. 2). According to Prescott Hewett, extravasations of blood after injury are more common in this space than in any other part within the skull. The blood so poured out may become more or less discoloured, and present in time the aspect of a thin and peculiar membrane; or the collection may form itself into a species of cyst ("arachnoid cyst") that was for some time a source of much confusion to pathologists.

The subdural space contains a small amount of fluid, and acts, probably, like the pleural and peritoneal sacs in preventing the effects of friction during the movements of the brain.

The **subarachnoid space** is between the arachnoid and the pia mater, and it is here that the chief

part of the cerebro-spinal fluid is lodged. This space is larger in some places than in others. It is insignificant over the convexity of the brain, but is very extensive at the base of the skull in the parts beneath the cerebellum, the medulla, the pons, and the interpeduncular space as far forwards as the optic nerves. Thus these very important parts of the brain do not rest upon bone, but rest rather on the subarachnoid collection of fluid as upon a water-bed, to use a comparison of Mr. Hilton's. The only part of the base of the brain that rests directly upon bone is that part in contact with the orbital plates and lesser wings of the sphenoid. The posterior two-thirds of the brain rests upon the "water-bed," and is thus admirably protected.

It is well known that the brain may be damaged by *contre-coup*. That is to say, if the head be struck at one particular part, the brain may be found uninjured at the spot struck, but damaged at a corresponding place on the opposite side of the skull. The cerebro-spinal fluid is much concerned in modifying the effects of *contre-coup*. Thus, if the vertex be struck, the important structures at the base of the brain would be in the greatest danger of being severely injured, did they lie in actual contact with the bone. Moreover, when a blow falls upon the occiput, there may be no damage to the brain beneath the spot struck, but the yielding mass is thrown forward within the skull, and were it not for the "water-bed," the under parts of the cerebrum would be torn against the many projections in the base of the skull. These projections, which are so conspicuous in the dry skull, are moulded off in the living by the dura mater, and also by the blood sinuses which occupy the hollows about these projections, and also certain margins of bone. As it is, the only part that usually suffers is the under surface of the frontal lobe (a comparatively unimportant segment), which, being brought violently in contact with the irregular orbital plate, is readily contused.

The subarachnoid space communicates with the ventricles through the foramen of Majendie. This

foramen leads into the fourth ventricle, and is an aperture in the pia mater that closes in that ventricle. From the fourth ventricle fluid can pass along the iter into the third ventricle, and from thence to the lateral ventricles by the foramen of Monro.

The cerebro-spinal fluid prevents the ill effects that irregularities in the blood circulation might have upon the brain, situate as it is within an unyielding cavity. If the great nerve centres in the lateral ventricles are swollen by congestion, they are not met by an unyielding wall, but merely displace some of the cerebro-spinal fluid through the foramen of Majendie, until such time as their circulation is normal again.

Hilton has shown that closure of this foramen may lead to that excessive accumulation of fluid within the ventricles known as hydrocephalus. The fluid also drains into the veins of Galen, hence pressure on these may bring about a like result. It has been proposed to relieve the pressure within the lateral ventricles in cases of hydrocephalus by draining the cerebro-spinal fluid into the subdural space. It is absorbed at any pressure above that within the cerebral veins (Hill). If the brain, too, becomes enlarged by congestion, it is not met by unyielding bone, but rather by an adjustable water-bed, and during its period of enlargement it merely displaces into the spinal part of the subarachnoid space some of the fluid that surrounds it. This mutual effect is well illustrated in a case reported by Hilton of a man with a fracture of the base, from whose ear cerebro-spinal fluid was escaping. The discharge of this fluid was at once greatly increased by expiratory efforts when the nose and mouth were held closed, and the veins compressed in the neck. The subarachnoid space is most easily tapped by a lumbar puncture (*see* p. 548).

The **surface relationships of the brain** (*see* Figs. 8 and 9).—The longitudinal fissure of the brain is indicated by a line drawn along the vertex from the glabella to the external occipital protuberance. It is narrow in front, but as it contains the longitudinal sinus, which rapidly enlarges as it passes backwards,

it becomes of considerable breadth behind, and as a rule lies somewhat towards the right of the median line, owing to the predominance of the left cerebral

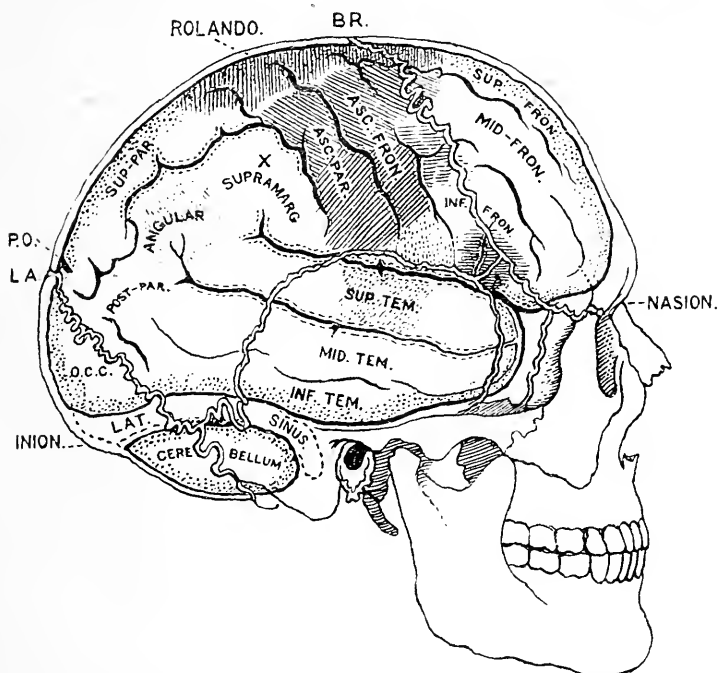


Fig. 8.—Showing the Relation of the Brain and Sensori-motor Areas of Cortex to the Skull. (*Modified from Quain.*)

BR., Bregma—at the junction of coronal and sagittal sutures; L.A., lambda—at the junction of lambdoidal and sagittal sutures; X, position of parietal eminence. The sensori-motor areas are shaded: the leg and trunk areas with vertical lines; the arm and hand areas with lines slanting forwards; the face and mouth areas with lines slanting backwards; the tongue, pharynx, and larynx areas are stippled. The motor centre for speech in Broca's convolution is shaded with horizontal lines. The "word-hearing" centre is indicated on the superior temporal convolution, and that for the "word-seeing" centre on the angular convolution. The area shaded with horizontal lines on the posterior parts of the middle and inferior frontal convolutions is the centre for combined movements of the head and eyes.

hemisphere. Between the external occipital protuberance and the ear, the lateral sinus bounds the lower level of the cerebrum and the upper of the cerebellum. A line drawn from the external occipital protuberance to the upper margin of the external

auditory meatus indicates fairly the position of the sinus, yet it must be remembered that just behind the ear its convexity passes above the level of this line. In front of the ear the upper border of the zygoma in its posterior two-thirds marks the lower border of the temporal lobe. The pole of the temporal lobe is  $\frac{3}{4}$  of an inch behind the outer margin of the orbit. On the forehead a line drawn behind the external angular process and above the eyebrows to the glabella indicates the lower level of the frontal lobe.

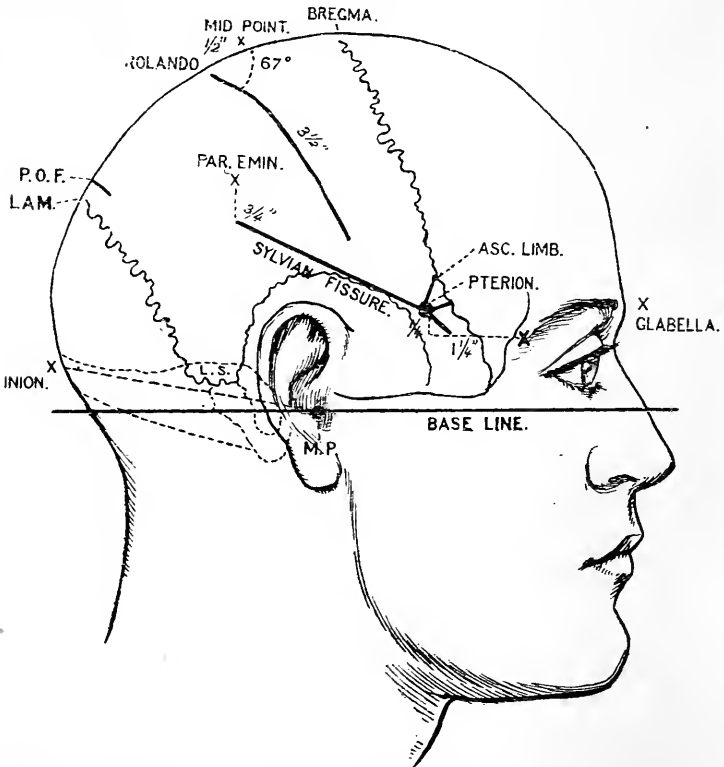


Fig. 9.—Showing the Lines which indicate the Position of the Principal Fissures of the Brain.

M.P., Meatal point—the centre of the external auditory meatus; INION, over external occipital protuberance; L.A.M., lambda; P.O.F., parieto-occipital fissure; x on fronto-malar suture at external angular process; L.S., lateral sinus, crossing the posterior inferior angle of parietal. (See also Fig. 3, p. 11.)



The cerebellum is best explored at a point  $1\frac{1}{2}$  inches behind and  $\frac{1}{4}$  of an inch below the level of the external auditory meatus (see Fig. 3, p. 11). It is deeply placed, being covered by the insertions of the occipital muscles.

Of the many methods which have been suggested for marking out the **fissure of Rolando**, the most simple and accurate is the following:—A point over the sagittal suture is taken midway between the glabella and external occipital protuberance. Half an inch behind the mid point terminates the upper end of the Fissure (see Fig. 9). A line  $3\frac{1}{2}$  inches long drawn downwards and forwards from this point, at an angle of  $67^\circ$  to the line of the sagittal suture, will indicate the position of the fissure of Rolando in the adult. In the child the fissure is shorter and the contained angle is  $5^\circ$  smaller. The angle is easily obtained by folding twice the corner of a square piece of paper at, and removing a fourth of, the right angle. This line may lie not exactly over the fissure, for it varies somewhat in position according to the shape of head. The sensori-motor areas of the brain are mostly represented in the ascending frontal and parietal convolutions which bound the fissure of Rolando. The average width of each of these convolutions is  $\frac{3}{4}$  of an inch. The coronal suture is about 2 inches in front of the fissure of Rolando at its upper part and  $1\frac{1}{4}$  inches at its lower.

The **fissure of Sylvius** is indicated thus:—A point is taken  $1\frac{1}{4}$  inches behind and  $\frac{1}{4}$  of an inch above the most prominent point of the external angular process (see Fig. 9). This point on the temple overlies the anterior inferior angle of the parietal bone—the *pterion*. The pterion marks the junction of the three limbs of the fissure of Sylvius with its stem. A line drawn backwards and upwards from the pterion to a point  $\frac{3}{4}$  of an inch below the parietal eminence indicates the situation of the posterior horizontal limb or ramus (Fig. 9). This ramus is bounded below by the superior temporal convolution, which contains in its middle third the "word-hearing" centre (Fig. 8). Above, it is bounded from before backwards by the basilar part of the inferior

frontal convolution, the lower ends of the ascending frontal and parietal convolutions, and the supramarginal gyrus. In the three parts first named are situated centres for movements of the tongue, larynx, pharynx and mouth. A penny piece placed directly behind the termination of the Sylvian line will cover the angular convolution in which the "word-seeing" centre is placed (Fig. 8). The parietal eminence covers the supramarginal convolution. The *ascending limb* of the fissure of Sylvius is indicated by a line  $\frac{3}{4}$  of an inch long drawn upwards and slightly forwards from the pterion, while the short *anterior horizontal limb* is indicated by a line  $\frac{1}{2}$  an inch long drawn forwards from the same point. Between the ascending and anterior limbs is situated the *pars triangularis* of the inferior frontal convolution in which the centre for "motor speech" is placed. The *stem* of the Sylvian fissure is  $\frac{1}{2}$  an inch long and runs downwards and forwards under the great wing of the sphenoid (Fig. 8). The temporal pole lies below it.

The four angles of the parietal bone have important relationships to the brain. The *anterior inferior* angle covers the posterior part of the inferior frontal convolution and the anterior horizontal and ascending limbs of the fissure of Sylvius. The anterior branch of the middle meningeal artery ascends beneath it. The *anterior superior* angle at the bregma covers the terminal part of the superior frontal convolution and the centre for movements of the hip. The *posterior superior* angle at the bregma lies over the upper part of the occipital lobe and  $\frac{1}{2}$  an inch behind the parieto-occipital fissure. The *posterior inferior* angle covers the convexity of the lateral sinus and marks the lower limit of the cerebrum. In its anterior half the posterior limb of the Sylvian fissure lies beneath the squamosal suture, but behind it passes entirely beneath the parietal bone. It will be thus seen that the parietal bone covers the whole of the parietal lobe, the posterior parts of the frontal and temporo-sphenoidal lobes, and the upper margin of the occipital.

The **inferior temporal convolution** passes

backwards above the upper border of the zygoma and external auditory meatus and rests on the thin roof of the tympanum. Hence it is the most common site of abscess which may follow middle-ear disease. (Fig. 8.)

The **basal ganglia** of the brain—the corpus striatum and optic thalamus—are capped on their outer aspect by the Island of Reil. The Island lies buried in the anterior half of the fissure of Sylvius, and hence the surface markings for the fissure may be also used for the Island and the basal ganglia. A half-circle, with a radius of  $\frac{1}{2}$  an inch, drawn in front of the pterion, will indicate the anterior limit of the basal ganglia, while behind they terminate behind the mid point of the posterior limb of the fissure of Sylvius.

A point taken  $1\frac{1}{2}$  inches vertically above the external auditory meatus marks the junction of the descending and posterior horns with the body of the *lateral ventricle*. This point lies behind the pulvinar of the optic thalamus.

The **sensori-motor areas of the brain**.—A knowledge of the position of these areas is most important in enabling certain brain lesions to be localised and in guiding the surgeon in operations upon the cerebral cortex. The precise extent of each area is not yet accurately determined, and to some extent they overlap. The areas in front and behind the upper third of the fissure of Rolando are centres for movements of the lower limb and trunk, the middle third for the upper limb, and the lower third for the face, mouth, tongue, larynx, and pharynx (Fig. 8).

The areas for the *lower limb* are confined to the posterior part of the superior frontal convolution, the anterior part of the superior parietal lobule, and to the upper parts of the ascending frontal and parietal convolutions lying between (Fig. 8). Areas for the lower limb are also found in the paracentral lobule on the mesial surface of the brain. The hip, knee, ankle, and the toe areas are represented from before backwards. The shoulder, elbow, wrist, thumb and finger areas follow each other from above downwards in the middle third

of the ascending frontal and parietal convolutions. The posterior parts of the middle and inferior frontal convolutions, just anterior to the ascending frontal fissure, give rise to combined movements of the head and eyes when stimulated. The centres of movement for the face, mouth, and muscles of mastication are situated in the lower third of the two ascending convolutions. The areas for the larynx and pharynx lie in the pars basilaris of the third frontal convolution, while the motor centre for speech lies in the pars triangularis of the same convolution. The "word-hearing" centre is situated in the superior temporal convolution, while the "word-seeing" centre is placed in the angular gyrus (Fig. 8).

Of the **brain** generally little has to be said. In a surgical sense, it presents itself simply as a large mass of soft tissue that may be damaged by shaking as gelatine may be shaken in a case. As it is of very yielding structure, and does not entirely fill the cranial cavity, it may, as it were, be thrown about with the skull, and be damaged by collision with its walls. Of the exact mechanism of concussion or shaking of the brain little is known, and it cannot be said that experiments, such as those of M. Gama, with a bulb of isinglass within a glass matrass, tend to throw much light upon the subject. In contusion or bruising of the brain it is noticed that the lesion is very much more frequently situate on the under surface, both as regards the cerebrum and cerebellum, than any other part (Prescott Hewett). To this statement, however, there is the striking exception that those parts of the base of the cerebrum that rest upon the large basal collection of the cerebro-spinal fluid are the least often contused. These parts include the medulla, the pons, and the interpeduncular space.

The brain is very lavishly supplied with blood-vessels. The main arterial trunks (vertebral and internal carotid) are both rendered tortuous before entering the skull, with the object probably of diminishing the effects of the heart's systole upon the brain. On entering

they are almost immediately blended into an anastomosing circle (circle of Willis), which has the effect of equalising the cerebral circulation. Embolism of the middle cerebral artery leads to a wide-spread disturbance of the cerebral cortex. It supplies the third frontal, the upper and middle temporal, the angular supramarginal, and lower two thirds of the ascending frontal and parietal gyri. The only parts of the sensorimotor areas which escape destruction in such a case are those for the lower limbs and trunk. The anterior cerebral artery supplies these centres, the mesial surface of the frontal and parietal lobes, and the adjacent part of the cortex on the outer aspect. The occipital lobe and temporo-sphenoidal convolutions are supplied by the posterior cerebral artery. Ligature of one common carotid may produce no effect upon the brain, although the mortality after this operation is mainly due to cerebral complications. One carotid and the two vertebrals would appear to be able to bring enough blood to the brain, which blood will be as evenly distributed as hitherto by the circle of Willis. Both common carotids have been ligatured, or one carotid has been secured, when its fellow of the opposite side has been occluded by disease, and no marked cerebral disturbances have followed. In no case, however, has the patient recovered when the interval between the closing of the two vessels was less than a few weeks. The vertebral arteries can carry a sufficient amount of blood to the brain if only the strain be thrown upon them gradually, and the brain be allowed to accommodate itself slowly to the change. After ligaturing all four arteries in the dog, the anastomosis between the spinal and cerebral arteries within the foramen magnum was sufficient to maintain life (Hill). Plugging of any of the smaller cerebral arteries by emboli, as a rule, leads at once to a marked disastrous result. Such embolism is met with in surgery in connection with aneurism of the common carotid. In simply examining such aneurisms, a little piece of the clot contained in the sac has been detached, has been carried up into the

brain, and has produced a plugging of one of the cerebral vessels. Thus, hemiplegia has followed upon the mere examination of a carotid aneurism, as in a case recorded by Mr. Teale, of Leeds. Fergusson's treatment of aneurism at the root of the neck, by displacing the clots by manipulation, has been abandoned on this same score. In the second case treated by manipulation by this surgeon, a case of subclavian aneurism, paralysis of the left side of the body followed at once upon the first handling of the tumour.

The pulsations of the brain may be communicated to any tumours or collections of fluid that reach the surface of the brain through an aperture in the skull. Such pulsations are synchronous with the arterial pulse, but the sphygmographic tracings of the cerebral pulsation exhibit also the "respiratory curve," conveyed directly from the thorax by the blood within the veins. The valve at the lower end of the jugular vein prevents direct regurgitation of blood from the heart to the brain, but it does not prevent the transmission of pressure.

Although wounds of the brain bleed freely, the bleeding is checked without difficulty, the vessels being capable of ready contraction. Large tumours have been excised from the cortex of the brain, without undue trouble from hæmorrhage. The terminal branches of the cerebral arteries anastomose freely in the pia mater, but the minute arteries which perforate and supply the cortex are terminal. Hence any pressure applied to the surface of the brain will lead to anæmia of that piece of cortex, and, if the pressure is continued, to its destruction.

## CHAPTER IV.

## THE ORBIT AND EYE.

**THE orbit.**—The antero-posterior diameter of the orbit is about  $1\frac{3}{4}$  inches, its vertical diameter at the base a little over  $1\frac{1}{4}$  inches, and its horizontal diameter at the base about  $1\frac{1}{2}$  inches. The diameters of the globe are as follow: transverse, 24 mm.; antero-posterior, 24.5 mm.; vertical, 23 mm. (Brailey). The eye-ball is therefore nearer to the upper and lower margins of the orbit than it is to the sides, and the greatest interval between the globe and the orbital wall is on the outer side. The interior of the orbit is most conveniently reached by incisions made to the outer side of the globe, and, in excision of the eye-ball, the scissors are usually introduced on that side when the optic nerve has to be divided. In excising the left eye, however, it may be more convenient to divide the optic nerve from the inner side. The *bones* forming the floor, the roof, and the inner wall of the orbital cavity are very thin, especially in the last-named situation. Thus, foreign bodies thrust into the orbit have readily penetrated into the cranial cavity, into the nose and ethmoidal cells, and, when directed from above, into the antrum. In several instances, a sharp-pointed substance, such as the end of a stick or foil, has been thrust into the brain through the orbit, and has left but little external evidence of this serious lesion. Nelaton mentions a case in which the internal carotid artery was wounded through the orbit. Certain cases of pulsating orbital tumour which depend upon a communication between the carotid artery and the cavernous sinus have a traumatic origin.

A reference to the *relations of the orbital walls* will show that a tumour may readily invade the orbit by spreading (1) from the base of the skull, (2) from the nasal fossæ, (3) from the antrum, and (4) from the temporal or zygomatic fossæ. In any of these instances

the growth may enter the orbit by destroying the intervening thin layers of bone, and in tumours of the antrum this is the usual mode of entry. It may, however, extend more readily from the cranial cavity through the optic foramen or sphenoidal fissure, from the nose through the nasal duct, and from the two fossæ named through the sphe-no-maxillary fissure. After violent blows upon the temple blood has found its way into the orbit through the sphe-no-maxillary fissure, and has led to subconjunctival ecchymosis. Distension of the frontal sinus by retained mucus or pus may lead to a prominent tumour at the upper and inner margin of the orbit, above the level of the tendo oculi, which may cause displacement of the globe downwards, outwards, and forwards. The bones of the orbit are peculiarly apt to be the seat of ivory exostoses, which may in time entirely occupy the orbital cavity. At the upper and outer angle of the orbit a congenital sebaceous cyst is sometimes met with. It lies beneath the orbicularis muscle, and is often connected at some depth with the orbital periosteum.

The **capsule of Tenon**.—The best description of this capsule has been given by Mr. Lockwood; of his researches Prof. Cunningham provides the following *résumé* :—

The capsule is a firm loose membrane spread over the posterior  $\frac{5}{8}$ ths of the globe, the cornea alone being free from it. In front it lies under the ocular conjunctiva, with which it is intimately connected, and it ends by blending with that membrane close to the margin of the cornea. Behind it fuses with the sheath of the optic nerve, where the latter pierces the sclerotic. The surface of the membrane towards the globe is smooth, and is connected to the eye-ball by some soft yielding areolar tissue. It thus forms a kind of dome for the globe, a species of socket or bursa in which it moves. The posterior surface of the capsule is in contact with the orbital fat. The tendons of the ocular muscles pierce the capsule opposite the equator of the globe. The lips of the openings through which the four



recti pass are prolonged backwards upon the muscles, in the form of sheaths, very much as the infundibuliform fascia is prolonged upon the cord from the internal abdominal ring. Mr. Lockwood points out that each of these four apertures is strengthened by a slip of fibrous tissue, the intracapsular ligament. As the capsule is fixed at various points to the wall of the orbit, these ligaments act as pulleys, and protect the globe from pressure during contraction of the muscles. When the insertions of the recti muscles are divided in cases of strabismus, the capsule is distinctly seen after the conjunctiva has been cut through, and requires also to be divided before the section of the muscle can be properly made. The capsule is of some importance in this procedure. After its division the muscle does not entirely retract and lie shrunken within the orbit. Its connections with the capsule still give it some hold upon the globe, and still enable it to act upon that structure. Moreover, the attachments of the capsule to the margins of the orbit prevent the muscles from entirely retracting, and even when the globe has been removed, they give them some basis to act upon, and thus tend to preserve some little mobility in the stump.

Of these orbital attachments the suspensory ligament of Lockwood is the most important. It stretches across the fore part of the orbit after the fashion of a hammock, and supports the eye-ball. Its two extremities are attached respectively to the malar and lachrymal bones. Below the eye-ball it widens out, and blends with the capsule of Tenon. Strong bands, known as the check ligaments, pass from the sheaths of the external and internal recti muscles to the malar and lachrymal bones respectively. They limit excessive rotation of the globe in an outward or inward direction. The action of the superior rectus is checked by its connection with the levator palpebræ, and that of the inferior rectus by the connection of its tendon with the suspensory ligament.

Mr. Lockwood points out that in removing the upper jaw the surgeon should take care to preserve

the attachments of the suspensory ligaments. If these be destroyed the eye-ball sinks downwards.

The orbit behind Tenon's fascia is occupied by a large quantity of loose fat, in addition to the ocular muscles, the vessels, and nerves. It is by the absorption of this fat that the sunken eye is produced in cases of emaciation and prolonged illness. This tissue affords a ready means for the spread of **orbital abscess**. Such an abscess may follow injuries, certain ocular inflammations, periostitis, etc., or may spread from adjacent parts. The pus may occupy the entire cavity, displacing the eye-ball forwards, limiting its movements, and causing, by interference with the circulation, great redness of the conjunctiva and swelling of the lids.

Foreign bodies, some of them of remarkable size and shape, have lodged for long periods of time in the orbital fat without causing much trouble. Thus Lawson reports a case where a piece of an iron hat-peg, three inches long, was embedded in the orbit for several days without the patient being aware of it. A stranger case, in some ways, is that reported by Furneaux Jordan: "A man, who was employed in threshing, became the subject of severe ophthalmia. At the expiration of several weeks, the patient, whilst pressing his finger on the lower eyelid, suddenly ejected from a comfortable bed of warm pus a grain of wheat, which had shot forth a vigorous green sprout." The orbital fat affords also an excellent nidus for growing tumours. Fractures of the inner wall of the orbit involving the nasal fossæ or sinuses, may lead to extensive emphysema of the orbital cellular tissue. The air so introduced may cause the globe to protrude, may limit its movements, may spread to the lids, and will, in any case, be increased in amount by blowing the nose, etc.

The **orbital muscles**.—The four recti muscles end in thin, flat membranous tendons. The tendon of the external or internal rectus muscle is frequently divided for strabismus. The width of the tendons varies from 7 mm. to 9 mm. They are inserted into the sclerotic near the cornea. The internal rectus is

inserted 6·5 mm. from the corneal margin, the external 6·8 mm., the inferior 7·2 mm., and the superior 8 mm. (Merkel).

The external and inferior recti are the longest, the internal rectus is the broadest, and the superior is the narrowest and slightest.

The **orbital arteries** are small, and seldom give rise to trouble when divided in excising the globe, since they can be readily compressed against the bony walls of the cavity. Pulsating tumours of this part may be due to traumatic aneurisms of one of the orbital arteries, or may depend upon an arterio-venous aneurism formed between the internal carotid artery and the cavernous sinus. Pressure also upon the ophthalmic vein (as it enters the sinus), by an aneurism of the internal carotid vessel, may produce all the symptoms associated with pulsating orbital tumours.

The **orbital nerves** may be damaged in wounds of the orbit, or in fractures of the orbit and of the base of the skull. They may be pressed upon by tumours from various parts, by aneurisms, hæmorrhagic and inflammatory effusions. Thus Lawson records a case in which the optic nerve was divided by a stab through the upper eyelid, without the globe being injured, and without any bone being fractured. The same nerve has also been completely torn across in fractures of the orbit, and has been pressed upon in fractures involving the lesser wing of the sphenoid. The third, fourth, and sixth nerves, and the first division of the fifth, may be affected in cases of aneurism involving the internal carotid artery, where they lie in relation with the cavernous sinus. They may readily be pressed upon, also, by any growth involving the sphenoidal fissure, such as a periosteal node springing from the margin of the fissure, while the sixth nerve, from its more intimate connection with the base of the skull, has been directly torn across in a fracture involving that part (Prescott Hewett).

In **paralysis of the third nerve** there is drooping of the upper lid (ptosis); the eye is almost

motionless, presents a divergent squint from unopposed action of the external rectus muscle, and cannot be moved either inwards, upwards, or directly downwards. Rotation, in a direction downwards and outwards, can still be effected by the superior oblique and outer rectus muscles. The pupil is dilated and fixed; the power of accommodation is much impaired, there is diplopia, and sometimes a little protrusion of the globe from relaxation of the recti muscles. These symptoms refer to complete paralysis of the nerve. In cases of partial paralysis, only one or two of the above symptoms may be present.

In **paralysis of the fourth nerve** there is often but little change to be seen, since the function of the superior oblique muscle, supplied by this nerve, may, in part, be performed vicariously. "There is usually only very slight defect in the mobility of the eye; what there is occurs chiefly in the inner and lower angle of the field of vision; there is deviation of the eye inwards and upwards on lowering the object, and simply upwards when it is turned far towards the healthy side" (Erb). In any case there will be diplopia, especially in certain positions of the globe.

In **paralysis of the sixth nerve** there is convergent strabismus, with consequent diplopia, and an inability to rotate the eye directly outwards. Paralysis of the sixth nerve may be accompanied by paralysis of the nerve to the internal rectus of the opposite side, giving rise to conjugate deviation of the eyes. Such a condition indicates a lesion in the nucleus of the sixth nerve, for although the fibres for the internal rectus pass out with the third nerve they take their origin with the sixth.

Sometimes all the oculo-motor nerves of the eye are paralysed, and in such cases the lesion is probably situated either at their nuclei or origin or at the cavernous sinus, in the wall of which the nerves lie close together.

In **paralysis of the first division of the fifth** there is a loss of sensation in all the conjunctiva, except

such as covers the lower lid (supplied by the palpebral branch of the infraorbital nerve), loss of sensation in the globe, and in skin supplied by the supratrochlear and supraorbital nerves, and in the mucous and cutaneous surfaces supplied by the nasal nerve. The area of anæsthesia is much less than the anatomical distribution of the nerve, owing to the extent to which cutaneous nerves overlap. No reflex movements (winking) follow upon irritation of the conjunctiva, although the patient can be made to wink on exposing the eye to a strong light, the optic nerve in this case transmitting the impression to the facial nerve. Sneezing also cannot be excited by irritating the mucous membrane in the anterior part of the nose. Destructive ulceration of the cornea may follow this paralysis, due partly to damage to the trophic branches contained in the paralysed nerve, partly to the anæsthesia which renders the part readily injured, and partly to the loss of the reflex effect of the sensory nerves upon the calibre of the blood-vessels, whereby the inflammation is permitted to go uncontrolled (Nettleship).

In **paralysis of the cervical sympathetic** there is narrowing of the palpebral fissure from some drooping of the upper lid, apparent recession of the globe within the orbit, and some narrowing of the pupil from paralysis of the dilator muscle of the iris, which muscle is supplied by the sympathetic. The drooping of the upper lid may be explained by the fact that each eyelid contains a layer of unstriated muscle fibre. That in the upper lid arises from the under surface of the levator palpebræ, and is attached to the tarsal cartilage near its upper margin (Fig. 12). This layer of muscle, which, when in action, would keep up the lid, is under the influence of the cervical sympathetic. The recession of the globe is supposed by some to be due to paralysis of the orbitalis muscle of H. Müller. This muscle bridges over the sphenomaxillary fissure, is composed of unstriated fibres, and is innervated by the sympathetic. Contraction of the muscle (as produced by irritation of the cervical

sympathetic in animals) causes protrusion of the globe, while section of the sympathetic in the neck produces retraction of the eye-ball (Cl. Bernard). No changes are observed in the calibre of the blood-vessels of the globe.

The **globe**; the **cornea**.—The thickness of the cornea varies from .9 mm. in the central parts to 1.1 mm. at the periphery. One is apt to be a little deceived as to its thickness, and on introducing a knife into the cornea, the instrument, if not entered at the proper angle, may be thrust for some little distance among the laminae of the part. In front the cornea is covered by stratified epithelium. When this layer has been removed by abrasion, a white deposit of lead salts may take place in the exposed corneal tissue in cases where lead lotions are used. The bulk of the cornea is made up of a great number of fibrous lamellae, between which are anastomosing cell spaces containing the corneal corpuscles. If the nozzle of a fine syringe be thrust

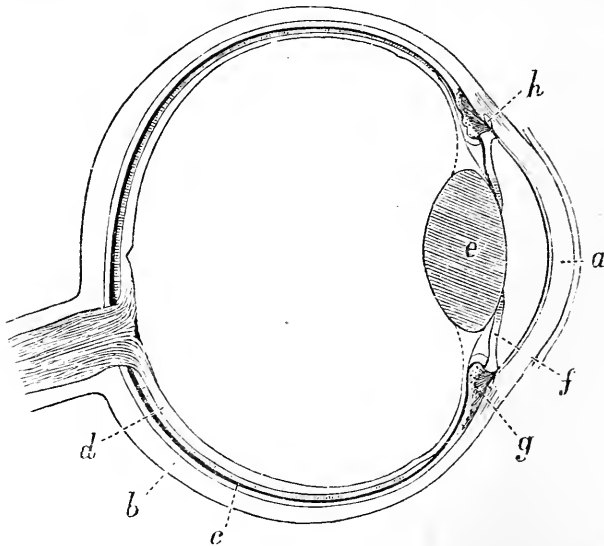


Fig. 10.—A Horizontal Section of the Globe through the middle.

*a*, Cornea ; *b*, sclerotic ; *c*, choroid ; *d*, retina ; *e*, lens ; *f*, iris ; *g*, ciliary process ; *h*, canal of Schlemm.

into the corneal tissue, the network of cell spaces can be filled with injection (Recklinghausen's canals). When suppuration takes place within the proper corneal tissue, it is probably along these canals, modified by inflammation, that the pus spreads, thus producing onyx. The cornea contains no trace of blood-vessels, except at its extreme periphery, where the capillaries of the sclerotic and conjunctiva end in loops. This lack of a direct blood supply renders the cornea prone to inflame spontaneously in the cachectic and ill-nourished. When inflamed, the tissue always becomes opaque. In the affection known as interstitial keratitis, blood-vessels from the arteries at the margin of the cornea penetrate into the substance of the cornea for some distance. As these vessels will be some little way below the surface, and will be covered by the hazy corneal tissue that is the result of the disease, their scarlet colour is much toned down, and a strand of such vessels is called a "salmon patch." In the condition known as pannus, the cornea appears to be vascularised; but here, owing to continued irritation, vessels, derived from the neighbouring conjunctival arteries, pass over the cornea just beneath its epithelial covering, leaving the cornea proper as bloodless as ever. The term *arcus senilis* is applied to two narrow white crescents that appear at the periphery of the cornea, just within its margin, in the aged, and in certain morbid conditions. The crescents are placed at the upper and lower margins, and their points meet midway on either side of the cornea. They are due to fatty degeneration of the corneal tissue, and the change is most marked in the layers of the cornea just beneath the anterior elastic lamina, *i.e.* in the part most influenced by the marginal blood-vessels. In spite of its lack of a direct blood supply, wounds of the cornea heal kindly. The cornea is very lavishly supplied with nerves, estimated to be from forty to forty-five in number. They are derived from the ciliary nerves, enter the cornea through the fore part of the sclerotic, and are distributed to every part of the tunic. In glaucoma, a disease of which the

phenomena depend upon greatly increased intraocular pressure, the cornea becomes anæsthetic. This depends upon the pressure to which the ciliary nerves are exposed before their branches reach the cornea. (See also Nerve supply of the eye-ball, page 54.)

The **sclerotic, choroid, and iris**.—The *sclerotic* is thickest behind, and thinnest about  $\frac{1}{4}$  of an inch from the cornea. When the globe is ruptured by violence it is the sclerotic that most commonly yields, the rent being most usually a little way from the cornea, *i.e.* in or about the thinnest part of the tunic. A rupture of the cornea alone from violence is not common. The sclerotic may be ruptured while the lax conjunctiva over it remains untornd. In such a case the lens may escape through the rent in the sclerotic, and be found under the conjunctiva. At the point of penetration of the optic nerve the sclerotic is thin, and pierced by numerous holes for the passage of nerve bundles. This weakened part, the lamina cribrosa, plays an important part in glaucoma (page 62). It gives the stippled appearance to the optic papilla. Brailey states that the lateral parts of the sclerotic are thinner than the upper and lower segments, the inferior part being the thickest and the external wall the thinnest. It happens, therefore, that under the influence of intraocular pressure the eye expands more laterally than in the vertical direction. It is mainly to the denseness and unyielding character of the sclerotic that must be ascribed the severe pain (due to pressure on nerves) experienced in those eye affections associated with increased intraocular tension (glaucoma, etc.).

The *choroid* is the vascular tunic of the globe, and carries its main blood-vessels. Between the choroid and sclerotic are two thin membranes, the lamina supra-choroidea and lamina fusca, which are separated from one another by a lymph space. In injuries to the globe, therefore, extensive bleeding may take place between these two coats, and indeed a like hæmorrhage may be the result simply of a sudden diminution in the ocular tension produced by such an operation as



iridectomy or cataract extraction. The choroid alone has been ruptured (usually at its posterior part) as the result of a blow upon the front of the eye. The choroid is one of the few parts of the body that may be the seat of melanotic growths. These growths are sarcomatous tumours containing a large amount of pigment, and occur only where pigment cells are found. In the choroid coat pigment cells are very abundant.

The *iris* is, from its great vascularity, very easily inflamed. From its relations to the cornea and sclerotic it happens that inflammation in those tunics can spread without difficulty to the iris. On the other hand, the vessels of the iris and choroid are so intimately related that inflammations set up in the iris itself have every inducement to spread to the choroidal tunic. When the iris is inflamed its colour becomes altered, owing to the congestion of the part and to the effusion of lymph and serum that takes place in its substance. The swelling to which it becomes subject, together with the effusion, produce a blurring of its delicate reticulated structure, as seen through the cornea. Owing also to the swollen condition of the little membrane, the pupil becomes encroached on, and appears to be contracted, while the movements of the membrane are necessarily rendered very sluggish. If it be remembered that the greater part of the posterior surface of the iris is in actual contact with the lens capsule, it will be understood that inflammatory adhesions may readily take place between the two parts (Fig. 11). After iritis, therefore, it is common to find the posterior surface of the iris (most often its pupillary margin) adherent to the lens capsule by bands of lymph, either entirely or in one or more different points. Such adhesions constitute posterior synechiæ, the term anterior synechiæ being applied to adhesions between the iris and the cornea. In iritis also the lens may become involved, and the condition of secondary or inflammatory cataract be produced. The iris is not very closely attached at its insertion. Thus, in case of injury to the eye, it may be torn more

or less from its attachments without any damage being done to the other tunics. The iris has been completely torn away in a few instances, and has escaped through a wound of the globe. The ciliary processes have been thus exposed. Congenital absence of the iris has been recorded. In cases of penetrating wounds of the cornea the iris is easily prolapsed. It is so delicate and yielding a membrane that in performing iridectomy the necessary piece of the iris can be seized and pulled out through the corneal incision without offering sensible resistance. The membrane also derives much support from its contact with the lens, for in cases where the lens has been displaced into the vitreous, or has been removed by operation, the iris is observed to be tremulous when the globe is moved. Although very vascular, the iris seldom bleeds much when cut, a circumstance that is probably due to the contraction of the muscular fibres that exist so plentifully within it. Sometimes the iris presents a congenital gap in its substance that runs from the pupil downwards and a little inwards. This condition is known as coloboma iridis, and is due to the persistence of the "choroidal cleft." In other cases there can be seen, stretching across the pupil, some shreds of the pupillary membrane. Normally this membrane, which is apparent for a few days after birth in some animals, is entirely absorbed before birth.

It will now be convenient to take note of the blood and nerve supply of the globe.

**Blood supply of the eye-ball.**—1. The short ciliary arteries (from the ophthalmic) pierce the sclerotic close to the optic nerve, run some little way in the outer coat of the choroid, and then break up into a capillary plexus that makes up the main part of the inner choroidal coat. In front this plexus gives some vessels to the ciliary processes. The veins from these vessels are disposed in curves as they converge to four or five main trunks (*venæ vorticosæ*), which pierce the sclerotic midway between the cornea and the optic nerve. In the choroid they lie external to the arteries.

2. The two long ciliary arteries (from the

ophthalmic) pierce the sclerotic to the outer side of the optic nerve, and run forwards, one on either side, until they reach the ciliary region, where they break up into branches that, by anastomosing, form a vascular circle about the periphery of the iris (the *circulus major*). From this circle some branches pass to the ciliary muscle, while the rest run in the iris in a converging manner towards the pupil, and at the margin of the pupil form a second circle (the *circulus minor*).

3. The anterior ciliary arteries (from the muscular and lachrymal branches of the ophthalmic) pierce the sclerotic (perforating branches) about a line behind the cornea, join the *circulus major*, and give off branches to the ciliary processes, where they form copious anastomosing loops. These arteries lie in the subconjunctival tissue. Their episcleral or non-perforating branches are very small and numerous, and are invisible in the normal state of the eye. In inflammation, however, of the iris and adjacent parts, these vessels appear as a narrow pink zone of fine vessels round the margin of the cornea, that run nearly parallel to one another, are very closely set, and do not move with the conjunctiva. This zone is known as the zone of ciliary congestion, or the circumcorneal zone.

4. The vessels of the conjunctiva are derived from the lachrymal and the two palpebral arteries. These vessels, in cases of inflammation, are readily distinguished from those last described. They are of comparatively large size, are tortuous, are of a bright brick-red colour, can be easily moved with the conjunctiva, and as easily emptied of their blood by pressure. The differences presented by these two sets of vessels serve in one way to distinguish inflammation of the conjunctiva from that involving deeper parts. The conjunctival vessels around the margin of the cornea form a closer plexus of anastomosing capillary loops, which become congested in severe superficial inflammation of the cornea, and may then form a zone around the margin of the cornea, which can, however, be distinguished from the "ciliary zone" by the general characters just named. The retina

has a vascular system of its own, supplied through the *arteria centralis retinae*, which is nowhere in direct communication with the choroidal vessels, except just at the entrance of the optic nerve. Indeed, the outer layers of the retina which are in relation with the choroid coat are entirely destitute of vessels. Thus, when the central artery of the retina becomes plugged, sudden blindness follows, and as the meagre collateral circulation that is established by the minute anastomoses about the entrance of the nerve is quite insufficient, the retina soon becomes œdematous. A permanent plugging of the central artery means, therefore, a practical extinction of the vascular system of the retina. In some cases of embolism only a branch of the retinal artery is plugged, the patient retaining vision except in that part of the retina supplied by the branch. The fovea centralis, the centre of acute vision, receives twigs from both the superior and inferior temporal branches of the *arteria centralis retinae*.

In cases of hæmorrhage between the choroid and retina the blood must come from the choroidal vessels; and in hæmorrhage into the vitreous, which often follows injury, the blood may be derived from the retinal vessels, since they run in the inner layers of that membrane, or from the vessels in the ciliary region.

**Nerve supply of the eye-ball.**—1. The ciliary nerves derived from the lenticular ganglion and the nasal nerve pierce the sclerotic close to the optic nerve, and pass forwards between the sclerotic and the choroid, supplying those parts. They enter the ciliary muscle, form a plexus about the periphery of the iris, and then send fibres into the iris, which form a fine plexus as far as the pupil. They send branches through the fore part of the sclerotic to the cornea. Thus the eye-ball obtains through these nerves its sensory fibres from the nasal branch of the first division of the fifth, its motor fibres for the ciliary muscle and sphincter iridis from the third nerve, and many sympathetic fibres, among which are those that supply the dilator muscle of the iris. 2. The conjunctiva is supplied by four nerves:

above, the supratrochlear; on the inner side by the infratrochlear; on the outer side, the lachrymal (all branches of the first division of the fifth); and below by the palpebral branches of the second division of the fifth. As the ciliary nerves pass forwards between the choroid and the sclerotic, it will be seen that they are readily exposed to injurious pressure against the unyielding sclerotic in cases of increased intraocular tension.

The sensation of the globe itself is derived solely from the first division of the fifth. In inflammatory affections of the globe, as in corneitis or iritis, besides the pain actually felt in the eye, there is pain referred along other branches of the first division of the fifth. The explanation of this fact has to be sought for in the common origin of the ophthalmic division from the upper sensory nucleus of the fifth nerve in the floor of the fourth ventricle. Not only are the nerve cells connected with the eye-ball disturbed, but the neighbouring cells are also affected, and by a psychological error the pain is reflected along the nerves with which they are connected. There is pain over the forehead along the supratrochlear, supraorbital, and lachrymal branches (circumorbital pain), and pain down the side of the nose following the nasal nerve. Or the pain may spread to the second division of the fifth, and discomfort be felt in the temporal region (orbital branch of second division), or be referred to the upper jaw and upper teeth. These affections are associated also with much lachrymation, the lachrymal gland being also supplied through the first division of the fifth. Photophobia, or intolerance of light, is common in inflammatory affections of the eye. In this condition there is spasm of the orbicular muscle, keeping the eye closed, or closing it on the least exposure to irritation. Although the orbicular muscle is supplied by the facial nerve, its fibres are derived, not from the nucleus of the seventh, but from the oculo-motor nucleus, situated near the upper sensory nucleus of the fifth, and connected with it by reflex paths. Photophobia is most marked in superficial affections of the cornea, and is often much benefited by a

seton in the temporal region. Inflammation of the iris and glaucoma are accompanied by hyper-æsthesia and referred pains over the outer frontal and anterior temporal areas (Head). The nerve centres for the skin of this region and the eye-ball are closely connected, a relationship which may explain the application of counter irritation to the temples in eye disease. Inflammation of the cornea gives rise to no referred pains (Head). Strain of the ciliary muscle, which occurs with errors of refraction, leads to referred pains and areas of hyper-æsthesia over the mid orbital region of the forehead. The relations between the nasal nerve and the orbital contents receive many illustrations in practice. Thus, if the front of the nose be struck, or the skin over its lower part be irritated, as by squeezing a painful boil, profuse lachrymation will frequently be produced. Snuff, too, by stimulating the nasal branch of the ophthalmic nerve, often makes the eyes of the uninitiated to water ; and it is well known that there are many disturbances about the nose, and the anterior part of the nasal fossæ, that can " make the eyes water." Herpes zoster often provides a remarkable illustration of the intimate relation between the nasal nerve and the eye. In this affection, when the regions of the supra-orbital and supratrochlear branches of the first division are alone implicated, the eye is usually unaffected ; but when the eruption extends over the part supplied by the nasal nerve, *i.e.* runs down the side of the nose, then there is very commonly some inflammation of the eye-ball. In frontal neuralgia watering of the eye (irritation of the lachrymal branch) is very frequently met with.

The **dangerous area of the eye**.—Penetrating wounds of the cornea alone, or of the sclerotic alone, behind the ciliary region, are by no means serious : but wounds involving the ciliary body, or its immediate vicinity, are apt to assume the gravest characters. Inflammation in the ciliary region is peculiarly obnoxious, on account of the important vascular and nerve anastomoses that take place in the part. Indeed, as regards blood and nerve supply, there is no more important

district in the eye-ball. From the ciliary body also inflammations can spread, more or less directly, to the cornea, iris, choroid, vitreous, and retina. Plastic, or purulent inflammation of the ciliary body, after injury, is the usual starting point of *sympathetic ophthalmia*. In this terrible affection destructive inflammation is set up in the sound eye, which is, however, not usually involved until two or three months after the other eye has been injured. "Although at present the exact nature of the process which causes sympathetic inflammation is unknown, and though its path has not been fully traced out, it is certain (1) that the change starts from the region most richly supplied by branches of the ciliary nerves, viz. the ciliary body and iris; (2) that its first effects are generally seen in the same part of the sympathising eye; (3) that the exciting eye has nearly always been wounded, and in its anterior part; and that decided plastic inflammation of its uveal tract is always present; (4) that inflammatory changes have in some cases been found in the ciliary nerves and optic nerve of the exciting eye" (Nettleship). It is now generally believed that the sound eye is directly infected from the diseased one. The subarachnoid spaces which surround the optic nerves are in continuity at the chiasma, and offer a path whereby infection may spread from one eye to the other.

The **lens** measures  $\frac{1}{3}$  of an inch from side to side, and  $\frac{1}{5}$  of an inch from before backwards. It, together with its capsule, is in all parts perfectly transparent and perfectly non-vascular. The lens may easily be loosened or displaced by partial rupture of its suspensory ligament, and may find its way into the anterior chamber, or, more commonly, back into the vitreous. The lens, if disturbed, may swell, and by the pressure thus exercised cause great damage to the important structures adjacent to it. The capsule is very brittle and elastic, and when torn its edges curl outwards. It has to be lacerated in all cataract operations, and may be ruptured by many forms of violence applied to the eye-ball. When the capsule is wounded the aqueous humour enters,

and is imbibed by the lens fibres, which in consequence swell up and become opaque, thus producing a traumatic cataract. In the various forms of cataract the whole lens, or, more commonly, some portion of it, becomes the seat of opacity. This often commences in the nucleus, and for a long while remains limited to that part; or it may first involve the cortex, and in such a case the opacity takes the form of a series of streaks that point towards the axis of the lens, and are dependent upon the arrangement of the lens fibres. "In so-called 'concussion cataract,' where after a blow on the eye a part of the lens becomes opaque, it appears probable that the capsule has been very slightly torn opposite to the opacity" (Lawford).

Of the **retina** it is only necessary to observe that its connection with the choroid is so slight that it may easily be detached from that membrane by hæmorrhagic or other effusions, and may indeed be so detached by a simple blow upon the globe. Even when extensively detached it remains, however, as a rule, attached at both the optic disc and the ora serrata. The optic nerve as it passes from the brain receives its perineural sheath from the pia mater, and, in addition, two other sheaths: an outer from the dura mater, and an inner from the arachnoid. These sheaths remain distinct and separate, and the two spaces enclosed may be injected, the outer from the subdural, the inner from the subarachnoid space. Thus inflammatory affections of the cerebral meninges can readily extend along the optic nerve to the optic disc through these spaces in the nerve sheath, while in cases of intracranial disease other than meningeal, the mischief may extend from the brain to the disc along the interstitial connective tissue in the nerve. These connections may serve in part to explain the frequent association of optic neuritis with intracranial disease. Optic neuritis usually implies that the optic disc or papilla is inflamed, but in exceptional cases the changes are limited to that part of the nerve behind the globe (retro-bulbar neuritis). The length of the optic nerve within the orbit is 28 to 29 mm.



The **aqueous and vitreous humours.**—The aqueous fills the space between the capsule and suspensory ligament of the lens and the cornea. The iris divides this space into two parts, the anterior and posterior chambers. Since, however, the iris is largely in actual contact with

the lens, it happens that the posterior chamber is represented by a little angular interval between the iris, the ciliary processes, and the suspensory ligament of the lens (Fig. 11). The depth of the anterior chamber is 3·6 mm. The cornea at its circumference breaks up into bundles of fibres, which are partly continued into the front of the iris, and which constitute the ligamentum pectinatum iridis. Between

the processes of this ligament there are intervals which lead into certain cavernous spaces called the spaces of Fontana. These spaces in their turn communicate with a large circular canal situate in the sclerotic close to its junction with the cornea, and known as the canal of Schlemm. This space is in communication with the veins of the anterior part

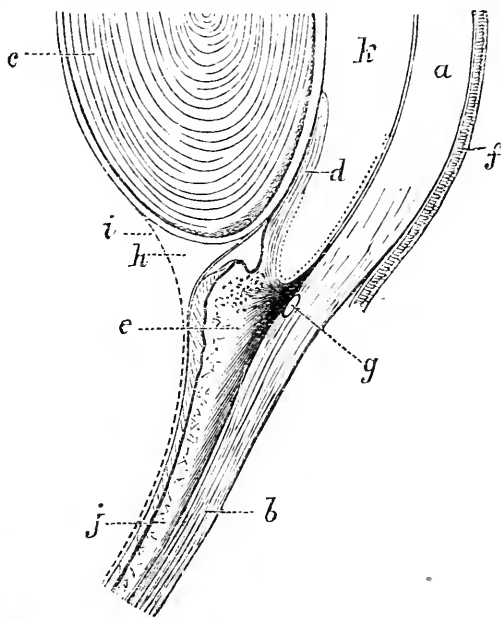


Fig. 11.—Section of Globe, showing Iris, Lens, Ciliary Region, etc. (After Allen Thomson.)

a, Cornea; b, sclerotic; c, lens; d, iris; e, ciliary process; f, conjunctiva; g, canal of Schlemm; h, canal of Petit; i, anterior margin of vitreous humour; j, choroid covered by retina; k, aqueous chamber.

of the sclerotic,\* and thus through this somewhat complicated channel the aqueous chamber is brought into relation with the venous circulation. This relation probably explains the ready absorptive powers of the aqueous. Thus, if pus finds its way into the anterior chamber (hypopyon) it is usually readily absorbed. The same applies to moderate extravasations of blood in the chamber, and the speedy removal of such effusions contrasts with the difficulty that is experienced in the absorption of blood from the vitreous chamber. The treatment of soft cataracts by the "needle operation" depends for its success upon the absorptive powers of the aqueous. In this procedure, the lens capsule having been torn through, and the cataract broken up with needles, the removal of the opaque débris is left to the aqueous, and it is not long before its efficacy in that direction is seen.

The **vitreous** takes little active share in ocular maladies. It may be secondarily affected in inflammation of adjacent parts, may be the seat of hæmorrhages, and is often occupied by opaque bodies of various kinds. Foreign bodies have lodged in the vitreous for considerable periods without causing any symptoms. The *muscæ volitantes* that so often trouble the myopic are due to little opaque matters in the vitreous, and very often have exactly the appearance that the corpuscles of the vitreous present when seen under the microscope.

The vitreous is readily separated from the retina except behind, opposite the disc where the artery to the lens enters in the fœtus.

This vessel is a branch of the central artery of the retina, and may persist as a fibrous cord in adult life. In some rare cases it has continued to transmit blood, and in such instances its pulsation can be seen by the ophthalmoscope.

**Glaucoma** is a disease the symptoms of which are

\* The precise manner in which these spaces communicate with the neighbouring veins has not been demonstrated histologically. The statement is founded mainly upon the experiments of Schwalbe.

all dependent upon an increase in the intraocular tension of the globe. The increased tension is due to an excess of fluid within the eye-ball, and this would appear to be due to certain changes, seldom absent in the glaucomatous, that interfere with the normal escape of this fluid. Normally there is a constant movement of fluid from the vitreous through the suspensory ligament into the posterior chamber, and thence round the pupillary margin of the iris to the anterior chamber. This fluid is derived mainly from the ciliary body, and in a less degree from the posterior surface of the iris. Atrophy of the epithelium on the ciliary body is said to lead to diminished tension. From the anterior chamber the fluid can escape into the veins through the gaps in the ligamentum pectinatum already alluded to (Fig. 11). It is remarkable that in nearly every case of glaucoma these gaps are occluded by the complete obliteration of the angle between the periphery of the iris and the cornea, which angle is normally occupied by the ligamentum pectinatum. The importance of the peripheral part of the anterior chamber in relation to the outflow of fluid from the eye is shown in many ways. If this part be blocked by the iris in perforation of the cornea, or by the lens in some dislocations of that body, increased tension of the globe is apt to follow. A like increase of tension is said to attend the application of the actual cautery to the sclero-corneal margin and some cases of episcleritis. Dr. Brailey believes that some outflow also takes place along the optic nerve. It is well known that pressure upon that nerve may produce œdema of the disc. The relief given to glaucoma by iridectomy appears to depend upon the circumstances that the operation practically opens up again these channels of communication from the aqueous, since the procedure, to be successful, should involve an incision so far back on the sclerotic as to fully pass through the angle just alluded to. It is needful also that the iris should be removed quite up to its attachment, and that the portion resected should be considerable. The symptoms of glaucoma are all explained by the effects

of the abnormal tension. Thus, the ciliary nerves are compressed against the unyielding sclerotic, and give rise to intense pain, while the disturbance in their functions shows itself in the fixed and dilated pupil and in the anæsthetic cornea. Perhaps the first parts to suffer from compression are the retinal blood-vessels, and the effect upon them will be most obvious at the periphery of the retina, *i.e.* at the extreme limit of the retinal circulation. Hence follows that gradual narrowing of the visual field which is constant in glaucoma, while the pressure upon the optic nerve produces those flashes of light and other spectra which occur in the disease. The weakest part of the sclerotic is at the disc at the lamina cribrosa. This part rapidly yields under the pressure, and so produces the "glaucomatous cup." Pressure in the opposite direction pushes the lens forward, and thus narrows the anterior chamber; while the general interference with the ocular circulation is shown in the distended vessels that appear upon the globe.

The **eyelids**.—The skin over the eyelids is extremely thin and delicate, and shows readily through its substance any extravasation of blood that may form beneath it. Its laxity, moreover, renders it very well adapted for certain plastic operations that are performed upon the part. Its loose attachments cause it to be readily influenced by traction, and the shrinking of cicatrices below the lower lid is very apt to draw that fold away from the globe, and so produce the condition of eversion of the lid known as ectropion. The contraction of the conjunctiva after inflammatory conditions, or after it has been subjected to destructive agencies, is prone, on the other hand, to curl either lid inwards towards the globe, and thus to produce entropion. The lids present many transverse folds; one of these on the upper lid, deeper and more marked than the rest, divides the lid into two parts, the part below being that which covers the globe, the part above being that in relation with the soft structures of the orbit. In emaciation the lid becomes much sunken in the line of this fold.

Incisions should follow the direction of these folds. The lids are very freely supplied with blood, and are often the seat of nævi and other vascular growths. Rodent ulcer so frequently attacks this part that it was originally known as "Jacob's ulcer of the eyelid."

The following layers are found in either lid in order: (1) The skin; (2) the subcutaneous tissue; (3) the orbicularis palpebrarum; (4) the tarsal cartilage and ligament; (5) the layer of Meibomian glands; and (6) the conjunctiva. In the upper lid the levator palpebræ is found passing to the tarsal cartilage. The subcutaneous tissue is very lax, and hence the lids swell greatly when œdematous, or when inflamed, and when the seat of hæmorrhage. On this account it is inadvisable to apply leeches to the lids, on account of the extensive "black eye" that may follow. This tissue is peculiar in containing no fat. At the edge of the lids are found the eyelashes, the orifices of the Meibomian glands, and of some modified sweat and sebaceous glands. This edge, like other points of junction of skin and mucous membrane, is apt to be the seat of irritative affections. Being a free border also,

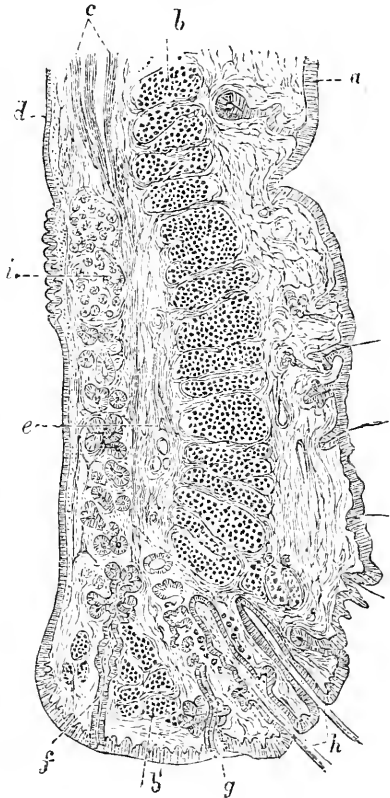


Fig. 12—Vertical Section through Upper Eyelid. (After Waldeyer.)

*a*, Skin; *b*, orbicularis; *b'*, its ciliary part; *c*, involuntary muscle of eyelid; *d*, conjunctiva; *e*, tarsal cartilage; *f*, Meibomian gland; *g*, modified sweat gland; *h*, eyelashes; *i*, post tarsal glands.

the circulation is terminal, and stagnation in the blood current is not difficult to produce. Sycosis, an inflammation involving the hair follicles and some of the glands at the edge of the lid, is among the most common of ophthalmic affections. The common styte also is a supuration in the connective tissue or in one of the glands at the margin. On everting the lid the Meibomian glands can be seen through the conjunctiva as lines of yellowish granules. The common tarsal cyst is a retention cyst developed in one of these glands.

Two arteries supply either lid: a palpebral branch of the ophthalmic running along the inner part of each lid, and a branch of the lachrymal along the outer part of each lid. Four nerves supply the upper eyelid, the supraorbital, the supra- and infra-trochlear, and the lachrymal. One nerve supplies the lower lid, the infra-orbital. Some of the lymphatics of the eyelids enter the pre-auricular glands, hence in cases of chancre of the lid the glandular enlargement has nearly always been noticed in front of the parotid gland (Fig. 21, p. 164).

The **conjunctiva**.—The ocular part of this membrane is thin, very loosely attached, and not very extensively supplied with blood; the palpebral portion is thicker, more closely adherent, and more vascular. At the edge of the cornea the conjunctiva becomes continuous with the epithelium covering that tunic. The looseness of the ocular conjunctiva allows it to be freely moved about, and is of great value in some operations: as, for example, in Teale's operation for symblepharon, where a bridge of conjunctiva, dissected up from the globe above the cornea, is drawn down over the cornea to cover a raw surface in contact with the lower lid. This lax tissue favours the development of œdema (chemosis), which in extreme cases may reach such a degree that the patient cannot close his eye. The vessels also, being feebly supported, are prone to give way under no great provocation. Thus, subconjunctival hæmorrhages may occur from severe vomiting, or during a paroxysm of whooping cough. Blood also may find its way beneath the membrane in fractures

of the base of the skull. Hæmorrhages beneath the membrane are unlike other extravasations (bruises), in that they retain their scarlet colour. This is due to the fact that the thinness of the conjunctiva allows oxygen to reach the blood and retain for it an artērial character. Severe inflammation of the conjunctiva may lead to considerable cicatricial changes, as is the case in other mucous membranes, and especially, perhaps, in the urethra. The contraction of the conjunctiva after destructive processes is apt to lead to entropion. If both the ocular and the corresponding part of the palpebral conjunctiva have been destroyed, the two raw surfaces left will readily adhere; the lid will become fused to the globe, and the condition called symblepharon be produced. This condition concerns the lower lid, and is generally brought about by lime or other caustics being accidentally introduced between the under lid and the globe.

In one common form of inflammation of this membrane a number of little "granulations" appear upon the palpebral conjunctiva. These are not real granulations, since no true ulceration of the part takes place, but they appear to be made up, some of nodules of adenoid tissue, others of enlarged mucous follicles and of hypertrophied papillæ, all of which structures are normally found in the membrane. The condition is known as "granular lids," and is associated with the formation of much new tissue in the deeper parts of the membrane. From the absorption of this new tissue and of these granulations a contracting cicatrix results, leading to much puckering of the membrane, and often to entropion and inversion of the eyelashes. In purulent ophthalmia the cornea is in great risk of destruction, owing to the strangulation of its vessels, and to the effects possibly of the discharge directly upon the membrane.

The **lachrymal apparatus**.—The lachrymal gland is invested by a special fascia which separates it from the general cavity of the orbit; and, according to Tillaux, this little body can be removed without

opening the greater space of the orbit. The gland may inflame, and become so enlarged as to appear as a tumour, which may displace the globe downwards and inwards, and press forwards the oculo-palpebral fold of conjunctiva. If an abscess forms, it most usually

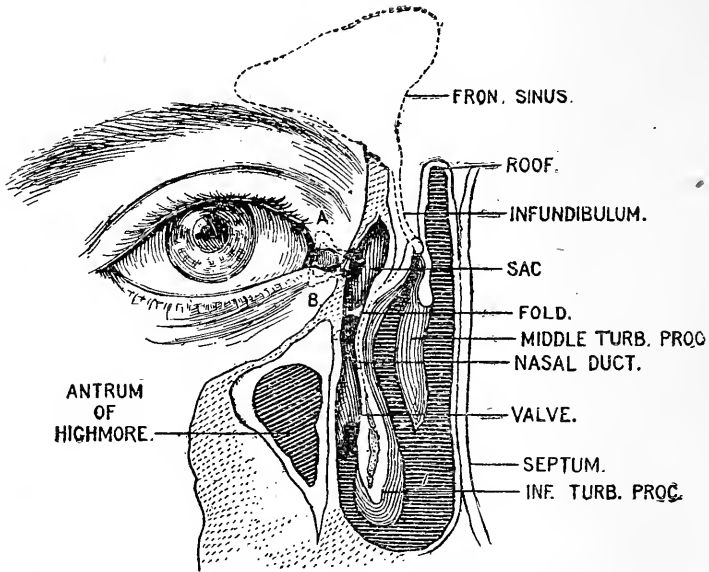


Fig. 13.—Vertical Section at the Root of the Nose to expose the Nasal Duct. (After Merkel.)

The outline of the frontal sinus, with its duct, the infundibulum, is indicated. The position of the upper and lower lacrimal canaliculi is shown (AB).

breaks through the skin of the upper lid. Cysts of the gland (dacryops) are due to obstruction and distension of some of its ducts.

The lacrimal sac is situated at the side of the nose, near the inner canthus, and lies in a groove on the lacrimal and superior maxillary bones (Fig. 13). On its outer side, and a little anteriorly, it receives the lacrimal canals. In front of the sac is the tendo oculi. If the two lids be forcibly drawn outwards this tendon can be readily felt and seen, and is the great guide to the sac. It can also be felt as it is tightened, when



the lids are firmly closed. It crosses the sac at right angles, and at about the junction of its upper third with its lower two-thirds. A knife entered immediately below the tendon would about open the middle of the sac, and it may be noted that a lachrymal abscess, when about to discharge, always points below the tendon. Epiphora, or overflow of tears, is due in the main to two causes: (1) To an obstruction in any part of the lachrymal passages from the puncta to the opening of the nasal duct in the nose; (2) to any cause that removes the lower punctum from its contact with the globe, as may be the case in ectropion, in entropion, in swelling of the lower lid, etc. Facial palsy causes epiphora, because, the orbicular muscle being relaxed, the punctum falls away from the globe, and, moreover, the passage of the tears is no longer aided by the suction action effected by the muscle in the process of winking. The canaliculi may readily be slit up by a proper knife, and a probe can without difficulty be passed down the nasal duct from the lachrymal sac. The duct is a little over half an inch in length, and the probe that traverses it should pass downwards, and a little backwards and outwards. The nasal duct perforates the mucous membrane of the nose below the inferior turbinate process very obliquely, so that its inner wall acts as a valve. If this is destroyed by ulceration, as sometimes occurs in syphilis, the lachrymal sac may be inflated by blowing the nose. In the upper part of the duct the mucous membrane is thrown into a spiral fold, which, after inflammatory conditions, may give rise to stricture (Fig. 13).

As affections of the lachrymal sac are often very painful, it may be noted that the nerve supply of the sac is derived from the infratrochlear branch of the nasal nerve.

## CHAPTER V.

## THE EAR.

**THE PINNA and external auditory meatus.**

—The pinna may be congenitally absent, or may be supplemented by supernumerary portions of the auricle, which may be situated upon the cheek or side of the neck. In the latter situation the so-called supernumerary auricle consists in an irregular leaf of fibro-cartilage developed from the margins of one of the lower branchial clefts. (*See* page 166.) The tag-like supernumerary auricles that are found on the cheek just in front of the pinna or meatus are due to the irregular development or want of fusion of one or more of the six tubercles from which the pinna itself is developed. The pinna may present a congenital fistula. This may be due to a defective closure of the first branchial cleft. This cleft is represented in the normal ear by the Eustachian tube, the tympanum, and the external auditory meatus, the pinna being developed from the integument behind the cleft. In these congenital fistulæ, when well marked, the pinna is cleft just in front of the tragus, or through the helix, and there is more or less failure in the closing of the meatus and tympanum, while the membrana tympani will be more or less deficient or entirely absent. In other cases the "fistula" appears merely as a narrow sinus or a depression, running through the helix. Some of the smaller and more superficial fistulæ are due not to a defective closure of the branchial cleft but to want of complete fusion between certain of the tubercles from which the pinna is primarily developed. Accidental removal of the pinna is usually associated with but comparatively little diminution in the acuteness of hearing.

The *skin* covering the auricle is thin and closely adherent. The subcutaneous tissue is scanty, and contains but very little fat. In inflammatory conditions of the surface, such as erysipelas, the pinna may become

extremely swollen and very great pain be produced from the tenseness of the parts. The pinna and cartilaginous meatus are very firmly attached to the skull so that the body, if not of great weight, may be lifted from the ground by the ears.

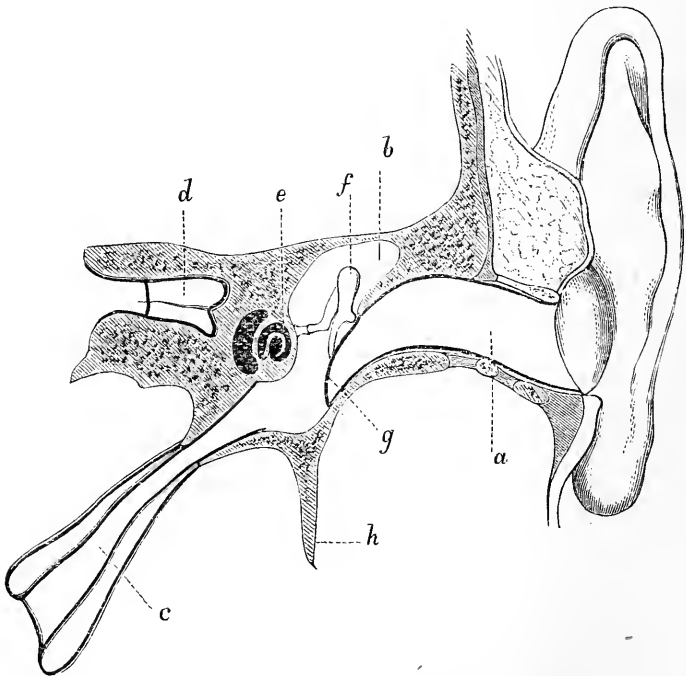
In chronic gout, little deposits of urate of soda (called tophi) are often met with in the pinna, and are usually placed in the subcutaneous tissue at the edge of the helix. M. Paul has pointed out that, when ear-rings are worn, the usual hole made by the ring may become converted into a vertical slit, or the ear-ring may cut its way out, leaving a slit in the lobule. This it may do several times if re-applied, thus producing many slits in the same lobule. He considers such conditions as absolutely diagnostic of scrofula.\*

The **external auditory meatus** is about  $1\frac{1}{4}$  inches long. It is directed forwards and inwards, having the same direction as the petrous bone. The external meatus, the promontory, the cochlea, and the internal meatus lie nearly in the same line. The canal has a vertical curve about its middle, with the convexity upwards. To straighten the canal for the introduction of specula and other instruments, the pinna should be drawn upwards and a little outwards and backwards. The osseous part forms a little more than one-half of the tube, and is narrower than the cartilaginous part.

In the infant at one year, a third only of the meatus is formed of bone. The rest is cartilaginous. In a child of five or six years of age the bony and cartilaginous portions of the meatus are about of the same length (Symington). The meatus is relatively as long in a child as it is in an adult. The narrowest portion of the meatus is about its middle. The outer orifice is elliptical, with its greatest diameter directed from above downwards; therefore specula should be elliptical in shape rather than round. The inner end of the tube, on the other hand, is slightly wider in the transverse direction. Owing to the obliquity of the membrana

\* See "Scrofula and its Gland Diseases," by the Author. Lond. 1882.

tympani, the floor of the meatus is longer than the roof. The cartilaginous segment of the tube presents many sebaceous glands that may be the seat of minute and very painful abscesses. It also presents numerous ceruminous glands, which secrete the cerumen of the ear, and which, when their secretion is excessive, may produce the plugs of wax that often block the meatus. Lacerated wounds of the cartilaginous meatus are apt to bleed freely, owing to the difficulty with which the vessels bound up with the cartilage contract. In the floor of this part of the meatus are certain fissures, fissures of Santorini. They are filled up with fibrous tissue. They permit of easier movement of the carti-



[Fig. 14.—Section through the External Meatus, Middle Ear, and Eustachian Tube (Tillaux).]

*a*, External auditory meatus; *b*, attic of tympanum; *c*, Eustachian tube; *d*, internal auditory meatus; *e*, cochlea; *f*, ossicles; *g*, membrana tympani; *h*, styloid process.

luginous meatus. It is through these gaps in the cartilage that a parotid abscess may burst into the meatus. There are neither hairs nor glands in the lining of the bony part of the tube.

The skin of the meatus, when inflamed, may produce an extensive muco-purulent discharge, otitis externa. Polypi are apt to grow from the soft parts of the canal, and exostoses from its bony-wall. Foreign bodies are frequently lodged in the meatus, and often involve great difficulties in their extraction. It would appear that in many cases more damage is done by the surgeon than by the intruding substance. Mason reports three cases where a piece of slate-pencil, a cherry-stone, and a piece of cedar-wood were lodged in the canal for respectively forty years, sixty years, and thirty years.

The *upper* wall of the meatus is in relation with the cranial cavity, from which it is only separated by a dense layer of bone. Thus, abscess or bone disease in this part may possibly lead to meningitis. A case is reported where an inflammation of the cerebral membrane followed upon the retention of a bean within the meatus. The *anterior* wall of the canal is in relation with the temporo-maxillary joint and with part of the parotid gland. This may serve in one way to explain the pain often felt in moving the jaw when the meatus is inflamed, although, at the same time, it must be remembered that movement of the lower maxilla produces a movement in the cartilaginous meatus, and that both the canal and the joint are supplied by the same nerve (the auriculo-temporal). From its relation to the condyle of the jaw, it follows that this wall of the meatus has been fractured by that condyle in falls upon the chin. Tillaux states that abscess in the parotid gland may spread into the meatus through the anterior wall of the passage. The *posterior* wall separates the meatus from the mastoid cells, and through this partition inflammation may extend from one part to the other, especially as the cartilage of the tube is deficient at its upper and posterior parts. Directly behind the posterior wall is the lateral

sinus. The *inferior* wall of the bony meatus is very dense and substantial, and corresponds to the vaginal and styloid processes.

**Blood supply.**—The pinna and external meatus are well supplied with blood by the temporal and posterior auricular arteries, the meatus receiving also a branch from the internal maxillary. In spite of this supply, the pinna is frequently the seat of gangrene from frost-bite. This is due to the fact that all the vessels are superficial and are close beneath the surface, that the part is much exposed to cold, and that the pinna lacks the protection of a covering of fat. The same conditions predispose to gangrene of the nose from external cold. Bloody tumours (*hæmatomata*) are often met with on the pinna, and are said to be more common in lunatics. They appear to be frequently due to injury, and to consist of an extravasation between the perichondrium and the cartilage.

**Nerve supply.**—The outer surface of the pinna is supplied by the auriculo-temporal nerve, with the exception of the skin over the antitragus, the vertical part of the antihelix, the corresponding part of the helix and its fossa, and the lobule, which parts are all supplied by the great auricular nerve. The inner surface is almost entirely supplied by the latter nerve, the small occipital nerve giving a branch to the upper extremity, and Arnold's nerve a branch to the back of the concha, near the mastoid process. The meatus is supplied mainly by the auriculo-temporal, with, in addition, a contribution from Arnold's nerve, which goes to the lower and back part of the canal, not far from its commencement. Arnold's nerve, a little branch from the pneumo-gastric, has been credited with a good deal in connection with the nerve relations of the ear. After a heavy dinner, when the rose-water comes round, it is common to see the more experienced of the diners touch the lower part of the back of the ear with the moistened serviette. This is said to be very refreshing, and is supposed to prove to be an unconscious stimulation of Arnold's nerve, a nerve whose main trunk goes

to the stomach. Hence, this little branch has been facetiously termed "the alderman's nerve."

**Ear coughing, ear sneezing, ear yawning.**—It is not uncommon to have a troublesome dry cough associated with some mischief in the meatus. Sometimes the mere introduction of a speculum will make the patient cough. A case is reported, where a troublesome cough persisted for eighteen months, and at once ceased on the removal of a plug of wax from the ear. In such cases the irritation is conveyed to the respiratory and cough centres in the floor of the fourth ventricle by Arnold's nerve, a small branch of the vagus. Gaskell has shown that the vagus also contains the disassociated visceral fibres of the fifth nerve. Hence, disturbances may be set up in the vagal nuclei through branches of the fifth nerve, such as the auriculo-temporal. The connection of the nerves of the external auditory meatus with the vagal nuclei also explains the sneezing or vomiting which is sometimes caused by the presence of foreign bodies in the external meatus. The same nerve connection also explains the occurrence of repeated yawning, sometimes set up by ear ailments. Irritation conveyed along the inferior dental or lingual nerves may be referred along the auriculo-temporal. Hence the need to examine the tongue and lower teeth in cases of earache. Head has pointed out that disease of the ear, the tonsil, the tongue or the lower jaw may be associated with an area of tenderness in the skin along and below the jaw.

It is a common practice to introduce ear-rings, with the idea of relieving obstinate affections of the eye. No anatomical basis can be offered to explain such treatment. The lobule is supplied by the great auricular nerve which springs from the second and third cervical nerves, while the eye is supplied by the ophthalmic division of the fifth. The lower sensory nucleus of the fifth is a direct continuation upwards of the grey matter from which the posterior roots of the cervical nerves arise.

Hilton reports a case of obscure pain in the ear which was found to be due to an enlarged gland in the neck,

that pressed upon the trunk of the great auricular nerve.

**Membrana tympani.**—This membrane is very obliquely placed, forming with the horizon an angle of  $45^{\circ}$ . At birth it appears to be more nearly horizontal, although it is not really so. In cretins, and in some idiots, it is said to retain this apparent inclination. Owing to the sloping downwards of the bony wall of the meatus at its inner end, that wall forms with the lower edge of the membrane a kind of sinus in which small foreign bodies may readily lodge (Fig. 14). The ring of bone to which the membrane is attached is deficient at its upper and anterior part. The gap so formed is called the notch of Rivini, and is occupied by loose connective tissue, covered by a continuation of the lining of the meatus, and through it pus may escape from the middle ear into the auditory canal without perforating the membrane. When the membrane gives way owing to a violent concussion transmitted through the air, it often gives way opposite the notch, its attachments here being obviously less secure than elsewhere. The membrane possesses but little elasticity, as shown by the very slight gaping of the part after it has been wounded. It is for this reason, among others, that perforations made in the membrane by the surgeon heal so very rapidly. The membrane has been ruptured during fits of sneezing, coughing, vomiting, etc. The same lesion has followed a box on the ear, and even simple concussions such as that produced by a loud report.

The *umbo*, or deepest point of the depression in the diaphragm, is just below the centre of the entire membrane, and corresponds to the attachment of the end of the handle of the malleus. The rest of the handle can be seen through the membrane during life. The head of the malleus is in no connection with the membrane, being situated in the *attic* of the tympanum above the level of the membrane. The segment of the membrane above the *umbo* is very freely supplied by vessels and nerves; it corresponds to the handle of the



malleus, and to the chain of ossicles, and is opposite to the promontory and the two fenestræ. The chorda tympani nerve also runs across this supraumbilical portion. The segment below the umbo, on the other hand, corresponds to no very important parts, and is less vascular and less sensitive. Paracentesis of the tympanum through the membrana tympani should therefore always be performed in the subumbilical segment. If performed above the umbo the knife may strike the incus and loosen that bone from its frail attachments, or the chorda tympani be cut, which would give rise to a paralytic secretion of saliva. The malleus and stapes are too firmly attached to be readily separated.

The membrane is supplied by the stylo-mastoid artery, and the tympanic branch of the internal maxillary, and obtains its nerve supply from the auriculo-temporal.

The **tympanum**.—The width of the tympanic cavity, as measured from its inner to its outer wall, varies from  $\frac{1}{12}$ th to  $\frac{1}{6}$ th of an inch. The narrowest part is that between the umbilicus of the membrana and the promontory. A fine rod thrust through the centre of the membrana tympani would hit the promontory on the *inner* wall of the cavity. Above the promontory is the fenestra ovalis, and below and behind it the fenestra rotunda. Skirting the upper and posterior margin of the inner wall of the tympanum is the aqueduct of Fallopius, containing the facial nerve. The wall of the aqueduct is so thin that inflammatory mischief can readily extend from the middle ear to the facial nerve. The *upper* wall is very thin, and but little bone separates it from the cranial cavity. The suture between the squamous and petrous bones is found in this wall, and by means of the sutural membrane that separates the bones in the young, inflammatory changes may readily spread from the tympanum to the meninges. The petro-squamous suture unites at the end of the first year and usually contains the petro-squamous vein, a remnant of the primitive jugular. The *floor* is very narrow. Its lowest part is below

the level of both the membrana tympani and the orifice of the Eustachian tube, and hence pus may readily collect in this locality. It is separated by a thin piece of bone from the internal jugular vein behind, and from the internal carotid artery in front. Fatal hæmorrhage from the latter vessel has occurred in connection with destructive changes in this part of the ear. The

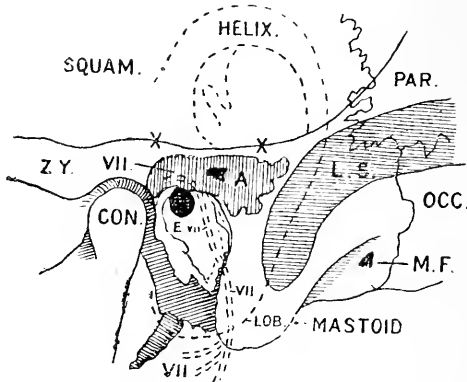


Fig. 15.—Showing the Position and Relationships of the Antrum of the Mastoid (see also Fig. 3).

A, Antrum. The suprameatal triangle is indicated in front of the letter. The shaded space in front of the triangle and above the meatus is the attic of the tympanum; × × on the continuation of the upper border of the zygoma backwards indicating the position of the tegmen tympani; E, placed on the floor of the external auditory meatus. The tympanum is seen in the depth of the meatus; VII. showing the position of the facial nerve; L.S., lateral sinus; M.F., mastoid foramen; ZY., root of zygoma; CON., condyle of jaw. The outline of the auricle is indicated by a single dotted line; that of the facial nerve by a double dotted line.

posterior wall in its upper part presents the opening of the antrum of the mastoid.

The **antrum of the mastoid** (Fig. 15) lies above and behind the external auditory meatus and opens into the attic of the tympanum. Implication of this space and of the mastoidal cells, which open into it and surround it, forms one of the most serious complications of middle ear disease. It is large enough to contain a small bean, and is present at birth, being developed with the cavity of the tympanum. It is closely surrounded by important structures. Its roof, formed by

the tegmen tympani, a plate of bone only 2 mm. thick, separates it from the third temporal convolution. Small veins perforate the roof to join the petro-squamous vein, in the remnant of the suture of the same name. In the infant the communication is even more free, for this suture does not close until the end of the first year. The facial nerve passes downwards on its *inner* wall, where the antrum opens into the attic, and behind the facial nerve, also on the inner wall, is the external semi-circular canal. Facial paralysis or giddiness may follow operations on the antrum if the inner wall is injured. The antrum is separated *behind* from the lateral sinus and cerebellum by a plate of bone which varies in thickness from 3 mm. to 6 mm. The temporo-sphenoidal lobe, the lateral sinus, and the cerebellum are the common seats of secondary infection in cases of middle ear disease. At the mouth of the antrum and in the attic of the tympanum are situated the incus, the head of the malleus, and their ligaments, structures which may be diseased and require removal.

At birth the *outer* wall of the antrum is formed by the post-meatal process of the squamosal, a plate of bone 2 mm. thick. Every year, until about the twentieth, this process of bone increases about 1 mm. in thickness, and hence in the adult the mastoidal antrum lies at a depth of 20 mm. from the surface, but it must be remembered that the depth varies considerably. In the child it is comparatively superficial, and pus may easily escape or be evacuated. The suture between the post-meatal part of the squamosal and the petro-mastoid disappears in the second year of life and so shuts off a possible route that pus may take to reach the surface. A shallow triangle (*see* Fig. 15) above and behind the meatus, formed by the post-meatal process of the squamosal, lies directly over the antrum and serves as a guide to it. It may also be reached by following the junction of the posterior wall and roof of the external auditory meatus. The drill is entered 5 mm. behind the meatus and on a level with its upper margin. Its roof lies 5 mm. above the

level of the meatus. The posterior auricular artery passes upwards behind the meatus, beneath the concha of the auricle, and lies within the field of any operation on the middle ear.

The **mastoid cells** develop with the growth of the mastoid process. The mastoid process appears in the third year, but the cells are not formed until puberty. Three varieties of the mastoid process are recognised, each of which is about equally common: (1) those in which the cells are large and communicate with each other and with the antrum, (2) those in which the central cells are large and communicate with the antrum, while the peripheral are small and closed, (3) those in which all the spaces are small and closed. The cells surround the antrum, and may pass backwards to the masto-occipital suture, forwards to the suprameatal region, upwards to the masto-parietal suture, and downwards to the apex of the mastoid. Inflammatory conditions may lead to a thickening of the walls of the mastoidal cells, and the bone may become so dense as almost to resist the chisel. Veins drain into the periosteum of the mastoid from the more superficial cells, and by these, inflammation may reach the surface and give rise to oedema and swelling behind the ear.

In cases where the outer surface of the mastoid has been spontaneously perforated, a tumour has appeared on the skull that contained air, and that could be increased in size by forcing air into the ear through the Eustachian tube. Such tumours are known as *pneumatoceles*, and the process that leads originally to the perforation of the bone is of obscure nature. In some cases it seems to have been simply atrophic, and in other instances to have been due to "caries sicca."

On the *anterior* wall of the tympanum is the opening of the **Eustachian tube**. This tube is  $1\frac{3}{4}$  inches long, and by opening into the pharynx serves to keep a proper supply of air in the tympanum, and so equalise the pressure upon the two sides of the membrane. The floor of the tympanum is below the level of the outer

opening of the Eustachian tube. The line of direction of the tube lies almost exactly midway between the transverse and antero-posterior axes of the base of the skull. In the adult it inclines downwards, so as to form an angle of  $40^\circ$  with the horizon. In the child this angle is only  $10^\circ$  (Symington). In adults  $\frac{3}{4}$ ths of the tube is cartilaginous and  $\frac{1}{4}$ th bony (Symington). On the outer side of the tube lie the tensor palati, the third division of the fifth nerve, and the middle meningeal artery. On the inner side are the retro-pharyngeal tissue and (quite posteriorly) the internal carotid artery. The pharyngeal orifice of the tube is usually shut. During swallowing, however, it is opened, by the action mainly of the tensor palati muscle. If the nose and mouth be closed and the cheeks blown out, a sense of pressure is produced in both ears. The hearing, at the same time, is dulled, and the change is due to the bulging out of the membrana tympani by the air thus forced into the tympanum. This method of inflating the middle ear is known as Valsalva's method.

In "Poltzer's method" of passing air into the Eustachian tube, the patient's mouth is closed, while into one nostril the nozzle of a caoutchouc bag filled with air is introduced, and the nostrils are then held firmly closed. The patient is asked to swallow a mouthful of water, while at the same moment the bag is forcibly emptied, and the air, having no other means for escape, is thus driven into the open Eustachian tube. The surgeon listens for the little noise caused by the entrance of the air by means of a tube that passes between the patient's meatus and his own. Prolonged closure of the Eustachian tube leads to deafness, and thus impairment of hearing may follow upon great thickening of the mucous membrane of the tube due to the extension of inflammatory mischief from the pharynx. In the deafness associated with enlarged tonsils and post-nasal growths, the hypertrophic change extends to the mucous lining of the tube, and in the cases of many pharyngeal growths and nasal polypi, the orifice of the tube is mechanically obstructed. The near relation of the

pharyngeal end of the tube to the posterior nares serves to explain a case where suppuration in the mastoid cells followed upon plugging of the nares for epistaxis. A probe passed up the Eustachian tube from the pharynx would hit the joint between the incus and the stapes, and would enter the mastoid cells (Tillaux).

The upper edge of the pharyngeal orifice of the tube is about half an inch below the basilar process, half an inch in front of the posterior wall of the pharynx, half an inch behind the posterior end of the inferior turbinated bone, and half an inch above the soft palate (Tillaux). In the fœtus the orifice is below the hard palate; at birth on the same level. The form of the opening is that of a triangle. The opening of the tube is effected by the tensor palati, levator palati, and salpingo-pharyngeus.

Just behind the elevation formed at the orifice of the Eustachian tube there is a depression in the wall of the pharynx, known as the lateral recess or fossa of Rosenmüller (Fig. 16). It may be mistaken for the orifice of the tube, and may readily engage the point of a Eustachian catheter. In cases in which the pharyngeal tonsil (Luscha's tonsil) is enlarged, this fossa on either side may be greatly deepened and made to form a narrow diverticulum. (See page 131.) To pass the Eustachian catheter, the instrument is carried along the floor of the nares with its concavity downwards, "until its point can be felt to drop over the posterior edge of the hard palate into the pharynx. The instrument should now be withdrawn until its point can be felt to rise again on the posterior edge of the hard palate; having arrived at this point, the catheter should be pushed onwards about one inch, and during its passage its point should be rotated outwards through a quarter of a circle."\* This manœuvre should engage it on the orifice of the tube.

**Blood supply.**—The tympanum is supplied by the following arteries: the tympanic of the internal

\* Smith and Walsham's "Operative Surgery," p. 12. 2nd Ed. 1876.

maxillary and internal carotid, the petrosal of the middle meningeal, and the stylo-mastoid of the posterior auricular. The fact that some of the tympanic veins end in the superior petrosal and lateral sinuses gives another explanation of the frequent occurrence of thromboses of those channels in inflammatory affections of the middle ear. The petro-squamous vein, which crosses the roof of the middle ear, also receives branches from the antrum and attic and joins the lateral sinus behind and the meningeal veins in front (Cheatele).

The connection between deafness and tinnitus aurium and affections of the stomach has to be sought for in the central connections of the eighth and tenth nerves. The blood supply of the labyrinth is derived entirely from the vertebral artery (Woakes).

The **chorda tympani** nerve, from its exposed position in the tympanum, is very likely to be damaged in suppurative disease of the middle ear; and Urban-tschitsch and Schulte have shown that such disease in this part may be associated with anomalies of taste.

The **osseous labyrinth** is formed independently of the other bony parts of the ear. Portions of this labyrinth have necrosed and have been expelled in recognisable fragments. In a case recorded by Dr. Barr the whole of the osseous labyrinth (the cochlea, vestibule, and semicircular canals) was removed entire as a necrosed fragment from the auditory meatus.

---

## CHAPTER VI.

### THE NOSE AND NASAL CAVITIES.

1. **THE nose.**—The *skin* over the root, and the greater part of the dorsum, of the nose, is thin and lax. Over the alæ, however, it is thick, very adherent to the deeper parts, and plentifully supplied with sebaceous and sweet glands. Inflammation of the integuments over the cartilaginous portion of the nose is apt to be very painful, and to be associated with much vascular

engorgement. The pain depends upon the tenseness of the part, which prevents it from swelling without producing much pressure upon the nerves, while the engorgement depends upon the free blood supply of the region, and the fact that the edge of the nostril being a free border, the circulation there is terminal, and apt therefore to favour congestion.

The great number of sebaceous glands about the lower part of the nose renders it a favourite spot for acne. It is here that the form of acne termed *acne hypertrophica* is met with, a condition that produces the appearance known as "grog blossoms." The nose, too, is frequently attacked by lupus, and it is indeed over the dorsum of the nose that lupus erythematosus is most commonly met with. Rodent ulcer also is apt to appear in this region, especially in the fold between the ala of the nose and the cheek.

The integument of the nose is very well supplied with blood, and for this reason the part is well suited for the many plastic operations that are performed upon it. Wounds in this region heal kindly, and even the extensive wound made along the line between the nose and the cheek in removal of the upper jaw leaves very little deformity. In many reported cases portions of the nose have been entirely severed, and have united to the face on being immediately re-applied. In spite of its full blood supply, the nose, for reasons already given when speaking of the pinna (page 72), is prone to gangrene from exposure to severe cold. A specimen in the museum of the Royal College of Surgeons illustrates a remarkable form of gangrenè of the nose. The specimen is the larynx of a man who cut his throat and lost a great quantity of blood. Before he died his nose sloughed.

The skin over the root of the nose is supplied by the nasal branch of the first division of the fifth; as is also the skin over the alæ and in the region of the nostril. The middle or greater part of the side of the nose is supplied by the second division of the fifth, and is the seat of pain in neuralgia of that trunk. The



fact that the nasal nerve is a branch of the ophthalmic trunk, and has intimate connections with the eye, serves to explain the lachrymation that often follows painful affections about the nostril, as, for example, when the edge of the nostril is pinched (page 46).

The **cartilaginous part** of the nose is often destroyed by lupus, by syphilitic ulceration, and other destructive affections. The parts so lost have been replaced by the various methods included under the head of rhinoplasty. It is well to bear in mind the limits of the cartilaginous segment of the nose, and to remember that in introducing a dilating speculum the instrument should not be passed beyond those limits. In the subjects of inherited syphilis the bridge of the nose is often found to be greatly depressed. This depends upon no actual loss of parts, but rather upon imperfect development from local mal-nutrition, that mal-nutrition following upon a severe catarrh of the mucous membrane. The deformity only occurs, therefore, in those who have had "snuffles" in infancy.

The **nasal bones** are often broken by direct violence. The fracture is most common through the lower third of the bones, where they are thinnest and least supported. It is rarest in the upper third, where the bones are thick and firmly held, and where, indeed, considerable force is required to produce a fracture. Since no muscles act upon the ossa nasi, any displacement that occurs is due solely to the direction of the force. Union takes place after these fractures with greater rapidity than perhaps obtains after fracture of any other bone in the body. In one case noted by Hamilton, "the fragments were quite firmly united on the seventh day." If the mucous membrane of the nose be torn, these fractures are apt to be associated with emphysema of the subcutaneous tissue, which is greatly increased on blowing the nose. The air in such cases is derived, of course, from the nasal fossæ. In fractures of the upper third of the ossa nasi the cribriform plate may be broken, but it is questionable whether this complication can occur when the fracture is limited

to the lower third of the bones. The root of the nose is a favourite place for meningoceles and encephaloceles, the protrusion escaping through the suture between the nasal and frontal bones. Such protrusions, when occurring in this place, are often covered by a thin and vascular integument, and have been mistaken for nævoid growths.

2. The **nasal cavities**.—The **anterior nares** have somewhat the shape of the heart on a playing card, and the aperture as a whole measures about  $1\frac{1}{4}$  inches vertically, and a little less than  $1\frac{1}{4}$  inches transversely, at its widest part. The plane of the nostril is a little below that of the floor of the nares. To examine the nasal cavities, therefore, the head should be thrown back, and the nose drawn upwards. The anterior nares can be well explored by the finger introduced into the nostril, and the nasal apertures are just so wide on each side of the septum as to allow the finger to be passed far enough back to reach another finger introduced into the posterior nares through the mouth. An effectual way of removing soft polypi in the adult is by tearing them away by the two fingers so introduced. The operation is a little rough. By the most gentle introduction of the finger into the nostril it is often possible to feel the end of the inferior turbinated bone. The anterior nares, and front of the nasal cavities, can be well explored by Rouge's operation. In this procedure the upper lip is everted, and a transverse cut made through the mucous membrane into the soft parts that connect the upper lip with the upper jaw. The incision extends between the second bicuspid teeth of either side. The soft parts connecting the upper lip and nose to the bone are divided without damaging the skin, and the flap is dissected up until the nares are sufficiently exposed.

The **posterior nares**.—If a little mirror, somewhat similar to that used in laryngoscopy, be cautiously introduced behind the soft palate through the mouth, and illumined from the mouth, the following parts may, under favourable circumstances, be seen :

the posterior nares, the septum, the middle turbinated bone, part of the superior and inferior turbinated bones, and part of the inferior meatus. The middle meatus is well seen, and also the Eustachian tube, and the mucous membrane of the upper part of the pharynx.

This mode of examination is very difficult to carry out, and is known as posterior rhinoscopy. The parts just named can all be felt by the finger introduced behind the soft palate through the mouth. The posterior nares are often plugged to arrest severe bleeding from the nose, and in order to cut a proper sized plug it is desirable to bear in mind the dimensions of the apertures. Each aperture is of regular shape, and measures about  $\frac{1}{2}$  an inch transversely by  $1\frac{1}{4}$  inches in the vertical direction in a well-developed adult skull.

As regards the nasal cavities generally, it is well to note that the floor is wider at the centre than at either end, that the vertical diameter is greater than the transverse, and is greatest also about the centre of the fossæ. Forceps introduced into the nose, therefore, are most conveniently opened if opened vertically. The width of the fossæ increases somewhat from above downwards, thus the superior turbinated bone is only 2 mm. from the septum, while a space of from 4 to 5 mm. intervenes between the inferior turbinated bone and the septum. The nasal cavity is so very narrow above the middle turbinated bone that that bone really forms the surgical roof of the nasal fossæ.

From a reference to the relations of the nasal fossæ (Fig. 16) it will be understood that inflammation of the lining membrane (coryza) may extend to the pharynx *viâ* the posterior nares; may extend up the Eustachian tube and cause some deafness; may reach the lachrymal sac and conjunctiva through the nasal duct; and may extend to the frontal sinuses and the antrum, producing frontal headache and cheek-ache. These relationships are often demonstrated in a severe "cold in the head." From the nearness of the nasal fossæ to the cranial cavity it happens that meningitis has followed upon purulent inflammations of the nose. Foreign bodies

of various kinds are often lodged in the nose, and may remain there for some years. Thus Tillaux reports the case of an old woman, aged 64, from whose nose he removed a cherry stone that had been there for twenty years.

In washing out the nasal cavities with the "**nasal douche**" the fluid is introduced by means of a syphon. The nozzle of the syphon tube is introduced into one nostril, the mouth is kept open, and the fluid runs through that nostril, passes over the soft palate, and escapes from the other nostril. The latter cavity is therefore washed out from behind forwards. The course of the fluid depends upon the fact that when the mouth is kept open there is such a disposition to breathe through it alone that the soft palate is drawn up and the nares cut off from the pharynx.

The **roof** of each nasal fossa is very narrow, being only about  $\frac{1}{8}$  of an inch in width. It is mainly formed by the thin cribriform plate, but its width is such that the danger of the roof being penetrated by so large a substance as a pair of polyp forceps has been greatly exaggerated. The cranial cavity has, however, been opened up through the roof of the nose by penetrating bodies introduced both by accident and with homicidal intent. Meningitis has followed inflammation of the nasal fossæ, the inflammation extending through the cribriform plate. Through the perineural and perivascular sheaths the lymphatic system of the nose is in continuity with that of the meninges, and by these channels infections may spread from the roof of the nose to the membranes of the brain. Fracture of this part also has been associated with very copious escape of cerebro-spinal fluid through the nostrils. A meningocele may protrude through the nasal roof. In a case reported by Lichtenberg the mass hung from the mouth, having passed through a congenital fissure in the palate. It was mistaken for a polyp, was ligatured, and death resulted from intracranial inflammation.

The **septum** is seldom quite straight in adults; the deviation being more often towards the left. It is,

however, straight in children, and remains so up to the seventh year. In adults the septum deviates in 76 per cent. of all persons. The deviation may follow an injury. It has been pointed out that a deviation of the septum may seriously interfere with the singing voice. The nose also is seldom quite straight, and French authors ascribe this to some deviation of the septum, often dependent upon the practice of always blowing the nose with the same hand. If the deviation of the septum be considerable, it may more or less block one nostril, and, until the opposite nostril is examined, be mistaken for a septal tumour encroaching upon the cavity. The flattened nose in acquired syphilis is usually due to destruction of the septum and more or less implication of the adjacent bones. Workmen exposed to the vapour of bichromate of potash are liable to a peculiar perforation of the septum known as "bichromate disease."

**Outer wall** (Fig. 16).—The inferior turbinated bone may interfere with the introduction of a Eustachian catheter if the curve of the instrument be too great. The anterior end of the bone is about  $\frac{3}{4}$  of an inch behind the orifice of the nostril. The opening of the nasal duct is about 1 inch behind the orifice of the nostril, and about  $\frac{3}{4}$  of an inch above the nasal floor. This opening is usually slit-like and narrow. The nasal duct pierces the nasal mucous membrane in the same oblique and valvular manner as the ureter enters the bladder. The height of the inferior meatus is about  $\frac{3}{4}$  of an inch. The superior meatus is a very short and narrow fissure, and into its upper and fore part open the posterior ethmoidal cells. The middle meatus opens widely in front upon a part of the outer wall called the atrium, and unless care be taken to keep the point of any instrument well towards the floor of the fossa, it is easier to pass the instrument into the middle than into the inferior meatus. Upon the wall of the middle meatus is a deep gutter (the hiatus semilunaris), which runs from above downwards and backwards (Fig. 16). Into this groove open the infundibulum (the aperture of the frontal sinus), the

anterior ethmoid cells, and, near its posterior end, the antrum. The aperture of the frontal sinus appears as a small round hole at the upper and anterior end of the groove. The ethmoid cells open a little way lower down on the groove, while the antrum has its orifice at or near the hinder part of the hiatus. This orifice is slit-like, situated about the centre of the middle meatus, and is quite 1 inch above the floor of the nasal fossæ (Fig. 16). The orifice is nearer to the roof than the floor of the antrum, and thus no facility is offered for the escape of accumulated fluids.

The middle turbinated bone is high up. Its highest point (its anterior extremity) is nearly on a level with the tendo oculi.

Rhinolithes (stone-like masses of calcareous matter, formed, as a rule, around foreign substances) are most often found in the inferior meatus.

The width of the nasal **floor** is about  $\frac{1}{2}$  an inch, or a little over. Its smooth surface greatly favours the passage of instruments. It presents a gentle slope from before backwards. At its anterior part is a depression of mucous membrane over the incisor foramen. This foramen is a vestige of the great communication that once existed between the cavities of the nose and mouth.

The **mucous membrane** lining the nasal cavities varies in parts. It is very thick and vascular over the turbinate bones and over the lower two-thirds of the septum, while over the nasal floor and in the intervals between the turbinate bones it is very much thinner. The mucous membrane lining the various sinuses and the antrum is conspicuously thin and pale. The membrane is provided with many glands, which are most conspicuous over the lower and hinder parts of the outer wall and over the posterior and inferior parts of the septum. These glands may be the subject of considerable hypertrophy. They are capable of providing also a very copious watery secretion, which has in some cases of chronic coryza following injury been so free as to be mistaken for an escape of cerebro-spinal fluid.

There is also much adenoid, or lymphoid, tissue in the nasal mucous membrane, which is the primary seat of the chief scrofulous affections that invade this part. So thick and lax is the normal mucous membrane over

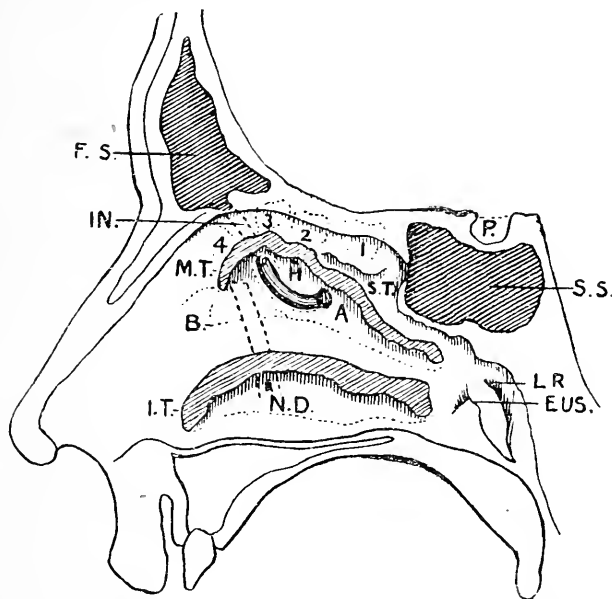


Fig. 16.—Outer Wall of the Nose, showing the Openings of the Sinuses. The middle (M.T.) and inferior (I.T.) turbinate processes have been cut off at their attachments, but their outlines are indicated.

F.S., Frontal sinus; IN., infundibulum opening into the middle meatus at the upper end of the hiatus semilunaris; H. placed on the bulla ethmoidalis below the opening of the middle ethmoidal cell (2) and above the hiatus semilunaris; A. the opening of the antrum at the posterior end of the hiatus; B. on the atrium in front of the beak of the middle turbinate process; S.D., opening of the nasal duct; (1), posterior ethmoidal cell opening in superior meatus; (3) anterior ethmoidal cell opening into infundibulum; (4), lacrymo-ethmoidal cell, also opening into infundibulum; P. position of pituitary body; s.s., sphenoidal sinus; L.R., lateral recess of pharynx; EUS., Eustachian tube.

the lower borders and posterior extremities of the middle and inferior turbinated bones that it forms in these situations a kind of soft cushion. This condition is mainly due to the presence of a rich submucous venous plexus, the vessels of which run, for the most part, in an antero-posterior direction. Over the lower turbinate

bone the veins form a kind of cavernous tissue, "the erectile body." When turgid with blood it swells so as to obliterate the interval between the bone and the septum. When the seat of chronic inflammation, the mucous membrane over the inferior bone may appear as a polypoid swelling. The great vascularity of the mucous membrane is probably for the purpose of raising the temperature of the inspired air. From the construction of the fossæ the inspired air is encouraged to pass along the middle meatus, the expired air along the lower meatus. From the comparatively lax attachment of the mucous membrane of the septum to the parts beneath, it happens that hæmatomata are often met with beneath the septal mucous membrane after a blow on the nose.

**Polypi** are often met with in the nose. They are of two kinds, the mucous or myxomatous polyp that springs usually from the mucous membrane over the middle or inferior turbinate bones, and the fibrous or sarcomatous polyp that usually takes origin from the periosteum of the nasal roof or from that of the base of the skull. Polypi of the latter kind spread in every available direction. They expand the bridge of the nose, close the nasal duct and cause epiphora, depress the hard palate, and encroach upon the mouth, invade the antrum and expand the cheek, grow down into the pharynx, pushing forwards the velum palati, and may penetrate even through the inner wall of the orbit. In one remarkable case, quoted in the *Lancet* for 1877, a tumour, springing from the sheath of the superior maxillary nerve just after its exit from the foramen rotundum, projected into the nasal fossæ. It was mistaken for a polyp, and attempts to remove it led to meningitis and death.

The **blood supply** of the nasal cavity is extensive, and is derived from the internal maxillary, ophthalmic, and facial arteries. With regard to the veins, it may be noted that the ethmoidal veins that come from the nose enter the ophthalmic vein, while in children a constant communication exists between the nasal veins



and the superior longitudinal sinus through the foramen cæcum. This communication may also be maintained in the adult. These connections may, in part, serve to explain the occurrence of intracranial mischief as a consequence of certain inflammatory affections of the nasal cavities. Bleeding from the nose, or *epistaxis*, is a common, and often a serious, circumstance. Its frequency is to a great extent due to the vascularity of the mucous membrane, to its laxity, and to the fact that the veins, especially those over the lowest turbinate bone, form extensive plexuses, and produce a kind of cavernous tissue. The epistaxis is often due, therefore, to interference with the venous circulation, as seen in cases of cervical tumour pressing upon the great veins, in the paroxysms of whooping cough, and the like. The beneficial effect of raising the arms in epistaxis is supposed to depend upon the extra expansion of the thorax thus produced, and the aspiratory effect thus brought to bear upon the cervical veins. The bleeding may be copious and long continued. Thus Spencer Watson reports a case where the epistaxis continued on and off for twenty months without obvious cause. Martineau mentions an instance in which 12 lb. of blood were lost in sixty hours, and Fraenkel records a case where 75 lb. of blood are said to have escaped from first to last. In several instances the hæmorrhage has proved fatal. The seat of the bleeding is often not easy to detect, even when the examination is post mortem. In many cases the bleeding point is situated on the septum,  $\frac{1}{2}$  an inch above and behind the nasal spine.

The **nerve supply** of these parts is derived from the olfactory nerve, and from the first and second divisions of the fifth nerve. The lachrymation that often follows the introduction of irritants into the front of the nares may be explained by the fact that that part of the cavity is supplied freely by the nasal nerve, a branch of the ophthalmic trunk. As an example of transference of nerve force in the opposite direction may be noted cases where a strong sunlight falling upon the eyes has produced an attack of sneezing.

Troubles involving the vagal centres, such as cough and bronchial asthma, have followed affections of the nasal cavities. The vagus nerve contains visceral fibres which originally belonged to the fifth nerve. The olfactory nerves are situated in the upper third of the cavity, and thus in smelling intently the individual sniffs deeply and dilates the nostril. The inability to dilate the nostril in facial paralysis may explain the partial loss of smell sometimes noted in such cases. It is said (Althaus) that anosmosia, or loss of the sense of smell, when following upon an injury to the head, may be due to a rupture of the olfactory nerve fibres as they pass through the cribriform foramina. The olfactory roots cross the edge of the lesser wings of the sphenoid, and in falls on the forehead are liable to injury. The olfactory centre is situated in the hippocampal gyrus. Surgery affords some examples of the possible violence of the act of sneezing. Thus a man sneezed vigorously when his hand was firmly supported upon an object, and produced a subcoracoid dislocation of his shoulder (*Lancet*, 1878). In another case the ninth rib on the left side was fractured during a fit of sneezing (*Med. Times*, 1862). Mr. Pitts (*Lancet*, 1883) has, however, reported the strangest case of all, a case in which all the coverings of a large femoral hernia were ruptured during the act of sneezing, so that the bowels escaped.

Some of the **lymphatics** of the nasal fossæ enter certain glands placed behind the pharynx, in front of the rectus capitis anticus major. Hence, as Fraenkel has pointed out, "retro-pharyngeal abscess may arise in consequence of diseases of the nose." Other lymphatics go to the submaxillary, parotid, and upper deep cervical lymph glands, and it is common to find the former set of glands enlarged in nose affections, especially in the scrofulous. The lymphatics of the nose also communicate with those of the meninges through the cribriform plate.

The **sinuses**.—These may be briefly dealt with. The *frontal* sinuses (Figs. 13 and 16) are not present

in early youth, but develop as age advances. They do not exist before the age of ten years, but are well developed by twenty. They are formed by outgrowths of the nasal mucous membrane, which cause the diploe to be absorbed as they advance. Large frontal sinuses do not necessarily imply large external prominences over the glabella and superciliary eminences. One sinus may develop at the expense of the other, and the septum may be displaced or absent. The body of the sinuses lies behind the glabella, and they extend outwards over the inner two-thirds of the orbit and backwards for about  $\frac{1}{2}$  an inch. They are larger in men than in women. They are absent on one side in 25 per cent. of cases, and on both sides in 15 per cent. Bony tumours often grow from the interior of these sinuses, and are known as enostoses. It is obvious that a depressed fracture may exist over a frontal sinus without the cranial cavity being damaged. In such cases the inspissated contents of the sinus have been mistaken for brain matter escaping. Since the sinuses communicate with the nose, much emphysema may follow upon fracture of the sinus wall. Insects have found their way into these cavities. "Centipedes are particularly liable to be found in the frontal sinuses, where they may remain for years, the secretions of these cavities furnishing them with sufficient nourishment" (Fraenkel). Larvæ have also been found here, and maggots that have developed within the nose have managed to make their way to the frontal sinuses. A case is reported where epistaxis, extending over many years, was due to an insect (the pentastoma tænioides) that had settled in these sinuses. One day it was sneezed out, and no further bleeding occurred (*Med. Times*, 1876). The last-named parasite is said to be often met with in the frontal sinus of the dog. The infundibulum is  $\frac{3}{4}$  of an inch long, and runs downwards and slightly backwards to open at the anterior end of the hiatus semilunaris. Along the hiatus the secretion of the frontal sinus is conveyed to the antrum, which in cases of chronic inflammation may become a cesspool for the sinus

(Fig. 16). The *infundibulum* is frequently tortuous, and can be catheterised from below with difficulty even after the beak of the middle turbinate process is removed. Hence in cases of obstruction the frontal sinus is trephined over the glabella, and a probe passed downwards and slightly backwards to drain the sinus into the nose. The frontal diploic vein, which joins the frontal vein at the supraorbital notch, receives blood from the frontal sinus. By this channel infection may be disseminated in the frontal bone from disease of the frontal sinus.

The sphenoidal sinus opens on the roof of the nose behind the superior meatus (Fig. 16). It is deeply placed, and not very accessible for operation when the seat of disease. The pituitary body, within the sella turcica, rests on its roof, and tumours of this body frequently invade the sinus.

The walls of the sinuses are thin and easily perforated, as the following case, which occurred recently at the London Hospital, will show. A man stumbled forwards on his umbrella as he left a public-house in Whitechapel, the point entering his face above the bicuspid teeth. He walked to the hospital, and died three days afterwards. The ferrule of the umbrella was found embedded in the pons, the point having traversed the antrum of Highmore and the sphenoidal sinus.

The *antrum* exists at birth, but attains its largest dimensions in old age. The walls of the cavity are thicker in children than in adults. Tumours of various kinds are apt to develop in this cavity, and to distend its walls in various directions. Thus the growth breaks through the thin inner wall and invades the nose, it pushes up the roof of the cavity and invades the orbit, it encroaches upon the mouth through the floor of the antrum, and makes its way also through the somewhat slender anterior wall into the cheek. The densest part of the antrum wall is that in relation to the malar bone, and this part does not yield. There is little inducement for any growth to spread backwards, although it sometimes invades the zygomatic and pterygo-

maxillary fossæ. As the infraorbital nerve runs along the roof of the antrum, while the nerves of the upper teeth are connected with its walls, these structures are pressed upon in growths springing from the antrum, and much neuralgia of the face and teeth is often produced. In tapping the antrum a spot is usually selected just above the second bicuspid tooth, since the bone is here thin and is conveniently reached. In some cases it is sufficient to extract a molar tooth, since the fangs of these teeth often enter the cavity of the antrum. The teeth usually selected are either the first or the third molar. Not unfrequently the antrum communicates at its upper anterior part with the frontal sinus.

As the result of a fall, one of the upper teeth has been entirely driven into the antrum and lost to view. In one case, reported by Haynes Walton, an upper incisor was found lying loose in the antrum three and a half years after the accident that had driven it there.

---

## CHAPTER VII.

### THE FACE.

THE parts of the face, other than those already dealt with, will be considered under the following heads: (1) The face generally; (2) the parotid region; and (3) the upper and lower jaws and parts connected with them. The lips will be considered with the "cavity of the mouth" (chap. viii.).

1. The **face generally**.—The skin of the face is thin and fine, and is more or less intimately adherent by a delicate subcutaneous tissue to the parts beneath. The skin generally is very freely supplied with sebaceous and sudoriparous glands, and hence the face is very commonly the seat of acne, an eruption that specially involves the sebaceous follicles. It happens from the thinness of the skin, and from the absence of dense fasciæ, that facial abscesses usually soon point and seldom attain large size.

The cellular tissue of the face is lax, and readily lends itself to spreading infiltrations, so that in certain inflammatory affections the cheeks and other parts of the face may become greatly swollen. In general dropsy, also, the face soon becomes "puffy," the change first appearing, as a rule, in the lax tissue of the lower lid. The skin over the chin is peculiarly dense and adherent to the parts beneath, and in most respects closely resembles the integument of the scalp. When such parts of the integuments of the face as cover prominent bones, such as the parts over the malar bone, the chin, the upper lid, are struck by a blunt instrument or in a fall, the wound produced has often the appearance of a clean incised wound, just as obtains in contused wounds of the scalp.

The mobility of the facial tissues renders this part very suitable for the performance of plastic operations of various kinds, and their vascularity generally insures a ready and sound healing. Although there is a large quantity of fat in the subcutaneous tissue in this region, yet fatty tumours are singularly rare upon the face. They appear, indeed, to avoid this region. Thus M. Denay reports the case of a man who had no less than 215 fatty tumours over different parts of his body, but not one upon his face. The thickness of the tissues of the cheek and lips favours the embedding of foreign substances in those parts. Thus, a tooth that has been knocked out has remained for some time embedded in the lip. Henry Smith reports a remarkable case, where he removed a piece of tobacco-pipe 3 inches long from the cheek, in the tissues of which it had been embedded for several years. The soft tissues of the cheek greatly favour the spread of destructive processes. Thus in *cancrum oris*, a form of gangrene of the face attacking the young, the whole cheek may be lost in a few days. Great contraction is apt to follow upon loss of substance in the cheek, so that in some cases the jaws may be firmly closed, as is seen after recovery from advanced *cancrum oris*. The face is peculiarly liable to be the seat of certain ulcers, especially the rodent and lupoid

ulcer, and is the part most often attacked by "malignant pustule," a disease transmitted to man from cattle afflicted with a malady known in this country as "murrain," and in France as "charbon."

**Blood supply.**—The tissues of the face are very vascular, and are liberally supplied with blood-vessels in all parts. The finer vessels of the skin often appear permanently injected or varicose in the drunken, or in those who are exposed to cold, or are the subjects of certain forms of acne. Thus, *nævi*, and the various forms of erectile tumour, are common about the face. For a like reason also wounds of the face, while they may bleed readily when inflicted, are apt to heal with singular promptness and accuracy. All wounds, therefore, of this part should have their edges carefully adjusted as soon after the accident as possible. Extensive flaps of skin that have been torn up in lacerated wounds often retain their vitality in almost as marked a manner as do like flaps torn up from the scalp. Extensive injuries of the face associated with great loss of substance are often repaired in a most remarkable manner, as has been illustrated in gunshot wounds where a considerable portion of the face and upper jaws has been blown away. The low mortality after severe injuries to the face is due, however, not only to the excellent powers of repair the part possesses, but also to the fact that the face contains no organs essential to life, that its bones are soft and thin and do not favour extensive splitting, and that there are several passages and cavities in the region through which discharges may escape. One of the most terrible instances of injury not immediately fatal is reported by Longmore: "An officer of Zouaves, wounded in the Crimea, had his whole face and lower jaw carried away by a ball, the eyes and tongue included, so that there remained only the cranium, supported by the neck and spine." He lived twenty hours.

The pulsations of the facial artery can be best felt at the lower border of the jaw, where the vessel crosses just in front of the anterior border of the masseter

muscle. It is here covered only by the integument and platysma, and can be readily compressed against the bone or ligatured. The anastomoses of the artery upon the face are so free that when the vessel is divided both ends, as a rule, require to be secured. The facial vein is only in contact with the artery near the lower border of the jaw; on the face it is separated from it by a considerable interval. The vein is not so flaccid as are most superficial veins; it remains more patent after section, it possesses no valves, and communicates at one end indirectly with the cavernous sinus, and at the other with the internal jugular vein in the neck. This vein has also another, but less direct, communication with the intracranial veins. It is as follows: the facial vein receives the "deep facial vein" from the pterygoid plexus, and this plexus communicates with the cavernous sinus by means of some small veins which pass through the foramen ovale and the fibrous tissue of the foramen lacerum medius. These dispositions of the facial vein may serve to explain the mortality of some inflammatory affections of the part. Thus carbuncle of the face is not unfrequently fatal by inducing thrombosis of the

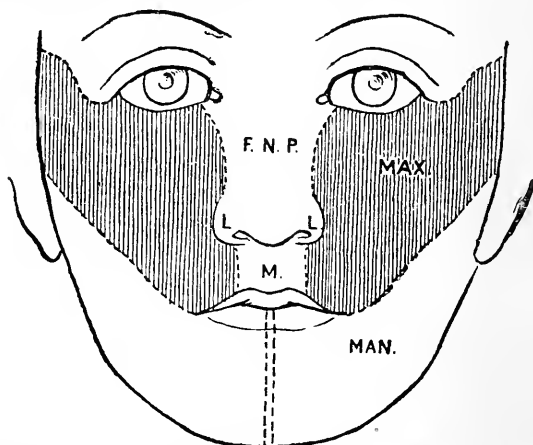


Fig. 17.—Showing the Development of the Face. (*Modified from Merkel.*)

F.N.P., Part formed from the fronto-nasal process; L., from its lateral and M., from its mesial parts; MAX., formed by the maxillary process; MAN., formed by the mandibular process.



cerebral sinuses, and a like complication may occur in any other diffuse and deeply extending inflammatory condition. The unusual patency also of the facial vein favours septic absorption, and its direct communication with the great vein in the neck may explain those abrupt deaths from thrombosis that have followed upon the injection of facial nævi in infants.

A reference to the development of the face assists to explain the distribution of the fifth nerve and the occurrence of certain abnormalities (Fig. 17). The face is developed from five processes, a mesial—the fronto-nasal, and two lateral—the maxillary and mandibular. The fronto-nasal process forms the middle part of the upper lip and the nose. It may fail to develop when the condition of cyclops is produced. It springs from the frontal region and carries with it a branch of the first division of the fifth, the nasal nerve. The second division of the fifth is the nerve of the maxillary process, while the third is that of the mandibular.

**Nerve supply.**—The nerves of the face are very liberally distributed, the fifth being the sensory nerve, the facial the motor. It follows, from the great number of nerve filaments about the part, and the extensive sensory nucleus of the fifth nerve, that severe irritants applied to the face may set up a widespread nerve disturbance. Dr. George Johnson mentions a case where a piece of flint embedded in a scar on the cheek set up facial neuralgia, facial paralysis, and trismus, and induced a return of epileptic attacks. The positions of the supra- and infra-orbital foramina and of the mental foramen are indicated as follows. The supraorbital foramen is found at the junction of the inner with the middle third of the upper margin of the orbit. A straight line drawn downwards from this point so as to cross the gap between the two bicuspids in both jaws will hit both the infraorbital and mental foramina. The infraorbital foramen is a little over  $\frac{1}{4}$  of an inch below the margin of the orbit. The mental foramen in the adult is midway between the alveolus and the lower border of the jaw, and is a little over  $\frac{1}{4}$  of an inch below

the *cul-de-sac* of mucous membrane between the lower lip and jaw. At puberty the foramen is nearer to the lower border of the maxilla, and in old age it is close to the alveolus. The *infraorbital nerve* has been divided for neuralgia at its point of exit, the nerve being reached either by external incision or through the mouth by lifting up the cheek. In other cases the floor of the orbit has been exposed, the infraorbital canal (the anterior half of which has a bony roof) has been opened up, and large portions of the trunk of the nerve have been in this way resected. *Meckel's ganglion* has been repeatedly excised for the relief of neuralgia involving the second division of the fifth nerve. A triangular flap of skin is turned up from the front of the cheek, and the infraorbital canal is exposed. The anterior wall of the antrum is opened with a trephine, and the bone is cut away from the floor of the infraorbital groove so that the nerve lying in that canal is fully exposed. The nerve is followed back to the posterior wall of the antrum. This wall having been trephined, the sphenomaxillary fossa is opened up and Meckel's ganglion exposed. Beyond the ganglion the foramen rotundum can be made out. The infraorbital artery runs with the nerve, and that vessel, together with its anterior dental branch to the incisor and canine teeth, will probably be divided. The infraorbital vein ends in the pterygoid plexus. The ganglion is surrounded by the terminal branches of the internal maxillary artery. It is a triangular body, with a diameter of about  $\frac{1}{3}$  of an inch. It is a little convex on its outer side, and is of a reddish colour.

The following are the relations of the ganglion in the sphenomaxillary fossa :—

*Above.*

The second division of the fifth nerve.

*Outer side.*

Termination of internal maxillary artery.  
External pterygoid muscle.

**Meckel's  
ganglion.**

*Inner side.*

Vertical plate of palate.  
Spheno-palatine foramen.

*Behind.*

Vidian canal.  
Sphenoid bone.

*The inferior dental nerve* has been divided at the mental foramen by an incision made through the mucous membrane. Through this incision the nerve can be stretched and the cutaneous portion of it excised. Its trunk has been reached, and a part excised, through a trephine hole made in the body of the lower jaw. This operation, however, inflicts great damage upon the bone, and cannot be recommended. The artery, moreover, is liable to be wounded.

The nerve has been divided also before its entry into the mental foramen in the following manner. The mouth being held widely open, an incision is made from the last upper molar to the last lower molar just to the inner side of the anterior border of the coronoid process. The cut passes through the mucous membrane down to the tendon of the temporal muscle. The finger is introduced into the incision, and passed between the ramus of the jaw and the internal pterygoid muscle until the bony point is felt that marks the orifice of the dental canal. The nerve is here picked up with a hook, isolated, and divided.

*The buccal nerve* may be the seat of severe neuralgia, and may be thus divided through the mouth: "The surgeon places the finger-nail upon the outer lip of the anterior border of the ascending ramus of the lower jaw at its centre, and divides in front of this border the mucous membrane and the fibres of the buccinator vertically. He then seeks for the nerve, separating the tissues with a director, and divides it" (Stimson).

*The trunk of the third division of the fifth nerve* has been divided at the foramen ovale through a flap wound made in the cheek. Considerable damage of the soft parts results.

After section of a branch of the fifth nerve the area of anæsthesia is surprisingly small. When the first or ophthalmic division has been cut, only a narrow strip of skin above the eyebrow is destitute of the sense of touch, while the area insensitive to pain and temperature is slightly wider. Owing to the overlapping of neighbouring nerves the area is much less than the anatomical

distribution of the ophthalmic nerve. If the second division is cut, the area of anæsthesia is confined to a narrow space between the orbit and the mouth; on section of the third division, to a strip running downwards in front of the ear and along the course of the lower jaw (Head).

*Excision of the Gasserian ganglion.*—For cases of intolerable and intractable neuralgia Rose proposed the excision of the Gasserian ganglion. It is the sensory ganglion of the fifth nerve, and corresponds to the ganglion on the posterior root of a spinal nerve. The nerve fibres of the fifth necessarily undergo degeneration when it is excised.

The operation usually performed is the following: An omega-shaped flap of skin is raised from the temples, having the zygoma at its base and the temporal ridge at its convexity. The tissues are reflected down to the floor of the temporal fossa. The superficial and deep temporal vessels have to be tied. A wide trephine opening is made in the squamosal and great wing of the sphenoid on a level with the upper border of the zygoma and the dura mater exposed. This is usually followed by a profuse hæmorrhage from the middle meningeal vessels which cross the field of operation. The dura mater and the superimposed temporo-sphenoidal lobe are raised from the bone, when the third and second divisions of the fifth nerve are brought into view as they escape by the foramen ovale and foramen rotundum. They are seen to spring from the Gasserian ganglion situated over the apex of the petrous bone and on the outer wall of the cavernous sinus. The motor root which supplies the muscles of mastication lies under the ganglion and should not be cut. The ganglion is embedded in the dura mater and surrounded by a prolongation of the subarachnoid space (Meckel's space), which is necessarily opened. Only the part of the ganglion connected with the second and third divisions is removed, the part connected with the ophthalmic division being left, as it is firmly embedded in the outer wall of the cavernous sinus and in close proximity to

the internal carotid artery and oculo-motor nerves. The hippocampal convolution containing the olfactory centres lies immediately over the ganglion.

The **malar bone**.—Such is the firmness of this bone, and so direct is its connection with the skull, that violent blows upon it are very apt to be associated with concussion. Resting as it does upon comparatively slender bones, it is very rare for the malar bone to be broken alone. It may, indeed, be driven into the superior maxillary bone, fracturing that structure extensively, without being itself in any way damaged. A fracture of the malar bone may lead to an orbital ecchymosis, precisely like that which often attends a fracture of the skull base.

2. The **parotid region**.—The main part of the parotid gland is lodged in a definite space behind the ramus of the lower jaw (Fig. 18). This space is increased in size when the head is extended, and when the inferior maxilla is moved forwards, as in protruding the chin. In the latter movement, the increase in the antero-posterior direction is equal to about  $\frac{2}{3}$  of an inch. It is diminished when the head is flexed. When the mouth is widely opened the space is diminished below, while it is increased above by the gliding forwards of the condyle. These facts should be borne in mind in operating upon and in exploring the parotid space. It will be found also that in inflammation of the parotid much pain is produced by all those movements that tend to narrow the space occupied by the gland. The obliquity of the ramus of the jaw in infancy and old age causes the lower part of the space to be, in the former instance relatively and in the latter instance actually, larger than it is in the adult.

The gland is closely invested by a *fascia* derived from the cervical fascia. The superficial layer of the parotid fascia is very dense, is continuous behind with the fibrous sheath of the sterno-mastoid, and in front with that of the masseter. Above it is attached to the zygoma, while below it joins the deep layer. The deep layer is slender, is attached to the styloid process,

forms the stylo-maxillary ligament, and is connected with the sheaths of the pterygoid muscles and the

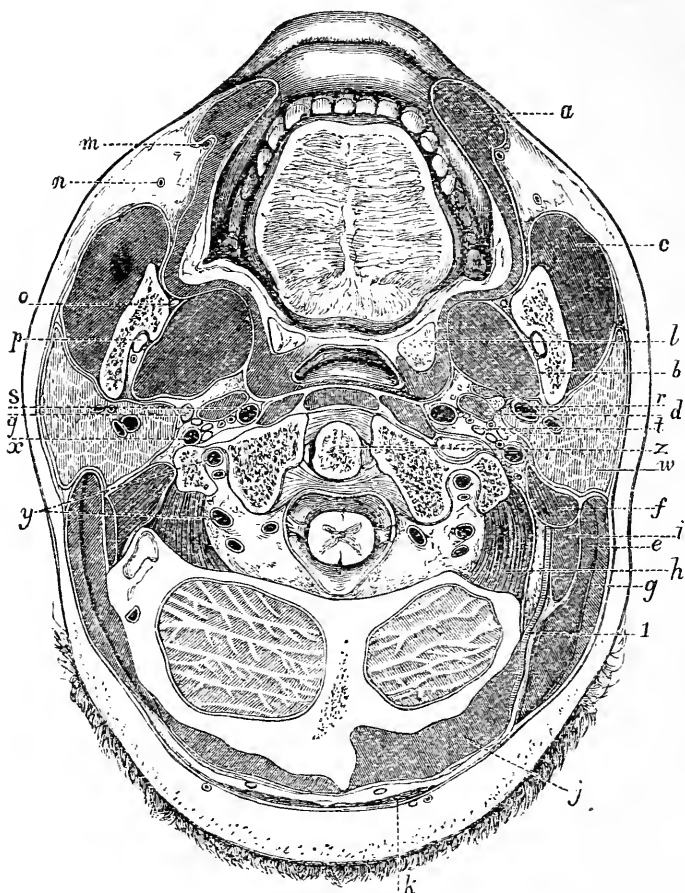


Fig. 18.—A Horizontal Section through the Face and Neck just above the level of the Lower Teeth (Braune).

*a*, Orbicularis oris and, behind it, the buccinator; *b*, internal pterygoid; *c*, masseter; *d*, stylo-glossus, stylo-pharyngeus, and styloid process; *e*, splenius capitis; *f*, digastric; *g*, sterno-mastoid; *h*, obliquus superior; *i*, trachelo-mastoid; *j*, biventer cervicis and complexus; *k*, trapezius; *l*, tonsil; *m*, facial artery; *n*, facial vein; *o*, gustatory nerve; *p*, inferior dental nerve and artery; *q*, styloid process; *r*, external carotid artery; *s*, internal carotid artery; *t*, vagus; *u*, parotid gland; *x*, internal jugular vein, with the vagus, spinal accessory, and hypo-glossal nerves to its inner side; *y*, vertebral artery; *z*, odontoid process; *1*, occipital artery.

pterygoid process. The gland is, therefore, encased in a distinct sac of fascia, which is entirely closed below, but is quite open above. Between the anterior edge of the styloid process and the posterior border of the external pterygoid muscle there is a gap in the fascia, through which the parotid space communicates with the connective tissue about the pharynx. It is well known that in post-pharyngeal abscesses there is very usually a parotid swelling, and in several instances the pus, or at least some portion of it, has been evacuated in the parotid region. In these cases the matter most probably extends from the pharyngeal to the parotid region through the gap just described. From the disposition of the fascia it follows that very great resistance is offered to the progress of a *parotid abscess* directly outwards through the skin. The abscess often advances upwards to the temporal, or zygomatic fossæ, in the direction of least resistance, although progress in that line is resisted by gravity. It frequently makes its way towards the buccal cavity or pharynx, or it may break through the lower limits of the fascia and reach the neck. It must be borne in mind that the gland is in direct contact with the cartilaginous meatus, with the ramus of the jaw and other bony parts, and is closely related with the temporo-maxillary joint. Thus, a parotid abscess has burst into the meatus, has led to periostitis of the bones adjacent to it, and has incited inflammation in the joint of the lower jaw.

In several cases reported by Virchow the pus appears to have found its way into the skull along branches of the fifth nerve, for the environs of the Gasserian ganglion were found infiltrated with pus. The auriculo-temporal and great auricular nerves supply the gland with sensation, and the presence of these nerves, together with the unyielding character of the parotid fascia, serves to explain the great pain felt in rapidly growing tumours and acute inflammation of the gland. The pain is often very distinctly referred along the course of the auriculo-temporal nerve. Thus, a patient with parotid growth recently under my care had pain in

those parts of the pinna and temple supplied by the nerve, pain deep in the meatus, at a spot that would correspond to the entrance of the meatus branch of the nerve, and pain in the joint of the lower jaw, which is supplied by the auriculo-temporal.

*The most important structures in the gland* are the external carotid artery, with its two terminal branches, and the facial nerve. The artery, as Tillaux has pointed out, is behind the ramus of the jaw, as high up as the junction of the inferior with the middle third of its posterior border. It then enters the parotid gland, and, passing a little backwards and outwards, comes nearer to the surface, and at the level of the condyle of the jaw breaks into its two terminal branches. The artery, therefore, does not enter the gland at its inferior border, and is not in actual relation with the parotid space at its lowest part. The vessel, moreover, is not parallel with the edge of the ramus, but passes through the parotid gland with some obliquity.

*The facial nerve* is represented by a line drawn across the gland, in a direction forwards and a little downwards from the spot where the anterior border of the mastoid process meets the ear. The nerve is not quite so intimately bound up in the gland as is the carotid artery, and in rapidly growing tumours of the gland facial paralysis from pressure upon this nerve is not uncommon.

The nerve has been stretched close to its point of exit from the stylo-mastoid foramen for the relief of facial tic. It is best found at a spot about  $\frac{1}{4}$  of an inch in front of the centre of the anterior border of the mastoid process. It will be found above the posterior belly of the digastric, which serves as a guide to it in the depth of the wound.

It follows, from the complex relations of the parotid, that its entire removal as a surgical procedure is an anatomical impossibility. In opening a *parotid abscess* a cut is usually made over the angle of the jaw, and a director pushed upwards into the substance of the gland, after the plan advised by Hilton. The gland



is separated by a mere layer of fascia from the internal carotid artery, the internal jugular vein, the vagus, glosso-pharyngeal, and hypoglossal nerves (Fig. 18). Thus, in stabs in the parotid region it may be difficult at first to tell whether the internal or the external carotid is wounded. It has been suggested that the cerebral hyperæmia sometimes noticed in severe parotitis (mumps) may be due to the pressure of the enlarged gland upon the internal jugular vein.

*Tumours of the parotid* are very apt to contain cartilaginous tissue. It is well known that metastases after mumps are quite common in the testis. It is significant in this connection that the testis is one of the few parts of the body, apart from bone, where cartilaginous matter forms a frequent constituent of the neoplasms of the part. Mr. Paget has pointed out that inflammation of the parotid is peculiarly frequent after injuries and diseases of the abdomen and pelvis. It occurs also very often as a sequela of some specific fevers, but more especially after typhoid. The anatomical or physiological basis of this connection has not been made out.

Many lymphatic glands are placed upon the surface and in the substance of the parotid gland. They receive lymph from the frontal and parietal regions of the scalp, from the orbit, the posterior part of the nasal fossæ, the upper jaw, and the hinder and upper part of the pharynx. When enlarged these glands may form one species of "parotid tumour."

**Stenson's duct** is about two and a half inches long, and has a diameter of  $\frac{1}{8}$ th of an inch, its orifice being the narrowest part. At the anterior border of the masseter muscle the duct bends suddenly inwards to pierce the buccinator muscle. The bend is so abrupt that the buccal segment of the duct may be almost at right angles with the masseteric. This bend should be taken into consideration in passing a probe along the duct from the mouth. The duct opens on the summit of a papilla placed on a level with the second upper molar tooth. The course of the duct across

the masseter is represented by a line drawn from the lower margin of the concha to a point midway between the ala of the nose and the red margin of the lip. It lies about a finger-breadth below the zygoma, having the transverse facial artery above it and the infra-orbital branches of the facial nerve below it. The duct has been ruptured subcutaneously, leading to extravasations of saliva. Wounds of the duct are apt to lead to salivary fistulæ. When the fistula involves the buccal segment of the duct it may be cured by opening the duct into the mouth on the proximal side of the fistula. Fistulæ of the masseteric segment are, on the other hand, very difficult to relieve. At least one-half of the buccal part of the duct is embedded in the substance of the buccinator muscle. A salivary fistula over the masseter may involve the parotid gland itself, or that part of it known as the *socia parotidis*. Inflammatory conditions may spread to the parotid from the mouth along Stenson's duct.

3. The **upper and lower jaws**, and parts connected with them.

The **superior maxilla** (for antrum, *see* Nose, page 93; for hard palate, *see* Mouth, page 127).—This bone, on account of its fragility and the manner in which it is hollowed out, is very readily fractured. The fracture may be due to direct violence, as by a blow from a "knuckle-duster," or it may be broken by a force transmitted from the lower jaw through the teeth, as in cases of severe blows or falls upon the chin. It may be broken by a blow upon the head, when the chin is fixed, no other bone being damaged; and, lastly, it may be crushed, as above stated, by the driving in of the malar bone. The displacement of the fragments depends upon the direction and degree of the force employed, no muscles having effect. The bone being very vascular, serious injuries, involving great loss of substance, are often wonderfully repaired. Its hollowness and the cavities that it helps to bound render it possible for large foreign bodies to be retained in the deeper parts of the face. Thus, Longmore reports "the case of

Lieutenant Fretz, of the Ceylon Rifles, who was able to do his military duties for nearly eight years with the breech and screw of a burst musket lodged in the nares, part of the tail-pin and screw protruding through the hard palate into the mouth." The bone may undergo extensive necrosis, especially in that form of necrosis induced in workers in match factories by exposure to the fumes of phosphorus. In one case (*Med. Times*, 1862) of necrosis following measles the mischief was limited to the pre-maxillary, or incisive bone.

The periosteum of the superior maxilla is, like the pericranium, not disposed to form new bone. In ordinary cases of necrosis of the upper jaw no reproduction of bone takes place, the gap being left permanent. In the lower jaw abundant new bone is produced by the periosteum, and extensive losses may be repaired. It is remarkable, however, that in course of years this new bone is liable to be very extensively reabsorbed.

**Excision of the superior maxilla.**—The entire bone has been frequently removed when the seat of an extensive tumour, and under certain other conditions. The *bony connections* to be divided in the operation are the following: (1) The connection with the malar bone at the outer side of the orbit; (2) the connection of the nasal process with the frontal, nasal, and lachrymal bones; (3) the connections of the orbital plate with the ethmoid and palate (this plate is often left behind, or is cut through near the orbital margin); (4) the connection with the opposite bone and the palate in the roof of the mouth; and (5) the connection behind with the palate bone, and the fibrous attachments to the pterygoid processes. In the four first-named instances the separation is effected by a cutting instrument; in the last-named, by simply twisting out the bone. *Soft parts divided*: These may be considered under three heads: The parts cut (1) in the first incision; (2) in turning back the flap; and (3) in separating the bone.

(1) The following are the parts cut in order from above downwards in the usual, or "median," incision,

an incision commencing parallel with the lower eyelid, and continued down the side of the nose, round the ala, and through the middle of the upper lip: Skin, superficial fascia, orbicularis palpebrarum, palpebral branches of infraorbital nerve and artery, part of lev. labii superioris, angular artery and vein, lev. labii sup. alæque nasi, lateralis nasi artery and vein, nasal branches of infraorbital nerve, compressor naris, depressor alæ nasi, attachment of nasal cartilage to bone, orbicularis oris, sup. coronary artery and vein, and mucous membrane of lip. Various branches of the facial nerve to the muscles may be cut. (2) In turning back the flap, the muscles above named will be dissected up, together with the tendo oculi, if the nasal process is removed entire, the levator anguli, the buccinator, a few fibres of the masseter, and, on the orbital plate, the inferior oblique muscles. The infra-orbital nerve and artery will be cut as they leave their foramen. In the flap itself will be the trunks of the facial artery and vein, the transverse facial artery, and the facial part of the facial nerve. (3) In separating the nasal process the lachrymal sac and infratrochlear nerve will be damaged, and the nasal duct and external branch of the nasal nerve cut across. In separating the bones below, the coverings of the hard palate are divided, and the attachment of the soft palate to the palate bone, unless the removal of that process can be avoided. "Any attempt to dissect off and preserve the soft covering of the hard palate is futile" (Heath). Posteriorly, the trunk of the infraorbital nerve is again divided (this time in front of Meckel's ganglion), together with the posterior dental and infraorbital arteries, and some branches of the spheno-palatine artery. The deep facial vein from the pterygoid plexus will probably be cut, and, lastly, near the palate will also be divided the large palatine nerve and the descending palatine artery.

It will be seen that no large artery is divided in the operation. The inferior turbinated bone comes away of course, with the maxilla.

The **inferior maxilla; fracture.**—This bone is to a great extent protected from fracture by its horse-shoe shape, which gives it some of the properties of a spring, by its density of structure, by its great mobility, and by the buffer-like interarticular cartilages that protect its attached extremities. The bone is usually broken by direct violence, and the fracture may be in any part. The symphysis is rarely broken, on account of its great thickness. The ramus is protected by the muscular pads that envelop its two sides, and the coronoid process is still more out of the risk of injury, owing to the depth at which it is placed and the protection it derives from the zygoma. The weakest part of the bone is in front, where its strength is diminished by the mental foramen and by the large socket required for the canine tooth. It is about this part, therefore, that fracture is the most common. The bone may be broken near, or even through, the symphysis by indirect violence, as by a blow or crushing force that tends to approximate the two rami. Thus, the jaw has been broken near the middle line by a blow in the masseteric region. The amount of displacement in fractures of this bone varies greatly, and is much influenced by the nature and direction of the force. In general terms, it may be said that when the body of the bone is broken the anterior fragment is drawn backwards and downwards by the jaw depressors, the digastric, mylo-hyoid, genio-hyoid, and genio-hyo-glossus; while the hinder fragment is drawn up by the elevators of the jaw, the masseter, internal pterygoid, and temporal. It must be remembered that the mylo-hyoid muscle will be attached to both fragments, and will modify the amount of displacement. Fractures of the ramus are seldom attended with much displacement, muscular tissue being nearly equally attached to both fragments.

In fractures of the body of the bone the dental nerve often marvellously escapes injury, a fact that is explained by the supposition that the bones are not usually sufficiently displaced to tear across the nerve. Weeks after the accident, however, the nerve has become

so compressed by the developing callus as to have its function destroyed.

One, or both, condyles have often been broken by falls or blows upon the chin. The gums being firm and adherent, it follows that they are usually torn in fractures of the body of the maxilla, and hence the bulk of the fractures in this part are compound.

The **temporo-maxillary articulation** is supported by a capsule which varies greatly in thickness in different parts. By far the thickest part of the capsule is the external part (the external lateral ligament). The internal part is next in thickness, while the anterior and posterior portions of the capsule are thin, especially the former, which is very thin. Thus, when this joint suppurates, the pus is least likely to escape on the external aspect of the articulation, and is most likely to find an exit through the anterior part of the capsule, although this part is to a great extent protected by the attachments of the external pterygoid muscle. Immediately behind the condyle of the jaw are the bony meatus and, a little to the inner side, the middle ear. In violent blows upon the front of the jaw these structures may be damaged, and it is interesting to note that the strongest ligament of the joint (the external lateral) has a direction downwards and backwards, so as to immediately resist any movement of the condyle towards the slender wall of bone that bounds the meatus and tympanum. Were it not for this ligament, a blow upon the chin would be a much more serious accident than it is at present.

It follows, from the proximity of the joint to the middle ear, that disease in the articulation may be set up by suppuration in this part. In one case (Holmes' "System of Surgery"), suppurative disease, spreading from the middle ear, not only involved the joint, but induced necrosis of the condyle of the lower jaw. The necrosed condyle was removed entire from the auditory meatus, into which cavity it had projected.

**Dislocation.**—This joint permits only of one form of dislocation, a dislocation forwards. It may

be unilateral or bilateral, the latter being the more usual, and it can only occur when the mouth happens to be wide open. Indeed, the dislocation is nearly always due to spasmodic muscular action when the mouth is open, although in some few cases it has been brought about by indirect violence, as by a downward blow upon the lower front teeth, the mouth being widely opened. It has occurred during yawning, violent vomiting, etc. In more than one case the accident happened while a dentist was taking a cast of the mouth. Hamilton quotes a bilateral dislocation in a woman during the violent gesticulations incident to the pursuit of scolding her husband. When the mouth is widely opened, the condyles, together with the interarticular fibro-cartilage, glide forward. The fibro-cartilage extends as far as the anterior edge of the eminentia articularis, which is coated with cartilage to receive it. The condyle never reaches quite so far as the summit of that eminence. All parts of the capsule save the anterior are rendered tense. The coronoid process is much depressed. Now if the external pterygoid muscle (the muscle mainly answerable for the luxation) contract vigorously, the condyle is soon drawn over the eminence into the zygomatic fossa, the interarticular cartilage remaining behind. On reaching its new position it is immediately drawn up by the temporal, internal pterygoid, and masseter muscles, and is thereby more or less fixed. A specimen in the Musée Dupuytren shows that the fixity of the luxated jaw may sometimes depend upon the catching of the apex of the coronoid process against the malar bone.

**Subluxation of the jaw** is a name given to a slight and quite incomplete dislocation of the jaw not infrequently met with in delicate women. It is due to a displacement of the interarticular cartilage, and can be cured by exposing the cartilage and attaching it by suture to the fibrous structures around the joint (Annandale).

**Excision of the inferior maxilla.**—Considerable portions of the lower jaw can be excised through

the mouth without external wound. In excising one entire half of the maxilla a cut is made vertically through the lower lip down to the point of the chin, and is then continued back along the inferior border of the jaw, so as to end near the lobule of the ear, after having been carried vertically upwards in the line of the posterior border of the ramus. The soft parts divided may be considered under three heads: Those concerned (1) in the first incision; (2) in clearing the outer surface of the bone; (3) in clearing the inner surface of the bone.

1. (a) In the anterior vertical cut: Skin, etc., orbicularis oris, inferior coronary and inferior labial vessels, branches of submental artery, levator menti, mental vessels and nerve, some radicles of anterior jugular vein. (b) In the horizontal cut: Skin, etc., platysma, branches of superficial cervical nerve, branches of supramaxillary part of facial nerve, facial artery and vein at edge of masseter, and inframaxillary branch of facial nerve (not necessarily divided). (c) The posterior vertical incision would not go down to the bone, and would merely expose the surface of the parotid gland and part of posterior border of masseter muscle.

2. In clearing the outer surface the following parts are dissected back: Levator menti, the two depressor muscles, buccinator, masseter (crossed by part of parotid gland, transverse facial vessels, facial nerve and Stenson's duct), masseteric vessels and nerve, temporal muscle.

3. In clearing the inner surface: Digastric, genio-hyoid, genio-hyo-glossus, and mylo-hyoid muscles, a few fibres of superior constrictor, internal pterygoid muscle, inferior dental artery and nerve, mylo-hyoid vessels and nerve, internal lateral ligament, rest of insertion of temporal muscle, mucous membrane.

*Parts in risk of being damaged.*—The facial nerve, if the posterior vertical incision be carried too high up. The internal maxillary artery, temporo-maxillary vein, auriculo-temporal nerve (structures all closely related to the jaw condyle), external carotid artery, lingual



nerve, the parotid, submaxillary, and sublingual glands. After subperiosteal resection the entire bone has been reproduced.

**Deformities.**—The lower jaw may be entirely absent, or may be of dwarfed dimensions, or be incompletely formed. These conditions are congenital, and depend upon the defective development of the mandibular or first visceral arch, out of which the lower jaw is formed (Fig. 17). They are often associated with branchial fistulæ, supernumerary ears, macrostoma, and like congenital malformations.

With regard to the **nerves** connected with the jaws, little need be said. The upper teeth are supplied by the second division of the fifth, the lower by the third. Some remarkable nerve disturbances have followed, by reflex action, upon irritation of the dental nerves. Thus cases of strabismus, temporary blindness, and wry-neck have been reported as due to the irritation of carious teeth. Hilton gives the case of a man who was much troubled by a carious tooth in the lower jaw (supplied by the third division of the fifth), and who developed a patch of grey hair over the region supplied by the auriculo-temporal nerve (a branch also of the third division).

Caries of the teeth is frequently associated with areas of hyperæsthesia on the side of the face and neck. The dental and cutaneous nerves of these areas are connected centrally, and to these areas pain is referred. Disease of the peri-dental membrane does not give rise to referred pains (Head).

The **muscles of mastication** are often attacked by spasm. When the spasm is clonic the chattering of the teeth is produced that is so conspicuous a feature in rigor. When the spasm is tonic the mouth is rigidly closed, and the condition known as trismus, or lockjaw, is produced. Trismus is amongst the first symptoms of tetanus. It is also very apt to be produced by irritation of any of the sensory branches of the third division of the fifth, since the motor nerve supply of the muscles themselves is derived from that trunk. Thus trismus

is very common in caries of the *lower* teeth, and during the "cutting" of the *lower* wisdom tooth. It is much less common in affections of the upper set of teeth, since they are supplied by a more remote division of the fifth nerve.

**Teeth.**—As a test of age the following periods for the eruption of teeth are given by Mr. C. Tomes: *Temporary teeth*: Lower central incisors, six to nine months; upper incisors, ten months; lower lateral incisors, and four first molars, a few months later; then, after a rest of four or five months, the canines; and, lastly, the second molars; the whole being in place by the end of the second year. *Permanent teeth*: First molars, sixth or seventh year; next in order the lower central incisors, then the upper central incisors, and a little later the laterals, the eighth year; first bicuspid, ninth or tenth year; second bicuspid and canines, about the eleventh year, the lower preceding the upper; the second molars, the twelfth or thirteenth year; the wisdom teeth, eighteen to twenty-five or later.

An **alveolar abscess** is an abscess about the fang of a tooth. In the case of single-fanged teeth the pus may escape along the groove of the fang. With other teeth the pus tends to pierce the alveolus. If the point of the fang is within the reflection of the mucous membrane from the gum to the cheek the abscess will break into the mouth, but if the point of the fang is without that reflection, or if the pus can gravitate without the line of the reflection, then the pus may break through the cheek. Alveolar abscess of the upper incisors and canines never breaks through the cheek. When connected with the upper molars it sometimes does. When connected with any of the lower teeth the abscess may find its way through the skin of the cheek.

The upper wisdom tooth is developed in the posterior border of the upper jaw, and the lower wisdom on the inner aspect of the ascending ramus. They may fail to come into position or remain buried. They may give rise to an abscess which frequently points in the neck, at some distance from its seat of origin.

## CHAPTER VIII.

## THE MOUTH, TONGUE, PALATE, AND PHARYNX.

**THE lips.**—The principal tissues composing the lips have the following relation to one another, proceeding from without inwards: (1) Skin; (2) superficial fascia; (3) orbicularis oris; (4) coronary vessels; (5) mucous glands; and (6) mucous membrane. The free border of the lip is very sensitive, many of the nerves having end bulbs closely resembling tactile corpuscles. The upper lip is supplied with sensation by the second division of the fifth nerve, and the lower lip by the third division. Over these labial nerves a crop of herpes often appears (*herpes labialis*). The free border of the lower lip is more frequently the seat of epithelioma than is any other part of the body. The lips contain a good deal of connective tissue, and may swell to a considerable size when inflamed, or œdematous. They are very mobile, and are entirely free for a considerable extent from bony attachment of any kind. It follows that destructive inflammations of the lips, and such losses of substance as accompany severe burns, produce much contraction and deformity of the mouth. Contracting cicatrices, also, in the vicinity of the mouth are apt to drag upon the lips, everting them or producing kindred distortions. It is fortunate that the laxity of the tissues around the mouth, and the general vascularity of the part, greatly favour the success of the many plastic operations performed to relieve these deformities.

The lips are very vascular, and are often the seat of nævi and other vascular tumours. The coronary arteries are of large size, and their pulsations can generally be felt when the lip is pinched up. These vessels run beneath the orbicularis oris muscle, and are consequently nearer to the mucous membrane than they are to the skin. When the inner surface of the lip is cut against the teeth, as the result of a blow, these

arteries are very apt to be wounded. As such wounds are concealed from view, the consequent hæmorrhage has sometimes given rise to an erroneous diagnosis. Thus, Mr. Erichsen quotes the case of a drunken man, the subject of such a wound, who, having swallowed, and then vomited, the blood escaping from a coronary artery, was for a while supposed to be suffering from an internal injury. As the anastomoses between the arteries of the lip are very free, it is usually necessary to tie both ends of the vessel when it has been cut across.

The mucous glands in the submucous tissue are large and numerous. From closure of the ducts of these glands, and their subsequent distension, result the "mucous cysts" that are so common about the lips. It has been shown (Holmes' "System of Surgery," vol. ii.) that one form of enlarged lip may depend upon a general hypertrophy of these glands in the submucous tissue. "Hare-lip" is noticed below in connection with the subject of cleft palate.

The **buccal cavity**.—The following points may be noticed in the examination of the interior of the mouth. On the floor of the mouth, and on either side of the frænum linguæ, can be observed the sublingual papilla with the openings of Wharton's ducts. The duct of Bartholin (one of the ducts of the sublingual gland) runs along the last part of Wharton's duct, and opens either with it or very near it. Wharton's duct is singularly indistensible, and hence is partly explained the intense pain usually observed when that duct is obstructed by a calculus. The near proximity of this duct to the lingual nerve may serve also to account for the pain in some cases. The submaxillary gland can be made out through the mucous membrane at a point a little in front of the angle of the jaw, especially when the gland is pressed up from the outside. On the floor of the mouth, between the alveolus and the anterior part of the tongue, is a well-marked ridge of mucous membrane, that is directed obliquely forwards and inwards to the sublingual papilla near the frænum. It indicates the position of the sublingual gland, and also,

so far as it goes, the line of Wharton's duct and the lingual nerve. These structures, with the sublingual artery, lie beneath the mucous membrane between the gland and the side of the tongue. The ducts of the sublingual gland, some ten to twenty in number, open into the mouth along the ridge of mucous membrane just referred to. Ranula, a cystic tumour filled with mucous contents, is often met with over the site of the sublingual gland, and is due to the dilatation of one of the gland ducts that has become obstructed, or to an occluded mucous follicle. The mucous membrane of the floor of the mouth, as it passes forward to be reflected on the gums, is attached near to the upper border of the jaw. Here also are situated some mucous glands which may become cystic. The genio-hyo-glossus is attached near the lower border. Between these two parts (the mucous membrane and the muscle) there is, according to Tillaux, a small space lined with squamous epithelium. To this cavity the name is given of the sublingual bursa mucosa. It is constricted in its centre by the frænum linguæ, and is said to be the seat of mischief in "acute ranula."

When the mouth is widely opened the pterygo-maxillary ligament can be readily seen and felt beneath the mucous membrane. It appears as a prominent fold running obliquely downwards behind the last molar teeth. A little below and in front of the attachment of this ligament to the lower jaw, the gustatory nerve can be felt as it lies close to the bone just below the last molar. This nerve is sometimes divided for the relief of pain in cases of carcinoma of the tongue. Mr. Moore's method of dividing it is as follows: "He cuts the nerve about  $\frac{1}{2}$  an inch from the last molar tooth, at a point where it crosses an imaginary line drawn from that tooth to the angle of the jaw. He enters the point of the knife nearly  $\frac{3}{4}$  of an inch behind and below the tooth, presses it down to the bone, and cuts towards the tooth" (Stimson). This nerve, as it lies against the bone, has been crushed by the slipping of the forceps in the clumsy extraction of the lower molar teeth.

The coronoid process of the lower jaw can be easily felt through the mouth, and is especially distinct when that bone is dislocated. It may be noted that a fair space exists between the last molar tooth and the ramus of the inferior maxilla, through which a patient may be fed by a tube in cases of trismus or ankylosis of the jaw.

A congenital dermoid cyst is sometimes found in the floor of the mouth between the tongue and the lower jaw. Such cysts have been supposed to be due to the imperfect closure of the first visceral or post-mandibular cleft.

The **gums** are dense, firm, and very vascular. In the bleeding that follows the extraction of teeth much of the blood is supplied by them. The gums are particularly affected in mercurial poisoning, and are also especially involved in scurvy. In chronic lead-poisoning a blue line often appears along their margins. This is due to a deposit of lead sulphide in the gum tissues, which is thus derived: Food débris collected about the teeth in decomposing produces hydrogen sulphide, which, acting upon the lead circulating in the blood, produces the deposit. The blue line, therefore, is said not to occur in those who keep the teeth clean.

The **tongue**.—On the under surface of the tongue, less than  $\frac{1}{2}$  an inch from the frænum, the end of the ranine vein can be seen beneath the mucous membrane. Two elevated and fringed lines of mucous membrane may be seen on the under surface of the organ converging towards its tip. They indicate the position of the ranine artery, which is more deeply placed than the vein, close to which it lies. It is extremely rare for the tongue to be the seat of congenital defect. The author of the able monograph on the tongue in Holmes' "System of Surgery" has discovered only one instance of congenital absence of the organ. Fournier gives a case where the tongue was so much longer than usual that the chest could be touched with its tip while the head was held erect.

In rare cases the **frænum linguæ** may be

abnormally short, constituting the condition known as "tongue-tie," which is really a very uncommon affection. The frænum when divided should be cut as near the jaw as possible, so as to avoid the ranine vessels. Division of these vessels in relieving tongue-tie has led to fatal hæmorrhage, the bleeding being encouraged by the efforts of sucking. "If the frænum and subjacent muscle fibres be too freely divided, energetic sucking on the part of a hungry child may tear the wound of these very lax tissues farther and farther open, until the tongue, having lost all its anterior support, turns over into the pharynx, and is firmly embraced by the muscles of deglutition, which force it down upon the epiglottis, and the latter upon the larynx, until suffocation is produced" (Holmes' "System of Surgery," vol. ii.). In complete anæsthesia, as in that produced by chloroform, when all the muscular attachments of the tongue are relaxed, the organ is apt to fall back and to press down the epiglottis, so causing suffocation.

The tongue is firm and dense, but contains, nevertheless, a sufficient amount of connective tissue to cause it to swell greatly when inflamed. Foreign bodies may easily be embedded in its substance. In the *Lancet* for 1846 is noted a case where a portion of a fork is said to have been buried in the tongue for thirty-two years. The surface epithelium is thick, and in chronic superficial inflammation of the organ it often becomes heaped up, forming dense opaque layers, *ichthyosis linguæ*, *plaques des fumeurs*, *leucoma*, etc. From the mucous glands, situated chiefly beneath the mucous membrane near the base of the tongue, the mucous cysts are developed that are sometimes met with in this part.

The tongue is very vascular, and is in consequence often the seat of nævoid growths. Its main supply is from the lingual artery. This vessel approaches the organ from the under surface, and as cancer usually shows a tendency to spread towards the best blood supply, it is to be noticed that carcinoma of the tongue nearly always tends to spread towards the deep attachment of the member. At the same time it must be observed

that the main lymphatics follow the same course as the main blood-vessels. The vascularity of the tongue is the great bar to its easy removal, hæmorrhage being the complication most to be dreaded in such operations.

The tongue is well supplied with nerves, that endue it not only with the special sense of taste, but also with common sensation. According to Weber's experiments, tactile sensibility is more acute on the tip of the tongue than it is on any other part of the surface of the body. It should be borne in mind that the lingual nerve supplies the forepart and sides of the tongue for two-thirds of its surface, while the glosso-pharyngeal nerve supplies the mucous membrane at its base, and especially the papillæ vallatæ. In painful affections of the tongue in the district supplied by the lingual nerve, the patient often is troubled with severe pain deep in the region of the meatus of the ear, and an area of skin from the ear along the lower border of the jaw may be tender (Head). The anterior two-thirds of the tongue is a derivative of the mandibular arch, which also forms the anterior boundary of the meatus. Hence the nerve supply of the anterior part of the tongue from the third division of the fifth nerve and the reference of pain to its cutaneous termination. The posterior third of the tongue is derived from the second (hyoid) and third visceral arches and is associated with tender areas in the skin over the larynx (Head). Spasmodic contraction of the masticatory muscles is sometimes found to accompany painful lingual ulcers when involving the region of the gustatory nerve. There would seem to be but little connection between an abscess over the occipital region and wasting of one half of the tongue. But Sir James Paget reports the following case: "A man received an injury to the back of his head that was apparently not severe. In time the right half of the tongue began to waste, and continued to waste until it was less than half the size of the unaltered side. An abscess formed over the occiput, from which fragments of the lower part of the occipital bone were removed. After the removal of all the dead bone the tongue began to recover,



and in one month had nearly regained its normal aspect." Here the atrophy was due to wasting of the lingual muscles produced by pressure upon the hypoglossal nerve, which leaves the skull through the anterior condyloid foramen in the occipital bone. The case illustrates the importance of remembering even small foramina, and the structures they transmit.

The tongue contains much lymphoid tissue, a considerable part of which (the lingual tonsil) is massed under the mucous membrane at the posterior part of the organ. Hypertrophy of this tissue may lead to troublesome symptoms by interference with the proper action of the epiglottis. The lingual and pharyngeal adenoid tissue, with the tonsils proper, form a complete ring of lymphoid tissue round the isthmus of the fauces.

The lymphatics of the tongue are large and numerous, and offer a free channel for the dissemination of cancerous emboli. The tongue is one of the commonest sites for cancer, and the disease commonly affects the anterior two-thirds, which is derived from the mandibular arch. So is the lower lip, which also is a common site. Cancer spreads along the lymphatic vessels, which for the greater part accompany the lingual vein and artery and pour their lymph and emboli in the upper deep cervical glands, behind and below the angle of the jaw. The normal paths are soon choked, and the lymph has to follow circuitous by-paths. The lymphatic glands over the submaxillary gland, the lymphoid tissue in that gland and in the sublingual, become the seats of secondary deposit. The submental gland may also be affected.

In the strange congenital affection known as *macroglossia* the tongue becomes much enlarged, and in some cases may attain prodigious dimensions. Thus, in one case it measured  $6\frac{1}{2}$  inches in length and 10 inches in circumference. It has protruded so far from the mouth as to reach even to the episternal notch. It has been so large as to deform the teeth and alveolus, and in one case dislocated the jaw. The enlargement is primarily due to the greatly dilated condition of the lymphatic channels of the organ (hence the name,

lymphangioma. cavernosum, proposed by Virchow), and to an increased development of lymph tissue throughout the part. The portion most conspicuously affected is the base of the tongue, where the lymphatics are usually the most numerous.

A *dermoid cyst* may be met with on the under surface of the tongue. It is usually placed in the median line between the genio-hyo-glossi muscles. Such cysts are probably due to some infolding of the integumental layer during development.

**Accessory glands about the tongue.**—

Streckeisen states that accessory glands, belonging to the thyroid body, are frequently found in the vicinity of the hyoid bone. Some may be superficial to the mylo-hyoid muscle, others may be just above the hyoid bone, and others in the hollow of that bone. Cysts lined with ciliated epithelium may sometimes be found in the same situations. All these structures are the remains of the neck of the central diverticulum which is protruded from the ventral wall of the pharynx in the embryo, and from which the isthmus and pyramidal parts of the thyroid gland are formed. The *foramen cæcum* on the tongue indicates the spot where this diverticulum leaves the pharynx. It marks the junction of the mandibular with the hyoid part of the tongue. Ducts lined with epithelium have been found leading from the foramen cæcum to accessory glands about the hyoid bone. It is probably from these glandular and epithelial collections about the hyoid bone that certain deep-seated forms of cancer of the neck are developed. Some of these take the form of malignant cysts described by the author (*Path. Soc. Trans.*, 1886).

**Excision.**—Many different methods have been adopted for the removal of the entire tongue. It has been removed through the mouth by the ecraseur or the scissors, the latter operation being performed with or without previous ligature of the lingual arteries in the neck. It is difficult, however, to fully expose the deeper attachments of the organ through the comparatively small orifice of the mouth. To obtain more

room the cheek has been slit up in one procedure, while the lower lip and symphysis of the lower jaw have been divided in another.

In another series of operations the tongue has been reached, or the organ has been fully exposed, by an incision made between the hyoid bone and the inferior maxilla. More recently Kocher has exposed the tongue from the neck, and has reached it by an incision commencing near the ear and following the anterior border of the sterno-mastoid muscle as far as the hyoid bone, whence it turns upwards along the anterior belly of the digastric muscle. This method allows free removal of the upper deep cervical glands, the lymphatic glands, and tissue over and in the submaxillary and sublingual glands which form the seat of secondary cancerous deposits.

In the removal of the entire organ, the following parts are of necessity divided: The frænum, the mucous membrane along the sides of the tongue, the glosso-epiglottic folds, the genio-hyo-glossus, hyo-glossus, stylo-glossus, palato-glossus muscles, the few fibres of the superior and inferior linguales muscles that are attached to the hyoid bone, the terminal branches of the gustatory, glosso-pharyngeal, and hypo-glossal nerves, the lingual vessels, and, at the side of the tongue near its base, some branches of the ascending pharyngeal artery, and of the tonsillar branch of the facial artery.

Bleeding from the stump of the tongue, after removal, can be instantly and almost entirely arrested by pressing the root of the tongue forwards with two fingers passed down behind it into the pharynx. The lingual arteries as they lie divided in the floor of the mouth are difficult to secure. They are embedded in muscle, and appear to be peculiarly brittle.

When both linguals have been ligatured in the neck (through the hyo-glossus muscle) before removing the tongue, bleeding still takes place from the dorsalis linguæ branches of the lingual and from small branches of the ascending pharyngeal and facial arteries.

The **palate**.—The arch of the hard palate varies

in height and shape in different individuals, and it has been said that the arch is particularly narrow and high in congenital idiots. The outline of this arch is of some moment in operations upon the palate.

**Cleft palate.**—The palate is often the seat of a congenital cleft. The cleft is precisely in the middle line. It may involve the uvula or the soft palate alone, or may extend forwards and involve the hard palate as far as the alveolus. If it extend beyond the alveolus, the cleft will leave the middle line and will follow the suture between the superior maxillary bone and the os incisivum, appearing therefore between the incisor and canine teeth. The os incisivum or premaxillary bone is developed with the central part of the upper lip from the fronto-nasal process (Fig. 17, p. 98). Each premaxillary may be developed by two centres, hence the cleft is sometimes between the central and lateral incisor. Sometimes at the end of the cleft the upper lip is fissured (hare-lip). *Hare-lip* is exceedingly rare in the middle line. The slit usually corresponds to the suture just named, and is therefore opposite the interval between the lateral incisor and canine teeth. Sometimes the cleft in the palate on reaching the alveolus will run on either side of the os incisivum, so that that bone is entirely separated from the superior maxilla. Such cases are associated with double hare-lip, and the os incisivum appears as a nodule attached to the nose and suspended in the centre of the gap. The bone in these cases contains, as a rule, the germs only of the central incisors, the lateral incisors having been lost in the cleft. Hare-lip very commonly exists without any cleft of the palate. Except in very rare instances, a cleft of the hard palate will not exist without a cleft of the soft. In some cases the os incisivum may be entirely absent, and then the double hare-lip that exists may appear as a large median gap in the lip. When the hard palate is entirely cleft the edges of the cleft are more or less perpendicular, whereas when the cleft is very slight as regards its antero-posterior length, the palate tends to preserve more or less of its normal curve.

The buccal cavity, when first formed in the fœtus, exists as a wide cleft in the face bounded above by the fronto-nasal process, at the sides by the superior maxillary processes, and below by the first visceral arch, from which the lower jaw is formed (Fig. 17, p. 98). The nasal and buccal cavities are one. "The separation of the cavity of the mouth, strictly so called, from the nasal fossæ, is effected by the development of the palatal or pterygo-palatal processes of the maxillary plate, which, advancing inwards from the two sides, meet and coalesce with each other and with the septum descending from above in the middle line. . . . When the union of the opposite parts takes place, the nasopalatine canal is left as the vestige of the previous fissures. The median union of the palate begins in front about the eighth week in the human embryo, and reaches the back part, when completed, in the ninth and tenth weeks" (Allen Thomson, in Quain's "Anatomy").

In this way the hard and soft palates are formed, and the upper lip completed; and it will be understood that hare-lip and cleft palate depend simply upon imperfect closure of the fœtal gap between the nasal and buccal cavities.

The mucous membrane covering the **hard palate** is peculiar in that it is practically one with the periosteum covering the bones; and, therefore, in dissecting up this membrane the bone is bared, as the mucous membrane and the periosteum cannot be separated. The membrane is thin in the middle line, but is much thicker at the sides near the alveoli, the increased thickness depending mainly upon the introduction of a number of mucous glands beneath the surface layers, such glands being absent in the middle line. The density and toughness of the soft covering of the hard palate render it very easy to manipulate when dissected up in the form of flaps in the operation for the cleft palate.

The main blood supply of both the bones of the hard palate and its mucous covering is derived from the descending palatine branch of the internal maxillary

artery. This vessel, which is practically the only vessel of the hard palate, emerges from the posterior palatine canal near the junction of the hard palate with the soft, and close to the inner side of the last molar tooth. The vessel runs forwards and inwards, to end at the anterior palatine canal. Its pulsations on the palate can often be distinctly felt. In dissecting up muco-periosteal flaps from the hard palate, it is most important to make the incision in the mucous membrane close to, and parallel with, the alveolus, so that this artery may be included in the flap and its vitality therefore not be endangered. By such an incision, also, unnecessary bleeding is avoided. In dissecting up the flap it should be remembered that the artery runs much nearer to the bone than to the mucous surface.

The **soft palate** is of uniform thickness, its average measurement being estimated at about  $\frac{1}{4}$  of an inch. When the soft palate is cleft, the edges of the fissure are approximated during swallowing by the uppermost fibres of the superior constrictor. This approximation may narrow the cleft to one-third or one-half of its previous size. The muscles that tend to widen the cleft are, in the main, the levator palati and tensor palati. It is necessary that these muscles should be divided before attempting to close the cleft by operation. The levator palati crosses the palate obliquely from above downwards and inwards on its way to the middle line, lying nearer to the posterior than the anterior surface of the velum. The tensor palati turns round the hamular process, and passes to the middle line in a nearly horizontal direction. The hamular process can be felt through the soft palate just behind and to the inner side of the last upper molar tooth. There are three principal methods of dividing these muscles: (1) Ferguson's: A small knife, with the blade at right angles to the stem, is passed through the cleft, and is made to divide the levator palati by an incision on the posterior aspect of the palate, transverse to the direction of the muscle. The tensor is not divided in this procedure. (2) Pollock's: A thin narrow

knife, with the cutting edge upwards, is introduced into the soft palate a little in front, and to the inner side of the hamular process. The tendon of the tensor muscle is above the knife, and is cut as the knife is pushed upwards and inwards. The knife is inserted until its point presents at the upper part of the cleft. As it is being withdrawn, it is made to cut the posterior surface of the velum to a sufficient depth to divide the levator palati (Fig. 19). (3) Bryant's: Here the palate muscles are divided by a cut with the scissors that involves the entire thickness of the velum, the cut being at the side of the velum, and nearly parallel with the cleft.

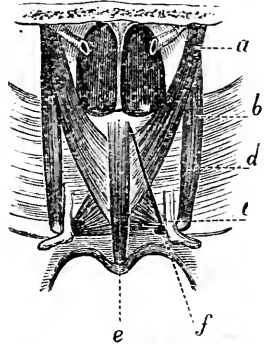


Fig. 19.—The Muscles of the Soft Palate, from behind.

*a*, Levator palati; *b*, tensor palati; *c*, hamular process; *d*, wall of pharynx; *e*, azygos uvulae; *f*, the point of entry of the knife in Pollock's operation; above it is the line of incision made on withdrawing the knife.

The blood supply of the soft palate is derived from the descending palatine branch of the internal maxillary artery, the ascending pharyngeal artery, and the ascending palatine branch of the facial artery. The latter vessel reaches the velum by following the levator palati muscle, and must be divided in the section made of this muscle in the procedures just described.

The muscles of the palate are supplied by several nerves. The levator palati, azygos uvulae, and palatopharyngeus are innervated with the muscles of the pharynx by the spinal accessory; the palatoglossus with the muscles of the tongue from the hypoglossal, and the tensor palati with the tensor tympani from the third division of the fifth nerve through the otic ganglion.

The **pharynx** is about five inches in length. It is much wider from side to side than from before backwards. It is widest at the level of the tip of the greater cornua of the hyoid bone, where it measures about

2 inches. It is narrowest where it joins the gullet opposite the cricoid cartilage, its diameter here being less than  $\frac{3}{4}$  of an inch. The pharynx is not so large a space as supposed, for it must be remembered that during life it is viewed very obliquely, and erroneous notions are thus formed of its antero-posterior dimensions. The distance from the arch of the teeth to the commencement of the gullet is about 6 inches, a measurement that should be borne in mind in extracting foreign bodies. Foreign bodies passed into the pharynx are most apt to lodge at the level of the cricoid cartilage, a point that, in the adult, is a little beyond the reach of the finger. The history of foreign bodies in the pharynx shows that that cavity is very dilatible, and can accommodate for some time large substances. Thus, in a case reported by Dr. Geoghegan, a man of 60, who had for months some trouble in his throat for which he could not account, was supposed to have cancer. On examination, however, a plate carrying five false teeth, and presenting niches for five natural ones, was found embedded in the pharynx, where it had been lodged for five months. The plate had been swallowed during sleep (*Med. Press*, 1866). In the *Lancet* for 1868 is an account of a mutton chop that became lodged in the pharynx of a gluttonous individual. The chop presented the ordinary vertebral segment of bone, together with  $1\frac{1}{2}$  inches of ribs, and was "pretty well covered with meat." Attempts to remove it failed, and it was finally vomited up. Dr. Hicks (*Lancet*, 1884) reports the case of a woman who committed suicide by cramming half a square yard of coarse calico (belonging to her nightdress) into her mouth and throat.

The walls of the pharynx are in relation with the base of the skull, and with the upper six cervical vertebræ. The arch of the atlas is almost exactly on a line with the hard palate. The axis is on a line with the free edge of the upper teeth. The termination of the pharynx corresponds to the sixth cervical vertebra. The upper vertebræ can be examined, as regards their anterior surface, from the mouth. When the



bones about the pharynx are diseased, the necrosed parts may be discharged by that cavity. Thus portions of the atlas and axis have been expelled by the mouth, as also have been some fragments of comparatively large size thrown off by the occipital and sphenoid bones.

The mucous membrane of the pharynx is vascular, and readily inflamed; and such inflammations are peculiarly dangerous, in that they may spread to the lining membrane of the larynx. The submucous tissue of the aryteno-epiglottic folds and of the neighbouring part of the pharynx is peculiarly loose, and in cedematous conditions the upper aperture of the larynx may be almost closed. Much adenoid tissue is distributed in the mucous membrane of the pharynx, and it is this tissue that is the primary seat of inflammation in scrofulous pharyngitis. A distinct collection of adenoid tissue stretches across the hinder wall of the pharynx between the openings of the Eustachian tubes. It is known as *Luschka's tonsil*, or the pharyngeal tonsil. This deposit of adenoid tissue may undergo hypertrophic change and the condition known as "adenoid vegetations" or "post-nasal growths" be produced. These growths may cause deafness, and may block the posterior nares. They need to be removed by operation. The lateral recess, behind the opening of the Eustachian tube, also contains adenoid tissue (Fig. 16, p. 89). The tissue immediately outside the pharynx walls is lax, and favours the spread of effusion. Thus, in acute inflammation of the pharynx the effusion has been found to extend along the œsophagus, reaching the posterior mediastinum and advancing even to the diaphragm. In the lax connective tissue between the pharynx and the spine abscess is not infrequent, due, as a rule, to caries of the vertebræ (post-pharyngeal abscess). In this connective tissue, and opposite the axis, is also found a lymphatic gland that receives lymphatics from the nares. This gland may prove the seat of a suppuration. Such collections may so push forward the posterior pharyngeal wall as to depress the soft palate,

or may cause severe dyspnoea by interference with the larynx. The matter may discharge itself through the mouth, or may reach the neck by passing behind the great vessels and the parotid gland, presenting ultimately beneath or at one border of the sterno-mastoid muscle.

Many structures of importance are in relation with the lateral walls of the pharynx, the principal being the internal carotid artery, the vagus, glosso-pharyngeal, and hypoglossal nerves. The internal carotid is so close to the pharynx that its pulsations may be felt by the finger introduced through the mouth. These, and other deep structures in the neck, may be wounded by foreign bodies, that, passing in at the mouth, have been thrust through the pharynx into the cervical tissues. The internal jugular vein is at some distance from the pharynx, especially at its upper part (Fig. 18, p. 104). The styloid process, when prominent, and an ossified stylo-hyoid ligament, can also be felt at the side of the pharynx. In more than one case an ossified stylo-hyoid ligament has been mistaken for a foreign body, and an attempt made to excise it. Langenbeck has three times extirpated the pharynx for malignant disease, but without success. He reaches it from the neck through an incision that, beginning below the jaw, midway between the symphysis and angle, is carried over the great cornu of the hyoid bone, and ends close to the cricoid cartilage. The posterior belly of the digastric and the stylo-hyoid muscles are detached from the hyoid bone, while the omo-hyoid muscle, the lingual, facial, and superior thyroid arteries, and the superior laryngeal nerve are divided.

The **tonsil** is lodged between the anterior and posterior palatine arches. It is in relation externally with the superior constrictor muscle, and corresponds, as regards the surface, to the angle of the lower jaw. It is questionable whether the enlarged tonsil, when it is the subject of other than malignant enlargement, can ever be felt externally. When hypertrophied, the mass tends to develop towards the middle line, where

no resistance is encountered, and to effect but little change in its external relations. The mass, often mistaken for the enlarged tonsil in the neck, is formed of enlarged glands, situate near the tip of the great cornu of the hyoid bone, and overlying the internal jugular vein. These glands receive the tonsillar lymphatics, and are almost invariably enlarged in all tonsil affections. The fact that these glands are so frequently the first to enlarge when the cervical glands become tubercular points to the tonsil as a common site of primary infection. It must be remembered that many structures are interposed between the tonsil and the skin, and as the hypertrophied body projects freely into the pharyngeal cavity, one would not expect that it could be readily felt, even were the interposed tissues less extensive than they are. The tonsil is closely enough attached to the pharyngeal wall to be affected by the movements of the pharyngeal muscles. Thus it is moved inwards by the superior constrictor muscle during the act of swallowing, and may be drawn outwards, on the other hand, by the stylo-pharyngeus muscle. The ease with which a tonsil can be reached depends, other things being equal, upon the extent to which it can be withdrawn by the stylo-pharyngeus, and upon the development of the anterior palatine arch, which, to some extent, hides the tonsil. A child with a prominent anterior palatine arch, containing a well-developed palato-glossus muscle, and with a vigorous stylo-pharyngeus, can for a long time elude the tonsil guillotine.

Deafness is often complained of when the tonsil is hypertrophied. This is not due to closure of the Eustachian tube by the direct pressure of the enlarged mass. Such pressure is anatomically impossible. The large tonsil may, however, affect the patency of the tube, by disturbing the soft palate, and through it the tensor palati muscle, which is much concerned in keeping open the Eustachian tube. The deafness in these cases is probably due rather to an extension of the hypertrophic process to the lining membrane of the tube than to any pressure effects, since it is usually

not improved until some time after the tonsil has been removed. The tonsil tissue is for the most part collected around a number of recesses. The decomposition of retained epithelial structures within those recesses produces the fœtid breath often noticed in cases of enlarged tonsil, and probably incites the attacks of inflammation to which such tonsils are liable. Calculi may form in these crypts and give rise to a spasmodic cough. In this case the glosso-pharyngeal nerve conveys the afferent impulse to the respiratory centre.

The tonsil is very vascular, receiving blood from the tonsillar and palatine branches of the facial artery, from the descending palatine branch of the internal maxillary, from the dorsalis linguæ of the lingual, and from the ascending pharyngeal. Hence the operation of removing the tonsil is often associated with free bleeding. The internal carotid artery is close to the pharynx, but some way behind the gland (Fig. 18, p. 104). The vessel is, indeed, about  $\frac{1}{2}$  of an inch posterior to that body, and is in comparatively little danger of being wounded when the tonsil is excised. The internal jugular vein is a considerable distance from the tonsil. The facial artery, in its cervical stage, is close to the tonsil. Of important cervical structures, the nearest to the tonsil is the glosso-pharyngeal nerve. The ascending pharyngeal artery is also in close relation with it. Although of small size, bleeding from this vessel has proved fatal, as the following interesting case, reported by Mr. Marrant Baker, will show: A man, aged 23, fell when drunk, and grazed his throat with the end of a tobacco-pipe he was smoking at the time. He thought nothing of the accident. In two days he came to the hospital with what appeared to be an acutely inflamed tonsil. The tonsil was punctured, but nothing escaped save a little blood. Several hæmorrhages occurred from the tonsil wound, and on the fourth day after the accident 1 inch of the stem of a clay pipe was discovered deeply embedded in the glandular substance. It was removed, and the common

carotid tied. The patient, however, never rallied from the previous severe hæmorrhages, and soon died. The autopsy showed that the stem of the pipe, which had not been missed by the patient, had divided the ascending pharyngeal artery (*St. Bart.'s Hosp. Reports*, 1876).

The tonsil is often the seat of *malignant growths*. Such tumours have been removed through the mouth, but are more conveniently dealt with through an incision in the neck along the anterior edge of the sternomastoid (Cheever's operation).

---

## CHAPTER IX.

### THE NECK.

**Surface anatomy; bony points.**—The hyoid bone is on a level with the fourth cervical vertebra, while the cricoid cartilage is opposite the sixth. The upper margin of the sternum is on a level with the disc between the second and third dorsal vertebræ. (*See page 169.*) At the back of the neck there is a slight depression in the middle line which descends from the occipital protuberance, and lies between the prominences formed by the trapezius and complexus muscles of the two sides. At the upper part of this depression the spine of the axis can be made out on deep pressure. Below this, the bony ridge formed by the spines of the third, fourth, fifth, and sixth cervical vertebræ can be felt, but the individual spines cannot usually be distinguished. At the root of the neck the spinous process of the vertebra prominens is generally very obvious. The transverse process of the atlas may be felt just below and in front of the tip of the mastoid process. By deep pressure in the upper part of the supraclavicular fossa, the transverse process of the seventh cervical vertebra can be distinguished. If deep pressure be made over the line of the carotid vessels at the level of the cricoid cartilage, the prominent anterior tubercle of the transverse process of the

sixth cervical vertebra can be felt. This is known as the "carotid tubercle." The carotid artery lies directly over it; and in ligaturing that vessel some surgeons make important use of this tubercle as a landmark. If a horizontal section of the neck, in a muscular subject, taken about the level of the sixth cervical vertebra, be viewed, the whole of the body of the vertebra divided will be seen to lie within the anterior half of the section.

The **middle line**.—In the receding angle below the chin the hyoid bone can be felt and its body and greater cornua well made out. About a finger's breadth below it is the thyroid cartilage. The details of this latter are readily distinguished, and below it the cricoid cartilage, crico-thyroid space, and trachea can be easily recognised. The separate rings of the trachea cannot be felt. The trachea is less easily made out, as it passes down the neck. As it descends it takes a deeper position, and at the upper border of the sternum lies nearly  $1\frac{1}{2}$  inches from the surface.

The rima glottidis corresponds to the middle of the anterior margin of the thyroid cartilage.

Unless enlarged, the thyroid gland cannot be made out with certainty. According to Mr. Holden, the pulse of the superior thyroid artery can be felt at its upper and anterior part.

The anterior jugular veins descend on either side of the middle line upon the sterno-hyoid muscles. They commence in the submaxillary region, pierce the fascia just above the inner end of the clavicle, and, passing behind the origin of the sterno-mastoid muscle, are lost to view. The inferior thyroid veins lie in front of the trachea, below the isthmus.

The **side of the neck**.—*Muscles*. The sterno-mastoid muscle, especially in thin subjects and when thrown into action, is a prominent feature in the neck. The anterior border of the muscle is very distinct. The posterior border is less prominent, especially at its upper part. A communicating branch from the facial vein generally runs along the anterior border of the muscle to meet the anterior jugular vein at the lower part of

the neck. The interval between the sternal and clavicular parts of the muscle is generally well marked. If a needle be thrust through this interval, quite close to the clavicle, it would just touch the bifurcation of the innominate artery on the right side and would pierce the carotid vessel on the left. The posterior belly of the digastric muscle corresponds to a line drawn from the mastoid process to the anterior part of the hyoid bone. The anterior belly of the omo-hyoid follows an oblique line drawn downwards from the fore part of the hyoid bone, so as to cross the line of the carotid artery opposite the cricoid cartilage. The posterior belly can be made out in thin necks, especially when in action, running nearly parallel with and just above the clavicle. Although not taking quite the same direction, yet the posterior borders of the sterno-mastoid and anterior scalene muscles practically correspond to one another.

*Vessels.*—The common carotid artery is represented by a line drawn from the sterno-clavicular joint to a point midway between the angle of the jaw and the mastoid process. The vessel bifurcates at the upper border of the thyroid cartilage, or not unfrequently nearly  $\frac{1}{2}$  an inch above that point. The omo-hyoid crosses it opposite the cricoid cartilage, and at about the same level the artery is crossed by the middle thyroid vein. The line of the internal jugular vein is just external to that for the main artery. Both the artery and vein lie under the anterior border of the sterno-mastoid. The superior thyroid artery comes off just below the great cornu of the hyoid bone, and curves forwards and downwards to the upper edge of the thyroid cartilage. The lingual arises opposite the tip of the great cornu, and runs just above that process on its way to the tongue. The facial artery is very tortuous, but its general course in the neck is represented by a line drawn from the anterior border of the masseter at the lower border of the jaw to a point just above the tip of the great cornu, while the occipital follows a line that starts from the latter point and runs across the base of the mastoid process.

The external jugular vein follows a line drawn from the angle of the jaw to the middle of the clavicle.

The subclavian artery describes a curve at the base of the posterior triangle. One end of the curve corresponds to the sterno-clavicular joint, the other end to the centre of the clavicle, the summit of the curve rising to a point about  $\frac{1}{2}$  an inch above that bone. In the angle between the posterior edge of the sterno-mastoid and the clavicle the pulsations of the artery may be felt. Just above the bone the artery may be compressed against the first rib. The compression is most easily applied when the arm is well drawn down, and the direction of the pressure should be downwards and inwards.

The subclavian vein lies below the artery, and is entirely under cover of the clavicle.

The suprascapular and transverse cervical arteries run parallel with the clavicle, the former quite behind the bone, the latter just above it. The pulsations of the latter vessel can generally be felt.

*Nerves.*—The position of the chief superficial nerves of the neck may be fairly indicated by six lines, all drawn from the middle of the posterior border of the sterno-mastoid muscle. A line drawn forwards from this spot so as to cross the sterno-mastoid at right angles to its long axis corresponds to the superficial cervical nerve. A second line drawn up across the muscle to the back of the pinna, so as to run parallel with the external jugular vein, corresponds to the great auricular nerve; and a third line, running along the posterior border of the sterno-mastoid muscle to the scalp, marks the course of the small occipital nerve. These lines, continued downwards, so as to cross the sternum, the middle of the clavicle, and the acromion, will indicate respectively the suprasternal, supraclavicular, and supra-acromial nerves.

The spinal accessory nerve reaches the anterior border of the sterno-mastoid muscle at a point about 1 inch below the tip of the mastoid process. It emerges from beneath that muscle about the middle of its pos-



terior border, crosses the posterior triangle, and passes beneath the trapezius at a point between the middle and lower thirds of the anterior border of that muscle.

The phrenic nerve commences deeply at the side of the neck, about the level of the hyoid bone, and runs downwards to a point behind the sternal end of the clavicle. About the level of the cricoid cartilage it lies beneath the sterno-mastoid (which covers it wholly in the neck) about midway between the anterior and posterior borders of the muscle. The brachial plexus can be felt, and even seen in very thin subjects. Its upper limits may be represented by a line drawn across the side of the neck from a point about opposite to the cricoid cartilage to a spot a little external to the centre of the clavicle.

The **neck**.—The **skin** in the submaxillary region is lax and thin, and is often found of considerable value for making flaps in plastic operations about the mouth. The platysma myoides is closely connected with the skin, and to its action is due the turning-in of the edges of such wounds as are athwart the line of direction of the muscle. The amount of subcutaneous fat in the cervical region varies in different parts. In the suprahyoid region it is apt to undergo extensive development, producing the diffused lipoma known as "double-chin."

The skin over the nape of the neck is very dense and adherent, and these two circumstances, in addition to the free nerve-supply of the parts, serves to explain the severe pain that often accompanies inflammation in this region. Common carbuncle is very commonly met with behind at the root of the neck, in the middle line. Why it especially selects this spot it is difficult to say. It may be noted, however, that this region has no very extensive blood supply, that the middle line of the body is in all parts of comparatively slight vascularity, and that at the nape of the neck covered and uncovered parts of the body meet, so that the spot is liable to considerable fluctuations of temperature. Setons and issues were, in less recent times, often applied to the dense integuments at the back of the neck, just below the occiput.

These measures were accredited with not infrequently producing tetanus.

When the **sterno-mastoid** muscle of one side is rigidly contracted, either from paralysis of the opposite muscle or from spasmodic contraction, or from some congenital defect, the condition known as wry-neck is produced. The position of the head in wry-neck illustrates precisely the effect of the sterno-mastoid when in full action. The head is bent a little forwards, the chin is turned towards the sound side, and the ear on the affected side leans towards the sterno-clavicular joint. In many cases the trapezius and scalene muscles are also affected. Spasmodic contraction of the muscle may be due to reflex irritation. Thus, it has accompanied inflammation of the cervical glands in the posterior triangle. Such inflammation has irritated some branches of the cervical plexus, and the sterno-mastoid muscle, although it is supplied mainly by the spinal accessory nerve, receives a nerve from that plexus (*viz.*, from the second cervical). The course of the reflex disturbance in such cases is therefore not difficult to follow. It is to be remembered, also, that the spinal accessory nerve passes between the upper two or three deep cervical lymph glands which may compress it. A like contraction has also been produced by direct irritation of the second cervical nerve in cases of disease of the first two cervical vertebræ. For the relief of some forms of wry-neck, the sterno-mastoid muscle is divided subcutaneously, as in an ordinary tenotomy operation, about  $\frac{1}{2}$  an inch above its attachment to the sternum and clavicle. Two structures stand considerable risk of being wounded in this operation, *viz.*, the external jugular vein lying near the posterior border of the muscle, and the anterior jugular which follows its anterior border and passes behind the muscle, just above the clavicle, to terminate in the first-named vein. With common care, there should be no risk of wounding the great vessels at the root of the neck. For spasmodic wry-neck the spinal accessory nerve and the communicating branches of the third and fourth cervical nerves

have been cut. The spinal accessory nerve is found at the anterior border of the sterno-mastoid,  $1\frac{1}{2}$  inches below the mastoid process.

There is a curious congenital tumour, or induration, sometimes met with in this muscle in the newly born. It is usually ascribed to syphilis, but, in most cases, is probably due to some tearing of the muscle fibres during the process of delivery.

The **cervical fascia**.—The layers of fascia that occupy the neck, and that are known collectively as the deep cervical fascia, are dense structures, having a somewhat complex arrangement and a great amount of importance from a surgical point of view. This fascia limits the growth of cervical tumours and abscesses, and modifies the direction of their progress, but I do not think that its effect in this matter is quite so definite as is usually maintained. It is true that deep-seated cervical abscesses are often found to follow just such a course as the arrangement of the fasciæ would lead us to suppose, while, on the other hand, instances are by no means uncommon where the abscess or growth appears to ignore these membranes and adopt a course of its own.

The deep cervical fascia may be divided into (*a*) the superficial layer, and (*b*) the deeper processes.

(*a*) The superficial layer forms a complete investment for the neck, and covers in all the cervical structures, except the platysma and some superficial veins and nerves, with the completeness of a perfectly fitting cravat. It commences behind at the spinous processes of the vertebra, and, having invested the trapezius muscle, starts, at the anterior border of that muscle, as a single layer, to cross the posterior triangle. Arriving at the posterior border of the sterno-mastoid muscle, it splits, to enclose that structure, appearing again as a single layer at the anterior border of the muscle, from whence it passes to the middle line of the neck to join the fascia of the opposite side, entirely covering in on its way the anterior triangle. The part that occupies the posterior triangle is attached above to

the mastoid process and superior curved line of the occipital bone, and below to the clavicle, so that the space is completely closed in by the fascia in all parts, although, just above the clavicle, it is pierced by the external jugular vein on its way to the deeper trunks. Over the anterior triangle, the fascia is attached above to the border of the lower jaw. Behind that bone it passes over the parotid gland to the zygoma, forming the parotid fascia, while a deeper layer passes beneath the gland (between it and its submaxillary colleague), to be attached to points at the base of the skull. It is from this deeper part that the stylo-maxillary ligament is developed. In front the fascia is attached to the hyoid bone, and just below the thyroid body it divides into two layers again, one to be attached to the front of the sternum and the other to the back. Both these

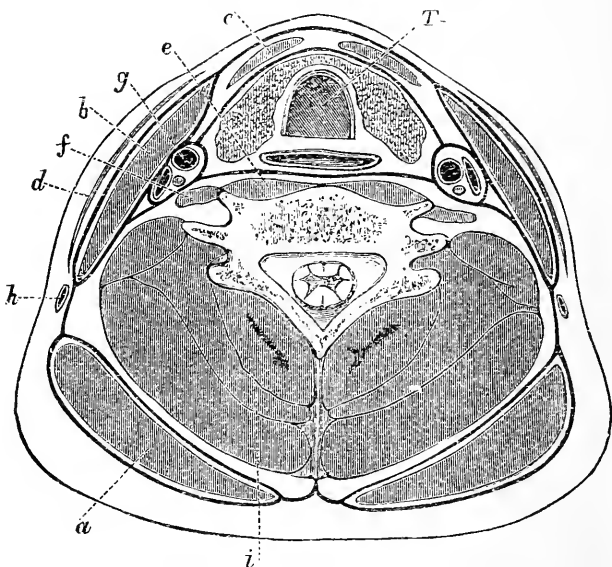


Fig. 20.—Transverse Section through the lower part of the Neck, to show the arrangements of the Cervical Fascia (Diagrammatic).

*a*, Trapezius; *b*, sterno-mastoid; *c*, depressors of hyoid bone; *d*, platysma; *e*, anterior spinal muscles; *f*, scalenus anticus; *g*, carotid artery; *h*, external jugular vein; *i*, posterior spinal muscles; *T*, trachea, with gullet behind and thyroid body in front.

layers lie in front of the depressors of the hyoid bone, and they form between them a little space (which extends so far laterally as to enclose the sternal head of the sterno-mastoid), the widest part of which is below, and which there corresponds in width to the thickness of the sternum. It will be perceived that, in dividing the sternal head of the sterno-mastoid, the operation is performed within this little chamber formed by the two layers just named, and it is well to note that the anterior jugular vein also occupies this chamber on its way to the external jugular trunk. This superficial layer of the fascia, considered generally, would oppose in all parts the progress of abscesses or growths towards the surface, and would encourage or compel them to take a deeper position.

(b) The deeper processes. (1) From the superficial layer a process comes off near the anterior border of the sterno-mastoid muscle, which, passing beneath the depressors of the hyoid bone, invests the thyroid body and front of the trachea, and passes down, in front of that tube and of the large vessels, to the fibrous layer of the pericardium. (2) The prevertebral fascia is a layer that descends on the prevertebral muscles behind the pharynx and gullet. It is attached above to the base of the skull, and, below, descends into the thorax, behind the œsophagus. Laterally, it joins the carotid sheath, and is then prolonged outwards and downwards over the scalene muscles, the brachial plexus, and subclavian vessels. It follows these vessels beneath the clavicle, where it forms the axillary sheath and becomes connected with the under surface of the costo-coracoid membrane. (3) The sheath of the carotid artery and its accompanying vein and nerve are derived in part from fascia No. 1, and in part from fascia No. 2.

The effects of this disposition of the fascia may be illustrated by noting the course probably taken by cervical abscesses in various positions. (1) An abscess in the posterior triangle will be bounded towards the surface by the superficial layer of fascia. Towards

the floor, or deep part, of the triangle it will be bounded by the lateral portion of fascia No. 2. The abscess may extend some way under the clavicle until arrested by the union of the costo-coracoid membrane with fascia No. 2. It would readily extend under the edge of the trapezius muscle, and could pass beneath the sterno-mastoid muscle and carotid artery to the anterior and deeper parts of the neck. (2) An abscess in the anterior triangle in front of the depressors of the hyoid bone would probably come forward, owing to the thinness of the fascia in front of it: but, if pent up, it would tend to progress towards the anterior mediastinum or into the lateral parts of the neck in front of the carotid vessels. (3) An abscess behind the hyoid depressors and about the trachea or thyroid body, or in the immediate vicinity of the carotid vessels (an abscess situate, in fact, between the deep fasciæ Nos. 1 and 2), would find itself in a narrow strait, and after pressing much upon adjacent parts would most readily spread downwards into the mediastinum. (4) An abscess immediately in front of the spine, and beneath the deep fascia No. 2, might extend down into the posterior mediastinum, or move towards the posterior and lateral parts of the neck, following the brachial plexus, and so reach the posterior triangle, or even the axilla.

In many cases a cervical abscess has burst into the gullet, or trachea, and even into the pleura. In some instances the great vessels have been opened up. In one remarkable case reported by Mr. Savory (*Med. Chir. Trans.*, 1881), not only was a considerable portion of the common carotid artery destroyed by the abscess, but also a still larger portion of the internal jugular vein and a large part of the vagus nerve. This, and like examples of the destructive action of some cervical abscesses, depend, no doubt, upon the unyielding character of the cervical fascia, which hems in the pus on all sides, and drives it to resort to desperate measures to effect an escape. "It is noteworthy," remarks Mr. Jacobson, "that communications between abscesses and deep vessels have usually taken place beneath two of

the strongest fasciæ in the body, the deep cervical fascia and the fascia lata" (Hilton's "Rest and Pain").

**The apex of the lung** extends into the neck, and reaches a point from 1 to 2 inches above the anterior end of the first rib. A point between the sternal and clavicular heads of the sterno-mastoid and  $\frac{1}{2}$  an inch above the clavicle will mark its highest limit. It lies behind the clavicle, anterior scalene muscle, and subclavian vessels. The right lung commonly extends higher up than the left.

The pleura has been opened in careless operations on the subclavian artery, and has also been torn in dragging deep-seated tumours from the base of the neck. The pleura and lung have been wounded in stabs of the neck and by fragments of bone in severe fractures of the clavicle. Cervical abscesses have opened into the pleura, and, apart from this, pleurisy has followed inflammation of the cellular tissue at the root of the neck.

Hernia of the lung into the neck has occurred during violent coughing, an appreciable tumour being produced (Dr. Knox, *Lancet*, vol. i. ; 1885).

**Cervical ribs.**—These structures have led to many errors in diagnosis, have been mistaken for exostoses, and where the subclavian artery is carried over them have led to the diagnosis of aneurism. They are met with at all ages and in both sexes, and represent the cervical ribs of lower vertebrates. As a rule, one such rib is found on either side of the seventh cervical vertebra; sometimes it is movable, sometimes it is ankylosed to the vertebra and its transverse process. A vestige is always present in the fœtus. It may be very short, and represented only by a head, neck, and tubercle. Such forms have been mistaken for exostoses. It may be long, and may then end free, or be joined to the first rib, or the first costal cartilage by ligament, or even by cartilage. In such instances the subclavian artery passes over the cervical rib, and its distinct pulsation under such circumstances has led to the diagnosis of aneurism. To the longer form of cervical

ribs the scalenus anticus, and the scalenus medius, may be attached.

In thin subjects the rib forms a distinct projection in the neck.

**Cut throat and wounds of the neck.**—The skin of the neck is so elastic and mobile that it is readily thrown into folds when a knife, and especially a blunt knife, is drawn across it. Thus, in cases of cut throat several distinct skin cuts may be found that were all produced by one movement of the knife. The wound in cut throat, whether suicidal or homicidal, most frequently involves the thyro-hyoid membrane, next in frequency the trachea, and then the thyroid cartilage.

1. If the wound be above the hyoid bone the following parts may be cut: Anterior jugular vein; anterior belly of digastric; mylo-hyoid, genio-hyoid, genio-hyo-glossus, and hyo-glossus muscles; the lingual artery; branches of the facial artery; the hypoglossal and gustatory nerves; the submaxillary gland. The substance of the tongue may be cut, and the floor of the mouth freely opened. In any case where the attachments of the tongue are divided the organ is apt to fall back upon the larynx and produce suffocation.

2. If the wound be across the thyro-hyoid space the following may be the parts cut: Anterior jugular vein; sterno-hyoid, thyro-hyoid, omo-hyoid muscles; thyro-hyoid membrane; inferior constrictor; superior laryngeal nerve; superior thyroid artery; and if near hyoid bone the trunk of the lingual artery may be cut. The pharynx would be opened in a deep wound, and the epiglottis divided near its base. Division of the epiglottis in wounds in this situation is always a serious complication.

3. If the wound involve the trachea the following may be the parts cut: Anterior jugular vein; sterno-hyoid, sterno-thyroid, and omo-hyoid muscles; part of sterno-mastoid; thyroid gland; superior and inferior thyroid arteries; superior, middle, and inferior thyroid veins; recurrent nerves and the gullet.

In wounds of the neck the great vessels often escape



in a marvellous manner. They are protected in part by the depth at which they are situated, and in part by their great mobility, lying as they do in an atmosphere of loose connective tissue. Dieffenbach relates a case of cut throat in which both gullet and trachea were divided without any damage to the great vessels. In cut throat the vessels are greatly protected by the projecting thyroid cartilage above and by the contracting of the sterno-mastoid muscles below. Deep gashes made across the crico-thyroid space, or through the upper part of the trachea, reach the great vessels more easily than would wounds made with equal force in any other part of the neck.

In some cases of gunshot wound the vessels seem to have been actually pushed aside, and to have owed their safety to their mobility. Thus, in a case reported by Longmore, the bullet passed entirely through the neck from one side to the other. It passed through the gullet, damaged the posterior part of the larynx, but left the great vessels intact. In another recorded case a boy fell upon the point of a walking-stick. The end of the stick passed entirely through the neck from side to side, entering in front of one sterno-mastoid muscle and emerging through the substance of the opposite one. It probably passed between the pharynx and the spine. The boy, who left the hospital well in eighteen days, owed his safety to the laxity of the cervical connective tissue and to the mobility of the main structures in the neck.

In connection with the subject of wounds of the neck it must be remembered that the most important part of the spinal cord can be reached from behind, through the gap between the atlas and axis. In this situation the cord has been divided by one stab of a knife, the instrument entering between the two bones. Langier gives some ingenious cases of infanticide where the lethal weapon was merely a long needle. The needle was introduced into the spinal canal between the atlas and axis, and the cord readily cut across.

Wounds at the side of the neck have divided con-

siderable portions of the brachial plexus without involving other structures.

The **hyoid bone** may be broken by direct violence, as from blows, or in the act of throttling. It is sometimes found broken in those who have been hanged. The fracture may involve the body of the bone, but more usually the greater cornu is found broken off. In the *New York Medical Record* (1882) is the report of the case of a man who felt something snap under his chin while yawning. On examination the hyoid bone was found to be fractured. The bone was also found broken in a patient who threw her head violently backwards to save herself from falling (Hamilton). The fracture is associated with great difficulty and pain in speaking, in moving the tongue, in opening the mouth, and in swallowing, symptoms that may be readily understood. A bursa lies between the thyro-hyoid membrane and the posterior surface of the hyoid bone. It may, when enlarged, form one of the cystic tumours of the neck.

The **larynx and trachea**.—The position of the larynx in the neck is influenced by age. In the adult the cricoid cartilage reaches to the lower part of the sixth cervical vertebra. In a child of three months it reaches the lower border of the fourth cervical, and in a child of six years the lower border of the fifth vertebra. At puberty it attains the adult position. The upper end of the epiglottis in the adult is opposite the lower border of the third cervical vertebra. In a child of three months it reaches the lower border of the atlas, and at six years the lower border of the axis (Symington). With the laryngoscope the following parts may be made out: The base of the tongue and glosso-epiglottic ligaments; the superior aperture of the larynx, presenting in front the epiglottis, at the sides the aryteno-epiglottidean folds (in which are two rounded eminences corresponding to the cornicula and cuneiform cartilages), and at the back the arytenoid commissure of mucous membrane. Deeply down can be seen the true and false vocal cords, the ventricle, the anterior wall of the larynx, a little of the cricoid cartilage, and more or less of the

anterior wall of the trachea. If the glottis be very fully dilated the openings of the two bronchi may be dimly seen.

The thyroid and cricoid **cartilages**, and the greater part of the arytenoid, are in structure hyaline, as are the costal cartilages. Like the last-named, they are liable to become more or less ossified as life advances. Ossification commences in the thyroid and cricoid cartilages at about the age of 20, and in either cartilage the process commences in the vicinity of the cricothyroid joint. The arytenoid ossifies later. Ossification of the laryngeal cartilages is more marked in males than in females. The larger cartilages are liable to be fractured by violence, as by blows, throttling, etc. The thyroid is the one most frequently broken, and usually in the median line. The posterior superior angle of the thyroid cartilage marks the position of the pyriform fossa, a wide recess, above and external to the aryteno-epiglottic folds. Foreign bodies may be arrested in this fossa.

The **rima glottidis** is the aperture between the true vocal cords in front and the bases of the arytenoid cartilages behind. It is the narrowest part of the interior of the larynx, and it is well to be familiar with its proportions in reference to the entrance of foreign bodies and the introduction of instruments. In the adult male the rima measures nearly 1 inch (23 mm.) from before backwards; from side to side, at its widest part, it measures about one-third of the length; this diameter may be increased to one-half of the length in extreme dilatation. In the female and in the male before puberty the antero-posterior diameter is from 17 mm.

The **mucous membrane** of the larynx varies in thickness in different parts, and in the amount of its submucous tissue. The membrane is thickest, and the submucous tissue most abundant, in the following parts, taken in order of degree: The aryteno-epiglottidean folds, the mucous membrane of the ventricle, the false cords, and the laryngeal aspect of

the epiglottis. These are the parts that become most congested and swollen in acute laryngitis; and the serious condition known as œdema of the glottis depends mainly upon effusion into the lax submucous tissue in the aryteno-epiglottidean folds. The mucous membrane is firmly bound to the true vocal cords and covered by stratified epithelium, while the rest of the larynx is lined, like the trachea, with ciliated epithelium. Owing to the nature of its covering and exposure to friction the true vocal cord is not an uncommon site of epithelioma. The affection known as "clergyman's sore-throat" has an interesting anatomical basis. The mucous membrane of the larynx is well provided with mucous glands, whose function it is to keep moist the parts concerned in phonation. When an individual speaks aloud for a long time the lining of the larynx tends to become dry, on account of the large amount of cold air that is drawn in directly through the mouth. To still keep these parts moist the mucous glands have to exhibit increased energy, and in those who speak much in public the glands may in time become so over-worked as to inflame. It is the inflammation of these glands that constitutes the present affection. The glands are not distributed equally over all parts of the larynx, but are most numerous in the membrane covering the arytenoid cartilages and parts immediately about them, the base of the epiglottis, and the interior of the ventricle. It is in these parts, therefore, that the changes in chronic glandular laryngitis, or dysphonia clericorum, are most marked.

**Excision of the larynx.**—The entire larynx has been removed for carcinomatous disease, but the operation, although not immediately fatal, has not been followed by very satisfactory results. It is removed through an incision in the middle line. In this incision are divided the platysma, the fascia, and the anterior jugular vein. The larynx is separated from its connections, the following structures being divided: sterno-thyroid, thyro-hyoid, stylo-pharyngeus, palato-pharyngeus, and inferior constrictor muscles, laryngeal

branches of superior and inferior thyroid arteries, superior and inferior laryngeal nerves, hyo-epiglottic and glosso-epiglottic ligaments. The larynx is then separated from the trachea, and is dissected off from below up. In separating the gullet and pharynx there is great risk of "button-holing" the former tube. Extirpation of half the larynx is attended with less risk, and in early cases with the cancer limited to one vocal cord it may be sufficient to remove the corresponding parts of the thyroid, cricoid and arytenoid cartilages.

The lymphatic vessels of the upper half of the larynx follow the superior laryngeal vessels and pass to the upper deep cervical glands. A small lymphatic gland, the first to become the seat of secondary cancerous deposit, is situated below the horn of the hyoid on the thyro-hyoid membrane. (Fig. 21, p. 164.) The lymphatics of the lower half of the larynx accompany the inferior thyroid vessels and pass through lymph glands by the side of the trachea.

**Tracheotomy and laryngotomy.**—The trachea is about  $4\frac{1}{2}$  inches in length, and from  $\frac{3}{4}$  to 1 inch in its extreme width. It is surrounded by an atmosphere of very lax connective tissue, which allows a considerable degree of mobility to the tube. The mobility of the trachea is greater in children than in adults, and adds much to the difficulties of tracheotomy. In this procedure the windpipe is opened in the middle line by cutting two or three of its rings above, below, or through the isthmus of the thyroid gland. Since the trachea, as it descends, lies further from the surface, and comes in relation with more and more important structures, it is obvious that, other things being equal, the higher in the neck the operation can be done the better. The length of trachea in the neck is not so considerable as may at first appear, and, according to Holden, not more than some 7 or 8 of the tracheal rings (which number 16 to 20 in all) are usually to be found above the sternum. The distance between the cricoid cartilage and the sternal notch varies greatly, and depends upon the length of

the neck, the age of the patient, and the position of the head. If 2 inches of trachea are exposed above the sternum when the head rests easily upon the spine, then in full extension of the head some  $\frac{3}{4}$  of an inch more of the windpipe will, as it were, be drawn up into the neck. According to Tillaux, the average full distance between the cricoid cartilage and the sternum is, in the adult, about  $2\frac{3}{4}$  inches (7 cm.). The full distance in a child between three and five years is about  $1\frac{1}{2}$  inches (4 cm.), in a child between six and seven about 2 inches (5 cm.), and in children between eight and ten years about  $2\frac{1}{4}$  inches (6 cm.). As may be imagined, the dimensions of the trachea on section vary greatly at different ages, and even in different individuals of the same age. This leads to the question as to the proper diameter of tracheotomy tubes. Guersant, who has paid much attention to this matter, says that the diameter of the tubes should run from 6 mm. to 15 mm.\* The tubes with a diameter of from 12 mm. to 15 mm. are for adults. The tubes below 12 mm. are for children, and are divided into four sets.

|        |                 |        |                     |                                   |
|--------|-----------------|--------|---------------------|-----------------------------------|
| No. 1. | { with a dia- } | 6 mm.  | { is suitable for } | $1\frac{1}{2}$ to 4 years of age. |
|        | { meter of }    |        | { children from }   |                                   |
| No. 2. | „               | 8 mm.  | „                   | 4 to 8 „                          |
| No. 3. | „               | 10 mm. | „                   | 8 to 12 „                         |
| No. 4. | „               | 12 mm. | „                   | 12 to 15 „                        |

In children under eighteen months the diameter of the tube should be about 4 mm.

In performing *tracheotomy* it is most important that the head be thrown as far back as possible, and that the chin be kept strictly in a line with the sternal notch, so that the relations of the middle line of the neck be preserved. Full extension of the head not only gives the surgeon increased room for the operation, but also brings the trachea nearer to the surface, and by stretching the tube renders it much less mobile.

In cutting down upon the trachea in the middle line of the neck from the cricoid cartilage to the sternum

\* The reader may be reminded that 12 mm. = about  $\frac{1}{2}$  an inch, and 6 mm., therefore, = about  $\frac{1}{4}$  of an inch,

the following parts are met with. Beneath the integument lie the anterior jugular veins. As a rule these veins lie some little way apart on either side of the median line, and do not communicate except by a large transverse branch which lies in the interfascial space at the upper border of the sternum. Sometimes there are many communicating branches right in front of the tracheotomy district, or the veins may form almost a plexus in front of the trachea, or there may be a single vein which will follow the middle line. Then comes the cervical fascia, enclosing the sterno-hyoid and sterno-thyroid muscles. The gap between the muscles of opposite sides is lozenge-shaped, and is such that the trachea can be exposed without dividing muscle fibres. The isthmus of the thyroid usually crosses the 2nd, 3rd, and 4th rings of the trachea. Above it a transverse communicating branch between the superior thyroid veins is sometimes found. Over the isthmus is a venous plexus, from which the inferior thyroid veins arise, while below the isthmus these veins lie in front of the trachea together with the thyroidea ima artery (when it exists). The inferior thyroid vein may be represented by a single trunk occupying the middle line. In the infant before the age of two years the thymus extends up for a variable distance in front of the trachea. At the very root of the neck the trachea is crossed by the innominate and left carotid arteries and by the left innominate vein; and lastly, abnormal branches of the superior thyroid artery may cross the upper rings of the wind-pipe.

The evil of wounding the thyroid isthmus is greatly exaggerated. I have frequently divided this structure in performing tracheotomy without any inconvenience resulting. Like other median raphe, the middle line of the thyroid isthmus has but a slight vascularity, and it has been shown that one side of the thyroid gland cannot be injected from the other (*i.e.* by injection that would cross the isthmus). The difficulty of tracheotomy in infants depends upon the shortness of the neck, the amount of the subcutaneous fat, the

depth at which the trachea lies, its small size, its great mobility, and the ease with which it can be made to collapse on pressure. To the finger, roughly introduced, the infant's trachea offers little resistance. Its mobility is such that we hear of its being held aside unknowingly by retractors, while the operator is scoring the œsophagus (Durham). In the child, too, the great vessels often cross the trachea higher up than in the adult, and some inconvenience may also arise from an unduly prominent thymus. In one case, in an infant, the end of a tracheotomy tube pressing on the front of the trachea produced an ulcer that opened the innominate artery (*Brit. Med. Jour.*, 1885). In introducing the cannula, if the tracheal wound be missed, it is easy to thrust the instrument into the lax tissue beneath the cervical fascia and imagine that it is within the windpipe.

In *laryngotomy* the air passage is opened by a transverse cut through the crico-thyroid membrane. The crico-thyroid space only measures about  $\frac{1}{2}$  an inch in vertical height in well-developed adult subjects, while in children it is much too small to allow of a cannula being introduced. The crico-thyroid arteries cross the space, and can hardly escape division. They are, as a rule, of very insignificant size, and give no trouble. Occasionally, however, these vessels are large, and "cases are recorded in which serious and even fatal hæmorrhage has occurred from these vessels" (Durham). In introducing the cannula it may readily slip between the crico-thyroid membrane and the mucous lining instead of entering the trachea.

**Foreign bodies** often find their way into the air passages, and have been represented by articles of food, teeth, pills, buttons, small stones, and the like. They are usually inspired during the act of respiration, and may lodge in the superior aperture of the larynx, or in the rima, or find their way into the ventricle, or lodge in the trachea, or enter a bronchus. If a foreign substance enters a bronchus it usually selects the right, that bronchus having its aperture more immediately under the centre of the trachea than has the left tube,



Quite recently, in a dissecting-room subject, I found two threepenny pieces lying side by side, in the right bronchus, so as to entirely block the tube. The danger of inhaled foreign substances depends not so much upon the mechanical obstruction they offer, as upon the spasm of the glottis they excite by reflex irritation. A body may, however, lodge in the ventricle for some time without causing much trouble, as in a case reported by Desault, where a cherry-stone lodged for two years in this cavity without much inconvenience to its host. In one strange case a bronchial gland found its way into the trachea by producing ulceration of that tube, was coughed up, and became impacted in the rima glottidis. The patient was saved from immediate suffocation by tracheotomy. Foreign bodies have been removed from the right bronchus through a tracheotomy wound. In this way MacCormac removed from the bronchus the blade of a tooth forceps.

**The thyroid body.**—Each lobe should measure about 2 inches in length, about  $1\frac{1}{4}$  inches in breadth, and  $\frac{3}{4}$  of an inch in thickness at its largest part. When distinctly beyond these measurements the thyroid may be considered to be enlarged. Its usual weight is between one and two ounces. Of its three surfaces, the anterior is covered by the infra-hyoid muscles, its inner rests on the larynx and trachea, while its outer covers the carotid sheath. Its prominent posterior border is in contact at its lower part with the recurrent laryngeal nerve and œsophagus. Each lobe extends from about the middle of the thyroid cartilage to the sixth ring of the trachea. It is larger in females than in males, and the right lobe is usually larger than the left. In connection with these matters it may be noted that thyroid enlargements (bronchocele, goitre) are more common in females than in males, and in any case are more apt to be first noticed on the right side. The body being closely adherent to the trachea and larynx, it follows that it moves up and down during deglutition, and this circumstance is of the utmost value in the diagnosis of bronchocele from other cervical tumours.

The thyroid when enlarged may distort and narrow the trachea, and this is all the more likely to be the case when the enlargement occurs rapidly, since the body is held down by the sterno-hyoid, sterno-thyroid, and omo-hyoid muscles. The enlarged gland is apt to press especially upon the veins of the neck, producing engorgement of the face and head, upon the sterno-mastoid muscle, and the other muscles named, upon the cervical nerves, and particularly the recurrent laryngeal. In some cases of dyspnœa produced by rapidly growing bronchoceles, Bonnet has proposed subcutaneous section of the muscles. Since the isthmus must bind together the enlarging lobes of a bronchocele, Sir Duncan Gibb, on the other hand, proposed to divide the isthmus in cases where dyspnœa resulted. This operation he performed several times with great relief to the patient. The posterior border of the thyroid body being in contact with the sheath of the great vessels, it follows that the gland when enlarged may readily receive pulsations from those vessels. It generally touches also the lower part of the pharynx, and the upper part of the gullet behind, and enlargement in this direction may, in connection with the interference with the movement of the larynx in deglutition, serve to explain the difficulty in swallowing often noticed in bronchocele.

The isthmus of the thyroid gland is developed from a diverticulum which is protruded from the ventral wall of the pharynx in the embryo between the mandibular and hyoid parts of the tongue. The foramen cæcum of the tongue represents the spot where the diverticulum leaves the pharynx. From this foramen a duct (the thyro-glossal) may be found to lead to accessory gland masses about the hyoid bone. In the vicinity of this bone accessory glands and small cysts lined with epithelium are not infrequently met with. These glands, together with the so-called pyramid or middle lobe, are the remains of the neck of the primitive diverticulum. The pyramid, which is nearly always connected to the hyoid bone by the levator thyroideæ, exists in 79 per cent. of the subjects examined

(Streckeisen). The lateral lobes are developed from the fourth visceral clefts. The median diverticulum occasionally fails to join one of the lateral, in which case the isthmus is partially absent. Small accessory thyroid bodies are frequently present.

The *parathyroid bodies* appear to play an essential part in the function of the thyroid. They are of the size of small peas, and have a structure similar to that of the suprarenal bodies. Two are usually found on each side, one at the lower pole of the lateral lobe, the other behind the lobe amongst the terminal branches of the inferior thyroid artery.

Atrophy of the thyroid gland, or its destruction by disease, is apt to lead to a general condition of the body known as *myxœdema*. The condition closely resembles cretinism, especially as met with in goitrous subjects. Myxœdema may follow the entire excision of the gland by operation, and has been produced in monkeys by experimental removal of the same. One prominent feature in myxœdema is the swelling of the subcutaneous tissues from an accumulation therein of a mucinoid substance. "The probable function of the thyroid gland, as established by experiments and clinical observation, concerns, in the first place, the control of the mucinoid substances in the tissues of the body, and albuminoid metabolism to some extent; and in the second place, hæmapœsis, *i.e.* manufacture of blood corpuscles" (Victor Horsley).

Vaso-motor nerves reach the thyroid through the lower part of the cervical sympathetic chain, and by the same course nerves pass upwards to the eye. These nerves appear to be connected centrally, probably in the medulla, for in certain conditions enlargement of the thyroid is accompanied by protrusion of the eye (exophthalmic goitre). The lymphatics of the thyroid are numerous, and pass to the deep cervical and superior mediastinal lymph glands.

In *excision of the thyroid gland* a Y-shaped median cut is usually made that divides the skin, fascia, platysma, and anterior jugular veins. The sterno-hyoid, sterno-

thyroid, omo-hyoid, and portion of the sterno-mastoid have usually to be divided. The tumour is carefully separated. The capsule that invests the vascular gland must not be torn through. The thyroid vessels are ligatured *in situ* before the removal of the mass. The superior thyroid meets the gland at the apex of the lateral lobe and is there secured. The inferior thyroid artery enters the lower part of the lobe at its posterior aspect. In securing this vessel, and in liberating the lower part of the tumour, the recurrent laryngeal nerve is in great danger of being damaged. The thyroidea ima artery exists in 10 per cent. of all cases.

The **gullet** commences opposite the sixth cervical vertebra, and pierces the diaphragm opposite the tenth dorsal vertebra. The point is marked on the back by the overlapping spine of the ninth dorsal vertebra. By placing the stethoscope a little to the left of this spine fluid may be heard to enter the stomach. It presents three curves: one is antero-posterior, and corresponds to the curve of the spinal column; the other two are lateral. The gullet commencing at the middle line deviates slightly to the left as far as the root of the neck; from thence to the fifth dorsal vertebra it gradually returns to the middle line, and finally it turns again to the left, at the same time passing forwards, to pierce the diaphragm. Its length is from 9 to 10 inches. Its transverse diameter has been carefully estimated by Dr. Mouton, by filling the gullet with plaster-of-Paris *in situ*, and then measuring the cast thus obtained. Dr. Mouton found that there were three narrow parts in the gullet, one at its commencement, one about  $2\frac{3}{4}$  inches from that point, and a third where the tube passed through the diaphragm. The diameter at each of these points was a little over  $\frac{1}{2}$  an inch (14 mm.); the diameter elsewhere was about  $\frac{3}{4}$  of an inch (17 mm. to 21 mm.). By forcible distension the two upper narrow parts could be distended to a diameter of 18 to 19 mm., the lower part to 25 mm., and the rest of the gullet to a diameter of nearly  $1\frac{1}{2}$  inches (35 mm.). It follows that foreign bodies when swallowed

are most apt to lodge either at the commencement of the gullet or at the spot where it passes the diaphragm. The same parts also are those most apt to show the effects of corrosives that have been swallowed.

Among the relations of the œsophagus, the following may be noted as receiving illustration in surgical practice. The gullet is in nearly all its course in close relation with the front of the vertebral column. In the neck the trachea is immediately in front of it. In the thorax it is in close connection with the aorta, and has the vena azygos behind it and on its right-hand side. It is, moreover, partly in contact with both pleuræ, but more especially with the membrane of the right side; and, lastly, the recurrent laryngeal nerve ascends between it and the trachea. (*See Figs. 47 and 49, pp. 353 and 361.*)

Now, foreign bodies impacted in the gullet are very apt to lead to ulcerations that may open adjacent parts. Thus, in the Musée Dupuytren is a specimen showing a five-franc piece that had stuck in the gullet, and had produced an ulcer that had opened the aorta. In another instance a "smasher" swallowed a counterfeit half-crown piece. Eight months afterwards he died of hæmorrhage. The coin had sloughed into his aorta. In another case (*Lancet*, 1871), a fish-bone, lodged in the gullet opposite the fourth dorsal vertebra, had caused two perforating ulcers; one on the right side had caused plugging of the vena azygos major, while the other on the left had made a hole in the aorta. Less frequently impacted foreign substances have found their way into the trachea and into the posterior mediastinum. Dr. Ogle reports a case (*Path. Soc. Trans.*, vol. iv.) where a piece of bone impacted in the gullet induced ulceration of an intervertebral disc and subsequent disease of the spinal cord. Carcinoma of the gullet, also, when it spreads, is apt to invade adjacent parts, and especially to open into the trachea or bronchi. If it spreads to the pleura, it will usually involve the right pleura, as being the membrane more in relation with the gullet. Cancer of the gullet has so spread as to invade the thyroid body, the pericardium, and

the lung, and has opened up the first intercostal artery in one case, and the right subclavian in another (Butlin's "Sarcoma and Carcinoma," 1882).

The sensory nerve supply of the œsophagus comes mainly from the fifth dorsal segment of the cord (Head). In cases of cancer or burns of the gullet pain is referred to the skin of this segment (*see* Fig. 39, p. 295).

The operation of **œsophagotomy** consists in incising the gullet for the purpose of removing an impacted foreign body. The gullet is usually reached from the left side, since it projects more on that aspect. The incision is made between the sterno-mastoid and the trachea, in the same direction as the incision for ligaturing the common carotid. The cut extends from the top of the thyroid cartilage to the sterno-clavicular joint. The omo-hyoid muscle is drawn outwards, or cut. The great vessels, larynx and thyroid gland, are drawn aside, and care must be taken not to wound these structures nor damage the thyroid vessels, thoracic duct, or the recurrent nerve. The gullet, when exposed, is opened by a vertical incision.

In **œsophagostomy** an opening is made into the gullet through a like incision in cases of stricture of the tube high up, the object being to feed the patient through the opening made, in place of performing gastrostomy. The risk, however, of setting up severe diffuse inflammation in the loose planes of connective tissue deep in the neck is very great, and in some twenty-six cases in which the operation has been already performed death has, in nearly all instances, supervened at the end of a few hours or days.

**Great vessels.**—The course, relations, and abnormalities of the great cervical vessels, together with the operations whereby they may be ligatured, and the details pertaining to those procedures, are so fully given, not only in works on operative surgery, but also in the chief anatomical text-books, that nothing need be said upon the matter in this place. The bifurcation of the common carotid is a favourite locality for aneurism, being a point where some resistance

is offered to the blood current. These tumours, also, are common at the root of the neck, where they are often due to extension of aneurismal disease from the aorta, although in many cases they have an independent origin. It is in the neck that the treatment of aneurism by the distal ligature is most often carried out. There is no place in the body where Brasdor's operation can be carried out with the completeness with which it can be adopted in the neck. In this procedure a main trunk is ligatured on the distal side of an aneurism, no branches intervening between the sac and the ligature. The cure by this measure depends upon the fact that blood does not continue to go to parts when once the need for blood in them is diminished. Thus, after amputation at the hip joint, the femoral artery, having no need to carry to the stump the amount of blood it brought to the limb, often shrinks to a vessel no larger than the radial. When an aneurism low down in the carotid artery is treated by ligature of the vessel near its bifurcation by Brasdor's method, the blood, having now, as it were, no object in entering the carotid trunk, soon ceases to fill the vessel entirely, and the artery (and in successful cases the aneurism) shrinks in consequence. Wardrop's operation, or the distal ligature of large branches for the relief of aneurism of a main trunk, is now, perhaps, quite limited as to its performance to the ligature of the carotid and subclavian arteries for innominate aneurism. Since in this procedure large branches come off between the sac and the ligature, it is not easy to fully understand how the operation acts beneficially. It is assumed to owe its success to the same principle that underlies Brasdor's operation. The right carotid and subclavian have also been ligatured for aortic aneurism with some success, and here also the reason for the good effected by the operation is difficult to appreciate. It has been pointed out that the innominate artery lies more or less directly in the axis of the ascending aorta, while the left carotid and subclavian arteries arise at an angle to that axis, and it is upon this fact that reasons have been founded for

selecting the vessels of the right side (Barwell). The matter is, however, complicated by the knowledge that when vegetations are swept off the aortic valves they enter the left carotid with infinitely greater frequency than they do the right. The whole subject, indeed, requires investigation.

The cervical connective tissue being lax, aneurisms in this part can grow and spread rapidly, and usually soon produce "pressure symptoms." As examples of these may be noted oedema and lividity of the face of the upper limb from pressure upon the main veins, laryngeal symptoms from pressure upon the recurrent nerve or trachea, spasm of the diaphragm from pressure upon the phrenic nerve, damage to the sympathetic, and giddiness and impaired vision from anæmia of the brain.

The vertebral artery has been ligatured with doubtful benefit in cases of epilepsy. It is surrounded by vasomotor nerves derived from the inferior cervical ganglion, which also are necessarily tied. The artery is reached through an incision made along the posterior border of the sterno-mastoid muscle just above the clavicle. The "carotid tubercle" (*see* page 136) is then sought for, and vertically below it lies the artery in the gap between the scalenus anticus and longus colli muscles. The procedure is surrounded with considerable difficulties.

Dr. Bright and Dr. Ramskill have stated that disease involving the vertebral artery just before it enters the skull may lead to pain at the back of the head. It is well known that the suboccipital nerve lies in close connection with the artery over the posterior arch of the atlas, and that it gives a branch to the great occipital nerve which is distributed to the back of the head. The close connection of artery and nerve and this communicating branch may serve to explain the symptom noted. In some of Dr. Ramskill's cases there was difficulty of articulation. This he ascribes to pressure upon the hypoglossal nerve, which is also in close relation with the vertebral artery. The innominate artery



has been temporarily compressed through an incision made in the median line near to the vessel. The posterior aspect of the artery is exposed and compressed by the finger against the sterno-clavicular articulation.

In cases of bleeding from branches of the external carotid it is better, when possible, to ligature the trunk of that vessel in preference to securing the common carotid. The latter procedure has a high death rate (50 per cent.), due (1) to brain mischief, following the lessened blood stream through the internal carotid, and (2) to secondary hæmorrhage, due to the very free anastomosing channels.

**Air in veins.**—The veins of the neck are under the influence of the respiratory movements. The veins do not collapse owing to attachments to the surrounding fasciæ. During inspiration these vessels become more or less emptied; during expiration they become enlarged and turgid. With greatly impeded breathing they may attain formidable size. Since ether usually causes some respiratory difficulty, it is seldom administered in operations on the neck. The only other veins that are under the influence of the aspiratory power of the thorax are the axillary vein and its larger tributaries. When any one of these vessels is wounded, and the wound is for the moment dry, air may very readily be drawn into it during the inspiratory act, just as air is drawn into the trachea. The air causes embolism of the pulmonary capillaries.

The **lymphatic glands of the head and neck** are numerous, and arranged in the following sets (Fig. 21):—

- (1) Submaxillary glands, 10 to 15 in number, situated at the lower border of the jaw beneath the cervical fascia;
- (2) the supra-hyoid, 1 or 2 in number, situated between the chin and hyoid bone near the middle line;
- (3) parotid or pre-auricular set, situated in and over the parotid gland;
- (4) post-auricular, or mastoid, 2 to 4 in number, situated over the mastoid process;
- (5) occipital, 3 to 5 in number, over the insertion of the complexus muscle;
- (6) superficial cervical glands, often absent, situated

over the sterno-mastoid along the external jugular vein ; (7) laryngeal, 1 to 3 in number, below the great horn

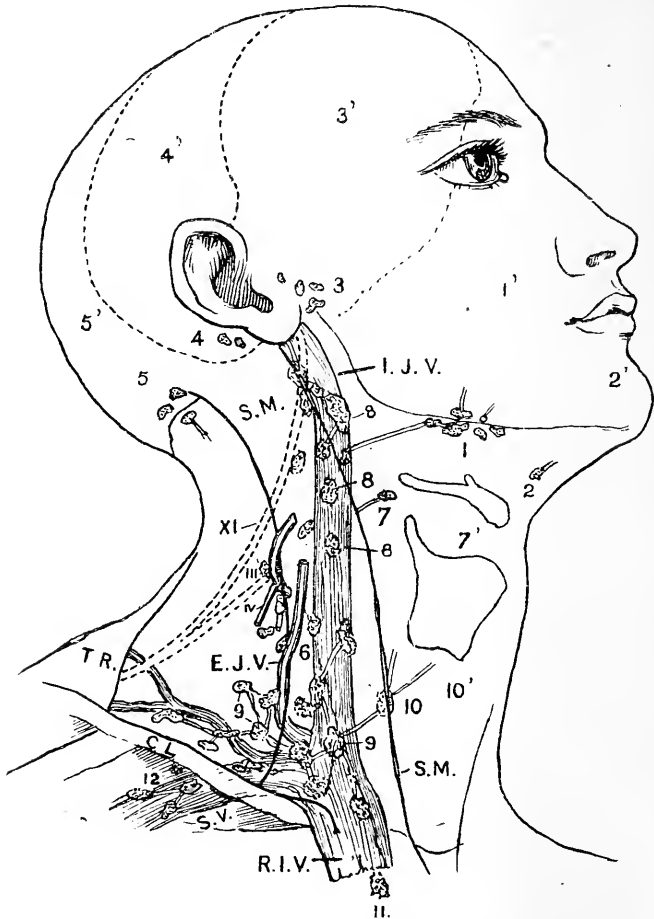


Fig. 21.—Showing the position of the Lymphatic Glands of the Head and Neck. The outlines of the sterno-mastoid (S.M.) trapezius (TRAP.), internal jugular, subclavian, and right innominate veins are shown.

- 1, Submaxillary glands, 1' area drained; 2, suprahyoid glands, 2' area drained; 3, parotid glands, 3' area drained; 4, post auricular glands, 4' area drained; 5, occipital glands, 5' area drained; 6, in front of external jugular vein, marking position of the superficial cervical glands; 7, laryngeal gland; 8, 8, 8, upper deep cervical glands; 9, 9, 9, lower deep cervical glands; 10, gland receiving lymph from thyroid; 11, superior mediastinal glands; 12, axillary glands.

of the hyoid; (8) the upper deep cervical set, 10 to 20 in number, situated over the upper part of the internal jugular vein and bifurcation of the common carotid artery; (9) lower deep cervical set, surrounding the terminal parts of the internal jugular, subclavian, external jugular, and transverse cervical veins. This set becomes continuous with the axillary and mediastinal glands.

These glands are very often enlarged and inflamed, and it is in this part of the lymphatic system that the changes in scrofula are most commonly met with. The inflammatory affections in glands would appear to be always of a secondary nature (if we exclude some cases of inflammation incited by injury, and perhaps by exposure to severe cold), and to follow disturbances in those parts of the periphery whence they respectively receive their lymph. It may be convenient, therefore, to group the relations of certain glands to certain parts of the periphery.

*Scalp.*—Posterior part = occipital and post-auricular glands. Frontal and parietal portions = parotid glands (Fig. 21).

Vessels from the scalp also enter the superficial cervical set of glands.

*Skin of face and neck* = submaxillary, parotid, and superficial cervical glands.

*External ear* = superficial cervical glands.

*Lower lip* = submaxillary and suprahyoid glands.

*Buccal cavity* = submaxillary glands and deep cervical glands (upper set).

*Gums of lower jaw* = submaxillary glands.

*Tongue.*—Anterior portion = suprahyoid and submaxillary glands. Posterior portion = deep cervical glands (upper set).

*Tonsils and palate* = deep cervical glands (upper set).

*Pharynx.*—Upper part = parotid and retro-pharyngeal glands. Lower part = deep cervical glands (upper set).

*Larynx, orbit, and roof of mouth* = deep cervical glands (upper set).

*Nasal fossæ* = retro-pharyngeal glands, deep cervical

glands (upper set). Some lymphatics from the posterior part of the fossæ enter the parotid glands.\*

In the removal of the deep cervical glands a number of structures are liable to be wounded. The glands frequently become firmly adherent to the internal jugular vein; the uppermost glands surround the spinal accessory nerve; the superficial cervical nerves pass among those of the lower deep cervical set; the thoracic duct has been wounded in removing glands from the left supra-clavicular fossa.

**Branchial fistulæ.**—Certain congenital fistulæ are sometimes met with in the neck, which are due to partial persistence of one of the branchial clefts. These clefts are placed in the foetus between the branchial arches. The arches are usually described as five in number. The first lays the foundation for the lower jaw and malleus. From the second are developed the incus, the styloid process, the stylo-hyoid ligament, and lesser cornu of the hyoid bone. From the third is formed the body and greater cornu of the hyoid bone, while the fourth and fifth take part in the formation of the soft parts of the neck below the hyoid bone. The first cleft is between the first and second arches. "The cervical branchial fistulæ appear congenitally as very fine canals opening into minute orifices in one or both sides of the fore part of the neck, and leading backwards and inwards or backwards and upwards towards the pharynx or œsophagus" (Paget). Their length is about  $1\frac{1}{2}$  to  $2\frac{1}{2}$  inches, and their diameter varies from that of a bristle to that of an ordinary probe. They usually exist about the line of the third or fourth cleft, and are most often met with just above the sterno-clavicular joint. Others are found about the level of the top of the thyroid cartilage at the anterior edge of the sternomastoid muscle. About some of these fistulæ, or in spots where they commonly open, flat pieces of cartilage may be found. The more prominent of these have been termed supernumerary auricles. Certain dermoid cysts of the neck arise from unobliterated branchial spaces,

\* From "Scrofula, and its Gland Diseases," by the Author.

and it would appear also that certain polycystic congenital tumours, occurring as one form of "hydrocele of the neck," may be developed from an imperfectly closed cleft. I have elsewhere detailed the dissection of one of these tumours that appeared to be associated with a partially closed second branchial cleft (*Path. Soc. Trans.*, 1881).

His has shown that many branchial fistulæ and cysts are formed from the cervical sinus. The cervical sinus is produced in the neck of the embryo by a rapid growth in the second and third arches which causes them to grow backwards and overlap the fourth and fifth. The piece of epiblast thus included in the neck usually disappears, but it may persist and give rise to a cyst or, if open, to a fistula. It is to be remembered that the branchial clefts are only depressions in the wall of the pharynx, not complete fissures. Hence fistulæ rarely communicate with the pharynx

## Part II.

---

### CHAPTER X.

#### THE THORAX.

1. **THE thoracic walls.**—The two sides of the chest are seldom symmetrical, the circumference of the right side being usually the greater, a fact that is supposed to be explained by the unequal use of the upper limbs. In Pott's disease, involving the dorsal region, when the spine is much bent forwards, the thorax becomes greatly deformed. Its antero-posterior diameter is increased, the sternum protrudes, and may even be bent by the bending of the spine, the ribs are crushed together, and the body may be so shortened that the lower ribs overlap the iliac crest.

In **pigeon-breast** deformity the sternum and cartilages are rendered protuberant, so that the antero-posterior measurement of the chest is much increased, while a deep sulcus exists on either side along the line of junction of the ribs and their cartilages. It is by the sinking in of the parietes along this line that the protuberance is produced. Shaw gives the following explanation of this deformity: "When an inspiration is taken, a threatened vacuum is created within the chest, air rushes in by atmospheric pressure, and at the end of the inspiration the balance of pressure without the chest and within it are equalised. If in inspiration there is an impediment to the entrance of air, the atmospheric pressure upon the external wall of the chest must produce some effect, being unbalanced by a like pressure upon the inner chest wall. In children, and especially in rickety children, the thorax is very pliable

and elastic, and if a constant impediment exists to the entrance of air, as afforded, for example, by the greatly enlarged tonsils, the thoracic walls may yield in time to the unbalanced pressure brought to bear upon them at each inspiration. The weakest part of the thorax is along the costo-chondral line on either side, and it is here that the parietes yield most conspicuously in such cases, and by this yielding the deformity is produced."

**Deformities of the chest** result from abnormal curvatures of the dorsal part of the spinal column. The ribs are firmly bound to the vertebræ by the costo-vertebral and costo-transverse ligaments, and hence alteration in the position of vertebræ is attended by changes in the costal series. When the spinal muscles are no longer able to keep the vertebræ firmly erect, the spinal column yields under the weight of the upper half of the body. In *scoliosis* of the spine not only is a lateral curvature formed, but the vertebræ undergo a rotation at the same time. The vertebral bodies move towards the convexity and their spines towards the concavity of the curvature (Fig. 22). The ribs on the concave side are carried forwards on the transverse processes and their angles open out, the side of the chest becoming flattened behind. On the other side (convex) the angles are unduly prominent, for the ribs are carried backwards at their vertebral extremities and bent inwards in front. The transverse diameter of the chest thus becomes oblique (Fig. 22). On the concave side the intercostal spaces are diminished in size, the ribs even coming into contact, while on the convex side the spaces are increased in size. The thoracic viscera are necessarily distorted in shape and altered in position.

The **sternum**.—The upper edge of the sternum corresponds to the disc between the second and third dorsal vertebræ, and the sterno-xiphoid joint to the middle of the ninth dorsal. In the fœtus at full term the upper edge of the sternum is opposite the middle of the first dorsal vertebra (Symington). A transverse ridge may be felt upon its anterior surface that

corresponds to the junction of the manubrium and gladiolus, and is in a line with the second costal cartilages. The skin over the sternal region is the part of the surface most frequently the seat of keloid. The bone is rarely *fractured*, being soft and spongy, and supported by the elastic ribs and their cartilages, as by a series of springs. In the old, when the cartilages

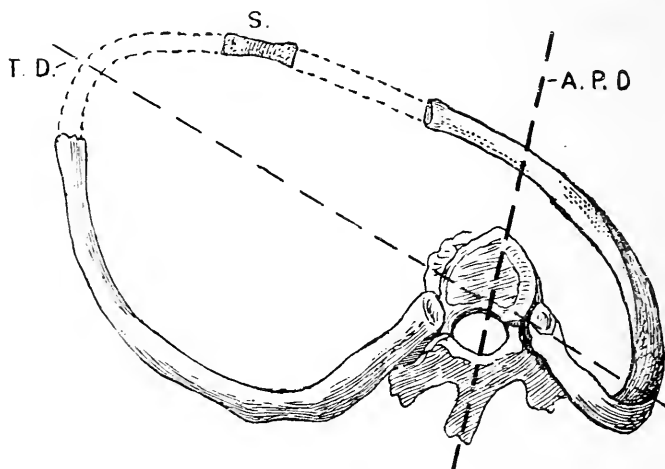


Fig. 22.—Showing the changes in the Thorax which follow Scoliosis of the Spine. (After Rébard.)

A. P. D., Antero-posterior axis of the vertebra; T. D., transverse diameter of the chest; S., sternum.

are ossified and the chest more rigid, the tendency to fracture is increased. The sternum is most often found fractured in connection with injuries to the spine, although it may be broken by simple direct violence. The bone may be fractured by violent bending of the spine backwards, and by abrupt bending of it forwards. In the former instance the lesion is probably due to muscular violence, to the abdominal muscles and the sterno-mastoid pulling one against the other. In the latter instance the lesion is commonly brought about by the violent contact of the chin with the bone. In all instances the fracture is usually transverse, and



most often occupies the line between the manubrium and the gladiolus. As these two parts of the bone are not entirely united until middle life, and are often not united at all, it follows that the lesion is in many cases a dislocation rather than a fracture. The manubrium in these injuries generally remains *in situ*, while the gladiolus with the ribs is displaced forwards in front of it. Malgaigne cites the case of a youth who, from constant bending at his work as a watchmaker, caused the second piece of the sternum to glide backwards behind the manubrium. Here, probably, the connection between the two bones was not very substantial.

From its exposed position and cancellous structure, the sternum is liable to many affections, such as caries and gummatous periostitis. The comparative softness also of the bone is such that it has been penetrated by a knife in homicidal wounds. The shape and position of the bone have also been altered by pressure, as seen sometimes in artisans following employments requiring instruments, etc., to be pressed against the chest.

Certain holes may appear in the middle of the sternum, and through them mediastinal abscesses may escape, and surface abscesses pass deeply into the thorax. These holes result from imperfect union of the right and left sternal bars, out of which the sternum is formed. In the case of E. Groux, the bone was separated vertically into two parts. The gap could be opened by muscular effort and the heart exposed, covered only by the soft parts. The sternum has been trephined for mediastinal abscess, and for paracentesis in pericardial effusion, and it has been proposed also to ligature the innominate artery through a trephine hole in the upper part of the bone.

The **ribs** are placed so obliquely that the anterior end of one rib is on a level with the posterior end of a rib some way below it in numerical order. Thus the first rib in front corresponds to the fourth rib behind, the second to the sixth, the third to the seventh, the fourth to the eighth, the fifth to the ninth, the sixth to the tenth, and the seventh to the eleventh. If a

horizontal line be drawn round the body at the level of the inferior angle of the scapula, while the arms are at the side, the line would cut the sternum in front at the attachment of the sixth cartilage, would cut the fifth rib at the nipple line, and the eighth rib at the vertebral column. The second rib is indicated by the transverse ridge on the sternum already alluded to. The lower border of the pectoralis major leads to the fifth rib, and the first visible serration of the serratus magnus corresponds to the sixth. The longest rib is the seventh, the shortest the first. In breadth the bones decrease from the first to the twelfth. The most oblique rib is the ninth.

The ribs are elastic and much curved, and, being attached by many ligaments behind to the column, and in front to the yielding cartilages, resist injuries tending to produce fracture with the qualities possessed by a spring. A rib may be fractured by *indirect violence*, as by a wheel passing over the body when lying prostrate on the back. In such a case the force tends to approximate the two ends of the bone, and to increase its curve. When it breaks, therefore, it breaks at the summit of its principal curve, *i.e.* about the centre of the bone. The fragments fracture outwards, and the pleura stands no risk of being penetrated. When the rib is broken by *direct violence*, lesion occurs at the spot encountered by the force, the bone fractures inwards, the curve of the rib tends to be diminished rather than increased, and there is much risk of the fragments lacerating the pleura.

Those most often broken are the sixth, seventh, and eighth, they being under ordinary circumstances the most exposed. The rib least frequently fractured is the first, which lies under cover of the clavicle. Fractures are more common in the elderly than in children, owing to the ossification of the cartilages that takes place in advancing life. When a rib is fractured, no shortening occurs, the bone being fixed both in front and behind, while vertical displacement is prevented by the attachments of the intercostal

muscles. Thus no obvious deformity is produced unless a number of consecutive ribs are the subjects of fracture. These bones have been broken by *muscular violence*, as during coughing, and in violent expulsive efforts such as are incident to labour. In such instances the ribs are probably weakened by atrophy or disease.

In many instances of gun-shot wound the curve of the rib has saved the patient's life. In such cases the bullet has entered behind near the dorsal spine, has been conducted round the chest, along the curve of a rib beneath the skin, and has escaped again near the sternum. This property, however, of the ribs for turning bullets refers rather to the days of round bullets, and not to modern conical projectiles.

In **rickets** changes take place at the point of junction of the ribs and cartilages leading to bony elevations, which produce, when the ribs on both sides are affected, the condition known as the "rickety rosary."

The **intercostal spaces** are wider in front than behind, and between the upper than the lower ribs. The widest of the spaces is the third, then the second, then the first. The narrowest spaces are the last four. The first five spaces are wide enough to admit the whole breadth of the index finger. The spaces are widened in inspiration, narrowed in expiration, and can be increased in width by bending the body over to the opposite side.

**Paracentesis** is usually performed in the sixth or seventh space, at a point midway between the sternum and the spine, or midway between the anterior and posterior axillary lines. If a lower space be selected there is danger of wounding the diaphragm, especially upon the right side. If the eighth or ninth space is selected the incision is made just external to the line of the angle of the scapula. The trochar should be entered during inspiration, the space being widened thereby, and should be kept as near as possible to the lower border of the space, so as to avoid the intercostal vessels. Tapping of the chest through any space posterior to the angles of the ribs is not practicable,

owing to the thick covering of muscles upon the thoracic wall in this place, and the fact that the intercostal artery, having a more horizontal course than the corresponding ribs, crosses the middle of this part of the space obliquely. Beyond the angle the intercostal vessels lie in a groove on the inferior border of the rib forming the upper boundary of the space. The vein lies immediately above the artery, and the nerve immediately below it. In the upper four or five spaces, however, the nerve is at first higher than the artery.

Owing to the protection it derives from the ribs and the intercostal muscles, it happens that the intercostal artery is seldom wounded, and when wounded it will be understood that considerable difficulty is experienced in securing the vessel without doing damage to the pleura and adjacent parts.

Pus may readily be conducted along the loose tissue between the two layers of intercostal muscles. Thus, in suppuration following upon disease of the vertebræ, or of the posterior parts of the ribs, the pus may be conducted along the intercostal spaces to the sternum, and may thus present at a considerable distance from the real seat of the disease.

**Removal of ribs.**—In order to obtain a free opening into the pleural cavity a portion of one or even two ribs may be excised.

In some cases of long-standing empyema with open sinus all that part of the bony wall of the thorax which corresponds to the outer boundary of the suppurating cavity is removed in order that the cavity may collapse and be in a position to close. This latter measure is known as Estlander's operation, or thoracoplasty. In some instances portions of as many as nine ribs have been excised, and the total length of bone removed has reached 50 to 60 inches.

In removing a rib the bone is entirely bared of periosteum with the rugine, and the excision is extra-periosteal. In this way the intercostal vessels are not exposed, and, if divided subsequently, can be readily secured when the ribs are out of the way.

The **internal mammary artery** runs parallel to the border of the sternum, and about  $\frac{1}{2}$  an inch from it. It may give rise to rapidly fatal hæmorrhage if wounded. The vessel may readily be secured in the first three intercostal spaces, and with some difficulty in the fourth or fifth space. It is most easily reached through the second space, and cannot be secured through any space below the fifth.

The **female breast** extends from the second rib above to the sixth below, and from the side of the sternum to the mid-axillary line (Stiles). In cases of retained lactation the twelve to fifteen irregular lobes which make up the body of the gland can be felt radiating outwards from the nipple. The lactiferous ducts, which correspond in number to the lobes, open at the apex of the nipple, within which each shows a dilatation or ampulla. Branching processes of adjoining lobes unite and enclose spaces within the body of the gland, containing connective tissue and masses of fat. After the menopause, when the glandular tissue is absorbed in great part, and during the resting condition, fat forms the greater part of the female breast. Besides the main body of the gland, Stiles has drawn attention to numerous peripheral processes which lie in the surrounding connective tissue.

Although the principal part of the breast rests on the pectoralis major, quite one-third of the gland crosses the outer border and rests on the serratus magnus within the axilla. It also covers the origins of the obliquus abdominis externus and rectus abdominis. In excision or inflammation of the breast it is important to bind the arm by the side to keep the parts from being disturbed by the pectoralis major. Peripheral processes of the gland and many of its deep lymphatics enter the pectoral sheath, hence the removal of this structure, and even part of the muscle, if complete extirpation of cancer is to be assured. The loose retro-mammary tissue which binds the mamma loosely to the pectoral sheath may be the seat of abscess, or sometimes of a bursal cyst.

The nipple is situated on the fourth intercostal space, about  $\frac{3}{4}$  of an inch from the junction of the ribs with their cartilages. It contains erectile and muscular tissue, and is richly supplied by cutaneous branches of the third and fourth spinal nerves. The skin is pigmented, thin and sensitive, and often the seat of painful fissures and excoriations. In painful diseases of the breast, tender areas occur over the fourth and fifth spinal segments (Fig. 39, p. 295) (Head).

The breast is developed by a solid invagination of epiblast at the point afterwards marked by the nipple. About the sixth month of foetal life the primitive mammary bud branches out in all directions within the subcutaneous tissue. Thus it comes about that the subcutaneous fascia is condensed around the gland, forming its capsule. The retro-mammary part of the capsule is connected at the interlobular spaces with the superficial layer, which in turn is fixed to the skin by subcutaneous bands, or skin ligaments.

It is through *lymph channels* that cancer spreads, and those of the breast, which is one of the commonest sites of cancer, are of especial importance if complete eradication of the disease is to be obtained. The lymph vessels are arranged in the following sets: (1) Peri-lobular, round the acini and lobules; (2) periductal, round the lactiferous ducts; (3) interlobar, situated in the interlobar septa and joining (4) the retro-mammary network with (5) the superficial mammary in the anterior part of the capsule. If the interlobar septa are invaded by cancer they contract, and through their cutaneous attachments cause depressions in the skin; if the process invades the periductal vessels, the nipple is retracted. The mammary lymphatic system is connected with the subcutaneous network of vessels, to which cancer may spread, producing that variety of the disease known as *cancer en cuirasse*. Through communications with the lymph channels of the pectoral fascia and muscle, cancer of the breast may spread to these structures. The gland then becomes firmly fixed to the deeply seated structures. The great bulk

of the lymph vessels pass from the breast to the *pectoral glands*, six to eight in number, situated along the anterior border of the axilla, and to the *central axillary set*, twelve to fifteen in number, situated beneath the axillary tuft of hair and on the inner side of the axillary vein. From these two sets the lymph vessels pass to the *deep axillary glands* lying along the front and inner side of the axillary vessels. The deep axillary glands become continuous with the lower deep cervical glands. It is mainly along this path that cancer tends to spread, but vessels leave the inner segment of the breast and pass to the anterior intercostal glands situated in the upper four intercostal spaces and lying on each side of the internal mammary vessels, while occasionally a few vessels pass to the cephalic gland situated in the hiatus between the deltoid and pectoralis major muscles. When the normal channels become clogged with cancerous emboli the lymph passes by circuitous paths. The *subscapular glands*, surrounding the subscapular vessels on the posterior wall of the axilla, may become infiltrated; through the lymphatics of the arm, which end in the central axillary glands, the structures round the shoulder may become the seats of secondary deposit, and through the communication between the lymph system of one breast with that of the other, across the sternum, a secondary deposit may even occur in the opposite breast (Stiles).

The breast is thinnest along a line drawn from the sterno-clavicular joint to the nipple. Abscesses situated beneath the breast not unfrequently make their way through the gland at some point along this line. Abscesses of the breast should be opened by incisions radiating from the nipple, to avoid wounding the lactiferous ducts.

The intercosto-humeral nerve pierces the central set of axillary glands. It becomes compressed when these glands are invaded by cancer, and pain is referred to the termination of the nerve over the posterior aspect of the arm above the elbow. Various parts of the

brachial plexus may also become involved or the axillary vein or lymphatics occluded, the arm being swollen and œdematous in consequence.

The following groups of *arteries* supply the gland and are cut in excision of the organ: (1) The long thoracic, alar thoracic, thoracic branches of the acromio-thoracic axis; (2) anterior perforating branches from the internal mammary at the second, third, and fourth intercostal spaces; (3) lateral branches from the second, third, and fourth intercostal arteries.

Supernumerary nipples and breasts may occur. They are commonly found in a line between the axilla and the groin. In the embryonic stage of all mammals an epiblastic mammary ridge is found in this position. In man it disappears except at one point, but occasionally some isolated part may persist and proceed to form a breast. Embryology fails to explain the occurrence of breasts on the buttock or back, where they are occasionally found.

## 2. The **thoracic viscera.**

The **lung**.—The apex of the lung rises in the neck from 1 to 2 inches above the anterior end of the first rib. Its highest point lies  $\frac{1}{2}$  an inch above the sternal end of the clavicle, in the interval between the sternal and clavicular heads of the sterno-mastoid muscle. The anterior edges of the two lungs lie behind the sternoclavicular articulations, pass obliquely behind the manubrium, and meet in the middle line at the junction of the manubrium with the gladiolus. The edge of the right lung then continues vertically downwards behind the middle line of the sternum to the sixth chondro-sternal articulation, where it slopes off along the line of the sixth rib. The edge of the left lung keeps close to that of the right as far as the fourth chondro-sternal articulation, where it turns off to the left, following a line drawn from the fourth cartilage to the apex of the heart. Occasionally it does not diverge, but completely covers the pericardium up to the edge of the sternum. In the child, owing to the thymus, the lungs are more separated in front. The right reaches the middle line, but the



left only reaches the left edge of the sternum (Symington). The lower border of the lung corresponds to a slightly convex line drawn round the chest from the sixth chondro-sternal articulation in front to the eleventh dorsal spine behind. In the mammary line this would correspond to the sixth rib, in the mid-axillary line to the ninth rib, and vertically downwards from the inferior angle of the scapula, with the tenth rib. The cartilages of the false and floating ribs lie below the pleural line. The pleura extends farther down than the lung, reaching in front to the level of the seventh chondro-sternal union, behind to the twelfth dorsal spine, and at the sides to a point some  $2\frac{1}{2}$  inches above the lower margin of the thorax. Thus it will be seen that the pleura and diaphragm may be wounded in many places without the lungs being involved. The lowest part of the pleura is only separated from the kidneys by the thin layer of the diaphragm. The pleura is in relation with the twelfth rib, but occasionally it descends  $\frac{1}{2}$  an inch or more below this point, and may be wounded in operations on the kidney. It extends lower down in the child than in the adult. The left lung descends to a slightly lower level than the right.

In penetrating wounds involving the pleura, air may enter the pleural cavity, producing pneumo-thorax, and this air may be subsequently pressed by the respiratory movements into the subcutaneous tissues through the wound in the parietal pleura, and lead to surgical emphysema. The cohesion between the smooth pulmonary and parietal layers of pleura is such that occasionally collapse does not follow, but the intimate connection between them makes it difficult for the pulmonary to escape when the parietal layer is wounded. In wounds of the lung without external wound, as when that organ is torn by a fractured rib, the air escapes from the lung into the pleura, and may thence pass into the subcutaneous tissues through the pleural wound, thus producing both pneumo-thorax and emphysema.

It is well to note that emphysema may occur about

certain non-penetrating wounds of the thorax when they are of a valvular nature. In such cases the air is drawn into the subcutaneous tissues during one respiratory movement, and is forced by another into the cellular tissue, the valvular nature of the wound preventing its escape externally. When the pleural "cavity" is opened, the lungs, owing to the amount of elastic tissue they contain, become more or less collapsed; yet a few cases have been recorded where the lung has protruded at the time of the accident through the wound in the parietes. In such instances the glottis must have been closed, and the lung fully distended at the time of the injury; and it must be further assumed that the viscus was practically protruded before air could enter the pleural space. It is noticeable that these recent herniæ are most common at the anterior part of the chest where the lungs are the most movable, and the injuries that bring them about are often associated with violent respiratory efforts at the time of the accident. In wounds of the lung the blood may escape in three directions: into the tissue of the organ (pulmonary apoplexy), into the bronchi (causing hæmoptysis), and into the pleura (causing hæmothorax). In some instances the lung has been ruptured without wound and without fracture to the ribs. These cases are difficult to interpret, and probably the best explanation suggested is that put forward by M. Gosselin. This surgeon believes that at the time of the injury the lungs are suddenly filled and distended with air by a full inspiration, and that the air, prevented from escaping by occlusion of the larynx, thus becomes pent up in the pulmonary tissue, and the lung not being able to recede from the superincumbent pressure, its structure necessarily gives way.

Owing to the fineness of its capillaries, and to the fact that all venous blood returned to the heart must pass through the lungs before it can reach other parts of the body, it follows that pyæmic and other secondary deposits are more commonly met with in the lung than in any other of the viscera.

*Lung cavities* resulting from tuberculosis, gangrene, or bronchiectasis, have been successfully incised and drained, and the same measure has been applied to hydrated cysts of the lung. Deep incisions in the lung

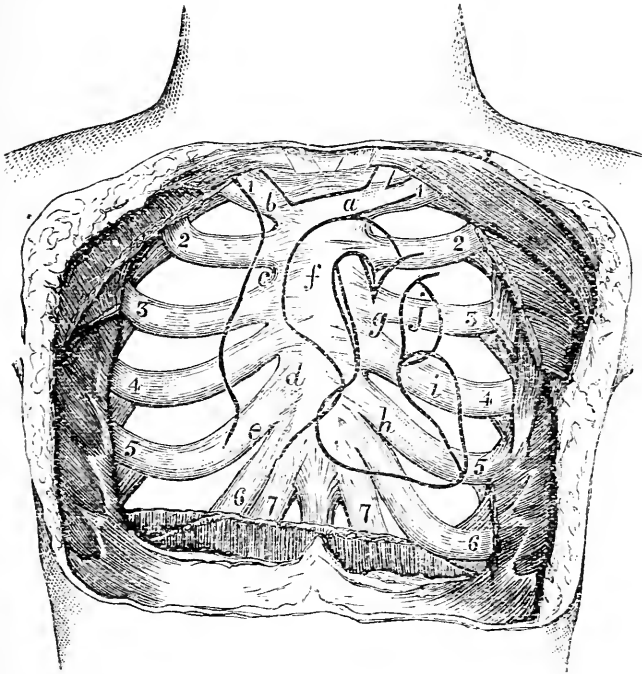


Fig. 23.—Diagram to show the relations of the Heart to the Surface.  
(After Rüdinger.)

*a*, Left innominate vein; *b*, right innominate vein; *c*, superior vena cava; *d*, right auricle; *e*, inferior vena cava; *f*, aorta; *g*, pulmonary artery; *h*, right ventricle; *i*, left ventricle; *j*, left auricle.

are followed by less hæmorrhage than might be expected from such a vascular organ.

The **trachea** divides opposite the junction of the manubrium and gladiolus in front, and the fourth dorsal vertebra behind (Fig. 47, p. 353). In the newly born the trachea bifurcates opposite the third vertebra (Symington).

Certain foreign substances that have been drawn into the air passages have shown a remarkable facility for escaping through the parietes. Thus Mr. Godlee records the case of a child from an abscess in whose back a head of rye-grass escaped that had found its way into the air passages forty-three days previously.

The **heart**.—The relations of the heart to the surface are as follows. Its *upper limit* corresponds to a horizontal line crossing the sternum about the upper border of the third cartilages. Its *right border* to a curved line arching from the third right cartilage at the sternum to the seventh right chondro-sternal articulation, and reaching about  $1\frac{1}{2}$  inches from the middle line. Its *lower border* follows a line from the seventh right chondro-sternal articulation to the apex. Its *apex* is opposite the fifth interspace, at the junction of the ribs, with their cartilages. Its *base* is opposite the fifth, sixth, seventh and eighth dorsal vertebræ. Its *left border* is represented by an arched line drawn from the apex to the third left cartilage at the sternum.

The orifice of the *pulmonary artery* is behind the upper edge of the third left cartilage close to the sternum. The vessel proceeds upward under cover of the second left outer space and cartilage. The *aortic orifice* is behind the left border of the sternum close to the lower edge of the third cartilage. The trunk ascends behind the second cartilage of the right side, and would be wounded by a stab through that cartilage close to the sternum. The concavity of the aortic arch corresponds to the point between the first and second pieces of the sternum. The auriculo-ventricular orifices are behind the sternum, the right being opposite the fourth spaces, and the left on a level with the fourth cartilages. The *innominate* and *left carotid* arteries come off at a spot corresponding to the middle of the manubrium, and run behind the right and left sterno-clavicular joints respectively. The *superior vena cava* would be wounded by a knife entering either the first or the second right interspace close to the sternum. The *left innominate* vein lies transversely

just below the upper border of that bone. The *right auricle* would be wounded in stabs passing through the sternal ends of the third, fourth, and fifth cartilages on the right side, or through the corresponding intercostal spaces if the knife were kept fairly near to the sternum. (See Fig. 23, which shows the relations of the heart and great vessels as given by Rüdinger, and which differs somewhat from the above account.)

Wounds of the heart most frequently involve the right ventricle, that segment of the heart being the part most exposed anteriorly. Next in frequency is the left ventricle wounded, and then the right auricle. Other things being equal, a wound of the ventricle is less rapidly fatal than is a wound of the auricle, owing to the thickness of the ventricular wall, and to its capacity for contracting and preventing the escape of blood. Death in cases of wound of the heart would appear in a great number of cases to be due to an impression upon the nervous centres rather than to actual hæmorrhage. Many instances have been recorded to show that the heart may be very tolerant of foreign bodies in its substance. Thus a man lived for twenty days with a skewer traversing the heart from side to side (Ferrus). In another case a lunatic pushed an iron rod, over 6 inches in length, into his chest, until it disappeared from view, although it could be felt beneath the skin receiving pulsation from the heart. He died a year following, and the metal was found to have pierced not only the lungs but also the ventricular cavities (Tillaux). Wounds of the heart have been sutured, the insertion of the stitches causing only momentary disturbance of its action. *A propos* of chest wounds, Velpeau cites the case of a man in whose thorax was found a part of a foil that entirely transfixed the chest from ribs to spine, and that had been introduced fifteen years before death. In the museum of the Royal College of Surgeons is the shaft of a cart that had been forced through the ribs on the left side, had passed entirely through the chest, and had come out through the ribs on the right side. The patient had lived ten years.

**Paracentesis of the pericardium** has been performed through the fourth or fifth spaces on the left side close to the sternum, care being taken to avoid the internal mammary artery. The operation has also been performed through a trephine hole made in the middle line of the sternum. The extent to which the pericardium is left uncovered by the left pleura varies in extent, but as a rule it may be tapped at any point in the fourth and fifth intercostal spaces, not further than an inch from the sternum, without danger to the pleura.

The **mediastina**.—Abscess in the anterior mediastinum may have developed *in situ*, or may have spread down from the neck. In like manner posterior mediastinal abscesses may arise from diseases of the adjacent spine, or lymphatic glands, or may be due to the spreading downwards of a retro-pharyngeal or retro-oesophageal collection of matter.

The azygos veins, commencing as they do below in the lumbar veins, and having more or less direct communications with the common iliac, renal, and other tributaries to the vena cava, are able to a great extent to carry on the venous circulation in cases of obstruction of the main trunk.

These veins are apt to be pressed upon by tumours (such as enlarged gland masses) developed in the posterior mediastinum, and to produce in consequence some œdema of the chest walls by engorgement of those intercostal veins that they receive. Tumours growing in the posterior mediastinum may cause trouble by pressing upon the trachea or gullet, or by disturbing the vagus nerve or the cord of the sympathetic (Figs. 47 and 49, pp. 353 and 361). The numerous lymphatic glands which surround the trachea, bronchi, and œsophagus are often the seat of tuberculosis. They become adherent to these organs and may ulcerate into them.

Krabbel reports a case of fracture of the ninth dorsal vertebra associated with rupture of the thoracic duct. The patient died in a few days, and the right pleura was found to contain more than a gallon of pure chyle.

## Part III.

### THE UPPER EXTREMITY.

#### CHAPTER XI.

##### THE REGION OF THE SHOULDER.

A STUDY of the region of the shoulder comprises the clavicle, the scapula, the upper end of the humerus, and the soft parts that surround them, together with the shoulder joint and axilla.

**Surface anatomy.**—The clavicle, acromion process, and scapular spine are all subcutaneous, and can be readily felt. In the upright position, when the arm hangs by the side, the clavicle is, as a rule, not quite horizontal. In well-developed subjects it inclines a little upwards at its outer end.\* In the recumbent posture, the weight of the limb being taken off, the outer end rises still higher above the sternal extremity. The degree of the elevation can be best estimated by a study of frozen sections. Thus, in making horizontal sections of the body, layer by layer, from above downwards, Braune found that by the time the sternoclavicular articulation was reached, the head of the humerus would be cut across in the lateral part of the section (Fig. 24).

The deltoid tubercle of the clavicle may, if large, be felt through the skin, and be mistaken for an exostosis. The acromio-clavicular joint lies in the plane of a vertical line passing up the middle of the front of the arm. A

\* In some women, in the feeble, and in some narrow-shouldered men, the clavicle may be horizontal, or its outer end may incline downwards.

prominence is sometimes felt about this joint in place of the level surface that it should present. This is due to an enlargement of the end of the clavicle, or to a thickening of the fibro-cartilage sometimes found in the joint. In many cases it has appeared to me to be due to a trifling luxation upwards of the clavicle depending upon some stretching of the ligaments. It is certain that the dry bone seldom shows such an enlargement as to account for this very common prominence at the acromial articulation. The sternal end of the clavicle is also, in muscular subjects, often large and unduly prominent, and sufficiently conspicuous to suggest a lesion of the bone or joint when none exists.

The roundness and prominence of the point of the shoulder depend upon the development of the deltoid and the position of the upper end of the humerus. The deltoid hangs like a curtain from the shoulder girdle, and is bulged out, as it were, by the bone that it covers. If the head of the humerus, therefore, be diminished in bulk, as in some impacted fractures about the anatomical neck, or be removed from the glenoid cavity, as in dislocations, the deltoid becomes more or less flattened, and the acromion proportionately prominent. The part of the humerus felt beneath the deltoid is not the head, but the tuberosities, the greater tuberosity externally, the lesser in front. A considerable portion of the head of the bone can be felt by the fingers placed high up in the axilla, the arm being forcibly abducted so as to bring the head in contact with the lower part of the capsule. The head of the humerus faces very much in the direction of the internal condyle. As this relation, of course, holds good in every position of the bone, it is of value in examining injuries about the shoulder, and in reducing dislocations by manipulation, the condyle being used as an index to the position of the upper end of the bone.

In thin subjects the outline and borders of the scapula can be more or less distinctly made out, but in fat and muscular subjects all parts of the bone, except the spine and acromion, are difficult of access in the



ordinary positions of the limb. To bring out the superior angle and vertebral border of the bone, the hand of the subject should be carried as far as possible over the opposite shoulder. To bring out the inferior angle and axillary border, the fore-arm should be placed behind the back. The angle formed at the point of junction of the spine of the scapula and the acromion is the best point from which to take measurement of the arm, the tape being carried down to the external condyle of the humerus. The upper border of the scapula lies on the second rib, its lower angle on the seventh.

When the arm hangs from the side with the palm of the hand directed forwards, the acromion, external condyle, and styloid process of the radius all lie in the same line. The groove between the pectoralis major and deltoid muscles is usually to be made out. In it run the cephalic vein and a large branch of the acromiothoracic artery. Near the groove, and a little below the clavicle, the coracoid process may be felt. The process, however, does not actually present in the interval between the two muscles, but is covered by the innermost fibres of the deltoid. The position of the coraco-acromial ligament may be defined, and a knife thrust through the middle of it should strike the biceps tendon and open the shoulder joint.

When the arm hangs at the side with the palm forwards, the bicipital groove may possibly be defined. It looks directly forwards.

Just below the clavicle is a depression, the subclavicular fossa, which varies considerably in depth in different subjects. It is obliterated in subcoracoid dislocations of the humerus, in fractures of the clavicle with displacement, by many axillary growths, and by some inflammations of the upper part of the thoracic wall. In subclavicular or intracoracoid dislocation, the fossa is replaced by an eminence. In this region, at a spot to the inner side of the coracoid process, and corresponding nearly to the middle of the clavicle, the pulsations of the axillary artery can be felt on deep

pressure, and the vessel be compressed against the second rib. Just below the clavicle the interspace between the sternal and clavicular portions of the pectoralis major can often be made out.

The anterior and posterior borders of the axilla are very distinct. The anterior border formed by the lower edge of the pectoralis major follows the line of the fifth rib. The depression of the armpit varies, other things being equal, with the position of the upper limb. It is most deep when the arm is raised from the side at an angle of about  $45^{\circ}$ , and when the muscles forming the borders of the space are in a state of contraction. As the arm is raised above the horizontal line the depression becomes shallower, the head of the bone projects into the space and more or less obliterates it, while the width of the fossa is encroached upon by the approximation of the anterior and posterior folds. The coraco-brachialis muscle itself forms a distinct projection along the humeral side of the axilla when the arm is raised to a right angle with the body. If the arm be brought nearly close to the side, the surgeon's hand can be thrust well up into the axilla, and the thoracic wall explored as high up as the third rib.

The axillary glands cannot be felt when they are in a normal condition. The central set lies beneath the axillary tuft of hair.

The direction of the axillary artery, when the arm is raised from the side, is represented by a line drawn from about the middle of the clavicle to the humerus at the inner side of the coraco-brachialis. A line drawn from the third rib near its cartilage to the tip of the coracoid process indicates the upper border of the pectoralis minor, and the spot where this line crosses the line of the axillary artery points out the position of the acromio-thoracic artery. A line drawn from the fifth rib near its cartilage to the tip of the coracoid process indicates the lower border of the pectoralis minor, and the position of the long thoracic artery which runs along that border. The line of the subscapular artery corresponds to the lower border of the

subscapularis muscle along which it runs, but the position of this border can only be approximately indicated on the living or undissected subject.

The circumflex nerve and posterior circumflex artery cross the humerus in a horizontal line, that is

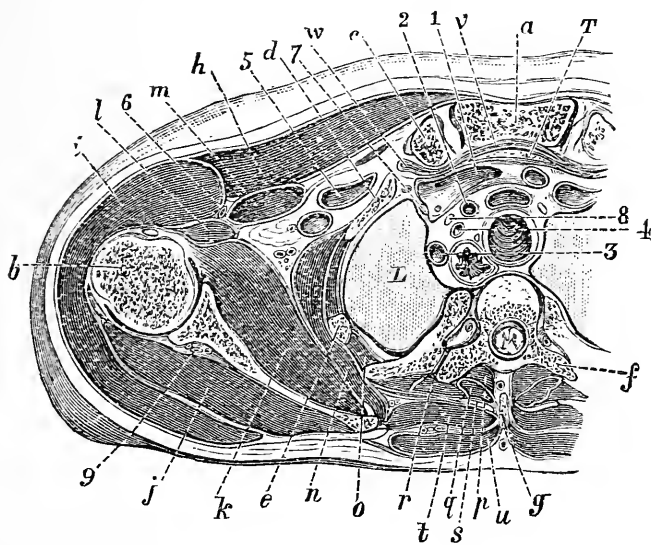


Fig. 24.—Horizontal Section of the Body just below the Upper Border of the Manubrium (Braune).

a, Manubrium; b, head of humerus; c, clavicle; d, first rib; e, second rib; f, third dorsal vertebra; g, spine of second dorsal; h, pectoralis major; i, deltoid; j, infraspinatus; k, subscapularis; l, coraco-brachialis and biceps; m, pectoralis minor; n, serratus magnus; o, intercostals; p, semispinalis and multifidus spinae; q, biventer cervicis and complexus; r, longissimus dorsi; s, splenius colli; t, rhomboideus; u, trapezius; v, sterno-thyroid; w, sternohyoid; x, thymus; L, lung; 1, left innominate vein; 2, left carotid artery; 3, left subclavian artery; 4, vertebral artery; 5, left subclavian vein; 6, cephalic vein; 7, phrenic nerve; 8, vagus; 9, transverse scapular artery.

about a finger's breadth above the centre of the vertical axis of the deltoid muscle. This point is of importance in cases of supposed contusion of the nerve. The dorsalis scapulae artery crosses the axillary border of the scapula at a point corresponding to the centre of the vertical axis of the deltoid muscle. These various indications of the positions of the main branches of

the axillary artery are made while the arm hangs in its natural position at the side.

The **clavicle**.—The skin over the clavicle is loosely attached, and is easily displaced about the bone. This circumstance may serve to explain why the skin so often escapes actual wound in contusions of the clavicular region, and in part explains the infrequency of penetration of the integument in fractures of the clavicle. The position of the supra-clavicular nerves in front of the bone renders them very liable to contusion, and accounts for the unusual amount of pain that is said to sometimes follow blows over the collar bone. Tillaux believes that the severe pain that in rare cases persists after fracture of the clavicle is due to the implication of these nerves in the callus formed. The three nerves that cross the clavicle are branches of the third and fourth cervical nerves, and it is well to note that pain over the collar bone is sometimes a marked feature in disease of the upper cervical spine. This symptom is then due to irritation of these nerves at their points of exit from the spinal canal.

Beneath the clavicle the great vessels and the great nerve-cords lie upon the first rib. The vein is the most internal, and occupies the acute angle between the collar bone and the first rib. It will be seen that growths from the bone may readily press upon these important structures, and that the vein, from its position, as well as from the slighter resistance that it offers, is likely to be the first to be compressed. These structures have also been wounded by fragments of bone in fracture of the clavicle. Fortunately, between the clavicle and these large nerves and vessels the subclavius muscle is interposed. This muscle is closely attached to the under surface of the bone, is enveloped in a dense fascia, and forms one of the chief protections to the vessels in case of fracture. This interposing pad of muscle is also of great service in resection operations, as can be well understood. Braune states that by pressing the clavicle against the first rib in the dead body a stream of injection in the thoracic duct can, in some cases, be entirely

arrested. Behind the clavicle the following structures may be noted, viz., the innominate, subclavian, and external jugular veins, the subclavian, suprascapular, and internal mammary arteries, the cords of the brachial plexus, the phrenic nerve and nerve of Bell, the thoracic duct, the omo-hyoid, scalene sterno-hyoid and sterno-thyroid muscles, the apex of the lung. The sternal end of the bone is not far removed from the innominate or left carotid artery, the vagus and recurrent nerves, the trachea, and the œsophagus.

These relations of the clavicle are given to show the dangers in the way of partial or complete resections of the bone. The difficulties and risks of the operation increase as one progresses from the acromial to the sternal end. Resection of the acromial third of the bone is comparatively easy, but resection of the sternal portion is most difficult and dangerous. The entire clavicle has been removed with success, and the operation has been followed by less impairment of the arm movements than would be imagined.

The clavicle forms the sole direct bony connection between the upper limb and the trunk, and in severe accidents, this connection being broken through, it is possible for the extremity to be torn off entire. Thus Billroth reports the case of a boy aged fourteen, whose right arm, with the scapula and clavicle, was so torn from the trunk by a machine accident that it was only attached by a strip of skin two inches wide. Other like cases of avulsion of the limb have been reported.

**Fractures of clavicle.**—The clavicle is more frequently broken than is any other single bone in the body. This frequency is explained by the fact that the bone is very superficial, is in a part exposed to injury, is slender and contains much compact tissue, is ossified at a very early period of life, and above all receives a large part of all shocks communicated to the upper extremity. The common fracture, that due to indirect violence, is oblique, and very constant in its position, viz. at the outer end of the middle third of the bone. The bone breaks at this spot for the

following reasons. It is here that the clavicle is the most slender; it is here that the two curves of the bone meet; it is here that a very fixed part of the bone, viz. the outer third, joins with a more movable portion. The position of the coraco-clavicular ligaments is no doubt of the greatest import in localising the fracture in this position, since a clavicle experimentally subjected to longitudinal compression does not break at this spot (Bennett). The *displacement* that occurs is as follows. The inner fragment remains unchanged in position, or its outer end is drawn a little upwards by the sternomastoid. It will be seen that any action of this muscle would be resisted by the pectoralis major and the rhomboid ligament. The outer fragment undergoes a threefold displacement. (1) It is carried directly *downwards*. This is effected mainly by the weight of the limb aided by the pectoralis minor, the lower fibres of the pectoralis major, and the latissimus dorsi. Since the line of action of the trapezius muscle is altered by the fracture, that muscle is no longer able to keep the shoulder up, and its altered action therefore contributes to the downward displacement. (2) It is carried directly *inwards* by the muscles that pass from the trunk to the shoulder, viz. the trapezius, the levator anguli scapulae, the rhomboids, the latissimus dorsi, and especially by the pectorals. To these may be added the subclavius. (3) The fragment is *rotated* in such a way that the outer end projects forwards, the inner end backwards. This rotation is brought about mainly by the two pectorals, assisted prominently by the serratus magnus. The normal action of this latter muscle is to carry the scapula forwards, and the clavicle, acting as a kind of outrigger to keep the upper limb at a proper distance from the trunk, moves forwards at the same time and keeps the scapula direct. When this outrigger is broken the serratus can no longer carry the scapula directly forwards. The bone tends to turn towards the trunk, and the point of the shoulder is therefore seen to move inwards as well as forwards. The fragments in this fracture must consequently overlap, and as the dis-

placement is difficult to remedy, it follows that in no bone save the femur is shortening so uniformly left as after an oblique fracture of the clavicle. The degree of shortening very seldom exceeds one inch. The deformity associated with this fracture is well remedied when the patient assumes the recumbent position. In this posture, the weight of the limb being taken off, the downward displacement is at once remedied. The point of the shoulder falling back also tends to relieve in part the inward displacement, and the rotation of the outer fragment forwards. It is through the scapula, however, that these two latter displacements are in the main removed. In the recumbent posture the scapula is pressed closely against the thorax, with the result that its outer extremity (and with it, of course, the outer fragment of the clavicle) is dragged outwards and backwards. Some surgeons, recognising this important action of the scapula in remedying the displacement in these cases, strap the scapula firmly against the trunk, while at the same time they elevate the arm.

Fractures due to *direct* violence are usually transverse, and may be at any part of the bone. When about the middle third they present the displacement just described. When the fracture is between the conoid and trapezoid ligaments no displacement is possible. When beyond these ligaments, the outer end of the outer fragment is carried forwards by the pectorals and serratus, and its inner end is a little drawn up by the trapezius. In this fracture there is no general displacement downwards of the outer fragment, since it cannot move in that direction unless the scapula go with it, and the scapula remains fixed by the coracoclavicular ligaments to the inner fragment of the clavicle.

The clavicle may be broken by *muscular violence* alone. Polaillon, from a careful analysis of the reported cases, concludes that the muscles that break the bone are the deltoid and clavicular part of the great pectoral. In no case does the fracture appear to have been produced by the sterno-mastoid muscle. The commonest movements producing fracture appear to

be violent movements of the limb forwards and inwards, or upwards. These fractures are usually about the middle of the bone, and show no displacement other than that of both fragments forwards, *i.e.* in the direction of the fibres of the two muscles first named.

The clavicle is more frequently the seat of *green-stick fracture* than is any other bone in the body. Indeed, one-half of the cases of broken collar bone occur before the age of five years. This is explained by the fact that the bone is ossified at a very early period, and is in a breakable condition at a time when most of the other long bones still present much unossified cartilage in their parts. Moreover, the periosteum of the clavicle is unduly thick, and not very closely attached to the bone, circumstances that greatly favour subperiosteal fracture.

A reference to the *relations* of the bone will show that important structures may be wounded in severe fractures associated with much displacement and with sharp fragments. Several cases are reported of paralysis of the upper limb (as a rule incomplete) following upon fracture of this bone. In some cases this symptom was due to actual compression, or tearing of some of the great nerve cords by the displaced fragments. In other cases the nerve injury, while due to the original accident, was yet independent of the broken clavicle. Paralysis of the biceps, brachialis anticus and supinator longus, muscles supplied through the upper cord, may result from heavy weights being carried on the shoulder. Cases are reported of wound of the subclavian artery, of the subclavian vein, of the internal jugular vein, and of the acromio-thoracic artery. In several instances the fracture has been associated with wound of the lung, with or without a fracture of the upper ribs.

The clavicle begins to ossify before any bone in the body. At birth the entire shaft is bony, the two ends being still cartilaginous. The bone has one *epiphysis* for its sternal end that appears between the eighteenth and twentieth year, and joins the shaft about twenty-five. It is a mere shell, is closely sur-



rounded by the ligaments of the sternal joint, and cannot, therefore, be well separated by accident.\*

**Sterno-clavicular joint.**—Although this is the only articulation that directly connects the upper limb with the trunk, yet it is possessed of such considerable strength that luxation at the joint is comparatively rare. The amount of movement in the joint depends to a great extent upon the lack of adaptability between the facet on the sternum and the sternal end of the clavicle. The disproportion between these parts is maintained by the inter-articular cartilage, which reproduces only the outline of the clavicular surface. The cavity of the joint is V-shaped, since the clavicle only touches the socket at its inferior angle when the arm hangs by the side. When the arm is elevated, however, the two bones are brought in more immediate contact, and the joint cavity becomes a mere slit. Thus, in disease of this articulation it will be found that of all movements of the joint the movement of the limb upwards is the most constant in producing pain. The joint is supplied by the suprasternal nerve.

The movements permitted at this point are limited, owing to the anterior and posterior sterno-clavicular ligaments being moderately tense in all positions of the clavicle. Movement *forwards* of the clavicle on the sternum is checked by the posterior ligament, and resisted by the anterior ligament. This latter ligament is more lax and less substantial than is the posterior band. Its weakness serves in part to explain the frequency of the dislocation forwards.

Movement of the clavicle *backwards* on the sternum is checked by the anterior ligament, while the passage of the head of the bone is resisted by the powerful posterior band. The movement is also opposed by the rhomboid ligament. To produce, therefore, a dislocation

\* Mr. Heath (*Lancet*, Nov. 18, 1882) reports a case which is probably unique. It concerns a lad, aged 14, who, when in the act of bowling at cricket, tore the clavicle away from its epiphyseal cartilage, which remained *in situ*. The muscle producing the accident was apparently the pectoralis major.

backwards considerable force must be used. Movement of the clavicle *upwards* on the sternum is checked by the rhomboid ligament, the interclavicular ligament, the interarticular cartilage, and in a less direct manner by the two remaining ligaments of the joint. Thus it happens that dislocation upwards is the least common of the luxations at this articulation.

**Disease of the sterno-clavicular joint.**—This articulation is really divided into two joints by the interarticular cartilage, each being provided with a distinct synovial membrane.

These joints are liable to the ordinary maladies of joints, and it would appear that the disease may commence in, and be for some time limited to, one only of the synovial sacs. In time the whole articulation usually becomes involved, but even in advanced cases the mischief is sometimes restricted to the synovial cavity on one side of the cartilage. According to some authors, this joint is more frequently involved in pyæmia than is any other. When effusion has taken place into the sterno-clavicular joint, and especially after suppuration has ensued, the swelling usually makes itself evident in front, owing to the fact that the anterior sterno-clavicular ligament is the thinnest and least resisting of the ligamentous structures about the articulation. For the same reason the pus usually escapes from the anterior surface, when it discharges itself spontaneously. It may, however, make an opening for escape through the posterior ligament, and under these circumstances has found its way into the mediastinum. The relations of this joint to the great vessels at the root of the neck should be borne in mind. In one case reported by Hilton a large abscess formed in the articulation, and the collection, receiving pulsations from the subjacent artery (the innominate or right subclavian), was supposed at one time to be an aneurism. It is remarkable that disease of this joint never leads to ankylosis. This circumstance may be explained (1) by the constant slight movement in the part, which prevents the diseased structures from being kept at rest,

(2) by the occasional persistence of the interarticular cartilage, and (3) by the utter lack of adaptability of the two bony surfaces involved.

### **Dislocations of the sterno-clavicular joint.**

—The clavicle may be dislocated from the sternum in one of three directions, which, given in order of frequency, are : (1) forwards, (2) backwards, (3) upwards. The relative frequency of these dislocations can be understood from what has been already said as to the action of the ligaments in restricting movements. The displacement *forwards* involves entire rupture of the capsule, and more or less damage to the rhomboid ligament. The head of the bone, carrying with it the sterno-mastoid, rests on the front of the manubrium. The dislocation *backwards* may be due to direct or indirect violence, and has occurred spontaneously in connection with the chest deformity in Pott's disease. The capsule is entirely torn, as is also the rhomboid ligament. The head is found in the connective tissue behind the sterno-hyoid and sterno-thyroid muscles. In this position it may cause severe dyspnoea, or dysphagia, by pressure upon the trachea or gullet. It may so compress the subclavian artery as to arrest the pulse at the wrist, or so occlude the innominate vein as to produce semi-coma (Fig. 24, p. 189). In one case the head of the bone had to be excised to relieve a troublesome dysphagia. In the luxation *upwards*, due usually to indirect violence, the head rests on the upper border of the sternum between the sterno-mastoid and sterno-hyoid muscles. It involves more or less complete tearing of all the ligaments of the joint, together with avulsion of the interarticular fibro-cartilage.

The non-adaptability of the joint surfaces in this part serves to explain the ease with which these luxations are usually reduced, and the difficulty of retaining the clavicle in position after it is replaced.

**Acromio-clavicular joint.**—This articulation is shallow, and the outlines of the two bones that enter into its formation are such that no obstacle is offered to the displacement of the clavicle from the acromion.

The joint, indeed, depends for its strength almost entirely upon its ligaments. The plane of the joint would be represented by a line drawn from above downwards and inwards between the two bones. This inclination of the joint surfaces serves to explain the fact that the usual luxation of this part takes the form of a displacement of the clavicle upwards on to the acromion. The capsule that surrounds the joint is lax and feeble, and it is partly from its comparative thinness that effusion into this joint, when it is the seat of disease, makes itself so soon visible. The joint, however, depends mainly for its strength upon the powerful conoid and trapezoid ligaments. The effects of shock at this joint are lessened by the presence of a partial fibro-cartilage which projects between the bones from the upper part of the capsule.

As the movements permitted in this joint may be impaired by accident or disease, it is well to note the part the articulation takes in the movements of the extremity. The scapula (and with it, of course, the arm), as it glides forwards and backwards upon the thorax, moves in the arc of a circle whose centre is at the sterno-clavicular joint, and whose radius is the clavicle. As the bone moves forwards it is important, for reasons to be immediately given, that the glenoid cavity should also be directed obliquely forwards. This latter desirable condition is brought about by means of the acromio-clavicular joint. Without this joint the whole scapula as it passed forwards with the outer end of the clavicle would precisely follow the line of the circle above mentioned, and the glenoid cavity would look in an increasingly inward direction. It is essential that the surface of the glenoid cavity should be maintained as far as possible at right angles to the long axis of the humerus. When these relations are satisfied, the humerus has the support behind of a stout surface of bone, and it is partly to obtain the value of this support that the boxer strikes out from the side, *i.e.* with his humerus well backed up by the scapula. If there were no acromio-clavicular joint the glenoid fossa would offer little support to the humerus when the limb was

stretched forwards, and a blow given with the limb in that position, or a fall upon the hand under like conditions, would tend to throw the humerus against the capsule of the shoulder joint, and so produce dislocation. Normally, therefore, as the scapula and arm advance, the angle between the posterior border of the acromion and the adjacent portion of the clavicle becomes more and more acute, and the glenoid fossa is maintained with a sufficiently forward direction to give substantial support to the humerus.\* It will thus be seen that rigidity of this little joint may be a cause of insecurity in the articulation of the shoulder, and of weakness in certain movements in the limb.

**Dislocations of the acromio-clavicular Joint.**—The clavicle may be displaced *upwards* on to the acromion or *downwards* beneath it. Pollaillon has collected thirty-eight cases of the former luxation, and six only of the latter. This disproportion is, in the main, explained by the direction of the articulating surfaces of the joint. Both luxations are usually due to direct violence. The dislocation *upwards* is very commonly only partial, and is associated only with stretching and some trifling rupture of ligaments. In the complete form, where the end of the clavicle rests entirely upon the acromion, there is rupture, not only of the capsule, but also to a greater or less extent of the coraco-clavicular ligaments. In the complete dislocation *downwards*, also, there is a rupture of the capsule, with extensive tearing of the conoid and trapezoid ligaments. These luxations are usually easily reduced, but it will be understood, from the direction of the articular surfaces, that in the displacement upwards it is very difficult to retain the clavicle *in situ* when once reduced.

**Scapula.**—At the posterior aspect of the bone the muscles immediately above and below the spine are somewhat precisely bound down by the deep fascia. Thus, the supraspinatus muscle is enclosed in a fascia,

\* For an excellent account of the mechanism of these joints see Morris's "Anatomy of the Joints," p. 202 *et seq.* 1879.

that, being attached to the bone all round the origin of the muscle, forms a cavity open only towards the insertion of the muscle.

The infraspinatus and teres minor muscles are also enclosed in a distinct, but much denser, fascia that is attached to the bone beyond these muscles, and blends in front with the deltoid sheath so as to form a second enclosed space. The arrangement of these fasciæ serves to explain the trifling amount of ecchymosis that usually follows upon fractures of the scapular blade. The extravasation of blood about the fracture is bound down by the fasciæ over these muscles, and is unable, therefore, to reach the surface.

Thus also pus, in the supra- and infra-spinous fossæ, tends to be pent up, and to come forward in the one case at the insertion of the subscapular muscle, and in the other instance about the insertion of the teres minor. Owing to the rigidity of the fascia over the infraspinatus and teres minor muscles, it happens that dense tumours growing from this fascia may readily be mistaken for growths from the bone itself.

The inferior angle of the scapula is crossed by a part of the latissimus dorsi, and by means of this muscle is retained in contact with the thorax. In certain injuries the angle may slip from beneath the muscle and appear as a marked projection. This lesion is productive of some loss of power in the limb. In many cases where this accident is supposed to have occurred, it is probable that the symptoms present are due rather to paralysis of the nerve of Bell.

**Fractures of the scapula**, and especially of the body of the bone, are not common, owing to the mobility of the part and the thick muscles that cover in and protect its thinner portions. It rests also upon a soft muscular pad, and derives, no doubt, additional security from the elasticity of the ribs.

The most common lesion is a fracture of the *acromion process*. This is often but a separation of the epiphysis. There are two, sometimes three, epiphyseal centres for the acromion. Ossification appears in them about

puberty, and the entire epiphysis joins with the rest of the bone from the twenty-second to the twenty-fifth year. Several cases of supposed fracture of the acromion united by fibrous tissue are probably but instances of an imperfectly-united epiphysis, and may have been independent of injury. In five bodies out of forty Symington found the acromial epiphysis united to the spine by a fibrous union, and from the statistics of other observers it appears that this is the case in quite 10 per cent. of adults. In fractures of the process much displacement is quite uncommon, owing to the dense fibrous covering the bone derives from the two muscles attached to it. This dense periosteum also explains the circumstance that many fractures are incomplete and crepitus often absent. When the fracture is in front of the clavicular joint, displacement of the arm is impossible. When it involves the joint, a dislocation of the collar-bone is common. When behind the joint, the arm, having lost its support from the thorax, is displaced in somewhat the same way as obtains in the common fracture of the clavicle. The *coracoid process* may present a genuine fracture, or may be separated as an epiphysis. As an epiphysis, it joins the main bone about the age of seventeen. The supra-glenoid tubercle, from which the long head of the biceps takes its origin, is part of the coracoid epiphysis. In spite of the powerful muscles attached to it, the displacement is usually slight, inasmuch as the coraco-clavicular ligaments are seldom torn. These ligaments, it may be noted, are attached to the base of the process. In some few cases the process has been torn off by muscular violence.

Among the more usual fractures of the *body of the scapula* is a transverse or oblique fracture of its blade below the spine. Owing to the infraspinatus, subscapularis, and other muscles being attached to both fragments, none but a trifling displacement is usual. A fracture may occur through the *surgical neck*. The surgical neck is represented by a narrowed part of the bone behind the *glenoid fossa*, and in the line of the

suprascapular notch. The smaller fragment will, therefore, include the coracoid process, the larger, the acromion. The amount of deformity in these cases depends upon whether the coraco-clavicular and acromio-clavicular ligaments are entire or torn. If they be torn, the small fragments and the entire limb are displaced downwards, and the injury somewhat resembles a subglenoid dislocation. From this, however, it is distinguished by the crepitus, by the ease with which the deformity is removed and the equal ease with which it returns, by the position of the head of the humerus in regard to the glenoid fossa, and by the conspicuous fact that the coracoid process is displaced downwards with the limb.

*Tumours* of various kinds grow from the scapula and mainly from the spongy parts of the bone, viz., the spine, the neck, the inferior angle. The bone may be removed entire, with or without amputation of the upper limb. An *inter-scapulo-thoracic* amputation is usually performed for malignant tumours which involve structures in the neighbourhood of the shoulder joint. In this operation the upper extremity, including the scapula and the clavicle beyond the origin of the sterno-mastoid, is removed. An elliptical incision is made in front and behind the shoulder, the upper end of the ellipse lying on the clavicle, the lower at the angle of the scapula. The operation is commenced at the clavicle so as to secure the axillary vessels. The artery is tied before the vein so that the limb may continue to empty its blood into the circulation. The main vessels to be noted in connection with this operation are the suprascapular at the superior border of the bone, the posterior scapular about the vertebral border, the subscapular running along the lower border of the subscapularis muscle, the dorsalis scapulæ crossing the axillary edge of the bone, and the acromial branches of the acromio-thoracic artery.

The **axilla**.—The axilla may be regarded surgically as a passage between the neck and the upper limb. Axillary tumours and abscesses may spread up into



the neck, and in like manner cervical growths and purulent collections may extend to the arm-pit. The skin forming the base of the axilla is provided with many short hairs and with numerous sebaceous and sudoriferous glands. In this integument small superficial abscesses are often met with, that arise usually from suppuration of

these glandular structures, and that are brought about by the friction of the skin against the clothing. Owing to the tendency of the axillary integument to become chafed and inflamed under friction, the axilla is *not* a good locality to select for the use of the mercurial inunction as applied in syphilis. Beneath the skin and superficial fasciæ is the axillary fascia, and beyond this dense membrane is the axillary space. The connective tissue with which the axillary space is mainly occupied is

very loose, and, while this laxity favours greatly the free movement of the arm, it at the same time permits of the formation of large purulent collections and immense extravasations of blood.

It is important to remember the disposition of the **fasciæ** about this region. There are three layers principally concerned. (1) The deep pectoral fascia

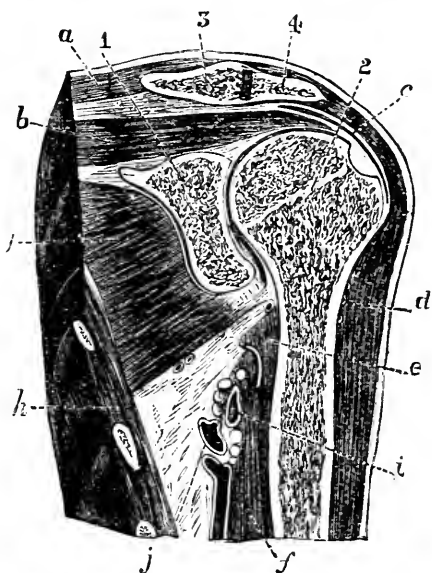


Fig. 25.—Vertical Section through the Axilla and Shoulder-joint (Rüdinger).

1, Scapula; 2, humerus; 3, clavicle; 4, acromion; a, trapezius; b, supraspinatus; c, subacromial bursa and deltoid; d, circumflex artery and nerve; e, latissimus dorsi; f, coraco-brachialis and biceps; g, subscapularis; h, serratus magnus; i, axillary artery; j, axillary vein.

that covers in and encloses the pectoralis major. (2) The clavi-pectoral fascia that, adherent above to the clavicle, fills in the space between that bone and the pectoralis minor, then splits to invest this muscle, and joins the deep pectoral layer at the anterior fold of the axilla to form with it the axillary fascia. The upper part of this fascia is generally known as the costo-coracoid membrane. The whole membrane is sometimes known also as the "suspensory ligament of the axilla," since it draws up the axillary fascia towards the clavicle, and is mainly instrumental in producing the "hollow" of the armpit. (3) The axillary fascia that is formed by the union of the two preceding fasciæ, and stretches across the base of the axilla from its anterior to its posterior fold. It is thinnest under the axillary hairs.

**Abscess about the axillary region** may be considered (1) when it is beneath the pectoralis major, or between the two pectoral muscles, and (2) when it is beneath the pectoralis minor and clavi-pectoral fascia, and therefore in the axillary space. (1) An abscess in this situation is placed between the deep pectoral and the clavi-pectoral fasciæ, the latter separating it from the axillary space. Such an abscess undermines the great pectoral, and tends to present either at the anterior margin of the axilla, or in the groove between the great pectoral and deltoid muscles, being guided thither by the attachment of the fasciæ. (2) A purulent collection in the axilla may soon fill that space and distend it entirely. Its progress towards the skin is arrested by the axillary fascia, its progress backwards by the serratus magnus muscle, which, by its attachment to the scapula, hermetically closes the axillary space behind. In front the advance of the abscess is prevented by the pectoral muscles and clavi-pectoral fascia, while on the inner side is the unyielding thorax, and on the outer side the upper limb. The abscess, therefore, as it fills the axilla pushes forwards the pectoralis major, more or less obliterates the hollow of the armpit, thrusts back the scapula, and widens the angle between the serratus magnus and the subscapularis muscles. There

is a great tendency, therefore, for unrelieved abscesses to extend upwards into the neck, that being the direction in which the least amount of resistance is encountered. From the neck the purulent collection may extend into the mediastinum. In one case an axillary abscess, set up by shoulder-joint disease, perforated the first intercostal space and set up fatal pleurisy.

In opening an axillary abscess, and, indeed, in most incisions into this space, the knife should be entered at the centre of the floor of the axilla, *i.e.*, midway between the anterior and posterior margins, and near to the inner or thoracic side of the space. The vessels most likely to be damaged by an indiscreet incision are the subscapular, running along the lower border of the subscapularis muscle; the long thoracic, following the lower border of the small pectoral; and the main vessels lying close to the humerus. The knife, if properly entered, should be midway between the two first-named vessels, and quite away from the main trunks. There is an artery (the external mammary) that sometimes comes off as the lowest branch of the axillary trunk, and crosses the middle of the axilla, to be distributed to the thorax below the long thoracic. This vessel would probably be wounded in the incision above named. The artery is, however, very inconstant, is small, and is not far below the surface. It is usually met with in female subjects.

**Lymphatic glands.**—The axillary glands are numerous, and of much surgical importance. They may be arranged in four sets. (1) The greater number are placed to the inner side of the axillary vein beneath the axillary tuft of hair. This *central set* of glands receives the lymph from the upper extremity and breast. Pain in the axilla which follows whitlow or any septic infection of the arm is due to inflammation of this group, which is pierced by the inter-costo-humeral nerve. (2) The deep axillary set lies along the axillary vessels. It receives the lymph from the central set and becomes continuous with the lower deep cervical glands in the subclavian triangle (Fig. 21, p. 164). (3) Other glands lie

upon the serratus magnus muscle on the thoracic side of the axilla, and just behind the lower border of the pectoral muscles. They receive the lymphatics from the front of the chest, the principal lymph vessels of the breast, and the superficial lymphatics of the abdomen. as low down as the umbilicus. Their efferent vessels for the most part pass on to join the central set of glands. These glands will be the first to be enlarged in certain breast affections, and after blistering and other superficial inflammations, etc., of the chest and upper abdomen. Paulet has seen them affected in inflammation of the hand. The axillary process of the female breast is in contact with this set. (4) The remaining glands are situated at the back of the axilla, along the subscapular vessels. They are joined by the lymphatics from the back.

It may here be convenient to note that one or two glands are commonly found in the groove between the deltoid and pectoralis major muscles. They receive some vessels from the outer side of the arm and a part of the shoulder and breast. The superficial lymphatics over the upper part of the deltoid go to the cervical glands (Tillaux), over the lower half to the axilla. The lymphatics from the suprascapular fossa follow the suprascapular artery, and join the lowest cervical glands. The superficial lymphatics of the back that converge to the axilla are derived from the neck over the trapezius muscle, and from the whole dorsal and lumbar regions as far down as the iliac crest.

The complete removal of axillary glands is an operation frequently undertaken. It will be understood from their position that these bodies, when diseased, are very apt to become adherent to the axillary vessels, and especially to the vein. The latter vessel has frequently been wounded or excised during the removal of gland tumours, and in one case at least the artery was accidentally cut (Holmes).

The **axillary vessels**.—The axillary vein is formed by the union of the basilic with the two venæ comites of the brachial artery. This union commonly

takes place at the lower border of the subscapular muscle, and the vein is therefore shorter than the artery. Sometimes the vein does not exist as a single trunk until just below the clavicle. This condition, when it exists, is very unfavourable to operations upon the artery, as many transverse branches cross that vessel to unite the veins that lie on either side of it. The axillary vein, being comparatively near the heart, is readily influenced as regards its contained blood by the inspiratory movement. Thus it happens that in many instances of wound of the vessel, or of its larger tributaries, air has been drawn into the venous canal and death has ensued. The entrance of air into the main vein is perhaps aided by the circumstance that the costo-coracoid membrane (upper part of clavi-pectoral fascia) is adherent to the vessel, and thus tends to maintain it in a patent condition when wounded. This connection with the fascia is supposed by some to account in part for the furious bleeding that occurs from this vein when it is divided.

The vein is more often wounded than is the artery, it being larger, more superficial, and so placed as to more or less overlap the arterial trunk. On the other hand, in injury to the vessel by traction, as, for example, in reducing dislocations, the artery suffers more frequently than the vein. In all positions of the upper limb the artery keeps to the outer angle of the axillary space. The relation of the vein, however, to the first part of the axillary artery, the part above the pectoralis minor, is modified by the position of the limb. Thus, when the arm hangs by the side the vein is to the inner side of the artery, and a little in front of it, but when the limb is at a right angle with the trunk the vein is drawn so far in front of the artery as to almost entirely conceal that vessel.

Aneurism is very frequent in the axillary artery, a fact to be explained by the nearness of the vessel to the heart, by the abrupt curve it presents, by its susceptibility to frequent and extensive movements, and by its liability to share in the many lesions of the upper limb. In violent and extreme movements of the limb

the artery may be more or less torn, especially if its walls are already diseased.

In ligaturing the first part of the axillary artery it is well to note that the pectoralis major has sometimes a cellular interval between two planes of muscle fibre, and this may be mistaken for the space beneath it (Heath). If the pectoralis minor has an origin from the second rib, it may more or less entirely cover the artery and require division. The cord of the brachial plexus nearest to the artery may be mistaken for that vessel, or easily included in a ligature intended for it. A ready guide to the axillary vessels in this operation is to follow the cephalic vein. The anterior internal thoracic nerve appears between the vein and artery as it passes to the pectoralis minor. It also may be useful occasionally as a guide.

In applying a ligature to the third part of the artery, it should be borne in mind that a muscular slip sometimes crosses the vessels obliquely, passing from the latissimus dorsi to join the pectoralis major, coracobrachialis, or biceps muscles. This slip may give rise to confusion during the operation, and may be mistaken for the coraco-brachialis.

The **axillary nerves**.—Any of the axillary nerves may be injured by a wound, the median being the most frequently damaged, and the musculo-spiral the least frequently. The comparative immunity of the latter is explained by its deep position, its situation at the inner and posterior aspect of the limb, and its large size. The nerves are very seldom torn by a traction on the limb short of more or less complete avulsion. Indeed, if forcibly stretched, they are disposed rather to become torn away from their attachments to the spinal cord than to give way in the axilla. Thus, Flaubert records a case where the last four cervical nerves were torn away from the cord during a violent attempt to reduce a dislocated shoulder.

The **deltoid region**.—This region, comprising as it does the "point" of the shoulder, is limited in all parts by the deltoid muscle. The deltoid covers

the upper end of the humerus and the shoulder joint. Between the joint and the surface, therefore, are only the skin and superficial fascia, the deltoid in its sheath, and some loose connective tissue (the subdeltoid tissue) in which is found the great subacromial bursa. This subdeltoid tissue sometimes assumes the form of a distinct thick membrane, and may have an important influence upon the localisation of purulent collections proceeding from the joint. The fatty tissue over the deltoid is a favourite seat for lipomata, and it is in this situation that the tendency of these growths to change their position is sometimes seen. Thus, Erichsen records a case where the tumour slid downwards from the shoulder to the breast.

Emerging from the interval between the two teres muscles, and winding horizontally round the shaft of the humerus, quite close to the bone, and about the line of the surgical neck, are the circumflex nerve and posterior circumflex artery. This nerve affords an example of an arrangement pointed out by Mr. Hilton, viz., that a principal nerve to a joint not only supplies the articular surfaces, but also some of the main muscles that move that joint and the skin over those muscles. This nerve supplies the shoulder joint, the deltoid and teres minor muscles, and the skin over the lower two-thirds of the shoulder and upper part of the triceps. "The object of such a distribution of nerves to the muscular and articular structures of a joint, in accurate association, is to ensure mechanical and physiological consent between the external muscular or moving force and the vital endurance of the parts moved, viz., of the joints, thus securing in health the true balance of force and friction until deterioration occurs" (Hilton). This nerve is frequently damaged in injuries to the shoulder. It may be severely bruised by a simple contusion of the part, and this bruising may be followed by paralysis of the deltoid. It would appear, however, that damage to the circumflex is much less frequent after contusions of the shoulder than was formerly maintained. It will also be readily understood that

the nerve is often torn in fractures of the surgical neck of the humerus, in dislocations of that bone (especially the luxation backwards), and in violent attempts at reducing such dislocations. The nerve, from its position, is very apt to be seriously pressed upon by growths springing from the upper end of the humerus. From its connection with the joint, it follows that in chronic inflammation of that part the inflammation may extend along the nerve, producing a neuritis that may lead to paralysis of the deltoid (Erb).

The **shoulder-joint**.—From one surgical point of view, joints may be divided into (1) those that depend for their strength mainly upon ligaments; (2) those that are mechanically strong, and that derive their stability to a great extent from the arrangement of their component bones; and (3) those that rely for their support principally upon muscles. As an example of the first kind may be cited the sterno-clavicular joint, of the second form the elbow-joint, and of the third the shoulder-joint. The articulation the least prone to dislocation is the one that derives its strength from tough unyielding ligaments, while the one most often luxated belongs to the third variety, its strength being greatly dependent upon muscles that may be taken by surprise, and that may themselves, from disordered action, prove sources of weakness. These are, of course, not the only features in the etiology of dislocation. A great deal depends upon the amount of movement permitted in a given joint, and the degree of leverage that can be brought to bear upon its parts.

The arch formed by the coracoid and acromion processes and the ligament between them forms an essential support to the head of the humerus, and is an important constituent of the articulation. With this arch the humeral head is in immediate relation, though not in actual contact (Fig. 25, p. 203). In paralysis of the deltoid the head may be separated by some distance from the coracoid process, and Nannoni records the case of a child with old-standing paralysis of the deltoid, between whose humeral head and acromial vault four



fingers could be lodged. It is well to note that at least two-thirds of the head of the bone are not in contact with the glenoid cavity when the arm hangs by the side, and Anger points out that in this position three-fourths of the circumference of the humeral head are in front of a vertical line drawn from the anterior border of the acromion process. In this posture, also, the head is wholly to the outer side of the coracoid process. The margin of the glenoid cavity is more prominent on the inner than on the outer side, while the strongest part of the margin and the broadest part of the fossa are below. This is significant, since it points to an attempt to strengthen a part of the joint that practice shows to be the weakest in the articulation, viz., the lower and inner portion of the capsule. It is at this place that the head of the bone leaves the joint in dislocation of the shoulder.

The capsule of the shoulder-joint is very lax, and would lodge a bone-head twice as large as that of the humerus. According to Henry Morris, no one part of the capsule is constantly thicker than the rest, as is the case in the hip-joint. The inner part of the capsule looks into the axilla, and is there free between the two tuberosities, between the lesser one in front and the posterior part of the greater one behind. It is between these two projections that the humeral head can be felt through the axilla.

Of the **bursæ** about the joint, the subacromial bursa is the one most frequently the seat of disease. This sac, when distended with fluid, may be mistaken for the results of chronic inflammation of the joint (Fig. 25, p. 203).

Experiment shows that the walls of this bursa may be actually torn in twists of the arm, especially when either flexed or extended (Nancrede). When the sac is distended most pain is elicited in the position of abduction, for in this posture the bursal walls are normally folded up, so as to form a sort of collar in advance of the greater tuberosity. When the walls are thickened and distended by inflammation, abduction must press the bursa very forcibly under the acromion, and so cause

pain. In elderly people the sac sometimes communicates with the joint. The subscapular bursa is in free communication with the capsule of the joint in front.

The **biceps tendon** strengthens the upper part of the joint, keeps the humerus against the glenoid cavity in the various positions of the limb, and prevents the head of the bone from being pulled too closely upwards under the acromion. The tendon may be ruptured, and in such a case, in addition to the general weakening of the limb, and the peculiar projection formed by the contraction of the muscle, the head of the humerus is usually drawn upwards and forwards until arrested by the coraco-acromial arch. Thus, a kind of slight false dislocation may be produced. In certain violent wrenches of the limb the tendon may slip from its groove and be displaced to one or other side, usually to the inner side. In these cases also the head is drawn up under the acromion, and is prominent in front, while abduction is rendered less free than is normal owing to the great tuberosity being sooner brought in contact with the acromion. The intracapsular part of the tendon may disappear in cases of chronic rheumatic arthritis, owing to friction against the abraded articular surface of the humerus. It acquires an attachment to the bicipital groove in such cases.

**Joint disease.**—This articulation is liable to all forms of joint disease. The capsule, as just stated, is very lax, but the humerus is kept in contact with the glenoid cavity by muscular and atmospheric pressure. In joint disease, however, the effusion may effect a considerable separation of the two bones. Braune, having pierced the glenoid cavity through the supraspinous fossa, injected tallow at considerable pressure into the joint. When fully distended the humerus was found to be separated from the scapula by more than  $\frac{1}{2}$  an inch, and this may serve to explain the lengthening of the limb often noted in joint disease of this part with much effusion. When the greatest degree of distension of the capsule was reached the humerus became slightly

extended and rotated in. It is significant that in shoulder-joint disease it is common for the arm to be found close to the side, the elbow carried a little back (extension), and the limb rotated inwards. This position may also be due to the rigid contraction of the muscles about the joint that is usually observed. When such contractions exist it may be inferred that the powerful latissimus dorsi has a little advantage over its opponents, and may be answerable for the rotation in and slight projection backwards of the arm. The inner part of the epiphyseal cartilage is just within the capsule, the outer, anterior, and posterior parts are entirely subperiosteal. It happens, therefore, that the pus in suppurative epiphysitis will find its way into the joint.

There may be three diverticula from the synovial membrane: (1) One that runs some way down the bicipital groove with the tendon; (2) a *cul-de-sac* beneath the subscapularis, formed by a communication between the synovial cavity and the bursa under that muscle; and (3) a *cul-de-sac* of like nature beneath the infraspinatus muscle. The first-named is constant; the second is frequently present; the third is rare. When the joint is filled with effusion, the capsule is evenly distended and the shoulder evenly rounded. Special projections usually occur at the seats of the diverticula. Thus a swelling often appears early in the course of a synovitis in the groove between the pectoralis major and the deltoid muscles, and this swelling may appear bilobed, being cut in two by the unyielding biceps tendon (Paulet). Fluctuation can best be felt by examining the uncovered part of the capsule in the axilla beyond the subscapular muscle. When the joint suppurates pus usually escapes at one of the *culs-de-sac* just mentioned, most often through the one that follows the biceps tendon. Pus may thus extend for some way along the bicipital groove. Pus escaping through the subscapular *cul-de-sac* is apt to spread between the muscle and the venter of the scapula, and to present at the lower and back part of the axilla. Purulent collections beneath the deltoid are nearly

always conducted towards the anterior aspect of the limb, being unable to proceed backwards owing to the denseness of the fascia covering in the deltoid and infraspinous muscles. In one recorded case, pus that had escaped from the shoulder-joint followed the course of the musculo-spiral nerve, and opened on the outer side of the elbow.

The various forms of ankylosis are common at the shoulder-joint, and to afford a freer range of movement to the limb in the more intractable of these cases, Tillaux proposes to divide the clavicle.

**Dislocations.**—Dislocations at this joint are more common than at any other joint in the body. This is explained by the shallowness of the glenoid fossa, the large size and globular shape of the head of the humerus, the extensive movements of the arm, the long leverage it affords, and the dependence of the articulation for its strength mainly upon muscles. The upper limb and shoulder are also peculiarly exposed to injury.

The principal forms of luxation of the humerus at the shoulder are : 1. *Subcoracoid*, forwards and a little downwards ; the usual form. 2. *Subglenoid*, downwards and a little forwards ; rare. 3. *Subspinous*, backwards ; rare.

In all complete dislocations the head of the bone leaves the joint cavity through a rent in the capsule. In so-called "false luxations" the capsule is not torn. For example, in the cadaver, if the deltoid be divided the humeral head can be displaced under the coracoid process without rupture of the capsule, and the same thing may occur during life, in cases where the muscle has long been paralysed.

In all cases of dislocation at this joint the *primary* displacement is always *downwards* into the axilla. It is well known that dislocations at the shoulder are usually due to violence applied to the limb while the arm is abducted, or to severe direct violence forcing the bone downwards. Now when the limb is abducted the head of the humerus projects below the glenoid fossa, and rests upon the inferior and least protected part

of the capsule. The fibres of this portion of the capsule being tightly stretched in this position, it requires no extraordinary force to tear the ligament and drive the bone into the axilla.

Thus it happens that in luxations at this joint the rent in the capsule is at its inferior and inner aspect. The head of the bone being thus driven downwards into the axilla, may, for certain reasons, remain there (subglenoid form), or more usually it will be drawn forwards and inwards by the powerful pectoralis major, aided by other muscles whose action is now less resisted and by the weight of the unsupported limb (subcoracoid form); and lastly, the direction of the violence being applied markedly from in front, the head of the bone may be thrust backwards under the acromion or spinous processes (subspinous form). The overwhelming frequency of the subcoracoid variety is explained by the greater advantage at which those muscles act that draw the bone forwards, in comparison with those that would draw it backwards, and by the very trifling opposition offered to the passage of the head forwards when compared with the substantial obstacles in the way of its passage backwards under the scapular spine.

**Features common to all dislocations at the shoulder.**—As the roundness of the deltoid depends to a great extent upon the presence beneath it of the humeral head, and as in all these luxations (save perhaps in the slighter grades of the subspinous form) the head is removed practically from its connection with the deltoid, that muscle is always more or less flattened. This flattening is augmented by the stretching of the muscle, which in some degree is constantly present. Stretching of the deltoid involves abduction of the arm, and this symptom is fairly constant in all the luxations. The biceps being also more or less unduly tense, the elbow is found flexed and the fore-arm supinated. In every form there is some increase in the vertical circumference of the axilla, since the head, having left the glenoid fossa, must occupy some part comprised within that circumference. Again, Dr. Dugas

has pointed out that "if the fingers of the injured limb can be placed by the patient, or by the surgeon, upon the sound shoulder while the elbow touches the thorax (a condition that obtains in the normal condition of the joint), there can be no dislocation; and if this cannot be done there *must* be one, for no other injury than a dislocation can induce this physical impossibility." This depends upon the fact that in consequence of the rotundity of the thorax it is impossible for both ends of the humerus to touch it at the same time, and in luxation at the shoulder the upper end of the bone is practically touching the trunk. Lastly, from the position of the great vessels and nerves it will be seen that in the subcoracoid and subglenoid luxations the head of the bone may press injuriously upon those structures. Thus may result cedema of the limb and severe pain or loss of muscular power. The artery is usually saved by its greater elasticity; but Bérard reports a case of displacement forwards where the axillary artery was so compressed by the humeral head as to induce gangrene of the limb.

The close connection of the circumflex nerve with the humerus renders it very liable to injury, especially in the subglenoid and subspinous forms of dislocation.

**Special anatomy of each form.**—1. *Subcoracoid.*—The articular head of the humerus lies on the anterior surface of the neck of the scapula, and the anatomical neck rests on the anterior lip of the glenoid fossa. The head is thus placed immediately below the coracoid process, and is in front of, internal to, and a little below, its normal site. The great tuberosity faces the empty glenoid cavity (Fig. 26). The subscapularis muscle is stretched over the head of the humerus, and is usually in some part torn. The supraspinatus, infraspinatus, and teres minor are stretched or torn, or the great tuberosity may even be wrenched off. The coraco-brachialis and short head of the biceps are tense, and are immediately in front of the head of the humerus instead of to its inner side. The long tendon of the biceps is deflected down-

wards and outwards. It is sometimes, although rarely, torn from its groove. The deltoid is put upon the stretch. The prominence formed by the humeral head in the front of the axilla depends to some degree upon the amount of rotation. If the bone be rotated out the projection is most distinct; but if rotated in, its head sinks into the axilla and is brought more in contact with the

scapula than with the skin. The head of the bone being always carried a little downwards, some lengthening must in all cases *really* exist; but with the ordinary method of measuring the limb this lengthening may be replaced by a normal measurement, or even by apparent shortening, if the head of the bone be carried a good deal forwards and inwards, and the limb be abducted. When the head has left the glenoid

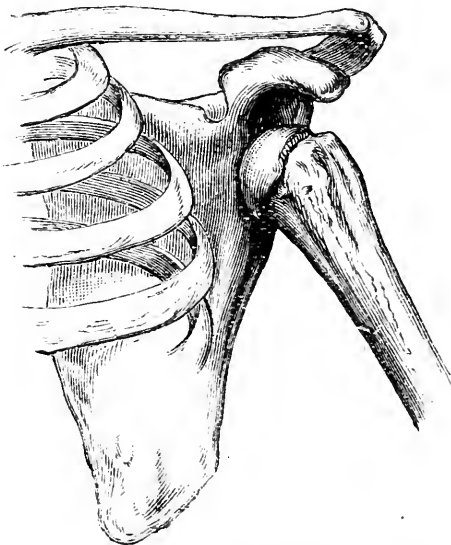


Fig. 26.—Subcoracoid Dislocation of the Humerus.

cavity abduction tends to bring the external condyle nearer to the acromion, and these are the two points between which the measurement is usually taken. Thus the apparent length of the arm depends mainly upon the degree of abduction of the humerus, or the obliquity of the axis of the bone.

2. **Subglenoid.**—The head is below, and a little in front of and internal to, its normal position. It cannot go directly downwards, owing to the situation of the long head of the triceps, but escapes in the interval

between that muscle and the subscapularis. The articular head rests on the anterior aspect of the triangular surface just below the glenoid fossa that gives origin to the triceps. The upper border of the great tuberosity is in close relation with the lower margin of the joint. It is generally stated, on the authority of Malle, that the circumstance which prevents the head of the bone from being drawn upwards is the entirety of the anterior part of the capsule, the rent being in the lower part only of that ligament. The subscapularis muscle is much stretched or torn, and the head usually lies beneath its tendon, and upon some fibres of the disturbed muscle. The supraspinatus will be torn. The infraspinatus will be stretched or torn, and the two teres muscles will not be much affected unless there be considerable abduction of the arm. The coraco-brachialis and biceps will be stretched, but owing to the amount of abduction usually present the biceps tendon is but little deflected from a straight line. The deltoid is greatly stretched, and its tension serves to produce the extreme flattening of the shoulder and the great abduction common in this injury. Some lengthening is seldom absent, although it is always modified by the abduction that exists.

3. **Subspinous.**—The head usually rests on the posterior surface of the neck of the scapula, the groove of the anatomical neck of the humerus corresponding to the posterior lip of the glenoid fossa. The head is thus placed beneath the acromion; but it may be displaced still farther back, and may rest on the dorsum scapulæ, and beneath the scapular spine (Fig. 27). The subscapularis tendon is drawn right across the glenoid fossa, and is often torn from its attachment. The head pushes back the hinder part of the deltoid, the infraspinatus and teres minor muscles. These latter cover the bone, and are stretched over it. The supraspinatus is tense, as is also the biceps, while the teres major and latissimus dorsi are relaxed. The great pectoral is rendered unduly tense, and this serves in part to explain the rotation inwards of the humerus,



and the adduction forwards, that are usually observed, those movements being more or less unopposed. The circumflex nerve is often torn.

In reducing dislocations, especially such as are of long standing, serious damage may be inflicted on the axillary structures. The axillary artery suffers most frequently, the vein rarely, and the nerves still less often. The artery, being placed externally, is apt to contract adhesions to the soft parts covering the head of the displaced bone, and to be, therefore, torn when those parts are disturbed.

### **Fractures of the upper end of the**

**humerus.**—1. **Anatomical neck.**—The upper part of the capsule is exactly attached to the anatomical neck, and in this situation the fracture may run beyond the ligament and be partly extracapsular. The lower part of the capsule is inserted some little way below the anatomical neck, and in this position, therefore, the lesion must be intracapsular. From the line of attachment of the lower part of the capsule to the humerus, fibres are reflected upwards to the margin of the articular cartilage on the head of the bone. These fibres, if unruptured, may serve to connect the fragments. If entirely separated, the head of the bone must necrose, having no such source of blood supply as the head of the femur derives from the round ligament. It is easy for the small and comparatively dense upper fragment to be driven into the wide surface of cancellous bone exposed on the upper surface of the lower fragment.

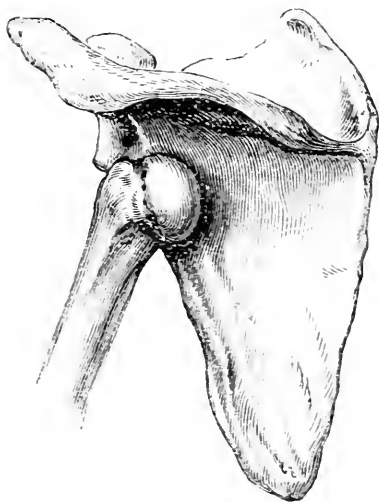


Fig. 27.—Subspinous Dislocation of the Humerus.

When impaction occurs, there may be some flattening of the deltoid, since the head is rendered of less dimensions by that impaction, and consequently causes a less projection of the deltoid. It may be possible to detect the impaction by examination through the axilla when the arm is fully abducted. The difficulty of obtaining crepitus in non-impacted fractures will be obvious when the small size of the upper fragment is considered, together with its great mobility, and the obstacles in the way of so fixing it that one broken end may be rubbed against the other.

The amount of displacement is to be measured by the laxity of the capsule. The usual deviation is a projection of the upper end of the lower fragment towards the anterior and inner side of the articulation, brought about mainly by the muscles attached to the bicipital groove. In no case could the two bone-ends overlap.

2. **Separation of the upper epiphysis.**—The lower border of this epiphysis is represented by a horizontal line crossing the bone at the base of the great tuberosity and placed between the anatomical and surgical necks. It would be fairly indicated by a transverse saw-cut through the widest part of the bone. The three component nuclei of this epiphysis (head, greater and lesser tuberosities) fuse together about the fifth year, and the entire mass joins the shaft about the twentieth year. The upper fragment may be carried and rotated a little outwards by the muscles attached to the great tuberosity, while the lower fragment is drawn inwards and forwards by the muscles inserted into the bicipital groove. Thus, a part of the smooth upper end of the lower fragment commonly forms a distinct projection below the coracoid process. In such case the axis of the limb would be altered, and the elbow carried a little from the side. Often, however, the displacement is solely in the antero-posterior direction, the lower fragment projecting forwards. So wide are the two bone surfaces at the seat of injury that it is scarcely possible for them to overlap one another.

3. **Surgical neck.**—The surgical neck is situated between the bases of the tuberosities and the insertions of the latissimus dorsi and teres major muscles. A common displacement of parts is the following. The upper fragment is carried out and rotated out by the supra- and infra-spinatus and teres minor. The upper end of the lower fragment is drawn upwards by the

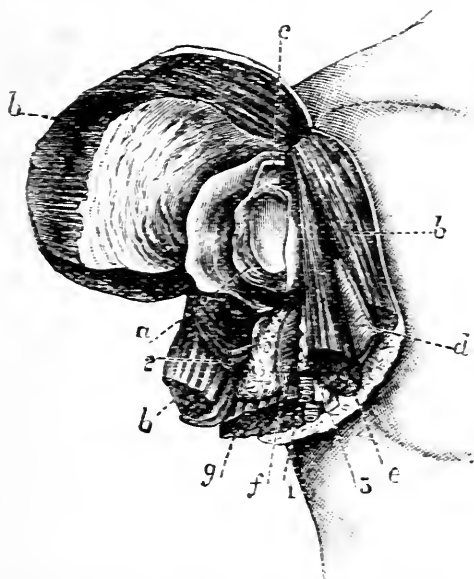


Fig. 28.—Amputation at Shoulder-joint (dap-method) (Agatz).

*a*, Glenoid cavity; *b*, deltoid; *c*, long head of biceps; *d*, pectoralis major; *e*, biceps and coraco-brachialis; *f*, latissimus dorsi and teres major; *g*, triceps; 1, axillary vessels; 2, circumflex vessels; 3, brachial plexus.

deltoid, biceps, coraco-brachialis, and triceps, inwards by the muscles attached to the bicipital groove, and forwards by the great pectoral. Thus, it forms a projection in the axilla, and the axis of the limb is altered so that the elbow projects from the side. This displacement, however, is by no means constant. Pean, Anger, and others maintain that the usual deformity is a projection of the upper end of the lower fragment forwards, and that this deviation is due to the nature and direction

of the violence, and not to muscular action. In some cases there is no displacement, the broken ends being retained *in situ*, probably, by the biceps tendon and the long head of the triceps. In at least one instance (Jarjavay) the lower fragment was so drawn upwards and outwards, apparently by the deltoid, as to nearly pierce the skin of the shoulder. Hamilton comes to the general conclusion "that complete or sensible displacement is less common at this fracture than in most other fractures," and in this conclusion many surgeons agree.

**Amputation at the shoulder joint.**—"*Flap method*"; "deltoid flap." In the outer flap are only the deltoid and a few small vessels derived from the acromio-thoracic and the two circumflex arteries. The cephalic vein and descending branch of the acromio-thoracic artery are in the inner flap. The anterior and posterior borders of the inner flap show portions of the deltoid muscle. Along its lower border from before backwards are sections of the pectoralis major, the short head of the biceps and coraco-brachialis, the axillary vessels and nerves, the latissimus dorsi and teres major, the triceps, and the posterior portion of the deltoid. The trunks of the posterior circumflex artery and nerve are found divided on the posterior part of the surface of the flap, between the sections of the triceps and deltoid, and not far from the angle between the two flaps.

*Oval method* (Spence). The parts cut and the order of their division are practically the same as obtain in the *anterior* and *inferior* borders of the two flaps made in the previous method. The anterior incision, being a little more vertical than is the gap between the two flaps, divides more of the pectoralis major and cuts the cephalic vein higher up. The posterior circumflex vessels and nerve are separated from the bone by the finger and are retained, one advantage of the procedure being that only a few of the terminal branches of that artery are divided.

## CHAPTER XII.

## THE ARM.

THE arm, upper arm, or brachial region is considered to extend from the axilla above to the region of the elbow below.

**Surface anatomy.**—In women, and in those who are fat, the outline of the arm is rounded and fairly regular. It is less regular in the muscular, in whom it may be represented by a cylinder, somewhat flattened on either side and unduly prominent in front (biceps muscle). The outline of the biceps muscle is distinct, and on either side of it is a groove. The inner of the two grooves is by far the more conspicuous. It runs from the bend of the elbow to the axilla, and indicates generally the position of the basilic vein and brachial artery. The outer groove is shallow, and ends above at the insertion of the deltoid muscle. So far as it goes it marks the position of the cephalic vein.

The insertion of the deltoid can be well made out, and is an important landmark. It indicates very precisely the middle of the shaft of the humerus, is on the same level with the insertion of the coraco-brachialis muscle, and marks the upper limit of the brachialis anticus. It corresponds also to the spot where the cylindrical part of the humeral shaft joins the prismatic portion, to the point of entrance of the nutrient artery, and to the level at which the musculo-spiral nerve and superior profunda artery cross the back of the bone.

When the arm is extended and supinated, the brachial artery corresponds to a line drawn along the inner border of the biceps, from the outlet of the axilla (at the junction of its middle and anterior thirds) to the middle of the bend of the elbow. The artery is superficial, and can be felt in its entire extent. In its upper two-thirds, it lies on the inner aspect of the shaft of the humerus, and can be compressed against the bone by pressure in a direction outwards and slightly back

wards. In its lower third the humerus lies behind it, and compression, to be effectual, should be directed backwards.

The inferior profunda would be represented by a line drawn from the inner side of the humeral shaft at its middle to the back part of the internal condyle. The nutrient artery enters the bone at its inner aspect opposite the deltoid insertion, and the anastomotic vessel comes off about 2 inches above the bend of the elbow.

The ulnar nerve follows first the brachial artery, and then a line drawn from the inner side of that vessel, about the level of the insertion of the coraco-brachialis to the gap between the inner condyle and the olecranon. The main part of the internal cutaneous nerve is beneath the inner bicipital groove, while the superficial portion of the musculo-cutaneous corresponds to the lower termination of the outer groove.

The **arm**.—The skin of the arm is thin and smooth, especially in front and at the sides. It is very mobile, being but loosely attached to the deeper parts by a lax subcutaneous fascia. In circular amputations of the arm this looseness of the integument allows it to be sufficiently drawn up by traction with the hand only. It is from the integument covering the anterior surface of the biceps that the flap is fashioned in Tagliacozzi's operation for the restoration of the nose. The fineness of the skin of this part, and its freedom from hairs, render it very suitable for this procedure. The scanty attachments of the skin of the arm allow it to be readily torn or stripped away in lacerated and contused wounds. Sometimes in these lesions large flaps of integument are violently dissected up. The looseness of the subcutaneous tissues favours greatly the spread of inflammatory processes, while its comparative thinness allows of the early manifestation of ecchymoses.

The limb is completely invested with a deep fascia, the brachial aponeurosis, as by a sleeve. The fascia is held down at the sides by the two intermuscular septa which are attached along the outer and inner

margins of the humerus, running from the deltoid insertion to the outer condyle on the one side, and from the coraco-brachialis insertion to the inner condyle on the other. By means of this aponeurosis and its septa the arm is divided into two compartments, that can be well seen in transverse sections of the limb. These compartments serve to confine inflammatory and hæmorrhagic effusions. The anterior of the two spaces has the less substantial boundaries, owing to the thinness of the brachial fascia as it covers the biceps. Effusions can readily pass from one compartment to the other by following the course of those structures that, by piercing the intermuscular septa, are common to both spaces. These are the musculo-spiral and ulnar nerves, the superior and inferior profunda, and anastomotic arteries. The principal structures that pierce the brachial aponeurosis itself are the basilic vein, a little below the middle of the arm, the internal cutaneous nerve, about the middle, and the external cutaneous nerve, just above the elbow. The two first named are in the inner bicipital groove, and the last named in the outer.

The skin over the point of insertion of the deltoid was commonly selected as a suitable place for an issue at a time when that remedy was popular. The reasons for such selection were the absence of blood-vessels of any size in the parts beneath, and the freedom of the spot from muscular movement. The brachialis anticus is closely adherent to the bone, while the biceps is free. It follows, therefore, that in section of these muscles, as in amputation, the latter muscle retracts more considerably than does the former. It is well, therefore, in performing a circular amputation, to divide the biceps muscle first, and then after it has retracted to cut the brachialis anticus.

The **brachial artery**.—The line of this vessel has already been given. It is well to note that in the very muscular the artery may be overlapped to a considerable extent by the biceps muscle. Compression of the brachial, unless performed carefully with the

fingers, can hardly avoid at the same time compression of the median nerve. Thus, no doubt, arises the severe pain that is often complained of when tourniquets, or circular indiarubber bands, are applied to the limb. It must also be remembered that the internal cutaneous nerve lies in front of the vessel, or close to its inner side, until it pierces the fascia; that the ulnar nerve lies along the inner side of the artery as far as the coracobrachialis insertion; and that behind the commencement of the vessel is the musculo-spiral nerve. The venæ comites are placed one on either side of the artery, and communicate frequently with one another by short transverse branches which directly cross the vessel, and which may give trouble in operations upon the artery. If in ligaturing the artery at its middle third the arm rests upon any support, the triceps may be pushed up and mistaken for the biceps. If the incisions be too much to the inner side the basilic vein may be cut, or the ulnar nerve exposed and mistaken for the median. Tillaux states that in the operation a large inferior profunda artery has been taken for the brachial. Inasmuch as the median nerve often derives distinct pulsation from the subjacent vessel, it happens that in the living subject it has been confused with the main artery itself.

Abnormalities in the arrangement of the brachial artery are so frequent (they occur in 12 to 15 per cent. of arms) as to be of surgical importance. It is not unusual to find a collateral branch (*vas aberrans*) arising from the upper part of the brachial or lower part of the axillary, passing down the arm, superficial to the median nerve, and ending in the radial or sometimes the ulnar artery. The *vas aberrans* may replace the brachial, in which case the artery will be found superficial instead of deep to the main vessel, and the profunda vessels arise from the remnant of the real brachial artery. This superficial brachial vessel may pass under the *supra-condyloid process*, a hooked projection of bone which occasionally springs from the inner aspect of the humerus, 2 inches above the epicondyle.



The **musculo-spiral nerve**, from its close contact with the bone, which it crosses at the level of the deltoid insertion, is frequently injured and torn. Thus it has been damaged in severe contusions, in kicks, in stabs, in bites from horses, and very frequently in fractures of the humeral shaft; or the nerve may be sound at the time of fracture, and become subsequently so involved in the callus formed as to lead to paralysis of the parts it supplies. In a case reported by Tillaux, where paralysis followed some time after a fracture, the nerve was found embedded in callus, and on cutting some of the redundant mass away a good recovery followed. In several instances the nerve has been paralysed by the pressure of the head when a man has slept with his head resting on the arm in the position of full supination and abduction. It is said to be often paralysed in Russian coachmen who fall asleep with the reins wound round the upper arm. It has also been frequently damaged by the pressure of badly constructed crutches, especially those that afford no proper support for the hand. Indeed, it is the nerve most often affected in "crutch paralysis," the ulnar being the trunk that suffers next in frequency.

**Fracture of the shaft of the humerus** is usually due to direct violence. The shaft may, however, be broken by indirect violence, and of all bones the humerus is said to be the one most frequently fractured by muscular action. As examples of the latter may be noted the throwing of a ball, the clutching at a support to prevent a fall, and the so-called trial of strength known as "wrist turning." When the bone is broken *above* the deltoid insertion the lower fragment may be drawn upwards by the biceps, triceps, and deltoid, and outwards by the last-named muscle; while the upper fragment is drawn inwards by the muscles attached to the bicipital groove. When the fracture is *below* the deltoid insertion, the lower end of the upper fragment may be carried outwards by that muscle, while the lower fragment is drawn upwards to its inner side by the biceps and triceps. The

deformity, however, as a rule depends much more upon the nature and direction of the force that breaks the bone than upon any muscular action. The displacements just noted *may* be met with, but usually they are quite independent of the relation of the deltoid insertion to the seat of fracture, and cannot be tabulated. The weight of the arm seldom allows of more than three-quarters of an inch of shortening.

The humerus is more frequently the seat of *non-union* after fracture than is any other bone. This result is quite independent of the position of the fracture in relation to the nutrient artery. Hamilton's explanation is briefly this: the fracture is usually so adjusted that the elbow is flexed; this joint soon becomes fixed by muscular rigidity, and when any movement is made as if to flex or extend the fore-arm on the arm, that movement no longer occurs at the elbow joint, but at the seat of fracture. Thus, if the arm be in a sling, and the patient allows the hand to drop by relaxing that sling, it is maintained that the bulk of that movement will take place about the fracture line. There are many objections to this theory. If true, the tendency to movement about the fragments would be the greater the farther the fracture is from the elbow joint, but non-union is more common at the middle than at the upper third of the shaft. Probably many causes conspire to bring about non-union of fractures of this bone, among which may be mentioned the imperfect fixing of the joint above the fracture, and the inadequate support afforded to the elbow, whereby the weight of the arm and of the splints tends to drag the lower fragment out of the proper line it should form with the upper fragment. The most effective cause would appear to be due to the entanglement of muscular tissue between the broken ends, for it must be remembered that the shaft of the bone is closely surrounded by muscular fibres that are directly adherent to its surfaces. Thus, in an oblique fracture the end of one fragment may be driven into the brachialis anticus, while the other end projects into the substance of the triceps,

and immediate contact of the bones may be consequently prevented.

**Amputation through the middle of the arm.**—Circular method: The parts divided in this amputation are fully shown in Fig. 29. Flap method: Two flaps of about equal size and shape may be cut antero-posteriorly, the arm being well rotated outwards.

In the anterior flap would be the biceps and the greater part of the brachialis anticus, with the musculocutaneous nerve between them, and a small piece of the triceps from the inner side of the limb. The brachial vessels, the median and ulnar nerves, and possibly the inferior profunda artery, are also found in this flap, about the inner angle of the stump. The basilic vein and internal cutaneous nerve lie about the inner border of the anterior flap,

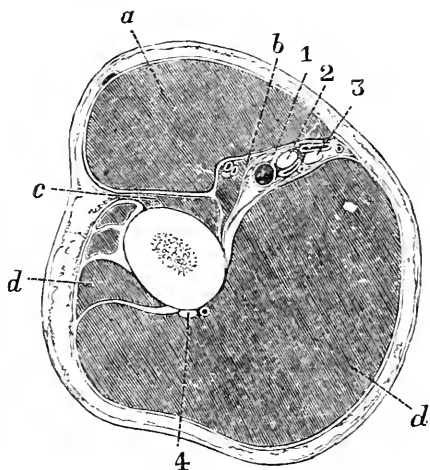


Fig. 29.—A Transverse Section through the middle of the Arm (Braune).

*a*, Biceps; *b*, coraco-brachialis; *c*, brachialis anticus; *d*, triceps; 1, brachial artery; 2, median nerve; 3, ulnar nerve; 4, musculo-spiral nerve.

and the cephalic vein about its outer border. In the posterior flap would be the triceps, any small part of the outer portion of the brachialis not divided in the anterior flap, the superior profunda artery, and the musculo-spiral nerve. If the amputation be lower down in the arm, the ulnar nerve and inferior profunda artery may be found in the posterior instead of the anterior flap. Since the nutrient artery enters the bone about the insertion of the coraco-brachialis and runs towards the elbow, it would be divided in these amputations, and might give trouble.

## CHAPTER XIII.

## THE REGION OF THE ELBOW.

**Surface anatomy.**—On the anterior aspect of the elbow are seen three muscular elevations. One, above and in the centre, corresponds to the biceps and its tendon; while, of the two below and at the sides, the outer corresponds to the supinator longus and the common extensor mass, and the inner to the pronator radii teres and the common set of flexor muscles. The arrangement of these elevations is such that two grooves are formed, one on either side of the biceps and its tendon. The grooves diverge above, and join the outer and inner bicipital grooves, while below they meet over the most prominent part of the tendon, and thus form together a V-shaped depression. The distinctness of these details depends upon the thinness and muscular development of the individual. In the inner of the two grooves are to be found the median nerve and the brachial artery and its veins; while deeply placed below the outer groove are the terminations of the musculo-spiral nerve and superior profunda artery, with the small radial recurrent vessel. The biceps tendon can generally be very distinctly felt. Its outer border is more evident than is its inner edge, owing to the connection of the bicipital fascia with the latter side of the tendon. Extending transversely across the front of this region is a crease in the integument, the “fold of the elbow.” This fold is not a straight line, but is convex below. It is placed some little way above the line of the articulation, and its lateral terminations correspond to the tips of the two condylar eminences. In backward dislocations of the elbow the lower end of the humerus appears about 1 inch below this fold, whereas in a fracture of the humerus just above the condyles the fold is either opposite to the prominence formed by the lower end of the upper fragment, or is below it. This crease is obliterated on extension.

At the apex of the V-shaped depression, about the spot where the biceps tendon ceases to be distinctly felt, and at the outer side of that tendon, the median vein divides into the median basilic and the median cephalic. At the same spot also the deep median vein joins the superficial vessels. The median basilic vein can be seen to cross the biceps tendon, to follow more or less closely the groove along the inner border of the muscle, and to join, a little above the internal condyle, with the posterior ulnar vein to form the basilic trunk. The median cephalic, following the groove at the outer margin of the biceps, joins, about the level of the external condyle, with the radial vein to form the cephalic vein. The brachial artery bifurcates about a finger's breadth below the centre of the bend of the elbow. "The coronoid process of the ulna can be indistinctly felt, if firm pressure is made in the triangular space in front of the joint" (Chiene). The points of the two condyles can always be felt. The internal condyle is the more prominent and the less rounded of the two. The humero-radial articulation forms a horizontal line, but the humero-ulnar joint is oblique, the joint surfaces sloping downwards and inwards. Thus it happens that while the external condyle is only  $\frac{3}{4}$  of an inch (18 mm.) above the articular line, the point of the internal condyle is more than 1 inch (28 mm.) above that part (Paulet). From the obliquity of the joint surfaces between the ulna and humerus, it follows that the fore-arm, when in extension, is not in a straight line with the upper arm, but forms with it an angle that opens outwards. Thus, when traction is made upon the entire upper limb from the wrist, some of the extending force is necessarily lost, and such traction, therefore, should be applied from the elbow, as is the usual practice in reducing a dislocation of the shoulder by manipulation. A line drawn through the two condyles will be at right angles with the axis of the upper arm, while it will form an angle with the axis of the fore-arm. Thus if we look at the upper arm, the two condyles are on the same level, whereas, when viewed from the fore-arm, the

inner condyle lies at a higher level than does the external process.

The joint line of the elbow is equivalent only to about two-thirds of the width of the entire line between the points of the two condyles (Fig. 31, p. 243). The prominence of the condyles forms a capital *point d'appui* for traction by encircling bands applied to the limb above the elbow joint. At the back of the elbow the prominence of the olecranon is always to be distinctly felt. It lies nearer the internal than the external condyle. In extreme extension the summit of the olecranon is a little above the line joining the two condyles. When the fore-arm is at right angles with the arm, the tip of the process is below the line of the condyles, and in extreme flexion it lies wholly in front of that line. Between the olecranon and the inner condyle is a depression that lodges the ulnar nerve and the posterior ulnar recurrent artery.

To the outer side of the olecranon, and just below the external condyle, there is a depression in the skin which is very obvious when the limb is extended. This pit is to be seen even in those who are fat, and also in young children. In it the head of the radius can be felt, and can be well distinguished when the bone is rotated in pronation and supination. The pit corresponds to the hollow between the outer border of the anconeus and the muscular eminence formed by the two radial extensors of the carpus and the supinator longus. The highest point of the bone that can be felt moving on rotation will correspond to the radius immediately below the line of the elbow joint, and is a valuable guide to that articulation. The upper limit of the elbow joint reaches a line drawn between the point of the two condyles. The tubercle of the radius can be felt just below the head of the bone when the limb is in the position of extreme pronation.

The **region of the elbow**.—The *skin* in front of the elbow is thin and fine, and is readily excoriated by tight bandaging and by improperly applied splints. The thinness of the skin allows the subjacent veins to

be easily seen through the integuments, but the distinctness with which these veins appear depends mainly upon the amount of subcutaneous fat. In the very stout they may be quite invisible, and it may be difficult or impossible to render them evident by the usual means adopted in venesection. Tillaux points out that if such people are bled a pellet of fat will often project into the wound and prevent the flow of blood.

The arrangement of the **superficial veins** in front of the elbow, so as to form an **M-shaped** figure, is familiar, but it must be confessed that it is by no means constant (Fig. 30). So far as I have seen, it would appear that the precise **M-like** arrangement figured in most books is only present in about two-thirds, and perhaps in only one-half, of all cases.

The median vein breaks up into the median cephalic and median basilic, just to the outer side of the biceps tendon, and, therefore, the latter vein passes in front of the tendon, of the brachial artery and its veins, and of the median nerve. From these structures it is separated by the bicipital fascia. The median basilic vein may cross the brachial artery abruptly, and be comparatively free of it, except at the point of crossing, or it may run for some distance quite in front of the artery, or, crossing it early, it may lie parallel with the vessel, although at a different level, for the greater part of its course. As regards size, the median basilic is

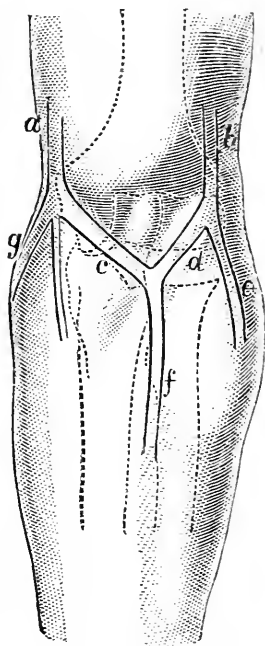


Fig. 30.—The Left Elbow from in front.

- a, Basilic vein; b, cephalic vein; c, on the ulna points to median basilic vein; d, on the radius points to median cephalic vein; e, radial vein; f, median vein; g, posterior ulnar vein.

usually the largest of these veins, the median cephalic coming next, and the median itself third, while the ulnar and radial veins are the smallest of the series. These veins are liable to many abnormalities, some of the most conspicuous being in cases where the main arteries of the part also are abnormal. The deviation is more usual in the veins on the radial than in those on the ulnar side of the limb. Thus it is common for the radial or the median cephalic veins, or both, to be either very defective or entirely absent. In spite of the relation the median basilic vein bears to the brachial artery, it is nevertheless the vein usually selected in venesection and transfusion. The reasons for its selection are these : it is usually the largest and most prominent of the veins, and the one the nearest to the surface ; it is also the least movable vein, and the one the least subject to variation. The bicipital fascia forms an excellent protection to the brachial artery during phlebotomy. The density of that membrane varies, and depends mainly upon the degree of muscular development. In thin subjects the median basilic vein may receive pulsations from the subjacent artery. According to one observer, the walls of this vein are often as thick as those of the popliteal vein. The ulnar, radial, and median veins seldom yield enough blood on venesection, since they are below the point of junction of the deep median vein, and thus do not receive blood from the deep veins of the limb. The brachial artery has, as may be supposed, been frequently injured in bleeding ; and at the period when venesection was very commonly practised, arterio-venous aneurisms at the bend of the elbow were not infrequent. Since the principal superficial lymphatic vessels run with these veins, and since some of them can scarcely escape injury in phlebotomy, it follows that an acute lymphangitis is not uncommon after the operation, especially when, the point of the lancet being unclean, septic matter is introduced into the wound.

The internal cutaneous nerve, which usually runs in front of the median basilic vein, may be wounded in bleeding from that vessel. The injury to the nerve,



according to Tillaux, may lead to "traumatic neuralgia of extreme intensity, and very chronic." A "bent arm" may follow after venesection, and Mr. Hilton believes this to be often due to injury to the filaments of the musculo-cutaneous nerve, especially to the inclusion of those filaments in a scar left by the operation. The cutaneous branches of this nerve lie over the median cephalic vein. These peripheral fibres being irritated, the muscles supplied from the same segment of the cord (biceps and brachialis anticus) are caused to contract by reflex action. Hence the bent arm. In one case he cured a bent arm following bleeding by resecting the old scar, which on removal was found to have included within its substance some nerve filaments.

There is a **lymphatic gland** situated over the internal intermuscular septum of the arm, and just above the internal condyle. It receives some of the surface lymphatics from the inner side of the fore-arm, and two or three inner fingers. In position, it is the lowest gland in the upper limb.

The **brachial artery**.—In forcible flexion of the limb the artery is compressed between the muscular masses in front of the joint, and the radial pulse is much diminished or even checked. The artery may divide in the lower third of the arm, and in such cases the ulnar artery may pass over the bicipital fascia. Aneurisms at the bend of the elbow have been treated by flexion of the limb, that position bringing more or less direct pressure to bear upon the sac. In full extension of the joint the artery becomes flattened out, and the radial pulse diminished. In the over extension possible with fractured olecranon the pulse may be stopped at the wrist. Forcible extension of an elbow that has become rigid in the bent position has caused rupture of the brachial artery.

The **ulnar nerve** is, from its position at the elbow, very liable to be injured. It passes on a groove behind the internal epicondyle. The nerve may pass in front of the internal condyle, and an instance is reported where the nerve slipped forward over that

eminence whenever the elbow was bent (Quain). In cases where an abnormal brachial passes beneath a supra-condyloid process the median nerve goes with the artery. In exposing the ulnar nerve (for nerve stretching, etc.) behind the elbow the nerve may be found quite covered by an occasional muscle, the epitrochleo-anconeus.

The **elbow joint**.—The strength of this joint depends not so much upon either ligaments or muscles as upon the coaptation of the bony surfaces. The relations of the olecranon and coronoid process to the humerus are such that in certain positions the strength of the joint is very considerable.

The elbow, being a pure hinge-joint, permits only of flexion and extension. These movements are oblique, so that in flexion the fore-arm inclines inwards, carrying the hand towards the middle third of the clavicle. If it were not for the obliquity of the joint line it would be possible for the hand to be placed flat upon the shoulder of the same side, but this movement is only possible after some excisions of the joint, for in this operation the oblique direction of the articular surfaces is not reproduced. In extreme extension the ulna is nearly in a straight line with the humerus as regards their lateral planes, while in extreme flexion the two bones form an angle of from  $30^{\circ}$  to  $40^{\circ}$ .

**Bursæ**.—Of the bursæ about the joint the large subcutaneous bursa over the olecranon is very commonly found enlarged and inflamed; and when inflamed may lead to extensive mischief in the limb. Its enlargement is favoured by certain employments involving pressure on the elbow; thus, the disease known as "miner's elbow" is merely an enlargement of this sac. There is a bursa between the biceps tendon at its insertion and the bone, the relations of which to the nerves of the fore-arm are worth noting. A case, for instance, is reported where this bursa became chronically enlarged, and by pressing upon the median and posterior interosseous nerves produced loss of power in the fore-arm (Agnew).

Of the **ligaments** of the elbow-joint, the anterior

and posterior are comparatively thin, and the latter especially soon yields to the pressure of fluid within the joint in disease of the articulation. The internal lateral is the strongest and most extensive of the ligaments of the part. From its rigidity, its extended attachment, and the fact that it serves to limit not only flexion and extension, but also any attempt to wrench the fore-arm laterally from the arm, it happens that it is the ligament that suffers the most often in "sprains" of the elbow. As this ligament is attached to the whole length of the inner border of the olecranon, it may assist in preventing separation of the fragments when that process has been fractured.

**Joint disease.**—In disease of this joint the effusion first, and most distinctly, shows itself by a swelling around the margins of the olecranon. This is explained by the facts that the synovial cavity is here nearest to the surface, and that the posterior ligament is lax and thin. Some swelling is also soon noticed about the line of the radio-humeral joint, and fluctuation in this situation serves to distinguish joint effusion from simple enlargement of the bursa beneath the triceps tendon. Deep-seating swelling may be noted about the front of the joint beneath the brachialis anticus, owing to the thinness of the anterior ligament; and lastly, about the external condyle. The density of the internal ligament prevents a bulging of the synovial membrane on the inner side. When the joint suppurates the pus will most easily reach the surface by travelling upwards and backwards between the humerus and the triceps, and the abscess points, therefore, very commonly at one or other border of that muscle. The pus may escape beneath the brachialis anticus in front, and discharge itself near the insertion of the muscle. When the bone is diseased the sinuses form usually directly over the part attacked. The diseased elbow tends to assume the posture of semi-flexion, and it is interesting to observe that that is the position assumed by the joint when forcible injections are made into its cavity (Braune). The joint, in fact,

holds the greatest amount of fluid when it is semi-flexed. As regards muscular rigidity of the elbow, due to reflex irritation from disease, it is well to note that all the nerves of the articulation supply muscles acting upon the joint, notably the musculo-spiral and musculo-cutaneous. The relation of the ulnar nerve to the joint serves to explain cases where severe pain has been felt along the fore-arm and in the fingers, in parts corresponding to the distribution of that nerve. The upper epiphysis of the radius and the greater part of the lower epiphysis of the humerus are intrasynovial, *i.e.* come within the capsule of the joint. The comparatively small upper epiphysis of the ulna is only partly within the capsule (Fig. 31, p. 243).

**Dislocations of the elbow.**—These are many, and may be thus arranged. (1) Dislocations of *both radius and ulna* either backwards, outwards, inwards, or forwards (in order of frequency). (2) Dislocations of the *radius alone* either forwards, backwards, or outwards (in order of frequency). (3) Luxation of the *ulna alone* backwards.

As a preliminary it may be convenient to note some general anatomical considerations in connection with these various displacements.

(a) *Antero-posterior luxations are much more common than are lateral luxations.*—Displacements in the antero-posterior direction are more common because the movements of the joint take place in that direction, and the width of the articular surface of the humerus from before backwards is comparatively small. On the other hand, there is normally no lateral movement of the elbow, and the width of the articulation from side to side is considerable. The antero-posterior ligaments are feeble, while the lateral ligaments are strong, and the joint, moreover, receives more muscular support at its sides than it does either behind or in front. The mutual support afforded by the bones to one another is weakened in the antero-posterior direction during certain movements. Thus in full flexion the olecranon has but a feeble hold upon the humerus, while in

extension the hold of the coronoid process upon that bone is even less. In a lateral direction, however, movement has but a very slight effect upon the support the bones mutually derive from one another.

(b) *Both bones of the fore-arm are more often luxated together than is either the radius alone or the ulna alone.* This depends upon the powerful ligamentous connection between the radius and ulna on the one hand, and the absence of such connection between the humerus and the radius on the other. In the dead subject it is not difficult to dislocate the two bones of the fore-arm, but it is extremely difficult to separate the radius from the ulna without great breaking and tearing of parts.

(c) *The commonest dislocation of the two bones together is backwards, the rarest is forwards.*—In the former instance the movement is resisted by the small coronoid process, in the latter by the large and curved olecranon. For like reasons the luxation outwards is less rare than is the displacement inwards, since the articular surface of the humerus inclines downwards and inwards on the inner side, and thus affords a greater obstacle in that quarter.

(d) *If a single bone be dislocated it will usually be the radius.*—This follows from the absence of reliable union between that bone and the humerus, from the greater exposure of the radius (“the handle of the hand”) to indirect violence, and from its greater mobility. The luxation is usually forwards, due to the fact that the forms of violence that tend most often to displace the bone tend also to draw it forwards. Paulet asserts that the posterior part of the annular ligament is “much more resistant” than is the anterior part. The luxation of the ulna alone occurs in the backward direction, for reasons that will be obvious.

Dislocations of the elbow of all kinds may be partial or complete. More usually they are complete when in the antero-posterior direction, and partial when the luxation is lateral.

Some more detailed notice may now be taken of

the only two forms of dislocation at the elbow that are at all common.

(1) **Displacement of both bones backwards.**—This may be effected during forced extension. Here the point of the olecranon pressed against the humerus acts as the fulcrum of a lever of the second kind, and tends to tear the ulna from the lateral bone. The addition of violence to the fore-arm in a backward or upward direction would effect the actual displacement. This condition may be illustrated by a fall, as in running, upon the fully extended hand. The lesion may also be produced by certain violent wrenchings of the limb. Malgaigne maintained that the particular kind of wrench most effectual in producing luxation was a twisting inwards of the fore-arm while the elbow was semi-flexed. In this way the internal lateral ligament was ruptured, and the coronoid process twisted inwards and downwards under the humerus, and the bones thus displaced back. This lesion would be difficult to effect while the joint was fully flexed. In the complete form the coronoid process is opposite to the olecranon fossa. It can hardly occupy that hollow (as sometimes described), since the connection of the ulna to the radius, and the projection of the latter bone behind the outer condyle, would prevent it from actually falling into the fossa. The anterior and the two lateral ligaments are usually more or less entirely torn, while the posterior and the orbicular ligaments escape. The biceps is drawn over the lower end of the humerus, and is rendered moderately tense. The brachialis anticus is much stretched and often torn. The anconeus is made very tense. Both the median and ulnar nerves may be severely stretched.

(2) **Dislocation of the radius forwards.**—This may be due to direct violence to the bone from behind, or to extreme pronation, or to falls upon the extended and pronated hand. The anterior, external, and annular ligaments are torn. There would seem to be a lack of evidence in support of Hamilton's statement that "sometimes the anterior and external lateral are alone broken, the annular ligament being then

sufficiently stretched to allow of the complete dislocation." The biceps being relaxed, the pronators act, and the limb is either pronated or assumes a position midway between pronation and supination. Some stretching of the supinator brevis would probably modify the amount of pronation. A difficulty in the reduction is often due to the torn annular ligament coming between the head of the radius and the humeral condyle.

**Sprain of the elbow.**—Mr. J. Hutchinson, jun., has shown that in young children, under five years, forcible traction of the limb in the supinated position may cause the radius to slip downwards, away from the orbicular ligament, which is displaced upwards. Flexion of the elbow in the pronated position restores the ligament to its normal position. It is clear that this displacement is the anatomical basis of the common sprain of the elbow met with in young children, and usually due to violent traction of the hand. The oblique ligament, which passes from the ulna downwards and outwards to the radius below the insertion of the biceps and the supinator brevis resists such a displacement.

**Fractures of the lower end of the humerus.**

—These are: (1) A fracture just above the condyles; (2) "the T-shaped fracture" involving the joint; (3) fractures of the internal, and (4) of the external condyle; (5) fracture of the internal epicondyle; and (6) separation of the lower epiphysis. All these fractures are more common in the young.

1. The fracture "at the base of the condyles," as it is sometimes called, is usually situate a little above the olecranon fossa, where the humeral shaft begins to expand. It is commonly transverse from side to side, and oblique from behind downwards and forwards. It is generally the result of a blow inflicted upon the extremity of the elbow. Probably the tip of the olecranon driven sharply against the bone acts like the point of a wedge, and takes an important share in the production of the fracture. The lower fragment, together with the bones of the fore-arm, is generally

carried backwards by the triceps, and upwards by that muscle, the biceps, and the brachialis anticus. The median or ulnar nerves, especially the latter, may be severely damaged.

2. The "T-shaped fracture" is but a variety of the lesion just noted. In addition to the transverse fracture above the condyles, there is also a vertical fracture running between the two condyles into the joint. The lower fragment is thus divided into two parts. The displacement is the same. The fracture is very usually due to a fall upon the bent elbow, and here possibly also the tip of the olecranon acts as a wedge, producing the transverse fracture, while the prominent ridge along the middle of the greater sigmoid cavity, acting as a second wedge, produces the vertical fracture into the joint.

3, 4, and 5. For surgical purposes it is well to limit the term "condyle" to such parts of the extremity of the humerus as are within the capsule, and the term "epicondyle" to such parts of the lower projections of the bone as are without the joint.

In the so-called fracture of the *inner condyle* the line of separation generally commences about  $\frac{1}{2}$  an inch above the tip of the epicondyle (and, therefore, outside the joint), and running obliquely outwards through the olecranon and coronoid fossæ, enters the articulation through the centre of the trochlear surface (Hamilton). The fragment is often displaced a little upwards, backwards, and inwards, the ulna going with it.

In the fracture of the *external condyle* the line commences also above the epicondyle and outside the joint, and running downwards enters the joint usually between the trochlear surface and the surface for the radius. The displacement is trifling and inconstant.

On account of its insignificant size, a fracture of the *external epicondyle* is scarcely possible. Fractures of the *inner epicondyle* are, however, quite common, the joint remaining free (Fig. 31). This epicondyle exists as a distinct epiphysis, which unites at the age of eighteen, and which at any time before that age may



be separated from the bone by direct injury or muscular violence. Owing to the dense aponeurotic fibres that cover the part, much displacement of the fragment is uncommon. When displacement exists, it is in the general line of the common flexor muscles that arise from the tip of the process. In such cases the ulnar nerve, which lies behind the process, is often damaged.

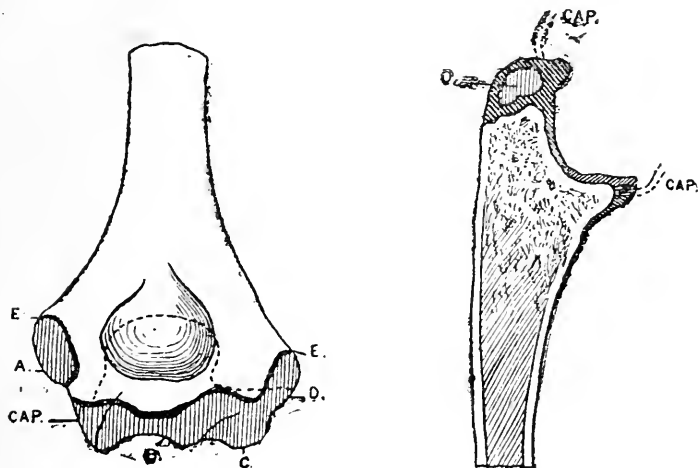


Fig. 31.

i. Lower Epiphysis of the Humerus from behind.

ii. Section of Upper Extremity of the Ulna, showing the small size of its epiphysis.

A, Centre for internal epicondyle; B, C, D, united centres for the trochlea, capitellum, and external epicondyle; E, E, epiphyseal line; CAP., line (stippled) at which capsule is attached.

CAP., Attachment of capsule; o, epiphysis of olecranon.

6. The *lower epiphysis* (Fig. 31). The line of this epiphysis is irregular, running across the bone between the tips of the two condyles. It presents several ossific nuclei, which, with the exception of the nucleus for the inner epicondyle, unite with the main bone about the seventeenth year. Thus, after the age of seventeen the growth of the bone must depend upon the activity of the upper epiphysis, which does not unite until twenty. Excision of the elbow, therefore,

after the sixteenth or seventeenth year, will not be followed by arrest of development in the limb, even if the epiphyseal line has been transgressed by the saw. Several cases are, however, reported of marked arrest of growth in the limb following upon injuries to the lower epiphysis before the sixteenth year, and to the upper epiphysis before twenty. Since the epiphyseal line is almost wholly within the capsule, it follows that but little displacement, other than a slight movement backwards, is consequent upon the separation of the mass.

**Fractures of the olecranon** are commonly due to direct violence, and in a few cases to severe indirect violence applied to the lower end of the humerus or upper end of the ulna. Instances of fracture by muscular action are few, and open to some question. The fracture is most commonly met with about the middle of the process, just where it begins to be constricted, and is usually transverse in direction. The amount of displacement effected by the triceps varies, and depends upon the extent to which the dense periosteum about the process and the ligaments that are attached to it are torn. The olecranon is developed mainly from the shaft of the ulna (Fig. 31). There is a small epiphysis, however, at the summit of the process which joins the rest of the olecranon at the age of seventeen. It is a mere shell of bone. In young subjects this scale-like epiphysis may be separated by violence, or the cartilaginous olecranon may be dissevered from the rest of the bone. The common fracture of the adult olecranon does not follow the epiphyseal line.

**Fracture of the coronoid process** is an extremely rare accident. It is impossible to understand how the process can be torn off by the action of the brachialis anticus, as some maintain, since that muscle is inserted rather into the ulna at the base of the projection than into the process itself. Nor can it be separated as an epiphysis, as supposed by others, since it does not exist as such.

**Fractures of the head or neck of the radius** are rare, and occur usually with dislocation or other

severe injury. The head is commonly found split or starred, and the lesion, if limited to the head, could hardly be diagnosed. The upper epiphysis of the radius is entirely within the limits of the annular ligament, and could scarcely be separated in a simple lesion. It is a mere disc of cartilage joining the shaft at the age of seventeen. When the neck is broken the upper end of the lower fragment is drawn well forwards by the biceps muscle.

**Resection of the elbow** may be performed in many ways. In all procedures there is danger of injuring the ulnar nerve, and some little difficulty often in clearing the prominent internal condyle. If the knife be kept close to the bone, no vessel of any magnitude should be divided. The muscles most disturbed are the triceps, anconeus, supinator brevis, extensor carpi ulnaris, extensor carpi radialis brevis, and brachialis anticus. It is most important to preserve the periosteum over the olecranon, so that the triceps may still have some attachments to the forearm. It is never necessary to divide the insertion of the brachialis anticus, still less of the biceps, although some few fibres of the former muscle may be separated in removing the upper surface of the ulna. By the subperiosteal method the periosteum is carefully peeled off from all the parts to be resected, and is preserved. By this means the triceps retains a hold upon the ulna, and the restoration of the joint is more complete. The functions of the joint may be well restored after resection, especially when performed by the subperiosteal method, but it would appear that after no method are the anatomical details of the joint reproduced. Thus, in a successful case, the new joint will assume the bimalleolar form, and will resemble the ankle rather than the elbow joint. The humerus throws out two malleoli on the sites of the normal condyles, and in the concavity between them the ulna and radius are received. Between the ulna and the humerus new ligaments form and a new annular ligament for the radius is also developed.

## CHAPTER XIV.

## THE FORE-ARM.

**Surface anatomy.**—At its upper half, and especially in its upper third, the limb is much wider in its transverse than in its antero-posterior diameter. A horizontal section through this part will show a cut surface that is somewhat oval in outline, and is at the same time flattened in front and more convex behind. This outline is best seen in muscular subjects, and depends chiefly upon the development of the lateral masses of muscle that descend from the condyles. In the non-muscular, the limb, even in its highest parts, tends to assume a rounded rather than an oval outline. In women and children, also, the limb is round, owing to the comparatively slight development of the lateral muscular masses, and to the accumulation of fat on the front and back of the limb. The posterior surface of the fore-arm in a vigorous subject presents along its outer border a prominence formed by the supinator longus and the two radial extensors, which become tendinous below the centre of that border. On the lower third of this edge is a slight eminence, directed obliquely downwards, outwards and forwards, and due to the crossing of the extensors of the thumb. In the middle of the posterior surface is another elevation, running down from the outer condyle, and formed mainly by the extensor communis. To the inner side of this eminence is a groove, well seen in the very muscular, that indicates the posterior border of the ulna. The ulna is subcutaneous throughout its entire extent, and can be readily examined. The upper half of the radius is too deeply placed to be well made out, but the lower half of the bone can be easily felt beneath the skin. The course of the radial artery is represented by a line drawn from the outer border of the biceps tendon at the bend of the elbow to a point in front of the styloid process of the radius. The pulse is felt between the styloid process

and tendon of the flexor carpi radialis where the artery rests on the lower extremity of the radius. The middle and lower thirds of the ulnar artery follow a line from the inner condyle to the radial side of the pisiform bone. The upper third would be represented by a line drawn from the middle of the bend of the elbow to meet the first line at the junction of the upper and middle thirds of the inner border of the fore-arm. Such a line would be slightly curved, with its concavity outwards. The tendons, etc., that can be demonstrated at the lower extremity of the fore-arm will be considered in the description of the wrist.

**Vessels.**—It is well to note the very free anastomoses that exist along the greater part of the limb between the ulnar and radial arteries. This fact was illustrated by a case under my care, some time ago, in the London Hospital. A seaman had inflicted upon his left fore-arm three deep transverse wounds across the front of the limb with a sharp knife. The wounds were about  $1\frac{1}{2}$  inches apart. The radial artery was divided in each of the wounds, and that vessel, therefore, presented six cut ends. It would appear to be sufficient to ligature the proximal and distal ends of the wounded vessel, and to leave the two isolated portions of the artery, each about  $1\frac{1}{2}$  inches in length, alone. I applied ligatures to five of the divided ends, leaving the lower end of the upper isolated piece of the artery untied, and watched the effect. During the course of the day, when the man had rallied from the profound faintness due to the great loss of blood he had experienced, copious bleeding took place from this single unsecured end of the vessel, and it, of course, had also to be tied.

There is a singular absence of large blood-vessels or nerves along the posterior aspect of the fore-arm, and it is significant that this is the aspect of the limb most exposed to injury. For a hand's-breadth below the olecranon there is almost an entire absence of superficial veins.

The **median nerve** passes between the two heads

of the pronator teres, and may possibly be compressed by that muscle when in vigorous action. In this way may be, perhaps, explained the cramp on the flexor side of the limb that sometimes occurs after certain violent exercises. The amount of muscular tissue in the deep head of the muscle varies considerably.

The **bones of the fore-arm**.—Transverse sections

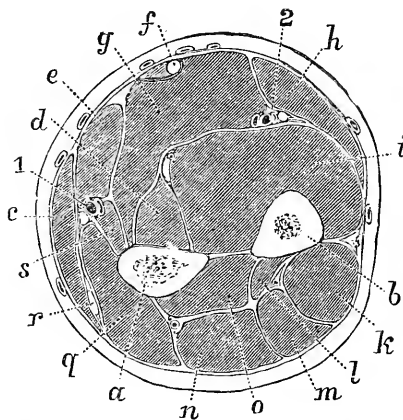


Fig. 32.—A Transverse Section through the middle of the Fore-arm (Braune).

*a*, Radius; *b*, ulna; *c*, supinator longus; *d*, flexor longus pollicis; *e*, flexor carpi radialis; *f*, palmaris longus; *g*, flexor sublimis digitorum; *h*, flexor carpi ulnaris; *i*, flexor profundus digitorum; *k*, extensor carpi ulnaris; *l*, extensor indicis; *m*, extensor minimi digiti; *n*, extensor communis digitorum; *o*, extensor ossis et extensor secundi internodii pollicis; *q*, extensor carpi radialis brevis; *r*, extensor carpi radialis longior; *s*, pronator radii teres; *l*, radial vessels and nerve; *2*, ulnar vessels and nerve.

of the limb at various levels show that the radius and ulna are in all parts nearer to the posterior than the anterior aspect of the extremity (Figs. 32 and 33).

This relation is the more marked the higher up the section. The two bones are nearest to the centre of the limb about the lower end of the middle third. At the upper part of the fore-arm the muscles are found mainly at the sides and in front.

The lower the section proceeds down the limb, the less will the bones be covered at the sides, and the more equally will the soft parts be found distributed about the

anterior and posterior aspects of the limb. It will be noticed that where one bone is the most substantial the other is the most slender, as near the elbow and wrist; and that it is about the centre of the limb that the two are most nearly of equal strength. The proximity of the two bones, and especially of the ulna, to the posterior aspect of the limb permits them to be easily

examined from that surface, while it is from the same aspect that resections and other operations upon the bones are most readily performed. It will be understood, moreover, that in compound fractures, due to penetration of fragments, the wound is more usually on the posterior aspect of the limb.

The important movements of *pronation* and *supination* take place between these bones, and round an axis corresponding to a line drawn through the head of the radius, the lower end of the ulna, and the metacarpal bone of the ring-finger. Pronation is mainly checked by the lower and middle parts of the interosseous membrane, the posterior radio-ulnar ligament, the inner part of the posterior ligament of the wrist, and the opposition of the bones. Supination is chiefly limited by the lowest fibres of the interosseous membrane, the anterior radio-ulnar ligament, and the internal lateral ligament of the wrist. "The chief influence in checking supination is not to be found in ligament at all, but in the contact of the posterior edge of the sigmoid cavity of the radius with the tendon of the extensor carpi ulnaris, as it lies in the groove between the styloid process and the round head of the ulna" (H. Morris). Of the two movements, supination is the more powerful. This is illustrated in many ways. In using a screw-driver or a gimlet the movements of pronation and supination are conspicuously involved, but the main force is applied during supination. It is significant that the thread of a corkscrew is so turned that it shall be inserted by supination rather than by pronation.

The only position in which the two bones are parallel to one another is in the mid-position between pronation and supination. It is in this posture only that the interosseous membrane is uncoiled throughout. Hence the selection of this position in the adjustment of most fractures of the fore-arm. The interosseous space is an irregular ellipse, a little larger below than above. It is narrowest in full pronation, widest in supination, and nearly as wide in the mid-position.

It may be noted that the oblique ligament tends

to resist forces that would drag the radius away from the humerus, and takes the place and the function of a direct ligament, passing from the humerus to the radius, while the interosseous membrane, from the obliquity of its fibres, makes the ulna take a share in the strain put upon the radius when that bone is forced upwards, as in resting on, or pushing with, the palm.

**Fractures of the fore-arm.**—The two bones are more often broken together than is either the radius or the ulna alone. The radius, when broken alone, is usually fractured by indirect violence, since it receives more or less entirely all shocks transmitted from the hand. The ulna, on the contrary, is more often broken by direct violence, it being the more superficial and exposed of the two bones. For example, in raising the arm to ward off a blow from the head, the ulna becomes uppermost. When the two bones are broken together, the violence may be direct or indirect. Malgaigne reports a case where both bones were broken by muscular violence in a patient while shovelling earth. Here the bones probably were broken between the two opposed forces represented by the biceps and brachialis anticus above and the weight of the loaded shovel in the hand below. When *both bones* are broken and the fractures are oblique, shortening may be produced by the united action of the flexors and extensors. The displacement varies greatly, and depends rather upon the direction of the violence than upon muscular action. Thus Hamilton says: "I have seen the fragments deviate slightly in almost every direction." If union be delayed, the delay is usually in the radius, since it is the more mobile of the two bones. When the *radius alone* is broken (1) between the insertions of the biceps and pronator teres, the upper fragment is flexed by the biceps and fully supinated by that muscle and the small supinator. The lower fragment will be pronated by the two pronators, and drawn in towards the ulna by means of those muscles. If such a fracture be put up with the hand midway between the prone and supine position, the following evils result: the upper



fragment is fully supinated by the muscles; the lower fragment is placed in the mid-position by the splints. It follows that the proper axis of the bone is not reproduced, and the use of the biceps and supinator brevis as supinators is entirely lost. Thus patients so treated usually recover with great loss in the power of supination; and to avoid this ill result, it is advised to put the limb up in full supination, so that the two fragments may unite in their proper axis, the upper fragment being supinated by the muscles, the lower by the splints. (2) When the fracture is between the insertions of the two pronators, the upper fragment may be carried a little forwards by the biceps and pronator teres, and drawn towards the ulna by the latter muscle. The bone will probably be in the mid-position, the two supinators (biceps and supinator brevis) attached to the fragment being more or less neutralised by the pronator that is also connected with it. The lower fragment will be adducted to the ulna by the pronator quadratus, and its upper end will be still further tilted towards that bone by the action of the supinator longus upon the styloid process. When the *ulna* is broken alone, as, for example, about its middle, the upper fragment may be drawn a little forwards by the brachialis anticus, while the lower fragment will be carried towards the radius by the pronator quadratus.

The displacement, however, in all cases is influenced as much by the direction of the violence as by the action of muscles. When the fragments, after fracture of one or of both bones, fall in towards one another, so as to meet across the interosseous space, attempts are sometimes made to separate the broken ends and to preserve the integrity of the space by the use of graduated pads. These pads, however, if supplied with sufficient force to separate the fragments, will probably compress one or both of the arteries of the limb, and cause great distress by pressure upon the median nerve.

The fact that the bulk of the venous blood of the fore-arm is returned by surface veins may explain the ready occurrence of severe œdema in the limb when

fractures are treated with improperly applied splints or bandages. Since the arteries also can be readily affected by pressure, it follows that gangrene of the limb, as a result of improper treatment, is more common after fracture of the fore-arm than after fracture in any other part.

**Amputation of the fore-arm.**—In amputation of the fore-arm by double transfixion flaps, at about

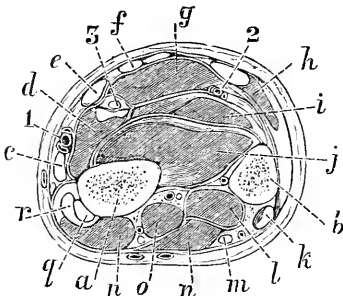


Fig. 33—A Transverse Section through the lower third of the Fore-arm. (Braune).

*a*, Radius; *b*, ulna; *c*, supinator longus; *d*, flexor longus pollicis; *e*, flexor carpi radialis; *f*, palmaris longus; *g*, flexor sublimis digitorum; *h*, flexor carpi ulnaris; *i*, flexor profundus digitorum; *j*, pronator quadratus; *k*, extensor carpi ulnaris; *l*, extensor indicis; *m*, extensor minimi digiti; *n*, extensor communis digitorum; *o*, extensor secundi internodii pollicis; *p*, extensor primi internodii pollicis; *q*, extensor carpi radialis brevis; *r*, extensor carpi radialis longior, with, in front of it, the extensor ossis metacarpi pollicis; 1, radial vessels; 2, ulnar vessels; 3, median nerve.

the upper part of the middle third the parts would be cut in the following manner: On the face of the anterior flap would be seen from without inwards the supinator longus (cut the whole length of the flap), then the flexor sublimis (cut to a like extent), and, lastly, the flexor carpi ulnaris. Between the supinator longus and the flexor sublimis the divided end of the pronator teres is seen; and between the flexor sublimis and the skin would lie the flexor carpi radialis and the palmaris longus. The latter would appear as a tendon at the inner border of the flap. In the angle between the two flaps would

be found in front of the radius a little of the flexor longus pollicis, and in front of the ulna, the flexor profundus, the latter cut much the longer. Quite close to the radius, and for the most part behind it, would be the lowest part of the small supinator, while behind the ulna would be the cut fibres of the upper end of the extensor ossis. On the face of the posterior flap would be seen from without inwards the extensor carpi radialis longior

and breviar, the extensor communis, the extensor of the little finger, and the extensor carpi ulnaris. The radial artery will run the whole length of the anterior flap, and be cut near its outer border to the inner side of the supinator longus. The ulnar artery will be cut shorter, will be in front of the bone, and between the flexor sublimis and flexor profundus. The anterior interosseous vessels will be divided immediately in front of the interosseous membrane. The posterior interosseous vessels will be cut long, and will be found between the superficial and deep muscles.

Fig. 33 shows the relation of the parts as they would be cut in a circular amputation of the limb through the lower third.

---

## CHAPTER XV.

### THE WRIST AND HAND.

**Surface anatomy.**—The following structures can be made out about the *wrist*: Commencing at the outer side, the lower extremity and styloid process of the radius can be well defined. The bone is here superficial in front and behind. The styloid process lies more anteriorly than does the corresponding process of the ulna, and also descends about  $\frac{1}{2}$  an inch lower down the limb. The outer surface of the radius at the wrist is crossed by the tendons of the extensor ossis metacarpi and extensor brevis pollicis. These are very distinct when the thumb is abducted, and the slit-like interval between the two can be felt. About the centre of the front of the wrist is the palmaris longus tendon, which is usually the most conspicuous of the tendons on this aspect of the joint. It will be found absent in quite 10 per cent. of wrists examined. It is rendered most prominent when the wrist is a little flexed, the fingers and thumbs extended, and the thenar and hypothenar eminences as much approximated as possible. A little to its outer side is the larger but less prominent

tendon of the flexor carpi radialis. In the narrow groove between these two tendons lies the median nerve, and on the radial side of the flexor carpi radialis is the radial artery.\* The venæ comites surround the artery, and when distended alter the character of the pulse (Hill). Towards the inner border of the wrist the flexor carpi ulnaris tendon is evident, descending to the pisiform bone. It is rendered most distinct when the wrist is slightly flexed and the little finger pressed forcibly into the palm. In the hollow which this posture produces between the last-named tendon and the palmaris longus lie the flexor sublimis tendons, and just to the radial side of the flexor carpi ulnaris the pulsations of the ulnar artery can be felt. Beneath the thin skin in front of the wrist a part of the plexus of veins can be seen that end in the median and anterior ulnar trunks. The ulnar nerve grooves the radial side of the pisiform bone.

At the back of the wrist the following tendons can be readily distinguished from without inwards: the extensor longus pollicis (extensor secundi internodii), the extensor communis, and the extensor carpi ulnaris. Of these, the most prominent is the first-named. It is rendered most distinct when the thumb is forcibly abducted and extended. The tendon leads up to a small but prominent bony elevation on the back of the radius that marks the outer border of the osseous groove for its reception. This tendon, when it reaches the radius, points to the centre of the posterior surface of that bone, and indicates also roughly the position of the interval between the scaphoid and semilunar bones. The lower end of the ulnar is very distinct. When the hand is supine, its styloid process is exposed at the inner and posterior aspect of the wrist to the inner side of the extensor carpi ulnaris. In pronation, however, the process is rendered less distinct, while the head projects prominently on the posterior part of

\* Sometimes the superficialis volæ arises higher and is larger than usual. It then runs by the side of the radial in front of the wrist, and, giving additional volume to the pulse, has been the foundation of the so-called "double pulse."

the wrist, and is found to lie between the tendons of the extensor carpi ulnaris and extensor minimi digiti.

*The wrist joint.*—The tip of the styloid process of the ulna corresponds to the line of the wrist joint, and a knife entered below that point would enter the articulation. A knife entered horizontally just below the tip of the styloid process of the radius would hit the scaphoid bone. A line drawn between the two styloid processes would slope downwards and outwards, its two extremities would represent the extreme inferior limits of the radio-carpal joint, and would fairly correspond to the chord of the arc formed by the line of that joint. The line between the styloid processes would be nearly  $\frac{1}{2}$  an inch below the summit of the arch of the wrist joint.

There are several folds in the skin on the front of the wrist; of these, the lowest is the most distinct. It is a little convex downwards, precisely crosses the neck of the os magnum in the line of the third metacarpal bone (Tillaux), and is not quite  $\frac{3}{4}$  of an inch below the arch of the wrist joint. It is about  $\frac{1}{2}$  an inch above the carpo-metacarpal joint line, and indicates very fairly the upper border of the anterior annular ligament.

*The palmar surface of hand.*—The palm is concave in the centre where the skin is adherent to the palmar fascia. This "hollow of the hand" is of somewhat triangular outline, with the apex upwards. On either side are the thenar and hypothenar eminences. At the upper end of the former eminence, a bony projection is felt, just below and internal to the radial styloid process, that is formed by the tubercle of the scaphoid and ridge on the trapezium. The interval separating these two processes of bone cannot always be made out. At the upper extremity of the hypothenar eminence is the projection of the pisiform bone, and just below it the unciform process can be identified. Below the hollow of the palm, and opposite the clefts between the four fingers, three little elevations are seen, especially when the first phalanges are extended, and the second and third are flexed. These correspond to the fatty tissue between the flexor tendons and the digital slips

of the palmar fascia. The grooves that may be seen to separate the elevations correspond to those slips.

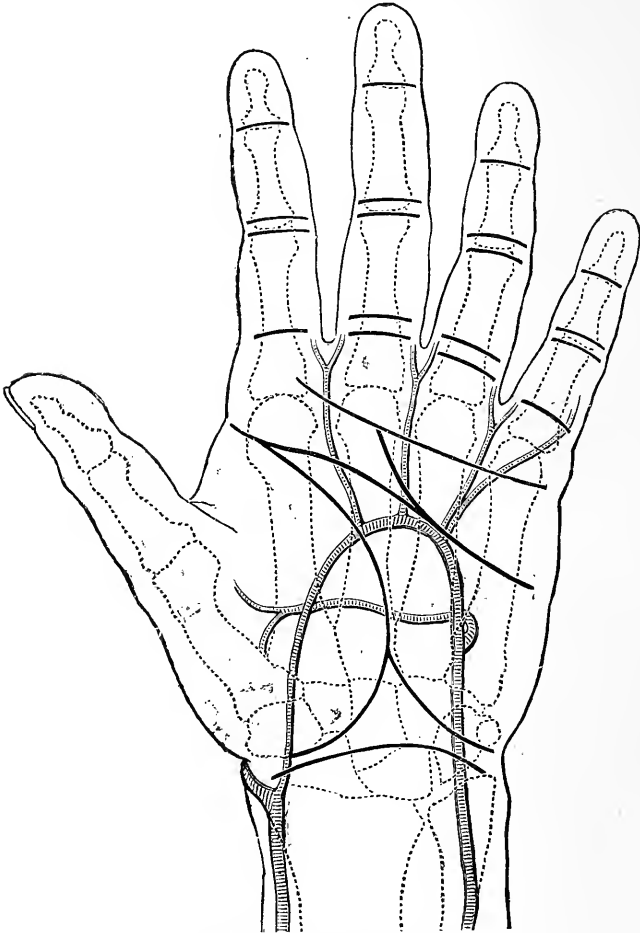


Fig. 34.—Surface Markings on the Palm of the Hand.

The thick black lines represent the chief creases on the skin.

Of the many creases in the skin of the palm three require especial notice. The first starts at the wrist, between the thenar and hypothenar eminences, and

marking off the former eminence from the palm ends at the outer border of the hand at the base of the index finger. The second fold is slightly marked. It starts from the outer border of the hand, where the first fold ends. It runs obliquely inwards across the palm with a marked inclination towards the wrist, and ends at the outer limit of the hypothenar eminence. The third, lowest, and best-marked of the folds starts from the little elevation opposite the cleft between the index and middle fingers, and runs nearly transversely to the ulnar border of the hand, crossing the hypothenar eminence at the upper end of its lower fourth. An unimportant crease running obliquely from the third to the second fold gives to these markings the outline of the letter M. The first fold is produced by the opposition of the thumb, the second mainly by the bending simultaneously of the metacarpo-phalangeal joints of the first and second fingers, and the third by the flexion of the three inner fingers. The second fold, as it crosses the third metacarpal bone, about corresponds to the lowest point of the superficial palmar arch. The third fold crosses the necks of the metacarpal bones, and indicates pretty nearly the upper limits of the synovial sheaths for the flexor tendons of the three outer fingers. A little way below this fold the palmar fascia breaks up into its four slips, and midway between the fold and the webs of the fingers lie the metacarpo-phalangeal joints. Of the transverse folds across the fronts of the fingers corresponding to the metacarpo-phalangeal and phalangeal joints, the highest is single for the index and little finger and double for the other two. It is placed nearly  $\frac{3}{4}$  of an inch below the corresponding joint. The middle folds are double for all the fingers, and are exactly opposite the first interphalangeal joints. The lowest creases are single, and are placed a little above the corresponding joints (1 to 2 mm., according to Paulet). There are two single creases on the thumb corresponding to the two joints, the higher crossing the metacarpo-phalangeal articulation obliquely. The free edge of the web of the fingers,

as measured from the palmar surface, is about  $\frac{3}{4}$  of an inch from the metacarpo-phalangeal joints. The superficial palmar arch may be represented by a curved line across the palm starting from the pisiform bone and running in a line with the palmar border of the thumb when outstretched at right angles with the index finger. The deep arch is between  $\frac{1}{4}$  and  $\frac{1}{2}$  an inch nearer the wrist, and its position may be accurately marked by a line drawn from the base of the fifth metacarpal to the base of the second. The digital arteries bifurcate about  $\frac{1}{2}$  an inch above the clefts between the fingers.

*The dorsal surface of the hand.*—On the outer side of the wrist, when the thumb is extended, a hollow is obvious between the *extensores ossis metacarpi and brevis pollicis* and the *extensor longus pollicis*. French writers have termed this hollow “*tabatière anatomique*.” Across this hollow and beneath the tendons just named runs the radial artery. Under the skin over the space can usually be seen a large vein, the cephalic vein of the thumb. Across the space also runs the internal division of the terminal branch of the radial nerve. In the floor of the “snuff-box” are the scaphoid bone and the trapezium. The *extensor longus pollicis* crosses the apex of the first interosseous space. The sesamoid bones of the thumb and the joint between the trapezium and the first metacarpal bone can all be well made out. The latter articulation is situate on the floor of the “*tabatière*.” On the back of the hand the various tendons and the surface veins, too, can all be clearly distinguished. Between the first and second metacarpal bones is the first dorsal interosseous muscle, which forms a conspicuous prominence when the thumb is pressed against the side of the index finger. The three rows of knuckles are formed by the proximal bones of the several joints.

**The wrist and hand.**—*The skin* of the palm and of the front of the fingers is thick and dense, while that on the back of the hand is much finer. The palm, the fronts, and sides of the fingers, and the dorsal aspects of the last phalanges, all show an entire absence of hair



and of sebaceous glands. These parts are, therefore, exempt from the maladies that attack hair follicles and their gland appendages. On the dorsum of the hand, and of the first and second rows of phalanges, there are numerous hairs and sebaceous follicles. Sweat glands are more numerous in the skin of the palm than in any other part. According to Sappey they are four times more numerous here than they are elsewhere. Krause has estimated that nearly 2,800 of these glands open upon a square inch of the palm. Only about half the number are found upon the dorsum of the hand. The profuseness with which the palm may perspire is well known, and is very marked in certain conditions. The cutaneous nerve-supply of the hand is very free. The nerves present Pacinian bodies, which are far more numerous in the hand than in any other part, and in no portion of the surface are tactile corpuscles more numerous or more highly developed. With the exception of the tip of the tongue, a more acute degree of tactile sensibility is met with in the hand than in any other part. The most sensitive district is the palmar surface of the third phalanx of the index finger, while the least sensitive to tactile impressions is the dorsum of the hand. It may be said that the tips of the fingers are about thirty times more acute to the sense of touch than is the skin of the middle of the fore-arm, which is among the least sensitive portions of the integument as regards tactile-influences.

The *subcutaneous tissue* of the front of the hand, and especially of the palm, is scanty and dense, and somewhat resembles the subcutaneous tissue of the scalp in that the skin is closely adherent to it, and the fat it contains is arranged in minute lobules lodged in lacunæ. Cutaneous ligaments bind the skin down at the creases of the palm and fingers. The subcutaneous tissue on the dorsum is, on the other hand, lax, and has but a frail association with the skin. Thus it follows that subcutaneous extravasations of blood are practically impossible in the palm and on the anterior aspect of the fingers, while they may be very extensive on the

dorsum. In like manner œdema of the extremity is conspicuously marked upon the dorsal surface, while the palm remains comparatively free even in severe cases. Surface inflammations also of the dorsum are attended with considerable swelling, while those of the front of the hand show no such feature. At the same time the adhesion of the palmar integument to the deeper parts is so close that surface wounds do not gape, and are in a position to encourage ready healing. The denseness of the integuments of the palm renders inflammation of the part extremely painful, owing to the tension that is so readily produced, whereas inflammation in the lax tissues of the dorsum may reach some magnitude without causing great pain. The palm of the hand is well adapted to meet the effects of pressure and friction. The cuticle is thick, the skin is adherent, and immediately beneath it lies the dense palmar fascia. This fascia efficiently protects the palmar nerves and the main vessels, while it must be noted that the front of the hand, and especially the palm, is singularly free from surface veins. Indeed, the great bulk of the blood from the hand is returned by the superficial veins on the dorsum of the fingers and hand.

The lymphatics of the palm are, moreover, scant and very minute, whereas on the dorsum they are large and profusely distributed. The ulnar border of the palmar part of the hand is much used in pressure and in "hammering" movements, and it is significant that this surface is well protected by soft parts, and presents a singular absence of large nerves, that, if present, would be liable to sustain damage from such movements.

The form of the *nail* varies somewhat in individuals, and, according to certain authors, there are special types of nail to be met with in some constitutional diseases. Thus are described the tubercular, the rachitic, the arthritic nail. By the Hippocratic hand is meant a hand the tips of the fingers of which are clubbed and the nails of which are much curved. This condition would appear to be due to impeded circulation, to retardation in the return of venous blood, and perhaps

also to imperfect oxygenation of that blood. It is most often met with in congenital heart disease, in phthisis, empyema, chronic lung affections, and certain thoracic aneurisms. There are several forms of inflammation affecting the matrix of the nail and the soft parts immediately around it (onychia, paronychia). Such inflammations lead to great deformity of the structure itself. When a nail is thrown off by suppuration or violence a new nail is produced, provided any of the deeper epithelial cells are left. During convalescence from certain illnesses (*e.g.*, scarlet fever), a transverse groove will appear across all the nails. This groove indicates the portion of nail formed during the illness, and by watching its movement the rate of growth of the nail can be estimated. The nail grows at the average rate of  $\frac{1}{32}$ nd of an inch per week. It may be noted that each digital nerve gives a special branch of large size to the pulp beneath the nail, and this explains the intense pain felt when a foreign body is thrust under the nail.

The **fasciæ**.—Beneath the skin of the palm is the dense palmar fascia. This fascia gives almost as much strength to the hand as would so much bone, while its unyielding character, its comparative freedom from vessels and nerves, render it well suited to withstand the effects of pressure. The fascia gives slips to each finger; each slip sends fibres to join the digital sheaths of the tendons, the skin, and the superficial transverse ligament. In the disease known as Dupuytren's contraction, the palmar fascia, and especially its digital slips, becomes contracted. One or more or all of the fingers may be involved in the contraction. The first phalanx is drawn or flexed towards the palm, and later the second phalanx becomes bent also. The skin is drawn in towards the fascia, since the two structures are normally connected with one another. Experiment shows that by dragging upon the fascia the first phalanx can be readily bent, and also, but with less ease, the second phalanx. The middle part of the palmar fascia represents the tendon of the palmaris longus in the hand.

The structures of the palm are divided into three spaces by the fasciæ (Fig. 35). Thus the muscles of the thenar and hypothenar eminences are both enclosed in a thin fascia proper to each. The two spaces formed by these membranes are enclosed in all directions, and are capable, though only in a feeble way, of limiting suppuration when it commences in them. Between these two spaces is a third space, which is roofed in by

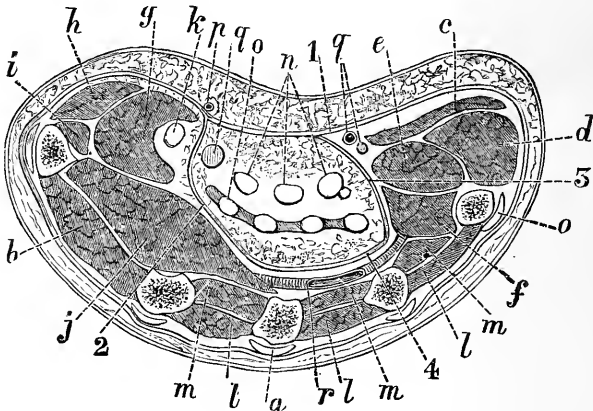


Fig. 35.—Horizontal Section of the Hand through the middle of the Thenar and Hypothenar Eminences (Tillaux).

*a*, Metacarpal bone; *b*, first dorsal interosseous; *c*, palmaris brevis; *d*, abductor min. digiti; *e*, flexor brevis min. dig.; *f*, opponens min. dig.; *g*, flexor brevis poll.; *h*, abductor poll.; *i*, opponens poll.; *j*, adductor poll.; *k*, flexor long. poll.; *l*, dorsal interossei; *m*, palmar interossei; *n*, flexor sublimis; *o*, flexor profundus; *p*, superf. volæ; *q*, median nerve, and (on inner side) ulnar artery and nerve; *r*, deep palmar arch; 1, palmar fascia; 2, outer septum; 3, inner septum; 4, deep fascia of palm.

the palmar fascia. This cavity is closed in at the sides, but is open above and below. Above there is a free opening beneath the annular ligament and along the flexor tendons into the fore-arm, while below there are the seven passages provided for by the division of the palmar fascia. Of these seven passages, four, situate at the roots of the several fingers, give passage to the flexor tendons, while the remaining three correspond to the webs between the fingers, and give passage to the lumbricales and the digital vessels and nerves.

When pus, therefore, forms on the palm, beneath the palmar fascia, it cannot come forward through that dense membrane, but escapes rather along the fingers or makes its way up into the fore-arm. So rigid is the resistance offered by the palmar fascia, that pent-up pus will make its way through the interosseous spaces and appear on the dorsum of the hand, rather than come through the coverings of the palm. The passage of pus, however, towards the dorsum is resisted by a layer of fascia that lies deeply beneath the flexor tendons, and covers in the interossei muscles, the bones, and the deep palmar arch. This fascia joins on either side the fasciæ enclosing the thenar and hypothenar "spaces" (Fig. 35).

In opening a palmar abscess, when it points above the wrist, the incision should be in the long axis of the fore-arm, should be above the annular ligament, and is most conveniently made a little to the ulnar side of the palmaris longus, for a cut in this position would escape both the ulnar and radial arteries and also the median nerve.

The tendons about the wrist are bound down and held in place by the annular ligaments. So dense is the anterior ligament, that even in extensive abscess of the palm reaching into the fore-arm, and in severe distension of the synovial sheaths beneath the ligament, it remains firm, and will not yield. The lower border of the posterior annular ligament corresponds to the upper edge of the anterior band, and these structures together act the part of the leather bracelet that the labourer sometimes wears around his wrist, and that, in fact, takes the function of an additional annular ligament.

The **fibrous sheaths** for the flexor tendons extend from the metacarpo-phalangeal joints to the upper ends of the third phalanges. The pulp of the third phalanx, therefore, rests practically upon the periosteum. Opposite the finger joints the sheaths are lax and thin, and spaces may occur between the decussating fibres of the sheaths, through which the

synovial membrane lining the sheath may protrude. It is, I believe, through this less protected part of the sheath that suppuration without often finds its way into the interior of the sheath. The sheaths in the rest of their course are dense and rigid, and when cut across remain, in virtue of this rigidity, wide open (Fig. 36). Thus, after the division of the sheath, as in amputation, an open channel is left leading into the palm of the hand, and offering the greatest facility for the spread of pus into that part. It is this rigidly open fibrous sheath that probably may explain the frequency of suppuration

in the palm after amputation of a part of a finger, and I am decidedly of opinion that some steps should be taken to protect or shut off this channel in any case where the sheath has been accidentally or intentionally divided.

The tendons accurately fill the fibrous sheaths. A gangliform growth on the tendon as it enters the sheath, or a constriction of the sheath with an inequality in the tendon, gives rise to the condition known as "snap" finger. Such a digit cannot be extended by will, but when pushed a little way "springs back with a snap like the blade of a pocket knife" (Abbe). "Congenital contraction"

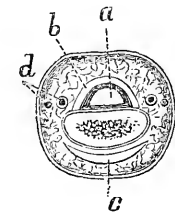


Fig. 36. — Horizontal Section through middle of Second Phalanx (Tillaux).

*a*, Flexor tendon; *b*, fibrous sheath of tendon; *c*, extensor tendon; *d*, digital artery and nerve.

of the little finger is very common in a slight degree. In marked cases, the proximal phalanx is hyper-extended and the middle flexed. Lockwood found in such a case that the condition was due to a contraction in the fibrous sheath in front of the joint. Contracted finger following whitlow is due to an adhesion of the tendons to their sheath. Paralytic contraction of the flexor muscles also brings about permanent contracture of the fingers.

**Synovial sacs and sheaths.**—There are two synovial sacs beneath the annular ligament for the flexor tendons, one for the flexor longus pollicis, the other for the flexor sublimis and profundus tendons.

The former extends up into the fore-arm for about  $1\frac{1}{4}$  inches above the annular ligament, and follows its tendon to its insertion in the last phalanx of the thumb. The latter rises about  $1\frac{1}{2}$  inches above the annular band, and ends in diverticula for the four fingers. The process for the little finger usually extends to the insertion of the flexor profundus tendon in the last phalanx. The remaining three diverticula end about the middle of the corresponding metacarpal bones. The synovial sheaths for the digital part of the tendons to the index, middle, and ring fingers end above about the neck of the metacarpal bones, and are thus separated by about  $\frac{1}{4}$  to  $\frac{1}{2}$  an inch from the great synovial sac beneath the annular ligament. Thus there is an open channel from the ends of the thumb and little finger to a point in the fore-arm some  $1\frac{1}{2}$  inches above the annular ligament. The arrangement explains the well-known surgical fact that abscesses of the thumb and little finger are apt to be followed by abscesses in the fore-arm, while such a complication is not usual after suppuration in the remaining fingers. The synovial sac for the flexor tendons is narrowed as it passes beneath the annular ligament, and thus it happens that when distended with fluid or with pus, it presents an hour-glass outline, the waist of the hour-glass corresponding to the ligament. The two synovial sacs beneath the ligament sometimes communicate with one another.

In one form of *whitlow*, that form where the pus occupies the synovial sheaths of the tendons on the fingers (thecal abscess), the suppuration can often be seen to end abruptly where the sheath ends, when the index, middle, or ring finger is involved, viz., opposite the neck of the corresponding metacarpal bones. In another form of *whitlow* (the abscess in the pulp at the end of the finger) the periosteum of the third phalanx is readily attacked, there being no intervening tendon sheath over that bone. In this affection the bone often necroses and comes away, but it is significant to note that it is very seldom that the whole of the phalanx perishes. The upper part, or base, of the bone usually

remains sound, and is probably preserved by the insertion of the flexor profundus tendon. It is also interesting to bear in mind that the base of the bone is an epiphysis that does not unite to the shaft until the eighteenth or twentieth year.

The tendons do not lie free within the sac, but are bound to it by folds of synovial membrane in much the same way as the bowel is bound to the abdominal parietes by its mesentery. These folds may be ruptured in severe sprains, when the nutrient vessels for the tendon, which are contained in them, may be torn. Rupture is followed by effusion into the sac. These folds are almost absent within the digital sheaths, the slight ligamenta longa and brevia, near the insertion of the tendons, being the sole representatives. Synovial sacs are lined by a squamous epithelium, and have extremely free communication with the lymphatic vessels of the part. Hence the free absorption of infective matter from such cavities.

Beneath the posterior annular ligament there are six synovial sheaths for tendons, corresponding to the six canals formed by that ligament. The sheath most frequently inflamed is that for the extensores ossi metacarpi and brevis pollicis. It runs from a point about  $\frac{3}{4}$  of an inch above the radial styloid process to the first carpo-metacarpal joint. The other sheaths reach *above* to the upper border of the annular ligament, that for the two radial extensors, however, beginning about  $\frac{1}{2}$  an inch above the ligament. The sheaths for the extensor communis and the extensor minimi digiti extend *below* to the middle of the metacarpus. That for the extensor indicis barely reaches the metacarpus. The other sheaths follow the tendons to their insertions. The synovial lining and folds of these sheaths are injured in Colles' fracture of the radius. The tendons become adherent to their sheaths and fixed unless this be prevented by passive movements of the tendons.

**Blood-vessels and lymphatics.**—The hand is very well supplied with blood, and indeed the finger pulp is one of the most vascular parts in the body.



Cases are recorded where the tip of the finger has been accidentally cut off, and has grown again to the limb on being immediately re-applied. The position of the palmar arches has been pointed out. Wounds of these arches, and indeed of most of the arteries of the palm and wrist, are serious, on account of the difficulty of reaching the bleeding point without seriously damaging important structures, and on account of the free anastomoses that exist between the vessels of the part. The deep palmar arch may be wounded by a penetrating wound from the dorsum, and indeed Delorme has pointed out that this arch may be ligatured from the dorsum after a preliminary resection of the upper part of the third metacarpal bone. It is well known that hæmorrhage from either of the palmar arches cannot be checked by ligature of the radial or ulnar artery alone, on account of the connection of the arches with those vessels; and it is also known that simultaneous ligation of the two vessels may have no better effect, owing to the anastomoses between the palmar arches and the interosseous vessels. The anastomosis is carried on by means of the carpal arches. The anterior carpal arch communicates with the anterior interosseous artery above, and with the deep palmar arch, by the recurrent vessels below. The posterior carpal arch communicates with the two interosseous vessels above, and with the deep palmar arch below, by means of the perforating branches from the latter vessel. The anastomosis between the two palmar arches is well known, and is freely established both by the main vessels themselves and by the communion that exists between the digital arteries from the superficial arch and the palmar interosseous branches from the deeper vessels. In bleeding from the palm, the simultaneous ligation of the radial and ulnar arteries may also entirely fail in those cases where the arches are freely joined, or are more or less replaced by large and abnormal interosseous vessels, or by a large "median" artery. When either the radial or the ulnar part of the arches is defective, the lack is usually supplied by the other vessel; and it is well to

note that the deficiency is most common in the superficial or ulnar arch. Pressure applied to the palm to arrest bleeding is apt to cause gangrene, owing to the rigidity of the parts and the ease with which considerable pressure can be applied.

The radial artery, as it curves round the back of the hand to reach the deeper part of the palm, is in close contact with the carpo-metacarpal joint of the thumb. This fact must be borne in mind in amputation of the entire thumb, and also in resection of the first metacarpal bone. The superficialis volæ, if large, may bleed seriously. It adheres to the surface of the annular ligament, and may therefore be difficult to pick up when wounded.

From the larger size and great number of the lymphatics about the fingers and on the dorsum of the hand, it follows that lymphangitis is more common after wounds of those parts than it is after wounds of the palm.

The **bones and joints.**—The inferior radio-ulnar joint is supported by the powerful triangular fibro-cartilage, which forms the strongest and most important of all the ligamentous connections between the two bones. The synovial sheath of the extensor minimi digiti sometimes communicates with this joint, and may therefore be involved when that articulation is diseased.

The strength of the wrist joint depends not so much upon its mechanical outline or its ligaments as upon the numerous strong tendons that surround it, and that are so closely bound down to the bones about the articulation. Its strength depends also upon its proximity to the numerous bones and joints of the hand, whereby all movements and shocks are distributed between several articulations. Moreover, in the case of the wrist the long lever does not exist on the distal side of the joint. The movements of the wrist are greatly supplemented by those of the mid-carpal joint. The anterior ligament of the wrist is the strongest ligament of the joint, while the posterior is the weakest.

The former structure limits extension, and the latter flexion; and in connection with this arrangement it is interesting to note that injury from forced extension is more common than from forced flexion. Thus, when a man falls upon the hand, he more usually falls upon the palm (forced extension) than upon the dorsum (forced flexion). Owing to the thinness of the posterior ligament, together with the more superficial position of the hinder part of the joint, it follows that the effusion in wrist-joint disease is first noticed at the back of the hand. As the tendons on the front and at the back of the wrist fairly balance one another, the hand in wrist joint disease shows little tendency to be displaced, but is fixed rather in the mid-position between flexion and extension. It can be understood that in this disease the neighbouring synovial sheaths are readily involved.

In connection with this joint it may be noted that the middle finger is, from its great length, the one most exposed to injury and to shocks received by the fingers. Its metacarpal bone is directly received by the strongest carpal bone, the *os magnum*, and the latter bone is brought by means of the semi-lunar into connection with the widest and strongest part of the radius.

But little movement is allowed in the metacarpocarpal joints of the first three fingers, but in the like joints of the thumb and little finger movements are free, and their preservation is of great importance to the general usefulness of the hand. The glenoid ligaments in front of the three finger joints are firmly attached to the distal bone, and but loosely to the proximal. Thus it happens that in dislocation of the distal bone backwards, the glenoid ligament is carried with it, and offers a great obstacle to reduction. In flexing the second and third finger joints alone, it will be seen that the first phalanx is steadied by the extensor tendon as a preliminary measure, and in paralysis of the extensors flexion of these two joints alone is not possible.

Very few persons have the power of flexing the last finger joint without at the same time bending the

articulation above it; but in certain inflammatory affections about the last phalanges the terminal joint is sometimes seen to be fixed in a flexed posture while the other finger joints are straight. In the condition known as "mallet" finger the distal phalanx is fixed in a flexed position. The condition is due to a partial or complete rupture of the extensor tendon of the finger, commonly the result of a blow over the terminal knuckles.

**Colles' fracture.**—This name is given to a transverse fracture through the lower end of the radius, from  $\frac{1}{2}$  to 1 inch above the wrist joint. It is associated with a certain definite deformity, and is always the result of indirect violence, a fall upon the outstretched hand. There are good reasons why the bone should break in this situation. The lower end of the radius is very cancellous, while the shaft contains a good deal of compact bone. At about  $\frac{3}{4}$  of an inch from the articular surface these two parts of the bone meet, and their very unequal density greatly tends to localise the fracture in this situation. As to the mechanism of this lesion, many different opinions are still held, and a vast deal has been written on the subject. I subjoin Professor Chiene's account of this lesion, because it may be taken as representing with admirable clearness the views most generally accepted at the present time as to the nature of this injury. Into the discussion itself I do not propose to enter. The deformity in Colles' fracture is entirely due to the displacement of the lower fragment. "The displacement is a triple one: (a) backwards, as regards the antero-posterior diameter of the fore-arm; (b) rotation backwards of the carpal surface on the transverse diameter of the fore-arm; (c) rotation through the arc of a circle, the centre of which is situated at the ulnar attachment of the triangular ligament, the radius of the circle being a line from the ulnar attachment of the triangular ligament to the tip of the styloid process of the radius. (a) When a person in falling puts out his hand to save himself, at the moment the hand reaches the ground the force

is received principally by the ball of the thumb, and passes into the carpus, and thence into the lower end of the radius. If, at the moment of impact, the angle between the axis of the fore-arm and the ground is less than  $60^\circ$ , the line representing the direction of the force passes upwards in front of the axis of the fore-arm; the whole shock is therefore borne by the lower end of the radius, which is broken off, and, the force being continued, the lower fragment is driven backwards. When at the moment of impact the angle is greater than  $60^\circ$ , the line of the force, instead of passing in front of the axis of the arm, passes up the arm, and the usual result is either a severe sprain of the wrist or a dislocation of the bones of the fore-arm backwards at the elbow joint. (b) The carpal surface of the radius slopes forwards, and therefore the posterior edge of the bone receives the greater part of the shock; there is, as a result, rotation of the lower fragment backwards on the transverse diameter of the fore-arm. (c) The carpal surface of the radius slopes downwards and outwards to the radial edge of the arm; therefore the radial edge of the bone receives the principal part of the shock through the ball of the thumb. As a result, this edge of the lower fragment is displaced upwards to a greater extent than the ulnar edge of the fragment, which remains firmly attached to the ulna by the triangular ligament." This rotation also depends upon the integrity of the inferior radio-ulnar ligament in a typical Colles' fracture. These ligaments hold on to the ulnar part of the lower fragment, and prevent its being displaced to so great an extent as is the radial part of the fragment. By means of this rotatory displacement, the tips of the two styloid processes come to occupy the same level, or the radial process may even mount above the ulnar. In nearly every case there is some penetration of the fragments, the compact tissue on the dorsal aspect of the upper fragment being driven (by a continuance of the force that broke the bone) into the cancellous tissue on the palmar aspect of the lower fragment. It is only in very rare

instances that the fragments are so separated as to ride the one over the other. In such cases the radio-ulnar ligaments are probably ruptured, and the wrist ceases to present the typical deformity of a Colles' fracture. That the deformity in Colles' fracture is due to the nature and direction of the force is indirectly proved by an isolated case or so, where the patient fell upon the *back* of the hand, with the result that the radius was broken in the usual position of a Colles' fracture, but the lower fragment was carried *forwards* instead of backwards. According to R. W. Smith and others, the peculiar deformity is produced by muscular action, principally by the supinator longus, the extensors of the thumb, and the radial extensors. Lecomte and many French writers assert that the fracture is due to a tearing (*arrachement*) of the bone by strain upon the ligaments of the wrist. Thus they assert that in forcible extension of the hand the carpal condyle is thrust against the anterior wrist ligaments; these are intensely stretched, and tear off the lower end of the radius, fracturing it through what is acknowledged to be the weakest part of the bone. It is true that in young subjects the lower epiphysis of the radius can be separated in the cadaver by very forcible flexion or extension of the wrist (B. Anger). This epiphysis is often separated by accidental violence. It joins the shaft about the twentieth year. Its junction with the shaft is represented by a nearly horizontal line, and the epiphysis includes the facet for the ulna and the insertion of the supinator longus. Fractures of the lower end of the radius, due to direct violence, are usually associated with but trifling displacement.

There is no special anatomical interest attaching to fractures of the carpus, metacarpus, or phalanges.

**Dislocations.**—(1) *At the wrist joint.*—So strong is this articulation, for the reasons above given (page 268), that carpo-radial luxations are extremely rare. For the same reasons, when they do occur they are usually complicated, and are associated with tearing of the skin, or rupture of tendons, or fractures of the

adjacent bones. The luxations of the carpus may be either backwards or forwards, the latter being extremely rare. They would appear to be produced with equal ease by a fall upon either the front or the back of the hand. Bransby Cooper gives the case of a lad who fell upon the outstretched palms of both his hands: both wrists were dislocated, one backwards, the other forwards.

There are five articular synovial cavities connected with the carpus. They occur in the following situations: (a) Between the carpus and fore-arm bones; it may communicate with the lower radio-ulnar cavity through the triangular fibro-cartilage; (b) between the unciform and the fourth and fifth metacarpals; (c) between the metacarpal of the thumb and trapezium; (d) between all the carpal bones and extending to the carpo-metacarpal joints of the second and third digits; (e) between the pisiform and cuneiform bones. Hernial protrusions and gangliform growths from these synovial membranes are frequently seen on the dorsum of the carpus.

(2) *Some dislocations about the hand (os magnum).*—In forcible flexion of the hand, the os magnum naturally glides backwards and projects upon the dorsum. In very extreme flexion (as in falls upon the knuckles and dorsum of the metacarpus), this movement of the bone backwards may be such as to lead to its partial dislocation, the luxation being associated with some rupture of ligaments. In one recorded case this luxation was produced by muscular force. The patient, a lady, while in labour, "seized violently the edge of her mattress, and squeezed it forcibly." Something was felt to give way in the hand, and the head of the os magnum was found to be dislocated backwards.

*Dislocations at the metacarpo-phalangeal joint of the thumb.*—In this luxation the phalanx is usually displaced backwards, and the lesion is of interest on account of the great difficulty often experienced in reducing the bone. Many anatomical reasons have been given to explain this difficulty, which are well

summarised by Hamilton in the following passage: "Hey believes the resistance to be in the lateral ligaments, between which the lower end of the metacarpal bone escapes and becomes imprisoned. Ballingall, Malgaigne, Erichsen, and Vidal think the metacarpal bone is locked between the two heads of the flexor brevis, or, rather, between the opposing sets of muscles which centre in the sesamoid bones, as a button is fastened into a button-hole. Pailloux and others affirm that the anterior ligament, being torn from one of its attachments, falls between the joint surfaces, and interposes an effectual obstacle to reduction. Dupuytren ascribes the difficulty to the altered relations of the lateral ligaments, . . . to the spasm of the muscles, and to the shortness of the member, in consequence of which the force of extension has to be applied very near to the seat of the dislocation. Lisfranc found in an ancient luxation the tendon of the long flexor so displaced inwards, and entangled behind the extremity of the bone, as to prevent reduction." Mr. Jonathan Hutchinson, junr., has recently investigated some cases and found that reduction is prevented by the fibro-cartilaginous plate. The plate is firmly attached to the phalanx and is dislocated with it. When subcutaneously divided on the extensor aspect of the thumb, the dislocation may be reduced with ease.

**Avulsion** of one or more fingers may be effected by severe violence. In such cases the finger torn off usually takes with it some or all of its tendons. These tendons are practically drawn out of the fore-arm, and may be of considerable length. Billroth figures a case where the middle finger was torn out, taking with it the two flexor and extensor tendons in their entire length. When one tendon only is torn away with the finger, it is usually that of the flexor profundus.

**Amputation at the wrist joint** by the circular method. (See the author's "Operative Surgery.") In the *dorsal wound* would be cut the following tendons: the extensores longus, indicis, communis, minimi digiti, and ulnaris, the radial nerve, and the dorsal



branch of the ulnar nerve. The two radial extensors will be cut short in the radial angle of the wound, as will also be the *extensores ossis and brevis*. The radial artery will be divided close to the radius. In the *palmar wound* would be found the ulnar artery, the *superficialis volæ*, the ulnar and median nerves, the *opponens*, *flexor brevis*, and *abductor pollicis* in part, the *flexor brevis*, *opponens*, and *abductor minimi digiti* in part (the bulk of the *opponens* being left behind on the hand), and the tendons of the *flexor sublimis* and *flexor carpi radialis*. The tendons of the *flexor profundus* and *flexor longus pollicis* are usually cut short close to the bones.

**Amputation of the thumb** at the carpo-metacarpal joint by flaps. In the *palmar* flap would be cut the *abductor*, the short and long *flexor*, the *opponens*, and *adductor pollicis*. The *extensores ossis and brevis* would be cut short in the posterior angle of the flap. The *extensor longus* and a considerable portion of the *abductor indicis* would be found in the *dorsal* flap. The vessels divided would be the two dorsal arteries of the thumb and the *princeps pollicis*. There is great danger, in this operation, of wounding the *radialis indicis* and the radial artery itself where it begins to dip into the palm.

**Nerve supply of the upper limb.**—The symptoms which follow a lesion to the nerves of the upper limb depend on the point injured. If the fifth spinal nerve be crushed between its origin in the spinal cord and its exit from the intervertebral foramen, either from fracture or caries of the cervical vertebræ, the injury is followed by paralysis, partial or complete, of the *deltoid*, *biceps*, *brachialis anticus*, and *supinator longus*, while a strip of skin on the outer side of the limb from the *deltoid* to the *styloid process* of the radius is insensitive to touch or pain (Fig. 38). Injury to the cord just above the origin of the eighth cervical vertebra will leave the skin of the ulnar half of the arm anæsthetic, while the muscles of the fingers, hand, and wrist, and some of those at the elbow and shoulder, will be paralysed. The fibres for the innervation of the various groups of arm

muscles pass out in quite an orderly manner by the fifth cervical to the first dorsal nerve from corresponding segments of the cord. Those for the abductors of the shoulder pass out by the fifth; for the adductors by the sixth and seventh; for the flexors of the elbow by the fifth and sixth; for the extensors by the seventh and eighth; for the extensors of the wrist and fingers by the sixth and seventh; and those for the flexors by the eighth and first dorsal. It is important to remember that a cervical spinal nerve makes its exit from the canal opposite the origin of the next spinal nerve.

The following is Dr. Herringham's account of the usual spinal origin of the fibres in the nerves of the upper limb, and of the usual supply of the chief muscles. (The figures indicate the fifth, sixth, seventh, and eighth cervical nerves, and the first dorsal nerve.)

*Nerves.*—Nerve of Bell, 5, 6, 7; suprascapular, 5 or 5, 6; external cutaneous, 5, 6, 7; internal cutaneous, 1 or 8, 1; nerve of Wrisberg, 1; circumflex, 5, 6; median, 6, 7, 8, 1; ulnar, 8, 1; musculo-spiral, 6, 7, 8, or 5, 6, 7, 8.

*Muscles.*—3, 4, 5, lev. anguli scap.; 5, rhomboids; 5 or 5, 6, biceps, brachialis ant., supra- and infra-spinatus, teres minor; 5, 6, deltoid, subscapularis; 6, teres major, pronator teres, flexor carpi rad., supin. longus and brevis, superficial thenar muscles; 5, 6, 7, serratus magnus; 6 or 7, extensores carpi rad.; 7, coraco-brachialis, latiss. dorsi, extensors at back of fore-arm, outer head of triceps; 7, 8, inner head of triceps; 7, 8, 1, flexor sublimis, flexores profund., carpi uln., long. poll., pronator quad.; 8, long head of triceps, hypothenar muscles, interossei, deep thenar muscles.

In the *cutaneous nerve supply of the fingers*, it must be remembered that on the palmar aspect the thumb, the two outer fingers, and the radial side of the ring finger are supplied by the median, the remaining one and a half fingers by the ulnar (Fig. 37). On the dorsal aspect the thumb is supplied by the radial, the index and middle fingers are supplied (as far as the base

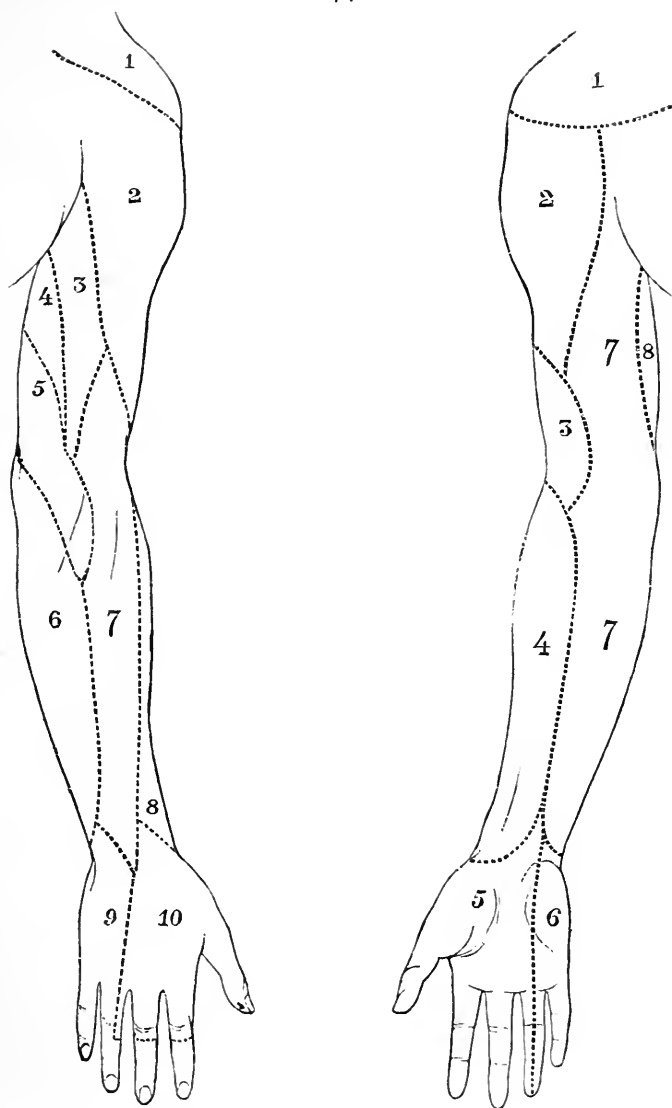


Fig. 37.—Cutaneous Nerve Supply of Upper Limb.

*Anterior aspect:* 1, Cervical plexus; 2, circumflex; 3, ext. cut. of muscul. spir.; 4, ext. cutaneous; 5, median; 6, ulnar; 7, int. cutaneous; 8, n. of Wrisberg.

*Posterior aspect:* 1, Cervical plexus; 2, circumflex; 3, int. cut. of muscul. spir.; 4, intercosto-humeral; 5, n. of Wrisberg; 6, int. cutaneous; 7, ext. cut. of muscul. spir.; 8, ext. cutaneous; 9, ulnar; 10, radial.

of the second phalanx) by the radial, and over the second and third phalanges by the median. The little finger and the ulnar side of the ring finger are supplied by the ulnar. The radial side of the ring finger, as far as the base of the second phalanx, is supplied by the radial, and the rest of this side of the digit by the median (Fig. 37). The cleft between the middle and ring fingers is occasionally supplied by the ulnar, or partly by the ulnar and partly by the radial. The roots and spinal segments to which these nerves belong may be ascertained from Fig. 38. The roots are distributed in order of origin, the fifth cervical beginning on the radial or outer side of the shoulder and the second dorsal, or sometimes the third, ending on the ulnar or inner aspect of the upper arm. The hand is mainly supplied by the seventh. The neighbouring spinal nerves, as is also the case with ordinary terminal branches, overlap widely in their distribution. The area of anæsthesia is much less than the area of anatomical distribution. The pain referred along the ulnar half of the arm in cases of angina pectoris and aneurism of the aorta is due to the common origin of the cardiac and aortic sympathetic nerves, and those for the ulnar segment of the arm from the first dorsal segment of the spinal cord (Head).

**Injuries to the main nerves of the upper limb.**—The entire brachial plexus has been ruptured, leading to complete paralysis of the upper limb. In these cases it would appear that the nerves are torn away from their attachments to the cord rather than broken across at some distance from it. In several instances the biceps muscle has retained some of its functions, while the whole of the other muscles have been paralysed, a circumstance perhaps explained by the high origin of the bicipital nerve from the spinal cord.

**Paralysis of the musculo-spiral nerve.**—When complete, the hand is flexed and hangs flaccid ("drop wrist"), and neither the wrist nor the fingers can be extended. The latter are bent and cover the thumb, which is also flexed and adducted. When

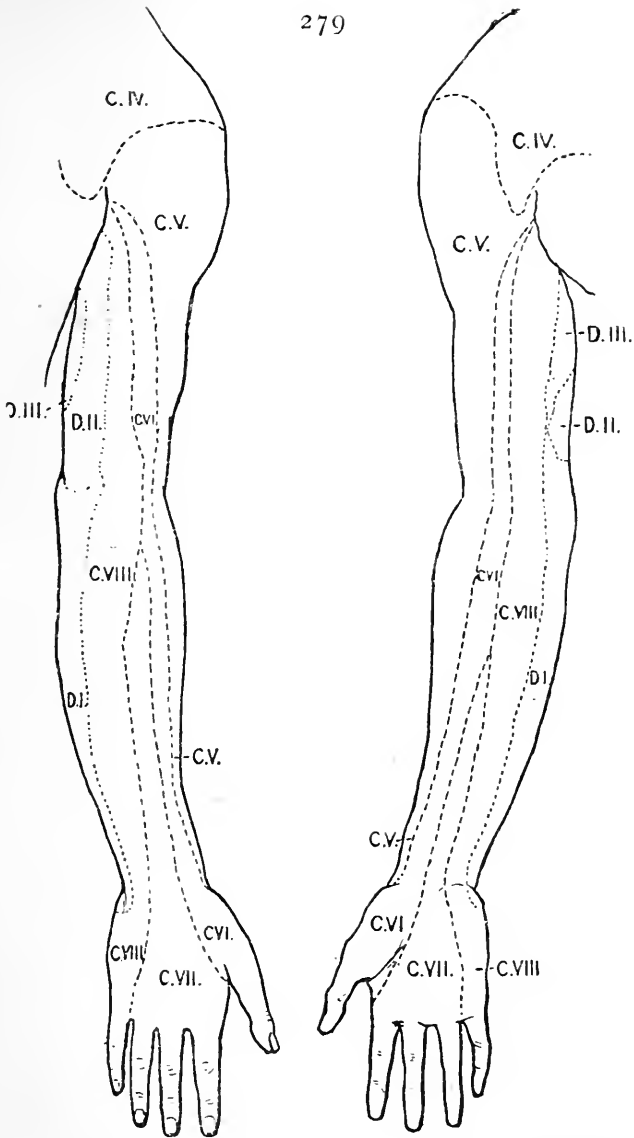


Fig. 38.—Showing the Sensory Distribution of the Spinal Nerves in the Upper Limb.

The dotted lines indicate approximately the area of each nerve. No attempt is made to show the extent to which the root areas overlap. (For the nerves supplying each area see Fig. 37.)

attempts are made to extend the fingers, the interossei and lumbricales alone act, producing extension of the last two phalanges and flexion of the first. Supination is lost, especially if the elbow be extended so as to exclude the action of the biceps muscle. Extension at the elbow is lost, and sensibility is disturbed over the skin supplied by the nerve (Erb).

**Paralysis of the median nerve.**—Flexion of the second phalanx is impossible in every finger, as is also a like movement of the last joint of the index and middle fingers. Partial flexion of the third phalanges of the two inner digits is possible, the inner part of the flexor profundus being supplied by the ulnar nerve. Flexion of the first phalanx with extension of the second and third can still be performed in all the fingers by the interossei. The thumb is extended and adducted, and can neither be flexed nor opposed. Bending of the wrist is only possible when the hand is forcibly adducted by means of the flexor carpi ulnaris, which is not paralysed. Pronation is lost. Sensation is disturbed over the skin supplied by the nerve (Erb).

**Paralysis of the ulnar nerve.**—Ulnar flexion and adduction of the hand are limited. Complete flexion of the two inner fingers is impossible. The little finger can scarcely be moved at all. The action of the interossei and two inner lumbricales is lost. The patient is unable to adduct the thumb, and sensibility is impaired over the cutaneous area supplied by the nerve (Erb).

After complete division of any one of the three great nerves of the upper limb, the loss of sensation in the cutaneous parts supplied by that nerve is often quite slight. This is accounted for by the interlacings that occur between the principal nerves of the arm, so that when a given trunk is injured the sensory impressions are returned by another route. Thus are explained those cases where the median has been sutured after accidental division, with the effect that within a few hours sensation has returned to the cutaneous parts supplied by the nerve. Such return of sensation

is probably due to the supplementary action of the interlacing nerve fibres bound up with other trunks, and not to the "immediate union of a divided nerve," as was at one time announced.

**Epiphyses of the upper limb.**—The epiphyses about the elbow join the shafts of their respective bones at 17 years (except the tip of the internal condyle, which joins at 18). The epiphyses at the shoulder and wrist extremities of the bones join at 20. The nutrient canals of the three bones run towards the elbow. The nutrient artery of the humerus comes from the brachial or inferior profunda, those of the radius and ulna from the anterior interosseous.

The *nerve* supplying the humerus is the musculocutaneous. The radius and ulna are supplied by the anterior interosseous of the median.

## Part IV.

### THE ABDOMEN AND PELVIS.

#### CHAPTER XVI.

##### THE ABDOMEN.

**THE abdominal parietes.**—*Surface anatomy.*  
 —The degree of prominence of the abdomen varies greatly. The protuberance of the belly in young children is mainly due to the relatively large size of the liver, which occupies a considerable part of the cavity in early life. It also depends upon the small size of the pelvis, which is not only unable to accommodate any abdominal structure (strictly so called), but can scarcely provide room for the pelvic organs themselves. Thus in infancy the bladder and a great part of the rectum are virtually abdominal viscera. After long-continued distension, as, for example, after pregnancy, ascites, etc., the abdomen usually remains unduly prominent and pendulous.

In examples of prolapse of the mesentery the upper part of the abdomen becomes sunken in and the lower part unduly prominent. (*See page 320.*)

In cases of great emaciation it becomes much sunken, and its anterior wall appears to have collapsed. This change is most conspicuous about the upper part of the region. Here the anterior parietes immediately below the line of the costal cartilages, instead of being in the same plane with the anterior thoracic wall, may so sink in as to be almost at right angles with that wall on the one hand, and with the lower part of the abdominal parietes on the other. In such cases the abdominal walls just below the thoracic line may appear to be



almost vertical when the patient is in the recumbent posture. This change of surface is of importance in gastrostomy, since the subjects for that operation are usually much emaciated, and the incision has to be made close below the costal line.

The position of the linea alba above the umbilicus is indicated by a slight median groove, but no such indication exists below the navel. The linea semilunaris may be represented by a slightly curved line drawn from about the tip of the ninth costal cartilage to the pubic spine. In the adult it would be placed about 3 inches from the navel. Above the umbilicus the line is indicated on the surface by a shallow depression. The outline of the rectus can be well seen when the muscle is in action. It presents three "lineæ transversæ," one usually opposite the xiphoid cartilage, one opposite the umbilicus, and a third between the two. The two upper of these lines are obvious on the surface in well-developed subjects.

The site of the umbilicus varies with the obesity of the individual and the laxity of the abdomen. It is always below the centre of the line between the xiphoid cartilage and the pubes. In the adult it is some way above the centre of the body, as measured from head to foot, while in the fœtus at birth it is below that point. It corresponds in front to the disc between the third and fourth lumbar vertebræ, and behind to the tip of the third lumbar spinous process. It is situated about  $\frac{3}{4}$  of an inch to 1 inch above a line drawn between the highest points of the two iliac crests.

The anterior superior spine, the pubic spine, and Poupart's ligament are all conspicuous and important landmarks. The pubic spine is nearly in the same horizontal line with the upper edge of the great trochanter. It is very distinct in thin subjects. In the obese it is entirely lost beneath the pubic fat. In such individuals, however, it can be detected, when the subject is a male, by invaginating the scrotum so as to pass the finger beneath the subcutaneous fat. In the female the position of the process may be made out by

adducting the thigh and thus making prominent the tendon of origin of the adductor longus muscle. This muscle arises from the body of the pubes immediately below the spine, and by running the finger along the muscle the bony prominence may be reached. If the finger be placed upon the pubic spine it may be said that a hernia descending to the inner side of the finger will be inguinal, while one presenting to the outer side will be femoral. In the erect position of the body the anterior superior spine is a little above the level of the promontory of the sacrum, while the tip of the xiphoid cartilage corresponds to about the lower part of the tenth dorsal vertebra.

In that part of the back which corresponds to the abdominal region the erector spinæ masses are distinct, and in any but fat subjects their outer edges can be well defined. Between these masses is the spinal furrow, which ends below in an angle formed by the two great gluteal muscles. Immediately above the middle of the crest of the ilium is Petit's triangle, or the gap between the external oblique and latissimus dorsi muscles. The fourth lumbar spine is about on a level with the highest part of the iliac crest. In counting the ribs it is well to commence from above, since the last rib may not project beyond the outer edge of the erector spinæ, and may consequently be overlooked.

The aorta bifurcates opposite the middle of the body of the fourth lumbar vertebra just to the left of the middle line. This spot corresponds very nearly to the highest point of the iliac crest, and will therefore be situate about  $\frac{3}{4}$  of an inch below and to the left of the umbilicus. A line drawn on either side from the point of bifurcation to the middle of Poupart's ligament will correspond to the course of the common and external iliac arteries. The first 2 inches of this line would cover the common iliac, the remainder the external.

The cœliac axis comes off opposite the lower part of the twelfth dorsal vertebra, at a spot about 4 or 5 inches above the navel, and that corresponds behind to the twelfth dorsal spine. The superior mesenteric

and suprarenal arteries are just below the axis. The renal vessels arise about  $\frac{1}{2}$  an inch below the superior mesenteric, opposite a spot some  $3\frac{1}{2}$  inches above the umbilicus, and on a level behind with the gap between the last dorsal and first lumbar spines. The inferior mesenteric artery comes off from the aorta about 1 inch above the umbilicus. The deep epigastric artery follows a line drawn from the middle of Poupart's ligament to the umbilicus. Along the same line may sometimes be seen the superficial epigastric vein.

The abdominal "rings" will be referred to in the paragraph on hernia.

**Anterior abdominal parietes.**—The *skin* over the front of the abdomen is loosely attached in the region of the groin. This condition is taken advantage of in certain operations, *e.g.*, Wood's procedure for the radical cure of hernia. It also allows of the incision for herniotomy in the inguinal region being made by transfixing a fold of the skin that has been pinched up over the external ring. The skin is more adherent to the deeper parts in the middle line than elsewhere, but not so adherent as to hinder the spread of inflammation from one side of the abdomen to the other. In cases of great obesity two transverse creases form across the belly, one crossing the umbilicus and the other passing just above the pubes. In the former of the two creases the navel is usually hidden from sight. In cases of ankylosed hip-joints transverse creases are often noted running across the middle of the belly. They are produced by the freer bending of the spine that is usually permitted in ankylosis, some of the simpler movements of the hip joint being transferred to the column when the articulation is rendered useless.

After the skin has been stretched, from any gross distension of the abdomen, certain silvery streaks appear in the integument over its lower part. They are due to an atrophy of the skin produced by the stretching, and their position serves to indicate the parts of the parietes upon which distending forces within the

abdomen act most vigorously. They are well seen after pregnancy, ascites, ovarian tumours, etc.

Beneath the skin is the *superficial fascia*, which over the lower half of the abdomen can be readily divided into two layers. The great bulk of the subcutaneous fat of this region is lodged in the more superficial of the two layers. In cases of great obesity the accumulation of fat is perhaps more marked beneath the skin of the abdomen than it is elsewhere. A layer of fat 6 inches in depth has been found in this region in cases of great corpulence. The superficial vessels and nerves lie for the most part between the two layers of the fascia, so that in obese subjects incisions may be made over the abdomen to the depth of an inch or so without encountering blood-vessels of any magnitude.

The deep layer of the superficial fascia contains elastic fibres, and corresponds to the tunica abdominalis or "abdominal belt" of animals. It is attached to the deeper parts along the middle line as far as the symphysis, and to the fascia lata just beyond Poupart's ligament. In the interval between the symphysis and the pubic spine it has no attachment, but passes down into the scrotum and becomes the dartos tissue. Extravasated urine that has reached the scrotum may mount up on to the abdomen through this interval, and will then be limited by the deeper layer of the fascia. It will not be able to pass down into the thigh on account of the attachments of the fascia, nor, for a like reason, will it tend to pass over the middle line. In the same way emphysematous collections following injuries to the chest, when beneath the deeper layer of the fascia, receive a check at the groin, and lipomata also that grow beneath the membrane tend to be limited by the middle line and that of Poupart's ligament.

The anterior *abdominal parietes* vary in thickness in different subjects. In cases of great emaciation the outlines of some of the viscera may be readily made out or even seen through the thinned wall. In some cases of chronic intestinal obstruction the outlines of the distended intestine are visible, and their move-

ments can be watched; in instances of obstruction of the pylorus the movements of the dilated and hypertrophied stomach can often be seen. The relative thickness of the abdominal wall in various subjects depends rather upon the amount of the subcutaneous fat than upon the thickness of the muscles. This muscular boundary affords an admirable protection to the viscera within. By contracting the abdominal muscles the front of the belly can be made as hard as a board, and in acute peritonitis this contraction can sometimes be seen to produce a remarkable degree of rigidity.

A blow upon the abdomen when the muscles are firmly contracted will probably do no injury to the viscera unless violence be extreme. The rigid muscular wall acts with the efficacy of a dense indiarubber plate. It may be bruised or torn, but it will itself receive the main shock of the contusion.

The probable effect on the contained viscera of a blow upon the abdomen will depend upon many factors; but, so far as the walls themselves are concerned, the effect greatly depends upon whether the blow was anticipated or not, and upon the extent of the padding of fat that is furnished to the parietes. If the blow be anticipated the muscles of the belly will be instinctively contracted, and the viscera be at once provided with a firm but elastic shield. Thus the abdominal muscles have been found bruised and torn while the viscera were intact, and, on the other hand, in cases probably where the muscles were inert or taken unawares a viscus has been found to be damaged without any conspicuous lesion in the belly wall. If the blow be anticipated also the body will probably be abruptly bent and the viscera be—as it were—removed from danger.

Along the **linea alba** the abdominal wall is thin, dense, and free from visible blood-vessels. Hence in most operations upon the abdominal cavity the incision is made in the middle line. Along the outer border of the rectus muscle (*i.e.* about and just beyond the linea semilunaris) the parietes are also thin and lacking in vessels, and consequently that situation is well suited

for an incision. Except in some operations on the kidney, stomach, or gall bladder, incisions are seldom so placed. In most cases it is a question of either opening the abdomen in the middle line or in one of the iliac regions. Below the navel the two recti muscles are almost in contact, and here the linea alba can scarcely be said to exist. Above the umbilicus the two muscles tend to separate a little, and the "line" increases greatly in width. In pregnancy and in other forms of distended abdomen the median interval between the recti may be much increased.

The structures immediately behind the linea alba are, from above downwards, the liver, stomach, and transverse colon above the umbilicus, and the small intestines and bladder (when distended) below it. There are often little spaces between the fibres of the linea alba, and through these pellets of fat from the sub-peritoneal tissue may grow. If of fair size these little masses may be mistaken for irreducible herniæ. Similar growths of fat may extend through the inguinal or femoral openings, and constitute the so-called "fatty herniæ."

The fibrous ring of the **umbilicus** is derived from the linea alba. To this ring the adjacent structures, skin, fasciæ, and peritoneum, are all closely adherent. The adhesion is such, and the amount of tissue between the skin and peritoneum is so scanty, that in operating upon an umbilical hernia it is scarcely possible to avoid opening the sac.

The umbilicus represents the point where the lateral abdominal walls finally close. At the sixth week the opening is funnel-shaped and contains the yolk sac and a fold of the bowel to which it is attached. This condition may persist and give rise to a congenital hernia of the umbilicus. In the foetus three vessels enter at the navel, and immediately separate on reaching the abdominal cavity, the vein passing directly upwards and the arteries obliquely downwards. Running down from the umbilicus in the middle line is also the remains of the urachus. In the foetus, the spot where the three

vessels part company is about the centre of the navel, and it thus happens that in a congenital umbilical hernia the gut as it escapes separates the three vessels, which become to some extent spread over it. The congenital hernia, indeed, works its way in among the structures of the cord and receives its main covering from them. These herniæ are fortunately rare, for in certain instances they extend some way into the cords, and in at least two reported cases the gut was cut across by the accoucheur in dividing the cord at birth.\* As the abdomen increases in height the contraction of the two obliterated arteries and of the urachus drags upon the cicatrix and pulls it backwards and downwards. Thus, in the adult umbilical ring, as viewed from the inner side, the cords representing not only the obliterated arteries and the urachus, but also the vein, appear to start from the lower border of the cicatrix. In adult herniæ, indeed, the gut escapes above both the obliterated arteries and the vein. The upper half of the cicatrix is thin when compared to the lower half, and is supported also by less firm adhesions.

In some cases a fistula is found at the navel that discharges urine. This is due to a patent urachus. The urinary bladder is formed by a dilatation of the stalk of the allantois. The part below this dilatation becomes the first part of the urethra, that above becomes the urachus. In one instance of patent urachus the abnormal opening was 1 inch in diameter. The patient, a man aged 40, had a stone, which was extracted by passing the finger into the bladder through the opening at the umbilicus.

Sometimes a fistula discharging fæces is met with at the navel. This depends upon the persistence of the vitello-intestinal duct, a duct that at one time connects the rudimentary intestine with the yolk sac, and that generally disappears without leaving any trace. The

\* The congenital hernia must be distinguished from the infantile umbilical hernia so commonly met with after separation of the cord. For an account of these congenital herniæ, see paper by the author in the *Lancet*, vol. i., 1881, p. 323.

persistent duct, when it occurs, is known as Meckel's diverticulum, and springs from the ileum from one to four feet above the ileo-cæcal valve. This fœtal relationship also explains the presence of a fibrous cord which is sometimes seen connecting Meckel's diverticulum with the umbilicus. It may cause strangulation of the bowel.

The position of the transverse intersections of the **rectus muscle** should be borne in mind. They adhere to the anterior layer of the rectus sheath, but not to the posterior. They are able, therefore, in some extent to limit suppurative collections and hæmorrhages beneath the sheath on its anterior aspect. This muscle is often the seat of one form of "phantom tumour." These tumours are mostly met with in the hysterical and hypochondriac, and when associated with some vague abdominal symptoms are apt to mislead. They are due to a partial contraction of the muscle, usually to a part between two intersections, and are said to be more common in the upper part of the rectus. When the fibres of the muscle are contracted the "tumour" is obvious, but when they relax it disappears. The phantom tumour, however, is not always a matter of little moment. It may be associated with grave disease within the abdomen, and be due to reflex muscular contraction, the starting point of such reflex act being in the viscera.

I have, for example, seen a conspicuous phantom tumour in the upper part of the right rectus associated with cancer of the stomach, with ulcer of the duodenum, and with malignant disease of the peritoneum.

Other vanishing tumours depend upon distension of the intestines by flatus or by fæcal matter. In great distension of the abdomen the fibres of the rectus may be much stretched, since they bear the brunt of the distending force. The direction of the fibres also renders them liable to be torn in the opisthotonos, or extreme arching of the back, of tetanus. Portions of the muscle have also been ruptured by muscular violence.

‡ In women, as a result of many pregnancies, the recti



may become separated. The separation is usually below the umbilicus, and the condition is known as *divarication of the recti*.

Luschka quotes a case in which the separation of the muscles was so great that the interval between them took in almost the whole of the anterior wall of the abdomen. The recti muscles were found in the flanks.

The **lateral muscles** of the front abdominal wall are separated from one another by layers of loose connective tissue. These extensive layers favour the spread of interstitial abscesses of the abdominal parietes. Such abscesses will be guided in their course by the attachments of the muscles between which they spread, and will be limited by the semilunar lines in front, by the lower parts of the ribs and their cartilages above, by Poupart's ligament and the iliac crest below, and by the edge of the erector spinæ behind. The same remark applies to hæmorrhagic or emphysematous collections between these muscles.

Between the abdominal parietes and the peritoneum is a layer of loose connective tissue, the **subserous connective tissue**. The looseness of this layer greatly favours the spread of abscess, to the progress of which it offers little resistance. Such an abscess may spread from the viscera, especially from those that have an imperfect peritoneal covering, as, for example, the kidney, the vertical parts of the colon, etc. The laxity of this tissue has been of service in certain surgical procedures. Thus the external and common iliac arteries can be reached by an incision made some way to the outer side of the vessels and without opening the peritoneum. That membrane having been exposed in the lateral wound, the artery is reached by working a way with the finger through the subperitoneal tissue, and by actually stripping the serous membrane from its attachments. Ligature of the iliac vessels at the present day is usually effected through a direct incision which opens the peritoneal cavity. The method just detailed belongs to pre-antiseptic days. The laxity of the subserous layer also favours that

stretching of the peritoneum which occurs under certain circumstances. Sarcomata are not unfrequently met with in the subserous or retroperitoneal connective tissue, and when so placed the laxity of that tissue allows them to spread readily, especially when they attack the retroperitoneal tissue lining the posterior walls of the abdominal cavity.

**Wounds of the abdomen** may give trouble in their treatment, since, when inflicted, they may open up several layers of fascia and so lead to bagging of pus and to the spread of suppuration should an abscess follow the lesion. When the more muscular parts are divided the condition of the layers incised is such that great facilities are offered for the embedding of small foreign bodies, such as pieces of glass, etc., which, hidden between the muscular layers, may well be overlooked. Mr. Pollock records a case where the metal part of a steel fork with two prongs was overlooked and allowed to remain buried in the abdominal walls for a considerable time.

The constant respiratory movements of the belly walls do not favour that rest which is so essential to the healing of wounds.

In penetrating wounds the contraction of the muscles may encourage the protrusion of the viscera, especially when the incision is transverse to the direction of the muscular fibres. In reducing small portions of protruded viscera it is quite possible to push them into one of the connective tissue spaces between the muscles or into the subserous tissue instead of into the peritoneal cavity. In applying sutures to wounds involving the whole thickness of the parietes it is necessary that the threads should include the peritoneum so that early healing of that membrane may be brought about. Without such precaution a gap may be left in the surface of the peritoneum which would favour the formation of a hernia in the site of the old wound.

**Blood-vessels.**—The only *arteries* of any magnitude in the abdominal walls are the two epigastric arteries, some branches of the deep circumflex iliac,

the last two intercostal vessels, the epigastric branch of the internal mammary, and the abdominal divisions of the lumbar arteries. The superficial vessels are of small size, although Verneuil reports a case of fatal hæmorrhage from the superficial epigastric vessel.

The superficial *veins* on the front of the abdomen are numerous, and are very distinct when varicose. A lateral vein, extending from the axilla to the groin, uniting the axillary and femoral veins, is often rendered in this way very prominent. The surface abdominal veins may take no part as alternative blood channels in cases of obstruction of the inferior vena cava. Clinical experience shows that these veins may be also enormously varicose in instances where the inferior cava is quite patent. In one case under my care there was extensive varicosity of the surface veins from the pectoral region to the groin that involved one side of the body only. It has been shown, moreover, that the valves of these vessels are so arranged that the blood in the surface veins above the navel goes to the axilla, while that in the veins of the subumbilical region runs to the groin.

Schiff has shown that certain small veins connect the portal vein with the epigastric veins at the umbilicus.

As regards the surface *lymphatics* of the front of the abdomen, it may be said in general terms that those above the umbilicus go to the axillary glands, and those below to the glands of the groin.

**Nerves.**—The abdominal wall is supplied by the lowest seven dorsal or intercostal nerves, and by the first lumbar nerve. These nerves run obliquely to the long axis of the abdomen downwards and inwards from the sides to the middle line and hence are damaged more extensively in vertical than in oblique incisions. Their direction is represented by a continuation of the lines of the ribs: they are placed parallel to one another and at fairly equal distances apart. It is important to note that they supply not only the abdominal integument, but also the muscles of the belly, viz., the rectus,

the two oblique muscles, and the transversalis. The segments of the spinal cord which supply the skin also innervate the underlying muscles, an association of great importance (Fig. 39). If a cold hand be suddenly placed upon the belly the muscles at once contract and the abdomen is instinctively rendered rigid. The safety of the viscera, so far as at least protection from contusions is concerned, depends upon the readiness with which the muscles can contract at the first indication of danger. As has been already stated, the viscera have a very efficient protection against the effects of blows when the belly muscles are in a state of rigid contraction. The sensitive skin acts the part of a sentinel, and the intimate association of the surface nerves with the muscular nerves allows the warnings of this sentinel to be readily given and immediately acted upon. If the skin and the muscles were supplied from different segments a longer interval would elapse between the warning to the skin and the muscular contraction than occurs when those two parts are both supplied by the same. The rigidity of the muscles in certain painful affections of the skin over the abdomen is often very conspicuous. I might instance the case of a man with a burn over the belly. While the burn is protected by the dressings the abdominal muscles are lax and the parietes move with the respiratory act. The moment the dressings are removed, the surface becoming painful, its spinal centre becomes excited and the muscles at once contract and the belly becomes rigid. It will be noticed that six of the abdominal nerves supply intercostal muscles, and are thus intimately associated with the movements of respiration. The abdominal muscles are of course concerned in the same movements. These associations are illustrated when cold water is suddenly dashed upon the belly. The subject of such experiment at once experiences a violent respiratory movement in the form of a deep gasp. When the abdominal muscles are firmly fixed the lower ribs are also rigid, and respiration is limited to the higher ribs and to the thorax proper.

There are other practical points about these nerves. In caries of the spine, and in certain injuries to the column, the spinal nerves may suffer injury as they

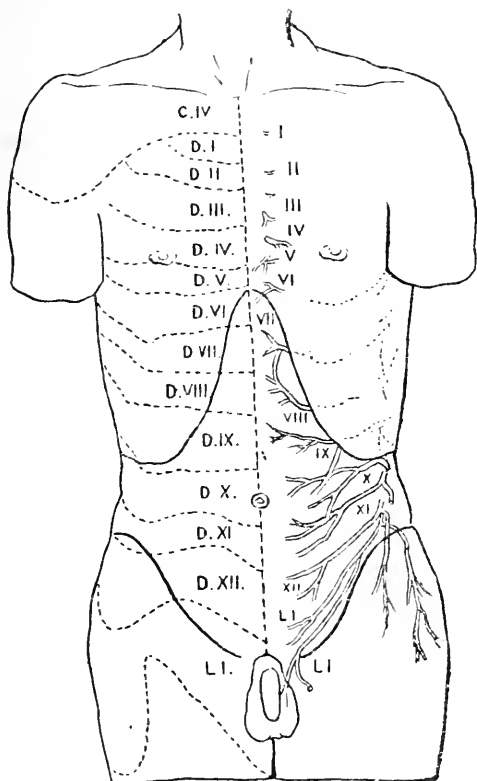


Fig. 39.—Showing approximately the areas of skin supplied by spinal nerves on the anterior surface of the trunk.

The areas are marked on the right side by dotted lines, and the number of the spinal nerve by which each is supplied, is indicated. The nerves are shown on the left side.

issue from the vertebral canal. This injury may show itself by modified sensation in the parts supplied by such nerves. Thus in Pott's disease the patient often complains of a sense of tightness about the abdomen, as if a cord were tied around it. This sense of con-

striction depends upon an impaired sensation in the parts supplied by a certain pair of nerves; or, if the sense of constriction be wider spread, by two or more pairs of nerves. In other cases a sense of pain may take the place of that of constriction. It would hardly be believed that spinal disease has been mistaken for "belly-ache." But many such cases have been recorded. A child complains of pain over the pit of the stomach or about the umbilicus, and this feature may quite absorb for a while the surgeon's attention. The abdomen is carefully poulticed, while the only mischief is in the vertebral column. Other symptoms, however, develop, and it becomes evident that the pain is due to pressure upon the nerves supplying the skin over the epigastric or umbilical regions, and that that pressure is a circumstance in the course of spinal bone disease. A case came under my notice in which a man complained of intense and abiding pain over the stomach. The pain was made worse by food and as all means used failed to relieve it, the abdomen was opened by an exploratory incision. Nothing abnormal was discovered. A little later it became evident that the pain was due to a malignant tumour situated in the bodies of the dorsal vertebræ. There had never, before the operation, been any suspicion of spinal disease. The site of the painful part depends, of course, upon the position of the spinal ailment, and thus the cutaneous symptoms may serve to localise the caries in the vertebræ. Thus the skin over the "pit of the stomach" is supplied by the sixth and seventh dorsal nerves and the tenth nerve is nearly in a line with the umbilicus. The position of the areas supplied by each spinal nerve on the trunk is shown in Fig. 39. The umbilicus may be at the upper or lower border of the area of the tenth, according to the individual. A spinal root may be cut and yet scarcely a trace of anæsthesia result owing to the overlapping of the nerve distributions.

The nerves of the body wall have still more important associations. The spinal segments with which they are connected are also in communication

with the viscera of the abdomen and thorax through the sympathetic system. Hence diseased conditions in the abdominal viscera give rise to disturbances in the spinal segments, with which they are connected, and the brain, being accustomed to localise pain only along the spinal nerves, makes a mistake and refers the pain along the spinal nerve of the segment disturbed. Not only is pain referred, but the skin supplied from the disturbed spinal segments\* becomes tender, and through a study of these, Head has been able to localise the visceral centres, thus affording the surgeon a means for increased accuracy of diagnosis. The abdominal viscera are supplied from the sixth dorsal to the first lumbar spinal segments, the nerves passing to their destinations through the rami communicantes, splanchnic nerves and sympathetic plexuses of the abdomen. No visceral nerves escape by the second, third or fourth lumbar nerves, hence these are never the seats of visceral referred pains. The pelvic viscera are supplied from the fifth lumbar to the third or sometimes fourth sacral nerve through the nervi erigentes.

The following are the segments with which each viscus is connected (Head):—Stomach, 6, 7, 8, 9 D.; intestine, 9, 10, 11, 12 D.; rectum, 2, 3, 4 S.; liver and gall bladder 7, 8, 9, 10 D.; kidney and ureter, 10, 11, 12 D., 1 L.; prostate, 10, 11 D., 5 L., 1, 2, 3 S.; epididymis, 11, 12, 1 D.; testis and ovary, 10 D.; appendages, 11, 12 D., 1 L.; uterus, 10, 11, 12 D., 1 L., 3, 4 S.

Pain referred to districts supplied by the lower abdominal nerves in connection with spinal caries may mislead the surgeon from the real seat of the malady, and may arouse a suspicion of mischief in the kidneys or bladder.

\* Head regards each area as supplied by a segment of the spinal cord, and not necessarily by one spinal nerve. The areas he has demarcated on the trunk, with some exceptions, correspond, however, very closely with the anatomical distribution of spinal nerves.

It may be noted that some of these nerve disturbances, especially the sense of a constricting band, are common in certain affections of the spinal cord, such as locomotor ataxia, etc.

This nerve relationship is illustrated in disease in many ways. Thus, in acute peritonitis and in laceration of certain of the viscera the abdominal muscles become rigidly contracted, so as to insure as complete rest as possible to the injured parts. In acute peritonitis the belly is very hard, the respirations are purely thoracic, and so entirely do the cutaneous portions of these nerves enter into the situation, that the patient is often unable to tolerate even the most trifling pressure upon his abdomen.

**Congenital deformities of the abdomen.—**

In the foetus the intestinal canal is cut off from the yolk sac by the gradual growth of the ventral plates and their ultimate union in the middle line. This union occurs latest at the umbilicus, and when complete the abdominal cavity is entirely enclosed. In some cases of imperfect development the anterior abdominal wall is more or less entirely absent, and the viscera are either entirely uncovered or protected only by a scanty membrane. This condition is usually associated with other deformities, which are inconsistent with any but very brief existence. In many cases the abdominal walls are fairly complete, but there is a lack of union in the middle line about the umbilicus. Thus result the various forms of congenital exomphalos, which may vary in severity from a small hernia to a protrusion of the whole of the more movable viscera. One of the most remarkable deformities is that known as *extroversion of the bladder*. Here, not only is a part of the belly wall absent, but also a part of the genito-urinary apparatus. In complete cases there is an absence of the umbilicus and of the anterior abdominal wall below it. There is no symphysis pubis, an absence of the anterior wall of the bladder, of the principal part of the penis, and the whole of the roof of the urethra. The scrotum, also, as may be expected from a reference to the development of that part, is bifid.



**Hernia.**—1. *Inguinal hernia.*—In this form of rupture the herniated bowel occupies the inguinal canal for the whole or part of its entire length. This canal runs obliquely from the internal to the external abdominal ring, and is about  $1\frac{1}{2}$  inches in length. It represents the track followed by the testis in its descent. It is, in a sense, a passage right through the abdominal walls, and is occupied by the spermatic cord. It is not a free canal, however, in the same sense as one would speak of an open tube, but is rather a potential one, a tract of tissue so arranged as to permit of a body being thrust along it. It is a breach in the abdominal wall, not a doorway; a breach that is forcibly opened up and widened in the acquired forms of hernia. When a hernia occupies the inguinal canal it is covered in front by the integuments, the external oblique aponeurosis, and the lower fibres of the internal oblique and transversalis muscles. It rests behind upon the transversalis fascia, the conjoined tendon, and the triangular ligament; over it arches the transverse and internal oblique muscles, while below it is the angle formed by the union of Poupart's ligament with the transversalis fascia. The herniated bowel is contained within a "sac," which is always formed of peritoneum. In congenital hernia the sac exists already formed in the form of an abnormally patent "processus vaginalis." In acquired hernia the sac consists of that part of the parietal peritoneum which the gut pushes before it in its descent.

The external abdominal ring is readily felt by invaginating the scrotum with the point of the finger, and then passing the digit up in front of the cord. If the nail be kept against the cord the pulp of the finger can readily recognise its triangular slit-like opening. Under ordinary circumstances in adults it will just admit the tip of the little finger.\* The internal ring is situate

\* In cases of congenital or acquired absence of the cord the external ring may be almost obliterated. Paulet quotes from Malgaigne the case of an old man whose testicle had been removed in infancy, and in whom the external ring was so small as to be scarcely recognisable.

about  $\frac{1}{2}$  an inch above the middle of Poupart's ligament.

There are two principal forms of inguinal hernia, which can be best understood by a view of the anterior abdominal parietes from within. From such an aspect it will be seen that the peritoneum is marked by three linear ridges that run, roughly speaking, from the umbilicus to the pelvic brim. One of these ridges follows the middle line from the navel to the symphysis and represents the urachus; a second, that may be indicated by a line drawn from the middle of Poupart's ligament to the navel, represents the deep epigastric artery; while between these two, and much nearer to the epigastric vessel than to the middle line, is the line formed by the obliterated hypogastric artery. By means of these ridges the peritoneum is made to present three fossæ, an external to the outer side of the epigastric artery, an internal between the urachus and the hypogastric artery, and a middle between the tract of the latter vessel and the epigastric trunk. The internal ring (so called) is just to the outer side of the epigastric artery, and the site of the summit of the inguinal canal is indicated by a depression in the peritoneum. When a hernia follows the inguinal canal throughout its entire length, it is called *oblique*, *indirect*, or *external*; "oblique" or "indirect" from its taking the oblique direction of the canal, "external" from the position of its neck with reference to the epigastric vessel. The coverings of such a hernia would be the same as those of the cord, viz., the skin, the superficial, intercolumnar, cremasteric and infundibuliform layers of fascia, the subserous tissue, and the peritoneum. When the hernia escapes to the inner side of the deep epigastric artery, through the space known as Hesselbach's triangle, it is called a *direct* or *internal* hernia, for reasons that will be obvious. There may be two forms of direct hernia. In one form the gut escapes through the middle fossa above described, in the other through the inner fossa between the hypogastric artery and the outer edge of the rectus muscle. The middle fossa is nearly

opposite to the summit of the external ring. A hernia escaping through that fossa would enter the inguinal canal some little way below the point of entrance of an oblique hernia, and would have the same coverings as that hernia, with the exception of the infundibuliform fascia. The first covering, indeed, that it would receive from the canal structures would be the cremasteric fascia. The inner fossa corresponds, so far as the inguinal canal is concerned, with the external ring. A hernia escaping through this fossa would be resisted by the conjoined tendon and the triangular ligament. These structures are either stretched over the hernia so as to form one of its coverings, or the conjoined tendon is perforated by the hernia, or lastly the gut deviates a little in an outward direction so as to avoid the tendon and appear at its outer side (Velpeau). In any case the hernia is forced almost directly into the external abdominal ring. The coverings of such herniæ are the skin and superficial fascia, the intercolumnar fascia, the triangular ligament and conjoined tendon (with the exceptions above mentioned), the transversalis fascia, subserous tissue, and peritoneum.

An examination of the abdominal wall, apart from clinical experience, would lead one to suspect that the direct hernia would be more common than the indirect, since the parietes are certainly less resisting opposite Hesselbach's triangle than they are in the parts immediately external to the epigastric artery. Indeed, just to the outer side of the conjoined tendon the belly wall is remarkably thin. These conditions, however, seem to offer less facilities for the escape of a hernia than does the inguinal canal itself. The funnel-shaped depression in the peritoneum at the summit of that canal seems to offer particular inducements for rupture, and there are, besides, certain congenital defects in the vaginal process of the peritoneum that render hernia almost unavoidable along the inguinal canal.

**Direct versus indirect inguinal hernia.**—The indirect hernia, as just hinted, may be congenital,

the direct is never congenital. In the congenital oblique hernia the outline of the inguinal canal and the relations of the various parts concerned are but little disturbed, and the differences between this form of rupture and the direct variety are conspicuous. The acquired oblique hernia, however, does not present such a contrast to the direct form as may be expected. In the first-named rupture, from constant dragging upon the parts the internal ring becomes more or less approximated to the external ring, and the length of the canal and consequently the obliquity of the hernia are considerably reduced. Thus the axes of the two forms of rupture do not present such differences as to make their nature at once obvious. The direct hernia, however, on reduction, will pass directly back into the belly, while the indirect will, even in old cases, take a slight but appreciable direction outwards. After the reduction of the direct hernia, the edge of the rectus muscle may be readily felt to the inner side of the aperture, the protrusion being, indeed, at the semilunar line. From the slight inducement offered to its progress, and from its insignificant neck, the direct hernia is usually small and globular, while for opposite reasons the oblique rupture may attain large size, and tends to assume a pyriform outline.

**Forms of oblique hernia depending upon congenital defects in the "vaginal process."**

*The descent of the testis.*—It is well known that the testis in the foetus descends from the region of the kidney into the scrotum by making a way through the abdominal wall that is afterwards known as the inguinal canal.

Its descent is preceded by the passage into the scrotum of a process of the peritoneum, the vaginal process. The testicle usually enters the internal ring about the seventh month of foetal life, and by the eighth month is in the scrotum. The testis is guided to its final resting place by the gubernaculum, a band of muscular fibres. This band is attached below to the anterior abdominal parietes, to the pubes near the root of the penis, to the

bottom of the scrotum, and to the tuber ischii and sphincter ani (Lockwood). The last-named attachments serve to explain the occasional passage of the testis beyond the scrotum into the perineum (testis in perineo). In one example of this condition I found it necessary to divide a band passing from the tuber ischii to the testis before I could place the gland in the scrotum.

Following the gubernaculum upwards, it is attached, first of all, to the vaginal process, which, therefore, descends before the testis, then to the gland and epididymis, and, lastly, to the peritoneum about the bowel (cæcum, ileum, or mesentery on the right side, and sigmoid flexure on the left side). The latter connections serve to explain the condition of infantile hernia, in which a bag or diverticle of peritoneum is drawn down into the scrotum *after* the testis (Lockwood). This diverticle can then become the sac of a hernia.

The vaginal process is often found open at birth, but it is more usually found cut off from the peritoneal cavity, the portion thus isolated forming the tunica vaginalis. This vaginal process will have a narrowed part or neck, as it passes along the inguinal canal, and will be free to enlarge again on reaching the scrotum. The manner in which it is cut off is as follows. It becomes obliterated in two places, at the internal ring and at a spot just above the epididymis, the obliteration usually beginning at the higher point first. Supposing obliteration to have taken place at these two points, the vaginal process between them will be represented by an isolated tube. This soon shrinks, closes, and dwindles to an insignificant fibrous cord. It may, however, remain patent in part, and if fluid accumulates in this patent portion, an "encysted hydrocele of the cord" is produced. As regards the mode of closure, three contingencies may happen, each giving rise to a particular form of hernia: (1) The "process" may not close at all; (2) it may close at the upper point only; and (3) it may close at the lower point only.

(1) When the vaginal process is entirely open, gut can readily descend at once into the scrotum. Such a

condition is called a **congenital hernia**. Here the intestine is found to occupy a large sac of the peritoneum, the open orifice of which is placed at the internal inguinal ring. The neck of the sac is long and narrow, the parts around have not been disturbed to permit the bowel to pass, and the actual sac itself is very thin. It is on account of these anatomical conditions that the effects of strangulation fall as a rule heavier upon this form of hernia than upon the corresponding acquired form. The term "congenital" is misleading, as the hernia is very rarely present at birth, although it is common in early life.

(2) When the process is closed only at the internal ring the unduly large tunica vaginalis is found to extend up to that orifice. Behind this processus or tunica vaginalis a diverticle of peritoneum is drawn down into the scrotum by the gubernaculum, and becomes the sac of a hernia (Lockwood). This is known as an **infantile** or **encysted hernia**. In such a case the tunica vaginalis lies in front of the sac, and therefore three layers of peritoneum would have to be cut through before the gut could be reached. The term "infantile" was given to this rupture because the first cases reported were met with in infants; the term "encysted," because the hernial sac was considered to be enclosed by the sac of the tunica vaginalis. The condition of parts that favours the development of this rupture serves also to explain those anomalous cases of congenital hernia that appear suddenly and for the first time in adult life. Here, under some unwonted exertion, the peritoneum that separates the large tunica vaginalis from the general peritoneum at the internal ring gives way, and the gut at once passes into the cavity beyond, and so appears in the condition of a congenital hernia.

The infantile hernia also includes cases in which the sac descends behind an entirely unclosed vaginal process.

(3) In the last-named circumstance a tubular process of peritoneum leads down as far as the top of the testicle and there ends, the normal tunica vaginalis

being beyond. Hernia into this process is called a **hernia into the funicular process.**

In the first of these forms the testicle is quite enveloped in the hernia. In the second and third forms, as well as in the acquired form, it is to be felt quite distinct from the rupture, being actually behind and below it. A congenital hernia may form in cases where the testicle has not descended at all. In such instances the vaginal process may occupy the would-be canal, and along this process a hernia may descend. It is well known that the testicle may make its first appearance in the scrotum months and even years after birth. In such cases the vaginal process may be normally developed at birth (*i.e.* may occupy the scrotum), or it may be abortive.

In the foetus the inguinal canal is relatively much shorter than it is in the adult. As the pelvis develops, however, the relations of the canal approach more to the normal. In the congenital hernia the relations of the canal are not disturbed as they are in the acquired form. Thus it happens that such ruptures have long and narrow necks, and the difficulty in steadying this neck constitutes one of the special obstacles in the effectual reduction of the hernia.

There is another possible congenital defect that may predispose to hernia, viz. an abnormally long mesentery. If, in the dead subject, the inguinal canal be opened up, and an attempt made to draw a piece of gut down from the abdomen into the scrotum, it will be found that it cannot be done, owing to the shortness of the mesentery. In any case of scrotal hernia, therefore, the mesentery must become lengthened, and it is a question whether or not an abnormally long mesentery may exist as a congenital defect, and so predispose the patient to rupture. More information is required upon the subject.

The **inguinal canal in the female** is much smaller and narrower, although a trifle longer, than it is in the male. It is occupied by the round ligament, and offers such slight inducement to the formation of a rupture, that acquired inguinal hernia is as rare

among females as it is common among men. In the female foetus a process of peritoneum descends for a little way along the round ligament. It corresponds to the processus vaginalis of males, and is known as the canal of Nuck. If this process remains patent, as it not infrequently does, it may lead to a rupture that corresponds to the congenital hernia of males. Indeed, in quite early life the inguinal rupture is about the only form met with in female children, if exception be made of umbilical hernia. In all such instances of early inguinal hernia the gut has travelled down a patent canal of Nuck.

It only remains to be said, that in endeavouring to reduce an inguinal hernia by *taxis* the thigh should be flexed and adducted, for in that position the abdominal parietes that bound the inguinal canal are the most relaxed. This position of the thigh affects the inguinal region mainly through the attachments of the fascia lata to Poupart's ligament.

In **herniotomy** an incision is made along the middle of the tumour and in its long axis, being so arranged that its centre shall correspond to the external ring. The superficial external pudic artery is usually divided in the operation. It is impossible to distinguish the various layers of tissue that cover the hernia, the only one, as a rule, that is recognisable being the layer from the cremaster. In dividing the constriction it is usually recommended to cut upwards in all forms of inguinal hernia. The only vessel in risk of being damaged is the deep epigastric. In the oblique form of rupture an incision directly upwards would quite avoid this artery; but in a direct hernia, where there is reason to suppose that the vessel is in close connection with the neck of the sac, it is well that the incision be directed a little inwards as well as upwards. It should be remembered that the incision required to relieve a constriction is, if properly applied, of the most insignificant character.

**Femoral hernia.**—In this form of rupture the gut leaves the abdomen through the femoral ring and passes down into the thigh along the crural canal. The



name "crural canal" is given to the narrow interval between the femoral vein and the inner wall of the crural sheath. Like the inguinal canal, it is a potential rather than an actual canal, and exists only when the sheath has been separated from the vein by dissection or by a hernial protrusion of some kind. The canal is funnel-shaped, about  $\frac{1}{2}$  an inch in length, and ends opposite the saphenous opening. Femoral herniæ are always acquired, and possess a sac, made by themselves out of the parietal peritoneum covering the crural ring and its vicinity. The canal is larger in women than in men, and thus it happens that this species of rupture is much more common in the former sex. The tendency to this hernia in women appears also to be increased by the weakening effects of pregnancy upon the abdominal walls. As the gut descends it pushes in front of it its sac of peritoneum and the septum crurale (the name given to the subserous tissue that covers in the femoral ring) and enters the crural sheath. The adhesions of the sheath limit its downward progress when it has travelled about  $\frac{1}{2}$  an inch, and it therefore passes forwards through the saphenous opening, pushing before it the cribriform fascia. It then receives a covering from the superficial fascia and the skin. Owing to the rigidity of the structures about the femoral ring, the neck of the sac must always be small. For similar reasons its dimensions while in the femoral canal must of necessity be insignificant, but when once it has escaped through the saphenous opening the loose subcutaneous fasciæ of the groin afford it ample opportunities for increase. When the hernia has passed through the saphenous opening it tends to mount upwards over Poupart's ligament, in the direction of the anterior superior iliac spine. Even when it overlaps the ligament considerably it can hardly be mistaken for an inguinal hernia, since it must always lie to the outer side of the pubic spine. The upward tendency of a femoral hernia has been variously explained. It has been ascribed to a supposed curve in the crural canal, the concavity of which is forwards. Scarpa believed it to receive

its direction from the frequent flexion of the thigh. Probably one of the most important factors in the matter is the unyielding character of the lower edge of the saphenous opening. This edge tends to direct the gut forwards, while the traction upon the mesentery, that is inevitable as the rupture proceeds, may be conceived as favouring an upward direction. The coverings of a hernia that has found its way beneath the skin are often very scanty.

*Relations.*—When a hernia occupies the crural canal there are in front of it the skin and superficial fasciæ, the iliac part of the fascia lata, the crural arches, the cribriform fascia, and the anterior wall of the crural sheath. Behind are the posterior wall of the crural sheath and pubic portion of the fascia lata, the pectineus muscle, and the bone. The boundaries of the femoral ring are, in front, Poupart's ligament and the deep crural arch; behind, the bone covered by the fascia lata and the pectineus; on the inner side, the conjoined tendon, Gimbernat's ligament, and the inner part of the deep crural arch; on the outer side, the femoral vein in its sheath. The spermatic cord lies (in the male) just above the anterior border of the ring, and the epigastric artery skirts its upper and outer part. The little pubic branch of this artery passes round the ring to ramify over Gimbernat's ligament. In one case out of three and a half the obturator artery arises from the epigastric. Out of one hundred and one cases where the vessel so arose it reached its destination in fifty-four instances by passing along the outer side of the crural ring, a position quite free from danger in herniotomy. In thirty-seven cases it passed backwards across the ring, and in ten instances round its inner border (R. Quain). When in the last-named position the vessel could hardly escape being wounded in the operation upon a femoral hernia. Indeed, several cases have been recorded of fatal hæmorrhage from this abnormal vessel in such operations. In one instance the pulsations of the abnormal artery were felt before the parts were divided. In addition to the

vessels about the ring there is also a pubic vein, which, ascending from the obturator vein in the thyroid foramen, enters the external iliac vein. Its relation to the crural ring varies in the same way as the abnormal artery last named.

The size of the femoral canal and the degree of tension of its orifices varies greatly with the position of the limb. If the thigh be extended, abducted, and rotated outwards, these parts are made very tense, while they are the most lax when the limb is flexed, adducted, and rotated inwards. It is consequently in the latter position that the thigh should be placed when the taxis is being attempted. In herniotomy the incision is made along the inner side of the tumour, and is so arranged that its centre corresponds to about the upper part of the saphenous opening. The constriction is usually at the neck of the sac, and caused by Gimbernat's ligament. It is divided by an incision directed upwards and inwards.

**Obturator hernia.**—In this form the gut, pushing before it the peritoneum, the sub-peritoneal fat, and the pelvic fascia, escapes through the obturator canal. The direction of this canal is, from behind, downwards, forwards and inwards.

Beyond the canal the hernia may pass between the obturator membrane and the obturator externus muscle and remain deeply placed, or it may make its way through the muscle or emerge above it and be then covered by the pectineus and adductor brevis. The obturator artery is, as a rule, at the outer and posterior part of the sac. It is very rarely in front of it. The obturator nerve is generally found to the outer side of the sac, less commonly it is in front of it. The proximity of the nerve renders it very liable to be pressed upon, and pain along the nerve is often a marked feature of the rupture. The hernia presents beneath the pectineus muscle, to the inner side of the capsule of the hip, behind and to the inner side of the femoral vessels, and to the outer side of the adductor longus tendon. Pain on moving the hip is generally a conspicuous

symptom. The obturator externus may be made tense by rotation inwards of the slightly abducted thigh. This hernia is much more common in females; and it is worthy of note that the orifice of the obturator canal can be examined, to some extent, through the vagina. Professor Wood reports a remarkable case where a hernial protrusion of a part of the adductor longus through a rent in its aponeurosis was mistaken for an obturator hernia.

**Rare forms of hernia.**—In *perineal hernia* the sac, covered by the recto-vesical fascia, escapes through the anterior fibres of the levator ani muscle, between the prostate and the rectum. In the *ischio-rectal hernia* the protrusions take place into the ischio-rectal fossa. In *pubendal hernia* the sac lies in the posterior inferior half of the labium pudendi, escaping between the ascending ramus of the ischium and the vagina; it has been mistaken for a cyst. In *sciatic hernia* the gut escapes through the great sacro-sciatic notch in front of the internal iliac vessels, above or below the pyriformis, and appears under the gluteus maximus muscle. As regards *umbilical hernia*, nothing remains to be added to what has been already said (page 288), save that the sac from its position nearly always contains omentum, and may contain stomach. In *lumbar hernia* the gut escapes in front of the quadratus lumborum muscle, and appears on the surface through the triangle of Petit (the gap between the latissimus dorsi and external oblique muscles), and therefore just above the highest point of the iliac crest. The sac must either force before it or (in cases of injury) come through the fascia lumborum and internal oblique muscles, since those structures form the floor of the triangle. The hernia may escape through the “upper lumbar triangle”—a gap near the last rib where the aponeurosis of the transversalis is covered only by the latissimus dorsi. Macready (*Lancet*, Nov. 8th, 1890) has collected twenty-five examples of this hernia. *Diaphragmatic herniæ* may be congenital or acquired. The former variety is by far the more common, and is

due to simple arrest in the development of the diaphragm and persistence of the original connection between the thorax and abdomen. The acquired form usually follows a laceration of the diaphragm from injury. In any case some of the abdominal viscera are protruded, through the gap in the midriff, into the thoracic cavity. Owing to the presence of the liver on the right side, these herniæ are much more common on the left side. Of the organs, the stomach is the most frequently dislodged, then the transverse colon, omentum, small gut, spleen, liver, pancreas, and kidneys, in the order named (Leichtenstern). The hernia may escape through the foramen for the gullet, but never through that for the vena cava, nor through the hiatus aorticus. The parts commonly selected are the connective tissue intervals between the sternal and costal origins of the diaphragm in front and its vertebral and costal origins behind. These herniæ are more common in males.

**Posterior abdominal parietes.**—The lateral and posterior walls of the abdomen are lined inside with two fasciæ, the transversalis and iliac. The transversalis fascia lines the whole of the transversalis muscle, and is much thicker below than above. Above it joins the fascia covering the diaphragm, while below it is attached to the iliac crest and to the whole of Poupart's ligament, save at that spot where it passes into the thigh to form the anterior layer of the crural sheath. The iliac fascia encloses the ilio-psoas muscle, the part over the psoas being the thinner. This part is attached on the inner side to the sacrum, and to the spine at the points corresponding to the psoas origin. Above, it is attached to the ligamentum arcuatum internum, and on the outer side to the anterior layer of the lumbar fascia along the outer edge of the psoas. Below, the fascia encloses the iliacus, and is attached to the iliac crest, to the pelvic brim, and to Poupart's ligament, save at that part where the membrane passes beneath the ligament to form the posterior wall of the crural sheath. It follows the ilio-psoas muscle to its insertion, and ends by blending with the fascia lata.

The arrangement of these fasciæ greatly influences the progress and direction of abscess. Thus an abscess beneath the transversalis fascia will be very definitely enclosed. If it progresses backwards it will be stopped at the outer edge of the psoas muscle. If it spreads downwards it will be arrested by the attachments of the fascia to the iliac crest and to Poupart's ligament, and will be unable to spread (unless the fascia be pierced) into either the pelvis or the thigh. On the inner side it will be checked at the middle line; and above, although it will meet with no actual resistance, it would be indisposed to spread, since its movements would be against gravity. Thus it happens that collections so placed point either just above the iliac crest or Poupart's ligament, or run down along the spermatic cord and distend the inguinal canal.

The iliac fascia encloses the ilio-psoas in a very distinct osseo-aponeurotic space. Between the fascia and the muscle (especially its iliac division) there is a good deal of loose connective tissue, and thus every facility is offered for the progress of subfascial abscesses in this region. The osseo-aponeurotic space is practically closed on all sides within the abdomen, and is only open below where the fascia passes with its muscle into the thigh. This opening being at the most dependent part of the space, it follows that the psoas or iliac abscess very commonly points on the upper part of the thigh, just to the outer side of the femoral vessels. An abscess in the iliac fossa, although most likely to reach the thigh, might mount up to the superior attachments of the fascia, and point at the iliac crest or at the outer part of Poupart's ligament. Or it may disregard the inner attachments of the fascia and gravitate into the pelvis. If the patient should occupy for long the recumbent posture, there is no reason why it should not extend upwards along the psoas muscle.

The term *iliac abscess*, however, is often applied to collections that are not within the space formed by the iliac fascia, but that are situated rather in the subserous connective tissue. This tissue is very extensive in the

iliac fossa, and favours the formation of large purulent collections. Kœnig's experiments of injecting fluid into this subserous space show that an abscess so placed may spread in any direction by simply dissecting off the peritoneum. Clinically, however, such collections are greatly limited by gravity. They are apt to remain in the iliac fossa, bulging out the abdominal wall just above Poupart's ligament, and occupying the angle formed by the union of the iliac and transversalis fasciæ. In some cases they are disposed to extend into the pelvis.

The abscess, when in the subserous tissue, is brought in close contact with certain of the viscera, especially with the cæcum and sigmoid flexure, and into these portions of the colon it may open. Thus, I have seen a case of iliac abscess due to pelvic necrosis that opened into the sigmoid flexure, and at the same time discharged through sinuses about the groin. In this case some pus passed by the anus, while on the other hand some fecal matter escaped by the groin. Retro-peritoneal abscesses in the pelvis (pelvic cellulitis) may mount up into the iliac fossæ, may appear as "iliac abscesses," and may ultimately discharge themselves by many openings in the lower parts of the anterior abdominal wall.

It may be well to note that the common and external iliac vessels, the lymphatics, and the ureters are *outside* the iliac fascia, and rest upon its abdominal surface, while the anterior crural nerves and abdominal parts of the lumbar nerves are *within* the osseo-aponeurotic space. Thus the suprafascial abscess may, with little difficulty, reach the thigh by following the iliac vessels; while the subfascial collection would pursue the anterior crural nerve.

A *psoas abscess*, or abscess within the fascial sheath of the psoas muscle, is usually due to spinal caries, although it may appear independently of that disease. If the lumbar spine be involved the matter can pass directly into the substance of the muscle, which it will more or less entirely destroy. If the mischief be in the dorsal spine, the matter gravitates along

the front of the column until it reaches the diaphragm, which it pierces by an inflammatory process. It is now brought into relation with the heads of the psoas, and has to pass through a narrow strait. "It is prevented from enlarging on the fore part by the ligamenta arcuata, and at the back by the spine and lowest rib; hence, in order to proceed it has to force its way in the line of the psoas muscle. That, however, can only be done by penetrating into its interior. It accomplishes this, in the first place, by inserting its most advanced part, like a wedge, between the two origins (viz. from the bodies of the vertebræ and from the corresponding transverse processes): it then splits and distends the fibres, so as to form a cavity for the reception of the pus . . . and the psoas at length is converted more or less thoroughly into an abscess" (Shaw). The pus, following the muscle, at last reaches the thigh, and usually points, just below the groin, to the outer side of the femoral vessels.

The abscess, however, often shows much variation. It may avoid the psoas, or leave it when once it has entered it, and make its way into the lumbar region to find an exit in the loin. Or it may extend into the iliac fossæ and open above the groin, or mount up over the iliac crest and discharge in the gluteal region. It may pass along the inguinal canal and be mistaken for a hernia. It may sink into the pelvis, and may open into the bladder, or discharge itself through the great sciatic foramen, or through a sinus in the perineum. Some of the latter cases have led to much confusion in diagnosis, since there would appear to be little connection between caries of the spine and a perineal abscess.

**Lumbar region.**—The muscles that form the lateral and posterior walls of the abdomen, and that fill in the interval between the iliac crest and the lowest rib, are the external oblique and latissimus dorsi, the internal oblique, the transversalis muscle and fascia lumborum, the erector spinæ and quadratus lumborum.

The external oblique and latissimus dorsi muscles



are separated by a small triangular interval below (the triangle of Petit), but above they overlap. The interval between these two muscles may be represented by a line drawn vertically, upwards from the middle of the crest of the ilium. The outer edge of the quadratus lumborum corresponds to this line, just above the iliac crest; but as the border of the muscle slopes upwards and backwards, it may be about an inch behind the line, at a point midway between the crest and the last rib. The edge of the muscle is overlapped by the internal oblique, and its inner half or two-thirds is overlapped by the erector spinæ. The subcutaneous tissue in the lumbar region is very extensive, and is a favourite locality for chronic abscess. The looseness and extent of the tissue also permit of large extravasations of blood. It is in the muscles and fascia along the spine in this region that the rheumatic affection known as lumbago has its seat.

Between the last rib and the iliac crest is stretched the dense fascia lumborum, the posterior aponeurosis of the transversalis muscle. It is pierced near the rib by the last intercostal artery and nerve, and near the ilium by the ilio-hypogastric nerve and its accompanying artery. It is along these structures that an abscess may possibly find its way through the fascia in certain cases. The fascia divides behind into three layers, to enclose in definite spaces the quadratus and erector spinæ muscles. Within these spaces or compartments suppuration may be for some time limited. A lumbar abscess commencing in some adjacent part, as in the spine or in the loose tissue around the kidneys, usually spreads backwards by piercing the fascia lumborum or the quadratus muscle. It then finds its way through the internal oblique, and appears on the surface between the external oblique and latissimus dorsi muscles, and at the outer border of the erector spinæ. It should be noted that the quadratus muscle is very thin, and offers little resistance to protrusions from within, while a great part of the muscle is firmly supported behind by the erector spinæ.

**The author's operation for caries of the lumbar vertebræ.**—The lumbar vertebræ, and, possibly, the last dorsal, may be reached by an incision through the loin. A vertical cut is made along the outer edge of the erector spinæ muscle. The fibres of that muscle having been drawn aside, the middle layer of the fascia lumborum is incised, and the quadratus lumborum is exposed. This muscle is divided vertically, and then the front of the vertebræ may be reached by introducing the finger under the psoas muscle. Through this incision the author has removed the whole of the body of the first lumbar vertebra that had been separated as a sequestrum. (*Med.-Chir. Trans.*, 1884.) The lumbar arteries are avoided by keeping close to the transverse process of the vertebræ. Through this incision a psoas abscess may be most conveniently opened.

---

## CHAPTER XVII.

### THE ABDOMINAL VISCERA.

**THE peritoneum.**—Certain of the viscera, as, for example, the stomach, spleen, and small intestines, are so closely invested with peritoneum that they could not be wounded without that membrane being wounded also. Inflammatory affections of such viscera are also very apt to involve the peritoneum. Other organs, such as the kidney, descending colon, pancreas, etc., are so imperfectly covered with the serous membrane that a wound of those organs need not involve it, nor need it be implicated in even extensive inflammatory changes. Large abscesses may, for instance, form about the kidney and discharge themselves through the skin without any peritonitis being induced. Spontaneous perforation of the small intestine must involve the peritoneum, while, on the other hand, the cæcum and descending colon may become perforated, and the matter escape into the subserous tissue without the

serous membrane being in any way involved. It is noteworthy in connection with bacterial infection that it is singularly easy to set up inflammation of the peritoneum if the membrane be approached from its inner surface, but comparatively difficult if it be approached from without. Thus a small puncture of the membrane may, on the one hand, lead to fatal peritonitis, while, on the other, it may be extensively torn from its attachments (as in ligaturing the common iliac artery from the side) without any peritonitis following. Or, again, a little pus escaping on the inner surface of the membrane may lead to inflammation, while the outer surface may be bathed with pus for a long while (as in large perirenal abscesses) without any peritonitis being produced. Inflammation of the peritoneum may lead to the formation of a great variety of bands and adhesions, beneath which pieces of intestine may be caught and strangulated.

The peritoneum will allow of very considerable stretching if only that stretching be effected gradually. This is frequently seen in cases of gradual distension of the bowel, in the formation of the sac in hernia, and in the growth of retro-peritoneal tumours. Abrupt stretching of the membrane leads to certain rupture of it. The parietal peritoneum may be ruptured by violence without damage to any of the viscera.

The **great omentum** is, from its position, very apt to be wounded. In small wounds of the front of the belly it very often protrudes and acts as an excellent plug to prevent the escape of other and more important structures. It is often found in hernia, especially in umbilical hernia, where it is almost constant. Its limits vary, and it has an inclination to the left side. This depends upon the fact that the omentum is developed from the meso-gaster, and accounts for the fact that herniæ containing omentum are much more common on the left side. The omentum, like the other parts of the peritoneum, is apt to inflame, and to contract adhesions to the neighbouring parts. These adhesions are often of the greatest service in limiting inflam-

matory and hæmorrhagic extravasations, by matting the bowels together and forming spaces between them. In perforation of the bowels from disease, an opportune adhesion of the omentum over the aperture may prevent escape of the intestinal contents.

Large masses of tissue may be nourished through an adherent omentum. Thus when the proper blood supply of an ovarian tumour has been cut off by twisting of its pedicle, the growth may be nourished through the omentum, if that structure is adherent to it. Rutherford Morrison proposes to relieve congestion of the portal circulation by setting up an anastomosis between the omental vessels and the systemic circulation. When an adhesion between the omentum and parietal peritoneum is produced artificially, large anastomotic vessels open up and communicate with the vascular network beneath the parietal peritoneum, thus possibly relieving tension in cases of obstructed portal circulation. In cases of obesity fat collects conspicuously in the great omentum. In herniæ the omentum generally contracts adhesions to the sac, and becomes irreducible, or it may form a kind of second sac about the gut itself ("omental sac"). The end of the omentum, by becoming adherent to distant parts, as to the pelvic viscera, may form itself into a firmly attached band, beneath which the bowel may be fatally strangled. In like manner the intestine has been strangulated through slits and holes that have developed in the omentum, usually as a result of inflammatory adhesions. When the great omentum contains much fat it must act as an excellent protection to the bowels, and must, as a layer of non-conducting material, help to maintain the equality of their temperature.

The **mesentery**.—The parietal attachment of the mesentery is liable to some variation. The point at which this attachment commences above is practically constant. It corresponds with the ending of the duodenum, is about on a level with the lower border of the pancreas, and is just to the left of the second lumbar vertebra. (See page 332.) From this point the

insertion of the mesentery follows an oblique line that runs downwards and to the right, crossing the great vessels, and then ending in a somewhat uncertain manner on the right iliac fossa. Its right or upper layer is continuous with the under layer of the transverse meso-colon, and with the peritoneum that invests the ascending colon. Its left or lower layer joins with the serous membrane that encloses the descending colon, that forms the sigmoid mesentery, and that descends over the lumbo-sacral eminence into the pelvis. The parietal attachment of the mesentery measures, as a rule, about 6 inches. From its oblique attachment it follows that, when hæmorrhage takes place in the abdomen on the right side of the mesentery, the blood first is conducted into the right iliac fossa, when on the left side, into the pelvis. This may explain the circumstance that collections of blood are more common in the right than in the left iliac fossa.

The length of the mesentery from the spine to the bowel varies in different parts of the canal; its average length is 8 inches. The longest part is that which goes to the coils of intestine that lie between a point 6 feet from the duodenum, and a point 11 feet from the same part of the gut (Author).\* Such coils will, therefore, include 5 feet of the intestine, and the mesentery here may reach the length of 10 inches. These coils are apt to hang in the pelvis, and may be easily herniated. The length of the mesentery plays an important part in hernia. If the fresh body of an adult be opened, and the condition of the viscera and peritoneum be normal, it will be found that it is impossible to drag a loop of small intestine through the femoral canal (artificially enlarged) on to the thigh, or down the inguinal canal into the scrotum. In fact, no coil can, in any part, be drawn out of the abdomen below a horizontal line on a level with the spine of the pubes. It is evident, therefore, that in femoral or scrotal hernia the mesentery must be elongated or its attachments lowered.

\* See "The Anatomy of the Intestinal Canal and Peritoneum in Man," by the Author. London, 1885.

The mesentery is relatively longest in infancy and childhood, and a freer escape of the intestines from the abdomen is allowed in subjects under puberty. The disposition of the membrane permits also a freer downward excursion of the bowels on the right side, and this has been offered as an explanation of the undue frequency of right-sided inguinal herniæ in childhood (Lockwood).

The root of the mesentery, and, indeed, the whole of the peritoneum covering the posterior abdominal wall, may glide a little downwards and constitute a "prolapse of the mesentery." This condition has been fully investigated by Mr. Lockwood, who states that it seldom occurs before middle age, that it causes the mass of the intestines to incline to the left and thus encourages double and left-sided herniæ. These herniæ are well known to be more common after middle age.

Mr. Lockwood states that in acquired hernia the mesentery is found to have had its attachments lowered rather than to have been increased in length.

Certain holes are sometimes found in the mesentery, through which intestine has been strangulated. Some of these holes, especially those that are slit-like, are due to injury, others are due to congenital defect of the mesentery. I have shown that the latter holes are round, are in the mesentery of the lower ileum, and occupy an oval area, circumscribed by an anastomotic arch between the ileo-colic branch of the superior mesenteric artery and the last of the intestinal arteries. This area is often the seat of atrophied peritoneum, and shows an absence of fat, of visible blood-vessels, and of glands. It would be easy for a knuckle of gut to be forced through the thinned membrane, which is sometimes already cribriform.

For an account of "mesenteric hernia," see page 334.

Herniæ have occurred through the foramen of Winslow.

I have described a strangulated hernia in this position which was exposed by operation.

## THE STOMACH.

*Above.*

Liver, small omentum, diaphragm.

*In front.*(From left to right)  
diaphragm, abdominal  
wall, liver.**Stomach.***Behind.*Transverse meso-colon,  
pancreas, crura, solar  
plexus, great vessels,  
spleen, left kidney,  
and capsule.*Below.*

Great omentum, transverse colon, gastro-splenic omentum.

When empty, the stomach lies at the back of the abdomen, beneath the liver and some way from the surface. When distended, the greater curvature is elevated and carried forwards, the anterior surface is turned upwards, and the posterior downwards (Fig. 48, p. 356). The direction of the rotation depends upon the fixity of the smaller curvature. When distended, the stomach is brought well against the anterior belly wall, and may occupy the whole of the middle line as far as the navel. Thus the stomach is much more exposed to injury when full than when empty. The *cardiac orifice* is situated behind the seventh left costal cartilage, about 1 inch from the sternum (Fig. 40). The *pylorus*, when the viscus is empty, lies just to the right of the middle line, from 3 to 4 inches below the sterno-xiphoid articulation, on the level of a line drawn between the bony ends of the seventh ribs. When the stomach is distended the pylorus may be moved nearly 3 inches to the right (Braune). The cardiac orifice is on a level behind with the ninth dorsal spinous process, the pylorus with the twelfth dorsal spine (Fig. 41). A horizontal line drawn between the extreme tips of the tenth costal cartilages will about correspond to the lower border of the non-distended stomach. The tenth cartilage has a distinct tip and plays over the cartilage of the ninth rib, producing under the finger a special crepitus. The *fundus* of the stomach occupies the left dome of the diaphragm and reaches on the left side as high as the level of the sixth sterno-

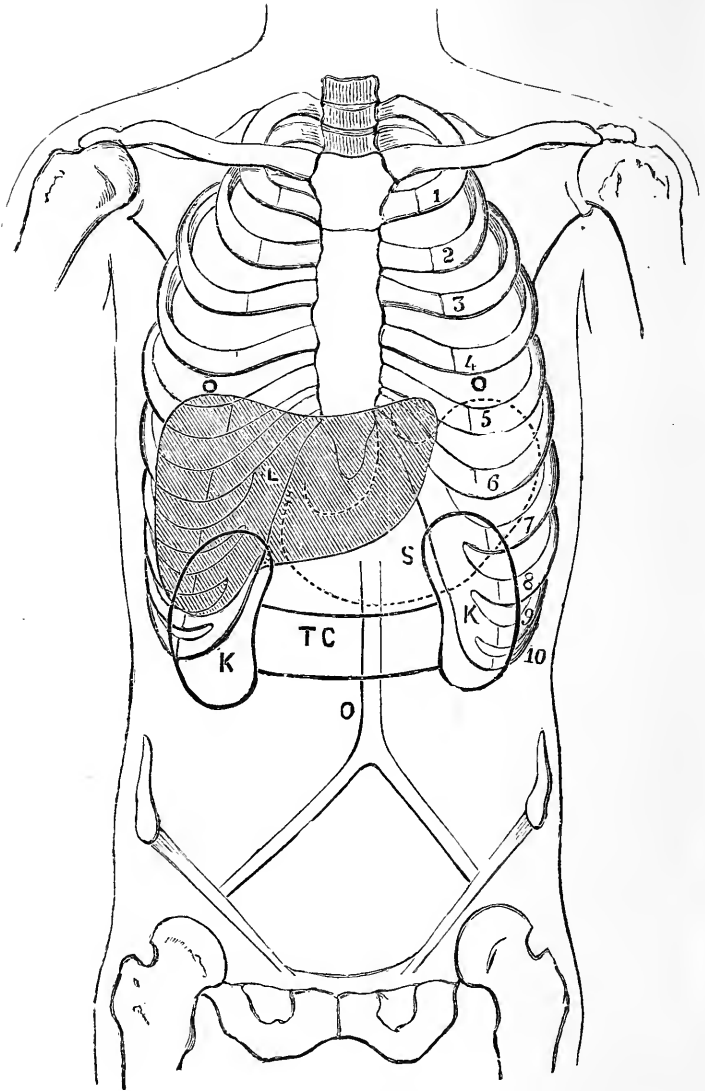


Fig. 40.—Diagram showing the Relations of the Viscera to the Parietes (Anterior view).

s, Stomach ; L, liver ; K, kidney ; TC, transverse colon ; o, umbilicus.



chondral articulation, being a little above and behind the heart apex. The close relations of the stomach to the diaphragm and thoracic viscera serve in part to explain the shortness of breath and possible palpitation of the heart, etc., that may follow upon distension of the organ (Fig. 43, p. 337). The near proximity of the heart to the stomach is illustrated by a case where a thorn (of the *Prunus spinosa*),  $\frac{1}{2}$  an inch long, had been swallowed and had then found its way through the diaphragm and pericardium into the wall and cavity of the right ventricle.

On reference to the development of the stomach, it will be seen that it is originally placed vertically in the abdomen. This position may be to a great extent maintained in adult life. The feats of an acrobat who styles himself "the sword swallower" can hardly be explained on any other supposition than that his stomach is vertical; but whether such condition is congenital, or has been produced by the manœuvre he practises, must be an open question.

Although the mobility of the stomach is not considerable, yet it is frequently found to occupy both diaphragmatic and epigastric herniae. In the condition known as *ptosis of the stomach* the whole organ is displaced downwards. The stomach is fixed to the liver and to the diaphragm (round the cardiac orifice) by the gastro-hepatic omentum, and in such cases of ptosis this band is said to be found stretched.

The viscus is susceptible of enormous dilatation when the pylorus is obstructed. The distended organ may reach as low as Poupart's ligament.

The stomach rests behind on the lesser sac of the peritoneum, which plays the part of a bursa to it. Gastric ulcers rarely perforate into the lesser sac, but when they do the contents can only escape by the foramen of Winslow, and may not be seen when the abdomen is opened. The sac is opened by perforating the great omentum at the greater curvature of the stomach.

The stomach has been frequently wounded. In most cases a fatal result rapidly follows upon these

injuries, for the contents of the stomach escape into the peritoneal cavity and set up an acute peritonitis. The most certainly and rapidly fatal cases, therefore, are those in which the stomach was full of food at the time of the accident. The empty stomach, being deeply placed and lying against the posterior abdominal wall in a collapsed state, is but little exposed to injury. A small punctured wound of the stomach need not be followed by escape of contents, since the loosely attached mucous membrane may escape from the wound and effectually plug it. This was illustrated many times in the Boer war, the viscus having been perforated by a Mauser bullet. The stomach has protruded through wounds in the abdominal walls, and has been returned, with no evil results following. In a few cases the belly wall in front of the stomach has been wounded, the viscus has protruded, its anterior wall has been wounded by the same injury that penetrated the parietes, and a fistulous opening leading into the stomach cavity has resulted. The best example of such cases is afforded by the well-known instance of Alexis St. Martin, the subject of so many physiological experiments. In this man the abdominal parietes in front of the stomach were torn away by a gunshot wound, a part of the anterior wall of the stomach sloughed, and a permanent fistula resulted. Dr. Murchison reports the case of a woman in whom a gastric fistula was produced by the continued pressure of a copper coin worn over the epigastric region. This coin was deliberately worn by the patient in order to excite a lesion that would arouse the sympathy of her friends. The pressure led to an ulceration that finally opened up the stomach. In many cases the fistula has been due to ulcerative diseases commencing in the stomach itself and spreading outwards.

Some remarkable cases have been recorded where foreign substances have been swallowed and have lodged in the stomach. Certain of these cases serve to illustrate the capacity of the stomach, and among the most striking is an instance where the viscus at death was

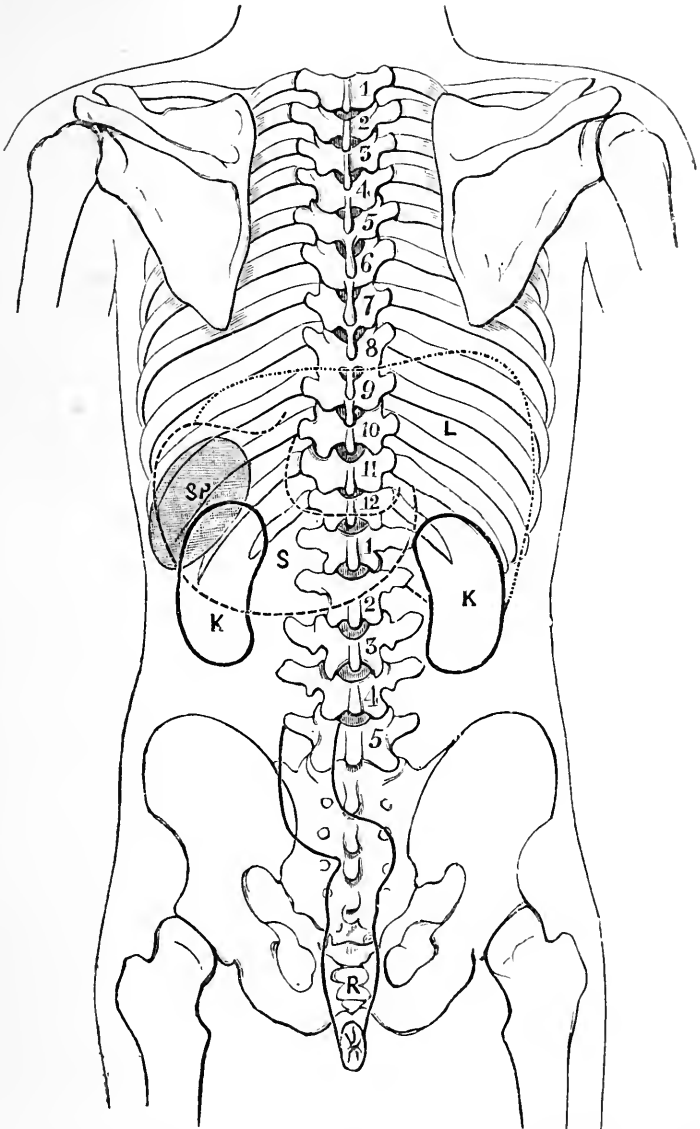


Fig 41.—Diagram to show the Relations of the Viscera to the Parietes (Posterior view).

s, Stomach; L, liver; K, kidney; SP, spleen; R, rectum.

found to contain thirty-one entire spoon-handles, each about 5 inches long, four half-handles, nine nails, half an iron shoe-heel, a screw, a button, and four pebbles. The whole mass weighed 2 lb. 8 oz. The patient was a lunatic. The *pylorus* has an average diameter of 16 mm. This about corresponds to the diameter of a sixpenny-piece. It is normally in a closed state, and should be capable of taking the fore-finger when open. In spite of the narrowness of the pylorus, large substances that have been swallowed have been passed by the anus without trouble. Among these may be noted a metal pencil-case  $4\frac{1}{4}$  inches long, 10 ounces of garden nails, and fragments of crockery-ware swallowed by a lunatic; a fork, a door-key, and other strange bodies. Needles and similar sharp substances that have been swallowed have travelled out of the stomach or bowels and have found their way to the surface at various points in the body. In a patient under my care at the London Hospital I extracted from beneath the skin, near the groin, a needle swallowed some months previously. In a case reported in the *Lancet* a needle was extracted from the middle of the thigh six months after it had been swallowed, and like instances are recorded elsewhere.

The lymphatics of the stomach pass mostly to the glands situated between the layers of the small omentum along the lesser curvature of the stomach. Some also pass to the glands scattered along the greater curvature of the stomach. In cancer of the pylorus, the glands along the lesser curvature are the first to become affected, and from these the disease spreads to the coeliac glands near the commencement of the thoracic duct. Owing to a free communication between the lymphatics of the pylorus, pancreas, and liver, the disease frequently involves these organs.

**Gastrotomy** and **gastrostomy**.—Gastrotomy consists in opening the stomach through the anterior abdominal wall for the purpose of removing a foreign body, for making an examination, or for dealing with a simple or malignant ulcer; gastrostomy, in opening the

stomach in a like situation with the object of establishing a gastric fistula through which the patient may be fed in cases where the gullet is occluded by disease. The uncovered part of the stomach, accessible in these operations, is represented by a triangular area, bounded on the right by the edge of the liver, on the left by the cartilages of the eighth and ninth ribs, and below by a horizontal line passing between the tips of the tenth costal cartilages (Fig. 40). In the empty condition five-sixths of the stomach lies beneath the left hypochondriac region, only part of the pyloric end being exposed in the triangular area. The incision in these operations must be situate in this triangle, and may be made either parallel to, and about two fingers' breadths from, the free border of the costæ, or along the left semilunar line. In the former incision the three flat muscles of the abdomen are cut through. In gastrostomy the stomach is not opened at the time of the operation, but is merely secured to the wound, and a few days are then allowed to elapse so that adhesions may form. At the end of this time the viscus is opened. The opening must needs be very small.

**Resection of the pylorus.**—The pylorus is frequently the seat of cancer. As a means of relieving the patient, the whole of the diseased pylorus has been removed, and the divided ends of the stomach and duodenum united by sutures. The situation of the cancerous pylorus within the abdomen varies considerably, as the diseased part is very apt to shift its position. It is often found to have sunk down by its weight to a point below the umbilicus, and to have contracted adhesions to adjacent organs. The diseased part has to be isolated and the omental connections of the right end of the stomach freely divided. The vessels that are almost certainly divided are the pyloric, the gastro-epiploica dextra, and the gastro-duodenal. The operation has not been attended with much success. The cancer is apt to become diffuse, to spread to adjacent tissues, and to lead to early lymphatic invasion of the greater and lesser omenta.

**Gastrectomy.** — Considerable portions of the

stomach have been excised in cases of cancer, and the entire organ has been removed (total gastrectomy) for the same cause. Up to the time of writing some fifteen examples of this operation have been recorded with more or less immediate death in five. Schlatter's original case of gastrectomy, performed in 1897, died in fourteen months from secondary deposits. Ricord published a case in which he removed the whole stomach, the first piece of the duodenum, and part of the pancreas. The patient was alive and well eleven months after the operation (*Gaz. des Hôpitaux*, March 22nd, 1900). It has yet to be shown that the operation is of genuine value. There is difficulty in uniting the gullet to the small intestine; both vagi nerves are divided as they emerge through the diaphragm, and the solar flexus is apt to be roughly handled; the operation is an extreme test for a weakened patient, and the after conditions of those who survive is not free from distress. There is, however, less disturbance of digestion than would be imagined.

#### **Other operations on the stomach.—**

Many other operations are performed upon the stomach which call merely for mention in this place. One of the most useful and the most frequently performed is *gastro-enterostomy*. Here an opening (or stoma) is made between the stomach and the upper part of the jejunum. The operation is performed in cases of stenosis of the pylorus, in cases of dilatation of the stomach without much stenosis, in certain examples of ulcer, and in many other conditions. In the operation of *pyloroplasty*, a non-malignant stricture of the pylorus is divided and the pyloric passage thus made free. In *gastroplication* certain conditions of dilated stomach are dealt with by taking in a fold or pleat in the stomach wall and in thus lessening its capacity.

**The small intestines.\***—The average *length* of the small intestine in the adult is  $22\frac{1}{2}$  feet, the ex-

\* The account of the intestines is derived from the Author's work "On the Intestinal Canal and Peritoneum in Man." London. 1885.

tremes being 30 feet and 15 feet. In the fœtus, at full term, the lesser bowel measures about  $9\frac{1}{2}$  feet. It is roughly reckoned that the first 8 or 9 feet of the adult bowel belongs to the jejunum, and the remaining 12 or 13 feet to the ileum.

The division into jejunum and ileum is quite arbitrary. There is no one point where it can be said that the jejunum ends and the ileum commences. When the small intestines are exposed by accident or operation, it is often difficult, especially when there is abdominal disease, to recognise the upper from the lower part of the gut. It may be noted, however, that the jejunum is wider than the ileum (its diameter being  $\frac{1}{4}$  of an inch greater than that of the ileum), and its coats are thicker and more vascular. If the gut be empty, and can be rendered translucent by being held against a light, the lines of the valvulæ conniventes can be well seen. These folds are large and numerous in the jejunum, but become small and scanty in the upper ileum, and are wanting in the lower third of that bowel. Injuries to the jejunum are more serious than are those of the ileum, since an intestinal lesion is (other things being equal) the more serious the nearer it approaches to the stomach. The fatality of umbilical herniæ probably depends in part upon the fact that the contained bowel is often jejunum. The coils of small intestine occupy no certain *position* in the abdomen. In the fœtus, and during the earliest part of extra-uterine life, the bulk of the small intestine is placed to the left of the middle line. This is on account of the relatively large size of the liver, to the weight of which the lesser bowel no doubt acts as a counterpoise. In the majority of adult bodies the small intestine is disposed in an irregularly curved manner from left to right. The gut, starting from the duodenum, will first occupy the contiguous parts of the left side of the epigastric and umbilical regions; the coils then fill some part of the left hypochondriac and lumbar regions; they now commonly descend into the pelvis, re-appear in the left iliac quarter, and then occupy in order the hypogastric,

lower umbilical, right lumbar, and right iliac regions. Before reaching the latter situation they commonly descend again into the pelvis.

Much interest attaches to the coils of small intestine that are *found in the pelvis*. These are the coils that are apt to become involved and adherent in cases of pelvic peritonitis, and that would probably form the protrusion in most cases of obturator, sciatica, and pudendal hernia. No small intestine occupies the foetal pelvis. The amount found in the adult pelvis depends mainly upon the state of distension of the bladder and rectum, and upon the position of the sigmoid flexure. The coils that are most usually found in this position belong to the terminal part of the ileum, and to that part of the intestine that has been already alluded to as possessing the longest mesentery (page 319). The ileum is the part of the intestine that is most frequently found in inguinal and femoral herniæ. It is also the part most usually involved in cases of strangulation by internal bands, by holes in the mesentery, etc.

Of all the viscera the small intestines are the most exposed to *injury*, and at the same time it must be noted that by their elasticity, and by the ease with which their coils slide over one another and so elude the effects of pressure, they are the best adapted to meet such injuries as contusions and the like. A minute punctured wound of the small gut does not lead to extravasation of contents. The muscular coat contracts and closes the little opening. Thus, in excessive tympanitis the bowels are often freely punctured in many places with a fine capillary trochar, to allow the gas to escape, without any evil resulting. A case of intestinal obstruction of sixteen weeks' duration is reported, in which the abdomen was punctured 150 times (*Boston Med. Journ.*). If the wound be a little larger the loose mucous membrane becomes everted or protruded through the wound and effectually plugs it. Gross found that a longitudinal cut in the small bowel  $2\frac{1}{2}$  lines in length was immediately reduced to a wound  $1\frac{3}{4}$  lines in length by muscular contraction, and that the



eversion of the mucous membrane in addition to this contraction entirely sealed the opening. Even the opening made in the intestine—for example, in the jejunum—by the penetration of a Mauser bullet may be attended by no escape of contents. A contracted empty piece of bowel becomes nearly twice as long when distended.

Owing to the greater power of the circular layer of muscle a longitudinal wound gapes more than a transverse wound, and, in consequence of the greater muscular development of the jejunum, wounds of that part gape more than do those of the ileum. Transverse wounds gape most when inflicted across the free border of the gut, since in that place the longitudinal muscular fibres are thickest.

In one remarkable case a man was stabbed in the belly. It was subsequently found that there was a small puncture in the ileum, which had been plugged by the mucous membrane and further secured by recent lymph. The man did well until the fourth day, when he died somewhat suddenly. It was then found that an intestinal worm (*Ascaris lumbricoides*) had worked its way through the wound, breaking down the adhesions, and had escaped into the peritoneal cavity. Extravasation followed, and thus the worm was the immediate cause of the man's death.

The calibre of any portion of the small intestine depends mainly upon the condition of its muscular wall. The tube may become much contracted when empty. In peritonitis and in certain other conditions the muscular coat is paralysed and the bowel becomes intensely dilated by gas (tympanitis).

**Meckel's diverticulum.**—From one to four feet from the end of the ileum is sometimes seen a diverticulum (Meckel's) that represents the remains of the vitello-intestinal duct (page 289). It may be expected in 2 per cent. of the bodies examined. This diverticulum usually exists as a tube of the same structure as the intestine. Its length varies. It may sometimes extend as a patent tube as far as the umbilicus. It

is more often but a few inches long, and may then end in a free conical or globular extremity, or in a fibrous cord. This diverticulum may cause intestinal obstruction in many ways. Its end may contract adhesions, and beneath the bridge thus formed a loop of bowel may be strangled. It may twist itself about a piece of intestine so as to form a knot round it. It may, from its adhesions, so drag upon the ileum as to cause "kinking" of the tube at its point of origin. In more than one case it has been found in an external hernia. It may become invaginated and start an intussusception of the bowel.

**The duodenum and fossa duodeno-jejunalis.**—The first portion of the duodenum is nearly horizontal. It measures about 2 inches in length and passes backwards from the pylorus to near the upper end of the right kidney. The second portion, about 3 inches in length, descends vertically in front of the inner border of the right kidney to the level of the third lumbar vertebra. The third portion, some 5 inches in length, crosses from right to left in front of the third vertebra, and then ascends for a short distance on the surface of the left psoas muscle, to end in the jejunum to the left of the second lumbar vertebra. The first portion, which is movable, is invested by peritoneum, in the same manner as the stomach. The second part is covered by peritoneum in front only, except at the spot where it is crossed by the transverse colon. The third part is also covered by peritoneum only on its anterior aspect, this membrane being, however, free of the gut where the superior mesenteric vessels cross it.

The first portion has found its way into herniæ in company with the stomach, but the second and third parts are never herniated. The end of the duodenum, the duodeno-jejunal bend, is very firmly held in place by a band of fibrous tissue that descends upon it from the left crus of the diaphragm and the tissue about the celiac axis. This band is called the suspensory muscle of the duodenum (Treitz). It serves also to

support the mesentery. No matter to what extent the stomach may be displaced by distension, or the intestines disturbed by a like cause, the position of the duodeno-jejunal bend will be found to remain unaltered. All sections of the duodenum have been ruptured by violence. Owing to its large non-peritoneal surface, the bowel, if approached from behind, may be wounded without opening the peritoneum (Fig. 47, p. 353).

In connection with the spread of disease by continuity of tissue, it is well to note that the duodenum is in relation with the liver, gall bladder, pancreas, transverse colon, spine, right kidney, bile duct, portal vein, gastro-duodenal and superior mesenteric vessels, aorta and vena cava.

In the duodenum are Brunner's glands, which are sometimes the seat of a perforating ulcer in cases of burns. They are mostly seated in the first segment of this bowel, and the perforation, therefore, usually opens into the peritoneal cavity. A diverticulum is sometimes present. The liver and pancreas are both developed as epithelial buds from the duodenal part of the canal in the embryo. Congenital strictures of the intestine are not uncommonly placed in the duodenum.

The peculiar vertical curve of the duodenum closely resembles that of the syphon trap used in drains. Mr. Mayo Collier has pointed out that this part of the bowel probably acts as a real syphon trap, and so prevents the regurgitation of intestinal gas into the stomach. The duodenum of the horse appears to act also in this manner.

Passing from the front of the terminal (ascending) part of the duodenum, a fold of peritoneum is often seen, that joins the parietal peritoneum to the left of the piece of gut in question. This fold marks off a fossa of triangular outline, the orifice of which is directed upwards. I have found the fossa in about 50 per cent. of the bodies examined. It is called the **fossa duodeno-jejunalis**; it is usually large enough to lodge the tip of the finger, and its opening lies just below the duodeno-jejunal bend (Fig. 42). This fossa is the anatomical cause of *mesen-*

*teric, meso-colic, meso-gastric, or retro-peritoneal hernia.* The commencement of the jejunum presses into the fossa, enlarges its cavity, and ultimately separates the peritoneum from its posterior attachments. More and more of the small intestine passes into the increasing pouch, until at last, as in the case reported by Sir Astley Cooper and many others, nearly the whole of the small intestine may be found lodged in an enormous median retro-peritoneal sac, the mouth of which is the orifice

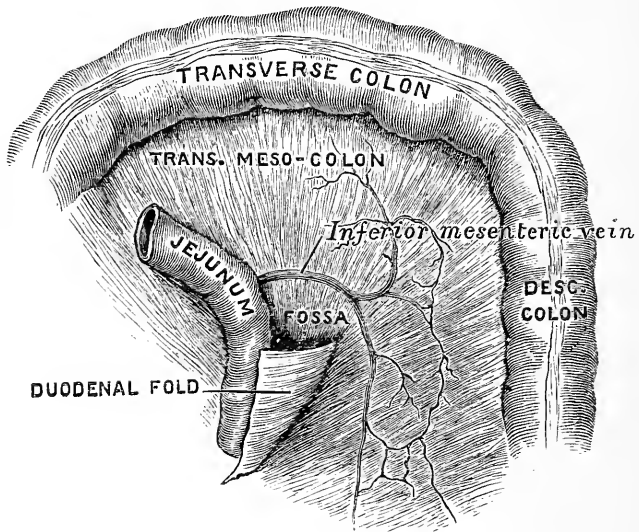


Fig. 42.—The Fossa Duodeno-jejunalis (Treves).

of the fossa duodeno-jejunalis. The duodenum can be seen to enter the sac and the end of the ileum to leave it. The sac usually extends downwards on the left side, and may reach the promontory of the sacrum. These herniæ vary in size, but are as a rule large. The cœcum and ascending colon have their normal position, but the transverse and descending parts of the colon are stretched over and displaced by the sac. The renal artery is behind the hernia, and the inferior mesenteric artery is in front of it and to the left. A branch of this

vessel, the colica sinistra, is near to the orifice of the sac in its lower part.

**Operations on the small intestine.**—*Enterotomy* is the operation of opening the small intestine above some obstruction that threatens to be fatal or insuperable. The incision is made in the linea alba, below the umbilicus, or in one or other iliac region, as is considered more convenient. An incision some 2 or 3 inches in length will probably suffice. The peritoneum having been opened, a knuckle of small bowel close above the obstruction is seized, is secured to the parietal wound, and then opened. The small intestine has also been opened to remove impacted foreign bodies and large gall stones. In such cases the intestinal wound is usually closed immediately. *Enterectomy.*—Portions of the small intestine have been resected with success for various diseased conditions. In one case more than two yards of the small intestine were cut away on account of multiple stricture. The patient, a young woman, made an excellent recovery. Resections have also been successfully performed in cases of bullet wound or stab involving the lesser bowel, and in other injuries. Tumours of the gut have been removed by a partial resection. Non-malignant strictures of the bowel have been treated by incision and dilatation.

The bowel above an obstruction has been connected to the bowel below an obstruction by the operation called *intestinal anastomosis* or *short circuiting*.

In uniting divided intestine by suture (*enteroraphy*) it is essential that the serous coat of the ends of the bowel should be brought together. This is best effected by the suture known as Lembert's, with the addition of a special and separate line of sutures for the mucous membrane. Experience shows that if leakage occurs after resection or suture of intestine it will most likely occur along the attachment of the mesentery. This circumstance is thus explained by Mr. Anderson. The two layers of the mesentery diverge as they approach the bowel, and so leave a triangular space, the base of which, averaging about  $\frac{1}{16}$ ths of an inch in width

is formed by the uncovered muscular tissue. It is the existence of this bare piece of intestine that renders adjustment of the serous coat at the attachment of the mesentery a matter of some difficulty.

**The ileo-cæcal region.**—The cæcum is, to a certain extent, rudimentary in man, as it is also in the carnivora. In herbivorous animals it is of great size, and appears to serve as a reservoir for the elaboration and absorption of food. It has been said that the cæcum in man exists as an anatomical protest against vegetarianism. The appendix persists as the remains of the larger cæcum of lower mammals. In the human foetus it can be seen to be but the narrowed extremity of a capacious cæcum. The foetal type of cæcum, which is very characteristic, may persist throughout life. From the point of view of evolution the appendix would appear to be becoming obliterated. Like other functionless parts that persist as developmental relics, it is very frequently the seat of disease, and it is worthy of note that such disease tends to cause the entire obliteration of the part (as after many forms of so-called appendicitis).

It must be understood that the term *cæcum* is applied to that part of the colon that lies below the entrance of the ileum. The average breadth of the adult cæcum is 3 inches, its average length (vertical measurement)  $2\frac{1}{4}$  inches.

The cæcum is usually lodged in the right iliac fossa, and is so placed that its apex corresponds with a point a little to the inner side of the middle of Poupart's ligament. When distended with gas or fæcal contents it occupies the whole of the right iliac fossa. A point  $1\frac{1}{2}$  inches above and internal to the anterior superior iliac spine lies over the ileo-cæcal valve.

A slightly distended cæcum so located may be emptied by flexing the thigh upon the abdomen. The cæcum is always entirely invested by peritoneum. Its posterior surface is never in connection with the areolar tissue of the iliac fossa (Fig. 43). The peritoneum is reflected from the commencement of the ascending

colon on to the posterior parietes below the level of the iliac crest. A mobile cæcum may hang over the pelvic brim, or occupy the pelvis, or even find its way into an inguinal hernia of the left side.

The cæcum is not infrequently found in an inguinal or femoral hernia of the right side (cæcal hernia). Such herniæ are, except in a few rare instances, provided with a proper and complete peritoneal sac.

Foreign bodies that have been swallowed are

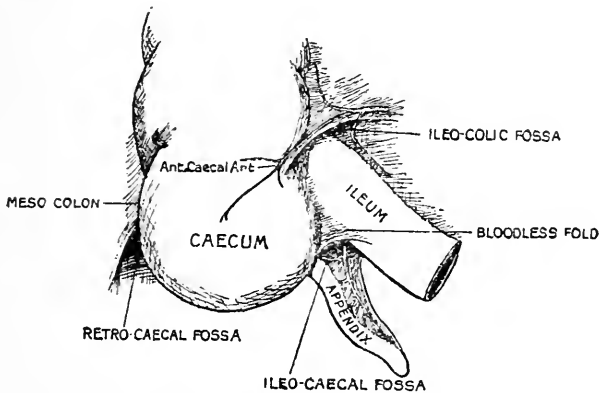


Fig. 43.—The peritoneal fossæ of the ileo-cæcal region.

very apt to lodge in the cæcum, and in that situation may cause ulceration and even perforation of the bowel, producing one form of typhlitis.

In cases of fæcal retention, also, the largest accumulation of fæcal matter is very usually met with in the cæcum, and upon that part of the bowel when distension is extreme the greatest strain usually comes.

Stercoral ulcers (ulcers due to the pressure and irritation of retained fæces) are more often met with in the cæcum than in any other part of the colon. Solitary follicles are numerous in the mucous membrane of the cæcum. Intestinal concretions also are not uncommon in this part.

The cæcum is susceptible of enormous distension,

provided that it be gradually effected, and, in certain instances, a dilated cæcum has been found to occupy a large part of the abdominal cavity. When the abdomen is opened in any doubtful case of intestinal obstruction, the condition of the cæcum is of great value in pointing to the seat of the obstacle. In stenosis of the colon it will be found greatly distended, while in obstruction of the small gut it will be empty, or, at least, in a normal condition.

**The appendix** varies in length. Its average measurement in the adult is 4 inches, the extremes being 1 inch and 6 inches. Its position varies, although, as a rule, it is seen to lie behind the end of the ileum and its mesentery, and to point in the direction of the spleen. It frequently also lies behind the cæcum. I have seen the appendix so placed with reference to the bowel that it would have been encountered in a right lumbar colotomy. In such cases the appendix has been pushed behind the cæcum and caught in the meso-colon during the later months of foetal life, when the colon migrates from the neighbourhood of the liver to the right iliac fossa. The appendix may hang within the pelvis and, in inflammatory conditions, contract adhesions to the ovary or other pelvic structures. I have found an inflamed appendix adherent to the liver and another in the left iliac fossa. It has found its way down both the right and the left inguinal canals.

The tip of the process may adhere to a neighbouring peritoneal surface, and thus form a "band," beneath which a piece of small intestine may be strangulated.

Foreign bodies occasionally lodge in the appendix, and it is very often found to be occupied by a faecal concretion or calculus. These substances excite inflammation, and, as a result, the appendix may become perforated. Troubles in the vermiform process are the most frequent causes of perityphlitis, a term applied to localised inflammation of the peritoneum in the vicinity of the cæcum.

From the position of the appendix it will be understood how it has happened that inflammation of the



organ has been mistaken for ovaritis, for peri-renal inflammation, or even for hip disease. In appendicitis there is often pain down the right thigh and stiffness of the right hip. The mesentery of the appendix (Fig. 43), which contains an artery derived from the ileo-colic, may be so short as to produce obstructive kinks in the appendix. The mucous lining is so crowded with solitary lymphoid follicles as almost to occlude its lumen. In some forms of appendicitis these follicles are involved. They are surrounded by lymph spaces, from which vessels pass to the lymph glands in the mesentery, and others pass upwards behind the ascending colon (Lockwood). It is probably through these latter vessels that infection passes from the appendix and gives rise to abscesses in the subdiaphragmatic region. The muscular coat of the appendix is scanty, and through breaks in it the submucous tissue communicates with the subserous. Inflammation of the mucous membrane may therefore spread without hindrance to the peritoneum.

It is in the ileo-cæcal region that *intussusception* most frequently occurs. In this condition one part of the intestine is prolapsed or "telescoped" into the lumen of an immediately adjoining part. In the ileo-cæcal variety (the commonest form) the narrow ileum, and subsequently the cæcum, are prolapsed into the colon. The ileo-cæcal valve forms the summit of the protrusion or intussusceptum. By a gradual increase of the condition the intussusceptum bowel may at last reach the rectum, and the ileo-cæcal valve has, in fact, been recognised protruding from the anus. In the ileo-colic variety (the rarer form) the end of the ileum is prolapsed through the valve. The valve and the cæcum remain in their normal situations, and the summit of the intussusceptum is formed only by the ileum.

There are three fairly constant peritoneal fossæ, which are sometimes the seat of hernia, in the ileo-cæcal region (Fig. 43). They are (1) the ileo-colic, situated between the ascending colon and termination of the ileum; a fold containing the anterior cæcal artery bounds it

above; (2) the ileo-cæcal fossa, between the termination of the ileum and the cæcum; it is bounded in front by the bloodless fold and behind by the mesentery of the appendix; (3) the retro-cæcal fossa, behind the cæcum; it is bounded on the right by the lower termination of the ascending meso-colon.

The **large intestine**.—From the cæcum to the sigmoid flexure, this portion of the bowel is accessible to pressure except at the hepatic and splenic flexures, which are deeply placed. The hepatic flexure is under the shadow of the liver, and the splenic curve, which reaches a higher level, is behind the stomach. The position of the transverse colon can often be well marked out. It crosses the belly transversely, so that its lower border is on a level with the umbilicus (Fig. 40, p. 322). In cases of fæcal accumulation, the outline of the colon, with the exception of the two flexures above named, may be distinctly defined. In distensions of the small intestine the belly tends to present the greatest degree of swelling in front, and about and below the navel. In distension of the larger gut, the front of the abdomen may remain (for a while at least) comparatively flat, while the distension will be most obvious in the two flanks and in the region just above the umbilicus. Tumours of the transverse colon, and of the lower two-thirds of the ascending and descending colon, can be well defined, even when of moderate size, and in cases of intussusception the progress of the mass along the colon can often be traced with great ease, and the effects of enemata and other methods of reduction carefully watched. The diameter of the large intestine (excluding the rectum) gradually diminishes from the cæcum to the sigmoid flexure, the diameter of the former being about  $2\frac{1}{2}$  inches, of the latter  $1\frac{1}{2}$  inches. The narrowest part of this segment of the bowel is at the point of junction of the sigmoid flexure with the rectum, and it is significant that it is at this point that stricture is the most common.

The tendency to stricture increases as one proceeds downwards from the cæcum to the anus. A stricture

is frequent in the descending colon, less frequent in the transverse colon, while in the ascending colon it is comparatively rare. Strictures are not uncommon about the flexures of the bowels.\*

When gradually distended the colon may assume enormous dimensions, and it will be readily understood that in some cases of great faecal accumulations the thoracic organs may, with certain abdominal viscera, be displaced. In one case, for example, the heart was so displaced by the distended colon that the apex beat was found to be  $1\frac{1}{2}$  inches above and 1 inch to the inner side of the left nipple. When the faecal collection had been removed it returned to its normal position. Thus it happens that a distended colon is often associated with shortness of breath, with palpitation, and other thoracic symptoms.

The *ascending* and the *descending colon* are placed vertically. The average length of the ascending colon in the adult (as measured from the tip of the caecum to the hepatic flexure) is 8 inches. The average length of the descending colon (from the splenic bend to the commencement of the sigmoid flexure) is  $8\frac{1}{2}$  inches. The descending colon is very little liable to variation. In cases of non-descent of the caecum the ascending colon may be absent (page 345). I have pointed out that in 52 per cent. of adult bodies there is neither an ascending nor a descending meso-colon, and that a meso-colon may be expected on the left side in 36 per cent. of all cases, and on the right side in 26 per cent. These points are of importance in connection with the somewhat uncommon operation of lumbar colotomy. The breadth of the meso-colon, when it exists, varies from 1 to 3 inches. The line of attachment of the left meso-colon is usually along the outer border of the kidney, and is vertical. That of the right meso-colon is, as a rule, less vertical, runs along the inner border of the kidney, and crosses its lower end obliquely from right to left.

The *transverse colon* has an average measurement

\* See "Intestinal Obstruction." By the Author. London. 1899.

of 20 inches. It is not quite horizontal, since the splenic flexure is on a higher level than the hepatic flexure, as well as posterior to it. Faecal masses lodged in the transverse colon have given rise to many errors in diagnosis. In some instances this part of the colon is displaced towards the pelvis, so that V- or U-shaped bends are produced. In such cases the point of the V or U may reach the symphysis pubis, while the two colic flexures occupy their proper situations. These deviations are described in detail in my work on Intestinal Obstruction.

The right-hand part of the transverse colon is in intimate relation with the gall bladder, and is commonly found to be bile-stained after death. In some cases where gall stones have been lodged within the gall bladder, the walls of that structure have ulcerated from pressure, the ulceration has involved the subjacent transverse colon, and thus a fistula has been established between the gall bladder and the gut, through which large stones have been passed. Hepatic abscesses also have discharged themselves through the transverse colon. The transverse colon often finds its way into an umbilical hernia, and has been found to be concerned in many of the cases of hernia into the foramen of Winslow.

*The sigmoid flexure.*—The segments of gut termed the sigmoid flexure and “the first part of the rectum” form together a single simple loop that cannot be divided into parts. This loop begins where the descending colon ends, and ends at the commencement of the so-called “second part of the rectum;” at a spot, in fact, where the meso-rectum ceases, opposite about the third piece of the sacrum. This loop, when unfolded, describes a figure that, if it must be compared to a letter, resembles the capital Omega. It may well be termed the Omega loop, and the term rectum be limited to the short piece of practically straight gut, that is now described as the second and third parts of the rectum. The average length of the loop in the adult is  $17\frac{1}{2}$  inches. The two extremities of the loop are about 3 or 4 inches apart.

If they are approximated to one another, as by contracting peritonitis at the root of the sigmoid meso-colon, a kind of pedicle is established, about which the loop may readily become twisted. Such a twist of the bowel constitutes a volvulus of the sigmoid flexure; and it may be here said that volvulus of the intestine is more commonly met with in this loop than in any other part of the canal.

The line of attachment of the meso-colon of the Omega loop (the sigmoid meso-colon) crosses the psoas muscle and the iliac vessels near their bifurcation; it then turns abruptly down, and running nearly vertically, terminates at the middle line.

In the left wall of this meso-colon, close to the point where it lies over the iliac vessels, a fossa is sometimes to be found. It is produced by the sigmoid artery, and is about  $1\frac{1}{2}$  inches in depth. It is called the inter-sigmoid fossa, and is the seat of *sigmoid hernia* (Fig. 44, M.C.). Two cases of strangulated hernia in this fossa have been recorded.

The sigmoid flexure, or Omega loop, when empty, normally occupies the pelvis. When distended this piece of bowel may become so enormously dilated as to reach the liver. The chief examples of extraordinary dilatation of the colon concern this loop. Faecal masses are very frequently lodged in the free end of the loop and certain intestinal concretions have been met with in the same situation.

I have shown by experiment that the "long tube," when introduced through the anus, cannot be passed beyond the sigmoid flexure in ordinary cases, and with a normal disposition of the bowel.

In cases of congenital absence, or deficiency of the rectum, the sigmoid flexure is often opened in the groin and an artificial anus established there. This operation, known as Littre's operation, is, it must be confessed, not very successful. One difficulty has been said to depend upon the uncertain position of the sigmoid flexure in cases of congenital deformity, it being sometimes on the right side and sometimes in the pelvis

at the middle line. It is rarely, however, found in these positions. Out of 100 post-mortem examinations on young infants, Curling found the loop on the left side in eighty-five cases. Out of ten children who were operated on for imperforate anus, the loop was found in the left fossa in only one case (Montgomery).

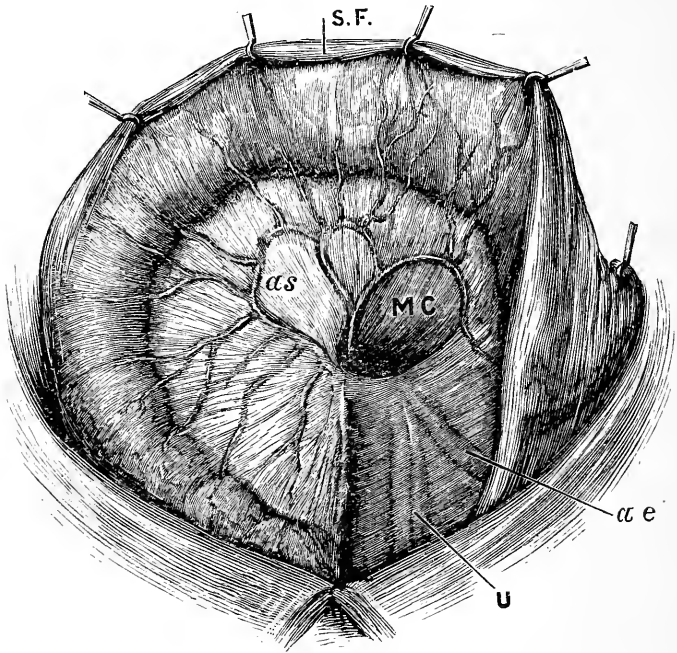


Fig. 44.—Sigmoid Flexure turned upwards to show the Inter-sigmoid fossa (Jonnesco).

s F, Sigmoid flexure;  $\alpha s$ , Sigmoid artery; MC, Meso-sigmoid fossa;  $\alpha e$ , external iliac artery; u, Ureter in front of internal iliac vessels.

The sigmoid flexure is the part of the colon opened in the operation of *left iliac* or *inguinal colotomy*. In performing this operation the length of the sigmoid meso-colon and the consequent mobility of the coil are of much importance.

The sigmoid flexure, when empty and contracted, can be felt through the parietes in moderately thin subjects.

**Congenital malformations of the colon.**—

These are of moment with regard to operative procedures. It may be very briefly said that in the fœtus the small bowel occupies at one time the right side of the abdomen, while the large gut is represented by a straight tube that passes on the left side vertically from the region of the umbilicus to the pelvis. The cæcum is at first situated within the umbilicus, and then ascends in the abdomen towards the left hypochondrium. It next passes transversely to the right hypochondrium, and then descends into the corresponding iliac fossa. It may be permanently arrested at any part of its course. Thus the cæcum may be found about the umbilicus, or in a congenital umbilical hernia, or in the left hypochondriac region (the ascending and transverse parts of the colon being absent), or it may be found in the right hypochondrium, the ascending colon only being unrepresented.

The whole of the large intestine has at one time an extensive mesentery, and in some rare cases this condition may persist throughout life. When it does persist, it may lead to one form of volvulus of the bowel.

**Lumbar colotomy.**—The operation so named consists in opening the colon in the loin behind the peritoneum, for the purpose of establishing an artificial anus. The operation is performed, when possible, upon the left side, in preference to the right, inasmuch as the descending colon is nearer to the anus. The operation has, however, been almost entirely superseded by iliac colotomy except in a few uncommon conditions. The position of the descending colon in the loin may be represented by a line drawn vertically upwards from a point  $\frac{1}{2}$  an inch behind the centre of the iliac crest (Fig. 50, p. 365). In performing left lumbar colotomy an ink line may be drawn vertically upwards from the centre of the crest of the ilium. It will hit the outer end of the last rib. An incision is made across the centre of this line parallel to the last rib, and so planned that the centre of the incision corresponds to the centre of the line. The

superficial tissues having been incised, the following structures are then divided in layers in the following order: (1) The latissimus dorsi and external oblique muscles to an equal extent. (2) The internal oblique

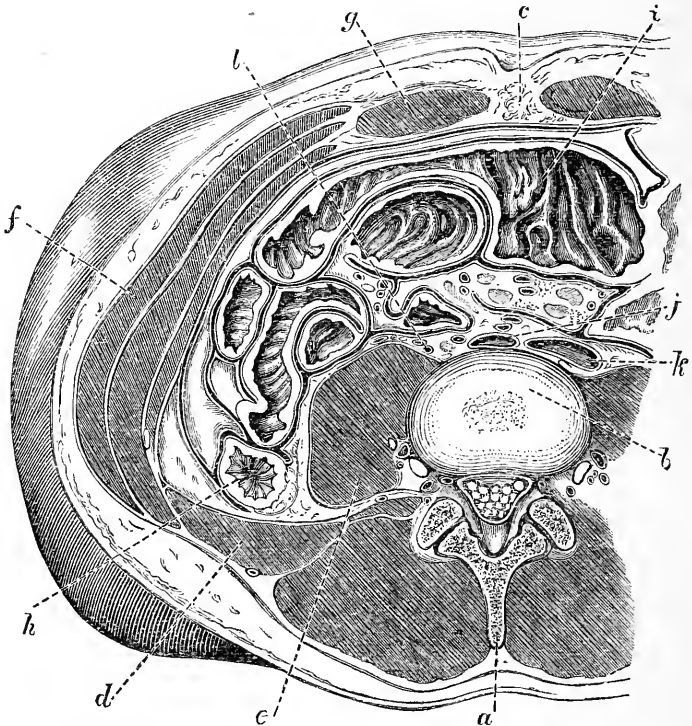


Fig. 45.—Horizontal Section through the Body at the Level of the Umbilicus. (After Braune.)

*a*, Spine of the fourth lumbar vertebra; *b*, disc between third and fourth vertebra; *c*, umbilicus; *d*, quadratus lumborum; *e*, psoas; *f*, external oblique, with internal oblique and transversalis muscles beyond; *g*, rectus; *h*, descending colon; *i*, transverse colon; *j*, aorta; *k*, inferior vena cava; *l*, ureter.

in the entire length of the incision. (3) The fascia lumborum, with a few of the most posterior fibres of the transversalis muscle. (4) The transversalis fascia. The quadratus lumborum will be exposed in the posterior inch or so of the incision, and usually does not need to



be cut. At the seat of the operation the descending colon occupies the angle between the psoas and quadratus lumborum muscles, and the non-peritoneal surface is exactly represented by that part of the bowel that faces this angle (Fig. 45). Thus, if during the operation the curved finger be placed in this angle, and the patient be rolled over to the left side, the bowel that falls into the finger cannot well be other than the descending colon. The gut is drawn forwards, stitched to the wound, and opened by a transverse cut. The width of the non-peritoneal surface varies from  $\frac{4}{5}$ ths of an inch to 1 inch in the empty state, and may attain to 2 inches or more in the distended condition (Braune). The part of the descending colon usually opened is the highest portion of that bowel, so that the finger can often be thrust into the transverse colon, or the opening of the intestine can be seen. In this, as in other circumstances, the large bowel may be distinguished from the small by its sacculi, its three longitudinal muscular bands, and its appendices epiploicæ. As regards dimensions, the small intestine may, especially in cases of obstruction, be much larger than the so-called large intestine. When empty, the diameter of the descending colon is about equal to that of the jejunum, the measurement in the two cases being about  $1\frac{1}{2}$  inches. The average diameter of the ileum is  $1\frac{1}{4}$  inches, and of the cæcum and commencing colon  $2\frac{1}{2}$  inches.

Lumbar colotomy is often performed through a vertical or oblique incision in the place of the one just given.

The operation does not materially differ from that described, when it is performed on the right side.

**Iliac or inguinal colotomy.**—In this very common, excellent, and simple operation the sigmoid flexure is exposed and opened in the left iliac region. A line is drawn from the anterior superior iliac spine to the umbilicus, and an incision some 2 inches in length is made at right angles to this line and at a distance of about  $1\frac{1}{2}$  inches from the point of the bone. The three muscles of the abdomen and the peritoneum having

been divided, the loop of the sigmoid flexure is brought into the wound, is secured, and is (at once or at a later period) opened.

The cæcum may be opened on the right side, and as a rule the most convenient incision is an oblique one placed external to the deep epigastric artery.

**Colectomy** consists in excising a portion of the colon. The cæcum has been removed, and considerable segments of the rest of the large intestine. The treatment of cancer of the colon by excision is attended with very considerable success. Portions of the ascending and descending parts of the colon have been excised through an incision in the loin, but colectomy is much more readily carried out through an anterior wound. I have reported a case in a young girl, in which I excised the whole rectum and anus, the sigmoid flexure, and the whole of the descending colon. The divided transverse colon was brought out at the anus. The child made a perfect recovery. The parts removed are in the Museum of the Royal College of Surgeons. The operation of *intestinal anastomoses* or *short circuiting* is very frequently practised on the colon. Thus, in an obstruction on the descending colon incapable of removal, the transverse colon may be united to the sigmoid flexure.

The **liver**—The liver is moulded to the arch of the diaphragm, and lies over a part of the stomach (Fig. 48). The convex surface is protected on the right side by the ribs, from the seventh to the eleventh inclusive, and in front by the xiphoid cartilage and the costæ from the sixth to the ninth inclusive, the diaphragm being interposed. The diaphragm separates the liver from the thin margin of the base of the right lung, which descends in front of it. Its pointed left extremity reaches the position of the apex beat, and in the early years of life, when the left lobe is relatively large, it may touch the spleen, a relationship sometimes met with in the adult. In the subcostal or infrasternal triangle, the liver lies in front of the stomach and beneath the anterior abdominal wall. The lower edge,

as it crosses the subcostal angle, is represented by a line drawn from the ninth right to the eighth left costal cartilage (Fig. 40, p. 322). In the erect posture the lower edge on the right side is about  $\frac{1}{2}$  or  $\frac{1}{4}$  of an inch below the margins of the costal cartilages.

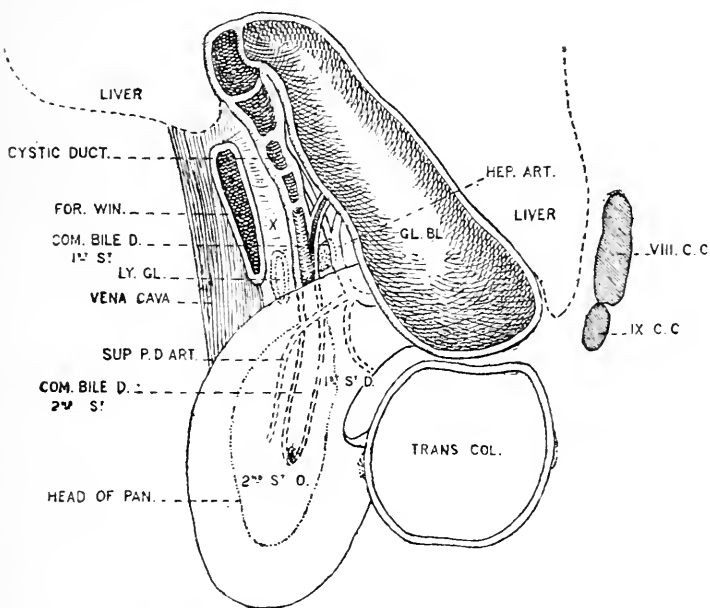


Fig. 46.—Diagrammatic Representation of the Gall Bladder and Bile Ducts from the right side.

The position of the portal vein is indicated by x; GL. BL., gall bladder; COM. BILE D. 1st ST., omental stage of common bile duct; COM. BILE D. 2nd ST., retro-duodenal stage of common bile duct; HEP. ART., hepatic artery giving off the gastro-duodenal and superior pancreatico-duodenal artery; FOR. WIN., foramen of Winslow; IX. C.C., tip of ninth costal cartilage; 1st ST. D., first stage of duodenum; 2nd ST. D., second stage of duodenum; TRANS. COL., section of transverse colon; LY. GL., lymph glands in the gastro-hepatic omentum.

In the recumbent position the liver ascends about an inch, and is entirely covered by the costæ, except at the subcostal angle. It descends also in inspiration and rises in expiration. The liver reaches its highest level in the nipple line at a point marked by the fifth rib. To the left it slopes downwards to the apex

beat, the line crossing the sternum at the insertion of the sixth pair of ribs. To the right of the nipple line, it rapidly descends, passing the seventh rib in the axillary line and the ninth below the angle of the scapula. Behind, the liver comes to the surface below the right lung, at a part corresponding, both in position and width, to the tenth and eleventh dorsal vertebræ. On the extreme right the liver descends to the level of the second lumbar spine (Figs. 41 and 48). The under surface of the liver is in contact with the stomach, the first and second parts of the duodenum, the small omentum, the right kidney, and the beginning of the transverse colon.

The fundus of the gall-bladder approaches the surface behind the ninth costal cartilage, close to the outer border of the right rectus muscle.

The liver is retained in shape by, and moulded upon, the diaphragm above and the abdominal organs below. When removed from the body the shape is lost which it possesses clinically. It presents many variations in form. One of the commonest is a linguiform process, usually known as *Riedel's lobe*, which projects from the margin of the right lobe under the tenth costal cartilage. It is found more frequently in women than in men, and may be mistaken for a floating kidney or an abdominal tumour.

In the condition known as *ptosis of the liver* the organ slides from the dome of the diaphragm, and may descend to the level of the umbilicus or reach the iliac fossa. With the descent there is also a rotation on its transverse axis, so that its diaphragmatic surface comes almost completely to the front. In such a case the factors which maintain the liver in position have to be considered. They are : (1) its fixation to the diaphragm by the inferior vena cava and the fibrous tissue on the non-peritoneal posterior surface of the right lobe in the neighbourhood of the inferior vena cava. This is its chief support. (2) The peritoneal folds, which include the right and left lateral, coronary, and falciform ligament, also attach it to the diaphragm. (3) The muscular

abdominal walls. These keep the other abdominal viscera constantly pressed against the lower surface of the liver. It must be remembered that in respiration the liver plays the part of shuttlecock to the battledore of the diaphragm and abdominal parietes. In many women over forty the right lobe of the liver projects quite 2 inches below the eleventh rib.

The liver is more often *ruptured* from contusion than is any other abdominal viscus. This is explained by its large size, its comparatively fixed position, and its great friability of structure. Death in such injuries usually ensues from hæmorrhage, since the walls of the portal and hepatic veins, being incorporated with the liver substance, are unable to retract or to collapse. The hepatic veins also open direct into the vena cava, and, being unprovided with valves, could allow of the escape of an immense quantity of blood, if any retrograde current were established. The hepatic vessels are thin-walled, and it is almost impossible to ligature them, except by buried sutures. It is possible for the liver to be ruptured without the peritoneal coat being damaged. Such injuries may be readily recovered from. The liver presents, behind, a fairly extensive non-peritoneal surface, at which rupture or wound may occur without extravasation into the abdominal cavity. From the relation of the liver to the right lower ribs, it follows that this viscus may be damaged when the ribs are fractured, and in some cases the broken ends of the bones have been driven through the diaphragm into the liver substance. *Stabs* through the sixth or seventh right intercostal space, over the liver region, would wound both the lung and the liver, would involve the diaphragm, and open up both the pleural and peritoneal cavities. The intimate relation of the liver to the transverse colon is illustrated by a case where a toothpick, 4 inches in length, was found in the substance of the liver. It had worked its way there, from the colon, along an abscess cavity that connected the two viscera. The relation of the liver to the heart may be illustrated by a case still more

remarkable. In this instance a loose piece of liver, weighing 1 drachm, was found in the pulmonary artery. The patient had been crushed between two waggons, the liver was ruptured, and the diaphragm torn. A piece of the liver had been squeezed along the vena cava into the right auricle, whence it had passed into the right ventricle, and so into the pulmonary artery. The heart itself was quite uninjured. Portions of the liver may protrude through abdominal wounds, and are usually easy to reduce. In one instance of such protrusion the surgeon did not find the reduction easy, so he placed a ligature round the projecting part of the viscus, and then cut this obstinate portion of the liver off. The patient recovered. Considerable portions of the liver have been removed with success. It is remarkable from what grave injuries of the liver recovery is possible. Thus, Dr. Gann (*Lancet*, June, 1894) reports the case of a man of 28, who had a harpoon driven through the whole thickness of the right lobe of the liver, so that it projected at the posterior border. The blade was 7 inches long, and had two barbs. It was removed by operation twenty-eight hours after the accident, and the patient made a good recovery.

From a reference to the relations of the liver, it will be readily understood that an *hepatic abscess* may open into the pleura, and in some cases, indeed, the pus from the liver has been discharged from the bronchi. Thus, it has been possible for a patient to cough up some portion of his liver, although, of course, in a very disintegrated and minute form. Hepatic abscess may burst in one or other of the following directions, placed in order of their frequency: (1) Into the right lung; (2) into the bowel; (3) upon the surface of the body. Such abscesses have, in rare cases, opened into the stomach. The liver is very frequently the seat of the secondary abscess of pyæmia, and, according to Mr. Bryant's statistics, abscesses in this viscus are more common after injuries to the head than after injuries elsewhere. They are rare in pyæmia following affections of the urinary organs, and are equally rare in the pyæmia

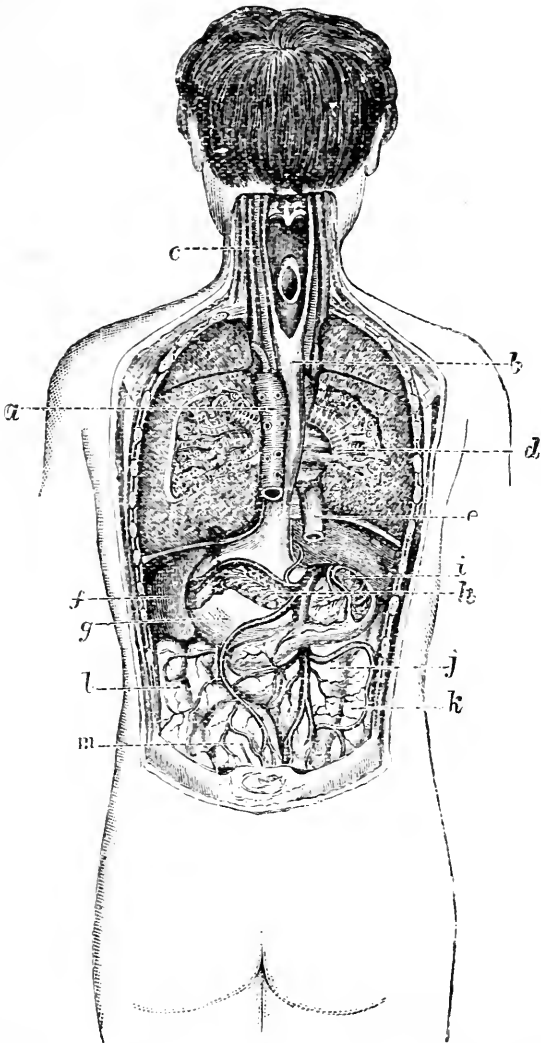


Fig. 47.—View of some of the Abdominal Viscera from behind (Rüdinger).

*a*, Thoracic aorta; *b*, œsophagus; *c*, common carotid artery and internal jugular vein; *d*, root of right lung; *e*, inferior vena cava; *f*, spleen; *g*, stomach, and to its right the liver; *h*, pancreas; *i*, descending part of duodenum (opened); *j*, superior mesenteric vein joined by splenic above; *k*, ascending colon; *l*, descending colon; *m*, superior hæmorrhoidal vein joining inferior mesenteric.

after burns. The liver is more often the seat of *hydatid cyst* than are all the viscera taken together. The cyst may discharge itself externally, or into the pleural or peritoneal cavities, or into any adjacent part of the intestine.

The **gall bladder** may be absent, as is the case with some animals, or reduced to a cicatrix from disease. Its mucous membrane has a peculiar reticulated, honey-comb appearance. It is often occupied by gall stones. These concretions are composed mostly of cholesterin, a normal constituent of bile, and vary in size from a hemp seed to a hen's egg. The escape of gall stones is rendered more difficult by the presence of a spiral fold of mucous membrane in the neck and duct of the gall bladder. The gall bladder, at its neck, forms an acute angle with the cystic duct, the spiral fold being necessary to keep the passage open. In the erect position the long axis of the gall bladder is directed upwards and backwards, and the cystic duct downwards and forwards (Fig. 46). The cystic duct lies in the gastro-hepatic omentum, where it joins the hepatic to form the common bile duct. It is accompanied by the cystic artery.

A gall stone may be arrested, and require removal, from any part of the cystic or common bile ducts. The common bile duct is 3 inches long, and its lumen  $\frac{1}{5}$ th of an inch wide, but by the passage of the gall stones it may become three times its normal diameter. The upper half of the common bile duct lies in the gastro-hepatic omentum, in front of the foramen of Winslow, with the portal vein behind it and to the right (Fig. 46). The hepatic artery lies close to it on the left, and its branch, the superior pancreatico-duodenal, crosses the common bile duct as it passes to its second or deeper stage. A stone arrested in the lower half of the duct is difficult of access. The duct lies buried between the head of the pancreas behind and the duodenum in front and to the outer side. It may be necessary in such a case to open the duodenum and extract the stone through its posterior and inner wall. Two lymphatic glands lie in the gastro-hepatic omentum by the side of the bile duct, and have been mistaken for gall stones when calcified.



The gall bladder receives its nerve supply from the eighth and ninth segments of the cord (Head) through the great splanchnic and cœliac plexus.

The gall bladder and the bile duct have been ruptured alone without rupture of the liver. The injury is rapidly fatal, owing to the escape of bile into the peritoneal cavity. Large gall stones are passed direct into the bowel through a fistulous tract that has been established between the gall bladder and the intestine. Gall stones have suppurated out through the anterior belly wall, and have been removed from abscesses in the parietes. Thus Dr. Burney Yeo reports a case where more than one hundred gall stones were discharged through a spontaneous fistula in the hypogastric region, 5 inches below the umbilicus. In cases where the bile duct is occluded by gall stones, or by other causes, the gall bladder may become enormously distended, and may form a tumour extending some way beyond the umbilicus. So large a tumour has been formed that the mass has been mistaken for an ovarian cyst. The gall bladder as it enlarges tends to follow a line extending from the tip of the right tenth cartilage across the median line of the abdomen below the umbilicus. For the relief of this condition, *cholecystotomy*, or incision into the gall bladder, has been performed. In this operation the incision or puncture is made over the most prominent part of the tumour. Impacted gall stones have been removed entire from the bile duct through an incision so made, or the stone has been crushed *in situ* and extracted in fragments.

In *cholecystectomy* the whole of the gall bladder is excised and the cystic duct closed. The bile finds its way into the intestine direct through the common duct.

In *cholecystenterostomy* a fistula is established between the gall bladder and the intestine. The operation is carried out in cases in which there is an insuperable obstruction in the common duct. The gall bladder thus takes the place of the common duct.

The **spleen**.—The spleen is deeply situated in the left hypochondriac region, and in the normal condition

cannot be palpated, being quite covered in front by the cardiac end of the stomach. It most closely approaches the surface in the parts covered by the tenth and eleventh ribs. Above this it is entirely overlapped by the edge of the lung. It is in all parts separated from the parietes by the diaphragm. "It lies very obliquely, its long axis coinciding almost exactly with the line of the tenth rib. Its highest and lowest points are on a level,

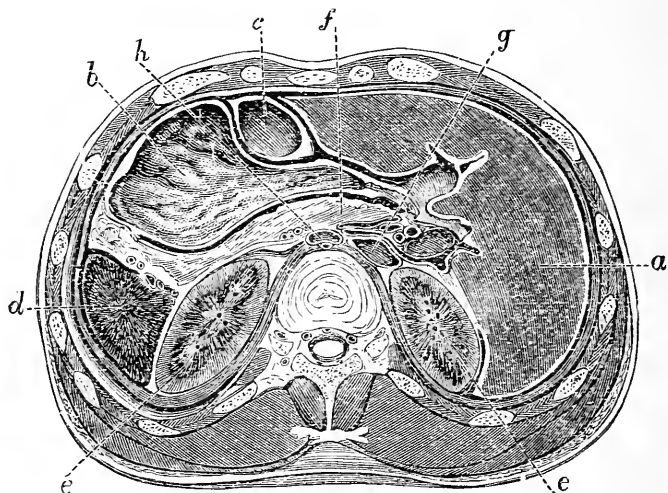


Fig. 48.—Horizontal Section through Upper part of Abdomen.  
(Rüdinger.)

*a*, Liver; *b*, stomach; *c*, transverse colon; *d*, spleen; *e*, kidneys; *f*, pancreas; *g*, inferior vena cava; *h*, aorta with thoracic duct behind it.

respectively, with the ninth dorsal and first lumbar spines; its inner end is distant about  $1\frac{1}{2}$  inches from the median plane of the body, and its outer end about reaches the mid-axillary line" (Quain) (Figs. 41 and 47). It possesses three surfaces, gastric, renal, and phrenic, well shown in Fig. 48.

A dislocated or floating condition of the spleen is rare. Its renal surface is fixed firmly to the upper half of the left kidney; its gastric surface is kept in apposition to the stomach by the gastro-splenic omentum;

its upper pole is attached near the cardiac orifice of the diaphragm by a suspensory fold of peritoneum, while its lower rests on the costo-colic peritoneal fold, and has the tail of the pancreas and colon in contact with it. The tension of the abdominal walls exerts a general pressure on it through the other abdominal organs. When the spleen enlarges, as in ague, its crenated anterior border may be felt beneath the tenth costal cartilage. The movable or floating spleen is met with only in adults. The organ may be so displaced as to reach the iliac fossa.

*Injuries.*—Although extremely friable in structure, the normal spleen is not very frequently ruptured. Its connections, indeed, tend to minimise the effects of concussions and contusions. It is swung up by the peritoneum, rests upon the elastic costo-colic fold, and is protected by the stomach and lungs to a considerable extent. When the spleen, however, is enlarged, it is very readily ruptured, and often by quite insignificant violence. Thus, several cases have been recorded of rupture of an enlarged spleen by muscular violence. For instance, a woman ruptured her spleen in an attempt to save herself from falling, and another in springing aside to avoid a blow. The patients in each instance were natives of India, and the latter case gave rise to a charge of homicide. The spleen being extremely vascular, it follows that ruptures of the viscus are usually, but not necessarily, fatal from hæmorrhage. It is well to note, in connection with this matter, that the spleen contains most blood during digestion. A case is reported, however, of a boy who met with an accident just after dinner, and who managed to walk some distance, although his spleen, as the autopsy revealed, was separated into three portions. He lived some days. In severe fractures of the ninth, tenth, and eleventh ribs the spleen may be damaged and lacerated.

The capsule of the spleen contains muscular tissue, and must possess some contractile power. This fact may serve to explain cases of recovery from limited

wounds of the organ, such as small gunshot wounds. In such lesions the capsule may contract and greatly narrow the hole in the viscus, while the track of the bullet or knife may become filled with blood-clot, and the bleeding thus be stayed.

The spleen may be greatly *enlarged* in certain diseased conditions. The hypertrophied spleen may attain such dimensions as to fill nearly the whole abdomen, and in one case a cystic tumour so completely occupied both iliac fossæ that it was mistaken for an ovarian cyst, and the operation for ovariectomy was commenced. It is said that the enlarged spleen, in its earlier stages, encroaches upon the thoracic cavity relatively more in the child than in the adult. This is explained by the statement that the costo-colic fold, upon which the spleen rests, is much more resisting in the young than it is in those of more mature age.

**Extirpation of the spleen** has been successful in cases of abdominal wounds with protrusion of the viscus. It has also been performed with fair results in many cases of hypertrophied spleen, and of wandering spleen. The operation is not justifiable in cases of leukæmic enlargement of the organ, it having proved invariably fatal in such instances. In cases of wounds with protrusion, the spleen is, of course, removed through the wound. In other instances the incision is usually made in the middle line, the most convenient being one so arranged that the umbilicus corresponds to the centre of the cut. Some surgeons prefer an incision along the outer edge of the left rectus muscle. The viscus is then slowly pressed out of the wound. The great difficulty is with the gastro-splenic omentum, which has to be divided and its vessels secured. In drawing out the spleen there is much risk of tearing the splenic vessels, especially the vein. Special care has to be taken to avoid damage to the pancreas. The splenic artery, with its large accompanying vein, lies in the lieno-renal ligament, in contact with the tail of the spleen below.

The **pancreas** lies behind the stomach, in front

of the first and second lumbar vertebræ. It crosses the middle line on a level with a point about 3 inches above the umbilicus. In emaciated subjects, and when the stomach and colon are empty, it may sometimes be felt on deep pressure. It is in relation with many most important structures, but presents little of surgical interest (Figs. 47 and 48). So closely is it mixed up with the solar plexus that this structure is necessarily involved in any operative procedures on the head and neck. It has, I believe, never been ruptured alone, and it could scarcely be wounded without the wound implicating other and more important viscera. It has been found herniated in some very rare cases of diaphragmatic hernia, but never alone. Its duct ends in the ampullated extremity of the common bile duct, and through it septic infections of the duodenum may spread to the pancreas. A secondary duct may be present. It opens an inch nearer the pylorus than the main duct.

It may become invaginated into the intestine, and portions of the gland have sloughed off and been passed in the stools.

The common bile duct in its second stage lies between the head of the pancreas and the duodenum. It thus happens that in carcinoma of this part of the gland the duct may become entirely occluded and jaundice result. Or the duodenum and even the colon may be more or less obstructed by pressure, or the neighbouring vessels be closed. Cancer of the pylorus may spread to the head of the pancreas by direct extension. The lymphatics of the two parts also freely communicate.

The pancreas lies behind the lesser sac of the peritoneum, its anterior surface being covered by the posterior wall of the sac. It lies in front of the aorta, in the fork between the cœliac axis above and the superior mesenteric artery below. The portal vein passes upwards behind the neck of the gland.

Certain remarkable *cysts* are sometimes developed in the pancreas. They may attain great size and nearly fill the abdomen.

## THE KIDNEY.

*In front.**Right.*

Under surface of liver.  
 Second part of duodenum.  
 Commencement of transverse  
 colon. Ascending colon.

*Left.*

Fundus of stomach.  
 Descending colon.  
 Pancreas.

*Externally.*  
 Liver.

**Kidney.**

*Externally.*  
 (On left side) Spleen.

*Behind.*

Lower part of arch of diaphragm.  
 Quadratus lumborum. Psoas.

Last rib and transverse processes of upper two lumbar vertebræ.

The kidneys are deeply placed, and cannot be felt or distinctly identified when normal. They are most accessible to pressure at the outer edge of the erector spinæ, just below the last rib (Fig. 50). The dulness of the right kidney merges above in that of the liver, while on the left side it is impossible to distinguish between the dulness of the kidney and spleen. The right kidney lies nearly  $\frac{3}{4}$  of an inch lower down than does the left; but even the lower end of the right gland only just reaches to the level of the umbilicus. The upper end of the left kidney is on a level with the eleventh dorsal spine behind, the right being a little lower (Figs. 41 and 49). The inferior extremity of the left gland is about  $1\frac{1}{2}$  inches from the iliac crest, that of the right about  $1\frac{1}{4}$  inches. The kidney lies a little lower in the female than in the male. In many instances in the female its lower end reaches the iliac crest, and may even go below it. Such positions are much less common in the male. A vertical line carried upwards from the middle of Poupart's ligament has one-third of the kidney to its outer side and two-thirds to its inner side. The hilum lies about 2 inches from the middle line, and is opposite to the gap between the first and second lumbar spines. The kidney has been reached by the finger when the entire

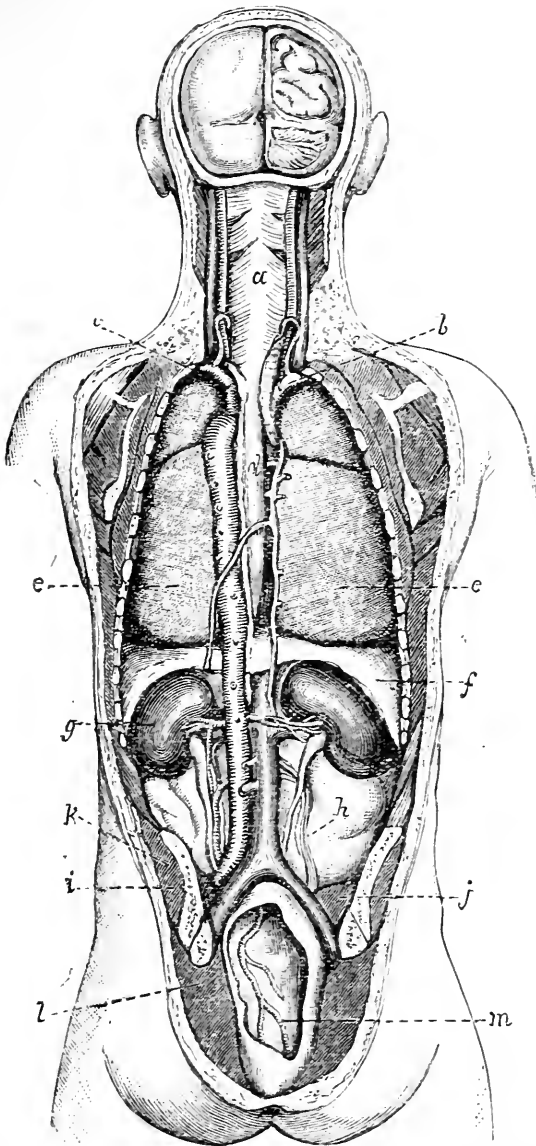


Fig. 49.—View of the Kidneys, etc., from behind (Rüdinger).

*a* Pharynx; *b*, innominate artery; *c*, subclavian artery; *d*, œsophagus, with the aorta and thoracic duct on one side and the azygos vein on the other; *e*, lungs; *f*, diaphragm; *g*, kidney; *h*, on peritoneum, points to spermatic vessels crossed by ureter; *i*, os innominatum above sacro-iliac-synchondrosis; *j*, psoas; *k*, gluteus medius; *l*, gluteus maximus; *m*, rectum and sup. hæmorrhoidal artery.

hand has been introduced into the rectum, but the procedure has failed to prove of much use in diagnosis. A skiagram of the kidney is obscured by the shadows of the last rib and transverse processes of the two upper lumbar vertebræ.

The anterior surface is but slightly covered by peritoneum, being only in contact with that membrane in such parts as are not in relation with the cellular tissue at the back of the colon and at the back of the duodenum or pancreas. The external border is more closely in connection with the peritoneum, while the posterior surface is quite devoid of that membrane (Figs. 47 and 49). Crossing the posterior surface of the kidney obliquely from above downwards and outwards are branches of the last dorsal nerve and of the first lumbar artery, together with the ilio-hypogastric and ilio-inguinal nerves. *Rupture* of the kidney is more often recovered from than is a like lesion of any other of the more commonly injured abdominal viscera. This depends upon its extensive non-peritoneal surface, whereby the extravasation of blood and urine that follows the accident is very often entirely extraperitoneal. The gland may be readily wounded from behind or from the loin, without the peritoneum being injured. When the spine is much bent forwards, the kidney lies in the angle of the bend, at a part where the flexion of the column is the most acute. In extreme flexion, therefore, of the spine, it may be squeezed between the ilium and the lower ribs. Thus, hæmaturia is not uncommon after injuries to the back associated with extreme bending of the spine forwards, as when a heavy weight falls upon the bowed shoulders.

The kidney is embedded in a large quantity of loose fatty tissue, and suppuration extending in this tissue constitutes a *perinephritic abscess*. Such an abscess may be due either to disease of the kidney itself, to affections of the adjacent parts (spine, colon, etc.), or to injuries. The pus is at first in front of the quadratus lumborum, and then usually makes its way through that muscle or through the lumbar fascia. It then



presents itself at the outer edge of the erector spinae, having passed between the adjacent borders of the external oblique and latissimus dorsi muscles. It may, however, spread into the iliac fossa, or extend into the pelvis along the loose connective tissue behind the descending colon and rectum, or open into the colon or bladder, or even into the lung. Most rarely of all does it perforate the peritoneum. *Renal abscess* usually opens upon the non-peritoneal surface of the gland. It may open into the adjacent colon. In one case a renal abscess, due to stone, made its way from the right kidney into the pyloric end of the stomach, so that a communication was established between those two organs. The perirenal fat is of much surgical importance, as its laxity permits of a ready enucleation of the organ. It is more abundant behind than in front. When this tissue has been destroyed or modified by inflammation, the kidney becomes fixed, and its removal a matter of great difficulty. This is illustrated by the removal of a large tuberculous kidney which has been long diseased.

**Movable kidney.**—The kidney is fixed in position mainly by the tension of the peritoneum that passes over it, and that is connected with the fatty tissue supporting the gland. If this fatty tissue be absorbed for any reason, the kidney can be readily moved about and displaced in the subserous tissue; the peritoneum at the same time becomes lax, and the gland by its own weight can drag still further upon it. Moreover, a laxity of the peritoneum from any cause may loosen the firm connections of the kidney, and allow the organ to become more movable. Thus, the movable kidney is often met with in badly nourished subjects, and especially in those who have become emaciated by disease. It is far more common in women than in men. In the former sex the influence of pregnancy appears to have especial effect, acting, probably, by dragging upon the peritoneum, and by loosening its connections, as well as by inducing, after delivery, a general laxity of the abdominal walls. The right

kidney is far more often movable than is the left, owing probably to the displacing influence of the liver. The abdominal walls undoubtedly play a considerable part in maintaining the kidneys in position by keeping the other abdominal viscera steadily compressed against them. The upper third of the kidney rests on the diaphragm, and with every breath it rises and falls a little, a movement which must be considered in any operation to fix the kidney. I have recorded (in conjunction with Dr. MacLagan) three cases in which a movable kidney pressed against the neck of the gall bladder and obstructed the flow of bile. The movable kidney can, of course, only be moved within a segment of a circle whose radius corresponds to the length of the renal vessels, and yet its displacement may be considerable.

The dragging pains which are felt with a movable kidney are due to a stretching of the renal plexus, which is connected with the solar plexus and enters the kidney with the arteries. The kidney receives its nerve supply from the tenth, eleventh, twelfth dorsal, and first lumbar segments of the spinal cord through the small and lesser splanchnics (Head). Pain is referred along the sensory nerves derived from these segments.

**Abnormalities of the kidney.**—One, or less frequently both, kidneys may be misplaced. The left is more often out of place than the right, and may be found over the sacro-iliac synchondrosis, or the promontory of the sacrum, or be discovered in the iliac fossa or pelvis. The misplaced kidney is often misshaped. The kidney may exhibit a more or less extreme degree of lobulation, a condition present in the newly born. The ureter may be double.

The two kidneys may be fused. “The lowest degree of fusion is seen in the horse-shoe kidney. The two kidneys are united at their inferior portions by a flat, riband-like, or rounded bridge of tissue, which crosses the vertebral column. In the higher degrees the two lateral portions approach one another more and more

until they reach the highest degree, in which a single disc-like kidney, lying in the median line, and provided with a double or single calyx, represents complete fusion" (Rokitansky). When the two kidneys are united by a web of connective tissue, the condition is no bar to

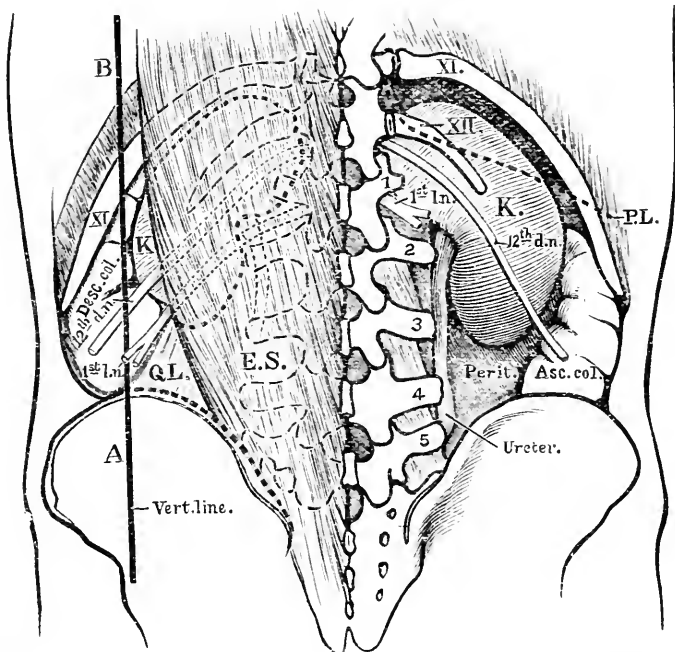


Fig. 50.—Showing the Relationships of the Kidney and Colon in the Lumbar Region from behind. (Adapted from Merkel.)

P.L., Lower line of pleura; XI, eleventh rib; XII, twelfth rib; 12th d.n., twelfth dorsal nerve; 1st l.n., ilio-inguinal and ilio-hypogastric nerves; A.V., vertical line representing position of descending colon (desc. c.); Q.L., quadratus lumborum; E.S., erector spinae; peritoneum (perit.) is shown reflected from the front of the kidney to the colon on the right side.

operation. There may be an entire absence of one kidney. The single kidney may be lateral or median in position. Henry Morris gives the following estimate of the frequency of these abnormal conditions. Congenital absence or extreme atrophy of one kidney may be expected in about one in 4,000 cases, the horse-shoe

kidney in one in 1,600, and the single fused kidney in one in 8,000 cases.

**Operations on the kidney.**—(1) *Nephrotomy*. Incision into the kidney for exploration, or the evacuation of pus. (2) *Nephrolithotomy*. Incision into the gland for the removal of a calculus. (3) *Nephrectomy*. Removal of the entire organ. (4) *Nephroraphy*. The operation of securing a movable kidney in its normal position. In the first, second, and fourth operations the kidney is reached through the loin by an oblique incision, such as is used in colotomy (page 345), the cut, however, being carried a little farther backwards. In nephrectomy a like incision may be used. The cut is carried backwards about 1 inch over the erector spinæ, and a part of the quadratus lumborum will probably have to be divided. The perinephritic tissue is opened up, and the gland enucleated from the capsule of fat in which it lies. In some instances the last rib has been resected to obtain more space for the operation. The pleura reaches the neck of the twelfth rib and occasionally it descends as far as the transverse process of the first lumbar vertebra (Fig. 50). In one case the twelfth rib was rudimentary, and the eleventh rib was removed under the impression that it was the twelfth. The pleura was opened and death ensued.

When the kidney is free from its fatty capsule, the vessels at the hilum are secured separately by ligatures. The numerous nerves to the kidney are no doubt included with the vessels. They constitute a surgical pedicle of the kidney. At the hilum the vein lies in front, the artery and its branches next, and the ureter behind and towards the lower part. The artery is about the size of the brachial, and usually divides into four, five, or six branches before it reaches the kidney. This fact must be borne in mind if the structures at the hilum are separately secured. Some of these branches constantly enter the hilum behind the ureter and are liable to injury in exploration of the pelvis of the kidney. The vein is also represented at the hilum by three or four branches. The renal artery may be represented

by two, three, four, or even five vessels. Some may enter the upper end of the kidney or its anterior surface. In removing large renal tumours an abdominal incision is advised, the cut being made either along the corresponding semi-lunar line, and on a level with the diseased mass, or in the *linea alba*. The abdominal operation is the more usual one, and has the advantages of greater ease and rapidity in performance and gives an opportunity of examining the condition of both kidneys. In chronically inflamed conditions of the kidney—as, for example, in long standing tuberculous disease—the kidney becomes adherent, and on the right side is apt to become closely bound down to the *vena cava*. Much care is needed in clearing the great vein when so adherent. In removing a very adherent kidney the diaphragm has been torn.

The **ureters** are strong tubes about 15 inches long, with thick muscular walls, and are placed entirely behind the peritoneum. The average width is that of a goose-quill. The ureter rests from above downwards upon (1) the *psoas* muscle and the *genito-crural* nerve; (2) the common iliac vessels on the left side, and the external iliac vessels on the right; (3) after passing downwards on the internal iliac artery it then enters the posterior false ligament of the bladder, and so reaches the bladder wall. In the female it passes through the base of the broad ligament, where the uterine artery loops over it  $\frac{3}{4}$  of an inch from the necks of the uterus. It rests on the roof of the upper part of the vagina before entering the bladder, and a calculus arrested in that stage may be distinctly felt. The narrowest part of the tube is the portion within the bladder walls, and when renal calculi pass along the ureter they are often arrested at this point. The ureters permit of great distension, and in certain cases of gradual dilatation they have attained a width equal to that of the thumb and even of the small intestine. Several cases are recorded of rupture of the ureter from external violence. When such an accident occurs a large urinary collection usually forms behind the peritoneum, which, leading

to suppuration, will produce a fluctuating tumour beneath the parietes.

The ureter expands in the hilum of the kidney into a funnel-shaped cavity—the pelvis. This in turn divides into the calyces. In the pelvis or calyces calculi are frequently lodged. The calyces are too narrow to admit an exploring finger. The ureter has been successfully resected and sutured. It is supplied by nerves from the renal plexus and by vessels from the renal, inferior vesical and sub-peritoneal plexus. Impacted calculi have been removed from the ureter.

**The nerve supply of the abdominal viscera.**

—Some account has already been given of these nerves and the spinal segments from which they are derived (page 297). The abdominal viscera are mainly supplied by the sympathetic system through a series of remarkable plexuses. The most important of these is the solar, from which is more or less directly derived the nerve supply of the stomach, liver, spleen, kidneys, suprarenal capsules, pancreas, and such parts of the intestine as are in connection with the superior mesenteric artery. The solar plexus and its appendages receive the splanchnic nerves and some branches from the vagus, while communications from the phrenic go to the hepatic and suprarenal plexuses. Through these nerves the calibre of the blood-vessels and the amount of blood in the abdomen are regulated. They contain not only sensory fibres for the abdominal viscera but constrictor and dilator fibres for the bowel. It may be well understood that an impression brought to bear upon extensive nerve net-works with such wide central connections and with such important relations would produce considerable effects. These effects we see in the profound collapse, vomiting, and other grave symptoms that attend severe injuries to the viscera, and especially to those that are the most directly associated with these large plexuses. The descending colon and sigmoid flexure are supplied by the inferior mesenteric plexus, a cord that has but an indirect con-

nection with the solar plexus; and this fact may serve to account for the less serious symptoms often seen in strangulation of the colon when compared with a like lesion of the small gut. The upper part of the colon, although supplied by the superior mesenteric plexus, is only supplied by that part of it that is most remote from the great centres, and it is a conspicuous fact that the nearer the lesion is to the stomach, the graver, other things being equal, are the nervous phenomena produced. It would appear that some lesion of these nerve plexuses is sometimes active in producing a remarkable pigmentation of the skin. This is seen in Addison's disease, a disease marked by a general bronzing of the surface, and usually associated with some disintegration of the suprarenal capsules. The very direct relation of these bodies to the solar plexus is well known. In pregnancy also, in abdominal tuberculosis, in cancer of the stomach, and in liver diseases, a pigmentation of the face is sometimes seen, that may in such instances be probably ascribed to a disturbance of the great abdominal nerve centres.

In some diseases of the liver and stomach "sympathetic" pains are complained of between the shoulders or about the inferior angles of the scapulæ. They commonly appear some distance below the angle of the scapula. The nerves for the stomach are derived principally from the seventh and eighth and those for the liver from the eighth and ninth spinal segments. The skin areas of these segments may become tender when the organs are diseased and to some point in these areas pain is referred (Fig. 39). The shoulder tip pain which often accompanies liver disease is situated in the area supplied by the fourth cervical segment, but as yet no satisfactory anatomical explanation has been offered of this symptom.

There would seem to be but little connection between a disease in the sigmoid flexure and a pain in the knee, yet in cases of cancer in the flexure, and in instances where it has been distended with fæces, such a pain has been complained of. The pain is conveyed along

the obturator nerve, which lies beneath the sigmoid flexure, and could be readily pressed upon by the gut when diseased.

The **blood-vessels of the abdomen.**—Some of the visceral branches of the abdominal aorta are of large size, and would bleed very copiously if wounded. Thus, the coeliac axis, and the superior mesenteric artery, are as large as the common carotid; the splenic, hepatic, and renal vessels are about the size of the brachial; while the largest part of the inferior mesenteric trunk has dimensions equal to those of the ulnar artery. Aneurisms of the aorta are especially apt to occur at the coeliac axis, that being a point where a number of large branches are abruptly given off, and where the course of the circulation undergoes in consequence a sudden deviation. Although two, or in some places three, anastomotic arches occur between the branches of the superior mesenteric artery before they form a final net-work in the bowel, yet embolism of a comparatively small branch may lead to gangrene of the gut (Lockwood).

When it is remembered that the lumbar glands lie about the vena cava and iliac veins, it will be understood that great enlargement of those bodies may cause œdema from pressure.

A number of minute but most important anastomoses exist between some of the visceral branches of the abdominal aorta and certain of the vessels supplied to the abdominal parietes. These anastomoses are situated behind the peritoneum, and mostly concern such viscera as have a fair surface uncovered by that membrane. The *visceral* branches that join the anastomoses are derived from the hepatic, renal, and supra-renal arteries, and from the vessels supplying the lower part of the duodenum, the pancreas, the cæcum, and the ascending and descending segments of the colon. The *parietal* vessels joining with the above are derived from the phrenic, lumbar, ilio-lumbar, lower intercostal, epigastric, and circumflex iliac trunks. In a case detailed by Professor Chiene (*Journ. Anat. and Phys.*,



vol. iii.) the cœliac axis and mesenteric vessels were plugged, but blood in sufficient amount to supply the viscera had reached the branches of these arteries through their parietal communications. Rutherford Morrison found that anastomotic veins, quite as big as the radial, were formed between the omental and parietal veins, when he brought about an adhesion between the omentum and abdominal wall in a case of dropsy due to portal obstruction. The anastomosis gives an anatomical demonstration of the value of local blood-lettings and of counter-irritants in inflammatory affections of certain of the viscera, and also a scientific basis to the ancient practice of poulticing the loin and the iliac region in nephritis and in inflammation about the cœcum.

Cases have been recorded of communications between the external iliac vein and the portal vein. These have generally been effected by the deep epigastric vein joining with a pervious umbilical vein in the vicinity of the navel.

**Thoracic duct.**—Some six cases of wound of this duct have been reported, the injury being usually a stab. In each case lymph and chyle in large quantities escaped from the wound. In one instance the duct is said to have been injured by a bullet that entered just below the left scapula, since from the wound in the integuments large quantities of lymph escaped freely. The duct has been found to have been obliterated, and that, too, without producing any marked symptoms during life. It has been cut and ligatured during removal of glands from the supra-clavicular triangle, with no bad result. Mr. Leaf has shown that the thoracic duct communicates freely with the azygos veins in the posterior mediastinum and with the lymphatic vessels of the right side of the thorax and neck.

## CHAPTER XVIII.

## THE PELVIS AND PERINEUM.

**THE mechanism of the pelvis.**— Besides forming a cavity for certain viscera, a support for some abdominal organs, and a point for the attachment of the lower limb and of many muscles, the pelvis serves to transmit the weight of the body both in the standing and sitting postures. The transmission is effected through two arches, one available for the erect position, the other for the posture when sitting. The sacrum which supports the spinal column is the centre or keystone of both these arches. When standing, the arch is represented by the sacrum, the sacro-iliac synchondroses, the acetabula, and the masses of bone extending between the two last-named points. If all other parts of the pelvis were to be cut away but these, the portions left would still be able to support the weight of the body, and would represent in its simplicity the arch through which that weight is transmitted. When sitting the arch is represented by the sacrum, the sacro-iliac synchondroses, the tubera ischii, and the strong masses of bone that extend between the two last-named parts. Morris terms these two arches the femoro-sacral and the ischio-sacral. On examining the innominate bone it will be seen that its thickest and strongest parts are such as are situate in the line of these. "When very considerable strength is requisite in an arch, it is continued into a ring so as to form a counter-arch, or what is called a *tie* is made to connect together the ends of the arch, and thus to prevent them from starting outwards. By these means a portion of the superincumbent weight is conveyed to the centre of the counter-arch, and borne in what is called the sine of the arch. The body and horizontal rami of the pubes form the tie or counter-arch of the femoro-sacral, and the united rami of the pubes and ischium the tie of the ischio-sacral arch. Thus the ties of both arches are united in front at the

symphysis pubis, which, like the sacrum or keystone, is common to both arches. . . . This explains how it is that so much strain is made upon the symphysis when any increased weight has to be supported by the pelvis, as in pregnancy; why there is such powerlessness, with inability to stand or sit, in cases in which this joint is weakened or diseased; and why the anterior portion of the pelvis yields under the weight of the body, and becomes deformed in rickets and mollities ossium.\* The pelvic deformity in rickets, it may be here observed, varies greatly according to the age at which the disease sets in, and the usual attitude of the child when it becomes affected. The deformity sometimes produced in very young infants has been ascribed to muscular contraction (ilio-psoas, erector spinæ, gluteus medius, etc.). In the rickety pelvis, *par excellence*, the two acetabula approach one another, the anterior part of the pelvis yields, so that the symphysis is pushed forward, and the cavity becomes greatly narrowed in its antero-posterior diameter. In severe cases the anterior arch may practically collapse, and the horizontal rami of the pubes be for some little way parallel to one another.

In the erect attitude the pelvis is so inclined that the plane of the brim of the true pelvis forms with the horizon an angle of from  $60^{\circ}$  to  $65^{\circ}$ ; the base of the sacrum is about  $3\frac{3}{4}$  inches above the upper border of the symphysis, while the tip of the coccyx is a little higher than its lower border. The centre of gravity of the whole body (adult) is at a spot just above the sacro-lumbar angle, and exactly over the mid-point of a line drawn between the heads of the femora. The obliquity of the pelvis materially assists in breaking shocks, and in distributing forces applied from below throughout the pelvic ring. In modifying the effect of shocks, also, it is aided by the arches of the pelvis and by the buffer-like discs of cartilage at the symphysis and sacro-iliac joints.

**Fractures of the pelvis.**—From what has

\* Henry Morris on "The Joints," p. 116, where a most valuable account of the mechanism of the pelvis will be found.

been already said, it may be surmised that the weakest parts of the pelvis are at the symphysis and the sacro-iliac joints. The bones of these parts, however, are so very firmly knit together by powerful ligaments that it is very rare for these articulations to give way, fracture of the adjacent bones being more common. The commonest fracture of the pelvis is in the weak counter arch, and involves the rami of both the pubes and the ischium. The fracture is often associated with some tearing of ligaments about the sacro-iliac synchondrosis, and is met with in accidents due to the most varied forms of violence. This last remarkable circumstance is thus explained by Tillaux. If the pelvis be compressed in (a) an antero-posterior direction, the main brunt of the force comes upon the weak counter arch, which fractures from *direct* violence. The force, continuing, tends to push asunder the two iliac bones, and so cause rupture of the *anterior* ligaments at the sacro-iliac joint. If the force be applied (b) transversely, the two acetabula tend to be pressed towards one another, the counter arch becomes more bent, and ultimately gives way by *indirect* violence. The violence, continuing, forces the two ilia towards one another, the strain then falls upon the sacro-iliac synchondrosis, and the *posterior* ligaments of that joint are apt to yield, or portions of the bone adjacent to the joint are torn away. In cases of falls, when the patient alights upon the feet or ischial tuberosities, it can be understood how in many instances the main arches will escape injury owing to their great strength, while the counter arch becomes fractured. Any part of the pelvis, including the sacrum, may be broken by well-localised direct violence. More or less of the iliac crest, the anterior superior and posterior superior spines, have been knocked off. The first-named part may be separated as an epiphysis. It joins the bone at about the twenty-fourth year. In one case the anterior inferior spinous process was torn off by the rectus muscle during the act of running a race. The os innominatum has been broken into its three

anatomical portions. This accident cannot take place after about the seventeenth year, since by that time the Y-shaped cartilage is usually fully ossified, and the three elementary bones are fully united. Before such consolidation occurs abscess in the hip joint not very unfrequently makes its way through the cartilage into the pelvis. The acetabulum has been fractured, and the head of the femur driven through its thinnest part into the pelvis. In fractures of the pubes and ischium the bladder has been torn by the sharp fragments. In one case a loose piece of bone that had been driven into the bladder became the nucleus for a stone. The urethra and vagina also have been lacerated, or seriously compressed by the displaced bones. In fractures of the sacrum the rectum has been torn, or has been so compressed by the lower fragment (which is almost always carried forwards) as to be nearly closed.

**Special parts of the pelvis. Symphysis.**—Separation of the bones at the symphysis without fracture has occurred from severe violence. Malgaigne reports three cases where the separation was brought about by muscular violence only, by extreme action of the adductor muscles of the two sides. The Sigaultean operation consisted in dividing the symphysis pubis in cases of contracted pelvis, with the idea of obtaining more room during labour, and of so avoiding Cæsarian section. The union consists of fibro-cartilage and transverse peripheral fibrous bands. It varies in depth from  $1\frac{1}{2}$  to  $1\frac{3}{4}$  inches, and may be divided subcutaneously when the bones gape quite  $\frac{1}{2}$  an inch. It has been shown, however, that to gain  $\frac{1}{2}$  an inch in the antero-posterior diameter the bones must be separated to the extent of 2 inches. Such a separation involves laceration of the sacro-iliac ligaments, and more or less damage to the attachments of the pelvic viscera.

The **sacro-iliac synchondrosis** may be the seat of disease. Normally, there is no movement at this joint, but when the ligaments are softened by disease, and effusion occurs between the opposed bones, some

movement may be demonstrated. As this joint lies in the line of the great arches of the pelvis, it follows that when inflamed, much pain is felt in the part, both when the patient is standing and when sitting. When abscess forms it tends to come forwards, owing to the anterior ligaments being less dense than the posterior. Having reached the pelvic aspect of the joint, the pus may occupy the iliac fossa, or gain the ilio-psoas sheath. Or it may follow the lumbo-sacral cord and great sciatic nerve and point in the thigh behind the great trochanter, or it may be guided by the obturator vessels to the inner side of the thyroid foramen, and ultimately appear at the inner side of the thigh. The abscess may, however, proceed backwards, and point over the posterior aspect of the joint.

The nerve relations of this joint are important. It is supplied by the superior gluteal, by the lumbo-sacral cord and the first sacral nerve, and by the first and second posterior sacral nerves (Morris). The lumbo-sacral cord and the obturator nerve pass over the front of the joint, the former being very closely connected with the articulation. It will be understood from these relations that in the sacro-iliac disease pain is felt over the sacral region (upper sacral nerves) and in the buttock (gluteal nerve). Much pain is also often complained of in the hip or knee-joint, and along the inner part of the thigh (obturator nerve). In one or two reported cases there has been severe pain in the calf and back of the thigh, with painful twitchings in the muscles of those parts (lumbo-sacral cord and connection with great sciatic nerve). *Dislocation of the sacrum* at this joint is prevented by the remarkable double-wedge-shaped outline of the bone, and by the very dense ligaments that bind it in its place. The thick end of the main wedge of the sacrum is in front, and therefore the strongest ligaments are to be found behind the bone, as if to prevent it from slipping forwards, or from becoming rotated forwards on its transverse axis.

*Trendelenburg's operation.*—In order to bring the two pubic bones and the deficient soft parts together

in ectopia vesicæ, Trendelenburg divides the sacro-iliac synchondroses on either side. The knife is made to cut the posterior sacro-iliac ligaments, the interosseous and superior ligaments, and the interarticular cartilage. The operation, which has been very successful, is limited to children between the ages of two and five. The distances between the anterior superior iliac spines has—in a child aged two and a-half years—been lessened 2 inches by this operation.

**Spina bifida.**—This term refers to certain congenital malformations of the vertebral canal associated with the protrusion of some of its contents in the form of a fluid tumour. The malformation usually consists in an absence of the neural arches and spines of certain of the vertebræ, and the tumour therefore projects posteriorly. Spina bifida is most common in the lumbosacral region, the neural arches of the last lumbar and of all the sacral vertebræ being absent. The neural arches close first in the dorsal and last in the lumbosacral region. Next in frequency it is found limited to the sacral region. It is rare elsewhere. (1) The membranes may protrude alone (*spinal meningocele*). (2) The membranes may protrude together with the spinal cord and its nerves (*meningo-myelocele*). (3) The membranes may protrude with the cord, the central canal of which is dilated, so as to form a sac cavity (*syringo-myelocele*.) (See Fig. 80, p. 546.)

The meningo-myelocele is the most common form. The first-named variety is rare, the last-named very rare. When the cord occupies the sac it usually adheres to its posterior wall, the nerves running transversely across the sac to reach the intervertebral foramina. When compressed, the cerebro-spinal fluid is forced into the subarachnoid spaces at the base of the brain, which is forced upwards against the anterior fontanelle, where its impact may be felt. The tumour becomes enlarged and tense when the child cries. The distension of the cerebral and spinal veins forces the fluid in the direction of least resistance.

As might be expected, spina bifida is very commonly

associated with some evidence of injury to the nerves arising from the lower part of the spinal cord. In the majority of instances certain of these nerves would appear to have become atrophied through pressure. In some cases the nerve affection takes the form of club-foot of a severe grade. In other instances there is more or less complete paralysis of the lower limbs, bladder, and rectum.

“The anatomy of the spina bifida assumes a primary defect of development of the mesoblast, from which the structures closing in the vertebral furrow are developed. After the closure of the neural furrow it would appear that the processes of mesoblast, which subsequently insinuate themselves between the primitive spinal cord and its overlying epiblast, are formed in an insufficient degree to meet and combine” (Committee of the Clinical Society, London, 1885).

**Sacro-coccygeal tumours.**—The sacro-coccygeal region is very often the seat of congenital tumours, some of them of such a shape as to form “human tails”; and to this part of the pelvis has also been found attached a third lower limb leading to the condition known as “tripodism.”

Parasitic foetuses are also frequently found attached to this segment of the spine. In many of the instances of attached foetuses the two individuals have been joined together at this part of the column. Some of the sacro-coccygeal tumours contain epithelial cysts and fragments of skin, muscle, nerve, bone, cartilage, and mucous membrane. These strange masses spring from the anterior part of the coccyx, between it and the rectum. By some they are supposed to arise from Luschka's gland, by others (Sutton) from the structures known to embryologists as the post-anal gut and the neurenteric passage.

The **sacro-coccygeal joint** may be dislocated or diseased. In either affection great pain is kept up from the frequent movement of the part by the muscles attached to the coccyx (the gluteus maximus, coccygeus, levator ani, and sphincter). In the luxation the bone



may project into the rectum, and thus give trouble. The joint and the parts about it may be the seat of such severe neuralgia ("coccygodynia") as to require excision of the coccyx, or a free division of the structures that cover it behind. The joint and the fibrous tissue about it are supplied by the following nerves: the posterior divisions of the second, third, and fourth sacral, and the anterior and posterior divisions of the fifth sacral and coccygeal. In old age the coccyx becomes ossified to the sacrum.

The **thinnest parts of the os innominatum** are at the bottom of the acetabulum, and in the hollow of the wing of the ilium. In the latter situation the bone has been successfully trephined for iliac abscess.

The **floor of the pelvis** and the **pelvic fascia**.—The outlet of the bony pelvis is occupied in the recent state with the following structures from behind forwards: the pyriformis, the sacro-sciatic ligaments, the coccygeus, the levator ani, and the triangular ligament of the urethra. These form the floor of the pelvis. The three structures last named serve to separate the pelvic cavity from the perineum.

The walls and floor of the pelvis are lined by a fascia, the pelvic fascia, of which a brief general description may be given. This fascia is divided into two distinct parts, a parietal layer and a visceral layer. (1) The parietal layer begins at the brim of the true pelvis, to which it is attached. From this attachment it passes down along the pelvic wall, forming a lining for that part, covering in the obturator internus muscle, and becoming adherent below to the rami of the pubes and ischium, and to the tuber ischii. More posteriorly it gives a thin covering to the pyriformis muscle. (2) The visceral layer comes off from the parietal along a line running from the lower part of the symphysis pubis to the ischial spine. This line is known as the white line, and corresponds to the origin of the levator ani from the pelvic fascia.

Starting from this line the visceral layer passes down into the pelvis on the abdominal surface of the levator

ani, and attaches itself to all the pelvic viscera with which it comes in contact, forming fibrous expansions or "ligaments," that serve to hold the viscera in place. Were there no pelvic viscera, this layer of the fascia would be continued evenly across the pelvic floor from one side to the other, just as the subperitoneal fascia is continued over the under surface of the diaphragm. Having given "reflections" to the pelvic organs the visceral layer passes on, and, covering the opposite levator muscle, ends at the opposite white line. This visceral layer is usually known as the recto-vesical fascia.

As regards the parietal division, it will be seen that that part of it above the origin of the visceral layer (*i.e.*, above the white line) is in the pelvic cavity, while that part below the line is in the perineum. To this lower segment the name obturator fascia is commonly given. Now, the peritoneum lines some part of the pelvic floor, and covers a great part of the pelvic viscera. Between this peritoneum and the visceral layer of the pelvic fascia is a good deal of loose connective tissue. Inflammation may be set up in this tissue, may spread readily in it, and may of course lead to suppuration. Such suppuration will be limited to the pelvic cavity, and will be hindered from escaping from that cavity by the pelvic fascia. Inflammations of any extent so located are included under the term pelvic cellulitis. Suppuration, therefore, above the visceral layer of the pelvic fascia will be limited to the pelvic cavity, while that below the fascia will be limited to the perineum, to either the urethral or the anal segment of that district. Thus it will be seen that the pelvic fascia is of much surgical importance. Wounds through the perineum that involve this fascia will be serious, in that they will open up the loose tissue on the pelvic aspect of the fascia in which inflammation so readily spreads, while unless the fascia be wounded the pelvic cavity cannot be said to have been opened.

The fascia is so reflected upon the viscera that certain parts of them are excluded by the attachments of the membrane from the pelvic cavity. The parts so excluded

are the following: the prostate, the neck of the bladder, all that part of the base of the bladder that is between the seminal vesicles, the seminal vesicles themselves, and about the last  $2\frac{1}{2}$  or 3 inches of the rectum. On the side of the rectum the fascia reaches the level of a line drawn from the top of the seminal vesicles to the middle of the fifth piece of the sacrum. In the middle line it reaches a point some little way below the rectovesical *cul-de-sac* of the peritoneum. These excluded portions of the various viscera may be wounded without the pelvic cavity being opened up, and suppuration spreading from them would tend to spread towards the perineum, and not into the pelvis. *Pelvic cellulitis*, to use the term in the strict sense, means inflammation of the connective tissue between the pelvic fascia and the peritoneum.\* This connective tissue is chiefly situated between the anterior wall of the bladder and the pelvis, about the base and neck of the bladder, between the latter viscus and the rectum; and in the female, between the layers of the broad ligament and about the lower part of the uterus and commencement of the vagina. All this connective tissue is continuous, and inflammation in one part of it may spread to the other parts. In women the mischief is often found between the folds of the broad ligament, or in the hollow between the uterus and the rectum. As may be supposed, the abscess formed in such cases tends to mount up in the pelvis, being unable to escape below, and usually points in the inguinal region, or in the supra-pubic region, having spread along the obliterated hypogastric artery. It may, however, open into one of the pelvic viscera or into the peritoneum, but both these terminations are rare. Out of thirty-seven cases of puerperal pelvic cellulitis with suppuration, twenty-four burst externally, and for the most part in the inguinal region (McClintock).

\* Clinically the term pelvic cellulitis includes also pelvic peritonitis, and often inflammation of one or other of the viscera. Indeed, many so-called cases of pelvic cellulitis are examples of localised pelvic peritonitis with or without suppuration.

It should be borne in mind that the *blood-vessels of the pelvis* are placed on the peritoneal aspect of the fascia. The branches of the internal iliac artery, therefore, that leave the pelvis, escape by piercing that membrane. The obturator artery is an exception to this rule, since it passes over the upper border of the parietal pelvic fascia (Cunningham). The *nerves in the pelvis* lie behind or outside the fascia, and, therefore, the pelvic vessels and the pelvic nerves are, excepting the obturator, separated from one another by this layer of tissue.

The **male perineum**.—The perineum is a lozenge-shaped space bounded by the symphysis, the rami of the pubes and the ischia, the ischial tuberosities, the great sacro-sciatic ligaments, the edges of the two great gluteal muscles, and the coccyx. A transverse line drawn across the space between the anterior extremities of the tubera ischii, and just in front of the anus, divides the perineum into two parts. The anterior part forms nearly an equilateral triangle, measuring about  $3\frac{1}{4}$  inches on all sides. It is called the urethral triangle. The posterior part is also somewhat triangular, contains the rectum and ischio-rectal fossa, and is called the anal triangle. The whole space measures about  $3\frac{1}{2}$  inches from side to side, and about 4 inches from before backwards in the middle line. The average antero-posterior diameter of the pelvic outlet in the male averages  $3\frac{1}{4}$  inches. This measurement in the undissected subject is increased to 4 inches by the curving of the surface. The average transverse diameter of the male pelvic outlet is  $3\frac{1}{2}$  inches, and corresponds to the measurement of the perineum above given.

The bony framework of the perineum can be felt more or less distinctly all round, and in thin subjects the great sacro-sciatic ligaments can be made out beneath the great gluteal muscle. The anus is in the middle line between the tubera ischii, its centre being about  $1\frac{1}{2}$  inches from the tip of the coccyx. The *raphé*, a central mark or ridge in the skin, can be followed from the anus along the middle line of the perineum, scrotum, and

penis. No vessels cross this line, and, therefore, in making incisions into the perineum this line is always chosen when possible. In the middle line, midway

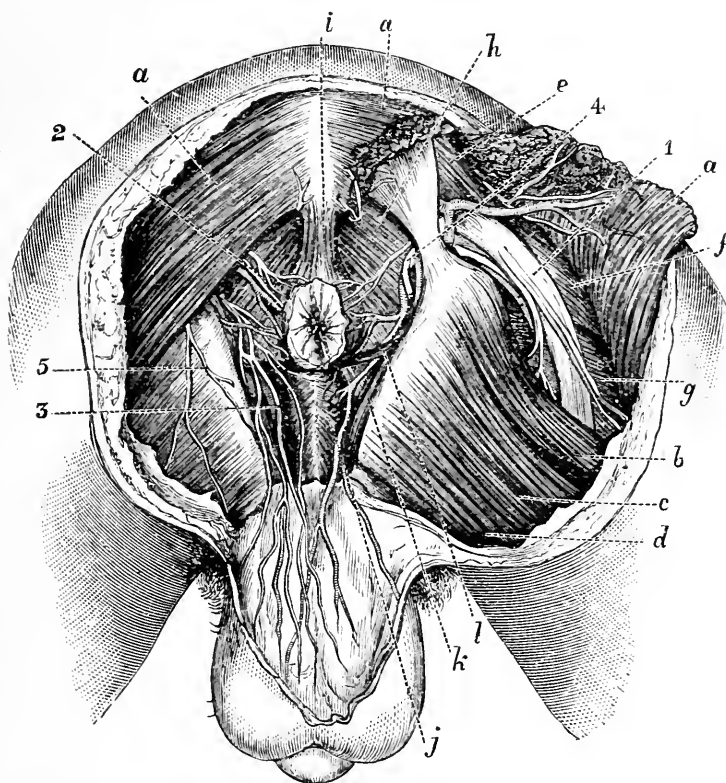


Fig. 51.—The Male Perineum. (After Rüdinger.)

*a*, Gluteus maximus; *b*, semi-tendinosus and biceps; *c*, adductor magnus; *d*, gracilis; *e*, pyramidalis; *f*, obturator internus; *g*, quadratus femoris; *h*, levator ani; *i*, external sphincter; *j*, accelerator urinæ; *k*, cretor penis; *l*, transversus perinei; 1, great sciatic nerve; 2, external hemorrhoidal vessels and nerve; 3, superficial perineal vessels and nerves; 4, pudic nerve (cut) and pudic artery; 5, pudendal branch of small sciatic nerve.

between the centre of the anus and the spot where the scrotum joins the perineum, is the central point of the perineum. The two transverse perineal muscles, the accelerator urinæ and the sphincter ani meet at this

point, which also corresponds to the centre of the inferior edge of the triangular ligament. The bulb is just in front of it, as is also the artery to the bulb, and in lithotomy, therefore, the incision should never commence in front of this spot.

The perineal space is separated from the pelvic cavity by the levator ani muscles and recto-vesical fascia, as already mentioned. The *depth* of the perineum means the distance between the skin and the pelvic floor. This depth depends, to a great extent, upon the amount of fat under the integument. It varies considerably in different parts, measuring from 2 to 3 inches in the hinder and outer parts of the perineum, and less than 1 inch in the anterior parts of the space.

The **ischio-rectal fossa** is of pyramidal shape, its apex being at the white line, and its base being formed by the skin between the anus and the ischial tuberosities. It measures about 2 inches from before back, 1 inch from side to side, and is between 2 and 3 inches in depth. Its boundaries are: on the *outer* side, the obturator internus muscle, covered by the parietal layer of the pelvic fascia; on the *inner* side, the levator ani, covered by the anal fascia; in *front*, the base of the triangular ligament and the transversus perinei muscle; and *behind*, the gluteus maximus, great sacro-sciatic ligament, and coccygeus. The pudic vessels and nerves are on the outer wall, embedded in the fascia over the obturator muscle, and are placed about  $1\frac{1}{2}$  inches above the lower border of the tubera ischii.

The part of the rectum which occupies the space between the two fossæ is supported by the levatores ani, external sphincter, and recto-vesical fascia. Its lateral wall is exposed for a distance of nearly 3 inches, its posterior wall for about 1 inch (Quain). The fossa is occupied by a mass of fat which affords to the rectum the support of an elastic cushion. This fatty tissue is badly supplied with blood, and this fact, in addition to the dependent situation of the part, and its exposure when the patient sits upon damp, cold seats, etc., leads to abscess being very frequent in the space (*ischio-rectal*

*abscess*). These abscesses are hemmed in on all sides, soon fill the fossa, and then tend to discharge themselves in the two directions where the resistance is least, viz., through the skin and through the wall of the rectum. When this double discharge of the abscess has taken place, a complete *fistula in ano* is established. It is well to note that in all *fistulae in ano* the opening into the rectum is nearly always within  $\frac{1}{2}$  an inch of the anus. An opening into the bowel higher up is resisted by the attachment of the levator ani, by the anal fascia and by the recto-vesical fascia.

Crossing the space obliquely from its hinder part to the anus are the external hæmorrhoidal vessels and nerves; crossing the anterior and outer corner of the fossa are the perineal vessels and nerves, and about the posterior border of the space are the fourth sacral nerve and some branches of the small sciatic nerve. It will be readily understood, therefore, that ischio-rectal abscesses are associated usually with extreme suffering until they are relieved. The most severe pain is probably due to the stretching of the external hæmorrhoidal nerve by the abscess as it progresses towards the surface. In opening an abscess in the fossa the main structures to avoid are the rectum, the pudic and external hæmorrhoidal vessels.

**Anus.**—(See paragraph on the Rectum.)

**The urethral triangle.**—The skin of the perineum between the anus and the scrotum is thin, and shows very readily any extravasations of blood that may form beneath it. The superficial fascia is divided into two layers, of which the more superficial is quite unimportant, and contains what little subcutaneous fat exists in this part.

The deeper layer, known as the perineal fascia or fascia of Colles, is attached on either side to the rami of the pubes and ischium, and behind to the base of the triangular ligament. In front it becomes continuous with the dartos tissue. This fascia, therefore, by its attachments forms with the triangular ligament a well-isolated aponeurotic space, containing the bulb with

all that part of the spongy urethra between the triangular ligament and the attachment of the scrotum, the penile muscles, the transverse perineal muscles, vessels, and nerves, and the perineal vessels and nerves. When extravasation of urine follows upon a rupture of the part of the urethra above named, the course of the escaping fluid is directed by the fascia of Colles. It fills the aponeurotic space. It is unable to gain the ischio-rectal fossa on account of the attachment of the fascia to the triangular ligament. The lateral attachments of this membrane prevent the urine from passing into the thighs. It is, therefore, guided into the scrotum, and there finds itself beneath the dartos tissue. It distends the scrotal tissues, and then mounts up on to the abdomen through the gap left between the symphysis pubis and pubic spine. It must be remembered that the fascia of Colles, the dartos tissue, and the deeper layer of the superficial fascia of the abdomen, are continuous, and merely represent different parts of the same structure. Pus or blood within this aponeurotic space would follow the same course if the effusion were extensive enough. The pain occasioned by such effusion can be understood when it is noted that the three chief sensory nerves of this region (the three long scrotal nerves) are included within the space.

The **triangular ligament** has a depth of about  $1\frac{1}{2}$  inches in the middle line, and is formed of two layers, of which the posterior is derived from the pelvic fascia. The membranous urethra, surrounded by the compressor urethræ, lies between the two layers, and runs about 1 inch below the symphysis, and about  $\frac{3}{4}$  of an inch above the central point of the perineum. The artery to the bulb passes inwards between the two layers about  $\frac{1}{2}$  an inch above the base of the ligament and  $1\frac{1}{2}$  inches in front of the anus. The dorsal vein and the terminal part of the pudic artery and nerve pierce the anterior layer of the ligament about  $\frac{1}{2}$  an inch below the symphysis. In uncomplicated rupture of the membranous urethra, the urine extravasated would be limited to the space between the layers of the ligament, until



subsequent suppuration had made a way for it to escape. When extravasation occurs behind the triangular ligament, the effusion barely escapes the pelvic cavity, and usually by following the rectum gains the anal part of the perineum.

Just beyond the triangular ligament is the prostate, surrounded by its capsule, and the prostatic venous plexus. In dissecting down from the surface to the prostate, we meet, as Cunningham has well pointed out, alternate strata of fascial and muscular tissue, forming seven layers in all, viz. : (1) Superficial fascia ; (2) superficial perineal *muscles* ; (3) triangular ligament (ant. layer) ; (4) compressor urethræ *muscle* ; (5) triangular ligament (post. layer) ; (6) levator ani *muscle* ; (7) capsule of prostate.

**Stone in the bladder.**—Stones of the bladder which were formerly removed by a perineal incision are now commonly crushed and washed out through the urethra by the operation of *litholapaxy*. This operation is carried out readily even in male children. If too large for crushing, the supra-pubic operation is performed to give sufficient room for extraction. Although the perineal operations are now but very rarely performed, a description of the parts involved helps to give a proper conception of their important anatomical relationships.

**Lateral lithotomy.**—The *first incision*, 2 or 3 inches in length, is commenced just to the left of the middle line and just behind the central point of the perineum, *i.e.*, about  $1\frac{1}{4}$  inches in front of the anus. The incision is carried downwards and outwards into the left ischio-rectal fossa, and ends at a point between the tuber ischii and posterior part of the anus, and one-third nearer to the tuberosity than to the gut. In the early part of this incision the staff may just be touched, as it lies in the membranous urethra, the incision becoming more and more shallow as the knife is withdrawn. The parts cut in the first incision are : (1) Skin and superficial fascia ; (2) transverse perineal muscle, artery and nerve ; (3) the lower edge of the anterior layer of the

triangular ligament; (4) the external hæmorrhoidal vessel and nerves. (Figs. 51 and 52.)

In the *second incision* the knife, guided by the fore-finger of the left hand, is passed upwards behind the triangular ligament, is engaged in the groove on the staff as it lies in the membranous urethra, and then, having its edge turned towards the left tuber ischii, is steadily carried along the groove into the bladder. In this incision the parts divided are: (1) Membranous and prostatic portions of urethra; (2) posterior layer of triangular ligament; (3) compressor urethræ; (4) anterior fibres of levator ani and left lateral lobe of prostate. The finger is then introduced along the staff into the bladder, the staff is removed, and, the forceps being inserted, the stone is extracted, traction being made in the proper axis of the pelvis.

*Parts that may be wounded.*—(a) In the first incision: (1) the bulb, or the artery of the bulb. These parts can be avoided by commencing the incision well behind the "central point," and by causing the holder of the staff to draw it, the scrotum, and the penis well up. The staff should be held as close up under the pubes as possible. The bulb is very small in children, large in adults, and largest in old men. (2) The rectum may be cut if much distended, or if the incision be made too vertical or carried too far back. In all cases the gut should be well emptied by enema before the operation. (3) The pudic vessels can hardly be wounded unless the incision is very carelessly made, and the knife carried almost against the bone as it is being withdrawn. (b) In the second incision the knife may be passed beyond the prostate, and may so incise the visceral layer of the pelvic fascia as to open up the pelvic cavity. It will be understood that the lateral lobe of the prostate may be cut freely without this cavity being endangered. The gland is enveloped by the pelvic fascia, but the incision made into the prostate is well below the superior reflection of the membrane. The incision in the neck of the bladder, therefore, must be strictly limited to the prostate. The prostatic plexus of veins cannot avoid being wounded.

The left ejaculatory duct would be cut if the prostatic incision were carried too far backwards.

In *children* the pelvis is relatively narrower than in the adult, the bladder is more an abdominal than a pelvic organ, and the neck of the bladder, therefore, is high up. The viscus, moreover, is very movable, and has less substantial attachments than has the adult's bladder. It thus happens that in forcing the finger into the bladder after the second incision, the viscus has actually been torn away from the urethra. In children the prostate is rudimentary, and thus more of the actual neck of the bladder itself has to be cut. From the small size of this gland, also, it happens that in some cases the knife has passed too far beyond the prostatic area, and has opened up the pelvic fascia. In children also the peritoneum descends lower on the posterior surface of the bladder, and may be wounded by a careless operator.

**Median lithotomy.**—In this operation the knife is entered in the middle line, just in front of the anus. The staff has a central groove, and the point of the knife should hit the instrument as near as possible to the apex of the prostate. As the knife is withdrawn the whole of the membranous urethra is incised, and a wound made in the median raphe of about  $1\frac{1}{4}$  inches in length. The incision is made by cutting upwards. A probe is then introduced into the bladder, and, the staff being removed, the finger is passed into that viscus by steady dilatation of the parts, with some laceration of the prostate. The object in this operation is to enter the bladder with the least amount of cutting, and by dilatation rather than incision.

*Parts divided.*—(1) Skin and superficial fascia ; (2) sphincter ani ; (3) central point of perineum ; (4) lower border of triangular ligament ; (5) whole length of membranous urethra ; (6) compressor urethræ.

*Advantages.*—(1) The bleeding is much less than in the lateral operation, the slight vascularity of the raphe being well known. (2) The pelvic fascia is much less likely to be wounded if the bladder be entered by

dilation rather than by incision, as in the lateral procedure.

*Disadvantages.*—(1) The bulb is in great risk of being wounded. It must, however, be noted that wounds of the bulb in the middle line do not bleed readily, as a rule. (2) The amount of space obtained for the removal of the stone is very slight. (3) In children the operation in its integrity is scarcely possible, since the prostate is quite rudimentary, and the slight attachments of the parts are such that, in using forcible dilatation, the bladder may readily be torn from the urethra. If the incision be made upwards, and one finger be retained in the rectum, the risk of wounding the gut is not great.

In lithotomy, and in other operations for reaching the neck of the bladder through the perineum, it should be remembered that the bladder lies at a depth of from  $2\frac{1}{2}$  to 3 inches from the surface when the body is in lithotomy position. (Fig. 52.)

**Suprapubic lithotomy.**—This operation has been revived of late years, and in cases in which litholapaxy is contraindicated has practically supplanted the two forms of lithotomy just described. In order to bring the summit of the bladder well above the symphysis, both bladder and rectum may be dilated. Into the former viscus, tepid water or boracic lotion is injected. It is found that in the adult 8 to 10 ounces is sufficient to ensure the desired distension. The rectum is dilated by some operators by means of a soft rubber bag. The gut, when thus distended, pushes forward the bladder, and gives it a firm basis upon which to rest. In the adult from 10 to 14 ounces are usually introduced into the bag. Distension of the rectum alone will elevate the bladder, but it will usually have no effect upon the reflection of peritoneum. In operating upon children the rectal bag is very seldom required, and many surgeons do not employ it in any case. In the case of a male child, aged five, the injection of 3 ounces of water into the bladder caused the reflection of peritoneum to mount to more than 1 inch above

the symphysis. An incision, some 3 inches in length, is made immediately above the symphysis in the median line. The bladder is exposed below the peritoneum, is drawn forwards by a hook, and opened.

The **bladder**.—When empty the bladder is flattened and of triangular outline, and lies against the anterior wall of the pelvis. The empty bladder may be found in one of two conditions (as demonstrated by Dr. Hart in the adult female bladder). It may be small, oval, and firm, with its upper wall convex towards the abdomen. In vertical antero-posterior section the urethra forms with the cavity of the bladder a curved slit (the systolic empty bladder). It may be larger, and soft, with its upper surface concave towards the abdomen, and fitting into the concavity of the lower wall or surface. In the section named, the urethra forms, with the bladder cavity, a Y-shaped figure, the two diverging limbs of the Y corresponding to the concavity named (the diastolic empty bladder). When moderately distended it is of rounded outline; when completely distended it assumes an oval outline, and rises out of the pelvis. As *distension of the bladder* increases, the summit of the viscus is brought more and more in contact with the anterior abdominal wall, the organ becoming also more convex on its posterior than on its anterior surface. This tendency for the summit of the distended bladder to press itself against the anterior parietes is of good service in tapping the organ above the pubes, and in suprapubic lithotomy. When greatly distended it may reach the umbilicus, and may even touch the diaphragm. The usual capacity of the organ is about one pint, but when fully occupied it may hold some quarts. When both bladder and rectum are quite empty the apex of the bladder and the pre-vesical reflection of the peritoneum are a little below the upper margin of the symphysis pubis. As the distended bladder ascends above the pubes it dissects the serous membrane from the parietes, and the layer so lifted off forms a *cul-de-sac* or fold of peritoneum between the upper part of the anterior surface of the

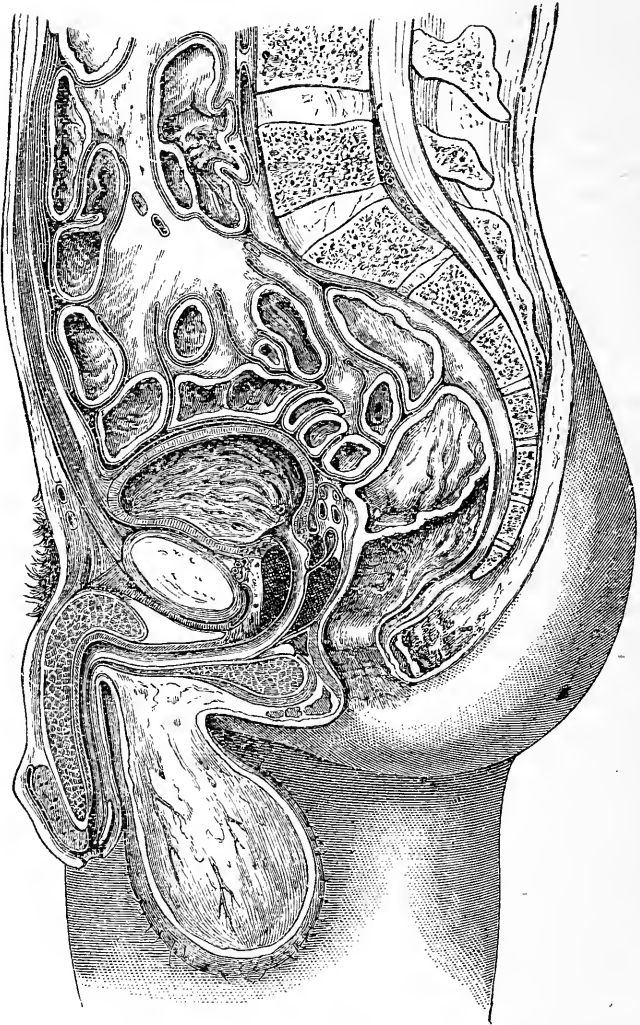


Fig. 52. —A Vertical Antero-posterior Section of the Male Pelvis (Braune).

bladder and the parietes. When the apex of the bladder is 2 inches above the pubes the peritoneal reflection is probably not more than  $\frac{3}{4}$  of an inch above the same

point of bone. When the apex of the bladder is midway between the umbilicus and the pubes there may be 2 inches (vertical) of the anterior abdominal wall in the middle line and immediately above the symphysis devoid of peritoneal lining. Thus it happens that the distended viscus may be readily tapped above the pubes without the peritoneum being wounded. As the bladder becomes distended, not only does it rise into the abdomen, but it extends also towards the perineum, diminishing the length of the prostatic and membranous urethra. In suprapubic lithotomy that tendency to extend downwards is prevented by the rectal bag (page 390).

Between the anterior surface of the bladder and the symphysis, and shut in by the peritoneum above, is a loose layer of connective tissue. The looseness of this connective tissue permits the bladder to readily alter its dimensions without disturbing the connections of the organ. In injuries to the pelvis and to the front of the bladder a diffuse inflammation may be set up in this tissue and assume serious proportions. I have reported a case where an extensive suppuration in this area followed upon aspiration of the bladder above the pubes, and led to death. Like suppuration has followed suprapubic lithotomy. In rupture of the anterior wall of the viscus the urine escapes into this district of cellular tissue; a limited suppuration may follow and recovery ensue.

The bladder, although fairly fixed, has been found in inguinal, femoral, and vaginal herniæ. In the erect position its neck (in the male) lies on a horizontal line drawn from before backwards through a point a little below the middle of the symphysis, and is placed about  $1\frac{1}{4}$  inches (3 cm.) behind that articulation (Tillaux).

*Relations to the peritoneum.*—The anterior surface is entirely devoid of peritoneum, while the superior surface is entirely covered by that membrane. At the sides there is no peritoneum in front of, or below, the obliterated hypogastric arteries. On the posterior aspect of the bladder the serous membrane extends down as far as a transverse line, uniting the upper

parts of the two seminal vesicles, so that the upper ends of the vesicles, as well as the ureters, where they enter the bladder, are covered by peritoneum. This recto-vesical pouch of peritoneum in the adult extends to within about 3 inches of the anus, and does not reach below a line 1 inch above the base of the prostate. Harrison Cripps gives the distance of the pouch from the anus as  $2\frac{1}{2}$  inches when the bladder and rectum are both empty, and as  $3\frac{1}{2}$  inches when those viscera are distended. (See Bladder in the Child, page 398.)

**Puncture of the bladder per rectum.**—

The base of the bladder is adherent to the rectum by dense areolar tissue over a triangular area, the apex of which is formed by the prostate, the sides by the diverging seminal vesicles, and the base by the recto-vesical fold of peritoneum. This triangle is equilateral, and in the dissected specimen measures about  $1\frac{1}{2}$  inches on all sides. It corresponds to the trigone on the inner surface of the viscus. It is through this triangle, and as near as possible to the prostate, that the bladder is tapped when the operation is performed *per rectum*. The recto-vesical fold of peritoneum is raised, and is carried still farther from the anus when the organ is distended.

**Rupture of bladder.**—The bladder may be ruptured by violence applied to the anterior abdominal wall apart from pelvic fracture or external evidence of injury. Such a rupture can, however, hardly happen to the empty bladder, which should be full or distended at the time. It is very rare for the rupture to be on the anterior surface only. As a rule, the tear involves the superior or abdominal surface, and implicates the peritoneum. The injury, therefore, is very fatal (five recoveries out of seventy-eight cases). In some cases of vesical rupture the surgeon has opened the abdomen and has stitched up the rent in the viscus with perfect success. The bladder may be torn by fragments of bone in fractures of the pelvis, or by violence applied through the rectum or vagina. A case, for example, is reported (Holmes' "System of Surgery") of a man



who fell upon a pointed stake fixed in the earth. The stake passed through the anus, pierced the rectum, and entered the bladder near the prostate. The patient recovered, the wound having been made in the triangular area on the fundus of the bladder alluded to above, and therefore outside the peritoneum. The viscus may be ruptured by an accumulation of urine, as seen in cases of congenital closure of the urethra in some infants. In the museum of the Royal College of Surgeons is a preparation of "the bladder of a woman which burst near the entrance of the ureter in consequence of neglected retention of urine." In neglected cases of stricture in the male the urethra gives way rather than the bladder, and an extravasation of urine into the perineum follows. A small puncture of the bladder, as, for example, that made by a fine trochar, is at once closed by the muscular contraction of its wall.

The **mucous membrane** of the bladder is very lax, to allow of its accommodating itself to the varying changes in the size of the viscus. Over the trigone, however, it is closely adherent, and were it not so the loose mucous membrane would be constantly so prolapsed into the urethral orifice during micturition as to block up the neck of the bladder. The trigone is bounded by three orifices, for the urethra and the two ureters, and forms an equilateral triangle, measuring about  $1\frac{1}{2}$  inches on all sides. It is here that the effects of cystitis are most evident, and the unyielding character of the mucous membrane over the trigone serves in part to explain the severe symptoms that follow acute inflammation of that structure. Since the orifice of the urethra forms the lowest part of the bladder in the erect posture, it follows that calculi gravitate towards the trigone, and are very apt to irritate that part of the interior. The same remark applies to foreign bodies in the viscus. The mucous membrane about the trigone and neck is very sensitive, whereas the interior of the remainder of the bladder appears to be singularly defective in common sensation. This can be well noted in using sounds and catheters.

The **sensory nerves** for the bladder are derived mainly from the third sacral segment, to a less degree from the second and fourth, and pass to the bladder from the third and sometimes fourth sacral nerve through the *nervi erigentes*. The skin of the scrotum, penis, and mucous membrane of the urethra are supplied from the same segments. Hence, in diseases of the bladder, especially of the trigone, pain is referred along the distribution of the perineal nerves. The *motor nerves* of the bladder come from the eleventh and twelfth dorsal and first lumbar segments, and pass to the bladder by the hypogastric and pelvic plexuses. Both the sensory and motor centres are concerned in the reflex act of micturition. Being situated at different levels of the cord one centre may be affected without the other.

In the **muscular coat** of the bladder the fibres are collected into bundles which interlace in all directions. When the viscus becomes hypertrophied these bundles are rendered very distinct, and produce the appearance known as "fasciculated bladder." This simply means that the muscle of the bladder, having been unduly exercised to overcome some obstruction to the escape of urine, increases in size, as do other much exercised muscles, and that increase serves to demonstrate the arrangement of the individual bundles. In a fasciculated bladder the muscular bundles present much the appearance of some of the *columnæ carneæ* in the heart. It will be understood that the bladder wall between the muscular bundles is comparatively thin, and may yield when the viscus is distended. By such distension the mucous membrane becomes bulged out between the unyielding muscle bundles, so that sacculi are formed, and the appearance known as "sacculated bladder" is produced. In these sacculi urine may lodge and decompose, phosphatic deposits may collect, and calculi may develop (encysted calculi). In some cases the parietes yield, especially at one part, and one large saccule is produced. In this way a sacculus may be formed which in time may become almost as large

as the bladder itself, and give rise to the erroneous description of "double bladder," etc.

The anterior wall of the bladder is thicker and stronger than the posterior, and in cases of hypertrophy the increase appears to mainly involve the anterior wall. The difference between the two parts is well shown in frozen sections (Symington).

The ureters run for  $\frac{3}{4}$  of an inch in the muscular wall of the viscus, and their oblique course, together with the action of the muscular tissue about them, tends to prevent regurgitation of urine. In cases of retention the ureters become distended; but this is due rather to accumulation of urine within them than to its reflux from the bladder.

In cases of great distension of the bladder the neck of the viscus is opened up by the pressure from within, and the patient exhibits the feature of overflow of urine.

The **female bladder** is less capacious than that of the male. Its neck is situate a trifle nearer to the symphysis than it is in the male, and lies in a horizontal line continued back from the lower border of the symphysis. There being no prostate, the neck of the bladder is very distensible, and this fact, taken in connection with the shortness and dilatability of the urethra, allows of most stones being extracted by forceps without cutting. By simple dilatation, stones of a diameter of  $\frac{3}{4}$  of an inch have been removed. Through the dilated urethra the orifices of the ureters can be seen and examined. The intimate relation of the bladder to the vagina allows it to be examined well from the latter passage, and the comparative thinness of the dividing wall serves to explain the frequency of vesico-vaginal fistulæ. Strange foreign bodies have been introduced into the female bladder, such as hair-pins, crochet hooks, sealing-wax, penholders, and the like.

The orifice of the ureter is 3 cm. from the cervix uteri, and 4 cm. from the vesical opening of the urethra. Its close relation to the cervix renders it liable to injury in supravaginal amputation of that part, and in certain operations on the uterus.

The **bladder in the child** is egg-shaped, and its vertical axis is relatively much greater than it is in the adult. The larger end of the egg-shaped cavity is directed downwards and backwards. It can hardly be said that there is any base or fundus to the child's bladder. The viscus is situated mainly in the abdomen, the pelvis being small and very shallow. At birth the orifice of the urethra is on a level with the upper edge of the symphysis. Although the bladder projects so freely into the abdomen, its anterior wall is still entirely uncovered by peritoneum. On the posterior wall the serous membrane extends lower down than in the adult, reaching the level of the urethral orifice at the time of birth, and the level of the prostate in young male children. The prostate is exceedingly small in children. Thompson states that at the age of seven years it only weighs thirty grains, whereas in subjects between eighteen and twenty it weighs two hundred and fifty grains. The bladder wall in the child is so thin that in sounding for stone it is said that a "click" may be elicited by striking the pelvis through the parietes of the viscus.

The **prostate**.—The prostate is situated about  $\frac{3}{4}$  of an inch below the symphysis pubis, and rests upon the rectum in front of the bend between the second and third segments of that viscus. It is, therefore, placed within  $1\frac{1}{2}$  to 2 inches from the anus, and can be readily examined from the bowel.

The secretion from the gland is discharged through a number of long and very narrow ducts. In certain forms of prostatic irritation, little white opaque threads, very much like short pieces of cotton, are found in the urine, and are actual casts of the prostatic ducts.

The prostate is enveloped in a firm capsule derived from the pelvic fascia, and it is to this fascia that we look for an explanation of the course of prostatic abscess.

The **prostatic abscess** usually bursts into the urethra, that being the direction in which least resistance is encountered. If it does not enter the urethra, it will probably open into the rectum, there being only one layer of the pelvic fascia, and that layer not a thick one,

between the two organs. Indeed, the posterior part of the prostatic capsule, and the anterior part of the sheath of the rectum, are continuous. Failing these two points of exit, the abscess may progress towards the perineum. This course, however, is not very usual, the advance of the abscess being resisted by the dense posterior layer of the triangular ligament, with the lower edge of which the prostatic capsule is continuous. If the abscess reaches the perineum, it will do so by running along the side of the rectum. The abscess cannot make its way into the pelvic cavity, its movement in that direction being resisted by the pubo-prostatic ligaments which form one of the very densest portions of the pelvic fascia. This encasement of the gland in an unyielding membrane will serve to in part explain the severe pain felt in acute prostatic abscess. In acute prostatitis pains are referred over the tip of the last rib (tenth dorsal nerve), over the posterior iliac spine (eleventh dorsal nerve), or even to the soles of the feet (third sacral nerve). It derives its nerve supply from the lower three dorsal and upper three sacral segments; hence the widely distributed character of the referred pains (Head).

**Hypertrophy of the prostate.**—The average measurements of the normal prostate are  $1\frac{1}{2}$  inches across at its widest part, and  $1\frac{1}{4}$  inches from before backwards, or from apex to base. After the age of fifty-three the organ is very apt to become hypertrophied; and, according to Sir Henry Thompson, this hypertrophy may be considered to exist when the gland measures 2 inches from side to side, or when it weighs 1 ounce. The usual weight of the prostate is 6 drachms. If the enlargement mainly affect the lateral lobes, it will be understood that the hypertrophy may attain considerable dimensions without retention of urine being produced. On the other hand, a comparatively trifling enlargement of the middle lobe may almost entirely block the orifice of the urethra. If the affection be general, the prostatic urethra is lengthened, and if one lateral lobe be more enlarged than the other, the canal deviates to one side. When the enlargement particularly

affects the middle lobe, the prostatic urethra, which is normally almost straight, becomes considerably curved, the curve being sometimes very abrupt.

It is important to note that enlargement of the middle lobe alone can hardly be made out by rectal examination.

The severity of the symptoms in a case of hypertrophy of the prostate bears little or no relation to the apparent size of the gland as felt *per rectum*. A portion of the enlarged body may project into the bladder. This usually takes the form of a projecting middle lobe which, when viewed from the interior of the bladder, may appear as a distinct well-rounded pedunculated or sessile growth.

In the operation of *prostatectomy* this projecting and most troublesome mass is removed through a suprapubic incision. The prostate is a sexual organ, and its size and development depend on the presence and activity of the testes. Castration prevents its development or causes atrophy if already developed. Removal of one testicle causes a partial atrophy, and section of the vasa differentia has usually a similar effect. These two facts show that the atrophy is not due to the removal of any internal secretion which the testicle may impart to the blood. The effect is probably produced through the nervous system. The prostate and testicle derive their nerves mainly from the tenth dorsal spinal segment. Between the prostate and its capsule is an extensive plexus of veins, the prostatic plexus, into which enters the dorsal vein of the penis. This plexus is cut in lateral lithotomy, and it is through its vessels that septic matter is probably absorbed in cases of pyæmia following that operation. Its lymphatics, which are numerous, pass to a group of glands on the wall of the pelvis, between the external and internal iliac arteries.

The **male urethra** is about  $8\frac{1}{2}$  inches in length (21 cm.),  $1\frac{1}{4}$  inches being devoted to the prostatic urethra,  $\frac{3}{4}$  of an inch to the membranous, and  $6\frac{1}{2}$  inches to the penile or spongy portion. Between the ages of four and six years its length is 8 to 9 cm., and between ten and thirteen years 10 to 11 cm. The canal may be

divided into a fixed and a movable part. The fixed part extends from the neck of the bladder to the posterior extremity of the penile urethra at the point of attachment of the suspensory ligament. The fixed part describes an even curve, fairly represented by the line of a "short curve" metal catheter. The two ends of the curve lie about in the same line, viz. one drawn across the lower end of the symphysis, and at right angles to the vertical axis of that articulation. The curve is formed around this line, its summit corresponding to a prolongation of the vertical axis of the symphysis, and to about the centre of the membranous urethra. This part of the tube lies about 1 inch below the pubic arch. The movable portion of the urethra forms, when the penis is dependent, a second curve in the opposite direction, so that the whole canal follows somewhat the outline of the letter S.

The prostatic portion of the urethra will be nearly vertical. It is surrounded by circular muscular fibres which may give rise to a spasmodic stricture. This part of the canal corresponds to the posterior ventral part of the urogenital sinus of the cloaca, which receives the Wolffian and Müllerian ducts. The sinus pocularis or uterus masculinus, in the floor of this part of the urethra, represents the united ends of the rudimentary Müllerian ducts.

That part of the urethral canal which lies beyond the prostate is of different origin, and is a portion of the anterior segment of the cloaca, which has been formed into a canal by a superficial union of the tegumentary folds in the median line.

The penile or spongy portion of the urethra is surrounded by the erectile tissue of the corpus spongiosum urethræ, which is thickest on the under side of the canal. A very thin layer of erectile tissue surrounds the membranous urethra lying beneath the fibres of the compressor urethræ.

*In introducing a catheter* it must be noted that while the instrument passes along the movable urethra, the canal accommodates itself to the catheter, but while

traversing the fixed segment the instrument must accommodate itself to the unyielding canal. In introducing a catheter in the recumbent posture the penis is held vertically upwards, and in this way the curve formed by the movable urethra is obliterated. The instrument is best kept close to the surface of the groin, and over and parallel to Poupart's ligament. When the fixed urethra is reached, the handle of the catheter is brought to the middle line, and then, being kept strictly in the median plane of the body, is depressed between the legs, so that the front of the instrument may follow the natural curve of the canal. The greatest difficulty in the introduction is generally experienced at the point where the movable and fixed parts of the urethra meet; or, rather, in practice, at a spot a little behind this point, viz. at the anterior layer of the triangular ligament. At this spot the tube abruptly becomes not only very fixed, but also very narrow, and a part of it is reached where muscular tissue is very abundant, and where resistance from muscular spasm is therefore likely to be most marked.

It thus happens that when a false passage has been made by a catheter in a case where no stricture exists to offer a definite obstruction, the instrument is usually found to have left the canal just in front of the triangular ligament.

Some other points in connection with catheterism will be noted subsequently.

The **urethral canal** must not be regarded as forming an open tube like a gas-pipe. Except when urine or an instrument is passing along it, the tube appears on section as a transverse slit, the superior and inferior walls being in contact. This fact should be remembered in amputation of the penis by the *écraseur*. In the fossa navicularis the tube appears as a vertical slit.

The *prostatic* part of the canal is the widest and most dilatable portion of the whole urethra. It is widest at its centre, having here a diameter of nearly  $\frac{1}{2}$  an inch; at the bladder end its diameter is about



$\frac{1}{3}$  of an inch, while at the anterior extremity of this part of the urethra the measurement is a little less than  $\frac{1}{3}$  of an inch. When small catheters are being introduced their points may lodge in the orifice of the utricle, unless the tip of the instrument be kept well along the roof of the canal. The ejaculatory ducts open into the prostatic urethra, and thus it happens that inflammation of this part of the canal may spread back along those ducts to the seminal vesicles, and from thence along the vas deferens to the epididymis. It is by spreading along these parts that inflammation of the testicle is set up in gonorrhœa, involving the prostatic urethra, and it will be understood that a like inflammation may follow lateral lithotomy, impacted stone in the prostatic urethra, prostatic abscess, and the like. Stricture never occurs in this part.

The *membranous urethra* is, with the exception of the meatus, the narrowest part of the entire tube. Its diameter is about  $\frac{1}{3}$  of an inch. It is fixed between the two layers of the triangular ligament, and is the most muscular part of the canal. - It is at this spot, therefore, that what is known as "spasmodic stricture" usually occurs. In any case, the contraction of the compressor urethræ often offers an appreciable amount of resistance to the passage of a catheter or sound.

The *penile urethra* is dilated at either end; viz. at the parts occupying the bulb and the glans penis respectively. The diameter of the bulbous urethra is midway between that of the prostatic and membranous segments of the canal, while that of the greater part of the penile urethra is midway between that of the bulbous and membranous portions. It is in the bulbous urethra that organic stricture is the most commonly met with. The *meatus* measures from  $\frac{1}{5}$  to  $\frac{1}{4}$  of an inch, and therefore if a catheter will pass the meatus it will pass along any part of the canal if normal. Its aperture is very resisting, and has often to be incised to allow the larger instruments to pass.

The *narrowest parts* of the urethra, therefore, are at (1) the meatus, and (2) in the membranous segment,

especially at its anterior end. It is at these points that calculi passed from the bladder are most apt to lodge. The widest portions of the canal, on the other hand, are at (1) the fossa navicularis, (2) the bulbous part of the urethra, and (3) the centre of the prostatic portion.

Keegan has shown that the urethra of a male child two or three years of age will take a No. 9 catheter. In boys between eight and ten years a No. 11 lithotrite may be passed.

It will be obvious, therefore, that the operation of lithotripsy may be performed upon quite young male children, and that fragments of crushed calculus of no small dimensions may be removed from the bladders of such patients by washing.

The **mucous membrane** presents, in addition to many mucous glands, several lacunæ, the orifices of which for the most part open towards the meatus. These lacunæ are most numerous in the bulbous urethra, and occupy the floor rather than the roof of the canal. In passing small catheters, therefore, the point of the instrument should be kept along the upper surface of the tube, so that it may not become engaged in any of these spaces. The largest lacuna, the lacuna magna, is situate in the *roof* of the fossa navicularis, and may readily engage the point of a small instrument.

Otis has endeavoured to show that a definite relation exists between the circumference of the penis and the circumference of the urethra, a relation represented by the proportions 2·25 : 1, and makes use of instruments of large size, which, when passed, seem to demonstrate rather the dilatibility of the canal than any certain anatomical relationship.

The urethra may be *ruptured* by the patient falling astride of some hard substancè. In such an injury it is crushed between the hard substance and the pubic arch. The part of the canal, therefore, that is most often damaged is the membranous segment, and the posterior part of the penile division. The more the body is bent forwards at the time the perineum is

struck, the greater is the length of penile urethra that may be crushed against the pubes.

The **female urethra** is about  $1\frac{1}{2}$  inches in length, and has a diameter of from  $\frac{1}{4}$  to  $\frac{1}{3}$  of an inch. It is capable, however, of great distension. In the erect position the canal is nearly vertical, and in the recumbent posture almost horizontal.

**Penis.**—The skin covering the bulk of the organ is thin and fine, and the subcutaneous tissue is scanty and lax. It follows, from the looseness of this tissue, that the skin is very distensible and movable. The latter fact should be borne in mind in circumcision, for in performing that operation the skin of the penis can be so readily drawn forwards over and beyond the glans, that if it is excised as far back as possible the greater part of the organ may be left bare. This applies, of course, mainly to children. The laxity of the subcutaneous tissue permits the organ to become enormously swollen when œdematous, or when extravasated urine finds its way into the part. Over the glans penis the mucous membrane is so adherent that there is practically no subcutaneous tissue. It happens, therefore, that when Hunterian chancres appear on this part they can never be associated with other than the most trifling induration, there being no tissue in which the thickening can develop. At the corona, on the other hand, the submucous tissue is lax and plentiful, so that the induration can readily form, and it is about this spot, therefore, that the syphilitic sore attains often its most characteristic development. The vascularity of the penis, and the rapid engorgement that ensues when the return of its venous blood is impeded, serve to explain the ready and extensive swelling of the organ that follows when any constricting band is placed about it. This should be borne in mind in tying in a catheter by securing it by tapes around the penis. The blood spaces in the corpus spongiosum may be rendered indistensible from gonorrhœal inflammation while those of the corpora cavernosa remain free. The corpus spongiosum then acts like the string of a bow during the erection of the

penis. Through the superficial lymphatics disease may spread from the skin and meatal region of the penis to the inner of the inguinal glands. Deeper vessels pass with the prostatic veins to the internal iliac group of glands on the lateral wall of the pelvis. Some vessels pass directly to the external iliac glands through the crural ring. The penis is often the seat of arrests of development, presenting a variety of appearances. Among them may be mentioned *hypospadias*, where the inferior wall of the urethra and corresponding part of the corpus spongiosum are wanting, and *epispadias*, where the superior wall of the canal and corresponding parts of the corpora cavernosa are more or less entirely deficient. The raphe along the penis, scrotum, and perineum marks the union of the genital folds in the fœtus. These folds correspond to the labia minora and majora of the female. The male urethra from the sinus pocularis to the meatus is thus formed.

**Scrotum.**—The *skin* of the scrotum is thin and transparent, so that in bruising of the parts the discoloration due to the extravasation of blood beneath the surface is readily and distinctly seen. It is also very elastic, and allows of great distension, as is seen in large scrotal herniæ and testicular tumours. The integument of the part is indeed redundant, and the excision of a portion of it will hardly be missed. Even in gangrene of the scrotum, when both testicles have been exposed, the parts have been entirely restored without any inconvenient shrinking or contraction. The *rugæ* on the surface of the scrotum favour the accumulation of dirt, and the irritation set up by such accumulation may be the exciting cause of the epitheliomata that are not uncommon in this part. When the surface is sweating, the *rugæ* tend to favour a retention of the moisture between their folds; from this and other circumstances it happens that the scrotum is liable to eczema and to those syphilitic skin disorders that are often localised by irritation. The *rugæ* are a sign of health, since they depend upon the vigorous contraction of the muscle fibres in

the dartos tissue. In the enfeebled, or under the relaxing effects of heat, the scrotum becomes smooth and pendulous. In lacerated wounds, especially when portions of the skin are torn away, the dartos is of great value in assisting to close the gap by its contraction, and in thus covering the exposed parts. To promote such contraction the wound is dressed with cold applications. In a simple incised wound, as in castration, the dartos is apt to turn in the edges of the skin and cause some difficulty in applying the sutures. This difficulty may be avoided by relaxing that tissue for a while by the application of a warm sponge to the wound.

The *subcutaneous tissue* is lax and very extensive, and permits of considerable extravasations of blood forming beneath the surface. It is inadvisable, therefore, to apply leeches to the scrotum itself, since they may lead to an undesirable outpouring of blood beneath the skin, and to the appearance of a considerable ecchymosis. Leeches in testicular affections had better be applied over the region of the cord.

The scrotum, from its dependent position, and from the looseness and extent of its cellular tissue, is often the first part of the body to become œdematous in dropsy, and is apt to show that œdema in a marked degree. The scrotum also is the part most frequently the seat of elephantiasis, which is due essentially to a distension of the lymphatic vessels and spaces of the connective tissue. The vitality of the scrotum is not considerable, and it therefore not unfrequently sloughs in parts when severely inflamed. For this reason strapping should be applied with some care over the enlarged testis, for against the hard mass of the affected gland the integument of the scrotum can be subjected to considerable pressure when the strapping is tightly applied. In such a case I have seen the whole of one side of the scrotum slough from an indiscreet use of this familiar method of treatment.

The laxity of the subcutaneous scrotal tissues is an essential feature in those operations for the radical

cure of inguinal hernia where the fundus of the sac is invaginated, through an incision in the scrotum, into the orifice of the inguinal canal. Lastly, the great mobility of the scrotum affords an admirable source of protection to the testicle; for when the part is struck or squeezed the testis can slip about within the scrotum, as a smooth ball would within a loose indiarubber bag, and so very often eludes all injury.

The **testicle** may be retained within the abdominal cavity, or may lodge for varying periods of time, or for life, in the inguinal canal. It may, on the other hand, pass beyond the scrotum into the perineum, or may miss the inguinal canal altogether and escape through the femoral canal and saphenous opening on to the thigh. The testis proper is entirely invested by the visceral layer of the tunica vaginalis, except over a small part of its posterior border where the vessels enter. The epididymis is entirely covered with the serous membrane at its sides, is more or less so covered in front, but is free or uncovered along the greater part of its posterior border. It is about the posterior border of the epididymis that the visceral layer of the tunica vaginalis joins the parietal layer. It is mainly by this uncovered part of the epididymis, and by the vessels, etc., that enter there, that the testicle is fixed, for were the whole organ to be entirely enveloped by the serous membrane, it would lie more or less loosely in the serous cavity as lies the small intestine in the abdomen. This condition occasionally occurs, and in such cases the testicle is liable to strangulation from twisting on its mesentery. The more intimate and extensive connection of the serous tunic with the testis or gland proper serves in part to explain the greater frequency with which hydrocele appears in inflammation of this part of the organ, as compared with its occurrence when the epididymis is alone inflamed. It is owing to the reflections of the tunica vaginalis that in cases of common hydrocele the testicle remains firmly set at the lower and posterior part of the swelling, and yet so extensively is the organ surrounded by that membrane

that the position of the gland in the larger hydroceles is often difficult to determine. In some cases the testicle occupies the front of the scrotum, the epididymis being placed anteriorly, and the body of the gland being located behind it. The vas deferens descends also along the front of the cord. In these cases the testicle is just in the position it would occupy if it had been turned round upon its vertical axis. The condition is known as *inversion of the testicle*, and should be sought for in cases of hydrocele, as in several instances the testis has been pierced by the trochar when tapping collections in which the inversion existed.

The proper gland tissue is invested by a very dense membrane, the *tunica albuginea*. The epididymis, on the other hand, lacks any such firm fibrous investment. The unyielding character of the tunica albuginea serves in great part to explain the intense pain felt in acute affections of the testis proper, a degree of pain which is not reached when the less tightly girt epididymis is alone involved. It will be understood also that in inflammation of the epididymis the part swells rapidly and extensively, while in a like affection of the body of the gland the swelling is comparatively slow to appear.

The tunica albuginea must also for some time resist the growth of testicular tumours. When the testicle suppurates and matter finds an escape through the skin, it is the unyielding character of the tunica albuginea that is mainly answerable for any "fungus" that may form. This fungus merely means the escape of swollen, softened, and inflamed structures through a hole in a more or less rigid membrane, and were that membrane yielding no such protrusion would form. A "fungus" never develops in connection with suppuration of the epididymis alone; at the most an abscess at that part will lead to a troublesome sinus.

It should be borne in mind that the lymphatics of the scrotum go to the inguinal glands, those of the testicle to the lumbar. The testicle is developed in front of the tenth dorsal vertebra, and receives its nerve supply from the tenth dorsal segment. Its nerves pass

by the small splanchnics, solar and aortic plexuses, to the spermatic artery, on which they reach the gland. The epididymis receives its nerve supply from the pelvic plexus, along the vas deferens. In 10 per cent. of cases where castration of both testicles has been performed in adults, the operation was followed by acute mania.

The **spermatic cords**.—The structures in the cord are (1) the vas deferens, (2) the cremaster muscle, (3) the spermatic and (4) cremasteric arteries, and (5) the artery to the vas deferens, (6) the pampiniform plexus of veins, (7) the genito-crural nerve, (8) sympathetic nerve fibres, and (9) lymphatics. The *vas*

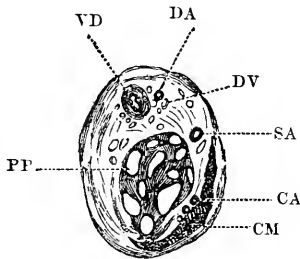


Fig. 53.—Section of the Left Spermatic Cord of an Adult, at the level of the External Abdominal Ring, viewed from above. (From a specimen prepared by Mr. W. G. Spencer.)

VD, Vas deferens; DA, deferential artery; DV, deferential veins; SA, spermatic artery; CA, cremasteric artery; CM, cremaster muscle; PP, pampiniform plexus.

*deferens* lies along the posterior aspect of the cord (Fig. 53), and can be detected by the firm, cord-like sensation which it gives when pinched between the thumb and finger. Mr. Birkett (Holmes' "System") gives three cases of rupture of the vas deferens during severe and sudden exertion. The duct appears to have in each case given way within the abdomen at some point between the internal ring and the spot where it approaches the ureter. The injury is followed, as may be supposed, by atrophy of the corresponding testicle. Resection of part of the vas has been practised to bring about atrophy of enlarged prostate. The size of the *cremaster muscle* depends mainly upon the weight it has to



suspend. In atrophy of the testicle it almost entirely disappears, while in cases of large slow-growing tumours of the gland it attains considerable proportions. If in children or young adults the skin over the middle of the thigh just below Poupart's ligament be tickled the testicle of the same side will usually be seen to be suddenly drawn upwards. The tickling concerns the crural branch of the genito-crural, while the motor nerve of the cremaster is the genital division of the same trunk. The interval of time that elapses between the irritation of the skin and the movement of the testicle has been appealed to as affording evidence of the state of nerve health and of the readiness with which nerve impulses are conducted. Of the *arteries*, the spermatic comes from the aorta and lies in front of the vas, the cremasteric arises from the deep epigastric and lies among the superficial layers of the cord in its outer segment, while the deferential artery from the superior or inferior vesical lies by the side of the vas (Fig. 53). The first-named vessel is the size of the posterior auricular, and the two latter the size of the supraorbital. The three arteries of the cord are divided in castration, and may all require ligature. It is advisable to secure the vessels in sections, rather than adopt the clumsy plan of involving the whole cord in one common ligature. The *veins* are divided roughly into two sets. The anterior is by far the larger set, runs with the spermatic artery, and forms the pampiniform plexus. The posterior set is small and surrounds the vas, running with the deferential artery. The veins of the spermatic and pampiniform plexus are very frequently varicose, and then constitute the affection known as **varicocele**. Many anatomical causes render these veins liable to this affection: they occupy a dependent position, and the main vein is of considerable length, and follows a nearly vertical course; the vessels are very large when compared with the corresponding artery, and so the *vis a tergo* must be reduced to a minimum; they occupy a loose tissue, and are lacking in support and in the aid afforded to other veins (as in the limbs) by muscular contraction; they are

very tortuous, form many anastomoses, and have few and imperfect valves; they are exposed to pressure in their passage through the inguinal canal. The left veins are more frequently affected than the right. Mr. Spencer has shown that the veins in the left cord are always much larger than those of the right. It may also be pointed out that the left testicle hangs lower than the right; that the left spermatic vein enters the left renal at a right angle, while the right spermatic vein passes obliquely into the vena cava; and that the left vein passes beneath the sigmoid flexure, and is thus exposed to pressure from the contents of that bowel. The congenital origin of varicocele is now very generally allowed.

When the varicose veins are exposed by operation it is impossible to isolate or even recognise the arteries.

The **female generative organs** require but little notice in the present volume. The *labia majora* have the same pathological tendencies as has the scrotum, to which, indeed, they anatomically correspond. They are liable to present large extravasations of blood, are greatly swollen when œdematous, are prone to slough when acutely inflamed, and are the usual seats of elephantiasis in the female. A hernia may present in one or other labium (pudendal hernia), the neck of the sac being between the vagina and the pubic ramus.

“On everting one of the labia minora and pressing the hymen inwards, a small red depression may generally be seen on the vulva, somewhat posteriorly. It leads to the orifice of *Cowper's duct*” (Doran). Cowper's gland, an oval body about  $\frac{1}{2}$  an inch in length, lies against the posterior part of the vaginal orifice, under the superficial perineal fascia, and covered by the fibres of the sphincter vaginæ. It wastes after thirty. Abscess of the gland and cystic dilatation of its duct are not uncommon.

The *vagina* is lodged between the bladder and rectum, while the upper fourth of its posterior surface is covered with peritoneum, and is therefore in relation to the abdominal cavity. Thus it happens that the bladder,

the rectum, or the small intestines, may protrude into the vagina by a yielding of some parts of its walls and thus produce a vaginal cystocele, rectocele, or enterocele.

The anterior wall of the vagina measures a little over 2 inches, the posterior wall about 3 inches. The long axis of the canal forms an angle of  $60^{\circ}$  with the horizon, and is therefore almost parallel to the pelvic brim. The loose areolar tissue at the base of the broad ligament lies on each side of the upper extremity of the vagina. The ureter terminates in the bladder, on the upper part of its roof.

The abdominal cavity may be opened through a wound of the vagina. In one or two instances of such injuries several feet of intestine have protruded through the vulva. In one reported case an old woman, the subject of a brutal rape, walked nearly a mile with several coils of the small bowel hanging from her genitals.

From the comparative thinness of the walls that separate the vagina from the bladder and rectum, it happens that vesico-vaginal and recto-vaginal fistulæ are of frequent occurrence. The vagina is very vascular, and wounds of its walls have led to fatal hæmorrhage. It is very dilatable, as can be shown when the canal is plugged to arrest hæmorrhage from the uterus.

The *uterus* weighs about one ounce. The uterine cavity and the cervical canal together measure about  $2\frac{1}{2}$  inches. This must be borne in mind when passing a uterine sound. The blood-vessels run transversely to the length of the uterus, so that a ligature may be placed completely around the organ without affecting the circulation above or below. Ligature of the *uterine artery* has been practised to arrest the growth of uterine tumours. The artery rises from the internal iliac  $\frac{1}{2}$  an inch below the pelvic brim and passes to the neck of the uterus in the broad ligament. It is  $2\frac{1}{2}$  inches long and loops over the ureter midway. It is reached by incising the broad ligament between the Fallopian tube behind and the round ligament in front. It is found in the loose areolar tissue under the wound.

The *lymphatics* from the fundus of the uterus and appendages pass to the lumbar glands, a few also pass along the round ligament to the inguinal glands. The lymphatics of the cervix, which is frequently the seat of cancer, pass to the internal iliac glands on the lateral wall of the pelvis.

The unimpregnated uterus is very rarely wounded, owing its immunity to the denseness of its walls, to its small size, to its great mobility, and to its position within the bony pelvis.

The *ovary* is so placed that the outer part of the Fallopian tube turns downwards external to it. "Both ovaries lie in a sagittal plane against the side walls of the pelvis, with their long axes nearly vertical; so that their surfaces are internal and external, borders anterior and posterior, and extremities upper and lower" (Symington). It lies in the angle between the external and internal iliac arteries and may be indistinctly palpated through the vagina. Its nerves come from the tenth dorsal segment of the cord. The sensory nerves for the cervix are derived from the lower sacral segments. The lymphatics of the ovary pass to the lumbar glands. The ovaries exert atrophic influence on the breast. By their removal it was hoped that cancer of the breast might be arrested, but the procedure has not been followed by much success. The main ovarian vessels lie close to the outer part of the organ, after passing along a short fold of peritoneum, which runs from the brim of the pelvis to the ovary, and is termed the infundibulo-pelvic ligament. This ligament forms the outer part of the pedicle in ovariectomy.

The **rectum** in the *adult* is situated entirely within the true pelvis, and presents three marked curves, one in the lateral and two in the antero-posterior direction (*see* page 342). In the *infant*, however, a good deal of the rectum is in the abdominal rather than the pelvic cavity, the gut is nearly straight, and occupies a more or less vertical position. For these reasons, together with the fact that the sacrum is straight, the prostate small, and the connections of the bowel

loose, prolapsus ani is much more common in children than in adults. Children are, besides, especially liable to such exciting causes of prolapse as worms and rectal polypi.

The rectum is about 8 inches in length. Its upper part, for some 3 inches, is entirely invested by peritoneum. The *serous membrane* gradually leaves its posterior surface, then its sides, and lastly its anterior surface. Anteriorly, the peritoneum, in the form of the rectovesical pouch, extends in the male to within 3 inches of the anus, while on the posterior aspect of the gut there is no peritoneum below a spot 5 inches from the anus. Thus, in excision of the rectum, more of the bowel can be removed on the posterior than on the anterior part of the tube. It will be seen, also, that carcinomatous and other spreading ulcers are more apt to invade the peritoneal cavity when they are situated in the anterior wall of the intestine. The internal sphincter surrounds the lower part of the rectum, an inch above the anus, and extends over about  $\frac{1}{2}$  an inch of the intestine. Mr. Cripps has shown that the posterior edge of the levator ani forms a distinctly felt free border, which crosses the rectum, nearly at a right angle at a point from  $1\frac{1}{2}$  to 2 inches from the anus. The third stage of the rectum (anal canal) is firmly fixed by the levator ani and is seldom involved in prolapse of the rectum.

By inserting the finger into the rectum the prostate and seminal vesicles can be readily felt and examined, and that triangular surface of the bladder explored through which puncture *per rectum* is made (page 394).

It will be understood that the prostate, when enlarged, may encroach upon the cavity of the rectum and greatly narrow its lumen. The position of the seminal vesicles with regard to the bowel is such that in violent attempts at defæcation they may be pressed upon by the rectal contents, and so in part emptied, producing a kind of spermatorrhœa. Defæcation also often causes much pain in inflammatory affections of the prostate and adjacent parts.

The anterior surface of the rectum in the female

is in relation, so far as the finger can reach, with the vagina, and in examining the lower part of the rectum, it is convenient to protrude its mucous membrane through the anus by means of the finger introduced into the genital passage.

The rectum is dilated, and is very distensible just above the anus. In fæcal accumulations it may be distended to a considerable size, and strange foreign bodies of large dimensions have been found in the ampulla. Among the latter may be mentioned a bullock's horn, an iron match-box, and a glass tumbler. Experiment has shown that when the rectum is distended in the male, the recto-vesical fold of peritoneum is raised, and the bladder is elevated and pushed forwards. In the female the fundus uteri is raised and pushed towards the symphysis. The rectum is artificially distended in suprapubic lithotomy, in order to bring the bladder into better position (page 390).

If the sphincter be very gradually dilated, the *entire hand*, if small, may be introduced into the rectum in both males and females. The circumference of the hand should not exceed 8 inches. By a semi-rotary movement, and by alternately flexing and extending the fingers, the hand can be insinuated into the commencement of the sigmoid flexure. Owing to the mobility of this part of the bowel a large extent of the abdomen may be explored through the bowel wall. The structures that can be readily felt are the kidney, the aorta, the iliac vessels, the uterus and ovaries, the bladder and its surroundings, the pelvic brim, the sacro-sciatic foramina, the ischial spine, the sacrum, etc. In some subjects even a small hand cannot be passed beyond the reflection of the peritoneum over the second part of the gut. In such instances the peritoneum offers a resistance like a tight garter, and prevents the farther advance of the hand without great risk of laceration of the parts (Walsham).

Owing to the constrained position of the hand and the cramping of the fingers, this method of examination has proved to be of but limited service.

Mr. Davy has invented a wooden "lever," by which the common iliac arteries may be compressed against the pelvic brim through the rectum. The lever has been used in arresting hæmorrhage during amputation through the hip joint. The instrument, however, is of little practical value.

The *attachments of the rectum* by means of the pelvic fascia are not very firm; since, in some severe and rare cases of prolapse, all the walls of the gut may be protruded at the anus. In excision of the rectum, also, advantage is taken of this mobility.

The *mucous membrane* is thick, vascular, and but loosely attached to the muscular coat beneath. This laxity, which is more marked in children, favours prolapse, an affection in which the mucous membrane of the lower part of the rectum is protruded at the anus. The mucous membrane presents three prominent semi-lunar folds, about  $\frac{1}{2}$  an inch in depth, which are placed more or less transversely to the long axis of the bowel. The first projects backwards from the fore part of the rectum opposite the prostate, the second projects inwards from the left side of the tube opposite the middle of the sacrum, the third is near the commencement of the bowel on the right side. These folds, especially when the gut is empty, may offer considerable resistance to the introduction of a bougie or long enema tube, and their position should be therefore borne in mind.

The *vessels*, and especially the veins, at the lower part of the rectum, are apt to become varicose and dilated, and form piles. The tendency to piles can in part be explained by the dependent position of the rectum, by the pressure effects of hardened fæces upon the returning veins, and by the fact that part of the venous blood returns through the systemic system (internal iliac vein) and part through the portal system (inferior mesenteric vein). This connection with the portal trunk causes the rectum to participate in the many forms of congestion incident to that vein. The veins of the rectum, also, can be affected by violent expiratory efforts. For the last 4 inches, moreover, of the bowel, the

arrangement of the vessels is peculiar, and is such as to favour varicosity. The arteries, "having penetrated the muscular coats at different heights, assume a longitudinal direction, passing in parallel lines towards the edge of the bowel. In their progress downwards they communicate with one another at intervals, and they are very freely connected near the orifice, where all the arteries join by transverse branches of considerable size" (Quain). The veins form a plexus with a precisely similar arrangement. The veins beneath the mucous membrane of the anal canal perforate the muscular coat of the rectum about 1 inch above the rectum. At the point of perforation they are liable to be compressed.

The *lymphatics* of the second and third stages of the rectum pass to the internal iliac group of lymphatic glands on the lateral wall of the pelvis. Hence in cancer of the lower part of the rectum these glands and the vessels leading to them are the earliest seats of secondary infections. The lymphatics of the first stage pass to the glands in front of the sacrum and between the layers of the meso-rectum.

The second and third stages of the rectum may be most freely exposed from behind (Fig. 51, p. 383). In *Kraske's operation* for the extirpation of cancer of the rectum an incision is made along the sacrum in the middle line, from the level of the posterior inferior iliac spines to the anus. A flap is turned out on the left side including the skin and origin of the gluteus maximus. The attachments of the left sacro-sciatic ligaments, coccygeus, and levator ani, to the sacrum and coccyx are divided and turned outwards. The lateral and median sacral arteries and a plexus of veins are raised with the fibrous tissue from the anterior surface of the sacrum by a periosteal elevator. The left halves of the fourth and fifth sacral vertebræ, with the left half of the coccyx, are removed. The fourth, fifth sacral and coccygeal nerves are necessarily cut, but an attempt should be made to save the third sacral nerve, owing to the importance of its function. The



second and third stages of the rectum are then exposed, with the hæmorrhoidal vessels and reflection of peritoneum. By opening the peritoneal cavity the greater part of the first stage of the rectum may be brought into the wound. After the diseased part is removed, with the presacral and internal iliac lymphatic glands, the upper end of the rectum is brought down and sutured to the anal part. An attempt should be made to save the levator ani and third sacral nerve, in order that the integrity of the pelvic diaphragm be maintained. The rectum is supplied with sensory and motor nerves from the second, third, and fourth sacral segments through the corresponding nerves. Some motor nerves are also derived from the lower two dorsal and upper lumbar segments. These nerves reach the rectum through the hypogastric and pelvic plexuses. The stimulus which maintains the reflex act of defæcation passes from the mucous membrane of the anal canal.

**Anus.**—The skin about the anus is thrown into numerous folds, and it is in these that the ulcer or fissure of the anus forms. When the anus is closed the vertical columns of Morgagni meet. At their upper ends they are united by small valvular folds of membrane, which prevent the escape of liquid contents. These valves may be torn by the passing scybalous masses, and from the rent thus caused a fissure of the anus may be produced (Ball). The extreme painfulness of these ulcers is due to the exposure of a nerve-fibre at their base, and to the constant contraction of the sphincter muscle that they excite. Relief is given by incising the base of the ulcer, so as to divide some part of the sphincter; or by violently dilating the anus, so as to tear up the base of the ulcer and paralyse for a while the action of the disturbing muscle. A fine white line around the anus, at the junction of the skin and mucous membrane, indicates the interval between the external and internal sphincters (Hilton).

The anus may be torn during defæcation, when the stools are hard. A case is reported of a woman who, during violent efforts at defæcation, felt something

give way, and discovered fæces in her vagina. The recto-vaginal wall had ruptured 2 inches from the anus. During labour the child's head has passed into the rectum, and has been delivered *per anum*.

As congenital defects, the anus and entire rectum may be absent; or the anus be not evident, and the rectum be more or less complete; or the anus and lowest part of the rectum may be normal and the upper part of the bowel be quite wanting.

**Nerves of pelvis and perineum.** — The pelvic viscera are supplied by the pelvic plexus of the sympathetic. This plexus is joined by at least three spinal nerves, the second, third, and fourth sacral.

It is well known that in certain affections of the bladder, rectum, prostate, etc., pain is felt along the perineum, in the penis, over the buttock, and down the thigh. These parts are supplied by the pudic and smallsciatic nerves, and the reason for the pain is explained by the origin of the sensory nerves for those organs from the same segments of the spinal cord. The upper part of the rectum is provided with but little sensation, as illustrated by the passage of instruments, by the comparative painlessness of malignant and other growths high up in the bowel, and by the little inconvenience felt when the gut is distended with hardened fæces. From this apathy it has probably happened that, in the self-administration of enemata, patients have thrust the tube through the rectum into the peritoneal cavity. The last 2 inches of the bowel, on the other hand, are extremely sensitive.

The nerve relations between the anus and the neck of the bladder are very intimate. Painful affections of the anus often cause bladder troubles, and retention of urine is very common after operations upon piles. Maladies, on the other hand, that involve the bladder neck are often associated with tenesmus and anal discomfort. This relation is maintained by the pelvic plexus, but mainly by the fourth sacral nerve. This nerve gives special branches direct to the neck of the bladder, and then goes to supply the muscles of the anus

(the sphincter and levator) and the integument between the anus and the coccyx.

The mucous membrane of the urethra, the muscles of the penis, and the greater part of the skin of the penis, scrotum, perineum, and anus, are supplied, from the second, third, and fourth sacral segments, by the pudic nerve. Thus, it will be understood that irritation applied to the urethra may cause erection of the penis (as illustrated by chordee in gonorrhœa), or may produce contraction of the urethral muscles (as seen in some forms of spasmodic stricture). The disturbance caused by accumulated secretion beneath the prepuce in young children may provoke great irritability of the organ, and it is well known that painful affections of the perineum and anus may be associated with priapism. The distribution of the third sacral segment in the perineum by means of the long pudendal nerve will explain the pain about the buttock and down the back of the thigh that is often complained of during the growth of perineal abscess and in painful affections of the scrotum. This nerve crosses just in front of the tuber ischii, and may be so pressed upon by using a hard seat as to cause one-sided neuralgia of the penis and scrotum. It is also in close connection with the ischial bursa, and neuralgia of the same parts has been met with in cases of inflammation involving that structure.

The testicle is supplied mainly from the tenth dorsal segment by the spermatic plexus. The kidney is also partly supplied from the same segment. This is illustrated by the pain felt in the renal region in neuralgia of the testicle, by the pain felt in the testicle and by the vigorous retraction of that organ observed in certain affections of the kidney, such as in acute nephritis, and in the passage of renal calculi. By means of the renal plexus the testicle is brought into direct communication with the semi-lunar ganglia and solar plexus, which receives some of the terminal fibres of the vagus. This communication serves to explain the great collapse often noticed in sudden injuries to the testicle, and especially

the marked tendency to *vomit*, so often observed in such lesions. So far as its nerves are concerned, the testicle is nearly in as intimate relation with the great nerve-centre of the abdomen as is a great part of the small intestine, and one would expect a sudden crush of the testis to be associated with as severe general symptoms as would accompany a sudden nipping of the ileum in a rupture. Such a resemblance in symptoms is actually to be observed in practice.

## Part V.

### THE LOWER EXTREMITY.

#### CHAPTER XIX.

##### THE REGION OF THE HIP.

THIS region will be considered under the following heads: 1. The buttocks. 2. The region of Scarpa's triangle. 3. The hip joint. 4. The upper third of the femur.

1. The **buttocks**.—**Surface anatomy**.—The bony points about the gluteal region can be well made out. The crest of the ilium is distinct, as is also the anterior superior spine. The posterior superior spine is less evident, but can be readily felt by following the crest to its posterior termination. This spine is on a level with the second sacral spine, and is placed just behind the centre of the sacro-iliac articulation. The great trochanter is a conspicuous landmark. It is covered by the fascial insertion of the gluteal maximus. Its upper border is on a level with the centre of the hip joint, and is somewhat obscured by the tendon of the gluteus medius which passes over it. The comparatively slight prominence of the trochanter in the living subject, as compared with the great projection it forms in the skeleton, depends upon the completeness with which the gluteus medius and minimus fills up the hollow between the trochanter and the ilium. When these muscles are atrophied the process becomes very conspicuous. In fat individuals its position is indicated by a slight but distinct depression over the hip.

If a line be drawn from the anterior superior spine to the most prominent part of the tuber ischii, it will

cross the centre of the acetabulum, and will hit the top of the trochanter. This line, known as Nelaton's line, is frequently made use of in the diagnosis of certain injuries about the hip. For like diagnostic purposes Bryant makes use of a "triangle." As the patient lies in the recumbent posture, a vertical line is dropped from the anterior superior spine. A second line is drawn backwards from the same point to the top of the great trochanter. The triangle is completed by a third line joining the first two, and drawn at right angles to the vertical line. A measurement of this third or test line will show if any shortening has taken place in the neck of the femur. It may be noted that the top of the trochanter is nearly on a level with the pubes.

The tubera ischii are readily felt. They are covered by the fleshy fibres of the gluteus maximus when the hip is extended. But when the hip is flexed, the processes become to a great extent uncovered by that muscle. The muscular mass of the buttock is formed by the gluteus maximus behind and by the gluteus medius and minimus and tensor vaginæ femoris in front. The latter muscle can be seen when in action, *i.e.*, when the thigh is abducted and rotated in.

The fold of the buttock is considerably above the level of the lower border of the gluteus maximus, with which it therefore does not correspond. When the hip is fully extended, as in the erect posture, the buttocks are round and prominent, the gluteal fold is transverse and very distinct. When the hip is a little flexed, the buttocks become flattened, the gluteal fold becomes oblique and to a large extent disappears. Among the early symptoms of hip disease are flattening of the buttock and loss of the gluteal fold. These symptoms depend upon the flexion of the hip, which is practically constant in every case of the malady before treatment. It is incorrect to say, as some books still assert, that these changes are due to wasting of the gluteal muscles, since they appear at too early a period for any considerable muscular atrophy to have taken place. It is true that these symptoms are much exaggerated

by the wasting of the muscle that occurs later on in the course of the hip affection.

With regard to the vessels and nerves of the buttock, if a line be drawn from the posterior superior spine to the top of the great trochanter when the thigh is rotated in, a point at the junction of the inner with the middle third of that line will correspond to the gluteal artery as it emerges from the sciatic notch. A line drawn from the posterior superior spine to the outer part of the tuber ischii crosses both the posterior inferior and ischial spines. The former is about 2 inches and the latter about 4 inches below the posterior superior process. The sciatic artery reaches the gluteal region at a spot corresponding to the junction of the middle with the lower third of this line. The position of the pudic artery as regards the buttock is not difficult to indicate, since it crosses over the ischial spine in passing from the great to the small sacro-sciatic foramen.

A line drawn from the point just given for the sciatic artery down the back of the limb, so as to lie about midway between the great trochanter and the ischial tuberosity, will correspond to the course of the great sciatic nerve.

The **skin** over the buttock is thick and coarse, and is frequently the seat of boils. From the appearance it presents in very fully injected specimens, it would appear that its blood supply is not quite so free as it is in many other parts of the surface.

The subcutaneous fascia is lax, and contains a large quantity of fat. It is to this fat rather than to muscular development that the buttock owes its roundness and prominence. The enormous buttocks of the so-called "Hottentot Venus," whose model is in many museums, depend for their unusual dimensions upon the greatly increased subcutaneous fat. The amount of adipose tissue normally in the part renders the buttock a favourite place for lipomata. The laxity of the superficial fascia permits large effusions both of blood and pus to take place in the gluteal region, and ecchymoses

of the buttock can probably reach a greater magnitude than is possible elsewhere.

The **deep fascia** of the buttock, a part of the fascia lata of the thigh, is a structure of much importance. This dense membrane is attached above to the iliac crest, and to the sacrum and coccyx. Descending in front over the gluteus medius, it splits on reaching the anterior edge of the gluteus maximus into two layers, one of which passes in front of the muscle and the other behind. The gluteus maximus is thus enclosed, like the meat in a sandwich, between two layers of fascia, and the two lesser gluteal muscles are bound down within an osseo-aponeurotic space, which is firmly closed above, and only open below towards the thigh and internally at the sciatic foramina. Extravasations of blood may take place beneath this fascia without any discoloration of the skin to indicate the fact, the blood being unable to reach the surface through the dense membrane. Such extravasations may be long pent up, and, as they would fluctuate, may be mistaken for abscess.

Deep inflammations beneath this fascia, and especially when beneath the gluteus medius, may be associated with much pain, owing to the circumstance that the inflammatory effusions will be pent up between a wall of bone on one side and a wall of dense fascia and stout muscle on the other. Abscesses so pent up may travel for a considerable distance down the thigh before they reach the surface, and Farabeuf relates a case where a gluteal abscess travelled to the ankle before it broke.

Under other circumstances the gluteal abscess may make its way into the pelvis through the sciatic foramina, or a pelvic abscess may escape through one of these foramina and appear as a deep abscess of the buttock.

The thickened part of the fascia lata that runs down on the outer side of the limb, between the crest of the ileum above and the outer tuberosity of the tibia and head of the fibula below, is known as the ilio-tibial band. This band is tightly stretched across the gap between the iliac crest and the great trochanter, and if pressure



be made with the fingers between these two points, the resistance of this part of the fascia can be appreciated. It is obvious that in fracture of the neck of the femur, when the great trochanter is made to approach nearer to the crest, this band will become relaxed, and Dr. Allis (Agnew's "Surgery," vol. i.) has drawn attention to this fascial relaxation as of value in the diagnosis of fractures of the femoral neck.

The lower free edge of the **gluteus maximus** is oblique, and is some way below the transverse line of the fold of the buttock.

It would appear that even this great muscle may be ruptured by violence. Thus Dr. MacDonnell (*Brit. Med. Journ.*, 1878) reports the case of a robust man, aged sixty-three, who, while trying to lift a heavy cart when in a crouching position, felt something give way in his buttock, and heard a snap. He fell, and was carried home, when it was found that the great gluteal muscle was ruptured near the junction with its tendon.

At least three **bursæ** exist over the great trochanter, separating that process from the three gluteal muscles respectively. The most important of these is the bursa between the gluteus maximus and the bone. When this sac is inflamed much difficulty is experienced in moving the limb, and the thigh is generally kept flexed and adducted. This position means absolute rest from movement on the part of the gluteal muscles, which, when acting, would extend and abduct the limb, and bring pressure to bear upon the tender bursa.

The bursa is quite close to the bone, so close that it is said that caries of the trochanter has followed upon suppuration of the little sac (T. P. Teale). There is a bursa over the ischial tuberosity that is often inflamed in those whose employments involve much sitting, the bursa being directly pressed upon in that position. This sac is the anatomical basis of the disease known in older text-books as "weaver's bottom," or "lighterman's bottom." When enlarged this bursa may press upon the inferior pudendal nerve.

**The arteries and nerves of the buttock.—**

The gluteal artery is about the same size as the ulnar, and the sciatic as the lingual. The former vessel may sometimes be of much greater magnitude, and has led, when wounded, to rapid death from hæmorrhage. Wounds of the gluteal vessels will probably involve only the branches of the artery, since the greater part of the main trunk is situate within the pelvis. Gluteal aneurisms are not very uncommon, and with regard to the treatment of these tumours it may be noted that the gluteal artery, or, better, the internal iliac trunk, can be compressed through the rectum. Compression so applied has been adopted for the treatment of gluteal aneurism by Dr. Sands, of New York (*Amer. Journ. Med. Sc.*, 1881), but without much effect. Aneurism of the commencement of the gluteal artery could hardly fail to provoke nerve symptoms, since the vessel runs between the lumbo-sacral cord and first sacral nerve.

Both the gluteal and sciatic arteries have been ligatured through the buttock, through incisions made directly over the course of the vessels.

Henle has collected six cases where the femoral artery ran down along the back of the thigh to the popliteal space in company with the great sciatic nerve. The abnormal vessel was in each case continued from a greatly enlarged sciatic artery.

The **great sciatic nerve** is a continuation downwards of the main part of the sacral plexus. It is in this nerve that the form of neuralgia known as sciatica is located. A reference to the immediate relations of this nerve will show that it may readily be exposed to many external influences. Thus, in the pelvis it may be pressed upon by various forms of pelvic tumour, and sciatica be produced in consequence. Its anterior surface is in close relation with some of the principal pelvic veins, and according to Erb one form of sciatica may be traced to an engorged condition of these vessels. Aneurism of certain branches of the internal iliac artery within the pelvis, sciatic hernia, and accumulation of fæces within the rectum, may all

cause neuralgia of this important trunk. It is said to have been injured also by the pressure of the foetal head during tedious labours, and to be affected by violent movements of the hip, a circumstance readily understood if the close relation of the nerve to the hip-joint be borne in mind. The nerve is also near enough to the surface to be influenced by external cold, and to this influence many forms of sciatica are ascribed. At the lower edge of the great gluteal muscle the trunk is still nearer to the surface, and this fact receives illustration in a case reported in Ziemssen's Cyclopædia, where paralysis of the nerve followed its compression by the contracting scar of a bed-sore.

**Nerve stretching.**—The great sciatic nerve has been frequently cut down upon and stretched for the relief of certain nervous affections of the limb. In connection with this procedure it is important to know how great an amount of traction may be brought to bear upon this and other nerves without the cord giving way. Trombetta, who has paid much attention to this matter, gives the following weights as those required to break the undermentioned nerves: great sciatic, 183 pounds; internal popliteal, 114 pounds; anterior crural, 83 pounds; median, 83 pounds; ulnar and radial, 59 pounds; brachial plexus in the neck, 48 to 63 pounds; and brachial plexus in the axilla, 35 to 81 pounds. (In each instance fractions have been omitted.) It must be borne in mind, however, as pointed out by Mr. Symington (*Lancet*, 1878), that in forcibly stretching the great sciatic nerve the trunk may be torn away from its attachments to the soft spinal cord before a sufficient force has been applied to rupture the nerve at the point stretched. The same observation applies to other large nerve-cords, such as those of the brachial plexus, that are stretched at a spot not far from their spinal connections. The great sciatic nerve may be stretched by flexing the extended lower extremity on the belly. This measure has served to cure certain cases of sciatica.

The skin of the buttock is well supplied with nerves,

and tactile sensibility is almost as acute in this part as it is over the back of the hand, while it is more acute than is like sensibility in such parts as the back of the neck, the middle of the thigh, and the middle of the back. The sensation of the gluteal integument is derived from a number of different nerves, and it may possibly interest a school-boy who has been recently birched to know that the painful sensations reached his sensorium through some or all of the following nerves : offsets of the posterior branches of the lumbar nerves, some branches of the sacral nerves, the lateral cutaneous branch of the last dorsal nerve, the iliac branch of the ilio-hypogastric nerve, offsets of the external cutaneous nerve, and large branches of the small sciatic. These nerves are derived from four spinal segments—the twelfth dorsal, first lumbar, second and third sacral (Fig. 78, p. 534). The second and third sacral also supply the sexual organs, hence the physiological effects which may follow application of punishment to this part, as in the celebrated case of J. J. Rousseau.

It should be remembered that the pelvic viscera can be readily reached through the sciatic foramina from the buttock. I once saw a case at the London Hospital of a man who was admitted with an apparently insignificant stab of the buttock. He died in a few days, of acute peritonitis ; and the autopsy showed that the dagger had passed through the great sacro-sciatic foramen, had entered the bladder and allowed urine to escape into the peritoneal cavity. The rectum has also been damaged in injuries to the buttock, and Anger records a case of an artificial anus situate upon the buttock, that had followed a gunshot wound, which, after involving the buttock, had opened up the cæcum. It is by this route that Kraske's operation for resection of the rectum is performed.

2. The **region of Scarpa's triangle.**—**Surface anatomy.**—The most important landmarks in the region of the groin, the anterior superior iliac spine, the spine of the pubes, and Poupart's ligament, are readily made out. To the two spines reference

has already been made (page 423). Poupert's ligament follows a curved line, with its convexity downwards, drawn between these two projections. It can be felt in any but stout persons, its inner half more distinctly than its outer, and even in very fat individuals its position is indicated by a slight furrow. Owing to its attachment to the fascia lata the ligament is relaxed, and rendered less distinct when the thigh is flexed and adducted, or when it is rotated in.

The line, often called "Holden's line," is thus described by that surgeon: "When the thigh is even slightly bent, there appears a second furrow in the skin, below that at the crural arch. This second furrow begins at the angle between the scrotum and the thigh, passes outwards, and is gradually lost between the top of the trochanter and the anterior superior spine of the ilium. It runs right across the front of the capsule of the hip-joint. For this reason it is a valuable landmark in amputation at the hip-joint. The point of the knife should be introduced externally where the furrow begins, should run precisely along the line of it, and come out where it ends; so that the capsule of the joint may be opened with the first thrust. . . . Effusion into the joint obliterates all trace of the furrow, and make a fulness when contrasted with the opposite groin." It must be confessed that this line is not always so distinct as Mr. Holden's description would lead us to believe, and in many subjects it is quite impossible to make it out at all.

The sartorius muscle is brought into view when the leg is raised across the opposite knee, and the adductor longus is rendered distinct when the thigh is abducted, and the individual's attempts to adduct the limb are resisted. Even in the obese the clear edge of this muscle can be felt when it is in vigorous action, and the fingers can follow its border up to the very origin of the muscle, just below the pubic spine.

The lymphatic glands in this region can sometimes be felt beneath the skin, especially in thin children. The femoral ring lies on a horizontal line drawn from

the pubic spine to the top of the great trochanter, at about 1 inch to the outer side of the first-named process ; or its position may be indicated by noting the pulsations of the femoral artery against the pubes ; and then, by allowing  $\frac{1}{2}$  an inch to the inner side of that vessel for the femoral vein, the site of the femoral ring will be reached. The position of the saphenous opening is sometimes indicated by a slight depression in the integuments. It lies just below Poupart's ligament, and its centre is about  $1\frac{1}{2}$  inches below and external to the pubic spine. In thin subjects the long saphenous vein can be often made out, passing to the saphenous opening.

If a line be drawn from a point just to the inner side of the middle of Poupart's ligament to the tubercle for the adductor magnus, on the inner condyle of the femur, when the thigh is slightly flexed and abducted, it will correspond in the upper two-thirds of its extent to the position of the femoral artery. Just below Poupart's ligament the femoral vein lies to the inner side of the artery, while the anterior crural nerve runs about  $\frac{1}{4}$  of an inch to its outer side. The profunda femoris arises about  $1\frac{1}{2}$  inches below Poupart's ligament, and the internal and external circumflex vessels come off about 2 inches below that structure.

The head of the femur lies close below the ligament, and just to the outer side of its central point. In very thin subjects this part of the bone can be indistinctly felt through the soft parts when the thigh is extended and rotated outwards.

The **skin** over Scarpa's triangle is, unlike that of the buttock, comparatively thin and fine. The looseness of its attachment, also, to the parts immediately beneath, permits it to be greatly stretched, as is seen in cases of large femoral herniæ, and in certain inguinal tumours of large size. It may even give way under severe traction, as occurred in a case reported by Berne. The patient in this case was a child aged 11, the subject of hip disease. The thighs were flexed upon the abdomen, and, forcible extension being applied to relieve the deformity, the skin gave way just below the groin,

and separated to the extent of some  $2\frac{1}{2}$  inches. Contracting scars in the region of the groin may produce a permanent flexing of the hip, and this result is not uncommon after deep and severe burns this neighbourhood. It may at the same time be noted that horizontal wounds about the groin can be well adjusted by a slight flexion of the thigh.

Instances are recorded where a supernumerary mammary gland, provided with a proper nipple, has been found located in the groin. Jessieu relates the case of a female who had a breast so placed, and who suckled her child from this part. (See page 178.) In a few cases the testicle, instead of descending into the scrotum, has escaped through the crural canal, and made its appearance in Scarpa's triangle. It has even mounted up over Poupart's ligament after the manner of a femoral hernia, being probably urged in that direction by the movements of the limb.

The **superficial fascia** in this region is not very dense, and has little or no influence upon the progress of a superficial abscess. This fact receives extensive illustration, since the glands in Scarpa's triangle frequently suppurate, and yet the pus in the great majority of the cases readily reaches the surface in spite of the circumstance that the denser layer of the superficial fascia (for in this region it is divided into two layers) covers in those glands, and should hinder the progress of pus towards the surface. Although the subcutaneous fat is not peculiarly plentiful in this region, yet Scarpa's triangle is a favourite spot for lipomata. It is in this place that the fatty tumour often exhibits its disposition to travel, and several cases are reported where such a tumour has started at the groin, and travelled some way down the thigh. The journey is always in the direction of gravity, and rendered possible by the lax capsule of the tumour, by the looseness of the tissue in which it is embedded, and by the fluidity of fat at the normal temperature of the body.

The **fascia lata** completely invests the limb, being, so far as the front of the thigh is concerned

attached above to Poupart's ligament, to the body and ramus of the pubes, and the ramus of the ischium. Its integrity is interrupted only by the saphenous opening. This fascia exercises some influence upon deep abscesses and deep growths. Thus a psoas abscess reaches the thigh by following the substance of the psoas muscle, and finds itself, when it arrives at Scarpa's triangle, under the fascia lata. In a great number of cases it points where the psoas muscle ends, but in other and less frequent instances its progress is decidedly influenced by the fascia lata, and it moves down the limb. Thus guided, a psoas abscess has pointed low down in the thigh, and even at the knee, and Erichsen reports a case where such an abscess (commencing, as it did, in the dorsal spine) was ultimately opened by the side of the tendo Achillis.

The ilio-psoas **muscle**, being stretched, as it were, over the front of the hip joint, and participating in many of the movements of that joint, is peculiarly liable to be sprained in violent exercises. Between this muscle and the thinnest part of the hip capsule is a bursa, which often communicates with the joint. When chronically inflamed, this bursa may form a large tumour on the front of the thigh that may, according to Nancrede, attain the size of a child's head. To relieve this bursa from pressure when inflamed, the thigh always becomes flexed, and a train of symptoms is produced that are not unlike those of hip disease.

The bursa is quite close to the pelvic bones, and in one case at least suppuration of this bursa led to necrosis of those bones (Nancrede). The deep origins of the ilio-psoas lie behind the cæcum and kidney, and may elicit symptoms from those organs when contracted. The sartorius is a muscle that, from its length, peculiar action, etc., one would hardly expect to find ruptured from violence, yet in the Musée Dupuytren there is a specimen of such a rupture about the middle of the muscle united by fibrous tissue. The adductor muscles, and especially the adductor longus, are frequently sprained, or even partially ruptured, during horse exercise, the grip of



the saddle being for the most part maintained by them. "Rider's sprains," as such accidents are called, usually involve the muscles close to their pelvic attachments. Much blood is often effused when the fibres are ruptured, and such effusion may become so dense and fibrinous as to form a mass that has been mistaken for a detached piece of the pubes (Henry Morris). The term "rider's bone" refers to an ossification of the upper tendon of the adductor longus or magnus, following a sprain or partial rupture. Cases are reported where the piece of bone in the tendon was  $\frac{1}{2}$  an inch, 2 inches, and even 3 inches long.

**Blood-vessels.**—The femoral artery occupies so superficial a position in Scarpa's triangle that it is not unfrequently wounded. The vessel also has been opened up by cancerous and phagedænic ulcerations of this part, the occurrence leading to fatal hæmorrhage. Pressure is most conveniently applied to the artery at a spot immediately below Poupart's ligament, and should be directed backwards, so as to compress the vessel against the pubes and adjacent parts of the hip capsule. Lower down, compression should be applied in a direction backwards and outwards, so as to bring the artery against the shaft of the femur, which lies at some distance to its outer side. Pressure rudely applied by a tourniquet may cause phlebitis by damaging the vein, or neuralgia by contusing the anterior crural nerve.

From the near proximity of the artery and vein, it happens that arterio-venous aneurisms following wound have been met with in this situation. Aneurism is frequent in the common femoral, and many reasons can be given why that vessel should be attacked. It is just about to bifurcate into two large trunks, its superficial position exposes it to injury, it is greatly influenced by the movements of the hip, and its coat may even be damaged by those movements, if excessive.

Phlebitis of the femoral vein has in many cases followed contusion of the vessel in its upper or more superficial part, and a like result has even followed

from violent flexion of the thigh. The long saphenous vein is often varicose, and one form of the varicosity is said to depend upon constriction of the vein by an unduly narrow saphenous opening. One sometimes meets with cases that may probably be due to this cause; but the evidence is not sufficient to sanction the operation proposed for such cases, viz., an enlargement of the saphenous opening itself. That varicose veins are, in the majority of cases, of congenital origin is now very generally allowed.

The anterior crural **nerve** lies on the ilio-psoas muscle, and it is said that neuralgia, and even paralysis of the nerve, may follow upon inflammation of that muscle and upon psoas abscess. The superficial position of the trunk exposes it to injury. The genito-crural nerve (the nerve that supplies the cremaster muscle) gives a sensory filament to the integument of the thigh in Scarpa's triangle. Irritation of the skin over the seat of this nerve, which is placed just to the outer side of the femoral artery, will cause, in children, a sudden retraction of the testicle. The same result is often seen in adults, also, on more severe stimulation. In this manner the condition of the second lumbar segment of the cord may be tested.

The **lymphatic glands** in this region are numerous, and as they are frequently the seat of abscess, it is important to know from whence they derive their afferent vessels. They are divided into a superficial and deep set. The superficial set, averaging from ten to fifteen glands, are arranged in two clusters, one parallel and close to Poupart's ligament (the horizontal series), the other parallel and close to the long saphenous vein (the vertical series). The deep set, about four in number, are placed along the femoral vein, and reach the crural canal.

The inguinal glands receive the following lymphatics :

*Superficial vessels of lower limb* = vertical set of superficial glands.

*Superficial vessels of lower half of abdomen* = middle glands of horizontal set.

*Superficial vessels from outer surface of buttock* = external glands of horizontal set.

*From inner surface of buttock* = internal glands of horizontal set. (A few of these vessels go to the vertical glands.)

*Superficial vessels from external genitals* = horizontal glands, some few going to vertical set.

*Superficial vessels of perineum* = vertical set.

*Deep lymphatics of lower limb* = deep set of glands.

The lymphatics that accompany the obturator, gluteal, and sciatic arteries, and the deep vessels of the penis, pass to the pelvis and have no concern with the inguinal glands.

One of the deep glands lies in the crural canal and upon the septum crurale. Being surrounded by dense structures, it is apt to cause great distress when inflamed and great pain when the hip is moved. In some cases, by reflex disturbance, it has produced symptoms akin to those of strangulated hernia. Some branches of the anterior crural nerve lie over the inguinal lymph glands, and Sir B. Brodie reports a case in which these branches were stretched over two enlarged glands, like strings of a violin over its bridge, so that violent pain and convulsive movements were set up in the limb.

The efferent vessels from the inguinal glands pass through a chain of lymphatic glands stretching along the course of the external and common iliac vessels. Three of these glands lie immediately above Poupart's ligament. The efferent vessels of the internal iliac group of glands into which the pelvic lymphatics drain, join the chain along the common iliac vessels. The lumbar glands are continuous with these.

Elephantiasis Arabum is more common in the lower limb than in any other part, and leads to an enormous increase in the size of the extremity (Cochin or Barbadoes leg). Its pathology is intimately concerned with the crural lymphatics. The lymphatics are obstructed by a small thread worm, *filaria sanguinis hominis*. The lymph vessels and lymph spaces in the

connective tissue become greatly distended, and the elements of the connective tissue hypertrophied.

The **hip joint**.—The hip joint is an articulation of considerable strength (Fig. 59, p. 455). This strength depends not only upon the shape of the articulating bones, which permits of a good ball and socket joint being formed, but also upon the powerful ligaments that connect them and the muscular bands that directly support the capsule. These advantages, however, are to some extent counterbalanced by the immense leverage that can be brought to bear upon the femur, and the numerous strains and injuries to which the joint is subjected, as the sole connecting link between the trunk and the lower limb.

The *acetabulum* is divided into an articular and a non-articular part. The former is of horse-shoe shape, and varies from 1 inch to  $\frac{1}{2}$  an inch in width. The bone immediately above the articular area is very dense, and through it is transmitted the superincumbent weight of the trunk. The non-articular part corresponds to the area enclosed by the horse-shoe, and is made up of very thin bone. In spite of its thinness it is very rarely fractured by any violence that may drive the femur up against the pelvic bones, since no ordinary force can bring the head of the thigh-bone in contact with this segment of the os innominatum.

Pelvic abscesses sometimes make their way into the hip joint through the non-articular part of the acetabulum, and an abscess in the hip joint may reach the pelvis by the same route. But both such circumstances are rare. In some cases of destructive hip disease the acetabulum may separate into its three component parts. Up to the age of puberty these three bones are separated by the Y-shaped cartilage. At puberty the cartilage begins to ossify, and by the eighteenth year the acetabulum is one continuous mass of bone. The breaking up of the acetabulum by disease, therefore, is only possible before that year.

The manner in which the various movements at the hip are limited may be briefly expressed as follows.

*Flexion*, when the knee is bent, is limited by the contact of the soft parts of the groin, and by some part of the ischio-femoral ligament; when the knee is extended the movement is limited by the hamstring muscles. *Extension* is limited by the ilio-femoral or Y-ligament. *Abduction* by the pubo-femoral ligament. *Adduction* of the flexed limb is limited by the ligamentum teres and ischio-femoral ligament, and of the extended limb by the outer fibres of the ilio-femoral ligament and upper part of the capsule. *Rotation outwards* is resisted by the ilio-femoral ligament, and especially by its inner part, during extension, and by the outer limb of that ligament and the ligamentum teres during flexion. *Rotation inwards* is limited during extension by the ilio-femoral ligament, and during flexion by the ischio-femoral ligament and inner part of the capsule.

**Hip joint disease.**—Owing to its deep position and its thick covering of soft parts, this articulation is able to escape, to a great extent, those severer injuries that are capable of producing acute inflammation in other joints. Acute synovitis is indeed quite rare in the hip, and the ordinary disease of the part is of a distinctly chronic character. It follows also, from the deep position of the articulation, that pus, when it is formed in connection with disease, remains pent up, and is long before it reaches the surface. Suppuration in this region, therefore, is often very destructive. When effusion takes place into the joint, the swelling incident thereto will first show itself in those parts where the hip capsule is the most thin. The thinnest parts of the capsule are in front and behind; in front, in the triangular interval between the inner edge of the Y ligament and the pectineo-femoral ligament, and behind at the posterior and lower part of the capsule. It is over these two districts that the swelling first declares itself in cases of effusion into the joint, and as these parts are readily accessible to pressure, it follows that they correspond also to the regions where tenderness is most marked and is earliest detected.

In chronic hip disease, certain false positions are

assumed by the affected limb, the meaning of which it is important to appreciate. These positions may be arranged as follows, according, as nearly as possible, to their order of appearing.

(1) The thigh is flexed, abducted, and a little everted ; and associated with this there is (2) apparent lengthening of the limb and (3) lordosis of the spine ; (4) the thigh is adducted and inverted, and incident to this there is (5) apparent shortening of the limb ; (6) there is real shortening of the limb.

1. The first position is simply the posture of greatest ease. It depends mainly upon the effusion into the joint. If fluid be forcibly injected into a hip-joint the thigh becomes flexed, abducted, and a little everted. In other words, the articulation holds the most fluid when the limb is in this position, and the patient places it there to relieve pain by reducing the tension within the capsule to a minimum. Flexion is the most marked feature in this position. Its effect is pronounced. It relaxes the main part of the **Y** ligament, which, when the limb is straight, is drawn as an unyielding band across the front of the joint. Abduction relaxes the outer limb of this ligament and the upper part of the capsule. Eversion slightly relaxes the inner limb of the **Y** ligament and the ischio-femoral ligament. The latter movement is the least marked, since eversion, even in the flexed position of the joint, is resisted by the outer part of the **Y** ligament. Any but a moderate degree of abduction would be limited by the pubo-femoral ligament, especially as that band is rendered most tense when abduction is combined with flexion and rotation outwards. The attachments of the psoas muscle are approximated and its pressure over the joint relaxed.

2. The apparent lengthening is due to the tilting down of the pelvis on the diseased side, and is the result of the patient's attempts to overcome the effects of the position just described. The limb is shortened by flexion and abduction, and to bring the foot again to the ground and to restore the natural parallelism of

the limbs, the pelvis has to be tilted down on the affected side. Thus, an apparent lengthening is produced, which is seen when the patient lies upon a bed and the abduction is made to disappear. Real lengthening of the limb can scarcely be produced by the effusion into the joint. By forcible injection into the joint Braune could only separate the articulating surfaces about  $\frac{1}{8}$ th of an inch.

3. The lordosis, or curving forwards, of the spine occurs in the dorso-lumbar region. It depends upon the flexion of the limb, and is the result of an attempt to conceal that false position, or at least to minimise its inconveniences (Fig. 54). When the thigh is flexed at the hip by disease, the lower limb can be made to appear straight by simply bending the spine forwards in the dorso-lumbar region without effecting the least movement at the disordered joint. Indeed,

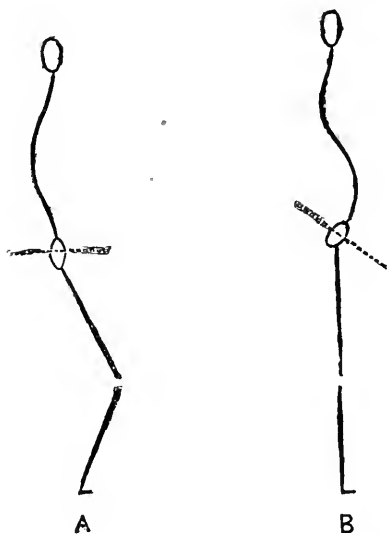


Fig. 54.—Diagram to show the Mode of Production of Lordosis in Hip Disease.

A, Femur flexed at hip, pelvis (represented by the dotted line) straight, and spine normal. B, The flexion concealed or overcome by lordosis of the spine; the pelvis rendered oblique.

the movement proper to the hip is in this case transferred to the spine. A patient with a flexed hip as the result of disease can lie on his back in bed, with both limbs apparently perfectly straight, he having concealed the flexion, as it were, by producing a lordosis of the spine. If the lordosis be corrected, and the spine be made straight again, then the flexion of the hip reappears, although all the time the hip-joint has been absolutely rigid. This lordosis generally appears a little late in the disease,

and after the limb has become more or less fixed in the false positions by contraction of the surrounding muscles.

4. Sooner or later, in hip disease, the thigh becomes adducted and inverted, while it still remains flexed. The head of the femur then rests on the upper and posterior part of the acetabulum, quite half of it being outside the socket. This position has been variously accounted for. According to one theory, it is due to softening and yielding of some parts of the inflamed capsule. This view is set forth by Mr. Barker, in his admirable monograph on joint disease in Holmes' "System of Surgery," in the following words: "As the inflamed capsule commences to soften, its weakest part yields first, *i.e.* the posterior inferior. This now admits of more flexion still. . . . The horizontal posterior fibres, which in the distended condition of the capsule help in the eversion, are the next to stretch, admitting of inversion, which is now the more possible as the Y is relaxed by flexion, and its inner limb has no strain to be taken off by eversion. Finally, the upper and outer anterior fibres yield, and adduction then takes place." This explanation is a little unsatisfactory; and it is more probable that this false position, and especially the adduction, depends upon muscular action. The muscles about the joint are in a state of irritability. They are contracted by a reflex action that starts from the inflamed articulation, and since the adductor muscles are supplied almost solely by the obturator nerve, it is not unreasonable to expect them to be especially disturbed if the large share that the obturator nerve takes in the supply of the hip be borne in mind. The adductors are also rotators outwards, but this latter movement would be resisted by the strong outer limb of the Y ligament, as well as by the ligamentum teres, both of which are rendered tense by rotation outwards during flexion. The whole matter, however, requires further investigation.

5. Apparent shortening of the limb is due to tilting up of the pelvis on the diseased side, and bears the same



relation to adduction that apparent lengthening bears to abduction. To overcome the adduction, and to restore the natural parallelism of the limbs, the patient tilts up one side of his pelvis (Fig 55). It thus happens

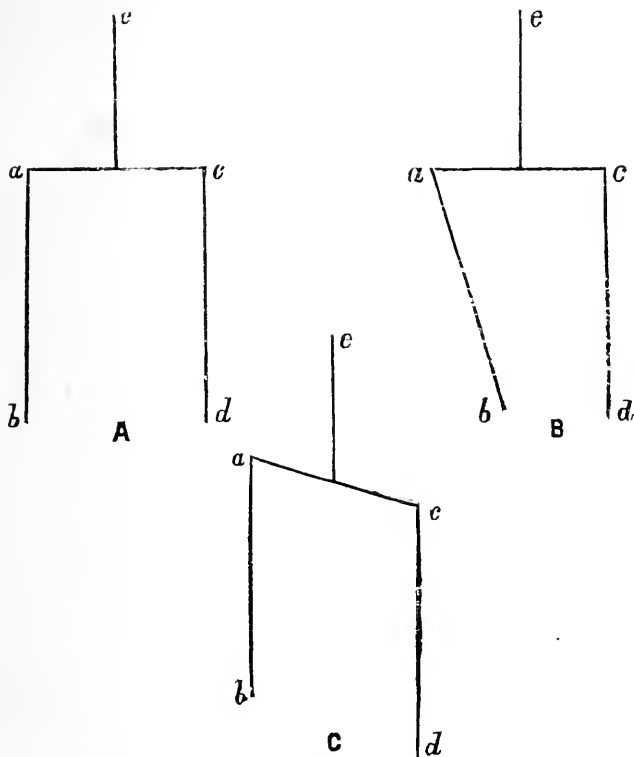


Fig. 55.—A, Parts in Normal Position. b, Femur adducted. c, The Adduction corrected by tilting up the Pelvis.

*ac*, Line of pelvis; *ab*, limb on diseased side; *cd*, limb on sound side; *e*, the spine. It will be found that in Figs. B and C, the angle at *a* is the same in the two cases.

that a patient with his femur flexed and adducted by disease may lie in bed with both limbs quite straight and parallel, but with one limb obviously shorter than the other. The flexion in such a case is concealed by lordosis, and the adduction by the tilting of the pelvis.

In some cases of simultaneous disease in both hip-joints that has been indifferently treated, both thighs may remain adducted. The limbs are unable, of course, to remedy their position by the usual means, when the disease is double, and consequently one limb is crossed in front of the other, and the peculiar mode of progression known as "cross-legged progression" is produced.

6. The real shortening depends upon destructive changes in the head of the bone, or upon dislocation of the partly disintegrated head on to the dorsum ilii, through yielding of the softened capsule and the crumbling away of the upper and posterior margin of the acetabulum.

When hip disease commences in bone it usually involves the epiphyseal line that unites the head of the femur to the neck. This line is wholly within the joint, and the epiphysis that forms the head unites with the rest of the bone about the eighteenth or nineteenth year.

When the bone is primarily involved the position of flexion and abduction with eversion may not be observed at all, there being no effusion at first into the joint. In such cases the limb becomes at once flexed and adducted, and this posture is probably due solely to muscular spasm, and to an attempt to prevent the head of the femur from pressing against the acetabulum, and so causing pain.

It is well known that patients with hip disease often complain of pain in the knee. This referred pain may be so marked as to entirely withdraw attention from the true seat of disease. Thus I once had a child sent to the hospital with a sound knee carefully secured in splints, but without any appliance to the hip, which was the seat of a somewhat active inflammation. This referred pain is easy to understand, since the two joints are supplied from the same segments of the spinal cord. In the hip, branches from (1) the anterior crural enter at the front of the capsule; (2) branches from the obturator at the lower and inner part of the capsule;

and (3) branches from the sacral plexus and sciatic nerve at the posterior part of the joint. In the knee, branches from (1) the anterior crural (nerves to vasti) enter at the front of the capsule; (2) branches from the obturator at the posterior part of the capsule; and (3) branches from the internal and external popliteal divisions of the great sciatic nerve at the lateral and hinder aspects of the joint.

Pain, therefore, in the front of the knee, on one or both sides of the patella, has probably been referred along the anterior crural curve, and pain at the back of the joint along the obturator or sciatic nerves.

In hysterical individuals joint disease may be imitated by certain local nervous phenomena, the articulation itself being quite free from structural change. This affection most commonly shows itself in the hip or knee, and the "hysterical hip," or "hysterical knee," takes a prominent place in the symptomatology of hysteria. It is not quite easy to understand why these two large joints should be so frequently selected for the mimicry of disease. Hilton has endeavoured to explain the fact upon anatomical grounds, having reference to the nerve supply of these joints in relation to the nerve supply of the uterus. The uterus is mainly supplied by an offshoot from the hypogastric plexus, and by the third and fourth sacral nerves. Now, the hypogastric plexus contains filaments derived from the lower lumbar nerves; and from the same trunks two nerves to the hip and knee (the anterior crural and obturator) are in great part derived. The great sciatic also contains a large portion of the third sacral nerve. The common origin of the joint and uterine nerves forms the basis of Hilton's explanation of the relative frequency of hysterical disease in the large articulations of the lower limb. The explanation, however, is unsatisfactory, since the uterus receives many of its nerves from the ovarian plexus, and the theory is founded upon the unwarranted supposition that all hysterical disorders are associated with some affection of the uterus or its appendages. More recently Head has revived a modified

form of Hilton's theory. He explains the connection not through an anatomical association of nerves, but through an association of the centres from which nerves arise in the spinal cord. The spinal segments from which the obturator nerve arises, the second, third, and fourth, contain no visceral nerves, and, therefore, cannot be associated with visceral conditions. On the other hand, the sacral segments from which the great sciatic nerve arises are those which supply the pelvic viscera.

**Fractures of the upper end of the femur** may be divided into (1) fractures of the neck wholly within the capsule; (2) fractures of the base of the neck not wholly within the capsule; (3) fractures of the base of the neck involving the great trochanter; (4) separations of epiphyses. It can be scarcely possible, apart from gunshot injuries, to fracture the neck of the femur by direct violence, owing to the depth at which the bone is placed, and the manner in which it is protected by the surrounding muscles. The violence, therefore, that causes the lesion is nearly always supplied indirectly to the bone, as by a fall upon the feet or great trochanter, or by a sudden wrench of the lower limb.

M. Rodet, by a series of experiments, concludes that the situation of the fracture can be predicated by a knowledge of the direction in which the violence has acted. "Thus, a force acting vertically, as in falling on the feet or knees, will produce an oblique intracapsular fracture; a force acting from before backwards, a transverse intracapsular fracture; one from behind forwards, a fracture partly within and partly without the capsule; and a force applied transversely, a fracture entirely without the capsule." (Quoted by Henry Morris; Holmes' "System of Surgery.")

1. The true intracapsular fracture may involve any part of the cervix within the joint, but is most usually found near the line of junction of the head with the neck. This fracture is most common in the old, in whom it may be produced by very slight degrees of violence. The liability of the aged to this lesion is explained upon the following grounds. The angle

between the neck and shaft of the femur, which will be about  $130^\circ$  in a child, tends to diminish as age advances, so that in the old it is commonly about  $125^\circ$ . In certain aged subjects, as a result probably of gross degenerative changes, this angle may be reduced to a right angle. This diminution of the angle certainly increases the risk of fracture of the neck of the bone. There is often, also, in advanced life, much fatty degeneration of the cancellous tissue of the cervix with thinning of the compact layer. Dr. Merkel (*Amer. Journ. Med. Sc.*, 1874) also asserts that in old persons there is an absorption of that process of the cortical substance which runs on the anterior part of the neck between the lesser trochanter and the under part of the head. This process he calls the "calcar femorale," and maintains that it occupies the situation at which the greatest pressure falls when the body is erect. These fractures are but rarely impacted; but when impacted, the lower fragment, represented by the relatively small and compact neck, is driven into the larger and more cancellous fragment made up of the head of the bone. The fracture may be subperiosteal, or the fragments may be held together by the reflected portion of the capsule. These reflected fibres pass along the neck of the bone from the attachment of the capsule at the femur to a point on the cervix much nearer to the head. "These reflected fibres occur at three places, one corresponding in position to the middle of the ilio-femoral ligament, another to the pectineo-femoral, and the third on the upper and back part of the neck" (Henry Morris). Fractures of this part very rarely indeed unite by bone. Blood is brought to the head of the bone by the cervix, the reflected parts of the capsule, and the ligamentum teres. When the first two sources of blood supply are cut off by the fracture the third does not appear to be sufficient to allow of great reparative changes taking place in the upper fragment. The fractures that heal by bone are probably either impacted, or subperiosteal, or not wholly intracapsular.

2. With regard to fractures at the base of the

neck, it must be remembered that a wholly extracapsular fracture of the neck of the femur is an anatomical impossibility. If the fracture is wholly without the capsule, then it must involve a part of the femoral shaft, and cannot be entirely through the cervix. In the front of the bone the capsule is attached to the femur along a part of the inter-trochanteric line, and strictly follows the line of junction between the cervix and the shaft. Behind, the capsule is inserted into the neck about  $\frac{1}{2}$  an inch in front of the posterior inter-trochanteric line. It is therefore possible for a fracture of the neck to be extracapsular behind, but not in front, and many of these lesions at the base of the neck have this relation to the capsule. The Y ligament is so thick, being in one place about  $\frac{1}{4}$  of an inch in thickness, that a fracture involving the base of the cervix may run between its fibres at their attachment, and be neither extra nor intracapsular. When fractures at the junction of the neck and shaft are impacted, the upper fragment, represented by the compact and relatively small cervix, is driven into the cancellous tissue about the great trochanter and upper end of the shaft. As a result of this impaction the trochanter may be split up, and the bones may become free again through the extent of this splintering.

With regard to the **symptoms of a fracture of the neck of the femur**, the following may be noticed: (a) The swelling often observed in the front of the limb, just below Poupart's ligament, is due either to effusion of blood into the joint or to projection of the fragments against the front of the capsule; (b) the shortening is brought about by the glutei, the hamstrings, the tensor vaginæ femoris, the rectus, sartorius, and ilio-psoas, the adductors, gracilis and pectineus; (c) the eversion, or rotation outwards of the limb, is mainly due to two causes: (1) The weight of the limb, which causes it to roll outwards, as is seen in persons insensible or asleep, the line of gravity passing through the outer part of the thigh; (2) the fact that the compact tissue on the posterior aspect of the neck is much more fragile than that on the anterior aspect.

Thus the cervix is often more extensively fractured behind than in front, or the fracture may be impacted behind but not in front, and in either case the limb will tend to become everted. As a third cause may be mentioned the action of the ilio-psoas, the adductor and pectineus muscles, and of the small rotator muscles, all of which will tend to roll the femur outwards.

3. Fracture of the base of the neck, involving the great trochanter. In this lesion the head, the cervix, and a part of the great trochanter are separated from the shaft and rest of the trochanter.

4. Separation of epiphyses. There are three epiphyses in the upper end of the femur: one for the head, which unites between eighteen and nineteen; one for the lesser trochanter, which unites about seventeen; and one for the greater trochanter, which unites about eighteen. The neck is formed by an extension of ossification from the shaft. A few cases are recorded where it is supposed that the caput femoris was separated at the epiphyseal line by violence, but the accident is, I believe, illustrated by no actual specimens. Mr. Henry Morris has collected five cases of separation of the epiphysis of the great trochanter. This separation, if complete, could hardly avoid being intracapsular in part, since the capsule is attached to the anterior superior angle of the trochanter itself.

In the condition known as *coxa vara* the neck of the femur sinks under the weight of the body, coming to form an angle of  $90^\circ$  or less with the shaft of the femur. It occurs in adolescents. Owing to the prominence of the trochanter and shortening of the limb which necessarily result, the condition may be mistaken for a fracture of the neck of the femur or a congenital dislocation of the hip-joint.

**Dislocations of the hip.**—These injuries are comparatively rare, on account of the great strength of the articulation, and when they occur in a healthy joint are always the result of a considerable degree of violence. A dislocation of the hip may be congenital, or may be spontaneously produced by muscular efforts,

as shown in a few rare cases, or may be the result of disease of the articulation. *Congenital dislocation of the hip joint* is due in most instances to a failure in the development of the acetabulum. In such cases the acetabulum retains the shallow character seen during the second month of foetal life. The outgrowth of the acetabular rim fails, especially the iliac part. The head of the femur is flat and the neck short, and the bone slips backwards on the dorsum ilii when the child learns to walk. The weight of the body is supported by the muscles and ligaments round the hip-joint. If replaced the head again slips from the shallow cavity. In time osteophytic outgrowths from the ilium lead to the formation of a new cavity.

In *dislocations due to violence* the head of the bone may be found displaced in four directions, producing the four regular dislocations of the hip. In two the head of the femur is posterior to a line drawn vertically through the acetabulum, and in the other two it is found anterior to that line.

(1) Backwards and upwards. Head rests upon ilium, just above and behind acetabulum. The "*dislocation upon the dorsum ilii.*" (2) Backwards. Head rests upon ischium, and, as a rule, about on a level with the ischial spine. The "*dislocation into the sciatic notch.*" (3) Forwards and downwards. Head rests on thyroid foramen. The "*obturator or thyroid dislocation.*" (4) Forwards and upwards. Head rests upon the body of the pubes, close to its junction with the ileum. The "*dislocation upon the pubes.*"

The above arrangement represents also the order of frequency of these luxations, No. 1 being the most common dislocation of this part, and No. 4 the most rare.

**General facts.**—In all these dislocations of the hip, (a) the luxation occurs when the limb is in the position of abduction; (b) the rent in the capsule is always at its posterior and lower part; (c) the head of the bone always passes at first more or less directly downwards; (d) the Y ligament is untorn, while the ligamentum teres is ruptured.



(a) It is maintained that in all luxations at the hip, the pelvis and femur are in the mutual position of abduction of the latter at the time of the accident. The direction of the neck of the femur and of the acetabulum, and the position of the cotyloid notch, all favour dislocation in the abducted posture. The lower and inner part of the acetabulum is very shallow, and the lower and posterior part of the capsule is very thin. In abduction, the head of the bone is brought to the shallow part of the acetabulum; it moves more than half out of that cavity; it is supported only by the thin weak part of the capsule, and its further movement in the direction of abduction is limited only by the pectineo-femoral ligament, a somewhat feeble band. In abduction the round ligament is slack, and in abduction with flexion both the Y ligament and the ischio-femoral ligaments are also relaxed. In the position of abduction, therefore, no great degree of force may be required to thrust the head of the bone through the lower and posterior part of the capsule and displace it downwards.

(b) The above being allowed, it will be understood that the rent in the capsule is always at its posterior and lower parts. "Generally the rupture is jagged and irregular, but will be found to extend more or less directly from near the shallow rim of the acetabulum, across the thin portion of the capsule to the femur near the small trochanter, and then to run along the back of the ligament close to its attachment to the neck of the bone" (Henry Morris).

(c) If the position of the limb at the time of the accident be considered, it will be seen that the femur will in *every* case be displaced downwards. There is, indeed, but one primary dislocation of the hip—a luxation downwards. The four forms given above are all secondary, the bone having in each instance first passed downwards before it moved to any of the positions indicated. This point has been ably demonstrated by Mr. Henry Morris, whose account of the anatomy of hip dislocations is most valuable. The head having left the acetabulum, its ultimate destination will depend

upon the character of the dislocating force. "If the limb be flexed on the pelvis, and rotated inwards, or the pelvis be correspondingly moved on the thigh at the moment of displacement, the head of the femur will take a backward course and rest on the dorsum ilii or some part of the ischium. On the other hand, extension and outward rotation will cause the head of the bone to travel upwards and forwards, and what

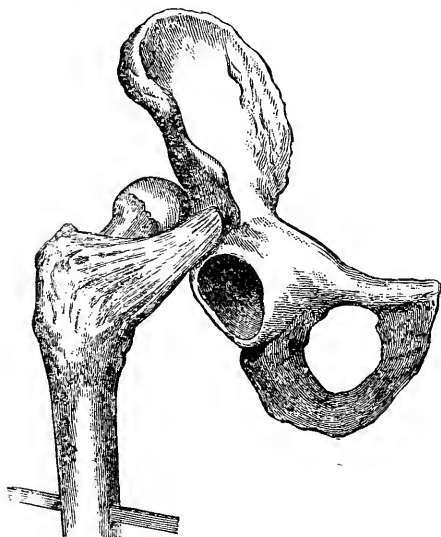

Fig. 56.—Dislocation upon the Dorsum ilii (Bigelow).

is called a dislocation on to the pubis will occur. . . . If the dislocation is neither accompanied nor followed by rotation or fixed flexion or extension, the head of the femur will remain below the acetabulum, and will occupy the foramen ovale if it takes a slightly forward direction in its descent, or some position near the tuberosity of the ischium if it leaves its socket in a backward and downward direction" (Henry Morris).

(d) The Y ligament is never torn in any "regular" dislocation. It is saved by its great density and the circumstance that it is probably more or less relaxed at the time of the luxation. The method of reducing these dislocations by manipulation depends for its success mainly upon the integrity of the Y ligament, which acts as the fulcrum to a lever of which the shaft of the femur is the long arm and the neck the short. In the backward luxations the head is behind the Y ligament, and in the forward displacements in front of it.

The **anatomy of each form.**—Nos. 1 and 2. *The dislocations backwards.* Here the femoral head, having been displaced in the way indicated, is carried towards the dorsum or sciatic notch by the glutei, hamstring, and adductor muscles. The bone having taken a general direction backwards, the height to which it ascends depends mainly upon the nature of the dislocating force, and also upon the extent of the rupture in the capsule and the laceration of the obturator internus tendon and other small external rotators. The dorsal dislocation is, therefore, a more advanced grade of the sciatic. The more extreme the flexion and inward rotation at the time of the accident, the more likely is the dislocation to be sciatic. More moderate flexion and inward rotation will produce a luxation upon the dorsum. In the dorsal luxation the head is above the obturator internus tendon, while in the sciatic form it is below it (Bigelow). Morris has been able to find but one case of direct dislocation of the femur backwards on to the ischium. In every instance it passes first in a downward direction, and then backwards.

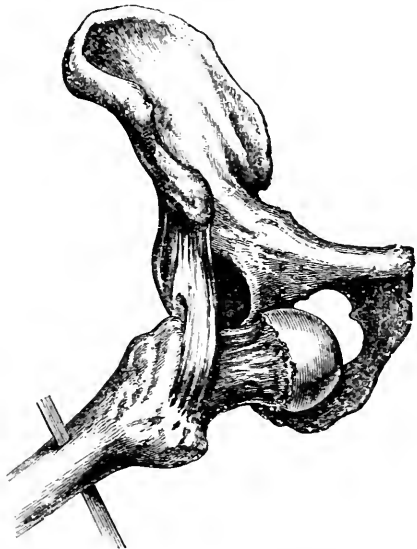


Fig. 57.—Obturator or Thyrcid Dislocation (Bigelow).

Bigelow states that there is no evidence to show that the head of the femur has ever been actually displaced into the sciatic notch.

In these backward dislocations the ilio-psoas muscle

is greatly stretched. The quadratus femoris, the obturators, the gemelli, and the pyriformis are more or less lacerated. The pectineus is often torn, and the glutei muscles even may be ruptured in part. The great sciatic nerve may be compressed between the femoral neck and the rotator muscles, or between the head of the bone and the tuber ischii. In both of the

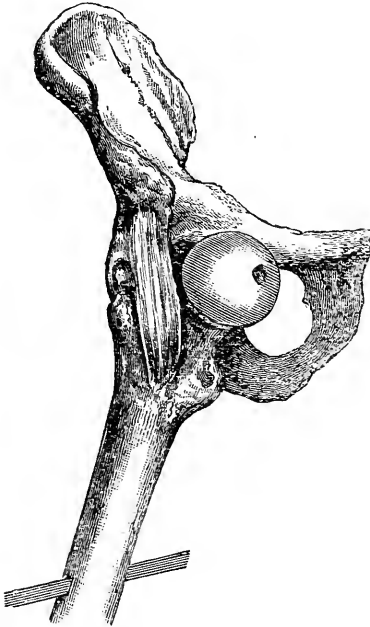


Fig. 58.--Dislocation upon the Pubes (Bigelow).

backward luxations there is shortening, due to the circumstance that the line between the anterior superior spine and the femoral condyles is lessened by the displacement backwards of the bone, with the additional shortening in the dorsal dislocation brought about by the passing of the femoral head above the level of the acetabulum. The adduction and inversion in the main depend upon the position of the head and cervix, which must follow the plane of the bone upon which they lie. This position is maintained by the tense Y ligament. The damage done to the chief external rotators

places them also *hors de combat*. The flexion is due to the tension of the Y ligament and of the ilio-psoas muscle.

Nos. 3 and 4. The *dislocation forwards*. If the head after leaving the acetabulum simply moves a little forwards along the inner edge of the socket, the thyroid luxation is produced. If it goes farther and moves upwards, the pubic displacement will result. The latter dislocation is therefore but an advanced form of the

first-named. Whether the head will remain in the thyroid foramen or ascend on to the pubes depends on whether extension and rotation outwards accompanies

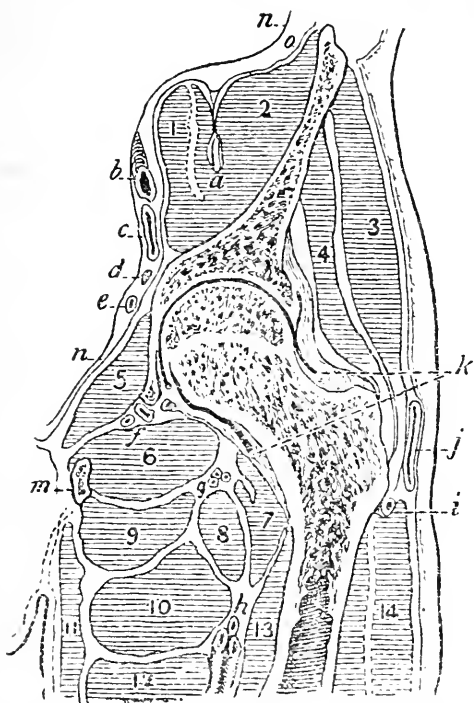


Fig. 50.—Vertical section of the Upper Third of the Thigh showing the structures in relationship with the hip-joint. (After Braune.)

Muscles.—1, psoas; 2, iliacus; 3, gluteus medius; 4, gluteus minimus; 5, obturator internus; 6, obturator externus; 7, ilio-psoas; 8, pectineus; 9, adductor magnus; 10, adductor brevis; 11, gracilis; 12, adductor longus; 13, vastus internus; 14, vastus externus; a, anterior crural nerve; b, external iliac artery; c, external iliac vein; d, obturator nerve; e, obturator artery; f, branches of obturator vessels to hip joint; g, internal circumflex vessels; h, deep femoral vessels; i, branch of external circumflex; j, bursa over great trochanter; k, reflections of capsule to neck of femur; m, asc. ramus of pubes; n, peritoneum; o, iliac fascia.

the displacement. If these occur the pubic form is produced. In these injuries the pectineus, gracilis, and adductors will be more or less torn, while the ilio-psoas, glutei, and pyriform muscles are much stretched.

The obturator nerve may be stretched or torn, and in the pubic luxation the anterior crural nerve may be involved. The abduction and eversion of the limb noticed in these luxations depend partly upon the position of the head of the bone, fixed more or less by the Y ligament, and partly upon the action of the gluteal muscles and some of the small external rotators, which are tightly stretched. The flexion of the limb is mainly due to the stretching of the ilio-psoas muscle.

In the thyroid luxation the extremity is said to be lengthened. This lengthening is, however, apparent, and is due to the tilting down of the pelvis on the injured side. In the pubic dislocation there is shortening, the head being carried above the acetabular level.

Of the modes of *reducing these dislocations* by manipulation little can be said here. The more usual proceedings may be briefly summarised as follows :

- First.*—Flex the thigh in the adducted position in luxations Nos. 1 and 2. } To relax the Y ligament.  
 Flex the thigh in the abducted position in luxations Nos. 3 and 4. }
- Secondly.*—Circumduct out in Nos. 1 and 2. } To bring back the head to the rent in the capsule by the same route that it has escaped.  
 Circumduct in in Nos. 3 and 4. }
- Thirdly.*—Extend in all cases. To induce the head to again enter the acetabulum.

In reducing dislocations of the hip it may be noted that the internal condyle of the femur faces in nearly the same direction as the head of the bone.

In **amputation of the thigh at the hip-joint** many methods may be employed. A common procedure consists of a circular incision which divides the soft parts to the bone at the junction of the upper with the middle thirds of the thigh, and is combined with a vertical incision over the great trochanter, through which the upper extremity of the femur is

exposed and the joint disarticulated. (See section, Fig. 59.) Hæmorrhage from the femoral, gluteal, and sciatic vessels is prevented either by compressing the termination of the abdominal aorta a little below and to the left of the umbilicus, or by encircling the junction of the thigh and body with a loop of elastic bandage. The bandage must pass inside the ischial tuberosity to compress the contents of the sacro-sciatic foramen, over the groin to compress the femoral vessels, and above the iliac crest to prevent it from slipping downwards. In the circular incision the *vessels* divided are: the superficial and deep femoral, the second perforating artery, descending branches of the external circumflex and sciatic vessels, and long saphenous vein; the *nerves* divided are: the external, middle and internal cutaneous, the internal saphenous, the deep muscular branches of the anterior crural, the obturator, the great and small sciatic; the *muscles* divided are: the sartorius, quadriceps extensor cruris, adductors magnus and longus, gracilis, and hamstrings. In the vertical incision (Fig. 59) the ilio-tibial band and the insertions of all the gluteal muscles are divided to the bone. Communicating branches between the ascending and transverse branches of the external circumflex artery in front with the gluteal sciatic and first perforating behind are cut. The capsule of the joint is divided, the head of the femur thrust from its socket, and the ligamentum teres cut. The attachments of the following structures to the upper third of the femur have to be separated: the gluteus maximus, medius, minimus, pyriformis, gemelli, obturator internus and externus, quadratus femoris, adductor magnus, brevis, pectineus, psoas and iliacus, with the capsular ligament.

By the method of disarticulation at the hip-joint known as the anterior racket, no elastic tourniquet and no compression of the iliac vessels are needed.

The vertical part of the racket-shaped incision is placed over the femoral vessels, and those vessels are secured by two ligatures each and are then severed

between the ligatures. The circumflex arteries are in the same way secured before division.

If carefully performed, very little blood is lost in the anterior racket amputation.

---

## CHAPTER XX.

### THE THIGH.

UNDER the term "the thigh" it will be convenient to describe that part of the lower limb that extends between the regions just described and the districts of the knee and popliteal space.

**Surface anatomy.**—In muscular subjects the outline of the thigh is irregular, but in the less muscularly developed, who are provided with a good share of subcutaneous fat, the limb, in this section of it, is more or less evenly rounded. The prominence of the rectus muscle is noticeable on the front of the thigh, especially when the muscle is in action. To the inner side of this structure, and conspicuous along the lower half of the thigh, is the eminence formed by the vastus internus. The mass to the outer side of the rectus is composed of the external vastus muscle, and occupies the greater part of the limb in this region, being, however, more conspicuous below.

Running down the anterior and inner aspect of the thigh, from the apex of Scarpa's triangle, is a depression which indicates the interval between the quadriceps muscle and the adductors. Along this groove the sartorius lies. Over the surface of the vastus internus a longitudinal depression is often to be observed, formed by the pressure exercised by the superimposed ilio-tibial band of the fascia lata. The hamstring muscles cannot usually be distinguished the one from the other above the popliteal space, nor is their separation from the adductors indicated. The separation, however, between them and the vastus externus is distinct, and corre-



sponds to the position of the external inter-muscular septum. The line of the femoral vessels has already been given. The long saphenous vein follows in the thigh the course of the sartorius muscle, and may be represented on the surface by a line drawn from the region of the saphenous opening (page 432) to the posterior border of the sartorius muscle at the level of the inner condyle of the femur. The long saphenous nerve follows the course of the femoral artery, lying first to the outer side of that vessel and then gradually crossing it. In the lower fourth of the thigh the nerve passes under cover of the sartorius muscle to the inner side of the knee, and is accompanied by the superficial branch of the anastomotic artery. A line drawn down the back of the limb from a point midway between the great trochanter and tuber ischii to the middle of the ham will correspond to the great sciatic nerve and one of its continuations, the internal popliteal. The great trunk usually bifurcates a little below the middle of the thigh.

The **skin** of the thigh is coarse on the outer side of the limb, but internally it is thin and fine, and is apt to be readily excoriated by ill-applied bandages or splints. It is but loosely attached to the subjacent parts, a circumstance that greatly favours the performance of circular amputations in this region. At one place, however, it is a little more adherent, viz., along the groove that separates the vastus externus behind from the hamstring muscles, and that corresponds to the outer intermuscular septum. The laxity of the subcutaneous tissue favours extensive extravasations beneath the skin, and permits of large flaps of integument being torn up in cases of injury to this part of the extremity.

The **fascia lata** invests the limb at all parts like a tightly fitting sleeve. It is thickest at its outer side, where it forms the dense ilio-tibial band. It is thinnest at the upper and inner aspect of the thigh, where it covers the adductor muscles. It increases considerably in strength as it approaches the front of the knee, and

attaches itself to the tibia and lateral margins of the patella. This fascia resists, especially at its outer part, the growth of tumours and abscesses, and limits deep extravasations of blood. It has occasionally been ruptured in part by violence, and through the rent so formed the subjacent muscle has bulged, forming what is known as a hernia of the muscle. This condition has been met with in the case of the quadriceps muscle, and also of the adductor longus. Such "herniæ" are probably associated with some rupture of the fibres of the muscles implicated. Two deep processes of the fascia are attached to the femur, and form the outer and inner intermuscular septa. The outer septum separates the vastus externus from the biceps, and the inner the vastus internus from the adductors. Together with the fascia lata, these septa divide the thigh into two aponeurotic spaces, which can be displayed in a transverse section of the limb. These divisions, however, are of little surgical moment, and the inner septum is often so thin and feeble that it could have little effect in directing the course of an abscess.

In circular amputations of the thigh the **muscles** are apt to retract a little unevenly, since some are attached to the femoral shaft while others are free. The muscles so attached are the adductors, vasti and crureus, while the free muscles are the sartorius, rectus, hamstrings, and gracilis.

In spite of its great strength the tendon of the quadriceps may be ruptured by muscular violence. A good example of such an accident is recorded by Mr. Bryant (*Med. Times*, 1878). A man aged forty-two stumbled in the dark, and fell down a pit ten feet deep. On examination the tendon was found to be torn across, and the gap above the patella produced by the rupture occupied no less extent than the lower third of the thigh. A somewhat more remarkable accident is reported to have happened to the sartorius muscle. This muscle, just before its insertion into the tibia, gives off an aponeurotic expansion from its anterior border to the capsule of the knee-joint. In the case alluded to (*Lancet*, 1873),

this expansion is said to have been ruptured, and the muscle itself to have been found dislocated backwards in consequence. The accident befell a man aged forty, who was squatting, in the position assumed by tailors, upon the floor of a waggon, when his companion tripped over him and fell across his bent knees. Something was felt to have given way near the ham, and on examination the above lesion was diagnosed.

The femoral **artery** may be ligatured at any part of its course in the thigh, and the comparatively superficial position of the vessel renders it very liable to be injured. In the middle third of the thigh it lies beneath the sartorius in Hunter's canal. The thigh affords many instances of the remarkable way in which isolated branches of a main artery are often alone damaged. Thus, Langier relates the case of a man-cook, who, in running round a table, struck the upper and outer side of his thigh against the corner of it. This led to a subcutaneous rupture of the external circumflex artery. Unfortunately the extravasation was cut into, and the patient, after being subjected to many modes of treatment, died from the effects of repeated hæmorrhage. Dr. Butcher (*Dub. Journ. Med. Sc.*, 1874) gives the case of a man who was stabbed in the thigh over the femoral vessels during a scuffle. Profuse bleeding followed, and it was found that the only vessel wounded was the internal circumflex artery, just at its point of origin from the profunda. The case was treated promptly and the man did well.

**Fractures of the femur.**—The shaft of the femur may be broken at any part, but the lesion is most common at the middle third of the bone, and least frequent at its upper third. If broken by direct violence the fracture is usually transverse, and if by indirect violence it is usually oblique. The probability of a fracture being due to direct violence diminishes in the bone from below upwards, while the probability of a lesion from indirect violence increases in the same direction. Thus it happens that the fractures of the upper third of the bone are usually oblique,

while those of the lower third are more commonly transverse. In the middle third the numbers of the transverse and oblique fractures are more nearly balanced. The femur has often been broken by muscular violence, but it is doubtful if this has ever occurred in other than a diseased bone. In many of these cases the amount of force that breaks the bone is most insignificant. Thus Vallin reports the case of a girl aged eighteen, described as robust, who broke the femur about its middle while in the act of mounting a table for the purpose of undergoing a vaginal examination. In oblique fractures in the upper third of the bone the line of fracture usually runs downwards and inwards, while in oblique fractures of the middle third the direction is more commonly downwards and forwards, with a slight lateral inclination that is sometimes inwards and sometimes outwards. Fractures of the lower third of the bone are discussed in connection with the region of the knee (chap. xxi.).

With regard to fractures of the upper and middle thirds, the displacements of the fragments depend greatly upon the obliquity of the fracture. As a rule the lower fragment is drawn up behind the upper one by the hamstrings, aided by the rectus, gracilis, sartorius, tensor vaginæ, and adductors, and is carried a little to its inner side under the influence of the last-named muscles. The lower end of the upper fragment usually projects forwards and a little outwards. This is produced by the agency of the lower fragment, which tilts the upper piece of bone in the direction named. In the fracture of the upper third of the shaft the projection forwards of the upper fragment is aided by the ilio-psoas muscle. Thus the deformity produced in fractures of the femoral shaft is usually angular in character. The eversion of the foot noted in fractures of the femur is due to the weight of the limb, which causes the helpless member to roll out, aided probably by the action of the external rotator muscles.

Certain spiral fractures (helicoidal fractures of Leriche) may be produced in the lower part of the shaft

as the result of torsion. M. Féré finds by experiment that if the limb be carried forwards in front of the opposite knee, and the foot rotated outwards, a spiral fracture can be produced at the junction of the lower and middle thirds of the femur. A like fracture at the same level, but with the direction of the spiral

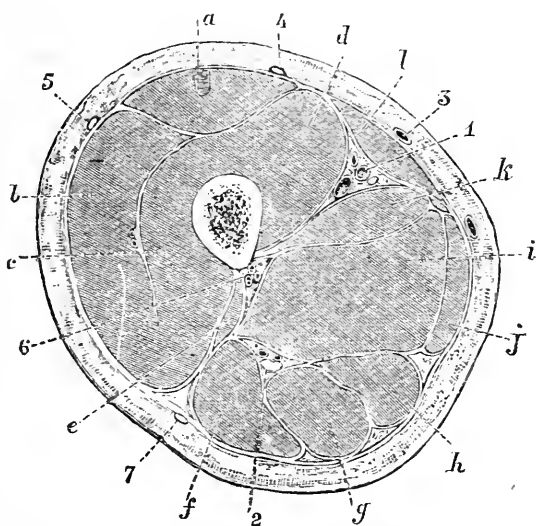


Fig. 60. —Transverse Section through the Middle of the Thigh (Braune).

*a*, Rectus femoris; *b*, vastus externus; *c*, crureus; *d*, vastus internus; *e*, short head of biceps; *f*, long head of biceps; *g*, semitendinosus; *h*, semimembranosus; *i*, adductor magnus; *j*, gracilis; *k*, adductor longus; *l*, sartorius; *1*, femoral artery; *2*, great sciatic nerve; *3*, great saphenous vein; *4*, middle cutaneous nerve; *5*, external cutaneous nerve; *6*, perforating branches from profunda; *7*, small sciatic nerve.

reversed, can be produced by carrying the limb outwards and then rotating it inwards.

#### **Shortening of the limb after fracture.**—

It is doubtful if a fracture of the shaft of the femur can, after any treatment, become united without some shortening resulting, save in a few exceptional cases. It is important, in connection with this subject, to remember that the lower limbs may be normally of

unequal length. Dr. Wight, of Brooklyn, has fully investigated this matter, and has arrived at the following conclusions: (1) The greater number of normal lower limbs are of unequal length; (2) the left limb is often longer than the right; (3) the average inequality of normal lower limbs is probably about  $\frac{1}{4}$  of an inch; (4) the average amount of shortening after a fracture of the femur that has been well treated is about  $\frac{3}{4}$  of an inch; (5) in about one case in ten or eleven the two limbs will be found to be of equal length after the union of the fracture; (6) one limb can never be a certain standard of length for the opposite limb. Dr. Garson, as a result of the careful examination of some seventy skeletons, states that both the lower limbs are of equal length in only about 10 per cent. of all cases. He also found that the femur was more frequently the seat of variation than the tibia.

**Amputation of the thigh.**—In a circular amputation of the thigh about its middle the following parts would be divided (Fig. 60): the quadriceps, sartorius, gracilis, long and great adductors, and the three hamstring muscles; the femoral and profunda vessels, the descending branches of the external circumflex artery, the lower perforating vessels, and the long saphenous vein; the main branches of the anterior crural nerve (middle cutaneous, internal cutaneous, and muscular, together with the long saphenous nerve), the anterior branch of the external cutaneous nerve, the obturator, and the great and small sciatic nerves. Owing to the unequal manner in which the divided muscles retract, a simple circular amputation is not well adapted for the thigh. A more convenient method of amputation is represented by the elliptical method, the lower extremity of the ellipse being on that side of the limb on which muscular retraction is the more marked, *i.e.* on the posterior side of the thigh.

## CHAPTER XXI.

## THE REGION OF THE KNEE.

IN this chapter will be considered the articulation of the knee, the soft parts about the joint, the popliteal space, the lower end of the femur, the patella, and the upper ends of the tibia and fibula.

**Surface anatomy.**—In the front of the knee the patella can be distinctly felt and seen. Its inner border is a little more prominent than the outer. When the limb lies in the extended posture, with the quadriceps relaxed, the patella can be moved to and fro, and appears to be but loosely attached. When the quadriceps is contracted the bone is drawn upwards, and becomes firmly fixed against the femur. In flexion of the joint the patella sinks into the hollow between the tibia and the intercondyloid notch, and is very firmly fixed. In this position some part of the trochlear surface of the femur can be made out above the patella. On each side of the knee-cap a hollow exists which may be completely filled up with fat in the obese.

When the limb lies in the extended posture the ligamentum patellæ is not to be very distinctly made out. It becomes a little more conspicuous in the flexed position, and is most prominent when the quadriceps muscle is vigorously contracted.

On the inner side of the knee the following parts can be felt from above downwards: the tubercle for the adductor magnus, and the tendon of insertion of that muscle; the inner condyle of the femur, which is very prominent, and forms the chief part of the rounded eminence on this aspect of the joint; and below this the inner tuberosity of the tibia. Between the two latter processes of bone the interarticular line is easily to be felt. On the outer side of the joint is the external condyle of the femur, which is much less conspicuous than its fellow of the opposite side, and below it is the

corresponding tuberosity of the tibia, forming a marked prominence. Immediately in front of the biceps tendon the upper part of the external lateral ligament can be felt when the joint is a little flexed. Between the tendon and the patella, the lower part of the ilio-tibial process of the fascia lata can be detected as a prominent rounded band, descending to the external tuberosity of the tibia. It is most distinct when the knee-joint is forcibly extended by muscular action, and often stands out conspicuously beneath the skin. The tubercle of the tibia and the head of the fibula are both to be readily felt, and are nearly on the same level.

The popliteal space only appears as a hollow when the knee is bent. In the extended limb the hollow is replaced by an evenly rounded eminence. The crease in the skin that passes transversely across the ham is some way above the line of the knee-joint. On the outer side of the space the biceps tendon can be very readily felt, especially when the muscle is in action. Just behind it, and along its inner border, lies the peroneal nerve. It can be rolled under the finger as it crosses the head of the fibula to pass beneath the peroneus longus muscle. On the inner side of the ham three tendons can be felt. Nearest to the middle of the space is the long prominent tendon of the semitendinosus. Internally to it is the larger and less distinct semimembranosus tendon, and still more to the inner side the gracilis may be made out.

The popliteal vessels enter the ham obliquely at its upper and inner part, and under cover of the semimembranosus muscle. The outer border of this muscle is the guide to the upper portion of the artery. The vessels in their descent reach a point behind the middle of the knee-joint, and then pass vertically downwards. The termination of the popliteal artery is on a level with the lower part of the tubercle of the tibia. When the limb is flexed, the pulsations of the artery can be felt and the vessel compressed against the femur a little below its point of entry into the popliteal space. The upper articular arteries run transversely inwards



and outwards just above the femoral condyles. The lower articular arteries are also placed transversely, the inner vessels running just below the internal tuberosity of the tibia, and the outer just above the head of the fibula. The deep branch of the *anastomotica magna* descends to the inner condyle of the femur in the substance of the *vastus internus*, and along the front of the *adductor magnus* tendon. The internal saphenous vein passes up along the back part of the internal condyle of the femur, and then follows the *sartorius* muscle to the thigh. It is just below the interarticular line that the long saphenous nerve usually joins the vein. The short saphenous vein follows the middle line of the calf just below the ham, and pierces the deep fascia at the lower part of the popliteal space. This vessel is much less conspicuous than is the long saphenous vein, and is, indeed, not often to be seen unless varicose.

The internal popliteal nerve descends in the middle line, and continues the line that marks the course of the great sciatic trunk.

In their normal condition the popliteal glands are not to be felt.

The limits of the synovial membrane of the knee-joint, and the position of the various bursæ about this articulation, will be dealt with in some of the subsequent paragraphs.

**The front of the knee.**—The skin over the front of the knee is dense and very movable. This mobility affords considerable protection to the knee-joint, especially in stabs with bluntish instruments, and in any injury where the gliding movement of the skin may direct the violence away from the articulation. The comparative looseness of the integument is sometimes utilised in the operation of removing so-called "loose cartilages" from the knee-joint. It permits the incision into the joint to be very indirect, and, the skin being dragged out of place during the operation, it follows that, when the procedure is complete, the surface wound and that in the knee capsule no longer correspond.

In flexion, the skin is drawn tightly over the patella, and, as is the case elsewhere, where integument lies more or less directly upon the bone, a contusion over the knee-cap may produce a lesion precisely like an incised wound.

In the *Lancet* for 1877 is recorded the case of a very stout woman, aged fifty-seven, who, stumbling on a hard road, fell upon her bent knee. The skin was burst across the front of the knee, and a wound was produced that was 7 inches in length, and was as cleanly cut as if made by a scalpel.

There is but little subcutaneous fat in front of the articulation, and thus it happens that in amputations through the knee-joint the anterior flap is very thin, and is composed of little other than the simple integument.

As blisters, and various forms of counter-irritant, are often applied to the front of the knee in cases of disease, it may be well to take note of the blood-supply of this part, and of the relations between the surface vessels and nerves and those of the joint. The vessels that give branches to the front of the knee, and that are concerned in the supply of the part to which blisters are usually applied, are the anastomotic, the four articular branches of the popliteal, and the anterior tibial recurrent. Now of these arteries, and especially of the anastomotica magna and superior articular, it may be said that, shortly after their origin, they divide into two branches, or two sets of branches, one going to the surface and the other to the articulation of the knee and deeper parts about it. It may be supposed, therefore, that, in applying a counter-irritant in front of the knee for the relief of a joint affection, a greatly increased quantity of blood is drawn into the superficial divisions of the above-named vessels, and less blood is thereby left to flow by their deeper branches to the seat of disease. The skin over the front of the knee is supplied by nerves from the third lumbar segment (Head). Through the obturator nerve the joint is also partly supplied from this segment.

The superficial lymphatics in the region of the knee

lie for the most part on the inner aspect of the joint, and follow the course of the long saphenous vein. Ulcers, and other inflammatory affections of the skin over the articulation, are more apt to be associated with lymphangitis and with enlargement of the inguinal glands when situate on the inner aspect of the joint than when placed in front or to the outer side of it.

The **bursæ** over the front of the knee.—(1) The patellar bursa is a large sac placed in front of the patella and upper part of the patellar ligament, and separates those structures from the skin. It is frequently divided by septa into superficial and deep compartments. It is very often found enlarged in those who kneel much, in housemaids, stone-masons, *religieuses*, etc. The parts about are well supplied with nerves, and hence much pain is usually associated with acute inflammation of this sac. It is in close contact with the patella, and, in one case reported by Erichsen, suppuration of the bursa led to caries of that bone (Figs. 61, 62, and 65). (2) There is a small bursa between the patellar ligament and the tubercle of the tibia (Fig. 62). When inflamed, it causes more pain than is observed in affections of the previous bursa, since it is firmly compressed between two rigid structures, the ligament and the bone. It is separated from the synovial cavity by the pad of fat that lies behind the patella. It would appear, however, to sometimes communicate with the joint, since Hamilton has collected three cases where incision into this bursa led to suppuration of the articulation. There is a pad of soft fat between the ligament and the tibial tubercle, which often protrudes a little at either side of the former structure, and has been mistaken for an enlarged bursa. (3) The bursa between the quadriceps tendon and the femur will be considered in connection with the synovial cavity.

The **popliteal space**.—The *skin* over the space is not so movable as is that over the front of the knee. When destroyed by injury, by burns, or by extensive ulceration, the contraction of the resulting cicatrix may lead to a rigidly bent knee. The skin in

this place has also been ruptured by forcible extension applied to the limb in cases of contracted knee. Beneath the skin and superficial tissue is the popliteal *fascia*, a dense membrane that covers in the space. It is but a continuation of the fascia lata of the thigh, and is continuous below with the fascia of the leg. It passes without bony attachment over the hamstring muscles that bound the ham. This fascia limits, often in a very marked manner, the progress of popliteal abscesses and growths towards the surface. Its unyielding character is a prime cause in the production of the severe pain with which such collections and tumours are often associated. The popliteal abscess, unable to reach the surface, is encouraged to extend either up into the thigh or down the leg. The ham may hold a very considerable quantity of pus. Velpeau has seen a case where a litre (1 pint, 15 oz.) of pus was evacuated from this region in a patient who presented before the operation but an insignificant swelling in the site of the collection. Duplay records two cases of ulceration of an abscess into the popliteal artery, and Ollivier an instance where the abscess, unable to find a way to escape, ultimately entered into the knee-joint.

Pus may reach the ham from the buttock or pelvis by following the great sciatic nerve, or may extend from the thigh through the opening in the great adductor for the femoral vessels.

The **hamstring muscles** are frequently found contracted in neglected cases of knee-joint disease, and produce thereby more or less rigid flexion of the leg upon the thigh. Irritation from disease of the knee-joint may lead to contracture of the hamstring muscles. These muscles are supplied through the great sciatic nerve from the fifth lumbar segment, from which the knee-joint derives in part its nerve supply. Muscles on the flexor aspect of a bent joint undergo a permanent shortening if the position be maintained for a considerable space of time.

Contraction of these muscles in knee-joint disease tends not only to flex the knee but also to draw the

tibia backwards, and produce in some cases a partial luxation.

The hamstring tendons may be ruptured by violence, the tendon most frequently torn being that of the biceps. The muscles are greatly stretched when the trunk is bent forcibly forwards at the hip-joint, the knee remaining extended. Extreme movement in this position has ruptured some of the fibres of this muscle. The difficulty experienced in touching the toes with the fingers while the knees are kept stiff depends upon the resistance offered by the stretched hamstrings. In tenotomy of the biceps tendon the peroneal nerve is in great risk of being wounded. It may be noted that contraction of the muscle tends to increase the distance between the tendon and the nerve, and to render the former more superficial. The peroneal nerve is in still greater risk of being wounded in resecting the head of the fibula, an operation, however, that is seldom performed.

**The vessels of the ham.**—The popliteal vessels are, from their depth, but seldom wounded. It must be borne in mind that the lower part of the artery may be reached from the anterior aspect of the leg by an instrument passing between the tibia and fibula. Thus Spence reports the case of a farmer who received a wound in front of the leg, just below the knee, from the slipping of his knife while cutting a stick. It was discovered subsequently that the knife had entered the interosseous space and had wounded the popliteal artery at its bifurcation. It had indeed nearly severed the anterior tibial artery from the main trunk.

The popliteal artery has been ruptured by external violence, as when a wheel has passed over the region of the vessel. Mr. Harrison Cripps (*Lancet*, 1876) believes that the rupture is, as a rule, the result of a force acting in an oblique direction from below upwards upon the lower expanded end of the femur. This artery is more frequently the seat of aneurism than is any other artery in the body, save only the thoracic aorta. In 551 cases of spontaneous aneurism, collected

by Crisp, the popliteal vessel was the seat of the disease in 137 instances, the thoracic aorta having been affected in 175 of the cases. This marked disposition to aneurism depends upon many factors. The vessel is subjected to a great deal of movement, and often to very violent movement. Experiments upon the dead body show that the inner and middle coats of the vessel may be ruptured by extreme flexion of the knee, and that a like rupture may in a smaller percentage of cases be brought about by forcible extension. Moreover, except when the limb is in the position of extension the popliteal artery is, like the thoracic aorta, much curved. Then, again, the vessel breaks up into two large vessels, and it is well known that the point of bifurcation of an artery is a favourite spot for aneurism. Lastly, the artery is supported only by the lax tissue of the popliteal space, and the support of strong muscles given elsewhere to so many large vessels is practically absent. Some popliteal aneurisms have been successfully treated by flexing the knee and retaining the limb for some time in that position. That flexion can have a direct effect upon the lumen of the vessel is shown by the diminished pulse at the inner ankle produced by forcibly bending the leg upon the thigh. The artery and vein are so adherent that it is difficult to separate the two when applying a ligature to the arterial trunk. This adhesion must have been appreciated by any who have taken pains to "clean" the artery in a dissection of the ham.

The popliteal vein is a remarkably substantial vessel, and has walls so dense and thick that on section they often look more like the tunics of an artery. On the ground of this peculiarity, and of its close adhesion to its companion vessel, Tillaux asserts that "it is unlike any other vein in the economy." It is worthy of note that the vein, although more superficial than the artery, is very rarely ruptured by violence. As a rule, the artery alone is torn. In a few cases both the vessels may suffer; but I can find no instance recorded of rupture of the popliteal vein alone.

From the relations of the artery to the vein and nerve it will be understood that a popliteal aneurism may soon lead to œdema of the leg and to nerve symptoms depending upon pressure on the internal popliteal trunk. It has more than once also made its way into the knee-joint, with the posterior ligament of which the artery is in such close relation.

The short saphenous vein lies almost in the middle line, and not being usually apparent through the skin, may be divided in an incision made into the lower part of the popliteal space. Hérapat has suggested that varices of this vein may depend upon the narrowness of the opening in the fascia lata through which the vessel passes to reach the main trunk.

The **lymphatic glands** in the ham are from four to five in number and are deeply placed about the great vessels. When enlarged they have been mistaken for aneurism and other popliteal tumours. They receive the deep lymphatics of the leg. A small gland is often met with beneath the fascia, close to the point of entry of the short saphenous vein. It receives some lymphatics that follow that vessel.

The **bursæ about the ham** are usually six in number, two on the inner side of the space and four on the outer. *Inner side.*—(1) A large bursa between the internal condyle of the femur and the inner head of the gastrocnemius and the semimembranosus. This is the largest bursa in the space, and after adult life it usually communicates with the joint. It is, of all the bursæ in this region, the one most often enlarged, and when affected may attain great size. In one reported case the sac measured 5 inches by 3.5 inches. In the extended position of the limb the enlarged bursa feels firm and resisting, but on flexion it becomes flaccid and can often be made to entirely disappear. Probably the slit-like communication between the bursa and the joint is closed when the posterior ligament is tightened by extension, and is opened when it is relaxed on bending the knee. In the latter posture the contents of the bursa can be reduced into the cavity of the knee-

joint, and so the tumour disappears. (2) A little bursa between the semimembranosus tendon and the tuberosity of the tibia. It never communicates directly with the joint, but has sometimes an opening into the bursa just described. *Outer side.*—(1) A bursa between the popliteus tendon and the external lateral ligament that does not usually communicate with the joint. (2) One between the popliteus tendon and outer tuberosity of the tibia, that is merely a diverticulum from the synovial membrane. This sac may open into the tibio-fibular articulation, and so bring that cavity in connection with the knee-joint. (3) A bursa between the outer head of the gastrocnemius and the femoral condyle. It is not constant and is not connected with the articulation. (4) A bursa between the biceps tendon and the external lateral ligament. The peroneal nerve runs across this sac, a circumstance that may explain some of the pain experienced when the bursa is enlarged.

It is not improbable that wounds of bursæ in this region containing fluid have been mistaken for wounds of the joint, and the escaping serum for synovia.

The **knee-joint.**—This articulation is the largest in the body. The joint owes its great strength to the powerful ligaments that unite the two component bones, and to the muscles and fasciæ that surround it. It derives no strength from the shape of the articular surfaces, since they are merely placed in contact with one another. In spite of its frequent exposure to injury, dislocations at the knee are extremely rare. The lateral ligaments are comparatively feeble, are tense in extension and relaxed in flexion. The laxity of these ligaments is such that partial luxations of the tibia are possible without rupture of these bands, especially in cases where the joint is found slightly flexed after the accident. The crucial ligaments are very powerful, and are more or less tense in all positions of the joint. The anterior of these ligaments especially resists extension, forward displacement of the tibia, and rotation inwards of the leg. The posterior band



resists flexion and displacement backwards of the tibia. In the movement of extension the tibia slides a little forwards and is rotated a little outwards. In flexion that bone glides backwards and rolls a little inwards. Extension generally is limited by the crucial and posterior ligaments; flexion by the ligamentum patellæ and anterior part of the capsule, in addition to the crucial

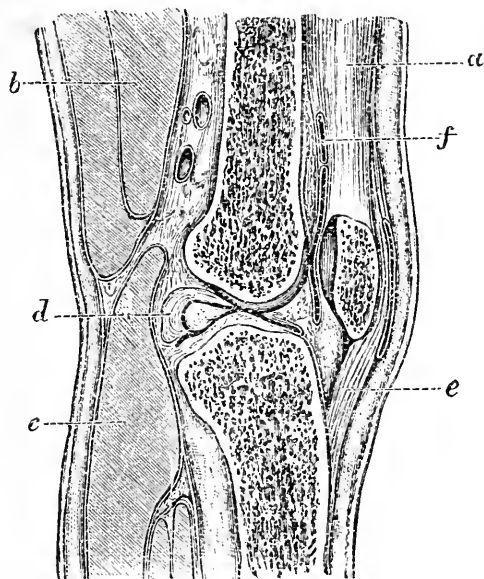


Fig. 61.—Vertical Section of Normal Knee-joint (Braune).

a, Quadriceps; b, semimembranosus; c, gastrocnemius; d, posterior crucial ligament; e, ligamentum patellæ; f, bursa between quadriceps and femur.

ligaments. Rotation is possible only in the flexed position. The thinnest part of the posterior ligament is the portion below the oblique fibres derived from the semimembranosus. If pus finds its way from the joint into the ham, it will probably escape through this part of the ligament.

In the contracted knee associated with fibrous ankylosis, the chief contraction, so far as the joint tissues are concerned, is in the posterior ligament, in

the lateral ligaments, and in the fibrous and fatty tissue between the former ligament and the posterior crucial band.

The *synovial membrane* of the knee-joint extends upwards as a large cul-de-sac above the patella and beneath the extensor tendon. This cul-de-sac reaches a point an inch or more above the upper margin of the trochlear surface on the femur, and is rendered very distinct when the joint is distended with fluid (Fig. 62). When the knee is bent the cul-de-sac is drawn down, and therefore this position of the limb is advised when operations are about to be performed upon the lower end of the femur. Above the synovial pouch is a bursa that separates the quadriceps tendon from the femur, and is usually over an inch in its vertical measurement (Fig. 62). From the examination of two hundred and sixty knee-joints in both infants and adults Schwartz found that this bursa communicated with the synovial cavity in seven cases out of ten in young children, and in eight cases out of ten in adults.

It will thus be seen that when this communication exists, a stab over the femur, about 2 inches above the trochlear surface of the bone, or about the same distance above the top of the patella, when the limb is extended, will practically open the knee-joint.

Cases are reported of extravasation of blood into this bursa that, although at first limited to the sac, have, on rough handling, extended into the knee-joint, a circumstance leading to the supposition that in some cases the orifice of communication may be very small.

The crucial ligaments, although more or less completely invested by the synovial membrane, are yet entirely outside the synovial cavity, and divide the cavity behind into an outer and inner condylar recess. The posterior ligament is continuous with the posterior part of the capsule.

The upper third of the patellar ligament is in relation to the synovial membrane, from which, however, it is separated by a pad of fat. The lower two-thirds of the ligament are in relation to the bursa and fatty tissue

that intervene between the band and the tibia. A knife passed horizontally backwards at the apex of the patella would, when the limb is extended, just miss the joint line between the femur and tibia, and would hit the latter bone (Fig. 61). If, however, there be any

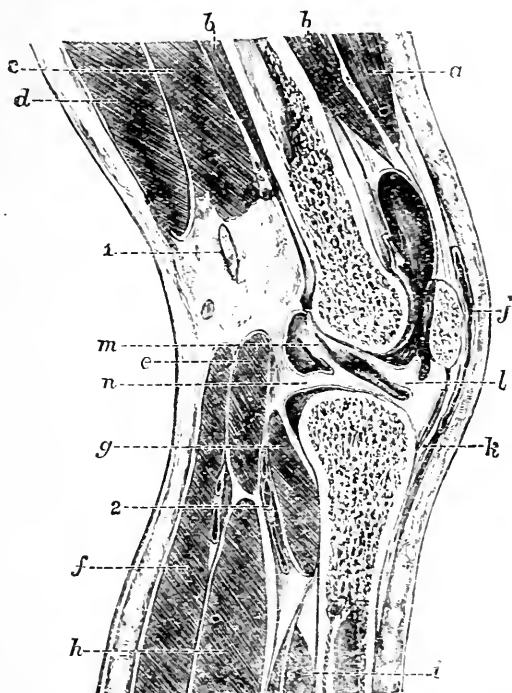


Fig. 62. —Vertical Section of Knee-joint distended with Fluid (Braune).

*n*, Vastus externus; *b*, crureus; *c*, short head, and *a*, long head, of biceps; *e*, plantaris; *f*, gastrocnemius; *g*, popliteus; *h*, solens; *i*, tibialis posticus; *j*, bursa patellæ; *k*, ligamentum patellæ; *l*, ligamentum mucosum; *m*, anterior crucial ligament; *n*, external semilunar cartilage; *1*, external popliteal nerve; *2*, popliteal artery.

effusion in the joint, or the limb be a little flexed, a knife so introduced would pass between the two bones (Fig. 62).

**Joint disease.**—Owing to its superficial position the knee-joint is the articulation that is most frequently

the seat of inflammation due to injury and exposure to cold. When distended with fluid, the effusion soon shows itself above and at the sides of the patella, by bulging forward the synovial sac, which is here more nearly in relation to the surface than it is elsewhere. Fluctuation is soon to be detected, and the patella, being pushed away from the femur, is said to "float" upon the distending fluid (Fig. 62).

The inflamed knee-joint, if left to itself, almost invariably assumes the flexed position. This may be explained upon three hypotheses, and it is probable that each of the three reputed factors takes part in producing this position in cases of disease.

(1) The capacity of the joint is increased on flexion. The pain of acute synovitis is due mainly to the increasing distension of the joint with fluid, and it is natural that the patient should instinctively place the limb in the position in which the joint will hold the greatest amount of fluid, and in which the interarticular tension is reduced to a minimum. It cannot be said, however, that the greater the degree of flexion the greater the capacity of the joint cavity. By experimental injections into the knee, Braune found (a) "that the capacity of the synovial cavity reaches its maximum in a definite degree of flexion, and that the angle at which this happens is twenty-five degrees;" (b) that "the minimum of the capacity of the synovial cavity coincides with the maximum of flexion." Thus it happens that the tension within an inflamed knee will be greater in extreme flexion than it is in full extension.

(2) By flexing the limb, the more powerful ligaments (such as the ligamentum posticum, the posterior crucial and lateral ligaments) are relaxed, while the ligaments rendered tense by the position are the patellar and the anterior part of the capsular, the latter of which is but a yielding membrane.

(3) The sensory nerves of the joint being disturbed, contraction of muscles may be anticipated from reflex action, and of the muscles so excited the flexors may be expected to have the advantage, as being the more

powerful and the more favourably placed for acting upon the articulation.

**Dislocation of the semi-lunar cartilages.—**

One or other of these cartilages may be displaced from its attachments to the tibia, and become nipped or locked between that bone and the femur. The result is a sudden pain in the limb, associated with a fixing of the knee in a flexed position. The accident is usually brought about by a twist given to the leg when the knee-joint is more or less bent. In 200 cases of internal derangement of the knee-joint, Bennett found that the internal cartilage was affected in 155 cases and the external in only 45. The left knee was the seat of derangement nearly three times as often as the right, and the lesion occurred nine times more frequently in men than in women. In every one of twelve cases operated on by Marsh, the anterior extremity of the internal semilunar cartilage was found bruised and torn from its tibial attachment. It may be noted in connection with the causation of the lesion, that in flexion and extension the two cartilages move with the tibia upon the femur, but in the rotation movements of the leg one or other disc is fixed and the tibia rotates beneath them. Dr. Scott Lang has pointed out that displacement of the internal disc occurs through violence applied when the leg is rotated outwards, while displacement of the external cartilage can only occur when the leg is rotated inwards. "Rotation outwards is performed chiefly by the biceps: consequently, when this movement is taking place, the tibia will be found to be held closely to the external condyle of the femur, and the outer cartilage is thus held firmly in its place between the two bones. But the gap between the internal condyle and the tibia will be increased, and the movable cartilage is apt to slip between the internal condyle and the corresponding part of the tibia. When the tibia is rotated inwards the internal cartilage is held in like manner between the bones by the internal rotators, while the gap between the external condyle and the tibia is increased" (Scott Lang). The external cartilage is

smaller than the internal, is rounder, is more movable, and possibly on these accounts is less likely to be "nipped" between the bones. It is attached in part to the femur through the posterior crucial ligament, and is grooved by the tendon of the popliteus, two factors which add to its security.

**Genu-valgum**, or knock-knee.—The appearances produced by this affection are familiar. When a person stands erect, the feet together, the tibiæ are practically vertical, and the femora meet them at a certain angle. The degree of this angle depends, in normal subjects, to a great extent upon the relative width of the pelvis. In genu-valgum the tibiæ cease to be vertical in the erect position; their lower ends deviate more and more from the middle line, until the distance between the two malleoli becomes considerable when the individual stands upright and when he is not concealing any of the deformity by rotating the limb.

The progress of the genu-valgum may be divided into three stages. In the *first* stage there is a yielding or elongation of the internal lateral ligament, and of the fascial structures on the inner side of the joint. That the yielding of this ligament alone will permit of a lateral movement at the articulation being accomplished is illustrated by cases of sprains of the knee, where the ligament has been torn, and where much lateral bending has been in consequence permitted. It is probable that the crucial ligaments yield also a little, and it is upon the posterior band attached to the internal condyle that the strain possibly first comes. In the *second* stage there is a contraction of the tissues on the outer side of the joint that have been relaxed by the new position of the limb. These structures are the ilio-tibial band of the fascia lata, the external lateral ligament, and the biceps tendon. This contraction tends to give permanency to the deformity. In the *third* stage the bones become changed. On the outer side of the joint the external condyle and the outer tuberosity of the tibia are pressed together, and through these bones the greater part of the weight of the body will

be transmitted. As a result of the continual pressure the parts waste a little, and by their atrophy contribute not only to the extent of the deformity but also to its permanency. On the inner side the internal condyle tends to become separated from the tibia, and an interval to develop between the two bones as the deformity advances. This interval is prevented from actually existing by the development of the condyle, which enlarges, and so still maintains its contact with the tibia. Mikulicz has pointed out that "the alteration

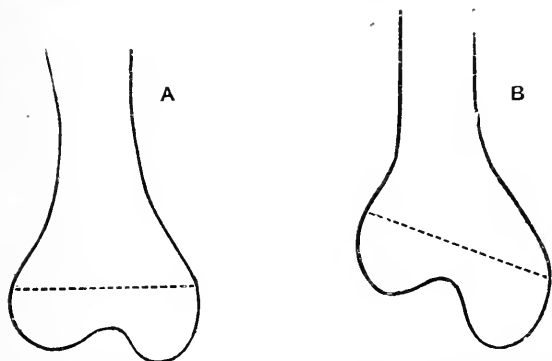


Fig. 63.—A, Normal femur; B, femur in an advanced case of knock-knee, showing the enlargement of the internal condyle. The dotted line in each case represents the line of the epiphysis.

in length on the inner side of the femur arises not from alteration of the epiphysis, but is confined to the lowest part of the diaphysis." This is shown in the diagram (Fig. 63), where it will be seen that the enlargement of the internal condyle is due almost entirely to increased growth in the diaphysis. The increased growth does not affect the antero-posterior diameter of the condyles. Hence, when the knee is flexed, all trace of the deformity disappears.

**The patella.—Fractures.**—This bone is more often broken by muscular violence than is any other in the body. Although the patella may be fractured by both muscular and direct violence, it would appear that the former is the agent that most often produces

the lesion. Thus, in 127 cases of simple transverse fracture collected by Hamilton, he considers that muscular action was the cause of the injury in 106 instances. The form of fracture due to muscular violence is very uniform. It is nearly always transverse, simple, and through the centre of the bone, or just above that point or just below it. Fractures due to direct violence may present the same appearance, but they are more often starred, or oblique, or even longitudinal. Experiments upon the cadaver show that a simple transverse fracture about the centre of the bone cannot be

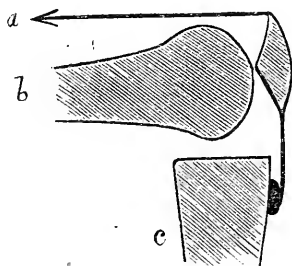


Fig. 64.—Diagram to show Mechanism of Fracture of the Patella by muscular action.

a, Line of action of quadriceps muscle; b, femur; c, tibia.

produced with any degree of certainty by a direct blow. The position of the knee that most favours fracture by muscular action is that of flexion. When the knee is bent, the patella rests upon the femoral condyles along its transverse axis only. Nearly the whole of its upper half is unsupported behind, and the extensor muscle acts in a line nearly at right angles to the vertical axis of the bone. Thus, by violent contraction of the quadriceps, the patella may be snapped across the condyle

as a stick is snapped across the knee (Fig. 64). As the fracture usually causes the patient to fall, it has been supposed that the contact with the ground, rather than any previous muscular action, may have caused the lesion. But, as Hamilton has pointed out, if a person falls upon the bent knee when the limb also is flexed upon the trunk, the part that comes in contact with the ground is not the patella, but the tubercle of the tibia.

In the great majority of cases the lesion not only involves the bone but also the cartilage and fibrous structures that cover it respectively behind and in front; the synovial membrane also is torn, and the



patellar bursa opened up. Thus the synovial contents may come in actual contact with the skin. "It is anatomically possible, if the fracture involve only the lower and non-articular portion of the patella, and if the amount of the separation of fragments is slight, that the fatty tissue behind the apex of the patella, over which the synovial membrane is reflected, may save the latter from injury" (Henry Morris). In all cases where there is much separation of the fragments, the fibrous expansion attached to either side of the patella must be torn through. Indeed, none but a slight separation of the parts is possible until that expansion is ruptured. Braune has demonstrated this by experiment, by sawing through the patella without damage to the lateral ligamentous structures, and noting that but trifling separation of the fragments was possible until these structures had been divided. In stellate fractures, due to direct violence, these fibrous expansions from the extensor tendon may be uninjured, and no separation of any magnitude be permitted between the portions of the broken bone.

The patella is more readily broken by muscular violence than is either the extensor tendon or the ligamentum patellæ. In the flexed position it will be seen (Fig. 64) that the bone is placed at a considerable disadvantage when compared with the two other structures. Richet reports a case where violent contraction of the quadriceps caused the tubercle of the tibia to be torn away from the bone without any other lesion of the parts immediately concerned being produced.

The patella may be congenitally absent. It is developed in the tendon of the quadriceps, remaining cartilaginous until the end of the second year. Its sesamoid nature is seen in the tendency to unite by fibrous rather than by bony union after fracture. It receives its blood supply from nearly all the arteries round the knee-joint.

**Dislocation of the patella.**—This bone may be dislocated outwards or inwards, or turned upon its

edge so that its anterior and posterior surfaces are placed laterally. The luxation outwards is by far the most common. This depends upon the fact that the quadriceps, the patella, and the ligamentum patellæ do not, when the muscle is contracted, follow the lines of the femur and tibia. They are more nearly in a

straight line, that passes to the outer side of the angle formed by the femur with the leg at the knee-joint. Muscular contraction, therefore, tends to draw the knee-cap outwards, a tendency that is in all normal circumstances corrected by the increased prominence of the external condyle. The vastus externus also is said to be more powerful than the internus.

Dislocations of this bone are usually due to muscular action, and are most apt to occur in the extended position

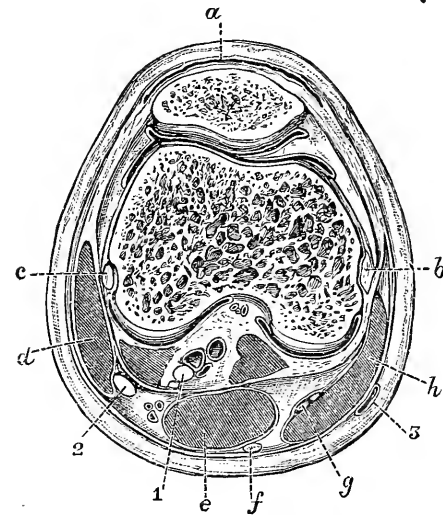


Fig. 65.—Transverse Section of left Knee-joint through the centre of the Patella (Braune).

*a*, Bursa patellæ; *b*, internal lateral ligament and inner condyle; *c*, external lateral ligament and outer condyle; *d*, biceps; *e*, semimembranosus; *f*, semitendinosus; *g*, gracilis tendon; *h*, sartorius; 1, internal popliteal nerve; 2, external popliteal nerve; 3, internal saphenous vein.

of the limb, the position in which the patella is not fixed and its ligament and the anterior part of the joint capsule attached to the bone are the most lax. The lateral luxations are usually incomplete, but may be complete. In the former case the anterior part of the capsule need not be torn, but in the latter form it can scarcely escape extensive rupture.

In the dislocation of the patella upon its edge, the

inner border of the bone usually projects forwards, while the outer is placed between the condyles. But little is known as to the mechanism of this dislocation.

In **dislocations of the knee**, which are very rare, the tibia may be displaced outwards, inwards, forwards, or backwards. The two lateral luxations appear to be more common than the antero-posterior. The former are nearly always partial, the latter usually complete. Considerable violence is required to produce these luxations, owing to the great strength of the ligaments and the great width of the bones involved. Direct violence to the tibia or femur, associated often with a twisting of the former bone, is the common cause of the lesion. It is probable that in all luxations of the knee the crucial ligaments are torn. The lateral ligaments also are usually ruptured, but in the partial luxations they may be sometimes found to be intact. The tendinous expansion of the vasti in front of the knee seldom escapes some laceration, even in the partial dislocations. The projection of the spine of the tibia between the femoral condyles offers an obstruction to lateral luxation. In the antero-posterior displacements, the tibia is more often luxated forwards than backwards. In these injuries, not only are the crucial and lateral ligaments torn, together with the anterior part of the capsule, but the posterior ligament, the gastrocnemius, the biceps, and less often the semi-membranosus, suffer more or less extensive laceration. The popliteal vessels and nerves are much compressed, and appear to be more severely injured by the femur in the forward dislocation than by the tibia in the backward displacement.

**The lower end of the femur.**—The condylar part of the femur is composed almost wholly of cancellous bone, but with a slight layer of compact tissue. It is so spongy that it may be pierced by a bullet, as pointed out by Legouest, without any splintering of the bone being produced and without damage to the articulation. The *fractures* that may be met with in the lower end of the bone are the following: (1) A

fracture of the shaft above the condyles; (2) a separation of the lower epiphysis; (3) a fracture separating either the outer or inner condyle; (4) a T-shaped fracture, *i.e.*, a transverse fracture above the condyles with a vertical one between those processes. These lesions are, as a rule, due to well localised direct violence. Fractures Nos. 1 and 4 may be produced by indirect violence, as by a fall upon the feet from a height. Henry Morris states that lateral flexion, or force applied in a lateral direction, is best calculated to produce a separation of the epiphysis. Hamilton reports a strange case in a man aged 21, whose outer condyle was fractured by the twist of the leg, which happened while he was undressing himself to bathe. The only fracture that requires special notice in this place is the fracture of the shaft just above the condyles. The lesion is situated generally about 2 inches above the line of the epiphysis, and corresponds to the spot where the compact shaft joins the softer and more cancellous tissue of the lower end of the bone. It is near the place, also, where the femoral artery crosses the bone to reach the ham, and it has thus happened that the vessel has been wounded by splinters in this particular injury. The fracture is usually oblique, from behind, downwards and forwards. The lower fragment will be drawn upwards by the same muscles that produce shortening in other fractures of the shaft (page 462), and its sharp upper end is very apt to be pulled forcibly into the popliteal space by the gastrocnemius muscle. This latter displacement is difficult to remedy. If the limb be extended, the fragment is only drawn the more into the ham, and it is therefore possible for the limb to appear straight and yet have the knee-joint much bent. In several cases of this injury I divided the tendo Achillis, and then placed the limb upon a straight splint, following a practice suggested by Mr. Bryant. The effect upon the position of the fragments was in each case very good (*Brit. Med. Jour.*, 1883). The lower fragment of the femur may be replaced by completely flexing the leg on the thigh. (Hutchinson and Barnard.)

The **upper end of the tibia** is sometimes the seat of fracture, although of all parts of this bone the upper third is the part least often broken. One or other of the tuberosities may be broken off, or there may be a transverse or oblique fracture of the upper end of the shaft associated with a vertical one running up into the joint between the two tuberosities. Such accidents are the result, in nearly every instance, of great direct violence. Dr. Hutton reports a case, probably unique, in which the spine of the tibia, the central part of the head of the bone, and a considerable portion of the left articular surface were torn from the rest of the tibia. The anterior crucial ligament was attached to the fragment. The patient had been wrestling while in a state of intoxication, and had been heavily thrown. Madame Lachapelle reports a case of separation of the upper epiphysis of the tibia caused by traction during parturition; but I am not aware of any reported case of separation of this epiphysis due to violence or under circumstances other than these.

The spongy tissue in the head of this bone and in the lower end of the femur is, *par excellence*, the favourite seat for myeloid sarcomata.

In **excising the knee-joint** through an incision commencing at the back of one condyle, and continued across the joint, just below the patella, to the back of the other condyle the following structures are divided: Skin, fascia, patellar plexus of nerves (formed by the middle and internal cutaneous and the patellar branch of the long saphenous), bursa patellæ, anterior part of the capsule, ligamentum patellæ, synovial membrane, lateral and crucial ligaments, the superior and inferior articular arteries, the *anastomotica magna*, and the anterior tibial recurrent vessels.

The incision over the inner condyle need not be made so far back as to divide the internal saphenous vein and nerve. In sawing the femur it is most important that the exact inclination of the joint surface of the bone be reproduced. If improperly sawn the patient would be bow-legged or knock-kneed. The

rule, therefore, is that the saw be applied parallel to the articular surface and perpendicular to the shaft.

In young subjects care must be taken that the saw-cuts do not pass beyond the epiphyseal line. The upper limit of the *femoral epiphysis* will be represented by a horizontal line drawn across the bone at the level of the tubercle for the adductor magnus. If the whole

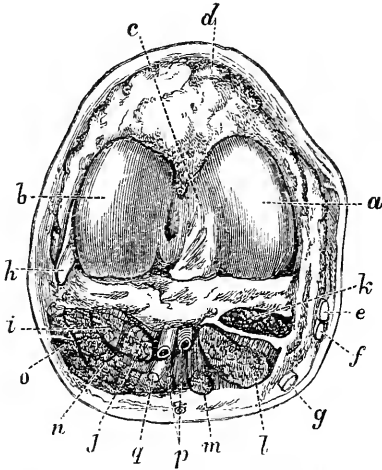


Fig. 66. —Disarticulation at the Knee-joint by single Anterior Flap (Agatz).

a, Int. condyle; b, ext. condyle; c, intercondyloid fossa; d, lig. patellae; e, sartorius; f, gracilis; g, semitendinosus; h, ext. lat. ligament; i, popliteus; j, plantaris; k, semimembranosus; l and m, inner head of gastrocnemius; n, outer head of gastrocnemius; o, biceps; p, popliteal vessels; q, int. pop. nerve.

of the trochlear surface be removed in the excision the whole of the epiphysis will have been taken away. A single nucleus appears in this epiphysis shortly before birth, and joins the shaft about the twentieth year. The limits to the *tibial epiphysis* are represented behind and at the sides by a horizontal line that just marks off the tuberosities. It includes, therefore, the depression for the insertion of the semimembranosus, and also the facet for the fibula. In front the epiphyseal line slopes downwards on either side to a point on the upper end of the shin,

so as to enclose the whole of the tubercle of the tibia. The centre joins the main bone at the twenty-first or twenty-second year. The popliteal artery runs some risk of being wounded in excision of the joint. The vessel is separated by some little distance from the popliteal surface of the femur (Fig. 66), but is in very close relation to the tibia, the posterior ligament alone intervening at the upper level of the bone.

It thus happens that the risk of wounding the artery is greater when the tibia is sawn than when the lower part of the femur is being removed.

Excision of the knee is, to a large extent, replaced by arthrectomy. Indeed, excision of this joint carried out in the complete manner just described must be classed as a quite rare operation.

**Amputation through the knee-joint.**—To illustrate the anatomy of the part an amputation by a single anterior flap may be selected. In fashioning the anterior flap (which is composed only of integument), and in opening the joint, the patellar plexus of nerves, the superficial branches of the plexus of arteries, the ligamentum patellæ, and the anterior part of the capsule will be cut. Nearer the condyles of the femur the anastomotic and the two superior articular arteries will be divided. The long saphenous vein and nerve will be divided at the inner angle of the flap. On the cut surface made by the posterior incision will be found divided the sartorius, gracilis, and semitendinosus, the semimembranous, both heads of the gastrocnemius, the popliteus, plantaris, and biceps. The popliteal vessels, the sural arteries, the short saphenous vein, the internal and external popliteal nerves, the external saphenous and the small sciatic nerves will also be found divided in the same incision.

The most convenient amputation at the knee-joint is by equal lateral flaps (Stephen Smith's operation). This operation has been attended by excellent results, and in actual practice the method of amputation by a single anterior flap is but very rarely employed.

---

## CHAPTER XXII.

### THE LEG.

**Surface anatomy.**—The anterior border of the tibia can be felt in its entire length, forming, as it does, the prominence of the shin. It should be remembered

that this border presents a somewhat flexuous course, being curved outwards above and inwards below. The broad internal surface of the bone is subcutaneous, and the internal border can be followed from the tuberosity to the malleolus. The head of the fibula can be distinctly made out, but the upper half of the shaft of the bone is lost beneath the mass of muscle on the outer side of the limb. The lower half of the fibular shaft can be felt, and the bone just above the malleolus becomes subcutaneous in the interval between the peroneus tertius and the two other peroneal tendons. The fibula is situated so far behind the line of the tibia that a knife thrust transversely through the leg from the inner side behind the tibia will appear in front of the fibula on the outer side (Fig. 68). Between the tibia and fibula the outline of the tibialis anticus muscle can be well defined when it is in action. To its outer side is the less conspicuous and narrower eminence formed by the extensor communis digitorum. In well-developed limbs the groove that separates these two muscles is very distinct, and forms the best guide to the anterior tibial artery. In the lower third of the leg these muscles become tendinous, and between them the extensor longus pollicis can be felt as it comes to the surface. The long and short peroneal muscles can be defined, and their tendons followed behind the malleolus. When in active contraction the interval between the two muscles is often well marked. The gastrocnemius muscle and the more superficial parts of the soleus are brought well into view when the body is raised upon the toes. The two heads of the former muscle are then quite conspicuous, and it can be seen that the inner head is the larger and descends lower in the leg.

The popliteal artery bifurcates on a level with the lower part of the tubercle of the tibia. The course of the posterior tibial vessel is represented by a line drawn from the middle of the limb at the lower part of the ham to a spot midway between the inner malleolus and the prominence of the heel. The artery becomes



superficial in the lower fourth of the leg, where it may be felt pulsating between the tendo Achillis and the tibia. The peroneal artery arises about 3 inches below the knee, follows the posterior surface of the fibula, and ends behind the outer malleolus. The position of the anterior tibial artery may be indicated by a line drawn from a point midway between the outer tuberosity of the tibia and the head of the fibula to the centre of the front of the ankle-joint. Both the saphenous veins can often be made out in the leg. The inner or larger vein passes in front of the malleolus and ascends just behind the internal border of the tibia. With it runs the long saphenous nerve. The short saphenous vein lies behind the outer malleolus, and passing up the middle of the calf ends at the ham. It is accompanied by the external saphenous nerve.

The **leg**.—The *skin* is somewhat more adherent to deeper parts in the leg than it is in the thigh. The difference in the degree of this adhesion is obvious when skin-flaps are dissected up from the two parts in cases of amputation. Over the internal surface of the tibia and the greater part of the shin, the integument lies directly upon the periosteum and bone, nothing intervening save a scanty amount of subcutaneous fascia. Thus blows and kicks over these parts of the leg are apt to be associated not only with much pain but also with much bruising or tearing of the integument. A "graze on the shin" is one of the commonest of lesions, and is produced by a degree of violence that upon a well-covered part would have little or no effect. It will be understood that ulcers over these feebly protected parts may, if they spread in depth, readily expose the bone and lead to some disease of its substance, or to at least some inflammation of its periosteum. Scars left by deep ulcers or burns are also often found to be quite adherent to the bone.

The **aponeurosis** of the leg invests it like a tightly-drawn buskin, being lacking only over the subcutaneous surfaces of the bones. It is attached to the head and the anterior and inner borders of the

tibia, the head of the fibula, and the two malleoli. It is continuous above with the fascia lata, and below with the fascia of the foot and the annular ligaments. It is thicker in front than behind, and is especially thick at the upper part of the leg just below the knee. Here the fascia offers great resistance to the growth of tumours springing from the head of the tibia. From the deep surface of the aponeurosis two septa pass inwards to be attached to the anterior and external borders of the fibula. They serve to isolate the two larger peroneal muscles from the other muscles of the limb, and form a closed space which might form a definite and well localised cavity for pus. Beneath the gastrocnemius and soleus a layer of fascia extends between the two bones and covers in the deep layer of muscles. It is thin above but denser below, and would have some influence in directing the progress of a deep abscess.

In the upper third of the leg there is a septum between the tibialis anticus and extensor communis digitorum, which must be found in the operation for ligaturing the upper part of the anterior tibial artery. I have never had the good fortune to see the very distinct "white line" that many text-books describe as indicating the position of this septum.

In the substance of the soleus muscle there is a tendinous expansion connected with the border of the tibia, that runs backwards and towards the middle line. In cutting through the soleus to apply a ligature to the posterior tibial artery, this intersection may be mistaken for the aponeurosis on the deep surface of the muscle.

Several cases are reported of rupture of some part of the gastrocnemius muscle during violent exertion. The tendo Achillis has been ruptured under like circumstances. It is said that the plantaris tendon is also not unfrequently torn across, producing a sudden sharp pain in the calf during exertion, to which the French give the name "*coup de fouet*."

**Vessels.**—The large arteries of the leg, being all in close proximity with the bones, are apt to be injured

by sharp fragments in fractures of the limb. This especially applies to the peroneal artery, which runs along the fibula in a fibrous canal, and is in considerable risk of being wounded in fractures about the middle of that bone. It is at the point of bifurcation of the popliteal artery that emboli are peculiarly apt to lodge. They plug the vessel and practically block the three main arteries of the leg. Gangrene, therefore, not unfrequently follows the occurrence. Billroth states that in all the cases of gangrene of the leg due to embolism that he has met with, the plug was found situated at the bifurcation of the popliteal trunk ("Clinical Surgery," 1881). According to some French surgeons, aneurism of the commencement of the posterior tibial artery is more often associated with gangrene of the leg than is a popliteal aneurism. The reason they assign is the following: The aneurism on the former vessel not only interferes with the passage of the blood into the posterior tibial and peroneal arteries, but also compresses the anterior tibial vessel and with it the anterior tibial recurrent, an artery that is of so great importance in establishing the collateral circulation.

**Varicose veins** are more commonly met with in the leg than in any other part of the body, save, perhaps, in the hæmorrhoidal and spermatic veins. This depends upon the great length of the veins of the lower limb, the large columns of blood their valves have to support, their vertical position, the liability of the great trunks (iliac), into which they ultimately enter, to be compressed, and upon the fact that the superficial veins, being outside the fascia, lose that assistance to the circulation derived from muscular contraction. From a physical point of view the vascular system must be regarded as a vertical column of fluid. The lower the level the greater is the pressure on the containing walls. The saphenous veins are thin-walled, distensible tubes situated outside the rigid-walled cylinder formed by the deep fascia of the leg and thigh, low in the body, where the pressure from gravity is greatest (Hill). The use of garters especially affects the long saphenous vein,

which lies close to the bone at the spot about which these contracting bands are usually applied. Between the two layers of the muscles of the calf Verneuil describes a venous plexus, which he believes to be more often the seat of varices than are the vessels of the surface. A varicose condition of these deeply placed veins may explain the "aching legs" complained of by those who stand a great deal. The intramuscular veins are very large. Callender showed that the six chief veins which pass from the soleus muscle alone to enter into the posterior tibial and peroneal trunks have a united diameter of not less than 1 inch. Varix would appear to commence most often at points where the deep veins join the superficial vessels. There is good reason for this, for at these points three forces meet, the general directions of which are shown in the annexed diagram (Fig. 67). There is the weight of the superincumbent column of blood (*a*) acting from above, the resistance offered by the next valve below the point of entry of the deep vein acting from below (*b*), and the force with which the blood is driven by the contracting muscles out of the deep vein into the superficial trunk

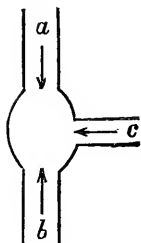


Fig. 67.

acting at an angle to both these lines of force (*c*). Unfortunately for the subjects of varices, the two principal veins (the saphenous) are accompanied by sensory nerves, and there is no doubt that much of the pain incident to varicose veins in the leg depends upon pressure on these nerves.

With reference to **pain in the leg**, it must be remembered that the nerves that bring sensation to the part arise at a considerable distance from their points of termination, and that the causes of pain in the limb may be situated far away from the seat of trouble. Thus Sir B. Brodie mentions the case of a gentleman who suffered from severe pain in the left leg, from the foot to the knee, in the course of the peroneal nerve. No cause could be found for it. At the patient's death, however, a large tumour was found attached to the

lumbar spine, which had evidently compressed the left great sciatic nerve.

There would appear to be little connection between disease in the rectum and a pain in the leg, yet in one case at least that connection was marked. "Only recently," writes Mr. Hilton, "I saw a gentleman from South Wales, who was the subject of stricture of the rectum from malignant disease. He suffered pain in the knee-joint and in the back part of the leg. This led me to suspect, what really turned out, upon careful examination, to be the case, that a large mass of cancer was involving the nerves on the anterior part of the sacrum, and also, no doubt, the obturator nerve."

Dr. Ralfe mentions cases of renal calculus attended by severe pain in the sole of the foot, and I have met with many instances of this association, the pain being most commonly in the heel.

**Fractures of the leg.**—Of the bones of the leg the tibia and fibula are more often broken together than singly, and of separate bones the fibula is more often fractured than is the larger bone.

1. *The tibia and fibula.* As regards the resistance it offers to violence the fibula presents about the same degree of strength in all its parts, save at the malleolus and at its upper extremity. Its great length and the manner of its attachment to the tibia (its two ends being fixed and its main part being unsupported) render it a slender bone, and but for the efficient protection it derives from the thick pad of muscles that surrounds it, it would no doubt be very frequently broken. This is all the more likely to be the case, since the bone is placed upon the more exposed aspect of the limb.

The shaft of the tibia presents various degrees of strength, according as we regard its upper, middle, or lower third. According to Dr. Leriche, the average transverse diameter of the adult tibia just below the tuberosities is a little over  $1\frac{3}{4}$  inches. The transverse diameter at the base of the malleolus is a little less than  $1\frac{3}{4}$  inches, and that of the narrowest part of the bone is a little more than 1 inch. This narrow part is at the

junction of the lower with the middle third of the shaft, and is the weakest point in the bone.

The relation of the compact to the cancellous tissue is about the same in all parts of the shaft; but according to MM. Fayel and Duret, the spongy tissue is arranged in two independent vertical columns, one occupying the upper two-thirds and the other the lower third of the bone. The minimum of resistance (these authors assert) is at the point where these two systems meet. Thus it happens that the most common spot for a fracture of the tibia is at the junction of the middle with the lower third of the shaft. It is here that the bone yields when broken by indirect violence, while the lesions depending upon direct violence may be at any part of the shaft. Owing to the thin covering of soft parts, and the slight barrier interposed between the fracturing force and the bone, it comes to pass that fractures of the leg are more often compound and comminuted than are those of any other bones of the extremities. If the fracture be oblique, as is commonly the case when the violence is indirectly applied, the line of breakage usually extends from behind, downwards, forwards, and a little inwards. The lower fragment, with the foot, is drawn up behind the rest of the bone by the muscles of the calf, and is usually displaced also outwards by the obliquity of the fracture line. Often the lower fragment is slightly rotated outwards by the rolling over of the foot, a rotation produced by the simple weight of the limb. If the fracture be transverse there may be little or no displacement. The fibula is usually broken at a higher level than the tibia, and its lower fragment follows, of course, with absolute precision the corresponding fragment of the larger bone. A remarkable spiral fracture (*fracture hélicoïde*), involving the lower third of the tibia, has been described by French surgeons. It is associated with a more or less vertical fissure that involves the ankle-joint, and with a fracture of the fibula high up. MM. Leriche and Tillaux have shown that this injury is due to torsion, especially to some twisting of the leg while the foot is fixed.

2. *The fibula alone.* Fractures of this bone in its lower fourth are usually due to indirect violence, and will be dealt with in connection with the ankle-joint. When it is broken in any other part the fractur-

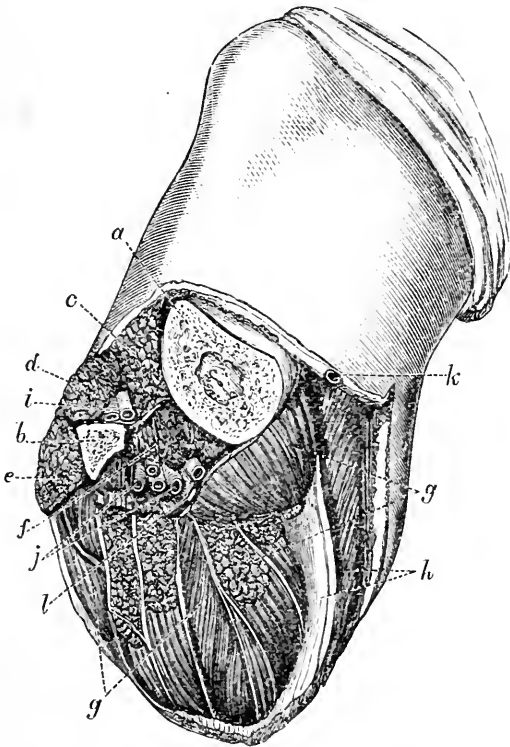


Fig. 68.—Amputation of Leg at junction of Upper with Middle Third by single Posterior Flap (Agatz).

*a*, Tibia; *b*, fibula; *c*, tibialis anticus; *d*, ext. com. digit; *e*, peron. long.; *f*, tib. post.; *g*, soleus with flex. long. digit; *h*, gastrocnemius; *i*, anterior tibial vessels; *j*, post. tibial and peroneal vessels; *k*, int. saphen. vein; *l*, post. tibial nerve.

ing force is usually directly applied, the lesion transverse, and the displacement insignificant, or scarcely obvious. The tibia acts as an efficient splint.

3. *The tibia alone.* The malleolus may be broken

by a blow, or the lower epiphysis separated. The latter comprises the whole of the inner malleolus and the facet with which the fibula articulates. It joins the shaft during the eighteenth or nineteenth year. Fractures of the tibia alone are nearly always due to direct violence, and whilst most common in the lower third of the bone, become more rare as the knee is approached. When transverse there may be no visible displacement,

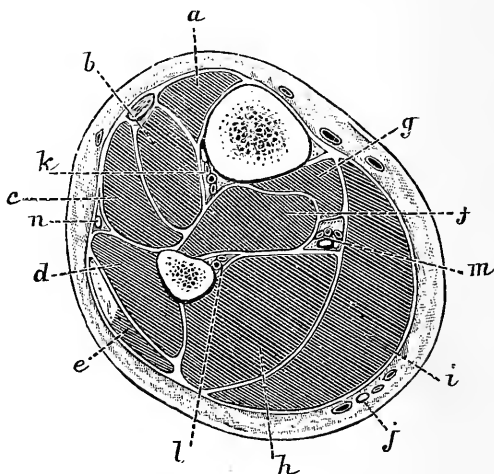


Fig. 69.—Transverse Section through the Lower Third of the Leg (Braune).

*a*, Tibialis anticus; *b*, extensor longus pollicis; *c*, extensor communis digitorum; *d*, peroneus brevis; *e*, peroneus longus; *f*, tibialis posticus; *g*, flexor longus digitorum; *h*, flexor longus pollicis; *i*, gastrocnemius and soleus; *j*, short saphenous nerve and vein; *k*, anterior tibial vessels and nerve; *l*, peroneal vessels; *m*, posterior tibial vessels and nerve; *n*, musculo-cutaneous nerve.

the fibula acting as a splint. Thus Mr. H. Morris mentions the case of a woman who walked into and out of a hospital with a transverse fracture of the tibia that was not detected on examination, and was not indeed discovered until two days after the accident. When the fracture is just above the ankle the lower fragment may be moved in whatever direction the foot is forced, such displacement being resisted and limited by the inferior tibio-fibular ligaments.



In **rickets** the tibia is, of all the bones of the extremities, the one that most frequently becomes bent. It yields at its weakest part (the lower third), and there the bone will be found to have developed a curve forwards and a little outwards.

**Amputation of the leg** at the junction of the upper with the middle third by unequal antero-posterior flaps may be taken as an example. This is not the best method of amputation, but it serves best to illustrate the anatomy of the part. In the anterior flap the following structures would be cut: Skin, cutaneous nerves, fascia, tibialis anticus, extensor communis digitorum, and a little of the extensor proprius pollicis, the peroneus longus, and a small part of the upper extremity of the peroneus brevis, the anterior tibial vessels and nerve, and the musculo-cutaneous nerve. In the posterior flap the following would be the parts divided: Skin, external and internal saphenous veins and nerves, fascia, gastrocnemius, plantaris, soleus, tibialis posticus, flexor longus digitorum, a little of the upper end of the flexor longus pollicis, the posterior tibial vessels and nerve, and the peroneal vessels.

Fig. 68 shows the stump left after the amputation through the lower part of the upper third of the leg by means of a single flap cut from the calf. It serves to show the relations of the chief parts divided,<sup>c</sup> and gives a good idea of the stump that would be left in an amputation by an anterior skin flap and a posterior transfixion flap cut from the calf.

In Fig. 69 is shown a transverse section of the leg at the lower third, from which can be gathered an idea of the number and position of the parts cut in amputations through that part.

An excellent method of amputation at the upper part of the leg is by a single external flap containing the anterior tibial artery in its entire length.

## CHAPTER XXIII.

## THE ANKLE AND FOOT.

**Surface anatomy.**—*Bony points.*—The outlines of the two malleoli can be very distinctly defined. The external is somewhat the less prominent, descends lower, and lies farther back than the internal process. The tip of the outer malleolus is about  $\frac{1}{2}$  an inch behind and below the tip of the corresponding bony prominence. The antero-posterior diameter, however, of the internal malleolus is such that its posterior border is on a level with that of the outer process behind.

On the dorsum of the foot the individual tarsal bones are not to be distinguished, although the astragalus forms a distinct projection upon that surface when the foot is fully extended.

On the inner side of the foot the tuberosity of the os calcis may be felt most posteriorly. In front of it, and about 1 inch vertically below the inner malleolus, is the projection of the sustentaculum tali. About  $1\frac{1}{4}$  inches in front of the malleolus the tubercle of the scaphoid can be distinctly made out. In the interval between it and the last-named process lies the inferior calcaneo-scaphoid ligament, and the tendon of the tibialis posticus. Farther towards the front of the foot can be felt the ridge formed by the base of the first metatarsal bone, and between it and the scaphoid tubercle lies the inner cuneiform bone. Lastly, the shaft of the first metatarsal bone, its expanded head, and the sesamoid bones that lie on the plantar aspect of the metatarsal phalangeal joint can be more or less distinctly defined. On the outer side of the foot the external surface of the os calcis is subcutaneous in nearly the whole of its extent. Less than 1 inch below and in front of the malleolus is the peroneal tubercle, with the short peroneal tendon above it and the long one below it. Some  $2\frac{1}{2}$  inches from the outer malleolus the projection of the base of the fifth metatarsal bone is very evident,

and extending for an inch or so behind it lies the cuboid bone.

*Joint lines.*—The ankle-joint lies about on a level of a point  $\frac{1}{2}$  an inch above the tip of the inner malleolus. Immediately behind the tubercle of the scaphoid is the astragalo-scaphoid articulation, and a line drawn transversely across the dorsum of the foot, just behind the process, very fairly corresponds to the mid-tarsal joint (the joint compounded of the astragalo-scaphoid and calcaneo-cuboid articulations).

¶ If the latter articulation be approached from the outer side it will lie opposite a point midway between the outer malleolus and the prominent base of the fifth metatarsal bone.

The lines of the articulations between the first and fifth metatarsal bones and the inner cuneiform and the cuboid respectively are easily indicated, being placed just behind the bases of the former bones. The metatarso-phalangeal articulations are situated about 1 inch behind the webs of the corresponding toes. The proximal phalanx and part of the middle are buried in the web.

*Tendons.*—The tendo Achillis stands out very conspicuously at the back of the ankle, and between it and the malleoli are two hollows which are evident in even obese individuals. Over the front of the ankle the tendons of the extensor muscles are readily to be distinguished, especially when the joint is flexed. From within outwards they are: the tendons of the tibialis anticus, extensor longus pollicis, extensor longus digitorum, and peroneus tertius. Beneath the tendons of the extensor of the toes, and on the outer part of the dorsum of the foot, the prominent fleshy mass formed by the extensor brevis digitorum can be felt and, when in action, seen. Above and behind the inner malleolus the tendons of the tibialis posticus and flexor longus digitorum can be discerned, the former lying nearer to the bone. Nearer to the middle line runs the flexor longus pollicis. Behind the outer malleolus the long and short peroneal tendons can be felt, lying close to the edge of the fibula, the tendon of the smaller muscle being the closer to it.

☞ In the middle of the sole of the foot the resisting plantar fascia can be felt, and some of its processes made out when the toes are drawn up by the extensors. The fleshy mass on the inner margin of the foot is formed by the abductor and flexor brevis pollicis; that on the outer side by the abductor and flexor brevis minimi digiti.

*Vessels.*—The anterior tibial artery and nerve are placed opposite the ankle joint, between the tendons of the extensor proprius pollicis and longus digitorum. The dorsal artery runs from the middle of the ankle to the interval between the bases of the first and second metatarsal bones. It may be felt pulsating against the bones along the outer side of the extensor proprius pollicis tendon, which is the readiest guide to it. The plantar arteries start from a point midway between the tip of the malleolus internus and the centre of the convexity of the heel. The internal vessel follows a line drawn from this point to the middle of the under surface of the great toe. The external vessel crosses the sole obliquely to within a thumb's breadth of the base of the fifth metatarsal bone. From thence it turns more transversely across the foot, running inwards over the bases of the metatarsal bones to inosculate with the dorsalis pedis artery at the back of the first interosseous space. On the dorsum of the foot the subcutaneous veins may be seen forming an arch convex towards the toes, and from the ends of the arch vessels may be followed into the internal and external saphenous veins.

The **ankle and foot.**—The **skin** about the ankle and over the dorsum of the foot is thin and but loosely attached to the subjacent parts. It becomes readily excoriated, as is often the case where splints or instruments have been improperly applied. Since the skin over the malleoli lies directly upon the bone, while that covering the dorsum of the foot is but slightly separated from the bones of the tarsus, it follows that the integuments in this region are readily contused, and may suffer gangrene from an amount of pressure

that would cause but little trouble in other parts. Over the sole the integument is dense and thick in all those parts that come in contact with the ground. In the normal foot, the heel, the outer margin of the foot, and the line of metatarso-phalangeal joints are in contact with the ground when the sole is placed flat upon it. Along the inner margin of the foot the integument is thin and fine. The skin of the sole, like that of the palm of the hand, is remarkably adherent to subjacent parts. When cut it shows no tendency to gape, and thus exploratory incisions made into the part (as for the discovery of foreign substances) have often to be of greater dimensions than would be needed elsewhere.

The subcutaneous tissue about the ankle and foot varies greatly both in quantity and character. It is abundant and well provided with loose fat in the immediate neighbourhood of the tendo Achillis. Over the front of the ankle and dorsum of the foot it is very lax and fairly extensive, although possessing but little adipose tissue in its meshes. In the sole the subcutaneous tissue is most developed where most pressure is received. Thus, beneath the heel it is often  $\frac{3}{4}$  of an inch in thickness, and is more extensively distributed along the outer than along the inner margin of the foot. It is here composed mainly of little lobules of fat bound down and enclosed by numerous fibrous bands that pass vertically from the skin to the deep fascia. Over the centre of the sole it is more scanty, and the union between the integument and the plantar fascia is more direct. It very closely resembles the subcutaneous tissue found in the palm and upon the scalp. Beneath the heel it forms an actual pad or cushion that must much diminish the force of shocks transmitted to the body through the foot. The laxity of the tissue upon the dorsum of the foot permits of great swelling occurring in cases of diffuse inflammation of the part and in conditions producing œdema. In the commencement of general dropsy the dorsum of the foot is often the first part of the whole body to show the morbid swelling. In the sole, on the other hand, inflammatory affections

and effusions of various kinds can produce but little external change, owing to the unyielding character of the parts concerned. Collections of pus upon the dorsum may form readily and extend rapidly, but in the sole of the foot and in the heel the abscess remains small, is unable to spread, and causes intense pain by reason of the dense structure of the tissues involved.

The integuments of the foot are well supplied with nerves, being furnished with branches from no less than six nerve trunks, the musculo-cutaneous, the anterior tibial, the two saphenous, and the external and internal plantar.

Many Pacinian bodies are found upon these cutaneous branches, and end-bulbs are met with in the skin on the sole of the dorsum. It must be remembered that these nerves come from a considerable distance (the long saphenous from the lumbar plexus, and the remainder from the sacral), so that pain experienced in the foot may be due to causes very remotely situated. Thus, Sir B. Brodie mentions a case of severe neuralgia of the foot, after each evacuation of the bowels, caused by the descent and pressure of internal piles. The integuments of the foot respond acutely to sensations of pain, of pressure, of temperature, and to certain unwonted forms of tactile impression, such as tickling. Tactile sensibility, however, as measured by the æthesiometer, is not acute, the dorsum of the foot showing, in regard to this matter, no more sensitiveness than does the skin of the buttock.

Over the "tread of the foot," and especially under the ball of the great toe, the peculiar affection known as "perforating ulcer" is most commonly met with. This ulcer occurs as an occasional symptom in certain nerve maladies, and particularly in locomotor ataxy.

The **fasciæ of the foot and the tendons about the ankle.**—The fasciæ on the dorsum occur in two layers, a superficial one that is continued from the anterior annular ligament, and a deeper placed over the extensor brevis and interossei muscles. These membranes are both thin and insignificant, and exercise

no influence from a surgical point of view. The plantar fascia is divided into three parts, a central or main portion which is extremely dense and powerful, and two lateral expansions which are thin and surgically insignificant. The outer of the two lateral portions is, however, of some substance, and forms a very thick band between the os calcis and fifth metatarsal bone, that may become rigidly contracted in some forms of talipes. The central expansion assists greatly in supporting the antero-posterior arch of the foot, which it tends to maintain in the manner that the bowstring maintains the arch of the bow.

The sinking of the arch that occurs in "flat foot" is associated with marked yielding of this fascia. The plantar fascia is often found much contracted (as a rule, secondarily) in certain forms of club-foot, such as talipes equinus and congenital varus. The term "talipes cavus" is applied to a deformity that depends mainly or entirely upon a contraction of the plantar fascia. The best place in which to divide this membrane is at a spot about 1 inch in front of its attachment to the os calcis. This is its narrowest part, and the knife (which should be introduced from the inner side) will be behind the external plantar artery which runs beneath the expansion. An abscess situated beneath the membrane will be very closely bound down, and will advance in any direction other than through the membrane itself so as to point in the centre of the sole. Such deep collections cause intense pain, and often much destruction, before they are discharged. They may open upon the dorsum, or may extend up along the tendons to the region of the ankle. There are certain foramina or spaces in the substance of this layer occupied usually by fat. Through one or more of these an abscess will, in exceptional cases extend, and then spread out beneath the integuments. Such an abscess will have, therefore, two cavities united by a small hole, and will form the *abcès en bissac* or *en bouton de chemise* of the French. The plantar fascia divides into slips near the roots of the toes, and forms a series of arches, beneath

which pass the tendons, vessels, and nerves bound for the digits. Two intermuscular septa connected with the membrane separate the flexor brevis digitorum from the abductor pollicis on the one side and the abductor minimi digiti on the other. They are, however, membranes of too feeble a structure to much affect the progress of a deep plantar abscess.

The anterior *annular ligament* is divided into two parts; an upper band in front of the tibia and fibula, and a lower band in front of the upper limits of the tarsus. Beneath the former there is only one synovial sheath, that for the tibialis anticus; beneath the latter are three sheaths: one for the peroneus tertius and extensor communis, one for the extensor proprius pollicis, and a third for the tibialis anticus.

According to Holden, there is often a large irregular bursa between the tendons of the extensor longus digitorum and the projecting end of the astragalus. This bursa sometimes communicates with the joint of the head of the astragalus.

Beneath the internal annular ligament are three synovial sheaths for the tendons of the tibialis posticus, flexor longus digitorum, and flexor longus pollicis. Inflammation involving the sheath for the tibialis posticus may spread to the ankle joint, with which the tendon is in close relation. Beneath the outer annular ligament is the single synovial sheath for the long and short peroneal tendons.

In severe sprains of the ankle not only are the ligaments about the joint more or less ruptured, but the various synovial sheaths just named are apt to be torn. The long abiding trouble in the part that often follows severe sprains depends to a great extent upon damage to these sheaths, and to extravasations of blood, and subsequently of inflammatory material, within them.

There are few **bursæ** of any magnitude about the foot, save one between the tendo Achillis and os calcis, and another over the metatarso-phalangeal joint of the great toe. The first-named bursa rises up about  $\frac{1}{2}$  an inch above the os calcis, and bulges out on either



side of the tendon. When inflamed it may produce symptoms like those of ankle-joint disease, and when suppurating may lead to caries of the os calcis. The enlargement of the bursa over the metatarso-phalangeal joint of the great toe constitutes a *bunion*. It lies in the subcutaneous tissue between the internal sesamoid and the skin, and is not present at birth. This condition is generally brought about by improperly shaped boots, which force the great toe outwards, place it obliquely to the long axis of the foot (with which it should be parallel), and render the metatarsal joint very prominent. The cartilage over the inner part of the head of the metatarsal bone disappears, and a communication between the bursa and joint may be set up. The result of this deformity is a great weakening of the toe and adjacent part of the foot, a lengthening of the internal lateral ligament of the joint, and a displacement outwards of the tendon of the extensor proprius pollicis. Bursæ are often developed over the malleoli in tailors, and especially over the external process, the part most pressed upon when sitting cross-legged. In club-foot, bursæ are found over any points that are exposed to undue pressure.

The **tendons** about the ankle are not unfrequently ruptured by violence. Those that most often are so injured are the tendo Achillis and the tendons of the tibialis posticus, and long and short peroneal muscles. The tendo Achillis usually breaks at a point about  $1\frac{1}{2}$  inches above its insertion, where it becomes narrowed and its fibres are collected into a very definite bundle.

In some forms of violence the synovial and fibrous sheaths that bind down a tendon may be ruptured and it may be allowed to become displaced. This has happened to the tibialis posticus and peroneal muscles. In each instance the dislocated structure comes forwards upon or in front of the malleolus. No tendon in the body is so frequently displaced as is that of the peroneus longus.

The tendons about the ankle are frequently divided

by operation. The tendo Achillis is usually cut about 1 inch above its insertion, the knife being entered from the inner side to avoid the posterior tibial vessels. The tibialis posticus tendon is, as a rule, divided just above the base of the inner malleolus. There is, however, enough room between the annular ligament and the scaphoid bone to cut it on the side of the foot. The anterior tibial tendon may be divided readily either in front of the ankle or at its insertion into the internal cuneiform bone. On section of a tendon a gap is felt, owing to retraction by the muscle. The cut ends are still united by the fibrous tissue in which they lie, and from which they derive their blood supply. If cut within a sheath the synovial membrane forms a loose binding between the cut ends. A fibrous band between the cut ends is ultimately formed from the effusion which fills the gap. The new band is firmly adherent to the sheath in which it lies, and at first will limit the movements of the tendon.

Part of the tendon of a sound muscle may be yoked to that of one which has become paralysed, thus restoring certain movements to the foot.

**Blood-vessels.**—The lines of the various arteries have been already indicated. Wounds of the plantar arch are serious, on account of the depth at which the external plantar artery lies, and the impossibility of reaching the vessel without making a large wound in the sole that would open up important districts of connective tissue and do damage to tendons and nerves. The arch is formed by the junction of the external plantar artery with the dorsal artery of the foot, a continuation of the anterior tibial vessel. In cases, however, of bleeding from the arch, ligature of both the posterior and anterior tibial vessels at or just above the ankle would not necessarily arrest the hæmorrhage. After ligature of these vessels blood would still be brought indirectly to the arch by means of the peroneal artery. By its anterior peroneal branch this vessel communicates with the external malleolar branch of the anterior tibial artery, and with the tarsal branch of the dorsalis pedis.

By its terminal branch it communicates with the two last-named vessels, and also with the internal calcaneal branches of the external plantar artery. As a matter of practice, however, elevation of the limb, together with pressure upon the wounded point and compression of the main artery, are sufficient to check most hæmorrhages from the plantar arch.

It must be remembered that this arch can be wounded by penetrating wounds inflicted upon the dorsum of the foot; and Dr. Delorme has shown how readily various parts of the arch may be ligatured from the dorsum after portions of one or other of the metatarsal bones have been removed. Thus by resecting the upper part of the shaft of the fourth metatarsal bone in one case, the main part of the shaft of the third bone in another, and the upper part of the shaft of the second bone in a third instance, he has been enabled to expose and ligature the greater part of the plantar arch from the dorsal aspect of the foot.

The dorsalis pedis artery, from its superficial position and its close contact with the bones of the foot, is frequently divided in wounds and ruptured in severe contusions. The posterior tibial artery at the ankle is well protected by the projecting malleolus, the dense annular ligament, and the tendons that run by its side.

The superficial veins of the foot, like those of the hand, are found mainly upon the dorsum of the member. The sole, as a part exposed to pressure, is singularly free from them. About the malleoli, and especially about the inner process, these veins form a considerable plexus. Hence it is that appliances that fit tightly around the ankle are apt to produce œdema and pain in the parts beyond. The dull pain in the feet that is often caused by tight elastic-side boots is probably due to the same cause. It will be understood that wounds and suppurations about the dorsum of the foot are more apt to be attended by phlebitis than are like lesions when situated upon the sole. Venesection is sometimes performed in the foot, the vein opened being either one of those forming the dorsal plexus, or more usually the

internal saphenous vein just above the malleolus. The vessels are rendered conspicuous by placing the foot in hot water and then applying a constricting band around the leg.

The **lymphatics** form a very fine and elaborate plexus in the coverings of the sole, from which vessels arise that reach the borders and dorsum of the foot, and principally the inner border. The main lymph vessels of the part are found upon the dorsum and about the radicles of the two saphenous veins. Those on the inner side of the foot are by far the more numerous; they follow pretty generally the course of the internal saphenous vein, and end in the inguinal glands. The external vessels pass up along the outer ankle and outer side of the leg. The bulk of them pass obliquely across the ham to join the inner set above the knee; others reach the inner set by crossing the front of the tibia, while a few follow the short saphenous vein and end in the popliteal glands. Thus, so far as the foot is concerned, lymphangitis is more common after wounds of the dorsum than after wounds of the sole, although in the latter locality the frequent retention of pus beneath the dense fascia greatly favours lymphatic inflammations. Since many vessels cross the shin on their way from the outer to the inner set of vessels, it will be seen that abrasions, etc., of that part of the limb are very apt to be followed by inflammation of the lymph canals. A lesion on the inner side of the foot, and most lesions on the dorsum, will be associated with enlargement of the inguinal glands; while a like mischief on the outer border of the foot may affect either the inguinal or the popliteal chain of glands.

The **ankle-joint** is a very powerful articulation, its strength being derived not only from the shape of its component bones, but also from the unyielding ligaments and many tendons that are bound about it like straps. Of the ligaments, the two lateral are very strong, and have an extensive hold upon the foot. The anterior and posterior are extremely thin and insignificant, although the latter is supported by the tendon

of the flexor longus pollicis, which crosses it. When effusion takes place into the joint, it first shows itself in front, beneath the extensor tendons, and just in front of the lateral ligaments. This is due to the feebleness of the anterior ligament and the extent and looseness of the synovial sac in relation with that structure. More extensive effusions cause a bulging behind through yielding of the thin posterior part of the capsule, and fluctuation can then be obtained on either side of the tendo Achillis. In no ordinary case can fluctuation be detected distinctly beneath the unyielding lateral ligaments. Moreover, the loose synovial sac of the ankle-joint extends both in front and behind beyond the limits of the articulation, while, at the sides, it is strictly limited to the joint surfaces. The ankle is a perfect hinge-joint, and permits only of flexion and extension. The very slightest amount of lateral movement is allowed in extreme extension, when the narrower, or hinder, part of the astragalus is brought into contact with the widest, or anterior, part of the tibio-fibular arch. When obvious lateral movement exists at the ankle, the joint must be the seat of either injury or disease; and it is important not to mistake the lateral movements permitted between certain of the tarsal bones for movements at the ankle-joint. Flexion is limited by the posterior and middle parts of the internal ligament, by the posterior part of the external ligament, by the posterior ligament, and by the contact of the astragalus with the tibia. Extension is limited by the anterior fibres of the inner ligament, the anterior and middle parts of the outer ligament, by the anterior part of the capsule, and the contact of the astragalus with the tibia.

Owing to its exposed position, this joint is very liable to become inflamed from injury or other external causes. When inflamed, no distortion is, as a rule, produced, the foot remaining at right angles with the leg. It would appear that this position is due to the circumstances that the flexor and extensor muscles about balance one another, and it does not seem that

the capacity of the joint is affected by the posture of the foot. The synovial cavity of the ankle is in communication with the inferior tibio-fibular articulation.

In connection with the subject of "referred pains," it should be remembered that the nerves supplying the ankle-joint bring that articulation into relation with the lumbar segments of the spinal cord through the internal saphenous, and the sacral segments through the anterior tibial nerve.

**Dislocations at the ankle-joint.**—The foot may be dislocated at the ankle in five directions, which, placed in order of frequency, are, outwards, inwards, backwards, forwards, and upwards between the tibia and fibula. These dislocations are nearly always associated with fracture of either the tibia or fibula, or of both bones.

1. *The lateral dislocations:* Outwards, inwards. These luxations differ somewhat from those met with in other joints. In the great majority of cases they consist of a lateral twisting of the foot, of such a kind that the astragalus is rotated beneath the tibio-fibular arch. There is no great removal of the upper surface of the astragalus from that of the tibia, but rather is one or other edge of the former bone brought in contact with the horizontal articular surface of the latter. Although much deformity is produced, the actual separation of the foot from the leg is not considerable. In some rare cases a true lateral dislocation in the horizontal direction has been met with.

These injuries are due to sudden and violent twistings of the foot, and are in nearly every instance associated with fractures of the tibia or fibula. The luxation outwards is due to forcible eversion of the foot, the luxation inwards to violent inversion.

It is of interest, in the first place, to note the relation of the *fibula* to injuries at the ankle-joint, especially as a fracture of the lower end of the shaft of that bone may follow alike upon both inversion and eversion of the foot. The lower 3 or 4 inches of the fibula may

be considered to form a lever of the first kind (Fig. 70, A). The fulcrum is at the inferior tibio-fibular articulation, one arm of the lever is the malleolus below that joint, while the other arm may be regarded as formed by the lower 2 or 3 inches of the shaft of the bone. Now

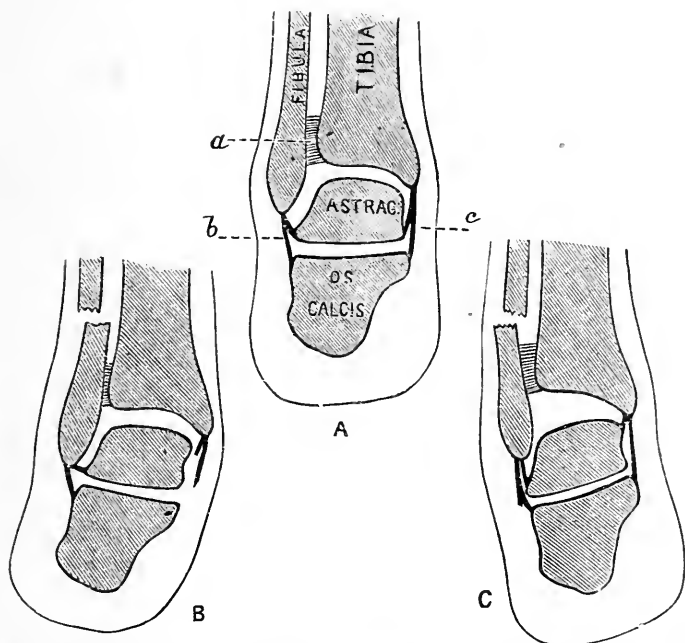


Fig. 70. —Diagrams to illustrate the Mechanism involved in Fractures of the Lower End of the Fibula.

A. Parts in normal position; a, tibio-fibular ligaments; b, external lateral ligament; c, internal lateral ligament; B, fracture of fibula due to eversion of foot; C, fracture of fibula due to inversion of foot.

the lower ends of the tibia and fibula are bound together by very powerful ligaments, viz., the anterior and posterior tibio-fibular, the transverse, and the inferior interosseous. I would venture to particularly insist that in no ordinary lesion about the ankle, whether fracture or dislocation, do these ligaments give way. If they should yield, then an anomalous form of fracture

or luxation will be produced. In forcible eversion of the foot, the internal lateral ligament becomes stretched and tears, the astragalus is rotated laterally beneath the tibio-fibular arch and is brought into violent contact with the end of the outer malleolus. This process is pushed outwards, and acts as one end of a lever. The fulcrum is secured by the unyielding tibio-fibular ligaments, and the fibula breaks at the other end of the lever, a point some 2 or 3 inches above the end of the bone (Fig. 70, B). In forcible inversion of the foot, the astragalus undergoes a little lateral rotation in the opposite direction; the external lateral ligament is greatly stretched, and tends to drag the end of the outer malleolus inwards. If the ligament yields, the case will probably end as a sprained ankle, or pass on to a dislocation inwards of the foot. But, if it remains firm, the end of the fibular lever (the tip of the malleolus) is drawn towards the middle line, the fulcrum is secured by the tibio-fibular ligaments, and the shaft breaks at the other end of the lever, some few inches above the end of the bone (Fig. 70, c). It will be seen that in the fracture due to eversion the upper end of the lower fragment is displaced towards the tibia, while, in the lesion due to inversion, it is displaced from that bone. From a careful examination of all the cases of fracture of the lower end of the fibula admitted into the London Hospital during the time I held the post of surgical registrar there, I convinced myself that the lesion is much more frequently due to eversion than to inversion of the foot. I think it may be said that a fracture of the lower end of the fibula due to simple inversion of the foot is not possible unless the external lateral ligament remains entire.

In the *outward* luxation, better known as *Pott's fracture*, the condition is such as has just been described in connection with the effects of eversion of the foot upon the fibula. That bone is always broken some 2 or 3 inches above the malleolus, the deltoid ligament is torn, or the tip of the inner malleolus wrenched off. The astragalus is so rotated laterally that the foot is



much everted, its outer edge is raised, while its inner edge rests upon the ground. The inferior tibio-fibular ligaments remain intact. If they yield, an unusual form of fracture or dislocation is produced, as already stated. Boyer relates a case, considered to be unique, where the foot was luxated outwards, but without any fracture of the fibula. That bone, however, had been forced upwards entire, and its head dislocated from the articular facet of the tibia. A horizontal dislocation outwards, without rotation of the foot and without fracture of the fibula, is possible if the inferior tibio-fibular ligaments are entirely torn.

In *Dupuytren's fracture* (a rare injury) the fibula is fractured from 1 to 3 inches above the malleolus, the inferior tibio-fibular ligaments are entirely lacerated, or the portion of the tibia to which they are attached is torn away, and remains connected with the lower fragments of the fibula. The foot is dislocated horizontally outwards, and is drawn upwards, the extent of the upward displacement depending upon the height at which the fibula breaks.

In the *inward luxation* the external lateral ligament is torn or the tip of the outer malleolus dragged away, the deltoid ligament is intact, but the internal malleolus is commonly broken by the violence with which the astragalus is brought into contact with it. That bone itself may be broken, and is in any case rotated laterally, so that the foot is inverted and its inner border much raised. In all forms of this dislocation, whether simple or complicated, the inferior tibio-fibular ligament remains intact.

2. *The antero-posterior dislocations:* Backwards; forwards. These injuries are brought about by great force applied to the foot while the leg is fixed, or more commonly by sudden arrest of the foot during some violent impulse given to the body, as on jumping from a carriage when in motion. In the luxation backwards the astragalus is displaced behind the tibia, while the articular surface of the latter bone rests upon the scaphoid and cuneiform bones. The anterior and posterior

ligaments are entirely torn, and a great part also of the two lateral bands. The fibula is broken some 2 or 3 inches above the malleolus, and there is usually a fracture also of the inner malleolus.

The luxation forwards is of extreme rarity. In the few reported cases one or both malleoli were broken. R. W. Smith believes that the dislocation is never complete.

3. *The dislocation upwards.* In this rare accident

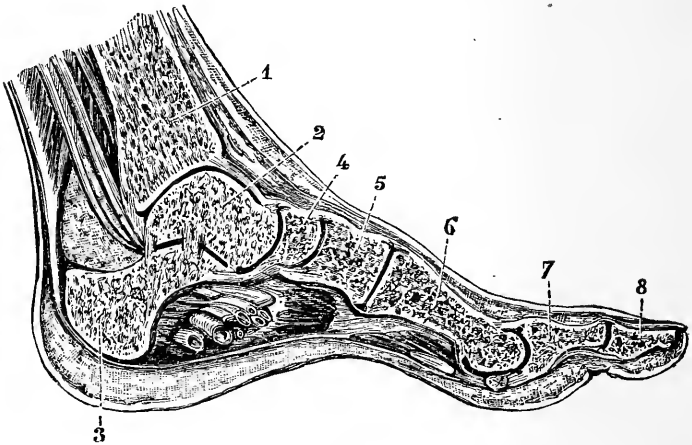


Fig. 71. —Antero-Posterior Section of the Foot (Rüdinger).

1, Tibia; 2, astragalus; 3, os calcis; 4, scaphoid; 5, int. cuneiform; 6, first metatarsal bone; 7 and 8, phalanges of great toe.

the inferior tibio-fibular ligaments are ruptured, the two bones are widely separated at their lower ends, and the astragalus is driven up between them. The anterior and posterior ligaments are entirely ruptured, but the lateral ligaments usually escape with but some slight laceration. The accident appears to be generally caused by a fall, the patient alighting flat upon the soles of the feet. Mr. Bryant records a case in which both feet were similarly dislocated upwards.

The **foot**.—There are two *arches* in the foot, an antero-posterior and a transverse.

1. The antero-posterior arch has its summit at the astragalus. It may be considered as composed of two piers. The hinder pier consists of the os calcis, the anterior pier of the scaphoid, cuneiform and metatarsal bones. The astragalus forms the keystone of the arch, the head of the bone especially performing that function (Fig. 71).

The foot rests upon the heel, the heads of the metatarsal bones, and the outer margin of the foot (Fig. 72). The hinder pier is solid, is made up of a strong bone, and contains only one joint. It serves to support the main part of the weight of the body, and gives a firm basis of attachment to the muscles of the calf. The anterior part of the arch, on the other hand, contains many small bones and a number of complicated joints. It serves to give elasticity to the foot, and to diminish the effect of shocks received upon the sole of the foot. The comparative value of the two piers of the arch in this latter respect can be estimated by jumping from a height and alighting first upon the heels and then upon the balls of the toes. The inner part of the arch is much more curved than the outer, and forms the instep.

2. The transverse arch is most marked across the cuneiform bones. It gives much elasticity to the foot and affords protection to the vessels of the sole.

These two arches result from the shape of the component bones, and are maintained by the various ligaments and muscles of the sole. The peroneus longus tendon, and nearly all the ligaments which connect the first and second rows of tarsal bones on both the plantar and dorsal aspects, are inclined forwards and inwards, and by this arrangement are well adapted to maintain the integrity of the transverse as well as of the antero-posterior arch.

**The chief joints of the foot.**—The articulation between the os calcis and astragalus forms a double joint. The posterior joint, that behind the interosseous ligament, has a separate synovial sac, while the anterior

communicates with the synovial cavity of the mid-tarsal articulation. The two bones are held together not only by the interosseous, the internal, external, and posterior calcaneo-astragaloid ligaments, but are supported also by the external calcaneo-scaphoid ligament, the two lateral ligaments of the ankle, and the tendons about the part. The articulation permits of adduction and abduction, and of some rotation of the foot beneath the astragalus. Adduction is associated with some turning of the toes inwards in the movement of inversion, and abduction with some turning of them outwards in eversion of the foot.

**Dislocation of the astragalus.**—This bone is sometimes luxated alone, being separated from its connections with the os calcis, the tibia, the fibula, and the scaphoid bone. The displacement may be either forwards, backwards, or laterally. The lateral luxations are nearly always oblique, the bone passing as a rule forwards as well as inwards or outwards. The luxation forwards is by far the most common lesion, the next in frequency being a luxation outwards and forwards. The backward displacement is extremely rare. The dislocations are usually complete, are very often compound, especially when in the lateral direction, and are commonly associated with fracture of the tibia or fibula, or of the astragalus itself. A lateral complete dislocation is impossible without fracture of one or other malleolus. In these injuries the interosseous ligament between the os calcis and astragalus is entirely torn, as are also the greater part of the lateral ligaments of the ankle, and the various bands that connect the astragalus with the os calcis and scaphoid. In all instances the malleoli are brought nearer to the sole. In the antero-posterior luxations the foot as a rule undergoes no rotation, but in the luxation of the bone forwards and outwards it becomes inverted, and in the displacement forwards and inwards everted.

**Dislocation of the os calcis.**—This bone, although often fractured, is very rarely luxated. When displaced, however, it is usually displaced outwards,

and is torn away from its attachments to the astragalus and cuboid, or from the former bone alone.

**Subastragaloid dislocations of the foot.**

—In these lesions, which are not very uncommon, the astragalus remains in position between the tibia and fibula, while the rest of the foot is dislocated below that bone. The luxation, therefore, concerns the calcaneo-astragaloid and astragalo-scaphoid joints. The foot may be displaced either forwards, backwards, or laterally. The forward dislocation is extremely rare, and the lateral luxations are nearly always oblique. In the most usual displacements the foot is dislocated outwards or inwards, and is at the same time carried backwards. These luxations are often compound, especially when lateral. They are, as a rule, incomplete as regards the calcaneo-astragaloid joint, while, on the other hand, the displacement of the astragalus from the scaphoid is in nearly every instance complete. In all cases the interosseous ligament between the os calcis and astragalus must be torn, and there will also be more or less laceration of the astragalo-scaphoid ligament, and of one or both of the lateral bands of the ankle joint. The malleoli are very often fractured.

It is only necessary to notice in any detail the two lateral luxations, as being the only common forms. In the inward dislocation the foot is inverted, its inner border is raised, is shortened, and rendered concave, while its outer border is lengthened and made convex. The deformity much resembles that of talipes varus. The head of the astragalus with the outer malleolus forms a projection at the outer aspect of the foot, while below them a deep hollow exists. The inner border of the os calcis is very prominent at the internal side of the limb, while the inner malleolus is buried in the hollow left by the displacement of that bone. The calcaneum and scaphoid are approximated. In the outward luxation the foot is abducted, its outer border is raised, and the deformity produced is not unlike that of talipes valgus. The outer malleolus is lost in the hollow caused by the eversion of the foot, while the tibial malleolus

and head of the astragalus form a projection on the inner aspect of the limb.

The **medio-tarsal joint** is composed of two articulations, the astragalo-scaphoid and calcaneo-cuboid. The ligaments supporting the former joint are the external and inferior calcaneo-scaphoid and the astragalo-scaphoid; while the latter articulation is maintained by the internal and dorsal calcaneo-cuboid ligaments, and the long and short plantar. Movement is somewhat freer in the astragaloid than in the calcaneal segment of the joint. The movements permitted in the articulation as a whole consist of flexion and extension, with some rotation around an antero-posterior axis whereby the sole can be turned in or out. Flexion is associated with inward rotation of the sole and adduction of the toes, extension with outward rotation of the sole and abduction of the toes. It should be noted that the movements of turning the toes either in or out take place mainly at the hip-joint; while the turning of one edge of the foot either up or down is a movement that mostly concerns the medio-tarsal and calcaneo-astragaloid joints. The chief deformities in club-foot take place about the former articulation.

**Club foot.**—It is usual to divide the various forms of talipes, or club-foot, into four main divisions, viz. (1) T. equinus; (2) T. calcaneus; (3) T. varus; and (4) T. valgus. Four secondary forms result from combinations of these principal varieties, viz. T. equino-varus, T. equino-valgus, T. calcaneo-varus, and T. calcaneo-valgus.

1. *Talipes equinus*. In this deformity the heel is drawn up, and the patient walks upon the balls of the toes. The contracting muscles are those of the calf attached to the tendo Achillis. In a well-marked case the os calcis is much raised, and may even be brought in contact with the tibia. The astragalus is displaced downwards, and projects upon the dorsum. The foot tends to become more and more bent at the medio-tarsal joint, until at last the scaphoid may even touch

the os calcis. The ligaments of the sole are usually much contracted.

2. *Talipes calcaneus*. In this form of club-foot the toes are drawn up, and the patient walks upon the heel. The contracting muscles are the extensors on the anterior aspect of the limb. The os calcis is rendered more vertical, and the astragalus becomes so obliquely placed that part of its upper articular surface may project beyond the tibia in a backward direction.

3. *Talipes varus*. This is the commonest form. Certain features of the foetal foot are retained in an exaggerated degree. In a well-marked congenital case there is a fourfold deformity: (1) The heel is drawn up by the muscles attached to the tendo Achillis; (2) the foot is adducted; and (3) its inner edge is drawn upwards by the contraction of the tibialis anticus and posticus; (4) the sole is contracted by the flexor longus digitorum muscle and the shrinking of the plantar fascia and ligaments. In this variety of talipes the os calcis is drawn into a more vertical position. The astragalus is displaced forwards and downwards, so that some part of its upper articular surface becomes superficial on the dorsum. The neck of the astragalus is elongated and deflected downwards and inwards to a greater extent than in the normal foot. In the adult the neck of the astragalus is deflected inwards to the axis of its body at an angle of  $10^{\circ}$ ; in the newly born at an angle of  $25^{\circ}$ ; and in talipes varus at an angle of  $50^{\circ}$ . The scaphoid is displaced upwards and backwards, until its inner border often touches the internal malleolus. The three cuneiform bones follow the scaphoid, and the cuboid becomes the lowest bone in the tarsus. The outer border of the cuboid forms an angle with the os calcis, and the tendons of the peroneus longus slip backwards from the groove in the cuboid to lie on the os calcis. The anterior border of the internal lateral ligament is contracted and unduly prominent.

4. In *talipes valgus* the foot is abducted and its outer border drawn upwards. The contracting muscles are the two peronei. In a well-marked congenital

case the os calcis is found a little raised and the astragalus is displaced forwards and downwards. The scaphoid is so rotated that its inner part is depressed and its outer raised. The internal portion of the bone forms one of the two projections obvious on the inner side of the foot, the other prominence being formed by the head of the astragalus. The cuboid is found to be a little rotated outwards. The arch of the foot is lost, and all those ligaments are stretched that serve to support and maintain that arch.

Of the mixed, or secondary, forms of talipes nothing need be said. They are the results merely of a combination of the primary varieties.

As trouble is often caused in talipes by pressure being brought to bear upon an unusual part of the foot, it is well to note upon what portion of the member the patient treads in the different varieties of the deformity. In varus the "tread" is mainly upon the outer side of the fifth metatarsal bone; in valgus upon the internal malleolus and scaphoid; in equinus upon the bases of all the toes; in equino-varus upon the base of the little toe; in equino-valgus upon the base of the great toe; in all forms of calcaneus upon the heel. In cases of extreme and obstinate club-foot wedges of bone are sometimes removed by the operation known as *Tarsectomy*. Thus in talipes equino-varus the base of the wedge will be on the outer side of the foot and will be mainly represented by the cuboid; the apex will be at the scaphoid.

**Flat-foot** and **splay-foot** are the names given to a deformity due probably to the yielding of certain ligaments, whereby the arch of the foot is lost and the sole becomes more or less perfectly flat. The foot, at the same time, is abducted, and the outer border is often a little raised, so that the patient walks mainly upon the inner side of the foot. This deformity is met with in those who stand a great deal, and is the direct result of yielding of the tarsal ligaments and plantar muscles from long-continued pressure. When the weight of the body is brought to bear on the foot placed



flat upon the ground, it will be transmitted in an oblique direction from above downwards and inwards (Fig. 72, B'). The foot therefore tends to become abducted, a tendency resisted by such powerful ligaments as the internal

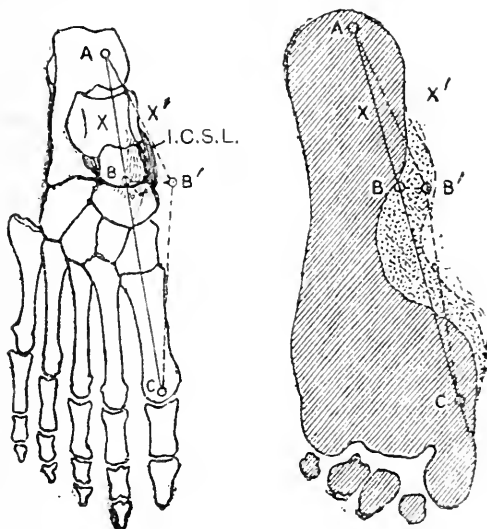


Fig. 72 —Showing some of the Alterations which take place in the Arch in Flat-Foot.

I. The skeleton of the normal foot seen from above.

A B C, Line of the inner arch formed by the os calcis, astragalus, scaphoid, internal cuneiform, and first metatarsal bone; A B' C, the line of the arch in flat-foot; X, a point on the astragalus indicating where the centre of the weight of the body is transferred to the arch; X', corresponding point in flat-foot; the position of the inferior calcaneo scaphoid ligament is indicated (I.C.S.L.).

II. The shaded part represents the impress of a normal foot. The stippled area represents the additional part of the arch which rests on the ground in flat-foot

The lines A B C and A B' C as in I.

lateral of the ankle and those connecting the os calcis with the astragalus. In flat-foot these ligaments yield, and the toes consequently are turned out or abducted. The ligament, however, that is mainly affected in this deformity is the inferior calcaneo-scapoid. This strong band of fibres supports the head of the astragalus and

holds up the keystone of the plantar arch. When it yields, the head of the astragalus is pressed forwards, downwards, and inwards by the superincumbent weight, and the foot beyond becomes, as a consequence, over-extended and turned out. The os calcis slants inwards, and its anterior end is depressed. The sustentaculum tali, the head of the astragalus, and the scaphoid tubercle form prominences on the inner side of the foot, and may rest on the ground (Fig. 72). The long and short plantar ligaments also, which contribute so much to the maintenance of the arch of the foot, in time yield, and allow of a still greater degree of deformity. There is a stretching also of the deltoid ligament. In neglected cases the distortion is rendered more or less permanent by alterations in the shape of the tarsal bones, and by a contraction of such ligaments as have been relaxed by the deformity. The foot being abducted, and its outer border a little raised, the peronei muscles become relaxed, shortened, and contribute to the permanency of the disorder. It will be understood that the abnormal pressure brought to bear upon the various tarsal bones and articulations will cause severe pain to be often associated with this affection. The calf muscles waste, owing to the arch of the foot having lost its rigidity and being no longer able to support the weight of the body.

It may be noted that the medio-tarsal joint, which is so conspicuously involved in the distortion, is supplied by the anterior tibial, musculo-cutaneous, and external plantar nerves.

The **tarsal bones**, owing to their spongy character, are readily broken by direct violence, as in severe crushes. The soft parts that cover these bones being scanty upon the dorsal aspect of the foot, it follows that these accidents are often compound and associated with much laceration of the integuments.

The tarsal bone the most frequently fractured is the os calcis. This bone may be broken by a fall upon the heel, and in many instances has been the only one fractured by such an accident. A few cases have been

recorded of fracture of the calcaneum by muscular violence, the muscles producing the lesion being those attached to the tendo Achillis. Thus, Sir A. Cooper reports the case of a woman, aged forty-two, in whom a large fragment of the posterior part of the os calcis - was torn away by the muscles and drawn some  $2\frac{1}{2}$  inches away from the heel. The accident was caused by her taking a false step. Abel has collected three cases of fracture of the sustentaculum tali. He believes that this injury may be produced by falls upon the sole or by extreme supination (rotation outwards) of the foot, whereby the astragalus is forced violently against the process.

The astragalus alone may be broken by a fall upon the feet, and such accidents are often associated with fractures of both that bone and the os calcis. It must be noted, however, that in a fall, when the patient alights upon the feet, the tibia and fibula are much more likely to be broken than are the tarsal bones, since the bones of the leg transmit the weight of the body directly, whereas that weight is much diffused and broken

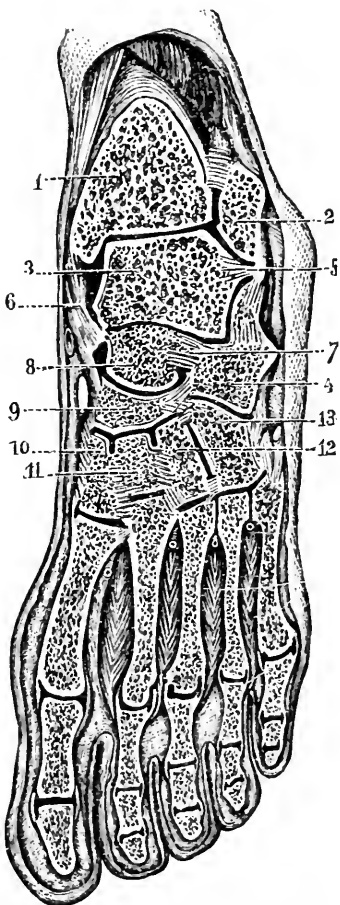


Fig. 73.--Oblique Antero-Posterior Section of the Foot (Rüdinger).

- 1, Tibia; 2, fibula; 3, astragalus; 4, os calcis; 5, external lateral ligament; 6, internal lateral ligament; 7, interosseous ligament between astragalus and os calcis; 8, head of astragalus; 9, scaphoid; 10, 11, and 12, the three cuneiform bones; 13, cuboid.

up when passing through the foot with its many bones and joints.

The metatarsal bones and phalanges are nearly always broken by direct violence. I had, however, under my care at the London Hospital a man who had broken the shafts of the three outer metatarsal bones by simply slipping off the edge of the curb.

With regard to the luxations of the foot not yet considered, it may be said that the cuboid is never dislocated alone. Walker reports a case of dislocation of the scaphoid alone, that structure being quite separated from the astragalus and cuneiform bones. The accident was brought about by alighting upon the ball of the foot when jumping, and the little bone was found projecting on the dorsum. Mr. Bryant has mentioned an instance of dislocation of the scaphoid inwards. As a rule, however, this bone when displaced is dislocated along with the astragalus.

Of the cuneiform bones the one most often luxated alone is the internal. The attachments of the tendons of the tibialis anticus and peroneus longus about the internal cuneiform and first metatarsal bones renders it common for the latter to follow its tarsal colleague when dislocated. Mr. Luke has recorded a case of incomplete luxation of all three cuneiform bones upwards, and at least three cases have been described of dislocation of the internal bone upwards and backwards, together with a like displacement of all the metatarsals.

One or more of the metatarsal bones may be luxated, or the entire series may be displaced upwards, downwards, inwards, or outwards, the first-named lesion being the most common. In rarer instances, one bone has been thrown in one direction and its fellow or fellows in another.

**Ossification of the tarsus.**—At birth the tarsus is mainly cartilaginous. Ossification begins in the os calcis in the sixth month and in the astragalus in the seventh month of foetal life. The centre for the cuboid appears at birth, and in the scaphoid, the last to ossify, in the third year. It is

not until puberty that the cartilage of the tarsal bone is completely ossified.

Dislocation of the proximal phalanx of the great toe is often very difficult to reduce, as is also the case in the corresponding luxation of the thumb. When the displacement is dorsal, the difficulty is probably due to the sesamoid bones, which in this joint take the place of the glenoid ligament or fibro-cartilaginous plate of the other toes. "Like the glenoid ligaments, the sesamoid bones are much more firmly connected with the phalanx than with the metatarsal bone, and thus get torn away and shut back behind the head of the metatarsal bone; or it may be that the sesamoid bones, retaining their connections with the lateral ligaments of the joint as well as with the short flexor tendons, are separated from one another, and so allow the head of the metatarsal bone to pass forwards, and thus become nipped, as it were, in a button-hole between them" (Henry Morris). A partial dislocation of the proximal phalanx outwards on the head of the metatarsal bone of the great toe constitutes the condition known as hallux valgus. The inner lateral ligament of the joint is elongated, while the outer is contracted. In hallux rigidus this joint is slightly flexed and rigid, due probably to a reflex contraction of the flexor brevis hallucis. The second toe is commonly longer than the others and is more liable to assume the form known as "hammer toe." The proximal phalanx in such a form is extended, while the middle is strongly flexed. The condition is commonly inherited and is due to a contraction of the glenoid and lateral ligaments of the proximal phalangeal joint. The extensor tendon is also contracted.

There are six **synovial cavities** in the foot, excluding that of the ankle-joint, viz., one for the posterior calcaneo-astragaloid joint, a second for the anterior calcaneo-astragaloid and astragaloid-scaphoid joints, a third between the os calcis and cuboid, a fourth between the latter bone and the two outer metatarsals, a fifth for the joint between the inner cuneiform and first

metatarsal bones, and a sixth for the remaining articulations (Fig. 73). These synovial cavities tend greatly

to diffuse disease among the various bones of the foot when once one bone has become inflamed. The best position, therefore, for bone disease, with reference to the question of extension, would be in the hinder parts of either the os calcis or astragalus, and one of the worst positions would be assumed by disease involving the scaphoid bone.

**Syme's amputation** at the ankle. —In the heel-flap are cut the integuments, the external saphenous nerve and vein, the peroneus longus, peroneus brevis, tibialis posticus, flexor longus digitorum, flexor longus pollicis, tendo Achillis, points of origin of the flexor brevis digitorum and of the two abductor muscles, and the internal and external plantar arteries and nerves.

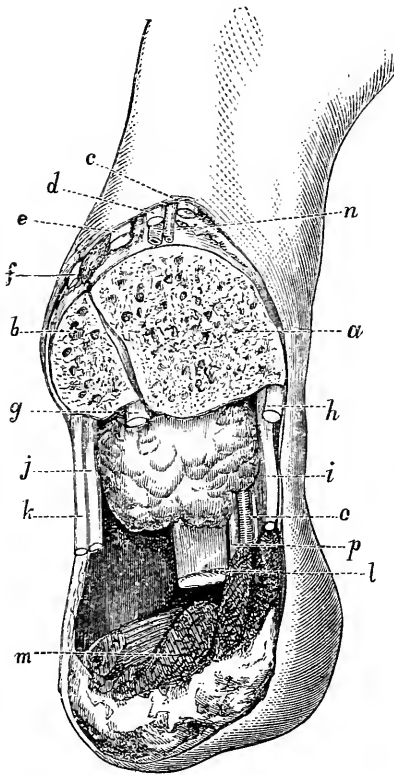


Fig. 74. — Syme's Amputation (Agatz).

*a*, Tibia; *b*, fibula; *c*, tibialis anticus; *d*, extensor proprius pollicis; *e*, extensor communis digitorum; *f*, peroneus tertius; *g*, flexor longus pollicis; *h*, tibialis posticus; *i*, flexor longus digitorum; *j*, peroneus brevis; *k*, peroneus longus; *l*, tendo Achillis; *m*, some muscles of the sole that are not usually left in this operation; *n*, anterior tibial vessels; *o*, posterior tibial vessels; *p*, posterior tibial nerve.

In the dorsal flap are cut the integuments, tibialis anticus, extensor communis digitorum, extensor proprius pollicis, peroneus tertius, anterior tibial vessels

and nerve, musculo-cutaneous nerve, and internal saphenous nerve and vein. The position of the principal structures divided is shown in Fig. 74. It is not usual to dissect up any of the muscular tissue of the sole, as shown in Agatz's plate. It should be noted that the integuments of the heel derive their blood supply, which is very free, mainly from the external calcaneal branch of the posterior peroneal artery, and the internal calcaneal from the external plantar.

If the heel incision is carried sufficiently far back to divide the trunk of the posterior tibial artery, the heel flap is deprived of the last-named source of blood supply. The posterior tibial artery bifurcates upon a line drawn from the tip of the inner malleolus to the centre of the convexity of the heel.

The nerves supplying the integuments of the heel are the calcaneal branch of the external saphenous and the calcaneal and plantar cutaneous twigs from the posterior tibial.

In **Pirogoff's amputation** the parts divided in the anterior flap are the same as in Syme's operation. In the heel or sole flap the same structures also are cut as in the corresponding flap in a Syme, with the exception that the tendo Achillis is not divided, the

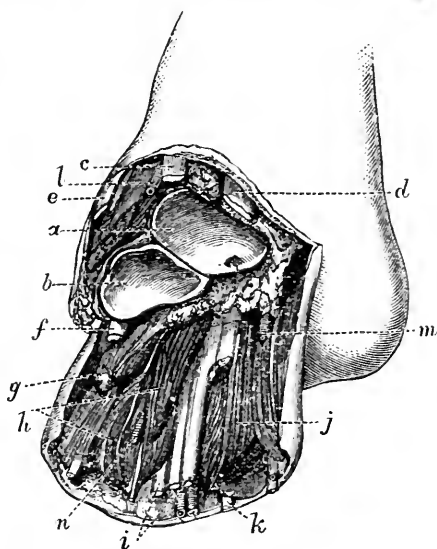


Fig. 75.—Chopart's Operation (Agatz).

a, Astragalus; b, os calcis; c, extensor proprius pollicis; d, tibialis anticus; e, extensor communis digitorum; f, peroneus longus; g, abductor minimi digiti; h, flexor brevis digitorum; i, flexor longus digitorum; j, abductor pollicis; k, flexor longus pollicis; l, dorsalis pedis artery; m, internal plantar artery; n, external plantar artery.

flexor brevis digitorum, abductor pollicis, abductor minimi digiti, and flexor accessorius are divided more extensively, and the plantar vessels are cut farther from the bifurcation.

**Chopart's operation** is an amputation at the

medio-tarsal joint. In the dorsal flap are cut the integuments, the extensor communis and brevis digitorum, extensor proprius pollicis, tibialis anticus, peroneus tertius and brevis, the musculo-cutaneous, anterior tibial, and two saphenous nerves, the dorsal artery, and the dorsal plexus of veins. In the plantar flap are found divided the integuments, plantar fascia, flexor brevis digitorum, abductors of the great and little toes, flexor accessorius, and tibialis posticus tendon. If the flap be well dissected up from the bones, parts of the short flexors of the great and little toes, the abductor pollicis, and transversus pedis will be found cut in the flap. The tendons

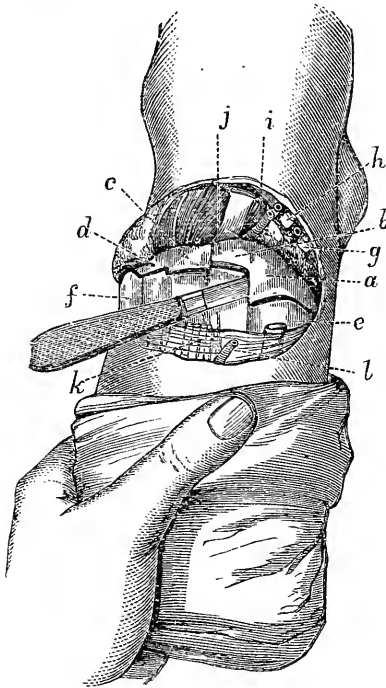


Fig. 76.—Lisfranc's Operation (Agatz).

*a, b, c*, Inner, middle, and outer cuneiform bones; *d*, cuboid; *e, f*, the metatarsal bones; *g*, tibialis anticus; *h*, extensor proprius pollicis; *i*, extensor communis digitorum; *j*, extensor brevis digitorum; *k*, extensor tendons; *l*, dorsalis pedis artery.

of the long flexors of the digits and great toes, the peroneus longus, and the plantar vessels and nerves are also divided (Fig. 75).

**Lisfranc's operation**, or amputation through the tarso-metatarsal line of joints. In the dorsal flap



the same structures are divided as are cut in the corresponding flap in Chopart's amputation. In the plantar flap also the parts divided are the same as in that procedure, with the exception that the flexor accessorius and the tendon of the tibialis posticus escape section. In opening the line of joints it should be noted that the articulations between the three outer metatarsals and the corresponding tarsal bones form a line sufficiently straight to be traversed by the knife in one cut when once the blade has been introduced.

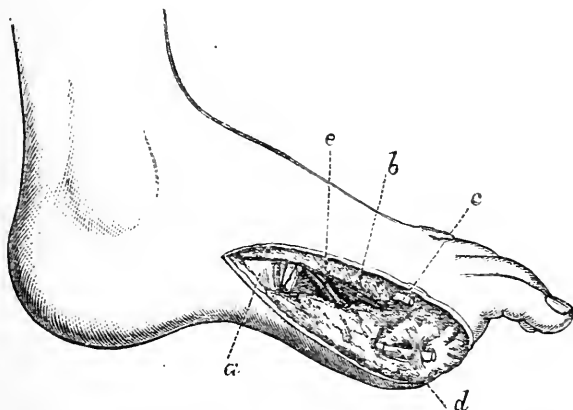


Fig. 77.—Amputation of Great Toe, with its Metatarsal Bone (Agatz).

*a*, internal cuneiform bone; *b*, adductor pollicis; *c*, extensor longus pollicis; *d*, flexor longus pollicis; *e*, plantar branch of dorsalis pedis artery.

The joint also between the first metatarsal and internal cuneiform bones is in a straight line and readily opened. The most difficult part of the disarticulation concerns the separation of the second metatarsal bone, which is deeply lodged between the tarsal segments. The chief bond of union between this bone and the tarsus is effected by a strong interosseous ligament that passes between it and the internal cuneiform. In Fig. 76 the knife is placed in the position required to divide that ligament.

In the **subastragaloid amputations** a disarticulation is effected at the astragalo-scaphoid and

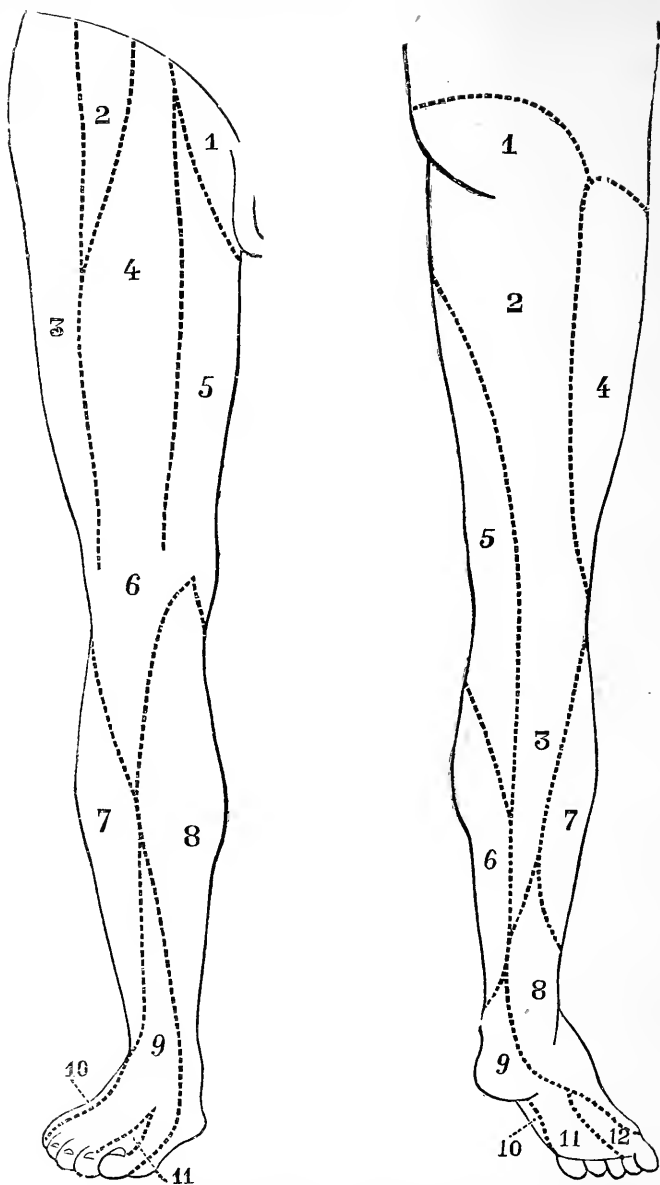


Fig. 78.—Cutaneous Nerve-Supply of Lower Limb.

*Anterior Aspect.*—1, Ilio-inguinal; 2, genito-crural; 3, external cutaneous; 4, middle cutaneous; 5, internal cutaneous; 6, patellar plexus; 7, branches of external popliteal; 8, internal saphenous; 9, musculo-cutaneous; 10, external saphenous; 11, anterior tibial.

*Posterior Aspect.*—1, 2, and 3, small sciatic; 4, external cutaneous; 5, internal cutaneous; 6, internal saphenous; 7, branches of external popliteal; 8, short saphenous; 9, posterior tibial; 10, internal saphenous; 11, internal plantar; 12, external plantar.

astragalo-calcaneal joints. The astragalus is the only bone of the foot left behind, and forms the summit of the stump.

Fig. 77 shows the position of the more important structures that are divided in amputation of the great toe together with its metatarsal bone.

**The nerve supply of the lower limb.**—In Fig. 78 is shown the cutaneous nerve-supply of the inferior extremities on both the anterior and the posterior aspect, and in Fig. 79 are seen the cord segments from which they are derived. Paralysis of the lower limbs are common, but are more often due to some lesion in the inferior segment of the cord than to damage received by any one individual nerve. Cases, however, are recorded where a single trunk has been injured and a limited form of paralysis has followed in consequence.

**Paralysis of the anterior crural nerve** has been caused by injuries to the lower part of the vertebral column implicating the cauda equina, by fractures of the pelvis, by tumours of the pelvis, by psoas abscess, by fractures and dislocations of the femur, and by stabs in the region of the groin. In this nerve lesion the patient is unable to flex the hip and to raise the body from the recumbent position (ilio-psoas). The power of extending the leg at the knee is lost (quadriceps extensor cruris); the function of the sartorius is destroyed and that of the pectineus impaired. Sensation is impaired in parts supplied by the internal and middle cutaneous nerves and the long saphenous nerve.

**Paralysis of the obturator nerve** alone is a rare condition, although it may be found associated with a like lesion of the preceding trunk. It may be brought about by the pressure exercised upon the nerve in cases of obturator hernia and by the foetal head during delivery. The muscles implicated are the adductors, gracilis, pectineus, and external obturator. The patient is unable to press the knees together, or to cross the legs. Rotation outwards is difficult, and sensation is affected in the skin supplied.

**Paralysis of the internal popliteal nerve.**

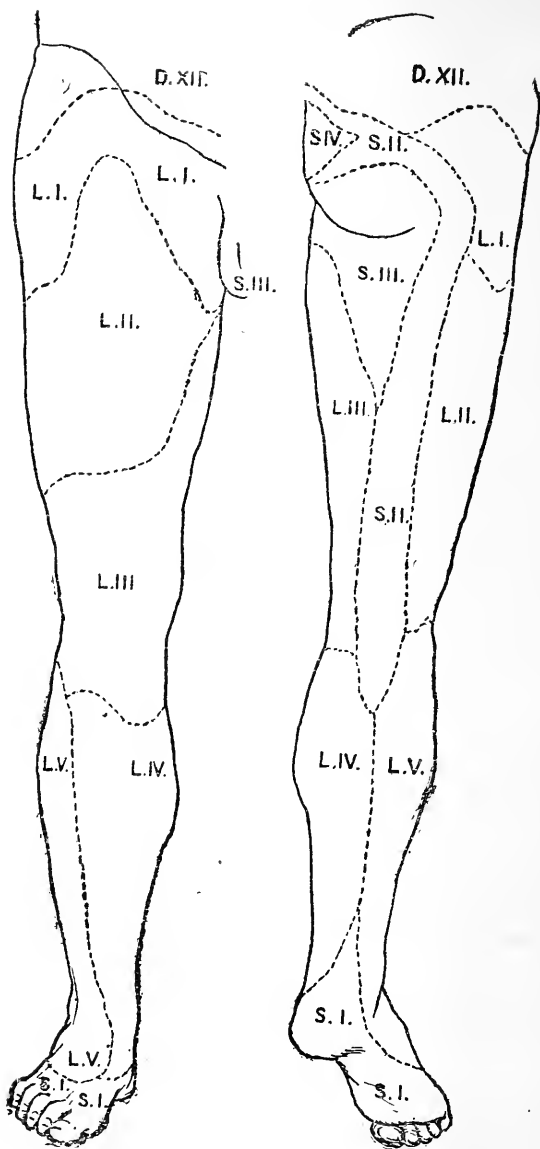


Fig. 179.—Showing the Skin Areas in the Lower Extremity supplied by the Lumbar and Sacral Segments of the Spinal Cord. (After Head.)

On each area is indicated the segment of the cord by which it is supplied. For the nerves supplying each area see Fig. 78.

—There is inability to extend the ankle and to flex the toes (flexor longus digitorum, flexor proprius pollicis, tibialis posticus, gastrocnemius, and soleus). The patient is unable to stand upon the toes, owing to loss of function in the two last-named muscles. The power of adducting the foot and of raising its inner border is impaired (tibialis posticus), and lateral movement in the toes is lost owing to paralysis of all the small muscles of the sole. Sensation is impaired over the plantar aspect of the toes, the sole, and in part of the lower half of the back of the leg.

In **paralysis of the external popliteal nerve** the action of the muscles on the front of the leg is lost. The foot hangs down and the toes catch the ground in walking. The foot can be neither flexed nor abducted (extensor communis digitorum, extensor proprius pollicis, peroneal muscles). Adduction is imperfect, owing to paralysis of the tibialis anticus. Extension of the toes is only possible to the slight extent effected by the interossei. The arch of the foot becomes flattened owing to loss of the support furnished by the peroneus longus. Sensation is impaired over the front and outer side of the leg and on the dorsum of the foot, and also over some part of the back of the leg, owing to paralysis of the communis peronei.

When the **great sciatic nerve** is paralysed there will be, in addition to the loss of function in the two preceding nerves, an inability to flex the knee owing to paralysis of the hamstrings, while rotation of the limb may be impaired by loss of power in the quadratus femoris and obturator internus.

A knowledge of the **segments of the cord from which the nerves of the lower limb arise** often assists the surgeon in localising certain lesions. Section of a nerve root, as may happen in fracture of the spine, or destruction of its centre in the spinal cord, gives rise to paralysis in a definite group of muscles and anæsthesia of a certain area of skin. The skin areas supplied by the lumbar and sacral segments are shown in Fig. 79, and these segments, according to Kocher, innervate

the following groups of muscles: *Third lumbar*, the psoas, iliacus, pectineus, sartorius and adductors; *fourth lumbar*, quadriceps extensor cruris; *fifth lumbar*, gluteus medius and minimus, tensor vaginæ femoris and hamstrings; *first sacral*, gluteus maximus, short external rotators of hip-joint, peronei, extensors of toes and flexors of ankle; *second sacral* gastrocnemius soleus, long flexors of toes and extensors of the ankle-joint and muscles of the sole.

## Part VI.

### CHAPTER XXIV.

#### THE SPINE.

THE vertebral column combines in a remarkable way many very different and complicated functions. It acts as the central pillar of the body, and as the column that supports the weight of the head. It connects the upper and lower segments of the trunk. It gives attachments to the ribs. It has the property of mitigating the effects of shocks that are transmitted from various parts of the body. It permits, to a wonderful degree, of a number of most complicated movements; and, lastly, forms a solid tube for the reception of the spinal cord.

It owes much of its elasticity, and of its power of breaking up divers forces communicated to it, to its curves. Of the four curves, two, the dorsal and sacral, are primary, are due to the formation of the thoracic and pelvic cavities, and depend mainly upon the shape of the bones. The other two, the cervical and lumbar, are compensatory curves, and depend mainly upon the shape of the intervertebral discs. The dorsal and sacral curves appear in foetal life; the lumbar and cervical curves appear after birth, and depend on the assumption of the erect position. The infant's spine appears straight. The only marked curve seen in the back of the young child is a general curving of the column backwards, a kyphosis. When the infant is first encouraged to sit erect, this is the outline assumed by the spine, and in some weakly children, and especially in those afflicted with rickets, this curvature is often very pronounced. The discs are twenty-three

in number and make up nearly one-fourth of the entire length of the spine. If the discs be removed, and the vertebræ be articulated in the dry state, the cervical and lumbar convexities almost disappear, and the column tends to present one great curvature, the concavity of which is forwards, and the most marked part of which corresponds to a point just below the middle of the dorsal region. This somewhat resembles the curve seen in the spines of the aged, and in such individuals it may be to no small extent due to the shrinking of the intervertebral discs.

It is by means of the discs that the movements of the spine are in the main permitted, and it will be found that they are most developed in regions where most movement is allowed. They act also as springs in giving elasticity to the column, and in economising muscular action, while at the same time they play the part of buffers in modifying the effect of shocks transmitted along the spine.

Although the motion permitted between any two individual vertebræ is not extensive, yet the degree of movement capable of being exercised in the column as a whole is considerable. This movement is least free at the dorsal region, and is most extensive in the neck and loins. In the lumbar region (the base of the column) exists the greatest degree of motion permitted in the spine, and here is allowed, not only forward and backward flexion, but also lateral bending, and a certain amount of rotation. In the cervical region flexion in the antero-posterior direction is not so ready as it is in the loins, although the neck enjoys the greatest degree of rotation and of lateral flexion.

**Scoliosis.**—In very few people do the spines of the vertebræ lie in a perfectly straight line down the back. There is commonly a slight degree of lateral curvature. If the pelvis be tilted laterally, as when the limbs are unequal in length, a compensatory lateral curve is produced. In scoliosis, lateral curvature is combined with a rotation of the vertebræ, the spinous processes turning to one side of the median line and the bodies to the



opposite. It is a disease of adolescents, due to a weakness of the spinal muscles, which are unable to maintain the vertebræ in the position necessary for the erect posture. Each vertebra is provided with three levers, a posterior (the spinous process) and two lateral (the transverse processes and attached rib). The erector spinæ acts on the lateral levers; the multifidus spinæ and muscles for the upper extremity on the posterior. It is through training these muscles by suitable exercises that the vertebræ can be restored to, and maintained in, their normal positions.

**Sprains of the vertebral column.**—The many joints and ligaments of the part, and the varied and violent movements to which it may be exposed, render it very liable to be the seat of sprains. These injuries, however, cannot reach any great magnitude, for so closely are the individual vertebræ articulated, that any force severe enough to produce other than slight tearing of the ligaments will tend to cause a fracture or dislocation of the bones.

Sprains are most commonly met with in the cervical and lumbar segments of the spine. This localisation is due to the mobility of those parts, and to their tendency to diffuse any violence transmitted to them, and so to render it more general. For it is to be noted that the more localised an injury, the more likely it is to produce a fracture or dislocation rather than a sprain.

In the cervical region, also, the tendency to sprain is increased by the near articulation of the column with the head, and the possibility of any violence applied to the skull being transmitted to the spine.

Sprains of the spine are not apt to be associated with the external evidences of ecchymosis, since between the skin and the column there intervene not only many layers of muscles, but also dense expansions of fascia.

It has already been pointed out that sprains in the loin, produced by severe bending forwards of the column, may be associated with some damage to the kidney and consequent hæmaturia (page 362).

A sprained back is often the seat of a considerable degree of pain and stiffness, that persists long after the immediate effects of the lesion must have passed away. Such a condition may be understood by noticing that the column presents a vast number of separate articulations, each provided with cartilage, synovial membrane, and capsular ligaments. These joints have no qualities that exempt them from the common evils incident to sprains of more superficial articulations; and there is little doubt that the long-felt pain and inconvenience often depend upon some synovitis of the vertebral joints. In a few cases this synovitis has gone on to suppuration, and in one instance at least the pus so formed found its way into the spinal canal and induced some mischief in the cord.

**Fractures and dislocations of the spine.—**

The effects of violence applied to the column are much diminished by the general elasticity of the spine, by its curves, and by the circumstance that it is composed of a number of separate segments. Each vertebra meets the one immediately above or below it at three points of contact, the body and the two articulating processes. The bodies are separated by the inter-vertebral disc, which acts as an excellent spring or buffer in modifying the effects of violence. The articulating processes are more or less wedge-shaped, the thin edge of one being applied to the base of the other. When a force is applied to the column that tends to compress the vertebræ together, the bases of the two wedges are brought in more and more close relation, and thus an increasing resistance is offered to the compressing power.

The parts of the spine most liable to injury are (1) the atlo-axial; (2) the cervico-dorsal; and (3) the dorso-lumbar. In the atlo-axial region the parts not only enjoy a very considerable degree of movement but are very directly influenced by many forms of violence applied to the head. In the two other regions it will be noted that a flexible part of the spine joins a comparatively rigid segment of it, and thus violence applied to the column in either of these districts is apt

to be concentrated rather than diffused. The sternum and ribs act as a splint to the dorsal part of the column. The mechanism is in a way illustrated by the circumstance that a fishing-rod when it snaps commonly breaks near a joint, that is to say, at a spot where a flexible segment of the rod meets a less elastic portion. In the dorso-lumbar region, moreover, the vertebræ, although they have to support almost as much weight as have those of the lumbar region proper, are yet disproportionately small in size. Being placed, also, near the middle of the column, they can be influenced on all sides by a powerful amount of leverage. The gravity of all injuries to the spine depends upon the risk of damage to the cord enclosed in the column. Apart from this complication, fractures and dislocations in this region are apt to do well, and if the patient survive, the former lesions nearly always heal readily.

The position of the cord within the vertebral canal and the arrangement of its membranes are such that it presents many facilities for escaping injury from violence. These will be dealt with subsequently in speaking of the cord itself. It may, however, be noted here that the construction of the vertebræ, and their relation to one another, are of a character to afford much protection to the cord, even in cases where they themselves are extensively damaged. "Being lodged in the centre of the column, it (the cord) occupies neutral ground to forces which might cause fracture. For it is a law in mechanics that when a beam, as of timber, is exposed to breakage, and the force does not exceed the limits of the strength of the material, one division resists compression, another laceration of the particles, while the third, between the two, is in a negative condition." (Jacobson, Holmes' "System.") Now, it happens that fractures of the spine are most often due to violence that bends the column forwards. The anterior segment, in such a case, will be subject to compression, the posterior to laceration, and the intermediate portion will be in a neutral condition. When the spine is examined, it will be found that its anterior part, composed of the large

cancellous bodies, is excellently adapted to resist the effects of compression, while its posterior parts, composed of slighter and more compact bones and surrounded by many strong ligaments, are well arranged to resist the effects of a tearing force. The spinal cord, situated between these two divisions, occupies the position of least danger.

The vertebræ may be fractured without being dislocated, but a dislocation without a fracture is rarely possible.

It would appear, indeed, that a luxation of the spine, with no fracture of the bone, cannot occur in either the dorsal or lumbar regions. Mr. Jacobson, in the essay above referred to, writes: "I believe I am correct in stating that there is no case recorded, and thoroughly verified, in recent years, of dislocation of the lumbar or dorsal vertebræ unaccompanied with any fracture of the body, transverse or articular processes." Dislocation without fracture has been met with in the cervical spine, although even there, if we except the first two vertebræ, it is very rare. When it occurs it most often involves the fifth vertebra, which, with the rest of the column above it, is displaced forwards and downwards. Luxations in other directions have been noted, but they are extremely uncommon. The possibility of luxation in the cervical region without dislocation is explained by the small size of the vertebral bodies, the obliquity of their articular processes, and the relatively slight opposition they offer to displacement when compared with like processes in the other parts of the column. The luxation is usually bilateral and incomplete, and the result of a forcible bending of the head and upper part of the spine forwards and downwards. When situated high up the displacement may be appreciated by an examination of the part through the pharynx. In the complete bilateral dislocation the cord is usually hopelessly crushed. These luxations have been reduced by forcible extension, although the circumstances under which such a procedure is advisable are neither frequent nor very distinctly marked.

Since, in severe injuries, dislocation and fracture are so usually associated, it is common to deal with these lesions under the title of "*fracture-dislocation.*"

Fracture-dislocation may be due to (1) indirect, or (2) direct violence. 1. The injuries from indirect violence are by far the more common. They are due to a violent bending of the head, or of the spine above the seat of lesion, forwards and downwards. Thus, the cervical spine has been more than once broken by a "header" into shallow water; while the dorsal vertebræ have been fractured and displaced by the acute bending of the column, produced by a heavy sack falling upon the back of the neck.

This form of injury is most commonly met with in the cervical and upper dorsal regions. These parts of the column possess great mobility, the bodies that compose them are not large, and are influenced by violence applied to the head. In a well-marked case there is some crushing of the vertebræ involved, and the usual deformity depends upon the sliding of the centrum above downwards and forwards upon the centrum below. Complete displacement of any two vertebræ from one another is prevented by a locking of the posterior processes. In some cases the luxation is complete, a condition that is least frequently met with in the lumbar spine.

In the cervical and dorsal regions, the parts, after the dislocation, may often be returned to their normal position; but in the loins this replacement is usually impossible, owing to the locking of the large and powerful articular processes. In the neck the laminæ and spines may be fractured, while the articulating processes, being broad and nearly horizontal, usually escape, even when there is much displacement of the parts. In the dorsal spine the laminæ and articular processes are always torn when displacement occurs. In the lumbar region the articular processes usually escape fracture, although they are violently torn asunder. In all cases there is more or less laceration of the intervertebral discs, the supraspinous, inter-

spinous, and capsular ligaments are torn, as are also the ligamenta subflava. When the bodies are much crushed and displaced the anterior and posterior common ligaments are commonly ruptured.

2. In the fracture-dislocations due to direct violence the lesion may be at any part of the spine. Some form of direct violence is applied to the back, and the column tends to become bent backwards at the spot struck. In the previous class of injuries it will be noted that the anterior segments of the vertebræ suffer compression, while the posterior suffer from the effects of laceration and a tearing asunder of their parts. In lesions due to direct violence the circumstances of the injury are reversed, the posterior segments tend to be crushed together, while the bodies on the front of the spine are separated.

Much displacement is very rarely met with in this form of accident. To produce separation of the vertebræ the violence must be very extreme, and as a rule the force expends itself upon a crushing of the hinder portions of the spinal segments. It follows from this, also, that injury to the cord is less common and less severe in lesions due to direct violence than in those due to indirect violence. In the atlo-axial region the atlas and occipital bone have been dislocated from one another by direct violence, although the most frequent lesion is a dislocation of the former forwards upon the axis, a lesion usually, if not always, associated with fracture of the odontoid process.

The spinous processes may be broken off as a result of well-localised blows. The prominent spines in the lower cervical region and the long processes of the dorsal tract of the column are those that usually suffer. The lumbar spines are less frequently broken, being comparatively small and well protected by the great muscles of the back.

The transverse processes and laminae can scarcely be fractured alone.

In several instances of fracture-dislocation and of fracture alone the spine has been *trepined*, or rather

portions of the laminae and spinous processes have been resected (*laminectomy*). By this means the spinal canal has been freely opened up, effused blood has been allowed to escape, and the cord has been freed from pressure. The laminae are divided as near the transverse process as possible, and the tough ligamenta subflava require careful division. Dr. White, of Philadelphia, has collected (1889) thirteen recent examples of operation for fracture with only one death.

The column is reached through a median incision, and the great muscular masses are cleared from the spinous processes and laminae on either side. The wound being nearly median, the bleeding is not excessive. The dorsal spinal plexus of veins lies, along the spines and over the laminae. On the deep surface of these veins lie the posterior longitudinal spinal veins.

This operation has also been carried out with success in cases of paralysis due to the pressure upon the cord by displaced bone or inflammatory exudations in caries of the spine (Pott's disease). It has to be noted, however, in the last-named class of case, that the condition exhibits a tendency to spontaneous cure.

The **spinal cord** is in the adult about 18 inches in length, and extends from the lower margin of the foramen magnum to the lower edge of the body of the first lumbar vertebra. In some cases it ends at the second lumbar, and in other instances at the last dorsal vertebra. It is to be noted also that in flexion of the spine the cord is a little raised. When the body is bent and the arms stretched out the lumbar part is raised 10 mm. In the earlier months of foetal life the medulla spinalis occupies the whole length of the vertebral canal, but after the third month the canal and lumbar and sacral nerves grow so much faster than does the cord itself, that by the time of birth it reaches no farther than the third lumbar vertebra. It is obviously a great advantage, in cases of injury, that the spinal cord does not occupy that part of the vertebral pillar which joins the base of the column, and which permits not only of considerable movement, but is liable also to

frequent wrenches and strains. It is important to recollect that although the cord itself ends at the spot indicated, the dura mater, the arachnoid, and the collection of cerebro-spinal fluid extend as far as the second piece of the sacrum. Injuries inflicted, therefore, upon the spine as low down as this latter point may cause death by inducing inflammation of the meninges.

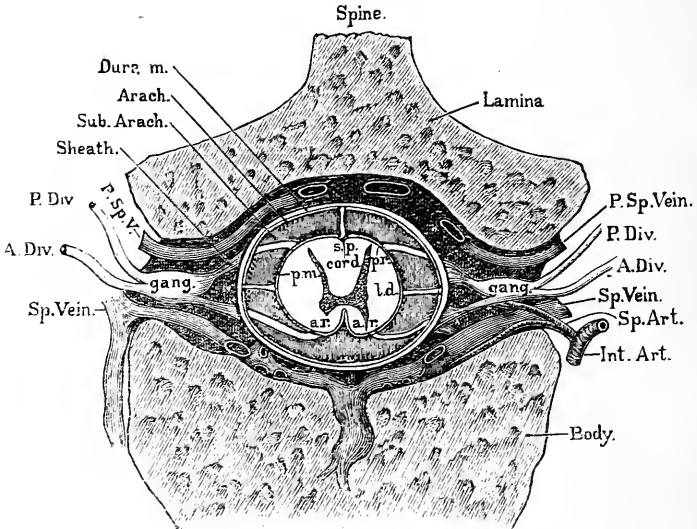


Fig. 80.—Section through Spinal Cord, Membranes, and Spinal Canal.

A.R., at origin of anterior root; P.R., at origin of posterior root; s.p., septum posticum; P.M., pia mater; L.D., ligamentum denticulatum; the arachnoid (arach.), dura mater (dura m.), and sub-arachnoid space are shown.

The cord in the dorsal region measures about 10 mm. from side to side, and 8 mm. in the antero-posterior direction. The cervical enlargement is largest opposite the fifth or sixth cervical vertebræ, where it measures about 13 mm. from side to side. The greatest part of the lumbar enlargement is opposite the twelfth dorsal vertebra, where its lateral measurement is about 12 mm.

The *spinal dura mater* is a strong and substantial membrane, and between it and the walls of the ver-



tebral canal a considerable space exists occupied by loose areolar tissue and a plexus of veins (Fig. 80). It is tough, and may remain undamaged when the cord is completely severed by a crushing force. It will be readily understood that injury and inflammation of the meninges, as results of lesions applied to the spine, are much less frequent than are like complications after injuries to the skull. The looseness of the spinal dura mater, its freedom from any but slight and occasional attachments to the bone, and the space around it in which effusions can extend with little possibility of becoming limited, will explain the rarity in the spine of those complications which follow upon depressed bone and extravasations of pus and blood in connection with the dura mater within the skull. The plexus of thin-walled veins that occupies the interval between the theca and the bones may prove a source of extensive hæmorrhage in cases of injury to the column. The blood so poured out tends to gravitate to the lowest part of the canal, and when sufficient in quantity may produce pressure effects upon the medulla spinalis.

Over the arches at the posterior aspect of the vertebræ is situate a plexus of vessels (the dorsal spinal veins) that receives blood from the muscles and integuments of the back. These vessels communicate through the ligamenta subflava with the venous plexuses within the spinal canal, and by means of this communication inflammation from without may be conducted to the theca of the cord. Thus spinal meningitis has followed upon deep bed-sores, and upon suppurative affections situated in the immediate vicinity of the spinal laminae.

Within the dura mater are two spaces, the subdural and the subarachnoid, as in the skull. The arachnoid is closely applied to the dura mater, the subdural being merely a potential space, while the subarachnoid is extensive and occupied by cerebrospinal fluid, which surrounds the cord and is continuous with the great subarachnoid spaces at the base of the brain (Fig. 80). By means of this open communication inflammatory affections may readily spread from the

cord to the brain. Into these spaces blood may be extravasated in cases of injury. Instances have been recorded where the theca has been opened by a wound, and the cerebro-spinal fluid has escaped in large quantities. The fluid normally contains '05 per cent. of albumen, but if the membranes are inflamed the percentage is double that amount. In certain conditions the pressure of the fluid may rise to such an extent as to cause death. In normal conditions the fluid is absorbed at any pressure above that of the surrounding veins (Hill). In the recumbent posture the pressure should support a column of water 2 inches high. In disease it may rise to ten times that amount. The pressure may be relieved by a lumbar puncture, made by thrusting a needle 8-10 cm. long into the subarachnoid space in the lumbar region of the spine. A point is selected between the third and fourth lumbar spines,  $\frac{1}{2}$  an inch from the middle line. The needle perforates the ligamentum subflavum between the laminae. Convulsions follow if the pressure be reduced much below the normal. At this level the cord cannot be injured, but the needle may pierce one of the lower nerve roots, giving rise to twitching in some of the muscles of the lower extremity.

The position of the cord is such that it is not readily reached in incised and punctured *wounds*. The only spots at which it is easy of access are the intervals between the atlas and occiput and the atlas and axis. Many cases have been recorded of fatal wound of the cord in these positions. Lower down in the column the medulla spinalis may be reached if the wound have a certain direction. Thus a case is reported where a pointed body entered the canal between the ninth and tenth dorsal vertebrae, having been introduced from below upwards.

Several examples of damage to the cord by sword or bayonet wounds have been put on record, but in most of these instances the wound was associated with some fracture of the protecting bone.

The pia mater forms a strengthening sheath for the

cord. On it the arteries ramify before entering to supply its substance. The vertebral, intercostal, lumbar, ilio-lumbar, and lateral sacral arteries send twigs along the nerve roots to the cord.

**Concussion of the cord.**—After certain injuries to the back a train of symptoms, usually of a severe and complicated character, has been described, which has been assigned to a concussion or shaking of the spinal cord.

In these injuries it is assumed that, as a result of a sudden shock transmitted to it, the cord undergoes certain molecular changes, which lead to a more or less severe disturbance of its function. The condition has been compared to concussion of the brain, although it must be owned that the symptoms often accredited to concussion of the cord have a character more complex than that seen in like lesions of the more complex organ.

A great many surgeons are inclined to dispute the existence of this lesion, or rather decline to recognise the connection between a certain train of symptoms and a simple molecular disturbance of the cord. It is very probable that in many of the reputed instances of cord-concussion the symptoms (if we except such as are assumed and such as depend upon changes in the brain) are due to a more distinct damage to the medulla spinalis, to hæmorrhages, to pressure, and to other gross changes. Without entering into any discussion upon the subject, it may be sufficient to point out some of the anatomical objections that appear to oppose themselves to the common conception of concussion of the cord. The spinal cord is swung or suspended in its bony canal, and is separated from the walls of that canal on all sides by a considerable interval. It is, indeed, only held in position by the nerve trunks that pass out from it through the intervertebral foramina, and by its connections with the theca. Above, it is connected with that part of the brain that lies upon the largest intracranial collection of the cerebro-spinal fluid (page 32), and it would appear that the most violent movements possible of the brain within the skull could be

but very feebly communicated to the spinal cord. The cord, moreover, within its theca, is surrounded on all sides by a space occupied by cerebro-spinal fluid. It is difficult to understand, therefore, how a structure so protected can be so violently disturbed by a shock received upon the body as to undergo a grave and progressive loss of function. The cord is, indeed, somewhat in the position of a caterpillar suspended by a thread in a phial of water. It would probably be difficult to permanently disturb the internal economy of such an insect (even if it had a structure as elaborate as the cord) by other than violence that would be comparatively excessive.

**Contusion and crushing of the cord.**—As has already been observed, the gravity of fractures and dislocations of the spine depends upon the extent of the damage received by the cord. In these accidents it is very usual for some part of the injured vertebræ to be projected into the spinal canal, so as to press upon or actually crush the delicate nerve centre that it contains.

It is needless to observe that the cord is extremely soft, and thus it happens that it may be entirely broken up by violence without the membranes being perceptibly damaged. Indeed, in fracture-dislocations it is unusual for the theca to be torn, and it is possible for the cord to be quite crushed at some one spot without the corresponding pia mater being in any way lacerated. The amount of damage inflicted upon the cord will vary, of course, with the magnitude of the accident; but, other things being equal, it will be found to be more severely injured in fracture-dislocations of the cervical and dorsal segments than in like lesions in the lumbar spine. In the atlo-axial region the amount of displacement that follows upon luxation of the two bones from one another is such that the cord is, as a rule, severely crushed, and death ensues instantaneously, as is seen in cases of death by hanging. In the cervical and upper dorsal segments of the column the vertebral bodies are small, the spine is mobile, the fractures met with in the parts are usually due to indirect violence,

and are associated with much displacement. In the lower dorsal region, again, the greater rigidity of the spine renders any displacement, when it does occur, likely to be considerable. In the lumbar region, on the other hand, it must be noted that the cord only extends to the lower border of the first vertebra. The bodies of the vertebræ, also, in this district, are very large and cancellous, and can undergo a severe amount of crushing without a corresponding degree of displacement being produced. The part is also well protected by the large intervertebral discs, and by the immense masses of muscle that surround the spine in the loins. Such portion also of the spinal cord as extends into the lumbar region is protected by the many cords of the cauda equina, which, by their looseness and comparative toughness, tend to minimise the effects of violence.

The degree of displacement of bone required to produce pressure effects upon the cord is often greater than would be supposed. At post-mortem examinations portions of injured vertebræ have been found encroaching upon the spinal canal to a considerable extent in cases where no evidences of damage to the cord existed during life. Dr. J. W. Ogle reports the case of a man who, after an injury to the neck from a fall, presented no spinal symptoms until three days had elapsed. He ultimately became paralysed, and died thirty-two days after the accident. The autopsy revealed a dislocation forwards of the sixth cervical vertebra, of such an extent that the body below projected at least  $\frac{1}{2}$  an inch into the spinal canal.

The remarkable manner in which the cord will accommodate itself to a slowly progressing pressure is often well seen in the results of chronic bone disease in the column.

The symptoms due to injury to the cord and to the nerves contained in the spinal canal will obviously depend upon the situation and extent of the lesion. The diagnosis of the situation and the lesion is complicated by the relation the nerves bear to the various

vertebræ, and by the fact that the majority of the great trunks arise from the cord at a spot above the point at which they issue from the vertebral canal. The two highest nerves, the first and second cervical, pursue an almost horizontal course in their passage from the cord to their points of exit from the canal. The remaining nerves take a more and more oblique direction, until at last the lowest nerve trunks run nearly vertically downwards as they pass to their respective intervertebral foramina.

*Points of exit.*—The first cervical nerve leaves the canal above the first cervical vertebra. The remaining cervical trunks escape also above the vertebræ after which they are named, the eighth cervical nerve leaving the canal between the last cervical and the first dorsal vertebræ. The dorsal, lumbar, and sacral nerves have their points of exit *below* the vertebræ after which they are named. Thus, the first dorsal nerve will pass through the foramen between the first and second dorsal vertebræ, and so on.

*Points of Origin from the Cord.*

- The first cervical nerve arises from the cord opposite the interval between the atlas and occiput.
- The second and third cervical nerves arise from the cord opposite the axis.
- The fourth, fifth, sixth, seventh, and eighth cervical nerves arise from the cord opposite the third, fourth, fifth, sixth, and seventh vertebræ respectively.
- The first four dorsal nerves arise from the cord opposite the discs *below* the seventh cervical and the first, second, and third dorsal vertebræ respectively.
- The fifth and sixth dorsal nerves arise from the cord opposite the lower borders of the fourth and fifth vertebræ.
- The remaining six dorsal nerves arise from the cord opposite the bodies of the sixth, seventh, eighth, ninth, tenth, and eleventh vertebræ.
- The first three lumbar nerves arise from the cord opposite the twelfth dorsal vertebra.
- The fourth lumbar nerve arises from the cord opposite the disc between the twelfth dorsal and first lumbar vertebræ.
- The last lumbar nerve, together with the sacral and coccygeal nerves, arise from the cord opposite the first lumbar vertebra.

It will be seen, therefore, that in taking note of

the symptoms due to crushing the entire nerve contents of the vertebral canal at a certain spot, consideration must be taken, not only of the effects of damaging the medulla at that point, but also of the result of lacerating nerve trunks that may issue there, although their origins are above the seat of lesion. The cord is also very often only damaged in part, or it may entirely escape, while one or more nerves are crushed by the fractured vertebræ or by fragments of bone separated by the lesion.

In fracture-dislocations the upper vertebral body, as already stated, usually glides forward, with the result that the anterior and antero-lateral parts of the cord are brought into violent contact with the protecting border of the vertebræ below the seat of lesion.

It is in these parts of the cord that the main motor tracts run, and thus it happens that motion is more often lost in the parts below the site of the injury than is sensation. If there be partial motor and sensory paralysis, the disturbance of the former function is likely to be in excess of that of the latter. In no case, indeed, does there appear to have been a loss of sensation without, at the same time, some disturbance in the powers of movement. If the grey matter of the cord be not severely damaged, reflex movements appertaining to that segment of the cord can usually be induced in the paralysed parts by proper stimulation. If those reflex movements be lost, it may be inferred that the grey matter is broken up, and that the entire spinal medulla has been crushed at the seat of lesion.

The higher up the fracture in the column the greater is the tendency for the function of respiration to be interfered with. If the lesion be at the upper end of the dorsal spine, then not only will all the abdominal muscles be paralysed, but also all the intercostals. A fracture associated with injury to the cord, when above the fourth cervical vertebra, is, as a rule, instantaneously fatal. The phrenic nerve comes off mainly from the fourth cervical nerve, receiving contributions also from the third and fifth. The fourth nerve issues

just above the fourth cervical vertebra. If the cord be damaged immediately below this spot, the patient can breathe only by means of the diaphragm, and if the lesion be so high as to destroy the main contribution to the phrenic, respiration of any kind becomes impossible.

Certain disturbances of the act of micturition are frequent in cases of injury to the cord. The reflex centre for this act is lodged in the lumbar enlargement. The irritation of the vesical walls, produced by the increasing distension of the bladder, provides the needful sensory impulse. This impulse is reflected to the nerves controlling the bladder muscles, and especially to the detrusor urinæ, and by their contraction the organ is emptied (page 396). The action, however, can be to some extent inhibited by influences passing down from the brain to the lumbar centre, and the tendency to a frequent discharge of urine is resisted by contraction of the sphincter. When, therefore, any part of the cord is damaged that lies between the lumbar centre and the brain, inhibition can have no effect. Immediately after the accident the temporary suspension of reflex actions from shock produces some retention of urine, and after that the bladder empties itself at frequent intervals, the patient being unconscious of the act and unable to influence it.

If the centre itself be damaged in the lumbar cord, the patient, after a little retention, will suffer from absolute incontinence; and a like result will follow if the nerve connections between the cord and bladder below the spinal centre have been destroyed. The principal nerves connecting the medulla spinalis with the bladder are the third and fourth sacral.

The act of defæcation also is apt to be disturbed in a like manner. Here there is, as in the previous case, a reflex centre in the lumbar enlargement, with motor and sensory nerves connecting it below with the rectum and its muscles; and also between this centre and the brain are tracts, but little known, along which inhibitory actions can extend.




When the centre itself is damaged, or the connection severed that unites it with the viscus, the patient will suffer from incontinence of fæces and will be unable in any way to control the act. When the cord is damaged at any spot between the centre and the brain, then the act of defæcation will be performed at regular intervals, without either the patient being conscious of the act or being capable of inhibiting it.

In some injuries to the cervical cord the patient has suffered from severe vomiting for some time after the accident, or has exhibited a remarkable alteration in the action of his heart. Mr. Erichsen, for example, reports the case of a man who, after a severe blow upon the cervical spine, continued to vomit daily for several months. In the other category, instances have been recorded when the pulse has sunk as low as 48, or even as 36, and 20, after lesions to the column in the neck.

These changes are supposed to be due to disturbance of the vagus, and it is further suggested that the morbid influence is conveyed to the vagus by the spinal accessory nerve with which it is so freely associated.

It should be remembered that the spinal accessory trunk has origin from the cord as low down as the sixth or seventh cervical nerves. Some details concerning the position of centres in the spinal cord, connected with areas of skin, groups of muscles and viscera, have been given already when dealing with the nerve supplies of the extremities and abdomen (*see* pages 533 and 368).

**Operations upon the cord.** — Mr. Victor Horsley and others have cut down upon the spine and removed a tumour from the spinal cord with perfect success, and with relief to the symptoms from which the patient was suffering. The spinal canal has also been exposed in certain cases where callus in an old fracture of the spine was pressing upon the cord, or where a small osseous growth was encroaching on the canal.



# INDEX.

---

- Abdomen, blood vessels of, 284, 292,  
370  
 ,, blows on the, 387  
 ,, congenital deformities  
 of the, 298  
 ,, fascia of, 286, 311  
 ,, lymphatics of the, 292  
 ,, nerves of, 293, 368  
 ,, parietes of, 282, 285, 286,  
 291, 311  
 ,, skin of the, 285  
 ,, surface anatomy of the,  
 282  
 ,, wounds of the, 292  
 " Abdominal belt," 286  
 ,, ,, connective tis-  
 sue and abs-  
 cesses, 291  
 Abdominal viscera, nerve supply  
 Abscess, alveolar, 116 [of, 368  
 ,, axillary, 204  
 ,, cervical, 143, 144  
 ,, gluteal, 426  
 ,, hepatic, 352  
 ,, iliac, 312  
 ,, in antrum, 95  
 ,, mastoid cells, 76  
 ,, testis, 409  
 ,, the abdominal parietes,  
 292, 315  
 ,, the scalp, 6  
 ,, the temporal fossa, 8  
 ,, intercostal, 174  
 ,, ischio-rectal, 384  
 ,, lumbar, 312, 315  
 ,, mammary, 177  
 ,, mediastinal, 144, 184  
 ,, orbital, 44  
 ,, palmar, 263  
 ,, parotid, 103  
 ,, pelvic, 381, 438  
 ,, perinephritic, 362  
 ,, perityphlitic, 338  
 ,, plantar, 505  
 ,, popliteal, 470  
 ,, post-pharyngeal, 131  
 ,, prostatic, 398  
 Abscess, psoas, 313, 434  
 ,, renal, 363  
 ,, retro-peritoneal, 313  
 ,, thecal, 265  
 Acetabulum, 438  
 ,, fractures of, 375  
 Acromio-clavicular joint, 197  
 ,, ,, disloca-  
 tions of, 199  
 Acromio-thoracic artery, 190  
 Acromion process, fracture of, 200  
 Addison's disease, 369  
 Adductor longus muscle, 431, 435  
 Air in veins, 163, 207  
 " Alderman's nerve," 73  
 Alexis St. Martin's case, 330  
 Alveolar abscess, 116  
 Amputation (*see* Arm, Leg, etc.,  
 amputation of, etc.)  
 Anal triangle, 383  
 Anastomotic magna, 468  
 Aneurism, aortic, 160, 370  
 ,, axillary, 207  
 ,, in the neck, 160, 162  
 ,, of the posterior tibial  
 artery, 493  
 ,, popliteal, 472  
 Ankle, 500, 510  
 ,, fasciæ of, 504  
 ,, joint, 500, 510  
 ,, ,, amputation at, 528  
 ,, ,, disease of, 511  
 ,, ,, dislocations at, 512  
 ,, ,, fractures about, 512  
 ,, surface anatomy of, 500  
 ,, tendons of, 504, 507  
 Annular ligaments of ankle, 506  
 ,, ,, fingers, 263  
 ,, ,, wrist, 263, 266  
 Anterior crural nerve, 436, 445, 533  
 Antrum of Highmore, 93  
 ,, mastoid, 76  
 Anus, 385, 419  
 ,, imperforate, 344  
 Aorta, abdominal, 284, 370  
 ,, thoracic, 160, 182  
 Aortic orifice, 182

- Aponeuroses (*see* Fasciæ)  
 Appendicitis, 336 ‡  
 Appendix vermiformis, 336, 338  
 Aqueous humour, 59  
 Arachnoid, 30, 547  
 Arcus senilis, 49  
 Arm, 223  
 „ amputation of, 229  
 „ fascia of, 224  
 „ nerves of, 275  
 „ skin of, 224  
 „ surface anatomy of, 223  
 Arnold's nerve, 72  
 Arteries (*see* Axillary, etc., and Blood-vessels)  
 Arteriotomy, 12  
 Arterio-venous aneurisms, 45, 234, 435  
 Astragalus, dislocations of, 518  
 „ fractures of, 525  
 Atlas, 131  
 Atlo-axial portion of spine, 540  
 Auditory meatus, external, 69  
 „ „ its relations, 71  
 Auricle (*see* Ear)  
 Auricles, supernumerary, 68  
 Auriculo-ventricular orifices, 182  
 Axilla, 188, 202  
 „ suspensory ligament of, 204  
 Axillary abscess, 204  
 „ artery, 187, 188, 207  
 „ fasciæ, 203  
 „ glands, 177, 205  
 „ nerves, 203  
 „ vein, 206  
 Axis, 131  
 Azygos veins, 184  
 Barbadoes leg, 437  
 Base of skull, fractures of, 25  
 Basilic vein, 233  
 Bend of elbow, 230  
 Bent arm after venesection, 235  
 Biceps tendon in arm, 212  
 „ „ ham, 471  
 Bile duct, rupture of the, 355  
 „ „ relationships of, 254  
 Bladder, 391, 420  
 „ distension of, 391  
 „ double, 397  
 „ extroversion of, 293  
 „ fasciculated, 396  
 „ female, 397  
 „ foreign bodies in, 397  
 „ found in herniæ, 393  
 „ male, 391  
 „ mucous membrane of the, 395  
 „ nerves of, 396  
 Bladder, of child, 398  
 „ puncture of, above pubes, 393  
 „ „ perrectum, 394  
 „ relations to the peritoneum, 393  
 „ rupture of the, 394  
 „ sacculated, 396  
 „ stabbed through buttock, 430  
 „ stone in the, 387  
 Blood-vessels of abdomen, 284, 292, 370  
 „ abdominal walls, 292  
 „ auditory meatus, 71  
 „ brain, 38  
 „ breast, 178  
 „ buttock, 425, 428  
 „ foot, 502, 508  
 „ globe, 52  
 „ hand, 258, 266  
 „ heel, 529  
 „ knee, 471  
 „ leg, 492  
 „ nares, 90  
 „ neck, 137, 160  
 „ orbit, 45  
 „ palate, 127  
 „ pelvis, 382  
 „ perineum, 386  
 „ pinna, 72  
 „ rectum, 417  
 „ retina, 54  
 „ scalp, 12  
 „ Scarpa's triangle, 432, 435  
 „ spermatic cord, 410  
 „ tympanum, 80  
 Brachial artery, 223, 231, 235  
 „ „ abnormalities of, 226  
 „ „ in phlebotomy, 234  
 „ „ ligature of, 226  
 „ fascia, 224  
 „ plexus, 139, 148, 178, 278  
 Brachialis anticus, 225  
 Brain, 32, 38  
 „ and skull relations, 32  
 „ basal ganglia of, 37  
 „ blood-vessels of the, 38  
 „ concussion of the, 38  
 „ convolutions of, 35  
 „ cortex of, 37  
 „ fissures of, 35  
 „ injuries to, 32  
 „ membranes of, 28

- Brain, motor centres of, 37  
 ,, sulci of, 35  
 ,, surface relationships of, 32  
 ,, wounds of, 40  
 Branchial fistule, 68, 166  
 Brasdor's operation, 161  
 Breast (*see* Mamma), 175  
 ,, abscess of, 177  
 Bregma, 15  
 Bronchi, 152, 154  
 ,, foreign bodies in, 154  
 Bronchial lymphatic glands, 184  
 Brouchocele, 155  
 Brunner's glands in burns, 333  
 Bryant's method of dividing the  
 muscles of the palate,  
 129  
 ,, triangle, 424  
 Buccal cavity, 118  
 ,, ,, in embryo, 127  
 ,, nerve, 101  
 Bunions, 507  
 Bursæ about the elbow, 236  
 ,, ,, foot, 506  
 ,, ,, ham, 473  
 ,, ,, shoulder, 209, 211  
 ,, over the great trochanter,  
 427  
 ,, ,, ischial tuber-  
 osity, 427  
 ,, ,, knee-joint, 469,  
 473  
 ,, patellar, 469  
 ,, subacromial, 211  
 Buttocks, 423  
 ,, arteries and nerves of  
 the, 425, 428  
 ,, fascia of, 426  
 ,, fold of, 424  
 ,, surface anatomy of, 423  
 Cæcum, 336, 348  
 ,, foreign bodies in, 337  
 ,, hernia of, 337  
 ,, in intestinal obstruction,  
 339  
 ,, opening of, 348  
 ,, position of, 336  
 Caesarian section, 375  
 Calcaneo-astragaloid joint, 518  
 ,, -cuboid articulation, 520  
 ,, -scaphoid ligament, 524  
 Canal of Nuck, hernia in, 306  
 Cancrum oris, 96  
 Capsule of Tenon, 42  
 Cardiac orifice of stomach, 321  
 Carotid artery, 76, 132, 133, 137,  
 144, 161, 183  
 ,, ,, aneurism of, 161  
 Carotid artery, destroyed by abs-  
 cess, 144  
 ,, ,, ligation of, 161  
 ,, ,, wounds of, 146  
 ,, tubercle, 136, 162  
 Castration, 411  
 Cataract, 58  
 Catheterism of Eustachian tube, 80  
 ,, of urethra, 461  
 Centre of gravity of an adult body,  
 372  
 Cephalhaematomata, 7  
 Cephalic vein, 187, 230, 233  
 Cerebral circulation, 38  
 ,, localisation, 37  
 Cerebro-spinal fluid, 27, 547.  
 Cervical (*see* Neck)  
 ,, sympathetic, paralysis of,  
 47  
 Cervico-dorsal part of spine, 540  
 Charbon, 97  
 Cheek, 96  
 Cholecystectomy, 355  
 Cholecystenterostomy, 355  
 Cholecystotomy, 355  
 Chopart's operation, 530  
 Chorda tympani, 81  
 Choroid, 50  
 Ciliary zone, 56  
 Circumcision, 405  
 Circumcorneal zone, 56  
 Circumflex artery, external, rup-  
 ture of, 461  
 ,, ,, internal, wound  
 of, 461  
 ,, ,, posterior, 189,  
 209  
 ,, nerve, 189, 209  
 Cirroid aneurism, 13  
 Clavicle, 185, 186, 190  
 ,, dislocations of, 197, 199  
 ,, excision of, 191  
 ,, fractures of, 191  
 ,, movements of, 198  
 ,, ossification of, 194  
 ,, relations of, 190, 194  
 Cleft palate, 126  
 Clergyman's sore-throat, 150  
 Club-foot, 520  
 Coccygeus, 378, 379  
 Coccygodynia, 379  
 Cochlin leg, 437  
 Coeliac axis, 284, 370  
 Colectomy, 348  
 Colles' fascia, 385  
 ,, fracture, 266, 270  
 Coloboma iridis, 52  
 Colon, 340  
 ,, ascending, 341

- Colon, descending, 341  
   ,, malformation of, 343, 345  
   ,, operations on, 345  
   ,, stricture of, 340  
   ,, transverse, 340, 341  
 Colotomy, iliac, 347  
   ,, lumbar, 345  
 Compression of brain, 29  
   ,, cord, 550, 553  
 Concussion of brain, 38  
   ,, cord, 549  
 Congenital club-foot, 520  
   ,, exomphalos, 298  
   ,, fistulæ, 68, 166  
   ,, hernia, 302, 304, 305  
   ,, hydrocele, 303  
   ,, malformations of anus  
     and rectum, 420  
   ,, malformations of blad-  
     der, 298  
   ,, malformations of colon,  
     343, 345  
   ,, malformations of penis,  
     406  
   ,, tumour of sterno-mas-  
     toid, 140  
 Conjunctiva, 64  
 Contre-coup, fracture by, 25  
 Convolutions of brain, motor cen-  
   tres on, 37  
   ,, of brain, relations of,  
     32  
   ,, of brain, relations of,  
     to skull, 32  
 Coraco-acromial arch, 210  
 Coracoid process, 187  
   ,, fracture of, 201  
 Cord, spinal, 545  
   ,, concussion of, 549  
   ,, contusion of, 550  
   ,, injuries to the, symp-  
     toms of, 551  
 Cornea, 48  
 Coronal suture, 15  
 Coronoid process, 244  
 Corpus striatum, 37  
 Coryza, 85  
 Coup de fouet, 492  
 Cowper's duct, 412  
 Craniectomy, 28  
 Cranio-tabes, 16  
 Cranium, bony vault of, 15  
 Cremaster muscle, 410  
 Cremasteric artery, 410  
 Cretinism, 157  
 Cribriform plate, 84  
 Cricoid cartilage, 148, 149  
 Crico-thyroid space, 136, 154  
 Crutch paralysis, 227  
 Cuboid bone, 500  
 Cuneiform bone, inner, 500  
   ,, " dislocation  
     of the, 526  
   ,, " fracture of  
     the, 526  
 Curves of the vertebral column,  
   537  
 Cut throat, 146  
 Cyphosis, 538  
 Dartos, 386, 407  
 Deltoid muscle, 208  
   ,, region, 187, 208  
   ,, tubercle, 185  
 Descending palatine artery, 127  
 Diploic veins, 13  
 Dislocation (*see* the several bones  
   and joints)  
 Dorsal vein of penis, 386  
 Dorsalis pedis artery, 508  
   ,, scapulæ artery, 189  
 Dorso-lumbar part of spine, 540  
 Drop-wrist, 278  
 Duodenal fossa, 332  
 Duodenum, 332  
   ,, suspensory muscle of,  
     332  
 Dupuytren's contraction, 261  
   ,, fracture, 515  
 Dura mater, 28, 546  
   ,, fungus of, 30  
 Dysphonia clericorum, 150  
 Ear, 68  
   ,, bleeding from, in fractures of  
     base of skull, 26  
   ,, blood supply of, 72  
   ,, coughing, 73  
   ,, external, 68  
   ,, frost bite of, 72  
   ,, gangrene of, 72  
   ,, hæmatomata of, 72  
   ,, nerves of, 72  
   ,, polypi of, 71  
   ,, sneezing, 73  
   ,, tophi in, 69  
   ,, watery discharge from, 27  
   ,, yawning, 73  
 Elbow, 230, 232  
   ,, bursæ about, 236  
   ,, dislocations of the, 238  
   ,, fold of the, 230  
   ,, fractures about, 241  
   ,, gland of, 235  
   ,, joint, 236  
   ,, " disease of, 237  
   ,, " sprains of, 237, 241  
   ,, resection of the, 245; *or,*

- Elbow, surface anatomy of the, 230  
 „ veins about, 233  
 Elephantiasis arabum, 437  
 Emissary veins of skull, 13  
 Emphysema, 179  
 Encephalocele, 17  
 Encysted hydrocele of the cord, 304  
 Enterectomy, 335  
 Euteroraphy, 335  
 Enterotomy, 335  
 Epididymis, 409  
 Epiphysis, lower, of femur in excision of knee, 488  
 „ „ in knock-knee, 481  
 „ of acromion, separation of, 200  
 „ of clavicle, separation of, 194  
 „ of coracoid process, 201  
 „ of femur, separation of, 444, 449, 485  
 „ of humerus, separation of, 220, 243  
 „ of olecranon, 244  
 „ of pelvis, separation of, 374  
 „ of radius, separation of, 244, 272  
 „ of tibia, separation of, 488, 498  
 „ of third phalanx in whitlow, 266  
 „ of upper limb, 281  
 Epipteric bone, 19  
 Epispadias, 406  
 Epistaxis, 90  
 Estlander's operation, 174  
 Eustachian catheter, to pass, 80  
 „ tube, 78  
 Excision (*see* special parts)  
 External auditory meatus, 68  
 „ auditory meatus, blood supply of, 72  
 „ auditory meatus, nerve supply of, 72  
 „ carotid, bleeding from, 163  
 Extravasation of urine, 286, 386  
 Eye-ball, 48  
 „ blood supply of the, 52  
 „ dangerous area of, 56  
 „ nerves of the, 54  
 Eyelids, 62  
 Face, 95  
 „ development of, 99  
 Face, injuries to, 97  
 „ nerves of, 99  
 „ vessels of, 97  
 Facial artery, 27  
 „ nerve, 98, 106  
 Fascia, abdominal, 311, 386  
 „ axillary, 203  
 „ bicipital, 234  
 „ cervical, 141  
 „ clavi-pectoral, 204  
 „ iliac, 311  
 „ lata, 426, 433, 459  
 „ lumbarum, 315  
 „ obturator, 379  
 „ of arm, 224  
 „ of buttock, 426  
 „ of Colles, 385  
 „ of deltoid region, 208  
 „ of foot, 504  
 „ of leg, 491  
 „ of palm, 26, 261  
 „ of scalp, 1, 6  
 „ of Scarpa's triangle, 433  
 „ of thigh, 426, 433, 459  
 „ orbital, 42  
 „ palmar, 261  
 „ parotid, 103  
 „ pectoral, 203  
 „ pelvic, 379  
 „ perineal, 385  
 „ popliteal, 470  
 „ prevertebral, 143  
 „ recto-vesical, 380  
 „ temporal, 7  
 „ transversalis, 311  
 Fasciculated bladder, 396  
 Femoral hernia, 306  
 „ vessels, 432, 435, 461  
 Femur, dislocations of, 449  
 „ fractures of, 446, 461  
 Fenestra ovalis, 76  
 „ rotunda, 76  
 Ferguson's method of dividing the muscles of the palate, 128  
 Fibula, 497  
 „ fractures of, 495, 497, 512  
 Fifth nerve, 101  
 „ section of, 101  
 Finger "snap," 264  
 „ little, congenital contraction of, 264  
 „ "mallet," 270  
 Fissure of Rolando, 35  
 „ Sylvius, 35  
 Fissures of brain, relations of, 35  
 „ parietal, 19  
 Fistula at the navel, 289  
 „ between the gall bladder and gut, 342

- Fistula, congenital, 68, 166  
 ,, gastric, 324  
 ,, in ano, 385  
 ,, lachrymal, 67  
 ,, salivary, 108  
 ,, vesico-vaginal, 413
- Flat-foot, 522
- Fold, gluteal, 424
- Fontanelle, sagittal, 19  
 ,, temporary occipital, 18
- Fontanelles, 15
- Foot, abscess of, 505  
 ,, amputations of, 528  
 ,, arches of, 517  
 ,, blood-vessels of, 502, 508  
 ,, chief joints of, 517  
 ,, dislocations of, 518, 527  
 ,, fasciæ of, 504  
 ,, fractures of, 525  
 ,, integuments of, 502  
 ,, lymphatics of, 510  
 ,, nerves of, 504  
 ,, surface anatomy of, 500  
 ,, synovial membranes of, 527  
 ,, the, 500, 504, 517
- Foramen cæcum of tongue, 124  
 ,, of Majendie, 32  
 ,, Monroe, 33
- Fore-arm, 246  
 ,, amputation of the, 252  
 ,, bones of the, 248  
 ,, fractures of the, 250  
 ,, luxations of the, 238  
 ,, surface anatomy of the, 246  
 ,, vessels of the, 247
- Fossa duodeno-jejunalis, 333  
 ,, ischio-rectal, 382, 384  
 ,, nasal, 84  
 ,, of Rosenmüller, 80  
 ,, subclavicular, 187
- Fracture (*see* the several bones)  
 ,, dislocation of the vertebral column, 540  
 ,, hélicoïde, 462, 496
- Frænum linguæ, 120
- Frontal sinus, 92  
 ,, infundibulum of, 93
- Fungus of the dura mater, 30  
 ,, testicle, 409
- Gall bladder, 354  
 ,, fundus of, 350  
 ,, nerve supply of, 355  
 ,, operations on, 355  
 ,, rupture of the, 355  
 ,, obstructed by movable kidney, 364
- Gall stones, 342, 354
- Gangrene of nose, 82  
 ,, pinna, 72  
 ,, the leg and embolism, 493
- Gasserian ganglion affected by abscess spreading from parotid, 105  
 ,, removal of, 102
- Gastroctomy, 327
- Gastrocnemius muscle, 490  
 ,, rupture of the, 492
- Gastro-enterostomy, 328
- Gastrostomy, 326
- Gastrotomy, 326
- Generative organs, female, 412  
 ,, male, 405
- Genito-crural nerve, 410, 436
- Genu-valgum, 480
- Gladiolus, 171
- Glans penis, 405
- Glaucoma, 50, 60
- Glottis, 149
- Gluteal abscess, 426  
 ,, aneurisms, 428  
 ,, artery, 425, 428  
 ,, bursæ, 427  
 ,, fascia, 426  
 ,, fold, 424  
 ,, region, 423
- Gluteus maximus, 427  
 ,, rupture of, 427
- Goitre, 155
- Great occipital nerve, 162
- Groin, region of, 430
- Gullet (*see* Oesophagus)
- Gums, 120
- Gustatory nerve, Moore's method of dividing the, 119
- Hæmatomata of scalp, 7  
 ,, on septum nasi, 90  
 ,, the pinna, 72
- Hæmoptysis, 180
- Hæmorrhage from choroid, 50  
 ,, frænum linguæ, 121  
 ,, intercostal vessels, 174  
 ,, tongue, 121  
 ,, tonsil, 134  
 ,, in lithotomy, 382, 388  
 ,, into vitreous, 54  
 ,, in tracheotomy, 153  
 ,, meningeal, 29



- Hæmorrhoidal vessels and nerves, 385, 417  
 Hæmothorax, 180  
 Hallux rigidus, 527  
 " valgus, 527  
 Hamstring muscles, 460, 470  
 Hand, 255, 258  
 " amputation of, 274  
 " blood-vessels and lymphatics of, 258, 266  
 " dislocations of, 272, 273  
 " fasciæ of, 260, 261  
 " surface anatomy of, 255  
 " synovial sheaths of, 264  
 Hanging, mode of death from, 550  
 Hard palate, 127  
 Hare-lip, 126  
 Heart, 182  
 " its relation to the surface, 182  
 " valves of, 182  
 " wounds of, 183  
 Heel, blood-vessels of, 529  
 " integuments of, 529  
 Helicoidal fractures of Leriche, 462, 498  
 Hernia, congenital, 299, 304, 305  
 " diaphragmatic, 310  
 " direct, 300  
 " encysted, 304  
 " femoral, 306  
 " infantile, 304  
 " inguinal, 299, 305  
 " into the funicular process, 305  
 " ischio-rectal, 310  
 " lumbar, 310  
 " mesenteric, 333  
 " obturator, 309  
 " omental, 318  
 " perineal, 210  
 " pudendal, 310  
 " rare forms of, 310  
 " retro-peritoneal, 334  
 " sciatic, 310  
 " umbilical, 288, 310  
 " vaginal, 413  
 Herniotomy, 306, 309  
 Hip, dislocations of, 449  
 " joint, 438  
 " " amputation at the, 456  
 " " congenital dislocations of, 450  
 " " disease, 439, 444  
 " " fractures about, 446  
 " " movements of, 439  
 " " region of the, 423  
 Hippocratic hand, 260  
 Holden's line, 431  
 Hottentot Venus, 425  
 Human tails, 378  
 Humerus, dislocations of, 214  
 " fractures of, 219, 227, 241  
 " " non-union after, 228  
 Hydatid cyst in the liver, 354  
 Hydrencephalocele, 17  
 Hydrocele, 303, 408  
 " of the neck, 167  
 Hydrocephalus, 16, 32  
 Hyoid bone, 136, 148  
 " " accessory glands about, 156  
 " " fracture of, 148  
 Hypertrophy of the prostate, 399  
 Hypoglossal nerve, 162  
 Hypopyon, 60  
 Hypospadias, 406  
 Hypothenar eminence, 255  
 Hysterical hip, 445  
 " knee, 445  
 Ichthyosis linguæ, 121  
 Ileo-cæcal intussusception, 339  
 " region, 336  
 " valve, 339  
 Ileo-colic intussusception, 339  
 Ileum (*see* Intestine, small)  
 Iliac abscess, 312  
 " colotomy, 347  
 " fascia, 311  
 Ilio-psoas muscle, 312, 434  
 Ilio-tibial band, 426, 459, 466  
 Indirect hernia, 300  
 Inequality of limbs in length, 464  
 Infantile hernia, 304  
 Inferior dental nerve, dividing the, 101  
 " maxilla, deformities of, 115  
 " " dislocations of, 112  
 " " excision of, 113  
 " " fracture of, 111  
 " " subluxation of the, 113  
 " thyroid veins, 136, 146  
 Infraorbital foramen, 100  
 " artery, 100  
 " nerve, 100  
 Inguinal canal, 299, 305  
 " colotomy, 347  
 " hernia, 299, 305  
 Innominate artery, 154, 161, 162, 182  
 " bone, 372  
 Intercostal artery, 174  
 " spaces, 173  
 Intercosto-humeral nerve, 177  
 Internal mammary artery, 175  
 Interparietal bone, 19

- Inter-scapulo-thoracic amputation, 202  
 Intersigmoid fossa, 343  
 Intervertebral discs, 537  
 Intestine, foreign bodies in, 338  
 " large, 340  
 " " operations on, 345.  
 " " stricture of, 340  
 " resection of, 348  
 " small, 328  
 " " diverticula of, 331  
 " " injury of, 329, 330  
 " " length of, 328  
 " " operations on, 335  
 " " position of, 329  
 Intestinal anastomoses, 348  
 Intussusception, 339  
 Inversion of the testicle, 409  
 Iridectomy, 52  
 Iris, 50  
 Iritis, 51  
 Ischio-rectal abscess, 384  
 " fossa, 382, 384  
 " hernia, 310  
 Isthmus of the thyroid, 153  
 " " division of, 153, 156  
 Jacob's ulcer of the eyelid, 63  
 Jaws (*see* Inferior and Superior maxilla)  
 Jejunum (*see* Intestine, small)  
 Joints, (*see* general classification of the, 210)  
 Jugular vein, 76, 132, 134, 138, 146  
 Keloid, its frequent seat, 170  
 Kidney, 360  
 " abnormalities of, 364  
 " abscess of, 362  
 " hilum of, 360  
 " horse-shoe, 364  
 " its relations, 360  
 " movable, 363  
 " nerve supply of, 364  
 " operations on, 366  
 " pelvis of, 368  
 " rupture of, 362  
 " vessels, point of origin of, 285  
 Knee, blood supply of the, 471  
 " bursæ about, 469, 473  
 " dislocations of the, 485  
 " fractures about, 485  
 " integuments of, 469  
 " joint, 474  
 " " amputation through, 489  
 " " disease of, 477  
 Knee joint, excision of the, 487  
 " " region of, 465  
 " " surface anatomy of the, 465  
 Knock-knee, 480  
 Kraske's operation, 418  
 Labia majora, 412  
 Labyrinth of ear, 81  
 Lachrymal abscess, 66  
 " apparatus, 65  
 " gland, 65  
 " sac, 66  
 Lacuna magna, urethral, 404  
 Lambda, 15  
 Lambdoid suture, 15  
 Lamina cribrosa, 50, 62  
 " fusca, 50  
 " suprachoroidea, 50  
 Laminectomy, 455  
 Laryngeal glands, 165  
 Laryngotomy, 151, 154  
 Larynx, 136, 148  
 " excision of, 150  
 " foreign bodies in, 154  
 " fracture of, 149  
 " lymphatics of, 151  
 " mucous membrane of, 149  
 Lateral lithotomy, 387  
 Leg, 489  
 " amputation of, 499  
 " fasciæ of, 491  
 " fractures of, 495  
 " rickets affecting bones of, 499  
 " skin of, 491  
 " surface anatomy of, 489  
 " vessels of, 492  
 Lens, 57  
 " artery to the, 60  
 Levator ani, 379, 384  
 " " relation to fistula in ano, 385  
 " palati, 128  
 " palpebræ, 63  
 Ligamentum patellæ, 465, 476, 483  
 " " pectinatum iridis, 59  
 Ligament, pterygo-maxillary, 119  
 Lighterman's bottom, 427  
 Linea alba, 283, 287  
 " semilunaris, 283  
 Lingual artery, 121  
 " tonsil, 123  
 Lipomata in deltoid region, 209  
 " in neck, 139  
 " in Scarpa's triangle, 433  
 " on the buttock, 425  
 " rare on face, 96  
 Lips, 117

- Lisfranc's amputation, 530  
 Litholapaxy, 387  
 Lithotomy, lateral, 387  
   "       "       in children, 389  
   "       "       parts divided  
   "       "       in, 388  
   "       median, 389  
   "       "       versus lateral,  
   "       "       389  
   "       suprapubic, 390  
 Littre's operation, 343  
 Liver, 348  
   "   abscesses of, 352  
   "   fixation of, 350  
   "   operations on, 352  
   "   in pyæmia, 352  
   "   protrusion of, 352  
   "   ptosis of, 350  
   "   relations of, 348  
   "   Riedel's lobe, 350  
   "   ruptures of, 351  
   "   wounds of, 351  
 Lockjaw, 115  
 Lordosis in hip disease, 441  
 Lower limb, length of, 464  
   "       lymphatics of, 436  
   "       nerve supply of, 533  
 Lukæmic enlargement of the  
   spleen, 353  
 Lumbar colectomy, 348  
   "   colotomy, 345  
   "   fascia, 315  
   "   glands, 370  
   "   hernia, 310  
   "   puncture, 548  
   "   region, 314  
   "   spine, 538  
   "       injuries to, 539, 546,  
   "       548, 553, 554  
 Lung 178  
   "   and secondary deposits, 180  
   "   cavities, drainage of, 181  
   "   hernia of, 148, 180  
   "   in neck, 148, 178  
   "   relations of to surface, 178  
   "   rupture of, 180  
   "   wounds of, 179, 180  
 Luschka's tonsil, 80, 131  
 Lymphangioma cavernosum, 124  
 Lymphatic glands and vessels (*see*  
   each region)  
 Macro-glossia, 193  
 Malar bone, 103  
   "       fracture of, 103  
 Malleoli, 500  
   "       fractures of, in disloca-  
   "       tions of the foot, 513  
 Mamma, 175  
   "   arteries of, 178  
   "   cancer of, 176  
   "   capsule of, 176  
   "   development of, 176  
   "   in groin, 433  
   "   lymphatics of, 176  
   "   nerves of, 177  
 Mammary abscess, 177  
 Manubrium, 171  
 Mastication, muscles of, 115  
 Mastoid antrum, 76  
   "   cells, 78  
   "       perforation of, 78  
 Maxillæ (*see* Inferior and Superior)  
 Meatus, the auditory, 68  
 Meatuses of nose, 87  
 Meckel's diverticulum, 290, 331  
   "       ganglion, 100  
 Median lithotomy, 389  
   "       nerve, 226, 247, 280, 429  
 Mediastina, 184  
   "       abscess of, 144, 184  
 Medio-tarsal joint, 501, 520  
   "       amputation at, 530  
 Meibomian glands, 63  
 Melanotic growths of choroid, 51  
 Membrana tympani, 74  
 Membranous urethra, 403  
 Meningeal artery, 9, 29  
   "       hæmorrhage, 29  
 Meninges of brain, 28  
   "       spinal cord, 546  
 Meningitis from abscess in the ear,  
   71, 75, 77, 86  
   "       (spinal) from bed-sores,  
   547  
 Meningocele, 17, 83, 86  
 Mesenteric arteries, 284, 370  
   "       hernia, 333  
   "       holes, 320  
 Mesentery, 318  
   "       length of, 319  
   "       prolapse of, 320  
 Meso-colic hernia, 334  
   "       -colon, 341  
 Metacarpo-phalangeal joint of  
   thumb, dislocations at, 273  
 Metatarsal bone of great toe, am-  
   putation of, 531  
   "       bones, fractures of the,  
   526  
 Metatarso-phalangeal articulations,  
   501  
   "       "       joint of great  
   "       toe, dislocation at, 526  
 Middle meningeal artery, 29  
 Miner's elbow, 236  
 Motor centres on the cortex, 37

- Motor paralysis in injuries to cord, 553
- Mouth, 118
- Mucous polyp of nose, 89
- Mumps, 105
- Muscæ volitantes, 60
- Musculo-spiral nerve, 227, 278
- Myxœdema, 157
- Nail, 260
- Nares, anterior, 84
- "    posterior, 84
- Nasal bones, 83
- "    "    fracture of, 83
- "    "    cavity, 84
- "    "    cavities, lymphatics of, 92
- "    "    blood-vessels of, 90
- "    "    nerve supply of, 91
- "    douche, 85
- "    duct, 67
- "    fossæ, 84
- "    mucous membrane, 88
- "    polypus, 89
- Neck, 135
- "    abscess of, 143, 144
- "    fasciæ of, 141
- "    fistulæ of, 166
- "    great vessels of, 137, 160
- "    hydrocele of, 167
- "    integuments of, 139
- "    lung in, 145, 177
- "    lymphatic glands of, 163, 164, 165
- "    middle line of, 136
- "    nerves of, 138
- "    ribs in, 145
- "    side of, 136
- "    surface anatomy of, 135
- "    wounds of, 146
- Nelaton's line, 424
- Nephrectomy, 366
- Nephro-lithotomy, 366
- Nephroraphy, 366
- Nephrotomy, 366
- Nerve stretching, 429
- "    supply of lower limb, 537
- "    "    upper limb, 275
- Nerves (*see* the various regions)
- "    division of (*see* the various trunks).
- "    of the spinal cord, their points of exit, 552
- Neuralgia, facial, 99
- "    of scalp, 12
- Nipple, 176
- "    in groin, 433
- Nipples, supernumerary, 178
- Nose, 81
- Nose, cartilaginous part of, 83
- Notch of Rivini, 74
- Obturator hernia, 309
- "    nerve, 370, 442, 533
- "    or thyroid dislocation, 449, 454
- Occipital bone at birth, 17
- "    "    necrosis of, causing wasting of tongue, 122
- "    "    glands, 163
- Œdema of the glottis, 149
- Œsophagostomy, 160
- Œsophagotomy, 160
- Œsophagus, 158
- "    cancer of, 160
- "    foreign bodies in, 159
- "    nerve supply of, 160
- "    operations on, 160
- "    relations of, 159
- Olecranon, 232
- "    fractures of, 244
- Omega loop of colon, 342
- Omental hernia, 318
- "    sac, 318
- Omentum, great, 317
- Ophthalmia, sympathetic, 57
- Optic disc, 58
- "    neuritis, 58
- "    thalamus, 37
- Ora serrata, 58
- Orbicularis-palpebrarum, 63
- Orbit, 41
- "    abscess of, 44
- "    arteries of, 45
- "    dimensions of, 41
- "    fasciæ of, 42
- "    fracture of, 41
- "    muscles of, 44
- "    nerves of, 45
- "    pulsating tumours of, 45
- "    relations of, 41
- Os calcis, dislocations of the, 518
- "    "    fractures of the, 524
- "    épaetal, 18
- "    incisivum in hare-lip, 126
- "    innominatum, 372, 375
- "    magnum, dislocation of, 273
- Ovary, 414
- Pacinian bodies in the foot, 504
- "    "    "    hand, 259
- Palate, 125
- "    cleft, 126
- "    hard, 127
- "    soft, 128
- Palmar (*see* Hand)

- Palmaris longus tendon, 523  
 Pancreas, 359  
 Pancreatic cysts, 359  
 Paracentesis of the pericardium,  
     184  
     "    thorax, 173  
     "    tympanum, 75  
     "    ventricles of  
         brain, 37  
 Paralysis in spinal injuries, 553  
     "    of anterior crural nerve,  
         533  
     "    cervical sympathetic,  
         47  
     "    external popliteal  
         nerve, 533  
     "    fourth nerve, 46  
     "    great sciatic nerve,  
         533  
     "    internal popliteal  
         nerve, 533  
     "    median nerve, 280  
     "    musculo-spiral nerve,  
         279  
     "    obturator nerve, 533  
     "    orbital nerves, 45  
     "    sixth nerve, 46  
     "    ulnar nerve, 280  
 Parietal bone, relationships of, 36  
     "    fissures, 19  
 Parieto-occipital fissure, 36  
 Parathyroid bodies, 157  
 Parotid abscess, 103  
     "    fascia, 103  
     "    gland, 107  
     "    nerve supply, 105  
     "    region, 103  
     "    structures, 106  
     "    tumour, 107  
 Patella, 413, 465, 473  
     "    dislocation of, 483  
     "    fractures of, 481  
 Patellar ligament, 465, 476, 483  
 Pelvic arch, 372  
     "    cellulitis, 313, 381  
     "    fascia, 379  
     "    symphysis, 375  
 Pelvis, 372  
     "    floor of, 379  
     "    fractures of, 373  
     "    mechanism of, 372  
     "    nerves of, 420  
     "    vessels of, 382  
 Penile urethra, 303  
 Penis, 405  
     "    malformations of, 406  
 Perforating ulcer, 504  
 Pericardium, tapping of, 184  
 Pericranium, 5  
 Perineal hernia, 310<sup>1</sup>  
 Perinephritic abscess, 362  
 Perineum, depth of, 384  
     "    fasciæ of, 385  
     "    male, 382  
     "    nerves of, 420  
     "    vessels of, 382  
 Peritoneum, 316  
     "    fossa of, 329  
 Perityphlitis, 338  
 Peroneal artery, 491  
     "    tubercle, 500  
 Peroneus tertius, 501  
 Petit's triangle, 284, 315  
 Petro-squamous suture, 77  
 Phantom tumour, 290  
 Pharynx, 129  
     "    foreign bodies in, 130  
     "    mucous membrane of, 131  
     "    relations of, 132  
 Photophobia, 55  
 Phrenic nerve, 139, 368  
 Pigeon breast, 168  
 Piles, 417  
 Pinna (*see* Ear), 68  
 Pirogoff's amputation, 529  
 Plantar (*see* Foot)  
 Plantaris tendon, rupture of, 492  
 Plaques des fumeurs, 121  
 Platysma myoides, 139  
 Pleura, 179  
     "    wounds of, 179, 180  
 Pneumatocele, 78  
 Pneumo-thorax, 179  
 Politzer's method of inflating the  
     middle ear, 79  
 Pollock's method of dividing the  
     muscles of the palate, 128  
 Polypus of nose, 89  
 Popliteal abscess, 470  
     "    bursæ, 473  
     "    fascia, 470  
     "    glands, 468, 473  
     "    nerves, 429, 468, 471, 533  
     "    space, 469  
     "    vessels, 471, 492  
 Post-nasal growths, 89  
 Pott's disease of spine, 545  
     "    "    operations in, 168, 545  
     "    fracture, 514  
 Profunda arteries in arm, 226  
     "    femoris, 432, 435  
 Prolapsus ani, 417  
 Pronation, movement of, 249  
 Pronator radii teres, 230  
 Prostate, 398, 415  
     "    abscess of, 398  
     "    hypertrophy of, 399  
 Prostatectomy, 490

- Prostatic plexus of veins, 400  
 Psoas abscess, 313  
   " muscle, 311, 434  
 Pterion, 35  
 Ptosis, 45  
 Pubic spine, 283  
 Pudendal hernia, 310, 412  
 Pulmonary apoplexy, 180  
   " artery, 182  
 Puncta lachrymalia, 67  
 Pylorus, 321, 326  
   " resection of the, 327  
  
 Radial artery, 246, 268  
   " nerve, strength of the, 429  
 Radius, dislocations of the, 239, 240  
   " fractures of the, 244, 250, 270  
 Ranula, 119  
 Rectocele, 413  
 Recto-vaginal fistula, 413  
 Rectum, 414  
   " attachments of the, 417  
   " effects of distension of, 416  
   " foreign bodies in, 416  
   " of infant, 414  
   " introduction of hand into, 416  
   " lymphatics of, 418  
   " mucous membrane of, 417  
   " nerves of, 419  
   " serous membrane of, 415  
   " vessels of, 417  
 Rectus abdominis muscle, 290  
 Referred pain, 296  
 Renal abscess, 363  
 Resections (*see* the various parts)  
 Respiration in fracture of the spine, 553  
 Retina, 58  
 Retro-peritoneal hernia, 334  
 Rhinolithes in the nose, 88  
 Rhinoplasty, 224  
 Rhinoscopy, 84  
 Ribs, 171  
   " cervical, 145  
   " excision of, 174  
   " fractures of, 172  
 Rickets, effect of, on pelvis, 373  
   " " the ribs, 173  
   " " skull, 16  
   " " tibia, 499  
 Rider's bone, 435  
   " sprains, 435  
 Riedel's lobe, 350  
 Rima glottidis, 136, 149  
 Rolando, fissure of, 35  
 Rosenmüller, fossa of, 80  
 Rouge's operation, 84  
  
 Sacro-coccygeal joint, 378  
 Sacro-iliac synchondrosis, 375  
 Sacrum, 372  
   " dislocation of the, 376  
 Sagittal fontanelle, 19  
 Salivary fistula, 108  
 Saphenous opening, 432  
   " veins, 436, 459, 467, 493  
 Sartorius muscle, 431  
 Scalene muscles, 137, 140  
 Scalp, abscess of, 6  
   " dangerous area of, 3  
   " fatty tissue in, 2  
   " hæmatoma of, 7  
   " its mobility, 3  
   " lymphatics of, 15, 165  
   " nerves of, 12, 14  
   " neuralgia of, 14  
   " sebaceous tumours of, 2  
   " sutures in wounds of, 3  
   " suppuration in the, 6  
   " temporal region of, 7  
   " vascularity of the, 4  
   " vessels of, 12  
   " wounds, 4  
 Scaphoid bone, dislocation of the, 526  
 Scapula, 186, 199  
   " excision of, 202  
   " fractures of, 200, 201  
 Scarpa's triangle, 430  
   " fascia of, 433  
   " glands of, 436  
   " vessels of, 432, 435  
 Sciatic artery, 425, 428  
   " dislocation, 449  
   " nerve, 'great, 425, 428, 444, 535  
 Sciatica, 428  
 Sclerotic, 50  
 Scoliosis, 538  
 Scrofula, sign of, in pinna, 69  
 Scrofulous pharyngitis, 131  
 Scrotum, 406  
   " and elephantiasis, 407  
   " œdema, 407  
   " application of leeches to the, 407  
   " subcutaneous tissue of the, 407  
 Semilunar cartilages of knee, dislocation of the, 479  
 Semimembranosus tendon, 466, 470  
 Sensori-motor areas of brain, 37  
 Septum of nose, 86  
 Shoulder, 185  
   " bursæ about, 209, 211  
   " dislocation of the, 214

- Shoulder, fractures about the, 219  
 „ joint, 210  
 „ „ amputation at the, 222  
 „ „ disease of the, 212  
 „ surface anatomy of, 186  
 „ tip pain from liver ailments, 369
- Sigaultean operation, 375
- Sigmoid flexure, 342, 369
- Sinus, cervical, 167  
 „ lateral, 12  
 „ superior longitudinal, 12  
 „ sphenoidal, 93
- Sinuses of skull, 12, 30  
 „ (air) of skull, 92
- Skull, 15  
 „ abnormalities of, 18  
 „ deformities of, 16, 18, 21  
 „ development of, 16  
 „ emissary veins of, 13  
 „ fractures of, 20  
 „ necrosis of, 5, 19  
 „ of infant, 16, 19, 20, 21, 22  
 „ soft parts covering, 1  
 „ sutures of, 15, 27  
 „ thickness of, 28  
 „ trephining the, 8  
 „ venous tumours of, 14
- Soft palate, 128
- Solar plexus, 368
- Soleus, 492
- Spermatic artery, 410  
 „ cord, 410  
 „ plexus of veins, 411
- Sphenoidal sinus, 94
- Sphincter ani, 384, 419
- Spina bifida, 377
- Spinal accessory nerve, 140  
 „ cord, 541, 545  
 „ „ concussion of, 549  
 „ „ contusion and crushing of, 550  
 „ „ loss of motion due to injury of the, 553  
 „ „ loss of sensation due to injury of the, 553  
 „ „ operations on, 555  
 „ „ wounds of, 548  
 „ injuries and defæcation, 554  
 „ „ micturition, 554  
 „ „ respiration, 553  
 „ „ vomiting, 555  
 „ meninges, 547  
 „ meningitis, 547, 548  
 „ nerves, distribution, 296  
 „ „ points of origin, 552
- Spine, 537  
 „ curves of, 537  
 „ fractures and dislocations of, 540  
 „ scoliosis of, 538  
 „ sprains of, 539  
 „ trephining the, 545, 555
- Spinous processes, fracture of, 544
- Splay foot, 522
- Spleen, 355  
 „ capsule of the, 357  
 „ dislocation of, 356  
 „ enlarged, 358  
 „ extirpation of the, 358  
 „ injuries to the, 357  
 „ relations of, 355  
 „ rupture of, 357
- Stenson's duct, 107
- Sterno-clavicular joint, 195  
 „ disease of, 196  
 „ dislocations of, 197  
 „ joint, movements of, 195  
 „ -mastoid muscle, 136, 140, 143, 144  
 „ -xiphoid joint, 169
- Sternum, 169  
 „ fractures of, 170  
 „ holes in, 171  
 „ separation of segments of, 171  
 „ trephining the, 171
- Stomach, 321  
 „ displacement of, 323  
 „ fistulæ of, 324  
 „ foreign bodies in, 324  
 „ hernia of, 323  
 „ lymphatics of, 326  
 „ operations on, 326, 328  
 „ ptosis of, 323  
 „ relations of, 321, 323  
 „ vertical, 323  
 „ wounds of the, 323
- Strabismus, 43, 45
- Subacromial bursa, 211
- Subarachnoid space, 30, 547
- Subastragaloid amputation, 531  
 „ dislocations of the foot, 519
- Subclavian artery, 138, 161  
 „ vein, 138, 190
- Subclavicular fossa, 187
- Subclavius muscle, 190
- Subdural space, 30, 547
- Sublingual bursa mucosa, 119  
 „ gland, 118  
 „ papilla, 118
- Submaxillary glands, 163
- Suboccipital nerve, 162

- Subserous connective tissue of the abdomen, 291  
 Sulci of brain, relations of, 33  
 Superficial cervical glands, 163  
 Superior maxilla, 108  
 " " cleft of, 126  
 " " excision of the, 109  
 " " fractures of, 108  
 " " necrosis of, 109  
 " thyroid artery, 137  
 " vena cava, 182  
 Supination, movement of, 249  
 Supinator longus, 232  
 Supraclavicular nerves, 190  
 Supracondyloid process, 226  
 Suprahyoid glands, 163  
 Supraorbital foramen, 99  
 Suprapubic lithotomy, 390  
 Sustentaculum tali, 500  
 " fracture of, 525  
 Sutures of skull, 15, 18, 27  
 " " closure of, 22  
 " " position of, 15  
 " " relations of, to  
 " " brain, 32  
 " " relations of, to  
 " " surface, 15  
 " " separation of, 27  
 Sycosis, 64  
 Sylvius, fissure of, 35  
 Symblepharon, 65  
 Syme's amputation, 528  
 Sympathetic ophthalmia, 57  
 Symphysis of pelvis, 375  
 Synostosis of skull, 22  
 Synovial cavities of the foot, 527  
 " " hand, 273  
 " sheaths in the hand, 264  
 Synovitis, acute, in the hip-joint, 439  
 " " in the knee, 477  
 Tabatière anatomique, 258  
 Tagliacozzi's operation, 224  
 Talipes calcaneus, 521  
 " cavus, 505  
 " equinus, 520  
 " and the plantar fascia, 505  
 " mixed forms of, 522  
 " valgus, 521  
 " varus, 521  
 Tarsal bones, fractures and dis-  
 locations of, 525;  
 " cartilage, 63  
 " cyst, 64  
 Tarsectomy, 522  
 Tarsus (*see* Foot)  
 Taxis, 309  
 Teeth, 116  
 " wisdom, 116  
 Temporal abscess, 8  
 " fascia, 7  
 " fossa, 7  
 Temporo-maxillary articulation,  
 112  
 " -maxillary articulation,  
 dislocations at, 112  
 Tendo Achillis, 486, 503, 511  
 " oculi, 66  
 Tenon's capsule, 42  
 Tenotomy and the peroneal nerve,  
 471  
 " of hamstrings, 471  
 " sterno-mastoid, 140  
 Tensor palati, 128  
 Testicle, 408, 421  
 " descent of, 302  
 " fungus of, 409  
 " in the foetus, 302  
 " inversion of, 409  
 " investments of, 408  
 " nerves of, 421  
 " tunic of, 409  
 Thecal abscess, 265  
 Thenar eminence, 255  
 Thigh, 458  
 " amputation of the, 464  
 " fasciæ of, 459  
 " fractures of, 461  
 " integuments of, 459  
 " muscles of, 460  
 " surface anatomy of, 458  
 Thoracic duct, 166, 184, 371  
 Thoracoplasty, 174  
 Thorax, 168  
 " deformities of, 169  
 " paracentesis of, 173  
 " viscera of, 178  
 " walls of, 168  
 " wounds of, 183  
 Thumb, amputation of the, 275  
 " dislocation of, 273  
 Thymus, 154  
 Thyroid body, 136, 137, 155  
 " accessory glands of,  
 124, 156  
 " development of, 156  
 " excision of, 157  
 " in tracheotomy, 153  
 " cartilage, 136, 149  
 " nerves of, 157  
 Thyroidea ima artery, 153, 158  
 Tibia and fibula, fractures of, 495  
 " fractures of, 487, 497  
 " in rickets, 499  
 " shaft of, its strength, 495;  
 Tibial vessels, 492, 508




- Tibialis anticus muscle, 490  
 Tongue, 120  
   " accessory glands about,  
     124, 156  
   " dermoid cyst of, 124  
   " blood supply of, 121  
   " epithelium of, 121  
   " excision of, 124  
   " lymphatics of, 123  
   " mucous cysts of, 121  
   " nerve supply of, 122  
 Tongue-tie, 121  
 Tonsil, 132  
   " bleeding from, 134  
   " foreign body in, 134  
   " hypertrophy of, 133  
   " " and deaf-  
     ness, 133  
   " lingual, 123  
   " Luschka's, 80, 131  
   " pharyngeal, 80, 131  
 Trachea, 136, 148, 152, 181  
   " foreign bodies in, 154, 182  
 Tracheotomy, 151, 152  
 Transverse cervical artery, 138  
   " colon, 340, 341  
   " process of the atlas, 135  
   " " cervical ver-  
     tebrae, 135  
 Trapezium, 258  
 Trendelenburg's operation, 376  
 Trephining, 8, 549  
   " for intracranial abscess,  
     10  
 Triangular ligament of the urethra,  
   379, 386  
 Trigone, 395  
 Trismus, 115  
 Tubera ischii, 372, 424  
 Tunica abdominalis, 286  
   " albuginea, 409  
   " vaginalis, 303, 408  
 Tympanum, 75  
 Ulna, dislocation of the, 238  
   " fracture of the, 250  
 Ulnar artery, 247  
   " nerve, 224, 235, 280, 429  
   " vein in venesection, 233  
 Umbilical fistula, 289  
   " hernia, 288, 310  
 Umbilicus, fibrous ring of, 288  
   " position of, 283  
   " vessels of, 293  
 Umbo of membrana tympani, 74  
 Urachus, 288  
 Ureter, 367  
   " and regurgitation of urine,  
     397  
 Ureter, distension of, 367  
   " resection of, 368  
   " rupture of, 367  
 Urethra, female, 405, 421  
   " male, 400, 421  
   " " curve of, 401  
   " " membranous, 401  
   " mucous membrane of, 401  
   " narrowest parts of, 403  
   " penile, 400  
   " prostatic, 400  
   " rupture of the, 404  
 Urethral triangle, 385, 386  
 Uterus, 413  
   " lymphatics of, 414  
 Vagina, 412  
 Vaginal cystocele, 413  
 Valsalva's method of inflating the  
   middle ear, 79  
 Varicocele, 411  
 Varicose veins, 411, 493  
 Vas deferens, 410  
 Veins (*see* various parts)  
   " air in, 163, 207  
   " emissary of skull, 13  
   " of diploe, 13  
 Venesection at the elbow, 234  
   " in the foot, 509  
   " on the arm, 234  
 Venous tumours of skull, 14  
 Vermiform appendix, 338  
 Vertebra, caries of, 316  
   " prominens, 135  
 Vertebral artery, 162  
   " column, 537  
 Vesico-vaginal fistula, 413  
 Vitello-intestinal duct, 289, 337  
 Vitreous humour, 59, 60  
 Volvulus of the sigmoid flexure,  
   343  
 Vulva, 412  
 Wardrop's operation, 161  
 Weaver's bottom, 427  
 Wharton's duct, 118  
 White line at anus, 419  
   " in the pelvic fascia, 380  
 Whitlow, 265  
 Wormian bones, 19  
 Wrist, 253  
   " joint, 255, 268  
   " " amputations at, 274  
   " " dislocations at, 272  
   " " fractures about, 270  
   " " movements at, 268  
   " surface anatomy of the, 255  
 Wry neck, 140  
 Zygoma, fracture of, 12

PRINTED BY  
CASSELL & COMPANY, LIMITED, LA BELLE SAUVAGE,  
LONDON, E.C.









QM531

T72

Treves

1901

