





Class SF911


Book W7

Copyright N<sup>o</sup> 1912

**COPYRIGHT DEPOSIT.**









# SURGICAL AND OBSTETRICAL OPERATIONS

BY

W. L. WILLIAMS

!!

Professor of Surgery and Obstetrics in the New York State  
Veterinary College, Cornell University

---

Embodying portions of the OPERATIONS-CURSUS of Dr. Pfeiffer,  
Professor of Veterinary Science in the  
University of Giessen

---

THIRD EDITION, REVISED AND ENLARGED

---

0  
2  
3  
2  
4  
3

1912  
CARPENTER & COMPANY  
ITHACA, N. Y.

SF 911  
W7  
1912

COPYRIGHT, 1912  
BY  
CARPENTER & CO.

Press of  
Andrus & Church  
Ithaca, N. Y.



\$ 2.50  
© Cl. A314825  
No. 1



## PREFACE TO THE THIRD EDITION.

The author caused to be published in 1900 a booklet entitled : " A Course in Surgical Operations by W. Pfeiffer and W. L. Williams," consisting of an authorized translation of Dr. Pfeiffer's Operating-Cursus with such changes, additions and omissions as were deemed desirable. Three years of constant use, with such criticisms as came to the author from others, served to point out desirable changes of so sweeping a character as to demand a practically new treatise specially adapted to American conditions, and to render the continuance of a formal joint authorship inexpedient and in 1903 the author published a more extended volume under the present title, followed by a large second edition in 1906. In this third edition the author has continued to draw freely upon Dr. Pfeiffer's Operations-Cursus in the preparation of the text which in many chapters is practically copied therefrom, including the illustrations with grateful acknowledgement of his profound obligations. On the other hand nothing has been copied or extracted except it could be freely adopted as the author's own view, releasing Dr. Pfeiffer from all responsibility for the character of any of the contents.

The volume is primarily designed for the use of the author's classes in laboratory surgery and embryotomy in which the student performs the surgical operations described, on animals procured for the express purpose, under chloroform anaesthesia whenever possible, after which the subject is destroyed while still anaesthetized ; at the same time it has been aimed to render the volume of the greatest possible value to the practitioner consistent with this plan. The operations included under this scheme are necessarily limited to those which can be reasonably well performed on comparatively sound animals of little value and regularly procurable for laboratory purposes. The list covers a wide

range and is designed to give to the student as thorough training as is practicable in a laboratory course and includes well nigh all the more important varieties of confinement, anaesthesia, disinfection, sutures, bandaging, dressing and other adjuncts to operative work. The chapter on trephining of the facial sinuses has been dealt with at much greater length in the present edition in order to fully and clearly describe the author's method of operating.

The operation for the surgical relief of roaring in horses has undergone a complete revolution since the publication of our second edition in 1906 and the technic therefor which we had begun to develop in 1905 and tentatively inserted in the second edition has undergone phenomenally rapid changes until now it would appear that the technic had acquired a certain degree of permanency, though still too new to expect it to remain unchanged. The introduction of the ventricular burr by Dr. J. H. Blattenberg and various suggestions in the details of technic by Prof. Hobday of England and others has materially aided in bringing the operation to its present state of reliability and caused the operation introduced by us in 1905 to become accepted throughout America and Europe to the exclusion of other methods. We have accordingly omitted the chapter on arytectomy from this edition, as an obsolete operation and have inserted an entirely new chapter upon the operation for roaring in which we have endeavored to bring the technic thoroughly up to date.

Generally but one method of operating is described, the one chosen being that which in the author's experience has proven the most valuable in actual practice, and no operation has been introduced purely for practice but each one has been tested and known to have practical value.

When two methods of operating are given, they are inserted because each has definite points of superiority over the other and one method may be specially applicable in a

given case, another in a different patient where the same operation is to be performed as for example, a milk cow is best spayed through the vagina while a heifer must be operated upon by an incision through the abdominal walls.

Considerable stress has been laid upon the surgical anatomy of the parts involved in each operation; some uses of the various operations are mentioned; some of the chief dangers of each are pointed out and in some cases references to literature upon the operation or the diseases for which the operation is designed, are cited.

Figures 1, 2, 6, 7, 9, 10, 11, 15, 16 and 17 and Plates Nos. XII, XIV, XVI, XXIII, XXIV, XXVII, XXVIII, XXIX, XXXI, XXXIV, XXXV, are from Dr. Pfeiffer's Operations-Cursus; and the remaining Plates and figures were either drawn under the direction of the author by Mr. C. W. Furlong, formerly instructor in Industrial Drawing and Art in Sibley College, Cornell University, or were made from original photographs.

W. L. WILLIAMS.

*Cornell University, March, 1912.*

# CONTENTS.

## I.

### I. OPERATIONS ON THE HEAD :

	Page.
Extraction of Teeth.....	1
Repulsion of Teeth.....	8
Trephining the Facial Sinuses.....	16
Trephining of the Frontal Sinuses.....	19
Trephining the Superior Maxillary Sinuses.....	32
Trephining the Inferior Maxillary Sinuses.....	41
Trephining the Nasal Fossae.....	45
Poll Evil Operation.....	53
Ligation of the Parotid Duct.....	61
Entropium Operation.....	62
Staphylotomy.....	63
Trifacial Neurotomy.....	64

### II. OPERATIONS ON THE NECK :

Opening the Guttural Pouches.....	70
Tracheotomy.....	76
The Operation for Roaring.....	78
Intra-tracheal Irrigation.....	87
Intravenous Injection.....	88
<i>a.</i> Phlebotomy with Fleams.....	91
<i>b.</i> Phlebotomy with Lancet.....	92
<i>c.</i> Phlebotomy with Trocar.....	93
Ligation of the Carotid Artery.....	93
Œsophagotomy.....	98

### III OPERATIONS ON THE TRUNK AND ON THE GENITAL ORGANS :

Puncture of the Chest.....	100
Puncture of the Intestine.....	101
Subcutaneous Caudal Myotomy.....	103
Caudal Myectomy for Gripping of the Reins.....	105
Amputation of the Tail.....	109
Urethrotomy.....	114
Amputation of the Penis.....	117
Vaginal Ovariectomy in the Mare.....	123
Vaginal Ovariectomy in the Cow.....	130
Ovariectomy in the Cow by the Flank.....	133

Ovariectomy in the Bitch by the Flank.....	134
Ovariectomy in the Bitch by the Linea Alba.....	141
Ovariectomy in the Cat.....	142
Castration of Cryptorchid Horses.....	143

## IV. OPERATIONS ON THE EXTREMITIES :

Tenotomy of the Flexor Tendons of the Foot.....	154
Tenotomy of the Peroneal Tendon (Stringhalt Operation).....	157
Tenotomy of the Cunean Tendon (Spavin Operation).....	159
Neurotomy.....	161
Digital Neurotomy.....	167
Plantar Neurotomy.....	169
Median Neurotomy.....	174
Ulnar Neurotomy.....	179
Sciatic Neurotomy.....	185
Anterior Tibial Neurotomy.....	191
Resection of the Lateral Cartilages.....	196
Resection of the Flexor Pedis Tendon.....	202
Amputation of the Claws of Ruminants.....	204
Bayer's Sutures.....	209

## II.

## EMBRYOTOMY OPERATIONS :

Cephalotomy.....	212
Decapitation.....	214
Subcutaneous Amputation of Anterior Limb.....	215
Amputation at the Humero-radial Articulation.....	218
Detruncation.....	218
Destruction of the Pelvic Girdle, Anterior Presentation.....	222
Amputation of the Limbs at the Tarsus.....	226
Intra-pelvic Amputation of the Posterior Limbs, Breech Presentation.....	230
Evisceration of the Fetus.....	239



## INTRODUCTION.

Many details must be omitted in the succeeding text which are of importance in each operation, but which, if inserted, would render the volume unwieldy in size for the purpose designed.

These details are in a measure alike in each case, and it is assumed that the student has already familiarized himself with them. The more important of these may be summarized as follows :

1. The subject should be securely confined in each case as directed, because the method designated has been found effective in the operation under description, and serves to fix the relations of the parts in such a way as to conform to the surgical anatomy of the region as outlined in the text. It is to be constantly borne in mind that a change in the attitude of the animal may cause profound alterations in the relations of parts which displacement may greatly embarrass the operator, or even prevent his carrying out the operation according to the technic given. In securing an animal for operation the whole body should be confined in a way that will sufficiently control movements and will insure safety to the patient and operator ; the part to be operated upon must be so fixed as to properly limit its motion and in a position to afford the greatest facility for the carrying out of the operation according to the technic given.

2. Anaesthesia should be carefully carried out everywhere possible, because in addition to the humane sentiments involved, the resulting perfect control of the animal is an essential in aseptic or antiseptic surgery. The student should make a careful study of anaesthesia in these exercises and acquire invaluable experience and confidence for their use in actual practice.

3. Disinfection must be scrupulously applied in every detail since upon its effectiveness must rest the verdict of success or failure as measured by modern surgical thought. The operator's finger nails should be well trimmed, smoothed and cleansed, and his hands and arms thoroughly scrubbed with a stiff brush in hot water and soap for a period of fifteen minutes, and all dirt and old epidermal scales removed. The parts should then be disinfected. This may be accomplished by immersing the hands in a hot concentrated solution of permanganate of potassium for ten minutes and then decolorizing them in a strong solution of oxalic acid in boiled water.

Or the hands may be disinfected after the washing with soap and water by immersing and scrubbing them for ten minutes in a 1 to 1000 solution of corrosive sublimate, but in order to make this thoroughly effective the solution needs be alcoholic, or the hands should first be immersed in alcohol, ether, or other substance capable of dissolving fats and permitting the disinfectant to penetrate to every part without being obstructed by sebum or fat. Great care should be exercised by the student not to touch any object with his hands after they have been disinfected for the operation, unless such object has also been disinfected or sterilized, or in case it becomes necessary to touch objects not sterile, the disinfecting process should be repeated before proceeding further with the operation. This constitutes one of the most difficult of all details for the beginner to acquire, and each failure should be remedied by repeating the process over and over until the habit of maintaining effectual asepsis is acquired and fixed.

The operative field should always be carefully shaved before beginning the operation, and the shaved area should always be ample, so as to insure against contamination from adjacent hairs, as well as to give a clear view of the field. The area should then be disinfected in a reliable



manner, that advised for the operator's hands serving as a type. Whenever circumstances will permit the operative field should be kept in an antiseptic bath or pack for twenty-four hours prior to the operation in order that the deeper parts of the skin, especially the hair follicles and sebaceous glands, shall become thoroughly disinfected, a process well nigh impossible in a short period.

The suturing, dressing and bandaging of the wound should be carried out carefully in every case and no operation left without completing it in the best manner possible.

The student should make each operation as real as possible and not omit any detail even if he thinks he already knows it sufficiently well, as the repetition of a supposedly familiar detail serves an important purpose in the fixing of a habit which is inestimably more valuable to the surgeon than any theoretical knowledge of technic.

The safe surgeon is he who has so accustomed himself to the technique of asepsis and antisepsis that he carries it out rigidly in an automatic manner and is thus free to concentrate his entire attention on the surgical problems before him.

The student who consults his interests will go yet farther and prior to undertaking any operation on the living subject will study the regional anatomy of the part on the cadaver and learn therefrom all that he can of the structure of the part which he must finally complete upon the living animal. No dissection of the cadaver can ever teach true surgical structure as the dead tissues can not be like the living, but such dissection can and does give great aid and should be pursued as far as it can lead and enough will still remain to be learned on the living subject. It is to be constantly remembered that *anatomy* deals with the structure of the *dead* body while surgical operations are performed upon the *living* structures: they are not alike.

The student should further take occasion to study in connection with each operation the object or objects for which it is performed in practice, its effect on the diseased or other parts, the untoward results to be anticipated, etc.

Suggestions occur from time to time in the text designed to aid the student in these lines and help weave connecting bonds between the operation, its objects and results.

Surgical operations may in themselves be valueless or worse and acquire value only when properly correlated to disease and skillfully performed.

# Surgical and Obstetrical Operations.

## I. SURGICAL OPERATIONS.

### I. OPERATIONS ON THE HEAD.

#### TOOTH OPERATIONS.

**Prefatory remarks.** The grinding teeth of the horse consisting of three premolars and three molars in each row are of such dimensions and attachments that their removal in case of disease or defect often presents difficulties of no small degree.

These teeth attain their greatest size at the time of eruption and most of each tooth remains firmly imbedded in its alveolus while a very shallow crown projects into the buccal cavity. The teeth are gradually pushed out of their alveoli as their crowns are worn away by attrition as age advances and the proportion of the intra- to the extra-alveolar part gradually decreases until in very old animals the alveoli become obliterated and the last vestige of what was once the apex of the fang rests insecurely in the buccal mucosa.

The facility with which teeth may be extracted increases as the age of the animal, being as a rule easily drawn with forceps in old, while in case of freshly erupted teeth in young horses it may be almost or quite impossible to extract them with forceps of any kind, except in those cases where they have become somewhat loosened as the result of disease or accident. When aberrations in development occur, leading to the formation of dental tumors or odontomes the possibility of extraction by means of forceps is frequently wholly excluded. In cases where dental disorder has led to empyema of the facial sinuses, even if the tooth may be drawn by means of forceps, further operation is generally

necessary, in order to assure a prompt recovery, by the removal of the effects of the disease of the tooth.

The removal of molars may therefore involve extraction with forceps, trephining the dental alveolus and repulsion of the tooth and trephining of the sinuses because of empyema or other pathologic conditions referable to the dental affection; consequently all of these should be studied as related topics.

## 1. EXTRACTION OF TEETH.

### *Plates I and II.*

**Instruments.** Extracting forceps, fulcra of various sizes, mouth speculum with abundant lateral working room, exporteur forceps, toothpick, splinter forceps, reflecting lamp.

**Technic.** In simple cases with a quiet animal the patient may be sufficiently confined by being backed into a corner or very much better by securing in stocks. In complicated cases or very resistant animals it is best to place the patient upon the operating table or in default of this, cast and secure in lateral recumbence on the sound side.

Apply the speculum and identify the diseased tooth by manual exploration; determine if the tooth is of unnatural size or form, if it is loose, if the gums are separated from the neck at any point, if it is out of line with the other teeth in the row, if it is painful to the touch, if it be split, etc. An external tooth fistula or a tumefaction over the affected member may aid in distinguishing it. Aid may also be had by illuminating the mouth with a reflecting electric or other lamp.

Remove any accumulations of partially masticated food by means of the toothpick or fingers.

In applying the forceps, have an assistant draw the tongue out at the commissure of the lips on the side oppo-

site to the affected member and introducing one hand into the mouth, place the index finger on the posterior border of the diseased tooth and with the other hand, push the opened forceps backward upon the dental row until they reach the diseased member, then firmly grasp it with the instrument, pressing the jaws down as deeply as possible against the alveolus.

In many cases the diseased tooth can be clearly seen, especially with the aid of the reflecting lamp, and the forceps may be readily applied by sight, which is frequently preferable to the sense of touch.

Withdraw the free hand from the mouth, grasp the forceps handles firmly and loosen the tooth in its alveolus by establishing and maintaining as long as necessary a gentle to and fro lateral movement. The tooth is thus loosened in its alveolus by causing it to revolve very slightly back and forth on its long axis, thereby spreading the alveolar cavity. When the tooth has become well loosened, the fact is indicated by its revolving with the forceps and by an audible crepitant sound caused by the passage of air bubbles to and fro through the blood and lymph in the alveolus. Maintain the forceps in position with one hand and with the other introduce the fulcrum to a point where the depression on its superior surface will receive the projecting rivet-head of the instrument or in an otherwise secure position affording a safe support, while the inferior surface rests evenly upon the crown of a tooth anterior to that which it is desired to extract, as is shown in Plate I. The fulcrum needs be held firmly in place in order to prevent it from gliding away under pressure.

In extracting the first premolars there is no opportunity for resting the fulcrum on teeth anterior thereto and consequently forceps have been made with fulcra beyond the forceps jaws resting upon teeth more posteriorly situated. This is not essential. If the tooth is thoroughly loosened,

*Plate I.*

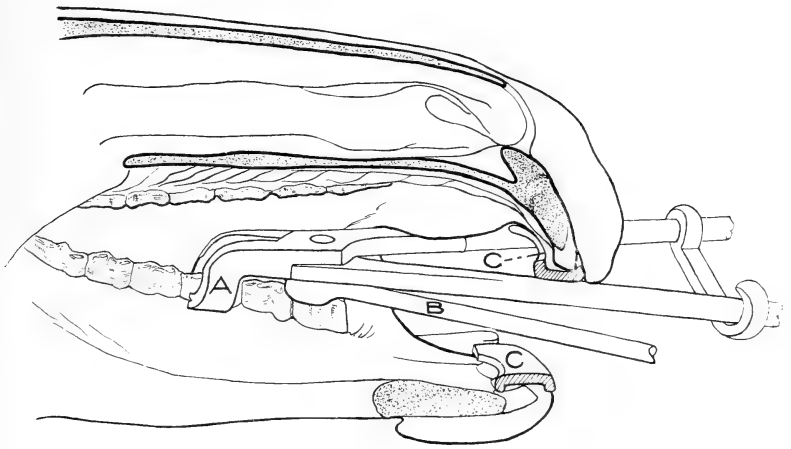
*Extraction of Teeth.*

Sagittal section through the oral cavity, showing plan for extracting the third inferior premolar, viewed from within the mouth.

A Forceps jaws applied to third premolar.

B Fulcrum resting upon first premolar.

CC, Plates of mouth speculum resting upon incisor teeth.







as it should be, one hand placed in the interdental space with the dorsal surface against the jaw and the volar grasping the instrument, will serve as an effective fulcrum.

In other cases an iron or steel fulcrum is not essential, but a stick of hard wood of proper size and form acts quite as efficiently and may even keep its position better because the teeth upon which it rests sink into it somewhat. On the whole the fulcrum is not so important as some have considered it, since, after a tooth is loose enough to be drawn with its aid, a very trifling additional loosening will permit it to be easily lifted from its alveolus without it.

The tooth fang is extracted by forcing the handles of the forceps toward the jaw in which it is located, so that as it is gradually drawn out the forceps tend to pivot on the fulcrum in a way to permit the tooth to emerge from its alveolus in the direction of its long axis. By referring to Plate II it will be seen that the long axes of the different teeth vary, that of the molars being obliquely forwards from fang to crown towards the incisors, while the crowns of the premolars are directed obliquely backwards toward the molars. The slant of the teeth is most marked at the ends of each arcade while at the middle they acquire an almost perpendicular position.

In drawing the last molar the back of the forceps will generally strike against the opposite dental arcade before the tooth has completely emerged from its alveolus and in order to complete its removal it may be necessary to take a deeper hold with the extracting forceps or withdrawing these complete the operation with the aid of exporteur forceps, or still better frequently with the hand. In young horses where the teeth are very long we have found it impossible to complete the extraction until the tooth had been divided transversely by means of the tooth cutting forceps.

**The dangers** in the extraction of teeth are chiefly :

1. The transverse fracture of the tooth, leaving the fang still fixed in the alveolus, a danger not infrequently un-

avoidable when the crown has become greatly weakened by disease so that it lacks the necessary power of resistance ; under most other conditions transverse fracture may be largely guarded against by the careful securing of the patient in a manner to effectively prevent sudden throwing of the head while the forceps are applied, and by using good judgment in the amount of force exerted while loosening the tooth in its alveolus. As stated above we should not expect to be able to extract with forceps the teeth of very young horses which have not become partly detached by disease or in which the fangs are the seat of odontomes.

2. Fracture of the alveolar walls is an accident which may generally be prevented by proper care in the application of force and the avoidance of any attempt to extract a tooth when the existence of an enlargement of the fang is apparent or suspected.

3. The tooth may slip from the forceps into the pharynx and be swallowed, an accident avoidable by inserting the hand into the mouth as the tooth begins to emerge from its alveolus, and if need be, grasp it with the fingers.

## 2. REPULSION OF TEETH.

### *Plate II.*

**Uses.** The removal of molars, pre-molars, tooth fangs from which the crowns have been broken away, alveolar odontomes, etc., which can not be removed safely by means of the forceps.

**Instruments.** Mouth speculum, razor, convex scalpels, trephine, bone gouge, Luer's sharp bone forceps, (rongeur forceps) light and heavy bone chisels, mallet, tooth punch, curette, compression artery forceps, scissors, needles, thread, absorbent cotton, antiseptic gauze, extracting forceps, splinter forceps, tenacula, metal probe.

**Technic.** Secure the animal in the lateral recumbent position with the affected side up. The operating table affords by far the best means for securing for the convenience and safety of operator and patient. If the sinuses are so involved as to make possible the inhalation of pus, blood or other injurious matter, perform tracheotomy in ample time to avert danger. Anæsthetize locally or generally as required. Shave and disinfect the operative area and trephine according to the method described in the following chapter, down through the alveolar plate immediately over the fang of the affected tooth. Avoid dulling the trephine by striking it against the tooth fang.

If an external fistula exists the identity of the affected tooth is best determined by passing a metallic probe through it against the diseased fang while one hand is passed into the mouth and the location of the probe more fully ascertained. Care should be exercised in trephining to not injure the adjoining teeth.

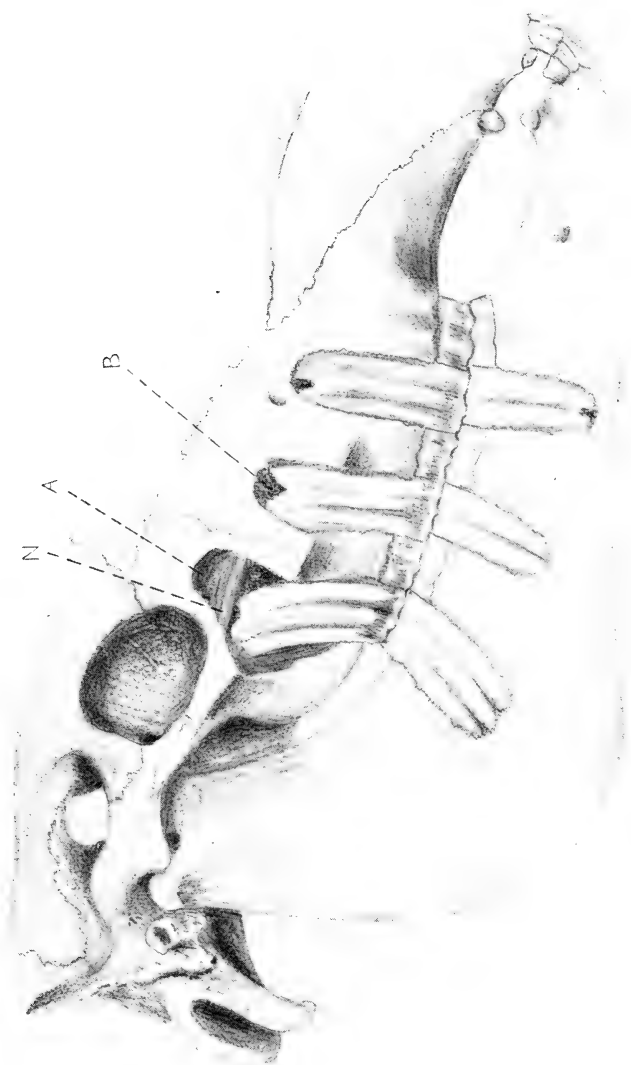
After removing the disc of bone isolated by the trephine, control all hemorrhage and then enlarge the opening and remove the bony tissues till the tooth fang is bared its entire width. Insert a scalpel or bone chisel between the external face of the bone and the soft tissues at the oral margin of the trephine opening and with one hand in the oral cavity with the fingers resting upon the alveolar border on the lateral side of the tooth to serve as a guide, push the scalpel or chisel along between the bone and soft tissues until it emerges from the gums alongside the affected tooth and extend this separation backwards and forwards until the soft tissues are completely detached from the alveolar wall over the entire area of the diseased member.

When operating upon the superior molars, the fangs of which are covered by the zygomatic ridge, the chisel or scapel cannot be pushed directly from the trephine opening into the mouth between the soft tissues and the bone because the line is concave instead of direct. In these cases it is

*Plate II.*

*Repulsion of Molars.*

Head of four year old horse, with the second premolars and first and third molars laid bare to illustrate plan for repulsion ; A, superior maxillary sinus ; B, inferior maxillary sinus ; N, conduit of superior maxillary division of trifacial nerve.





best to detach the soft parts from the zygoma only at first and then remove the alveolar plate of the ridge with the bone forceps or chisel, after which the line into the mouth is direct and the instrument can then be readily pushed between the soft and osseous tissues for the remainder of the distance and the separation completed.

In operating upon the inferior molars covered by the masseter an opening through the muscle may be made near its lower border large enough to admit the trephine or the muscle may be detached at its point of insertion to the inferior maxillary bone and two parallel incisions carried upwards a short distance, permitting the raising of a flap, or what is generally best for the second and third molars, a curved incision is made at the antero-inferior border of the masseter muscle parallel to the parotid duct and satellite vessels and just posterior to them and the muscle lifted up and drawn backwards sufficiently to expose the bone immediately over the tooth fang.

With a light, narrow bone chisel cut away and remove the external alveolar plate over the entire extent of the tooth, from the oral margin of the trephine opening into the mouth cavity. Hold the chisel so that the outer edge is inclined from the affected tooth toward the adjoining one, thus making a bevelled channel through the alveolar plate tending to loosen the isolated section of bone by driving it outwards. Drive the chisel for a short distance on one side, then upon the other, and thus break the alveolar plate away in small sections and avoid an extension of the fracture to neighboring alveoli and damage to adjacent teeth. Care should be taken that the bone chisel is sharp otherwise extensive fractures of the bone may occur. With gouge and chisel remove all remnants of bone over the lateral side of the tooth laying it completely bare as shown in Plate II.

The soft tissues of the part should not be disturbed beyond the excision of the circular piece, corresponding to

the disk of bone removed by the trephine and the detaching of them from the portion of bone to be chiseled away.

When the tooth has been bared so that every part of its lateral surface can be seen or felt, the punch may be placed against the end of the fang, a few firm, quick blows given with the mallet, so directed that the force is in a line with the long axis of the tooth, and the organ driven into the mouth where it is seized by the forceps or the hand and removed. If it is not readily and safely dislodged in this way, place the heavy bone chisel against it and with the aid of the mallet comminute the tooth by breaking it transversely and splitting it longitudinally, in which process the fragments are generally loosened from the alveolar walls and can then be readily removed with the aid of the gouge, or heavy dressing or splinter forceps. Remove carefully all fragments of tooth or of loosened bone, cleanse and disinfect the wound, pack with iodoform gauze and dress daily.

In cases where a fistulous opening remains after repulsion of molars without the removal of the alveolar wall, or if a tooth has been drawn by means of the forceps and the alveolus fails to heal, the bony plate should be removed in the above manner.

**Dangers.** Wounding of the adjoining tooth is to be avoided chiefly by carefully locating the fang of the affected one and placing the instrument as exactly as possible over its centre, by using a trephine not exceeding 2 to 2.5 cm. in diameter and cautiously sawing through the compact layer of the external plate only, removing the cancellated tissue with the gouge and extending the opening in the desired direction after the outlines of the tooth fang have been clearly determined. If an adjoining fang is wounded, the tooth should be removed as it will not heal but will result in a permanent tooth fistula.

Fracture of the alveolar walls of the inferior maxilla may occur during the removal of the external alveolar plate with the chisel or of the repulsion of the tooth with the



punch. The first is to be averted by care in having the chisel sharp, by observing the precaution of making a bevelled cut through the bone, by using only moderate blows and driving the instrument alternately for a short distance on each side. The second danger of extensive fracture may be averted by being cautious to see after each stroke on the punch that it has not slipped inward along the median side of the tooth, pressing the internal plate away from the tooth and tending to produce a longitudinal fracture nearly or quite as long as the dental arcade. Careful digital exploration in the mouth may discover this fracture while still "simple" but a stroke or two more will convert it into the very much more serious "compound" fracture opening into the oral cavity. Keeping one hand constantly in the mouth at the point of impact is always desirable as a precautionary measure.

Transverse fracture of the tooth while yet in situ by means of the bone chisel, as above described, is a great safeguard against this injury by lessening the force required in repulsion and by the removal of the tapering fang, which then leaves a more secure base for the punch to act upon. It should never be forgotten that the impact from the punch must always be as nearly parallel to the long axis of the tooth as is possible.

The fracture of the superior maxilla and bony palate is not so probable as the preceding and is preventable by moderate care in the denuding of the tooth before punching, by comminution of the tooth in proper cases, by the careful adjustment of the punch and applying the force in the proper direction.

**Literature.** Odontomes, Sir Bland Sutton, Jour. Comp. Med. and Vet. Arch, Vol. XII. p. 1; A Clinical Study of Odontomes, W. L. Williams, Am. Vet. Review, Vol. XV, p. 1; Notes on Odontomes, do; Am. Vet. Rev. Vol. XXIII, p. 82 and Oest. Mon. Thierheilkunde, Bd. XXIV, s. 122.

## TREPHING OF THE FACIAL SINUSES.

*Plates III-XI.*

**Prefatory Note.** The facial sinuses of the horse constitute an exceedingly intricate and extensive group of cavities, communicating more or less freely with each other or with the exterior through the medium of the upper air passages, of which they are to be regarded as a part.

Their arrangement and relations permit them to frequently become the seat of, or central figure in many forms of disease which require for their differential diagnosis, amelioration or cure, the operation known as trephining. Their extent and relations to each other and to surrounding parts varies greatly with age and may be profoundly changed as a result of disease, amounting not infrequently in the frontal, superior and inferior maxillary sinuses ceasing to exist as separate cavities and becoming merged into one vast diverticulum. The general position, extent and relations of these are indicated by Plates III-XI.

It is to be noted that in cross sections the superior and inferior maxillary sinuses appear to be reversed in relation to their nomenclature. It is difficult to make a cross section of these sinuses in such a manner that the antero-inferior extremity of the superior sinus does not show below and external to the inferior one. The inferior maxillary sinus is *inferior* in the sense that it is nearer to the nasal opening so that with the head in a vertical position or in a longitudinal section the inferior sinus is below the superior, while if the head be placed horizontally or a cross section made, a small portion of the superior sinus may show below the inferior.

The uses of trephining are in a measure common to all the sinuses and are chiefly for the relief of empyema of the cavities involved, necrosis of the bony or cartilaginous walls, tumors of various kinds, especially dental in the young and

malignant growths in the old, foreign bodies in the sinuses, differential diagnosis of diseases of this region, etc.

Veterinarians trephine the sinuses by two fundamentally different plans ; with, and without excision of the cutaneous disk corresponding to the piece of the bone removed. The first is generally used in Great Britain and North America, while the last is the prevailing method in continental Europe and other parts of the world. The reason assigned for these variations in method are conflicting. To us there seem to be adequate reasons for preferring the excision of the cutaneous disk. We regard as the chief considerations in an operation the following : the avoidance of infection ; the prevention of pain during the operation or the after-treatment ; the reduction of the scar to a minimum ; rapidity and certainty of recovery ; convenience in operating and dressing. Inevitably a septic operation, the degree of infection is largely dependent upon the area of the wound, the facility for maintaining cleanliness and the degree of disturbance to the tissues while being dressed. The wound area in the bone is alike in all cases but that in the skin varies greatly. If we compare the usual European technic with that given below we would find the wound area approximately 2.2 sq. in. in the European method, while in the latter we have only about .44 sq. in. or proportionately the wound area in the soft tissues in the two operations would be as 5 : 1.

It is very evident that the technic given below affords immeasurably better facility for maintaining cleanliness in the wound and with a minimum amount of insult to the tissues in the process of dressing.

The amount of pain caused in the operation which should be eliminated by local anaesthesia depends chiefly upon the extent of the skin incision which is essentially equal in the two plans so that the only difference would be in the

dissection of the skin from the bone in the European operation. The pain caused in dressing must be greater in the European method because the detached, overhanging skin must be moved and disturbed each time causing pain and inviting infection. The question of pain in dressing must always be seriously considered as it not only affects the time required for dressing and its efficacy, but has an important relation to the docility of the animal after recovery, some horses having their dispositions permanently ruined by the irritation due to the oft repeated painful dressing of wounds.

The cicatricial contraction of the tissues of the horse is so great that the removal of a circular disk of skin  $\frac{7}{8}$  to  $1\frac{1}{2}$  in. in diameter on the face does not leave a visible scar so that the question of blemish falls back upon that of infection, which, as we have asserted above is far more probable by the continental European method.

The rapidity and certainty of recovery are dependent upon the considerations above discussed. The removal of the cutaneous disk is certainly easier and quicker than the other method. The convenience for dressing is evidently superior by the English and American method.

The opening of the sinuses into the nostrils is based upon the surgical principle that suppurating cavities should be provided with ample drainage from the most dependent part. The direction to leave the external wound open, at first thought seems antagonistic to general surgical principles but it should be remembered that the wound consists only of the incision through the skin, connective tissue and bone penetrating a suppurating cavity, and that any object which we can place in this opening can only serve to dam back the secretions of the cavity and can not prevent them from coming in contact with the wounded surface. It must further be regarded that the respiratory mucosa of the upper air passages are not irritated or injured in any

manner so far as we can observe clinically by the direct admission of air into them through a trephine, or other artificial opening, but on the contrary the suppuration in a sinus is constantly aggravated by the retention of the pus and exclusion of air and recovery facilitated by thorough drainage and aeration.

---

### 3. TREPHINING OF THE FRONTAL SINUSES.

#### *Plates III-XI.*

**Uses.** Fracture of the bony walls, necrosis, tumors.

The ample communication below with the superior maxillary sinus (See FE, Plates V and VI) prevents the accumulation of pus or fluids in the frontal sinuses even if formed therein unless the former becomes filled and the contents back up into the latter. In empyema of the frontal sinuses, trephining can not give relief, but calls for a repetition of the operation on the maxillary sinuses.

**Instruments.** Razor, scissors, convex scalpels, artery forceps, tenacula, probe, trephine, curette, gouge, Luer's sharp bone forceps (rongeur forceps), hammer, chisel, probe-pointed bistoury, dressing forceps, disinfecting and dressing materials.

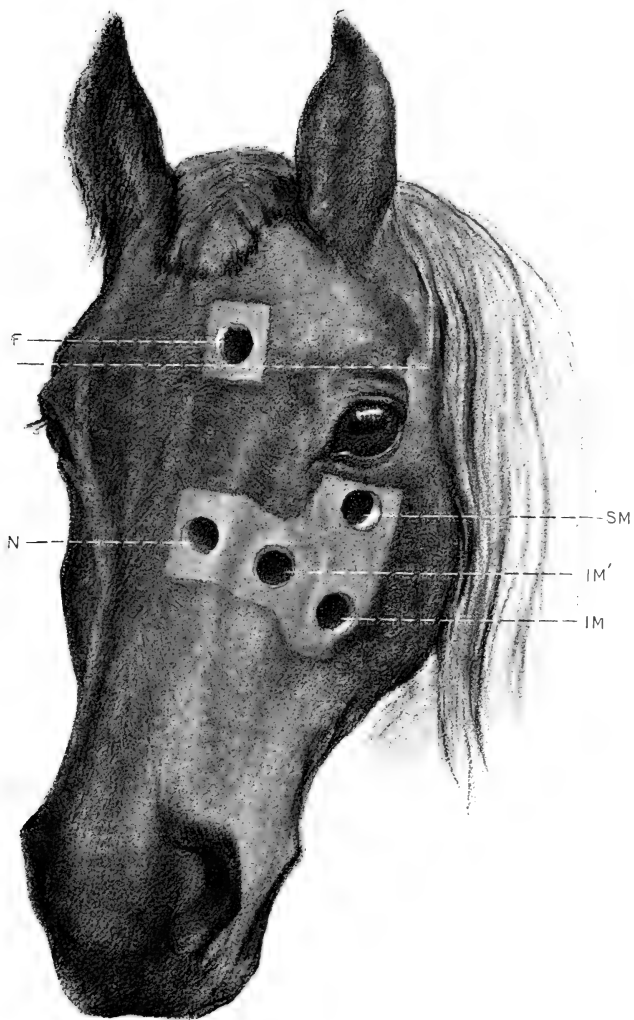
**Technic.** The operation may be performed upon the standing animal with the aid of local anaesthesia of the skin, the bone having virtually no sensation. Restless animals may be further secured with the twitch, in the stocks, upon the operating table or by casting on the sound side.

Clip and shave the hair from the region of the frontal bone at that point which the operator has reason to believe is nearest the center of disease. The highest point at which the sinus may be trephined is indicated by F in Plate III. The most central portion of the cavity is reached by trephin-

***Plate III.***

***Trephining the Facial Sinuses.***

F, highest point at which an opening may be made into the frontal sinus without wounding the cranium and brain; N, opening into nasal sinus; SM, opening into superior maxillary sinus; IM, opening into external portion of inferior maxillary sinus; IM', opening into the median portion of the inferior maxillary sinus.







ing on a level with the inferior border of the orbital cavity on the lines FE, Plates V and VI. Trephining at this point gives the operator access to the superior maxillary sinus, SM, Plates IV-VI, through the fenestrum, FE, Plates V and VI. The lowest and generally most essential point for trephining is at ST, Plates IV and V, where the opening affords free drainage externally from the most dependent part of the cavity and at the same time offers ample opportunity for securing dependent nasal drainage by breaking through the superior turbinated bone at ST, Plates IV, V and XI.

By consulting Plates VII-IX, it will be seen that after reaching the level of the nasal septum, a trephine opening immediately against the median line like that at F, Plate III would wound the septum and superior turbinated bone and penetrate the nasal cavity. Consequently the operator must avoid making the trephine opening in this region near the median line, but must keep  $1\frac{1}{2}$  to 2 inches laterally therefrom.

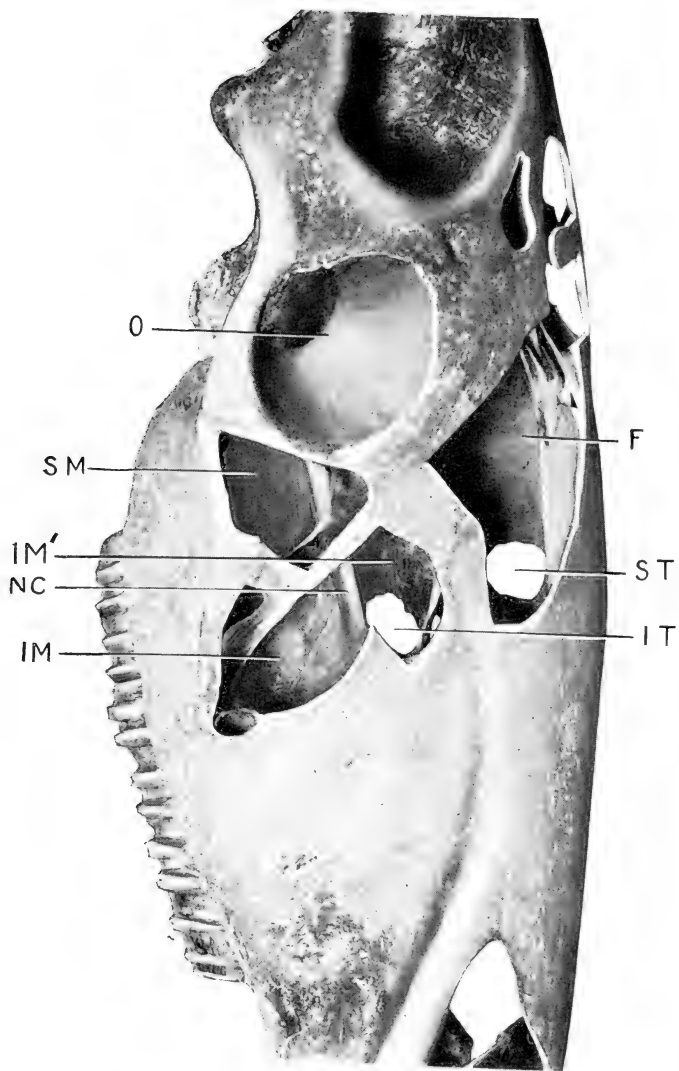
With a heavy convex scalpel make a circular incision at the desired point as large as the area of the trephine, directly through the skin, subcutem and periosteum down to the bone and remove in one piece the entire mass of encircled soft tissues by seizing the skin with a tenaculum and forcibly separating the periosteum from the bone with the scalpel or bone chisel. Control the hemorrhage.

With the center-bit of the trephine extended place it accurately upon the denuded area perpendicular to the surface of the bone and grasping the handle firmly turn it to and fro until the bit has penetrated the bony plate and the saw has cut a distinct groove to serve as a guide when the center-bit should be retracted and the operation continued until the disc of bone is detached, being careful to maintain the trephine perpendicular to the surface. The operation is facilitated by grasping the shaft of the trephine between

***Plate IV.***

***Trephining of Facial Sinuses.***

Right side of face, viewed laterally, showing extent and relations of the sinuses. O, orbital cavity; SM, superior maxillary sinus; IM', median portion of inferior maxillary sinus; NC, nerve conduit of superior maxillary trunk of the trifacial; IM, lateral portion of inferior maxillary sinus; F, frontal sinus; ST, opening through superior turbinated bone for the establishment of drainage from the frontal and superior maxillary sinuses into the nasal passage; IT, opening through inferior turbinated bone for the establishment of drainage from the median portion of the inferior maxillary sinus into the nasal cavity.





the thumb and fingers of one hand, constituting a support in which it may turn back and forth. The pressure under which the trephining is carried out must not be too great or the instrument may become wedged and broken.

When the bony plate which has been isolated begins to loosen, remove the trephine and break, or pry out the piece of bone with the bone gouge or chisel. Smooth any uneven edges of bone with a heavy scalpel or by re-inserting the trephine and using it as a rasp. The abnormal contents of the sinus may now escape through the opening or be removed with the curette, forceps or scissors, and the cavity irrigated with an antiseptic fluid.

Leave the trephine wound entirely open and irrigate the sinuses daily with antiseptics.

The frontal, being in free communication below with the superior maxillary sinus, the irrigating fluids may fall directly into the latter until it becomes filled. The superior turbinated bone of the same side forming the median wall of the frontal sinus, it is commonly perforated by necrosis, in cases of serious disease establishing a communication between the frontal and nasal cavities, through which pus and irrigating fluids readily escape into the nostril.

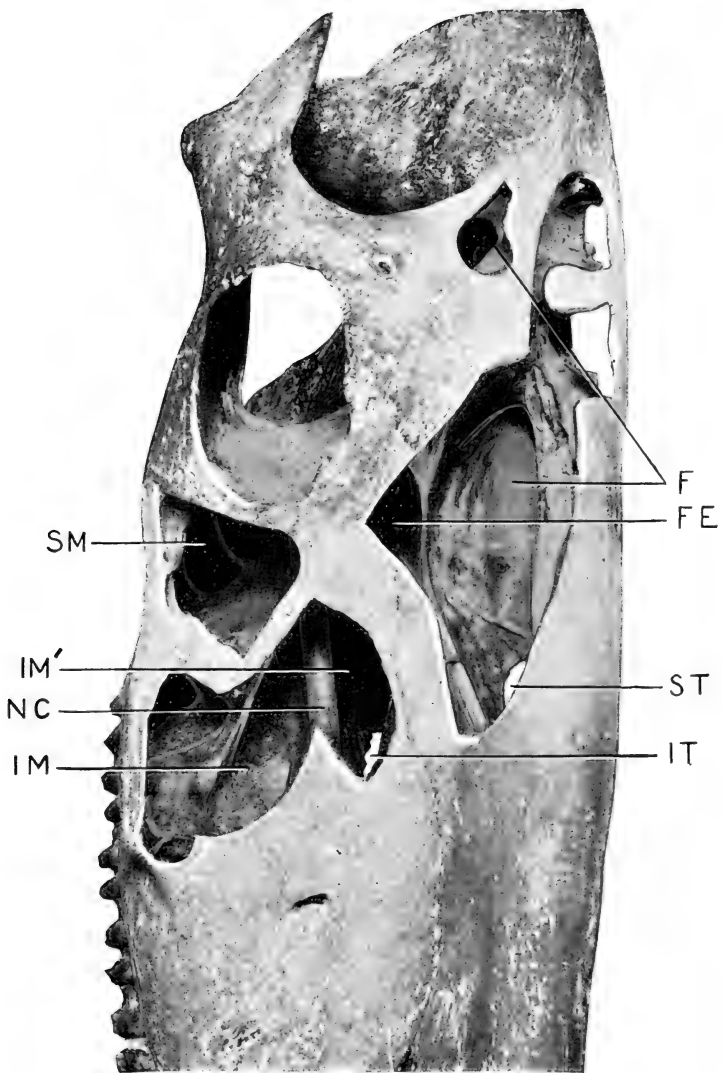
It has been assumed that pus or other contents in considerable quantity might pass from the superior maxillary sinus into the nasal cavity through the normal communicating slit between the two cavities but a careful study of anatomical arrangement of these parts, opposite N, Plates VII-X, shows very clearly that it is impossible as the margins of the slit acts as a valve and closes it when pressure is applied from within.

In order to prevent the aspiration by the patient of the contents of the sinuses, whether pus, blood or irrigating fluids, and to facilitate their escape from the nostril, any irrigation on the recumbent animal should be carried out with the poll elevated and the head flexed.

**Plate V.**

***Trephining of Facial Sinuses.***

Oblique lateral view of the face with the sinuses exposed. SM, superior maxillary sinus; IM', median portion of inferior maxillary sinus; NC, nerve conduit of superior maxillary division of trifacial nerve; IM, lateral portion of inferior maxillary sinus; F, frontal sinus; FE, fenestrum of communication between the frontal and superior maxillary sinuses; ST, artificial opening through the superior turbinated bone at the lowest part of the frontal sinus establishing a free communication with the nasal passage; IT, artificial opening through the inferior turbinated bone at the bottom of the median portion of the inferior maxillary sinus, affording drainage into the nasal passage.







By studying Plates IV–X it will be seen that any collection of pus or other pathologic contents in the frontal sinus at F would result in poor drainage so far as may be obtained by trephining through the external wall only. The drainage, whether the contents have formed within the frontal sinus itself, or have entered it through the fenestrum, FE, Plates V and VI, from the superior maxillary sinuses should be completed by making an artificial communication through the turbinated bone between the frontal sinus and the nasal fossa at ST, Plates IV, V and XI. This is to be accomplished by breaking through the thin walls of the turbinated bone by means of a probe or other suitable instrument and enlarging the opening sufficiently with the probe-pointed bistoury or with the finger. In locating the exact point for making this opening in the turbinated bone it is advisable to pass a slightly curved heavy probe, a pair of long curved uterine dressing forceps or some other slightly curved and somewhat rigid instrument up the nostril to the operative region and having an index finger in the sinus against the median wall, the movements of the sound can easily be felt and the wall be broken down either by pushing the sound up into the sinus or thrusting the finger downwards into the nasal passage.

In order to prevent aspiration of pus, blood or other fluids after the perforation of the highly vascular turbinated bone, the animal must be allowed to get up immediately or if under general anaesthesia a trachea tube should be inserted sufficiently early to avoid danger.

Thread a long probe with a heavy suture about 75 cm. long and inserting it through the trephine opening into the nasal passage draw it out through the nostril and removing the probe, attach a strip of gauze 75 cm. long to one end of the suture, draw it out through the nostril and tie the ends together on the side of the face to prevent dislodgement. Retain the gauze in position for about forty-eight hours to

insure the permanency of the opening through the turbinated bone. In case of severe hemorrhage the nasal and sinusal cavities may be tamponed for twenty-four hours with a long strip of gauze which may be secured if necessary by suturing to the lips of the trephine wound. In practice the operation can be best carried out generally with the animal in the standing position the operative area being first anaesthetized by the use of cocaine or by inducing artificial oedema. In the standing position we largely avoid the danger of aspiration of fluids and the hemorrhage is greatly lessened.

---

#### 4. TREPHINING THE SUPERIOR MAXILLARY SINUSES.

##### *Plates III-X.*

**Uses.** Empyema, diseased teeth, odontomes or other tumors.

**Instruments.** Same as for the frontal sinuses.

Anatomically there are two maxillary sinuses, superior, SM, and inferior, IM, Plates III-X, having a thin imperforate bony partition between them. This partition shifts somewhat in position with age and in case of disease undergoes profound changes in location and is frequently totally obliterated in cases of empyema, dental cysts and other affections. If the sinusal partition be present, good drainage of the superior sinus may demand the surgical destruction of the partition so that some authors advise trephining directly upon the partition in order to open the two cavities simultaneously.

In extensive disease of either sinus the partition between the two frequently becomes obliterated so that there remains but one sinus to open ; in limited disease the opening of both cavities is ill advised. In extensive disease the existence of a partition may generally be ignored in operating and

the trephine opening be aimed at the probable focus of the malady and, should this fail to reach the desired locality, the proper location for the opening may now be determined by digital or other examination through the first opening. A second operation should then be made to directly reach the seat of the affection and if need be, yet a third to secure proper drainage.

Shave and disinfect as much of the area as may be required bounded above by the inferior border of the orbital cavity, laterally by the zygomatic ridge, inferiorly by the lower end of the zygoma and medianwards by the middle line of the face. Determine the proper point for operation by percussion or otherwise. If it be desired to enter the superior maxillary sinus only, SM, Plates III-X, locate the opening beneath the orbital cavity and in front of the zygomatic ridge, SM, Plate III, or at any point directly beneath this to midway between SM and IM, Plate III, at about the level of the dotted line IM'.

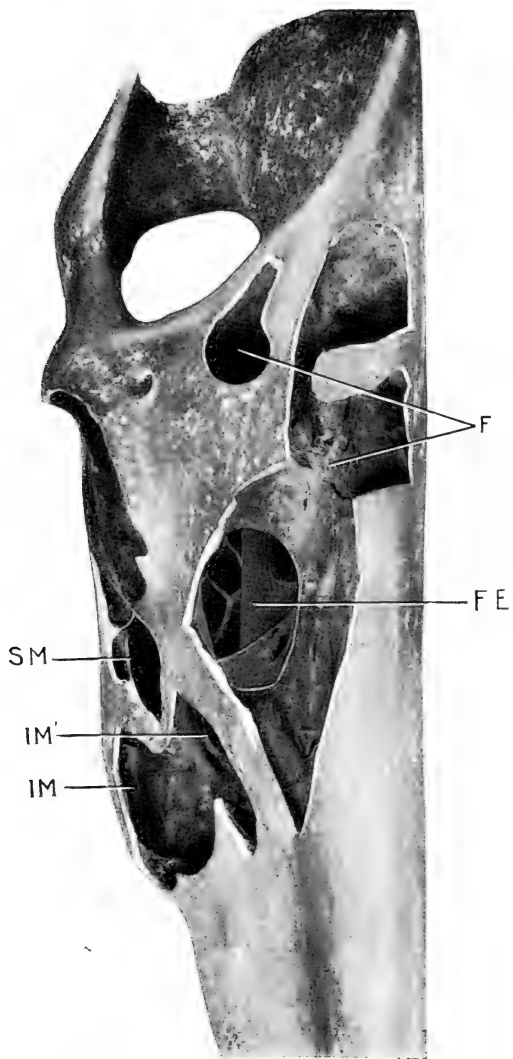
The trephining is carried out as described for the frontal sinuses on page 19. After the trephining has been completed remove any purulent collection or tumors or carry out any other necessary operation in the affected sinuses and after cleansing, if the trephine opening does not insure perfect drainage of the lateral sac, either lower it by cutting away its inferior border with the bone forceps or make a second trephine opening at the necessary point.

Since empyema of the superior maxillary sinuses is due in the vast majority of cases to infection derived from diseased teeth or dental alveoli it is essential after the sinus has been opened that the operator search carefully and minutely over the alveoli of the molars for naked, eroded tooth fangs or for fistulæ leading down into the dental alveoli. If dental disease is recognized the trephining of the sinus is to be supplemented by repulsion of the offending tooth as described on page 8.

*Plate VI.*

*Trephining of Facial Sinuses.*

Frontal view of right side of face with sinuses exposed. SM, superior maxillary sinus; IM', median portion of inferior maxillary sinus; IM, lateral portion of inferior maxillary sinus; F, frontal sinus; FE, communication between the frontal and superior maxillary sinuses.





Under the influence of disease the sinuses may extend far beyond their normal location or may contract or become largely obliterated by being filled with new bone or soft tissue. The median portion of the superior maxillary sinus on the inner side of the bony conduit of the trifacial nerve, NF, Plates IV-X, can not always be completely drained through the opening SM, Plate III, and provision for this must then be made by trephining into the lower part of the frontal sinus and thence breaking through the superior turbinated bone, ST, Plates IV-V, into the nasal passage or at times it may be feasible to break through the inner wall of the superior maxillary sinus on the median side of the nerve conduit into the nasal cavity. If the inferior maxillary sinus is also involved good nasal drainage may be had by breaking down the inter-sinusal partition and then penetrating the inferior turbinated bone at IT, Plates IV-V, and inserting through this opening a long and thick strip of gauze which is brought out through the nostril and the ends tied together on the side of the face to prevent displacement. Retain this in position, renewing daily until the permanency of the opening is assured.

It generally occurs in extensive empyema of the sinuses that an opening in the turbinated bone takes place by necrosis and in some cases affords the desired drainage while in the majority the pathologic opening is so placed that it is incomplete.

Leave all wounds entirely open and irrigate daily with antiseptic solutions.

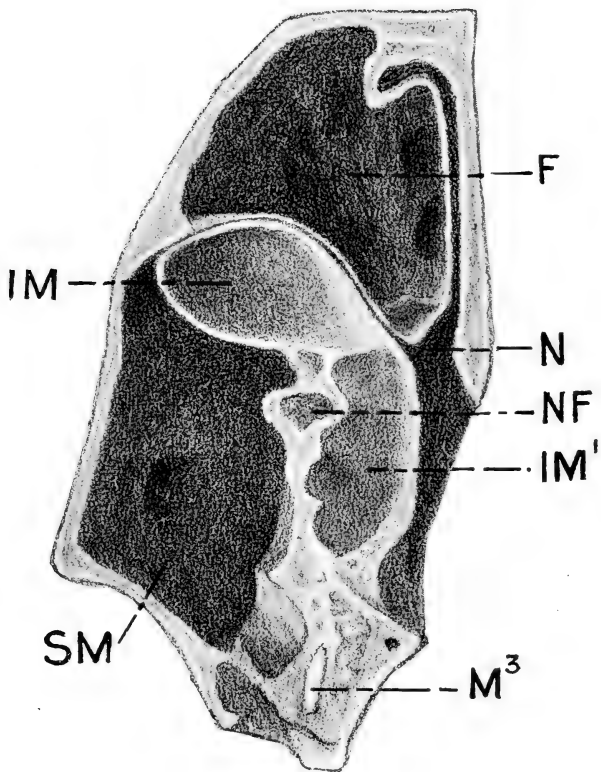
**Dangers.** Care must be exercised to not injure the superior maxillary division of the trifacial nerve, NF, Plates IV-X, either in trephining or after the sinuses have been opened. The bony conduit of this nerve is in rare cases entirely resorbed by pressure from dental cysts or other causes, leaving it stretched across the cavity as a white nacrous cord, intensely sensitive. Any injury to this nerve

***Plate VII.***

***Trephining of Facial Sinuses.***

Cross section of the right half of the head of a horse at the posterior border of the last molar. F, frontal sinus; IM, lateral portion of inferior maxillary sinus at extreme posterior or superior part; IM', median portion do.; N, nasal chamber opposite the communication between it and the superior maxillary sinus; NF, conduit of superior maxillary branch of the trifacial nerve; SM, superior maxillary sinus; M<sup>3</sup>, fragment of last molar.







causes intense pain and renders the animal very resistant to the necessary manipulations in the after care of the wound and may leave the patient permanently nervous about the handling of its face.

Hemorrhage is generally not severe and may occur from the skin, where it may be readily controlled by compression or ligation; from the intra-osseous vessels, where it may be checked by pressure with absorbent cotton, by pushing a small portion of cotton into the channel of the vessel with a needle or tenaculum or by plugging the vessel with a conical piece of wood; from the wounded turbinated bones where it may be stopped by packing with gauze. These tampons should be removed after twenty-four hours.

---

## 5. TREPHING THE INFERIOR MAXILLARY SINUS.

### *Plates III-XI.*

**Uses and Instruments.** Same as in the preceding.

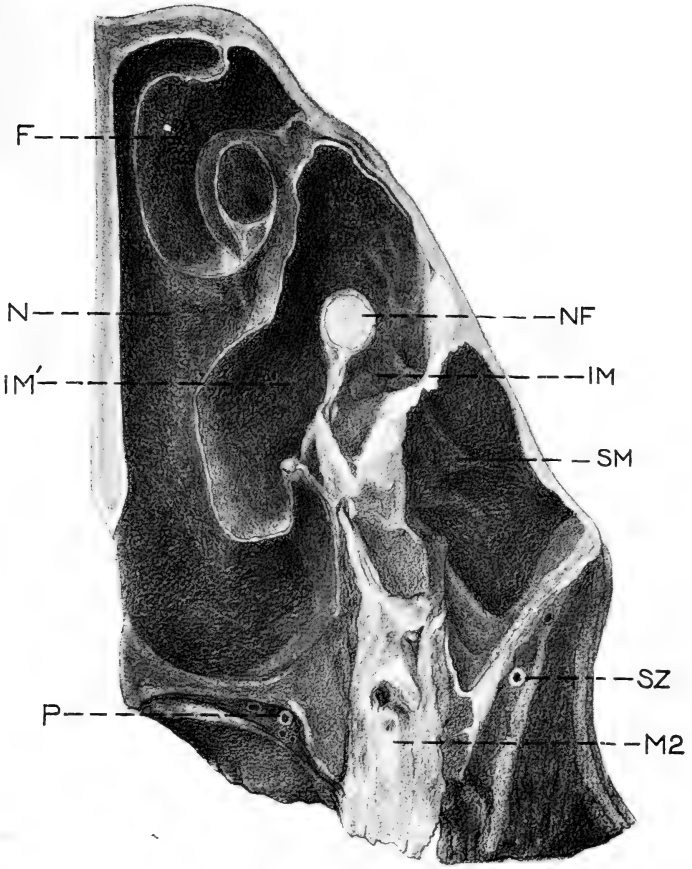
**Anatomical Outline.** The inferior maxillary sinus is an exceedingly irregular cavity, differing in details of form and extent in individuals and at various ages. As shown in the illustrations its disposition might be compared to a pair of saddle bags hanging over the nerve conduit, the lateral and median chambers not very unlike in extent. As suggested in Plates IV-V, the floor of the lateral cavity is broken up by irregular bony septa, which in some cases cut the sinus up into quite separate cavities. Sometimes it extends downwards barely below the end of the zygoma, at other times it reached down below the infra-orbital foramen. There is hence no rule by which the operator may at all times make his opening precisely at the lower extremity of the sinus.

**Technic.** The general technic is the same as for the frontal and superior maxillary sinuses, but two trephine

*Plate VIII.*

*Trephining the Facial Sinuses.*

Cross section of the left side of the head of an aged horse at the second molar, seen from the front. F, frontal sinus; N, nasal sinus, opposite the communication between the nasal and inferior maxillary sinuses; IM, lateral portion of inferior maxillary sinus; IM', median portion of inferior maxillary sinus; SM, superior maxillary sinus; NF, superior maxillary division of trifacial nerve in its bony conduit; SZ, subzygomatic artery; P, palatine artery; M2, second molar.





openings should always be made. The first opening should be made close against the median side of the zygoma near its lower or nasal extremity, Plate III, IM, and the inferior border lowered sufficiently with the bone forceps to provide thorough drainage for the lateral compartment of the sinus.

The second opening is to be made on the median side of the nerve conduit, NC, Plates IV-V as indicated at IM' in Plate III. The location may be accurately determined by palpating with the index finger through the first opening at IM, Plate III. This compartment can not be well drained upon the face through either of the trephine openings and a third opening, penetrating the inferior turbinated bone at IT, Plates IV-V, is essential to ideal results by affording free drainage into the nasal chamber. The opening through the inferior turbine is made in the same manner as described for the opening through the superior turbine from the frontal. Thorough search should be made throughout the sinus for the causes of disease, teeth, etc., these removed and followed by after treatment the same as advised for the two preceding operations.

## 6. TREPHEINING THE NASAL FOSSAE.

### *Plates VII-X.*

**Uses.** Operations upon the septum nasi, or the turbinated bones, or the removal of tumors or foreign bodies from the nasal passages.

**Instruments.** Same as for the frontal sinuses (page 19).

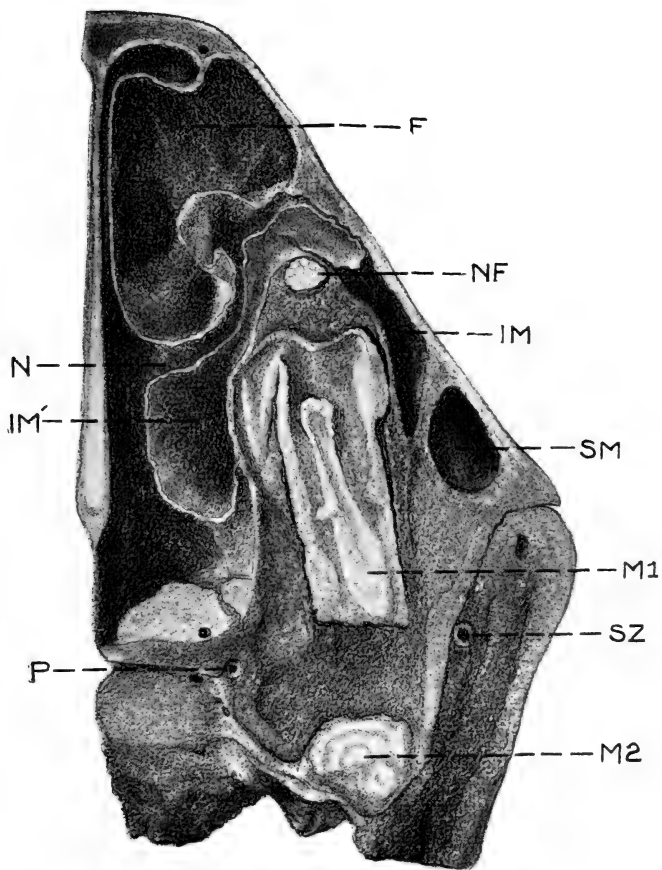
**Technic.** The trephining, N, Plate III, is carried out by the method described above, in the nasal bone, close by the median line of the face and according to indications at any point from a level of the dotted line, SM, Plate III, to the juncture between the nasal and pre-maxillary bones near the upper extremity of the false nostril.

***Plate IX.***

***Trephining the Facial Sinuses.***

Cross section obliquely downwards and backwards through the right half of the head of a two-year old colt at the first molar. F, frontal sinus; N, nasal passage at point of communication with the inferior maxillary sinus, IM; IM', median portion of inferior maxillary sinus; SM, extreme lower end of superior maxillary sinus opened; M<sub>1</sub>, first molar; M<sub>2</sub>, second molar; P, palatine artery; SZ, sub-zygomatic artery.







A study of Plates VII-X will show that the trephining of these cavities requires great care in order to avoid wounding either the highly vascular septum nasi or even more vascular turbinated bones. The operation should be immediately against the septum since otherwise the superior turbinated bone may be wounded or an important intra-osseous artery in the nasal bone, just above its union with the superior turbinated, as shown in Plate IX, may be severed.

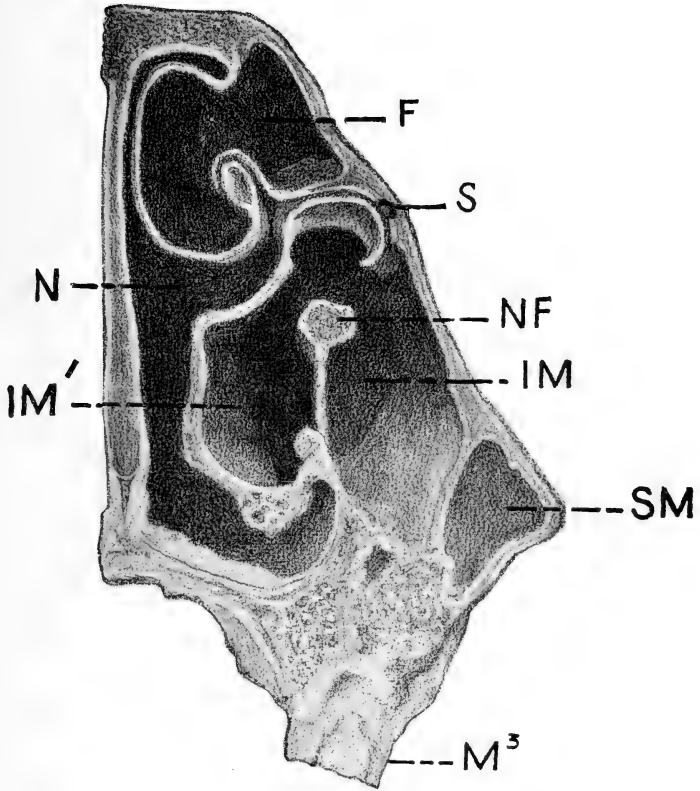
If the turbinated bone is penetrated the frontal, and through it, the superior maxillary sinus is opened and exposed to infection with all its consequences. Special care is accordingly necessary that the trephining should not be carried too deeply, that the bone be barely penetrated, and that the osseous disc be carefully removed in order to avoid the wounding of the turbinated bone, which lies in close proximity to the nasal bone. The operative area is narrow and the trephine used should not exceed 2 cm. in diameter.

Whenever possible the operation should be carried out on the standing animal which decreases the hemorrhage and the danger from aspiration of fluids. The hemorrhage may be further controlled in operations upon the septum nasi and turbinated bones by spraying the parts with adrenaline chloride and cocaine. Even in the standing animal, if extensive operations are to be carried out on the very vascular septum nasi or on the turbine, it is advisable to preform tracheotomy before trephining, and retain the trachea tube in position until all danger has passed. When the animal is confined in the recumbent position the patient's safety demands that tracheotomy be performed in almost all cases before any operation is begun upon the septum nasi or turbinated bones. After tracheotomy, anaesthesia may be maintained by means of an ordinary funnel with its tube bent at right angles and inserted into

*Plate X.*

*Trephining of Facial Sinuses.*

Cross section of the left side of the head anterior to the last molar, and through the widest part of the inferior maxillary sinus. M<sup>3</sup>, last superior molar; SM, superior maxillary sinus at its antero-inferior extremity; IM, inferior maxillary sinus, lateral portion; IM', do. median portion; N, nasal fossa; S, sound lodged in lachrymal duct; NF, trifacial nerve; F, frontal sinus.





the trachea tube while the chloroform is dropped on a towel spread over its mouth. After completing any required operation upon the septum, turbinated bones or other parts, hemorrhage may be controlled by packing one or both nasal fossae with single strips of gauze of sufficient size and carefully securing them by sutures to the sides of the trephine wound or otherwise.

---

## 7. POLL EVIL OPERATION.

### *Plate XI.*

**Instruments.** Clipping shears, razor, sharp scalpels, one dozen compression artery forceps, probe-pointed bistoury, probe, Luer's bone forceps, bone gouge, curette, suture and dressing material.

**Technic.** Clip the foretop and mane and shave the forehead and the top of the neck back to a distance of 8 or 10 cm. or as much farther as may be required to pass beyond and behind the supposed extension of disease, and disinfect the area. Confine the animal in lateral decubitus preferably upon the operating table, place under complete anaesthesia and remove the halter or other headgear.

With sharp scalpel make a longitudinal incision on the median line of the head and neck beginning at a point presumably posterior to the diseased area and carrying it over the poll down onto the forehead for a distance of 4 or 5 cm. below the foretop. Continue this incision through the skin, the subcutem, the adipose tissue, AT, Plate XI, and either through, or passing around alongside the neck ligament, LN, into the diseased area beneath the latter. Dissect the ligamentum nuchæ away from the adjoining tissues as far back as diseased, divide it obliquely upward and backward as indicated at AA, and detach anteriorly from the base of the occiput. Be careful to remove every

*Plate XI.*

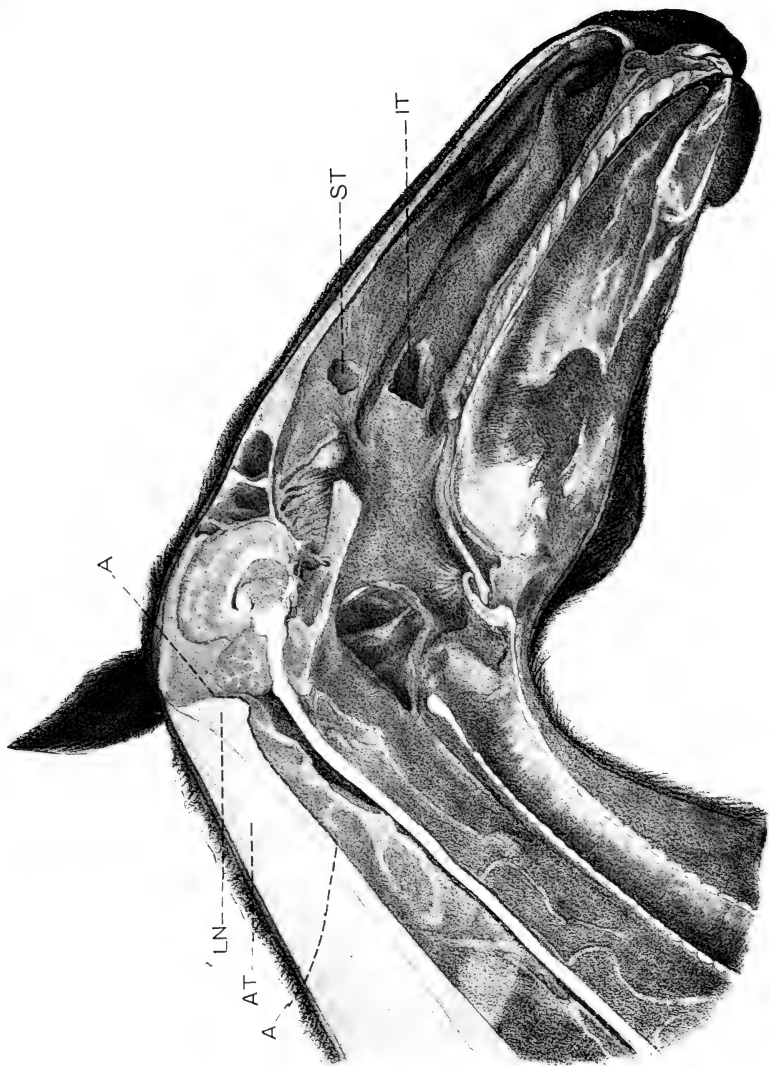
*Poll Evil Operation.*

Sagittal section of the head and neck. AA, line of incision in operation for poll evil; LN, ligamentum nuchae; AT, adipose tissue.

*Trephining the Facial Sinuses.*

ST, opening from frontal into nasal sinus through the superior turbinated bone; IT, opening through inferior turbinated bone from the inferior maxillary sinus into the nasal passage.







portion of the ligament in the area indicated and all calcareous deposits or other diseased tissues.

With Luer's forceps groove a channel about 2 cm. wide from behind to before directly upon the median line, through the occipital protuberance to the depth of about 2 cm. making the bottom as near as possible on a level with the wound in the soft tissues as indicated by the dotted line, AA. Using Luer's forceps as a curette detach all vestiges of the neck ligament from the base of the occiput and leave the bone bare and smooth. If the Luer or ronguer forceps are not available the grooving of the occiput may be accomplished with a strong curved bone gouge. Or the grooving of the occiput and curetting away of the attachments of the neck ligament to the base of the occiput may be very effectually accomplished with a hoof knife. *Be careful to avoid penetrating the cranial cavity or the occipito-atloid articulation.* If the operator is not perfectly clear regarding the anatomy of the parts he would do well to have before him a sagittal section of the head of a horse which may serve as a guide. In curetting the ligamentous attachments from the occiput the operator should keep the index finger of the left hand at the bottom of the wound, against the occipito-atloid ligament in order to protect it from injury. The operation is rendered safer also by rigid control of the hemorrhage to which end he needs an ample number of compression artery forceps.

Control the hemorrhage, cleanse and disinfect the wound, pack with iodoform gauze and suture for its entire length except the anterior part, where the tampon should slightly protrude, and dust the margin of the wound with iodoform and tannin. Remove the tampon after forty-eight hours and dress antiseptically daily. The sutures may or may not be removed according to conditions. In carrying out this operation our chief aim should be to remove all diseased parts, to afford perfect drainage anteriorly, to secure and maintain antiseptics, and to keep the wound directly on the median line from which no visible scar will result.

## ***Plate XII.***

### ***Ligation of the Parotid Duct.***

Fig. 1. Segment of the left ramus of the inferior maxilla of the horse seen from the right and beneath. *sp*, usual operative field ; *a*, external maxillary artery ; *v*, external maxillary vein ; *st*, *st*, parotid duct.

Fig. 2. Life size of operation field on external side of maxilla ; *a*, external maxillary artery ; *v*, external maxillary vein ; *st*, parotid duct ; *m*, masseter muscle.

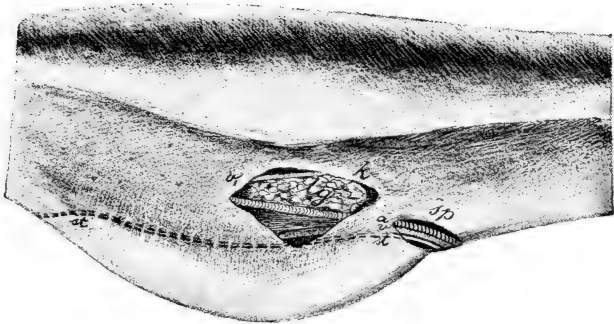


FIG. 1.

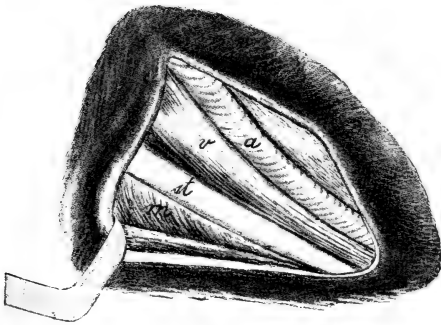


FIG. 2.



## 8. LIGATION OF THE PAROTID DUCT.

*Plate XII.*

**Objects.** The destruction of the parotid gland in case of fistula from wounds or abscesses.

**Instruments.** Razor, convex scalpel, straight probe-pointed scalpel, tenaculum forceps, ligation forceps, tenacula, needle holder, probe, suture and dressing material.

**Technic.** In case of salivary fistula insert a probe toward the gland through the fistula into the duct and with a sharp scalpel lay the duct free for a distance of from 1 to 2 cm. on the glandular side of the fistulous opening. If the fistula has its location on the side of the cheek, cast the horse and shave and disinfect the region on the inferior maxilla where the artery, vein and parotid duct turn around its inferior border. When the operator glides his finger over the vascular region forward and backward there is felt a resistant cord, the pulsating external maxillary artery about 3 mm. in diameter. Between this and the oral border of the masseter muscle make an incision about 4 cm. long parallel to the artery through the skin and skin muscle. Pick up the loose connective tissue with a pair of forceps and excise it. Immediately behind the external maxillary artery, *a*, Figs. 1 and 2, Plate XII, is the external maxillary vein, *v*, and behind this and immediately at the border of the masseter muscle lies the parotid duct, *st*.

In case of salivary calculi which cannot be removed through the mouth or of cystic dilation of the parotid duct, make the cutaneous incision at the affected point, open the canal, and after the removal of the calculus, etc., close the duct wound by means of intestinal sutures in such a way that the external surfaces of the lips of the wound in the wall of the duct are brought in contact, or ligate the duct on the proximal side of the point of operation and destroy the gland.

Ligation of the duct is accomplished by passing a strong silk thread beneath the duct by means of a curved aneurism needle, carrying the ligature around the duct and tying with a surgeon's knot. The parotid duct may also be previously split and an internal wound made at the point of ligation. Close the skin wound by means of a continuous suture and cover the operative surface with iodoform collodion or with wound gelatine.

### 9. ENTROPIUM OPERATION.

**Instruments.** Razor, scissors, convex scalpel, tenaculum and ligation forceps, tenacula, needle holder, needles, thread, absorbent cotton.

**Technic.** Quiet adult horses may be operated upon in the standing position with the aid of local anaesthesia, other horses and small animals should be secured in lateral re-




FIG. 1.

Entropium operation on the superior and inferior eyelids of the dog. cumbency preferably upon the operating table. Shave and disinfect the skin of the inverted eyelid. Grasp the skin of the eyelid midway between the inner and outer canthi with the forceps and elevate a skin fold parallel with the border of the eyelid to such a height that the inverted member assumes its normal position. Pass a finger into the



conjunctival sac to make sure that the conjunctiva is not drawn into the skin fold. Clip the fold off with the scissors immediately below the forceps, removing an oblong piece. Between the border of the eyelid and that of the wound the skin should be left intact for at least .5 cm. Ligate or compress any bleeding vessels and close the wound by means of interrupted sutures. The wound may be covered with iodoform collodion or wound gelatine or dusted over with iodoform-tannin. It is usually unnecessary and inadvisable to cover the parts with hood or other appliance since so long as the wound is healing properly the animal will not disturb it.

## 10. STAPHYLOTOMY.

**Object.** An operation devised by Dr. M. H. McKillip for making a manual exploration of the Eustachian tubes, guttural pouches, larynx, pharynx and posterior nares; and for operations upon these structures. The form and extent of the soft palate of the horse is such as to render it extremely difficult to make a manual exploration of the parts above and behind it, and impossible to make a visual examination except with the aid of the expensive and complicated rhino-laryngoscope, which only aids in diagnosis while staphylotomy combines with this operative advantages, permitting the free introduction of the hand into the laryngopharyngeal region.

**Instruments.** Mouth speculum, short curved probe-pointed bistoury with a ring to fit the middle finger.

**Technic.** Cast the patient or secure on the operating table in lateral recumbency and turn the nose upward. Adjust the mouth speculum and open the mouth as wide as possible; draw the tongue well out with the left hand while the right carrying the knife on the middle finger is passed

carefully through the fauces until it hooks over the posterior border of the soft palate. The knife is then gently drawn forward making an incision along the median line of the soft palate from its posterior, free border to its attachment on the palatine bone. The hand is then withdrawn and the speculum removed for a few minutes to permit the patient to rid its pharynx of any blood clots or mucus that may have accumulated. Readjusting the speculum as before, the right hand is again passed through the fauces and now that the palate is divided a manual exploration may perfectly reveal the presence of any abnormality in the region.

## 11. TRIFACIAL NEUROTOMY.

### *Plate XIII.*

**Object.** The relief of involuntary shaking of the head.

**Instruments.** Razor, scissors, convex scalpel, tenacula, aneurism needle, compression artery forceps, needles, thread, absorbent cotton, a strong piece of muslin 12 cm. square.

**Technic.** Secure in lateral recumbency, preferably upon the operating table, and produce complete anaesthesia. Remove the halter, bridle, or other headgear. Shave and disinfect an area 8 to 10 cm. square over the infra-orbital foramen. Locate by touch the infra-orbital foramen, IOF, Plate XIII, below the levator labii superioris proprius muscle and displace this slightly upward toward the median line of the nose until the foramen can be clearly felt below the muscle. With the scalpel begin an incision somewhat superior to the foramen and near its nasal border and make a wound downward and forward in the direction of the commissure of the lips about 5 cm. long through the skin, muscle and connective tissue down to the nerve and control hemorrhage with the greatest care. If the larger branches of the glosso-facial vessels are severed they should be ligated

or twisted. It is even better to ligate or compress these vessels prior to severing them.

Hold the lips of the wound apart with two tenacula or by placing a strong suture through each wound margin and through the skin at a point 6 to 8 cm. distant and tying the sutures tightly, dilate the wound thoroughly and dissect away the connective tissue from the nerve until every part of it is clearly in view. Pass an aneurism needle beneath the nerve trunk and lifting it from the bone make a search for a small artery which usually passes along beneath it through the foramen and if this can be found either ligate it immediately at its point of emergence and again 5 cm. lower down and divide between the two ligatures or separating it from the nerve protect carefully against injury. With a probe-pointed bistoury or scissors sever the nerve at the foramen and grasping the distal end dissect away about 5 cm. of the trunk and excise. Be very careful to include all branches and especially one or two superior or dorsal twigs which are directed upward just as they emerge from the foramen. After the hemorrhage has been brought under complete control and all blood clots have been removed cleanse the wound carefully, dust over with iodoform and close with continuous sutures.

In order to protect this first wound during the operation upon the other side take the piece of muslin mentioned among the needs for the operation, and folding it several times in a square, place it over the wound and suture it firmly at each corner to the skin. Turn the animal to the opposite side and repeat the operation on the other nerve except the application of the square piece of muslin which is here unnecessary. If circumstances will at all permit it is far safer to operate upon only one side first, allowing this to heal and then operate upon the other side.

As soon as the animal stands, remove the protective piece of muslin from the first wound, disinfect both wounds, dust

*Plate XIII.*

*Trifacial Neurotomy.*

LL, levator labii superioris proprii muscle ;  
IOF, infra-orbital foramen ; NF, superior max-  
illary division of the trifacial nerve.



LL ---  
IOF ---  
NF ---



them over with iodoform and tannin or cover with wound gelatine and leave undisturbed to heal by primary union. Avoid halter, bridle or other fixtures which might injure the wounds after the operation.

In some cases the operation may be performed upon the standing animal under local anaesthesia and whenever this is possible it is greatly to be preferred since the hemorrhage is far lessened and the danger from sepsis reduced, but with most affected animals the standing operation is impracticable.

**Dangers.** The chief danger in the operation is from infection, which sets up a severe neuritis in the proximal end of the nerve, aggravates the symptoms and causes much suffering. In order to prevent infection the aseptic precautions need be unusually strict in every detail and the anaesthesia profound. Carefully avoid wounding the neighboring vessels and control completely any hemorrhage that occurs in order to avoid a hematoma in the wound, which always invites infection.

**Literature.** Involuntary twitching of the head relieved by trifacial neurectomy. W. L. Williams, *Jour. Comp. Med. and V. A.*, vol. XVIII, p. 426. Involuntary shaking of the head and its treatment by trifacial neurectomy. *do.* *Am. Vet. Rev.*, vol. XXIII, p. 321 and *Œst. Monatsch. Thierheilkunde*, Bd. XXIV, s. 211.

## II. OPERATIONS ON THE NECK.

### 12. OPENING OF THE GUTTURAL POUCHES.

#### *Plate XIV.*

**Instruments.** Razor, Scissors, convex sharp-pointed and straight probe-pointed scalpels, artery forceps, tenacula, probe, trocar, curette, drainage tubing, suture and dressing material.

**Technic.** I. *Viborg's method.* The operation is possible on the standing animal, but generally the patient must be cast or placed on the operating table and secured in lateral decubitus with the head extended. By extending the head and compressing the jugular vein there is brought out the triangle immediately behind the posterior border of the inferior maxilla and below the parotid gland comprised between the posterior angle of the inferior maxilla, the terminal tendon of the sterno-maxillaris muscle and the external maxillary vein.

In this so-called Viborg's triangle after the removal of the hair and the disinfection of the skin which is maintained stretched, make a 5 cm. long incision through the skin and skin muscle immediately beneath the aforementioned tendon and parallel to it. In case of pronounced swelling in Viborg's triangle the operator must determine the location for the incision by the position of the sterno-maxillaris muscle. The skin, subcutem and cervical fascia having been incised to a sufficient extent, force a passage with the finger or with closed probe pointed scissors or other blunt instrument through the loose connective tissue on the median side of the parotid gland, to the guttural pouch and penetrate it at its lowest point with the finger or trocar. In order to open the empty guttural pouch as an exercise operation it is desirable to grasp a portion of its wall by means of forceps. Through the operative wound a drainage



tube can be introduced into the pouch, and fixed in position by sutures. The opening can be enlarged in an antero-posterior direction to the extent of 5 to 8 cm. or large enough to admit the operator's hand. Through this enlarged wound, the operator may palpate the Eustachian tube and other portions of the interior of the pouch and perform desired operations.

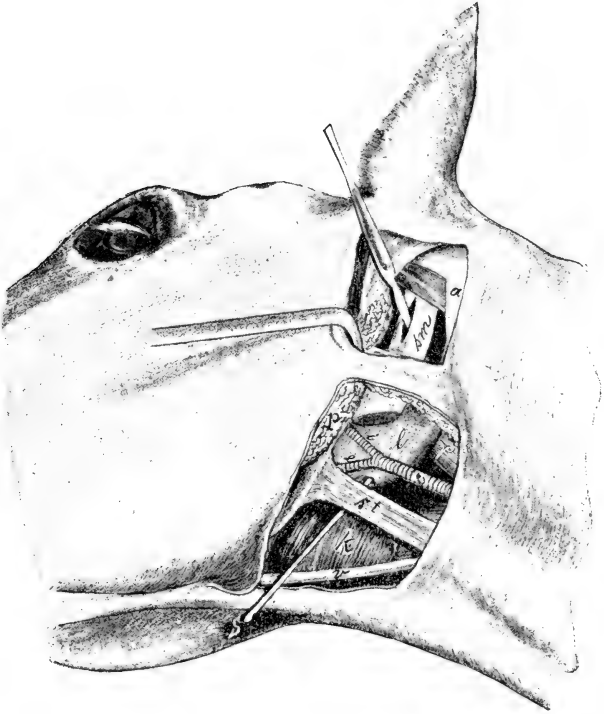
**A far more common operation** in veterinary practice than the opening of the guttural pouches, is the opening of stranglers abscesses of the sub-parotid lymph glands, lying between the inner face of the parotid gland and the external face of the guttural pouch. The operation here used is the same as Viborg's for the guttural pouch but does not penetrate that cavity because the inner wall of the abscess has pushed the external wall of the pouch inward so that the former largely occupies the usual location of the latter. The dyspnoea generally prohibits casting the animal and necessitates operating in the standing position. In some cases the dyspnoea is so severe as to demand tracheotomy before the opening of the abscess can be undertaken because the excitement aggravates the difficult respiration to the point of suffocation.

II. *Chabert's method.* Secure the horse in the lateral recumbent position, remove the hair and disinfect the skin beneath the wing of the atlas. Make an incision about 1 cm. in front of the lower half of the wing of the atlas and parallel to it, about 6 cm. long extending through the skin and skin muscle down to the parotid gland. The incision is facilitated by rendering the skin tense with the left hand and care is to be taken not to wound the auricular nerve which passes directly along the atlas. Then draw backward the posterior lip of the wound and separate with blunt instruments the posterior border of the parotid gland from the atlas, to which it is bound by loose connective tissue, and draw it forward with tenacula. At the bottom of the

*Plate XIV.*

*Opening of the Guttural Pouches (Hyoyertebrotomy)  
According to Viborg and Chabert.*

Head and neck of recumbent horse viewed from the side. *sm*, stylo maxillaris muscle; *p*, parotid gland; *l*, guttural pouch; *k*, larynx; *st*, sterno-maxillaris muscle; *r*, rectus capitus anticus major muscle; *c*, external carotid artery; *e*, external maxillary artery; *i*, internal maxillary artery; *v*, external maxillary vein; *s*, probe; *a*, wing of atlas.





opening thus formed there is seen the stylo-maxillaris muscle, *sm*, Plate XIV, lying against the median side of the parotid gland covered only by the aponeurosis of the mastoido-humeralis muscle. With the handle of the scalpel inclined toward the wing of the atlas penetrate in the direction parallel to the long axis of their fibers the aponeurotic expansion of the mastoido-humeralis, and the stylo-maxillaris muscle. The puncture is thus located between the ninth and tenth nerves on one side and the internal carotid artery on the other. Since the wall of the guttural pouch rests against the median side of the digastricus or sterno-maxillaris muscle it is opened by this incision. The operator inserts an index finger along the blade of the knife at first and then withdrawing the instrument passes the other index finger also into the penetrant wound and by forcibly parting these, dilates it. The abnormal contents are then removed by means of forceps, curetting and irrigation. In order to prevent adhesion of the wound lips in the firmly stretched stylo-maxillaris muscle, introduce a strong drainage tube into the pouch and fix it to the external borders of the wound by a suture.

III. *Dieterich's method.* This operation is effected at a point between I and II, the opening of the pouch being made immediately behind the stylo-maxillaris muscle. In order to accomplish this the cutaneous wound over the wing of the atlas must be prolonged below it. After detaching the posterior border of the parotid gland the operator searches in the loose areolar tissue with the index finger of the left hand for the vascular angle which is formed by the occipital, internal carotid and external carotid arteries which may be detected by pulsation—the same is located at a depth of from 8 to 10 cm. Place the volar surface of the finger in the vascular angle and push a sharp scalpel along its dorsal side to the pouch which here becomes opened on its posterior lateral surface.

This method has the advantage over Chabert's that for the removal of hard contents (chondroids) the opening can be readily dilated, even to such an extent that the entire hand may be passed into the air sac and the opening of the Eustachian tube be explored as in Viborg's operation.

## 12. TRACHEOTOMY.

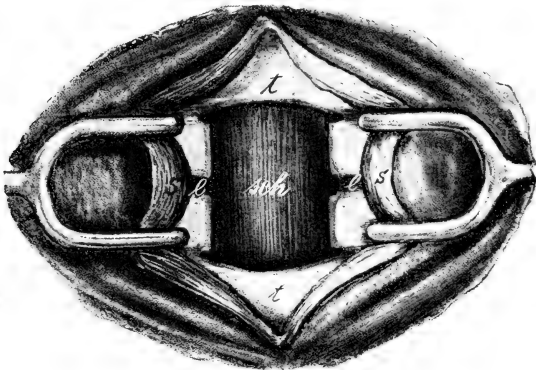
### *Fig. 2.*

**Instruments.** Razor, scissors, convex scalpel, tenacula, tenaculum and ligation forceps, trachea tube, and suture material.

**Technic.** In the superior third of the cervical region, in the neighborhood of the fourth to the sixth tracheal ring, shave and disinfect the skin on the anterior surface of the neck to the extent of 10 cm. long by 5 cm. wide. The operation is best performed upon the standing animal with the head extended. In lateral decubitis the operation is carried out with some difficulty, and generally the operator fails to get the incision on the median line. The operator stands before the right shoulder of the horse with an assistant opposite him.

Render the skin tense along the median line of the trachea with the left hand and then make a drawing cut 5 to 8 cm. long from above to below with the scalpel. The incision should be made carefully upon the median raphe of the skin which is virtually destitute of sensation and requires no anaesthesia. After the skin muscle is cut through, in order to avoid hemorrhage, separate the two sterno-thyroid muscles by means of tenacula along the median raphe in the white strip of connective tissue. The opening into the trachea may be made in a variety of ways. The quickest and most crude method is to slit it from above downwards through two or three tracheal rings, and press-

ing the several ends apart insert the tube through the opening. Since the tracheal rings are incomplete, being open on their dorsal surfaces, cutting through the ventral portion divides each ring into two separate parts and their being pushed apart, distorts them and tends to the causation of chondritis and collapse of the trachea, a danger which increases with the duration of time that the tube is maintained in position. It is therefore most suitable for hurried operation in impending suffocation where the tube will probably be needed for a short time only.



*Fig. 2.*

TRACHEOTOMY. *s*, sterno-thyro-hyoïdeus muscle; *t*, trachea; *sch*, mucous membrane of the posterior wall of the trachea; *l*, interannular ligament.

A second method of operation, illustrated in Fig. 2, consists in making a transverse incision through the inter-annular ligament between the two last exposed tracheal rings the length of the diameter of the tube to be inserted. Make a perpendicular incision upward from each end of this at a point 1 to 1.5 cm. from the median line through one or two tracheal rings, according to the size of the tube. With forceps or tenaculum grasp the segments of partially de-

tached cartilage and remove them by cutting through the inter-annular ligament.

A third and to us preferable method is to insert a narrow bladed scalpel transversely at about the lower third of the lowermost bared tracheal ring and cutting outwards and upwards in a curved line, pass through the first inter-annular ligament and continue into the succeeding segment until near its superior border, when the incision is curved downward to eventually reach the starting point, the isolated section of the trachea being securely grasped with a pair of forceps before its excision is completed. By this method no tracheal ring is severed.

The trachea tube is to be removed and cleansed daily as long as its use is necessary, and when discontinued the wound should be left open and dressed antiseptically.

---

### 13. THE OPERATION FOR ROARING.

#### *Plate XV. Figs. 3-5.*

**Instruments.** Razor, hypodermic syringe, scalpels, tenaculum, artery forceps, laryngeal speculum, two long curved dressing forceps, hard rubber syringe with long pipe, ventricular burr, reflecting lamp, razor-shaped scalpel, long curved scissors.

The following technic has for its aim two fundamental objects which are to be kept constantly in mind :

1. It is aimed to bring about a prompt, firm, complete and permanent adhesion of the arytenoid cartilage and vocal cord against the inner face of the thyroid cartilage in the normal position of forced inspiration, so that no air can become impacted into the ventricle to force the vocal cords and arytenoid cartilage downwards and inwards to obstruct the free ingress of air.



2. It is aimed to complete the operation without wounding a cartilage either in the essential operation when removing the ventricular mucosa, during the invading incision through the crico-thyroidean membrane, and later, should dyspnoea occur, by inserting the laryngeal tube through the existing incision instead of performing tracheotomy.

**Technic.** Docile animals are readily operated upon in the standing position. The animal should be confined in stocks, or otherwise, in such a manner that his head may be securely held in an elevated and extended position. The safety of the operator further demands that the patient shall be so secured that he can neither rear nor strike.

Resistant animals need be cast or confined upon the operating table. General anaesthesia upon the recumbent animal is usually unnecessary, and is only demanded in those cases of unusual resistance to confinement, where the patient may injure itself by its violent struggles.

Ordinarily ample anaesthesia, whether from the standpoint of surgical efficiency or of sentiment, is obtainable by the use of local anaesthetics, preferably of cocaine and adrenaline.

Shave and disinfect the operative area, and inject subcutaneously a sufficient amount of the local anaesthetic.

Make a longitudinal incision over the larynx through the skin and fascia as accurately as possible on the median raphe, commencing opposite to the anterior extremity of the thyroid cartilage and extending downward and backward to the region of the first tracheal ring. Separate the sterno-thyro-hyoideus muscle on the median line with the scalpel blade or handle as preferred. Control the hemorrhage. If the operation is performed upon the standing animal with the aid of cocaine and adrenaline, the incision is virtually bloodless.

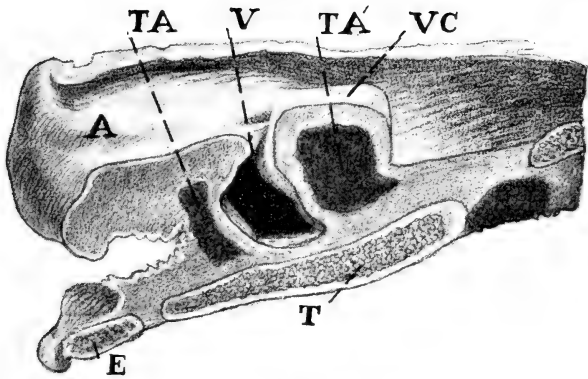
Locate the crico-thyroidean ligament, triangular in form, bounded anteriorly and on both sides by the thyroid cartilage

*Plate XV.*

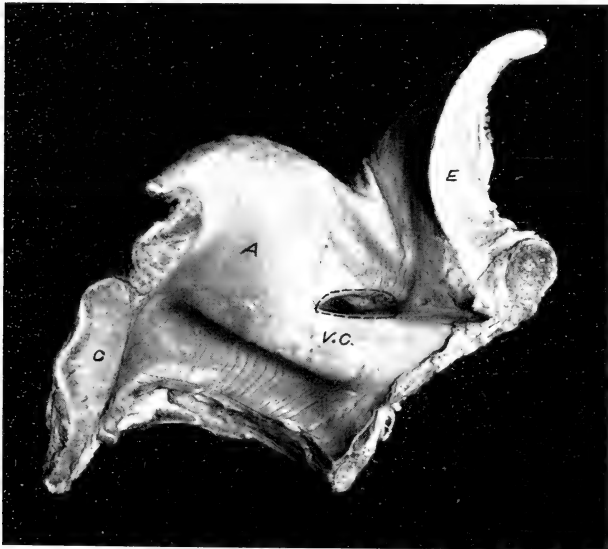*Operation for Relief of Roaring.*

FIG. 1. Longitudinal section through the ventricle of the larynx; A, arytenoid cartilage; TA, anterior fasciculus of thyro-arytenoideus muscle; TA', posterior bundle thyro-arytenoideus; VC, vocal cords; V, laryngeal ventricle; T, thyroid cartilage; E, epiglottis.

FIG. 2. Sagittal section of the larynx. C, cricoid cartilage. Other lettering same as Fig. 1.



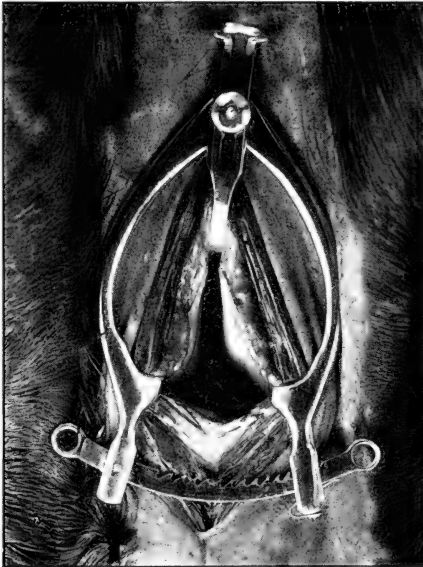
*Fig. 1.*



*Fig. 2.*



and posteriorly by the cricoid ring. Error may occur here and the space between the cricoid and first tracheal rings be mistaken for the crico-thyroidean ligament. This is readily obviated by careful digital palpation, which reveals the triangular crico-thyroidean ligament with its rounded apex directed forward and its lateral borders sharply defined by the hard borders of the alæ of the thyroid cartilage, while the base of the triangle rests upon the more elastic anterior border of the cricoid cartilage.



*Fig. 3.*

Laryngeal dilator in position.

Having carefully identified the crico-thyroidean ligament, place the back of the scalpel against the anterior border of the cricoid cartilage, accurately upon the median line, the point directed obliquely backwards toward the cavity of the trachea. Push the scalpel through the ligament into the

laryngeal cavity, and carry the incision forwards on the median line to the body of the thyroid cartilage.

Detach the slotted piece from the laryngeal retractor (Fig. 4) and insert the closed retractor into the incision through the ligament, the ratchet end of the speculum being directed toward the trachea, the curved spurs on the jaws of the retractor resting within the cricoid ring. Open the dilator to the full extent of the crico-thyroidean space. Insert the hook of the slotted piece into the cavity of the thyroid cartilage and secure in position by means of the thumb screw.

Illuminate the cavity of the larynx. In the standing animal, when facing good light, the natural illumination suffices. The illumination may be improved with the aid of a hand mirror.

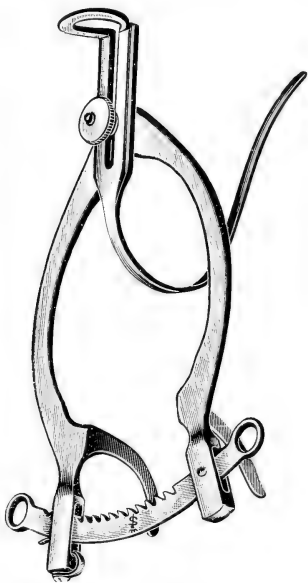
Excellent illumination is always available by means of a reflecting electric lamp. With a good lamp the illumination may be perfectly controlled in a dark room or in the darkness of night. When the animal is cast and turned upon his back, the light rays should enter the larynx from above obliquely downward and forward. If the operation is being done in the open field by sunlight, the patient's head should be directed away from the sun, or good illumination fails.

Observe the motion of the arytenoid cartilages, and determine, if not previously done, whether the unilateral or bilateral operation is to be performed. Inject into the larynx and laryngeal ventricle or ventricles a sufficient quantity of a solution of cocaine and adrenaline to blanch and anaesthetize the mucosa. The ventricles are more conveniently injected if the syringe nozzle is bent near the tip.


The ventricles commonly contain some mucus, which interferes with the securing of the mucosa and should be taken up and removed by means of a small piece of absorbent cotton pressed into the ventricle with the long curved dressing forceps.

When the ventricular mucosa has been effectively anaesthetized introduce the burr into the ventricle and draw the

sheath on the burr shaft away from the burr for the distance of about 1 cm. Press the burr gently against the bottom of the ventricle, hold the canula to prevent its revolving, and give the burr one or two turns to the right until the resistance indicates that the mucosa is securely engaged. The canula is now pushed against the burr and gentle traction applied to the handle, revolving the burr and canula



**Fig. 4.**  
Laryngeal dilator.



**Fig. 5.**  
Ventricular burr, modified  
after Blattenberg.

now and then a trifle, until the everted mucosa from the bottom of the ventricle appears beyond the mouth of the ventricle. Grasp the everted portion of the mucosa securely with the long curved dressing forceps and then continue traction with these until the ventricular mucosae has been completely everted. Then cut away the everted mucosa by excising it with the razor-shaped scalpel or by means of

long scissors at approximately the point indicated by the dotted line in Plate XV.

If the right side of the larynx appears to be affected also, or if for other reasons it seems desirable, repeat the operation upon the right ventricle.

(The operation may also be performed without the use of the ventricular burr, but it is more difficult, especially upon the standing animal. The technic is the same until the removal of the ventricular mucosa is reached, when, instead of the burr, the mucosa of the ventricle at its arytenoid border is grasped with the forceps, tension is applied, and the mucosa is incised along the arytenoid border and thence along the summit of the vocal cord. The incision is continued at the point indicated by the dotted line in Plate XV until the ventricular mucosa has been isolated from that of the larynx in general. Cautiously exerting tension with the forceps upon the incised border of the ventricular mucosa, dissect it away from the loose underlying areolar connective tissue either with the Moeller razor-shaped scalpel or with a scalpel handle.)

However the mucosa is removed the operator should take care that the removal is complete, since any remnant incautiously left behind in the ventricle may prevent the desired adhesion of the arytenoid to the thyroid cartilage or a small patch of mucosa being left deep in the ventricle might permit adhesion of other parts, imprisoning the mucous islet and ending in a mucous cyst.

When the mucosa has been removed from one or both ventricles, all blood coagula should be wiped away, any shreds of tissue removed and the denuded tissues painted over with tincture of iodine. The application of the tincture of iodine is best made with the long curved dressing forceps carrying a small pledget of cotton saturated with the drug. The operator needs have care in this application lest the horse in forcible expiration blow some of the iodine in his face and eyes.



If the patient has been cast, anaesthetized and turned upon his back, turn him upon his side, remove the confining apparatus, and, while he is recovering from the anaesthesia, keep the laryngeal incision open and the larynx free from blood. The hemorrhage from the operation is the greatest when it has been performed under general anaesthesia, less if cast and the operation performed under local anaesthesia and by far least of all when it is performed upon the standing animal with the aid of cocaine-adrenaline anaesthesia.

As soon as the operation has been completed upon the standing animal, the head may be released and the patient returned to the stall. It may be allowed to eat or drink at convenience. The same is true of the patient cast for the operation, and only local anaesthesia applied. Patients cast and chloroformed should be prevented from eating or drinking for some hours and should be fed sparingly for three or four days.

During the first 48 hours after operating, especially after the bilateral operation, the patient should be closely watched in reference to dyspnoea either from hematoma in the ventricles or from edema or emphysema of the parts. If dyspnoea becomes at all apparent, tracheotomy should be promptly performed, or what we greatly prefer, a laryngeal tube should be inserted and fixed securely to the margins of the external wound by means of stout sutures, and further security given by passing strong tapes about the neck and tying firmly.

Ordinarily the ventricular wounds should not be disturbed after the operation. The external wound should be dressed antiseptically daily till healed; a period of about three weeks. Horses used for ordinary work purposes may usually be returned to their work after five to six weeks.

#### 14. INTRA-TRACHEAL IRRIGATION.

**Objects.** The washing out of oils or other insoluble or irritant substances accidentally introduced into the trachea and bronchi while drenching or otherwise, and the disinfection of the trachea and bronchi.

**Instruments.** Same as for tracheotomy, and a gravity irrigating apparatus fitted with 3 m. of rubber tubing about 1 cm. in diameter, 5 liters of .6 per cent. sodium chloride solution at a temperature of 37 to 39° C. In cases of suppurative bronchitis, peroxide of hydrogen may be added to the solution.

**Technic.** Operate on the standing animal. Perform tracheotomy (page 76). Elevate the gravity apparatus containing the irrigating fluid 1 to 2 m. above the patient, have the animal's head slightly elevated, insert the free end of the rubber hose in the trachea tube and let the fluid flow into the trachea in a moderate stream until it is filled and the animal makes expulsive efforts, when the inflow is stopped and the animal permitted to lower his head and expel the fluid, then raise the head again and repeat until the fluid is expelled clear. Repeat the operation according to requirement.

---

#### 15. INTRAVENOUS INJECTION.

*Fig. 6.*

**Instruments.** Scissors, hypodermic syringe.

**Technic.** The operation is performed on the standing animal on either jugular vein at about the juncture of the upper and middle thirds of the neck; to most operators the right jugular is the more convenient. At the place designated the subscapulo-hyoideus muscle lies between the jugular vein and the carotid artery and affords some protection against injury of the latter. After clipping the hair,

the skin should be carefully disinfected preferably with tincture of iodine. The vein lies in the jugular groove between the mastoido-humeralis and the sterno-maxillaris muscles covered only by the skin and skin muscle.

Stand by the shoulder of the horse and compress the jugular with the thumb as shown in Figure 6 or with the second to the fourth fingers, in which case the ball of the thumb rests on the mastoido-humeralis muscle, in a way that the vein becomes filled above the point of compression in the



*Fig. 6.*

Intravenous Injection.

shorn area and stands out as a swollen cord. In the case of fleshy necked horses efficient compression is more readily attained if the head is somewhat elevated and extended by an assistant. If the vein cannot be made prominent in this way the compression should be alternately applied for a time and then withdrawn suddenly, when the course of the vein reveals itself by a wave-like movement along the jugular groove.

In cattle digital compression of the jugular is not usually efficient in causing distension. It is more practical to distend the jugular by passing a looped cord around the base of the neck and drawing it tightly. The very conical neck of the cow tends to cause the cord to slip forward and loosen, which may be obviated by having an assistant grasp the cord at the top of the neck and hold it in place. A very efficient method for distending the jugular of the cow is to stretch a strong cord tightly between two posts at the height of the base of the neck, lead the animal against it and secure the head firmly to a post in front of the animal sufficiently tight to cause the lower part of the neck to press firmly against the cord.

Just above the point of compression the vein is the most fully distended and firmly fixed. After testing the hypodermic needle to see that it is open hold it between the second and third fingers while the thumb covers its basal opening and thrust it through the skin, cutaneous muscle and jugular wall, in the direction of the vein obliquely forwards and upwards 1 to 2 cm. deep, so that the point of the needle enters the vessel at its most distended part. In this way it is easy to prevent injury to the median wall of the vein. If the vein has been properly punctured blood will flow from the needle upon the removal of the thumb. If the vein is not entered at the first attempt the needle should be partly withdrawn and then pushed in again in a slightly different direction.

**Be careful that the hypodermic syringe contains no air.** *The material to be injected should be warmed to approximately the body temperature.* The syringe is then connected with the needle and the contents slowly discharged into the vein. In withdrawing the needle be careful to press the skin firmly against the underlying part. The omission of this precaution frequently results in the formation of a subcutaneous hematome.

## 16. PHLEBOTOMY.

*Fig. 6.*

**Instruments.** Razor or scissors, fleams, lancet, phlebotomy trocar, spring lancet, pins, suture material.

**Technic.** a. *Phlebotomy with fleams* may be performed on either jugular vein. The operation is preferably carried out on the standing animal, but is not difficult when the patient is recumbent. The point of operation is at about the boundary line between the upper and middle cervical regions, because it is here that the subscapulo-hyoideus muscle which separates the jugular vein from the carotid artery is most voluminous and consequently affords the greatest protection to the latter. At this point clip or shave and disinfect the skin. Grasp the extended blade of the fleam at the hinge with the thumb and index finger of one hand, while the third and fourth fingers compress the jugular vein at a point far enough below that the fleam blade rests upon the shaved part. In fleshy-necked animals the course of the vein may be clearly made out by causing its repeated distension and relaxation. In some very heavy necked horses, or in very restless animals, efficient distension of the jugular is best obtained by cording the neck as described under "Intravenous Injection."

It is well to be careful that the point of the fleam blade is not allowed to prick the skin prematurely and render the animal restless. The instrument should be held perpendicular to the surface and parallel to the long axis of the vein. The most elevated point of the vessel should be struck by the blade in such a way that the skin, subcutaneous muscle and jugular wall are penetrated parallel to the long axis of the vessel.

Drive the fleam blade into the vein by a short, sharp blow with a small stick of heavy wood. The extension on the fleam blade prevents its being driven too deeply. The size

of the blade to be used depends upon the thickness of the skin and other tissues covering the vein. If the vein is opened, dark red blood escapes from the wound in a large stream. If the operation does not succeed at the first effort, one should select an undamaged portion of the skin for a second attempt so that the opening into the vein may be direct and clean.

When the vein is opened lay the instrument aside. The compression of the vessel must be continued in order to insure the flow of blood, to prevent aspiration of air and also to provide that the lips of the skin wound shall not become displaced in relation to that of the vein by which the escape of blood would be impeded or stopped. The flow of blood may be favored by inducing masticatory movements by the animal. The amount of blood withdrawn varies between 3 and 8 liters, according to the size of the animal and the object to be attained.

The wound may be closed by an interrupted or a pinned suture. For the latter, relieve the compression on the vein and grasp the lips of the skin wound between the finger and thumb and stick the pin perpendicularly through the middle of them a few mm. from their borders. Apply a noose of silk ligature, previously prepared, over the pin and close and tie the loop. In applying the pin and loop, take care not to elevate the skin from the underlying part, which tends to the production of a hematome.

b. *With the lancet* the operation is preferably performed on the right side of the neck. Compress the vein as illustrated in Fig. 6, and hold the lancet between the thumb and index finger in such a manner that it can only penetrate as far as into the vein, and then push it in quickly just in front of the compressing thumb through the skin, subcutem and venous wall as deep as the fingers holding the lancet will permit.

Hold the blade perpendicular to the long axis of the vein, and avoid directing the point dorsalwards, which would

endanger the superior wall of the vessel or cause the lancet to glide over the wall and not enter the vein. When the lancet has entered the vein, extend the wound somewhat toward the head by flexing the hand dorsally. In cattle it is necessary to compress the vein by means of a cord tightly drawn around the neck, the operator taking the same position as in the horse while an assistant holds the animal by the horns or nose, or the vein may be still more effectively distended by causing the patient to press against a tightly stretched cord with the base of the neck as advised for intravenous injection on page 88. Close the wound as in *a*.

Phlebotomy with the spring lancet is carried out in a similar manner, the jugular being compressed in the same way, and the lancet, with the spring set, placed over the vein in such a way that the opening will be made in the same direction and manner as with the fleams. The lancet blade is then released and penetrates the vein. The compression below is continued as in other cases.

*c. Phlebotomy with the trocar* is performed in the same manner as has been described for intravenous injection. So long as the flow of blood continues the compression of the vein must not be intermitted. The phlebotomy trocar should be about 5 mm. in diameter.

---

## 17. LIGATION OF THE CAROTID ARTERY.

### *Plate XVI.*

**Objects.** The control of hemorrhage from wounds or the prevention of hemorrhage during the removal of tumors or other operations in the parotid region.

**Instruments.** Scissors, scalpel, tenacula, aneurism needle, mouse-toothed forceps, ligation forceps, suture material.

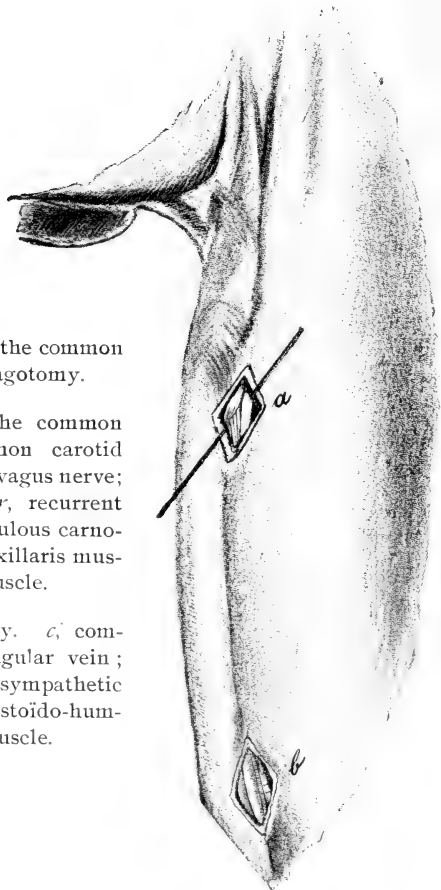
**Technic.** The operation is possible on the standing animal with the aid of cocaine or other local anaesthetic but

**Plate XVI.**

FIG. 1.—*a*, Ligation of the common carotid artery; *b*, Œsophagotomy.

FIG. 2.—Ligation of the common carotid artery; *c*, common carotid artery; *j*, jugular vein; *v*, vagus nerve; *s*, sympathetic nerve; *r*, recurrent nerve; *p*, cervical panniculous carnosus muscle; *m*, sternomaxillaris muscle; *st*, levator humeri muscle.

FIG. 3.—Œsophagotomy. *c*, common carotid artery; *j*, jugular vein; *o*, *o'*, Œsophagus; *s*, sympathetic nerve; *t*, trachea; *st*, mastoïdo-humeralis (lavator humeri) muscle.



**Fig. 1.**



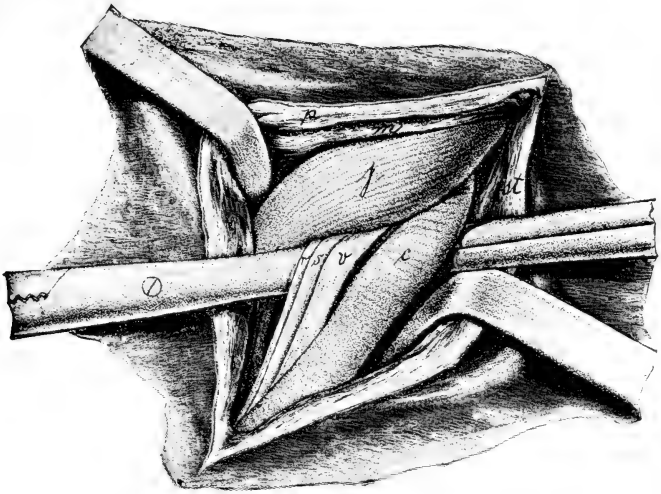


Fig. 2.

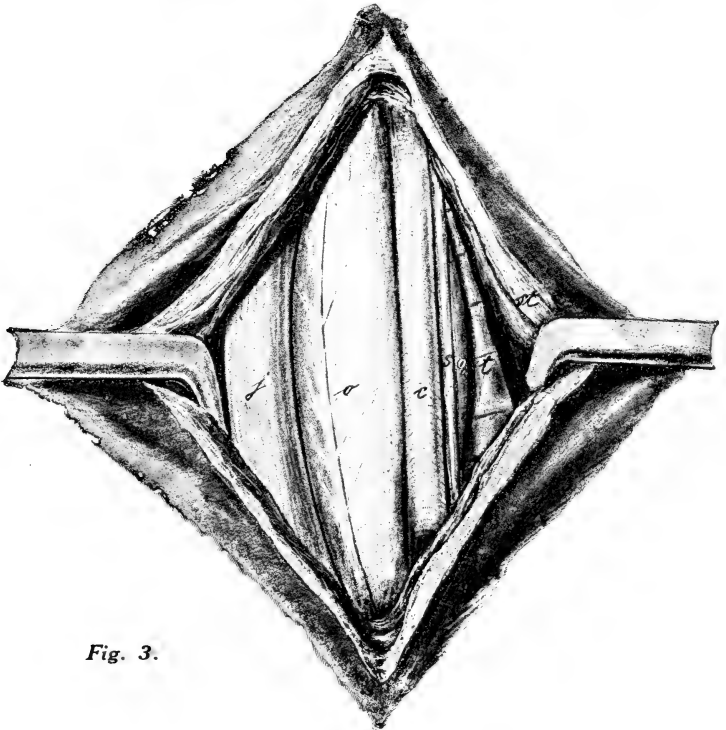


Fig. 3.



it is preferable to confine the patient in lateral recumbency and anaesthetize.

The operation is made at the same point as for phlebotomy and the same cutaneous wound, *a*, Plate XVI, may be used for this purpose. The incision should be at least 10 cm. long extending through the skin, fleshy panniculus and subscapulo-hyoideus muscles and then a passage forced with the fingers to the trachea. At the region of the neck indicated, the carotid passes along the border between the lateral and dorsal surfaces of the trachea, accompanied dorsally by the vagus and sympathetic nerves and ventrally by the recurrent. (In Fig. 2, Plate XVI, the vagus and sympathetic nerves, *v* and *s*, are pushed out of their normal position and appear ventrally to the carotid.) Pass the index finger over and behind the carotid until the trachea is reached, and encircling the inner and lower sides of the artery, force a way through the surrounding areolar tissue and draw the vessel out through the wound. As a rule the carotid is still loosely surrounded by connective tissue, which comes from the deep fascia of the neck and in which also the three above mentioned nerves are found. These nerves must be carefully separated from the carotid and must on no account be included in the ligature. Ligate the carotid twice with an interval of about 2 cm. between the two ligatures and divide the artery midway between them. The second ligature is necessary in order to prevent hemorrhage from the distal end through collateral anastomoses and it is essential to sever the artery in order to avoid its rupture by the stretching of the undivided carotid during movements of the neck where the nutrition has been cut off at the point of ligation. Provide drainage for the wound and suture the muscle and skin.

## 18. OESOPHAGOTOMY.

*Plate XVI.*

**Instruments.** Razor, scissors, convex scalpel, straight probe-pointed bistoury, tenacula, artery forceps, absorbent cotton, suture material.

**Technic.** The operation can be carried out on the standing or the recumbent animal. At its origin the œsophagus lies above the trachea somewhat to the left of the median line and as it descends it gradually deviates farther until in the lower cervical region it lies down along the left side of the trachea.

The operation is performed at any point between the pharynx and chest where the lodgment of a foreign body or other condition may demand it. When the œsophagus is empty the operation is best performed in the lower third of the neck at *b*, Fig. 1, Plate XVI.

An incision 10 cm. long through the skin and skin muscle is made on the left side between the anterior border of the mastoido-humeralis muscle and the jugular vein. With the two index fingers divide the loose connective tissue down to the œsophagus, which lies between the left scalenus muscle, trachea and jugular vein. Along the supero-external border of the trachea runs the carotid artery, accompanied dorsally by the vagus and sympathetic and ventrally by the recurrent nerves. The œsophagus feels like a round muscle within which one can distinguish a firmer cord, the mucous membrane. When brought into view the organ has a pale red color, and it, with the trachea is surrounded by the deep fascia of the neck. Pass one finger around the œsophagus from behind, draw it away from the trachea, force a passage through the deep fascia of the neck and draw it out through the external wound. After making an incision through the œsophageal muscle and mucous membrane introduce a probe pointed bistoury or a scissors blade

into the lumen of the œsophagus and split its wall. The mucous membrane is white and lies in thick longitudinal folds.

When there is a foreign body in the œsophagus the operation is performed at the point where it is lodged, in the manner described and the incision should be made only large enough to permit its removal. In diverticuli of the œsophagus an elliptical piece of the mucous membrane which has been overstretched is cut out. The œsophageal wound is closed by a laminated suture, that is, the mucous membrane is united by means of an intestinal suture and the muscular wall closed over this. The skin and muscular wound may either be left open or closed with the Bayer suture and bandaged, with a drainage tube in the lower angle.

### III. OPERATIONS ON THE TRUNK AND GENITAL ORGANS.

#### 19. PUNCTURE OF THE CHEST.

*Fig. 7.*

**Objects.** The relief of hydrothorax or pyothorax.

**Instruments.** Razor, scissors, trocar, 1 m. of rubber tubing of the same size as the trocar, vessel for receiving the escaping fluid, dressing material.

**Technic.** Operate upon the standing animal, the point of operation in the horse being the seventh intercostal space on the left side, and the sixth on the right. Dogs may be



*Fig. 7.*

Puncture of the chest; puncture of the intestine.

laid upon the table. The anterior ribs are so covered by the shoulder that they cannot be counted from before backwards and must be enumerated from behind forwards. In the horse there are usually eighteen ribs and in the dog fourteen. Counting 11 or 12 intercostal spaces from behind

we reach in the horse the point of operation on the left and right sides respectively. Clip or shave the designated intercostal area immediately above the thoracic vein. Grasp the trocar firmly with the thumb and index finger of one hand at such a distance from the point as will permit the canula to enter the chest. After the skin over the seat of operation has been drawn aside by the hand, place the trocar at the anterior border of the rib with the point inclined slightly forward and with a sharp blow with the palm of the other hand drive the instrument through the skin, cutaneous and intercostal muscles, internal thoracic fascia and pleura into the pleural sac. When the resistance ceases, the thoracic cavity has been entered. Remove the stilette and permit the pus, lymph, or other fluid to escape. This flow is at first continuous, but later becomes rhythmic, synchronous with respiration. The intermission of the flow during inspiration permits air to enter the pleural cavity unless precautions are taken against it; this is most readily obviated by slipping one end of the rubber tubing over the exposed part of the canula and placing the other extremity in the receptacle for the fluid where it will be submerged. This will not only prevent aspiration of air into the chest but will act as a siphon to aid in the withdrawal of the fluid from the pleural cavity. In the absence of the tubing the entrance of air may be avoided by closing the canula with the finger after each expiration.

---

## 20. PUNCTURE OF THE INTESTINES.

*Figs. 7-8.*


**Object.** The relief of intestinal tympany.

**Instruments.** Razor, scissors, trocar.

**Technic.** Puncture of the intestine is preferably performed on the standing horse but may be carried out on the recumbent animal. The point of operation is in the right

flank about equi-distant from the last rib, the extremities of the transverse processes of the lumbar vertebrae and the external angle of the ilium in the standing horse; at the uppermost point of the abdomen in the recumbent animal, that is, at the most prominent part of the distension. After the skin at this place has been clipped or shaved and disinfected gasp the trocar with the index finger and the thumb of the left hand and holding the instrument perpendicular to the body surface, give it a firm, quick blow with the palm of the right hand and drive it through the abdominal wall into the intestine.

With a properly constructed trocar of the dimensions suggested in Figure 8 no preliminary puncture with the lancet is required or advisable. The cutting end of the stilette should be very long, tapering and sharp so that it will cut as freely as a lancet. By performing the operation as directed the trocar ordinarily punctures the caecum.



*Fig. 8.*

Intestine trocar with sheath. Outside diameter of canula 3 mm., length of canula, 16 cm.

Withdraw the stilette and permit the gas to escape through the canula. The canula may become occluded by particles of ingesta entering it and these should be removed by reinserting the stilette. The intestine first punctured may collapse and the flow of gas cease while the tympany continues in other parts; this may be overcome by reintroducing the stilette and pushing the trocar through the distal wall of the bowel and into the intestine beyond. If this does not succeed, the trocar may be withdrawn and reinserted in a neighboring area or if need be on the opposite side of the animal.



In withdrawing the canula replace the stilette and press the skin against the abdomen with the thumb and finger of one hand while the trocar is drawn out with the other. This tends to prevent particles of ingesta from following the canula out of the intestine and becoming lodged at some point in the track of the wound to set up inflammatory processes there.

Before introduction, the trocar should always be rendered sterile but should not bear irritant antiseptics, which becoming lodged in the wound tend to irritate the tissues and produce abscesses. Puncture of the intestine is so often extremely urgent that deliberate aseptic precautions are not always practicable and trocarization only too frequently results in abscesses in the abdominal wall. Its prevention must depend chiefly upon the disinfection of the skin and instrument. It becomes important to use an instrument which is clean in advance. If the one one shown in Fig. 8 is well disinfected after using and the sheath is filled with alcohol before it is screwed on, the instrument will remain sterile until it is again unsheathed when the alcohol will quickly evaporate and leave the trocar aseptic.

---

## 21. SUBCUTANEOUS CAUDAL MYOTOMY.

### *Fig. 9.*

**Object.** The correction of curved tail.

**Instruments.** Sharp straight tenotome, bandage.

**Technic.** The point or points of curvature and their extent are to be carefully noted by having the animal trotted away from the operator. The curvature is generally due to unequal development of the two levator or extensor muscles, Fig. 9.-*e*, though quite rarely the depressors, *f*, may be implicated.

Confine the animal in stocks, or in default of these, control by means of a twitch and sideline. Cleanse and disinfect the tail and have it sharply bent by an assistant in the opposite direction to the curvature. Locate the longitudinal furrow between the levator and depressor muscles on what has now become the convex side and at the lower margin of the levator and just above *v*, Fig. 9, insert the tenotome at the most prominent part of curvation, the incision being parallel with the muscular fibers, and push

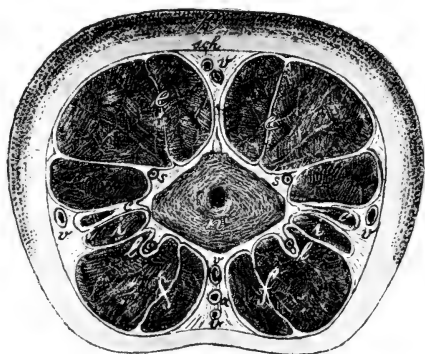


Fig. 9.

Transverse section of the tail. *n*, caudal vertebra; *c*, sacro-coccygeus lateralis muscle; *e*, sacro coccygeus superior; *f*, depressor longus and brevis muscles (sacro-coccygeus inferior); *i*, intertransversales muscles; *a*, coccygeal artery; *s*, supero-lateral coccygeal artery; *l*, infero-lateral coccygeal artery; *v*, caudal veins (dorsal, ventral, lateral); *sch*, caudal fascia; *h*, skin.

the instrument entirely through the muscle to the vertebra, then turning the cutting edge upwards, at the same time advancing the point toward the median line, sever the entire muscle.

The superior lateral caudal artery, *s*, Fig. 9, bleeds profusely if severed, and wounding of it may usually be avoided by withdrawing the tenotome a trifle in passing that point.

Wounding the skin over the muscular incision is avoided by placing the thumb of the left hand over the line of incision so the knife will be recognized as soon as the muscle and caudal fascia are cut through. Remove the knife in the same manner as introduced. Release the horse and have him trotted again. *If the operation is sufficient, the tail should curve in about the same degree as before, but in the opposite direction.* If this has not been attained examine carefully and sever any remaining bundles of muscle, and this not sufficing repeat the operation as before at another point 5 or 6 cm. above or below the first, severing the muscle again. Or if the depressor appears implicated, sever it in a similar manner. In extreme cases the entire lateral half of the caudal muscles, tendons and aponeurosis may be severed.

Apply an antiseptic pad to the wound and retain it by a moderately firm bandage, which serves at once as an occlusive dressing and effective hemostatic. Remove the bandage after 24 hours. By this plan of operation it is not intended to tie the tail to the side of the animal during the time of healing but when bandaging immediately after the operation, the tail should be held away from the side toward which it formerly curved so that the bandage may tend to prevent the return of the organ to its former position.

---

## 22. CAUDAL MYECTOMY.

### *Fig. 9 and Plate XVII.*

**Objects.** For the prevention of the gripping of the reins by the tail.

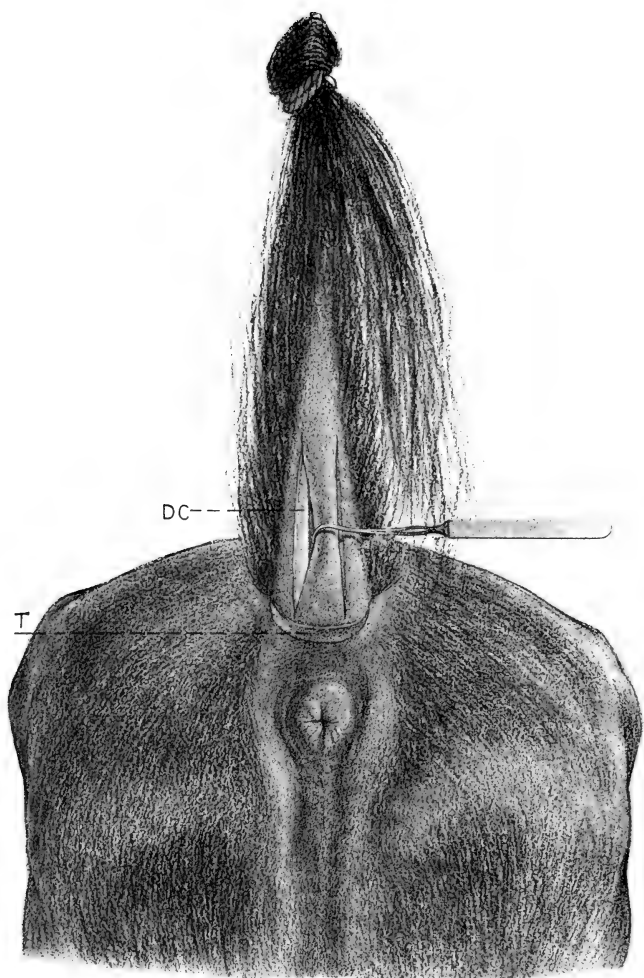
**Instruments.** Elastic ligature, straight bistoury, tenacula, absorbent cotton, bandages.

**Technic.** Confine the animal in lateral decubitus or in stocks, cleanse and disinfect the parts and apply the elastic

*Plate XVII.*

*Caudal Myectomy To Prevent Gripping  
of the Reins.*

DC, Depressor coccygeus longus muscle; T,  
tourniquet.





ligature as close as possible to the root of the tail. Have an assistant hold the tail upwards, *i. e.*, dorsalwards, and tightly stretched. Make an incision 15 to 20 cm. long, over the middle of the inferior surface of each depressor longus muscle, beginning close against the elastic ligature and extending toward the apex, severing at once the skin and caudal fascia down to the muscle. Let an assistant retract the lips of the incision with tenacula while the operator dissects the depressor longus muscle, DC, Plate XVII, from the adjacent tissues at either side, sever it by a transverse incision close against the ligature and dissect away the entire muscle down to the lower end of the wound and there excise it. Repeat the operation on the opposite side.

Make two elongated tampons of absorbent cotton, of the size and form of the muscles removed, saturate these with 1-1000 sublimate solution, insert neatly in the wounds and over this to aid in securing antisepsis and to equalize the pressure apply a pad of absorbent cotton, saturated with sublimate solution, covering the wounds and encircling the tail and secure by a moderately firm bandage as closely as possible to the elastic ligature. Remove the ligature, when hemorrhage may ensue, which is to be controlled by the application of a second bandage extending higher up on the tail. Remove the bandage in 24 hours and dress as before for a second day after which treat as an open wound. Care should be taken to not apply the bandage too tightly or leave it in place for more than 24 hours, since otherwise necrosis of the tail is liable to occur and necessitate amputation.

### 23. AMPUTATION OF THE TAIL.

#### *Plate XVIII.*

**Objects.** The treatment of malignant, or incurable diseases of the tail.

**Instruments.** Elastic bandage, scalpel, razor, artery forceps, bone cutting forceps, suture material.

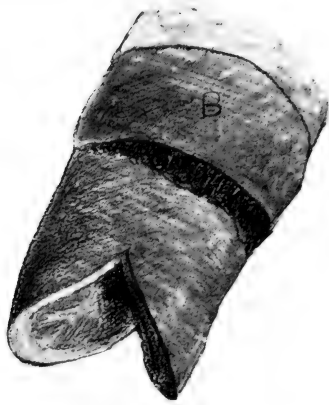
*Plate XVIII.*

*Amputation of the Tail.*

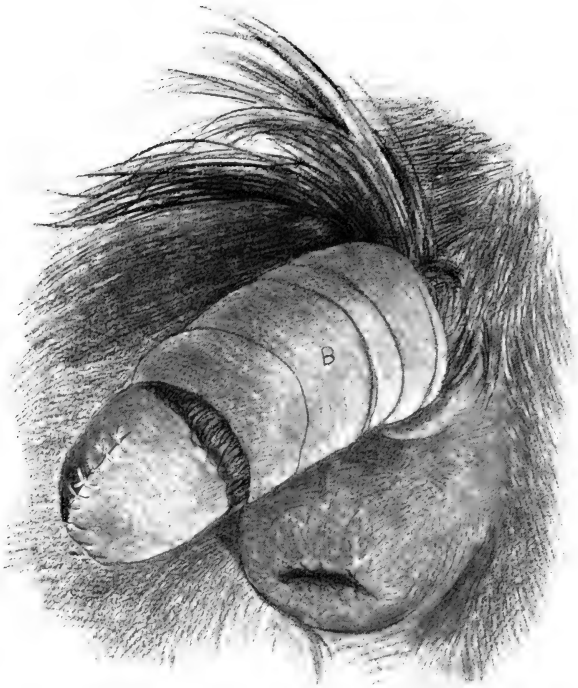
Fig. 1.—Tail amputated showing flaps unsutured; B, Bandage securing hairs turned upward out of operator's way.

Fig. 2.—Operation completed showing sutures; B, Bandage applied to secure hairs of tail upwards out of operator's way.






*Fig. 1.*



*Fig. 2.*



**Technic.** The animal may generally be operated upon in a standing position secured in the stocks or with the aid of the side line. Local anaesthesia may be applied by injecting cocaine or other drug deeply upon the nerve trunks as well as just beneath the skin. The animals' attention may be attracted by means of the twitch if found necessary. The point of amputation is determined by the location of the disease. Over the area of operation clip the hair, shave and thoroughly disinfect. Apply the tourniquet or elastic bandage at the base of the tail so as to render the operation bloodless.

Above the seat of operation turn the hair upward toward the root of the tail and secure it there by means of the bandage, B, Fig. 1, Plate XVIII. Locate as accurately as possible the position of a joint at the point where it is desired to operate and with the scalpel begin an incision on the median line on the upper side of the organ about 1 cm. above the articulation and carry this obliquely outward for a distance of 4 to 6 cm. according to the size of the tail and then continue it downward, backward and inward along the side and inferior surface until directly opposite to the place of beginning. Make a similar incision upon the opposite side of the tail, cut through all the connective tissue and muscles down to the bone and then disarticulate with the aid of the scalpel. Search for the arteries and control the hemorrhage by torsion or ligation. The vessels will be more readily found by loosening the tourniquet so as to permit the blood to flow.

Some operators prefer to begin the incision at the side of the tail instead of upon the dorsal surface and in that way have a dorsal and ventral flap instead of right and left as indicated in Fig. 1, Plate XVIII. The excision having been completed the flaps are brought together by means of strong silk or silk worm gut sutures as shown in Fig. 2. The

sutures should be begun at the apex of the two flaps and comparatively deep.

Disinfect the stump thoroughly and if the hair is sufficiently long it is well to draw it down over the wound, to which an antiseptic covering has been applied, and retain the dressing in position by tying a cord around the hair just beyond the point of amputation.

## 24. URETHROTOMY. LITHOTOMY.

*Figs. 10-11.*

**Objects.** For the removal of calculi from the bladder or urethra or performing other operations on these parts.

**Instruments.** Catheter, convex scalpel, scissors, artery and compression forceps, tenacula, lithotome, lithotomy forceps, lithotrite, absorbent cotton, drainage tube, suture material.

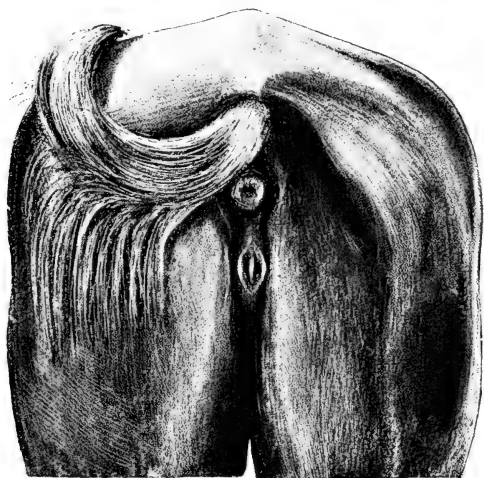
**Technic.** Urethrotomy may be performed on horses in a standing position, the hind feet being secured with hobbles.

It is best, however, to operate under anaesthesia with the patient in lateral or dorsal recumbency, either on the operating table or cast, being careful to secure as gently as possible, having first emptied the bladder if practicable, since rupture of an overdistended viscus may readily occur during violent struggles by the animal.

The point of operation will depend upon the location of the calculus or other obstacle. If it is found in the pelvic portion of the urethra or in the bladder, the operation is made at the ischial notch, Fig. 10. First the penis is drawn out from the prepuce and the catheter introduced into the urethra and pushed upward until it has passed the ischial notch. After disinfection of the skin, render it tense and make a 5 cm. long incision on the median line at the ischial arch through the skin, bulbo-cavernosus muscle, spongy portion of the urethra, and the urethral mucous membrane

down to the catheter, Fig. 11, k. In order to prevent infiltration of urine after the operation, special care is to be taken to make the lower end of the wound slanting in such a manner that the deeper margin is higher than the superficial.

After the catheter has been drawn back away from the ischial arch, introduce the lithotomy forceps into the urethra or bladder, grasp the stone and draw it outward in its natural direction. The grasping of the stone with the forceps is



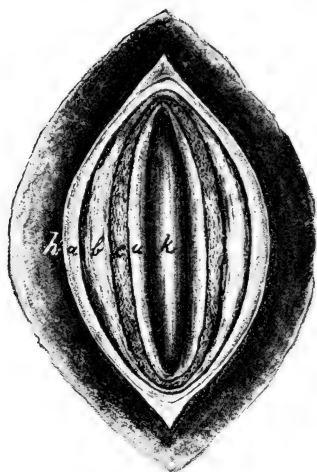
*Fig. 10.*

Urethrotomy at the ischial notch.

materially aided by means of the left hand introduced into the rectum. One must avoid grasping, along with the stone, the mucous membrane of the bladder. Partial filling of the bladder with a tepid aseptic solution will aid in grasping the calculus and in avoiding the implication of the bladder walls. By careful rotary movement and pushing the forceps backward and forward the operator can determine before traction is exerted if the forceps can be with-

drawn easily and without much resistance through the neck of the bladder.

If the stone is so large that it cannot pass the neck of the bladder lithotripsy may be performed. This operation requires time and patience, since as a rule it is not possible to encompass the entire calculus with the forceps. That is, the narrowness of the neck of the bladder prevents the sufficiently wide opening of the forceps. The stone con-



*Fig. 11.*

Urethrotomy (life size). *h*, skin; *a*, retractor penis muscle; *b*, bulbo-cavernosus muscle; *c*, spongy urethra; *u*, urethra; *k*, catheter.

sequently must be gradually broken off at its periphery and the individual pieces of calculus removed. The character of the surface of the stone has an evident bearing upon the practicability of lithotripsy.

The surgical dilation of the pelvic urethra with the lithotome is usually far more practical than the crushing of the stone. Introduce the instrument and divide the urethra upward on the median line as the instrument is withdrawn.

In order to prevent injury to the rectum it should be emptied of feces before the operation is undertaken. After the removal of the stone, the operator may push the catheter again over the ischial arch and unite the lips of the wound in the urethral mucous membrane by means of intestinal sutures. Flush the bladder and urethra by means of a warm, 3 per cent. boric acid solution injected through the catheter and then withdraw the latter. Finally, suture the skin wound and insert a drainage tube or iodoform gauze in the lower angle.

Or the whole wound may be left entirely open and dressed daily with antiseptics. In case the pelvic urethra has been divided the suturing of the external wound is of questionable utility.

(For student practice on an anaesthetized horse, introduce a stone into the bladder through the urethral wound and practice grasping and removing it with the lithotomy forceps.)

---

## 25. AMPUTATION OF THE PENIS.

### *Plate XIX and Fig. 12.*

**Instruments.** Scalpel, elastic ligature, strong silk suture, strong piece of tape 1 m. long, artery and compression forceps.

**Technic.** The operation is carried out on the recumbent animal under local or general anaesthesia, the upper hind foot being drawn backward or upward or otherwise so fixed as to not obstruct the field of operation. The point of operation is determined by the character of the disease and the object to be attained. It may be made at any point from the glans penis to the attachment of the corpus cavernosum to the ischium. If possible amputate in front of the preputial ring.

*Plate XIX.*

*Amputation of Penis.*

Fig. 1.—First stage of operation. T, Elastic ligature used as tourniquet; CS, Corpus spongiosum of urethra; S, Skin; CC, Corpus cavernosum; U, Urethra; L, Ligature; C, Catheter.

Fig. 2.—Completed operation showing sutures.  
U, Urethra.



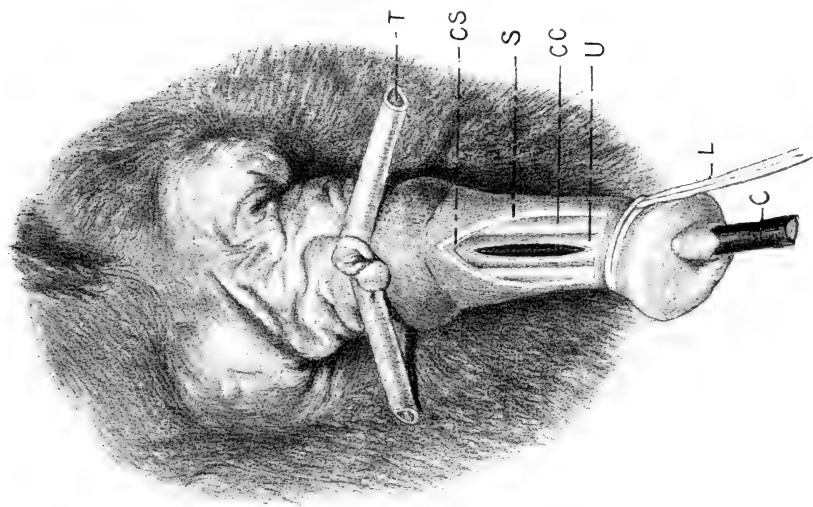


Fig. 1.

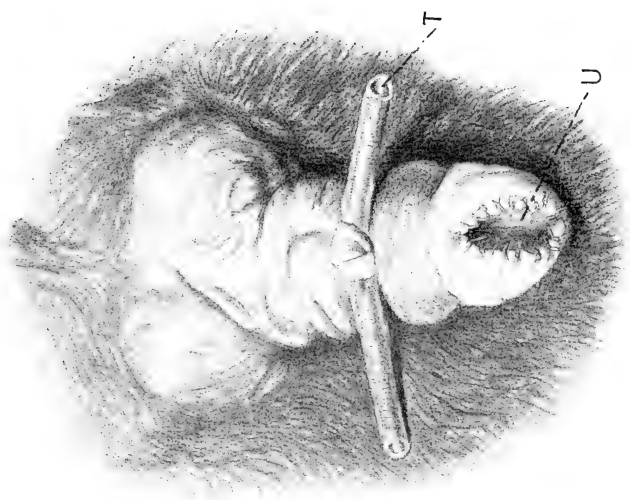
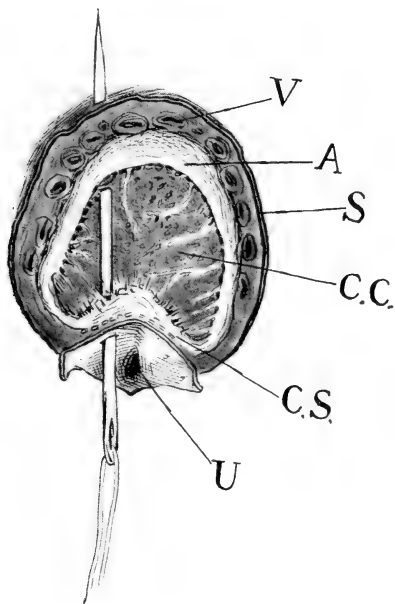


Fig. 2.



After the penis has been drawn out, and the preputial region carefully cleansed and disinfected, an assistant grasps the organ just behind the preputial ring and holds it firmly. A catheter is then introduced into the urethra and pushed upwards beyond the point where it is designed to amputate the organ and a temporary elastic ligature, T, is then applied



*Fig. 12.*

Amputation of the penis, showing needle inserted for a suture.

V, Dorsal vessels of penis ; A, Fibrous tunic of the corpus cavernosum ; S, Skin ; CC, Corpus cavernosum ; CS, Corpus spongiosum of urethra ; U, Urethra.

above the assistant's hand around the penis, or a piece of tape is looped around it above the hand and is made to serve both as a tourniquet and as a means for holding the penis. Or the penis may be grasped in front of the ligature with double tenaculum forceps and held.

Apply a small cord just behind the glans penis, L, Fig. 1, Plate XIX, and then make a triangular incision on the ventral surface of the organ about 4 cm. long by 3 cm. wide, the base of the triangle being forward as shown in Fig. 1; carry this incision through the skin, S, the corpus spongiosum, CS, and along the corpus cavernosum, CC, down to the urethra, U. Dissect away the tissues in the triangular area without opening or wounding the urethra and when this has been completed make a longitudinal incision from near the apex of the triangle to its base through the urethral walls to the catheter. Beginning at the apex of the triangular wound insert a series of interrupted sutures as shown in Fig. 2, Plate XIX in such a manner that they pass through the urethral wall and the skin so that when tied the wounded surfaces are completely hidden and the urethral mucous membrane is brought into apposition with the integument. Continue these sutures down to the base of the triangle after which remove the catheter and excise the organ by a cut extending in a slightly oblique direction from below upwards and forwards. Take a straight needle armed with the silk suture and passing it through the margin of the urethral wound, the adjacent fibrous capsule of the corpus cavernosum and across but not through the erectile tissue, insert it again into the superior portion of the fibrous capsule and carry it out through the adjacent dorsal vessels and the skin as shown in Fig. 12, and, bringing the ends of the sutures together, tie in such a way that the urethral mucous membrane and the margin of the skin are brought into immediate contact and the blood vessels securely closed in such a manner as to guard against hemorrhage. By this plan when the sutures are tied, the cut borders of the fibrous envelope are brought together over the erectile tissue, thus preventing hemorrhage from that tissue also. Insert as many sutures as may be required to completely and securely close the wound

and finally leave every part wholly covered with epithelium. By this plan it is hoped to avoid stricture of the urethra in the process of healing. Remove the tourniquet and release the patient.

## 26. VAGINAL OVARIOTOMY IN THE MARE.

*Figs. 13-14.*

**Objects.** The alleviation of vice when related to ovarian irritation or disease.


**Instruments.** Colin's scalpel, ratchet ecrasure, 55 cm. long, vaginal tensor.

**Preparation of patient.** It is highly important that the animal should be kept on a scant laxative diet for at least 24 hours and preferably longer prior to the operation, so that the alimentary canal shall be somewhat empty and thus decrease the intra-abdominal tension and relieve the operator from much annoyance due to the pressure of the viscera.

**Technic.** The vagina of the mare is unique in its physiological behavior. Under venereal excitement or the introduction of the operator's hand or of tepid water the organ has the power of "ballooning" or dilating to a degree not so marked in other animals; the vaginal walls become erected, hard, and stand apart from each other, filling the pelvic cavity, resting firmly against the pelvic bones and ligaments at every part except at the points where the bladder and rectum intervene and these organs are pressed out flat and occupy a minimum amount of space. In the quiescent state the vaginal walls are in contact and from the perinaeum forward to within about 10 cm. of the uterine os, the vulva and vagina are connected above with the rectum by the pelvic connective tissue, while anterior to this point the vagina is covered by peritoneum, and it is

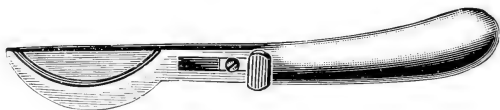
in this area that the incision needs be made in the operation. The ballooning of the vagina profoundly alters the relation of this operative area, and changes it from the horizontal in the quiescent organ to the perpendicular in the ballooned condition. These variations permit of two methods of operating: I. On the ballooned organ without anaesthesia and with the animal confined in the standing position. II. On the quiescent organ in the recumbent position under anaesthesia:

I. *Without anaesthesia.* Secure in the stocks with the head elevated, a rope over the back to prevent rearing,



*Fig. 13.*

Special spraying ecraser, 55 cm. long.



*Fig. 14.*

Colin's scalpel.

straps beneath the body to prevent lying down, straps or ropes before and behind the animal to prevent backward and forward movements, all four feet pinioned to the floor, and the tail firmly secured and stretched to a beam above. Apply a bandage to the tail extending for a distance of 12 to 15 inches from the base of the tail in order to secure the tail hairs out of the way of the operator.

With soap, water and brush cleanse the tail, perineum and vulva thoroughly, being especially careful to remove all

detachable masses of sebum ; 50 per cent. alcohol may be used sparingly to aid in removing this. Too free a use of alcohol excoriates the delicate skin. Cleanse the clitoris carefully. Follow the washing with a free application of 1:1000 aqueous sublimate solution to the external parts and for a short distance inside the vulvar lips and to the clitoris. Do not introduce irritant disinfectants into the healthy vagina nor deeply into the vulva as it may cause severe straining during and subsequent to the operation and by injuring the vulvo-vaginal mucosa favor subsequent infection of the vaginal wound.

Wash away the sublimate solution with a tepid 0.6 per cent. soda bicarbonate solution, and fill the vulvo-vaginal canal with the same. After thorough disinfection of the hands and arms remove the disinfectants by washing in sterile soda solution, which at the same time renders the hand unctuous and readily introduced through the vulva. Armed with the guarded sterilized scalpel, Fig. 14, introduce the right hand into the vagina promptly and when it is well "ballooned" unsheath the knife and placing it just above the os uteri parallel to the long axis of the uterus and a few mm. to the right or left of the median line in order to avoid a loose fold of mucous membrane generally existing there, the blade being held vertical, that is the cutting surface parallel to the longitudinal muscular fibers of the vagina, and guarding the possible extent of its introduction with the thumb and fingers, push it directly forward in a straight line with a quick thrust through vaginal mucosa, the muscular walls and the peritoneum, until the disappearance of resistance indicates that the latter has been penetrated. This is the most critical step in the operation.

If the hand is introduced into the vagina immediately after the injection of the sterile saline solution the vagina will generally be found "ballooned" or will quickly become inflated under manual movements. If the solution is thrown

out the vagina may collapse and closely invest the hand, in which case more of the liquid should be injected when it will again dilate. If the hand is introduced without the knife, withdrawn and then introduced with it, it will be frequently found that the vagina has collapsed and needs a second filling with the fluid. Patience until dilation is accomplished and promptness to act when attained are prime requisites to success.

The knife should be pushed through the vagina quickly making a clean wound the width of the blade, when the latter is to be withdrawn and laid aside. It should be remembered that in this "ballooned" state, the anterior wall of the vagina is but 2 or 3 mm. thick and easily penetrated. Introduce the hand again, push one finger into the incision, then a second and third, and eventually holding all the fingers in the form of a cone push the entire hand into the peritoneal cavity. Immediately below the incision and continuous with the tissues involved in the wound lies the uterus with a transverse diameter of 4 to 6 cm. With the palm of the hand downward, trace the uterus forward a distance of 15 to 18 cm., where it ends abruptly in two cornua of about the same size as the body, which are given off horizontally at almost right angles. Trace these to the right and left for a distance of 14 or 15 cm., where they end obtusely, and 3 or 4 cm. beyond this in a direct line, resting upon the anterior border of the broad ligament is the dense oval ovary varying in size from 2.5 to 7 cm. in diameter.

Prepare the ecraseur for use by withdrawing the chain until the loop is of barely sufficient size to admit of its being readily slipped over the ovary. Grasp this loop and the end of the ecraseur tube in the hand, carry the instrument to the ovary and drop the loop over it from above. Pass some of the fingers beneath the ovary and push it up through the chain loop and grasp it there with the thumb



and index finger. Holding the ovary with one hand tighten the chain quickly with the other, examine to make sure that a loop of intestine is not caught, draw the ovary well through and get a large portion of the oviduct, and crush off promptly, holding to the gland until carried out through the vulva. Remove the other ovary in the same way. Generally it is most convenient to remove the left ovary with the right hand and vice-versa but each may be removed with either hand. Wash away any blood from the external parts, apply sublimate solution freely to the vulva, perineum and tail. Keep the patient quiet for five or six days, and feed lightly on a laxative diet.

II. In operating under anaesthesia the animal should be cast or confined upon the operating table in lateral recumbency preferably with the posterior part of the body somewhat higher than the anterior so as to avoid visceral pressure in the pelvic cavity. Place the animal under complete anaesthesia. Prepare the parts in the same manner as already described. Carry the knife into the vagina in the manner previously described and render the roof of that organ tense by pushing the os uteri downward and forward with the hand or by means of a vaginal tensor or speculum. It is important that the vagina be held well down toward the floor of the pelvis so as to carry it away from the rectum, posterior aorta and iliac arteries while the incision is being made. The incision is now to be made just above and behind and a trifle to one side of the os uteri in essentially the same manner as under I, except that when the vaginal tensor is used the cut is made upward and backward instead of directly forward. The remainder of the operation is identical with what we have described under I. Under anaesthesia the vagina is flaccid and can not be made to "balloon."

**DANGERS.**

**Wounding of the rectum** is scarcely possible under the first method if care is taken not to attempt the incision until the vagina is well "ballooned," and then making the stab wound directly forward. If made upwards when the organ is so erected the accident is highly probable, and with the undilated vagina where it is necessary to cut upwards the danger is ever present. Its prevention demands that in the first method, the operator await the complete "ballooning" and then make his incision as directed. In the second method, the accident is to be prevented by being careful to push the vagina down away from the rectum and hold it away while the incision is being made. If the wound in the rectum passes through the pelvic connective tissue behind the peritoneum it is of little consequence, but the operation should be abandoned; if the bowel is opened into the peritoneal cavity the accident is generally fatal.

**Wounding of the iliac arteries**, which generally produces prompt death from hemorrhage, results from the incision being made upwards instead of forwards when the vagina is "ballooned" or from a failure to hold the roof of the vagina down and away from the part while making the incision in the flaccid organ as is the case with the recumbent animal under anaesthesia. It is most likely to occur with timid operators who become nervous, especially when the vagina does not "balloon" promptly or the mare is not well secured. The accident is wholly unnecessary if the operator will await the "ballooning" in the first operation while by the second method it is prevented by proper care in holding the vagina downward and forward during the incision. When it has occurred it is generally beyond remedy though in some cases the prompt intravenous injection of adrenaline chloride may stay the hemorrhage and save life of the patient.

**Wounding of the uterus** may occur when the incision is directed downward and may greatly embarrass the operator and confuse him by passing the hand through the incision into the uterine cavity. It is to be avoided in the first operation (without anaesthesia) by carefully directing the incision straight forwards. When the accident occurs it is of little consequence beyond the embarrassment and may be overcome by again dilating the vagina with fresh injections of the soda solution and making a new incision, or if preferred the first cut may be corrected by placing an index finger against the peritoneum at the upper part of the wound, and with a sudden and vigorous thrust break through into the peritoneal cavity, or the error may be corrected by again using the scalpel and directing the incision properly. If it is attempted to rupture the peritoneum with the finger it must be done by a sharp thrust since otherwise a large section of the membrane will be pushed away from the subjacent tissues.

**Incomplete penetration of the vaginal wall** is liable to occur if the scalpel is *dull* or the vagina imperfectly "ballooned" and flaccid, or if the operator is unduly timid. It is best prevented by avoiding the causes as related, and once it has occurred it is generally best to again "balloon" the organ in the operation without anaesthesia and make a new incision either to the right or left of the first. It may be overcome also by thrusting the index finger through the peritoneum as described in the preceding paragraph or completing the cut with the scalpel.

**The mistaking of a ball of feces for the ovary** has occurred to inexperienced operators and the fatal error of removing the portion of the rectum surrounding the fecal pellet committed. The blunder is uncalled for; the fecal ball is movable in the bowel, the intestine is far more massive than the broad ligament, and the ovary is to be definitely identified by its being lodged in the broad ligament just

beyond the end of the cornua, which is continuous with the uterus. If, therefore, one traces the uterus forward to the cornua, thence along each of these to their extremities and along the borders of the broad ligament to the ovary, as above directed, the error will not occur.

**The incision may be made too low** and pass beneath the broad ligament. It is to be avoided by being careful to keep close to the median line and above the os uteri. If it occurs the operation may be completed from beneath without very great difficulty only that the ovary now lies above the hand and must be drawn down from on top the broad ligament in order to fix the ecraseur upon it.

**Infection** constitutes always the most serious danger and is to be avoided by properly securing the animal, by the avoidance of irritant antiseptics in the vagina, by rigid antisepsis at every stage, and by carrying out the mechanical parts of the operation deliberately, vigorously and neatly. If infection should occur it will generally take the form of pelvic cellulitis with abscesses and rectal stricture. Enemas of a normal salt or soda solution affords the surest relief of the stricture and impaction in front of it. The abscesses must be watched and opened early into the vagina or rectum, and the case treated internally and locally according to general surgical principles.

---

## 27. VAGINAL OVARIOTOMY IN THE COW.

**Objects.** Increasing the fat- or milk-producing qualities and the cure of nymphomania or other ovarian disease.

**Instruments.** Colin's scalpel, vaginal dilator, Miles' spaying shears, spaying ecraseur.

**Technic.** Confine the cow in the standing position in the stocks, secure the head firmly and pass two boards beneath the abdomen and sternum to prevent lying down, and a rope over the middle of the back to prevent arching of the spinal column and straining.

Wash and disinfect the tail and the perineum and flush out the vagina with a 0.5 per cent. solution of carbolic acid or lysol at a temperature of about 100° F. Insert the vaginal dilator with one hand and push the prolongation at the anterior end into the os uteri. With the other hand elevate the handle of the dilator and depress and push forward the uterus, thus rendering the roof of the vagina tense and pushing it downward away from the rectum. Carry the scalpel into the vagina with the right hand and resting it in the oval of the dilator make an incision through the roof of the vagina, beginning at a point 8 to 10 cm. posterior to the os uteri and extending backward on the median line for a distance of 2 or 3 cm. Be careful to make the incision entirely through the mucosa, muscle and peritoneum at the first cut, since any failure to complete it tends to cause the peritoneum to separate from the muscular coat and form a pocket between them, while the serous membrane being very elastic renders it difficult to complete the incision. Introduce two fingers through the incision, and reaching over the side of the vagina to the right or the left, the right or left ovary respectively is recognized lying immediately against the lower part of the vagina, just at the anterior border of the pubis, in a mass consisting of the cord-like Fallopian tube and the fimbriæ of its pavilion. The ovary may be distinguished as a firm oval mass 2 to 4 cm. in length and 1 to 2 cm. in its lesser diameter attached to the broad ligament. If not promptly recognized by the sense of touch, trace the vagina and uterus forwards with the fingers from the vaginal incision to the cornua and follow them as they bend forward and downward, and then backward and upward to the oviducts, until the ovary is reached where it is attached to the broad ligament, just beyond the fimbriated end.

Grasp the ovary between the fingers and draw it through the incision into the vagina. Introduce the scissors or emasculator with the other hand, and when the ovary is

reached open them barely sufficient to admit the ovarian attachments between the blades and cut the gland away along with a portion of the broad ligament. Or introduce the ecraseur and drawing the ovary through the loop of the chain and holding it securely until the instrument is tightened, crush it off in this way.

It is essential that plenty of the broad ligament and oviduct be excised with the ovary to insure the entire removal of the latter, because the accidental leaving of the smallest particle of ovarian tissue will cause a development of this into abnormally large cystic ovisacs, and will tend to increase instead of decrease nymphomania. Should the animal be pregnant the ovary on the gravid side is dragged downward and forward out of reach of the operator's fingers, and if it is desired to complete the operation it may be necessary to enlarge the vaginal wound and introduce the entire hand, when the ovary can be reached and removed. Generally no after care is necessary.

**The Dangers** are similar to those of the mare. The iliac arteries may be wounded in the same manner as in the mare and is preventable by being careful to push the vaginal roof well downwards away from the rectum and sacrum. In rare instances fatal hemorrhage follows the cutting off of the ovaries with the scissors especially in cows sterile because of diseased ovaries accompanied by a want of tone. For this reason it is safer in cows sterile from diseased ovaries to use the ecraseur but even this instrument is not wholly proof against hemorrhage and fatalities have been rarely recorded after its use so that some veterinarians have advised ligation of the arteries instead, but this is a complex process which requires much time for its accomplishment. Another danger appears in the presence of the rumen, the supero-posterior portion of which when filled with food projects into the pelvic cavity and if the cut is directed forwards a stab wound readily penetrates its walls with fatal results. Make the cut upwards and backwards.

## **28. OVARIOTOMY IN THE COW BY THE FLANK.**

**Instruments.** Clipping shears, convex scalpel, spaying shears, or ecraseur, heavy needle and thread.

**Uses.** Same as the preceding, applicable to heifers or to cows in which the vulva is too small to admit the operator's hand or in case of diseased vagina or uterus.

The animal may be secured as in the preceding or confined in lateral recumbency with the hind legs extended backward and the anterior limbs forward. To accomplish this loop a rope about the two fore feet, another about the two hind feet, and drawing upon these, cast the animal and secure it in recumbency with the legs extended and body stretched by fastening the ropes to two strong posts about 8 to 10 m. apart. The operation may be performed in either flank.

Clip the hair from the upper part of the flank, disinfect an area 15 to 25 cm. square and make an incision about 12 cm. long beginning at a point equi-distant from the anterior tuberosity of the ilium, the ends of the transverse processes of the lumbar vertebrae and the last rib and extend it downwards perpendicularly severing the skin and subcutaneous muscle. Divide the external oblique muscle in the direction of its fibres by means of the scalpel handle or the fingers and repeat the process upon the internal oblique after which puncture the peritoneum with the scalpel. Some operators cut directly through the entire abdominal wall at a single stroke, but this comes to the operator only by experience.

Force one hand through the opening into the peritoneal cavity and search for the ovaries at the same point and by the same method as in the preceding operation, that is, locate the uterus within the pelvic cavity, between the rectum and bladder and trace it, the cornu, and broad ligament to the ovary. The uppermost ovary can be drawn out through the wound and cut off with the scissors or ecraseur; the lower one must be held with one hand and

the instrument introduced along the arm and when the ovary is reached, apply the scissors or ecraseur and cut or crush it off. The beginner must always remember that the positive means for identifying the ovaries is by tracing the uterus from the vagina along its cornua to the oviduct and thence to the organ in the broad ligament. Cleanse the wound and close the skin incision with continuous sutures.

---

## 29. OVARIOTOMY IN THE BITCH BY THE FLANK.

### *Plate XX.*

**Instruments.** Spaying knife, suture material.

**Techic.** Confine the animal in lateral recumbency, preferably upon the right side for a right handed operator, the head somewhat depressed, the limbs extended and the body well stretched. Clip, shave and disinfect a sufficient area in the exposed flank at a point just anterior to and beneath the external angle of the ilium. With one hand grasp the skin fold of the flank and render the skin of the region tense, while with the other holding the spaying knife like a pen make at first a drawing incision from below upward about 2 to 3 cm. long, ending above at a point slightly below the external angle of the ilium, the incision extending through the skin and subcutaneous tissues; without removing the knife from the wound elevate the handle and with a quick thrust make a stab wound extending through the external and internal oblique muscles and peritoneum at a single cut. The operator can determine when the peritoneal cavity has been entered by the disappearance of resistance.

Introduce an index finger into the peritoneal cavity, and as soon as this has been entered follow directly along the peritoneum upward and backward toward the angle of the ilium where the uterine cornua lie covered over by the broad ligament. The internal generative organs of the



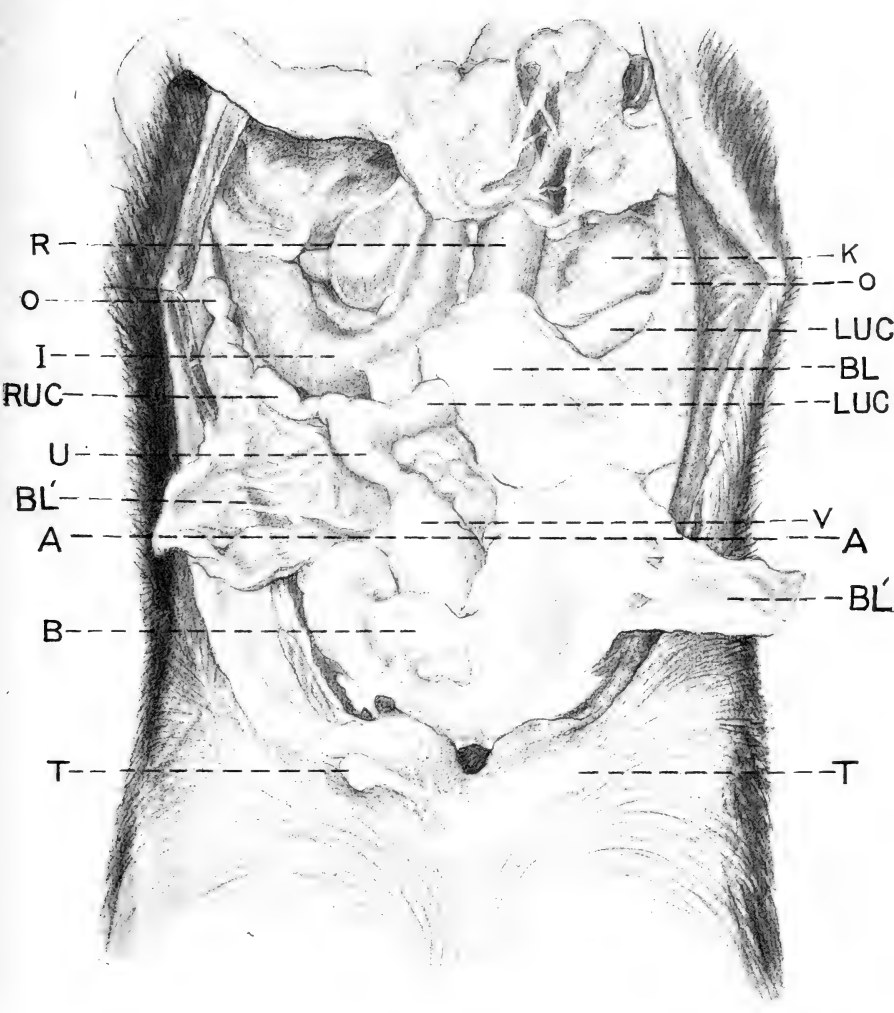
bitch are unique among our domesticated animals. The uterus, U, Plate XX, is small and physiologically unimportant, the cornua, RUC and LUC, are ample in size and constitute physiologically the uterus. The distance from the cornual extremity, LUC, to the ovary, O, which is occupied by the Fallopian tube is very brief so that the cornua and ovary are well nigh in contact. The ovary, O, O, is very small, smooth and completely hidden in the pavilion which here constitutes a sac having a very small longitudinal opening of 2 to 5 mm. The most remarkable feature of the apparatus from a surgical standpoint is the great development of the broad ligament which is broader than the distance from the lumbar region to the abdominal floor, while the uterus and uterine cornua are stretched between the vagina, V, and the ovary, O, so that they are suspended in the sub-lumbar region resulting in a double fold of the broad ligament hanging down like a curtain between the parietal peritoneum and the uterus and cornua on either side. The broad ligament of the bitch is consequently suspended at one point from the sub-lumbar region, at the other from the uterus, so that instead of that organ being suspended by the ligament the relation is reversed and the ligament is suspended from the uterus, or rather uterine cornua.

In Plate XX the right broad ligament, BL', is laid out upon the side exposing the right uterine cornu, RUC, while on the left side the ligament is divided at about its center and the posterior portion, BL', is laid out on the flank, while the anterior, BL, is left in its normal position concealing a portion of the cornu, LUC. Unlike our other domesticated animals, the broad ligament is heavily loaded with fat which gives it an appearance very similar to the omentum, but the net-work is far less conspicuous or wanting, the omentum also extends back into this region so that the two are in contact.

*Plate XX.*

*Ovariotomy in the Bitch.*

Abdomen of a non-pregnant bitch lying on the back with the abdominal floor removed and the omentum pushed away. TT, the two posterior teats; B, bladder; V, vagina; U, uterus; LUC, LUC, left uterine cornua with a portion of its broad ligament, BL, lying across it; RUC, right uterine cornua with its broad ligament, BL', turned outwards exposing the full length of the cornua. On the left side the ligament is divided so that the anterior half rests in its normal position while the posterior half, BL', is turned back. O,O, ovaries; R, rectum; K, left kidney; AA, a line indicating the level of the external tuberosities of the ilia.



R ————— K  
O ————— O  
I ————— LUC  
RUC ————— BL  
U ————— LUC  
BL' ————— V  
A ————— A  
B ————— BL'  
T ————— T



The ovary being indistinct and hidden is difficult to identify directly, and the cornua being covered over by the duplicature of the broad ligament is not readily reached, so that the finger generally comes in contact first with the broad ligament of the uppermost cornu hanging loose in the peritoneal cavity: engage this between the end of the finger and the abdominal wall and draw it out through the wound, grasp it and continue drawing upon the folds of the ligament, especially upon the median or under-most portion until the naked cornu appears through the opening, seize it and draw out the anterior portion until the ovary follows, then grasp the latter with the thumb and index finger of one hand and the ovarian ligament with the same members of the other and tear the ligament through between them by linear tension. Extend the tear through the broad ligament as high toward its lumbar attachment as is convenient and backward to the neighborhood of the uterine bifurcation. Draw upon the exposed cornu until the point of bifurcation appears, when the other branch is to be grasped and drawn out through the opening. In young puppies the securing of the second cornu is very difficult and requires great care to prevent the rupture of the first. The object may be facilitated by pressing the upper flank of the bitch downward, thereby greatly diminishing the transverse diameter of the abdomen.

The succeeding operation (30) avoids this difficulty in a large measure. Should the distal cornu be ruptured and with its ovary drop away from the operator, it becomes necessary to turn the animal over and make a second incision on the opposite side, somewhat further forward. When the second cornua has been secured draw it out as far as practicable and holding it tense insert an index finger along it until the ovary is reached, which is recognized by its slightly greater size and density succeeding the brief neck representing the Fallopian tube between the end of the cornu and

ovary, while beyond it can be felt the ovarian ligament. Engage the ligament between the end of the index finger and the abdominal wall, and with a firm and vigorous movement, using the finger end and nail as a curette, rupture the ovarian ligament by drawing the finger toward the incision, and with the aid of tension upon the cornu draw the ovary out through the abdominal incision and divide the broad ligament as before. Remove the cornua with the attached ovaries by rupturing them transversely near the bifurcation by means of linear tension.

If the bitch be pregnant and especially if far advanced the uterine cornua will lie upon the abdominal floor, much enlarged and very much more flaccid than the nongravid uterus and feeling very much like intestines. The change in the position of the uterus has caused the unfolding of the duplicature of the broad ligament so that it no longer covers the cornu. In such cases the operation is performed in the same way except that rupturing the blood vessels by linear tension does not insure against hemorrhage and it is necessary to ligate the ovarian and uterine arteries with catgut or silk. In cases of pregnancy the entire cornua should be drawn out and a strong ligature placed around the uterus or vagina, and the ovaries, uterine cornua and their contents be removed *en masse*. Release the upper posterior limb and close the cutaneous wound by a continuous suture.

**Dangers.** Rupture of the uterine cornu alluded to above. It is always to be remembered that the leaving of one ovary in position even though the other gland with the two cornua and uterus are removed, induces intense oestrus and renders the animal if anything more disagreeable than before the operation.

The ureter may be mistaken for the cornu but is smaller, is closely attached to the abdominal walls, and does not have the broad ligament with its large deposit of fat. The kidney is far larger than the ovary, more exposed, and located more anteriorly.

The iliac arteries are at times caught and ruptured by the finger but the blunder is uncalled for except through nervousness of the operator.

Instances of puncturing the bladder in making the incision have been reported. If the bitch has been led out and caused to urinate prior to operating, the accident is made practically impossible.

---

### 30. OVARIOTOMY IN THE BITCH BY THE LINEA ALBA.

#### *Plate XX.*

**Instruments.** Same as in the preceding.

**Technic.** Confine in the dorsal position with the head sharply declined. Shave and disinfect an area on the median line about 6 cm. square extending forward from the pubic brim. Make an incision on the median line about 4 cm. long beginning just in front of the pubic brim and extending forward cutting entirely through the skin, the linea alba and peritoneum. Insert an index finger and identify the uterus or broad ligament by its location and form. The finger usually comes in contact first with the urinary bladder which may more or less obstruct the passage to the uterus according to its degree of distension. When empty as shown at B, it offers practically no obstruction. When very much distended it may be evacuated by gentle pressure with the fingers. The operator should be careful not to draw the bladder out through the incision as its replacement may prove difficult and its puncture with a hypodermic needle or an enlargement of the abdominal incision may be necessary in order to bring about its return. Push the bladder aside if necessary and just above it and below the rectum the uterus should be readily distinguished and either it or the broad ligament caught by the finger and brought out through the incision after which the operation proceeds

in the same manner as by the flank method. By passing an index finger forward to reach the lower surface of the rectum in front of the uterus and then drawing it backwards the finger passes between the former and the cornua and the latter are picked up. It has a distinct advantage over the flank method in that in puppies there is not so much difficulty in bringing out the ovaries, nor the danger of the rupture of the cornua and the ovary being retained.

By the use of retractors in the abdominal incision the operator is enabled to see the uterus in position and grasp it by means of forceps, obviating the necessity for introducing the finger into the peritoneal cavity.

The sutures must extend entirely through the abdominal wall and be carefully placed in order to prevent hernia. Interrupted sutures are preferable. If the operation has been properly performed no bandage is necessary and the patient will not disturb the sutures. If asepsis has not been strictly followed infection may occur and the consequent irritation cause the patient to tear the sutures out, which may lead to protrusion of the intestines or other abdominal viscera. If the sutures do not include the deeper layers of the abdominal wall hernia is liable to occur and require a second operation.

### 31. OVARIOTOMY IN THE CAT.

**Instruments.** Same as for the bitch.

**Technic.** The cat may be spayed by either the flank method or through the linea alba. The point of incision in either case is the same as in the bitch but owing to the smaller size of the animal it is necessary to make the wound quite small. The abundance of fur renders it essential that an ample area be shaved and the surrounding hair be saturated with a disinfectant and carefully brushed away



from the operative area. The cat being more subject to infection than the bitch the aseptic precautions must be of the strictest possible character. The operative area must be thoroughly disinfected and cleansed and equal care must be taken not to introduce irritant disinfectants into the wound. A great danger also exists in the tendency of the muscle layers of the abdomen to readily become separated by pressure from the finger and form a pocket in which wound discharges accumulate and constitute a dangerous seat for infection. Great care must therefore be taken to make a clean incision directly into the peritoneal cavity and to avoid separating the peritoneum from the muscles or the muscular layers from each other. The uterus and ovaries of the cat are naked and far more easily distinguished than in the bitch, there being no extra deposit of fat in the broad ligament. The sutures are to be applied to the wound in the same manner as in the bitch.

---

## 32. CASTRATION OF CRYPTORCHID HORSES.

### *Plates XXI and XXII.*

**Instruments.** Scalpel, emasculator.

**Technic.** Confine the animal by casting in the dorsal position with the hocks well flexed and both posterior limbs completely abducted so as to fully expose the inguinal region. Or secure upon the operating table on the side opposite to the retained gland and abduct the upper posterior limb by drawing it upward by means of a pulley. Cleanse and disinfect the inguinal region. Anaesthize. Make an incision about 10 to 12 cm. long through the skin and dartos directly over the normal position of the scrotum, parallel to the median raphe about 4 or 5 cm. distant from it. Insert the two index fingers in the wound, press them into the areolar tissue toward the external inguinal

ring and drawing them apart separate the tissues sufficiently to permit the entrance of the hand. With the fingers held in the shape of a cone bore a passage in the areolar tissue through the external abdominal ring and continue in a direction approximately toward the external angle of the ilium until the aponeurosis of the small oblique muscle near the crural arch is reached. Unless rectal exploration has shown that the testicle is within the abdomen, take care in traversing the inguinal space between the external and internal rings that the gland is not passed by unrecognized (inguinal cryptorchidy) lying in this region covered by peritoneum and the cremasteric fascia. Sometimes the epididymis has descended to the scrotal region while the testicle remains within the abdomen, thus resulting in a long, narrow inguinal canal.

Pass the hand upwards, outwards and forwards along the aponeurosis of the small oblique until the crural arch is reached slightly anterior to the crural ring in which the pulsating femoral artery can be felt, and palpate at this point in the muscular wall for the internal inguinal ring which varies greatly in different individuals but usually reveals itself to the fingers as an oblong slit or ring about one inch in length covered only by peritoneum. Through this usually extends a portion of the gubernaculum testis or of the vas deferens.

Examining Plate XXI, the peritoneal view of the internal ring is shown crossed by the dotted line, V, of the upper or right testicle, into which extends a short distance the tail of the epididymis. In the lower or left testicle the ring has been opened and the gland lies in a position corresponding to the right and showing the epididymis and vas deferens lying in the processus vaginalis, P. The surgical relation of the parts is further illustrated in Plate XXII, where the testicle is completely withdrawn into the peritoneal cavity and spread out over the right flank. The processus

vaginalis, P, is outlined by a dotted line into which is introduced a curved sound, S, along side of which lies the gubernaculum, G. The gubernaculum, it will be observed is divisible into three sections, a slender one, G, which by passing along behind the peritoneum escapes from the abdominal cavity at the postero-external commissure of the ring to extend to the scrotum. The second portion of this organ, G', is much thicker and extends from G to the epididymis at E, while the third division, G'', extends from the epididymis to the testicle.

In Plate XXII it is shown that the testicle under all ordinary conditions is inevitably attached through its gubernaculum testis to the postero-external commissure of the ring and that it has a second definite attachment to the seminal bladder through the medium of the vas deferens, V, and a third by means of the testicular artery, A. The gubernaculum and the vas deferens constitute the essential guides in locating and recognizing the testicle.

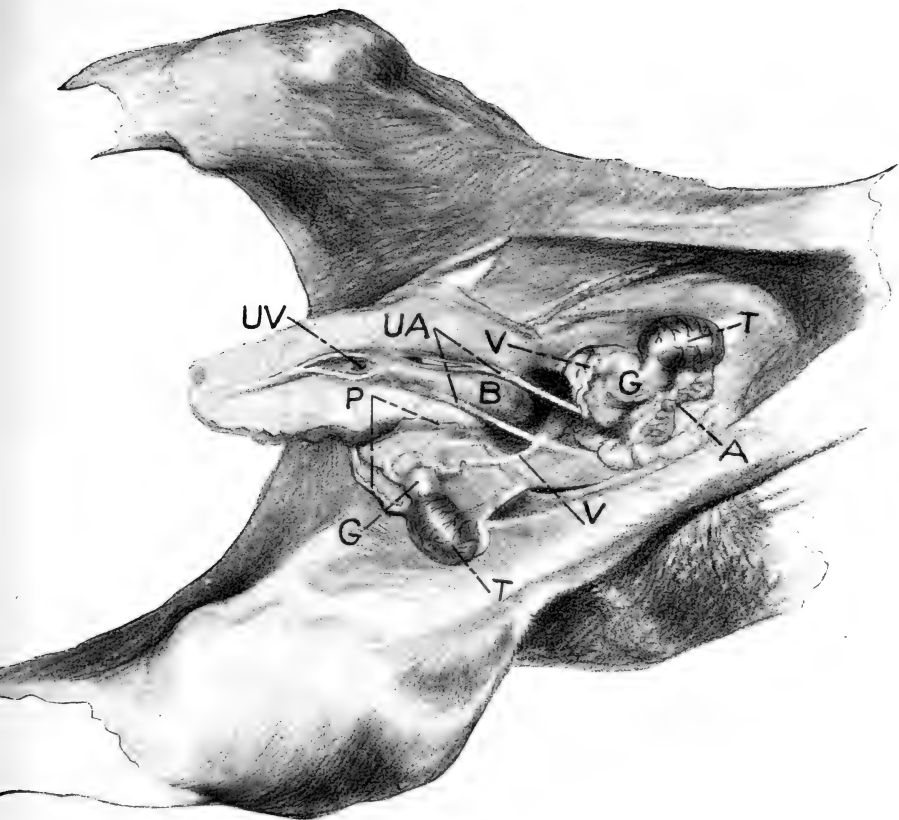
By forming a hollow cone with the fingers about the internal ring, the vas deferens, epididymis and gubernaculum tend to drop out into the processus vaginalis where they may be grasped with the fingers without the peritoneum having been ruptured. The vas deferens and epididymis present characteristics which are unmistakable to the trained touch consisting of a small firm cord (vas deferens) or a small mass of fine threads (tail of epididymis) which roll freely between the thumb and finger and give a sensation which is unlike that produced by any other tissue in the body.

Grasp the part firmly and tearing through the peritoneum seize the vas deferens and carefully draw it out through the external wound. (In teaching cryptorchid castration to the beginner we make our opening down to the internal ring and grasp the vas deferens between the thumb and finger without penetrating the peritoneal cavity and then

*Plate XXI.*

*Castration of Cryptorchid Horse.*

Urino genital apparatus of 24 hr. colt. T, T, testicle; A, testicular artery; G, gubernaculum testis; V, V, vas deferens; B, urinary bladder; UA, umbilical arteries retracted within abdomen; P, processus vaginalis; UV, umbilical vein.





passing a pair of long uterine dressing forceps along the hand, fasten them upon the vas deferens. The student then completes the operation, using the forceps as a guide. He thus learns the relations and character of the parts and recognizes the internal ring with the peritoneum still stretched across it, intact.)

In case the vas deferens can not be felt before rupturing the peritoneum, it may be broken through with the index finger and inserting the finger into the cavity, the gubernaculum is found attached to the postero-external border of the ring, and but a short distance therefrom the finger comes in contact with the vas deferens or with the tail of the epididymis where the gubernaculum crosses it at E, in Plate XXII. Having reached the vas deferens the operation is proceeded with as above. Thus far the operator has not concerned himself with the location of the testicle but relies wholly upon the vas deferens or gubernaculum, since when either of these is recognized the testicle is virtually within his power.

He thus proceeds upon the basis that he is not to *find* the testicle for the reason that it is not *lost* but that it has definite relations and attachments which permit of certain displacements of the organ itself but not of its attachments.

Having drawn the vas deferens out through the wound tension is exerted upon it which tends to cause the testicle to follow but sometimes the gland is too large to pass the internal ring and the latter needs be dilated by inserting an index finger in it or the testicle needs be guided through the opening.

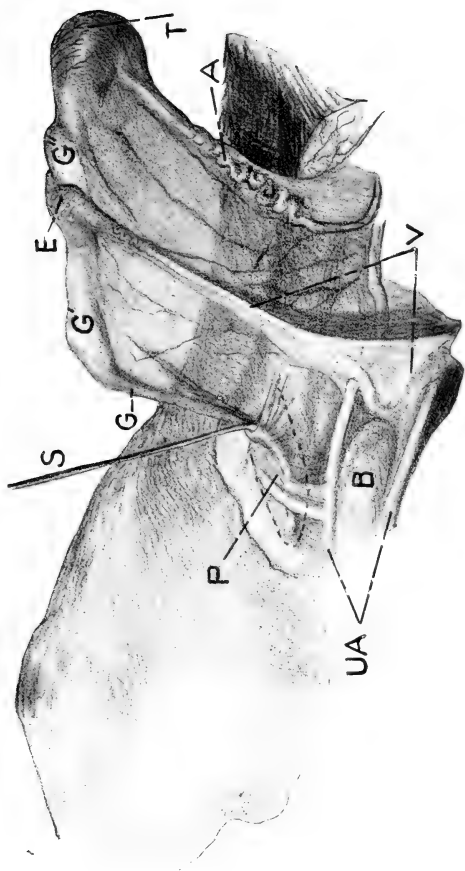
We have described herein one method of castrating a cryptorchid horse where the cryptorchidy is due to an arrest in the development of the gland and of its descent. There are other methods employed which introduce variations at each step, many operators making the incision over the external ring\* instead of near the median line. Other

*Plate XXII.*

*Castration of Cryptorchid Horse.*

Right inguinal region and testicle of 24 hrs. colt. P, processus vaginalis surrounded by a dotted line and containing a curved sound, S; G, first portion of gubernaculum testis; G', second portion of gubernaculum testis extending to the epididymis, E; E, epididymis; G'', gubernaculum extending from epididymis (globus minor) to the testicle; T, testicle; A, testicular artery; V, V, vasa deferentia; B, urinary bladder; UA, umbilical arteries.







operators avoid opening the internal ring and penetrate the peritoneal cavity somewhat in front of and above the ring through the small oblique muscle. When one plan has been learned the variations are easily applied.

There are other causes of cryptorchidy which in rare cases require a different procedure in order to extract the gland varying with individual cases but the essentials for the tracing and recognition of the testicle are the same.

Prior to attempting the operation it is well to make a rectal exploration and determine as far as may be the location of the testicle, whether it be on the right or left side, and its character, should it be in any way pathologic.

After the testicle is brought to the surface it may be removed with the emasculator or by such means as the operator may prefer. Cryptorchid testicles when due to arrest in development are not vascular and there is little tendency to hemorrhage after excision. Place an antiseptic tampon in the wound, pushing it well up against the internal ring and retain it in position by means of sutures for a period of 24 to 48 hours when it is removed and the wound dressed antiseptically.

The operation for cryptorchidy in the smaller animals is essentially the same as in the horse except that the incision is to be made ordinarily through the flank as in spaying. The same attachments are to be our guide and the operation is to proceed upon almost parallel lines.

## IV. OPERATIONS ON THE EXTREMITIES.

### 33. TENOTOMY OF THE FLEXORS OF THE PHALANGES.

#### *Plate XXIII.*

**Objects.** The relief of contraction of the flexor tendons of the foot.

**Instruments.** Razor, scissors, sharp tenotome, bandage material.

**Technic.** Tenotomy is generally performed on the flexor of the third phalanx, seldom on the superficial flexor or flexor of the second phalanx.

**Confine upon the operating table** with the affected member undermost and the foot fully extended. In default of a table confine in lateral recumbency and apply an extension splint to the foot as shown in Plate XXIII.

On the median side at the middle of the metacarpus or metatarsus the skin is shaved and disinfected over the tendon of the flexor pedis muscle. The location named lies between the lower extremity of the great carpal or tarsal sheath above and the superior extremity of the tendinous sheath of the fetlock below, so that neither of these is wounded during the operation, but the tendon is severed at a point where it is invested by loose connective tissue which retains the divided ends in their normal line of direction, somewhat fixed, and favors their ultimate reunion.

Grasp the metacarpus or metatarsus in this area from above and behind in such a manner that the thumb rests upon the median or upper surface, and the index and second fingers on the lateral or under side of the flexor pedis tendon. While the left thumb pushes the skin toward the bone, that is, forward, a sharp pointed tenotome held perpendicularly in the right hand is introduced with the cutting edge toward the hoof through the skin, subcutem and anti-brachial fascia down to the flexor pedis tendon. Immedi-



*Plate XXIII.*

*Tenotomy of the Flexor Pedis Tendons.*

Right fore foot of horse bound upon the extension splint.

s, Tendon of the superficial flexor muscle ; p, deep flexor tendon.

ately on the anterior border of the tendon insert the tenotome so far that the point of it can be felt on the lateral or outer side through the skin with the left hand.

Care is to be exercised in making this invading incision to not include the metacarpal, or metatarsal, arteries, veins and nerves. The vascular bundle lying immediately against the anterior border of the flexor of the third phalanx, it is easy to err by inserting the tenotome in front of the vessels, that is between the suspensory ligament and vessels instead of between the flexor of the third phalanx and vessels. It is safer to make the skin incision far enough posteriorly to insure safety to the vessels, cut down upon the tendon, then incline the handle of the tenotome backwards, push the point of the tenotome obliquely forward and downward behind and beneath the vascular bundle and then carrying the handle forward bring the instrument to a perpendicular position while it is forced down along the anterior surface of the tendon until it nears the inferior border when the tenotome handle should be carried yet further forward so that the point is directed obliquely backward, to facilitate its passing between the vessel bundle and the tendon out to the skin. The invading incision thus describes the segment of a circle, with its concavity backward toward the tendon.

The cutting edge of the instrument is then turned against the tendon, that is, it is directed backward, the foot is extended by an assistant with the aid of a rope bound around the pastern and looped over the hoof, and the tendon is cut through under light pressure, the operator pressing the handle of the knife forward and downward, using the metacarpus or suspensory ligament as a fulcrum upon which the back of the tenotome rests as a lever. A loud cracking, as well as the disappearance of resistance to extension shows that the tendon has been severed.

After the removal of the knife and seeing that there is a wide space between the ends of the tendon, the foot is un-

bound from the splint and a bandage applied to the metacarpus, which rests upon the fetlock joint and remains in position for eight days. Healing of the cutaneous wound by primary union.

---

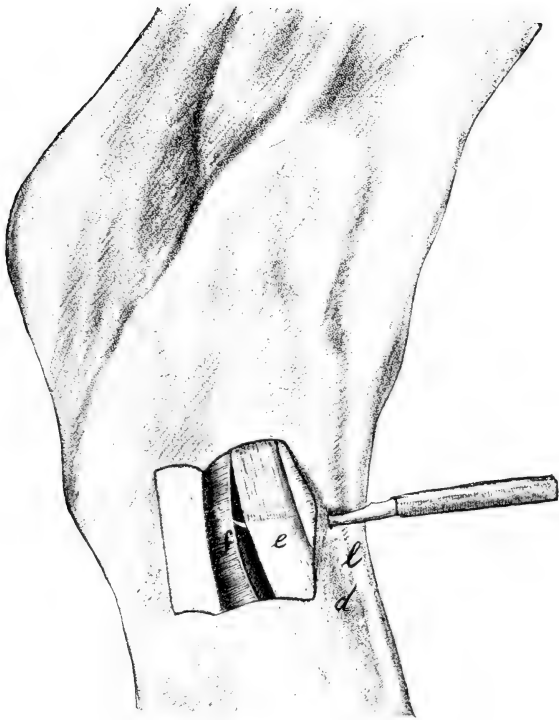
#### 34. PERONEAL TENOTOMY.

##### *Plate XXIV.*

**Object.** The relief of Stringhalt.

**Instruments.** Razor, scissors, sharp tenotome.

**Technic.** On the lateral side of the metatarsus a triangle, *d*, opening toward the tarsus is formed by the tendons of the extensor pedis longus muscle, *l*, and the lateral extensor of the foot, *e*, which unite on the anterior surface of the middle of the metatarsus. The synovial sheath of the extensor pedis longus muscle extends inferiorly to near the point of juncture of the two tendons; the sheath of the lateral extensor ends below 3 to 4 cm. above the point of union. In the middle of this space without a sheath, which is 3 to 4 cm. long, and below the annular ligament of the hock the operation is carried out. After the skin has been shaved and disinfected, confine in the stocks or operate upon the standing horse, with the aid of local anaesthesia, a twitch being applied to the nose and the opposite hind foot held up with the side-line. The tendon of the lateral extensor is easily felt under the skin as a hard cord about 0.7 to 1 cm. in diameter. Stretch the skin and with the back of the hand toward the hock grasp and compress the tendon with the thumb and index finger of one hand, insert the tenotome with the cutting edge toward the foot perpendicularly upon the tendon through the skin, subcutem and aponeurosis derived from the crural fascia; push it from before backward under the tendon, turn the cutting edge against it, and with the hock extended sever the tendon as well as the



*Plate XXIV.*

*Peroneal Tenotomy for Stringhalt.*

Right hind foot seen from the external side. The skin covering the lateral extensor of the foot is laid back in the form of a flap, the crural fascia divided. *e*, Peroneal tendon; *f*, crural fascia; *l*, tendon of the anterior extensor pedis muscle; *d*, the triangle formed by *l* and *e*.



fascia through to the skin. In accomplishing the section of the tendon the knife is to be used as a lever of the first class with the anterior border of the metatarsus acting as a fulcrum. If the tendon has been completely severed its retracted ends may be felt under the skin 1 to 2 cm. above and below the wound. After the operation an antiseptic bandage is applied, resting upon the fetlock. The bandage should remain eight days and the cutaneous wound heal by first intention. Care should be taken to not wound the tendon of the extenson pedis longus muscle.

Recently it has been proposed to permanently obliterate the function of the peroneus muscle by severing its tendon within its tarsal sheath above and below the tarsus and withdraw the isolated section. The same object may be attained by merely severing the tendon within its sheath below the tarsus, if the operation is carried out under aseptic precautions because when thus performed the epithelium advances over the retracted cut ends and leaves them free in the sheath.

---

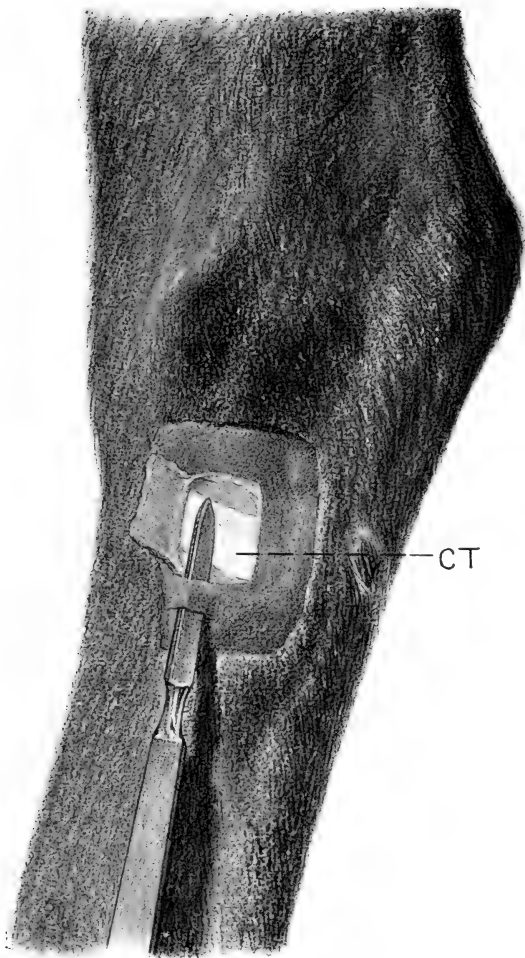
### 35. CUNEAN TENOTOMY.

#### *Plate XXV.*

**Object.** The relief of spavin lameness.

**Instruments.** Razor, scissors, straight scalpel, Peters' spavin knife.

**Technic.** Most horses can be operated on standing, with the aid of cocaine, otherwise cast, or secure on the operating table, on the affected side and extend the tarsus. Shave and disinfect an area 5 to 6 cm. square on the inferior median surface of the hock over the course of the cunean tendon of the chief flexor of the metatarsus, as indicated in Plate XXV. Locate the tendon, CT, by palpation as it passes obliquely downward and backward and make a transverse incision with a straight scalpel or tenotome, in the form of



*Plate XXV.*

*Cunean Tenotomy.*

For the relief of spavin lameness. CT, cunean tendon. The dotted line crosses the ergot.

a stab wound, merely sufficient to afford passage for the blade of the instrument, about 1 cm. below its inferior border at a point midway between the anterior and posterior borders of the hock, or slightly anterior thereto. Push the tenotome flatwise between the skin and tendon, as shown in the plate, force it upwards to the superior border of the tendon, then turn the cutting edge toward it and elevating the handle, using the superior border of the skin wound as a fulcrum, cut the tendon through from without inwards. By firm pressure upon the skin over the tenotome periosteotomy is simultaneously accomplished. The completion of the operation is evidenced by the separation of the cut ends of the tendon leaving a well-marked depression at the point of division. Disinfect the wound, apply an antiseptic tarred bandage resting upon the fetlock and including the hock and allow to remain undisturbed for six days. Healing by primary union. After the incision through the skin has been made, the Peters' knife may be used instead of the straight scalpel, and the tendon and periosteum cut through at two or three different points, the cuts diverging upwards from the cutaneous wound, V-shaped.

---

### NEUROTOMY.

**General Remarks.** Neurotomy is performed for a variety of objects, such as the relief of pain in a sensitive nerve itself, as in trifacial neurotomy, p. 64, the relief of pain or lameness in a part supplied by a sensory nerve, or the inhibition of motor power, as in the "cribbing" operation by severing the spinal accessory where it passes into the sterno-maxillaris muscle.

The following neurotomies are designed to relieve pain and the consequent lameness dependent upon a pathologic condition of some part or tissue on the distal side of the

point of operation and to which the divided sensory nerve is destined.

Neurotomy of a sensory nerve is always a painful operation, and its performance without anaesthesia is unjustifiable from a humane standpoint, and cannot be so well done either from the view of mechanical correctness or the carrying out of antiseptic standards. Some neurotomies can be well performed on the standing animal if it is quiet and the operator is experienced, the parts being rendered insensitive by means of cocaine or other local anaesthetic; in the greater neurotomies general anaesthesia may be desirable or necessary from the humane or operative standpoint.

The confinement of animals for neurotomy on the sensory nerves of the extremities for the relief of lameness is always to be viewed as a critical procedure for the reason that the operation is generally made because of the local manifestation of a more or less general disease which may be accompanied by general fragility of the skeleton, and as a result most casting accidents occur in cases of confining for neurotomy or firing in cases of lameness belonging to the great group of dry arthritis or spavin family. Casting must, therefore, be done with the greatest possible care, and the operating table is to be constantly and greatly preferred.

Neurotomy is properly a last resort in lameness and should not otherwise be performed. It has two great and ever present dangers. If the part deprived of sensation is too badly diseased to bear the weight and resist the insult resultant upon the part being called to do its normal or even an extra amount of work, it must ultimately give way, the bones become fractured, the tendons separate from the bone, the intra-ungular tissues lose their integrity and the hoofs become detached (exungulation) or other degenerative changes take place as a result of causing a part to do a work for which its condition unfits it.

The second great danger occurs from wounds or other traumatism to the tissues distal to the operation when the

unnerved parts are not rested as they would be in natural conditions when injured, and as a result reparative changes are prevented and supplanted by retrograde processes with ultimate death of the part and of the animal.

In other words sensory neurotomy robs an organ or tissue of the enormously conservative force of pain. Pain causes the animal to rest the affected part, protects the painful tissues against disintegrating and destructive insults and favors restorative processes; robbed of this protective influence of pain by the severance of the sensory nerves, the diseased tissues are without their natural protection.

Nerves are generally accompanied by satellite arteries and veins which are always liable to be wounded during the neurotomy and are more embarrassing because of the hemorrhage clouding the operation field and inviting error than dangerous because of the loss of the blood itself. It is essential to a good operation that the hemorrhage be kept under control throughout so that each tissue will stand out in relief and the nerve reveal its identity in addition to its location, size and relations, by its intensely white, nacrous, striated character. The test of compressing the nerve in order to identify it by the resultant pain is unsurgical and unnecessarily cruel.

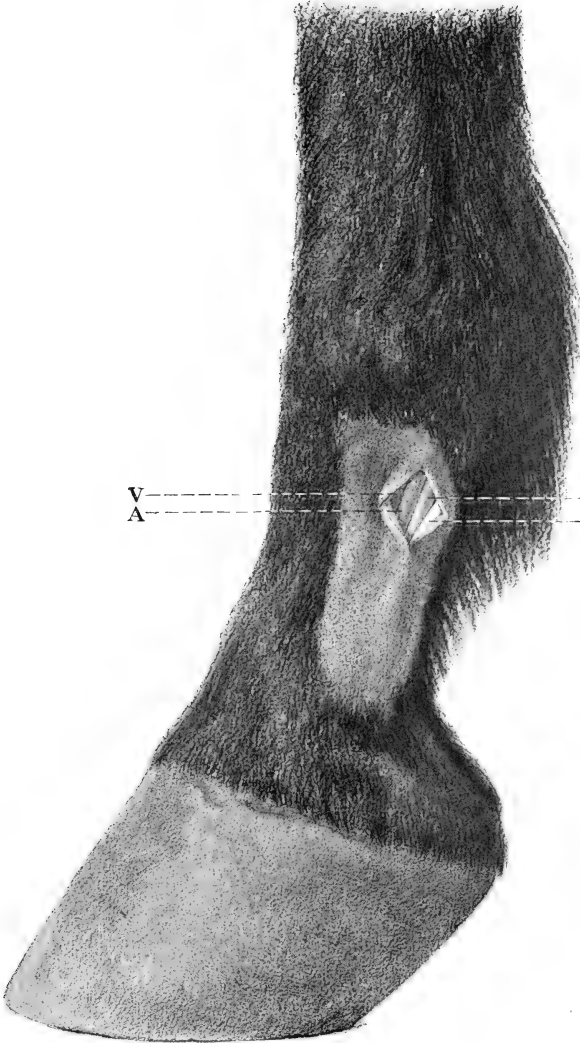
Sepsis holds an important place in considering the dangers of neurotomy because the infection of a sensitive nerve causes very great pain and if considerable, tends to cause a false neuroma or fibroma in the connective tissue of the nerve trunk, calling for a second operation in order to remove the tumor, and resultant lameness.

Neurotomies should consequently be performed only in properly selected cases, the smallest possible trunk that will sufficiently relieve the pain should be selected for the operation, it should be performed with due regard for suffering and for asepsis, should be performed quickly and neatly, the incisions being free, laying the nerve trunk bare without tearing up the tissues and clouding them and at every point aim at celerity, accuracy and neatness.

*Plate XXVI.*

*Digital Neurotomy.*

V, Digital vein ; A, digital artery ; N, principal digital nerve ; L, ligament.



V  
A

N  
L





## 36. DIGITAL NEUROTOMY.

*Plate XXVI.*

**Objects.** The relief of navicular lameness in cases where plantar neurotomy is not deemed necessary or advisable.

**Instruments.** Razor, scissors, scalpel, probe pointed bistoury, tenacula, aneurism needles, bandages.

**Technic.** Digital neurotomy may generally be performed on the standing animal, the operative area having first been anaesthetized by means of cocaine or otherwise, a twitch applied to the upper lip and the affected foot held up by an assistant. If necessary because of restlessness of the animal or inexperience of the operator, confine on the operating table or cast the animal and apply the extension splint to the foot to be operated on as shown in Plate XXIII, except that the lower binding cords rest on the metacarpus instead of the pastern.

Extending downwards from the fetlock joint toward the coronet, between the posterior border of the first phalanx and the anterior border of the flexor tendons there is a slight furrow, at the posterior part of which, close to the external margin of the tendon, lies the median or principal digital nerve accompanied in front by the digital artery, A, anterior to which lies the digital vein, V. Immediately behind the nerve and generally lying a trifle deeper, is quite commonly found a second venous trunk of considerable size. Near the middle of the first phalanx the nerve is crossed externally in an oblique direction from above to below and from behind to before by a white ligamentous band, L, slightly broader than the nerve extending from the base of the ergot of the fetlock to the retrorsal process of the pedal bone. This must not be mistaken for the nerve, N, and need not be if it is remembered that the latter is accompanied on the same plane and in a like direction by the satellite artery, A, and vein, V, enclosed with it in a fibrous sheath. At the uppermost part of the first phalanx the nerve lies in front of this ligament,

a short distance inferiorly it passes beneath it, while from the middle of the pastern downwards the nerve lies behind the ligament.

The operation is practicable at any point over the line of the nerve from the top to the bottom of the shaved area in Plate XXVI or from the superior end of the first phalanx down to a level with the superior border of the lateral cartilage, but preferably at about the point shown in Plate XXVI, near the superior end of the first phalanx. At the desired point and over the groove between the flexor pedis tendon and the phalanges shave and disinfect an area 4 to 5 cm. square. In the center of this area at the anterior border of the flexor tendon, with the scalpel held perpendicular to the skin, make an incision from above downwards a distance of from 2 to 3 cm. cutting cleanly through the skin and subcutaneous fascia down upon the nerve. The incision is favored by tensing the skin between the thumb and index finger of the left hand, but care should be taken not to displace it backwards or forwards. Dilate the wound by pressure upon the skin with the thumb and index finger or otherwise and carefully incise longitudinally the fibrous sheath enveloping the nerve and artery. Pass an aneurism needle beneath the nerve, and forcing it upward and downward, separate thereby the nerve from the surrounding tissues. Insert a probe pointed bistoury, or scissors beneath the nerve, and divide it at the upper angle of the wound and excise a section 3 cm. long. Disinfect and bandage with or without suturing the wounds. Leave the bandage in place 6 to 8 days.

## 37. PLANTAR NEUROTOMY.

*Plate XXVII.*

**Object.** The relief of navicular, or ringbone lameness or other painful, non-suppurating disease of any parts below the fetlock joint.

**Instruments.** Razor, scissors, convex scalpel, compression artery forceps, tenacula, aneurism needles, suture material, elastic ligature.

**Technic.** It is well to shave the site of operation and thoroughly disinfect the region of the metacarpus and fetlock with soap, brush, and sublimate or creolin solution and 50% alcohol, and apply a bandage saturated with sublimate or creolin solution to the fetlock joint 24 hrs. before the operation in order to secure thorough disinfection.

Confine the animal and fix the limb as in the preceding operation. After the removal of the disinfecting bandage, and producing local anaesthesia pass the fingers from before to behind with light pressure over the region just above the fetlock joint, where there is felt immediately in front of the flexor pedis tendon a channel-like depression extending from above the fetlock downward over it. Just at the anterior margin of the flexor pedis tendon and at the posterior part of the groove lies the threadlike cord of the nerve, *n*, 3 mm. thick, which glides away from underneath the fingers with a distinct recoil. The site of operation lies immediately above the fetlock in the posterior third of the metacarpus or one may operate at any point higher up as far as beyond the middle of the metacarpus or metatarsus so long as care is taken to include the anastomosing branch given off by the median plantar nerve at about the middle of the metacarpus and bending obliquely around behind the tendons to join the lateral nerve somewhat lower down. At this point stretch the skin between the thumb and index finger of one hand and make an in-

**Plate XXVII.**

**Plantar Neurotomy.**

*a*, lateral digital artery ; *v*, lateral digital vein ;  
*n*, common lateral digital nerve ; *d*, anterior  
branch ; *o*, posterior branch ; *s*, superficial flexor  
tendon ; *p*, perforans tendon ; *i*, suspensory  
ligament of fetlock ; *m*, metacarpus.





cision 3 to 5 cm. long, the lower angle of which is usually just above the fetlock joint, cutting directly through the skin, subcutem and connective tissue sheath down onto the nerve, laying it bare. The borders of the cutaneous wound are held apart with tenacula and by palpation with the fingers or by vision it is determined if the nerve lies in the middle of the wound. If necessary continue the dissection with the scalpel until the nerve is clearly revealed; it is distinguished by its faintly yellowish color, its fine longitudinal striæ and its location behind the metacarpal artery.

Immediately above the fetlock joint the median metacarpal or metatarsal nerve divides into an anterior smaller, *d*, and posterior larger branch, *o*. This division should be laid bare in order that the operator may not erroneously cut one branch only. Immediately above this point of division the aneurism needle is passed under the nerve, pushed well through and forced up and down, separating the nerve from the adjacent tissues, the scissors or a small probe-pointed bistoury is passed beneath and it is cut through quickly at the superior angle of the wound. The distal end of the nerve is then dissected free downward and excised at the lower angle of the wound so that a section 3 to 5 cm. long is removed. The cutaneous wound is united by a continuous suture and a temporary bandage applied. If the horse has been secured by casting, the extension splint, if it has been used, is then removed, the foot replaced in the hobble and the horse turned to the other side. The operation on the opposite metacarpal nerve is carried out in the same way after which a sterile bandage is applied and allowed to remain eight days. Healing by primary union.

## 38. NEUROTOMY OF THE MEDIAN NERVE.

*Plate XXVIII.*

**Objects.** The relief of lameness due to disease so located in the anterior limb that it cannot be so well overcome by plantar neurotomy.

**Instruments.** Razor, scissors, convex scalpel, artery and compression forceps, tenacula, aneurism needles, suture material.

**Technic.** The operation is performed on the median surface of the anterior limb immediately below the humero-radial articulation on the recumbent horse after the affected foot has been fully extended on the operating table or in default of this removed from the hobbles and bound upon the extension splint as shown in Plate XXIII. Anaesthetize.

The foot is drawn out firmly from the shoulder, inclined somewhat forward. The operator places himself between the neck and the forearm of the patient and, after the median region of the elbow joint has been washed with soap and water, searches for the median nerve where it glides over the posterior part of the joint to disappear behind the radius. Shave the skin at and below this point, disinfect it with sublimate or creolin solution and 50% alcohol. The nerve, *n*, lies as a rule somewhat in front of the middle of the median side of the forearm against the postero-internal margin of the radius and can be felt, about 5 to 6 mm. in diameter, lying somewhat deeply. The position of the nerve varies with the different attitudes of the forearm. In fat and fleshy horses the identification of the nerve is more difficult. It may be felt upon the standing animal.

With the nerve lying between the thumb and index finger of the left hand, at the point where it begins to disappear behind the radius after having passed over the humero-radial articulation, stretch the superposed skin and immediately upon and parallel to it make an incision 5 cm. long, first through the skin, then through the aponeurotic expansion

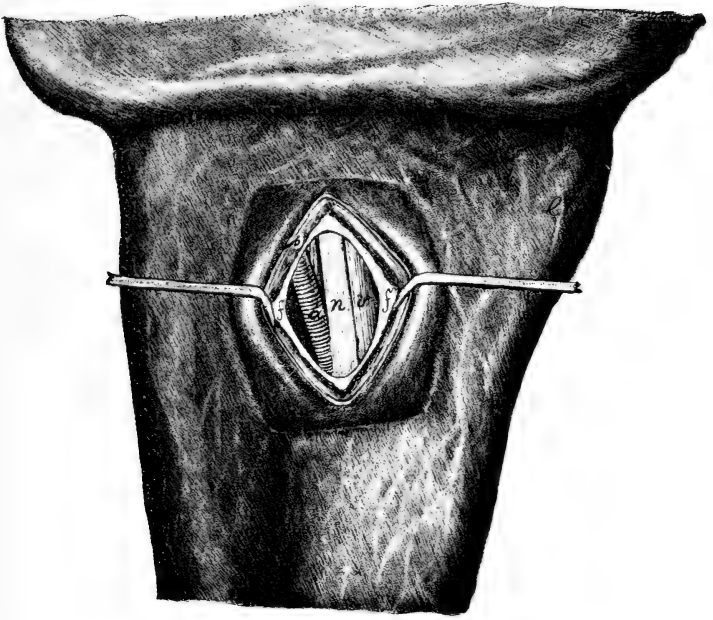


of the sterno-aponeurotic muscle. Check any hemorrhage from the skin, subcutis, or muscle. The tenacula are inserted cautiously in the lips of the wound, and these being drawn apart the white anti-brachial fascia is brought into view and a search is made with the index finger to determine the exact location of the nerve, the fascia is divided with the scalpel and an oval piece excised with the scissors immediately over the nerve. If much fatty tissue is found beneath the fascia it may be dissected away carefully with the scalpel or cut away with the scissors. There now comes into view a delicate reddish colored fascia-like membrane, the nerve sheath, behind which a dark cord, the brachial vein, V, is visible, the latter being intimately connected with the nerve sheath. The vein lies mostly behind and beneath the nerve and may project out from beneath the border of the same. *The operator needs be careful not to prick this vein with the tenacula, as the hemorrhage therefrom is exceedingly annoying during the operation. Avoid the use of tenacula after penetrating the fascia and retract the wound lips cautiously with aneurism needles instead.* Still further forward and deeper may be felt the pulsating brachial artery. Incise the nerve sheath carefully and divide it upward and downward with the scalpel or scissors, whereupon the yellowish and distinctly fibrous nerve comes into plain view. Pass an aneurism needle beneath the nerve pushing it so far through that the distal end is readily grasped and drawing it up and down with the two hands, separate the nerve from the adjacent tissues throughout the length of the wound. *Be careful to not cut the nerve too high and erroneously include the motor nerve of the flexor of the metacarpus and the flexors of the foot, which is generally given off posteriorly just below the humero radial articulation.* Lift the nerve up and cut it through at the superior angle of the wound by a sudden clip with the scissors or with the probe pointed bistoury. Lay the peripheral end of the nerve bare to the lower angle of the wound, and excise at least 3 cm. of it.

*Plate XXVIII.*

*Median Neurectomy.*

Median surface of the right humero radial articulation. *a*, brachial artery; *n*, median nerve; *v*, brachial vein; *f*, antibrachial fascia; *p*, sterno-aponeuroticus muscle.





Tamponade the wound with dry iodoform gauze and approximate the skin with a continuous suture. The tampon and sutures remain 1 to 2 days.

Since sensation of the lower part of the limb is partly maintained by the deep branch of the ulnar nerve which at the lower part of the carpus, covered by the tendon of the oblique flexor becomes the lateral plantar nerve, neurotomy of the median nerve does not always completely effect the desired end. In order to produce complete anaesthesia of the foot, therefore, it is necessary to perform ulnar neurotomy.

---

### 39. NEUROTOMY OF THE ULNAR NERVE.

#### *Plates XXIX-XXX.*

**Object.** An adjunct operation of the preceding by which the enervation of the carpus and foot is completed.

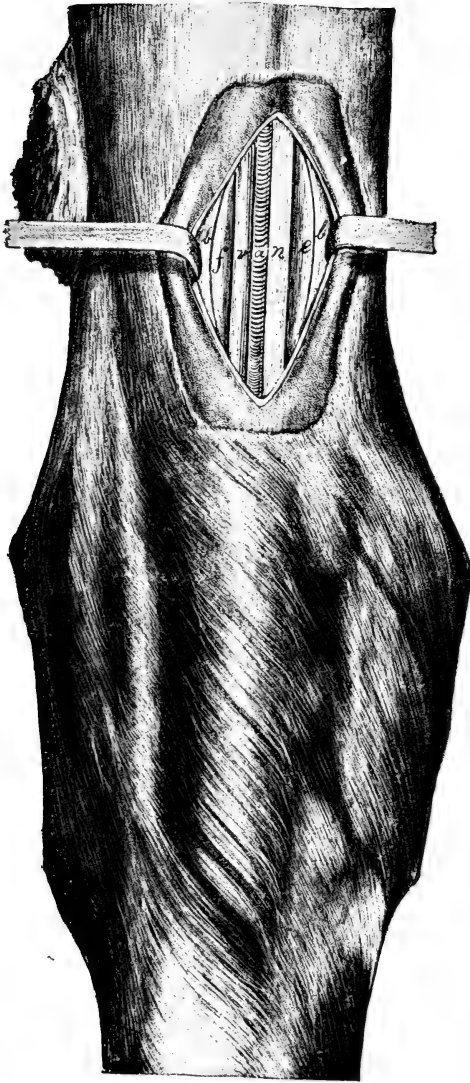**Instruments.** Same as in the preceding.

**Technic.** Above and behind the carpus there may be felt a groove between its external and middle flexors, EF and OF, Plate XXX. At this point 10 cm. above the pisiform bone the skin is shaved and disinfected and an incision 6 cm. long made through the skin and antibrachial fascia. This incision extends just outside the median line of the posterior surface of the radius in such a way that the superior angle of the wound is about 1 cm. farther outward than the lower. Beneath the fascia between the aforesaid muscles is seen the ulnar nerve, Plate XXIX, *n* Plate XXX, NU, on the median or inner side of it the collateral ulnar vein, Plate XXIX *v*, and between the two and somewhat deeper the collateral ulnar artery, *a*. The nerve, about 3 mm. in diameter is picked up with the aneurism needle, severed at the upper and lower angles of the wound, the lips of the wound united by a continuous suture and a bandage applied. Healing by first intention.

*Plate XXIX.*

*Ulnar Neurotomy.*

Right forearm seen from behind. *e*, external flexor of the carpus; *f*, oblique (middle) flexor of the carpus; *a*, collateral ulnar artery; *b*, antibrachial fascia; *n*, ulnar nerve.

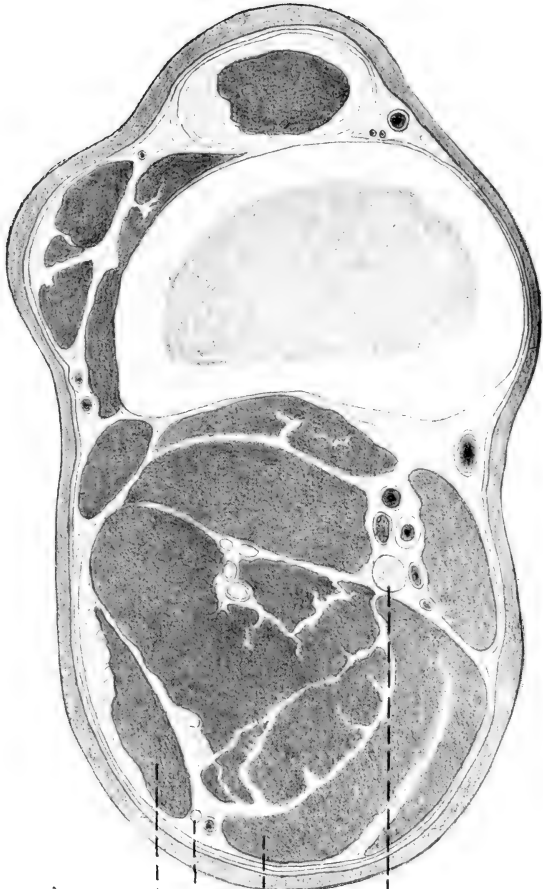


*Plate XXX.*

*Ulnar Neurotomy.*

Cross section through the forearm, about 10 cm. above the pisiform bone, viewed from below. EF, external flexor of the carpus; OF, oblique flexor of the carpus; NU, ulnar nerve; NM, median nerve. Lying on its median side is the ulnar artery, the satellite vein of which is not shown.





EF

NU

OF

NM



## 40. SCIATIC NEUROTOMY.

*Plates XXXI-XXXII.*

**Objects.** The destruction of sensation in the tarsus and parts beyond for the relief of otherwise incurable spavin lameness, diseases of the tendons, etc.

**Instruments.** Same as in the preceding.

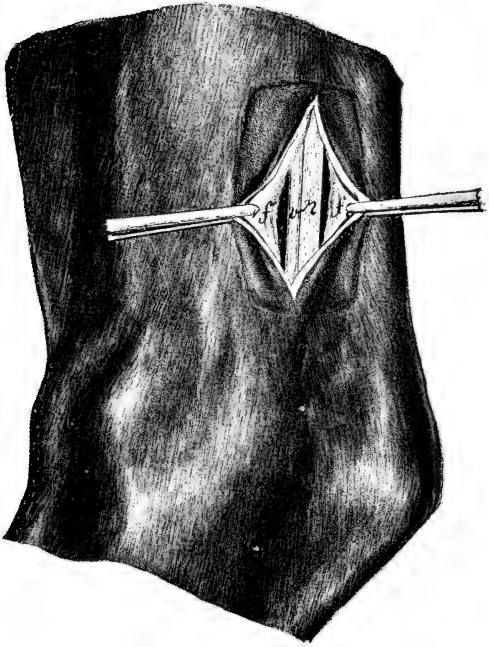
**Technic.** Expert surgeons may operate on the standing animal under local anaesthesia. Place the animal on the operating table on the diseased side, extend the affected limb and draw the upper leg forward or backward and secure it out of the way. Produce complete general or local anaesthesia. The posterior tibial or sciatic nerve, *n*, Plate XXXI and NS, Plate XXXII, is then sought by grasping the leg with the left hand from behind in such a manner that the thumb rests above and the fingertips below it. Reaching forward with the fingers to the deep flexor of the foot grasp the leg with moderate firmness and draw the hand slowly backward. Immediately behind the perforans muscle and between this and the tendo-Achilles the nerve, nearly 1 cm. in diameter, glides away forward from between the fingers with a distinct recoil. If the nerve can not be recognized in this manner the hock should be more strongly extended, by which means the nerve may be caused to recede from the perforans muscle, so that it can more readily be felt near the middle of the groove extending between it and the tendo-Achilles.

At this point on the median side of the leg the skin is shaved, disinfected and an incision made through it 5 cm. long, parallel to the tendo-Achilles. The white rigidly-stretched crural fascia is now divided in the same direction after which it should be determined by palpation that the nerve lies in the middle of the wound. Excise with the scissors an elliptic or oval piece of the fascia or hold it apart along with the lips of the cutaneous wound by means

*Plate XXXI.*

*Sciatic Neurotomy.*

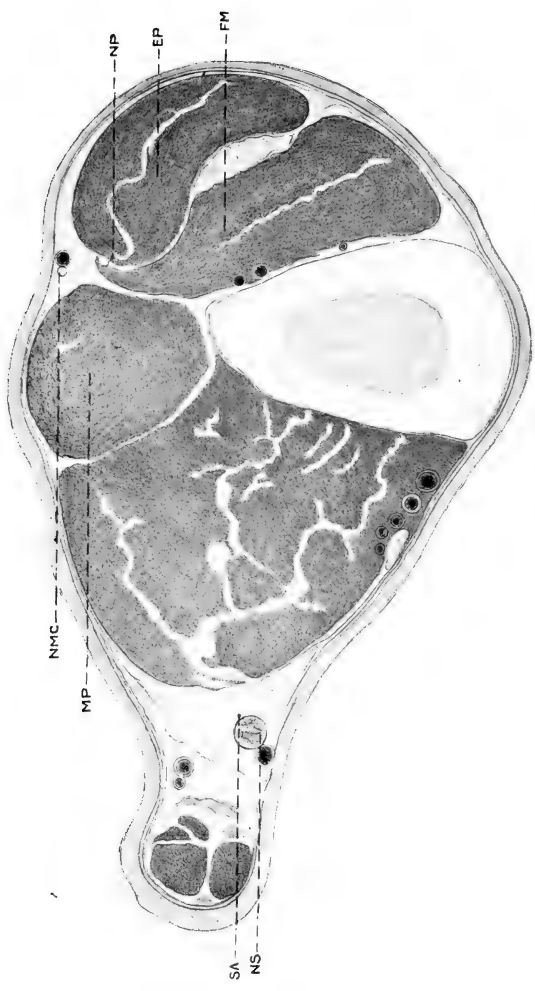
Right hind leg viewed from the median side,  
*f*, crural fascia; *n*, sciatic (tibial) nerve; *v*,  
plantar vein.



*Plate XXXII.*

*Tibio-Peroneal Neurotomy.*

Cross section through the tibia at about 10 c.m. above the tibio-astragaloid articulation. SA, recurrent tibial artery; NS, sciatic nerve; NMC, musculo-cutaneous branch of anterior tibial nerve; NP, deep or sensory branch of anterior tibial or peroneal nerve; EP, extensor pedis muscle; MP, peroneus muscle; FM, flexor metatarsi muscle.







of the tenacula. In poor horses the contour of the nerve, covered only by loose connective tissue, stands out prominently, in fat horses it is surrounded by a large amount of adipose tissue. Cut through this fat and connective tissue and expose the tibial nerve, *n*, Plate XXXI and NS, Plate XXXII, to view; immediately before it lies the plantar vein and on the lateral side is situated the recurrent tibial artery, SA, Plate XXXII. The cross section in Plate XXXII is located somewhat below the point for operation and the vein has crossed obliquely over the nerve so that it appears *behind* instead of *in front* of it, as is the case generally at the point where the operation is performed. Separate the vessels completely from the nerve with the handle of the scalpel, pass an aneurism needle from before backward beneath it through to the handle and grasping both ends force the instrument upwards and downwards in order to separate the nerve trunk from the adjacent tissues. Cut the nerve off at the upper and lower angles of the wound removing a section at least 5 cm. long. Suture the cutaneous wound and apply a bandage allowing it to remain eight days. Healing should occur by first intention.

---

#### 41. ANTERIOR TIBIAL NEUROTOMY.

##### Neurotomy of the Deep Branch of the Peroneal Nerve.

##### *Plates XXXII-XXXIII.*

**Object.** An adjunct operation to the preceding since this nerve supplies sensation to the tarsus in common with the sciatic. The two constitute what is known as Bossi's double neurotomy for spavin.

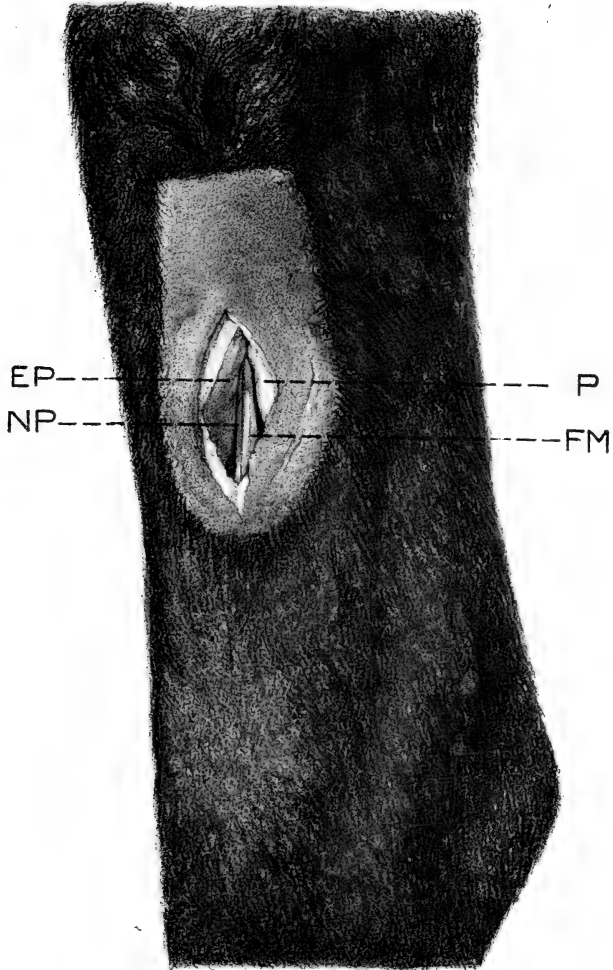
**Instruments.** Same as in the preceding.

**Technic.** Confine as in the preceding but with the affected leg uppermost. Locate the furrow dividing the

*Plate XXXIII.*

*Anterior Tibial Neurotomy.*

EP, extensor pedis muscle; P, peroneus muscle; NP, deep branch of the peroneal or anterior tibial nerve; FM, flexor metatarsi muscle.





extensor pedis longus, EP, Plates XXXII-XXXIII, and the peroneus muscles, P, Plate XXXIII, MP, Plate XXXII, and shave and disinfect an area 6 cm. long by 3 cm. wide directly over this depression and extending upward from a point 6 to 7 cm. above the tibio-astragaloid articulation.

At a point 8 to 10 cm. above the flexure of the hock make an incision through the skin and subcutis 5 or 6 cm. long over the line of division between the two extensors of the foot. Superficially the operator passes near by the musculo-cutaneous division of the anterior tibial nerve, NMC, Plate XXXII, which must not be mistaken for the deep branch.

The peroneus muscle, MP, Plate XXXII, and P, Plate XXXIII, is separated from the extensor pedis longus, EP, Plates XXXII and XXXIII, by a strong aponeurotic sheath continuous with the tibial aponeurosis. Penetrate the tibial aponeurosis *anterior* to the aponeurotic partition directly against the extensor pedis, EP, and passing along the posterior border of this muscle to a depth of 2 to 4 cm., there appears the thin margin of the flexor metatarsi magnus, FM, Plates XXXII and XXXIII, which lies immediately against the extensor pedis without a visible connective tissue partition but revealing itself by a markedly lighter shade of color and its ready separation from the extensor with the scalpel. The deep branch of the peroneal nerve, NP, Plates XXXII and XXXIII, lies loosely imbedded on the anterior side of the margin of the flexor metatarsi facing the extensor pedis, at times visible at the margin, at others placed more deeply reaching in some cases a distance from the margin of 4 or 5 mm. Within this range is seen the slender nerve trunk almost devoid of surrounding connective tissue and measuring about 2 mm. in diameter. Pass the aneurism needle beneath it and remove a piece 3 to 4 cm. long. Close the cutaneous wound with interrupted sutures and dress antisptically without a bandage.

## 42. RESECTION OF THE LATERAL CARTILAGE.

## The Bayer Quittor Operation.

*Plate XXXIV.*

**Object.** The cure of quittor or necrosis of the lateral cartilage.

**Instruments.** Elastic ligature, drawing knife, scissors, razor, hoof rasp, hoof plane, craniotomy or other heavy forceps for the removal of the horn, artery forceps, elevator or long bone chisel, right and left sage knives, curette, needle holder, thread, needles, iodoform ether, iodoform gauze, tampons, absorbent cotton, bandages.

**Technic.** For a few hours before the operation place the affected foot in a bath of creolin or other antiseptic solution after having first rasped the diseased quarter *lightly* and make a semicircular groove in the horn of the lateral wall and quarter down to the horny lamina, as shown at *s* in Fig. 1, Plate XXXIV. It is essential to not materially thin the horn on the quarter with the rasp since by weakening it, it yields and breaks and cannot be properly detached from the sensitive laminae.

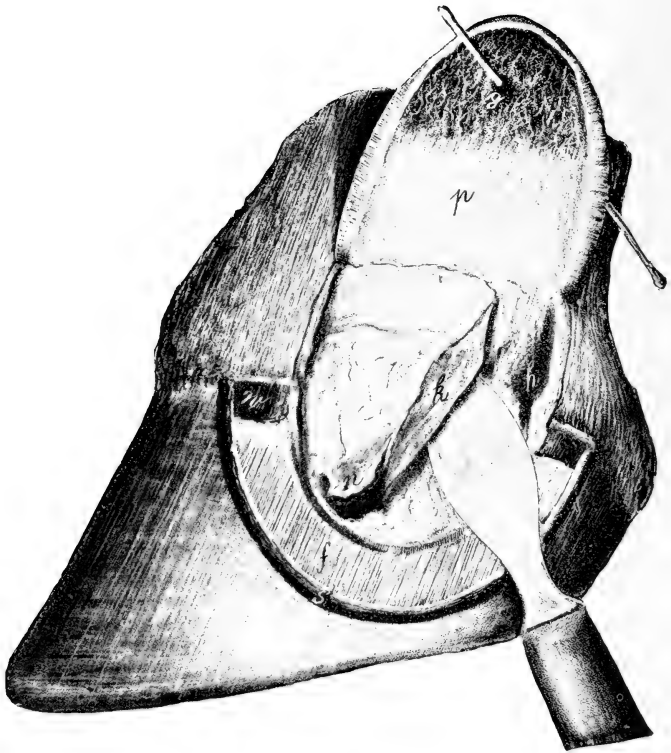
The operation is performed upon the recumbent, anaesthetized animal, in such a position that the diseased cartilage of the affected foot lies upward. The operating table constitutes incomparably the best means of confinement in every respect. After the application of the elastic ligature in the metacarpal or metatarsal region the groove in the horn is deepened with the drawing knife down to the sensitive laminae without injuring them. The groove must be so located that it extends beyond the anterior and posterior borders of the lateral cartilage, and downwards to within 1 or 2 cm. of the margin of the os pedis and approximately perpendicular to the surface of the horn wall so that it will form a secure support for the dressing to be later applied. The hair on the coronary band is clipped or shaved and the

entire foot up to the fetlock joint thoroughly cleansed with brush, soap, creolin or sublimate solution and 50 per cent. alcohol. The fetlock and pastern are carefully wrapped in a towel saturated with sublimate solution or other disinfectant. The hoof should be similarly wrapped except the operative area and every precaution taken against the transfer of infecting material from neighboring parts into the wound. The elevator or long bone chisel is then inserted beneath the lowest part of the semi-circular piece of horn which has been isolated, the horn is elevated from the sensitive structures somewhat, grasped with the heavy forceps and carefully loosened from the sensitive parts by drawing upward parallel to the laminae until the coronary band is reached and the traction is then directed backwards toward the heel, separating the wall from the coronary papillæ and keraphyllous tissue. Care is to be taken here to avoid lacerating the underlying tissues, especially when the traction is first directed backwards. If the soft tissues threaten to tear this should be arrested by the timely use of the scalpel or sage knife as conditions may suggest.

After the coronary band has been smoothed with the scissors, make two perpendicular incisions through the skin and coronary band, one behind the anterior and the other in front of the posterior border of the groove in the horn and connect the two by means of a semi-circular incision in the sensitive laminae. This U-shaped incision should be so made that between it and the horny wall there is left an area of sensitive laminae 1 to 2 cm. wide, in order that there may be sufficient room in the soft tissues for the application of the sutures, as shown in Fig. 2. The lines of incision through the coronary band should be so located as to include between them the entire lateral cartilage.

The isolated flap is now dissected closely against the os pedis and its ala and from the lateral surface of the cartilage, the operator lifting the flap with forceps or tenaculum.

*Plate*

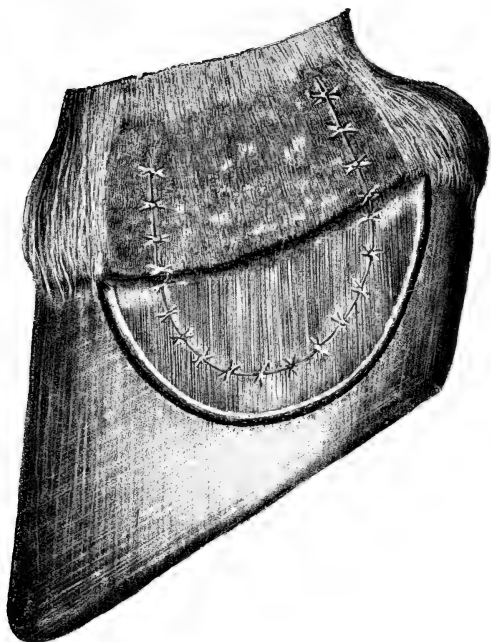


*Fig. 1.*

*Resection of the Lateral Cartilages of the os Pedis.*

Horny wall removed, sensitive laminae and cutaneous flap held upwards. Posterior half of the cartilage excised. *f*, sensitive laminae; *w*, coronary band; *k*, anterior half of cartilage; *h*, cavity caused by the removal of the posterior half of the cartilage; *n*, necrotic cartilage; *p*, parachondral surface of the skin and sensitive laminae; *s*, perpendicular, crescent-shaped incision in the horny wall; *g*, fistula.





*Fig. 2.*

*Resection of the Lateral Cartilages of the os Pedis.*

Completed operation showing the sutures in place and the parts ready for the application of dressings.

Above the cartilage toward the fetlock the operator must keep the fingers of one hand against the external skin in order to avoid cutting through it or thinning it too much at this point. The flap is held turned upwards by an assistant or a strong suture is passed through it and turning it upwards the suture ends are carried around the pastern and tied.

As a rule there is now seen a prominent, greenish colored necrotic piece of cartilage surrounded by brownish red masses of granulations. By means of an incision through the cartilage parallel to the long axis of the foot, divide it into anterior and posterior halves and extirpate the latter first by dissecting it out on the inner side from the parachondral tissue with the sage knife. Begin the excision of the cartilage by engaging the supero-anterior angle of the posterior half with the tenaculum and exerting moderate traction dissect it away from the underlying tissues first along the line of the dividing incision down to the base and then cut backward toward the heel cutting the cartilage away from its continuous bone. *The point of the knife must be constantly directed against the cartilage.*

Since the inner surface of the anterior half of the cartilage lies immediately against the capsular ligament of the coronopedal articulation the latter should be sharply extended by an assistant seizing the toe and forcing it forward. By this means the capsular ligament is drawn away from the cartilage during its extirpation.

The anterior half of the cartilage, *k*, is then removed in the same way, except with the greatest possible care to avoid puncturing the coronopedal articulation. The chief precaution is to dissect only with the point of the sage knife, using at all times that knife, right or left, which will result in the concave surface being presented toward the cartilage; then by carefully keeping the line of excision *immediately against* the cartilage, material danger of penetrating the

joint is avoided. Remnants of cartilage at its juncture with the retrossil process of the os pedis, and granulations are to be removed with the curette. Cut away with the scissors and knife any remnants of cartilage adherent to the flap, *p*, thin if necessary the entire flap and excise the fistulous openings, *g*. After thorough disinfection of the entire field of operation sprinkle it over thickly with powdered iodoform and return the flap to its former position and retain it there by a sufficient number of interrupted sutures as shown in Fig. 2. The first sutures to be applied should be at the border line between the skin and coronary band so as to insure accurate apposition at this point. Sprinkle the wound surface with iodoform and cover the parts over with iodoform gauze and tampons which rest firmly upon the perpendicular wall of horn. Finally invest the hoof and pastern up to the fetlock joint with an abundance of oakum saturated with 1-1000 sublimate solution and lay a heavy tar bandage over it, the turns of which must completely invest it at every point and render the dressing impermeable to moisture. Remove the elastic ligature. If the animal is free from fever, feels and eats well, the bandage is left in position from 12 to 14 days. Healing by first intention.

The two chief dangers in the operation are the opening of the corona-pedal articulation and the persistence of a scar in the coronary band resulting in a quarter crack.

If the operation has been kept thoroughly antiseptic, the opening of the articulation is not necessarily serious.

The question of preventing a weakening scar at the coronary incision is one of strict antiseptis and accurate suturing. The operation frequently fails under indifferent technic. It is an operation for the careful surgeon only.

## 43. RESECTION OF THE FLEXOR PEDIS TENDON.

*Fig. 15.*

**Object.** The removal of necrotic tissues and disinfection in cases of infected wounds, chiefly of nail wounds of the navicular bursa.

**Instruments.** Elastic ligature, drawing knife, sage knives, scissors, tenaculum forceps, curette, scalpels, tenaculæ, bandage material.

**Technic.** Before the operation thin the horn of the sole, frog and bars until the soft parts can be seen through them and apply an antiseptic bandage saturated in creolin solution for 24 hours if time will warrant. Secure the patient on the operating table or by casting in lateral recumbency with the affected foot extended. Anaesthetize. Cleanse and disinfect the entire foot with soap, brush, creolin or sublimate solution and 50% alcohol and apply the elastic tourniquet in the metacarpal or metatarsal region. Apply towels saturated with antiseptics as in preceding operation. Make a transverse incision through the base of the frog 2 to 3 cm. from the balls through the horny and sensitive portions and the fatty cushion down to the flexor pedis tendon. Follow this by two converging incisions extending forward and inward in an oblique direction corresponding to the semi-lunar crest of the os pedis, the line of incision being in the bars about  $\frac{1}{2}$  cm. outward from the lateral groove of the frog and uniting at its apex. This triangular piece of frog which has been isolated by the incision is now grasped with the tenaculum and dissected away. The remnants of the fatty frog should be removed with the sage knife or scalpel by means of a horizontal incision, and there is then revealed the flexor pedis tendon which may be greenish or yellowish colored and necrotic, or may be covered with reddish colored granulations.

Should there be present also suppurative pododermatitis the bars on the affected side must be excised along with the other portions.

The position and extent of the navicular bone can be determined by palpating the flexor tendon. A transverse incision is then made over the middle of the navicular bone

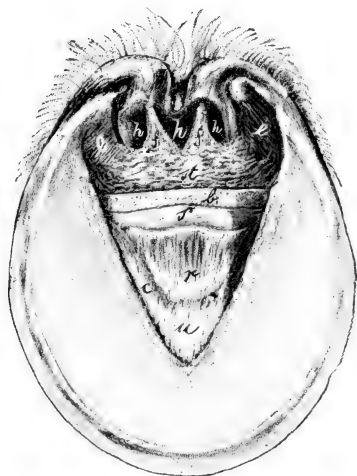


Fig. 15.

**Resection of the Flexor Pedis Tendon.**

Solar surface of the foot. *c*, Semi-lunar crest of os pedis; *u*, os pedis; *r*, navicular-pedal ligament; *s*, navicular bone; *b*, flexor pedis tendon; *e*, sensitive laminae of the bars; *st*, fatty frog; *f*, sensitive frog; *h*, horny frog.

through the flexor pedis tendon into the navicular bursa, the distal end of the tendon grasped with the tenaculum forceps and lifted up from the navicular bone with the aid of two lateral curved incisions. Between the inferior or anterior border of the navicular bone and the semi-lunar crest of the os pedis stretches the capsular ligament of the inferior articulation reinforced by dense fibrous bands. The flexor

pedis tendon is united to this by a few bundles of fibres. Dissect the tendon carefully away from the capsular ligament, avoiding opening the articulation, and then cut it away from the semi-lunar crest of the os pedis. If necrotic or discolored pieces of the fatty cushion or the tendon still remain, remove these with scissors, scalpel or curette. Curette the roughened cartilage of the navicular bone and remove any necrotic or inflamed, softened portions of the bone. In extensive necrosis of the suspensory ligaments of the heel and of the ligaments extending from the fetlock joint to the lateral cartilages, the necrotic portions as well as the neighboring fatty cushion with its numerous elastic fibres, must be resected. In case of purulent areas extending along the tendon and opening above in the heel, draw through the tract a large strip of gauze thoroughly saturated with tincture of iodine and allow it to remain. If the suppurating area extends well up into the heel without an opening, incise from above and handle as preceding. Disinfect the operation wound, irrigate with iodoform ether and tamponade it with dry iodoform gauze. Over this apply a firm pad of oakum saturated with 1-1000 sublimate, enclose the entire hoof up to the fetlock in oakum and apply over this a bandage. Over this apply a tar bandage and remove the elastic ligature. In the absence of fever the bandage remains in position for 8 to 12 days.

---

#### 44. AMPUTATION OF THE CLAWS OF RUMINANTS.

##### *Plate XXXV.*

**Uses.** The cure of "foul in the foot" or panaritium when complicated with suppurative arthritis or osteitis.

**Instruments.** Half round rasp, sage knives, scissors, convex scalpel, artery forceps, drawing knife, elastic ligature, dressing materials.

**Technic.** Cast the animal and secure the foot to be operated upon in an extended position, apply the elastic ligature and after disinfecting the claws rasp away the horn on the lateral side of the diseased claw, especially at the posterior part of it, until the horny wall becomes so thin that it can readily be pressed in with the fingers. Anaesthetize. The corono-pedal articulation can be felt, about 3 cm. below the coronary band, by grasping the claw with the left hand in such a manner that the thumb rests upon the thinly rasped horn while with the other hand the claw is moved from side to side. At the lowest point of the articulation push the sage knife into the joint, the concavity of the knife being directed toward the leg, and make a curved incision at first forward and upward to the neighborhood of the coronary band, then with strong flexion of the foot a second curved incision backward and upward which, however, extends only to the navicular bone. By this incision the operator divides the horn, the sensitive lamina, the external corono-pedal ligament and the capsular ligament of the corono-pedal articulation. Pass the knife between the navicular and pedal bones and extend the incision downwards perpendicular to the solar surface through it, separating the navicular bone from the os pedis. In this manner the navicular bone is preserved as well as the ball of the heel, the latter of which is of special significance in healing. The inner wall of the claw with the powerfully developed corono-pedal ligament is divided from before backward. After the vessels which can be seen are ligated, the articular surfaces of the navicular and coronary bones curetted and the necrotic remnants of tendon removed an antiseptic bandage is applied and a tar bandage placed over it for protection. The bandage remains for 12 or 14 days.

If the structures above this point of amputation are irretrievably involved the digit should be amputated higher up, at the articulation of the first and second phalanges or through the first phalanx. In these higher amputations a flap operation is generally practicable.

*Plate XXXV.*

*Amputation of the Claws of Ruminants.*

FIG. 1. *d*, horny wall, rasped thin; *g*, articular condyle of 2nd phalanx; *a*, *b*, *c*, course of incision.

FIG. 2. Median claw preserved. Viewed from the solar surface outward. *a*, external corono-pedal ligament; *i*, internal do; *k*, tendon of the flexor pedis muscle; *g*, distal articular surface of the 2nd digit; *g'* articular surface of 3rd digit; *g''*, navicular bone; *l*, lateral claw; *m*, median claw; *b*, bulb of the heel.



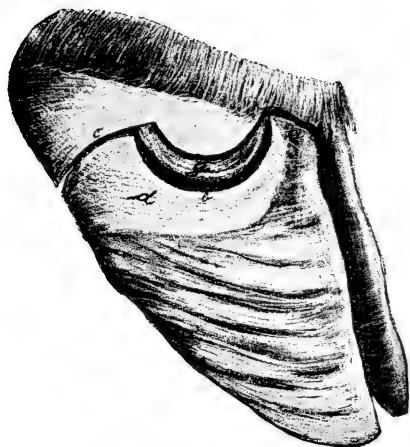


Fig. 1.

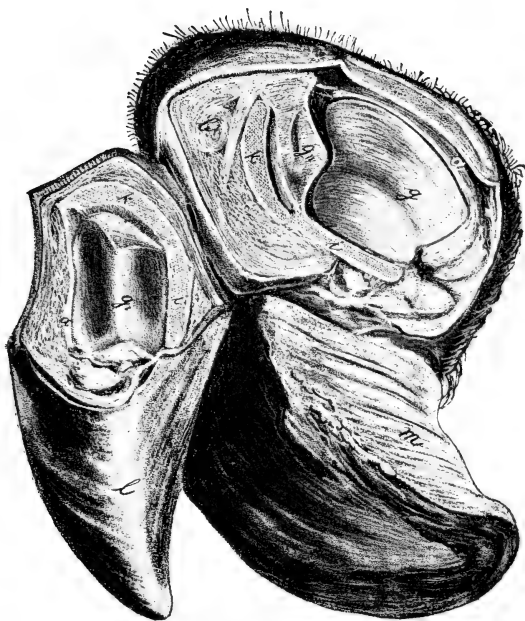



Fig. 2.

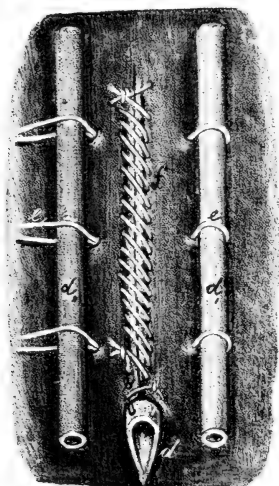


## 45. THE BAYER SUTURE.

*Figs. 16 and 17.*

**Uses.** The closure of large or penetrant wounds with convenient and secure means for applying and retaining antiseptic dressings.

**Instruments.** Large curved suture needle armed with strong silk thread, about 20 cm. long, which is doubled and

*Fig. 16.****Retention, and Continuous Approximation Sutures.***

*d, d', d''*, drainage tubes; *e*, retention suture (closed end); *e'*, open end; *b*, fixation suture for the drainage tube; *f*, continuous approximation suture.

passed through the needle eye in such a manner that the loop extends considerably beyond the cut ends; small needles and thread; needle forceps; rubber tubing preferably two large pieces and one small with lateral openings; thin wooden

splints 15 cm. long, 2 to 4 cm. wide, with rounded ends ; iodoform gauze ; iodoform ether 1:10.

**Technic.** After the skin has been shaved over an area having a radius of 5 to 6 cm. from the wound, the suture needle is inserted 2 to 3 cm. from the lips through the skin and subjacent tissues, a piece of the rubber tubing, *d'*, passed

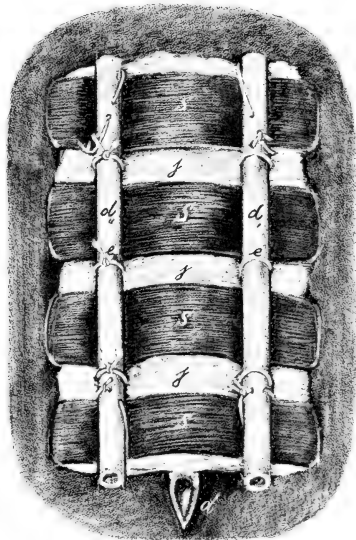


Fig. 17.

**Splint Bandage.**

*d, d', d''*, drainage tubes ; *e*, retention suture (closed ends) ; *e'*, do, open end ; *j*, iodoform gauze ; *s*, splints. through the closed end of the suture and the thread drawn tight. If before threading the needle a clove hitch is made at the middle of the thread, or if threaded as above directed and the thread is thrown about the tube in a double noose, the two threads will be kept in contact as they leave the tube to enter the soft tissues and thus prevent to some degree, the pressure necrosis otherwise taking place, due to the tense

threads of the suture separating from each other. The needle is then passed through the opposite lip of the wound from within to without at the same distance from the lips, the needle removed, the free ends drawn taut and a single knot tied against the skin to prevent the separation of the two threads for the reasons just stated above. The second large tube, *d''*, is laid between the open ends of the double silk thread and these are tied upon it with a triple knot, after they have been drawn sufficiently tight that the approximated wound lips form a crest. If the lips of the wound can be grasped with the hand and held together in such a manner as to form a ridge 3 or 4 cm. long, the suture needle may be passed through both simultaneously. The first suture should be located about 3 cm. beneath the upper angle of the wound, the other retention sutures follow at distances of about 5 cm. from each other and applied in the same way.

The lips of the wound are then united by continuous approximation sutures like an overcasted seam. This suture ends at least 2 cm. above the lower angle of the wound. The third tube, for drainage, is introduced beneath the latter sutures and fixed by a special suture.

The entire cutaneous surface lying between the drainage tubes is covered with iodoform gauze, and between each two retention sutures there is laid over this gauze the wooden splints previously cut to the proper size, the ends of which are pushed under the tubing. The upper- and lowermost splints should be secured to the drainage tubing by means of sutures passed through them. The entire bandage is finally saturated with iodoform ether. The bandage and retention sutures remain eight days, the approximation sutures fourteen.

## II. EMBRYOTOMY OPERATIONS.

### *Fig. 18.*

**General Considerations.** The following exercises in embryotomy operations are designed to give to the student a general view of the subject by a simple plan as carried out through the aid of a skeleton provided with an artificial uterus into which are placed freshly killed, newly born calves in such a position as may be desired and the operations carried out by the student as described. At the same time it is hoped to offer through these descriptions to the veterinary obstetricist a simple and effective plan for performing embryotomy which has been fully tested by the author in an extensive obstetrical practice. In describing these operations we purposely limit the instruments to be used to the fewest number and simplest kinds, yet using all that are essential in the performance of any of the following obstetrical operations. We designate the same instruments for each operation. They are, see Fig. 18: a hooked ring knife; a Colin's scalpel; an embryotomy chisel; long blunt hook; short blunt hook; repeller; probe pointed sector; injection pump; mallet; several cotton ropes 1 cm. in diameter with a small spliced loop at one end.

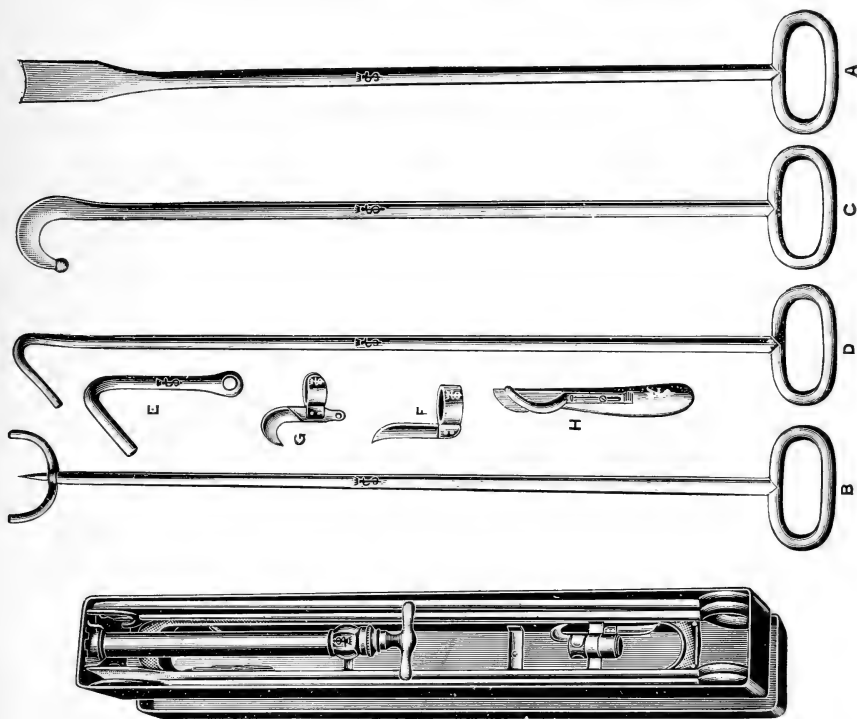
---

### 46. CEPHALOTOMY.

**Object.** The diminution of the size of the head on account of its oversize or of the smallness of the maternal pelvis, so that it may pass through the pelvic canal.

**Technic.** In these cases the head is usually engaged in the canal sufficiently tight that no further fixation is necessary. Should further fixation be desired, fix the long blunt hook deeply in one orbit. After thoroughly cleansing and disinfecting the parts inject a copious amount of tepid lysol

or bacterol solution into the vagina, then carry the chisel carefully guarded by one hand into the passage and place it accurately upon that part of the head of the fetus where it is desired to begin the operation ; generally on the median line of the nose with the blade of the chisel standing parallel to the septum nasi of the fetus. Holding the blade



*Fig. 18.*

*Aseptic Embryotomy Outfit.*

A, embryotomy chisel ; B, repeller ; C, sector ; D, long blunt hook ; E, short blunt hook ; F, ring knife ; G, hook knife ; H, Colin's scalpel. The lower figure represents the entire set with injection pump arranged in aseptic metal case.

of the chisel firmly against the part with one hand in such a manner as to effectively guard the instrument from slipping aside and wounding the maternal organs, steady and direct the handle with the other hand and have an assistant drive the chisel by means of blows of proper vigor with the mallet into the bones of the face and head. Do not drive the chisel deeper than the length of the blade without stopping and forcibly revolving it upon its long axis and breaking the foetal bones apart. The partially detached pieces of bone may be torn away with the fingers or in case the skin is quite adherent to them the bone may be held with the fingers of one hand, the chisel introduced with the other and using it as a spatula complete the separation. Repeat the use of the chisel as often as may be necessary in order to bring about the required diminution of the head, care being taken at all times not to wound the maternal parts and to conserve as far as practicable the skin of the fetal face and head in order that it may protect the maternal parts from the jagged bones during the passage of the remains of the head. The removal of the partially detached pieces of bone may in many cases be greatly facilitated by looping a cord over them and having an assistant apply traction sufficient to pull them away, the operator guarding the maternal organs by holding the piece of bone during its detachment and extraction, in the palm of his hand.

---

#### 47. DECAPITATION.

**Objects.** The facilitation of repulsion and correction of the deviation of fetal parts. The operation is generally carried out when the fetal head is far advanced in the pelvic canal or has passed beyond the vulva.

**Technic.** Attach a cord to the inferior maxilla or around the neck of the fetus and have one or more assistants draw the head out as far as possible.



Some obstetrists have found difficulty in applying traction to the inferior maxilla by means of a cord. First make a perforating wound with the knife between the rami of the lower jaw, then carry the looped cord over the jaw and push it beyond the perforating incision with the loop resting within the mouth and finally pass the free end of the cord through the perforation from the buccal cavity outwards, and drawing upon this the inferior maxilla is so engaged that it will permit the application of powerful traction.

Make a circular incision through the integument encircling the head at a convenient point and separate the skin backward toward the occiput by forcing the hand between it and the bones or by using the chisel as a spatula or dissecting it away with the Colin's scalpel, continuing the separation over the occiput to the atloid region. Make a transverse incision below across the trachea and œsophagus and surrounding muscles and above through the ligamentum nuchae. Grasp the head firmly with both hands and twist it forcibly on its long axis rupturing the articular ligaments and the remaining muscles and other soft tissues, detaching the head at the occipito-atloid articulation. The removal of the head greatly diminishes the bulk of the fetus and it may now be repelled, or deviated parts brought into the desired position or other operations performed.

---

#### 48. SUBCUTANEOUS AMPUTATION OF ANTERIOR LIMBS.

**Objects.** Amputation of the anterior limbs is very frequently called for in obstetric practice especially in the mare, chiefly in cases of transverse presentation with all four feet presenting and the head retained where it may be impossible to safely correct the deviation; in cases of wry neck in the foal in the anterior presentation, when it is impossible to correct the deviation of the head, or in any case in the mare or cow where deviation of the head cannot

be corrected or is not so readily overcome as is the amputation of the limb.

**Technic.** Our herbivorous animals being devoid of a clavicle, the anterior limb is attached to the thorax by means of the skin and muscles only and is therefore comparatively easily amputated. Attach a cord to the pastern of the limb, the shoulder of which lies most exposed or is most readily reached and have one or two assistants exert traction on it and draw it out as far as possible with safety to the mother. Insert one hand armed with the hooked embryotomy knife up to the top of the scapula or as nearly thereto as can be reached, the knife being well guarded in the palm of the hand which rests against the limb of the fetus ; press the knife into the skin and subcutaneous tissues and drawing the hand downward slit them freely and deeply from the top of the scapula down to the pastern. Lay aside the knife and force the fingers between the skin and subjacent tissues of the limb and while the assistant maintains gentle traction, separate the skin upward by forcing the hand or the ball of the thumb through the loose connective tissue until the upper region of the scapula is reached. The separation of the skin from the subjacent parts may require at certain points, like the olecranon or carpus, the aid of the chisel or knife to divide firm bands of connective tissue. This separation of the skin from the subjacent parts has removed the chief source of resistance to the tearing of the limb away from the body. The next most important obstacle is the pectoral muscles which should be torn asunder by separating them into small bundles and tearing them through with the fingers between the sternum and limb, or the process may be aided by incision with a knife or the chisel. When these are well divided the remaining impediment to tearing the shoulder away consists largely of the trapezius and rhomboideus muscles at the top, the latissimus dorsi behind, the great serratus and the angularis scapula which

only come into action when the shoulder is nearly severed. It is only necessary then to separate the skin from the limb and divide the pectoral muscles in order to readily draw the limb away by traction. Divide the skin now around the pastern and have two or three assistants exert traction upon the limb while the operator places his hand against the sternum and pushes in the opposite direction. Or the operator may increase his repulsion by using the repeller and pushing upon the crutch with his hand while an assistant pushes upon the repeller handle. The impact upon the maternal organs due to the traction may be reduced to almost any desired degree by applying a corresponding degree of repelling force to the sternum of the fetus. If the repelling force applied to the fetal sternum equals the traction upon the limb the impact of the fetus against the maternal organs becomes nil.

If traction does not bring the limb away promptly the operator should attempt to extend the division of the muscles attaching the limb to the thorax while moderate traction upon the limb is continued.

Further diminution of the size of the fetus may now be had by removal of the other limb in the same way which is especially desirable in the transverse presentation with all four limbs in the passages or we may reduce the size of the trunk by evisceration as described under 54.

This diminution suffices to permit the remnant of the fetus to be withdrawn with the head deviated to the side, the total resistance being no greater than had the head and neck presented normally. It also renders the fetal body very flaccid, and easy of repulsion and simplifies the correction of any deviations of parts.

**49. AMPUTATION AT HUMERO-RADIAL ARTICULATION.**

**Object.** Amputation at this point is rarely desirable, but may at times be necessary in the mare in order to remove an anterior limb when it is impossible, on account of the position to reach the shoulder.

**Technic.** Attach a cord to the pastern and have an assistant render the leg tense by exerting moderate traction, as in the preceding. Introduce the hand armed with the embryotomy knife, carefully concealed in the palm, and girdle the skin around the articulation. Passing above the head of the olecranon on the posterior side, divide the attachment of the anconeal group of muscles with the knife by cutting from behind forward. Then divide transversely, as far as possible, the muscles and ligaments passing over the articulation. Rotate the limb forcibly on its long axis while strong traction is maintained, and rupture the principal ligaments until the limb is completely detached and comes away. In cases of limited room it may sometimes be easier to detach the skin of the limb from the pastern up to the articulation, as in the preceding chapter, rather than to girdle it.

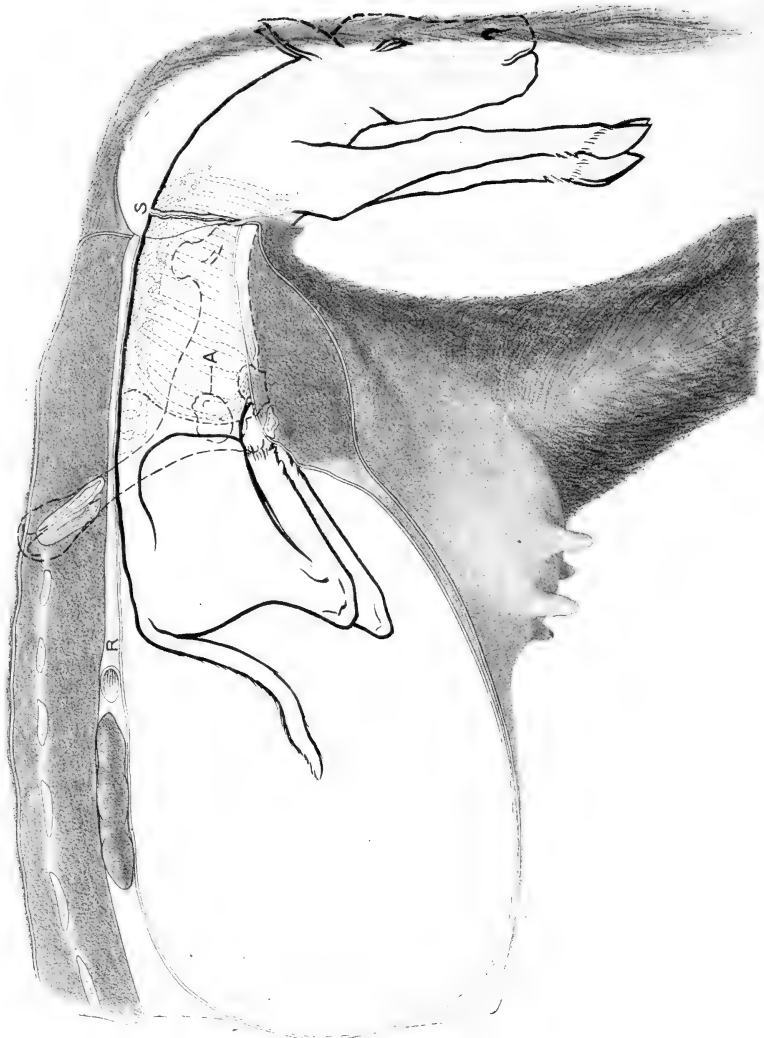
---

**50. DETRUNCATION.***Plate XXXVI.*

**Object.** In case a fetus in the anterior presentation and dorso-sacral position has one or both posterior limbs deviated forward and the feet engaged in or against the pelvis, it may be necessary, or at least advisable in the mare, that the trunk of the fetus be divided in order to bring about delivery without serious or fatal injury to the mother.

**Technic.** Secure the two hind feet by means of cords, if possible, prior to other manipulations. Apply cords to the two anterior limbs and the head, have one or two assistants draw the anterior part of the fetus as far out as is practicable and safe, and then girdle the fetal body immediately





*Plate XXXVI.*

*Detruncation.*

Embryotomy in anterior presentation; dorso-sacral position, the two hind feet engaged in the pelvis. S, point of incision through the skin. The dotted line behind and parallel to the last fetal rib indicates point for severing the muscles and spinal column.

against the maternal vulva by making an incision through the skin and skin muscle. If practicable it is best at this point to remove one shoulder subcutaneously, (48), and follow by evisceration, (54), in order to give greater operative room and increased mobility of the fetus. Insinuate the hand between the skin and the deeper structures and forcibly separate the integument from the fetal body backward until the last rib is passed, as shown at the curved line in Plate XXXVI. Force the finger tips through the abdominal wall behind the last rib and passing along the entire border of each posterior rib, separate the abdominal walls from the ribs and sternum. After the abdominal muscles have been detached, and the fetus has been eviscerated, rotate the thorax upon its long axis which will cause a division of the vertebral column near the dorso-lumbar articulation and the anterior portion of the fetus falls away.

Secure the two posterior feet with cords, unless this has already been done, spread the detached skin, which has been pushed back from the thorax, carefully over the amputation stump of the lumbar vertebrae, repel these by means of the hand while an assistant draws upon the cords attached to the feet, push the remnant of the fetal trunk into the uterus and advance the feet along the genital passages, thus converting it into a posterior presentation. Ordinarily this would result in a dorso-pubic—which should be converted into the dorso-sacral position, when its extraction can be readily brought about.

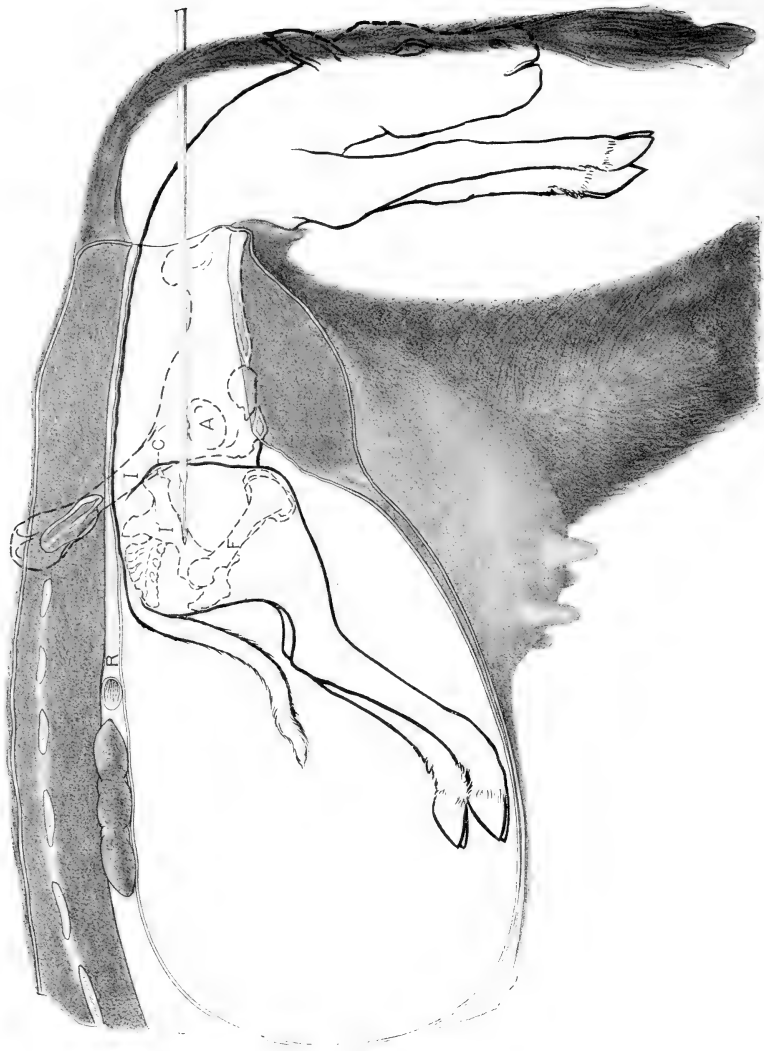
## 51. DESTRUCTION OF THE PELVIC GIRDLE IN THE ANTERIOR PRESENTATION.

### *Plate XXXVII.*

**Object.** In somewhat rare instances perhaps most frequently in the cow the pelvis of the mother and fetus become interlocked, the antero-external angle of the fetal ilium, I', becoming locked with the shaft of the maternal







*Plate XXXVII.*

*Destruction of the Pelvic Girdle.*

Embryotomy in anterior presentation: dorso-sacral position, the fetal and maternal pelvis interlocked. C, chief point of impact between the two pelvis; I, maternal ilium; I', fetal ilium, showing chisel passing through its shaft; R, rectum; A, outline of maternal coxo-femoral articulation.

ilium I at C in such a manner that any safe degree of traction fails to dislodge it.

**Technic.** Remove one anterior limb subcutaneously, (48), and eviscerate, (54), through an opening made by the removal of two or three of the exposed ribs. Introduce the chisel through this opening and carry it back with the hand, place it against the shaft of the fetal ilium, I', have an assistant drive it through the shaft from before to behind and then withdrawing the chisel replace it against the pubic brim either at the symphysis pubis or opposite the obturator foramen, and drive it through the pubis and ischium at either of these points. The coxo-femoral articulation is thus detached and isolated so that the entire limb may drop backward beyond its fellow, the remnant of the severed ilium, I', can drop downward or move in any direction and the entire pelvis thus loses its rigidity and undergoes great diminution in size so that it can readily be withdrawn.

---

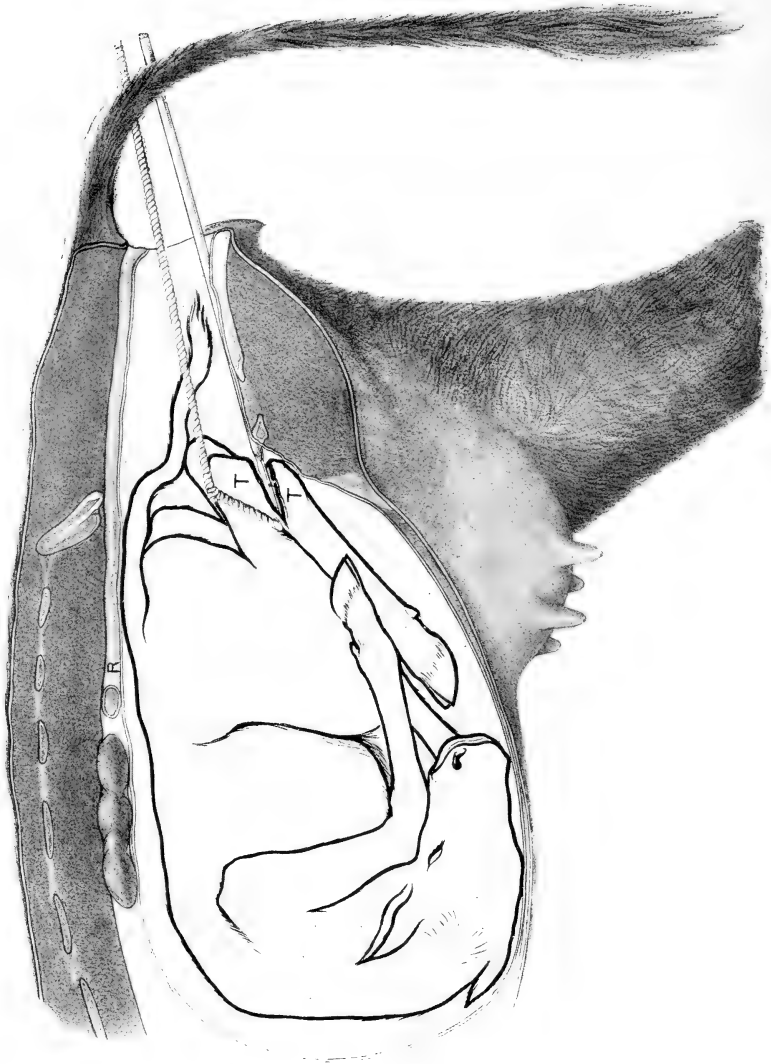
## 52. AMPUTATION OF THE LIMBS AT THE TARSUS.

### *Plate XXXVIII.*

**Object.** It sometimes happens in the mare, far more rarely in the cow that in the posterior presentation with the hind limbs retained at the hock owing to the unusual size of the fetus or its having been dead for some time, dry and emphysematous, that the deviation can not be overcome or its correction would entail an unnecessary amount of labor. In these cases it is frequently easier for the obstetricist and safer for the mother to amputate the limb at the tarsus.

**Technic.** Pass a cord around the leg above the tarsus as indicated in Plate XXXVIII and have an assistant hold the leg steady by gentle traction. Introduce the chisel carefully guarded in the palm of the hand, and place it against the lower part of the tarsus as shown between T, T. The chisel should be placed as nearly as possible perpen-





*Plate XXXVIII.*

*Amputation of the Posterior Limbs at the Tarsus.*

Embryotomy in the posterior presentation with irreducible retention of the posterior limbs. T, T, Tarsus in process of amputation by means of the chisel.

dicular to the long axis of the metatarsus. The proper direction of the chisel may at times be greatly favored by placing the cord upon the metatarsus instead of the tibia thus forcing the tarsus toward the sacrum of the mother and tending to throw the metatarsus straight across the pelvic cavity. When the fetus is in the dorso-sacral position and it is desired to amputate the left limb, the chisel should be held in the palm of the left hand with its dorsal surface against the vaginal walls and the instrument carefully guarded and guided during the entire operation. The amputation should preferably be through the lower section of the tarsus but may be made through the head of the metatarsus. Do not drive the chisel entirely through the hock without removal as it may become caught and clamped between the divided bones, but drive for a few inches along the lateral side being sure that the skin at that point is severed along with the bone, then loosen the chisel by rotation and lateral motion and drive somewhat deeper into the tarsus until it is completely severed. Withdraw the severed metatarsus and remove any dangerous spicules of bone remaining on the stump and see that the latter is safely secured by a cord passing around the leg above the os calcis. Repeat the operation on the other hock in a similar manner using the right hand to guide the chisel. Extend the two limbs into the passages by traction and effect a posterior delivery.

---

### 53. INTRA-PELVIC AMPUTATION OF THE POSTERIOR LIMBS, BREECH PRESENTATION.

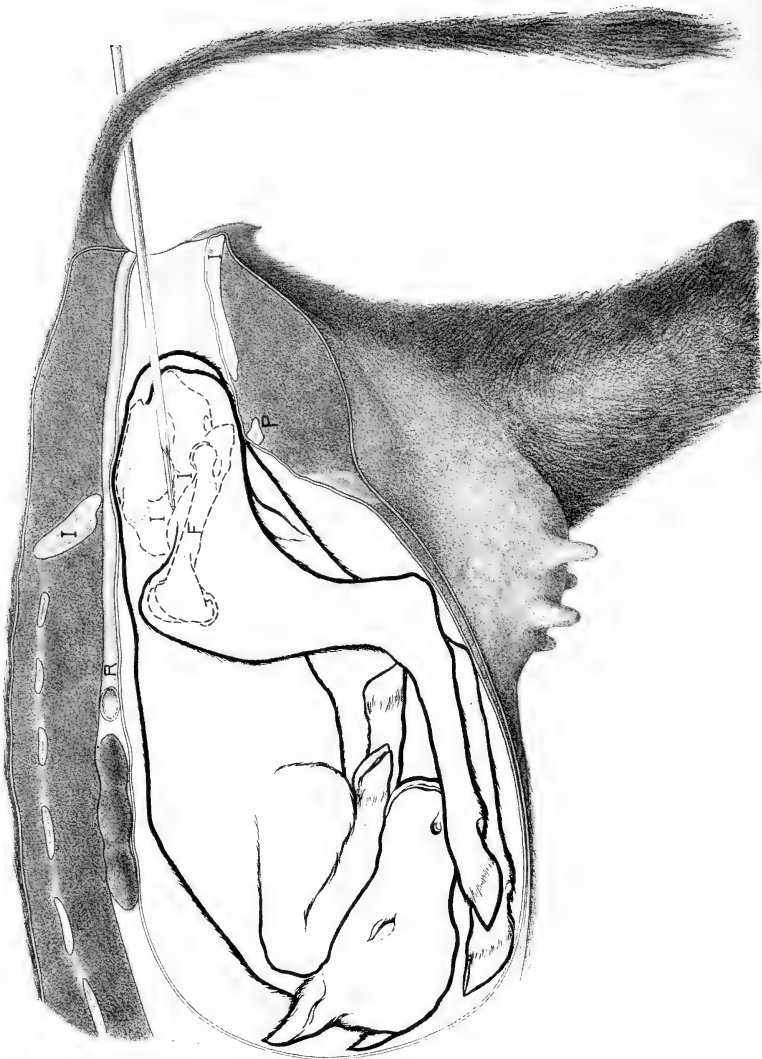
#### *Plates XXXIX-XL.*

**Uses.** The overcoming of dystocia due to a posterior presentation with the hind limbs completely retained in the uterus, the so-called breech presentation, in cases where the deviation can not be readily corrected.

**Technic.** Introduce one hand armed with the embryotomy knife through the maternal passages until the peri-







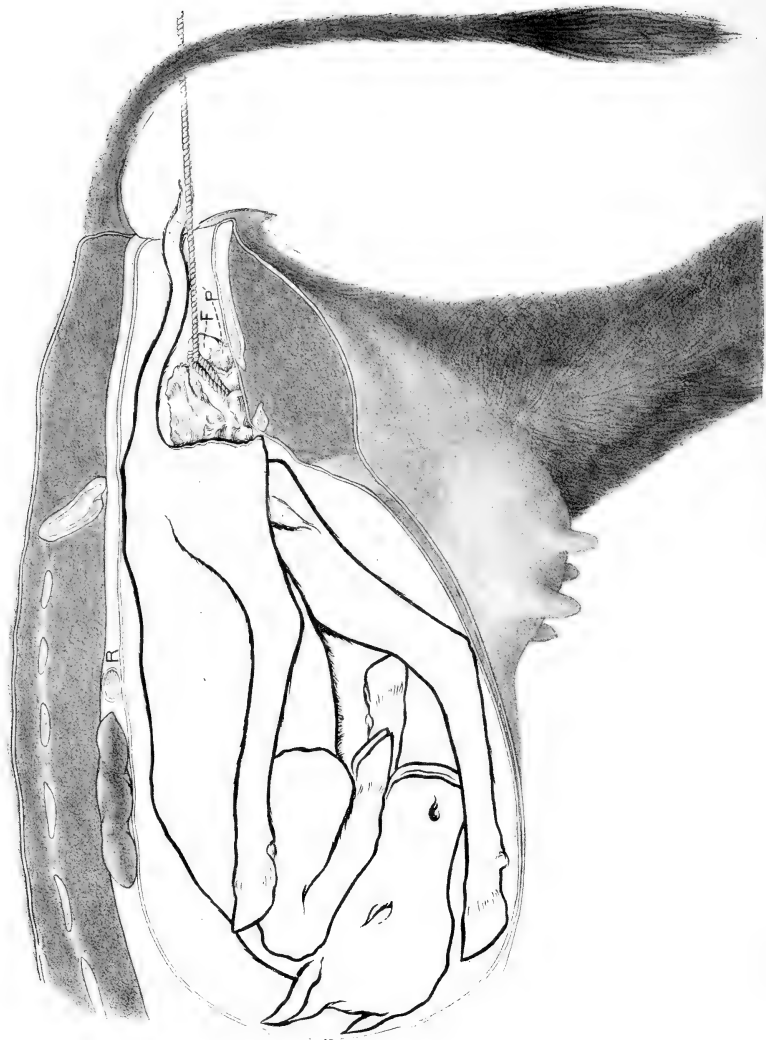
*Plate XXXIX.*

*Intra-pelvic Amputation of the Posterior Extremities.*

Embryotomy in the posterior presentation with the hind legs completely retained Breech presentation. F, trochanter of the fetal femur; P', the fetal pubis. The rope is looped over the isolated coxofemoral articulation including portions of ilium, pubis and ischium.

neum of the fetus is reached and make a free incision through that region involving the anus in the male fetus and the anus and vulva in the female and enlarge the incision sufficiently to admit the operator's hand into the fetal pelvis. Locate the great sciatic ligament and with the knife divide the ligament from end to end, thus enlarging the pelvic cavity and giving ample operating room. If the pelvis of the fetus is too small to admit the hand of the operator at all before severing the sciatic ligament, this may be accomplished by cautiously cutting from behind forward with Colin's scalpel or with the chisel. When this has been severed and sufficient operating room attained, carry the chisel with the hand and place it against the shaft of the ilium as shown between I' I' in Plate XXXIX as nearly perpendicular to the long axis of the iliac shaft as possible and keeping the hand in touch with the chisel blade, have an assistant drive it through the bone until it and its periosteum are completely severed. Revolve the chisel on its long axis and force the cut ends of the bone apart. Disengage the chisel and place it against the symphysis pubis or against the ischium opposite the obturator foramen and drive it through the ischium and pubis at this point. Using the chisel as a lever, separate the isolated portion of the pelvis as completely as practicable from the surrounding tissues, and with the fingers separate the muscles from the detached pelvic bone for a short distance from the severed ends on either side. Carry a cord in, pass the loop over the ends of the severed section and tightening it secure the isolated portion of the pelvis and have one or more assistants exert traction as indicated in Plate XL. The chief obstacle to the withdrawal of the limb is the great gluteus muscle which should be sought for, identified and torn through with the fingers at a distance of 5 or 6 cm. from its attachment to the great trochanter. Other important points of resistance are the attachment posteriorly of the skin, vulva and anus to the ischium through the medium





**Plate XL.**

***Intra pelvic Amputation of the Posterior Extremities.***

Embryotomy in the posterior presentation with the hind legs completely retained. Breech presentation. I, maternal ilium; I' I', fetal ilium; I'', maternal ischium; P, pubis; F, fetal femur. The chisel is shown passing through the shaft of the fetal ilium.

of aponeurosis and anteriorly, chiefly on the median line, the prepubic tendon ; these are to be cut, if necessary, with the chisel or knife. Vigorous traction may now be applied by means of the cord, the operator in the meantime guarding the most advanced end of the detached piece of pelvis with the palm of his hand in order to prevent injury to the maternal organs. Sometimes this detached piece of the pelvis tears away from the femur when traction is applied and comes away alone. In such a case the cord is to be applied over the head and trochanter of the femur and traction again applied drawing the limb away in a reversed position, the skin being turned back or everted as it advances until the region of the hock is reached where the integument does not so readily separate and only requires to be cut loose and the member allowed to come away. During the removal of the limb the operator is to constantly note the progress with his hand and sever by tearing or cutting any tendons or muscles which offer special obstruction to the operation. Repeat the operation upon the opposite limb in the same manner except that but one incision need be made through the bone, that is, through the shaft of the ilium. During the entire work the operation is carried out subcutaneously or rather intra-fetally and the maternal parts are amply guarded against injury. The size of the fetal trunk may be further reduced if desirable, by evisceration, (54), and followed still further by the introduction of the chisel guided by the hand and the ribs, on one or both sides, severed one after another until the chest can completely collapse. Or the ribs may be yet more conveniently severed by introducing the sector in the body cavity, pushing it forward until the first rib is reached catching the spherical end over the rib and drawing backwards, sever each rib in turn. If need be some of these may be removed and one of the anterior limbs caught by a cord around the scapula and extracted intra-fetally. The remnant of the fetus is to be extracted by means of a cord fastened about the lumbar region of the spine.



**54. EVISCERATION.**

Evisceration of the fetus is frequently desirable in obstetric practice and has a variety of uses. It decreases the size of the fetal trunk considerably and permits its more ready passage through the genital canal, as in the anterior presentation; with lateral deviation of the head it renders the fetal trunk flaccid through the removal of the viscera supporting the body walls and permits the body remnant to be bent or moved more readily for the correction of any malpresentation; it permits freedom of intra-fetal operations directed against other parts, as for detruncation, or for the destruction of the pelvic girdle in the anterior presentation, and when a fetus is emphysematous, evisceration permits the gases of decomposition to pass into the fetal body cavity and thence externally. The escape of gases is very greatly favored further by the cutting of the ribs.

**Technic.** Evisceration may be variously performed, but is generally demanded in either the anterior or posterior presentation and a description of these will suffice.

In the anterior presentation, unless the fetus is far advanced through the vulva, evisceration is best performed by the removal of one or more of the anterior ribs. The ribs are generally best reached by the removal of the shoulder, as already described under subcutaneous amputation of the anterior limbs, (48). When the ribs have been laid bare in the manner described the operator can thrust the finger tips through the intercostal muscles in the first space and enlarge the opening thus made by tearing through the muscles upwards to the spinal column and downwards to the sternum; then grasping the posterior border of the rib near its middle, fracture it by means of a sudden and vigorous pull. The fractured ends may then be grasped and pulled, broken or twisted off. The chisel may be brought into use if required in order to divide the rib, the hand of the operator constantly guiding and guarding the chisel blade. The opera-

tion is then to be repeated if required, upon the second and third ribs in the same manner until an opening into the chest is secured ample in size for the introduction of the operator's hand.

Force one hand through the opening and tear the mediastium above and below from the thoracic walls, and then grasp either the trachea at its bifurcation or the heart and tear them away. The heart, which constitutes the greater bulk of the thoracic viscera, is best grasped in the palm of the hand, with the fingers engaging the aorta and pulmonary arteries. When the thoracic viscera have been withdrawn, thrust the fingers through the diaphragm and locating the liver, isolate the diaphragmatic area to which it is attached, and engaging both with the fingers remove the two together. The liver constitutes, in a normal fetus, the chief intra-abdominal mass, occupying more space than all other organs combined. After the liver has been removed the intestinal tube, with its contents, is withdrawn without difficulty, as its attachments are feeble. The kidneys may also be removed.

Evisceration in the posterior presentation is preferably performed through the pelvis, generally in connection with intra-pelvic amputation of the posterior limbs, (53). It may be performed without destruction of the pelvic girdle by making an incision through the perineal region and then severing the sacro-sciatic ligament as directed under 53. When admission has been gained to the abdominal cavity introduce the hand and withdraw the alimentary tube, then rupture the diaphragm about the liver and tear away the latter organ in the same manner as in the anterior presentation. The liver is so friable that it cannot well be removed by grasping the organ itself, but comes away entire with the central part of the diaphragm.

Remove the heart and lungs as above directed.







JUN 21 1912



LIBRARY OF CONGRESS



0 020 948 660 A