

★ No. R1525. Z166



A TEXT-BOOK

OF

SPECIAL PATHOLOGICAL ANATOMY

BY

ERNST ZIEGLER

PROFESSOR OF PATHOLOGY IN THE UNIVERSITY OF FREIBURG

TRANSLATED AND EDITED

FROM THE EIGHTH GERMAN EDITION

BY

DONALD MAC ALISTER M.A. M.D.

LINACRE LECTURER OF PHYSIC AND TUTOR OF ST JOHN'S COLLEGE, CAMBRIDGE

AND

HENRY W. CATTELL M.A. M.D.

DEMONSTRATOR OF MORBID ANATOMY IN THE UNIVERSITY OF PENNSYLVANIA

SECTIONS I-VIII

New York

THE MACMILLAN COMPANY

LONDON: MACMILLAN & CO. LTD.

1898

All rights reserved

*RB25
Z66

Reface
0740.68

COPYRIGHT, 1896,
By THE MACMILLAN COMPANY.

Set up and electrotyped September, 1896. Reprinted August,
1897; August, 1898

Reface 1898
L

VRAREL OLUBA
3HT 70
NOTBOB 70YTD

Norwood Press
J. S. Cushing & Co. — Berwick & Smith
Norwood Mass. U.S.A.

11.11.12/11/4

PREFACE

SINCE the publication in 1884 of the first English edition of Ziegler's *Special Pathological Anatomy*, great advances have been made in our knowledge of its subject-matter. These have been duly embodied in the five successive German editions that have appeared in the meantime. The work has accordingly been so altered and enlarged that in preparing a third English edition we have had entirely to rewrite the text, and to recast the bibliographical and other supplementary portions. The number of pathological papers and monographs to which reference might fitly be made is now so great that only the more recent and important can be dealt with. But the student of historical tastes will find ample references to the earlier literature in the previous English editions; and by omitting them in this much valuable space has been gained.

The second volume, containing the sections on the alimentary tract with the liver and pancreas, the respiratory and genito-urinary systems, the eye, and the ear, is already in the press and will shortly be published. We hope to follow it with a new version of the part on *General Pathological Anatomy*, prepared with the author's sanction and assistance from the latest German edition.

We desire here to record our thanks to Dr W. G. Spiller, of Philadelphia, for his help in preparing the translation of Sections VI and VII.

DONALD MAC ALISTER
HENRY W. CATTELL

JULY, 1896.

CONTENTS

SECTION I

BLOOD AND LYMPH

CHAPTER	PAGE
I. THE BLOOD	3
II. THE LYMPH	13

SECTION II

THE VASCULAR MECHANISM

III. MALFORMATIONS OF THE HEART AND GREAT VESSELS	17
IV. MORBID ALTERATIONS OF THE HEART AS A WHOLE	26
V. MORBID CHANGES IN THE ENDOCARDIUM	30
VI. MORBID CHANGES IN THE MYOCARDIUM	44
VII. INFECTIVE GRANULOMATA, TUMOURS, AND PARASITES OF THE HEART	55
VIII. MORBID CHANGES IN THE PERICARDIUM	58
IX. MORBID CHANGES IN THE ARTERIES	65
X. MORBID CHANGES IN THE VEINS	91
XI. MORBID CHANGES IN THE LYMPH-VESSELS	96

SECTION III

THE SPLEEN AND THE LYMPH-GLANDS

XII. MORBID CHANGES IN THE SPLEEN	103
XIII. MORBID CHANGES IN THE LYMPH-GLANDS	117

SECTION IV

THE OSSEOUS SYSTEM

XIV. THE BONE-MARROW	137
XV. ATROPHIC AFFECTIONS OF BONE	141
XVI. REGENERATION AND HYPERTROPHY	154

CHAPTER	PAGE
XVII. INFLAMMATIONS OF BONE	170
XVIII. INFECTIVE GRANULOMATA OF BONE	183
XIX. DISORDERS OF OSSEOUS DEVELOPMENT AND GROWTH	196
XX. TUMOURS, CYSTS, AND ANIMAL PARASITES OF BONE	231
XXI. DEGENERATIONS OF THE JOINTS AND SYNARTHIROSES	245
XXII. REGENERATION AND HYPERTROPHY IN JOINTS	250
XXIII. ACUTE AND CHRONIC INFLAMMATIONS OF JOINTS	260
XXIV. TUBERCULOSIS AND SYPHILIS OF JOINTS	282
XXV. LOOSE BODIES IN THE JOINTS	287

SECTION V

THE MUSCLES AND TENDONS

XXVI. THE MUSCLES	291
XXVII. THE TENDONS, SHEATHS, AND BURSÆ	314

SECTION VI

THE CENTRAL NERVOUS SYSTEM

XXVIII. THE SPINAL CORD AND ITS MALFORMATIONS	323
XXIX. DEGENERATION AND INFLAMMATION OF THE SPINAL CORD	330
XXX. THE FORMS OF MYELITIS	344
XXXI. HYDROMYELIA AND SYRINGOMYELIA	349
XXXII. MULTIPLE SCLEROSIS	353
XXXIII. NEURONIC OR SYSTEMIC AFFECTIONS	357
XXXIV. INFECTIVE GRANULOMATA AND TUMOURS OF THE CORD	370
XXXV. THE MEMBRANES OF THE CORD	373
XXXVI. STRUCTURE AND FUNCTIONS OF THE BRAIN	381
XXXVII. MALFORMATIONS OF THE BRAIN	388
XXXVIII. DISORDERS OF THE CEREBRAL CIRCULATION	404
XXXIX. ATROPHY OF THE BRAIN	407
XL. LOCAL DEGENERATIONS AND INFLAMMATIONS OF THE BRAIN	412
XLI. INFECTIVE GRANULOMATA OF THE BRAIN	432
XLII. SCLEROSIS OF THE BRAIN	434
XLIII. TUMOURS AND ANIMAL PARASITES OF THE BRAIN	436
XLIV. THE PIA MATER AND ARACHNOID	442
XLV. THE DURA MATER, PINEAL GLAND, AND PITUITARY BODY	460

SECTION VII

THE PERIPHERAL NERVOUS SYSTEM

CHAPTER		PAGE
XLVI.	STRUCTURE OF PERIPHERAL NERVES	469
XLVII.	DEGENERATION AND INFLAMMATION OF NERVES	470
XLVIII.	REGENERATION OF NERVES	478
XLIX.	TUMOURS OF NERVES	481

SECTION VIII

THE SKIN

L.	INTRODUCTORY	489
LI.	DISORDERS OF CIRCULATION	491
LII.	PIGMENTARY DISORDERS	495
LIII.	ATROPHY OF THE SKIN	499
LIV.	INFLAMMATORY AND PARASITIC DISORDERS	502
LV.	INFLAMMATORY HYPERTROPHIES AND TUMOURS	548
LVI.	NON-INFLAMMATORY HYPERTROPHIES AND TUMOURS	554
LVII.	THE SEBACEOUS GLANDS, HAIR, AND NAILS	570
INDEX		i-xxxii at end of vol.

INDEX OF FIGURES

FIG.	PAGE
1. Section through a degenerating patch from the brain	13
2. Malformation of the heart	18
3. Heart of a human embryo 4·3 millimetres long	20
4. Heart of a human embryo at the fifth week	20
5. Posterior half of the heart of a human embryo at the fifth week	21
6. Diagrammatic scheme of the aortic arches of the embryo of an amniotic vertebrate	22
7. Diagrammatic scheme of the transformations of the aortic arches in a mammal.	22
8. Hypertrophy of the left ventricle	27
9. Section of fatty endocardium	30
10. Mucoid degeneration of the connective tissue of the aortic valve	30
11. Proliferous growth of the endocardium with a thrombus	32
12. Mycotic endocarditis of an aortic valve	34
13. Mycotic endocarditis (pustulosa) of the tricuspid valve	35
14. Warty endocarditis (verrucosa) of the aortic valve	35
15. Villous endocarditis (polyposa)	36
16. Ulcerative endocarditis of the aorta, showing ulcers, valvular perforations, and valvular thrombi	36
17. Mycotic endocarditis (villosa), with valvular thrombi, and acute valvular aneurysm	37
18. Section through an endocarditic vegetation	39
19. Posterior segment of the mitral valve, with thickened and calcified thrombi, and stenosis of the auriculo-ventricular opening	40
20. Thickened and distorted aortic valves	40
21. Aortic insufficiency and mitral stenosis	41
22. Brown atrophy of the cardiac muscle	44
23. Fatty degeneration of the cardiac muscle	44
24. Rupture of the heart in arterio-sclerotic myomalacia	47
25. Myomalacia cordis	48
26. Fibroid induration of the heart	49
27. Thrombosis within the heart	50
28. Partial cardiac aneurysm	51
29. Mycotic myocarditis	53
30. Cor villosum	59
31. Adhesive pericarditis	60

FIG.	PAGE
32. Granulation-tissue formed within a fibrinous pericarditic deposit of some weeks' duration	61
33. Fatty degeneration of the cells of the intima of the aorta, viewed from the flat surface	65
34. Fatty degeneration of a cerebral capillary	65
35. Hyaline degeneration of the blood-vessels of an atrophic lymph-gland	66
36. Commencing calcification of the middle coat of the aorta	66
37. Atheromatous cerebral artery	68
38. Section of the aorta in acute proliferous aortitis	70
39. Embolic suppurative arteritis	73
40. Occlusion of a pulmonary vessel by connective tissue after embolism	74
41. Remains of emboli in a branch of the pulmonary artery	75
42. Section of a thrombus in process of organisation	76
43. Diagrammatic section of a ligated vessel	77
44. Syphilitic arteritis	79
45. Tuberculous arteritis	80
46. Periarteritis nodosa	80
47. Periarteritis nodosa	81
48. Aneurysms of the aorta	82
49. Aneurysms of the hypogastric artery	83
50. Rupture of the intima and media of the aorta, with the formation of a dissecting aneurysm	85
51. Aneurysmal dilatation and partial rupture of the ascending aorta	86
52. Obliteration of the right femoral vein	92
53. Varices of leg	93
54. Section of the dark-red spleen-pulp	103
55. Amyloid degeneration in and about the splenic follicles	106
56. Lymphoid follicle of the spleen with central necrosis	109
57. Portion of tissue and isolated cells from a splenic follicle undergoing partial necrosis	111
58. Hypertrophy of the follicles of the spleen	113
59. Chronic tuberculosis of the spleen	115
60. Amyloid swelling of the adenoid reticulum	118
61. Deposit of pigment-carrying cells in a lymph-gland after resorption of an extravasation of blood	119
62. Section of a slate-coloured lymph-gland of the lung	120
63. Inflammatory oedema of a lymph-gland, with catarrhal desquamation of the endothelium of the lymph-channels	121
64. Fibrinous lymphadenitis	122
65. Fibrinous mesh-work in the lymphadenoid follicles of the tonsil in croupous pharyngitis from diphtheria	123
66. Fibrous hyperplasia of a lymph-gland	124
67. Recent tuberculosis of a lymph-gland	126
68. Large-celled hyperplasia of a tuberculous lymph-gland	127
69. Alveolar sarcoma of a lymph-gland	132
70. Carcinoma developing in an enlarged axillary lymph-gland	132
71. Resorption of bone	141

FIG.		PAGE
72.	Eccentric atrophy of the lower ends of the tibia and fibula, with osteoporosis	142
73.	Senile atrophy of the calvarium	143
74.	Hypoplasia of the pubis, ischium, and ilium of the left side	144
75.	Extreme atrophy of the cranial bones produced by the pressure of the developing brain	145
76.	Deformity of the superior and inferior maxillae and their alveolar processes produced by cicatrization after a burn	146
77.	Atrophy of the last thoracic and upper lumbar vertebrae, from the pressure of an aortic aneurysm	147
78.	Section of a vertebra affected with osteomalacia	150
79.	Osteomalacia of the pelvis	151
80.	Osteomalacia of the tibia	152
81.	The formation of new bone on the surface of old bone by means of a layer of osteoblasts	155
82.	Myelogenous formation of bone from aggregations of osteoblasts	156
83.	Formation of osteoid trabeculae from proliferous periosteum	157
84.	Periosteal formation of cartilage	157
85.	Formation of bone from cartilage in a callus fourteen days old	158
86.	Formation of bone from connective tissue	158
87.	Proliferous periosteum four days after fracture of the bone	161
88.	Longitudinal section through a fracture of the fibula fourteen days old	162
89.	Reunited fracture of the tibia and fibula, with synostosis of the bones	164
90.	Fracture of the spine nine months old, with great displacement of the vertebrae	165
91.	Fracture of the fibula, repaired by syndesmosis	166
92.	Pseudo-arthritis after fracture of the neck of the femur	167
93.	Resorption and apposition of bone	168
94.	Apparent dilatation of the radius	169
95.	Necrosis of the lower third of the diaphysis of the femur	172
96.	Necrosis of the left tibia with periosteal bone-formation, following acute osteomyelitis	172
97.	Phosphorus-necrosis of the lower jaw	176
98.	Periosteal hyperostosis of the tibia	177
99.	Skeleton of a hand with hyperostosis of the bones	178
100.	Ostitis deformans of the head and neck of the femur	179
101.	Spondylitis deformans	180
102.	Fungous granulations with tubercles from the spongy tissue of the calcaneum	183
103.	Central tuberculosis of bone in an advanced stage	185
104.	Periosteal deposition of bone in chronic myelogenous tuberculosis	186
105.	Osteosclerosis of the femur resulting from chronic tuberculosis	187
106.	Tuberculosis of the spinal column	188
107.	Formation of osteophytes upon the atrophied cortical layer of the femur in chronic tuberculous arthritis	189

FIG.		PAGE
108.	Angular flexure of the vertebral column from the destruction of the first lumbar vertebra	190
109.	Angular flexure of the spine with bony ankylosis of the bodies of the vii-xii thoracic vertebrae after partial destruction by tuberculous disease	191
110.	Gummatous syphilitic caries of the parietal bone	193
111.	Syphilitic caries and necrosis of the calvarium	193
112.	Syphilitic hyperostoses of the left femur	194
113.	Normal endochondral ossification	197
114.	Partial agenesis of the bones of the cranial vault in anencephalia	199
115.	New-born micromelic infant, with cretinoid expression of face	200
116.	Skeleton of a female cretinoid dwarf	201
117.	Skeleton of a female dwarf	201
118.	Head of a microcephalic child (Helen Becker)	202
119.	Endochondral ossification in a new-born child with abnormally short limbs	203
120.	Bones of the middle finger of the right hand of the cretinoid dwarf of Fig. 116	204
121.	Micromelic pseudo-rachitis (foetal rickets) of the upper limb	204
122.	Agenesis of the wings of the sacrum with sacro-iliac synostosis	205
123.	Leontiasis ossea	208
124.	Syphilitic osteochondritis	212
125.	Rickets	214
126.	Rickets	216
127.	Formation of a medullary space within an epiphysial cartilage in rickets	217
128.	Adult femur with rachitic curvature of the diaphysis	219
129.	Adult femur with rachitic flexure of the lower epiphysis	219
130.	Flat rickety pelvis	220
131.	Rickety (pseudo-osteomalacic) pelvis with the promontory of the sacrum sunk forward	221
132.	Congenital hydrocephalus in a child about one year old	224
133.	Scoliosis and kyphosis of the spine	226
134.	Spondylolisthesis	228
135.	Osseous resorption and apposition in the neighbourhood of a metastatic carcinomatous deposit in the diaphysis of the humerus	231
136.	Myelogenous osteosarcoma of the tibia	232
137.	Osteosarcoma of the cranium	233
138.	Section through an osteoid-chondroma of the humerus	234
139.	Ossifying large-celled sarcoma of the tibia	235
140.	Multiple ivory exostoses of the cranium	236
141.	Cartilaginous exostosis of the upper diaphysial end of the tibia	237
142.	Ivory osteoma of the parietal bone	238
143.	Multiple myelomata of the cranial vault	241
144.	Deposit of needle-like crystals of sodium urate in an articular cartilage	246
145.	Senile softening of cartilage	247

FIG.	PAGE
146. Metaplasia of cartilage into mucoid tissue in fungous arthritis	249
147. Preliminary stage of fibrous intercartilaginous ankylosis	253
148. Fibrous intercartilaginous ankylosis	254
149. Complete bony ankylosis of the head of the femur with the acetabulum	255
150. Nearthrosis of the hip	257
151. Bony ankylosis of the lower jaw	258
152. Chronic dry ulcerative arthritis	265
153. Chronic arthritis deformans	267
154. Arthritis and ostitis deformans with arborescent lipoma of the hip-joint	268
155. Chronic polyarthritis deformans	269
156. Arthritis deformans of the head of the femur	270
157. Arthritis deformans of the head of the femur	271
158. Spondylitis deformans	274
159. Chronic ankylosing arthritis	276
160. Hand with gouty nodes about the joints	279
161. Tuberculous (fungous) arthritis	283
162. Tuberculous arthritis	284
163. Tuberculous caries about the acetabulum of the left hip-joint	285
164. Section through an atrophic muscular bundle from a case of progressive spinal amyotrophy	296
165. Progressive muscular atrophy	297
166. Dropsical muscle-fibres	298
167. Transverse section through a muscle-bundle containing dropsical fibres	298
168. Waxy degeneration or coagulative necrosis in typhoid fever	298
169. Spinal amyotrophy with lipomatosis	301
170. Lipomatosis with atrophy of the calf-muscles	302
171. Muscle-fibres in process of regenerative proliferation, taken from wounds of different ages	304
172. Ossification in a 'drill' bone	311
173. 'Hour-glass' hygroma of the sheath of the digital flexor tendons	315
174. Section through a dilated prepatellar bursa with free and fixed rice-like bodies	318
175. Sessile rice-like bodies from a prepatellar bursa	318
176. Wall of the thickened bursa of the olecranon with nodular fibrous growths	319
177. Scheme of the position and connexions of the ganglion-cells and posterior roots of the spinal cord	324
178. Diagrammatic cross-section of the spinal cord showing the tracts of the white matter	325
179. Diagram of the nuclei of the cerebral nerves in the floor of the fourth ventricle	326
180. Atrophy of the left anterior horn from intra-uterine amputation of the left fore-arm	330
181. Contraction of the vertebral canal by crushing and protrusion of the sixth thoracic vertebra	331

FIG.	PAGE
182. Compression of the lumbar cord by cavernous tissue with dilated veins formed on the dorsal surface of the pia mater	332
183. Transverse section through the apex of the left anterior horn of a normal spinal cord at the level of the fourth cervical nerves	335
184. Transverse section through the apex of an atrophic anterior horn at the level of the fourth cervical nerves	335
185. Degeneration of the cord from compression	336
186. Myelitis from compression	337
187. Sclerotic tissue from the posterior column (disseminated sclerosis)	338
188. Grey gelatinous degeneration of the anterior horn of the cord	339
189. Ascending degeneration of the cord above a compressed portion	342
190. Ascending degeneration of the cord	342
191. Sclerosis and contraction of the entire grey matter of the cord	346
192. Transverse sclerosis of the cord	347
193. Hydromyelia with sclerosis of the surrounding tissue	349
194. Syringomyelia in the region of the posterior columns of the cervical cord	350
195. Gliosis and syringomyelia in the lumbar region of the cord	350
196. Cervical region (multiple sclerosis)	353
197. Thoracic region (multiple sclerosis)	353
198. Lumbar region (multiple sclerosis)	353
199. Multiple (secondary) sclerosis	354
200. Multiple (primary) sclerosis	354
201. Disseminated sclerosis of the brain	355
202. Tabes dorsalis in an advanced stage	359
203. Transverse section of the posterior white columns in tabes dorsalis	359
204. Sclerosis and cicatricial contraction of the left anterior horn of the fourth cervical nerve after acute anterior poliomyelitis	363
205. Gelatinous degeneration of both anterior horns of the lumbar region, with total loss of the ganglion-cells and nerve-fibres, after acute anterior poliomyelitis	363
206. Amyotrophic lateral sclerosis	366
207. Degeneration and sclerosis of the column of Burdach, of the column of Goll, and of the crossed pyramidal tracts	368
208. Combination of sclerosis of the posterior columns with marginal sclerosis	368
209. Tuberculous spinal meningitis	374
210. Syphilitic induration and adhesions in the lumbar cord	375
211. Venous angioma of the pia mater	377
212. Fibroma and papillomatous angio-sarcoma of the cauda equina with central glioma of the lumbar cord	378
213. Papillomatous angio-sarcoma with hyaline degeneration	378
214. External surface of the left cerebral hemisphere	382
215. Median surface of the cerebrum	383
216. Frontal section of the cerebrum	384
217. Diagrammatic scheme of the course of the nerve-fibres within the brain (<i>after</i> Ramon y Cajal)	385

FIG.		PAGE
218.	Basal aspect of the cerebral axis	386
219.	Head of the microcephalic child Helen Becker	388
220.	Brain of the microcephalic child Helen Becker	389
221.	Brain weighing 600 grammes	389
222.	Hypoplasia and microgyria	390
223.	Frontal section through the brain of Fig. 222	391
224.	Frontal section through the brain of a deaf-mute with bilateral hypoplasia and partial agenesis of the temporal lobes and the cortex of the insula	393
225.	Agenesis of isolated portions of the cerebral convolutions	394
226.	Porencephalic left hemisphere of a child of ten weeks	395
227.	Porencephalic right hemisphere of a child of ten weeks	395
228.	Congenital ventricular and meningeal hydrocephalus	397
229.	Frontal section through the brain of a hydrocephalic idiot	399
230.	Hypoplasia of the cortex of the cerebellum	401
231.	Atrophy of the cerebral cortex in progressive paralytic dementia	408
232.	Degenerate and disintegrating nerve-cells and nerve-fibres	412
233.	Fatty degeneration of the ganglion-cells and the blood-vessels	413
234.	Calcified ganglion-cells and nerve-fibres	413
235.	Teased preparation from a degenerating patch in the brain, with hypertrophic neuroglia	414
236.	Section from the border of a patch of softening in the brain (en- cephalomalacia)	415
237.	Ischaemic softening of the cerebral cortex	418
238.	Ischaemic softening of the brain	420
239.	Apoplectic cicatrix from the centre of a cerebral hemisphere	423
240.	Frontal section through the infundibulum of a brain with a bullet- wound	425
241.	Experimental encephalitis produced by a puncture through the cerebral cortex of a rabbit	426
242.	Transverse section of a bullet-wound in the brain	427
243.	Section from a nodose ganglionic neuroglioma of the central lobe of the cerebrum	437
244.	Telangiectatic glioma	437
245.	Glioma of the pons and medulla oblongata	438
246.	Section from a cerebral glioma, with stellate cells	439
247.	Chronic meningo-encephalitis with atrophy of the cerebral cortex	447
248.	Chronic disseminated tuberculous meningo-encephalitis	448
249.	Large solitary tubercle of the cerebellar pia mater	450
250.	Gummatous syphilitic meningo-encephalitis	452
251.	Alveolar endothelioma of the pia mater	455
252.	Papillomatous carcinoma of the choroid plexus	456
253.	Papillomatous carcinoma with gelatinous degeneration of the stroma from the choroid plexus	457
254.	Endothelioma of the dura mater	462
255.	Section from a psammoma of the dura mater	463
256.	Degeneration of the sciatic nerve	471

FIG.		PAGE
257.	Advanced degeneration of the motor nerves in a case of atrophy of the anterior horns of the spinal cord	471
258.	Transverse section from an atrophic sciatic nerve (multiple sclerosis)	472
259.	Chronic neuritis with partial atrophy of the nerve-fibres	474
260.	Old and newly-formed nerve-fibres	478
261.	Section of a fasciculus of the median nerve just above the point of severance by a stab four months previously	479
262.	Amputational neuroma of the sciatic nerve in longitudinal section (amputation nine years previously)	479
263.	Multiple neurofibromata	481
264.	Multiple fibromata in one of the nerves of the sciatic plexus	482
265.	Plexiform neuroma of the sacral region	483
266.	Lobulated plexiform neuroma of the temporal region and neurofibroma of the vagus (<i>after</i> Bruns)	484
267.	Acne rosacea	491
268.	Endemic vitiligo	497
269.	Atrophy and cystic degeneration of the hair-follicles and sebaceous glands of the scalp	500
270.	Section through a syphilitic mucous patch (<i>condyloma latum ani</i>)	504
271.	Section through the margin of a blister due to a burn	505
272.	Blister from a burn in process of healing	507
273.	Miliaria crystallina	512
274.	Acute pemphigus	514
275.	Section of a variolous vesicle becoming pustular	518
276.	Colony of <i>Streptococcus erysipelatis</i>	522
277.	Section of the skin in <i>erysipelas bullosum</i>	523
278.	Phlegmon of the subcutaneous tissue, with an oedematous bulla	524
279.	Malignant pustule	526
280.	Hypertrophic lupus of the face	533
281.	Patch of lupus vulgaris	534
282.	Initial sclerosis of syphilis	535
283.	Pustular syphilide (<i>infantile syphilitic pemphigus</i>)	537
284.	<i>Leontiasis leprosa</i>	539
285.	Ulcerous leprosy (<i>lepra mutilans</i>) of the leg and foot	540
286.	Leprous node of the skin	541
287.	Cup or scutulum of favus	543
288.	Hair affected with favus	544
289.	Section of the skin in scabies	546
290.	Longitudinal section of a node of <i>molluscum contagiosum</i>	547
291.	Section of a corn	548
292.	Cutaneous horn removed from the back of the hand	549
293.	Cutaneous horn from the arm	549
294.	<i>Condyloma acuminatum</i>	549
295.	Lymphangiectatic elephantiasis of the leg	551
296.	Congenital ichthyosis	555
297.	Congenital ichthyosis	556

FIG.		PAGE
298.	Ichthyotic wart	556
299.	Congenital cavernous angioma of the skin	557
300.	Section of a hypertrophic angioma of the skin and subcutaneous tissue	558
301.	Subcutaneous cavernous lymphangioma	559
302.	Section through two papillae from a tuberous hard wart	560
303.	Section through a slightly tuberous soft wart	561
304.	Neurofibroma molluscum	562
305.	Multiple neurofibromata of the skin	563
306.	Neuromatous elephantiasis or pachydermia of the thigh	564
307.	Skin with neurofibromata from a case of pachydermia (Fig. 306)	565
308.	Atrophy and cystic degeneration of the hair-follicles and sebaceous glands of the scalp	571

SECTION I

BLOOD AND LYMPH

CHAPTER I

THE BLOOD

1. THE **blood** is a liquid of peculiar composition, abounding in cells or corpuscles, and equivalent in amount to about one-thirteenth of the body-weight. A cubic millimetre of the blood of a man contains on the average 5,200,000, that of a woman about 4,800,000, red corpuscles, with from 5,000 to 10,000 white corpuscles. Thus for every white corpuscle there are from 500 to 1,000 red corpuscles. In 100 cubic centimetres of blood there are in men 14.5 grammes of haemoglobin, and in women, 13.2 grammes (HÜFNER).

The amount of blood even in health is subject to considerable variation; it may, under certain pathological conditions, differ notably from the average proportion given above.

When the amount of blood in the body is simply increased, without change in its composition, the condition is described as **plethora vera**; when the increase is due to an augmentation of the water and the salts, we speak of the condition as **plethora serosa**. Diminution of the total amount of blood in circulation is called **anaemia** or **oligaemia**; concentration of the blood, through loss of water and salts, the blood-albumen remaining normal in amount, is termed **anhydraemia**; relative dilution of the blood, from diminution of the albumen it contains, is designated **hydraemia** or **hypalbuminosis**.

Plethora vera may occur when, before the removal by surgical operation of parts of the body, the blood has been pressed back from them into the general circulation to prevent haemorrhage, as in amputation by ESMARCH'S bloodless method (*plethora apocoptica*); or when blood has been injected directly into the vascular system. The complete emptying of the placenta in parturition may force an excessive amount of blood into the body of the new-born infant, and so give rise to temporary plethora.

Plethora caused by such an increase of the blood in circulation is a transient condition, the organism promptly excreting the excess of water and then destroying the surplus of red corpuscles. True plethora, however, of a more abiding kind, occurs in specially predisposed persons whose luxurious habits of life favour excessive blood-formation. This excess, in certain cases, may be so

considerable as to be recognisable during life, by means of the abnormally large, full, and at times tense pulse, and the unusually powerful action of the heart; and after death by the increased capacity and fulness of the entire vascular system, as well as by the cardiac hypertrophy thereby induced.

Plethora serosa as a transient condition may result from an increased supply of water to the blood. As a chronic condition, it may be due to diminished excretion of water, from disease of the kidneys or the heart. Simple **hydraemia** results from abnormal loss and insufficient re-formation of the blood-albumen: **anhydraemia**, from increase of the water excreted and deficiency of that ingested. After severe haemorrhage more water is taken up by the blood, and the condition of hydraemia follows and persists until the loss of albumen and red blood-corpuscles is again made good.

Anaemia may occur from single or repeated haemorrhages, abnormal disintegration of blood, and insufficient formation of red corpuscles. Its characteristic symptom is the **diminution of the amount of haemoglobin in the blood**. The proportion may fall to six or even three grammes per 100 cubic centimetres of blood. Usually the number of red corpuscles is somewhat reduced, and the result is **oligocythaemia**. In **chlorosis**, however, the causes of which are as yet undetermined, the red blood-corpuscles are deficient in haemoglobin, but their number is not diminished.

Increased destruction of the red blood-corpuscles is frequently referable to special causes acting injuriously on the blood. It occurs after burns of the skin, and from the action of many poisons, such, for example, as sulphuretted hydrogen, arseniuretted hydrogen, potassium chlorate, picric acid, toluylendiamine, and many of the poisonous fungi. Infective diseases accompanied by fever may also exercise a destructive influence on the blood, owing to the action of their specific poisons and to the abnormal increase of the body-heat; and the like result may follow from the presence of certain parasites in the blood, as in malaria. Excessive cooling of the skin in specially-disposed persons may occasion a destruction of the red blood-corpuscles (**periodic or paroxysmal haemoglobinuria**). There are also several forms of severe anaemia which are grouped together as **pernicious anaemia**, among the features of which is increased blood-destruction or haematolysis, but the cause of this is still uncertain. These forms are therefore provisionally termed *cryptogenetic* anaemias. In some cases the condition is connected with definite physiological conditions, or with organic diseases, such as for example pregnancy or childbirth, ulcerative affections of the bowels, or the presence of intestinal parasites (*Bothriocephalus*). In other cases no organic disease is demonstrable, the anaemia appearing as a primary blood-disease. In the two instances last named opinions differ as to the cause of the blood-changes—

whether they are due to an alteration in the blood-plasma, to the presence of specific poisonous substances in the blood causing its destruction, or to some abnormal frailty on the part of the blood-corpuscles.

Deficiency in the formation of blood should be admitted as a cause of anaemia only when we can demonstrate the presence of morbid conditions in the bone-marrow, where especially the production of red corpuscles takes place, or when defective food-supply or disease in the alimentary tract or in other organs has obviously caused impairment of the general nutrition, the evidence of any active blood-destruction being at the same time wanting. Even in such cases, however, it is often impossible to make out the connexion between the organic disease and the anaemia. There is, for example, a form of cachectic anaemia which is met with in certain pathological conditions of the lymphadenoid tissues (Arts. 30 and 35), of the spleen, of the lymph-glands, and of the intestine, though the formation of blood in the bone-marrow is not perceptibly impaired.

Increased destruction of red blood-corpuscles is often capable of demonstration by the microscope, the blood containing morbidly-altered red corpuscles and the products of their disintegration.

The altered and dying red blood-corpuscles often exhibit the most varied and diverse forms: thus we have globular, spindle-shaped, crescent-, club-, bobbin- and nail-shaped varieties; others again are drawn out into threads, constricted in the middle, or wholly irregular. This condition is known as **poikilocythaemia**. Occasionally very small or very large red blood-corpuscles are met with, and these are termed respectively **microcytes** and **macrocytes**. Portions of the stroma of the red corpuscles may also display partial discoloration, while other portions are strongly coloured, and in some cases the several constituents of the corpuscle appear to be separated (*plasmochisis*).

Besides these corpuscular forms, which are undoubtedly due to disintegration, we find in grave anaemia others which we must regard as immature or morbidly altered embryonic forms of the red corpuscle. Of this nature are the **nucleated red corpuscles**, which are normally to be found only in the bone-marrow. The normal embryonic forms, which are nucleated cells of ordinary size, have been termed *normoblasts*, the morbid embryonic forms, which are abnormally large, *megaloblasts*. The diameter of the latter may be twice or even four times that of the normal corpuscle. According to EHRLICH and MÜLLER, megaloblasts are chiefly met with in severe pernicious anaemia, and exemplify a morbid mode of blood-formation, which in normal conditions occurs only during the period of embryonic development. It is to be noted, however, that in pernicious anaemia not only is the rate of blood-destruction augmented, but the rate of formation of

blood in the bone-marrow, which in this affection contains numerous embryonic forms of the red blood-cells, is simultaneously increased (COHNHEIM, RINDFLEISCH, NEUMANN, MÜLLER). It is not possible, however, to decide whether the multiplication of the normoblasts and the appearance of megaloblasts in the bone-marrow is caused by a primary disorder of that tissue, or is the consequence of an antecedent disease of the blood. In the latter case the phenomenon would indicate an increased growth of the haematoblasts of the bone-marrow with a view to the restoration of the blood.

According to STINZING and GUMPRECHT, the average proportion of the dry residue in normal blood is in man 21·6 per cent., and in woman 19·8 per cent. In severe anaemia this proportion may sink to 8·5 per cent., so that a condition of hydraemia is present. Oligaemia may however exist, though the composition of the blood remains normal. In leukaemia (Art. 2), on the contrary, the proportion of dry residue is relatively high, though the amount of haemoglobin is diminished.

The proportion of haemoglobin in the blood varies considerably at different ages. It is highest at birth; in the first years of life it falls to one-half, rising again between the fifth and forty-fifth year to about two-thirds of its original amount; thereafter it again declines. During gestation the proportion of haemoglobin is diminished.

The researches of BOLLINGER and HEISSLER furnish the following data concerning the variations of the quantity of blood in the lower animals: in pigs, from 2·25 to 8·70; in horned cattle, from 6·03 to 10; in dogs, from 4·4 to 12·4; in horses, from 5·9 to 13·5; in sheep, from 6·56 to 10·43 per cent., of the body-weight. Fat pigs are remarkably poor in blood.

The amount of *fat* in the blood, which normally is very small and during digestion reaches about 1·2 per cent., may under pathological conditions reach a much higher percentage, the blood becoming milky and turbid from the small oil-globules (*lipaemia*) it contains.

The amount of *fibrin-ferment* contained in the blood is, in diseased conditions, subject to considerable variation; so that on post-mortem examination we can distinguish certain cases in which there is an abundant formation of fibrin, or *hyperinosis*; and in other cases a deficiency of fibrin-formation, or *hypo-inosis*. The former condition is found especially in inflammatory diseases, such as croupous pneumonia and erysipelas; the latter, in death by suffocation, and in poisoning by sewer-gas, by alcohol, and by hydrocyanic acid.

We can remove the anaemia resulting from haemorrhage by the *transfusion* of blood, that is, by supplying to the affected person blood capable of performing its functions. Transfusion into the human subject of the blood of lower animals serves no purpose, but rather causes further injury, inasmuch as the human red corpuscles break down in the blood-serum of animals. The same thing happens when the blood of one species of animal is injected into the vascular system of an animal of another species.

*References on Plethora, Anaemia, Hydraemia, Lipaemia,
and Transfusion.*

- BIERFREUND: Haemoglobin in surgical diseases *Langenbeck's Arch.* xli 1891
 BIERMER: Pernicious anaemia *Corresp. f. Schweiz. Aerzte* ii 1872
 BIRCH-HIRSCHFELD: Epidemic haemoglobinuria in infants *D. med. Woch.*
 1879

- BIRCH-HIRSCHFELD and EHRLICH: Grave anaemias *Verh. Congr. f. inn. Med.* XI Wiesbaden 1892
- BIZZOZERO and SANGUIRICO: Transfusion *A. ital. de biol.* VII 1886
- BLECHMANN: Pathology of the bone-marrow *A. d. Heilk.* XIX 1878
- BOLLINGER: Haemoglobinuria in horses *Z. f. Thiermed.* III; Plethora vera *Münch. med. Woch.* 1886
- COHNHEIM: *Allgem. Path.* I 1882; The bone-marrow in pernicious anaemia *V. A.* 68 1876
- DAREMBERG: Destructive action of blood-serum *A. de méd. exp.* III 1891
- EHRLICH: Colorimetry of the blood *Gesamm. Mittheil.* I Berlin 1891
- EICHHORST: *Die progressive perniciöse Anämie* Leipzig 1878; *Art. Chlorosis Eulenburg's Realencyklop.* 1894 (with references)
- d'ESPINE and PICOT: Pernicious anaemia in infants *Rev. de méd.* X 1890
- GABBI: Normal haematolysis *Ziegler's Beiträge* XIV 1893
- GRAEBER: *Zur klinischen Diagnostik der Blutkrankheiten* Leipzig 1888
- GRAM: The size of the red corpuscles in health and disease *Fortschr. d. Med.* II 1884
- GROSSGLICK: Hydraemic plethora *A. de physiol.* II 1890
- GUMPRECHT: Lipaemia *D. med. Woch.* 1894 (with references)
- HALLA: Haemoglobin and corpuscles in acute fevers *Prag. Z. f. Heilk.* IV 1883
- HAYEM: *Du sang et de ses altérations organiques* Paris 1889
- HESSLER: The theory of plethora *Münch. pathol. Arbeiten* Stuttgart 1886
- HOPPE-SEYLER: *Physiol. Chemie* Berlin 1877-81
- VON HÖSSLIN: Excretion of haematin and albumen in chlorosis *Münch. med. Woch.* 1890
- HUNTER: Pernicious anaemia *Lancet* 1888, 1890, *Practitioner* 1888-89; Transfusion *Journ. of Anat.* XXI and *B. M. J.* 1887
- IMMERMANN: *D. A. f. klin. Med.* XIII, *Ziemssen's Cyclop.* XVI New York 1877
- KRÜGER: Foetal blood at birth *V. A.* 106 1886
- LAACHE: *Die Anämie* Christiania 1883, *D. med. Woch.* no. 43 1884
- LABADIE-LAGRAVE: *Traité d. malad. du sang* Paris 1893
- LEICHTENSTERN: *Hämoglobingehalt d. Blutes* Leipzig 1878
- LICHTHEIM: Periodic haemoglobinuria *Volkman's klin. Vorträge* 134 1878, *Corresp. f. Schweiz. Aerzte* 1883
- VON LIMBECK: *Klin. Pathol. d. Blutes* Jena 1892 (with references)
- LUKJANOW: *Allgem. Path. d. Blutes u. d. Lymphe* Leipzig 1892 (with references)
- MACKENZIE: Anaemia *B. M. J.* 1891
- MAISSURIANZ: *Exper. Studien üb. d. Veränd. d. Blutkörper im Fieber* Dorpat 1882
- MAUREL: *L'anémie par insuffisance de l'hématose* Paris 1891
- MÜLLER, FR.: Pernicious anaemias *Charité-Ann.* XIV 1889; Examination of blood *Cent. f. allgem. Path.* III 1892 (with references); Atypical blood-formation in pernicious anaemia *D. A. f. klin. Med.* LI 1893 (with references)
- MÜLLER: Progressive pernicious anaemia *Inaug. Diss.* Zürich 1877
- NEUMANN: Bone-marrow in pernicious anaemia *Berl. klin. Woch.* 1877
- VON NOORDEN: Grave anaemias *Charité-Ann.* XVI 1891; *Path. des Stoffwechsels* Berlin 1893
- OSLER: Pernicious anaemia *Cent. f. med. Wiss.* 1877
- QUINCKE: *V. A.* 54 1871; *Volkman's klin. Vorträge* 100 1876; *D. A. f. klin. Med.* XXV, XXVII 1880
- QUINQUAUD: Blood-lesions in various diseases *A. gén. de méd.* 1879
- VON RECKLINGHAUSEN: *Allgem. Path. d. Kreislaufs u. d. Ernährung* Stuttgart 1883
- REINERT: *Die Zählung d. Blutkörperchen* Leipzig 1891 (with references)
- RIEDER: *Atlas d. klin. Mikroskopie d. Blutes* Leipzig 1893
- RINDFLEISCH: Defective blood-formation in pernicious anaemia *V. A.* 121 1893

- SADLER: Estimation of corpuscles and haemoglobin *Fortschr. d. Med.* (supplement) 1892
- SCHAUMANN: *Bothryocephalen-Anämie* Berlin 1894
- SCHIFF, H.: The red corpuscles in infants *Prager Z. f. Heilk.* XI 1890
- STIERLIN: Estimation of corpuscles and haemoglobin in infants *D. A. f. klin. Med.* XLV 1889
- STINZING and GUMPRECHT: Proportion of water and dried residue in the blood in health and disease *D. A. f. klin. Med.* LIII 1894 (with references)
- TUMAS: Variations in the blood in certain infective diseases *D. A. f. klin. Med.* XLI 1887
- VANLAIR and MASIUS: *De la microcythémie* Brussels 1877
- VIERORDT: *Daten und Tabellen f. Mediciner* Jena 1893
- VOGEL: *Virchow's Handb. d. spec. Path.* Erlangen 1854
- WALDSTEIN: Progressive anaemia with subsequent leukaemia *F. A.* 91 1883
- WEINTRAUD: Changes in the red corpuscles *F. A.* 131 1893
- WORM-MÜLLER: *Transfusion u. Plethora* Christiania 1875

2. The proportion of white corpuscles in the blood (which usually amounts on the average to one white cell to five hundred red) is subject, even under physiological conditions, to great variation, being markedly increased during digestion and during gestation. Under pathological conditions this increase may reach still higher degrees, and may be associated with a diminution of the red blood-cells. If the condition of increase is transient it is spoken of as *leucocytosis*; if lasting, as *leukaemia*.

Pathological leucocytosis may occur, though not invariably, after haemorrhages, in cachectic conditions accompanying malignant disease (REINBACH), and just before death. It is met with in a large class of diseases that are accompanied by inflammatory exudations (*inflammatory leucocytosis*), such as croupous pneumonia, inflammations of the serous membranes, pyaemia, erysipelas, scarlet fever, diphtheria, and quinsy. It is absent, on the other hand, in measles and influenza. In typhoid fever the proportion of leucocytes may even diminish. Experimentally, leucocytosis may be induced in animals by the injection of pus-micrococci, sterilised cultures of certain bacteria, bacterial proteins or albumoses, vegetable proteins, hemialbumose, and nucleinic acid, as well as by the administration of certain blood-poisons. The leucocytosis is usually preceded by a transient diminution of the leucocytes (*hypoleucocytosis*), which, according to GOLDSCHIEDER and JACOB, is caused by the retention of the leucocytes within the capillaries of the viscera, and especially in those of the lungs.

Physiological leucocytosis is seldom marked in degree (on the average it amounts to 33 per cent., RIEDER), and it leaves unaffected the proportion between the different forms of leucocytes. Inflammatory leucocytosis reaches a higher degree of intensity, especially in pneumonia. Thus a proportion of one leucocyte to 100, or even to 15 or 20 red corpuscles, may occur, and the increase is generally confined to the multinuclear leucocytes.

The causation of pathological leucocytosis is not certainly established. It is supposed by most authorities that an increased

supply of leucocytes is carried to the blood from the parts in which leucocytes are normally produced; but perhaps there is also an increased production of these cells. The latter hypothesis would seem to correspond best with the observed facts.

The change in the blood known as **leukaemia** (VIRCHOW) is characterised by a more or less considerable increase of white blood-cells, accompanied in general by a corresponding reduction in the number of red corpuscles. The proportion between the two may be so altered that their numbers become equal, or in extreme cases the white may slightly outnumber the red. Of the white corpuscles, the uninuclear cells in particular are increased above the normal proportion, while among the red blood-cells nucleated forms are met with.

In well-marked leukaemia the blood is strikingly pale, clear, and limpid. The heart and the large blood-vessels often contain after death peculiar clay-coloured clots, rich in white corpuscles, instead of the usual semi-translucent fibrinous deposits; or the clots are covered with a white, creamy, pus-like film composed of colourless cells. The diagnosis of less-marked cases of leukaemia may require the aid of the microscope, by means of which even a slight relative increase in the proportion of white cells may be recognised.

The increase of the white blood-cells in leukaemia is primarily referable to an increased supply of cells from those organs which produce leucocytes. Accordingly the spleen, the lymph-glands, and the marrow of the bones, show in different degrees and combinations signs of hyperplastic proliferation; sometimes only one or two of the above organs are altered and increased in bulk, or all three may exhibit proliferation. We can thus distinguish lymphatic, splenic (lienal), and myelogenous forms of leukaemia, as well as combinations of these forms. Further proof of this mode of origin is afforded by the fact that the blood contains cell-forms which correspond with the characteristic cells of the organs indicated. Thus in lymphatic leukaemia we find chiefly the small uninuclear cell-forms, which correspond to the cells of lymphadenoid tissue. On the other hand in myelogenous and mixed leukaemias large uninuclear cells appear, which correspond to those found in the bone-marrow (*myelocytes*) but not in normal blood; in this case, too, the eosinophile cells in the blood are increased in number.

Finally, it is capable of demonstration that in leukaemia the tissue-elements of the organs which produce leucocytes exhibit abundant examples of karyokinetic cell-division. It is to be noted, however, that an increase of the colourless cells may undoubtedly take place outside of the above-named organs (BIZZAZZO, SPRONCK, MÜLLER, STRÖBE), for the leucocytes have been observed to divide by mitosis, not only in the circulating blood but also within certain organs in which they are retained; in this

way their number is further increased. It is also possible that those cells which reach the blood-current are in part endowed with a longer life than the ordinary leucocytes. The last-named phenomena suggest an explanation of the fact that in very rare cases (LEUBE, FLEISCHER) leukaemia may occur unaccompanied by any recognisable changes in the spleen, the marrow of bone, or the lymph-glands. Moreover, there is nothing to prevent us assuming that from organs not perceptibly hypertrophied an abnormal number of colourless cells may be supplied to the blood.

The diminution of the number of red corpuscles which takes place in the majority of cases of leukaemia is referable to the fact that the process of their formation is disordered. The nucleated red corpuscles, which are specially apt to appear in the blood in myelogenous and mixed leukaemias, are to be regarded as immature cells that have escaped from the marrow of bone.

The richness of the blood in colourless cells generally leads to secondary changes in the different organs. These are indicated chiefly by an accumulation of leucocytes in the capillaries, and later on by the migration of some of them into the tissues. Such *leukaemic infiltrations* occur mainly in the liver, but are not wholly absent in other organs and tissues. Sometimes they form not only diffuse infiltrations, but also more definite deposits, which, in the form of greyish-white nodular patches, can be recognised without the aid of the microscope; they are spoken of as *leukaemic lymphomata*. These aggregations originate not simply in a passive accumulation of leucocytes; the cells probably increase also by subdivision and multiplication *in situ*.

In the blood, in the spleen, and in the bone-marrow of those affected with leukaemia **Charcot's crystals** are not infrequently found after death. These are recognisable as sharp acicular octahedral crystals.

The aetiology of leukaemia is not known. It is improbable that all the diseases which are designated as leukaemia at the present time have the same genesis and causation. The course of the disease is usually a chronic one, though acute cases are occasionally met with.

The proportion of multinuclear cells under normal conditions amounts to about 70 per cent., that of eosinophile cells to about 1 or 2 per cent., of the colourless elements of the blood (ZAPPERT). The view that leukaemia is the result of disease of the blood-producing organs is maintained chiefly by VIRCHOW, NEUMANN, MOSLER, EHRLICH, and MÜLLER; while BIESIADECKI, RENAUT, LÖWIT, and others believe it to be a primary disease of the blood itself, in which the colourless elements, perhaps in consequence of some pathological alteration of the blood-plasma (LÖWIT), do not pass through the normal cycle of changes, but retaining their vitality are deposited in the tissues, and so lead to organic disorders. The peculiarities of the cells appearing in the blood, and in particular the occurrence of cells which resemble those of the bone-marrow, and like them present the same neutrophile granulation (EHRLICH), support the theory that leukaemia is primarily a disease of the organs that

produce the red and white blood-corpuses. This does not exclude the possibility that the colourless cells which reach the blood may increase within the vessels in some pathological manner, and maintain their vitality beyond the normal period. It is a noteworthy fact, however, that affections of the spleen and of the lymph-glands (see Sect. III), which are anatomically identical with those occurring in leukaemia, may exist without any accompanying leukaemia (pseudo-leukaemia, splenic and lymphatic anaemia). Thus hypertrophy of the spleen and lymph-glands does not always lead to an increased influx of colourless cells into the blood.

Summaries of the present state of our knowledge of leucocytosis and of leukaemia are given in the memoirs of RIEDER and MÜLLER, cited below.

References on Leucocytosis and Leukaemia.

- ASKANAZY: Acute leukaemia *V. A.* 137 1894
 BIONDI: White corpuscles in leukaemia *A. p. le scienze med.* XIII 1889
 BIZZOZERO: *V. A.* 97, 99; *Cent. f. med. Wiss.* 1868, 69, 79
 CHARCOT and ROBIN: Crystals *Comptes rend. Soc. de biol.* no. 49 v 1853
 EHRLICH: Colorimetry of the blood *Gesamm. Mittheil.* I Berlin 1891
 EICHHORST: Acute leukaemia *V. A.* 130 1892
 FELSSENTHAL: Haematology *A. f. Kinderheilk.* XVI 1892
 FLEISCHER and PENZOLDT: *D. A. f. klin. Med.* XXVI Leukaemia 1880
 GABRITSCHIEWSKI: Eosinophile cells in bronchial asthma *A. f. exp. Path.* 28 1890
 GEIGEL: Red corpuscles in pseudo-leukaemia *D. A. f. klin. Med.* XXXVII 1885
 GOLDSCHNEIDER and JACOB: Variations in leucocytosis *Z. f. klin. Med.* 25 1894 (with references)
 HAYEM: *Du sang* Paris 1889
 JOAS: Inflammatory leucocytosis *Ziegler's Beiträge* X 1891
 KANTHACK: Leucocytosis from bacterial products *B. M. J.* 1892
 LABADIE-LAGRAVE: *Maladies du sang* Paris 1893
 VON LIMBECK: Inflammatory leucocytosis *Z. f. Heilk.* X 1889; Leukaemia and leucocytosis *Cent. f. allgem. Path.* II (p. 922); *Klin. Pathol. d. Blutes* Jena 1892
 LÖWIT: *Wien. Sitzungsber.* 88 1883, 92 1885, 95 1887; *Physiol. u. Pathol. d. Blutes* Jena 1892; Leukaemia *Cent. f. allgem. Path.* v 1894
 MAUREL: *Recherches expér. sur les leucocytes* Paris 1891
 MOSLER: *Ziemssen's Cyclop.* VIII New York 1878
 MUIR: Leucocythaemia *Journ. of Path.* I 1892
 MÜLLER, H. FR.: Leukaemia *D. A. f. klin. Med.* XLVIII 1891; Lymphaemia *ibid.* I 1892 and *Ziemssen's Arbeiten* III 1893; Morphology of leukaemic blood *Cent. f. allgem. Path.* v 1894 (with references)
 MÜLLER and RIEDER: Eosinophile cells *D. A. f. klin. Med.* XLVIII 1891; *Ziemssen's Arbeiten* III 1893
 NEUMANN: *Cent. f. med. Wiss.* 1868-69; *Arch. f. Heilk.* XI; *Berl. klin. Woch.* 1878; *V. A.* 116 1889
 REINBACH: Leucocytes in malignant disease *A. f. klin. Chir.* XLVI 1893
 RICHTER and SPIRO: Leucocytosis from cinnamic acid *A. f. exp. Path.* 34 1894
 RIEDER: *Leukocytose* Leipzig 1892 (with references); *Atlas d. Blutes* Leipzig 1893
 ROBERT: Leucocythaemia *Journ. of Path.* 1892
 SCHMIDT: Formation of corpuscles in liver and spleen *Ziegler's Beiträge* XI 1892
 SCHULZ: Leucocytosis *D. A. f. klin. Med.* LI and *Ziemssen's Arbeiten* III 1893
 TCHISTOVITCH: Fibrinous pneumonia *Annal. de l'Inst. Pasteur* v 1891
 TROJE: Leukaemia and pseudo-leukaemia *Fortschr. d. Med.* X
 VEHSEMAYER: Leukaemia *Münch. med. Woch.* 1893

- VIRCHOW: Cellular pathology (Berlin 1859) London **1860**, *Gesamm. Abhandl.*
1862
- VOGEL: Disorders of the composition of the blood *Virchow's Handb. d. spec.*
Path. I Erlangen **1854**
- WALDEYER: Hyperplasia of bone-marrow *V. A.* 52 **1871**
- WERTHEIM: Blood-formation in leukaemia *Z. f. Heilk.* XII **1891**
- WESTPHAL: Charcot's crystals in lymph *D. A. f. klin. Med.* XLVII **1891**
- ZAPPERT: Eosinophile cells in the blood *Z. f. klin. Med.* 23 **1893**
- ZENKER: Charcot's crystals *D. A. f. klin. Med.* XVIII **1876**

CHAPTER II

THE LYMPH

3. The **lymph** is a liquid transuded from the blood-vessels, together with certain products of tissue-metabolism, and in special parts also (*e.g.* the lacteals) substances brought to the lymph from

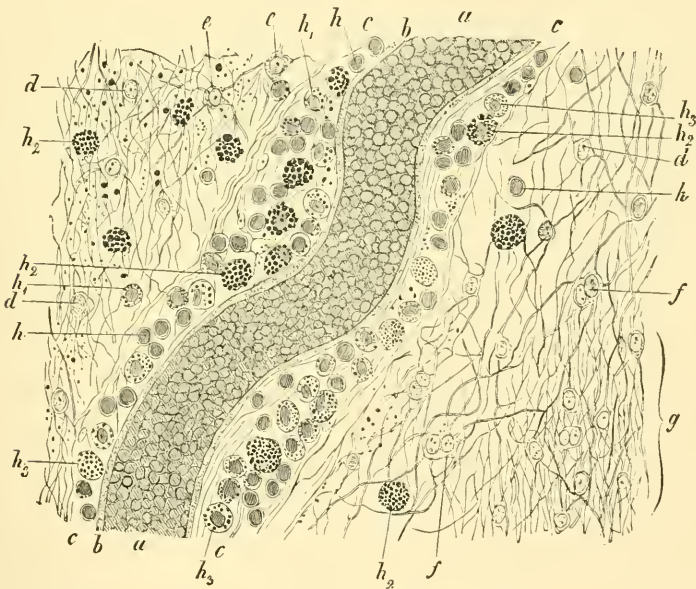

FIG. 1. SECTION THROUGH A DEGENERATING PATCH FROM THE BRAIN.

(Perosmic acid preparation : × 200)

- | | | | |
|---|----------------------------------|----------------|-------------------------------------------------------|
| a | blood-vessel filled with blood | h | lymphoid cells |
| b | tunica media | h ₁ | lymphoid cells containing a few oil-globules. |
| c | adventitia with its lymph-sheath | h ₂ | fat-granule carriers |
| d | unaltered neuroglia-cells | h ₃ | pigment-granule cells, some containing red corpuscles |
| e | fatty neuroglia-cells | | |
| f | binuclear neuroglia-cells | | |
| g | sclerotic tissue | | |

without. The lymph-glands contribute a number of lymphoid elements in addition to the few cells derived from the blood.

Morbid conditions of the blood, as well as diseases of the tissues, accordingly give rise in general to changes in the lymph; and substances taken up into the tissues from without very frequently reach the lymphatic channels.

Many of the changes in question are not physically demonstrable, being due to substances that are dissolved in the lymph. As regards the morphological elements of the pathologically altered lymph, the changes in them relate to the number and nature of the cells it contains, and to the addition of products of the disintegration of the tissues, or of foreign matters derived from without. As illustrative of such changes in the normal contents of the lymph, we may refer to Fig. 1, representing the degenerative process resulting from a haemorrhage in the brain. Here the circumvascular lymph-vessels (Fig. 1 *c*) contain, along with the unchanged lymphoid elements, certain cells which are loaded partly with colourless (h_1 h_2) detritus of the brain-substance, partly with disintegrated blood-corpuscles (h_3). In a lymphatic vessel proceeding from an inflamed tissue the number of cellular elements in the lymph is very markedly increased. Often mixed with the lymph are found cast-off endothelial cells, some subdividing, others degenerate. Not infrequently local coagulation of the lymphatic contents, with the formation of fibrin, is observed. If a new growth has broken into a lymphatic vessel, we may find the tumour-cells in the lymph. Where bacteria have invaded the tissues, colonies of microbes may develop in the lymph-channels.

SECTION II

THE VASCULAR MECHANISM



CHAPTER III

MALFORMATIONS OF THE HEART AND GREAT VESSELS

4. **Malformations of the heart** are of frequent occurrence, and have great practical importance, inasmuch as they often on the one hand cause non-viability of the foetus, and on the other, where life after birth is possible, induce conditions of more or less imperfect circulation, and a disposition to other and more extensive lesions. Not infrequently also, in circumstances involving great demands upon the activity of the malformed heart, they lead ultimately to a fatal issue.

In most cases we have to deal with primary arrest of development and with disturbances of growth, resulting in an imperfect development of some part of the heart or in abnormality of its position and configuration. Only in rare instances do morbid processes *in utero*, such as inflammations, inhibit or disturb the normal development of the heart.

In the majority of cases the primary failure lies in the absence or defective development of the septa which divide the simple cavity of the embryonic heart into a right and a left ventricle, and into a right and a left auricle, and the truncus arteriosus into the aorta and pulmonary artery.

In addition to these defects we meet with malformations of the valves, stenosis and closure of the auriculo-ventricular, the arterial, and the venous orifices; and lastly malposition and faulty development of the large arterial trunks and their branches, and of the veins entering the auricles.

Stenosis of the pulmonary artery (Fig. 2 *d d*₁), a somewhat frequent malformation, may involve the arterial trunk as well as the conus arteriosus and the ostium, the valves being at the same time more or less malformed. Sometimes there is complete closure or atresia of the pulmonary orifice. These malformations occur in association both with closed and complete ventricular septa and with defects (*e*) in the ventricular or auricular septum, the former combination being however infrequent. Very often these malformations are combined with anomalies in the position of the large arterial trunks, both of these vessels arising from the right ventricle, or the aorta from the right ventricle (*a e*) and the pulmonary artery from the left ventricle (*d d*₁), a condition which might be termed *transposition of the arterial trunks*. If

the diameter of the pulmonary orifice measure less than a certain amount, the pulmonary circulation can be adequately maintained only when the ductus arteriosus remains patent.

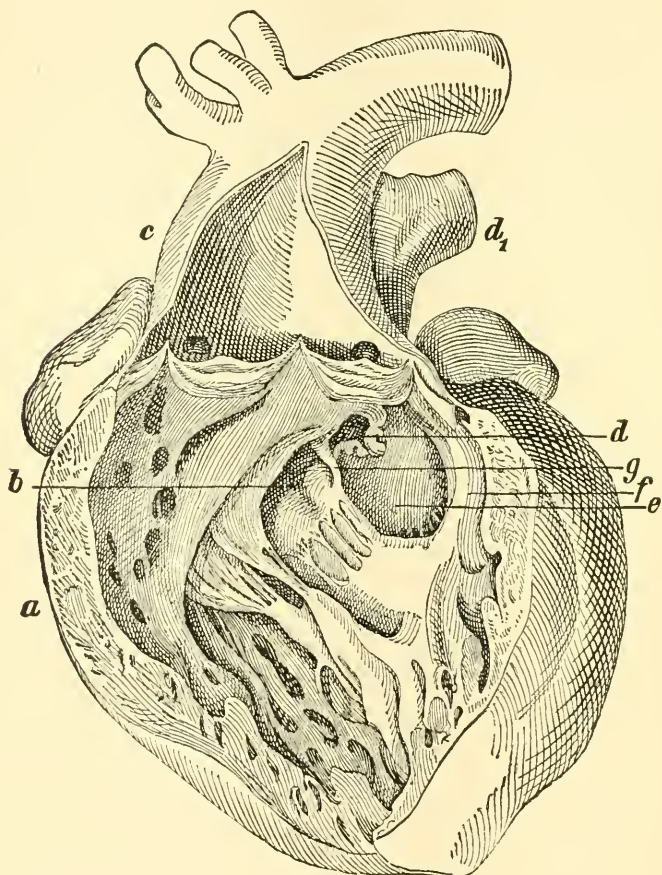


FIG. 2. MALFORMATION OF THE HEART.

(With transposition of the large blood-vessels, stenosis of the pulmonary orifice, and defect of the anterior part of the ventricular septum: from ROKITANSKY)

- | | |
|-------------------------------------------------------------------------------------------------------------------------------------------------------------------------------------------------------------------------------------------------------------------------------------------------------|--------------------------------------------------------------------------------------------------------------------------------------------------------------------------------------------------------------|
| <p>a right ventricle opened near its margin
 b stenosed right ostium venosum
 c aorta arising from the right ventricle
 d orifice of the pulmonary artery d_1 lying posteriorly
 e defect of the anterior ventricular septum</p> | <p>f anterior portion of the septum extending to the aorta on the left, between the anterior and left segment of the valve
 g membranous portion of the right side of the pulmonary artery</p> |
|-------------------------------------------------------------------------------------------------------------------------------------------------------------------------------------------------------------------------------------------------------------------------------------------------------|--------------------------------------------------------------------------------------------------------------------------------------------------------------------------------------------------------------|

Stenosis and atresia of the aorta occur, like the analogous conditions of the pulmonary artery, both with and without defect of the interventricular septum. These malformations are some-

times accompanied by transposition of the aorta, or may be combined with other forms of cardiac malformation.

When the aortic orifice is markedly constricted or entirely closed, the ventricular septum being properly developed, the foramen ovale and the ductus arteriosus usually remain open, so that the circulation is carried on chiefly by the action of the right heart, and the blood of both the systemic and the pulmonary circulations is driven through the pulmonary artery. The left ventricle and left auricle are in these cases generally small and imperfectly developed.

Stenosis of the aorta between the opening of the ductus arteriosus and the origin of the left subclavian (*isthmus aortae*), a slight form of which is not infrequent, may in exceptional cases be very marked; and instances are described in which the aorta is entirely closed, or even wholly wanting. The collateral circulation is then established by means of anastomoses between the branches of the subclavian and the descending thoracic and abdominal aorta.

Stenosis and atresia of the venous orifices occur in the right as well as in the left auricle.

Misplacement (or transposition) of the large blood-vessels occurs along with other malformations of the orifices, of the vessels, and of the septa, as well as in the absence of such malformations. In these cases the vessels sometimes maintain their connexion with their proper ventricles; at other times an interchange takes place.

Defects of the ventricular septum may involve the entire partition (*cor biloculare biatriatum*), in which case only one ventricle is present. They are more frequently, however, limited to the anterior or posterior region of the septum, or even to a portion of one of these. The defect may be combined with a like defect of the auricular septum (*cor biloculare*), or with malformations of the arterial trunks and orifices, as well as of the venous orifices. Persistence of the truncus arteriosus may be associated with defects of the anterior septum; the latter however occurs much more frequently in association with stenosis of the pulmonary artery. In partial defects of the septum the aorta is generally displaced to the right.

Defects of the auricular septum, more or less extensive, are met with either by themselves, or in conjunction with other malformations. Most frequently the foramen ovale remains open; less often a defect is found beneath the membranous margin of the foramen. Total absence of the septum constitutes the *cor biloculare biventriculare*.

Malformations of the valvular segments may occur in the auriculo-ventricular valves, which are sometimes abnormally short, or adherent to each other; abnormal constriction and occlusion of the orifices are also met with. In the latter condition the circula-

tion can take place only when an opening persists in the auricular septum.

The number of the segments of the semilunar or sigmoid valves may be excessive or defective at either of the arterial orifices.

Persistence of the ductus arteriosus is brought about chiefly as a result of other defects in development, such as stenosis of the pulmonary artery, of the aorta, or of one of the venous orifices. It also occurs apart from any other form of cardiac malformation.

From their complexity, it is not always easy to gain a clear conception of the genesis of these malformations. More exact knowledge of the history of the development of the heart, which we owe to HIS and BORX, has materially aided our understanding of their origin, in regard both to defects of the septa and to malformations of the arterial and venous orifices.

The human heart is originally formed out of a straight tube, which later on becomes curved and S-shaped (HERTWIG). From the anterior extremity of this arise the two primitive aortic arches, while its posterior extremity receives the two vitelline veins (*venae omphalo-mesentericae*). When the tube (Fig. 3) has reached a certain size and position in the embryo, the several parts become differentiated, the widening venous portion and the arterial portion being separated by a narrower tube, the auricular canal (*ac*): the cavities are thenceforward recognisable as auricle (*a*) and ventricle (*v*). At the same time the auricles develop lateral pouches (*aa*), which become the *appendices auricularum*.

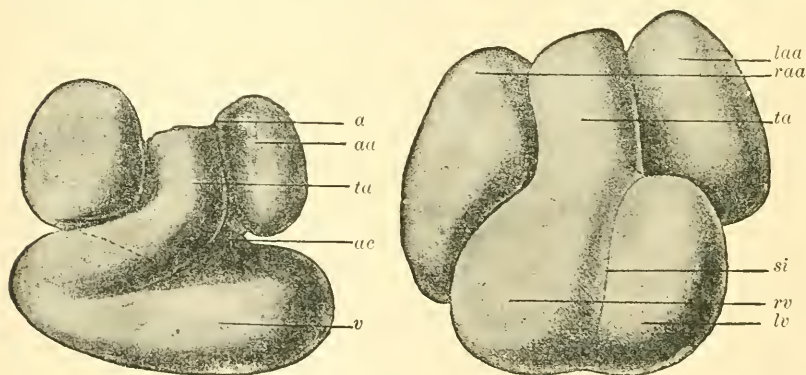


FIG. 3. HEART OF A HUMAN EMBRYO 4.3 MILLIMETRES LONG.

(From HIS)

<i>v</i> ventricle	<i>ac</i> auricular canal
<i>ta</i> truncus arteriosus	<i>a</i> auricle with appendix auriculæ <i>aa</i>

FIG. 4. HEART OF A HUMAN EMBRYO AT THE FIFTH WEEK.

(From HIS)

<i>rv</i> right ventricle	<i>ta</i> truncus arteriosus
<i>lv</i> left ventricle	<i>laa</i> left appendix auriculæ
<i>si</i> sulcus interventricularis	<i>raa</i> right appendix auriculæ

In the region of the auricular canal where the auriculo-ventricular valves are subsequently formed, the endothelial tube narrows and is markedly flattened in the sagittal direction, so that its opposite walls come nearly into contact.

The rudimentary ventricle (Fig. 3 *v*) forms a bent tube which narrows

toward the aortic bulb (*ta*). This is soon grooved externally by a straight furrow, the sulcus interventricularis (Fig. 4 *si*), running from above downwards, by which the ventricle is divided externally into a right and a left half, of which the former is continued into the truncus arteriosus. The formation of septa within the heart follows in the portion of the ventricle corresponding to the externally visible interventricular sulcus (Fig. 4 *si*). On the inferior and posterior wall a ridge arises (Fig. 5 *vs*), which is the rudiment of the septum ventriculorum, and grows from below upwards. Very soon on the posterior wall of the auricle, to the left of the venous orifice (Fig. 5 *sr*), a process of connective tissue (*si*) appears in the region of the auricular canal, whose walls at this stage assume the form of an annular projecting fold directed downward (the rudimentary valvular segments), and this process divides the auriculo-ventricular orifice into a right and a left half. His terms this portion of the septum the *septum intermedium*.

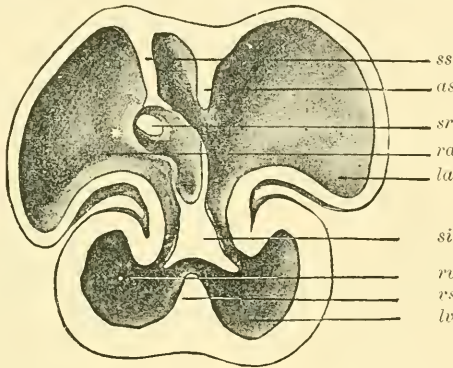


FIG. 5. POSTERIOR HALF OF THE HEART OF A HUMAN EMBRYO AT THE FIFTH WEEK.

(From His)

<i>lv</i>	left ventricle	<i>sr</i>	mouth of the sinus reuniens (<i>sinus venosus</i> of BORN)
<i>rv</i>	right ventricle	<i>as</i>	auricular septum (auricular crescent of HIS, <i>septum primum</i> of BORN)
<i>si</i>	septum intermedium	<i>ss</i>	septum spurium * Eustachian valve
<i>la</i>	left auricle		
<i>ra</i>	right auricle		
<i>vs</i>	ventricular septum		

In the seventh week this septum unites with the septum of the ventricles, and forms thus the middle segment of the auriculo-ventricular valves. The other segments of the mitral and tricuspid valves are formed from the wall of the ventricular cavity.

The differentiation of the truncus arteriosus into an aorta and a pulmonary artery follows directly upon the formation of the ventricular septum. It begins with a flattening of the tube, and this is followed by the appearance of two longitudinal ridges on the flattened sides, which grow toward each other and then unite. Later on, the aorta and pulmonary artery become externally distinct.

The process of division in the truncus arteriosus begins above, and extends downward till it reaches the ventricular cavity. The partition then unites with the ventricular septum by a secondary process of cohesion. The inferior portion of the truncus forms the membranous portion of the ventricular septum. The development of the semilunar valves begins before the division of the truncus. Four prominences of a gelatinous texture are formed; and of these two are bisected in the process of division of the arterial channels, so that presently three prominences appear in each trunk.

The auricular septum begins to develop on the superior wall of the auricle, from which point it grows (Fig. 5 *as*) downward, until, in the region of the auricular canal, it reaches the septum intermedium (*si*) and coheres with it; thus the auricle as well as the auricular canal is divided into halves. Here, however, the division again becomes incomplete, for an opening appears in the septum, the foramen ovale, which closes only after birth.

The truncus arteriosus at a certain stage of embryonic development gives origin to five pairs of primitive aortic arches, from whose confluence the aorta dorsalis arises (Fig. 6). Upon the division of the heart into its several differentiated portions, transformations occur in the arterial arches, whereby the division of the circulation into the major and minor systems is effected. The plan of the embryonic vascular system, originally symmetrical, now becomes asymmetrical. The manner in which this is effected is shown in the two diagrammatic schemes of Figs. 6 and 7. The essential points in the process of transformation are the division of the truncus into aorta and pulmonary artery, the obliteration of some of the primitive aortic arches, and the further development of the remainder.

In Fig. 7 the parts which persist are black or shaded, while those ultimately obliterated are left white. The connecting link between the pulmonary artery and the aorta, the ductus arteriosus, is obliterated last, since it closes only after birth.

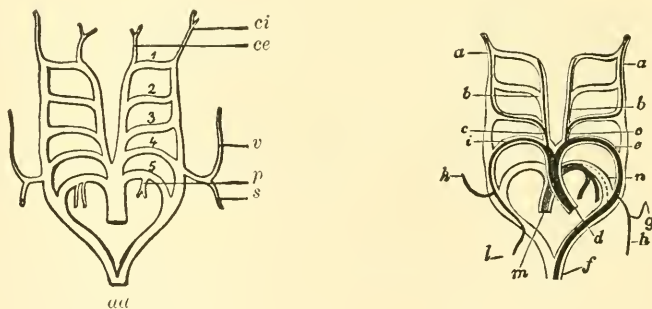


FIG. 6. DIAGRAMMATIC SCHEME OF THE AORTIC ARCHES OF THE EMBRYO OF AN AMNIOTIC VERTEBRATE.

(From HERTWIG)

- | | | | |
|-----------|------------------------------|----------|------------------|
| 1-5 | first to fifth aortic arches | <i>v</i> | vertebral artery |
| <i>ad</i> | aorta dorsalis | <i>s</i> | subclavian |
| <i>ci</i> | internal carotid | <i>p</i> | pulmonary artery |
| <i>ce</i> | external carotid | | |

FIG. 7. DIAGRAMMATIC SCHEME OF THE TRANSFORMATIONS OF THE AORTIC ARCHES IN A MAMMAL.

(From RATHKE)

- | | | | |
|----------|------------------------------|-----------|------------------------|
| <i>a</i> | internal carotid | <i>k</i> | right vertebral artery |
| <i>b</i> | external carotid | <i>h</i> | left subclavian |
| <i>c</i> | common carotid | <i>il</i> | right subclavian |
| <i>d</i> | the descending aorta | <i>m</i> | pulmonary artery |
| <i>e</i> | fourth arch on the left side | <i>n</i> | ductus arteriosus |
| <i>g</i> | left vertebral artery | | |

The venous trunks, with the exception of the ascending vena cava, are originally paired and symmetrical, and unite in the *sinus reuniens* (Fig. 5 *sr*); this later on disappears as an independent structure, and is absorbed into the auricles. Through the further development of some and the involution of other veins, the ultimately asymmetrical venous system is produced.

A comparison of the malformations of the heart with the stages of its development shows that the malformations result essentially from defective or perverted

development of the septum, the ventricle, the auricle, and the truncus arteriosus, and from failure of their normal coherences. This is true not only of defects in the septum, but also of anomalies of position and abnormal narrowness of the arteries. Union of the septum intermedium with the wall of the auricular canal leads to closure of the auriculo-ventricular orifice, or at least to an abnormal coherence of the valvular segments. Abnormal subdivision of the truncus arteriosus may also induce malformations of the valves; and incomplete development of the rudiments of the valves may result in morbid alterations of their texture. Disorders of evolution in the aortic arches are apt to give rise to anomalies of the arterial trunks.

References on the Development of the Heart.

- BORN: Development of the mammalian heart *A. f. mikrosk. Anat.* XXXIII 1889;
Anat. Anzeiger III (p. 606) 1888
 HERTWIG: *Lehrb. d. Entwicklungsgeschichte* Jena 1893
 HIS: *Anatomie menschl. Embryonen* III Leipzig 1885; *Beitr. z. Anat. d. menschl. Herzens* Leipzig 1886

References on Malformations of the Heart.

- ARNOLD: Development of auricular septum *V. A.* 51 1870; Congenital diverticulum of the heart *V. A.* 137 1894
 BABES: Peculiar cases *Jahrb. f. Kinderheilk.* XIV 1879
 VON BUHL: Cases *Z. f. Biol.* XVI 1880
 CHIARI: Cor triloculare *Jahrb. f. Kinderheilk.* XIV, XV 1879-80
 DILG: Rare cardiac anomalies *V. A.* 91 1883
 DITTRICH: Variations in the aortic arch *Prag. Z. f. Heilk.* VII 1886
 EPPINGER: The diaphragmatico-retromediastinalis muscle and primary defects of the septum *Cent. f. allg. Path.* v (p. 859)
 EPSTEIN: Cardiac defects *Prag. Z. f. Heilk.* VII 1886
 FÖRSTER: *Die Missbildungen d. Menschen* Jena 1865
 GELPKE: *Selten. Fall von angeb. Herzfehler* Basle 1883
 GREENFIELD: *Trans. Path. Soc.* XXVII London 1876
 KOLLMANN: Anomalies of vena cava inferior *Anat. Anzeiger* VIII 1893 (with references)
 VON KRZYWICKI: The membranous interventricular septum *Ziegler's Beiträge* VI 1889
 KUSSMAUL: Pulmonary stenosis *Z. f. rationale Med.* 1866
 LEO: *V. A.* 103 1886; Pulmonary stenosis and atresia *D. med. Woch.* 1886
 MACKENZIE: *Trans. Path. Soc.* XXXI London 1880
 MANN: Cor triloculare biatriatum *Ziegler's Beiträge* VI 1889
 MARCHAND: *Ahlfeld's Berichte und Arbeiten* 1881-82
 MARTINOTTI: *Gazetta d. cliniche* 1886, *Anat. Anzeiger* I 1886
 MARTINOTTI and SPERINO: *A. ital. de biol.* VI 1885
 MIDDENDORP: Pulmonary atresia *Internat. Monatsschr. f. Anat.* III 1886
 ORTH: Defect in ventricular septum *V. A.* 82 1880
 PISENTI: Rare tricuspid anomaly *Lavori patol. di Perugia* 1890
 POTT: Foetal affections *Jahrb. f. Kinderheilk.* XIII 1879
 PREISZ: Congenital defects of the heart *Ziegler's Beiträge* VII 1889
 RAUCHFUSS: *Gerhardt's Handb. d. Kinderkrankh.* IV
 REIL: *D. A. f. klin. Med.* XVII
 ROKITANSKY: *Defecta d. Scheidewände d. Herzens* Vienna 1875
 RUGE: Defects of the auricular septum *V. A.* 126 1891
 SCHMALZ: Pathogenesis of cardiac defects *D. med. Woch.* 1888
 TÖNNIES: *Ueb. eine selt. Missbild. d. Herzens* Göttingen 1886
 VENTURI: Rare cardiac lesions *Rev. de méd.* XIII 1893
 WAGNER: Pulmonary atresia and tricuspid stenosis with complete ventricular septum *Inaug. Diss.* Giessen 1889

References on Aortic Stenosis near the Ductus arteriosus.

- BARIÉ: Congenital stenosis of descending aorta *Rev. de méd.* vi 1886
 EPPINGER: Congenital aortic stenosis *Prag. Vierteljahrsschr.* 112 1871
 LEBERT: Aortic stenosis near ductus arteriosus *V. A.* 4 1852
 LUTICH: Obliteration of aorta near ductus *A. d. Heilk.* xvii 1876
 MARTENS: Two cases of aortic atresia *V. A.* 121 1890
 SOMMERBRODT: Obliteration of aorta near ductus *V. A.* 91 1883

5. It is not rare for the heart to be abnormally small in proportion to the body-weight. This condition is described as **cardiac hypoplasia**. The heart is either abnormally small at birth, or fails to attain sufficient development later. Sometimes in adults the heart may be no bigger than it normally is in children of seven or eight years. Such extreme cases are rare, but minor degrees of hypoplasia are often met with. According to VIRCHOW, cardiac hypoplasia is common in patients of both sexes suffering from chlorosis or haemophilia. In the majority of cases there is an accompanying hypoplasia of the arterial vascular system, the aorta and arterial trunks being narrow and thin-walled: the genital organs may also be ill-developed, and sometimes the entire body is undersized. The abnormal thinness and narrowness of the arteries are often associated with anomalies in their distribution; while corrugated and lattice-like irregularities of the surface, and fatty deposits, are observed in the inner coat of the aorta. In many cases rupture of such an aorta has been recorded.

Congenital hypertrophy of the whole or a part of the heart is seen when, from alterations in the ostial orifices and vascular trunks, the forward propulsion of the blood is rendered difficult.

Among the malpositions of the heart in the thorax we occasionally find the condition termed *transpositio cordis*, or **dexiocardia**. Here the heart is situated on the right side, the malposition being part of a general *situs viscerum inversus*, and but rarely unaccompanied by other anomalies. In cases of fissural malformation of the anterior thoracic and abdominal wall the heart is not uncommonly displaced forwards (*ectopia cordis*). The pericardium in these cases may be present or absent.

According to THOMA, the average weight of the heart in the new-born infant is 20.6 grammes; at the age of 17, 233.7 grammes; in full manhood, 303 grammes. In women this weight is about 40 grammes less. The length of the fully developed heart (BENEKE) is on the average about 9.0 centimetres, the breadth 10.7 cm., the thickness 3.6 cm. The thickness of the right ventricular wall is 2.0 to 3.0 millimetres; that of the left ventricular wall, 7.0 to 8.0 mm. In cases of hypoplasia the volume of the heart may be reduced by a third or more.

According to BENEKE, the circumference of the ascending aorta in new-born infants, at its commencement, measures 20 mm.; in the adult, 68 mm.: the circumference of the pulmonary artery at birth and in the adult is 23 mm. and 65 mm. respectively. Above the bifurcation of the aorta into the common iliac arteries the circumference in adults is 32 mm.

References on the Size of the Heart and Large Blood-vessels.

- BAMBERGER: *Lehrb. d. Krankh. d. Herzens* Vienna **1857**
BENEKE: *Grundlagen d. Constitutionsanomalieen* Marburg **1878**
VON BUHL: *Münch. pathol. Mittheil.* Stuttgart **1878**
CAMMANN: *New York Med. Gaz.* vi **1870-71**
THOMA: *Grösse u. Gewicht d. anat. Bestandtheile* Leipzig **1882**
VIERORDT: *Anat. Daten u. Tabellen* Jena **1893**
VIRCHOW: *Chlorose u. Anomal. am Gefässapparate* Berlin **1872**

CHAPTER IV

MORBID ALTERATIONS OF THE HEART AS A WHOLE

6. **Diminution in the size of the heart** depends essentially upon atrophy of its muscular and adipose tissues, and occurs most frequently in persons whose general nutrition is defective, and whose blood is greatly reduced in amount. In senile marasmus and in cancerous cachexia the weight of the heart may sink below half the normal amount. The adipose layer of the atrophic heart is almost, or even entirely, absent, and is replaced by a gelatinous translucent material resembling mucous tissue. The vessels coursing over the surface of the heart are, as the result of the shrinking of the underlying tissue, more or less tortuous. The muscular layers, on account of the wasting of their muscle-cells, are thinned and frequently coloured brown, or yellowish-brown, by the formation of pigment and fat in their substance. The cardiac cavities are small, and the endocardium, condensed by the contraction of the tissue that was formerly spread out over a larger surface, is less transparent than normal.

Enlargement of the heart, when not due to the presence of a tumour, is caused either by dilatation of its cavities, by the hyperplasia of its muscular structure, or by an increase of the sub-pericardial adipose tissue.

Dilatation of the heart is often the result of morbid changes in its muscle, which make the walls yield more readily to pressure (fatty degeneration). In other cases it is caused by some resistance to the emptying of the heart-cavities (stenosis of the orifices, adhesions of the pericardium, diseases of the lungs, especially chronic emphysema and pleuritic adhesions), or by alterations of the valves, which, if the ventricles and auricles are relaxed, permit a regurgitation of blood from the arteries into the ventricles, and from the ventricles into the auricles (valvular insufficiency). The dilatation, according to the cause upon which it is dependent, sometimes affects only one ventricle or auricle, sometimes the entire heart, and may be so great that the circumference of the heart reaches twice the normal measurement or even more. Locally circumscribed changes in the walls (ischaemic softening of the heart-muscle, cardiac scleroses, Art. 11) cause local protrusions, which are termed **aneurysms of the heart** (Fig. 28).

Dilatation of the heart is at first accompanied by thinning of the walls of the distended portion; but the distension may be combined with hypertrophy of the muscular structure. This occurs when the dilatation is produced by an increased resistance to the outflow of blood from the heart, or by regurgitation of blood into the heart during diastole.

Hypertrophy of the cardiac muscle is the result of persistent increase of the work of the heart; but this condition induces true hypertrophy only when the demands upon the heart do not exceed a certain limit and the muscle is well nourished. The causes of increased cardiac action are insufficiency and steno-

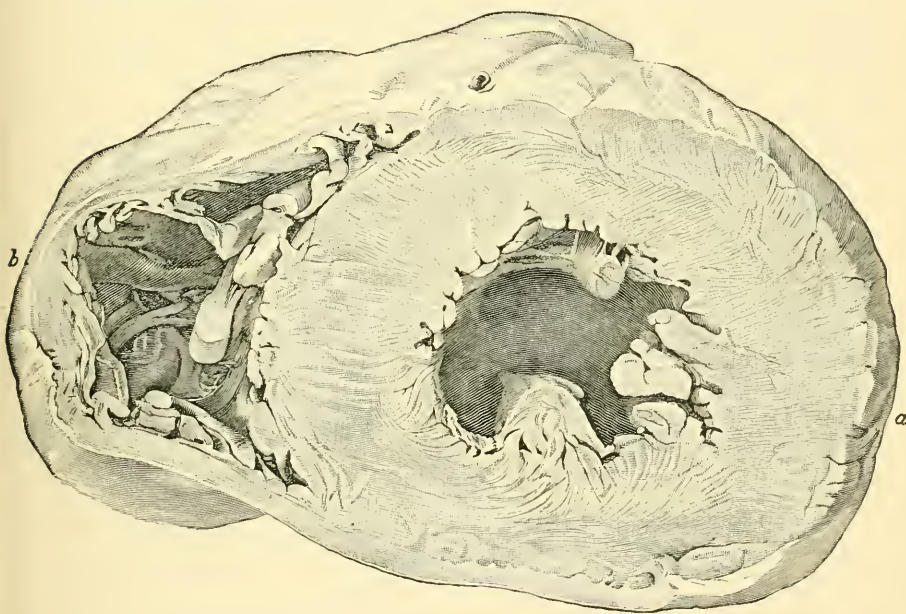


FIG. 8. HYPERTROPHY OF THE LEFT VENTRICLE.

(Produced by insufficiency and stenosis of the aortic valves: transverse section: natural size)

a left ventricle

b right ventricle

sis of the valves (Art. 9, Figs. 19 and 20), abnormal narrowness of the arterial trunks, destruction of renal tissue whereby the blood-pressure within the systemic circulation is increased, diseases of the lungs (emphysema, pleuritic adhesions) which increase the pressure in the minor circulation, adhesions of the pericardium to the heart and lungs, increase of the total amount of blood in the body, nervous excitement, and severe bodily exertion. Idiopathic hypertrophy of the heart, in other words, simple overgrowth of the heart-muscle from internal causes, has not been

shown to occur. The increase in size of the heart-muscle is therefore always symptomatic; it is dependent on increased work, from whatever cause arising. The hypertrophy accordingly appears first in that portion of the heart which is primarily exposed to the abnormal strain. In disease of the aortic valves and in cases of contracted kidney, this portion is the left ventricle (Fig. 8 a); in insufficiency and stenosis of the pulmonary valves, and in cases of increased resistance within the pulmonary circulation, it is the right ventricle.

Hypertrophy of the heart-muscle causes in the first instance a thickening of the auricular or the ventricular wall (Fig. 8 a). The trabeculae and the papillary muscles share also in the hypertrophy, and may undergo marked increase in their circumference. The weight of a hypertrophied heart may reach twice the normal amount, or even more; hearts weighing 600 to 700 grammes and more are thus met with.

The increase in the size of the heart-muscle is due to hyperplasia of the individual muscle-cells. It is difficult to determine whether any increase in the number of cells also occurs: when the hypertrophy takes place in the first years of life this is not improbable.

In hypertrophied hearts the cavities are sometimes dilated, sometimes normal, and sometimes smaller than normal, presenting the conditions known as **eccentric, simple, and concentric hypertrophy**, respectively. The dilatation of the heart, as a consequence of increased resistance to the circulation, may precede the hypertrophy, or takes place subsequently in an already hypertrophied heart, owing to secondary degeneration of the muscles.

Lipomatosis or fatty enlargement of the heart may be a local manifestation of a general deposit of fat over the entire body; it is characterised by an increase in the yellowish-white cardiac *panniculus adiposus*. More marked forms of lipomatosis or adiposity tend to produce collections of fat in the intermuscular and sub-endocardial connective structures, so that the muscular substance is as it were infiltrated with fatty tissue, and a layer of fat appears beneath the endocardium. Marked lipomatosis may impair the functional power of the cardiac muscle.

References on Hypertrophy of the Heart.

- AUFRECHT: *Path. Mittheil.* no. 11 Magdeburg 1883
 BAMBERGER: *Volkmann's klin. Vorträge* 173
 BAUER and BOLLINGER: *Idiopath. Herzvergrößerung* (from beer-drinking) *München* 1894
 BOLLINGER: Idiopathic cardiac hypertrophy (from beer-drinking) *München. path. Arbeiten* 1886
 VON BUHL: Eccentric hypertrophy *München. path. Arbeiten* 1878
 DU CASTEL: *A. gén. de méd.* 1880
 COHNHEIM: *Allgemeine Path.* 1 II Berlin 1882
 GOLDENBERG: Atrophy and hypertrophy of cardiac muscle-fibres *V. A.* 103 1886

- GRAWITZ and ISRAËL: Renal disease and cardiac hypertrophy (experimental researches) *V. A.* 77 **1879**
- ISRAËL, O.: Renal disease and secondary vascular changes *V. A.* 86 **1881**
- LETULLE: *Les hypertroph. cardiaques secondaires* Paris **1879**
- LEYDEN: Cardiac disease and over-exertion *Z. f. klin. Med.* XI **1886**
- MÜLLER: *Massenverhältnisse d. menschl. Herzens* Leipzig **1883**
- RIEGEL: Increased blood-pressure in nephritis *Z. f. klin. Med.* VII **1884**
- ROY and ADAMI: Overstrain of the heart *B. M. J.* **1888**
- SCHMIDT: The heart in thoracic aneurysm *E. L. Wagner's Festschrift* Leipzig **1887**
- SPATZ: *D. A. f. klin. Med.* XXX **1882**
- TANGL: Hypertrophy and normal growth of the heart *V. A.* 116 **1889**
- THOMA: *Gewicht d. Bestandth. d. menschl. Körpers* Leipzig **1882**
- TRAUBE: *Gesamm. Beiträge* III **1878**
- ZANDER: Bright's disease and cardiac hypertrophy *Inaug. Diss.* Königsberg **1881**
- ZIELONKO: Cardiac hypertrophy *V. A.* 62 **1874.**

CHAPTER V

MORBID CHANGES IN THE ENDOCARDIUM

7. The **endocardium** is a delicate membrane lining the heart, composed of connective tissue, and containing few blood-vessels. The valvular segments are portions of the endocardium; those guarding the aorta and pulmonary artery are devoid of vessels, while those at the mitral and tricuspid orifices are vascular. The **chordae tendineae** are provided with small vessels arising from the papillary muscles.

The endocardium is frequently the seat of degenerative changes, which in most instances affect the parietal layer, and in other cases the valves. In the latter situation the degenerative change not rarely gives rise to disorder of the valvular functions.

Fatty degeneration is the most frequent of these changes. This change is manifested by the formation of circumscribed

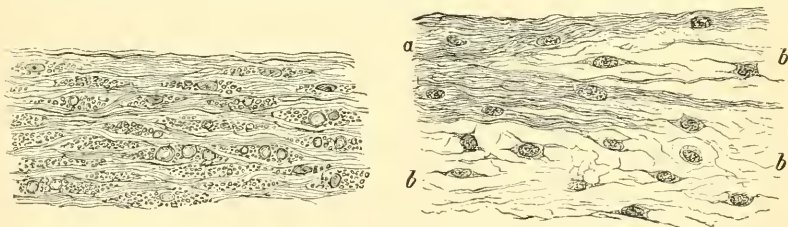


FIG. 9. SECTION OF FATTY ENDOCARDIUM.

(From the mitral valve of a child dead of scurvy: perosmic acid preparation, mounted in glycerine: $\times 350$)

FIG. 10. MUCOID DEGENERATION OF THE CONNECTIVE TISSUE OF THE AORTIC VALVE.

(Perosmic acid preparation, from a frozen section mounted in glycerine: $\times 350$)

a connective tissue

b mucoid tissue

patches of an opaque white colour, which are found most commonly on the valves, and less frequently upon the parietal endocardium. The fatty changes take place first in the connective tissue, and later in the superficial endothelial cells, the protoplasm of which appears beset with oil-globules. In the graver degrees of degeneration the interstices of the connective tissue are entirely filled with oil-globules of different sizes (Fig. 9). This condition usually occurs in aged persons whose vascular system elsewhere shows signs of similar change. But it may also occur in younger

persons, and is found in association with the most varied diseases, such as chronic heart-disease, anaemia, marasmus, toxic and infective conditions, and the like.

Mucoid degeneration of the endocardial tissue occurs chiefly in old age, but it also accompanies morbid thickening of the valves, and is almost entirely confined to them. It generally occurs in patches, leading to the formation of circumscribed thickenings and prominences upon the free margins of the valves. These patches present a gelatinous appearance, and are composed of mucoid tissue containing cells (Fig. 10 *b*), or of non-cellular mucous substance. In the former case the texture of the patch resembles that of the gelatinous tissue of the valves of the foetal heart.

The mucoid degeneration is often combined with fatty changes; thus one portion of the valvular tissue may appear fatty and another gelatinous, or the cells of the tissue are fatty while the ground-substance becomes mucoid.

Sclerosis of the connective tissue of the endocardium is seen chiefly on the free margins of the valves, the condition being so frequently met with in old age that it may almost be regarded as a physiological change. This condition leads to the formation of flattened and diffuse thickenings of the valve, or to nodular prominences, within which the tissue is dense and either obscurely fibrillar or quite homogeneous, and contains few or no cellular elements.

Sclerosis of the valvular tissue is frequently combined with fatty, mucoid, and calcareous change, and necrotic disintegration of the degenerated tissue may ultimately take place, leading to the formation of patches of softening. Ulcers arise when such softened and degenerated areas break down, and in the neighbourhood of these ulcers reparative processes are usually set up, leading to infiltration of the tissue with leucocytes. This combination of morbid changes is described as **atheromatous degeneration**; it is a frequent cause of valvular insufficiency in the aged. Hard calcareous masses are sometimes formed by the deposit of calcium salts in the neighbourhood of the atheromatous patches, and in many cases these masses seriously obstruct the movements of the valves.

When from any cause the natural texture of the surface layer of the heart is altered, or when it becomes rough or irregular, finely-granular **thrombi** are apt to form on the affected spots. These take the form of circumscribed yellowish or reddish deposits, which are often (but not quite correctly) described (Art. 8) as endocarditic vegetations (Fig. 11 *b*). The deposits form as a rule when the circulation is irregular or weak, and appear as small yellowish or reddish-yellow nodes, or as rough warty masses. They are generally found on the valves, both about the ostial attachment and on the free surface. If these thrombi are not washed off by the blood-current, proliferation

takes place in the underlying endocardium (Fig. 11 *e*); this penetrates the thrombus and gives rise to a more or less complete substitution of cellular connective tissue for its substance. Many gradually increasing thickenings of the valves are no doubt the result of repeated thromboses of this kind. Larger thrombi may undergo more or less complete calcareous infiltration, and cases occur in which the valvular sinuses of the aorta are beset with a number of calcified thrombi in the form of irregular serrated excrescences, firmly adherent to the surface of the valves.

Slight **amyloid degeneration** of the connective tissue of the heart-wall is not infrequently observed; it occurs under the same conditions as amyloid degenerations of other organs. Degeneration so marked as to be recognisable without the aid of the iodine or methyl-violet reaction is rare, though cases have been recorded (HESCHL, ZIEGLER, WILD) in which hyaline patches and streaks, as well as circumscribed hyaline nodules, had formed in the connective tissue of the endocardium and in that of the myocardium and epicardium.

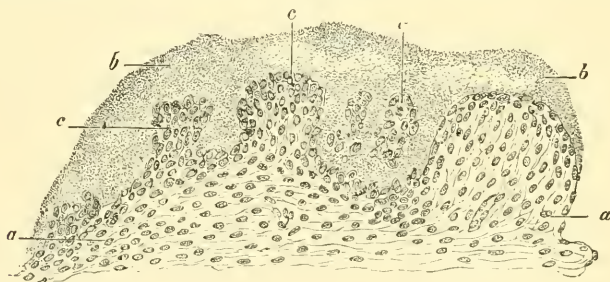


FIG. 11. PROLIFEROUS GROWTH OF THE ENDOCARDIUM WITH A THROMBUS.

(From the slightly-thickened and vascular aortic valve of a male patient, aged 49; preparation hardened in Müller's fluid, stained with alum-carmin and eosin, and mounted in Canada balsam: $\times 60$)

- | | |
|----------------------------------------------------------------------|--------------------------------------|
| <i>a</i> hyperplastic connective tissue of valve, with blood-vessels | <i>b</i> granular thrombi |
| | <i>c</i> fibro-cellular excrescences |

In rare cases, a combination of amyloid change with a peculiar **hyaline degeneration** of the connective tissue is observed. The tissue thickens and becomes completely hyaline, and then breaks up into translucent fragments, some portions yielding the characteristic iodine or methyl-violet reaction, while other portions do not. By continuous extension of the degeneration through the intermuscular connective tissue, during which the muscle-cells in the affected area disappear, a large portion of the muscular substance of the heart may be destroyed. The heart-wall is thus converted into a rigid semi-translucent mass, resembling the fat or rind of boiled bacon, and the endocardium may at the same time be thickly studded with hyaline granules.

References on Degeneration of the Endocardium and on the Structure of the Valves.

- COËN: Vessels of the valves *A. f. mikrosk Anat.* XXVII 1886
 DARIER: Vessels of the valves *A. de physiol.* II 1888
 HESCHL: Amyloid heart-muscle *Wien. med. Woch.* 1870

HONEGGER: Changes in the intima of the heart and arterial trunks *Inaug. Diss.* Zürich 1882

KYBER: *Amyloide Degeneration* Dorpat 1871, and *V. A.* 81 1880

SOYKA: Amyloid heart-muscle *Prag. med. Woch.* 1876

VIRCHOW: *Gesamm. Abhandl.* Frankfurt 1856

WILD: Amyloid and hyaline degeneration *Ziegler's Beiträge* 1 Jena 1885

ZIEGLER: Endocarditic vegetations *Verh. Congr. f. inn. Med.* Wiesbaden 1888

8. By **endocarditis** is meant an inflammatory disease of the endocardium, due to the influence of an irritant which has gained access to the blood. The valves are the structures most frequently affected, although the condition may be limited to other portions of the endocardium.

Endocarditis is frequently a secondary affection, dependent upon inflammatory disorders in other organs, such as suppurating wounds, purulent peritonitis, and pneumonia. Not infrequently however the endocarditis forms the first local manifestation of an infection, the exciting agent of which has left no recognisable traces at the seat of its entrance into the body. Embolic occlusion of certain vessels, and metastatic inflammations in other organs, in particular the kidneys, spleen, brain, and skin, are not infrequently associated with endocarditis.

According to the researches of WEICHELBAUM, WYSSKOWITSCH, FRÄNKEL, SÄNGER, BONOME, KLEBS, HIRSCHBERG, STERN, NETTER, and others, the causation of endocarditis is not always the same. Various micro-organisms may act as the exciting cause, and among them we find certain that are known to be associated with other organic diseases, such as traumatic infections, osteomyelitis, and pneumonia, while some have not yet been correlated with any other infective disorder. Of the former the most important are the *Staphylococcus pyogenes aureus*, the *Streptococcus pyogenes*, and the *Diplococcus pneumoniae*; while the *Staphylococcus pyogenes albus*, and the *Bacillus pyogenes foetidus* (PASSET), seem to play only a subordinate part. LEYDEN and others consider that endocarditis may be caused by the *Gonococcus*. The organisms found in connexion with endocarditis, but not as yet associated with other organic diseases, include both micrococci and bacilli. Thus WEICHELBAUM has described, as met with in some cases of endocarditis, *Micrococcus endocarditidis rugatus*, *Micrococcus endocarditidis capsulatus*, *Bacillus endocarditidis griseus*, *Bacillus endocarditidis capsulatus*, and a bacillus which he failed to cultivate; and FRÄNKEL and SÄNGER have met with a non-motile foetid bacillus.

According to these authors, the experiments they have carried out render it very probable that all of these bacteria are pathogenic in their nature, and that the first-named organisms are certainly so. The aetiological significance of the others is not as yet established, and it may well be that their occurrence in cases of endocarditis is either a post-mortem phenomenon, or is

due to secondary settlements of the microbes in the diseased tissues during life. Thus, for example, the presence of tubercle-bacilli in the endocarditic deposits of tuberculous patients (CORNIL, KUNDRAT, HELLER, BIRCH-HIRSCHFELD) is very probably due to a secondary invasion, though it should be noted in this connexion that tubercles are occasionally found on the valves, and that these may be overlaid with thrombi. Not infrequently the areas affected with endocarditis contain at the same time two, or even three, different forms of bacteria.

The action of the bacilli at their place of settlement leads in all cases to a more or less marked degeneration of the affected tissue. If the bacteria (Fig. 12 *b*) extend from the surface deep

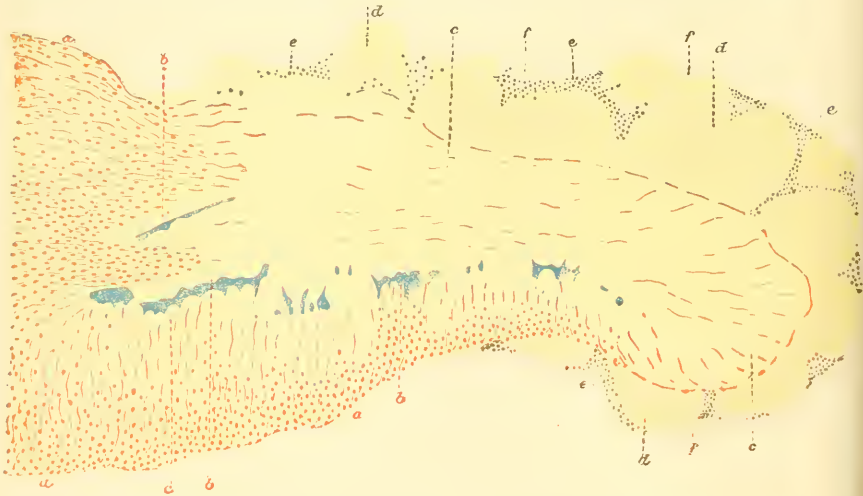


FIG. 12. MYCOTIC ENDOCARDITIS OF AN AORTIC VALVE.

(*Staphylococcus pyogenes aureus*: preparation hardened in alcohol, embedded in celloidin, stained with gentian-violet and resorcin, and mounted in Canada balsam: $\times 40$)

- | | |
|----------------------------------------|-------------------------------------|
| a normal valve tissue | d granular lamellar thrombi |
| b colonies of micrococci | e fibrillar fibrin, with leucocytes |
| c necrotic tissue containing no nuclei | f red blood-corpuscles |

into the tissue, the result is in many cases a somewhat widely extended necrosis, so that the tissue beset with bacteria appears to have lost its nuclei (Fig. 12 *c*). In consequence of the changes which the chemicophysical constitution of the tissue undergoes through the growth and spread of the bacteria, thrombi very soon form on the surface of the affected areas. The thrombi mostly take the form of finely-granular flakes or films which contain no cellular elements. At times leucocytes and red blood-corpuscles may be found attached to the flakes (Fig. 12 *f*), and fibrillar fibrin is simultaneously deposited on them (*e*). The thrombi are thus composed of different elements, and belong to the 'mixed' variety.

On the semilunar valves of the aorta and pulmonary artery, which are free from blood-vessels, inflammatory exudations appear, but only at a later stage (Fig. 12). If, however, the bacterial colonies are situated on the vascular portions of the mitral and tricuspid valves, an inflammatory exudation quickly follows, and is accompanied by more or less extensive cellular infiltration of the affected valve-tissue (Fig. 13 *e f*).

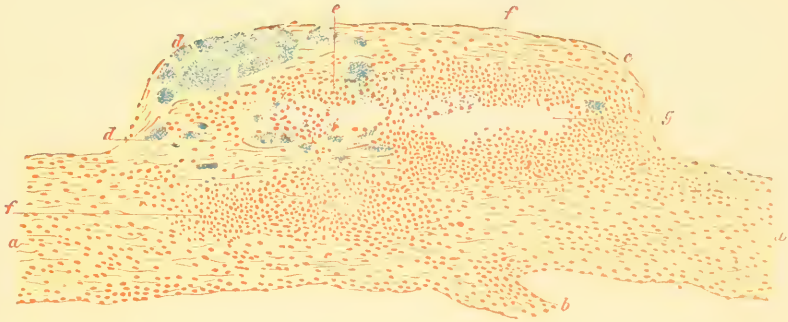


FIG. 13. MYCOTIC ENDOCARDITIS (PUSTULOSA) OF THE TRICUSPID VALVE.

(Following an infected wound of the left foot, accompanied by haemorrhagic septic pneumonia: preparation hardened in alcohol, and treated with gentian-violet, iodine, and resurin: $\times 60$)

- | | | | |
|---|----------------------------------------------|---|---------------------------------------|
| a | tissue of the posterior segment of the valve | e | pus-cells and staphylococci |
| b | chorda tendinea | f | pus-cells unaccompanied by micrococci |
| c | pustular elevation on the valve | g | small abscess |
| d | <i>Staphylococcus pyogenes aureus</i> | | |

The first change visible to the naked eye consists of a barely-perceptible cloudiness of the affected part.

The course and issue of endocarditis is chiefly dependent upon the extent of the degeneration and necrosis to which the bacteria give rise; but the intensity of the inflammatory process which has thus been started, as well as the magnitude and character of the resulting thrombosis, must also be taken into consideration.

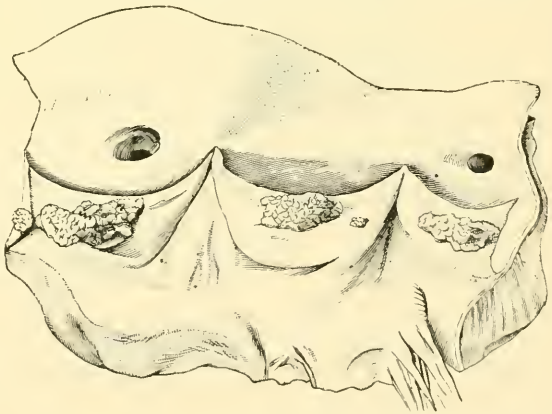


FIG. 14. WARTY ENDOCARDITIS (VERRUCOSA) OF THE AORTIC VALVE.

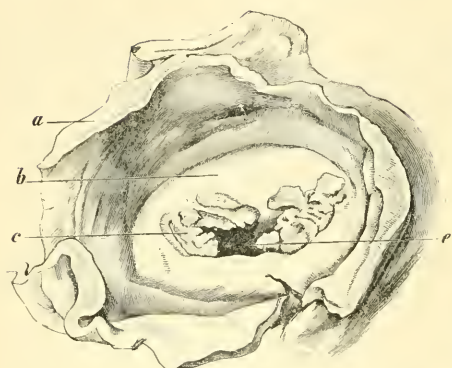


FIG. 15. VILLOUS ENDOCARDITIS (POLYPOSA).
(Mitral valve, with recent endocarditic thrombi,
seen from the auricle; natural size)

- a auricular wall
- b posterior segment of the valve
- c thrombus
- e auriculo-ventricular opening

When the extent of the degeneration and necrosis is small, and the affected area remains covered with thrombi projecting above the surface in the form of small wart-like yellowish or reddish masses, single, or in groups or rows, we have the variety known as **warty endocarditis** (*verrucosa*) (Fig. 14). When the deposits are extensive, and polypoid or shaggy in appearance, the condition is called **polypous** or **villous endocarditis** (Fig. 15 *e* and Fig. 17 *b*). When the necrosis is more ex-

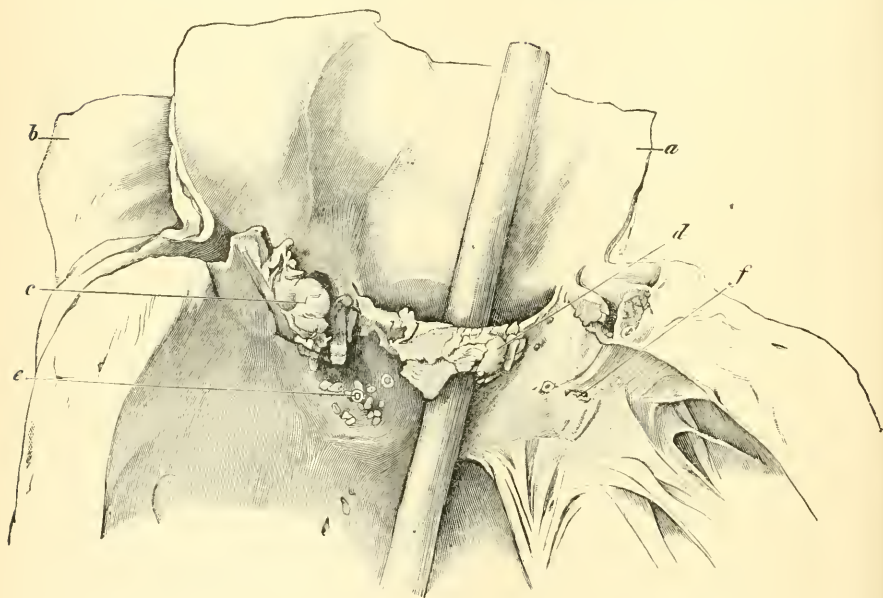


FIG. 16. ULCERATIVE ENDOCARDITIS OF THE AORTA, SHOWING ULCERS, VALVULAR PERFORATIONS, AND VALVULAR THROMBI.

(Natural size)

- a aorta
- b pulmonary artery
- c valvular segment covered with thrombi
- d perforated segment covered with thrombi
- e ulcers on the ventricular septum
- f ulcers on the ventricular surface of the larger mitral segment

tensive and the necrotic tissue and the thrombi formed on it have been separated, so that ulcerous excavations are visible, we have an **ulcerous** or **diphtheritic endocarditis**. Sometimes the infected thrombi are cast off, and passing into the circulation lodge elsewhere in the tissues as foci of suppuration: the process may then be described as **pyaemic** or **suppurative endocarditis** (*pus-tulosa*) (Fig. 13).

Ulceration may be combined with the formation of warty thrombi in the most various ways. On the margins of an endocarditic ulcer (Fig. 16 *e d* and Fig. 17 *b*), new thrombi are apt to form, but they are usually larger and looser than in endocarditis verrucosa, and often possess rather a villous than a warty appearance.

As already stated, endocarditis most frequently affects the valvular apparatus, more rarely the parietal endocardium of the left heart, still more rarely the endocardium of the right heart; it is most frequently observed in the latter situation when the endocarditis is due to traumatic infection. In the course of left-sided valvular endocarditis, warty deposits may also be formed on the valves of the right side of the heart.

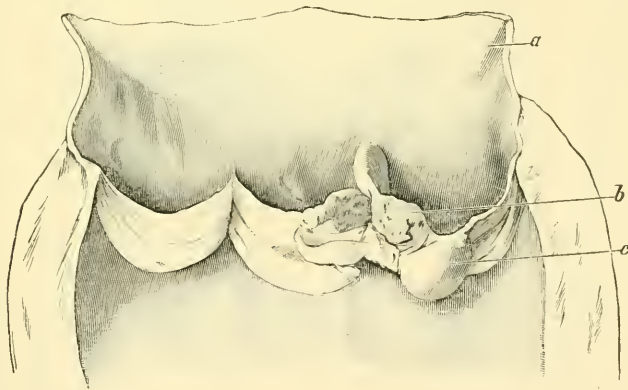


FIG. 17. MYCOTIC ENDOCARDITIS (VILLOSA), WITH VALVULAR THROMBI, AND ACUTE VALVULAR ANEURYSM.

(Natural size)

a aorta

b valvular thrombus

c aneurysm

Warty endocarditis affects chiefly the free margins of the valvular segments; the ulcerative forms are less frequently confined to this situation. The ulceration attacks different portions of the valves, and very frequently spreads to the chordae tendineae, and to the walls of the aorta and of the heart. When the tissue of a valvular segment is gradually destroyed on one side, the diseased area sometimes yields under the pressure of the blood, and thus may

be formed an acute **valvular aneurysm** (Fig. 17 *c*). Later on the segment may be broken through (Fig. 16 *c d*), and valvular perforations and ruptures are then produced. Not infrequently the diseased chordae tendineae are broken. The bacterial invasion may penetrate deeply into the heart-muscle and into the wall of the aorta, and lead to myocarditis and arteritis, with more or less extensive ulceration. The ulceration often causes much loss of substance, leading to aneurysmal bulging of the wall, and under certain conditions to rupture. If at any time the thrombi or shreds of disintegrated tissue become detached from the affected areas, they are carried away as **emboli** by the circulating blood, and are arrested in various organs, notably in the brain, spleen, and kidney. Endocarditis is often associated with **myocarditis**; the latter being caused by direct or indirect infection from the blood (Art. 12).

The warty thrombotic deposits are often referred to as **endocarditic vegetations** or efflorescences, though this term, at least in so far as it is applied to the early stages of the process, is not strictly accurate; for at first there is no true outgrowth from the endocardium (Art. 9). The term represents an opinion formerly held and still maintained by some, that the warty elevations begin as inflammatory swellings of the endocardium, that they consist chiefly of the swollen endocardial tissue, and that the thrombi which cover them are secondary deposits.

As micro-organisms are found only in some of the so-called endocarditic vegetations, it is still a subject of discussion whether all cases of endocarditis are of bacterial origin. If we regard every thrombotic deposit and the associated proliferation of the underlying tissue (Arts. 7 and 9) as manifestations of endocarditis, the question must be answered in the negative, for some of the thrombi described as vegetations are not primarily due to the presence of bacteria, but are found in association with other changes of the endocardium. In the present state of knowledge, it is better to reckon as cases of primary acute endocarditis those affections of the endocardium only which are referable to bacterial invasion.

Valvular perforations due to inflammation are not to be confounded with **fenestration** of the valves. This latter condition is found not infrequently as a congenital malformation, or as a consequence of loss of tissue in the neighbourhood of the free margins of the semilunar valves. To distinguish between the two conditions the difference in situation should be noted. Moreover signs of inflammatory infiltration, or of fibrous thickening, appear around the openings in the case of valvular perforations, but are absent in cases of fenestration.

9. When the lesion caused by the presence of the bacteria has reached a certain stage, along with inflammatory infiltration certain reparative processes are set up in the adjacent tissue. These are chiefly indicated by the formation of germinal tissue (Fig. 18 *d*), and afterwards of connective tissue. In the relatively benign warty forms of endocarditis, the degenerative processes extend over a small area only, and it seems that the bacteria do not in this instance penetrate deeply. Very soon, beneath the nodular or loosely fimbriated thrombotic deposit, the infiltrated and growing endocardial connective tissue (Fig. 18 *a b*) rises above the surface, and by continued proliferation extends (*h*) into the

substance of the thrombus (*c e*). Cases are occasionally met with in which the fibrin of the thrombus has thus to a large extent given place to connective tissue growing from below, or is traversed from base to surface by strings of cells and fibrous strands. In this way the original thrombotic deposit is displaced by an inflammatory granulomatous growth, and this is fittingly described as an **endocarditic vegetation**.

In ulcerative endocarditis, in which the bacteria extend deeply into the tissue and cause necrosis, the reparative process begins only after loss of substance has taken place, and then starts in the walls and floor of the ulcer. In other respects, however, the

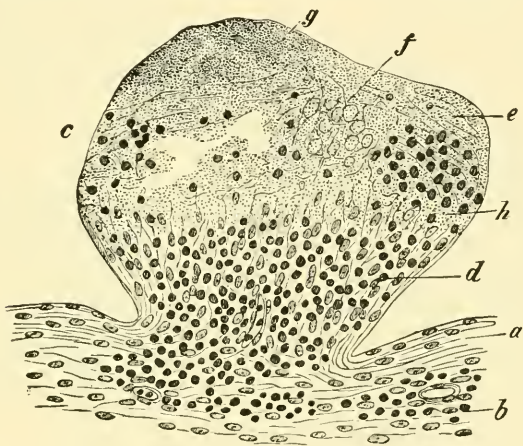


FIG. 18. SECTION THROUGH AN ENDOCARDITIC VEGETATION.

(From the auricle: preparation hardened in alcohol, stained with haematoxylin: $\times 150$)

- | | |
|------------------------------------------------------------------------------------------|----------------------------------------------------------------------------------------|
| <i>a b</i> endocardial and subendocardial connective tissue, infiltrated with leucocytes | <i>f</i> colourless denucleated protoplasmic masses |
| <i>c</i> the vegetation | <i>g</i> finely-granular masses (? micrococci) |
| <i>d</i> inflammatory growth rising above the endocardial surface | <i>h</i> zone of transition between the inflammatory growth and the fibrinous thrombus |
| <i>e</i> granular coagula | |

process follows the same course as that just described, the only points of difference being that the thrombotic deposits are larger, the inflammatory infiltration more diffuse and more marked, and the proliferation more abundant, than in warty endocarditis.

Small thrombotic deposits, provided they are not broken off and carried away by the blood-stream, are as a rule entirely replaced by connective tissue. Of the larger valvular thrombi (Fig. 15 *c*), such as occur chiefly in ulcerative endocarditis, a considerable portion often remains. This becomes shrunken and calcified, and the affected valve is thereafter covered with an adherent hard calcified and chalk-like deposit (Fig. 19 *c*, Fig. 20 *b*).

These ulcerative processes, as well as the thrombotic deposits and new connective-tissue growths (provided they remain attached to the valve and attain an appreciable size), lead to deformities of the valvular segments which interfere with their function, and so give rise to the conditions known as **stenosis** (Fig. 21 *e* and Fig. 20) and **insufficiency** or incompetence (Fig. 19 *e*, Fig. 20, and Fig. 21 *e e*).

Stenosis of a valvular orifice is due mainly to thickening and rigidity of the valves, from adherent and calcified thrombi (Fig. 19 *e* and Fig. 20 *b*), or to coherence of adjacent valvular segments (Fig. 21 *d*). The thickened chordae tendineae (*f*) often become adherent to the free margins of the mitral and tricuspid

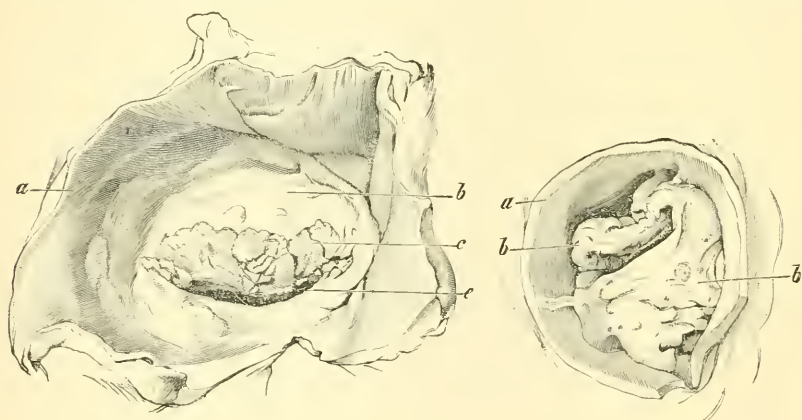


FIG. 19. POSTERIOR SEGMENT OF THE MITRAL VALVE, WITH THICKENED AND CALCIFIED THROMBI, AND STENOSIS OF THE AURICULO-VENTRICULAR OPENING.

(Seen from the auricle: natural size)

- | | |
|--------------------------------------|-------------------------------------------------------|
| <i>a</i> auricular wall | <i>c</i> thrombus, partly calcified, partly organised |
| <i>b</i> thickened posterior segment | <i>e</i> auriculo-ventricular opening |

FIG. 20. THICKENED AND DISTORTED AORTIC VALVES.

(Seen from above, showing thickened segments, with extensive partly organised and partly calcified thrombi: aortic stenosis: natural size)

- | | |
|-----------------------------------------------------------|-------------------------------------------------------|
| <i>a</i> transverse section of the aorta above the valves | <i>b</i> calcified thrombi in the sinuses of Valsalva |
|-----------------------------------------------------------|-------------------------------------------------------|

valves, as well as to each other; so that finally the valvular apparatus is reduced to a rigid funnel, compressed from before backward, and with only a narrow slit-like opening (Fig. 21 *e*). From the mutual coherence of the segments guarding the aorta or pulmonary artery, and the presence thereon of calcified thrombi, the orifice of the vessel becomes a mere inextensible slit, which may be so narrow that a goose-quill can hardly be pushed through it.

Insufficiency arises chiefly from the shortening and deformity of the valves (Fig. 21 *e*), and from the gradually increasing rigidity of their tissue, which prevents the close apposition of the segments. Ulcerative destruction and rupture of the valvular curtains and chordae tendineae may of course give rise in acute fashion to insufficiency of the valve.

If the seat of the endocarditis be the parietal lining of the

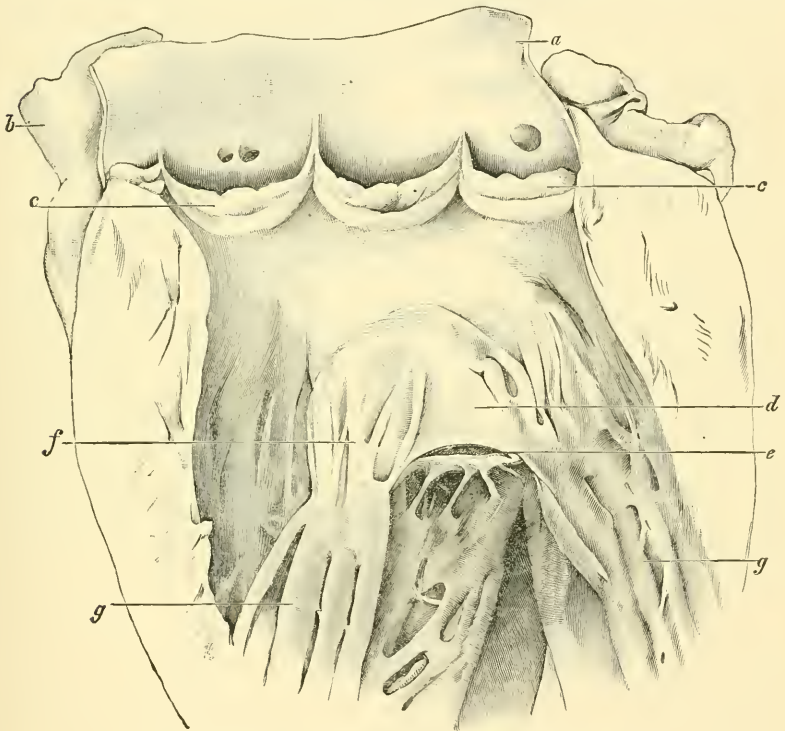


FIG. 21. AORTIC INSUFFICIENCY AND MITRAL STENOSIS.

(Natural size)

- | | |
|-------------------------------------------------------------|---------------------------------------------------------------|
| <i>a</i> aorta | <i>e</i> stenosed opening of the mitral valve |
| <i>b</i> pulmonary artery | <i>f</i> thickened, shortened, and coherent chordae tendineae |
| <i>c</i> shortened and shrunken valves with thickened walls | <i>g</i> papillary muscle |
| <i>d</i> mitral valve | |

heart, it leaves upon the affected area lustrous white indurated thickenings, which usually lie on the surface, but in certain cases radiate into the neighbouring muscular tissue. Diffuse or circumscribed thickenings may form upon the chordae tendineae.

In rare cases, the newly-formed connective tissue may undergo cicatricial contraction, which leads to **stenosis of the heart**, or

rather of the conus arteriosus of a ventricle. This condition is apt to occur after foetal endocarditis, and affects most frequently the right heart; but it may supervene during extra-uterine life, and is then found to involve the left ventricle.

With the replacement of a thrombus by connective tissue, and its subsequent calcification, the progressive process in general comes to an end, though in the interior of the thickened valves changes which modify the structure of the new connective tissue may for a long time continue to take place. Usually the tissue-cells and the new blood-vessels diminish in number, the texture becomes more dense, and hyaline degeneration, fatty changes, and calcification often follow.

How long the virulent bacteria retain their vitality is not known, but probably they are quickly destroyed. The appearance of new deposits upon old thickenings of the valves is not always dependent upon fresh settlements of bacteria. Very frequently these deposits are merely thrombi due to roughnesses or other superficial alterations of the endothelium, or to some irregularity of the circulation. Such formations are however of considerable importance, inasmuch as they may lead to fresh proliferation, and this may still further impair the efficiency of the valves.

The consequence of these affections of the valves is that the circulation of the blood is impeded (Art. 6). The difficulty of emptying the ventricles, and the regurgitation of the blood into them, causes the vessels lying behind the diseased valve to be overfilled and distended. In order to overcome the resulting hindrance to the circulation hypertrophy of the heart-muscle develops, beginning in that part of the organ which has to drive the blood through the diseased valve.

References on Endocarditis.

- BABES: Endocarditis *Ann. de l'Inst. de Path.* I Bucharest 1890
 BIONDI: Endocarditis in tuberculosis *Cent. f. path. Anat.* VI (p. 105)
 BIRCH-HIRSCHFELD: Tuberculosis of the heart *Cent. f. allg. Path.* II (p. 807)
 VON BUIL: Perforation of the cardiac septa *Z. f. Biol.* XVI
 CHARCOT and VULPIAN: Ulcerative endocarditis *Gaz. méd. de Paris* 1865
 VON DUSCH: *Gerhardt's Handb. d. Kinderkr.* IV
 EBERTH: Diphtheritic endocarditis *V. A.* 57 1873; Mycotic endocarditis *V. A.* 72 1878; *Bakteritische Mykosen* Leipzig 1872
 E. FRÄNKEL and SÄNGER: Aetiology of endocarditis *V. A.* 108 1887
 HANOT: Tuberculous endocarditis *A. gén. de méd.* 1893
 HAUSHALTER: Endocarditis from pneumococci *Rev. de méd.* VIII 1888
 HEIBERG: Ulcerat. endocard. with fungus-growth in the heart *V. A.* 56 1872;
Der puerperale pyämische Process Leipzig 1873
 HELLER: Bacterial (tuberculous) endocarditis *V. A.* 62 1874
 HOWARD: Ulcerat. endocard. from Bacill. diphtheriae *Johns Hopkins Hosp. Bullet.* 1893
 HUCHARD: *Maladies d. cœur et d. vaisseaux* Paris 1893
 KÖSTER: Embolic endocarditis *V. A.* 72 1878
 KUNDRAT: Ulcerat. endocard. in cancer and tuberculosis *Wien. med. Blätter* 1885

- KUSNEZOW: Cardiac ganglia in endocarditis *V. A.* 132 **1893**
LANCEREAUX: Ulcerat. endocard. *Gaz. méd. de Paris* **1862**, *A. gén. de méd.* **1873**
VON LANGER: Vessels of the valves in valvular endocarditis *V. A.* 109 **1887**
LEDOUX and LEBAUD: Ulcerat. endocard. *A. gén. de méd.* **1886**
LEYDEN: Gonorrhoeal endocarditis *D. med. Woch.* **1893**
LION: *Essai sur les endocard. infectieuses* Paris **1890**
LITTEN: *Z. f. klin. Med.* **1881**
MACKENZIE: Ulcerat. endocard. *Trans. Path. Soc.* XXXIII London **1882**
MAIER, R.: Primary diphtheritic endocarditis *V. A.* 62 **1874**
MALVOZ: Parasitic tricuspid endocard. *Rev. de méd.* VIII **1888**
MAYER: Pulmonary endocarditis *D. A. f. klin. Med.* XXIV
MEIER, R.: *Ueb. Endocarditis ulcerosa* Zürich **1870**
NAUWERCK: Parietal endocarditis *D. A. f. klin. Med.* **1883**
NETTER and MARTHA: Vegetative ulcerat. endocard. in biliary affections *A. de physiol.* XVIII **1886**
NETTER: Pneumonic ulcerat. endocard. *A. de physiol.* XVIII **1886**
OSLER: Malignant endocard. *B. M. J.* **1885**
PONFICK: Cardiac ulcers *V. A.* 58 **1873**
RIBBERT: Experim. myo- and endo-carditis *Fortschr. d. Med.* **1886**
ROLLET: Cardiac stenosis *Wien. med. Jahrb.* **1881**
ROSENBACH: Theory of endocarditis *D. med. Woch.* **1887**
SANSOM: *Valvular diseases* London **1886**
TAFEL: Structure of endocard. vegetations *Inaug. Diss.* Tübingen **1888**
TRIPPIER: Tuberculous endocarditis *A. de méd. exp.* II **1890**
VERAGUTH: Normal and inflamed cardiac valves *V. A.* 139 **1895**
VIRCHOW: Puerperal endocard. *Monatsschr. f. Geburtsk.* **1858**; *Ueb. die Chlorose* Berlin **1871**
WEICHELBAUM: Pathol. anat. of endocarditis *Ziegler's Beiträge* IV **1888**;
Aetiology of endocard. *Cent. f. Bakteriologie* II **1887**
WILMS: Gonorrhoeal endocard. *Münch. med. Woch.* **1893**
WYSSOKOWITSCH: Acute endocard. *Cent. f. med. Wiss.* no. 33 **1885**
WYSSOKOWITSCH and ORTH: Theory of endocarditis *V. A.* 103 **1886**
ZIEGLER: Structure of endocarditic vegetations *Verh. Congr. inn. Med.* VII **1888**

CHAPTER VI

MORBID CHANGES IN THE MYOCARDIUM

10. The **myocardium** is composed chiefly of cylindrical muscle-cells, whose protoplasm is to a great extent differentiated into transversely-striated fibrils; these fibrils are firmly united together at their ends or by lateral branches, and are surrounded by a connective tissue containing blood-vessels. Pathological changes may take place both in the muscle-cells and in the connective tissue, but they are more commonly met with in the former structures than in the latter.

Atrophic and degenerative changes of the muscle-cells are those that most frequently occur, and they are often the cause of death. In such a case death takes place through paralysis of the heart.

Simple atrophy of the heart-muscle is a frequent accompaniment of senile decay, and of premature marasmus due to malignant disease, pulmonary tuberculosis, and other affections. It is indicated by a decrease in the size of the muscle-cells, and often also by a simultaneous increase of yellow pigment-granules within them (Fig. 22), so that the atrophied heart-muscle acquires a brownish colour, the condition being spoken of as **brown atrophy**.

Fatty degeneration of the heart-muscle is apt to occur in the course of various forms of poisoning, of infective diseases, and of long-continued fever; also, and very frequently, as a consequence of chronic general and local anaemia, as in stenosis of the coronary arteries, and of general disorders of the circulation, as in valvular disease with imperfect compensation and in pulmonary emphysema, in which the gaseous interchanges necessary for the functional activity of the blood are interfered with.

Histologically, fatty degeneration is characterised by the appearance of small oil-globules in the muscle-cells (Fig. 23); these are mostly arranged in rows, and

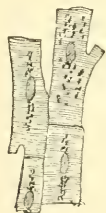

FIG. 22. BROWN ATROPHY OF THE CARDIAC MUSCLE. (Teased preparation: $\times 350$)

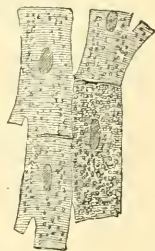


FIG. 23. FATTY DEGENERATION OF THE CARDIAC MUSCLE. ($\times 350$)

in extreme cases may pervade the entire cell. Marked fatty change is indicated to the eye by the yellowish colour imparted to the heart-muscle.

In chronic fatty degeneration of the heart, the change often appears in patches, and gives rise to a yellowish mottling of the tissue, which is generally most marked on the inner surface of the heart-wall, the trabeculae, and the papillary muscles. The mottling often recalls the grain of some fine cabinet wood or the pattern of a delicately striated feather. When pigmentation accompanies the fatty change the tint becomes yellowish-brown.

Granular and hyaline degeneration of the cardiac muscle, often combined with cloudy swelling or fatty degeneration of the muscular fibres, occur in the course of toxic affections and of the infective fevers (diphtheria, typhoid fever). They are also met with in connexion with traumatic injuries, inflammations, and local ischaemias (Art. 11). These forms of degeneration may, under certain conditions, reach such an intensity that the muscle presents a dull non-lustrous appearance and its section is of a grey or yellowish tint. Hyaline or waxy degeneration may be combined with segmentation or rather fragmentation of the contractile substance of the muscle (as in diphtheria); in such cases the lines of rupture do not always seem to correspond with the cell-boundaries.

In dilated hearts, whose substance is soft, flabby, and friable, the muscle-cells are often loosened from each other, the individual cells being then easily torn apart or actually separated by transverse clefts (RENAUT); this change has been described as segmentary myocarditis (*myocardite segmentaire*). The segmentation or dissociation of the fibres is not the manifestation of any definite form of heart-disease, but may occur under the most varied conditions. It is found, for example, in persons who have died from ischaemic softening or myomalacia (Art. 11), from certain forms of poisoning, and from infections, such as typhoid fever, diphtheria, small-pox, pyaemia, and nephritis; and in persons who have died suddenly from violence. It is therefore probable that the dissociation of the muscle-cells may take place partly by reason of morbid changes in the muscles (hyaline degeneration), partly from excessive stimulation of their fibres leading to some perverted mode of contraction (VON RECKLINGHAUSEN). Thus in most cases the actual segmentation probably takes place *in articulo mortis*, the degenerative change not leading directly to the separation of the fibres, but only predisposing them to rupture. According to DUNIX, when decomposition sets in soon after death (owing to the spread of the *Bacillus coli* within the body), the cementing substance of the muscle-cells may speedily give way.

In hearts whose muscle is degenerate large thrombi are often found, particularly in the auricular appendices and in the recesses

between the trabeculae, whence, by continued deposition, they grow forward into the cavity of the heart, and give rise to the so-called **cardiac polypi**. In rare cases they form ball-like masses detached from the surface of the heart.

HESCHL (*Oesterr. Z. f. prakt. Heilkunde* 1860) and ROTH (*Corresp. f. Schweizer Aerzte* 1884) have described cases of partial calcification of the heart-muscle, taking the form of whitish points and streaks. ROBIN and JUBEL-RÉNOY (*A. gén. de méd.* 1885) have described large calcareous deposits in fibroid patches or cicatrices of the heart-wall.

According to LANCEREAUX, IWANOWSKY, PUTJATIN (Morbid changes in the cardiac ganglia in chronic diseases of the heart *V. A.* 74 1878), OTT (Normal and pathological relations of the cardiac ganglia *Prag. Z. f. Heilk.* ix 1888), and others, in persons who have suffered from chronic heart-disease, degenerative changes and fibrous hyperplasia may be observed about the cardiac ganglia in the septum, in the wall of the auricles, and at the orifices of the aorta and pulmonary artery.

References on Atrophy and Degeneration of the Heart-muscle.

- BROWICZ: Changes in the cement-substance of the muscle-fibrils *V. A.* 134 1893
 ZUM BUSCH: The composition of cardiac thrombi and their relation to the vessel-wall *Inaug. Diss.* Freiburg 1891
 COMBA: Cardiac changes in experimental diphtheria *Lo Sperimentale* 1894 (with references)
 CURSCHMANN: Fatty degeneration from overstrain *D. A. f. klin. Med.* xii 1874
 DUNIN: Causes of fragmentation of the cardiac muscle *Ziegler's Beiträge* xvi 1894
 EICHHORST: *Die trophischen Bezieh. d. N. vaji zum Herzmuskel* Berlin 1879
 EISENLOHR: Changes in cardiac nerves and ganglia *Münch. path. Arbeiten* 1876
 FANTINO: Myocardial changes after section of the extracardiac nerves *Cent. f. med. Wiss.* 1888
 FRIEDREICH: *Virchow's Handb. d. spec. Path.* v 1867
 GOEBEL: Fatty degeneration of the heart *Cent. f. allg. Path.* iv 1893 (with references)
 HAMILTON: Waxy degeneration *Journ. of Anat.* xvii 1883-84
 HESSE: The heart in diphtheria *Jahrb. f. Kinderheilk.* xxxvi 1893
 HIS and ROMBERG: Cardiac innervation *Fortschr. d. Med.* viii 1890
 ISRAËL: Fragmentation of the myocardium *V. A.* 133 1893
 KREHL: Idiopathic disease of cardiac muscle *D. A. f. klin. Med.* xlviii 1891; Fatty degeneration *ibid.* li 1893
 LEYDEN and MUNK: *Die acute Phosphorvergiftung* Berlin 1865
 LIEBERMEISTER: Fatty degeneration in fever *D. A. f. klin. Med.* 1866
 OESTREICH: Fragmentation of the myocardium *V. A.* 135 1894
 PERLS: Fatty degeneration in oligæmia *V. A.* 59 1873
 PONFICK: Fatty degeneration in oligæmia *Berl. klin. Woch.* 1873
 RABOT and PHILIPPE: Acute diphtherial myocarditis *A. de méd. exp.* iii 1891
 VON RECKLINGHAUSEN and ZENKER: Disorders of the myocardium *Trans. internat. med. Congr.* ii Berlin 1891
 RENAUT: Chronic segmentary myocarditis *Gaz. méd. de Paris* 1890
 ROMBERG: The cardiac muscle in typhoid, scarlatina, and diphtheria *D. A. f. klin. Med.* xlviii 1891
 SCHEMEN: The cardiac muscle in pharyngeal diphtheria *V. A.* 121 1890
 TEDESCHI: Fragmentation of the myocardium *V. A.* 128 1892
 UNRUH: Myocarditis in diphtheria *Jahrb. f. Kinderheilk.* 1883

11. **Myomalacia cordis** is the name given to softening of the cardiac muscle consequent on arterial anaemia or ischaemia, the commonest causes of the ischaemia being sclerosis, atheroma, calcification, and thrombosis of the coronary arteries and their branches ; more rarely it may be due to embolism of these arteries.

The appearance of the areas of softening differs according to their age and the amount of blood contained in them. Shortly after the occurrence of the ischaemia the patches are still firm, and appear only as dull yellowish discolorations of the heart-muscle. After a time they become softened and friable, and assume a yellowish-white tint ; sometimes, if the substance has already softened, the cut surface of a cross-section sinks in so as to become concave.

If, in consequence of the obliteration or occlusion of the arteries, an extravasation of blood takes place from the capillaries, a **haemorrhagic infarct** is produced. The infarcted area is at first either uniformly dark-red, or mottled with dark-red, brown, and yellow. It may be yellow in the middle and red at the border. After a time it may become greyish-yellow, greyish-brown, or even of a rusty tint. Later on both the anaemic and the haemorrhagic areas take on a greyish translucent appearance, and the surface retracts when cut.

The areas of softening are found most frequently in the left ventricle, especially near the apex on the anterior or posterior wall. Occasionally they are found in other places, such as the wall of the right ventricle or of one of the auricles, though they are very seldom found in the latter situation. In rare instances the papillary muscles may be the seat of softening ; under certain conditions indeed an entire papillary muscle may be converted into a friable yellowish mass, more or less infiltrated with extravasated blood. If the softening extends to the endocardium,

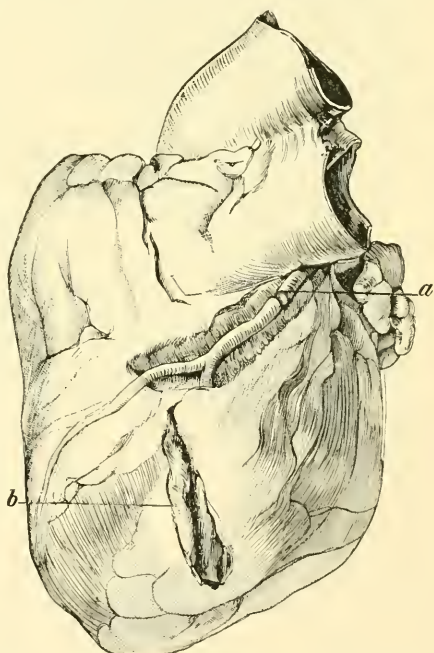


FIG. 24. RUPTURE OF THE HEART IN ARTERIO-SCLEROTIC MYOMALACIA.

- a* branch of the left coronary artery, the lumen of which has been closed by sclerotic and thrombotic changes
b point of rupture

thrombi are usually formed over the spot, in the shape of flattened superficial deposits or of polypoid coagula.

If the area of softening is extensive, and involves the whole or nearly the whole thickness of the heart-wall, **rupture of the heart** may result (Fig. 24 *b*), and blood escapes into the pericardial sac. The rent is usually jagged and irregular.

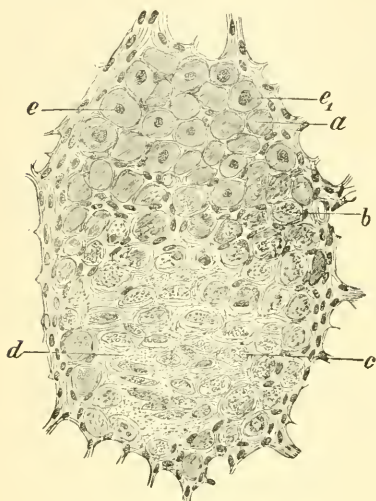


FIG. 25. MYOMALACIA CORDIS.

(Section through a degenerating muscular bundle: preparation hardened in Müller's fluid: stained with haematoxylin and carmine, and mounted in glycerine: $\times 250$)

- a* transverse section of a normal muscle-cell
- b* disintegrating muscle-cell
- c* muscle-cell resolved into granular detritus
- d* connective tissue devoid of nuclei
- e* nucleus of normal muscle-cell
- e*₁ swollen nucleus

The tissue-changes underlying the varying appearances of the softened patches are partly retrogressive and partly constructive in their character. The original ischaemia brings about the destruction of numbers of muscle-cells, and consequently in the yellowish-coloured areas can be detected muscle-fibres in different stages of degeneration and disintegration (Fig. 25 *b*), whose fragments ultimately break down into granular detritus (*c*). In the case of small lesions, after the disintegration of the muscle-cells the process may come to an end; in other cases further changes take place in the connective-tissue elements. These changes are indicated by the fact that the cell-nuclei here and there no longer stain well with reagents (*d*), while granular deposits appear on the pale and lustreless connective-tissue fibrils.

In those cases in which haemorrhage is associated with the destruction of the muscular tissue, we find blood-corpuscles

both in the meshes of the connective tissue and taking the place of the disintegrated muscular elements. These corpuscles are partly intact, and partly degenerate. Later on pigment-granules are found in the tissues. In cases of rupture of the heart the cardiac wall in the neighbourhood of the rent is infiltrated with blood.

Inflammatory exudations very soon supervene upon the tissue-necrosis and haemorrhagic extravasation, and regenerative processes start from the connective tissue of the neighbouring parts. The proliferation leads to the formation of granulation-tissue, with the production of new vessels, while the products of disintegration of the tissue and of the blood are partly dissolved and partly taken up by the cells themselves. Presently the inflam-

mation, whose presence is indicated chiefly by the infiltrated leucocytes, subsides; the granulations are converted into connective tissue, which in the course of time contracts and becomes denser, and a **fibroid cicatrix** is produced (Fig. 26 *c* and Fig. 27 *a b*). This may be recognised by the naked eye as a dense whitish scar-like patch, and is termed a fibroid induration or **sclerosis**. No regeneration of the disintegrated muscle takes place within the region occupied by the scar. The muscular fibres sometimes found within the cicatricial tissue are merely pre-existing fibres that have escaped destruction.

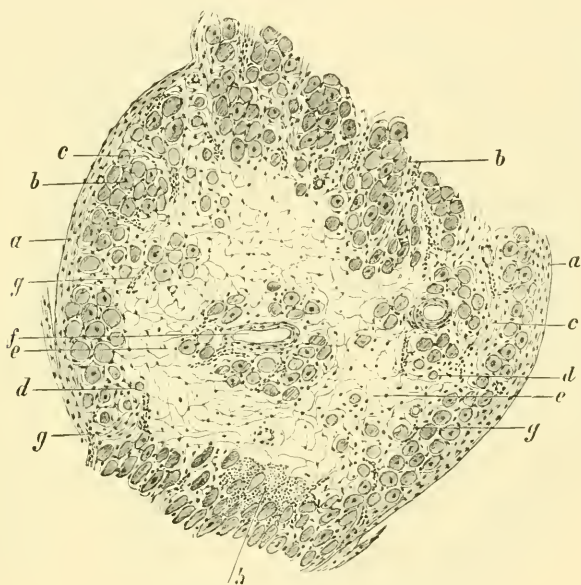


FIG. 26. FIBROID INDURATION OF THE HEART.

(Section through a fibroid trabecula; haematoxylin staining; $\times 40$)

- | | |
|---------------------------------------------------------------------|----------------------------------------------------------------------|
| <i>a</i> endocardium | <i>e</i> dense connective tissue with few nuclei and no muscle-cells |
| <i>b</i> transverse section of a normal muscle-cell | <i>f</i> vein surrounded by a few intact muscle-cells |
| <i>c</i> hyperplastic connective tissue rich in cells | <i>g</i> small blood-vessels |
| <i>d</i> atrophied muscle-cells amid hyperplastic connective tissue | <i>h</i> cellular infiltration |

Small areas of softening naturally leave behind them small patches of sclerosis, which lie hidden in the muscle, giving rise to no perceptible thinning of the wall, and causing no important disturbance of the function of the heart. They are therefore of importance only when, through the successive closure of many small arteries, their number is so increased that the cardiac muscle is at length studded with innumerable small patches of fibroid degeneration.

It not infrequently happens, however, that the area of ischaemic softening, and of the resulting sclerosis, reaches considerable dimensions (Fig. 27 *a b*). This most commonly occurs in the neighbourhood of the apex on the anterior wall, less frequently in the posterior wall, of the left ventricle, and on the interventricular septum, where the cicatrices sometimes involve the greater portion of the wall of the ventricle (*a b*). That the process chiefly

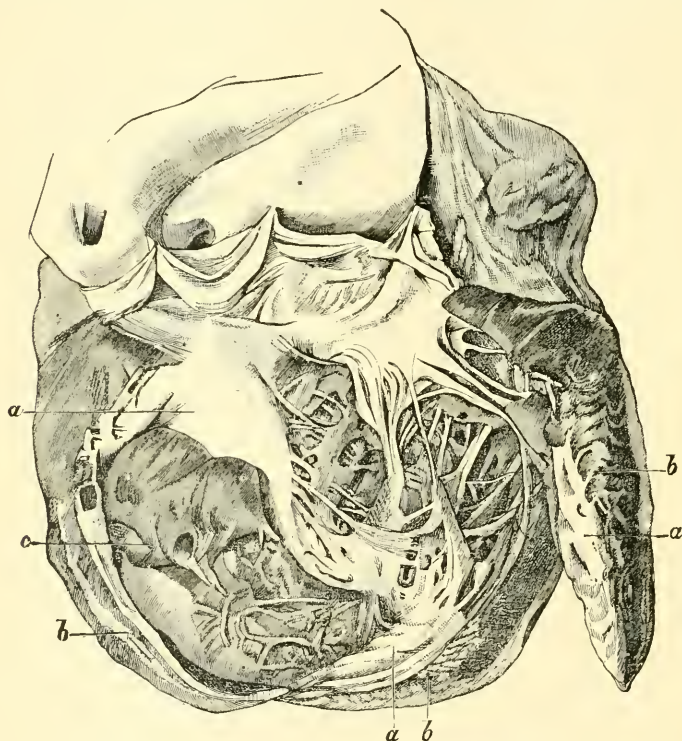


FIG. 27. THROMBOSIS WITHIN THE HEART.

(Resulting from fibroid induration and aneurysmal bulging of the cardiac wall: two-thirds natural size)

- a* sclerotic patch with thickened endocardium
- b* fibroid induration of the myocardium
- c* thrombus

affects this region is due to the fact that the descending branches of the coronary arteries (Fig. 28 *a*) are here especially apt to be constricted and occluded.

If a large portion of the heart-muscle is converted into cicatricial connective tissue, a partial bulging of the cardiac wall may occur, due to the blood-pressure upon the sclerotic area (Fig. 27 *b* and Fig. 28 *b*); in this way is formed a **partial cardiac aneurysm**, corresponding to the area of the fibroid induration. These aneur-

ysms are most frequently found in the anterior wall of the left ventricle above the apex; they may also be found in the posterior wall of the ventricle, or in the septum ventriculorum. In the latter situation they project toward the right side of the heart. As a rule these aneurysmal pouches are small, reaching about the size of a walnut; but in some cases they attain a considerable magnitude, and lead to incomplete emptying of the blood from the ventricle and to the formation of thrombi upon the internal surface of the depression (Fig. 27 *c*). In certain conditions the tissue of the sclerotic area may become calcified (ROBIN).

Haemorrhages not dependent upon the obstruction of arteries rarely occur in the cardiac muscles. They are however met with in patients who have suffered from extreme venous engorgement (as in suffocation), and associated with various infective diseases, with leukaemia and anaemia, with haemorrhagic purpura (*morbus maculosus Werlhofii*), and with poisoning by phosphorus, arsenic, morphine, etc. Much more frequently, in the last-named conditions, small ecchymoses and large suggillations are to be found in the endocardial and sub-endocardial as well as in the epicardial and sub-epicardial tissues. If the patient does not die, the blood effused is absorbed.

In rare cases, **partial cardiac aneurysms** fall under observation which have not been preceded by fibroid degeneration of the cardiac wall. They are found most frequently in the membranous portion of the septum ventriculorum, which bulges in the direction of the right heart and occasionally even ruptures. Writers on the subject attribute the abnormal stretching of the *pars membranacea* to increased pressure in the left ventricle, to traction exerted by the tricuspid valve, or to atheromatous and inflammatory changes in the septum. More rarely aneurysms of the right and posterior sinuses of Valsalva are observed; these bulge toward the right heart, and occasionally rupture. In very rare cases cardiac aneurysms are met with elsewhere, which are caused by congenital local thinning of the heart-wall. Hernial protrusions of the endocardium between the muscular fascicles of the cardiac wall are of the nature of congenital malformations.

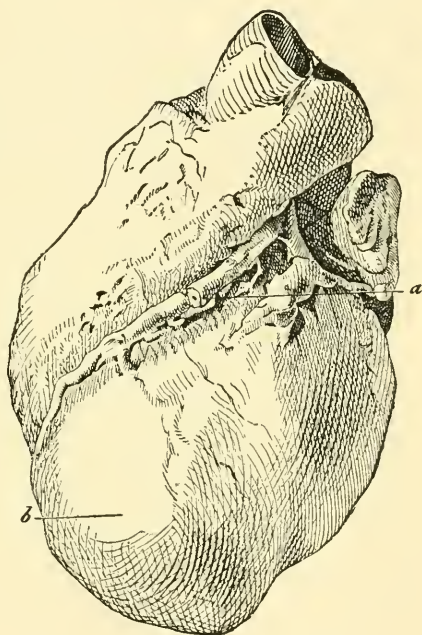


FIG. 28. PARTIAL CARDIAC ANEURYSM.
(Resulting from arterio-sclerotic myomalacia and fibroid induration)

a coronary artery, with thickened intima and contracted lumen
b aneurysm

References on Myomalacia, Fibroid Induration, and Aneurysms of the Heart (see also Art. 12).

- BECK: Rupture of the heart and chronic cardiac aneurysm *Ziegler's Beiträge* II 1888
- BÜTGER: Spontaneous rupture of the heart *A. d. Heilk.* IV 1863
- BUDOR: *Oblitération d. artères cardiaques et lésions du myocarde* Paris 1888
- HUBER: Effect of coronary disease on the heart *V. A.* 89 1882
- HUCHARD: *Maladies du cœur et des vaisseaux* Paris 1893
- KOLSTER: Myomalacia cordis *Skandinaviskt Arkiv* IV 1892
- LEYDEN: Coronary sclerosis and its effects *Z. f. klin. Med.* III 1884; *D. med. Woch.* 1885
- MEYER, G.: Spontaneous rupture of the heart *D. A. f. klin. Med.* XLIII 1888
- NICOLLE: *Les grandes scléroses cardiaques* Paris 1890
- PERNICE: Aortic atheroma and myocardial sclerosis *A. p. le science med.* XI 1887
- QUAIN: *Fatty disease of the heart* London 1885
- ROBIN and JUHEL-RÉNOY: Calcareous degeneration of the heart *A. gén. de méd.* 1885
- STEVEN: Fibroid degeneration *Journ. of Path.* II 1893
- VITI: Sclerosis of the myocardium *A. ital. di clin. med.* II 1890
- WEIGERT: Pathological coagulative processes *V. A.* 79 1880
- WILKS and MOXON: *Pathol. Anatomy* London 1875
- ZIEGLER: Causes of contracted kidney *D. A. f. klin. Med.* XXV 1879; Myomalacia cordis *V. A.* 90 1882

12. Inflammation of the cardiac muscle, or **myocarditis**, other than the secondary myocarditis due to ischaemic necrosis (Art. 11), is caused chiefly by infective or toxic agencies. In these cases the irritant, having reached the endocardium or the pericardium, penetrates into the underlying tissue, or is brought to the muscle through the blood-vessels. Traumatic injury of the heart-wall may also result in inflammation.

Purulent myocarditis occurs in connexion with pyaemic infection, and is caused by micro-organisms, which either attack the myocardium directly from the endocardium, or are brought to it by the blood-channels (Fig. 29 a). Even in the latter case, however, an ulcerative endocarditis is frequently the starting-point of the bacterial invasion, though the condition may occur as the result of a general infection of the blood. So far as is known, the micro-organisms that are brought to the heart-muscle in the blood are the same as those found in endocarditis, and as a rule they also find their way to other organs, such as the kidneys. These micro-organisms usually come from suppurating wounds or from other seats of bacterial invasion, though in some instances they gain access to the body without leaving any recognisable traces at their point of entrance. When in some such manner multitudes of bacteria (chiefly micrococci) reach the heart-muscle, the affected person may succumb speedily, and at the autopsy the cardiac wall is seen to be beset with numerous small opaque greyish-yellow spots, which represent bacterial colonies. Within these the muscle is degenerate or completely destroyed, and in general some degree

of inflammatory infiltration of the tissue has already taken place (Fig. 29 *a b*). If death does not occur for some time yellowish-white accumulations of pus may be found in the affected areas; and when the patient has survived for a longer period **abscesses** may be formed. Small deposits of pus may be re-absorbed, and leave scars or calcareous residues. Larger abscess-like accumulations generally burst into the heart or the pericardium, if the patient survive so long, or the whole wall may give way and cause rupture of the heart.

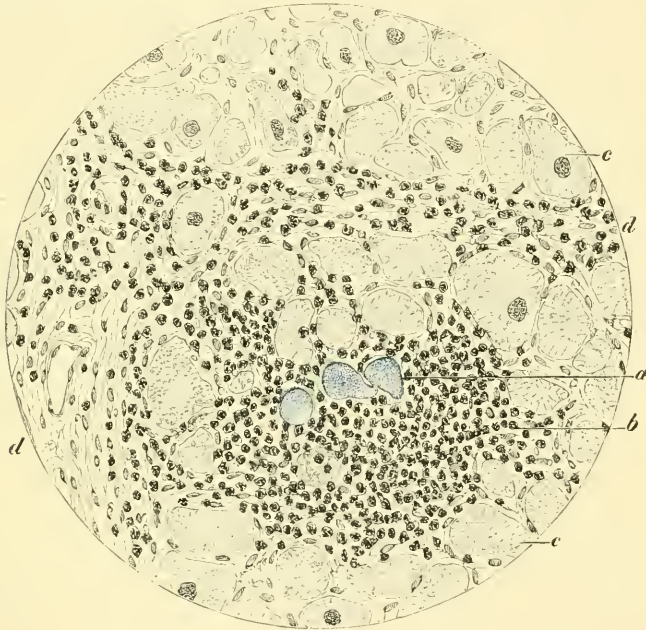


FIG. 29. MYCOTIC MYOCARDITIS.

(From a case of puerperal parametritis: preparation hardened in alcohol, stained with gentian-violet and resurin, and mounted in Canada balsam: $\times 500$)

- | | |
|----------------------------------------------------------|------------------------------------------|
| <i>a</i> intravascular colonies of <i>Staphylococcus</i> | <i>c</i> transverse section of muscles |
| <i>b</i> cellular infiltration | <i>d</i> intermuscular connective tissue |

Indurative myocarditis, leading to the formation of scleroses, when it is not a consequence of ischaemic softening (Art. 11), is likewise caused by specific infections and intoxications (often by those of diphtheria, scarlet fever, typhoid fever, small-pox, and pneumonia); it may also be the terminal stage of an infection due to pyogenic micrococci, as these microbes do not invariably set up suppuration. The bacterial poison acts partly by causing degeneration of the muscle-cells (Art. 10) and partly by inducing alterations in the vessel-walls, leading to the formation of inflammatory infiltrations, in which connective-tissue proliferation may

later on take place. If a considerable portion of the muscle perishes in this way, cardiac scleroses are ultimately formed which are similar to those found after ischaemic softening (Art. 11). They are usually however of small size, and form mere specks or streaks of scar-tissue. Should they attain any considerable extent, they are commonly combined with fibroid thickenings of the endocardium. They rarely give rise to the formation of cardiac aneurysms.

In hearts that have undergone morbid changes as the result of antecedent endocarditis, scattered areas of sclerosis may often be found in large numbers. These are situated in the subendocardial tissue, or in the cardiac muscle itself. Consequently it may be assumed that the injurious agencies which induce endocarditis affect also the myocardium, giving rise in it to inflammation, muscular degeneration, and fibrous hyperplasia. Slight degrees of inflammation, from infection or poisoning, may be recovered from without giving rise to loss of muscular substance or to indurative changes.

Wounds of the myocardium, if they remain aseptic, heal by proliferation of connective tissue, and cicatrices are thus formed in the muscle. No regeneration of muscular tissue, or at most a very slight regeneration, takes place. The first results of traumatic injury here, as elsewhere, are haemorrhage and inflammatory reaction.

References on Myocarditis and Wounds of the Heart (see also Arts. 10, 11).

- BARD and PHILIPPE: Chronic interstitial myocarditis *Rev. de méd.* XI 1891
 BERENT: Healing of cardiac wounds *Inaug. Diss.* Königsberg 1892
 BONOME: Healing of aseptic cardiac wounds *Ziegler's Beiträge* v 1889
 HESSE: The heart in diphtheria *Jahrb. f. Kinderheilk.* XXXVI 1893
 HIS: Insufficiency of the heart-muscle *Corresp. f. Schweizer Aerzte* 1892; The heart in gonorrhoea *Arbeiten d. med. Klinik Leipzig* 1893
 HUGUENIN: Diphtherial myocarditis *Rev. de méd.* VIII 1888; *La myocardite infectieuse diphthérique* Paris 1890
 KELLE: Primary chronic myocarditis *D. A. f. klin. Med.* XLIX 1892
 KOCH: *Mittheil. a. d. Gesundheitsamte* Berlin 1881
 KÖSTER: *Ueber Myocarditis* Bonn 1888
 KREHL: Pathology of valvular defects *D. A. f. klin. Med.* XLVI 1890
 LEYDEN: Diphtherial myocarditis *Z. f. klin. Med.* IV and *D. med. Woch.* 1882
 MARTIN: Pathogeny of cardiac scleroses *Rev. de méd.* 1883
 MARTINOTTI: *Le ferite del cuore* (wounds of the heart) 1888
 RABOT and PHILIPPE: Diphtherial myocarditis *A. de méd. exp.* 1891
 ROMBERG: Myocardial affections in typhoid, scarlatina, and diphtheria *D. A. f. klin. Med.* XLVIII, XLIX 1891-92
 ROTH: Cardiac abscess *V. A.* 38 1867
 ROTHSCHILD: The origin of cardiac scleroses *Inaug. Diss.* Freiburg 1890
 WAGNER, E.: Myocarditis *A. d. Heilk.* 1861
 WUNDERLICH and WAGNER: Inflammation of the left auricle *ibid.* 1864
 ZEMP: Wounds of heart and aorta *Inaug. Diss.* Zürich 1894

CHAPTER VII

INFECTIVE GRANULOMATA, TUMOURS, AND PARASITES OF
THE HEART

13. **Tubercle** is the commonest of the infective granulomata affecting the heart. In acute miliary tuberculosis the heart does not always escape the general invasion, the tubercles being usually found beneath the endocardium of the right ventricle. Large caseous nodes, and diffuse fibroid and caseous inflammatory areas, are not of frequent occurrence, and when present are usually associated with chronic tuberculous pericarditis; it is but rarely that they are limited to the myocardium or the endocardium.

Syphilitic gummata are very rare. They lie in the heart-wall embedded in dense hyperplastic fibrous tissue, and according to their stage of development appear as soft grey or greyish-red patches or as dry caseous yellowish nodes, which may break into the cavities of the heart. Simple inflammatory indurations of the cardiac muscle occur somewhat more frequently, as a consequence of inherited or acquired syphilis; though some of the lesions which are described as syphilitic inflammations should rather be classed with the arterio-sclerotic indurations (Art. 11). Syphilitic inflammation of the valves is very rare. In hereditary syphilis gummatous masses are very rarely found in the heart, fatty degeneration of the muscles being a more frequent lesion.

In **actinomycosis** of the lungs and of the mediastinum the specific infection may attack the pericardium first and then the myocardium. It leads to the formation of greyish granulations, which afterwards become fatty and yellowish-white in colour and sometimes suppurate.

Among the **primary tumours** met with in the heart are sarcoma, lympho-sarcoma, fibroma, lipoma, myxoma, and rhabdomyoma. These form nodular or polypoid growths that extend into the cavities of the heart. They are all rare. Some of the cardiac tumours described are of congenital origin.

Secondary tumours, especially carcinomatous growths, are found somewhat more frequently. The cancer-germs, other than those which penetrate to the heart-wall from the pericardium, reach the muscle by way of the circulation. The growths may be found in the midst of the cardiac muscle, or near its inner or

outer surface. In the latter case they are apt to protrude into the cardiac or the pericardial cavity.

Tumours also attack the heart by extension from neighbouring parts, such as the mediastinum, the oesophagus, the stomach, and the lungs.

The effect of such tumours on the heart naturally varies with their size and situation. Large growths may lead ultimately to inefficiency of the heart's action. Thrombi readily form upon tumours which project into the internal cavities. Softening and ulceration of new growths may lead to rupture of the heart.

Of **parasites** *Cysticercus* and *Echinococcus* are met with in the heart. *Echinococcus* (hydatids) may lead to rupture of the heart, and by bursting into its cavities give rise to embolism of the systemic or pulmonary arteries.

References on Tuberculosis and Syphilis of the Heart.

- CURSCHMANN: Cardiac syphilis *Arbeit. d. med. Klinik Leipzig* 1893
 DEMME: Cardiac tubercle *Ber. Jenner'schen Kinderspitals Berne* 1887
 EHRLICH: Syphilis *Z. f. klin. Med.* 1 1880
 GRÄFFNER: Valvular gumma *D. A. f. klin. Med.* xx 1877
 GRENOUILLER: Cardiac syphilis *Thèse Paris* 1878
 KOCKEL: Cardiac syphilis *Arbeit. d. med. Klinik Leipzig* 1893
 LANCEREAUX: *Traité de la syphilis* 1873
 LANG: *Path. u. Therap. d. Syphilis* I Wiesbaden 1885; *Syphilis d. Herzens* Vienna 1889
 LEYDEN: Tuberculosis *D. med. Woch.* 1895-96
 MĀRČEK: Cardiac syphilis *A. f. Dermat. suppl.* 1893 (with references)
 OPPOLZER: Rupture of a gumma into the heart *Wien. med. Woch.* 1860
 POLLAK: Tuberculosis of the myocardium *Z. f. klin. Med.* 21 1892 (with references)
 VON RECKLINGHAUSEN: Myocardial tubercle *V. A.* 16 1859
 SÄNGER: Myocardial tuberculosis *A. d. Heilk.* xix 1878
 TEISSIER: Syph. endocarditis and myocarditis *Ann. de dermat. et de syph.* 1882
 TRIPIER: Tuberculous endocarditis *A. de méd. exp.* 1890
 VIRCHOW: *Krankh. Geschwülste* II: *V. A.* 35 1866
 WALDEYER: Myocardial tuberculosis *V. A.* 35 1866

References on Tumours of the Heart.

- ALBERS: Lipoma *V. A.* 10 1856
 BANTI: Lipoma *Lo Sperimentale* 1886
 BERNET: Lipoma *V. A.* 41 1867
 BERTHENSEN: Primary tumours of the heart *A. de méd. exp.* v 1893, and *V. A.* 132 1893 (with references)
 CZAPEK: Primary cardiac tumours *Prag. med. Woch.* 1891 (with references)
 FRÄNKEL, E.: Primary sarcoma *Festschrift z. Eröffn. allg. Krankenhaus. Hamburg* 1889
 JÜRGENS: Primary cardiac tumours *Berl. klin. Woch.* 1890
 KANTZOW: Myoma *V. A.* 35 1866
 KOLISKO: Congenital myoma *Wien. med. Jahrb.* 11 1887
 MARTINOTTI: Tumours of the heart *Gaz. delle Clin.* 23 Turin 1886
 VON RECKLINGHAUSEN: Myoma *Monatsschr. f. Geburtshk.* xx 1862
 RIEDER: Rhabdomyoma *Jahrb. Hamburg. Staatskrankenhauses* I Leipzig 1890
 SALVIOLI: Myxoma *Rivista clin. di Bologna* 1878

- SKRZECZKA: Angioma *V. A.* 11 **1857**
TEDESCHI: Cardiac tumours *Prag. med. Woch.* **1893** (with references)
VIRCHOW: Myxoma *Charité-Ann.* vi; Myoma *V. A.* 30 **1864**
WAGNER: Sarcoma *A. d. Heilk.* vi **1865**
WALDVOGEL: *Fibrom d. Herzens* Göttingen **1885**
WIEGAND: Myxoma *Oesterr. med. Woch.* **1876**
ZANDER: Fibroma *V. A.* 80 **1880**

References on Parasites of the Heart.

- BUDD: Hydatid *Med. Times and Gaz.* xvii London **1858**
DAVAINE: *Entozoaires* Paris **1877**
GOODHART: Hydatid *Trans. Path. Soc.* xxvii London **1876**
GRIESINGER: Echinococcus *A. f. physiol. Heilk.* v **1846**
MOSLER: Echinococcus *Z. f. klin. Med.* vi **1883**
MOXON: Hydatid *Trans. Path. Soc.* xxi London **1870**
OESTERLEN: Echinococcus in the heart *V. A.* 42 **1868**

CHAPTER VIII

MORBID CHANGES IN THE PERICARDIUM

14. The pericardium is one of the serous membranes, that line the body-cavities and mark them off from the contiguous organs and tissues. On its inner surface it is covered with flattened endothelial cells, resting upon a stratum of connective tissue. Normally it is a closed sac, in which the heart is as it were invaginated, and contains within its cavity from 5 to 20 cubic centimetres or more of a clear liquid.

Occasionally it is found that the pericardium is more or less defective. The **defects** occur most frequently in cases of ectopia ; it is only in rare cases that they are unaccompanied by other malformations. Cases are recorded in which the pericardium was entirely wanting, or reduced to a mere fringe at the base of the heart. Sometimes there may be a hole on the left side, which allows the apex of the heart to project into the left pleural cavity. **Diverticula** of the pericardium are very rare.

In cases of venous engorgement the superficial veins of the heart are often markedly overfilled, and after long-continued venous obstruction they may become abnormally distended and varicose.

In extreme venous hyperaemia, such as occurs in suffocation, **haemorrhages** are often observed in the neighbourhood of the minor epicardial vessels, in the form of small dark-red ecchymoses. These are often present in large numbers, especially over the base of the heart. Similar ecchymoses also occur in phosphorus-poisoning and in certain infective disorders, as well as in scurvy, purpura, leukaemia, and anaemia. They may under certain conditions reach a large size.

In cases of rupture of the heart, of the first part of the aorta or pulmonary artery, or of the branches of the coronary arteries, large quantities of blood may accumulate in the pericardial sac, producing the condition which is known as **haemo-pericardium**. Haemorrhages often occur in the pericardial cavity from the rupture of the new blood-vessels formed in the course of inflammatory processes ; in this case the blood is usually mixed with liquid exudations.

In chronic venous engorgement the pericardial sac is sometimes the seat of **passive dropsy**, and may then contain a very large quantity of liquid, which markedly distends the sac and produces a condition referred to as **hydro-pericardium**.

*References on Malformations of the Pericardium.*BRISTOWE: Pericardial diverticulum *Trans. Path. Soc.* xx London 1869CHIARI: Absence of parietal layer *Wien. med. Woch.* 1880COËN: Pericardial hernia and diverticula *Boll. d. scienze med.* xv Bologna 1886FABER: Absence of the pericardium *V. A.* 74 1878

15. The most important affection of the pericardial sac is the inflammatory lesion known as **pericarditis**. This manifests itself in different ways. In the majority of cases it is of haematogenous origin, in other words the exciting agent is brought to the pericardium by the blood, as in pericarditis accompanying acute articular rheumatism, small-pox, scarlatina, nephritis, etc. In other cases the inflammation begins in the mediastinum, in the lungs, in the pleura, in the mediastinal or peribronchial lymph-glands, in the oesophagus, in one of the neighbouring organs of the abdominal cavity, or in the heart itself, and from these extends to the pericardium. Among the micro-organisms which cause pericarditis are the pyogenic micrococci, the diplococcus of pneumonia, and the tubercle-bacillus; but the presence of micro-organisms cannot be demonstrated in all cases of pericarditis.

In the less severe forms of inflammation the pericardial liquid increases somewhat in quantity, and becomes slightly turbid.

The turbidity is due to extravasated leucocytes and desquamated endothelium. These changes are, however, rarely the only ones observed, as the pericardium is specially liable to the formation of fibrinous exudations. Minute fibrinous coagula usually make their appearance, and when the inflammation is slight cohere into

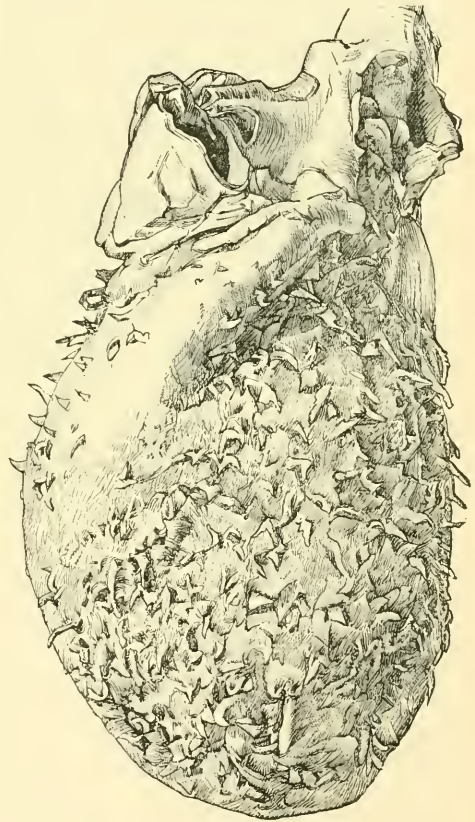

FIG. 30. COR VILLOSUM.

small granules. These granules are deposited upon the pericardium, and give rise to a cloudiness of its surface, which is rendered very obvious by scraping the heart with the blade of a knife. The fibrinous masses are partly granular and partly hyaline, the underlying endothelium being usually converted into denudeated flakes or plates. The deposits are found chiefly on the epicardium, and generally upon the posterior wall of the ventricles; in other cases they are spread over the entire surface of the heart. Even in these slighter forms, therefore, the pericarditis is a **sero-fibrinous** inflammation.

If the inflammation be somewhat more severe, a large amount of fibrin is deposited upon the surface of the pericardium. Here and there occur large and protuberant tenacious masses of

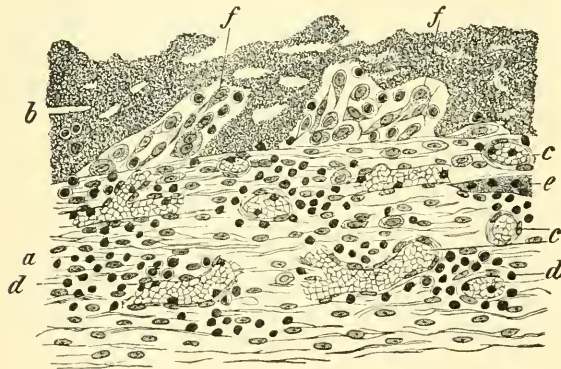


FIG. 31. ADHESIVE PERICARDITIS.

(Preparation hardened in Müller's fluid, stained with haematoxylin and neutral carmine, and mounted in Canada balsam: $\times 150$)

- a the epicardium
- b fibrinous membrane overlying it
- c dilated and congested blood-vessels
- d leucocytes infiltrating the tissues
- e lymph-vessels filled with cells and coagula
- f formative cells within the deposit

of the inflammation, being sometimes large and sometimes inconsiderable. If the quantity is not great, it often happens that the deposits of fibrin upon the two contiguous surfaces of the pericardium cohere, and thus give rise to more or less firm **adhesions**.

In the first stages of the inflammatory process the pericardial connective tissue (Fig. 31 a) is more or less infiltrated with leucocytes (d), the lymph-vessels (e) are filled with exudations, and the blood-vessels (c) are distended with blood. From the third to the fourth day numerous vascular buds and loops appear upon the surface of the pericardium; these penetrate into the deeper layers of the fibrin, and are quickly converted into blood-vessels containing blood. At the same time large formative cells appear

fibrin, of a whitish colour, the superficial strata of which are shaggy, reticulate, or corrugated, a condition known as **cor villosum** (Fig. 30). Frequently, from the presence in them of extravasated red blood-corpuseles, these deposits of fibrin are reddish in colour.

The amount of exuded liquid found in the pericardial sac varies at different periods in the course

in the deeper layers of the fibrinous deposit, together with numerous leucocytes (*f*). The formative cells are round, club-shaped, spindle-shaped, or branched, and are disposed in layers. By the mutual apposition and cohesion of these cells a germinal cellular tissue is formed (**plastic or adhesive pericarditis**).

In the course of the next few weeks a highly vascular granulation-tissue (Fig. 32 *d*) is formed, which encroaches on and penetrates the deposited fibrin (*c*), ultimately causing it to disappear. In this way the fibrin is at length replaced by new-formed cellular tissue, and this in turn is converted into cicatricial connective tissue.

If the exudation be scanty, and the newly-formed tissue be confined to definite areas, the process results in the formation of lustrous whitish fibroid patches upon the surface of the heart. Such areas are usually described as **milk-spots**, or *maculae tendineae*. At times only a single spot is formed; in other cases the entire surface of the ventricles, of the auricles, and of the large blood-vessels is covered with

spots of various sizes. Filamentous or stringy adhesions between the visceral and parietal layers of the pericardium are often formed here and there, and thread-like processes are sometimes found attached to the milk-spots. These are to be regarded as the ruptured remains of former adhesions to the opposite pericardial wall.

If the amount of fibrinous exudation thrown out in the course of the pericarditis be very considerable, and if the inflammatory

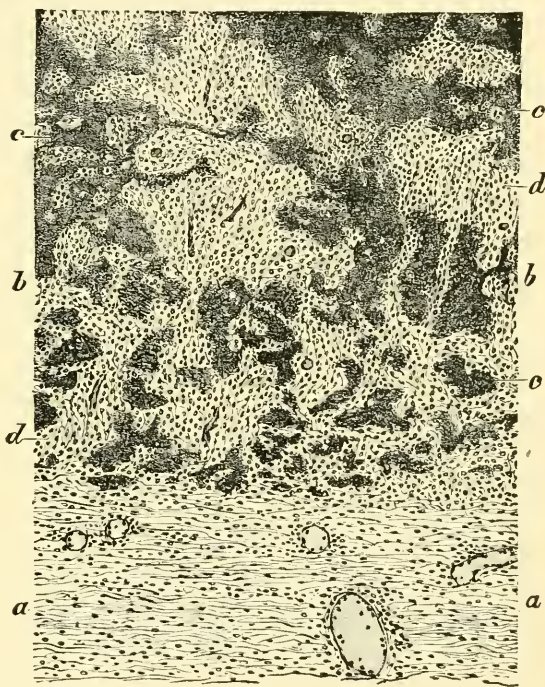


FIG. 32. GRANULATION-TISSUE FORMED WITHIN A FIBRINOUS PERICARDITIC DEPOSIT OF SOME WEEKS' DURATION. (Preparation hardened in Müller's fluid, stained with hæmatoxylin and eosin, and mounted in Canada balsam: $\times 45$)

a epicardium *b* deposit upon the epicardium, composed of granulation-tissue *d* and fibrin *c*

process and the associated formation of new tissue continue for any length of time (Fig. 32 *b*), the superficial deposits and the fibrous adhesions between the layers of the pericardium become very numerous, and the process is then usually referred to as **adhesive pericarditis**, a term that is of course also applicable to the more circumscribed adhesions just described. With the increase in the number and density of these fibrous adhesions, the pericardial sac grows smaller and smaller, until at length complete coherence, or **concretio pericardii**, leads to entire **obliteration of the pericardial cavity**.

In the majority of cases the whole of the liquid and solid exudation is re-absorbed, though here and there remnants of fibrin may remain behind as dry caseous deposits, which later on undergo calcification. The newly-formed connective tissue may also become more or less infiltrated with calcareous salts, forming hard plates and scales, which in certain cases surround the heart as with a coat of mail.

In mild cases of pericardial inflammation, the neighbouring parts remain unaffected, provided they themselves have not been the starting-point of the inflammation. In severe inflammations the pleura and the tissues of the mediastinum may be involved in the process, and thus adhesive pleurisy, with indurative mediastinitis, is set up. These lead to the formation of pleural adhesions, and to fibroid thickening of the mediastinal tissue.

The pericardial inflammatory process may, in certain circumstances, assume from the outset a purulent or sero-purulent character; and we have thus a **purulent** or a **sero-purulent pericarditis**. This occurs as a rule in connexion with pyaemic infection, or by extension from pleural and mediastinal suppurations or from ulcerative processes affecting the bronchial lymph-glands, the oesophagus, the stomach, etc. Under similar conditions, and in cases of rheumatism, nephritis, etc., **fibrino-purulent pericarditis** is occasionally met with, the exudation being turbid with pus-cells and yellowish-white flakes composed of pus and fibrin.

If the patient does not die, the process terminates by the re-absorption of the exuded matters. This is accompanied by the formation of new connective tissue, which issues in thickening and adhesion of the pericardium. Purulent exudations may in like circumstances become inspissated and then undergo calcification. Very extensive suppuration of the pericardial tissue itself is rare; but on the other hand the suppurative process often spreads by continuity to neighbouring tissues.

By the rupture of ulcers of the oesophagus and of the stomach, as well as by traumatic laceration of the pericardium, air may enter its cavity, a condition described as **pneumo-pericardium**.

References on Pericarditis.

- BAMBERGER: *Wien. med. Woch.* 1872
 BANTI: Aetiology of pericarditis *D. med. Woch.* 1888; Uraemic pericarditis
Cent. f. allg. Path. v 1894
 BAUER: Diseases of the pericardium *Ziemssen's Cyclop.* vi 1876
 CERF: Pericardial adhesions *Inaug. Diss.* Zürich 1875
 FEIERABEND: Calcification *Wien. med. Woch.* 1866
 GOULD: Calcification *Trans. Path. Soc.* xxviii London 1877
 GUTMANN: *Berl. klin. Woch.* 1880
 MÜLLER: *D. A. f. klin. Med.* xxiv
 NEUMANN: *A. f. mikrosk. Anat.* xviii
 RIEGEL: *Gerhardt's Handb. d. Kinderkr.* iv
 ZAHN: Purulent pericarditis *V. A.* 72 1878

16. Among the **infective granulomata** of the pericardium **tuberculosis** is the most common. This condition is usually due to tuberculous infection of the neighbouring organs, the lungs, the pleurae, or the peribronchial and mediastinal lymph-glands. Tubercle-bacilli may however reach the pericardium by way of the circulation also.

Slight degrees of infection are indicated by the formation of grey tubercles, which are usually to be found on a part only of the inner surface of the pericardium. The area around the tubercle is generally hyperaemic; and not infrequently a delicate gelatinous cellular tissue, traversed by newly-formed vessels, is there produced. The pericardial liquid is usually more or less increased in quantity and is at times blood-stained. From rupture into the pericardium of neighbouring caseous nodes, the exudation sometimes becomes purulent in character.

In cases of advanced tuberculosis the tubercles are more abundant, and usually extend over the entire surface of the heart. At the same time agglomerations of tubercles and cheesy nodes of different sizes are formed, and these usually lie in a mass of greyish-red vascular granulation-tissue. The cavity of the pericardium contains an abundant sero-sanguineous exudation, generally accompanied by fibrinous deposits by which the tubercles may be to some extent covered over, so that the course of the disease is that of a fibrinous pericarditis. The pericardial layers are more or less extensively, at times entirely, coherent, being united by a continuous greyish semi-translucent film of granulations and connective tissue, which contains grey and cheesy tubercles, and larger caseous agglomerations of these.

In **actinomycosis** of the lungs and mediastinum the pericardium may be permeated by granulations undergoing fatty degeneration, while its cavity is filled with a purulent or fibrino-purulent exudation.

Syphilitic inflammation of the pericardium is very rare, and is usually associated with syphilis of the myocardium; it leads to the formation of pericardial adhesions.

Primary tumours of the pericardium are extremely rare. **Secondary growths** are somewhat more common, and invade the pericardium either from the lungs and mediastinum, or the oesophagus and stomach, or by metastasis from more distant organs. Among those most frequently found invading the membrane are lympho-sarcoma of the mediastinum and carcinoma of the oesophagus and of the stomach.

Of the **animal parasites** occurring in the pericardium, *Cysticercus*, *Echinococcus*, and *Trichina* are those most frequently recorded.

References on Tuberculosis and Syphilis of the Pericardium.

EICHHORST: Tuberculous pericarditis *Charité-Ann.* II 1875

HAYEM and TISSIER: Tuberculous pericarditis *Rev. de méd.* IX 1889

KAST: Purulent pericarditis in tuberculosis of mediastinal glands *V. A.* 96
1884

LEUDET: *A. gén. de méd.* II 1862

MŘAČEK: Syphilis of the heart *A. f. Dermat. suppl.* 1893 (with references)

PROUST: *Gaz. méd. de Paris* 1865

RIEGEL: *Gerhardt's Handb. d. Kinderkr.* IV

CHAPTER IX

MORBID CHANGES IN THE ARTERIES

17. **Atrophy** of the arterial walls, which may be wide-spread, occurs in association with chronic anaemia and general marasmus, as well as with atrophy of individual organs. Thus after the amputation of a limb the arterial trunks of the stump become of smaller size. Partial disappearance of some of the component parts of the vessel-wall, of the muscular fibres for example, takes place as a consequence of inflammatory or degenerative conditions affecting it, and also of abnormal distension of the vessel.

Fatty degeneration of the intima of the arteries is manifested by the appearance of opaque whitish or yellowish-white spots on its surface, and is very frequently found *post mortem* in the larger vessels (Fig. 33), as well as in the small arteries and capillaries (Fig. 34).

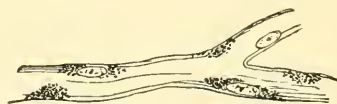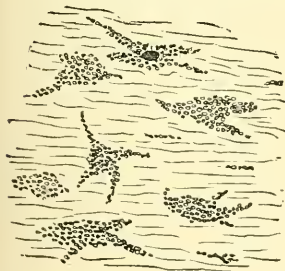


FIG. 33. FATTY DEGENERATION OF THE CELLS OF THE INTIMA OF THE AORTA, VIEWED FROM THE FLAT SURFACE.

FIG. 34. FATTY DEGENERATION OF A CEREBRAL CAPILLARY.
(*Perosmic acid preparation*: $\times 350$)

The process begins with a fatty degeneration of the endothelial cells, which become (Figs. 33 and 34) filled with globules of oil. The endothelium sometimes becomes detached, and is carried off into the circulation. In extreme fatty degeneration of the deeper layers of the intima, small areas of disintegration are formed, and these may become a nucleus for the accumulation of cells, which take up into their substance some of the oil-globules. Proliferation may also take place around such areas.

The causes of the fatty change are to be sought in disturbances of the circulation, changes in the composition of the blood, and the presence of poisonous substances in the circulation.

Fatty degeneration of the media attacks chiefly the muscle-cells. From the resulting diminution of the strength of the media rupture of the artery may occur. Calcareous infiltration is often associated with fatty degeneration, the blood-vessel thereby losing its elasticity and becoming rigid.

Amyloid degeneration is of common occurrence in the arteries, the vascular system being especially prone to be affected by this change. The degeneration is particularly noticeable in the intima of the large blood-vessels, and in the media and sometimes in the adventitia of the smaller vessels.

Hyaline degeneration of the arteries first appears in the intima of the vessels of large calibre, the connective tissue being rendered homogeneous and losing its nuclei. A second variety of homogeneous degeneration of the vessels is well seen in the smallest arteries and capillaries (Fig. 35 *a b*), and [with

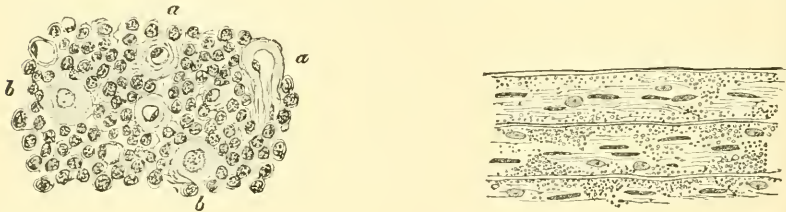


FIG. 35. HYALINE DEGENERATION OF THE BLOOD-VESSELS OF AN ATROPHIC LYMPH-GLAND.

(Preparation hardened in alcohol, stained with alum-carmin and picric acid, and mounted in Canada balsam: $\times 200$)

a hyaline vessel, lumen still patent

b hyaline vessel, completely occluded

FIG. 36. COMMENCING CALCIFICATION OF THE MIDDLE COAT OF THE AORTA.

(The deposit lies between the elastic lamellae: $\times 250$)

special frequency in the glomeruli of the kidneys, in the choroid, in the brain, and in the lymph-glands.

The degenerate vessels have a homogeneous appearance, and their walls are markedly thickened (Fig. 35). The endothelium is at first unaffected, and the lumen of the vessel unaltered (*a*), though in later stages the lumen becomes contracted and finally occluded by the hyaline deposit (*b*).

A form of **granular degeneration** of the arterial muscle-fibres is described by LÖWENFELD. In this form the muscle-cells swell up, assume a granular appearance, lose their nuclei, and finally disintegrate. The change may take place in isolated cells, or in groups of cells, and causes a marked diminution of the strength of the media to resist pressure.

Calcification of the arteries (Fig. 36) occurs chiefly in cases where the nutrition of the vessel-wall is impaired, or its tissue is otherwise morbidly altered. It is usually associated with fatty

degeneration, hyaline degeneration, sclerosis, and atheroma (Art. 18). The intima or the media is the seat of deposit of the calcareous salts. In the former situation it is the sclerotic and atheromatous patches themselves which become calcified, so that frequently actual calcareous plates are formed, which are capable of being entirely separated from the surrounding tissue. If the media be the seat of the calcareous deposit, the process may go so far that the whole vessel is converted into a hard and rigid tube. Large and middle-sized arteries so affected often show upon their inner surface a ribbed or corrugated appearance, the calcification of the degenerate media taking place in bands or stripes.

The calcareous salts are deposited in small glistening granules (Fig. 36), which finally coalesce into compact masses. Haematoxylin imparts a deep bluish-violet coloration to tissues affected with calcification.

In extreme cases the calcified arteries may actually become ossified, portions of the calcified areas appearing to be permeated by vessels and medullary spaces, from which a bone-like substance is ultimately built up.

Necrosis of the vessel-walls results most frequently from inflammations which occur in the neighbourhood of the vessels, and which themselves end in tissue-necrosis and disintegration. Of this nature are in particular the diphtheritic inflammations, and caseous tuberculosis. Necrosis affecting the vessels exhibits the same characters as that in the contiguous parts.

References on Hyaline Degeneration and Calcification.

- ARNDT: Morbid anatomy of the central organs *V. A.* 49 **1870**
 COHN: Ossification of arteries *V. A.* 106 **1886**
 GULL and SUTTON: Arterio-capillary fibrosis *Med.-chir. Trans.* London **1872**
 HOLSCHERNIKOFF: Hyaline degeneration of cerebral vessels *V. A.* 112 **1888**
 JUNGE: Hyaline degeneration *A. f. Ophthalm.* v
 KROMAYER: Miliary aneurysms and colloid degeneration in the brain *Inaug. Diss.* Bonn **1885**
 LEYDEN: *Z. f. klin. Med.* III
 LÖWENFELD: *Spontane Hirnblutungen* Wiesbaden **1886**
 LUBIMOFF: *V. A.* 57, *A. f. Psych.* **1874**
 MALLORY: Calcareous concretions in the brain *Journ. of Path.* III **1894**
 MARCHAND: *Art. Arteries Eulenburg's Realencyklop.* **1894** (with references)
 NEELSEN: Degeneration of cerebral capillaries *A. d. Heilk.* XVII **1876**
 OELLER: Hyaline degeneration of vessels in lead amblyopia *V. A.* 86 **1881**
 SCHWEIGGER: *A. f. Ophthalm.* v
 THOMA: Disorders of the renal circulation in chronic nephritis *V. A.* 71 **1879**
 WIEGER: Hyaline degeneration of lymph-glands *V. A.* 78 **1879**
 ZIEGLER: Causes of contracted kidney *D. A. f. klin. Med.* xxv **1879**

18. The term **sclerosis** is used to designate a condition of the arteries in which the intima presents a greater or less degree of indurative thickening. If this condition is general, the process may be called **diffuse arterio-sclerosis**; if it is local, so that larger or smaller prominences of a flattened or rounded form

appear on the inner coat of the vessel, we speak of it as **circumscribed** or **nodose arterio-sclerosis**. A certain degree of thickening of the intima of the peripheral arteries is a physiological condition in old age, and the change often begins to be apparent even in middle life. Circumscribed thickenings are however always of a pathological nature. Diffuse sclerosis may be combined with local thickenings. The affected parts sometimes appear translucent and almost gelatinous in texture, and sometimes cartilaginous, or densely fibrous.

The local thickenings of the intima (Fig. 37 *efg*), known as **sclerotic plates** or atheromatous *plaques*, occur in arteries of every size, from the ascending aorta to the finest arterioles. They may be few in number or very numerous; and they are especially frequent in the aorta, where often it is difficult to find even a small area of the intima that remains entirely unaffected. When few in number, the sclerotic patches are usually situated near the point of origin of arterial branches.

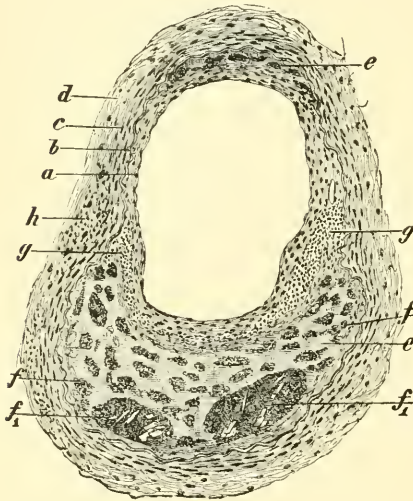


FIG. 37. ATHEROMATOUS CEREBRAL ARTERY.

(Preparation stained with haematoxylin, and mounted in Canada balsam: $\times 50$)

- a* intima considerably thickened
- b* bounding elastic lamella of intima
- c* media
- d* adventitia
- e* necrotic denucleated tissue with masses of fatty detritus
- f* and *f*₁ detritus with cholesterin-plates
- g* infiltrated leucocytes in the intima
- h* infiltrated leucocytes in the adventitia

and whitish, or mixed in character. The yellowish-white *plaques* are known as **atheromatous patches**, and the eroded spots as **atheromatous ulcers**, the process as a whole being described as **atheroma** of the arteries.

Calcareous infiltration is often associated with these conditions, and affects especially the diseased spots, so that actual plates or scales of chalk form in the sclerotic patches. The

media may appear unchanged, or it may contain scar-like tissue, either alone or in combination with calcareous deposits.

The firm yellowish-white plates are composed of new-formed connective tissue, which presents evidence of premature degeneration, generally of the nature of hyaline change. In consequence of this degenerative process, the substance of the connective tissue becomes homogeneous, and loses first its fibrillation and ultimately its cells. Sometimes the hyaline degeneration is combined with extensive fatty degeneration, which primarily affects the cells. Highly granular fibrous tissue may be found side by side with the hyaline patches. In those patches which appear gelatinous, the tissue presents the characteristics of mucous tissue, its cells being sometimes preserved unchanged, sometimes fatty, and sometimes already broken down.

The degenerate and necrotic connective tissue not infrequently becomes calcified, and indeed the calcareous plates above described are practically always produced in tissue that is already morbidly altered. More frequently the degenerate tissue undergoes disintegration, its place being taken (Fig. 37 *e*) by a mass of granular detritus (*f*) more or less intermingled with oil-drops, and often containing plates of cholesterin (*f*₁). This detritus constitutes the so-called **atheromatous pulp**.

The necrotic processes usually begin in the outer layers of the sclerotic thickening (Fig. 37 *e, f*), but they may spread towards the interior, and ultimately extend so far that the layer of connective tissue towards the lumen of the vessel gives way, whereupon the atheromatous patch becomes an ulcer.

Cellular infiltrations (*g*) are often found near the seat of atheromatous degeneration, due to the fact that the destruction of tissue leads to immigration of leucocytes and proliferation of the surrounding tissue-elements. The media may remain unchanged, but usually it also presents evidence of cellular infiltration round its capillaries, and fibro-cellular strands run through those parts of it whose structure is altered or destroyed. Further, it not infrequently happens that the media shows areas of hyaline and fatty degeneration and calcareous infiltration. The adventitia may be unchanged; or it may present diffuse or patchy fibroid induration, as well as foci of cellular infiltration.

In certain cases the adventitia, as well as the media, possesses very numerous *vasa vasorum* (Fig. 38), which may run as far as the innermost layers of the media, and sometimes even of the intima (Fig. 38 *f*). The vessels in the latter case are usually accompanied by clusters of leucocytes (*d d*₁ *d*₂).

Sclerosis and atheroma differ in their mode of development, and their **aetiology** differs accordingly.

In many cases the condition develops very gradually as a manifestation of senile decay, sometimes affecting the aorta chiefly or alone, sometimes isolated arteries in single organs or in

several simultaneously, sometimes nearly all the arteries in the body. When no special injurious influence can be discovered as a probable cause, we must assume that the changes which age

brings with it are themselves sufficient, in many cases, to give rise to this condition of the vascular system.

Injurious agents of many kinds have by various authorities been credited with the power of exerting, through the medium of the blood, a noxious action on the arterial intima. Chronic alcoholism, lead-poisoning, and gout are thus deemed to be of special importance. In recent years particular attention has been directed to the infective processes in this connexion, and articular rheumatism, endocarditis, typhoid fever, scarlatina, and syphilis are given as among the causes of arterial sclerosis.

So far as the sclerotic process is at present understood, it is probable that it may start from degenerative changes of various kinds. Some of these antecedent changes are associated with old age, others with premature decay or marasmus, others with infective or

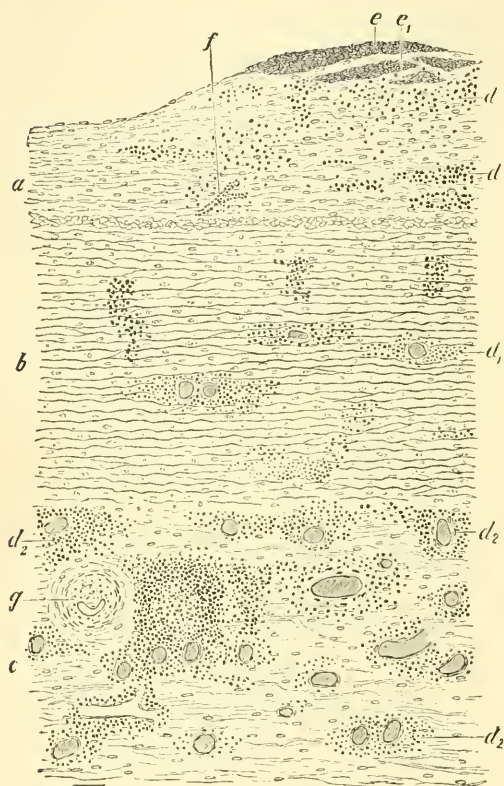


FIG. 38. SECTION OF THE AORTA IN ACUTE PROLIFEROUS AORTITIS.

(*Thrombo-arteritis prolifera*: specimen hardened in Müller's fluid and alcohol, stained with Bismarck brown, and mounted in Canada balsam: $\times 25$)

- a intima thickened by previous inflammation with cellular infiltration *d*
- b media with infiltrated leucocytes *d*₁
- c adventitia with infiltrated leucocytes *d*₂
- e granular fibrin lying on the intima
- e the same within the intima
- f blood-vessel within the hyperplastic intima
- g small artery contracted by sclerosis of its intima

toxic agencies, or again with mechanical injuries such as strain or rupture of some of the coats of the vessel. The primary alteration or damage is then followed by inflammatory action, and this by proliferation of the vessel-walls.

Sclerosis and atheroma are therefore sequences of a prolifer-

ous or hyperplastic **arteritis**, whose originating causes are of various and diverse kinds (Art. 19).

If the process which issues in arterial sclerosis be observed while it is still in progress, foci of proliferation and often of inflammatory infiltration will be found in the intima, and frequently in the media and adventitia as well. In the walls of the larger vessels these are generally seen surrounding the *vasa vasorum* (Fig. 38 $d_1 d_2$). Thus, according to the situation in which the disease is most marked, we distinguish the varieties known as **endarteritis**, **mesarteritis**, and **periarteritis**. The intima may suffer such extensive changes, through the development of sclerosis and atheroma, that the condition may be specifically described by the term **chronic endarteritis deformans**.

If the changes occur chiefly in the intima, the process of new tissue-formation takes place upon its inner free surface, and chiefly beneath the thrombi which are there deposited in the manner already described in treating of proliferation of the endocardium (Art. 7, Fig. 11). Occasionally some of these thrombi still persist at the time of death. The thrombi are sometimes soft in consistence, grey, translucent, and almost gelatinous; again they may be yellowish, reddish, or mottled in colour, and warty, matted, or villous in form, resembling the so-called endocarditic vegetations (*arteritis verrucosa*). Cases occur in which the aorta presents, along with sclerotic thickenings and atheromatous patches, a great number of the above-mentioned thrombotic deposits (*aortitis verrucosa*). The microscope then shows that the wall of the aorta contains not only the older fibroid indurations and hyperplasias (Fig. 38 *a*), but also numerous foci of proliferation and inflammation ($d d_1 d_2$), and that the thrombotic deposits are already partly penetrated by ingrowths of connective tissue from the underlying intima ($e e_1$). The whole process thus assumes the character of a proliferous thrombo-arteritis (Art. 19).

Arterial sclerosis may terminate in the narrowing and **obliteration** of the vessels (*endarteritis obliterans*), or in their gradual **dilatation** and rupture. Occlusion may arise from the coalescence of the thickenings of the intima, or from thrombosis behind the contracted and roughened segments. Thrombosis takes place not only in the small arteries, but also in the large ones; even the common carotid and subclavian may be obliterated in this manner. The most frequent seat, however, of such occlusion is in the arteries of the brain, heart, and kidneys; in these situations it may affect both the larger and the smaller vessels. Dilatation and rupture of the arterial wall occur when the media is the coat chiefly affected, as the resisting power of the vessel is thereby greatly diminished.

The results of arterial stenosis and obliteration are necrosis, degeneration, and atrophy of the tissues deriving their nutrition

from the affected vessels. If the *vasa vasorum* are occluded by sclerosis (Fig. 38 *g*), atheromatous degeneration of the vessel-wall is liable to result.

Hypertrophy of the arteries, in which the connective tissue as well as the muscle-fibres undergo multiplication and increase, occurs in vessels that serve for the establishment of a collateral circulation, or that are called upon to supply large masses of new tissue with blood. The arteries in such cases increase in length and in thickness, and often become tortuous. When, in connexion with the formation of new tissue, fresh vessels are formed by budding, some of the new-formed capillaries must, through the complete development of their walls, be converted into arteries.

In cases of increased arterial pressure, such as occurs in chronic renal disease, hypertrophy of the arterial walls may take place throughout the greater part of the vascular system.

References on Sclerosis and Atheroma of the Arteries

(see also Art. 19).

- CHARCOT: Vascular system *Oeuvres complètes* v Paris 1888
 DUPLAIX: *La sclérose* Paris 1883
 FRIEDLÄNDER: Arteritis obliterans *Cent. f. med. Wiss.* 1876
 GIOVANNI: Pathogenesis of endarteritis *A. ital. de biol.* i 1882
 HOLLIS: Atheroma *Journ. of Path.* iii London 1894
 HONEGGER: *Degeneration d. Intima. d. Herzens u. d. Gefässstämme* Zürich 1882
 ISNARD: Sclerosis *A. gén. de méd.* 1886
 KOSTER: *Pathogenese d. Endarteriitis* Amsterdam 1874
 LANCEREAUX: *Traité d'anat. pathol.* ii Paris 1881
 LANDOUZY and SIREDEY: Arteritis and cardiac affections in typhoid *Rev. de méd.* 1885
 LANGHANS: Anatomy of the arteries *V. A.* 36 1881
 LEYDEN: Cardiac affections from overstrain *Z. f. klin. Med.* xi 1886
 LÖWENFELD: *Pathogenese d. Hirnblutungen* Wiesbaden 1886
 MARCHAND: *Art. Arteries Eulenburg's Realencyklop.* 1894
 MARTIN: Pathogenesis of atheroma *Rev. de méd.* 1881
 PEKELHARING: Endothelial proliferation in arteries *Ziegler's Beiträge* viii 1890
 RANVIER and CORNIL: Histology of the intima *A. de physiol.* 1868
 ROMBERG: Sclerosis of the pulmonary artery *D. A. f. klin. med.* XLVIII 1891
 THALMA: Chronic endarteritis *V. A.* 77 1879
 THOMA: Diffuse arteriosclerosis *V. A.* 104; *Senile Veränderungen* Leipzig 1884; Vascular and fibrous hyperplasia in the arterial wall *Ziegler's Beiträge* x 1891
 VIRCHOW: *V. A.* 4, 77, 79, and *Gesamm. Abhandl.* 1856 (p. 496)
 WEISSMANN and NEUMANN: Elastic fibres in arteriosclerosis *Allg. Wien. med. Zeit.* 35 1890

19. **Inflammation of the arteries**, or arteritis, may be induced by morbid changes in the blood, by traumatic injuries, and by the extension of inflammatory processes from the neighbourhood of the vessel-wall. Mechanical violence may lead to arteritis by tearing or wounding the vessel, or by crushing its coats, as in surgical ligation. Non-traumatic inflammations are for the

most part due to infection or poisoning; mere disorders of nutrition may, however, lead ultimately to processes of an inflammatory character. Among the infective agencies the most common are the pyogenic micrococci, the tubercle-bacillus, and the virus of syphilis. These irritants lead to arterial inflammation by acting upon the arterial wall from the lumen of the artery, from the *vasa vasorum*, or from the adjacent tissues.

Very frequently arteritis is connected with the presence of foreign bodies in the blood-current, more particularly with thrombosis, the thrombosis itself often in its turn starting from an antecedent arteritis elsewhere.

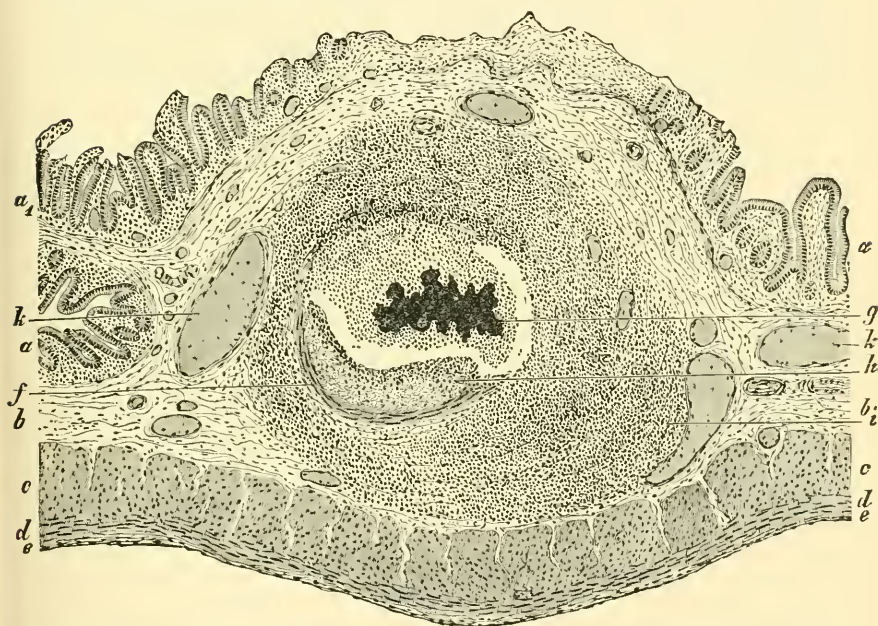


FIG. 39. EMBOLIC SUPPURATIVE ARTERITIS.

(From the submucosa of the intestine; preparation hardened in alcohol, stained with fuchsin, and mounted in Canada balsam: $\times 30$)

- | | | | |
|--------------------------------|---------------------------------------------------------------------------|----------|-----------------------------------------------------|
| <i>a a₁ b c d e</i> | layers of the intestine | <i>h</i> | thrombus adherent to the arterial wall |
| <i>f</i> | transverse section of a remnant of the arterial wall | <i>i</i> | periarterial purulent infiltration of the submucosa |
| <i>g</i> | embolus surrounded by pus-cells within the dilated and suppurating artery | <i>k</i> | veins engorged with blood |

Corresponding to its manifold causation, the character and course of arteritis present many differences, and it is accordingly impracticable to describe all its varieties. We may, however, give prominence to certain main types, with which the remainder may easily be connected. Among these types we may distinguish—thrombo-arteritis, haematogenous arteritis without thrombosis,

arteritis extending from the surrounding tissues, the specific arteritis caused by the tubercle-bacillus, that caused by the virus of syphilis, and finally the disease known as *periarteritis nodosa*.

Thrombo-arteritis may manifest itself in connexion with spontaneous thrombosis, or with embolism. In the first class we place the thrombosis which follows ligation, injury, or disease of the vessel-wall. The particular variety of arteritis occurring in connexion with thrombosis is determined by the nature of the thrombus, and may be purulent or proliferous in character.

Purulent thrombo-arteritis results from spontaneous thrombosis or embolism when the coagulum contains pyogenic micro-organisms. The vessel-wall may undergo either necrosis or purulent infiltration (Fig. 39 *i*) as a result of the action of the bacteria, and this may lead to suppurative softening of the arte-

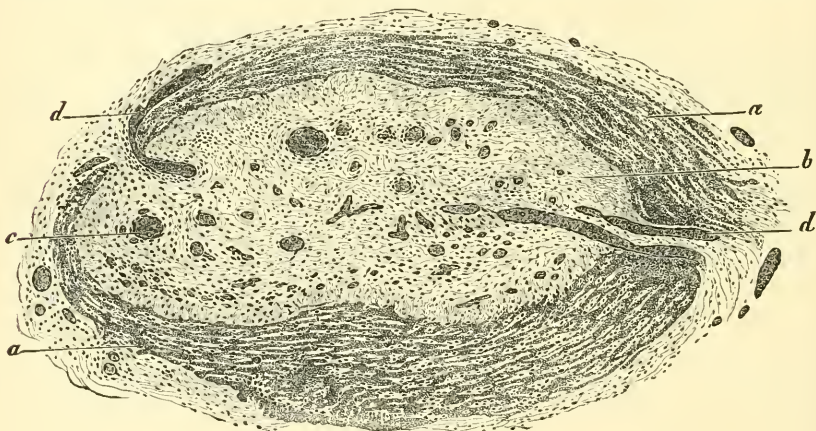


FIG. 40. OCCLUSION OF A PULMONARY VESSEL BY CONNECTIVE TISSUE AFTER EMBOLISM.

(Preparation hardened in Müller's fluid, stained with haematoxylin and eosin, and mounted in Canada balsam: $\times 45$)

a arterial wall b connective tissue within the lumen of the vessel
c d new-formed blood-vessels

rial coats. The larger arteries, in process of purulent infiltration, appear yellowish-white in colour, swollen, and brittle. Under the pressure of the blood the vessel-wall may yield, producing an infective or pyaemic aneurysm (Fig. 39), or the artery may rupture. Periarterial abscesses (*i*) may result from the accumulation of pus and suppuration of tissue around the vessel. This condition is very apt to be brought about in the smaller arteries when they are occluded by infective emboli (Fig. 39 *g*).

Proliferous or plastic thrombo-arteritis occurs in cases where the primary thrombus or embolus is not infective, and leads, according to the amount of proliferation induced, to occlusion of

the vessel (Fig. 40) or to circumscribed thickenings of the wall. The thickenings may consist of flattened prominences, of firmly adherent ridges, or of bands and strings which cross the lumen of the vessel (Fig. 41 *b*). When the contracting thrombus or embolus is only in part replaced by connective tissue, while another part becomes calcified, warty or knotty prominences are formed on the wall of the artery. These we might call arterial calculi, or **arterioliths**.

The new connective tissue which develops in the substance of and so replaces a thrombus owes its existence to proliferation of the cells of the vessel-wall. When the process leads to complete occlusion of the artery, it is called **endarteritis obliterans**.

While the formation of new tissue is progressing the arterial wall is in a condition of proliferation and inflammation, and we accordingly find it infiltrated with connective-tissue cells and leucocytes. Sooner or later, in the inner coats of the vessel, the leucocytes are accompanied by large fibroblasts, and these extend out from the intima into the thrombotic mass (Fig. 42 *h*). In the course of time these cells form germinal tissue, which takes the place of the thrombus, and finally becomes converted into connective tissue (Fig. 40 *b*). If the endothelium of the intima be still preserved, it takes part in the proliferation; if it be destroyed the new-formation of connective-tissue cells proceeds solely from like cells in the coats of the vessel.

The blood-vessels (Fig. 40 *d*) which supply the connective tissue that takes the place of the thrombus come in the first instance from the *vasa vasorum*, but they ultimately communicate with the part of the arterial channel that is still open. In thrombi due to ligation, the new-formation of connective tissue and the new vessels generally start from the point at which the ligature was applied (Fig. 43 *d*₁), but the part of the wall of the vessel in the neighbourhood of the thrombus also furnishes new tissue. In wounds of the vessels it is the region covered by the thrombus that is principally concerned in the reparative process.

Haematogenous arteritis, not associated with thrombosis, originates from the non-vascular intima on the one hand, and from the *vasa vasorum* on the other hand (Fig. 38); according

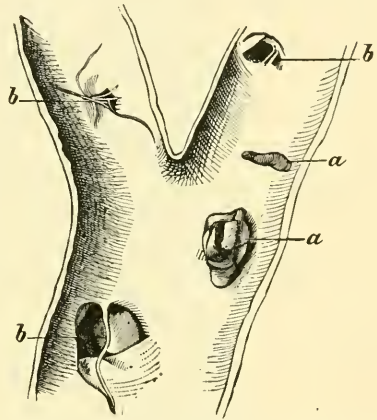


FIG. 41. REMAINS OF EMBOLI IN A BRANCH OF THE PULMONARY ARTERY.

- a* shrunken embolus permeated by connective tissue
- b* fibrous bands running across branches of the artery

to the primary seat of the lesion, we distinguish it as endarteritis, mesarteritis, or periarteritis.

The aetiology of this form of arteritis, when it is not due to purulent infection, tuberculosis, or syphilis, is still uncertain: we may however say that certain specific infections and poisons, as well as simple disorders of nutrition, may give rise to it (Art. 18). The arteritis is almost always of a plastic nature; it leads to the formation of new connective tissue, and consequently to thickening of the intima. It is often the cause of indurative fibroid degeneration of the media and adventitia, and indeed of all those conditions that are characteristic of arterial sclerosis (Art. 18).

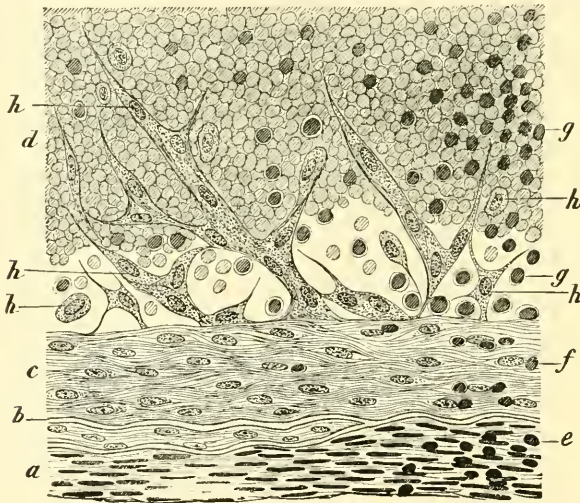

FIG. 42. SECTION OF A THROMBUS IN PROCESS OF ORGANISATION.

(From the femoral artery of an aged man, three weeks after ligation: haematoxylin staining: $\times 300$)

- | | | | |
|---|-------------------------------------------|---|-----------------------------------------------------------------------------|
| a | tunica media | e | cells infiltrating the media |
| b | fenestrated elastic membrane | f | cells infiltrating the intima |
| c | intima thickened by previous inflammation | g | leucocytes, partly within the thrombus and partly between it and the intima |
| d | coagulated blood | h | various kinds of formative cells |

Consecutive or **secondary arteritis**, due to inflammation of the tissues in which the arteries lie embedded, may be suppurative, gangrenous, or hyperplastic, according to the nature of the affection of the surrounding tissues. The forms leading to suppuration and gangrene occur chiefly within infected wounds and ulcers, such as those of the stomach, intestine, and lungs; they are a common cause of the rupture of blood-vessels in these situations. If the artery contains a thrombus, as for example after ligation, this also may undergo suppurative softening.

Secondary arteritis leading to the formation of new connective

tissue is usually the result of chronic inflammation in an organ containing the vessel. The fibrous hyperplasia affects chiefly the adventitia, but it may spread also to the media and intima.

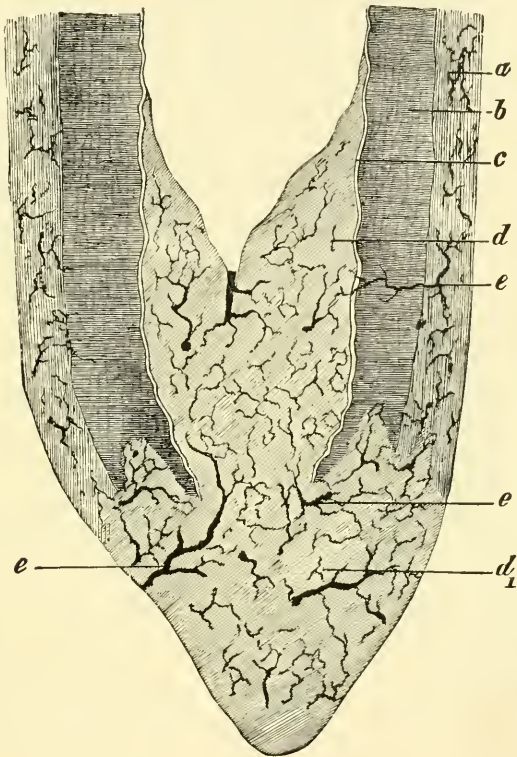


FIG. 43. DIAGRAMMATIC SECTION OF A LIGATED VESSEL.

(The thrombus is supposed to be entirely replaced by vascular fibrous tissue)

- | | | | |
|---|--------------------------------------------|----------------|---------------------------------------------|
| a | adventitia | d ₁ | new-formed fibrous tissue outside the lumen |
| b | media | e | new blood-vessels |
| c | intima | | |
| d | new-formed fibrous tissue within the lumen | | |

References on Arteritis (see also Art. 18).

- APPOLLONIO: Organisation of ligation-thrombi *Ziegler's Beiträge* III 1888
 AUERBACH: Occlusion of arteries after ligation *Inaug. Diss. Bonn* 1877
 BALLANCE and EDMUNDS: *Ligation in continuity* London 1891
 BARBACCI: Acute aortitis verrucosa *Il Morgagni* 1890
 BAUMGARTEN: *Organisation d. Thrombus* Leipzig 1877, and *V. A.* 78 1879
 BUBNOFF: Organisation of thrombi *V. A.* 44 1868
 BUCHWALD: Aortitis verrucosa *D. med. Woch.* 1878
 BURDACH: Senfleben's experiment (connective-tissue formation in doubly-ligated vessels) *V. A.* 100 1885

- CHARRIER and KLÖPPEL: Cerebral arteritis *Rev. de méd.* XIV 1894
 DÉJÉRINE and HUET: Obliterating aortitis *Rev. de méd.* VIII 1888
 DUTIL and LAMY: Progressive obliterating arteritis *A. de méd. exp.* V 1893
 FRIEDLÄNDER: *V. A.* 68, and *Cent. f. med. Wiss.* 1876
 DE GIOVANNI: Endarteritis *A. ital. d. biol.* I 1882
 HERZOG: *Die Rückbildung des Nabels* Munich 1892
 KÖSTER: *Ber. d. Niederrhein. Gesellsch. f. Heilk.* Bonn 1877
 KOSTER: *Pathogenese d. Endarteriitis* Amsterdam 1874
 LANDOUZY and SREDEY: Angiocardiac affections in typhoid *Rev. de méd.* VII 1887
 LÉGER: Acute aortitis *Thèse* Paris 1877
 MARCHAND: *Art. Arteries Eulenburg's Realencyklop.* 1894
 MARTIN: Dystrophic scleroses *Rev. de méd.* VI 1886
 MAYR and VON BUHL: Aortitis verrucosa *Bayr. ärztl. Intelligenzbl.* 1870
 NAUWERCK and EYRICH: Aortitis verrucosa *Ziegler's Beiträge* V 1889
 PERNICE: Aetiology of chronic endarteritis *Riforma medica* 1888
 PFITZER: Cicatrisation of cut vessels *V. A.* 77 1879
 PICK: The endothelium in endarteritis after ligation *Prag. Z. f. Heilk.* IV 1885
 RAAB: Results of ligation *A. f. klin. Chir.* 23, and *V. A.* 75 1879
 RATTONI: Arteritis in typhoid *Il Morgagni* XXX 1887
 SAUNDBY: Obliterating arteritis *Journ. of Anat.* XVII 1882
 SCHNOPFHAGEN: *Wien. Sitzungsber.* LXXII 1875
 SCHULTZ: Healing of wounds in vessels *D. Z. f. Chir.* IX
 SENFTLEBEN: Occlusion of arteries after ligation *V. A.* 77 1879
 STROGANOW: The cellular elements in aortitis *A. de physiol.* 1876
 TALMA: Chronic endarteritis *V. A.* 77 1879
 THÉRÈSE: Arteritis after infective disorders *Rev. de méd.* 1893
 TROMPETER: Endarteritis *Inaug. Diss.* Bonn 1876
 VIRCHOW: Thrombosis, embolism, etc. *Gesamm. Abhandl.* 1856, *V. A.* 1 1847
 ZAHN: Cicatrisation of transverse lacerations of the intima and media *V. A.* 96

20. **Syphilitic arteritis** is found either as an independent disorder or as part of a local syphilitic affection. In the first variety the affected vessel shows white or grey thickening of the intima and of the adventitia. The vessel, such as a cerebral artery, may be beset with greyish translucent or whitish patches: or a certain length of it may be transformed into a white or greyish-white cord. This form is not to be distinguished, either by the eye or with the microscope, from arterial thickening due to non-syphilitic fibrous hyperplasia. The second form of syphilitic arteritis occurs in the midst of foci of syphilitic inflammation, the vessels being surrounded either with diffuse cellular infiltrations (the so-called gummatous granulations) or with dense cicatricial tissue.

If the process is still recent, and in the stage of granulation, the thickening of the intima (Fig. 44 *a*) consists of cellular tissue. The cells are in part small and round, in part larger and spindle-shaped or stellate, corresponding to the various forms of fibroblasts. The adventitia is similarly altered (*d*). The media (*c*) is generally infiltrated only to a moderate extent with cells. If the syphilitic affection is of longer standing, and connective tissue has already been formed in the inflamed areas, the thickened arterial coats are more fibrous and contain fewer cells. The media is

either in good condition or is in places atrophic and fibroid. There is nothing specific in the histological character of the process; but it may be remarked that in ordinary arteritis leading to sclerosis the cellular infiltration is not usually so abundant as it is in syphilitic inflammation, and that the adventitia in particular is not so subject to marked alteration.

The thickening of the arterial coats in syphilis is often very considerable; it may indeed become so extreme that the lumen of the affected artery is partially or entirely occluded (*arteritis syphilitica obliterans*).

Tuberculous arteritis arises from the infection of arteries by way of the blood, and from the extension of a periarterial focus of tuberculosis into the vessel-wall; the latter mode of invasion is much more common than the former.

When infection has taken place, either discrete tubercles or diffuse inflammatory infiltration and hyperplasia may be developed (Fig. 45 *a a₁ c d*); the latter may lead to very considerable thickening of the vessel-wall, and often causes thrombosis. If the granulations become caseous, the vessel-walls undergo the same transformation (*e*). If the diseased vessel be not closed by thrombosis before the caseation sets in, it often ruptures and so gives rise to haemorrhage. When no rupture takes place bacilli may pass from the vessel-wall into the lumen, and thus be disseminated by the blood-stream.

Fibrous hyperplasia of the vessel-wall may also be set up as a consequence of tuberculous inflammation. Most commonly it is the adventitia which becomes thickened, though at times a like thickening affects the intima as well. It may become so considerable that the lumen of the affected vessel is greatly contracted, or even occluded. The same result follows when thrombosis takes place in a vessel whose wall is the seat of caseating tuberculous granulations.

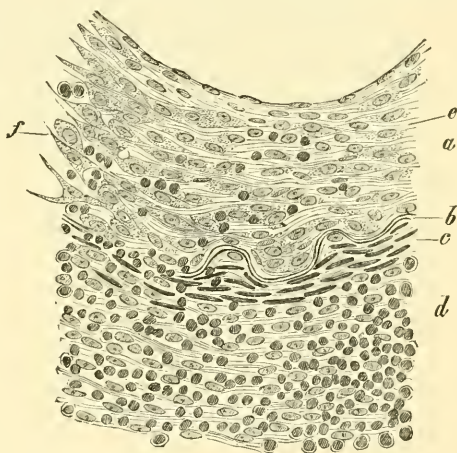


FIG. 44. SYPHILITIC ARTERITIS.

(From the sylvian artery of a young man aged 20 : preparation hardened in alcohol, stained with carmine, and mounted in Canada balsam: $\times 150$)

- a* greatly thickened intima
- b* fenestrated membrane, broken through on the left
- c* muscular coat
- d* adventitia
- e* fibro-cellular tissue
- f* new-formed cellular tissue

Periarteritis nodosa is a peculiar disease of the arterial system described by KUSSMAUL, R. MAIER, and P. MEYER, whose nature is not yet clear; it is characterised by the occurrence on the arterial wall of great numbers of whitish nodules (Fig. 46 *a*). They are found not only on the vessels that can readily be dissected out with scalpel and scissors, in the muscles, the serous membranes, and so on, but also on the arteries of the parenchyma of the spleen, the abdominal glands, the uterus, and the mucous membranes.

The nodes on arteries of somewhat larger size are situated on one side of the vessel-wall; in the case of the smaller ones they entirely surround the lumen. The thickening is due to cellular infiltration and proliferation of all the coats of the vessel

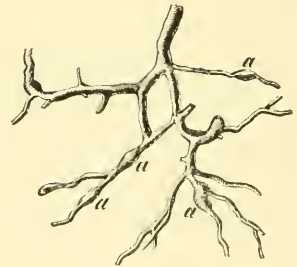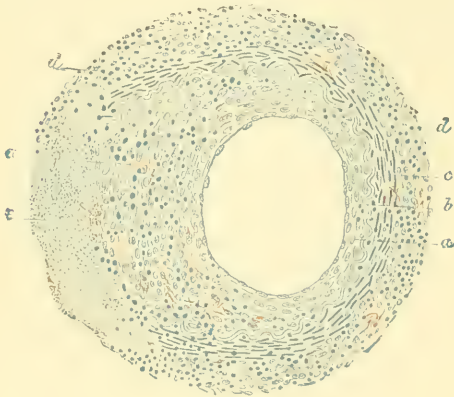


FIG. 45. TUBERCULOUS ARTERITIS.

(Preparation stained with fuchsin and methylene-blue, and mounted in Canada balsam: $\times 100$, but the bacilli have been sketched in under a higher magnifying power)

- | | |
|-------------------------------------------------------------------------------------------------------------------------------------------------------------|------------------------------------------------------------------------------------------------------------------------------------------------------------------------|
| <p><i>a</i> intima <i>a</i>₁ proliferous intima infiltrated with cells and containing tubercle-bacilli</p> <p><i>b</i> inner elastic lamella</p> | <p><i>c</i> media</p> <p><i>d</i> proliferous adventitia infiltrated with cells and containing tubercle-bacilli</p> <p><i>e</i> caseous portion of the vessel-wall</p> |
|-------------------------------------------------------------------------------------------------------------------------------------------------------------|------------------------------------------------------------------------------------------------------------------------------------------------------------------------|

FIG. 46. PERIARTERITIS NODOSA.

(Vessels taken from the mesentery of the small intestine: natural size)

a node-like swelling

(Fig. 47), the hyperplastic intima projecting into the lumen of the artery (*b*), while the media (*c d*) is transformed into cellular tissue of considerable thickness, and the adventitia and the surrounding tissue (*e*) are thickly studded with cells. The affection might thus be fitly described as *arteritis proliferans nodosa*. Thrombosis may accompany the process, which sometimes also leads to aneurysmal dilatation of the weakened and yielding arterial wall. When the inflammation and proliferation are excessive the tissues surrounding the artery are apt to be affected in the same way. The thrombosis leads to ischaemic necrosis of the parts lying behind the occlusion. The most likely explanation of the disease is that

it is an infective one. The sudden onset of the affection, its rapid course, and the marked wasting that accompanies it, are in favour of this theory (VON KAHLDEN).

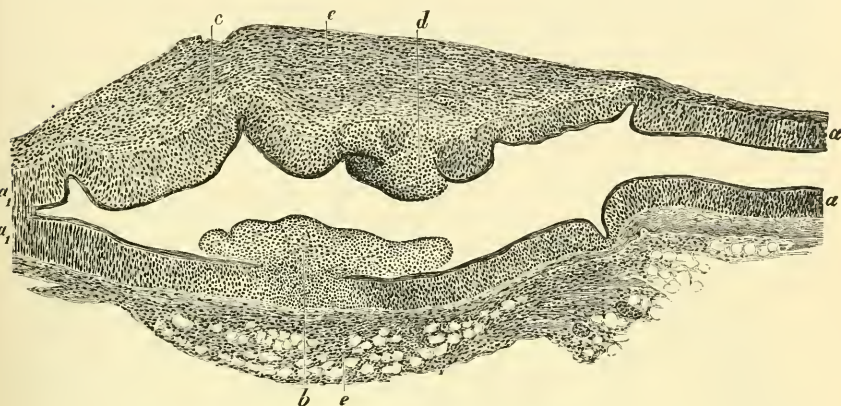


FIG. 47. PERIARTERITIS NODOSA.

(Longitudinal section of node shown in Fig. 46 a: preparation hardened in Müller's fluid, and stained with haematoxylin and eosin: $\times 30$)

- | | |
|-----------------------------------------------------------------------------|---------------------------------------------------------------|
| a a ₁ normal vessel-wall | c diffuse overgrowth of the media |
| b circumscribed swelling of the intima growing into the lumen of the vessel | d projection of intima and media into the lumen of the vessel |
| | e periarterial cellular infiltration |

References on Syphilitic and Tuberculous Arteritis.

- BAUMGARTEN: Syphilis of cerebral vessels *V. A.* 86 1881
 CHIARI: Syphilitic arteritis *Wien. med. Woch.* 1881
 CORNIL: Tuberculosis *Journ. de l'anat.* xvi 1880, and *Pathological Histology* I London 1882
 CORNIL and BABES: *Les bactéries* Paris 1890
 EHRLICH: Syphilitic arteritis *Z. f. klin. Med.* i 1879
 GUARNIERI: Tuberculosis meningitis *A. p. le scienze med.* vii 1884
 HEUBNER: *Dieluetische Erkrank. d. Hirnarterien* Leipzig 1874
 HUBER: Syphilis of blood-vessels *V. A.* 79 1880
 KIENER: Tuberculosis of serous membranes *A. de physiol.* vii 1880
 LANG: *Path. u. Therap. d. Syphilis* II Wiesbaden 1885
 VON LANGENBECK: Syphilitic arteritis *A. f. klin. Chir.* xxvi
 MARTIN: *Recherches sur le tubercule* Paris 1879 [II 1890
 MÉNÉTRIÉR: Vascular lesions in phthisical pulmonary cavities *A. de méd. exp.*
 MÜGGE: Pulmonary vessels in disseminated tuberculosis *V. A.* 76 1879
 NASSE: Arterial tuberculosis *V. A.* 105 1886
 STANZIALE: Syphilis of cerebral arteries *Annal. di neurol.* 1893
 WEIGERT: Tuberculosis *V. A.* 77 1879, 88 1882

References on Periarteritis nodosa.

- EPPINGER: *Pathogenesis d. Aneurysmen* Berlin 1887
 FLETCHER: Periarteritis nodosa *Ziegler's Beiträge* xi 1892
 VON KAHLDEN: *ibidem* xv 1894 (with references)
 KUSSMAUL and MAIER: A peculiar arterial affection *D. A. f. klin. Med.* i
 MEYER, P.: Periarteritis nodosa *V. A.* 74 1878
 WEICHELBAUM and CHVOSTEK: *Allg. Wien. med. Zeit.* no. 28 1877

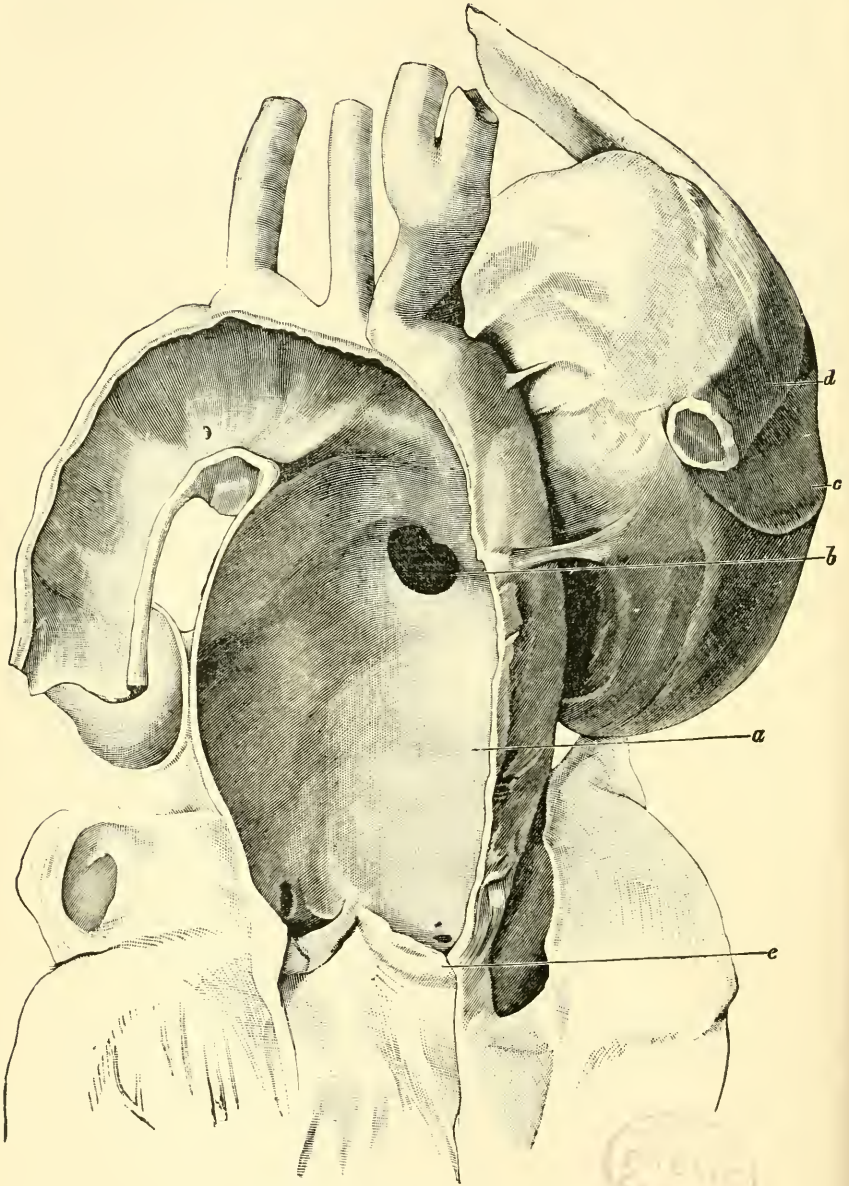


FIG. 48. ANEURYSMS OF THE AORTA.

(From a woman aged 30: half natural size)

- | | |
|-----------------------------------------------------------------------------------------------------------------------------------------------------------------------------------------------|-------------------------------------------------------------------------------------------------------------------------------------------|
| <p><i>a</i> spindle-shaped dilatation or ectasis of the ascending aorta</p> <p><i>c</i> aneurysm due to rupture communicating by the opening <i>b</i> with the lumen of the dilated aorta</p> | <p><i>d</i> rib adherent to the wall of the aneurysmal sac showing marked atrophy from pressure</p> <p><i>e</i> shrunken aortic valve</p> |
|-----------------------------------------------------------------------------------------------------------------------------------------------------------------------------------------------|-------------------------------------------------------------------------------------------------------------------------------------------|

21. Arteries whose walls have lost their elasticity and power of resistance may dilate to an abnormal extent or even rupture under the pressure of the blood, whether this be normal or for any reason exceptionally increased. In this manner more or less severe and sometimes fatal haemorrhages frequently occur. The dilatation and rupture may be acute, and if death does not take place the vessel may return to its normal condition by contraction and ultimate repair of the rent. In other cases the result is permanent sacculation or dilatation of the vessel, or an external sac containing blood may remain in communication with its channel. All these results are usually comprehended under the name of **aneurysm**. If the wall of the aneurysm consists of the coats of the artery, we speak of it as an aneurysm proper, or **true aneurysm**. If the arterial channel remains in communication with a sac consisting of new-formed tissue, we speak of it as a **false aneurysm**.

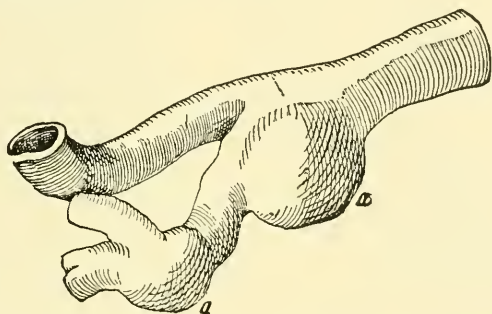


FIG. 49. ANEURYSMS (a) OF THE HYPOGASTRIC ARTERY.

(Reduced by one-sixth)

If we classify aneurysms according to their external form and their local relations to the affected vessel, we may first consider a group of pathological conditions which are described as arterial **ectases**. An ectasis is a spindle-shaped, sometimes almost cylindrical (Fig. 48 a), or in other cases somewhat pouched dilatation of an artery, over a greater or less extent of the vessel's course. Such a widening occurs with special frequency in the aorta, and may extend over its whole length, or affect a limited portion only, such as the ascending aorta or the arch. Sometimes in the course of a vessel there are several fusiform enlargements, or in addition to the dilatation the artery is tortuous and convoluted, a condition which is termed **cirroid aneurysm**: it occurs most frequently in the great vessels lying within the pelvis.

The second group is formed by the **saccular aneurysms** which project from one side of the affected artery (Fig. 48 c, Fig. 49 a), and are more or less sharply marked off from the lumen of the vessel.

By many authorities the saccular forms alone are described as aneurysms. The several varieties can however hardly be separated, inasmuch as transitional and combined forms exist (Fig. 48), and they have to some extent the same aetiology and mode of development.

The production of an aneurysm is probably in all cases referable to some morbid weakening of the arterial coats. In certain instances it is perhaps dependent on a local imperfection of development in the coats; but as a rule it is due to some of the injurious influences incidental to post-embryonic life. Fusiform, cylindrical, and pouched dilatations, and tortuous or cirroid elongations of arteries, which we have classed together as arterial ectases, are caused by stretching of the weakened arterial walls, and may be called **aneurysms by distension**. The formation of large saccular aneurysms is probably always preceded by rupture of one or more of the arterial coats, and we may therefore describe them, in contradistinction to the former class, as **aneurysms by rupture**.

Aneurysms by distension are due as a rule to the changes comprehended under the term **arteriosclerosis**; they may, however, be caused by acute inflammation of the vessel-wall, and in certain cases are probably the result of imperfect development. Conical aneurysms, occurring at the origin of arterial branches, may be caused by excessive traction upon the vessels (THOMA).

Aneurysms by rupture also occur with great frequency in association with arteriosclerosis: accordingly the class of aneurysms, which from their mode of origin we may call **arteriosclerotic**, forms the largest and for the physician the most important group. They are most commonly met with in the aorta, particularly in its thoracic portion, but they often occur in the arteries of the brain, and are not very rare elsewhere, as for example in the carotids, the abdominal arteries, the femorals, and their branches.

Rupture of the arterial coats takes place both in arteries of normal calibre, and in vessels already dilated. It usually occurs during the early stages of arteriosclerosis, and in the case of the aorta in persons who are between 35 and 40 years of age. Occasionally at the time of rupture little or no sclerotic thickening of the coats can be recognised (Fig. 50); but as a rule the intima shows some such change (Fig. 51 *a*). The rupture sometimes affects only the innermost coat of the vessel, sometimes also the middle, and at times the outermost coat as well. Various forms of arteriosclerotic aneurysms by rupture may be distinguished accordingly. If all the coats are broken through, haemorrhage into the surrounding tissues naturally results, and if the effused blood cannot find an outlet this gives rise to the formation of a blood-tumour or **haematoma**, which afterwards may undergo further changes.

If the intima and media are torn through (Fig. 50 *c*), a **dissecting aneurysm** (*d d*) may be formed, whose outer wall is

constituted chiefly by the adventitia (*e*), which has been loosened from the media by the pressure of the escaping blood, or by the adventitia and the outer strata of the media together. This result is most commonly observed in the ascending aorta (Fig. 50) and in the small arteries of the brain, which are surrounded by a loosely-adhering adventitia. If the adventitia of the aorta does not give

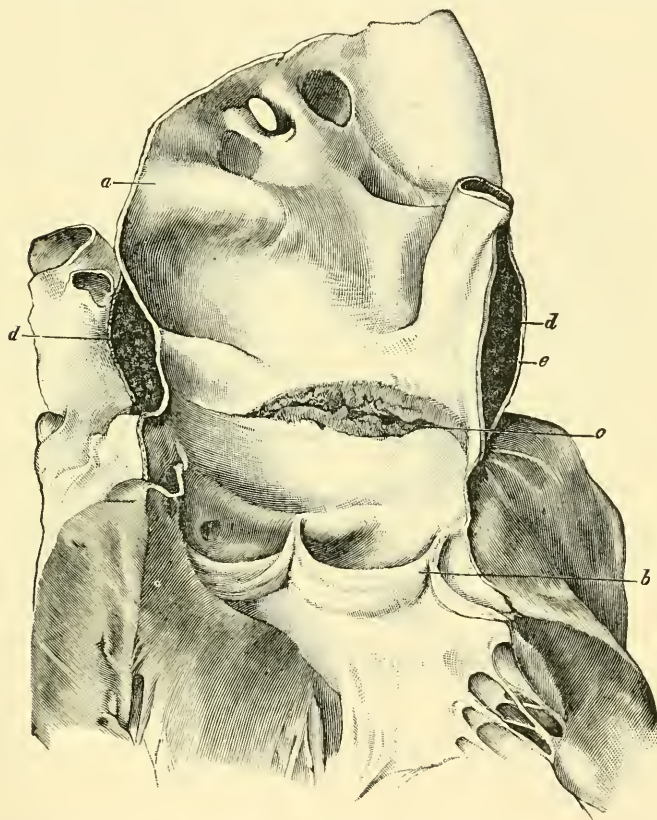


FIG. 50. RUPTURE OF THE INTIMA AND MEDIA OF THE AORTA, WITH THE FORMATION OF A DISSECTING ANEURYSM.

(From a man aged 50)

a aorta
b aortic valve

c transverse rent through the intima and media
d coagulated blood under the adventitia *e*

way at the time of the rupture of the intima and media it may be stripped loose over a large extent of surface, so that the underlying accumulation of blood may reach as far as the points of exit of the branches of the thoracic and abdominal aorta.

As a rule death takes place very soon after rupture; but life is

sometimes prolonged for a while, particularly in those cases in which the blood forces its way from the subadventitial sac back again to the blood-stream, at some point farther on in the course of the vessel (BOSTRÖM). The new blood-channel formed by the adventitia is then strengthened by the formation of connective tissue around it, and it may even acquire an endothelial lining.

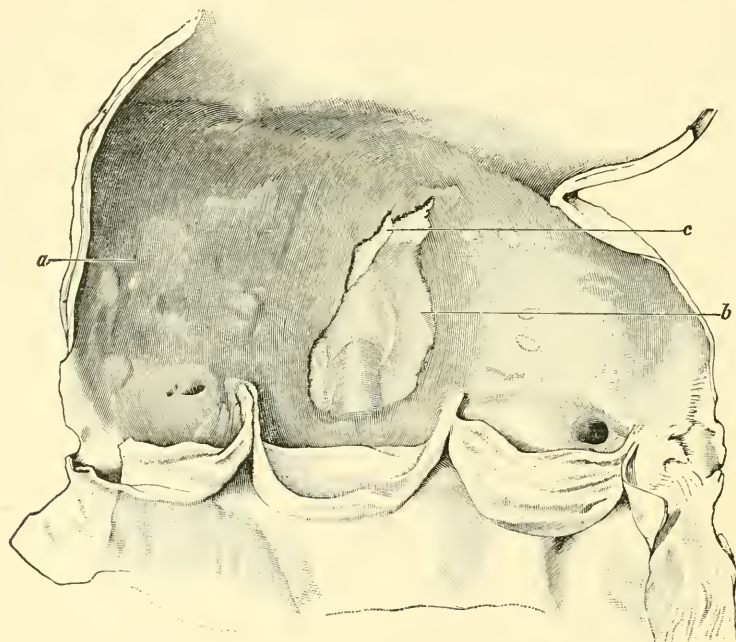


FIG. 51. ANEURYSMAL DILATATION AND PARTIAL RUPTURE OF THE ASCENDING AORTA.

(From a man aged 36: natural size)

a dilated aorta with sclerotic plates in the intima *b* rent in the intima through which the media is visible
c rent in the media

Since in cases of complete rupture and of dissecting aneurysm we cannot always detect morbid changes in the coats of the vessels, it is very probable that in the absence of these changes traumatic injury to, or defective development of, the vessel-wall is the primary cause of the lesion. When a portion of the intima of a vessel such as the aorta gives way, with or without accompanying rupture of the media, and without dissection of the other coats, a *locus minoris resistentiae* is formed at that part. A local dilatation of the remaining layers of the arterial wall thereupon takes place, and a **saccular aneurysm** is produced. This result is not however inevitable, for we frequently see rents

in the large vessels that have actually healed by means of newly-formed connective tissue, and show no signs of yielding. When the process results in lateral dilatation of the vessel-wall, a very large blood-sac (Fig. 48 *e*) may ultimately be formed at the affected spot. These sacs communicate with the lumen of the vessel by a more or less wide opening (Fig. 48 *b*), which is commonly narrow compared with the size of the artery or of the sac itself. Frequently several such aneurysms co-exist in sclerotic and dilated vessels, so that for example an ectatic ascending or transverse aorta may present three, four, or even more sacculations.

Arteriosclerotic aneurysms of the aorta and other great vessels often attain considerable size, and cause distortion and displacement of the contiguous viscera. Aneurysms of the thoracic aorta frequently extend to the sternum and ribs, or to the spinal column, and then exert pressure on these bones. Under these conditions the bony substance becomes eroded and atrophic, and large portions of the vertebral bodies, the sternum, or the ribs may be thus absorbed (Fig. 48 *d*). The nerve-trunks, the trachea, and the walls of adjacent blood-vessels such as the pulmonary artery, are in like manner pressed on and atrophied.

In the wall of the sac itself, which is subjected to steadily increasing distension, inflammatory infiltration and proliferation are set up, and these result in fibrous hyperplasia. Within the sac laminated thrombi may form, which fill it up to a greater or less extent, and cause proliferation of the underlying wall, but do not necessarily lead to the healing of the aneurysm by obliteration of its cavity.

Sooner or later the aneurysm ruptures, and blood is effused into the surrounding tissues. The haemorrhages that occur so frequently in the brain come very often from the rupture of aneurysmal dilatations in atheromatous arteries. Large thoracic aneurysms frequently project into the lumen of the trachea, the bronchi, or the oesophagus, after causing the absorption of the walls of these structures by pressure; then the aneurysmal sac ruptures, and massive haemorrhage takes place into the respiratory tract, or into the oesophagus. In other cases the aneurysms rupture externally through the intercostal spaces, and instances are recorded in which they have ruptured into the pulmonary artery or into the veins. In the latter instance the aneurysmal sac has previously become adherent to the wall of the vein, and when rupture into the latter ensues the condition is known as **true varicose aneurysm**.

Embolic aneurysm is another special variety, of which we may distinguish two forms. The first owes its existence to the fact that sharp-cornered particles of calcified material are swept from ulcerated valves or other parts of the vascular system to a peripheral artery, into whose walls they penetrate. This may

cause rupture and fatal haemorrhage (cerebral apoplexy), or if the walls of the vessel do not at once give way entirely, an aneurysm by rupture may be formed. In the latter case the walls of the sac are composed either of tissue derived entirely from the surrounding structures, or in part at least of the outer walls of the vessel. These aneurysms are thus essentially due to mechanical erosion, and accordingly are really traumatic in origin.

The second form of embolic aneurysm is that known as the mycotic or infective aneurysm (Fig. 39). This form is due to emboli infected with bacteria (*g*), which set up at their point of lodgment suppurative inflammation and degeneration of the vessel-wall and its surroundings. The emboli usually come from infective endocarditic thrombi. The walls of the vessel (*f*), becoming friable and softened by ulceration, either wholly or partially give way. If the outer coats do not rupture, a saccular or fusiform aneurysm may form by their dilatation. In horses embolic aneurysms are often produced by the *Strongylus armatus*, which lives in the blood-vessels (notably in the mesenteric artery), and causes at its point of lodgment thrombosis and degenerative changes in the vessel-wall. Laceration of the inner and dilatation of the outer coats are the ultimate result. We might call these parasitic aneurysms.

Aneurysms by erosion are usually found in suppurating wounds and in tuberculous foci, especially in cavities of the lungs. The suppuration or the tuberculous inflammation involves the outside of the vessel (Fig. 45), softens it, and so renders it more liable to laceration. In favourable cases the portion of the vessel thus affected may protect itself by the formation of thrombi, followed by proliferation, with the result that its lumen is ultimately obliterated. Frequently, however, the vessel-wall ruptures and haemorrhage takes place; or as a result of the destruction of the outer coats, the inner ones protrude, producing **hernial aneurysms**. The protruding inner walls may be already covered by thrombi; or the vessel-wall may be thickened by the formation of connective tissue. Hernial aneurysms either rupture, or induce the formation of new connective tissue about them, and in this way their walls are strengthened.

Traumatic aneurysms are produced by the action of mechanical violence of any kind upon the vessel, in consequence of which the inner, the outer, or all of the arterial coats may be torn through. What happens in the first instance will be understood from what has already been said. When the vessel-walls are entirely torn through, and the blood cannot escape to the exterior or into some cavity of the body, a blood-tumour is formed, bounded by the surrounding tissues: this is an **arterial haematoma**. In the course of time a connective-tissue sac may be developed round the coagulated mass of blood, and its contents undergo contraction. If through the original point of rupture in the vessel-

wall blood again gains access to the sac, a **spurious aneurysm** is formed.

When an artery and a vein are wounded simultaneously, and a communication between the two is established by the formation of an intermediate hæmatoma, a traumatic **spurious varicose aneurysm** is the result. This accident may happen in the operation of blood-letting from the median vein of the arm, in which the brachial artery is sometimes cut. When by a wound direct communication is opened between an artery and a vein, so that the arterial blood flows into the vein without the intervention of a sac, and the vein is distended under the arterial blood-pressure, we have a condition that is termed an **aneurysmal varix**.

The formation known as **racemose** or **anastomotic aneurysm**, or vascular arterial tumour, has nothing in common with true aneurysms. It is rather a pathological multiplication of the vessels over a whole arterial region, and is probably always dependent upon some local congenital anomaly of development. Convoluted coils and plexuses of hypertrophic and dilated arteries are thus formed, and the condition might appropriately be described as a **racemose arterial angioma**.

Aneurysms are sometimes congenital (PHÄNOMENON: Aneurysm of the abdominal aorta *Arch. f. Gynäk.* xvii 1881), and in infants may be due to the presence of septic thrombi or to the fact that the ductus arteriosus exerts an excessive traction on the wall of the aorta or pulmonary artery (THOMA).

Out of 159 cases of arterio-venous aneurysm collected by BRAMANN, wounds by stabbing, hacking, or cutting were given as the cause in 108, gunshot injuries in 29, and contusions in 5. In 9 cases the condition arose spontaneously.

References on the Formation of Aneurysms.

- BERTRAND: *Les oblitérations mésentériques* Paris 1878
 BOSTRÖM: Healed dissecting aneurysm *D. A. f. klin. Med.* xlii 1887
 BUDAY: Embolic aneurysm of common iliac *Ziegler's Beiträge* x 1891
 CHARCOT: Vascular system *Oeuvres complètes* v Paris 1888
 CHARCOT and BOUCHARD: Pathogenesis of cerebral hæmorrhage *A. de physiol.* i 1868
 CORNET: Aneurysms of the pulmonary artery *Thèse* Paris 1885
 EICHLER: Cerebral aneurysms *D. A. f. klin. Med.* xxii 1878
 EPPINGER: Pathogenesis of aneurysms *A. f. klin. Chir.* 35 1887; Miliary cerebral aneurysms *V. A.* 111 1888
 FRÄNKEL, E.: Healed rupture of aorta *Festschr. z. Eröffnung d. Krankenhauses* Hamburg 1889
 FRIEDLÄNDER: Dissecting aneurysm *V. A.* 78 1879
 HELMSTEDTER: Spontaneous aneurysms *Inaug. Diss.* Strassburg 1873
 KRAFFT: Origin of true aneurysms *Inaug. Diss.* Bonn 1877
 LÖBKER: *Art. Aneurysm Eulenburg's Realencyklop.* 1894 (with references)
 LÖWENFELD: *Ätiologie d. Hirnblutungen* Wiesbaden 1886
 MALMSTEN: *Aorta-aneurysmens Etiologi* Stockholm 1888
 MANHOT: Origin of aneurysms *V. A.* 121 1890
 MARCHAND: *Art. Arteries Eulenburg's Realencyklop.* 1894 (with references)
 PONFICK: Embolic aneurysms *V. A.* 58 1873 and 67 1876
 ROKITANSKY: *Krankheiten d. Arterien* Vienna 1852
 ROTH: Cerebral aneurysms *Corresp. f. Schweiz. Aerzte* 1874
 SELTER: Aneurysm of the splenic artery *J. A.* 131 1893

- THOMA: Researches on aneurysm *V. A.* 111-113 **1888**, and *D. med. Woch.* **1889**; Elasticity of arteries *V. A.* 116 **1889**; Traction-aneurysm of the infantile aorta *V. A.* 122 **1890**
 VIRCHOW: Dilatation of the smaller vessels *V. A.* 3 **1851**

References on Arterio-venous Aneurysms.

- BRAMANN: Arterio-venous aneurysm *Langenbeck's Arch.* XXXIII **1886**
 BROcq: Communications between aorta and pulmonary artery *Rev. de méd.* v **1885**
 CZERNY: Varicose aneurysm *V. A.* 62 **1875**
 HALLA: Varicose aneurysm of aorta and superior vena cava *Prag. Z. f. Heilk.* III **1882**
 SATTLER, H.: Pulsating exophthalmus (aneurysm between cerebral carotid and cavernous sinus) *Graefe u. Sämisch's Handb. d. Augenheilk.* VI **1880**
 STIMSON: Carotid and jugular *New York Med. Journ.* XXXVIII **1883**
 WEIGERT: Splenic artery and vein *V. A.* 100 **1885**
 WIEDENMANN: Arterio-venous aneurysm of upper extremity *Beiträge von Bruns* x **1893**

CHAPTER X

MORBID CHANGES IN THE VEINS

22. It may be stated that in general the **veins** are subject to the same morbid changes as the arteries, though many pathological processes affecting them are less markedly characteristic and involve less important consequences than the corresponding lesions of the arteries.

Fatty degeneration of the intima and media follows a similar course to that of the arteries, and gives rise to the appearance of whitish spots on the venous coats.

Calcification occurs upon the whole but rarely, and is seldom marked. The most complete examples of calcification may be found in veins whose walls have undergone fibroid degeneration.

Fibroid thickening of the intima, a process analogous to arteriosclerosis, and described as **phlebosclerosis**, appears both in diffuse and in circumscribed forms, particularly in the veins of the lower extremities. The affection is however less pronounced than in the arteries, and its effects are in general of minor importance.

An inflammatory condition of the veins leading to the formation of new connective tissue, **proliferous** or **hyperplastic phlebitis**, is met with chiefly after venous thrombosis, or as a consequence of inflammatory proliferation of neighbouring parts: it begins in the first case as a **thrombo-phlebitis**; in the second, as a **periphlebitis**. As thrombosis is one of the commonest plastic affections of the veins, thrombo-phlebitis is a comparatively frequent disorder. It occurs often in the veins of the lower extremities and of the pelvis, and not rarely in the large veins of the trunk and in the sinuses of the dura mater. The cellular infiltration and proliferation of the vessel-walls, and the gradual replacement of the thrombus by fibrous tissue, take place in the same manner as in proliferous thrombo-arteritis.

After an interval of some months, the site of the former thrombus is sometimes indicated only by thickening of the intima and by a few fibrous bands traversing the lumen of the vessel (Fig. 52 *b c*); but sometimes the vein at the affected spot is cicatricially contracted (Fig. 52 *a*) and obliterated, so that the process might be described as **phlebitis obliterans**. Obliteration takes place not only in small but also in large veins, such as the femoral

vein and the inferior vena cava; and the vessel may thus, for a distance of several centimetres, be converted into a solid fibrous cord.

If a contracting venous thrombus is only partially replaced by connective tissue, the rest of it becoming calcified, vein-stones or **phleboliths** are formed.

Proliferous periphlebitis develops when proliferation takes place in the tissues contiguous to the veins, and leads in the first instance to a thickening of the adventitia only, though it may ultimately extend also to the inner coats.

Wounds of the veins heal in the same manner as those of the arteries.

Suppurative phlebitis is most frequently associated with suppurative and septic inflammation of the adjacent tissues, and is thus at the outset a periphlebitis. Purulent infiltration of the vessel-wall may however extend to the inner coats, and is then indicated by their yellowish-white appearance, or in putrid inflammations by their dirty-grey or greyish-green discoloration. Under certain conditions infective inflammations spread for a considerable distance within the adventitia of the veins, so that the vessels appear as if sheathed in reddened and infiltrated tissue.

If pyogenic bacteria reach a venous thrombus, septic softening is set up within it, and at the same time degenerative changes, necrosis, and inflammation affect the vessel-wall; the result is thus **suppurative thrombo-phlebitis**. When the veins are infected in this manner, the pathogenic bacteria very readily reach the blood.

Tuberculous periphlebitis and **phlebitis** arise in the same way as tuberculous arteritis (Art. 20), and lead to cellular infiltration and hyperplasia of the venous walls, which afterwards become indurated or undergo caseous degeneration. The process may finally extend to the intima, enabling the tubercle-bacilli to enter the blood-current

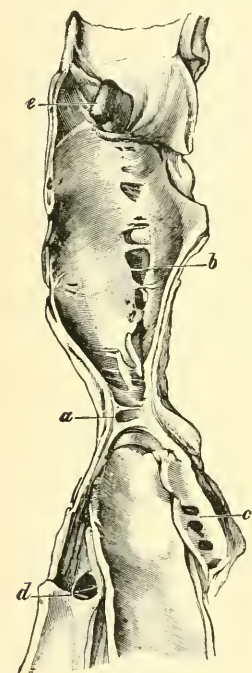


FIG. 52. OBLITERATION OF THE RIGHT FEMORAL VEIN.

(Remains of a thrombosis which occurred three years before death; natural size)

a obliterated portion of the vein (the right iliac vein was also obliterated)

b c d fibrous bands within the vein and its branches

e recent thrombus

and to disseminate the tuberculosis by metastasis.

Syphilitic periphlebitis and **phlebitis** are observed most frequently in the branches of the portal vein, and in the umbilical vein of new-born children affected with syphilis.

References on Phlebitis and Phlebosclerosis (see also Art. 19).

EBERLING: On phlebitis *Inaug. Diss.* Bonn 1880

EPPINGER: Obliteration of vena cava inferior *Prag. med. Woch.* 1876 1878
1879, and *Schmidt's Jahrb.* 1884

HEUKING and THOMA: Organisation of marasmic thrombi *V. A.* 109 1887

MÜGGE: Tuberculosis of pulmonary veins *V. A.* 76 1879

SACK: Phlebosclerosis compared with arteriosclerosis *V. A.* 112 1883, *Inaug. Diss.* Dorpat 1887

SCHÜPPEL: Syphilitic periphlebitis *A. d. Heilk.* xi

SCHÜRHOFF: Pathogenesis of miliary tuberculosis *Cent. f. allg. Path.* iv 1893

23. **Phlebectases** or **varices** (Fig. 53) are dilatations of the veins, which are caused chiefly by mechanical interference with the outflow of blood from them: the impediment may be local or general venous engorgement, compression of the veins, thrombosis, failure of the heart, or the like. Their formation is favoured by the presence of morbid changes in the venous walls and the tissues surrounding them.

In many cases the veins are uniformly dilated in a cylindrical form, or show spindle-shaped bulgings. In other cases the dilated veins are coiled in a tortuous or serpentine fashion (Fig. 53), with numerous lateral pouches, so that the several convolutions ultimately lie close one to another.

Simple stretching of the vessel-walls under the internal pressure of the blood may suffice to explain the first variety, while the second implies rather some abnormal local weakness of the venous wall, for such varices are occasionally found in

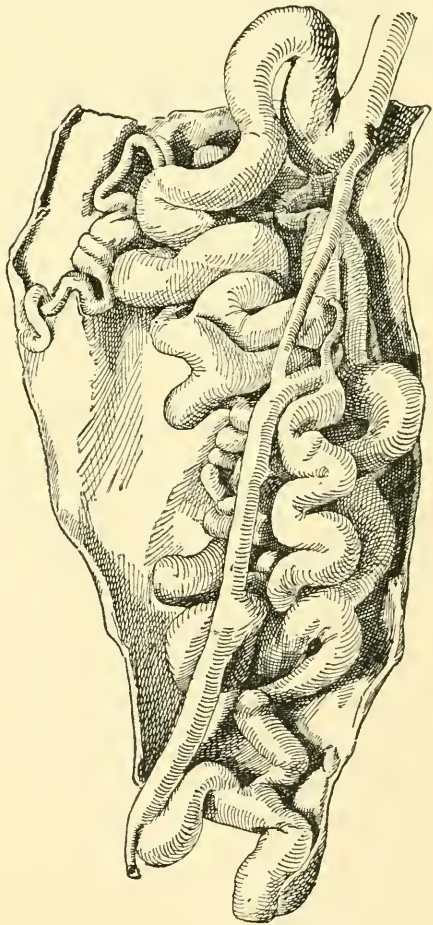


FIG. 53. VARICES OF LEG.

(Injected preparation: one-half natural size)

places where engorgement does not apparently exist. When the veins are markedly pouched and tortuous, without any perceptible thinning of their coats, some hyperplasia of the venous walls must of course have taken place.

If the walls of tortuous veins touch each other, fusion may occur at the point of contact, and in this way anastomosing venous sinuses are formed. The result is a kind of cavernous tissue; with wide blood-spaces.

Varices occur very frequently in the lower extremities, and form beneath the skin tangled convolutions consisting of serpentine and saccular blood-sinuses (Fig. 53). They may be produced in persons obliged to sit or stand for a long time together, but they arise with special frequency in cases of long-continued interference with the venous circulation, such as results from the pressure of the pregnant uterus or of tumours in the pelvis. They are also frequent in the pelvic veins, the veins of the broad uterine ligament, the spermatic cord (**varicocele**), the prostate, the bladder, the scrotum, the labium pudendi, and the lower portion of the rectum. The veins which form a plexus around the rectum, by their dilatation, frequently give rise to the tuberous or grape-like varicose prominences known as **haemorrhoids** or piles.

The circulation through the liver is sometimes obstructed by reason of morbid processes affecting the interlobular connective tissue (cirrhosis of the liver). As a result we find engorgement and dilatation of the portal veins, and of the oesophageal and spermatic veins which anastomose with them. The like dilatation has been observed in the persistent channel of the umbilical vein in the round ligament of the liver (BAUMGARTEN), and in the parumbilical veins; in this case the communicating veins of the round and suspensory ligaments, and the veins of the anterior abdominal wall, may also be dilated and tortuous, leading to the formation of the so-called *caput medusae*.

Varices not infrequently rupture and so give rise to haemorrhage; this is especially apt to happen in the case of haemorrhoids, which are torn and bruised by the passage of the faeces. Veins may also rupture subcutaneously. In the neighbourhood of the varices oedema and inflammation are often set up, and lead either to suppuration with the formation of abscesses or ulcers, or to overgrowth of connective tissue. The former is most common in the neighbourhood of haemorrhoids, where infection is apt to occur; the latter in the lower extremities, where from oedema and fibrous hyperplasia thickening and induration of the tissues is a frequent result, giving rise to the condition described as **phlebectatic elephantiasis** or **pachydermia**. In the affected parts traumatic injury readily induces ulceration, and the so-called **varicose ulcers** have but little tendency to heal. They often extend over a considerable area, and the floor and margins tend

to become callous and indurated from the formation in them of dense cicatricial tissue.

Thrombosis in dilated veins is not infrequently associated with proliferous or purulent thrombo-phlebitis. Calcification of the remains of the coagulum leads to the formation of phleboliths.

References on Varices.

- BAUMGARTEN: The umbilical vein in hepatic cirrhosis *Arbeiten path. Inst.* 1
Tübingen **1891**
- CORNHEIM: Death from rupture of splenic varices *V. A.* 37 **1866**
- CORNIL: Pathology of varicose veins *A. de physiol.* iv **1872**
- EPSTEIN: Structure of normal and varicose veins *V. A.* 108 **1887**
- JACOBS: Pathological anatomy of haemorrhoids *Inaug. Diss.* Bonn **1890**
- KIRCHENBERGER: *Aetiologie u. Histogenese der varic. Venenerkrank.* Vienna **1893**
- KÖSTER: Intestinal phlebectases *Berl. klin. Woch.* **1879**
- VON LESSER: Varices *V. A.* 101 **1885**
- PUCHELT: *Das Venensystem in seinen krankhaften Verhältnissen* Leipzig **1843**

CHAPTER XI

MORBID CHANGES IN THE LYMPH-VESSELS

24. The morbid changes occurring in the lymphatic system do not admit of complete treatment apart from the pathological anatomy of the parenchyma of the various organs. The lymphatics have their ultimate radicles in the substance of the tissues, and the first part of their course is formed by the meshes and clefts into which the lymph derived from the blood is poured. The efferent channels, in other words the smallest lymph-vessels, are canals devoid of special walls, and marked off from the surrounding connective tissue only by a layer of flat endothelial cells. Not until we come to the larger lymphatics do we find, outside the endothelium, any special connective-tissue wall.

It must be very rare for demonstrable changes to take place in these minute lymph-channels without simultaneous disease of the tissues that enclose them; they and the tissues are in too intimate relation for one to suffer without the other. The same holds good even of the larger lymphatics, though they have walls of their own in addition to their endothelial lining. It is indeed only the largest lymphatics of all that we can regard, from a pathological point of view, as independent structures.

Inflammation frequently affects the lymph-vessels, giving rise to the affections known as **lymphangitis** and **perilymphangitis**. It is generally secondary to some inflammation of the tissues, the lymph from the inflamed area acting as an irritant to the vessels through which it flows and to the tissues that immediately surround them. But rarely does an irritant capable of setting up inflammation reach the lymphatics from any other source than from a previously inflamed part. The secondary inflammation may extend far beyond the seat of the primary affection; thus it may spread from a wound in the hand up into the lymphatics and glands of the axilla. During life the affection is indicated by the presence of red and painful streaks extending from the initial wound to the nearest lymph-glands.

In minor degrees of lymphangitis the lymphatic endothelium is swollen, its nuclei are increased, and its cells in part undergo multiplication. In the more severe inflammations the endothelial cells are cast off and perish; while at the same time the lymph-vessels contain an abnormal number of lymphoid elements, and

not infrequently the lymph is fibrinous and coagulable. In purulent lymphangitis the lymph-vessels may be distended with small collections of pus, and sometimes assume a sacculated or moniliform appearance. The tissue surrounding the lymphatics, as well as the vessel-walls themselves, is more or less infiltrated with leucocytes, and its capillaries are markedly distended with blood. In long-continued lymphangitis the lymph-vessels contain epithelioid and multinuclear cells derived from the endothelium.

The issue of lymphangitis is either complete restoration *ad integrum* by re-absorption of the exudation and regeneration of the lost endothelium, necrosis and abscess of the vessel and the tissue surrounding it, or lastly fibrous hyperplasia and induration of both. The latter occurs in chronic inflammatory conditions, and may lead to the obliteration of the lymphatic vessel.

Like the non-specific inflammations, the specific inflammations set up by the infective granulomata may invade the lymphatic system. The lymphangitis thus induced often exhibits no special peculiarities; but in other cases the specific granulomatous proliferation is induced. In this respect **tuberculosis** is the best example, as the affection leads to the formation of characteristic nodes within the lymph-channels.

References on Lymphangitis.

- BAUMGARTEN: Transformation of the endothelium of the intestinal lymphatics *Cent. f. med. Wiss.* 1882
 ENZMANN: *Path. Anat. d. Duct. thoracicus* Basle 1883
 FISCHER and LEVY: Lymphangitis of the extremities *D. Z. f. Chir.* xxxvi 1893
 LEDDERHOSE: Traumatic lymphangitis of the leg *V. A.* 137 1894
 LEJARS: Tuberculous lymphangitis *Études sur la tuberculose (Verneuil)* III Paris 1891
 LÖSCH: The lymph-vessels in inflammation *V. A.* 44 1868
 ORTH: Puerperal fever *V. A.* 58 1873
 VIRCHOW: Puerperal metritis and parametritis *V. A.* 23 1862
 WALDEYER: *A. f. Gynäk.* III 1872

25. Inflammatory processes affecting the wall of a lymphatic and the surrounding tissue, pressure from without, the irruption of tumours or parasites into the lymph-channel, and other like causes, often bring about **occlusion** of the vessel. If the number of lymphatics thus obliterated is not great, while other vessels remain open so that the lymph of the part can find an exit, no further change is usually induced. Even the thoracic duct may be occluded without serious danger, for other collateral paths are opened up. But if the efflux of lymph is entirely prevented, as in filarial disease, lymphatic engorgement ensues and the vessels become gradually dilated, forming what is called **lymphangiectasis**. This affection may also develop without demonstrable impediment to the outflow of lymph, generally as a result of

repeated attacks of local hyperaemia or inflammation, but at times also without any such cause being apparent.

Lymphangiectasis following inflammation is observed chiefly in connexion with the form of cutaneous and subcutaneous hyperplasia known as **elephantiasis**. The skin is thickened, and on section allows an abundance of clear lymph to escape from the dilated lymphatics. Sometimes the epidermis is raised in blisters by the accumulated lymph.

Dilated chyloferous lymphatics are very often met with in the mesentery: the usual cause is obstruction due to inflammatory or neoplastic growths seated in the mesentery or thoracic duct. Sometimes the obstruction is due to lymphatic thrombosis. The dilated vessels look like straight cylindrical ridges or convoluted saccular or moniliform cords; their contents are either white and limpid or pulpy and caseous.

Lymphangiectasis, not associated with engorgement or inflammation, is generally congenital or depends upon congenital defects. The affection known as lymphangiectatic **macroglossia** and **macrocheilia**, a peculiar overgrowth of tongue and lips, is due essentially to dilatation of the lymphatics of the parts. Lymphangiectases of the skin, such as are often met with in the inguinal region, scrotum, labia pudendi, lower limbs, and thorax, are of the same nature. They sometimes take the form of diffuse thickenings which are termed **lymphangiectatic elephantiasis**, or of circumscribed tumour-like swellings, and are hence classed with the tumours as **lymphangiomata**. It is not possible to draw a sharp line between the swellings of this nature which we might fitly call tumours and the others.

In addition to the lymphatic tumours described as lymphangiomata we have a class of new-growths specially affecting the lymphatic vessels, and known as **endotheliomata**. They have been described chiefly as tumours of the serous membranes, of the pia and dura mater, and of the skin; and are either flattened and diffuse or rounded and circumscribed swellings. They are classed with the sarcomata, and are characterised by endothelial proliferation and by the formation of peculiar nests and clusters of cells lying in a kind of fibrous stroma. Their structure thus resembles in many points that of carcinoma.

When tumours break into the lymphatic channels the endothelial cells may take part in the neoplastic proliferation, and produce connective tissue. It is doubtful whether they have the power of producing cancer-cells. According to the prevailing opinion, cancer-cells are produced only by multiplication of cells of a similar nature that have reached the lymph-channels.

References on Obstruction and Dilatation of the Lymphatics.

- BÜGEHOLD: Wounds of the thoracic duct *A. f. klin. Chir.* XXIX **1883**
DÉSERT: Lymphatic dilatations *Thèse Paris* **1877**
ENZMANN: Path. anatomy of thoracic duct *Inaug. Diss.* Bonn **1883**
FRIEDRICH: Engorgement of the lymphatics *Würzburg. Verhandl.* II
GEORJEVIC: *A. f. klin. Chir.* XII
HELLER: Closure of the thoracic duct *D. A. f. klin. Med.* x
LÖSCHNER: Cases of lymphatic dilatation *Prag. med. Woch.* **1889**
ZUR NIEDEN: Case of lymphangiectasis and lymphorrhagia *Inaug. Diss.* Freiburg **1882**
PETERS and KLEBS: *Prag. Viertelj. f. prakt. Heilk.* no. 125
STILLING: Thrombosis of thoracic duct *V. A.* 88 **1882**
TILGER: Lymph-cysts in the gastro-hepatic ligament *V. A.* 139 **1895** (with references)
WEGNER: Lymphangiectasis *A. f. klin. Chir.* XX **1877**

SECTION III

THE SPLEEN AND THE LYMPH-GLANDS

CHAPTER XII

MORBID CHANGES IN THE SPLEEN

26. The **spleen** is an organ which plays a peculiar and important part in the metabolism of the blood; and its relation to the vital functions of the blood accounts in some measure for its anatomical structure and for its special relation to the vascular mechanism. The characteristic tissue of the organ is the red **spleen-pulp**, which is composed of blood-vessels and adenoid tissue.

The spleen-pulp (Fig. 54) consists of cellular tissue, having a delicate membranous reticular stroma, which is strengthened by stouter fibrous strands or septa originating in the capsule or in the connective tissue about the hilum, and traversed by delicate arterioles (*c*) and by wide thin-walled venous capillaries or venules (*a a₁*). The mode of communication between the arteries and the veins is not yet finally determined. BANNWARTH is of opinion that the arterial capillaries empty their blood into the pulp, and that the venous capillaries take up their blood from it. Others maintain that there is direct communication between the arterioles and the venules, but the walls of the vessels are said to be not continuous but perforated. The walls of the small veins (*a a₁*) and arterial capillaries (*c*) consist of a somewhat closer stratum of the reticulum of the pulp, and of an endothelial lining of flattened spindle-cells (*b*), the nuclei of which

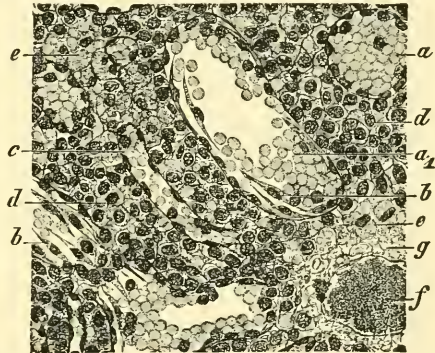


FIG. 54. SECTION OF THE DARK-RED SPLEEN-PULP.

(From a child dead of acute pyaemia: preparation hardened in Müller's fluid and alcohol, and stained with gentian-violet: $\times 200$)

- a* transverse section and
- a₁* longitudinal section of the venous capillaries or venules of the pulp
- b* endothelium of venule
- c* arterial capillary
- d* pulp-trabeculae with colourless cells and red blood-corpuses
- e* disintegrated red blood-corpuses and cells containing corpuscles
- f* colonies of micrococci in a vein
- g* necrotic tissue

project into the lumen of the vessel. The pulp-tissue lying between the vessels contains lymphoid cells and larger rounded colourless cells with one or more nuclei (*d*), ordinary red corpuscles, together with corpuscle-carrying cells (*e*), pigment-granule cells, and free yellowish or brownish or rust-coloured pigment.

In addition to the pulp, the spleen contains lymphadenoid structures known as **malpighian follicles** (or corpuscles). They form whitish granules within the red pulp, and are developed by a partial transformation of the fibro-cellular sheaths of the arteries into reticular connective tissue. They either are situated at the side of the arteries or surround them, and have a diameter of from 0.2 to 0.8 mm. They contain only small capillary vessels which enter into the substance of the pulp.

The external form of the spleen is somewhat variable, but it is generally more or less flattened or tongue-shaped. It is often remarkably lobulated, or at least deeply indented. One or more supernumerary spleens or **spleniculi**, from the size of a bean to that of a hazel-nut, are occasionally found near the spleen. Misplacements of the spleen are common. The weight of the normal organ in an adult varies between 130 and 250 grammes.

Complete **absence of the spleen** is very rare, but does occur in persons who are otherwise perfectly well-formed. The malpighian follicles are often so small as to be unrecognisable by the naked eye, or seen only with difficulty.

The **functions** of the spleen are as yet imperfectly ascertained, though it is perhaps now established that the red corpuscles are broken up within it. The corpuscles pass into the spleen-pulp and are disintegrated within its cells, **haemosiderin** being thus formed. New red blood-corpuscles are probably not produced in the spleen, but colourless cells are supplied to the blood from the malpighian follicles.

When elsewhere in the body an increased destruction of red and colourless blood-corpuscles takes place, the products of disintegration are in large part brought to the spleen, and are there destroyed and re-absorbed. The increased afflux of matters in process of disintegration is usually accompanied by congestive hyperaemia of the spleen, and is apt to produce a swelling of the organ, which has been described as a **spodogenous** splenic tumour (*σποδοσ* ashes). When the material so brought is chiefly composed of dead red corpuscles and their *débris*, the number of splenic cells containing corpuscles and pigment is increased; this may lead to a rust-coloured pigmentation of the organ, from an increase in the number of cells containing granules of haemosiderin. If dying or dead leucocytes reach the spleen, they also are taken up by the cells of the pulp and destroyed.

Foreign matters, such as coal-dust, circulating in the blood, are especially apt to be deposited in the spleen-pulp, where they

lodge chiefly in the adventitial sheaths of the arteries. If a follicle be situated at the side of a vessel, the coal-dust seems to be deposited with preference on the opposite side (ARNOLD), but the deposit may completely surround the arteriole. When an arteriole traverses the centre of a follicle, the pigment is generally found in its immediate vicinity, spreading thence into the substance of the follicle.

References on the Structure and Functions of the Spleen.

- BANNWARTH: Researches on the spleen *A. f. mikrosk. Anat.* 38 1891
 DE FILIPPI: 'Ferratin' *Ziegler's Beiträge* XVI 1894
 FOÀ: Physiopathology of the spleen *A. ital. de biol.* IV 1883
 FOA and CARBONE: Histology *Ziegler's Beiträge* V 1889
 GABBI: Normal haematolysis *Ziegler's Beiträge* XIV 1893
 HAYEM: *Du sang* Paris 1889
 HOFFMANN: Functions of hepatic and splenic cells *Inaug. Diss.* Dorpat 1890
 LAGUESSE: Splenic tissue *Anat. Anzeiger* VI 1891
 MALININ: Histology etc. of the spleen *V. A.* 115 1889
 MÜLLER: *Der feinere Bau der Milz* Leipzig 1865
 NEUMANN: *A. d. Heilk.* XV, *Berl. klin. Woch.* 1880, *Z. f. klin. Med.* III
 PONFICK: Haemoglobinæmia *Verh. Cong. inn. Med.* Wiesbaden 1883
 STIEDA: Capillaries of the spleen *V. A.* 24 1862
 TIZZONI: *A. ital. de biol.* I 1889; *Mem. della R. Accad.* VI Bologna 1886
 TIZZONI and GRIFFINI: *Atti dei Lincei* ser. 3 X and XV 1883, and *A. ital. de biol.*
 I III IV VI 1884
 VULPIUS: Surgery and physiology of the spleen *Beiträge von Bruns* XII 1894
 (with references)
 WICKLEIN: Pigment of the spleen *V. A.* 124 1891

27. Simple **atrophy** of the spleen occurs chiefly in aged or marasmic patients. The organ is small, the capsule wrinkled and sometimes thickened; the pulp seems loose, pale, and tough, its cells are scanty, the vessels are imperfectly filled with blood, and the trabeculae appear relatively prominent.

Amyloid degeneration appears most frequently in the form of the so-called **sago spleen**, in which the amyloid deposits are found chiefly in the reticular tissue of the periarterial malpighian follicles, and thence extend to the pulp (Fig. 55 b). The spleen is usually somewhat enlarged, and of a much firmer consistence than normal. In the brownish-red or greyish-red pulp, instead of the normal whitish follicles, are found light-brown hyaline translucent masses, resembling grains of boiled sago, and in size considerably larger than the normal follicles. These bodies are composed of a hyaline substance (Fig. 55 b), within which usually only the nuclei of the connective tissue and scattered leucocytes are still to be seen. When the degeneration affects the pulp by extension, or when it begins therein, the resulting degeneration is more diffuse, and the spleen becomes firmer and is more uniformly hyaline. Its resemblance to the rind of boiled bacon has led to the name of lardaceous or **bacon spleen** which is generally applied to it.

The arteries are sometimes free from the amyloid change (*a*), but sometimes they also have undergone degeneration. In amyloid degeneration of the pulp the walls of the capillaries and of the veins are markedly degenerate and thickened.

According to STILLING, an amyloid spleen may contain, in the media of the arteries and in the tissue immediately surrounding them, as well as in the trabeculae of the reticulum, **hyaline masses** that do not give the characteristic amyloid reaction with iodine. Under like conditions to those which cause amyloid degeneration a **hyaline degeneration**, affecting the vessels and the reticulum of the follicles, is sometimes observed.

Rupture of the spleen may take place spontaneously when the organ becomes abnormally enlarged. Traumatic rupture is more

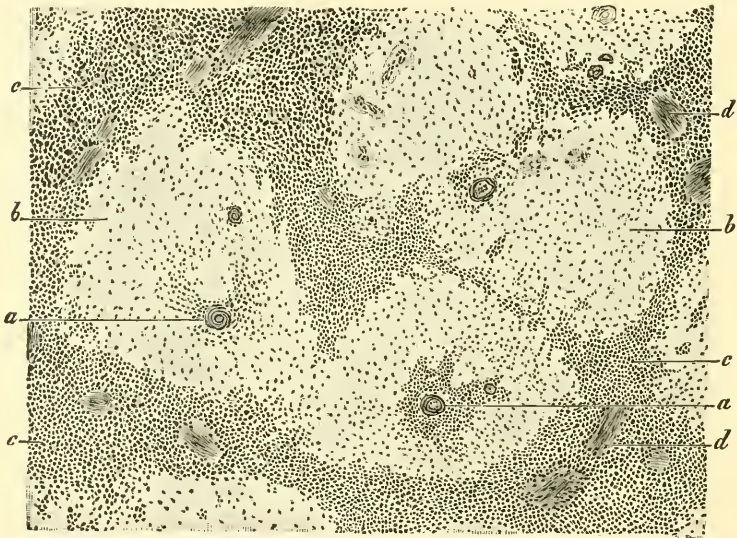


FIG. 55. AMYLOID DEGENERATION IN AND ABOUT THE SPLENIC FOLLICLES.

(Preparation hardened in Müller's fluid, stained with haematoxylin and eosin, and mounted in Canada balsam: $\times 30$)

a transverse section of branches of the splenic artery
b amyloid patches *c* pulp *d* trabeculae

common, and may occur in a healthy spleen or in one which has already undergone morbid changes. Ruptures of any considerable size are followed by very grave haemorrhage. If the haemorrhage be stayed by the formation of a coagulum filling the rent, the wound may heal as in other organs, the clot being gradually absorbed and finally replaced by a scar. The same process takes place in other wounds of the spleen.

28. **Passive hyperaemia** or engorgement of the spleen, with

its attendant consequences, follows upon such disorders of the circulation as interfere with the emptying of the splenic veins. When the hyperaemia is recent, the spleen is increased in size, filled with blood, and of a dark blackish-red colour. Its veins are distended, and the pulp contains more than the normal proportion of red blood-corpuscles. When engorgement of the spleen has persisted for some time, the organ is usually found to be either normal in size or somewhat enlarged: it is rarely smaller. It is commonly more cup-shaped than in health, and its edges are more rounded. Its firmness and toughness are always increased, and sometimes it is almost hard (cyanotic induration), owing to the greater density of the pulp. The trabeculae stand out sharply; and the capsule is often thickened. The chief textural alteration in such a spleen consists in the increased amount of fibrous tissue it contains, the increase showing itself in the trabeculae and in the walls and sheaths of the vessels. Occasionally the septal strands of the reticulum of the pulp are found to be slightly thickened.

Thrombosis of the splenic veins leads to notable swelling of the spleen. Through the calcification of thrombi in dilated branches of the splenic veins, concretions resembling calcified parasites (such as *Pentastoma*) are formed.

Anaemia of the spleen, such as follows from great haemorrhage or from pressure exerted by the adjacent organs, manifests itself by the very pale colour of the pulp.

Embolic infarction of the spleen is usually consequent upon the loosening of portions of cardiac or aortic thrombi: the infarcts are generally from the first pale and anaemic; they are less frequently haemorrhagic. They are of various dimensions; small ones may be of the size of a cherry, larger ones may extend over as much as half or more or even over the whole of the spleen.

The infarcts that are usually seen at post-mortem examinations are either of a dirty-yellow colour throughout, or the centre is of a dull or greyish-yellow or reddish-brown tint, while the margin remains dark.

In the red or haemorrhagic infarct the veins and capillaries, as well as the splenic pulp, are fully distended with blood. The follicles are infiltrated with extravasated blood only at their margins, the centres being usually unaffected. In anaemic infarcts the red corpuscles are in part disintegrated into granular masses, and in part deformed and decolorised. The nuclei of the trabeculae are no longer visible, the trabeculae themselves being swollen and beset with oil-globules. The lymphoid follicles are either necrotic, or in process of breaking up into granular and fatty detritus, few nuclei being visible. At a later stage the reticulum and cells are alike transformed into a granular mass—in other words the entire tissue perishes by necrosis. Traces of the normal structure remain only in the marginal zone of the infarct,

in which staining-reagents still bring out the nuclei of the cells and the trabeculae.

Inflammation and hyperplasia of the surrounding splenic tissue follow the necrosis, and the necrotic mass is thus by degrees re-absorbed. After a time a dense shrunken radiating cicatrix is formed in the site of the infarct; it is often pigmented, or flecked with shining white spots. Large infarcts are sometimes imperfectly re-absorbed, so that the cicatrix encloses a necrotic caseous patch.

If bacteria reach the seat of infarction, purulent or gangrenous inflammation may be set up instead of the changes just described.

References on Engorgement and Infarction of the Spleen.

- BILLROTH: Pathology of the spleen *V. A.* 23 **1862**
 BONNE: *Thrombose der Vena lienalis* Göttingen **1884**
 GUILLEBEAU: *Histologie d. hæmorrhag. Infarkte* Berne **1880**
 HAMILTON: Infarction *Liverpool med.-chir. Journ.* 5 **1883**
 LITTEN: Infarcts *Z. f. klin. med.* 1
 NIKOLAÏDES: Histology of the engorged spleen *V. A.* 82 **1880**
 PILLIET: Senile changes in the spleen *A. de méd. exp.* v **1893**
 SOKOLOFF: Venous hyperaemia *V. A.* 112 **1888**
 WEIGERT: Morbid coagulative processes (infarction) *V. A.* 79 **1880**

29. **Congestive hyperaemia** occurs most frequently as a morbid condition in those infective diseases which are accompanied by contamination of the blood with parasites or poisons. An **acute enlargement of the spleen** is thus produced, the organ often reaching a considerable size. The capillaries and the veins undergo a marked widening of their lumen, and the mass of the spleen-pulp contains more blood-corpuscles than in its normal condition. The pulp is stained an intense red, and is so soft that on section it may be easily scraped away. The malpighian follicles sometimes stand out distinctly as white nodules; sometimes they are scarcely recognisable amid the swollen pulp.

The congestive hyperaemia may pass away rapidly, but it often persists for some time, and further changes are set up in consequence. This is especially the case with the enlargement accompanying typhoid fever, pyaemia, relapsing fever, ague, acute nephritis, scarlatina, and anthrax. When the enlargement has existed for a time the pulp appears no longer red, but greyish, or pale reddish-grey, and is excessively soft, so that if the body be not entirely fresh the pulp will be almost diffluent. With the paling of the colour the volume usually increases, reaching sometimes the double or quadruple of its normal size. In extreme cases the swelling may lead to bursting of the capsule, and thus to rupture of the splenic tissue.

Enlargements of the spleen which are characterised by a greyish-red or greyish-white colour of the pulp, are to be regarded as due to inflammation, and the process is called **splenitis**. In red

spleens also histological changes are often found that show the process to be an inflammatory one, hyperaemia having passed into inflammation. In severe cases the splenic capsule is sometimes involved and becomes covered with fibrinous or fibrino-purulent or purulent exudations, so that we may speak of the condition as **perisplenitis**.

The hyperaemia and inflammation of the spleen accompanying infective diseases are caused partly by the micro-parasites intercepted and retained within the splenic tissue, partly by the toxic products elaborated by them. Accordingly in many of the infec-

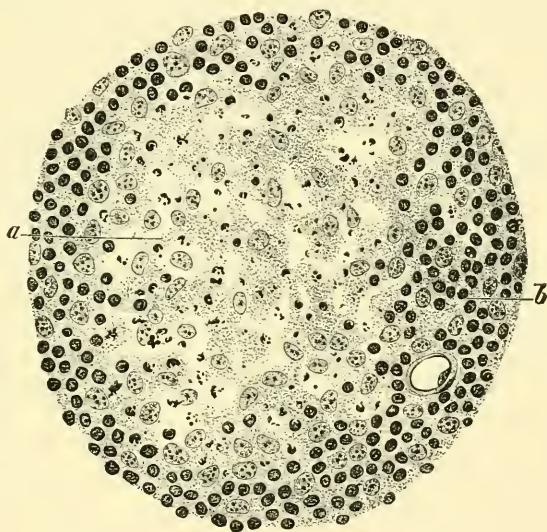


FIG. 56. LYMPHOID FOLLICLE OF THE SPLEEN WITH CENTRAL NECROSIS.

(From a case of diphtheria: preparation hardened in Flemming's acid solution, stained with safranin, and mounted in Canada balsam: $\times 300$)

- a central portion of the follicle, with numerous small masses of cellular detritus and a protoplasmic network containing feebly-stained nuclei
 b peripheral zone containing leucocytes

tions (pyaemia, typhoid fever, relapsing fever, anthrax, diphtheria, malaria), the presence of such parasites is demonstrable in the blood-vessels (Fig. 54), in the pulp (Fig. 57), or in the follicles. When excessive destruction of the blood from any cause takes place, the products of disintegration thus formed may also be deposited in the spleen, and produce 'spodogenous' enlargement.

The micro-organisms brought to the spleen and the special poisons they elaborate not rarely give rise to more or less extensive **necrosis** of its tissue, affecting the follicles or the pulp. In pyaemic infection necroses occur in the neighbourhood of the

colonies of bacteria developing within the spleen (Fig. 54 *g*). In diphtheria, on the other hand, in which the pulp is usually only slightly swollen and fairly firm, the follicles appear prominent by reason of their size and their dull white colour. Necrosis of numerous lymphoid cells within the follicles is often observed, their nuclei breaking down and their protoplasm becoming liquefied to such an extent that the follicles (Fig. 56) consist only of nuclear detritus (*a*), while at the same time the adenoid reticulum is reduced to a network of swollen cells with pale nuclei.

In relapsing fever the swollen and red or reddish-brown spleen contains areas resembling ischaemic infarcts (Art. 28), pale-yellow necrotic patches, and also small spots of necrosis limited to the follicles, within which (NIKIFOROFF) the cells are dead and devoid of nuclei. In patients who have died during an acute exacerbation of relapsing fever, the spleen shows, near the patches of necrosis, areas in which some only of the cells have lost their nuclei (Fig. 57 *c*), and in these areas can be seen more or less numerous groups of the specific spirilla lying free (*a*) or enclosed within nucleated or denucleated cells.

In typhoid fever also the swollen spleen contains large pale-yellow necrotic masses, resembling anaemic infarcts, due probably not to any direct action of the specific bacteria, but to disorder of the circulation from coagulative changes within the blood-vessels. It is very probable that the extensive necrosis met with in the spleen in relapsing fever is also due to the same cause.

Besides the above-named degenerations and necroses, which occur only in certain of the infections, acutely-swollen spleens show a more or less marked increase of the cellular elements contained in the pulp—in red spleens chiefly of the red blood-corpuscles, in pale spleens of the colourless elements. Among the latter occur numerous multinuclear leucocytes. At times fibrinous coagulation takes place, especially in cases associated with necrosis. Moreover, according to the nature of the infection and the stage the disorder has reached, we may find disintegrated and fatty leucocytes and large pulp-cells containing bacteria or other parasites (such as the *Plasmodium malariae*), or large uninuclear cells (Fig. 57 *f*) containing red corpuscles (sometimes as many as ten) or haemosiderin derived from them, together with leucocytes, whole or disintegrated. All these cells may be found within the dilated blood-vessels, or in the pulp. The endothelium of the veins may also be swollen or in part desquamated, and so likewise the cells of the pulp-reticulum. Karyokinetic figures are seen more or less frequently in the living cells both of the follicles and of the pulp.

The further course and the consequences of congestive hyperaemia and inflammation of the spleen differ in different cases.

As the general disease passes away the infiltration and swelling of the spleen-pulp usually diminish. The red and white blood-

cells accumulated in the pulp are gradually passed on or destroyed, and the spleen recovers its normal size and appearance.

In other cases it happens that after inflammation the spleen remains permanently altered. In the first place diffuse or circumscribed thickenings appear on the capsule, and take the form of flattened lenticular nodules or large cicatricial patches. These appear as a rule when the spleen has been covered over with a fibrinous exudation, the absorption of which has taken place but slowly, while part of it is replaced by granulation-tissue. **Adhesions** of the spleen to the surrounding structures are a common result of the process.

The inflammatory changes sometimes result in more or less extensive atrophy of the spleen, the pulp-tissue decreasing per-

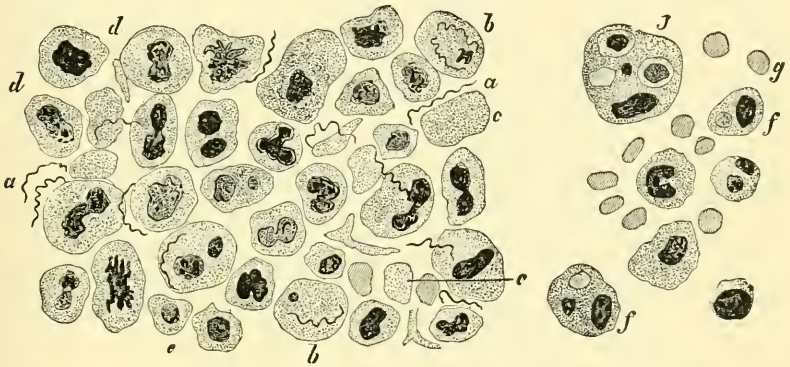


FIG. 57. PORTION OF TISSUE AND ISOLATED CELLS FROM A SPLENIC FOLLICLE UNDERGOING PARTIAL NECROSIS.

(After NIKIFOROFF: from a case of relapsing fever: preparation fixed in bichromate of potassium and corrosive sublimate, and stained with methylene-blue: \times about 600)

- | | | | |
|---|-----------------------------|---|-------------------------------------------------------------------------|
| a | free spirilla | e | small uninuclear pulp-cells |
| b | lymphocytes with spirilla | f | phagocytes containing leucocytes and red corpuscles with their detritus |
| c | lymphocytes without nuclei | g | free red blood-corpuscles |
| d | large uninuclear pulp-cells | | |

ceptibly in bulk. This happens chiefly in cases accompanied by indurative thickening of the capsule, which hinders the expansion of the organ. The trabeculae are sometimes unchanged, but occasionally they too are thickened.

Enlargement with induration of the splenic tissue is especially apt to follow repeated attacks of hyperaemia and inflammation, as in malarial fever, and is dependent either upon an actual increase of the pulp-tissue or upon the formation of new connective tissue within the reticular framework. Deposits of haemosiderin or of malarial pigment may lead to a simultaneous pigmentation of the spleen. The pigment lies in the free cells of the pulp, in the connective-tissue cells of the trabeculae, or in the vessel-walls.

Inflammation may also end in **suppuration**, which is usually circumscribed, and leads to the formation of a **splenic abscess**. In some cases however, the foci of suppuration are scattered so closely throughout the entire substance of the organ that we might fitly describe it as universal. Small abscesses may heal, and be replaced by connective tissue; large ones may diminish in size by the absorption of the pus, their cavities being closed up by granulations and cicatricial tissue, which afterwards undergo calcification. The splenic abscess often breaks through the capsule; and should the spleen be free from old adhesions the pus entering the peritoneal cavity gives rise to fatal peritonitis. If adhesions to contiguous organs have been previously formed the abscess may break into the stomach, intestine, pleura, or lungs.

References on Acute Enlargement of the Spleen in Infective Diseases, and on Purulent Splenitis.

- BARDACH: The spleen in infective diseases *Ann. de l'Inst. Pasteur* 1889
 BESNIER: Art. *Rate* in *Dict. encyclop. des sciences méd.*
 BIGNAMI: Chronic malaria *Cent. f. allg. Path.* v. (p. 356)
 BILLROTH: Normal and morbid anatomy of the spleen *V.A.* 23 1862
 BIRCH-HIRSCHFELD: Acute splenic tumour *A. d. Heilk.* XIII 1872
 EHRLICH: idem *Charité-Ann.* IX Berlin 1884
 FRÄNKEL: Splenic abscess in typhoid *Jahrb. Hamburg. Staatskrankenanstalt* 1 Leipzig 1891
 FRIEDREICH: Acute splenic tumour *Volkman's klin. Vorträge* 75 1874
 GERHARDT: Enlargement of the spleen in pneumonia *Charité-Ann.* XIII 1888
 HESS: The large cells in acute splenic hyperplasia *Ziegler's Beiträge* VII 1890
 KLEIN: *Trans. Path. Soc.* XXVIII London 1877
 LANCEREAUX: Gangrene of the spleen *Gaz. méd. de Paris* 1863
 LÜBIMOFF: Pathology of biliary typhoid *V.A.* 98 1884
 MARTINOTTI and BARBACCI: Acute splenic tumour in infections *Cent. f. allg. Path.* 1 1890
 METSCHNIKOFF: Phagocytosis in relapsing fever *V.A.* 109 1887
 MÜLLER: Histology of acute enlargement of spleen *Inaug. Diss.* Freiburg 1890.
 NIKIFOROFF: The spleen in relapsing fever *Ziegler's Beiträge* XII 1892
 PONFICK: Studies on relapsing fever *V.A.* 60 1874
 SOKOLOFF: Pathology of acute splenic tumour *V.A.* 66 1876
 SOUDAKEWITSCH: Researches on relapsing fever *Ann. de l'Inst. Pasteur* 1891
 WEIGERT: *Beiträge z. Lehre von d. Pocken* (necrosis of spleen) II 1875

30. Persistent or progressive splenic enlargement, due to an increase of the essential tissue of the spleen, must be regarded as a **hyperplasia** of the organ. It occurs, apart from inflammatory conditions, as a definite disease associated with certain morbid changes in the blood, which manifest themselves either by leukaemia (Art. 2) or by simple anaemia. The former combination is called **leukaemic**, and the latter **pseudo-leukaemic, hyperplasia** of the spleen. In their histological structure these two forms of splenic tumour are very much alike, and cannot be distinguished by mere examination of the spleen, without reference to the condition of the blood. The aetiology of the disease is unknown; its course is a chronic one, though acute cases

are recorded in which death took place in a short time. The change in the spleen is in some instances the only primary organic affection present; in other cases it is combined with analogous changes in the lymph-glands (Art. 38) and in the bone-marrow (Art. 41). The morbid hyperplasia may start first in the spleen, in the lymph-glands, or in the bone-marrow.

The hyperplasia as a rule extends uniformly over the entire spleen; it is rarely limited to isolated patches. So far as is known the affection commences with an increase of the entire parenchyma, the constituent elements all undergoing hyperplasia. The tissue is bright-red and soft, the follicles being nowhere markedly prominent. In a much rarer form of the affection the malpighian follicles (Fig. 58 *a*) first become hypertrophied, and stand out as greyish nodules or as white lobulated clusters or beaded strings.

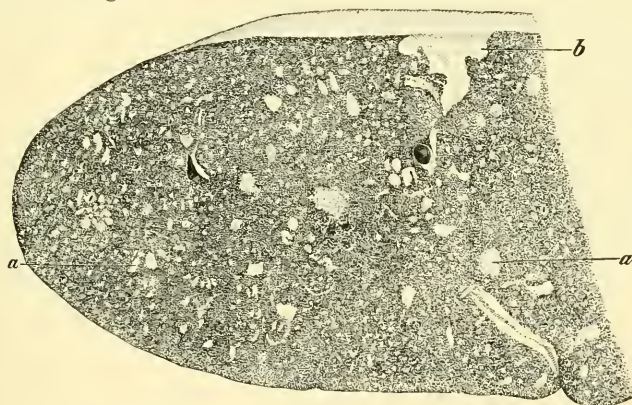


FIG. 58. HYPERTROPHY OF THE FOLLICLES OF THE SPLEEN.

(From a case of spleno-lymphatic leukaemia in a child: natural size)

a white lymphoid follicle

b yellowish ischaemic infarct

As the parenchyma increases in size the originally soft tissue becomes firmer, and at the same time paler. The follicles are often at this stage but slightly enlarged, but they sometimes become hypertrophied and form whitish nodes and clusters of considerable size (Fig. 58). The capsule is generally somewhat thickened and beset with coarse fibrous patches of various sizes, and adhesions are often formed between it and the surrounding organs. The enlargement thus brought about may be very considerable, the weight of the spleen sometimes reaching three or more kilogrammes.

In the earlier stages the hyperplastic enlargement of the pulp and follicles, apart from the amount of blood that may be present, is primarily due to an increase in the number of the constituent cells. Later on the connective tissue increases in amount, and so

leads to the greater consistence of the organ. When the follicles develop into nodes of any size they compress the spleen-pulp more or less between them, and this part of the structure often becomes atrophied in consequence. It is then found to contain fatty degenerate cells and pigment-granules either free or enclosed in cells. The section thus assumes a peculiar mottled or marbled appearance, the brown and yellow pigmented and atrophied pulp alternating with greyish and yellowish follicular nodules. The disorders of circulation consequent upon these textural alterations often lead in the later stages to the formation of haemorrhagic infarcts and anaemic necroses (Fig. 58 *b*); these, according to their age, appear as red, brown, or yellow and clay-coloured patches. Haemorrhagic and anaemic necroses, after reabsorption has taken place, sometimes leave behind fibrous and occasionally pigmented cicatrices. In hyperplastic spleens of long standing the enlarged follicles have to a great extent lost their original structure, and consist of fibro-cellular tissue with no trace of the original reticulum. The pulp also becomes in places more fibrous, and loses much of its characteristic structure.

A second form of splenic hyperplasia is met with in cases where enlargement of the spleen accompanies hypertrophic or atrophic cirrhosis of the liver. In this form also the spleen may attain a very considerable size, so that its weight reaches from 500 to 1000 grammes or more. Under certain conditions it may even exceed the weight of the liver.

The enlarged spleen in cirrhosis of the liver is similar in appearance to the leukaemic and the pseudo-leukaemic spleen, though the follicles are not enlarged. It is usually regarded as due to chronic venous engorgement (Art. 28); but the appearance of the pulp is against this view. It is fairly soft in consistence and not so dark-red as in the hyperaemic spleen, and the enlargement may be very considerable even when there is no engorgement. In moderately-enlarged spleens the pulp is rich in red and colourless corpuscles, while its structure is not materially altered. Where the enlargement is extreme, on the contrary, the characteristic structure of the pulp may be more or less effaced and the reticular tissue in part replaced by large-celled connective tissue with a fibrillated ground-substance. It is somewhat remarkable that in these cases the spleen contains a certain number, sometimes a very large number, of fatty degenerate leucocytes.

References on Splenic Hyperplasia.

- ARNOLD: Cell-division in splenic hyperplasia *V. A.* 95 **1884**
 BANTI: Enlarged spleen in hepatic cirrhosis *Lo Sperimentale* **1894**
 BIRCH-HIRSCHFELD: *Gerhardt's Handb. d. Kinderkr.* III
 GOWERS: *Trans. Path. Soc.* XXIX London **1878**
 LANGHANS: Malignant lymphosarcoma *V. A.* 54 **1872**
 MOSLER: *Path. and Therap. der Leukämie* Berlin **1872**

TROUSSEAU: *Adenia Clinique méd.* III

VIRCHOW: *V. A.* 5 1853, and *Gesamm. Abhandl.* 1856

WESTPHAL: *Pseudo-leukaemia D. A. f. klin. Med.* LI 1893 (with references)

31. **Tubercles** are very frequently found in the spleen. In acute general tuberculosis, miliary tubercles are nearly always present both in the parenchyma and in the capsule. In chronic tuberculosis the disease when it affects the spleen gives rise to caseous nodes of various sizes (Fig. 59 *a*), whose centres generally soften and break down. The tubercles are situated in the malpighian follicles, in the arterial sheaths, and in the pulp.

In **leprosy**, aggregations of cells containing bacilli make their appearance in the spleen.

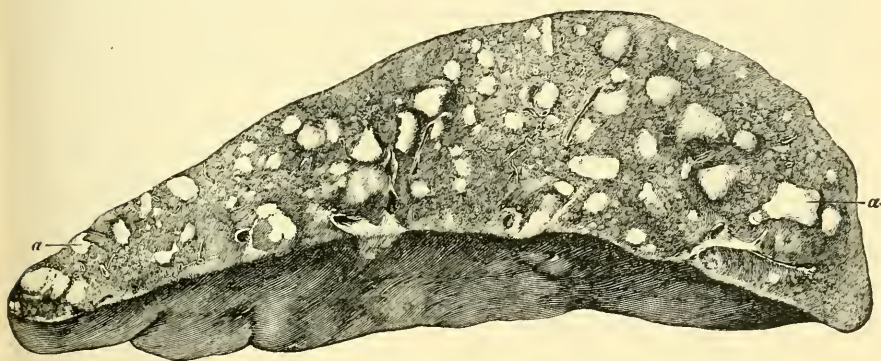


FIG. 59. CHRONIC TUBERCULOSIS OF THE SPLEEN.

(From a child: natural size)

a large caseous nodes

Gummata rarely develop in the spleen, though they are sometimes met with both in congenital and in acquired syphilis. They may be single or multiple, forming grey translucent nodes, which in later stages become yellow and opaque with a greyish-white translucent periphery.

Syphilis may also manifest itself by a general hyperplastic enlargement of the spleen, which is observed mainly in the congenital form of the disease; in some cases the pulp-cells, in others the fibrous constituents, take the chief part in the overgrowth. While the spleen of a new-born infant weighs about 9 grammes or 0.3 per cent. of the body-weight, in syphilitic infants the average weight of the spleen is, according to BIRCH-HIRSCHFELD, 14 grammes or 0.7 per cent. of the body-weight, and it may be as great as 100 grammes (ZIEGLER).

Actinomycosis of the spleen leads to purulent inflammation.

References on Syphilis of the Spleen.

- BÄRENSPRUNG: *Die hereditäre Syphilis* Berlin 1864
 BAUMGARTEN: Miliary gummata in the spleen *V. A.* 97 1884
 BEER: *Die Eingeweidesyphilis* Tübingen 1884
 BIRCH-HIRSCHFELD: *A. d. Heilk.* 1875, *Gerhardt's Handb. d. Kinderkrankh.* IV
 GOLD: *Vierteljahresschr. f. Derm. u. Syph.* 1880
 LANG: *Vorles. über Syphilis* II Wiesbaden 1885
 VIRCHOW: *Die krankh. Geschwülste*
 WAGNER: Syphiloma *A. d. Heilk.* IV 1863
 WEIL: *D. A. f. klin. Med.* XIII 1874

32. **Primary neoplasms** of the spleen are very rare. Fibroma, sarcoma, angioma, and lymphangioma have been met with. LANGHANS has described a case of pulsating cavernous angioma of the spleen, with metastases in the liver. The new-growth occupied nine-tenths of the already greatly-enlarged bulk of the spleen.

Cysts containing serous liquid may occur in the splenic capsule: they are produced by the abstriction of portions of the peritoneal endothelium (RENGGLI). They are however very rare.

Metastatic growths, especially of carcinoma and sarcoma, are more common than the primary forms. They usually take the shape of rounded nodules.

Pentastoma, *Echinococcus* (hydatids), and *Cysticercus* are met with as **animal parasites** of the spleen.

References on Tumours of the Spleen.

- BARBACCI: Lymphangioma *Lo Sperimentale* 1891
 EILELT: *Prag. Vierteljahrsschrift* 76 1862
 FINK: Fibroma and lymphangioma *Prag. Z. f. Heilk.* VI 1885
 LANGHANS: Cavernous tumour *V. A.* 75 1879
 MARTIN: Cavernous tumours and sarcoma of the spleen in the horse *Jahresber. d. K. Thierarzneischule* Munich 1882-83
 RENGGLI: Multiple cysts of the spleen *Inaug. Diss.* Zürich 1894
 SCHEFFER: *Jahrb. f. Kinderheilk.* XV 1880
 SPILLMANN: Cystic haematoma *A. de physiol.* 1876
 WEICHELBAUM: Sarcoma and lymphoma *V. A.* 85 1884

CHAPTER XIII

MORBID CHANGES IN THE LYMPH-GLANDS

33. The **lymph-glands** are structures of peculiar formation intercalated in the course of the lymphatic vessels: they consist on the one hand of the lymph-paths or sinuses communicating with the lymphatics (Fig. 61 *b* and Fig. 62 *b e*), on the other of the lymphatic follicles (Fig. 61 *a* and Fig. 64 *a*) and the inter-follicular septa. The supporting framework of both sets of structures is a reticular connective tissue, whose trabeculae contain nuclei at their intersections and are covered with a layer of endothelium, and whose meshes enclose free lymphoid cells. In the lymphatic follicles a central region can be distinguished, the cells of which are somewhat larger and stain less readily than the lymphocytes of the peripheral zone. Among the larger cells a number always contain nuclei in process of division, so that this region is to be regarded as the germinal centre (Fig. 64 *a*) of the lymph-gland, from which new cells are continually being produced and supplied to the lymph flowing through the gland. The delicate reticular framework is supported by a many-layered fibrillar capsule; from this trabecular septa extend into the interior and unite at the hilum of the gland, thus dividing the parenchyma into separate segments or loculi.

Simple atrophy of the lymph-glands is to some extent a normal accompaniment of advanced age, when the lymph-glands and the lymphadenoid follicles of the mucous membranes tend to become smaller. When this shrinkage takes place early in life, or in an aged person to an unusual degree, it must be regarded as pathological.

The lymphoid elements, especially those in the centre of the gland, are first and most markedly affected. They may entirely disappear, the remaining connective tissue being changed into adipose tissue, beginning at the hilum. This change is most frequently observed in the mesenteric glands.

Atrophied lymph-glands, when they are not pigmented, have a light-grey tint and are usually firmer than normal; when they become fatty they exhibit the characteristic appearance of adipose tissue.

Amyloid degeneration of the lymph-glands usually accompanies amyloid disease of other organs; it is rarely met with by

itself. When the glands alone are affected the change is nearly always due to some chronic tuberculous suppuration within the territory whence their lymph-supply is drawn; at times the glands themselves are also beset with tubercles. If the amyloid change is at all advanced it is often distinguishable by the dull greyish tint and firm consistence of the glands on section; to make certain, however, we must employ the iodine or methyl-violet reaction, or examine the glands microscopically. At times

the lymph-sinuses are chiefly affected; in other cases, and this occurs more frequently, the follicles and the septa.

The process of degeneration begins with a hyaline thickening of the reticular trabeculae (Fig. 60 *a*). Then the thickened trabeculae become nodulated (*b*) and finally by coalescence form continuous homogeneous blocks or flakes. The nuclei of the reticulum (*c d*) often remain unaltered for an astonishingly long time, but ultimately they disappear. The lymphoid elements diminish in proportion as the reticulum thickens, and may here and there disappear entirely.

Hyaline degeneration

occurs within the lymph-glands, especially affecting the walls of the blood-vessels (Fig. 35). Other portions of the gland may also be converted into hyaline masses. The caseation of tuberculous lymph-glands is sometimes preceded by a homogeneous degeneration of their cells.

References on Degeneration of the Lymph-glands.

- BAUMGARTEN: Tuberculosis *Z. f. klin. Med.* ix
 BILLROTH: *Pathol. Histologie* Berlin 1858
 FLEMMING: On regeneration of tissues *A. f. mikrosk. Anat.* xxiv 1884
 HOYER: Researches on lymph-glands *A. f. mikrosk. Anat.* xxxiv 1890
 KOEPE: The lymph in its relation to the development of cells in the lymph-glands *A. f. Anat.* supplement 1890
 LIONVILLE: Mediastinal adenopathy in the aged *A. de physiol.* 1869
 RANVIER: *Traité d'histologie* Paris 1875-88
 VALLAT: Hyaline degeneration in tubercle and gumma *V. A.* 89 1882
 WIEGER: Hyaline degeneration in the lymph-glands *V. A.* 78 1879

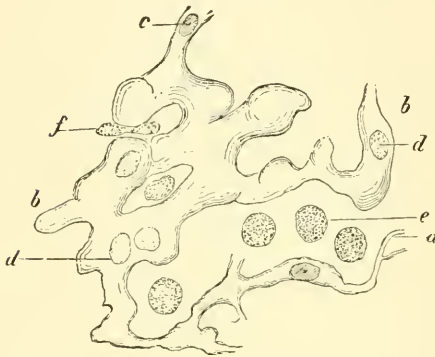


FIG. 60. AMYLOID SWELLING OF THE ADENOID RETICULUM.

(After EBERTH: methyl-violet preparation: $\times 350$)

- a normal reticulum
- b swollen reticulum
- c unaltered nucleus
- d degenerate nuclei
- e normal lymphoid corpuscles
- f atrophied lymphoid corpuscles

34. Minutely-divided **foreign substances** that have gained access to the lymphatic vessels are intercepted and retained for a longer or shorter time in the glands. Dead cells thus brought to the lymph-glands are there disintegrated. Thus, during the re-absorption of extravasated blood, the detritus of the red blood-corpuses is conveyed to the lymph-glands and there accumulates, enclosed within the carrier-cells.

At first the pigment-carrying cells are met with mainly in the lymph-sinuses (Fig. 61 *b*), but afterwards they enter the follicles (*a*) and the reticular mesh-work. If they are numerous the lymph-gland will present a dark brownish-red or rust-coloured appearance, not unlike that of the reddish-brown spleen-pulp.

Other substances may in like manner be retained in the glands, and if they have any colour of their own the gland of course becomes pigmented. The most familiar instance of this is the grey or black **pigmentation of the bronchial glands** at

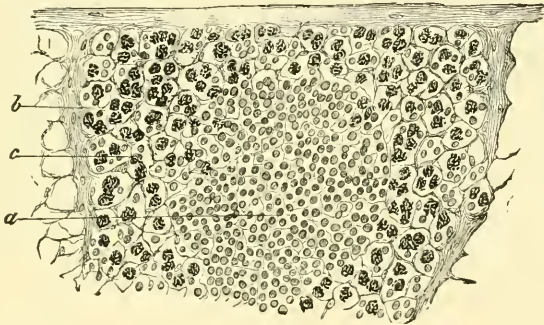


FIG. 61. DEPOSIT OF PIGMENT-CARRYING CELLS IN A LYMPH-GLAND AFTER RESORPTION OF AN EXTRAVASATION OF BLOOD.

(Preparation hardened in Müller's fluid, stained with carmine, and mounted in Canada balsam: $\times 100$)

a follicle near the surface *b* lymph-sinus in a septum *c* pigment-granule cell

the hilum of the lung. In persons who have had their skins tattooed the glands which receive the corresponding lymphatics are often found after a time to contain some of the insoluble pigment. After inflammation of the skin its pigment may be carried to the lymph-glands.

The **consequences** of this deposit of inert foreign matters in the glands depend on their amount and on their physico-chemical nature. Many substances, such as calcium carbonate, are dissolved; others, like charcoal or cinnabar, remain and lead to permanent pigmentation. They lie enclosed in lymphoid cells (Fig. 62 *c*) or lodged in the cells of the reticulum or the trabeculae. If the amount present is small the changes induced are trifling; larger amounts lead to shrinking and induration of

the gland. The lymphoid elements dwindle and disappear, while the meshes of the reticulum become filled with pigment-carrying cells (Fig. 62 *c* and *c'*) and free pigment. The reticulum may be unaltered, or in part hyperplastic (*a*), in which case it is made up of large branching and anastomosing cells. Dense fibrillar connective tissue (*b*) is often formed in places, and this too contains pigment.

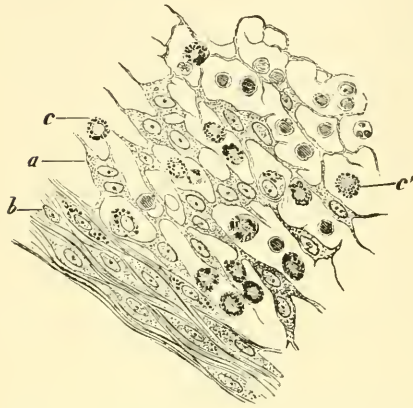


FIG. 62. SECTION OF A SLATE-COLOURED LYMPH-GLAND OF THE LUNG.

(Preparation hardened in alcohol, stained with carmine, and mounted in Canada balsam: $\times 250$)

a reticulum made up of large branched cells
b fibrillar connective tissue
c and *c'* round cells containing pigment

When insoluble dust is carried to the gland in great abundance, **softening** as well as inflammation and hyperplasia of the surrounding structures may take place. This sometimes gives rise to adhesions of the gland to the parts in its immediate neighbourhood, and not infrequently results in **ulceration** of the adjacent tissues.

Chemically-active substances have of course a very different effect, as also such living micro-organisms as

may reach the glands. They usually set up more or less intense inflammation, and not infrequently lead to active proliferation and hyperplasia.

References on the Deposition of Foreign Substances in the Lymph-glands.

ARNOLD: *Staubinhalation und Staubmetastase* Leipzig 1885

DE FILIPPI: 'Ferratin' *Ziegler's Beiträge* XVI 1894

GABBI: Normal haematolysis *Ziegler's Beiträge* XIV 1893

GROHE: Melanaemia *V. A.* 20 1861

HINDENLANG: Pigmentation of lymph-glands in purpura *V. A.* 79 1880

OEKONOMIDES: Chronic affections of the bronchial glands *Inaug. Diss.* Basle 1882

ORTH: The lymph-glands in resorption of extravasated blood *V. A.* 55 1872

RIEHL: Pigmentation of lymph-glands in Addison's disease *Z. f. klin. Med.* x

SCHMORL: Transport of pigment from the skin *Cent. f. allg. Path.* iv 1893

VIRCHOW: *Cellularpathologie* 4th edition (p. 224) Berlin 1871

35. Inflammation of lymph-glands or **lymphadenitis** is usually of lymphogenous origin, but it may also be set up by irritants brought to the glands by way of the blood. The most frequent causes of the inflammation are bacteria, or the chemically-active poisons or 'toxins' produced by them.

The chief symptom of **acute inflammation** is swelling of the gland (in the inguinal region the swelling is called a **bubo**). This is primarily due to excessive dilatation of the blood-vessels of the gland, and is afterwards increased by the accumulation of inflammatory exudations in the gland-tissue. The appearance of the inflamed gland varies with the intensity of the hyperaemia and the condition of its parenchyma; its colour is sometimes greyish-red to dark-red, sometimes light-grey or greyish-white: in consistence the tissue is usually soft and moist. In severe cases of longer duration patches of necrosis appear, which are small (as in diphtheria) or large (as in typhoid fever), and have a turbid

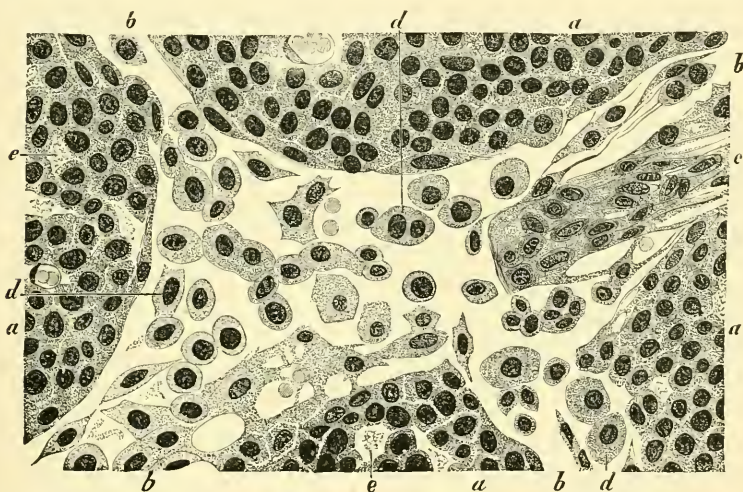


FIG. 63. INFLAMMATORY OEDEMA OF A LYMPH-GLAND, WITH CATARRHAL DESQUAMATION OF THE ENDOTHELIUM OF THE LYMPH-CHANNELS.

(From a cervical gland of a child dead of scarlet fever; preparation hardened in Müller's fluid, stained with haematoxylin and eosin, and mounted in Canada balsam: $\times 300$)

- | | |
|-------------------------------------|----------------------------|
| a lymphoid tissue | b lymph-channel |
| c connective-tissue trabeculae | d desquamated endothelium, |
| e clear space distended with liquid | |

greyish-white tint. In other instances yellowish-white foci of liquefaction and suppuration are visible (as in pyaemia or syphilitic chancre). The circumglandular tissue is usually also inflamed, oedematous, or infiltrated with purulent or fibrino-purulent or haemorrhagic exudations.

The irritant which gives rise to lymphadenitis may lead to primary necrosis or at least to degeneration of the tissue of the gland. Thus in septic suppuration more or less extensive necrosis occurs in the neighbourhood of the bacterial colonies. In diphtheria we find in the germinal centres of the lymph-follicles necrotic foci similar to those already figured and described in the case of

the follicles of the spleen (Fig. 56). Within these areas the nuclei of the lymphocytes and of the reticulum are disintegrated or deprived of their chromatin, the reticulum itself is replaced by peculiar formations that appear granular or homogeneous according to the method of preparing the tissue for examination. In diphtheria, such changes take place chiefly in the tonsils and follicular glands of the pharynx, and in the lymph-glands corresponding to the area of mucous membrane inflamed; but they are not absent in other aggregations of lymphadenoid tissue, such as the mesenteric glands and the agminate and solitary follicles of the

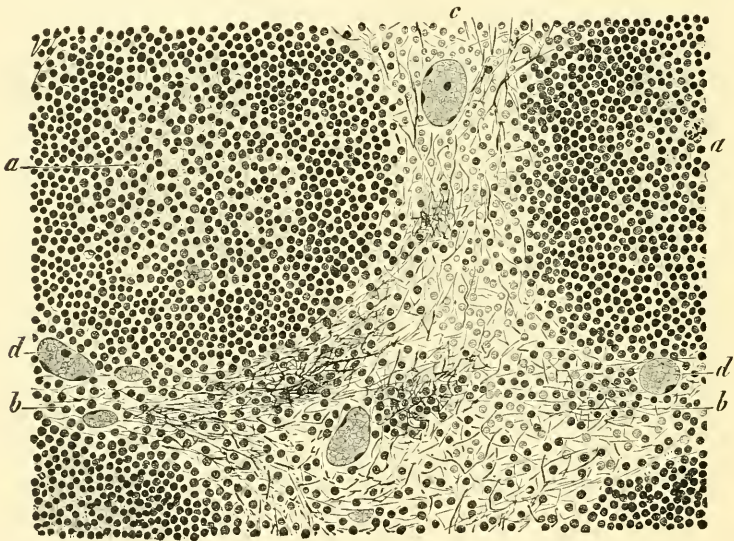


FIG. 64. FIBRINOUS LYMPHADENITIS.

(Red and swollen cervical gland from a child who suffered from laryngitis and tracheitis due to diphtherial croup: preparation hardened in Müller's fluid, stained with haematoxylin and eosin, and mounted in Canada balsam: $\times 200$)

a lymph-follicle with well-marked germinal centre

b c lymph-channels with fibrino-haemorrhagic exudation
d distended blood-vessel

intestine. Similar but less pronounced changes are occasionally met with in connexion with other varieties of acute lymphadenitis, as for instance in the mesenteric glands after acute intestinal inflammation. In other cases again conditions of fatty degeneration are observed, partly in the cells of the follicles and septa, and partly in the cells of the lymph-channels.

The exudation is at the outset composed chiefly of liquid, which is poured into the lymph-channels and often flushes them out to such an extent (Fig. 63b) that they become at first almost devoid of cellular elements. This often leads to desquamation of the

endothelium of the lymph-channels, which then contain large cast-off cells (Fig. 63 *d*), and they may thus be said to be in a condition of **desquamative catarrh**.

In more intense inflammation the exudation assumes a fibrinous, fibrino-haemorrhagic, or purely haemorrhagic character. The admixture of a few red blood-corpuscles with the contents of the lymph-channels is very common both in the catarrhal form and in ordinary inflammatory swelling. The fibrinous exudation appears most frequently in the lymph-channels (Fig. 64 *b c*). These may be in parts markedly distended, and contain a loose fibrinous mesh-work enclosing leucocytes and red blood-corpuscles. In diphtheria the lymphadenoid follicles of the tonsils, the follicular glands of the tongue, and the cervical lymph-glands, are the chief seats of the fibrinous exudation; and they are sometimes, whether they are necrotic or otherwise unaffected, permeated by a close mesh-work of fibrinous filaments (Fig. 64 *a*).

Fibrinous exudations in the glands occur mainly in connexion with croupous inflammations (such as diphtheria or pneumonia) of the corresponding mucous membranes, and with typhoid fever; the necrotic foci which in typhoid are formed in the mesenteric glands may be thickly beset with fibrinous threads. The blood-vessels in these inflammations often show signs of hyaline thickening.

When inflammation leads to **suppuration** a large number of multinuclear leucocytes are collected in the lymph-glands, and abscesses are formed. These cause a larger or smaller portion of the gland to undergo liquefaction and disintegration, and not infrequently extend to the adjacent parts, giving rise to **purulent periadenitis**.

The process of **resolution** after inflammation consists chiefly in the removal of the exudation, the fibrin and cells it contains being disintegrated and liquefied: the cells frequently show signs of swelling and fatty degeneration before they disappear. The *débris* of the exudation, and in particular of the red blood-corpuscles, is largely taken up by the surviving proliferous cells.

Signs of proliferation are soon visible both in the free and in

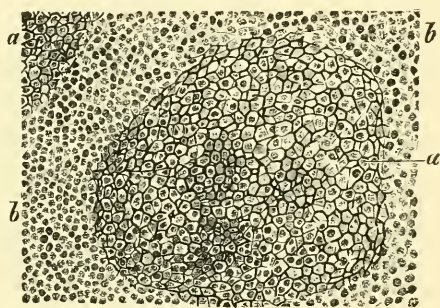


FIG. 65. FIBRINOUS MESH-WORK IN THE LYMPHADENOID FOLLICLES OF THE TONSIL IN CROUPOUS PHARYNGITIS FROM DIPHTHERIA.

(Preparation hardened in alcohol, stained with methyl-violet, and partly decolorised with iodine, xylol, and aniline-oil: $\times 150$)

- a* follicle with fibrinous mesh-work
b interfollicular tissue containing lymphoid cells

trophy). It may however happen, as in the case of glandular hyperplasia from the irritation of dust, that the connective-tissue elements undergo proliferation, and this leads to fibroid induration of the substance of the gland (Fig. 66 *a b*).

References on Lymphadenitis.

- BERTHÉRAND: *Traité des adénites* Paris 1852
 BILLROTH: *Pathologische Histologie* Berlin 1858
 BULLOCH and SCHMORL: The lymph-glands in epidemic diphtheria *Ziegler's Beiträge* XVI 1894
 KLEIN: *Trans. Path. Soc.* XXVIII London
 OEKONOMIDES: Chronic affections of the bronchial glands *Inaug. Diss.* Basle 1882
 OERTEL: *Pathogenese d. epidemischen Diphtherie* Leipzig 1887
 PETERS: Hyaline degeneration in diphtheria of the respiratory tract *V. A.* 87 1887
 RIBBERT: Regeneration and inflammation of the lymph-glands *Ziegler's Beiträge* VI 1889
 ROLLET: *Art. Bubo Dict. encyclop. des sciences méd.* Paris 1870
 ROUX and LANNOIS: Infective adenitis (*Staphylococcus pyogenes aureus*) *Rev. de méd.* X 1890
 SPIETSCHKA: Aetiology of the venereal bubo (no microbes detected) *A. f. Derm.* XXVIII 1894
 THOMAS: Researches on dysentery *A. gén. de méd.* 2nd series VII 1835
 VON ZEISSL: *Art. Bubo Eulenburg's Realencyklop.* (with references)

36. **Tuberculous lymphadenitis**, often called scrofulous lymphadenitis, is usually caused by the invasion of tubercle-bacilli carried by the lymph, more rarely by infection from the blood. When the disease is lymphogenous the organs from which the infected lymph comes are as a rule tuberculous. The point of entry of the bacilli may however remain free from tuberculosis, so that the lymph-glands (bronchial or cervical) exhibit the first local manifestation of the disease.

The tubercles usually form first in the lymphoid follicles and septa, and their eruption is indicated by the appearance of uninuclear or binuclear epithelioid cells (Fig. 67 *a*), and later on of giant-cells (*c*), some containing bacilli. They lie close to each other, compressing the original lymphoid cells, and finally take the form of the familiar large-celled tuberculous nodule (Fig. 67 *a*).

The eruption of tubercles may be accompanied by signs of more or less intense inflammation, as a consequence of which the lymph-glands appear swollen and reddened. The number of leucocytes in the tissue is increased, owing in part to the migration of white corpuscles from the blood-vessels, and probably also to an increased production of lymphoid cells. When mature (*a*) and caseous (*a*₁) tubercles are present, the cut surface shows the characteristic light-grey and whitish nodules.

In the later stages of the process the swollen lymph-glands, from the continued production of caseating tubercles, appear beset

with large yellowish-white caseous patches, which tend to become confluent. After a time the entire lymph-gland, or at least a large portion of it, may be converted into a cheesy mass, which later on becomes softened or calcified.

The signs of inflammation and the accumulation of leucocytes in the glandular parenchyma are often inconsiderable. The process then consists essentially in the progressive new-formation of epithelioid cells, which form small nodular masses. These become confluent (Fig. 68 *b c*), and the lymphadenoid tissue (*a*) is accordingly more and more encroached on and reduced to isolated strands,

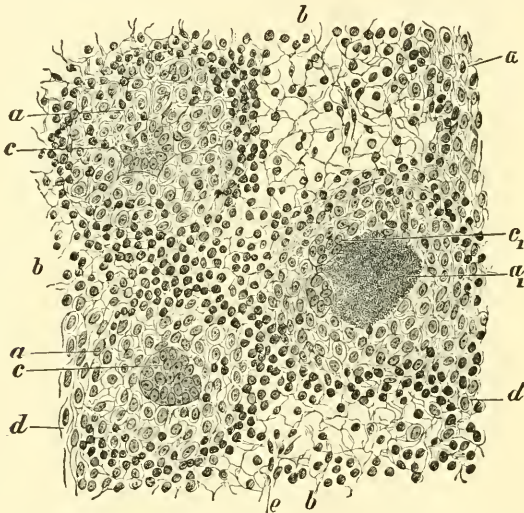


FIG. 67. RECENT TUBERCULOSIS OF A LYMPH-GLAND.

(Preparation hardened in Müller's fluid, stained with haematoxylin, agitated in a test-tube, and mounted in Canada balsam: $\times 150$)

- | | |
|-------------------------------------------------|--------------------------------------------------------------------|
| <i>a</i> fresh tubercle | <i>c</i> ₁ giant-cell at the border of a caseous nodule |
| <i>a</i> ₁ caseous tubercle | <i>d</i> large-celled lymphadenoid tissue outside the tubercles |
| <i>b</i> lymphadenoid tissue | <i>e</i> lymphoid cells |
| <i>c</i> giant-cell in the centre of a tubercle | |

while the remainder of the structure is made up of large rounded (*b*) and stellate or spindle-shaped (*c*) cells, that form a striking contrast to the lymphoid cells. Caseous necrosis seems not to supervene for a long while, though after a time the large-celled tissue is here and there converted into a mass of homogeneous hyaline material or of lustrous blocks and flakes devoid of nuclei.

The hyperplastic process just described, which leads to what is anatomically a large-celled hyperplasia of the lymphoid tissue, is always associated with an increase in the size of the gland, which may become as large as a pigeon's egg or even a hen's egg, and is dense and firm in texture. The section appears either uni-

formly grey and translucent, or seems to be made up of small greyish granules. When exposed to the air for a time, the cut surface acquires a brownish colour. When caseation has occurred, the tissue contains uniform yellowish patches resembling the surface of a cut potato.

This large-celled hyperplasia, with tardy and inconsiderable caseation, is one of the less dangerous forms of tuberculous lymphadenitis, for it appears to remain for a long time limited to the affected gland. It is chiefly met with in the cervical glands, but is not uncommon in those at the root of the lung, where it is generally combined with pigmentary induration due to the inhalation of carbonaceous dust.

In many cases, especially in children, the multiplication of tubercle-bacilli within the lymph-gland, and the cellular prolifera-




FIG. 68. LARGE-CELLED HYPERPLASIA OF A TUBERCULOUS LYMPH-GLAND.

(Preparation hardened in Müller's fluid, stained with alum-carmin, and mounted in Canada balsam : $\times 150$)

a remnants of lymphadenoid tissue b large-celled tissue c spindle-celled tissue

tion and inflammation thereby induced, are quickly followed by caseation, so that the glands have hardly begun to swell before they show cheesy enclosures. By the time they have reached any considerable size they are already converted into soft or even diffiuent caseous masses encapsuled only by a thin layer of indurated non-caseous tissue. By continued caseation and softening, the process may extend to the neighbouring parts, and so lead either to an induration or to a caseous and purulent periadenitis. Caseation of a subcutaneous gland may result in its rupture through the skin. In deeply-seated glands rupture not infrequently occurs into neighbouring cavities and channels, such as the pericardial sac, the veins, the bronchi, the oesophagus, or the intestine. Whether these processes are in all cases due solely to the action of the tubercle-bacilli, or whether the microbes act in coöperation with other irritants, is not yet definitely determined.

References on Tuberculous Lymphadenitis.

- ARNOLD, J.: Tubercle of the lymph-glands and spleen *V. A.* 87 **1882**
 BAUMGARTEN: *Volkmann's klin. Vorträge* 218 and *Z. f. klin. Med.* ix **1885**
 CORDUA: Tubercle and lymphoma of the glands *Arbeiten path. Inst. Göttingen* **1893**
 CORNIL: *Journ. de l'anat. norm. et pathol.* **1878**
 FRANKEL, A.: *Prag. Z. f. Heilk.* **1885**
 KOCH: Aetiology of tuberculosis *Berl. klin. Woch.* **1882**
 LOOMIS: Primary tuberculosis of bronchial glands *Records of Loomis Lab.* II New York **1892**
 NEUMANN: Tubercle of bronchial glands in children *D. med. Woch.* **1893**
 OEKONOMIDES: Chronic bronchial gland affections *Inaug. Diss.* Basle **1882**
 SCHUCHARDT and KRAUSE: Tubercle-bacilli in lymph-glands *Fortschr. d. Med.* I **1883**
 SCHÜPPEL: *Lymphdrüsentuberculose* Tübingen **1871**
 WYSSOKOWITSCH: *Ueb. die Beziehungen der Scrofulose zur Tuberculose* Wiesbaden **1890**

37. **Syphilitic infection** of the lymph-glands takes place mainly from specific contamination of the lymph brought to them; it is rarely conveyed to them by the blood. The syphilitic initial sclerosis is followed by a scarcely perceptible swelling of the nearest glands, which is referred to as **indolent** or **hard bubo**. In the further course of the disease glandular affections may arise in connexion with any of the various inflammatory manifestations of secondary syphilis, and sometimes assume a gummatous character.

The infected lymph-glands are more or less swollen, and may reach the size of a walnut. As a rule the swelling is due essentially to an accumulation of leucocytes, though it sometimes depends on large-celled hyperplasia. After a certain time, which usually extends considerably beyond the duration of the primary affection, it may be months or even years afterward, the enlarged lymph-glands generally diminish in size and recover, owing to diminution of the number of round-cells contained within their tissue. It may, however, happen that the process results in fibrous induration or in gummatous caseation of the diseased gland.

In **leprosy** the infected glands contain numbers of large cells enclosing multitudes of lepra-bacilli, and bacilli lying free in the gland-tissue.

References on Syphilitic Lymphadenitis.

- BÄUMLER: *Ziemssen's Cyclop.* III **1886**
 CORNIL: *Gaz. méd. de Paris* **1878**, and *Journ. de l'anat. et de la physiol.* **1878**
 DOYEN: *A. gén. de méd.* **1883**
 LANCEREAUX: *Traité de la syphilis* Paris **1873**
 LANG: *Pathol. und Therap. d. Syphilis* Wiesbaden **1885**
 LUSTGARTEN: Subcutaneous glandular affections in late syphilis *Wien. med. Presse* **1890**
 VAJDA: *Viertelj. f. Derm. u. Syphilis* II **1875**
 VIRCHOW: *Krankhafte Geschwülste* II

38. Under the head of **progressive lymphadenoid hyperplasia**, or **lymphadenia**, may be comprehended a peculiar group of affections, whose aetiology is still altogether obscure, their common character consisting in a progressive increase of the lymphadenoid tissues. On the one hand individual lymph-glands become notably augmented in bulk, forming tumours varying in size from that of a large bean or walnut to that of a hen's egg, while on the other hand fresh glands are continually becoming affected by the hyperplastic process. The process may commence in the lymph-glands proper, such as those of the axilla, or in the lymphadenoid tissue of the spleen (Art. 30) or of the mucous membranes, such as that in the tonsils and intestinal follicles, and thence extend continuously over an ever-widening area, in certain cases indeed over the whole of the lymphadenoid tissues. Analogous changes often appear in the bone-marrow, and lymphadenoid growths may be found in places which normally contain no such tissue. The similarity of the disease, in its course and progress, to some of the infections, for example to certain forms of tuberculous lymphadenitis, makes it in some measure probable that lymphadenia is also infective in its nature, though at the present time there is no proof whatever that this is the case.

On macroscopic examination the enlarged lymph-glands exhibit in section a whitish or greyish-white, less commonly a greyish-red surface, and in rare cases contain also a few necrotic foci. According to their degree of consistence we may distinguish them into soft and hard forms. Intermediate forms are, however, met with, and in a given case the several affected glands may possess different degrees of hardness.

Under the microscope the normal structure of the gland is in some cases still recognisable, the follicles, septa, and sinuses being clearly differentiated; in such examples the increase in size is essentially due to the overgrowth of the lymphoid follicles. The condition is therefore fitly described as a glandular hypertrophy or **lymphadenoma**. In other cases the structure so far deviates from the normal that recognition of the several components is no longer possible, the entire tumour being made up of lymphadenoid tissue of perfectly uniform texture, whose reticulum encloses an extraordinarily large number of free cells. The tissue of the trabeculae and capsule, and sometimes also that immediately surrounding the capsule, is closely studded with rounded cells. Lastly, the reticular framework may also undergo a hypertrophic modification, becoming stouter and coarser, and in part even converted into stringy fibrous tissue, which is far removed in texture from the typical adenoid reticulum.

Its marked deviation in structure from the normal type of the gland has caused this form of overgrowth to be classed with the sarcomata, under the head of **lymphosarcoma**. Lymphosarcomata are described as soft or hard according to the extent to

which the connective-tissue element is developed, and the corresponding degree of consistence of the tissue.

The characters of a particular glandular tumour may be so well marked that it is easy to determine whether it should be classed as a lymphadenoma or as a lymphosarcoma. Cases occur, however, in which the features of the two varieties are combined, so that along with heteroplastic tissue resembling that of a lymphosarcoma there are in the same gland definite and typical lymphoid follicles and septa. As a consequence, writers often make no distinction between lymphadenoma and lymphosarcoma, but have used the terms indifferently for both classes of growths.

By many the difficulty is evaded by describing all the progressive lymphadenoid growths as **malignant lymphoma**.

Progressive lymphadenia is a disease which may last for a few weeks (as in acute leukaemia), or for several years, before it ends in death. In some of the cases, associated with soft forms of lymphadenoma and of lymphosarcoma, the blood contains an increased number of colourless corpuscles. The affection, thus allied with leukaemia, is then called **leukaemic adenia**, and the glandular tumour is described as **leukaemic lymphadenoma** or **lymphosarcoma**. In other cases this symptom is absent, and the disease is associated only with marasmus and general anaemia, or the blood may exhibit no demonstrable change. These cases are met with chiefly in connexion with hard lymphosarcoma, though in some of them the soft variety is alone present. The affection is variously referred to as **Hodgkin's disease**, simple **adenia** (TROUSSEAU), lymphosarcoma (VIRCHOW), malignant lymphoma (BILLROTH) in the stricter sense, or **pseudo-leukaemia** (COHNHEIM).

We do not yet know why the progressive hyperplasia of the lymph-glands is sometimes associated with leukaemia and sometimes not. The cells contained in the reticular framework are either exactly like normal lymphocytes, especially in lymphadenoma, or some of them are distinctly larger, as in lymphosarcoma; but there are no invariable and characteristic differences between the glandular tumours that are accompanied by leukaemia and those that run their course without this symptom. In some instances, particularly in lymphosarcoma, along with uninuclear and binuclear cells, a few multinuclear giant-cells are observed. According to GOLDMANN, the tumours may also contain eosinophile cells in somewhat large numbers. Proliferous changes, indicated by karyokinesis in the nuclei, can be detected both in the free cells and in the cells of the reticulum.

References on Lymphadenia.

- ARNOLD: Cell-division in acute lymphadenoid hyperplasia *V. A.* 95 **1884**
 BERGMANN: *Gerhardt's Handb. d. Kinderkrankheiten*
 BRENTANO and TANGI: Aetiology of pseudo-leukaemia *D. med. Woch.* **1891**
 BRIGIDI and PICCOLI: Simple adenia and hyperplasia of the thymus *Ziegler's Beiträge XVI* **1894**
 COHNHEIM: Pseudo-leukaemia *V. A.* 33 **1865**; *Allgem. Pathologie I* **1882**
 COMBENALE: Case of adenia *Rev. de méd.* XII
 CORDUA: Tuberculous adenitis and lymphoma *Arbeiten path. Inst. Göttingen* **1893**
 DEMANGE: Lymphadenia *Thèse Paris* **1874**
 DRESCHFELD: Lymphosarcoma *D. med. Woch.* **1891**
 EBERTH: Adenia *V. A.* 49 **1870**
 FLEMING: Regeneration of the tissues *A. f. mikrosk. Anat.* XXIV **1884**
 GOLDMANN: Malignant lymphosarcoma *Cent. f. allg. Path.* III **1892**
 HODGKIN: Morbid appearances of the absorbent glands and spleen *Med.-chir. Trans.* XVII London **1832**
 HUBERT: *Les néoplasmes des ganglions lymphatiques* Paris **1878**
 KELSCH and VAILLARD: Lymphadenoid tumours with leukaemia *Ann. Inst. Pasteur* IV
 KUNDRAT: Lymphosarcomatosis *Wien. klin. Woch.* **1893**
 LANGHANS: Malignant lymphosarcoma (pseudo-leukaemia) *V. A.* 54 **1872**
 PAULSEN: Multiplication of cells in hyperplastic lymph-glands and tonsils *A. f. mikrosk. Anat.* XXIV **1884**
 VIRCHOW: *Krankhafte Geschwülste* II
 WAGNER, HARTING, and HESSE: *Eulenburg's Vierteljahrsschr.* XXX, XXXI
 WEISHAUP: Relation of pseudo-leukaemia to tubercle *Arbeiten path. Inst. I* Tübingen **1891**
 WESTPHAL: Pseudo-leukaemia *D. A. f. klin. Med.* LI **1893** (with references)
 WINIWARTER: Lymphadenoma *Langenbeck's Arch.* XVIII **1875**
 WUNDERLICH: Pseudo-leukaemia *A. d. Heilk.* VII **1866**
 ZEHNDER: Regeneration of the lymph-glands *V. A.* 120 **1890**

39. **Sarcoma** is the only primary tumour met with in the lymph-glands. It generally occurs in single glands, or several of the same group are simultaneously affected and cohere into a nodular tumour. It often overpasses the limits of the gland and invades the adjoining tissues, forming adhesions with the skin if the gland is subcutaneous. Secondary growths are usually developed in various organs; but, in contrast with lymphadenoma, the nearest lymph-glands generally escape. Soft small-round-celled sarcoma, spindle-celled sarcoma, fibro-sarcoma, and alveolar sarcoma (Fig. 69) or alveolar angiosarcoma, are all forms that occur. The two latter have a somewhat carcinoma-like structure, the epithelioid cells (*b c*) being grouped in clusters and nests within an alveolar stroma (*a*).

It appears that the neoplasm may start in various parts of the gland-tissue. According to PUTIATA, alveolar sarcoma begins in the tissue around the vessels. In other instances, especially in spindle-celled sarcoma, the connective-tissue framework is the primary seat of the neoplastic proliferation (WINIWARTER). Some authors, like PUTIATA, maintain that the lymphoid elements may be transformed into tumour-cells.

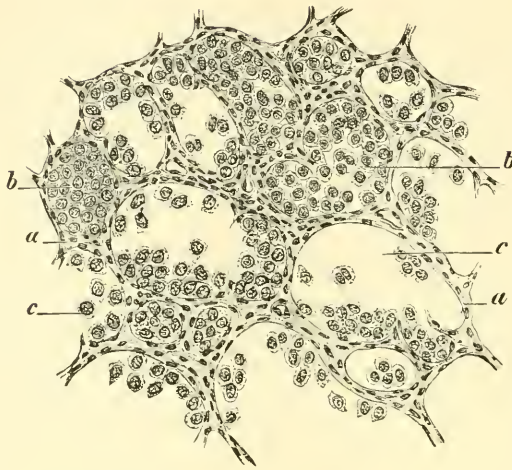


FIG. 69. ALVEOLAR SARCOMA OF A LYMPH-GLAND.

(Preparation hardened in Müller's fluid, stained with alum-carmin, and mounted in Canada balsam : $\times 100$)

a stroma b cell-nests c alveoli with scattered cells

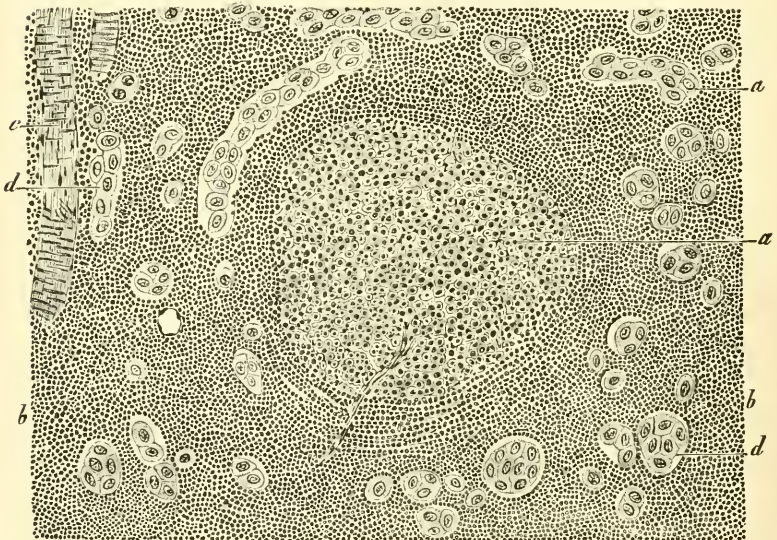


FIG. 70. CARCINOMA DEVELOPING IN AN ENLARGED AXILLARY LYMPH-GLAND.

(Preparation hardened in alcohol, stained with haematoxylin, and mounted in Canada balsam : $\times 60$)

a germinal centre of a lymphoid follicle b lymph-sinus c artery d cancer-nests

Carcinoma is the most common among the secondary or **metastatic growths**. It leads to the conversion of the lymph-glands into tumours of various sizes, whose general structure accurately reproduces the characters of the primary growth.

The development of the cancer takes place within the lymph-sinuses, and there, by multiplication of the tumour-cells brought to them by the lymph, clusters and strings of large cancer-cells (Fig. 70 *d*) are formed, which compress and encroach upon the lymphocytes. A fibrous stroma is formed from the lymphadenoid tissue, which encloses in its meshes the growing cancer-nests.

Sarcomatous metastases, like the carcinomatous, may develop from sarcoma-cells which have gained access to the gland by way of the lymphatics.

References on Tumours of the Lymph-glands

- AFFANASIEW: Cancer-growth *Cent. f. med. Wiss.* 1876
BILLROTH: *Pathol. Histologie* Berlin 1858; Morbid histology of the lymph-glands *V. A.* 21 1861
BOZZOLO: Dissemination of cancer in the glands *Cent. f. med. Wiss.* 1876
GUSSENBAUER: Secondary growths in the glands *Prag. Z. f. Heilk.* II 1881
KERESZTSZHEGY: Retroperitoneal sarcoma *Ziegler's Beiträge* XII 1892
NEELSEN: Endothelial cancer *D. A. f. klin. Med.* XXXI 1882
PUTIATA: Sarcoma of lymph-glands *V. A.* 69 1877
WINIWARTER: Lymphadenoma *Langenbeck's Arch.* XVIII 1875
ZAHN: Alveolar epithelioid sarcoma *A. d. Heilk.* 1874
ZEHNDER: Cancer-growth in lymph-glands *V. A.* 119 1890

SECTION IV

THE OSSEOUS SYSTEM

CHAPTER XIV

THE BONE-MARROW

40. The **bone-marrow** in children is a soft tissue of a bright red colour, which is particularly rich in cells and blood-vessels, and is accordingly referred to as **red** or **lymphoid marrow**.

The supporting framework of this tissue is composed of delicate reticular connective tissue. The abundant capillaries and veins are wide and thin-walled.

The majority of the cells enclosed in the reticulum are spherical, and possess either a clear vesicular nucleus with highly refractive nucleoli and nucleolar filaments, or an apparently homogeneous nucleus which is ill-defined, and in fresh sections is seen only with difficulty. These cells vary in size, those with a vesicular nucleus being generally larger than those with a homogeneous nucleus; the former have, moreover, a more granular protoplasm. The homogeneous nuclei take nuclear stains more deeply than the vesicular nuclei.

While these cells constitute the majority, the lymphoid marrow always contains a number of leucocytes with eosinophile granules, flattened cells containing no fat, globular cells containing fat, nucleated and non-nucleated red blood-corpuscles, cells enclosing red blood-corpuscles and pigment, and uninuclear and multinuclear giant-cells.

According to the researches of NEUMANN, BIZZOZERO, COHNHEIM, TIZZONI, RINDFLEISCH, HAYEM, GROHÉ, DENYS, H. E. ZIEGLER, and others, the bone-marrow takes part in the process of blood-formation, and the nucleated red corpuscles found in it are regarded as representing a preliminary stage in the development of these corpuscles. The presence in the bone-marrow of cells containing blood-corpuscles and pigment tends to prove that the red blood-corpuscles are likewise destroyed in that tissue.

The marrow is richest in cells in early life; later on, and especially in the long bones, the number of cells decreases, and by the imbibition of fat the greater portion of the cells of the reticulum are at the same time transformed into fat-cells. After the fourteenth to the sixteenth year, the marrow of the long bones usually consists mainly of fatty tissue; this when it contains only a small amount of blood is of a yellow colour, with a larger amount

of blood it is yellowish-red, and its cut surface has an oily lustre. This is called **yellow marrow**, in contradistinction to the red or lymphoid form. It should however be remarked that between the two forms there are many intermediate stages. In the flat bones and in the short cancellous bones the marrow remains permanently red, and either retains the essential characters of lymphoid marrow, or by the imbibition of fat changes to a transitional form between this and yellow marrow.

In advanced age the number of free cells contained in the bones sometimes decreases still more markedly, while at the same time the fat tends to disappear. The resulting free space is filled by a clear liquid containing mucin; the marrow thus acquires a translucent gelatinous appearance, and is hence termed **gelatinous marrow**.

References on Bone-marrow (see also Arts. 1 and 41).

- ARNOLD: Karyokinesis in marrow-cells *V. A.* 93 **1883** and 97 **1884**
 BAYERL: Production of red corpuscles in epiphysial cartilage *A. f. mikrosk. Anat.* XXIII **1884**
 BIZZAZERO: *Sul midollo degli ossa* Naples **1869** reviewed in *V. A.* 52 **1871**;
 Atrophy of fat-cells in the bone-marrow *A. f. mikrosk. Anat.* XXXIII **1889**
 FLEMING: *Zellsubstanz Kern u. Zelltheilung* Leipzig **1882**
 GEGENBAUR: *Jena. Z. f. Med. u. Naturwiss.* I-III
 KÖLLIKER: *Gewebelehre d. Menschen* I Leipzig **1889**
 MORAT: *La moelle des os* Paris **1873**
 NEUMANN: The bone-marrow in blood-formation *Cent. f. med. Wiss.* **1868**;
Berl. klin. Woch. **1877**, **1878**, **1880** and *Z. f. klin. Med.* III **1881**
 TIZZONI and FILETI: *Atti dei Lincei* ser. 3 XI **1881**
 WERNER: Cell-division in the giant-cells of the marrow *V. A.* 106 **1886**

41. The modes in which the bone-marrow is affected by general diseases and the primary changes other than inflammatory that take place in it may be classified under three heads. In the first place, as the result of various diseases conditions of **atrophy and degeneration** are induced, which are characterised chiefly by diminution of the fat and decrease in the number of cells, in a measure also by degenerative changes in the tissue-elements. For example, in senile decay, in chronic pulmonary emphysema, in phthisis, in chronic diseases of the kidney, and in starvation (NEUMANN), the adipose tissue of the marrow disappears more or less completely. If no increase takes place in the number of cells, and if the vacant spaces are filled by a liquid containing mucin, the marrow assumes a gelatinous translucency and changes into the gelatinous variety already mentioned.

Many infective diseases (such as typhoid fever, relapsing fever, typhus fever, etc.) are attended by **fatty degeneration** of the cells and capillaries of the marrow. In relapsing fever (PONFICK) and in variola (CHIARI) **necrotic foci** may be formed. These and other infections of the blood often lead to inflammation of the bone-marrow.

Hypertrophy of the fatty tissue of the marrow occurs as a concomitant of general atrophy of the entire skeleton (Art. 43) and of the articular cartilages, and is at times so excessive that the bone, composed almost entirely of fat, has a lower specific gravity than water.

In very many cases, concurrently with the decrease in fat, we find an increase in the number of the marrow-cells, so that the tissue assumes more and more the characters of red or lymphoid marrow. This is observed especially in oligæmia, leukaemia, chronic pulmonary tuberculosis, chronic suppurative otitis, and cancerous cachexia; but it is not a constant phenomenon in these conditions. For example, GROHÉ found in 157 patients who had died of phthisis 119 cases with red marrow. Red marrow is also met with, especially when death has occurred in the later stages of the disease, in typhoid fever (GROHÉ), in croupous pneumonia, and in septic affections (GOLGI, LITTEN), in acute endocarditis (PONFICK), in small-pox (GOLGI), etc.

The tint of lymphoid marrow varies from greyish-red to dark-red according to the amount of blood it contains. In severe cases of pernicious anaemia the whole of the marrow of the long bones may be dark-red in colour, resembling raspberry jelly. The coloration usually begins at the epiphyses and extends thence towards the middle of the bone. In leukaemia the marrow is often mottled with tints varying from flesh-pink to greyish-red, greyish, or greyish-yellow, and sometimes parts are yellow or greenish-yellow and look like pus.

In the red marrow the colourless marrow-cells are always abundant; and the nucleated and non-nucleated red blood-corpuscles are in general increased in number. Numerous cells containing blood-corpuscles and pigment are often found in the tissue, especially in cases of pernicious anaemia, typhoid fever, typhus fever, relapsing fever, and intermittent fever. 'Charcot-Neumann crystals' (in the form of small colourless octahedra) are also frequently present; they are thought by some authorities to be a substance containing mucin (SALKOWSKY), by others (SCHREINER) to be a phosphatic product of the decomposition of albumen.

The increase in the number of colourless and of coloured cells in the bone-marrow is generally explained by the assumption that, in the above-named diseases, the cells of the bone-marrow itself undergo proliferous multiplication. If the anaemia and cachexia result from repeated hæmorrhages or from organic disease, this increase may be regarded as a regenerative process.

According to NEUMANN, BIZZOZERO, HOYER, and others, however, there is a form of leukaemia in which the marrow-changes are primary, and are therefore the originating cause of the alteration in the blood. This form is accordingly termed medullary or **myelogenous leukaemia** (Art. 2).

The increase in the number of nucleated red corpuscles is

generally interpreted as indicating an increase in the haemogenic activity of the marrow. It is not improbable, however, that it is dependent upon some retardation of the normal transformation of the young blood-corpuscles into the mature form.

Increased destruction of the red blood-corpuscles, or the presence of minute foreign bodies circulating in the blood, leads to deposition of corpuscular detritus and other foreign matters in the marrow. The deposition of insoluble ferrated compounds, derived from the disintegration of haemoglobin, is the commonest example, and may be described as **siderosis** of the bone-marrow. This condition may also result from jaundice, and may be experimentally produced by abnormally increasing the amount of iron ingested. The ferrated particles lie for the most part within the marrow-cells and the blood-corpuscles.

Grave disorders of the local circulation, especially such as impede the outflow of blood from the bone, and traumatic injuries, often give rise to haemorrhage from the delicate capillaries of the marrow. Some of the extravasated blood may be absorbed unchanged, but the greater part is disintegrated, and numbers of granule-carrying cells containing pigment make their appearance during the absorption of the products of disintegration.

References on Changes in the Bone-marrow accompanying various Diseases (see also Art. 43).

- ARNSTEIN: Intermittent fever *V. A.* 61 **1874**
 BLECHMANN: Pathology of the bone-marrow *A. d. Heilk.* XIX **1878**
 CHIARI: Osteomyelitis in small-pox *Ziegler's Beiträge* XIII **1893**
 COHNHEIM: The marrow in pernicious anaemia *V. A.* 68 **1876**
 EISENLOHR: Pernicious anaemia and cancer *D. A. f. klin. Med.* XX **1877**
 DE FILIPPI: Researches on 'ferratin' *Ziegler's Beiträge* XVI **1894**
 GEELMUYDEN: The bone-marrow in disease *V. A.* 105 **1886** (with references)
 GOLGI: Small-pox *Revista clin. di Bologna* **1873**
 GROHÉ: The marrow in various diseases *Berl. klin. Woch.* **1881, 1884**
 HEUCK: Leukaemia *V. A.* 78 **1879**
 LITTEN: Corpuscle-carrying cells in the marrow *Cent. f. med. Wiss.* **1881**
 LITTEN and ÖRTH: The bone-marrow in various diseases *Berl. klin. Woch.* **1877**
 MUIR: The bone-marrow in pernicious anaemia *Journ. of Path.* II **1894**
 NOTHLAGEL: Lymphadenia ossium (a peculiar pernicious disease of the bones) *Virchow's Festschrift (internationale)* II Berlin **1891**
 PONFICK: Sympathetic affections of the marrow in internal diseases *V. A.* 56, 60 **1874**; Leukaemia *V. A.* 67 **1876**
 RIESS: Corpuscle-carrying cells *Cent. f. med. Wiss.* **1881**
 ROBIN: *A. d' anat. et de physiol.* **1874**
 SALVIOLI: *Rivista clin. di Bologna* **1878**
 STÖCKER: Marrow-changes in certain febrile affections *A. f. wiss. Thierheilk.* XIII **1887**
 WALDSTEIN: Progressive anaemia with leuco-cythaemia *V. A.* 91 **1883**

CHAPTER XV

ATROPHIC AFFECTIONS OF BONE

42. The osseous tissue of the skeleton developed during foetal life and soon after birth is for the most part a temporary structure of limited duration. The immature bones of the new-born child are re-absorbed and disappear in the course of years, and are replaced by others whose texture and composition are of a different kind.

The researches of morbid anatomists have shown that the dissolution and re-absorption of mature osseous tissue, under pathological conditions, are among the commonest of morbid

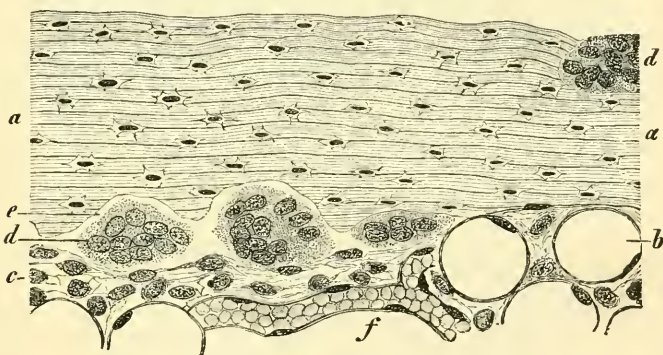


FIG. 71. RESORPTION OF BONE.

(Section of a bony trabecula in the neighbourhood of the resected end of the femur: preparation hardened in Müller's fluid and alcohol, decalcified in picric acid, stained with alum-carmin, and mounted in Canada balsam: $\times 200$)

a trabecula	c round-cells	e Howship's lacunae
b fat-cells of the marrow	d osteoclasts	f blood-vessel

phenomena. As a rule the morbid process follows the lines of the normal process known as **lacunar resorption**.

At the point where the bone is about to be absorbed multinuclear cells or **myeloplaxes** (Fig. 71 *d*) appear in the marrow or periosteum, and attach themselves to the surface of the bony trabeculae. KÖLLIKER has termed the multinuclear cells that are met with in normal osseous resorption **osteoclasts**, a name which

has also come into general use for the myeloplaxes of pathological resorption.

After a time deep erosions, generally referred to as **Howship's lacunae** or **foveolae** (Fig. 71 *e*), form at the points where the osteoclasts are adherent. It is assumed that the osteoclasts effect the active dissolution of the underlying osseous tissue.

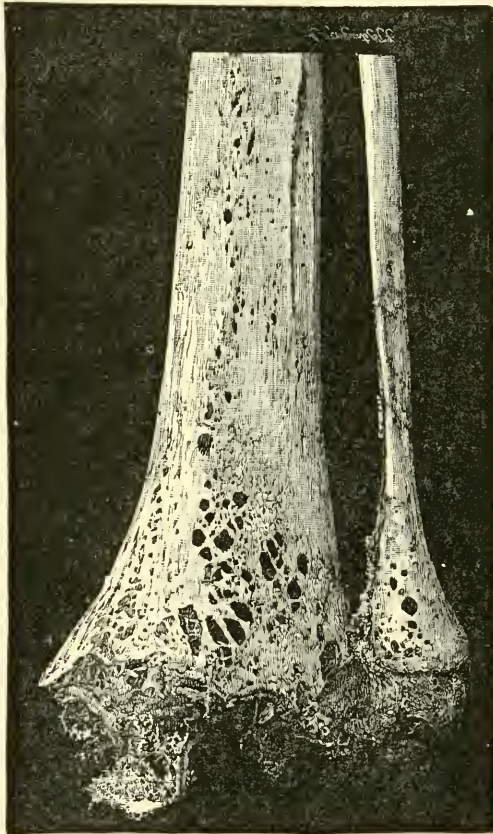


FIG. 72. ECCENTRIC ATROPHY OF THE LOWER ENDS OF THE TIBIA AND FIBULA, WITH OSTEOPOROSIS.

(Natural size)

When a large portion of the bone is being absorbed, the osteoclasts appear in great numbers, and lie close together. Correspondingly numerous grooves and pits are produced on the bone, and its surface thus presents a rough and eroded appearance. During the continuance of the process the surface is covered with these grooves. When the resorption ceases the surface again

becomes smooth, either from absorption of the prominent interlacunar ridges, or from the deposition of new osseous tissue in the eroded lacunae.

If the resorption proceeds chiefly from the side of the marrow, the result is **eccentric atrophy** (Fig. 72); the external form of the affected bone remains unaltered, while its cavities and nutrient canals become wider, and its lamellae and trabeculae thinner. When resorption is mainly external, on the other hand, there is **concentric atrophy** (Fig. 73 and Fig. 74), or local defects are produced. If the compact osseous tissue becomes porous from the widening of the Haversian canals (Fig. 72), the condition is termed **osteoporosis**. In cases of excessive atrophy the marrow

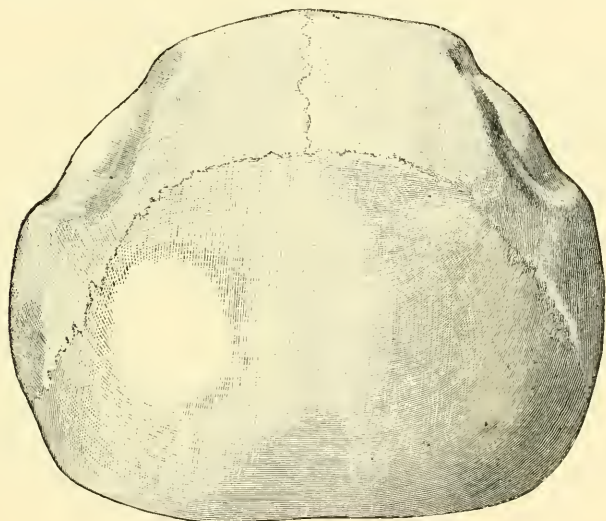


FIG. 73. SENILE ATROPHY OF THE CALVARIUM.

(With defects of the outer table and diploë in the middle portions of the parietal bones: reduced to one-third natural size)

of the enlarged medullary cavities often consists of pure adipose tissue, a condition which has led to the process being described as a 'fatty degeneration of the bones.'

In old age lacunar resorption affects large portions or even the whole of the skeleton, and it is then termed **senile atrophy**. It sometimes occurs in a marked degree in the flat bones, in the vault of the skull (Fig. 73), in the scapula, and in the pelvis, chiefly in parts that are not covered by muscles. In the skull the resorption of the parietal bones (Fig. 73) may go so far as to destroy the entire outer table and diploë, and even some portions of the inner table. In a few spots the bone may be entirely destroyed and so perforated. Next in frequency to the parietal

bones the supra-occipital is most apt to be affected, the frontal bone but rarely. As the erosion is not uniform, shallow grooves appear on the external surface of the skull. The bone at the foci of resorption looks dull and lustreless, indeed almost rough, and the surface is studded with a number of small medullary cavities filled with blood.

In the diploë the addition of new bone to the old usually gives rise to condensation of the tissue before resorption begins. De-

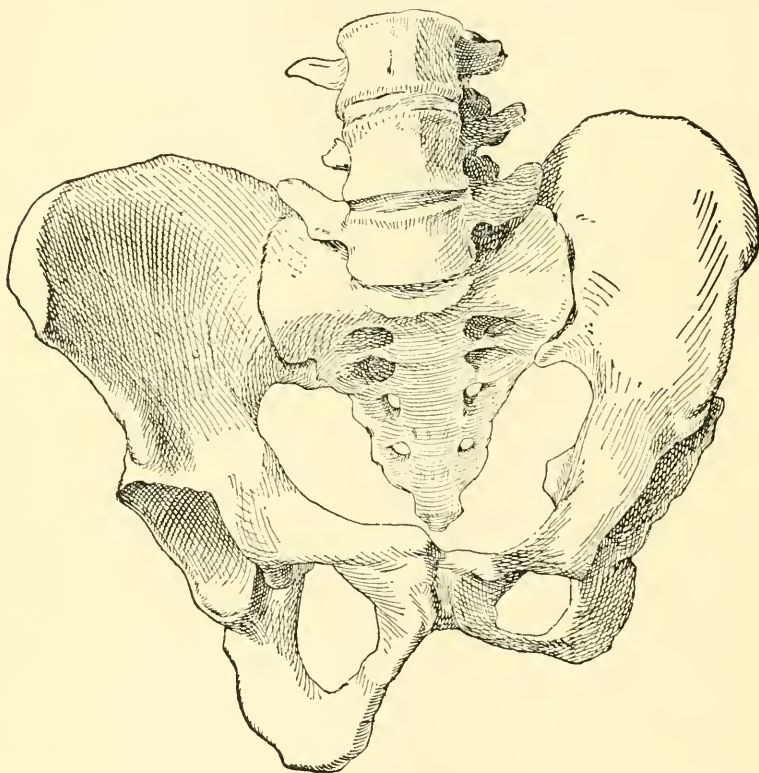


FIG. 74. HYPOPLASIA OF THE PUBIS, ISCHIUM, AND ILIUM OF THE LEFT SIDE.

(From *coritis* which had prevented the use of the left leg in early life: the right acetabulum is displaced inwards, the pelvis being therefore obliquely contracted: rather less than half the natural size)

posits of osseous tissue also occur on the inner surface of the skull, especially in the frontal bone.

In the facial part of the skull senile atrophy affects mainly the upper and lower maxillae, the alveolar processes of which are sometimes entirely absorbed.

In the vertebrae and in the bones of the extremities both concentric and eccentric atrophy take place, the bony trabeculae being

thereby in places thinned or even entirely absorbed. Should the greater part of the trabeculae be absorbed at any particular point, so that the continuity of their connexions is interrupted, the bone is liable to give way at that point (Art. 50).

Resorption may be so excessive that the remaining bony tissue becomes incapable of withstanding an ordinary strain, and so fractures with great readiness: this condition has been termed symptomatic osteopsathyrosis, or **fragilitas ossium**.

Absence of functional use (Fig. 74) is a frequent cause of premature lacunar resorption of the bones: this form of **atrophy**

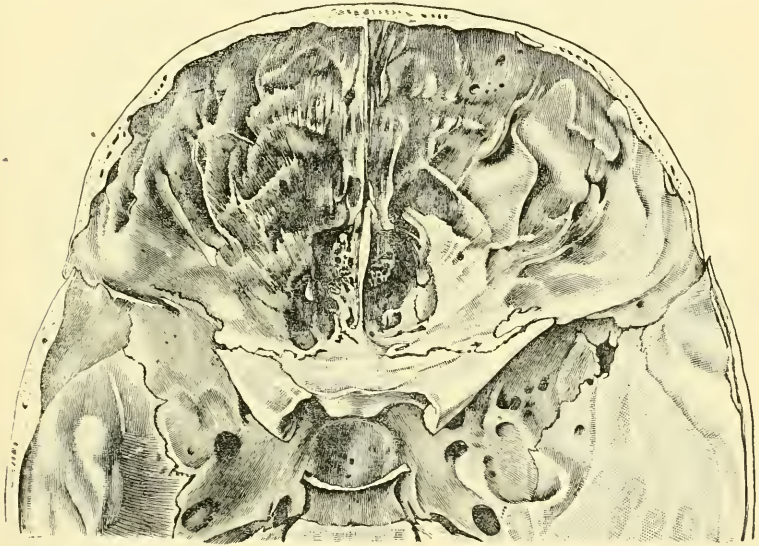


FIG. 75. EXTREME ATROPHY OF THE CRANIAL BONES PRODUCED BY THE PRESSURE OF THE DEVELOPING BRAIN.

The position of the cerebral convolutions is indicated by deep impressions, that of the sulci by sharp bony ridges. The ethmoid is bulged downwards, and the wings of the sphenoid and the lower border of the squama of the petrous bone are forced forwards and downwards.

(Skull brachycephalic and hypsocephalic: premature synostosis of the lateral and lower portions of the coronary suture, with compensatory increase in height in the region of the parietal bones and the sagittal suture: five-sevenths of the natural size)

from disuse occurs not only when a limb or part of a limb is deprived of its normal activity, but also when portions of a single bone cease to perform their function of support.

Atrophy of the first kind occurs in the stumps of amputated limbs, and in the bones of limbs that have ceased to be used (Fig. 74); while atrophy of the second kind is observed in fractured bones where the fragments have overlapped during the process of healing, the atrophy affecting those trabeculae which from the

altered direction of the stress are no longer required to act as supporting structures.

Those forms of bony atrophy which appear as the sequelae of nervous diseases are termed **neuroparalytic** and **neuropathic atrophies**. When they occur in paralysed limbs it is natural to attribute them to mere disuse. But not infrequently diseases of the spinal cord and brain, that are unaccompanied by paralysis

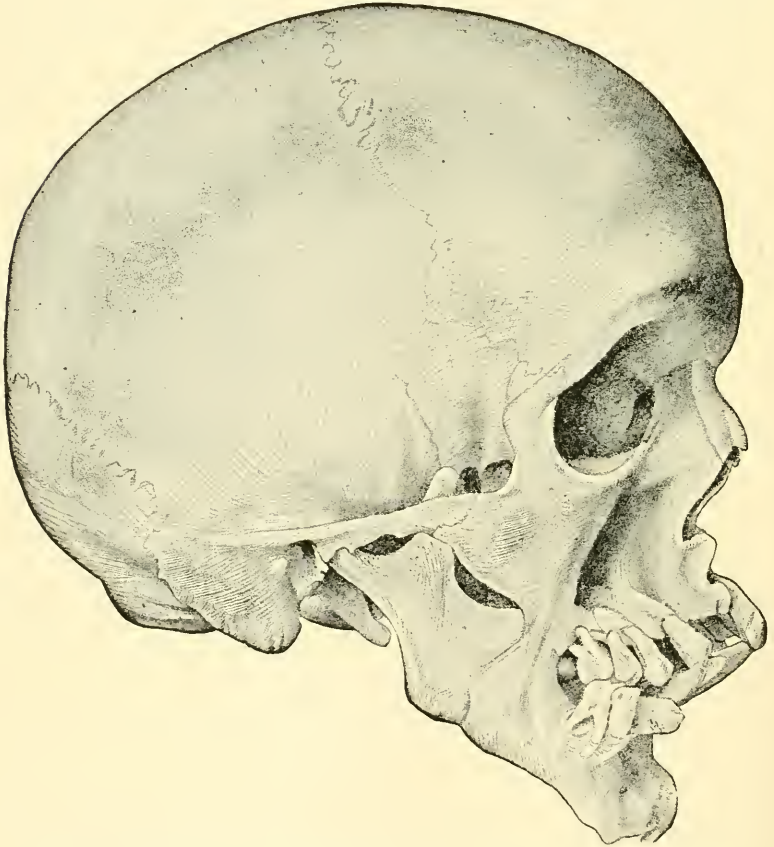


FIG. 76. DEFORMITY OF THE SUPERIOR AND INFERIOR MAXILLAE AND THEIR ALVEOLAR PROCESSES PRODUCED BY CICATRISATION AFTER A BURN.

(Deep incurving of the anterior surface of the superior maxilla: nearly horizontal position of the alveolar process: decrease in size of the inferior maxilla, and almost entire disappearance of the angle between the ascending and horizontal rami: bony ankylosis between the superior and the inferior maxilla)

of the limbs, such as posterior sclerosis (tabes) and paralytic dementia, are associated with remarkable wasting and fragility of the bones, and commonly with articular changes also (see Art. 75).

Atrophy from pressure is another and very frequent form

produced by persistent local pressure on a bone. Thus an increase of the cranial contents may induce such atrophy of the cranial bones that the entire internal surface is roughened, the inner table more or less absorbed, and the *teymen tympani* thinned and perforated. Should the convolutions of the brain be pressed against the bone, the result may be a deepening of the impressions which are normally present (Fig. 75), while the sulci receive corresponding ledges and ridges of bone. The pachionian bodies of the pia mater produce deep pits in the bone, which sometimes penetrate to the outer table. The frontal sinuses and the antrum of Highmore may become enlarged from the accumulation of liquid or the pressure of tumours. Cutaneous scars undergoing great contraction may press upon the underlying bone and induce extensive resorption (Fig. 76), with the result of very considerable distortion and disfigurement. Such scars usually result from burns. The pressure of aneurysms of the aorta upon the vertebrae, sternum, or ribs may produce more or less extensive erosions (Fig. 77), and may even entirely destroy the bone at the point of pressure. Tumours of the soft parts which exert pressure upon the adjacent bones often have a similar effect.

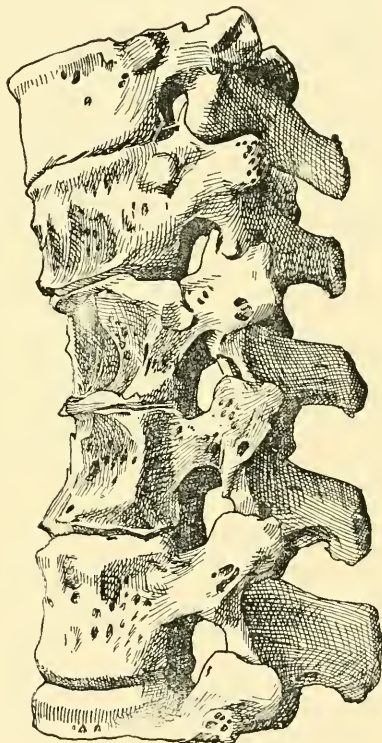


FIG. 77. ATROPHY OF THE LAST THORACIC AND UPPER LUMBAR VERTEBRAE, FROM THE PRESSURE OF AN AORTIC ANEURYSM.

(Reduced to two-fifths of the natural size)

Finally, every periostitis or osteomyelitis that reaches a certain degree of intensity and persists for a certain length of time (Chap. XVI), and every tumour that develops in the bone-marrow or on the inner surface of the periosteum, give rise to some resorption of bone.

Pressure, inflammation, and the development of tumours result generally in local atrophy of bone; but a local inflammation, such as destructive arthritis, may induce abnormal resorption over entire bones, and so lead to *fragilitas ossium*. Small and local superficial defects, visible by the unaided eye, are termed erosions; if larger portions are destroyed, or at least strikingly altered and

rarefied, we speak of the affection as **caries** (Chap. XVI). When the bony tissue is, by the action of some noxious agency, not merely eroded but killed outright, and in considerable mass, we speak of the process as **necrosis**. Caries and necrosis may be combined in many ways, producing a condition which is called **necrotic caries**.

Both in marked lacunar atrophy and in far-advanced osteomalacia (Art. 43) **cysts** may form in the interior of the bones, with clear or turbid liquid or hæmorrhagic contents. They arise in these affections from the total disintegration and liquefaction of the constituent parts of the tissue, and may reach a great size, in certain cases nearly equalling the bone in diameter. At times the bone may be actually distended by a secondary accumulation of liquid. Cysts are occasionally produced within bones from new-growths which have undergone liquefactive softening, for example from enchondroma, myxoma, and sarcoma. Cysts may also occur which have no perceptible connexion with new-growths or with excessive resorption.

According to certain authorities (LOBSTEIN: *Traité d'anat. pathol.* Paris 1833; GURLT: *Lehre von Knochenbrüchen* Berlin 1862; VOLKMANN: *Handbuch der Chirurgie* II 1872; ENDERLEN: Osteopsathyrosis *V. A.* 131 1893), there is an idiopathic form of *fragilitas ossium* in which no rarefaction of the osseous tissue is apparent. This malady is congenital, or develops from some unknown reason in adult life, and may appear in different members of the same family. If the views of these authorities be correct, we must assume that in the persons so affected the organic substratum of the bony trabeculae possesses some morbid character which manifests itself by abnormal brittleness of the bones.

References on Lacunar Resorption of Bone.

- APOLANT: Resorption in the development of osseous tumours *V. A.* 131 1893
 BÜRKNER: Perforation of the tegmen tympani *A. f. Ohrenheilk.* XIII
 BUSCH: *Berl. klin. Woch.* no. 14 1884
 CAMERON: Bone-absorption *Glasgow Med. Journ.* 1881
 FLESCH: Perforation of the tegmen tympani *A. f. Ohrenheilk.* XIV
 KÖLLIKER: *Normale Resorption d. Knochengewebes* Leipzig 1873
 LIEBERKÜHN and BERMAN: *Resorption d. Knochensubstanz* Frankfurt 1877
 MACEWEN: *Ann. of Surgery* 1887
 OCHOTIN: Osteoclasts *V. A.* 124 1891
 POMMER: The osteoclast-theory *V. A.* 92 1883
 VON RECKLINGHAUSEN: Fibroid or deforming ostitis *Virchow's Festschrift (Assistenten)* Berlin 1891
 STEINER: Frontal sinuses *Langenbeck's Arch.* XIII
 STEUDENER: *Knochenentwicklung u. Knochenwachstum* Halle 1875
 WEGNER: Myeloplaxes *V. A.* 56 1872; Resorption of long bones *V. A.* 61 1874
 ZIEGLER: Proliferation, metaplasia, and resorption of bone *V. A.* 73 1878

References on Atrophy from Disuse.

- BUSCH: *Berl. klin. Woch.* 1884
 KÖSTER: *Verhand. phys.-med. Gesellschaft Würzburg* 1873
 MARTINI: Architecture of morbidly-altered bones *Cent. f. med. Wiss.* 1872

- POENSGEN: Atrophy in connexion with false joints *Berl. klin. Woch.* **1886**
 ROUX: *A. f. Anat. und Physiol.* **1885**
 WOLFF: Trophic disorders in primary joint-affectioins *Berl. klin. Woch.* **1883**;
Das Gesetz d. Transformation d. Knochen Berlin **1892** reviewed in *Cent. f. allg. Path.* v

References on Neuropathic Atrophy.

- BONNET: Paralysis *Gaz. des hôp.* **1876**
 BROCHIN: Tabes *Gaz. des hôp.* no. 12 **1875**
 BRUNS: *Berl. klin. Woch.* no. 11 **1882**
 BUZZARD: Tabes *B. M. J.* i **1880**
 CHARCOT: Tabes *A. d. physiol.* **1874**
 DAVEY: Paralysis *B. M. J.* **1874**
 GUDDEN: Paralysis *A. f. Psych.* ii **1870**
 HUTCHINSON: Tabes *B. M. J.* i **1880**
 MERCER: Paralysis *B. M. J.* **1874**
 MORSELLI: Paralysis *Riv. speriment. di freniatria* **1876**
 NASSE: Section of nerves *Pflüger's Arch.* xxiii **1880**
 OULMONT: Tabes *Progrès méd.* no. 28 **1877**
 STURGE: Tabes *B. M. J.* i **1880**
 WEIR-MITCHELL: *Amer. J. Med. Sciences* no. 113 **1873**
 WESTPHAL: *Berl. klin. Woch.* no. 29 **1881**

References on Cysts of Bone.

- BOSTRÖM: *Naturforscherversamml. Festschrift* Freiburg i. B. **1883**
 FROBIEP: *Chirurg. Kupfertafeln* Plates 438, 439, 440 Weimar **1820**
 VIRCHOW: *Monatsber. Akad. d. Wissenschaften* Berlin **1876**
 ZIEGLER: Subcartilaginous changes in arthritis deformans and bone-cysts
V. A. 70 **1877**

43. **Halisteresis ossium** (*άλος* of salt, *στερησις* deprivation) or decalcification is a form of atrophy of bone in which at first nothing but solution of the calcareous salts takes place, while the organic matrix or cartilage, though somewhat altered, is preserved for a certain length of time.

The solution of the lime-salts begins on the periphery of the trabeculae (Fig. 78 *b*), and advances progressively from these to the deeper layers. The boundary-line of the still calcified portion (*a*) sometimes runs parallel to the surface of the trabeculae; at other times it has an irregular contour, showing depressions similar to those known as Howship's lacunae. Between the calcified and the completely decalcified parts there is sometimes a zone in which, as in commencing ossification, calcareous particles of various sizes are visible.

According to the researches of VON RECKLINGHAUSEN and APOLANT, in halisteric atrophy the existing Haversian canals are generally widened, and new canals and clefts appear in the ground-substance of the bone. This condition is the result of decalcification, and gives rise to the peculiar lattice-like or rather feather-like markings which are seen in suitably prepared microscopic sections of the bone.

The matrix of the decalcified bone is sometimes homogeneous, and sometimes finely or coarsely fibrous. Not infrequently the normal lamellar stratification can still be distinctly traced, the lamellae being continuous with those of the still calcified part. Some of the bone-corpuscles are clearly visible, while others have disappeared, or are represented only by small oval spaces, without visible stellate processes.

The width of the decalcified portion is naturally subject to considerable variation. In extreme cases of halisteresis the amount of persisting calcified bony substance is very small, numbers of

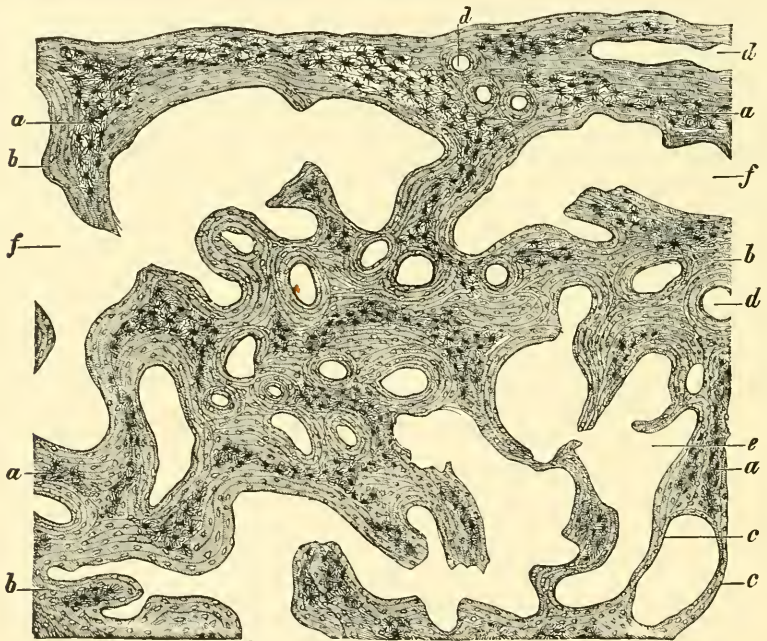


FIG. 78. SECTION OF A VERTEBRA AFFECTED WITH OSTEOMA.

(Preparation hardened in alcohol, cut without decalcification, stained with eosin, and mounted in thick Canada balsam: $\times 45$)

- | | | | |
|---|--------------------------------------|---|-------------------------------------------------------------|
| a | remains of calcified bone | e | larger medullary cavities |
| b | decalcified bone | f | larger spaces arising from the absorption of the trabeculae |
| c | decalcified and atrophied trabeculae | | |
| d | Haversian canals | | |

individual trabeculae being entirely decalcified (c). The decalcified cartilaginous matrix may persist for a time, and is probably capable, by again taking up lime-salts, of being transformed once more into firm bone. If however the process of decalcification continues, it is generally followed by the disintegration and solution of the matrix.

Halisteresis may occur as a local affection in limited portions of a bone, for example in the site of tumours which destroy the

no adequate clue to the causes of the disease. During the progress of the malady the bone-marrow is hyperaemic, and frequently contains scattered haemorrhagic foci, or traces of them such as pigmentary deposits. During the stage of hyperaemia the fat of the marrow appears to be decreased and the cells to be increased. The marrow may again assume its fatty character, or it may become gelatinous. Where the bony substance has in large measure disappeared, the marrow usually becomes liquid, and larger or smaller smooth-walled cysts are produced. Under certain conditions, the tissue filling the medullary cavities having become liquid, and the exterior wall being reduced to a thin decalcified stratum covered with periosteum, a long bone may assume the appearance of a mere membranous sac.

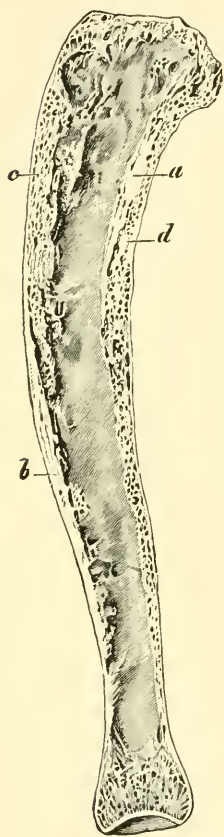


FIG. 80. OSTEOMALACIA OF THE TIBIA.

(Frontal section of left tibia bent outward as a result of osteomalacia; one-third natural size)

- a b relatively well-preserved cortical strata
- c rarefied cortical stratum
- d newly-formed osteoid tissue

Bones that have been severely affected by osteomalacia always lose their firm consistency; they are readily broken, bent, or indented, and a knife may with ease be passed through their entire thickness. Sometimes in the case of the long bones a mere cortical layer of the thinness of paper alone retains the form of the bone, while the almost entirely decalcified bodies of the vertebrae may be squeezed out like a sponge. In these circumstances it is not surprising that the skeleton undergoes manifold variations of form during life. Various curvatures and angularities, with shortening of the total length, may take place in the spinal column, according to the weight it has to bear, and the softness and pliability of the several segments. Forward curvature is called **lordosis**, backward curvature **kyphosis**, and lateral curvature **scoliosis**. In kyphosis of the thoracic vertebrae, the ribs are pushed together and the sternum is bent at an angle. In addition to this, the lateral parts of the ribs are forced in, or even sharply bent, by atmospheric pressure during inspiration, and by the weight of the body when recumbent on the side. In the pelvis (Fig. 79) the base of the acetabulum yields to the pressure of the head of the femur, and is forced toward the interior of the pelvis, while the symphysis pubis is pressed outward and forward. In the erect posture the promontory of the sacrum sinks downward (a), and

the iliac crests are bent by the traction of the muscles attached to them. These distortions give rise to various degrees of contraction and deformity of the pelvis, which are often increased by shrinking and atrophy of its several bones. Bending, angular yielding (Fig. 80), and fracture are of frequent occurrence in the bones of the extremities.

When the weight borne by the bones, or traumatic injury, gives rise to curvature, angularity, or fracture, new bony tissue may be formed even though halisteresis is still in progress, and fractures may thus become consolidated by the development of well-defined callus. In curvature of the long bones the new-formation of osseous tissue on the convex parts of the curve is often very considerable (Fig. 80 *d*). One difference between this new-formation and osseous repair in healthy persons (Arts. 44 and 45) is that in the former case the new tissue becomes calcified only in part, namely in the centre alone of the bony trabeculae, and persists for a long time in the condition of osteoid or semi-cartilaginous tissue. This new osteoid tissue is readily distinguished from the old and decalcified tissue by the fact that the former contains large bone-corpuses with well-developed cells, and that its matrix has a different structure. New osteoid tissue is not infrequently formed in bones that have not perceptibly bent or yielded.

References on Halisteresis and Osteomalacia.

- APOLANT: Resorption and apposition in osseous tumours *V. A.* 131 1893
 BEYLARD: *Du rachitisme . . . et de l'ostéomalacie* Paris 1852
 BOULEY: *De l'ostéomalacie* Paris 1874
 BOULEY and HANOT: *A. de physiol.* I 1874
 CHARCOT: Senile osteomalacia *Oeuvres complètes* VII Paris 1890
 EISENHART: Puerperal osteomalacia *Arbeiten med.-klin. Inst.* III Munich 1893
 (with references)
 FEHLING: Puerperal osteomalacia *A. f. Gynäk.* 39 1890
 HANAU: Osteomalacia *Corresp. f. Schweizer Aerzte* 1892
 HERMANN: Infantile osteomalacia *Ziegler's Beiträge* II 1886
 HIRSELBERG: Osteomalacia and softening ostitis *Ziegler's Beiträge* VI 1889
 KASSOWITZ: *Die normale Ossification* part II Vienna 1882-85
 KILIAN: *Das halisterische Becken* Bonn 1857
 LITZMANN: *Die Formen d. weibl. Beckens* Berlin 1861
 MOMMSEN: Osteomalacia *V. A.* 69 1877
 PETRONE: Microbes of nitrification and osteomalacia *Riforma med.* 1892
 POMMER: *Osteomalacie u. Rachitis* Leipzig 1885
 VON RECKLINGHAUSEN: Ostitis deformans, osteomalacia, and ossifying carcinoma *Virchow's Festschrift (Assistenten)* Berlin 1891
 REHN: *Gerhard's Handb. d. Kinderkr.* IV, and *Jahrb. f. Kinderheilk.* new series XII, XIX
 RIBBERT: Senile osteomalacia *V. A.* 80 1880; *Anatom. Untersuch. über Osteomalacie* Cassel 1893 (with references)
 RINDFLEISCH: Senile osteomalacia *A. f. mikrosk. Anat.* XVII
 SENATOR: *Ziemssen's Cyclop.* XVI New York 1877
 STILLING and VON MERING: Experimental osteomalacia *Cent. f. med. Wiss.* 1889
 VIRCHOW: *Cellularpathologie* 1871, and *V. A.* 4 1852
 VOLKMAN: *Handbuch d. Chirurgie* II 1872

CHAPTER XVI

REGENERATION AND HYPERTROPHY

44. The osseous part of the skeleton, when it has reached its full development, is a structure that cannot be increased in size by the intercalation of new tissue between the elements of the old. The theory set forth by many authorities (WOLFF, GUDDEN), and maintained even in recent times, that the osseous tissues are capable of increase by expansive or interstitial growth, can at most be admitted in the case of bones that have not yet attained their maturity. The mature bone grows only by the apposition or addition of new bony elements outside the old, and even when the medullary cavity of the bone appears to grow wider it is only because apposition of bony matter on the exterior is accompanied by resorption of the interior.

New osseous tissue is formed by the periosteum, by the marrow, and by the diaphysial and epiphysial cartilages. It is the internal stratum of the periosteum, variously described as the cambium layer (BILLROTH), proliferous stratum (VIRCHOW), osteoplastic stratum (STRELZOFF), or periosteal marrow (RANVIER), that normally produces bone, although this power is not entirely lacking in the outer layer. From its mode of origin, the inner periosteal layer is equivalent in its nature and structure to the bone-marrow, and is for the most part in unbroken continuity with it.

The bony tissue that develops from the marrow and the periosteum begins either as a purely cellular structure or as a tissue that, before its ossification, is composed of cells embedded in a hyaline or fibrillated matrix. The process of ossification consists essentially in the conversion of certain parts of the preliminary structure, destined to form the substratum of the bone, into a dense tissue containing lime-salts, while the remaining cells not thus utilised become enclosed within peculiar stellate cavities in the osseous matrix and are termed **bone-corpuscles**.

In the formation of bone from the cartilages of the diaphyses and epiphyses the cartilage is almost entirely absorbed by the adjacent medullary tissue, and the new bone is derived essentially from the cells of the marrow (Art. 54).

The production of new bone under pathological conditions is exactly similar to the normal process of ossification. Most fre-

quently the production is effected by the aid of **osteoblasts** or bone-forming cells derived from the periosteal or medullary cells, which multiply by karyokinetic subdivision.

When the new osseous formation is designed merely to strengthen existing trabeculae, the osteoblasts are grouped on the surface of the old bone in the form of a close fringe or border, and are distinguishable by their size and their clear vesicular nuclei (Fig. 81 *c*). The osteoblasts, at the expense of the greater portion of their protoplasm, then give rise to a dense fibrillated connective-tissue framework or matrix, which contains small stellate cavities, the so-called bone-corpuseles. These cavities remain open, and are occupied by such of the osteoblasts as are not used up in the formation of the matrix (Fig. 81 *b*). By the deposition of lime-salts in the matrix the newly-formed tissue receives the characters and appearance of bone, and forms a new lamella on the surface of the old (*b*), the cells it encloses representing the residual osteoblasts.

When fresh trabeculae are to be formed in the periosteum or the marrow, and these structures are in process of proliferation, the osteoblasts group themselves within the cellular germinal tissue in rows and clusters of various sizes. Between them is formed a dense fibrillated matrix, stained red by carmine (Fig. 82 *e f* and Fig. 83 *c*), which encloses the remaining osteoblasts within irregularly-branched or stellate spaces. The tissue so built up grows more and more like bone in texture, and is accordingly termed **osteoid tissue**. When it is infiltrated with lime-salts it is converted into osseous tissue, the thickness of which may afterwards be greatly increased by the apposition of new bone, elaborated by layers of osteoblasts (Fig. 82 *g*).

The tissue formed by the proliferous periosteum or marrow not infrequently in the first instance resembles cartilage (**chondroid tissue**); this may afterwards be converted into osteoid tissue, or may develop into well-formed cartilage (Fig. 84 *b*).

The formation of cartilage (*b*) from the proliferous germinal tissue is characterised by the appearance of a hyaline matrix between the formative cells or **chondroblasts**. The hyaline matrix, when treated with haematoxylin, takes a reddish-violet or purple stain (Fig. 84 *f*). The persisting chondroblasts (*d*) are ultimately enclosed within rounded cavities, about which the




FIG. 81. THE FORMATION OF NEW BONE ON THE SURFACE OF OLD BONE BY MEANS OF A LAYER OF OSTEOBLASTS.

(Preparation hardened in Müller's fluid and alcohol, decalcified with picric acid, stained with haematoxylin and carmine, and mounted in Canada balsam: $\times 300$)

- a* old bone
- b* newly-formed lamella
- c* osteoblasts

matrix becomes somewhat condensed and so forms a sort of capsule.

The newly-formed cartilage, except in the case of chondromata, is usually short-lived, and is soon transformed into osseous tissue or into marrow. This change is always preceded by the penetration of blood-vessels into the substance of the cartilage (Fig. 85 *c*), accompanied by the formation of processes of cellular medullary tissue (*d e*). Some of the marrow-cells come with the ingrowing blood-vessels; others are derived from the cartilage itself (*i k*), which in the neighbourhood of the blood-vessels

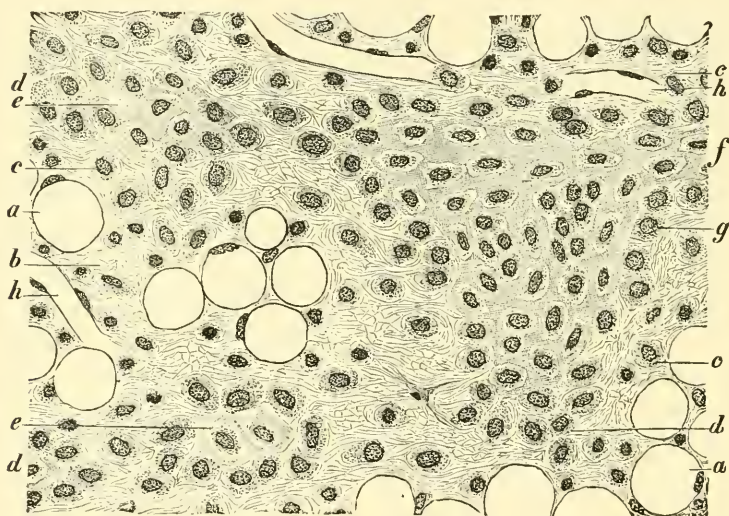


FIG. 82. MYELOGENOUS FORMATION OF BONE FROM AGGREGATIONS OF OSTEOBLASTS.

(Section from the internal callus of a fortnight-old fracture of the fibula in a man aged 25; preparation hardened in Müller's fluid and alcohol, decalcified with picric acid, stained with haematoxylin and carmine, and mounted in Canada balsam: $\times 150$)

- | | | | |
|---|------------------------------------------------------|---|-----------------------------------------------------|
| a | fat-cells of the marrow | f | osseous trabeculae in process of formation |
| b | fatless marrow | g | osteoblasts surrounding the newly formed trabeculae |
| c | single osteoblasts | h | blood-vessel |
| d | groups of osteoblasts | | |
| e | first stage in the development of the osseous matrix | | |

breaks up and becomes proliferous. If the cartilage is not in this way entirely dispersed and displaced, its remnants, reduced to a few trabeculae, are transformed into osteoid tissue (Fig. 85 *f*) and then into true bone, whose trabeculae may afterwards receive appositional increments from the action of osteoblasts (Fig. 85 *g*).

In a similar manner epiphysial cartilage, whose physiological growth has ceased, is transformed into bone. The formation of bone in this case is likewise preceded by the development of medullary processes and spaces, originating either in an ingrowth

of marrow from adjacent parts, or in preliminary dissolution and subsequent proliferation of the cartilage itself.

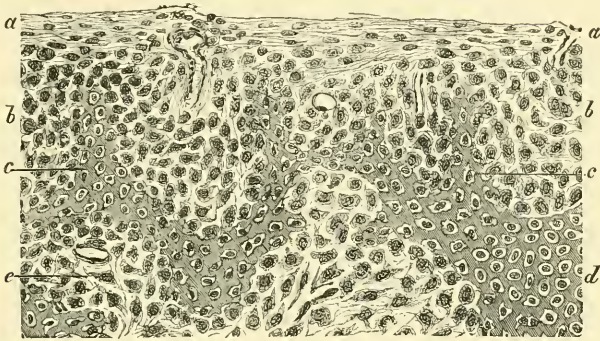


FIG. 83. FORMATION OF OSTEOID TRABECULAE FROM PROLIFEROUS PERIOSTEUM.

(Preparation from a fortnight-old fracture: hardened in Müller's fluid and alcohol, decalcified with picric acid, stained with haematoxylin, and mounted in Canada balsam: $\times 50$)

- | | |
|--------------------------------------------|--------------------|
| a external fibrous layer of the periosteum | c osteoid tissue |
| b germinal tissue | d chondroid tissue |
| | e medullary tissue |

Bone-formation also, and not infrequently, occurs in mature tissues that have ceased to be proliferous, their substance undergoing metaplastic transformation. When connective tissue is

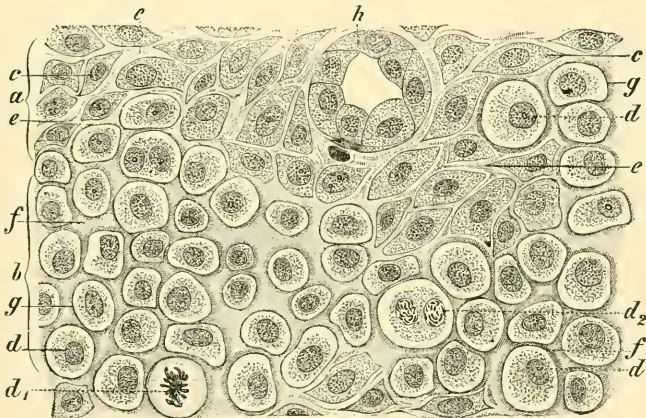


FIG. 84. PERIOSTEAL FORMATION OF CARTILAGE.

(From a fracture five days old: preparation treated with Flemming's nucleus-fixing solution and haematoxylin, and mounted in glycerine: $\times 250$)

- | | |
|---------------------------------------------------------------|------------------------------------------|
| a cellular germinal tissue | e matrix of the germinal tissue |
| b chondroid tissue | f matrix of the cartilage |
| c proliferous periosteal formative cells | g capsule of cartilage-cell |
| d cartilage-cells | h proliferous endothelium of a capillary |
| d ₁ d ₂ karyokinesis in cartilage-cells | |

thus changed into osseous tissue, the steps of the process are these: In a particular region the fibrous groundwork of the tissue (Fig. 86 *a*) becomes more condensed (*b*), and lime-salts are de-

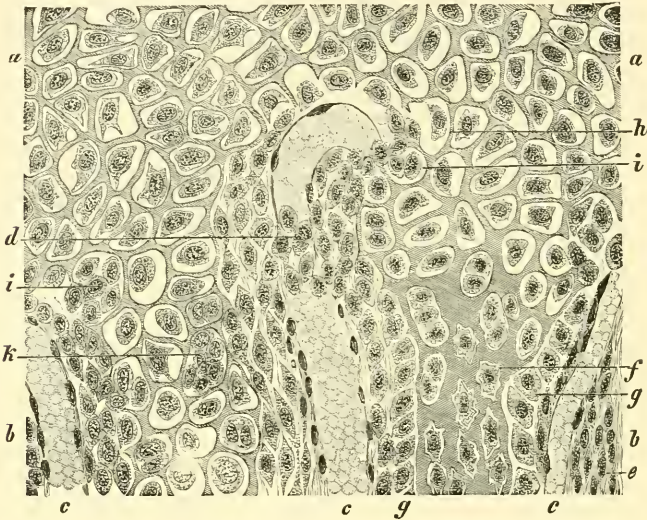


FIG. 85. FORMATION OF BONE FROM CARTILAGE IN A CALLUS FOURTEEN DAYS OLD. (Preparation hardened in Müller's fluid, decalcified with picric acid, stained with carmine, and mounted in Canada balsam: $\times 200$)

- | | |
|------------------------------------------|-----------------------------------------------------------------------|
| <i>a</i> hyaline cartilage | <i>h</i> cartilage-cells set free by the disappearance of the matrix |
| <i>b</i> medullary spaces | <i>i</i> proliferous cartilage-cells in a capsule that has burst open |
| <i>c</i> blood-vessel | <i>k</i> proliferous cartilage-cells in a closed capsule |
| <i>d</i> cellular medullary tissue | |
| <i>e</i> fibro-cellular medullary tissue | |
| <i>f</i> osteoid tissue | |
| <i>g</i> osteoblasts | |

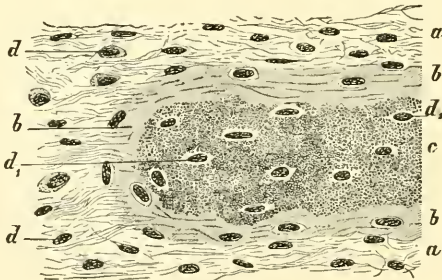


FIG. 86. FORMATION OF BONE FROM CONNECTIVE TISSUE.

(Section through a developing trabecula from an ossifying fibroma in the periosteum of the superior maxilla: preparation hardened in alcohol, cut without previous decalcification, stained with hæmatoxylin, and mounted in Canada balsam: $\times 200$)

- | | |
|------------------------------------------------------------------|---------------------------------------|
| <i>a</i> connective tissue | <i>c</i> calcareous infiltration |
| <i>b</i> condensed tissue forming the groundwork of the new bone | <i>d</i> connective-tissue cells |
| | <i>d</i> ₁ bone-corpuscles |

posited in it (*c*); the connective-tissue cells (*d*) are then by degrees enclosed in irregularly-shaped cavities, and thereby become converted into bone-corpuscles (*d*₁).

Since the time when it was conclusively ascertained that bones grow by apposition, various writers (OLLIER, HUMPHRY, VIRCHOW, STRELZOFF, GUDDEN, J. WOLFF, VOLKMANN, HUETER, RUGE, EGGER, and others) have maintained that growth may likewise take place interstitially. They have sought to prove this by various methods, including the microscopic examination of growing bones, the insertion of pegs or the piercing of drill-holes at various points in their length, and the fixing of rings and metal discs beneath the periosteum. None of these methods have however sufficed to demonstrate that interstitial growth actually takes place in bones that have already attained maturity.

According to KÖLLIKER, three varieties of bone may be distinguished in the skeleton, namely, (1) true lamellar bone in the Haversian systems; (2) lamellar bone with Sharpey's fibres, in the intermediate or fundamental lamellae of the long bones; and (3) true fibrous or membrane bone in the flat bones of the skull.

The lamellar bone is produced by osteoblasts, and consists entirely of a gelatine-yielding calcified fibrillated substance, without any cementing material. The bundles of fibrils form by their apposition continuous layers or sheets, and in contiguous layers may run parallel or decussate with each other.

The lamellar bone with Sharpey's fibres, or lamellar fibrous bone, consists of true lamellar osseous tissue formed by osteoblasts, and of non-calcified fibrous bundles, or Sharpey's fibres, which originate from the periosteum. The compact substance of the long bones in the foetus and in young children contains a remarkable mesh-work of ramifying and interwoven Sharpey's fibres, and has therefore been called plexiform osseous tissue (EBNER). True fibrous bone arises from connective tissue and cells, the connective-tissue matrix becoming entirely calcified.

References on the Structure and Regeneration of Bone.

- ADAMKIEWICZ: Bone-grafting *Wien. Akad. Anzeiger* xxvi 1889
 BAJARDI: Repair of fractures *Moleschott's Untersuch.* xii
 BARTH: Implantation of bone *Ziegler's Beiträge* xvii 1895
 BONOME: Regeneration of bone *V. A.* 100 1885
 BRUNS: Transplantation of bone-marrow *A. f. klin. Chir.* xxvi; *Die Lehre von den Knochenbrüchen* Stuttgart 1886
 BUSCH: New-formation of bone *A. f. klin. Chir.* xxi, and *D. Z. f. Chir.* x
 EBNER: *Wiener Sitzungsber.* lxxii Vienna 1875
 FLOURENS: *Le développement des os* Paris 1842; *Théorie exp. de la formation des os* Paris 1847
 GUDDEN: *Das Schädelswachstum* Munich 1874
 HAAB: Growth of bone *Unters. Zürich. path. Inst.* iii Leipzig 1875
 HUMPHRY: Growth and repair of bone *Med.-chir. Trans.* London xxxvi, xli, xlv, xlv; *Journ. of Anat.* xiii 1878
 KÖLLIKER: *Die normale Resorption d. Knochengewebes* Leipzig 1873; *Structure of bone Würzburger phys.-med. Sitzungsber.* 1886, and *Z. f. wiss. Zoologie* xlv 1887; *Gewebelehre des Menschen* i Leipzig 1889
 KRAFFT: Histogenesis of periosteal callus *Ziegler's Beiträge* i 1886
 LANGER: *Das Gefäßsystem der Röhrenknochen* Vienna 1875
 LAURENT: *Recherches sur la greffe osseuse* Brussels 1893
 MACEWEN: Bone-grafting *Proc. Roy. Soc.* xxxii London 1881
 MOSSÉ: Heteroplastic grafts of bone *A. de méd. exp.* 1894
 OGSTON: *Journ. of Anat.* xii 1877

- OLLIER: *Traité de la régénération des os* Paris 1867; Osseous grafting in man *A. de physiol.* 1889; Surgical osteogenesis *Verh. internat. med. Congr.* III Berlin 1891
- VIRCHOW: *V. A.* 13 1858; *Cellularpathologie* 4th edition 1871; *Berl. klin. Woch.* 1875; *Krankhafte Geschwülste* II
- WOLFF: *A. f. klin. Chir.* IV, XIV; *V. A.* 50 1870, 61 1874, 64 1875, 101 1885; *Berl. klin. Woch.* 1875, 1884

45. When the continuity of a bone is interrupted by traumatic injury, so that **fracture** or **fissure** is caused, proliferation of the cells of the periosteum and marrow is speedily set up, and in the course of a few weeks, if the wound remains uninfected and free from suppuration, results in the **repair** of the fracture. The newly-formed osseous material which unites the fragments of the bone is termed **callus**; according to its source it is distinguished as exterior or periosteal, interior or myelogenous, or intermediary callus. Immediately after the injury by which a bone is splintered, or broken transversely or obliquely, the ends of the fragments (Fig. 88), as well as such splinters as may have been broken off from them (Fig. 88 *b*), are usually more or less displaced in relation to each other. The periosteum is generally torn at the seat of fracture and in part stripped from the bone; while the neighbouring soft parts are also torn and crushed to a varying extent. A certain amount of blood is extravasated into the bone-marrow and the surrounding tissues.

As a result of these lesions inflammation sets in soon after the injury is inflicted, so that the tissues are infiltrated with liquid in the first place and later on with extravasated cells. The periosteum accordingly appears reddened and swollen during the first few days after the fracture. Its fibrous layers are distended and separated by albuminous liquid, and small round-cells appear here and there through its texture (Fig. 87 *g*). Similar changes occur in the tissues contiguous to the periosteum, as well as in the parts where the marrow is torn. After the second day cells can be detected which contain fragments of disintegrated blood-corpuscles, leucocytes, and the detritus of damaged tissue.

In simple fractures the inflammation at no time reaches a high degree of intensity. After a few days the inflammatory symptoms usually decrease; at the end of the fifth or sixth day the number of extravasated leucocytes in the tissues is small, and unless the damage has been severe they usually disappear entirely within the next few days.

On the second day after the fracture the first signs of proliferation show themselves in the cells of the periosteum and of the bone-marrow. Here and there the cells and nuclei become swollen (Fig. 87 *a*), and the various forms of karyokinetic nuclear division follow in their regular order (*b c*). During the next few days the number of proliferous cells increases, and at the same time the endothelium of the blood-vessels (*d*) undergoes active

proliferation. By the third or fourth day the osteoblastic layer of the periosteum has been transformed into a highly-vascular germinal tissue (Fig. 87) consisting of somewhat large polymorphous cells. Some of these exhibit karyokinetic figures, and all are embedded in a homogeneous or fibrillated matrix, enclosing isolated leucocytes. The blood-vessels are frequently almost occluded by their proliferous endothelial cells.

The cells of the external layer of the periosteum also undergo proliferation; but here the fibrous structure of the membrane remains visible throughout.

From the fourth day onward the germinal tissue begins to be differentiated. In the layers nearest to the bone appear little patches, that presently unite into trabeculae, of osteoid and occasionally of chondroid tissue (Fig. 83 *c d* and Fig. 84). These patches and trabeculae are after a short time transformed into

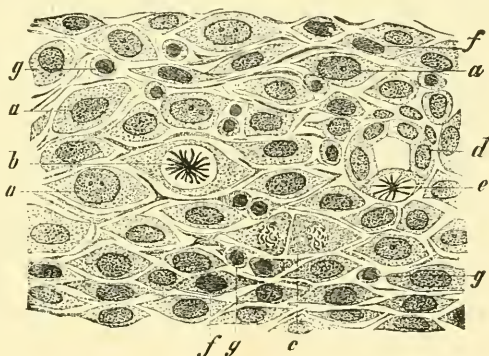


FIG. 87. PROLIFEROUS PERIOSTEUM FOUR DAYS AFTER FRACTURE OF THE BONE.

(Preparation treated with Flemming's nucleus-fixing solution, stained with haematoxylin, and mounted in glycerine: $\times 250$)

- | | |
|--------------------------------------------------------------|-------------------------------------------------------|
| <i>a</i> pale formative cells with large nuclei | <i>e</i> endothelial cell showing karyokinetic figure |
| <i>b</i> osteoblasts showing karyokinesis | <i>f</i> small deeply-stained formative cells |
| <i>c</i> two cells with nuclear stars shortly after division | <i>g</i> leucocytes |
| <i>d</i> blood-vessels with proliferous endothelium | |

osseous tissue. The highly-vascular germinal tissue lying between these cellular aggregations retains its loose structure, and by degrees assumes the characters of bone-marrow. In the course of the next few days the number of osteoid trabeculae forming on the broken surfaces steadily increases, and by the end of the first week the extremities of the two fragments are covered with a multitude of young osteophytes (Fig. 88 *d d*₁) and osteoid trabeculae (*e e*₁).

The region of periosteal osteophytic growth in the long bones always extends for some distance toward the epiphyses, and in

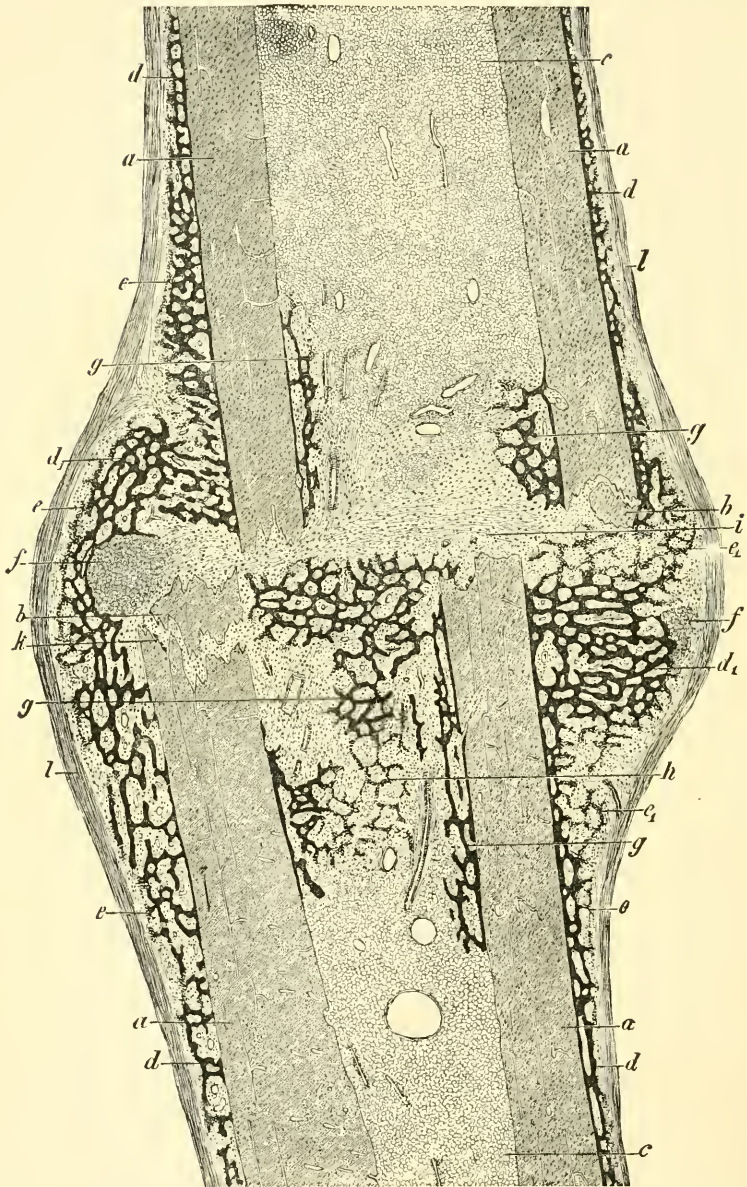


FIG. 88. LONGITUDINAL SECTION THROUGH A FRACTURE OF THE FIBULA FOURTEEN DAYS OLD.

(From a man aged 25: preparation hardened in Müller's fluid, decalcified with picric acid, stained with haematoxylin and carmine, and mounted in Canada balsam: $\times 7$)

- a cortical layer of the fibula b small splinters c fatty marrow d d₁ periosteal osteophytes
- e e₁ trabeculae of osteoblasts and osteoid tissue f newly-formed cartilage
- g myelogenous osseous trabeculae h myelogenous trabeculae of osteoblasts and osteoid tissue
- i connective tissue covering the fractured ends
- k osteoblasts l external fibrous layer of the periosteum

such a manner that the proliferation is greatest nearest the seat of fracture and decreases gradually as it recedes from this point.

In the neighbourhood of the fractured ends the periosteal germinal tissue may be in the first instance transformed more or less completely into hyaline cartilage (Fig. 88 *f*); this however is only temporary, and is soon changed into spongy bone (Fig. 85). Sometimes fibrous connective tissue is formed in small patches, but this too is later on elaborated into osseous tissue.

The new tissue which develops from the inner layer of the periosteum generally gives rise at first to a spindle-shaped swelling of the periosteum over the ends of the broken bone. Usually during the second or third week the proximal and distal fragments are bridged over by the periosteal proliferation, and as the development of firm osseous trabeculae proceeds, the separated fragments are again united. If splinters have been detached (Fig. 88 *b*) but not deprived of vitality, they are joined to the ends of the bone by osseous trabeculae that grow between them or cover them over. While the outer periosteal callus is thus being formed, an internal myelogenous callus (Fig. 88 *g*) usually develops at the same time in the marrow. The process is as follows: the proliferous osteoblasts form trabeculae (*h*); these are then transformed into osteoid tissue, and finally into osseous tissue. The inner callus is generally much less bulky than the outer, and may under certain conditions be represented merely by a few trabeculae.

The intermediary callus that forms between the fragments is almost entirely produced by the ingrowing of the external periosteum.

At a very early stage processes of resorption are set up both in the old and in the newly-formed bone. As regards the former, the jagged ends of the fragments (*k*) and the separate splinters (*l*) are absorbed. In the course of some months, after union has taken place, the portion of the callus which is unessential to the function of the bone is again removed. A certain amount of **involution** also occurs in the callus, and those trabeculae which are especially exposed to mechanical stress are thickened by apposition. In the old bone those parts which have become useless by reason of their altered statical conditions (WOLFF) are absorbed. After months or years the texture and form of the fractured bone thus approach very nearly to their original condition, and the boundary line between the old and the new bone disappears, so that in cases where there has been but little displacement of the ends, the line of fracture may be marked only by an inconsiderable thickening (Fig. 89 *a b*). In cases where the dislocation of the broken ends has been more pronounced, greater deformity of course remains.

At the same time that resorption takes place in the outer

callus, processes of involution are set up in the indurative thickening of the connective tissues of the contiguous soft parts, which usually accompanies the healing of the fracture.

The bulk of the callus varies greatly in different cases, and depends, apart from the individual peculiarities of the patient, upon the nature of the osseous tissue at the seat of fracture, upon the size of the bone, and upon the kind of fracture. The greatest amount of callus forms in fractures through the diaphyses of the long bones. The callus is much smaller in fractures near the epiphysial ends of the long bones, in the small cancellous bones, and in the flat bones, such as the scapula, innominate, and cranial bones. In the latter case the external callus is very small indeed, and scarcely shows above the surface; it may afterwards be entirely absorbed. The fissure between the edges of the fragments is often incompletely bridged over by osseous tissue. In fractures which extend from the diaphysis into a joint, the extra-capsular callus is strongly developed, while the intra-capsular callus is scanty. In some cases, the joint is bridged over by osteophytes arising from the extra-capsular callus.

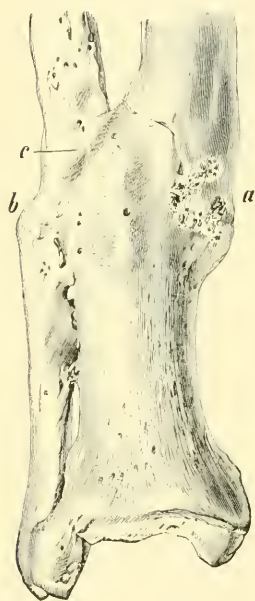

FIG. 89. REUNITED FRACTURE OF THE TIBIA AND FIBULA, WITH SYNOSTOSIS OF THE BONES.

(Half the natural size)

- a line of fracture in the tibia
- b in the fibula
- c osseous union between the tibia and fibula

In **incomplete fractures**, by which the continuity of the bone is only in part interrupted, and no portion is entirely severed from its connexions, the formation of callus is limited. The like holds for 'greenstick' fracture of the long bones, denting or depression of the flat bones, contusion or crushing of the spongy bones, and for simple cracks or splittings of bones in general.

In **complete fractures**, in which there is an entire separation of the broken parts, the amount of callus is dependent, other conditions being equal, upon the amount of separation and upon the number of fragments. The callus is least when the separation is so slight as not to tear the periosteum. It is very much greater when there is marked lateral displacement, or overlapping of the fragments in the longitudinal direction, and when the displaced fragments meet at an angle (Fig. 90). A comminuted fracture with much splintering requires a greater amount of callus for its repair than does a simple transverse or oblique fracture.

If splinters of bone are broken off and widely separated,

union between them and the bone may not take place. Necrotic fragments produce and keep up an inflammatory irritation, which lasts until they are absorbed. Living fragments that preserve their periosteal covering may increase in size through apposition; but they are ultimately absorbed. Fragments enclosed in the callus are either thickened by apposition or rarefied by resorption, their fate depending on whether or not they are capable of subserving the statical function of the restored bone.

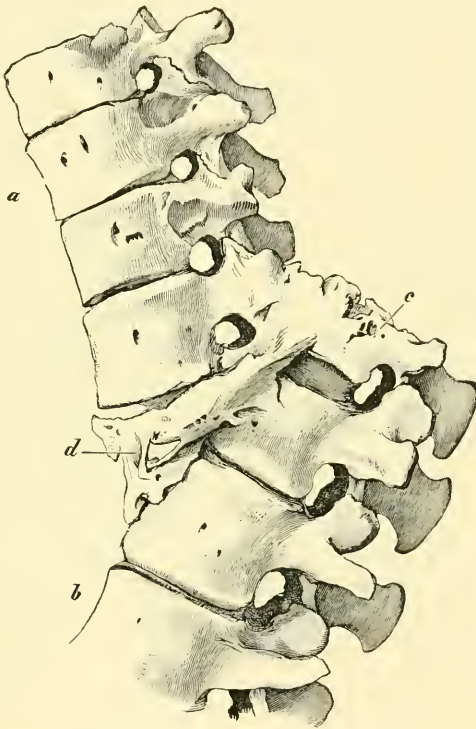


FIG. 90. FRACTURE OF THE SPINE NINE MONTHS OLD, WITH GREAT DISPLACEMENT OF THE VERTEBRAE.

(Reduced about one-half)

a thoracic vertebrae
b lumbar vertebrae
c callus formed on the lower half of the fractured first lumbar vertebra

d upper portion of the first lumbar vertebra, torn and dislocated forwards and downwards, and united by osseous bridges to the anterior surface of the second and third lumbar vertebrae

When contiguous bones, such as the tibia and fibula, are broken, the tissue produced by the proliferation of the torn periosteae may coalesce, and so lead to the formation of a **synostosis** (Fig. 89 *c*).

If the ends of the fragments are widely separated by the traction of muscles (as in transverse fracture of the patella and

fracture of the olecranon) or otherwise, or if the fragments are continually subject to relative displacement, bony union may fail to take place. This may happen when soft parts are caught between the ends of the fragments, as sometimes occurs at the upper extremity of the humerus and femur; or when one of the fragments is ill-nourished and possesses little osteoplastic tissue. The latter condition arises chiefly in the case of intra-capsular fractures, and more particularly in intra-capsular fracture of the neck of the femur (Fig. 92). Senile debility and marasmic conditions of the body may delay the formation of callus. Lastly, even in perfectly healthy patients, osseous union sometimes fails.

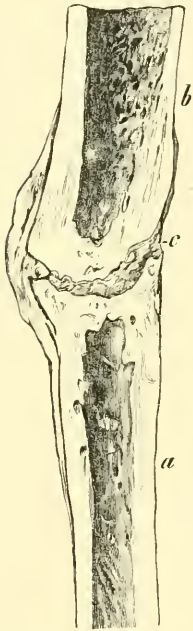


FIG. 91. FRACTURE OF THE FIBULA, REPAIRED BY SYNDES-
MOSIS.

(Two-thirds of the
natural size)

- a lower fragment
- b upper fragment
- c syndesmosis

When the ends of the fragments are immovably united by firm fibrous bands (Fig. 91 *e*) instead of by bone, a pathological **syndesmosis** is formed; but when the union of the fragments is looser and more or less movable a **false joint** (Fig. 92) or **pseudo-arthritis** is the result. In many cases the pseudo-arthritis consists of a loose ligamentous mass uniting the fragments, and this, by a gradual change of form in the ends of the bone, may form a new joint or **nearthritis**. In such cases a false head (Fig. 92 *d*) and acetabulum (*e*) may be produced, the opposed surfaces being covered with dense connective tissue, or in rare instances with cartilage, and the periphery of the surfaces of contact being invested with a sort of capsule (*f*).

Other things being equal, the duration of the process of repair in a given fracture depends upon the size of the bone. According to GURLT, the average time required for the healing of a broken digital phalanx is two weeks; of a rib, three weeks; of a forearm, five weeks; of an upper arm, six weeks; of a tibia, seven weeks; of a femur, ten weeks; and of the neck of the femur, twelve weeks. In children, the process is much more rapid. In children under two years of age, the majority of fractures unite in from two to three weeks. Sometimes in otherwise perfectly sound patients the healing is, for some unknown reason, unduly delayed.

Pieces are sometimes **resected** from the shaft of a bone by surgical operation, or the articular ends of two bones are removed and the resected ends fitted together; in such cases the result may be either bony union or the formation of a new joint.

References on the Repair of Fractures.

- BARDELEBEN: *Lehrbuch d. Chir.* II Berlin 1880
 BERGMANN: Injuries of the head *Deutsche Chirurgie* part 30 1880
 BRUNS, P.: *Die Lehre von den Knochenbrüchen* Stuttgart 1886
 DUHAMEL: *Mém. académie royale des sciences* Paris 1841
 DUPUYTREN: *Leçons orales de chirurgie* 2nd edition Paris 1839
 GURLT: *Handb. d. Knochenbrüchen* I Berlin 1862
 KASSOWITZ: *Die normale . . . Ossification* Vienna 1881
 MALGAIGNE: *Traité des fractures* Paris 1855
 RIGAL and VIGNAL: Formation of callus *A. de physiol.* 1881
 ROUX: Ankylosis of the knee *A. f. Anat. u. Physiol.* 1885
 STIMSON: *Treatise on Fractures* Philadelphia 1883
 WAGNER: *Der Heilungsprozess nach Resection* Berlin 1853
 WEBER: *Heilung gebrochener Röhrenknochen* 1825
 WOLFF: *Das Gesetz d. Transformation d. inneren Architectur d. Knochen bei pathol. Veränderungen* 1881; *Das Gesetz d. Transformation d. Knochen* Berlin 1892

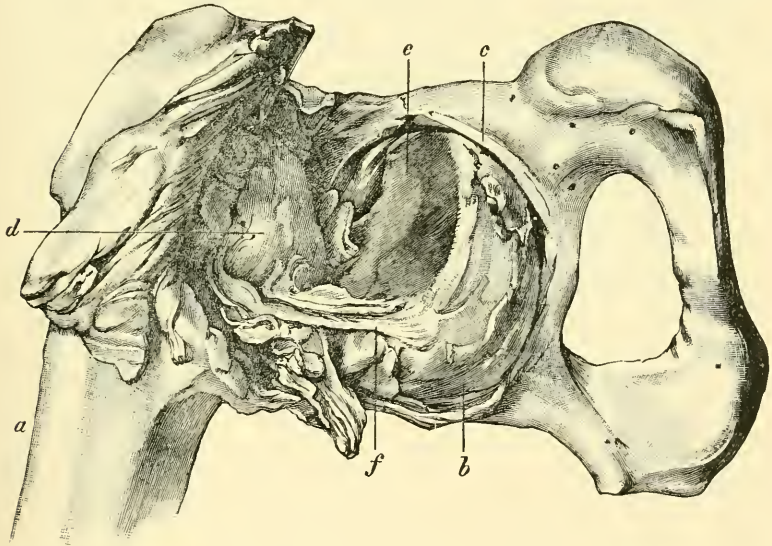


FIG. 92. PSEUDO-ARTHROSIS AFTER FRACTURE OF THE NECK OF THE FEMUR.
 (Three-fifths of the natural size)

- | | |
|----------------------|---------------------------------------------------------|
| a shaft of the femur | d rounded surface of fractured neck of the femur |
| b head of the femur | e smooth concave surface of fractured head of the femur |
| c acetabulum | f fibrous bands forming part of a new capsule |

46. In many cases the production of new bone must be regarded as a purely reparative process, as for example after fracture or resection, where the new bone firmly reunites the severed portions. In other cases the formation of new osseous tissue leads to **hypertrophy** of the bone. Of this nature is the proliferation which accompanies inflammation (Chaps. XVI and XVII). In growing bones hypertrophy sometimes makes its

appearance without any recognisable cause (Chap. XVIII). In other cases the increased production of bone is referable to the presence in the blood of certain chemical substances, such as phosphorus and arsenic. New bone is also frequently produced in the neighbourhood of tumours of the marrow or periosteum, or it may develop in the mass of the tumour itself.

When by long-continued periosteal and endosteal hyperplasia a bone increases greatly in size, the condition is termed **hyperostosis**. The term **osteosclerosis** is applied to that condition in

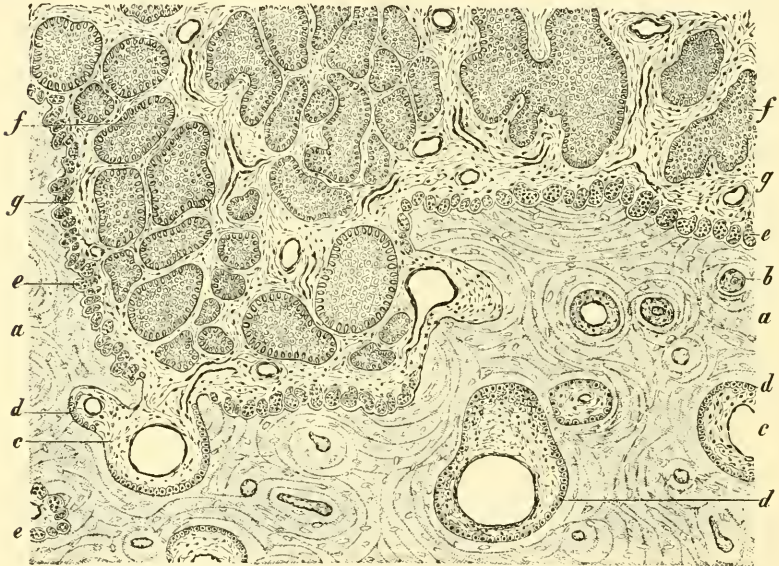


FIG. 93. RESORPTION AND APPPOSITION OF BONE.

(From the neighbourhood of a metastatic cancer-node in the diaphysis of the humerus: preparation hardened in Müller's fluid and alcohol, decalcified with picric acid, stained with haematoxylin, and mounted in Canada balsam: $\times 50$)

- | | | | |
|---|-------------------------------------------------|---|-----------------------------------|
| a | cortical layer of the humerus | d | osteoblasts |
| b | normal Haversian canal | e | osteoclasts and Howship's lacunae |
| c | dilated Haversian canal with wide blood-vessels | f | cancer-nodes |
| | | g | stroma of the cancer |

which the medullary spaces of a spongy bone are encroached upon by the deposition of osseous tissue upon the old trabeculae, or by the formation of new ones, so that the cancellous tissue becomes close and dense in texture. Circumscribed osseous deposits in the interior of a bone are termed **enostoses**; small circumscribed periosteal deposits are termed **osteophytes**; larger ones, **exostoses**. The latter develop at the point of insertion of tendons, and near the attachment of cartilages. When exostoses developed from the outer layer of the periosteum are not firmly united to the bone, they are known as **movable exostoses**. Extensive formations of

osseous tissue on the exterior of a bone are spoken of as **periostoses**. All these formations arise chiefly in connexion with inflammations; but they may be produced without demonstrable cause. Osseous tissue developed from a cartilaginous basis is termed **chondroid exostosis**. Some exostoses are produced without passing through a cartilaginous stage, and are known as **fibroid exostoses**. Very frequently the processes of bone-resorption and bone-apposition are combined, and the latter may either precede or follow the former.

Thus a tumour, developing in the interior of a bone (Fig. 93 *f g*) may by lacunar resorption occasion the disappearance of the adjoining bony substance; while apposition of bone takes place simultaneously in the Haversian canals beyond, and in the periosteum, either by the deposition of osteoblasts (*d*) on the old bone, or by the formation of new periosteal trabeculae. The result is

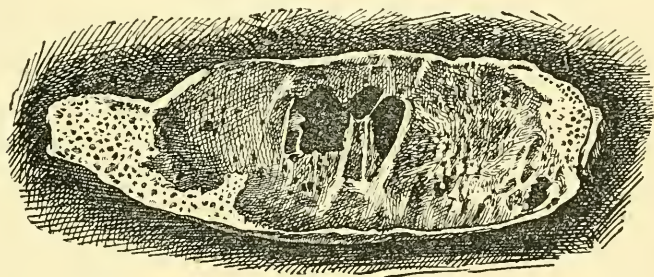


FIG. 94. APPARENT DILATATION OF THE RADIUS.

(From a child, the dilatation arising from internal resorption and external apposition, accompanying central tuberculosis: natural size)

that as the tumour grows and the old bone entirely disappears, although the growth rises above the former surface, it nevertheless remains continually covered by a surrounding crust or shell of bony tissue.

In a similar manner the destruction of a long bone by tuberculous granulations may be accompanied by the deposition of new bone on the external surface. If this new layer is in its turn destroyed, while fresh apposition once more takes place on the exterior, the bone has the appearance of dilating, and at the same time its walls become thinner (Fig. 94).

In a bone that has been amputated or resected, resorption and apposition always occur in the sawn or chiselled portions; and when from any cause new osseous tissue has been formed at any point, resorptive processes are probably always set up in it at a subsequent stage. In this manner, projecting osteophytes may disappear, and roughenings of the bony surfaces may become smoothed out again.

CHAPTER XVII

INFLAMMATIONS OF BONE

47. The **acute haematogenous inflammations** of bone constitute a group of affections that are most commonly produced by pathogenic micro-organisms, though other noxious agencies may also give rise to them.

Among the infective diseases by which the inflammations of bones and joints may be induced, the following are the most noteworthy: multiarticular rheumatic arthritis, pyaemia, scarlatina, measles, typhoid fever, relapsing fever, dysentery, small-pox, mumps, gonorrhoea, and acute infective osteomyelitis and periostitis. The latter disease, which originates from the invasion of pyogenic micrococci, owes its name to the fact that the associated inflammation of the marrow and periosteum forms a characteristic feature of the disease. In acute articular rheumatism inflammation of the joints appears as an essential symptom, and is generally accompanied by inflammation of the endocardium and of various serous membranes. In scarlatina, typhoid fever, measles, pyaemia, and gonorrhoea, the inflammations of bones and joints are not pathognomonic, but occur as more or less frequent complications; these must accordingly be regarded as metastatic in their nature, inasmuch as they are due to infection conveyed to the seat of inflammation from another part of the body.

In gonorrhoea the joints only are affected by metastatic inflammation; in relapsing fever and small-pox we may have osteomyelitis; in pyaemia, scarlatina, measles, and typhoid fever, both otitis and arthritis may occur.

The signs of inflammation are primarily manifested in the vascular tissues of the bones, namely the periosteum and the marrow; and, according as it affects chiefly the one or the other tissue, the inflammation is described as **periostitis** or **osteomyelitis**. Inflammation of the bone-marrow or of the cortical stratum of the spongy bones is often termed **ostitis**. Slight and transient inflammations leave the substance of the bone intact, or give rise only to a trifling amount of resorption and apposition. Severe inflammations often terminate in **caries** and **necrosis** of the osseous tissue.

The gravest form of acute inflammation of bone is **acute infective osteomyelitis** and periostitis. This disease makes its appearance most frequently in young persons, and is an infective disorder accompanied by fever. The inflammation is intense and of a purulent or septic character; it is usually confined to one of the long bones, but occasionally attacks more than one. The femur is most frequently the seat of the disease, then the tibia, less often the long bones of the arm, and still more rarely the short and flat bones.

The disease arises either spontaneously, without any manifestation of previous infection, or in association with typhoid fever, measles, or scarlatina. Whether in the latter case it is to be regarded as due to the virus of the initial affection or to a second infection of a specific kind cannot as yet be determined, although the latter supposition is the more probable.

Micrococci are constantly found in true infective osteomyelitis, *Staphylococcus pyogenes aureus* and *albus* being the forms most frequently detected (ROSENBACH, GARRÉ, KRASKE). The disease thus belongs to the group of **septic pyaemias**.

The process may originate either in the marrow or in the periosteum, and it is characterised by inflammation which leads to suppuration, sometimes to putrid decomposition or gangrene. The infiltration of the periosteum is sometimes confined to that membrane itself, and sometimes involves the contiguous loose connective tissue. When recent it gives rise to redness and swelling and occasionally to haemorrhages; in later stages the infiltrated tissues assume a yellow or grey tint. The marrow is at first hyperaemic and at times shows signs of haemorrhagic infiltration. Later on suppurative foci of a dirty-yellow or grey colour are formed, usually in the diaphyses, but occasionally in the epiphyses also. In severe cases the entire marrow of the diaphysis suppurates, and the Haversian canals of the cortical stratum may become filled with pus. Large quantities of pus sometimes also collect between the periosteum and the bone. When some of the inflammatory foci are situated near a joint, this too may become inflamed, and serous and purulent effusions are poured out into its cavity.

The disease frequently issues in hyperpyrexia and in death. Metastatic abscesses sometimes result from the septic inflammation and thrombosis of the veins of the bone-marrow. Sub-periosteal abscesses may rupture externally.

At the seat of the purulent or septic inflammation there is always some necrosis of the bone (Figs. 95 and 96), but cases occur in which the infection produces no suppuration, so that speedy recovery by re-absorption of the inflammatory exudation is possible.

In the graver forms the course of the disease depends primarily upon the size and number of the necrotic foci. In suppuration of

the entire marrow of the diaphysis, accompanied by a total separation of the periosteum, the whole of the shaft may become necrotic. A limited suppuration will naturally cause but slight necrosis (Fig. 96 *a*). Partial necroses (Fig. 95 *a*) lie just under the periosteum or in the deeper parts of the bone, according to the situation of the initial suppuration. Necroses are distinguished as total or partial, central or superficial, according to their size and situation.

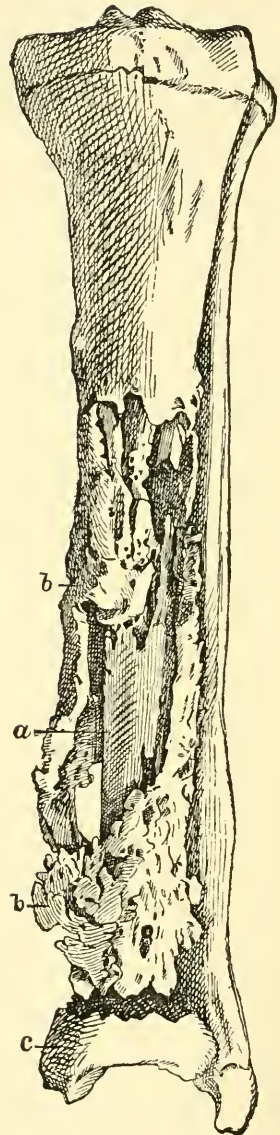
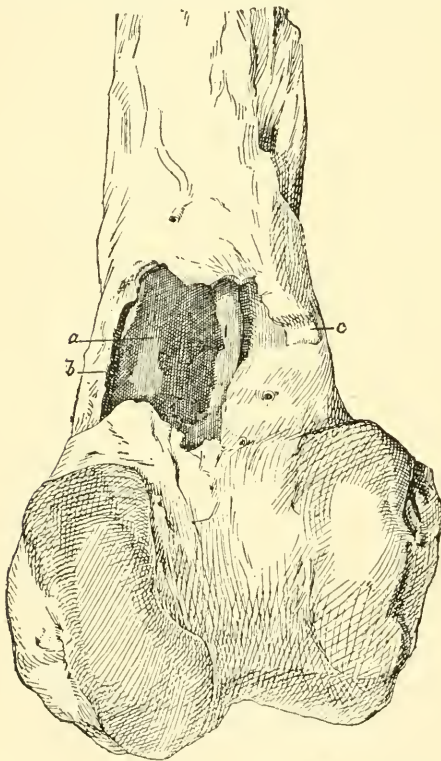


FIG. 95. NECROSIS OF THE LOWER THIRD OF THE DIAPHYSIS OF THE FEMUR.
(From a case of fifteen years' standing: preparation preserved in spirit: four-fifths of the natural size)

a sequestrum *b c* edges of the opening in the thickened bone

FIG. 96. NECROSIS OF THE LEFT TIBIA WITH PERIOSTEAL BONE-FORMATION, FOLLOWING ACUTE OSTEOMYELITIS.

(Three-fifths of the natural size)

a sequestrum *b* periosteal bone-formation *c* separated epiphysis

Soon after the commencement of suppuration, granulations spring up at the margins of the affected region, and mark it off from the adjoining tissue. At the same time signs of proliferation appear in the marrow and in the periosteum, indicated chiefly by the formation of osteoplastic germinal tissue and of multinuclear osteoclasts. With the appearance of the latter cells, active resorption begins at the border between the dead and the living tissue, and this, after the lapse of weeks, leads to the separation of the former from the latter. If the inflammation of the diaphysis in a young patient reaches the epiphysial cartilage (which does not disappear until after the nineteenth or twentieth year), separation of the epiphysis (Fig. 96 *c*) results.

The separation of the dead from the living tissue having been accomplished, the bone encloses a suppurating cavity or **abscess** containing the separated fragment of bone, which is known as the **sequestrum** (*a*). Generally at the same time one or more openings (Fig. 95 *b c*) in the bone are formed, which are at first covered over by pus-secreting granulations. Round about the openings masses of new osseous tissue of various size have already been formed, producing condensation or thickening of the bone. When the entire thickness of the bone has perished, the new bony tissue can arise only, except at the ends, from the periosteum. In this way it surrounds the sequestrum on all sides so as to encase it in a rigid sheath or **splint** (Fig. 96 *b*), which holds together the surviving fragments. In partial necrosis new bone is formed both in the periosteum and in the interior of the bone; in the latter case the growth originates in the marrow. As a rule new bone is absent only at the opening through which the pus from the abscess-cavity makes its exit.

Small sequestra may be absorbed in the course of a few weeks or months: larger sequestra may for years (Figs. 95 and 96) keep up a condition of inflammation, and finally have to be removed by operation. Sometimes they can be extracted through openings by which pus is being discharged; but more frequently the encasing splint of new bone has first to be chiselled away. After the removal of the sequestrum the wound closes by granulation and cicatrisation, and by renewed proliferation of the periosteum and marrow. When the process is completed the bone is covered with osteophytes and altered to an irregular shape, while its interior is partly condensed or sclerotic, partly rarefied or osteoporotic. By gradual apposition and resorption the bone in time returns more or less to its normal condition; but even in the case of partial necrosis, years may pass before the cancellous portion regains its normal structure, and the original loss of substance is entirely made good. The periosteal thickenings, and the other changes in the spongy and in the cortical strata, are rarely if ever entirely effaced.

The **metastatic inflammations** of bone which occur occasion-

ally in pyaemia, typhoid fever, scarlatina, and measles sometimes follow a clinical course similar to the analogous forms of infective osteomyelitis and periostitis. Usually, however, they give rise only to small foci of suppuration and abscesses; sometimes indeed (as in small-pox) the inflammation of the bone-marrow, or of the periosteum, may be so slight and transient as to leave behind no permanent textural alteration.

If any of the larger nutrient arteries are occluded by emboli during the metastatic inflammation, the process may be combined with **anaemic necrosis**.

In recent years OLLIER, SCHLANGE, RIEDINGER, ROSER, and others (see SCHLANGE: Some rare affections of bone *Arch. f. klin. Chir.* xxxvi 1887; RIEDINGER: Ganglion periostale or Periostitis albuminosa *Festschr. für A. von Külliker* 1887; ROSER: Periostitis albuminosa *Centralbl. f. Chir.* 1887) have described certain mild forms of inflammation of the bones characterised by the presence of accumulations of clear rosy albuminous liquid, resembling synovial fluid, under the names of **periostitis** and **ostitis albuminosa**. These attack chiefly the larger long bones of young persons between the ages of 15 and 20, and are unaccompanied by fever. According to GARRÉ the affection is in some cases only a slight form of infective osteomyelitis, which as we know does not always take a severe course, and does not invariably lead to suppuration: it sometimes gives rise merely to transient inflammatory disturbance, followed by the formation of new bone.

References on Osteomyelitis and Periostitis.

- APPELRATH: *Infectiöse Osteomyelitis* 1890
 CHIARI: Variolous osteomyelitis *Ziegler's Beiträge* xiii 1893
 COLZI: *Etiologia dell' osteomielite acuta* Florence 1890
 DMOCHOWSKI and JANOWSKI: Pyogenic action of the typhoid bacillus *Ziegler's Beiträge* xvii 1895
 FISCHER and LEVY: Bacteria in osteomyelitis and periostitis *Z. f. Chir.* xxxvi 1893
 FRÖHNER: Acute osteomyelitis in short and flat bones *Beiträge von Bruns v* 1889
 GANGOLPHE: *Maladies infectieuses des os* Paris 1893
 GARRÉ: Rare forms of acute infective osteomyelitis *Kocher's Festschrift* Wiesbaden 1891; Special forms of acute infect. osteomyel. *Beiträge von Bruns x* 1893
 HAAGA: Statistics of acute spontaneous osteomyelitis *Beiträge von Bruns v* 1889
 IVANOFF: Subacute osteomyelitis in adolescence *Thèse* Paris 1885
 JABOULAY: The microbe of acute osteomyelitis *Thèse* Lyons 1885
 JORDAN: Acute osteomyelitis *Beiträge von Bruns x* 1893
 KLEBS: *Pathol. Anat. d. Schusswunden* Leipzig 1882
 KLEMM: Bone-affections in typhoid *A. f. klin. Chir.* xlvi 1893
 KOCHER: Causation *D. Z. f. Chir.* xi 1878
 KRASKE: Aetiology of acute osteomyelitis *A. f. klin. Chir.* xxxiv 1887
 LANNELONGUE and ACHARD: Experimental study of osteomyelitis *Annales de l'Inst. Pasteur v* 1891
 LEGIEUX: *Periosteitis u. Osteitis albuminosa* 1890
 OGSTON: *Journ. of Anat.* xvii 1882
 REYNIER and LEGENDRE: Aetiology of certain forms of periostitis etc. *A. gén. de méd.* 1885
 ROSENBACH: *Mikroorganismen bei d. Wundinfektionskrankh.* Wiesbaden 1884
 STRUCK: *Microbes D. med. Woch.* 1883

TUBBY: Acute infective ostitis *Guy's Hosp. Reports* XLVII London 1890

ULLMANN: *Osteomyelitis acuta* Vienna 1893

VOLLERT: Albuminous periostitis (so-called) *Volkman's kl. Vorträge* 352 1890

WITZEL: *Knochenentzündungen bei acuten infect. Erkrankungen* Bonn 1890

48. When a bone is crushed, torn, broken, or injured in any way by traumatic violence, haemorrhage and inflammation are induced (Art. 45). These conditions rapidly pass away, and the injury is repaired by regenerative growth of the periosteum and marrow.

If the traumatic injury, such as a fracture, is accompanied by simultaneous perforation of the skin (**compound fracture**), whereby a communication is established between the external air and the bone, and contamination of the wound by pathogenic micro-organisms takes place, an intense inflammation is set up that completely perverts the process of repair.

In favourable cases pus-secreting granulations are formed in the wound: these cover over the exposed bone, and force themselves in between the fragments. After a time new bone is formed in the periosteal granulations, and repair may be completed without necrosis. More frequently, however, the infection leads to suppuration, and wherever considerable accumulations of pus take place the tissues perish and the bone over a greater or smaller area becomes necrotic.

In certain cases a large part of the marrow of the fractured bone becomes the seat of suppuration, and the periosteum also is destroyed to a greater or less extent. The suppuration may extend from the bone to the nearest joint, to the intermuscular connective tissue, and so on. These complications render the course of the affection similar to that of haematogenous purulent periostitis and osteomyelitis (Art. 47), and tend to produce sequestra which can be loosened and extruded from the body only by long-continued processes of resorption. The formation of callus is for the most part limited to the periosteum surrounding the necrotic fragments.

Such a course of events is specially characteristic of **gunshot injuries**, of which an open wound and extreme comminution of the bone are the usual concomitants. It may also however take place in amputation-stumps, when the operation-wound becomes septic and inflamed from the invasion of bacteria.

Not infrequently the irritant causing the inflammation penetrates from the exterior into the periosteum and the bone, without antecedent traumatism. This generally happens when the tissues contiguous to the bone are the seat of inflammation. But the irritant sometimes reaches the bone without previously exciting inflammation in the immediately adjacent structures. Thus suppurating ulcers of the scalp or of the nasal mucous membrane, purulent inflammations of the pelvic connective tissue, and the

like, may extend to the periosteum and marrow of the contiguous bones, and there set up suppuration, caries, and necrosis. Periosteal inflammation is apt to be set up in a finger the skin of which has been injured and infected, as in pararitium or **whitlow**.

49. **Chronic inflammations of bone**, apart from the tuberculous, syphilitic, and actinomycotic forms, are chiefly the result of acute inflammations which have induced conditions that give rise to long-continued irritation. This is the case with all haematogenous, traumatic, and metastatic inflammations that issue in necrosis. The changes accompanying chronic inflammation of the periosteum and bone-marrow may thus be inferred from what has already been described. Pus-secreting granulations are

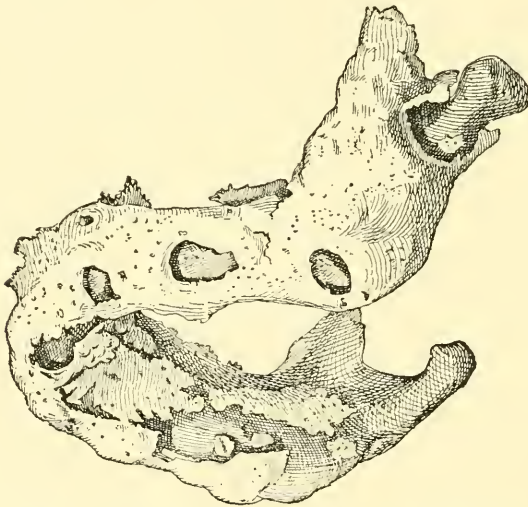


FIG. 97. PHOSPHORUS-NECROSIS OF THE LOWER JAW.

(The necrotic jaw-bone is enclosed in a sheath of new bone: after VON SCHULTHESS-RECHBERG)

formed at the seat of necrosis, and these surround and enclose the central or peripheral sequestrum. From the cavities thus formed (so-called **cloacae**), fistulous tracks or sinuses lined with granulations pass outward, and permit the pus to escape. The processes of resorption and apposition alternate in the rest of the bone, and lead partly to osteoporosis, partly to hyperostosis.

Phosphorus-necrosis deserves separate mention. This affection makes its appearance among the workers in match-factories, and almost always attacks the jaw-bones (Fig. 97), very rarely affecting the other bones of the face. It is caused by the absorption of yellow phosphorus, which obtains access to the bone from the mouth. An essential preliminary factor in the aetiology of

this local destructive action on the jaw is the presence of some wound or sore of the gum, or the loss of a tooth, whereby the saliva, carrying with it the chemical poison and certain pathogenic micro-organisms, gains access to the deeper structures (KOCHER).

A slight inflammation of the periosteum is usually the first manifestation, and thereupon the periosteum and the marrow proliferate and produce new bone, the maxilla thus becoming thickened and sclerotic. Later on suppuration takes place in the periosteum and occasionally in the marrow, leading to necrosis of larger or smaller portions of the bone; and these after a time exfoliate. In some cases the entire inferior maxilla perishes. If the patient continues to be exposed to the vapours of phosphorus, the crust of new bone enclosing the dead portion may itself become necrotic.

Occasionally the periostitis is acute from the outset, and leads directly to suppuration and necrosis, without the formation of new osseous deposits.

Chronic inflammation of bone also results from the like inflammation in the immediately adjacent tissues, as for instance from cutaneous ulcers (Fig. 98) or hyperplastic inflammations resulting in elephantiasis. The inflammatory process in these cases leads to cicatricial thickening of the periosteum, beneath which the bone is sometimes eroded, sometimes beset with osteophytes and diffuse hyperostoses. Now and again these overgrowths reach a very considerable size (Fig. 98).

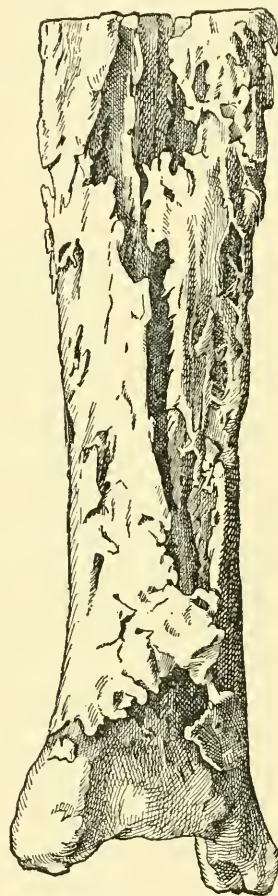


FIG. 98. PERIOSTEAL HYPEROSTOSIS OF THE TIBIA.

(At the base of a chronic ulcer of the leg: two-thirds of the natural size)

References on Phosphorus-necrosis.

- BIBRA and GEIST: *Die Krankh. d. Arbeiter in Phosphorzündholzfabriken* 1847
 GEIST: *Die Regeneration d. Unterkiefers* Erlangen 1852
 HÄCKEL: Phosphorus-necrosis *Langenbeck's Arch.* XXXIX 1890
 HERVIEUX: *Les maladies . . . à la fabrication des allumettes* Paris 1846
 JOST: Phosphorus-necrosis *Beiträge von Bruns* XII 1894
 KLEINMANN: *Die Phosphornekrose* Leipzig 1893
 KOCHER: *Zur Kenntniss d. Phosphornekrose* Bienne 1894

VON SCHULTHESS-RECHBERG: Phosphorus-necrosis *Inaug. Diss.* Zürich 1879

TRÉLAT: *La nécrose causée par le phosphore* Paris 1857

VOLKMANN: *Pitha und Billroth's Handb. d. Chirurgie* II 1872

WAGNER: Effect of phosphorus on the organism *V. A.* 55 1872

50. Of chronic inflammations whose course throughout is slow and insidious, there are (apart from those associated with gout) two varieties. The one is termed hypertrophic osteitis, or **ostitis hypertrophicans**, the other is **ostitis deformans**. The aetiology of both these groups of affections is still altogether obscure.

Typical **ostitis hypertrophicans** is a feature of the peculiar maladies which have lately been described under the names

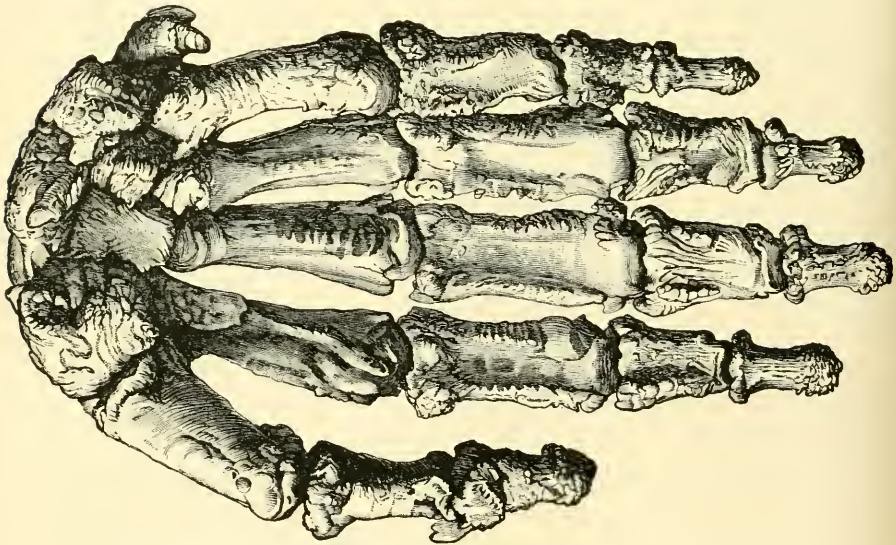


FIG. 99. SKELETON OF A HAND WITH HYPEROSTOSIS OF THE BONES.
(From a case of acromegaly: after ARNOLD)

acromegaly (MARIE), pachyaeria (VON RECKLINGHAUSEN), and pulmonary hypertrophic osteoarthropathy or *ostéoarthropathie hypertrophiante d'origine pneumique* (MARIE). It gives rise in early and in adult life to changes which result in the enlargement of the distal portions of the bones of the extremities and of the face, and are often combined with deformities of the vertebral column. The anatomical researches of ARNOLD, MARIE, THOMSON, and others, have shown that the increased size of the parts is chiefly due to hyperostosis (Fig. 99), periosteal osteophytes being deposited on the bone, in the shape of tuberous and pointed exerescences which alter the form of its surface. Their development, due to some chronic irritation of the periosteum,

and perhaps of the marrow, is not confined to the terminal portions of the limbs, but may extend over the greater part of the skeleton, and give rise, for example, to numerous osteophytic protuberances on the femur and the pelvic bones. In acromegaly the pituitary body is said to be always enlarged (Art. 129), and in certain cases hypertrophic osteoarthropathy seems to be associated with chronic pulmonary affections, probably of a tuberculous nature.

Ostitis deformans is a disease of the osseous system peculiar to old age, and is characterised chiefly by the combination it

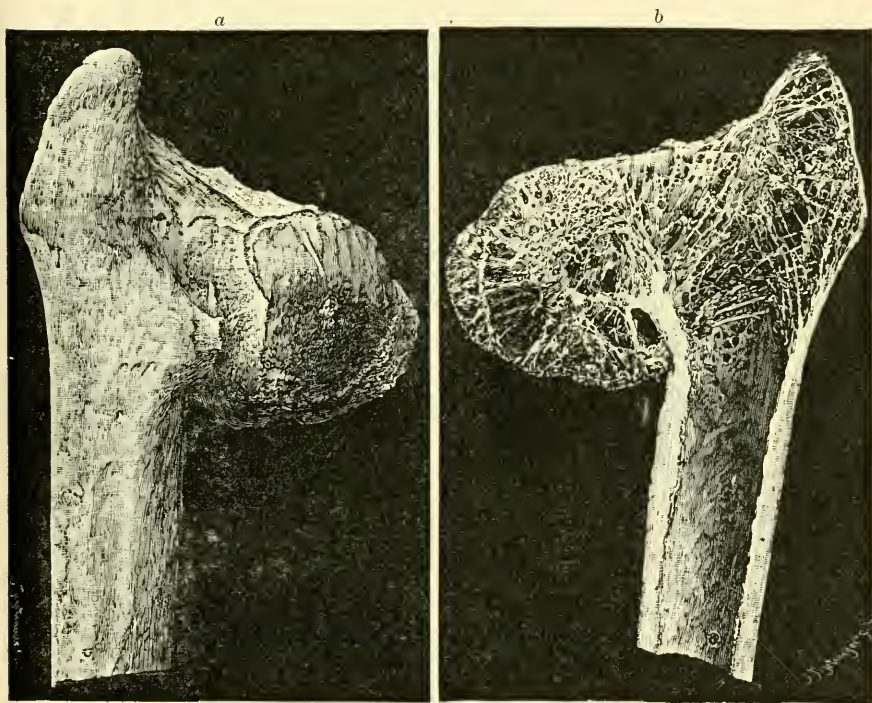


FIG. 100. OSTITIS DEFORMANS OF THE HEAD AND NECK OF THE FEMUR.
(Four-fifths of the natural size)

a external view

b section

presents of wide-spread resorption and apposition of bone. The process may be limited to particular bones or groups of bones, such as the femur (Fig. 100 *a b*), the bones of the cranium, or the spine (Fig. 101); or a large portion of the skeleton may be implicated.

Resorption of bone-substance takes place both in the cancellous and in the cortical regions; in the latter case it produces osteoporosis, which may markedly diminish the strength of the bone.

The osseous trabeculae may entirely disappear from the cancellous bone, and be replaced by fatty or gelatinous or even fibrous tissue containing few cells (*osteomyelitis fibrosa*), in which cysts are sometimes formed by liquefaction.

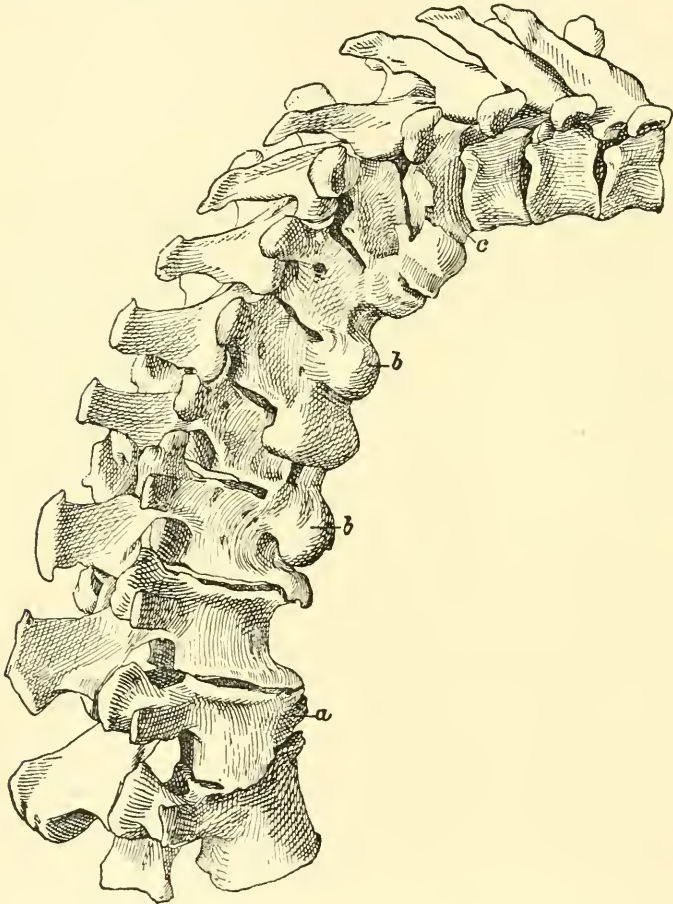


FIG. 101. SPONDYLITIS DEFORMANS.

(One-half the natural size)

- | | |
|--------------------------------------------------------------------------------------------------|--------------------------------------------------------------------------------|
| <p><i>a</i> body of a lumbar vertebra the thickness of which is markedly diminished in front</p> | <p><i>b</i> rounded protuberances uniting the bodies of adjacent vertebrae</p> |
| | <p><i>c</i> body of a thoracic vertebra which has collapsed</p> |

The apposition of new bone starts from the marrow or from the periosteum. In the former case the spongy parts become denser, and the medullary spaces are partially filled up with new bone; in the latter the bone itself is often greatly thickened (Fig. 100 *a b* and Fig. 101 *b*), its increase in bulk, particularly in the case of the

skull, being quite apparent in the living patient. This combination of resorption and apposition always leads to the more or less complete destruction of the characteristic architecture of the bones (Fig. 100 *b*). In the thickened skull for example the distinction between the inner and outer tables and the diploë may be entirely lost.

In cases of osteitis deformans, when the bone is weakened by excessive resorption it may give way by bending or even by abrupt angular flexure; the long bones are especially subject to this kind of deformation. Thus the humerus or the tibia may be bent into a curve, or the neck of the femur may be displaced on the shaft, and be forced into a more horizontal position by the weight of the body.

When the cancellous tissue becomes excessively weak it may collapse entirely. This occurs chiefly in the vertebral column (Fig. 101 *a c*), where particular vertebrae sometimes become wedge-shaped by the sinking in of the fore-part of their bodies, and the spine accordingly becomes curved, generally in the anterior direction (kyphosis).

Certain cases of osteitis deformans are from a histological point of view comparable with **arthritis deformans**; the main difference lying merely in the special seats affected by the processes of resorption and apposition (Art. 73). Other cases are more nearly allied to osteomalacia, particularly those in which bulging or bending of the bones is associated with pathological formations of new osseous tissue (Art. 43, Fig. 80).

References on Hypertrophic Ostitis (including Acromegaly and Pulmonary Osteoarthropathy).

- ARNOLD: Hypertrophic ostitis *Ziegler's Beiträge* VIII 1891
 BRAMWELL: Illustrated cases of acromegaly *Atlas of clin. med.* II part 3 Edinburgh 1893
 DRESCHFELD: Case of acromegaly *B. M. J.* I 1894 (with references)
 DUCHESNAU: *Étude anat. et clin. de l'acromégalie* Paris 1892
 FRIEDREICH and ERB: Hypertrophic ostitis *D. A. f. klin. Med.* 1888
 HOLSTI: Autopsy of a case *Z. f. klin. Med.* XX 1892
 LEFEBVRE: Pulmonary osteoarthropathy *Thèse* Paris 1891
 MARIE and SOUZA-LEITE: Pulmonary osteoarthropathy *Bulletin méd.* 1889; Acromegaly *Brain* XII 1890; Osteoarthropathy and acromegaly *Rev. de méd.* 1890; *Essays on acromegaly* (New Syd. Soc.) London 1891 (with references)
 MARINESCO: Case *A. de méd. exp.* IV 1891
 VON RECKLINGHAUSEN: Pachyacia *V. A.* 119 1890
 THOMSON: Skeleton in acromegaly *Journ. of Anat.* 1890
 THORBURN: Cases of pulmonary osteoarthropathy *B. M. J.* I 1893 (with references and figures)

References on Ostitis Deformans (see also Arts. 47 and 74).

- LUNN: Four cases of ostitis deformans *Trans. Clin. Soc.* xviii London **1885**
MOIZARD and BOURGES: *A. de méd. exp.* iv **1892**
PAGET: *Med.-chir. Trans.* London 60 **1877**, 65 **1882**
VON RECKLINGHAUSEN: Ostitis deformans, osteomalacia, and osteoplastic carcinosis *Virchow's Festschrift (Assistenten)* Berlin **1891**
RICHARD: Paget's bone-disease *Thèse Paris* **1887**
STILLING: *V. A.* 119 **1890**
ZIEGLER: Subcartilaginuous changes in arthritis deformans and cysts of bone
V. A. 70 **1877**; Metaplasia and resorption of bone *V. A.* 73 **1878**

CHAPTER XVIII

INFECTIVE GRANULOMATA OF BONE

51. **Tuberculosis**, the most common of chronic bone-diseases, may start in the marrow, in the periosteum, or in any joint or synarthrosis.

It occurs most frequently in young persons, although it sometimes makes its first appearance in advanced age. In the majority of cases the infection comes to the bones by way of the blood;

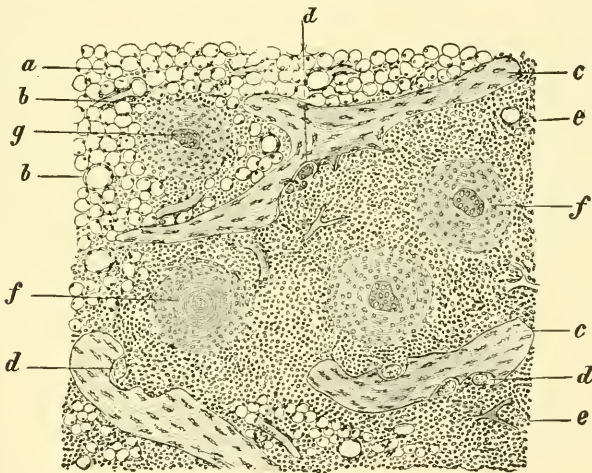


FIG. 102. FUNGOUS GRANULATIONS WITH TUBERCLES FROM THE SPONGY TISSUE OF THE CALCANEUM.

(Preparation hardened in Müller's fluid and alcohol, decalcified with picric acid, stained with haematoxylin, and mounted in Canada balsam: $\times 60$)

- | | | | |
|---|-----------------|---|----------------------------------------|
| a | fatty marrow | e | granulation-tissue |
| b | blood-vessel | f | tubercle within the granulation-tissue |
| c | bony trabeculae | g | isolated tubercles |
| d | osteoclasts | | |

but cases are also conceivable in which the bacilli may enter through the lymphatics of the bone, or pass into it from contiguous foci of tuberculous disease.

The tuberculous process begins by the formation at one spot of grey or greyish-red granulations, or at times perhaps by the

simultaneous production of a number of such eruptions. The granulomatous foci are characterised anatomically by the presence in them of grey and yellow tubercles (Fig. 102 *f*). If the primary seat of the tuberculous process is in the interior of a bone, such as a vertebra or a tarsal bone, or in the diaphysis or epiphysis of one of the long bones, and if it lies deeply and remote from the articular ends, the changes it occasions may go on for a time without involving periosteum or joint.

Lacunar resorption of the bone always occurs at the seat of the tuberculous granulations (Fig. 102 *d*), while these sooner or later undergo caseous degeneration in the central portion of the affected spot. If the trabeculae are not already destroyed, they become necrotic within the zone of caseation.

A tuberculous focus once started increases by peripheral extension, and by the appearance of new foci in the immediately adjoining tissue. The more rapidly this proceeds, the sooner do large caseous nodes develop, which contain a considerable number of necrotic trabeculae. If on the other hand the process advances but slowly, the osseous trabeculae within the granulomatous region may be entirely absorbed.

When the process has reached a certain point, rounded or oblong caseous nodes are seen in the substance of the bone, each surrounded by a grey or greyish-red marginal zone of granulation-tissue. The nodes are of various sizes, from that of a pea to that of a hazel-nut, and contain carious or necrotic trabeculae, or larger, usually oblong and splinter-like, fragments of dead bone, which are permeated by caseous granulation-tissue, and are marked off from their surroundings by a zone of greyish tuberculous granulations. In still later stages the foci of the first kind are often softened and liquefied, and the enclosed osseous trabeculae for the most part destroyed. Thus a cavity or **cavernous excavation** is formed (Fig. 103 *h*, Fig. 104 *a*, and Fig. 105 *a*), which is surrounded by granulations and contains caseous pus and osseous detritus. In the case of the larger foci the necrotic fragment of bone becomes a more or less completely loosened **sequestrum** (Fig. 103 *f*), immersed in caseous and purulent matter, and lying in a cavity or **cloaca** which is closed in by granulation-tissue (*e*).

Such foci are usually developed singly or at any rate only in small numbers. It is but rarely that any considerable number of them form in rapid succession or simultaneously. When this does occur in the long bones, the tuberculous foci may extend over the greater portion of the medullary cavity. In this case the parts affected by the specific inflammation very rapidly undergo caseous degeneration, so that no true granulomatous deposits are produced.

The size of the tuberculous foci in particular cases and the course the disease takes depend upon conditions for which our present knowledge is insufficient to account. The smallest foci are doubtless capable of repair, the necrotic masses being then

liquefied, re-absorbed, and replaced by new connective tissue or by marrow and bony tissue. Larger foci make perceptible pauses in their progress, and their cavernous excavations (Fig. 103 *h*) are walled off from the rest of the marrow by a mass composed of dense connective tissue (*d*) and granulation-tissue containing trabeculae (*e*).

When a bone contains a tuberculous focus the surrounding

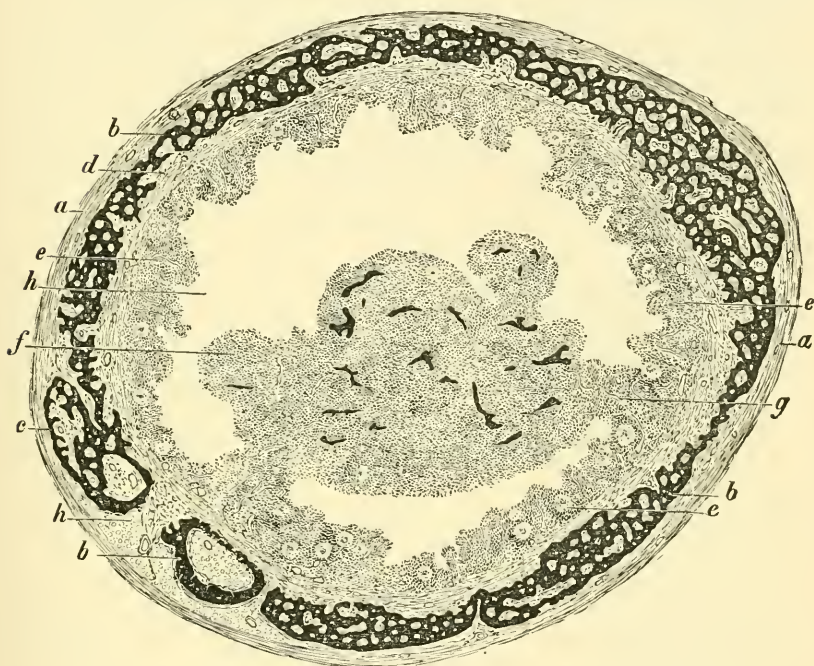


FIG. 103. CENTRAL TUBERCULOSIS OF BONE IN AN ADVANCED STAGE.

(Transverse section through the lower part of the diaphysis of the tibia: preparation hardened in alcohol, decalcified with picric acid, stained with haematoxylin and carmine, and mounted in Canada balsam: $\times 4$)

- | | |
|--------------------------------------------------------------------|----------------------------------------------------------------------------------|
| <i>a</i> periosteum | <i>f</i> sequestrum permeated by granulation-tissue, with scanty trabeculae |
| <i>b</i> rarefied cortical layer | <i>g</i> connecting process between the marginal granulations and the sequestrum |
| <i>c</i> periosteal osseous deposit | <i>h</i> cavity formerly filled with pus and caseous matter |
| <i>d</i> fibrous tissue on the inner surface of the cortical layer | |
| <i>e</i> tuberculous granulation-tissue | |

portions of it are never entirely free from proliferous changes. Large foci of long standing sometimes extend over considerable areas of the bone, and induce wide-spread resorption and apposition of bony tissue. Should progressive resorption take place in the interior, while new bone is being formed by the periosteum, a condition is produced which has been already described in Art. 46 (Fig. 49). This condition was formerly termed *spina ventosa*,

and in it the entire bone increases in girth, while the medullary cavity simultaneously widens. If the internal resorption is but slight (Fig. 104 *a*), and is accompanied by external apposition, the bone thickens and increases in size by the formation of numerous lamellae (*b*) which are bound together by transverse bars. The former condition is usually met with in the smaller of the long bones, the latter in the larger bones, as in these the tuberculous process is generally confined to a circumscribed region.

In the larger bones osteoplastic processes are generally set up also in the marrow near the tuberculous foci, and in certain cases these produce condensation and sclerosis of the affected bony tissue (Fig. 105 *c*).

The periosteum may be infected primarily, or by extension from the bone, or from a neighbouring joint or synarthrosis. The course of the **tuberculous periostitis** thus induced varies according as the process remains merely local or extends over large

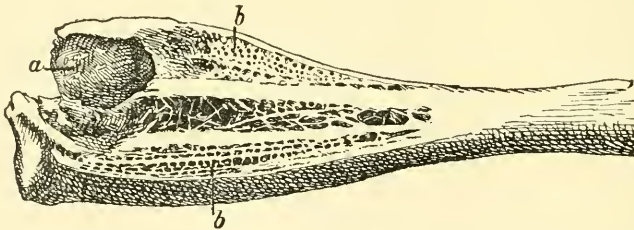


FIG. 104. PERIOSTEAL DEPOSITION OF BONE IN CHRONIC MYELOGENOUS TUBERCULOSIS.

(From the lower end of the right humerus of a child: natural size)

a tuberculous cavity

b lamellar and cancellous deposits

areas of the bone-surface. In the first case more or less sharply defined granulomatous foci containing tubercles are formed, and in the neighbourhood of these the bone undergoes resorption. The result is known as **peripheral caries** (Fig. 106 *d e*). If the periostitis is consecutive to primary disease of the bone or joint, in addition to the peripheral caries there are corresponding changes in the interior of the bone, and the periosteal disease is often continuous with the deeper tuberculous focus.

Sooner or later the periosteal tuberculous areas, if they do not recover, become caseous and then soften. In this way, as in the marrow, are formed **caseous nodes** surrounded by a zone of granulations and indurated connective tissue, or large sacculated **cold abscesses** (Fig. 106 *f*) bounded by a pyogenic membrane of connective tissue and granulation-tissue containing tubercles. The contents of these abscesses undergo steady increase by the secretion of pus from this membrane, and by the loosening and separation of caseous masses from their walls.

From its original site the abscess may extend into contiguous

parts, and so form secondary or **consecutive abscesses**. In other cases it ruptures early either outwards to the surface of the body or into some internal part, and so forms fistulous tracks or **sinuses**, about which the tissues become indurated and covered with tuberculous granulations. Sometimes these granulations grow so luxuriantly that they rise like a mushroom over the external orifice of the sinus. While the caries accompanying the tuberculous periostitis is gradually extending, proliferation of the periosteum takes place in the adjoining parts, and often leads to the formation of a considerable amount of new bone. Cases however occur in which regenerative proliferation is very slight, or all but entirely absent. This is especially apt to happen in the case of the cranial bones.

In some instances atrophic resorption of the bone follows rapidly on the infection of the periosteum, and may be very extensive. The resorption may be followed in its turn by the formation of new bone from the periosteum.

The loss of substance in the cortical stratum of the larger long bones, the femur for instance, may go so far that the bone is reduced to the thickness of paper (Fig. 107 *a*), and is composed of only a single layer of Haversian lamellae. Should new bone be again produced, the surface becomes studded with osteophytes (*b*), and these ultimately form a continuous layer of highly-vascular cancellous bone (*c*) which is covered over externally by the fibrous layer of the periosteum (*d*).

Tubercles may appear in the osseous system in general miliary tuberculosis; but nothing very definite is known as to their frequency and extension.

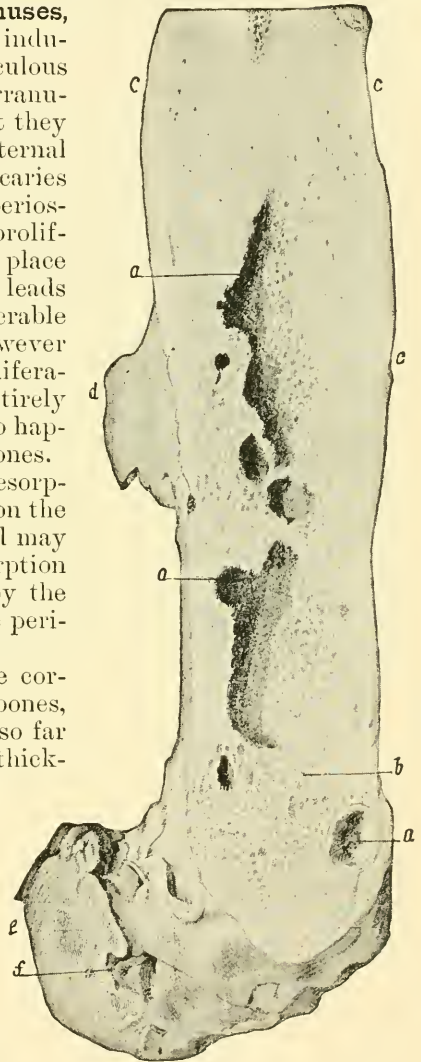


FIG. 105. OSTEOSCLEROSIS OF THE FEMUR RESULTING FROM CHRONIC TUBERCULOSIS.

(Longitudinal section of the lower half of the femur: six-sevenths of the natural size)

a tuberculous abscess *d* exostosis
b spongy bone *e* articular cartilage
c sclerotic bone with an erosion at *f*

The changes occasioned by tuberculosis in the bones and joints are treated of in text-books of surgery and morbid anatomy under various names. Among them may be mentioned the following — malacic or fungous caries (*caries mollis* or *fungosa*), scrofulous caries, tuberculous caries, bone-necrosis, bone-abscess, fungous arthritis, *synovitis hyperplastica granulosa*, *fungus articuli*, scrofulous arthritis, articular caries, arthroace, white swelling (*tumor albus*), *caries sicca*, cold articular abscess, etc.

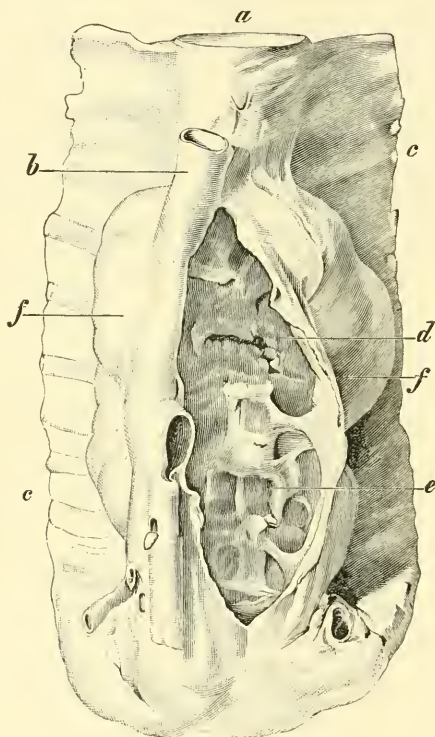


FIG. 106. TUBERCULOSIS OF THE SPINAL COLUMN.

(One-half the natural size)

- | | | |
|-------------------------------------------------------------|---------------|-----------------------------------------------------------|
| <i>a</i> vertebral column | <i>c</i> ribs | <i>e</i> superficial erosions in several vertebral bodies |
| <i>b</i> aorta | | <i>f</i> abscess-wall |
| <i>d</i> vertebral body almost entirely destroyed by caries | | |

References on Tuberculosis of Bone.

- CHEYNE, W.: *B. M. J.* 11 1890; *Tuberculous disease* London 1895
 FRIEDLÄNDER: *Volkman's klin. Vorträge* 64 1873
 KIÉNER and POULET: *Tuberculous osteoperiostitis A. de physiol.* 1 1883
 KÖNIG: *Die Tuberculose der Knochen u. Gelenke* Berlin 1884
 KRAUSE: *Die Tuberculose der Knochen u. Gelenke* Leipzig 1891
 LANNELONGUE: *Tuberculose vertébrale* Paris 1888
 MEINEL: *Die Knochentuberkeln* Erlangen 1842
 MÖGLING: *Surgical tuberculosis Mittheil. chir. Klinik* Tübingen 1884

into the joint: or indirectly by the transport of tubercle-bacilli from these foci into the joint by way of the lymphatics.

In tuberculosis of the carpus and of the tarsus several bones and joints are usually involved simultaneously. Entire bones may be destroyed by caries and necrosis, so that in their place nothing but masses of granulomatous tissue are found, which enclose only small carious sequestra. In a similar manner entire phalanges of the fingers or of the toes are destroyed.

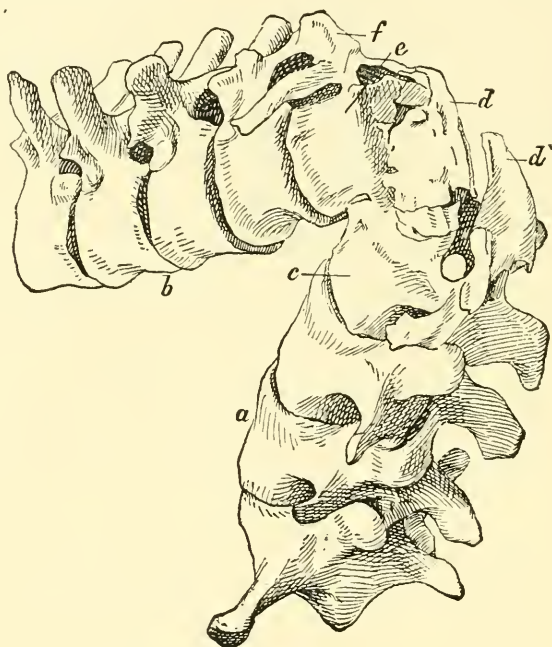


FIG. 108. ANGULAR FLEXURE OF THE VERTEBRAL COLUMN FROM THE DESTRUCTION OF THE FIRST LUMBAR VERTEBRA.

(Two-thirds of the natural size)

- | | |
|-----------------------------------------------------------------------------------------------------------------|-------------------------------------------------------------------------|
| <i>a</i> lumbar vertebrae | and partly due to new bone-formation |
| <i>b</i> thoracic vertebrae | |
| <i>c</i> second lumbar vertebra | <i>e</i> twelfth thoracic vertebra |
| <i>d</i> osseous lamellae partly formed by the remains of the arches and processes of the first lumbar vertebra | <i>f</i> deformed arches of the eleventh and twelfth thoracic vertebrae |

In the vertebral column the process is occasionally limited to one or more parts of a single vertebra, thus producing merely superficial caries or deep but circumscribed excavations. Frequently, however, it leads to greater destruction of the bodies and arches of the vertebrae (Figs. 108 and 109), and of the intervertebral discs (Fig. 108); in certain cases, the entire body or arch of one or more vertebrae may be destroyed (Fig. 109).

When the spinal column is thus weakened and unable to support the weight of the upper part of the body, it is apt to collapse at the damaged place and to bend forward at an angle (**Pott's disease**).

If the remains of the carious bodies of the vertebrae project backwards, or are forcibly displaced in any direction, the spinal cord may be compressed and degenerative processes set up within it. In tuberculous caries of the bodies of the vertebrae, **abscesses** (Fig. 106.f) form by accumulation of purulent matter in

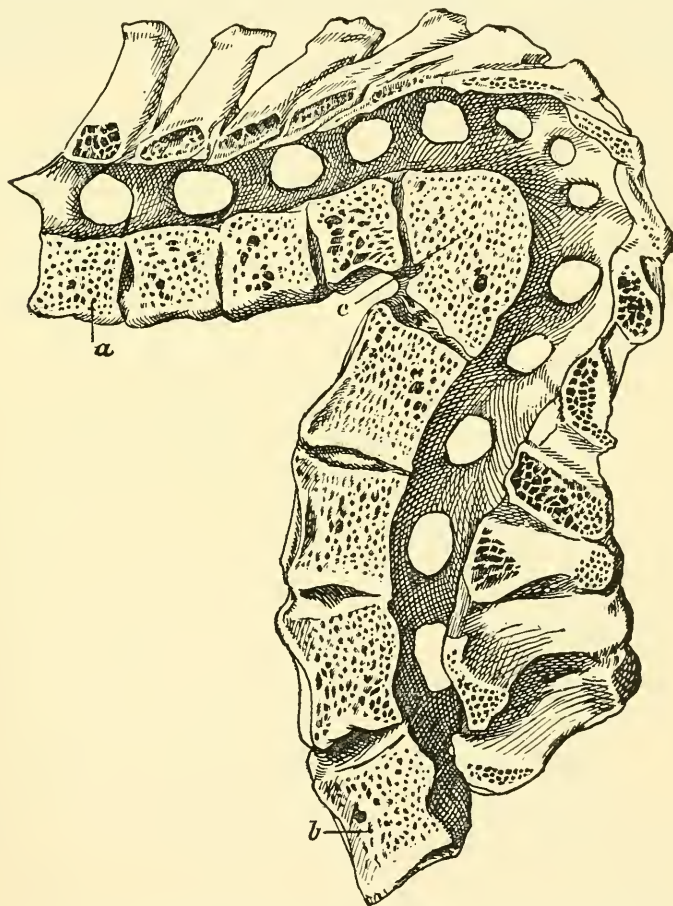


FIG. 109. ANGULAR FLEXURE OF THE SPINE WITH BONY ANKYLOSIS OF THE BODIES OF THE VII-XII THORACIC VERTEBRAE AFTER PARTIAL DESTRUCTION BY TUBERCULOUS DISEASE.

(Reduced to three-fifths of the natural size)

a third thoracic vertebra
b fourth lumbar vertebra

c bony mass formed by the fusion of the bodies of the VII-XII thoracic vertebrae

front of the spinal column, and these are apt to burrow and extend downward. In disease of the lower portion of the vertebral column abscesses thus formed often burrow along the ilio-psoas muscle to the crest of the pubic bone, and finally point below Poupert's ligament.

Tuberculosis of the **pelvic bones** leads to more wide-spread caries, with the formation of 'cold' abscesses. The symphysis pubis and the sacro-iliac synchondrosis may thus be destroyed.

In tuberculosis of the flat **cranial bones**, caseous masses are formed in the bone-marrow as well as beneath the periosteum: these cause necrosis of the bone and give to it a yellowish-white appearance, while the periosteum itself is stripped off by the accumulation beneath it of caseous pus, and is at the same time studded with caseous nodules.

Tuberculous caries of the atlas, the axis, and the base of the skull, sometimes causes loosening of the connexions between the spinal column and the skull, with consequent dislocation of the latter, and compression of the medulla oblongata by the odontoid process.

Isolated tuberculous foci in the bones are capable of **repair**. Any loss of substance that may have taken place is then filled up by connective tissue, and ultimately by osseous tissue. If a curvature of the spine has not been rectified by proper appliances, the column will become fixed in the position it has taken up by the formation of new osseous and connective tissue: the remnants of a number of vertebrae may in these circumstances coalesce to form a single bone (Fig. 109 *e*), in which the boundaries of the original segments are no longer discernible. The carious tissues on the articular ends of contiguous bones often become firmly united across the joint by connective tissue and osseous trabeculae (fibrous and bony ankylosis). If the joint still contains fragments of cartilage, these are apt to be transformed into fibro-cartilage and connective tissue.

Very frequently however the repair is only partial. While the greater part of the diseased region may be filled up by tissue free from tubercles, yet some remain here and there, and from these residual deposits the morbid process often starts anew.

53. **Syphilitic disease** of the bones makes its appearance only in the later stages of syphilis, and results either in caries and necrosis or in the formation of new osseous tissue.

The **gumma** is the formation characteristic of syphilis in bone. This is a local inflammatory product, which is usually met with in the periosteum, and less frequently in the marrow.

Recent periosteal gummata take the form of flattened swellings of elastic consistence, and on section exhibit a gelatinous texture. In later stages the gummatous tissue becomes either somewhat whiter and like inspissated pus, or of a firmer consistence, resembling rather ordinary granulation-tissue interspersed with patches

of fibroid cicatricial tissue. In the latter case the gumma frequently encloses denser and drier white caseous masses, due to fatty degeneration and necrosis of part of the inflammatory tissue.

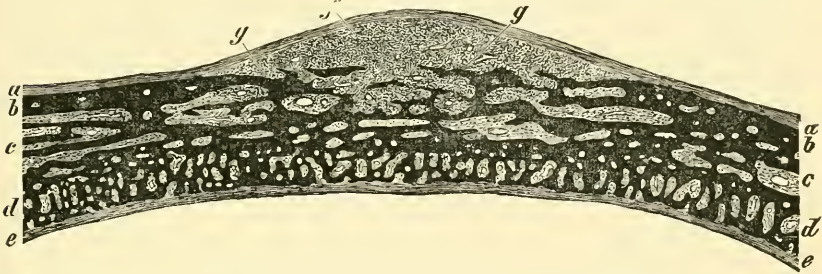


FIG. 110. GUMMATOUS SYPHILITIC CARIES OF THE PARIETAL BONE.

(From a child eight weeks old suffering from congenital syphilis; preparation hardened in Müller's fluid and alcohol, decalcified with picric acid, stained with haematoxylin and carmine, and mounted in Canada balsam: $\times 65$)

- | | | | |
|---|---------------------------|---|---------------------------|
| a | external periosteum | e | dura mater |
| b | external table | f | syphilitic focus or gumma |
| c | spongy intervening layer | g | carious bony trabeculae |
| d | internal periosteal layer | | |

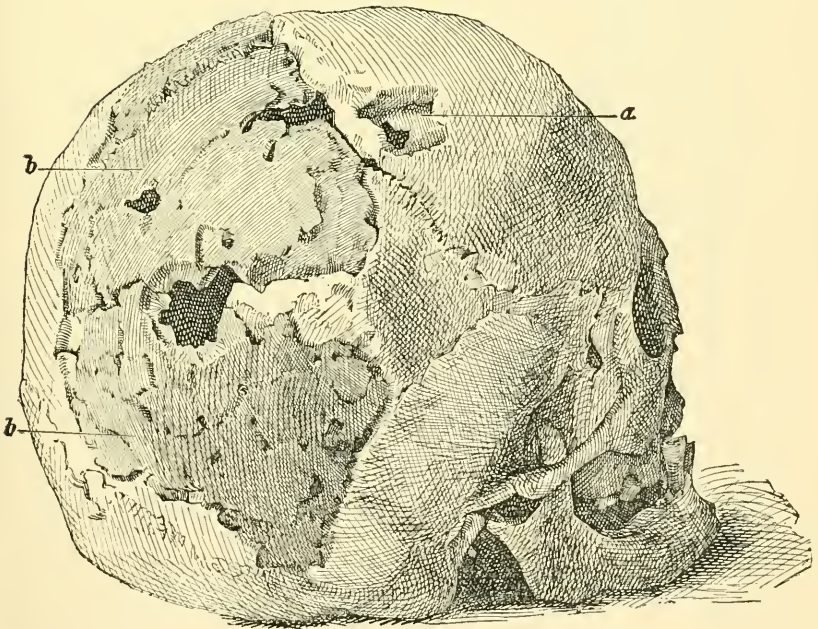


FIG. 111. SYPHILITIC CARIES AND NECROSIS OF THE CALVARIUM.
(Reduced one-half)

- | | | | |
|---|--------------------|---|----------------------------------|
| a | carious excavation | b | large fragments of necrotic bone |
|---|--------------------|---|----------------------------------|

When the process has continued for a long time, nothing may remain but a callous scar-like thickening enclosing no remnants of granulation-tissue or of caseous matter.

At the point where the gumma is formed (Fig. 110 *f*), resorption of osseous tissue (*g*) always takes place. The resorption is most active in the case of those nodes that are distinguished by an abundance of round-cells and by their pus-like appearance. Such foci are most frequently found in the external periosteum of the cranial bones (Fig. 110 *a* and Fig. 111): they may however make their appearance in any of the bones of the skeleton, and also in the internal periosteum or dura mater of the skull. When situated in the external periosteum, the outer table of the skull is first rendered carious (Fig. 110 *b* and Fig. 111 *a*); but usually the specific inflammation soon attacks the diploë, and may ultimately extend to the surface of the dura mater.

Isolated foci may be small and inconsiderable, and these of course give rise only to slight loss of substance. With increase in the size of the focus the erosion of the bone also increases; and when numerous foci are formed the vault of the skull becomes riddled with irregularly-formed pits and holes of various sizes. If the inflammatory process extends deeply, and the dura mater becomes involved, the circulation in the portions of bone lying between the excavations is more and more interfered with, and thus the **sypilitic caries** may become associated with more or less extensive necrosis (Fig. 111 *b*). Cases occur in which this combination of caries and necrosis causes destruction of the larger portion of the cranial vault.

In a similar manner erosions and excavations of various sizes are produced in other bones.

Osteomyelitic gummata occur somewhat frequently in the phalanges and in the diploë of the skull, while they are seldom seen in the larger long bones: yet in the latter situation they are occasionally met with in great numbers. They form foci that are gelatinous, fibro-gelatinous, dirty-yellow

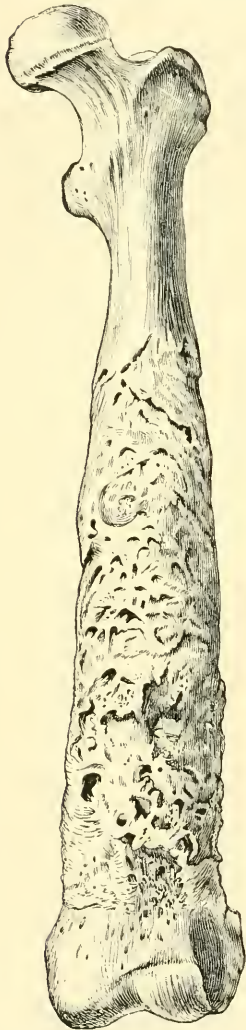

FIG. 112. SYPHILITIC HYPEROSTOSES OF THE LEFT FEMUR.
(Reduced to two-fifths of the natural size)

latter situation they are occasionally met with in great numbers. They form foci that are gelatinous, fibro-gelatinous, dirty-yellow

and puriform, or caseous (CHIARI). The osseous tissue enclosed within these foci is carious and necrotic, while the bone about them is the seat of more or less marked hyperostosis.

In the course of gummatous periostitis numbers of **osteophytes** are often formed in the vicinity of the gummatous foci, which, particularly in the long bones, attain at times a considerable size. Should recovery take place, the gaps in the periosteum are made good by scar-tissue or by newly-formed bone. Parts that have undergone necrosis keep up a state of inflammation until they are resorbed, or until a sequestrum is formed and exfoliated; and at the same time give rise to extensive production of new bone in the adjacent parts.

The new-formation of bone, which in these instances is obviously due to the local inflammation, takes place in other cases of syphilis as an independent process, and leads to more or less marked thickening of the bone, or **hyperostosis**, dependent on the osteogenic activity of the periosteum. Such hyperostoses usually occur on the long bones (Fig. 112), but are also met with on other bones, and at times are spread over the entire skeleton. As the result of simultaneous endosteal bone-formation, the older bone may be rendered sclerotic and correspondingly increased in density: in other cases it undergoes **osteoporosis** and so becomes rarefied and porous.

In cases of **leprosy** (SAWTSCHENKO), granulomatous foci containing bacilli may be formed in the bone-marrow.

Actinomycotic inflammation, as soon as it reaches the periosteum, leads to peripheral caries and occasionally to necrosis. Most frequently it is the maxillae, the spine, and the bones of the thorax that are attacked, and sometimes very extensive destruction of the bones is thus brought about.

In **glanders** caseous nodes and patches of suppuration have been observed in the periosteum and synovial membranes.

References on Syphilis and Leprosy of the Bones (on Congenital Syphilis see also Art. 58).

- BOWLBY: Syphilis *St. Barth. Hosp. Reports* xxvi London 1890
 CHIARI: Syphilis *Vierteljahresschr. f. Derm. u. Syph.* 1882
 HAAB: Syphilis *V. A.* 65 1875
 JASINSKI: Syphilitic diseases of the vertebral column *A. f. Derm.* xxiii 1891
 LANCEREUX: *Traité hist. et prat. de la syphilis* Paris 1874
 LANG: *Vorlesungen über Path. u. Therap. d. Syphilis* Wiesbaden 1885
 MEYER, L.: Syphilis *Z. f. Psych.* xviii
 PARROT: Syphilis *A. de physiol. norm. et pathol.* 1872 and 1876
 SAWTSCHENKO: Leprous osteomyelitis *Cent. f. Bakteriologie v* 1889; Changes in the bones in leprosy *Ziegler's Beiträge* ix 1891
 SOLOWEITSCHIK: Syphilitic affections of the skull *V. A.* 48 1869
 VIRCHOW: *V. A.* 15 1858, and *Krankhafte Geschwülste* ii 1865

CHAPTER XIX

DISORDERS OF OSSEOUS DEVELOPMENT AND GROWTH

54. The bones composing the skeleton originate either from connective tissue that is but slightly differentiated, or from a provisional cartilaginous substratum. Examples of the first mode of origin are seen in the flat bones of the skull: these are called **membrane-bones**, because they are due to ossification partly of the integument and partly of the wall of the cephalo-enteric cavity or head-gut (GEGENBAUR). Examples of bones originating in cartilage are seen in the remaining parts of the skeleton: these bones constitute the **internal skeleton**, in contradistinction to the external or integumentary skeleton.

Ossification in the membranous substratum of the integumentary bones takes place in general by the development of trabeculae containing lime-salts, together with bone-corpuscles and bone-cells, in the germinal or embryonic tissue, which is composed of cells with a more or less abundant homogeneous or fibrillar matrix. These trabeculae are at a later stage thickened by the apposition of new germinal tissue. When an osseous plate is thus formed, it increases in thickness by the formation of new bone from the adjacent superficial layer of connective tissue, which layer is thenceforward called the **periosteum**.

Ossification begins in exactly the same manner in the parts of the skeleton that are pre-formed in cartilage. Trabeculae are developed in certain definite places in the tissue surrounding the cartilage, or **perichondrium**. This mode of bone-formation corresponds to that observed in the periosteum of the flat or membrane-bones; it continues throughout life, and is termed **periosteal ossification**. There is another mode allied to this, called **endochondral ossification**, in which the marrow-tissue of the osseous strata surrounding the cartilaginous substratum penetrates the cartilage while it is in process of internal calcification. Wherever the marrow penetrates, the cartilage all but completely disappears, and medullary spaces are thus produced. This is the first stage of endochondral ossification: throughout its subsequent course it is characterised by certain peculiar features.

In the neighbourhood of the spot where a medullary space encroaches on the cartilage, proliferation commences in that tissue (Fig. 113 *b*) and results in the formation of small groups of cells in the place of the isolated cartilage-cells. As these groups increase in number and in the size of their component cells, they tend to arrange themselves in linear order (*c d*). The alignment always takes place in a direction parallel to one of the long axes of the bone, and as it is uniform throughout the entire thickness of the cartilaginous matrix, there is developed from the **proliferous zone** (*b*) a zone of parallel columns of cartilage-cells (*c*), the largest cells being in juxtaposition to the bone already formed. This region of large cartilage-cells is distinguished as the **hypertrophic zone** (*d*).

In this way the cartilage extends in the direction of the long axis of the bone, but the increase in length of the pre-formed cartilaginous substratum as a whole is dependent on its own continued longitudinal growth. This growth is most marked in bones destined to become elongated in shape: it is less per-

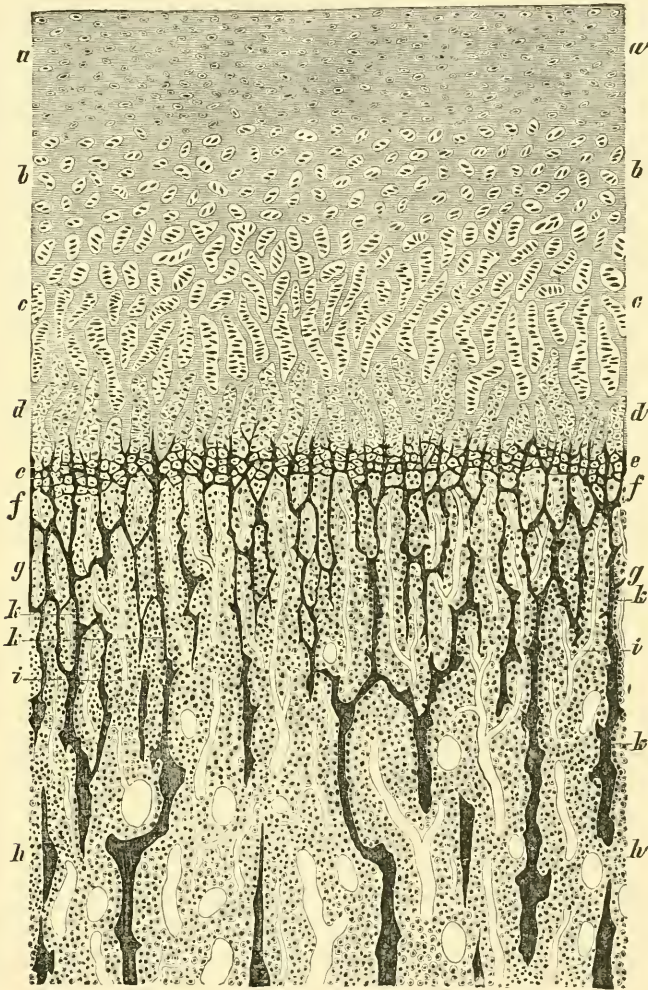


FIG. 113. NORMAL ENDOCHONDRAL OSSIFICATION.

(Longitudinal section from the upper end of the femoral diaphysis of a new-born child: preparation hardened in Müller's fluid, decalcified with picric acid, stained with haematoxylin and carmine, and mounted in Canada balsam: $\times 55$)

- | | | | |
|---|---------------------------------------------------|---|----------------------------------|
| a | hyaline cartilage | f | zone of primary medullary spaces |
| b | zone of commencing proliferation of the cartilage | g | zone of primary ossification |
| c | columns of cartilage-cells | h | fully-developed cancellous bone |
| d | columns of hypertrophic cells | i | blood-vessels |
| e | zone of provisional calcification | k | osteoblastic layer |

ceptible in bones whose ultimate length is inconsiderable compared with their breadth.

When the columns of cells have attained a certain size, **calcification** sets in within the matrix and in the capsules of the cartilage-cells (*e*), and is initiated by the deposition therein of fine calcareous granules.

The further growth of the cartilage is thereupon stopped. The zone of calcified cartilage (*e*) never reaches any considerable size, but forms simply a narrow whitish stratum or seam.

After persisting for a short time the zone of calcified cartilage disappears: the contiguous highly-vascular marrow (*f*) invades the cartilage, dissolves its calcified matrix, leaving only a few scattered remnants, and extends into the dehiscent capsules of the cartilage-cells. Only a few slender and jagged trabecular fragments of the matrix remain, and these as a rule contain no cartilage-cells. The cartilage-cells lose their identity in the marrow: it is still uncertain whether they are disintegrated or persist and become changed into marrow-cells, though the latter is the more probable supposition.

The zone of primary medullary spaces (*f*) at first contains only the trabecular fragments of the cartilaginous matrix; and these, with few exceptions, are changed by a peculiar metaplasia into bony tissue, the process beginning at the periphery (KASSOWITZ). Some of these bony trabeculae are dissolved, and the primary medullary spaces, whose width corresponds to that of from one to three columns of cartilage-cells, accordingly coalesce to form medullary cavities of larger calibre. The remaining trabeculae undergo ossification in the ordinary way (*k*) by the development of osteoblasts from the cellular medullary tissue. These attach themselves to the persistent cartilaginous trabeculae, and ultimately transform them into bone.

In this manner, then, the cartilage is replaced by bony tissue, its chief function in relation to the bone being to determine its form and the extent of its longitudinal growth. In some degree, also, the internal structure of the new bone is determined by the cartilage, since the persistent trabeculae of the cartilaginous matrix serve as the foundations of the osseous trabeculae.

Endochondral ossification proceeds in both a proximal and a distal direction, and produces the axially-directed **diaphysis** or shaft of the bone, while the cartilaginous end-pieces are named the **epiphyses**. Toward the end of foetal life blood-vessels penetrate the lower epiphysial cartilage of the femur from the perichondrium, and form a close network in the centre. After antecedent calcification of the cartilage, a new centre of ossification forms in this network, and from this centre the epiphysis ossifies along radiating lines. In the other long bones the epiphysial **centres of ossification** appear later. Inasmuch as ossification is in this case also preceded by proliferation of the cartilage, the bone produced in the epiphysis develops in all directions from the centre. When the ossification extends to the perichondrium the longitudinal growth of the bony epiphysis is but slight, and stops entirely on the side toward the diaphysis.

The layer of cartilage lying next to the joint persists as the **articular cartilage**. The portion of the epiphysial cartilage next the diaphysis remains to the end of the growing stage, namely from the twentieth to the twenty-seventh year. After the epiphysis is ossified, columns of cartilage-cells are produced only on the side that is next the diaphysis. When the ossification of this side of the epiphysis is complete, the shaft ceases to grow in length, and becomes united to the epiphysis by continuous bony tissue.

55. If for any reason the cartilaginous substratum of any part of the internal or of the integumentary skeleton does not attain its proper development, or if a part already formed in cartilage is destroyed *in utero* by morbid processes such as ischaemia or inflammation, the corresponding bone or part of a bone is not

produced, with the result that the skeleton is defective. Such defects are described as results of **local agenesis**. Most frequently it is a portion of the skull (Fig. 114), or of the vertebral arches, that remains undeveloped: in the bones of the extremities and in the bodies of the vertebrae such defects are somewhat less often met with. Both conditions are usually accompanied by defects in the related soft parts; yet imperfections in the bones of the extremities and of the trunk, due to simple cartilaginous hypoplasia, may occur without any corresponding malformation of the soft parts. **Partial defects** of individual bones, such as are found chiefly in the cranium (Fig. 114) and in the limbs, are due to some arrest of development at a stage when the main part of the bone has been already formed, and is in process of active growth. Defects at the distal ends of the tibia, of the fibula, and of the radius occur in association with malformations of the feet and hands.

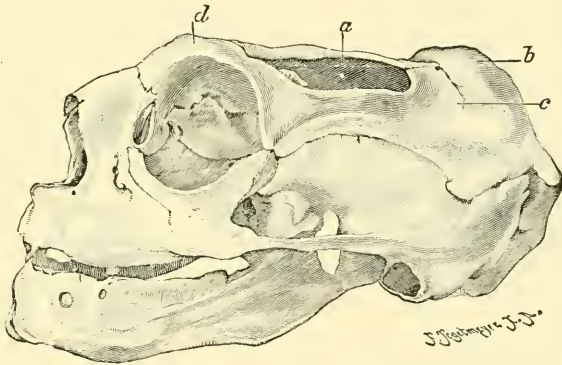


FIG. 114. PARTIAL AGENESIS OF THE BONES OF THE CRANIAL VAULT IN ANENCEPHALIA.

(Reduced to two-thirds of the natural size)

a frontal bone *b* parietal bone *c* squamous portion of occipital bone

56. It sometimes happens that while the cartilaginous substratum of each individual part of the skeleton is normally developed as regards form, its growth in size is in some way checked or retarded. In the long bones this gives rise to deficiency of length or of girth, in the flat bones to insufficient area or thickness. In certain cases the arrest of development shows itself in an abnormal slenderness of the individual bony trabeculae.

Arrest or impairment of the development of the bones may take place *in utero*, and lead to malformations of the skeleton of the new-born child (Fig. 115). In other cases the arrest does not begin till after birth, and then gives rise only to subsequent stunting or dwarfing of the skeleton or of some parts of it.

If the interference with development extends uniformly over the entire skeleton, the result is a condition of general dwarffish

under-growth (Fig. 116), described as **microsomia** or **nanosomia**. In this case the separate parts of the skeleton retain their normal proportional relations, or at least present but slight variations from the normal.

When the arrest is limited to particular regions of the skeleton, the growth of these alone is affected, and the proportional relations of the several parts are accordingly more or less disturbed (Figs. 116 and 117).

When it is chiefly the longitudinal growth of the extremities that is affected, the result is **micromelia** (Figs. 115 and 117).

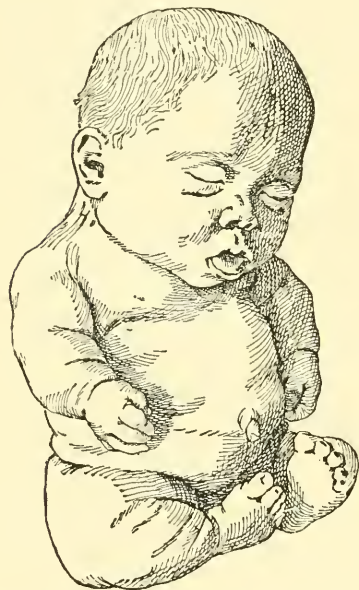

FIG. 115. NEW-BORN MICROMELIC INFANT, WITH CRETINOID EXPRESSION OF FACE.

(Reduced to one-fourth of the natural size)

Deficiency of superficial extent in the cranial bones produces **microcephalia** or **nancephalia** (Fig. 118). Shortening of the base of the skull causes the bridge of the nose to appear sunken, or the nose as a whole to be retracted and flattened. Imperfect development of the alae of the sacrum causes transverse contraction of the pelvis (Fig. 122).

When any region of the skeleton is ill-developed, there is usually some corresponding deficiency in the related soft parts; but it not infrequently happens that the latter grow too large in proportion to the corresponding bones, and being thus thrown into folds and bulgings appear themselves to be deformed.

The **cause** of arrest of development in the skeleton, whether general or local, undoubtedly lies in some instances in the constitution of the embryo itself, and either depends on **inheritance** or is the manifestation of a **spontaneous variation** or 'sport.' In other cases the anomaly of development is due to some **acquired lesion**, referable to intra-uterine or extra-uterine injury. In many cases the cause of the defective development of the skeleton may be traced to imperfection in the functional activity of the thyroid gland, a condition met with chiefly in connexion with **cretinism**. Cretinism sometimes appears sporadically, at other times assumes an endemic form, apparently under the influence of some as yet undetected miasmatic virus; and it may also result from removal of the thyroid gland by surgical operation. As regards the other

causes, of an acquired nature, which result in defective development of the bones, we are still in ignorance.

From a histological point of view, arrested longitudinal growth

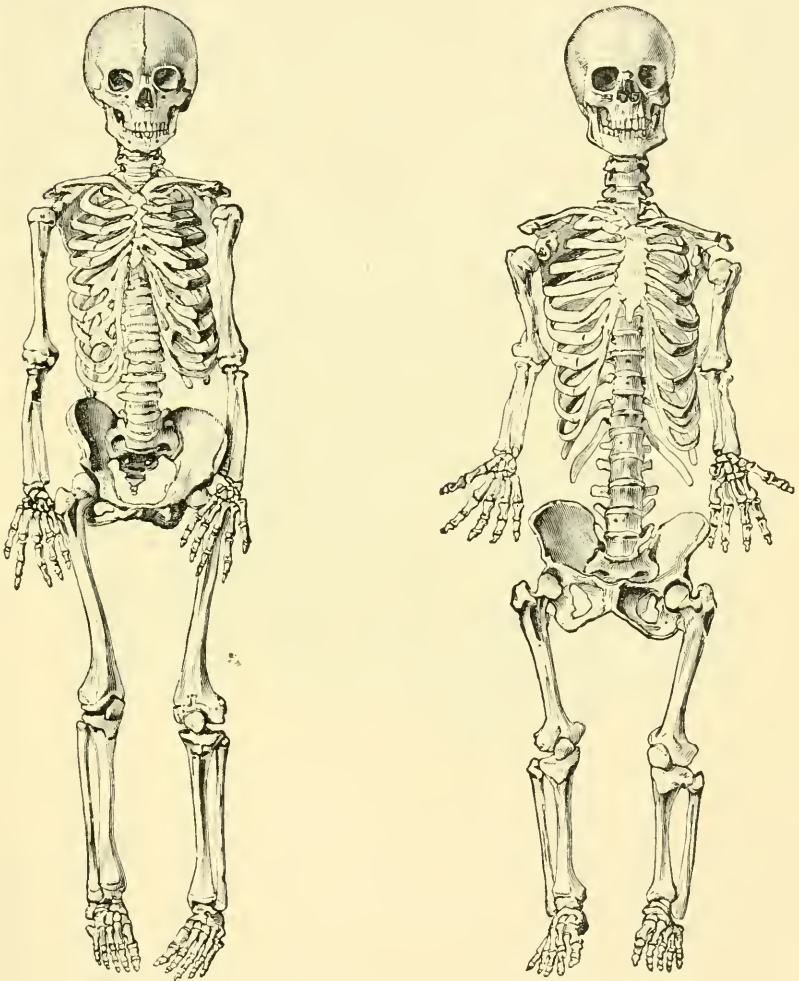


FIG. 116. SKELETON OF A FEMALE CRETINOID DWARF.

(Aged 31: height 118 centimetres: skull clinoccephalic)

The epiphysal cartilages of the long bones and pelvic bones persist, as also the frontal suture. The several parts of the skeleton are fairly proportionate, except that the upper extremities are relatively short.

FIG. 117. SKELETON OF A FEMALE DWARF.

(Aged 58: height 117 centimetres)

The bones of the limbs are very short, the trunk is relatively long. The epiphysal cartilages have not persisted, and the articular ends of the bones are thickened.

in the cartilage-bones, and defective lateral growth in the membrane-bones, are due either to failure of bone-formation at the zone of ossification in the diaphysis, or to premature synostosis at the margins of bones that normally continue for a time united only by sutures of cartilage or connective tissue. Deficient thickness or girth arises from scanty periosteal deposition on the exterior: slenderness of the cancellous trabeculae is the result of imperfect myelogenous apposition of osseous tissue on the primary trabeculae developed in the cartilage or from the periosteum, or in other words of **imperfect osteogenesis**.

In bones formed from cartilage failure to increase in length is in many cases due solely to defective proliferation of the cartilage at the zone of ossification: instead of the normal array of col-

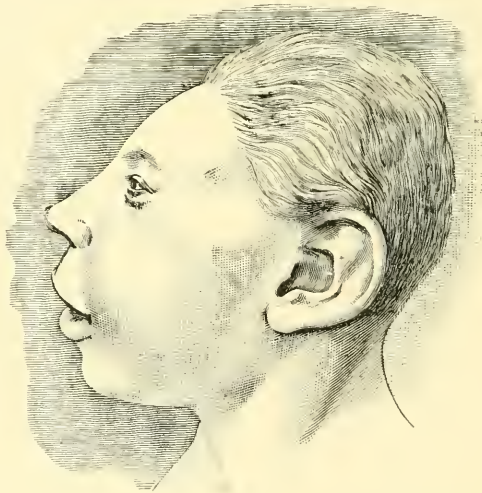


FIG. 118. HEAD OF A MICROCEPHALIC CHILD (HELEN BECKER).
(Aged five years: after a photograph taken by A. ECKER in 1868)

umns containing numerous cartilage-cells, the columns are few and the cells scanty, or the columns are entirely absent (compare Fig. 119 *b e* with Fig. 113 *b e d e*).

In cases of well-marked arrest of growth the columns of cartilage-cells (*b*), even in the larger long bones, fail to attain any considerable height; they sometimes, indeed, are shorter than in normally-developing digital phalanges. This condition has been termed *chondrodystrophia hypoplastica* (KAUFMANN) or *achondroplasia* (PARROT).

In these cases the process of ossification following upon the dissolution of the cartilage does not differ from the normal process (*f*), and the formation of bone from the periosteum takes place in the usual way. The disposition and arrangement of the

persistent remnants of calcified cartilage are, however, abnormal; and accordingly the architectural structure of the cancellous or spongy bone (compare Fig. 119 *e* with Fig. 113 *h*) produced by the endochondral ossification is altered, while at the same time the entire bone is abnormally thick in proportion to its length.

Should endochondral ossification be checked during the course of development, the growth of the bone in its long axis will cease. If at this stage the epiphysial cartilages that are destined to disappear with adolescence are still persistent, they may remain permanently. It thus happens that some dwarfs, after the twen-

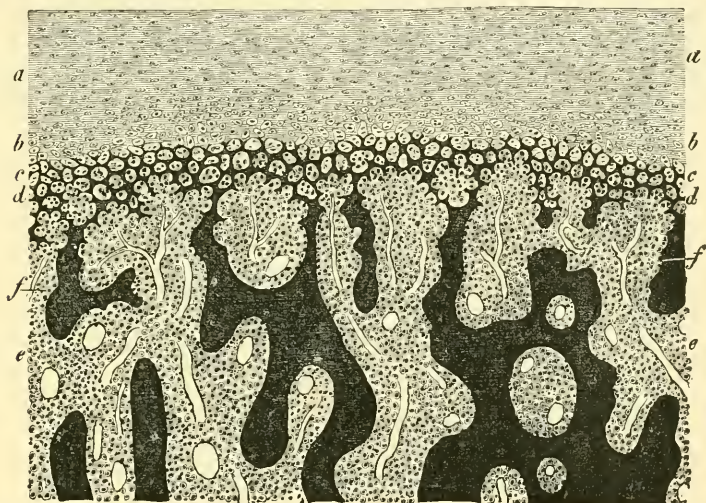


FIG. 119. ENDOCHONDRAL OSSIFICATION IN A NEW-BORN CHILD WITH ABNORMALLY SHORT LIMBS.

(Longitudinal section through the upper zone of ossification in the diaphysis of the femur: preparation hardened in alcohol, decalcified with picric acid, stained with haematoxylin and carmine, and mounted in Canada balsam: $\times 55$)

- | | | | |
|---|--------------------------------------------|---|----------------------------------|
| a | hyaline cartilage | d | zone of primary medullary spaces |
| b | zone of proliferous cartilage | e | cancellous bone |
| c | zone of cartilage undergoing calcification | f | osteoblastic layer |

tieth year has been passed (Fig. 116), not only have cartilaginous epiphysial junctions at the ends of the long bones (Fig. 120), but even between the several bones of the pelvis and the different segments of the sternum. Furthermore, sutures such as the frontal, which usually disappear at an early age, may remain united throughout life (Fig. 116).

In addition to such simple failure of longitudinal development of the bones, from inadequate proliferation of the cartilage-cells, as is observed in micromelic infants and in the subjects of thyroid cachexia (including cretins), certain peculiar perversions of endochondral ossification are met with, which have had their origin in

intra-uterine disease. These are characterised macroscopically by the shortness of the diaphyses (Fig. 121 *a*) and by a more or less marked thickening of their ends (Fig. 121 *b*). Microscopically they exhibit irregularities in the proliferation and calcification of the cartilage, with corresponding anomalies of ossification. The cartilage indeed proliferates, but no cellular columns are formed; and it may thereafter either soften or become calcified and ossified in an irregular manner, the condition being termed **chondrodystrophia malacica** (KAUFMANN) or **micromelia chondromalacica**. In other cases increased proliferation of

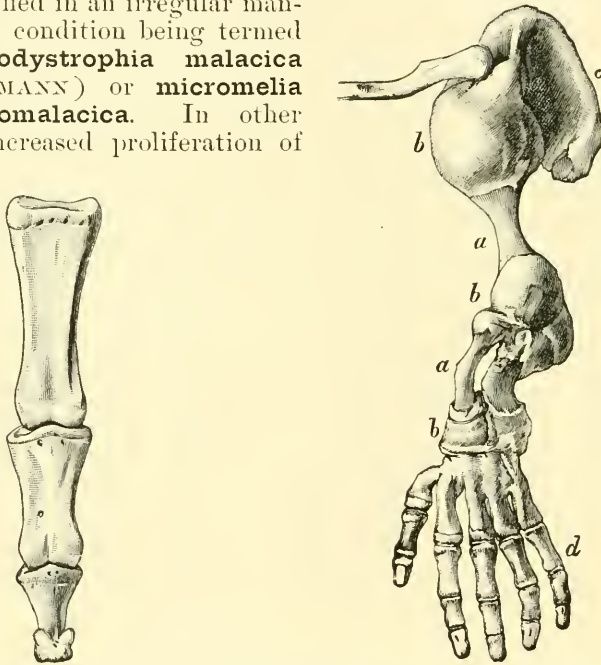


FIG. 120. BONES OF THE MIDDLE FINGER OF THE RIGHT HAND OF THE CRETINOID DWARF OF FIG. 116.

(The epiphysial line remains cartilaginous: natural size)

FIG. 121. MICROMELIC PSEUDO-RACHITIS (FOETAL RICKETS) OF THE UPPER LIMB.

(An example of *Chondrodystrophia hypertrophica*: reduced to four-fifths of the natural size)

a diaphysis *b* epiphysis of the bones of the fore-arm *c* scapula

the cartilage in all directions occasionally sets in, producing excessive thickening of the ends of the diaphyses. This may be combined with extreme irregularity of ossification, and is now and then accompanied by an ingrowing of the periosteum between the cartilage and the bone, which of course involves the entire cessation of longitudinal growth. Inasmuch as the abnormal proliferation of the cartilage is in these cases the most striking feature of the process, the condition might be suitably described as **chondrodystrophia hyperplastica**.

Premature synostosis takes place both in situations that normally are not subject to ossification, and in parts that are ossified only in advanced life, or at least at some later period of growth.

Among the synchondroses liable to premature ossification we may take for examples the cartilaginous junction between the anterior and posterior portions of the body of the sphenoid, and between the body of the sphenoid and the basilar portion of the occipital bone. The former of these begins to ossify at birth; the latter between the twelfth and thirteenth years. Premature

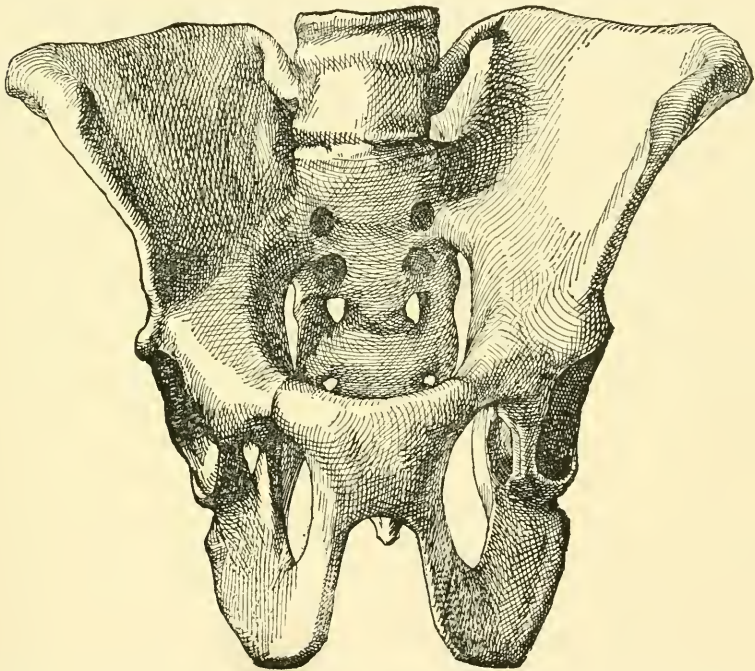


FIG. 122. AGENESIS OF THE WINGS OF THE SACRUM WITH SACRO-ILIA SYNOSTOSIS. (*Pelvis ankylosed and transversely contracted; sacrum sunk deeply into the pelvis: somewhat less than half the natural size*)

synostosis of these bones, like deficient proliferation of the cartilages, results in shortening of the base of the skull (VIRCHOW), and so gives rise to depression of the bridge of the nose.

In the sacro-iliac synchondrosis deficiency of distal growth in the lateral portions of the sacrum, and premature synostosis with the ilium (Fig. 122), result in imperfect lateral expansion of the pelvis. By bilateral synostosis a symmetrical transverse contraction (Fig. 122), and by unilateral synostosis an unsymmetrical or oblique transverse contraction of the pelvis is produced.

Under certain conditions, imperfect development of the sacrum itself also produces transverse contraction of the pelvis (LITZMANN).

The sutures between the flat cranial bones are the best examples of the syndesmoses, and they usually persist until adult age. Since expansive growth in superficial extent occurs along the lines of the sutures, through apposition of bone at their margins, premature ossification produces arrest of the growth of the skull as a whole, and the result is **cranio-stenosis**.

In premature synostosis of all the sutures, the cranium remains small in all its dimensions, producing **microcephalia**. Premature ossification of the coronary and lambdoid sutures checks longitudinal expansion, that of the sagittal, speno-parietal, parieto-temporal, and frontal sutures, prevents lateral development of the skull. If the cerebrum increases notably in bulk after partial synostosis has begun, compensatory overgrowth takes place in the sutures still unossified, and room for the growing brain is thus provided. Such local deficiency and compensatory overgrowth cause the form of the cranium to deviate more or less from that characteristic of the race to which the affected person belongs, and not infrequently a skull is thus produced which differs from every normal type.

Inadequate endochondral growth in linear dimensions is in some cases, but by no means always, combined with premature synostosis of the synchondroses and syndesmoses. The former condition may be present though there is no premature synostosis; and the latter, especially in the cranium, may appear unaccompanied by any disturbance of normal endochondral growth.

Intra-uterine arrest of the longitudinal development of the bones is generally described by writers under the name of **micromelic foetal rickets**, and a very large number of cases have been recorded. The term rickets or rachitis is, however, inappropriate, for the abnormal processes at the zone of endochondral ossification are not analogous to those observed in rickets, and the disorders of periosteal ossification characteristic of rickets are entirely absent. It is still an open question whether true rickets ever occurs as an intra-uterine affection. MORI believes that he has demonstrated its existence in one case.

Even in members of the same race, the **form of the skull** is subject to marked variation, and the variation is still greater when different races are compared. The characteristic measurements of the cranium are its length, height, and breadth. The cephalic index is the ratio of its length (taken as 100 units) to its breadth. The altitudinal index is the ratio of its length to its height. The accepted horizontal plane is that passing through the upper edges of the external auditory meatus and the lower orbital margins.

According to the variations of the cephalic index, we distinguish the *dolichocephalic* (index less than 75) and the *brachycephalic* (index more than 80) types. Intermediate forms are called *mesocephalic*. If the ratio of the breadth to the height is less than 70, the skull is *platycephalic*; if between 70 and 75, *orthocephalic*; if above 75, *hyposcephalic*. The character of the facial profile is indicated by the *facial angle* of CAMPER, namely the angle between a line on the level of the external auditory meatus and the floor of the nasal cavity and a line touching the middle of the forehead and the anterior portion of the alveolar process of the superior maxilla. If this angle be 80° or more, the skull

is called *orthognathous*; if it is between 80° and 65° , *prognathous* (GEGENBAUR). The mean cubic capacity of the male cranium is 1450 cubic centimetres; that of the female is 1300 cubic centimetres (WELCKER).

Pathological types of skull are due in part to premature synostosis. Among them we distinguish the *hydrocephalic* type (from dropsy of the ventricles), the *cephalonic* (or big head), the *microcephalic* (or small head), the *dolichocephalic* (or long head), the *sphenocephalic* (or wedge-shaped head due to compensatory development of the anterior fontanelle), the *leptocephalic* (or narrow head), the *clinocephalic* (or saddle-shaped head), the *trigonocephalic* (or triangular head due to narrowing of the frontal bone, from foetal synostosis of the frontal suture), the *brachycephalic* (or short head), the *pachycephalic* (in which the bones of the cranium are thickened), the *oxycephalic* (or pointed head), the *platycephalic* (or flat head), the *trochocephalic* (or round head), and the *plagiocephalic* (or unsymmetrical oblique head).

References on Hypoplasia and Premature Synostosis of Bones.

- AEBY: *Schädelformen d. Menschen und Affen* Leipzig 1862
 BODE: Foetal rickets *V. A.* 93 1883
 DOLEGA: Cretinism from impeded bone-growth *Ziegler's Beiträge* IX 1891
 EBERTH: *Die fötale Rachitis* Leipzig 1878
 FISCHER: *Monatsschr. f. Geburtsk.* XIV, and *A. f. Gynäk.* VII 1875
 FRIDOLIN: Skull-deformities in early life *V. A.* 100 1885
 GRAWITZ: Foetal cretinoid development of bone *V. A.* 100 1885
 GRÜNDLER: Cachexia strumipriva *Brun's Mittheil. chir. Klinik* 1 Tübingen 1884
 HOFMEISTER: Results of experimental removal of the thyroid *Beiträge von Brun's* XI 1894
 KAUFMANN: *Die sogenannte fötale Rachitis* Berlin 1892; Hyperplastic dystrophy of cartilage *Ziegler's Beiträge* XIII 1893
 KIRCHBERG and MARCHAND, F.: Foetal rickets (*micromelia chondromalacica*) *Ziegler's Beiträge* V 1889
 KLEBS: Cretinism *A. f. exp. Path.* II 1874
 KÜSTNER, O.: Trigonocephalia *V. A.* 83 1880
 LITZMANN: Transverse contraction of pelvis *A. f. Gynäk.* XXV 1884; *Die Formen des Beckens* Berlin 1861
 MORI: Intra-uterine rickets *Cent. f. allg. Path.* IV 1893
 MÜLLER, H.: Foetal rickets *Würzburg. med. Zeit.* I 1860
 PALTAUF: *Ueber den Zwergwuchs* Vienna 1891
 ROHRER: Case of a dwarf *V. A.* 101 1885
 SALVETTI: Foetal rickets *Ziegler's Beiträge* XVI 1894
 SCHAUTA: Anomalies of the pelvis *Müller's Handb. d. Geburtshülfe* 1888
 STILLING: Imperfect osteogenesis *V. A.* 115 1889
 URTEL: Foetal rickets *Inaug. Diss.* Halle 1873
 VIRCHOW: *Gesamm. Abhandl.* Frankfurt 1856; *Entwicklung d. Schädelgrundes* Berlin 1857; *Würzburg. Verhandl.* VII 1857; *V. A.* 5, 13, 94 1883
 WELCKER: *Wachsthum u. Bau d. menschlichen Schädels* Leipzig 1862
 WINKLER: Foetal rickets with micromelia *A. f. Gynäk.* II 1871

57. Excessive longitudinal growth of the bones depends upon abnormal proliferation of cartilage in the process of endochondral ossification, and excessive thickness upon abnormal addition of osseous tissue by apposition. The two processes, when they affect the entire osseous system, lead to **hypertrophy of the skeleton**, or gigautic overgrowth.

Growth of the bones beyond the ordinary dimensions proper to the race, and to the ancestral stock, may be noticeable even

at birth, though more usually it makes its appearance during the period of adolescence, or even after the time when growth normally ceases. The increase in the several parts of the skeleton may be symmetrical and uniform; more commonly, however, the hypertrophy is unequal, so that the normal relative proportions of the parts are disturbed. At the same time the hypertrophied parts may be irregularly enlarged, and so become more or less deformed. Such deformity is most frequently observed in the bones of the skull (Fig. 123) and at the ends of the limb-bones.

The causes of excessive development of the osseous structures

are still obscure. It is natural to assume that the variety that begins in the early or intra-uterine period of growth is due to heredity. When the hyperplasia first makes its appearance during extra-uterine growth, it is possible that external influences play an important part in the causation, in addition to some hereditary predisposition. Perhaps chemical agents may be influential in producing these changes. In support of this theory the experimental investigations of WEGNER, MAAS, and GIES might be cited. These investigations show that phosphorus and arsenic, when given in small doses during the period of adolescent growth, produce an increase of bone at every point which is the site of physiological apposition.

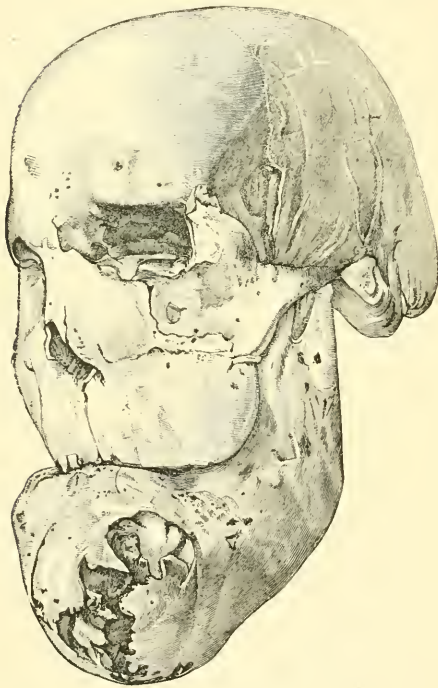

FIG. 123. LEONTIASIS OSSEA.
(Case observed by BUHL)

Abnormal osseous hypertrophy may continue to progress until death, or it may cease after a few years.

Overgrowth of individual portions of the skeleton, or **partial gigantism**, occurs in the bones of the skull (Fig. 123), and affects the bones of the cranial vault as well as those of the face. The overgrowth is sometimes uniform, at other times irregular in its distribution; occasionally also the bones so affected possess a tuberos or lobate surface. VIRCHOW has termed the condition

leontiasis ossea. Cases are recorded in which the weight of the skull reached five kilogrammes.

Where a particular part of the body, such as the foot, or a toe or finger, are from any cause overgrown, the bones of the part are frequently hypertrophied to a corresponding extent. As examples of excessive growth of individual bones, and of the development of new or supernumerary ones, the following are specially noteworthy—the development of the anterior portion of the transverse process of the seventh cervical vertebra into a rib: the lengthening of the twelfth rib, and the formation of a rudimentary thirteenth rib: and the abnormal enlargement of the bony surfaces and points of attachment of tendons, described under the various names of apophyses, tuberosities, tubercules, spines, and crests.

Tumour-like formations of new bone sometimes occur in situations where no outgrowths normally exist. Such tumours appear on the cranium as well as on the other portions of the skeleton, and are sometimes composed of compact ivory-like bone, and at other times of spongy or cancellous tissue: they may be multiple. Many cases are reported in which tuberous or spicular bony growths have been formed over the entire skeleton, or the greater portion of it, the protuberances being usually covered with a layer of cartilage at their growing margins (Art. 62). On the larger long bones these growths are generally found at the articular ends, and near the cartilaginous stratum between diaphysis and epiphysis. They may however occur in any other situation—for example, on the flat surfaces and the crest of the ilium, on the ischium, or on the pubes.

The mode of origin and the significance of these and other similar formations are very various. The occurrence of supernumerary ribs is taken as evidence that man is descended from ancestors who possessed a larger number of ribs, and in this respect one is reminded of the structure of the anthropoid apes. The enlargement of tuberosities, crests, and the like, is regarded as merely a local overgrowth of parts whose development is normally subject to wide variations, possibly favoured in certain instances by some excessive traction exercised by the muscles.

The **causes** of general or local gigantic overgrowth, of diffuse hyperostosis of the cranium, and of circumscribed tumour-like osseous formations, are for the most part still unknown. Sometimes chronic or frequently recurring inflammation, such as cutaneous erysipelas of the head (VIRCHOW), appears to be a cause. In other cases traumatic injury leads to osseous hyperplasia. Cases are reported in which a kick in the face by a horse (BUHL) or an operation on the face (JOURDAIN) has resulted in hyperostosis not of the injured part only but of the entire skull. The phenomenon is not unnaturally accounted for by the assumption

that in these particular instances the periosteum and marrow possessed an inherited predisposition to excessive osteogenesis.

As regards multiple hyperostoses, the theory of inherited predisposition seems to offer the only explanation, and its relevance is rendered probable by the fact, on the one hand, that these hyperostoses generally make their appearance during the period of growth, and, on the other hand, that they frequently run in families. When multiple hyperostosis appears for the first time in a family, it is probably to be regarded as a spontaneous variation or 'sport,' to be classed with other like anomalies of development.

References on Hypertrophy of the Skeleton and on Local Overgrowths and Exostoses.

- AHLFELD: *Die Missbildungen* I Leipzig 1880-82
 BESSEL-HAGEN: Anomalies of bones and joints *Langenbeck's Arch.* 41 1891
 VON BUHL: Giant with cranial hyperostosis *Mittheil. München. path. Inst. Stuttgart* 1878
 FISCHER: Cranial hyperostosis *D. Z. f. Chir.* XII 1880
 FRÄNKEL, M.: Pseudo-elephantiasis *V. A.* 46 1869
 FRIEDREICH: Hyperostosis of the skeleton *V. A.* 43 1868
 FRITSCHE and KLEBS: *Pathologie des Riesenwuchses* Leipzig 1884
 HEYMAN: Hereditary multiple exostoses *V. A.* 104 1886
 KESSLER: Case of lipomatous macropodia *Inaug. Diss. Halle* 1869 (with references)
 LABURTHE: *Les exostoses de développement* Paris 1871
 POORE: Hereditary exostoses *Lancet* II 1873
 VIRCHOW: *Krankhafte Geschwülste* II 1865
 WEBER, C. O.: *Die Exostosen* Bonn 1856
 WITTELSHÖFER: Gigantic overgrowth of fingers *A. f. klin. Chir.* 24 1879

References on Bony Hyperplasia from the Effects of Arsenic and Phosphorus.

- GIES: Influence of arsenic *A. f. exp. Path.* VIII 1877
 KASSOWITZ: *Z. f. klin. Med.* VII 1883
 MAAS: *Tageblatt d. Leipz. Naturforscherversammlung* 1872
 WEGNER: Influence of phosphorus *V. A.* 55 1872
 ZIPPELIUS: *D. Z. f. Thiermed.* II 1876

58. If the diaphysis of one of the long bones becomes chronically inflamed from the presence in it of a tuberculous focus or of a necrotic sequestrum resulting from acute osteomyelitis, and if the inflamed region is situated not too near the epiphysial cartilage and the patient is young, not only hyperostosis of the diaphysis but **increased longitudinal growth** are occasionally induced. The like may ensue when the periosteum and marrow of the diaphysis have been subjected to chronic irritation from any other cause, such as a cutaneous ulcer, or the insertion of metal or ivory pegs; but the irritation must be neither too slight nor too intense, and the resulting inflammation must not extend to the end of the diaphysis (OLLIER, VON LANGENBECK, VON BERGMANN, and others).

In exceptional cases, arthritis results in morbid overgrowth in length of the bones contiguous to the affected joint (VON LANGENBECK, WEINLECHNER, SCHOTT, and others). According to OLLIER, VON LANGENBECK, VON BERGMANN, HAAB, WEINLECHNER, SCHOTT, and others, inflammatory elongation of one bone sometimes induces similar overgrowth of another neighbouring bone.

When the focus of inflammation is not too near the epiphysial cartilage, the excessive longitudinal growth seems to take place uniformly. If the inflammatory focus is nearer the growing cartilage, slight irregularities appear in the formation of the medullary cavities, and these are followed by similar irregularity in the ossification. This may occur both in the intermediary or epiphysial and in the articular cartilage: in both situations a more or less complete destruction of the cartilage is the result. When the growth of the epiphysial cartilage ceases the bone is able to increase but slightly in length, the articular cartilage even in very young persons producing but little bone.

When it lies within the region of inflammation, the epiphysial cartilage is very rapidly destroyed. In suppurative osteomyelitis it sometimes undergoes complete necrosis, and longitudinal growth at the affected end naturally comes to a standstill.

As has been already observed, under these conditions **separation of the epiphysis** is brought about.

The disorders of endochondral ossification produced by inherited syphilis, commonly described as **syphilitic osteochondritis** (Fig. 124), have attracted the attention of pathologists. In the slighter forms of this malady there are, properly speaking, no definite inflammatory foci, and the affection consists essentially of irregularity in the deposition of the calcareous salts and in the formation of the medullary spaces. In the severer forms the neighbourhood of the articular cartilage is beset with greyish-red foci of osteomyelitis, which as they break down into pus become yellowish-white or yellowish-green. These are of various sizes, and within them the osseous trabeculae are necrosed or dissolved. The disease usually attacks the lower end of the femur; next in order of frequency the distal ends of the tibia and the bones of the forearm are involved; and lastly, the other parts of the skeleton.

The disorder of calcareous deposition consists in an interruption of the zone of calcification (Fig. 124 *e*) by scattered islands of uncalcified (*d*) or at most slightly calcified tissue, while in other situations the calcareous deposits extend far into the cartilage.

The irregular formation of the medullary spaces proceeds *pari passu* with the irregular calcification. Here, also, the advancing zone is not evenly formed, and some of the medullary spaces (*e*) extend deeply into the substance of the proliferous

cartilage. As these medullary spaces are generally vascular, the alteration may be observed with the unaided eye; and in like manner the irregular formation of the whitish zone of calcification is often very clearly recognisable.

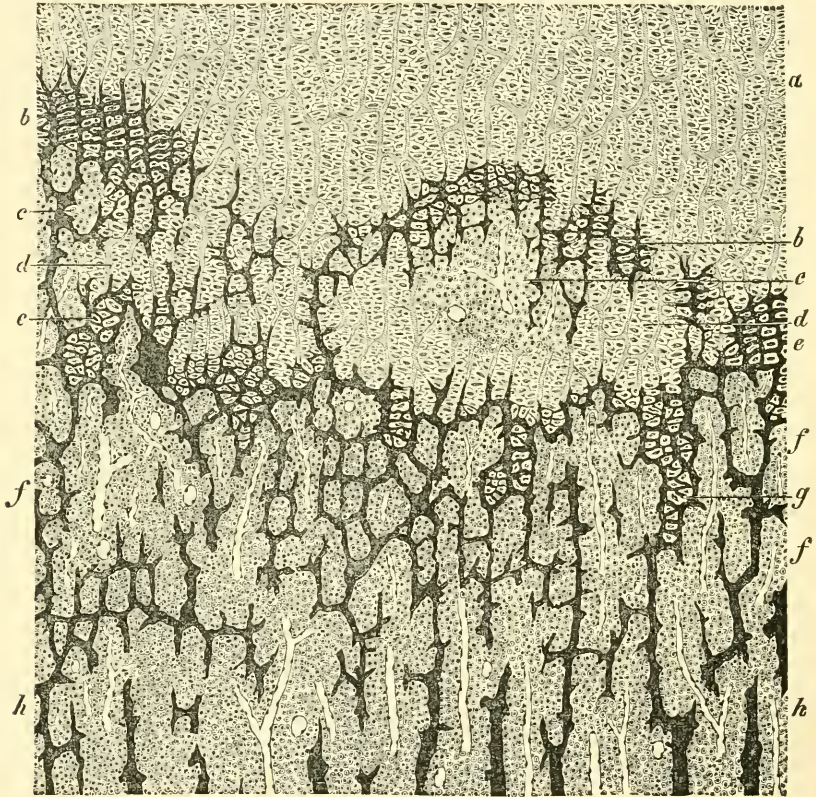


FIG. 124. SYPHILITIC OSTEOCHONDRITIS.

(Section through the upper border of the diaphysis of the tibia in a new-born child affected with hereditary syphilis: preparation hardened in Müller's fluid and alcohol, decalcified with picric acid, stained with haematoxylin and carmine, and mounted in Canada balsam: $\times 50$)

- | | | | |
|---|-----------------------------------------------------|---|--------------------------------------------------------------------|
| a | proliferous hypertrophic cartilage | e | calcified cartilage |
| b | foei of calcification in advance of the normal zone | f | zone of formation of medullary spaces and dissolution of cartilage |
| c | medullary spaces beyond the normal limits | g | remnants of calcified cartilage |
| d | uncalcified islets of cartilage | h | mature bone |

The cartilage itself is sometimes unaltered, but at times it shows signs of excessive proliferation, so that the zone of proliferous and hypertrophic columns of cartilage-cells is enlarged.

Corresponding to the alterations in the cartilage, the transitional zone (*f*) between cartilage and bone, consisting of medul-

lary tissue and remnants of the calcified cartilaginous matrix, is broadened out and uneven. The trabeculae are sometimes scanty and slender, sometimes stout and numerous; in the latter case they often include cartilage-cells (*g*).

The elaboration of the osseous lamellae on the side of the bone-marrow is more or less retarded, so that on this account also the transitional zone between perfect bone and cartilage (*f*) is broadened.

By the formation of granulomatous foci of disintegration, the remnants of the cartilaginous matrix and the new osseous trabeculae may be more or less completely destroyed; while portions of the cartilage also may become necrotic. Occasionally in this manner the epiphyses are at length separated.

Syphilitic osteochondritis is a frequent, though not a constant, concomitant of hereditary syphilis in new-born infants.

HAAB and VERAGUTH have described cases of separation of the epiphyses in still-born syphilitic infants, in which the severance occurred within the epiphysial cartilage, and resulted from antecedent disintegration, fibrillation, and fragmentation of its substance. According to their observations the condition was due to a putrefactive process, which may probably affect in a similar manner still-born putrefied foetuses that are not syphilitic.

References on Inflammatory Stimulation and Arrest of the Growth of Bone.

- BERGMANN: *Petersburg. med. Zeit.* XIV 1868
 BIDDER: *A. f. exp. Path.* I 1873; *A. f. klin. Chir.* XVII
 BOCKEL: Effect of coxalgia on the growth of the limb *A. de physiol.* 1870
 HAAB: *Unters. Zürich. path. Inst.* part III Leipzig 1875
 HUMPHRY: *Med.-chir. Trans.* London 1862
 JAHN: Impaired bone-growth from injury of the intermediary epiphysial cartilage (histological) *Inaug. Diss.* Strassburg 1891
 VON LANGENBECK: *Berl. klin. Woch.* 1869
 MAAS: *A. f. klin. Chir.* XIV
 OLLIER: *Traité de la régénération des os* 1, and *Gaz. hebdom. de méd. et de chir.* 1873
 PONCET: *De l'ostéite au point de vue de l'accroissement des os* Paris 1873
 SCHNEIDER: *A. f. klin. Chir.* IX 1868
 SCHÜLLER: Artificial stimulation of bone-growth *Berl. klin. Woch.* 1889
 WEINLECHNER and SCIOTT: *Jahrb. f. Kinderheilk.* II 1869

References on Congenital Syphilitic Osteochondritis.

- FISCHER: Hereditary syphilis of the bones *München. med. Woch.* 1890
 HAAB: Separation of epiphyses *V. A.* 65 1875
 KASSOWITZ: *Die normale Ossification etc.* Vienna 1881
 MÜLLER: Pathology of hereditary syphilis *V. A.* 92 1883
 PARROT: Changes in the osseous system of infants in congenital syphilis *A. de physiol.* IV 1872
 STILLING: Syphilitic osteochondritis *V. A.* 88 1882
 VERAGUTH: Separation of epiphyses *V. A.* 84 1881
 WALDEYER and KÖBNER: Hereditary syphilis of bone *V. A.* 55 1872
 WEGNER: Hereditary syphilis of bone in young children *V. A.* 50 1870

59. **Rickets**, also termed rachitis, or the "English disease," is a general disorder of nutrition which appears during childhood, and is characterised anatomically by increased bone-resorption,

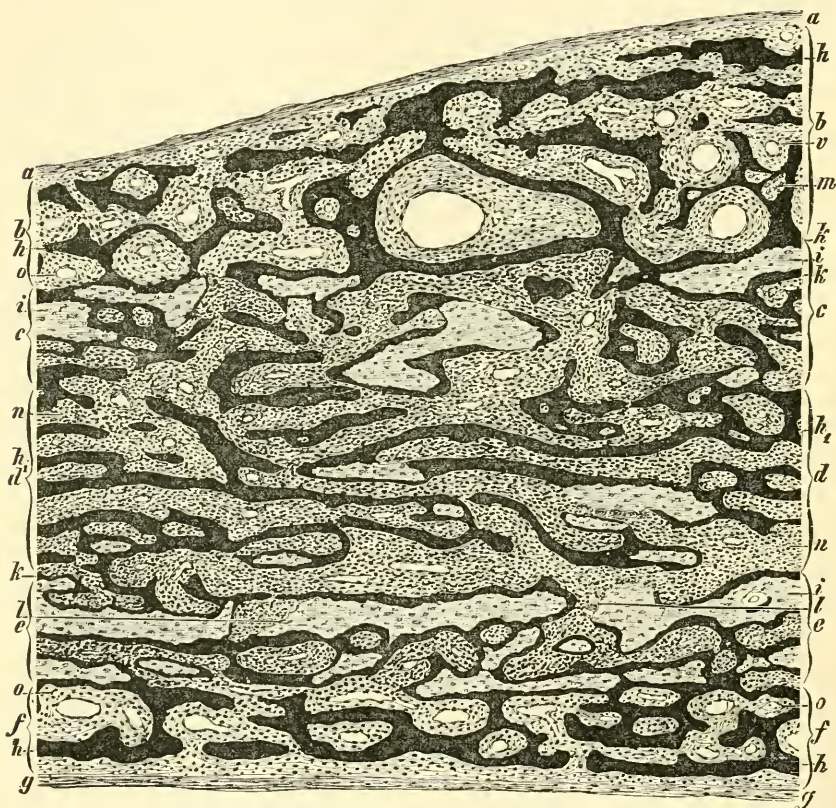


FIG. 125. RICKETS.

(Section through the parietal bone of a two-year-old child: preparation hardened in Müller's fluid and alcohol, cut without decalcification, and stained with haematoxylin and neutral carmine: $\times 30$)

- | | | | |
|---|--------------------------------------------------|---|-------------------------------------------------------------------------------|
| a | external periosteum | k | superposition of osteoid tissue upon the old bone |
| b | external periosteal deposit of bone | l | area of resorption, with osteoclasts |
| c | region of the outer table | m | newly-formed bone within a trabecula of osteoid tissue |
| d | region of the spongy diploë | n | marrow rich in cells in proximity to the old bone |
| e | region of the vitreous lamella | o | marrow poor in cells but rich in vessels within the periosteal osteoid tissue |
| f | region of the inner periosteal osteophytic layer | | |
| g | internal periosteum | | |
| h | and h ₁ trabeculae of osteoid tissue | | |
| i | remnants of old bone | | |

by deficient calcification of the cartilages, and by the formation and persistence of imperfect uncalcified bone or osteoid tissue.

As has already been more than once remarked, resorption of the osseous tissue already formed always takes place during the

period when the bones are growing, but it is confined to definite regions. In rickets the state of things is so far altered that the amount of **lacunar resorption** is excessive, with the result that in marked cases considerable portions of the already-completed bony skeleton are again destroyed. In the long tubular bones and in the short bones, the cortical stratum is thereby rendered more or less osteoporotic, and the osseous trabeculae of the cancellous tissue become attenuated or disappear. The compact substance of the flat bones of the skull may be reduced to a few lamellae (Fig. 125 *i*), so that the characteristic differentiation of the bony structure into an outer and inner table (compare Fig. 110 with Fig. 125) and a diploë is entirely effaced.

At an early stage peculiar and anomalous processes of ossification are associated with these changes, uncalcified bone or osteoid tissue being abundantly produced and deposited on the remnants (*i*) of the older osseous trabeculae (*k*), or forming new trabeculae of its own (*h h₁*). These new trabeculae are elaborated by the bone-marrow (*h₁*) and the periosteum (*h*), both of which are highly vascular and hyperaemic. The formation of osteoid trabeculae within the marrow takes place in a manner similar to that observed in the case of internal callus (Art. 45), except that no such striking multiplication of osteoblasts precedes the appearance of the compact groundwork of the bone. The provisional tissue as it stands is more directly transformed into osteoid trabeculae. Even when new osteoid tissue is deposited upon old, or upon persisting bony trabeculae, the provisional tissue consists not only of epithelioid osteoblasts, but also of fusiform and stellate cells with a fibrillar intercellular substance.

The trabeculae (*h*) elaborated by the periosteum are formed in a manner similar to the trabeculae of external callus (Art. 45), in other words they originate from a matrix that is partly cellular and partly fibro-cellular. Cartilage may also be formed in the periosteum of the long bones, and this later on becomes transformed in the way already described. The marrow of the myelogenous and of the periosteal osteoid tissue consists of highly-vascular partly reticular and partly fibrillar connective tissue, enclosing free round-cells.

The above-mentioned processes, in somewhat advanced cases of rickets, lead to the development upon the surface of the bones of vascular and hyperaemic tissue of spongy texture, which though it is capable of resisting moderate pressure with the finger is easily cut through with the knife. It is specially abundant at points where periosteal apposition is normally active, *e.g.* on the diaphyses of the long bones and about the regions of active periosteal growth (Fig. 125 *b*) on the exterior of the flat bones of the skull.

When the older bone has been subject to much resorption (*c d e*), it too may easily be cut through with the knife.

The trabeculae of osteoid tissue are devoid of calcium-salts,

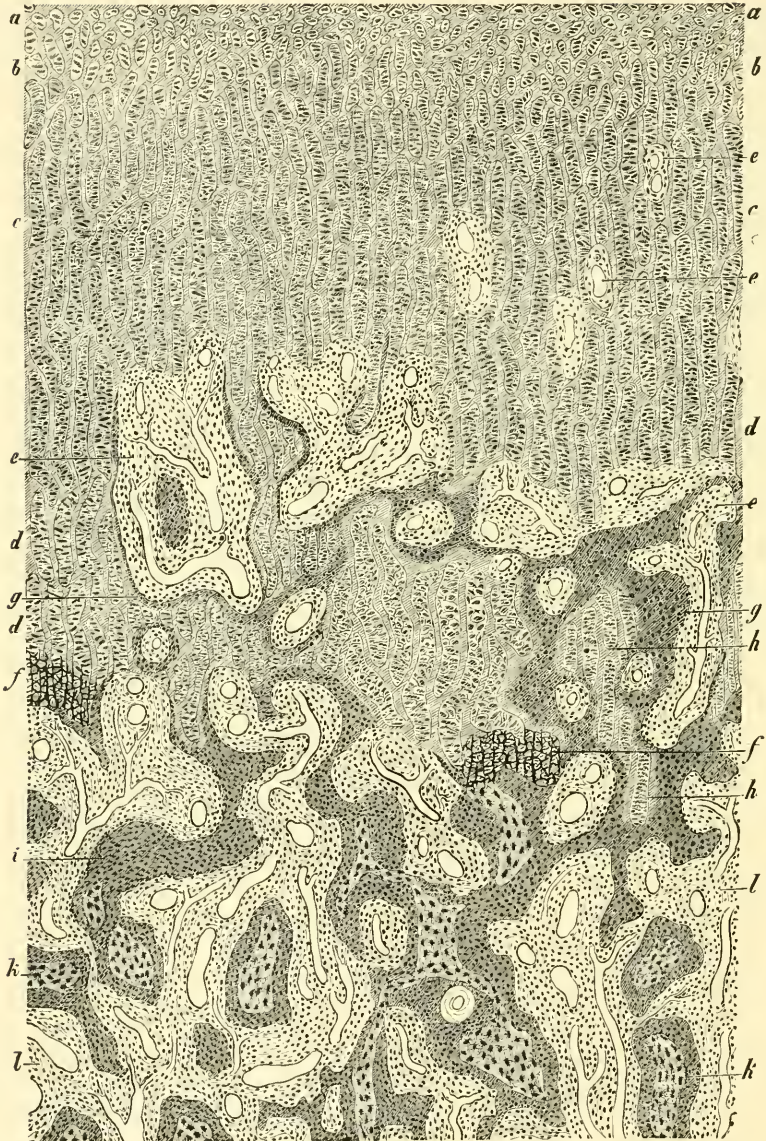


FIG. 126. RICKETS.

(Longitudinal section through the line of ossification of the upper end of the diaphysis of the femur of a one-year-old child, suffering from rickets of moderate severity: preparation hardened in Müller's fluid, stained with haematoxylin and carmine, and mounted in Canada balsam: $\times 50$)

a unaltered hyaline cartilage *b* cartilage in the first stage of proliferation *c* zone of columns of proliferous cartilage-cells *d* columns of proliferous hypertrophic cells *e* vascular medullary spaces within the cartilage *f* calcified cartilage *g* osteoid tissue *h* remnants of cartilage amid osteoid tissue *i* trabeculae of osteoid tissue devoid of calcium-salts *k* trabeculae formed of osteoid and completely-ossified tissue *l* vascular fibro-cellular medulla

and consist of a fibrous reticulated matrix (KASSOWITZ) which stains deeply with carmine, and contains rather large bone-corpuscles and cells. These last undergo marked fluctuations as to number, and are distributed sometimes uniformly and sometimes irregularly. So long as the rachitic affection persists, these trabeculae remain free from calcium-salts, or take them up only at a very late stage, and then at first only in the central parts (*m*). Not until recovery begins does complete calcification take place, and the bone, considerably enlarged and thickened by the luxuriant periosteal overgrowth, becomes at length hard and rigid.

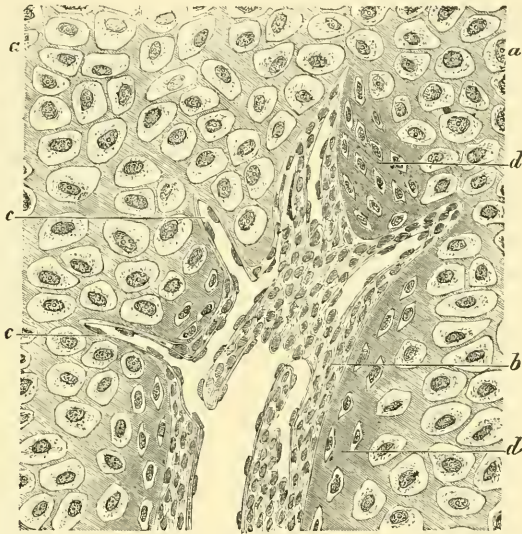


FIG. 127. FORMATION OF A MEDULLARY SPACE WITHIN AN EPIPHYSEAL CARTILAGE IN RICKETS.

(Preparation hardened in Müller's fluid and alcohol, double-stained with haematoxylin and carmine, and mounted in Canada balsam: $\times 130$)

a cartilage b medullary space c vascular processes d osteoid tissue

The disorders of periosteal and myelogenous ossification in rickets are always accompanied by corresponding anomalies of endochondral ossification. The absence of a zone of calcification at the line of growth is the most salient feature. In severe forms of rickets there may be no calcareous deposition at all. In slighter cases of the disease the cartilage still shows scattered islands of calcification (Fig. 126 *f*).

A second characteristic feature is enlargement of the zone of proliferation in the cartilage (*b e*), and usually of the columns of hypertrophic cells (*d*). A third feature is the formation of vascular medullary cavities (*e*), which grow out in an entirely irregular manner from the bone-marrow into the cartilage.

These three alterations have these results—first, that the transition from cartilage to bone is not indicated by the usual white line (Art. 54), its place being occupied by at most a few small white specks; and secondly, that the zone of proliferous cartilage, distinguishable from the inactive cartilage by its translucency, is more or less broadened. At the same time the line of demarcation between cartilage and bone is not even, but in many places distorted and interrupted, the medullary spaces extending visibly for very various distances into the cartilage. At the same time blood-vessels in abnormal abundance penetrate from the perichondrium into the cartilage.

The substitution of uncalcified cartilage by medullary spaces is always started by the ingrowing of a blood-vessel, which may be naked or accompanied by groups of cells (Fig. 127 *c*). The changes the cartilage thereby undergoes (compare Fig. 85) are exactly similar to those which take place in periosteal cartilage in process of ossification. As the cartilaginous capsules rupture, the cartilage-cells become free and are changed into marrow-cells (Fig. 85 *i*).

Where the cells in the neighbourhood of new vascular spaces persist, the cartilage may, by special modes of transformation, assume directly the appearance of osteoid tissue (Fig. 127 *d* and Fig. 85 *f*). When the proliferous cartilage has been coloured bluish-violet by double-staining with haematoxylin and carmine, the osteoid tissue will become dark-red.

With the increase in size of the medullary spaces the mass of the cartilage naturally decreases. But it must be regarded as characteristic of rickets that nevertheless the cartilage is neither completely destroyed nor completely transformed. Trabeculae of cartilage (Fig. 124 *h*) persist, here and there, between the medullary spaces, and we may say that the more severe the disease the greater is the number of these residual trabeculae.

The persisting cartilaginous trabeculae are gradually changed into osteoid tissue from their periphery inwards, and at other points osteoid trabeculae are formed from the bone-marrow (Fig. 126 *i*) at the same time. A zone of osteoid tissue (Fig. 124 *i*) thus arises behind the area of proliferous and vascular cartilage (*c d*), whose trabeculae enclose more or less numerous islets of unaltered cartilage (*h*). This zone may reach a width of 5, 10, or 15 millimetres, or even more in the long bones, and forms a highly-vascular structure which, in its physiological characters, corresponds exactly to the periosteal osteophytic layers, and offers a certain elastic resistance to the pressure of the finger, though it yields on the application of greater force, and is pliable.

The arrangement of the osteoid trabeculae (Fig. 124 *i*) is entirely different from the type characteristic of normal ossification (compare Fig. 113), and in form also they are entirely different from normal osseous trabeculae. Their increased thickness

is the result of apposition from the bone-marrow, which, in the neighbourhood of osteoid tissue, and sometimes also in the neighbourhood of proliferous cartilage, contains a notable proportion of fibrillar ground-substance, enclosing spindle-shaped and stellate cells and relatively few round-cells. The flat and spindle-shaped osteoblasts, together with the fibro-cellular tissue, play the part of plastic or formative material deposited upon the osteoid trabeculae.

Deposition of calcium-salts in the osteoid tissue at length begins to take

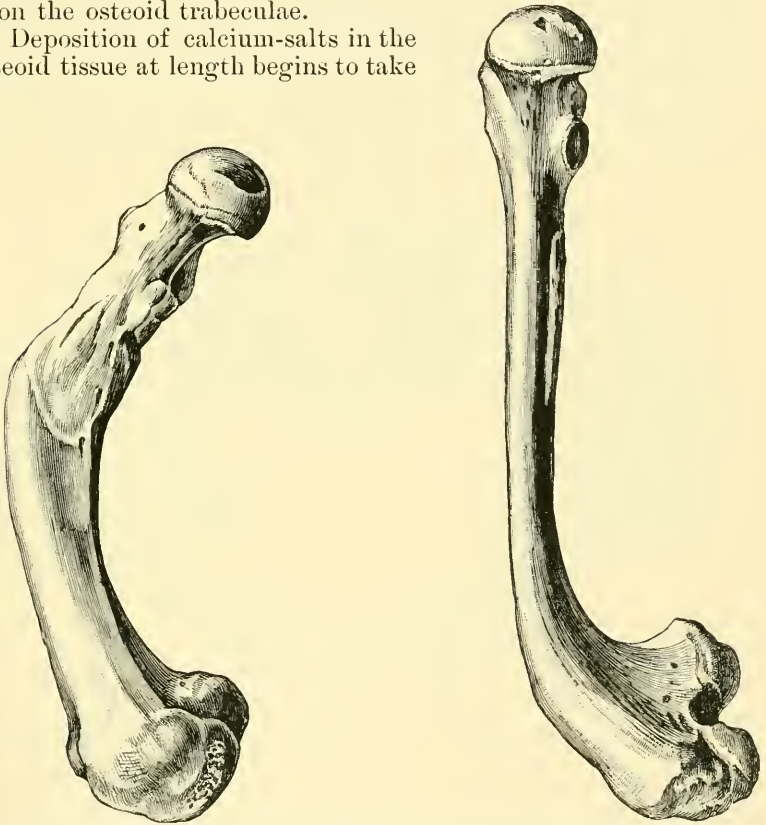


FIG. 128. ADULT FEMUR WITH RACHITIC CURVATURE OF THE DIAPHYSIS.
(Reduced to one-third of the natural size)

FIG. 129. ADULT FEMUR WITH RACHITIC FLEXURE OF THE LOWER EPIPHYSIS.
(Reduced to one-third of the natural size)

place at a certain distance from the cartilage, the distance varying with the severity of the rachitic affection. This deposition always begins in the centre of the osteoid trabeculae. To the purely osteoid tissue is thus added a zone of osteoid trabeculae (Fig. 124 *k*) whose centres are by a process of calcification transformed into true bone.

The resultant effect of the rachitic disorder of ossification on the form and structure of the skeleton may be inferred from the nature of the separate processes. The abundant proliferation of the epiphysial cartilage produces thickening of the articular ends of the bones, while by the luxuriant periosteal formation of uncalcified osteophytes the diaphyses of the long bones and the external strata of the flat bones are thickened. After the rachitic process has ceased the bone is thus abnormally thick, clumsy, and heavy.

The softness of the osteoid tissue produces a more or less free mobility of the cartilaginous epiphyses upon the diaphysis, on account of which at times the ends of the latter are sharply bent (Fig. 129). By pressure in the direction of the axis of the

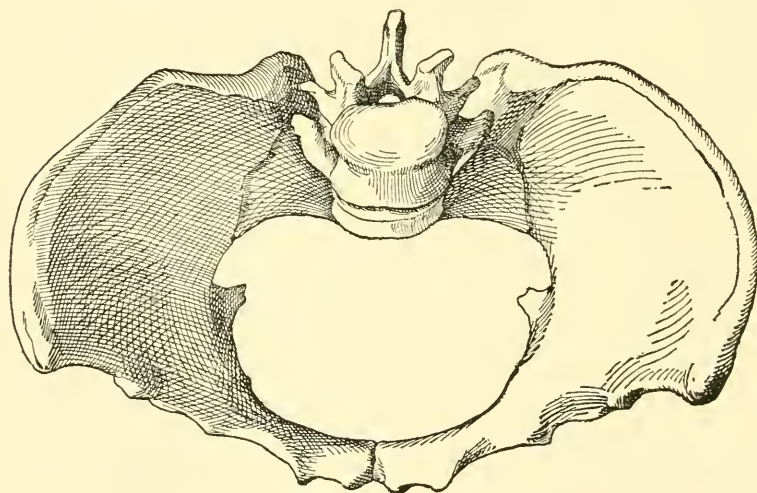


FIG. 130. FLAT RICKETY PELVIS.

(The sacrum projects far into the pelvis, the posterior spines extend over the posterior aspect of the sacrum farther than normal, the iliac bones are small and diverge widely in front, the acetabula are directed anteriorly: two-fifths of the natural size)

diaphysis, the soft epiphysial cartilages are at the same time depressed. Deficiency of longitudinal growth results from the irregularity and incompleteness of the endochondral ossification.

The rarefaction of the cortical and cancellous parts, and the lack of calcium-salts in the newly-formed periosteal and myelogenous strata, produce softness of the bones. This softness, in the long bones of the limbs, and in those of the thorax, of the shoulder, and of the pelvic girdle, gives rise in the early stages of rickets to easy indentation and fracture, and in the later stages to flexure and curvature (Fig. 128). In the short bones, especially those of the trunk, flattening may result from compression.

The form assumed by the bones of the extremities, of the pelvic

and pectoral girdles, and of the vertebral column, is determined chiefly by the traction of muscles and by the weight of the body. In the case of the thorax, in addition to the action of the muscles of respiration, the external atmospheric pressure comes into play.

As the result of these various stresses, the long bones of the limbs, and especially of the legs, are apt to become curved and distorted. If the periosteal ossification is that which is most interfered with, the diaphysis becomes evenly curved (Fig. 128); if, on the other hand, it is the endochondral ossification that is chiefly disordered, the result is angular flexure or oblique dis-

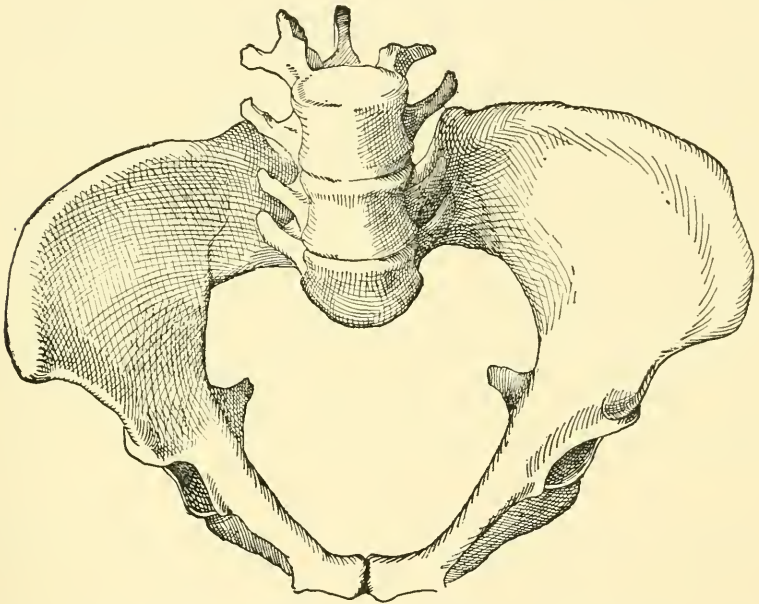


FIG. 131. RICKETY (PSEUDO-OSTEOMALACIC) PELVIS WITH THE PROMONTORY OF THE SACRUM SUNK FORWARD.

(The acetabula are approximated, the symphysis is pressed forward, the iliac venters are small: two-fifths of the natural size)

placement of the epiphyses (Fig. 129). The pelvis, in less severe cases of rickets, is usually flattened (Fig. 130), the sacrum sinking into the pelvic cavity and with its wings forming a plane rather than a concave surface at the posterior portion of the pelvic inlet. At the same time the lower portion of the sacrum is bent sharply forward; the venters of the ilia are small, and diverge anteriorly from each other; the pubic arch is wide; and the acetabula point more anteriorly than is normal. In severe cases, where the pelvic bones are very soft (Fig. 131), the promontory of the sacrum projects sharply forward and extends inward

beyond the wings of the sacrum, the acetabular region is pressed inward, and the symphysis is carried forward; so that the pelvic inlet, as in osteomalacia, becomes heart-shaped. This form is termed the **pseudo-osteomalacic pelvis**.

In the spine, kyphotic, lordotic, and scoliotic curvatures are produced (Art. 60). The thorax sinks in, especially at the points where the ribs join the cartilages. The bony ribs frequently form a re-entrant angle with the soft proliferous portions of the costal cartilages. When this deformity of the thorax is extreme, the sternum is thrust forwards like a keel, forming the *pectus carinatum*, or **pigeon-breast**. Occasionally, the sternum also sinks in and is compressed laterally, so that a concave depression is formed at its lower end; this constitutes the infundibular or **funnel-shaped thorax**.

When resorption of the flat cranial bones has been excessive, particular portions may revert to the condition of membrane (*craniotabes rachitica*), while the remaining portions are composed principally of spongy osteoid tissue. The fontanelles are accordingly large, while the sutures appear broadened, pliant, and membranous, and bordered by soft edges. Large areas of the occipital and parietal bones are sometimes thus softened, and feel like mere skin, the firm and resistant bone they contain being reduced to a few islands.

Dentition is delayed in rickets. The disease is most frequent in the first and second years of life. It may supervene however up to the tenth year, and not infrequently osseous changes, which are attributable to rickets, make their appearance at the time of puberty, and induce abnormal pliability of the bones.

KASSOWITZ maintains that rickets is an inflammatory disease of bone, which starts at the seats of osseous apposition and gradually affects the entire structure. This view he bases upon his minute researches concerning the process. He seeks to explain all the pathological phenomena by the theory that the vascularity of the osteogenic tissues is morbidly increased. This vascularity, in its turn, is due to a peculiar vulnerability of the vessels concerned, in which morbid changes are induced by defective nutrition, as well as by noxious substances circulating in the blood.

The assumption of KASSOWITZ, that the tissues within a part affected with rachitic disease are hyperaemic, is well-founded; hyperaemia is however not identical with inflammation, and the entire process does not bear an inflammatory character. The increased vascularity is only a symptom or concomitant, it is not the underlying cause of the phenomena of rickets.

Most authorities regard rickets as a disorder of nutrition, attributable mainly to a deficient supply of calcareous salts to the bones. This theory finds support in various observations made upon animals. For example, according to ROLOFF, rickets is induced in suckling lambs when the mother is fed with food deficient in lime. Young lions and leopards become rachitic when fed upon flesh from which all bone has been removed.

The cause of the deficiency in calcium-salts may lie in absence of these salts from the food, in lack of power on the part of the intestine to absorb them, or in failure of the system to utilise them properly when absorbed.

According to RIEDEL, however, the absorption and excretion of lime in

rachitic and in healthy children fed on similar diet is the same. The essential cause of rickets can therefore scarcely lie in any lack of power on the part of the organism to assimilate calcium-salts.

According to SALKOWSKI and SEEMANN, the ingestion of an excessive amount of food containing potash may have this effect, as phosphate of potassium combines with the chlorine of the blood-plasma and so causes therein a deficiency of chlorides. This in its turn leads to deficient formation of hydrochloric acid in the stomach, and this again renders the solution and assimilation of the calcium-salts impossible. According to the investigations of LEHMANN, MÜLLER, and MUNK, increased excretion of phosphorus and of lime occurs in starvation; the bones are therefore in process of catabolic disintegration.

References on Rickets.

- BAGINSKY: Pathology of rachitis *V. A.* 87 **1882**
 BEYLARD: *Du rachitisme etc.* Paris **1852**
 FAGE: Discussion *Trans. Path. Soc.* XXXII London **1880**
 FLEISCHMANN: Rachitis of the lower jaw *Wien. med. Presse* **1877**
 FRIEDLEBEN: Constitution of growing and rachitic bones in children *Jahrb. f. Kinderheilk.* III
 GLISSON: *De rachitide* London **1650**
 HALLIBURTON: *Chemical Physiol. and Pathol.* London **1891**
 HUTCHINSON: Pathology *B. M. J.* II **1880**
 KASSOWITZ: *Normale ossification etc.* II Vienna **1882-85**; *Jahrb. f. Kinderheilk.* XIX, *Z. f. klin. Med.* VII **1883**
 MÜLLER; H.: *Z. f. wiss. Zool.* IX **1858**
 POMMER: *Osteomalacie und Rachitis* Leipzig **1885**
 REHN: *Gerhardt's Handb. d. Kinderkrankh.* III; *Jahrb. f. Kinderheilk.* XII and XIX; *Trans. internat. med. Congress* IV London **1881**
 RIEDEL: Absorption and excretion of calcium-salts in rachitic children *A. f. exp. Path.* XXXIII **1893**
 RITTER VON RITTERSHAIN: *Pathol. u. Ther. d. Rachitis* Berlin **1863**
 ROLL: *Path. u. Ther. d. Hausthiere* (2nd edition)
 ROLOFF: *V. A.* 37 **1866**; Osteomalacia and rickets *A. f. wiss. u. prakt. Thierheilk.* II **1876**
 SCHÜTZ: Rickets in the dog *V. A.* 46 **1869**
 SEEMANN: *V. A.* 77 **1879**
 STIEBEL: *Virchow's Handb. d. spec. Pathol.* I Erlangen **1854**
 VIRCHOW: Normal growth of bone and rachitic changes in it *V. A.* 5 **1853**
 VOIT: *Tagebl. d. Naturforscherversamm.* Munich **1877** and *Z. f. Biol.* XVI
 ZANDER: Rachitis *V. A.* 83 **1881**
 ZIPPELIUS: Diseases due to phosphorus *D. Z. f. Thiermed.* II **1876**

60. The mature **forms of bones and joints** are due partly to qualities inherent in the embryonic basis of the skeleton, and partly to external influences exerted upon the latter during its development and growth. The articular ends are fashioned before the joint-cavity is developed, and before the bones are liable to any relative movement; while projections for the attachment of muscles arise on the bony surfaces before any muscular action takes place. To this extent the evolution of the general form is dependent upon inherited tendencies. The minuter details of form, which are elaborated during the period of foetal growth, during infancy and adolescence, or even at a later stage, are not inherited but acquired as the bones develop in relation to the structures that environ them. These details of form include the

enlargement of the rudimentary tuberosities and ridges, or the formation of new ones, for the attachment of tendons and ligaments, and the production of depressions and grooves for the lodgment of blood-vessels or other soft parts. It is in such details that individual variations and peculiarities of form consist.

Abnormal statical and dynamical conditions influencing the skeleton during its development and growth produce changes of form that are beyond the limits of individual variation, and must accordingly be considered as pathological. When the disturbing influences act during intra-uterine life, the child may be born with more or less marked deformity of the skeleton. Deformities arising after birth appear sometimes in early childhood, sometimes not until puberty or until an even later period.

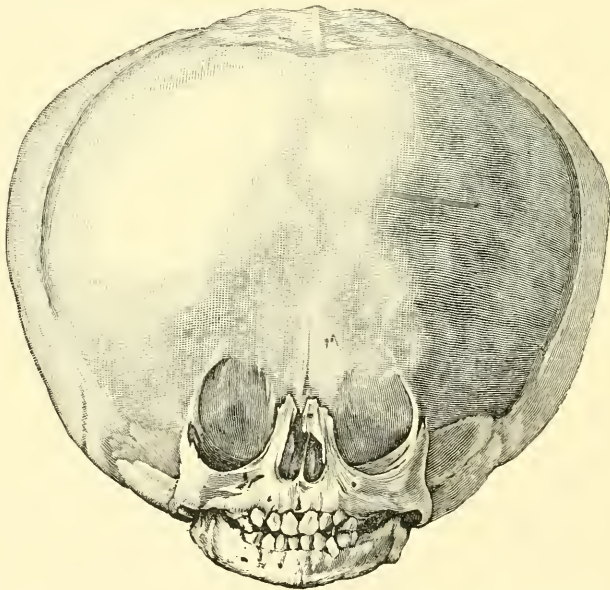


FIG. 132. CONGENITAL HYDROCEPHALUS IN A CHILD ABOUT ONE YEAR OLD.
(Circumference of head, 63 centimetres : reduced to two-fifths of the natural size)

The formation of the cranial portion of the **skull** is, to a certain extent, dependent upon the development of the brain. If the brain remains small and ill-developed, the size of the cranial cavity will remain less than normal: if the cranial contents are abnormally bulky, their osseous envelope will be correspondingly enlarged. An excessive development of nervous tissue or the accumulation of liquid, as in hydrocephalus (Fig. 132), may produce the latter deformity. Where the brain increases rapidly in size, as in infantile hydrocephalus, the growth of bone may be unable to keep pace with the enlargement of the cranial contents,

and thus a greater or less extent of the skull continues to be membranous; and not until the growth of the brain ceases can complete ossification of the skull take place. The same is true in regard to the orbit, whose capacity, like that of the cranial cavity, depends to some extent on the bulk of its contents. Similar relations may be shown to exist between other parts of the skeleton and the soft parts related to them. As a further example we may take the thorax, whose form depends more or less upon the development of the viscera it encloses.

Bones and joints that at birth are normally formed may nevertheless become deformed during their later development. Certain parts that are still growing may be overloaded, while others are left free from stress; as a consequence, perfectly sound bones are liable to become changed in shape, and this naturally happens more readily when the bones are abnormally soft and yielding, as is the case in rickets. Continuous pressure on one side of a bone produces retardation and occasionally arrest of growth, or even resorption; on the side free from pressure, on the other hand, osseous apposition may be increased, or at least not diminished. At the same time shrinking and shortening of the ligaments and muscles take place on the side that is pressed upon, while on the free side, which is under tension, the ligaments lengthen and thicken.

Scoliosis (Fig. 133) is one of the most frequent deformities of the skeleton caused by inequality of pressure: it is a lateral curvature of the spine, the commonest form being that in which the thoracic vertebrae are bent to the right, with compensatory bends to the left of the lumbar and often also of the cervical regions. The abnormal statical conditions giving rise to this deformity may be furnished by excessive distension of one side of the thorax by a pleural effusion, by the unilateral development of a large tumour, by unilateral contraction of the thorax following the absorption of a pleural effusion, by cirrhosis of the lung, by fixation of the pelvis in an oblique position, and so on. But it is more usually due to a frequently-assumed and finally habitual faulty posture of the body, such as constant standing on one leg, sitting upon one buttock, forcing up the right shoulder by habitually resting the right arm upon a table, etc.

If the bones possess a certain amount of pliability (as in rickets), flattening of the bones and ligaments on the side subject to pressure will be produced. When a certain amount of bending has once occurred, and the centre of gravity of the trunk and head has thus been shifted, the curvature rapidly increases and marked lateral deviation takes place. This is usually accompanied by posterior protrusion or curvature of the thoracic spine, which is known as **kyphosis** (Fig. 133). Generally the vertebral column is at the same time rotated, so that the bodies of the vertebrae point to the convex side. In marked kyphosis the ver-

tebrae become wedge-shaped. Sometimes ossification of the ligaments takes place, and osteophytes form on the surface of the vertebrae.

A second form of deformity due to pressure is the affection of the hip described as **coxa vara** (BRUNS). This consists in a bending of the neck of the femur downwards so that its angle of inclination to the shaft is diminished to a varying extent. The condition is due to abnormal pliability of the bone from rachitic disease in childhood or at puberty.

Genu valgum (or knock-knee) belongs to this class of deformities; it is a unilateral or a bilateral deformity of the knee-joint, in which the femur forms with the tibia an obtuse angle, pointing inwards. This condition, like the foregoing, makes its appearance during the period of growth, usually between the ages of two and four years (*genu valgum infantum*), or at puberty, from the fourteenth to the seventeenth years (*genu valgum adolescentium*). At the latter age it is especially common among persons who stand much and at the same time perform hard manual labour, such as bakers', blacksmiths', and joiners' apprentices, and waiters.

The cause of the angular deformity is either that the external articular surfaces of the tibia and of the femur are retarded in

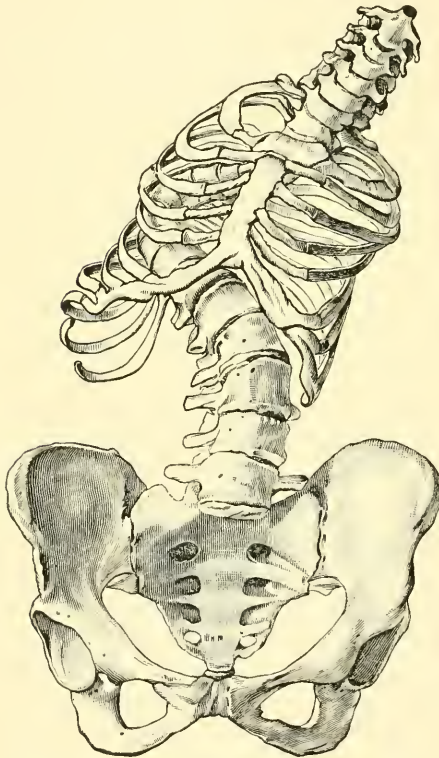


FIG. 133. SCOLIOSIS AND KYPHOSIS OF THE SPINE.

their growth or actually depressed from abnormal pressure on and excessive pliability of the bone, or that the epiphysial ends of the tibia and of the femur (Fig. 129) are sharply bent outwards.

Genu valgum may also occur after traumatic separation of the epiphyses with dislocation of the fragments, or after reunion in a faulty position of a fractured condyle (*genu valgum traumaticum*). Lastly, it is sometimes due to carious destruction of the external condyle of the femur (*genu valgum inflammatorium*), and to arthritis deformans.

Acquired **flat-foot**, or **pes valgus acquisitus**, is another deformity due to pressure: it consists of an alteration in the shape of the foot during the period of growth, whereby the bones forming the inner border of the plantar arch sink in, while the entire foot is at the same time rotated outwards. All the factors that tend to induce the valgus position of the foot, and such postures as produce undue strain on the arch and the plantar and tibialis posticus muscles, aid in producing flat-foot, provided the ligaments and bones are incapable of offering a sufficient resistance. Long standing (as in the case of waiters, smiths, and joiners), and the carrying of heavy weights, act in the former manner. Among factors of the latter class are genu valgum, rachitic curvature of the leg, and the strained positions assumed in stilt-walking and in standing on the narrow rounds of a ladder, when the instep rather than the ball of the foot is used as the point of support. In this case the pressure is applied to the anterior part of the calcaneum, the inner border of the plantar arch being unsupported, with the result that the foot as a whole is rotated outwards.

In pes valgus, the internal lateral ligament and ultimately the astragalo-calcaneal ligament are stretched and elongated. The fasciae and ligaments of the plantar surface, and especially the calcaneo-scaphoid ligament, are lengthened by the sinking in of the plantar arch. In marked cases of flat-foot the arch disappears entirely, and the sole may even become convex downwards, so that in the standing posture the scaphoid rests upon the ground, the head of the astragalus projects inwards (LORENZ), and the astragalus itself seems as if it had slipped down to the inner side of the calcaneum. The tarsal bones and their articular surfaces are more or less deformed. The superior articular ridges of the calcaneum, of the scaphoid, and of the cuboid, are ill developed. The latter is also stunted in its antero-posterior growth. The displaced head of the astragalus is sometimes entirely free, and as it is unsupported by the displaced scaphoid, it is borne up only by the stretched and thickened astragalo-scaphoid ligament (VOLKMANN).

Hallux valgus is also to be regarded as a pressure-deformity. It results from the wearing of pointed shoes, which force the great toe outwards, and often push it beneath the second toe.

Deformities of the articular surfaces of the bones often result from contracture or paralysis of a muscle or group of muscles, due either to a primary myopathy or to such central disorders of innervation as result in muscular changes (neuropathic contractures). Most frequent are the deformities arising from paralysis, and the changes thus induced are generally termed **paralytic contractures**. The paralysis usually results from some lesion of the central nervous system, such as anterior poliomyelitis or compression of the cord from caries of the spine: it may however

be the result of some lesion of the peripheral nerves, due for example to traumatic injury.

If the muscles of an extremity are paralysed, the limb will remain in the position into which it naturally falls by its own weight. A paralysed foot assumes a position of plantar flexion and is turned inwards, when the patient lies upon his back; it thus takes up the position characteristic of *pes equino-varus*. If the foot remains in this position and the patient is young, the plantar flexion, and the depression and inward rotation of the outer border of the foot, continue to increase; the plantar fascia, the tendo Achillis, and the calf-muscles shorten, while the articular surfaces of the bones, subject at certain points to persistent pressure, and at others unrestrained, change their forms. The

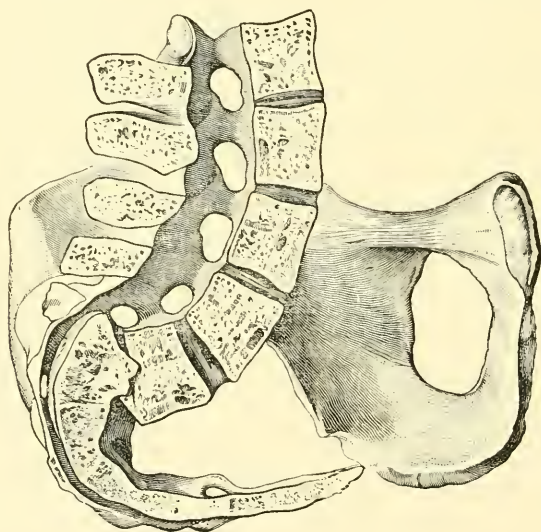


FIG. 134. SPONDYLOLISTHESIS.

(Sagittal section through the spinal column: after KLEINWÄCHTER)

ultimate result is that the foot is fixed in its distorted posture, and forms what is termed *pes equino-varus paralyticus*.

After paralysis of the calf-muscles only, the same condition is apt to arise, as the patient usually fails to exercise the extensor muscles of the foot.

In like manner other paralytic deformities may be brought about, such as paralytic flat-foot and talipes calcaneus, paralytic scoliosis, paralytic genu valgum or genu recurvatum. Genu recurvatum is due to the attempt of the patient to stand on the paralysed limb: to avoid the giving way of the knee-joint by flexion, he brings it into a position of forced extension, in which

it is maintained by the weight of the body and the tension of the posterior ligaments.

The particular deformity produced by a given paralysis depends in great measure on the position spontaneously assumed by the paralysed limb, and on the manner in which its own weight and that of the body act upon it.

Primary and cicatricial contractions of the fasciae and ligaments, when they hold the joint continuously in a fixed position, have the same effect as muscular contractures and paralyses.

Spondylolisthesis of the fifth lumbar vertebra deserves special mention: it is a deformity in which, by the action of the weight of the trunk, the body of the fifth lumbar vertebra and the portion of the spinal column above it slip forward over the base of the sacrum (Fig. 134). At first the vertebra slips in a plane parallel to the adjacent upper face of the lumbosacral intervertebral disc. But with increasing dislocation the vertebral body slides farther and farther into the true pelvis, and finally comes to rest with its basal surface upon the ventral aspect of the sacrum, while its dorsal surface lies nearly on a level with the basal surface of the sacrum.

In spite of the displacement of the body of the fifth lumbar vertebra, its lower articular processes do not lose contact with the articular processes of the sacrum. The vertebral arch with the spinous process does not in fact take part in the spondylolisthesis, the anterior half or body of the vertebra being alone displaced. This dislocation is made possible by the elongation of the inter-articular portion of the arch of the fifth lumbar vertebra, the elongation being in its turn a result of the pressure exerted on the lower part of the vertebral column when the trunk is in the erect posture. The elongation of the inter-articular portion of the fifth lumbar vertebra in the sagittal direction may occur with or without interruption of the continuity of the bone. In some cases it is brought about by traumatic violence, fracture, or inflammation (STRASSER); in other cases it is due to anomalies of development in the laminae and inter-articular parts of the arch (NEUGEBAUER, CHIARI). It is often impossible, however, to determine the cause of spondylolisthesis in a given case.

In this connexion, the thoracic deformity known as **funnel-breast** (EBSTEIN) should be noted. In this the lower portion of the sterno-costal region assumes a cup-shaped or infundibular form. The deformity may be congenital or acquired; in the former case the explanation usually given is, that it is due sometimes to a primary disorder of development in the sternum and ribs, sometimes to pressure exerted on the sternum *in utero* by the lower jaw when the foetal head is strongly flexed upon the trunk, or by the lower limbs as they are drawn up tightly against the body. In extra-uterine life the condition is due to abnormal softness of the sternum, such as is caused by rickets, permitting the bone to yield to the atmospheric pressure during inspiration (Art. 59).

References on Disturbances of Growth due to Mechanical Causes.

- ADAMS, W.: *Club-foot etc.* London 1866
- ALBERT: *Zur Theorie der Skoliose (Samml. klin. Schriften)* Vienna 1890
- ARBUTHNOT-LANE: Some points in the physiol. and pathol. of the changes produced by pressure in the bony skeleton of the trunk and shoulder-girdle *Guy's Hosp. Reports* XLIII London 1886
- BESSEL-HAGEN: *Pathologie des Klumpfußes* 1 Heidelberg 1889
- CHLARI: Spondylolisthesis *Prag. Z. f. Heilk.* XIII 1892 (with references)
- COEN: Infundibular breast *Bullet. d. science med. di Bologna* XIV 1884
- DRACHMANN: Scoliosis *Berl. klin. Woch.* 1885
- EBSTEIN: Infundibular breast *D. A. f. klin. Med.* XXX and XXXIII 1883
- FICK: *A. f. Anat. u. Physiol.* 1859, *Z. f. rationale Med.* IV, and *Die Ursachen d. Knochenformen* Marburg 1859
- FLEISCH: Infundibular breast *V. A.* 57 1873
- HENKE: *Anatomie und Mechanik d. Gelenke* Leipzig 1863, *Z. f. rationale Med.* (3rd series) v 1859, XVII 1863, and *Topograph. Anatomie* Berlin 1884
- HENKE and REYHR: *Wien. Sitzungsber.* LXX
- HERBST: Infundibular breast *D. A. f. klin. Med.* XLV 1887
- HOFFA: *Orthopädische Chirurgie* Stuttgart 1894
- HOFMEISTER: Coxa vara *Beiträge von Bruns* XII 1894 and XIII 1895
- HOLL: Congenital flat-foot *Langenbeck's Arch.* XXV 1880
- HÜTER: *V. A.* 25-28, and 46 1869; *Langenbeck's Arch.* II IV IX; *Die Formveränd. am Skelet des menschl. Thorax* Leipzig 1865; *Klinik. d. Gelenkkrankheiten* Berlin 1876-78
- KLEINWÄCHTER: *Art. Pelvis Eulenburg's Realencyklop.* 1894
- KLEMPERER: Infundibular breast *D. med. Woch.* 1888
- KOCHER: Aetiology of Pes varus congenitus *D. Z. f. Chir.* IX 1878
- KRUENBERG: Spondylolisthesis *A. f. Gynäk.* XXV 1884 [1880]
- KÜSTNER, O.: Congenital flat-foot and Genu valgum *Langenbeck's Arch.* XXV
- LANGER: *Druckschr. d. Wien. Akad.* XII XVI XVIII XXIX and XXXII
- VON LESSER: Cubitus valgus *V. A.* 92 1883; Scoliosis *V. A.* 113 1888
- LORENZ: *Erworbener Plattfuß* Stuttgart 1883; *Seitlichen Rückgratverkrümmungen* Vienna 1886
- LÜCKE: Flat-foot *Volkmann's klin. Vorträge* 16 1871, 35 1872
- MACEWEN: *Osteotomy* London 1880
- VON MEYER, H.: *Statik. u. Mechanik. d. menschl. Knochengerüsts* 1873; *Ursache u. Mechanismus der Entstehung des erworbenen Plattfußes* Jena 1883; *Flat-foot* *D. Z. f. Chir.* XXI 1884; *Der Klumpfuß u. seine Folgen für das übrige Knochengerüst* Jena 1890
- MICHAUD: Congenital club-foot *A. de physiol.* III 1870
- MIKULICZ: Genu valgum *A. f. Anat. u. Physiol.* 1878, *Langenbeck's Arch.* 1879
- MÜLLER: Flexure of the neck of the femur *Beiträge von Bruns* IV
- NEUGEBAUER: Spondylolisthesis *A. f. Gynäk.* XIX and XX; *Zur Entwickelungsgesch. des spondylolisth. Beckens* Halle 1882 (trans. New Syd. Soc. London 1888)
- NICOLADONI: *Die Architectur d. skoliotischen Wirbelsäule* Vienna 1889; *Architectur d. kindlichen Skoliose* Vienna 1894; *Die Skoliose des Lendensegments* Vienna 1894
- PAYR: *Hallux valgus* Vienna 1894
- STAFFEL: Statical causes of deformity *D. med. Woch.* 1885
- STRASSER: Spondylolisthesis *Breslau. ärztl. Zeitschr.* 1882
- SWEDLIN: Spondylolisthesis *A. f. Gynäk.* XXII 1883 (with references)
- TORNIER: Forms of joints and their origin *A. f. Entwickelungsmechanik* I 1894
- VERNEUIL: Genu valgum *Gaz. des hôp.* 1877
- VOLKMANX: *Samml. klin. Vorträge* 1, *Pitha and Billroth's Handb. d. Chir.* II 1872
- WOLFF: *Das Gesetz der Transformation der Knochen* Berlin 1892

CHAPTER XX

TUMOURS, CYSTS, AND ANIMAL PARASITES OF BONE

61. All the **primary tumours** of the osseous system belong to the group of histioid or connective-tissue tumours. The periosteum and the bone-marrow form the matrix for the development of the new-growth. The tissues resulting from their proliferation correspond to the various types of connective tissue, fibrous, mucoid, cartilaginous, and osseous, or of cellular and more or less vascular sarcomatous tissue. All forms of **secondary tumours** are met with in the bones : of these the **carcinomata** occur by far the most frequently.

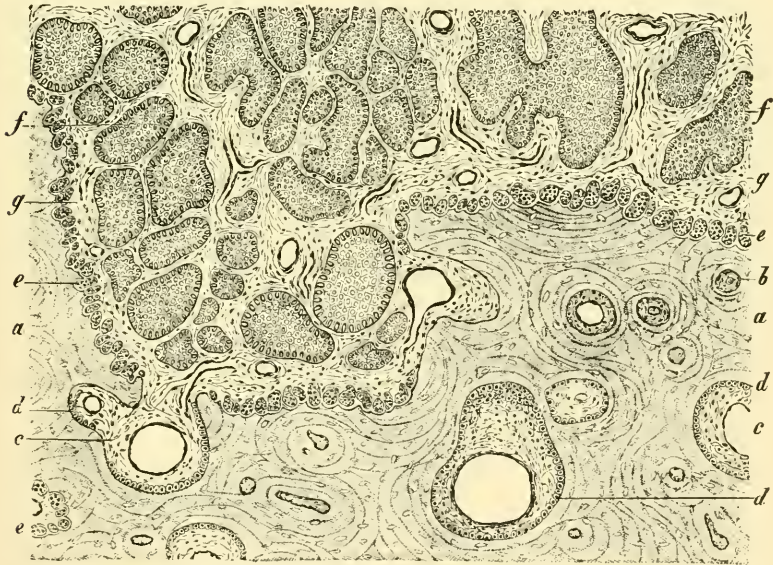


FIG. 135. OSSEOUS RESORPTION AND APPPOSITION IN THE NEIGHBOURHOOD OF A METASTATIC CARCINOMATOUS DEPOSIT IN THE DIAPHYSIS OF THE HUMERUS. (Preparation hardened in Müller's fluid and alcohol, decalcified with picric acid, stained with haematoxylin, and mounted in Canada balsam : $\times 50$)

- | | | | |
|---|------------------------------------------------------|---|-----------------------------------|
| a | cortical layer of the humerus | d | osteoblasts |
| b | normal Haversian canals | e | osteoclasts and Howship's lacunae |
| c | widened Haversian canals, with dilated blood-vessels | f | cancer-nests |
| | | g | stroma of the cancer |

Tumours of bone may be classified, according to their starting-point, as periosteal or myelogenous, or as mixed forms originating simultaneously in the marrow and in the periosteum. The **periosteal forms** of new-growth arise usually from the osteogenic layer of the periosteum, and lie between the bone and

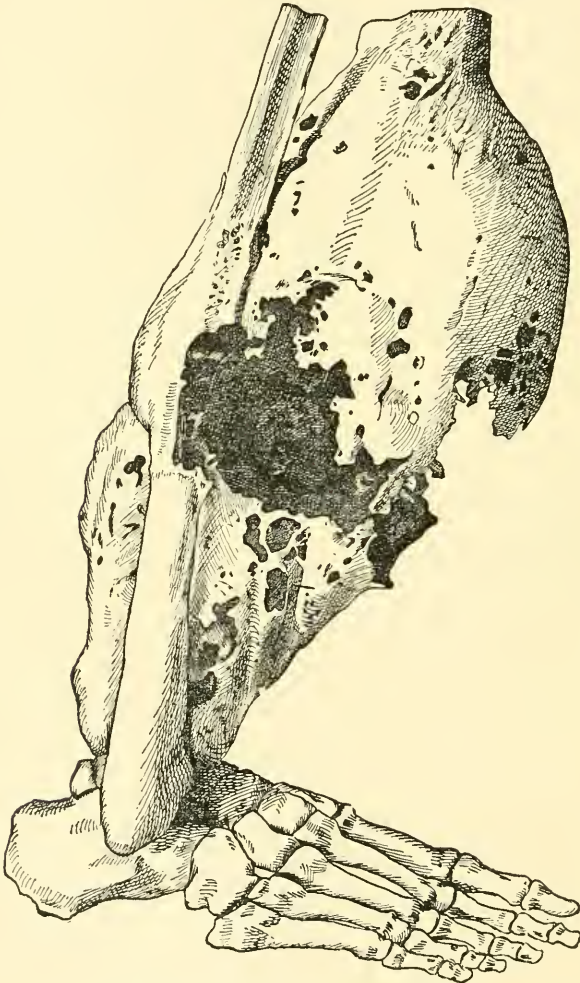


FIG. 136. MYELOGENOUS OSTEOSARCOMA OF THE TIBIA.
(Reduced to three-fifths of the natural size)

the external fibrous layer of that membrane. These tumours are thus sharply marked off from the external tissues. In other cases the growth involves the external layer of the periosteum, and at a later stage infiltrates the contiguous tissues. This is especially

apt to occur in the development of cellular sarcomata. Periosteal tumours are usually situated upon one side of the bone, though in certain instances a long bone may be completely surrounded by the new-growth.

The bone lying beneath the tumour is sometimes unchanged, but in other cases the osseous tissue more or less completely disappears, particularly when the new-growth penetrates into the Haversian canals or is developed from their walls.

Myelogenous tumours are sometimes sharply marked off from the surrounding tissues, and sometimes pass gradually into them,

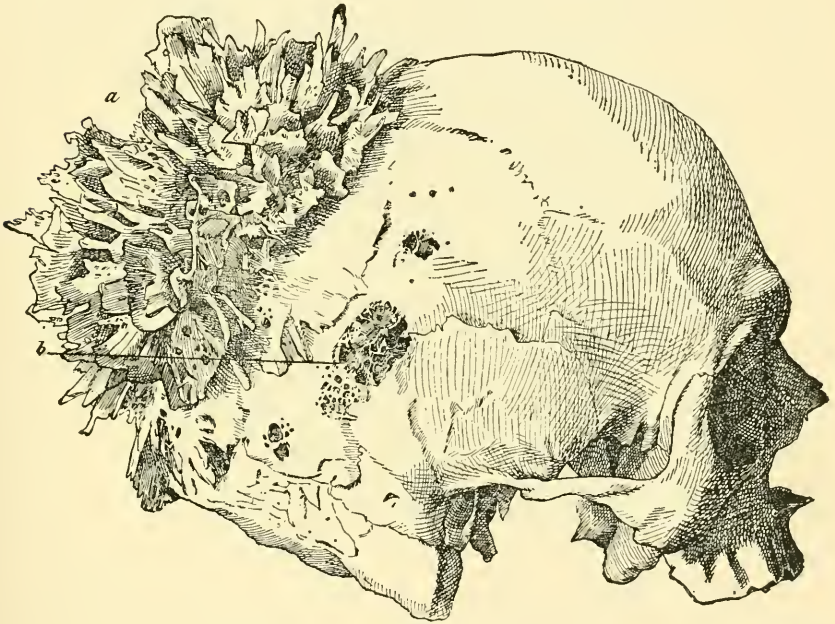


FIG. 137. OSTEOSARCOMA OF THE CRANIUM.

(Reduced to one-half the natural size)

a osseous skeleton of the principal growth *b* carious area beset with bony spicules, the seat of a secondary tumour

or spread in a diffuse manner through the marrow. They always cause more or less resorption of the bony tissue, the process being of the lacunar type (Fig. 135 *e*): halisteresis has not yet been shown to occur in this connexion.

While the interior of the bone is being destroyed, new bone (*d*) is simultaneously being produced from the marrow or periosteum in the neighbourhood of the tumour. Even when the entire thickness of the old bone has been absorbed by the progressive growth of the tumour, the new-growth may still be sur-

rounded by a bony shell (Fig. 136); for as fast as the bone is destroyed within, new osseous deposits are produced from the periosteum on the outer surface. The girth of the bone is thus increased, and the bone appears distended or inflated. As the tumour develops the osseous layer becomes thinner. Whether the tumour, when its diameter exceeds the thickness of the bone within which it has been growing, will break through its bony shell or not depends upon the firmness of the periosteum and the rapidity of the tumour's growth. The periosteum of the larger

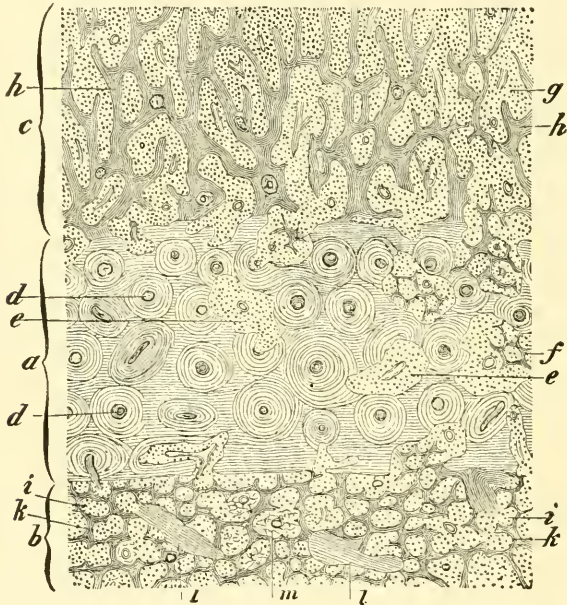


FIG. 138. SECTION THROUGH AN OSTEOID-CHONDROMA OF THE HUMERUS.

(Preparation as seen through a simple lens : double-stained with haematoxylin and eosin)

- | | |
|------------------------------------------------------------------------------------------------------------------------------------------------------------------------------------------------------------------------------------------------------|------------------------------------------------------------------------------------------------------------------------------------------------------------------------------------------------------------------------------------------------------------------------|
| <p><i>a</i> cortical layer of the humerus
 <i>b</i> medullary cavity
 <i>c</i> periosteal deposit
 <i>d</i> normal Haversian canals
 <i>e</i> dilated Haversian canals filled with cartilage containing new-formed bone <i>f</i></p> | <p><i>g</i> cartilage formed from the periosteum containing osseous trabeculae <i>h</i>
 <i>i</i> cartilage formed from the marrow with new-formed osseous trabeculae <i>k</i>
 <i>l</i> old osseous trabeculae
 <i>m</i> remnants of medullary tissue</p> |
|------------------------------------------------------------------------------------------------------------------------------------------------------------------------------------------------------------------------------------------------------|------------------------------------------------------------------------------------------------------------------------------------------------------------------------------------------------------------------------------------------------------------------------|

long bones is capable of offering great resistance to penetration (Fig. 136), and often covers over even rapidly-growing tumours with a shell of new osseous tissue. But it often happens that the osseous covering is incomplete, and the tumour as it grows breaks through it at various points. The periosteum of the flat bones, on the other hand, and especially those of the cranium, seems incapable of producing much in the way of an outer shell, and consequently myelogenous tumours projecting

above the surface of these bones are nearly always devoid of an osseous covering.

Very frequently the tumour itself produces new bone (Fig. 137), and this in a manner similar to that described in connexion with osseous regeneration and hyperplasia. There is however a point of difference, inasmuch as the metaplastic production of bone from existing tissue occurs much more extensively and frequently in the neoplastic than in the regenerative process. Connective tissue and cartilage (Fig. 138 *g i*) are the tissues most frequently transformed into bone (*h k*), although bony trabeculae are sometimes formed in the substance of cellular sarcomatous tissue. At times nothing but osteoid tissue is produced. The matrix often becomes calcified by the deposition in it of calcareous salts (Fig. 139 *c d*).

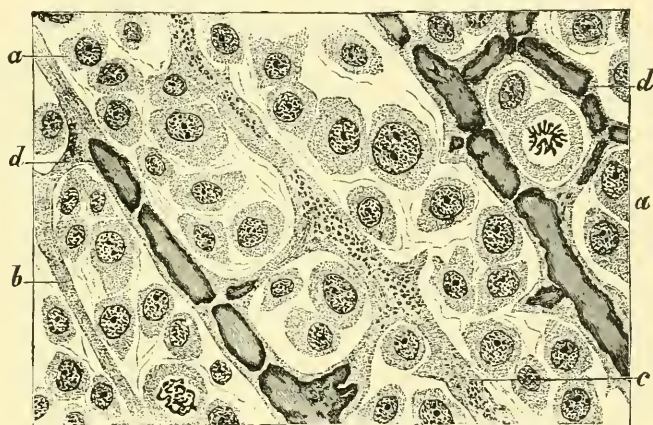


FIG. 139. OSSIFYING LARGE-CELLED SARCOMA OF THE TIBIA.

(Preparation hardened in Müller's fluid and alcohol, stained with haematoxylin and eosin, and mounted in Canada balsam: $\times 365$)

a polymorphous tumour-cells
b alveolar stroma

c trabeculae of the stroma with fine calcareous granules
d calcified trabeculae

Tumours of which bone is the chief component, the softer elements playing merely the part of medullary tissue, are termed **osteomata**. When the soft tissues form the most important part of an osseous growth, it is regarded as a mixed tumour, and a compound term expressing this fact (such as osteo-sarcoma) is used to describe it.

Tumours of bone are usually single, although fibromata, myxomata, osteomata, and enchondromata, as well as many varieties of sarcomata, at times develop from the first as multiple growths.

As regards the **aetiology** of osseous tumours, the fact that they often appear as the result of traumatic injuries (as in callus-growths), and of inflammatory processes, is worthy of note. They

are moreover apt to originate in situations where ossification has been irregular, or where residual portions of provisional tissue, particularly cartilage (VIRCHOW), have remained unutilised in the process of ossification. Such residues are met with chiefly at the ends of the diaphyses of the long bones, and there the remnants of epiphysial cartilage sometimes become the starting-point of enchondromata.

62. **Osteomata** are usually formed in the periosteum, and occasionally in the bone-marrow. In the former situation they are called **exostoses** (Figs. 140 and 141), in the latter they are known

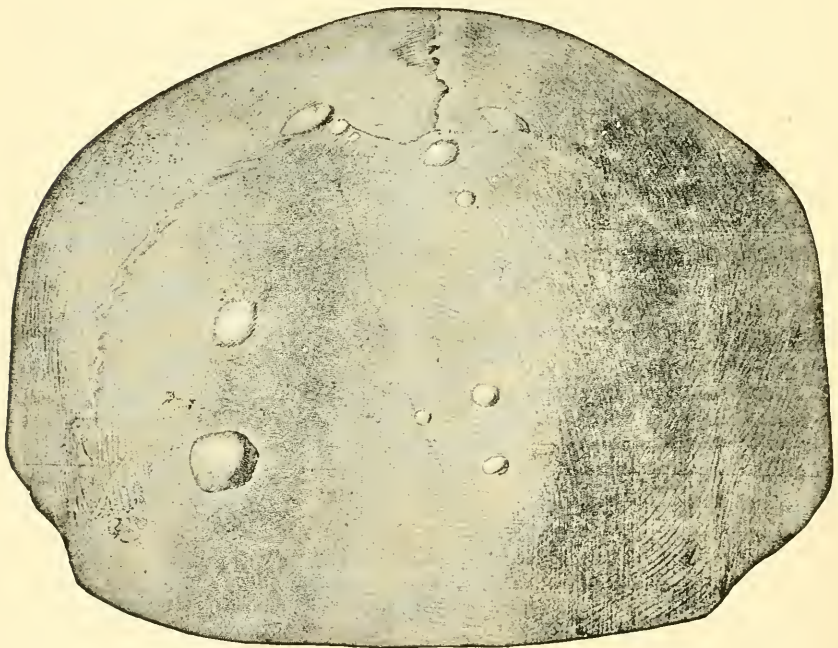


FIG. 140. MULTIPLE IVORY EXOSTOSES OF THE CRANIUM.
(Reduced to five-sixths of the natural size)

as **enostoses**. When exostoses are produced directly from the periosteum, they are spoken of as fibrous exostoses (Fig. 140); when cartilage is first produced and the bone is formed from this, they are known as cartilaginous exostoses (Fig. 141).

The tumour may be composed of dense and compact osseous tissue, and is termed a compact or ivory osteoma (Figs. 140 and 142); or it may be spongy and cancellous, and is then a spongy osteoma (Fig. 141). When it contains medullary cavities of considerable size, like those of the long bones, it is termed a medullary osteoma.

Small osteomata are conical, rounded, button-shaped, or mushroom-shaped (Fig. 140); larger ones form lobate, tuberous (Figs. 141 and 142), spinous, or pectinate excrescences. The latter variety usually occurs at the point of insertion of a tendon, ligament, or fascia. Fibrous exostoses are covered only with connective tissue; cartilaginous exostoses are capped with a layer of cartilage as well as with connective tissue. The first form is met with chiefly on the skull and on the flat bones of the trunk; the second variety affects the diaphysial ends of the larger long bones, and arises from the periosteum or the epiphysial cartilages,

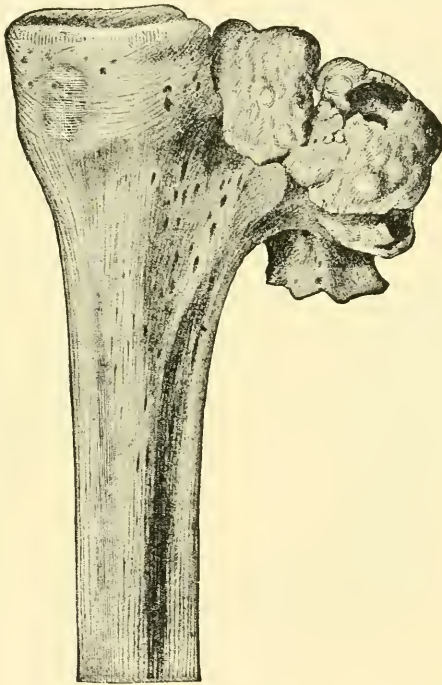


FIG. 141. CARTILAGINOUS EXOSTOSIS OF THE UPPER DIAPHYSIAL END OF THE TIBIA.
(Reduced to two-thirds of the natural size)

from residual islands of cartilage, or from the articular extremities. They are at times congenital. Cartilaginous exostoses in the neighbourhood of joints have occasionally a capsule which overlies the layer of cartilage, and corresponds in structure to synovial membrane; in rare cases (RINDFLEISCH, FEHLEISEN) it contains free cartilaginous bodies. The growth is spoken of as a bursate exostosis, and is probably developed from the articular cartilage (VON BERGMANN) or from some embryonic residue appertaining to the joint (FEHLEISEN).

bone. Such growths are described as **osteofibromata**, or **ossifying fibromata**.

Chondromata grow either from the periosteum or within the substance of the bone. They may originate from the bone-marrow or from pre-existing cartilage, such as epiphysial cartilage (ecchondroma) or some abnormally-persistent residue of the primary cartilaginous basis of the bone that has escaped ossification (VIRCHOW).

Chondromata arise with greatest frequency in the bones of the hand, less frequently in those of the foot or other part of the limbs or trunk, and still more rarely in the bones of the cranium. The tumours are often multiple, especially when they grow from the hands or feet, and are commonest in children and young adults; in some cases they are congenital. If they have their origin in the centre of a bone they are at first covered with a bony shell; they are however apt to break through this, and then grow beyond the limits of the bone. They form nodose or tuberous excrescences, and occasionally reach a considerable size, especially when they grow from the larger long bones, the ribs, or the scapula.

Chondromata are very liable to degenerative transformations, such as fatty, calcareous, or mucoid change. These changes may go on to complete dissolution of the matrix and of the cells, and cystic cavities filled with liquid are thus produced. Osteochondromata are produced when metaplastic ossification takes place in an originally cartilaginous growth (Fig. 138 *f h k*). Such tumours develop both in the periosteum and in the bone-marrow (Fig. 136 *a b c*): when the new-formed osseous trabeculae are very close and abundant the growth acquires an extraordinary degree of hardness.

Myxomata and **myxofibromata** are rare tumours, which arise both in the periosteum and in the bone-marrow. In the periosteum they form rounded growths surrounded externally by a layer of dense connective tissue. When they grow in the marrow they destroy the bone, and by complete liquefaction of their substance sometimes give rise to cysts. They occur both as single and as multiple growths, and sometimes, as in the femur, appear simultaneously in the periosteum and in the bone-marrow. In the denser parts of a myxoma bone may be developed, producing an **osteomyxoma**.

Lipomata are very rarely met with in the bones.

Sarcomata are the most common of bone-tumours, and they appear in various forms. We have first the group of **myelogenous sarcomata**; of these, if we take note only of the most essential differences, there are four types. The first two include sarcomata that are either soft and myeloid, or firm growths of the ordinary sarcomatous structure. These are found chiefly in the bone-marrow of the upper and lower maxilla (intra-osseous epulis),

and in the epiphyses of the long bones, especially of the tibia and of the humerus. They rarely start in the diaphysis itself; but as they grow from the epiphysis they usually invade the diaphysis. At first the new-growth produces no external change in the bone, but induces merely a kind of carious destruction of the cancellous tissue: sometimes the weakening of its structure thus induced leads to spontaneous fracture. As the growth enlarges it distends the bone, and ultimately takes the form of a bulky tumour (Fig. 136) surrounded by a shell of osseous and connective tissue. At times this envelope gives way, and the soft neoplastic tissue grows into the adjacent structures.

The structure of myeloid sarcoma is generally that of the soft small-round-celled variety, especially in the long bones. The denser forms are spindle-celled or fibromatous, as in maxillary sarcoma, or are of more than one cellular type. Very frequently the several parts of the tumour are of diverse structure. The firmer fibro-cellular or spindle-celled parts often contain giant-cells, and the growth has accordingly been called **giant-celled sarcoma**, or *tumeur à myéloplaxes* (NÉLATON). Often the entire tumour, or a portion of it, is everywhere permeated by wide blood-vessels, and its tissue is then said to be **telangiectatic**. At times the tumour produces small trabeculae or larger bars and spicules of osteoid tissue or of bone, and then becomes an **osteoid-sarcoma** or an **osteosarcoma** as the case may be.

When the tumour has reached a considerable size, as happens chiefly in the larger long bones and in the pelvis, retrogressive changes take place within it, such as fatty degeneration, haemorrhage, haematogenous pigmentation, softening, liquefaction, and cystic excavation. In certain instances the greater part of the tumour thus perishes, and the osseous capsule enclosing a small quantity of tumour-tissue, with or without fragments of bone, alone remains. The remnants of tumour-tissue are in part attached to the inner surface of the capsule, in part traverse it as ramifying strands and septa, that enclose in their meshes liquid mingled with solid detritus, of clear or turbid, pale or blood-stained appearance.

A third group of myelogenous sarcomata includes the **alveolar** varieties, characterised by the honeycomb structure of their fibrous stroma, which encloses nests of relatively large sarcoma-cells. One variety of alveolar sarcoma, that appears to be commonest in the bones of the trunk and of the head, has a firm and well-developed stroma; another, chiefly met with in the long bones, and described as an **endothelioma** (BILLROTH, HILDEBRAND, DRIESSEN), has a delicately-formed alveolar framework. The smaller tumour-nodes lie hidden within the bone; the larger tumours form protuberant cushion-like outgrowths from the surface, and are covered with periosteum.

The fourth variety of myelogenous sarcoma is met with chiefly in advanced life, and takes the form of multiple whitish

spots that are not sharply differentiated from the surrounding tissues. They appear most frequently in the bones of the skull (Fig. 143) and of the trunk, though sometimes nearly all the bones of the skeleton are affected. The bony tissue is destroyed at the spots where the tumour is developing, and but little new bone is produced. Cases however do occur, in which the production of new bone is so excessive as to present the appearance of eburnation. The cranial bones (Fig. 143) and the bones of the spinal column, the pelvis, the ribs, etc. may be beset with well-defined excavations of various sizes, with eroded borders, the tumour itself rising little if at all beyond the edge of the pit. This peculiar growth is a small-round-celled sarcoma, with the structure of a soft lympho-sarcoma, and like the latter is referred to as **myeloma**.

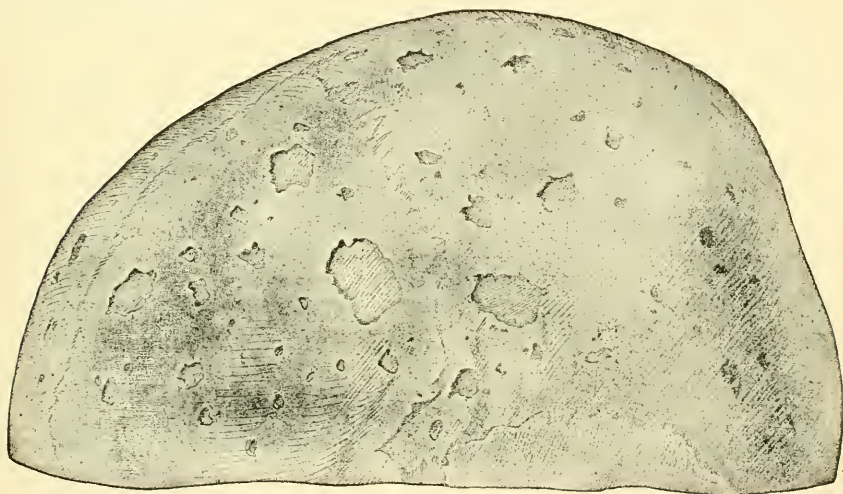


FIG. 143. MULTIPLE MYELOMATA OF THE CRANIAL VAULT.

(Reduced to two-thirds of the natural size)

Periosteal sarcomata are soft or firm new-growths, of the round-celled, spindle-celled, or polymorphous-celled type; the last two forms are the more common. They may occur in any part of the skeleton, the denser varieties affecting by preference those situations in which fibromata are usually found. No sharp distinction can be drawn between fibromata and periosteal tumours of this kind. They are usually seated upon the sides of the bone, though they sometimes entirely surround it. Bony tissue is often produced in them, especially in the parts immediately adjacent to the old bone. In certain cases the entire tumour is permeated by osseous trabeculae; of these some lie loose in the tissue, while others are framed together and form a kind of skeleton for the tumour, the spicules springing in radial lines and plates from the

old bone (Fig. 137). The last-named variety is called **osteosarcoma**, or **ossifying sarcoma**.

Sarcoma of bone, and in particular the softer varieties, may give rise to metastases both in the bones and in other organs; but it is rare for sarcoma starting as a primary growth in other organs to give rise to metastases in the bones.

Chondrosarcomata and **chondro-osteosarcomata** occur as intermediate or mixed forms.

Pure **angiomata** are very rarely met with in bone; but many sarcomata, especially the myelogenous kinds, contain telangiectatic portions. If the vessels of the new-growth are very abundant, the tumour may during life exhibit pulsation. **Haematomata** are occasionally produced by haemorrhages into the tissue of the tumour, or into cysts due to local softening of it.

Carcinoma of bone is never primary, though it is common as a secondary growth, and arises either by the direct invasion of a carcinoma growing in the neighbouring soft parts or by metastasis from remoter organs. Invasion by direct extension is exemplified in the case of the skull, the sternum, and the parts of the ribs lying directly beneath the mamma, *i.e.* in the bones adjacent to favourite seats of carcinoma. Metastatic growths are of course met with in the most diverse situations.

Carcinomatous growths take the form either of circumscribed nodes or of diffuse infiltrations; in the latter case they often give rise to extensive destruction of the bone.

Cancerous infiltration is usually accompanied by marked proliferation of the periosteum and of the marrow, and the substance of the bone is destroyed by a process of lacunar resorption. The bone is thus gradually replaced by a cancerous tissue whose characters correspond generally with those of the parent tumour, though sometimes it exhibits peculiarities referable to the seat of its metastatic development. In hard or scirrhus carcinomata, numerous uncalcified or osteoid trabeculae, together with calcified osseous tissue, are formed in the fibro-cellular stroma derived from the periosteum and the bone-marrow. The place of the old bone is thus at length occupied by osteoid tissue and more rarely by calcified bone, containing cancer-nests in the medullary spaces. As but few of the new trabeculae are calcified, the bone at times presents an appearance similar to that seen in osteomalacia, and accordingly the term **carcinomatous osteomalacia** is sometimes applied to this condition. In medullary carcinoma new bone is rarely formed, and the process takes the form of a carcinomatous caries.

References on Tumours of Bone (see also Art. 57).

- BAUMGARTEN: Sarcoma *V. A.* 76 **1879**
 VON BERGMANN: Exostosis bursata *Petersburg. med. Woch.* **1876**
 BILLROTH: Sarcoma *Beitr. z. path. Histol.* Berlin **1858**; Alveolar sarcoma *Langenbeck's Arch.* xi **1869**
 BOUISSON: Pulsatile tumours *Thèse Paris* **1857**
 CARRERA: *Essai sur les tumeurs fibroplastiques des os* Paris **1855**
 DRIESSEN: Endothelioma of the bones *Ziegler's Beiträge* xii **1893** (with references)
 FEHLEISEN: Exostosis bursata *Arbeit. chir. Klinik von Bergmann* Berlin **1886**
 FRANÇOIS: Enchondroma of the pelvis *Thèse Paris* **1876**
 GENTILHOMME: Pulsatile tumours of the bones *Thèse Paris* **1863**
 GRAWITZ: Sarcoma *V. A.* 76 **1879**
 HAMMER: Primary sarcomatous osteitis *V. A.* 137 **1894** (with references)
 HEYFELDER: Fibroma *V. A.* 11 **1856**
 HILDEBRAND: Endothelioma of bone *D. Z. f. Chir.* 31 **1891**
 KLEBS: Chondroma *V. A.* 31 **1865**
 LAMBL: Sarcoma *V. A.* 8 **1855**
 LÜCKE: Ossifying angioma *D. Z. f. Chir.* 30 **1889**
 MARKWALD: Multiple myeloma (endothelioma) *Cent. f. allg. Path.* **1894** (p. 859)
 MÜLLER, FR.: *Ueber die erectilen Knochtumoren* Freiburg **1855**
 NASSE: Sarcoma *V. A.* 94 **1883**
 NAUWERCK, G.: Central hyperplastic angioma of the femur *V. A.* 111 **1888**
 NÉLATON: *Tumeurs à myéloplaxes* Paris **1860**
 NOTHNAGEL: Lymphadenia ossium *Virchow's Festschrift (internationale)* **1891**
 ORLOW: Exostosis bursata *D. Z. f. Chir.* 31 **1890**
 PUJO: *Des tumeurs primaires des os* Montpellier **1871**
 VON RECKLINGHAUSEN: Multiple enchondromata of the bones etc. *V. A.* 118 **1889**; Mutual relations of osteomalacia, osteoplastic carcinoma, etc. *Virchow's Festschrift (Assistenten)* Berlin **1891**
 RICHET: *Hæmatoma A. gén. de méd.* iv **1864**
 RUSTIZKY: Sarcoma *D. Z. f. Chir.* 3 **1873**
 SAUREL: *Mém. sur les tumeurs des gîngives connues sous le nom d'épulis* Paris **1858**
 SCHLÄPFER, E.: *Das Rippenchondrom* Leipzig **1881**
 SENFTLEBEN: Fibroma and sarcoma *Langenbeck's Arch.* i
 SPIEGELBERG: Multiple sarcoma of the bones *Inaug. Diss.* Freiburg **1894**
 STEUDEL: Multiple enchondromata *Beiträge von Bruns* viii **1891**
 VERNEUIL and MARCHAND: *Art. Moelle Dict. encyclop. des sci. méd.* 2nd series ix **1875**
 VIRCHOW: Chondroma *Deutsche Klinik* **1864**, *Monatsber. d. Akad. d. Wiss.* Berlin **1875**, and *Die krankhaften Geschwülste*; Sarcoma *Deutsche Klinik* **1858, 1860**
 VOLKMANN: *Pitha and Billroth's Handb. d. Chir.* ii **1872**
 WARTMANN: *Rech. sur l'enchondrome* Paris **1880** (with references)
 WEBER, C. O.: *Die Exostosen und Enchondrosen* Bonn **1856**, *V. A.* 35 **1865**
 WEISFLOG: Callus-tumours *Beiträge von Bruns* x **1893**
 WIELAND: Primary multiple sarcomata of the bones *Inaug. Diss.* Basle **1893**
 ZAHN: Sarcoma *D. Z. f. Chir.* 22 **1885**
 ZIEGLER: Myxoma and chondroma *V. A.* 73 **1878**

63. The **cysts** that are met with in bones are almost always of the variety known as cysts of disintegration, being due to the dissolution and liquefaction of the trabeculae and marrow of the bone, or of tissue newly formed within it. To the former class belong the cysts already mentioned as arising in the course of osteomalacia, to the latter the cysts formed in osseous tumours.

Disintegration and liquefaction are very common in the substance of myelogenous tumours, fibromata, osteo-fibromata, chondromata, myxomata, and sarcomata. Cysts are thus produced, containing a liquid which may be turbid from the presence of cellular detritus or of blood and the products of its disintegration, clear, mucoid, or more like serum in character. As we have already stated, tumours in bone, and particularly sarcomata, may in this way be almost entirely destroyed, leaving only multilocular cysts with an enveloping layer of bone and periosteum, the interlocular septa being composed partly of sarcomatous and connective tissue and partly of bone.

Maxillary cysts are peculiar growths affecting the alveolar processes of the upper and lower jaws: they will be referred to in relation to the morbid anatomy of the mouth (Art. 181).

Of the **animal parasites**, *Echinococcus* and *Cysticercus cellulosae* are found in the bones.

The former is most frequently met with in the long tubular bones, but it occurs also in the pelvic, cranial, and vertebral bones, and in the phalangeal bones of the fingers.

The *Echinococcus* or hydatid occurs both in the form of single cysts and in that of internal or external daughter-cysts. The hydatid in bone, as in other organs, may reach a considerable size. By the formation of numerous exogenous cysts a bone, such as the femur or tibia, is sometimes thickly studded with hydatid vesicles, while others grow up beneath the periosteum. The presence of the enlarging cysts causes pressure and consequent atrophic resorption of the bone. When the hydatids are multiple and numerous, the intervening osseous tissue often becomes necrotic. Large cysts or a collection of numerous small cysts may, like neoplastic growths, cause distension or 'inflation' of the bone.

Cysticercus cellulosae is of the rarest occurrence in bones.

References on Cysts of Bone.

- BOSTRÖM: *Festschr. d. Naturforscherversammlung* Freiburg 1883
 FRORIEP: *Chirurg. Kupfertafeln* plates 438-440, and 474 Weimar 1820
 SCHLANGE: Cysts of the tibia *A. f. klin. Chir.* XXXVI 1887
 SCHNEIDER: The theory of bone-cysts *Inaug. Diss.* Berlin 1886
 SCHUH: *Die Erkenntniß d. Pseudoplasmen* Vienna 1851
 VIRCHOW: *Monatsber. d. Akad. d. Wiss.* (phys.-math. series) Berlin 1876
 VOLKMANN: *Pitha and Billroth's Handb. d. Chir.* II
 ZIEGLER: Subchondral changes in arthritis deformans and cysts of bone *V. A.* 70 1877

References on Hydatids of Bone.

- HAIN: *Berl. klin. Woch.* 1884
 MÜLLER: *Beiträge von Bruns* II 1886
 NEISSER: *Die Echinokokkenkrankheit* Berlin 1877
 RESZEY: *D. Z. f. Chir.* VII 1877
 SCHNITZLER: Echinococcus of bone *Internat. klin. Rundschau* 1892
 VIRCHOW: *V. A.* 79 1880

CHAPTER XXI

DEGENERATIONS OF THE JOINTS AND SYNARTHROSES

64. The primary mode of union between the several bones of the skeleton is by **synarthrosis**. In this form of articulation two parts of the skeleton are united by tissue differing from either part, but continuous with both. The uniting tissue is developed from the plastic germinal material that is not destined to be utilised for bone-formation. When the connexion between two bones is effected by means of fibrous tissue, we have a **syndesmosis**; of this nature are ligaments, interosseous membranes, and sutures. If the uniting tissue consists of cartilage, the joint is a **true sychondrosis**; if partly of cartilage and partly of connective tissue, it is described as a **false sychondrosis**. When at a later stage bone is developed in and extends across the syndesmosis or sychondrosis, so that bones previously separate are united by osseous tissue, the result is called **synostosis**.

When a cavity develops between two adjacent parts of the skeleton, in such a manner that the contiguous ends of the bones are separated by an empty space, and are united only on the exterior by fibrous tissue, we have a movable joint or **diarthrosis**. The portions of the bones next to and bounding the joint-cavity are always covered with cartilage. The fibrous connexion between the bones, the articular **capsule**, consists of an outer layer of firm fibrous texture, the capsular ligament, with a thin inner layer of soft and highly-vascular connective tissue, the **synovial membrane**, which is lined on its inner surface with a layer of flat cells, and secretes a lubricating liquid, the **synovia**. In many places the synovial membrane is thrown into folds and villous processes.

The degenerative changes that affect joints and synarthroses usually concern the cartilage, though they may extend to the connective-tissue components also.

Fatty changes not infrequently occur in the cartilage of the diarthroses and sychondroses, oil-globules appearing in the cartilage-cells. The degeneration supervenes both in states of general malnutrition (as in old age), and in local disorders of nutrition brought about by disease of the vessels of the part, by inflammation, and the like. In aged persons the capsule and the cells and matrix of the cartilage may likewise undergo a form of hyaline

degeneration, the cartilage with its cells fusing into a homogeneous mass or breaking up into hyaline flakes. The change is looked upon as of the nature of **amyloid degeneration**, inasmuch as the degenerate parts give the characteristic amyloid reaction with iodine (VIRCHOW) and methyl-violet (WEICHELBAUM). **Calcareous deposits** are met with chiefly in old age and in connexion with chronic inflammatory disease, and appear mainly about the margins of the articular cartilages, in places where the matrix is already in process of fibrillation and degeneration.

After haemorrhages near the cartilage, and in extreme jaundice, amorphous and crystalline masses of **haematoidin** are apt to be deposited in its superficial cells. In rare cases diffuse patches of brown or dusky discoloration appear in the cartilage: this condition, known as **ochronosis** (*ὄχρος* yellow, *νόσος* disease), results from the saturation of the matrix with a colouring matter whose source is still a matter of dispute.

In **gout** (Art. 70) chalky masses of **urates** in the form of acicular crystals (Fig. 144) are deposited in the matrix and cell-capsules of the cartilage.

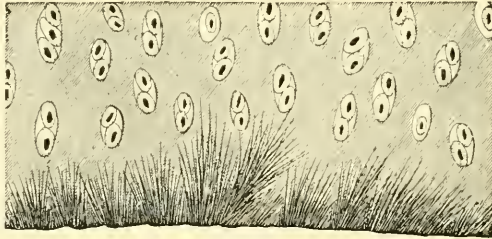


FIG. 144. DEPOSIT OF NEEDLE-LIKE CRYSTALS OF SODIUM URATE IN AN ARTICULAR CARTILAGE.

(After LANCEREAUX: $\times 200$)

In the degeneration usually spoken of as **mucoïd softening**, the cartilage assumes a fibrillar appearance (Fig. 145 *b*), probably because the cementing substance between the fibrillae of the matrix is liquefied, and so acquires a different refractive power. In a section parallel to the general direction of the fibrillae the matrix presents the appearance of fine striation (*b*); in transverse section it appears minutely punctate (*d*). Frequently with the striation is associated cleavage of the matrix into larger fibrous fasciculi (Art. 73), or disruption into fragments of various size (*g*), which are later on broken up into comminuted granular masses and then dissolve entirely. The substance of the cartilage may also, without antecedent fragmentation, become turbid and disintegrate into a mass of molecular detritus.

In many cases the cells of cartilage in process of softening are entirely destroyed, after undergoing degenerative transformations

of various kinds, but chiefly fatty changes. Not infrequently, however, proliferation takes place at the same time, and this leads to the formation of groups of cells (*c*) enclosed within a common mother-capsule.

Softening of cartilage is of very frequent occurrence in old age; it is most commonly observed in the costal cartilages. The cut surface of the fibrillated matrix has a grey translucent appearance; but when calcification is associated with the softening the section is white and opaque. When in particular spots the cartilage is completely dissolved, cystic cavities filled with liquid are formed.

Softening also not infrequently takes place, in advanced age, in the articular cartilages and in the synchondroses, both on the

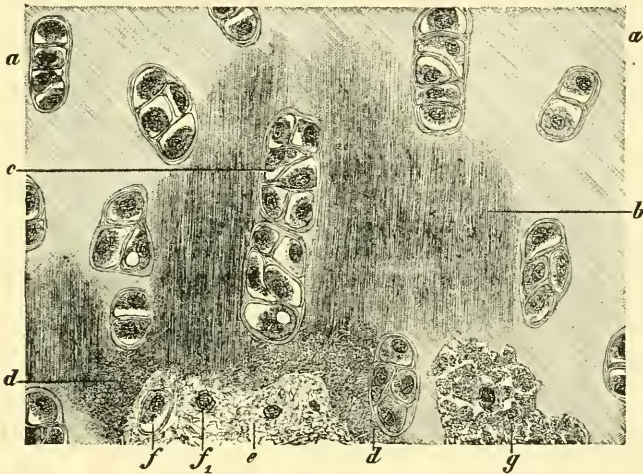


FIG. 145. SENILE SOFTENING OF CARTILAGE.

(Section from a costal cartilage: preparation hardened in Müller's fluid, stained with picro-carminé, and mounted in glycerine: $\times 200$)

- | | |
|-----------------------------------------------|------------------------------------------|
| <i>a</i> hyaline cartilage | <i>e</i> remains of the liquefied matrix |
| <i>b</i> fibrillated matrix | <i>f</i> liberated cartilage-cells |
| <i>c</i> group of proliferous cartilage-cells | <i>g</i> matrix broken up into fragments |
| <i>d</i> turbid and granular matrix | |

surface and in the layers nearest the bone. It very frequently accompanies chronic inflammation, and plays a very important part in the several forms of chronic arthritis (Arts. 71-74).

If the softening cartilage is so situated that vascular tissue is able to grow into it from adjacent parts, as when it adjoins the bone-marrow or the perichondrium, its loss of substance is sooner or later made good by new-formed vessels and cells; and thus in the place of the tissue destroyed marrow and even bone is ultimately formed. Costal cartilages containing softened patches in their interior are for this reason often found to be also in part ossified.

Cartilage is very resistant to pressure. Hence aneurysms of the aorta which press against the vertebral column or the ribs, and thereby cause destruction of the bone, make no visible impression upon the cartilage. Under very long-continued morbid pressure the cartilage may, however, become fibrillated and ultimately converted into fibrous tissue. In like manner the continued absence of a pressure that is normal causes the inactive cartilage to become cloudy and fibrillated.

Purulent and granulative inflammations easily lead to erosion, caries, and necrosis of the cartilage.

The fibrous components of the diarthroses and synarthroses are subject to changes analogous to those observed in cartilage. Fatty degeneration of the cells, pigmentation, amyloid degeneration (WEICHELBAUM), calcification, incrustation with urates, disintegration, and ulceration, all occur in these tissues under the same conditions as in cartilage.

References on Degenerative Changes in the Articular and other Cartilages.

- BOSTRÖM: Ochronosis of cartilage *Virchow's Festschrift (internationale)* II 1891
 ECKER: Softening of cartilage *A. f. physiol. Heilk.* II 1843
 FLEISCH: *Unters. über die Grundsubstanz des hyalinen Knorpels* Würzburg 1880
 GURLT: *Beiträge z. pathol. Anat. d. Gelenkkrankheiten* Berlin 1853
 MOLL: *Exper. Unters. über den anatomischen Zustand d. Gelenke bei andauernder Immobilisation derselben* Berlin 1885
 SOLGER: Optical behaviour of articular cartilage after treatment with alcohol *V. A.* 102 1885; Circumcellular and intercellular deposits in cartilage *A. f. mikrosk. Anat.* XXXIV 1889
 TILLMANS: Structure of cartilage *A. f. Anat.* 1877
 VIRCHOW: Amyloid degeneration of cartilage *Würzburg. Verhandl.* VII. *V. A.* 8 1855; Softening of cartilage *V. A.* 4 1852; Ochronosis *V. A.* 35 1866
 ZAHN: Pigmentary deposits in cartilage *V. A.* 72 1878

65. When the matrix of the cartilage undergoes softening and dissolution, its cells retaining their vitality, blood-vessels sometimes penetrate into the softened region at the same time or soon afterwards. Under these conditions the cartilage-cells may continue to live (Fig. 146 *c*), and by their proliferation and **metaplasia** form an integral portion of the tissue which ultimately takes the place of the cartilage.

Mucoid tissue is that which is usually formed by the metaplasia of cartilage. It consists of a network of stellate cells (*b*), in the meshes of which is a liquid containing mucin. If at a later stage cells brought by the blood, or introduced from proliferous tissue in the neighbourhood, collect in the interstices of the cellular network, the tissue acquires more and more the characters of **lymphoid marrow**. It is partially changed into **fatty marrow** by the conversion of the cells of the network into fat-cells. When the tissue becomes markedly fibrillar, its texture resembles that of fibrous connective tissue.

Metaplasia occurs very frequently in the articular cartilages, both as an idiopathic (generally senile) disorder of nutrition and as an accompaniment of various chronic inflammatory processes.

If the cartilage is freely permeated by medullary spaces containing blood-vessels extending from the adjacent marrow-tissue, the intervening cartilaginous bridges and cancelli are often converted directly into osseous trabeculae. In this manner the cartilage is replaced by cancellous bone.

In many chronic disorders of nutrition affecting the joints and synchondroses, the hyaline cartilage is converted directly into fibro-cartilage, and ultimately into ordinary connective tissue, whose fibres are arranged in parallel, wavy, or interlacing bundles.

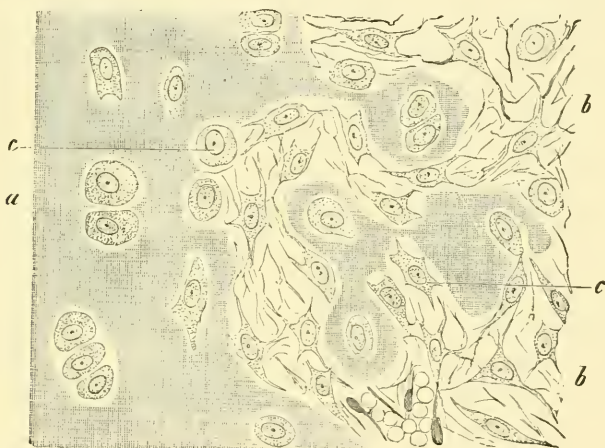

FIG. 146. METAPLASIA OF CARTILAGE INTO MUCOID TISSUE IN FUNGUS ARTHRITIS.

(Preparation hardened in Müller's fluid, stained with haematoxylin, and mounted in Canada balsam: $\times 400$)

a hyaline cartilage

b tissue composed of stellate cells

c cartilage-cells liberated by the dissolution of the matrix, and converted into mucoid tissue

This is especially the case in chronic rheumatic polyarthritis (Art. 74), and in tuberculous disease of the joints during the process of repair.

Changes similar to those just described in reference to cartilage take place in the fibrous structures of the joints, syndesmoses, and sutures. Thus, for example, the villous synovial fringes may be converted into adipose tissue, by free assimilation and inclusion of fat into their substance. Ossification takes place chiefly in the sutures, where it is indeed a physiological process. It is to be regarded as pathological only when it takes place prematurely, or where it occurs in syndesmoses that normally remain unossified throughout life.

CHAPTER XXII

REGENERATION AND HYPERTROPHY IN JOINTS

66. **Regenerative proliferation** takes place both in the cartilaginous and in the fibrous components of the joints, but attains any considerable extent in the latter only. The restoration of cartilage that has once been destroyed is usually very imperfect.

Hypertrophic proliferation may occur in the articular cartilage as well as in the fibrous tissues of the joint, and in both is apt to attain considerable dimensions. The overgrowth may be general or local: in the cartilage it gives rise to nodose or tuberculous prominences, in the articular capsule and the synovial membrane to diffuse thickenings or to papillary excrescences. These overgrowths are the most characteristic appearances of the disease known as chronic *arthritis deformans* (Art. 73). For the rest, hypertrophy of the fibrous structures appears for the most part in connexion with ordinary articular inflammations, and in the course of tuberculous arthritis. It results in the formation of new connective tissue, and sometimes of cartilaginous and osseous tissue.

When a costal cartilage is injured in any manner, none but degenerative changes are usually induced at the seat of the lesion. These consist in swelling of the cells, vacuolation, granular turbidity, fatty degeneration, and disintegration. Only in rare instances, and then only in young persons, does proliferation appear in proximity to the zone of degeneration, and it is always confined within narrow limits. The fracture of a costal cartilage does not heal by regenerative proliferation of the cartilage itself, the broken ends being united only by means of proliferation starting from the perichondrium; this produces fibrous tissue and bone, but never cartilage.

If a fragment of cartilage within a joint is detached by violence, the defect thereby caused is never, or at most very imperfectly, made good by new cartilage. When the defect extends to the spongy tissue of the bone, or approaches the periosteum, the hiatus is filled up with new connective tissue, though even then a depression usually remains at its site. The like happens when the fracture involves both bone and articular cartilage.

Loose fragments of cartilage detached from the articular surface, or loose fragments of bone covered with cartilage, do not

as a rule unite again with the original surface of rupture, but either form **loose bodies** that are movable within the joint, or become attached to the synovial membrane by new-formed vascular connective tissue, which covers them over with a fibrous envelope (Art. 67).

When a joint is subjected to traumatic violence, the capsule is either bruised and overstretched, or its continuity is broken by a more or less extensive rent. In **sprains**, the ligaments are overstretched and forcibly elongated, and some of their fibres are ruptured. In traumatic luxation or **dislocation** the articular ends of the bones are either completely or partially (as in subluxation) displaced from their normal positions, and their mutual relations are disturbed. Such displacements are of course possible only when they are accompanied by considerable laceration of the soft tissues. In complete dislocation the laceration is so extensive that the head of the bone escapes through the rent in the articular capsule. Occasionally the articular cartilage and the bone are injured at the same time (complex dislocation).

The first results of the injury are, as in fracture of bone, more or less severe haemorrhage from the torn vessels, and subsequent inflammation; these give rise to effusion into the joint, and to infiltration of the articular capsule and the adjoining tissues. If the injury is not complicated by septic infection, which is especially liable to occur in articular injuries and luxations associated with penetrating wounds of the skin, the inflammation at no time reaches a high degree of severity, and sooner or later passes away, the extravasated blood and the inflammatory effusion being re-absorbed. Only in very rare cases do small residues of the extravasation and effusion remain unabsorbed, and these, by the action of immigrant cells, are afterwards converted into loose seed-like bodies of firm texture, resembling that of dense fibrous tissue (Art. 77).

When a dislocated limb is promptly returned to its proper position, regenerative processes are very soon set up in the capsule: the rent in the capsule is thus repaired and the ruptured ligaments are reunited. The new-formed material is plastic cellular tissue, which in course of time is converted into connective tissue resembling that of the rest of the capsule. An excess of new tissue is at first thrown out; but after the lapse of months or years the capsule generally resumes its normal appearance. Lesions of the articular structures produced by sprains, contusions, penetrating wounds, etc., and ruptured synarthroses, are repaired in a similar manner. Any tissue that has been killed outright by the injury or has undergone necrosis is resorbed. Simultaneous fissures or fractures of the intra-articular parts of the bones heal in the manner already described in Art. 45.

References on the Repair of Injuries to Cartilage.

- BARTH: Regeneration of hyaline cartilage *Cent. f. med. Wiss.* 1869
 BÖHM: Normal and morbid anatomy of the joints *Inaug. Diss.* Würzburg 1868
 EWETZKY: Inflammation of cartilage *Unters. Zürich. pathol. Inst.* III Leipzig 1875
 FLEISCH: *Grundsubst. d. hyalinen Knorpels* Würzburg 1880
 GENZMER: Cicatrisation of cartilage-wounds *V. A.* 67 1876
 SCHWALBE: *Sitzungsber. d. Gesellsch. f. Med. u. Naturwiss.* Jena 1878
 SPIE: *Fractures compliquées des cartilages diarthrod.* Paris 1881
 TIZZONI: Pathological histology of cartilage *A. per le scienze med.* II 1877

67. When the ends of two bones lying within a joint are removed by **resection**, and the cut surfaces are firmly and rigidly apposed, proliferation promptly sets in about the site of the operation, provided septic infection be excluded. The changes thus induced are similar to those attending simple fracture, differing only in the fact that the production of plastic or germinal tissue is confined within moderate limits. If the bones are in the end firmly and permanently united by tissue springing from the periosteum and the bone-marrow, the result is termed **ankylosis**. When the uniting substance consists merely of connective tissue, we have fibrous ankylosis; when bone also is formed in it, the term bony ankylosis is applied to the union.

If the resected ends are not kept rigidly apposed, and relative movement is permitted, the two bones will ultimately become united by flexible tissue. This leaves them free to move one upon the other, and accordingly a more or less perfect new joint, or **nearthrosis**, is produced between them.

Osseous resorption and apposition ensue in the resected ends, and the bones are thereby to a varying extent altered in form. In certain cases the ends, in the course of some months, assume forms whose configuration somewhat resembles that of the normal joint-surfaces.

At an early stage the free surfaces of the bones are covered over, from the periphery inwards, with connective tissue derived in part from the bone but mostly from the periosteum. The opposed layers of connective tissue sometimes become coherent, and thus, if the joint is kept fixed in one position, establish a firm union between the ends of the bones. In certain cases, if suitable relative movements of the bones are kept up, a cavity is formed between them. The cavity has smooth walls, and is either single or subdivided by membranous adhesions. Such a cavity fulfils the function of a new joint-cavity, and sometimes even contains a liquid resembling synovia.

The connective tissue that covers the ends of the bones is usually firm, dense, and fibrous. In young persons, hyaline cartilage and fibro-cartilage are sometimes developed in it (LÜCKE, CZERNY, WEICHELBAUM). In some cases this formation extends over the larger portion of the free surfaces.

After resection of the head of a bone, its socket or acetabulum being preserved, changes analogous to those above described occasionally take place.

References on the Formation of New Joints after Resection.

BAJARDI: *A. ital. de biol.* I 1882

BECK: *Langenbeck's Arch.* V 1864

CZERNY: *ibidem* XIII 1871

DOUTRELEPONT: *ibidem* VI 1865, *Berl. klin. Woch.* 1867

JAGETHO: *D. Z. f. Chir.* 4 1876

VON LANGENBECK: *Langenbeck's Arch.* III, XVI; *Deutsche Klinik* XVI 1864

LÜCKE: *Langenbeck's Arch.* XVI 1874

OLLIER: *Traité de la régénération des os* II Paris 1867, *Bulletin Soc. de chir.* VIII Paris 1882

SACK: Regenerative processes in the hip-joint after resection *D. Z. f. Chir.* 32 1891

SANDER: *Langenbeck's Arch.* XI 1869

SHOEMAKER: *Langenbeck's Arch.* XVII 1875

WAGNER: *Ueber den Heilungsprozess nach Resection der Knochen* Berlin 1853 (trans. by HOLMES: *Process of repair* London 1859)

WEICHELBAUM: *Langenbeck's Arch.* XVI 1874

68. When large portions of the tissues of a joint are destroyed by inflammation or other morbid process, while (at the same time or subsequently) other portions undergo proliferation, an **intra-capsular ankylosis** may be formed, and the ends of the bones are thereby fixed in one position. If the bones are absolutely

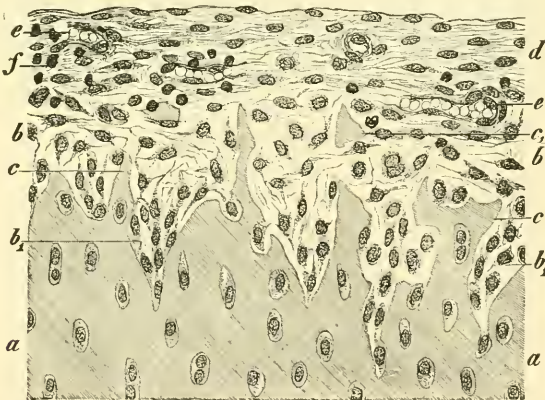


FIG. 147. PRELIMINARY STAGE OF FIBROUS INTERCARTILAGINOUS ANKYLOSIS.

(Section through the connective tissue growing over and adherent to the articular cartilage, with metaplasia of the surface-layers of the latter into mucoid and connective tissue: from a case of tarsal tuberculous arthritis and periarthritis: preparation hardened in Müller's fluid and alcohol, stained with haematoxylin and carmine, and mounted in Canada balsam: $\times 100$)

a hyaline cartilage

b b₁ mucoid tissue

c c₁ hyaline cartilage persisting
between the ingrowths of
mucoid tissue

d connective tissue

e f blood-vessels and proliferous
cells

fixed we have complete or true ankylosis; if some movement is still possible, partial or spurious ankylosis is the result.

Such ankyloses are generally formed in the following manner. From the sides of the joint connective tissue grows over the morbidly-altered articular surfaces of the bones, and that which covers one bone becomes adherent both to the surface underlying it and to the tissue covering the opposite articular surface. If by the antecedent disease the articular cartilage has been only partially destroyed, so that the bones are still in part covered with cartilage, the vascular connective tissue (Fig. 147 *ef*) growing over the articular surfaces becomes attached to this cartilage (*a*).

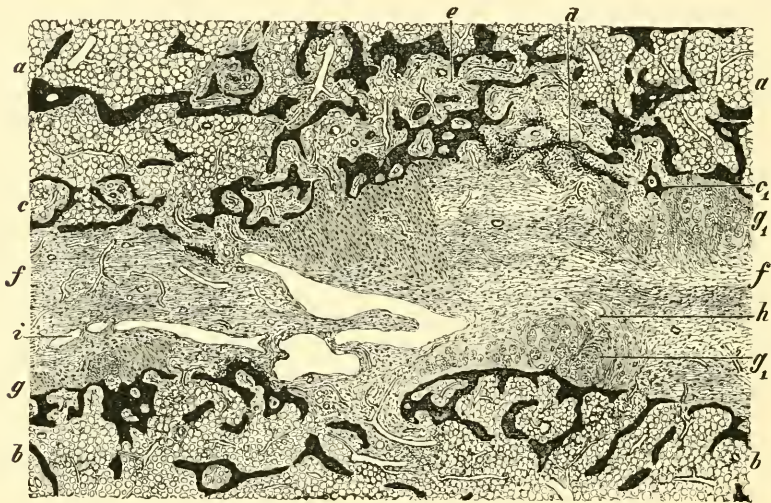


FIG. 148. FIBROUS INTERCARTILAGINOUS ANKYLOSIS.

(Section from the tibio-tarsal joint: preparation hardened in Müller's fluid and alcohol, decalcified with picric acid, stained with haematoxylin and carmine, and mounted in Canada balsam: $\times 12$)

- | | |
|-------------------------------------------------|--------------------------------------------------------------------------|
| <i>a</i> cancellous tissue of the tibia | <i>e</i> bone-marrow rich in vessels and cells, but containing no fat |
| <i>b</i> cancellous tissue of the astragalus | <i>f</i> vascular connective tissue derived from the articular cartilage |
| <i>c</i> c_1 newly-formed osseous tissue | <i>g</i> g_1 remains of the articular cartilage |
| <i>d</i> osseous tissue in process of formation | <i>h</i> fibrillar cartilage |

Usually the matrix of the subjacent cartilage undergoes dissolution (*c c*₁), and the cartilage is first transformed into mucoid (*b b*₁) and finally into connective tissue. The cartilage may also, by fibrillation of its matrix, be converted directly into connective tissue. By these means a **fibrous intercartilaginous ankylosis** is produced (Fig. 148). If the amount of connective tissue uniting the cartilages is very small, the condition might be described as **cartilaginous ankylosis**.

Should the articular cartilage have been entirely destroyed

by antecedent disease, new connective tissue derived either from the sides of the joint in the manner just described, or directly from the bone-marrow itself, may unite the exposed bony surfaces. In either case a **fibrous interosseous ankylosis** takes place.

When the cartilage is only in part destroyed, so that cartilaginous islands remain, the adhesions produced by proliferation from the sides of the joint and from the bone-marrow give rise to a fibrous ankylosis that is partly interosseous and partly inter-

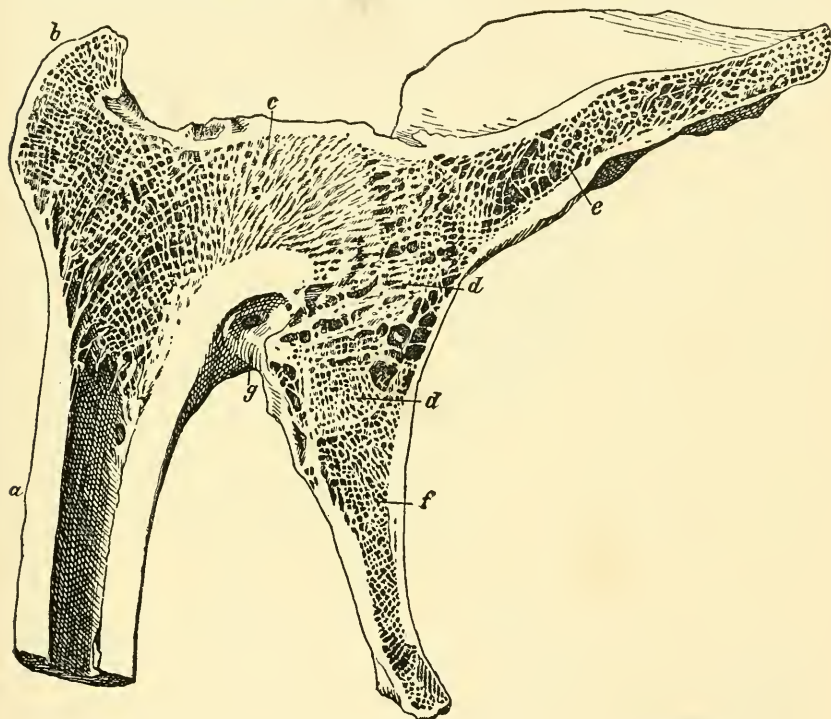


FIG. 149. COMPLETE BONY ANKYLOSIS OF THE HEAD OF THE FEMUR WITH THE ACETABULUM.

(Due to inflammatory destruction of the articular cartilages: reduced to two-thirds of the natural size)

- | | | | |
|---|-----------------------------------------------------------|---|----------------------------------------------------------------------------------------|
| a | femur | e | ilium |
| b | trochanter major | f | os pubis |
| c | neck of the femur | g | osseous buttress between the overhanging margin of the head of the femur and the shaft |
| d | deformed and depressed epiphysis of the head of the femur | | |

cartilaginous (*ankylosis fibrosa partim interossea partim intercartilaginea*).

Destruction of the articular cartilage may be followed by the production, over the exposed spots, not only of connective tissue but of bone; and if the new osseous tissue unites the opposed ends of the bones, **bony ankylosis** is the result (Fig. 149).

The new bone may be produced directly from proliferous germinal tissue or by the secondary ossification of an existing fibrocartilaginous ankylosis (Fig. 148 *d*). The bony connexion sometimes consists of a few bars or bridges of bone crossing the joint-cavity, or the latter may be so far obliterated that the cancelli of the articular head of the bone (Fig. 149 *d*) run into and are directly continuous with those of the socket (*e f*). The fusion is occasionally so complete that the site of the joint-cavity almost ceases to be traceable.

The different varieties of intra-capsular ankylosis may combine, giving rise to **mixed forms** in which the uniting medium consists of bone, cartilage, and connective tissue. Under certain conditions the articular ends of bones are greatly deformed by osteogenic proliferation, whereby their normal range of movement becomes more and more limited, and finally ceases altogether, the bones becoming immovably locked. This occurs in arthritis deformans (Art. 73), and might be described as **ankylosis from deformity**.

Joints also become immovable, or movable only with difficulty, from the thickening and shrinking of the capsule. Such an immobilisation of the joint, which occurs chiefly in the case of the fingers, is best described by the term **capsular ankylosis**.

Changes in the parts about a joint, such as fibroid induration of the connective tissues, adhesion of tendons and muscles, new-formation of osteophytes and spicules of bone, muscular paralysis, etc., are apt to impair or abolish its mobility, and produce what might be described as **extra-capsular ankylosis**, or, where shortening and rigidity of the muscles and ligaments are the primary causes, as **articular contracture**.

HÜTER describes all impairments of the mobility of the joints as **contractures**, and according to their mode of origin distinguishes them as **arthrogenous, myogenous, or cicatricial**. The myogenous forms are due to changes in the muscles; the cicatricial forms to contraction and induration of the para-muscular, para-tendinous, and subcutaneous connective tissue; the arthrogenous forms to various diseases of the joints, and particularly to inflammation.

References on Ankylosis.

- ALBERT: *Med. Jahrb.* III 1873
 HÜTER: *Klinik. d. Gelenkkrankheiten* Leipzig 1876-78
 KÖSTER: *Verh. d. Würzburger med.-phys. Gesellsch.* 1872
 LÜCKE: *Langenbeck's Arch.* III 1862
 MARSH: Bony ankylosis *B. M. J.* II 1895
 MARTINI: *Cent. f. med. Wiss.* 1872
 PASCHEN: *D. Z. f. Chir.* 1874
 VOLKMAN: *Pitha and Billroth's Handb. d. Chir.* II 1872
 WEBER, O.: *V. A.* 13 1858
 WILLEMS: Cartilaginous ankylosis *Inaug. Diss.* Bonn 1880

69. An **unreduced dislocation**, in which the displaced limb remains permanently in an abnormal position, results in changes within the affected joint of a kind varying with the malposition and other relations of the parts.

The socket or articular end of the bone, from which a distal bone has been dislocated, becomes covered over with connective tissue derived mainly from the torn capsule, but partly also from the soft parts about the affected joint. The connective tissue adheres to the cartilage, and this in course of time itself undergoes fibrillation, its surface layers being gradually converted into

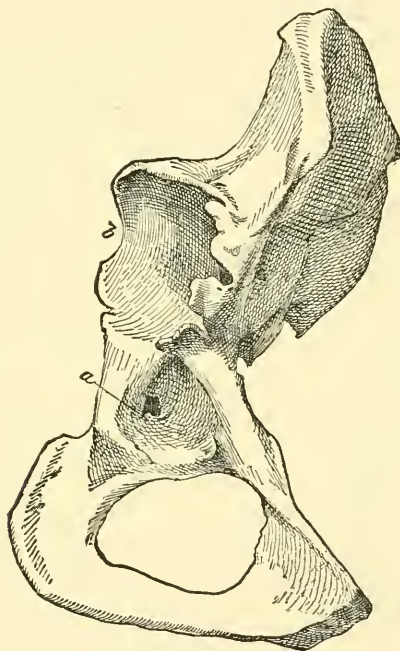


FIG. 150. NEARTHROSIS OF THE HIP.

(Reduced to one-half the natural size)

a old acetabulum which has become shallower *b* new articular cavity

connective tissue which fuses with the new connective tissue overlying it. The depth of the articular cavity is at the same time diminished by the apposition of new bone in its central portion (Fig. 150 *a*).

A similar fate may befall the proximal end of the dislocated bone, should it remain free in the soft tissues and out of contact with some other bony surface. If, however, it is pressed against bone, proliferation may ensue, and lead either to ankylosis (Fig. 151) or to the formation of a **new joint** (Fig. 150 *b*).

At the point of contact with the dislocated bone, the proximal bone becomes foveolated or dented, by a process of resorption akin to atrophy from pressure. The excavation however is usually very slight, and may be entirely absent (VON LANGENBECK). Very soon after the dislocated bone is forced against it, the periosteum near the spot that is pressed upon begins to proliferate, and after the lapse of some weeks a bony ridge is thrown up round the articular head of the dislocated bone. In this way is formed a new glenoid or acetabular cavity, which is covered externally by the fibrous layer of the periosteum (Fig. 150 *b*).

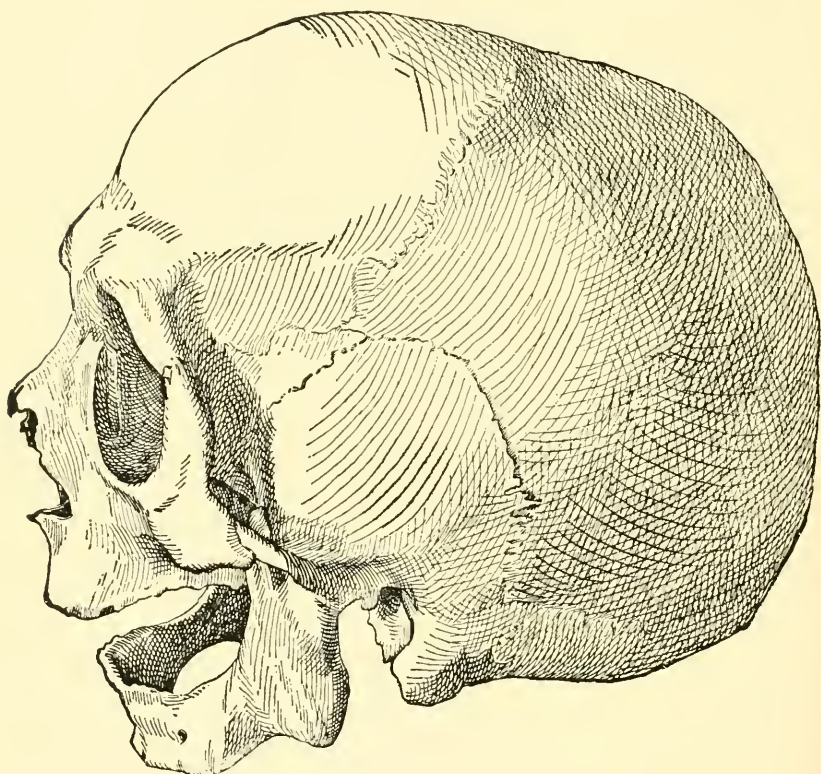


FIG. 151. BONY ANKYLOSIS OF THE LOWER JAW.

(The condyle of the lower jaw is united with the anterior surface of the tuber articulare of the glenoid cavity: from a case of unreduced dislocation)

While this process is going on in the proximal bone, a fibrous envelope is gradually formed about the head of the distal bone, partly by the remains of the old capsule and partly by the surrounding soft parts. This envelope becomes adherent to the surface of the proliferous periosteum, and thus a new joint-capsule is fashioned. If the dislocated bone remains unmoved while the

above-described changes are proceeding, firm fibrous or osseous **ankylosis** takes place between it and the supporting bone (Fig. 151), part of the articular cartilage being converted into fibrous or even into osseous tissue. If the dislocated limb is subjected to movement during the period of repair, a more or less perfect nearthrosis may be produced (Fig. 150 *b*). In this case the surfaces of the old articular head and of the new socket remain free from adhesions, or at least these are but scanty and loose enough to allow of some mobility in the new joint. At the same time the free surface of the new socket becomes smooth, while the free portion of the articular cartilage is preserved, or converted into eburnated or sclerotic bone. Between the two is formed a joint-cavity bounded by the new articular capsule. This cavity is lined with flat connective-tissue cells, and contains a viscid liquid or synovia. Cartilage is occasionally produced in the new connective tissue of the socket, so that the structure of the new joint ultimately approximates closely to that of a normal joint.

References on the Formation of Nearthroses.

- BAJARDI: *A. per le scienze med.* IV, *Osservatore* xv Turin 1879
BILLROTH: *Allgem. chir. Pathol.* Berlin 1883
VON FRORIEP: *Veraltete Luxationen* Weimar 1834
GRINEWSKY: *Cent. f. Chir.* 1879
HÜTER: *Klinik d. Gelenkkrankheiten* Leipzig 1877
ISRAEL: *Langenbeck's Arch.* XXIX 1883
KÜSTER: *ibidem* XXIX 1883
VON LANGENBECK: *Deutsche Klinik* I 1864
MALGAIGNE: *Traité des fractures et des luxations* II Paris 1855

CHAPTER XXIII

ACUTE AND CHRONIC INFLAMMATIONS OF JOINTS

70. **Acute inflammations** of joints may be traumatic, haematogenous, or secondary to affections of the contiguous structures. In the latter case they are most usually the sequelae of inflammatory infective diseases of the bones. The haematogenous varieties also are usually of an infective nature, and occur chiefly in connexion with such diseases as articular rheumatism, pyaemia, erysipelas, scarlatina, measles, typhoid fever, pneumonia, dysentery, and gonorrhoea. Articular inflammations are indeed pathognomonic of acute polyarthritic rheumatism. In the other infective diseases, articular inflammations are due to some exceptional action of the specific poison, or to secondary pyaemic infection. In the particular pyaemic infection known as septic osteomyelitis and periostitis, the articular inflammation appears either simultaneously with the disease of the bones, or only as a secondary result of it.

The vascular tissue of the synovial membrane is the structure that most actively participates in the inflammatory process, which is thus primarily a **synovitis**. The ligaments and other parts surrounding the joints, and the articular cartilages, are, however, ultimately affected, producing what has been termed parasynovitis (HÜTER) and chondritis. When the synovial membrane, the ligaments, the cartilage, and the bones are all involved, the condition is aptly described as **panarthrit** (VOLKMANN, HÜTER). In mild cases the inflammatory process may be limited to the synovial membrane, which then becomes the seat of congestive hyperaemia and exudation. In severe cases changes in the cartilage almost always take place, particularly when the morbid process is long maintained, and turbidity, disintegration, and dissolution of the cartilaginous matrix ensue. These changes produce local defects in the cartilage, which are referred to as **cartilaginous erosions** and **cartilaginous caries**. More or less extensive **necrosis** of the cartilage is not uncommon, especially in purulent and tuberculous inflammations; it may extend to the subchondral bone-marrow, and so destroy the nutrient substratum of the cartilage. Cartilaginous **sequestra** are formed by the exfoliation of the necrotic portions.

According to the character of the exudation, two varieties of acute articular inflammation may be distinguished—the serous and the purulent.

Serous arthritis or **synovitis**, or acute articular dropsy, is characterised by the effusion of a serous liquid containing minute flakes of fibrin, and gives rise to more or less extensive swelling of the joint. When the fibrinous coagula are abundant, the affection may be called sero-fibrinous synovitis. The synovial membrane, with its villous fringes and folds, is more or less injected and swollen, and at times exhibits small extravasations of blood.

In acute **purulent arthritis** or **synovitis**, or empyema of a joint, the synovial membrane secretes a purulent or fibrino-purulent exudation, which becomes mingled with the synovial liquid. The synovial membrane itself and the articular ligaments are swollen and infiltrated with cells. When abundant diapedesis of the red blood-corpuscles takes place, the inner surface of the joint assumes a dark-red colour. Purulent synovitis is occasionally a later stage of the serous or sero-fibrinous variety, though frequently the exudation is purulent from the outset. Serous synovitis occurs with greatest frequency in the knee-joint, and often without any definite cause that can be detected. In other cases it is due to infection. The swelling, as a rule, is not very painful. In cases accompanied by excessive stretching of the joint-capsule, the articular ends of the bones may become so displaced as to induce **spontaneous dislocation**.

Acute polyarthritic rheumatism is characterised by the painful swelling of several joints at one time. **Gouty arthritis**, caused by the deposition of urates in the articular structures, gives rise to exquisitely painful swellings, that most frequently occur in the metatarso-phalangeal joints of the great toe (*podagra*) and in the finger-joints (*chiragra*): the adjacent parts of the periosteum, tendons, ligaments, and skin are always simultaneously affected.

The articular inflammations associated with gonorrhoea, pyæmia, puerperal fever, scarlatina, and measles are usually of the purulent variety. The gonorrhoeal form is confined almost exclusively to the knee-joint; the other forms attack various joints.

Acute articular inflammations usually end in recovery. Serous effusions into the knee-joint are very apt to recur, and may give rise to chronic troubles. Thus, after acute articular rheumatism, hyperplastic proliferation of the synovial membrane, fibrous metaplasia of the cartilage, and finally fibro-cartilaginous ankylosis are apt to take place. In purulent inflammations the symptoms may become more severe as time goes on: the synovial membrane becomes thickened, its internal surface becomes covered with fibrino-purulent deposits, and even the capsular ligaments become infiltrated (panarthritis). The synovial membrane then begins to suppurate, the cartilage becomes turbid and undergoes fibrillation or partial necrosis, and lymphangitic abscesses are formed in the

neighbourhood of the joint. Finally, the inflammation may extend to the bone, so that the marrow becomes the seat of suppuration, and the osseous trabeculae undergo caries and necrosis. When the articular head is thus considerably reduced in size, and the ligaments are relaxed or destroyed, displacement of the bones may take place (spontaneous dislocation).

In such cases complete recovery or repair is impossible. If the process comes to an end at all, it is by the formation of granulation-tissue (secondary granular synovitis of HÜTER), and ultimately of cicatricial tissue. When the articular ends are thereby firmly united to each other, fibrous ankylosis is the result; and if regenerative proliferation is set up in the osseous tissue during the process of healing, the ankylosis becomes bony.

Purulent effusions sometimes remain in a joint for a long time without producing any serious destructive change; this condition is by many referred to as **catarrhal synovitis**.

Synchondroses and syndesmoses are liable to become inflamed and suppurate in the same manner as other joints. If they are in this way entirely destroyed, the bones they unite sometimes fall apart.

When no septic infection occurs to complicate an articular injury due to violence, such as a fracture, bruise, sprain, or laceration of the capsule, sero-cellular, fibrinous, or haemorrhagic effusion into the joint, and moderate infiltration of the synovial membrane and of the capsular ligaments, are the usual results. The like takes place when, by some violent movement, synovial fringes or loose bodies within the joint are caught and crushed, the articular ligaments being at the same time severely strained.

Inflammations of this character usually pass away rapidly; but sometimes, and particularly if they are of frequent recurrence, they lead to lasting changes and to chronic arthritis (Arts. 71 and 73). In rare cases, the coagula of haemorrhagic or fibrinous effusions are not completely re-absorbed, but are changed by a kind of organisation into small fibrous loose bodies (VON RECKLINGHAUSEN). Cuts, stabs, and gunshot wounds of the joints combined with penetrating wounds of the skin, and complex dislocations in which the joint is opened and infected, usually lead to severe purulent and septic inflammation, in the course of which the articular capsule not infrequently ulcerates and becomes necrotic, and the adjacent bones are destroyed by caries and necrosis.

The fact that many persons exhibit from childhood a marked tendency to serous effusion into the knee-joint whenever that joint is subjected to slight injury, as from a mere mis-step, is probably to be accounted for by the presence of some undue development of the synovial folds and fringes, which are therefore apt to be incarcerated and bruised. It is also possible that in these cases the entire synovial membrane is abnormally susceptible to injury.

Blood effused into a joint is probably prevented from coagulating by the healthy synovial membrane: in a joint that is but slightly injured, blood may therefore remain liquid for a long time, whereas coagulation takes place quickly when the joint-capsule is extensively injured or inflamed.

References on Arthritis in Infective Diseases.

- BÄUMLER: Typhoid fever *D. A. f. klin. Med.* III
 BIDDER: Variola *D. Z. f. Chir.* II 1873
 BOKAY: *Jahrb. f. Kinderheilk.* XIX
 BONNET: *Arthrite à la suite de la fièvre typhoïde* Paris 1878
 BOULLOCHE: Pneumococcus arthritis *A. de méd. exp.* III 1891
 BRUNNER: Croupous pneumonia *Corresp. f. Schweizer Aerzte* 1892
 DMOCHOWSKI and JANOWSKI: Action of typhoid bacilli *Ziegler's Beiträge* XVII 1895
 FRIEDHEIM: Spontaneous dislocation of the hip following typhoid fever *Inaug. Diss.* Berlin 1885
 HARKIN: *Dublin Journ. of Med. Sci.* LXXII 1881
 HARTLEY: Gonorrhoeal arthritis *New York Med. Journ.* XLV 1887
 HENOCH: Scarlatina *Charité-Annalen* VII 1882
 HEUBNER and BAHRDT: Scarlatina *Berl. klin. Woch.* 1884
 KAMMERER: Gonorrhoeal infection *Cent. f. Chir.* 1884
 KRAUSE: *Berl. klin. Woch.* 1884
 KRÄUTER: Dysentery *Nachkrankheiten der Ruhr* Cassel 1871
 LASÈGUE: *A. gén. de méd.* VI 1880
 NEISSER: Arthritis from gonococci *D. med. Woch.* 1894
 PAULI: Diphtherial arthritis *Berl. klin. Woch.* 1883 [III 1891
 PICQUÉ and VEILLON: Purulent arthritis following pneumonia *A. de méd. exp.*
 SCHÜLLER: Various infections *D. Z. f. Chir.* XIV 1880; *A. f. klin. Chir.* XXXI
 1884; Articular inflammations *Eulenburg's Realencyklop.* 1886
 VOSHEN, C.: *Jahrb. f. Kinderheilk.* new series XIX 1879
 WITZEL: *Die Gelenk- und Knochenentzündungen bei acut infectiösen Erkrankungen* Bonn 1890

References on the Behaviour of Blood in Joints.

- KOCHER: *Cent. f. Chir.* 1880
 VON LANGENBECK: *Verhandl. d. deutsch. Gesellsch. f. Chir.* (10th Congress)
 RIEDEL: *D. Z. f. Chir.* XII 1879
 SCHEDE: *Cent. f. Chir.* 1877
 VOLKMANN: *ibidem* 1880

71. Even when we leave out of consideration the tuberculous and syphilitic forms of **chronic arthritis**, there still remain a large number of processes to which the term is applied, and which differ greatly both in their aetiology and in the anatomical changes they induce. Since all parts of a joint are usually affected together, the condition is generally one of panarthritis (HÜTER, VOLKMANN). Five varieties of chronic arthritis may be distinguished according to their anatomical peculiarities: namely, chronic serous arthritis, chronic purulent arthritis, dry chronic ulcerative arthritis, chronic deforming arthritis, and chronic ankylosing arthritis. From an aetiological point of view it is somewhat difficult to define the several varieties precisely; but if all the infective processes be placed together, five groups may be distinguished according to the circumstances of their origin: namely, chronic senile arthritis, chronic traumatic arthritis, chronic infective arthritis, chronic neuropathic arthritis, and chronic gouty arthritis.

No sharp lines can be drawn between these various aetiological groups so far as their morbid anatomy is concerned, for in different joints of the same patient at the same time we meet with varieties of arthritis that differ in their histological characters.

The serous and purulent varieties of arthritis are characterised by free exudation into the joint, and form a class in contrast to the three other varieties, in which there is no sensible increase in the amount of liquid within the joint. In this respect chronic articular inflammations may be divided into two chief classes, the **exudative** and the **dry** forms.

Chronic serous arthritis or **synovitis**, otherwise called chronic articular dropsy or hydrarthros, either follows upon acute serous synovitis, especially when the latter is recurrent, or begins insidiously without passing through an acute stage. It is characterised by the accumulation of thin synovial liquid within the joint. The changes in the capsule and in the cartilage are usually slight, although in long-continued cases the synovial membrane may be thickened, its villous folds and fringes may be enlarged, and the cartilage may proliferate and become fibrillated. Frequently the synovial membrane grows over the margins of the articular surfaces, and forms thereon a sort of vascular *pannus*. HÜTER describes this variety of articular inflammation as smooth or pannous hyperplastic synovitis.

The affection appears most commonly in the knee, more rarely in the shoulder, the hip, and the elbow, and is not infrequently bilateral. When the effusion is very abundant, the knee-joint is swollen, the patella is lifted, and the bursae under the extensor tendon, on both sides of the patella and in the popliteal space, are tightly distended.

The cause of articular dropsy is sometimes traumatic, the effusion following contusions, sprains, and accidental incarceration of hypertrophic synovial folds and of loose bodies within the joint. In other cases, rheumatism and exposure to cold are given as the causes. Very slight injuries seem sufficient to give rise to increased secretion of synovial liquid in persons specially predisposed thereto. Hernial protrusions of the synovial membrane, appearing externally between the fibrous bands of the capsule, have frequently been observed to contain an excessive quantity of liquid, and to assume considerable proportions. Such herniae are oftenest met with in the knee, wrist, and elbow-joint (BILLROTH).

Chronic purulent arthritis is usually consecutive to acute inflammations that are haematogenous, traumatic, or due to extension from adjoining parts; it is sometimes however associated with other chronic affections of the joint, such as chronic tuberculosis. The joint in these cases is filled with pus, and the capsular ligaments and synovial membrane are infiltrated and covered with fibrino-purulent deposits. Sooner or later the cartilage becomes cloudy and fibrillated, and undergoes carious and necrotic disin-

tegration. At a later stage the neighbouring bone-marrow may suppurate, and so give rise to caries and necrosis of the ends of the bones. The articular capsule also is apt to suppurate at various points, and abscesses are thus formed around the joint. Recovery may take place, with formation of cicatricial adhesions between the carious ends of the bones, and regenerative osseous proliferation from the periosteum and bone-marrow; in this manner fibrous and bony ankylosis are at length brought about.

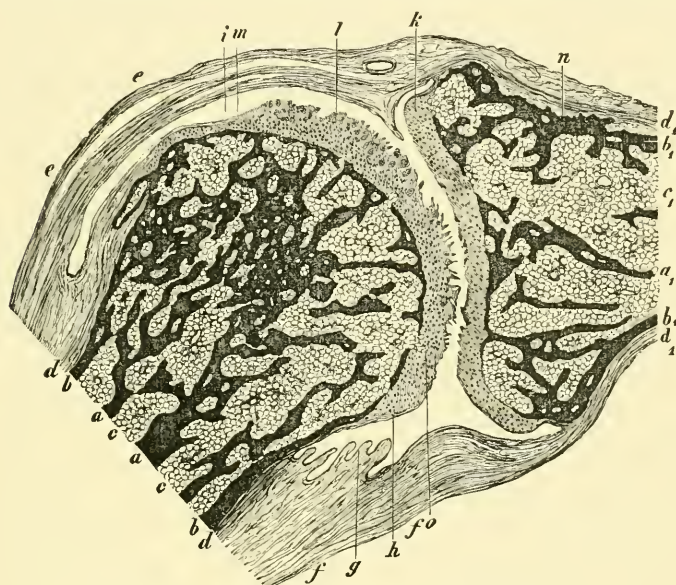


FIG. 152. CHRONIC DRY ULCERATIVE ARTHRITIS.

(First inter-phalangeal joint of the index finger fixed in the position of flexion from chronic senile polyarthritis: preparation hardened in alcohol, decalcified with picric acid, and stained with picro-carmin: $\times 55$)

- | | |
|-----------------------------------------------------------------------------------------------------------|------------------------------------------------------------------------------------|
| a cancellous bone | i articular cavity |
| b cortical layer | k normal cartilage of the concave articular surface |
| c bone-marrow | l split and fibrillated surface of the cartilage of the convex head |
| d periosteum of the first phalanx | m erosion of the cartilage covered over by an outgrowth from the synovial membrane |
| a ₁ b ₁ c ₁ d ₁ the corresponding parts of the second phalanx | n carious cortical layer of the bone of the first phalanx |
| e section through the dorsal portion of the articular capsule | o newly-formed medullary spaces in the cartilage |
| f section through the thickened palmar portion of the articular capsule | |
| g enlarged synovial fringes | |
| h portion of the synovial membrane extending over the articular cartilage | |

Synarthroses, like joints, may suppurate, and afterwards be replaced by cicatricial and osseous ankyloses.

The cause of the suppuration is probably always of the nature of microbial infection. Substances which induce suppuration by their chemical action are not likely to gain access to a joint.

72. **Dry chronic ulcerative arthritis** is an affection whose essential characters are fibrillation, cleavage (Fig. 152 *l*), and erosion of the articular cartilages. The fibrillation is often accompanied by a scanty proliferation of the cartilage-cells, though this feature may be entirely absent. At the margins of the articular surfaces the cartilage often disappears entirely as such (*m*), being converted into mucoid or connective tissue by the action of the proliferous synovial membrane. In far-advanced cases of the disease the greater part of the articular cartilage is destroyed, and the denuded bone often ulcerates to a considerable extent. At times also some dissolution of the cartilage takes place from the side of the bone-marrow (*o*), but this feature is of small importance in comparison with the other changes. Sclerotic thickening of the capsule (*f*), and enlargement of the synovial folds and fringes (*g*), frequently accompany the erosion of the cartilage, and sometimes lead to fixation of the affected joint (Fig. 152) by capsular ankylosis. On the other hand, the tissue of some of the ligaments may become loosened and break down. Calcareous deposits and patches of amyloid degeneration make their appearance both in the degenerate cartilage and in the fibrous tissue of the capsule and ligaments. When the bone is denuded, it may become sclerotic and eburnated by the apposition of new trabeculae derived from the marrow.

The disease appears chiefly in old age as a senile disorder of nutrition, and has accordingly been called **malum senile**; but it is sometimes a neuropathic disorder, and sometimes a sequel of rheumatic and other forms of inflammation. Lastly, the like condition arises when from any cause a joint is kept fixed in one position; in this case the articular cartilage undergoes fibrillar and granular disintegration, especially at those points which are no longer subjected to the normal pressure (REYHER, MOLL). The synovial membrane grows over the articular surface from the periphery, and becomes continuous with the fibrillated cartilage. When a joint that has long been fixed is forcibly flexed or extended, the ligaments, shortened from lack of their normal tension, may rupture (VOLKMANN), and the synovial outgrowths over the bony surfaces may be crushed, with the result that haemorrhage and inflammation with serous effusion ensue.

As regards the senile form of the disease, the hip-joint is that most frequently affected (*malum coxae senile*); the shoulder, elbow, phalangeal joints, and the knee (patella), are affected next in order of frequency. In tabes, on the contrary, the knee, the shoulder, and the elbow-joint are the usual seats of disease. Where the articular ends of the bones are much wasted, the capsule becomes relatively too wide, and the bones, thus allowed abnormal freedom of movement, are apt to become displaced (dislocation from deformity).

The senile, as well as the rheumatic and neuropathic forms,

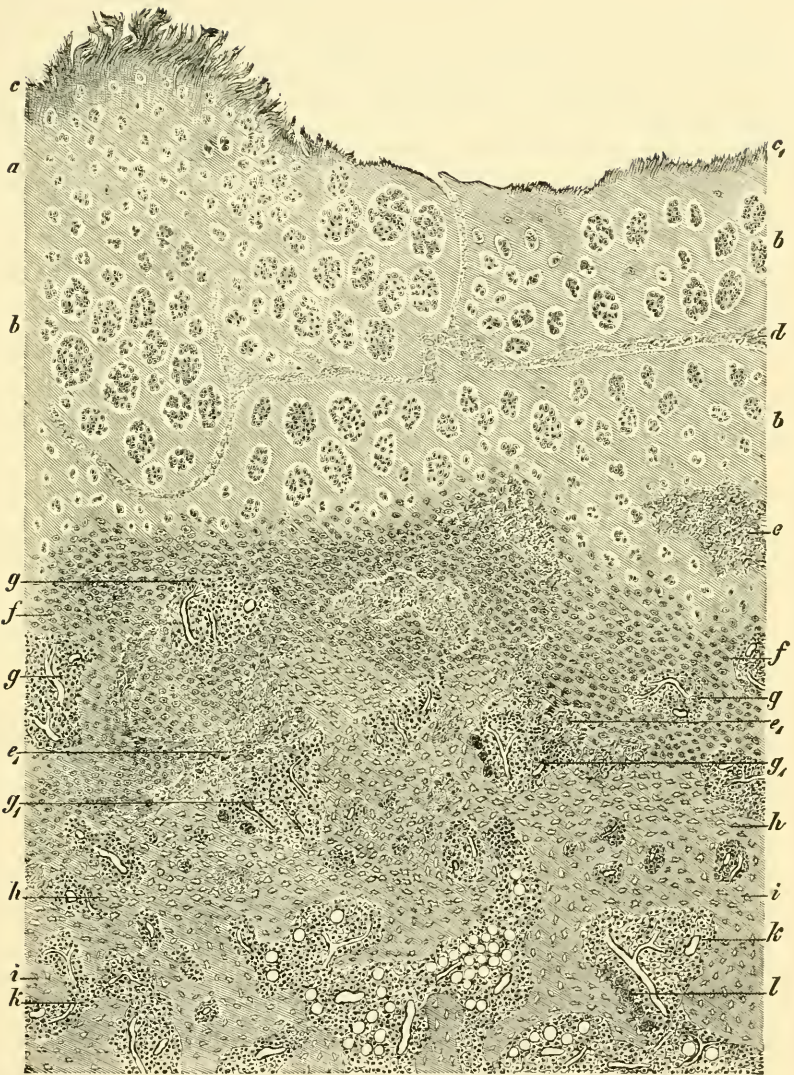


FIG. 153. CHRONIC ARTHRITIS DEFORMANS.

(Section through the articular cartilage of the head of the femur: preparation hardened in Müller's fluid, decalcified with picric acid, stained with haematoxylin and carmine, and mounted in glycerine: $\times 40$)

- | | | | |
|---|-----------------------------------------------------|------------------|------------------------------------------------------------|
| a | hyaline cartilage | f | highly-cellular cartilage with uniformly distributed cells |
| b | hyaline cartilage with proliferous cartilage-cells | g g ₁ | newly-formed medullary spaces |
| c | c ₁ fibrillated surface of the cartilage | h | newly-formed and i old osseous tissue |
| d | clefts in the cartilage | k | old medullary spaces |
| e | e ₁ areas of softening in the cartilage | l | seat of resorption with osteoclasts |

are usually associated with atrophic changes in the bones, and these are often very extensive. Excessive peripheral resorption (Fig. 152 *n*) and consequent attenuation of the bones near a joint, when accompanied by thickening of the capsular ligaments, give the joint itself a thick and nodose appearance, which has sometimes caused the condition to be attributed to arthritis deformans. When the atrophic process affects the bodies of the vertebrae,

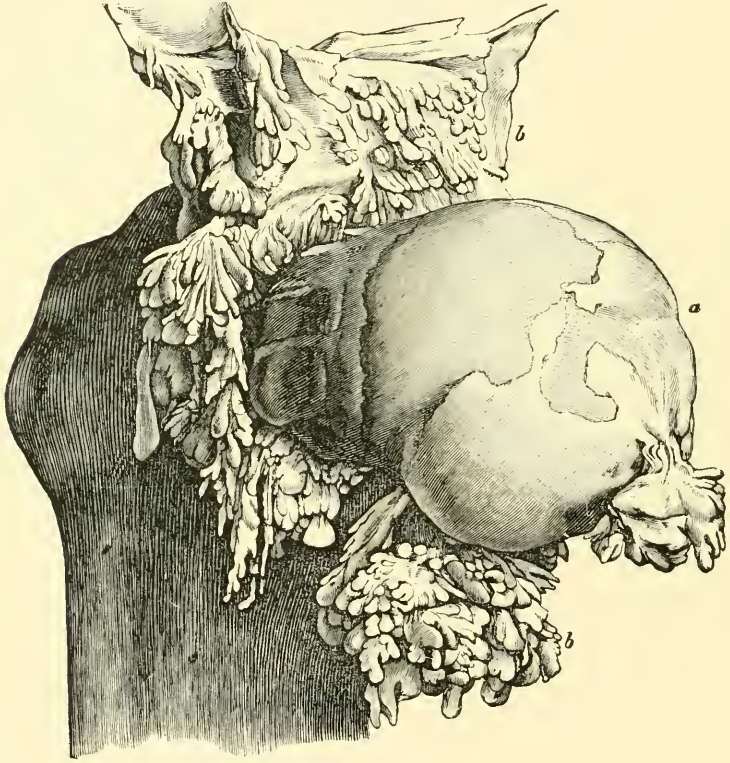


FIG. 154. ARTHRITIS AND OSTITIS DEFORMANS WITH ARBORESCENT LIPOMA OF THE HIP-JOINT.

(Reduced to two-thirds of the natural size)

a deformed head of the femur whose neck is perpendicular to the long axis of the shaft
b synovial membrane with hypertrophic fringes of lipomatous tissue

causing them to become relatively shallower (Fig. 158), the result is curvature of the spine, usually kyphotic.

73. The disease of the joints called **chronic arthritis deformans** is distinguished from other forms by the remarkable hyperplastic proliferation, accompanied by degenerative changes in the cartilages and bones, that takes place in it. The hyperplasia is indeed so abundant as to give a special character to the affection.

The changes in the cartilages consist of fibrillation (Fig. 153 $e e_1$) and cleavage or splitting (d) of the superficial layers; to this is usually superadded extensive softening ($e e_1$) with consequent formation of cavities in the deeper layers next the bone. Along with these degenerative processes free hyperplastic proliferation (b) takes place, and often leads to considerable nodose thickening of the cartilage.

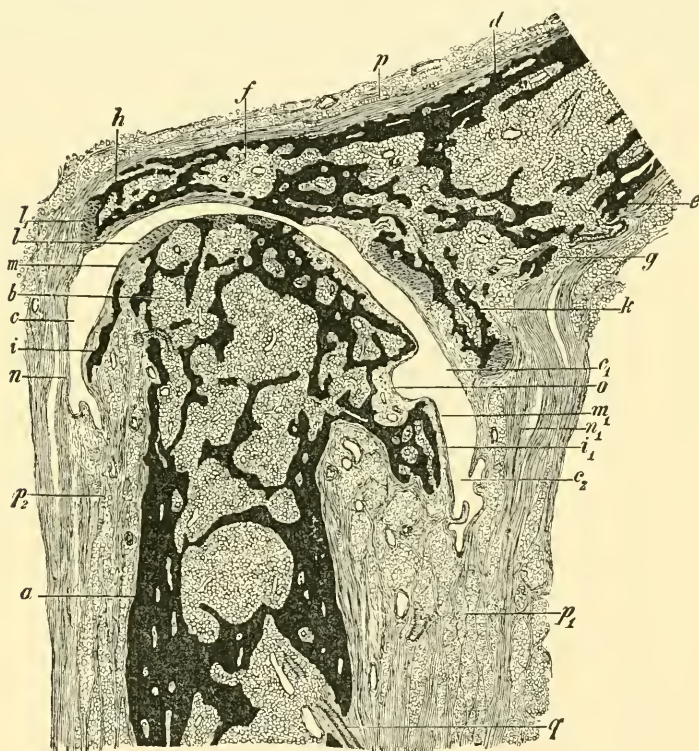


FIG. 155. CHRONIC POLYARTHRITIS DEFORMANS.

(Section through the first inter-phalangeal joint of the index finger of an old woman: preparation hardened in Müller's fluid and alcohol, decalcified with picric acid, stained with neutral carmine, and mounted in Canada balsam: $\times 6$)

- | | | | |
|---|------------------------------------------------------------------------------------------------------|---------------------------------|---------------------------------------------------------------------------|
| a | diaphysis of the second phalanx | h | newly-formed bone on the dorsal border of the articular socket |
| b | articular head of the second phalanx | i i ₁ | newly-formed bone on both sides of the articular head |
| c | dorsal c ₁ c ₂ palmar portion of the articular cavity | k | collapsed portion of the articular socket |
| d | dorsal portion of the cortical layer of the first phalanx, with numerous excavations from resorption | l l ₁ | remains of the articular cartilage |
| e | palmar portion of the cortical layer of the first phalanx | m m ₁ | fibrous covering of the articular surface |
| f | articular socket of the first phalanx | n n ₁ | articular capsule |
| g | defect in the cortical layer of the first phalanx | o | superficial defect in the articular head covered over with fibrous tissue |
| | | p p ₁ p ₂ | periosteum |
| | | q | the nutrient foramen with its artery |

The deeply-situated cavities due to softening are sooner or later lined with vascular medullary tissue ($g g_1$) growing up from the bone. The substance of the cartilage itself is often directly permeated by the growing marrow. When the deeper layers of the cartilage are thus traversed in all directions by medullary spaces, the remaining islands and bridges between these are generally converted into osteoid tissue (h) and ultimately into calcified bone. Occasionally, proliferous outgrowths of cartilage are produced once more in the osteoid trabeculae, and form nodular exerescences that project into the medullary spaces.

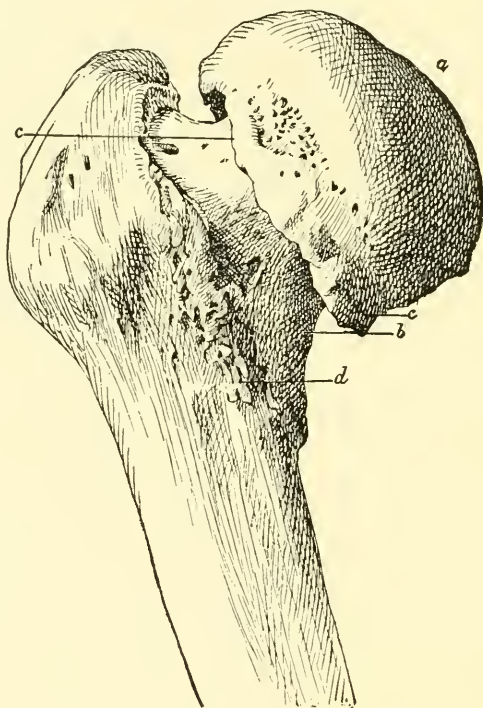


FIG. 156. ARTHRITIS DEFORMANS OF THE HEAD OF THE FEMUR.

(Reduced to two-thirds of the natural size)

- | | |
|---------------------------------------------------------------------------------------------|---------------------------------------------------------------------------------------------------------------------|
| <p><i>a</i> flattened and eburnated articular surface</p> <p><i>b</i> neck of the femur</p> | <p><i>c</i> overhanging rim of the head</p> <p><i>d</i> osteophytes in the region of the intertrochanteric line</p> |
|---------------------------------------------------------------------------------------------|---------------------------------------------------------------------------------------------------------------------|

While these changes are going on in the cartilage, the tissues of the capsule also become proliferous: the capsule and the synovial membrane are thereby thickened; and the synovial folds and villous fringes (Fig. 154) increase and multiply, projecting more and more into the articular cavity until at length the internal surface of the synovial membrane becomes entirely covered with

villi. When fat is later on deposited in the synovial folds and fringes, the result is a condition known as **arborescent lipoma** (Fig. 154). At times, cartilaginous masses from the size of a pea to that of a hazel-nut are formed in the membrane, and especially in its villi; and some of these masses undergo ossification. When they become detached from their base they become loose or movable bodies within the joint (Art. 77).

The changes in the bones are for the most part retrogressive, and are chiefly of the nature of resorption (Fig. 153 *l*); they lead

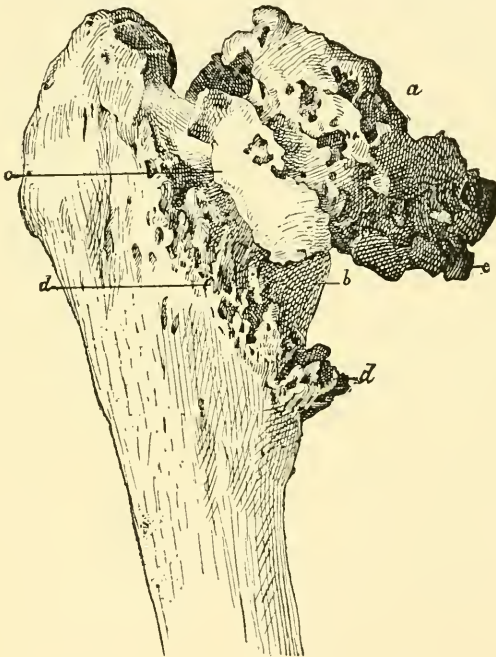


FIG. 157. ARTHRITIS DEFORMANS OF THE HEAD OF THE FEMUR.

(Reduced to two-thirds of the natural size)

- | | |
|------------------------------------------------------------------------------------------------|----------------------------------------------------------------------------------------------------------------------------------|
| <p><i>a</i> atrophied head, with numerous excavated pits</p> <p><i>b</i> neck of the femur</p> | <p><i>c</i> osseous overgrowth on the border of the head</p> <p><i>d</i> osseous overgrowth along the intertrochanteric line</p> |
|------------------------------------------------------------------------------------------------|----------------------------------------------------------------------------------------------------------------------------------|

to lacunar atrophy of the osseous trabeculae, and sometimes entire lamellae are destroyed (Fig. 155 *g o*), so that the bone gives way at the affected part (*k*). The new osteoid tissue formed from the cartilage (Fig. 153 *h*) often undergoes disintegration and softening, and cavities are thus formed within it.

The subchondral marrow (Fig. 153 *k*) frequently loses the greater part of its fat, and is converted into the gelatinous or lym-

phoid variety. When the local atrophy of the bone is complete, patches of gelatinous connective tissue devoid of osseous trabeculae are formed: in other instances dissolution and liquefaction of the bone-marrow takes place, and cysts are accordingly produced. At a later stage, the tissue adjacent to the cysts becomes more or less condensed, and sometimes a number of osseous trabeculae are developed in it by a kind of metaplasia.

The manifold changes already described as taking place in the ends of the bones and in the joint-capsules lead, in the course of years, to very marked deformities of the joints. If the disease extends to the diaphysis of a long bone, deformities may also be produced in parts remote from the joint (Art. 50).

Proliferation of the cartilage, with subsequent ossification, occurs mainly at the periphery of the articular head and of the articular cavity. In the former situation it gives rise to tuberous excrescences (Fig. 155, *i*, *i*₁, Fig. 156 *e*, and Fig. 157 *e*); it causes the socket or acetabulum to be wholly or partially encircled with a ridge by which the cavity is often notably enlarged and deepened (Fig. 155 *h*). Occasionally some of the tuberosities, composed of cartilage and bone, break off and form loose bodies within the joint.

The central parts of the articular head that are most subjected to pressure and friction are usually flattened (Fig. 156); while the articular socket, on the other hand, becomes wider.

All of these changes take place whether the articular cartilage is preserved or not, and, in the former case, depend upon a subchondral atrophy of the bone (Fig. 155 *g*), as a result of which the cartilage (*k*) is undermined and collapses. If the cartilage becomes fibrillated and destroyed, the underlying bone is of course exposed, and in particular those parts of it that have been newly formed by subchondral ossification. Such bone is often very dense, and in places has the compact texture and appearance of ivory. If the affected limb continues to be movable, the hard bony surface of the articular head, as a result of constant movement, is often polished smooth; or if the movements take place in one plane only, it is marked with parallel grooves. The acetabular cavity in that case is correspondingly polished or grooved, and the surfaces are said to be **eburnated**.

Subchondral cysts, due to softening, come to the surface as the superficial layers are eroded, and appear as more or less extensive depressions or excavations (Figs. 155 *o* and 157 *a*). The portions of the bone that are denuded of cartilage may be covered over by extensions of the synovial membrane (Fig. 155 *m* *m*₁); but the covering is absent in parts exposed to special friction as the joint is moved. Apposition of bone from the marrow may take place upon the parts thus left exposed.

Both hyperplasia and atrophy are often so considerable that the resulting deformity of the articular ends of the bones is

extremely great. Thus, the head of the femur may completely disappear; and if new bone is being actively formed at the peripheral parts, while resorption is proceeding in the interior, an entirely new head may be formed, which is attached to the shaft with little or nothing of a neck intervening. More frequently still, a marked flattening and broadening of the head and neck of the femur take place (Fig. 156). In rare cases the head becomes almost conical, the apex of the cone corresponding to the insertion of the ligamentum teres.

It is not possible to describe all the varieties of articular deformity that are met with in arthritis deformans; but from what has been said we can without much difficulty form some conception of the kind of changes that may take place. The one common feature is that they are all produced by bone-resorption on the one hand, and bone-apposition on the other. The resultant effect of the entire process in a given case depends upon which of these predominates.

Owing to the alteration in the shape of the articular ends of the bones, the mobility of the joint becomes more and more impaired. In the shoulder and hip-joint, for example, the possible movements may be limited to a single plane, and finally be abolished altogether, so that what we have called ankylosis from deformity is the result.

The joint thus fixed assumes very different positions in different cases: some of the fingers, for example, are flexed, others over-extended, and others again exhibit more or less lateral deviation. This variety of position is favoured by the variable amount of thickening present in the capsule and the synovial membrane.

The deformity of the articular surfaces occasionally gives rise to mutual displacements of the bones, a condition described as dislocation from deformity.

Arthritis deformans is commonest in the hip-joint and knee (Figs. 156 and 157), but it may affect any of the articulations, and is not rare in the shoulder and elbow-joint. The affection may also appear in the synarthroses, and particularly in those of the vertebral column, when it is called **spondylitis deformans** (Fig. 158). As periosteal proliferation (*b*) with subsequent ossification takes place in this situation, the vertebrae at length become firmly and immovably united together by osseous bridges; these are formed chiefly on the anterior aspect of the column. If meanwhile resorption is in progress within the bodies of the vertebrae and gives rise to inequalities in their vertical dimensions (*a c*), pronounced curvature of the spine is the result. As a rule the trunk is thereby bent forwards into a position of extreme kyphosis.

Arthritis deformans may be either a uniarticular or a multi-articular affection. The uniarticular variety appears to arise spon-

taneously, or follows a single traumatic lesion (such as fracture of the joint) or a recurrent injury, as well as certain infective inflammations. It attacks both the larger and the smaller joints, but more frequently the former. On the other hand, the multiartic-

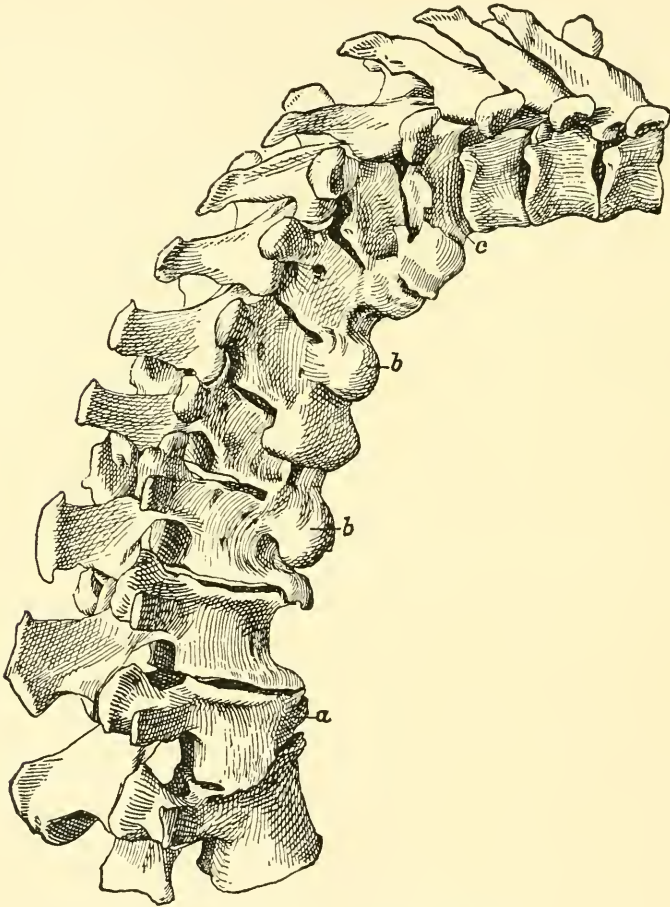


FIG. 158. SPONDYLITIS DEFORMANS.

(Reduced to one-half the natural size)

a body of a lumbar vertebra whose anterior height is considerably reduced
b nodose bony growths uniting the adjacent vertebral bodies together

c body of a thoracic vertebra which has collapsed

ular variety most commonly affects the inter-phalangeal joints, and but rarely the larger ones. It is usually a senile affection, or is dependent on disease of the nervous system.

At the outset, in the multiarticular variety, the changes induced correspond with those observed in dry chronic arthritis or *malum senile* (Fig. 152). The later anatomical changes, however, are such that no difficulty need be felt in classing the disease under the head of arthritis deformans. It usually continues throughout to be limited to the smaller joints, although at times it extends also to the larger ones.

From the contraction of the joint-capsule, and the often extreme deformity of the articular surfaces, the finger-joints are fixed in the most varied positions, flexed, over-extended, distorted sideways, and so on. The heads of the bones are fringed with marginal exostoses and often considerably thickened (nodular polyarthritis), so that the joints closely resemble in external appearance those of the hands in chronic gout.

74. **Chronic ankylosing arthritis** (*arthritis ankylopoetica*) is characterised chiefly by vascularisation and fibrous metamorphosis of the articular cartilage, and by coherence of the opposed cartilaginous surfaces.

These changes may appear first in a single joint and are then either the result of antecedent acute exudative inflammation, or the final stage of certain chronic destructive inflammatory processes, chiefly those originating in tuberculous infection (Art. 76). They constitute the most important anatomical feature of the disease called **chronic rheumatic polyarthritis**, or *arthritis pauperum*. This is an affection that either follows upon an attack of acute articular rheumatism, or commences insidiously and lasts many years, indeed throughout the rest of the patient's life. It involves various joints in succession, and in rare cases all the joints of the body, causing the bones one after the other to become immovable from ankylosis.

At a stage when the changes in a joint are not far advanced, the synovial membrane appears rather more injected than usual, and its fringes and villi are perhaps somewhat enlarged: the surface of the cartilage is rough, fibrillated, and often converted into a tough felted mass; here and there adhesions have already formed between the adjacent cartilaginous surfaces, and the fibrous cartilage is traversed by a few blood-vessels. While the superficial changes are proceeding medullary spaces are being formed in the deeper layers of the cartilage by means of outgrowths from the medullary spaces of the underlying bone, the new marrow being distinguished by its great vascularity. The cartilage lying between the new medullary spaces is in places converted into osteoid or into osseous tissue.

These changes resemble in many respects those characteristic of arthritis deformans, with the important differences that the cartilage proliferates but little, and that the changes in its surface layers are less of the nature of disintegration than of fibrous metaplasia.

Some of the blood-vessels supplying the cartilage in process of fibrillation come from the synovial membrane, and grow over the articular surface from its periphery or from synovial villi adherent to the cartilage; others spring from the subchondral bone-marrow, and penetrate the cartilage from below. Once the cartilage is here and there channelled by medullary spaces containing vessels, the fibrous metaplasia of its superficial layers and the cohesion of the opposed surfaces make rapid progress, being actively reinforced by the new vessels growing into it from above and below.

The ultimate result of all these changes is fibrous ankylosis of the joint, which becomes firmer as the cohesions become more

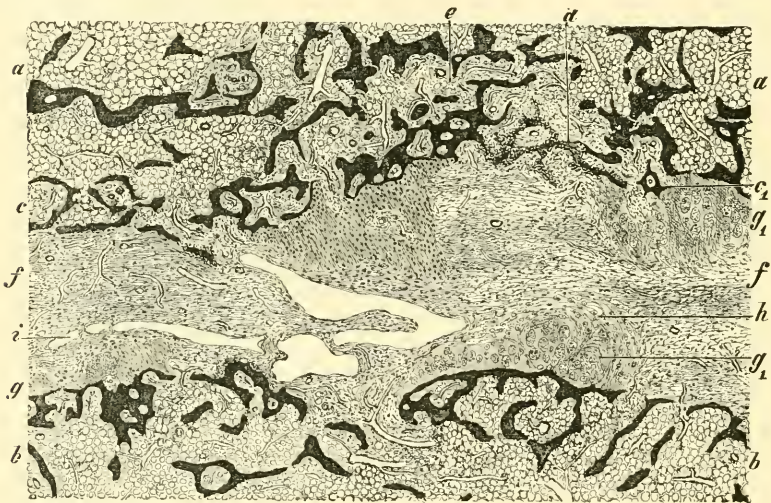


FIG. 159. CHRONIC ANKYLOSING ARTHRITIS.

(Section from the tibio-tarsal joint: preparation hardened in Müller's fluid and alcohol, decalcified with picric acid, stained with haematoxylin and carmine, and mounted in Canada balsam: $\times 12$)

- | | |
|-----------------------------------------------------------|----------------------------------------------------------------|
| a cancellous portion of the tibia | f vascular fibrous tissue derived from the articular cartilage |
| b cancellous portion of the astragalus | g g ₁ remains of the articular cartilage |
| c c ₁ new-formed osseous tissue | h fibrillated cartilage |
| d osseous tissue in process of formation | i remains of the joint-cavity |
| e bone-marrow devoid of fat but rich in vessels and cells | |

extensive. At first the joint-cavity is traversed only by one or two vascular bands: later on the original cavity is reduced to a few small loculi containing synovial liquid (Fig. 159 *i*), and the parts of the cartilages (*f h*) that have been converted into fibrous tissue are fused into one compact mass. How much of the cartilage (*g g₁*) still remains untransformed naturally depends upon the stage the process has reached. In the course of months and years the entire cartilage may perish in successive portions, being

converted into fibrous tissue either directly or through an intermediate fibrillated stage (*h*).

In cases of far-advanced disease the situation of the original joint-cavity is indicated merely by a layer of fibrous tissue; in still later stages even this disappears and makes way for a tissue differing very slightly, if at all, from the marrow of cancellous bone.

Even in the early stages of the process, production of bone within the cartilage (*e e*₁) may be associated with the fibrous metaplasia and the formation of medullary spaces. It commences in the strata of the cartilage next the bone and extends by degrees to the articular cavity. After fibrous ankylosis is established the ossification extends into the fibrous connexions, and the articular ends of the bones are thus at length united by osseous tissue. At the same time, or perhaps a little later, fat is deposited in the new-formed medullary tissue that is henceforth to fulfil the function of ordinary bone-marrow, and so it becomes identical in character with the rest of the yellow marrow. Cases are met with in which, by these changes, the joint is so completely replaced by continuous bone that the former situation of the joint-cavity can scarcely be traced.

References on Chronic Dry Ulcerative Arthritis, Arthritis Deformans, and Ankylosing Arthritis.

- ARBUTHNOT-LANE: Causation and pathology of so-called rheumatoid arthritis and of senile changes *Trans. Path. Soc.* XXXVII London 1886
- BLEZINGER: Spondylitis deformans *Inaug. Diss.* Tübingen 1864
- BRAUN: *Beitr. z. Kenntn. d. Spondylitis deformans* Hanover 1875
- CANTON: Chronic arthritis *Trans. Path. Soc.* XII, XIII London 1860-62
- CHARCOT: *Lec. clin. sur les malad. des vieillards* Paris 1866; *Maladies des vieillards, goutte et rhumatisme: Oeuvres complètes* VII Paris 1890
- DRACHMANN: *Nordiskt med. Arkiv* V 1873 (abstract in *Virchow's Jahresber.* 1873)
- ECKER: Erosion and destruction of articular cartilages *A. f. physiol. Heilk.* 1843
- GIES: Experimental researches *D. Z. f. Chir.* XVI 1882
- GURLT: *Beitr. zur path. Anat. d. Gelenkkrankheiten* Berlin 1853
- HITZIG: Arthritis deformans *Berl. klin. Woch.* 1872
- HÜTER: *Klinik d. Gelenkkrankheiten* Berlin 1877
- SAMARAN: Changes in cartilage in chron. rheumatism and arthritis deformans *Inaug. Diss.* Berlin 1878
- SCHÖMANN: *Das Malum corae senile* Jena 1851
- SCHÜLLER: *Pathologie d. Gelenkentzündungen* Vienna 1887; *Art. Arthritis Eulenburg's Realencyklop.* 2nd edition; Chronic rheumatic arthritis *Langenbeck's Arch.* XLV 1892, *Berl. klin. Woch.* 1893
- SENATOR: *Ziemssen's Cyclop.* XVI New York 1880
- VIRCHOW: *V. A.* 4 1852 and 47 1869
- VOLKMANN: *Pütha and Billroth's Handb. d. Chir.* II Erlangen 1872
- WILKS: Rheumatic arthritis *Trans. Path. Soc.* London 1858, and *Guy's Hosp. Reports* IV London 1858
- WEBER, O.: Changes in cartilage *V. A.* 13 1858

- WEICHELBAUM: *V. A.* 55 1872, *Wien. Sitzungsber.* LXXV 1877
 WERNHER: *Beitr. z. Kenntn. d. Krankh. d. Hüftgelenkes* Giessen 1847
 ZIEGLER: Subchondral changes in arthritis deformans *V. A.* 70 1877

References on Changes in the Joints after Long Immobility.

- HÜTER: *Klinik d. Gelenkkrankheiten* Leipzig 1877
 MENZEL: *Langenbeck's Arch.* XII
 MOLL: *Unters. üb. d. anat. Zustand d. Gelenke bei andauernder Immobilisation*
 Berlin 1885
 REYHER: *D. Z. f. Chir.* III 1873
 VOLKMANN: *Hydrarthros Berl. klin. Woch.* 1870

75. From what has been stated in Arts. 71 and 74, it will be understood that for no one of the several anatomical types of arthritis is there any single and uniform mode of causation: a given type may be produced by various causes, and a single cause may give rise to a number of different types of chronic arthritis.

Senile arthritis, as a rule, takes the form of chronic dry ulcerative arthritis; but it sometimes leads to changes that pertain to and are characteristic of arthritis deformans. The latter is met with chiefly in cases where the affection is multiarticular and extends over a large portion or the whole of the skeleton. The disease has the appearance not so much of an inflammation as of a disorder of nutrition.

Traumatic arthritis, in no way complicated by infection, may assume any of the forms we have described; it usually, however, takes that of chronic serous synovitis or of arthritis deformans. Erosions are most apt to occur when the injury is due to continuous pressure, and when the limb is kept in an abnormal position. Adhesions form after wounds of a joint with effusion of blood into it, and after reduction of dislocations; arthritis deformans, on the other hand, follows upon fracture of the joint, and upon unreduced dislocation.

Infective arthritis, other than that due to tuberculosis, begins as serous or purulent synovitis, and this may be followed by all or any of the above-named anatomical changes. Arthritis deformans is most likely to result when the inflammation at no time takes on an ulcerative character. Fibrous metaplasia of the cartilage, and fibrous or osseous ankylosis of the joint, are generally associated with ulcerative destruction of cartilage, bone, and capsular tissue; these changes may however take place after slight and at no time destructive "rheumatic" inflammation. In the former case the changes are in their way reparative, and run a course that sooner or later reaches its end. The articular affection called chronic rheumatic polyarthritis is, on the contrary, a progressive disease, and the changes in the joints continue to advance till the end of life. It almost entirely coincides with the form whose morbid anatomy is indicated by the term chronic ankylosing arthritis, al-

though changes sometimes occur in this affection which appertain, from the anatomical point of view, to arthritis deformans.

Spinal and neurogenous arthropathies are observed chiefly in connexion with tabes dorsalis, syringomyelia, degeneration of

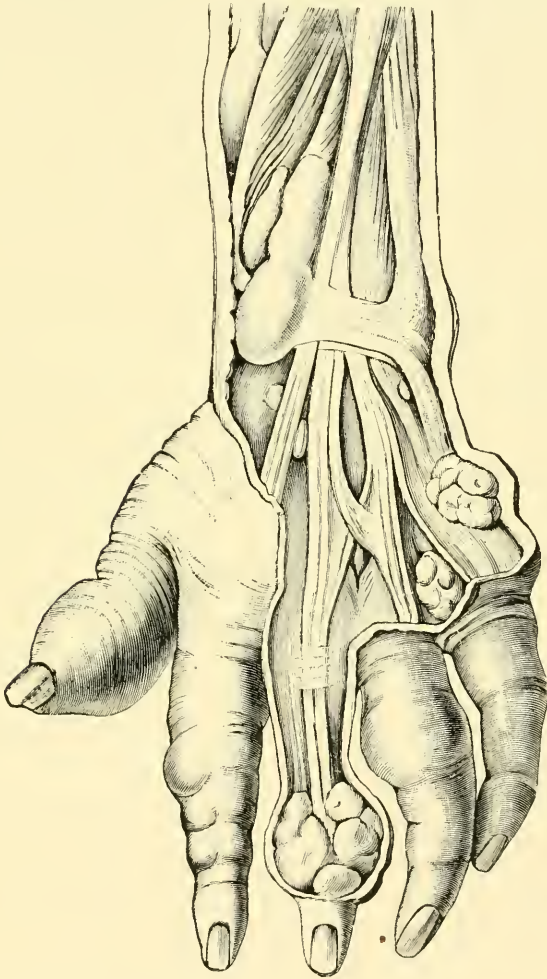


FIG. 160. HAND WITH GOUTY NODES ABOUT THE JOINTS.
(From LANCEREAUX)

the anterior horns of grey matter, degeneration from compression or crushing of the spinal cord, and section of nerves.

In tabes, arthropathies are prone to arise in the knee, the shoulder, and elbow, more rarely in the hand, foot, and finger-

joints. These neuropathic forms are characterised by rapid destruction of the articular ends of the bones, and by thickening and ulcerative destruction of the synovial membrane and articular ligaments. Serous effusion into the joint, swelling of the surrounding tissue, and sudden spontaneous dislocation, may accompany the other changes. How far these conditions are due to nervous influence, how far to mechanical injury, and how far to disorders of the circulation, are questions that still await an answer.

Gouty arthritis is due to a constitutional disease that is usually inherited. The articular affection commences with the effusion of a clear liquid (GARROD) into the structures composing the joint, and from this crystalline deposits are precipitated (Fig. 144). The crystals consist of sodium urate, sodium chloride, calcium carbonate and phosphate, hippuric acid, and compounds of uric acid with calcium, magnesium, and ammonium. They form white chalky or mortar-like masses, and are usually found in the matrix of the articular cartilage and in the tissue of the ligaments. After long continuance of the process they are also discoverable in the periosteum, in the bones, and in the tissues surrounding the joint, particularly in the adjacent tendons, bursae, etc.

The deposition usually takes place paroxysmally, and leads to severe reactive inflammation of the affected tissues, which is at first manifested by hyperaemia and oedematous swelling of the fibrous tissues of and about the joint, and of the overlying skin. Frequent recurrence of such attacks results in fibrillation and erosion of the cartilage, proliferation of the periosteum accompanied by ossification, thickening of the synovial membrane, and permanent swelling of the tissue round the joint. This thickening and swelling produces the nodular masses known as **tophi** or gouty nodes, which enclose chalky deposits (Fig. 160). In far-advanced cases extensive erosions of cartilage and bone occur in the encrusted articular ends of the bones; and around the deposits in the adjacent structures the tissue inflames, proliferates, and ultimately softens and breaks down. In this way are formed abscess-like cavities filled with uratic concretions and pus, and these at length rupture externally. The disease in this form is most apt to appear in the smaller joints of the hands and feet, but it may attack any other joint.

References on Neuropathic Affections of the Joints (see also Arts. 95 and 98).

BENEDIKT: *D. A. f. klin. Med.* XI

BLUM: *Les arthropathies d'orig. nerv.* Paris 1875

BRAMWELL: *Diseases of the spinal cord* Edinburgh 1895

BRUNS, P.: *Berl. klin. Woch.* 1883

CHARCOT: *A. de physiol.* I 1868, *Oeuvres complètes* I-III and IX

- GRAF: Joint affections in syringomyelia *Beiträge von Bruns* x
 HITZIG: Joint-affections in hemiplegia *V. A.* 48 **1869**
 VON KAHLDEN: Case of arthropathy in tabes *V. A.* 109 **1887**
 KOCH: *V. A.* 73 **1878**, *A. f. klin. Chir.* xxiii **1879**
 KOSCHENIKOW: Joint-affections in hemiplegia *A. f. Psych.* xxiv **1892**
 MARINESCO: Neuro-spinal arthropathies *Rev. Neurolog.* 30 **1894**
 MITCHELL, WEIR; Spinal arthropathies *Amer. Journ. Med. Sci.* **1875**
 ROTTER: Arthropathies in tabes *A. f. klin. Chir.* xxxvi **1887**
 SOKOLOFF: Joint-affections in glioma of the cord *D. Z. f. Chir.* 34 **1892**
 SONNENBURG: Arthropathia tabidorum *A. f. klin. Chir.* xxxvi **1887**
 STRUMPELL: Tabes *A. f. Psych.* xii **1882**
 TALAMON: Osseous and articular lesions in nervous diseases *Revue mensuelle* ii **1878**
 WEIZSÄCKER: Tabic arthropathies *Beiträge von Bruns* iii Tübingen **1887**
 WESTPHAL: *Berl. klin. Woch.* **1881**

References on Gouty Arthritis.

- BERKART: Pathology of the gouty paroxysm *B. M. J.* i **1895**
 BRAUN: *Beitr. zu einer Monographie d. Gicht* Wiesbaden **1860**
 CHARCOT: *Gaz. des hôp.* **1866**, **1867**; *Oeuvres complètes* vii Paris **1890**
 DUCKWORTH: *Treatise on Gout* London **1890**
 EBSTEIN: *Die Natur und die Behandlung der Gicht* Wiesbaden **1882**
 GARROD: *Gout and rheumatic gout* London **1876**
 HÜTER: *Klinik d. Gelenkrankheiten* Leipzig **1876**
 LANCEREAUX: *Atlas d'anatomie pathol.* Paris **1871**
 MELDON: *A treatise on gout, rheumatism and rheum. gout* London **1886**
 SENATOR: *Ziemssen's Cyclop.* xvi New York **1880**
 TROUSSEAU: *Clinical Medicine* (New Syd. Soc.) London **1871**
 VIRCHOW: *V. A.* 44 **1868**

CHAPTER XXIV

TUBERCULOSIS AND SYPHILIS OF JOINTS

76. **Articular tuberculosis** appears both as a primary and as a secondary affection. In the former case the process may commence in any portion of the synovial membrane; in the latter it is an extension of tuberculous disease of the bones or bursae adjacent to the joint. The tuberculous foci situated in the marrow or periosteum of the articular ends of the bones infect the joint either by continuous extension through the intervening tissues, or by the transport of bacilli through the lymph-channels.

When the synovial membrane is infected at any one point, and the tubercle-bacilli develop and multiply, the infection is usually disseminated within the joint, and grey tubercles appear at different places on the membrane. The tubercles become more numerous as time goes on, and finally the membrane is studded over with them. They are rarely aggregated into caseous or fibro-caseous nodes of any great size.

When the tubercles are isolated, as in general miliary tuberculosis (KÖNIG), the rest of the synovial tissue may undergo no perceptible change. Where the tubercles are more abundantly developed, hyperaemia, diffuse inflammatory changes, proliferation, and exudation are induced. The synovial tissue is accordingly reddened, swollen, and moderately infiltrated with cells; or more or less extensively converted into soft greyish-red granular tissue, beset with grey or whitish tubercles (**fungous or granular arthritis**). The joint-cavity contains an effusion that is serous (*hydrops tuberculosus*), sero-fibrinous, slightly turbid with pus, fibrino-purulent, or simply purulent (tuberculous empyema of the joint). Purulent effusion is most common when the synovial tissue is partly converted into granular tissue. The deposits of fibrin take the form of shreds and films overlying the granulations. Sometimes the joint contains rice-like or melon-seed bodies, formed from clots of fibrin or detached fragments of tissue (Art. 77).

The tuberculous granular tissue may extend from the periphery towards the cartilage, and grow over it for a certain distance (Fig. 161 *i*). Whenever the granulation-tissue continues for a time in contact with the cartilage, the latter is destroyed, the granulation-cells dissolving its matrix and pene-

trating into the cell-capsules (*g h*). Resorption of the underlying bone (*d k*) usually accompanies the dissolution of the cartilage.

Frequently the granulations grow from the periphery into the interior of the articular cartilage, and thus separate its superficial layers from the deeper ones. They also extend into the subchondral bone-marrow, and press against the encrusting cartilage from this side. If they here attain to considerable dimensions, as when the subchondral tissue is from the outset the seat of tuberculous granulation, the cartilage is apt to be broken through from below, and so to become separated from the bone.

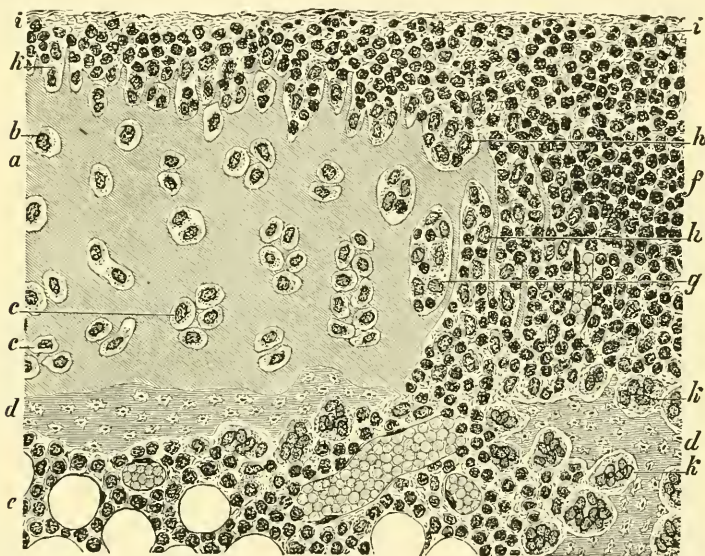

FIG. 161. TUBERCULOUS (FUNGOUS) ARTHRITIS.

(Section through the cartilage and subchondral tissue of the head of the femur, showing resorption of cartilage and bone by the fungous granulations: preparation hardened in Müller's fluid and alcohol, decalcified with picric acid, stained with haematoxylin, and mounted in Canada balsam: $\times 100$)

- | | |
|-----------------------------------------------|---------------------------------------------------------------|
| <i>a</i> hyaline cartilage | <i>g</i> proliferous cartilage-cells mingled with round-cells |
| <i>b</i> isolated, and | <i>h</i> dehiscient cell-capsules |
| <i>c</i> grouped, proliferous cartilage-cells | <i>i</i> granulations covered over with fibrin |
| <i>d</i> osseous trabeculae | <i>k</i> osteoclasts |
| <i>e</i> bone-marrow | |
| <i>f</i> granomatous tissue | |

Side by side with the formation of tuberculous granulations, there is usually a certain amount of non-tuberculous proliferation of the synovial membrane and often of the bone-marrow also; this is probably a result of the accompanying inflammation. In the synovial membrane the proliferation leads to the formation of new papillomatous villi. In general, however, the only result is that the synovial membrane becomes thickened, and grows

over the articular surface from its margin in the form of loose gelatinous or dropsical fibrous tissue, more or less completely vascularised (Fig. 162 *d*). This finally covers over the whole cartilage, whose superficial layers, thus subjected to entirely new conditions, are converted into mucoid (*b b*₁) and soft connective tissue. Vessels also sometimes grow into the substance of the cartilage, and directly transform it in places into mucoid tissue.

The proliferous bone-marrow usually forms a mere reddened zone or seam beneath the cartilage, though the process occasionally extends to the deeper layers of the marrow. The marrow loses its fat, and is converted either into gelatinous or into lymphoid marrow. If the condition persists for a time, more or less

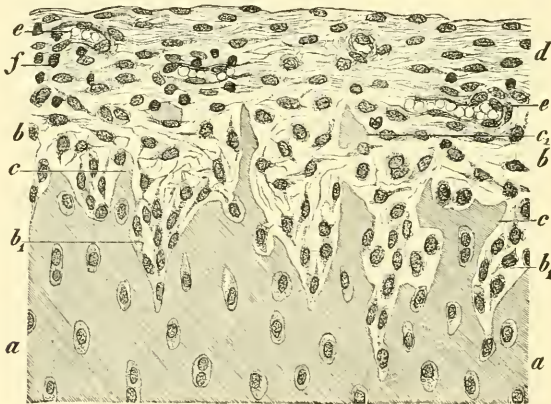


FIG. 162. TUBERCULOUS ARTHRITIS.

(The articular cartilage is covered over with fibrous tissue and transformed by metaplasia into mucoid tissue: preparation hardened in Müller's fluid and alcohol, stained with haematoxylin and carmine, and mounted in Canada balsam: $\times 100$)

- | | |
|---------------------------------------------------------------------------------|-------------------------|
| <i>a</i> hyaline cartilage | <i>d</i> fibrous tissue |
| <i>b b</i> ₁ mucoid tissue | <i>e</i> blood-vessel |
| <i>c</i> hyaline cartilage persisting between
the ingrowths of mucoid tissue | <i>f</i> round-cells |

extensive resorption of the bone (Fig. 161 *d k*) takes place, the cartilage becoming permeated by medullary spaces.

While the above-described processes are in progress within the joint, the surrounding soft parts are the seat of oedematous swelling: the fibrous structures become more and more brawny and coarsely fascicular, and the skin appears pale, smooth, and glistening (**tumor albus** or **white swelling**). Sooner or later foci of granulation develop in the parts about the joint, and presently **caseous nodes** and **cold tuberculous abscesses** are produced. These often rupture externally and lead to the formation of fistulous tracks or **sinuses**, the walls of which are composed of tuberculous granulations and of brawny fibrous tissue.

Such sinuses are usually due to the external rupture of tuberculous foci in bones or joints; they may however arise independently from lymphangitic granulomatous nodes.

Tuberculous arthritis affects both the large and the small articulations, and is one of the commonest of joint-affections.

In the large joints of the limbs (Fig. 163), when the disease has lasted long enough, not only the entire cartilage but also parts of the capsule and of the adjacent bone (*b c*) may have disappeared: the head of the bone may be more or less destroyed, the acetabular socket (*a*) widened out, and the bone in its neighbourhood (*b c*) carious and eroded. Such changes occasionally lead to spontaneous displacement of the articulating bones, which is described as **dislocation from caries**.

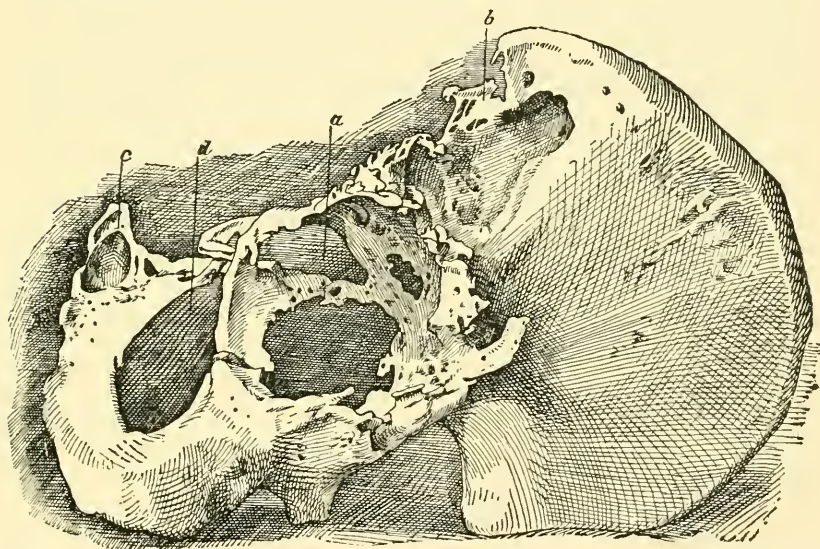


FIG. 163. TUBERCULOUS CARIES ABOUT THE ACETABULUM OF THE LEFT HIP-JOINT.

(Reduced to one-half the natural size)

a perforation of the acetabulum
b carious defects in the ilium

c carious defects in the os pubis
d obturator foramen

The condition of tuberculous caries is sometimes clinically described as **arthrocace**.

Syphilitic affections of the joints make their appearance either at the time of the secondary eruptive stage or in the tertiary stage of the disease. In the secondary stage the affection takes the form of serous synovitis, resembling that associated with acute articular rheumatism. In rare cases a like effusion takes place even in the later stages; but as a rule the tertiary syphilitic arthropathies are of a chronic kind, and are characterised by the formation of gummatous nodes and thickenings in the cap-

sule, proliferation of the synovial membrane, and fibrillation and erosion of the cartilage. Syphilitic arthritis may appear as a primary affection of the joint, or may be due to the extension into it of specific inflammation from the periosteum or bone-marrow.

References on Articular Tuberculosis.

- CHEYNE, WATSON: *B. M. J.* II 1890, I 1891; *Tuberculous disease of bones and joints* London 1895
 DURET: White swelling *Bullet. Soc. d'Anat.* IV Paris 1879
 KÖNIG: *Die Tuberculose d. Knochen u. Gelenke* Berlin 1884
 KÖSTER: Fungous arthritis *V. A.* 48 1869
 MÜLLER: Genesis of articular tuberculosis *Cent. f. Chir.* 1886
 OERTEL: *Aetiologie d. fungösen Gelenkentzündung* Berlin 1880
 OGSTON: *Journ. of Anat.* X 1875
 PAWLOWSKY: Experimental researches *Annales de l'Inst. Pasteur* VI 1892
 RIEDEL: Pathology of the knee-joint *D. Z. f. Chir.* X 1878, XV 1881
 SCHÜLLER: *Experimentelle und histologische Untersuchungen über die Entstehung der scrofulösen und tuberculösen Gelenkleiden* Stuttgart 1880
 VOLKMANN: *Pitha and Billroth's Handb. d. Chir.* II 1872; *Samml. klin. Vorträge* 168-169 1879
 WEICHELBAUM: Cartilaginous changes *V. A.* 73 1878

References on Articular Syphilis.

- BASCH: Syphilitic arthritis *A. f. Derm.* XXIII 1891
 BÄUMLER: *Ziemssen's Handb.* III Leipzig 1886; *D. A. f. klin. Med.* IX 1870
 FINGER: *Wien. med. Woch.* 1884
 GIES: *D. Z. f. Chir.* XV 1881
 GÜTERBOCK: *Langenbeck's Arch.* XXXI 1884
 LANCEREAUX: *Traité hist. et prat. de la syph.* 1873
 LANDERER: *Langenbeck's Arch.* XXX 1884
 LANG: *Pathol. u. Therap. d. Syphilis* Wiesbaden 1885
 OEDMANSSON: *Nordiskt med. Arkiv* I 1869
 SCHÜLLER: *Pathologie und Therapie der Gelenkentzündung* Vienna 1887
 VIRCHOW: *Berl. klin. Woch.* 1884

CHAPTER XXV

LOOSE BODIES IN THE JOINTS

77. In the foregoing paragraphs we have already more than once referred to **loose bodies** within the joints, arising as the result of traumatic injury or of inflammatory processes and tuberculous affections. In clinical descriptions they are sometimes referred to generally as "loose cartilages," or *mures articuli*.

The following classification of these bodies may be made, according to their histological structure: (1) Foreign bodies which have penetrated from without; (2) bodies composed of cartilage; (3) bodies composed of bone, or of cartilage and bone; (4) bodies composed of fatty tissue; (5) bodies composed of fibrous tissue; (6) bodies composed of fibrin. Any of these forms, not originally composed of bone, may undergo calcification.

They may arise (1) from the detachment of fragments of normal cartilage or bone; (2) from the detachment of overgrown synovial villi that have become cartilaginous, fibrous, or lipomatous; (3) from flakes of cartilage or bone formed upon the inner surface of the capsular ligament, or formed outside the joint and then invaginated (LAENNEC); (4) from the detachment of hyperplastic outgrowths from the cartilage; (5) from the exfoliation of fragments of necrotic tissue, as in tuberculosis (NEUMANN, SCHUCHARDT, GOLDMANN); (6) from deposits of fibrin in cases of hæmorrhagic or fibrinous effusion; (7) from foreign bodies forced into the joint. The most important are those resulting from the separation of hyperplastic excrescences, as in arthritis deformans. These, as a rule, are composed of cartilage, produced by proliferation of the cartilaginous nodules normally existing in the synovial folds and in the walls of the capsule. They vary in size from that of a millet-seed to that of a hazel-nut, or even larger, and are often ossified in the centre. They usually occur in the knee and in the wrist, more rarely in the hip, shoulder, elbow, and ankle joints. They may be very numerous, instances of ten, twenty, fifty, and even more having been recorded.

References on Loose Bodies.

- ABERNETHY: *Surgical observations on injuries of the head etc.* London 1810
- BERRY: Fifty loose bodies in knee *B. M. J.* II 1890
- CAVAGNIS: Tuberculous origin of rice-like bodies *Verneuil's Études sur la tuberculose* II Paris 1890
- FILTER: *Solitäre Lipome d. Kniegelenkes* 1890
- FISCHER: Aetiology *D. Z. f. Chir.* XII 1879
- GIES: Chondromatous bodies *D. Z. f. Chir.* XVI 1882
- GOLDMANN: Synovial ganglion containing rice-like bodies *Ziegler's Beiträge* VII 1889
- KLEIN: Pathogenesis *V. A.* 29 1864
- KONIG: *Tuberculose d. Knochen u. d. Gelenke* Berlin 1884
- LANDOW: Fibrin and its transformations in chronic articular effusions *Langenbeck's Arch.* XLVII 1894
- PAGET: *St. Barthol. Hosp. Reports* VI London 1870
- PATTESON: *Journ. of Anat.* XXIV 1889
- PICHON: *Corps étrangers intra-articulaires* Paris 1890
- POULET and VAILLARD: Osseo-cartilaginous and osseous bodies *A. de physiol.* V 1885
- RANKE: Fibrinous effusions *A. f. klin. Chir.* XX
- REAL: Nature of loose bodies *D. Z. f. Chir.* XXXVIII 1893
- VON RECKLINGHAUSEN: *De corporibus liberis articularum* Königsberg 1864
- RIEDEL: Pathology of the knee-joint *D. Z. f. Chir.* X 1878
- SCHUCHARDT: Rice-like bodies in tendon-sheaths and joints *V. A.* 114 1888
- THIELE: Pathogenesis *Inaug. Diss.* Bonn 1879
- VIRCHOW: *Krankhafte Geschwülste* I 1863
- VOLKMANN: *Pütha and Billroth's Handb. d. Chir.* II 1872, and *Beiträge zur Chirurgie* 1875
- WEICHELBAUM: Pathogenesis *V. A.* 57 1873

SECTION V

THE MUSCLES AND TENDONS

CHAPTER XXVI

THE MUSCLES

78. The **striated fibres** that form the essential component of the voluntary muscles are of cylindrical form, varying from 15 to 55 microns (micro-millimetres) in diameter, and at times reaching 5 centimetres in length. They are composed of a sheath, a contractile substance, and nuclei. The contractile substance is of soft consistence and peculiar structure, being made up of fibrils transversely striped with bands that on optical examination appear alternately light and dark.

The muscle-nuclei are scattered over the surface of the contractile muscle-cylinder; in form they are prolate spheroids, their long axes being invariably parallel to the axis of the cylinder. An aggregation of granular protoplasmic material is often observed at their poles.

The sheath or sarcolemma consists of an elastic transparent structureless membrane, which forms a tube enclosing the contractile substance and closely investing its surface.

The length of a muscle varies with the amplitude of its possible range of contraction in the longitudinal direction. Its thickness, on the other hand, is determined by the tension to which it is subjected during contraction. A muscle so placed that in proportion to its length it undergoes but little longitudinal contraction is under relatively unfavourable conditions; and it accordingly shortens until a certain definite proportion is established between its length and the range of its contraction. When its tension is persistently maintained below the normal, the muscle loses in thickness. If the muscle is rendered permanently incapable of altering its length, and if at the same time it receives neither voluntary nor reflex nervous impulses, its fibres perish by degeneration, and are absorbed.

A muscle-fibre which is prevented from contracting, but is subject to stimulation by vigorous nervous impulses, may increase in bulk and consequently become thicker. In time, however, such a fibre becomes over-fatigued, and the result is generally fatty degeneration and atrophy.

When a muscle receives abnormally powerful impulses through the nerves, it usually hypertrophies, should exhaustion from over-fatigue not supervene. Excessive tension of a muscle results in

enlargement of its cross-section, while increased range of contraction induces permanent elongation.

Impairment of the functional power of a muscle may be caused by section of its tendon or of the muscle itself, or by fixation of the bones connected by a joint which is moved by the muscle. In both cases muscular **atrophy from disuse** is the result, and is most pronounced when the muscle is, under the new conditions, in no way stimulated to contract. Such atrophy is still more rapid in disorders of the innervation of the muscle, such as result from morbid changes in the nervous system. There is indeed a whole series of **neuropathic atrophies** in which wasting and disappearance of the muscles is directly referable to disease of the central or peripheral nervous system.

As regards the central nervous system, degeneration and atrophy of the large ganglion-cells in the anterior horns of the spinal cord and grey nuclei of the medulla, and of the anterior nerve-roots proceeding from these cells, are the chief causes of the class of muscular atrophies specially distinguished as **spinal** and **bulbar amyotrophies**. The extent of the muscular atrophy is naturally proportional to the extent of the disease in the cord. It may be confined to single muscles or to special groups of muscles in focal diseases such as acute anterior poliomyelitis, myelomalacia, disseminated sclerosis, tumours, degeneration from compression, etc. On the other hand, atrophic degeneration successively affecting the ganglion-cells of the anterior horns throughout the cord will be accompanied by muscular atrophy gradually extending to all the striated muscles receiving their nerve-supply from the affected region. In this way paralytic affections are induced, whose essential symptom is muscular atrophy increasing in extent and intensity as years go on; this type of disease has accordingly been designated progressive spinal atrophy of the muscles, or more briefly **progressive spinal amyotrophy**. It appears in its typical form in vigorous persons who have been previously healthy, and as a rule first supervenes in those muscles that have been most subject to exertion. Manual labourers often suffer first in the muscles of the hand, particularly the interosseous and lumbrical muscles, or those of the thenar and hypothenar eminences. In other cases the disease begins in the muscles of the shoulder-blade or of the arm. From the parts first affected the atrophy slowly extends to other muscles or groups of muscles *per saltum*, and usually involves both sides of the body, but in irregular sequence. In severe cases the atrophy extends over the greater part of the muscular system. The muscles innervated from the medulla oblongata may also be attacked (progressive bulbar paralysis). Occasionally the process is arrested after a number of muscles have undergone atrophy. The muscles of the legs are attacked, if at all, only in the later stages. In particular muscles the striated fibres may almost completely disappear, so that only

the fibrous structures connected with them remain. The atrophic muscles are sometimes pale, sometimes colourless, sometimes stained with brownish pigmentation.

Besides the typical form of progressive spinal muscular atrophy, first accurately described by DUCHENNE and ARAN, atypical forms also occur, which begin in other situations than those described, for example in the lower extremities, whence the atrophy gradually extends upwards.

The neuropathic muscular atrophies may also, according to the nature of the nerve-lesion, be limited to single muscles, or indeed to single parts of one muscle; or they may extend over large portions of the body (as in the muscular atrophy of tabes dorsalis). In the latter case the atrophy is due to multiple degenerations of the nerves. Probably the amyotrophy associated with chronic lead-poisoning, and affecting chiefly the extensors of the arm, belongs to this latter class.

Muscular atrophy and degeneration may further be due to excessive exertion, the result of over-excitation (as in tetanus), hard physical labour, or undue stretching such as is produced by tumours growing beneath or between the muscles.

Local anaemia following the embolic occlusion of arteries, though a frequent cause of degeneration in many other organs, is of slight importance as a factor in muscular degeneration, inasmuch as the abundant anastomoses of the muscular vessels enable collateral circulation to be readily established. On the other hand, anaemic necrosis is not an infrequent occurrence in cases of extensive arterio-sclerosis with diminished power of the heart, especially in advanced age. So, too, local compression (as in the case of bed-sores or decubital necroses), haemorrhage into the muscular tissue, inflammatory infiltration, etc., at times result in **anaemic degeneration**. In states of general depression of nutrition, or of debility from chronic disease, the muscles often waste and become pale from loss of their colouring matter (myohaemaglobin). Infective febrile diseases, in which the bodily temperature is raised, and in which the constitution of the blood or of the tissue-juices becomes altered from the presence in them of toxic substances, also exert a deleterious influence upon the muscles, and induce in them degenerative changes of various kinds.

Inflammation, hyperplasia of connective tissue, and proliferous new-growths cause wasting of the muscles, partly by compressing their fibres and partly by disordering their circulation, nutrition, and specific function.

In many forms of muscular wasting it is impossible to determine with certainty the causes of the atrophy, and we are, therefore, obliged to regard it as a **primary myopathy**. This is especially the case with certain forms of progressive muscular atrophy, the course of which is similar to that of the progressive spinal disease, but in which no corresponding changes in the spinal cord can be

demonstrated. Such lesions are accordingly distinguished from spinal amyotrophy by the term **progressive muscular dystrophy**. We may distinguish, according to the time of appearance of the muscular wasting, an infantile form, one of adolescence, and one of adult life (ERB): or again, according to the parts affected, a form in which the muscles of the trunk, the lower extremities, and the pelvis are those chiefly involved, the atrophy in some cases being accompanied by excessive development of fat in the muscular connective tissue (Art. 80); and a second form in which the progressive atrophy mainly affects the muscles of the face, shoulder, and scapula (DUCHENNE, LANDOUZY, DÉJÉRINE, HITZIG).

References on the Adaptation of Muscles to Altered Conditions of Contraction.

- GUBLER and A. FICK: *Moleschott's Untersuch. z. Naturlehre* VII Giessen 1860
 ROUX, W.: *Der Kampf d. Theile im Organismus* Leipzig 1881, *A. f. Anat. u. Physiol.* 1883, and *Jena. Zeitschr. f. Naturwiss.* XVI 1883
 STRASSER: *Zur Kenntn. d. funct. Anpassung d. quergestreiften Muskeln* Stuttgart 1883
 WEBER, FR.: *Verhandl. d. k. sächs. Gesellsch. d. Wiss.* 1851

References on Spinal and Neurogenous Muscular Atrophy.

- ARAN: *A. gén. de méd.* 1850, and *Gaz. des hôp.* 1855
 BABES and KALINDERO: Atrophy and pseudohypertrophy of muscles, *Annales de l'Inst. de Path.* II Bucharest 1891
 BERNHARDT: Hereditary progressive spinal and bulbar amyotrophy *V. A.* 115 1889; Juvenile form *Berl. klin. Woch.* 1887
 BRAMWELL: *Diseases of the spinal cord* Edinburgh 1895
 CHARCOT: *Diseases of the nervous system* (New Syd. Soc.) London 1877-83; *Oeuvres complètes* II, III 1886-87
 CHARCOT and MARIE: Peculiar form of amyotrophy *Rev. de méd.* VI 1886
 DÉJÉRINE: Muscular atrophy in ataxia *Rev. de méd.* IX 1889
 DRESCHFELD: Classification of amyotrophies *Brain* VIII 1886
 DUBREUILH: Muscular atrophy from lesions of peripheral nerves *Rev. de méd.* X 1890
 DUCHENNE: *A. gén. de méd.* 1853; *L'électrisation localisée* Paris 1872
 ERB: Diseases of the spinal cord *Ziemssen's Cyclop.* XIII New York 1877
 EULENBURG and GUTTMANN: *Die Pathologie des Sympathicus* 1868
 FRIEDREICH: *Ueber progressive Muskelatrophie* Berlin 1873
 GESSLER: *Die motorische Endplatte u. ihre Bedeutung für d. motor. Lähmung* Leipzig 1885
 GOMBAULT: The peripheral nerves in a case of progressive myopathy *A. de méd. exp.* I 1889
 GRIMM: Case of progressive amyotrophy *V. A.* 48 1869
 HAYEM: *A. de physiol.* 1869; *Rech. sur l'anat. path. des atrophies musculaires* Paris 1877
 HITZIG: Juvenile muscular affections, and spinal dystrophy *Berl. klin. Woch.* 1889
 HOFFMANN: Progressive neuritic amyotrophy *A. f. Psych.* XX 1889
 JOFFROY and ACHARD: Muscular atrophy in hemiplegia *A. de méd. exp.* III 1891
 KAHLER: Progressive spinal amyotrophy *Prag. Z. f. Heilk.* V 1884

- KRAUSS: Researches on tenotomy and neurotomy *V. A.* 113 1888
 KUSSMAUL: *Volkmann's klin. Vorträge* 54
 LEYDEN: *Rückenmarkskrankheiten* II Berlin 1875
 MULLER: Multiple neuritis *A. f. Psych.* XIV 1883
 PARISOT: Pathogenesis of muscular atrophies *Thèse Nancy* 1886
 PICK, A.: *Art. Muscular atrophy Eulenburg's Realencyklop.* IX
 PREISZ: Case of muscular pseudohypertrophy *A. f. Psych.* XX 1889
 RAYMOND: *Malad. du syst. nerv., atrophies musculaires et malad. amyotrophiques* Paris 1889
 RINDSKOPF: Muscle-fibres after neurotomy *Inaug. Diss.* Bonn 1890
 ROGER: Experimental progressive muscular atrophy *Annales de l'Inst. Pasteur* VI 1892
 ROSS: *Diseases of the nervous system* London 1881
 RUSSINI: New form of neuropathic muscular atrophy *Bull. delle scienze med.* Bologna 1892
 STRÜMPPELL: Multiple degenerative neuritis *A. f. Psych.* XIV 1883; Progressive muscular atrophy *Z. f. Nervenheilk.* III 1893
 VIERORDT: Multiple neuritis *A. f. Psych.* XIV 1883
 WERDNIG: Spinal amyotrophy in early infancy *A. f. Psych.* XXVI 1894

References on Lead and Arsenic Paralysis.

- ALEXANDER: *Klinische und experimentelle Beiträge zur Lähmung nach Arsenikvergiftung* 1889
 FRIEDLÄNDER: Lead *V. A.* 75 1878
 HARNACK: Lead *A. f. exp. Path.* IX
 LESSER: Arsenic *V. A.* 74 1878
 MAIER, R.: Lead *V. A.* 90 1883
 MONAKOW: Lead *A. f. Psych.* X 1880
 OELLER: *Zur path. Anatomie d. Bleilähmung* Lead Munich 1883, *D. Med. Woch.* 1883
 VULPIAN: *Mal. du syst. nerv.* Paris 1879
 VON WYSS: Lead *V. A.* 92 1883
 ZUNKER: Lead *Z. f. klin. Med.* 1

References on Muscular Atrophy in Connexion with Inflammation of Joints and Injuries to Muscles.

- CHARCOT: *Diseases of the nervous system* (New Syd. Soc.) London 1877-83; *Progrès méd.* 1882
 FISCHER: Extensor versus flexor atrophy *D. Z. f. Chir.* VIII 1877
 HOFFA: *Pathogenese der arthrit. Muskelatrophie* Leipzig 1892
 LUECKE: *D. Z. f. Chir.* XVIII 1882
 RAYMOND: Atrophy from traumatic arthritis *Rev. de méd.* X 1890
 STRASSER: *Zur Kenntniss der functionellen Anpassung d. Muskeln* Stuttgart 1883
 STRUMPELL: Muscular atrophy after acute articular rheumatism *Münch. med. Woch.* 1888
 VALTAT: Muscular atrophy in articular maladies *A. gén. de méd.* II 1877

References on Primary Myopathic Progressive Muscular Atrophy
 (see also Art. 80).

- BUSS: Dystrophia muscularis progressiva *Berl. klin. Woch.* 1887
 DUCHENNE (of Boulogne): *De l'électrisation localisée* Paris 1872
 ERB: Juvenile form *D. A. f. klin. Med.* XXXIV 1884; *Dystrophia muscularis progressiva* Leipzig 1891
 FRIEDREICH: *Ueber progressive Muskelatrophie* Berlin 1873

muscle generally disappears as the muscle atrophies, so that the tissue becomes pale, at times almost colourless. In other cases pigment is separated from the myohaemoglobin and deposited within the muscle in the form of small yellowish and brownish granules (Fig. 165 *e*), the muscle thereby acquiring a brownish colour. Shortening may be associated with the wasting, the muscular tissue being replaced from the ends inwards by tendinous fibrous tissue.

Degeneration and wasting of muscle-fibres take the most various forms, according as they occur in muscles whose nerves are paralysed or whose tissues are pervaded by inflammatory infiltrations or proliferous tumour-cells, or in muscles that have been crushed, starved, overstretched, over-fatigued, or poisoned by infective toxins or chemical substances. In such cases simple atrophy is less common: more frequent are cloudy swelling, fatty change, vacuolation, fragmentation, lacunar erosion, and waxy degeneration.

Cloudy swelling with albuminous degeneration is characterised by the appearance of multitudes of minute albuminous granules in the protoplasm of the muscle; **fatty degeneration** by the formation of minute globules of fat in the interior of the contractile substance (Fig. 165 *a*). Wide-spread fatty degeneration gives a yellowish colour to the muscle. In dropsical or **vacuolar degeneration** clear drops are formed in the interior of the muscle-fibres (Figs. 166 and 167).

either singly or in considerable numbers, so that the fibre appears eribriform (Figs. 166 and 167 *b*), or is reduced to a froth-like consistence. In **lacunar erosion** small pits are formed in the ensheathing sarcolemma, resembling Howship's lacunae in the bones. These pits are caused by the intrusion of cells that lie in the internal perimysium and indent the sarcolemma, or, penetrating the sarcolemma, compress the contractile substance and cause it to disappear. This process is most commonly observed in metastatic carcinomatous infiltration of the muscles. In **fragmentation** of the muscular fibres, the contractile substance breaks

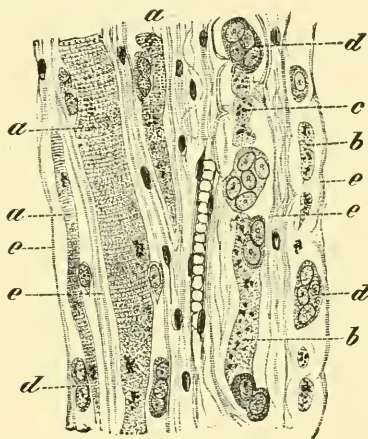


FIG. 165. PROGRESSIVE MUSCULAR ATROPHY.

(From a case of ascending atrophy of the anterior horns of the spinal cord: teased preparation: $\times 300$)

- a* striated muscle-fibre somewhat atrophied, containing fat and pigment-granules
- b* pale homogeneous remains of the contractile substance, containing fine granules
- c* yellow pigment-granules
- d* proliferous muscle-cells
- e* sarcolemma

up into fibrils or discs; these may preserve their normal appearance or may have already undergone cloudy or hyaline change. **Waxy** or **hyaline degeneration** is characterised by necrosis with coagulation of the contractile substance, whereby it acquires a homogeneous glassy appearance and breaks up into hyaline flakes

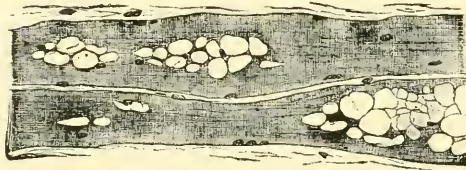


FIG. 166. DROPSICAL MUSCLE-FIBRES.

(From the calf-muscle of a patient with chronic oedema of the legs: preparation fixed in Flemming's acid solution, stained with saffranin, and mounted in Canada balsam: $\times 45$)

(Fig. 168 *b*). It occurs most frequently in typhoid fever, and also, though somewhat more rarely, in the course of other infective diseases, such as septicaemia, small-pox, etc. It is observed principally in the recti muscles of the abdomen and the adductors of the thigh. Sometimes it appears as a result of crushing, inflammation, burns, and tetanic contraction of the muscles, and accompanies the development of

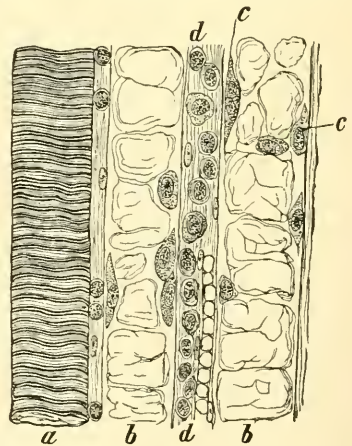
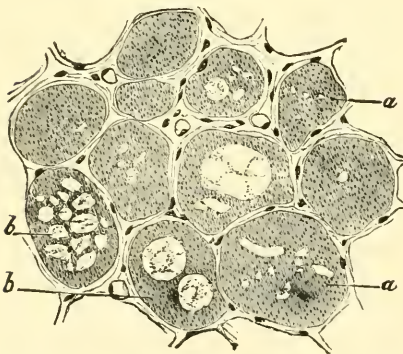


FIG. 167. TRANSVERSE SECTION THROUGH A MUSCLE-BUNDLE CONTAINING DROPSICAL FIBRES.

(Preparation hardened in Müller's fluid, stained with haematoxylin, and mounted in Canada balsam: $\times 66$)

a muscle-fibre with small and large drops of liquid *b*

FIG. 168. WAXY DEGENERATION OR COAGULATIVE NECROSIS IN TYPHOID FEVER.

(Teased preparation: $\times 250$)

a normal striated fibre

b degenerate fibre broken up into hyaline blocks

c enlarged muscle-nucleus

new-growths in the muscle-substance. When the degeneration is extreme, the muscle-nuclei are apt to disappear.

When the degeneration and necrosis involve single fibres only, the condition is not recognisable by the unaided eye. Degeneration of a large number of fibres causes the muscles to assume a pale, cloudy, and lustreless appearance, like those of boiled fish.

Slight cases of albuminous, fatty, or vacuolar degeneration may recover on the resumption of normal conditions of innervation and nutrition; severer forms (Fig. 165 *b*) end in complete disintegration and destruction of the muscle-fibres. In waxy degeneration the contractile substance perishes, breaks up into smaller and smaller pieces (Fig. 168 *b*), and is at last absorbed.

Partially degenerate muscles that are stimulated to contraction sometimes rupture and give rise to haemorrhage.

Both in simple and in degenerative atrophy proliferation of the nuclei of some of the fibres is not uncommon. This proliferation leads sometimes to the formation of long chains of nuclei, and sometimes to the formation of nuclear clusters that push aside the rest of the fibre. In other cases sharply-defined uninuclear and multinuclear cells are formed beside the atrophic fibres (Fig. 165 *d*). Both processes are to be regarded as indications of regenerative hyperplasia of the muscle-cells, though they usually do not lead to the formation of new muscle-fibres: the nuclei themselves subsequently perish, especially when the conditions unfavourable to preservation of the muscle are persistent. It must be noted, nevertheless, that the groups of nuclei often survive for a long time; and even when the muscle itself disappears, numerous sarcolemma-sheaths may still be found which contain pigment-granules together with groups of nuclei or multinuclear cells.

Gangrenous necrosis of the muscular tissue occurs most frequently as a result of severe infective inflammations (Art. 82), and in connexion with decubital bed-sores; in other words, where the skin and subcutaneous tissues of emaciated patients become gangrenous from exposure to continued pressure. The muscles become discoloured, changing to dark-brown or dark-grey, and fall to shreds or become dry and shrivelled by evaporation. **Dry gangrene** or mummification of the muscles ensues when mortified portions of the limbs thus dry up on exposure to the air.

Amyloid degeneration is very rare, and seems to supervene only as a local condition, and in parts altered by antecedent inflammation. The degeneration involves the internal perimysium and the sarcolemma, which are thereby thickened and acquire a translucent appearance, while the contractile substance disappears. The process has been observed in the muscles of the tongue and larynx (ZIEGLER), where the amyloid substance formed hard nodular deposits.

Calcification of the muscles is most frequently observed in the

parts surrounding inspissated residual abscesses and in inflammatory cicatricial indurations. H. MEYER has met with calcification in the wasted fibres of muscles that had undergone extreme atrophy.

According to BENEKE (*V. A.* 99 **1884**), waxy degeneration in non-striated muscle-fibres gives rise to appearances (of hyaline streaks, bands, and fragmentary flakes) similar to those observed in striated fibres; as in the latter case, it depends on a process of swelling and coagulation of the muscular substance. It may be artificially reproduced by soaking non-striated muscle in solution of sodium chloride (0.75 per cent.).

References on Simple and Degenerative Atrophy of Muscle (see also Art. 78).

- ARNOLD: *Ueber das Vorkommen heller Muskeln beim Menschen* Heidelberg **1886**
 AUFRECHT: *D. A. f. klin. Med.* xxii
 BABES: Histology of muscles in primary myopathies *Annales de l'Inst. de Path.* (*X^{me} ann.* 1888-9) ii Bucharest **1891**
 COLBERG: Trichinosis *Deutsche Klinik* **1864**
 ERB: Waxy degeneration *V. A.* 43 **1868**; *Dystrophia muscularis progressiva* Leipzig **1891**
 ERBKAM: Degeneration and regeneration of striated muscles after contusion *V. A.* 79 **1880**
 FRÄNKEL: Muscular changes in phthisis *V. A.* 73 **1878**
 FRANKL and FREUND: *Wien. Sitzungsber.* lxxxviii **1883**
 FRIEDREICH: *Ueber progressive Muskelatrophie* Berlin **1873**
 GOLGI: Normal and morbid histology of voluntary muscle *A. per le scienze med.* v **1881**
 HAYEM: *Rech. sur l'anat. pathol. des atrophies musculaires* Paris **1878**
 HEIDELBERG: Pathology of striated muscle *A. f. exp. Path.* viii **1878**
 HEPF: Pseudotrachinosis, a peculiar form of acute parenchymatous polymyositis *Berl. klin. Woch.* **1887**
 KNOLL: Phosphorus-poisoning, starvation, and paralysis *Tagebl. d. Naturforscherversamm.* Heidelberg **1889**
 KRAUS: Histology and chemistry of muscle after tenotomy and neurotomy *V. A.* 113 **1888**
 LESER: Ischaemic paralysis and contracture *Volkmann's klin. Vorträge* 249 **1885**
 LEWIN: Pathology of progressive amyotrophy *Z. f. Nervenheilk.* ii **1892**
 LICHTHEIM: Trichinosis *Cent. f. allgem. Path.* ii (p. 122)
 LITTEN: Embolism of muscle, absorption of dead muscle-fibres *V. A.* 80 **1880**
 MARCHAND: Acute fatty-albuminous degeneration *Breslauer ärztl. Zeitschr.* **1880**
 VON MILLBACHER: *D. A. f. klin. Med.* xxx
 NESTI: Waxy degeneration *Lo Sperimentale* **1894**
 NEUMANN: Development of new-growths *V. A.* 20 **1861**
 RÖTH: Muscular changes in fatigue *V. A.* 85 **1881**
 SCHAEFFER: Histological changes in muscle-fibres adjacent to tumours *V. A.* 110 **1887**
 SCHULTZE: *Ueber den mit Hypertrophie verbundenen Muskelschwund und ähnliche Krankheitsformen* Wiesbaden **1886**
 STRAHL: Waxy degeneration of striated muscle *Inaug. Diss.* Leipzig **1880**
 VIRCHOW: *V. A.* 4; *Cellularpathologie* Berlin **1871**
 VOLKMANN: Regeneration of striated muscle *Ziegler's Beiträge* xi **1892**
 WAGENER: Waxy degeneration *A. f. mikrosk. Anat.* x **1874**
 WAGNER: The muscles in typhoid *A. f. mikrosk. Anat.* x **1874**

WALDEYER: Degeneration and regeneration of muscle in typhoid and after inflammations *V. A.* 34 1865

WEIHL: Experimental researches on waxy degeneration *V. A.* 61 1874

ZENKER: *Ueb. d. Veränd. d. willkür. Musk. bei Typhus abdominalis* Leipzig 1864

References on Amyloid Degeneration and Calcification of Muscle.

HESCHL: Calcification *Oesterr. Zeitschr. f. prakt. Heilk.* VII 1861

MEYER: Calcification *Z. f. wiss. Med.* I 1851

ROKITANSKY: Calcification *Zeitschr. d. Aerzte* Vienna 1848

ZIEGLER: Amyloid degeneration *V. A.* 65 1875

80. In simple as well as in pigmentary and fatty atrophy the **perimysium** often shows no perceptible change. Those cases in which the atrophy is unmistakably due to local disease of the

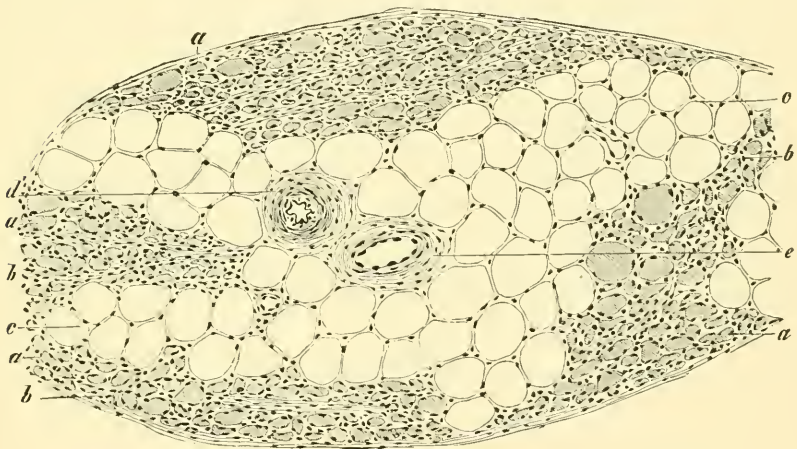


FIG. 169. SPINAL AMYOTROPHY WITH LIPOMATOSIS.

(From the calf-muscle of a patient suffering from atrophy of the anterior horns of the spinal cord: preparation hardened in Müller's fluid, stained with Bismarck-brown, and mounted in Canada balsam: $\times 60$)

a transverse section of atrophic muscle-fibres
b internal perimysium

c fatty tissue
d artery
e vein

fibrous structures of the muscle, for example to inflammation or neoplastic growth, naturally form an exception. But instances occur, as in certain cases of progressive atrophy, wherein the internal perimysium appears at times to be more fully developed and more abundantly nucleated than in the healthy muscle, and it is frequently transformed into fatty tissue (Figs. 169 and 170). This development of connective and fatty tissue is sometimes so marked that the apparent bulk of the muscle does not diminish, but rather increases. The appearance has led to the application to this affection of the term muscular pseudohypertrophy. It

would be more correct to describe it as **lipomatous pseudohypertrophic atrophy** of the muscles.

So far as our knowledge at present goes, the multiplication of the nuclei and the increase of the connective tissue of the internal perimysium are sometimes the cause and sometimes the effect of the wasting of the muscle. Thus the condition of fatty hyperplasia may arise in paralysed muscles, in which the atrophy undoubtedly precedes the proliferation. The development of fat in the connective tissue that takes place in progressive muscular atrophy, as well as in local atrophy from disuse, is in many instances evidently a secondary condition. The atrophy of the muscles (Fig. 169 *a b*) may be already so far advanced that whole

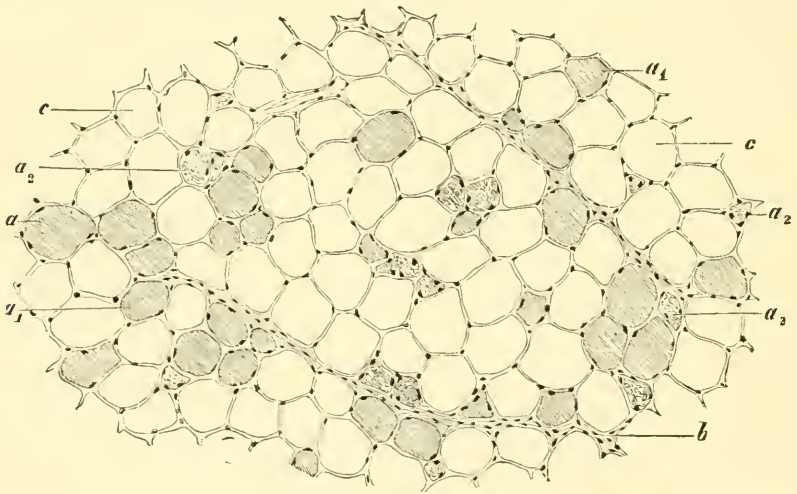


FIG. 170. LIPOMATOSIS WITH ATROPHY OF THE CALF-MUSCLES.

(Preparation treated as in Fig. 169; $\times 60$)

- | | | | | | | | |
|----------|--------------------------------|-----------------------|------------------------------|-----------------------|------------------------------------------------|----------|-------------------------------------|
| <i>a</i> | transverse section of a normal | <i>a</i> ₁ | of an atrophic muscle-fibre, | <i>a</i> ₂ | transverse section of a sarcolemma-sheath with | <i>b</i> | disintegrated contractile substance |
| | | | | | | <i>c</i> | connective-tissue septa |
| | | | | | | | <i>c</i> |

muscle-bundles no longer contain a single healthy fibre when the deposition of fat (*c*) begins, the fat in this case often remaining strictly confined to the immediate neighbourhood of the blood-vessels (*d*). The process can therefore be regarded only as an amyotrophy with subsequent lipomatosis of the connective tissue.

In other cases the internal perimysium increases first, and is transformed into fatty tissue while the muscles are still well preserved, much in the way observed in the process of fattening cattle. The muscle-fibres (Fig. 170 *a*) are thereby forced asunder, and as they thereupon or afterwards disappear (*a*₁ *a*₂), sometimes with disintegration of their protoplasm into fragmentary detritus, it certainly looks as if the overgrowth of fatty tissue were the

cause of the muscular atrophy. It is nevertheless possible that the muscular atrophy and the lipomatosis of the connective tissue may be contemporaneous and related to some common cause, or that the muscular atrophy is due to some independent cause.

The most typical example of lipomatous pseudohypertrophy is furnished by a special form of progressive muscular atrophy observed in childhood, or at least in early youth, and especially in boys. **Pseudohypertrophic muscular paralysis**, as it is clinically termed, often appears in several children of the same family, and is at times hereditary. It chiefly affects the muscles of the trunk, the pelvis, the lower limbs, and the shoulder-girdle, while the hands and arms commonly escape. Most of the atrophic muscles are at the same time enlarged in girth by the development of fat within them; but this enlargement is sometimes absent. The affection is probably a primary myopathy, nearly related to the other primary myopathic atrophies that occur in youth and exhibit the same distribution, though at times they involve the face as well as the shoulder and scapular regions (DUCHENNE of Boulogne, LANDOUZY, DÉJÉRINE). It should therefore be classed with the muscular affections grouped under the term **progressive muscular dystrophy** (ERB). Probably the disease depends upon some unknown congenital perversion of the muscular tissue, of which all we can say is that, at the time of active growth or even later, it leads to the development of connective tissue and fat in the internal perimysium and to atrophy of the muscle-fibres. According to ERB, SCHULTZE, and HITZIG, there are also muscular dystrophies in which a state of true hypertrophy of the muscle-fibres precedes the onset of atrophy.

References on Lipomatous Pseudohypertrophy (see also Art. 78).

- BARTH: Atrophia musculorum lipomatosa *A. d. Heilk.* 1871
 BERGER: *A. f. Psych.* XIV 1883
 BILLROTH: *Langenbeck's Arch.* XIII 1872
 BRIEGER: *D. A. f. klin. Med.* XXII 1878
 CHARCOT: *A. de physiol.* IV 1871
 DUCHENNE (of Boulogne): *Sur la paralysie muscul. pseudohypertrophique* Paris 1868; *A. gén. de méd.* XI 1868; *Gaz. des hôp.* 45 1872
 ERB: *Dystrophia muscularis progressiva* Leipzig 1891
 GOWERS and CLARKE: *Lancet* I 1874, II 1879
 HANDFORD: *Trans. Path. Soc.* XL London 1888
 HASHIMOTO: Pseudohypertrophy *Z. f. klin. Med.* XI
 HITZIG: Juvenile muscular atrophy *Berl. klin. Woch.* 1889
 LUTZ: *D. A. f. klin. Med.* III 1867
 NICHOLSON: Hereditary cases *Lancet* I 1889
 PEKELHARING: Pseudohypertrophy *V. A.* 90 1882
 PREISZ: Pseudohypertrophy *A. f. Psych.* XX 1889
 RANKE: Rarer form *Jahrb. f. Kinderheilk.* X 1876
 SCHULTZE: *V. A.* 75 1879, 90 1882; *Ueber mit Hypertrophie verbundenen Muskel-schwund und ähnliche Krankheitsformen* Wiesbaden 1886
 SEIDEL: *Die Atrophia muscul. hypertrophica* Jena 1867
 SUCKLING: Case in an adult *B. M. J.* II 1884; *Birmingham Med. Rev.* XV 1884

81. **Hypertrophy** of the muscles may be brought about by increased muscular work, and is manifested both by lengthening and by thickening of the fibres, and probably also by increase in their number.

In rare cases (FRIEDREICH, AUERBACH, and BERGER) hypertrophy of single groups of muscles is met with, and is either congenital or acquired in later life. In the latter case, injury or disease (as in typhoid fever) may give rise to the condition. According to ERB, SCHULTZE, and HITZIG, in progressive muscular

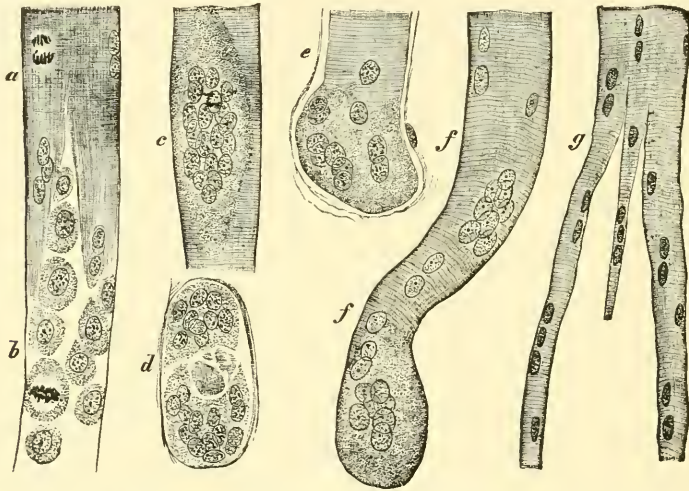


FIG. 171. MUSCLE-FIBRES IN PROCESS OF REGENERATIVE PROLIFERATION, TAKEN FROM WOUNDS OF DIFFERENT AGES.

(Preparation hardened in Flemming's acid solution, stained with saffranin, and mounted in Canada balsam: $\times 350$)

- | | |
|-------------------------------------------------------------------------------------------------------------------------------------------------------------------------------------------------------------------------------------------------------------------------------------------------------------------------------------------------------|---------------------------------------------------------------------------------------------------------------------------------------------------------------------------------------------------------------------------------------------------------------------------------------------------------------------------------------------------------------------------------|
| <p><i>a</i> split stump of a muscle-fibre with pointed ends, showing karyokinetic figures (three days after rupture)</p> <p><i>b</i> proliferous muscle-nuclei transformed into cells with abundant protoplasm, one of them in process of mitotic subdivision</p> <p><i>c</i> portion of a muscle-fibre eight days after constriction by ligature</p> | <p><i>d</i> giant-cell enclosing a fragment of necrotic muscle (from a muscular cicatrix twenty-six days old)</p> <p><i>e</i> and <i>f</i> muscle-fibres ending in protoplasmic masses or muscle-buds (<i>e</i> from a cicatrix ten days old, <i>f</i> from a cicatrix twenty-one days old)</p> <p><i>g</i> subdividing muscle-fibre (from a cicatrix forty-three days old)</p> |
|-------------------------------------------------------------------------------------------------------------------------------------------------------------------------------------------------------------------------------------------------------------------------------------------------------------------------------------------------------|---------------------------------------------------------------------------------------------------------------------------------------------------------------------------------------------------------------------------------------------------------------------------------------------------------------------------------------------------------------------------------|

dystrophy, and even in certain cases of spinal amyotrophy, single muscle-fibres or whole fasciculi may be hypertrophic. In the condition known as **Thomsen's disease**, or **congenital myotonia** (STRÜMPPELL, ERB), due to some congenital injury and manifested by disorders of voluntary movement, by tense rigidity and slow relaxation of the muscles, and by apparent hypertrophy with diminished contractile power, ERB states that there is considerable hypertrophy of the separate muscle-fibres, with marked increase of their nuclei and modification of their finer structure. The

modification consists in a homogeneous appearance of the fibres on section, with indistinctness of their striation and the formation of vacuoles within them. Further investigation is required before we can be certain that these details are correct. The measurements of the fibres regarded as hypertrophic have hitherto been made only in fragments of muscle taken from the living subject, and as the very process of excision induces contraction and physiological thickening of the fibres, no strict comparison with fibres from the dead body is possible.

Regeneration of muscle starts in all cases from the elements of the muscle itself, in such wise that after an injury affecting all the constituent structures the connective tissue reproduces connective tissue, and the muscle-fibres new muscle-fibres, and the latter thereupon penetrate into the newly-formed connective tissue. After section of a muscle a scar of connective tissue is first formed out of granulations in the usual way; but this scar in the course of a few weeks becomes permeated by new muscle-fibres.

The formation of the new muscle-fibres begins by proliferation of the muscle-cells (Fig. 171 *a*), followed by an increase of their protoplasm. In this way, at the ends or in the course of the fibres, multinuclear aggregations of protoplasm are formed (Fig. 171 *c e f*); these continue to grow and ultimately form so-called muscle-buds, from which by a subsequent process of differentiation striated contractile substance is produced. The growing muscle-fibre at times undergoes longitudinal subdivision (*a b*), either before or after the formation of the muscle-buds, so that one older fibre may give rise to two or three younger fibres (*g*).

Not only do those muscle-nuclei proliferate that remain attached to the intact contractile substance, but also those that have become detached at the seat of injury or degeneration, and these become transformed into large uninuclear or multinuclear cells (*b d*). It is still uncertain how far these cells contribute to the regeneration of the muscle. The greater number probably perish, though it is possible that the protoplasmic masses formed by them are converted into contractile substance. If the sarcolemma contains products of the disintegration of the old muscle-fibres, the new-formed multinuclear cells or sarcoblasts may assimilate them, or at least enclose (*d*) and ultimately destroy them.

References on Hypertrophy of Muscle and Congenital Myotonia.

- AUERBACH: True hypertrophy *V. A.* 53 1871; Real and apparent hypertrophy *Cent. f. med. Wiss.* 1889
BANHAM: Thomsen's disease *Brain* x 1887
BERGER: *D. A. f. klin. Med.* ix
BERNHARDT: Muscular rigidity and hypertrophy *V. A.* 75 1879
BLUM: True hypertrophy *Inaug. Diss.* Würzburg 1879
BUZZARD: Congenital myotonia *Lancet* i 1887
DRESCHFELD: Thomsen's disease *B. M. J.* i 1890

- ERB: *Die Thomsen'sche Krankheit* Leipzig **1886** (see also under Art. 79); *D. A. f. klin. Med.* XLV **1889**
- EULENBURG: *Hypertrophia vera Ziemssen's Cyclop.* XIV New York **1877**
- FRIEDREICH: *Ueber progressive Muskelatrophie* Berlin **1871**; *Ueber wahre und falsche Muskelhypertrophie* Berlin **1873**
- GRENIER: *Thomsen's disease Thèse* Paris **1890**
- KRAU: *Case of true hypertrophy Inaug. Diss.* Greifswald **1876**
- LAQUER: *True general muscular hypertrophy D. med. Woch.* no. 26 **1886**
- MARTIUS and HANSEMANN: *Myotonia congenita intermittens V. A.* 117 **1889**
- SCHULTZE: See under Art. 80
- SEIFERT: *Case of Thomsen's disease D. A. f. klin. Med.* XLVII **1891**
- THOMSEN: *Myotonia A. f. Psych.* VI **1876**, XXIV **1892**
- WHITE, HALE: *Thomsen's disease Guy's Hosp. Reports* XXXI London **1889**

82. **Myositis**, or inflammation of the muscles, is usually a secondary result of inflammations in the neighbouring parts and of traumatic injuries; but it is also occasionally induced by contamination of the blood, or by disturbances of the circulation. Inflammations of the first-named kind extend as a rule from the bones and joints, or from parts of the skin and mucous membrane overlying the muscles. They may, however, also reach the muscles from other contiguous parts of the body, such as the pleura, the tissue about the kidney, or the peritoneum.

Haematogenous inflammations, due to contamination of the blood, are for the most part of the nature of bacterial infection; they arise, for example, from pyaemic infection due to wounds, infective osteomyelitis, puerperal pyaemia, acute rheumatic arthritis, glanders, or typhoid fever. It is, however, to be remarked that infiltration does not invariably result from the inflammation; frequently the condition gives rise to little else than degeneration of the contractile substance.

The slightest forms of myositis, such as are due to alteration of the blood, as in typhoid fever, to slight injuries such as strains, bruises, haemorrhages, and the like, or to extension from inflammations of the contiguous parts, are generally transient. They are manifested by infiltration of the perimysium with liquid, and accumulation of round-cells in the connective tissue. The muscular fibres often remain intact throughout. When they also suffer, cloudy swelling, fatty degeneration, and coagulative necrosis make their appearance.

A febrile disease has in recent years been described by various writers under the name of **acute primary polymyositis** (P. WAGNER, UNVERRICHT, HEPP, STRÜMPELL, LEWY). Its clinical symptoms are pain, disorders of voluntary movement, and oedematous swelling of the tongue and it may be of most of the muscles of the body. STRÜMPELL has found in the affected muscles granular and vacuolar degeneration of the fibres, with loss of striation and proliferation of the nuclei, and aggregations of small cells in the intermuscular connective tissue.

Inflammations that do not destroy the structure of the muscle

recover without leaving permanent alterations. Scars and indurations result from more intense inflammations. In cases of purulent inflammation (purulent myositis) suppuration of the muscle may be the ultimate result. The muscle, which at the commencement of the inflammation was hyperaemic and swollen, begins to change colour, becomes mottled with red, brown, yellow, and greyish-green, and is soft and friable; it may finally change to yellow or greyish-yellow, or from admixture with blood, to brown or greyish-green, and break down into a semi-liquid pulp, containing shreds of macerated muscle. At a later stage **abscesses** are formed; sometimes these are single, but at times they are very numerous, so that an entire muscle or group of muscles becomes riddled with abscesses of all sizes, and the intervening muscular tissue is changed in colour to grey, yellow, greenish, or dirty-brown.

Purulent and gangrenous inflammations of muscle occur only as consequences of infection, and their course is accordingly dependent upon the nature of the exciting cause; malnutrition may, however, favour the disintegration of the muscular tissue. Open infected wounds, phlegmonous inflammation of the subcutaneous cellular tissue, severe erysipelas, or faecal abscesses starting from the intestine, are the most frequent causes of suppuration, gangrenous necrosis, and putrid inflammation of muscle. The haematogenous forms (as in infective osteomyelitis) are rarer, and commonly have a merely purulent character. When the stage of suppuration and abscess has been reached, and the muscular tissue has consequently been destroyed, a permanent loss of substance remains. Small abscesses may be re-absorbed, larger ones may heal after evacuation of the pus either externally or into the intestine, the pleural cavities, the lungs, etc. At the place where a collection of pus meets the living tissue, the inflammatory process gives rise to the formation of granulations, and afterwards of connective tissue: when recovery takes place, a **cicatrix** or **induration** remains within the muscle, and in the course of time becomes smaller through contraction. Probably such cicatrices are, at a later stage, partially replaced by muscular tissue.

Should the inflammatory process be long kept up in a muscle by some persistent cause of irritation, due, for example, to the proximity of an inflammatory lesion, a cutaneous ulcer, an inflammation of the bone, a foreign body, or a hydatid—or if the inflammatory process be recurrent, as in those inflammations that lead to elephantiasis of the skin and subcutaneous tissue—**hyperplasia** of the connective tissue, similar to that which occurs in the healing of suppurative lesions, is apt to be induced.

In situations where the muscle is completely destroyed, its place is afterwards occupied by dense connective tissue only. If the muscular fibres are partially preserved, the hyperplastic tissue

gradually encroaches along the planes of the perimysium; and thus the muscle is at length more or less completely pervaded by dense white bands and septa of connective tissue, in which the muscle-fibres are as it were embedded.

References on Myositis.

- BILLROTH: *Beitr. z. path. Histol.* Berlin **1858**; *V. A.* 8 **1855**
 GIES: Myositis chronica *D. Z. f. Chir.* XI **1878**
 GUSSENBAUER: *Langenbeck's Arch.* XII
 HACKENBRUCH: Interstitial myositis *Beiträge von Bruns* X **1893** (with references)
 KRAFFT-EBING: Psoas-abscess in typhoid *D. A. f. klin. Med.* VII
 LEWY: Primary acute polymyositis *Berl. klin. Woch.* **1893**
 LÖWENFELD: Polymyositis acuta *Münch. med. Woch.* **1890**
 OPOLZER: Muscular rheumatism *Allg. Wien. med. Zeitung* VI **1861**
 PERRONCITO: *Contrib. alla patologia del tessuto muscolare* Turin **1882**
 ROSENTHAL: Muscular rheumatism *Oesterr. Z. f. prakt. Heilk.* **1864**
 SENATOR: Acute and subacute multiple neuritis and myositis *Z. f. klin. Med.* XV **1888**; Acute polymyositis *D. med. Woch.* **1893**
 SPINA: Experimental myositis *Wien. med. Jahrb.* **1878** (p. 349)
 STIERLIN: Septic necrosis of muscle *V. A.* 128 **1892**
 STRÜMPFEL: Primary acute polymyositis *Z. f. Nervenheilk.* I **1891**
 TREVES: Acute myositis *B. M. J.* II **1886**
 UNVERRICHT: Polymyositis acuta progressiva *Z. f. klin. Med.* XII **1887**; Dermatomyositis acuta *D. med. Woch.* **1891**
 VIRCHOW: *V. A.* 4; *Cellularpathologie* Berlin **1871**
 WAGNER: Acute polymyositis *D. A. f. klin. Med.* XI **1886**
 WALDEYER: Changes in muscle in inflammation and in typhoid *V. A.* 34 **1865**
 WALTHER: Acute purulent myositis (idiopathic) *D. Z. f. Chir.* XXV **1886**

83. **Tuberculosis** of the muscles is usually secondary to tuberculous disease of neighbouring organs; but primary haematogenous tuberculosis is also occasionally met with.

As regards the first form, it is generally tuberculous disease of the bones and joints that causes the affection in the muscles, inducing in them inflammatory processes which lead to indurative thickening of their connective tissue, the formation of cheesy nodes and cold abscesses enclosed by a granulating membrane containing tubercles, and the formation of sinuses with indurated walls covered with granulations. At the hip-joint the surrounding muscles may in great part become altered in this manner; and in tuberculous caries of the lumbar vertebrae cold abscesses are often formed which extend along the ilio-psoas muscle to Poupart's ligament, and thence burrow to the surface between the muscles of the thigh. Occasionally the pus descends along the surface of the psoas only, the muscular connective tissue becoming somewhat hyperplastic and the substance of the muscle slightly discoloured. In other cases tubercles are formed and suppurative disintegration ensues in the muscular tissue itself, which becomes riddled with pus-secreting cavities and at length is more or less completely destroyed. Similarly in tuberculosis of the cervical and thoracic

vertebrae, the connective tissue in and between the adjacent muscles is often the seat of indurative, caseous, and necrotic tuberculous inflammation.

In like manner tuberculous disease of a mucous membrane, such as that of the tongue or the vocal cords, or tuberculosis of the skin (as in lupus), is liable to invade the muscles. In both cases tubercles, isolated and in groups, make their appearance in the muscular connective tissue: these afterwards caseate and break down, while new foci are formed in the surrounding portions, and the intermuscular connective tissue becomes hyperplastic.

The available researches on haematogenous tuberculosis of the muscles are as yet few and incomplete, so that we cannot say what share the muscles take even in general miliary tuberculosis. Undoubtedly when tubercle-bacilli are disseminated by way of the blood, tubercles sometimes develop in the muscular connective tissue, and single or multiple nodules are thus formed, which later on become foci of cheesy disintegration with indurated walls, or give rise to cold abscesses enclosed by granulating walls containing tubercles. Soft tumour-like growths, resembling sarcomata, and partly caseous, are also occasionally formed. All of these forms are somewhat rare; their frequency has, however, probably been under-rated hitherto. They occur in all or any of the muscles, and sometimes attain considerable dimensions.

Syphilitic affections of the muscles lead either to indurative thickening of the muscular connective tissue, with atrophy of the muscle-fibres (syphilitic fibroid myositis), or to the formation of caseous gummata embedded in cicatricial tissue. These last occur most frequently in the muscles of the upper extremities, in those of the neck, throat, and back, and in the tongue and the external sphincter of the anus (NEUMANN). In some instances they form nodes of considerable size.

In **glanders** large and small abscesses are formed in and between the muscles. In **actinomycosis** affecting the muscles soft fatty granulations, masses of indurated connective tissue, and abscesses are produced.

References on Tuberculosis and Syphilis of Muscle.

- BIDDER: *D. Z. f. Chir.* XVI
 FEOKTISTOW: Tuberculosis *V. A.* 98 1884
 LANG: *Vorles. üb. Path. u. Therap. d. Syphilis* Wiesbaden 1885
 LANZ and DE QUERVAIN: Haematogenous tuberculosis of muscle *A. f. klin. Chir.* 46 1893
 LEWIN: Myositis syphilitica *Charité-Ann.* 1891
 LINHARDT: Muscular syphilis *Oesterr. Zeitschr. f. prakt. Heilk.* 1859; *Schmidt's Jahrb.* no. 108
 MARCHAND: Tuberculosis *V. A.* 72 1878
 MAURIAC: *Lç. sur les myopathies syphilitiques* Paris 1878
 MÜGLING: Surgical tuberculosis *Beiträge von Bruns* I 1883
 MÜLLER: Muscular tuberculosis *Beiträge von Bruns* II 1886

NEISSER: *Ziemssen's Cyclop.* XIV New York 1874-80

NEUMANN: *Myositis syphilitica Vierteljahresschr. f. Derm.* xv 1888

OSTERMAYER: *Syphilitic myositis A. f. Derm.* 1892

VIRCHOW: *Die krankhaften Geschwülste*

84. **Bony formations** in the shape of splinters, plates, and spicules sometimes develop, under pathological conditions, in the perimysium of the muscular bundles, in the fasciae, ligaments, and tendons, and in the intermuscular connective tissue.

One variety arises in an isolated way and develops either without any perceptible external cause and without inducing any signs of irritation, or after a single or recurrent traumatic injury; it sometimes appears also as an outcome of chronic inflammation of the affected part.

The traumatic forms are most frequently met with in the deltoid and pectoral muscles and in the adductors of the thigh, where their production is demonstrably connected with the slight but repeated injuries inflicted, in the former case by the impact of a heavy rifle against the shoulder, in the latter by the pressure of the saddle. They are accordingly described as 'drill' and 'rider's' bones. Such bones are much more rarely found in other muscles; but they have been described as occurring in the arm-muscles of gymnasts.

In a second variety the production of bone in the muscles is the essential symptom of a peculiar disease of young persons, which is commonly described as **progressive ossifying myositis**.

This affection is characterised by the appearance of doughy and often painful swellings in the muscles, fasciae, tendons, and periosteum, followed by local ossification as soon as the swelling subsides. These swellings are sometimes traceable to slight injuries, but occasionally no external cause can be discovered.

The disease usually begins in the muscles and fasciae of the neck, back, and thorax, and thence extends to all parts of the body. As the process goes on for years, with occasional periods of arrest, large portions of these tissues may become the seat of bone-formation. Flakes, scales, and knobbed and branching fragments of osseous tissue appear in the muscles, fasciae, and tendons in ever-increasing numbers. The contraction of the muscles, and the movements of the limbs, of the vertebral column, of the head, and of the lower jaw, are more and more interfered with; and thus when at length bony ankylosis of the joints ensues, movement is no longer possible, and the body becomes like a rigid statue.

The way in which the bony growths are distributed through the tissues varies in different cases. Sometimes the perimysium of the muscular bundles and fibres is the tissue chiefly affected; in other cases it is rather the tendons and fasciae that undergo ossification. Frequently most of the bony growths are from the first

seated directly upon the bone, and so form exostoses; occasionally also parts of the bones themselves are overgrown. It is therefore difficult to draw a sharp line of distinction between such cases and cases of multiple exostosis without ossification in the muscles.

The formation of new bone (Fig. 172) always takes place in the connective tissue and in a manner corresponding precisely to that exemplified in periosteal ossification. Thus bone may be formed either from proliferous germinal tissue (*g*) or from connective tissue (*a*), and that either directly or indirectly (*b b₁ c d*) through an intermediate cartilaginous stage.

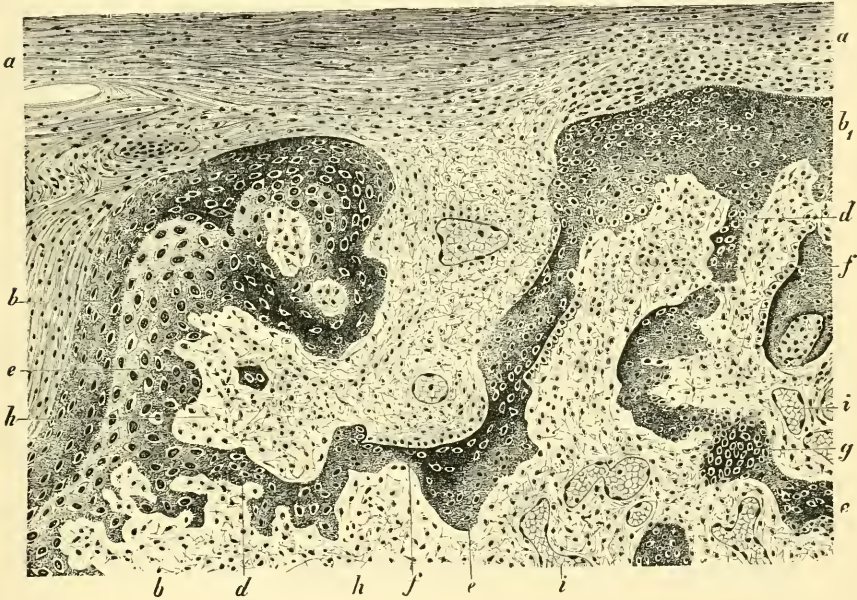


FIG. 172. OSSIFICATION IN A 'DRILL' BONE.

(Preparation hardened in Müller's fluid, decalcified with picric acid, stained with haematoxylin and carmine, and mounted in Canada balsam: $\times 100$)

- | | |
|------------------------------------------------------------|---------------------------------------------|
| <i>a</i> external fibrous covering of the bone | <i>f</i> layer of osteoblasts |
| <i>b b₁</i> small-celled cartilage stained red | <i>g</i> osseous trabeculae developing from |
| <i>c</i> large-celled cartilage stained bluish-red | groups of osteoblasts |
| <i>d</i> osseous trabeculae formed from residual cartilage | <i>h</i> marrow-tissue |
| <i>e</i> fully-developed osseous trabeculae | <i>i</i> blood-vessels |

Throughout the whole process the muscle-fibres remain passive. As they are encroached on and compressed by the bone growing in their perimysium, and are rendered functionally useless by the gradual fixation of the limbs and joints, they in the end undergo degeneration and atrophy.

In the isolated as well as in the multiple and progressive variety the morbid ossification is most probably due to some peculiar

ilarity of constitution in the fibrous tissues of the muscles, fasciae, ligaments, and tendons. These tissues appear to be endowed *ab origine* with certain qualities that normally are possessed only by the periosteum. Periosteal tissue has, so to speak, strayed into the texture of the tendons, fasciae, ligaments, and muscles, or no sharp delimitation of territory has been effected between the tissues that meet about the bone. In certain cases coexisting malformations of the limbs (such as microdactylia) have been described.

References on Ossifying Myositis.

- BERTHIER: Muscular osteoma *A. de méd. exp.* vi 1894
 BILLROTH: *Langenbeck's Arch.* x: Rider's bone *Deutsche Klinik* vii 1855
 CAHEN: Myositis ossificans *D. Z. f. Chir.* 31 1890
 GERBER: Myositis ossificans progressiva *Inaug. Diss.* Würzburg 1875
 KOHLS: idem *Jahrb. f. Kinderheilk.* xxi 1884
 KÜMMEL: idem *Langenbeck's Arch.* xxix 1883
 LEHMANN: Myositis ossificans lipomatosa *D. med. Woch.* 1888
 MAYS: Myositis ossificans progressiva *V. A.* 74 1878
 MÜNCHMEYER: idem *Z. f. rationale Med.* v and xxxiv 1869
 NICOLADONI: idem *Wien. med. Blätter* 1878
 PINTER: Cases of myositis ossificans *Z. f. klin. Med.* viii 1884
 RABECK: Myositis ossificans progressiva *V. A.* 128 1892
 SCHMIT: Rider's bone *Rev. de chir.* x 1890
 VIRCHOW: *Die krankhaften Geschwülste* II
 ZOLLINGER: Case of wide-spread ossification *Inaug. Diss.* Zürich 1867

85. **Primary tumours** of the muscles themselves are somewhat rare, the intermuscular and fascial connective tissues being much more frequently the structures in which deep-lying neoplasms of the limbs and trunk are developed.

Fibromata, lipomata, angiomata, myxomata, and chondromata are all rare. Rhabdomyomata have been observed only in a few cases (BILLROTH, VON BUHL).

Sarcomata, fibro-sarcomata, myxo-sarcomata, and myxo-liposarcomata are the most frequent neoplasms of muscle; they form tumours of various sizes, within which the muscle-fibres perish. The growth develops from the connective tissue.

Carcinomata occur only as secondary growths, generally in cases where carcinoma of the breast, the lips, the skin, or the stomach invades the neighbouring muscles, or is diffused by the lymphatics: more rarely the growth is disseminated by the transport of cancer-germs through the blood-vessels. The cancerous growth takes the form either of a diffuse infiltration of the muscular tissue or of more or less numerous nodules, often arranged in rows corresponding to the general direction of the muscular bundles. The muscle-fibres are destroyed as the cancer grows. Not infrequently the cancer-cells force their way into the sarcolemma-sheaths, and produce in the contractile substance pits and excavations resembling Howship's lacunae.

The **animal parasites** of muscle include *Trichina*, *Cysticercus cellulosae* (measle), and *Echinococcus* (hydatids).

References on Tumours and Hydatids of Muscle.

- BILLROTH: Rhabdomyoma (cystic myoma) *V. A.* 9 **1856**
VON BUHL: Rhabdomyoma *Z. f. Biol.* I **1865**
CRISTIANI: Malignant growths of striated muscle *A. de physiol.* x **1887**
DEMARQUAY: Angioma *L'Union méd.* **1861**
MANEC: Enchondroma *Gaz. des hôp.* **1863**
MARGUET: *Kystes hydatiques des muscles volontaires* Paris **1888**
MUSCATELLO: Angioma *V. A.* 135 **1894**
NEUMANN: Secondary carcinoma *V. A.* 20 **1861**
PAGET: Fibroma *Surgical Pathology* (edit. TURNER) II London **1876**
SECOURGEON: Enchondroma *Gaz. des hôp.* **1859**
SOKOLOW: Sarcoma *V. A.* 57 **1873**
VOLKMAN, R.: Histology of muscular carcinoma *V. A.* 50 **1870**; *Bemerkungen über die vom Krebs zu trennenden Geschwülste* Halle **1858**
WEBER, O.: Carcinoma *V. A.* 39 **1867**
WEIL: Muscular carcinoma *Oesterr. med. Jahrb.* **1873**

CHAPTER XXVII

THE TENDONS, SHEATHS, AND BURSAE

86. The **tendons** proceeding from the muscles consist of bundles or fascicles of dense non-vascular connective tissue, bound together by loose vascular interfascicular tissue. Externally, the fascicles are enclosed in a fibrous sheath connected with the interfascicular tissue.

The **tendon-sheaths** are membranous envelopes surrounding the tendons, but almost completely separated from them, within which they are therefore free to move to and fro. The space between is lubricated by synovial liquid secreted by the sheath.

The non-vascular tissue of the tendinous fascicles is not liable to primary changes, but the tendon is often affected by extension of disease from adjacent parts, and the tendon-sheaths are subject to various diseases peculiar to themselves. Wounds, bruises, strains, and excessive exercise of the tendons and their sheaths, as well as inflammations in the neighbouring parts, often lead to the inflammatory affections known as **tendinitis** and **tendo-vaginitis** (teno-synovitis).

Haematogenous inflammation of the tendons and sheaths is also possible when matters capable of exciting inflammation are conveyed to them by the blood, such as pyogenic micrococci, gonococci, and pneumococci.

In **acute dry tendo-vaginitis** deposits of fibrin are formed upon the inner surface of the sheaths, so that when the hand is placed upon them a rubbing or creaking sensation is felt as the tendon moves to and fro. The condition is most frequently observed in the tendons of the back of the forearm in manual labourers.

Acute purulent tendo-vaginitis is very frequently set up after injuries, and by extension of purulent inflammation from a contiguous part (as from a whitlow or 'felon'). It is indicated by the accumulation of pus in the space between sheath and tendon, and by cellular infiltration of the loose interfascicular tissue. The tendon itself becomes cloudy and swollen: not infrequently the interfascicular tissue suppurates, the fibres of the tendon are loosened, and the fascicles fall apart and become necrotic. If the inflammation recovers without necrosis, adhesions are commonly

formed between sheath and tendon; but complete restoration of the normal relations is not impossible.

In cases of gout, urates are sometimes deposited in the tissue of the tendons, and induce necrosis or inflammation accompanied by the formation of new fibrous tissue. The tissue surrounding and between the fascicles undergoes active proliferation, and the fascicles are forced asunder by the growing cellular tissue; the parts encrusted with crystalline deposits are at the same time surrounded by germinal tissue with or without giant-cells. The process might accordingly be described as **proliferous gouty tendinitis** and tendo-vaginitis.

Tuberculous tendo-vaginitis is met with as a primary affection, and also as a secondary result of tuberculosis in contiguous bones or joints. The tubercles develop mainly in the walls of the tendon-sheaths, and their formation is often accompanied by effusion or exudation. In the more advanced stages of the disease fungous pus-secreting granulations are formed and cover over the surface of the tendons. At the same time the walls of the sheaths become thickened by fibrous hyperplasia, and by the deposition of tubercles singly and in groups.

Chronic irritation causes an increased quantity of liquid to be secreted by the sheath of a tendon, and it is thereupon distended into a kind of cyst; this is described as a **hygroma** of the tendon-

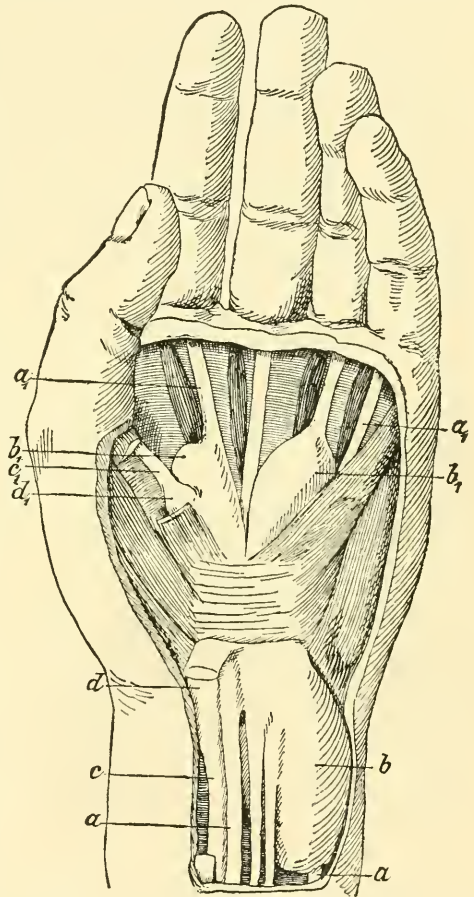


FIG. 173. 'Hour-glass' HYGROMA OF THE SHEATH OF THE DIGITAL FLEXOR TENDONS.

(Preparation from the Museum of Clinical Surgery at Tübingen: reduced to one-half the natural size)

- | | | |
|----------|-----------------------|------------------------------------------|
| <i>a</i> | <i>a</i> ₁ | tendons of the flexor sublimis digitorum |
| <i>b</i> | <i>b</i> ₁ | hygroma of their sheaths |
| <i>c</i> | <i>c</i> ₁ | tendons of the flexor longus pollicis |
| <i>d</i> | <i>d</i> ₁ | hygroma of their sheaths |

sheath, or **hydrops tendo-vaginalis**. It is commonest in the tendons of the hand (Fig. 173 $bb_1 dd_1$), and especially in the sheaths of the flexor tendons of the palm. As the sheaths pass under the anterior annular ligament, the swelling is constricted in the middle, and takes the shape of an hour-glass or double sac. In some cases the sheaths of the digital portions of the flexor tendons degenerate, in others the sheaths of the back of the hand, and more rarely the sheaths of the tendons of other muscles. Hygromata of the tendon-sheaths are generally symptomatic of tuberculous disease, and often contain so-called **rice-bodies** (*corpuscula oryzoidea*). These are small loose bodies like grains of rice or melon-seeds, and are derived either from exfoliated necrotic fragments of the proliferous sheaths (Fig. 175), or from fibrinous coagula. They are composed mainly of homogeneous matter or of flaky scales; sometimes they are made up of stratified layers enclosing a few cells.

Divided tendons, if they do not suppurate, are re-united by connective tissue; this does not exactly correspond in structure with the original tendon, but is more like cicatricial tissue, with a greyish-white and somewhat duller appearance. **Repair** is effected by proliferation of the tendon-cells and of the surrounding fibrous tissue.

Arborescent lipoma is a very rare affection of the sheaths of the tendons; it consists of branching papillomatous outgrowths, containing fat and growing from the synovial lining.

According to HIRSCHSPRUNG (*Jahrb. f. Kinderheilk.* XVI 1881), TROISIER (*Progrès méd.* 1883-84 and *Union méd.* 1884), REIN (*IV Congr. f. inn. Med.* Wiesbaden 1886, and *Gerhardt's Handb. der Kinderkrankh.* III), BARLOW and WARNER (*Trans. Internat. Med. Congr.* London IV 1881), and PRIOR (*Münchener med. Woch.* 1887), nodules from the size of a pin's head to that of a bean are apt to develop in the course of articular rheumatism (nodular rheumatism) within the circumarticular ligaments and tendons, on the periosteum, and on the subcutaneous aponeuroses. These **rheumatic nodules** persist but a short time, and are composed of germinal fibro-cellular tissue. They commonly disappear within two months at most.

References on the Morbid Anatomy of Tendons and Sheaths.

- ADAMS: *On the reparative process in human tendons after subcutaneous division* London 1860; *Trans. Path. Soc.* XXI London 1871
 BELTZOW: Development and repair of tendons *A. f. mikrosk. Anat.* XXII 1883
 BEGER: Tuberculosis *D. Z. f. Chir.* XXI 1884
 BERKART: Pathology of the gouty paroxysm *B. M. J.* I 1895
 BILLROTH: Regeneration of tendons *Beiträge z. path. Histol.* Berlin 1858
 BONER: Regeneration of tendons *V. A.* 7 1853
 BUSSE: Repair of tendons *D. Z. f. Chir.* XXXIII 1892
 CAZANOW: White tumours of the synovial sheaths *Thèse Paris* 1866
 DOMBOWSKI: Repair after tenotomy *Inaug. Diss.* Königsberg 1869
 GINSBURG: Inflammation and regeneration of tendons *V. A.* 88 1882
 HAECKEL: Lipoma arborescens *Cent. f. Chir.* 1888

- JACOBY and GOLDMANN: Tendovaginitis suppurativa gonorrhoeica *Beiträge von Bruns* XII 1894
 PIROGOFF: *Ueber die Durchschneid. der Achillessehne* Dorpat 1840
 SCHUCHARDT: Tuberculosis and syphilis of tendon-sheaths *V. A.* 135 1894
 VERNEUIL: Tuberculosis *Gaz. des hôp.* 1860
 VIERING: Regeneration of tendinous tissue *V. A.* 125 1891

References on Hygroma of the Sheaths and Bursae.

- GARRÉ: Primary tenosynovitis *Beiträge von Bruns* VII 1891
 GOLDMANN: Rice-like bodies of the sheaths and bursae *Ziegler's Beiträge* VII 1890
 HOEFMANN: Ganglion and chronic fungous tenosynovitis (proliferous hygroma) *Inaug. Diss. Königsberg* 1876
 LANDOW: Fibrin and its transformations in hygroma of the sheaths *Langenbeck's Arch.* XLVII 1895
 NEUMANN, E.: Picrocarmine-staining in the study of inflammation *A. f. mikr. Anat.* XVIII 1880
 NICAISE, POULET, and VAILLARD: Tuberculous nature of hygromata and tenosynovitis with rice-like bodies *Rev. de chir.* 1885
 SCHUCHARDT: Rice-like bodies in sheaths and joints *V. A.* 114 1888
 WEICHEL: Ganglion crepitans Acrelii *Inaug. Diss.* Giessen 1858

87. The **bursae** are saccular cavities containing clear synovia and enclosed by a fibrous membrane with a smooth inner surface, and situated in the connective tissue. They are formed in places where the muscles or tendons move over bony parts, or where skin, fasciae, and muscles are continually exposed to pressure and slipping movement. They are thus to some extent acquired structures; and accordingly some of them are inconstant, while others develop, in special circumstances, in parts that ordinarily do not possess them.

In acute inflammation of the bursae, variously termed **acute bursitis** or **acute hygroma**, a serous, sero-fibrinous, or purulent effusion is poured out and distends the sac, and thus a fluctuating tumour is formed. The inflammation usually arises from contusions, wounds, or bruises, more rarely from haematogenous infection. Purulent inflammation sometimes extends from the bursa to contiguous parts.

Chronic bursitis most frequently takes the form of a collection of liquid in the bursal sac (*hydrops bursarum* or hygroma). At first the contents of the sac are usually mucilaginous and viscid; later on they become thinner and more limpid, losing their mucilaginous character. Few hygromata exceed the size of a middle-sized apple, though much larger cysts have more than once been observed.

The commonest seat of hygroma is in front of the patella ('housemaid's knee'); here it is due to cystic degeneration of the prepatellar bursa, a sac consisting of three intercommunicating pouches.

The wall of the hygroma is usually thin; but if the condition

is of long standing it may be considerably thickened (Fig. 174), and may afterwards acquire a dense scar-like consistence, with here and there patches of calcification. Deposits of urates have been observed in the bursae in cases of gout. At times the wall is notably thickened from the outset, and then the amount of liquid present in the sac is small.

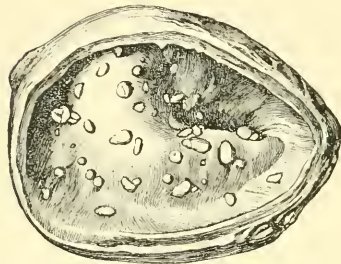


FIG. 174. SECTION THROUGH A DILATED PREPATELLAR BURSA WITH FREE AND FIXED RICE-LIKE BODIES.
(Natural size)

Bursal hygromata occasionally contain rice-like bodies (Fig. 174), resembling those found in the hygromata of the sheaths of tendons. They consist of flaky (more rarely stratified) homogeneous masses (Fig. 175 *c b*), and sometimes enclose spindle-cells. They arise either by the exfoliation of circumscribed hyaline necrotic patches from the wall of the hygroma, or from fibrin deposited from the exudation in the form of free lenticular grains, which become adherent to and gradually coalesce with the cyst-wall. They are usually indicative of tuberculous disease. Occasionally the cyst-wall produces villous outgrowths in the form of small pedunculated fibrous grains; these become necrotic and fall away from their filamentous peduncles, and may thus give rise to the loose rice-like bodies in question. When the finger is pressed upon one of these hygromata filled with loose bodies, a peculiar feeling of crepitation is perceived: such a cyst is accordingly described as a **crepitant ganglion**.

In rare cases nodules of fibrous tissue or of proliferous cartilage are developed in the walls of hygromata, and lead to the formation of loose bodies varying in size from that of a pea to that of a chestnut.

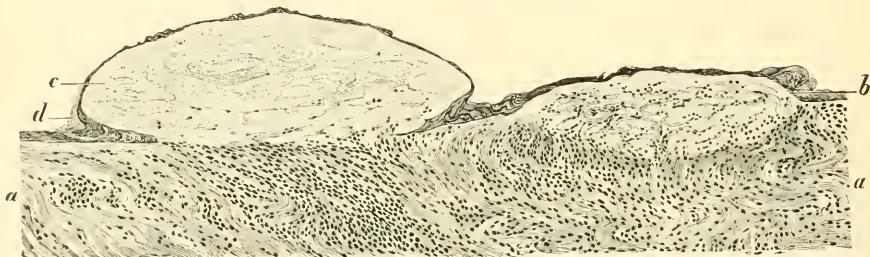


FIG. 175. SESSILE RICE-LIKE BODIES FROM A PREPATELLAR BURSA.

(Section from the specimen of Fig. 174: preparation hardened in Müller's fluid, stained with haematoxylin and eosin, and mounted in Canada balsam: $\times 45$)

- | | |
|-----------------------------------------------------------------------------------------------|-------------------------------------------------------------------------------|
| <i>a</i> wall of the bursa | <i>c</i> rice-like body resting on the surface and containing scattered cells |
| <i>b</i> hyaline mass in the wall of the bursa, part containing nuclei and part being denuded | <i>d</i> deposit of fibrin |

Haemorrhages may occur both in previously normal bursae and in hygromata, as a result of injury or of some disturbance of the circulation. Such haemorrhages are accompanied by more or less copious precipitation of fibrin, and give rise to bursal haematomata.

Tuberculous inflammation of the bursae may be either a primary or a secondary affection. The development of tubercles in the wall of the sac is sometimes associated with serous effusion, producing **tuberculous hygroma**. Fungous granulations appear upon the inner wall of the sac in the more advanced stages of the process, the wall thereby becoming thickened and permeated by granulomatous growths that afterwards undergo caseous degeneration.

A **ganglion** is a round, oval, or lobate cyst, varying in size from that of a pea to that of a pigeon's egg, and containing a reddish-yellow crystalline jelly, or a mass of colloid matter. According to the investigations of LEDDERHOSE, the ganglion is really a new-formation, usually

appearing in the tissue immediately adjacent to a joint, more rarely at some little distance from it, and due to gelatinous or colloid degeneration of the connective tissue and to the coalescence of numerous smaller cavities filled with the gelatinous matter so produced. On the dorsal aspect of the intercarpal joints the ganglion usually lies either above the space between the trapezoid and the os magnum, or over that between the scaphoid and the semilunar bone. The formation is probably induced by the chronic recurrence of slight mechanical injuries. It sometimes disappears spontaneously by the absorption of its contents.

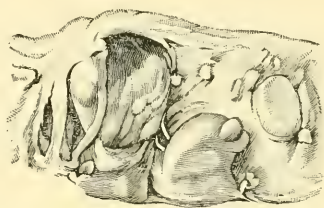


FIG. 176. WALL OF THE THICKENED BURSA OF THE OLECRANON WITH NODULAR FIBROUS GROWTHS.

(Seen from the inner surface: natural size)

References on Diseases of the Bursae and on Ganglion.

BARWELL: *Diseases of the joints* London 1861

FALKSON: Ganglion and fungous tenosynovitis *Langenbeck's Arch.* xxxii 1885

HEINEKE: *Die Anatomie und Pathologie der Schleimbeutel und Sehnenscheiden* Erlangen 1868

LEDDERHOSE: Aetiology of carpal ganglia *D. Z. f. Chir.* 37 1893 (with references)

MICHON: Tumours of the fore-arm *Thèse Paris* 1851

RIEDEL: Tuberculosis of the bursae *D. Z. f. Chir.* 10, 11

SCHUCHARDT: Origin of subcutaneous hygroma *V. A.* 121 1890

TEICHMANN: The theory of ganglion *Inaug. Diss.* Göttingen 1856

TRENDELENBURG: *Langenbeck's Arch.* xxi

VIRCHOW: *Würzburger Verhandlungen* ii 1851, and *Die krankhaften Geschwülste* I

VOGT: *Deutsche Chirurgie* part 64 1881

VOLKMANN: *Pitka and Billroth's Handb. d. Chirurgie* ii Erlangen 1872

SECTION VI

THE CENTRAL NERVOUS SYSTEM

CHAPTER XXVIII

THE SPINAL CORD AND ITS MALFORMATIONS

88. The **spinal cord** has the form of a somewhat flattened cylinder, and is composed of white and grey matter. The white matter invests the exterior, while the grey matter lies in the interior and extends uninterruptedly throughout the entire length of the cord.

The **grey matter** has in transverse sections the form of an **H** (Fig. 178), with two **anterior** (*e.a.*) and two **posterior** (*e.p.*) **horns**, and a middle connecting portion, the **grey commissure**. The grey commissure encloses a tubular cavity lined with cylindrical cells, the **central canal** (*e.c.*), which divides the commissure into an anterior and a posterior portion. The anterior horns are throughout more voluminous than the posterior, though their size and configuration vary considerably in the different segments of the cord. They are smallest in the thoracic region.

In the lower cervical and upper thoracic portions of the cord the anterior horn has a lateral process opposite the grey commissure (*e.l.*) described as the intermedio-lateral tract, or **lateral horn**. Numerous minor processes radiate from the margins of the grey matter into the white; these have been called **septula medullaria**. On the outer side of the neck of the posterior horn, behind the lateral horn, is a network of grey matter interspersed with white, which has received the name of **processus reticularis**.

At the apex of the posterior horn is the **gelatinous substance** of Rolando, which contains ganglion-cells, and passes anteriorly into the **spongy substance** of the posterior horn.

The **anterior roots** of the spinal nerves take their exit from the apex of the anterior horns, the **posterior roots** enter at the apex of the posterior horns.

The **white matter** in each half of the cord consists essentially of longitudinal medullated nerve-fibres embedded in a fibrous supporting structure, and is divided by the grey matter into three main portions, of which that medial to the anterior root is known as the **anterior column**, that medial to the posterior horn and root as the **posterior column**, and that between the anterior and posterior horns as the **lateral column**.

The **grey matter** abounds in ganglion-cells and fine and coarse nerve-fibres, which are supported by the **neuroglia**. Around the central canal is a mass of tissue known as the **substantia gelatinosa centralis**, composed essentially of neuroglia and containing no ganglion-cells.

The neuroglia-cells (**Deiters' cells** or astrocytes) consist of a small cell-body and numerous fine filamentous processes; most of these processes are of no great length, in other words the majority of the stellate neuroglia-cells are of the short-rayed type. Among the neuroglia-cells must also be reckoned the

cylindrical cells lining the central canal, each of which terminates in a thread-like process.

The **ganglion-cells** (nerve-cells or neurocytes) are mostly uni-polar, having only one axis-cylinder or polar process (axon or neuraxon), and numerous dendritic protoplasmic processes (dendrites), which anastomose and interlace into a close-meshed felt. According to the function of the cells, and the course of their polar processes, various kinds of ganglion-cells are distinguished as motor, commissural, etc. (GOLGI, RAMON Y CAJAL, KÖLLIKER, LENHOSSÉK).

The **motor-cells** lie in two groups in the cervical and lumbar regions, in one group in the thoracic region, of the anterior horn. They are very large, and each gives origin to a nerve-fibre that passes forward and obliquely downwards, and becomes the axis-cylinder of the anterior root of a motor nerve (Fig. 177).

Each of the **commissural-cells** sends

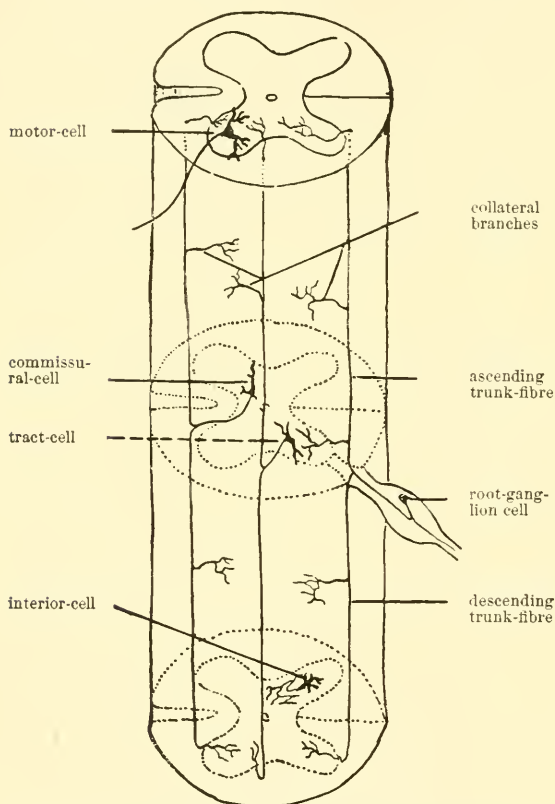


FIG. 177. SCHEME OF THE POSITION AND CONNEXIONS OF THE GANGLION-CELLS AND POSTERIOR ROOTS OF THE SPINAL CORD.

(After STÖHR)

its polar process through the anterior commissure to the anterior column of the opposite side (Fig. 177); here it divides into an ascending and a descending trunk-fibre, each of which at different levels gives off branch-fibres to the grey matter, and at length ends in branches of the same kind.

The **tract-cells** which, partly scattered, partly in groups, are situated in the central part of the anterior horn and in the lateral and posterior horns, send their axis-cylinder processes, after these have given off fine collateral twigs into the grey matter, into the anterior, the lateral, or the posterior column (Fig. 177). There each process divides into ascending and a descending trunk-

fibre, each of which at different levels gives off lateral and terminal branches to the grey matter of the corresponding side.

The **combination-cells** of RAMON Y CAJAL have axis-cylinder processes that subdivide within the grey matter in which they lie, sending one branch to the anterior column of the same side, the other to that of the opposite side.

The **interior-cells**, which are found only in the posterior horns (Fig. 177), have each an axis-cylinder process which subdivides into fine terminal branches within the grey matter of the same or of the opposite side (GOLGI).

The **root-ganglion cells** lie in the ganglionic enlargements of the posterior roots, and each has a polar process which divides close to its origin into two fibres, one with a peripheral and the other with a central course. These cells are therefore sometimes regarded as bipolar (Fig. 177). The fibre which enters the cord through the posterior root divides again into an ascending and a

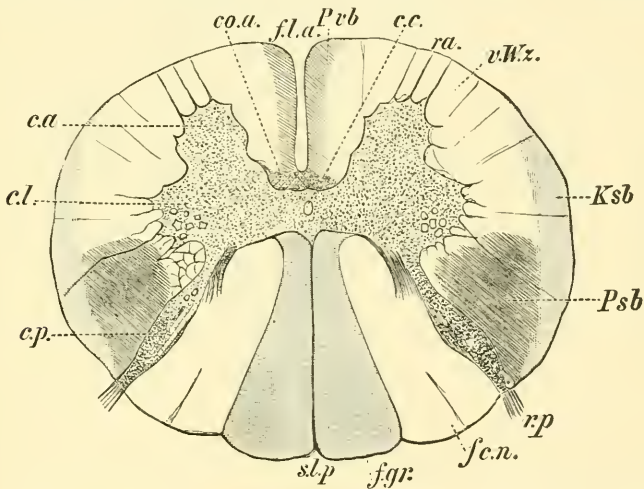


FIG. 178. DIAGRAMMATIC CROSS-SECTION OF THE SPINAL CORD SHOWING THE TRACTS OF THE WHITE MATTER.

<i>c.a.</i> (<i>cornu anterius</i>) anterior horn	<i>f.gr.</i> (<i>funiculus gracilis</i>) Goll's column
<i>c.l.</i> (<i>cornu laterale</i>) lateral horn	<i>f.cn.</i> (<i>funiculus cuneatus</i>) Burdach's column
<i>c.p.</i> (<i>cornu posterius</i>) posterior horn	<i>Ksb</i> (<i>Kleinhirnseitenbahn</i>) direct cerebellar tract
<i>c.c.</i> central canal in the grey commissure	<i>Psb</i> (<i>Pyramidalseitenbahn</i>) crossed pyramidal tract
<i>co.a.</i> anterior white commissure	<i>Pvb</i> (<i>Pyramidalvorderbahn</i>) direct pyramidal tract
<i>ra.</i> (<i>radix anterior</i>) anterior root	<i>v.W.z.</i> (<i>Vordere Wurzelzone</i>) anterior radicular zone
<i>rp.</i> (<i>radix posterior</i>) posterior root	
<i>f.l.a.</i> (<i>fissura longitudinalis anterior</i>) anterior fissure	
<i>sl.p.</i> (<i>septum longitudinale posterius</i>) posterior septum	

descending trunk. Each of these, after giving off collateral branches to the grey matter at different levels of the cord, ends in terminal branches within the grey matter, and so effects direct connexion between the root-ganglia and the ganglion-cells (including the motor-cells) of the grey matter of the cord.

The **white matter**, which consists chiefly of longitudinal medullated nerve-fibres of various thicknesses, has a supporting framework composed partly of connective tissue accompanying the blood-vessels, partly of neuroglia whose stellate cells (astroblasts) are long-rayed, having many long processes as well as short ones which twine about the medullary sheaths of the nerve-fibres. According to their function and their course, various tracts or systems of fibres are distinguished in the white matter.

passing downwards, and ascend along the outer border (Fig. 178 *Ksb*) of the lateral columns to the superior vermis of the cerebellum.

The remaining regions of the anterior and lateral columns have been named by FLECSIG the anterior ground-bundle, the lateral ground-bundle, and the lateral limiting tract, respectively. The last-named is situated between the crossed pyramidal tract and the posterior horn. BECHTEREW, passing from before backwards and from within outwards, describes the succession of parts thus: the anterior ground-bundle, the lateral ground-bundle, the fibres of the lateral tract, the antero-lateral tract (GOWERS' bundle, anterior to the direct cerebellar tract), and the medial bundle of the lateral column. These all have their centres in the grey matter of the cord, and passing partly upward, partly downward, give off collateral branches and end at different levels in the grey matter. GOWERS' bundle contains chiefly ascending fibres, which arise from cells partly in the anterior horns, partly in the central zone of the grey matter. Their terminal ramifications have not been made out.

In the **posterior columns** we distinguish the postero-external **column of Burdach** or funiculus cuneatus (Fig. 178 *fc. n.*), placed externally, and the postero-internal **column of Goll** or funiculus gracilis (*f.gr.*), placed medially. They both chiefly include radicular fibres from the root-ganglia, which divide and pass partly upward, partly downward, and from point to point during their course give off collateral branches to the grey matter. The descending branches terminate after a short course, the ascending branches are of various lengths. Some of the longer fibres, passing into the column of Goll, give off collateral branches, and extend as far as the clavate nucleus of the funiculus gracilis in the medulla. Others end in the nucleus cuneatus, others in the vesicular column of Clarke, and others again in the grey matter of the posterior and anterior horns of the same side. A few pass through the posterior grey commissure to the opposite side.

Besides the radicular fibres, the posterior columns contain some few fibres from the grey matter. In the posterior roots are also some outgoing fibres passing to the root-ganglia.

The **medulla oblongata** forms the meeting-place of spinal cord and brain, and here accordingly the cord undergoes certain changes of structure and configuration. First, the central canal is displaced dorsally and opens out into the **fourth ventricle** (Fig. 179). Secondly, the grey matter is as it were redistributed, white and grey forming between them peculiar reticulations and discrete aggregations of ganglion-cells, which give origin to the cerebral nerves (Fig. 179 *III-X*).

Accompanying the dispersal of the grey matter there is displacement of the conducting tracts of white matter. The crossed pyramidal tracts at the decussation of the pyramids pass over to the opposite side and assume a ventral position, while the short connecting tracts, that unite different parts of the grey matter, sink deeper into the interior. The column of Goll and the column of Burdach pass, as the funiculus gracilis (Fig. 179 *a*) and funiculus cuneatus (*b*), to the side of the fourth ventricle, and form with the direct cerebellar tracts and the arcuate fibres of SOLLY the restiform body (*c*), and farther on the inferior peduncles of the cerebellum (*e*).

Fresh masses of grey matter now make their appearance, and form the substratum of the olives, the parolivary bodies, the nucleus gracilis, the nucleus cuneatus, and other like structures. Arcuate fibres also are seen along with the longitudinal fibres; they lie partly on the exterior and partly in the interior strata and are interlaced with the longitudinal fibres.

References on the Structure of the Spinal Cord (see also Art. 106).

- ADAMKIEWICZ: Blood-vessels of the cord *Wien. Sitzungsber.* 1881, 1882
 BECHTEREW: *Die Leitungsbahnen im Gehirn und Rückenmark* Leipzig 1893
 CAJAL, R. Y: Structure of the central nervous system *A. f. Anat. u. Physiol.* 1893
 CRAMER: *Beitr. z. Anatomie der Medulla oblong. u. d. Brücke* Jena 1894
 EDINGER: *Zwölf Vorles. über den Bau der nervösen Centralorgane* Leipzig 1894
 FLECHSIG: *Die Leitungsbahnen im Gehirn und Rückenmark* Leipzig 1876, and *A. d. Heilk.* XVIII, XIX
 GAD: *Centren u. Leitungsbahnen im Rückenmark* 1884
 GOLGI: Minute structure of the cord, *A. ital. per le mal. nerv.* XVIII 1881, *Anat. Anzeiger* V 1890; *Untersuch. üb. d. feineren Bau des Nervensystems* Jena 1894
 GOLL: *Denkschr. d. med. chir. Gesellschaft d. Cantons Zürich* 1860
 GOWERS: Antero-lateral tract *Lancet* I 1886
 HIS: Histogenesis and interconnexions of the nerve-elements *Trans. internat. med. Congr.* II Berlin 1891; *A. f. Anat.* (supplement) 1890; *Die Neuroblasten und deren Entstehung im embryonalen Mark* Leipzig 1889
 KADYI: *Ueb. d. Blutgefäße des menschl. Rückenmarks* Lemberg 1889
 KÖLLIKER: The spinal cord *Z. f. wiss. Zool.* 51 1890; *Handb. d. Gewebelehre* II 1893
 LENHOSSÉK: *Der feinere Bau des Nervensystems* Berlin 1895
 LISSAUER: Course of fibres in posterior horn *A. f. Psych.* XVII 1886
 MARIE: *Diseases of the spinal cord* (New Syd. Soc.) London 1895
 OBERSTEINER and HILL: *Anatomy of central nervous system* London 1890
 ODDI and ROSSI: Afferent paths in the cord *A. ital. de biol.* XV 1891
 RIESE: Results of Golgi's method of silver-staining *Cent. f. allg. Path.* II 1891
 TOLDT: *Lehrbuch der Gewebelehre* Stuttgart 1888
 UNVERRICHT: Double decussation *Neurol. Cent.* IX 1890

89. The **malformations** of the spinal cord that are associated with malformations of the vertebral canal are dealt with in the volume on General Pathological Anatomy. When the vertebral canal is normally formed, the spinal cord is seldom malformed to any great extent; frequently, however, it exhibits minor deviations from the normal condition, some of which are associated with disorders of its function.

The external form of the spinal cord is seldom much altered; but cases of abnormal slenderness and shortness (**micromyelia**), of local defects and partial duplications (**diastematomyelia**), and of **asymmetry**, are now and then met with. Defects of single nerve-roots are not infrequent.

The cause of abnormal slenderness and of asymmetry of the cord is in part defective development of particular tracts, in part unequal distribution of the pyramidal tracts, the fibres of one side crossing entirely, or nearly so, at the decussation of the pyramids, while most of the fibres of the other tract descend on the original side.

Defective development of the tracts is sometimes primary and sometimes secondary; both forms are met with in the posterior column (KAHLER, WESTPHAL, JÄDERHOLM, SCHULTZE), as

well as in the others (KAHLER, PICK, WESTPHAL, FLECHSIG, FÜRSTNER). The defect may at a later period form the starting-point of a progressive disease. The causes of primary agenesis and hypoplasia are for the most part beyond our knowledge: the secondary varieties are chiefly due to absence or imperfect development of the centres or terminal organs connected with the tracts in question, or to separation of these from their centres. For example, agenesis or destruction of the motor area of the cortex cerebri causes incomplete development or even destruction of the corresponding pyramidal tracts. Sometimes defective development of the tracts and centres occurs in connexion with other local developmental defects, such as imperfect formation of the central canal and the structures surrounding it.

Abnormal arrangement of the grey matter and displacement of certain parts of it into the white matter, a condition known as **heterotopia**, may occur in any portion of the cord, and result in very marked abnormality; the condition is, however, infrequent. It should be noted that post-mortem mechanical injury of the cord may occasion distortions and displacements of the grey matter that look very like such heterotopic malformations.

Abnormality of the **central canal** and of the **grey commissure** is not uncommon; it chiefly takes the form of morbid enlargement and partial duplication of the canal, and of morbid overgrowth of the neuroglia of the grey commissure with the formation of cysts of disintegration in the proliferous tissue (compare Hydro-myelia and Syringomyelia, and Multiple Sclerosis, Arts. 95 and 96).

References on Malformations of the Spinal Cord.

- ADAMKIEWICZ: Absence of dorsal posterior roots *V. A.* 88 **1882**
 BENEKE: Diastematomyelia with spina bifida *Wagner's Festschr.* Leipzig **1887**
 BONOME: Partial duplication *A. per le scienze med.* xi **1887**
 BRAMWELL: *Diseases of the spinal cord* Edinburgh **1895**
 BUCHHOLZ: Developmental anomalies *A. f. Psych.* xxii **1890**
 FLECHSIG: *Ueber Systemerkrankungen* Leipzig **1878**
 FÜRSTNER and ZACHER: Developmental anomalies *A. f. Psych.* xii **1882**
 VAN GIESON: Artefacts of the nervous system *New York Med. Journ.* **1892**
 KOSSOWITSCH: Structure of the cord in a microcephalic child *V. A.* 128 **1892**
 LEBEDEFF: Duplication of the central canal in animals *V. A.* 86 **1881**
 LENHOSSÉK: Duplication of the cord *Cannstatt's Jahresber.* **1858**
 LEYDEN: *Klinik der Rückenmarkskrankheiten* 1 Berlin **1874**
 NONNE: On a peculiar family affection *A. f. Psych.* xxii **1890**
 OELLACHER: Duplication of central canal *Wien. Sitzungsber.* LXVII **1873**,
Innsbrucker Sitzungsber. **1875**
 PICK: Defects of the cord *Prager med. Woch.* **1881**; Duplication *A. f. Psych.* viii **1877**
 VON RECKLINGHAUSEN: Spina bifida *V. A.* 105 **1886**
 RUFFINI: Heterotopia of grey matter *Ziegler's Beiträge* xvi **1894**
 STEINLECHNER-GRETSCHISCHNIKOFF: Structure of the cord in microcephalia
A. f. Psych. xvii **1886**
 SULZER: Spina bifida with duplication of cord *Ziegler's Beiträge* xii **1893**

CHAPTER XXIX

DEGENERATION AND INFLAMMATION OF THE SPINAL CORD

90. The nerve-fibres and the ganglion-cells of the cord are structures that are exceedingly sensitive to injurious influences, and the nerve-fibres in particular are very easily destroyed. In many cases the **causes of atrophy and degeneration** of the nervous elements of the cord and medulla oblongata can be determined with certainty from the course of the disease and the morbid changes discovered; but in other, and these not infrequent cases, the cause cannot be made out. **Marasmus** or general wasting from old age or disease, and general **anaemia**, may induce simple atrophy or degenerative changes; and long-continued **disuse** or cessation of function also causes considerable wasting in the

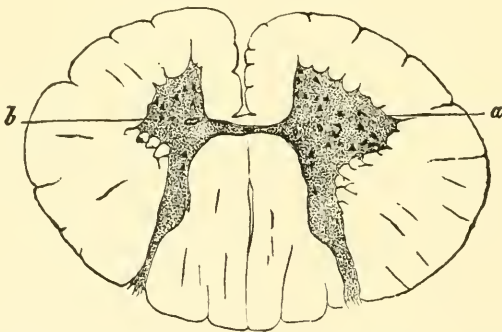


FIG. 180. ATROPHY OF THE LEFT ANTERIOR HORN FROM INTRA-UTERINE AMPUTATION OF THE LEFT FORE-ARM.

(From VON KAHLDEN)

a normal, b atrophic, anterior horn

nerve-tracts concerned. For example, amputation of a limb gives rise, after an interval of some years, to perceptible atrophy of the posterior columns and sensory roots, of the anterior horns (Fig. 180 *b*) and vesicular columns of Clarke, and often of the motor tracts of the corresponding side, the atrophy being manifested by diminution in size and in number of the ganglion-cells (*b*) and nerve-fibres. The number of nerve-elements thus lost is usually

greater in young persons than in adults, and is greatest of all when the peripheral organs have been destroyed during intra-uterine life.

A further cause of degeneration of nervous tissue is found in **disorders of the circulation**; and **ischaemia** from arteriosclerosis, hyaline arterial degeneration, thrombosis, or embolism, gives rise, as does also haemorrhage by rupture or by diapedesis, to a marked local degeneration of the cord known as **ischaemic** and **haemorrhagic myelomalacia**. It is very probable that there are many **poisonous substances** which are capable of inducing not only functional disturbance but also degenerative changes in the central nervous system, and particularly in the spinal cord. At any rate, in many diseases, such as chronic tuberculosis, diabetes, and syphilis, degeneration of the cord is a not uncommon symptom, and is hardly otherwise to be explained than on the assumption that not only the general anaemia, but also the presence of special noxious substances in the blood, have a degenerative effect on the nerve-fibres. Moreover, it has been demonstrated by TUCZEK that chronic ergotin-poisoning induces in man a typical degeneration of the posterior columns. This shows that poisons do exist outside the body, which, when ingested, exert a degenerative action on the central nervous system. A like action on the ganglion-cells, and especially on the motor-cells, is ascribed by many authorities to arsenic, lead, and mercury.

Among the most common causes of degeneration of the cord are **traumatic injuries** and **gradual compression**. The former result chiefly from fracture and dislocation of the spinal column, with consequent protrusion of bone into the vertebral canal (Fig. 181), or displacement of the vertebral bodies and arches (Fig. 90), whereby the cord is nipped and lacerated. Mere contusion or severe concussion of the spine may also give rise to textural change and degeneration of the cord, and of course cuts, stabs, and gunshot wounds are capable of destroying its structure.

From the researches of LEYDEN and NIKIFOROFF it appears that the rapid variations of **atmospheric pressure** to which divers and caisson workers are subject, when they come up from a

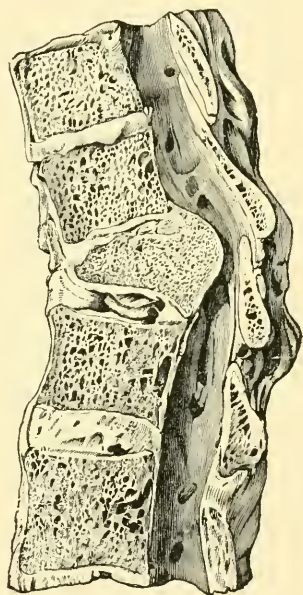


FIG. 181. CONTRACTION OF THE VERTEBRAL CANAL BY CRUSHING AND PROTRUSION OF THE SIXTH THORACIC VERTEBRA.

great depth to the surface, are apt to cause destruction of the substance of the cord, with laceration of the nerve-fibres. The cause is probably the rapid liberation into the tissues of bubbles of nitrogen absorbed by the blood under the high pressure to which it is exposed.

Compression of the cord is most frequently occasioned by tuberculous proliferation in the epidural space, by tumours (Fig. 182), and by displacement of the vertebrae or collapse of their bodies from caries. The compression ensues sometimes very gradually, sometimes rapidly; indeed, between compression and crushing no sharp line of distinction can be drawn. When the compression increases but slowly, the degeneration is chiefly due to interference with the circulation of the blood and lymph.

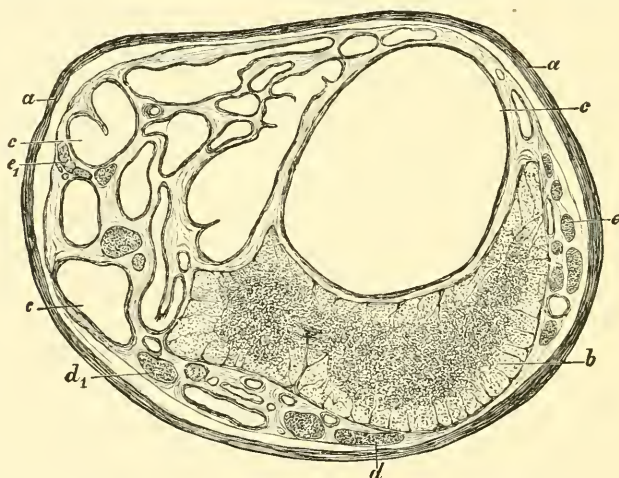


FIG. 182. COMPRESSION OF THE LUMBAR CORD BY CAVERNOUS TISSUE WITH DILATED VEINS FORMED ON THE DORSAL SURFACE OF THE PIA MATER.

(Preparation hardened in Müller's fluid and alcohol, embedded and cut in celloidin, stained with haematoxylin and carmine, and mounted in Canada balsam: $\times 4$)

a dura mater

b compressed cord

c venous spaces

d d₁ transverse section through the anterior roots

e e₁ transverse section through the posterior roots

Inflammations of the substance of the cord or of the pia mater lead in the first instance to local degeneration within the infiltrated region; they may however give rise to more extensive degeneration, especially when wide-spread oedema accompanies the local cellular infiltration. For example, purulent or tuberculous spinal meningitis may be combined with oedema involving the whole of the cord (Art. 103, Fig. 209), whereby its sectional diameter may be doubled.

The **causes of inflammation** of the cord are of many kinds; and according to the nature of the inflammatory irritant and its

mode of action we may classify the several varieties as traumatic, infective, toxic, haematogenous, lymphogenous, and conducted or secondary. Inflammation is frequently caused by the forms of degeneration already referred to, since the more intense local degenerations are apt to be combined with exudative processes, and in the later stages with hyperplastic proliferation. It is thus impossible to draw a sharp line between simple degenerations and inflammations, and accordingly the term **myelitis** has been applied both to processes that from the outset are characterised by inflammatory exudation, and to others that begin as degenerations and only in the later stages of their course are combined with morbid exudation and proliferation.

References on Atrophy of the Spinal Cord from Loss or Undergrowth of the Limbs.

- DAVIDA: The nerve-roots and ganglia in perobranchius *V. A.* 88 **1882**
 DRESCHFELD: Amputation *Journ. of Anat.* xiv **1879** (with references)
 EDINGER: Cord and brain in congenital absence of the fore-arm *V. A.* 89 **1882**
 (with references)
 FRIEDLÄNDER and BRAUN: Changes in the cord after amputation *Fortschr. d. Med.* iv **1886**
 GRIGORIEW: Changes in cord after amputation of limbs *Z. f. Heilk.* xv **1894**
 HAYEN and GILBERT: Changes in nervous system after amputation *A. de physiol.* iii **1884**
 HOMÉN: idem *Ziegler's Beiträge* viii **1890**
 VON KAHLDEN: Inflammation and atrophy of the anterior horns *Ziegler's Beiträge* xiii **1893**
 LEYDEN: *Klinik der Rückenmarkskrankheiten* ii Berlin **1876**
 PELLIZZI: Changes in the spinal cord after amputations *A. ital. de biol.* xviii **1892**
 REYNOLDS: Amputation *Brain* ix **1886**
 VULPIAN: Examination of the cord in cases of amputation *A. de physiol.* **1868**, **1869**, *Gaz. des hôp.* **1872**

References on Anaemic, Traumatic, Toxic, and Infective Degenerations and Inflammations (see also Art. 91).

- BECK: Case of anaemic softening *Inaug. Diss.* Tübingen **1887**
 BELMONDO: Pellagra *Riforma medica* **1889**
 BONOME: Tetanus *A. per le scienze med.* xv **1891**
 CLEMENS: Concussion of the spinal cord *Deutsche Klinik* **1863-65**
 CRAMER: Morbid anatomy of Landry's paralysis *Cent. f. allg. Path.* ii **1892**
 DEMANGE: Sclerotic lesions of the spinal vessels *Rev. de méd.* **1885**
 EHRLICH and BRIEGER: Effect on the grey matter of the lumbar cord of temporary ligation of the aorta *Z. f. klin. Med.* **1884**
 EISENLOHR: Acute affections of the medulla and pons *A. f. Psych.* ix **1878**
 FLEINER: Changes in the sympathetic and cerebro-spinal systems in Addison's disease *Cent. f. allg. Path.* ii **1891**
 GRÜNFELD: Action of ergot on the cord *A. f. Psych.* xxi **1890**
 VON KAHLDEN: Addison's disease *Ziegler's Beiträge* x **1891**; Inflammation and atrophy of the anterior horns *ibidem* xiii **1893**; Poliomyelitis anterior *Cent. f. path. Anat.* v
 KETSCHER: Morbid anatomy of paralysis agitans (atrophy of the nerve-elements and thickening of the vessels) *Prager Z. f. Heilk.* xiii **1893**

- KLEBS: Explanation of Landry's paralysis *Virchow's Festschrift (Assistenten)* Berlin 1891
- LAMY: Spinal lesions of vascular origin *A. de physiol.* VII 1895
- LEYDEN: *Klinik der Rückenmarkskrankheiten* Berlin 1874-76; Cord-affections due to sudden lowering of air-pressure *A. f. Psych.* IX 1879; Multiple neuritis and ascending atrophy after influenza *Z. f. klin. Med.* XXIV 1893
- LICHTHEIM: Pernicious anaemia *Verh. d. VI Congr. f. inn. Med.* 1889; Changes in the cord in general diseases *Cent. f. allg. Path.* I 1890
- MAYER: Anaemia of the cord *Prager Z. f. Heilk.* IV 1883
- VON MONAKOW: Lead-poisoning *A. f. Psych.* X 1880
- NAUWERCK: Origin of softening of the cord *Ziegler's Beiträge* II 1887
- NIKIFOROFF: Changes in the cord from sudden lowering of the air-pressure *Ziegler's Beiträge* XII 1892
- NONNE: Pernicious anaemia *A. f. Psych.* XXV 1893
- OBERSTEINER: Concussion of the cord *Wiener med. Jahrb.* 1879
- OPIENHEIM: Morbid anatomy of lead-palsy *A. f. Psych.* XVI 1885
- OTTO: Aneurysms of the spinal vessels *A. f. Psych.* XVI 1885
- POPOFF: Arsenic, lead, and mercury *V. A.* 93 1883; Changes in the nervous system in rabies *V. A.* 122 1890
- PUGIBET: Paralysis in dysentery *Rev. de méd.* VIII 1888
- DE QUERVAIN: Changes in the nervous system after removal of the thyroid (negative result) *V. A.* 133 1893
- REINHOLD: Focal and systemic degeneration *Cent. f. allg. Path.* II 1891
- SCHAFFER: Pathology of rabies *Ziegler's Beiträge* VII 1890
- SCHULTZE: Lead-palsy *A. f. Psych.* XVI 1885
- STIEGLITZ: Experimental researches on lead-poisoning (degeneration of the ganglion-cells of the anterior horns and roots) *A. f. Psych.* XXIV 1892
- SUMMA: Changes in the cord in phthisis *Inaug. Diss.* Freiburg 1891
- TIZZONI: Effects of removal of the adrenals in rabbits *Ziegler's Beiträge* VI 1889
- VON TSCHISCH: Poisoning with morphine, atropine, silver nitrate, and potassium bichromate *V. A.* 100 1885
- TUCZEK: Ergotism *A. f. Psych.* XIII 1882, XVIII 1887
- WESTPHAL: Nervous affections after small-pox and typhoid *A. f. Psych.* III 1872

91. **Simple atrophy** of the spinal cord or of its parts, without any very striking alteration of structure, appears as a senile change or as a result of disuse, for example after the amputation of a limb (Fig. 180). It also appears in the absence of these conditions, and from causes unknown to us. It may involve the nerve-fibres as well as the ganglion-cells, and it is at first indicated by diminution in size (Fig. 184 *a a*₁), and later on by complete disappearance, of these elements. The most important variety is progressive atrophy of the anterior horns, characterised chiefly by progressive diminution in size of the ganglion-cells. The anterior horns, which normally abound in ganglion-cells (Fig. 183 *a*), come at length to contain only a few scattered cells, and in certain spots none at all, while the nerve-fibres of the grey matter and of the anterior roots for the most part disappear outright (Fig. 184).

Degeneration of the cord and myelitis are, so far as the nervous elements are concerned, indicated in the early stages by disintegration of the myelin into drops of peculiar form (Fig. 185 *a d*), that soon yield the reaction of fat with perosmic acid,

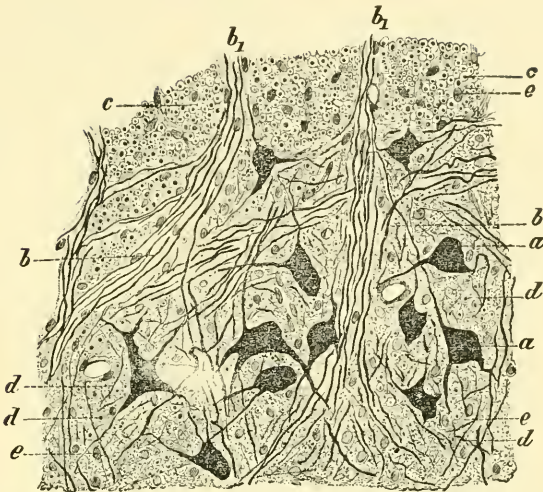


Fig. 183. TRANSVERSE SECTION THROUGH THE APEX OF THE LEFT ANTERIOR HORN OF A NORMAL SPINAL CORD AT THE LEVEL OF THE FOURTH CERVICAL NERVES.

(Preparation hardened in Müller's fluid and alcohol, stained with haematoxylin and carmine, and mounted in Canada balsam : × 150)

- | | |
|-------------------------------------------------------------------------------------------------------------------------------------------------------------------------------------------------------------------------------------|-------------------------------------------------------------------------------------------------------------------------------------------------------------------|
| <p><i>a</i> ganglion-cells
 <i>b</i> horizontal tracts of nerve-fibres within the grey matter
 <i>b₁</i> anterior nerve-roots
 <i>c</i> transverse sections of nerve-fibres in the adjacent white matter</p> | <p><i>d</i> fine and coarse nerve-fibres running in various directions, some cut transversely some longitudinally
 <i>e</i> nuclei of the neuroglia-cells</p> |
|-------------------------------------------------------------------------------------------------------------------------------------------------------------------------------------------------------------------------------------|-------------------------------------------------------------------------------------------------------------------------------------------------------------------|

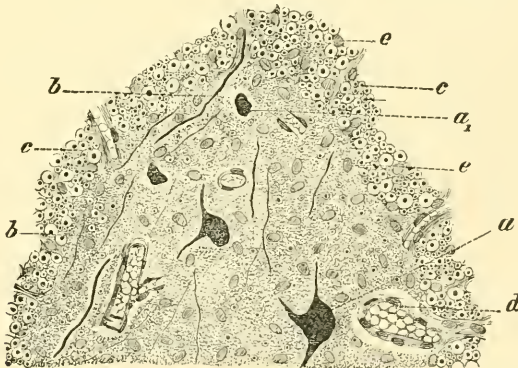


Fig. 184. TRANSVERSE SECTION THROUGH THE APEX OF AN ATROPHIC ANTERIOR HORN AT THE LEVEL OF THE FOURTH CERVICAL NERVES.

(From a woman of about forty who died from ascending atrophy of the anterior horns: preparation hardened in Müller's fluid and alcohol, stained with haematoxylin and carmine, and mounted in Canada balsam : × 150)

- | | |
|-------------------------------------------------------------------------------------------------------------------------------------------------|-----------------------------------------------------------------------------------------------------------------------------------------------|
| <p><i>a</i> normal ganglion-cells
 <i>a₁</i> atrophic ganglion-cells
 <i>b</i> surviving nerve-fibres of the grey matter</p> | <p><i>c</i> transverse section of nerve-fibres of the white matter
 <i>d</i> blood-vessel
 <i>e</i> nuclei of the neuroglia-cells</p> |
|-------------------------------------------------------------------------------------------------------------------------------------------------|-----------------------------------------------------------------------------------------------------------------------------------------------|

and breaking up into minute globules (*e*) disappear; by irregular and often marked swelling with subsequent disintegration of the axis-cylinders (*e c₁*); and by swelling with vacuolar, hyaline, and fatty degeneration, sometimes followed by disintegration, of the ganglion-cells (**white softening**). Inequalities in the amount of the myelin ensheathing the axis lead to the formation of varicose nerve-fibres (*b*); irregular swelling of the axis itself to the formation of varicose axis-cylinders (*c₁*).

If an inflammatory exudation with cellular infiltration co-exists with the general disintegration, leucocytes are intermingled with the detritus of the nerve-matter, or cellular infiltration appears about the blood-vessels, as the leucocytes collect first in the

lymph-sheaths that surround the vessels and are continuous with the sub-arachnoid spaces. In cases of haemorrhage red blood-corpuses are of course contained in the disintegrating tissue (**red softening**).

The neuroglia-cells often remain unchanged, even in cases where there is much disintegration of the nerve-elements; but not infrequently they perish with the nerve-cells within the region of degeneration: in this way the destruction of the substance of the spinal cord may be so complete that only the vessels and the larger meshes of the supporting connective tissue remain. Even these may however be destroyed, at least in part, in cases

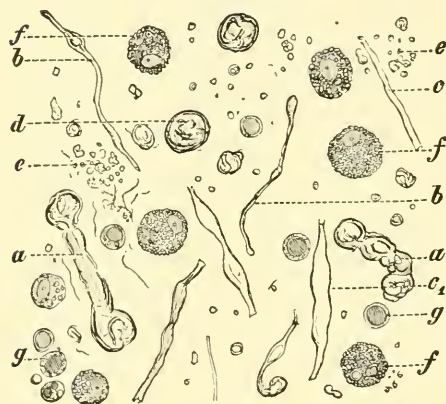


Fig. 185. DEGENERATION OF THE CORD FROM COMPRESSION.

(Teased preparation from the white matter: $\times 300$)

- a* nerve-fiber with coagulated myelin sheath
- b* axis-cylinder with some adherent myelin
- c* naked axis-cylinder
- c₁* naked and swollen axis-cylinder
- d* free myelin drops
- e* free detritus of the myelin and axis-cylinders
- f* spherical cells with fat-granules
- g* small-round-cells

of extensive necrosis and suppuration of the cord.

In primary inflammation and in non-inflammatory degeneration, an accumulation of migratory cells within the altered tissue takes place, owing to the presence in it of the products of disintegration. These cells, taking up by their amoeboid movements the detritus of the cord, and in particular the granules of myelin, are converted into **fat-granule cells** (Fig. 185*f*). When haemorrhage has supervened, **pigment-granule cells** are formed, which are loaded with the products of disintegration of the blood (**yellow softening**).

When the tissue is completely disintegrated, the various pro-

ducts of disintegration and the granule-carrying cells are mingled together; and if the neuroglia remains, those cells occupy the place of the destroyed nerve-fibres in the meshes of the supporting framework (Fig. 186 *d*). The granule-cells, which are first seen some days after the onset of the degeneration, may be leucocytes extravasated from the blood-vessels; to these, however, newly-formed cells derived from the proliferation of the connective tissue of the vessels and vessel-sheaths, and sometimes of the pia mater also, are soon added, and in the later stages of the process these proliferous cells probably predominate.

During disintegration of the nerve-tissue liquid always collects along with the infiltrated cells within the region of disintegration; in this liquid the products of disintegration become partially dissolved. According to STROEBE, rounded homogeneous or occa-

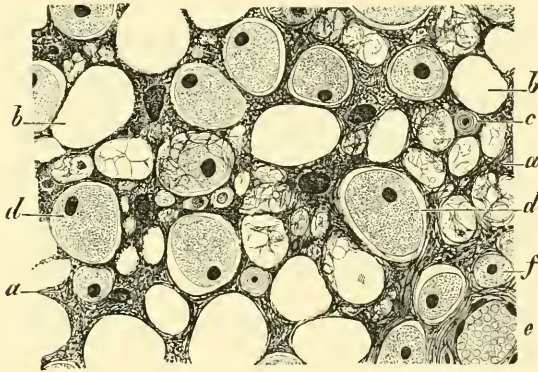


FIG. 186. MYELITIS FROM COMPRESSION.

(Fourth week after the compression: preparation hardened in Müller's fluid and alcohol, stained with hæmatoxylin and carmine, and mounted in Canada balsam: $\times 500$)

- | | |
|------------------------------------------------|----------------------------------------------------------------|
| <i>a</i> supporting tissue of the white matter | <i>d</i> large fat-granule cells, the fat being dissolved out |
| <i>b</i> vacant nerve-spaces | <i>e</i> blood-vessel |
| <i>c</i> persistent nerve-fibres | <i>f</i> adventitia of the blood-vessel with fat-granule cells |

sionally stratified globules, the so-called **corpora amylacea**, are developed from the swollen axis-cylinders; these resist solution and remain permanently lodged in the tissue. In certain very rare cases, when the destructive process involves isolated cells only, the altered ganglion-cells are liable to become calcified.

The pigment-granule cells sometimes remain a long time within the area of disintegration, and then perish. Those, however, that originate from proliferous connective tissue have the power, after the dissolution of the detritus they enclose, of taking part in the formation of new connective tissue. Some may pass into the circumvascular lymph-spaces of the cord (Fig. 186 *f*) and thence reach the pia mater and the subarachnoid spaces.

intervascular network (*d*) whose meshes are filled with liquid, can still be recognised.

The complete development of sclerosis always requires a considerable time, it may be many months. The original structure of the cord remains distinct in the white matter, provided it is not entirely disintegrated, inasmuch as the spaces formerly occupied by the nerve-fibres are not completely filled up by neuroglia (Fig. 187 *b*). As the fibres run for the most part in the longitudinal direction, in a cross-section they are cut transversely (Fig. 187 *b*): there are, however, places where they run mainly in a horizontal direction, and there of course the cross-section will cut them longi-

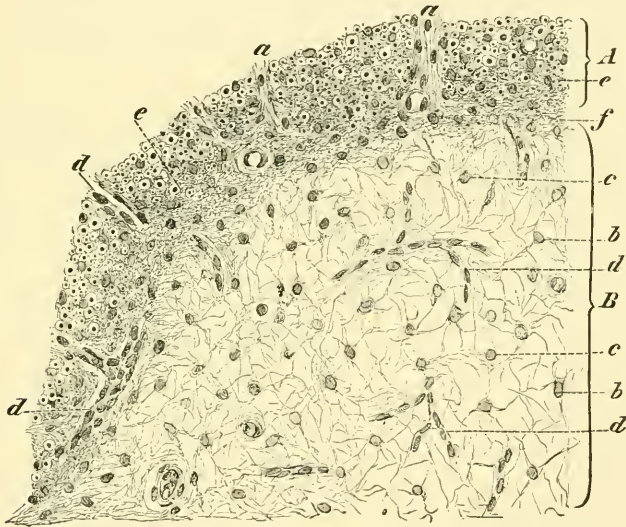

FIG. 188. GREY GELATINOUS DEGENERATION OF THE ANTERIOR HORN OF THE CORD.

(From the lumbar cord twenty months after the onset of acute poliomyelitis: preparation hardened in Müller's fluid, stained with haematoxylin and carmine, and mounted in Canada balsam: $\times 200$)

- | | |
|-------------------------------------------------------------------------------|------------------------------------------------------------------|
| <i>A</i> white matter | <i>c</i> round-cells with no processes |
| <i>B</i> apex of the anterior horn | <i>d</i> blood-vessels |
| <i>a</i> atrophic anterior roots devoid of nerve-fibres | <i>e</i> sclerosis of the adjoining portion of the white columns |
| <i>b</i> branched neuroglia-cells forming a network of fine glistening fibres | <i>f</i> dense sclerosis of the border of the anterior horn |

tudinally. The closeness and density of the sclerotic tissue vary greatly with the duration of the process and the nature of the degeneration.

In the grey matter the fully formed sclerotic tissue is sometimes close, sometimes loose in texture (Fig. 188 *B*). If the tissue collapses and shrinks, the sectional area of the cord, or it may be of the affected grey matter only, is diminished.

The sclerotic patches appear grey in colour, as they contain no

myelin. Dense scleroses look firm and dry even to the unaided eye. Loose-textured patches seem gelatinous, and do not indeed deserve the name of scleroses; a more suitable term to distinguish the condition from the true or hard scleroses would be **grey gelatinous degeneration**.

Connective tissue forms in the cord chiefly after severe lesions, such as section, laceration, and suppuration. The proliferation starts from the pia mater and from the adventitial sheaths of the vessels; and in the process of repair it builds up granulation-tissue, which later on passes into scar-tissue of the ordinary fibrous character.

References on the Histological Changes in Foci of Degeneration and Inflammation (see also Arts. 90 and 94).

- CRAMER: Commencing multiple sclerosis and acute myelitis *A. f. Psych.* XIX 1888
- EULENBURG: Art. Bulbar paralysis *Eulenburg's Realencyklop.* III 1894
- FRIEDMANN: Ganglion cells in acute myelitis *Neurol. Cent.* 1891
- HOMEN: Experiments on dogs *Comptes rendus* XCVI 1883; *La moelle épinière* Paris 1885
- VON KAHLDEN: Inflammation and atrophy of the anterior horns *Ziegler's Beiträge* XIII 1893
- LEYDEN: Myelitis from injection of Fowler's solution of arsenic *A. f. Psych.* VII 1877; Case of haematomyelia *Z. f. klin. Med.* XIII 1887
- NAUWERCK: Myelitis *Ziegler's Beiträge* II 1887
- ROSENBACH and SCHTSCHERBAK: Changes in the cord from compression *V. A.* 122 1890
- SCHAFFER: Paralysis agitans *Jahrb. f. Psych.* XII 1894
- SCHMAUS: *Die Compressionsmyelitis bei Caries d. Wirbelsäule* Wiesbaden 1889; Morbid anatomy of concussion of the spine *A. f. klin. Chir.* XLII 1891, *V. A.* 122 1890
- SPRONCK: Experimental researches on lesions of the cord due to transient anaemia *A. de physiol.* I 1888
- STROEBE: Experiments on degeneration and regeneration in the healing of wounds of the cord *Ziegler's Beiträge* xv 1892 (with references)
- TIETZEN: Acute softening of the cord *Inaug. Diss.* Marburg 1886
- TOOTH: Changes in nerve-fibres *B. M. J.* I 1889

92. If a nerve-fibre is interrupted by degeneration or inflammation, **secondary degeneration** always ensues in the portion of the fibre that is severed from the body of its ganglion-cell, and extends throughout the entire length of the distal portion. The explanation of this degeneration lies in the fact that the nerve-fibre is but a process of the cell, and can retain its life only so long as its connexion with the cell-body is maintained. According to the direction of normal conduction in the fibre, we distinguish between ascending and descending forms of secondary degeneration.

Descending degeneration is observed most frequently in the pyramidal tracts (Fig. 178 *Psb* and *Pvb*), and ensues in all cases in which the motor centres of the cerebral cortex, or the motor fibres in their course downward through the corona radiata, the

internal capsule, the crura cerebri, and the pyramidal tracts, are anywhere destroyed. It extends downwards to the point where the interrupted fibres enter the anterior horn of the cord. In rare cases the ganglion-cells of the anterior horns are also involved in the atrophy, whereupon the motor fibres passing out of the cord degenerate in their turn.

If the seat of the primary degeneration is in the cord, and the entire transverse section of the tracts is interrupted, the remainder of the antero-lateral columns below the interruption degenerate also. But the degeneration is not extreme for more than a distance of one or two centimetres; beyond this only a few isolated fibres are affected. Moreover, in particular fibres of the posterior ground-bundles secondary degeneration extends downwards for about six centimetres; the regions near the posterior septum on either side are however spared. The degenerate fibres are in part those which come from the posterior roots, and after their entrance into the cord pass downwards for some distance.

Ascending degeneration sets in after transverse lesions of the cord and of the fibres of the posterior roots. After complete interruption of the cord all the posterior tracts degenerate for a short distance above the injured region, the degeneration extending farther only in the columns of Goll (Fig. 178 *f. gr.*), where it advances up to the clavate nucleus of the funiculus gracilis. The degeneration following on destruction of the posterior roots is of the same kind, for the columns of Goll have their trophic centres in the root-ganglia. If the interruption of the cord is situated in the upper thoracic region, the direct cerebellar tract (Fig. 178 *Ksb*), proceeding from the column of Clarke to the upper vermis of the cerebellum, also degenerates above the injured spot; and so also does a bundle lying in front of this and passing along the outer margin of the lateral column (GOWERS' tract or antero-lateral fibres).

Secondary degeneration begins at the same time throughout the whole of the affected nerve-tract. It is recognisable on microscopic examination as early as the second day after the interruption of conductivity (STROEBE), the destruction of the myelin-sheaths having then already begun. After some days more disintegration of the axis-cylinder also can be demonstrated.

When the disintegration has reached a certain point, absorption of the detritus begins, and granule-carrying cells make their appearance. The spaces left vacant by the degeneration are partly filled up with liquid, partly with proliferous neuroglia; though months and even years may pass before the newly-formed neuroglial tissue becomes dense and closes up its meshes.

A degenerated tract examined after two or three months (Fig. 189 *B*), assuming that all or most of its fibres have perished, is found to consist mainly of a reticular mesh-work (Fig. 189 *b*), whose interspaces are empty or contain liquid, with here and there

masses of detritus and fat-granule cells (*d*). Generally speaking, all the fibres of a tract are not interrupted, and so the microscopic preparation of the tissue includes cross-sections of nerve-fibres. The reticular framework is only moderately thickened; but it stains more deeply with carmine than does normal tissue. After the lapse of from six to twelve months or more, most of the meshes have become smaller (Fig. 190), while the reticular tissue (*b*) has increased in bulk by hyperplasia.

Fat-granule cells (*d*) are still found after an even longer interval, lying partly in the spaces vacated by the nerve-fibres,

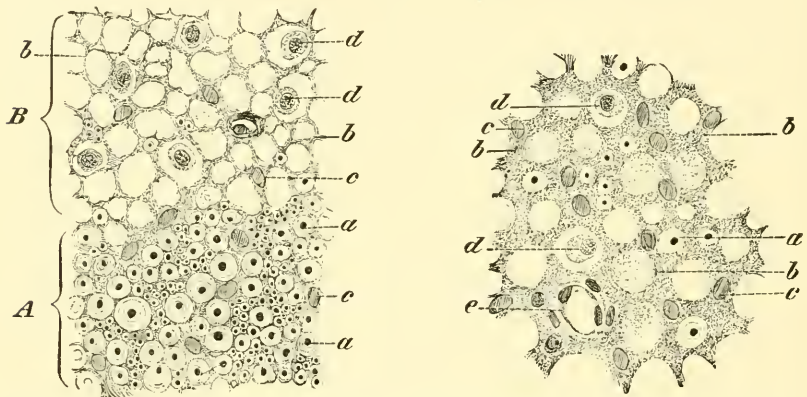


FIG. 189. ASCENDING DEGENERATION OF THE CORD ABOVE A COMPRESSED PORTION. (Preparation made two and a half months after the onset of the compression: hardened in Müller's fluid, stained with haematoxylin and carmine, and mounted in Canada balsam: $\times 250$)

- | | | | |
|---|--------------------------------------------------------|---|----------------------------------------------------------|
| A | transverse section through normal white matter | b | neuroglia-tissue |
| B | transverse section through the degenerate white matter | c | neuroglia-cells |
| a | normal nerve-fibres | d | fat-granule cells after removal of their fat by solution |

FIG. 190. ASCENDING DEGENERATION OF THE CORD.

(Preparation made eighteen months after the onset of compression: hardened in Müller's fluid, stained with haematoxylin and carmine, and mounted in Canada balsam: $\times 250$)

- | | | | |
|---|------------------------------------|---|-----------------------------------------------|
| a | transverse section of nerve-fibres | d | fat-granule cells after solution of their fat |
| b | hyperplastic neuroglia-tissue | | |
| c | nuclei of the neuroglia-cells | | |

partly also in the adventitial lymph-sheaths of the vessels in and about the area of degeneration. They are often also to be seen in the lymph-spaces of the pia mater.

So long as the degenerated tracts contain products of disintegration in considerable quantity, namely during the first two or three months, they appear white, opaque, and abnormally soft. After absorption of the detritus has taken place, the patches become grey, and at the same time diminish in bulk.

References on Secondary Degeneration.

- AUERBACH: Ascending degeneration *V. A.* 124 **1891**
- BARBACCI: Secondary degeneration *Cent. f. allg. Path.* II **1891** and III **1892**
- BIANCHI and D'ABUNDO: Descending degeneration after removal of motor centres *Neurol. Cent.* V **1886**
- BOYCE: Pyramidal tracts *B. M. J.* II **1893**
- BRAMWELL: *Diseases of the spinal cord* Edinburgh **1895**
- CHARCOT: *Leçons sur les maladies du syst. nerv.* Paris **1874**; *Leçons sur les localisations dans les mal. du cerveau* I **1876**
- FLECHSIG: *Die Leitungsbahnen im Gehirn und Rückenmark* **1876**; *A. d. Heilk.* XVIII **1877**; *Ueber Systemerkrankungen* Leipzig **1878**
- FÜRSTNER and KNOBLAUCH: Atrophy of fibres in the grey matter, and karyokinesis in the cord, in pathological conditions *A. f. Psych.* XXIII **1891**
- GIERLICH: Secondary degenerations in infantile cerebral paralysis *A. f. Psych.* XXIII **1891**
- GOMBAULT and PHILIPPE: Systemic lesions in the white tracts *A. de méd. exp.* **1894**
- HAYEM: Changes in the cord following avulsion of the sciatic nerve *A. de physiol.* V **1873**
- HOMÉN: *V. A.* 88 **1882**; *Contrib. expér. à la pathol. et à l'anat. pathol. de la moelle épinière* Helsingfors **1885**; Lesions of the cord due to hemisection *Comptes rendus* XCVI **1883** and *Fortschr. d. Med.* III **1885**
- ISARTIER: *Des dégén. second. de la moelle épin. conséc. aux lésions de la subst. cortic. du cerveau* Paris **1878**
- KAHLER and PICK: Secondary degenerations *A. f. Psych.* X **1879** (p. 328)
- KLIPPEL and DURANTE: Retrograde degenerations *Rev. de méd.* **1895**
- LANGLEY: Summary of observations *Brain* IX **1886**
- LEYDEN: *Klinik der Rückenmarkskrankh.* II
- LÖWENTHAL: *Fortschr. d. Med.* I, *Revue méd. de la Suisse romande* **1885**
- MARTINOTTI: Degenerations of the cord secondary to cortical lesions *Collezioni ital. di lettura sulla medicina* 3rd series 11 and 12 **1885**
- MEYER: Haemorrhage into the pons with degeneration of the fillet *A. f. Psych.* XIII **1882**
- MOTT: Ascending degenerations in monkeys *Brain* XV **1892** [LI **1893**
- MURATOFF: Bilateral degeneration of pyramidal tract *A. f. Anat. u. Physiol.*
- ODDI and ROSSI: Degenerations secondary to section of the posterior roots *A. ital. de biol.* XIII **1890**
- PATRIK: Ascending degeneration *A. f. Psych.* XXV **1893**
- SANDMEYER: *Cent. f. allg. Path.* II (p. 376)
- SCHAFFER: Secondary multiple degeneration *V. A.* 122 **1890**; Histology of secondary degeneration *A. f. mikrosk. Anat.* XXXIII **1893**
- SCHULTZE: *Cent. f. med. Wiss.* **1876**; *V. A.* 79 **1880**; *A. f. Psych.* XIII, XIV
- SHERRINGTON: Bilateral degeneration *Brain* VIII **1886**; Ascending degeneration *Journ. of Physiol.* XIV **1893**
- SINGER and MÜNZER: *Fortschr. d. Med.* **1891** (p. 755); *Denkschr. Wien. Akad.* **1890**
- SOTTAS: Degeneration secondary to lesions of posterior roots *Rev. de méd.* **1893**
- STROEBE: Experimental researches on degeneration and repair after injuries *Ziegler's Beiträge* XV **1894**
- TOOTH: Division of posterior roots etc. *B. M. J.* I **1889**; *Secondary degeneration of the spinal cord* London **1889**
- TÜRCK: *Z. der Gesellsch. d. Aerzte in Wien.* **1850**, and *Wien. Sitzungsber.* VI **1851**, XI **1853**, XIV **1855**
- WALLER: *London Journ. of Med.* IV **1852**, and *Müller's Arch.* **1862**
- WEIGERT: Morbid histology of neuroglia *Cent. f. allg. Path.* I **1890**
- WESTPHAL: Peculiar characters of secondary degeneration *A. f. Psych.* II **1870**
- ZIEHEN: Extirpation of motor centres and secondary degeneration *A. f. Psych.* XVIII **1887**

CHAPTER XXX

THE FORMS OF MYELITIS

93. All lesions of the spinal cord that result from cuts, stabs, or gunshot wounds, and from contusion, fracture, or dislocation of the spine, may be included under the head of **traumatic myelitis**. We may also include the crushing of the cord that occurs suddenly in caries of the vertebrae, when the spinal column gives way by collapse of the vertebral bodies, and the bones encircling the canal are relatively displaced.

The immediate result of such traumatic violence is more or less extensive bruising and stretching, or complete crushing of the cord, with the possible addition of haemorrhage. The lesion is slightest in simple concussion, and in those minor displacements of the bones of the spine that involve only slight and partial nipping of the cord. If no septic infection accompanies the injury, disintegration of the nerve-elements follows in the damaged region; sometimes the neuroglia and connective tissue also suffer, and the substance of the cord undergoes progressive colliquative softening. When there is no haemorrhage, the condition is called **white softening**; when haemorrhage is present, **red softening**. Destruction of the entire transverse section of the cord involves interruption of all the conducting tracts, and consequently leads to the secondary degenerations discussed in Art. 92; it also induces degeneration of the peripheral motor nerve-fibres whose ganglion-cells have perished. When the cord is only partially destroyed the resulting secondary degeneration is naturally more or less limited. The intensity of the inflammation induced by injury and softening is generally proportional to the severity of the lesion.

Repair is effected by the production of sclerosis or of a fibrous cicatrix. The former is the usual result after severe lesions combined with damage to the membranes; the latter follows slighter lesions which leave the pia mater intact. Where the sclerosis or cicatrix is of considerable size, the cord becomes notably contracted, and may be reduced to a mere string. If the wound of the cord become infected, suppuration may ensue, and extend to the adjoining structures, and in particular to the membranes. Disorders of the circulation of the blood and lymph, such as are

generally associated with the changes at the site of the lesion, may give rise to patches of white and red softening (STROEBE) at remote points, or to dilatation of the central canal.

Under the head of **myelitis from compression** are grouped all traumatic lesions wherein the spinal cord is subjected to gradually-increasing local pressure, and is thus caused to become degenerate. The most common cause of these lesions is tuberculous disease of the spine and dura mater, primary or secondary new-growths in the membranes or more rarely in the cord itself, or distension of the central canal with effused liquid or blood (Art. 95).

The degeneration of the cord is in such cases essentially due to disturbance of the circulation of the blood or lymph. It appears first in the white columns, the fibres of which at the point of pressure may within six hours from the beginning of compression swell up and disintegrate (KAHLER). The ganglion-cells usually persist much longer. The disintegration of the nerve-fibres always leads to the appearance of granule-carrying cells (Fig. 185 *f* and Fig. 186 *d f*). Secondary degeneration invariably accompanies the breaking down of the nerve-fibres at the seat of compression.

Proliferation of the neuroglia follows upon the disappearance of the nerve-fibres, and leads in the course of some months to sclerosis both of the part compressed and of the tissue along the track of the secondary degeneration (Fig. 190 *b*).

References on Myelitis from Traumatic Injury and Compression
(see also Arts. 90 and 91).

BRUNS: Traumatic destruction of the cord *A. f. Psych.* xxv 1893 (with references)

KAHLER: Compressive degeneration *Prag. Z. f. Heilk.* III 1882

KAHLER and PICK: Compression *A. f. Psych.* x 1879

LEYDEN: *Klinik d. Rückenmarkskrankheiten* 1874-76; Case of haematomyelia *Z. f. klin. Med.* xiii 1887

MICHAUD: *Sur la myélite et la méningite dans le mal vertèbr.* Paris 1871

MÜLLER, W.: *Beitr. z. path. Anat. u. Physiol. des Rückenmarks* Leipzig 1871

94. The affections included under the term **haematogenous myelitis** begin in part as degenerations with haemorrhage, in part as exudative inflammations characterised from the outset by the appearance of infiltrations round the blood-vessels.

Haematogenous myelitis is essentially a **focal disease** (solitary or multiple). Sometimes, however, when the foci are very numerous, and appear in combination with general disturbance of the circulation and inflammatory oedema, and with secondary degenerations, the lesion becomes so wide-spread that it might fairly be described as **diffuse myelitis**.

If the focus of disease be seated in the white matter the affec-

tion is known as **leucomyelitis** (λευκος white); if the grey matter be involved we have **poliomyelitis** (πολιος grey); extension of the inflammation over the whole cross-section, or the greater part of it, gives rise to **transverse myelitis**.

Opportunity is seldom afforded us to investigate the initial stages of the process, and often we cannot determine whether it has originated from ischaemia or haemorrhage, due to changes in the vessels, or whether it is to be attributed to the action of poisons or infections. Among the infective agents to be considered in this connexion are the pyogenic micrococci, the *Diplococcus pneumoniae*, the virus of rabies, tubercle-bacilli, lepra-bacilli, and the virus of syphilis. Among the poisons must be mentioned, first, such as arise autogenetically in the course of infective disease, and in the second place noxious substances of vegetable and mineral origin, such as ergot, lead, and arsenic.

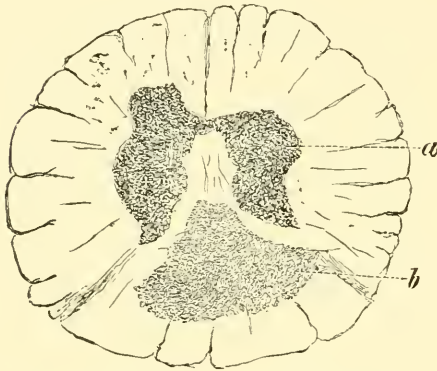

FIG. 191. SCLEROSIS AND CONTRACTION OF THE ENTIRE GREY MATTER OF THE CORD.

(From the lower thoracic region of the cord of a man aged about thirty, who suffered from acute poliomyelitis: preparation hardened in Müller's fluid, and stained with carmine: $\times 6$)

- a sclerotic grey matter
b sclerotic patch in the posterior columns

The most important changes accompanying haematogenous myelitis are the degeneration and disintegration of the nerve-elements, which take place in the manner described in Art. 91. The inflammatory exudation is usually not a very prominent feature, and is only temporary; in rare cases, however, it becomes

purulent, and then suppuration ensues, with the formation of an abscess. If the foci of suppuration are small the pus may be re-absorbed, and the cavities undergo cicatrisation; larger foci tend to become surrounded by an encysting envelope of granulation-tissue. Infection of the pia mater from such abscesses in the cord leads to meningitis.

The usual termination of myelitis is the formation of a grey sclerotic patch, within which the nerve-elements have more or less entirely perished (Fig. 191 *a b* and Fig. 192 *a b c*); but cases are met with in which such sclerotic induration is very slight, or altogether absent.

Transverse myelitis leads to a diminution of the sectional area of the cord, the white tracts presenting a greyish appearance when many nerve-fibres have been lost (Fig. 192 *c*), while in the grey matter (*a b*) the ganglion-cells and nerve-fibres are more or less

completely destroyed, and their place is taken by sclerotic tissue. Focal leucomyelitis gives rise to the formation of circumscribed grey patches (Fig. 191 *b*). Poliomyelitis often produces contraction and deformity of the grey matter (Fig. 191 *a*), though the form of the horns is sometimes preserved. All the varieties of focal degeneration induce secondary degenerations, which in leucomyelitis involve especially the tracts of the white matter, and in poliomyelitis the anterior roots also.

The absence of sclerosis in myelitic foci may be due to the fact that too short a time has elapsed since the onset of the primary disintegration. The proliferation of the neuroglia is however sometimes inconsiderable, even after the affection has existed for a long period; this is especially apt to be the case in the region of the grey matter.

Extensive destruction of the neuroglia is also unfavourable to proliferation, as is also advanced age on the part of the patient. Moreover, an inflammation which is restricted to the formation of an exudation within the lymph-sheaths of the vessels, and causes no injury to the nerve-elements, may pass away without inciting the neuroglia to proliferation.

Transmitted or consecutive myelitis is commonest as a result of acute spinal meningitis; the inflammation extends to the cord along the vessels, and leads to **meningo-myelitis** (Art. 103); from this may arise cellular infiltration of the vascular sheaths, diffuse oedematous swelling of the cord, and degeneration of the nerve-fibres and nerve-cells. In rare cases inflammatory irritants are disseminated by way of the central canal, as in cases of suppuration in or about the fourth ventricle. They give rise to **central myelitis** extending over the whole length of the cord, and manifested by oedema, cellular infiltration, and disintegration of the tissue, first of the grey commissure, later on of the anterior and posterior horns, and finally of the white columns.

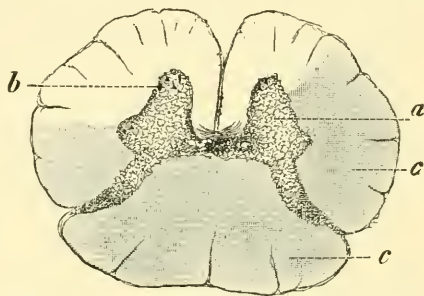


FIG. 192. TRANSVERSE SCLEROSIS OF THE CORD.

(From the lower thoracic region of the cord of a man aged about forty, who suffered from transverse myelitis: preparation hardened in Müller's fluid, and stained with carmine: $\times 6$)

- a* gelatinous-looking degenerate grey matter
- b* persisting ganglion-cells
- c* atrophic and sclerotic white matter

References on Myelitis (see also Arts. 90 and 96).

- ACHARD and GUINON: Diffuse acute myelitis *A. de méd. exp.* I 1839
- BOINET and SALEBERT: Motor troubles in malarial affections *Rev. de méd.* IX 1889
- BUSS: Disseminated acute myelitis of the medulla *D. A. f. klin. Med.* XLI 1887
- CHARCOT: *Diseases of the nervous system* (New Syd. Soc.) London 1877-83; *Oeuvres complètes* Paris 1887
- CRAMER: Commencing multiple sclerosis and acute myelitis *A. f. Psych.* XIX 1888
- DAMASCHINO and ROGER: Poliomyelitis *Gazette méd.* 1881
- DÉJÉRINE and HUET: Atrophic hemiplegia of infants *A. de physiol.* I 1888
- DRESCHFELD: Disseminated myelitis *B. M. J.* I 1894
- DUJARDIN-BEAUMETZ: *De la myélite aiguë* Paris 1872
- EISENLOHR: Acute dorsal myelitis *V. A.* 73 1878
- ETTER: Acute bulbar myelitis *Corresp. f. Schweizer Aerzte* 1883
- FRANCOTTE: Morbid anatomy of the cord *A. de neurol.* 1890
- FRIEDMANN: Ganglion-cells in acute myelitis *A. f. Psych.* XIX 1887; *Neurol. Cent.* 1891
- GRASSET and RANZIER: *Traité des maladies du système nerveux* Montpellier 1894
- HAMILTON: Experimental myelitis *Quart. Journ. of Microsc. Sci.* IX 1875
- HAMMOND: *Diseases of the nervous system* New York 1886
- HAYEM: Two cases of diffuse acute central myelitis *A. de physiol.* I 1874
- HERTER: Experimental myelitis *Philad. Med. News* 1889
- HLAVA: Poliomyelitis acuta disseminata *Arch. bohèmes de méd.* IV 1891
- KUSSNER and BRÖSIN: Myelitis acuta disseminata *A. f. Psych.* XVII 1886
- KÜSTERMANN: Acute myelitis *A. f. Psych.* XXV 1894
- LANGHANS: Tetanus und Lepra anaesthetica *V. A.* 64 1875
- LAVERAN: Case of subacute central myelitis with nephrocystitis and pyaemia *A. de physiol.* II 1875
- LEYDEN: *Klinik der Rückenmarkskrankheiten* Berlin 1874-1876; *Z. f. klin. Med.* I 1879; *A. f. Psych.* VI; Case of haematomyelia *Z. f. klin. Med.* XIII 1887; Acute myelitis *D. med. Woch.* 1892; Chronic myelitis *Z. f. klin. Med.* XXI 1892; *Cent. f. Nerrenheilk.* XXI 1892
- MACWEN: *Pyogenic infective diseases of the brain and spinal cord* Glasgow 1893
- MARIE: *Diseases of the spinal cord* (New Syd. Soc.) London 1895
- NAUWERCK: Chorea *Ziegler's Beiträge* I 1886; Myelitis *ibidem* II 1887
- REDLICH: Paralysis agitans (circumvascular sclerosis) *Jahrb. f. Psych.* XII 1893
- SCHIAFFER: Pathology of rabies *Ziegler's Beiträge* VII 1889
- SCHULTZE: *D. A. f. klin. Med.* XX; Poliomyelitis anterior acuta *V. A.* 68 1876
- ULLMANN: Abscess of the cord *Z. f. klin. Med.* XVI 1889
- VON VELDEN: Disseminated myelitis *D. A. f. klin. Med.* XIX
- WELLER: Cerebral and spinal changes in rabies *A. f. Psych.* IX 1879
- WESTPHAL: Myelitis *A. f. Psych.* IV 1874

CHAPTER XXXI

HYDROMYELIA AND SYRINGOMYELIA

95. **Hydromyelia** is a more or less marked dilatation of the central canal of the cord, associated with or produced by an accumulation of liquid within it. In some instances hydromyelia is congenital; it attains its extreme in certain cases of spina bifida, in which a saccular bulging of the medullary tube (myelocystocele or hydromyelocele) protrudes outwards through a gap in the bony wall of the spinal canal. In other cases the condition is acquired, and is referable to secondary or consecutive inflammatory affections of the central canal (Art. 94), to disturbance of the circulation of blood or lymph, or to degeneration affecting the wall of the central canal. It may thus form a complication of traumatic lesions or of degeneration from compression, and is not infrequently observed above the injured or compressed part.

The dilatation extends over a portion or the whole of the cord. In cross-section the canal is sometimes round, sometimes narrowed to a mere fissure (Fig. 193 *b*), sometimes three-cornered or entirely irregular. Not uncommonly it gives off local diverticula, and it has been found to be duplicated or triplicated. These conditions are probably due to local anomalies of development at the time when the medullary tube was in process of closure, whereby a double or triple canal was formed instead of a single one.

The dilated canal is lined with ependymal epithelium, though at the time of post-mortem examination the epithelium has often to a great extent disappeared. In acute dilatations due to inflammation, the neuroglia surrounding the central canal, and occasionally the tissue somewhat more remote, are apt to become softened (Art. 94). In other and chronic cases of hydromyelia, the wall of the canal appears hypertrophic from proliferation of

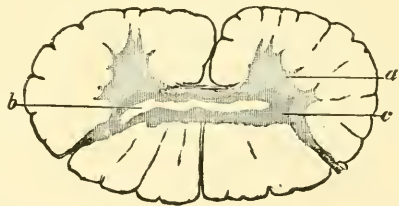


FIG. 193. HYDROMYELIA WITH SCLEROSIS OF THE SURROUNDING TISSUE.

(Preparation hardened in Müller's fluid, and stained with carmine: $\times 4$)

a grey matter *b* central cavity
c sclerotic tissue

the neuroglia (Fig. 193 *e*). Slight degrees of hydromyelia cause no perceptible change of form in the cord, but greater dilatations increase its total girth. Accumulation of pus or blood in the central canal leads to conditions which might be termed **pyomyelia** or **haematomyelia**.

The term **syringomyelia** is applied to a chronic affection of the cord, associated with morbid excavation of its substance; in the typical form the cavity is situated behind the central canal, and is surrounded by a zone of somewhat dense hyperplastic neuroglia (Fig. 194 *b c*). At first the hyperplasia takes place within the grey commissure; but it very often extends thence into the posterior white columns. The condition is especially common in the cervical region, but it may be met with in any portion of the cord or indeed throughout its entire length.

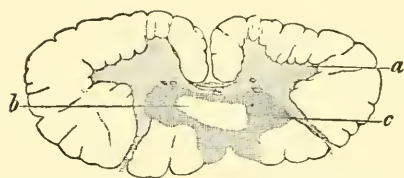

FIG. 194. SYRINGOMYELIA IN THE REGION OF THE POSTERIOR COLUMNS OF THE CERVICAL CORD ($\times 4$).

a grey matter *b* syringomyelic cavity
c sclerotic tissue

In typical cases the proliferation of the neuroglia precedes the excavation, the process thus beginning with a central **sclerosis**, or **gliosis** as it has been termed. In some cases the hyperplasia attains such proportions (Fig. 195 *A BC*) that the result might be described as an elongated **glioma**. The excavation (Fig. 194 *b* and Fig. 195 *c*) starts with disintegration of the proliferous neuroglia, due apparently to interference with its nutrition, inasmuch as the vessels supplying it exhibit hyaline thickening of their walls and narrowing of their lumen. The contents of the cavity consist usually of a colourless liquid, but occasionally of a yellow or brown gelatinous substance (Fig. 195 *C e*), or of blood and its products of disintegration.

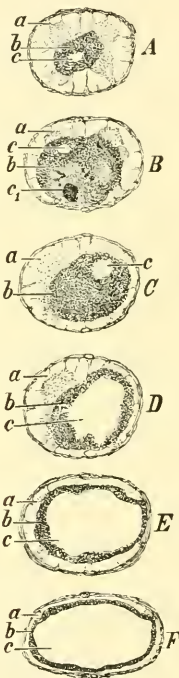


FIG. 195. GLIOSIS AND SYRINGOMYELIA IN THE LUMBAR REGION OF THE CORD.

(Natural size)

A B transverse section through the upper,
C D through the middle,
E F through the lower, portions of the lumbar cord
a substance of the cord
b hyperplastic neuroglia
c empty cavity
*c*₁ cavity with brown gelatinous contents

In certain cases, which may be regarded as atypical, similar cavities surrounded by overgrown neuroglia are formed in a different manner. Foci of myelitic disintegration already formed break down, and at a subsequent stage become surrounded with hyperplastic neuroglia (*myélite cavitaire*); in these cases however the amount of newly-formed neuroglia-tissue is usually very small.

If the hyperplasia assumes greater dimensions it may spread not only to the posterior columns, but also to the posterior and anterior horns of grey matter (Fig. 195 *b* in *A B C D E F*), and ultimately encroaches on the antero-lateral columns, so destroying a considerable part of the cross-section of the cord.

The excavation (*e*) occupies sometimes but a small portion (*A B C*), sometimes the greater part (*D E F*) of the hyperplastic area; in other cases there may be no excavation throughout a considerable part of the longitudinal extent of the altered tissue. Usually the appearance of the transverse section varies perceptibly at different levels.

Regarded from the outside, the cord may appear unchanged; but not infrequently it is contracted in places from imperfect development of the posterior columns, while the posterior median fissure is abnormally wide. Abundant accumulation of liquid (*E F*) within the cavity leads to an increase in the girth of the cord.

The central overgrowth of neuroglia and the subsequent excavation are for the most part referable to anomalies of development in the region of the commissure and the posterior columns, and accordingly the morbid appearances to which they give rise, though existing perhaps for decades, have probably had their beginning in early childhood. If similar changes follow on traumatic injury or inflammation, as has often been alleged, it is probable that they belong to the form of syringomyelia above referred to as atypical.

Hydromyelia and syringomyelia cannot be sharply distinguished. The cavities in syringomyelia can very often be shown to be here and there connected with the central canal (SCHLESINGER), and so are in some parts lined with ependymal epithelium, and have the appearance of central diverticula. Moreover, it is to be remembered that hydromyelia itself is often due to a congenital anomaly of development, and that it also is accompanied by morbid proliferation of the neuroglia. Whether the central canal has been primarily or only subsequently involved, is a question difficult of answer in any given case.

Syringomyelia is during life indicated chiefly by gradually-developing atrophy of the muscles, by trophic, vaso-motor, and sensory disturbances, partial anaesthesia, whitlows, fissures, and necrosis of the fingers, and by cutaneous ulceration. It appears to be at least twice as common in men as in women, and is most frequently observed in persons over twenty and under thirty years of age. The disease described by MORVAX as '*parésie analgésique à panaris des extrémités supérieures*' is a special type of syringomyelia.

The proliferation and excavation of the neuroglia in syringomyelia have been very differently interpreted by different writers. LEYDEN considers the formation of cavities, which he attributes to abstriction of parts of the central canal, as the primary feature, and the hyperplasia of the neuroglia as secondary to this. SIMON, HOFFMANN, WESTPHAL, SCHULTZE, with others, consider the central gliosis as primary, the cavities being formed by disintegration of the new tissue. The monograph of SCHLESINGER, cited below, gives a complete summary of the literature of the subject, together with elaborate researches of his own.

References on Hydromyelia and Syringomyelia.

- ASMUS: Illustrations *Bibliotheca med. chirurgica* part I Cassel **1893**
 BÄUMLER: Excavation of the cord *D. A. f. klin. Med.* XI **1887**
 BLOCQ: Syringomyelia *Brain* XIII **1890**
 BRAMWELL: Excavation in myelitis *Edinburgh med. -chir. Trans.* **1893-94**
 BRUHL: Syringomyelia *Thèse* Paris **1890**
 CHIARI: Pathogenesis of syringomyelia *Prager Z. f. Heilk.* IX **1888**
 CRAMER: Summary of researches for 1891 *Cent. f. allg. Path.* III **1892**
 CURSCHMANN: Affections of the hands and joints *Clinische Abbildungen* plates 17-23 Berlin **1894**
 FÜRSTNER and ZACHER: Cavities in the cord *A. f. Psych.* XIV **1883**
 GAUPP: Morbid anatomy of the cord *Ziegler's Beiträge* II **1888** (p. 510)
 HARRIS: Syringomyelia *Brain* VIII **1886**
 HOFFMANN: *Volkmann's klin. Vorträge* 20 **1891**
 JOFFROY and ACHARD: Excavating myelitis *A. de physiol.* **1887**; Morvan's disease with autopsy *A. de méd. exp.* II **1890**; Non-gliomatous syringomyelia *ibidem* III **1891**
 KAHLER and PICK: Syringomyelia and hydromyelia *Prager Vierteljahrsschrift* new series II **1879**, *A. f. Psych.* VIII **1878**
 KIEWLICZ: Case of transverse myelitis, syringomyelia, multiple sclerosis, and secondary degenerations *A. f. Psych.* XX **1889**
 KRAUSS: Case of syringomyelia *V. A.* 101 **1885**
 KRONTHAL: Pathology of excavation of the cord *Neurol. Cent.* VIII **1889**
 LANGHANS: Excavation from venous engorgement *V. A.* 85 **1882**
 LEYDEN: Hydromyelia and syringomyelia *V. A.* 68 **1876**
 MINOR: Central haematomyelia *A. f. Psych.* XXIV **1892**
 MIURA: Excavation of the cord *V. A.* 117 **1889**; Glioma and syringomyelia *Ziegler's Beiträge* XI **1891**
 MORVAN: *Gaz. hebdom.* **1883, 1886, 1887, 1889**
 O'CARROLL: Hydromyelia *Trans. Acad. Med. Ireland* IX **1890**
 REDLICH: Morbid anatomy *Prager Z. f. Heilk.* XII **1891**
 ROTH: Diffuse glioma, syringomyelia, and amyotrophy *A. de physiol.* V **1878**
 SCHAFFER and PREISZ: Hydromyelia and syringomyelia *A. f. Psych.* XXIII **1891**
 SCHLESINGER: *Die Syringomyelie* Vienna and Leipzig **1895** (with full references)
 SCHULTZE: Fissures, cavities, and gliomata of the cord *V. A.* 87 **1882, 102 1885**, and *Z. f. klin. Med.* XIII **1888**
 SIMON: Syringomyelia and new-growth in the cord *A. f. Psych.* V **1875**
 SOUZA-MARTIN: Leprous excavation *Semaine méd.* no. 20 **1894**
 THOMSON: Arthropathies *Edinburgh Hosp. Reports* II **1894**
 WESTPHAL: Excavation and neoplasm of the cord with affection of the medulla oblongata *A. f. Psych.* V **1875**, *Brain* VI **1883**
 WICHMANN: *Geschwulst- und Höhlenbildung im Rückenmark* Stuttgart **1887**

CHAPTER XXXII

MULTIPLE SCLEROSIS

96. **Multiple or disseminated sclerosis**, sometimes also called insular sclerosis, is an affection extending over the whole cord, and often over the brain also, which is characterised by the formation of a number of scattered grey patches in the nerve-tissue. In the spinal cord these lesions may be situated at any point of the white columns (Figs. 196, 197, and 198) or of the grey matter; and they show no preference for any special region of the medulla oblongata, of the pons, or of the cerebellum. Within the cerebrum, in some cases, the tissue adjacent to the lateral ventricles is notably affected; but the lesions are also found dispersed throughout the whole of the cerebral hemispheres, and sometimes involve the optic and olfactory nerves, and the roots of the other cerebral nerves.

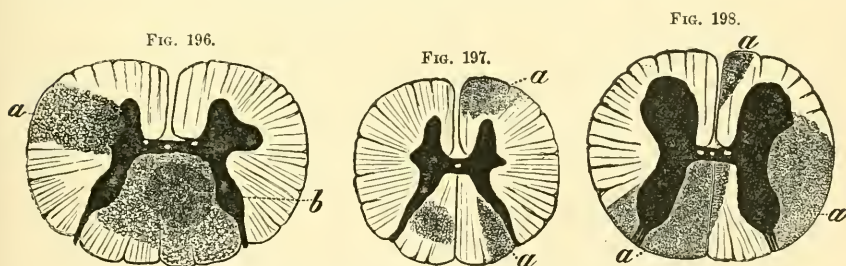
DIAGRAMS OF MULTIPLE SCLEROSIS ($\times 3$).

FIG. 196. CERVICAL REGION.

- a* sclerotic patches in the lateral column and left intermedio-lateral tract
b sclerotic patch in the posterior columns

FIG. 197. THORACIC REGION.

- a* sclerotic patches

FIG. 198. LUMBAR REGION.

- a* sclerotic patches

The affected patches are sometimes small, of about the size of a pin's head, and sometimes larger, the diameter of the cross-section measuring several centimetres. The roof of the lateral ventricles over its whole extent has sometimes been found transformed into a grey stratum several millimetres in thickness and one or two centimetres in breadth.

In some cases the patches on section appear of a uniform grey colour, firm and dry in texture, and sharply defined from the sur-

rounding tissue. In other cases they are less firm in consistence, the section of some at least is mottled with grey and white, and the

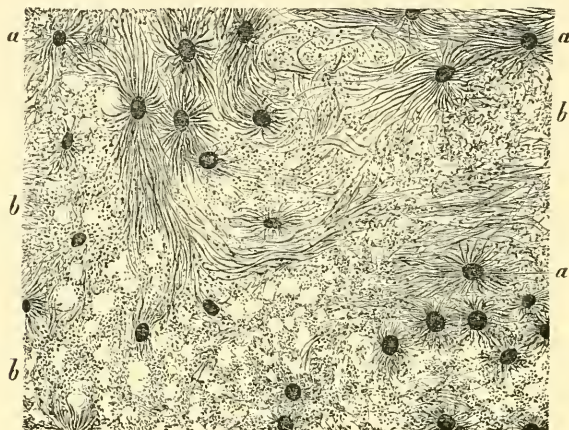


FIG. 199. MULTIPLE (SECONDARY) SCLEROSIS.

(Sclerotic patch from the posterior column: preparation hardened in Müller's fluid, stained by MALLORY'S method, and mounted in Canada balsam: $\times 500$)

a neuroglia-cells with numerous processes *b* sclerotic tissue with neuroglial fibres in cross-section

boundaries are less sharp. Whitish patches occur as well as the grey ones, and degeneration of the tracts of the cord is occasionally found accompanying the sclerosis.

Patches which lie just underneath the pia mater or ependyma can be recognised without the aid of the microscope by their grey colour. When the cord contains very numerous sclerotic patches and degenerate tracts, on transverse section the diseased portions may in aggregate area greatly exceed the normal tissue, the latter being limited to a few small remnants.

The grey patches are of two types as regards structure, the first containing sclerotic tissue enclosing spaces vacated by nerve-fibres, and almost or altogether devoid of such fibres (Fig. 199); while the second type consists of dense continuous tissue without tubular nerve-spaces (Fig. 200 *b* on the left), together with some tissue still including

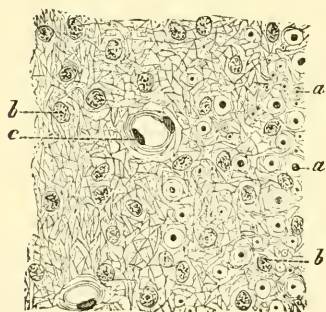


FIG. 200. MULTIPLE (PRIMARY) SCLEROSIS.

(Marginal portion of the sclerotic tissue from the posterior column of FIG. 199 *b*: preparation hardened in Müller's fluid, and stained with carmine: $\times 300$)

a transverse section of nerve-fibres
b neuroglia-cells *c* blood-vessel

nerve-fibres (*a*). The softer mottled patches always show signs of the disintegration of the nerve-fibres, namely drops of myelin and fat, degenerate fatty cells (Fig. 201 *e*), and fat-granule cells (*h₁* *h₂*).

The neuroglia is more or less abundantly developed, and in some parts may already exhibit the condition of marked sclerosis (*f* *g*). Degeneration of the vessels is often apparent at the same time, chiefly in the form of hyaline thickening of their walls; and accumulations of round-cells are visible in and about the adventitial lymph-sheaths of the vessels (*h*).

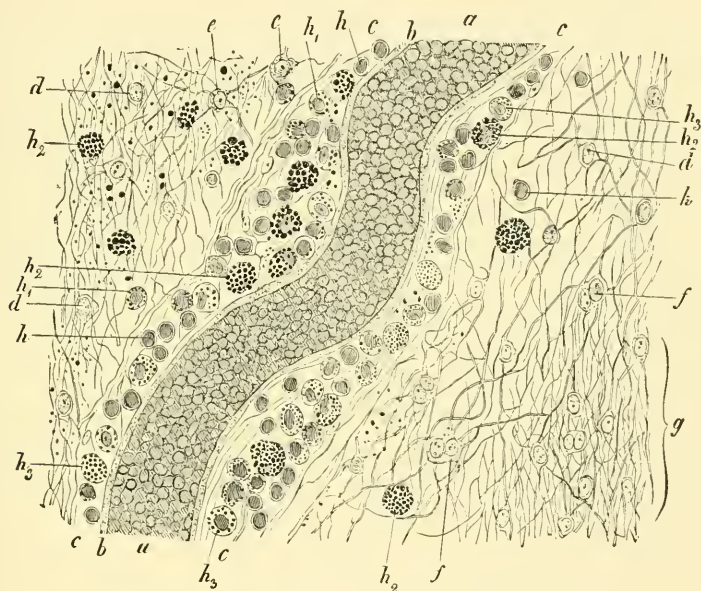

FIG. 201. DISSEMINATED SCLEROSIS OF THE BRAIN.

(Patch of degeneration in the cerebrum, with hyperplasia of the neuroglia: teased preparation, treated with perosmic acid: $\times 200$)

- | | |
|-----------------------------------------|--------------------------------------------------------------|
| <i>a</i> blood-vessel filled with blood | <i>g</i> sclerotic tissue |
| <i>b</i> tunica media | <i>h</i> round-cells |
| <i>c</i> adventitial lymph-sheath | <i>h₁</i> round-cells with scattered oil-globules |
| <i>d</i> unaltered neuroglia-cells | <i>h₂</i> fat-granule cells |
| <i>e</i> fatty neuroglia-cells | <i>h₃</i> pigment-granule cells |
| <i>f</i> binuclear neuroglia-cells | |

From a histological point of view two different forms of multiple sclerosis may be distinguished. The first might be described as secondary disseminated sclerosis (Figs. 199 and 201), and is the outcome of disseminated myelitis, in other words, of scattered foci of degeneration or inflammation. The other variety, which might be called primary disseminated sclerosis (Figs. 196, 197, 198, and 200), starts in morbid hyperplasia of the neuroglia, such as occurs in syringomyelia (Art. 95), and is prob-

ably referable to some anomaly of development. This form is most frequently met with in the posterior columns (Fig. 196) and in the parts about the cerebral ventricles. The sclerotic tissue is close and dense, with no visible spaces or meshes, and is found within tracts (Fig. 200 a) that show no other signs of degeneration.

References on Multiple or Disseminated Sclerosis (see Arts. 95 and 120).

- BABINSKI: Disseminated sclerosis and other varieties of sclerosis of the cord *A. de physiol.* v **1885**
- BASTIAN: *Trans. Clin. Soc.* xvii London **1884**
- BLOQ and LONDE: *Anat. path. de la moelle épinière* Paris **1891**
- BOURNEVILLE: *De la sclérose en plaques disséminée* Paris **1869**
- BRAMWELL: *Diseases of the spinal cord* Edinburgh **1895**
- BUCHWALD: Disseminated sclerosis *D. A. f. klin. Med.* x **1872**
- BUSS: Disseminated sclerosis *D. A. f. klin. Med.* xlv **1889**
- CHARCOT: *Leçons sur les malad. du système nerv.* Paris **1873**, trans. (New Syd. Soc.) London **1876**
- CHEADLE, DICKINSON, and DRESCHFELD: *Med. Times and Gaz.* i London **1878**
- CRAMER: Early disseminated sclerosis and acute myelitis *A. f. Psych.* xix **1888**
- ERB: *Ziemssen's Cyclop.* xiii New York **1874-80**
- FRIEDMANN: *Jahrb. f. Psych.* iv **1883**; Degenerative processes in the centrum ovale *Neurol. Cent.* **1887**
- FROMMANN: *V. A.* 54 **1871**; *Norm. und pathol. Anat. des Nervensystems* Jena **1876**, and *Gewebsveränd. b. multipler Sklerose* Jena **1879**
- FÜRSTNER and STÜHLINGER: Gliosis and excavation of the cerebral cortex in childhood *A. f. Psych.* xvii **1886**
- GOWERS: Miliary sclerosis of brain *Lancet* i **1886**
- GUÉRARD: Disseminated sclerosis *Thèse* Paris **1869** [*A. f. Psych.* xi **1881**]
- HARTDEGEN: Disseminated induration of the cerebrum in a new-born infant
- HESS: Disseminated sclerosis of the central nervous system *A. f. Psych.* xix **1888**
- JOLLY: Disseminated cerebral sclerosis *A. f. Psych.* iii **1872**
- KIEWLICZ: A case of transverse myelitis, syringomyelia, disseminated sclerosis, and secondary degenerations *A. f. Psych.* xx **1889**
- KÖPPEN: Histological changes in disseminated sclerosis *A. f. Psych.* xvii **1886**
- LEYDEN: *Deutsche Klinik* xv **1863**; *Klinik der Rückenmarkskrankh.; Charité-Annalen* iii; *A. f. Psych.* vi (sclerosis of the bulbar nuclei), and *Berl. klin. Woch.* **1878**
- MARIE: *Diseases of the spinal cord* (New Syd. Soc.) London **1895**
- NOLDA: Disseminated cerebral and spinal sclerosis in childhood *A. f. Psych.* xxiii **1891**
- OTTO: Disseminated sclerosis of the brain and cord *D. A. f. klin. Med.* x **1872**
- PELIZÄUS: Hereditary multiple sclerosis *A. f. Psych.* xvi **1885**
- POLLACK: Congenital multiple sclerosis *A. f. Psych.* xi **1880**
- POPOFF: Histology of disseminated sclerosis *Neurol. Cent.* **1894** [**1877**]
- PUTZAR: Disseminated sclerosis of the brain and cord *D. A. f. klin. Med.* xix
- RIBBERT: Disseminated sclerosis *V. A.* 90 **1882**
- SCHULTZE and RUMPF: *Cent. f. med. Wiss.* **1878**
- TAYLOR: Morbid anatomy of disseminated sclerosis *Z. f. Nervenheilk.* v **1894**
- TROISIÈRE: Two cases of sclerotic lesions of the cord *A. de physiol.* v **1872**
- UNGER: *Multiple Sklerose d. Centralnervensystems im Kindesalter* Vienna **1887**
- VULPIAN: *Maladies du syst. nerveux* ii Paris **1886**
- WESTPIAL: Systemic degeneration in the posterior columns with simultaneous multiple degeneration of the cord *A. f. Psych.* ix **1879**
- ZENKER: *Z. f. rationale Med.* xxiv **1885**, and *D. A. f. klin. Med.* viii **1870**

CHAPTER XXXIII

NEURONIC OR SYSTEMIC AFFECTIONS

97. It has already been pointed out (Art. 88) that the nervous components of the spinal cord and medulla oblongata consist of ganglion-cells and nerve-fibres, and that the latter are nothing more than processes of the nerve-cells which, after a longer or a shorter course, give off lateral and terminal branches. The nerve-fibres enter into relation with special terminal organs or with other nerve-cells, and so subserve the transmission of definite impulses from these cells or organs to other parts that are susceptible of stimulation.

The nerve-cell with its short dendritic processes, in combination with the long polar or axis-cylinder process and its lateral and terminal branches, form a morphological and physiological unit, or **neuron**, whose trophic centre is the nucleated protoplasm of the nerve-cell. When an axis-cylinder process is separated from its cell it straightway perishes (Art. 92).

The neurons whose situation, general course, and function are best known are the motor neurons. Their cells are situated in the psycho-motor regions of the cerebral cortex, in the motor nuclei of the medulla oblongata, and in the anterior horns of the cord; their axis-cylinder processes run in the pyramidal tracts, the anterior roots, and the peripheral motor nerves. Of the sensory neurons we know that their ganglion-cells lie in the spinal root-ganglia, while their axis-cylinder processes on the one hand pursue their course to the terminal organs along the peripheral sensory nerves, and on the other pass through the posterior roots and the posterior columns to the brain.

The diseases of the motor and of the sensory neurons of the cord, hitherto by most writers described as **systemic diseases**, are characterised by peculiar clinical symptoms, which even during the life of the patient enable us to form a diagnosis as to the seat of the malady. Thus long before the minuter structure of the cord was properly understood, certain of its systemic diseases, having well-marked clinical and anatomical characters, were recognised and distinguished.

The most important disease affecting the sensory neurons in the cord is tabes dorsalis. Among the special forms of disease occurring in the course of the motor neurons are acute anterior

poliomyelitis, acute bulbar paralysis, progressive atrophy of the anterior horns or progressive spinal amyotrophy, progressive bulbar paralysis, amyotrophic lateral sclerosis, and primary lateral sclerosis or spastic spinal paralysis.

98. **Tabes dorsalis**, sometimes also called grey degeneration or sclerosis of the posterior columns, or locomotor ataxia, is histologically a degeneration of the sensory neurons. The degeneration is most marked in the region of the posterior roots (LEYDEN) and of the posterior columns, but is demonstrable also in the peripheral sensory nerves (DÉJÉRINE, OPPENHEIM, SIEMERLING, WESTPHAL, GOLDSCHIEDER) and in the nerve-cells of the spinal root-ganglia (WOLLENBERG, STROEBE).

The malady begins most frequently in the lumbar cord, and is first manifested in the posterior roots or horns and in the immediately adjoining portions of the columns of Burdach. Presently, in the higher levels of the cord, the median portions of the columns of Goll also become involved, ascending degeneration very soon following upon the interruption of the nerve-fibres at any point. If the process begins, as happens in rare cases, in the cervical portion, similar lesions appear in that region, while in the thoracic and lumbar regions little or no degeneration can at first be detected. The situation of the fibres that first undergo degeneration in the posterior columns depends mainly on what roots are first affected, and at what height above the degenerate roots the section examined is taken.

In advanced tabes the degeneration and sclerosis often spread, in the thoracic region, over the whole extent of the posterior columns (Fig. 202). In the lumbar region the most anterior parts of the posterior columns almost always remain intact. In the cervical cord two lateral portions in the most anterior part of the posterior column are spared, or are at most but slightly affected. The morbid changes, if the degeneration is not already universal, are usually most marked in the lumbar and thoracic regions: but cases occur in which the cervical region is that most affected. The degeneration ascends within the funiculus gracilis to beyond the obex of the calamus scriptorius, and ceases about the level of the striae acusticae.

When the degeneration of the posterior columns is extreme, they appear grey or greyish-red, even on the exterior of the cord; in transverse section the tissue looks uniformly grey and translucent. At the same time the depth and width of the posterior columns are more or less diminished. The posterior roots also look grey and atrophic.

Within the grey matter the fibres entering the posterior horns, and those of the column of Clarke that originate in the posterior roots, become degenerate. In rare cases some of the ganglion-cells of the grey matter atrophy and disappear.

Not infrequently grey patches are found in the optic, oculo-

motor, and trifacial nerves, as well as in the substance of the brain. The spinal nerves are those which are most apt to be degenerate and atrophic, though the cerebral nerves are sometimes affected also (OPPENHEIM). The spinal root-ganglia have until recently been but little examined, but according to WOLLENBERG and STROEBE degenerative changes can also be recognised in them.

The most prominent feature in tabes is the progressive disintegration of the parts of the sensory neurons situate in the posterior roots, the posterior horns, and the posterior columns, the process generally lasting for several years, and in particular cases even for decades. In its earlier stages the disease is characterised by symptoms of sensory irritation, lightning pains, formication, and a sense of constriction round the waist, together with loss of the

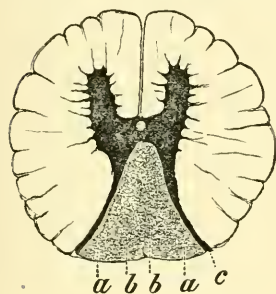


FIG. 202. TABES DORSALIS IN AN ADVANCED STAGE.

(Total degeneration and sclerosis of the posterior columns, and atrophy of the posterior roots of the cord: section in the thoracic region: $\times 5$)

a column of Burdach b column of Goll c atrophic posterior roots

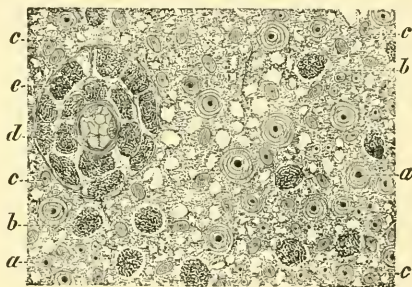


FIG. 203. TRANSVERSE SECTION OF THE POSTERIOR WHITE COLUMNS IN TABES DORSALIS.

(Preparation hardened in Müller's fluid, stained with haematoxylin, carmine, and perosmic acid, and mounted in glycerine: $\times 200$)

a cross-section of normal nerve-fibres of different thicknesses d blood-vessel
 b granule-cells e granule-cells inside the lymph-sheath of the blood-vessel d
 c nucleated reticular neuroglia

patellar reflex, insensibility of the pupil to luminous impressions, diplopia, amblyopia, and gastric disturbance (gastric crises). At a later stage disorders of gait (ataxia), diminished sensibility to touch and pain, loss of the muscular sense, difficulty of micturition, and lastly paralysis of the legs, are the ordinary symptoms.

Fat-granule cells make their appearance in the tubular spaces left vacant by the atrophy of nerve-fibres (Fig. 203 b) and in the lymph-sheaths of the vessels (e), so long as the destruction of the nerve-fibres continues in the posterior columns. Proliferation of the neuroglia ensues in the region of degeneration, resulting in

sclerosis (Fig. 203 *c*), by which the vacant nerve-spaces are contracted and more or less obliterated. Usually some nerve-fibres are still preserved, even in advanced cases (Fig. 203 *a*); but places may be found in the posterior columns that are entirely devoid of nerve-fibres.

The starting-point of the degeneration in tabes has not as yet been definitely made out. The most natural supposition is that the cells of the spinal root-ganglia are the first to degenerate, and that the changes in the posterior roots and columns, as well as in the peripheral nerves, are of the nature of secondary degenerations.

The researches of WOLLENBERG and STROEBE on the root-ganglia point in this direction; for STROEBE was able to show that, in cases of tabes, shrinking, abnormal pigmentation, vacuolation, fragmentation, nuclear degeneration, and in the end total disintegration took place in the ganglion-cells, accompanied by signs of proliferation in the connective tissue. Of special significance is the fact that WOLLENBERG and STROEBE discovered degenerative changes in the nerve-cells even in incipient cases of tabes. The recorded investigations are, however, as yet far too few to establish the above-mentioned supposition, and it must therefore be admitted as a possible view that the degeneration may begin in the central or in the peripheral part of the axis-cylinder process of the ganglion-cell. It is conceivable that some injurious agent, present either in the subarachnoid liquid or in the blood, may be capable of exerting a degenerative action on the sensory nerve-fibres; and the fact that, according to TUCZEK, chronic ergotin-poisoning induces a degeneration of the posterior columns in all points analogous to that which constitutes the anatomical lesion in tabes, must be regarded as favourable to this theory.

Clinical observers mention, as predisposing causes of tabes, cold, over-exertion, sexual excesses, etc. Of late FOURNIER, ERB, GOWERS, and others have maintained that more than half the cases are due to syphilis. If this may be taken as correct, we must assume that syphilitic infection gives rise to the formation within the organism of noxious products that have a specifically injurious effect on the sensory neurons.

According to the observations of WESTPHAL, CLAUS, and others, degeneration of the posterior columns very often occurs in persons who are suffering from paralytic dementia.

References on Tabes Dorsalis (see also Art. 92).

- ADAMKIEWICZ: *A. f. Psych.* x 1880 and xii 1882; *Die Rückenmarksschwindsucht* Vienna 1885
 BLOCQ and LONDE: *Anat. pathol. de la moelle épinière* Paris 1891
 BLOCQ and MARINESCO: Friedreich's disease *A. de neurol.* 1890
 BRAMWELL: *Diseases of the spinal cord* Edinburgh 1895

- BRAUN: A case of tabes with syphilitic meningitis *A. f. Psych.* XXII 1891;
 Combined systemic affection of the cord and peripheral nerves *D. A. f. klin. Med.* XLII 1888; Morbid anatomy of tabes *A. f. Psych.* XXIII 1891
- BULLEN: Tabes and general paralysis *Brain* XII 1890
- BUZZARD: Changes in blood-vessels *Brain* VI 1884
- CHARCOT: *Diseases of the nervous system* London 1876-80; *Oeuvres complètes* II
- DÉJÉRINE: *A. de physiol.* 1884; Alterations of cutaneous nerves in ataxic patients *A. de physiol.* II 1883; Muscular atrophy of ataxic patients *Rev. de méd.* IX 1889
- DÉJÉRINE and HUET: Peripheral traumatism and tabes *Rev. de méd.* VIII 1888
- DÉJÉRINE and SOLIER: Peripheral tabes *A. de méd. exp.* I 1889
- EDINGER: *Die Ursachen einiger Nervenkrankheiten* Leipzig 1894
- ERB: *Ziemssen's Cyclop.* XIII New York 1877; Aetiology of tabes *Berl. klin. Woch.* 1891; *Volkmann's klin. Vorträge* 53 1892
- EULENBURG: Syphilis as a cause of tabes *V. A.* 99 1885
- FLECHSIG: Is tabes dorsalis a systemic disease? *Neurol. Cent.* 1891
- FOURNIER: *De l'ataxie locomotrice d'origine syphilitique* Paris 1882; Statistics of syphilis *Schmidt's Jahrb.* 209 1886
- FRIEDREICH: Ataxia *V. A.* 26, 27 1863, 68 and 70 1877
- FROMMANN: *Norm. u. pathol. Anatomie d. Rückenmarks* Jena 1867
- FÜRSTNER: Changes in the spinal cord in progressive paralysis *A. f. Psych.* XXIV 1894
- GOLDSCHNEIDER: Atrophic paralysis in tabes *Z. f. klin. Med.* XIX 1891
- GOMBAULT and MALLET: A case of tabes originating in infancy *A. de méd. exp.* I 1889
- HADEN and SHERRINGTON: Extension to lateral columns *Brain* XI 1889
- HITZIG: Traumatic tabes *Festschr. zur Jubelfeier d. Univ. Halle* Berlin 1894
- KAHLER: Changes in the spinal cord resulting from compression *Prager Z. f. Heilk.* II 1882 [references]
- KLIPEL: Spinal lesions in general paralysis *A. de méd. exp.* VI 1894 (with KLEMPERER: Traumatic tabes *Z. f. klin. Med.* XVII 1890)
- KRAUSS: Morbid anatomy of tabes *A. f. Psych.* XXIII 1891
- LEYDEN: *Die graue Degeneration der hinteren Rückenmarksstränge* Berlin 1863; *Klinik der Rückenmarkskrankh.* II; *Art. Tabes dorsalis Eulenburg's Realencyklop.*; The latest researches concerning tabes *Z. f. klin. Med.* XXV 1894
- LISSAUER: *Fortschr. d. Med.* II 1885; The normal course of the fibres in the posterior horn of the spinal cord and their relation to tabes dorsalis *A. f. Psych.* XVII 1886
- MARIE: *Diseases of the spinal cord* (New Syd. Soc.) London 1895
- MENZEL: Hereditary ataxia *A. f. Psych.* XXII 1890
- NAGEOTTE: The primary lesion of tabes *Bull. de la Soc. anat.* Paris 1894
- NEFTEL: Aetiology of tabes *V. A.* 117 1889
- NONNE: Diseases of the motor and mixed nerves in tabes *A. f. Psych.* XIX 1888
- OPPENHEIM: Degenerative changes in the bulbar nerves in tabes *A. f. Psych.* XX 1889; Morbid anatomy of tabes *Berl. klin. Woch.* 1894
- OPPENHEIM and SIEMERLING: Pathology of tabes and of peripheral nervous diseases *A. f. Psych.* XVIII 1887
- PIERRET: Sclerosis of the posterior columns *A. de physiol.* IV 1872; The posterior tracts *ibidem* V 1873
- PITRES and VAILLARD: Peripheral neuritis in tabes *Rev. de méd.* VI 1886
- RAYMOND: The early spinal lesions of tabes *Rev. de méd.* 1891
- REDLICH: Morbid anatomy of tabes *Jahrb. f. Psych.* XI 1892
- SAKAKY: Tabes dorsalis with degeneration of the peripheral nerves *A. f. Psych.* XVI 1884
- SOLLY and CLARKE: Morbid anatomy *St. Thomas's Hosp. Reports* London 1870
- STROEBE: Changes in the spinal ganglia in tabes *Cent. f. allg. Path.* V 1894 (p. 853)
- STRÜMPPELL: Morbid anatomy of tabes *A. f. Psych.* XII 1882; The nature of tabes *Münch. med. Woch.* 1890

TAKACS: *Cent. f. med. Wiss.* 1878. *A. f. Psych.* IX 1878

TUCZEK: Changes in the spinal cord in ergotism *A. f. Psych.* XIII and XVIII; *Studien über Pellagra* Vienna 1893

WALKER: Sequelae of ergotism *A. f. Psych.* XXV 1893

WEIL: Incipient tabes *A. f. Psych.* XXVI 1894

WESTPHAL: Degenerations of the cord *A. f. Psych.* V, IX, XII, and XVI 1885

WOLFF: Degeneration of the posterior columns with meningo-myelitic patches *A. f. Psych.* XII 1881

WOLLENBERG: The spinal ganglia in tabes *A. f. Psych.* XXIV 1892 (with references)

WOODHEAD: Conditions in the medulla etc. *Journ. of Anat.* XVI 1882

99. **Acute anterior poliomyelitis** is a peculiar disease of the anterior horns of the spinal cord, with well-defined clinical symptoms. It generally occurs in children (whence the term infantile spinal paralysis is applied to it), more rarely in adults. In its typical form it begins with the symptoms of an infective febrile disorder, and after a few days this is associated with unilateral or bilateral motor paralysis, sometimes limited to the lower or upper limbs, sometimes involving all the extremities. After a certain time the paralysis, originally affecting a number of muscles, as a rule passes away as regards some of them; but after this no further recovery of power takes place in the muscles that remain paralysed, and they thereupon become more and more atrophic.

From the histological researches that have so far been made, the disease would appear to be of haematogenous origin, and in typical cases due to an undiscovered noxious agent acting like a specific poison upon the ganglion-cells of the anterior horns (CHARCOT, VON KAHLDEX, RISSLER), or in some cases upon the corresponding motor nuclei of the medulla oblongata. In severe cases of the disease the toxic action may be associated from the outset with inflammatory exudation or with haemorrhage at the seat of greatest destruction. In atypical cases, ending likewise in motor paralysis, the incipient morbid changes are not improbably of the nature of ischaemic or haemorrhagic degeneration due to alterations in the blood-vessels.

In recent cases the ganglion-cells exhibit various signs of degeneration, such as granular and cloudy swelling, vacuolation, hyaline change, general disintegration, and shrinking.

After the lapse of some months or years the number of ganglion-cells in the region corresponding to the paralysis is more or less diminished, the loss being sometimes apparent over the entire cross-section of the anterior horns, sometimes only in certain groups of ganglion-cells. The number of the ganglion-cells is moreover found to be somewhat diminished in regions outside that of the persisting paralysis, and in some cases the diminution is perceptible over the whole length of the cord.

The nerve-fibres in the anterior roots, corresponding to the ganglion-cells destroyed, break down and disappear. Some of the

fibres entering and leaving the grey matter likewise disappear, while others persist; the surviving fibres may indeed be present

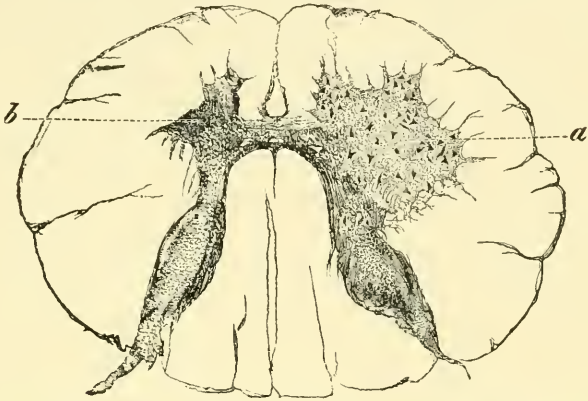


FIG. 204. SCLEROSIS AND CICATRICIAL CONTRACTION OF THE LEFT ANTERIOR HORN OF THE FOURTH CERVICAL NERVE AFTER ACUTE ANTERIOR POLIOMYELITIS.

(From a child three and a half years old, death ensuing eight months after the commencement of the paralysis: preparation hardened in Müller's fluid, stained with neutral carmine solution, and mounted in Canada balsam: $\times 7$)

a normal anterior horn with ganglion-cells *b* atrophic anterior horn

in considerable numbers even after great destruction of the ganglion-cells (VON KAHLDEN). The neuroglia and the blood-vessels at times show hardly any appreciable change, and the configuration of the transverse section of the diseased horn devi-

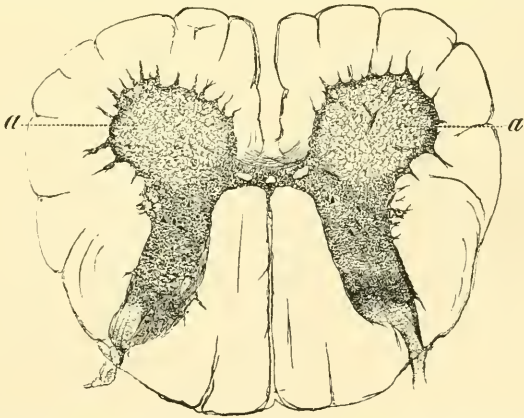


FIG. 205. GELATINOUS DEGENERATION OF BOTH ANTERIOR HORNS (*a*) OF THE LUMBAR REGION, WITH TOTAL LOSS OF THE GANGLION-CELLS AND NERVE-FIBRES, AFTER ACUTE ANTERIOR POLIOMYELITIS.

(From a man forty years of age, death ensuing twenty months after commencement of paralysis: preparation hardened in Müller's fluid, stained with haematoxylin and carmine: $\times 6$)

ates but little from the normal. More commonly, however, the horn after the lapse of months or years, at least at the part where the lesion was most intense, becomes shrunken and sclerotic (Fig. 204 *b*), the sclerosis often radiating into the adjoining white matter. In other cases again the degenerate portions of the anterior horns are not shrunken, but converted into a mass of gelatinous tissue almost or altogether devoid of ganglion-cells and nerve-fibres. This tissue is composed essentially of blood-vessels and loose-meshed neuroglia (Fig. 205 *a* and Fig. 188 *B*), while its interstices contain liquid, and in recent cases detritus of nerve-matter and granule-carrying cells.

The cause of the limitation of the disease to the anterior horns lies mainly in the fact that these possess a special vascular supply, independent of the vessels of the white matter, in the cornual arteries that enter the cord at the bottom of the anterior fissure. This is not, however, sufficient to account for the peculiar distribution of the degeneration in typical cases, and we must further assume that the poisonous matters which induce the disease have a selective or specific action on the motor ganglion-cells.

In other respects the disease is doubtless closely related to the forms of haematogenous myelitis that have no special seat of election; and indeed cases occur in which not only the anterior but also the posterior horns show signs of degeneration (Fig. 191), and others in which both the white and the grey matter undergo degeneration and inflammation.

References on Acute Anterior Poliomyelitis (see also Art. 94).

- BERNHEIM: Acute, subacute, and chronic anterior poliomyelitis of the adult engrafted on infantile paralysis *Rev. de méd.* **1893**
- CHARCOT: *Diseases of the nervous system* London **1876-80**
- DAMASCHINO: Infantile spinal paralysis and progressive muscular atrophy *Rev. de méd.* **1881**; *Gaz. des hôp.* **1885**
- DÉJÉRINE and HANOT: Atrophic paralysis of infancy *A. de physiol.* **I 1888**
- FRÄNKEL: Poliomyelitis with alteration of the white matter *Inaug. Diss.* Freiburg **1894**
- GOLDSCHIEDER: Poliomyelitis *Z. f. klin. Med.* **XXIII 1894**
- VON KAHLDEN: Inflammation and atrophy of the anterior horns *Ziegler's Beiträge* **XIII 1893**; Recent researches on anterior poliomyelitis *Cent. f. allg. Path.* **V 1894**
- PASTEUR: Poliomyelitis of bulbar nuclei *Lancet* **II 1887**
- RISSLER: Acute anterior poliomyelitis *Nordiskt med. Arkiv* **XX 1889**
- SCHULTZE: Acute anterior poliomyelitis *V. A.* **68 1876** and **73 1878**
- SIEMERLING: Morbid anatomy of infantile spinal paralysis *A. f. Psych.* **XXVI 1894**
- STRÜMPPELL: Aetiology of the spinal paralysis of children *Wagner's Festschr.* Leipzig **1887**
- TURNER: Recent case of poliomyelitis *Trans. Path. Soc.* **XXX London 1879**, and *B. M. J.* **I 1879**
- WILLIAMSON: The changes in the spinal cord in acute anterior poliomyelitis *Med. Chronicle* Manchester **1890**

100. Progressive atrophy of the motor neurons of the anterior horns (in other words, of the motor ganglion-cells and peripheral nerves) gives rise to a disease whose characteristic clinical symptom is wasting of certain muscles; this disease is accordingly described as **progressive spinal muscular atrophy**, or briefly as progressive amyotrophy.

The affection is due essentially to progressive degeneration and atrophy of the large motor ganglion-cells; these, without undergoing any notable change of structure, steadily diminish in size (Fig. 184), while the corresponding motor nerve-fibres and the muscles supplied by them also waste in proportion. The atrophy begins most frequently in the cervical region, and accordingly the hand-muscles (muscles of the thumb, hypothenar eminences, interossei, and lumbricales) are the first to waste, and the muscles of the forearm and shoulder follow later. Sometimes, however, the wasting begins in the lower limbs and ascends.

Progressive atrophy of the neurons whose cells are situate in the motor centres of the cerebral cortex, or primary sclerosis of the pyramidal tracts, is from the nature of the symptoms generally regarded as the anatomical basis of a form of progressive motor paresis and paralysis, combined with spasmodic rigidity of the muscles, reflex spasms and contractures, and increased tendon-reflexes, which is known as **spastic spinal paralysis**, or spasmodic tabes. These symptoms are, however, in most cases really due to transverse myelitis, disseminated sclerosis, compression of the cord, or hydromyelia. Primary degeneration limited to the pyramidal tracts has as yet been demonstrated in but very few cases. These cases are nevertheless sufficient to establish beyond a doubt the actual existence of a neuronie degeneration of this kind, and all that remains to be decided is whether the primary lesion is a degeneration of the axis-cylinders or some morbid change in the ganglion-cells.

On the other hand, a combination of progressive degeneration of the pyramidal tracts with atrophy of the anterior horns and the motor peripheral nerves is not uncommon, and forms the anatomical basis of the disease known as **amyotrophic lateral sclerosis**. Wasting of the muscles is a characteristic clinical feature of this disease, in common with progressive spinal amyotrophy; but it is distinguishable from the latter by the increased vigour of the tendon-reflexes.

The ultimate disappearance of the nerve-cells of the anterior horns takes place in the same way as in spinal amyotrophy, by progressive diminution in size, ending at length in the destruction of the majority of the cells (Fig. 206 *a*). In the region of the crossed pyramidal tracts (*b*), and in the direct pyramidal tracts also, provided all the motor fibres have not decussated, some of the fibres disappear as in the case of tabes, and this in time is followed by sclerotic induration of the neuroglia (*b*).

The process that takes place in the anterior horns of the cord may likewise involve the motor nuclei of the medulla oblongata (hypoglossal, vagus, accessory, facial, and glossopharyngeal), and lead to progressive wasting of the muscles innervated by them. The disease thereby occasioned is known as **progressive bulbar paralysis** or glosso-labio-laryngeal paralysis, and it may be accompanied by degeneration of the pyramidal tracts, or exist as an independent malady.

The cause of progressive atrophy of the motor neurons is still obscure, and we do not know whether the first perceptible changes occur in the axis-cylinder processes or in the cells themselves. In degeneration of the pyramidal tracts the atrophic process has been traced upwards to the cerebrum, and simultaneous wasting of the

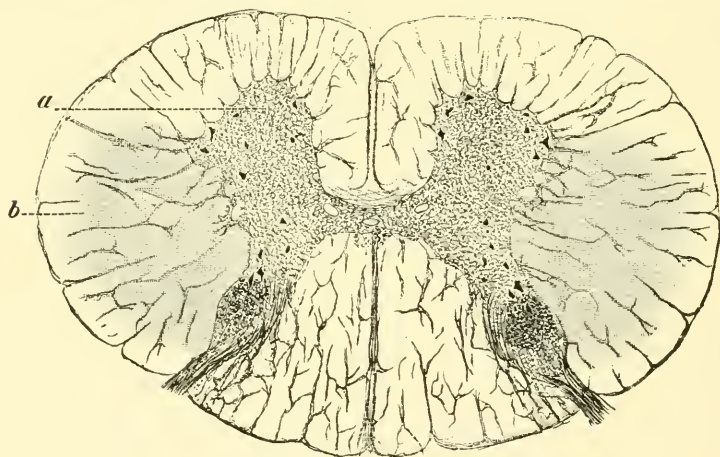


FIG. 206. AMYOTROPHIC LATERAL SCLEROSIS.

(*Transverse section through the cervical portion of the cord: $\times 10$*)

a anterior horns whose ganglion-cells have in great part disappeared *b* diseased part of the lateral columns corresponding to the total decussation of the pyramidal tracts

ganglion-cells of the cerebral cortex in the central gyri (CHARCOT, MARIE) has in some cases been recorded; but it has not been determined how far the atrophy of the nerve-fibres corresponds to that of the ganglion-cells of the cortex. It is worthy of note that in progressive paralytic dementia, in which the cerebral cortex undergoes atrophy, degeneration of the pyramidal tracts is a frequent concomitant.

So far as our present knowledge extends, it is probable that the morbid agent, whatever it be, exerts its influence in some cases on the nerve-cells and in others on the axis-cylinder processes, the peripheral portion of the fibres thereupon undergoing degeneration throughout their entire length. The morbid agent

is probably some toxic substance elaborated within the body (perhaps in the course of an infective disease) or introduced from without. According to MARIE, PROUST, and others, the use of the chick-pea (*Lathyrus cicera*) in food causes degeneration of the motor neurons. In certain cases there is probably also some hereditary or congenital disposition to disease of particular neurons or groups of neurons (Art. 101).

References on Progressive Spinal Amyotrophy, Amyotrophic Lateral Sclerosis, Progressive Bulbar Paralysis, and Spastic Spinal Paralysis (see also Art. 101).

- ALZHEIMER: Progressive spinal muscular atrophy *A. f. Psych.* xxiii 1891
- CHARCOT: *Diseases of the nervous system* London 1877-83; Two cases of spastic paralysis with autopsy *A. de neurol.* x 1885; *Oeuvres complètes* II 1886
- DÉJÉRINE: Labio-glosso-laryngeal paralysis *A. de physiol.* II 1883
- DRESCHFELD: Primary lateral sclerosis *Journ. of Anat.* xv 1881; Classification of neuropathic amyotrophies *Brain* viii 1886
- DUCHENNE (of Boulogne): *Gaz. hebdom.* 1859 and 1861
- DUCHENNE and JOFFROY: Atrophy of the nerve-cells of the cord and bulb *A. de physiol.* III 1870
- ERB: Spastic spinal paralysis *V. A.* 70 1877
- ERB and SCHULTZE: Progressive spinal muscular atrophy *A. f. Psych.* ix 1879
- FLECHSIG: *Ueber Systemerkrank. im Rückenmark* Leipzig 1878
- FÜRSTNER: Changes in the grey matter in disease of the lateral columns *Neurol. Cent.* viii 1889; Changes in the cord in progressive paralysis *A. f. Psych.* xxiv 1892
- GRASSET and RANZIER: *Maladies du système nerveux* Montpellier 1894
- HOFFMANN: Chronic spinal muscular atrophy in childhood *Z. f. Nervenheilk.* III 1893
- JOFFROY and ACHARD: Amyotrophic lateral sclerosis *A. de méd. exp.* II 1890
- KAHLER: *Prager Z. f. Heilk.* v 1884
- VON KAHLDEN: Inflammation and atrophy of the anterior horns *Ziegler's Beiträge* XIII 1893
- LEYDEN: *loc. cit.* Art. 97 and *A. f. Psych.* II, III, VII, and VIII 1870-78
- MARIE: *Diseases of the spinal cord* (New Syd. Soc.) London 1895
- MARINESCO: Amyotrophy (type Charcot-Marie) *A. de méd. exp.* VI 1894
- MINKOWSKI: Sclerosis of the lateral columns following syphilis *D. A. f. klin. Med.* xxxiv 1884
- MOELI: Amyotrophic lateral sclerosis *A. f. Psych.* x 1890
- MONRO, T. K.: *Chronic degenerative diseases* Glasgow 1895 (with references)
- MORGAN and DRESCHFELD: Idiopathic lateral sclerosis *B. M. J.* I 1881
- NONNE: Chronic anterior poliomyelitis *Z. f. Nervenheilk.* I 1892
- OPPENHEIM: Chronic anterior poliomyelitis *A. f. Psych.* xix 1888; Chronic atrophic spinal paralysis *A. f. Psych.* xxiv 1892
- PASTEUR: Bulbar infantile paralysis *Lancet* II 1887
- PICK: Amyotrophic lateral sclerosis *A. f. Psych.* viii 1878
- PIERRET and TROISIÈRE: Progressive muscular atrophy *A. de physiol.* II 1875
- PITRES: Secondary lateral sclerosis *A. de physiol.* 1876
- PROUST: Lathyrism *Bull. de l'Acad. de méd.* XII 1883
- ROSS: *Diseases of the nervous system* II London 1883 [berg 1891
- SCHÜLE: Is spastic spinal paralysis a disease *sui generis*? *Inaug. Diss.* Heidelberg
- SIEMERLING: Progressive chronic paralysis of the eye-muscles *A. f. Psych.* xxii (supplement) 1891; Anatomical conditions in congenital ptosis *ibidem* xxiii 1892
- STOFFELA: Spastic spinal paralysis *Wien. med. Woch.* 1878

- STRÜMPPELL: Spinal muscular atrophy and amyotrophic lateral sclerosis *D. A. f. klin. Med.* XLII 1887; Spastic spinal paralysis *A. f. Psych.* XVI 1886; Progressive muscular atrophy *Z. f. Nervenheilk.* III 1893; Primary systemic degeneration of the pyramidal tracts *Z. f. Nervenheilk.* V 1894
- SUCKLING: Combined disease of posterior and lateral tracts *Lancet* I 1886
- VIERORDT: Combined degeneration of the anterior horns and lateral columns *A. f. Psych.* XIV 1883
- WERDNIG: Early infantile progressive spinal amyotrophy *A. f. Psych.* XXVI 1894 (with references)
- WESTPHAL: Disease of the spinal cord in progressive paralysis *V. A.* 39 1867 and 40 1867; Combined diseases of the columns of the cord *A. f. Psych.* IX 1879; Amyotrophic lateral sclerosis *A. f. Psych.* XVII 1886
- WORMS: Progressive muscular atrophy with glosso-labio-laryngeal paralysis *A. de physiol.* 1877

101. In addition to the forms of degeneration just described, which affect functionally-related neurons, we not infrequently meet with cases wherein various functionally-independent groups of neurons are involved. The affections thus induced have hitherto been commonly described as **combined systemic diseases**. For example, along with degeneration of the sensory fibres of the posterior columns, degeneration of the pyramidal tracts (Fig. 207

FIG. 207.

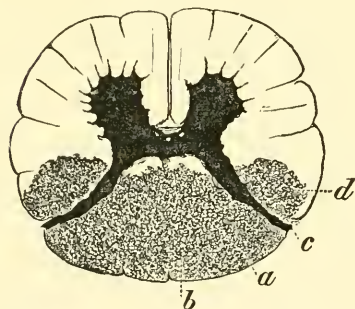


FIG. 208.

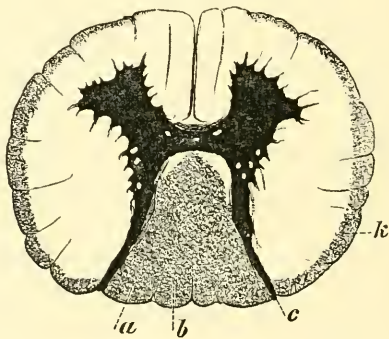


FIG. 207. DEGENERATION AND SCLEROSIS OF THE COLUMN OF BURDACH (*a*), OF THE COLUMN OF GOLL (*b*), AND OF THE CROSSED PYRAMIDAL TRACTS (*d*).

(Section through the uppermost part of the lumbar region of the cord : $\times 5$)
c atrophic posterior roots

FIG. 208. COMBINATION OF SCLEROSIS OF THE POSTERIOR COLUMNS WITH MARGINAL SCLEROSIS.

(Transverse section through the cervical portion of the cord : $\times 5$)

a column of Burdach
b column of Goll

k marginal sclerosis (direct cerebellar tract)

a b d), alone or in combination with the direct cerebellar tracts (Fig. 208 *k*) whose nerve-cells lie in the vesicular column of Clarke, is occasionally met with; and the clinical symptoms corresponding to the several sets of degenerations are then manifested simultaneously. In the malady known as **Friedreich's**

disease, or hereditary ataxia, which seems to be referable to a particular congenital and hereditary predisposition, the crossed pyramidal and the direct cerebellar tracts are diseased, along with the columns of Goll and Burdach. Again, degeneration of the great sensory and motor neurons and neuronic systems is sometimes combined with a like disease of the commissural-cells and of the tract-cells that send their processes into the antero-lateral columns, and this gives rise to the appearance of systemic or tract-like degeneration in the affected regions.

References on Combined Systemic Degenerations.

- ARNOLD: Combined diseases of the tracts *V. A.* 127 **1892**
 BLOQ and MARINESCO: Morbid anatomy of Friedreich's disease *A. de neurol.* **1890**
 BRAUN: Peculiar case of combined systemic disease of the cord and peripheral nerves *D. A. f. klin. Med.* XLII **1888**
 BURY: Hereditary ataxia *Brain* VIII **1886** (with summary of cases)
 DRESCHFELD: Friedreich's disease *Manchester and Liverpool med. and surg. Reports* IV **1876**
 FRIEDREICH: Ataxia *V. A.* 26, 27, 68 **1876**, and 70 **1877**
 GOODHART: Hereditary ataxia *Trans. Clin. Soc.* XXI London **1888**
 KAHLER and PICK: Combined systemic diseases *A. f. Psych.* VIII **1878**
 MONRO, T. K.: *Chronic degenerative diseases of the central nervous system* Glasgow **1895** (with historical references)
 ORMEROD: Summary of literature on Friedreich's disease *Brain* VII **1885**
 PUTNAM: A group of cases of systemic sclerosis of the spinal cord associated with diffuse collateral degeneration *Journ. of Nerv. and Mental Disease* XVI **1891**
 RÜTIMEYER: Hereditary ataxia *V. A.* 91 **1883** and 110 **1887**
 SCHMAUS: Degeneration of the lateral columns in tabes dorsalis *D. A. f. klin. Med.* XLVI **1890**
 SCHULTZE: Morbid anatomy of Friedreich's disease *Z. f. Nervenheilk.* v **1893**
 STRÜMPPELL: Combined systemic diseases *A. f. Psych.* XI **1881**, XVII **1886**
 WESTPHAL: *A. f. Psych.* v, VIII, and IX **1879**; *V. A.* 39 and 40 **1867**

CHAPTER XXXIV

INFECTIVE GRANULOMATA AND TUMOURS OF THE CORD

102. **Tuberculosis** of the spinal cord occurs in three different forms. In the first place, single nodes, or even a solitary node, may be formed in the substance of the cord, consisting of a central cheesy mass, sometimes enclosing a small cavity due to disintegration, with a marginal zone of grey somewhat translucent granulation-tissue. The nodes are sometimes as large as a hazel-nut, and induce more or less extensive degeneration of the nerve-substance, followed by secondary degeneration of the tracts. Large nodes interrupt entirely the continuity of the nerve-fibres. Secondary tubercles, due to lymphatic absorption, appear sooner or later in the pia mater near the affected region; and, according to an observation of OBOLONSKY, the tuberculous infection may spread by way of the central canal, so that new tubercles develop at a distance from the original caseous node.

The second most common form of tuberculosis of the cord arises by extension from the meninges; it is a tuberculous meningo-myelitis, in which aggregations of cells and tubercles develop round the vessels that enter the cord (Fig. 209). The tracts of nerve-fibres show manifold signs of degeneration, and in particular disintegration of the medullary sheaths and swelling of the axis-cylinders (*i*).

The third form is that of disseminated tuberculous of the cord, independent of meningeal tuberculous. In this form, typical tubercles and circumvascular accumulations of cells make their appearance both in the white and in the grey matter, and by disturbing the circulation and nutrition of the tissue give rise to numerous patches of local degeneration, as well as to secondary degeneration of the tracts.

The smallest tubercles are scarcely visible by the naked eye; the larger ones form grey and caseous nodes, which generally exhibit the characters of white softening.

Syphilitic affections of the cord start as a rule in the membranes, and are thus of the nature of meningitis and meningo-myelitis (Art. 104); syphilitic disease of the vessels may however give rise to degeneration and inflammation (syphilitic myelitis) in the interior of the cord. As has been already remarked, syphilis is said to be capable of causing extensive chronic

degenerative changes, such as, for example, the characteristic sclerosis of the posterior columns in tabes dorsalis.

In **leprosy** of the nerves (*lepra anaesthetica*) the spinal cord is in certain cases also involved. In some instances the affection is discoverable only by histological examination, and is manifested by degeneration and atrophy of the nerve-elements, and of the ganglion-cells in particular (TSCHIRJEW). In other cases patches of softening and hæmorrhagic infiltration are formed, and the microscope discloses in them disintegration of the nervous substance, extravasations of blood, and inflammatory exudations. According to the researches of SUDAKEWITSCH, made chiefly upon the Gasserian ganglion and on the spinal root-ganglia, the bacilli of leprosy enter the nerve-cells, and cause vacuolation and destruction of their protoplasm. CHASSIOTIS found large numbers of the bacilli of leprosy in the neuroglial tissue of the grey and white matter, but failed to find them in the ganglion-cells.

References on Tuberculosis of the Cord.

- GUARNERI: *A. per le scienze med.* II
 GUNSSER: Tuberculosis of the cord *Inaug. Diss.* Tübingen 1890
 HAYEM: *A. de physiol.* 1873
 JUNKER: Tubercle in the grey matter *Z. f. klin. Med.* I 1879
 KOHLS: Tumours of the spinal cord *Gerhardt's Handb. der Kinaerkrankheiten* 1880; *Wien. med. Blätter* 1885
 LEYDEN: *Klinik der Rückenmarkskrankheiten* Berlin 1874
 LIONVILLE: Tuberculous cerebro-spinal meningitis *A. de physiol.* III 1870; *Progrès méd.* 1874
 OBOLONSKY: Spread of tuberculosis by the central canal *Prager Z. f. Heilk.* IX 1888
 SACHS: Solitary tubercle of the cervical cord *Neurol. Cent.* 1887
 SCHULTZE: Tuberculosis of the cerebro-spinal nervous system *D. A. f. klin. Med.* XXV 1879
 VIRCHOW: *Die krankhaften Geschwülste*
 WILLIAMS: The spinal cord and its membranes in tuberculous and purulent basilar meningitis *D. A. f. klin. Med.* XXV 1880
 ZUNKER: Tuberculosis in the grey matter *Z. f. klin. Med.* I 1879

References on Syphilitic Degeneration of the Cord.

- BOETTIGER: *A. f. Psych.* XXVI 1894 (with references)
 GREIFF: *A. f. Psych.* XII 1882
 RUMPF: *Die syphilitischen Erkrankungen des Nervensystems* Wiesbaden 1887
 SCHMAUS: *D. A. f. klin. Med.* XLIV 1889
 WESTPHAL: The relation of syphilis to tabes *A. f. Psych.* XI 1881
 WILLIAMSON: Changes in the spinal cord in a case of syphilitic paraplegia *Med. Chronicle* XIV Manchester 1891

References on Leprosy of the Cord.

- CHASSIOTIS: Bacilli in the cord in anaesthetic leprosy *Monatsh. f. prakt. Dermat.* VI 1887
 DANIELSSEN and BOECK: *Traité de la spélalsked* Paris 1848
 LANGHANS: Anaesthetic leprosy *V. A.* 64 1875

LOOFT: Morbid anatomy of anaesthetic leprosy *V. A.* 128 **1892**

STEUDENER: *Pathologie der Lepra mutilans* Erlangen **1867**

SUDAKEWITSCH: Morbid anatomy of leprosy *Ziegler's Beiträge* II **1888**

THOMA: *Lepra arabum V. A.* 57 **1873**

TSCHIRJEW: Lesions of the cord in a case of anaesthetic leprosy *A. de physiol.* VI **1879**

103. Among the **tumours** of the spinal cord the **gliomata** are the only ones that occur with any frequency. They usually form elongated growths, situated chiefly about the central canal or behind it. They consist of dense or sometimes of delicate and gelatinous neuroglial tissue, and often enclose cavities, giving rise to the conditions of hydromyelia and syringomyelia (Art. 95). That in many cases they are the result of anomalies of development is beyond question. At times they are highly vascular, and are then distinguished by the special name of telangiectatic gliomata.

Fibromata, sarcomata, gliosarcomata, and angiosarcomata are but rarely met with in the cord; multiple fibromata may, however, appear in it in cases of general fibromatosis of the peripheral nerves. The growths as a rule take the form of rounded tumours, which give rise to more or less extensive degeneration.

References on Tumours of the Cord (see also Art. 95).

FÜRSTNER: Glioma *A. f. Psych.* XIV **1884**

GLASER: Central angio-sarcoma in the cervical and lumbar cord *A. f. Psych.* XVI **1886**

KLEBS: Glioma *Prager Vierteljahrsschr. f. d. prakt. Heilkunde* 133

KOHTS: Tumours of the spinal cord *Gerhardt's Handb. d. Kinderkrankheiten* Tübingen **1880**

LACHMANN: Glioma *A. f. Psych.* XIII **1882**

LEYDEN: *Klinik der Rückenmarkskrankheiten* **1874**

REISINGER: Glioma *V. A.* 98 **1884**

ROSENBERG: Tumours of the cord *Inaug. Diss.* Strassburg **1892** (with references)

ROTH: Glioma *A. de physiol.* **1878**

SCHÜPPEL: Glioma and glio-myxoma *A. d. Heilk.* VIII **1867**

SCHULTZE: Glioma *A. f. Psych.* VIII **1878**; *V. A.* 102 **1885**

VIRCHOW: *Die krankhaften Geschwülste*

VOLKMANN: Glioma *D. A. f. klin. Med.* XLII **1888**

CHAPTER XXXV

THE MEMBRANES OF THE CORD

104. The most important morbid changes in the internal membranes of the cord, the **pia mater** and **arachnoid**, are those due to **inflammation** from haematogenous infection, from the direct extension of inflammation in neighbouring parts, or from traumatic injury. The term **spinal meningitis** is applied to this condition. In purulent, sero-purulent, and fibrino-purulent inflammations a whitish exudation, containing a varying number of pus-corpuscles, and often fibrin also, collects in the subarachnoid space and within the pia mater. The exudation is sometimes confined to the posterior, sometimes to the anterior surface; again it may extend over the entire length, or only over a limited portion of the cord. In certain cases the inflammatory exudation appears simultaneously or at a later stage in the cerebral pia mater (cerebro-spinal meningitis), or cerebral meningitis is followed by the spinal affection.

Traumatic purulent meningitis is probably in most cases due to the infection of some pre-existing injury by the ordinary micrococci of suppuration, and this is also true of some of the haematogenous and conducted or consecutive forms of inflammation. In a special infective disease whereof inflammation of the cerebro-spinal meninges forms a characteristic feature, known as **epidemic cerebro-spinal meningitis**, the *Diplococcus pneumoniae* appears to be the ordinary exciting cause; other micrococci and bacilli have, however, been detected in this affection (ADENOT, NEUMANN, SCHAEFFER). BONOME discovered a peculiar streptococcus associated with an epidemic of cerebro-spinal meningitis that took place in the neighbourhood of Padua.

The fibres of the white matter of the cord adjoining the inflamed regions often undergo degenerative changes, the medullary sheaths disintegrating and the axis-cylinders swelling up. Occasionally the inflammation spreads along the vessels and the supporting strands of fibrous tissue to the substance of the cord itself, and thus produces **meningo-myelitis**. In the nerve-roots, likewise, inflammatory infiltrations and degenerative changes sometimes make their appearance, and then **neuritis** is superadded to the other disorders.

When recovery takes place after acute meningitis the exuda-

tion is absorbed, but more or less extensive white indurations, produced by proliferation of the connective tissue, remain behind: at times also adhesions of the pia mater to the arachnoid tissue and the dura mater are formed, and the nerves are thereby encased in cicatricial tissue and undergo partial atrophy. In the

cord itself atrophy and sclerosis along the marginal surface is an occasional result of the process.

Tuberculosis of the pia mater and of the arachnoid membrane may be limited to the vertebral canal,

or may accompany tuberculosis of the cerebral meninges; the latter is the more common occurrence, and the disease is then apt to involve the cervical portion of the theca vertebralis.

The tuberculosis is sometimes consecutive, and associated with tuberculous disease of the vertebrae and dura mater or of the substance of the cord; in other instances it is of haematogenous origin. It is at times manifested only by an eruption of tuberculous nodules. More commonly, however, a

more or less extensive inflammation is set up, in consequence of which the subarachnoid liquid becomes turbid, the pia mater is infiltrated with a thin yellowish-white sero-purulent or fibrino-purulent exudation, sometimes though not frequently mingled with extravasations of blood from

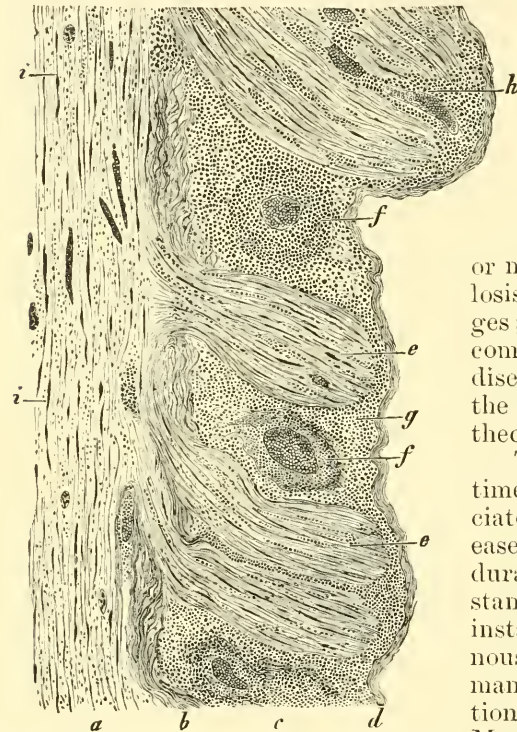


FIG. 209. TUBERCULOUS SPINAL MENINGITIS.

(Longitudinal section through the cord and posterior roots: preparation hardened in Müller's fluid, and stained with anilin-blue by STROEBE'S method: $\times 45$)

- a spinal cord b pia mater
c subarachnoid space d arachnoid membrane
e posterior roots infiltrated with cells and containing a few swollen axis-cylinders
f vessels with proliferous walls infiltrated with cells
g cellular infiltration in subarachnoid space
h masses of cells interpenetrating the nerves
i swollen axis-cylinders

small haemorrhages (Fig. 209 *b c g*). The tubercles are for the most part seated on the walls of the blood-vessels (*f*).

Tuberculous meningitis may spread also in the cord (*i*) and nerve-roots (*e h*), the process thereupon assuming the characters

of **tuberculous meningo-myelitis and neuritis**, and leading to more or less extensive degeneration of the nerve-elements (*e i*) in the affected region (Art. 102, with references).

Syphilitic spinal meningitis is on the whole a rare disease. It appears in the form of rounded or superficially diffused inflammatory infiltrations, involving to a variable extent the adjoining

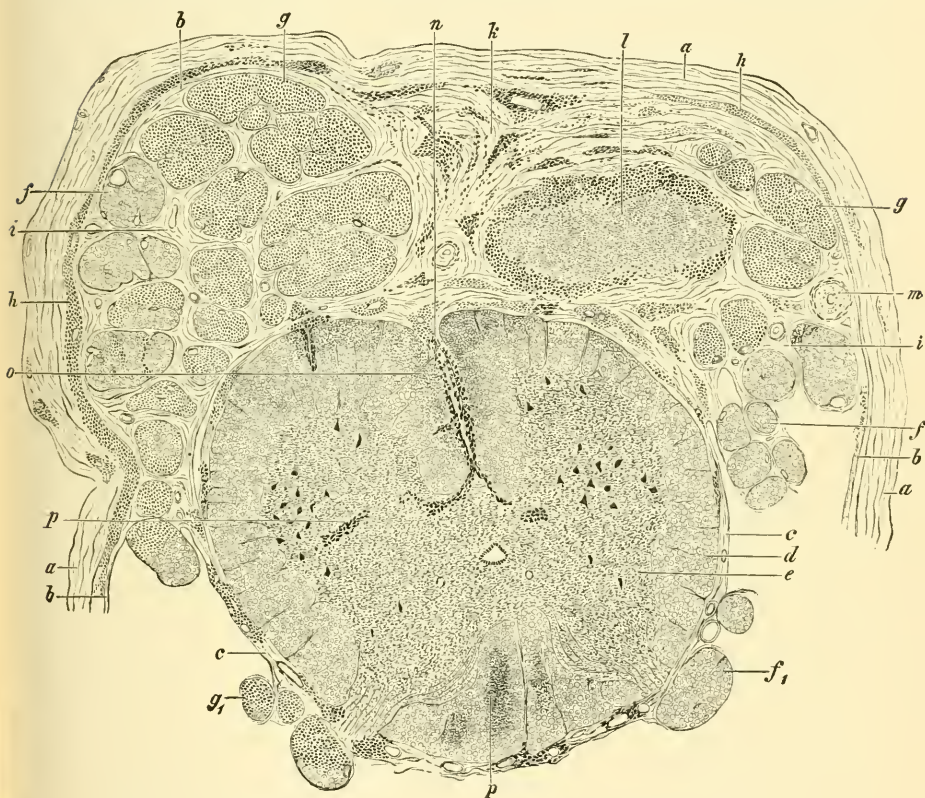


FIG. 210. SYPHILITIC INDURATION AND ADHESIONS IN THE LUMBAR CORD.

(Section through the cord and its membranes: preparation hardened in Müller's fluid and alcohol, and stained with haematoxylin and carmine: $\times 8$)

- | | | | |
|-------------------|--------------------------------------------------------------------------|---|-------------------------------------------------------------------------------------------------------------------------|
| a | thickened dura mater | k | newly-formed connective tissue uniting the dura mater, arachnoid membrane, and pia mater into a single cicatricial mass |
| b | arachnoid membrane | l | cheesy deposit |
| c | pia mater | m | transverse section of an artery with greatly thickened intima |
| d | white matter of the cord | n | inflammatory infiltration of the pia mater in the anterior fissure |
| e | grey matter of the cord | o | degenerate and sclerotic tissue in the medial parts of the anterior columns |
| f, f ₁ | cross-section of healthy nerve-roots | p | foci of degeneration in the posterior columns and of inflammation in the grey matter |
| g, g ₁ | cross-section of degenerate nerve-roots | | |
| h | cellular tissue connecting the arachnoid membrane and the dura mater | | |
| i | newly-formed connective tissue surrounding and uniting the nerve-bundles | | |

substance of the cord or even the dura mater. In particular cases it extends from the vertebrae and dura mater to the internal membranes.

The inflammation and proliferation lead in the course of time to thickening of the pia mater, to closer cohesion of this with the arachnoid, and to adhesions between both and the dura mater (Fig. 210 *h k*). The nerves lying within the region of inflammatory proliferation become surrounded by new-formed tissue (*i*), and gradually undergo atrophy as the proliferation invades the endoneurium also (*g g₁*). Partial necrosis of the inflamed and proliferous tissue occasionally results in the formation of cheesy deposits (*l*) within the cicatricial indurations. The adjacent substance of the cord, by compression and by disturbance of its nutrition due in part to obliteration of the vessels, may undergo more or less extensive atrophy and sclerosis (*o* and *p* below). Sometimes the inflammatory infiltration and proliferation extend along the connecting strands of fibrous tissue and the vessels into the interior of the cord (*n* and *p* left side).

Haemorrhages into the meninges are generally the result of traumatic injury; they occur also, however, in connexion with haemophilia, purpura, and infective diseases, and in rare cases they arise from causes that cannot be traced.

References on the Aetiology and Histology of Spinal Meningitis.

- ADENOT: Bacteriological researches on a case of meningitis *A. de méd. exp.* I
1889
- BONOME: Aetiology of epidemic cerebro-spinal meningitis *Ziegler's Beiträge* VIII
1890
- CENTANNI: A new micro-organism in meningitis *A. per le scienze med.* XVII
1893 (with references)
- FOÀ and BORDONI-UFFREDUZZI: Aetiology of epidemic cerebro-spinal meningitis *Z. f. Hygiene* IV 1888
- GOLDSCHMIDT: Aetiology of cerebro-spinal meningitis *Cent. f. Bakteriologie* II
1887
- HAUSER: Fränkel's pneumonia-diplococcus in cerebro-spinal meningitis *Münch. med. Woch.* 1888
- NETTER: Meningitis due to the pneumococcus *A. gén. de méd.* 1887
- NEUMANN and SCHAEFFER: Aetiology of purulent meningitis *V. A.* 109 1887
- ORTMANN: Aetiology of cerebro-spinal meningitis *A. f. exp. Path.* XXIV 1888
- WEICHELBAUM: Aetiology of acute cerebro-spinal meningitis *Fortschr. d. Med.* V 1887
- WIETING: Meningo-myelitis *Ziegler's Beiträge* XIII 1893

References on Syphilis of the Spinal Meninges and of the Cord.

- BOETTIGER: Syphilitic diseases of the spinal cord *A. f. Psych.* XXVI 1884
(with references)
- BUTTERSACK: Syphilitic diseases of the central nervous system *A. f. Psych.* XVII 1887
- CHARCOT and GOMBAULT: Disseminated lesions in a syphilitic woman *A. de physiol.* 1873
- DINKLER: Tabes dorsalis with syphilitic meningitis *Z. f. Nervenheilk.* 1893

JUILLARD: *Localisations spinales de la syphilis* Paris 1879

LANCEREAUX: *Traité de la syphilis* Paris 1879

MÜLLER: Syphilis of the cord *A. f. Derm.* XXIII 1891

PICK: Cerebro-spinal syphilis *Prager Z. f. Heilk.* XIII 1892

RUMPF: *Syphilitische Erkrankungen des Nervensystems* Wiesbaden 1887

SIEMERLING: Congenital cerebral and spinal syphilis *A. f. Psych.* XX 1888;
Syphilis of the central nervous system *ibidem* XXII 1890

SOTTAS: *L'anat. et la clin. des paralysies spinales syphilitiques* Paris 1894 (with references)

105. Among the **tumours** of the inner spinal membranes, small **osteomata** are the first to be mentioned; in the form of small white discs or plates they are often found in the arachnoid. According to ZANDA their formation is due to degenerative changes in the fibrous tissue, and they are furnished with new blood-vessels from the dura mater. Varicose dilatations of the pial

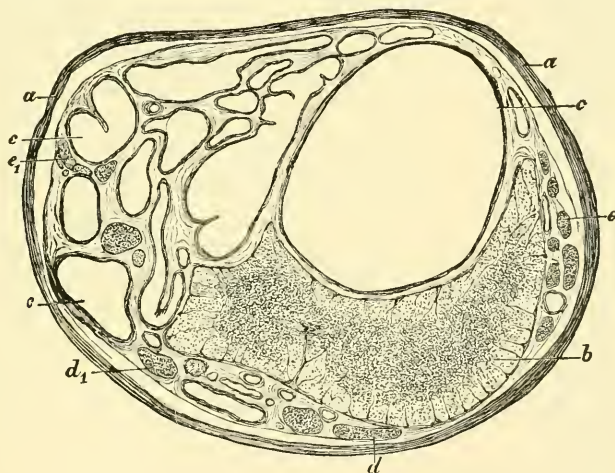


FIG. 211. VENOUS ANGIOMA OF THE PIA MATER.

(Cross-section of the lumbar cord: preparation hardened in Müller's fluid and alcohol, cut in celloidin, stained with haematoxylin and carmine, and mounted in Canada balsam: $\times 4$)

- | | | | |
|---|------------------------------------------------|------------------|------------------------------------------------------|
| a | dura mater | d d ₁ | transverse section through the anterior nerve-roots |
| b | spinal cord | e e ₁ | transverse section through the posterior nerve-roots |
| c | transverse section through venous blood-spaces | | |

veins are not uncommon, and sometimes lead to the formation of venous **cavernous angiomata** (Fig. 211 e), which as they grow produce compression of the cord (b) and of the nerve-roots (d d₁ e e₁).

Of the true tumours, most of the connective-tissue forms occur as primary growths, such as sarcomata, fibromata, myxomata, angiomas, angio-sarcomata, and lipomata. **Lipomata** are met with chiefly in cases of spina bifida. The **fibromata** form rounded

nodes, and have their origin most commonly in the perineurium of the nerve-roots (Fig. 212 *e d*). The **sarcomata** form rounded or superficial growths, and sometimes invade the substance of the cord. Some of the sarcomata, in which the neoplastic proliferation starts in the endothelium enveloping the fibrous connecting strands, and which possess an alveolar structure, are classed with the **alveolar endotheliomata**.

Tumours characterised by excessive vascular hyperplasia (Figs. 212 *e* and 213) are regarded as angiomata and angio-sarcomata.

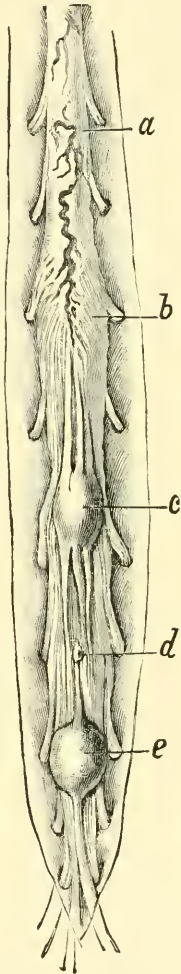


FIG. 212. FIBROMA AND PAPILLOMATOUS ANGIO-SARCOMA OF THE CAUDA EQUINA WITH CENTRAL GLIOMA OF THE LUMBAR CORD.

(Reduced to one-half the natural size)

- a thoracic portion of the cord
- b dilated lumbar portion with central glioma and excavation
- c and d fibromata
- e angio-sarcoma

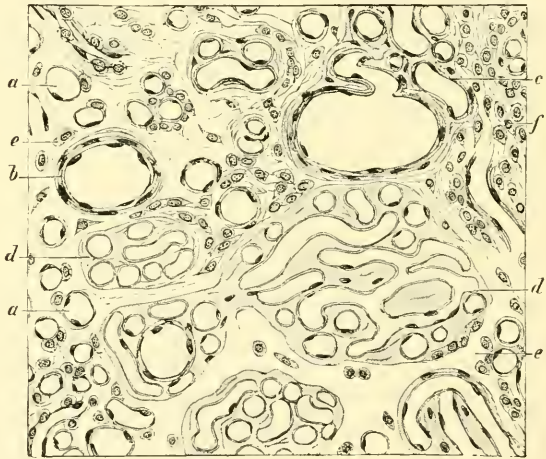


FIG. 213. PAPILLOMATOUS ANGIO-SARCOMA WITH HYALINE DEGENERATION.

From the cauda equina shown in Fig. 212 (*e*) (preparation hardened in Müller's fluid, stained with haematoxylin, and mounted in Canada balsam: $\times 150$)

- a small single vessels
- b large single vessels
- c vascular tufts cut partly in the longitudinal and partly in the transverse direction
- d denuded vessels in hyaline degenerated connective tissue
- e single cells lying between the vascular tufts
- f fibro-cellular tissue lying between the vascular tufts

They have sometimes a peculiar structure, recalling that of the placenta, and contain numerous papillary outgrowths composed of blood-vessels (Fig. 213 *a b*) and vascular tufts (*c d*), interspersed with single cells (*e*) or patches of myxomatous and sarcomatous tissue (*f*). The hyaline degeneration

(d) frequently associated with these neoplasms justifies us in classing them as **cylindromata**.

Among the **secondary tumours** carcinomata and sarcomata are met with, some forming circumscribed nodes, and others diffuse proliferous growths which fill the arachnoid cavity, envelope closely the cord and nerve-roots, and sometimes invade the substance of the cord itself.

References on Tumours of the Internal Spinal Meninges.

- BAIERLACHER: Cystosarcoma *Deutsche Klinik* 1860
 BRAUBACH: Lipoma *A. f. Psych.* xv 1884
 CHIARI: Cholesteatoma of the dorsal cord *Prager med. Woch.* 1883
 CRAMER: Multiple angio-sarcoma of the spinal pia mater *Inaug. Diss.* Marburg 1888
 GANGUILLET: Cylindroma *Inaug. Diss.* Berne 1878
 GAUPP: Morbid anatomy of the spinal cord and its membranes *Ziegler's Beiträge* II 1888
 LACHMANN: Glioma of the filum terminale *A. f. Psych.* XIII 1882
 LEYDEN: *Klinik der Rückenmarkskrankheiten* I Berlin 1874
 ROSENBERG: Tumours of the cord *Inaug. Diss.* Strassburg 1892 (with references)
 SCHULZ: Sarcoma of the spinal pia mater *A. f. Psych.* XVI 1885
 WESTPHAL: Multiple sarcomatosis of the brain and of the membranes of the cord *A. f. Psych.* XXVI 1894
 ZANDA: The development of the osteomata of the spinal arachnoid *Ziegler's Beiträge* v 1889

106. The spinal **dura mater** forms a theca or elongated sac loosely enveloping the cord, and separated from the vertebral canal by the epidural space. **Acute inflammation** of the dura mater, or pachymeningitis, as a rule results from inflammation of the neighbouring internal membranes and of the vertebrae, or is of traumatic origin. As the dura mater is close and stout in texture, inflammatory infiltration of its tissue can take place only to a slight extent, and is accordingly in most cases limited to its superficial layers. In the process of recovery after inflammation adhesions to the adjacent structures are apt to be formed.

Scattered patches of proliferation on the internal surface, succeeding the deposition of fibrin thereupon, are occasionally but not very frequently observed, and lead to the formation of delicate vascular false membranes. Within these membranes hæmorrhages of varying extent are apt to take place, and the process is therefore described as **internal hæmorrhagic pachymeningitis**. Its causation is unknown, except in those cases where it follows vertebral or pial disease, or where tuberculosis or syphilis are present. The slighter forms of the disease cause no recognisable changes in the cord itself. In the severer cases adhesions with the arachnoid and pia mater may be formed, and the inflammation may extend to the pia mater; in such cases degenerative changes soon make their appearance in the cord.

Tuberculosis of the spinal dura mater is almost always a secondary affection, usually proceeding from the vertebrae, more rarely from the cord and the pia mater. Numerous caseous deposits are produced in the epidural space, compressing the dural sac and the spinal cord it encloses. The dura mater is sometimes covered externally with caseous granulosomatous deposits, while on its internal surface are formed delicate pachymeningitic false membranes resembling the non-tuberculous membranes above referred to. If the tubercle-bacilli penetrate into the substance of the dural sac, disseminated tubercles, with or without caseating granulations, make their appearance on the internal surface of the membrane.

Syphilitic inflammation and granulosomatous proliferation occur both as primary and as secondary morbid processes in the dura mater; in the latter case they originate in the pia mater, very seldom in the vertebrae (Art. 104).

Among the **primary tumours** of the spinal dura mater, sarcomata, fibromata, and myxomata have been recorded. Lipomata have been repeatedly observed in the epidural space. **Hydatid cysts** may develop both in the epidural space and in the dural sac itself; they are, however, rare.

References on the Morbid Anatomy of the Spinal Dura Mater.

- ADAMKIEWICZ: *Pachymeningitis hypertrophica* Vienna 1890
 BURTIN: Hypertrophic spinal pachymeningitis *Thèse* Paris 1878
 CHARCOT: *Diseases of the nervous system* II London 1877-1883
 FRANCOIS: Fibroma of the spinal dura mater *Ann. de la Soc. med.-chir. de Liège* 1888
 JOFFROY: Spontaneous cervical pachymeningitis *Thèse* Paris 1873; *A. gén. de méd.* II 1876
 LANCEREAUX: *Traité historique et pratique de la syphilis* Paris 1873
 MICHAUD: Meningitis and myelitis in spinal disease *Thèse* Paris 1871
 NEISSER: *Die Echinococcenkrankheit* Berlin 1877

CHAPTER XXXVI

STRUCTURE AND FUNCTIONS OF THE BRAIN

107. The part of the central nervous system enclosed by the cranium consists of the cerebrum and cerebral axis, with the cerebellum.

The **cerebrum** is made up of two hemispheres, united by a commissure, the *corpus callosum*. The outer surface of the hemispheres is marked in a characteristic fashion by ramifying and intercommunicating furrows or *sulci*, between which the brain-substance is thrown into tortuous ridges and prominences, known as the *gyri* or convolutions.

Some of the sulci are characteristic of the human brain, and are always present; others are subject to considerable variation in different brains, and thus the details of the configuration of the gyri are by no means constant. The most important sulci are the **Sylvian fissure** (Fig. 214 *e*), the **central** or rolandian fissure (*a*), the **pre-central** (*b*), the **intraparietal** (*d*), the **superficial-temporal** or first-temporal (*f*), the **parieto-occipital** (*c*), the **anterior-occipital** (*i*), and the **inferior-occipital** (*h*) fissures.

The central or rolandian fissure (*a*) divides the cerebral hemisphere into an anterior and a posterior portion; the gyrus immediately in front of it is known as the **pre-central** or **ascending-frontal** (*A*) convolution, the one immediately behind it as the **post-central** or **ascending-parietal** (*B*) convolution.

The term **opercular** or **central lobe** is applied to the group of convolutions surrounding the central fissure, namely the pre-central, post-central, paracentral (uniting them above), and infra-central (uniting them below). The portion of the hemisphere in front of the pre-central fissure (*b*) is the **frontal lobe** in the narrower sense of the term, and is divided into the superior-frontal (*C*₁), the middle-frontal (*C*₂), and the inferior-frontal (*C*₃) convolutions. These three convolutions pass downwards round the anterior border of the hemisphere to its orbital surface.

Behind the post-central convolution lies the **parietal lobe** (*D*), divided by the intraparietal fissure (*d*) into a superior-parietal and an inferior-parietal lobule. The latter is made up of the marginal or supra-marginal gyrus (*E*) and the angular gyrus (*F*).

The parieto-occipital (*c*) and the anterior-occipital sulci (*i*) form the boundary between the parietal and the **occipital lobe** (*G*), and in the space between these two furrows the so-called annectant (or connecting) gyri pass over from the parietal to the occipital lobe.

The Sylvian fissure (*e*) forms the boundary between the lower and outer portions of the frontal, central, and parietal lobes and the **temporal lobe**. The gyrus bordering the lower side of this fissure is the first-temporal or superior temporo-sphenoidal convolution (*H*₁).

The gyrus which bends round the upper end of the sylvian fissure belongs, as we have said, to the inferior-parietal lobule, and is known as the marginal gyrus (*E*). Below the superior-temporal (also called the parallel) fissure (*f*) is the second-temporal gyrus (*H₂*). Its upper portion, though it bends round the fissure, is still regarded as belonging to the inferior-parietal lobule, and has received the name of the angular gyrus (*F*). Below the second-temporal fissure (Fig. 214 *g*) is found the third-temporal gyrus (Fig. 215 *G*). If the lips of the sylvian fissure are drawn apart, the island of Reil or **insula** becomes visible.

The median aspect of the first-frontal gyrus (Fig. 215 *A*) has received no special name: that of the operculum is known as the **paracentral lobule**. Both are bounded inferiorly by the callosal-marginal sulcus (*a*), which anteriorly separates the first-frontal from the **callosal gyrus** or **gyrus cinguli** (*K*),

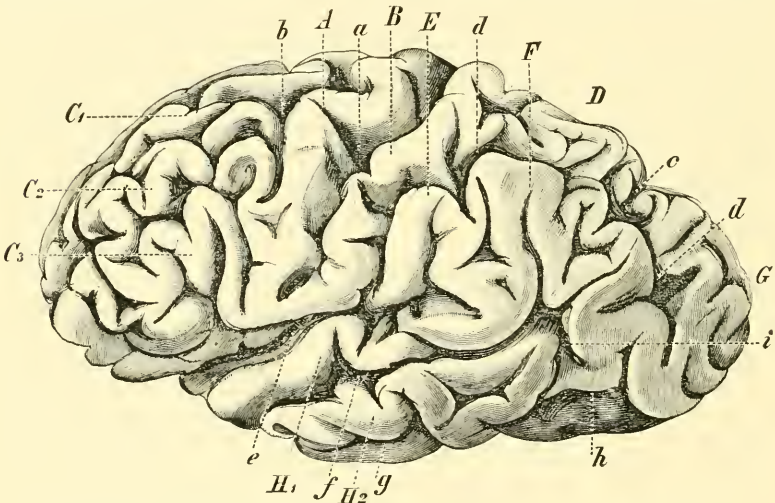


FIG. 214. EXTERNAL SURFACE OF THE LEFT CEREBRAL HEMISPHERE.

(Drawn from a brain treated with nitric acid and dried)

<i>a</i>	central fissure	<i>B</i>	post-central gyrus
<i>b</i>	pre-central fissure	<i>C₁</i>	superior-frontal gyrus
<i>c</i>	parieto-occipital fissure	<i>C₂</i>	middle-frontal gyrus
<i>d</i>	intraparietal fissure	<i>C₃</i>	inferior-frontal gyrus
<i>e</i>	sylvian fissure	<i>D</i>	parietal lobe
<i>f</i>	superficial-temporal fissure	<i>E</i>	marginal gyrus
<i>g</i>	second-temporal fissure	<i>F</i>	angular gyrus
<i>h</i>	inferior-occipital fissure	<i>G</i>	occipital lobe
<i>i</i>	anterior-occipital fissure	<i>H₁</i>	first-temporal gyrus
<i>A</i>	pre-central gyrus	<i>H₂</i>	second-temporal gyrus

and posteriorly by the paracentral lobule (*B*) from the **præcuneus** or quadrate lobule (*C*), the median portion of the superior-parietal lobule. The median portion of the occipital lobe is known as the **cuneus** (*D*), and is separated from the præcuneus by the parieto-occipital sulcus (*b*).

The fissure known as the transverse-occipital sulcus or **calcarine** fissure (*c*) separates the cuneus from the **lingual** gyrus (*E*). The latter passes anteriorly into the **hippocampal** gyrus (*H*), which is a continuation of the callosal gyrus (*K*).

Below the lingual and the hippocampal gyrus lies the **occipito-temporal** or collateral sulcus (*d*), and below this the occipito-temporal or **fusiform** gyrus (*F*).

The substance of the cerebrum (Fig. 216) is composed of the cortex (*co.*) and the medullary white matter. The former has a grey colour, and everywhere forms the outermost layer of the cerebrum; at the base it dips here and there into the interior, forming the grey structures known as the claustrum (*cl.*), the nucleus amygdalæ (*n.a.*), the caudate nucleus (*c.n.*), and the external segment of the lenticular nucleus or putamen (WERNICKE). The latter two nuclei are

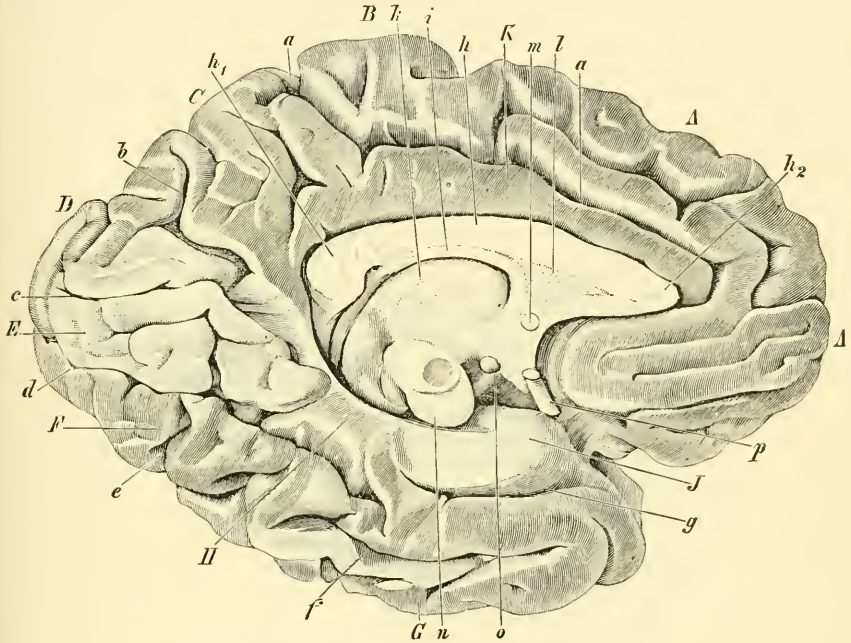


FIG. 215. MEDIAN SURFACE OF THE CEREBRUM.

(Drawn from a fresh preparation: reduced to one-half the natural size)

A	median surface of the first-frontal gyrus	d	occipito-temporal sulcus
B	paracentral lobule	e	pre-occipital sulcus
C	praecuneus	f	inferior-temporal sulcus
D	cuneus	g	fourth-temporal sulcus
E	lingual gyrus	h	corpus callosum
F	occipito-temporal gyrus	h ₁	splenium of the corpus callosum
G	inferior-temporal gyrus	h ₂	genu of the corpus callosum
H	hippocampal gyrus	i	fornix
J	uncinate gyrus	k	median surface of the optic thalamus with the soft commissure
K	callosal gyrus	l	septum pellucidum
a	calloso-marginal sulcus	m	anterior commissure
b	parieto-occipital sulcus	n	crus cerebri
c	transverse-occipital sulcus or calcarine fissure	o	corpus mammillarium (albicans)
		p	optic nerve

continuous anteriorly with one another as well as with the cortex (*substantia perforata anterior*). Posteriorly they are separated from one another by layers of white matter.

The grey masses known as the **optic thalamus** (*th.*) and the subthalamic body (*c.s.*) or nucleus of Luys, together with the inner two-thirds of the lenticular nucleus (*n.l.*), do not belong to the cerebral cortex, but to the cerebral axis.

The grey matter of the cerebrum contains, embedded in a matrix which after death has a finely granular appearance, a large number of stellate ganglion-cells of various forms, with plexuses and tracts of fine and coarse nerve-fibres.

The white or medullary substance consists essentially of medullated nerve-fibres, without sheaths, which have their origin or termination in the grey matter of the brain. According to RAMON Y CAJAL, these fibres are of four chief types, namely projective fibres, commissural fibres, associative fibres, and centripetal fibres.

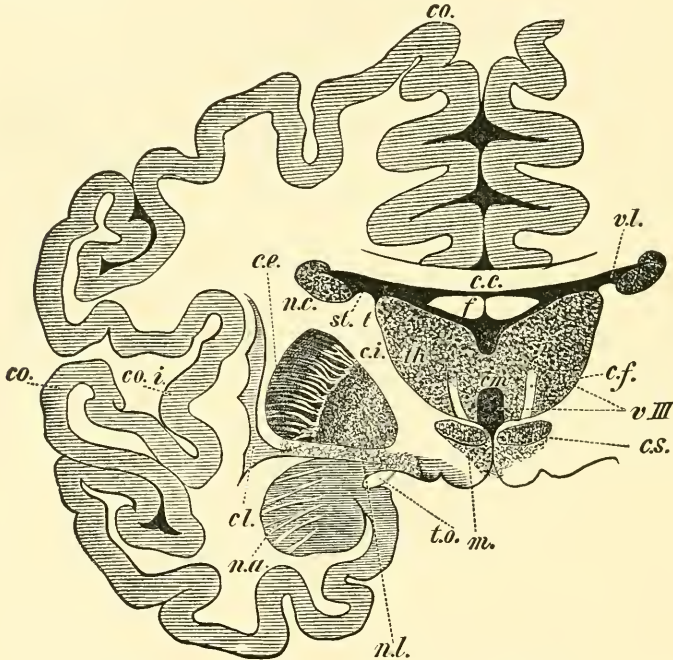


FIG. 216. FRONTAL SECTION OF THE CEREBRUM.

(Diagrammatic; after SCHWALBE)

co.	cortex	c.m.	soft commissure	c.f.	pillars of the fornix
co.i.	cortex of the insula	c.s.	subthalamic body	f.	fornix
cl.	claustrum	m.	substantia nigra	c.c.	corpus callosum
n.a.	nucleus amygdalæ	c.i.	internal capsule	v. III	third ventricle
n.c.	caudate nucleus	c.e.	external capsule	v. l.	lateral ventricle
n.l.	lenticular nucleus	st. t.	stria terminalis	t.o.	optic tract
th.	optic thalamus				

The projective fibres (Fig. 217 a) start from all parts of the cortex, and, after giving off collateral branches to the corpus callosum (A) and to the grey matter of the cerebral axis, constitute the greater part of the pyramidal tract (C). The commissural fibres (A), which pass through the corpus callosum, arise in the cortex of one hemisphere and end in the other. The fibres of the anterior commissure (B) arise in the region of the cuneus. The associative fibres (c), which form the main mass of the white matter, connect by their lateral and terminal branches the cortical cells with numerous other cortical regions.

On the surface of the brain various cortical areas or **centres** are distinguished according to their function. The **motor centres** extend over the two central convolutions and the paracentral lobule; the centres for the facial and the hypoglossal nerves lie in the lower third, those for the arms in the middle third, and those for the legs in the upper third and in the paracentral lobule. The several regions are not sharply separated, but pass one into the other. The centres for the movements of the trunk are said to be situated in the frontal lobe.

The motor **speech-centre**, or region wherein verbal images are translated into spoken words, is in right-handed persons situated in the posterior part of the left third-frontal gyrus. The sensory speech-centre, with which the memory of the sound of words is associated, lies in the left first-temporal gyrus.

The **centres for sensation** have in general the same situation as the motor centres, extending however to other regions, such as the parietal lobe (NOTH-NAGEL, BECHTEREW, WERNICKE).

The **visual centre** lies in the occipital lobe, chiefly about the region of the calcarine fissure and of the cuneus. The seat of the **olfactory centre** is not

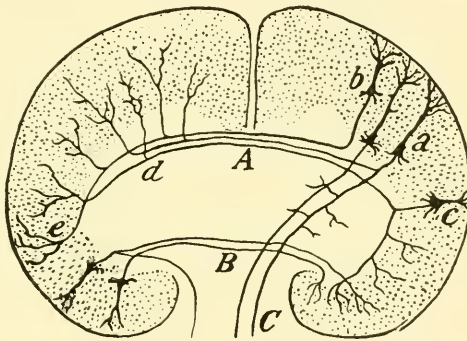


FIG. 217. DIAGRAMMATIC SCHEME OF THE COURSE OF THE NERVE-FIBRES WITHIN THE BRAIN (after RAMON Y CAJAL).

- | | | | |
|---|-----------------------------------------------------------------|---|------------------------------------------------------------------|
| A | corpus callosum | b | neuron with fibres to the corpus callosum |
| B | anterior commissure | c | neuron with associative fibres |
| C | pyramidal tract | e | terminal ramifications of various neurons in the cerebral cortex |
| a | neuron with projective fibres and collateral commissural fibres | | |

positively known; perhaps it is in the uncinate gyrus. The **auditory centre** is situated in the temporal lobe, and it is assumed that the centre in each hemisphere is connected with both auditory nerves.

Psychical functions are associated with the whole of the cerebral cortex. The frontal lobe is regarded as specially concerned in the performance of the higher mental functions.

The **cerebral axis** consists of the medulla oblongata (Fig. 218 *M.obl.*), pons (*Po.*), the crura (*Pe.*) the subthalamic nucleus (Fig. 216 *c.s.*) with the tuber cinereum (Fig. 218 *T.c.*) and corpora mammillaria (*C.m.*), the cerebellum (Fig. 218 *D. Gr. Fl.*), the corpora quadrigemina, and the optic thalamus (Figs. 216 *th.* and 215 *k.*).

All these parts may, from their mode of origin, be regarded as modifications of the spinal cord, and the cerebral nerves that are homologous with the spinal nerves start from this region (Fig. 218 *I-XII* and Fig. 179 *III-XII*).

The cerebral axis contains no parts that are related to psychical activity; its centres are partly automatic and partly reflex in their nature and functions.

The medulla oblongata, for example, contains the reflex centre for the closure of the eyelids, coughing, sneezing, sucking, etc., as well as centres that correlate subordinate reflexes of the spinal cord. It contains also the centres for the nerves of respiration, the motor nerves of the heart, and the vaso-motor nerves, as well as a centre which when stimulated induces general convulsions. Here are also the mechanisms for the co-ordination of the movements subserving vocal articulation (KUSSMAUL), for the perception of speech as mere sound, and for the perception of written characters as mere shapes. The mental presentation of the syllables and words to be uttered in articulate speech, and the association of the sounds and written shapes perceived with the appropriate verbal images, is effected in the cerebral cortex.

Stimulation of the pons causes convulsions and painful sensations; its destruction causes sensory, motor, and vaso-motor paralysis. In the cerebellum

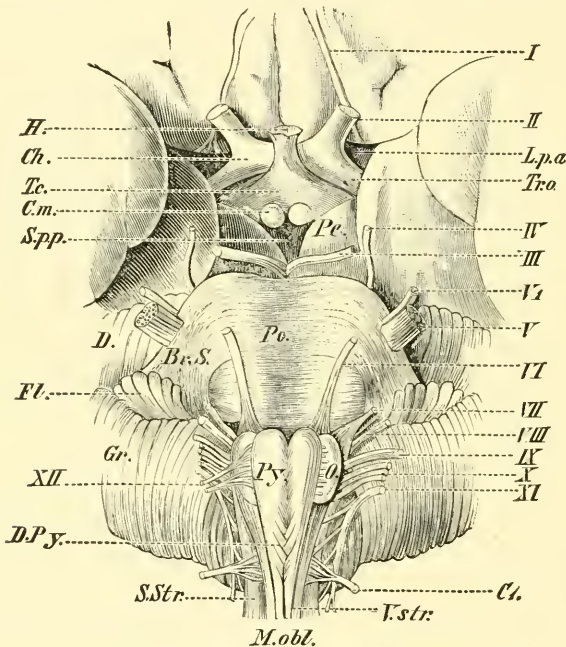


FIG. 218. BASAL ASPECT OF THE CEREBRAL AXIS.

- | | | | |
|---------------|--------------------------------------|----------------------------|------------------------------------------------|
| <i>S.Str.</i> | lateral column of the cord | <i>H.</i> | cut surface of the hypophysis (pituitary body) |
| <i>V.Str.</i> | anterior column of the cord | <i>Tr.o.</i> | optic tract |
| <i>M.obl.</i> | medulla oblongata | <i>Ch.</i> | optic chiasma |
| <i>Py.</i> | pyramid | <i>I</i> | olfactory nerve |
| <i>D.Py.</i> | decussation of the pyramids | <i>II</i> | optic nerve |
| <i>O.</i> | olive | <i>III</i> | oculomotor nerve |
| <i>Po.</i> | pons | <i>IV</i> | trochlearis nerve |
| <i>D.</i> | anterior lobe of the cerebellum | <i>V and V₁</i> | trifacial nerve |
| <i>Gr.</i> | digastric lobe of the cerebellum | <i>VI</i> | abducens oculi nerve |
| <i>Fl.</i> | flocculus of the cerebellum | <i>VII</i> | facial nerve |
| <i>Br.S.</i> | middle peduncles of the cerebellum | <i>VIII</i> | auditory nerve |
| <i>Pe.</i> | crus cerebri (cerebral peduncle) | <i>IX</i> | glosso-pharyngeal nerve |
| <i>S.p.p.</i> | substantia perforata posterior | <i>X</i> | vagus nerve |
| <i>L.p.a.</i> | lamina perforata anterior | <i>XI</i> | spinal accessory nerve |
| <i>C.m.</i> | corpora mammillaria (albicantia) | <i>XII</i> | hypoglossal nerve |
| <i>T.c.</i> | tuber cinereum with the infundibulum | <i>C₁</i> | anterior roots of the first cervical nerve |

and corpora quadrigemina are situated centres for the adjustment and co-ordination of the movements of the limbs and trunk, and so on. The functions of the optic thalamus and of the nucleus of the pons are unknown.

References on the Structure and Functions of the Brain (see also Art. 88).

- BECHTEREW: *Die Leitungsbahnen im Gehirn und Rückenmark* Leipzig 1894
 CAJAL, RAMON Y: *La structure du système nerveux* Paris 1894, and *A. f. Anat.* 1893
 CHARCOT: *Les localisations dans les maladies du cerveau* Paris 1878. trans. (New Syd. Soc.) London 1883
 DÉJÉRINE: *Anatomie des centres nerveux* Paris 1895
 ECKER: *Die Hirnwindungen des Menschen* Brunswick 1883
 EDINGER: *Bau der nervösen Centralorgane* Leipzig 1894
 EXNER: *Function der Grosshirnrinde* Vienna 1890: Recent physiological investigations on the cerebral cortex *Biol. Centralbl.* v 1885; Localisation *Wien. med. Woch.* 1886
 FERRIER: *The functions of the brain* London 1886: *Cerebral localisation* London 1890
 FLECHSIG: *Die Leitungsbahnen im Gehirn und Rückenmark des Menschen* Leipzig 1876, and *Plan d. menschl. Gehirnes* Leipzig 1883
 FRITSCHE and HITZIG: *A. f. Anat. u. Physiol.* (Reichert's) 1870
 VON GEHUCHTEN: *Le système nerveux de l'homme* Liège 1893
 GOLGI: *Der feinere Bau des Nervensystems* Jena 1894
 GOLTZ: *Ueber die Verrichtungen des Grosshirnes* Bonn 1881
 GROSSGLIK: Physiology of the frontal lobes *A. f. Anat. u. Physiol.* 1895
 HITZIG: *Untersuch. über das Gehirn* Berlin 1874; Functions of the brain *Biol. Centralbl.* vi 1886
 HORSLEY: *Brain and spinal cord* London 1892
 KÖLLIKER: *Handbuch der Gewebelehre* II Leipzig 1893
 KUSSMAUL: *Die Störungen der Sprache* Leipzig 1885
 LENIHOSSÉK: *Der feinere Bau des Nervensystems* Berlin 1895
 LUCIANI: *Das Kleinhirn* Leipzig 1893
 MERKEL: *Handbuch der topographischen Anatomie* I Brunswick 1884
 VON MONAKOW: Investigations on the optical centres and tracts *A. f. Psych.* XIV 1884, XVI 1885, XX 1889, XXII 1890, XXIII 1892, XXIV 1892
 MUNK: *Ueber die Functionen der Grosshirnrinde* Berlin 1890
 NOTHNAGEL: *Topische Diagnostik der Gehirnkrankheiten* Berlin 1879
 NOTHNAGEL and NAUNYN: Localisation of cerebral diseases *Verh. Congress. f. inn. Med.* Wiesbaden 1887
 OBERSTEINER: *Anleitung bei der Untersuchung des Baues der nervösen Centralorgane* Leipzig 1891
 OBERSTEINER and HILL: *Central nervous organs* London 1890
 OPPENHEIM: *Lehrbuch der Nervenkrankheiten* Berlin 1894
 SACHS: *Bau u. Thätigkeit d. Grosshirns* Breslau 1893
 SCHWALBE: *Lehrbuch der Neurologie* Erlangen 1881
 TOLDT: *Lehrb. d. Gewebelehre* 4th edition Stuttgart 1894
 WERNICKE: *Lehrb. d. Gehirnkrankh.* I Cassel and Berlin 1881

CHAPTER XXXVII

MALFORMATIONS OF THE BRAIN

198. The **malformations** of the brain relate most commonly to the cerebral hemispheres and the cerebellum, these being the parts which in their development from the primitive cerebral vesicles undergo the greatest amount of growth and the most important transformations. The parts of the cerebral axis arising from the vesicles of the hind-brain, mid-brain, and inter-brain, are also in some cases imperfectly developed.

Some of the malformations of the brain are associated with malformations of the cranium, such as agenesi of particular por-

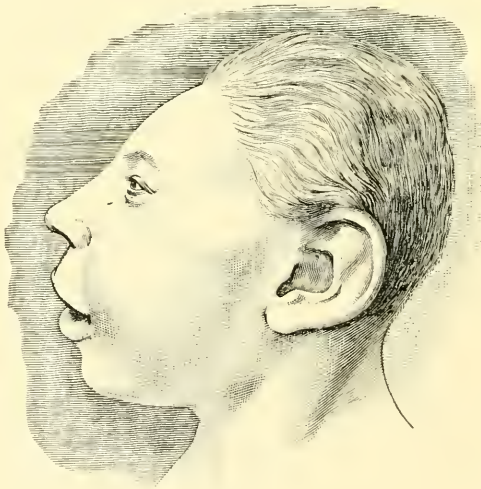


FIG. 219. HEAD OF THE MICROCEPHALIC CHILD HELEN BECKER.
(Aged 5 years: from a photograph taken by A. ECKER in the year 1868)

tions of it. Of this nature are total or partial anencephalia, and cephalocele or cerebral hernia, which occur in combination with acrania, cranioschisis, or craniorachischisis, or with mere osseous defects of the cranium.

Among the malformations that are met with when the skull is entire and closed, there are two main classes, one characterised

by hypoplasia or under-growth, the other by agenesis or total absence of particular portions of the brain. These two types cannot, however, be sharply separated, for hypoplasia is sometimes combined with, or passes into, partial agenesis. A third group, likewise incapable of sharp separation from the others, and in some instances appearing merely as a variety of hypoplasia or partial agenesis, includes anomalies of development in the fissures, minor sulci, and convolutions. In a fourth group might be placed anomalies of the minuter structure and organisation of the brain-

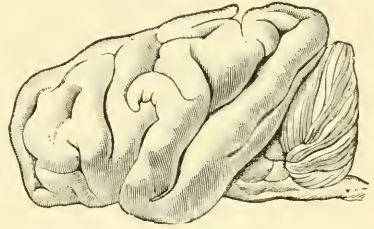


FIG. 220. BRAIN OF THE MICROCEPHALIC CHILD HELEN BECKER.

(Died at the age of 8: from VON BISCHOFF: weight of the brain 219 grammes, instead of the normal (VIERORDT) 1377 grammes)

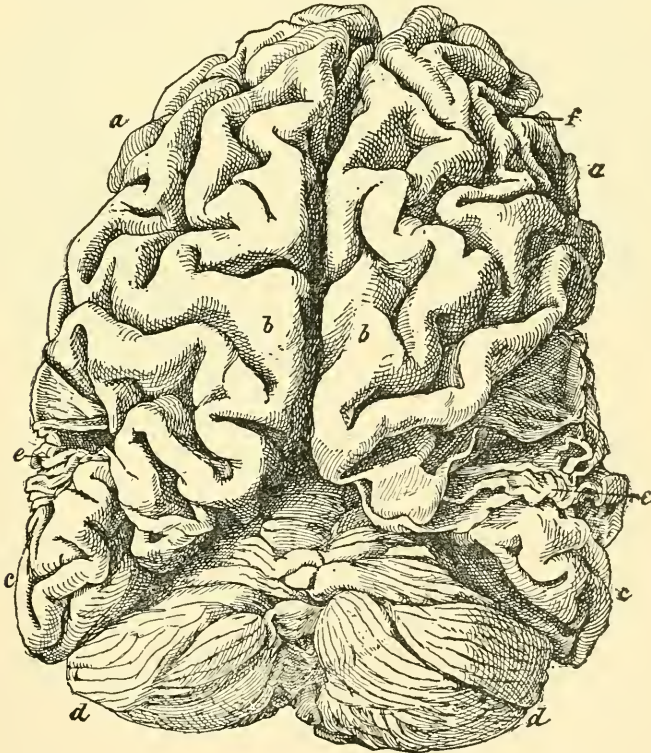


FIG. 221. BRAIN WEIGHING 600 GRAMMES

(From an imbecile epileptic woman of 37: reduced to three-fourths of the natural size)

- a frontal lobes b central convolutions c occipital lobes d uncovered cerebellum
 e undeveloped parietal lobes with membranous gyri f attenuated gyri of the right frontal lobe

substance, though such anomalies are often merely local manifestations of agenesis or hypoplasia. Lastly, certain conditions of hypertrophy might also be counted among the malformations.

Hypoplasia of the entire brain occurs, first, in the condition termed **micrencephalia** (Fig. 220), in which the hypoplasia is accompanied by smallness of the skull itself, in other words by some degree of microcephalia (Fig. 219). The malformation is sometimes present even at birth, but becomes more striking when, while the rest of the body grows, the brain and skull remain in the infantile condition. The mass of the brain, which in men

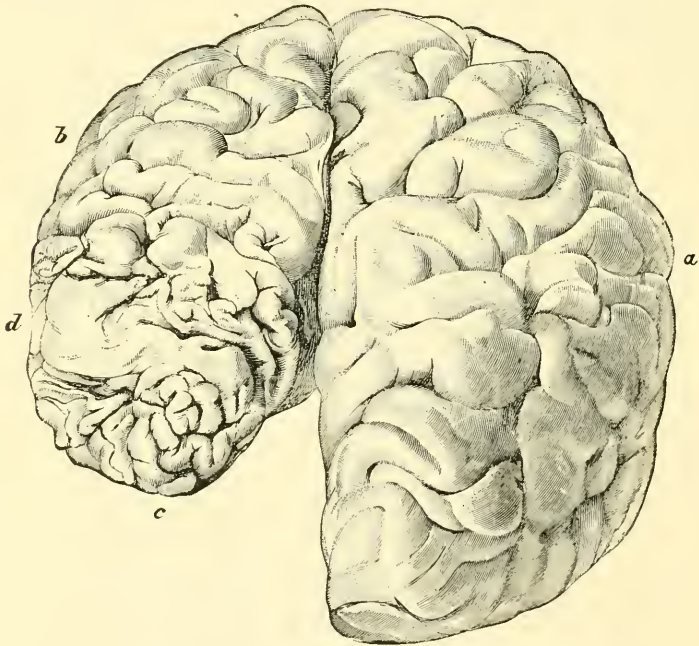


FIG. 222. HYPOPLASIA AND MICROGYRIA.

(From the left cerebral hemisphere of a deaf-mute: viewed from above after removal of the cerebellum: two-thirds of the natural size)

- | | |
|------------------------------------------------------------------------------------------------------------------------------|-----------------------------------------------------------------------|
| <p><i>a</i> right hemisphere
 <i>b</i> left hemisphere
 <i>c</i> undeveloped left occipital lobe with microgyria</p> | <p><i>d</i> membranous vesicle in the region of the parietal lobe</p> |
|------------------------------------------------------------------------------------------------------------------------------|-----------------------------------------------------------------------|

amounts on the average to 1375 grammes, and in women to 1245 grammes, varies in such cases from 900 to 200 grammes, and may thus be even below the normal for a new-born infant's brain (385 grammes).

The general formation of the under-grown cerebral hemispheres may still be normal; but there is often deficiency of the secondary sulci (Fig. 220), and at times of the primary sulci or

fissures also, the surface of the brain appearing scantily convoluted and imperfectly mapped out into lobes. In other cases, on the contrary, the gyri are here and there abnormally numerous and attenuated (Fig. 221 *f*), the condition being called **microgyria**. It sometimes happens that certain of the gyri consist of little more than membranous folds (Fig. 221 *e*), containing no proper brain-substance.

The cerebellum and the cerebral axis are sometimes stunted as well as the cerebrum; but these parts are usually less retarded in growth than the latter. The cord also often remains abnormally small, the pyramidal tracts and columns of Goll being the parts chiefly affected, and to a less degree the anterior columns and the direct cerebellar tracts.

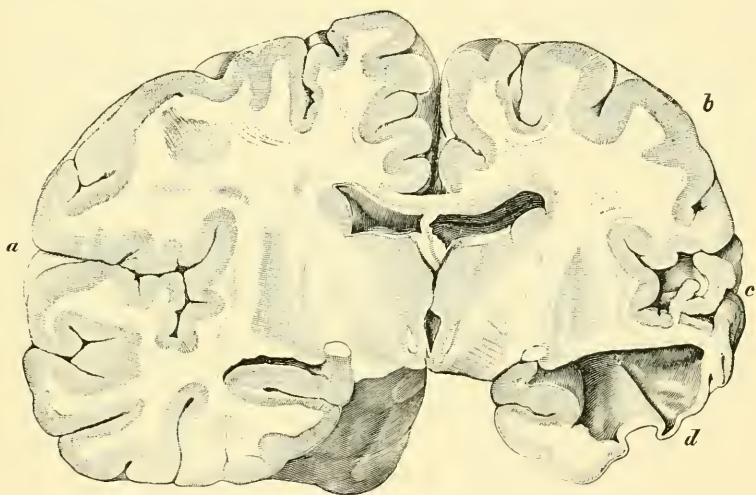


FIG. 223. FRONTAL SECTION THROUGH THE BRAIN OF FIG. 222.

(Three-fourths of the natural size)

a right hemisphere
b undeveloped left hemisphere
c area showing microgyria

d temporal lobe with dilated inferior cornu of the lateral ventricle and aplasia of the middle-temporal gyrus

Partial hypoplasia of the brain is most commonly met with in the cerebral and cerebellar hemispheres; it may also involve some portions of the cerebral axis. The diminution in size of parts of the cerebral hemispheres (Fig. 222 *c d*) gives rise to asymmetry of the cerebrum, and is often associated with imperfect development of the convolutions. These are abnormally small and thin (*e*), or the brain-substance is here and there represented only by a thin-walled vesicle (*d*), the cortex and the white matter at the affected spots being entirely undeveloped (Fig. 223 *d*) or at least stunted in their growth (*e*).

Hypoplasia of the cerebellum, a condition in which the development of parts or the whole of this organ is arrested, is not

uncommon, and cases are met with in which the size of the whole cerebellum is not greater than that of a walnut. Within the area of hypoplasia the gyri are usually much diminished in size (Fig. 230), so that we might describe the condition as cerebellar microgyria. In extreme hypoplasia of the cerebellum the tracts connecting it with the pons are also imperfectly developed.

Extreme hypoplasia of the cerebral hemispheres is apt to be associated with defective development of the pyramidal tracts. Among the deeper and basal structures, the corpus callosum and the fornix, the optic thalami, the corpora striata, the corpora mammillaria, the corpora quadrigemina, etc., are sometimes found to be stunted or defective.

Hypoplasia of the brain was formerly explained (VOGT) as due to atavism; but there can be no doubt that this view is erroneous, and that such hypoplasia is to be regarded as resulting from arrest of development, usually idiopathic but sometimes perhaps dependent on morbid influences exerted during the period of intra-uterine growth. In a few cases micrencephalia is caused by premature synostosis of the cranial bones.

References on Hypoplasia of the Cerebrum and Cerebellum
(see also Art. 109).

- ÆBY: Microcephalia *A. f. Anthropol.* VI and VII 1874; *Ueber das Verhältniss der Mikrocephalie zum Atavismus* Stuttgart 1878, and *V. A.* 77 1879
- ANTON: *Angeborene Erkrankungen d. Centralnervensystems* Vienna 1890
- ARNDT: Pathology of the cerebellum *A. f. Psych.* XXVI 1894
- VON BISCHOFF: Microcephalia *Abhandl. Akad. d. Wiss. in München* XI 1872
- CHIARI: *Jahrb. f. Kinderheilk.* XIV 1871
- CRAMER: Left-sided atrophy of the cerebellum *Ziegler's Beiträge* XI 1891
- FISCHER: Malformations of the cerebellum by arrest of growth *A. f. Psych.* V 1875
- FLESCU: *Verhandl. phys.-med. Gesell. zu Würzburg* VIII, *Sitzungsber.* 1874, and *Festschrift zum Jubiläum d. Universität Würzburg* 1882
- GIACOMINI: *I cervelli dei microcephali* Turin 1890, and *A. ital. de biol.* XV
- HADLICH: Cerebral malformation with cohesion of the hemispheres *A. f. Psych.* X 1880
- HUPPERT: Excessive smallness of the cerebellum *A. f. Psych.* VII 1877
- JENSEN: Brain of a microcephalic woman *A. f. Psych.* X 1880
- KAHLER and PICK: *Prager Z. f. Heilk.* II 1881, and *Berl. klin. Woch.* 1879
- MARCHAND: Three microcephalic brains *Nova Acta Leop. Carl. Akad.* LIII 1889, and LV 1890
- MUIR: Unilateral cerebral atrophy with defective vascular development on the same side *A. f. Psych.* VI 1876
- OTTO: Microgyria *A. f. Psych.* XXIII 1890
- PICK, A.: *Prager med. Woch.* 1880
- PIERRET: Atrophy of the cerebellum *A. de physiol.* IV 1872
- RÜDINGER: Microcephalic brain *Münch. med. Woch.* 1886
- SANDER: Two microcephalic brains *A. f. Psych.* I 1868
- SHUTTLEWORTH: *Jour. of Ment. Science* Oct. 1878 [*Psych.* XVII 1886
- STEINLECHNER-GRETSCHISCHNIKOFF: Spinal cord in microcephalia *A. f. Virchow: Gesamm. Abhandl.* 1856; *Berl. klin. Woch.* 1877, and *Verhandl. Berlin. anthropol. Gesellsch.* 1878
- VOGT, C.: *Ueber das Mikrocephalengehirn* Brunswick 1867
- WILLE: Malformations of the cerebrum *A. f. Psych.* X 1880 [Frankfort 1885
- WOLFF, J.: *Morphol. Beschreibung eines Idioten- und Mikrocephalengehirnes*

109. **Partial agenesi**s of the cerebrum, like hypoplasia, is most commonly met with in the region of the cerebral hemispheres; it may also extend to the deeper portions, and in particular to the commissures. When parts of the cerebrum are not properly developed, the resulting local defects are bridged over by the internal meninges (Fig. 224 *f g*). The lacunae are then filled up by the accumulation of liquid in the subarachnoid spaces and in the meshes of the pia mater. At times an equivalent enlargement of the adjoining ventricle, or an accumulation of liquid in the subdural space, takes place.

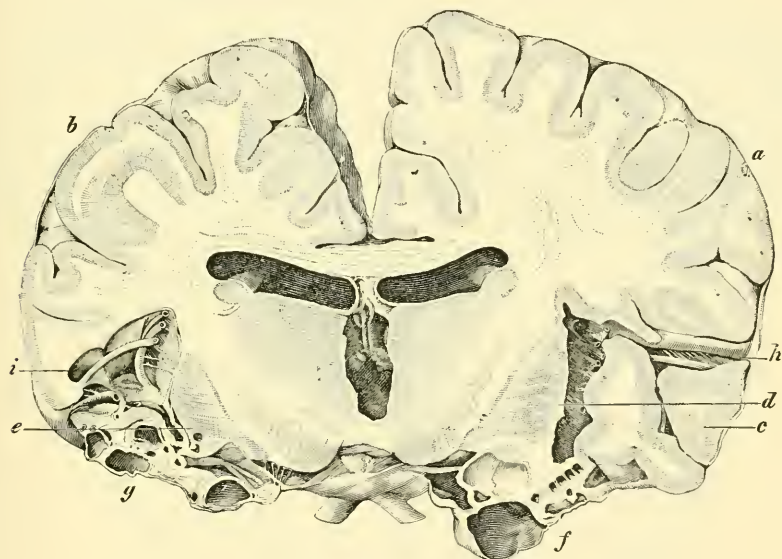


FIG. 224. FRONTAL SECTION THROUGH THE BRAIN OF A DEAF-MUTE WITH BILATERAL HYPOPLASIA AND PARTIAL AGENESIS OF THE TEMPORAL LOBES AND THE CORTEX OF THE INSULA.

(Three-fourths of the natural size)

- | | |
|-------------------------------------------------------------------------------------------------------------------------------|--------------------------------------------------|
| <i>a b</i> cerebral hemispheres | <i>f g</i> cysts formed by the internal meninges |
| <i>c</i> upper portion of the left temporal lobe | <i>h</i> left sylvian fissure |
| <i>d e</i> left and right lenticular nucleus on the outer surface of which the claustrum and cortex of the insula are wanting | <i>i</i> right sylvian fissure |

The size of the several defects varies greatly in different cases: indeed all intermediate stages between total anencephalia (as in acrania) and small circumscribed lacunae in a single convolution (Fig. 225 *a*) are met with.

Among the deeper and basal parts those most liable to be wanting are the corpus callosum, the fornix, the grey commissure of the third ventricle, and the corpora mammillaria. When the corpus callosum is absent the gyrus fornicatus and the gyrus hippocampi are usually undeveloped, and some of the remaining

gyri are often irregularly formed. More extensive defects involving the motor cortical area are generally accompanied by imperfections of the pyramidal tracts.

The **causes of partial agenesis** are often incapable of being certainly determined: we may assume, however, that in some instances the condition has its origin in primary anomalies of development inherent in the primitive rudiment of the brain; in other cases it arises from secondary morbid influences such as traumatism, inflammation, and disorders of circulation. In some instances agenesis seems to depend on the morbidly-perverted configuration of fissures or sulci; and it is probable that certain of the peculiar defects in the cerebral hemispheres comprehended under the term **porencephalia** are of this nature.

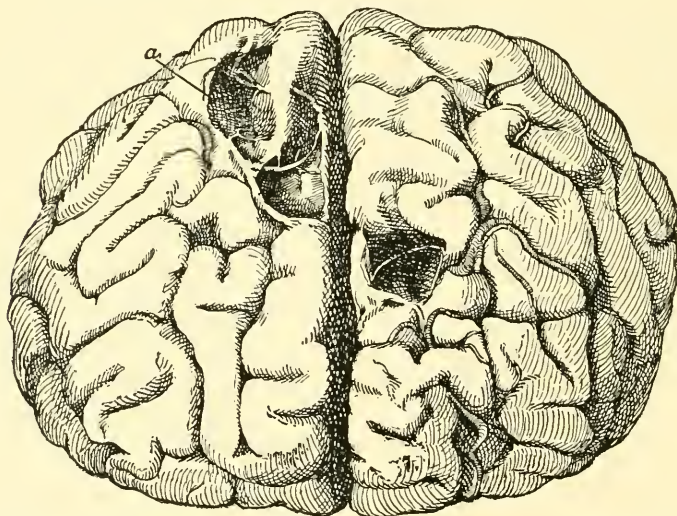


FIG. 225. AGENESIS OF ISOLATED PORTIONS OF THE CEREBRAL CONVOLUTIONS.

(From a woman who died of progressive paralysis: one-half the natural size)

a cavernous depressions

The typical form of this malformation consists of fissure-like or funnel-shaped depressions of the cortex (Fig. 226 *a a* and Fig. 227 *a a*). They are usually found either in the central and parietal lobes, or about their borders, and are distinguishable by the fact that the affected gyri are not destroyed, but only interrupted by a deep cleft, up to the edges of which they are well developed. In some instances they appear to start from the cleft and group themselves about it.

Externally these defects are bridged over by the arachnoid (Fig. 226 *b* and Fig. 227 *b*), while the pia mater (*c*) clings to and follows the gyri even to the deepest parts of the depression.

Deeper clefts sometimes reach to the ependyma of the ventricles (Fig. 226 *d*), or even communicate with their cavities, so that when the pia mater is removed the outer aspect of the basal ganglia is laid bare at the bottom of the hollow (Fig. 226 *e*).

As the normal fissures are due to infoldings of the cerebral vesicle while it is still thin-walled, and the minor sulci arise from

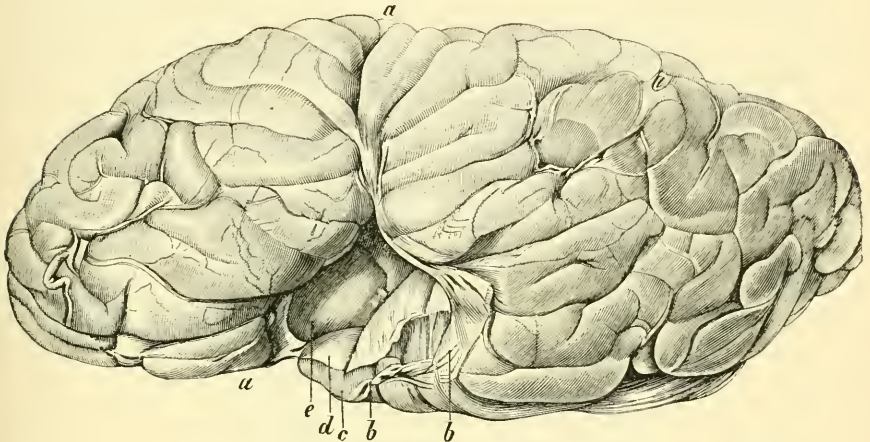


FIG. 226. PORENCEPHALIC LEFT HEMISPHERE OF A CHILD OF TEN WEEKS. (Natural size)

- a* large cleft-like depression
- b* cut edge of the arachnoid
- c* pia mater
- d* roof of the lateral ventricle laid open and thrown outwards
- e* optic thalamus

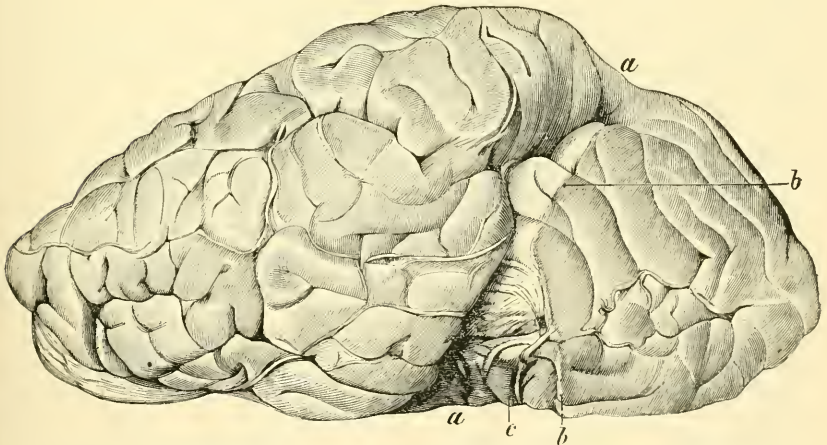


FIG. 227. PORENCEPHALIC RIGHT HEMISPHERE OF A CHILD OF TEN WEEKS. (Natural size)

- a* large cleft-like depression
- b* cut edge of the arachnoid
- c* pia mater

the unequal growth of particular portions of the developing hemispheres, we may fairly assume that pathological infoldings during the second and third months of embryonic life, or irregularities in the growth of the brain in the later months (perhaps occasioned by morbid accumulation of liquid in the subarachnoid spaces) are the efficient causes of pathological fissures and clefts and of abnormally deep cortical sulci. It is, however, to be observed that very similar fissures and funnel-like depressions sometimes arise from partial destruction of the cortical and medullary brain-substance; and we might describe these as a second and atypical variety of porencephalic defect, of intra-uterine origin but distinguishable from true porencephalia. The term **pseudo-porencephalia** would serve to indicate the distinction.

Porencephalia (or porencephalus) is used by different writers in different senses. Some would limit it to congenital defects of the brain; others would extend it to acquired defects. Some, again, apply it only to local and circumscribed depressions, while others do not hesitate to describe absence of an entire hemisphere as porencephalus. It is advisable to use the term only for certain definite varieties of congenital defect of substance, or at least to give some indication of the meaning attached to it in any given case.

References on Defects of the Brain, Porencephalia, and Absence of the Corpus Callosum (see also Art. 108)

- AHLFELD: *Die Missbildungen des Menschen* II Leipzig 1882
 AUDRY: Porencephalia *Rev. de méd.* viii 1888
 BIANCHI: Porencephalia *La psichiatria* Naples 1884
 BINSWANGER: Malformations of the brain (porencephalia) *V. A.* 87 1882 and 102 1885
 CHIARI: *Jahrb. f. Kinderheilk.* xv Leipzig 1882
 DE LA CROIX: Porencephalia *V. A.* 97 1884
 FÖRSTER: *Missbildungen d. Menschen* Jena 1885
 HESCHL: *Prager Vierteljahrsschr.* 1859, 1861, 1868; *Jahrb. f. Kinderheilk.* xv 1882, and *Arch. d. Gesellsch. d. Aerzte* Vienna 1878
 HEYDENREICH: Hemiacrania; trilobate encephalon *V. A.* 100 1885
 HUPPERT: Absence of corpus callosum *A. d. Heilk.* 1871
 JELGERSMA: Absence of corpus callosum *Biolog. Centralbl.* ix 1890
 JOLLY: Absence of corpus callosum *Z. f. rationale Med.* xxxiv 1869
 KAUFMANN: Absence of corpus callosum *A. f. Psych.* xviii 1887
 KIRCHHOFF: Defects of the cerebrum *A. f. Psych.* xviii 1887
 KLEBS: Hydro- and micro-anencephalia *Oesterr. Jahrb. f. Pädiatrik* 1876
 KUNDRAT: *Die Porencephalie* Graz 1892, and *Die Arhinencephalie* Graz 1882
 MARCHAND: Development of corpus callosum *A. f. mikrosk. Anat.* 37 1891
 ONUFROWICZ: Absence of corpus callosum in the brain of a microcephalic patient (Hofmann) *A. f. Psych.* xviii 1887
 OTTO: Porencephalia *A. f. Psych.* xvi 1885
 RIBBERT: Origin of anencephalia *V. A.* 93 1883
 RICHTER: The gyri of the human brain *V. A.* 106 1886
 ROSS: Porencephalus *B. M. J.* i 1882
 SANDER: Absence of corpus callosum *A. f. Psych.* i 1868
 SCHATTEBERG: Porencephalia in an adult *Ziegler's Beiträge* v 1889
 SCHÜLE: Case of arrested development *Z. f. Psych.* 26 1869
 SIGMUNDT: Porencephalia *Inaug. Diss.* Strassburg 1893 (with references)
 SPERLING: Porencephalia *V. A.* 91 1883
 ZUCKERKANDL: *Med. Jahrb. d. Gesellsch. d. Aerzte* Vienna 1883

110. When the bulk of the brain is too small relatively to the cranial cavity, the space not occupied by the brain and membranes is filled up with cerebrospinal liquid, and the result is hydrocephalic micrencephalia, or hydrocephalic partial anencephalia. The morbid accumulation of liquid takes place either in the ventricles or in the subarachnoid spaces, and accordingly we have the two forms—internal hydrocephalus or ventricular dropsy, and external or meningeal hydrocephalus.

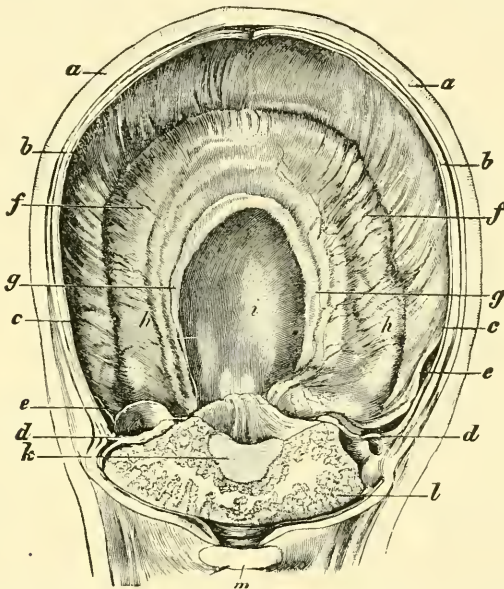


FIG. 228. CONGENITAL VENTRICULAR AND MENINGEAL HYDROCEPHALUS.

(Frontal section of the cranial cavity of a synophthalmous microstomous foetus viewed from behind: four-fifths of the natural size)

- | | | | |
|---|----------------------------------------------------------------------------------------------------|---|-------------------------------------------------------------------------------------------------------------|
| a | skin and subcutaneous tissue | h | subarachnoid space behind the cerebral vesicle |
| b | cranial vault | i | cavity of the cerebral vesicle communicating with the subarachnoid space by the enlarged transverse fissure |
| c | dura mater | k | section through the corpora quadrigemina |
| d | tentorium | l | section through the cerebellum |
| e | arachnoid membrane | m | atlas |
| f | posterior surface of the cerebrum, reduced to a thin-walled vesicle and covered with the pia mater | | |
| g | rounded border of the cerebral vesicle | | |

The accumulation of liquid is in many cases simply complementary, an effusion *ex vacuo*, and appears in the vicinity of the local defects; sometimes therefore the subarachnoid spaces (Fig. 226 b, Fig. 225 a, and Fig. 224 f g), and sometimes these together with portions of the ventricles (Fig. 222 d), are the seat of the hydrocephalic accumulation. But the morbid outpouring of liquid is undoubtedly in certain cases primary, though in many instances it is impossible to decide whether the disturbance of normal

development or the accumulation of liquid was the initial manifestation.

When the ventricular dropsy in a case of congenital malformation of the brain is a prominent and characteristic feature, the condition is usually known as congenital internal or ventricular hydrocephalus. If, in addition, the volume of the brain is abnormally small, the case may be regarded as an example of hydrocephalic micrencephalia.

Internal hydrocephalus is in many cases due to some disorder of development dating from early embryonic life, the cerebrum at birth having the appearance of a thin-walled vesicle (Fig. 228 *i*), which either fills the cranial cavity or is covered externally by a layer of liquid lying within the subarachnoid spaces (*h*). Such extreme disturbances of development are observed chiefly in infants whose heads are externally malformed, for instance in cases of cyclopia or synophthalmia (Fig. 228).

If the morbid accumulation of liquid takes place at a later period, when the brain is already developed, the general configuration of the cerebrum is undisturbed, and the chief feature of the affection is the dilatation of the ventricles (Fig. 229 *a b c*). The dilatation is sometimes bilateral and symmetrical, sometimes unsymmetrical (*e*), and sometimes unilateral.

At birth the enlargement is at times but slight, or it may be already considerable, so that the circumference of the cranial portion of the head more or less notably exceeds the normal measurement. After birth the accumulation of liquid is liable to progressive increase, the ventricles becoming enormously distended. The size of the cranium increases more and more, and the overlying skin becomes thin, the subcutaneous veins showing clearly through it. The several cranial bones are visibly separated from one another, and even when their normal rate of growth is increased they are unable to keep pace with the rapid expansion of the cranial contents. The fontanelles are thus widened, and the sutural edges of the bones are forced more and more asunder. Usually small supernumerary bones are developed in the membranous sutures and in the fontanelles (Fig. 132).

When at length death ensues, the dura mater, pia mater, and arachnoid are stretched to the utmost, the gyri are depressed and flattened out, and the sulci are effaced. The cerebral substance of the hemispheres surrounding the ventricles, which are expanded into large vesicular cavities, is reduced to a mere thin-walled capsule, which on the convexity is often but a few millimetres in thickness.

The liquid in the ventricles is clear and pale or light-yellow; the ependyma, apart from its distension, is unchanged; the basal ganglia are flattened out. The fourth ventricle and the cerebellum are usually unaltered, though the former is sometimes enlarged.

The condition described is that met with in many cases: in

others the lateral ventricles are less distended, or the dilatation is limited to one ventricle, or even to a part of one. One lateral ventricle, for example, may be so stretched that its roof consists merely of a thin membrane, while the other ventricle remains undistended. In like manner the fourth ventricle is sometimes alone dilated. In these cases the cranial cavity is usually not enlarged, the space for the expansion of the ventricle being gained by atrophic contraction of the rest of the brain.

Hydrocephalus of extreme degree leads to a fatal issue; in less marked cases the patient sometimes continues to live

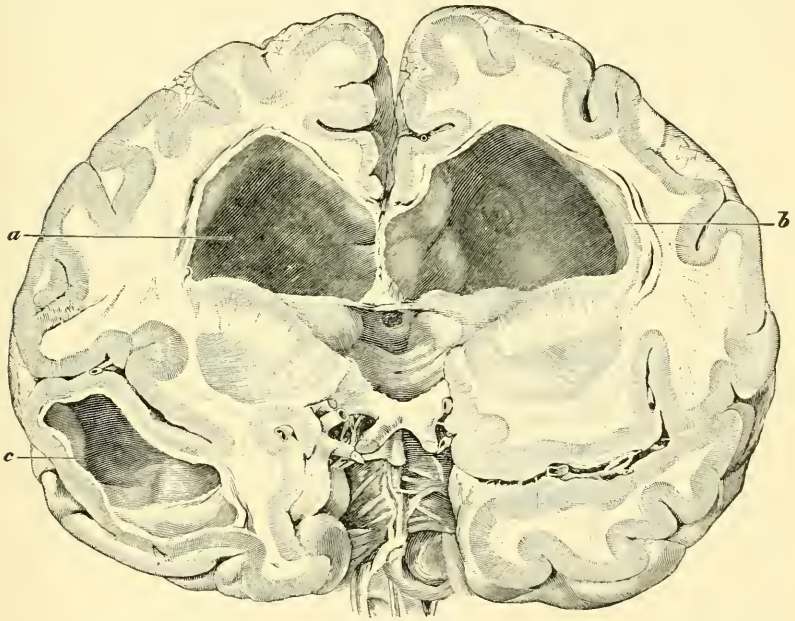


FIG. 229. FRONTAL SECTION THROUGH THE BRAIN OF A HYDROCEPHALIC IDIOT.
(Reduced to two-thirds of the natural size)

a b dilated lateral ventricle *c* dilated descending cornu on the right side

(Fig. 229). If the hydrocephalus is at all considerable, the brain becomes in part atrophic, the compressed portions becoming wasted, and the nerve-cells and nerve-fibres undergoing atrophy and calcification.

When the fourth ventricle is moderately distended, the cerebellum, the pons, and the medulla oblongata, or portions of these, are apt to remain ill-developed.

If the hydrocephalus is only slight, and does not increase after birth, the after-development of the brain in some instances proceeds in a normal way.

The **cause** of congenital internal hydrocephalus is still obscure. There are often no traces of changes capable of being regarded as inflammatory, nor as a rule can any obstruction to the outflow of venous blood be made out with certainty. Nevertheless, in particular cases the meninges or the choroid plexuses exhibit thickenings that are referable to past inflammation. A less doubtful sign of inflammation is turbidity of the ventricular contents, due to the presence of pus-corpuscles. It is possible that the affection in many instances depends on closure of the communications between the cavities of the ventricles and the subarachnoid spaces in the transverse fissure. These have appeared to be closed in some at least of the cases that have been described. As the lining pia mater of the transverse fissure in such cases is apt to be abnormally dense, perhaps the circulation in the veins of Galen is also obstructed.

When the cranial cavity is not enlarged and the convolutions not flattened by pressure, while the ventricles are dilated, it seems natural to assume that the dilatation is due to agenesis or aplasia of the brain, and that the accumulation of liquid serves to fill up the unoccupied space (*hydrops ex vacuo*).

In unilateral hydrocephalus the foramen of Monro has in certain cases been found to be closed. When portions only of a ventricle are dilated and cystic, the neighbouring portions of the cavity are often obliterated, the cyst being thus shut in on all sides.

References on Congenital Hydrocephalus.

- BAUER: *Jahrb. f. Kinderheilk.* new series XI Leipzig 1878
 BILLROTH: *Langenbeck's Arch.* III 1862
 BUTTENWIESER: *D. A. f. klin. Med.* X 1872
 VON GUNZ: *Jahrb. f. Kinderheilk.* V Vienna 1862
 HÄNEL: *Jahrb. f. Kinderheilk.* new series I Leipzig 1868
 HARRIS: *Trans. Obstetric. Soc.* VI London 1864
 HEUBNER: *Art. Hydrocephalus Eulenburg's Realencyklop.*
 KOLLER and SCHMIDT: *Jahrb. f. Kinderheilk.* VI Vienna 1863
 MAENNEL: *Jahrb. f. Pädiatrik* 1876
 PAPP and NEUPAUER: *Jahrb. f. Kinderheilk.* new series VII Leipzig 1874
 STEFFEN: *Gerhardt's Handb. d. Kinderkrankh.* V
 SZYMANOWSKY: *Langenbeck's Arch.* VI
 VIRCHOW, H.: Congenital hydrocephalus and microcephalus *Kölliker's Festschrift* 1887
 VIRCHOW, R.: *Gesamm. Abhandlungen* Frankfurt 1856; *Die krankhaften Geschwülste* I
 WEST: *Jahrb. f. Kinderheilk.* new series IX Leipzig 1876

111. Pathological **anomalies in the minute histological structure** of the brain may naturally be assumed to exist, first of all, in cases that exhibit to the naked eye evidence of imperfect development, such as general or local hypoplasia or local agenesis. Thus in hypoplasia of the cerebellum (Fig. 230) the several layers

of the cortex (*a b c d*) in the attenuated gyri are either imperfectly formed (*a₁ c₁*) or absent, and the diminution of bulk is due to scantiness of the characteristic cells and cell-processes. Special forms, like the cells of Purkinjé, may be entirely wanting. The like is true of ill-developed portions of the cerebrum. When some of the ganglion-cells of the cortex are not developed, the corresponding nerve-processes in the white matter are of course absent also.

A second variety of morbid histological structure is exemplified in cases of **heterotopia of the grey matter**. This malformation is characterised by the presence of grey nodules or streaks

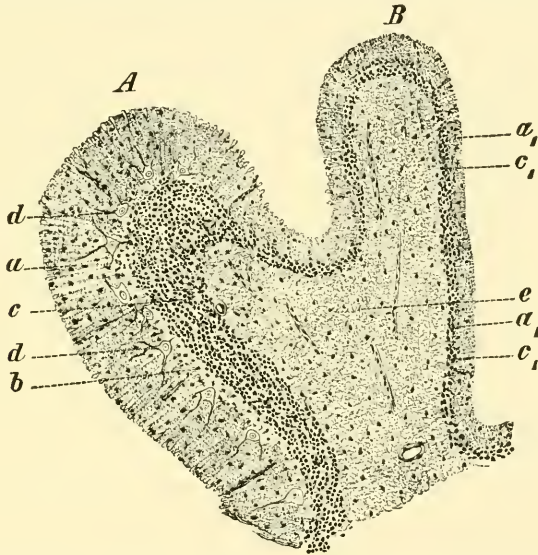


FIG. 230. HYPOPLASIA OF THE CORTEX OF THE CEREBELLUM.

(From a man aged 25, who died in an epileptic attack: preparation hardened in Müller's fluid and alcohol, stained with haematoxylin and carmine, and mounted in Canada balsam: $\times 25$)

- | | |
|----------------------------------------------|----------------------------------------------|
| <i>A</i> normal gyrus | <i>c</i> normal granular layer |
| <i>B</i> atrophic gyrus | <i>c₁</i> atrophic granular layer |
| <i>a</i> normal external layer | <i>d</i> cells of Purkinjé |
| <i>a₁</i> atrophic external layer | <i>e</i> medullary substance |
| <i>b</i> normal intermediate layer | |

in the white matter of the cerebrum or cerebellum, due to the development in these parts of tissue rich in nerve-cells but poor in medullated fibres. Another variety of abnormal structural development is shown in morbid variations of the texture of the neuroglia, sometimes with anomalous nerve-cells and nerve-fibres, giving rise either to induration or to the formation of grey sclerotic patches (Art. 96) or gliomatous tumours (Art. 121).

Hypertrophy of the brain, manifested by the abnormal size

of the organ, sometimes takes place during the growing stage in early life. Cases are recorded in which the brain weighed as much as 2200 grammes (brain of BYRON, 1807 grammes; of CUVIER, 1861 grammes; of TURGENIEFF, 2012 grammes; of CROMWELL, 2000 grammes). Great brain-weight may be associated with high intellectual gifts, but the opposite is also true. Moreover, a brain whose size and weight are below the average may be associated with great mental capacity.

All the malformations of the brain described in Arts. 108-111, when they are not incompatible with life, and development follows in other respects a normal course, are apt to be associated with more or less important disturbance of the cerebral functions. In extreme malformation mental development is arrested, and the condition known as **idiocy** results. It is impossible, however, to assign any particular malformation as the invariable anatomical basis of idiocy: there is no such thing as an idiotic brain. In idiocy, indeed, we may have imperfect development of the entire cortex, hydrocephalic enlargement of the ventricles, or local defect or hypoplasia such as smallness of the occipital lobe, microgyria, and the like. In other cases the brain in idiocy exhibits what are apparently but slight and insignificant malformations, such as heterotopia of the grey matter of the cortex, absence or smallness of the corpora mammillaria, corpus callosum, fornix, thalamus, optic nerves, corpus striatum, pineal gland, or olivary bodies, irregularity and imperfection of the gyri, asymmetry of the hemispheres, defective development or absence of associative fibres, and so on. There are cases also in which, so far as we are able to perceive, the anatomical relations of the brain are altogether normal. In others again idiocy is associated with hypertrophy of the brain due to increase of the neuroglia. Lastly, ischaemic and inflammatory processes of destruction affecting the cerebral cortex sometimes induce idiocy. On the other hand, malformations such as those just described, or even still greater defects, may exist in the brain, though during life there is nothing whatever to indicate their presence.

In **cretinism**, as in sporadic idiocy, no special and characteristic defect of the brain can be demonstrated.

BENEDIKT has for some years maintained that in **habitual criminals** certain peculiarities of configuration constantly recur in the cerebral surface, and infers that such criminals represent an anthropological variety of the human race. Their brains are said to resemble in some points those of lower animals, and are characterised by a tendency of the sulci to run into one another, so that they are continuous at points where in normal brains they would be interrupted. This hypothesis is, however, untenable. Apart from the fact that it is impossible to settle the exact definition of the term criminal, investigation has shown that such deviations from the normal type occur in the brains of persons who have never made themselves liable to penal proceedings.

The like holds good for the anomalies and malformations of the brain which are found in persons afflicted with mental diseases, epilepsy, etc. None of these abnormalities are characteristic of any particular morbid condition, and they are met with in the brains of persons whose cerebral functions were normal. All that we can say is that malformations of the brain, both serious and trifling, are more frequent in persons whose mental activities are in some degree aberrant than in those whose minds are normal. Thus heterotopia of the grey matter has been met with chiefly in lunatics, idiots, and epileptics: while in cases of progressive paralytic dementia it is not uncommon to find malformation of the brain in addition to the cortical changes characteristic of the disease.

Defects of substance in parts which we know by experience to be the seats of the centres for certain special functions, or which are traversed by certain

conducting tracts, may lead not only to imperfect mental development, but also to local disorders of the motor or sensory functions, including those of the special senses.

References on Heterotopia and Hyperplasia of the Grey Matter.

- GELMO: *Jahrb. f. Kinderheilk.* iv Vienna **1861**
 MATELL: Heterotopia of grey matter *A. f. Psych.* xxv **1893** (with references)
 MERKEL: Hyperplasia of the cortex and new-formation of grey matter *V. A.* 38 **1867**
 MESCHÉDE: Heterotopia of grey matter in the cerebellum *V. A.* 56 **1872**
 OSLER: Heterotopia (medullary neuroma) *Jour. of Anat.* xv **1881**
 OTTO: Hyperplasia of the cerebral cortex in the form of small tumours and heterotopia of grey matter *V. A.* 110 **1887**
 PFLEGER: Heterotopia of grey matter in the cerebellum *Cent. f. med. Wiss.* **1880**
 SIMON: New-formation of cerebral matter on the surface of the gyri *V. A.* 58 **1873**
 STEINER and NEUREUTTER: *Prager Vierteljahrsschr.* xx **1863**
 TÜNGEL: New-formation of cerebral grey matter *V. A.* 16 **1859**
 VIRCHOW: Heterotopia *Krankhafte Geschwülste* III, and *V. A.* 38 **1867**

References on Malformations of the Brain in Idiots, Cretins, and Criminals.

- BARDELEBEN: *D. med. Woch.* **1883**
 BENEDIKT: *Studien an Verbrecheregehirnen* Vienna **1879**, and *Cent. f. med. Wiss.* **1880**
 FLEISCH: *Untersuch. über Verbrecheregehirne* Würzburg **1882**, and *A. f. Psych.* xvi **1885**
 HERVOUET: Nervous system of an idiot *A. de physiol.* iv **1884**
 KLEBS: *Die Verbreitung des Kretinismus in Oesterreich* Prague **1877**
 KLINKE: Cortical tangential (associative) fibres in idiocy *A. f. Psych.* xxv **1893**
 KÖSTER: Microscopic morbid anatomy of the brain in idiots *Centralbl. f. Neurol.* **1889**
 LOMBROSO: *Luomo delinquente* Rome **1884**, and *Der Verbrecher in anthropologischer, ärztlicher, und juristischer Beziehung* (trans. by O. FRÄNKEL) Hamburg **1887**
 PETRINA: *Prager Z. f. Heilk.* II
 POPOFF: Morbid anatomy of idiocy *A. f. Psych.* xxv **1893**
 RÖSCH and MAFFEI: *Unters. über Kretinismus in Württemberg* Erlangen **1844**
 VIRCHOW: Cretinism *Gesamm. Abhandl.* Frankfurt **1856**

CHAPTER XXXVIII

DISORDERS OF THE CEREBRAL CIRCULATION

112. The quantity of blood contained in the brain and its membranes is subject to very considerable physiological variations. It is greater during periods of increased mental activity than during intervals of rest.

Increased afflux of blood to a particular vascular region causes an efflux of the circumvascular lymph, and of the cerebro-spinal liquid from the subarachnoid spaces and the ventricles, into other parts. When the hyperaemia is general, space is found for the excess of blood by the efflux of cerebro-spinal liquid into the lymph-vessels of the head, neck, and trunk, and into the venous sinuses of the dura mater.

Morbid **congestive hyperaemia** of the brain is occasioned when the activity of the heart is abnormally increased, or when the resistance to dilatation of the afferent arteries or of the arterioles of the meninges and the brain-substance is diminished. In the latter case the hyperaemia may remain local.

General **passive hyperaemia** or venous engorgement takes place when the return of the blood from the cranial cavity and the spinal canal is checked, as it is for instance in certain diseases of the heart and lungs. Moreover, paralytic dilatation of the cerebral arteries, by increasing the intra-cranial pressure, sometimes leads to obstruction of the venous circulation, or intensifies this condition if it already exists (GEIGEL, GRASHEY).

Local engorgement is generally due to intra-cranial vascular thrombosis, or to tumours and exudations pressing upon and obstructing the veins.

The signs of hyperaemia are most apparent in the meninges, whose vessels are more or less tensely distended with blood, and owing to the transparency of the internal membranes (pia mater and arachnoid) can be followed to their minutest ramifications. It must however be kept in mind that the post-mortem appearances are far from representing precisely the conditions that prevailed during life, for as soon as death takes place the blood is in a measure free to pass out of the cranial cavity, while that which remains tends to sink to the parts that are most dependent. Hyperaemia of the white matter is recognisable after death only

by the distension of the smaller veins, which on section allow their contents to exude as drops of blood of various sizes. Diffuse reddening of the tissue from dilatation of the capillaries is very uncommon after simple hyperaemia, owing to the fact that the coagulation or post-mortem rigidity of the white matter squeezes most of their contents out of the capillaries, while the opacity of the tissue prevents the red tint from shining through.

In the grey matter both the minuter venules and the capillaries may remain filled with blood, the latter by their distension giving rise to a diffuse or mottled reddening of the tissue.

Anaemia of the brain is manifested by the comparative emptiness of the arterioles and veins of the pia-arachnoid membranes, and by the paleness of the grey matter. The white matter on section shows few or no drops of blood on its surface.

Cerebral anaemia may be merely one result of general anaemia, or it may be due to morbid congestion of other organs or parts of the body (collateral anaemia). In some cases again it results from narrowing of the afferent arteries owing to spasmodic contraction or thickening of the arterial walls, or from changes within the cranium that interfere with the influx of blood. Such changes as diminish the available space within the cranial cavity act in the last mentioned way, namely subarachnoid effusion, dropsy of the ventricles, tumours, extravasations of blood in the subdural space or in the brain, and the like.

If a still greater exudation of liquid from the vessels takes place, either in consequence of vaso-motor disturbances or owing to changes in the vascular walls, and if the excess is not removed by a correspondingly increased efflux of lymph, **oedema of the brain** is induced. This condition is characterised chiefly by abnormal moistness and lustre of the tissue on section, the cut surface allowing liquid to escape, chiefly from the enlarged adventitial lymph-spaces surrounding the vessels.

General passive oedema arises from failure of the heart's functional activity or from interference with the circulation in the lungs, as well as from thrombosis of the sinuses of the dura mater. Local passive oedema is very common in the tissue adjacent to tumours, haemorrhagic patches, thrombosed veins, and so on.

Oedema from auto-intoxication (uraemia) arises chiefly in connexion with nephritis.

Inflammatory oedema involving the entire brain is usually a result of general infection: when it involves only a limited portion of the brain, it is often an accompaniment or a consequence of local inflammation, softening, haemorrhage, or tumour. According to certain authorities, excessive congestive hyperaemia of the brain, by increasing the intra-cranial pressure and so compressing the veins, is capable of giving rise to cerebral oedema, especially in children.

Engorgement or inflammation involving the ventricular plexuses sometimes leads to the accumulation of liquid in the cerebral ventricles, a condition described as **acquired hydrocephalus** (*hydrops ventriculorum*). Like congenital hydrocephalus it is associated with dilatation of the ventricles concerned. When acute it is usually the consequence of inflammatory processes: the chronic form on the other hand is generally due to venous engorgement, and is often induced by tumours that impede the outflow of venous blood from the ventricles.

Both the acute and the chronic forms are oftenest met with in the lateral ventricles, but dilatation of the fourth ventricle due to accumulation of liquid within it is by no means rare.

Dropsy of the ventricles, whether from engorgement or from inflammation, induces a certain amount of compression of the brain-substance, and this naturally leads to flattening of the convolutions over the affected part. When the hydrocephalus is extreme the convolutions are apt to be altogether effaced, while the sub-arachnoid liquid is driven away; the surface of the meninges accordingly appears dry, and the sulci almost cease to be traceable. The pial vessels are often emptied by the compression, so that only a few of those lying in the sulci contain any blood.

Dilatation of the ventricles may also arise from diminution of the mass of the brain-substance; the contents of the ventricles increase as the volume of the brain decreases, and occupy the space left free by the shrinkage (*hydrops ex vacuo*). In this form of ventricular dropsy the convolutions are not flattened.

References on the Intra-cranial Circulation and its Disturbances.

- ACKERMANN: Effects of suffocation on the quantity of cerebral blood *V. A.* 15
1858
- ALTHANN: *Physiologie und Pathologie der Circulation* Dorpat 1871
- BERGMANN: Cerebral injuries *Deutsche Chirurgie* part 30 Stuttgart 1880;
Cerebral pressure *A. f. klin. Chir.* XXXII 1885
- DEAN: Cerebro-spinal pressure *Journ. of Path.* 1 1892
- FALKENHEIM and NAUNYN: Cerebral pressure *A. f. exp. Path.* XXII 1886
- GEIGEL: *Die Mechanik der Blutversorgung des Gehirns* Stuttgart 1890; Cerebral circulation *V. A.* 121 1890
- GRASHEY: *Blutcirculation in der Schädel- u. Rückgratshöhle* Munich 1892
- JOLLY, F.: *Gehirndruck und Blutbewegung im Schädel* Würzburg 1871
- LEWY: Cerebral circulation *V. A.* 122 1890
- LEYDEN: Cerebral pressure and cerebral movements *V. A.* 37 1866
- MOSSO: *Kreislauf des Blutes im Gehirn* Leipzig 1881
- PAGENSTECHER, E.: *Experim. Studien über Gehirndruck* Heidelberg 1871
- ROSENBACH and SCITSCHERBAK: Brain-compression *V. A.* 122 1890
- ROY and SHERRINGTON: Experiments on brain-pressure *Journ. of Physiol.*
XI 1890
- SPENCER and HORSLEY: Increase of intra-cranial pressure *Proc. Roy. Soc.*
XLVIII London 1890

CHAPTER XXXIX

ATROPHY OF THE BRAIN

113. General **atrophy of the brain**, or at least of a considerable portion of it, is not uncommon as an accompaniment of advanced old age, and is now and then so marked that the bulk of the brain is very greatly reduced, the gyri are notably attenuated, and the sulci are widened. The reduction of bulk is due to wasting of the nerve-substance, affecting the medullated nerve-fibres as well as the ganglion-cells, and the cortex as well as the white matter.

In less-marked atrophy the brain-substance appears to the naked eye unchanged; while in extreme atrophy the adventitial lymph-channels are sometimes dilated, so that the vessels appear to lie loose within empty sheaths. Very small patches of softening are often formed at the same time in scattered spots (Art. 114), giving rise to a sieve-like appearance of the brain that has been called the *état criblé* and compared to that of Gruyère cheese. The space left vacant by the shrinkage of the brain is usually filled in part by liquid accumulated in the subarachnoid space, in part also by dropsical distension of the ventricles. The senile form of atrophy of the brain is partly active, partly passive; in other words it is due both to gradual destruction of the ganglion-cells and nerve-fibres, and to lowering of their nutrition. The latter factor probably always plays an important part in well-marked atrophy, and depends not only on the general senile failure of nutrition, but also on local impairment of the circulation caused by narrowing of the vessels (Art. 114).

Atrophy in earlier periods of life, in manhood or in youth, is no doubt for the most part attributable to disorders of nutrition: it must however be kept in mind that heredity has an important share in the causation of these conditions.

Premature degeneration and atrophy of the nerve-fibres and ganglion-cells of the brain are most frequently observed in the disease known as progressive general paralysis, or **paralytic dementia**, a disease characterised by gradual failure of intelligence, emotional instability, and insane delusions. The causes assigned for this affection are inherited psychopathic predisposition, and noxious influences of an acquired kind, such as excessive mental

exertion, intense emotional disturbance, alcoholism, certain infective diseases like syphilis, and traumatic injury. Premature cerebral atrophy is also met with in some cases of tabes (JENDRÁŠIK), in epilepsy of long duration (ZACHER), in ordinary insanity, in sun-stroke (CRAMER), in poisoning from carbonic oxide gas, etc.

According to the investigations of TUCZEK, ZACHER, FRIEDMANN, and others, both the medullated nerve-fibres of the cortex and white matter, and to a less extent the ganglion-cells of the cortex

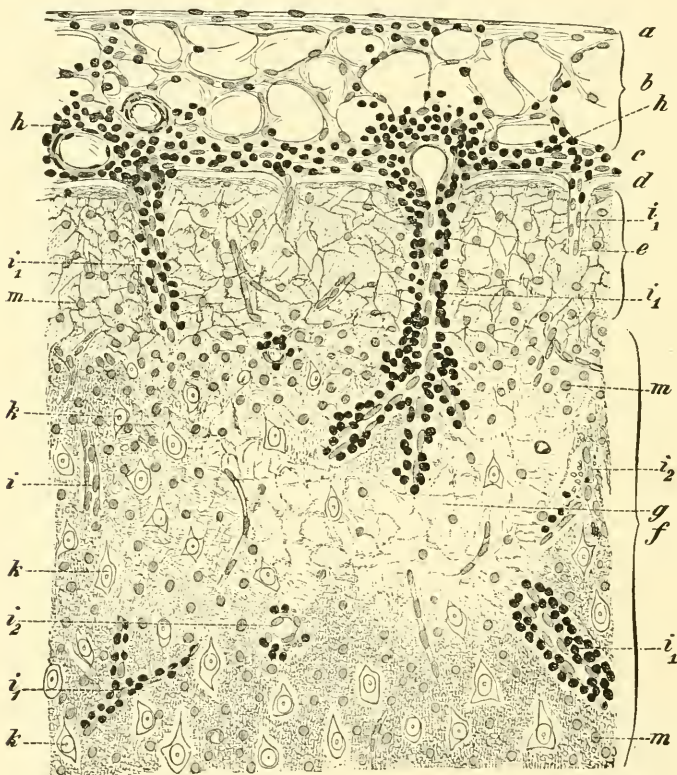


FIG. 231. ATROPHY OF THE CEREBRAL CORTEX IN PROGRESSIVE PARALYTIC DEMENTIA.

(Preparation hardened in Müller's fluid and alcohol, stained with abum-carminé and ammonium carminate, and mounted in Canada balsam: $\times 150$)

- | | | | |
|---|-----------------------------------------------------------------------------------------------------------------------------------------------------------------------------|----------------|----------------------------------------------------------------|
| a | arachnoid | | peared and the tissue is reduced to a fine reticulum |
| b | subarachnoid tissue | h | cellular infiltration of the pia mater |
| c | pia mater | i | unaltered blood-vessels |
| d | superficial layer of slender fibres | i ₁ | pial sheath of blood-vessel infiltrated with round-cells |
| e | layer with few cells in the external principal stratum: the ganglion-cells have disappeared in this layer and numerous stellate groups of lustrous fibres are visible in it | i ₂ | pial sheath of blood-vessel containing round-cells and pigment |
| f | layer with many cells: within this layer the ganglion-cells at g have disappeared | k | ganglion-cells of the cellular layer |
| | | m | neuroglia-cells |

(Fig. 231 *f g*), are liable to disappear in progressive paralysis; these two sets of atrophic changes may be so considerable in amount that the brain loses greatly in bulk, the gyri becoming attenuated and the sulci widened. In the spinal cord the pyramidal tracts and posterior columns occasionally undergo degenerative changes.

In extreme atrophy (Fig. 231) the number of ganglion-cells is diminished, both in the superficial layer, which normally contains but few cells (*e*), and in the underlying stratum which abounds in closely-set pyramidal cells (*f*); in some parts indeed the cells are entirely absent (*g*), so that when a section is mounted in Canada balsam its tissue appears discontinuous and perforated. The weight of an atrophic brain may be less than 1000 grammes.

The atrophy of the nerve-elements in progressive general paralysis is not distributed in any regular way; it may affect different elements within a single convolution. The frontal lobe, the gyrus fornicatus, and the island of Reil are apt to be specially affected. In tabes the lower and posterior portions of the brain appear to be liable to atrophy in spots (JENDRÁŠSIK). The ganglion-cells are said by various authorities to perish by simple atrophy, by pigmentary and hyaline degeneration and sclerosis, by vacuolar degeneration, by dropsical swelling, etc. Many of the changes described are doubtless caused by the methods employed in hardening the brain under investigation. It is probable that simple atrophy and fatty degeneration (Fig. 233) are the most common changes; at any rate fatty degeneration may often by suitable methods be demonstrated over a considerable extent of the brain.

Of changes accompanying the disappearance of the nerve-elements we may note accumulations of leucocytes (Fig. 231 *i*₁), as well as of red blood-corpuscles and yellow pigment-granules (*i*₂), within the adventitial lymph-sheaths of the cortical vessels, and sometimes in those of the white matter of the brain and cord; together with similar cellular infiltrations in the pia mater (*e h*), some surrounding the vessels, and others more widely diffused. These infiltrations are in many cases so abundant and so extensive that they form the most striking of all the morbid appearances in this affection, and they have accordingly led to the entire process being described as a chronic meningo-encephalitis. It must however be remembered that the symptoms of progressive paralysis may exist in a given case without any meningitis that can be discovered *post mortem*. Moreover cases of marked degeneration of the nerve-elements, accompanied by very insignificant infiltration, suggest that the inflammation (if present at all) is either a secondary result or a mere accidental concomitant of the degeneration, and that the essential feature of the affection consists in the degenerative processes. The efficient causes of the degeneration are, as we have said, probably different in different cases.

Other morbid changes to be mentioned are proliferation and

hyaline or fatty degeneration of the vessel-walls, and overgrowth of the supporting reticular tissue, the latter often standing out prominently in the form of a peculiar network (*e*). This is no doubt due to the fact that the neuroglia is rendered more distinctly visible by the destruction of the nerve-elements; but in certain cases there appears also to be some proliferation of the neuroglia-cells. The statement repeatedly made, that the ganglion-cells likewise undergo proliferation, is erroneous.

In atrophy of the cerebrum the **cerebellum** is usually not perceptibly wasted; cases have however come under anatomical examination in which the entire mass of the cerebellum, or one of its lobes, or it may be the vermis or some part of it, is more or less notably diminished in size. The whole cerebellum may indeed be reduced to about the size of a walnut. The slighter degrees of attenuation may be due to atrophy of certain cells and fibres. Where the diminution is very marked it is probably referable to hypoplasia or imperfect development of the cerebellum (Arts. 108 and 111, Fig. 230).

References on the Anatomy and Aetiology of Progressive General Paralysis and on Atrophy of the Brain.

- AFFANASIEW: Acute and chronic alcoholism *Ziegler's Beiträge* VIII 1890
 ARNDT: *État criblé* V. A. 63 1875
 BINSWANGER: *Grosshirnrindenerkrankung bei d. progress. Paralyse* Jena 1893
 (with references)
 CRAMER: Disappearance of fibres in the cerebrum *Cent. f. allg. Path.* I 1890;
 Disappearance of fibres in cases of sun-stroke *ibidem* I; Autopsy of the
 brain in a case of carbonic-oxide poisoning *ibidem* II 1891
 EMMINGHAUS: Post-febrile dementia *A. f. Psych.* XVII 1886
 FISCHL: Progressive paralysis *Prager Z. f. Heilk.* IX 1888
 FRIEDMANN: Degeneration in the cerebral white matter *Neurol. Centralbl.*
 1887; Degeneration in the cerebral white matter, with special reference
 to general paralysis *ibidem* 1887
 FÜRSTNER: Progressive paralysis *A. f. Psych.* XIV 1892
 GRASSET: *Maladies du système nerveux* Paris 1894
 GREENLEES: General paralysis *Brain* XI 1888
 GUDDEN: Progressive paralysis (traumatic and juvenile forms) *A. f. Psych.*
 XXVI 1894 (with references)
 HARTMANN: Psychical disturbances after injuries to the head *A. f. Psych.* XVI
 1885
 JOFFROY: General paralysis *A. de méd. exp.* IV 1892
 KAST: Cerebral infantile paralysis *A. f. Psych.* XVIII 1887
 KETSCHER: Paralysis agitans (atrophy of the nervous system) *Prag. Z. f.*
Heilk. XIII 1893
 KIPPEL: General paralysis *A. de méd. exp.* IV 1892
 KLIPPEL: General paralysis *A. de méd. exp.* III 1891
 KÖBERLIN: Spinal cord in general paralysis *Z. f. Psych.* 46 1892
 LISSAUER: Optic thalamus in general paralysis *D. med. Woch.* 1893
 LUBIMOFF: V. A. 55 1872, and *A. f. Psych.* 1874
 MENDEL: *Die progressive Paralyse der Irren* Berlin 1880; *Berl. klin. Woch.*
 1882
 MESCHÉDE: V. A. 34 1865 and 56 1872; General paralysis V. A. 124 1891
 MEYNER: *Vierteljahrsschr. f. Psych.* 1868

- MIERZEJEWSKY: *Les lésions cérébrales dans la paralysie générale* Paris 1875, and *A. de physiol.* 1876
- PICK: Cystic degeneration of the brain *A. f. Psych.* XXI 1890
- RIEGER: Syphilis and general paralysis *Schmidt's Jahrbücher* CCX 1886
- SCHÜLE: *Allg. Z. f. Psych.* XXV
- SIOLI: Heredity of mental diseases *A. f. Psych.* XVI 1885
- TAGOWLA: *Les fibr. nerv. à myéline intracorticales du cerveau dans la paralysie gén. et dans la démence* Paris 1890
- TUCZEK: *Dementia paralytica* Berlin 1884
- TÜRCK: Spinal cord *Wiën. Sitzungsber. (math.-phys.)* LI, LII, LVI
- VOISIN: *Paralysie gén. des aliénés* Paris 1879
- WESTPHAL: Progressive paralysis *A. f. Psych.* I; Spinal cord in progressive paralysis *V. A.* 39 and 40 1867
- WHITWELL: Vacuolation of ganglion-cells *Brain* XII 1890
- ZACHER: Paralysis *A. f. Psych.* XIII, XIV, XV, XVIII 1887, and *Neurol. Centralbl.* 1891
- ZIEHEN: Paralytic dementia *Eulenburg's encyclop. Jahrb.* 1893

References on Atrophy of the Cerebellum.

- ARNDT: Pathology of the cerebellum *A. f. Psych.* XXVI 1894 (with references)
- BECKER: Destruction of the vermis *V. A.* 114 1888
- CHIARI: Changes in the cerebellum in hydrocephalus *D. med. Woch.* 1889
- CLAPTON, E.: *Trans. Path. Soc.* XII London 1871
- CRAMER: Unilateral atrophy of the cerebellum, with slight atrophy of the opposite cerebral hemisphere *Ziegler's Beiträge* XI 1891
- DENISSENKO: *A. f. mikrosk. Anat.* XIV
- HUPPERT: Extreme smallness of the cerebellum *A. f. Psych.* VII
- MENZEL: Hereditary ataxia and atrophy of the cerebellum *A. f. Psych.* XXII 1890
- MEYER: Disappearance of fibres in the cerebellar cortex *A. f. Psych.* XXI 1889
- ÖBERSTEINER: *Allg. Z. f. Psych.* 27, and *Biolog. Centralbl.* III 1883
- SCHULTZE: Atrophy of the cerebellum *V. A.* 108 1887

CHAPTER XL

LOCAL DEGENERATIONS AND INFLAMMATIONS OF THE BRAIN

114. **Local degenerations** of the brain are usually the result of local anaemia or of haemorrhage; they may however be due to other disturbances of the circulation, to traumatic injury, to inflammation, or to compression. The nerve-tracts of the brain undergo degeneration also when the corresponding centres are destroyed. For example, after destruction of the psycho-motor centres of the cerebral cortex the pyramidal tracts passing down to the cord degenerate; according to HOSCH and VON MONAKOW, descending atrophy of the optic tract follows destruction of the optic centres. When the nerves proceeding from the cerebral axis are excised in early life, or their terminal organs are destroyed or removed (GUDDEN), atrophy takes place in the corresponding

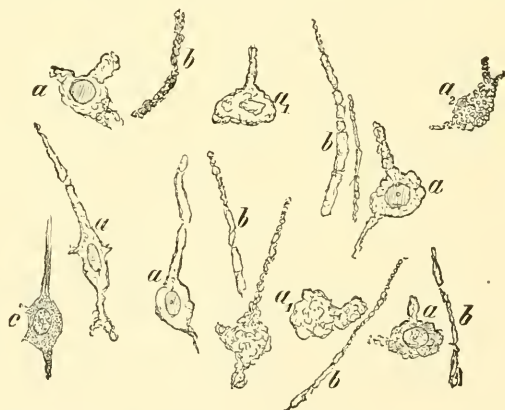


FIG. 232. DEGENERATE AND DISINTEGRATING NERVE-CELLS AND NERVE-FIBRES.

(From the cerebral cortex in the neighbourhood of a focus of traumatic encephalitis of eight days' duration: preparation macerated in Müller's fluid and afterwards teased out: $\times 300$)

- | | |
|-----------------------------------------------------------------------------------------------------------------------------------------------------------------------------------------------------------------|-------------------------------------------------------------------------------------------------------------------------------------------------------------------------------------------|
| <p>a swollen and hyaline ganglion-cells with swollen and partially disintegrated processes</p> <p>a₁ pale denuded ganglion-cells breaking up into segments and with irregularly crenate contours</p> | <p>a₂ ganglion-cells filled with droplets of fat</p> <p>b swollen axis-cylinders breaking into segments and undergoing granular degeneration</p> <p>c normal ganglion-cell</p> |
|-----------------------------------------------------------------------------------------------------------------------------------------------------------------------------------------------------------------|-------------------------------------------------------------------------------------------------------------------------------------------------------------------------------------------|

sensory or motor nuclei (Art. 90). After the loss of an eye the corresponding optic nerve atrophies in the human subject, and after some time this is followed by atrophy of the fibres of the optic tract belonging to the affected nerve: it is moreover stated that after blindness of many years' duration atrophy of the cortex of the occipital lobes takes place.

Local inflammations of the brain are in some cases haematogenous, in others of traumatic origin, and in others again they result from infection and inflammation of the meningeal and cranial envelopes.

In **acute destruction of the ganglion-cells**, such as is apt to occur in the neighbourhood of inflammatory lesions, as well as after contusion and in anaemic and haemorrhagic softening, the cells (Fig. 232 *c*) often swell up (*a*) and become

pale and hyaline; their processes also undergo swelling and hyaline degeneration. At times vacuolation takes place, the nuclei usually becoming swollen at the same time. After a short interval cleavage and disintegration of the cells make their appearance (*a*₁), and the nuclei break down and dissolve.

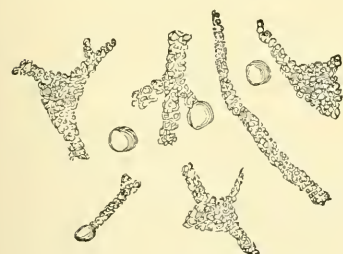


FIG. 234. CALCIFIED GANGLION-CELLS AND NERVE-FIBRES.

(From the brain of an idiot, with partial unilateral paresis and dropsy of one lateral ventricle: $\times 500$)

of lime. FRIEDLÄNDER met with calcified ganglion-cells in the brain as early as thirteen days after a traumatic injury. In chronic diseases the ganglion-cells occasionally assume a peculiar

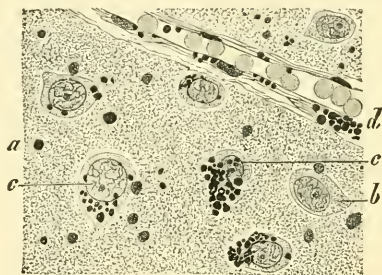


FIG. 233. FATTY DEGENERATION OF THE GANGLION-CELLS AND THE BLOOD-VESSELS.

(Preparation from the neighbourhood of a focus of ischaemic degeneration in the corpus striatum: fixed in Flemming's acid solution, and stained with saffranin: $\times 500$)

- a* ground-substance
- b* normal ganglion-cells
- c* fatty ganglion-cells
- d* blood-vessel with fatty wall

Along with the swelling and fragmentary disintegration, fatty degeneration (*a*₂) of the ganglion-cells sometimes sets in. It is generally met with in conditions in which chronic or frequently-repeated interference with the circulation has led to impaired nutrition of the ganglion-cells (Fig. 233).

When the ganglion-cells die from any cause, such as inflammation, anaemia, or concussion, and are not at once broken up and dissolved, they sometimes undergo calcification, and appear thickly studded with particles and rounded grains

homogeneous wax-like condition, a change which has by some been described as sclerosis.

When nerve-fibres perish the myelin usually coagulates in drops (Art. 91, Fig. 185), which fall to pieces and change into fat-globules; the process is thus usually described as fatty degeneration. The axis-cylinders often become hyaline, swell up, become varicose, and sooner or later break down completely, whereupon the detritus dissolves and disappears. The neuroglia-cells and the vessels within the focus of degeneration soon perish likewise, or at least undergo degenerative changes, chiefly of a fatty character; sometimes however they remain intact, and in this case they are apt to become proliferous.

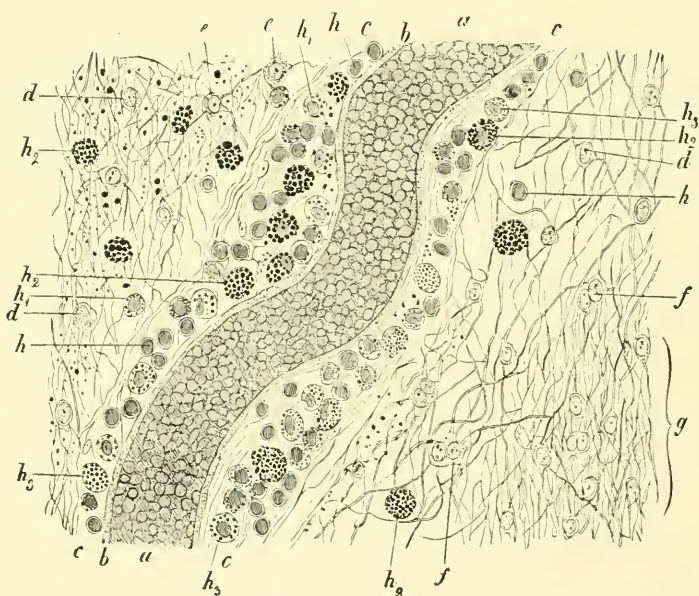

FIG. 235. TEASED PREPARATION FROM A DEGENERATING PATCH IN THE BRAIN, WITH HYPERTROPHIC NEUROGLIA.

(Preparation treated with perosmic acid: $\times 200$)

- | | | | |
|---|--------------------------------|----------------|--------------------------------------------|
| a | blood-vessel filled with blood | g | sclerotic tissue |
| b | tunica media | h | round-cells |
| c | adventitial lymph-sheath | h ₁ | round-cells with scattered droplets of fat |
| d | unaltered neuroglia-cells | h ₂ | fat-granule cells |
| e | fatty neuroglia-cells | h ₃ | pigment-granule cells |
| f | binuclear neuroglia-cells | | |

It may be taken as the ordinary rule that the products of disintegration of the degenerate and necrotic tissue are absorbed, sometimes quickly, sometimes more slowly. Some of the detritus is dissolved and absorbed at the seat of lesion; other portions are taken up as such into the lymph-channels, not in general directly but after inclusion within carrier-cells. Such cells always make

their appearance sooner or later in foci of disintegration; they are either migratory leucocytes from the blood-vessels, or the progeny of connective-tissue cells, and in virtue of their power of movement they take up into their substance the products of disintegration, and in particular the droplets of fat, and so form **fat-granule cells** (Fig. 235 *h* *h*₁ *h*₂). So long as any considerable quantity of detritus remains in the tissue these granule-cells are never absent, and in the later stages of the process they accumulate chiefly in the lymph-channels, more particularly in the adventitial sheaths of the blood-vessels (Fig. 235 *c*); in this way

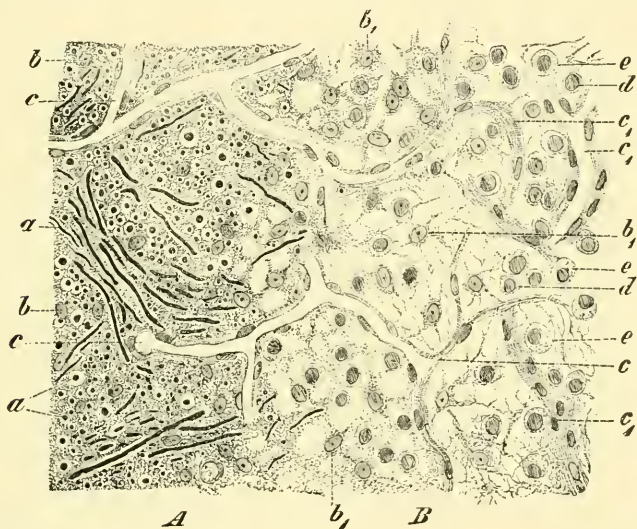


FIG. 236. SECTION FROM THE BORDER OF A PATCH OF SOFTENING IN THE BRAIN (ENCEPHALOMALACIA).

(Preparation hardened in Müller's fluid, stained with haematoxylin and carmine, and mounted in Canada balsam: $\times 250$)

- | | |
|-----------------------------------------------------------------------------------------|-------------------------------------------------------------------------------------------------------|
| <i>A</i> normal brain-substance | <i>c</i> blood-vessels |
| <i>B</i> degenerate brain-substance | <i>c</i> ₁ blood-vessels with thickened adventitial sheaths |
| <i>a</i> nerve-fibres of different thicknesses, cut partly across and partly lengthwise | <i>d</i> unaltered leucocytes migrated from the vessels |
| <i>b</i> neuroglia-cells within the normal brain-tissue | <i>e</i> fat-granule cells deprived of fat by treatment of the section with alcohol and oil of cloves |
| <i>b</i> ₁ neuroglia-cells in the zone of degeneration | |

they remove the products of disintegration, and so bring about their destruction. If the focus of degeneration contains extravasated blood, **pigment-granule cells** are formed in like manner (*h*₃).

When the nerve-elements only are destroyed, while the vessels and the neuroglia-cells are preserved, the resulting tissue consists of a network of vessels (Fig. 236 *c* *c*₁), within which the neuroglia-cells are more or less uniformly distributed (*b*₁). These by their

interlacing processes form a fine reticulum, whose meshes instead of nerve-fibres (*a*) or ganglion-cells contain liquid, with varying numbers of leucocytes (*d*) and fat-granule cells (*e*).

The adventitial sheaths of the vessels within the area of degeneration (Fig. 236 *e*₁) usually begin to proliferate at an early stage, and in the course of time elaborate a more or less abundant and often fairly dense connective tissue, which for long continues to enclose granule-cells in its meshes.

Sometimes the neuroglia-cells also proliferate, and then a felted fibrous patch of sclerotic tissue (Fig. 235 *g*) is formed; but such patches are usually of slight extent, and in many cases of cerebral softening they are entirely absent.

So long as a focus of degeneration contains disintegrating myelin and fat-granule cells it appears white and softer than the parts around it, or looks like a white turbid semi-liquid mass enclosed in a fine mesh-work. The process is accordingly termed **white softening** or degeneration. As the fatty detritus is re-absorbed, the liquid becomes more and more clear, and if the surrounding tissue does not close in and occupy the space, a **cyst** filled with clear or slightly turbid liquid and traversed by a delicate network of vessels is formed in the site of the degenerate patch. If proliferation of the neuroglia takes place, **sclerosis** ensues (Fig. 235 *g*), while proliferation of the adventitial sheaths of the blood-vessels leads to the formation of a **fibrous cicatrix** (Fig. 239).

In the course of degenerative processes the *corpora amylacea* that are normally present in the brain-substance are not infrequently to be found in increased numbers within the altered tissue.

Regeneration of the nerve-elements of the brain does not appear to take place, at least in man. When ganglion-cells with their corresponding tracts have once been destroyed, the function they performed can be restored only by means of vicarious action on the part of other equivalent tracts and centres.

It is an open question whether in persons whose limbs have been removed in mature life the corresponding cortical centres become atrophic. SANDER (*Cent. f. med. Wiss.* 1875), LUYSS (*Gaz. des hôp.* 1876), BOURDON (*Rech. clin. sur les centres moteurs des memb.* Paris 1887, and *Bull. de l'Acad. de méd.* XII 1883), and others state that they have observed signs of corresponding cortical atrophy in cases of amputation; but their statements are not quite convincing inasmuch as the width of the convolutions varies considerably, even in normal conditions. CHARCOT, FERRIER, and others have sought in vain for unmistakable evidence on the point. According to DAVIDA and EDINGER (*V. A.* 89 1882), in cases of congenital absence or imperfection of the limbs the corresponding cortical centres are defectively developed.

Whenever the tissue of the brain and cord, with their membranes and lymph-channels, contain granule-cells, we may in general take it as a proof that disintegration of nerve-elements has somewhere taken place. According to JASTROWITZ (*A. f. Psych.* II), this statement applies only to the case of persons more than seven months old; for from the fifth month of gestation until the

eighth month after birth the presence of granule-cells in certain parts of the brain and cord, varying with age, is a normal phenomenon related with the formation of the medullary sheaths of the nerve-fibres. The phenomenon was formerly (VIRCHOW: *Berl. klin. Woch.* No. 46 1883) regarded as pathological, and the process was described as congenital encephalitis. The granule-cells are either diffusely distributed or aggregated in masses, which form opaque white spots, and in the greyish-red semi-translucent brain-substance of the foetus are visible by the unaided eye.

References on Calcification of Ganglion-cells.

FRIEDLÄNDER: Calcification of ganglion-cells *V. A.* 88 1882

ROTH: Calcification of the cells of Purkinjé *V. A.* 53 1871

SALVIOLI: *Rivista clin. di Bologna* 1878

115. The brain is an organ whose **blood-vessels** are exceptionally liable to undergo morbid changes. Sclerosis and atheroma of the vessels occur more frequently here than in most of the other organs, and indeed the favourite seat of hyaline degeneration is in the walls of the small arteries and capillaries of the central nervous system and its membranes. Fatty degeneration and calcification of the cerebral vessels are also of very frequent occurrence: the latter change indeed, in certain rare instances, is so marked that in sections of the brain the cut vessels project as rigid points above the surface, while in microscopical preparations the majority of the capillaries appear in a state of hyaline degeneration and calcification. Moreover, small embolic fragments, passing from the heart or ascending aorta into the arterial blood-stream, are not infrequently conveyed to and lodge in the cerebral arteries.

When a cerebral artery is obstructed or occluded by thickening of its wall, from sclerosis or hyaline degeneration, or when the vessel already diseased is occluded by thrombosis or embolism, the result is **ischaemic necrosis** of the region it supplies, as the arteries in the interior of the brain are devoid of anastomotic branches of any considerable size, and collateral circulation can be established only with difficulty. The necrosis thus induced is followed very soon by **softening** of the brain-substance, or **encephalomalacia**.

Sometimes the occlusion of the vessel is unaccompanied by extravasation of blood from it, in which case the affected region presents the appearance of **white softening**. But if, in consequence of the initial disturbance of circulation, extravasation takes place from the parts of the vessel that are still accessible to the blood, but not traversed by it in the normal way, the damaged tissue assumes a red and later on a yellow or rusty colour, due to blood and its detritus—haematoidin and haemosiderin. This process is termed **red** or **yellow softening**.

The softening of the tissue is apparent even after a few days, and the histological indications of disintegration described in Art. 114 are very soon demonstrable, the appearance of myelin-

drops and of fat-globules and fat-granule cells constituting one of the early signs that disintegration has begun.

In the course of weeks the liquefaction of the tissue increases, and the focus of softening presently contains little more than a liquid rendered milky and turbid by the presence of detritus and fat-granule cells. As the blood-vessels are usually intact during this part of the process (Figs. 236 *e* and 237 *b*), the liquid is in general enclosed within the meshes of a fine reticulum formed by their persistent walls.

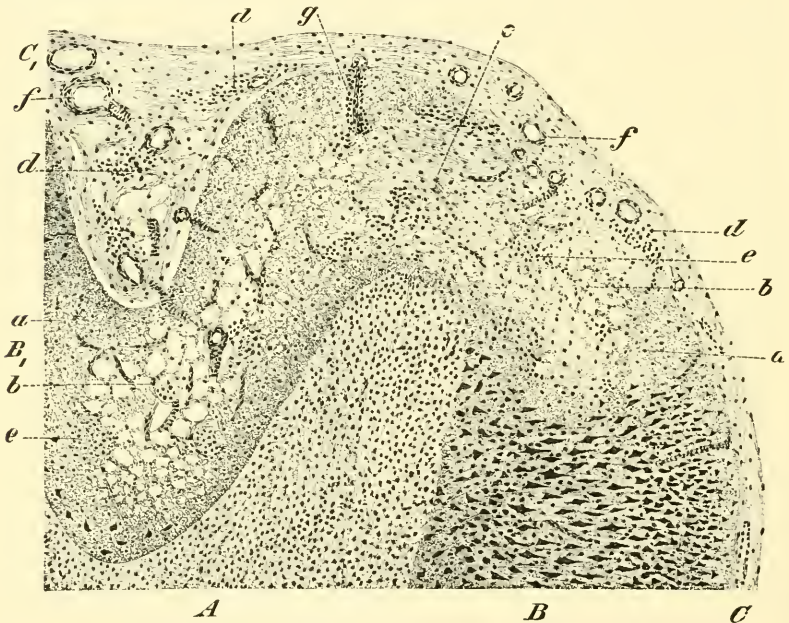


FIG. 237. ISCHAEMIC SOFTENING OF THE CEREBRAL CORTEX.

(From the brain of an idiot: preparation hardened in Müller's fluid and alcohol, stained with haematoxylin and carmine, and mounted in Canada balsam: $\times 25$)

- | | | | |
|----------------------|----------------------------------------------------------------------------------------------|----------|----------------------------------------------------------------------------------------------------|
| <i>A</i> | process of white matter | <i>c</i> | condensed fibrous-looking tissue |
| <i>B</i> | normal cortex with ganglion-cells | <i>d</i> | groups of cells aggregated in the subpial and subarachnoid spaces |
| <i>B₁</i> | softened cortex | <i>e</i> | groups of round-cells, fat-granule cells, and pigment-granule cells within the region of softening |
| <i>C</i> | normal pia-arachnoid membranes | <i>f</i> | larger blood-vessels |
| <i>C₁</i> | thickened pia-arachnoid membranes | <i>g</i> | aggregations of cells in the adventitial sheaths |
| <i>a</i> | cortex undergoing softening and devoid of ganglion-cells, the neuroglia being in part intact | | |
| <i>b</i> | portions of the cortex in which the vascular network is almost all that remains | | |

After a few months the liquid gradually becomes clearer, owing to the resorption of the products of disintegration. The turbidity however in some instances persists for a long time, as the products of fresh and progressive destruction of the surrounding tissue are added to the liquid.

Usually in the course of months a cavity or **cyst** is formed, which on section yields a certain quantity of slightly turbid liquid, and is traversed by a delicate network that collapses when the liquid is removed. So far as can be made out with the naked eye, the network consists essentially of vessels (Fig. 237 *b*); where it seems more compact its meshes are occupied by fine reticular neuroglia (Figs. 236 *b* and 237 *a*).

Induration due to proliferation of the neuroglia sometimes takes place round the region of softening, but it is usually small in amount. It is most apt to occur in the case of small foci in young persons, and when the softening is not caused by arterio-sclerosis. In many instances, even after months or years, the neuroglial proliferation is inconsiderable, the foci of softening being frequently surrounded by a zone of tissue within which the nerve-elements are still undergoing disintegration, and which accordingly is more or less densely beset with granule-carrying cells.

The vessels lying within the region of softening become in part obliterated. Fibro-cellular hyperplasia of the adventitial sheaths takes place, both in the occluded vessels and in those which remain patent, and this gives rise to thickening and induration of the parts involved.

The size of the region of softening is dependent upon the extent of the vascular territory that has been rendered anaemic, and it accordingly varies much in different cases. The smallest foci of degeneration may entirely escape notice by the unaided eye, or cause changes recognisable only on careful observation; while larger foci sometimes involve entire convolutions, large parts of the central white matter or of the basal ganglia, or even an entire lobe of the brain.

In advanced stages the smallest foci appear as minute gaps in the tissue filled with clear liquid; in other cases the tissue is riddled with holes or cribriform, looking not unlike a sponge with slender trabeculae and wide meshes. If destruction of tissue is limited to the region surrounding a small arterial branch, the space left vacant by the resorption of the detritus is generally filled up by an accumulation of liquid within the adventitial lymph-sheath, so that the vessel lies loosely in a wide lymph-sac, and recalls the appearance presented in local lymphatic engorgement.

Large numbers of these very small foci of softening lying close to one another give rise to a condition included under the term *état criblé*.

The contents of larger foci of softening are seldom quite clear, as the absorption of the products of disintegration takes place very slowly, and around the focus the gradual degeneration and disintegration of the nerve-substance still go on even after the lapse of months or years.

Large foci of softening (Fig. 238) situated just beneath or

near the pia mater generally cause the brain-substance there to collapse, and the space thus vacated is partially filled up by an accumulation of liquid in and under the meshes of the pia mater and arachnoid. The collapsed portion of the brain, when observed from the exterior, looks opaque, and is white, yellow, or brown in tint. When cut into it allows a liquid to escape that is generally milky, or less frequently pigmented, and loose shreds of tissue, consisting in great part of isolated vessels (Fig. 237 *b*), are all that is left of the pre-existing brain-substance.

The tissue of the internal meninges overlying foci of softening of some standing is usually hyperplastic (C_1), and its blood-vessels (f) are often thickened. Cellular infiltration of the tissue persists so long as the disintegration continues, both within

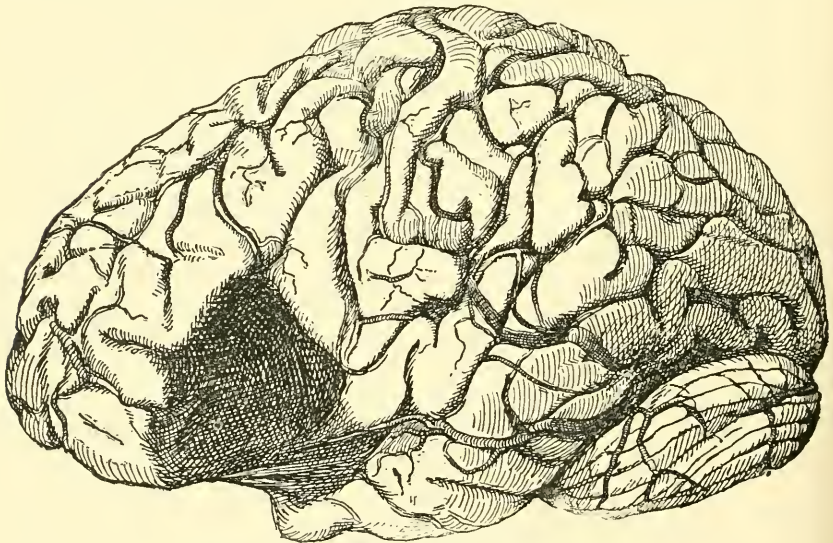


FIG. 238. ISCHAEMIC SOFTENING OF THE BRAIN.

(Involving the third-frontal, the lowest portion of the anterior-central, and the apex of the first-temporal convolutions, in a woman who had suffered from amnesic and ataxic aphasia: one-half the natural size)

the degenerate region and in the overlying membranes. In the thickened meninges calcareous concretions are often deposited. A large focus situated in the neighbourhood of a ventricle may cause the latter to become enlarged by reason of the collapse of the adjacent tissue.

In the cerebral hemispheres ischaemic softening occurs both in the parts supplied by the arteries of the basal ganglia and in the parts supplied by those of the cortex. When cortical centres are destroyed, motor and sensory paralyses ensue. Destruction of the occipital lobe and of the posterior portion of the parietal lobe results in loss of sight. Destruction of the central convolutions

and parietal lobe gives rise to paralysis of the limbs of the opposite side; while destruction of the left third-frontal gyrus (Fig. 238) in right-handed persons usually induces ataxic aphasia. The production of numerous small areas of softening in the cortex (Fig. 237) leads to the impairment, in varying degree, of many of its functions.

In the cerebral axis foci of softening occur in the most diverse places, and accordingly give rise to very various disorders of function. When they are situated in the course of the pyramidal tract, they interrupt the conduction of motor impulses.

References on Ischaemic Softening of the Brain.

- CHARCOT: *Les localisations dans les maladies du cerveau* Paris 1876; *Les maladies des vieillards* Paris 1867; *Le ramollissement cérébral et l'encéphalite, Oeuvres complètes IX* Paris 1890
- DURET: Circulation of the encephalon *A. de physiol.* 1874
- GEIGEL: Embolic ischaemia *V. A.* 121 1890
- GELPKE: Cerebral apoplexy and embolism of the cerebral arteries *A. d. Heilk.* XVI
- HEUBNER: *Dieluetische Erkrankung der Hirnarterien* Leipzig 1874
- HOVÉN: Anatomy of cerebral infantile paralysis *A. f. Psych.* XIX 1888
- KREUSER: Acquired porencephalia *Z. f. Psych.* 48 1891
- KROEMER: Chorea *A. f. Psych.* XXIII 1891
- LANCEREUX: *De la thrombose et de l'embolie cérébrale* Paris 1862
- LICHTHEIM: Aphasia *D. A. f. klin. Med.* XXXVI
- MALLORY: Calcareous concretions in the brain *Journ. of Path.* III 1894
- MARCHAND: Embolism and thrombosis of the cerebral arteries *Berl. klin. Woch.* 1894
- POELCHEN: Cerebral softening from carbonic-acid poisoning *V. A.* 112 1888
- PRÉVOST and COTARD: *Le ramollissement cérébral* Paris 1866
- SAVELEW: Cerebral embolism *V. A.* 135 1894 (with references)
- WALCKER: Occlusion of cerebral arteries *Inaug. Diss.* Zürich 1872

116. **Haemorrhages** are of very frequent occurrence in the brain, taking place both by diapedesis and by rupture. Capillary haemorrhages are not uncommon in congestive hyperaemia, and acute encephalitis generally begins with such haemorrhage. In some cases of malaria the brain is beset with numbers of bleeding points, and multiple haemorrhages of the kind are observed in other infective diseases (variola, anthrax), and in haemorrhagic purpura.

In all these cases the haemorrhages take the form of rounded or elongated spots from the size of a millet-seed to that of a pea, and often give the section a delicately-sprinkled appearance.

The extravasated blood lies partly in the substance of the brain itself, partly in the adventitial sheaths of the vessels. The accumulations of blood met with in the latter situation are often described as miliary dissecting aneurysms.

Extensive haemorrhages due to occlusion of the arteries by arterio-sclerotic thickening of the intima, or by embolism and

thrombosis, are rare; but small isolated haemorrhagic spots are not uncommon as a result of arterial obstruction.

Engorgement of the veins within the substance of the brain, such as occurs, for example, in the neighbourhood of tumours or of large haemorrhages, leads to the appearance of numerous small circumscribed extravasations around the capillaries and small veins, the blood lying partly within the adventitial sheaths, partly in the brain-substance itself.

Wounds, contusions, and concussions of the brain and cord, induced by various traumatic conditions, usually lead to haemorrhages, whose extent naturally varies with the size of the vessels that are ruptured.

Extensive spontaneous haemorrhage (**cerebral apoplexy**) results from the bursting of arteries, owing to the weakening of their walls by degenerative and inflammatory changes. Aneurysmal dilatations of the arteries often precede the rupture, though in many cases no such dilatation is discoverable. Increase of the blood-pressure within the aortic system favours the rupture of diseased vessels, but is incapable of causing sound arteries to give way.

Such spontaneous arterial haemorrhages take place most commonly in the region of the basal ganglia, in the internal capsule, and in the parts immediately adjacent. They are more infrequent in the pons, in the crura cerebri, in the cerebellum, and in the centrum ovale of the cerebrum. Spontaneous haemorrhage from rupture is rarest of all on the convex aspect of the brain.

This distribution is due to the fact that the arteries supplying the first-mentioned territories are subjected to greater blood-pressure than the small arteries that pass from the vascular ramifications within the pia mater into the cortical grey matter. In particular, the pressure is highest in the branches of the middle cerebral artery supplying the basal ganglia and the internal capsule.

By arterial haemorrhage the nervous and ganglionic elements are more or less extensively destroyed, while the surrounding structures are subjected to compression. Destruction of tissue indeed always results, except in the case of very small capillary haemorrhages, when the adjoining cerebral and spinal tissues are merely pushed aside and compressed by the extravasation of blood into the vascular sheaths. The bursting of arteries of the smallest calibre gives rise to haemorrhagic patches varying from the size of a pea to that of a hazel-nut: when larger branches give way entire regions of the brain may be destroyed, such as the greater part of the basal ganglia of one side with some of the adjoining white matter, or the entire white centre of one occipital lobe.

The seat of a recent haemorrhage has a dark-red softened appearance, the tissue being reduced to a coagulated or pulpy mass of detritus. When the haemorrhage has been extensive the

remainder of the brain is anaemic, the gyri are more or less flattened from the pressure of the extravasated blood, and the sulci are indistinct. Surrounding the primary focus are usually a number of small bleeding points, that give the brain-substance the appearance of being sprinkled with red; they are due to the disturbance of the circulation caused by the primary haemorrhage. When bleeding takes place in the neighbourhood of the ventricles, the blood may be poured into the ventricular cavities, and pass thence through the transverse fissures into the subarachnoid spaces.

In cortical haemorrhage the greater part of the blood is apt to spread along beneath the pia mater and to penetrate into the pial and subarachnoid meshes. When meningeal arteries give way, the membranes are naturally the chief seat of effusion, and the brain-substance is only involved to a subordinate extent. Should the arachnoid itself be torn, the blood may pass into the subdural space.

On coagulation the mass of extravasated blood contracts, and its liquid portions are in part removed by the lymphatics and blood-vessels. In this way the compression of the neighbouring tissue is gradually lessened and finally ceases. At the same time the blood-clot changes colour and becomes reddish-brown or chocolate-coloured. Moreover, some of the haemoglobin diffuses into the surrounding tissue and gives it a yellowish tinge. Presently disintegration of the effused blood and of the damaged cerebral matter takes place,

and the products of disintegration are in course of time almost entirely absorbed by the action of fat-granule and pigment-granule cells (Art. 114). The space thus left unoccupied is filled up either by the accumulation of liquid or by the collapse and contraction of the brain-substance. In the latter case a corresponding dilatation of the subarachnoid space or of the ventricles must occur. When part of the space is filled up with liquid, the result is an **apoplectic cyst**; when the surround-

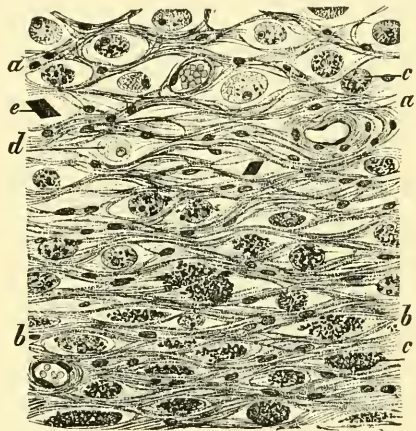


FIG. 239. APOPLECTIC CICATRIX FROM THE CENTRE OF A CEREBRAL HEMISPHERE.

(Preparation hardened in Müller's fluid, stained with haematoxylin and eosin, and mounted in Canada balsam: $\times 250$)

- a loose connective tissue
- b dense connective tissue
- c cells with brown pigment-granules
- d fat-granule cells whose fat has been dissolved out
- e crystal of haematoidin

ing tissue contracts and closes up the hiatus, an **apoplectic cicatrix** is formed, which is either very dense and close in texture, or encloses inspissated necrotic residues, and sometimes plates of cholesterin. The tissue of the cicatrix (Fig. 239) and the wall of the cyst are usually somewhat indurated, and of a yellow, brownish-red, or brown tint. The pigmentation is due to the fact that some of the colouring-matter derived from the disintegration of the blood is not absorbed, but remains *in situ*. The pigment consists largely of amorphous brown flakes and granules of haemosiderin (Fig. 239 *e*), with a small amount of amorphous or crystalline haematoidin (*e*). The induration is essentially due to hyperplastic connective tissue (*a b*) derived from the proliferous adventitial sheaths of the vessels.

In the case of haemorrhages that are inconsiderable, and in which the extravasation has been limited to the sheaths of the vessels and causes no destruction of tissue, the products of disintegration are in large part removed by the adventitial or circumvascular lymph-channels; pigment-granules, however, are liable to remain for a long time in the vascular sheaths.

References on Cerebral Haemorrhage and its Causation.

- CHARCOT: *Leçons sur les maladies des vieillards* Paris 1867; *Nouv. rech. sur la pathogénie de l'hémorragie cérébrale, Oeuvres complètes* IX 1890; *Localisation of cerebral and spinal diseases* (New Syd. Soc. trans.) London 1883
- CHARCOT and BOUCHARD: *Pathology of cerebral haemorrhage A. de physiol.* I 1868
- DÜRCK: *Changes and haemorrhages in the central nervous system V. A.* 130 1892
- EICHLER: *Aneurysms of the cerebral arteries D. A. f. klin. Med.* XXII
- GEIGEL: *Apoplectic shock in cerebral haemorrhage V. A.* 125 1891
- LÖWENFELD: *Ätiologie und Pathologie der Hirnblutungen* Wiesbaden 1886
- ROTH: *Correspl. f. Schweizer Aerzte* 1874
- TURNER: *Arteries of the brain from cases of cerebral haemorrhage Trans. Path. Soc.* London 1882

117. **Traumatic injury** affects the brain in various ways, and leads to various kinds of secondary changes.

Concussion of the brain, such as is produced by a fall upon the head or by a blow or knock, often causes a paralysis of the brain manifested by loss of consciousness, which sometimes is temporary, sometimes of longer duration, and not infrequently terminates fatally. In the latter case investigation occasionally reveals the presence of multiple cerebral haemorrhages: but these may be absent, and the paralysis must then be due to some widespread and general lesion of the brain, in which certain parts are torn from their connexions or directly deprived of vitality. The fact that after slight concussion, whose effects appear to be transient, isolated ganglion-cells sometimes undergo calcification is in favour of this hypothesis.

Contusion, crushing, and laceration of circumscribed portions of the brain, such as accompany penetrating gun-shot injuries (Fig. 240 *m*), wounds from cuts, stabs, or depressed fractures of the skull, and occasionally severe local concussions, lead to more or less extensive local destruction of the brain-substance, and in general to haemorrhage. The extent of the destruction naturally depends upon the character of the injury. In the case of gun-

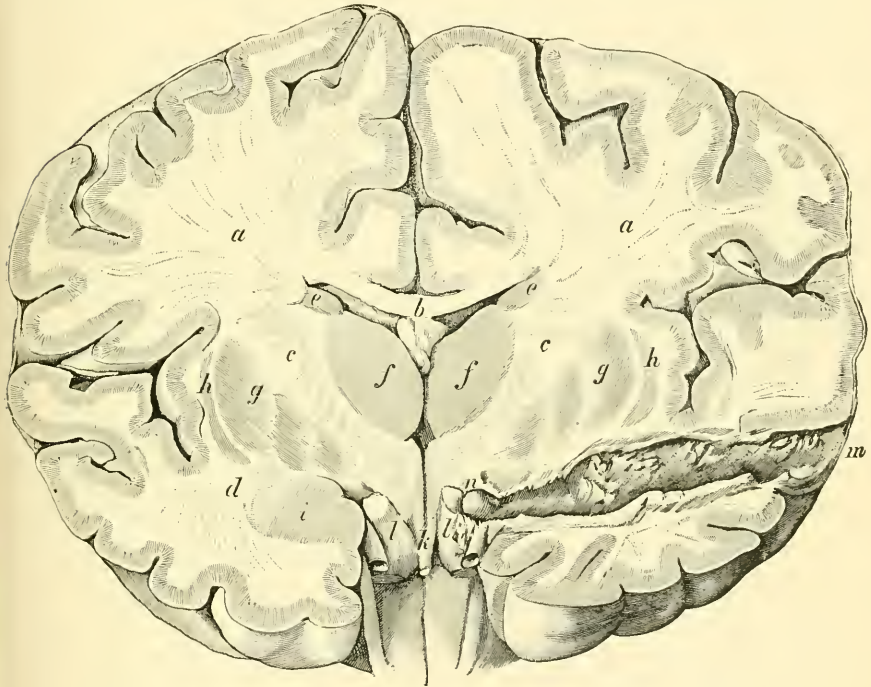


FIG. 240. FRONTAL SECTION THROUGH THE INFUNDIBULUM OF A BRAIN WITH A BULLET-WOUND.

(Seventeen days after the injury: the revolver-bullet is lodged in the optic tract: 11-14ths of the natural size)

<i>a</i> centrum ovale	<i>h</i> claustrum
<i>b</i> corpus callosum	<i>i</i> nucleus amygdalae
<i>c</i> internal capsule	<i>k</i> infundibulum
<i>d</i> temporal lobe	<i>l</i> optic tract
<i>e</i> corpus striatum	<i>m</i> track of the bullet
<i>f</i> optic thalamus	<i>n</i> bullet
<i>g</i> lenticular nucleus	

shot wounds the brain may be traversed from side to side by the track of the bullet (Fig. 240 *m n*), and if the latter has rebounded from the bone, the track may have a zigzag course. Punctured wounds, on the other hand, often give rise only to a comparatively short and narrow solution of continuity (Fig. 241 *a*).

If no septic infection reaches the seat of the traumatic softening, its course is in general similar to that of the ischaemic and haemorrhagic forms. Gradual dissolution of the damaged tissue takes place (Fig. 241 *b*), and more or less extensive inflammation and proliferation are set up (*c*). These processes start mainly from the vessels and the tissue about them; while the nerve-substance, often for some distance from the original seat of the traumatic lesion (*d*), undergoes degenerative changes.

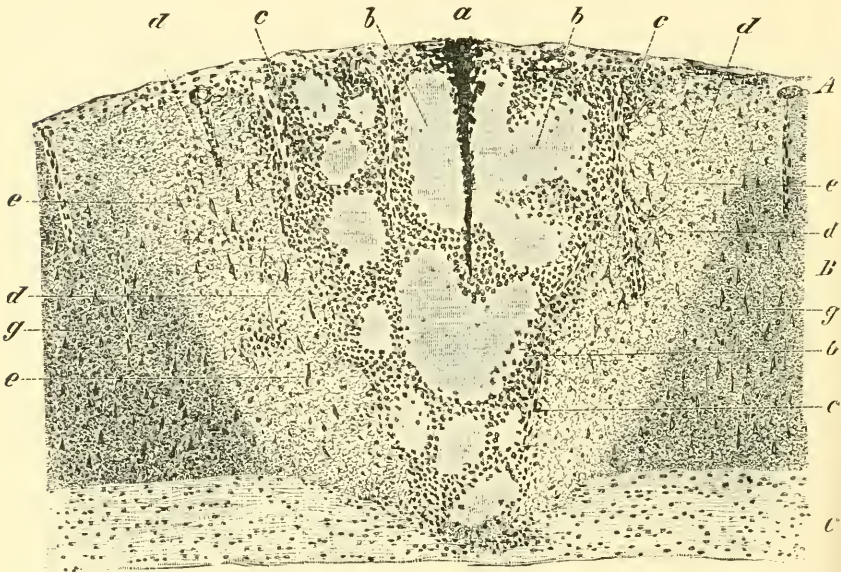


FIG. 241. EXPERIMENTAL ENCEPHALITIS PRODUCED BY A PUNCTURE THROUGH THE CEREBRAL CORTEX OF A RABBIT.

(Twelve days after the injury: preparation hardened in Müller's fluid, stained with haematoxylin and neutral carmine, and mounted in Canada balsam: $\times 25$)

- | | |
|------------------------------------------------|-------------------------------------------------------|
| A meninges | c zone of inflammatory infiltration and proliferation |
| B cerebral cortex | d zone of degeneration |
| C medullary white matter | e swollen and degenerate ganglion-cells |
| a track of the puncture | g normal cortical substance |
| b necrotic granular-looking denucleated tissue | |

Sub-meningeal injuries of the brain induce in the pia mater inflammation and proliferation, these processes being especially noticeable about the vessels that enter the brain (Fig. 241 *c*). In perforating gun-shot wounds granulation-tissue (Fig. 242 *b c*) is produced around the fistular track (Fig. 242 *a*), and after a certain time this is transformed into fibrous tissue (*d*), while the surrounding brain-substance (*e*) undergoes secondary disintegration.

We cannot determine at what period these processes come to

an end. In wounds from stabs or cuts, after the lapse of months or years, the tissue damaged by the traumatic injury is in some cases entirely or in great part absorbed, and the seat of the lesion is occupied by a cicatrix consisting largely of vascular connective tissue, and of a very small amount of hyperplastic neuroglia. But it must be noted that even after a long time granule-cells are still discoverable in the neighbourhood of the scar, indicating that the processes of disintegration have not entirely ceased.

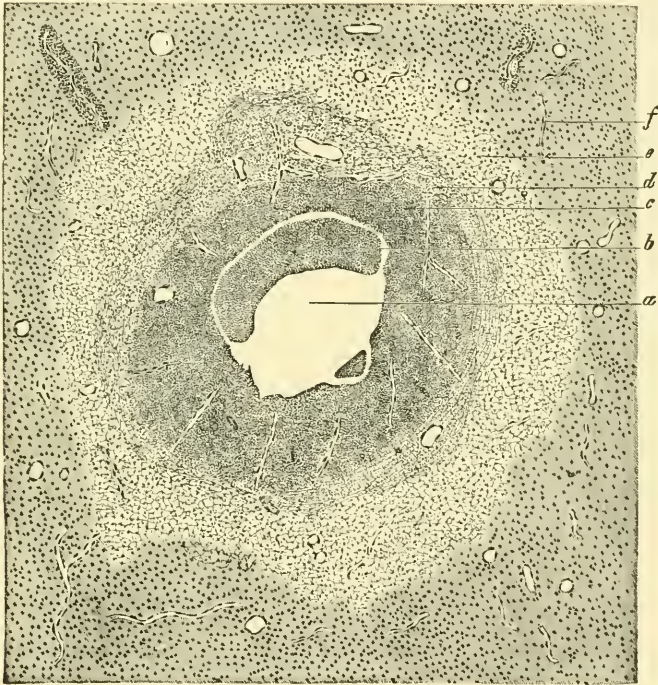

FIG. 242. TRANSVERSE SECTION OF A BULLET-WOUND IN THE BRAIN.

(From von KALDEN: forty-seven days after the injury: preparation hardened in Müller's fluid, stained with haematoxylin and carmine, and mounted in Canada balsam: $\times 5$)

- | | | | |
|---|----------------------------|---|-----------------------------------------------|
| a | bullet-track | d | fibrous layer of the wall of the bullet-track |
| b | mass of exudation | e | zone of softening |
| c | zone of granulation-tissue | f | normal brain-substance |

Cases are occasionally observed in which, after some local traumatic necrosis, the degenerative process continues for years to extend, and finally involves a large portion of the brain. After a blow on the forehead, by which perhaps a splinter of bone is driven into the pia mater and the underlying brain-substance, softening of the brain may ensue, and cause the destruc-

tion of the entire frontal lobe. In such cases the proliferation around the softened region is usually slight.

A cerebral wound, when it is infected in any way by pyogenic micro-organisms, is followed by purulent infiltration and ultimately by suppuration of the parts involved, and an **abscess** (Art. 118) is thus formed.

Compression, due to the gradual enlargement of an intracranial growth, such as a tumour or a haematoma of the dura mater, may for a long time be borne by the brain without damage, provided it is unaccompanied by disturbances of circulation; and deep indentations of the cortex, due to the growth of tumours of the dura mater, are sometimes observed in which no degeneration of the brain-substance has taken place. The brain evidently yields to the pressure of the growth, and room is provided by an outflow of lymph from the cranial cavity. If, however, the encroachment exceeds certain limits, disturbances of circulation and nutrition are induced, even when the compression increases very slowly.

Sudden compression of the cerebral substance, accompanied by such disturbances of the circulation as impede the outflow of blood from the brain or from parts of it, generally induces both functional disorder and structural change. This is most frequently exemplified in the case of haemorrhage into the brain or into the ventricles or meninges, and in the case of ventricular hydrocephalus (Art. 112). The like results are sometimes produced by the growth of intracranial tumours and abscesses, giving rise to such changes as flattening of the convolutions over the seat of compression, ischaemia, and not infrequently softening and disintegration.

References on Traumatic Injury of the Brain and its Consequences.

- BERGMANN: Injuries of the head *Deutsche Chirurgie* part 30 Stuttgart 1880
 COËN: Healing of stab-wounds of the brain *Ziegler's Beiträge* II Jena 1887
 FRIEDMANN: Progressive changes in the ganglion-cells in inflammation *A. f. Psych.* XIX 1887; Results of concussion of the brain *D. med. Woch.* 1891 and *A. f. Psych.* XXIII 1861
 GUDER: *Die Geistesstörungen nach Kopfverletzungen* Jena 1886
 HAYEM: *Les diverses formes d'encéphalite* Paris 1868
 JOLLY: *Studien aus d. Institute f. experim. Pathol.* Vienna 1870
 VON KAHLDEN: Healing of cerebral wounds *Cent. f. allg. Path.* II 1891
 KRAFFT-EBING: *Ueber die durch Gehirnerschütterung und Kopfverletzung hervorgerufenen psych. Krankh.* Erlangen 1868
 MILES: Microscopic pathology of cerebral traumatism *Journ. of Path.* I 1892
 SANARELLI: Reparative processes in the brain *Cent. f. allg. Path.* II 1891 (p. 429)
 WITKOWSKI: Cerebral concussion *V. A.* 62 1874
 ZIEGLER: Healing of cerebral wounds *Sitzungsber. phys.-med. Gesellsch. in Würzburg* 1878

118. **Acute haematogenous encephalitis** (insular or focal) is an affection that develops in the course of various infective diseases, and makes its appearance at one or more isolated spots or in numerous scattered foci. It occurs most frequently in the course of pyaemia, endocarditis, and epidemic cerebro-spinal meningitis, which infections are due to the pyogenic and pneumonic micrococci. In rare cases it appears in the course of other infective diseases, such as typhoid fever, acute articular rheumatism, scarlet fever, or ulcerative pulmonary tuberculosis. Apparently also the morbid agency that produces acute spinal myelitis (spinal infantile paralysis) may also give rise to encephalitis. In rabies (hydrophobia) not only the cord but the base of the brain and the hemispheres are sometimes studded with foci of inflammation.

So far as we at present understand, encephalitis occurring in the course of specific infective diseases is due partly to metastasis of the primary infection, partly to metastasis of some secondary pyogenic infection. In many cases the encephalitis is accompanied by meningitis.

The minutest encephalitic foci are not recognisable by the unaided eye, but the microscope reveals them as patches of small-celled infiltration surrounding the blood-vessels. Larger spots have a pink appearance or are represented by clusters of small dark-red haemorrhagic foci. When suppuration ensues the foci take the form of yellowish-white patches, whose tissue soon liquefies and becomes purulent.

Minute foci of infiltration are probably capable of recovery without leaving any permanent lesion, but larger foci always cause destruction of the cerebral tissue. When these latter recover it is by contraction and induration of the inflamed region, so that either a patch of sclerosis (Art. 120) or a fibrous scar is formed.

Haematogenous suppurative encephalitis, leading to the formation of **cerebral abscesses**, occurs most frequently in the course of pyaemic infection due to septic wounds, carcinomatous ulcers, or ulcerative pulmonary disease, as well as in some cases of septic pyaemia whose origin is not apparent (cryptogenetic pyaemia). In pyaemic endocarditis infective emboli carried into the cerebral vessels at first set up ischaemic or haemorrhagic softening of the brain, and this is sometimes followed by suppuration.

Haematogenous abscesses arise most frequently in the cerebrum and cerebellum, more rarely at the base of the brain, and they are at times multiple. They usually contain creamy yellowish-white or pale greenish-coloured pus. The smallest vary in size from that of a millet-seed to that of a pea. Large abscesses may occupy the greater part of a lobe, but in general they are of the size of a walnut or a bantam's egg.

When recent the abscess-wall appears ragged; the surrounding tissue is oedematous and swollen, and is often dotted with small

specks of haemorrhagic and inflammatory infiltration. An abscess extending up to the pia mater gives rise to meningitis. Escape of the pus into the cerebral ventricles sets up intense inflammation there.

Only the smallest abscesses are capable of repair by resorption of the pus and the formation of a scar. Larger abscesses, provided the inflammation recedes and the patient does not die from excessive intracranial pressure or from meningitis, become separated off from the surrounding tissue by a membranous layer of granulations, and may thus persist for many years. Even by the fourth week an abscess may be marked off from the surrounding cerebral substance by a grey or greyish-red zone. In the course of months this zone becomes broader, say from two to five millimetres thick, and at the same time undergoes induration. It consists simply of granulation-tissue, which is afterwards changed into fibrous cicatricial tissue. In old abscesses the limiting membrane thus consists of an inner layer of granulation-tissue and an outer fibrous layer.

The abscess, once encapsuled, gradually increases in size by the accumulation within it of pus secreted by the membrane; it is probable, however, that this secretion ceases in course of time, and at all events in chronic abscesses it is very scanty. The surrounding tissue is compressed, and is liable to become atrophic or even to perish outright by degenerative necrosis. At any moment also inflammatory oedema or fresh inflammatory infiltration may be induced, and bring about conditions that impair the functions of the brain and frequently put an end to life. Even the risk of rupture into a ventricle or of extension of the inflammation to the pia mater is not done away by the encapsulation. Cerebellar abscesses are apt to give rise to chronic dropsy of the ventricles, by pressure on or thrombosis of the venae Galeni. A large abscess can be cured only by operative evacuation of its contents.

The commonest example of inflammation transmitted by continuity to the brain from the neighbouring structures is that arising in connexion with leptomenigitis (Art. 123). Patches of encephalitis are, moreover, sometimes met with after inflammation of the cranial bones and dura mater, and that without any implication of the pia mater. Thus a cerebral abscess may develop as a result of suppuration in the middle ear or in the petrous portion of the temporal bone.

References on Focal Encephalitis.

- BÜCKLERS: Acute haemorrhagic encephalitis *A. f. Psych.* XXIV 1892
 DÉJÉRINE: Infantile cerebral hemiplegia *A. de physiol.* III 1891
 FOREL: Cerebral changes in rabies *Z. f. Thiermed.* III 1877
 FRIEDMANN: Acute non-purulent encephalitis *A. f. Psych.* XXI 1889
 HOVÉN: Cerebral infantile paralysis *A. f. Psych.* XIX 1888
 DUKE KARL THEODOR (of Bavaria): Accumulations of leucocytes in the cerebral cortex *F. A.* 69 1877

- KÖRNER: *Die otitischen Erkrankungen des Gehirns u. d. Hirnhäute* Frankfurt 1894 (with references)
- MACEWEN: *Infective diseases of the brain and spinal cord* Glasgow 1893
- MEYER and BAYER: Parenchymatous inflammation of the central nervous system *A. f. Psych.* XII 1882
- NAUWERCK: Morbid anatomy of chorea *Ziegler's Beiträge* 1 1886
- OPPENHEIM and HOPPE: Chronic progressive hereditary chorea (disseminated encephalitis resulting in sclerosis) *A. f. Psych.* XXV 1893
- PIANESE: *La natura infettiva della corea del Sydenham* Naples 1893
- RUMPF: Atrophy of the convolutions with spinal infantile paralysis *A. f. Psych.* XVI 1885
- STRÜMPPELL: Cerebral infantile paralysis *Jahrb. f. Kinderheilk.* XXII 1885; Acute primary encephalitis *D. A. f. klin. Med.* XLVII 1890
- THOMSEN: Paralysis of the ocular muscles *A. f. Psych.* XIX 1887
- WERNICKE: *Lehrb. d. Gehirnkrankheiten* Cassel 1881
- WOLLENBERG: Choreia *A. f. Psych.* XXIII 1891

References on Abscess of the Brain.

- BETTELHEIM: Abscess following empyema *D. A. f. klin. Med.* XXXV 1885
- EISELSBERG: Abscess following sunstroke *ibidem* 1885
- KÖRNER: Otitic abscess of the brain *A. f. Ohrenheilk.* 39 1890; *Die otitischen Erkrankungen des Gehirns, d. Hirnhäute u. d. Blulleiter* Frankfurt 1894 (with references)
- LEBERT: *V. A.* 10 1856
- MARTIUS: *Militärärztl. Zeitschr.* Berlin 1891
- NAETHER: Metastatic abscess *D. A. f. klin. Med.* XXXIV 1884
- NAUWERCK: Chronic abscess of the brain *D. A. f. klin. Med.* XXIX 1882
- SCHOTT: *Würzburger med. Zeitschr.* II 1862
- WAGNER: *D. A. f. klin. Med.* XXVIII 1881

CHAPTER XLI

INFECTIVE GRANULOMATA OF THE BRAIN

119. **Tuberculosis** of the brain usually has its origin in the meninges (Art. 125); and even in those cases in which tuberculous foci are seated in the brain-substance itself, their development starts in the vessels and their adventitial sheaths that penetrate from the pia mater.

According to the method whereby the tubercle-bacilli are conveyed to the brain, the tuberculosis may be described as haematogenous or lymphogenous. The latter form is chiefly a result of tuberculosis of the meninges or of the skull, and in particular of the petrous portion of the temporal bone.

Tuberculous meningitis (Art. 125), which is usually associated with the eruption of large numbers of tubercles, leads to the development of a certain number of these in the brain also; they are in general most numerous in the cortical parts, but are present also in the deeper parts of the centrum ovale and in the basal ganglia. They take the form partly of small foci of softening that are often haemorrhagic, partly of grey or yellowish-white cheesy nodes that are sometimes surrounded by a haemorrhagic zone. If but one part, or a small number of parts, of the brain be infected with tubercle-bacilli, so that the affection is not rapidly fatal, larger tuberculous nodes, or so-called **solitary tubercles**, are apt to be formed. These are mostly rounded or irregular masses, varying from the size of a pea to that of a walnut or a goose-egg, and consisting of tolerably firm yellowish-white caseous matter, surrounded by a grey zone of granulation-tissue, sometimes beset with visible tubercles. Not uncommonly processes of softening and liquefaction take place within these nodes, and abscess-cavities filled with yellowish-white or greenish-yellow pus may thus be formed.

The focal affections of the brain due to **syphilis** have their origin in the pia mater (Art. 126), whence they usually extend to the brain-substance by direct continuity. It is, moreover, to be kept in mind that arterio-sclerosis due to syphilis may lead to cerebral softening, and that possibly many atrophic affections of the brain (Art. 113), as well as insular and systemic scleroses (Art. 98), are results of syphilitic infection.

The foci known as gummatous nodes take the form of grey or greyish-red translucent inflammatory granulomatous growths. They are usually irregular in shape, and either undergo caseation and disintegration, or lead to cicatricial induration of the brain-tissue.

Actinomycosis of the brain is, on the whole, a rare disease, and as a rule is induced by the extension of the specific process from the face, throat, and nape of the neck, through the foramen magnum into the cranial cavity. Diffuse purulent inflammation and granulomatous proliferation are thereupon set up in the pia mater, and small suppurating nodules are developed in the membrane and at times in the underlying cerebral substance also. BOLLINGER (*Cent. f. med. Wiss.* 27 1877) observed an actinomycotic granuloma of the size of a hazel-nut, seated in the third ventricle of a woman in whom no other actinomycotic growths were found.

CHAPTER XLII

SCLEROSIS OF THE BRAIN

120. Multiple or **disseminated sclerosis** of the brain is usually but a part of a like affection extending over the entire central nervous system, and has already been referred to in connexion with the morbid anatomy of the spinal cord (Art. 96). Diffuse sclerosis of the brain and sclerosis of the ependyma demand separate description.

Diffuse sclerosis of the brain is characterised by more or less extensive induration of the cerebral substance, whose colour is little if at all altered thereby. It may involve the entire brain or one lateral half of it, or may be limited to single convolutions, or to deeper parts such as the corpus callosum. It sometimes appears in multiple ill-defined patches, and is associated with marked increase in bulk, or in certain cases with atrophy, of the affected portion of the brain. So far as the published records go, the induration would appear to be due to hyperplasia of the neuroglia; but this does not in all cases take place in the same way. Some of the cases are probably referable to anomalies of development; and of this kind are the scleroses met with in children, which are associated with enlargement of a part or the whole of the brain, and might accordingly be described as instances of cerebral hypertrophy. When the overgrowth due to hyperplastic proliferation involves limited portions of the brain, these tend to assume the appearance of tumours, and indeed between such scleroses and gliomata or neurogliomata (Art. 121) no sharp line of distinction can be drawn.

Induration in atrophic brains is also probably to be regarded as in part due to developmental disorder: in other cases such induration either represents the final outcome of a disease leading to degenerative change, or is the result of some long-continued injurious influence.

In those forms of atrophy that are met with in slowly progressive general paralysis (Art. 113), the brain-substance not infrequently appears more or less hardened, and under the microscope the neuroglia is sometimes seen to be hyperplastic.

The affection known as **ependymal sclerosis** is characterised by a thickening of the ependyma, which is either diffuse or in the form of small scattered prominences like grains of sand, and is

due to proliferation of the sub-epithelial neuroglia of the ventricles. When the proliferation occurs in scattered patches, the inner surface of the ventricle has a granular appearance and is rough to the touch; in the diffuse form the ependyma is smooth and white or greyish-white. It is accordingly usual to distinguish one form as *granular* and the other as *smooth* ependymal sclerosis.

The cause of the ependymal proliferation is not fully understood; but we can say that in many cases it develops in connexion either with chronic degenerative processes or with chronic inflammations. Thus it is apt to accompany the chronic leptomeningitis of general paralytic dementia (Art. 123), and it also makes its appearance in chronic ventricular hydrocephalus.

References on Cerebral Sclerosis and Ependymal Sclerosis
(see also Art. 96).

- BUCHHOLZ: Gliosis of the cerebral cortex *A. f. Psych.* XIX **1888**
 CHASLIN: Cerebral sclerosis *A. de m'éd. exp.* III **1891**
 COTARD: Cerebral hemiatrophy *Thèse Paris* **1886**
 FRIEDMANN: Case of ependymal proliferation with subependymal sclerosis of the ventricles in general paralysis *A. f. Psych.* XVI **1885**
 FROMMANN: *Norm. u. pathol. Anat. des centralen Nervensystems* Jena **1876**
 FÜRSTNER and STÜHLINGER: Gliosis and excavation in the cerebral cortex *A. f. Psych.* XVII **1886**
 GREIFF: Diffuse and disseminated sclerosis of the central nervous system and disseminated hyaline degeneration of the cerebral cortex *A. f. Psych.* XIV **1883**
 HARTDEGEN: Multiple induration of the cerebrum with peculiar hard tumours (gangliocellular glioma) of the lateral ventricles in a new-born child *A. f. Psych.* VI **1881**
 KAST: Cerebral infantile paralysis *A. f. Psych.* XVIII **1887**
 MARIE and JENDRÁSSIK: Cerebral hemiatrophy from sclerosis of a lobe *A. de physiol.* V **1885**
 SCHMAUS: Diffuse cerebral sclerosis *J. A.* 114 **1889**
 SCHNÖPFHAGEN: Ependymal sclerosis *Jahrb. f. Psych.* **1881**
 STRÜMPPELL: Diffuse cerebral sclerosis *A. f. Psych.* IX **1879**
 VIRCHOW: Granular appearance of the walls of the cerebral ventricles *Gesamm. Abhandl.* Frankfurt **1856**

CHAPTER XLIII

TUMOURS AND ANIMAL PARASITES OF THE BRAIN

121. Among the **tumours** of the brain, there are two that are peculiar to the central nervous system, namely neuroglioma and glioma.

Ganglionic neuroglioma is probably always referable to some disturbance of the normal development of the brain. It takes the form either of an apparent enlargement of some portion of the brain not marked off by any definite boundary from the surrounding tissue, or of a more circumscribed nodose tumour.

The pia mater overlying the enlarged portion is not altered, and the configuration of the gyri is in general left intact. On transverse section the difference in tint, normally so striking, between the cortex and the medullary white matter is indistinct or entirely absent: the tissue looks uniformly white or greyish-white, or the prevailing white appearance is variegated with a sprinkling of indistinct light-grey flecks. It is of firmer consistence than the normal tissue, and sometimes is firm and tough in texture.

The matrix of the growth consists of neuroglia (Fig. 243 *B*), similar in character to that of the patches in disseminated sclerosis; it is sometimes dense and firm, sometimes loose in texture (*C*) and approaching the consistence of so-called gelatinous sclerosis. The tissue contains ganglion-cells, not only in the region of the original cortex, but also within the white matter of the gyri and the centrum ovale; these cells are loosely scattered (*b*) or aggregated in groups (*A a*). Some of them are small; others are large (*abc*) and not unlike the large ganglion-cells of the spinal cord. Medullated nerve-fibres (*d*) are visible only in some parts of the tumour (*B*), but they never approach in size or number the fibres that are normally contained in the white matter of the brain.

Gliomata (Figs. 244 and 245) are most frequently met with in the cerebrum, less often in the basal region; in the cerebrum, they are generally situated just underneath the pia mater. In the majority of cases the external configuration of the surface of the brain is unaltered, the presence of the tumour being indicated externally only by a certain fulness over the portion of brain involved (Fig. 244 *b*), and by some discoloration of its surface. It is rare for any well-defined swelling to be visible

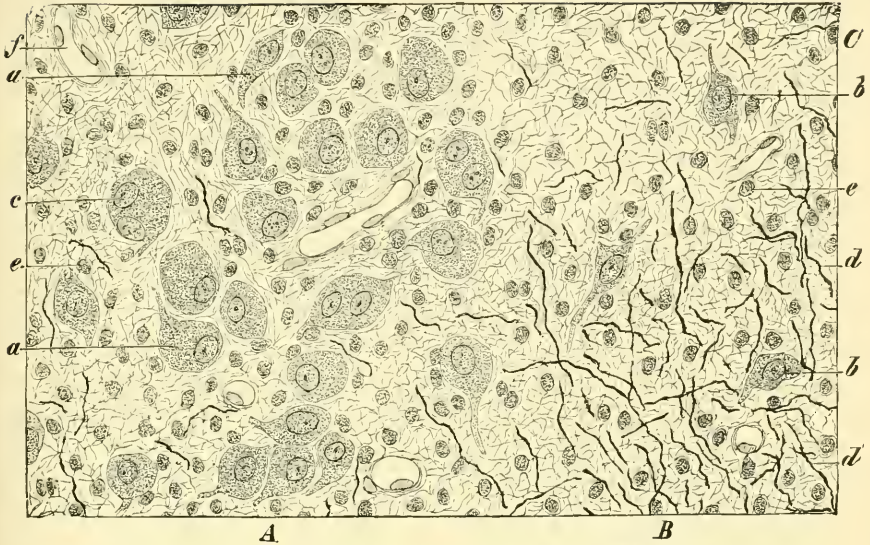


FIG. 243. SECTION FROM A NODOSE GANGLIONIC NEUROGLIOMA OF THE CENTRAL LOBE OF THE CEREBRUM.

(Preparation made by WEIGERT'S method, with haematoxylin and potassium ferrocyanide, and mounted in Canada balsam: $\times 300$)

- | | | | |
|---|------------------------------------|---|--------------------------|
| A | tissue abounding in ganglion-cells | c | binuclear ganglion-cells |
| B | tissue containing nerve-fibres | d | medullated nerve-fibres |
| C | gelatinous portion | e | neuroglia-cells |
| a | ganglion-cells in groups | f | blood-vessel |
| b | scattered ganglion-cells | | |

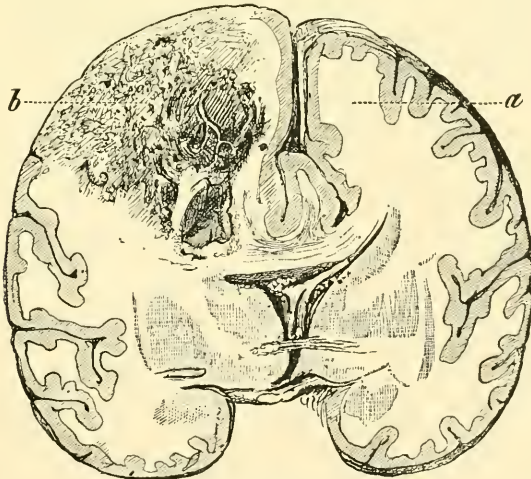


FIG. 244. TELANGIECTATIC GLIOMA.

(Frontal section through the brain: one-half the natural size)

- a right hemisphere b glioma in the left hemisphere

externally (Fig. 245 *ab*). On transverse section, the bulk of the tumour is occasionally seen to consist of tissue which in consistence and colour resembles pale, or in some cases hyperaemic, cortical substance. More commonly however the glioma is grey, greyish-white, or greyish-red, somewhat translucent or yellowish, or mottled in places by irregular patches of these different tints, and, it may be, flecked with opaque white spots and haemorrhagic foci (Fig. 244 *b*), its consistence being in some parts softer, in others firmer, than that of normal brain-matter. Its tissue often contains numerous vessels filled with blood, whose calibre greatly exceeds that of normal cerebral vessels. When the haemorrhages

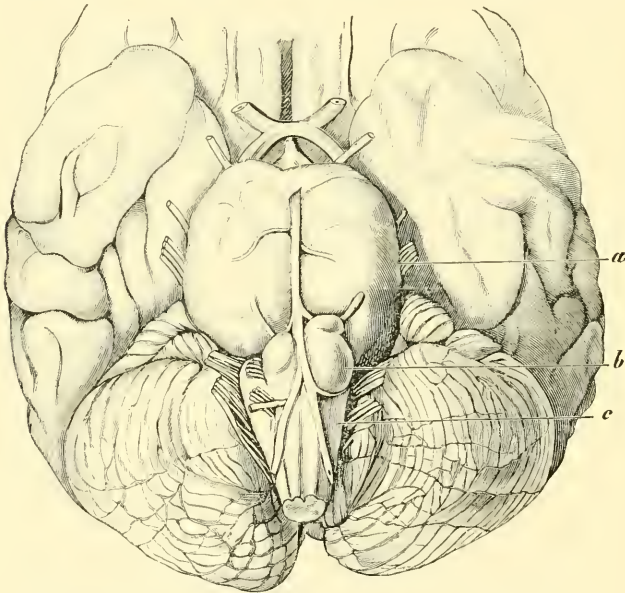


FIG. 245. GLIOMA OF THE PONS AND MEDULLA OBLONGATA.
(Basal aspect of the brain: three-quarters of the natural size)

- a* enlarged pons
- b* rounded prominences in the region of the pyramids and olivary bodies
- c* medulla oblongata

are very numerous, and occupy the greater part or the whole of the tumour, it may assume the appearance of an apoplectic patch. If a portion of the tissue has been destroyed by haemorrhage or softening, the tumour encloses cystic cavities with white or brown semi-liquid contents.

A glioma of the brain may attain a diameter of from three to eight centimetres or more. The adjoining cerebral substance either merges gradually into the mass of the tumour, or is visibly marked off from it and pushed aside by its growth. Not

uncommonly the surrounding tissue is softened, and sometimes even contains cysts of disintegration.

In the cerebral axis, gliomata are generally seated in the pons (Fig. 245 *a b*) or the medulla oblongata, and sometimes involve a considerable portion of these regions.

The tumours consist of stellate neuroglia-cells (Fig. 246), but the number and size of these cells vary greatly, some of them having numerous filamentous processes, while others have a few very long and branched ones. The cells are in general uniformly distributed, but are sometimes aggregated in small clusters. The cell-processes are sometimes loosely, sometimes closely, interwoven into a plexus of fibres. Wide interfibrillar meshes sometimes give a myxomatous appearance to the growth, and such tumours are generally described as gliomyxomata. In many cases, the majority of the vessels are dilated, and so abundant that the term telangiectatic glioma is applied to the tumour. The walls of the blood-vessels often exhibit hyaline thickening. Proliferation of the adventitia not infrequently takes place, and the vessels are thus surrounded by a thick sheath of cellular or fibro-cellular tissue.

The new growth extends by the proliferous multiplication of the neuroglia-cells. The nerve-fibres and ganglion-cells within the region of the proliferation ultimately perish, though they often persist for a remarkably long time. If the glioma presses against the pia mater, proliferation of its connective-tissue cells takes place, and this often results in the production of new fibrous tissue, followed later on by neoplastic proliferation and penetration of the glioma within the meshes of the new tissue.

The aetiology of glioma is not certainly known, but probably it is most apt to develop in places whose structure, owing to some embryonic peculiarity, deviates from the normal type. This view seems to be confirmed by an observation of STROEBE, that gliomata occasionally contain cysts lined with cylindrical epithelium.

Abundant cellular hyperplasia gives to some gliomata a sarcomatous appearance, and to these the term gliosarcoma is usually applied. It would be more correct, however, to describe such growths as medullary gliomata, inasmuch as the tumour-cells are derived from the cells of the neuroglia.

True **gliosarcoma** may, however, be produced when abundant

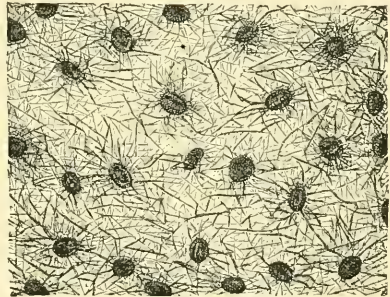


FIG. 246. SECTION FROM A CEREBRAL GLIOMA, WITH STELLATE CELLS.

(Preparation hardened in Müller's fluid, and stained by MALLORY'S method with haematoxylin: $\times 500$)

cellular proliferation takes place in the adventitial sheaths of the vessels of a glioma, and the resulting tissue forms an integral component of the tumour.

Sarcomata of the brain originate in its fibrous or connective-tissue components, such as the pia mater or the adventitial sheaths of the vessels penetrating therefrom. They are of the spindle-celled, round-celled, or polymorphous-celled varieties, and are generally of marrow-like consistence. They are more or less globular in shape, sharply defined from the surrounding tissue, of the most various sizes, and either solitary or multiple. Haemorrhage and softening often take place within them. By calcification they may in part be transformed into **psammomata**. When sub-pial they are apt to invade the meninges, and so give rise to numerous secondary metastases throughout the entire central nervous system. The surrounding brain-substance is often softened, the meninges are inflamed, and the ventricles dilated.

Small **angiomata** are not uncommon in the brain; they do not, as a rule, form actual tumours, but merely small reddish specks that look not unlike recent centres of inflammation. They are probably congenital (VIRCHOW), and are accordingly classed with the **vascular naevi**. Generally speaking, they are due to telangiectasis, or in rare cases to cavernous metamorphosis, within some definite vascular territory.

Fibroma of the central nervous system is rare; it takes the form of rounded nodose growths.

BIDDER has described an **osteoma** several centimetres in diameter which was seated in the corpus striatum. BENJAMIN, BERNHARD, TAUBNER, and others have recorded cases of **lipoma**. (On cholesteatomata and dermoid cysts see Art. 127.)

Sarcoma and carcinoma sometimes develop in the brain as **secondary tumours**, usually in the form of rounded nodes.

The **animal parasites** met with in the brain are *Cysticercus* and *Echinococcus* (Art. 127).

References on Tumours of the Brain (see also Art. 127).

- BARD: Tumours of nervous tissue *A. de physiol.* v 1885
 BENJAMIN: Cerebral lipoma *V. A.* 14 1858
 BERNHARD: *Hirngeschwülste* Berlin 1881
 DE BEAUCLAIR: Histological and statistical researches on tumours of the brain *Inaug. Diss.* Freiburg 1891
 BIDDER: Osteoma of the corpus striatum *V. A.* 88 1882
 BRAMWELL: *Intracranial tumours* Edinburgh 1888
 BUCHHOLZ: Cerebral glioma *A. f. Psych.* xxii 1891
 COATS: Sarcoma of pineal gland *Trans. Path. Soc.* xxxviii London 1887
 FÜRSTNER and STÜHLINGER: Hard glioma with cysts *A. f. Psych.* xvii 1886
 GERHARDT: Glioma *Festschr. zur III Säkularfeier d. Universität Würzburg* 1882
 GIESE: Tumours of the corpus callosum *A. f. Psych.* xxiii 1892
 GOLGI: Gliomata of the brain *Rivista sperim. di freniatria*
 HESCHL: Cerebral tumours *Wien. med. Jahrb.* 1872
 VON HIPPEL: Multiple sarcomata *Z. f. Nervenheilk.* ii 1892

- HOFFMANN, K.: Glioma *Z. f. rationale Med.* 34 **1869**
- JOLLY: Glioma of the pons and medulla oblongata *A. f. Psych.* XXVI **1894**
- LANCEREAUX: *Traité d'anatomie pathologique* III Paris **1889**
- LANGER: Cystic tumours of the infundibulum *Prag. Z. f. Heilk.* XIII **1892**
- LESAGE and LEGRAND: Neoplasms of the central nervous system *A. de physiol.* II **1888**
- MAIER, R.: Mixed tumour in the cerebrum *V. A.* 20 **1861**
- MEYER and BAYER: Relation of parenchymatous inflammations to glioma *A. f. Psych.* XII **1882**
- NEUMANN: Glioma *V. A.* 61 **1874**
- OSLER: Structure of certain gliomata *Philad. Med. News* 48 **1886**
- OTTO: Neuroglioma ganglionare *V. A.* 110 **1887**
- PETRINA: Glioma *Prager Vierteljahrsschr.* 133 and 134
- SIMON, TH.: Glioma *V. A.* 61 **1874**
- SOKOLOFF: Glioma *D. A. f. klin. Med.* XLI **1887**
- STROEBE: Origin of cerebral glioma *Cent. f. allg. Path.* v (p. 855)
- TAUBNER: Cerebral lipoma *V. A.* 110 **1887**
- TURNER: Sarcomatous growth in the fourth ventricle *Trans. Path. Soc. London* **1885**
- VIRCHOW: *Krankhafte Geschwülste*
- VOLKMANN: Glioma *D. A. f. klin. Med.* XLII **1888**

CHAPTER XLIV

THE PIA MATER AND ARACHNOID

122. The **pia mater** is a thin vascular membrane of connective tissue, which closely invests the entire surface of the brain, and furnishes an adventitial sheath to the vessels passing from it into the brain-substance.

The **arachnoid** is a delicate non-vascular membrane immediately underlying the dura mater, and so closely applied to it that only a capillary space intervenes (the subdural space). Between the arachnoid and the pia mater lie the subarachnoid spaces, traversed by delicate fibrous trabeculae and membranous septa (the subarachnoid tissue) that are overlaid with endothelium: the spaces contain the cerebro-spinal or subarachnoid liquid. The pia mater and arachnoid are together referred to as the **internal meninges** or leptomeninges.

Both membranes send vascular prolongations through the anterior and posterior transverse cerebral fissures into the ventricles, the *tela choroideae* or choroid plexuses. These establish communication between the subarachnoid spaces and the cavities of the third and fourth ventricles.

The conditions that give rise to **hyperaemia** and **anaemia** of the internal meninges, and the morbid appearances thereby produced, have already been dealt with (Art. 112).

Oedema of the pia mater and of the subarachnoid spaces is due to venous engorgement, or to inflammatory congestion and alteration of the vessel walls. It is manifested by accumulation of liquid within the subarachnoid spaces, which tends to widen the sulci, and the condition is known as **meningeal dropsy**.

In cases of atrophy of the brain meningeal dropsy *ex vacuo* is induced over the shrunken region, and the like takes place when from any cause the brain-substance undergoes local contraction or collapse. Subarachnoid and pial spaces that are shut off from the surrounding tissue are sometimes distended with liquid, and give rise to subarachnoid and pial **cysts**. These are liable to exert a certain pressure on the adjoining brain-substance, but the condition is on the whole infrequent. The choroid plexuses of the ventricles, on the other hand, are apt to undergo **cystic degeneration**, and then enclose a varying number of cysts from the size of a pea to that of a bean, or seldom larger. The cyst-wall consists

of vascular connective tissue, covered externally with polygonal epithelium and internally with an endothelial lining membrane. The interior of the cyst is sometimes traversed by fibrous trabeculae and vessels.

Haemorrhages into the pia mater are due, as a rule, to extreme venous engorgement, and give rise to the appearance of circumscribed haemorrhagic spots on the membrane, or to more or less extensive collections of blood in the subarachnoid spaces. Further causes of haemorrhage are traumatic injury and changes in the blood due to infection or poisoning. The rupture of atheromatous arteries within the pia mater naturally leads to haemorrhage into the subarachnoid spaces, and, when the arachnoid gives way, into the subdural space also. In cases of cerebral haemorrhage extending into the ventricles, blood may pass by way of the transverse fissures into the subarachnoid spaces. In cortical apoplexy the blood generally spreads beneath the pia mater.

The blood thus effused into the pia mater, the subarachnoid, and the subdural space, is altered and absorbed in the same way as in other organs. During the process of resorption the tissue involved is liable to proliferate and so lead to the formation of new connective tissue.

In infants who die shortly after birth subdural and intrameningeal haemorrhages are often observed. They are due to rupture of the sinuses or of the subarachnoid veins by displacement of the cranial bones during parturition.

References on Cysts of the Meninges, of the Choroid Plexuses, and of the Adventitial Lymph-Sheaths.

ARNDT: *État criblé* *V. A.* 72 1878

BIZZOZERO: *Rivista clin. di Bologna* 1868

GOLGI: *Rivista clin. di Bologna* 1876

HAECKEL: *Path. anat. of the choroid plexus* *V. A.* 16 1859

LUSCHKA: *Die Adergeflechte des menschlichen Gehirns* Berlin 1855

RIPPING: Cystic degeneration of the cerebral cortex *Z. f. Psych.* 30 1874 and 32 1875

SCHLESINGER: Lymphangiectasis of the cerebral cortex *A. f. Psych.* x 1880

SCHNOPFHAGEN: *Wiener Sitzungsber.* LXXIV 1876

123. Acute inflammation of the internal meninges, or **acute leptomeningitis**, is haematogenous, traumatic, or consecutive to disease of the brain, of the dura mater, of the skull-bones, of the orbit, or of the nasal cavity and its accessory spaces. In many cases specific bacteria are proved to be the cause of the inflammation, especially when it takes a purulent, sero-purulent, or fibrino-purulent form. These forms are in general due to pyogenic micrococci, and in some cases to the *Diplococcus pneumoniae*. A special micrococcus has been described by WEICHELBAUM and GOLDSCHMIDT, which they have called *Diplococcus intracellularis*. In one case NEUMANN and SCHEFFER discovered a bacillus which

resembled the typhoid bacillus. NETTER found in a case of meningitis following otitis media a bacillus resembling the pneumonia-bacillus of FRIEDLÄNDER.

In the disease known as epidemic **cerebro-spinal meningitis**, according to FOÀ, BORDONI-UFFREDUZZI, FRÄNKEL, WEICHELBAUM, and others, the *Diplococcus pneumoniae* appears to be the exciting cause in the majority of cases; but other micro-organisms have been observed (BONOME) in certain instances.

Meningitis sometimes arises in the course of endocarditis, croupous pneumonia, acute articular rheumatism, pleurisy, scarlet fever, typhoid fever, ulcerative phthisis, decubital ulcerations or bed-sores, and so on. It may be regarded in some cases as a local manifestation of the primary infection, in others as the result of a secondary infection.

In the form described as **acute serous leptomeningitis** the subarachnoid spaces and the pia mater are the seat of an inflammatory oedema accompanied by the signs of congestive hyperaemia: at the time of death, however, the subarachnoid liquid is often but little increased in quantity, and the hyperaemia has given place to a moderate distension of the vessels. The signs of inflammation may thus be demonstrable only by the aid of the microscope, which shows the pia mater to be sparingly infiltrated with leucocytes. A considerable accumulation of liquid is generally found in the ventricles, constituting an acute ventricular dropsy.

Acute serous leptomeningitis is most frequently observed in children, arising at the outset or during the course of infective diseases, such as measles, scarlet fever, etc. The aetiology of the affection is, however, often undiscoverable.

Purulent, fibrino-purulent, and sero-purulent **inflammations** are characterised by the effusion of a corresponding exudation into the subarachnoid spaces and the pia mater. The exudation is turbid and puriform, or actually purulent, or yellowish-white and pulpy, and collects chiefly in the sulci and about the vessels, though it often spreads in a thin layer over the whole surface of the convolutions. Occasionally haemorrhages are visible here and there, especially in suppuration following traumatic injury of the meninges; but they are not infrequent in haematogenous and consecutive or conducted inflammations. Sometimes the arachnoid tissue is so thickly infiltrated with pus that the convolutions can scarcely be made out through the overlying stratum.

The exudation is generally confined to the pia mater and the subarachnoid spaces; but it may extend into the cortex along the pial sheaths of the vessels. If the meningeal suppuration follows an injury to the meninges and the brain, the latter may also become the seat of suppuration; pus sometimes accumulates in the subdural space in such cases. Suppuration originating in the scalp, in the bones of the skull, or in the dura mater, is likewise apt to lead to subdural accumulations of pus.

The seat of the purulent inflammation is naturally dependent on the locality of the exciting cause. Haematogenous inflammations arise both at the base and on the convexity of the brain. In the disease known as cerebro-spinal meningitis the spinal membranes also are involved, often indeed to a greater extent than the cerebral meninges. Inflammation originating in the petrosal bone extends in the first instance to the adjacent portions of the brain. Traumatic forms, for obvious reasons, most frequently involve the convexity; but they sometimes start at the base, as for example after injury to the roof of the orbital cavity.

Within the region of suppuration not only the meshes of the tissue but the vascular walls are infiltrated with cells. If the process be long continued, degenerative changes make their appearance in the contiguous portions of the brain, being indicated by swelling and disintegration of the ganglion-cells and nerve-fibres.

When the inflammation extends through the transverse fissure and involves the choroid plexus, purulent or fibrino-purulent exudations appear in the ventricle, increasing the volume of its liquid contents and rendering these turbid, while the plexus becomes swollen and covered over with pus or fibrino-purulent deposits. The ependyma and the underlying cerebral substance become moister and sometimes undergo inflammatory softening. By the dilatation of the cerebral ventricles the brain is compressed, the gyri are flattened, and cerebro-spinal liquid is forced out from the subarachnoid spaces. The meningeal tissue in consequence is deprived of its normal moisture, and the arachnoid and the internal surface of the dura mater have accordingly a strikingly dry appearance.

Purulent inflammation of the meninges usually terminates in death; the less severe forms, however, are sometimes recovered from, the exudation being re-absorbed. They leave behind them white fibrous thickenings of the pia mater and arachnoid, and at times also adhesions to the dura mater, due to proliferous overgrowth of connective tissue during the process of recovery and re-absorption. Occasionally too the ventricles are permanently dilated.

References on the Aetiology and Morbid Anatomy of Acute Meningitis (see also Art. 103).

- ADÉNOT: *Des méningites microbiennes* Paris 1890
 BONOME: Aetiology of epidemic cerebro-spinal meningitis *Ziegler's Beiträge* 1890
 VON CAMPE: Morbid anatomy of the meningitic processes *Ziegler's Beiträge* II 1886 (p. 458)
 CENTANNI: A new micro-organism in meningitis *A. per le scienze med.* 1893
 VON HERWERDEN: Micro-organisms in epidemic meningitis *Inaug. Diss.* Utrecht 1893 (with references)
 HILDEBRAND: *Aetiologie d. Meningitis traumatica suppurativa* Jena 1886

- KÖRNER: *Die otitischen Erkrankungen des Gehirns u. d. Hirnhäute* Frankfurt 1894 (with references)
- NETTER: Suppurative meningitis *France méd.* 1889, abstracted in *Cent. f. Bakteriologie* VI 1889
- PITT: Meningitis from internal otitis *B. M. J.* I 1890 [(with references)]
- QUINCKE: Serous meningitis *Bergmann's Samml. klin. Vorträge* 67 Leipzig 1893
- STRÜMPPELL: *D. A. f. klin. Med.* xxx
- WUNDERLICH: *A. d. Heilk.* v and vii
- ZENKER: *D. A. f. klin. Med.* I 1865

124. The existence of **chronic leptomeningitis** is often inferred from the presence of white thickenings, diffuse or disseminated in spots or streaks, in the arachnoid and pia mater; but as a rule these appearances cannot be regarded as due to true chronic inflammation. In many cases such thickenings consist essentially of hyperplastic connective tissue, and are simply the result of past inflammatory processes. In other cases they are produced not so much by inflammation as by continued and often-repeated disturbances of circulation and nutrition, and in particular by venous engorgement. They are met with also in connexion with chronic renal disease and chronic alcoholism, and in this case also are chiefly due to fibrous hyperplasia, or occasionally to endothelial proliferation.

Chronic inflammation, indicated by persistent cellular infiltration of the meninges, for the most part takes place in the neighbourhood of bones affected with chronic suppuration, tuberculosis, and syphilis, and around tumours and foci of degeneration within the brain, etc.; and as might be expected from its mode of origin it is usually of limited extent. It attains its greatest degree of independent development in the form of cerebral disease that is associated with paralytic dementia, and has already been described in Art. 113.

When the morbid process has made considerable progress, the internal membranes, and especially the pia mater, are rendered strikingly turbid, white, and opaque, especially in the sulci along the vessels, and often on the surface of the gyri also. Most frequently the seat of the disease is in the anterior portions of the cerebrum, in other words the frontal, central, and parietal lobes, the other lobes being much less affected, and some parts escaping altogether. Cases however occur in which other portions, such as the temporal lobes, are those most markedly altered.

The most striking textural change is the cellular infiltration, principally of the pia mater (Fig. 247 *h*), and to a less degree of the subarachnoid tissue (*b*). This is in general accompanied by more or less extensive fibrous hyperplasia of these structures. In the later stages accumulations of round-cells (i_1), of red blood-corpuscles, and of brown or yellow pigment (i_2), are apparent in the adventitial sheaths of the cortical blood-vessels, and sometimes even of those supplying the white matter.

The cellular exudations are never uniformly distributed, but vary much even within the tissue of the pia mater. In the cortex comparatively few vessels are surrounded by aggregations of cells, and in the white matter the foci of infiltration are usually few and scattered. Some of the vessels, moreover, exhibit hyaline thickening or fibrous hyperplasia of their adventitial coats. The nerve-substance shows the changes described in Art. 113.

The **aetiology** and mode of origin of chronic meningo-encephalitis is as yet imperfectly understood. As hereditary predispo-

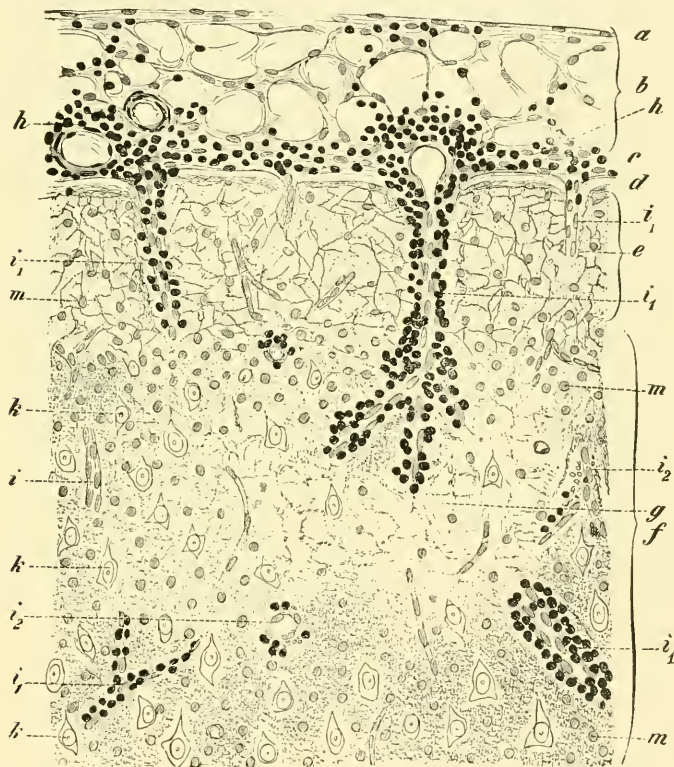


FIG. 247. CHRONIC MENINGO-ENCEPHALITIS WITH ATROPHY OF THE CEREBRAL CORTEX.

(Preparation hardened in Müller's fluid and alcohol, stained with haematoxylin, and mounted in Canada balsam: $\times 150$)

- | | | | | |
|---|-------------------------------------------------------------------------------------------------------------------------------------------------------------------------------|----------------|------------------------------------------------------------------|-------------------------------------|
| a | arachnoid | b | subarachnoid tissue | tissue is reduced to a delicate re- |
| c | pia mater | | | ticulum |
| d | external layer of slender fibres | h | cellular infiltration of the pia mater | |
| e | layer with few cells in the external part of the principal stratum: the ganglion-cells have disappeared and numerous stellate figures composed of lustrous fibres are visible | i | unaltered blood-vessel | |
| f | layer abounding in cells: the ganglion-cells have disappeared at g and the | i ₁ | blood-vessels whose pial sheaths contain round-cells | |
| | | i ₂ | blood-vessels whose pial sheaths contain round-cells and pigment | |
| | | k | ganglion-cells of the cellular layer | |
| | | m | neuroglia-cells | |

sition on the one hand, and on the other severe mental exertion and exciting or exhausting influences of every kind, may demonstrably act as antecedent conditions of the affection, infective agencies would seem in many cases to be inoperative in its causation. Infection can thus be assumed as a cause only when the process is immediately consequent on undoubtedly infective dis-

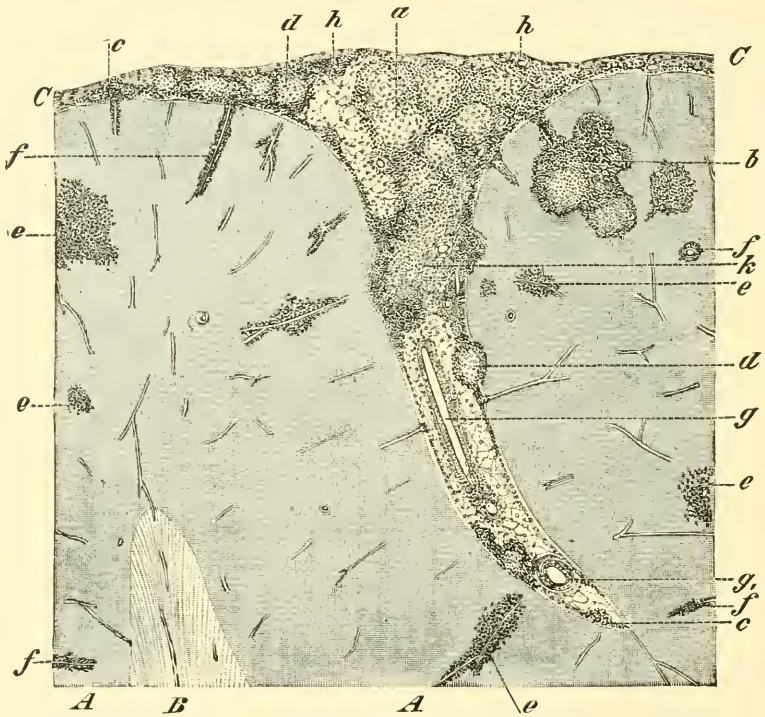


FIG. 248. CHRONIC DISSEMINATED TUBERCULOUS MENINGO-ENCEPHALITIS.

(Preparation hardened in Müller's fluid and alcohol, stained with alum-carminé, and mounted in Canada balsam: $\times 10$)

- | | |
|---------------------------------------------------------------------------------------------------------------------------------------------------------------------------------------------------------------------------------------------------------------------------------------------------------------------------------------------------------------------------------|----------------------------------------------------------------------------------------------------------------------------------------------------------------------------------------------------------------------------------------------------------------------------------------------------------------------------------------------------------------|
| <p>A cortical grey matter
 B white matter
 C meninges
 a conglomerate mass of firm fibro-cellular tubercles in the arachnoid tissue
 b conglomerate mass of tubercles in the cerebral cortex
 c small tubercle in the pia mater
 d mature solitary tubercle in the sub-arachnoid tissue</p> | <p>e circumscribed cellular infiltration round the vessels of the cortical substance (early stage of a tubercle)
 f cellular infiltration of pial sheaths of cortical vessels
 g g₁ longitudinal and transverse section of an artery
 h diffuse fibro-cellular thickening of the sub-arachnoid tissue</p> |
|---------------------------------------------------------------------------------------------------------------------------------------------------------------------------------------------------------------------------------------------------------------------------------------------------------------------------------------------------------------------------------|----------------------------------------------------------------------------------------------------------------------------------------------------------------------------------------------------------------------------------------------------------------------------------------------------------------------------------------------------------------|

eases, such as cerebro-spinal meningitis, typhoid fever, erysipelas, articular rheumatism, or syphilis. Even in these cases the secondary affection is just as likely to be due to disorders of nutrition consequent on or induced by the previous disease.

Most cases of chronic meningo-encephalitis would thus appear to be in their inception mainly dependent on degenerative changes set up by excessive functional activity or due to disorders of circulation and nutrition (Art. 113).

Chronic leptomeningitis is occasionally combined with internal proliferous pachymeningitis (Art. 128).

125. **Tuberculosis** of the internal meninges is, in most cases, of metastatic origin, though the disease may also extend by continuity from neighbouring tissues, such as the cranial bones and the dura mater, and thus involve the arachnoid and the pia mater.

When tubercle-bacilli in large numbers enter with the arterial blood the vessels of the pia mater, **disseminated miliary tuberculosis** is induced, and is manifested by the eruption of grey tubercles (Fig. 248 *c d e*). Most of these are seated in the meninges (*C*), but a few appear also in the cortex and white matter (*A B*). The tubercles lie chiefly in the vessel-walls, and consist essentially of cellular thickenings of the walls themselves (Fig. 209 *f*). In the brain itself the accumulations of cells may at first be limited to the pial sheaths (*f*); later on they extend to the cerebral parenchyma.

Disseminated metastatic tuberculosis of the central nervous system usually pursues a rapid course, and terminates fatally in a few weeks. Along with the eruption of tubercles diffuse inflammatory exudations make their appearance (Fig. 209 *g*); these are sometimes sero-purulent or fibrino-purulent, and infiltrate not only the meninges, but the nerve-substance itself, or collect in the cerebral ventricles. The process might thus be fitly described as **tuberculous meningo-encephalitis**. The inflammation is apt to extend from the pia mater to the external strata of the brain-substance and lead to swelling and disintegration of the nerve-fibres and ganglion-cells. Cellular infiltration of the cerebral nerves as they leave the base, with swelling and degeneration of their axis-cylinders and medullary sheaths, is not uncommon. It is only in rare and chronic cases that there is no or but little diffuse exudation, if the eruption of tubercles is at all abundant.

When the disease invades the choroid plexuses within the ventricles, tubercles and turbid exudations make their appearance, and the ventricles are distended, sometimes to a remarkable extent, with a more or less purulent effusion. The brain may thereby be so compressed that the convolutions are flattened and the sub-arachnoid liquid is displaced, so that the surface of the arachnoid appears abnormally dry.

As a rule the tubercles in the pia mater rapidly undergo caseation, and only in rare and chronic cases (Fig. 248) are tubercles developed that resemble the familiar large-celled nodules of the lymph-glands.

Metastatic tuberculosis is most frequently met with in the basal region supplied by the arteries entering the sylvian fissure, and

is usually bilateral : in some instances, however, the eruption is more marked on one side than on the other, and cases are not rare in which one side only is involved.

If the bacilli enter the region supplied by those arteries which pass from the sylvian fissure to the surface of the brain, more or less extensive unilateral or bilateral tuberculous meningitis of the convex aspect is induced. The arteries of the median plane of the cerebrum, occipital lobe, cerebellum, medulla oblongata, and spinal cord may be involved alone, or in combination with the arteries of the sylvian fissure ; their participation in the tuberculous process is indeed by no means uncommon.

When the tubercle-bacilli enter the region supplied by only a single branch of one of the meningeal vessels, but few tubercles

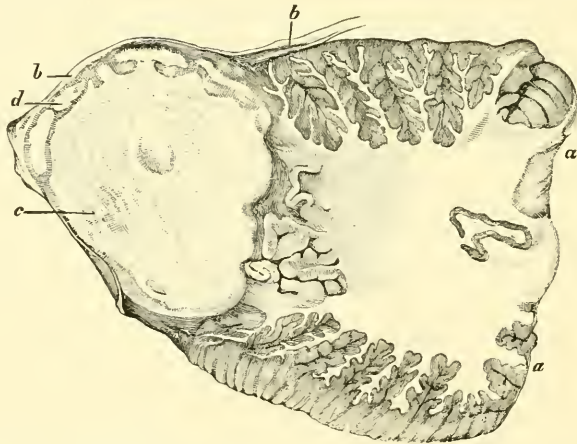


FIG. 249. LARGE SOLITARY TUBERCLE OF THE CEREBELLAR PIA MATER.

(Vertical section: natural size)

- | | |
|----------------------------------------------------------------------------------------|---------------------------------------------------------------------|
| <p>a cerebellum
b dura mater adherent to the tubercle
c laminated tubercle</p> | <p>d grey cortical zone with yellowish-white nodular enclosures</p> |
|----------------------------------------------------------------------------------------|---------------------------------------------------------------------|

are formed in the first instance. But as the patient does not in general die at once, the tubercles become aggregated into larger masses, and form either extensive foci occupying the sulci especially, or rounded nodes of the size of a walnut or even of a hen's egg or larger, commonly known as **solitary tubercles** (Fig. 249 *c*). The centre is usually yellowish-white, cheesy, sometimes firm and dense, in other cases softer and often more or less diffluent ; only in rare instances is it partially calcified. The nodes are marked off from the surrounding tissue by a greyish-red or grey and translucent zone of granulations (*d*), which not infrequently contains typical tubercles. From the brain-substance they are either clearly defined or pass gradually into it, and sometimes they are adherent to the dura mater. At the periphery of the solitary

tubercle the connective elements of the nerve-tissue often pass into a state of active proliferation, and produce dense fibro-cellular tissue.

Solitary tubercles of the pia mater affect the surrounding tissue by pressure (Fig. 249 *a*) and by impeding the circulation of blood and lymph. The other portions of the central nervous system may be entirely free from tubercles; but it not uncommonly happens that bacilli escape from the solitary tubercles and lead to the formation of disseminated meningitic nodes, as well as to diffuse meningitis. It is moreover not impossible for renewed infection of the blood to take place, for example, by rupture into the transverse sinus, and in this way metastatic miliary tuberculosis may be superinduced.

Tuberculosis which develops in the central nervous organs owing to conveyance of the virus from the adjacent structures naturally depends, as to its situation and distribution, on the position of the starting-point. Tuberculosis of the petrosal bone extends, as a rule, to the temporal lobe and the base of the frontal lobe. Once these parts are infected, the characteristic nodules form in varying numbers about the seat of infection, and these may in the course of time become aggregated into larger masses. Disseminated tuberculosis is superinduced by the diffusion of the bacilli through the cerebro-spinal lymphatics.

References on Tuberculosis of the Internal Meninges.

- VON CAMPE: *Meningit. u. meningoencephalit. Processe* Tübingen 1882
 HOCHÉ: Tuberculosis of the central nervous system *A. f. Psych.* XIX 1887
 HÜTTENBRENNER: Changes in the cerebral cortex in tuberculous inflammation of the pia mater *Prag. Z. f. Heilk.* VIII 1887
 RAYMOND: Various forms of tuberculous leptomeningitis *Rev. de méd.* VI 1886
 RINDFLEISCH: Miliary tubercle *V. A.* 24 1862
 SCHULTZE: Tuberculous cerebro-spinal leptomeningitis *V. A.* 68 1876
 VIRCHOW: *Krankhafte Geschwülste* II 1869

126. **Syphilis** of the central nervous system usually makes its appearance some years after the disease has become constitutional, that is to say, at the same time as the so-called tertiary symptoms; it rarely supervenes in the stage of secondary symptoms. The characteristic morbid change is the formation of circumscribed inflammatory nodes or **gummata**, which are usually situated in the meninges and the cortical stratum of the brain or of the cord, rarely in the interior.

Their formation begins with circumscribed inflammation in the pia mater and subarachnoid tissue, which is soon followed by the development of a greyish or greyish-red semi-translucent or gelatinous patch of granulation-tissue (Fig. 250). In the earlier stages this tissue is highly cellular (*d*), and contains a varying number of new-formed blood-vessels. As the process advances

some of the granulation-tissue usually becomes fibro-cellular (d_1), and some undergoes caseation (d_2).

In cases of severe inflammation of the pia mater the contiguous brain-substance never escapes, the morbid process extending to the cortex not only along the pial sheaths (f_1) of the vessels, but also directly (g).

Arterial branches (e) within the inflamed region are likewise involved, the adventitia, and the media and the intima also, becoming the seat of an inflammation characterised according to the

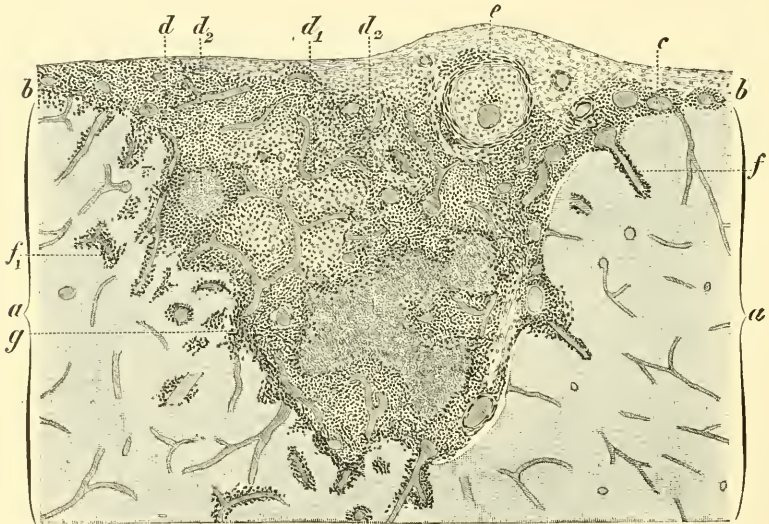

FIG. 250. GUMMATOUS SYPHILITIC MENINGO-ENCEPHALITIS.

(Preparation hardened in Müller's fluid and alcohol, stained with alum-carmin, and mounted in Canada balsam: $\times 15$)

- | | |
|------------------------------------------------------------------------------|-------------------------------------------------------------------------------|
| a cerebral cortex | f cellular infiltration of the pial sheaths of the cortical vessels |
| b internal meninges | f ₁ circumvascular cellular infiltration of the cortical substance |
| c vein surrounded by cellular infiltration | g diffuse cellular infiltration of the cerebral cortex |
| d recent cellular granulation-tissue | |
| d ₁ fibro-cellular granulation-tissue | |
| d ₂ caseous granulation-tissue | |
| e artery with greatly thickened intima and adventitia infiltrated with cells | |

stage of the process either by cellular infiltration and proliferation, or by fibro-cellular hyperplasia. The intima is in general the most affected (e), the hyperplastic thickening which it undergoes being often so considerable that the lumen of the vessel is greatly diminished, and sometimes even obliterated. Obliteration results as a rule when thrombosis is superadded to the endarteritic thickening.

The gummatous nodes may be either single or multiple, the single nodes being sometimes very small. Indeed, the specific in-

flammation and proliferation may be practically limited to certain spots on the vessel-wall, and these give rise to the thickening just referred to. More frequently, however, larger nodes are formed, and to these the term gummata is usually restricted. They extend over the surface of the brain, chiefly along the sulci, and their form is moulded accordingly. In the sylvian fissure they are elongated; at the base and in the cord they form flattened patches of various shapes. In rare cases the inflammatory infiltration of the membranes at the base of the brain is more diffuse and indefinite.

If the inflammation extends deeply into the cerebral substance, the node gradually assumes a rounded form, and occasionally grows to the size of a walnut; its external boundary, however, usually remains irregular. This is also apt to be the case with nodes developing *ab initio* in the interior of the brain. The very smallest foci are doubtless capable of re-absorption, but the larger nodes generally become indurated and in part caseous. When caseation takes place at several points within a node, its section appears mottled with grey and yellow, until by coalescence of the caseous spots the whole of the central portion becomes uniformly yellow.

The induration generally accompanies the caseation, but in some cases it takes place without the latter. It gives rise to cicatricial thickening of the meningeal tissue, often also to adhesions with the adjoining parts of the dura mater. When the gummatus node has already undergone partial caseation, the cicatrices enclose cheesy masses.

The tissue of the brain and cord naturally perishes within the region of the specific inflammation. Ischaemic and haemorrhagic softening of the surrounding tissue is often superadded; it is consequent on the local disturbance of circulation caused by arteritis and mechanical compression. In some cases these degenerative processes are very wide-spread and intense. Nerves included within the focus of inflammation become infiltrated, and at a later stage are so surrounded and permeated by dense hyperplastic connective tissue that they atrophy and disappear.

References on Syphilis of the Internal Meninges.

- BAUMGARTEN: Syphilitic arteritis *V. A.* 73 1878, 76 1879, 86 1881, and 111 1888
- BIERFREUND: Hereditary syphilis of the central nervous system *Ziegler's Beiträge* III
- BRAUS: *Die Hirnsyphilis* Berlin 1873
- BUTTERSACK: Syphilis of the central nervous system *A. f. Psych.* XVII 1886 (with references)
- FOURNIER: *La syph. du cerveau* Paris 1879, and *Leçons sur la syph.* 2nd edition Paris 1881
- HEUBNER: *A. d. Heilk.* XI 1870; *Die luetische Erkrankung der Hirnarterien* Leipzig 1874

- ILBERG: Gummata of the corpora quadrigemina *A. f. Psych.* XXVI 1894 (with references)
- JOFFROY and LÉTIENNE: Cerebral syphilis *A. de méd. exp.* III 1891
- KAHLER: Multiple syphilitic neuritis of the nerve-roots *Z. f. Heilk.* VIII 1887
- OPPENHEIM: *Zur Kenntn. d. syph. Erkrank. des Centralnervensystems* Berlin 1890
- PICK: Cerebrospinal syphilis *Prag. Z. f. Heilk.* XIII 1892
- RUMPF: *Die syphilitischen Erkrankungen des Nervensystems* Wiesbaden 1887
- SIEMERLING: Congenital cerebral and spinal syphilis *A. f. Psych.* XX 1888; Syphilis of the central nervous system *ibidem* XXII 1890
- STOEBER: *Des accidents méningitiques de la syph. héréditaire* Paris 1891
- VIRCHOW: *V. A.* 15 1859, and *Die krankhaften Geschwülste* II 1869
- WESTPHAL: *Allg. Z. f. Psych.* XX 1863, and *Charité-Annalen* I 1876

127. The **tumours** of the internal meninges of the brain, of the choroid plexuses, and of the ependymal lining of the ventricles, belong for the most part to the group of connective-tissue growths; but epithelial tumours (carcinomata) are also met with.

In the first place, there is a group of endothelial tumours classed with the **sarcomata** and taking the form of soft nodes, or less frequently of expanded superficial growths. Cases occur in which the endothelial neoplastic growth extends over the entire central nervous system (Fig. 251), leading to thickening and whitish turbidity of the meninges, and at the same time invading the substance of the brain and cord along the course of the pial sheaths of the vessels.

The cut surface of the endothelial sarcoma is marrowy, greyish-white or greyish-red, sometimes rather gelatinous, very seldom pigmented or melanotic. The growth starts in the adventitia of the vessels (Fig. 251 *f g h*), and partly also in the endothelium (*d e*) which covers the fibrous strands of the arachnoid, of the subarachnoid tissue, and of the pia mater. The newly-formed cells usually attain a high degree of development, and resemble in appearance the polymorphous epithelioid cells of carcinomatous growths. As moreover they lie embedded in a stroma formed from the meningeal tissue, and are grouped in dense masses within its meshes, they are classed with the alveolar sarcomata or **alveolar endotheliomata** (Fig. 251).

The existing records seem to show that this form of sarcoma is that most frequently met with in the internal meninges; but cases of ordinary sarcoma, myxosarcoma, and myxoma have been observed, and angiosarcoma, angiomyxoma, and angiomyxosarcoma are not unknown (Art. 104).

Fibromata, lipomata, chondromata, and osteomata are very rare; they have been noted in the meninges and in the ventricular plexuses, and form small nodular and lobular tumours, which compress and thrust aside the underlying cerebral and spinal substance.

Another rare tumour of the internal meninges is composed essentially of a dense fibrous stroma, enclosing large cystic cavi-

ties filled with lymph. It has a certain resemblance to connective tissue in a state of intense oedema, but is distinguished from this by the presence of abundant fibrous hyperplasia, which marks it off sharply from the surrounding tissue and forms in its interior comparatively stout and broad intercystic septa. The growth is therefore a neoplasm, and might be described as cystic lymphangioma or **cystic fibroma**.

An excessive development of the normal 'brain-sand' is very often observed in the ventricular or choroid plexuses, which thereby become perceptibly enlarged and acquire an opaque whitish appearance. Calcareous concretions are apt to be formed in meningeal tumours in combination with calcification of the vessels. When such calcareous deposits form a prominent component of the tumour, it is called a **psammoma** (Fig. 255).

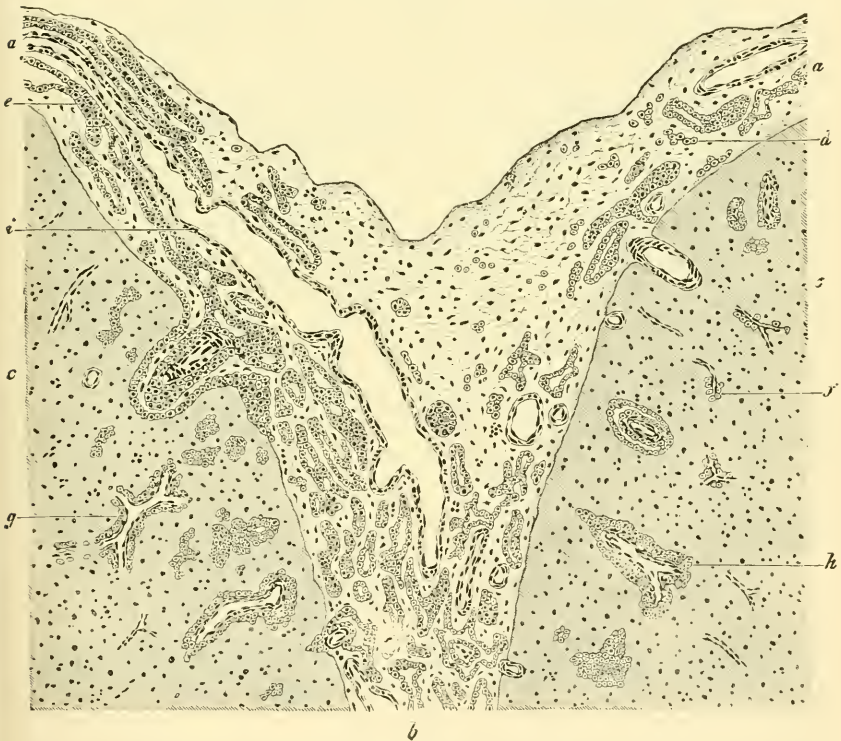

FIG. 251. ALVEOLAR ENDOTHELIOMA OF THE PIA MATER.

(Diffuse neoplasm extending over the entire surface of the central nervous system: preparation hardened in Müller's fluid, stained with haematoxylin and carmine, and mounted in Canada balsam: $\times 30$)

a b internal meninges

c cerebral cortex

d small groups of proliferous endothelial cells

e gland-like tubules composed of endothelial cells

f g h intracerebral circumvascular cellular growths

The concretions take the form either of stratified spherules or of needles and jagged or cactus-like bodies.

Carcinoma makes its appearance in the ventricles in the form of soft tumours (Fig. 252 *a*), usually connected with the plexuses, and originating from their epithelial lining, or more rarely from the ependymal epithelium. The nests of cancer-cells embedded in a fibrous stroma are of the cylindrical type. The vascular fibrous stroma sometimes grows out into papillae, and the tumour then assumes a papillomatous character (Fig. 253).

If, as not infrequently happens, the stroma undergoes mucoid degeneration (Fig. 253 *b e c₁*), the tumour takes on a very peculiar structure. The mucoid contents of the papillae become swollen,

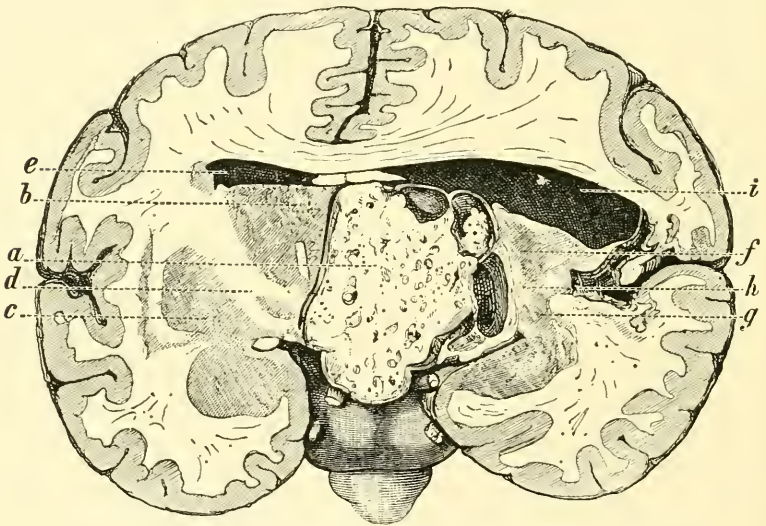


FIG. 252. PAPILLOMATOUS CARCINOMA OF THE CHOROID PLEXUS.

(Frontal section through the third ventricle: reduced to two-thirds of the natural size)

- | | |
|-----------------------------------|------------------------------------------|
| <i>a</i> tumour with cysts | <i>f</i> left optic thalamus |
| <i>b</i> right optic thalamus | <i>g</i> left lenticular nucleus |
| <i>c</i> right lenticular nucleus | <i>h</i> left internal capsule |
| <i>d</i> right internal capsule | <i>i</i> enlarged left lateral ventricle |
| <i>e</i> right lateral ventricle | |

and the latter undergo a cystic transformation (Fig. 252 *a* and Fig. 253 *d*), being separated from one another only by strings of epithelial cells (*e*), which thus form a kind of cellular stroma for the cysts excavated in the connective tissue. Within the cellular clusters epithelial pearls are sometimes developed (Fig. 253 *h*), which closely resemble the corresponding bodies formed in cancerous tumours of the skin, and present a striking contrast to the cylindrical cells of the growth.

The tumour is usually confined to the ventricle, and causes compression and displacement (Fig. 252 *f g h*) of the adjacent

cerebral substance, with ventricular dropsy (*i*). It may however invade the adjoining portions of the brain, and lead to the formation of secondary growths in the deeper parts of the organ (SPAET).

The mode of origin of the pearly tumour, or **cholesteatoma**, is not yet thoroughly understood. This growth is characterised by the presence in it of white pearls with a silky lustre. It is met with chiefly in the basal meninges, in the neighbourhood of the posterior and anterior transverse fissures; but it may appear in the interior of the brain also. The growths are solitary and surrounded by a fibrous capsule, or multiple, in the form of lustrous nodules and nodes seated loosely in the pia mater or

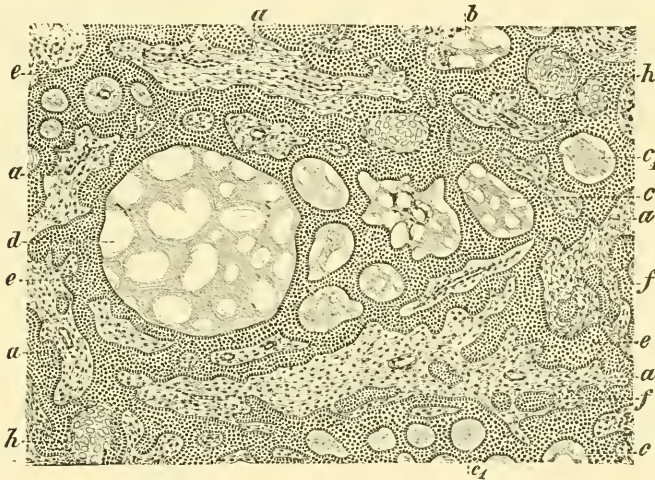


FIG. 253. PAPILLOMATOUS CARCINOMA WITH GELATINOUS DEGENERATION OF THE STROMA FROM THE CHOROID PLEXUS.

(Preparation hardened in Müller's fluid and stained with alum-carminé: $\times 25$)

- | | | | |
|---|----------------------------------------------------------------------------------------------------|----------------|------------------------------------------------------------------------------------------|
| a | vascular fibrous stroma | c ₁ | hyaline masses |
| b | papillae of connective tissue which have undergone partial mucoid degeneration | d | cysts formed from the degenerate stroma with contents coagulated in a reticulate fashion |
| c | papillae which have undergone complete mucoid degeneration, coagulated in the process of hardening | e | inter-papillary strings of cells |
| | | f | inter-papillary nests of cells |
| | | h | pearly bodies |

brain. The soft white mass of the growth consists mainly of epithelial scales, resembling the horny epidermis of the skin. Most authorities assume that the cells are of endothelial origin; but it seems more likely that they originate in the epiblast, and are indeed derived by descent from anomalous or misplaced epithelial cells. The fact that in rare cases the growths contain minute hairs is in favour of this supposition (ZIEGLER).

Intracranial **dermoid cysts** are on the whole rare. They are usually seated in the membranes, but sometimes penetrate into the cerebral substance.

Among the **secondary tumours** of the meninges all forms that are liable to metastasis have been described. It is worth noting that they sometimes spread freely in the subarachnoid spaces.

Of **animal parasites** *Echinococci* and *Cysticerci* are met with in the meninges. The former give rise to small or large and single or multiple hydatid cysts, which compress the cerebral substance and occasionally induce softening of the surrounding tissue.

Cysticercus (the cystic stage of *Taenia solium*) appears either in the ordinary form of a bladder of the size of a pea, with a scolex or immature head, or as *Cysticercus racemosus*. The latter takes the form of large lobulated vesicles, usually sterile, with a cluster of internal and external daughter-cysts surrounding the parent-cyst like a bunch of grapes. It sometimes induces proliferous hyperplasia in the surrounding tissue.

In the ventricles minute granular prominences are at times observed on the ependyma, which are simply compact **fibrinous deposits** permeated by formative cells and blood-vessels, and so partially organised after the manner of a thrombus.

References on Tumours of the Internal Meninges.

- ARNDT: Endothelioma (canceroid) *V. A.* 51 1870
 ARNOLD, J.: Myxosarcoma teleangiectodes cysticum *V. A.* 51 1870
 AUDRY: Tumours of the choroid plexus *Rev. de méd.* 1886
 BILLROTH: Myxoma of the cerebellar pia mater *A. d. Heilk.* III
 CAYLEY: Sarcoma *Trans. Path. Soc.* XXVI London 1874
 CHAMBARD: Primary carcinoma *Encéphale* I 1881
 CHIARI: Lipoma *Wien. med. Woch.* 29 1879
 DRESCHFELD: Psammoma *Journ. of Anat.* XIV 1879
 EBERTH: Epithelioma *V. A.* 49 1869
 EPPINGER: Cholesteatoma *Prager Vierteljahrsschr.* 126 1875
 FALKSON: Chondrocystosarcoma of the plexus of the third ventricle *V. A.* 75 1879
 FASCE: Melanotic endothelioma of the arachnoid *V. A.* 97 1884
 FÉRÉ: Lipoma of the pia mater *Progrès méd.* 1885
 JANSSEN: Sarcoma *V. A.* 139 1885
 LANCEREAUX: *Traité d'anat. pathologique* Paris II 1881, and III 1889
 LANGER: Cystic tumours of the infundibulum *Prag. Z. f. Heilk.* XIIII 1892
 LANNELONGUE: Intracranial dermoid cysts *A. de physiol.* I 1889
 MORRIS: Angioma *Trans. Path. Soc.* XXII London
 PARROT: Lipoma *A. de physiol.* II 1869
 PRICE: Cholesteatoma *Trans. Path. Soc.* XXXVIII London 1887
 RICHTER: Multiple sarcoma *Prager med. Woch.* XI 1886
 ROBIN: Endothelioma *Journ. de l'anat. et de la physiol.* 1869
 SELKE: Epithelial papilloma *Inaug. Diss.* Königsberg 1891
 SPAET: *Primärer multipler Epithelkrebs des Gehirns* Munich 1882
 TOCHÉ: *Étude sur deux cas d'endothéliome du cervelet* Paris 1888
 VIRCHOW: *Krankhafte Geschwülste*; Cholesteatoma *V. A.* 8 1855
 WILKS and MOXON: Chondroma *Lect. on Path. Anatomy* London 1889
 VON WUNSCHEIM: Primary carcinoma of the fourth ventricle *Prag. med. Woch.* 1891

References on Cysticercus in the Brain.

- ASKANAZY: Cysticercus at the base of the brain *Ziegler's Beiträge* VII **1889**
BRECKE: Cysticerci in the fourth ventricle *Inaug. Diss.* Berlin **1886**
GRIESINGER: Cysticercus racemosus *A. d. Heilk.* III **1862** (with references)
HAMMER: Cysticerci in the cerebral ventricles *Prager med. Woch.* **1889**
MARCHAND: Cysticerci *V. A.* 75 **1879**, and *Breslauer ärztl. Zeitschrift* **1881**
STIEDA: Cysticercus racemosus in the fourth ventricle *Thierfelder's Festschrift*
Leipzig **1895**
VIRCHOW: Cysticerci *V. A.* 18 **1860**
YAMAGIWA: Aetiology of Jacksonian epilepsy (*Distoma* in the brain) *V. A.*
119 **1890**
ZENKER: *Ueber den Cysticercus racemosus des Gehirnes* Erlangen **1882**

CHAPTER XLV

THE DURA MATER, PINEAL GLAND, AND PITUITARY BODY

128. The **dura mater** is a stout fibrous membrane, with a tendinous lustre, closely adherent to the inner surface of the cranium, and serving as its internal periosteum. It is accordingly liable to all the morbid changes that affect the periosteum of other bones. Certain special changes arise from its connexion with the central nervous system, and these require separate consideration.

In the first place the dura mater is frequently the seat of an inflammatory process known as **chronic internal pachymeningitis**, the result of various injurious agencies, whose exact nature is not fully understood. The inflammation is usually haematogenous, and in many cases is not associated with any inflammation of the internal meninges; it is, however, apt to accompany inflammatory conditions in the contiguous bones. It is sometimes unilateral and circumscribed, or it may be bilateral and disseminated in multiple patches, or generally diffused over the entire cranial surface.

The first morbid sign is the appearance of very thin fibrinous deposits on the internal surface of the membrane: these consist essentially of films of granular, fibrillar, or homogeneous fibrin, containing a few round-cells. After a time the films become pervaded by living cells and new-formed vessels growing as offshoots from the dural capillaries. A delicate fibrous tissue is thus elaborated, which lines the dura mater as a semi-transparent false membrane, with wide well-filled vessels.

The new-formed vessels have very thin walls, and are particularly prone to bleed, the slightest disturbances of the circulation apparently sufficing to set up **haemorrhage** by rupture or diapedesis. The consequence is that pachymeningitic false membranes nearly always contain recent extravasations and pigmented deposits, testifying to past haemorrhage: this peculiarity has led to the affection being described as **haemorrhagic pachymeningitis**. The extravasations are usually small, but now and then they are so extensive that they partially separate the false membrane from the dura mater, and form blood-cysts or **haematomata**, which exert more or less pressure on the brain. If the cyst gives way, blood will of course be effused into the subdural space.

Once the inflammation has begun, it seldom attains to complete resolution and recovery. The extravasated matters are by degrees re-absorbed, but if they are at all abundant the process is very slow and often imperfect, and the continued presence of the disintegrated blood keeps up an irritation that induces renewed inflammation. New exudations and new false membranes are thus produced, and at length a dense scar-like tissue results, which contains masses of pigment, residues of blood and fibrin, and calcareous deposits. Sometimes after resorption of a large extravasation a collection of liquid appears in its place between the dura mater and the cicatricial membrane; this has been called **hygroma** of the dura mater, or partial pachymeningitic hydrocephalus.

In older, denser, and more fibrous membranes, containing few cells, some of the vessels are gradually occluded by contraction; but such obliteration does not bring the process to an end, for other parts remain highly vascular, and fresh haemorrhages keep up and renew the inflammation.

Pachymeningitic membranes do not usually adhere to the underlying tissues; but sometimes fairly firm union takes place between them and the arachnoid, and then new-formed blood-vessels pass from the false membrane into the internal meninges.

There is also a **chronic external pachymeningitis**, in which the inflammatory changes are practically limited to the outer strata of the dura mater, and are associated with thickening of the membrane and resorption or hyperplasia of the bone. Moreover, the dura mater is frequently inflamed as the result of traumatic injury, or by extension of inflammations from the adjacent structures. Thus a cut or stab of the skull, which becomes infected with septic matter and suppurates, not infrequently gives rise to purulent pachymeningitis, and the like is apt to follow suppuration of the internal ear, of the petrous portion of the temporal bone, or of the orbit. In such cases the dura mater assumes a yellowish-white or greyish-yellow tint, and when haemorrhage accompanies the injury or disease it becomes dirty-grey, greyish-green, or brown.

Eruptions of **tubercle** in the dura mater are induced as metastases from tuberculous leptomeningitis or tuberculosis of the cranial bones. In some instances disseminated grey tubercles make their appearance on the internal surface, in others pachymeningitic membranes containing tubercles, or fungous growths, or caseous nodes, are produced. Caseous nodes are chiefly the result of tuberculous bone-disease, and may be seated on either surface of the dura mater, or in its tissue.

Syphilis gives rise to foci of cellular infiltration, or to granulatous growths, ending in cicatricial thickenings, that not infrequently enclose patches of caseous matter. When the process invades the arachnoid and pia mater, these tend to become adherent to the dura mater.

The majority of the **tumours** affecting the dura mater belong to the group of **sarcomata**. Spindle-celled sarcoma is the commonest; the round-celled and polymorphous-celled varieties are rarer. Alveolar sarcoma and endothelioma are also met with, the latter being characterised by the formation of nests and strings of cells (Fig. 254 *c d*) embedded in a fibrous stroma (*a*).

Endotheliomata form solitary or multiple growths, flattened or raised on a stalk like a mushroom (fungus of the dura mater), from the size of a pea to that of an apple, which project inwards and depress the underlying brain-surface into pit-like excavations. When they grow on the outer surface of the membrane they are

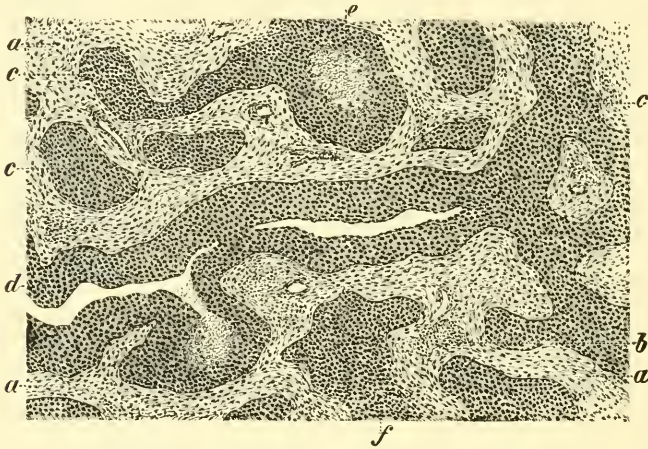


FIG. 254. ENDOTHELIOMA OF THE DURA MATER.

(Preparation hardened in Müller's fluid, stained with haematoxylin, and mounted in Canada balsam: $\times 25$)

- | | |
|--------------------------------------------------|--------------------------------------------------|
| <i>a</i> fibrous stroma | <i>e</i> fatty degeneration of a cellular mass |
| <i>b</i> group of round-cells | <i>f</i> mass of endothelial cells, on the right |
| <i>c</i> nests and strings of cells derived from | side passing gradually into the fibrous |
| the endothelium of the lymphatics | stroma |
| <i>d</i> tubular tract of endothelial cells | |

apt to penetrate the bone, causing it to atrophy and ultimately to give way and rupture. At their point of origin from the membrane they send out pseudopodial processes into its tissue, in the form of cellular strands that seem to force their way between its tough fibres, or to grow out from them. These strands of cells are derived from the endothelium of the lymphatics (*d*), whose course they follow and often mark out in a recognisable way by the mode of their configuration.

Excessive vascular development within a sarcoma leads to the formation of telangiectatic tumours. Calcification of the capillary vessels, and the formation of concretions in the shape of spherules, needles, and jagged fragments (Fig. 255 *a b c d e*) sometimes give the sarcoma the characters of a **psammoma**.

Fibromata are rare, but they do occur in all parts of the dura mater, and form rounded tumours. **Lipomata** are very rare.

Osteomata appear chiefly in the cerebral dura mater, and with special frequency in the falx cerebri. They usually take the form of irregularly-shaped plates of bone with spinous and ridge-like processes.

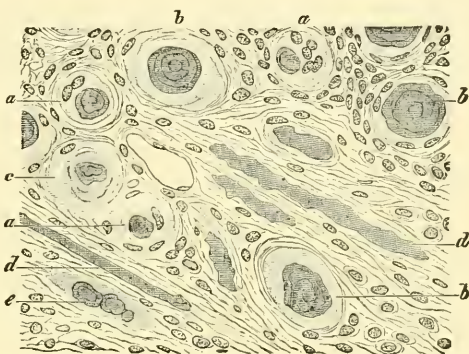

FIG. 255. SECTION FROM A PSAMMOMA OF THE DURA MATER.

(Preparation hardened in alcohol, decalcified with picric acid, and stained with haematoxylin and eosin: $\times 200$)

- | | | | |
|---|-------------------------------------------------------------------------------------------------------------|---|--------------------------------------------------|
| a | hyaline nucleated spherule enclosing a calcareous concretion | c | concretion enclosed in hyaline connective tissue |
| b | calcareous concretions surrounded by hyaline denudeated substance and enclosed in fibrous connective tissue | d | calcareous needles in the connective tissue |
| | | e | needle containing three concretions |

About the back of the sella turcica and basi-occipital (or olivus) small gelatinous tumours known as **ecchondromata** (or chordomata) are not uncommon; in texture they resemble the notochord, and it is therefore probable that they originate in some belated residues of this embryonic structure.

Of **secondary tumours** carcinoma is that most frequently met with in the dura mater.

References on Proliferous and Haemorrhagic Pachymeningitis.

- CHARCOT: *Sur les néomembranes de la dure mère, Oeuvres complètes IX*
 KREMYANSKI: *Internal haemorrhagic pachymeningitis V. A. 42 1868*
 LANCERAUX: *A. gén. de méd. 1862 and 1863, and Traité d'anatomie path. II*
 PAULUS: *Verkalkung und Verknöcherung d. Hämatomes der Dura mater Erlangen 1875*
 SCHUBERG: *Haematoma of the dura mater V. A. 16 1859*
 SPERLING: *Cent. f. med. Wiss. no. 29 1871*
 THOMSON: *Chronic external pachymeningitis Journ. of Path. II 1893*
 VIRCHOW: *Haematoma of the dura mater Würzburg. Verhandl. 1856*

References on Tumours of the Dura Mater.

- ARNOLD: Psammomata *V. A.* 52 **1871**
 BIZZOZERO and BOZZOLO: Primary tumours *Wiener med. Jahrb.* **1874**, and
Rivista clin. di Bologna IV **1874**
 CHELING: *Die schwammigen Auswüchse d. harten Hirnhaut u. d. Schädelknochen*
 Heidelberg **1891**
 ERNST: Psammoma *Ziegler's Beiträge* XI **1892**
 FIRKET: Enchondroma *Encéphale* I **1881**
 LEVI: The origin of concretions in psammomata *Inaug. Diss.* Freiburg **1890**
 LUSCHKA: Echondrosis of the basi-occipital *V. A.* 11 **1856**
 ROBIN: Epithelioma of the serous membranes *Journ. de l'anat.* Paris **1869**
 SCHÜPPEL: Calcareous sarcoma *A. d. Heilk.* X **1869**
 VIRCHOW: *Die Entwicklung des Schädelgrundes* (echondrosis of the basi-occipital) **1857**
 WHIPHAM: Round-celled sarcoma *Trans. Clin. Soc.* XIV London **1881**
 ZENKER: Echondrosis of the clivus *V. A.* 12 **1857**

129. The hypophysis cerebri or **pituitary body** is seated in the sella turcica, and is composed of two lobes; the anterior consists of a fibrous stroma enclosing numerous round and oval follicles filled with epithelial cells, the posterior chiefly of vascular connective tissue enclosing fusiform and stellate cells some of which are pigmented. At the junction of the two lobes the tissue is very vascular, and contains cavities lined with ciliated cylindrical epithelium (WEICHSELBAUM).

Cystic degeneration and hyperplastic overgrowth of the anterior lobe are the commonest changes, the cysts usually containing colloidal masses. This transformation is known as **adenoma** or struma of the pituitary body, and the growth sometimes reaches the size of a pigeon's or even of a hen's egg. It protrudes more or less from the sella turcica, presses on the adjoining brain-substance, or even projects into the ventricles, and causes atrophy of the underlying bone.

In some cases of **acromegaly** the pituitary body has been found *post mortem* to be considerably enlarged: it has indeed been maintained that such enlargement is correlated with the characteristic hypertrophy of the hands, feet, and jaw (Art. 50), as myxoedema is with disease of the thyroid gland.

According to WEICHSELBAUM, the ciliated epithelial cavities are very apt to undergo cystic degeneration. The contents of the cysts consist of homogeneous or granular matter secreted by the epithelial cells. The cysts with granular contents are lined with ciliated epithelium.

After adenoma the commonest tumours are **carcinoma** and **sarcoma**, which also take the form of nodose growths. WEICHSELBAUM has described a pair of small **lipomata** in the posterior lobe, and WEIGERT a **teratoma**.

Inflammation of the hypophysis may be associated with inflammation of the neighbouring parts: tubercles and gummata have been observed (WEIGERT) only in rare instances.

The **pineal gland** consists of fibrous tissue enclosing a number of rounded follicles, each of which contains a cellular reticulum, rounded cells with slender tapering processes (TOLDT), and a quantity of brain-sand.

The most frequent pathological changes observed in this organ are abnormal increase of the brain-sand (psammoma), hyperplastic enlargement, and cystic degeneration. Haemorrhage into the substance of the gland may lead to the formation of a haematoma.

Tumours of this organ are very uncommon.

The pineal gland may participate in inflammations of neighbouring structures.

References on Affections of the Hypophysis or Pituitary Body.

- BECK: Teratoma *Prag. Z. f. Heilk.* iv **1883**
 BERNHARDT: *Hirngeschwülste* Berlin **1881**
 BOYCE: Enlargement of the hypophysis in myxoedema *Journ. of Path.* i **1893** (with references)
 BOYCE and BEADLES: Study of the path. of the hypophysis *Cent. f. allg. Path.* **1894**
 BREITNER: Tumours of the hypophysis (adenoma) *V. A.* 93 **1883**
 EPPINGER: Haematoma of hypophysis *Viertelj. f. prakt. Heilk.* 126 **1875**
 HEUSSER: Tumours of the hypophysis (lymphosarcoma) *V. A.* 119 **1890**
 VON HIPPEL: Tumours of the hypophysis (cases) *V. A.* 126 **1891**
 INGERMANN: Tumours of the hypophysis (cases) *Inaug. Diss.* Berne **1889**
 KLEBS: Sarcoma *Prager Vierteljahrsschr. f. prakt. Heilk.* 125
 PISENTI and VIOLA: Histology of the pituitary gland *Atti Accad. med. chir. di Perugia* ii **1890**, and *Cent. f. med. Wiss.* **1890**
 RIBBERT: Tumour of the hypophysis *V. A.* 90 **1882**
 ROGOWITSCH: Changes in the hypophysis after removal of the thyroid gland *Ziegler's Beiträge* iv **1888**
 VIRCHOW: *Krankhafte Geschwülste*
 WAGNER: Tubercle *A. d. Heilk.* **1862**
 WEICHSELBAUM: Neoplasms of the hypophysis *V. A.* 75 **1879**
 WEIGERT: Teratoma, struma pituitaria, and gummata *V. A.* 65 **1875**

References on Tumours of the Pineal Gland.

- BLANQUINQUE: Tumour of the pineal gland *Gaz. hebd.* 8 **1871**
 COATS: Adenoid sarcoma containing cartilage *Trans. Path. Soc.* xxxviii London **1887**
 FRIEDREICH: Psammoma *V. A.* 33 **1865**
 MANOT: Tumour of the pineal gland *Lyon méd.* **1872**
 NIEDEN: *Cent. f. Nervenheilk.* **1879**
 REINHOLD: Case of tumour of the pineal gland *Inaug. Diss.* Freiburg **1886**
 TURNER: Spindle-celled sarcoma *Trans. Path. Soc.* xxxvi London **1885**
 WEIGERT: Teratoma *V. A.* 65 **1875**

SECTION VII

THE PERIPHERAL NERVOUS SYSTEM

CHAPTER XLVI

STRUCTURE OF PERIPHERAL NERVES

130. The **peripheral nervous system** is composed of **nerves** and **ganglion-cells**, together with the special terminal structures in which the nerves end. The nerves consist essentially of medullated and non-medullated nerve-fibres, which are prolongations of the polar processes of the ganglion-cells. Some of these cells are situated in the cord and medulla oblongata, but others are intercalated in peripheral parts of the sympathetic system, where the groups of nerve-cells occur that are known as sympathetic ganglia.

The **medullated nerve-fibres** are long cylindrical structures, whose central axis is occupied by the **axis-cylinder**. The latter is surrounded by the **medullary sheath**, consisting of myelin which during life is homogeneous, and this in turn is enclosed in a delicate connective-tissue envelope, the primitive sheath, neurilemma, or **sheath of Schwann**. The medullary sheath is at intervals interrupted, the axis-cylinder being then surrounded only by the sheath of Schwann (**Ranvier's nodes**); it is generally assumed that these nodes subserve the nutrition of the axis-cylinder. The nerve-fibre is in this way divided into segments of from one to two millimetres in length, each one of which contains a nucleus situated approximately in the middle and close to the sheath of Schwann, and around the nucleus a thin layer of protoplasm is spread on the internal surface of the sheath. External to the sheath of Schwann is a fibrillar sheath (**AXEL KEY** and **RETZIUS**) which also contains nuclei and a small quantity of protoplasm.

The **non-medullated nerve-fibres** possess no other covering for the axis-cylinder than the sheath of Schwann, with nuclei included in it at intervals.

Medullated and non-medullated nerve-fibres are united into nerves of different thicknesses. Those that have their origin in the brain and cord contain chiefly medullated fibres; in the nerves of the sympathetic system the non-medullated fibres predominate. The smaller nerves consist of a simple bundle of nerve-fibres; the larger trunks contain a variable number of such bundles or fasciculi.

Each fasciculus is surrounded by a fibrous envelope termed the **perineurium**. When several bundles combine to form a nerve-trunk, this also is surrounded by a perineurium, while the bundles themselves are bound together by loose connective tissue, often containing fat-cells, and known as the **epineurium**. The **endoneurium** consists of delicate fibrous septa passing from the perineurium of each bundle into the interior, and uniting the nerve-fibres into groups, while the finest processes pass into these and surround the individual fibres. The **blood-vessels** of the nerve-trunk run within the fibrous framework. At the peripheral end of each nerve-fibre the axis-cylinder breaks up into its primitive fibrils, and these form connexions with the terminal organs.

CHAPTER XLVII

DEGENERATION AND INFLAMMATION OF NERVES

131. The fibres of the peripheral nerves are very frequently the seat of degenerative changes which often lead to their total destruction, and in other cases give rise at least to permanent atrophy of the affected nerve-elements. In so far as these processes run their course without inducing other changes in the nerves, they might be described as instances of **simple degeneration**; but when they are complicated with inflammatory exudation and hyperplasia of the connective tissue, or when they originate in an inflammatory affection of the latter, they must be reckoned as of the nature of **neuritis**. By many writers simple degeneration is termed parenchymatous neuritis, while neuritis proper is distinguished as interstitial neuritis. Degeneration and inflammation of the nerves cannot be separated by any sharp distinction, inasmuch as on the one hand inflammatory changes often give rise to wide-spread degeneration, and on the other hand degeneration, in the later stages of its course, may induce signs of inflammation. The term neuritis is for this reason frequently applied to degenerative affections.

In the first place, nerves undergo extensive degeneration after **section**, the distal portion of the polar process thus separated from its nerve-cell degenerating throughout its entire length, while the proximal portion undergoes degenerative atrophy for a short distance only.

Even in the first few days after section the internodal segments of the medullary sheath throughout the whole of the distal portion become less refractive and appear turbid, while by the end of the third day deep indentations make their appearance in the sheath of Schwann and in the medullary sheath, owing to commencing segmentation of the latter. From the fourth to the sixth day the medullary sheath coagulates into large drops of myelin (Fig. 256 *b*) between the indentations. This leads in the course of a few days to the formation of masses of detritus, consisting of drops and granules of various sizes. By and by the detritus is absorbed by migratory leucocytes, and fat-granule cells are thus produced; but the process may last weeks or months before all the products of disintegration have disappeared.

Soon after the medullary sheath has begun to degenerate, the

axis-cylinder can be no longer, or at best very imperfectly, distinguished (Fig. 256 *a*), and it is presently destroyed altogether, partly by swelling and vacuolation, partly by disintegration into small fragments (Fig. 257 *c*). According to GESSLER, the dendritic terminal ramifications of the nerve within the muscles also disappear.

In a clean aseptic wound dividing the nerve, only a small portion of the central or proximal part of the trunk degenerates, the process ceasing at the first or second Ranvier's node above the point of section. Certain fibres degenerate for a greater distance, but only when inflammation or other injury, such as crushing, complicates the process. It must, however, be noted that in course of time some of the fibres in the central portion of the nerve become attenuated, the medullary sheath in particular being liable to atrophy.

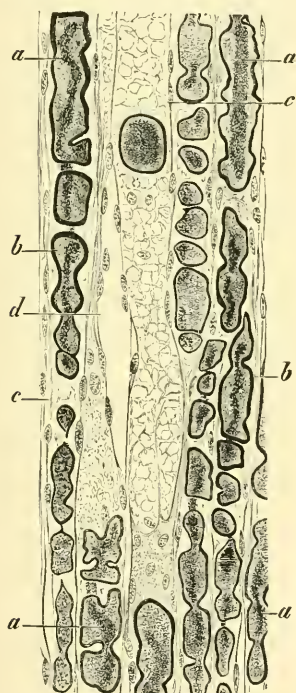


FIG. 256. DEGENERATION OF THE SCIATIC NERVE.

(Six days after section: preparation hardened in Flenning's acid solution, and stained with saffranin: $\times 300$)

a remains of the axis-cylinder
b disintegrated medullary sheath

c sheath of Schwann

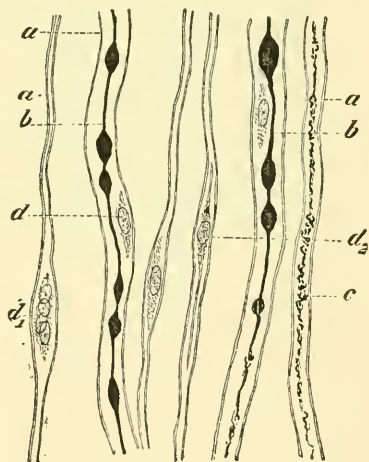


FIG. 257. ADVANCED DEGENERATION OF THE MOTOR NERVES IN A CASE OF ATROPHY OF THE ANTERIOR HORNS OF THE SPINAL CORD.

(Preparation hardened in Müller's fluid, treated with persmic acid, and teased out in glycerine: $\times 250$)

a sheath of Schwann
b axis-cylinders with adherent drops of myelin
c disintegrated axis-cylinders

d uninuclear cells
*d*₁ multinuclear cells
*d*₂ bipolar cells within the sheath of Schwann

Severe crushing and stretching have an effect very similar to that of section, and so also has continued compression, such as is occasionally caused by tumours, by the contraction of scar-tissue, by inflamed lymph-glands, and the like. The interruption of conductivity does not, however, at once involve all the nerve-bundles, but rather tends to take place successively in the several strands.

Diseases of the anterior horns of the spinal cord and of the **motor roots** that cause destruction of the motor ganglia or nerve-fibres are followed, as in the case of section, by degeneration of the peripheral part of the nerve-tracts; but when the destruction of the nerve-cells is gradual the atrophy of the nerve-fibres is

not so rapid, the medullary sheath wastes more slowly (Fig. 257 *b*), and within the same bundle we may find fibres that are sound and others that are in different stages of atrophy (Fig. 257 *b c*) or altogether degenerate. In some of the fasciculi every fibre may be disintegrated.

Haematogenous degeneration and inflammation of the nerves are due in some cases to infection or poisoning, in others to simple disorders of circulation and to haemorrhage, in others again to insufficient nutri-

tion dependent on general anaemia, cachexia, or narrowing of the arteries. The mode of origin of the degeneration in a given case is, however, often uncertain. Single or multiple neuritis or degeneration associated with typhus fever, variola, typhoid fever, diphtheria, influenza, tuberculosis, and the puerperal state, is probably due partly to autogenetic poisoning and partly to deficient nutrition of the nerves; in some cases it may be due to a local action of the specific infection concerned.

Degeneration of the motor nerves and the muscles from lead-poisoning is probably due to the direct toxic effect of the lead; but disturbances of the circulation caused by simultaneous disease of the vessels has perhaps a share in the result. The degeneration

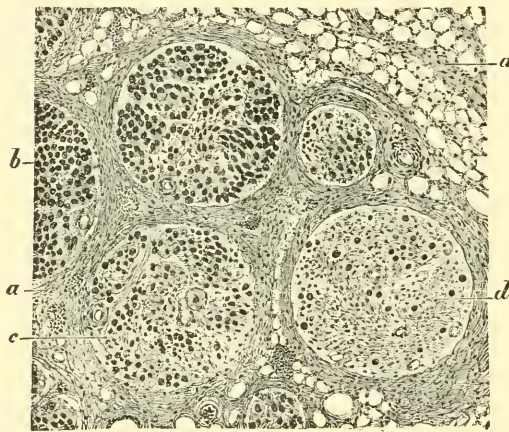


FIG. 258. TRANSVERSE SECTION FROM AN ATROPHIC SCIATIC NERVE (MULTIPLE SCLEROSIS).

(Preparation hardened in Müller's fluid, and stained after WEIGERT'S haematoxylin method for medullary sheaths: $\times 30$)

- a* epineurium
- b* transverse section of a normal nerve-bundle
- c d* transverse sections of atrophic nerve-bundles

of the peripheral nerves frequently observed in cases of chronic alcoholism is doubtless due to a direct toxic effect.

According to BAEZ and SCHEUBE, the disease known as **beri-beri** or **kakke**, epidemic in Japan, in the East Indies, and in South America, is an infective disorder (according to MIURA it is due to some form of poisoning), which is characterised primarily by multiple degeneration of the nerves (*panneuritis epidemica*). In Europe too forms of disease occur that affect various regions of the peripheral nervous system, and are known as multiple neuritis (LEYDEN), polyneuritis (PIERSON), and disseminated neuritis (ROTH); these are probably due to infection of some kind.

According to the investigations of DÉJÉRINE, PITRES, VAILLARD, OPPENHEIM, SIEMERLING, and others, degeneration of numerous peripheral nerves is a common accompaniment of tabes dorsalis, the peripheral portions of the sensory nerves of the skin being those that are most apt to become degenerate (Art. 98).

Transmitted or consecutive **lymphogenous neuritis** is that associated with inflammations in the tissues about the nerve. Purulent and tuberculous inflammations are those which most frequently extend in this way, as when the nerve-roots become involved in connexion with purulent or tuberculous meningitis. Sometimes the virus is disseminated within the nerves themselves, as appears to be the case in rabies or hydrophobia.

In simple degeneration of the nerves the connective tissue usually undergoes little or no change, while the sheath of Schwann (Fig. 256 *c* and Fig. 257 *a*) and its nuclei (Fig. 256 and Fig. 257 *d d₁ d₂*) often survive for a long time. The latter may even become proliferous (*d₁*). When the majority of the medullated fibres perish (Fig. 258 *e d*), the nerve acquires by degrees a grey colour, but does not become indurated unless there is hyperplasia of its connective tissue. The case is different when the affection is genuinely inflammatory and true **neuritis** sets in.

Acute neuritis is manifested by hyperaemia and exudation affecting the fibrous constituents of the nerve-trunks; and when the changes thereby induced are well marked they take the form of redness, swelling, and increase of moisture, or it may be of haemorrhagic extravasation and yellowish-white discoloration due to the appearance of pus. In the haematogenous forms of neuritis the exudation may from the outset implicate the endoneurium and epineurium. In neuritis that is consecutive to inflammation of the surrounding tissue, as in a suppurating wound, in purulent meningitis, or in pelvic cellulitis, the perineurium in the first place undergoes cellular infiltration, and this does not spread to the endoneurium until a later stage.

Slight inflammations may doubtless pass away without leaving any permanent change. More intense inflammation leads to disintegration of the medullary sheath, and often also to necrosis of part of the axis-cylinder. Purulent and gangrenous inflammations

induce suppuration and gangrenous necrosis of the nerve. Granulations and cicatricial tissue are produced in the case of nerves damaged by traumatic injury or lying in the midst of granulating tissue.

Subacute and chronic neuritis are induced by chronic inflammation of surrounding structures or by haematogenous or lymphogenous infection and poisoning; but the primary cause of the affection cannot always be made out.

These forms of inflammation lead to atrophy of the nerve-elements (Fig. 259 *f*) and to proliferation and hyperplasia of the connective tissue (*d e*); in view of the latter result the affection is sometimes described as **proliferous neuritis**.

When the process has continued for a time the nerve-fibres in the parts involved are found to have wholly disappeared, or are more or less atrophic (Fig. 259 *f*), while the connective tissue is highly cellular and increased in bulk.

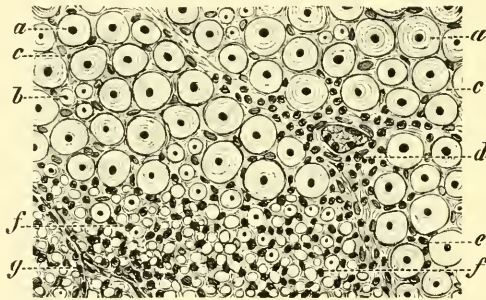


FIG. 259. CHRONIC NEURITIS WITH PARTIAL ATROPHY OF THE NERVE-FIBRES.

(Preparation hardened in Müller's fluid and alcohol, stained with haematoxylin and carmine, and mounted in Canada balsam: $\times 150$)

- | | |
|----------------------------------------------------------------------------------------------------------|-----------------------------------------------------------------------------------------------------------------|
| <i>a</i> cross-section of normal thick fibre | <i>e</i> leucocytes between the nerve-fibres |
| <i>b</i> cross-section of normal fine fibre | <i>f</i> thickened endoneurium with small spaces vacated by nerve-fibres and a few fine fibres still persisting |
| <i>c</i> endoneurium | <i>g</i> blood-vessel cut longitudinally |
| <i>d</i> proliferous septum of the endoneurium infiltrated with leucocytes and containing a blood-vessel | |

Tuberculous neuritis is observed most frequently in the roots of the cerebral and spinal nerves, and is usually secondary to tuberculous meningitis (Fig. 209). This form of neuritis also develops in nerves lying close to tuberculous lymph-glands or granulomatous foci in the periosteum or the tendon-sheaths. Sometimes the perineurium and the epineurium are in large part converted into granulomatous tissue, which later on becomes caseous, and the endoneurium of the separate nerve-bundles also may be involved. In other cases the nerves merely undergo fibroid induration. Local tuberculosis limited to a single nerve is rare.

Syphilitic neuritis is observed almost exclusively in the roots of the cerebral and spinal nerves, as a secondary result of syphilitic

meningitis (Fig. 210). The nerves are surrounded and permeated by syphilitic granulomatous tissue, and subsequently by connective tissue. The result is destruction of a greater or smaller portion of the nerve, with peripheral paralysis. The arteritis which accompanies the process, and causes narrowing and occlusion of the nutrient vessels of the nerves, is also apt to give rise to degeneration in them.

Leprosy very often affects the nerves, and one special form of the disease is described as *lepra nervorum, anaesthetica, or mutilans*. The settlement of the lepra-bacillus in the nerves induces cellular infiltration and proliferation, and these give rise to degeneration of the nerve-fibres and hyperplasia of the connective tissue, leading to the formation of spindle-shaped thickenings of considerable diameter. The diseased tissue contains multitudes of lepra-bacilli, either free or enclosed in cells.

Inflammation of the **sympathetic ganglia and fibres** induces changes in these structures similar to those produced in the spinal nerves. Thus tuberculous caseation of the suprarenal capsules extending to the surrounding tissue sometimes leads to inflammation and proliferation in the solar plexus and semilunar ganglia, resulting in degeneration of the fibres and ganglion-cells of the sympathetic. So too tuberculous disease of the bones of the vertebral column is apt to extend to the sympathetic nerves and ganglia.

In leprosy the bacilli penetrate not only the connective tissue but even the nerve-cells of the affected ganglia, and cause them to become degenerate and perish (SUDAKEWITSCH).

References on Traumatic, Infective, Toxic, and Cachectic Degeneration and Inflammation of the Nerves (see also Art. 98 for references on degeneration of nerves in *Tabes dorsalis*).

ARNHEIM: Diphtherial paralysis *A. f. Kinderheilk.* XIII 1891

AUCHÉ: Alterations of the peripheral nerves in diabetes *A. de méd. exp.* II 1890; Neuritis in cancer-patients *Rev. de méd.* X 1890

BABES and MARINESCO: Pathology of the nerve-endings in muscles *Ann. de l'Inst. de Path.* Bucharest II 1891

BAELZ: *Infectionskrankh. in Japan mit bes. Berücksicht. der Kakke oder Beriberi* Yokohama 1882, and *Z. f. klin. Med.* VI 1882

BAGINSKI: Changes in the end-organs of nerves after section *V. A.* 137 1894

BERNHARDT: Multiple neuritis in alcoholics *Z. f. klin. Med.* XI 1886

BLASCHKO: Disease of the sympathetic plexuses of the intestinal wall *V. A.* 94 1883

BONOME: idem *A. per le scienze med.* XIV

CAMPBELL: Alcoholic polyneuritis *Prager Z. f. Heilk.* XV 1893 [1885]

CATTANI: Experiments on nerve-stretching *A. per le scienze med.* VIII and IX

CENTANNI: Landry's paralysis *Ziegler's Beiträge* VIII 1890

CHARCOT: Alcoholic paralyses *Gaz. des hôp.* LVII 1884

COSSY and DÉJÉRINE: Degeneration of nerves separated from their centres *A. de physiol.* II 1875

CRAMER: Landry's paralysis *Cent. f. allg. Path.* II 1892; Peripheral neuritis *Cent. f. allg. Path.* 1893 (with references)

- DÉJÉRINE: Diphtherial paralysis *A. de physiol.* v 1878; Alcoholic neuritis *A. de physiol.* x 1887; Peripheral nature of certain so-called acute spinal paralyses *A. de physiol.* II 1890
- DÉJÉRINE-KLUMPKE: *Des polynévrites et des atrophies et paralysies saturnines* Paris 1889
- DRESCHFELD: Alcoholic paralysis *Brain* VII, VIII 1885-86
- DUBOIS: Case of multiple neuritis *Corresp. f. Schweiz. Aerzte* 1883
- EICHHORST: Acute progressive neuritis *V. A.* 69 1877; Lead-paralysis *ibidem* 125 1891; Diabetic neuritis *ibidem* 127 1892
- EISENLOHR: Acute polyneuritis *Berl. klin. Woch.* 1887
- EULENBURG: Puerperal neuritis *D. med. Woch.* 1895 (with references)
- FRANCOU: Multiple neuritis *Rev. de méd.* 1886
- FRIEDLÄNDER: Case of lead-paralysis *V. A.* 75 1879
- FRIEDLÄNDER and KRAUSE: Changes in the nerves after amputation *Fortschr. d. Med.* 1886
- GEPPERT: Case of multiple neuritis *Charité-Annalen* 1883
- GESSLER: Changes in the ends of the motor nerves after section *D. A. f. klin. Med.* xxxi; *Die motorische Endplatte u. ihre Bedeutung für die periph. Lähmung* Leipzig 1885
- GOLDFLAM: Multiple neuritis *Z. f. klin. Med.* xiv
- GOMBALT: Muscular atrophy due to lead *A. de physiol.* v 1873; The peripheral nerves in a case of progressive myopathy *A. de méd. exp.* I 1889
- HAYEM and GILBERT: Changes in the nervous system after amputation *A. de physiol.* III 1884
- HIRSCH: *Handb. d. histor.-geograph. Pathologie* (2nd edition) Stuttgart 1881-83, trans. by CREIGHTON (New Syd. Soc.) London 1883-85
- HOCHHAUS: Diphtherial paralysis *V. A.* 124 1891
- HOMÉN: Changes in the nervous system after amputation *Ziegler's Beiträge* VIII 1890
- JOFFROY: Spontaneous parenchymatous neuritis *A. de physiol.* VI 1879
- JOFFROY and ACHARD: Peripheral neuritis of vascular origin *A. de méd. exp.* I 1889; Cutaneous gangrene of the great toe in tabes *ibidem*; Peripheral neuritis *ibidem* II 1890
- KORASKOW and SERBSKI: Polyneuritic psychoses *A. f. Psych.* XXIII
- KRAUSE: Ascending and descending degeneration of nerves *A. f. Anat.* 1887
- LANCEREAUX: Alcoholic paralysis *Gaz. hebdom. de méd.* 1881
- LETULLE: Mercurial paralysis *A. de physiol.* IX 1887
- LEYDEN: *Die Entzündung der peripheren Nerven* Berlin 1888; Mercurial polyneuritis *D. med. Woch.* 1893; Neuritis following influenza *Z. f. klin. Med.* XXIV 1893
- LORENZ: Multiple degenerative neuritis *Z. f. klin. Med.* XVIII 1891
- LUNZ: Affections of the nervous system following acute infective diseases *A. f. Psych.* XVIII
- MAIER, R.: Experimental studies on lead-poisoning *V. A.* 90 1882
- MARCHAND: Disease of the sympathetic nerves, of the suprarenal capsules, and of the peripheral nerves, without bronzing of the skin *V. A.* 81 1880
- MAYER: *Degeneration d. Nerrenfasern* Prague 1881
- MIURA: Kakke *V. A.* 114 1888
- MOOS: Diphtherial degeneration of nerves *V. A.* 124 1891
- MÜLLER: Case of multiple neuritis *A. f. Psych.* XIV 1883
- NAUWERCK and BARTH: Landry's paralysis *Ziegler's Beiträge* v 1889
- NIEDIECK: Migratory neuritis and its consequences *A. f. exp. Path.* VII 1877
- OPPENHEIM: Multiple neuritis and alcoholic paralysis *Z. f. klin. Med.* XI
- PEKELHARING and WINKLER: *Rech. sur la nature et la cause du Beri-Beri* Utrecht 1888
- PIERSON: Acute polyneuritis *Volkmann's klin. Vorträge* no. 229 1883
- PITRES and VAILLARD: Gangrene of the limbs due to neuritis *A. de physiol.* v 1885; Alterations of the peripheral nerves in two cases of perforating ulcer and in other forms of trophic lesions of the feet *ibidem* v 1885; Non-trau-

- matic peripheral neuritis *A. de neurologie* v **1883**; Peripheral neuritis in chronic rheumatism *Rev. de méd.* vii **1887**; The peripheral nerves in tuberculous patients *ibidem* vi **1886**; Peripheral neuritis during convalescence from typhoid fever *Rev. de méd.* v **1885**; Acute ascending paralysis following typhoid fever *A. de physiol.* ix **1887**
- ROSS: Peripheral neuritis *Med. Chronicle* xii and xiii Manchester **1890**
- ROSENBACH: Neuritis *A. f. exp. Path.* viii **1878**
- ROSENHEIM: Acute infective multiple neuritis *A. f. Psych.* xviii **1887**
- ROTH: Acute disseminated neuritis *Corresp. f. Schweiz. Aerzte* xiii **1883**
- SCHAFFER: Morbid anatomy of rabies *Ziegler's Beiträge* vii **1890**
- SCHUEBE: Beri-beri *V. A.* 95 **1884**, and *D. A. f. klin. Med.* xxxi and xxxii; *Die Beri-Berikrankheit* Jena **1893**
- SCHULTZE: Lead-paralysis *A. f. Psych.* xvi **1885**
- SCHULZ: Multiple neuritis in alcoholics *Neurol. Cent.* **1885**
- SCHWARZ: Acute ascending paralysis *Z. f. klin. Med.* xiv **1888**
- SENATOR: Acute and subacute multiple neuritis and myositis *Z. f. klin. Med.* **1883**
- SIEMERLING: Alcoholic neuritis *Charité-Annalen* xiv **1889**
- STRÜMPFELL: Multiple degenerative neuritis *A. f. Psych.* xiv **1883**
- TEUSCHER: Degeneration of normal peripheral nerves *A. f. mikrosk. Anat.* xxxvi **1890**
- THOMSEN: Alcoholic neuritis *A. f. Psych.* xxi **1890**
- TREUB: Reflex paralysis and migratory neuritis *A. f. exp. Path.* x **1879**
- VANLAIR: Alteration of centripetal nerves following amputation *Bull. de l'acad. de méd. de Belgique* **1891**
- VIERORDT: The nature of lead-paralysis *A. f. Psych.* xviii **1887**
- VINCENT: Changes in the cardiac plexus following diphtheria *A. de méd. exp.* **1894**
- WESTPHAL: Changes in the radial nerve in lead-paralysis *A. f. Psych.* iv **1874**

CHAPTER XLVIII

REGENERATION OF NERVES

132. When a nerve has been cut through at any point, **regeneration** begins to take place within a few days, starting from the severed end of the central portion which is still connected with the nerve-cells. It commences by swelling of the central end of the axis-cylinder, which then grows out and usually subdivides. In this way

from two to five, or sometimes more (Fig. 261 *ef*), fine processes grow out from the axis-cylinder (Fig. 260 *abc*), which is still surrounded by its medullary sheath (Fig. 260 *a*). Each process soon becomes enclosed in a medullary sheath of its own, and then is capable of being stained by WEIGERT'S haematoxylin method. The rate of growth of these new fibres, according to VANLAIR, is from 0.2 to 1.0 millimetre a day. As the process does not start exactly at the point of section, but somewhat higher up, the fine processes as they grow outward lie at first within the old medullary sheath (Fig. 260 *c* and Fig. 261 *ef*), but they soon emerge from it. As they develop into complete nerve-fibres they receive a connective-tissue sheath or neurilemma, probably derived from the proliferous cells of the old neurilemma, or it may be from those of the endoneurium.

In the case of divided nerves that have not become reunited, granulation-tissue originating from the endoneurium, epineurium, and perineurium is formed on the central stump; and in course of time the

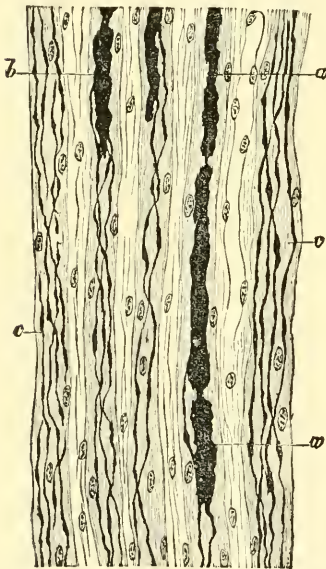


FIG. 260. OLD AND NEWLY-FORMED NERVE-FIBRES.

(Longitudinal section from an amputation stump: preparation hardened in Müller's fluid, stained by WEIGERT'S haematoxylin method (medullary sheaths coloured black), and mounted in Canada balsam: $\times 200$)

- a b* old nerve-fibres from which several young nerve-fibres have grown out
- c* neurilemma with young nerve-fibres

granulations develop into scar-tissue. The young nerve-fibres grow into the scar-tissue, and the fibrous extremity is thus pervaded by nerves crossing one another in all directions (Fig. 262 *b*). By their rapid development they not uncommonly give rise to considerable enlargement of the stump, and form what is known as an **amputational neuroma** (Fig. 262 *b*).

A nerve-fibre that has perished from any kind of injury, such as compression or poisoning, always admits of regeneration provided that the nerve-cell of which it is a process remains intact. The sprouting of the axis-cylinder is in this case accomplished within the old neurilemma, and the new nerve-fibres may reach their terminal organ inside this envelope; but it is also possible for them to break through the old neurilemma and reach their termination by traversing the endoneurium of the nerve-bundle, or even the epi-

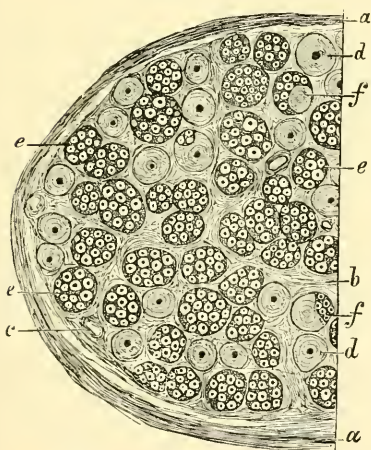


FIG. 261. SECTION OF A FASCICULUS OF THE MEDIAN NERVE JUST ABOVE THE POINT OF SEVERANCE BY A STAB FOUR MONTHS PREVIOUSLY.

(Preparation hardened in Müller's fluid, stained with neutral carmine, and mounted in Canada balsam: $\times 200$)

a perineurium

b endoneurium

c cross-section of a vessel

d old unchanged nerve-fibres

e bundles of newly-formed nerve-fibres

f newly-formed fibres together with the remains of the old fibre within the same medullary sheath

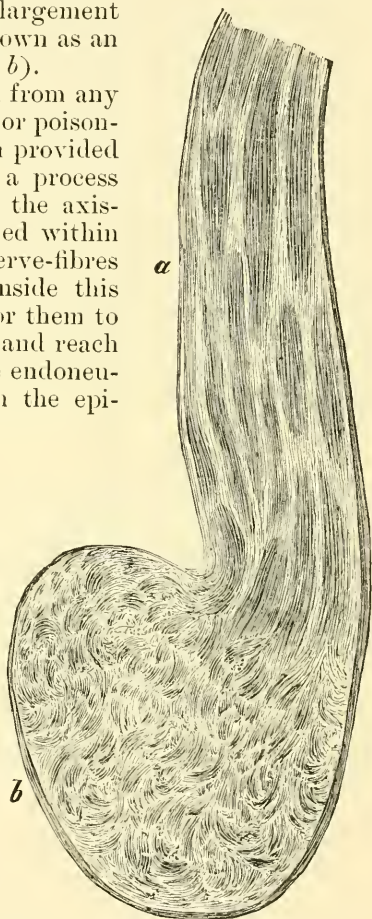


FIG. 262. AMPUTATIONAL NEUROMA OF THE SCIATIC NERVE IN LONGITUDINAL SECTION (AMPUTATION NINE YEARS PREVIOUSLY).

(Preparation hardened in Müller's fluid: $\times 3$)

a nerve

b neuroma

neurium of the nerve-trunk. When the fibres have once reached the terminal organ they subdivide into the special ramifications characteristic of the nerve. The manner in which connexion with the terminal organ is established is not yet precisely determined. According to GESSLER, GALEOTTI, and LEVI, the nerve-tissue of the motor endings in the muscles is regenerated *in situ*.

If the ends of a severed nerve are brought together, union is effected in the first place by the production of granulations and then by the formation of connective tissue. The nerve-fibres in the central end grow through the newly-formed connective tissue and so reach the peripheral end; some of them thus become again connected with their terminal organs, traversing in their course the old neurilemmata, or it may be the endoneurium or epineurium. Many fibres however pass out from the uniting cicatrix, or from the nerve at some point beyond it, into the surrounding tissue, and so fail to reach their proper terminations. When the course the nerves have to traverse in order to reach the terminal organ is a long one, several months may pass before the structure concerned is supplied with its proper number of nerve-endings.

References on the Regeneration of Nerves.

- GALEOTTI and LEVI: Reproduction of nerve-elements in muscular tissue undergoing regeneration *Ziegler's Beiträge* xvii **1895**
- GESSLER: Changes in the motor endings after section of nerves *D. A. f. klin. Med.* xxxi; *Die motor. Endplatte u. ihre Bedeutung für die periph. Lähmung* Leipzig **1885**
- KOLSTER: Repair of nerves after section *A. f. mikrosk. Anat.* xli **1893**
- MARCIGUEY: Regeneration of peripheral nerves *Thèse* Paris **1886**
- VON NOTTHAFT: Injuries of nerves *Z. f. wiss. Zoologie* 55 **1893**
- STROEBE: Degeneration and regeneration of peripheral nerves *Ziegler's Beiträge* xiii **1893**
- VANLAIR: Course and distribution of regenerated nerves *A. de physiol.* viii **1886**, vi **1894**; *La suture des nerfs* Brussels **1889**

CHAPTER XLIX

TUMOURS OF NERVES

133. The majority of the **tumours** occurring in the nerves and ganglia originate in the fibrous structures, and consist chiefly of some kind of connective tissue, the nerve-fibres themselves taking little or no part in their development.

In the case of simple nerves **fibromata** start as a rule in the endoneurium (Fig. 263 *a*), and tend to spread chiefly on the exterior (*b d*), though the internal parts may also be invaded (*c*). Thus the nerve-fibres in some cases lie axially in the growth and are surrounded by proliferous connective tissue (*b*); in other cases they are forced asunder by the intrusion of the latter (*c*).

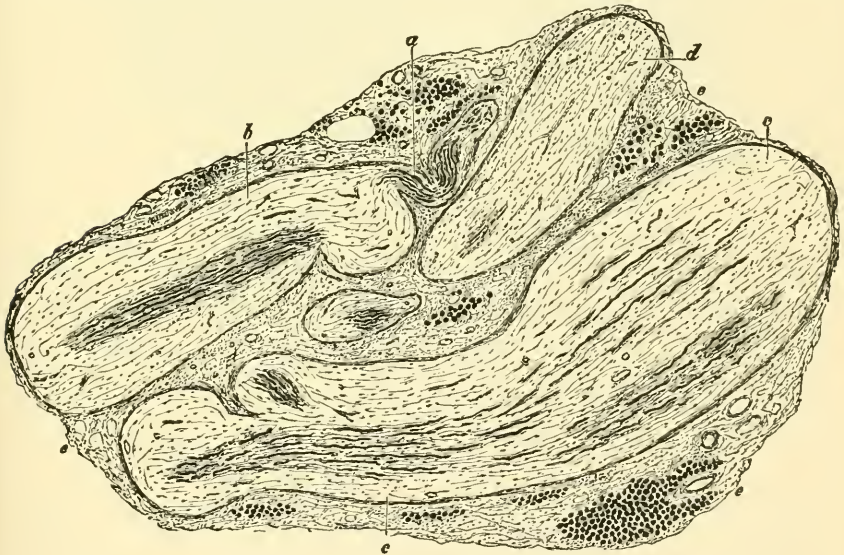


FIG. 263. MULTIPLE NEUROFIBROMATA.

(Section of a plexiform neuroma from a case of elephantiasis of the cheek and lower jaw, preparation hardened in Flemming's acid solution, stained with saffranin, and mounted in Canada balsam: $\times 8$)

- | | | | |
|------------|-----------------------------------------------------------------------------------------------------------------------|----------|--------------------------------------------------------------------------------------------|
| <i>a b</i> | nerve in which the outer strata of the endoneurium have undergone great proliferation, the nerve-fibres lying axially | <i>d</i> | nerve thickened by fibrous hyperplasia with a few persistent nerve-fibres at the lower end |
| <i>c</i> | nerve with hyperplastic endoneurium separating the nerve-fibres | <i>e</i> | loose cellular tissue lying between the nerves, containing much fat |

In compound nerves (Fig. 264) the fibrous hyperplasia usually begins in the endoneurium of the several nerve-bundles (*d e f*), but may extend to the perineurium of the trunk, and to the epineurial septa (*b*) between them. The nerve-fibres generally become atrophic as the hyperplasia extends, but they may also undergo proliferation and increase in number with the growth of the tumour. The tumour in such cases might be called a **neuroma**, or more correctly a **neurofibroma**.

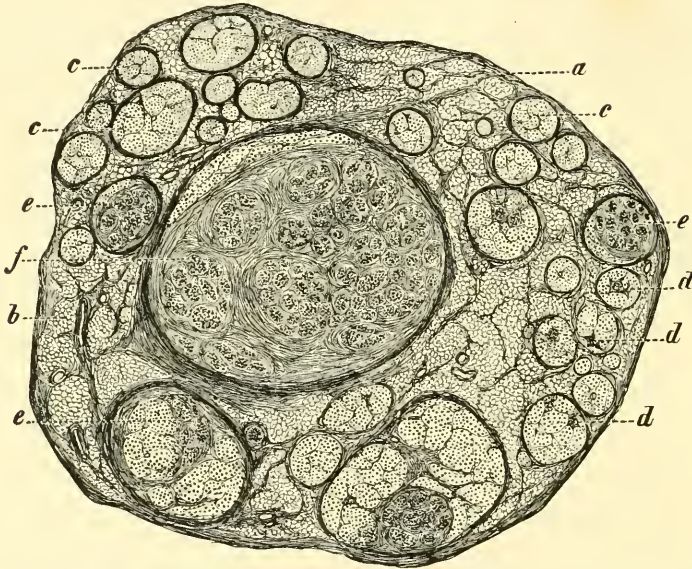


FIG. 264. MULTIPLE FIBROMATA IN ONE OF THE NERVES OF THE SCIATIC PLEXUS.

(Preparation hardened in Müller's fluid, stained with carmine, and mounted in Canada balsam: $\times 10$)

- | | |
|----------------------------------------------------------------------------------|--------------------------------------------------------------------------------------------------------------------|
| <i>a</i> perineurium of the entire nerve | <i>e</i> more advanced fibromatous formation in the interior of a nerve-bundle, enclosing atrophic fibres |
| <i>b</i> epineurium containing many fat-cells | <i>f</i> large fibromatous node in the interior of a nerve-bundle enclosing atrophic nerves, perineurium thickened |
| <i>c</i> cross-section of normal nerve-bundles enclosed in their own perineurium | |
| <i>d</i> commencing fibromatous formation in the endoneurium | |

These fibromata and neurofibromata are usually multiple. In rare cases they develop in large numbers in all the peripheral nerves, but they are more commonly limited to a few. They are sometimes seated in the course of the nerve-trunks, sometimes on the finer branches; in the latter case they are most apt to implicate the smaller cutaneous nerves. They take the form of soft nodes, varying greatly in size, and are generally described as multiple cutaneous fibromata, and classed with the soft fibromata or **fibroma molluscum**. Fibromata of the finer branches may be combined with the like formations in the nerve-trunks,

and the nerves are often at the same time diffusely thickened by fibrous hyperplasia. The individual nodes are sometimes so small that they can be detected only with the microscope, sometimes so large (Fig. 266 *b*) as to form growths of very considerable size. They consist usually of cellular fibrous tissue, but firmer growths with fewer cells are also met with.

Isolated fibromata usually form tumours that are well defined from the surrounding tissue. Sometimes, however, they form a convoluted and tortuous plexus of varying extent, made up of thickened nerves with fusiform and nodose swellings (Fig. 265); this is described as a pampiniform (BRUNS) or **plexiform** (VER-

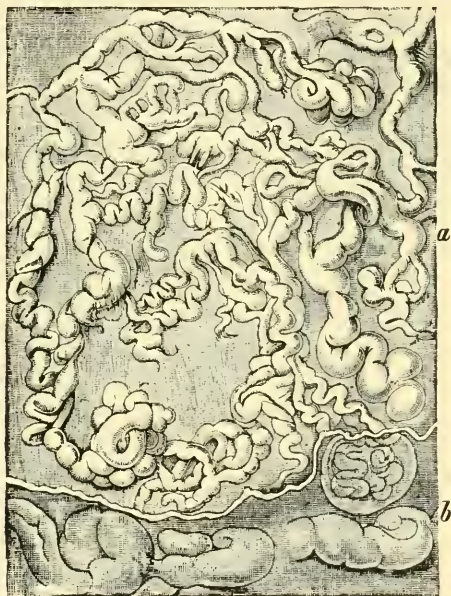

FIG. 265. PLEXIFORM NEUROMA OF THE SACRAL REGION.

(After a drawing by P. BRUNS: natural size: the nodose and convoluted plexus is at *a* uncovered, at *b* still covered, by connective tissue)

NEUIL) **neuroma**. It is met with both on the spinal and on the cerebral nerves, and most frequently in the skin and subcutaneous tissue. When well developed it gives rise in some instances to large puffy lobulated and folded thickenings of the skin (Fig. 266 *a*), in other cases to ill-defined nodose growths, which are regarded as of the nature of elephantiasis, and are accordingly described as neuromatous elephantiasis or pachydermia (Art. 169).

The development of both multiple and plexiform neurofibromata is dependent on some peculiarity of embryonic structure, which even in childhood often gives rise to growths of sensible

size. They are accordingly apt to be hereditary, and to recur in particular families.

Sarcomata, myxomata, and lipomata of the nerves appear as fusiform or nodose tumours, and like the fibromata develop from the connective tissue. They are however very much less common than the multiple fibromata, and are usually single. In somewhat rare cases fibromata undergo sarcomatous transformation (WESTPHALEN), and they then give rise to metastatic growths.

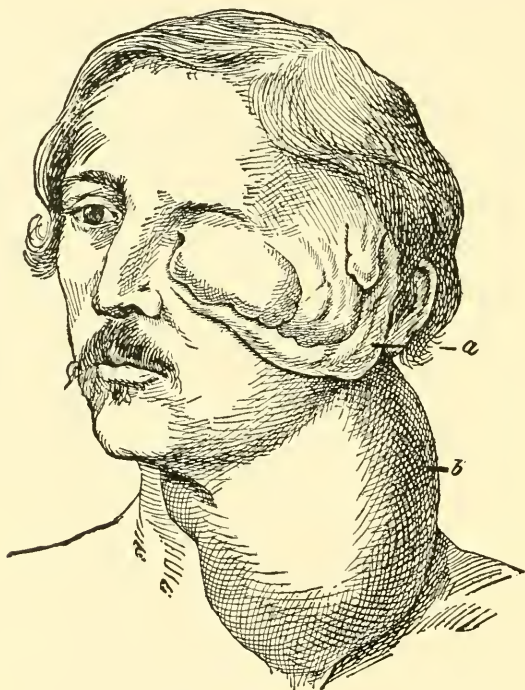


FIG. 266. LOBULATED PLEXIFORM NEUROMA (a) OF THE TEMPORAL REGION AND NEUROFIBROMA (b) OF THE VAGUS (after BRUNS).

References on Tumours of the Peripheral Nerves.

- BRUNS, P.: Plexiform neuroma *V. A.* 50 1870
 CARTAZ: idem *A. gén. de méd.* I 1876
 COURVOISIER: *Die Neurome* Basle 1886
 CZERNY: Neurofibroma *A. f. klin. Chir.* XVII
 ESMARCH and KULENKAMPF: *Die elephantiasischen Formen* Hamburg 1885
 GARRÉ: Secondary malignant neuroma *Beiträge von Bruns* IX 1892
 HAUSCH: Neuroglioma of the Gasserian ganglion *Münc. med. Woch.* 1886
 HERCZEL: Fibroma and sarcoma of the peripheral nerves *Ziegler's Beiträge* VIII 1890
 HÜTER: Myxoma *A. f. klin. Chir.* VII 1866 [1883
 KÖBNER: Case of congenital neuromata with lymphangiomata *Berl. klin. Woch.*

- KRAUSE: Malignant neuroma *Inaug. Diss.* Leipzig 1887, and *Volkmann's klin. Vorträge* no. 293-4 1887
- KRIEGE: Condition of nerve-fibres in multiple fibromata of the skin *V. A.* 108 1887
- LACROIX and BRUNAUD: Amyelinic plexiform neuroma *A. de méd. exp.* II 1890
- POMORSKI: Case of intercostal plexiform neuroma *Inaug. Diss.* Greifswald 1887
- VON RECKLINGHAUSEN: *Die multiplen Fibromen der Haut* Berlin 1882
- SATTLER: Tumours of the optic nerve *Billroth's Festschrift* Stuttgart 1892 (with references)
- VERNEUIL and DEPAUL: *Bull. Soc. de chir.* Paris 1857
- VIRCHOW: *Krankhafte Geschwülste* III; True neuroma *V. A.* 13 1858
- VOSSIUS: Tumours of the optic nerve *Graefe's Arch.* XXVIII
- WEIL: Cystic calcified fibro-neuroma *Prager Z. f. Heilk.* II 1881
- WESTPHALEN: Multiple fibromata of the skin with sarcomatous metaplasia and metastases *V. A.* 110 1887; Multiple fibromata of the skin, nerves, and ganglia with sarcomatous metaplasia *V. A.* 114 1888
- VON WINIWARTER: Plexiform neurofibroma of the arm *A. f. klin. Chir.* XIX 1876

SECTION VIII

THE SKIN

CHAPTER L

INTRODUCTORY

134. The **skin** is a structure which not only fulfils the passive office of covering and protecting the organism in general, but also performs certain active physiological functions of a special kind. It serves as an organ of touch, as a regulator of the body-temperature, as a secretory organ with definite secretions, and as a respiratory organ in so far as it takes part in the adjustment of the gaseous interchanges between the body and the external air. In accordance with the nature of its physiological functions it is in intimate relation with the tissues of the organism on the one hand, and with the external environment on the other. Thus no other organ in the body has so many different tasks to perform, and none is so constantly exposed to extraneous influences.

Its close relations with the rest of the body and with the outer world sufficiently account for the fact that the skin is especially liable to disease and injury. When a disease of the skin is caused by the injurious action of mechanical, thermal, or chemical agents, or by parasites coming from without, the disease is described as **idiopathic**. On the other hand, the term **symptomatic** is applied to cutaneous affections that appear as concomitants or consequences of other disorders, such as changes in the blood or lymph, or morbid conditions in other parts like the heart, liver, kidneys, genital organs, nervous system, etc. A further group, including such affections of the skin as are referable to anomalies of development, might be described as **developmental** diseases.

References on Diseases of the Skin in General.

- ANDERSON, McCALL: *Diseases of the skin* London 1894
Annales de dermatologie et syphiliographie Paris 1868-1896
Archiv für Dermatologie und Syphilis I-V Prague 1869-1873, continued as
Vierteljahresschrift für Dermatologie und Syphilis I-XV Vienna 1874-1888,
and again as *Archiv für Dermatologie und Syphilis* XXI-XXXII Vienna
1889-1896
AUSPITZ: *System der Hautkrankheiten* Vienna 1881; *Maladies de la peau* Paris
1887
BEHREND: *Lehrbuch der Hautkrankheiten* 2nd edition Berlin 1883
COLOMIATTI: *Anatomia patologica della pelle* Turin 1884
CROCKER: *Diseases of the skin* London 1888

- DUHRING: *Cutaneous medicine* Philadelphia **1895**
 FOX, T.: *Atlas of skin diseases* London **1877**
 HEBRA, F.: *Atlas der Hautkrankheiten* Vienna **1856-76**, trans. (New Syd. Soc.)
 London **1860-75**
 HEBRA, H.: *Die krankhaften Veränderungen der Haut* Brunswick **1884**
 HEBRA and KAPOSI: *Diseases of the skin* (New Syd. Soc.) i-v London **1866-80**
 IRSAI and BABES: Influence of nervous system on morbid alterations of the
 skin (experimental) *V. f. Derm.* ix **1882**
 JENNER: *Dermatolog. System auf path.-anat. Basis* Hamburg **1893**
 KAPOSI: *Pathol. und Therap. d. Hautkrankheiten* Vienna **1887**, (trans. by JOHN-
 STON) London **1895**
 KOPP: *Trophoneurosen der Haut* Vienna **1886**
 LELOIR and VIDAL: *Traité descriptif des maladies de la peau (avec atlas)* Paris
1890-95
 LELOIR: *Affections cutanées d'origine nerveux* Paris **1882**
 LESSER: *Lehrbuch d. Haut- und Geschlechts-krankheiten* Leipzig **1894**
 MORROW: *Atlas of venereal and skin diseases* New York **1893**
 NEUMANN: *Text-book of skin diseases* (trans. by PULLAR) London **1871**, (trans.
 by BULKLEY) New York **1872**; *Lehrbuch u. Atlas d. Hautkrankheiten*
 Vienna **1880-90**
 SCHWIMMER: *Die neuropathischen Dermatosen* Leipzig **1883**
 UNNA: *Monatshefte f. prakt. Dermatologie* Hamburg **1882** etc.; *Hautkrankheiten*
 (*Orth's Lehrbuch*) Berlin **1894**; *The histo-pathology of diseases of the skin*
 (trans. by WALKER) Edinburgh **1896**
 WILLAN: *Cutaneous diseases* London **1808**
 WILSON: *Diseases of the skin* London **1867**; *Lectures on dermatology* London
1871-1878

CHAPTER LI

DISORDERS OF CIRCULATION

135. The amount of blood circulating in the skin varies greatly even under physiological conditions, and its pathological variations are equally remarkable. They are liable to be caused by local vascular and textural changes, and in particular by vaso-

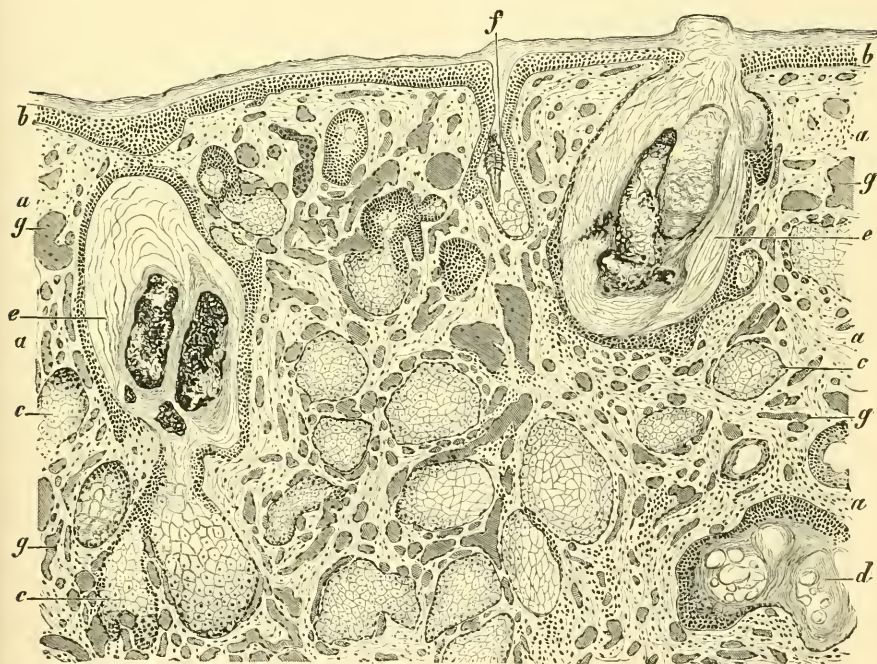


FIG. 267. ACNE ROSACEA.

(Section through the nasal skin: preparation hardened in Müller's fluid, stained with haematoxylin and eosin: $\times 25$)

- | | | | |
|---|--------------------------------------------------|---|-------------------------------------------------------------------------------------------------|
| a | corium, in parts slightly infiltrated with cells | e | excretory ducts of the sebaceous glands distended with horny cells and bacteria (stained black) |
| b | epidermis | f | <i>Demodex folliculorum</i> in the duct of a sebaceous gland |
| c | sebaceous gland | g | dilated blood-vessels |
| d | sebaceous gland with epithelial scales | | |

motor disturbances, as in the hyperaemia accompanying neuralgia or injury to the cutaneous nerves.

Hyperaemia of the skin may be diffuse or circumscribed, and gives rise to a reddening of the skin that disappears under the pressure of the finger. The tint varies from pale pink to the dark livid purple of cyanosis. The excess of blood is limited almost entirely to the upper strata of the corium, and to the papillary layer in particular.

Spots of hyperaemia when small constitute **roseola**; when large and diffuse **erythema**. Sometimes the hyperaemic parts are also notably swollen, and independently of the distension of the blood-vessels the tissues are saturated with transuded liquid; this occurs in **inflammatory oedema**. When the hyperaemia persists for a time, the epidermis is loosened and shed, and we have **desquamation**; after the hyperaemia has disappeared, especially if it has lasted for some time or has frequently recurred, a certain amount of pigmentary **discoloration** remains, due to the transformation of the extravasated red corpuscles into **pigment**. After death simple hyperaemia usually leaves no trace on the skin.

Engorgement or passive hyperaemia generally gives rise to ill-defined bluish-red blotches. A small spot is called a **livor** or **livedo**, a more diffuse lividity constitutes **cyanosis**.

Acne rosacea is characterised by deep-red spots, nodules, and tuberosities containing dilated blood-vessels, which develop slowly over the surface of the nose and cheeks. Its growth is due to long-continued distension of the blood-vessels (Fig. 267 *g*), combined with enlargement of the sebaceous glands (*c*) and dilatation of their excretory ducts by retained secretion (*e*). The excretory ducts sometimes harbour a *Demodex folliculorum* (*f*), which perhaps keeps up the chronic condition of irritation. The parts about the gland are apt to be inflamed.

Anaemia of the skin is manifested by its abnormal paleness, and is general or local. It may be due to direct external influences, to stimulation of the vaso-constrictor nerves, or to general anaemia.

Oedema of the skin, that is to say saturation of its tissue with serous liquid, is due either to engorgement of the veins or lymphatics, or to increased permeability of the walls of the arterioles. Oedematous skin is thick and puffy, and liquid runs from it when it is cut; in extreme cases the epidermis rises in blisters or blebs from the papillary layer.

Active or congestive hyperaemia is not always easy to distinguish from inflammation, into which it often passes as a second stage. The idiopathic erythemata arising from mechanical injury, heat, etc., and the symptomatic rashes, such as those accompanying infantile dentition and diphtheria, are usually accompanied by a certain amount of inflammatory exudation, more especially in the case of the idiopathic forms.

136. Recent **haemorrhages** into the skin give rise to red stains which do not disappear when pressed with the finger. Small irregular specks from the size of a millet-seed to that of a lentil are called **petechiae**. **Vibices** are small elongated simple or ramified streaks, and still larger irregularly-shaped stains are called **ecchymoses**.

When the haemorrhage gives rise to a nodular or papular unevenness of the skin it is called **lichen haemorrhagicus** or **purpura papulosa**. When the extravasated blood is collected into a tumour or raised swelling this latter is described as **ecchymoma** or **haematoma**; when it raises the epidermis into a large vesicle or bleb the result is a **haemorrhagic bulla** or blood-blisters.

The seat of haemorrhage varies; usually it is in the papillary layer and corium, and thence the extravasated blood passes up under the epidermis, and either raises it from the underlying layers or penetrates among its cells. If the blood gains entrance to the sweat-glands and escapes through their ducts we have **haematidrosis** or bloody sweat.

In cutaneous haemorrhages the changes passed through by the colouring matter of the extravasated blood may be followed in part by the naked eye. The bright red of recent blood passes through bluish-red and yellowish-green into brown. After a time the discoloration disappears as the pigment is absorbed, and the altered blood which has penetrated between the epidermal cells comes to the surface and is shed with them by the process of normal desquamation.

According to their mode of origin cutaneous haemorrhages are distinguished as idiopathic or symptomatic. Spontaneous as distinguished from traumatic haemorrhages are usually grouped together under the general name of **purpura**.

Spontaneous purpuric haemorrhages are either symptoms or secondary consequences of certain general affections, some of which are at present but little understood. The haemorrhages that accompany some forms of small-pox (**variola haemorrhagica** or **purpura variolosa**) are occasionally very extensive. They begin as small specks, without any definite arrangement, and in a few hours expand and coalesce into great blood-stained patches. Plague, snake-bites, septicaemia, scarlatina, endocarditis, and other infective and toxæmic conditions are often accompanied by cutaneous haemorrhages in the form of petechial or livid spots, due to changes in the blood or in the vessel-walls, or occasionally to embolic lodgments of bacteria in the arterioles of the skin.

Purpura or **peliosis rheumatica** is a peculiar affection which sets in with or without slight febrile symptoms, and with pains in the knees and ankles, followed by the appearance of large and small cutaneous haemorrhages about the knees. In **purpura simplex** and **purpura haemorrhagica** (*morbus maculosus Werlhofii*) cutaneous haemorrhages make their appearance in various parts of the body, accompanied by fever and general depression. In the latter affection the haemorrhagic patches may be as large as the palm of the hand, and copious bleeding from the mouth, nose, and throat occasionally ensues. The haemorrhages in **scurvy** or **purpura scorbutica** are a very marked feature,

and occur in the skin and the subcutaneous tissue as well as in the gums. The cause of all these affection is unknown; probably they are due to infective or toxæmic agencies (W. KOCH).

The lower limbs of aged persons, whose vascular system is in a state of atheromatous degeneration, are very frequently covered with hæmorrhagic spots. This condition is called **purpura senilis**, and results from disturbance of the circulation.

The **stigmata**, or spontaneous hæmorrhages from the skin, which in some patients and especially in hysterical women appear as the result of nervous excitation, and are often regarded as miraculous, might be described as **neuropathic hæmorrhages**.

References on Hæmorrhages of the Skin.

- CHEYNE and RUSSELL: Micro-organisms in purpura *B. M. J.* II 1883, I 1884
 FAISANS: Myelopathic purpura *Thèse Paris* 1882
 HANOT and LUZET: Streptococci in purpura *A. de méd. exp.* II 1890
 KOCH, W.: Haemophilia and its varieties *Deutsche Chirurgie* part 12 Stuttgart 1889
 KOGERER: The genesis of hæmorrhages *Z. f. klin. Med.* X 1885
 LÉLOIR: *Ann. de dermat.* V 1884
 MACKENZIE, S.: Nature of purpura *B. M. J.* II 1883
 TIZZONI and GIOVANNINI: The genesis of hæmorrhagic infection *Ziegler's Beiträge* VI 1889
 WAGNER, E.: Purpura and erythema *D. A. f. klin. Med.* XXXIX 1886
 ZWICKE: Diffuse ecchymoses of unknown origin *Charité-Annalen* VIII 1883

CHAPTER LII

PIGMENTARY DISORDERS

137. **Discolorations** of the skin may be diffuse or circumscribed. They are due either to an increase of the natural pigment of the rete Malpighii and corium, or to deposition of pigment derived from the blood or bile or from extraneous matters introduced into the system.

One kind of local morbid pigmentation is congenital, or at least has some congenital basis; in the latter case it usually appears in early life. Of this nature are the varieties described as pigmented moles (*naevi pigmentosi*), freckles, sun-spots, and xanthelasma.

Naevi pigmentosi, or **moles**, are congenital, and take the form of spots of various sizes; they are light-brown to dark-brown or black in colour. When smooth and level with the skin a mole is termed *naevus spilus*, when rough and warty *naevus prominens*, or *naevus verrucosus*, and when beset with hair *naevus pilosus*. The epidermis covering a mole is usually of normal thickness, and but rarely hypertrophic.

Freckles (*lentigines*) appear at various ages during childhood, and form yellowish to blackish-brown sharply-defined specks from the size of a pin's head to that of a pea, and closely resembling small naevi. They have no special seat of preference, and when once produced they persist throughout life.

Sun-spots (*ephelides*) are composed of irregular and jagged light-brown smooth specks, that generally appear in early life, most commonly between the fourth and the eighth year, upon the face, hands, and arms, and rarely in other portions of the body. They either persist for life or gradually disappear after a time. The development of the pigment is favoured by the action of sunlight.

Xanthelasma or **xanthoma** occurs as sulphur-yellow and brownish-yellow spots, which are either level with the skin (*xanthelasma planum*) or raised above it in nodular excrescences (*xanthelasma tuberosum*). The spots are commonest about the eye-lid, and seldom appear in other places.

All these forms possess a peculiar cellular structure, and are therefore reckoned among the neoplasms of the skin (Art. 168) that are referable to congenital conditions.

A second variety of morbid pigmentation evidently depends on certain physiological or pathological conditions of the body. Thus women who are pregnant or are suffering from uterine disease frequently exhibit pigmentation of the forehead, temples, cheeks, mammary areolae, and other parts, in the form of brown spots of different sizes, which tend to become confluent or enclose within them lighter areas. Such discolorations are described as **uterine chloasma**; they are doubtless related to special conditions of the reproductive organs, as they generally disappear with pregnancy, or after the cure of the primary uterine affection.

In patients suffering from wasting diseases, such as phthisis, brownish pigmentation of the skin is of frequent occurrence, the condition being termed **chloasma cachecticum**.

In **Addison's disease**, with the onset of the peculiar cachexia the skin assumes a diffuse dark-brown or bronze-like hue (*cutis aenea*), particularly about the face, neck, hands, nipples, and genitals. Darker and more sharply defined spots are simultaneously produced in the skin, and in the mucous membranes of the mouth and throat grey patches sometimes appear. The discoloration is usually associated with a characteristic degeneration of the suprarenal bodies, these organs being in general tuberculous.

A third kind of cutaneous pigmentation is due to local damage from thermal, chemical, or traumatic causes, or is due to disease of the skin itself. Thus by the action of strong sunlight the skin is apt to be more or less burned, and the discoloration thereby produced (**chloasma caloricum**) may last for some time. Slight and repeated injuries, such as those caused by parasites or by scratching, often leave pigmented spots (**chloasma traumaticum**). Mustard-plasters, cantharides, iodine, chrysa-robin, and the like, when applied to the skin are liable to produce stains (**chloasma toxicum**) that usually disappear after a certain length of time, but occasionally last for life.

The yellow and brown pigmentation appearing after cutaneous haemorrhages is caused by the deposition partly of haematoidin and partly of haemosiderin.

Icterus or jaundice leads to yellowish, yellowish-green, or olive-coloured staining of the skin by the bile-pigments. In **argyria**, due to the continued ingestion of silver-salts, the deposition of particles of reduced silver in the corium gives it a tint varying from slate-colour to dark-brown. In **tattooing** various insoluble colouring-matters are incorporated into the corium, and there remain.

138. The term **pigmentary atrophy** (*leucopathia* or *achroma*) refers to conditions in which the normal pigment of the skin is deficient or absent. The congenital variety (*leucopathia congenita*) is called **albinism**; the acquired form (*leucopathia acquisita*) is called **vitiligo**.

In the condition known as total or general **albinism** the normal

pigments of the body are absent from birth. The affected persons, who are called albinos, have a milk-white pinkish translucent skin; their hair is yellowish-white and silky; the iris and choroid are uncoloured, and therefore show the red tint of the blood they contain. Albinism is not very common among Europeans, but it is more frequent among negroes.

Partial albinism, that is, partial congenital deficiency of pigmentation, is rare among Europeans, though many cases have been observed in which the skin contained congenital white patches. According to SELIGSOHN and STRICKER, this anomaly is sometimes hereditary.

Vitiligo is characterised by the appearance in the skin of white unpigmented patches, usually surrounded by a zone of increased pigmentation. The patches appear as a rule in early life, sometimes as a sequela of infective disease, and they are often symmetrically distributed (Fig. 268).

Having reached a certain size they tend to remain unchanged; but they sometimes increase in size and coalesce, so that ultimately a large portion of the surface of the body is deprived of pigment, the latter becoming concentrated within a small space. Hairs growing on the decolorised patches become white (*poliosis circumscripta*).

The aetiology of vitiligo is not known. Among the Sarts in Turkestan the affection is endemic (MINCH). The histological change consists simply in the disappearance of the normal pigment in the decolorised area, while around it the pigment of

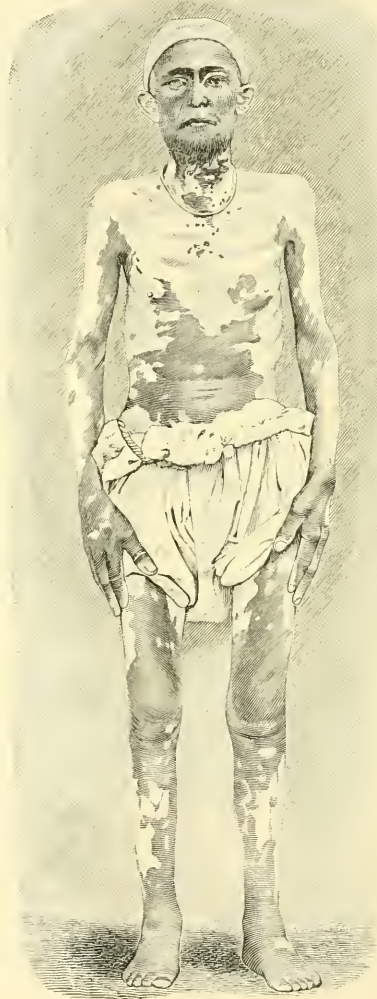

FIG. 268. ENDEMIC VITILIGO.
(After a photograph by MINCH)

the corium is increased. **LELOIR** is of the opinion that the anomalous distribution of pigment is referable to nervous influences.

Local acquired leucopathia may result from cutaneous inflammations, such as those accompanying furunculosis, eczema, lupus, leprosy, and syphilis. In the white patches thus produced the skin is sometimes smooth, sometimes scar-like, while round about them the natural pigmentation is often increased.

The disappearance of the colouring-matter from a pigmented spot is due either to its removal into other parts of the skin or into the lymph-glands, or to desquamation of the pigmented epidermal cells with imperfect reproduction of the pigment.

According to **MINCH**, vitiligo is somewhat widely distributed in Turkestan, and is considered contagious by the Sarts. Affected persons are accordingly segregated, and kept with the lepers within special enclosures. The disease is called by them *pyez*. It is probable that endemic vitiligo has often been confused with macular leprosy by writers who have described it as the 'white leprosy' of the Hebrews.

References on Albinism and Vitiligo.

- BEHREND**: *Art. Leukopathia Eulenburg's Realencyklop.* **1887**; *Canities ibidem* 3rd edition **1894**
- BEIGEL**: *Albinismus partialis, Vitiligo, u. Nigrismus* Dresden **1864**
- EHRMANN**: Anomalies of pigmentation *Allg. Wien. med. Zeit.* 35 **1890**; Cutaneous decoloration due to syphilides *A. f. Derm.* (supplement II) **1891**
- FALKENHEIM**: Anomalies of cutaneous decoloration *V. f. Derm.* xv **1888**
- JADASSOHN**: Transference of cutaneous pigment *A. f. Derm.* **1892** (p. 462)
- KAPOSI**: Pathogenesis of pigmentation and decoloration *Wien. med. Presse* 22 **1891**
- LANDOIS**: Sudden whitening of the hair *V. A.* 35 **1866**
- LEBRUN**: Vitiligo of nervous origin *Thèse* Lille **1886**
- LELOIR**: Cutaneous affections of trophic origin *A. de physiol.* **1881**
- MARC**: Pathogenesis of vitiligo *V. A.* 136 **1894**
- MINCH**: *Prokaza (Lepra arabum) na yuge Rossii* (Leprosy and vitiligo in Southern Russia) Kiev **1884-86**
- POELCHEN**: Vitiligo syphilitica *V. A.* 107 **1887**
- SCHMORL**: Transference of pigment *Cent. f. allg. Path.* v **1894**

CHAPTER LIII

ATROPHY OF THE SKIN

139. **Simple atrophy** implies a loss of substance in the several constituents of the skin, generally in connexion with some change in their structure. It may be local or extended diffusely over large areas, and is sometimes a primary, sometimes a secondary condition.

In the physiological retrogression of old age, or **senile atrophy**, certain textural changes take place in the skin, and these occasionally become very highly marked. The skin becomes thinner, and the papillae are depressed. In some spots where the papillae are not large they disappear entirely. The fibrous fasciculi of the corium become more and more scanty, while the elastic fibres are retracted and undergo hyaline degeneration (SCHMIDT), which leads to their swelling up and to their ultimate disintegration.

The vessels of the skin are here and there obliterated, so that in an injected preparation the close vascular network seen under normal conditions is lost. Deposition of pigment, in the form of yellowish-brown or dark-brown granules, often takes place, the granules lying either in the cells of the rete or around the vessels of the corium. The changes in the cutis are accompanied by corresponding changes in the epidermal elements. The softer strata of the epidermis become thinned out, so that the horny layer is separated from the papillae only by a few layers of cells. The horny layer itself is dry and brittle, and often scaly. Here and there aggregations of epidermal scales take place, forming whitish patches of various sizes, and constituting the condition known as **pityriasis simplex**.

In hairy parts the hairs fall out and are not renewed, the hair-follicles either being empty (Fig. 269 *d*), or containing only lanuginous or downy filaments (*e*). The hair-follicles themselves (*c d e*) are notably diminished in size, and their openings are not infrequently closed (*e*) by proliferous epithelial scales, so that the downy hairs they enclose do not reach the surface. If new hairs (*h*) continue to be produced within the follicles, small **cysts** (*g*) are formed, which contain a large number of minute hairs.

The hair-follicle, or the excretory duct of a sebaceous gland opening into it, may become distended by an accumulation of the sebaceous secretion. This gives rise to a somewhat large cyst

(atheroma or **wen**), filled with sebaceous matter and epidermal scales, or in some cases with minute hairs (*g*), which as it grows forces the hair-follicle (*h*) out of its place. As the hair-follicles perish the sebaceous glands (*f e*) generally become reduced in size, and finally disappear entirely. The sweat-glands on the other hand are not perceptibly altered.

Marasmic or **cachectic atrophy** of the skin occurs in patients affected with wasting diseases, in whom the subcutaneous fat disappears, as in chronic tuberculosis. Such atrophy often gives rise to desquamation of the epidermis in the form of scales (**pityriasis tabescentium**).

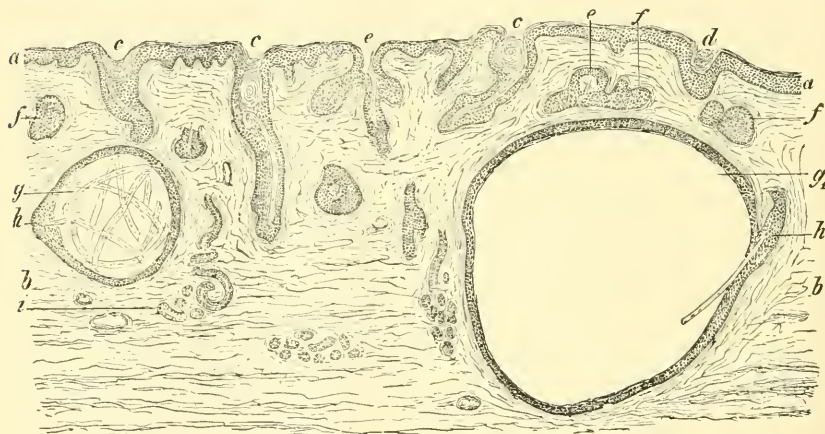


FIG. 269. ATROPHY AND CYSTIC DEGENERATION OF THE HAIR-FOLLICLES AND SEBACEOUS GLANDS OF THE SCALP.

(Preparation hardened in alcohol, stained with Bismarck-brown, and mounted in Canada balsam: $\times 20$)

- | | | | |
|---|-------------------------------------------------------------------------------------------------|----------------|-------------------------------------------|
| a | epidermis | e | hair-follicle with sebaceous gland |
| b | corium | f | atrophic sebaceous gland |
| c | atrophic hair-follicle containing downy hairs below and scales of horny epidermis at its outlet | g | cyst with small cast-off hairs |
| d | obliterated hair-follicle devoid of hair | g ₁ | cyst with enclosed atheromatous matter |
| | | h | small hair seated on the wall of the cyst |
| | | i | sweat-gland |

Linear atrophy from over-distension is generally the result of the excessive stretching of the abdominal walls and adjacent parts of the skin by the pregnant uterus, but the like may result in the abdomen or elsewhere from the growth of tumours or the accumulation of liquid beneath the skin. Streaks appear in the distended parts that at first are reddish in tint, and afterwards become white and lustrous (*lineae albicantes*). Within these streaks the papillae are flattened or entirely effaced. The fibrous fasciuli of the corium are stretched into parallelism, and are no longer interlaced and felted together (LANGE), while the elastic fibres are remarkably diminished in number: the persistent stretching in fact in-

duces atrophy of the elastic fibres and obliteration of the vessels (TROISIÈRE and MÉNÉTRIÈRE).

Cutaneous atrophy, with desquamation of the epidermis, exfoliation of the nails, abnormal distribution of the pigment in brown and white patches, and wasting of the glands and hair-follicles, is an occasional sequela of certain affections of the nerves, as in anaesthetic leprosy. After wounds and injuries of the peripheral nerves, the skin of the paralysed parts often becomes smooth, shining, and attenuated. Excoriation, and at a later stage inflammation, are easily induced. The nails become curved and fissured and the hair falls out and loses its colour.

References on Atrophy of the Skin.

- BUCHWALD: Idiopathic atrophy of the skin *V. f. Derm.* x 1883
 HEITZMANN: Atrophies of the corium *A. f. Derm.* xxii 1890
 LANGER: Texture of lineae albicantes *Anzeiger d. Gesellsch. der Aerzte Vienna* 28 1879
 PASSARGE and KRÖSING: *Schwund und Regeneration d. elastischen Gewebes: Dermatologische Studien* Leipzig 1894
 PHILIPPSON: Changes in the papillary layer due to the action of mechanical forces *V. A.* 120 1890
 SCHMIDT: Senile changes in the elastic fibres *V. A.* 125 1891
 TOUTON: Case of idiopathic atrophy *D. med. Woch.* 12 1886
 TROISIÈRE and MÉNÉTRIÈRE: Histology of linear atrophy of the skin *A. de méd. exp.* i 1889
 ZINSER: Symmetrical atrophy of the skin *A. f. Derm.* xxviii 1894

CHAPTER LIV

INFLAMMATORY AND PARASITIC DISORDERS

140. The **exciting causes** of inflammations in the skin are extremely various in their nature, and act in many different ways. Thus diverse kinds of **mechanical** injuries, such as blows, knocks, pricks, continuous pressure, rubbing, scratching, etc., give rise to different forms of inflammation, according to their mode of action.

To these must be added all the various forms of **contamination** of the skin, which either act as direct irritants, or by blocking up the ducts of the sebaceous and sudoriparous glands and the hair-follicles, and so alter the superficial layers of the epidermis and the cutaneous secretions as to interfere with the functions of the skin. Inadequate cleanliness often gives rise to itching, from irritation of the sensory nerves, and the scratching that is thereby induced increases the intensity of the irritation.

Abnormal **chilling and heating** of the skin are still more common causes of inflammation. Frequently-recurring changes of the surrounding temperature, or the application of intense cold or heat for a short time, produce the same effect as changes of less degree continuing for a longer period.

The skin is peculiarly subject to the influence of irritating and **corrosive chemical substances**, many of which set up inflammations that are more or less severe.

Various inflammatory affections of the skin are induced by the settlement in it of vegetable or animal **parasites**, which either reach it from without or are brought to it by the circulation.

Irritation of the nerves frequently leads, in a reflex manner, to congestive hyperaemia of the skin, and sometimes also to inflammatory exudation. Diseases of the central and peripheral nervous system often disturb the nutrition of the skin, and occasionally give rise to inflammatory affections.

Cutaneous anaesthesia renders the skin liable to injury of various kinds, and these are apt to result in traumatic inflammation. A disease of the nervous system that is associated with itching or formication may moreover expose the skin to mechanical irritation by the scratching it excites.

The susceptibility of the skin to the above-named forms of injury varies greatly in different persons. Thus a given injury may be without effect in one case, while in another it sets up

more or less intense inflammation of the skin. Many persons, for example, can wash their hands with weak solutions of corrosive sublimate or carbolic acid without injury to the skin, while others under similar conditions suffer from free desquamation of the epidermis, or it may be from severe eczema. Sometimes indeed the irritation is not confined to the part of the skin directly exposed to the action of the liquid, but extends over a very large portion of the body. A flea-bite, that in most people gives rise to no appreciable irritation, in others sets up wide-spread inflammatory swelling of the skin. So also there are persons who suffer from peculiar cutaneous inflammations whenever they eat strawberries, lobsters or crabs, oysters, sea-fish, and so on.

Children generally have a very susceptible skin, and thus slight irritations are in their case often followed by cutaneous inflammation.

The skin often suffers when the general nutrition is impaired, as in many infective diseases, in chronic disorders of the circulation, and the like; it sometimes indeed becomes so vulnerable that the slightest mechanical injury, such as gentle pressure, gives rise to degeneration, necrosis, and inflammation. This condition is exemplified in bed-sores or decubital necroses.

141. The mildest forms of inflammation of the skin are manifested by diffuse redness and swelling (**erythema**), or by the appearance of circumscribed elevations that are distinguished according to their size and shape as **papules**, **wheals**, **tubercules**, and **nodes**. Papules are small circumscribed solid elevations, wheals are larger and flattened, and tubercules are still larger and somewhat rounded in form and red in colour, or the margin only is reddened while the centre appears pale.

The histological changes in these milder forms of inflammation consist of infiltration of the tissues with serum, and more or less abundant extravasation of leucocytes. The epidermis is usually but little altered, though some of its cells may become swollen and beset with drops of liquid, and afterwards undergo liquefaction. At the same time proliferation is occasionally induced, and gives rise to an increased production of epidermal cells. Red blood-corpuscles are at times extravasated with the leucocytes, and mingling with the exudation pass from the tips of the papillae into the cellular layers of the epidermis.

In many cases the local inflammatory process is more intense, and the skin becomes saturated with exuded liquid. The result is that the swelling and redness are more pronounced, and further changes are induced that lead to the formation of **vesicles**, **pustules**, **scales**, **crusts**, and **scabs**. When the corium (Fig. 270 *c*) and the papillary layer are permeated by liquid, fibrinous, and cellular exudations (*h i*), some of these extend into the overlying epidermal strata (*f g h*), proceeding chiefly from the tips of the papillae (*i*). If the epidermal strata become saturated with liquid,

the cells that are not yet horny are apt to be more or less swollen (*d e f*). Drops of liquid generally appear within them, giving rise to so-called **vacuolation**, and some of them are entirely dissolved, and thus small cavities filled with liquid are produced (Fig. 277 *g g₁*). This is most likely to occur when, as in burns (Fig. 271), the epidermis is severely damaged and in part killed

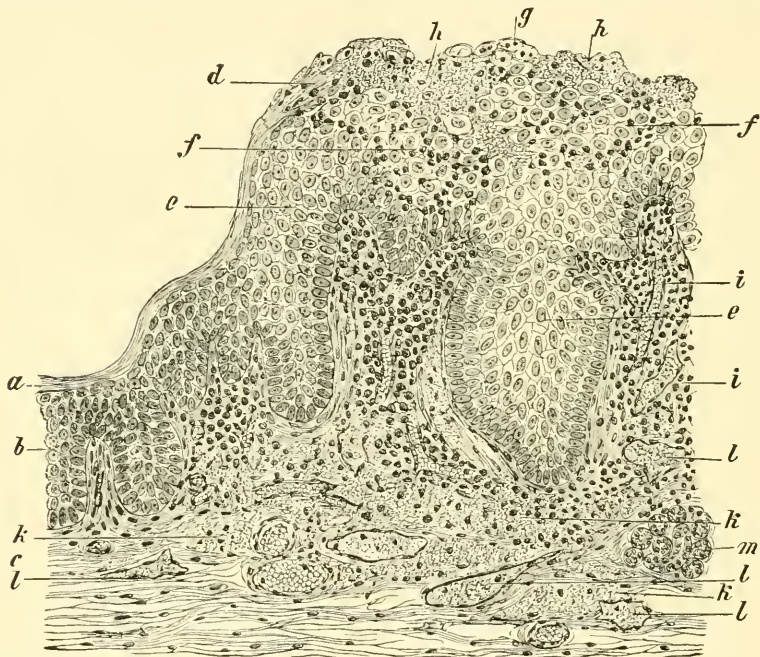


FIG. 270. SECTION THROUGH A SYPHILITIC MUCOUS PATCH (CONDYLOMA LATUM ANI).
(Preparation hardened in Müller's fluid, stained with Bismarck-brown, and mounted in Canada balsam: $\times 150$)

- | | |
|-------------------------------------------------------------------|---------------------------------------------------------------------------|
| <i>a</i> horny layer of the epidermis | <i>g</i> degenerate epidermal cells into which leucocytes have penetrated |
| <i>b</i> rete Malpighii | <i>h</i> granular coagula |
| <i>c</i> corium | <i>i</i> swollen and infiltrated papilla |
| <i>d</i> surface layer swollen up and infiltrated with leucocytes | <i>k</i> corium infiltrated with cells and fibrin |
| <i>e</i> swollen cells of the rete Malpighii | <i>l</i> lymphatic vessel |
| <i>f</i> swollen epidermal cells interspersed with round-cells | <i>m</i> sweat-gland |

by the primary injury, while at the same time a large amount of liquid is extravasated from the vessels. The epidermal cells overlying the tips of the papillae (Fig. 271 *d f*) are the first to swell up and dissolve, but later on the inter-papillary cells (*e g h*) undergo a similar change.

When the extravasated serum is able to pass through the horny layer of the epidermis and appears on the surface, the inflamed area is covered with a liquid and more or less coagulable

exudation (Fig. 270 *h*), and the surface is said to 'weep.' This is most likely to happen in parts where two cutaneous surfaces are in close contact and so are protected from drying, with the result that the cells of the horny layer become swollen and loosened.

Crusts and **scabs** are produced when the superficial exudation dries by evaporation. According to the proportion of red or white blood-corpuscles present in the exudation, the crust is gummy and semi-translucent, and brown or brownish-red in colour, or dirty brownish-yellow and opaque. Scabbing is most apt to occur when the horny layer of the epidermis is injured, or when the surface is broken by **excoriation** or exfoliation, fissures (**rhagades**) or chaps, through which the exudation easily reaches the surface.

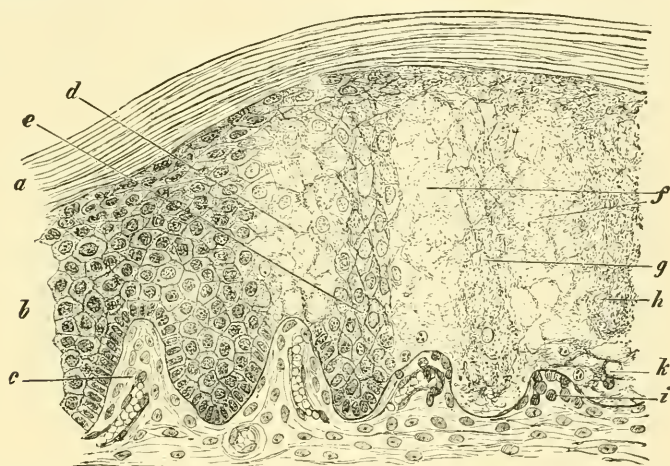


FIG. 271. SECTION THROUGH THE MARGIN OF A BLISTER DUE TO A BURN.

(Carminic staining: $\times 150$)

- | | |
|---------------------------------------------------------------------------------------------------------------------------------------------------------------------------------------------------------------------------------------------------------------------------------------|-----------------------------------------------------------------------------------------------------------------------------------------------------------------------------------------------------------------------------------------------------------------------------------------------------------------------------------|
| <p>a horny layer
 b rete Malpighii
 c normal papilla
 d swollen cells in some of which the nucleus is still visible, in others not
 e inter-papillary cells, those below being uninjured, while those above are swollen and elongated, and have lost their nuclei</p> | <p>f complete liquefaction of the cells over the papillae
 g inter-papillary cells, denuded, swollen, and separated from the cutis
 h complete degeneration of the inter-papillary cells separated from the cutis
 i depressed papilla infiltrated with cells
 k sub-epidermal coagulated fibrinous exudation</p> |
|---------------------------------------------------------------------------------------------------------------------------------------------------------------------------------------------------------------------------------------------------------------------------------------|-----------------------------------------------------------------------------------------------------------------------------------------------------------------------------------------------------------------------------------------------------------------------------------------------------------------------------------|

When the escape of liquid to the surface is prevented by the horny layer of the epidermis, the latter is raised by the exudation, and **vesicles** or **blebs** are produced (Fig. 271). If all the cells of the rete Malpighii are destroyed by a sudden and copious exudation, the vesicle is unilocular: but if the cellular structures are in part preserved and form more or less complete septa between the centres of liquefaction, the result is a multilocular vesicle.

The latter is the usual condition in recent vesicles, and the persistent cells and cellular septa undergo various deformations, due to continued pressure and tension. After a time most of the septa become liquefied and disappear.

The liquid distending the vesicles and blebs usually contains at first but few cells, and is therefore clear. At times it includes a large number of red corpuscles, giving rise to haemorrhagic blebs with red or pink contents. In other cases the liquid contains numerous leucocytes, which give it a whitish turbid appearance like that of thin pus: such a vesicle is usually described as a **pustule**. Often the course of the process is such that when the vesicle first appears its contents are clear, and afterwards they become turbid. The liquid may however be turbid from the outset, or the vesicle may dry up without passing through a stage of turbidity.

The contents of a pustule sometimes become inspissated by evaporation, and then it gives rise to a yellow, grey, or brown crust or scab.

In certain cutaneous inflammations, when the interference with the circulation of the papillae and corium is extreme and persistent, or when the exciting cause is such as directly to bring about necrosis of the tissue, the resulting loss of substance is not confined to the epidermal strata but extends to the deeper layers, and these are either cast off as large **sloughs** or **eschars**, as in diphtheritic inflammation and gangrene, or break down more gradually by suppuration. Such inflammations therefore terminate in necrosis, gangrene, abscess, or ulceration.

142. The inflammations of the skin are some of them acute processes, tending to recover after short duration, and some of them chronic, giving rise to more or less extensive textural changes.

In the slight forms of **acute inflammation**, the exudation is in general speedily re-absorbed, and the skin soon resumes its normal appearance. Not uncommonly, however, the process of recovery is accompanied by somewhat free desquamation of the epidermis, which is cast off in **scales** or shreds. The scales (*squamæ*) take the form of small bran-like flakes, of larger thin white or dirty-grey glistening lamellae, of thicker white plates, or of continuous membranaceous shreds, which are shed from the surface of the epidermis. The desquamation is called **furfuraceous** when the scales are small; it is **membranaceous** or **siliquose** when the flakes are larger. The scales occasionally cohere into irregular masses, or into thick cakes. The formation of scales is chiefly due to an increased or morbidly-altered production of horny epidermal cells.

Transient pigmentation is apt to arise when the inflammation is associated with extravasation of red blood-corpuscles.

Regenerative multiplication of the epidermal cells is soon

set up beneath the vesicles, pustules, and crusts. It generally starts from the border of the inflammatory area (Fig. 272 d_1), and thence extends to the denuded parts. If any epidermal cells persist between the papillae, the proliferation may start from them; and in some cases it appears to proceed from the cells of the hair-follicles and the ducts of the sebaceous and sudoriparous glands. In these ways the mass of the vesicle, pustule, or scab is gradually forced upwards, and separated from the underlying papillae by a cellular layer; this very soon becomes differentiated into the normal epidermal strata, and a new horny layer (d_2) is at length produced. When after a time the scab is thrown off, the epidermal surface beneath it is already more or less completely restored.

If the papillae and portions of the corium have been destroyed by the inflammatory process, the regeneration is apt to be incomplete, as a new papillary layer is not reproduced, or at best in an

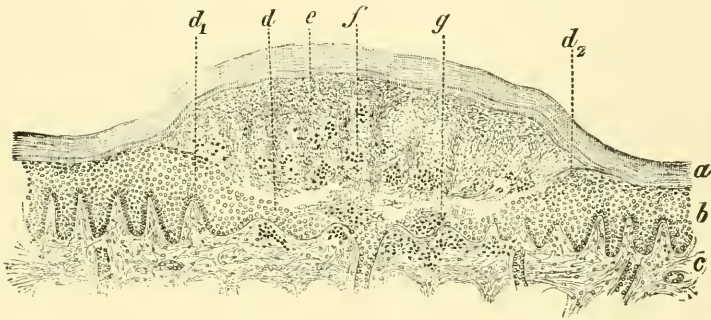


FIG. 272. BLISTER FROM A BURN IN PROCESS OF HEALING.

(Section through the skin of a cat's paw forty-eight hours after a burn: stained with alum-carmin, and mounted in Canada balsam: $\times 25$)

- | | | | |
|---|----------------------------------------------------------------------------|-------|--------------------------|
| a | horny layer | d_2 | new-formed horny layer |
| b | rete Malpighii | e | old degenerate epidermis |
| c | corium with sweat-gland h | f | pus-corpuscles |
| d | new-formed epidermal cells undergoing differentiation into layers at d_1 | g | secondary exudation |

imperfect manner. The affected part is indeed covered over with epidermis, and the loss of substance in the deeper strata is made good by new connective tissue, but its surface remains abnormally smooth and somewhat depressed: in fact a **scar** is left behind. For a time the scar appears redder than the surrounding skin, but in the end it usually becomes paler, and loses even its normal proportion of pigment. In some cases it is surrounded permanently by a pigmented zone or areola.

In the case of **chronic inflammations** both atrophic and hypertrophic conditions may be induced in the skin.

The growth of the epidermis is often disturbed, being abnormally diminished or increased, or morbidly perverted in some

way. Not infrequently there is continuous desquamation, the epidermal cells as they reach the surface not passing through the regular stages of cornification, but simply undergoing desiccation.

In conditions of chronic irritation, the papillae of the papillary layer tend to become hypertrophic and subdivide at their tips, while the corium and subcutaneous connective tissue becomes thickened and indurated. In other cases atrophy of these structures takes place, the papillae becoming flattened and the corium thinned. Certain forms are moreover accompanied by ulceration.

In chronic parasitic inflammations, healing at the centre of the affected spot, while the morbid process is advancing at the periphery, is a very common phenomenon. In this way peculiar ring-like patches with a normal or cicatrised centre are produced.

By the coalescence of several such radially-extending areas, larger patches with sinuous or serpentine outlines are formed (serpiginous inflammation).

143. Among the milder forms of cutaneous inflammation, indicated mainly by an erythematous flush, and to some extent by swelling, are a number of **rashes** or **exanthems** that are differentiated partly by their causation and partly by their external appearance; of these the following are the most important.

The eruption of **measles** (*morbilli, rubeola*) appears first on the face, forehead, and temples, and thence extends over the occiput, neck, shoulders, and trunk. It forms red and yellowish-red patches of the size of the finger-nail or larger. The patches are either level with the skin, or slightly raised into papules corresponding to the openings of the hair-follicles (*morbilli laeves* and *papulosi*). The skin and subcutaneous tissue, especially in the face, are somewhat swollen and oedematous. The patches tend to assume a crescentic form, and sometimes run together here and there, but they never become quite confluent. In a few hours after its appearance the eruption becomes pale, leaving the skin faintly yellow; and presently over the seat of the exanthem a slight branny desquamation takes place.

The eruption of **scarlatina** appears first on the neck and clavicular region, and thence extends over the back and breast to the limbs. At first it takes the form of minute red dots closely crowded together, which cause the skin to acquire a diffuse or uniform flush. The tint is at first pink, afterwards deep red, livid, or scarlet. The skin is swollen by the accompanying infiltration. The eruption lasts from one to three days, and occasionally as long as six or seven; it then fades and leaves the skin with a yellowish-brown staining. Afterward the epidermis desquamates in flakes and scales of various sizes: if the flakes are large the desquamation is called membranaceous, if small and thin it is furfuraceous. Occasionally the eruption is papular, vesicular, or pemphigoid, and not infrequently it is haemorrhagic (*scarlatina haemorrhagica*).

The exudation poured out into the connective tissue is somewhat rich in cells.

Erythema exsudativum multiforme is a cutaneous affection which begins as an eruption of flat slightly-prominent circumscribed and scattered spots (*erythema laeve*) on the back of the hands and feet and the neighbouring parts of the fore-arm and lower leg. The spots are at first of the size of a pin-head, but presently grow to that of a pea. They are vermilion in colour, and turn pale when pressed. They grow at the margins, while the centre becomes depressed and cyanotic: the larger spots may become confluent. Haemorrhages not infrequently occur at the seat of the eruption.

As the red margin extends and the centre fades we have *erythema annulare* or *circinatum*. If several rings encroach on each other we have *erythema gyratum*. A red spot surrounded by a pale zone, and that by a red zone, constitutes *erythema iris*. If the eruption becomes papular and nodular it is *erythema papulatum* or *tuberculatum*. If wheals are present it is *erythema urticatum* or *lichen urticatus*, if vesicles are formed *erythema vesiculosum*. If the formation of vesicles goes on at the margin while the centre recovers we have *herpes circinatus*, characterised therefore by its rings of vesicles. If the vesicle persists in the centre, it is *herpes iris*. Erythema with large blebs or bullae is *erythema bullosum*. A brown pigmentation usually remains behind after the eruption declines. When vesicles have been formed scales and scabs are left. The affection lasts from two to four weeks.

Some of these varieties of erythema are due to haematogenous infection occurring in the course of specific diseases such as pyaemia, puerperal fever, endocarditis, typhoid fever, and so on. In other cases the affection is a primary one, whose causation is uncertain, but is probably referable to infective or toxic agencies.

Erythema nodosum (*dermatitis contusifformis*, *urticaria tuberosa*) is characterised by the formation of large blotches and rounded nodes, usually on the lower limbs. The blotches are but slightly or not at all elevated, and are bright-red at the margin and purple at the centre. In two or three days they begin to fade, passing through tints of blue, yellow, and green. Though recovery is usually complete, severe forms of the inflammation are sometimes met with which lead to gangrene of the skin. The affection is probably of an infective nature.

Traumatic erythema is produced by many diverse forms of irritation of the skin, mechanical, thermal, or chemical. Mechanical irritation is exemplified by the friction of clothing or of two parts of the body in contact; the effects of thermal irritation by burns or frost-bites of the first degree; chemical irritants are such as turpentine, mercurial ointment, dilute acids, or the poison of insect-stings. Cold of slight intensity gives rise first to paleness, and then to hyperaemia from paralysis of the vaso-motor nerves.

Long-continued but not excessive congelation produces chilblains or *perniones*, which are red swellings due to hyperaemia and inflammatory infiltration of the skin of exposed parts.

Erythematous rashes occasionally result from the use of certain **medicaments**, such as belladonna, copaiba, salicylic acid, anti-pyrin, arsenic, calomel, chloral hydrate, and quinine: and they sometimes appear in diseases of the nervous system and in gastrointestinal disorders, especially in children.

Allied to exudative erythema are some of the circumscribed red rashes included under the term **roseola**. According to the condition with which it is associated the eruption is described as *roseola rheumatica*, *choleraica*, *typhosa*, *aestiva*, *autumnalis*, *infantilis*, etc.

Pellagra (*mal rosso*, *mal del sole*, *risipola lombarda*, Lombardian leprosy) is a peculiar disorder met with in Northern Italy, Southern France, Spain, and Roumania. It appears as an erythematous rash on the exposed parts of the body, especially in the spring and summer, and disappears in the autumn with desquamation of the epidermis.

Urticaria or nettle-rash (*cnidosis*) is a local eruption of wheals which rise and disappear very suddenly. The flattened centre of the wheal is white, and is bordered by a zone of red. Occasionally small vesicles (*urticaria vesiculosa*) or papules (*urticaria papulosa*) are formed. The wheal in some cases acquires a reddish-brown pigmentation (*urticaria pigmentosa*). The rash is either caused by external irritation, such as the stings of nettles, jelly-fish, fleas, bugs, lice, or gnats, or is a symptom of some irritable condition of the alimentary canal, or of the skin itself. In many persons urticaria follows the ingestion of oysters, crayfish, caviar, crabs, sea-fish, strawberries, and so on. Disorders of the reproductive organs are also capable of inducing it.

References on Erythema, Pellagra, and Urticaria.

- AUSPITZ: Erythema multiforme *V. f. Derm.* I 1874
 BOİCESCO: Erythema nodosum of malarial origin *A. roumaines de méd.* I Paris 1888
 CATRIN: Alterations of the skin in measles *A. de méd. exp.* III 1891
 CORDUA: Erythema multiforme *D. med. Woch.* 1885
 DEMME: Severe erythema *Fortschr. d. Med.* VI 1888
 DOUTRELEPONT: Urticaria pigmentosa *A. f. Derm.* XXII 1890
 ELSBERG: Urticaria pigmentosa *V. f. Derm.* XV 1888
 FINGER: Erythema multiforme and purpura *A. f. Derm.* XXV 1893
 FOX, T. C.: Urticaria pigmentosa or xanthelasmaïdeia *Med.-chir. Trans.* LXVI London 1883
 HOGGAN, G. and F. E.: Urticaria pigmentosa *Monatsh. f. prakt. Derm.* I 1882, II 1883
 LEWIN: Erythema exsudativum multiforme *Charité-Annalen* III 1878; *Untoward effects of drugs* Detroit 1883
 MAYR: Pellagra *Hebra und Kaposi's Diseases of the skin* (New Syd. Soc.) I London 1866

NEUSSER: *Die Pellagra in Oesterreich und Rumänien* Vienna 1887

PICK: *Urticaria pigmentosa* *Prager Z. f. Heilk.* II 1881

SCHIEBER: *Pellagra in Roumania* *V. f. Derm.* II 1875

SCHWIMMER: *Erythema multiforme* *Ziemssen's Handb. d. spec. Path.* XIV Leipzig 1874-83

WINTERNITZ: *Clinical study of pellagra* *V. f. Derm.* III 1876 (pp. 151, 387)

144. **Dermatitis combustionis erythematosa** is caused when heat acts on the skin in such a manner as not to kill the tissue but only to induce vaso-motor paralysis of its blood-vessels, resulting in congestive hyperaemia and slight exudation. This is what is known as a burn of the **first degree**. When the heat is more intense the superficial epidermis is destroyed, and the underlying vessels, though not killed outright, are so injured that copious exudation takes place from the papillary layer. The epidermal cells are thereupon more or less completely dissolved, and a unilocular or multilocular vesicle or **blister** (Fig. 271) is produced. This condition is spoken of as *dermatitis combustionis bullosa*, and constitutes a burn of the **second degree**. Burns which lead to sloughing of the cutis are burns of the **third degree**; those accompanied by charring of the tissues are termed burns of the **fourth degree**.

Burns of the second degree recover, provided the injured surface escapes septic infection, by regenerative multiplication of the epidermal cells (Art. 142, Fig. 272). Healing in the case of higher degrees of burning can take place only by the formation of granulations and of cicatricial tissue.

Severe cold produces effects similar to those caused by excessive heat. When blisters are formed in frost-bite we speak of the inflammation as **dermatitis congelationis bullosa**; and when the frozen tissue becomes necrotic and gangrenous the condition is described as **congelatio gangraenosa**. The two forms usually occur together. The dead parts have at first a livid red tint; later on they become dark-red and gangrenous, and are separated from the living tissue by an inflammatory line of demarcation.

The blisters caused by **cantharides** are of much the same character, but the swelling and liquefaction of the epidermis are usually less sudden and less extensive. Denucleated continuous masses are sometimes formed from the necrotic epidermal cells.

145. **Miliaria crystallina** or **sudamina** are small watery vesicles which sometimes appear in the course of puerperal fever, typhoid fever, acute rheumatism, pneumonia, etc., and last for a few days. They occur chiefly on the trunk. The eruption is due mainly to the retention of sweat in the excretory ducts of the glands, though a liquid rich in cells is also poured out into the epidermis (Fig. 273 *c d*), and the vesiculation follows the course already described in reference to the inflammatory process, the only difference being that it takes place at the mouth of a sweat-gland (*d*). Miliaria would thus appear to be in reality one of

the infective inflammatory rashes. Recovery from the sudaminal eruption takes place in a short time, the damaged epidermis being replaced and the dried remains of the vesicles cast off.

146. **Herpes** is an acute affection running a typical course (KAPOSI), and characterised by the formation of clusters of watery vesicles in certain anatomical regions of the body, the vesicles passing through a definite series of stages within a short period of time.

The eruption first appears as a group of minute elevations of the skin, which rapidly become infiltrated with clear serum and so form vesicles. The vesicles last from a few hours to one, two, or even four days, and then dry up into crusts. Beneath the

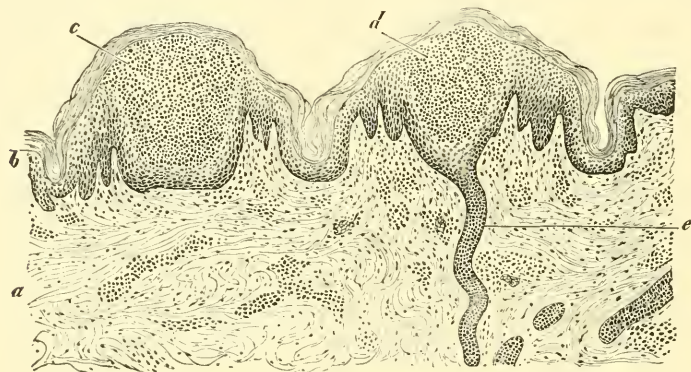


FIG. 273. MILIARIA CRYSTALLINA.

(From a man who died of pneumonia: preparation hardened in Müller's fluid, and stained with hæmatoxylin and eosin: $\times 30$)

a	corium	c d	sudaminal vesicle
b	epidermis	e	excretory duct of a sweat-gland

crusts regenerative proliferation of the epidermis takes place, the lost tissue being thus made good, and the crusts are thereby loosened and cast off.

The contents of the mature vesicles consist of serum, fibrinous coagula, and pus-corpuscles. The papillae and the corium are infiltrated to a varying extent with serous liquid and leucocytes, and occasionally hæmorrhages take place in them.

According to their seat and mode of origin, five forms of herpes are distinguished.

(1) **Herpes zoster** (*zona* or shingles) is an acute eruption of vesicles clustered over the area supplied by a cutaneous nerve, and seems to be dependent upon some disorder of the nerves or of their centres. It is almost always unilateral. The contents of the vesicles remain clear for three or four days: then they become turbid and purulent. Yellowish-brown crusts are formed as the vesicles dry up. The associated nervous disorder may be infective, toxic, traumatic, or secondary to some inflammation of the adjacent tissue. PFEIFFER and WASILEWSKI are of opinion that the characteristic distribution

of the vesicles corresponds to that of the arteries, not of the nerves, the latter being only secondarily affected.

(2) **Herpes labialis** or **facialis** is an acute eruption of vesicles on the lips or around the mouth and nostrils. The vesicles last two or three days, and dry up under a crust, without scarring. It is very often observed in connexion with pneumonia and intermittent fever, and more rarely in typhoid.

(3) **Herpes praeputialis** or **progenitalis** affects the penis, clitoris, or labia: its course is similar to that of herpes labialis.

(4) **Herpes iris** and **herpes circinatus** are according to KAPOSI the same as erythema iris and circinatum (Art. 143). The vesicles occur on the back of the hands or feet and the adjoining portions of the limbs, and form separate or concentric circles. The smaller vesicles fade after eight or ten days, by resorption and drying of their contents. BALZER (*A. de physiol.* 1883) found in the epidermal scales from five cases of herpes circinatus, in which the hairs were not affected, long branching double-contoured filaments and spores, which were larger than those of *Trichophyton tonsurans* (Art. 161).

(5) **Herpes tonsurans vesiculosus** is a special form of tinea (herpes) tonsurans (Art. 161), an affection caused by a vegetable parasite. Circles of vesicles of various sizes are formed by successive marginal crops starting from a centre, the older vesicles drying up as new ones develop.

References on Herpes Zoster.

BÄRENSPRUNG: *Charité-Annalen* IX, X, and XI 1861-63

BRIGHT: Connexion with sensory nerves *Medical cases* II London 1831

CURSCHMANN and EISENLOHR: *D. A. f. klin. Med.* xxxiv 1884

DUBLER: Neuritis in herpes zoster *V. A.* 76 1879

KAPOSI: *Wien. med. Woch.* 1874, 1875, 1877 and 1879; *Verhandl. der deutschen dermat. Gesellsch.* I Vienna 1889; *A. f. Derm.* XXI (supplement) 1889

LESSER, E.: *V. A.* 86 1881 and 93 1883

MACKENZIE: Herpes zoster and the nerve plexuses of the limbs *Journ. of Path.* I 1893 (with references)

PFEIFFER: *Die Verbreitung des Herpes zoster längs des Hautgebiets der Arterien* Jena 1889

WASILEWSKI: *Herpes zoster u. dessen Einreihung unter die Infektionskrankheiten* Jena 1892 (with references)

147. **Pemphigus** or pompholyx (Fig. 274) is an eruption characterised by the formation of blebs (*bullae*) upon the skin, varying in size from that of a small pea to that of a goose's egg.

The blebs are usually preceded by red spots and wheals, over which they rise; but sometimes they appear on what seems to be unaltered skin. The contents are at first clear and watery, or it may be slightly blood-stained, but afterwards they become turbid and purulent. The exudation at length dries up and crusts are formed, under which the loss of epidermis is repaired (*pemphigus vulgaris*).

In other cases this regeneration of the epidermis does not take place, and the separation of the epidermal covering of the bleb from the underlying strata extends, until at length the corium is denuded over a large area (*pemphigus foliaceus*). When the blebs are removed the exposed surface appears red and moist, until a crust is formed over it by the drying of the superficial exudation.

In such cases the corium is always more or less infiltrated, and sometimes it becomes partially necrotic and sloughs (*pemphigus*

diphtheriticus). Granulations are then produced, but they too are very liable to undergo necrosis (KAPOSI).

The cause of the disease would usually seem to be of the nature of an infection. DEMME, ALMQUIST, and others have found micrococci in the blebs. Pemphigoid eruptions have however been recorded which were apparently due to nervous influences (MEYER, DU MESNIL).

Six main varieties of pemphigus have been distinguished, according to their clinical course and causation (KAPOSI, NEUMANN).

(1) *Pemphigus acutus* is an acute affection manifested by an eruption of scattered blebs, with or without fever. The blebs last a few hours or days, and then dry up into crusts. When these fall off the corium is covered with new epidermis, and the attack is at an end.

(2) *Pemphigus chronicus vulgaris* is characterised by the formation of large tense blebs accompanied by a certain degree of fever. The eruption takes place in successive crops. According to the manner in which the blebs are grouped dermatologists describe the eruption as *pemphigus disseminatus* (scattered irregularly), *pemphigus confertus* (closely aggregated), *pemphigus circinatus* (in rings), or *pemphigus gyratus* and *serpiginosus* (in sinuous or serpentine lines). The disease lasts from two to six months, and is sometimes fatal (MOSLER).

(3) *Pemphigus foliaceus* is the severest form of the disease. It is distinguished by its progressive character, and the imperfect way in which new epidermis is produced. After a course of months or years the entire surface of the body becomes involved. The skin

is then in some parts dry, brown, and parchment-like; in others red and weeping; in others again covered over with crusts, and fissured in various ways.

(4) *Pemphigus vegetans* is a malignant variety which soon ends fatally. The skin is beset with small-sized blebs, from whose base, after the epidermal

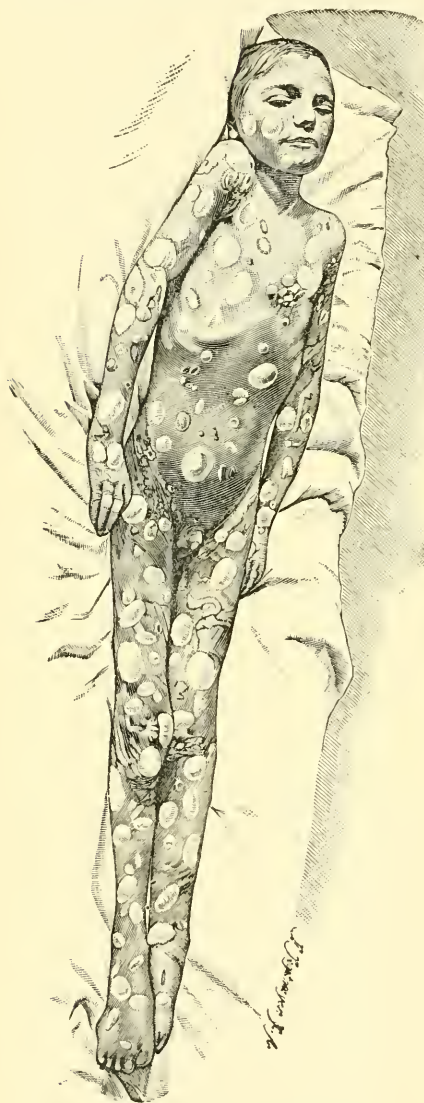


FIG. 274. ACUTE PEMPHIGUS.
(After a photograph by DEMME)

covering or shell is removed, rises a close crop of gland-like, warty, and button-shaped excrescences. These are surrounded first by an excoriated areola, and outside this by serpiginous vesicular elevations of the epidermis, and exude a foetid ichorous liquid that presently dries to a crust. The eruption begins in the skin of the external genitals, the inner surface of the thighs, the axillae, and the mucous membrane of the mouth, and in the end extends over the entire surface, invading also the mucous membrane of the pharynx, larynx, vulva, vagina, and rectum. This variety of pemphigus was formerly looked upon as of syphilitic origin.

(5) *Pemphigus neuroticus* accompanies certain affections of the nervous system.

(6) *Pemphigus syphiliticus* is dealt with in Art. 159.

References on Pemphigus.

ALMQUIST: Pemphigus neonatorum *Z. f. Hygiene* x 1891

BULLOCH: Diplococci in acute pemphigus *British J. of Derm.* 1895

CLAESSEN: idem *Berl. klin. Woch.* 1893

DEMME: Pemphigus acutus *Verhandl. Congr. f. inn. Med. v Wiesbaden* 1886, and *Wien. med. Blätter* 1886

DU MESNIL: Aetiology of pemphigus vulgaris *A. f. Derm.* xxx 1895

MEYER: Pemphigoid dermatitis with changes in the nervous system *V. A.* 94 1883

MOSLER: Chronic pemphigus *D. med. Woch.* 1890

NEUMANN: Pemphigus vegetans (framboesoides) *V. f. Derm.* xiii 1886

STRELITZ: Aetiology of pemphigus *A. f. Kinderheilk.* xvi 1892

148. **Ecze^ma** is a skin-disease which may be acute or chronic. The eruption consists of papules, vesicles, pustules, and crusts. The skin is more or less diffusely reddened and swollen, and often desquamates or 'weeps,' or is covered with large continuous scabs.

Ecze^ma is usually set up by external irritation. When the irritation is slight or the skin is not susceptible to its action, the eruption consists of small papules, and thus *eczema papulosum* is the mildest variety. More intense irritation causes small vesicles to arise, and we have *eczema vesiculosum*; when the vesicles dry up they are cast off as scabs. If the irritation is still more intense or the skin is highly susceptible, a considerable extent of it becomes painfully swollen and red (*eczema erythematosum*). On this erythematous area vesicles arise whose contents are at first clear, but soon become purulent (*eczema vesiculosum et pustulosum*). When the upper shell of the vesicle is removed (as by scratching), the exposed surface pours out liquid, and is said to 'weep' (*eczema malidans*). The epidermal surface, deprived of its horny layer by desquamation or otherwise, has often a deep-red tint (*eczema rubrum*). Yellowish crusts are formed by the evaporation of the sero-purulent exudation poured out on the surface (*eczema crustosum*), and pus sometimes gathers beneath the crust (*eczema impetiginosum* or *impetiginodes*). In other instances new epidermis is formed beneath the crust: when the crusts are cast off the surface then looks red and brawny, and scales are freely shed (*eczema squamosum*). As the disease dis-

appears the skin gradually recovers its normal appearance, though some slight pigmentation often remains.

An eczematous eruption consisting of pustules of the size of a small pea, and drying into scabs, is often described as **impetigo**. Much larger pustules, drying into brown scabs, constitute **ecthyma**. The exciting cause of the suppuration is probably the ordinary pyogenic micrococci.

Impetigo contagiosa (TILBURY FOX: *B. M. J.* I 1864) is a contagious eczematous eruption. It chiefly attacks ill-fed or weakly children, and affects the head and limbs: vesicles as big as a cherry-stone arise on a reddened base, and presently dry up into yellow crusts.

The inflammatory process in this affection is often chronic, and the skin is then beset with vesicles, pustules, crusts, and scabs, all at the same time.

Impetigo herpetiformis (HEBRA and KAPOSÍ) is a peculiar febrile affection, with an eruption of miliary pustules arranged in clusters and rings. It is very probably a secondary result of pyaemic infection, as it makes its appearance in the course of pyaemia.

The textural changes in the cutis consist of serous and cellular infiltrations of the connective tissue. The cellular infiltration is especially abundant in the pustular and impetiginous varieties, and the subcutaneous tissues are often infiltrated in the same way.

The liquid effused into the epidermis contains large numbers of leucocytes, which are found not only in the vesicles but also scattered among the unaltered epidermal cells, and even in their interior. In many cases the epidermis perishes outright, and even the papillae may be destroyed when the inflammation becomes suppurative (*eczema impetiginosum*).

The after-effects of eczema are various. The milder forms leave no trace behind, the skin being restored *ad integrum*. If the papillae in particular spots have been injured or destroyed they are not replaced, and a cicatrix is then produced. Chronic eczema gives rise to pigmentation of the skin, and to hypertrophy of both epidermis and corium; when the hypertrophy is great the skin appears thick and tough, as in elephantiasis, and when the papillae are likewise enlarged the surface becomes warty and tuberculated. Hypertrophy of the epidermis being generally accompanied by the formation of plates, scales, and flakes, an appearance recalling that of elephantiasis combined with keratosis (Art. 164) is produced. So long as the inflammation persists the hypertrophied tissue is thickly beset with clusters of round-cells.

References on Eczema and Impetigo.

- BOCKHART: Aetiology of impetigo, furunculosis, and sycosis *Monatsh. f. prakt. Derm.* Hamburg 1887
 DEMME: *Eczema Jahresbericht des Kinderspitals Berne* 1884

KAPOSI: Impetigo herpetiformis *V. f. Derm.* XIV 1887

DU MESNIL and MARX: Impetigo herpetiformis *A. f. Derm.* XXI 1889

NEISSER: Pathology of eczema *A. f. Derm.* (supplement) 1892

PAVLOFF: Impetigula capillitii *Monatsh. f. prakt. Derm.* IX Hamburg 1889

UNNA: Impetigo contagiosa *V. f. Derm.* VII 1880

149. **Small-pox** or **variola** is a febrile disease characterised by the eruption of papules, vesicles, and pustules, and due to the infection of the system with a specific virus. After a certain interval from the time of infection the skin, after the fading of a not infrequent prodromal erythema, becomes beset with hard red papules of the size of a pin-head, surrounded by a red areola. Some of the papules enlarge and change into clear vesicles most of which are 'umbilicated' or depressed in the centre. In two or three days the contents of the vesicle become turbid, and the vesicle changes to a pustule. At the same time the umbilication usually disappears, and a zone of intense hyperaemia is formed around the pustule. In three or four days it dries to a brownish scab, and this in a few days more falls off, leaving behind a slightly pitted spot, which may be red or white in colour: in a short time the spot also disappears.

Many of the pustules leave behind scar-like pits, which are at first dark-red, but afterwards become white. This is especially the case when, as not infrequently occurs, haemorrhage takes place into the pustule or into its neighbourhood, or when the eruption is so copious that the pustules run together (*confluent small-pox*). The skin then appears rough and tuberculated and is much swollen. When the cap of the pustule is forced off by the accumulating pus beneath, the suppurating corium is laid bare, and parts of it passing through the stages of suppuration or sloughing and gangrene may be destroyed. The affected spots have a yellow, dirty-grey, or black tinge.

The variety distinguished as haemorrhagic or black small-pox (*variola haemorrhagica*), which usually ends fatally, is remarkable for the dark-red colour (*purpura variolosa*, Art. 136) which overspreads the entire surface of the body as the fever sets in. Patches of haemorrhage appear, and speedily enlarge. In other cases a multitude of small hard papules appear on the skin, which is intensely swollen. Haemorrhagic patches follow in from one to two days, and coalesce into larger ones.

The formation of the variolous vesicle begins with swelling up of the cells of the mucous layer of the epidermis immediately over the tips of the papillae, the cells coalescing into pale denucleated masses. This is followed by solution of the majority of the affected epidermal cells in the exudation which at this stage is poured out from the papillary vessels, while at the same time the degenerative change is extending on all sides. Only small remnants of the epidermal tissue withstand solution, and these are chiefly shreds or degenerate masses consisting of denucleated

(or sometimes nucleated) cells, which are stretched and compressed by the accumulating exudation into fragmentary septa and threads.

Thus, at the climax of the process, the pock or vesicle consists of a cavity traversed by shreds and fibres (Fig. 275 *f*), which in the centre reaches to the horny layer (*i*), but towards its margin is separated from the latter (*i*₁) by some of the surface-layers of the epidermis. The floor of the cavity is formed of remnants of the inter-papillary portion of the rete Malpighii (*g*), and in part of denuded papillae (*h*). The papillae and the upper layers of the cutis are swollen and beset with round-cells, and the liquid contents of the vesicle already contain numerous pus-corpuscles (*f*₁).

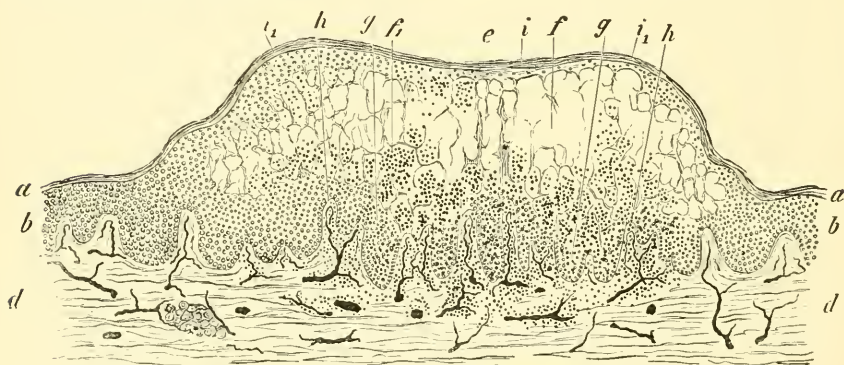


FIG. 275. SECTION OF A VARIOLOUS VESICLE BECOMING PUSTULAR.

(Injected preparation, stained with haematoxylin: $\times 25$)

- | | |
|-----------------------------------------------------------------------------------|----------------------------------------------------------------------------------------------------|
| <i>a</i> horny layer | the papillae, interspersed with pus-corpuscles |
| <i>b</i> rete Malpighii | <i>h</i> papilla infiltrated with leucocytes |
| <i>d</i> cutis | <i>i</i> umbilication over the thinnest part of the cap of the vesicle |
| <i>e</i> vesicle | <i>i</i> ₁ margins of the vesicle where the cap consists of several layers of epidermis |
| <i>f</i> cavity of the vesicle containing pus-corpuscles at <i>f</i> ₁ | |
| <i>g</i> remnants of epidermal cells between | |

As the vesicle becomes a pustule, the number of pus-corpuscles which pass into the cavity from the papillary vessels increases, and the shreds and septa break down. A crust is thus formed, and when resolution takes place beneath it the cellular infiltration is re-absorbed, and new epidermis grows in from the margins, where the cells are uninjured.

When the destruction of tissue by the pock is limited to the epidermis no scar remains; when the papillae slough or suppurate (*h*) the site of the pock is permanently marked by a cicatricial depression (**pock-mark** or **pit**).

The vesicles of **vaccinia** produced by vaccination are similar in their structure and course to the variolous vesicles.

The infective disease of children called **varicella** or **chicken-**

pox is characterised by the eruption of vesicles of different sizes, which appear upon a reddened base and mature very rapidly. Certain of the vesicles may resemble very closely the vesicles of small-pox.

References on the Formation of the Vesicles of Small-Pox.

- AUSPITZ: The eruption of small-pox *Wien. med. Woch.* **1867**
 AUSPITZ and BASCH: Histology of the variolous process *V. A.* 28 **1863**
 BABES: Variola *Ann. de l'Inst. de path.* Bucharest II **1891**
 KLEIN: Minute anatomy of the epidermis in sheep-pox *Q. J. microsc. science* XVII London **1877**
 TAPPE: *Die Aetiologie und Histologie der Schafpocken* Berlin **1881**
 TOUTON: *Unters. üb. d. Entstehung d. Hautblasen* Tübingen **1882**, and *Ziegler's Beiträge* II (p. 453) **1887**
 UNNA: The seat of the eruption in the epidermis *V. A.* 69 **1877**
 WEIGERT: *Anat. Beitr. z. Lehre. v. d. Pocken* Breslau **1874-5**

150. **Psoriasis** is a chronic disease of the skin characterised by the formation of dry glistening white scales. These are piled upon each other in small heaps, or over larger discoid patches which have a definite red base. The eruption begins in minute brownish-red nodules, which in the course of a few days become covered over with epidermal scales. When the nodules are numerous and discrete the disease is described as *psoriasis punctata*: where the patches and scales are larger we have *psoriasis guttata* and *psoriasis nummularis*. The larger scales also rest upon a reddened base.

As the disease passes away the base becomes pale, and the scales are shed. The skin may resume its normal appearance, or remain pigmented for a time. Often the patches heal in the centre, while the margins are still advancing. In this case the affection is named *psoriasis annularis* or *gyrata*.

Psoriasis may occur at any spot, but it chiefly affects the extensor surfaces of the knee and elbow, the scalp, and the sacral region. Both the hair and the nails may be destroyed in the course of the disease.

The histological changes induced by psoriasis relate essentially to the epidermis, the papillae, and the upper strata of the corium. The two latter are hyperaemic, and more or less densely infiltrated with leucocytes. When the disease has lasted for some time hyperplasia of the connective tissue, with enlargement of the papillae, is usually set up. The morbid process occasionally extends to the deeper layers of the corium and to the subcutaneous connective tissue.

As regards the epidermis, the cornification of its surface-layers is interfered with, the cells as they come to the surface appearing simply to shrivel and dry up, while the mutual cohesion of the cellular layers is loosened (*parakeratosis*). The aetiology of the disease is unknown.

References on Psoriasis.

- BEISSEL: Aetiology *Monatsh. f. prakt. Dermat.* v **1886**
 JAMIESON: *The histology of psoriasis* Edinburgh **1879**, and *Edin. med. Journ.* XXIV **1879**
 KROMAYER: Morbid anatomy of psoriasis *A. f. Derm.* XXII **1890**
 LANG, E.: Mycotic origin (*Epidermidophyton*) *V. f. Derm.* v **1878**, and *Volkmann's klin. Vorträge* no. 208 **1881**
 NEUMANN: Histology *Wien. med. Jahrb.* **1879**
 PECIRKA: Histology and nature of psoriasis *A. bohèmes de méd.* II **1887**, and *Monatsh. f. prakt. Derm.* VI **1887**
 RIES, E.: Morbid anatomy of psoriasis *V. f. Derm.* xv **1888**
 SCHÜTZ: Pathology of psoriasis *A. f. Derm.* XXIV **1892**
 THIN: Histology *B. M. J.* I **1881**
 WOLFF: Aetiology *V. f. Derm.* XI **1884**

151. **Pityriasis rubra** (HEBRA), or general exfoliative dermatitis, is a peculiar and rare affection of the skin, the only symptoms of which throughout its entire course are redness and desquamation. The scales are sometimes small, but they are often of considerable size. After a time the skin becomes smooth, shining, thin, and tense. The hair becomes thin and falls out, and when the disease has lasted for some years general marasmus and death ensue. The only textural change discoverable in recent cases is a moderate amount of cellular infiltration in the cutis and papillary layer. No special changes occur in the epidermis, apart from those associated with desquamation. In the later stages a certain amount of small-celled infiltration is also found in isolated patches, but it is very unequally distributed. The skin is generally much atrophied, the rete Malpighii being notably thinned, while the papillae are depressed or have altogether disappeared, and the corium and its fibrous bundles have much the same look as in senile atrophy (Art. 139). The sebaceous glands and the hair-follicles are obliterated. The cause of the affection is unknown.

Prurigo is a disease beginning in infancy, and generally persisting throughout life. In its early stages it is characterised by an eruption of urticarial wheals, accompanied by severe itching on the extensor surface of the limbs. When the affection has existed for some time inflammatory nodules are formed, chiefly by reason of the inevitable scratching, and over these the skin is excoriated and often covered with small crusts. Eczematous inflammation and erysipelas are apt to be superinduced. The cause of the disease has not been discovered. AUSPITZ, H. HEBRA, SCHWIMMER, and others, regard it as of neuropathic origin.

Lupus erythematosus is a somewhat rare cutaneous affection which begins with an eruption of one or more raised red specks or spots varying in size from that of a pin's head to that of a small pea (KAPOSI). Each spot is depressed in the centre, or glisten-

ing and scar-like, or capped with a thin adherent scale. The reddened margin advances gradually, while the centre cicatrises, and thus in the course of some months a red-bordered disc is formed (*lupus erythematosus discoides*). In other cases the disease advances not by the growth of old spots, but by the continual development of new ones (*lupus erythematosus disseminatus et aggregatus*).

The morbid process consists in an inflammation of the cutis, especially in the neighbourhood of the sebaceous and sudoriparous glands (KAPOSI and THIN). The epithelial cells of the glands themselves multiply by proliferation, the epidermis is swollen, and scales or sometimes vesicles are formed on its surface. In the later stages both the epidermal and the fibrous constituents of the skin become atrophied.

The affection occurs most frequently on the head, fingers, toes, knees, and elbows. Its cause is not known. The discoid form usually recovers, while the disseminated variety is subject to frequent relapses.

References on Pityriasis Rubra, Prurigo, and Lupus Erythematosus.

- ELSENBERG: Pityriasis rubra *V. f. Derm.* XIV 1887
 GAY: Prurigo *A. f. Derm.* III 1871
 HEBRA: Pityriasis rubra *V. f. Derm.* III 1876; *Die krankh. Veränd. der Haut* Brunswick 1884
 HEBRA and KAPOSI: *Diseases of the skin* IV (New Syd. Soc.) London 1878
 JADASSOHN: Pityriasis rubra *A. f. Derm.* XXIII 1891, and XXIV 1892 (with references)
 KROMAYER: Histology of prurigo *A. f. Derm.* XXII 1890
 LEOIR: Lupus erythematosus *A. de physiol.* II 1890
 PETRINI and BABES: Case of pityriasis rubra *Journ. de l'anat.* 1890
 SCHÜTZ: Microscopical preparations of lupus erythematosus *A. f. Derm.* XXII 1890
 TAYLOR and VAN GIESON: Observations on prurigo clin. and pathol. *New York Med. Journ.* 1891
 THIN: Pathology of lupus erythematosus *Med.-chir. Trans.* LVIII London 1874

152. **Lichen** (according to HEBRA and KAPOSI) is an eruption of papules which remain as such and do not pass into any higher form.

Lichen scrofulosorum (*scrofuloderma miliare*, NEISSER) is a chronic cutaneous affection in which pink or brownish-red flattened papules are formed, each capped with a small scale. The condition is met with chiefly in tuberculous patients, and usually affects the trunk. According to KAPOSI the morbid process consists in cellular infiltration and exudation in and around the hair-follicles and the sebaceous glands belonging thereto, and in the neighbouring papillae. JACOBI maintains that the affection is a tuberculous disease of the skin.

Lichen ruber acuminatus, according to KAPOSI, is characterised

by the appearance of scattered hard red miliary nodules, each capped with a little knot of epidermal cells, and tending to coalesce into diffuse red scaly patches. These increase in size by marginal extension, and in the course of years may spread over the entire surface of the body. On histological examination cellular infiltration can be detected in the papillary layer, and round about the vessels of the corium and the coiled tubules of the sweat-glands. On these changes supervenes some hypertrophy of the epidermis. LASSAR affirms that the disease is due to a bacillus.

In *lichen ruber planus* the papules are flattened and umbilicated. They have a lustre like that of wax, they do not desquamate, and they are either red or pale in tint. In the later stages the papillae underneath the thickened epidermis become atrophied.

References on Lichen.

BENDER: Lichen ruber *D. med. Woch.* 1887

CASPARY: Lichen ruber *V. f. Derm.* xv 1888

JACOBI: Pathogenesis of lichen scrofulosorum *Verhandl. der deutschen dermatol. Gesellsch.* Vienna 1892

KAPOSI: *A. f. Derm.* xxi 1889

LUKASIEWICZ: Lichen scrofulosorum *A. f. Derm.* xxvi 1894

NEISSER: The present position of the lichen-question *A. f. Derm.* xxviii 1894

NEUMANN: Lichen ruber and pityriasis pilaris *A. f. Derm.* xxiv 1892

POSPELOW: Lichen ruber planus *A. f. Derm.* xii 1885

RONA: Lichen ruber *Monatsh. f. prakt. Derm.* vii Hamburg 1888

TAYLOR: Lichen ruber *New York Med. Journ.* 1889

TÖRÖK: Histology of lichen planus *Ziegler's Beiträge* viii 1890

TOUTON: Lichen ruber planus *Berl. klin. Woch.* 1886

153. **Erysipelas** is an acute inflammation of the integument caused by a streptococcus (Fig. 276 *a*), which enters the skin by means of small wounds, and spreads chiefly by way of the lymphatic system (Fig. 276 *a b* and Fig. 277 *h i*). Occasionally the micrococci penetrate from the lymph-vessels to the circum-

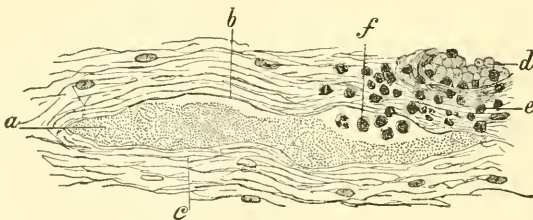


FIG. 276. COLONY OF STREPTOCOCCUS ERYSIPELATIS.

(Preparation from the ear of a rabbit two days after inoculation with the streptococcus: stained with gentian-violet, and mounted in Canada balsam: $\times 250$)

- a* streptococci within the lymph-vessel grouped partly in globular masses and partly in chaplets like torulae
- c* tissue surrounding the lymph-vessel, with pale non-staining nuclei

- d* vein
- e* circumvenous cellular infiltration
- f* cells within a lymph-vessel

jacent tissues. Degeneration (Fig. 276 *c*) and inflammation (Fig. 276 *d e* and Fig. 277 *m m*₁) are induced wherever the micro-organisms settle and multiply, though the degeneration is rarely extensive (Fig. 277 *l l*₁).

Clinically the affection takes the form of gradually-extending redness and swelling of the skin, accompanied by fever. In the early stages the skin appears tense and shining and of a bright red tint. Presently it becomes more livid or brown, the swelling goes down, and the epidermis is thrown off in scales and flakes.

Sometimes the exudation is more copious and tends toward the surface, in which case vesicles (Fig. 277 *c*) and blebs are formed, and the eruption is described as *erysipelas vesiculosum* or *bulbosum*. When the contents of the vesicles become purulent

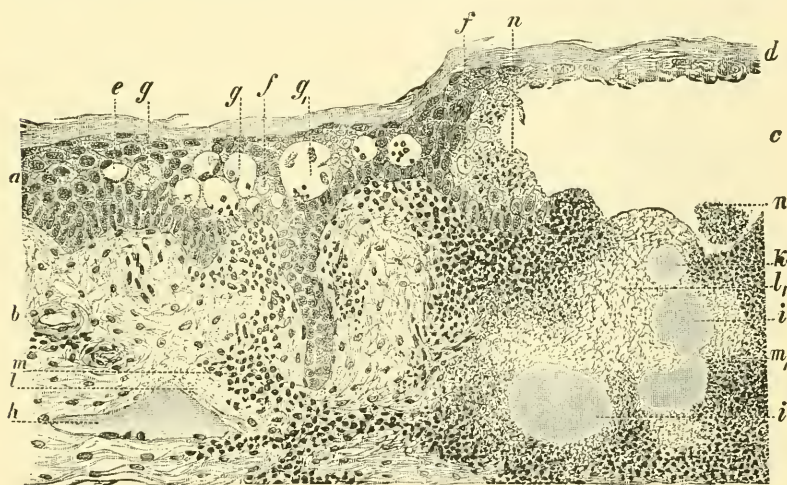


FIG. 277. SECTION OF THE SKIN IN ERYSIPELAS BULLOSUM.

(Preparation hardened in alcohol, stained with alum-carminé, and mounted in Canada balsam: $\times 60$)

<i>a</i> epidermis	<i>c</i> bleb or bulla	<i>i</i> lymph-vessel completely filled with streptococci
<i>b</i> corium	<i>d</i> roof of the bleb	<i>k</i> streptococci in the substance of the tissue
<i>e</i> vacuolated epidermal cell		<i>l l</i> ₁ necrotic tissue
<i>f</i> swollen cell and nucleus		<i>m</i> cellular infiltration
<i>g g</i> ₁ cavities produced by solution of epidermal cells, containing detritus of cells and pus-corpuscles		<i>m</i> ₁ fibrino-cellular infiltration
<i>h</i> lymph-vessel partly filled with streptococci		<i>n</i> fibrino-cellular exudation within the bleb

we have *erysipelas pustulosum*, which as the papules dry up into scabs passes into *erysipelas crustosum*; or if portions of the skin become necrotic (*l l*₁) and gangrenous, into *erysipelas gangraenosum*.

The histological change, other than the inflammatory hyperaemia, consists of more or less abundant cellular and serous (Fig. 277 *m*) or cellular and fibrinous (*m*₁) infiltration of the

skin. The blebs are formed by the swelling (*ef*), liquefaction, and disintegration of the cells of the rete Malpighii (*g g₁*). As the liquefaction commences at various points within the bleb, the cavities (*g g₁*) first formed are small, and separated from each other by cellular shreds that are elongated and distorted in various ways.

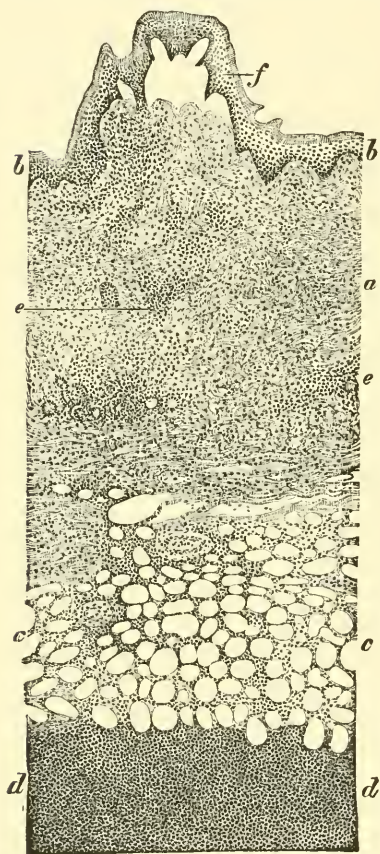


FIG. 278. PHELGMON OF THE SUBCUTANEOUS TISSUE, WITH AN OEDEMATOUS BULLA.

(Preparation hardened in Müller's fluid, stained with haematoxylin and eosin, and mounted in Canada balsam: $\times 30$)

- a* corium *b* epidermis
c inflamed and infiltrated adipose layer
d collection of pus
e cellular infiltration of the corium
f sub-epidermal oedematous bulla

Phlegmon or phlegmonous inflammation of the skin (sometimes called cellulitis) is usually caused by the *Streptococcus pyogenes*. Its favourite seat is in the subcutaneous tissue (Fig. 278 *d*) whence it extends towards the surface, and issues in suppuration. The corium is more or less densely infiltrated with cells (*e*). When the skin becomes swollen by the accompanying oedema the epidermis at certain points is sometimes raised *en masse*, and sub-epidermal bullae (*f*) are thus produced.

Phlegmonous inflammation involving the fingers is spoken of as **whitlow** or **felon** (*paronychia cutaneum* and *subcutaneum*, or *paronychia tendinosa*).

Where the epidermis is thin, the skin is usually reddened and often shining, especially when the corium is the seat of the inflammation, the process thus resembling erysipelas in its general course and appearance.

In mild cases the phlegmonous inflammation undergoes resolution and the exudation is absorbed; but as a rule suppuration takes place at some points, and gangrenous necrosis of the skin itself, or of underlying structures such as fasciae, is not uncommon. Superficial or deep abscesses containing necrotic

shreds and sloughs, and sometimes foetid pus, are thus produced, and these by and by rupture outwards. By direct extension the destructive process may extend laterally and vertically, and ulti-

mately lead to lymphangitis, lymphadenitis, and pyaemia. In favourable cases however the purulent infiltration and suppuration are limited by the development of granulations and cicatricial tissue in the wall of the abscess. Evacuation of the abscess is followed by extrusion of the dead tissue, the infiltration pervading the living tissue is re-absorbed, and cicatrization takes place.

154. **Acne** is the general name given to localised inflammations surrounding the hair-follicles and the associated sebaceous glands. It gives rise to small red nodules or pimples, in which may be noticed the dark head of a comedo, or a minute collection of pus.

The tissue around the hair-follicle and sebaceous gland may be simply hyperaemic and infiltrated with cells, or it may undergo partial suppuration, and according to the variations in the severity of the process the forms *acne indurata*, *acne punctata*, and *acne pustulosa* are distinguished. Ultimately however the sebaceous gland, and sometimes the hair-follicle also, are destroyed by suppuration.

Acne mentagra (*sycosis simplex* or *folliculitis barbae*) is a suppurative inflammation of the hair-follicle and the tissue about it. It gives rise to papules and pustules, many of which are perforated by hairs. The parts affected are those adjacent to the hairy portions of the body, especially the beard.

Parasitic sycosis resembles acne mentagra in its appearance, but it is said to be due to the invasion of a filamentous or mycelial fungus (Art. 161).

Boils or **furunculi** are due to inflammation of the tissue surrounding a sebaceous gland, hair-follicle, or sweat-gland, being distinguished from the pimples or pustules of acne by the much greater extent and intensity of the inflammation. A hard somewhat large dark-red swelling is at first produced, and this presently encloses in its centre a 'core' or slough of necrosed tissue: as the tissue around it suppurates the core is loosened, and ultimately cast off when the boil 'breaks.'

Carbuncle or **simple anthrax** resembles a boil in many respects; but it extends over a greater area, and gives rise to a firm livid swelling which may reach the size of the palm of the hand or more. The affected skin usually necroses, and is transformed into a dark livid pulp or a continuous slough. Necrosis and suppuration also ensue in the deeper portions of the tissue, the pus breaking through at various points. The sloughing mass is ultimately loosened and cast off, and an open granulating wound is left.

The pus from the pimples of acne, boils, and carbuncles usually contain staphylococci.

Small pustular abscesses resembling those of acne may develop around the sweat-glands: the process is sometimes referred to as **hidroadenitis**. See

VERNEUIL: Phlegmonous hidradenitis *A. gén. de méd.* 1864; POLLITZER: Suppurative hidradenitis *Monatsh. f. prakt. Derm.* Hamburg 1892; PETERSEN: Affections of the sweat-glands *A. f. Derm.* XXV 1893; DUBREUILH: Suppurative hidradenitis *A. de méd. exp.* v 1893.

155. **Malignant pustule** or **specific anthrax** is a cutaneous affection caused by the invasion of the *Bacillus anthracis*, and appears from one to fourteen days after infection. The infection

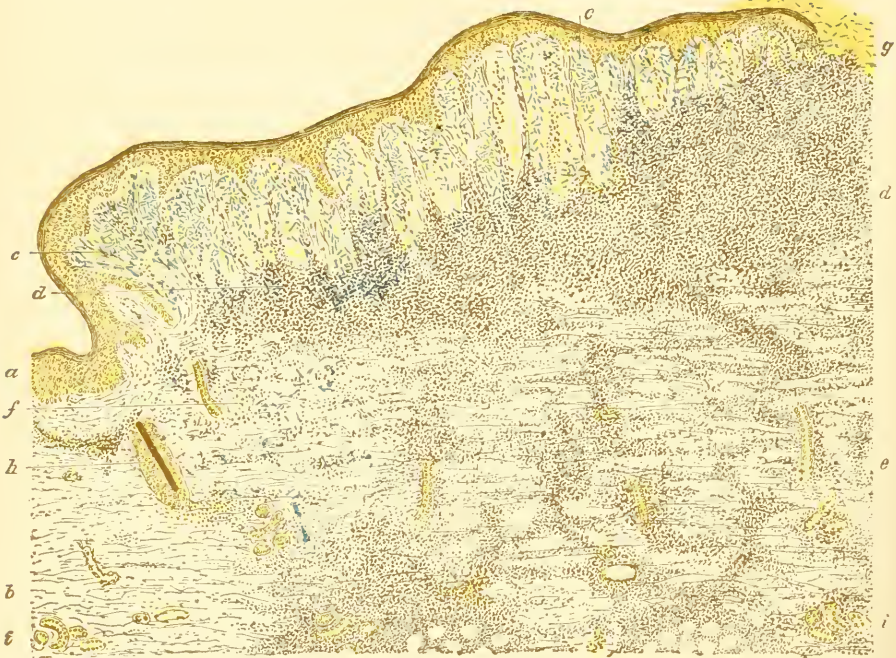


FIG. 279. MALIGNANT PUSTULE.

(Pustule ten days old from the arm of a man: preparation hardened in alcohol, stained with gentian-violet, iodine, and vesuvin, and mounted in Canada balsam: $\times 35$)

- | | | | |
|---|------------------------------------------------------------------------------------------------|---|------------------------------------------------------------|
| a | epidermis | e | deeper layers of the corium traversed by strings of cells |
| b | corium | f | corium containing bacilli and leucocytes |
| c | oedematous and swollen papillae infiltrated with inflammatory exudation and containing bacilli | g | blood-stained exudation on the surface, containing bacilli |
| d | surface of the corium infiltrated with cells and containing bacilli | h | hair-follicle |
| | | i | coiled tubules of sweat-glands |

starts in some slight wound, such as the sting of an insect. In most cases at the seat of inoculation a boil is formed, varying from six millimetres to several centimetres in diameter, and rising above the surface as a rounded or flattened swelling (Fig. 279). It is red or yellowish-red in colour, and after a time vesicles are often formed on its surface, and a clear or blood-stained liquid (*g*) may exude when the epidermis is partially exfoliated. As the

exudation dries crusts are formed, and these, if they lie over the centre of the swelling, occasionally cause it to appear depressed or umbilicated, the margin rising like a rampart round the boil. The tissue adjoining the pustule is in some cases but slightly altered, in others it is reddened and swollen or studded with small yellowish or livid vesicles (KOCH). When the process remains local the pustule becomes a gangrenous slough and is cast off, but if general infection by way of the blood takes place the affection is fatal. In rare cases local inoculation is followed at once by intense and wide-spread oedematous swelling, no pustule or other circumscribed elevation being formed.

Within a mature pustule of anthrax (Fig. 279) the papillary layer and the corium are beset with bacilli (*c d f*) and infiltrated with cellular (*d f*) and serous (*c*) exudations. The liquid exudation, containing blood and bacilli, is found chiefly about the papillary layer (*c*), and as the epidermis exfoliates transudes to the surface; the cellular infiltration (*d*) is densest in the deeper layers. When vesicles are formed the epidermis over the oedematous and swollen papillae is raised by the exudation.

In very rare cases (WEIGERT, WALDEYER) the bacilli are conveyed from the pustule to other parts of the skin, and give rise to red spots, papules, and vesicles.

Inflammations of the skin resembling that due to anthrax are occasionally set up by the invasion of pyogenic micrococci, the affection starting from some small wound of the surface.

Hospital gangrene or **phagedaena** (*gangraena nosocomialis*) is a traumatic infective disease which may attack any wound, but is most apt to occur in connexion with minor surface wounds, like those due to cupping or leech-bites. The infected wound assumes a dirty-yellow or grey tint and becomes gangrenous. When it contains granulations they become discoloured and change into a yellowish creamy pulp which speedily breaks down and liquefies, and the wound secretes a putrid serous or sanious liquid.

Decubital gangrene, or gangrenous bed-sore, is a progressive gangrenous necrosis of the integument, which occurs in emaciated patients whose circulation is enfeebled by oligæmia and cardiac weakness. Slight pressure is therefore enough to cause necrosis of the skin. The affected parts are livid or black, and under the influence of septic micro-organisms become putrid and break down. The commonest sites of such bed-sores are over the sacrum, great trochanters, and heels. They are often not limited to the skin, but extend to the deeper soft parts and even to the bones.

Perforating ulcer of the foot (*malum perforans pedis*) is a peculiar affection of the foot which begins with the formation of an induration, beneath which a deeply penetrating ulcer is rapidly produced, at whose base even the bone may become

inflamed and necrotic. Many writers (DUPLAY, MORAT, SCHWIMMER, PITRES, VAILLARD) regard the affection as a tropho-neurotic form of inflammation. It is however beyond doubt that simple mechanical injury, from pressure, friction, etc., is capable of producing it, and accordingly it occurs most frequently in parts that are subjected to pressure. The supervention of ulceration is favoured by the deficient nutrition of the tissues of the foot resulting from sclerosis and atheroma of its arteries, or it may be in certain cases from disorder of its innervation.

Tropical ulcer, Penjdeh boil, or oriental sore (HEYDENREICH: *Das Pende'sche Geschwür* St Petersburg 1888, reviewed in *Centralbl. f. Bakteriologie* v 1889), is a cutaneous affection that under various local names is endemic in sub-tropical countries. It begins as an eruption of single or multiple papules and pustules, which break down into ulcers varying in size from that of a pea to that of a plum, or even larger. They usually heal, leaving behind a superficial scar. According to HEYDENREICH, the exciting cause is a capsulated micrococcus.

Ainlum (DA SILVA LIMA: *Arch. of Derm.* vi 1888) is a peculiar disease of the toes to which negroes of African descent are liable. An encircling constriction appears at the level of the digito-plantar fold of the fifth or sometimes of the fourth toe, while the toe itself swells, and after a time its surface becomes raw and scaly. Ultimately the toe drops off by spontaneous amputation. The cause of the disease is unknown.

References on Perforating Ulcer of the Foot and Gangrene of the Skin.

- DOUTRELEPONT: Acute multiple gangrene of the skin *A. f. Derm.* XIII 1886, *A. f. Derm.* XXII 1890
 DUPLAY: Perforating ulcer *Arch. gén. de méd.* I 1873, and *Journ. de méd. et chir. prat.* 46 1875
 FISHER: idem *A. f. klin. Chir.* XVIII 1875
 LAGRANGE: Multiple origin of perforating ulcer *Semaine méd.* no. 48 1886
 MORAT and DUPLAY: *A. gén. de méd.* I 1873
 PITRES and VAILLARD: Nervous changes in perforating ulcer *A. de physiol.* v 1885
 SAVORY and BUTLIN: Perforating ulcer *Med.-chir. Trans.* LXII London 1879 (with references)
 SCHWIMMER: Chronic skin affections *Ziemssen's Handb. d. spec. Path.* XIV

156. **Ulcers of the skin.** A cutaneous ulcer is an open wound involving loss of substance in the cutis, the tissues of its floor and margins being infiltrated with inflammatory products and undergoing progressive molecular disintegration.

Ulcers are the result of necrosis befalling a portion of skin which has been previously infiltrated with inflammatory products. The progressive disintegration of tissue and the consequent enlargement of the ulcer depend either on some morbid predisposition in the tissue itself, or on the nature and mode of action of the injurious agent which sets up the inflammation. Examples of both these varieties of ulcer have been described in the pre-

eeding paragraphs, and will have again to be considered under the heads of tuberculosis, leprosy, and syphilis. Two special forms of ulceration of the skin must however be here referred to—the varicose and the venereal.

The **varicose ulcer** is primarily due to local venous engorgement, leading to dilatation of the cutaneous veins and oedematous infiltration of the tissues. The engorged skin becomes very susceptible to injury, comparatively slight scratches and wounds sufficing to induce cellular infiltration, suppuration, and necrosis. Ulcers are thus produced which, though they granulate readily, do not heal so long as the exciting cause persists. Not only does the granulating surface fail to 'skin over,' but it often continues to extend more and more widely, till in some cases it reaches an enormous size.

The surrounding fibrous tissue becomes thickened in consequence of the long-standing oedema and the formation of new connective tissue, and so assumes a brawny or callous appearance. The granulations exhibit no special characters when examined under the microscope, and may be either scanty or exuberant ('proud flesh').

The epidermis bordering on the granulations, and covering them over along a narrow marginal zone, often thrusts in prolongations and offshoots into the midst of them, but does not advance in the normal manner over their surface. The tissues around and underlying the ulcer usually exhibit changes due to persistent engorgement, such as cyanotic discoloration, desquamation of the epidermis, dilated veins, oedematous infiltration, etc. The most common site of these ulcers is on the leg.

The **venereal ulcer** or **soft chancre** (chancroid, *ulcus molle*) is a contagious local affection of venereal origin, and therefore usually situated on the genitals. It begins some twenty-four hours after infection as a vesicle or pustule, which rapidly becomes an ulcer with a yellowish base and a reddened border. It extends by the progressive molecular disintegration of the marginal tissue. The edges and floor of the ulcer are very thickly infiltrated with cells, and these as they near the surface pass through successive stages of degeneration and decay, and at length form a superficial layer of structureless detritus. A soft chancre may give rise to lymphangitis and lymphadenitis (bubo), but not to syphilitic infection. According to KREFTING, DUCREY, PETERSEN, MERMEL, and SPIETSCHKA, it is probable that the soft chancre is due to a bacillus, though it also contains pyogenic micrococci, and non-syphilitic bubos seem indeed to be mainly due to these latter organisms.

When a patient is infected simultaneously with the venereal poison of soft chancre and with syphilis, the base of the soft chancre becomes indurated in the third or fourth week after infection, and the soft chancre is thus converted into a **hard chancre**

(*ulcus induratum*). If the soft chancre has by this time already healed, the induration characteristic of syphilis appears in the cicatrix.

References on Soft Chancre.

- BENDER: *Cent. f. Bakteriologie* III 1888
 DUCREY: Experimental researches *Monatsh. f. prakt. Derm.* IX Hamburg 1889,
 and *Compte rendu du congr. internat. de dermatologie* Paris 1890.
 FINGER: Differentiation from the initial sclerosis of syphilis *V. f. Derm.* 1885
 KREFTING: Bacteriology of *ulcus molle* *A. f. Derm.* 1892
 LANG: *Das venerische Geschwür* Wiesbaden 1887
 MERMEL: The microbe of soft chancre *A. gén. de méd.* 1893
 PETERSEN: Bacilli of *ulcus molle* *Cent. f. Bakteriologie* XIII, and *A. f. Derm.*
 XXIX 1894
 SPIETSCHKA: Aetiology of venereal bubo *A. f. Derm.* XXVIII 1894

157. The **granulomata** affecting the skin are chiefly due to known infections, such as tuberculosis, syphilis, leprosy, and rhinoscleroma, though forms are occasionally met with whose cause is unknown. Some of these develop in connexion with traumatic injuries, others without any apparent external cause.

Traumatic granulomata start from various kinds of wounds, often of a trifling character, and take the form of papillomatous or fungating soft red growths, composed of granulation-tissue abounding in vessels and cells. Whether the growths are due to something special in the mode of irritation, or in the tissue itself, is not known. In adults they are commonest about the head: in new-born infants they not infrequently develop in the course of the first week about the umbilical stump, where they appear as small deep-red nodules which are sometimes as large as a pea. According to KÜSTNER these growths in rare cases enclose glandular tubules, similar in structure to those of the intestine, and probably derived from remnants of the omphalo-mesenteric duct.

Papillomatous dermatitis of the scalp (KAPOSI) or **sycosis framboesiformis** (HEBRA) is a granulomatous growth giving rise to firm red superficial tuberos and raspberry-like excrescences (*framboesiu non-syphilitica*), that are usually well covered with epidermis, though here and there they are moist or encrusted with scabs. They are seated most frequently on the back of the head and neck, and measure from 0.5 to 3 centimetres across at the base; when numerous they sometimes become confluent. The exciting cause is unknown. In histological structure they resemble tropical framboesia or **yaws**, an endemic contagious disease of the skin prevalent on the western coast of Africa, in Senegal, on the Congo, in the Malay Archipelago, and in South America.

Granuloma fungoides (*mycosis fungoides* (ALIBERT) or *papiloma areo-elevatum*) is a peculiar and rare cutaneous affection, taking the form of weeping and scaly eczematoid infiltrated

patches as large as the hand, or of papillomatous and nodular granulomatous growths from the size of a pea to that of a pigeon's egg. The growths may appear on any part of the body, and undergo ulceration, or heal up leaving patches of pigmentation. They are sometimes associated with swellings of the lymph-glands. The affection is accompanied by itching of the skin, and after a duration of some years it terminates fatally from general marasmus. Its aetiology is unknown.

Rhinoscleroma is a rare tumour-like granuloma due to a specific bacillus: it affects the skin of the nose, the fauces, and the larynx. On the nose it forms hard greyish-red nodes covered with normal epidermis; in the mucous membrane of the nasopharynx and larynx the growths are flat, becoming puckered and shrunken as they cicatrise. The nodes are composed of highly-cellular granulation-tissue, extending into the adjacent structures in the form of rounded or elongated offshoots. In some places the tissue contains vacuolated cells and hyaline bodies.

References on Rhinoscleroma and its Bacillus.

- ALVAREZ: Pathology of rhinoscleroma *A. de physiol.* vii 1886
 BENDER: Report on its aetiology *Cent. f. Bakteriologie* i 1887
 CHIARI: Laryngeal stenosis etc. *Wien. med. Jahrb.* 1882, *Prager Z. f. Heilk.* vi 1885
 CORNIL: *Leçons professées pendant l'année 1883-84* Paris 1885 (1st half-year), and *Journ. d. connaissances méd.* viii 1886
 CORNIL and ALVAREZ: History *A. de physiol.* vi 1885
 DITTRICH: Rhinoscleroma *Prager Z. f. Heilk.* viii 1887; Aetiology *Cent. f. Bakteriologie* v 1889
 VON FRISCH: Aetiology *Wien. med. Woch.* xxxii 1882
 JAFFINGER: *Das Sklerom d. Schleimhaut d. Nase etc.* Vienna 1892
 KÖBNER: *Verein f. inn. Med.* Berlin 1885
 LANG: Rhinoscleroma *Wien. med. Woch.* xxxiii 1883
 MIBELLI: Histology *Monatsh. f. prakt. Derm.* viii 1889
 MIKULICZ: Rhinoscleroma *A. f. klin. Chir.* xx 1876
 NIKIFOROFF: idem *A. f. exp. Path.* xxiv 1888
 PALTAUF: Aetiology *Wien. klin. Woch.* 1891, 1892
 PAWLOWSKY: Aetiology *Cent. f. allg. Path.* i (p. 601)
 PAYNE and SEMON: Case *Trans. Path. Soc.* xxxvi London 1884
 PELLIZZARI: *Il rinoscleroma* Florence 1883
 STEPANOW: Inoculation experiments *Cent. f. Bakteriologie* v 1889; Aetiology *Monatsschr. f. Ohrenheilk.* 1893
 WOLKOWITSCH: Histology and parasitic origin *Cent. f. med. Wiss.* xxiv 1886; Rhinoscleroma *A. f. klin. Chir.* xxxviii 1889
 ZAGARI: Aetiological researches *Giorn. internaz. d. scienze med.* xi Naples 1889

References on Granuloma Fungoides.

- ALIBERT: *Monographie des dermatoses* Paris 1835
 AUSPITZ, HOCHSINGER, and SCHIFF: *V. f. Derm.* 1885
 DÖNITZ and LASSAR: Mycosis fungoides *V. A.* 116 1889
 DUHRING: Fungoid neoplasm *Arch. of Derm.* v Philadelphia 1879
 GEBER: *D. A. f. klin. Med.* 1878
 HAMMER: *Gerhardt and Müller's Mittheil. med. Klin. zu Würzburg* ii Wiesbaden 1886

- HARDAWAY: *Arch. of Derm.* Philadelphia 1880
 HEBRA, F.: *Bericht v. k. k. Krankenhause* Vienna 1874 and 1875
 HEBRA, H.: *V. f. Derm.* II 1875
 KAPOSI: *Mycosis fungoides* *Wien. med. Woch.* 1887
 KÖBNER: *Mycosis fungoides* *D. med. Woch.* 1886, and *Fortschr. d. Med.* IV 1886
 LEDERMANN: *Mycosis fungoides* *A. f. Derm.* XXI 1889
 PALTAUF: *Lymphatic neoplasms of the skin* *Wien. klin. Woch.* 1892
 PAYNE: *Rare diseases of the skin* London 1889

References on Papillomatous Dermatitis of the Scalp.

- BAKER: *Trans. Path. Soc.* London 1882
 HEBRA, H.: *V. f. Derm.* II 1875
 KOHN: *A. f. Derm.* I 1869
 VERITÉ, A.: *Acad. de méd.* 9 May Paris 1882

References on Umbilical Granuloma.

- KÜSTER: *A. f. klin. Chir.* XVI 1874
 KÜSTNER: *V. A.* 69 1877
 WEBER, F.: *Beitr. zur path. Anat. der Neugeborenen* III Kiel 1851-3

158. **Tuberculosis of the skin** usually appears in the form of superficial ulcers on parts near orifices that are covered with mucous membrane, in other words about the head, the genitals, and the anus; they are rarely met with in other portions of the body. The ulcers are round or oval, their margins somewhat infiltrated and sinuous, and their bases and the adjacent tissue beset with nodular granulations.

A second form, formerly described as **scrofulodermia**, begins with the formation of circumscribed and isolated nodular granulomatous deposits seated chiefly in the subcutaneous connective tissue, and giving rise to swelling and lividity of the skin. These break through and discharge a thin yellowish-white liquid, and leave behind ulcers with livid undermined borders, and floors covered over with thin granulations and necrotic detritus. This form occurs chiefly in children as an accompaniment of widespread chronic tuberculosis (scrofula) of different organs, the tuberculous eruption, caseation, and destruction of tissue often starting in the lymph-glands. The commonest seat of the affection is about the face and in the cervical and nuchal regions.

Lupus vulgaris is a form of primary cutaneous tuberculosis, starting at one point, or in rare cases at more than one. It is accompanied or followed by tuberculosis of other organs, and occurs chiefly in children of from three to ten years of age. The affection usually attacks the face (Fig. 280) or the limbs; it seldom begins on the trunk.

The process consists essentially in the formation of vascular and non-vascular granulomatous nodes (Fig. 281 *d e*), often exactly resembling typical tubercles, and containing bacilli. The

nodes may break down and disappear by resorption, though as they soften the sub-epidermal foci often rupture through the skin (*g*), and give rise to suppurating ulcers which become covered over with crusts. Diffuse infiltration and fibrous hyperplasia generally take place between the nodes, or exuberant granulations grow up and protrude above the surface of the skin. Ingrowths of epidermis penetrating between the proliferous granulations (*h*) give the structure an appearance not unlike that of carcinoma.

From the outset or during the progress of the disease, which extends radially from the starting point, red and yellowish-brown smooth or scaly spots (*lupus maculosus*) appear over the deeper-lying nodes, and these readily give way when pressed upon with a probe. When the nodes lie close together, brownish-red or brownish-yellow spots are formed and afterwards sink in as the central portions of the nodes are re-absorbed. The surface at the same time becomes smooth owing to the destruction of the papillae, and the epidermis becomes fissured and exfoliates (*lupus exfoliatus*). As the tissue disintegrates ulcers are produced and become covered over with pus and crusts (*lupus exulcerans* or *eredens*). In other cases smooth radiating scars appear in the centre of the patch, while

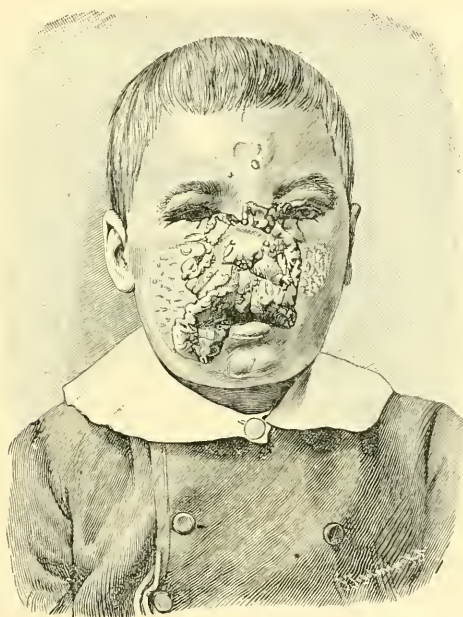

FIG. 280. HYPERTROPHIC LUPUS OF THE FACE.

(From a photograph by DEMME of Berne)

the process extends at the margins (*lupus serpiginosus*). Warty or papillomatous excrescences (*lupus framboesoides*, *papillaris*, *verrucosus*), or tuberous growths (*lupus tuberosus*, *nodosus*, *hypertrophicus*, *tumidus*), may develop beneath the epidermis or on the floors of the ulcers, the protuberances being generally covered over with crusts or epidermal scales. These changes usually give rise in the course of years to very extensive destruction, which in the face, for example (Fig. 280), produces extreme deformity and disfigurement. The nose, the lips, and the eye-lids may be nearly destroyed, and are generally much distorted by

the cicatrices. On the limbs thickenings similar to those of acquired elephantiasis are not uncommon. They consist of newly-formed connective tissue, granulomatous nodes, and necrotic tissue, and are usually beset with brown tuberosities or papillomatous growths, whose surface is moist or scaly and crusty.

Cadaveric or **necrogenous warts** are due to tuberculous inoculation of the skin; they are most apt to affect anatomists and dissecting-room attendants, and arise from inflammatory overgrowth of the papillary layer, with the formation of tubercles therein, and simultaneous hypertrophy of the epidermis. This is one of the forms of traumatic tuberculosis, and is analogous to the other varieties produced in the skin and subcutaneous tissue

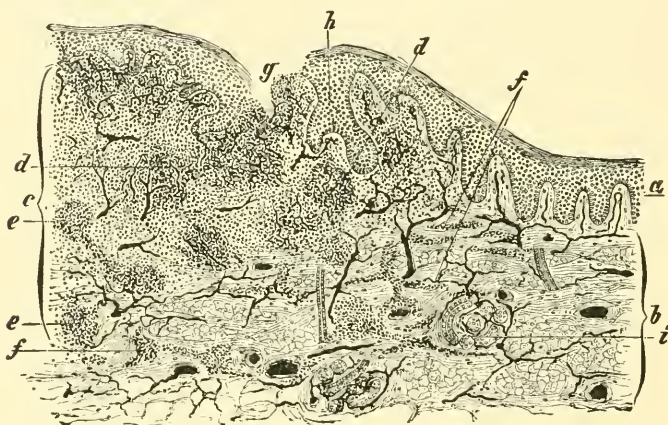


FIG. 281. PATCH OF LUPUS VULGARIS.

(Carmine preparation: $\times 25$)

- | | | | |
|---|-------------------------------------------------------------|---|-----------------------|
| a | normal epidermis | e | non-vascular nodule |
| b | normal cutis with sweat-gland | f | strings of cells |
| c | focus of lupus-tissue | g | lupus ulcer |
| d | vascular nodule surrounded by diffuse cellular infiltration | h | proliferous epidermis |
| | | i | sweat-gland |

by inoculation of the tuberculous virus, such as that sometimes developed in the lobes of the ears after they have been pierced for ear-rings. Pyogenic infection is liable to take place at the same time or subsequently, and give rise to pustular eruptions or to deep-seated purulent inflammation and lymphangitis. The result is an affection intermediate in character between suppuration and tuberculous disease.

When the tuberculous foci in the skin do not disintegrate and break down, large tumour-like nodes are apt to develop from them. Small cutaneous tubercles sometimes assume the appearance of lichen (Art. 152).

References on Tuberculosis of the Skin.

- BENDER: The connexion of lupus vulgaris with tuberculosis *D. med. Woch.* **1886**
- BLOCK: Aetiology and pathogenesis of lupus vulgaris *V. f. Derm.* XIII **1886**
- BRUGGER: Tuberculosis verrucosa cutis *V. A.* 119 **1890**
- DEMME: The bacilli in lupous patches *Berl. klin. Woch.* **1883**; Tuberculous eczema *Jahresber. d. Jenner'schen Kinderspitals* XX XXI Berne **1883-84**
- DOUTRELEPONT: Aetiology of lupus vulgaris *Compt. rend. internat. med. Congr. Copenhagen* **1884**, *V. f. Derm.* XI **1884**; Lupus and cutaneous tuberculosis *D. med. Woch.* **1887**; Cutaneous tuberculosis *A. f. Derm.* XXIX **1894**
- DUBREUILH and AUCHÉ: Cutaneous tuberculosis *A. de m'éd. exp.* II **1890**
- FINGER: The identity of lupus and tuberculosis *Cent. f. Bakteriologie* II **1887**; Tuberculosis verrucosa cutis (so-called cadaveric wart) *D. med. Woch.* **1888**
- FRIEDLÄNDER: Lupus *Volkman's klin. Vorträge* no. 61 **1874**; *V. A.* 60 **1874**
- HANOT: Cutaneous tuberculosis *A. de physiol.* VIII **1886**
- HAUG: Tuberculosis of the ear *Ziegler's Beiträge* XVI **1894**
- HELLER and HIRSCH: Tuberculosis verrucosa *A. f. Derm.* XXVI **1892**
- JADASSOHN: Inoculation of lupus *V. A.* 121 **1890**
- KARG: Tubercle-bacilli in a so-called cadaveric tubercule *Cent. f. Chir.* **1885**
- KNICKENBERG: Tuberculosis verrucosa *A. f. Derm.* XXVI **1892**
- LELOIR: Lupus *Verneuil's Études sur la tuberculose* II Paris **1890**; Erythematoid lupus vulgaris *A. de physiol.* III **1891** [1886]
- DE MAGNY: *Contrib. à l'étude de l'inoculation tuberculeuse chez l'homme* Paris
- MANGELSDORFF: Elephantiasis-like form of lupus in the limbs *Inaug. Diss.* Greifswald **1885**
- MOREL-LAVALLÉE: Scrofulo-tuberculosis of the skin *Verneuil's Études sur la tuberculose* II Paris **1888**
- PFEIFFER and PAGENSTECHEK: Lupus or tuberculosis (bacilli in lupous patches) *Berl. klin. Woch.* **1883**
- PICK: Tuberculous diseases of the skin *Prager med. Woch.* XIV **1889**
- RIEHL: Tubercle-bacilli in a necrogenous wart *Cent. f. Chir.* **1885**
- RIEHL and PALTAUF: Tuberculosis verrucosa cutis *V. f. Derm.* XIII **1886**

159. The initial manifestation of **syphilis** in the skin makes its appearance ten to thirty days after infection in the form of a sharply-defined resistant induration, within which the tissue is infiltrated with numerous small round-cells (Fig. 282 *a*), interspersed at times with large epithelioid cells (*b*) and multinuclear giant-cells (*c*). This indurated sore is called the **initial sclerosis** of syphilis (true **Hunterian chancre** or syphilitic induration).

Sometimes the initial sclerosis appears as a papule over which the epidermis speedily desquamates; but more frequently it has the appearance of a flat parchment-like disc, or is rounded, bean-shaped, or cylindrical in

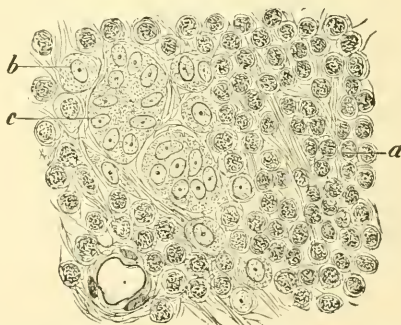


FIG. 282. INITIAL SCLEROSIS OF SYPHILIS.
(Preparation stained with alum-carmine:
× 350)

- a* infiltrated round-cells
b large unilinear formative cells
c multinuclear formative cells

form. After some weeks the sclerosis generally disappears, and in some cases leaves behind it a persistent scar-like induration: more frequently however the epidermis exfoliates and the superficial layers of the corium break down, leaving an erosion that becomes an ulcer or **hard chancre**. In rare cases a vesicle is formed, which afterwards bursts and leaves behind it an ulcerous sore.

The size of the ulcer with its indurated base varies in different cases, depending chiefly on its situation and surroundings; these are often such as to intensify the lesion and increase the amount of inflammation and ulceration. The surface of the ulcer secretes thin pus and at times casts off sloughs of necrotic tissue. The floor rarely granulates freely, but now and again papillomatous outgrowths arise from it (venereal papilloma). Under suitable treatment the ulcers generally heal, but some induration usually persists for a long while in the scar.

When the initial manifestation takes the form of a papule, a prominent nodule is produced varying in size from that of a grain of barley to that of a pea, and dusky blue to pale red in colour. This increases in size, remaining rounded or becoming more flattened as it spreads, but still raised slightly above the surface. On dry parts of the body the epidermis desquamates and the surface of the papule becomes crusted over; on the moist parts it 'weeps.' Ulcers are ultimately formed by disintegration of the tissue. Resolution may take place by resorption of the infiltration, and pigmented spots and scars, or occasionally small firm pale papules having the colour of the skin (LANG), remain behind.

The cutaneous eruptions or **syphilides** resulting from the dissemination within the body of the syphilitic virus may appear on any part of its surface, though they generally show first on the trunk, and afterwards on the face and limbs. They usually take the form of roseolar spots, papules, pustules, and superficial or deep-seated gummata; in rare cases pigmented and scaly spots appear without any antecedent eruption (LANG).

Syphilitic roseola appears most frequently on the trunk, but it sometimes spreads over the entire surface of the body, and consists of slightly-raised spots (maculo-papular syphilide), varying from the size of a pea to that of a finger-nail. The tissue within these spots is infiltrated and its cells are proliferous. In one or two weeks the eruption becomes dirty-brown or grey in colour, and usually disappears in three or four weeks.

The **papular syphilide** begins as an eruption of red specks from the size of a pin's head to that of a lentil, upon which papules arise varying in size from that of a millet-seed to that of a pea, and pointed, rounded, or flattened in shape. The eruption is distinguished, according to the size of the papules, as a small-papular (miliary) or large-papular (lenticular) syphilide. The first looks very like lichen ruber, and is therefore described as *lichen syphiliticus*. The tissue within the papules is infiltrated

with exudation (Fig. 270) and is in process of proliferation; giant-cells are sometimes developed in it.

The papules rising from dry surfaces are red, bluish, or brown, or differ in colour but little from the surrounding skin; as they fade they become covered with desquamated epidermal scales. They sometimes leave behind brown or grey pigmented spots, which afterwards grow paler and sometimes lose their pigment entirely. In certain cases vesicles and pustules supervene on the papules (vesicular syphilide, *herpes syphiliticus* or *impetigo syphilitica*), and as they dry up form scabs. On the palmar and plantar surfaces the papules as a rule remain flattened, becoming thickly covered, as the eruption declines, with membranous epidermal scales (*psoriasis palmaris et plantaris syphilitica*).

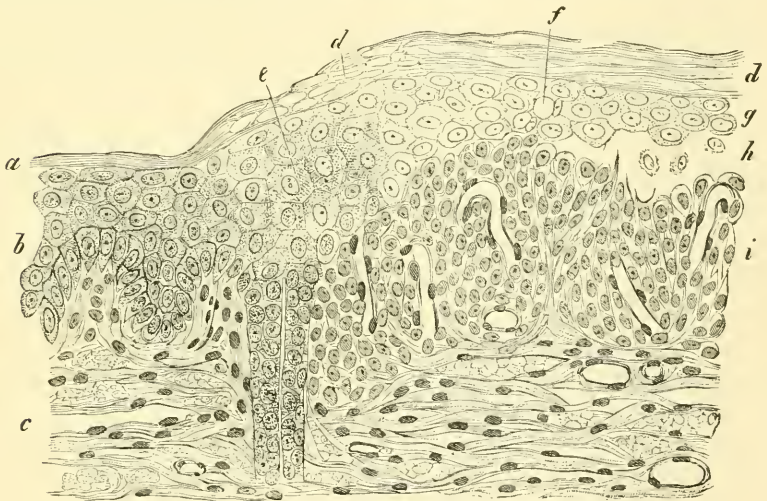


FIG. 283. PUSTULAR SYPHILIDE (INFANTILE SYPHILITIC PEMPHIGUS).

(Section through the margin of a bleb; haematoxylin staining: $\times 200$)

- | | | | |
|---|--------------------------------------|---|-----------------------------------------------------------------------------|
| a | normal horny layer of the epidermis | g | remnants of the rete Malpighii compressed by the contents of the bleb |
| b | normal rete Malpighii | h | bleb produced by the destruction of the deeper layers of the rete Malpighii |
| c | corium | i | granulations arising from the cutis |
| d | swollen and desquamating horny layer | | |
| e | swollen cells of the rete Malpighii | | |
| f | vacuolated epidermal cells | | |

In parts that from their position are always kept more or less moist, the syphilitic papules generally become exuberant, and form the broad flattened elevations known as **mucous patches** (*condylomata lata* or flat papules). The exudation infiltrating the tissue usually oozes through to the surface (Fig. 270 *f h*), and causes it to 'weep.' At the same time the superficial layers of epidermis become swollen (*d g*) and macerated. The patches are soft and more or less reddened or bluish in tint, and those lying near each other sometimes coalesce and ulcerate.

The **pustular syphilide** is due to the formation of pus beneath the horny layer of the epidermis, or to suppuration of the infiltrated tissue of the papules. In the former condition (Fig. 283 *h*) the papillary layer is exposed when the pustule separates, its tissue being infiltrated with liquid or covered with granulations (*i*). When the papillary layer and the corium are destroyed, the removal of the pustule, or of the crust formed from it as it dries, reveals a deep or shallow ulcer, which can heal only by the formation of a depressed cicatrix. In rare cases exuberant papillomatous growths appear on the floor of the ulcer (*framboesia syphilitica*).

The syphilitic pustule sometimes becomes umbilicated, and thus has arisen the term *variola syphilitica* or great-pox. When a number of pustules are clustered round a hair-follicle the condition is called *acne syphilitica*. Large pustules are often referred to as *pemphigus syphiliticus*, and still larger ones, each covered with a dirty crust, as *rupia syphilitica*.

The small-pustular syphilides, like the small-papular variety, are apt to be widely spread over the body, and appear at various stages of the disease. The rupial form, in which isolated pustules may grow to the size of a silver crown-piece or dollar, is associated with the tertiary stage. The rupial pustule tends to dry into a crust, beneath which the formation of pus goes on; this pus again dries, and so the size of the crust steadily increases. A depressed scar is left when the process comes to an end.

Gummata of the skin are similar in appearance to the initial sclerosis of syphilis, and form small rounded or flattened nodes, sharply defined, and of a dull-red or purplish colour. After existing for a while they disappear, leaving behind an atrophic glistening scar, or break down and form gummatous ulcers with infiltrated floors. As these heal they leave glistening white scars surrounded by a pigmented zone. Such ulcerating nodes not infrequently appear in large numbers, and sometimes become confluent. Papillomatous growths may arise from the floors of the ulcers (*framboesia syphilitica*). In the course of months or years large areas of the skin may thus be invaded, by the successive formation of fresh nodes and cicatrices. When an ulcer heals at one side while the other side advances, it takes a reniform or crescentic shape (*ulcus serpijinosum*).

In rare cases diffuse gummatous infiltrations covered with scales and scabs are formed: these ulcerate here and there, leaving indurated scars as they heal.

Gummata of the subcutaneous connective tissue take the form of nodes from the size of a bean to that of the fist, which after some considerable time soften and disappear by resorption, leaving a thin and puckered area on the overlying skin. Sometimes the nodes undergo partial caseation and calcification, or rupture externally, forming an ulcer with thickened and undermined edges,

and an indurated floor covered with necrotic shreds. When the ulcer is cleansed of dead tissue and detritus it heals by cicatrization. In severe cases such ulcers may be numerous and cause deep and wide-spread loss of tissue. The forehead, back of the neck, scapular region, and leg are the favourite seats. Cutaneous gummata generally accompany the later stages of syphilis, and accordingly seldom appear at the same time as the papular and pustular syphilides.

References on Syphilides.

- CAMPANA: *Dei morbi sifilitici e venerei* Genoa 1889 [1873-75]
 KAPOSÍ: *Die Syphilis der Haut und der angrenzenden Schleimhäute* Vienna
 LANG, E.: *Vorlesungen über Path. u. Therap. d. Syphilis* I Wiesbaden 1884
 (with references)
 LEWIN: Clavi syphilitici (callosities) *A. f. Derm.* xxv 1893 (with references)
 MICHELSON: Lichen syphiliticus *V. A.* 118 1889
 NEUMANN: Histological changes in cutaneous syphilis *V. f. Derm.* 1885
 TOMMASOLI and UNNA: Syphilides *Dermatol. Studien* II Hamburg 1890

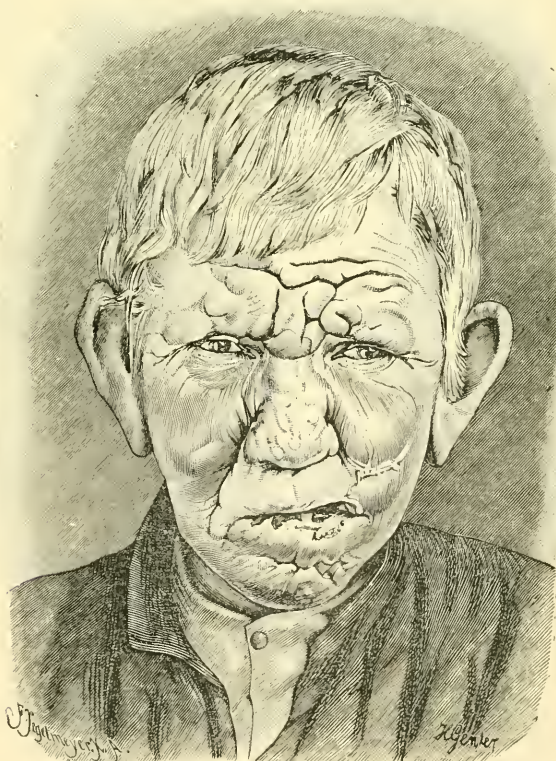


FIG. 284. LEONTIASIS LEPROSA.

(After G. MINCH: from his Russian work on "Leprosy in Southern Russia")

160. **Leprosy** affects chiefly the skin of the face (Fig. 284), the extensor surfaces of the knees and elbows, and the hands and feet (Fig. 285). It begins with an eruption of red spots, which either disappear and leave behind pigmented specks, or rise into nodes and tuberous swellings of a brownish-red colour (*lepra tuberosa, tubercularis, or nodosa*). Bullae are occasionally formed.

The exciting cause of all these changes is the lodgment and growth in the skin of the *Bacillus leprae*.

The nodes either remain unaltered for many months, or increase in size and coalesce into bulky protuberances (*elephantiasis graecorum, facies leontina*, Fig. 284). New nodes appear from time to time, preceded by erysipelatoid reddening and swelling of the skin. The peripheral nerves are apt to be involved, leading to atrophic conditions of the skin manifested by the appearance of white and brown stains (*lepra maculosa, morphoea nigra et alba*). Once cutaneous sensibility is lost the patient often injures himself unwittingly, and thus in the later stages ulceration is apt to be set up, and extending deeply into the tissue may bring about the loss of entire phalanges (*lepra mutilans*, Fig. 285).

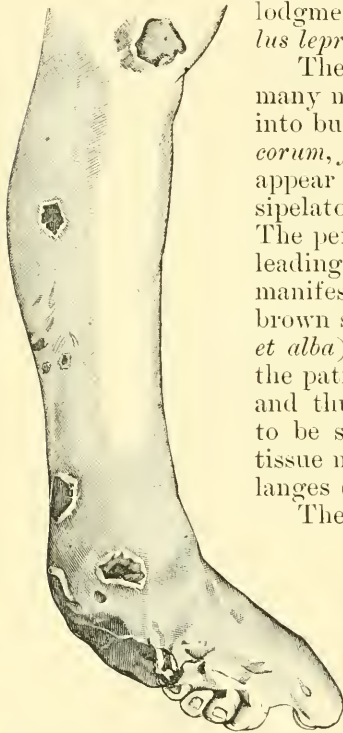


FIG. 285. ULCEROUS LEPROSY (*LEPRA MUTILANS*) OF THE LEG AND FOOT.
(After G. MINCH)

The multiplication of the specific bacilli leads to the formation of cellular or fibro-cellular nodes and strands (Fig. 286 *d f g h*), and these to thickening of the skin. They develop with especial frequency in the neighbourhood of the hair-follicles (*d*), and in the ducts (*f*) and coiled tubules (*g*) of the sweat-glands, though such a distribution cannot be made out in the case of all the cellular nodes (*h*) and strands.

The bacilli lie for the most part within the proliferous connective-tissue cells, and there accumulate in large numbers. According to TOUTON and UNNA the bacilli may pass into the hair-follicles and sweat-glands, and thence reach the surface.

References on Cutaneous Leprosy.

BABES: Seat of the bacilli in the tissues *A. de physiol.* II 1883

DOUURELLEPONT: Pathology of leprosy *Verhandl. d. deutschen dermat. Gesellsch.* Vienna 1892

FOX and FARQUHAR: *Endemic skin diseases of India* London 1876

GERLACH: Relation of macular to anaesthetic leprosy *V. A.* 125 1891

HANSEN, A.: *Bacillus leprae* *Quart. J. microsc. science* xx 1880; *V. A.* 79, 80, 114, 120 1880-1890

HILLIS: *Leprosy in British Guiana* London 1881

KÖBNER: *V. f. Derm.* III 1876

KÜHNE: Morbid anatomy *Monatsh. f. prakt. Derm.* III (supplement) Hamburg 1887

MINCH: *Prokaza na yuge Rossii* (Leprosy in Southern Russia) Kiev 1884-86

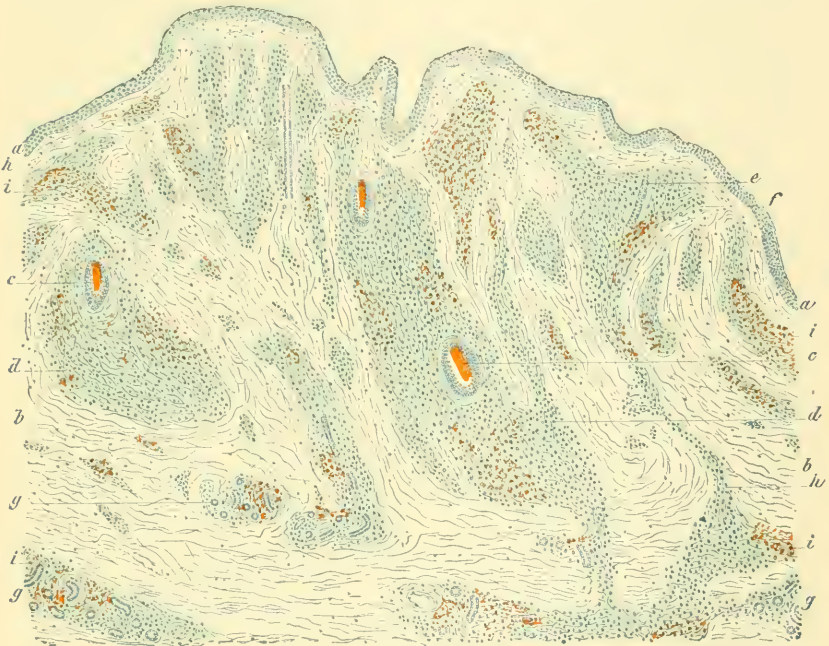


FIG. 286. LEPROUS NODE OF THE SKIN.

(Preparation hardened in alcohol, stained with fuchsin and methylene-blue, and mounted in Canada balsam: $\times 32$)

- | | |
|-------------------------------------------------------------|-------------------------------------------------------------------------------|
| a epidermis | f leprosy infiltration surrounding it |
| b corium | g leprosy infiltration round the coils of the sweat-glands |
| c hair-follicle | h leprosy deposits in no apparent relation to any of the cutaneous structures |
| d leprosy deposit in the neighbourhood of the hair-follicle | i colonies of bacilli |
| e duct of sweat-gland | |

NEISSER: *Histology* *V. A.* 103 1886; *Ziemssen's Handb. d. spec. Path.* XIV

PHILIPPSON: *Histology of hyperaemic spots in tubercular leprosy* *V. A.* 132 1893

RAMON Y CAJAL: *Giant-cells* *Gaceta sanit. de Barcelona* II 1890

RICKLI: *Morbid anatomy* *V. A.* 129 1892

SUDAKEWITSCH: *Morbid anatomy* *Ziegler's Beiträge* II 1887

TOUTON: *Bacilli in cutaneous leprosy* *V. A.* 104 1886

UNNA: *Monatsh. f. prakt. Derm.* (supplement) 1885, *Dermatol. Studien* I Hamburg 1886, *V. A.* 103 1886, *D. med. Woch.* 1886

WOLTERS: *Summary of researches* *Cent. f. Bakteriologie* XIII 1893

Glanders of the skin begins, in case the infection starts in a cutaneous wound, with an inflammatory swelling which is soon followed by the formation of an ulcer. These ulcers secrete thin pus and have ragged and eroded edges. Dissemination of the *Bacillus mallei* by way of the lymph-channels induces widespread erysipelatoid and phlegmonous inflammation, with the formation of pustules and ulcers. When the blood becomes infected (BOLLINGER, PÜTZ) the eruption takes the form of red spots and pock-like pustules, or at times of large pemphigoid blebs, which rupture and discharge viscid, bloody, and often foul-smelling pus. In other cases large boil-like swellings and abscesses are formed, which rupture and leave behind deep and ragged ulcers with suppurating edges. In some cases all these varieties of inflammation appear together, and so extensively (BOLLINGER) that hardly any part of the body remains unaffected.

Glanders either runs an acute course of two to four weeks, or a chronic one of two to six months or more: thus an acute and a chronic form are recognised, the latter being sometimes distinguished as farcy.

References on Cutaneous Glanders.

- GLASER: Glanders in man *Inaug. Diss.* Breslau 1876
 HARTGE: Moist glanders *St Petersburg. med. Woch.* 1890
 JAKOWSKI: Chronic glanders *Z. f. klin. Med.* xvii 1891
 KERNIG: Chronic glanders *Z. f. klin. Med.* xiii 1887
 LÖFFLER: Aetiology *Arbeiten a. d. k. k. Gesundheitsamte* i 1886

161. The **mycoses** of the skin due to mycelial fungi (*hyphomycetes*) are divisible into four main forms, known as favus, herpes tonsurans, pityriasis versicolor, and erythrasma.

Favus (*tinea favosa* or crusted ringworm) chiefly attacks the scalp, though it is also met with in other parts, such as the nails. It is characterised by the formation of pale-yellow cup-shaped friable crusts usually perforated by hairs, the so-called favus-cups (*scutula*). These crusts vary from the size of a pin-head to that of a sixpence or dime.

According to KAPOSI the favus-cup begins as a minute yellow punctiform spot perforated by a hair and lying beneath the epidermis. In a few weeks it grows to the size of a pin's head, and then appears as a pale-yellow cup-shaped disc visible through the skin. On section the disc (Fig. 287) is seen to consist of mycelial filaments and conidia (spores), lying beneath the attenuated horny layer of the epidermis (absent in the figure) in a crateriform excavation of the skin. If the cup is removed the surface of the excavation has a red and moist appearance. The cup itself is whitish and friable, and may be readily teased out when placed in water. The fungus of which it consists, apart from

the epidermal detritus accompanying it, is called *Achorion Schönleini* (from SCHÖNLEIN who discovered it in 1839).

If the favus-cups are not removed they coalesce into large continuous masses. When the horny skin which binds them down is cast off or broken through, these masses are exposed and dry up into yellowish mortar-like crusts. The hairs look dull and powdery, and are easily pulled out. This is due to the fact that the hyphae and conidia enter the opening of the hair-follicle and grow into the bulb (Fig. 288 *a*) and shaft of the hair, and also into the root-sheath (*b*). By the growth of the fungus not only

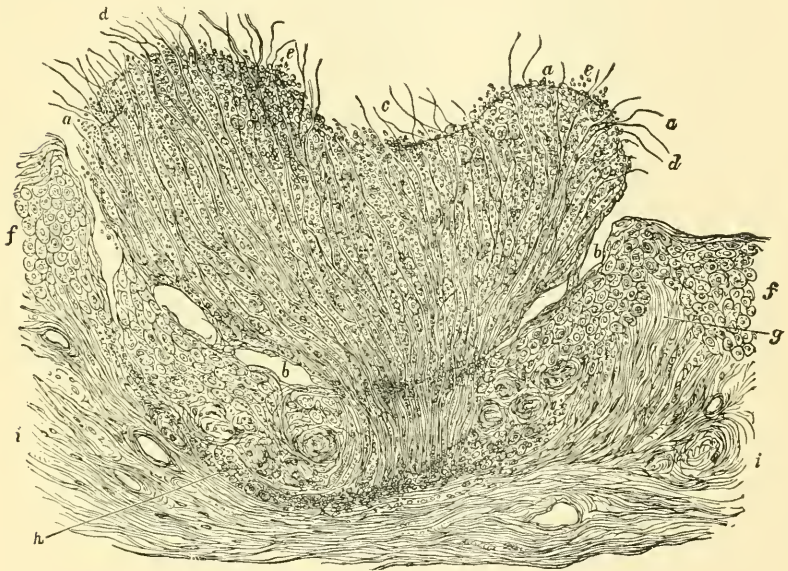


FIG. 287. CUP OR SCUTULUM OF FAVUS.

(After NEUMANN)

- | | | | |
|------------|-----------------------------------------------------|----------|---------------------------------------|
| <i>a</i> | free edge of the cup | <i>f</i> | epidermis |
| <i>b</i> | dead and disintegrated horny layer of the epidermis | <i>g</i> | altered papilla |
| <i>c d</i> | mycelial filaments | <i>h</i> | cellular infiltration beneath the cup |
| <i>e</i> | conidia | <i>i</i> | cutis |

may the hair itself be extruded, but the papilla may become atrophied by the pressure of the accumulating detritus. At the same time the tissue surrounding the hair-follicle is affected with more or less intense inflammation, which may assume an eczematous character.

When *Achorion* settles in a nail (*onychomycosis favosa*) yellowish sulphur-like deposits or uniform thickenings are formed in it, the components of the nail becoming disintegrated and undergoing cheesy degeneration.

Tinea tonsurans (*herpes tonsurans* or common ringworm) is an affection produced by the filaments and spores of *Trichophyton tonsurans* (discovered by GRUBY in 1844). The filaments are long, slender, and sparsely branched, and form few conidia and no

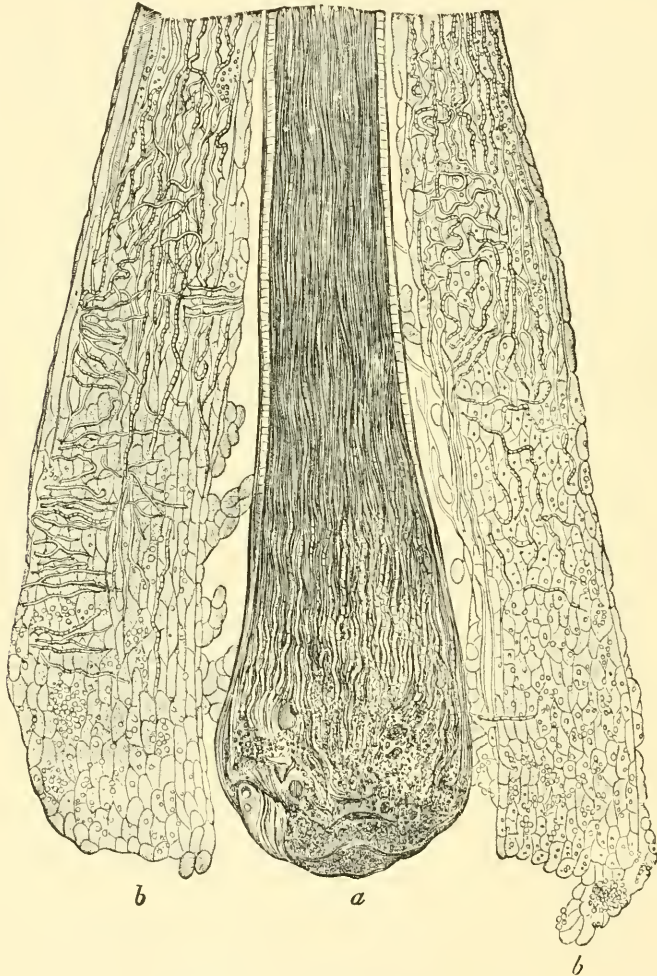


FIG. 288. HAIR AFFECTED WITH FAVUS.
(After KAPOSÍ)

a hair-bulb and shaft *b* root-sheath beset with hyphae (mycelial filaments) and conidia (spores)

scutula; but they readily penetrate into the shaft of the hair, and make it brittle. Tinea assumes a different appearance according as it occurs on hairy or non-hairy parts of the skin.

Tinea tonsurans capillitii, or ringworm of the scalp, gives rise to bare circular patches from the size of a sixpence to that of a crown-piece (KAPOSI). The surface appears as if badly shaven, the hairs over it being broken off short and frayed at the ends. The skin of the patches is smooth or scaly, and their margins are reddened. When the filaments penetrate the hair-follicles pustules and scabs are formed. Such patches are produced in several places at once, and continue to grow larger until the affection is cured.

On non-hairy parts rings of vesicles (*tinea* or *herpes tonsurans vesiculosus*) and red scaly spots, discs, and circles are produced. Sometimes a number of red spots appear in rapid succession at various points, and heal as rapidly, without attaining any great size.

In *herpes tonsurans vesiculosus* the fungi are found between the uppermost layers of nucleated epidermal cells (KAPOSI).

When the fungus attacks the nails (*onychomycosis tonsurans*) they become opaque and brittle, and split into laminae.

Sycosis parasitaria (*tinea sycosis* or barber's itch) is induced when the development of the fungi is accompanied by a more marked inflammation of the hairy parts. Infiltration and suppuration, with the formation of pustules, abscesses, and papillomatous growths are the result. According to KAPOSI and others **eczema marginatum**, which affects parts where two cutaneous surfaces rub against each other and the skin is kept moist by perspiration, is due to *Trichophyton tonsurans*. Vesicles and crusts are produced about the margin of a pigmented area. Contagious impetigo (Art. 148) is also said to be caused by *Trichophyton tonsurans* (H. HEBRA).

Pityriasis versicolor (*dermatomycosis furfuracea*, *tinea versicolor*, *mycosis microsporina*) is characterised by the appearance of pale or brownish-yellow patches, deepening to dark-brown or brownish-red, and varying in size from that of a pea to that of the palm of the hand; they extend uniformly over large areas, are irregular in outline, and their surface is smooth and shining or dull and scaly. They occur chiefly on the trunk, neck, and flexor surface of the limbs, never on the hands or feet or on the face. The epidermis when scraped off is found to contain mycelial filaments and conidia of a fungus called *Microsporon furfur* (discovered by EICHSTEDT in 1846). It does not penetrate the hairs or their follicles.

Erythrasma is characterised by the formation of sharply-defined brown or reddish-brown patches, sometimes as large as the hand, and not very scaly. They appear on the inner surface of the thighs. The filamentous fungus found in the epidermis is extremely small, and has therefore been called *Microsporon minutissimum*.

162. Scabies and epithelioma molluscum are the most important diseases of the skin due to **animal parasites**.

Scabies, or itch, is due to the settlement of *Acarus scabiei* in the epidermis. The itch-mite pierces the horny layer at some point, and bores its way obliquely through till it reaches the rete Malpighii or even the papillae. As the epidermal cells grow and approach the surface, the mite continues to work its way downward, so as always to keep below. In this way it gives rise to burrows (*cuniculi*) which penetrate the skin obliquely and are irregularly zigzagged and curved: they may reach the length of one or two centimetres. The mite sits at the blind end of the burrow (Fig. 289 *d*), leaving behind its excreta (*f*) in the form of yellow, brown, or black grains and lumps. The female also lays its eggs in the burrow, and as these are hatched the young mites may be seen in all stages of development (*e*).

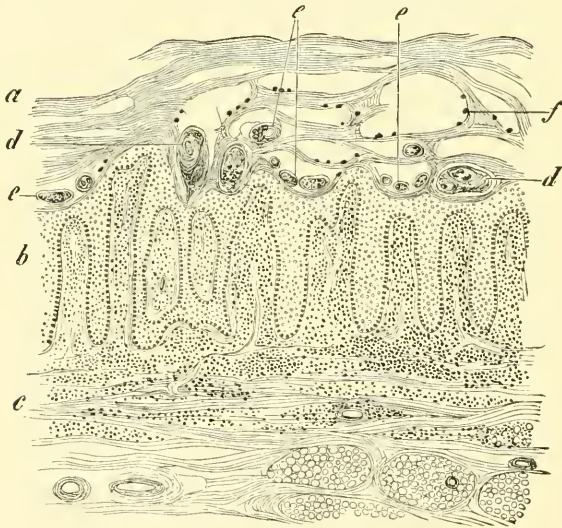


FIG. 289. SECTION OF THE SKIN IN SCABIES.

(Carminic staining: $\times 20$)

- | | |
|---------------------------------------------------------------------------------------------------------------------------------------------------------------------------------|--------------------------------------------------------------------------------------------------------------------------------------------------------------------------------------------|
| <p><i>a</i> horny layer of the epidermis traversed by the numerous burrows made by the itch-mite</p> <p><i>b</i> rete Malpighii with hypertrophied and infiltrated papillae</p> | <p><i>c</i> cutis infiltrated with cells</p> <p><i>d</i> section through an adult itch-mite</p> <p><i>e</i> eggs and embryos of various sizes</p> <p><i>f</i> excreta of the itch-mite</p> |
|---------------------------------------------------------------------------------------------------------------------------------------------------------------------------------|--------------------------------------------------------------------------------------------------------------------------------------------------------------------------------------------|

The irritation caused by the mite directly and by the scratching which it induces gives rise to eczematous inflammation of the skin, with the formation of vesicles and pustules. Pus may collect beneath the burrows of the *Acarus*.

When the affection becomes chronic the skin is often very gravely altered. The horny layer of the epidermis (*a*) is permeated by the burrows in all directions, and becomes hypertrophic. The cutis is infiltrated with cells (*c*) and thickened, and the papillae (*b*) become perceptibly elongated.

Molluscum contagiosum (*epithelioma contagiosum*, endocystic condyloma, or sebaceous wart) is a tumour-like growth in the skin, probably caused by parasitic sporozoa or coccidia (Fig. 290), and taking the form of umbilicated nodes with a waxy lustre and as large as a pea or bean. The growth consists of epithelioid cells arranged in a glandular manner (Fig. 290 *d*), derived from the epidermis and enclosing multitudes of the parasites (*ef*). On section it appears loculated, with a central space continuous

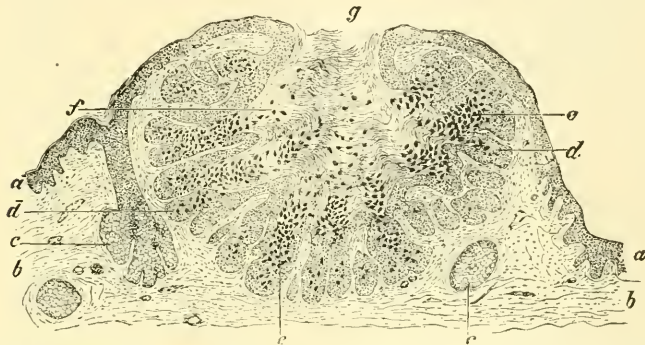


FIG. 290. LONGITUDINAL SECTION OF A NODE OF MOLLUSCUM CONTAGIOSUM. (Hardened in Müller's fluid, stained with haematoxylin and eosin, and mounted in Canada balsam: $\times 15$)
a epidermis *b* cutis *c* sebaceous glands *d* gland-like epithelioid structures
e sporozoa *f g* opening blocked with horny epidermis and sporozoa

with the apical depression, and looking not unlike a hypertrophied sebaceous gland, with which it was formerly confounded. The parasites multiply in the cells of the loculi, and as the epidermis grows tend to be thrust towards the central space (*f*), where they lie in a kind of false reticulum of desquamated horny epidermal cells. The affection is apt to appear simultaneously in persons who live together, and is accordingly regarded as contagious.

References on Molluscum Contagiosum.

- BALZER and GRANDHOMME: *A. de physiol.* 1886
 BATEMAN: *Delineations of cutaneous diseases* plate LXI London 1817
 BIZZOZERO and MANFREDI: *A. per le scienze med.* I 1876
 BÖCK, C.: *V. f. Derm.* II 1875
 CASPARY: *V. f. Derm.* IX 1882
 GEBER: *V. f. Derm.* IX 1882
 HUTCHINSON: *Cases Clinical Surgery* I London 1878
 KROMAYER: *Histogenesis* V. A. 132 1893
 MACKENZIE: *Cases B. M. J.* I 1879
 MORISON: Nature and affinities *Trans. Path. Soc.* XXXII London 1881
 NEISSER: *Epithelioma contagiosum* *V. f. Derm.* XV 1888
 SIMON, O.: *V. f. Derm.* III 1876, and *D. med. Woch.* 1876
 THIN: *Journ. of Anat.* XVI 1881
 TÖRÖK and TOMMASOLI: Nature of epithelioma molluscum *Cent. f. Bakteri-*
 VIRCHOW: *Contagiousness* V. A. 33 1865

[ologie VIII 1890

CHAPTER LV

INFLAMMATORY HYPERTROPHIES AND TUMOURS

163. **Hypertrophy** from external causes chiefly affects the epidermal and the papillary layers of the skin; but at times only the tissue of the corium, or all the layers together, are involved. In many cases the process runs its course with all the appearance of an inflammation, in others no inflammatory phenomena may be presented. In regard to some of the varieties of hypertrophy a certain inherent local predisposition of the tissue seems to be necessary in addition to the external exciting cause.

When a part of the skin is continually exposed to slight mechanical irritation, inducing often-repeated hyperaemia or slight inflammation, the epidermis may at length become hypertrophied.

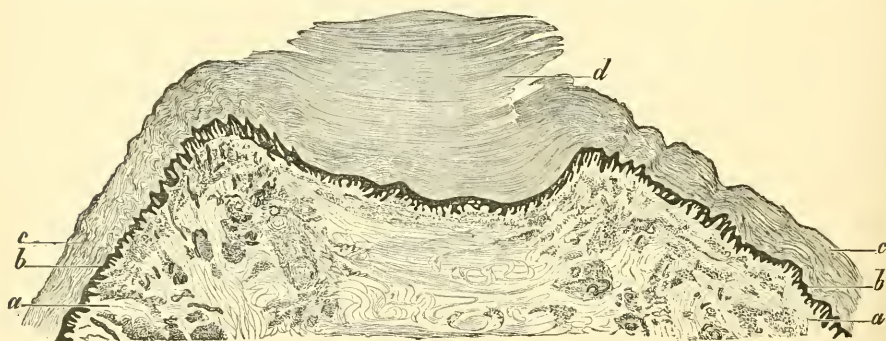


FIG. 291. SECTION OF A CORN.

(Preparation hardened in alcohol, stained with picro-carminé, and mounted in Canada balsam: $\times 8$)

- | | |
|----------------------------------------------|------------------------------------|
| <i>a</i> corium | <i>c</i> hypertrophied horny layer |
| <i>b</i> papillary layer with rete Malpighii | <i>d</i> stratified horny layer |

If the horny layer is chiefly involved, and callous or horny growths result, they are described as indurations or **callosities** (*tyloma*). They are commonest on the hands and feet.

When the callous thickening of the epidermis over a limited area extends inwards (Fig. 291 *d*) and presses on the papillae so as to lead to their atrophy, we have what is called a **corn** (*clavus*). The irritation of the papillary layer thereby caused, especially

when it is associated with external friction or pressure, induces more or less intense inflammation, manifested by hyperaemia and swelling of the tissue, and at times even passing into sup-
puration.

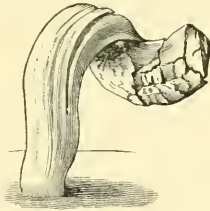


FIG. 292. CUTANEOUS HORN REMOVED FROM THE BACK OF THE HAND.
(Natural size)

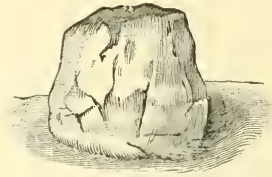

FIG. 293. CUTANEOUS HORN FROM THE ARM.
(Natural size)

Occasionally the hypertrophy takes the form not of a flattened or discoid thickening, but of a horn-like protuberance (*cornu cutaneum* or *keratoma*), which may reach a considerable size (Figs. 292 and 293). The base usually includes a few more or less elongated and hypertrophic papillae. The layers of the epidermal mass run at right angles to the surface of the skin. Cutaneous horns sometimes arise without any apparent cause on otherwise normal skin; in other cases they start from scars, wens, or tumours.

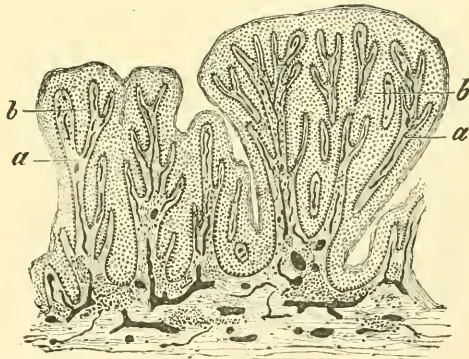


FIG. 294. CONDYLOMA ACUMINATUM.

(Injected preparation stained with haematoxylin: $\times 20$)

a enlarged and branched papilla

b thickened epidermis

Long-continued irritation affecting any portion of the skin sometimes induces local hypertrophy of the papillae, which increase in length and often become subdivided (Fig. 294 a) or branched. The cutaneous growth thus produced might be termed

inflammatory fibrous papilloma; it is usually described as a **venereal wart** or cauliflower excrescence (*condyloma acuminatum*). Such warts are usually seated upon some part of the external genitals or around the anus; the special chronic irritation which induces them is that due to discharges from urethral inflammation, chancrous pus, decomposed preputial or vaginal secretions, or the like. Though small and inconspicuous at first, they may ultimately grow into excrescences as large as an apple, firm in texture, usually whitish in tint, and resembling a head of cauliflower in general appearance. The papillae (*a*) as they grow tend more and more to subdivide; they are composed essentially of vascular fibrous tissue, but always enclose a number of leucocytes, and the base on which they stand is always infiltrated and proliferous. Lymphangitis is often set up at the same time, as appears by the accumulation of cells within and around the efferent lymph-vessels of the affected part.

The epidermis (*b*) overlying the hyperplastic papillae is thickened, and this to some extent effaces the unevennesses due to the branching of the papillae. This however applies only to the minor irregularities, the general papillary structure and configuration of the growths being quite recognisable from the outside.

Inflammatory fibrous papilloma and papillomatous granuloma fungoides (Art. 157) are formations which in their mode of origin and in their structure are very closely akin, and accordingly it is not easy to differentiate them precisely.

References on Cutaneous Horns.

- BÄTGE: Multiple circumscribed keratoses *Inaug. Diss.* Dorpat 1875, and *D. Z. f. Chir.* vi 1876
 LEWIN: Syphilitic horny growths *A. f. Derm.* xxv 1893
 MITWALSKÝ: Cutaneous horns about the eyelids *A. f. Derm.* xxvii 1894 (with references)
 PICK: Cutaneous horn of the glans penis *V. f. Derm.* ii 1875
 UNNA: Fibrokeratoma *D. Z. f. Chir.* xii 1879; Hereditary keratoma *V. f. Derm.* x 1883

164. **Acquired elephantiasis** (*elephantiasis arabum, pachydermia acquisita*) is a chronic and extensive hyperplasia of the skin and subcutaneous tissue (Fig. 295). The condition is associated with a chronic endemic disease occurring in many tropical and sub-tropical countries, such as Arabia, Egypt, Indo-China, many islands of the Malay Archipelago, Central America, and Brazil. In Europe the affection is only met with sporadically.

Two main varieties may be distinguished in endemic as well as in sporadic elephantiasis. The first variety begins with symptoms of inflammation and often of fever also: the other is insidious and gradual in its progress, and is unattended by any signs of inflammation. The inflammatory appearances, in both the endemic and

the sporadic forms, consist chiefly of recurrent erysipelatoid and lymphangitic attacks, which in the end leave behind them permanent hyperplastic thickening of the integument. The causation of these attacks is little understood. In the endemic form the process depends in many instances on the invasion of the subcutaneous tissues by *Filaria Bancrofti*, which with its embryos lodges in the lymph-vessels and gives rise to lymphatic obstruction and inflammation, chiefly about the external genitals, thighs, and abdomen. It must however be remarked that filarial infection and the resulting lymphatic obstruction do not always result in elephantiasis, and on the other hand that in most cases of endemic elephantiasis hitherto examined no *Filaria* has been discovered. Sporadic inflammatory elephantiasis, other than the kind just mentioned, may be induced by many diverse forms of chronic or recurrent inflammation, such as chronic eczema, tuberculosis of the skin and underlying bones, chronic irritation from the presence of foreign bodies, venous engorgement and varicose ulcers, prurigo, syphilitic periostitis, and chronic vaginitis and vulvitis. Lymphatic engorgement, from disease of the lymph-glands or any other cause, favours the supervention of elephantiasis, but does not by itself bring about hyperplasia of the integuments.

The aetiology of the non-inflammatory variety is still obscure, though it is highly probable that even when it does not attain a noticeable development (Fig. 295) until mature life, it is in part due to congenital causes, depending on some morbid condition inherited or acquired *in utero* (Arts. 165-168).

After the hyperplasia has in the course of years become considerable (Fig. 295), erysipelatoid inflammation is apt to recur in the part, showing that the altered tissues are peculiarly prone to inflammation.

Acquired elephantiasis may appear in almost any part of the



FIG. 295. LYMPHANGIECTATIC ELEPHANTIASIS OF THE LEG.

body, but is commonest in the lower limbs (Fig. 295) and external genitals. The enormous thickening and overgrowth of the integuments lead to great deformity of the affected part. The leg becomes thick and clumsy, and as the thickening extends downwards the distinction between foot and leg is gradually lost, and the limb at length looks like an elephant's. The scrotum grows till it forms an enormous tumour, sometimes weighing a hundred pounds or more.

The affected parts of the skin in elephantiasis are dense, hard, rough, white, and brawny-looking (*elephantiasis dura*), or soft, greyish, and lax in texture (*elephantiasis mollis*). When the tissue is cut into, a more or less abundant escape of lymph takes place. In the latter case the subcutaneous tissue often contains dilated and cavernous lymph-vessels (*elephantiasis lymphangiectatica*).

The blood-vessels may be dilated and hypertrophied, or altogether unaltered. The subcutaneous and even the deeper-lying connective tissue is liable to be involved in the general hypertrophy. The surface is either smooth, the horny layer being unaffected (*elephantiasis glabra*), rough and warty (*elephantiasis verrucosa*), tuberculated (*elephantiasis tuberosa*), or covered with papillomatous excrescences (*elephantiasis papillomatosa*). The horny layer is frequently thickened, forming either a continuous encasement, or an armour of polygonal scales and plates. The condition is sometimes described as acquired ichthyosis (Art. 166) or **keratosis**.

In elephantiasis consequent upon eczematous and ulcerous affections, the tissue is usually cellular, and in certain places has quite the appearance of granulation-tissue. In the form associated with tuberculous inflammation (Art. 158) the hyperplastic tissue also contains tubercles.

On the other hand, the tissue is in some cases poor in cells and coarsely fibrous in its texture, giving one the impression that the normal fibrous fasciculi are increased not so much in number as in individual thickness. Between these two extremes there are numerous transitional forms, varying in the proportion of cells contained in the tissue, in the coarseness of the fibrous fasciculi, and in the thickness of the individual fibrillae.

Scleroderma is a rare and very peculiar affection of unknown origin, which attacks adults. It takes the form of local or general stiffening and hardening of the skin without any apparent external cause: it is somewhat rapid in its onset, and then remains stationary or passes away, to be succeeded by a fresh attack or ultimately by a condition of cutaneous atrophy. It affects the face, the limbs, and also the trunk, the patient often being literally 'hide-bound.' The skin feels as hard as a board, or like that of a frozen corpse (KAPOSI). It is said (CHIARI, DINKLER, and WOLTERS) that in the hyperplastic stage the cutaneous fibrillae are swollen up, and that new connective tissue is developed from germinal cellular tissue. The vessel-walls are notably thickened at an

early stage, the lumen being thereby obstructed or occluded. Later on the hyperplastic connective tissue undergoes contraction.

Scleroderma or **sclerema neonatorum** is a hardening of the subcutaneous connective tissue met with in infants, and chiefly affecting the legs and feet. According to LANGER (*Wien. Sitzungsber.* 1881, and *Wien. med. Presse* XXII 1881) it is due to the solidification of the *panniculus adiposus* by cold when the infant becomes collapsed. The fat of children contains more palmitin and stearin and less olein than that of adults: it accordingly solidifies at 45° C. Adult fat at ordinary temperatures separates into two layers: the upper or liquid layer solidifies at 0° C., while the lower or semi-solid layer liquefies at 36° C.

References on Acquired Elephantiasis and Sclerodermia.

- CHIARI: Sclerodermia universalis *V. f. Derm.* v 1878
CROCKER: Clinical lectures on sclerodermia *Lancet* i 1885
DINKLER: Sclerodermia *D. A. f. klin. Med.* XLVIII 1892 (with references)
ERBEN: Aetiology of sclerodermia *V. f. Derm.* xv 1888
ESMARCH and KULENKAMPFF: *Die elephantiasischen Formen* Hamburg 1885
FAYRER and POWER: Elephantiasis arabum *Trans. Path. Soc.* XXX London 1879
THIN: Histology of elephantiasis *Trans. Path. Soc.* XXXI London 1880
VIRCHOW: *Die krankhaften Geschwülste* i
WOLTERS: Sclerodermia *A. f. Derm.* XXIV 1892 (with references); Sclerodactyly *ibidem* xxx 1895

CHAPTER LVI

NON-INFLAMMATORY HYPERTROPHIES AND TUMOURS

165. The skin and subcutaneous tissue are among the structures of the human body that are frequently the seat of **local malformations**. These textural anomalies are either already apparent at birth, or, during the period of active growth, rarely in mature years, develop from occult rudiments into visible forms. All the constituent tissues of the skin may be equally concerned in the morbid development, though more frequently certain components only are affected, and the resulting appearances vary accordingly. In one class of cases the epidermis and in some measure the papillary layer are chiefly involved; in a second the fibrous elements of the corium or of the subcutaneous tissue, or of both together; in a third the lymph-vessels; in a fourth the blood-vessels; in a fifth the nerves; in a sixth more than one of the above-named structures are simultaneously altered and abnormally developed.

In many cases the affected portions of the skin are not increased in size, the normal tissue being simply superseded by tissue of abnormal structure. In other cases the affected portion is enlarged, and the resulting formation is then reckoned as a **tumour** when it is local and circumscribed, or described as **elephantiasis** when it is wide-spread and gives rise to general bulkiness and deformity of the part concerned.

166. **Ichthyosis** or 'fish-skin' disease is an affection of the skin characterised by the formation of epidermal scales, flakes, and plates, and of warty growths. It depends on some developmental anomaly of the skin, and in particular of the epidermis, which *in utero* or not until after birth (Fig. 296) manifests itself by perversion of the histological characters and properties of the epidermal layers.

In **congenital ichthyosis** (Fig. 296) the surface is beset with horny plates, separated by fissures and furrows produced by the growth of the body (*keratoma diffusum*). The fingers and toes are usually hide-bound by a tough continuous horny layer, and their development is accordingly liable to be arrested. The plates are composed of closely-coherent layers of horny epidermal cells (Fig. 297 *c*), enclosing lanuginous hairs (*e*) and extending into the dilated hair-follicles (*d*).

Ichthyosis appearing after birth starts with an eruption of small yellowish-red or brownish-red somewhat infiltrated spots

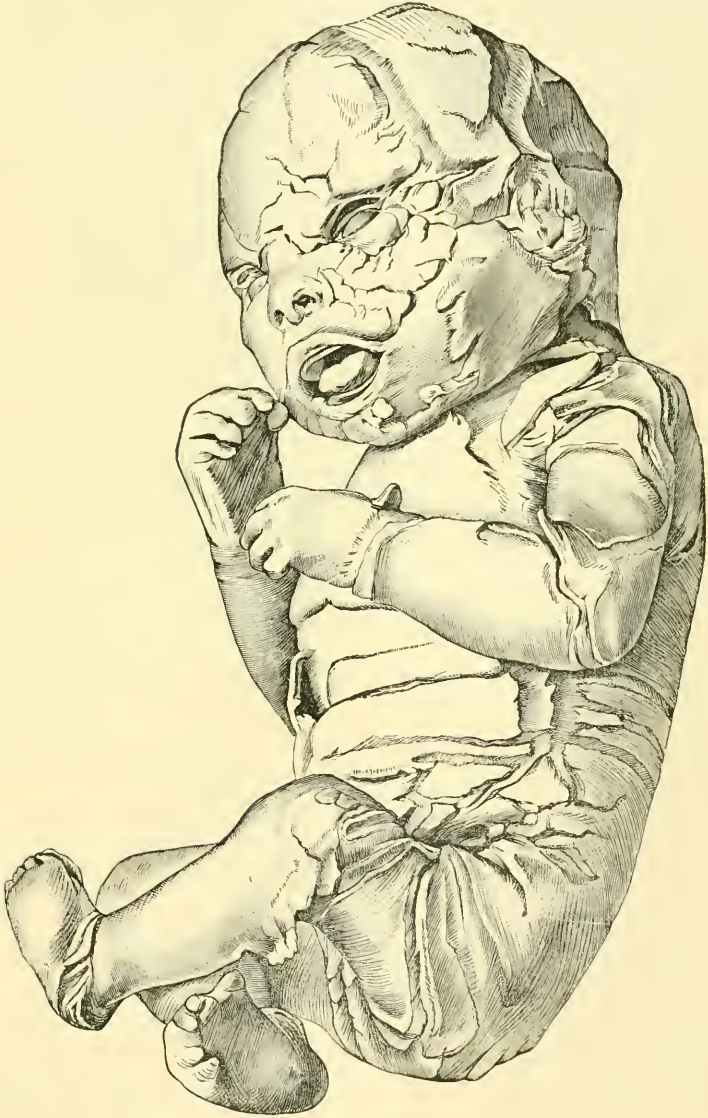

FIG. 296. CONGENITAL ICTHYOSIS.

(RÓNA), over which the epidermis becomes dry and glistening. When the disease is well advanced the horny layer is enormously thickened, laminated, and fissured; the rete Málpighii, on the

other hand, is in comparison but slightly developed, and passes without transition into the horny layer.

In *ichthyosis simplex* the papillae are not enlarged. In very slight cases the skin is simply beset with small nodules (KAPOSI),

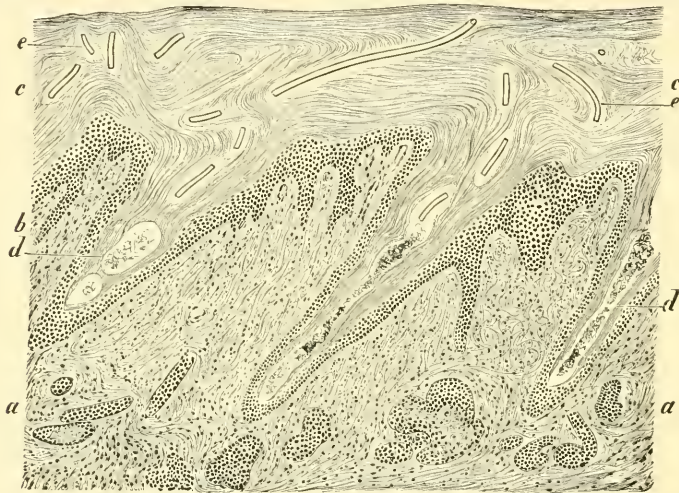

FIG. 297. CONGENITAL ICHTHYOSIS.

(Section through the skin of the trunk: preparation hardened in alcohol and stained with picro-carminé: $\times 40$)

- | | |
|---------------------------------------------|------------------------------------------------------|
| a corium with its glands | d dilated hair-follicles lined with horny epithelium |
| b papillary layer with rete Malpighii | e fine hairs |
| c hypertrophic horny layer of the epidermis | |

each covered with a thin scale and containing a coiled-up hair (*lichen pilaris* or *keratosis pilaris*). This condition is met with chiefly on the extensor surface of the limbs. In more marked cases contiguous plates or scales of various sizes up to that of a

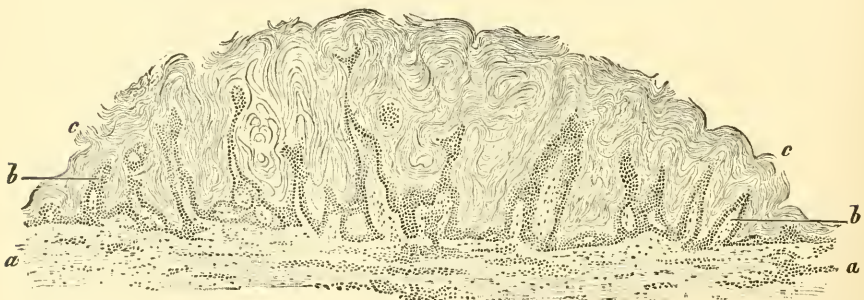


FIG. 298. ICHTHYOTIC WART.

(Preparation hardened in Müller's fluid, stained with hæmatoxylin and eosin, and mounted in Canada balsam: $\times 70$)

- | | | |
|----------|---------------------|--------------------------|
| a corium | b enlarged papillae | c stratified horny layer |
|----------|---------------------|--------------------------|

sixpence or dime are formed, attached at the centre, and giving the surface the appearance of crocodile-skin (*ichthyosis nitida*). These may subsequently become scurfy and dirty or discoloured (*ichthyosis nigricans*). When the papillae as well as the epidermis are hypertrophied, the surface becomes extraordinarily rough and irregular, the elevations sometimes standing up like short quills (*ichthyosis hystrix*). An **ichthyotic wart** (Fig. 298 *b c*) is produced when the overgrowth of the horny layer is limited to a small area, and the underlying papillae are enlarged.

References on Ichthyosis.

- BEGBIE: *Select Works* London 1882
 CARBONE: Congenital ichthyosis *A. per le scienze med.* xv 1891
 CASPARI: Congenital ichthyosis *V. f. Derm.* XIII 1886
 ESOFF: Pathology of ichthyosis *V. A.* 69 1872
 GASKOIN: Cases *St George's Hosp. Reports* IX X London 1879-80
 GIOVANNINI: Ichthyosis with hypertrophy of the sweat-glands *A. f. Derm.* XXVII 1894
 KYBER: Diffuse keratoma in an infant *Wien. med. Jahrb.* 1880
 LELOIR: Cutaneous affections of trophic origin *A. de physiol.* 1881
 RÓNA: Ichthyosis in infancy *A. f. Derm.* XXI 1889
 SCHABEL: Congenital ichthyosis *Inaug. Diss.* Stuttgart 1856
 UNNA: Hereditary palmar and plantar keratoma *V. f. Derm.* x 1883

167. **Angiomata** or haematangiomas of the skin are formations that appear in the period of embryonic development or of extra-uterine growth. They are described as **vascular naevi** when they take the form of circumscribed red spots; **moles** or soft warts when they are rounded and protuberant; and **elephantiasis** when they are associated with extensive thickening of

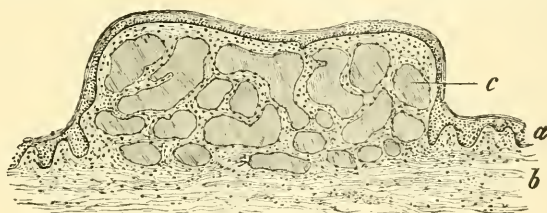


FIG. 299. CONGENITAL CAVERNOUS ANGIOMA OF THE SKIN.

(Preparation stained with haematoxylin: $\times 20$)

a epidermis

b corium

c cavernous blood-spaces

the skin. In all of these cases the textural peculiarity consists in morbid dilatation over a limited area of the blood-vessels of the skin or of the subcutaneous tissue, sometimes assuming the characters of a mere telangiectasis or simple angioma, in other cases of a cavernous angioma (Fig. 299 *c*) or of a hypertrophic angioma (Fig. 300).

Vascular naevi are bright-red or purplish blotches, commonly described as 'mother's marks' or 'port-wine stains' (*naevi vasculosi flammei*, and *naevi vasculosi vinosi*). They are small and circumscribed, or large and diffuse, in the latter case sometimes covering one-half of the face. Large naevi are at times formed from the coalescence of smaller ones, or are surrounded by small red spots. They either lie wholly in the corium and papillary layer, or extend into the subcutaneous tissue.

The skin over the affected area is sometimes of normal thickness, sometimes more or less hyperplastic (*naevus prominens*).

Vascular naevi taking the form of soft warts are bluish-red, or pale and without any special colour, the latter being the case when the growth tends to assume the form of a hypertrophic angioma whose thick-walled vessels contain little blood, or represent little more than cylindrical cellular cords (*endothelioma*).

Large angiomas giving rise to general elephantoid thickening of the skin and subcutaneous tissue are generally of the cavernous type (*elephantiasis cavernosa*). When the tissue

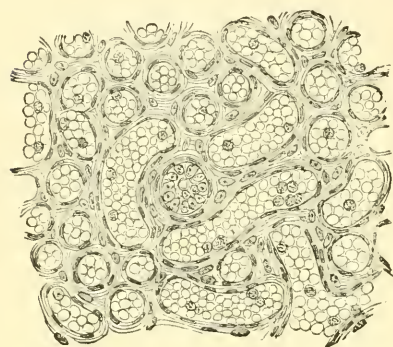


FIG. 300. SECTION OF A HYPERTROPHIC ANGIOMA OF THE SKIN AND SUBCUTANEOUS TISSUE.

(The duct of a sweat-gland has been cut across at the middle of the section: preparation stained with alumn-carminé, and mounted in Canada balsam: $\times 200$)

intervening between the dilated blood-vessels undergoes proliferation, the growth tends to become fibromatous, and to lose its telangiectatic character.

Of the same nature as angiomatous elephantiasis is the great enlargement of the nose (*rhinophyma* or 'bottle-nose') described in Art. 135 as supervening in some cases of **acne rosacea** (Fig. 267). There is however this difference, that in the latter the dilatation of the blood-vessels is slow and gradual, and that the sebaceous glands (Fig. 267 *c d e*) play an essential part in bringing about the thickening of the skin.

References on Angiomata of the Skin.

- ESMARCH and KULENKAMPFF: *Die elephantiastischen Formen* Hamburg 1885
 JARISCH: Cutaneous tumours *A. J. Derm.* XXVIII 1894
 VIRCHOW: *Die krankhaften Geschwülste* III
 VOLKMANN: *Beiträge zur Chirurgie* Leipzig 1875

168. **Lymphangioma**, like haematangioma, appears either as a local textural malformation of the skin without increase of its

bulk, as a circumscribed or diffuse protuberance or wart, or lastly as an elephantoid thickening of the skin. It may be pale, or reddened owing to the dilated blood-vessels it contains, in which case it resembles haematangioma. Pigmented varieties are moreover met with, and these include the formations described in Art. 137 as sun-spots, freckles, moles, and xanthoma.

Lymphangiomata may be distinguished according to their structure as telangiectatic, cavernous (Fig. 301), cystic, or hypertrophic; and according to their situation as cutaneous or subcutaneous. When the dilated lymph-vessels lie in the papillary layer beneath the epidermis, lymph sometimes permeates the latter, or forms vesicles or bullae upon it, especially when the tissue becomes from any cause inflamed.

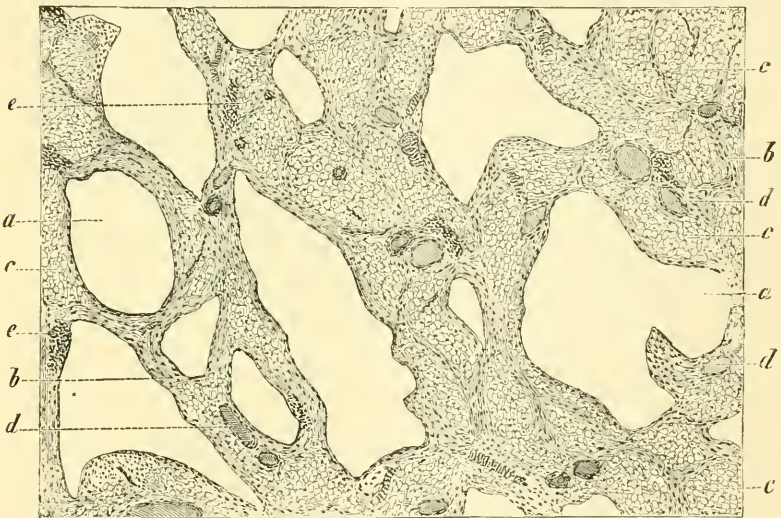

FIG. 301. SUBCUTANEOUS CAVERNOUS LYMPHANGIOMA.

(Preparation stained with alum-carmin, and mounted in Canada balsam : × 20)

- | | |
|------------------------|-------------------------|
| a dilated lymph-vessel | d blood-vessel |
| b connective tissue | e cellular infiltration |
| c fatty tissue | |

Lymphangiomata occur on the head and limbs, and also on the trunk. Those which give rise to elephantoid deformity about the external genitals, lips, or trunk, are sometimes purely lymphangiomatous in structure; but it not infrequently happens that somewhat extensive fibrous hyperplasia takes place in the affected part, and the growth assumes more and more the form of a fibromatous elephantiasis with numerous lymphatics.

The warty forms have also at times a typical structure, characterised by its wide lymph-spaces, this being especially the case in the wide-spread diffuse variety. But more frequently the

growth possesses the characters of **hypertrophic lymphangioma** or **endothelioma**, indicated by the presence of circumscribed nests of large cells lying in the corium (Fig. 302 *d d*₁). When the cell-nests are for the most part situated in the papillary layer, and the papillae are thereby enlarged (Fig. 302), uneven tuberous warts are formed. When the morbid overgrowth chiefly affects the corium, the warts are but slightly uneven (Fig. 303), or perfectly smooth, and project above the surface as little nodules (*endothelioma tuberosum*).

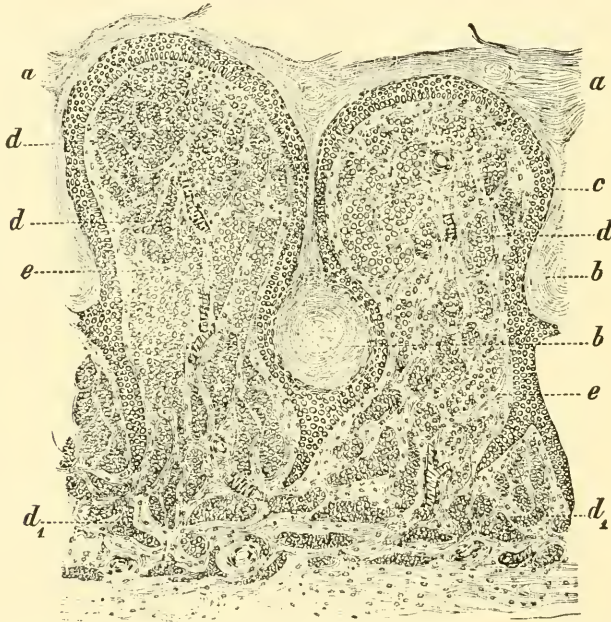


FIG. 302. SECTION THROUGH TWO PAPILLAE FROM A TUBEROUS HARD WART.

(Carminé-staining: $\times 50$)

- | | |
|-------------------------------------------------|-------------------------------------------------------------|
| <i>a</i> thickened horny layer of the epidermis | <i>d</i> cell-nests and clusters in the papillae, and |
| <i>b</i> 'pearl' of epidermal cells | <i>d</i> ₁ in the reticular tissue of the corium |
| <i>c</i> rete Malpighii | <i>e</i> connective tissue |

When the overlying horny layer remains unaltered (Fig. 303) they are soft (fleshy or soft warts, *verruca mollis* or *carnea*); but hypertrophy of this layer (Fig. 302 *a*) causes them to become hard (*verruca dura*) and similar in appearance to ichthyotic warts (Fig. 298).

Among the pigmented forms of hypertrophic lymphangioma, the pigmented naevi or **moles** are those which have the largest cell-nests, especially when the skin over them is thickened (*naevus pigmentosus prominens*, *verrucosus*, or *papillomatosus*). **Freckles** and sun-spots have small and scanty cell-nests. The

pigment lies partly within the nest-cells, partly in the ordinary connective-tissue cells and in the deeper layers of the epidermis: it consists of brown and yellow granules, but the cells are sometimes uniformly stained.

Xanthelasma or **xanthoma** (*vitiligoidea*) which appears as spots of a sulphur-yellow or brownish-yellow colour, level with the surface (*xanthelasma planum*) or raised in nodules (*xanthelasma tuberosum*), also contains clusters of large cells, but these differ from the nests of pigmented and unpigmented warts and moles in that they are larger and are infiltrated with oil-globules. Xanthoma might accordingly be described as a form of lipomatous lymphangioma or endothelioma. In some cases it is an inherited or family peculiarity, appearing most frequently about the eyelids. Now and then, though rarely, it appears as a multiple affection in various other parts of the body (*xanthelasma multiplex*).

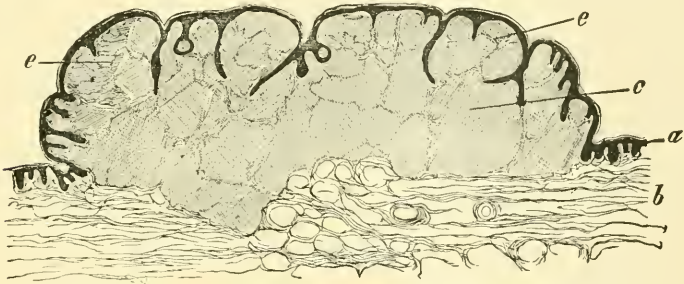


FIG. 303. SECTION THROUGH A SLIGHTLY TUBEROUS SOFT WART

(Aniline-brown staining: $\times 10$)

a epidermis
b cutis

c cellular growth in the cutis
e cellular growth in the papillae

Occasionally, in both the pigmented and the non-pigmented varieties of endothelioma, some of the cellular clusters are ill-defined from the connective tissue, passing gradually into it, or taking the form of diffuse cellular infiltrations within it. Malignant neoplasms are moreover apt to start in fleshy warts and moles; they are nearly always sarcomatous, and generally of the alveolar variety.

Moles are often beset with numerous thick hairs, and are then called hairy moles (*naevi pilosi*).

For a description of nerve-naevi see Art. 169.

Xeroderma pigmentosum (Kaposi), or progressive lentiginous melanosis (Pick), is a peculiar and rare affection of the skin, depending upon some congenital anomaly of structure, and appearing in early infancy in parts of the skin that are exposed to light. It begins with recurrent eruptions of red spots, which desquamate and disappear, leaving behind them pigmented specks like freckles, the surrounding capillaries being dilated, and the skin meanwhile becoming smooth and atrophic. At a later stage wart-like protuberances

appear on the affected parts, and these are apt to develop into cancerous growths (EISENBERG: *Xeroderma pigmentosum A. f. Derm.* XXII 1890). The affection usually runs in families (CROCKER: *Med.-chir. Trans.* LXVII London 1883; ANDERSON: *B. M. J.* I 1889).

PERTHES has described as **calcified endothelioma** certain multiple calcareous and tumour-like nodes found in the subcutaneous tissue, and is of opinion that some of the formations which have been described as examples of calcified epithelioma should be regarded as of the nature of endothelioma.

References on Lymphangioma (Endothelioma) of the Skin, including Xanthoma

ANDERSON: Xanthoma multiplex *B. M. J.* II 1892

BRYSK: Lymphangioma *A. f. klin. Chir.* XXIV

CHAMBERD: Histology of xanthelasma *A. de physiol.* VI 1879, *Ann. de dermat.* V 1884

DEMIÉVILLE: Pigmented moles and spots *V. A.* 81 1880

EHRMANN: Multiple symmetrical xanthelasma and lipoma *Beiträge von Bruns* IV 1883

ESMARCH and KULENKAMPFF: *Die elephantiasischen Formen* Hamburg 1885

HUTCHINSON, SANGSTER, and CROCKER: Report on cases *Trans. Path. Soc.* XXXIII London 1882

KÖBNER: Xanthoma starting from pigmented moles *V. f. Derm.* XV 1888

KROMAYER: Endothelioma tuberosum colloides *V. A.* 139 1895

LANGHANS: Lymphangioma of the lower extremity *V. A.* 75 1879

LEIZEN and KNAUSS: Xanthoma multiplex tuberosum *V. A.* 116 1889

ZUR NIEDE: Lymphangiectasis with lymphorrhagia *V. A.* 90 1882

PERTHES: Calcified endothelioma of the skin *Beiträge von Bruns* XII 1894 (with references)

VON PLANNER: Congenital naevus *V. f. Derm.* XIV 1887

POENSGEN: Xanthelasma multiplex *V. A.* 91 1883

PYE-SMITH: Xanthelasma *Guy's Hosp. Reports* XXII London 1877

VON RECKLINGHAUSEN: *Die multiplen Fibrome der Haut* Berlin 1882

SCHMIDT: Lymphangioma *A. f. Derm.* XXII 1890

TÖRÖK: Nature of xanthoma *Ann. de dermat.* IV 1893

TOUTON: Xanthelasma *V. f. Derm.* XII 1885

VARIOT: Congenital melanoderma *A. de physiol.* X 1887

DE VINCENTIS: Xanthoma *A. ital. de biol.* IV 1883

VIRCHOW: *Die krankhaften Geschwülste* III

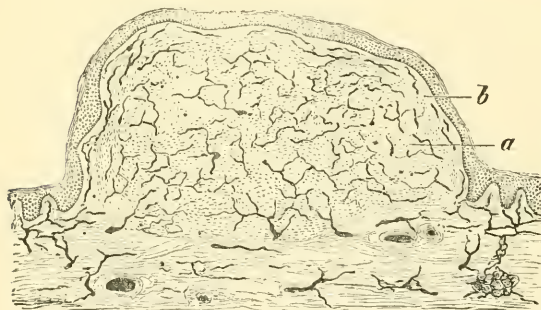


FIG. 304. NEUROFIBROMA MOLLUSCUM.
(Injected preparation stained with haematoxylin: $\times 20$)
a fibroma b thinned and flattened papilla

169. **Fibromata** of the skin usually occur in the form of multiple nodes, the smallest of which are barely visible, or lie embedded and hidden in the skin, while the larger ones often reach a considerable size and are elevated above the surface. Multiple cutaneous fibroma (Fig. 305) is usually a soft

growth, and has therefore received the name of **fibroma mol-luscum**. VON RECKLINGHAUSEN has shown that the tumour starts from the smaller cutaneous nerves, whose fibrous envelopes become proliferous and form aggregations of cellular and finely-fibrous tissue, seated in the form of nodes (Fig. 304) either wholly within the corium, or in the papillary layer also. The tumours are accordingly reckoned among the **neurofibromata** (Art. 133).

Neurofibroma may be limited to the region supplied by particular nerves, or distributed over the whole body. It is not infrequently associated with the appearance of fibromata on the large subcutaneous or deeply-lying trunks and branches of the nerves (Art. 133).

A large soft growth starting from a single nerve is spoken of as **elephantoid mol-luscum**. When the proliferous over-growth of the endoneurium gives rise to a convoluted or interlacing plexus of thickened and fibromatous nerves (Fig. 265) the formation is called a pampiniform or **plexiform neuroma**.

A neuroma of this kind sometimes causes more or less extensive thickening of the skin, partly from

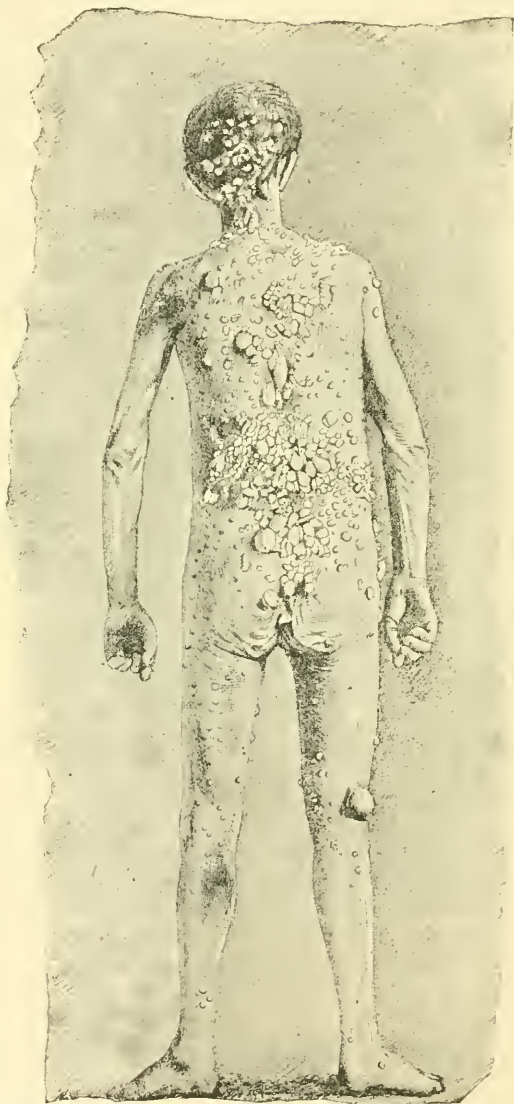

FIG. 305. MULTIPLE NEUROFIBROMATA OF THE SKIN.
(After VON RECKLINGHAUSEN)

its own bulk and partly from its association with diffuse fibrous hyperplasia of the corium and subcutaneous tissue, and the condition is then described as **neuromatous elephantiasis** or pachydermia (Fig. 306).

Neuromatous elephantiasis is one of the commonest of the cutaneous hyperplastic deformities due to congenital causes, and generally takes the form of loose overgrown and lobate foldings of the skin, reminding one of the hide of some of the pachyderms. It has been variously described as **dermatolysis**, pachydermatocele

(VALENTINE MOTT), elephantiasis mollis (VIRCHOW), and lobate elephantiasis (VOLK-MANN). The surface of the hypertrophied parts is smooth or tuberculous, and is sometimes beset with pigmented moles.

The number of neurofibromata present in the thickened and overgrown integument (Fig. 307 *f f*₁) may be large or small, and varies greatly in different parts. The nerve-fibres (*g*) usually lie in the centre of the nodes. The hyperplastic tissue (*c k*) lying between the growths is usually more cellular than is normal connective tissue.

Besides the haematangiomaticous, lymphangiomaticous, and neuroangiomaticous forms of elephantiasis, there is a

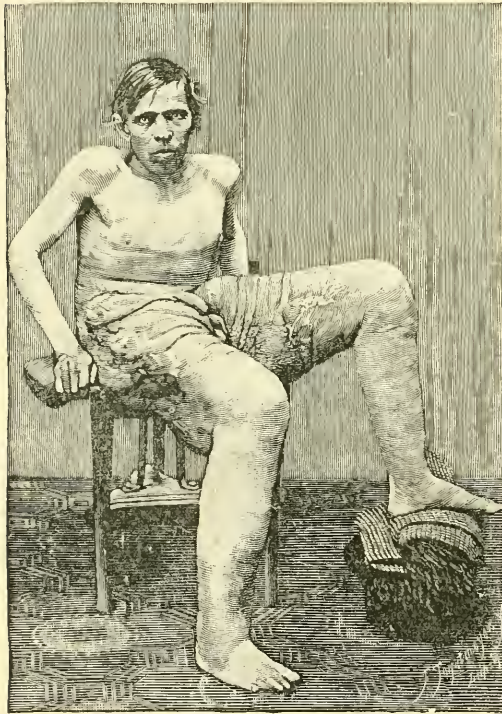


FIG. 306. NEUROMATOUS ELEPHANTIASIS OR PACHYDERMIA OF THE THIGH.

simply **fibrous elephantiasis**, in which all of the connective-tissue elements of the skin and subcutaneous tissue appear to be equally hyperplastic. Of this nature are some of the cases described as dermatolysis. Certain kinds of warts also are essentially due to excessive fibrous hyperplasia. It sometimes happens too that a morbid overgrowth of the adipose tissue brings about elephantoid deformity of certain portions of the body; this might be termed **lipomatous elephantiasis**. All of these varieties of elephantiasis may be combined in different ways in the same patient.

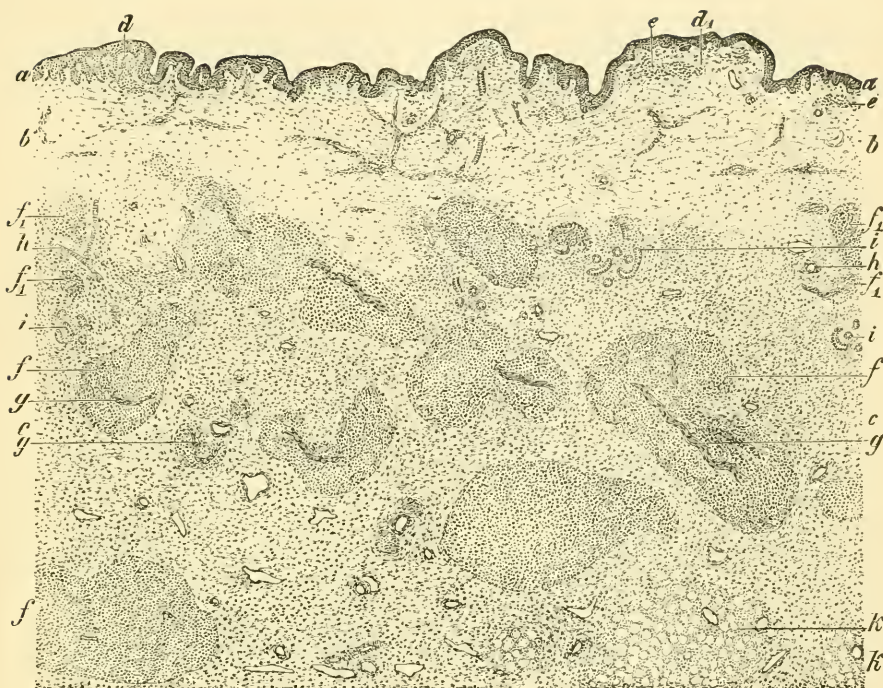


FIG. 307. SKIN WITH NEUROFIBROMATA FROM A CASE OF PACHYDERMIA (FIG. 306).
(Preparation hardened in alcohol, stained with alum-carmin, and mounted in Canada balsam: $\times 18$)

- | | | | |
|----------------|-----------------------------------|-----------------|-----------------------------------------------------------------|
| a | epidermis | ff ₁ | fibromata |
| b | normal corium | g | nerve-fibres within the fibromata |
| c | hyperplastic and cellular corium | h | vessels |
| d | enlarged papillae | i | coiled tubules of sweat-glands surrounded by proliferous tissue |
| d ₁ | hyperplastic sub-papillary tissue | k | lobules of proliferous fatty tissue |
| e | aggregations of cells | | |

Neuropathic papilloma (GERHARDT), *naevus unius lateris* (VON BÄRENSPRUNG), or nerve-naevus (TH. SIMON) takes the form of papillary pigmented wart-like nodules, which appear in the skin in small or large numbers, and in their distribution generally follow the course of one or more of the cutaneous nerves. According to VON BÄRENSPRUNG, GERHARDT, VON RECKLINGHAUSEN, and others, these excrescences are of neuropathic origin, and VON RECKLINGHAUSEN suggests that they are due to a congenital neuritis setting up vasomotor disturbances. Whether the affection has any special relation to the nerves appears to be still questionable.

References on Fibromata of the Skin and Neuromatous Elephantiasis.

- BRUNS: Plexiform neuroma *V. A.* 50 1870, and *Beiträge von Bruns* VIII 1891
 COURVOISIER: *Die Neurome* Basle 1886
 CZERNY: Neurofibroma *A. f. klin. Chir.* XVII
 ESMARCH and KULENKAMPFF: *Die elephantiasischen Formen* Hamburg 1885
 JORDAN: Congenital elephantiasis *Ziegler's Beiträge* VIII 1890

- LAHMANN: Multiple fibroma and its relation to neurofibroma *V. A.* 101 1885
 NAUWERCK and HÜRTHLE: Neuromatous elephantiasis *Ziegler's Beiträge* 1 1886
 PHILIPPSON: Fibroma molluscum *V. A.* 118 1889
 VON RECKLINGHAUSEN: *Die multiplen Fibrome der Haut* Berlin 1882
 VIRCHOW: *Die krankhaften Geschwülste* III

References on Neuropathic Papilloma.

- VON BARENSPRUNG: Naevus unius lateris *Charité-Annalen* XI 1863
 ESMARCH and KULENKAMPFF: *Die elephantiasischen Formen* Hamburg 1885
 KRÖNER: Papilloma neuropathicum (case) *Inaug. Diss.* Würzburg 1890
 NAEGELE: Papilloma neuropathicum frontis (case) *Inaug. Diss.* Würzburg 1886
 NEUMANN: Naevus papillaris (Thomson) *Oesterr. Jahrb. f. Pädiatrik* II 1878
 VON RECKLINGHAUSEN: *Die multiplen Fibrome der Haut* Berlin 1882
 SIMON: Nerve-naevi *A. f. Derm.* IV 1872
 SPIETSCHKA: Nerve-naevi *A. f. Derm.* XXVII 1894

170. Among the connective-tissue growths starting in the cutis, but of non-nervous origin, **fibroma** is one of the commonest: it usually takes the form of firm rounded nodes. **Keloid** is a very rare variety of fibroma. It appears in the form of a tuberos, discoid, band-like, stellate or radiating growth seated in the corium beneath the unaltered papillary layer. When fully developed the growth consists almost exclusively of bundles of coarse fibres. In its earlier stages it contains numerous spindle-cells.

Cicatricial keloid grows from a scar, and is not at all points covered with intact papillae. In other respects it may resemble true keloid. 'Addison's keloid,' now known as morphea, is not related to these neoplasms: it is a hypertrophic condition somewhat similar to scleroderma.

Leiomyoma is a rare tumour appearing in the form of single or multiple nodes from the size of a pin's head to that of a walnut. It may originate from the unstriped muscular fibres of the *arrectores pili*, or from those of the vessel-walls; in the latter case it is apt to be associated with local dilatation of the capillaries, or telangiectases, the combination being described as **angiomyoma**.

Sarcoma takes the form of nodular or papillomatous tumours, more or less raised above the surrounding surface. The larger sarcomata sometimes assume the shape of a short pedunculated mushroom, or of a large wart. They are usually solitary, but now and then instances occur in which a large number of sarcomatous growths appear in the skin simultaneously or in quick succession.

Cutaneous sarcoma may be round-celled, spindle-celled, or mixed. Melanotic and alveolar sarcomata are not uncommon; they originate from cellular warts and pigmented moles, and correspond closely with these in their general structure. They are highly malignant.

The diseases comprised under the term general **sarcomatosis** of the skin, and characterised by a rapidly-spreading eruption of

neoplastic nodes, are probably in certain cases due to some unknown form of infection, in others to the development of leukaemic or pseudo-leukaemic lymphoma (ARNING, HOCHSINGER, SCHIFF, JOSEPH, TOUTON).

Lipomata of the skin and subcutaneous tissue are very frequently met with, and sometimes reach a considerable size. The region of the shoulder is a favourite seat. Myxoma, enchondroma, and osteoma, are less common than lipoma. Myxoma and myxofibroma are generally connected with the external genitals in women.

Cancer (caneroid or epithelioma) is by far the most important of the epithelial neoplasms of the skin. The carcinomatous proliferation may start not only in the epidermis, but in the epithelium of the sebaceous glands and hair-follicles, probably also in that of the sweat-glands. Stratified spherules of horny epidermis are found in the epithelial ingrowths of many cases of cutaneous carcinoma, and the tumours have accordingly been described as squamous or horny cancers. In very rare cases calcification of the tumour takes place (Art. 171).

THIERSCH distinguishes a flat or superficial and a deep or infiltrating form. The former is met with chiefly in the lip, forehead, and nose; and is characterised by the fact that the epithelial ingrowths and processes are short and shallow. It generally appears as a slightly-raised ulcer with infiltrated borders, due to the breaking down of a primary cancerous node. Its growth is usually very slow, and it may cicatrise at the centre while the marginal ulceration continues to advance (cicatrising epithelioma). In other cases the process of disintegration is more rapid, and the ulcer steadily increases in depth and extent. This form is sometimes described as **rodent ulcer**, and chiefly affects the upper part of the face.

The deep or infiltrating form usually gives rise to irregularly-shaped ulcerations, due as in the former case to the breaking down of nodular epithelial growths. From the floor and edges of the ulcer often rise large warty protuberances, giving the affection the appearance of a papillomatous tumour. This form produces metastases oftener than the other.

The superficial and the deep forms are not very sharply differentiated the one from the other, and intermediate forms occur. In fact, the processes of cancerous infiltration, proliferation of the fibrous tissue, and ulcerous disintegration may be combined in numerous ways, and give rise to the great diversity of appearance observable in the several forms of the disease.

Epithelioma most frequently attacks parts where epidermis passes into mucous membrane — such as the lower lip, nose, eyelids, prepuce, anus, external female genitals, etc. Occasionally it seems to start in warts or callosities, or in scars, pustules, and ulcers, and not infrequently in the floor of an acutely-spreading

lupous ulcer or in a lupus-scar. It may begin subcutaneously, and then originates in the epithelium lining embryonic involutions of the skin (branchiogenous carcinoma) or forming part of the epiblastic medullary canal, which has persisted untransformed in the subcutaneous tissue. Other epidermoid structures connected with the skin may likewise become abstricted, and afterwards furnish a starting-point for deep-seated epithelial growths that have no visible relation to the superficial epidermis. The growths assume the characters of carcinoma or of papillary cystadenoma, are usually nodose in form, and are sharply marked off from the surrounding tissue. Probably some of them start from wens or atheromata (Art. 171), or from abstricted portions of hair-follicles.

English pathologists have distinguished between superficial epithelioma and what is termed **rodent ulcer** by surgeons. In the former the neoplastic cells are of an epidermal type, in rodent ulcer proper they are epithelial rather than epidermal, having small nuclei and but little stability, as if they were derived from gland-cells: they have been regarded as derived from the cells of the sweat-glands (THIN), or of the outer root-sheaths of the hairs. See THIERSCH (*loc. cit.*), MOORE (*Rodent cancer* London 1867), WARREN (*Med. Times and Gaz.* I 1880), THIN, FOX, BUTLIN, and others (*Trans. Path. Soc.* XXIX, XXX London 1878-79).

Adenoma of the sweat-glands is a rare tumour: it grows slowly, and appears in the form of small nodes.

Secondary neoplasms of the skin are on the whole not very common, though they do occur in connexion with both connective-tissue and epithelial tumours. Malignant growths of the skin itself are the most apt to spread in it, and give rise to daughter-tumours. Of growths in other organs, mammary carcinoma is that which most frequently gives rise to cutaneous metastases.

References on Tumours of the Skin (see also Art. 171).

- BABES: Keloid *V. f. Derm.* VII 1880
 BAYHA: Lupus-carcinoma *Beiträge von Bruns* III 1887
 BRAUN: Endothelioma of the skin *A. f. klin. Chir.* XLIII
 DARIER: Epithelioma of the sweat-glands *A. de méd. exp.* I 1889
 DÉNÉRIAZ: Keloid *Thèse* (Berne) Geneva 1887
 HESS: Subcutaneous ciliated cyst *Ziegler's Beiträge* VIII 1890
 HOCHSINGER and SCHIFF: Leukaemia of the skin *V. f. Derm.* XIV 1887
 ISRAEL: Follicular epithelioma *Virchow's Festschrift (Assistenten)* Berlin 1891
 JADASSOHN: Multiple myoma *V. A.* 121 1890
 JACOBSSON: Keloid *A. f. klin. Chir.* XXX
 JARISCH: Tumours of the skin *A. f. Derm.* XXVIII 1894
 JOSEPH: Pseudo-leukaemia of the skin *Verhandl. d. deutschen dermat. Gesellsch.* Vienna 1892
 KNAUSS: Cylindrical-celled epithelioma of the sweat-glands *V. A.* 120 1890
 KROMAYER: Endothelioma tuberosum colloides *V. A.* 139 1895
 LANGHANS: Keloid *V. A.* 40 1867
 LIRON: *Sur la chétoïde inguinale spontanée* Paris 1887

- LUKASIEWICZ: Multiple dermatomyomata *A. f. Derm.* XXIV 1892
- MATHIEU: Four cases of benign epithelioma *A. gén. de méd.* 1881
- MICHALEFF: Case of subcutaneous papilloma *Inaug. Diss.* Freiburg 1892
- NEELSEN: Keloid *A. f. klin. Chir.* XXIV
- PALTAUF: Lymphatic diseases of the skin *A. f. Derm.* XXIV 1892
- PERRIN: Cutaneous sarcomatosis *Thèse* Paris 1886
- PERTHES: Calcified endothelioma *Beiträge von Bruns* XII 1894
- PETERSEN: Multiple tumours of the tubular glands *A. f. Derm.* XXIV 1892;
Diseases of the sweat-glands *ibidem* XXV 1893 (with references)
- RIGAUD: Disseminated epithelioma *Thèse* Paris 1878
- SCHÜTZ: True keloid in combination with cicatricial keloid *A. f. Derm.* XXI
1894
- SPIEGLER: Carcinomatosis cutis (so-called) *A. f. Derm.* XXVII 1894
- STEINHÄUSER: Lupus-carcinoma *Beiträge von Bruns* XII 1894
- THIERSCH: *Der Epithelialkrebs, namentlich der Haut* Leipzig 1865
- TOMMASOLI: Epithelioma verrucosum abortivum *A. f. Derm.* XXVI 1894
- TOUTON: Sarcomatosis of the skin *Münch. med. Woch.* 1893 (with references)
- VOLKMAN, R.: Primary cancer of the limbs *Samml. klin. Vorträge* nos. 334-
335 1889
- YERSIN: Melanotic tumour *A. de physiol.* VII 1886

CHAPTER LVII

THE SEBACEOUS GLANDS, HAIR, AND NAILS

171. The epithelium of the **sebaceous glands** normally secretes an oily liquid (sebum) which condenses to a greasy lubricant. If the secretion becomes over-abundant we have what is called **seborrhoea** (*steatorrhoea*, *tinea* or *acne sebacea*, *ichthyosis sebacea*). In one variety scale-like or scurfy deposits are formed on the surface (*seborrhoea sicca*, *squamosa*, and *furfuracea*), and in another the skin seems smeared with an oily exudation (*seborrhoea oleosa*).

The scales and crusts consist of dried sebum and horny epidermis, and are apt to become discoloured, assuming a dirty-yellow, grey, or black tint: they sometimes take the form of large continuous scabs or flakes, from the under side of which processes pass into the openings of the sebaceous ducts.

Seborrhoea may be local or general. The local variety chiefly affects the scalp and the external genitals. General seborrhoea is rare, and is usually met with only in new-born infants; the abundant secretion of *vernix caseosa* which is normal in the intra-uterine period is in fact continued after birth. The abundant sebaceous secretion from the glands of the scalp which is normal during the first year of life sometimes gives rise, in neglected infants, to large fissured dirty cheesy-looking crusts or cakes, consisting of fatty matter, dirt, epidermal scales, and hairs.

When the scalp only is affected, the dried secretion taking the form of abundant branny scales, the affection is called **dandriff** (*pityriasis furfuracea capillitii*, or *porriigo amianthacea*); when the flakes are large and like fish-scales it is sometimes called *ichthyosis sebacea*.

Asteatosis (*xerodermia*), in which the sebaceous secretion is diminished, is rare as an idiopathic affection. It is usually secondary to other affections like ichthyosis, porriigo, psoriasis, pityriasis rubra, leprosy, etc. The skin becomes dry and fissured, and is shed in scales or flakes.

Various disorders of the skin are due to the accumulation of sebum in the glands or ducts in consequence of interference with its excretion. The obstruction is usually due to the drying of sebum or the deposit of dirt at the mouth of the duct. Changes

in the composition of the secretion sometimes give rise to its retention. The following varieties are distinguished.

(1) **Comedones** (Fig. 267 *e*) are small elevations of the skin due to plugging of the sebaceous ducts, or of the common opening of duct and hair-follicle. When the plug is squeezed out it appears as a whitish and somewhat firm pear-shaped or cylindrical mass of the size of a pin-head, the superficial end being stained black or brown. It consists of sebum and horny epidermal cells, and often contains one or more minute hairs.

(2) **Milium** (*grutum* or *acne albida*) consists of small roundish white or yellowish elevations of the skin, due to the accumulation

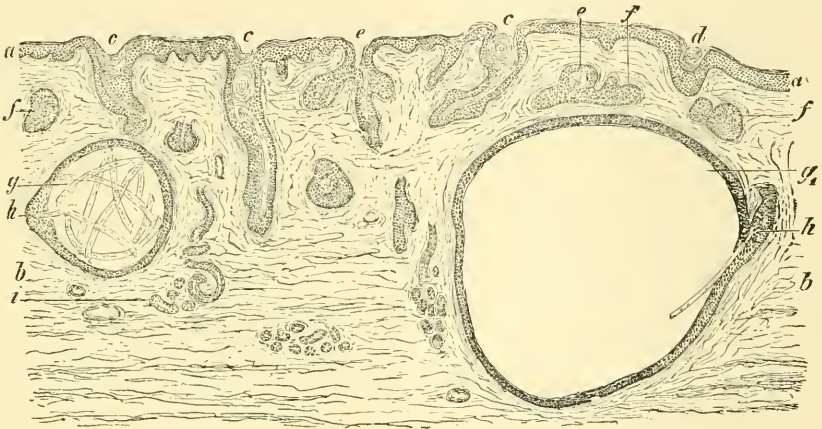


FIG. 308. ATROPHY AND CYSTIC DEGENERATION OF THE HAIR-FOLLICLES AND SEBACEOUS GLANDS OF THE SCALP.

(Preparation hardened in alcohol, stained with Bismarck-brown, and mounted in Canada balsam: $\times 20$)

- | | | | |
|---|-------------------------------------------------------------------------------------------------|----------------|-------------------------------------------|
| a | epidermis | e | hair-follicle with sebaceous gland |
| b | corium | f | atrophic sebaceous gland |
| c | atrophic hair-follicle containing downy hairs below and scales of horny epidermis at its outlet | g | cyst with small cast-off hairs |
| d | obliterated hair-follicle devoid of hair | g ₁ | cyst with enclosed atheromatous matter |
| | | h | small hair seated on the wall of the cyst |
| | | i | sweat-gland |

of epidermal cells in sebaceous glands. Milium sometimes gives rise to cystic dilatation of the associated hair-follicle. The skin of the eyelid is a favourite seat. When the nodule is incised and the contents evacuated, they are found to consist of a smooth or rough and lobate core composed of epidermal cells and sebum.

(3) When a group of sebaceous glands become enlarged by excessive accumulation of epithelial cells within them, polypoid and sometimes pedunculated excrescences are produced, which have been called **acrochordon**. Such growths appear generally in aged persons, about the eyelids and on the sides and nape of the neck.

(4) **Wens** or sebaceous cysts (*atheroma* or *steatoma*) are usually due to distension of the duct of a sebaceous gland and hair-follicle (Fig. 308 *g g₁ h*) by accumulated secretion. Remains of embryonic clefts, or epithelial structures which have in some abnormal fashion become embedded in the corium or subcutaneous tissue, sometimes form the starting-point for these cysts, which are occasionally as large as a hazel-nut or walnut, or may even reach the size of the fist. The contents consist of a pulpy greasy mass composed of fatty detritus, cast-off epidermal cells, and often cholesterin, enclosed within a fibrous capsule lined with stratified squamous epithelium. In the case of cysts originating from the hair-follicles and sebaceous glands the capsule is smooth on its inner surface, and the epithelium is many-layered. In the deep-seated cysts due to enclosure of foetal residues, the capsule possesses the structure of skin, including a papillary layer covered with epidermis. Such cysts are accordingly classed with dermoid tumours.

Papillary outgrowths at times rise from the inner surface of a wen, either from traumatic causes or idiopathically, giving rise to endocystic condylomata or papillomata; these may be regarded as akin to the forms comprised under the term papillary cystoma. Sometimes the entire cyst is packed with branching cauliflower-growths. In rare cases the structure of some parts of the growth resembles that of carcinomatous epithelioma. Processes of cornification and calcification, the latter affecting both the epithelium and the connective tissue, are apt to be set up in the capsule of a wen, transforming it into a hard globular tumour, which in some cases closely resembles an osteoma.

Wens are usually seated on the scalp, the back of the neck, or the face, more rarely on the trunk or limbs.

References on Wens and on Tumours originating from them.

- CASPARY: Adenoma sebaceum *A. f. Derm.* XXIII 1891
 CHENANTAIS: Calcified epithelioma of sebaceous glands *Thèse Paris* 1881
 CHIARI: Atheroma and encapsulated epidermoid tumours of the subcutaneous connective tissue *Tagebl. d. Naturforschervers. in Salzburg* 1881; The genesis of atheroma-cysts *Prager Z. f. Heilk.* XII 1891, and *Trans. internat. med. congr.* 1890 II Berlin 1891
 FÖRSTER: Dry canceroid *Verh. d. phys.-med. Gesellsch. in Würzburg* X
 FRANKE: Atheroma *A. f. klin. Chir.* XXXIV 1886-87; Carcinomatous degeneration of epidermoid tumours *V. A.* 121 1890
 LAGRANGE: *Anatomie pathologique et pathogénie du chalazion* Paris 1889
 VON NOORDEN: Calcified epithelioma *Beiträge von Bruns* III Tübingen 1888
 PETERS: Calcified endothelioma *Beiträge von Bruns* XII 1894
 WERNHER: Atheroma, an encapsulated epithelioma *V. A.* 8 1855
 WILCKENS: Ossification and calcification of the skin *Inaug. Diss.* Göttingen 1858

172. Each **hair** according to its size has a definite period of existence. When this is at an end, the hair is shed and its place

is taken by a new one. The replacement is effected by the cells at the tip of the papilla ceasing to grow and multiply, in consequence of which the old hair with its inner root-sheath is separated from the papilla, which thereupon atrophies. According to STIEDA the young hair is produced by a new papilla. Long thick hairs live longer than short and fine ones.

To maintain the uniform growth of the hair as a whole a constant relation must be kept up between the loss of old hairs and the production of new. When this relation is disturbed by hindrances to production, the result is **alopecia** or baldness. KAPOSI distinguishes the following forms.

(1) *Alopecia adnata*, or congenital deficiency of hair, is seldom an enduring condition.

(2) *Alopecia (clavities) acquisita* is natural in old age (*alopecia senilis*), but it may appear much earlier (*alopecia praematura*). In the baldness of age the skin exhibits the changes described in Art. 139 (Fig. 269); but it is to be noted that they do not appear till after the hair has disappeared, and they cannot therefore be the cause of baldness.

Alopecia praematura may be either idiopathic or symptomatic. In the former case the hair falls off without visible disease of the skin. Symptomatic baldness is usual as a result of inflammatory processes which induce appreciable changes in the scalp, such as eczema, erysipelas, lupus, syphilitic eruptions, etc., and it also accompanies or follows affections such as typhoid fever, syphilis, tuberculous cachexia, and the like. The continuous development of the hair from its bulb is interfered with by the inflammatory process, and the hair thus ceases to grow and is shed. If the papillae are not destroyed the hair may afterwards be reproduced.

When the denudation takes place over isolated patches the affection is described as **alopecia areata** (*area Celsi* or *porrigo decalvans*). Some writers (GRUBE, MALASSEZ, THIN, EICHHORST, LASSAR) consider this affection to be due to a parasitic fungus, while others (BÄRENSPRUNG, AUSPITZ, KAPOSI, SCHWIMMER, JOSEPH, MICHELSON, FOURNIER) look upon it as a trophoneurosis. Others again (such as EICHHOFF) think that alopecia areata is not always due to the same cause, while BEHREND attributes it to some local disturbance of the circulation. The loss of hair may take place over a single patch or in many, and in the end may extend to the entire surface of the body. According to BEHREND the affected hairs are infiltrated with minute air-bubbles down to the extreme end of the root. In most cases the bald spots sooner or later become covered over with downy hairs, and ultimately with normal hairs.

Baldness coming on during adolescence (*i.e.* after puberty), in which the hairs of successive crops become shorter and shorter lived, and the scalp is covered with an abundant branny or floury desquamation, is described as **alopecia pityrodes** or *furfuracea*.

Failure of the hair and exfoliation of the skin are simultaneous, the cutis is attenuated (PINCUS), and the hair-follicles are stunted and atrophic (Fig. 308 *c*). The scales consist of morbidly-altered and abnormally-solidified sebum.

Alopecia pityrodes is referable either to some inherited predisposition or to one or other of the diseases mentioned above.

Trichorhexis nodosa is an anomalous mode of growth of the hairs, in which swollen nodes are produced in their course, whereat they are apt to break off. It is rare as a general affection, but is not uncommon in the case of single hairs, particularly in the beard. According to MICHELSON it is due to abnormal dryness of the hair, and is of the same nature as the terminal splitting and forking which often take place in individual hairs.

Ringstreaked hairs (*pili annulati*) are marked with bands alternately light and dark. The light bands are somewhat swollen and enclose air-containing clefts (LANDOIS). According to BEHREND, in very rare cases hairs are met with in which what look like nodular thickenings occur at regular intervals, but in these it is the internodal portions that are morbidly altered, inasmuch as they are attenuated and devoid of the normal central canal.

The **nails** are frequently misformed or defective, and abnormally thin and brittle, or misplaced, generally as a result of inflammations or of direct injury.

References on Alopecia and on Reproduction of the Hair.

- VON BÄRENSPRUNG: Alopecia areata *Charité-Annalen* VIII
 BEHREND: Alopecia areata *Berl. klin. Woch.* 1887, and *V. A.* 109 1887 and 116 1889
 BESNIER: *Sur la pelade* Paris 1888
 BUCHNER: Aetiology of area Celsi *V. A.* 74 1878
 EICHHOFF: Is alopecia areata contagious? *Monatsh. f. prakt. Derm.* 1888
 EICHHORST: Alopecia areata *V. A.* 78 1879
 GIOVANNINI: The normal development of and certain changes that take place in the human hair *V. f. Derm.* XIV 1887; Reproduction of hair after epilation *A. f. mikrosk. Anat.* 36 1890, and *A. ital. de biol.* xv 1891; Morbid histology of baldness *Ann. de dermat.* II 1892
 JOSEPH: Aetiology of alopecia areata *Cent. f. med. Wiss.* 1866; *Monatsh. f. prakt. Derm.* 1886, and *V. A.* 107 1887
 LASSAR: Alopecia areata *D. med. Woch.* 1881
 MALASSEZ: Alopecia pityrodes *A. de physiol.* 1874
 MICHELSON: Aetiology of area Celsi *V. A.* 80 1880
 PINCUS: Alopecia pityrodes *V. A.* 37 1866, 41 and 43 1868
 SCHEIN: Growth of the human skin and hair *A. f. Derm.* XXIV 1892
 SCHULTZE: Theories concerning area Celsi *V. A.* 80 1880
 SCHWIMMER: *Die neuropath. Dermatosen* Vienna 1882
 VON SEHLEN: *Fortschr. d. Med.* I, and *V. A.* 99 1885
 STIEDA: Growth of hair *Biolog. Cent.* VII 1887
 UNNA: Alopecia pityrodes *Monatsh. f. prakt. Derm.* I 1882

References on Nodes of the Hair and Trichorhexis.

- BEHREND: Node-formation on the hair-shaft *V. A.* 103 **1886**
 EICHHORST: Trichorhexis nodosa *Z. f. klin. Med.* VII (supplement) **1883**
 LESSER: Pili annulati *V. f. Derm.* XIII **1886**
 MICHELSON: *Volkmann's klin. Vorträge* no. 120, and *Ziemssen's Handb. d. spec. Path.* XIV
 ROESER: Trichoptilosis *Ann. de dermat.* IX **1878**
 WOLFBURG: *D. med. Woch.* **1884**

173. Abnormal **overgrowth of hair** (*hypertrichosis, hirsuties, polytrichia*) is hereditary or at least congenital (*hypertrichosis hereditaria*), or acquired in later life (*hypertrichosis acquisita*). Congenital hypertrichosis is universal, the whole body being shaggy (as in 'hairy men'), or it is local and affects only particular parts. Universal hypertrichosis is usually a family peculiarity, and may affect the entire face and forehead. An abnormal growth of hair on the chin and upper lip in women is not uncommon. Moles and pigment-spots are often thickly beset with hairs. Many cases of sacral hypertrichosis have been recorded; it is generally associated with spina bifida occulta (VON RECKLINGHAUSEN). Acquired hypertrichosis has been observed in a few cases as an accompaniment of spinal diseases (ERB, SCHIEFFERDECKER) and as a consequence of chronic irritation of the skin (KAPOSI).

Overgrowth of the nails (*hyperonychia*) in length and thickness is frequently met with, and they are often at the same time distorted, rough, or tuberculated. Excessively long nails become curved into claws (*onychogryphosis*). When they become excessively broad they are apt to cut into the soft parts, giving rise to hæmorrhage and inflammation (ingrowing nails, *incarnatio unguis*).

Abnormal enlargement of the nails may take place without any perceptible cause. In other cases it is a concomitant of ichthyosis or psoriasis, or follows on inflammatory affections.

References on Hypertrichosis.

- BARTELS: Hypertrichosis *Z. f. Ethnol.* VIII **1876**, XI **1879**, XIII **1881**
 BEIGEL: Hypertrichosis *V. A.* 41 **1868**
 BONNET: *Hypertrichosis congenita universalis* Wiesbaden **1892**
 CHIARI: Hypertrichosis *Prag. med. Woch.* **1890**
 ECKER: *Ueber abnorme Behaarung d. Menschen* Brunswick **1878**
 FÜRST: *V. A.* 96 **1884**
 GEYL: Observations on hypertrichosis *Biolog. Cent.* VIII **1888**
 HILBERT: *V. A.* 99 **1885**
 MICHELSON: *V. A.* 100 **1885**, and *Ziemssen's Handb. d. spec. Path.* XIV
 VON RECKLINGHAUSEN: Spina bifida *V. A.* 105 **1886**
 VIRCHOW-ORNSTEIN: *Z. f. Ethnol.* VII **1875**, and VIII **1876**
 WILSON: Hairy men *Lectures on dermatology* London **1878**

INDEX OF SUBJECTS

(The numbers refer to the pages)

- abnormalities of the heart 17
 abscess, cerebellar 430
 cerebral 429
 cold articular 188
 of bone 186
 tuberculous 284
 consecutive of bone 186
 in tuberculous disease of vertebrae 191
 metastatic of bone-marrow 171
 of brain 428, 429
 heart-muscle 53
 muscle 307
 spinal cord 346
 periarterial 74
 splenic 112
 acarus scabiei 546
 acetabulum, changes in after resection 253
 achondroplasia 202
 achorion Schönleini 543
 achroma 496
 acne 525
 albida 571
 indurata 525
 mentagra 525
 punctata 525
 pustulosa 525
 rosacea 492, 558
 sebacea 570
 syphilitica 538
 acrania 388
 acrochordon 571
 acromegaly, hypertrophic ostitis in 178
 pituitary body in 464
 actinomycosis of brain 433
 heart 55
 muscle 309
 pericardium 63
 spleen 115
 Addison's disease, pigmentation of skin in 496
 adenia, simple 130
 adenoma of pituitary body 464
 sweat glands 568
 ainhum 528
 albinism 496
 alopecia 573
 acquisita 573
 adnata 573
 areata 573
 clavites 573
 pityrodes 573
 praematura 573
 senilis 573
 amyloid degeneration of fibrous tissue of joints 248
 lymph - glands 117
 joint-cartilages 248
 muscle 299
 spleen 105
 amyotrophy, bulbar 292
 progressive 365
 spinal 292, 358
 spinal 292
 anaemia 3, 4
 cachectic 5
 cryptogenetic 4
 of the skin 492
 pernicious 4
 anaemic infarction of spleen 107
 anaesthesia, cutaneous 502
 anencephalia, partial hydrocephalic 397
 aneurysm 83
 anastomotic 89
 arterial haematoma in 88
 arteriosclerotic 84, 87
 by distension 84
 erosion 88
 rupture 84
 cirroid 83
 congenital 89
 dissecting 84
 embolic 87
 cerebral apoplexy as a result of 88
 false 83
 haemorrhage in 87
 hernial 88
 infective 88
 locus minoris resistentiae in 86
 mycotic 88

(The numbers refer to the pages)

- aneurysm of aorta, changes in the wall
of 87
..... results of 87
..... parasitic 88
..... partial of the heart 50, 51
..... racemose 89
..... rupture of 87
..... saccular 83, 86
..... spurious 89
..... varicose 89
..... strongly armatus as a cause
of 88
..... traumatic 88
..... true 83
..... valvular 38
..... varicose 87
aneurysmal varix 89
angioma of brain 440
..... muscle 312
..... skin 500, 557
..... spinal meninges 378
..... spleen 116
angiomyxoma of meninges of the brain
454
angiomyxosarcoma of meninges of the
brain 454
angiosarcoma of meninges of the brain
454
..... meninges 378
..... spinal cord 372
angle, facial, of Camper 206
anhydraemia 3, 4
animal parasites of skin 545
ankylosis 252, 257
..... bony 192, 255
..... capsular 256
..... cartilaginous 254
..... extra-capsular 256
..... fibrous interosseous 255
..... firm fibrous 259
..... from deformity 256
..... intercartilaginous 254
..... in unreduced dislocation 259
..... mixed forms of 256
..... osseous 278
..... partim interossea partim in-
tercartilaginea 255
..... true 254
anthrax, simple 525
..... specific 526
antrum of Highmore 147
aorta, aneurysm of 87
..... circumference of 24
..... dorsalis 22
..... stenosis and atresia of 18
aortic arches 22
..... obliteration of 22
..... bulb 21
aortitis verrucosa 71
aphasia, ataxic, in softening of the
brain 421
apoplexy, cerebral 422
apoplexy, cortical 443
appendices auricularum 20
apposition of bone in resection of joints
252
arachnoid 442
..... of spinal cord 373
area Celsi 573
arterial angioma, racemose 89
..... arches, transformations of 22
..... coats, rupture of as a cause of
aneurysm 84
..... trunks, transposition of 17
..... tumour, vascular 89
..... walls, atrophy of 85
arteries, amyloid degeneration of 66
..... aneurysmal dilatations of cere-
bral 422
..... atheroma of 68
..... atheromatous degeneration of 72
..... patches of 68
..... plaques of 68
..... ulcers of 68
..... calcareous infiltration of 66, 68
..... calcification of 66
..... circumscribed arterio-sclerosis
of 68
..... diffuse arterio-sclerosis of 67
..... dilatation of 71, 83
..... fatty degeneration of intima of
65
..... media of
66
..... fibrous hyperplasia of 77, 79
..... granular degeneration of 66
..... haematoma accompanying 84
..... hyaline degeneration of 66
..... hypertrophy of 72
..... inflammation of 72
..... ligation of 75
..... morbid changes in 65
..... muscle-fibres of 66
..... obliteration of 71, 74
..... ossification of 67
..... rupture of 71, 83
..... sclerosis of 67
..... sclerotic plates of 68
arterio-sclerosis as a cause of aneurysm
84
..... circumscribed 68
..... diffuse 67
..... nodose 68
arteritis 38, 72
..... consecutive 76
..... fungous 188
..... gangrenous 76
..... gummatous granulations in 78
..... haematogenous without throm-
bosis 75
..... aetiology of 76
..... hyperplastic 71, 76
..... proliferans nodosa 80
..... proliferous 71

(The numbers refer to the pages)

- arteritis, serofulvous 188
 secondary 76
 suppurative 76
 syphilitic 78
 syphilitica obliterans 79
 thrombi in 71
 tuberculous 79
 verrucosa 71
 arterioliths 75
 arthritis ankylopoetica 275
 caseous nodes in tuberculous
 284
 chalky deposits in gouty 280
 chronic 263
 ankylosing 263, 275, 278
 deforming 263, 268
 dry 264
 ulcerating 278
 exudative 264
 gouty 263
 infective 263
 neuropathic 263
 purulent 263, 264
 senile 263
 traumatic 263
 deformans 181
 arborescent lipoma
 in 271
 articular ends of
 bones in 272
 chronic 268, 278
 hypertroph-
 ic prolifera-
 tion of joints
 in 250
 degenerative
 changes in 268
 hyperplastic prolif-
 eration in 268
 mobility of joints in
 273
 resorption of bone
 in 271
 subchondral cysts
 in 272
 dislocation from caries in tuber-
 culous 285
 dry chronic ulcerative 263
 fungous 282
 gouty 261, 280
 granular 282
 localisation of chronic serous
 264
 pauperum 275
 purulent 261
 seat of tuberculous 285
 senile 278
 serous 261
 sinuses in tuberculous 284
 topli in gouty 280
 tuberculous 189
 arthroace 188, 285
 arthropathy, cause of 279
 neurogenous 279
 situation of 279
 arthropathies, tertiary syphilitic 285
 articular contracture 256
 dropsy, chronic 264
 associative fibres of the cerebrum 384
 asteatosis 570
 astrocytes 324
 ataxia, hereditary 369
 atheroma 572
 of arteries 69
 blood-vessels of the brain
 417
 vasa vasorum in 69, 91, 72
 atheromatous pulp 69
 atlas, tuberculous caries of 192
 atrophy of the brain 407
 skin 499
 neuropathic, of muscle 292
 progressive muscular 293
 spinal muscular 365
 auditory centre 385
 auricular canal 20
 septum, defects of 19
 axis, causes of tuberculosis of 192
 cylinder 469
 disintegration of 341
 axon 324
 bacillus anthracis 526
 coli communis 45
 endocarditis capsulatus 33
 griseus 33
 leprae 540
 mallei 542
 tuberculosis 59, 63, 73, 74, 127,
 190, 282, 346, 380, 432, 449, 532
 bacon spleen 105
 barber's itch 545
 beri-beri 473
 bibliography (see references)
 blebs 505
 blister 511
 due to cantharides 511
 blood 3
 amount of 3
 fat in 6
 fibrin ferment in 6
 haemoglobin in 3, 6
 and lymph, Sect. I
 blister 493
 composition of 3
 corpuscles contained in 3
 current, foreign bodies in 73
 deficiency in formation of 5
 dry residue in normal 6
 proportion of white corpuscles in
 3, 8
 quantity of, in lower animals 6
 transfusion of 6
 boils 525

(The numbers refer to the pages)

- bone, abnormal brittleness of 148
 abscess of 188
 sequestrum of 173
 absorption of sequestrum 173
 actinomycosis of 195
 acute haematogenous inflammation of 170
 aetiology of tumours of 235
 anaemic necrosis of 174
 angioma of 242
 animal parasites of 231, 244
 appearance of, during resorption 142
 apposition in inflammation of 170
 resection of joints 252
 of 169, 179
 arrest of development of 199
 architectural structure of spongy 203
 atrophic affections of 141
 from disuse 145
 atrophy from pressure on 146
 inflammations 147
 the development of tumours 147
 in fractures 145
 in stumps 145
 carcinoma of 231, 242
 carcinomatous caries of 242
 caries of 148, 170
 cartilaginous 196
 caseous nodes in 186
 causes of deformity of the articular surfaces of 227
 cavernous excavation of 184
 central necrosis of 172
 changes in mature forms of 224, 225
 chondroma of 239
 chronic inflammation of 176
 complete fracture of 164
 compound fracture of 179
 concentric atrophy of 143
 connective tissue 196
 consecutive abscess of 187
 cysticercus cellulosaе of 244
 cysts of 148, 231
 decalcification of 149
 deformity of the articular surfaces of 227
 degenerations of chondroma of 239
 development of 141
 mature 223
 disintegration of myelogenous tumours of 244
 disorders of growth of 196
 osseous development 196
 eburnation of, in arthritis deformans 272
 eccentric atrophy of 143
 echinococcus of 244
 enchondroma of 235
 bone, erosions of 147
 failure of bony union in fracture of 166
 fatty degeneration of 143
 fibroma of 235, 238
 fissure of 160
 formation of new, in tumours of 234
 foveolae of 142
 fracture in resorption of 145
 fracture of 160
 fundamental lamellae of 159
 giant-celled sarcoma of 240
 glands of 195
 growth of by apposition 154
 gumma of 192
 gunshot injuries of 175
 haematoma of 242
 haemorrhage after traumatism 175
 halisteresis 150
 Haversian canals of 149
 Howship's lacunae of 142, 149
 hypertrophic zone of developing 196
 hypertrophy of 154, 167
 incomplete fracture of 164
 infective granulomata of 183
 inflammation of 170
 inflammation of, after traumatism 175
 'inflation' of the 244
 in general miliary tuberculosis 187
 interstitial growth of 159
 lacunar resorption of 141
 in carcinoma 242
 tuberculosis 184
 lamellar, with Sharpey's fibres 159
 length of time necessary for repair of fracture of 166
 leprosy of 195
 lipoma of 239
 liquefaction of myelogenous tumours of 244
 local agenesis of 199
 atrophy of 147
 matrix of, decalcified 150
 mature form of 223
 membrane 159
 metastatic inflammation of 173
 method of growth of 154
 mixed tumours of 232
 multilocular cysts of 244
 myelogenous alveolar sarcomata of 240
 myelogenous tumours of 232, 233
 myeloma of 241
 myeloplexes in resorption of 141
 myxofibroma of 239
 myxoma of 235, 239
 necrosis of 148, 170
 necrotic caries of 148
 splinters of 165

(The numbers refer to the pages)

- bone, neuromyolytic atrophy of 146
 neuropathic atrophy of 146
 new formation of in halisteresis
 153
 origin of 196
 primary tumours of 231
 osteoclasts in resorption of 141
 paralytic contractures of 227
 partial defects in individual 199
 necrosis of 172
 periosteal tumours of 232
 peripheral caries of 186
 phosphorus-necrosis of 176
 pressure of tumours on 147
 primary tumours of 231
 proliferous zone of developing 196
 reabsorption of 141
 regeneration of 154
 repair of isolated tubercles of 192
 resection of 166
 resorption of 17, 152, 169, 179, 194
 in arthritis deformans 271
 inflammation 170
 resection of joints
 252
 tumours 233
 retrogressive changes in sarcoma
 of 240
 rôle of osteoblasts in formation of
 155
 sacculated cold abscess of 186
 sarcoma of 235, 239
 secondary tumours of 231
 senile atrophy of 143
 septic pyaemia of 171
 sequestrum of 184
 sinuses of 187
 softness of, in rickets 220
 splint of 173
 superficial necrosis of 172
 suppuration of 175
 syphilis of 192
 syphilitic caries of 194
 necrosis of 194
 telangiectatic sarcoma of 240, 242
 total necrosis of 172
 traumatic violence to 175
 true fibrous 159
 lamellar 159
 tuberculosis of 183
 large, long 189
 short, spongy 189
 small, long 189
 tuberculous foci in 184
 tumour-like formations of 209
 tumours of 231
 bone-corpuseles 184
 bone-marrow 137
 atrophy of 138
 calcification of 242
 cells in 137
 bone-marrow, change from yellow into
 red 139
 Charcot-Neumann crystals
 in 139
 degeneration of 138
 development of red blood-
 corpuseles in 137
 fatty degeneration of cells
 and capillaries of 138
 gelatinous 138
 haemorrhage from 140
 hypertrophy of the fatty
 tissue of 139
 lymphoid 137
 metastatic abscess of 171
 morphology of 137
 necrotic foci in 138
 nucleated red blood-cor-
 puseles 137
 pigmented granule cells in
 140
 red 137
 siderosis of 140
 significance of changes in
 cellular composition of
 139
 thrombosis of veins of 171
 tint of lymphoid 139
 yellow 138
 bone-necrosis 188
 bottle-nose 558
 brain (see also cerebrum)
 abnormal enlargement of 575
 weight of 402
 abscess of 428
 actinomycosis of 433
 anaemia of 405
 the internal meninges
 of 442
 anencephalia 388
 angioma of 440
 animal parasites of 436, 440
 atrophy of 407
 carcinoma of 440
 cause of ependymal sclerosis of
 435
 choroid plexuses of 442
 compression of 428
 concussion of 424
 congestive hyperaemia of 404
 contusion of 425
 cortical apoplexy of 443
 crushing of 425
 cystic degeneration of the choroid
 plexus of 442
 cysticercus of 440
 diffuse sclerosis of 434
 disseminated miliary tuberculosis
 of pia mater of 449
 disseminated sclerosis of 434
 echinococcus of 440
 ependymal sclerosis of 434

(The numbers refer to the pages)

- brain, fatty degeneration of 409
 fibrino-purulent exudation into
 ventricles of 445
 fibroma of 440
 fissures and gyri of 382
 general atrophy of 407
 passive oedema of 405
 glioma of 436
 gliomyxoma of 439
 gliosarcoma of 439
 granular ependymal sclerosis of
 435
 gumma of 451
 haematogenous tuberculosis of 432
 haemorrhages into the pia mater
 of 443
 haemorrhagic softening of, in
 gumma 453
 hyperaemia of the internal me-
 ninges of 442
 hypoplasia of entire 390
 in cretinism 402
 infective granulomata of 432
 inflammatory oedema of 405
 in habitual criminals 402
 idiocy 402
 mental diseases 402
 ischaemic softening of, in gumma
 453
 laceration of 425
 lipoma of 440
 local degenerations of 412
 engorgement of 404
 inflammations of 412, 413
 passive oedema of 405
 lymphogenous tuberculosis of 432
 malformations of 388
 metastatic tuberculosis in basal
 region of 449
 morbid changes of blood-vessels
 of 417
 multiple sclerosis of 434
 oedema of, from auto-intoxication
 405
 pia mater of 442
 subarachnoid space
 of 442
 osteoma of 440
 papillary cystoma of 572
 partial hypoplasia of 391
 passive hyperaemia of 404
 pial cysts of 442
 premature atrophy of 407
 degeneration of 407
 purulent exudations into 445
 psammoma of 440
 quantity of blood in 404
 repair of abscess of 430
 resemblance of sclerosis of, to
 tumours of 434
 results of concussion of 424
 sarcoma of 440
- brain, sclerosis of 434
 secondary tumours of 440
 smooth ependymal sclerosis of 435
 solitary tubercles in 432, 450
 tubercle of the pia mater
 of 451
 structure and functions of 381
 subarachnoid cysts of 442
 sub-meningeal injuries of 426
 secondary disintegration of, after
 injury 426
 syphilis of 432, 451
 traumatic injury of 424
 softening of 426
 tuberculosis of 432
 tumours of 436
 internal meninges of
 454
 vascular naevus of 440
 ventricles of 445
 weight of 390
 atrophic 409
 wounds of 425
- brain-sand 455
 bronchial lymph-glands, pigmentation of
 119
 bubo 121
 hard 128
 indolent 128
 Burdach's column of spinal cord 327
 burn of the first degree 511
 second degree 511
 third degree 511
 fourth degree 511
 bursae 314
 morphology of 317
 tuberculosis of 319
 bursitis, acute 317
 chronic 317
- calcareous infiltration of the arteries
 66, 68
 calcification of blood-vessels of the
 brain 417
 muscle 299
 callosities 548
 callus 160
 exterior 160
 extra-capsular 164
 interior 160
 intermediary 160
 intra-capsular 164
 involution in 163
 myelogenous 160
 periosteal 160
 canceroid 567
 capsule, articular 245
 caput medusae 94
 carbuncle 525
 carcinoma of the brain 440
 branchiogenous 568
 of bone 231

(The numbers refer to the pages)

- carcinoma of bone, lacunar resorption in
 242
 dura mater of brain 463
 heart 55
 method of develop-
 ment of 55
 situation of 55
 meninges of the brain 454
 muscle 312
 pericardium 64
 pituitary body 464
 skin 567
 spinal meninges 379
 spleen 116
 ventricles of the brain
 456
- carcinomatous caries of bone 242
 osteomalacia 242
- cardiac aneurysm, partial 50, 51
 rupture of 51
 thrombi in 51
 ganglia, degenerative changes
 in 46
 fibrous hyperplasia of
 46
 hypoplasia 24
 dimensions of heart
 in 24
 muscle, aetiology of 27
 hypertrophy of 27
 polypus 46
- caries, articular 188
 fungosa 188
 fungous 188
 malacic 188
 mollis 188
 of cartilage 248, 260
 scrofulous 188
 sicca 188
 syphilitic 194
 tuberculous 188
- carpus, tuberculosis of 190
- cartilage, articular 198
 calcification of 198
 caries of 260
 conversion of hyaline, into
 fibro-cartilage 249
 conversion of hyaline, into
 fibrous tissue 249
 erosion of 248, 260
 formation of fatty marrow
 from 248
 lymphoid mar-
 row from 248
 mucoid tissue
 from 248
 granulative inflammation of
 248
 necrosis of 248, 260
 purulent inflammation of 24
 rôle of, in growing bone 155
 sequestra of 260
- cartilage, transformation of into bone
 156
 zone of calcified 198
 -cells, fate of 198
 metaplasia of 248
- caseous nodes in tuberculous arthritis
 284
- cavernous angioma of spinal meninges
 377
- central nervous system, Sect. vi
- centripetal fibres of the cerebrum 384
- cephalic index 206
- cephalocele 388
- cerebellum 385
 abscess of 430
 centres of 387
 hypoplasia of 391
 in atrophy of the cerebrum
 410
- cerebral apoplexy 422
 axis 385
 hypoplasia of 391
 cortex, psycho-motor regions of
 357
 hernia 388
- cerebro-spinal meningitis 444
- cerebrum, accumulation of leucocytes in
 409
 blood-corpus-
 cles in 409
 yellow pig-
 ment gran-
 ules in 409
 acute destruction of ganglion
 cells of 413
 agenesis of 389
 angular gyrus of 382
 anomalies in minute histologi-
 cal structure of
 400
 of development of
 the 388
 anterior occipital fissure of
 381
 apoplectic cicatrix of 424
 cysts of 423
 associative fibres of 384
 asymmetry of 391
 atheroma of blood-vessels of
 of 417
 atrophy of cortex of, after am-
 putation 417
 auditory centre of 385
 calcarine fissure of 382
 calcification of blood-vessels
 417
 callosal gyrus of 382
 calloso-marginal fissure of 382
 capillary haemorrhages of 421
 caudate nucleus of 383
 causes of partial agenesis of
 394

(The numbers refer to the pages)

- cerebrum, central fissure of 381
 centripetal fibres of 384
 cerebellum in atrophy of 410
 claustrum of 383
 collateral sulcus of 382
 commissural fibres of 384
 complications of agenesis of
 393
 hypoplasia
 of 392
 convolutions of 381, 389
 corpora amylacea of 416
 cortex of 383
 cortical centres of 385
 cuneus of 382
 cysts of 416, 419
 deficiency of secondary sulci
 of 390
 disorders of circulation of 404
 embolism of blood-vessels of
 417
 *état criblé* of 407, 419
 fat-granule cells in degenera-
 tions of 415
 fatty degeneration of blood-
 vessels of 417
 fibres of medullary substance
 of 384
 fibrous cicatrix of 416
 first temporal fissure of 381
 fissures of 381, 389
 fusiform gyrus of 382
 ganglion cells of 384
 gyri of 381
 gyrus cinguli of 382
 hæmorrhages of 421
 heterotopia of grey matter of
 401
 hippocampal gyrus of 382
 hypertrophy of 390, 401
 hypoplasia of 389, 390
 induration of 419
 inferior occipital fissure of 381
 intraparietal fissure of 381
 ischaemic necrosis of 417
 island of Reil of 382
 lenticular nucleus of 383
 lingual gyrus of 382
 location of hæmorrhage of
 422
 marginal gyrus of 382
 medullary white matter of 383
 minute structure of 389
 morphology of 381
 motor centres of 385
 neuroglia cells in degenera-
 tion of 414
 nucleus amygdalæ of 383
 nucleus of Lays of 383
 occipital lobe of 381
 occipito-temporal sulcus of
 382
 olfactory centre of 385
 optic thalamus of 383
 paracentral lobule of 382
 parallel fissure of 382
 parietal lobe of 381
 parieto-occipital fissure of 381
 partial agenesis of 393
 hypoplasia of 391
 pigment-granule cells in de-
 generation of 415
 præcuneus of 382
 precentral fissure of 381
 projective fibres of 384
 quadrate lobule of 382
 red softening of 417
 regeneration of nerve ele-
 ments of 416
 results of hæmorrhage of 422
 softening of 419
 rolandian fissure of 381
 sclerosis of 416
 blood-vessels of
 417
 sensory centres of 385
 softening of 417
 speech centre of 385
 subthalamic body of 383
 substantia perforata anterior
 of 383
 superficial temporal fissure of
 381
 sulci of 381
 sylvian fissure of 381
 temporal lobe of 381
 transverse occipital sulcus of
 382
 visual centre of 385
 white softening of 416, 417
 yellow softening of 417
 chalky deposits in gouty arthritis 280
 chancre, hard 529
 soft 529
 true Hunterian 535
 chancroid 529
 chicken-pox 518
 chilblains 510
 chiroagra 261
 chloasma cachecticum 496
 caloricum 496
 toxicum 496
 traumaticum 496
 uterine 496
 chlorosis 4
 cholesteatoma of the pia mater of the
 brain 457
 chondritis 260
 chondroblasts 155
 chondrodystrophia hyperplastica 204
 hypoplastica 202
 malacica 204
 chondroid tissue 155
 chondroma of bone 239

(The numbers refer to the pages)

- dermatomycosis furfuracea 545
 dermoid cysts, intracranial 457
 dextrocardia 24
 diaphysis 198
 increased longitudinal growth
 of 210
 diarthrosis 245
 diastematomyelia 328
 diplococcus intracellularis 443
 pneumoniae 59, 346
 pneumo- 314, 346, 373, 429,
 443, 444
 diphtheria, lymph-glands in 121
 spleen in 110
 dislocation 251
 ankylosis in unreduced 259
 changes in unreduced 258
 complex 251
 from caries in tuberculous ar-
 thritis 285
 deformity, 266, 273
 results of 251
 spontaneous 261, 262
 unreduced 257
 'drill' bones 310
 dropsy, meningeal 442
 dropsical degeneration of muscle 297
 ductus arteriosus, persistence of 20, 22
 dura mater of the brain, 460
 alveolar sarco-
 ma of 462
 carcinoma of 463
 enchondroma
 of 463
 endothelioma
 of 462
 fibroma of 463
 haematoma of
 460
 hygroma of 461
 lipoma of 463
 morphology of
 460
 osteoma of 463
 psammoma of
 462
 sarcoma of 462
 secondary tu-
 mours of 463
 syphilis of 461
 tuberculosis of
 461
 tumours of 462
 spinal cord, inflammation
 of 380
 tumours of 380
 dystrophy, progressive muscular 294, 303
 adolescent
 294
 adult 294
 infantile
 294
 eburnation of bone 241
 ecchymoma 493
 ecchymoses 493
 echinococcus of bone 244
 brain 440
 heart 56
 meninges of the brain
 458
 muscle 312
 pericardium 64
 spleen 116
 ectasis, arterial 83
 ecthyma 516
 ectopia cordis 24
 eczema 515
 acute 515
 aetiology of 515
 chronic 515, 516
 crustosum 515
 erythematosum 515
 impetiginodes 515
 impetiginosum 515, 516
 madidans 515
 marginatum 545
 papulosum 515
 rubrum 515
 squamosum 515
 vesiculosum 515
 et pustulosum 515
 elephantiasis 554, 557
 acquired 550
 aetiology of 551
 arabum 550
 associated with lymphan-
 giectasis 25, 98
 cavernosa 558
 dura 552
 endemic 550
 fibrous 564
 glabra 552
 graecorum 540
 haematangiomas 564
 lipomas 564
 lobate 564
 lymphangiectatica 552
 lymphangiomas 564
 mollis 552, 564
 neuromatous 483, 564
 papillomatosa 582
 phlebectatic 94
 situation of 551
 sporadic 550
 tuberosa 552
 verrucosa 552
 elephantoid molluscum 563
 embolism of blood-vessels of the brain
 417
 embolus 38
 encephalitis, acute haematogenous 439
 aetiology of 427
 focal 429
 insular 429

(The numbers refer to the pages)

- encephalomalacia 417
 enchondroma of bone 235
 the dura mater of the
 brain 463
 the skin 567
 endarteritis 71
 deformans, chronic 71
 obliterans 75, 71
 endocardial thrombosis, calcareous infil-
 tration of 32
 organisation of
 32
 endocarditis 33
 aetiology of 33
 course of 38
 diphtheritic 37
 polypous 36
 pustulosa 37
 pyaemic 37
 results of 39, 42
 situation of 37
 suppurative 37
 tubercle-bacillus in 34
 ulcerous 37
 vegetations 31
 verrucosa 36
 villous 36
 warty 36
 endocardium, amyloid degeneration of,
 combined with hyaline
 degeneration 32
 fatty degeneration of 30
 hernia of 51
 hyaline degeneration of 32
 morphology of 30
 mucoid degeneration of 31
 sclerosis of the connective
 tissue of 31
 thrombi on surface layer
 of 31
 endoneurium 469
 endothelioma 98, 240
 alveolar, of the meninges of
 the brain 454
 spinal menin-
 ges 378
 calcified 562
 of the dura mater of the
 brain 462
 skin 558, 560
 tuberosum 560
 English disease 214
 enostosis 236, 238
 eosinophile cells 9
 epulis, intraosseous 239
 ependyma, sclerosis of 435
 fibrinous deposits on 458
 ephelides 495
 epidermal cells, regenerative multiplica-
 tion of 506
 epidermis, desquamation of 501
 epineurium 469
 epiphyses, oblique displacement of, in
 rickets 221
 epiphysal cartilage 156
 epiphysis 198
 separation of the 211, 213
 epithelioma contagiosum 547
 of the skin 567
 epithelium, desquamation in scales 506
 shreds 506
 erosion of cartilage 248, 260
 eruptions, morphology of 503
 erysipelas 522
 aetiology of 522
 bullosum 523
 crustosum 523
 gangraenosum 523
 pustulosum 523
 vesiculosum 523
 erythema 492, 503
 annulare 509
 bullosum 509
 circinatum 509
 exsudativum multiforme 509
 gyratum 509
 iris 509
 laeve 509
 nodosum 509
 papulatum 509
 traumatic 509
 tuberculatum 509
 urticatum 509
 vesiculosum 509
 erythrasma 545
 eschar 506
 exanthems 508
 exostoses 168, 236, 311
 bursate 237
 cartilaginous 236
 chondroid 169
 fibroid 169
 fibrous 230
 movable 168
 multiple 238
 exudation in arthritis 261
 facial angle of Camper 206
 facies leontina 540
 fat-granule cells in degeneration of the
 cerebrum 415
 fatty degeneration of the arteries 65
 blood-vessels of the
 brain 417
 brain 409
 fibrous tissue of
 joints 248
 joint cartilages 248
 muscle 297
 favus 542
 felon 524
 fibroma of bone 235, 238
 the brain 440
 cutis 566

(The numbers refer to the pages)

- fibroma of the dura mater of brain 463
 spinal cord 380
 heart 55
 meninges of the brain 454
 molluscum 482, 563
 multiple cutaneous 562
 of muscle 312
 nerves 481
 the skin 562
 spinal cord 372
 meninges 377
 spleen 116
 fibrosarcoma of muscle 312
 filaria Bancrofti 551
 fish-skin disease 554
 flat-foot, causes of 227
 flat papules 537
 folliculitis barbae 525
 foramen ovale 22
 fourth ventricle 327
 fracture, green stick 164
 of bone 160
 inflammation in 160
 injury to periosteum in 160
 length of time necessary for repair of 166
 repair of 160
 fractures, atrophy of bone in 145
 fragilitas ossium 145, 147
 idiopathic form of 42, 148
 framboesia syphilitica 538
 non-syphilitica 530
 freckles 495, 560
 Friedreich's disease 369
 frontal lobe of the cerebrum 381
 fungus articuli 188
 funiculus cuneatus of medulla oblongata 327
 spinal cord 327
 gracilis of medulla oblongata 327
 spinal cord 327
 funnel-breast 229
 cause of 229
 furunculi 525
 ganglion 319
 -cells, acute destruction of 413
 calcification of 413
 fatty degeneration of 413
 of spinal cord 324
 of the cerebrum 384
 sclerosis of 414
 wax-like condition of 414
 crepitant 318
 gangraena nosocomialis 527
 gangrene, decubital 527
 hospital 527
 of muscle 299
 gangrenous bed-sore 527
 genu recurvatum 228
 valgum 226
 adolescentium 226
 causes of 226
 infantum 226
 inflammatorium 226
 paralytic 228
 traumaticum 226
 gigantic overgrowth 207
 causes of 208, 209
 gigantism, partial 208
 glanders, acute 542
 chronic 542
 of muscle 309
 the skin 542
 glioma, aetiology of 439
 elongated 350
 histology of 439
 of the brain 436
 spinal cord 372
 situation of 439
 size of 438
 telangiectatic, of the spinal cord 372
 gliomyxomata of the brain 439
 gliosarcoma of the brain 439
 spinal cord 372
 gliosis 350
 Goll's column of spinal cord 327
 gonococcus 314
 gout, joint cartilages in 246
 Gower's tract of spinal cord 327
 granular degeneration of muscle-fibres of arteries 66
 granulation tissue 48, 61, 63, 111, 124, 185, 262, 307, 530
 granule-cells, significance of 416
 granuloma fungoides 530
 of the skin 530
 traumatic 530
 grutum 571
 gumma of the brain 451
 pituitary body 464
 skin 538
 osteomyelitic 194
 haematolysis 4
 haematoma, arterial 88
 of bone 242
 the dura mater of the brain 460
 pineal gland 465
 skin 493
 haematidrosis 493
 haematomyelia 350
 haemoglobin, diminution of, in blood 4
 proportion of, in leukaemia 6
 haemoglobinuria, paroxysmal 14
 haemo-pericardium 58
 haemorrhage in heart muscle 51

(The numbers refer to the pages)

- haemorrhages, idiopathic cutaneous 493
 of the skin, neuropathic 494
 symptomatic cutaneous 493
- haemorrhagic infarction of spleen 107
 results of 108
- haemorrhoids 23, 94
- haemosiderin in spleen-pulp 104
- hair 570
 abnormal overgrowth of 575
 follicles, wasting of 501
 morphology of 572
- hairs, ring-streaked 574
- halisteresis, new formation of bone in 153
 ossium 140
- hallux valgus 227
- Haversian canal 169, 171
 lamellae 187
 systems 159
- heart, actinomycosis of 55
 aetiology of 26
 aneurysms of 26
 atrophic and degenerative changes of 44
 breadth of 24
 carcinoma of 55
 cicatrix of 54
 congenital hypertrophy of 24
 cysticercus of 56
 development of 20
 dilatation of 26
 degenerations in 45
 dimensions in 26
 diminution in size of 26
 echinococcus of 56
 enlargement of 26
 fibroid cicatrix of 49
 fibroid induration of 49
 fibroma of 55
 haemorrhagic infarct of 47
 idiopathic hypertrophy of 27
 ischaemic softening of 50
 length of 24
 lipoma of 55
 lipomatosis of 128
 lympho-sarcoma of 55
 malformations of 17
 milk-spots of 61
 motor centre of 386
 muscle, abscess of 53
 brown atrophy of 44
 calcification of 46, 51
 fatty degeneration of 44
 granular degeneration of 45
 hyaline degeneration of 45
 simple atrophy of 44
 waxy degeneration of 45
 myxoma of 55
- heart, parasites of 56
 primary tumours of 55
 results of hypertrophy of 28
 rhabdomyoma of 55
 rupture of 48, 58
 sarcoma of 55
 sclerosis of 49, 54
 secondary tumours of 55
 softening of 47
 stenosis of 41
 syphilitic gumma of 55
 thickness of 24
 tubercle of 55
 wall, amyloid degeneration of 32
 weight of 24
 hypertrophied 28
- hernia, cerebral 388
- herpes circinatus 501, 513
 facialis 513
 iris 509, 513
 labialis 513
 praeputialis 513
 progenitalis 513
 tonsurans 544
 vesiculosus 513, 545
 syphiliticus 537
 zoster 512
- hidradenitis 525
- hirsuties 575
- hospital gangrene 527
- 'housemaid's knee' 317
- Howship's lacunae 312
- hyaline degeneration in tumours of spinal meninges 378
 of arteries 66
 lymph-glands 11, 18
 muscle 298
- hydatid cysts of dura mater of spinal cord 380
- hydraemia 3, 4, 6
- hydrarthrosis 264
- hydrocephalic micrencephalia 397, 398
 partial anencephalia 397
- hydrocephalus, acquired 406
 causes of congenital internal 400
 internal 398
 congenital internal 398
 external 397
 internal 397, 398
 meningeal 397
 partial pachymeningitic 461
 results of 399
 ventricular 398
- hydromyelia 349
 congenital 349
- hydromyelocele 349
- hydro-pericardium 58
- hydrops bursarum 317
 *ex vacuo* 400, 406

(The numbers refer to the pages)

- hydrops tuberculosus 282
 ventriculorum 406
 hygroma 315, 317
 acute 317
 of the dura mater of the brain
 461
 tuberculous 319
 hypalbuminosis 3
 hyperaemic bone, osteomalacia in 152
 hyperinosis 6
 hyperonychia 575
 hyperostosis 162, 178
 in syphilis 195
 hypertrichosis 575
 acquisita 575
 hereditaria 575
 hypertrophic lymphangioma 560
 hypertrophy, concentric 28
 eccentric 28
 of bone 154
 papillae of skin 549
 skin 548
 the brain 401
 simple 28
 hyphomycetes 542
 hypinosis 6
 hypoleucocytosis 8
 hypophysis cerebri 464
 hypoplasia of brain, causes of 392

 icterus 496
 ichthyosis 554
 acquired 552
 congenital 554
 hystrix 557
 nigricans 557
 nitida 557
 sebacea 570
 simplex 556
 idiocy as a result of malformations of
 the brain 402
 impetigo 516
 contagiosa 516
 herpetiformis 516
 syphilitica 537
 incarnatio unguis 575
 index, altitudinal 206
 cephalic 206
 infective granulomata, of the heart 55
 insula 382
 interior-cells of spinal cord 325
 internal meninges 442
 of the brain, hyper-
 aemia 442
 anaemia of 442
 isthmus aortae 419
 itch 546

 jaundice 496
 joint-cartilage, mucoid softening of 246
 softening of 247
 urates in matrix of 246

 joints, acute inflammations of 260
 amyloid degeneration of the car-
 tilage of 246
 ankylosis of 252
 articular capsule of 245
 calcareous deposits in cartilage of
 246
 cartilages of, in gout 246
 changes in mature forms of 224,
 225
 the parts about 256
 chronic inflammations of 260
 classification of loose bodies in 287
 cuts of 262
 degenerations of 245
 fibrous tissues of
 248
 development of mature 203
 effusion of blood into 262
 empyaema of 261, 282
 false 166
 fatty changes in the cartilage of
 245
 formation of new 257
 gunshot wounds of 262
 haematoidin in cells of cartilage
 of 246
 hypertrophic proliferation of 250
 hypertrophy of 250
 loose bodies in 251, 262, 272, 282,
 287
 mature forms of 223
 mobility of, in arthritis deformans
 273
 new 252, 257
 origin of loose bodies in 287
 regeneration of 250
 regenerative proliferation of 250
 resection of 252
 result of acute inflammations of
 261
 sprains of 251
 stabs of 262
 synovial membrane of 245
 syphilis of 282, 285
 tuberculosis of 282

 kakke 473
 karyokinesis 10, 130
 keloid of the skin 566
 keratoma diffusum 554
 of the skin 459
 keratosis 552
 pilaris 556
 knee joint, serous effusion into 262
 knock-knee 226
 causes of 226
 kyphosis 152, 225

 lacunar erosion of muscle 297
 resorption in tuberculosis of
 bone 184

(The numbers refer to the pages)

- lathyrus cicera as a cause of scleroses of
the spinal cord 367
- leiomyoma of the skin 566
- lentiginos 495
- leontiasis ossea 209
- lepra anaesthetica 371, 475
.... bacilli 128, 346, 371, 475
.... maculosa 540
.... mutilans 475, 540
.... nervorum 475
.... nodosa 540
.... tuberculosis 540
.... tuberosa 540
- leprosy 540
..... Lombardian 510
..... of the lymph-glands 128
..... nerves 475
..... spleen 115
..... white 498
- leptomeninges 442
- leptomeningitis 430
..... acute 443
..... serous 444
..... aetiology of 445
..... chronic 446
..... combination of chronic
with internal proliferous
pachymeningitis 449
..... fibrino-purulent 444
..... location of chronic 446
..... purulent 444, 445
..... sero-purulent 444
..... tuberculous 449
- leucocytosis 8
..... experimental production of 8
..... inflammatory 8
..... pathological 8
..... physiological 8
- leucocytes, proportion of various forms
of 10
- leucomyelitis 346
- leucopathia 496
..... congenita 498
- leukaemia 8, 9
..... aetiology of 10
..... Charcot's crystals in 10
..... diminution of red cells in 10
..... dry residue in 6
..... eosinophile cells in 9
..... heart-clots in 9
..... lymphatic 9
..... lymph-glands 130
..... myelogenous 9, 139
..... neutrophile cells in 10
..... splenic 9
..... without pathological change
10
- leukaemic adenia 130
..... infiltrations 10
..... lymph-glands, lymphadenoma
of 130
- leukaemic lymphomata 10
- lichen 521
..... haemorrhagicus 493
..... pilaris 566
..... ruber acuminatus 521
..... planus 522
..... scrofulosorum 521
..... syphiliticus 536
- lineae albicantes 500
- lipaemia 6
- lipoma, arborescent 271
..... of bone 239
..... the brain 440
..... dura mater of the brain 463
..... spinal cord 380
..... heart 55
..... meninges of the brain 454
..... muscle 312
..... nerves 484
..... pituitary body 464
..... skin 507
..... spinal meninges 377
- literature (see references)
- livido 492
- livor 492
- locomotor ataxia 358
- locus minoris resistentiae 86
- loose bodies in joints 287
..... classification of 287
..... origin of 287
- 'loose cartilages' 287
- lordosis 152
- lupus disseminatus et aggregatus 521
..... erythematosus 520
..... discoides 521
..... exedens 533
..... exfoliatus 533
..... exulcerans 533
..... framboesioides 533
..... hypertrophicus 533
..... maculosus 533
..... nodosus 533
..... papillaris 533
..... serpiginosus 533
..... tuberosus 533
..... tumidus 533
..... verrucosus 533
..... vulgaris 532
- Lays, nucleus of 383
- lymph 13
- lymphadenia 129
..... progressive 130
- lymphadenitis 120
..... chronic indurative 124
..... tuberculous 125
- lymphadenoid hyperplasia, progressive
129
- lymphadenoma 129
- lymphangitis 96
..... issue of 97
- lymphangiectasis 97

(The numbers refer to the pages)

- lymphangiectatic elephantiasis 98
 lymphangioma 98
 of the skin 558
 of spleen 116
 lymphatics, dilated chyloferous 98
 occlusion of 97
 tuberculosis of 97
 lymph, cellular elements of 14
 changes in, dependent on changes
 in blood and tissues 14
 lymph-channels, desquamative catarrh
 of 123
 fibrinous exudation in
 123
 microbes in 14
 lymph-glands, abscess of 123
 acute inflammation of
 121
 amyloid degeneration of
 117
 calcification of 124
 carcinoma of 133
 caseation of 127
 chronic inflammation of
 124
 colour of atrophied 117
 fibrinous exudation in
 123
 fibroid induration of 125
 foreign substances in 119
 hyaline degeneration of
 118
 hyperplasia of 120
 in diphtheria 121
 inflammation of 120
 lymphosarcoma of 130
 metastatic growths of 133
 morbid changes in 117
 morphology of 117
 proliferation of 120
 resolution after inflam-
 mation of 123
 sarcoma of 131
 sarcomatous metastases
 of 133
 simple atrophy of 117
 softening of structures
 surrounding 120
 suppuration of 123
 syphilis of 128
 tubercle-bacilli in 127
 ulceration of adjacent tis-
 sues to 120
 lymphoid tissue, danger of large-celled
 hyperplasia of 127
 large-celled hyperplasia
 of 126
 lymphoma, malignant 130
 lymphosarcoma 129
 of the heart 55
 pericardium 64
 lymph-vessels, morbid changes in 96
 macrocheilia, lymphangiectatic 98
 macrocytes 5
 macroglossia, lymphangiectatic 98
 maculae tendineae 61
mal del sole 510
 malformations of the heart, aetiology of
 22
 malignant pustule 526
 malpighian follicles of spleen 104
mal rosso 510
 malum coxae senile 266
 perforans pedis 527
 senile 266, 275
 marrow, lymphoid, formed from carti-
 lage 248
 fatty 248
 matrix, calcified cartilaginous 213
 measles 508
 desquamation in 508
 medulla oblongata 327, 385
 arcuate fibres of Solly
 of 327
 decussation of the py-
 ramids in 327
 displacement of cen-
 tral canal in 327
 funiculus cuneatus of
 327
 funiculus gracilis of
 327
 motor centre of heart
 of 386
 nucleus cuneatus of
 327
 nucleus gracilis of 327
 olivary body of 327
 parolivary body of 327
 reflex centre of 386
 respiratory centre of
 386
 restiform body of 327
 vaso motor nerve
 centre of 386
 vocal articulation cen-
 tre of 386
 megaloblasts 5
 melanosis, progressive lentiginous 561
 membrane-bones 196
 meningeal dropsy 442
 tumours, calcareous concre-
 tions in 455
 meninges of the brain, alveolar endothe-
 lioma of 454
 angiomyxoma of
 454
 angiomyxosarco-
 ma of 454
 angiosarcoma of
 454
 animal parasites
 of 458
 carcinoma of 454

(The numbers refer to the pages)

- meninges of the brain, chondroma of 454
 cysticercus of 458
 cystic fibroma of 455
 dermoid cysts of 457
 echinococcus of 458
 fibroma of 454
 haemorrhages into the 376
 lipoma of 454
 myxoma of 454
 myxosarcoma of 454
 osteoma of 454
 psammoma of 455
 sarcoma of 454
 secondary tumours of 458
 osteomata of spinal 377
 tumours of spinal 377
 meningitis, cerebro-spinal 373, 444
 epidemic cerebro-spinal 373
 fibrino-purulent spinal 373
 purulent spinal 373
 seropurulent spinal 373
 spinal 373
 syphilitic spinal 375
 traumatic purulent 373
 tuberculous 374, 432, 449
 meningo-encephalitis, aetiology of chronic 447
 tuberculous 449
 myelitis 347, 373
 tuberculous, and neuritis 375
 tuberculous 370
 mesarteritis 71
 micrencephalia 390
 hydrocephalic 397
 micrococci, pyogenic 73, 74, 92, 170, 314, 346, 373, 428, 429, 443, 517, 527, 529
 micrococcus endocarditis capsulatus 33
 microcephalia 200, 206, 390
 microcosmia 200
 microcytes 5
 microdactylia 312
 microgyria 391
 cerebellar 392
 miromelia 200, 328
 chondromalacia 204
 micro-organisms, pathogenic 175
 microsporion furfur 545
 minutissimum 545
 miliaria crystallina 511
 milium 571
 misplacement of the large blood-vessels 19
 moles 557, 560
 molluscum contagiosum 547
 morbilli 508
 laeves 508
 papulosi 508
 morbus maculosus Werlhofii 493
 haemorrhage of the heart in 51
 morphoea 566
 nigra et alba 540
 mother's marks 558
 motor cells of spinal cord 324
 mucoid tissue 248
 mucous patches 537
 multinuclear osteoclasts 173
 mures articuli 287
 muscle, abscess of 307
 amyloid degeneration of 299
 anaemic degeneration of 293
 and tendons, Sect. v p. 289
 angioma of 312
 animal parasites of 312
 atrophy of, from disuse 292
 lipomatous pseudo-hypertrophic 302
 bony formations in 310
 calcification of 299
 carcinoma of 312
 causes of atrophy of 293
 cells of heart, atrophic and degenerative changes of 44
 chondroma of 312
 cicatrix of 307
 cloudy swelling of 297
 cysticercus cellulosa of 312
 degeneration of 297
 dropsical degeneration of 297
 dry gangrene of 299
 echinococcus of 312
 fatigue of 291
 fatty degeneration of 297
 fibroma of 312
 fibrosarcoma of 312
 gangrenous necrosis of 299
 glanders of 309
 haematogenous tuberculosis of 309
 healing of abscess of 307
 hyaline degeneration of 298
 hyperplasia of connective tissue of 307
 hypertrophy of 304
 induration of 307
 inflammation of 306
 lacunar erosion of 297
 length of 291
 lipoma of 312
 lipomatous pseudohypertrophic atrophy of 302
 local anaemia of 293
 morphology of 291
 myxoma of 312
 myxosarcoma of 312
 neuropathic atrophies of 292
 nuclei 291

(The numbers refer to the pages)

- muscle, primary tumours of 312
 progressive atrophy of 293
 bulbar paralysis of 292
 dystrophy of 294
 pseudohypertrophic paralysis of 303
 pseudohypertrophy of 301
 regeneration of 305
 results of degenerations of 299
 rhabdomyoma of 312
 sarcolemma of 291
 sarcoma of 312
 seat of atrophy of 293
 simple atrophy of 296
 striated fibres of 291
 syphilis of 309
 trichina of 312
 tuberculosis of 308
 vacuolar degeneration of 297
 wasting of 297
 waxy degeneration of 300
 muscular atrophy, progressive spinal 365
 fibres, fragmentation of 297
 mycosis fungoides 530
 microsporina 545
 myelin, coagulation of 414
myélite cavitaire 351
 myelitis 333, 334
 aetiology of 346
 central 347
 consecutive 347
 diffuse 345
 forms of 344
 from compression 345
 haematogenous 345
 haemorrhagic, a focal disease 345
 multiple 345
 solitary 345
 repair after 344
 results of 346
 termination of 346
 transmitted 347
 transverse 346
 myelocystocele 349
 myelocytes in leukaemia 9
 myelogenous sarcoma of bone 239
 myeloma of bone 241
 myelomalacia, haemorrhagic 331
 ischaemic 331
 myeloplaxes in bone resorption 141
myocardite segmentaire 45
 myocarditis 38
 indurative 13
 purulent 52
 segmentary 45
 myocardium, morphology of 44
 wounds of 54
 myohaemoglobin 293, 296
 myomalacia cordis 45, 47
 seat of 50
 myomalacia cordis, tissue-changes in 48
 myopathy, primary 293
 myositis 306
 gangrenous 307
 progressive ossifying 310
 purulent 307
 myotonia, congenital 304
 myxo-fibroma of bone 239
 lipo-sarcomata of muscle 312
 sarcoma of the meninges of the brain 454
 muscle 312
 myxoma of bone 235, 239
 dura mater of spinal cord 380
 the heart 55
 meninges of the brain 454
 muscle 312
 nerves 484
 the skin 567
 naevi, vascular 557, 558
 pigmentosi 495
 vasculosi flammei 558
 vinosi 558
 naevus pigmentosus papillomatosus 560
 prominens 560
 verrucosus 560
 pilosus 495, 561
 prominens 495, 558
 spilus 495
 unius lateris 565
 vascular of the brain 440
 verrucosus 495, 560
 nails 570, 574
 exfoliation of 501
 ingrowing 575
 overgrowth of 575
 nanocephalia 200
 nanosomia 200
 nearthrosis 166, 252, 259
 necrogenous warts 534
 necrosis, central 172
 of cartilage 248, 260
 vessel-walls 67
 partial 172
 superficial 172
 syphilitic 194
 total 172
 nerves 469
 ascending secondary degeneration of 340
 axis cylinder of 469
 cells of, spinal cord 324
 changes in, after disease of the anterior horns 472
 changes in, after diseases of the motor roots 472
 changes in, after section of 470
 degeneration of 470
 descending secondary degeneration of 340

(The numbers refer to the pages)

- nerves, effect of diseases of the anterior horns on 472
 elements, disintegration of, in myelitis 344
 of brain, regeneration of 416
 fibres, destruction of 414
 disintegration of in sclerosis of the spinal cord 355
 medullated 469
 non-medullated 469
 rate of growth of 478
 secondary degeneration of 340
 fibroma of 481
 haematogenous degeneration of 472
 inflammation of 472
 inflammation of 470
 sympathetic 475
 ischaemia of 331
 leprosy of 475
 lipoma of 484
 medullary sheath of 469
 myxoma of 484
 naevus 565
 neuroma of 482
 regeneration of 478
 sarcoma of 484
 simple degeneration of 470
 trunk, blood-vessels of 469
 tumours of 481
 nettle-rash 510
 neuromatous elephantiasis 564
 neuraxon 324
 neurilemma 469, 479
 neuritis 470, 473
 acute 473
 aetiology of 472
 chronic 474
 disseminated 473
 interstitial 470
 lymphogenous 473
 multiple 473
 of roots of spinal nerves 373
 parenchymatous 470
 proliferous 474
 subacute 474
 syphilitic 474
 tuberculous 375, 474
 neurofibroma 482
 of the skin 563
 neurocytes 324
 neuroglia-cells in degeneration of the cerebrum 414
 of spinal cord 324
 proliferation of 419
 proliferation of, in myelitis 345
 sclerosis of 350
 neuroglioma 436
 neuroglioma, ganglionic 436
 neuroma 482
 amputational 479
 pampiniform 483
 plexiform 483, 562
 neuromatous elephantiasis 483
 neuron 357
 aetiology of progressive atrophy of motor 366
 progressive atrophy of the motor 365
 nodes 503
 normoblasts 5
 occipital lobe of the cerebrum 381
 destruction of, in softening of the brain 420
 ochronosis 246
 oedema of the skin 492
 olfactory centre 385
 oligaemia 3, 6
 oligocythaemia 4
 onychogryphosis 575
 onychomycosis favosa 543
 tonsurans 545
 optic thalamus 383, 385
 functions of 387
 putamen of 383
 oriental sore 528
 osseous hyperplasia 209
 system, Sect. iv 135
 tissue, new 54
 pathological formations of 181
 plexiform 159
 tumours, aetiology of 235
 ossification 196
 anomalous processes of, in rickets 215
 centre of 198
 diaphysial centres of 198
 endochondral 196, 198
 epiphysial centres of 198
 myelogenous disorders of, in rickets 217
 of the arteries 67
 periosteal 196
 disorders of, in rickets 217
 ossifying fibroma 239
ostéarthropathie hypertrophicante d'origine pneumique 178
 osteoarthropathy, pulmonary hypertrophic 178
 osteoblasts 155, 159, 169, 325
 osteochondroma 239
 osteochondritis, syphilitic 211
 osteoclasts, in bone resorption 141
 synonymous, with myeloplaxes 142
 osteofibroma 239
 osteogenesis, imperfect 202

(The numbers refer to the pages)

- osteoid sarcoma 240
 tissue 155
 trabeculae 161
 osteoma 235, 236
 compact 236
 ivory 236
 medullary 236
 of the brain 440
 dura mater of the brain 463
 meninges of the brain 454
 skin 567
 spinal meninges 377
 shape of 237
 spongy 236
 osteomalacia 151
 carcinomatous 242
 causes of 151
 juvenile 151
 kyphosis in 152
 lordosis in 152
 scoliosis in 152
 senile 151
 osteomyelitis 170
 acute infective 171
 fibrosa 180
 haematogenous purulent 175
 micrococci in infective 171
 origin of infective 171
 osteomyxoma 239
 osteophytes 161, 168, 187, 195
 periosteal 178
 osteoplastic germinal tissue 173
 osteoporosis 143, 179
 in syphilis 195
 osteopsathyrosis, symptomatic 145
 osteo-sarcoma 235, 240, 242
 osteosclerosis 168
 ostitis, 170
 albuminosa 174
 deformans 178, 179, 181
 deformities of vertebrae in 181
 hypertrophic 178
 hypertrophicans 179
 pachyacia, hypertrophic ostitis in 178
 pachydermia 94, 483, 564
 acquisita 550
 pachydermatocele 564
 pachymeningitic hydrocephalus, partial 461
 internal haemorrhagic 379
 pachymeningitis, chronic external 461
 haemorrhagic 379, 460
 panaritium 176
 cutaneum 524
 subcutaneum 524
 panarthritides 260, 261, 263
 panneuritis epidemica 473
 panniculus adiposus, cardiac 28
 pannus, vascular 264
 papilloma areo-elevatum 530
 inflammatory fibrous 550
 neuropathic of the skin 565
 venereal 536
 papules 503
 parakeratosis 519
 paralysis, acute bulbar 358
 general progressive atrophy of brain in 407
 glosso-labio-laryngeal 366
 infantile spinal 362
 motor, in softening of the brain 420
 progressive bulbar 392, 358, 366
 pseudohypertrophic muscular 303
 sensory, in softening of the brain 420
 spastic spinal 358, 365
 parasynovitis 260
parésie analgésique à panaris des extrémités supérieures, 351
 parietal lobe of the cerebrum 381
 paronychia tendinosa 524
 passive hyperaemia of the spleen 106
 pectus carinatum 222
 peliosis rheumatica 493
 pellagra 510
 pelvic bones, tuberculosis of 192
 pelvis, lateral expansion of 205
 oblique transverse contraction of 205
 pseudo-osteomalacic 222
 symmetrical transverse contraction of 205
 transverse contraction of 206
 pemphigus 513
 acutus 514
 aetiology of 514
 chronic vulgaris 514
 circinatus 514
 confertus 514
 diphtheriticus 513
 disseminatus 514
 foliaceus 513, 514
 gyratus 514
 neuroticus 515
 serpiginosus 514
 syphiliticus 515, 538
 vegetans 514
 vulgaris 513
 Penjdeh boil 528
 pentastoma 107
 of the spleen 116
 perforating ulcer of the foot 527
 periadenitis, purulent 123
 periarteritis 71
 nodosa 80
 pericardial cavity, obliteration of 62

(The numbers refer to the pages)

- pericardial exudation, absorption of 62
 calcification of 62
 sero-sanguineous 63
 fluid, normal amount of 58
 pericarditis 59
 adhesive 61, 62
 extension of 62
 fibrino-purulent 62
 purulent 62
 sero-fibrinous 60
 sero-purulent 62
 pericardium, actinomycosis of 63
 adhesion of 60
 animal parasites of 64
 carcinoma of 64
 cysticercus of 64
 defects of 58
 diverticula of 58
 echinococcus of 64
 ectopia of 58
 haemorrhages in 58
 infective granulomata of 63
 lympho-sarcoma of 64
 morphology of 58
 passive dropsy of 58
 primary tumours of 64
 secondary tumours of 64
 syphilis of 63
 tuberculosis of 63
 perichondrium 196
 perilymphangitis 96
 perimysium, changes in, in atrophy 301
 perineurium 469
 periosteum 196
 injury to, in fracture 160
 spindle-shaped swelling of 163
 periostitis 170
 albuminosa 174
 haematogenous purulent 175
 tuberculous 186
 periostosis 169
 peripheral nerves, structure of 469
 nervous system, Sect. vii p. 469
 ganglion-cells of 469
 terminal sense organs of 469
 periphlebitis 91
 syphilitic 92
 tuberculous 92
 perisplenitis 109
 peritonitis in splenic abscess 112
 perniores 510
 pes equino-varus 228
 paralyticus 228
 valgus acquisitus 227
 petechiae 493
 petrosal bone, tuberculosis of 451
 phlebectases 93
 phlebitis, hyperplastic 91
 phlebitis, obliterans 91
 proliferous 91, 92
 suppurative 92
 syphilitic 92
 tuberculous 92
 phleboliths 92, 95
 phleboscrosis 91
 pia mater 442
 of the brain, carcinoma of 456
 cholesteatoma of 457
 disseminated miliary tuberculo-
 sis of 449
 haemorrhages in-
 to 443
 oedema of 442
 pearly tumour of 457
 solitary tubercles
 of 451
 spinal cord 373
 pigeon-breast 222
 pigment-granule cells in degeneration of
 the cerebrum 415
 piles 94
 pili annulati 574
 pineal gland 460, 465
 haematoma of 465
 hyperplastic enlargement of 465
 inflammation of 465
 pathological changes in 465
 psammoma of 465
 tumours of 465
 pit 518
 pituitary body 460
 in acromegaly 464
 adenoma of 464
 carcinoma of 464
 cystic degeneration of 464
 gumma of 464
 hyperplastic overgrowth
 of 464
 inflammation of 464
 lipoma of 464
 morphology of 464
 sarcoma of 464
 struma of 464
 teratoma of 464
 tuberculosis of 464
 tumours of 464
 pityriasis furfuracea capillitii 570
 rubra 520
 simplex 499
 tabescentium 500
 versicolor 545
 plasmodium malariae 110
 plasmoschisis 5
 plethora apocoptica 3
 cardiac hypertrophy in 4

(The numbers refer to the pages)

- plethora serosa 13
 a transient condition 4
 temporary 3
 vera 3
 pneumo-pericardium 62
 pock 518
 mark 518
 podagra 261
 poikilocythaemia 5
 poliomyelitis 346
 acute anterior 358, 362
 symptoms of acute anterior 362
 poliosis circumscripta 497
 polyarthritis, chronic rheumatic 275, 278
 nodular 275
 polymyositis, acute primary 306
 polypi, nasal 238
 polynuritis 473
 polypus, cardiac 46
 polytrichia 575
 pompholyx 513
 pons, functions of nucleus of 387
 glioma of 439
 results of stimulation of 386
 porencephalia 394, 396
 porrito amiantacea 570
 decalvans 573
 port-wine stains 558
 projective fibres of the cerebrum 384
 proliferous zone 196
 proud flesh 529
 prurigo 520
 psammomata of the brain 440
 dura mater of the brain 467
 meninges of the brain 455
 pineal gland 465
 pseudo-arthritis 166
-leukaemia 11, 130
-porencephalia 396
 psoriasis 519
 annularis 519
 guttata 519
 gyrata 519
 nummularis 519
 palmaris et plantaris syphilitica 537
 punctata 519
 seat of 519
 pulmonary artery, circumference of 24
 stenosis of 17
 purpura 493
 haemorrhagica 493
 papulosa 493
 scorbutica 493
 senilis 494
 simplex 493
 variolosa 493, 517
 pustule 503, 506
 putamen 383
 pyaemia, spleen in 109
 pyez 498
 pyomyelia 350
 pyramidal tracts, primary degeneration of, in amyotrophic lateral sclerosis 365
 rabies, virus of 346
 rachitis 214
 Ranvier's nodes 469
 rashes 508
 red blood-corpuscles, destruction of 4, 5
 ... corpuscles, nucleated 5
 references on
 acromegaly 181
 albinism 498
 alopecia 574
 anaemia 6
 aneurysms, arterio-venous 90
 formation of 89
 ankylosis 256
 aortic stenosis near the ductus arteriosus 24
 arteries, atheroma of 72
 calcification of 67
 hyaline degeneration of 67
 sclerosis of 72
 arteritis 77
 tuberculous 81
 syphilitic 81
 arthritis, ankylosing 277
 chronic dry ulcerative 277
 deformans 277
 gouty 281
 in infective diseases 263
 articular syphilis 286
 tuberculosis 286
 bone, arrest of growth of 213
 atrophy of, from disuse 148
 cysts of 149, 244
 disturbances of growth of, due to mechanical causes 230
 halisteresis of 153
 hydatids of 244
 hypoplasia of 207
 inflammatory stimulation of 213
 lacunar resorption of 148
 leprosy of 195
 local overgrowth of 210
 neuropathic atrophy of 149
 phosphorus-necrosis of 177
 premature synostosis of 207
 regeneration of 159
 repair of fractures of 167
 structure of 159
 syphilis of 195
 tuberculosis of 188
 tumours of 243
 bone-marrow 138
 changes in, accompanying various diseases 140

(The numbers refer to the pages)

- references on
 bony hyperplasia from the effects of
 arsenic and phosphorus 210
 brain, abscess of 431
 atrophy of 410
 cysticercus in 459
 cysts of the adventitial lymph-
 sheaths of 443
 choroid plexuses
 of 443
 meninges of 443
 defects of 396
 function of 387
 heterotopia of the grey mat-
 ter of 403
 hyperplasia of the grey mat-
 ter of 403
 ischaemic softening of 421
 malformations of, in cretins
 403
 criminals
 403
 idiots 403
 structure of 387
 syphilis of internal meninges
 of 453
 traumatic injury of 428
 tuberculosis of internal me-
 ninges of 451
 tumours of 440
 the dura mater of
 464
 internal meninges
 of 458
 bursae, diseases of 319
 hygroma of 317
 cartilages, degenerative changes in
 articular and other
 248
 repair of injuries to 252
 cerebellum, atrophy of 411
 hypoplasia of 392
 cerebral haemorrhage 424
 sclerosis 435
 cerebrum, hypoplasia of 392
 chancre, soft 530
 corpus callosum, absence of 396
 cutaneous horns 550
 dermatitis, papillomatous, of the
 scalp 532
 eczema 516
 elephantiasis, acquired 553
 neuromatous 565
 encephalitis, focal 430
 endocarditis 42
 endocardium, degenerations of 32
 ependymal sclerosis 435
 erythema 510
 exostoses 210
 ganglion 319
 ganglion-cells, calcification of 417
 glanders, cutaneous 542
- references on
 granuloema fungoides 531
 umbilical 532
 hair, nodes of 575
 reproduction of 574
 heart, aneurysms of 52
 development of 23
 fibroid induration of 52
 hypertrophy of 28
 malformations of 23
 muscle, atrophy of 46
 degeneration of 46
 myocarditis of 54
 myomalacia of 52
 parasites of 57
 size of 25
 syphilis of 56
 tuberculosis of 56
 tumours of 56
 wounds of 54
 herpes zoster 513
 hydraemia 6
 hydrocephalus, congenital 400
 hydromyelia 352
 hypertrichosis 575
 ichthyosis 557
 impetigo 516
 intracranial circulation and its dis-
 turbances 406
 joints, behaviour of blood in 263
 changes in, after long immo-
 bility 278
 formation of new, after resec-
 tion 253
 loose bodies in 288
 neuropathic affections of 280
 large blood-vessels, size of 25
 leprosy, cutaneous 540
 leucocytosis 11
 leukaemia 11
 lichen 522
 lipaemia 6
 lupus erythematosus 521
 lymphadenia 131
 lymphadenitis 125
 syphilitic 128
 tuberculous 128
 lymphangitis 97
 lymphatics, dilatation of 99
 obstruction of 99
 lymph-glands, degeneration of 118
 deposition of foreign
 substances in 120
 tumours of 133
 meningitis, aetiology of acute 445
 morbid anatomy of acute
 445
 molluscum contagiosum 547
 muscle, amyloid degeneration of 301
 calcification of 301
 degenerative atrophy of 300
 hydatids of 313

(The numbers refer to the pages)

references on

- muscle, hypertrophy of 305
 - lipomatous pseudohypertrophy of 303
 - simple atrophy of 300
 - syphilis of 309
 - tuberculosis of 309
 - tumours of 313
- muscles, adaptation of, to altered conditions of contraction 294
- muscular atrophy in connexion with inflammation of joints 295
 - in connexion with injuries to muscles 295
 - neurogenous 294
 - primary myopathic progressive 295
 - spinal 294
- myelitis 348
 - from compression 345
 - traumatic injury 345
- myositis 308
 - ossifying 312
- myotonia, congenital 305
- nearthroses, formation of 259
- nerves, cachectic degeneration of 475
 - inflammation of 475
 - infective degeneration of 475
 - inflammation of 475
 - regeneration of 480
 - toxic degeneration of 475
 - inflammation of 475
 - traumatic degeneration of 475
 - inflammation of 475
 - tumours of peripheral 484
- osteoarthropathy 181
- osteocondritis, congenital syphilitic 213
- osteomalacia 153
- osteomyelitis 174
- ostitis deformans 182
 - hypertrophic 181
- pachymeningitis, haemorrhagic 463
 - proliferous 463
- paralysis, aetiology of progressive
 - general 410
 - anatomy of progressive general 410
 - arsenic 295
 - lead 295
 - progressive bulbar 367
 - spastic spinal 367
- pellagra 510
- pemphigus 515
- periostitis 174
- periarteritis nodosa 81
- pericarditis 63

references on

- pericardium, tuberculosis of 64
 - syphilis of 64
- phlebitis 93
- phleboscclerosis 93
- pineal gland, tumours of 465
- pituitary body, affections of 465
- pityriasis rubra 521
- plethora 6
- poliomyelitis, acute anterior 364
- porencephalia 396
- prurigo 521
- psoriasis 520
- rhinoscleroma and its bacillus 531
- rickets 223
- sclerodermia 553
- skeleton, hypertrophy of 210
- skin, angioma of 558
 - atrophy of 501
 - diseases of, in general 589
 - endothelioma of 562
 - fibroma of 565
 - gangrene of 528
 - haemorrhages of 494
 - lymphangioma of 562
 - neuropathic papilloma of 566
 - syphilides of 539
 - tuberculosis of 555
 - tumours of 568
- small-pox, formation of vesicles of 519
- spinal amyotrophy, progressive 367
 - sclerosis, amyotrophic lateral 367
 - cord, anaemic degeneration of 333
 - inflammation of 333
 - atrophy of, from loss of the limbs 333
 - atrophy of, from undergrowth of the limbs 333
 - combined systemic degenerations of 367
 - disseminated sclerosis of 356
 - histological changes in foci of degeneration 340
 - histological changes in foci of inflammation 340
 - infective degeneration of 333
 - inflammation of 333
 - leprosy of 371
 - malformations of 329
 - multiple sclerosis of 356
 - secondary degeneration of 343

(The numbers refer to the pages)

- references on**
 spinal cord, structure of 328
 syphilitic of 376
 syphilitic degeneration
 of 371
 syringomyelia 352
 toxic degeneration of
 333
 inflammation of
 333
 traumatic degeneration
 of 333
 inflammation
 of 333
 tuberculosis of 371
 tumours of 372
 dura mater, morbid anatomy
 of 380
 meninges, syphilis of 376
 tumours of internal
 379
 meningitis, aetiology of 376
 histology of 376
 spleen, acute enlargement of, in in-
 fective diseases 112
 engorgement of 108
 function of 105
 infarction of 108
 structure of 105
 syphilis of 116
 tumours of 116
 splenic hyperplasia 114
 splenitis, purulent 112
 syphilis, articular 286
 tabes dorsalis 360
 tendons and sheaths, morbid anat-
 omy of 316
 tendon sheaths, hygroma of 317
 transfusion of blood 6
 trichorhexis 575
 tuberculosis, articular 286
 ulcer, perforating, of foot 528
 urticaria 510
 valves, structure of 32
 varices 95
 vitiligo 498
 wens 572
 tumours originating from 572
 xanthoma 562
 regeneration of bone 154
 muscle 305
 Reil, island of 382
 relapsing fever, spleen in 110
 resorption of bone in resection of joints
 252
 respiratory centre 386
 rhabdomyomata of the heart 55
 muscle 312
 rhagades 505
 rheumatism, acute polyarthritic 261
 rhinophyma 558
 rhinoscleroma 531
 rice-bodies 316
 in bursae 318
 rickets 214
 a disorder of nutrition 222
 an inflammatory disease 222
 anomalous process of ossifica-
 tion in 215
 catabolic disintegration in 223
 cranial sutures in 222
 deformities in 220
 dentition in 222
 disorders of myelogenous ossifi-
 cation in 217
 periosteal ossifica-
 tion in 217
 displacement of epiphyses in 221
 enlargement of zone of prolifer-
 ating cartilage in 217
 fontanelles in 222
 funnel-shaped thorax in 222
 hyperaemia of bones in 222
 lacunar resorption in 215
 micromelic foetal 206
 pectus carinatum in 222
 pigeon-breast in 222
 softness of the bones in 220
 rider's bones 310
 ringworm, common 544
 crusted 542
 risipola lombarda 510
 root-ganglion cells of spinal ganglia 325
 roseola 492
 aestiva 510
 autumnalis 510
 choleraica 510
 infantilis 510
 rheumatica 510
 syphilitic 536
 typhosa 510
 rubeola 508
 rupia syphilitica 538
 sarcoblasts 305
 sarcolemma 291
 sarcoma of bone 235, 239
 giant-celled 240
 myelogenous alveolar
 240
 retrogressive changes in
 240
 telangiectatic 240
 the brain, 440
 alveolar, of the dura mater of
 the brain 462
 of dura mater of the brain 462
 spinal cord
 380
 heart 55
 lymph-glands 131
 meninges of the brain 454
 muscle 312
 nerves 484

(The numbers refer to the pages)

- sarcoma, imperfect development of 206
 of pituitary body 464
 ossifying 242
 periosteal 241
 of skin 566
 spinal cord 372
 meninges 378, 379
 spleen 116
 sarcomatosis of the skin, general 566
 scab 503, 505
 scabies 546
 scales 503, 506
 scar 507
 scarlatina 508
 desquamation in 508
 haemorrhagica 508
 sclerema neonatorum 553
 sclerodermia 552
 sclerosis, amyotrophic lateral 365
 of the arteries 67
 aetiology of 69
 results of 71
 terminations of 71
 blood-vessels of the brain 417
 brain 416
 scoliosis 152, 225
 cause of 225
 paralytic 228
 scrofulodermia 532
 miliare 521
 scurvy haemorrhagicus 493
 scutula 542, 544
 sebaceous cysts 572
 changes in 572
 glands 570
 seborrhoea 570
 furfuracea 570
 oleosa 570
 sicca 570
 squamosa 570
 sebum 570
 sensory centres 385
 septula medullaria 323
 septum, auricular 22
 intermedium 21
 ventriculorum 21
 sequestra of cartilage 260
 sequestrum, abscess 173
 absorption of 173
 removal of 173
 Sharpey's fibres 159
 sheath of Schwann 469
 shingles 512
 shreds 506
 sinus reuniens 22
 in tuberculous arthritis 284
 situs viscerum inversus 24
 skeleton, acquired lesion of 200
 cause of arrest of development
 in 200
 hypertrophy of 207
 skeleton, inherited variation of 200
 internal 196
 osseous part of 154
 spontaneous variation of 200
 skin, Sect. VIII 489
 abnormal chilling of 502
 heating of 502
 acne of 525
 rosaceae of 492
 acquired elephantiasis of 550
 acute inflammation of 506
 aetiology of inflammation of 502
 amount of blood in 491
 anaemia of 492
 angioma of 557
 angiomyoma of 566
 animal parasites of 545
 argyria of 496
 atheroma of 499
 atrophy of 499
 in nervous affections 501
 bed-sores of 503
 blebs of 505
 blister of 511
 boils of 525
 burns of 511
 cachectic atrophy of 500
 cancer of 567
 cavernous lymphangioma of 559
 chaps of 505
 chloasma cachecticum of 496
 caloricum of 496
 toxicum of 496
 traumaticum of 496
 chronic atrophic inflammation of 507
 hypertrophic inflammation of 507
 inflammations of 507
 cicatrising epithelioma of 567
 contamination of 502
 crusts of 503, 505
 cutaneous lymphangioma of 559
 cyanosis of 492
 cystic lymphangioma of 559
 cysts of, containing hair 499
 decubital necroses of 503
 desquamation of 492
 epithelium of 506
 developmental diseases of 489
 diagnosis between active hyperaemia of, and inflammation 492
 discolorations of 495
 disorders of circulation of 491
 ecchymoma of 493
 ecchymoses of 493
 ethyma of 576
 eczema of 515
 enchondroma of 567
 endocystic condyloma of 572
 papilloma of 572

(The numbers refer to the pages)

- skin, endothelioma of 558
 ... epithelioma of 567
 ... eruptions of 503
 ... measles in 508
 ... scarlatina in 508
 ... erysipelas of 522
 ... erythemata of 492, 509
 ... eschars of 506
 ... exanthems of 508
 ... excoriation of 505
 ... exfoliation of 505
 ... fibroma of 562
 ... fissures of 505
 ... flea-bites of 503
 ... freckles of 495
 ... functions of 489
 ... furfuraceous desquamation of 506
 ... general sarcomatosis of 566
 ... glanders of 542
 ... granulomata of 530
 ... gummata of 538
 ... haematangioma of 557
 ... haematoma of 493
 ... haemorrhagic bulla of 493
 ... herpes of 512
 ... hyperaemia of 492
 ... hypertrophic angioma of 557
 ... lymphangioma of
 559, 569
 ... hypertrophy of 548
 ... icterus of 496
 ... idiopathic disease of 489
 ... impetigo of 516
 ... inflammatory disorders of 502
 ... fibrous papilloma of
 550
 ... hypertrophies of 548
 ... oedema of 492
 ... tumours of 548
 ... influence of corrosive chemicals on
 502
 ... irritation of the nerves
 of 502
 ... jaundice of 496
 ... keloid of 566
 ... Addison's 566
 ... cicatrical 566
 ... keratoma of 549
 ... leiomyoma of 566
 ... leprosy of 540
 ... leucopathia of 496
 acquisita 496
 ... lichen of 521
 haemorrhagic of 493
 ... linear atrophy of 500
 ... lipoma of 567
 ... livedo of 492
 ... livor of 492
 ... local malformations of 554
 ... lupus erythematosus of 520
 vulgaris of 532
 ... lymphangioma of 558
 ... marasmic atrophy of 500
 ... mechanical injuries of 502
 ... membranaceous desquamation of
 506
 ... miliaria of 511
 ... moles of 495
 ... molluscum contagiosum of 547
 ... morphology of 489
 ... mycoses of 542
 ... myxoma of 567
 ... neurofibroma of 563
 ... nodes of 503
 ... non-inflammatory hypertrophies of
 554
 tumours of 554
 ... oedema of 492
 ... osteoma 567
 ... papules of 503
 ... parasitic disorders of 502
 ... pemphigus of 513
 ... petechiae of 493
 ... phlegmon of 524
 ... phlegmonous inflammation of 524
 ... pigment in 492
 ... pigmental lymphangioma of 560
 moles of 495
 ... pigmentary atrophy of 496
 discoloration of 492
 disorders of 495
 ... pityriasis of 499, 520
 ... prurigo of 520
 ... psoriasis of 519
 ... purpura papulosa of 493
 ... pustules of 503, 506
 ... rashes of 508
 ... recent haemorrhages of 493
 ... regenerative multiplication of epi-
 dermal cells of 506
 ... rhagades of 505
 ... rodent ulcer of 567, 568
 ... roseola of 492, 570
 ... sarcoma of 566
 ... scabs of 503, 505, 507
 ... scales of 503
 ... secondary tumours of 568
 ... senile atrophy of 499
 ... serpiginous inflammation of 508
 ... siliqueous desquamation of 506
 ... simple angioma of 557
 atrophy of 499
 ... sloughs of 506
 ... stigmata of 494
 ... subcutaneous lymphangioma of 559
 ... sudamina of 511
 ... sun-spots of 495
 ... symptomatic disease of 489
 ... syphilis of 535
 ... tattooing of 496
 ... telangiectatic lymphangioma of 559
 ... terminations of bones of 511
 ... transient pigmentation of 506
 ... traumatic granulomata of 530

(The numbers refer to the pages)

- skin, tubercles of 503
 tuberculosis of 532
 ulcers of 528
 urticaria of 510
 uterine chloasma of 496
 vacuolation of cells of 504
 vesicles of 503, 505
 vibices of 493
 warts of 534
 wheals of 503
 xanthelasma 495
 xanthoma of 495
- skull, brachycephalic 206, 207
 capacity of 207
 causes of deformity of 224
 cephalonic 207
 clinoccephalic 207
 dolichocephalic 206, 207
 formation of cranial portion 224
 height of 206
 hydrocephalic 207
 hypsocephalic 206
 leptoccephalic 207
 measurements of 206
 mesocephalic 206
 microcephalic 207
 orthocephalic 206
 orthognathous 207
 oxycephalic 207
 pachycephalic 207
 pathological types of 207
 plagiocephalic 207
 platycephalic 206, 207
 prevention of longitudinal expansion of 206
 prognathous 207
 results of synostosis of 206
 sphenoccephalic 207
 trochocephalic 207
 trigonocephalic 207
 variations in form of 206
- slough 506
- small-pox 517
 confluent 517
 haemorrhagic 517
 pit of 518
 pock of 518
- Solly's arcuate fibres 327
- speech-centre, motor 385
- spina ventosa 185, 189
- spinal arthropathies 279
 cord, abnormality of central canal of 329
 grey commissure of 329
 abscess of 346
 acute inflammation of dura mater of 379
 agenesis of 329
 amyotrophic lateral sclerosis of 358
 angiosarcomata of 372
- spinal cord, anterior column of 323
 ground bundle of 327
 horns of 323
 arachnoid of 373
 ascending degeneration in 341
 asymmetry of 328
 causes of inflammation of 332
 central canal of 323
 sclerosis of 350
 Clarke's vesicular column of 326
 column of Burdach of 327
 Goll of 327
 columns in white matter of 325
 combined systemic diseases of 368
 compression of 332
 corpora amylacea of 337
 crossed pyramidal tracts of 326
 defective development of the tracts of 328
 degeneration of 330, 334
 descending degeneration of 340
 development of single tuberculous nodes in 370
 direct cerebellar tracts of 326
 pyramidal tracts of 326
 disseminated sclerosis of 353
 tuberculosis of 370
 dura mater of 379
 fat-granule cells in 336
 fibroma of 372
 dura mater of 380
 formation of connective tissue in 340
 funiculus cuneatus of 327
 gracilis of 327
 gelatinous substance of Rolando 323
 glioma of 372
 gliosarcomata of 372
 Gower's bundle of 327
 gradual compression of 331
 granule cells in degeneration of 342
 grey commissure of 323
 degeneration of the posterior columns of 358
 gelatinous degeneration of 340
 matter of 323, 324
 heterotopia of 329
 hydatid cysts of dura mater of 380
 hypoplasia of 329
 infective granulomata of 370

(The numbers refer to the pages)

- spinal cord, inflammation of 330, 332
 membranes of 373
 influence of anaemia on nervous elements of 330
 influence of disorders of circulation on nervous elements of 331
 influence of disuse on nervous elements of 330
 influence of marasmus on nervous elements of 330
 influence of poisonous substances on nervous elements of 331
 influence of rapid variations of atmospheric pressure on nervous elements of 331
 insular sclerosis of 353
 interior cells of 325
 lateral column of 323
 ground bundle of 327
 horns of 323
 limiting tract of 227
 leprosy of 371
 lipomata dura mater 380
 malformation of 323, 328
 membranes of 373
 morphology of 323
 multiple sclerosis of 353
 myxoma of dura mater 380
 neuroglia of 324
 neuronie affections of 357
 pia mater of 373
 pigment-granule cells in 336
 posterior column of 323, 327
 horns of 323
 postero-external column of 327
 internal column of 327
 primary lateral sclerosis of 308
 tumours of dura mater of 380
 processus reticularis of 323
 progressive atrophy of the anterior horns of 358
 pyramidal tracts of 326
 red softening of 334, 336
 reparative proliferation of 338
 restoration of foci of degeneration of 338
 sarcoma of 372
 dura mater of 380
 sclerosis of 338
 the posterior columns of 358
 septula medullaria of 323
 simple atrophy of 334
- spinal cord, spongy substance of posterior horn of 323
 Stilling's nucleus of 326
 substantia gelatinosa centralis of 324
 supuration of 344
 syphilis of 370
 inflammation of dura mater of 380
 systemic affections of 357
 telangiectatic glioma of 372
 traumatic injuries of 331
 tuberculosis of 370
 dura mater of 380
 tumours of 370, 372
 white matter of 323, 325
 softening of 334, 336
 yellow softening of 336
- spinal meninges, alveolar endothelioma of 378
 angioma of 378
 carcinoma of 379
 cavernous angioma of 377
 fibroma of 377
 hyaline degeneration in tumours of 378
 lipoma of 377
 sarcoma of 378, 379
 secondary tumours of 379
- spinal nerves, anterior roots of 323
 defects of roots of 328
 neuritis of roots of 373
 posterior roots of 323
- spine, kyphotic curvature of 222
 lordotic 222
 scoliotic 222
- splenic abscess, rupture of 112
- spleen, absence of 104
 actinomycosis of 115
 acute enlargement of 108
 adhesions of 111
 amyloid degeneration of 105
 hyaline masses in 105
 anaemia of 107
 anaemic infarction of 107, 110
 and the lymph-glands, Sect. II 101
 angioma of 116
 animal parasites of 116
 atrophy of 105, 111
 bacon 105
 carcinoma of 116
 cicatrix in 108
 congestive hyperaemia of 108
 cyanotic induration of 107
 cysticercus of 116
 cysts of 116
 echinococcus of 116
 embolic infarction of 107

(The numbers refer to the pages)

- spleen, engorgement of 106
 enlargement of, with induration 111
 in cirrhosis of the liver 114
 foreign matters in 104
 functions of 104
 gummata in 115
 hyaline degeneration of 106
 hyperaemia of, in infective diseases 109
 hyperplasia of 112
 karyokinetic figures in cells of 110
 in diphtheria 110
 inflammation of, in infective diseases 109
 results of 110
 in pyaemia 109
 relapsing fever 110
 leprosy of 115
 leukaemic hyperplasia of 112
 lymphangioma of 116
 malpighian follicles of 104
 metastatic growths in 116
 morbid changes in 103
 morphology of 103
 necrosis of 109
 passive hyperaemia of 106
 pentastoma of 116
 plasmodium malariae in 110
 primary neoplasms of 116
 pseudo-leukaemic hyperplasia of 112
 pulsating cavernous angioma of 116
 relation to blood metabolism 103
 sago 105
 sarcoma of 116
 spodogenous enlargement of 109
 spontaneous rupture of 106
 supernumerary 104
 suppuration of 112
 syphilis of 115
 traumatic rupture of 106
 tuberculosis of 115
 typhoid fever 110
 weight of, in hyperplasia 114
 syphilitic infarcts 115
- spleen-pulp, haemosiderin in 104, 111
 method of communication of arteries and veins in 103
 morphology of 103
- splenic abscess 112
 peritonitis in 112
 tumour, spodogenous 104
 veins, thrombosis of 107
- spleniculus 104
 splenitis 108
 spodogenous splenic tumour 104
- spondylitis deformans 273
 spondylolisthesis 229
 cause of 229
- sporozoa, parasitic 547
- sprain 251
- squamae 506
- staphylococcus pyogenes aureus 171
- steatoma 572
- steatorrhoea 570
- stigmata 494
- Stilling's nucleus 326
- streptococcus pyogenes 524
- strongylus armatus as a cause of aneurysm 88
- struma of the pituitary body 464
- stumps, atrophy of bone in 145
- subarachnoid space of the brain, oedema of 442
- subthalamic nucleus 385
- sudamina 511
- sulcus interventricularis 21
- sun-spots 495, 560
- sweat, bloody 493
 glands, adenoma of 568
- syccosis framboesiformis 530
 parasitic 525
 simplex 525
- sympathetic ganglia, inflammation of 475
 nerve-fibres, inflammation of 475
- synarthrosis 245
 degenerations of 245
 repair of ruptured 251
- synchondrosis, false 245
 inflammations of 262
 softening of 247
 true 245
- syndesmosis 206, 245
 inflammations of 262
 ossification of 249
 pathological 166
- synostosis 165, 245
 premature 205
 results of premature, of sacro-iliac synchondrosis 205
- synovia 245
- synovial membrane 245
 hernial protrusions of 264
- synovitis 260
 catarrhal 262
 chronic serous 264, 278
 hyperplastica granulosa 188
 pannous hyperplastic 264
 purulent 261, 278
 secondary granular 262
 serous 261, 285
 sero-fibrinous 261
 smooth 264
- syphilide, papular 536
 pustular 538
- syphilides 536

(The numbers refer to the pages)

- syphilis 535
 arthropathies in tertiary 285
 cutaneous eruptions of 536
 hyperostosis in 195
 initial sclerosis of 535
 lenticular 536
 miliary 536
 osteoporosis 195
 of muscle 309
 the brain 432, 451
 dura mater of the brain
 461
 dura mater of the spinal
 cord 380
 lymph-glands 128
 peripheral nerves 474
 spinal meninges 375
 spleen 115
 small papular 536
 vesicular 537
 virus of 73, 346
 syphilitic gumma of the heart 55
 induration 535
 phlebitis 92
 roseola 536
 syringomyelia 349, 350
 significance of the lesions
 of 352
 symptoms of 351
 tabes dorsalis 357, 358
 aetiology of 360
 ataxia in 359
 changes in 358
 fat-granule cells in 359
 gastric crises in 359
 sensory phenomena in 359
 symptoms of 359
 spasmodic 365
 taenia solium 458
 talipes calcaneus 228
 tarsus, tuberculosis of 190
 tattooing 496
 tegmen tympani, perforation of 147
 tela choroideae 442
 temporal lobe of the cerebrum 381
 tendinitis 314
 proliferous gouty 315
 tendons, morphology of 314
 repair of 316
 tendon-sheaths, arborescent lipoma of 316
 morphology of 314
 rice bodies in 316
 rheumatic nodules of 316
 teno-synovitis 314
 tendo-vaginal hydrops 316
 vaginitis 314
 acute dry 314
 purulent 314
 tuberculous 315
 teratoma of the pituitary body 464
 Thomsen's disease 304
 thorax, causes of deformity of 224
 funnel-shaped 222
 thrombo-arteritis 74
 plastic 74
 proliferous 74
 purulent 74
 phlebitis 91, 95
 suppurative 92, 95
 thrombosis within the heart 51
 thyroid cachexia 203
 tinea capillitii 545
 favosa 542
 sebacea 570
 sycosis 545
 tonsurans 544
 versicolor 545
 vesiculosus 545
 tophi in gouty arthritis 280
 tract cells of spinal cord 324
 transpositio cordis 24
 trichina of muscle 312
 the pericardium 64
 tricophyton tonsurans 513, 544, 545
 trichorhexis nodosa 574
 truncus arteriosus 21, 22
 tuber cinereum 385
 tubercle of the heart 55
 tubercles 503
 tuberculosis, articular 282
 of bone 183
 the brain 432
 bursae 319
 dura mater of the
 brain, 461
 dura mater of the
 spinal cord 380
 meninges of the
 brain 432, 449
 muscle 308
 pericardium 63
 periosteum 186
 peripheral nerves 474
 pituitary body 464
 skin 532
 spinal cord 370
 meninges 374
 spleen 115
 tuberculous abscess, cold 284
 empyema of a joint 282
 lymphadenitis 125
 meningo-encephalitis 449
 periphlebitis 92
 phlebitis 92
tumeur à myéloptaxes 240
 tumour albus 188, 284
 tyloma 548
 typhoid bacillus 444
 fever, spleen in 110
 ulcer of the skin 528
 perforating, of the foot 527
 rodent 567, 568

(The numbers refer to the pages)

- ulcer, tropical 528
 - varicose 94, 529
 - venereal 529
- ulcus induratum 530
 - molle 529
 - serpiginosum 538
- urticaria 510
 - papulosa 510
 - pigmentosa 510
 - tuberosa 509
 - vesiculosa 510
- vaccinia 518
- vacuolar degeneration of muscle 297
- vacuolation of cells of the skin 504
- valves, fenestration of 38
 - insufficiency of 40
 - perforation of 38
 - rupture of 38
 - stenosis of 40
- valvular segments, malformations of 19
 - tissue, atheromatous degeneration of 31
 - sclerosis of 31
- varicella 519
- varices 93
 - rupture of 94
 - situation of 94
- varicocele 94
- varicose aneurysm, true 87
 - spurious 89
 - ulcer 94
- variola 517
 - haemorrhagica 493, 517
 - syphilitica 538
- vasa vasorum 69, 71, 72, 73, 75
 - in atheroma 69, 71, 72
- vascular mechanism, Sect. II 15
 - system, asymmetrical arrangement of 22
- vaso-motor nerve-centre 386
- vegetation, endocarditic 38, 39
- veins, calcifications of 91
 - fatty degeneration of intima and media of 91
 - fibroid thickening of intima of 91
 - morbid changes in 91
 - subcutaneous rupture of 94
 - vitelline 20
 - wounds of 92
- venae Galeni, thrombosis of 430
 - omphalo-mesentericae 20
- venous orifices, stenosis and atresia of 19
- ventricles of the brain, carcinoma of 456
 - fibrino-purulent exudations into 445
 - purulent exudations into 445
- dropsy of 406
- ventricular dropsy 397
 - septum, defects of 19
- vernix caseosa 570
- verruca carnea 560
 - dura 560
 - mollis 560
- vertebrae, abscess in tuberculous disease of 191
 - pressure of aneurysms of aorta upon 147
 - tuberculosis of 190
- vesicles 503, 505
- vessel-walls, necrosis of 67
- vibices 493
- visual centre 385
- vitiligo 496, 497
 - aetiology of 497
 - distribution of 498
 - endemic, confounded with leprosy 498
- vitiligoidea 561
- vocal articulation centre 386
- warts, cadaveric 534
 - ichthyotic 557
 - sebaceous 547
 - soft 557
 - venereal 550
- waxy degeneration of muscle 298, 300
- wens 499, 572
- wheals 503
- white swelling 188, 284
- whitlow 176, 524
- xanthelasma 495, 561
 - multiplex 561
 - planum 495, 561
 - tuberosum 495, 561
- xanthoma 495, 561
- xerodermia 570
 - pigmentosum 561
- yaws 530
- zona 512

Works on the Medical Sciences and Connected Subjects.

PUBLISHED BY

THE MACMILLAN COMPANY.



- ANDERSON (J. W.).—Lectures on Medical Nursing. 16mo. 75 cents.
Essentials of Physical Diagnosis of the Chest and Abdomen. 75 cents.
- BALFOUR.—The Senile Heart. \$1.50.
- BALLANCE (C. A.) and EDMUNDS (W.).—A Treatise on the Ligation of
the Great Arteries in Continuity. With Illustrations. Royal 8vo. \$4.00.
- BARWELL (R.).—Lateral Curvature of the Spine. \$1.75.
- BLYTH (A. W.).—A Manual of Public Health. 8vo. \$5.25.
Lectures on Sanitary Law. 8vo. \$2.50.
- BRODIE (C. G.).—Dissections Illustrated. A Graphic Handbook for Students
of Human Anatomy. By C. GORDON BRODIE, F.R.C.C. 4to. Paper.
Part I. The Upper Limb. With 17 Coloured Plates. \$2.00.
Part II. The Lower Limb. With 20 Coloured Plates and 6 Diagrams. \$2.50.
Part III. Head, Neck, and Thorax. \$2.50.
- BRUNTON.—WORKS BY T. LAUDER BRUNTON, M.D., F.R.S.
On Disorders of Digestion: their Consequences and Treatment. 8vo. \$2.50.
Pharmacology and Therapeutics; or, Medicine Past and Present. \$1.50.
An Introduction to Modern Therapeutics. 8vo. \$1.50.
- BURDON-SANDERSON (J.).—Memoirs on the Physiology of Nerve, of Muscle,
and of the Electrical Organ. Edited by J. BURDON-SANDERSON, M.D.,
F.R.S.S.L. & E. 8vo. \$5.25.
- CARRINGTON (R. E.).—A Manual of Dissections of the Human Body.
Second Edition, revised and enlarged. \$2.50.
- DOWNIE (J. W.).—Clinical Manual for the Study of Diseases of the Throat.
By JAMES WALKER DOWNIE, M.B. \$2.50.
- ECCLES (A. S.).—Sciatica. A Record of Clinical Observations on the Causes,
Nature, and Treatment of Sixty-eight Cases. 8vo. \$1.00.
- FEARNLEY (W.).—A Course of Elementary Practical Histology. \$2.00.
- FITZGERALD (C. E.).—Lectures on Physiology, Hygiene, etc. With Illustrations
and Diagrams. 75 cents.
- FLÜCKIGER (F. A.) and HANBURY (D.).—Pharmacographia. Second Edition,
revised. 8vo. \$5.00.

- FOSTER (M.).**—A Text-book of Physiology. With Illustrations. 5th Edition, largely revised.
- | | |
|------------------------|-----------------------|
| Part I. Svo. \$2.60. | Part II. Svo. \$2.60. |
| Part III. Svo. \$1.75. | Part IV. Svo. \$2.00. |
- Part V. Appendix. Chemical Basis of the Animal Body. By A. SHERIDAN LEA. \$1.75.
- New Edition in one volume. Svo. Cloth, \$5.00. Sheep, \$5.50.
- FOSTER (M.) and BALFOUR (F. M.).**—Practical Embryology. With Illustrations. \$2.60.
- FOSTER (M.) and LANGLEY (J. N.).**—A Course of Elementary Practical Physiology. 5th Edition, enlarged. \$2.00.
- FOSTER (M.) and SHORE (L. E.).**—Physiology for Beginners. 16mo. Illustrated. 75 cents.
- GAMGEE (A.).**—A Text-book of the Physiological Chemistry of the Animal Body, including an Account of the Chemical Changes occurring in Disease. By ARTHUR GAMGEE, M.D., F.R.S.
- | |
|------------------------------------------------------------------------------------------------------------------------------|
| Vol. I. Svo. \$4.50. |
| Vol. II. The Physiological Chemistry of Digestion. With two Chromolithographic Charts by Spillon and Wilkinson. Svo. \$4.50. |
- GRESWELL (D. A.).**—A Contribution to the Natural History of Scarlatina. Svo. \$2.50.
- GRIFFITHS (W. H.).**—Lessons on Prescriptions. New Edition. 18mo. \$1.00.
- HAMILTON (D. J.).**—A Systematic and Practical Text-book of Pathology.
- | |
|-------------------------------------|
| Vol. I. Svo. \$6.25. |
| Vol. II. 2 Parts. Svo. Each \$5.00. |
- HOBLYN.**—Dictionary of Medical Terms. 12th Edition. \$2.25.
- HUXLEY (T. H.).**—Lessons in Elementary Physiology. With numerous Illustrations. Revised by Dr. FOSTER. 16mo. \$1.10.
- KAHLDEN (C.).**—Methods of Pathological Histology. By C. VON KAHLDEN, Assistant Professor of Pathology in the University of Freiburg. Translated and edited by H. MORLEY FLETCHER, M.A., M.D., Cantab., M.R.C.P., etc. With an Introduction by G. SIMS WOODHEAD, M.D. Svo. \$1.40.
- KANTHACK (A. A.).**—Lessons in Practical Bacteriology. *In the Press.*
- KLEIN (E.).**—Micro-organisms and Disease. Revised, with 120 Engravings. \$1.00.
- The Bacteria in Asiatic Cholera. \$1.25.
- MACEWEN.**—Pyogenic Infective Diseases of the Brain and Spinal Cord, Meningitis, Abscess of Brain, Infective Sinus Thrombosis. By WILLIAM MACEWEN, M.D., Glasgow. Svo. Buckram. \$6.00.
- Atlas of Head Sections. 53 Engraved Copperplates of Frozen Sections of the Head, and 53 Key Plates with Descriptive Texts. Folio. Bound in buckram. \$21.00.
- M'KENDRICK (J. G.).**—A Text-book of Physiology. In 2 volumes.
- | |
|-------------------------------------------|
| Vol. I. General Physiology. Svo. \$4.00. |
| Vol. II. Special Physiology. Svo. \$6.00. |
- Life in Motion; or, Muscle and Nerve. Illustrated. \$1.50.

- MACLAGAN** (T.).—**The Germ Theory.** Svo. \$3.00.
- MACLAREN** (ARCHIBALD).—**A System of Physical Education.** With Illustrations. *Clarendon Press Series.* 16mo. \$1.75.
- MACLEAN** (W. C.).—**Diseases of Tropical Climates.** \$3.00.
- MIERS** (H. A.) and **CROSSKEY** (R.).—**The Soil in Relation to Health.** By HENRY A. MIERS and ROGER CROSSKEY. \$1.10.
- MIGULA** (W.).—**An Introduction to Practical Bacteriology.** Translated by M. CAMPBELL, and edited by H. J. CAMPBELL, M.D. Illustrated. \$1.60.
- MIVART** (ST. GEORGE).—**Lessons in Elementary Anatomy.** With 400 Illustrations. 16mo. \$1.75.
- PALMBERG** (A.).—**A Treatise on Public Health, and its Application in Different European Countries** (England, France, Belgium, Germany, Austria, Sweden, and Finland). Edited by ARTHUR NEWSHOLME. Svo. \$5.00.
- PIFFARD** (H. G.).—**An Elementary Treatise on Diseases of the Skin.** With Illustrations. Svo. \$4.00.
- PRACTITIONER** (The).—**A Monthly Journal of Therapeutics and Public Health.** Edited by T. LAUDER BRUNTON, M.D., F.R.S., and DONALD MACALLISTER, M.A., M.D. Price 35 cents monthly. Annual Subscription, \$3.50.
Vols. I.—XLII. Half-yearly vols. \$2.50.
Cloth covers for binding volumes, 40 cents.
- RICHARDSON.**—WORKS by B. W. RICHARDSON, M.D.
On Alcohol. Paper, 30 cents.
Diseases of Modern Life. New Edition. *In the Press.*
- STEVEN** (J. L.).—**Practical Pathology.** \$1.75.
- STRAHAN** (S. A. K.).—**Suicide and Insanity: A Physiological and Sociological Study.** \$1.75.
- THORNE.**—**Diphtheria.** Its Natural History and Prevention. By R. THORNE. \$2.00.
- WHITE** (W. HALE, M.D.).—**A Text-book of General Therapeutics.** \$2.50.
- WILLIAMS** (C. T.).—**Aero-Therapeutics: or, the Treatment of Lung Diseases by Climate.** Being the Lumleian Lectures for 1893, delivered before the Royal College of Physicians. With an Address on the High Altitudes of Colorado. Svo. \$2.00.
- WILLOUGHBY** (E. F.).—**Handbook of Public Health and Demography.** 16mo. \$1.50.
- ZIEGLER.**—**A Text-book of Pathological Anatomy and Pathogenesis.** With Illustrations. Svo.
Part I. **General Pathological Anatomy.** New Edition. *In Preparation.*
Part II. **Special Pathological Anatomy.** Sections I.—VIII. \$4.00.
Part II. **Special Pathological Anatomy.** Sections IX.—XV. \$4.00.
- ZIEHEN** (THEODORE).—**Introduction to Physiological Psychology.** Translated by C. C. VAN LIEW and Dr. OTTO BEYER. With 21 Illustrations. \$1.50.

THE MACMILLAN COMPANY,

66 FIFTH AVENUE, NEW YORK.

A TEXT-BOOK OF PHYSIOLOGY.

By MICHAEL FOSTER,

M.A., M.D., LL.D., F.R.S.,

Professor of Physiology in the University of Cambridge, and Fellow
of Trinity College, Cambridge.

8vo. With Illustrations. Sixth Edition. Largely Revised.

-
- PART I. Blood; The Tissues of Movement; The Vascular Mechanism. \$2.60.
- PART II. The Tissues of Chemical Action; Nutrition. \$2.60. *In the press.*
- PART III. The Central Nervous System. \$1.75.
- PART IV. The Central Nervous System (concluded); The Tissues and Mechanisms of Reproduction. \$2.00.
- PART V. (Appendix) The Chemical Basis of the Animal Body. By A. SHERIDAN LEA, M.A., Sc.D., F.R.S. \$1.75.
-

"The present edition is more than largely revised. Much of it is re-written, and it is brought quite abreast with the latest wave of progress of physiological science. A chief merit of this work is its judicial temper, a strict sifting of fact from fiction, the discouragement of conclusions based on inadequate data, and small liking shown toward fanciful though fascinating hypotheses, and the avowal that to many questions, and some of foremost interest and moment, no satisfying answers can yet be given."—*New England Medical Journal.*

"It is in all respects an ideal text-book. It is only the physiologist, who has devoted time to the study of some branch of the great science, who can read between the lines of this wonderfully generalized account, and can see upon what an intimate and extensive knowledge these generalizations are founded. It is only the teacher who can appreciate the judicial balancing of evidence and the power of presenting the conclusions in such clear and lucid forms. But by every one the rare modesty of the author in keeping the element of self so entirely in the background must be appreciated. Reviewing this volume as a whole, we are justified in saying that it is the only thoroughly good text-book of physiology in the English language, and that it is probably the best text-book in any language."—*Edinburgh Medical Journal.*

"From its first issue as a single octavo volume of moderate size, in 1876, it has so grown that each of the five Parts is, in this sixth edition, nearly as large as the entire original work. From the beginning it was regarded as a masterpiece, and at once took a prominent place among text-books of physiology. . . . If one seeks for the reason of the high estimate in which this work is held on both sides of the Atlantic, by the most advanced students as well as by general readers, it may be found in the beauty and simplicity of the style, in the lack of personal prejudice on the part of the author, in his thorough familiarity with the progress of physiological knowledge, and in the rare judgment with which purely hypothetical ideas and those founded on sufficient evidence are discriminated. The work is therefore a most admirable guide to physiological progress as well as general physiological knowledge."—*The Nation.*

FOSTER'S TEXT-BOOK OF PHYSIOLOGY.

IN ONE VOLUME. 8vo. Cloth, \$5.00. Sheep, \$6.00.

Abridged and revised from the Sixth Edition of the Author's
larger Work published in five octavo volumes.

This new Edition contains all the Illustrations included in the larger work, and is published in one octavo volume of about 1400 pages. It contains all of the author's more important additions to the complete work, and is like the sixth edition of that copyrighted in this country.

NOW READY. 16mo. Price, 75 cents.

PHYSIOLOGY FOR BEGINNERS.

New Edition, with an Additional Chapter on Alcohol and Food.

By MICHAEL FOSTER and L. E. SHORE.

THE MACMILLAN COMPANY,

66 FIFTH AVENUE NEW YORK.

A SYSTEM OF MEDICINE.

BY MANY WRITERS. IN FIVE VOLUMES, MEDIUM 8vo.

EDITED BY

THOMAS CLIFFORD ALLBUTT,

*M.A., M.D., LL.D., F.R.C.P., F.R.S., F.L.S., F.S.A.,
Regius Professor of Physic in the University of Cambridge, etc.*

NOW READY.

VOL. I. PROLEGOMENA AND INFECTIOUS DISEASES.

8vo. Pages 977. Price, Cloth, \$5.00; Half Russia, \$6.00. Sold only by Subscription.

CONTENTS OF VOL. I.

DIVISION I. PROLEGOMENA.

Medical Statistics — Dr. Billings; Anthropology and Medicine — Dr. Beddoe; On Temperament — Dr. Rivers; On the Laws of Inheritance in Disease — Mr. Hutchinson; Medical Geography of Great Britain — Mr. Haviland; Inflammation — Dr. Adams; The Doctrine of Fever — Dr. Burdon-Sanderson; The General Pathology of Nutrition — Dr. Mott; General Pathology of New Growths — Mr. Shattock and Mr. Ballance; Principles of Drug Therapeutics — Dr. Leech; Climate in the Treatment of Disease — Dr. Hermann Weber and Dr. Michael G. Foster; Artificial Aërotherapeutics — Dr. Theo. Williams; Balneology and Hydrotherapeutics — Dr. Hermann Weber and Dr. Parkes Weber; The Medical Applications of Electricity — Dr. Lewis Jones; Massage, Technique, Physiology and Therapeutic Indications — Dr. Kearsley Mitchell; The General Principles of Dietetics in Disease; or, the Feeding of the Sick — Sir Dyce Duckworth; The Diet and Therapeutics of Children — Dr. Eustace Smith; Nursing — Miss Amy Hughes; The Hygiene of Youth — Dr. Dukes; Life Assurance — Dr. Symes Thompson.

DIVISION II. FEVERS.

PART I. Insolation or Sunstroke — Sir Joseph Fayrer.

PART II. The Infections.

The General Pathology of Infection — Dr. Kanthack; Septicæmia and Pyæmia — Mr. Watson Cheyne; Erysipelas — Mr. Watson Cheyne; Infective Endocarditis — Dr. Dreschfeld; Puerperal Septic Disease — Dr. Playfair; Furuncle Carbuncles — Dr. Melsome; Epidemic Pneumonia — Dr. Whitelegge; Epidemic Cerebro-Spinal Meningitis — Dr. Ormerod; Influenza — Dr. Goodhart; Diphtheria — Dr. Gee. Dr. Thorne, Dr. Kanthack, and Dr. Herringham; Tetanus — Sir George M. Humphry and Dr. Sims Woodhead; Enteric Fever — Dr. Dreschfeld; Cholera Asiatica — Dr. MacLeod, Mr. Ernest Hart, Dr. S. C. Smith, Dr. Kanthack, and Mr. J. W. W. Stephens; Plague — Dr. J. F. Payne; Relapsing Fever, or Famine Fever — Dr. Rabagliati and Dr. Westbrook.

UNIFORM WITH A SYSTEM OF MEDICINE.

A SYSTEM OF GYNÆCOLOGY.

BY MANY WRITERS.

EDITED BY

THOMAS CLIFFORD ALLBUTT,

*M.A., M.D., LL.D., F.R.C.P., F.R.S., F.L.S., F.S.A.,
Regius Professor of Physic in the University of Cambridge, Fellow of Gonville
and Caius College,*

AND

W. S. PLAYFAIR,


*M.D., LL.D., F.R.C.P.,
Professor of Obstetric Medicine in King's College, and Obstetric Physician
to King's College Hospital.*

TO BE COMPLETE IN TWO VOLUMES.

Price, per volume, Cloth, \$5.00; Half Russia, \$6.00. Sold only by Subscription.

THE MACMILLAN COMPANY,
66 FIFTH AVENUE, NEW YORK.

BOSTON PUBLIC LIBRARY



3 9999 05987 512 8

34

