



3 1761 04383 3870

SH
173
T8S35

ONTARIO RESEARCH FOUNDATION
43
FEB 1954
LIBRARY
TORONTO

BMED



TUMORS OF FISHES, AMPHIBIANS, AND REPTILES

by

H.G. ✓ SCHLUMBERGER AND BALDUIN LUCKE

Reprinted from

Cancer Research, Volume 8, Number 12, December, 1948.



SH
173
T8535



Tumors of Fishes, Amphibians, and Reptiles*

H. G. Schlumberger** and Balduin Lucké

(From the Laboratory of Pathology, School of Medicine, University of Pennsylvania, Philadelphia 4, Pennsylvania)

The study of tumors occurring spontaneously in animals and the experimental study of neoplasia are complementary. Such studies in the past have dealt largely with tumors in the higher vertebrates, mammals and birds; much less attention has been paid to the lower vertebrates, fishes, amphibians, and reptiles. But neoplastic processes are ubiquitous among vertebrates, and comparison has shown that tumors in cold-blooded animals are essentially identical in regard to their structure and behavior with the corresponding tumors of warm-blooded animals. Since no comprehensive account of spontaneous tumors of the former group exists, it was thought advisable to assemble the available literature as a guide to source material and as an aid to future investigations. This has been done in the present paper. In a complementary paper are reviewed the lines of experimental investigation which have been pursued (123a).

I. TUMORS OF FISHES

Fishes† are the most numerous class of vertebrates (73). Because of their economic importance, many species are caught in vast quantities. During the marketing and preparation of the catch for food, any existing tumors are apt to be noticed. For these reasons information about the neoplastic diseases of fishes is more adequate than for amphibians and reptiles. All the major varieties of tumors that occur in mammals, including man, and in birds have been recorded in fishes. These tumors will now be taken up in the following order: Tumors of epithelial tissue, tumors of mesenchymal tissues, pigment cell tumors, tumors of nervous tissues and hamartomas.

TUMORS OF EPITHELIAL TISSUES

In this group are included: papilloma, adenoma, tumors of dental origin, epithelioma, adenocarcinoma, "tumors" of the thyroid.

PAPILLOMA

The most common benign epithelial tumors of

* This study was aided by a grant from the Donner Foundation. A grant from the National Institutes of Health to Dr. Schlumberger has contributed to the cost of publication.

** Now at Ohio State University, Columbus, Ohio.

† In this review nomenclature for species follows current usage; where necessary the older names used in the reports have been replaced.

fish hitherto recorded are papillomas, which have been reported in at least 16 different species (Table 1). The tissue of origin in all is surface epiderm;‡ papillomas of the viscera have not as yet been observed. The tumors vary in appearance; some are finely lobulated, rather flat elevations; others, small round warty growths, and still others, large cauliflower-like masses. They are usually solitary, but multiple tumors are not rare. Histologically the tumors have typical papillomatous arrangements and show no tendency to invade the subjacent tissues.

Of particular interest are the more common tumors, some of which are perhaps transmissible. Among them are the small, multiple, wart-like papillomas described by Fiebiger (47). They developed in a group of climbing perch (*Anabas scandens*) which had been kept in the same aquarium for two years. The tumors were scattered over various parts of the body and ranged in size from that of a poppyseed to a pea. Microscopic examination revealed marked hyperplasia of the epidermis and papillary proliferation of the connective tissue of the corium; the latter was heavily infiltrated with leukocytes. Fiebiger called attention to the resemblance of these tumors to the infectious warts of mammals.

Another common tumor was described by Keyselitz (97) in barbels (*Barbus fluviatilis*) of the Mosel River. The growths were pea-sized, usually single, round or oval papillary masses located on the lips; rarely they extended to the adjacent skin. Histologically, closely packed epithelial masses were supported by coarse fibrous trabeculae which extended upward from the corium and were often infiltrated with leukocytes. Mitoses were absent. The nuclei of many epithelial cells contained one or more

‡ The epidermis of fishes is composed of stratified squamous epithelium in which typical keratinization as seen in man does not occur. Large numbers of mucous cells are present at all levels in the epidermis; they ultimately reach the free surface where they empty their contents. Characteristic of the epidermis of cyclostomes and teleost fishes are the very large "clavate" cells. These elongated club-shaped cells pass vertically through several layers of the squamous epithelial cells. The bulk of the cell body is composed of a homogeneous eosinophilic substance which probably is a secretion of the cell rather than living cytoplasm. In the center of the clavate cell is a small nucleus surrounded by a halo of clear cytoplasm. Detailed descriptions of the morphology of the skin of fishes are found in the articles by Kann (94) and Graupner and Fischer (64).

TABLE 1:• PAPILOMA

Species	Site	Author
Gudgeon <i>Gobio</i> (several species) (4)	Skin	Schroeders, 1908
Barbel <i>Barbus fluviatilis</i> (several)	Lips	Keysselitz, 1908
Climbing Perch <i>Anabas scandens</i> (several)	Body surface	Fiebiger, 1909a
Halibut <i>Hippoglossus hippoglossus</i>	Snout	Johnstone, 1912
Stint <i>Osmerus eperlanus</i> (37)	Lips, buccal cavity, fins	Breslauer, 1916
Gudgeon <i>Gobio nigrinatatus</i> (2)	Skin	Anitschkov & Pavlovsky, 1923
Gudgeon <i>Gobio blenniodes</i>	Skin	Anitschkov & Pavlovsky, 1923
Plaice <i>Pleuronectes platessa</i>	Body surface	Johnstone, 1925
Plaice <i>Limanda limanda</i> (3)	Body surface	Johnstone, 1925
Goldfish <i>Carassius auratus</i> (2)	Fins	Sagawa, 1925
Crucian Carp <i>Carassius carassius</i>	Skin of operculum	Takahashi, 1929
Sole <i>Solea solea</i> (2)	Skin of trunk	Thomas, 1930
Eel <i>Anguilla anguilla</i> (3)	Lower lip	Thomas & Oxner, 1930
Brown trout <i>Salmo trutta</i>	Skin of back	Thomas, 1932e
Electric eel <i>Electrophorus electricus</i>	Skin	Coates, Cox & Smith, 1938
Slippery Dick <i>Iridio bivittata</i> (30)	Skin	Lucké, 1938
Sucker <i>Catostomus commersonnii</i>	Skin near tail	Lucké & Schlumberger (not published)

* In this and the succeeding tables, the number of tumor-bearing animals, when in excess of one, follows the name of the species.

inclusions which were surrounded by an achromatic halo, and could be readily distinguished from nucleoli. In what appeared to be their earlier stages they were dense and compact; later they became fluffy and less distinct. The author compared them with the inclusions of vaccinia and other virus diseases.

In 37 specimens of the stint *Osmerus eperlanus* Breslauer (16) found tumors that likewise occurred mainly on the lips, less commonly on the mucosa of the oral cavity or on the fins. The fish were taken from the brackish water of an inlet of the Baltic sea. Upper and lower lips were affected equally; frequently the tumors were in apposition. Some were cauliflower-like growths, others were flat, varying in size from small nodules to masses as large as the head of the affected fish. Histologically all had a papillomatous structure. Usually they showed no tendency to invade, but occasionally the arrangement of the cells suggested early malignancy. Cytoplasmic inclusions were sometimes, but not regularly, encountered.

It may be pertinent here to discuss the tumors reported by Schroeders (179) and by Anitschkov and Pavlovsky (3) in several species of gudgeon *Gobio*, a small marine fish. The descriptions of the latter authors particularly exemplify the difficulty of classifying certain skin tumors of fishes; 3 tumors which they regarded as distinct types may represent merely different stages of the same neoplastic process. In their first case there were numerous small nodules and flattened elevations, the larger and more fully developed ones distinctly papillomatous, with their bases and the subjacent corium the site of a pronounced inflammatory reaction; the authors likened these growths to the chronic inflammatory papillary

hyperplasia of the skin and mucous membranes in man. In the second case a large rather flat solitary growth was found on the dorsum of the fish, *Gobio nigrinatatus*. Histologically this had the character of a benign papilloma and was not associated with an inflammatory process. In the third case a relatively massive, broadly sessile, cauliflower-like tumor, 2 x 1 x 1 cm., occupied the dorsum of a small *Gobio blenniodes*. It differed from the growth of the second case in the markedly irregular hyperplasia of its epithelial covering and in the delicacy of the supporting connective tissue trabeculae. The tumor did not infiltrate the subjacent tissues, and although the authors regarded it as a papillary carcinoma, the evidence for malignancy is inconclusive. The tumors reported by Schroeders (179) are in the same genus of fish, *Gobio*, and have the character of benign papillomas. In the absence of information regarding the further development and fate of these tumors, it is impossible to be certain of their true nature.

Mention must here be made of a non-neoplastic disease of fish, which has sometimes been confused with true tumor, the so-called pox-disease. It is particularly common in carp and may attain epidemic proportions. The disease has no relation to the various kinds of pox of man. Numerous milk-white, flattened elevations are present on the epidermis of the affected fish; so that it appears as if splashed with melted paraffin which has solidified. All parts of the body, including eyes and fins, may be affected. Microscopically the lesions present a simple hyperplasia of the epiderm; the corium usually remains unchanged and sends no papillae into the epithelial mass; however, a papillary structure is occasionally attained by the larger and more persistent growths. On histologic grounds no sharp dis-

inction can be drawn between these lesions and true neoplasms, but clinically the lesions of pox, unlike true tumors, usually regress and disappear entirely. A detailed and well illustrated account of this disease is given by Plehn (162).

To the cases of papilloma reported in the literature we are able to add new examples from two other species. The first concerns 2 large tumors which affected a common sucker *Catostomus commersonnii* caught in a Wisconsin Lake. The fish was 8 years old (as determined from examination of its scales), its total length was 31 cm., the sex was uncertain. The tumors were located on the right side; the larger measured 6.1 x 5.5 x 4.0 cm. and involved almost the entire lower half of the tail fin, the smaller tumor, which measured 20 mm. in diameter, was located on the tail, immediately in front of the caudal fin (Fig. 1). Both neoplasms were firm, hemispherical masses which had the typical lobulated appearance of papilloma (Fig. 2). Histologically, a delicate arborescent stroma supported great masses of epithelial cells (Fig. 3). Tall columnar cells formed the layers adjacent to the connective tissue stroma; toward the center of the epithelial masses the cells become polyhedral and in places suggest "pearl" formation (Fig. 4). The nuclei were conspicuous, and usually contained one or two prominent nucleoli. Among some of the epithelial masses were groups of large clavate cells (see footnote †); mucous cells were not found. The tumors were sharply circumscribed, and nowhere extended into the subjacent tissue; there was no inflammatory reaction.

Another kind of papillomatous growth occurred in a small fish, the slippery dick *Iridio bivittata*, which inhabits tropical and semitropical waters (116). Thirty tumor-bearing specimens were found among approximately 6,000 of these fish examined at the Dry Tortugas, Florida. The tumors had the appearance of flattened nodular elevations of the skin; they were grayish in color and soft in consistency, and often they attained large size (Fig. 5), were most usual on the lateral surfaces and commonly destroyed the fins. Histologically, delicate fibrous projections of the corium were covered with many layers of epithelial cells (Fig. 6). The growths frequently extended into the corium, but infiltration of the deeper tissues was not observed. The cells of most tumors were much larger than the cells of the normal epiderm; the cytoplasm was faintly granular; the nuclei large and round or oval (Fig. 7). The nature of this neoplastic disease is uncertain; whether these growths are true neoplasms or merely exaggerated non-neoplastic epidermal proliferations is yet to be determined. In some respects they seem to be related

to the tumors of gudgeons discussed above. Since fish affected with these tumors can readily be kept in indoor sea water aquaria, they should prove excellent material for experimental investigation.

Abstracts of other reported cases of papilloma

SCHROEDERS, 1908: In several species of gudgeon *Gobio* the author observed "fibro-epitheliomata." In some fish the tumors were solitary, in others multiple. In all instances they were sharply circumscribed, papillomatous, and yellow-white in color.

JOHNSTONE, 1912: An irregular cauliflower-like growth was observed on the snout of a halibut *Hippoglossus hippoglossus*, weighing 120 pounds. On section there was marked proliferation of the corium, the overlying epithelium was intact with little evidence of hyperplasia.

JOHNSTONE, 1925: About 1 dozen whitish warts, averaging 5 mm. in diameter, were scattered over the unpigmented side of a plaice *Pleuronectes platessa*. The growths were found to be impregnated with crystals of magnesium phosphate. The corium was thickened and showed evidence of connective tissue proliferation; the overlying epithelium was thin.

JOHNSTONE, 1925: Flat cutaneous warts were found on three plaice, *Limanda limanda* caught in the North Sea. One fish had a single tumor, 5 cm. in diameter, near the eye; another had multiple warts scattered over the body, and the third had 2 growths, one supra-orbital and another on the dorsal fin. All of the tumors were papillomas.

SAGAWA, 1925: In each of 2 goldfish *Carassius auratus* there was a wart-like tumor the size of a pea on each of the pectoral fins. The hyperplastic epithelium was arranged in papillary folds and in some areas appeared keratinized. Clavate and mucous cells were absent in the tumor, though they were plentiful in the normal skin.

TAKAHASHI, 1929: In a crucian carp *Carassius carassius* a tumor was located near the posterior margin of the left operculum. It was a sharply circumscribed grayish-white growth, 3 x 2 x 0.5 cm. Histologically, there was evidence of active epithelial proliferation with the formation of epithelial "pearls" and numerous mitoses. The stroma was scanty, the surrounding tissues were not invaded, and metastases were not found. After 16 months of observation the tumor appeared to be decreasing in size. A biopsy was taken and pieces transplanted to other fish; none of the transplants grew; no details were given.

THOMAS, 1930: In 2 soles *Solea solea* similar tumors were found behind and below the opercular opening on the pigmented side of each fish. Each of the tumors measured about 35 x 20 x 7 mm.; they were sessile and grossly lobulated; the overlying skin was devoid of scales. Massive pegs of epithelium with intact basement membrane extended deep into the subcutaneous tissue. Roentgenograms revealed that the adjacent bone was not involved. The author believed that these tu-

mors were due to chronic irritation of the postopercular skin by sand particles drawn into the mouth and expelled through the gill vent in the act of breathing.

THOMAS and OXNER, 1930: A tumor was located on the lower lip in each of 3 eels *Anguilla anguilla*. The lesions showed simple epithelial proliferation with a tendency to reduplication of the basal cell layer; the basement membrane was preserved.

THOMAS, 1932: A 32 cm. brown trout *Salmo trutta* bore an irregular tumor at the level of the posterior margin of the operculum. It measured 22 x 11 x 5 mm., was not sharply demarcated, and in both gross and microscopic structure was a typical papilloma.

COATES, COX and SMITH, 1938: A tumor appeared in the right mid-dorsal region of a six foot adult electric eel *Electrophorus electricus* caught in the Amazon river basin and maintained in good health in a fresh water tank at the N. Y. Aquarium for a period of more than four years. The growth began as a small elevation of the skin, pinkish-gray in color and a few millimeters in diameter. Its maximum size of 2 x 2.5 cm. was reached in about ten weeks, when it was excised. No recurrence took place in the remaining year and a half of life. The growth was a grape-like pedunculated mass composed of squamous epithelium commingled with very many mucous cells. The epithelium was supported by a central narrow fibrous core of connective tissue.

ADENOMA

Adenomas have been reported in 11 species of fish (Table 2). In 3 species the neoplasms involved structures which have no exact counterpart in man, namely, the parabranial bodies. These are two small, often quite rudimentary organs, which lie in front of the true gills, and, like them, are hidden from view by the opercula or gill covers. They are composed of an extremely vascular tissue; the numerous capillaries are surrounded by large cells with clear or coarsely granular acidophilic cytoplasm. The function of the parabranials is unknown; some investigators consider them to be endocrine organs.

Tumors of these structures have been observed in codfish *Gadus morhua* from St. Pierre and Miquelon,

and in 2 kinds of coalfish from the Pacific. In the coalfish *Pollachius brandti* and *Theragra chalcogramma* in which the normal parabranials vary in weight from 0.1 to 0.4 gm., tumors of 9 and of 16 gm., respectively, have been described (199). The tumor cells formed alveolar masses supported by a scanty but richly vascular stroma. The cells resembled those of the normal parabranial bodies, having a clear cytoplasm when they were adjacent to the blood vessels, but with a granular cytoplasm when more centrally located. The nuclei were large and vesicular; mitoses were common. Necrosis of the densely packed cells in the central part of the alveolar mass led to the formation of pseudoacini. Usually the tumors were not well delimited and infiltrated the neighboring tissues. The investigators who studied these growths at first hand fail to agree as to their character. Takahashi (199) considered them to be adenocarcinomas; Peyron and Thomas (150) believed that they were benign or, at most, of low-grade malignancy.

Besides these tumors, adenomas have been reported in various organs of 8 other species of fishes. The tissue of origin was the liver in 3 species, and the kidney, intestine, and ovary in the others. Most of these tumors were solitary; some attained a very large size, the tumor reported by Plehn in the liver of a trout was twice the size of a man's fist.

Bieseles (13) studied the chromosomes in an ovarian tumor of a goldfish. Unfortunately no histologic data are given and the author speaks of the growth as an "adenoma or adenocarcinoma." The average volume of the neoplastic chromosomes was twice that of chromosomes in the cells of a healing skin wound and in the nongerminal cells of a normal ovary. The normal nuclei never possessed more than 4 nucleoli, whereas 8 were found in the tumor cell nuclei. Bieseles concluded that the chromosomes of the goldfish tumor must be regarded as diplochromosomes.

An adenoma of the catfish *Ameiurus nebulosus*, which has not previously been described, occurred in the right kidney of a female whose total length

TABLE 2: ADENOMA

Species	Site	Author
Sand shark <i>Prionace glaucus</i>	Liver	Schroeders, 1908
Trout <i>Salmo trutta</i>	Liver	Plehn, 1909
Ling <i>Molva molva</i>	Ovary	Johnstone, 1915
Codfish <i>Gadus morhua</i> (2)	Parabranial body	Peyron & Thomas, 1929
Coal Fish <i>Pollachius brandti</i> (2)	Parabranial body	Takahashi, 1929
Coal Fish <i>Theragra chalcogramma</i>	Parabranial body	Takahashi, 1929
Purple Trout <i>Salmo mykiss</i>	Intestine	Thomas, 1931a
Rainbow Trout <i>Salmo gairdnerii</i>	Liver	Haddow & Blake, 1933
Platyfish <i>Platypoecilus maculatus</i> (several)	Kidney	Jahnel, 1939
Goldfish <i>Carassius auratus</i>	Ovary	Bieseles, 1943
Catfish <i>Ameiurus nebulosus</i>	Kidney	Lucké & Schlumberger (not published)

was 35 cm. The growth measured 8 x 8 x 6 mm., was pale gray, and sharply delimited, though not encapsulated; its cut surfaces were moist but not bloody. It was composed of acini that were irregular in size and shape, and often greatly dilated. The lining epithelial cells varied from low cuboidal to tall columnar elements; their nuclei were large, vesicular, and had prominent nucleoli; mitotic figures were uncommon. Papillary projections extended into some of the cystic spaces; the scanty stroma was poorly vascularized. This tumor was found in a fish which also had massive epitheliomas of the lip and mouth.

Abstracts of other reported cases of adenoma

SCHROEDERS, 1908: Multiple adenomas were found in the liver of a shark *Prionace glaucus* caught in the Black Sea. The surface of the liver was covered with whitish, spherical nodules ranging in size from a pin-head to a walnut. Similar nodules were found scattered throughout the substance of the liver. On section the nodules were firm and pale yellow. Histologically, the neoplastic cells resembled normal liver cells except that they were smaller and contained less fat. The transition from normal cells to tumor cells was gradual.

JOHNSTONE, 1915: One ovary of a ling *Molva molva* was occupied by a mass consisting of cystic spaces with walls of varying thickness. On section, a clear, glairy fluid was found in the cysts. Some areas of fibrosis were also present in this lesion which may be classified as a papillary cystadenoma of the ovary.

PLEHN, 1924: The liver of a lake trout *Salmo trutta* was the site of a mass of cysts filled with clear fluid or gelatinous material. The largest of the cysts measured 15 cm. in diameter; the entire tumor was twice as large as a man's fist. Between the cysts were remnants of normal liver, strands of connective tissue, and isolated bile ducts. The growth was regarded by Plehn as a cystadenoma of the liver.

PEYRON and THOMAS, 1929: The authors observed tumors of the parabranchial bodies in two codfish *Gadus morhua*. In one, a large tumor, 4 x 3 x 1.5 cm., occurred on the right side, elevated the operculum, and protruded beyond its posterior margin; the gills were compressed. In the other case the tumors were bilateral and the size of a cherry. The histologic appearance has been discussed above.

TAKAHASHI, 1929: In two specimens of coalfish *Pollachius brandti* each parabranchial body was the seat of a tumor. In both, the growths on the right were the size of a small hen's egg, those on the left were twice as large. In another variety of coalfish *Theragra chalcogramma*

a large tumor was present in the left parabranchial body. This tumor was soft in consistency, poorly circumscribed, and contained many cystic and necrotic areas. The surface was ulcerated. The histologic structure was as already described.

THOMAS, 1931 a: In a purple trout *Salmo mykiss*, 25 cm. in total length, the author found a broadly sessile, hemispheric tumor in the intestine midway between stomach and anus. It measured 20 x 18 x 8 mm., was gray-white and moderately firm; there was no ulceration of the surface. Histologically, the entire thickness of the intestinal wall was infiltrated by the cystic neoplasm. The lining epithelium of the cysts was stratified, the cells basophilic with occasional abnormal mitoses. Blood vessels were not numerous; collections of lymphocytes were abundant.

HADDOW and BLAKE, 1933: The authors described a hepatoma found near the anterior margin of the liver of a 4 to 5 year old rainbow trout *Salmo gairdnerii*. It was spherical, about 1.5 cm. in diameter, and paler and more firm than the surrounding hepatic tissue. No metastases were present. Microscopically the tumor was composed of actively proliferating polyhedral cells, only slightly different from the parent liver cells. The arrangement of the cells resembled that of normal liver, except for the presence in the tumor of an abundant fibrous stroma. Although the adenoma was not encapsulated, it had not infiltrated adjacent structures.

JAHNEL, 1939: This author notes the frequent occurrence of cystic adenomas of the kidney in the tropical aquarium fish *Platypoecilus maculatus*. No further details are given.

DENTAL TUMORS

Teeth are cutaneous appendages; in mammals they may be regarded as modified papillae of the oral mucosa. In elasmobranch fishes, such as sharks and rays, the small placoid scales, which give the rough granular feel to the skin of these animals, represent phylogenetically the most primitive teeth of vertebrates. Each scale has a pointed tooth-like shape; its base is embedded in the dermis, its apex protrudes above the surface. A central vascular connective tissue pulp is surrounded by a layer of odontoblasts which form the hard dentin. The free surface is coated by enamel, a product of modified epithelial cells.

In Table 3 is given a summary of dental tumors which have been observed in 4 species of fishes.

A neoplasm of "cutaneous teeth" was reported as a "dermal odontoma" by Ladreyt (108). The tumor,

TABLE 3: DENTAL TUMORS

Species	Site	Author
Trout—species not given (2)	Dental plates & hyoid bone	Plehn, 1912
Croaker <i>Micropogon opercularis</i>	Upper dental plate	Roffo, 1925
Haddock <i>Melanogrammus aeglefinus</i>	Maxilla	Thomas, 1926
Cat shark <i>Scyllium catulus</i>	Skin	Ladreyt, 1929

a cylindrical mass, measuring 3 x 1.2 cm., arose in the skin near the copulatory appendages of a cat shark *Scyllium catulus*. It was very firm, and had a small, very vascular cavity at its distal end. Histologically, a thick layer of cutaneous epithelium covered a more or less homogeneous mass, which the author believed represented enamel or dentin. The cavity noted grossly was occupied by greatly dilated blood spaces that appeared angiomatous.

Corresponding more closely to odontomas of man are the lesions described by Plehn (160) in the jaws of two fresh-water trout. In both cases the tumors consisted of large congeries of atypically formed teeth. Innumerable, more or less confluent, nodular tumors, had developed from all the tooth-bearing surfaces, *viz.*, both dental plates, the hyoid bones and, in one case, the vomer. As the author showed in a photograph, the tumors had attained such a large size that the fishes could not close their mouths, thus making feeding impossible.

Another example of an odontoma was reported by Roffo (172) in a marine fish, the croaker *Micropogon opercularis*. The tumor formed a firm, pale mass on the upper dental plate. Histologically it consisted of tooth germs irregularly scattered through a connective tissue stroma. The paper is accompanied by a number of excellent figures which show gross appearance, roentgenograms, and histologic structure of the neoplasm.

Only one case of adamantinoma has been recorded, by Thomas (202). The tumor formed a mass, 2.5 x 1 cm., that had infiltrated the maxilla and protruded into the oral cavity of a haddock *Melanogrammus aeglefinus*. Histologically it corresponded in all details to the cystic adamantinomas of man.

EPITHELIOMA (EPIDERMOID CARCINOMA)

Some of the neoplasms reported in the literature as epithelioma are only questionably malignant. In this review we have placed certain tumors which

were reported as epitheliomas under the heading of papilloma because of their structure and absence of invasion. There remain a considerable number of tumors of pavement epithelium that are invasive or exhibit other evidence of malignancy, which properly may be regarded as epidermoid carcinomas. They have been observed in 12 different species of fishes (Table 4). The tissues of origin were the skin, the lips or oral mucosa, and, in a single case, the urinary bladder. In general, these tumors had the structure of mammalian epidermoid carcinomas; in some cases, as in that of Bashford, Murray and Cramer (6) the resemblance to squamous cell carcinomas in mammals was reported as striking. It must be remembered, however, that the epithelial covering of fishes does not keratinize, hence the typical cornified "pearls" of mammalian epitheliomas are not formed, although nonkeratinized collections of concentrically arranged cells are frequently seen.

Several of the tumors under discussion resembled papillomas, in their general appearance, but differed in that they sent long, usually ill-defined pegs of solidly packed cells into the corium or deeper tissues. Thus, in the case reported by Murray (141) the tumor invaded the underlying skeletal muscle. None had metastasized at the time of examination.

The lips and oral mucosa are the most common sites of epitheliomas in fishes; neoplasms have been observed in these locations in 7 species. The first record of an epithelioma in a fish reported by McFarland (136), deals with such a tumor. A lobulated, papillary growth, 4 cm. in diameter, involved the lower lip and adjacent mucosa of a catfish *Ictalurus catus*; multiple small nodules were present on the upper lip and the neighboring skin. Histologically the neoplasm consisted of a fungoid mass which was composed of epithelial cells supported by a delicate vascular stroma. The larger tumor was definitely invasive. The tumor reported by Clunet

TABLE 4: EPITHELIOMA (EPIDERMOID CARCINOMA)

Species	Site	Author
Catfish <i>Ictalurus catus</i>	Both lips	McFarland, 1901
Carp <i>Cyprinus carpio</i> (2)	Skin of head	Dauwe & Pennemann, 1904
Carp <i>Cyprinus carpio</i>	Not given	Bashford, Murray & Cramer, 1905
Stickleback <i>Spinachia spinachia</i>	Skin of trunk	Murray, 1908
Tench, <i>Tinca tinca</i> (2)	Lips	Fiebiger, 1909a
Carp <i>Cyprinus carpio</i>	Fins & operculum	Fiebiger, 1909a
Goldfish <i>Carassius auratus</i>	Bladder	Plehn, 1909
Barbel <i>Barbus vulgaris</i>	Lower lip	Clunet, 1910
"LeNes" <i>Chondrostoma soetta</i>	Oral mucosa	Mazzarelli, 1910
Croaker <i>Pogonias chromis</i> (2)	Lips	Beatti, 1916
Whiting <i>Merlangus merlangus</i>	Mandible	Johnstone, 1924
Codfish <i>Pollachius virens</i>	Lower lip	Williams, 1929
Biajaca <i>Cichlasoma tetraacanthus</i>	Skin about orbit	Puente-Duany, 1930
Catfish <i>Ameiurus nebulosus</i> (166)	Lips, oral mucosa	Lucké & Schlumberger, 1941

(31) was located on the lower lip of a barbel *Barbus vulgaris*. It was the size of a hazel-nut and had infiltrated the floor of the mouth; structures suggestive of epithelial pearls were present and mitoses were numerous.

Fiebiger's report (47) of epitheliomas on the lips of two tench *Tinca tinca* is of interest in that the tumors occurred in fish from the same pond. The evidence of malignancy is not certain, for the author states that a fairly well preserved basement membrane surrounded the extensive epithelial pegs. In one of Beatti's (7) two cases of epithelioma in croakers, the basement membrane was intact in most regions, though in some areas epithelial pegs penetrated deeply. In the other this was more marked, and invasion of subcutaneous tissue had taken place.

We ourselves have been studying a transplantable epithelioma of the lip and mouth of catfish *Ameiurus nebulosus* taken from streams near Philadelphia (122). During a period of 2 years, 166 live tumor-bearing fish were obtained.* Since our previous publication approximately 100 additional cases have been studied. This neoplasm usually occurs as a solitary or multiple, large, red, fleshy mass upon the lips or dental plates (Figs. 8-11); less often it involves other parts of the mouth or the skin. In our series the lips and dental plates were affected in all but 6 cases. All of the neoplasms are grossly similar. They are broadly sessile, with a smooth or coarsely nodular surface; in consistency they are firm and resilient. Most of the tumors average from 1 to 2 cm. in diameter, but some are so massive as to prevent closure of the mouth (Fig. 10). In approximately one-half of the cases, both lips or dental plates are involved. In 53, or 60 per cent, of 89 fish the tumors were in direct apposition (Figs. 9 and 11). Histologically the tumors consist of closely packed masses of columnar or polyhedral cells, often growing as papillary pegs supported by a delicate richly vascular stroma (Fig. 12). The smaller tumors grow outward, with little sign of invasion. Larger growths commonly push broad solid pegs of epithelial cells deep into the subjacent tissues; in some, these pegs are bounded by a well preserved basement membrane, but in the more massive tumors they are definitely invasive, and flame-shaped

* Many of the tumor-bearing fish and several hundred normal fish which were used for experimental purposes have been furnished us through the kindness of Mr. C. R. Buller, Chief Fish Culturist of the State Fish Hatchery, at Bellefont, Pennsylvania, John J. Wopart, Jr., Superintendent of the State Fish Hatchery at Torresdale, Pennsylvania, and the late Dr. Robert O. Van Deusen, Director of the Philadelphia Aquarium. We wish to express our grateful appreciation to these gentlemen for the aid and advice given.

processes of loosely arranged cells extend far into the subjacent tissues (Fig. 13). In the more invasive tumors emboli of neoplastic cells are often found, though no metastases have been observed. It seems evident that the small, outward growing tumors are early stages of a neoplastic process which later assumes a more malignant character.

It has been possible to study living tumors almost from the time of their inception. Tumor-bearing fish were maintained under laboratory conditions for periods up to 9 months; during this time we observed that growth of most of the neoplasms was relatively slow but progressive. The inception and development of appositional growth was studied by direct microscopic examination of the mucosal surfaces. The earliest evidence of neoplastic change was the establishment of a more or less circumscribed patch of hyperemia on the mucosa. At this time the mucosal surface was smooth and showed no signs of proliferation; after approximately two weeks the patch became slightly elevated; one or two months later the local thickening had progressed to the formation of a definite tumor.

Detailed microscopic study of the blood vessels *in vivo* brought out the fact that they undergo profound alterations during the development of the tumor. At the site of future neoplastic growth they gradually form irregular, wide meshed networks that contrast sharply with the small, uniform capillary loops of the adjacent normal mucosa. The caliber of the blood channels in the neoplastic zone varies greatly; some are dilated and bear saccular expansions; others are constricted (Figs. 14 and 15). Many of the proliferating vessels have thick walls, whereas others are thin and delicate. In brief, the neoplastic growth is preceded and accompanied by a striking vascular reaction; the number, arrangement, and structure of the vessels are conspicuously atypical. The relation of blood-vessels to tumor growth has previously been investigated mainly in fixed tissue; the catfish epithelioma provides material for such an investigation in the living animal.

Abstracts of other reported cases of epithelioma

DAUWE and PENNEMANN, 1904: Each of two very large, old aquarium carp *Cyprinus carpio* developed a tumor on the dorsum of the head, in front of the eyes. Microscopically the lesions were identical and consisted of squamous epithelial cells that formed long pegs containing central areas of necrosis. The authors regarded the tumors as squamous cell carcinomas.

BASHFORD, MURRAY and CRAMER, 1905: These authors mention an epithelioma in a carp *Cyprinus carpio* but do not give the location. They state that the tumor presented a striking resemblance to squamous

cell carcinoma of mammals. Multiple inoculations were made into 6 carp with negative results.

MURRAY, 1908: In a male stickleback *Spinachia spinachia* a flat cone-shaped tumor was located on one side of the tail. The tumor, histologically a squamous cell carcinoma, arose from the skin and invaded the myotomes of the affected side, penetrating to the vertebrae. The surface was ulcerated, the center necrotic.

IEBIGER, 1909 a: An epithelioma was found on the lips of two tench *Tinca tinca*, both from the same pond. One bore a tumor at the angle of the mouth on the right that spread to both upper and lower lips. In the other fish the neoplasm involved the entire upper lip and extended backward on the left to the orbit. The surface of each tumor was nodular, containing collections of pigment cells and visible blood vessels. Histologically there was pronounced epithelial hyperplasia, but a fairly well preserved basement membrane surrounded the epithelial pegs. Mucous cells and clavate cells were present near the center of the cell masses.

IEBIGER, 1909 a: In a carp *Cyprinus carpio* multiple wart-like masses the size of peas had almost destroyed the right pectoral fin. They were also present on the ventral and dorsal fins, and on the right operculum. Histologically the tumors were malignant papillary epitheliomas that invaded the corium and contained many multinucleate giant cells.

PLEHN, 1909: The abdomen of a goldfish was greatly distended by a dilated urinary bladder, the outlet of which was obstructed by a tumor. Histologically it was composed of neoplastic cells that tended to form alveoli and had penetrated deeply into the sub-jacent tissue.

MAZZARELLI, 1910: A 4.5 x 3.5 cm. tumor arose from the pavement epithelium of the mouth of a "Le Nez" *Chondrostoma soetta*. The flattened epithelial cells had large nuclei; some mucous cells were present. Local liquefaction necrosis and cyst formation was observed in the epithelial pegs.

BEATTI, 1916: Tumors were found on the lips of 2 croakers *Pogonias chromis*. On the upper lip of one there was a small cauliflower-like growth; another papillomatous tumor was located on the forehead. The stratified epithelium as well as the connective tissue of the cutis were hyperplastic; the basement membrane in most regions was intact, though at one point epithelial pegs penetrated deeply. In the second fish the lower lip was the site of a firm, diffuse swelling. The histologic appearance of malignancy was more marked in this case than in the former; the epithelial pegs in-

vaded the subcutaneous tissue more deeply. The tumors may be classified as papillary epitheliomas with early but definite signs of invasion.

JOHNSTONE, 1924: In a whiting *Merlangus merlangus*, on the right side of the mandible and extending a short distance into the mouth, was a 1 x 1 cm. tumor. Histologically it was a typical epithelioma with extensive proliferation of epithelial pegs but an intact basement membrane.

WILLIAMS, 1929: The author reported a bilobed growth which had spread over the anterior portion of the lower jaw of a codfish *Pollachius virens* caught near the coast of Iceland. It may have arisen in the mucous cells which are abundant in the integument of fish. Evans, of the Pathology Department in Liverpool, thought that it corresponded to human epithelioma adenoides cysticum.

PUENTE-DUANY, 1930: A periocular tumor was found in the orbit of a small Cuban fresh water fish, the biajaca *Cichlasoma tetracanthus*; though the neoplasm had produced exophthalmos, the overlying skin was intact. Histologically, the epiderm was thickened, epithelial pegs penetrated into the dermis. In some areas these pegs fused with masses of clear, polyhedral cells having small round nuclei. These cells were the characteristic feature of the tumor; their origin was uncertain. The growth was recorded as an epithelioma, possibly arising on an inflammatory basis.

ADENOCARCINOMA

Malignant tumors of gland-cell origin are the predominant cancers in man. By contrast, but few examples, 7 in all, have hitherto been reported in fishes. This fact does not permit us to conclude that this kind of cancer is uncommon in fishes; it may mean that an adequate search has not yet been made. This supposition is the more plausible because most adenocarcinomas originate in the viscera, and not on the body surface as do the epitheliomas.

The tumors occurred in 6 different species (Table 5). All but one of the tumors were located within the body cavity. As shown in the table, in 2 cases the tumors had their origin in the kidney of eels *Anguilla anguilla*; both neoplasms were relatively large 7 x 3.5 cm., and both were invasive and destructive. A tumor in a red tai *Pagrosomus major*, arose behind the right kidney, but had no direct connection with it. It was large, 9 x 3.5 cm., uniformly

TABLE 5: ADENOCARCINOMA

Species	Site	Author
Eel <i>Anguilla anguilla</i>	Kidney	Schmey, 1911
Eel <i>Anguilla anguilla</i>	Kidney	Plehn, 1924
Coalfish <i>Pollachius brandii</i>	Glandula digitiformis	Takahashi, 1929
Coalfish <i>Theragra chalcogramma</i>	Mouth & operculum	Takahashi, 1929
Red Tai <i>Pagrosomus major</i>	Body wall	Takahashi, 1929
Pike <i>Esox lucius</i>	Ovary	Haddow & Blake, 1933
Moray <i>Muraena helena</i>	Palate	Ladreyt, 1935

soft, pale gray, and invaded the body wall. The component cells were cuboidal and had large spherical nuclei; the stroma was abundant. Takahashi (199) regarded it as an adenocarcinoma of unknown origin.

The ovarian tumor in a pike *Esox lucius* reported by Haddow and Blake (68) was a soft mass, 7 x 3 cm., near the anterior pole of the left ovary; several smaller nodules accompanied the main tumor. Microscopically, the structure was that of an adenocarcinoma, apparently derived from germinal epithelium.

The cancer of the digitiform or rectal gland in the coalfish *Theragra chalcogramma* reported by Takahashi (199) is of interest because of its extensive metastases and its origin in a structure having no homologue in man or the higher vertebrates. This gland is a short tubular body, the duct of which opens into the lower end of the intestine; its function is unknown. The mass was firm, coarsely nodular, grayish white, and as large as the head of a child. Histologically it was an adenocarcinoma that contained cystic spaces partly filled by papillary projections. Metastases and secondary tumors due to direct extension were present in the liver, stomach, intestine, spleen, urinary and swim bladders.

Abstracts of other reported cases of Adenocarcinoma

SCHMEY,⁹ 1911: A retroperitoneal mass 7 x 3.5 cm. was found in an eel *Anguilla anguilla* approximately 3 years old. The tumor could be readily freed from the abdominal musculature, but could not be separated from the left kidney. Microscopically it consisted of irregularly arranged tubules and cysts which passed over into normal renal substance without sharp demarcation.

PLEHN, 1924: The abdomen of an eel *Anguilla anguilla*, 53 cm. in length, was greatly distended by a tumor 7 x 3.5 cm. The lesion was apparently malignant, having destroyed the posterior half of the kidney and invaded the anterior portion, but no metastases were found. No histologic description accompanied the report.

TAKAHASHI, 1929: At the left angle of the mouth of a coalfish *Theragra chalcogramma* was a tumor that had extended into the skin of the operculum on the same side. The neoplastic epithelial cells were grouped to form alveoli and invaded the adjacent structures. The tissue of origin was not identified.

LADREY, 1935: The palate of a moray *Muraena helena* was the site of a large tumor which had its origin in the glands scattered throughout the mucosa. The malignancy of the tumor was manifested by partial absence of a basement membrane, atypical structure of the cells, and extensive local invasion. Metastases were not found. It is well known that the bite of Morays is poisonous, due to the secretion of venom by the mucous

glands in the palate. Tests showed that the venom of the cancerous glands was less active than that of the normal ones, but the effects it produced—hyperemia and cellular degeneration—were qualitatively the same.

THYROID "TUMORS"

No tumor or tumor-like lesion of fishes has received more attention than that of the thyroid gland. Such "tumors" are most frequently observed in trout reared in hatcheries and less often in other species living in ponds or aquaria (98, 131, 178, 190, 194) (Table 6). Attention was first called to this condition by Bonnet (14) who described an epidemic that destroyed over 3,000 lake trout *Salmo lacustris* in a fish hatchery between February and June of 1883. All had tumors at the ventral junction of the gills.

Scott (182), who observed enlargement of the thyroid of brook trout *Salvelinus fontinalis* reared in a single pond, was the first to identify it as "carcinoma" (1891). The lesion began as a local hyperemia of the oral mucosa followed by nodular roughening in the midline of the ventral wall of the pharynx just behind the tongue. The nodules increased in size, and ultimately filled the oral cavity, protruding beyond the opercula. On section the masses were found to be composed of distended irregular acini lined by cuboidal or columnar cells. Some of the alveoli were filled with colloid; the lumen of others was small and the cells arranged in papillary folds. Islands and acini of thyroid cells were found scattered throughout the adjacent tissues.

The view that these tumors are true cancers has been maintained by numerous investigators (25, 58, 78, 153, 156, 195). In 1914 Gaylord and Marsh published their monograph entitled "Carcinoma of the Thyroid in the Salmonoid Fishes" (53), based on tumors observed in several thousand trout at U.S. government fish hatcheries. A study of the histologic descriptions and many excellent photomicrographs reveals, however, that the large majority of the tumors are examples of hyperplasia and colloid storage, without evidence of malignant change. Nevertheless, it cannot be denied that among the thousands of goiters there probably were instances of adenocarcinoma. Gaylord and Marsh themselves reported two cases in which metastases were found. In one, the metastatic nodule was present in the wall of the rectum, where it was covered by intact rectal mucosa. In the other the metastasis was on the tip of the lower jaw and may merely represent aberrant thyroid tissue. This is made more likely in view of the studies of Gudernatsch (66) who pointed out

that the teleost thyroid is not encapsulated and that its follicles do not form a distinct organ but are scattered over a wide area. Although the main bulk of the thyroid develops about the stem of the ventral aorta between the first and second gill arches, groups of follicles are not uncommonly found among the adjacent muscle bundles and bone lamellae. This natural arrangement may be erroneously interpreted by the unwary as evidence of invasiveness.

In a series of papers published in 1910-1914 Marine and Lenhart (127-130) reported the results of their observations of this disease among brook trout in a large fish hatchery in Pennsylvania. They denied that the lesion is a carcinoma (128): "In view of the facts that young fish are more affected than old fish, that iodine stops the hyperplasia and causes it to return to the colloid state, that removal of the fish from the ponds to the open brook also effects a cure, that the clinical incidence of tumors is directly related to the water supply, and that the severity of the disease as determined by histological examination is likewise directly related to the water supply, we cannot accept the prevailing opinion that the disease is true cancer. On the other hand, we believe that the disease as studied by us is an extreme illustration of endemic goiter, the end stage of which is cretinism." The age incidence and development of the lesion was summarized by Marine (130): "It was found that the thyroid hyperplasia began in the fry as soon as feeding was instituted, and advanced overgrowth was present at the 4th

month of extra oval life; that the overgrowth progressively increased to the stage of clinical detectability, as ascertained by the reddening of the pharyngeal floor over the thyroid area, about the tenth month in this hatchery; that visible goiters usually manifested themselves about the beginning of the second year, though they may be present as early as the sixth month, depending on the favorableness of conditions for overgrowth, and progressively increased during the second and third years; that older fish were more resistant and tended toward spontaneous recovery." Marine does not deny, however, that the hyperplasia of the thyroid may in some instances progress to actual carcinoma.

In a recent monograph on the cause of thyroid hyperplasia in animals and man, Duerst (40) expressed the belief that the functional demand made upon the thyroid is in inverse proportion to the oxygen tension of the air or, in the case of fishes, of the surrounding water. He points out that carp and tench require only 3 to 4 cc. of oxygen per liter of water, while trout require 7 to 8 cc. When the oxygen content of the water falls to 3 to 4 cc. per liter the young trout develop thyroid hyperplasia, at 1.5 cc. per liter they die of asphyxia; whereas carp and tench survive at a 0.5 cc. per liter level. The predominance of thyroid tumors in the *Salmonidae* may be related to the high oxygen demands of these fishes and the low oxygen tension present in the tanks of the fish hatcheries. The fact, noted by Marine, that the goiters occur particularly in young

TABLE 6: THYROID TUMORS

Species	Author
Lake trout <i>Salmo lacustris</i> (3,000)	Bonnet, 1883
Brook trout <i>Salvelinus fontinalis</i> (many)	Scott, 1891
Rainbow trout <i>Salmo gairdnerii</i> (3)	Gilruth, 1901
Amer. Salmon <i>Salmo salar</i>	Gilruth, 1902
Trout several species (several)	Plehn, 1902
Trout several species (many)	Pick, 1905
Trout several species (6)	Jaboulay, 1908
Lake trout <i>Salmo lacustris</i>	H. M. Smith, 1909
Trout several species (thousands)	Marine & Lenhart, 1910, 1911, Marine, 1914
Trout several species (thousands)	Gaylord & Marsh, 1914
Dogfish <i>Squalus sucklii</i>	Cameron & Vincent, 1915
Sea Bass <i>Serranus scriba</i> & <i>S. cabrilla</i> (5)	Marsh & Vonwiller, 1916
Barbel <i>Barbus fluviatilis</i> (several)	Schreitmüller, 1924
Trop. Aquar. Fish <i>Jordanella floridae</i> (several)	Schreitmüller, 1924
Catfish <i>Clarias dumerlii</i>	Schreitmüller, 1924
Porgy <i>Box vulgaris</i>	Johnstone, 1924
Rainbow trout <i>Salmo gairdnerii</i> (many)	Leger, 1925
Aquar. Fish <i>Danio albolineatus</i>	Klemm, 1927
Aquar. Fish <i>Haplochilus chaperi</i> (several)	Klemm, 1927
Trout species not given	Peyron & Thomas, 1930
Salmon species not given	Peyron & Thomas, 1930
Aquar. Fish <i>Rasbora lateristriata</i> (several)	Smith, Coates, & Strong, 1936
Aquar. Fish <i>Heterandria formosa</i> (several)	Smith, Coates, & Strong, 1936
Aquar. Fish <i>Rasbora lateristriata</i> (several)	Smith & Coates, 1937
Suckfish <i>Echeneis naucrates</i> (16)	Lucké & Schlumberger (not published)

fish, and tend toward spontaneous regression in older animals, may be related to the extensive involution which the thyroid normally undergoes when the fish reaches sexual maturity—at the age of 3 or 4 years in trout. The involution of the thyroid is compensated for, at least as concerns its oxygen regulating function, by an increase in the number of erythrocytes in the circulating blood (40).

The possible relation of low oxygen tension in water to thyroid hyperplasia in fish receives support from the work of Marsh and Vonwiller (131). These investigators found enlarged thyroids in five sea bass *Serranus scriba* and *S. cabrilla* that died in the aquarium of Naples. Since these fishes were kept in fresh sea water, in which the content of iodine is high, depletion of the latter cannot account for the occurrence of the goiters, which histologically resembled those of the *Salmonidae*.

Thyroid enlargements have been seldom observed in marine fishes hence their appearance in a group of shark suckers *Echeneis naucrates* is of interest. These fish attach themselves to the belly of a shark by means of a modified dorsal fin that has been transformed into a suction plate. They are not strictly parasitic, since they derive no nourishment from the body of their host; the latter merely serves as a vehicle to carry them to their food supply. Three of these fish measuring nearly 3 feet in length were caught off the coast of New Jersey and exhibited for several weeks at a seaside resort. They were then transferred to the Fairmount Park Aquarium in the City of Philadelphia, where we had an opportunity to study them. The fish were kept in a large tank of aerated sea water and fed a diet of fresh shrimp, oysters, clams, and chopped fish. Approximately 6 weeks after arrival, a pink translucent, coarsely lobulated tumor appeared on the floor of the mouth in one of the fish. The animal was subsequently sacrificed, at which time the tumor measured 4 x 3 x 2.5 cm. almost filled the oral cavity, and obstructed the free flow of water over the gills (Fig. 16). Microscopically the tissue proved to be thyroid, consisting in part of greatly dilated acini filled with marginally vacuolated colloid and lined by cuboidal or columnar epithelium, which formed occasional low papillary projections (Fig. 18). Alternating with the large colloid spaces were areas in which the acini were very small. Thyroid tissue was found between lamellae of bone (Fig. 17), but there was nothing to suggest that this represented an invasion of the bone. The histologic picture closely resembled the hyperplasia with extensive colloid storage frequently observed in non-toxic colloid goiters of man. Bits of tissue were inoculated into the

anterior chamber of the eyes of three goldfish *Carassius auratus* and six large frogs *Rana pipiens*, but they grew in none and were rapidly resorbed.

A year later the second of these 3 fish had developed a goiter which in size and structure closely resembled the first. Three weeks thereafter 13 shark suckers, apparently free of goiters, were received from the New York City Aquarium and placed in the same tank with the one remaining shark sucker. Within 5 months, six of these fish showed marked enlargement of the thyroid (Fig. 19); after another 5 months all the fish were similarly affected. In all but one fish the goiters were confined to the oral cavity, measured between 1 and 3 cm. in diameter, and varied in color from pale pink to bright red. In the single remaining fish the thyroid had extended backward beneath each operculum, lifting that structure away from the side of the body. The animal rested upside down on the bottom of the tank, apparently to avoid further pressure on its gills and to facilitate breathing.

The etiology of the thyroid enlargement in these fishes is obscure. The oxygenation of the water appeared adequate. The iodine rich diet of shrimp, clams, and fish, which acted as a cure in the cases of goiter in trout reported by Marine, was apparently without effect. In none of the other marine fishes kept under identical conditions in the aquarium did goiters appear, nor were they known to occur in the fresh water fishes exhibited in the same building. The goiters of the shark suckers may be a response to some metabolic idiosyncrasy of these fish. This view is strengthened by the report of an official who stated that during his service of over twenty years he had frequently observed this lesion in the shark sucker, but never in any other fishes.*

Abstracts of other reported cases of thyroid tumors

GILRUTH, 1902: A five year old salmon *Salmo salar* and 3 rainbow trout *Salmo iridens* each bore a tumor the size of a walnut, that projected beyond both gill clefts and appeared to have started at the apex of the second branchial arch. On section the tumors were homogeneous, pale pink in color and soft in consistency. A fibrous capsule surrounded them, and connective tissue trabeculae extended from the capsule into the tumor parenchyma. The alveoli were irregular and lined by columnar or cuboidal epithelial cells. The tumors were well vascularized and frequent hemorrhages were present. Although the author identifies the mass as an endothelioma, it probably represents a simple hyperplasia

* We wish to express our grateful appreciation of the late Dr. Robert O. VanDeusen, superintendent of the Fairmount Park Aquarium, who placed these and many other interesting specimens at our disposal.

of the thyroid. The salmon was collected and described for Gilruth by H. C. Wilkie, the 3 trout by L. F. Cryson.

PLEHN, 1902: A preliminary report on "adenocarcinoma" of the thyroid in trout. The author discusses the normal anatomy of the gland in fishes and likens the pathologic changes in her specimens to adenocarcinomas of the thyroid in mammals.

PICK, 1905: The fishes studied by Pick had been bred in American fish hatcheries, and sent to him in Germany. Despite the variability of the histologic findings, Pick thought that the growths were unmistakable epitheliomas. He believed that primary simple endemic goiter undergoes a malignant transformation in consequence of some external deleterious influences.

JABOULAY, 1908: Six trout died following development of a malignant tumor of the thyroid. The author identified the tumors as adenocarcinomas that had invaded the surrounding tissues. He implicated hereditary factors as well as a contagious etiologic agent. The former opinion he supported by the fact that fish raised from eggs sent out of Germany suffered from the disease, whereas native trout under similar conditions remained well. Jaboulay believed that the infectious agent was a myxosporidium present in the water and taken into the digestive tract.

SMITH, 1909: A large tumor of the thyroid gland in a lake trout *Salmo lacustris*, was histologically a carcinoma of the alveolar type, not distinguishable from similar tissue of human origin.

CAMERON and VINCENT, 1915: The authors found a thyroid tumor in a dog fish *Squalus sucklii* which they considered histologically similar to those reported by Marine and Gaylord in trout. They pointed out that whereas in teleosts the thyroid is scattered and not encapsulated, in elasmobranch fishes it is definitely encapsulated and forms a compact organ. This point gives significance to their finding of invasion into the surrounding tissues. A quoted report by Adami suggests that histologically their specimen is a carcinoma.

SCHREITMÜLLER, 1924: The author described what he considered were examples of malignant neoplasia of the thyroid in *Jordanella floridae* and other oviparous and viviparous toothed carp, in barbels, and in a catfish (cited by Klemm).

JOHNSTONE, 1924: On the floor of the mouth of a porgy *Box vulgaris* on each side of the midline and in the region of the thyroid was a 2.5 x 1.3 cm. tumor which had lifted the operculum on that side. Histologically there were numerous large acini filled with colloid and lined by tall columnar cells.

LEGER, 1925: Thyroid tumors were found in rainbow trout *Salmo gairdnerii* at a hatchery in Grenoble. Leger states that most of them are adenomas, a few are adenocarcinomas, and he presents an example of the latter which had metastasized to the heart.

KLEMM, 1927: Tropical aquarium fish of the species *Haplochilus chaperi* (an oviparous toothed carp) appeared unwell when they had attained a length of 1.5 to 2 cm. Examination revealed that the opercula were lifted and breathing was rapid. On the pharynx a

reddened, hemispherical mass could be seen, 2.5 to 3 mm. in diameter, having the histologic characteristics of a colloid goiter. A similar lesion was found in a specimen of *Danio albolineatus*.

PEYRON and THOMAS, 1930: The authors review the problem of thyroid tumors in fishes, especially the Salmonidae. Though inconclusive, they seem to favor the view that most are malignant neoplasms and include two cases of their own: one in a salmon, the other in a trout, and both typical of the many other goiters described in the literature.

SMITH, COATES and STRONG, 1936: These authors observed thyroid hyperplasia in 2 species of tropical aquarium fishes *Rasbora lateristriata* and *Heterandria formosa*. They believed that the tumors are benign adenomas; the discussion is brief.

SMITH and COATES, 1937: The authors present a detailed morphologic study of the normal and hyperplastic thyroid in a tropical aquarium fish *Rasbora lateristriata* that reaches a length of 3 cm. In the hyperplastic gland there is a great irregularity in the size and an increase in the number of follicles. Cross sections of the normal gland reveal not more than 10 follicles, whereas in the thyroid tumor these may number 3,000. Scattered collections of lymphoid cells were not uncommon in the tumor which also showed increased vascularity. It infiltrated the adjacent muscle, cartilage, and bone. The disease was usually fatal in two months, as the tumor destroyed and replaced the gill structures.

TUMORS OF MESENCHYMAL TISSUES

In this group are included: fibroma, myxoma, chondroma, osteoma, lipoma, leiomyoma, rhabdomyoma, hemangioma, osteo-sarcoma, lymphosarcoma, and sarcomas not further classified.

FIBROMA

The most common neoplasms of the supporting tissues of fishes are the benign and malignant tumors of the connective tissue proper. Fibroma has been reported in 18 species (Table 7). The subcutaneous tissue and trunk musculature are most frequently involved; however, fibromas have been found in the oral cavity, peritoneum, stomach and esophagus. Guglianetti (67) reported a slow growing retro-orbital tumor in a goldfish *Carassius auratus* that was under observation for 3 years. The right eyeball protruded, the pupil was greatly dilated, and the lens opaque. The tumor measured 3.5 cm. in diameter, was elastic and rather soft in consistency. Histologically the growth consisted of connective tissue that was rich in nuclei and contained several areas of necrosis.

Subcutaneous fibromas in goldfish have been described by several authors (45, 175, 226). They were often multiple and in one instance (226) involved several fishes in the same pool. An infectious

TABLE 7: FIBROMA

Species	Site	Author
Carp <i>Cyprinus carpio</i>	Peritoneum	Crisp, 1853
Carp <i>Cyprinus carpio</i>	Body cavity	Gervais, 1876
Lake trout <i>Salmo lacustris</i>	Subcutaneous	Eberth, 1878
Codfish <i>Gadus morhua</i>	Subcutaneous	Bland-Sutton, 1885
Codfish <i>Gadus morhua</i>	Stomach wall	Bland-Sutton, 1885
Thwaite shad <i>Alosa finta</i>	Wall of stomach	Ryder, 1887
Crucian carp <i>Carassius carassius</i>	Abdominal wall & mesentery	Plehn, 1906
Bream <i>Abramis brama</i>	Coelom	Plehn, 1906
Pike <i>Esox lucius</i>	Musculature	Plehn, 1906
Codfish <i>Pollachius virens</i>	Oral cavity	Fiebiger, 1909a
Codfish <i>Gadus morhua</i>	Esophagus	Williamson, 1909
Goldfish <i>Carassius auratus</i>	Orbit	Guglianetti, 1910
Sardine <i>Arengus pilchardus</i>	Peritoneum	Johnstone, 1911
Haddock <i>Melanogrammus aeglefinus</i>	Subcutaneous	Johnstone, 1911
Halibut <i>Hippoglossus hippoglossus</i>	Retroperitoneal	Johnstone, 1913
Halibut <i>Hippoglossus hippoglossus</i>	Trunk muscle (multiple)	Johnstone, 1914
Carp <i>Cyprinus carpio</i>	Mesentery	Ronca, 1914
Codfish <i>Gadus morhua</i>	Orbit	Johnstone, 1914
Goldfish <i>Carassius auratus</i> (several)	Subcutaneous	Wago, 1922
Plaice <i>Pleuronectes platessa</i>	Dorsal fin	Johnstone, 1922
Haddock <i>Melanogrammus aeglefinus</i>	Subcutaneous (multiple)	Johnstone, 1924
Turbot <i>Rhombus maximus</i>	Dorsal fin	Johnstone, 1924
Codfish species not given	Stomach wall	Johnstone, 1925
Sardine <i>Arengus pilchardus</i>	Peritoneum	Johnstone, 1925
Goldfish <i>Carassius auratus</i>	Skin (multiple)	Sagawa, 1925
Goldfish <i>Carassius auratus</i>	Back muscles	Eguchi & Oota, 1926
Halibut <i>Hippoglossus hippoglossus</i>	Subcutaneous, on head	Johnstone, 1926
Plaice <i>Pleuronectes platessa</i>	Subcutaneous, on head	Johnstone, 1926
Crucian carp <i>Carassius carassius</i>	Ovary	Freudenthal, 1928
Coalfish <i>Theragra chalcogramma</i> (2)	Belly wall	Takahashi, 1929
Rockfish <i>Sebastes inermis</i>	Body wall	Takahashi, 1929
Codfish species not given	Wall of duodenum	Thomas, 1933a
Trop. Aquar. Fish <i>Rasbora daniconius</i>	Region of dorsal fin	Smith, Coates, & Strong, 1936
Brown trout <i>Salmo trutta</i>	Intra-abdominal	Kreyberg, 1937

agent could not be demonstrated, nor could the tumors be transplanted to other goldfish (45). The relationship of these growths to the subcutaneous fibrosarcomas of goldfish cannot be determined from the reports in the literature. A fibroma of the ovary in a related species, the carp *Carassius carassius* was reported by Freudenthal (52). The growth was nodular, white, and did not adhere to surrounding structures. Histologically the richly cellular parenchyma consisted of connective tissue, was not infiltrative, and contained no demonstrable parasites. Bits of the tumor were inoculated intraperitoneally into 2 other carp. One of these fish died on the following day; in the other no tumor tissue could be found when the animal was sacrificed 10 weeks later.

The first report of a soft tissue tumor in a fish was made by Crisp (33) at a meeting of the London Pathological Society in December, 1853. The neoplasm was a fibroma weighing 4 pounds and loosely attached to the peritoneum of a 10 pound carp. On section it was found to consist of dense, white bundles of fibrous tissue. The author called attention to the resemblance in origin and growth between this tumor and some of the tree fungi, point-

ing out that these excrescences, both in man and the lower animals, possessed a power of growth to some extent independent of the body to which they are attached.

Abstracts of other reported cases of fibroma

GERVAIS, 1876: A very large tumor was found near the ovaries in the abdominal cavity of a carp *Cyprinus carpio*. Histologically it was composed of connective tissue.

EBERTH, 1878: During a robbery at a fish hatchery in Switzerland, a large lake trout *Salmo lacustris* was injured by a blow on the head, but "the burglar failed to capture the tasty morsel." Though it bled from the wound, the fish was active and in a short time the wound had fully healed. At the site of the scar a nodular thickening developed which grew rapidly but remained covered by a smooth, intact layer of epithelium. Histologically the tumor was vascular, the tissue rather loose and somewhat gelatinous. In some areas the neoplasm resembled granulation tissue. The author identified it as a fibrosarcoma.

BLAND-SUTTON, 1885: In a codfish *Gadus morhua* a fibrous tumor lay in the loose tissue beneath the skin of the abdomen. The growth had undergone calcification.

BLAND-SUTTON, 1885: In the stomach of each of two codfish *Gadus morhua* was a pale gray tumor which on section was found to be composed of interlacing bundles of glistening white connective tissue.

RYDER, 1887: Described a fibroma near the pylorus of a thwaite shad (cited by Thomas, 1931 b).

PLEHN, 1906: A tumor the size of a hen's egg was attached to the peritoneum of a crucian carp *Carassius carassius* by a short pedicle. The mass was firm and had a smooth surface; the cut surface was pale pink. Histologically the tumor was a typical fibroma and was made up of interlacing bands of connective tissue. A few small areas of necrosis were present, no mitoses were found. Several smaller fibromas were scattered over the surface of the mesentery.

PLEHN, 1906: A firm tumor the size and shape of a hen's egg was found in the coelom of a bream *Abramis brama*. The neoplasm was composed of short spindle cells and fibers; no mitoses were found, no inflammatory cell infiltrates were present.

PLEHN, 1906: A pink tumor 3 x 2.5 cm., was present in the trunk muscles of a pike *Esox lucius*. The parenchyma was composed of connective tissue cells arranged in bundles, with many fat cells scattered among them. Mitoses were uncommon; occasional giant cells with peripheral nuclei were present. The author called the tumor a lipofibroma.

FIEBIGER, 1909 a: Arising from the oral mucous membrane of a codfish *Pollachius virens* was a tumor the size of a pigeon egg that consisted of bundles of connective tissue covered by a thick layer of epithelium.

WILLIAMSON, 1909: The author reported a fibroma of the esophagus in a codfish *Gadus morhua*.

JOHNSTONE, 1911: A fibroma 5.8 x 3.3 x 2.3 cm. was attached to the peritoneum in the region of the caecum of a sardine *Arengus pilchardus*. The surface was nodular and yellow-white in color. Histologically the tumor was composed of interlacing bundles of connective tissue.

JOHNSTONE, 1911: Behind the operculum of a haddock *Melanogrammus aeglefinus* was a well encapsulated tumor 7 x 6 x 6 cm. made up of bundles of mature connective tissue.

JOHNSTONE, 1913: A retroperitoneal fibroma weighing 2.5 kg. was found in a halibut *Hippoglossus hippoglossus*. The tumor, which was soft and friable and had a smooth, lobulated surface, was made up of bundles of connective tissue.

JOHNSTONE, 1914: Multiple fibromas were found in the trunk muscles of a halibut *Hippoglossus hippoglossus*. They were well encapsulated and could readily be shelled out.

JOHNSTONE, 1914: In the left orbit of a codfish *Gadus morhua* was a firm gray-white tumor 7 x 6 cm. The overlying skin was intact; the eye was displaced posteriorly and downward. The neoplasm was well encapsulated and consisted of interlacing bundles of connective tissue.

RONCA, 1914: A tumor the size of a hen's egg arose in the mesentery of a carp *Cyprinus carpio*. White in

color, it was soft in consistency and was made up of interlacing bundles of connective tissue.

WAGO, 1922: Multiple tumors, 0.5 cm. in diameter, were scattered over the body surface, fins, and eyes of a goldfish *Carassius auratus*. Spheroidal or polypoid in shape, they were smooth, not covered by scales, and firm in consistency. The cut surface was red and translucent. Histologically there was an abundance of delicate connective tissue and fusiform fibroblasts mingled with irregularly shaped cells widely separated from one another. No inflammatory cell infiltrates were seen. Though several fish with similar lesions were found in the same garden pool, an infectious agent could not be demonstrated. The author identified the tumor as myxofibroma.

JOHNSTONE, 1922: On the pigmented side of the dorsal fin of a plaice *Pleuronectes platessa* was a firm spherical tumor 3.5 x 3 cm.; on microscopic examination it proved to be a typical fibroma.

JOHNSTONE, 1924: Scattered over the trunk of a haddock *Melanogrammus aeglefinus* were local thickenings in the corium. Each of these measured about 5 mm. in diameter, and was covered by normal epidermis. The author identified the lesions as fibromas.

JOHNSTONE, 1924: On the dorsal fin of a turbot *Rhombus maximus* was a tumor that measured 1 x 1½ inches. Histologically it was a typical fibroma.

JOHNSTONE, 1925: An immature female sardine *Arengus pilchardus* bore a tumor 9 x 4 cm., which apparently arose in the peritoneum. The viscera were intact. Microscopically the tumor consisted of irregularly arranged bundles of connective tissue abundantly supplied with blood vessels.

SAGAWA, 1925: The author found multiple fibromas on the skin of a goldfish *Carassius auratus*. The tumors were firm and elastic, yellow-gray, sharply circumscribed, and varied from the size of a millet seed to that of a pigeon's egg. Histologically they were composed of young connective tissue which, however, did not take van Gieson's stain. Myelinated nerve fibers were also present. (These lesions may have been neurofibromas.)

JOHNSTONE, 1925: The cardiac end of the stomach of a 16 pound codfish bore a tumor 15 x 10 cm. On section it was white, glistening, and firm in consistency. Histologically the neoplasm was a fibroma.

JOHNSTONE, 1926: On the nonpigmented side of the head of a halibut *Hippoglossus hippoglossus* was a mass 8 inches in diameter; the overlying skin was intact. The tumor weighed 3 pounds, shelled out readily, was well encapsulated, and histologically was a typical fibroma.

JOHNSTONE, 1926: Two tumors were present on the head of a plaice *Pleuronectes platessa*. One on the lower border of the operculum measured 4½ x 3½ inches, the other was smaller, grew from the anterior border of the right orbit, and partly covered the eye. The overlying skin was intact. Both neoplasms consisted of bundles of connective tissues; few vessels were present.

EGUCHI and OOTA, 1926: A firm elastic tumor

was found on the back of a goldfish *Carassius auratus* near its head. Though no scales were present in the overlying skin, ulceration was absent. Histologically the lesion was composed primarily of spindle-shaped cells. Attempts to transplant the tumor to other goldfish were unsuccessful.

TAKAHASHI, 1929: Embedded in the trunk muscles of a coalfish *Theragra chalcogramma* was a gray-white tumor, 4 x 3.5 x 3.2 cm. The overlying skin was intact. The tumor parenchyma consisted of spindle and round cells; there was no evidence of infiltration. Bits of the neoplasm were inoculated into 18 crucian carp; in none was there any growth.

TAKAHASHI, 1929: A cherry-sized, firm uniformly white tumor was found in the body wall near the caudal fin of a rockfish *Sebastes inermis*. Histologically it consisted of bands and whorls of connective tissue.

THOMAS, 1933 a: A pedunculated fibroma 9 x 7.5 cm. was found attached to the mucosa of the intestine, near the pylorus. The host was a 9 year old codfish.

SMITH, COATES and STRONG, 1936: A small tropical aquarium fish *Rasbora daniconius* bore a sharply circumscribed, encapsulated, black tumor in the region of the dorsal fin. It consisted of loosely arranged interlacing bundles of elongated connective tissue cells.

KREYBERG, 1937: In a brown trout *Salmo trutta* a slightly lobulated, firm, pink tumor was discovered in the abdominal cavity. The mass measured 18 cm. in diameter, and was attached to the serosa of the intestine by a narrow pedicle. The parenchyma was composed of fibrous tissue, some of which was necrotic. No mitoses were present.

SARCOMA (UNCLASSIFIED)

The intermutability of mesenchymal tissues, and the complexity of tumors arising from these tissues, render their classification difficult (195a, 231a). Moreover, the boundary between non-malignant and malignant mesenchymal tumors is frequently vaguer than in epithelial tumors. Hence it is quite possible that some tumors here listed as sarcomas actually belong among the fibromas. It seems best therefore to list these two groups in proximity. No attempt has here been made to subdivide the sarcomatous tumors, other than separating the osteosarcomas and lymphosarcomas.

The sarcomas form the largest group of piscine neoplasms, having been observed in 31 species (Table 8). The predilection of the connective tissues to undergo malignancy is not unique to fishes; it also occurs in certain mammals such as the rat (24). The majority of the tumors listed in Table 8 had their origin in the dermis or subcutaneous tissues. However, this may not represent the true relative organ incidence since such growths would be more likely to attract attention than neoplasms of the viscera.

Of particular interest are a number of sarcomas that appear to arise on an environmental basis.

Three groups of investigators have reported instances in which subcutaneous sarcomas appeared in several goldfish *Carassius auratus* that had been kept in the same tank. Roffo (171) observed a small ulcerated tumor on the left side of a goldfish, just anterior to the dorsal fin. Histologically the neoplasm consisted of connective tissue arranged in bundles, among which were pleomorphic cells, some of which bore two or three nuclei. Similar tumors developed in 7 of 20 fish kept in the same aquarium. After the diseased fishes were removed and the tank was disinfected, no further tumors developed. Montpellier and Dieuzeide (138) reported that a single tumor was present in the body surface of each of five goldfish *Carassius auratus* that had been kept in the same aquarium. Histologically the lesions were identical, all were fibrosarcomas, the neoplastic fibroblasts had elongated clear nuclei with prominent nucleoli. Bits of one of the tumors were inoculated into the caudal fins of three goldfish. After the lapse of a year no tumors had developed. Six additional fish were inoculated and examined after a shorter period. They likewise failed to show tumor growth.

We ourselves (123c) have lately given an account of 30 tumor-bearing goldfish all but two of which were obtained from 3 small pools. It was found characteristic of this neoplastic disease that it is prevalent in certain pools and absent or rare in others. Where prevalent, the number of tumor-bearing fishes, as a rule, gradually increases. We have presented evidence that the factors which induce the tumors are environmental rather than hereditary. The neoplasms arise in the corium or subcutaneous tissue and are usually solitary. Their rate of growth is generally slow, although some grow rapidly and attain relatively large size (Figs. 20, 21). The histological character of these growths exemplifies the difficulty of accurately classifying mesenchymal tumors. The smaller tumors resemble fibromas or occasionally myxomas (Fig. 24), the larger fibrosarcomas (Figs. 22, 23), but the paucity of fiber-formation makes a purely fibroblastic origin doubtful. The precise histogenesis of these neoplasms is as yet undetermined. We have tentatively grouped them here with the sarcomas, although in our paper we have referred to them simply as "mesenchymal tumors." It is likely, though not as yet certain, that these tumors are similar to the goldfish tumors reported in the literature as fibrosarcomas or fibromas.

TABLE 8: SARCOMA (Unclassified)

Species	Site	Author
Minnow <i>Phoxinus laevis</i>	Corium of skin	Bugnion, 1875
Goldfish <i>Carassius auratus</i>	Dorsal fin	Bland-Sutton, 1885
Goldfish <i>Carassius auratus</i>	Not given	Semmer, 1888
Pike <i>Esox lucius</i>	Trunk muscle	Ohlmacher, 1898
Brook trout <i>Salvelinus fontinalis</i>	Trunk muscle	Plehn, 1906
Chub <i>Idus idus</i>	Trunk muscles	Plehn, 1906
Minnow <i>Phoxinus laevis</i>	Trunk muscle	Plehn, 1906
Crucian carp <i>Carassius carassius</i>	Testicle	Plehn, 1906
"LeNez" <i>Chondrostoma nasus</i>	Muscles of back	Plehn, 1906
Flounder <i>Psetta maeotica</i>	Subcutaneous (multiple)	Schroeders, 1908
Scorpion fish <i>Scorpaena porcus</i>	Subcutaneous	Schroeders, 1908
Pike <i>Esox lucius</i>	Kidney	Plehn, 1909
Danubian trout <i>Hucho hucho</i>	Liver	Plehn, 1909
Codfish <i>Pollachius virens</i>	Skin	Fiebiger, 1912
Ray <i>Raja macrorhynchus</i>	Fin ray	Drew, 1912
Eel <i>Anguilla vulgaris</i>	Mesentery	Wolff, 1912
Codfish <i>Gadus morhua</i>	Subcutaneous	Johnstone, 1912
Plaice <i>Pleuronectes platessa</i>	Subcutaneous	Drew, 1912
Codfish <i>Gadus morhua</i>	Trunk muscle	Johnstone, 1915
Croaker <i>Pogonias chromis</i>	Subcutaneous	Beatti, 1916
Conger eel <i>Conger conger</i>	Subcutaneous	Johnstone, 1920
Codfish species not given	Mouth	Johnstone, 1920
Dog salmon <i>Oncorhynchus keta</i>	Body wall	Kazama, 1922
Haddock <i>Melanogrammus aeglefinus</i>	Subcutaneous	Johnstone, 1922
Goldfish <i>Carassius auratus</i>	Subcutaneous	Schamberg & Lucké, 1922
Goldfish <i>Carassius auratus</i>	Subcutaneous	Johnstone, 1923
Codfish <i>Gadus morhua</i>	Subcutaneous	Johnstone, 1923
Ling <i>molva molva</i>	Subcutaneous	Johnstone, 1923
Turbot <i>Rhombus maximus</i>	Subcutaneous	Johnstone, 1923
Herring <i>Clupea harengus</i>	Testis	Johnstone, 1924
Eel <i>Anguilla vulgaris</i> (2)	Peritoneum	Plehn, 1924
Goldfish <i>Carassius auratus</i>	Subcutaneous	Roffo, 1924
Rainbow trout <i>Salmo gairdnerii</i> (2)	Not given	Leger, 1925
Codfish <i>Pollachius virens</i>	Subcutaneous	Johnstone, 1926
Codfish <i>Pollachius virens</i>	Mandible	Johnstone, 1926
Halibut <i>Hippoglossus hippoglossus</i>	Body wall	Johnstone, 1926
Croaker <i>Micropogon opercularis</i> (2)	Subcutaneous	Roffo, 1926
Codfish <i>Gadus morhua</i>	Subcutaneous	Thomas, 1927b
Codfish <i>Gadus morhua</i>	Ovary	Thomas, 1927b
Turbot <i>Rhombus maximus</i>	Body wall	Johnstone, 1927
Goldfish <i>Carassius auratus</i>	Subcutaneous	Dominguez, 1928
Dog salmon <i>Oncorhynchus keta</i>	Body wall	Takahashi, 1929
Dog salmon <i>Oncorhynchus keta</i>	Body wall	Takahashi, 1929
Hump-back salmon <i>Oncorhynchus gorbuscha</i>	Body wall	Takahashi, 1929
Coalfish <i>Theragra chalcogramma</i>	Body wall	Takahashi, 1929
Coalfish <i>Theragra chalcogramma</i>	Subcutaneous	Takahashi, 1929
Japanese bass <i>Lateolabrax japonicus</i>	Subcutaneous	Takahashi, 1929
Japanese bass <i>Lateolabrax japonicus</i>	Pharynx	Takahashi, 1929
Kisugo <i>Sillago japonica</i>	Base of head	Takahashi, 1929
Gurnard <i>Lepidoptrigla alata</i>	Left body wall	Takahashi, 1929
Codfish <i>Gadus morhua</i>	Body wall	Williams, 1931
Goldfish <i>Carassius auratus</i> (5)	Subcutaneous	Montpellier & Dieuzeide, 1932
Swordtail <i>Xiphophorus hellerii</i> (17)	Retrolubar	Jahnel, 1939
Goldfish <i>Carassius auratus</i> (30)	Subcutaneous	Lucké, Schlumberger & Breedis, 1948

One of the more malignant growths was successfully transplanted to the anterior chamber of the eye of a tumor-bearing fish; all other attempts at transplantation were unsuccessful.

A possible hereditary sarcoma has been reported by Jahnel (80). A retrolubar tumor appeared in each of four sibling tropical aquarium fish, known as swordtails, *Xiphophorus hellerii*. Seventeen other

siblings were traced, 9 of which developed tumors in one or both orbits. Histologically the tumors were identical, consisting of small round or spindle-shaped cells with large vesicular nuclei; interstitial tissue was almost absent. The tumor was markedly invasive, infiltrated the orbital muscles and even penetrated the skull. Mitotic figures were numerous. In one animal a large tumor was present in the left

eye, while the right appeared grossly normal; however, on section a microscopic tumor nodule was found between the retina and choroid. The author believes that the choroid is the origin of all these tumors and that the small tumor in the right eye was primary, not metastatic. Jahnel regarded these tumors, all of which were non-pigmented, as sarcomas. It is possible however that they actually were amelanotic melanomas. In this connection see the recent papers by Levine and Gordon (111b), and by Gordon (60a).

Abstracts of other reported cases of sarcoma

BUGNION, 1875: On the left side, near the base of the tail of a minnow *Phoxinus laevis* was a pea-sized, black tumor which had appeared in a period of 2 weeks. The overlying skin was intact, though the scales were absent. The neoplasm, which was moderately soft and very vascular, contained many giant cells. The black color was only present within and immediately beneath the skin and was due to the normal pigment cells of this region. Near the tip of the caudal fin was a small black speck from which the author was able to isolate myxosporidia. The main "tumor" may likewise have been the result of such an infection, representing merely chronic inflammation with foreign body giant cells. The author identified the growth as a giant cell sarcoma.

BLAND-SUTTON, 1885: A tumor was present on the posterior border of the dorsal fin of a goldfish *Carassius auratus*. The author states that it exhibited all the histologic characteristics of a spindle cell sarcoma.

SEMMER, 1888: In a brief communication the author lists the cases of animal tumors that came to his attention throughout 23 years at the Veterinary Institute in Dorpat. He mentions a sarcoma in a goldfish, but gives no details.

OHLMACHER, 1898: Immediately beneath the dorsal fin, and embedded in the trunk musculature of a lake pike *Esox lucius*, was a spherical white tumor 5 cm. in diameter. It infiltrated the surrounding muscle and was intimately connected with the vertebrae. Lying beneath the peritoneum were 12 widely scattered tumors varying from 1 to 3 cm. in diameter. The visceral peritoneum likewise bore 24 firm white nodules 1 to 2 cm. in width; no lesions were found in the viscera. The "primary" tumor in the abdominal wall resembled small round cell sarcoma of man. It consisted of large collections of densely packed round or oval cells with prominent nuclei surrounded by scanty cytoplasm. About these collections of cells was a delicate fibrillary and richly cellular connective tissue. The metastases were similar in structure, except that the stroma was more abundant. This tumor should probably be regarded as a lymphosarcoma.

PLEHN, 1906: In the trunk musculature of a brook trout *Salvelinus fontinalis* was a large cystic tumor that contained 117 cc. of cloudy yellow fluid in which were found leukocytes, and occasional bacteria. Similar tumors in trout from the same lake had been described

in 1884 by Bonnet, and later by Hofer. Though much of the tumor was necrotic, mitotic figures were common in the healthy portions. Most of the tumor cells were round and had large nuclei, but nests of spindle cells were also present. The author's diagnosis was cysto-sarcoma.

PLEHN, 1906: A chub *Idus idus*, 40 cm. long and 4 or 5 years old, bore a slightly bulging mass in the neck muscles, directly behind the head. On dissection, a solid white tumor the size of a pigeon egg was found. Though the center was necrotic, the periphery was actively growing and had invaded the surrounding tissue. Histologically it consisted chiefly of small round cells, though spindle cells were also present. Scattered among the tumor cells were numbers of well differentiated mucous cells.

PLEHN, 1906: Near the dorsum of the right side of a minnow *Phoxinus laevis* was a pea-sized tumor. Histologically it consisted of proliferating pleomorphic cells, the nuclei of which were very large, lobulated, and even ring-shaped. Many mitoses containing abnormal numbers of chromosomes were present.

PLEHN, 1906: A tumor arising in the testicle of a crucian carp *Carassius carassius* contained many large and small cysts. The walls were smooth and lined by flattened connective tissue; the cavities were filled with fluid or a colloidal mass. Some areas were very cellular, other regions were made up of fibrous tissue. The author identified the lesion as a cystic fibrosarcoma.

PLEHN, 1906: An egg-shaped mass, 4 x 5.5 cm., was present deep in the back muscles of "le Nez," *Chondrostoma nasus*. The tumor, which was white, spongy, and edematous, consisted of a delicate connective tissue reticulum among which were occasional multinucleate giant cells. Dilated lymphatics were numerous.

SCHROEDERS, 1908: On the pigmented surface of a flounder *Psetta maotica* were 8 granular tumors, yellow-gray in color. Some were almost spherical, with a diameter of 5 cm., others, flat and oblong, and as much as 10 cm. in length. The masses were soft and infiltrated the adjacent skin and muscle. Histologically the parenchyma was composed of round cells of uniform size, with many mitotic figures. (Lymphosarcoma?)

SCHROEDERS, 1908: A spindle cell sarcoma in the tail muscles of a scorpion fish *Scorpaena porcus* grew rapidly for two months when the fish was kept in an aquarium. Cachexia became marked and the animal died. Near the anal fin was an ulcerated area, 3 cm. in diameter; on section the adjacent muscles were found to be extensively infiltrated by the firm white tumor. In the liver was a white nodule the size of a pea that protruded above the surface and infiltrated the liver tissue. Under the epicardium of the heart were 6 white nodules, each the size of a pin-head. Two larger firm nodules were found in the wall of the auricle, occupying its entire thickness. Histologically the nodules in the liver and heart were similar to the primary lesion which consisted of bundles of connective tissue that were

growing between muscle fibers and had eroded the underlying bone.

PLEHN, 1909 and 1924: A large tumor of the kidney was found in a 10 pound pike *Esox lucius*. It had metastasized to the trunk muscles. Histologic studies were of little value due to poor fixation of the tissue, but the author regarded the tumor as a sarcoma.

PLEHN, 1909: On the surface of the liver of a large Danubian trout *Hucho hucho* were white nodules varying from the size of a millet seed to that of half a walnut. On section they were found not to be circumscribed, but had invaded the normal tissues. The author identified the lesion as a spindle cell sarcoma.

FIEBIGER, 1912: According to the author this is the first record of a fibrosarcoma in a salt water fish, the three previous cases were found in fresh water fishes. A cauliflower-like mass the size of an egg grew in the subcutaneous tissue of a codfish *Pollachius virens*. It was not sharply demarcated from the adjacent tissue; the overlying skin was ulcerated, and hemorrhages were numerous on the surface of its warty excrescences. The round, elongated, and even branched tumor cells infiltrated the muscle.

DREW, 1912: A circular tumor, 4 x 1¼ inches, was present on the dorsal surface near the lateral fin of a ray *Raja macrorhynchus*. It was a broadly sessile, cauliflower-like mass covered by a layer of epithelium. The parenchyma consisted of fibrous tissue apparently derived from the perichondrium of one of the fin rays. Nowhere was the tissue very cellular, but because of its mode of growth the author classified it as a sarcoma.

WOLFF, 1912: A tumor the size of a man's fist lay between the layers of the mesentery of a large eel *Anguilla vulgaris*. Histologically, nests of tumor cells surrounded the blood vessels and were separated from one another by bands of connective tissue. The author identified the growth as a fibrosarcoma.

JOHNSTONE, 1912: On the snout of a codfish *Gadus morhua* was a gray-black non-encapsulated tumor, 7.5 x 4 x 3 cm. The superficial epidermis was destroyed. Grossly it appeared to be a typical fibroma, but histologic examination showed evidence of infiltration and increased cellularity.

DREW, 1912: A plaice *Pleuronectes platessa* bore a white ovoid mass, three-fourths of an inch in diameter, on the operculum of the pigmented side. Histologically it was made up of connective tissue. No further details were given, and the growth was listed as sarcoma by the author.

JOHNSTONE, 1915: On the right side of an emaciated codfish *Gadus morhua* between the first ventral and second dorsal fin was an 8 cm. tumor that had invaded the adjacent muscle fibers and undergone central liquefaction necrosis. The tumor cells were spindle shaped; occasional giant cells were present.

BEATTI, 1916: Numerous subcutaneous nodules were present on each operculum, on the snout, on the body, and on one side of the tongue of a croaker *Pogonias chromis*. The parenchyma consisted of densely grouped spindle cells with abundant cytoplasm and small nuclei.

JOHNSTONE, 1920: On the top and left side of the head of a conger eel *Conger conger* were two firm, spherical tumors, each 10 cm. in diameter. Histologically there was no evidence of encapsulation; the parenchyma presented all the characteristics of a mixed cell sarcoma.

JOHNSTONE, 1920: Several tumors were present about the left orbit and within the mouth of a codfish. On the basis of their histologic structure the author classified them all as sarcomas of mixed cell type.

KAZAMA, 1922: Among 1,000 salmon *Oncorhynchus keta* the author found a single tumor-bearing animal. In a five year old fish, 85 cm. in length, there was a tumor, 6.5 x 6 x 3 cm., which arose from the body wall near the origin of the right pelvic fin. It was hemispherical, gray-white, and encroached on the peritoneal cavity. The tumor was composed of fusiform cells that destroyed and infiltrated the surrounding tissues; no mitoses were seen.

JOHNSTONE, 1922: On the top of the head of a haddock *Melanogrammus aeglefinus* was a tumor which the author called a sarcoma. No further details were given.

SCHAMBERG and LUCKÉ, 1922: A goldfish that had lived in a garden pool for 15 years bore three tumors on its right side. The growth which the authors regarded as primary was on the back just anterior to the dorsal fin; it measured 2.6 cm. in diameter and projected 1.5 cm. above the skin surface. The other tumors were located near the tail, one measured 1 cm. in diameter, the other 3 mm. All were dull white in color. Infiltration of the underlying muscle had occurred about the largest tumor. Histologically the growths were composed of loosely arranged spindle cells; the blood supply was scanty; the vessels very thin walled. The two smaller tumors did not infiltrate; the authors believed they represented metastases; this interpretation is now regarded as probably erroneous.

JOHNSTONE, 1923: At the base of the tail of a goldfish *Carassius auratus* was a tumor that measured 1 x 1.5 cm. Histologically it was made up of proliferating connective tissue that had invaded the surrounding muscle.

JOHNSTONE, 1923: A mass 6 x 3 x 3 cm. was located on the anterior border of the right orbit of a codfish *Gadus morhua*. The connective tissue was abundant, but in some areas there were large numbers of small round cells, the neoplasm infiltrated the dermis and muscle, but the skin was not ulcerated.

JOHNSTONE, 1923: On the right side of the head of a ling *Molva molva*, arising above and behind the orbit, was a tumor 11 x 5 cm. which grew forward over the eye and almost covered the pupil. No histologic details were given; it was classified by the author as a fibrosarcoma.

JOHNSTONE, 1923: On the pigmented side of a turbot *Rhombus maximus* was a tumor 8 x 3 cm. Histologically the lesion consisted of connective tissue among which were spindle cells. There was little evidence of malignancy, although the author diagnosed it a sarcoma.

JOHNSTONE, 1924: A creamy white tumor, slightly nodular and measuring 3½ x 1½ inches, was loosely

attached to the parietal peritoneum of a herring *Clupea harengus*. It was fused with testis and was composed of vesicular neoplastic cells. (Lymphosarcoma ?)

PLEHN, 1924: In each of two eels *Anguilla vulgaris* there was a firm connective tissue tumor that arose in the peritoneum and greatly distended the abdomen. The author gives no details but considers the tumors to be fibrosarcomas.

LEGER, 1925: In discussing thyroid tumors in trout the author mentions 2 fibrosarcomas in rainbow trout *Salmo gairdnerii*. They were red in color and very vascular. No further details were given.

JOHNSTONE, 1926: On the top of the head of an emaciated codfish *Pollachius virens* was a tumor that measured 2 inches in diameter. On section the lesion was soft and necrotic. No histologic studies were made, but the lesion was listed by the author as a sarcoma.

JOHNSTONE, 1926: A codfish *Pollachius virens* bore a spherical tumor 8 cm. in diameter, on the anterior median aspect of the mandible. The tumor extended into the soft tissues of the mouth. Histologically it consisted of neoplastic connective tissue cells.

JOHNSTONE, 1926: A superficial ulcer, measuring 8 x 5 inches and with raised edges, was observed on the trunk surface of a halibut *Hippoglossus hippoglossus*. The lesion was an ulcerated tumor that had deeply infiltrated the underlying muscle. Microscopic examination revealed that it was composed of loosely arranged spindle cells.

ROFFO, 1926: Each of two croakers *Micropogon opercularis* bore a tumor. In one a nodular ulcerated mass 2 cm. in diameter was found at the junction of the head and thorax; in the other a similar mass was present at the base of the tail. Histologically each was a spindle cell sarcoma.

THOMAS, 1927 b: A subcutaneous tumor the size of a hen's egg was found in the trunk of each of 3 codfish *Gadus morhua*. Several areas of necrosis were present; the cells were large and fusiform, arranged in bands and whorls that resembled the uterine fibroleiomyoma of man. The author regarded the tumor as a fibrosarcoma.

THOMAS, 1927 b: In a codfish *Gadus morhua* a tumor the size of an almond was present near the right ovary. The cells are fusiform; confluent vascular spaces lined by a rudimentary endothelium were abundant. The tumor was likened by the author to the fibrosarcomas of birds and mammals.

JOHNSTONE, 1927: Multiple small round cell sarcomas were found in a turbot *Rhombus maximus*. Two of the tumors were the size of a hen's egg and were located on the pigmented side of the fish; nine additional nodules were found scattered throughout the musculature. None of the tumors were encapsulated; the adjacent muscle was infiltrated. The cells were of the small round cell type and appeared to be malignant. The author believes that the numerous tumors were multicentric in origin rather than metastatic. (Lymphosarcoma ?)

DOMINGUEZ, 1928: A 25 cm. goldfish *Carassius auratus* was observed to have had a nodule the size of a pea

on its dorsal fin for 3 years. During the last year and a half the tumor had grown to a diameter of 1.5 cm. Several days before death a few "secondary" nodules were observed on the caudal fin. At autopsy, several other tumors regarded as metastatic were found in the liver and elsewhere. The primary tumor was very vascular and soft. Histologically it consisted of elongated fusiform cells with large oval nuclei.

TAKAHASHI, 1929: A tumor the size of a fist arose in the trunk musculature of a dog salmon *Oncorhynchus keta*. It was fluctuant, and was found to contain a central area of liquefaction necrosis. Histologically the tumor was composed of spindle cells that showed active mitosis and infiltrated the surrounding musculature.

TAKAHASHI, 1929: On the left side of a dog salmon *Oncorhynchus keta*, 15 cm. anterior to the tail fin, was a tumor 9 x 7 cm., lying athwart the lateral line. On the opposite side was a similar but smaller tumor. Both were soft in consistency, showed liquefaction necrosis, and infiltrated the surrounding muscle. The cells varied in size and shape and were rich in cytoplasm.

TAKAHASHI, 1929: Scattered over the body surface of a hump-back salmon *Oncorhynchus gorbuscha* were 9 tumor nodules ranging from 0.5 to 3 cm. in diameter. There was no sharp demarcation from the surrounding tissue and on histologic grounds the author identified the tumor, which was very cellular and contained many mitoses, as a round cell sarcoma. (Lymphosarcoma ?)

TAKAHASHI, 1929: In the middle of the trunk, above the lateral line of a coalfish *Theragra chalcogramma* was a tumor 4 x 3.5 cm. It was uniformly firm, and gray-white. Microscopically the parenchyma consisted of spindle cells, many of which were in mitosis. The surrounding tissue was infiltrated by the tumor.

TAKAHASHI, 1929: An oval, subcutaneous tumor larger than a hen's egg was found in the occipital region of a coalfish *Theragra chalcogramma*. Except at its base, the tumor was well demarcated from the surrounding tissue; mitotic figures were uncommon. The tumor was identified by the author as a spindle cell sarcoma.

TAKAHASHI, 1929: Eight tumors of varying sizes were present in the subcutaneous tissue of a Japanese bass *Lateolabrax japonicus*. The author identified the lesions as spindle cell sarcomas that were infiltrating the surrounding tissue.

TAKAHASHI, 1929: In the pharynx of a Japanese bass *Lateolabrax japonicus* was a tumor, 7.5 x 3 cm. Two similar lesions were present in the subcutaneous tissue of the right side. Histologically the parenchyma consisted of spindle cells with few mitotic figures.

TAKAHASHI, 1929: On the dorsum of the neck region of a kisugo *Sillago japonica* was a hemispherical, soft elevation that measured 2.2 x 1.3 cm. and was gray-white on section. It had infiltrated the adjacent tissues and was identified by the author as a spindle cell sarcoma.

TAKAHASHI, 1929: A vascular, gray, ulcerated tumor the size of a walnut was present in the trunk musculature of a gurnard *Lepidopterygion alata*. The tumor cells were large and round with rather small nuclei. The

author regarded the tumor as a large round cell sarcoma. (Lymphosarcoma ?)

WILLIAMS, 1931: An egg-shaped tumor, 12.8 x 8.8 cm., was present in the trunk muscles of a codfish *Gadus morhua*. Histologically it consisted of small round cells embedded in a connective tissue stroma. The tumor was vascular and infiltrated the adjacent muscle. (Lymphosarcoma ?)

MYXOMA

Although in mammals fully developed mucous tissue is found only in the umbilical cord, it has been described as occurring in certain areas of some fishes, particularly about the cranial cartilage of selachians. Six cases of myxoma have been reported; these were found in 5 species of fishes, all teleosts (Table 9). Of these, four have been identified by the authors as myxofibromas, the remaining two were classified as myxosarcomas because of their invasive character.

The benign tumors arose in the subcutaneous tissue; in one case they were multiple, and grouped about the base of the fins. One of the invasive tumors was retro-orbital, the other lay within the trunk musculature; no metastases were found.

Abstracts of reported cases of Myxoma

PLEHN, 1906: The right eye of a 6 or 7 year old tench *Tinca vulgaris* was displaced by a tumor arising below the orbit. It was hemorrhagic, not sharply demarcated, and infiltrated the surrounding tissues. Histologically, some areas consisted of dense masses of spindle cells; in other regions these were separated by a mucoid ground substance in which were many delicate fibrils.

SCHROEDERS, 1908: On the pigmented side of a flounder *Psetta maeotica* was a spherical pedunculated tumor 9 x 12 x 7 cm. The overlying skin was intact. The mass was elastic in consistency and translucent on section, with numerous transecting fibrous bundles. Microscopically the large spaces between the interlacing bundles of connective tissue were filled with an amorphous substance (mucin) that stained blue with hematoxylin. Within this were scattered stellate cells. Large blood vessels coursed along the fibrous trabeculae.

SCHROEDERS, 1908: About 10 tumors were present at the junction of the trunk and fins of a flounder *Psetta maeotica*. Most were broadly sessile; in a few the overlying skin was ulcerated. Elastic in consistency, the tumors on section were translucent and yellow-white. Histologically, interlacing bundles of connective tissue,

mostly arranged perpendicular to the skin, formed a coarse network, in the meshes of which was an amorphous ground substance containing stellate cells.

MACINTOSH, 1908: A plaice *Pleuronectes platessa* bore an elongated swelling on its right side. On dissection the tumor was gelatinous in consistency; the surrounding muscle was atrophied and the growth could be removed with ease. Histologically it was a loose, areolar connective tissue, enmeshed in which were many small cells and capillaries. The surrounding structures were not infiltrated.

JOHNSTONE, 1926: A tumor 2 inches in diameter, irregular in shape, and glistening white in color, was present in the body cavity of a sole *Solea solea*. Histologically the growth consisted of interlacing bundles of connective tissue and areas of areolar tissue containing stellate cells separated by large interspaces.

WILLIAMS, 1929: A tumor, 12.7 x 5.1 cm., was found in the trunk musculature on the non pigmented side of a turbot *Rhombus maximus*. The overlying skin was ulcerated. Histologically typical myxomatous tissue infiltrated the adjacent muscle.

CHONDROMA

Although the entire skeleton of selachians is composed of cartilage and this tissue is also abundant in the teleost fishes, only 8 reports of tumors of cartilage can be found in the literature (Table 10). Of these 2 were in selachians; one arose from the fin ray of a cat shark, the other from the lumbar vertebrae of a dogfish. An explanation for this dearth of material may be found in the fact that the selachians are not commonly used for food and are therefore seldom examined; however, the dogfish is frequently dissected in biology laboratories. Mulsow (140) reported a chondroma attached to the cranial bones in each of three crucian carp *Carassius carassius*. All the tumors were massive and nearly filled the cranial cavity. Unfortunately, no further data are available, but if the animals were siblings, the possibility that the tumors were comparable to multiple hereditary chondromas of man would need to be considered. There is no record in the literature of a malignant cartilagenous neoplasm of fishes.

Abstracts of reported cases of chondroma

MULSOW, 1915: A chondroma was found attached to the cranial bones in each of three crucian carp *Carassius*

TABLE 9: MYXOMA

Species	Site	Author
Tench <i>Tinca vulgaris</i>	Subcutaneous	Plehn, 1906
Flounder <i>Psetta maeotica</i>	Skin, head	Schroeders, 1908
Flounder <i>Psetta maeotica</i>	Skin, trunk & fins	Schroeders, 1908
Plaice <i>Pleuronectes platessa</i>	Body wall	MacIntosh, 1908
Sole <i>Solea solea</i>	Peritoneum	Johnstone, 1926
Turbot <i>Rhombus maximus</i>	Trunk musculature	Williams, 1929

TABLE 10: CHONDROMA

Species	Site	Author
Crucian carp <i>Carassius carassius</i> (3)	Skull bones	Mulsow, 1915
Barbel <i>Barbus fluviatilis</i>	Mandible	Surbeck, 1917
Sea pike <i>Elops saurus</i>	Subcutaneous	Surbeck, 1921
Minnow <i>Phoxinus</i>	Mandible	André, 1927
Dogfish <i>Squalus mitsukurii</i>	Lumbar vertebrae	Takahashi, 1929
Codfish <i>Pollachius virens</i>	Pre-orbital	Thomas, 1932d
Cat shark <i>Scylliorhinus canicula</i>	Skin	Thomas, 1933b
Jewel fish <i>Hemichromis bimaculatus</i>	Operculum	Nigrelli & Gordon, 1946

carassius. The tumors were massive and nearly filled the cranial cavity. These cases were cited by Thomas (1932 b) and illustrated by Plehn, 1924.

SURBECK, 1917: In a very lean barbel *Barbus fluviatilis* a tumor was found in the posterior region of the mandible. Approximately 1.5 cm. in diameter, it was formed by the apposition of 2 spherical masses. The skin over the anterior nodule was ulcerated, the mass was ossified. The posterior nodule was composed entirely of cartilage.

SURBECK, 1921: A sea pike *Elops saurus*, 100 cm. in length, bore a pedunculated tumor the size of 2 fists on its ventral surface behind the pectoral fins. It consisted of dense plaques of fibrous tissue and cartilage.

ANDRÉ, 1927: A minnow *Phoxinus* had a pedunculated mulberry-like mass attached to the tip of the mandible. The overlying skin was deeply pigmented, the head was pulled down by the weight of the tumor. Histologically, the tumor consisted of hyaline cartilage.

TAKAHASHI, 1929: A tumor, 10 x 7 x 5 cm., arose in the region of the third to sixth lumbar vertebrae of a dogfish *Squalus mitsukurii*. The overlying skin was ulcerated. The tumor, which consisted of hyaline cartilage, was fused with the third lumbar vertebra and showed a central area of liquefaction necrosis the size of a walnut.

THOMAS, 1932 d: Two symmetrical pre-orbital tumors, each measuring 1.5 x 3 cm., were found in a 6 year old codfish *Pollachius virens*. Covered by intact skin, they were broadly sessile upon the lachrymal bones, but were separated from them and adjacent tissues by a fibrous capsule. The tumors were very firm, partly calcified, and consisted of typical cartilage cells embedded in a fibrous matrix.

THOMAS, 1933 b: On the right flank below the pectoral fin of a cat shark *Scylliorhinus canicula* was a tumor, the surface of which was partly denuded. It arose from the connective tissue of the corium and possessed a peripheral zone of hyaline cartilage; the central portion was calcified.

NIGRELLI and GORDON, 1946: When first observed the tumor appeared as a small swelling at the anterior margin of the right operculum of a jewel fish *Hemichromis bimaculatus*. Within two months it had attained a size of 13 x 6 x 4 mm. The total length of the fish was 52 mm. Histologically the tumor proved to be an osteochondroma consisting chiefly of hyaline cartilage arranged in a more or less irregular pattern. The fish was the only pathologic specimen in about a hundred of the

same species and strain that were kept in a 150 gallon aquarium.

OSTEOMA

Osteomas are tumors frequently observed in 15 species of fishes (Table 11). The multiple osteomas in a butterfly fish reported by William Bell in 1793 is probably the first recorded account of neoplasm in a fish. The tumors in this case were the size of hazel-nuts and involved several haemal and neural spines. Since similar lesions were found in several specimens, the fish were classified as a separate species; viz., *Chaetodon arthriticus*. The tumor-bearing fish are, however, now grouped with the normal members of the species *Platax pinnatus*.

Several Japanese investigators (96, 175, 199) have described localized bony overgrowths on the ventral spinous processes (haemal spines) of the sixth to eighth caudal vertebrae of the red tai, *Pagrosomus major*. The largest series, consisting of 102 fish, was reported by Takahashi (199). The growths varied from the size of a pea to that of a large bean; rarely were they as large as a walnut. In 28 cases the tumor was single, in 64 there were 2 tumors; in 17, 3; and in 10, 4 or more. A line of fracture was visible in several of the very small tumors. Takahashi concludes that ossification of excess callus is the initial step in the formation of these tumors.

Three specimens of *Pagrosomus major* were chosen by us at random from the collection at the National Museum in Washington, and one bore tumors identical with those described by Takahashi (Fig. 25). Careful inspection of the roentgenograms (Fig. 26) and histologic sections failed to reveal convincing evidence of previous fracture. The cortex, which is very thin in the normal spinous process, was greatly thickened (Fig. 27). As the growths increased in size the cancellous bone became more prominent until only a thin cortical layer of dense bone remained (Fig. 28). The marrow spaces were filled with well vascularized adipose tissue; hematopoiesis does not occur in the bone marrow of fishes, hence its absence in the osteomas could be anticipated.

TABLE 11: OSTEOMA

Species	Site	Author
Butterfly fish <i>Platax pinnatus</i>	Neural and haemal spines	Bell, 1793
Scabbard fish <i>Lepidopus</i> sp.	Dorsal fin rays	Gervais, 1875
Butterfly fish <i>Platax pinnatus</i>	Vertebral spines	Gervais, 1875
Pike <i>Esox lucius</i>	Dental plate	Bland-Sutton, 1885
Codfish <i>Gadus morhua</i>	Superior maxilla	Bland-Sutton, 1885
Codfish <i>Gadus morhua</i>	Intervertebral disc	Bland-Sutton, 1885
Pike <i>Esox lucius</i>	Vertebra	Plehn, 1906
Flounder <i>Psetta maotica</i>	Vertebral spines	Schroeders, 1908
Carp <i>Cyprinus carpio</i>	Skull bones	Fiebiger, 1909c
Codfish <i>Gadus morhua</i>	Vertebrae	Williamson, 1913
Croaker <i>Pogonias chromis</i>	Two vertebrae	Beatti, 1916
Red Tai <i>Pagrosomus major</i> (6)	Mandible, haemal spines	Kazama, 1924
Red Tai <i>Pagrosomus major</i> (2)	Haemal spines	Sagawa, 1925
Codfish <i>Gadus morhua</i>	Pre-maxilla	Williams, 1929
Coalfish <i>Theragra chalcogramma</i> (8)	Dorsal fin spines	Takahashi, 1929
Flatfish <i>Paralichthodes olivaceus</i>	Vertebral spine	Takahashi, 1929
Red Tai <i>Pagrosomus major</i> (102)	Haemal spines	Takahashi, 1929
Rock fish <i>Sebastes inermis</i>	Dorsal fin	Takahashi, 1929
Speckled trout <i>Salvelinus fontinalis</i>	Fin rays	Thomas, 1932b
Cat shark <i>Scylliorhinus canicula</i>	Skin	Thomas, 1933b
Red Tai <i>Pagrosomus major</i>	Haemal spines	Lucké & Schlumberger (not published)
Angelfish <i>Chaetodipterus faber</i> (4)	First haemal spine	Lucké & Schlumberger (not published)
Angelfish <i>Chaetodipterus faber</i>	Shoulder girdle	Lucké & Schlumberger (not published)
File fish <i>Alutera schoepfi</i>	First interneural spine	Lucké & Schlumberger (not published)

In considering the etiology of these tumors the following characteristics must be taken into account: their frequent occurrence in a particular species, the predominance of the tumors in the spines of the sixth to eighth caudal vertebrae, and the predilection of the tumors for fishes over 20 cm. in length. A traumatic origin, as suggested by Takahashi, and Kazama (96) does not adequately explain all these features of the neoplasm. An elucidation of the problem must await study of the tumor in the living animal.

Chabanaud (27) has described a localized fusiform hypertrophy characteristic of certain spines of the dorsal fin in several species of fishes—*Corvina clavigera*, *C. nigrita*, and *Sciaenoides perarmatus*. The enlargement of the spines was absent in very young fish, but became manifest with increasing age. The author concluded that these hypertrophies were not accidental, but might be "integrated with the metabolism of the species."

Dr. L. P. Schultz, ichthyologist of the National Museum in Washington, called our attention to similar changes in the angelfish *Chaetodipterus faber*. In old individuals of this species a localized hypertrophy of the distal portion of the first interhaemal spine tends to develop (Figs. 29 and 30). The enlargement may become massive, in some instances measuring as much as 4.5 x 3 x 2.5 cm. Histologic examination revealed that the tumor con-

sists of cancellous bone and concentrically arranged bands of more condensed osseous tissue (Fig. 31). A similar laminated structure is found in the otoliths of fishes, where it is believed to result from periodic (seasonal) fluctuations in the rate of growth. The adipose tissue that had filled the marrow cavity was still recognizable in some regions, but elsewhere had almost disappeared. This overgrowth of bone probably represents a hyperostosis, rather than an osteoma.

Reports of the sporadic occurrence of osteomas in various species of fishes are not uncommon. The tumors are usually found in the fin rays and vertebral spines, though the maxillae have been affected twice, and Fiebiger (49) reports an osteoma the size of a child's fist that arose from the frontal bone of a 900-gram carp *Cyprinus carpio*. A sagittal section of the head revealed that much of the cranial cavity had been obliterated by the growth. Histologically the tumor consisted of bone and cartilage that in its arrangement resembled normal endochondral bone formation.

The collection of fishes in the National Museum contains the bones of an angelfish *Chaetodipterus faber* found in a Florida Indian kitchen-midden. Several of the spines bear symmetrical hyperostoses, and an irregular bony overgrowth which may be classified as an osteoma is present on one of the bones (cleithrum) of the shoulder girdle (Fig. 32).

Also in the collection is the skeleton of a file fish *Alutera schoepfi* in which a large osteoma arises from the first interneural spine (Fig. 33).

Abstracts of other reported cases of Osteoma

BELL, 1793: "The skeleton of the butterfly fish *Chaetodon arthriticus* is very singular, many of the bones having tumours, which, in the first fish I saw, I supposed to be exostoses arising from disease; but on dissecting a second, found the corresponding bones had exactly the same tumours, and the fishermen informed me they were always found in this fish; and therefore conclude them to be natural to it. In Mr. Hunter's collection are two or three of these bones, but I never knew what fish they belonged to . . . These tumours are spongy, and so soft as to be easily cut with a knife; they were filled with oil." (See discussion at beginning of this section.)

GERVAIS, 1875: In a scabbard fish *Lepidopus sp.* there were numerous osteomas on the dorsal fin rays.

GERVAIS, 1875: The author points out that many hyperostoses are found in fossil as well as in living fish. In both they are most common in the vertebrae and fin rays. Gervais found a large osteoma in the fin ray of a butterfly fish *Platax pinnatus*.

BLAND-SUTTON, 1885: The author describes a bony tumor that occurred on the dental plate of a pike *Esox lucius*. Scattered through the tissue were delicate spicules of bone.

BLAND-SUTTON, 1885: From the maxilla of a codfish *Gadus morhua* there arose a heavy, bony, disc-shaped tumor, 2 inches in diameter and half an inch in thickness.

BLAND-SUTTON, 1885: An exostosis (osteochondroma?), 1 cm. in diameter, grew from the vertebrae of a codfish *Gadus morhua*. It developed from the cartilaginous intervertebral discs.

PLEHN, 1906: A stony-hard tumor the size of a walnut arose from the last vertebra of a pike *Esox lucius*. The author identified the growth as an osteoma.

SCHROEDERS, 1908: Multiple osteomas were found on the vertebral spines of a flounder *Psetta maotica*. The tumors, 15 in number, ranged from the size of a pin-head to that of a walnut and were attached to the bony rays. All were covered by normal skin and were firm in consistency. Histologically they resembled normal bone.

WILLIAMSON, 1913: The author reports the case of a bone tumor in a codfish *Gadus morhua*. The site of origin was a vertebral body.

BEATTI, 1916: Multiple osteomas of two vertebrae in a croaker *Pogonias chromis* were described. The author states that he has seen several such lesions in this species of fish.

KAZAMA, 1924: Osteomas were found in 6 of 500 red tai *Pagrosomus major* examined. In one the tumor appeared as a nodular mass as large as a thumb-nail at the middle of the mandible. In the other 5 the tumors were multiple, developing on the ventral spinous processes at the site of union with the anal fin. The author suggests that trauma evoked the lesions.

SAGAWA, 1925: In each of 2 red tai *Pagrosomus major* a tumor the size of the tip of the little finger grew on a spinous process of one of the caudal vertebrae. Histologically, the lesion was an osteoma.

WILLIAMS, 1929: A protuberance 5 x 2 cm., grew from the anterior portion of the left premaxilla of a codfish *Gadus morhua*. The overlying skin was intact. The microscopic structure was that of typical bone, with Haversian canals and vascular spaces.

TAKAHASHI, 1929: The author reports 8 cases of exostosis (osteochondroma?) in *Theragra chalcogramma*. In 6 fish, tumors occurred in the spines of the dorsal fin; some were as large as a small hen's egg, and one was certainly an osteoma. In the remaining 2 cases symmetrical osteomas of thumb-nail size were present near the posterior margin of the operculum.

TAKAHASHI, 1929: A spherical, firm, bony tumor occurred on the spinous process of the third lumbar vertebra of a flatfish *Paralichthodes olivaceus*. Pressure by the tumor had produced local atrophy of the adjacent vertebral body.

THOMAS, 1932 b: A 5 year old speckled trout *Salvelinus fontinalis* bore many firm, white nodules, between 3 and 7 mm. in diameter, at the base of the rays supporting the ventral portion of the caudal fin. The overlying skin was normal, except for an absence of pigment in some areas. Stages of transition between fibroblasts and osteoblasts were noted. The appearance was that of connective tissue in which a bony metaplasia was taking place.

THOMAS, 1933 b: On the back of a cat shark *Scylliorhinus cannicula*, immediately anterior to the dorsal fin, was a firm white tumor 4 x 6 mm. Much of the tumor consisted of osteoid tissue, yet in some areas osteoblasts were present and true bone was formed.

OSTEOSARCOMA

Four tumors of fishes have been reported in the literature as osteosarcomas (Table 12). One was observed in a pike *Esox lucius*, the remaining 3 occurred in codfish *Gadus morhua* and *Pollachius virens*. The series is small and the diagnoses so open to question that no conclusions can be drawn as to the general characteristics of this tumor among fishes. The tumors were all single; no metastases

TABLE 12: OSTEOSARCOMA

Species	Site	Author
Pike <i>Esox lucius</i>	Anal fin	Wahlgren, 1873
Codfish species not given	Operculum	Murray, 1908
Codfish <i>Pollachius virens</i>	Vertebra	Williams, 1929
Codfish <i>Gadus morhua</i>	Pectoral fin	Thomas, 1932b

were observed. There is no evidence of malignant transformation of one or several of the multiple osteomas noted in the preceding section.

Abstracts of reported cases of Osteosarcoma

WAHLGREN, 1873: A nodular growth 8 x 5.5 cm. was present on the anal fin of a 3-foot pike *Esox lucius*. The overlying skin was intact. On section the tumor had the appearance of bacon and was traversed by irregular bony trabeculae. Microscopically the soft tissue consisted of small, irregular cells with one or more nuclei. The cells were surrounded by partially hyalinized connective tissue.

MURRAY, 1908: In the subcutaneous tissue of the operculum of a codfish was a hemispherical bony tumor measuring 2 cms. Histologically it was composed of irregular rounded masses of osseous tissue separated by strands of spindle cells. Thin walled, irregularly arranged capillaries were numerous.

WILLIAMS, 1929: Arising from one of the vertebrae of a codfish *Pollachius virens* was a tumor that infiltrated the adjacent muscle in all directions. Histologically it consisted of bone trabeculae and spindle cells.

THOMAS, 1932 b: Immediately behind the left pectoral fin of a young codfish *Gadus morhua* was a tumor 4.5 x 2 x 1.5 cm. that bulged into the peritoneal cavity and infiltrated the adjacent trunk muscles. The neoplasm was soft, the cut surface was gray-white and marked by many punctate hemorrhages. Among the pleomorphic cells were plaques of osteoid tissue and multinucleated giant cells.

LIPOMA

The fat storage depots of fishes correspond with those of man, though the subcutaneous tissues are not as heavily infiltrated. Nevertheless, in a catfish *Pygidium totae* found in Lake Tota, Colombia, these subcutaneous stores reach enormous proportions (Fig. 34). Dr. L. P. Schultz, ichthyologist of the National Museum, Washington, D. C., is undecided whether the adiposity is characteristic of this species, or whether it represents an abnormality. Histologically the tissue is composed of adult fat cells, the subjacent trunk musculature is not invaded, and the overlying skin is normal, without evidence of atrophy (Fig. 35). If this subcutaneous accumulation of fat is pathologic for the fish, it should probably be classified as a lipodystrophy rather than as a true lipoma.

Discrete lipomas have been reported 7 times in the literature; each tumor in a different species of fish (Table 13). All but 2 of the tumors were composed of adult fat cells. Takahashi (199) observed a lobulated lipoma, the size of a small nut, in the subcutaneous tissue behind the left eye of a Japanese samlet *Plecoglossus altivelis*. The tumor was well encapsulated, the fat cells varied in size, and the nuclei were oval or star-shaped. In 1929 Williams (228) reported a smooth spherical encapsulated tumor that had displaced the right eye of a dragonet *Callionymus lyra*. Histologically, it consisted of fat cells which the author believed had undergone malignant transformation. The connective tissue supporting stroma was myxomatous.

Abstracts of other reported cases of Lipoma

BERGMAN, 1921: On the trunk of a lake pike *Esox lucius* there was a subcutaneous tumor the size of a man's fist. Histologically the lesion was a lipoma.

BERGMAN, 1921: Beneath the skin of the pigmented surface of a plaice *Pleuronectes platessa* was a tumor that measured 6.5 x 3.5 x 3 cm. It was easily separated from the surrounding tissue and had produced a groove in the back musculature by pressure atrophy. It weighed 25 gm., was firm but elastic, and floated in water; its parenchyma was composed of adult fat cells.

KAZAMA, 1924: Within the ventral trunk musculature of a flounder *Paralichthys olivaceus* was a tumor about the size and shape of a little finger. It was encapsulated, soft in consistency, and made up of fat cells.

WILLIAMS, 1929: Protruding into the posterior portion of the body cavity of a halibut *Hippoglossus hippoglossus* was a tumor that measured 27.6 x 12.5 cm. It arose between the muscle bundles of the trunk. The cut surface appeared oily, was pale yellow, and had the consistency of cheese. Histologically the tumor was composed of well differentiated fat cells.

THOMAS, 1933 d: A coalfish *Pollachius carbonarius*, approximately 7 years old, bore a tumor, 3 x 2.5 x 2 cm., on the lower border of the liver. The surface was smooth and greenish, and covered by normal peritoneum. On section it was soft in consistency, homogeneous and without apparent fibrous trabeculae. The tumor consisted of adult fat cells, among which were islands of hematopoietic tissue.

LEIOMYOMA

The four cases of smooth muscle tumors reported

TABLE 13: LIPOMA

Species	Site	Author
Plaice <i>Pleuronectes platessa</i>	Subcutaneous	Bergman, 1921
Pike <i>Esox lucius</i>	Subcutaneous on trunk	Bergman, 1921
Flatfish <i>Paralichthys olivaceus</i>	Trunk muscle	Kazama, 1924
Halibut <i>Hippoglossus hippoglossus</i>	Trunk muscle	Williams, 1929
Dragonet <i>Callionymus lyra</i>	Subcutaneous on head	Williams, 1929
Jap. samlet <i>Plecoglossus altivelis</i>	Subcutaneous	Takahashi, 1929
Coalfish <i>Pollachius carbonarius</i>	Liver	Thomas, 1933d

in fishes (Table 14) are not convincingly neoplastic in character. In the three instances involving the stomach the lesions were diffuse and more suggestive of hyperplasia than of true tumor; one was associated with a parasitic infestation of the pyloric appendages. Plehn (157) reported a leiomyoma in a shiner *Alburnus lucidus* that arose in the trunk musculature, was infiltrated by lymphocytes, and contained minute hemorrhages. If the diagnosis of leiomyoma was correct, the tumor probably had its origin in the smooth muscle of blood vessels.

Abstracts of reported cases of Leiomyoma

PLEHN, 1906: On the ventral surface near the cardiac end of the stomach of an 8 or 9 year old rainbow trout *Salmo gairdnerii* was a bean-sized mass. The overlying mucosa was intact. Histologically the cells were identical with the normal musculature of the intestine; only the irregular arrangement was abnormal. No mitoses or inflammatory cell infiltrates were present.

PLEHN, 1906: In the trunk musculature of a shiner *Alburnus lucidus* between 1 and 2 years old, was a firm hemispherical tumor 1 cm. wide. Histologically it consisted of interlacing bundles of smooth muscle containing small "round cell" infiltrates and minute hemorrhages. Mitoses were uncommon.

PESCE, 1907: The stomach wall near the pylorus of a trout *Salmo carpio* was greatly thickened. The pyloric appendages were filled with cestodes. Histologically the cellular detail and organization differed greatly from what is regarded as normal in this region. The irregular fasciculi embedded in loose connective tissue meshes were diagnosed as fibroleiomyoma.

THOMAS, 1933 c: In a male, 3 year old herring *Clupea harengus*, 18 cm. long, the pyloric segment of the anterior gastric pouch was markedly hypertrophied. It formed a cone-shaped, white mass that was covered by peritoneum. The lumen of the stomach was normal. Histologically the mucosa and serosa were intact, the wall from two to three times its normal thickness. Oblique, regularly arranged connective tissue trabeculae formed partitions in the mass which consisted chiefly of smooth muscle fibers. There was no evidence of invasion of the surrounding structures.

RHABDOMYOMA

Rhabdomyoma has been reported in 8 species (Table 15). The record of twice as many tumors of striated muscle as of smooth muscle is probably due to the common location of rhabdomyoma in the trunk musculature where they are more readily ob-

served. Histologically the tumors closely resemble similar tumors found in man. Noteworthy is the report by Young (235) of a rhabdomyoma in each of two turbot. The fishes had been sent from England to New Zealand and kept there for ten years in separate tanks. Tumors measuring $3\frac{1}{2}$ by $1\frac{1}{2}$ inches developed in both turbot at approximately the same time and in the same location on the non-pigmented side of the body. The neoplasms were soft and yellow, and histologically consisted of large striated muscle fibers, many of which were edematous and had partly disintegrated.

The only rhabdomyoma that did not arise in the trunk musculature was reported by Fiebiger (48). It was found in the viscera of a codfish *Pollachius virens* and measured 12 x 9 x 6 cm. The tumor was encapsulated and could easily be separated from the surrounding organs. Small cysts and groups of cells that resembled hepatic cells were present among the striated muscle bundles. This suggests that the growth may have been primarily a teratoid tumor in which the muscle fibers formed the predominant element.

Abstracts of other reported cases of Rhabdomyoma

ADAMI, 1908: A red trout *Salmo clarkii* bore a 3 cm., spherical tumor on its left side 4 cm. behind the dorsal fin. It was embedded in the musculature and projected 1.5 cm. above the general body surface. The tumor was well circumscribed and separated readily from the surrounding tissue. Histologically it was composed almost wholly of multinucleate giant cells. Several of these were of great length and resembled regenerating muscle. In not a few, the part of the cell farthest from the grouped nuclei showed definite striations.

BERGMAN, 1921: On the right side of a stint *Osmerus eperlanus*, directly behind the head, was a tumor, 1.5 x 1 x 1.2 cm. The gray-white mass had the consistency of normal muscle and extended to the vertebral column. Histologically it was well circumscribed by a thin fibrillar capsule. The parenchymal cells were transversely striated muscle fibers and myeloblasts in various stages of development.

KOLMER, 1928: A tumor was present in the trunk musculature of an adult tench *Tinca tinca*. The overlying scales in this region were approximately twice normal size. Microscopically the tissue consisted of irregularly arranged striated muscle fibers that formed a typical rhabdomyoma.

LADREYT, 1930: Near the posterior border of the right pectoral fin of a wrasse *Labrus mixtus* was a pea-

TABLE 14: LEIOMYOMA

Species	Site	Author
Rainbow trout <i>Salmo gairdnerii</i>	Stomach wall	Plehn, 1906
Shiner <i>Alburnus lucidus</i>	Trunk muscle	Plehn, 1906
Trout <i>Salmo carpio</i>	Stomach wall	Pesce, 1907
Herring <i>Clupea harengus</i>	Wall of stomach	Thomas, 1933c

TABLE 15: RHABDOMYOMA

Species	Site	Author
Red trout <i>Salmo clarkii</i>	Trunk muscle	Adami, 1908
Codfish <i>Pollachius virens</i>	Viscera	Fiebiger, 1909b
Stint <i>Osmerus eperlanus</i>	Trunk muscle	Bergman, 1921
Turbot <i>Rhombus maximus</i>	Trunk muscle	Young, 1925
Tench <i>Tinca tinca</i>	Trunk muscle	Kolmer, 1928
Wrasse <i>Labrus mixtus</i>	Trunk muscle	Ladreyt, 1930
Herring <i>Clupea harengus</i>	Trunk muscle	Williams, 1931
Halibut <i>Hippoglossus hippoglossus</i>	Trunk muscle	Thomas, 1932a

sized tumor. The overlying skin was ulcerated, the surrounding musculature infiltrated by the neoplasm. Histologically it consisted of fusiform and giant cells as well as myocytes. The author attempted to trace the evolution of the connective tissue cells into mature muscle fibers.

WILLIAMS, 1931: In a herring *Clupea harengus*, 24 cm. in length, a tumor 3.1 cm. in diameter arose in the dorsal musculature immediately anterior to the dorsal fin. The overlying skin was intact. Histologically only the muscle fibers in the periphery showed striations.

THOMAS, 1932 a: Along the ventral border of a halibut *Hippoglossus hippoglossus* was a tumor measuring 1.7 x 1.5 cm. On section it was pearly white and finely fasciculated. There were no metastases. Histologically the posterior portion of the tumor consisted of undifferentiated cells, but toward the anterior region the normal myomeric architecture was approached. A pseudocapsule was present, the result of pressure on the adjacent myomeres which were infiltrated by the tumor. The author discussed the embryology of fish striated muscle and recognized many of the transitional forms in this tumor.

HEMANGIOMA

Hemangiomas have been reported in 11 species (Table 16). The earliest, and to date most interesting account of such tumors is that of Plehn (157). She observed three cases in the stickleback *Gasterosteus aculeatus* and states that these growths occur frequently in this fish. The tumors, which were deep red in color, arose on the ventral surface of the head, spread forward to the angle of the mouth, and thence over the operculum to the level of the eyes. They seemed to cause little functional em-

barrassment. The proliferation and dilatation of the vessels began in the corium and subcutaneous tissue, then infiltrated the tissues between the gill arches and hyoid bone. Solid cords of endothelial cells finally penetrated to and partly replaced the subjacent muscle.

Johnstone has reported 7 of the 12 recorded cases of vascular tumors in fishes. He identified 5 as examples of angiosarcoma; however, histologic data in support of this diagnosis are meager. Several of the lesions reported by investigators may represent a local inflammatory response rather than a true neoplasm; Drew, for example, found a copepod within the lesion in one of his cases.

Abstracts of other reported cases of Hemangioma

MURRAY, 1908: In the pectoral girdle of a codfish *Gadus morhua* there was a flat, dark-colored growth about 1.5 cm. in diameter. Microscopically it consisted of capillaries distended with blood.

DREW, 1912: A reddish tumor was present in the midline on the ventral surface of the head of a spotted ray *Raja maculata* at the level of the fifth gill arch. Histologically the appearance was identical with that of a hemangioma of man. The body of a copepod was found within the tumor.

DREW, 1912: A nearly spherical tumor, 1 inch in diameter, was found in the region of the basi-hyal bone of a conger eel *Conger conger*. It was white and covered by an irregularly thickened and ulcerated epidermis. The central portion of the tumor was necrotic. The neoplasm was made up of masses of endothelial cells which in some regions arranged themselves in long columns that suggested capillary formation.

DREW, 1912: A soft, red tumor was present on the

TABLE 16: HEMANGIOMA

Species	Site	Author
Stickleback <i>Gasterosteus aculeatus</i> (3)	Subcutaneous, head	Plehn, 1906
Codfish <i>Gadus morhua</i>	Pectoral girdle	Murray, 1908
Spotted ray <i>Raja maculata</i>	Subcutaneous	Drew, 1912
Conger eel <i>Conger conger</i>	Region of basi-hyal	Drew, 1912
Gurnard <i>Trigla lineata</i>	Operculum	Drew, 1912
Stickleback <i>Pungitius pungitius</i>	Iris	Johnstone, 1915
Mackerel <i>Scomber scombrus</i>	Body wall	Johnstone, 1924
Codfish species not given	Swim bladder	Johnstone, 1925
Ling <i>Molva molva</i>	Body wall	Johnstone, 1925
Plaice <i>Pleuronectes platessa</i>	Body wall	Johnstone, 1925
Codfish <i>Pollachius virens</i>	Trunk musculature	Johnstone, 1926
Hake <i>Merluccius merluccius</i>	Submucosa of rectum	Johnstone, 1926

inner surface of the operculum of a gurnard *Trigla lineata*. Histologically it consisted of a mass of dilated capillaries.

JOHNSTONE, 1915: The pupil of the left eye of a stickleback *Pungitius pungitius* was surrounded by a brown, raised, nodular swelling. The cornea was mottled with opaque specks, while small arborescent growths arose from its center. On section the tumor, consisting of a plexus of proliferating capillaries, occupied the subcutaneous subconjunctival and iridial tissues. The papillae noted on the cornea were masses of epithelial cells.

JOHNSTONE, 1924: In the body wall of a mackerel *Scomber scombrus* was a soft, red tumor, 5 x 1.5 cm., that infiltrated the adjacent musculature. It was composed of dilated capillaries supported by proliferating connective tissue.

JOHNSTONE, 1925: In the swim bladder of a codfish was a tumor that apparently arose from the plexus of vessels normally present in this region. It consisted of numerous dilated vessels supported by a loose connective tissue stroma infiltrated by collections of lymphoid tissue.

JOHNSTONE, 1925: A firm mass, 2 x 4 inches, was found in the trunk musculature of a ling *Molva molva*. A central dark area was interpreted by the author as clotted blood; the periphery consisted of many dilated vessels, capillaries, and proliferating angioblasts.

JOHNSTONE, 1925: The author reports single lesions, averaging from 2 to 3 cm. in diameter, that arose in the trunk musculature of 3 plaice *Pleuronectes platessa*. Histologically they were made up entirely of thin-walled vessels that infiltrated the surrounding tissue.

JOHNSTONE, 1926: Many hard nodules, 1/2 to 1 inch in diameter, were palpated throughout the trunk musculature of a codfish *Pollachius virens*. Histologically each nodule consisted of a mass of blood vessels and accompanying connective tissue stroma.

JOHNSTONE, 1926: The last 3 inches of the rectum of a hake *Merluccius merluccius* was swollen, deep red in color, and resembled a huge blood clot. On section the mucosa and submucosa were almost replaced by dilated vascular spaces, many of which contained actively proliferating angioblasts.

LYMPHOSARCOMA

A discussion of lymphosarcoma in fishes must be introduced by pointing out that circumscribed collections of lymphoid tissue in the form of nodes, do

not occur in these animals. They are found in the phylogenetic scale only in some birds (aquatic) and in all mammals (93). In elasmobranch fishes, hematopoiesis takes place in the spleen, the mesonephros, the submucosa of the intestine, and the subcapsular tissue of the gonads. In teleosts the mesonephros is generally the dominant hematopoietic organ; the spleen and submucosa of the intestine have only an accessory role. This distribution of the hematopoietic tissue accounts for the frequent location of lymphosarcoma in the kidney; i.e., in 15 of the 20 reported cases (Table 17).

In the older reports lymphosarcoma has not always been separated from other forms of sarcoma; it is probable that several of the tumors which in this review are included in the latter group are in fact lymphosarcomas.

Plehn (162) observed that the kidney of a goldfish *Carassius auratus* was increased to 20 times its normal size. The organ was firm and white; the normal renal tissue had been almost wholly replaced by lymphoid elements. Metastases were found in the liver. The author believes that renal insufficiency accounted for the generalized edema that was present. In a herring *Clupea harengus*, measuring 30 cm. in length, Johnstone (91) found an intracoelomic tumor, 5 x 2.5 cm. Histologically it was composed of connective tissue stroma packed with lymphoid cells. It is probable that the subcapsular tissue of the gonads was the primary site of the neoplasm. Recently, Nigrelli (142) has reported several interesting cases of metastasizing lymphosarcomas. Twelve fully grown pike *Esox lucius*, kept in one tank, succumbed at various intervals at the N. Y. Aquarium during the years 1940 and 1941. Both sexes were represented. There were no external manifestations of disease, but autopsies showed comparatively massive growths in the kidneys, with metastasis to the spleen and liver. Histologically the tumors were identified as lymphosarcomas composed mainly of large lymphoblasts supported by irregular strands of fibrous stroma and a delicate reticulum.

Another metastasizing tumor was found in a male

TABLE 17: LYMPHOSARCOMA

Species	Site	Author
Flatfish <i>Platichthys flesus</i>	Retro-orbital	Johnstone, 1912
Goldfish <i>Carassius auratus</i>	Kidney	Plehn, 1924
Herring <i>Clupea harengus</i>	Peritoneum	Johnstone, 1926
Conger eel <i>Conger conger</i>	Kidney	Williams, 1931
Amer. salmon <i>Salmo salar</i>	Kidney	Haddow & Blake, 1933
Pike <i>Esox lucius</i>	Subcutaneous	Haddow & Blake, 1933
Trop. Aquar. Fish <i>Rasbora lateristriata</i>	Peritoneum	Smith, Coates, & Strong, 1936
Pike <i>Esox lucius</i> (12)	Kidney	Nigrelli, 1947
Characin <i>Astyanax mexicanus</i>	Branchial region	Nigrelli, 1947

characin *Astyanax mexicanus* measuring 50 mm. in total length and about four years old. The growths occurred in the branchial region and had caused exophthalmia. The tumor probably originated in a paired mass of lymphoid tissue normally present in the posterior region of the branchial cavity. There was considerable local invasion extending even to the myocardium. Metastases were present in the corium of the skin, the gills, kidneys, pancreas, and liver.

Abstracts of other reported cases of Lymphosarcoma

JOHNSTONE, 1912: The left eye of a plaice *Platichthys flesus* was displaced by a retro-orbital tumor, measuring 2 x 2 cm. The growth consisted of connective tissue stroma in which were embedded masses of lymphocytes separated by large spaces, apparently lymph channels.

WILLIAMS, 1931: A very large bulge was seen in the ventral wall of a conger eel *Conger conger*; the overlying skin was intact. Dissection disclosed a retroperitoneal tumor, 16 x 9 cm., in the region of the kidney. Within the kidney the lymphoid tissue was greatly increased and the renal tubules were widely separated; mitoses were numerous.

HADDOW and BLAKE, 1933: In each kidney of a 5 year old American salmon *Salmo salar* there was a mass, 4.4 x 2.4 cm., that diffusely invaded these organs, resulting in almost complete destruction of the renal units. The haemal arch was occluded by a mass of tumor tissue, apparently by direct extension from the veins of the renal portal system.

HADDOW and BLAKE, 1933: Many subcutaneous tumors were found about the bases of the fins and within the buccal cavity of a partly decomposed pike *Esox lucius*. The neoplastic tissue was gray in color and did not infiltrate the surrounding musculature; visceral metastases were absent. Grossly the lesions appeared mucoid or fatty in character; histologically they appeared to be lymphoid in origin. The authors suggest lymphosarcoma as a possible diagnosis.

SMITH, COATES and STRONG, 1936: Neoplastic lymphoid tissue produced a mass that was first noted in the upper abdomen near the liver in a tropical aquarium fish *Rasbora lateristriata*. The intra-abdominal swelling could be seen distinctly during life through the semitransparent abdominal wall. After approximately 2 months the tumor had extended cephalad, involving the gill on the right side and pressing the operculum outward.

TUMORS OF PIGMENT CELLS

Fishes are provided with an abundance of pigment cells, not only in the epidermis and subcutaneous tissues, but in the peritoneum, mesentery, viscera, and central nervous system. The most common of these cells in fishes as in other vertebrates are the melanophores which elaborate melanin. The guanophores, laden with guanin crystals, and the iridio-

cytes, bearing crystals of inorganic salts, are responsible for the white background and the iridescence so characteristic of fish coloration. In addition, most fishes also possess yellow-pigmented xanthophores and red-pigmented erythrophores (allophores).

The close relationship of these variously pigmented cells has been generally accepted by investigators, and their origin usually sought in a common undifferentiated mesenchymal cell (8). In 1909 Borcca suggested that these cells may be derived from the neural crest. In recent years investigators working with amphibian and avian embryos have accumulated convincing evidence that in these animals the neural crest does supply the pigment cells (42). In the light of these findings it is probable that the pigment cells of fishes have their origin in neurectoderm.

MELANOMA

The most frequently observed pigment cell tumors of fishes are the melanomas located in the skin and subcutaneous tissues. They have been reported in 12 species (Table 18). Whether they are predominantly benign or malignant cannot be clearly established. Johnstone (82, 83, 85) and Prince (165) reported cases in which the lesions were multiple, but whether they represent metastases is difficult to determine. Besides these sporadic examples, melanotic tumors are commonly found in hybrids of the tropical aquarium fishes *Xiphophorus hellerii* and *Platypoecilus maculatus*. First reported by Haüssler (1928) and Kosswig (1929) they have been thoroughly investigated by Gordon and his co-workers (59 to 63, 169). Swordtails *Xiphophorus hellerii* possess only micromelanophores, or no melanophores at all; platyfish *Platypoecilus maculatus* bear both micro- and macromelanophores. It is the platyfish macromelanophore factor introduced into the hybrid that produces melanosis and melanotic neoplasms. Although the dominant inherited factor responsible for melanosis is that for macromelanophores of the platyfish, alone it is ineffectual. The swordtail strain also plays its part in the production of the lesion, since it contributes hereditary factors that initiate the multiplication of the macromelanophores in the hybrids.

According to the descriptions of Reed and Gordon (169), the neoplastic disease begins as a densely pigmented spot in the caudal fin. It increases in size and merges with other pigmented regions until a large area is involved. This stage has been observed in day-old fish as well as in embryos 6 days before hatching (59). Subsequently a local swell-

TABLE 18: MELANOMA

Species	Site	Author
Haddock <i>Melanogrammus aeglefinus</i>	Skin	Prince, 1892
Thorn-back ray <i>Raja clavata</i>	Skin of head	Johnstone, 1911
Thorn-back ray <i>Raja clavata</i>	Skin of head	Johnstone, 1912
Ray <i>Raja batis</i> (2)	Skin of fins	Johnstone, 1912
Ray <i>Raja batis</i> (2)	Skin of fins	Johnstone, 1913
Halibut <i>Hippoglossus hippoglossus</i>	Skin (multiple)	Johnstone, 1915
Eel-pout <i>Zoarces viviparus</i>	Skin	Bergman, 1921
Plaice <i>Pleuronectes platessa</i>	Skin of pigmented surface	Johnstone, 1925
Killifishes (<i>Platypoecilus maculatus</i> (<i>Xiphophorus hellerii</i>)	Skin	Haüssler, 1928 & 1934
Killifishes hybrids	Skin	Kosswig, 1929
Coalfishes <i>Theragra chalcogramma</i> (2)	Body wall	Takahashi, 1929
Mackerel <i>Pneumatophorus colias</i>	Skin	Takahashi, 1929
Angler fish <i>Lophius piscatorius</i>	Skin	Ingleby, 1929
Killifishes hybrids	Skin	Reed & Gordon, 1931
Thorn-back ray <i>Raja clavata</i>	Skin	Haddow & Blake, 1933
Grouper <i>Epinephelus gigas</i>	Branchial region	Dollfus, Timon-David & Mosinger, 1938
Silverside <i>Menidia beryllina peninsulæ</i>	Skin	Nigrelli & Gordon, 1944
Killifishes hybrids (11)	Eye	Levine & Gordon, 1946
Killifishes hybrids (many)	Skin	Gordon, 1948

ing develops due to proliferation of the pigmented cells. The transition from melanosis to neoplasm is not abrupt, and in the early stages a distinction between the two cannot be made. It should be pointed out here that non-neoplastic melanosis is not uncommon in fishes and has recently been reported by Smith and Coates (189) in the lung fish. The neoplastic cells may be devoid of pigment, a condition frequently observed in the metastases of human melanomas; or they may be very heavily pigmented.

The growth of these melanomas in tissue culture was studied by Grand, Gordon, and Cameron (63).

Recently Levine and Gordon (111b) have reported on the occurrence of pigmented ocular tumors in xiphophorin fishes. The species distribution of the neoplasms was as follows: 1 *Platypoecilus maculatus*, 1 *Xiphophorus pygmaeus*, 6 hybrid *P. maculatus*-*X. hellerii* out of a brood of 15, 2 hybrids out of a brood of 16, and 1 hybrid from a private collector. All fish were full grown, at least 6 months old and some over a year old, before the tumor developed. The average life span of the normal fish is about a year and a half. Exophthalmia developed gradually and was associated with blindness of the affected eye. The neoplasms were composed chiefly of pigmented epithelioid cells. They arose in the choroid, invaded the retina, later they perforated the eyeball and grew into the retroorbital tissues. No bacterial or virus agent could be identified. Although the authors stated in their paper that the tumor is not controlled by a genetic factor, more recent work has convinced Dr. Gordon that the tumors develop on a genetic basis (60a).

These tumors closely resemble the ocular neoplasms reported by Jahnel (80) and identified by him as fibrosarcomas; these have been discussed in the section on sarcoma. He likewise sought a genetic basis for their occurrence.

A hitherto undescribed type of pigmented tumor was found in a grouper *Epinephelus gigas*, by Dollfus, Timon-David, and Mosinger. It is of such interest that we shall quote an abstract made by Foulds (35a) in full. "The primary growth was almost certainly of branchial origin. In addition to tumors in the branchial region there were smaller subcutaneous tumors in the caudal, anal, and dorsal fins and in the liver and spleen. Some of the tumors, especially in the branchial region, were plainly epithelial, resembling basal cell tumors of mammals. Some of the cells were pigmented and, since pigmentation seemed associated with an eosinophilic degeneration, it appeared as if the melanin granules represented a degenerative phenomenon. In the liver and spleen, however, though almost all the tumor cells were pigmented there was no sign of a degenerative process; careful examination revealed rare tumor nodules with cells like those in the branchial tumors. None of the tumor cells resembled the melanocytes characteristic of lower vertebrates. Transitions were found between epithelial cells devoid of pigment and melanotic cells in which the abundance of pigment was explicable only by an active production of melanin. The most likely hypothesis is that the tumor cells of epithelial origin acquired secondarily the power of forming melanin. Previously described melanomas in fishes were predominantly sarcomatous in appearance. It is sug-

gested that the present tumor reopens the problem of the histogenesis of melanoblastomas and that of the specificity of the melanin-forming function."

Abstracts of other reported cases of Melanoma

PRINCE, 1892: In a cachectic female haddock *Melanogrammus aeglefinus* there was a brown tumor, 20 x 5 cm., just below the lateral line. The surface was ulcerated, the surrounding skin inflamed. Three pigmented spots were present near the tumor. Histologically both pigmented and nonpigmented cells were seen; the underlying muscle was not invaded.

JOHNSTONE, 1911: On the right side of the head, behind the eye of a thorn-back ray *Raja clavata*, was a black, elliptical tumor, 7.5 x 6 x 2 cm. The animal was so emaciated that the skeleton was visible. The skin over the neoplasm was intact, though infiltrated by tumor cells. Histologically the growth was made up of irregular interlacing bundles of spindle cells that were heavily laden with pigment and had infiltrated the surrounding tissues. No metastases were found.

JOHNSTONE, 1912: A thorn-back ray *Raja clavata*, 2 feet in length, bore a spherical tumor 7 cm. in diameter. The growth, which was located on the dorsum of the head at eye level, was black and very soft. The pigmented tumor cells were short spindles that infiltrated the adjacent tissues. At the posterior margin of one eye was a firm white tumor apparently a fibroma.

JOHNSTONE, 1912: Melanotic tumors were found in the skin of two rays *Raja batis*. One of the fish was caught off the coast of Ireland, the other near Scotland. In one the growth was found on the pectoral fin; it was small and was not examined histologically. In the other fish a flat black tumor, 10 x 6 x 1 cm., was present near the center of the dorsal surface of the left pectoral fin. Several 1 cm. nodules were scattered elsewhere on the fin surface; all were covered by normal epithelium. The tumor cells were pleomorphic, rich in melanin granules, and infiltrated the adjacent tissue.

JOHNSTONE, 1913: Melanotic sarcomas were found in two rays *Raja batis*. In one a flat pigmented lesion rose a millimeter or more above the surface of a pectoral fin. In the other, caught off the coast of Ireland at a depth of 70 fathoms, and measuring 5 ft. in width, there were many melanotic tumors scattered over the surface. The largest was on the back, measured 15 x 7 x 2.5 cm., and was very soft. On section, the densely pigmented spindle cells deeply invaded the adjacent muscle.

JOHNSTONE, 1915: Scattered over the body surface of a halibut *Hippoglossus hippoglossus* were numerous tumor nodules. Histologically, they consisted of spindle cells, some multinucleate, others containing melanin granules. The tumor cells infiltrated the surrounding muscle tissue.

BERGMAN, 1921: On the right side of the tail of an eel-pout *Zoarces viviparus* was a black tumor the size of a hazel nut. Cross sections of the body revealed strands of black tissue extending to the vertebrae and diffusely infiltrating the muscle. Most of the cells were

spindle shaped with a homogeneous cytoplasm that occasionally contained a few pigment granules. Other cells were branched, rich in pigment, and not distinguishable from melanophores. The author believed that the nonpigmented cells were melanophores that had developed too quickly for the pigment to form.

JOHNSTONE, 1925: Behind the pectoral fin on the pigmented side of a plaice *Pleuronectes platessa* was a circular tumor 3 x 0.5 cm. with raised edges and a mammillated surface, which was variegated black and orange. The corium was increased in width by the tumor cells, which resembled short thick connective tissue cells; the masses of pigment were mostly extracellular. The surrounding muscle was infiltrated.

HAÜSSLER, 1928: Melanomas, derived from melanophores in hybrids of the swordtail *Xiphophorus hellerii* and platyfish *Platypoecilus maculatus*, Mexican killifishes, were large and infiltrative, though no metastases were noted. The author reports 8 cases, involving 20 of the F₂ generation; there was one case in a male F₁. All tumors were located near the midline on the ventral surface.

KOSSWIG, 1929: Melanotic tumors were observed in hybrids of female *Xiphophorus hellerii* and male *Platypoecilus maculatus*. In F₁, the hybrids were much blacker than the male *Platypoecilus* because the black factor—Gene N—acts differently on the female *Xiphophorus* than on the female *Platypoecilus*. By again breeding a dark hybrid with *Platypoecilus*, the pigmentation became even more pronounced, and the proliferation of the melanophores formed small melanomas on the surface; they also infiltrated the internal organs.

TAKAHASHI, 1929: In the middle of the left side of the body near the lateral line of a coalfish *Theragra chalcogramma* was a tumor that measured 9 x 5 x 5 cm. It was mottled gray and black, rather soft in consistency and sharply demarcated, except at its base. The tumor cells were round, spindle, or starshaped, embedded in an abundant vascular connective tissue stroma. On the left side of another coalfish, more emaciated than the last, was a soft, uniformly black tumor, infiltrating the skeletal muscle. A subperitoneal, black, pea-sized nodule of the same histologic structure was probably a metastasis. The cells were oval, many contained pigment granules.

TAKAHASHI, 1929: On the left side of a chub mackerel *Pneumatophorus colias* was a tumor, 3 x 4 x 1.5 cm., which on section was yellow-brown in color. The tumor parenchyma consisted of small round or oval cells some of which contained small amounts of melanin. A few large pigment-bearing cells were scattered among them. The vascular tumor had a scanty stroma, and actively infiltrated the surrounding tissue.

INGLEBY, 1929: A black warty tumor, apparently arising in the subcutaneous tissue, was found in a northern angler fish *Lophius piscatorius*. The main mass of the tumor lay above the level of the skin and was not encapsulated. Histologically it consisted of large branched cells loaded with masses of pigment which in most instances completely obscured the nuclei. The

author suggested that the tumor represented a homologue of the pigmented mole in man.

HADDOW and BLAKE, 1933: The authors report two skin tumors in a thornback ray *Raja clavata*. Both neoplasms were sessile and lobulated. The larger measured 4 x 2.1 cm., was distinctly paler than the normal skin, but contained scattered deposits of melanin; the smaller, measuring 2 x 1.5 x 0.5 cm., was heavily laden with melanin. Histologically they were richly cellular, composed of dense collections of melanoblasts possessing extremely large nuclei. Each tumor was traversed by coarse fibrous trabeculae and rifted with many thin-walled blood sinuses. The melanin was present mainly in the form of intracellular granules, though some was found in the tissue spaces.

HAÜSSLER, 1934: A second report by this author about melanomas that occurred in hybrids of *Xiphophorus* and *Platypoecilus*. In the 5 cases presented the tumors were found in the region of the tail and were derived from macromelanophores. Whether the tumors were benign or malignant was not established.

NIGRELLI and GORDON, 1944: A melanotic tumor was found in a silverside *Menidia beryllina peninsulae*. The fish measured 4.7 cm. in length; the tumor covered an area of 5 x 1.5 x 1.0 mm. and extended along the sides of the body. In the normal fish a broad band of melanophores forms a syncytium in the region of the lateral line; these may have been the cells of origin of the tumor. Histologically, the pigment cell overgrowth in this fish appeared to be quite like the melanotic tumors reported in hybrid killifishes by Reed and Gordon. The tumor contained melanin-bearing cells of different sizes, corresponding somewhat to the variations in size normally encountered. The cells spread laterally in the corium, though in some areas they penetrated the epidermis as well as the underlying fascia, muscle, and bone.

ERYTHROPHOROMA

Tumors arising from the red pigment containing erythrophores (allophores) have been reported in a trout, a flatfish, a tunnyfish, a gurnard, and in hybrid killifish (Table 19). The most detailed account is that of Smith (188) describing the lesions in a flatfish *Pseudopleuronectes americanus*. A red tumor, 3 x 2 cm., was situated on the pigmented side 4 cm. behind the right operculum, where it invaded the subjacent tissues to the depth of the extraperitoneal muscles. Similar though smaller lesions

were scattered over the body: 2 near the posterior margin of the main mass, and 2 on the nonpigmented side. Visceral tumors were also present: 10 in the liver, 10 in the kidneys, and 3 in the spleen where they nearly replaced the normal parenchyma. Microscopically masses of spindle-shaped cells supported by delicate capillaries extended throughout the thickened corium as far as the underlying muscle bundles. Frozen sections of fresh tumor tissue showed small pigment granules, varying in color from vermilion to orange, and present in many of the cells. Smith regarded the large skin lesion as the primary site of the tumor and the smaller nodules as metastases.

In 1929 Kosswig reported erythrophoromas in two male fish produced by back-crossing an F₁ red finned black killifish hybrid to a pure line red-finned platyfish. In subsequent experiments (104) he obtained a similar lesion in an F₁ hybrid of *Xiphophorus montezuma* and *X. hellerii*. Kosswig interpreted the lesion as a dominant mutation in a somatic cell. Only in a single F₁ hybrid of *X. hellerii* and *Platypoecilus maculatus* did typical erythrophoroma develop. When this hybrid was crossed with a pure line *X. hellerii*, erythrophoromas were found in 5 of the offspring. Gordon (59) has suggested that the tumors described by Kosswig may represent melanomas which were invaded by erythrophores, rather than true erythrophoromas.

Abstracts of other reported cases of Erythrophoroma

TAKAHASHI, 1929: On the left side just behind the head of a gurnard *Chelidonichthys kumu* was a tumor, 8.5 x 7 x 7 cm., which infiltrated the muscles down to the vertebrae and bulged into the coelom. On section it was greenish-brown and firm. The tumor cells infiltrated the surrounding tissue, and were oval, with large vesicular nuclei and a scanty cytoplasm which in some instances contained yellow-green pigment granules. By chemical methods the cells were identified as allophores, a term accepted as synonymous with "erythrophore."

THOMAS, 1931 b: A subperitoneal erythrophoroma was found in a tunny fish *Gymnosarda alleterata*. The tumor was of the same size and color as a small orange. lay at the level of the liver, and was covered by peri-

TABLE 19: ERYTHROPHOROMA

Species	Site	Author
Gurnard <i>Chelidonichthys kumu</i>	Skin	Takahashi, 1929
Killifishes (<i>Platypoecilus maculatus</i> (9) (<i>Xiphophorus hellerii</i>)	Skin	Kosswig, 1929, 1931
Tunny fish <i>Gymnosarda alleterata</i>	Peritoneum	Thomas, 1931b
Trout species not given	Skin	Thomas, 1931b
Flatfish <i>Pseudopleuronectes americ.</i>	Skin	Smith, G.N., 1934
Killifishes (<i>P. maculatus</i> (<i>X. hellerii</i>)	Skin	Smith, Coates & Strong, 1936

toneum. Beneath the mesothelial cells of the peritoneum there was considerable proliferation of branched erythrocytes. The protoplasmic prolongations were uniformly stippled by granules of red pigment.

THOMAS, 1931 b: An orange-red tumor infiltrated the posterior portion of the anal fin of a trout; the branching erythrocytes were embedded in a dense connective tissue stroma. A small tumor, identical with that on the fin, found on the surface of the peritoneum, was interpreted by the author as a metastasis.

SMITH, COATES and STRONG, 1936: In a hybrid of *X. hellerii* and *P. maculatus* the authors found a tumor arising from the red pigment cells. Brick red in color, it grew in the region of the dorsal fin, invaded the skin and adjacent tissues but none of the deeper structures. Microscopically the pigmented tumor cells were large, round or fusiform, and bore occasional dendrites.

GUANOPHOROMA

Only a single example of a neoplasm taking origin from guanophores is on record. Takahashi (199) described a tumor, 7 x 5 x 1.5 cm., on the left side near the caudal fin of a "fat cod" *Hexagrammos atakii*. On section the tissue was silver-white and had a peculiar sheen. Histologically, it was densely infiltrated by short, yellow-white, needle shaped, doubly refractile guanine crystals of great brilliance. The crystals were present not only in the pleomorphic tumor cells but also in the interstitial tissues.

XANTHOPHOROMA

The only tumor purported to take its origin from the xanthophores in the skin of a fish was reported by Schroeders (179). An irregular orange-colored tumor, the size of a bean, was located on the right side of the trunk beneath and partly upon the dorsal fin of a blenny. In the vicinity of this tumor were several nodules the size of pin-heads. Histologically the tumor consisted principally of large epithelioid cells with vesicular nuclei and an orange-yellow pigment in the cytoplasm. Single and multinucleated, branched giant cells that also contained the pigment were scattered through the tissue. The author believed that the cells were derived from the endothelium of the lymphatic spaces and blood vessels. The center of the mass was hemorrhagic and necro-

tic. Whether it was a true neoplasm or a granulomatous reaction to injury must remain undecided.

TUMORS OF NERVOUS TISSUES

Only 7 papers dealing with tumors of the nervous system of 9 species of fishes were found in the literature (Table 20). There is as yet no record of a neoplasm of the brain or spinal cord: Takahashi (199) and Haddow and Blake (68) each report a ganglioneuroma arising in a spinal ganglion of a flatfish. Thomas (203) observed a similar tumor in a codfish and subsequently described a neuroepithelioma of the olfactory plate in a gilthead (210).

One of us (118) has studied the common nerve sheath tumors of the snappers *Lutianidae*. A total of 76 tumor bearing fishes were collected, which were members of three species: the gray snapper *Lutianus griseus*, the dog snapper *L. jocu*, and the schoolmaster, *L. apodus*. The neoplasms generally occurred along the course of the larger subcutaneous nerves, particularly those of the head and dorsal regions, as solitary or multiple relatively large firm white masses (Fig. 36). Histologically, they closely resembled the human neoplasms of the nerve sheath group and were composed of two kinds of tissue: one compact and richly fibrocellular (corresponding to the Antoni A type); the other loose, reticulated, and poorly cellular (Antoni B type). Palisade formations of nuclei and fibrils were found in approximately one third of the tumors (Fig. 37). In some regions the neoplasms were very cellular, the component cells forming characteristic whorls (Fig. 38).

Neurilemmomas of the autonomic nervous system have been reported by Young and Olafson (236) in 25 brook trout *Salvelinus fontinalis*. The tumors were tiny and not readily visible to the naked eye. The pancreas and mesentery were most extensively involved. The tumors were uniform and characteristic in their structure. A peripheral band of collagen surrounded concentric layers of fibrous tissue; at the center of the growths there often was a group of polyhedral cells with a variable amount of eosinophilic and finely granular cytoplasm. No inclusion bodies were seen, nor were bacteria found in the

TABLE 20: TUMORS OF NERVOUS TISSUES

Species	Site	Author
Codfish <i>Godus morhua</i>	Body wall	Thomas, 1927a
Flatfish <i>Limanda yokohamae</i>	Spinal ganglion	Takahashi, 1929
Gilt head <i>Sparus auratus</i>	Olfactory plate	Thomas, 1932c
Flatfish <i>Lepidorhombus megastoma</i>	Spinal ganglion	Haddow & Blake, 1935
Goldfish <i>Carassius auratus</i>	Subcutaneous	Picchi, 1933
Snapper <i>Lutianus griseus</i>	Subcutaneous	Lucké, 1942
<i>Lutianus apodus</i>		
<i>Lutianus jocu</i>		
Brook trout <i>Salvelinus fontinalis</i> (25)	Pancreas & mesentery	Young & Olafson, 1944

tissues. The authors believe that the occurrence of the tumors among inbred trout of all ages in a single hatchery suggests that hereditary factors may play a role in the genesis of the neoplasm.

Abstracts of other reported cases of tumors of Nervous Tissues

THOMAS, 1927 a: A tumor, the size of a fetal head, projected from the lateral body wall in the anal region of a codfish *Gadus morhua*. Histologically, the neoplasm consisted of fibrillar tissue among which were scattered islands of ganglion cells. The author believed the fibrillar tissue represented a syncytium of Schwann cells.

TAKAHASHI, 1929: Adjacent to several of the thoracic vertebrae in a plaice *Limanda yokohamae* was a tumor 4 x 2 x 2.5 cm. The growth was soft, gray, and infiltrated the adjacent tissue. It consisted of myelinated nerve fibers among which were many glial and nerve cells. The nerve cells were very large, with relatively small nuclei bearing large nucleoli. The anatomic position and histologic character of the tumor point to an origin in a spinal ganglion.

THOMAS, 1932 c: An adult gilthead *Sparus auratus* bore a very large tumor that reached from the anterior margin of the orbit to the maxilla. Extensive destruction of the nasal and ethmoid bones had taken place; the overlying skin was ulcerated. Epithelial rosettes and acini were present in some regions, lending a pseudocystic appearance to the tissue. Many of the acini were lined by columnar cells that frequently bore tufts of cilia. Among the connective tissue trabeculae were islands of nerve cells that gave origin to neurofibrils, which could be traced throughout the section. The author identified the tumor as a neuroepithelioma of the olfactory plate.

HADDOW and BLAKE, 1933: A tumor that occupied almost the whole thickness of the distal end of the trunk was found in a flatfish *Lepidorhombus megastoma*. Site of origin could not be determined accurately, but it apparently lay in the position of a spinal ganglion. The tumor was composed of a fibrillar groundwork of nervous tissue containing scattered groups of ganglion cells. Osmic acid preparations demonstrated the neurofibrils as nonmedullated. The ganglion cells were imperfect, degenerated, and vacuolated, possessing bipolar continuity with the nerve fibers of the tumor substance.

PICCHI, 1933: A tumor, the size of a pea, occupied the region of a caudal vertebra in a large goldfish *Carassius auratus*. In the periphery of the growth there was a many-layered capsule of pigmented cells; the central region was composed of long fine fibrils that did not stain with van Gieson's reagent; blood vessels were scarce and thin-walled. The author identified the tumor as a schwannoma. The growth did not recur after it was removed. Pieces of the tumor were injected into various cold-blooded animals—fishes, frogs, and salamanders, but in none was there any evidence of growth.

HAMARTOMA

Tumors arising in developmental faults have been recorded only twice in fishes. However, it should be noted that grossly abnormal development is not infrequently observed among fishes raised in hatcheries (124). Similar anomalies have been reported in amphibians (125, 181) and reptiles (34, 75).

Charlton observed a mackerel *Scomber scombrus* in which no pineal organ could be identified and the area was occupied by a series of epithelial folds. In 5 or 6 places, bead-like masses of hyaline cartilage were found among the epithelial cells. The author identified the lesion as a chondro-epithelioma that had destroyed the pineal body but caused little damage to the brain. A tissue malformation, this lesion may perhaps be classified as a hamartoma.

Labbé, in 1930, found a whiting *Merlangus merlangus* in which the normal horizontal convolutions of the intestine were absent, their place being occupied by a tumor. The latter consisted of embryonic epithelial cells separated by connective tissue trabeculae that were poorly vascularized. The author concluded that this was a tumor of embryonic cell rests, i.e., of cells which would have formed the mucosa of the intestine if differentiation had proceeded normally. Like the preceding case, this may represent a local tumor-like developmental fault.

TAXONOMIC DISTRIBUTION OF TUMOR-BEARING FISHES

It is well known that there are distinct differences in natural susceptibility to neoplastic growth for different taxonomic groups. For example, Ratcliffe (168a) in his extensive survey of tumors in captive wild animals and birds found that in mammals the digestive tract, and in birds the genito-urinary organs, are the predominant sites. Moreover, the organ incidence of the various orders, families and species also showed interesting differences. Thus, among birds the grass parakeet, *Melopsittacus undulatus*, had by far the highest incidence of renal tumors. Many other comparable examples are given for domesticated animals by Feldman (46a).

In fishes, differences in organ or tissue susceptibility are also present. As a class, they are more susceptible to neoplastic processes of their connective tissues than of other tissues. Tumors of nerve sheath are more common in the snapper family, *Lutianidae*, than among other groups; epithelioma of the lip is the most frequent tumor of a species of catfish, *Ameiurus nebulosus*, and multiple osteoma of the haemal spines more often affects the red tai, *Pagrosomus major*, than other species. However, the same kind of tumor may be found in different species of

fishes, taxonomically and geographically separated. For example, epithelioma of the lip has been reported in both salt and fresh water fishes; among the catfish in the streams of Pennsylvania (122, 136), the barbels in German rivers (97), the tench in a German pond (47), the eels from the brooks and coastal waters of France (217), the stints from the brackish water of the Jasmunder Bay on the Baltic Sea (16), the coalfish in the North Atlantic (228), and the croakers from the South Atlantic (7).

On the contrary, a single species may be affected by a variety of tumors in different organs. For example, in the pike, *Esox lucius*, tumors have been observed in the bones, muscle, subcutaneous tissue, dental structures, ovary, kidney and thyroid; the tumors include osteomas, osteosarcomas, fibrosarcomas, lipomas, adenocarcinomas and lymphosarcomas.

For convenience of reference, all tumor-bearing fishes of which we were able to find records in the literature, or which we have ourselves observed, have been assembled in Table 21. The classification of the fishes is one used by most ichthyologists.* The table is arranged according to orders, families and species of fishes, variety and site of tumor, author and date of publication. Only the zoological names are given; the common names may readily be found by referring to the tables of the various tumors. Inspection of Table 21 shows at once the great preponderance of tumor-bearing bony fishes over cartilagenous fishes; this may be readily accounted for by the numerical superiority and greater economic importance of the former group. Among the bony fishes, nearly one-half of all species affected are representatives of only 5 families, namely the salmonids (*Salmonidae*—salmon, trout), the cyprinoids (*Cyprinidae*—carp, dace, minnows, chubs, barbels), the codfishes (*Gadidae*), the flatfishes (*Bothidae*), and the flounders (*Pleuronectidae*). Members of these families are not likely to be more susceptible to neoplastic growth than other species; rather they are caught in vast numbers for food and hence more often examined.

II. TUMORS OF AMPHIBIANS

Nearly all amphibians belong to one of two orders: the Urodeles which retain their tails throughout life such as the salamanders, and the Anura

which are tailed only in the larval stage (frogs, toads). Although frogs and salamanders have been used in laboratories throughout the world for a century, remarkably few tumors have been reported in these animals, perhaps because they have not been looked for by investigators interested in oncology. There is no good reason for believing that amphibians are less susceptible to neoplastic growth than fishes or other vertebrates. For example, systematic search for tumors in one species of the common laboratory frog, *Rana pipiens*, has revealed that these animals are commonly affected with adenocarcinoma of the kidney.

URODELES

In the literature there are only 7 reports dealing with spontaneous tumors in urodeles (Table 21). The recorded tumors comprise carcinomas in 3 species, fibromas in 2, and melanomas in one species. This apparent rarity of tumors in urodeles is the more surprising since these animals, above all other vertebrates, have retained the capacity to regenerate complex tissues such as leg, tail and lens. Various "explanations" have been offered, but none appear biologically sound. It has been suggested, for example, that the ability of the salamander to regenerate lost limbs is evidence of the retention into adult life of such highly potent morphogenetic fields that an aberrant cell will be forced to differentiate by the organizer effect of the adjacent tissues and hence uncontrolled growth cannot occur. The failure of carcinogens to evoke a neoplastic response similar to that observed in mammals has been interpreted by some as evidence that urodeles are more resistant to tumor growth than are other classes of vertebrates. But as stated above the probability is great that tumors are not as rare as they seem to be in these animals; they simply have not been sought, hence have not been found.

Perhaps because of the paucity of spontaneous tumors, few experimental studies of neoplasia have been carried out on these animals. They have been limited largely to attempts at the production of tumors by means of carcinogenic agents, as in the experiments by Martella (132), Koch and his associates (99), Fedotov (46), Finkelstein (51), Shevchenko (186) and Tokin (218). Other experimental studies are those of the Champys (28) on a transmissible epithelioma in the newt, believed to be caused by a virus, and the work of the Brunsts (186a) on melanomas of the axolotl which probably arise on a hereditary basis. A detailed account of these various experiments is given elsewhere (123a).

* We are grateful for advice on this and other matters concerning classification and nomenclature to Dr. Carl L. Hubbs of the Scripps Institution of Oceanography and Dr. Robert R. Miller of the National Museum.

TABLE 21: TAXONOMIC DISTRIBUTION OF TUMOR-BEARING FISHES

ELASMOBRANCHII (Cartilagenous Fishes)		
SELACHII (Sharks; Rays)		
EUSELACHII		
SCYLLIORHINIDAE (Cat Sharks)		
Scylliorhinus catulus Dermal odontoma, skin	Ladreyt, 1929
" canicula Chondroma, skin	Thomas, 1933b
" " Osteoma, skin	Thomas, 1933b
GALEORHINIDAE (Gray Sharks)		
Prionace glaucus Adenoma, liver	Schroeders, 1908
TECTOSPONDYLI		
SQUALIDAE (Dog Fishes)		
Squalus suckleyi Goiter, thyroid	Cameron & Vincent, 1915
" mitsukurii Chondroma, lumbar vertebra	Takahashi, 1929
BATOIDEI		
RAJIDAE (Rays; Skates)		
Raja macrorhyncha Fibrosarcoma, fin ray	Drew, 1912
" clavata Melanoma, skin	Johnstone, 1911
" " Melanoma, skin	Johnstone, 1912
" " Melanoma, skin	Haddow & Blake, 1933
" maculata Hemangioma, skin	Drew, 1912
" batis Melanoma, skin	Johnstone, 1912
" " Melanoma, skin	Johnstone, 1913
PISCES (True Fishes)		
TELEOSTEI (Bony Fishes)		
ISOSPONDYLI (Soft-rayed Fishes)		
ELOPIDAE (Tarpon)		
Elops saurus Chondroma, subcutaneous	Surbeck, 1921
CLUPEIDAE (Herrings)		
Clupea harengus Lymphosarcoma, peritoneum	Johnstone, 1926
" " Rhabdomyoma, trunk muscle	Williams, 1931
" " Leiomyoma, wall of stomach	Thomas, 1933c
Arengus pilchardus Fibroma, peritoneum	Johnstone, 1911
" " Fibroma, peritoneum	Johnstone, 1925
SALMONIDAE (Salmon, Trout)		
Oncorhynchus keta Fibrosarcoma, body wall	Kazama, 1922
" " Fibrosarcoma, body wall	Takahashi, 1929
" " Fibrosarcoma, body wall	Takahashi, 1929
" gorboscha Fibrosarcoma, body wall	Takahashi, 1929
Salmo salar Goiter, thyroid	Gilruth, 1901
" " Goiter, thyroid	Wilkie, 1902
" " Lymphosarcoma, kidney	Haddow & Blake, 1933
" gairdnerii Goiter, thyroid	Gilruth, 1902
" " Leiomyoma, stomach wall	Plehn, 1906
" " Adenoma, thyroid	Leger, 1925
" " Fibrosarcoma, not given	Leger, 1925
" " Adenoma, liver	Haddow & Blake, 1933
" lacustris Fibroma, subcutaneous	Eberth, 1878
" " Goiter, thyroid	Bonnet, 1883
" " Adenocarcinoma, thyroid	Smith, H. M., 1909
" trutta Adenoma, liver	Plehn, 1909
" " Papilloma, skin	Thomas, 1932e
" " Fibroma, coelom	Kreyberg, 1937
" mykiss Adenoma, intestine	Thomas, 1931a
" carpio Leiomyoma, stomach wall	Pease, 1907
" clarkii Rhabdomyoma, trunk muscle	Adami, 1908
" several species Adenocarcinoma, thyroid	Gilruth, 1901
" " " Goiter, thyroid	Pick, 1905
" " " Adenocarcinoma, thyroid	Jaboulay, 1908
" " " Goiter, thyroid	Marine & Lenhart, 1910
" " " Goiter, thyroid	Gaylord & Marsh, 1914
" " " Goiter, thyroid	Peyron & Thomas, 1930
" sp. Odontoma, jaws	Plehn, 1912
" sp. Erythrophoroma, skin	Thomas, 1931b

TABLE 21: TAXONOMIC DISTRIBUTION OF TUMOR-BEARING FISHES—Continued

Salvelinus fontinalis	Goiter, thyroid	Scott, 1891
" "	Fibrosarcoma, trunk muscle	Plehn, 1906
" "	Osteoma, fin rays	Thomas, 1932b
" "	Neurofibroma, autonomic nerves	Young & Olafson, 1944
Hucho hucho	Fibrosarcoma, liver	Plehn, 1909
PLECOGLOSSIDAE			
Plecoglossus altivelis	Lipoma, subcutaneous	Takahashi, 1929
OSMERIDAE (Smelts)			
Osmerus eperlanus	Epithelioma, lips	Breslauer, 1916
" "	Rhabdomyoma, trunk muscle	Bergman, 1921
<i>APODES (Eels; Morays)</i>			
ANGUILLIDAE (True Eels)			
Anguilla anguilla	Adenocarcinoma, left kidney	Schmey, 1911
" "	Fibrosarcoma, mesentery	Wolff, 1912
" "	Fibrosarcoma, peritoneum	Plehn, 1924
" "	Adenocarcinoma, kidney	Plehn, 1924
" "	Papilloma, lower lip	Thomas & Oxner, 1930
CONGRIDAE (Conger Eels)			
Conger conger	Hemangioma, region of basi-hyal	Drew, 1912
" "	Fibrosarcoma, subcutaneous, head	Johnstone, 1920
" "	Lymphosarcoma, kidney	Williams, 1931
MURAENIDAE (Morays)			
Muraena helena	Adenocarcinoma, palate	Ladreyt, 1935
<i>HETEROGNATHI</i>			
CHARACINIDAE (Characins)			
Astyanax mexicanus	Lymphosarcoma, head	Nigrelli, 1947
<i>GYMNONOTI</i>			
ELECTROPHORIDAE (Electric eels)			
Electrophorus electricus	Papilloma, skin	Coates, Cox, & Smith, 1938
<i>EVENTOGNATHI</i>			
CATOSTOMIDAE (Sucker)			
Catostomus commersonnii	Papilloma, skin	Lucké & Schlumberger, unpubl.
CYPRINIDAE (Carps, Dace, Minnows, Chubs)			
Cyprinus carpio	Fibroma, peritoneum	Crisp, 1854
" "	Fibroma, mesentery	Gervais, 1876
" "	Epithelioma, skin	Dauwe & Pennemann, 1904
" "	Epithelioma, not given	Bashford, Murray & Cramer, 1905
" "	Osteoma, skull bones	Fiebiger, J., 1909c
" "	Epithelioma, fins & operculum	Fiebiger, J., 1909a
" "	Fibroma, mesentery	Ronca, 1914
Carassius carassius	Fibroma, abdominal wall & mesentery	Plehn, 1906
" "	Fibrosarcoma, testicle	Plehn, 1906
" "	Chondroma, skull bones	Mulsow, 1915
" "	Fibroma, ovary	Freudenthal, 1928
" "	Papilloma, skin	Takahashi, 1929
" auratus	Fibrosarcoma, dorsal fin	Bland-Sutton, 1885
" "	Fibrosarcoma, not given	Semmer, 1888
" "	Epithelioma, bladder	Plehn, 1909
" "	Fibroma, orbit	Guglianetti, 1910
" "	Fibrosarcoma, skin	Schamberg & Lucké, 1922
" "	Fibroma, subcutaneous	Wago, 1922
" "	Fibrosarcoma, subcutaneous	Johnstone, 1923
" "	Lymphosarcoma, kidney	Plehn, 1924
" "	Fibrosarcoma, subcutaneous	Roffo, 1924
" "	Papilloma, fins	Sagawa, 1925
" "	Fibroma, skin	Sagawa, 1925
" "	Fibroma, subcutaneous	Eguchi & Oota, 1926
" "	Fibrosarcoma, dorsal fin	Dominguez, 1928
" "	Fibrosarcoma, skin	Montpellier & Dieuzeide, 1932
" "	Neurofibroma, subcutaneous	Picchi, 1933
" "	Fibrosarcoma, cutaneous	Lucké, Schlumberger & Breddia, '48

TABLE 21: TAXONOMIC DISTRIBUTION OF TUMOR-BEARING FISHES—Continued

Barbus fluviatilis	Epithelioma, lips	Keysselitz, 1908	
" "	Chondroma, mandible	Surbeck, 1921	
" "	Adenocarcinoma, thyroid	Schreitmüller, 1924	
" vulgaris	Epithelioma, lower lip	Clunet, 1910	
Gobio several species	Papilloma, skin	Schroeders, 1908	
" nigronatatus	Papilloma, skin	Anitschkov & Pavlovsky, 1923	
" blennioides	Papilloma, skin	Anitschkov & Pavlovsky, 1923	
Idus idus	Fibrosarcoma, trunk muscle	Plehn, 1906	
Phoxinus laevis	Fibrosarcoma, corium near tail	Bugnion, 1875	
" "	Fibrosarcoma, trunk muscle	Plehn, 1906	
" sp.	Chondroma, mandible	André, 1927	
Tinca tinca	Myxoma, orbit	Plehn, 1906	
" "	Epithelioma, lips	Fiebiger, 1909a	
" "	Rhabdomyoma, trunk muscle	Kolmer, 1928	
Chondrostoma nasus	Fibrosarcoma, trunk muscle	Plehn, 1906	
Chondrostoma soeta	Epithelioma, trunk muscle	Mazzarelli, 1910	
Abramis brama	Fibroma, coelom	Plehn, 1906	
Alburnus lucidus	Leiomyoma, trunk muscle	Plehn, 1906	
Rasbora daniconius	Fibroma, dorsal fin	Smith, Coates, & Strong, 1936	
" lateristriata	Adenocarcinoma, thyroid	Smith, Coates, & Strong, 1936	
" "	Lymphosarcoma, peritoneum	Smith, Coates, & Strong, 1936	
Danio albolineatus	Goiter, thyroid	Klemm, 1927	
NEMATOGNATHI (Catfishes)				
AMEIURIDAE (Horned Pout; Channel Cats)				
Ictalurus catus	Epithelioma, lips	McFarland, 1901	
Ameiurus nebulosus	Epithelioma, lips, oral mucosa	Lucké & Schlumberger, 1941	
" "	Adenoma, kidney	Lucké & Schlumberger, unpubl.	
CLARIIDAE				
Clarias dumerlii	Adenocarcinoma, thyroid	Schreitmüller, 1924	
HAPLOMI (Pikes; Mud Minnows)				
ESOCIDAE (Pikes)				
Esox lucius	Osteosarcoma, anal fin	Walgren, 1873	
" "	Osteoma, dental plate	Bland-Sutton, 1885	
" "	Fibrosarcoma, trunk musculature	Ohlmacher, 1898	
" "	Fibroma, musculature	Plehn, 1906	
" "	Osteoma, caudal fin	Plehn, 1906	
" "	Fibrosarcoma, kidney	Plehn, 1909	
" "	Goiter, thyroid	Marine & Lenhart, 1910	
" "	Lipoma, subcutaneous	Bergman, 1921	
" "	Adenocarcinoma, ovary	Haddow & Blake, 1933	
" "	Lymphosarcoma, subcutaneous	Haddow & Blake, 1933	
" "	Lymphosarcoma, kidney	Nigrelli, 1947	
CYPRINODONTES (Toothed Carp)				
POECILIIDAE (Top Minnows)				
Platycoecillus maculatus	} hybrids	Melanoma, skin	Haüssler, 1928 & 1934
Xiphophorus hellerii		Melanoma, skin	Koswig, 1929
" "	"	Melanoma, skin	Reed & Gordon, 1931
" "	"	Erythrophoroma, skin	Smith, Coates, & Strong, 1936
" "	"	Melanoma, skin	Gordon, 1937
" "	"	Melanoma, eye	Levine & Gordon, 1946
Platycoecillus maculatus		Adenoma, kidney	Jahnel, 1939
Xiphophorus hellerii		Fibrosarcoma, retrobulbar	Jahnel, 1939
Heterandria formosa		Adenocarcinoma, thyroid	Smith, Coates, & Strong, 1936
CYPRINODONTIDAE (Killifishes)				
Haplochilus chaperi	Goiter, thyroid	Klemm, 1927	
Jordanella floridae	Adenocarcinoma, thyroid	Schreitmüller, 1924	
ANACANTHINI (Codfishes; Hakes)				
GADIDAE (Codfishes)				
Gadus morhua	Fibroma, subcutaneous	Bland-Sutton, 1885	
" "	Fibroma, stomach wall	Bland-Sutton, 1885	
" "	Osteoma, maxilla	Bland-Sutton, 1885	

TABLE 21: TAXONOMIC DISTRIBUTION OF TUMOR-BEARING FISHES—Continued

"	"	Osteoma, vertebral disc	Bland-Sutton, 1885
"	"	Hemangioma, pectoral girdle	Murray, 1908
"	"	Fibroma, oesophagus	Williamson, 1909
"	"	Fibrosarcoma, subcutaneous	Johnstone, 1912
"	"	Osteoma, vertebra	Williamson, 1913
"	"	Fibroma, orbit	Johnstone, 1914
"	"	Fibrosarcoma, trunk muscle	Johnstone, 1915
"	"	Fibrosarcoma, subcutaneous	Johnstone, 1923
"	"	Ganglioneuroma, body wall	Thomas, 1927a
"	"	Fibrosarcoma, subcutaneous	Thomas, 1927b
"	"	Fibrosarcoma, ovary	Thomas, 1927b
"	"	Osteoma, pre-maxilla	Williams, 1929
"	"	Adenoma, parabranchial body	Peyron & Thomas, 1929
"	"	Fibrosarcoma, body wall	Williams, 1931
"	"	Osteosarcoma, pectoral fin	Thomas, 1932b
"	sp.	Osteosarcoma, operculum	Murray, 1908
"	"	Fibrosarcoma, mouth	Johnstone, 1920
"	"	Fibroma, stomach	Johnstone, 1925
"	"	Hemangioma, swim bladder	Johnstone, 1925
"	"	Fibroma, duodenum	Thomas, 1933a
Melanogrammus aeglefinus	"	Melanoma, skin	Prince, 1892
"	"	Fibroma, subcutaneous	Johnstone, 1911
"	"	Fibrosarcoma, subcutaneous, head	Johnstone, 1922
"	"	Fibroma, subcutaneous	Johnstone, 1924
"	"	Adamantinoma, maxilla	Thomas, 1926
Molva molva	"	Adenoma, ovary	Johnstone, 1915
"	"	Fibrosarcoma, subcutaneous	Johnstone, 1923
"	"	Hemangioma, body wall	Johnstone, 1925
Pollachius brandti	"	Adenoma, parabranchial body	Takahashi, 1929
"	"	Adenoma, glandula digitiformis	Takahashi, 1929
"	carbonarius	Lipoma, liver	Thomas, 1933d
"	virens	Fibroma, oral cavity	Fiebiger, J., 1909a
"	"	Rhabdomyoma, mesentery	Fiebiger, J., 1909b
"	"	Fibrosarcoma, skin	Fiebiger, J., 1912
"	"	Fibrosarcoma, subcutaneous	Johnstone, 1926
"	"	Hemangioma, trunk	Johnstone, 1926
"	"	Fibrosarcoma, mandible	Johnstone, 1926
"	"	Osteosarcoma, vertebra	Williams, 1929
"	"	Epithelioma, lower lip	Williams, 1929
"	"	Chondroma, pre-orbital	Thomas, 1932d
Theragra chalcogramma	"	Adenoma, parabranchial body	Takahashi, 1929
"	"	Adenocarcinoma, mouth, operculum	Takahashi, 1929
"	"	Fibroma, body wall	Takahashi, 1929
"	"	Fibrosarcoma, body wall	Takahashi, 1929
"	"	Fibrosarcoma, subcutaneous	Takahashi, 1929
"	"	Osteoma, fin rays	Takahashi, 1929
"	"	Melanoma, subcutaneous	Takahashi, 1929
MERLUCCIIDAE (Hakes)				
Merluccius merluccius		Hemangioma, rectum	Johnstone, 1926
Merlangus merlangus		Epithelioma, mandible	Johnstone, 1924
"	"	Hamartoma, intestine	Labbé, 1930
HETEROSOMATA (Flounders; Flatfishes)				
BOTHIDAE				
Paetta maeotica		Osteoma, vertebral spines	Schroeders, 1908
"	"	Myxoma, skin, head	Schroeders, 1908
"	"	Myxoma, skin, trunk & fins	Schroeders, 1908
"	"	Fibrosarcoma, subcutaneous	Schroeders, 1908
Rhombus maximus		Fibrosarcoma, subcutaneous	Johnstone, 1923
"	"	Fibroma, dorsal fin	Johnstone, 1924
"	"	Rhabdomyoma, body wall	Young, 1925
"	"	Fibrosarcoma, body wall	Johnstone, 1927
"	"	Myxoma, trunk muscles	Williams, 1929
"	"	Ganglioneuroma, spinal ganglion	Haddow & Blake, 1933
Lepidorhombus megastoma				
PLEURONECTIDAE (Flounders)				
Hippoglossus hippoglossus		Papilloma, snout	Johnstone, 1912

TABLE 21: TAXONOMIC DISTRIBUTION OF TUMOR-BEARING FISHES—Continued

"	"	Fibroma, retroperitoneal	Johnstone, 1913
"	"	Fibroma, trunk muscle	Johnstone, 1914
"	"	Melanoma, skin	Johnstone, 1915
"	"	Fibroma, subcutaneous	Johnstone, 1926
"	"	Fibrosarcoma, body wall	Johnstone, 1926
"	"	Lipoma, trunk muscle	Williams, 1929
"	"	Rhabdomyoma, body wall	Thomas, 1932a
<i>Pleuronectes platessa</i>		Myxoma, body wall	MacIntosh, 1908
"	"	Fibrosarcoma, subcutaneous	Drew, 1912
"	"	Lipoma, body wall	Bergman, 1921
"	"	Fibroma, dorsal fin	Johnstone, 1922
"	"	Melanoma, pigmented skin	Johnstone, 1925
"	"	Papilloma, skin	Johnstone, 1925
"	"	Hemangioma, body wall	Johnstone, 1925
"	"	Fibroma, subcutaneous, head	Johnstone, 1926
<i>Platichthys flesus</i>		Lymphosarcoma, retro-orbital	Johnstone, 1912
<i>Limanda limanda</i>		Papilloma, body surface	Johnstone, 1925
<i>Pseudopleuronectes americanus</i>		Erythrophoroma, skin	Smith, G. M., 1934
<i>Limandella yokohamae</i>		Ganglioneuroma, spinal ganglion	Takahashi, 1929
SAMARIDAE				
<i>Paralichthys olivaceus</i>		Lipoma, trunk muscle	Kazama, 1924
"	"	Osteoma, haemal spine	Takahashi, 1929
SOLEIDAE (Soles)				
<i>Solea solea</i>		Myxoma, peritoneum	Johnstone, 1926
"	"	Papilloma, skin	Thomas, 1930
THORACOSTEI (Sticklebacks; Pipe Fishes; Sea Horses)				
GASTEROSTEIDAE (Sticklebacks)				
<i>Gasterosteus aculeatus</i>		Hemangioma, subcutaneous, head	Plehn, 1906
<i>Spinachia spinachia</i>		Epithelioma, skin	Murray, 1908
<i>Pungitius pungitius</i>		Hemangioma, iris	Johnstone, 1915
LABYRINTHICI				
ANABANTIDAE (Climbing Perch)				
<i>Anabas scandens</i>		Papilloma, skin	Fiebiger, 1909a
PERCOMORPHI (Mulletts; Barracudas; Tunnyfish; Bass; Snappers; Croakers, etc.)				
SCOMBRIDAE (Mackerels)				
<i>Scomber scombrus</i>		Hemangioma, body wall	Johnstone, 1924
"	"	Hamartoma, pineal	Charlton, 1929
<i>Pneumatophorus colias</i>		Melanosarcoma, skin	Takahashi, 1929
THUNNIDAE (Tunnies, Albacores)				
<i>Gymnosarda alleterata</i>		Erythrophoroma, peritoneum	Thomas, 1931b
TRICHIURIDAE (Hairtails)				
<i>Lepidopus</i> sp.		Osteoma, fin rays	Gervais, 1875
MENIDAE				
<i>Menidia beryllina peninsulac</i>		Melanoma, subcutaneous	Nigrelli & Gordon, 1944
SERRANIDAE (Sea Basses)				
<i>Serranus scriba</i>		Goiter, thyroid	Marsh & Vonwiller, 1916
"	"	Goiter, thyroid	Marsh & Vonwiller, 1916
<i>Lateolabrax japonicus</i>		Fibrosarcoma, subcutaneous	Takahashi, 1929
"	"	Fibrosarcoma, pharynx	Takahashi, 1929
<i>Epinephelus gigas</i>		Melanoma, branchial region	Dollfus, Timon-David & Mosinger, 1938
LUTIANIDAE (Snappers)				
<i>Lutianus griseus</i>		Neurofibroma, subcutaneous	Lucké, 1942
"	"	Neurofibroma, subcutaneous	Lucké, 1942
"	"	Neurofibroma, subcutaneous	Lucké, 1942
SPARIDAE (Porgies)				
<i>Pagrosomus major</i>		Osteoma, mandible, haemal spines	Kazama, 1924
"	"	Osteoma, haemal spines	Sagawa, 1925
"	"	Adenocarcinoma, body wall	Takahashi, 1929
"	"	Osteoma, haemal spines	Takahashi, 1929
"	"	Osteoma, haemal spines	Lucké & Schlumberger, unpubl.
<i>Sparus auratus</i>		Neuro-epithelioma, olfactory plate	Thomas, 1932c

TABLE 21: TAXONOMIC DISTRIBUTION OF TUMOR-BEARING FISHES—Continued

GIRELLIDAE		
<i>Box vulgaris</i>	Goiter, thyroid Johnstone, 1924
SCIAENIDAE (Croakers, Roncadores)		
<i>Pogonias chromis</i>	Epithelioma, lips Beatti, 1916
" "	Fibrosarcoma, subcutaneous Beatti, 1916
" "	Osteoma, vertebrae Beatti, 1916
<i>Micropogon opercularis</i>	Odontoma, upper dental plate Roffo, 1925
" "	Sarcoma, subcutaneous Roffo, 1926
SILLAGINIDAE		
<i>Sillago japonica</i>	Fibrosarcoma, base of head Takahashi, 1929
PLATACIDAE		
<i>Platax pinnatus</i>	Osteoma, vertebral spines Bell, 1793
" "	Osteoma, vertebral spines Gervais, 1875
EPHIPPIDAE		
<i>Chaetodipterus faber</i>	Osteoma, first haemal spine Schlumberger & Lucké, unpubl.
CATAPHRACTI		
SCORPAENIDAE (Scorpion Fishes, Rock Cods)		
<i>Sebastes inermis</i>	Fibroma, body wall Takahashi, 1929
<i>Scorpaena porcus</i>	Fibrosarcoma subcutaneous Schroeders, 1908
HEXAGRAMMIDAE (Greenlings)		
<i>Hexagrammos otakii</i>	Guanophoroma, subcutaneous Takahashi, 1929
TRIGLIDAE (Gurnards)		
<i>Trigla lineata</i>	Hemangioma operculum Drew, 1912
<i>Lepidotrigla alata</i>	Fibrosarcoma, body wall Takahashi, 1929
<i>Chelidonichthys kumu</i>	Allophoroma, subcutaneous Takahashi, 1929
CHROMIDES		
CICHLIDAE		
<i>Cichlasoma tetracanthus</i>	Epithelioma, skin Puente-Duany, 1930
<i>Hemichromis bimaculatus</i>	Osteochondroma, operculum Nigrelli & Gordon, 1946
PHARYNGOGNATHI		
LABRIDAE		
<i>Iridio bivittata</i>	Papilloma, skin Lucké, 1938
<i>Labrus mixtus</i>	Rhabdomyoma, trunk muscle Ladreyt, 1930
DISCOCEPHALI		
ECHENEIDIDAE (Remoras, Shark-pilots)		
<i>Echeneis naucrates</i>	Goiter, thyroid Lucké & Schlumberger, unpubl.
JUGULARES		
CALLIONYMIDAE (Dragonets)		
<i>Callionymus lyra</i>	Lipoma, subcutaneous Williams, 1929
BLENNIIDAE		
<i>Blennius sp.</i>	Xanthoma, skin Schroeders, 1908
ZOARCIDAE		
<i>Zoarces viviparus</i>	Melanoma, skin Bergman, 1921
PLECTOGNATHI		
MONACANTHIDAE		
<i>Alutera schoepfi</i>	Osteoma, interhaemal spine Schlumberger & Lucké, unpubl.
PEDICULATI		
LOPHIIDAE		
<i>Lophius piscatorius</i>	Melanoma, skin Ingleby, 1929

Abstracts of reported tumors in Urodeles

VAILLANT and PETTIT, 1902: A Japanese giant salamander *Megalobatrachus maximus* was kept in a Paris zoological garden from 1859 until its death in 1897. The presence of a tumor on the palmar surface of the right forefoot was first noted in 1874. It measured 10 cm. in diameter and had the appearance of a cluster of

grapes; the nodules varied from 0.5 to 2 cm. in width. The overlying epidermis was intact and on histologic examination appeared normal. The tumor parenchyma was very vascular and composed of interlacing bundles and whorls of pleomorphic connective tissue cells. The nuclei of the neoplastic cells differed greatly in size, some were large and vesicular, others small with abundant

chromatin. The authors identified the growth as a fibroma.

PICK and POLL, 1903: An elliptical tumor, 14 x 10 x 6 cm., was found to be broadly sessile on the testicle of a Japanese giant salamander, *Megalobatrachus maximus*. The tumor contained many cysts, some of which were as large as an apple. Two firm gray nodules, 1 cm. in diameter, were present near the middle and at the lower pole of the testicle. Histologically the cysts were lined by pleomorphic epithelial cells that formed papillary projections into the cyst cavities. The two smaller masses consisted of small alveoli, clumps, and strands of neoplastic cells that were occasionally found free in vascular spaces; in one area direct invasion of a vein could be demonstrated. The authors identified the tumor as a testicular carcinoma showing vascular invasion and local metastasis.

MURRAY, 1908: An adenocarcinoma arose in the skin glands of a newt, *Triton cristatus*, appearing as a mammillated mass at the angle of the jaw, and as nodules scattered over the tail. The pits seen on the surface of the tumors led into tubules that passed through the epidermal layer of the skin. The neoplasms had their origin in the epithelium of the dermal glands; the cells were pleomorphic, and arranged to form solid sheets, acini, or tubules. The surrounding tissue was not invaded, therefore the author suggested that perhaps the tumors were benign. Nevertheless, throughout his description he refers to them as carcinomas.

KRONTOVSKY, 1916: In an axolotl *Siredon mexicanum*, the author found a "malignant chromatophoroma." It was composed of atypical cutaneous melanophores which were undergoing active proliferation and invading the neighboring tissues. Finkelstein (51), who cited this case, points out that the tumor-bearing animal was found at Kiev in 1916. (See also the comments of Brunst [186a]). During the years 1920-1930 there were in the aquarium of the Kiev Roentgenological Institute axolotls with a hereditary tendency to melanoma. Finkelstein suggests that perhaps these animals are progeny of the original mutant described by Krontovsky.

SCHWARZ, 1923: On the forefoot of a Japanese giant salamander *Megalobatrachus maximus* the author found a pedunculated, almost spherical tumor that measured 2 cm. in diameter. Histologically, it was covered by stratified squamous epithelium, but the bulk of the tumor was composed of dense interlacing bundles of connective tissue; nuclei were not abundant. The neoplasm was rather well vascularized and showed no evidence of malignancy.

CHAMPY and CHAMPY, 1932 and 1935: Studied a carcinoma of the skin in *Triton alpestris*, which was transmissible to other newts of the same species. In 1931 the authors observed that 3 out of 5 newts kept in one tank simultaneously developed cutaneous tumors, which were found to be carcinomas composed of cylindrical and polyhedral cells often arranged as atypical glands. The tumors infiltrated the adjacent tissue. The 3 tumor-bearing animals were removed from the tank (the water of which was not changed) and replaced by 8 other newts belonging to 3 different species. These remained in the "contaminated" tank for one month and were then replaced by another group of 8 animals which remained in the contaminated tank for a month and were then replaced by another group of 8 animals. After 1½ to 2 years, 3 of the 4 in the first group of newts belonging to the homologous species *T. alpestris* developed tumors; individuals of other species were not affected. No tumors developed in the animals placed in the contaminated tank after the first month. Fragments of the tumor were inoculated subcutaneously into several newts; most of the animals died, but, in several, tumors were found about 2 years later at some distance from the site of inoculation. The authors believe that the experiments indicate the existence of a carcinogenic virus.

SHEREMETIEVA-BRUNST and BRUNST, 1948: Among hundreds of axolotls *Siredon mexicanum* the authors in 1932 found a male and a female of the gray variety that had minute black spots on the sides of their bodies. These gradually increased in size and progressed to melanotic tumors. The animals were mated and in successive generations a number of tumor-bearing animals were obtained. The tumors usually appeared first as melanotic areas in the skin at the end of the first year of life. Some of these progressed to tumors, and reached a diameter of several centimeters. The tumors sometimes remained circumscribed, but sometimes invaded the surrounding muscle and connective tissue. The cell of origin appeared to be the melanophore which is normally present in the corium. Histologically the growths resembled the melanomas of hybrid killifishes (q.v.). The tumor was found to be transplantable to other axolotls, either gray or albino. The Brunsts regard this melanoma as arising on a genetic basis.

ANURA

A considerable variety of spontaneous tumors have been recorded in frogs of several genera and

TABLE 22: TUMORS OF Tailed Amphibians (URODELES)

Species	Tumor	Site	Author
Giant salamander <i>Megalobatrachus maximus</i>	Fibroma	Subcutaneous	Vaillant & Pettit, 1902
" " <i>Megalobatrachus maximus</i>	Carcinoma	Testicle	Pick & Poll, 1903
Crested newt <i>Triton cristatus</i>	Adenocarcinoma	Skin glands	Murray, 1908
Axolotl <i>Siredon mexicanum</i>	Melanoma	Subcutaneous	Krontovsky, 1916
Giant salamander <i>Megalobatrachus maximus</i>	Fibroma	Subcutaneous	Schwarz, 1923
Alpine newt <i>Triton alpestris</i> (3)	Carcinoma	Skin	Champy & Champy, 1935
Axolotl <i>Siredon mexicanum</i> (many)	Melanoma	Skin	Sheremetieva-Brunst & Brunst, 1948

TABLE 23: TUMORS OF Tailless Amphibians (ANURA)

Species	Tumor	Site	Author
frog <i>Rana</i> sp.	Adenoma	Skin	Eberth, 1868
Meadow frog <i>Rana virescens</i>	Osteogenic sarcoma (?)	Femur	Ohlmacher, 1898
European edible frog <i>Rana esculenta</i>	Fibroma	Mouth	Vaillant & Pettit, 1902
Leopard frog <i>Rana pipiens</i>	Adenocarcinoma	Kidney	Smallwood, 1905
European edible frog <i>Rana esculenta</i>	Carcinoma	Ovary	Plehn, 1906
frog <i>Rana</i> sp. (2)	Adenocarcinoma	Skin	Murray, 1908
frog <i>Rana</i> sp. (2)	Adenoma	Skin	Pavlovsky, 1912
frog <i>Rana</i> sp.	Adenocarcinoma	Skin	Pavlovsky, 1912
European edible frog <i>Rana esculenta</i>	Hypernephroma	Kidney	Carl, 1913
frog <i>Rana</i> sp.	Adenoma	Skin	Pentimalli, 1914
European edible frog <i>Rana esculenta</i>	Adenoma	Skin	Secher, 1917/19
European edible frog <i>Rana esculenta</i>	Adenocarcinoma	Skin	Masson & Schwartz, 1923
Painted Escuerzo <i>Ceratophrys ornata</i>	Fibrosarcoma	Leg	Volterra, 1928
American Bull frog <i>Rana catesbiana</i>	Adenocarcinoma	Skin	Duany, 1929
European edible frog <i>Rana esculenta</i>	Sarcoma (?)	Leg	Gheorghiu, 1930
Leopard frog <i>Rana pipiens</i>	Adenocarcinoma	Kidney	Downs, 1932
Brown-throated frog <i>Rana fusca</i> (17)	Adenoma	Skin	Pirlot & Welsch, 1934
Brown-throated frog <i>Rana fusca</i>	Myxofibrochondroma (?)	Leg	Pirlot & Welsch, 1934
Leopard frog <i>Rana pipiens</i> (1200)	Adenocarcinoma	Kidney	Lucké, 1934, 1938
American Bull frog <i>Rana catesbiana</i>	Neurosarcoma	Sacral plexus	Lucké & Schlumberger (not published)
Green frog (tadpole) <i>Rana clamitans</i>	Myxosarcoma	Tail	Lucké & Schlumberger (not published)
European edible frog <i>Rana esculenta</i>	Hepatoma	Liver	Willis, 1948

species. The reports include adenomas in three species, hepatoma in one, carcinoma in four, sarcoma in three, and fibroma, myxoma and chondroma each in one species.

The more common and up to the present the most extensively studied tumor is the renal adenocarcinoma of the leopard frog, *Rana pipiens* (112, 113, 114). Over 1200 examples of such tumors have been examined in our laboratory since 1933. The tumors occur as solitary or multiple ivory-white masses, and may involve one or both kidneys (Fig. 39). The larger growths not uncommonly metastasize, especially to the liver and lungs (Fig. 40). Histologically, the majority of the tumors have the appearance of adenocarcinomas (Fig. 42), and are thus representative of the most common variety of cancer in man. The component epithelial cells are atypical and usually much larger and basophilic than normal kidney cells (Fig. 41). Mitotic figures are common. The stroma is scanty and poorly vascular. A capsule is lacking and even in very small tumors marginal extensions infiltrate the adjacent kidney. In the larger tumors the entire kidney is often destroyed.

In a relatively small group of the tumors, the appearance is less atypical, and the growths resemble adenomas rather than adenocarcinomas. But there are many gradations, and it is probable that all of these renal tumors are malignant.

A distinctive characteristic of the frog carcinoma is the frequent presence of acidophilic intranuclear inclusions which in their general appearance are like

those found in herpes and certain other diseases known to be due to viruses (Fig. 43). In their typical form, they are conspicuous and clearly recognizable. It is obvious, however, that there must be developmental stages and the character of these is still a matter of doubt. The inclusions are invariably confined to the cells of the tumors and do not occur in normal renal epithelium, nor in the cells of other organs. Experiments have supported the indications, first given by the presence of the intranuclear inclusions, that the tumor is in fact very probably caused by a species-specific virus (115).

Our experience with regard to the occurrence of metastasis is worthy of record. In the first series of 158 tumor-bearing frogs no metastases were found, and the conclusion was reached that this cancer, though locally destructive, does not become disseminated. Yet tumor emboli are frequently encountered in vascular spaces (Fig. 44). In a second series of 362 additional cases, metastasis was found in 22 frogs; and to date we have observed over 75 tumor-bearing frogs with metastasis, nearly all of them in animals with relatively large tumors. This experience emphasizes that large series of animals must be studied before an opinion about the character of a neoplasm should be expressed.

The frog tumors have served for many different kinds of experiments, such as manner of growth in the anterior chamber of the eye of homologous and of heterologous species (116, 120). By serial transplantation the tumor has been maintained for 14 generations (176a). It has been transplanted to

tadpoles (19, 22), and studied in tissue culture (117). The frog being poikilothermic lends itself particularly well to studies on the effect of temperature on the tumor as regards its rate and manner of growth (121), and as regards induction and augmentation of metastasis (123b). These experimental investigations are reviewed elsewhere (123a). Here it must suffice briefly to mention a few other studies to indicate the lines of research that have been pursued. Witschi (232) and Briggs (18, 20) have studied the abnormal growths which appear in tadpoles that develop from overripe eggs. Briggs (21) has also investigated the effect on development of eggs exposed to carcinogens, and has introduced carcinogens into tadpoles (17). Duran-Reynals (41) and Schlumberger (176a) have injected several carcinogens into adult frogs.

To the cases reported in the literature two additional anuran tumors may be added. One tumor occurred in a second-year tadpole of the green frog *Rana clamitans*. It formed a mass measuring 7 x 5 x 6 mm. on the dorsal fin, parts of which were destroyed by the growth (Fig. 45). Sections revealed that portions of the dorsal myomeres had been infiltrated and destroyed (Fig. 49). Histologically the tumor had the structure of myxosarcoma, being composed of large stellate and spindle shaped cells which were embedded in an abundant mucinous matrix (Fig. 47). No inflammatory reaction was present. The growth corresponded in every way to a true neoplasm. The tumor is unique in that no neoplasms in larval amphibians have been recorded.

The other tumor occurred in an adult bullfrog in which it formed a swelling in the left flank. On dissection, the growth was found to measure 2 x 1 x 1 cm. It probably had its origin in one of the nerves of the sacral plexus. It protruded into the coelomic cavity, and through the muscles of the back which it had invaded and partly destroyed (Fig. 48). Histologically, the mass was composed of interlacing bundles and whorls which resembled neoplastic connective tissue (Fig. 49, 50). In general appearance the tumor was similar to the more malignant nerve sheath tumors of man.

Abstracts of other reported cases of anuran tumors

EBERTH, 1868: About 60 nodules, small but varying in size, were found on the dorsal and ventral surfaces of a frog. The tumors were located in the corium, were covered by an intact epithelium, and did not infiltrate the adjacent tissues or metastasize. Histologically the tumors were composed of stratified squamous epithelium arranged to form tubules and acini that superficially resembled the normal skin glands. Eberth discussed the possible relation of parasites to the neoplasms, since

trematodes and nematodes frequently inhabit the cutaneous glands of frogs. Transplantation experiments yielded negative results.

OHLMACHER, 1898: The left femur of a frog *Rana virescens* presented a spindle shaped swelling that occupied the entire length of the femur and reached a maximum diameter of 8 mm. The periosteum was intact. Histologically the tumor consisted of trabeculae of bone and cartilage surrounded by large spaces. In the latter were rapidly proliferating mononuclear cells that appeared to be derivatives of the bone marrow. The author concluded that the lesion was a "medullary osteosarcoma." However, the description is more suggestive of callus formation after fracture. Murray (141) described a similar lesion in a frog and concluded that it probably represented callus rather than bone tumor.

VAILLANT and PETTIT, 1902: In their report of a tumor in a python the authors briefly mention a fibroma which they found in a frog, *Rana esculenta*. The tumor originated in the buccal cavity and protruded from the mouth.

SMALLWOOD, 1905: Bilateral renal tumors were found in a leopard frog *Rana pipiens* and were interpreted as having arisen in the adrenals and secondarily invaded the kidneys. Histologically the tumor was composed of cuboidal or columnar epithelial cells arranged as dilated and tortuous tubules, into the lumens of which the neoplastic cells often extended as papillary projections. This tumor was first reviewed by Murray (141) who failed to see any resemblance between the tumor cells and those of the normal adrenal. Subsequently one of us (112) obtained a slide of the tumor from Dr. Smallwood. A study of this section revealed that the lesion was a renal adenocarcinoma and bore no relation to the adrenal glands.

PLEHN, 1906: Between the ovaries and fat bodies of *Rana esculenta* were bilateral white cherry-sized tumors; 5 or 6 smaller nodules were scattered among the eggs in the ovaries. The neoplastic cells were large, pleomorphic, with vesicular nuclei; multinucleated giant cells were common. Normal and abnormal mitotic figures were abundant. Plehn believed that the tumors were carcinomas and represented a neoplastic growth of the primitive egg cells.

MURRAY, 1908: A hemispherical nodule was present on the inner aspect of the thigh of an adult male frog. The overlying skin was stretched, but apparently intact. The neoplastic squamous epithelial cells formed irregular tubules and acini separated by delicate connective tissue septae. The epithelium resembled that seen by Eberth in the benign adenomas. In this case, however, the structures were more bizarre and the subjacent muscles were infiltrated by the tumor cells. Murray regarded this growth and another similar one as adenocarcinomas of the skin.

PAVLOVSKY, 1912: The author presented two cases of adenoma and one of adenocarcinoma of the skin in frogs at a meeting of the Russian Pathological Society. The tumors were similar in that the neoplastic tubules communicated with the surface and were lined by tall

columnar epithelium of embryonal type; these cells did not resemble those normally found in the serous or mucous glands of the frog's skin. In the case identified as an adenocarcinoma the tumor cells invaded the surrounding connective tissue.

CARL, 1913: A tumor, about the size of a cherry, projected ventrally from the hilum of the left kidney in an adult female *Rana esculenta*. The growth was round, firm, red-brown, with a slightly uneven surface. The neoplastic cells were pleomorphic, with large nuclei, and resembled those of the adrenal. This appearance was heightened by their occasional arrangement as cords of cells; no glycogen, chromaffin, or fat was demonstrated. Carl identified the lesion as a malignant adrenal tumor; no metastases were found. Attempts to transmit it were unsuccessful.

PENTIMALLI, 1914: Scattered over the skin of the trunk and extremities of a frog were 24 nodular adenomas, the largest of which was the size of a small pea. The overlying skin adhered to some, over others it was ulcerated; the cut surfaces of the tumors were very bloody. Histologically the neoplasms were adenomatous, with frequent papillary proliferations extending into the cysts. No metastases were found; transplants failed to grow.

SECHER, 1917/19: An irregular cauliflower-like mass about 1 cm. in diameter was present on the outer surface of the thigh in *Rana esculenta*. The tumor resembled those described by Murray, though it was less infiltrative and apparently benign. The neoplastic epithelial cells were arranged as solid sheets or acini; the latter occasionally became small cysts. No metastases were present; parasites could not be found.

MASSON and SCHWARTZ, 1923: Three tumors, ranging from 5 to 15 mm. in diameter were located on the right thigh, the right flank, and the lower right abdomen of *Rana esculenta*. They were spherical, pale pink in color, firmly attached to the epiderm but not to the subjacent musculature. Columnar neoplastic epithelial cells lined tubular spaces and were supported by a layer of cuboidal cells. Some of the tubules were cystically dilated; elsewhere the cells formed solid strands. The connective tissue stroma was infiltrated by inflammatory and neoplastic cells which in some instances had penetrated as far as the endothelium of the lymph sacs. The writers were undecided whether the tumors were multicentric in origin or if a single one was the primary growth, the others secondary. Transplants did not grow.

VOLTERRA, 1928: A fibrosarcoma had produced considerable swelling of the left hind foot in an exotic frog *Ceratophrys ornata*. The tumor was dense, white, and homogeneous in appearance; the overlying skin was ulcerated; the bones of the foot were largely destroyed. Numerous metastatic nodules were present in the liver, two of them were as large as hazel-nuts. The neoplastic cells were spindle-shaped elements gathered into compact bundles; in many places the cells extended to the endothelial lining of the vessels. Mitoses were abundant, and frequently atypical.

DUANY, 1929: Two cutaneous tumors were found in

a bullfrog *Rana catesbiana* that had been brought to Havana some years before from the United States. The smaller growth, about the size of the frog's eye, was situated between and slightly behind the eyes. Directly back of this was another tumor as large as the animal's head. The neoplastic epithelial cells formed tubules that somewhat resembled the normal skin glands; the underlying tissues were not invaded. No metastases were found in the viscera, but the author raised the question whether the smaller nodule may have been a metastasis or extension from the larger tumor. He identified the tumor as an adenocarcinoma and noted its similarity to those described by Murray and by Masson and Schwartz.

GHEORGHIU, 1930: The author found a tumor the size of a nut in the right gastrocnemius muscle of *Rana esculenta*. The lesion involved the skin, was soft in consistency, and dull white in color. The cells were pleomorphic, though in some areas those of spindle shape predominated. Filaria as well as numerous bacteria were found throughout the sections. The tumor was easily transplantable and had been carried through 12 generations. About 80 per cent of the grafts "took"; they grew rapidly for from 15 to 20 days, then ulcerated, and the frogs died, probably from infection. The nature of these tumors is questionable; it is quite possible, as Cramer (32) pointed out, that the "tumors" were infectious granulomas.

Downs, 1932: A yellow-brown tumor almost filled the coelomic cavity and compressed the liver of *Rana pipiens*. The mass was cystic and surrounded a large part of the intestine. The neoplastic epithelial cells formed bizarre tubules which were identified as of intestinal origin. A section of the tumor was examined by one of us (112) and a striking resemblance to the renal adenocarcinoma noted. That the lesion was actually such a tumor is highly probable since remnants of kidney tissue were seen in the section.

PIRLOT and WELSCH, 1934: The authors found 17 cases of cutaneous adenoma among 1800 frogs *Rana fusca*. The tumors were frequently multiple and varied in diameter from 1 to 15 mm. Stratified columnar epithelial cells with large vesicular nuclei lined the irregular acini. Mitoses were numerous, but the basement membrane was intact and there was no evidence of local invasion or metastasis. Another growth observed by these investigators was a 15 x 7.5 mm. tumor adherent to the overlying skin of the leg in *Rana fusca*; the femur was intact. Masses of spindle-shaped connective tissue cells alternated with regions that were relatively acellular, and composed chiefly of fibrils. Islands of cartilage were present. In some areas a transition from connective tissue to cartilage was apparent. Three frogs were inoculated with the tumor tissue; in all there was a severe inflammatory reaction associated with resorption of the implant. These authors identified this tumor as a myxofibrochondroma, but their description leaves one in doubt as to the nature of the growth.

WILLIS, 1948: A solitary white tumor, 3 cms. in diameter, was found in the liver of an adult European

edible frog *Rana esculenta*. Microscopically, it had an alveolar structure and the general appearance of a well differentiated hepatoma.

Several pseudotumors have been reported in the literature. Gebhart (54) and Wagner (225) described connective tissue hyperplasia of the pylorus of frogs. The first writer implicated coccidia as the etiologic agent, whereas Wagner believed that fibrosis followed encystment of nematode worms and their eggs. Montpellier and Dieuzeide (137) wrote of a localized epithelial proliferation in three specimens of *Discoglossus pictus* that had been kept in the same tank. A characteristic histologic feature was the presence of large eosinophilic cytoplasmic inclusion bodies in the epithelial cells. However, the lesions gradually disappeared, and the authors concluded that they were not true tumors. The disease is somewhat similar to carp-pox, a virus disease of fishes.

III. TUMORS OF REPTILES

In 1908 Murray (141) wrote that no malignant neoplasms had been reported in reptiles up to that time. Scott (183) examined the records of over 6,000 autopsies performed on reptiles of various kinds at the London Zoological Gardens from 1900 to 1925. In only two did he find a neoplasm; both occurred in turtles. Bergman (11) found a macroscopic tumor in only one of 2,200 snakes which he examined; Patay (145a) however, observed a tumor-bearing individual in one of a group of 54 large ring snakes. Our experience with fishes and amphibians leads us to suspect that a careful study of large numbers of reptiles will reveal a tumor incidence not far different from that in other vertebrates.

The reptiles alive today are but a small remnant of the vast numbers that dominated the earth in the Mesozoic age. Among the most spectacular were the giant dinosaurs, in three of which tumor-like lesions were found in the caudal vertebrae. These have been variously interpreted as osteomyelitis, excess callus following fracture, and hemangioma. Moodie (139), who discussed one of these in detail

and cited two others reported by Hatcher (71) and Holland (76), believed that they were hemangiomas. However, the descriptions of Hatcher and Holland strongly suggest that the lesions noted by them were bony overgrowths following fracture, rather than neoplasms. Although the dinosaurs were reputedly capable of living for a thousand years, evidence of disease is rarely found in their fossil bones (139). Moodie also reported an osteoma of the third dorsal vertebra in a mosasaur, a large aquatic reptile that lived during the latter part of the Cretaceous.

TURTLES (CHELONIA)

The first tumor in a turtle of which we can find any record is an adenoma of the thyroid reported by Pick and Poll (154) in 1903. It was an egg-shaped, encapsulated mass, 6 x 4 x 2.5 cm., on the ventral aspect of a Brazilian fresh water turtle, *Platemys geoffroyana* (*Hydraspis hilarii*). The connective tissue stroma was moderate in amount and divided the parenchyma into elongated lobules. The latter was composed of tubular acini lined by tall columnar epithelial cells which rested upon 2 to 5 layers of small polyhedral cells with relatively large nuclei.

In a brief report on the causes of death in the London Zoological Gardens during 1911, Plimmer (163) records "a glandular cancer in the stomach of a tortoise." A more detailed description of this case was found by Scott (183) among the post-mortem records of the Zoological Society of London. This record identified the animal as an elephantine tortoise in which "there was a large mass, 8 x 5 inches of new growth springing from the mucosa of the stomach which was very red and swollen. The growth was white and gelatinous." There is no account of histologic studies.

In 1913 Plimmer (164) reported the death of a West African fresh water turtle, *Sternothererus niger*. "Death from rupture of the heart. The heart measured 1¾ x 1¼ inches. The pericardium was full of blood. The heart muscle was converted into a soft whitish growth, full of very large multinucleated cells." Since no mention is made of tumors elsewhere in the body, that found in the heart may

TABLE 24: TUMORS OF TURTLES (CHELONIA)

Species	Tumor	Site	Author
Turtle <i>Platemys geoffroyana</i>	Adenoma	Thyroid	Pick & Poll, 1903
Giant tortoise <i>Testudo elephantina</i>	Adenocarcinoma	Stomach	Plimmer, 1912
Black terrapin <i>Sternothererus niger</i>	Rhabdomyoma (?)	Heart	Plimmer, 1913
Green turtle <i>Chelonia mydas</i> (3)	Papilloma	Skin	Lucké, 1938
Green turtle <i>Chelonia mydas</i> (6)	Papilloma	Skin	Smith & Coates, 1938, 1939
Green turtle <i>Chelonia mydas</i> (many)	Papilloma	Gall bladder	Smith, Coates & Nigrelli, 1941
Horsfield's tortoise <i>Testudo horsfeldi</i>	Fibroadenoma	Lung	Tsvetaeva, 1941
Musk-turtle <i>Sternothererus odoratus</i> (2)	Papilloma	Skin	Schlumberger & Lucké (not published)

have been primary. The presence of the large multinucleated cells suggests that it may have been a rhabdomyoma.

One of us (116) has studied the multiple large papillomas of the skin and eyes in the edible green turtle *Chelonia mydas*. Three specimens, caught off Cape Sable, were available for examination. The tumors were located on the tail, flippers (Fig. 52), the axillae, neck, eyelids, corneas. In one instance bilateral corneal growths had produced blindness (Fig. 51). The tumors were hemispherical and had a rough warty surface which was ulcerated in some areas. They were sessile or had a broad pedunculated base, and ranged in size from small warts a few millimeters in diameter to masses 20 cm. in width. The tumors were rubbery in consistency and on section were white and bloodless. Histologically they were papillomas, with arborescent connective tissue papillae covered by several layers of keratinizing squamous epithelium (Figs. 53, 54).

The connective tissue component became more prominent as the tumor increased in size, and its cellularity gave evidence of active proliferation. Although this never yielded the picture associated with malignant connective tissue tumors, numerous spherical masses, from 3 to 5 cm., were found in the lungs of one of the turtles (Fig. 57). These were composed of dense fibrous tissue covered by ciliated columnar respiratory epithelium (Figs. 58, 59). Whether they were primary tumors of the lung or whether they represented a metastatic dissemination of the neoplastic connective tissue of the skin papillomas cannot be determined with certainty, but an origin *in situ* appears most probable. In this connection may be mentioned the brief note of Tsvetaeva (219) reporting a fibroadenoma of the lung in a Turkestan turtle, *Testudo horsfeldi*. Whether the animal bore any skin papillomas was not stated. Since many papillomas (warts) of man and other animals are of proved virus etiology, it is interesting to consider a similar etiology for these tumors of turtles.

Smith and Coates (191, 192) observed similar fibroepithelial growths in six specimens of *Chelonia mydas*. Besides the more common papillary structures, they also noted occasional smooth elevations which on section were composed of interlacing bands of connective tissue varying in density and covered by a slightly thickened epithelium. The investigators regarded these as fibromas. At times both types of growth coexisted. In a subsequent paper (192) the authors reported that in more than half of 250 tumors occurring in the six turtles examined they found ova of the parasitic trematode *Haplotrema*

constrictum (later [193] reclassified as *Distomum constrictum*). The authors believe that the ova were probably deposited in the preexisting vascular tumor tissue by the migrating flukes, and remained there without affecting the subsequent growth of the tumor. They concluded that the ova were not of primary importance in the etiology of the neoplasm.

Recently, however, Nigrelli (142) reported finding as many as 50 leeches, *Ozobranchus branchiatus*, in various stages of growth on a bit of the papilloma only $\frac{1}{2}$ inch square. The largest leeches measured 10 mm. in length, 5 mm. in width; all were strongly contracted. In the regions where the leeches were attached, the vascularity of the tumors was increased. The hirudin secreted by the leeches may have a direct stimulating effect on the growth of the tumor, or may affect it indirectly by improving the circulation. The author suggested further that the leeches may act as vectors for viruses or other parasites that may be causative in the development of the papillomas.

In these turtles Smith, Coates, and Nigrelli (193) observed a papillomatous disease of the gall bladder associated with the presence in that organ of the trematode *Rhytidodoides similis*. Occasionally the tumors formed discrete patches which surrounded and occluded the orifice of the cystic duct. Not infrequently the entire mucosa was thickened and rugose, the wall edematous and infiltrated with lymphoid elements. These changes were accompanied by capillary dilatation and connective tissue proliferation. The mucosal glands were dilated and tortuous but in none of the 100 affected gall bladders examined was there any evidence of malignant change. Although most of the worms lay free in the bile of the gall bladder, some were found attached to the papillomatous portions of the mucosa. The authors believe that the growths are the result of mechanical or chemical factors associated with the presence of the parasite.

Two musk turtles *Sternotherus odoratus* bearing skin papillomas were obtained by us from the Philadelphia Zoological Gardens. In one there was a growth, 5 x 5 x 8 mm., on the dorsum of the tail (Fig. 55) and another on the right front flipper. In the second animal a single tumor, 4 x 5 x 5 mm., was present on the left hind flipper. The three small tumors were very firm in consistency and deeply lobulated. On section they closely resembled the common warts of man. A loose, well vascularized connective tissue core was covered by multilayered stratified squamous epithelium showing hyperkeratosis and parakeratosis (Fig. 56). Long pegs of epithelial cells extended deeply into the underlying

connective tissue, but there was no evidence of malignancy. Bits of the tumors were transplanted to the subcutaneous tissue of three musk turtles and three mud turtles, *Kinosternum subrubrum*. After nine months the transplants had failed to grow, and there was no evidence of recurrence at the site of excision.

CROCODILES (CROCODILIA)

Only two instances of neoplasia in the *Crocodylidae* have been reported. In a discussion following the presentation of a paper on tumors in cold-blooded animals by Pick (153) at a meeting of the Berliner medizinische Gesellschaft in 1905, v. Hansemann (72) said, "I wish to add that I saw a lesion, very similar to that just described by Herr Heller in lizards, in a very large crocodile (the species was not given) in our (Berlin) Aquarium. We operated on the animal and it turned out that we were dealing with quite ordinary warts. Soon thereafter the animal died, whether as a result of the operation or from some other cause I cannot say. Nevertheless, I have the impression that the warts per se had nothing to do with its death."

A more detailed account of a neoplasm in a young porose crocodile *Crocodylus porosus* is given by Scott and Beattie (183). The first symptoms were an inability to rise, and a tendency to fall on its right side. A diagnosis of cerebellar tumor was made and the animal was destroyed. At autopsy a tumor somewhat larger than a cherry stone was found on the ventral surface of the cerebellum. On microscopic examination a few glial fibers were seen, but the mass was mainly composed of small round cells and a few larger, often multinucleated cells. Occasional mitotic figures were present; the neoplasm had invaded the adjacent nervous tissue. The entire right auricle of the heart was filled with a tumor that had also invaded the wall of the right ventricle and the interventricular septum. Histologically, it was similar to the growth found in the cerebellum. In the portal spaces of the liver were numerous groups of neoplastic cells; the latter were also diffusely scattered throughout the disorganized parenchyma. The authors concluded that the tumor was

a round cell sarcoma, primary in the liver, with metastases in the heart and cerebellum. Examination of the photomicrograph reveals nothing to suggest that the liver cell itself was the neoplastic cell of origin. It may be that the tumor arose in the blood forming tissues (hematopoiesis is active in the liver of some reptiles) and is comparable to lymphosarcoma of man.

LIZARDS (SAURIA)

Because lizards are seldom hunted for food or sport, it is not surprising that the six reports of tumors in these animals deal with individuals kept in captivity. All but one of the lesions were neoplasms of surface epithelium. The exception was a case described by Bland-Sutton (12) of multiple enchondromas in an Indian monitor, *Varanus dracoena*. The animal, which also suffered from rickets, had large tumors in the fifth and seventh cervical vertebrae. Two tumors were present in the distal metaphysis of the right humerus, one in the left humerus. Each of two metacarpal bones bore a tumor near its distal end, and four were found in the hyoid bone. Histologically the neoplasms were composed of hyaline cartilage. It may be noted that the possible etiologic relation of rickets to generalized chondromatosis in man was suggested by Virchow in 1863.

In a male lizard *Lacerta agilis*, Koch (100) found several papillomas on the frontal, parietal, and occipital regions of the head, as well as on the left side of the thorax. The normal shape of the head was altered by the tumors, which were wart-like in character and bluntly conical. They were firm in consistency and on microscopic examination presented the typical appearance of papillomas.

During the discussion of a paper by Pick (153), Heller (74) stated that he had seen keratinized masses in the inguinal regions of several lizards *Lacerta muralis fumensis*. The lesions attained a considerable height and histologically bore a certain resemblance to the keratinizing condylomata acumenata of man.

Plehn (159) observed similar lesions in another species of lizard, *Lacerta viridis*. The papillomas

TABLE 25: TUMORS OF LIZARDS (SAURIA)

Species	Tumor	Site	Author
Indian monitor <i>Varanus dracoena</i>	Enchondroma	Bones	Bland-Sutton, 1885
Lizard <i>Lacerta agilis</i>	Papilloma	Skin	Koch, 1904
Lizard <i>Lacerta muralis fumensis</i> (several)	Papilloma	Skin	Heller, 1906
Lizard <i>Lacerta viridis</i> (several)	Papilloma	Skin	Plehn, 1910
Tegu <i>Tupinambis teguixin</i>	Squamous cell carcinoma	Skin	Schwartz, 1923
Tegu <i>Tupinambis nigropunctatus</i>	Squamous cell carcinoma	Mouth	Ratcliffe, Schlumberger, & Lucké (not published)

occurred in several portions of the body and varied greatly in size. Though they occasionally presented firm swellings of considerable dimensions, they never penetrated deeply nor did they infiltrate the surrounding tissues.

A squamous cell carcinoma arising in the skin of the right forefoot of a tegu, *Tupinambis teguixin*, has been reported by Schwarz (180). The tumor was approximately spherical, measured 3 cm. in diameter, and had almost destroyed the metacarpal and proximal two phalanges of the fifth digit. The two proximal phalanges of the fourth toe were also extensively injured. The tumor parenchyma consisted of neoplastic epithelial cells that showed suggestions of keratinization and "pearl" formation. A vascular connective tissue stroma traversed the masses of tumor cells and even appeared to infiltrate the adjacent muscle. Large areas of necrosis were present throughout the neoplasm. Although the overlying skin was intact, the author believes that the tumor arose locally from the epidermal cells. The tumor was operatively removed, but the animal died a few weeks later; no metastases were found at autopsy.

In collaboration with Dr. Herbert L. Ratcliffe, pathologist to the Philadelphia Zoological Garden, we have studied a squamous cell carcinoma of the mouth in a black-spotted teguixin, *Tupinambis nigropunctatus*. When first observed, the tumor, which arose from the left upper gum, had a smooth, lobulated, pink surface and was very firm in consistency. It measured 2.5 x 2 x 1 cm., and during the following months increased fairly rapidly in size, doubling its dimensions in a year. At the end of that time a similar tumor appeared in the corresponding location on the right upper gum. In the following 18 months both tumors increased in size and exhibited central areas of necrosis and ulceration (Fig. 60). At intervals the animal became listless and refused its food. When this occurred a partial excision of the tumors was performed. This

was followed by a return of the animal's desire for food.

Several biopsies were taken, the vascularity of the tumor causing considerable bleeding. Attempts at tissue culture of this material were unsuccessful because oral bacteria were a constant contaminant. Transplants were made to the subcutaneous tissue of 23 lizards and the gums of four alligators, but the tumor failed to grow. A similar negative result followed transplantation to the anterior chamber of the eyes of 9 alligators, 9 green frogs, one bull frog, 6 chickens, 12 chicks, and 9 rats.

After being under observation for 2 years and 8 months the animal died from an accidental injury. At autopsy there was local infiltration of the adjacent tissues by the tumor, but no metastases. Histologically the neoplasm was composed of squamous epithelial cells supported by delicate connective tissue trabeculae. The neoplastic cells adjacent to the trabeculae were radially arranged and columnar in shape. Elsewhere they were polygonal, the basophilic cytoplasm was abundant, with prominent intercellular bridges. Frequently cell aggregates were found that resembled the epithelial "pearls" of human squamous cell carcinoma (Fig. 61). The nuclei were pleomorphic, and showed a marked tendency to produce giant forms with one or more prominent nucleoli (Fig. 62). Mitotic figures were numerous.

SNAKES (SERPENTES)

The recorded instances of tumors in snakes are very few, but several are of great interest. One such is the adenocarcinoma of the pancreas of Say's pine snake *Pituophis sayi*, which was reported by Ratcliffe (167). Grossly the pancreas was diffusely enlarged; upon histologic examination the parenchyma was found largely replaced by neoplastic epithelial cells. In a later publication Ratcliffe (168) reported that in a series of 136 snakes which had died in captivity, he found in the pancreas of 45 individuals

TABLE 26: TUMORS OF SNAKES (SERPENTES)

Species	Tumor	Site	Author
Python <i>Python sebae</i>	Adenocarcinoma	Ovary	Bland-Sutton, 1885
Python <i>Python sebae</i>	Cystic adenoma (?)	Stomach	Vaillant & Pettit, 1902
Ring snake <i>Tropidonotus natrix</i>	Adenocarcinoma	Kidney	Patay, 1933
Say's pine snake <i>Pituophis sayi</i>	Adenocarcinoma	Pancreas	Ratcliffe, 1935
Water snake <i>Homalopsis buccata</i>	Papillary carcinoma	Bile duct	Bergman, 1941
Pine snake <i>Pituophis melanoleucus</i>	Melanoma	Skin	Ball, 1946
Pine snake <i>Pituophis melanoleucus</i>	Melanoma	Labial folds	Ball, 1946
	Rhabdomyoma	Palate	Ball, 1946
Reticulated python <i>Python reticulatus</i>	Melanoma	Skin	Schlumberger & Lucké (not published)
Reticulated python <i>Python reticulatus</i>	Melanoma	Skin	Lucké & Breedis (not published)

lesions suggestive of the neoplasm which he had observed in the pine snake. The changes occurred most frequently in the *Crotalidae* (rattle-snakes, water moccasins) and *Colubridae* (pine snakes, black racer). The author traced the development of the lesions to necrotic foci of unknown etiology. The necrosis was apparently followed by an abortive and atypical regeneration of the terminal ductal epithelium, producing small, adenoma-like cell masses. These continued to proliferate while degeneration of acinar and islet epithelium progressed until sometimes the entire organ was replaced by atypical duct epithelium. Whether, or at what stage, the process ceases to be an atypical regeneration and assumes the character of a neoplastic tumor is difficult to determine. At the time of his report Ratcliffe regarded the lesions as early tumors; he has recently informed us that he now considers them to be regenerative rather than neoplastic. Continuing his study of this disease, he examined 261 snakes belonging to the most susceptible species, 60 to 90 days after capture. In contrast to the high incidence of the lesion in animals that had died in captivity only ten of the sacrificed snakes showed evidence of pancreatic neoplasia.

A report by Ball (4) of a malignant melanoma in each of two pine snakes *Pituophis melanoleucus* has recently appeared; we have had the opportunity of examining the tumors. The animals were a male and a female, kept in the same cage at the San Diego Zoological Gardens. In the female snake a dark rapidly growing tumor was noted on the tail after the animal had been in captivity for three years. The tail was amputated, but subsequently two black tumors appeared on the head and one on the abdomen. Two years after the primary tumor was first noted, a fusiform swelling developed anterior to the cloaca. This increased in size and the animal died six months later. At autopsy the tumor measured 11 x 6 x 5 cm. and had encroached on the coelomic cavity. Two metastatic nodules, approximately 2 cm. in diameter, were found in the liver. Histologically the neoplastic cells were spindle shaped with an abundant cytoplasm that frequently contained large numbers of fine pigment granules. The cells were arranged in interlacing bundles; the nuclei occasionally showed some evidence of palisading.

In the male animal a tumor was first noted after almost six years of captivity. The growth, which appeared on the upper labial fold, increased very rapidly in size and the snake was sacrificed 8 months after the tumor was first seen. Histologically it resembled that of the first animal and was identified as

a melanosarcoma. No metastases were found. However, a non-pigmented tumor 1.5 cm. in diameter was discovered on the palate. It was composed of large elongated cells with a fibrillar cytoplasm in which cross striations were occasionally seen. Scattered through the section were plump giant cells with multiple, centrally located nuclei. This tumor unquestionably was different from the others; it had all the structural characteristics of a rhabdomyoma.

The melanomas of the pine snakes lend added interest to our recent findings of similar neoplasms in two reticulated pythons, *Python reticulatus*. The first python* was a female, 18 feet in length, and 50 to 60 years of age, which had been on exhibition in the National Zoological Garden of Washington, D. C., for thirteen years, when a nodule the size of a walnut was noticed on the left lateral surface of the trunk. It was located halfway between the head and tip of the tail. During the following year the tumor grew rapidly, and when examined by us measured 11.5 x 8 x 3.5 cm. (Fig. 63). The mass was a variegated red-brown in color; the surface was faintly lobulated. The periphery was covered by expanded scales, but toward the center these were destroyed by a shallow ulceration. The tumor was quite vascular and bled profusely when we removed small portions for examination. It was firm in consistency; on section the surface was a mottled red, yellow, and black. Six months later the tumor had increased somewhat in size and the area of ulceration was larger. The animal was killed as unfit for exhibition.

At autopsy the tumor was found to have penetrated to the vertebral bodies. Its lateral spread had been somewhat restricted by the stout connective tissue septae that normally separate the larger muscle bundles (Fig. 64). Protruding into the coelomic cavity 20 cm. caudal to the heart, was a black, broadly sessile mass that measured 7 x 5 x 6 cm. (Fig. 66) and was covered by smooth transparent mesothelium. On section it was granular, black in color, and the pigment it contained rubbed off and discolored the fixing fluid. On the dorsal surface of each kidney were 6 to 7 widely scattered, roughly circular, umbilicated, yellow-white nodules varying from 0.5 to 1.2 cm. in diameter (Fig. 65).

Histologically the primary neoplasm was composed of interlacing bundles of spindle shaped cells (Fig. 67) which in some areas contained large num-

* We wish to express our appreciation to Dr. W. M. Mann, director of the National Zoological Garden, for placing this animal and the facilities of the Reptile House at our disposal.

bers of pigment granules (Fig. 68). Elsewhere, the cells were less elongated and the nuclei more vesicular, with prominent nucleoli; this appearance was most marked in the metastatic nodules in the kidney (Fig. 69). Occasionally there was a suggestion of palisading (Fig. 70) similar to that observed in the melanomas of the pine snakes. This resemblance of reptilian melanomas to the neurilemmomas of man may therefore perhaps be traced to the origin of both in neurectoderm.

In view of the successful transplantation of mouse tumors to the yolk sac of the chick embryo (201), the finely minced python tumor was inoculated into the yolk sac or onto the chorio-allantoic membrane of 80 embryos. The chick embryos all died within 48 hours after inoculation; in some, death was the result of bacterial infection; in others, the snake tissue appeared to be toxic to the embryo.*

The second python, also a female, was 20 feet long, and had been at the Philadelphia Zoological Garden for 20 years. No information as to age is available, other than that the snake was "full-grown" when received at the Garden. About a year before its death, the keepers noted a swelling in the right side of the upper jaw, and two black tumors on the body. The snake became weak, declined food, and had to be sacrificed.** At autopsy, the tumor was found to arise from the region of the angle of the jaw; it extended forward, was covered externally by unbroken skin, had a firm consistency, and measured 6 x 3 x 2 cm. The cut surfaces of the tumor were pale and had a fibrous appearance. A second tumor, 2 x 2 cm. in diameter, was located on the side of the body, about 8 feet from the tip of the tail. It was somewhat elevated, the covering skin was unbroken; its consistency was relatively soft and its color deep black. A similar, much smaller growth, 0.5 cm. in diameter, was found under the skin about 4 feet from the head. None of the tumors had invaded the neighboring tissues, and no metastases were found. Histologically, the tumors were composed of spindle-shaped cells, grouped in interlacing bundles. Melanin was fairly abundant in the two smaller growths, but the tumor of the jaw was almost amelanotic. The tumors were regarded as multiple non-malignant melanomas. Attempts to transplant them into the anterior chamber of the eye of a number of alligators, turtles and frogs were unsuccessful.

Two other reports of tumors of pythons belonging to a different species are on record. Bland-Sutton (12) observed in a python *Python sebae* which was destroyed at the London Zoological Garden that the viscera were studded with an enormous number of

firm yellow-white tumor nodules. The liver contained many similar nodules, varying from the size of a pea to that of a large walnut. In the lung were twenty pea-sized nodules; each kidney bore a mass the size of a walnut, and the ovaries were the seat of several that had attained the size of an orange. Histologically the tumor was identified as a "medullary cancer made up of alveoli containing masses of irregular cells." The source of the metastases could not be determined with accuracy, but the author believed that the ovaries were probably the primary site of the tumor.

More difficult to interpret is the case recorded by Vaillant and Pettit (222) in a python *Python sebae*, which died 8 days after a swelling near the middle of its body first became apparent and about 40 days after the animal had become indifferent to food. At autopsy a spheroidal mass that measured 28 cm. in diameter was found attached to the gastric mucosa and extending into the esophagus. The tumor apparently precipitated intussusception of the small intestine by the pyloric end of the stomach, accounting for the rapid increase in size of the swelling and the death of the snake. The neoplasm was very cystic; though most of the cysts were quite small, one or two contained almost a liter of foul purulent fluid. Connective tissue septae separated the cysts which were often lined by epithelial cells. The nature of this tumor is not recognizable from the authors' description. It may perhaps represent a cystic adenoma, but it may not be a neoplasm. Less difficult to interpret are two older reports of "tumors" in pythons (79, 224). In these cases the growths were almost certainly not true neoplasms; rather, they were probably organized blood clots.

In contrast to the questionable nature of these growths is the carcinoma of the kidney reported by Patay (145a) in a ring-snake, *Tropidonotus natrix*. The animal was a female, 75 cm. in length. The left kidney measured 4 x 2.5 cm. Its lower portion was occupied by a well circumscribed growth, approximately one-third the size of the entire organ. Histologically, the tumor consisted of atypical epithelial cells which in some areas were arranged as acini into which papillary projections protruded; elsewhere the cells were undifferentiated. The author regarded the tumor as a papillary adenocarcinoma, and likened it to similar tumors in mammals.

* This work was carried out for us through the courtesy of Col. Raymond Randall, director of the Division of Veterinary Medicine, Army Medical Center, Washington, D. C.

** Dr. Herbert Ratcliffe, Pathologist of the Philadelphia Zoological Garden, kindly gave us the snake for examination.

The last of the snake tumors on record is a papillary carcinoma of the bile duct in an East Indian watersnake *Homalopsis buccata*. It was the only tumor found by Bergman in 2200 wild snakes examined (11). He suggests that the apparent rarity of neoplasms in wild snakes may be attributed to the fact that a tumor-bearing individual living under natural conditions would probably be so handicapped that it would fall an easy prey to its enemies. The tumor was a small mass which projected into the lumen of the duct, partly occluding it and infiltrating the wall and the neighboring tissues. Histologically it consisted of atypical pleomorphic epithelial cells. It is of interest that a trematode was found in close proximity to this tumor, because in the gall bladders of other reptiles, green turtles, trematodes have been found associated with papillomatous growths (193).

REFERENCES

1. ADAMI, J. G. On a Giant-celled Rhabdomyosarcoma from the Trout. *Montreal Med. J.*, **37**:163-165. 1908.
2. ANDRÉ, E. Sur un Chondrome du Vairon. *Bull. Suisse Pêche et Pisciculture*, **28**:177-178. 1927. (Cited by Thomas, 1932d.²¹)
3. ANITSCHKOV, N., and PAVLOVSKY, E. N. Über die Hautpapillome bei Gobius u. ihre Beziehung zur Normalen Struktur der Fischhaut. *Ztschr. f. Krebsforsch.*, **20**:128-147. 1923.
4. BALL, H. A. Melanosarcoma and Rhabdomyoma in Two Pine Snakes, *Pituophis melanoleucus*. *Cancer Research*, **6**:134-138. 1946.
5. BASHFORD, E. F. The Zoological Distribution of Cancer. *Sci. Repts. Invest. Imp. Cancer Res. Fund*, **1**:3-11. 1904.
6. ———, MURRAY, J. A., and CRAMER, W. Transplantation of Malignant New Growths. *Ibid.*, **2**:13-17. 1905.
7. BEATTI, M. Geschwülste bei Tieren. *Ztschr. f. Krebsforsch.*, **15**:452-291. 1916.
8. BECHER, H. Über die Entwicklung der Farbstoffzellen in der Haut der Knochenfische. *Verhandl. Anat. Ges.*, **38**:164-181. 1929.
9. BELL, W. Description of a Species of Chaetodon. *Phil. Trans. Roy. Soc. London*, pp. 7-9. 1793.
10. BERGMAN, A. M. Einige Geschwülste bei Fischen: Rhabdomyom, Lipome, und Melanom. *Ztschr. f. Krebsforsch.*, **18**:292-302. 1921.
11. BERGMAN, R. A. M. Tumoren bij Slangen. *Geneesk. Tijdschr. v. Nederland-Indië*, **81**:571-577. 1941.
12. BLAND-SUTTON, J. Tumours in Animals. *J. Anat. & Physiol.*, **19**:415-475. 1885.
13. BISELLE, J. J. Diplochromosomes in a Goldfish Tumor. *Cancer Research*, **3**:411-412. 1943.
14. BONNET, R. Studien zur Physiologie u. Pathologie der Fische. *Bayer. Fischerie Zeit.*, **6**:79. 1883.
15. BORCCA, M. I. Sur l'origine du Coeur, des Cellules Vasculaires Migratrices et des Cellules Pigmentaires chez les Téléostéens. *Compt. rend. Acad. Sci. Paris*, **149**:688-689. 1909.
16. BREBLAUER, T. Zur Kenntnis der Epidermoidalgewächse von Kaltblutern. *Arch. f. mikroskop. Anat.*, **87**:200-264. 1916.
17. BRIGGS, R. W. Tumor Induction in *Rana pipiens* Tadpoles. *Nature*, **146**:29. 1940.
18. ———. The Development of Abnormal Growths in *Rana pipiens* Embryos Following Delayed Fertilization. *Anat. Rec.*, **81**:121-135. 1941.
19. ———. Transplantation of Kidney Carcinoma from Adult Frogs to Tadpoles. *Cancer Research*, **2**:309-323. 1942.
20. ———, and BERRILL, N. J. Transplantation Experiments with an Abnormal Ectodermal Growth of Frog Embryos. *Growth*, **5**:273-284. 1941.
21. BRIGGS, J. B., and BRIGGS, R. W. The Effects of a Water Soluble Carcinogen on Early Frog Development. *Cancer Research*, **3**:1-12. 1943.
22. BRIGGS, R. W., and GRANT, R. Growth and Regression of Frog Kidney Carcinoma Transplanted into the Tails of Permanent and Normal Tadpoles. *Cancer Research*, **3**:613-620. 1943.
23. BUGNION, E. Ein Fall von Sarcoma beim Fische. *Deut. Ztschr. f. Tiermed. u. Vergl. Path.*, **1**:132-134. 1875.
24. BULLOCK, F. D., and CURTIS, M. R. Spontaneous Tumors of the Rat. *J. Cancer Res.*, **14**:1-115. 1930.
25. CAMERON, A. T., and VINCENT, S. Notes on an Enlarged Thyroid Occurring in an Elasmobranch Fish (*Squalus sucklii*). *J. Med. Res.*, **27**,n.s.:251-256. 1915.
26. CARL, W. Ein Hypernephrom beim Frosch. *Centralbl. Allg. Path.*, **24**:436-438. 1913.
27. CHABANAUD, P. Fréquence, Symétrie et Constance Spécifique d'Hyperostoses Externes chez divers Poissons de la Famille des Sciaenides. *Compt. rend. Séances l'Acad. Sci.*, **182**:1647-1649. 1926.
28. CHAMPY, C. Quelques faits Favorables a l'Idée d'un Virus Cancéreux dans quelques Animaux (Cancers des Gallinacés, Cancers des Tritons). *Bull. Acad. Méd. Paris*, **108**:1631-1634. 1932.
29. CHAMPY, C., and CHAMPY, Mlle. Sur un Épithélioma Transmissible chez le Triton. *Bull. Assoc. franç. p. l'étude Cancer*, **24**:206-220. 1935.
30. CHARLTON, H. H. A Tumor of the Pineal Organ with Cartilage Formation in the Mackerel, *Scomber scombrus*. *Anat. Rec.*, **43**:271-276. 1929.
31. CLUNET, J. Recherches Expérimentales sur les Tumeurs Malignes. Paris. 1910. (Cited by J. Wolff, vol. 3, p. 302.²⁰)
- 31a. COATES, C. W., COX, R. T., and SMITH, G. M. Papilloma of the Skin in an Electric Eel, *Electrophorus electricus*. *Zoologica*, **23**:247-251. 1938.
32. CRAMER, W. Discussion. *Cancer Review*, **5**:406. 1930.
33. CRISP, E. Large Fungoid Tumor in a Carp. *Trans. Path. Soc. London*, **5**:347-348. 1854.
34. CUNNINGHAM, B. Axial Bifurcation in Serpents. *Duke University Press, Durham*. 1936.
35. DAUWE, F., and PENNEMANN, G. Contributions a l'Étude du Cancer chez les Poissons. *Ann. Soc. méd. Gand*, **84**:81-90. 1904.
- 35a. DOLLFUS, R. P., TIMON-DAVID, J., and MÖBINGER, M. A propos des Tumeurs Melaniques des Poissons. *Bull. Assoc. franç. p. l'étude Cancer*, **27**:37-50. 1938. (Abstr. by Foulds, *Am. J. Cancer*, **34**:463. 1938.)
36. DOMINGUEZ, A. G. Fibroblastic Sarcoma in a Goldfish. *Clin. Med. & Surg.*, **35**:256-257. 1928.
37. DOWNS, A. W. An Epithelial Tumor of the Intestines of a Frog. *Nature*, **130**:778. 1932.
38. DREW, G. H. Some Cases of New Growths in Fish. *J. Marine Biol. Assoc. United King.*, **9**:281-287. 1912.

39. DUANY, J. Un Epithelioma Glandular en una *Rana* Bull. Frog. Arch. Soc. Estud. Clin. Habana, **29**:186-195. 1929.
40. DUEBST, J. U. Die Ursachen der Entstehung des Kropfes. Bern: Hans Huber. 1941.
41. DURAN-REYNALS, F. A Note on the Action of some Carcinogenic Hydrocarbons on Amphibia. Yale J. Biol. & Med., **11**:613-617. 1939.
42. DUSHANE, G. P. The Embryology of Vertebrate Pigment Cells. I. Amphibia. Quart. Rev. Biol., **18**:109-127. 1943. II. Birds. *Ibid.*, **19**:98-117. 1944.
43. EBERTH, C. J. Multiple Adenome der Froscfhaut. Virch. Arch. f. path. Anat., **44**:12-22. 1868.
44. ———. Fibrosarcom der Kopfhaut einer Forelle. *Ibid.*, **72**:107-108. 1878.
45. EGUCHI, S., and OOTA, J. Of a Tumor in a Fish (Japanese). Aichi Igakkwai Zasshi, **33**(3); 1926. (Biol. Abst., **5**:20406. 1931.)
46. FEDOTOV, D. M. Disa. Acad. Sciences (Russian), **38**:53-57. 1943. (Cited by Finkelstein.⁶¹)
- 46a. FELDMAN, W. H. Neoplasms of Domesticated Animals. Philadelphia: W. B. Saunders. 1932.
47. FIEBIGER, J. Über Hautgeschwülste bei Fischen nebst Bemerkungen über die Pockenkrankheit der Karpfen. Ztschr. f. Krebsforsch., **7**:165-179. 1909a.
48. ———. Ein Rhabdomyom bei einem Kabljau. *Ibid.*, **7**:382-388. 1909b.
49. ———. Ein Osteochondrom bei einem Karpfen. *Ibid.*, **7**:371-381. 1909c.
50. ———. Bösartige Neubildung (Fibrosarkom) bei einem Seefisch. Oesterr. Fischerei Zeitung., **9**:308. 1912.
51. FINKELSTEIN, E. A. Tumor Growth in Invertebrates and in Lower Vertebrates (Russian). Usp. sovr. biol., **17**:320-348. 1944.
52. FREUDENTHAL, P. Fibrom (Spindelzellensarkom ?) im Ovarium einer Karausche (*Carassius vulgaris*). Ztschr. f. Krebsforsch., **26**:414-417. 1928.
53. GAYLORD, H. R., and MARSH, C. Carcinoma of the Thyroid in the Salmonoid Fishes. Bull. Bur. Fisheries, **32**:Doc. 790. 1912; 3d Ann. Rept. State Inst. Study Malig. Dis., Buffalo, N. Y. 1914.
54. GEBHART, W. Über zwei von Protozoen Erzeugte pylorus-tumoren beim Frosch. Virch. Arch. f. path. Anat., **147**:536-559. 1897.
55. GERVAIS, P. De l'Hyperostose chez l'Homme et chez les Animaux. J. de Zool., **4**:272-284 & 445-465. 1875.
56. ———. Carpe Atteinte d'une Énorme Tumeur Fibreuse de l'Abdomen. *Ibid.*, **5**:466. 1876.
57. GHZONGHIV, J. Contribution a l'Étude du Cancer de la Grenouille. Compt. rend. Soc. de Biol., **103**:280-281. 1930.
58. GILRUTH, J. A. Epithelioma Affecting the Branchial Arches of Salmon and Trout. Rept. New Zealand Dept. Agri. Vet. Div., 1901/1902. Pp. 312-315. 1902.
59. GORDON, M. The Production of Spontaneous Melanotic Neoplasms in Fishes by Selective Matings. Am. J. Cancer, **30**:362-375. 1937.
60. ———. Genetics of Melanomas in Fishes. V. The Reappearance of Ancestral Micromelanophores in Offspring of Parents Lacking these Cells. Cancer Research, **1**:656-659. 1941.
- 60a. ———. Genetics of Ocular-Tumor Development in Fishes. J. Nat. Cancer Inst., **7**:87-92. 1946.
- 60b. ———. Effects of Five Pigment Genes on the Site of Melanomas in Fishes and the Influence of Two Color Genes on their Pigmentation. In "The Biology of Melanomas," Spec. Publ. New York Acad. Sc., **4**:216-268. 1948.
61. ———, and FLATMAN, F. The Genetics of Melanoma in Fishes. VI. Mendelian Segregation of Melanophore Reaction Types in Embryos of a Melanomatous Mother. Zoologica, **28**:9-12. 1943.
62. ———, and SMITH, G. M. Progressive Growth Changes of a Heritable Melanotic Neoplastic Disease in Fishes from the Day of Birth. Am. J. Cancer, **34**:255-272. 1938.
63. GRAND, C. G., GORDON, M., and CAMERON, G. Neoplasm Studies. VIII: Cell Types in Tissue Culture of Fish Melanotic Tumors Compared to Mammalian Melanomas. Cancer Research, **1**:660-666. 1941.
64. GRAUPNER, H., and FISCHER, I. Beiträge zur Kenntnis der Goldfischhaut. Ztschr. f. Mik. Anat. Forschung., **33**:91-142. 1933.
65. GREENE, H. S. N. Familial Mammary Tumors in the Rabbit. IV. The Evolution of Autonomy in the Course of Tumor Development as Indicated by Transplantation Experiments. J. Exper. Med., **71**:305-323. 1940.
66. GUDERNATSCH, J. F. The Relationship between the Normal and Pathological Thyroid Gland of Fish. Bull. Johns Hopkins Hosp., **22**:152-155. 1911.
67. GUGLIANETTI, L. Fibroma dell' Orbita in un Ciprino. Arch. di Ottalmolog., **17**:289-297. 1910.
68. HADDOW, A., and BLAKE, I. Neoplasms in Fish: A Report of 6 Cases with a Summary of the Literature. J. Path. & Bact., **36**:41-47. 1933.
69. HAÜSSLER, G. Über Melanombildungen bei Bastarden von *Xiphophorus hellerii* und *Platypoecilus maculatus* var. *rubra*. Klin. Wchnschr., **7**:1561-1562. 1928.
70. ———. Über die Melanome der *Xiphophorus-Platy-poecilus* bastarde. Ztschr. f. Krebsforsch., **40**:280-292. 1934.
71. HATCHER, J. B. *Diplodocus*, Marsh, its Osteology, Taxonomy, and Probable Habits with a Restoration of the Skeleton. Mem. Carnegie Mus., Pittsburgh, **1**:36. 1901.
72. VON HANSEMANN, D. Discussion. Verhandl. d. Berlin med. Gesellschaft, **36**:231-232. 1906.
73. HEGNER, R. W. College Zoology, 5th ed., New York: Macmillan Company. 1942.
74. HELLER, J. Discussion. Verhandl. d. Berlin med. Gesellschaft, **36**:230-231. 1906.
75. HILDEBRAND, S. F. Twinning in Turtles. J. Heredity, **29**:243-253. 1938.
76. HOLLAND, W. J. The Osteology of *Diplodocus*, Marsh. Mem. Carnegie Mus., Pittsburgh, **2**:255. 1906.
77. INGLEBY, H. Melanotic Tumor in *Lophius piscatorius*. Arch. Path., **8**:1016-1017. 1929.
78. JABOULAY, M. Poissons Atteints de Goîtres Malins Héritaires et Contagieux. Lyon. Med., **110**:335-336. 1908.
79. JACQUART, H. Note sur une Tumeur Volumineuse, Entourant l'Éstomac, et Survenue à la Suite d'une Violence Extérieure, chez un Python Molure. Compt. rend. Soc. de Biol., 2e ser., **4**:142. 1857.
80. JAHNEL, J. Über einige Geschwülste bei Fischen, ein Beitrag zur Erblichkeitsfrage von Tumoren. Wien tierärztl. Monatschrift, **26**:325-333. 1939.
81. JOHNSTONE, J. Internal Parasites and Disensed Conditions in Fishes. Proc. & Trans. Liverpool Biol. Soc., **25**:88-122. 1911.
82. ———. *Ibid.*, **26**:103-104. 1912.

83. ———. Diseased Conditions in Fishes. *Ibid.*, **27**: 196-218. 1913.
84. ———. Internal Parasites and Diseased Conditions in Fishes. *Ibid.*, **28**:127-142. 1914.
85. ———. Diseased and Abnormal Conditions of Marine Fishes. *Ibid.*, **29**:80-113. 1915.
86. ———. On Certain Parasites, Diseased and Abnormal Conditions in Fishes. *Ibid.*, **34**:120-129. 1920.
87. ———. Diseases and Parasites of Fishes. *Ibid.*, **36**: 287-301. 1922.
88. ———. On Some Malignant Tumors in Fishes. *Ibid.*, **37**:145-157. 1923.
89. ———. Diseased Conditions in Fishes. *Ibid.*, **38**: 183-213. 1924.
90. ———. Malignant Tumors in Fishes. *Ibid.*, **39**:169-200. 1925.
91. ———. Malignant and Other Tumors in Marine Fishes. *Ibid.*, **40**:75-98. 1926.
92. ———. Diseased Conditions in Fishes. *Ibid.*, **41**: 162-167. 1927.
93. JORDAN, H. E. Comparative Hematology. Handbook of Hematology, **2**:703-862., New York: P. B. Hoeber. 1938.
94. KANN, S. Die Histologie der Fischhaute von Biologischen Gesichtspunkten Betrachtet. *Ztschr. f. Zellforsch. u. mikr. Anat.*, **4**:482-514. 1926.
95. KAZAMA, Y. On a Spindle Cell Sarcoma in a Salmon. *Gann*, **16**:12-13. 1922.
96. ———. Einige Geschwülste bei Fischen (*Pagrus major* et *Paralichthys olivaceus*). *Ibid.*, **18**:35-37. 1924.
97. KEYSSELITZ, G. Über ein Epithelioma der Barben. *Arch. f. Protistenkunde*, **11**:326-333. 1908.
98. KLEMM, E. Über die Schilddrüsengeschwülste bei Aquarienfischen. *Mikrokosmos*, **20**:184-187. 1927.
99. KOCH, C., SCHREIBER, B., and SCHREIBER, G. Tumeurs produites par le Goudron et le Benzopyrène chez les Amphibiens Urodèles. *Bull. Assoc. franc. p. l'étude Cancer*, **28**:852-859. 1939.
100. KOCH, M. Demonstration einiger Geschwülste bei Tieren. *Verhandl. d. Deut. Path. Gesell.*, **7**:136-147. 1904.
101. KOLMER, W. Partieller Riesenwuchs in Verbindung mit Grossum Rhabdomyom bei einer Schleie, *Tinca tinca*. *Virch. Arch. f. path. Anat.*, **268**:574-575. 1928.
102. KOSSWIG, C. Melanotische Geschwülstbildungen bei Fischbastarden. *Münc. med. Wchnschr.*, **76**:1070. 1929; *Zool. Anz., Suppl.* **4**:90-98. 1929.
103. ———. Zur Frage der Geschwülstbildungen bei Gattungsbastarden der Zahnkarpfen *Xiphophorus* und *Platypoecilus*. *Ztschr. f. indukt. Abstam. u. Vererb.*, **52**:114-120. 1929.
104. ———. Über Geschwülstbildungen bei Fischbastarden. *Ibid.*, **59**:61-76. 1931.
105. KREYBERG, L. An Intra-abdominal Fibroma in a Brown Trout. *Am. J. Cancer*, **30**:112-114. 1937.
106. KHONTOVSKY, A. Comparative and Experimental Pathology of Tumors (Russian). Kiev, 1916. (Cited by Finkelstein,⁸³ and by Brunst.^{100a})
107. LABBÉ, A. Une Tumeur Complexe chez un Merlan. *Bull. Assoc. franç. p. l'étude Cancer*, **19**:138-158. 1930.
108. LADREYT, F. Sur un Odontome Cutané chez un *Scyllium catulus*. *Bull. de l'Inst. Ocean. (Monaco)*, **539**:1-4. 1929.
109. ———. Sur un Rhabdomyosarcome chez un *Labrus mixtus*. *Ibid.*, **550**:1-4. 1930.
110. ———. Sur un Epithelioma de la Muqueuse Palatine chez un Murene (*Muraena helena*). *Ibid.*, **677**:1-16. 1935.
111. LEGER, L. Tumeurs Observés chez les Salmonides d'Élevage. *Compt. rend. Assoc. franç., p. Advanc. Sc.*, **49**:395-396. 1925.
- 111a. LEVINE, M. The Cytology of the Typical and the Amelanotic Melanoma. In "The Biology of Melanomas," *Spec. Publ. New York Acad. Sc.*, **4**:177-215. 1948.
- 111b. ———, and GORDON, M. Ocular Tumors with Exophthalmia in Xiphophorin Fishes. *Cancer Research*, **6**:197-204. 1946.
112. LUCKÉ, B. A Neoplastic Disease of the Kidney of the Frog, *Rana pipiens*. *Am. J. Cancer*, **20**:352-379. 1934.
113. ———. A Neoplastic Disease of the Kidney of the Frog, *Rana pipiens*. II. On the Occurrence of Metastasis. *Am. J. Cancer*, **22**:326-334. 1934.
114. ———. Carcinoma of the Kidney in the Leopard Frog: The Occurrence and Significance of Metastasis. *Am. J. Cancer*, **34**:15-30. 1938.
115. ———. Carcinoma in the Leopard Frog: Its Probable Causation by a Virus. *J. Exper. Med.*, **68**:457-468. 1938.
116. ———. Studies on Tumors in Cold-blooded Vertebrates. *Ann. Rept. Tortugas Lab., Carnegie Inst. Wash.* 1937/38. 92-94. 1938.
117. ———. Characteristics of Frog Carcinoma in Tissue Culture. *J. Exper. Med.*, **70**:269-276. 1939.
118. ———. Tumors of the Nerve Sheaths in Fish of the Snapper Family (Lutianidae). *Arch. Path.*, **34**:133-150. 1942.
119. ———, and SCHLUMBERGER, H. The Manner of Growth of Frog Carcinoma, Studied by Direct Microscopic Examination of Living Intraocular Transplants. *J. Exper. Med.*, **70**:257-268. 1939.
120. ———. Heterotransplantation of Frog Carcinoma: Character of Growth in the Eyes of Alien Species. *J. Exper. Med.*, **72**:311-320. 1940.
121. ———. The Effect of Temperature on the Growth of Frog Carcinoma. I. Direct Microscopic Observations on Living Intraocular Transplants. *J. Exper. Med.*, **72**:321-330. 1940.
122. ———. Transplantable Epitheliomas of the Lip and Mouth of Catfish. I. Pathology. Transplantation to Anterior Chamber of Eye and into Cornea. *J. Exper. Med.*, **74**:397-408. 1941.
123. ———. Common Neoplasms in Fish, Amphibians, and Reptiles. *J. Tech. Meth. Bull. Int. Assoc. Med. Mus.*, **22**:4-17. 1942.
- 123a. ———. Neoplasia in Cold-blooded Vertebrates. *Physiol. Rev.*, **29**:(in press). 1949.
- 123b. ———. Induction of Metastasis of Frog Carcinoma by Increase of Environmental Temperature. *J. Exper. Med.*, **89**:269-278. 1949.
- 123c. ———, and BREEDIS, C. A Common Mesenchymal Tumor of the Corium of Goldfish, *Carassius auratus*. *Cancer Research*, **8**:473-493. 1948.
124. LYNN, W. G. Conjoined Twins and Triplets in Trout. *Anat. Rec.*, **70**:597-616. 1938.
125. ———. Duplicitas Anterior in the Toad *Eleutherodactylus alticola*. *Anat. Rec.*, **80**:345-355. 1944.
126. MACINTOSH, On a Tumour in a Plaice. *Ann. & Mag. Nat'l Hist.*, **1**:373. 1908.

127. MARINE, D., and LENHART, C. H. On the Occurrence of Goitre (Active Thyroid Hyperplasia) in Fish. Bull. Johns Hopkins Hosp., **21**:95-98. 1910.
128. ———. Observations and Experiments on the So-called Thyroid Carcinoma of Brook Trout (*Salvelinus fontinalis*) and its Relation to Ordinary Goitre. J. Exper. Med., **12**:311-337. 1910.
129. ———. Further Observations and Experiments on the So-called Thyroid Carcinoma of Brook Trout and its Relation to Endemic Goitre. J. Exper. Med., **13**:455-475. 1911.
130. MARINE, D. Further Observations and Experiments on Goitre in Brook Trout. J. Exper. Med., **19**:70-88. 1914.
131. MARSH, M. C., and VONWILLER, P. Thyroid Tumor in Sea Bass (*Serranus*). J. Cancer Res., **1**:183-196. 1916.
132. MARTELLA, N. A. Effetti del Catrome sulla pelle dei Tritoni. Riv. di Biol., **18**:197-215. 1935.
133. MASSON, P., and SCHWARTZ, Un Cas d'Épithélioma Cutané chez le Grenouille Verte. Bull. de l'Assoc. franç. p. l'étude Cancer, **12**:719-725. 1923.
134. MAXIMOW, A. Bindegewebe und Blutbildende Gewebe. Handb. d. mik. Anat. d. Menschen, **2** pt.1:433-439. 1927.
135. MAZZARELLI. Epithelioma of the Mouth of *Chondrostoma soetta*. 1910. (Cited by Thomas, 1931b.²⁰⁷)
136. MCFARLAND, J. Epithelioma of the Mouth and Skin of a Catfish. Proc. Path. Soc. Phila., **4**:79-81. 1901.
137. MONTPELLIER, J., and DIEUZEIDE, R. Sur une Production Épithéliale de la Peau du *Discoglossus pictus*. Bull. de l'Assoc. franç. p. l'étude Cancer, **20**:169-179. 1931.
138. ———. Tumeurs cutanées du Cyprin (*Carassius auratus*). *Ibid.*, **21**:295-306. 1932.
139. MOODIE, R. L. Paleopathology. Chicago: University of Illinois Press. 1923.
140. MULSOW. Chondroma on Top of Head of Three Carp. 1915. (Cited by Thomas, 1932b;²⁰⁸ illustrated by Plehn, 1924b.²⁰⁹)
141. MURRAY, J. A. The Zoological Distribution of Cancer. Sci. Repts. Imp. Cancer Res. Fund, **3**:41-60. 1908.
142. NIGRELLI, R. F. The Occurrence of Leeches, *Ozobranchus branchiatus*, on Fibro-epithelial Tumors of Marine Turtles, *Chelonia mydas*. Zoologica, **28**:107-108. 1943.
143. ———. Spontaneous Neoplasms in Fishes. III. Lymphosarcoma in *Astyanax* and *Esox*. *Ibid.*, **32**:101-108. 1947.
144. ———, and GORDON, M. A Melanotic Tumor in the Silverside (*Menidia beryllina peninsulæ*). *Ibid.*, **29** 45-47. 1944.
- 144a. ———. Spontaneous Neoplasms in Fishes. I. Osteochondroma in the Jewelfish, *Hemichromis bimaculatus*. *Ibid.*, **31**:89-92. 1946.
145. OHLMACHER, H. P. Several Examples Illustrating the Comparative Pathology of Tumors. Bull. Ohio Hosp. Epilep., **1**:223-236. 1898.
- 145a. PATAY, R. Sur un Cas d'Épithélioma du Rein chez *Tropidonatus matrix* (Ophidiien colubridé). Compt. rend. Soc. de Biol., **114**:865-867. 1933.
146. PAVLOVSKY, E. N. Zur Kasuistik der Tumoren beim Frosch. Centralbl. f. allg. Path. u. path. Anat., **23**:94. 1912.
147. PENTIMALLI, F. Über die Geschwülste bei Amphibien. Ztschr. f. Krebsforsch., **14**:623-632. 1914.
148. PESCE, P. Rivista Mensile di Pesca. 1907. (Cited by Thomas, 1931a.²⁰⁶)
149. PEYRON, A. Sur la Fréquence des Tumeurs dans les Diverses Ordres de Vértébrés à Sang Froid et leur Rareté dans les Espèces Venimeuses. Compt. rend. Acad. Sci. d. Paris, **209**:261-263. 1939.
150. ———, and THOMAS, L. Contribution à l'Étude des Tumeurs du Revêtement Branchial chez les Poissons. Bull. de l'Assoc. franç. p. l'Étude Cancer, **18**:825-837. 1929.
151. ———. Les Tumeurs Thyroïdiennes des Salmonides. *Ibid.*, **19**:795-819. 1930.
152. PICCHI, L. Di un non Comune Tumore di un Pesce (Neurinoma). Sperimentale, **86**:128-130. 1933.
153. PICK, L. Der Schilddrüsenkrebs der Salmoniden (Edelfische). Berlin klin. Wchnschr., **42**:1435, 1477, 1498, 1532. 1905.
154. ———, and POLL, H. Über einige bemerkenswerthe Tumorbildungen aus der Thierpathologie, insbesondere über gutartige und Krebsige Neubildungen bei Kaltblütern. *Ibid.*, **40**:518, 572. 1903.
155. PIRLOT, J. M., and WELSCH, M. Étude Anatomique et Expérimentale de quelques Tumeurs chez la Grenouille Rousse (*Rana fusca*). Arch. Internat. d. Méd. Expér., **9**:341-365. 1934.
156. PLEHN, M. Bösartiger Kropf (Adenocarcinoma der Thyroidea) bei Salmoniden. Allg. Fisch. Zeit., München, **27**:117-118. 1902.
157. ———. Über Geschwülste bei Kaltblütern. Ztschr. f. Krebsforsch., **4**:525-564. 1906.
158. ———. Über einige bei Fischen Beobachtete Geschwülste und Geschwülstartige Bildungen. Berichte d.k. Bayer. Biol. Versuchs., München, **2**:55-76. 1909.
159. ———. Über Geschwülste bei niederen Wirbeltieren. 2e Conf. Internat. p. l'Étude Cancer, pp. 221-242. Paris: Félix Alcan. 1911.
160. ———. Über Geschwülste bei Kaltblütern. Wien. klin. Wchnschr., **25**:691-697. 1912.
161. ———. Zur Kenntnis der Ovarialtumoren bei Kaltblütern. Ztschr. f. Krebsforsch., **21**:313-319. 1924a.
162. ———. Praktikum der Fischkrankheiten. Stuttgart, 1924b.
163. PLIMMER, H. G. Report on the Deaths which Occurred in the Zoological Gardens during 1911. Proc. Zool. Soc. London, Pt.1, 235-240. 1912.
164. ———. Report on the Deaths which Occurred in the Zoological Gardens during 1912, Together with the Blood Parasites Found during the Year. *Ibid.*, Pt.1, 141-149. 1913.
165. PRINCE. Melanosarcoma in a Haddock. 1892. (Cited by Thomas, 1931b.²⁰⁷)
166. PUENTE DUANY, N. Tumoracion Periocular en un Pescado de Rio. Bol. de Liga contra el Cancer, **5**:240. 1930. (Abstr. Am. J. Cancer, **15**:918. 1931.)
167. RATCLIFFE, H. L. Carcinoma of the Pancreas in Say's Pine Snake, *Pituophis sayi*. Am. J. Cancer, **24**:78-79. 1935.
168. ———. Neoplastic Disease of the Pancreas of Snakes (*Serpentes*). Am. J. Path., **19**:359-366. 1943.
- 168a. ———. Incidence and Nature of Tumors in Captive Wild Mammals and Birds. Am. J. Cancer, **17**:116-135. 1933.
169. REED, H. D., and GORDON, M. The Morphology of Melanotic Overgrowths in Hybrids of Mexican Killifishes. Am. J. Cancer, **15**:1524-1537. 1931.

170. RÉNAUD, M. Tumeurs Thyroïdiennes des Poissons. Rev. crit. de Path. et de Thérap., 2:531. 1931. (Abstr. Am. J. Cancer, 16:529. 1932.)
171. ROFFO, A. H. Le Sarcome des Poissons. Neoplasmes, 3:231-234. 1924.
172. ———. Sobre un Tumor Paradentario en la Corvina. Bol. del Inst. de Med. Exper., 2:28-42. 1925.
173. ———. Sarcomas Fusocelular de Corvina. *Ibid.*, 3:206-207. 1926.
174. RONCA, V. I Tumori nei Pesci. Tumori, 4:61-71. 1914.
175. SAGAWA, E. Zur Kenntnis der Fischgeschwülste. Gann, 19:14-15. 1925.
176. SCHAMBERG, J. F., and LUCKÉ, B. Fibrosarcoma of the Skin in a Goldfish (*Carassius auratus*). J. Cancer Res., 7:151-161. 1922.
- 176a. SCHLUMBERGER, H. G. The Effect of Methylcholanthrene on the Frog's Kidney. J. Nat. Cancer Inst., 9:111-118. 1948.
- 176b. ———, and LUCKÉ, B. Serial Intraocular Transplantation of Frog Carcinoma for Fourteen Generations. Cancer Research, 9:52-60. 1949.
177. SCHMEY, M. Über Neubildungen Fischen. Frankfurt. Ztschr. f. Path., 6:230-253. 1911.
178. SCHREITMÜLLER, W. Blätter f. Aquarien- u. Terrar.-Kunde, 35:83. 1924.
179. SCHROEDERS, V. D. Tumors of Fishes. Dissertation (Russian). (Translation in Army Med. Library, Washington, D. C.) St. Petersburg. 1908.
180. SCHWARZ, E. Über zwei Geschwülste bei Kaltblütern. Ztschr. f. Krebsforsch., 20:353-357. 1923.
181. SCHWIND, J. L. Spontaneous Twinning in the Amphibia. Am. J. Anat., 71:117-151. 1942.
182. SCOTT, Note on the Occurrence of Cancer in Fish. Trans. & Proc. New Zealand Inst., 24:201. 1891. Text printed in full in monograph by Gaylord and Marsh, pp. 369-370. 1914.⁶⁹
183. SCOTT, H. H., and BEATTIE, J. Neoplasm in a Porose Crocodile. J. Path. & Bact., 30:61-66. 1927.
184. SECHER, K. Kasuistische Beiträge zur Kenntnis der Geschwülste bei Tieren. Ztschr. f. Krebsforsch., 16:297-313. 1917/1919.
185. SEMER, E. Über Allgemeine Carcinose u. Sarkomatose und über Multiple Fibrome u. Lipome bei den Haustieren. Deut. Ztschr. f. Tiermed. u. Vergl. Path., 14:245-247. 1888.
186. SHEVCHENKO, N. N. Bull. Exper. Biol. & Med. (Russian), 11:395-397. 1941. (Cited by Finkelstein.⁸¹)
- 186a. SHEREMETIEVA-BRUNST, E. A., and BRUNST, V. V. Origin and Transplantation of a Melanotic Tumor in the Axolotl. In "The Biology of Melanomas," Spec. Pub. New York Acad. Sc., 4:269-287. 1948.
187. SMALLWOOD, W. M. Adrenal Tumors in the Kidney of the Frog. Anat. Anzeiger, 26:652-658. 1905.
188. SMITH, G. M. A Cutaneous Red Pigmented Tumor (Erythrophoroma) with Metastases, in a Flatfish (*Pseudopleuronectes americanus*). Am. J. Cancer, 21:596-599. 1934.
189. ———, and COATES, C. W. Cutaneous Melanosis in Lungfishes (Lepidosirenidae). Biol. Bull., 71:282-285. 1936.
190. ———. The Histological Structure of the Normal and Hyperplastic Thyroid in *Rasbora lateristriata*. Zoologica, 22:297-302. 1937.
191. ———. Fibro-epithelial Growths of the Skin in Large Marine Turtles, *Chelonia mydas*. Zoologica, 23:93-98. 1938.
192. ———. The Occurrence of Trematode Ova, *Haplolocrema constrictum*, in Fibroepithelial Tumors of the Marine Turtle, *Chelonia mydas*. *Ibid.*, 24:379-389. 1939.
193. ———, and NIGRELLI, R. F. A Papillomatous Disease of the Gall Bladder Associated with Infection by Flukes, Occurring in the Marine Turtle, *Chelonia mydas*. *Ibid.*, 26:13-16. 1941.
194. ———, and STRONG, L. C. Neoplastic Diseases in Small Tropical Fishes. *Ibid.*, 21:219-224. 1936.
195. SMITH, H. M. Case of Epidemic Carcinoma in Thyroid of Fishes. Washington Med. Annals, 8:313. 1909.
- 195a. STOUT, A. P. Fibrosarcoma, the Malignant Tumor of Fibroblasts. Cancer, 1:30-63. 1948.
196. SURBECK, G. Bull. Suisse Pêche et Pisciculture, 18:1917. (Cited by Thomas. 1932d.⁸¹)
197. ———. *Ibid.*, 22:4-5. 1921. (Cited by Thomas. 1932d.⁸¹)
198. TAKAHASHI, K. Studie über Fischtumoren. All the tumors reported in the Japanese journals which follow are considered in detail in Ztschr. f. Krebsforsch., 29:1-73, 1929. Gann, 19:5-8, 1925; Trans. Jap. Path. Soc., 14:274-276, 1924; *ibid.*, 15:294, 1925; *ibid.*, 16:212, 1926.
199. ———. Studie über die Fischgeschwülste. Ztschr. f. Krebsforsch., 29:1-73. 1929.
200. ———. Studies on Tumors of Fishes from Japanese Waters. Proc. 5th Pacific Sci. Congress (Canada), 5:4151-4155, 1933; Univ. of Toronto Press, 1934.
201. TAYLOR, A., HUNGATE, R. E., and TAYLOR, D. R. Yolk Sac Cultivation of Tumors. Cancer Research, 3:537-541. 1943.
202. THOMAS, L. Épithélioma Odontoblastique des Maxillaires chez une Morue. Bull. Assoc. franç. p. l'étude Cancer, 15:464-470. 1926.
203. ———. Sur un Cas de Ganglioneurome Abdominal chez la Morue. *Ibid.*, 16:282-286. 1927a.
204. ———. Les Sarcomes Fibroblastique chez la Morue. *Ibid.*, 16:78-89. 1927b.
205. ———. Contribution à l'Étude des Lésions Pré-cancéreuses chez les Poissons. Les Papillomes Cutanées de la Sole. *Ibid.*, 19:91-97. 1930.
206. ———. Adenome Kystique d l'Intestin moyen chez une Truite Pourpre. *Ibid.*, 20:575-584. 1931a.
207. ———. Les Tumeurs des Poissons (Étude Anatomique et Pathogénique). *Ibid.*, 20:703-760. 1931b.
208. ———. Rhabdomyome chez un Flet. *Ibid.*, 21:225-233. 1932a.
209. ———. Deux Cas de Tumeurs Osseuses chez des Téléostéens. *Ibid.*, 21:280-294. 1932b.
210. ———. Sur un Cas de Stiboneuroépithélioblastome chez une Daurade. *Ibid.*, 21:385-396. 1932c.
211. ———. Chondromes Symétriques chez un Colin. *Ibid.*, 21:537-546. 1932d.
212. ———. Papillome Tégumentaire chez un Truite. *Ibid.*, 21:547-550. 1932e.
213. ———. Fibrome de l'Intestin Juxta-pylorique chez une Morue. *Ibid.*, 22:106-112. 1933a.
214. ———. Sur Deux Cas de Tumeurs Tégumentaires chez la Rousette. *Ibid.*, 22:306-315. 1933b.
215. ———. Sur un Cas de Leiomyome de l'Estomac chez un Hareng. *Ibid.*, 22:361-376. 1933c.

216. ———. Sur un Lipome Abdominal chez un Collin. *Ibid.*, **22**:419-435. 1933d.
217. ———, and OXNER, M. Papillomes de la Lèvre Inférieure chez *Anguilla vulgaris*. *Ibid.*, **19**:708-714. 1930.
218. TOKIN, B. *Disa. Acad. Sci. (Russian)*, **29**:518-521. 1940. (Cited by Finkelstein.²¹)
219. TSVETAeva, N. P. *Trudy, Mosk. zooparka (Russian)*, **2**:No. 2. 1941. (Cited by Finkelstein.²¹)
220. TYZLER, E. E. Tumors and Sporozoa in Fishes. *J. Boston Soc. Med. Sc.*, **5**:63-68. 1900.
221. VAILLANT, L., and PETTIT, A. Fibrome Observé sur un *Mégalostrachus maximus*, Schlegel, à la Menagerie du Muséum. *Bull. d. Mus. d'hist. nat. Paris*, **8**:301-304. 1902.
222. ———. Lesions Stomacales Observées chez un Python de Seba. *Ibid.*, **8**:593-595. 1902.
223. VOLTERRA, M. Über eine Seltene Bösartige Geschwülst bei einem Exotischen Frosch, *Ceratophrys ornata*. *Ztschr. f. Krebsforsch.*, **27**:457-466. 1928.
224. VULPIAN, A. Tumeur Récueillie chez un Python Molure. *Compt. rend. Soc. Biol. Paris, 2e ser.*, **3**:219-220. 1856.
225. WAGNER, H. Über Pseudotumoren am Pylorus des Froschmagens. *Virch. Arch. f. path. Anat.*, **150**:432-444. 1897.
226. WAGO, H. A Case of Fibroblastic Myxoma in a Goldfish. *Gann*, **16**:11. 1922.
227. WAHLGREN, F. Beiträge zur Pathologie der Wilden Tiere. *Deut. Ztschr. f. Tiermed. u. Vergl. Path.*, **2**:232-235. 1876. (Translated from the Swedish original in *Oefoers af Wet Akad. Forhandl.*, 1873.)
228. WILLIAMS, G. Tumorous Growths in Fish. *Proc. & Trans. Liverpool Biol. Soc.*, **43**:120-148. 1929.
229. ———. On Various Fish Tumors. *Ibid.*, **45**:98-109. 1931.
230. WILLIAMSON, H. C. Report on Diseases and Abnormalities of Fishes. *Ann. Rept. Fish. Bd., Scotland*, Pt. 3:56-62. 1909/1913. (Cited by Thomas, 1931a.²²)
231. ———. *Ibid.*, 1913. (Cited by Thomas, 1931a.²²)
- 231a. WILLIS, R. A. Pathology of Tumours. St. Louis: C. V. Mosby. 1948.
232. WITSCHI, E. Experimentally Produced Neoplasms in the Frog. *Proc. Soc. Exper. Biol. & Med.*, **27**:475-477. 1930.
233. WOLFF, B. Über ein Blastom bei einem Aal (*Anguilla vulgaris*) nebst Bemerkungen zur vergleichenden Pathologie der Geschwülste. *Virch. Arch. f. path. Anat.*, **210**:365-385. 1912.
234. WOLFF, J. Geschwülsterkrankungen bei Kaltblütern, **3**:283-316. 1913. In "Die Lehre von der Krebskrankheit," 4 vols. Jena: Gustav Fisher. 1913.
235. YOUNG, M. W. Muscle Tumors in the European Turbot. *J. Marine Biol. Assoc. United King.*, **13**,n.s.: 910-913. 1925.
236. YOUNG, G. A., and OLAFSON, P. Neurilemmas in a Family of Brook Trout. *Am. J. Path.*, **20**:413-417. 1944.

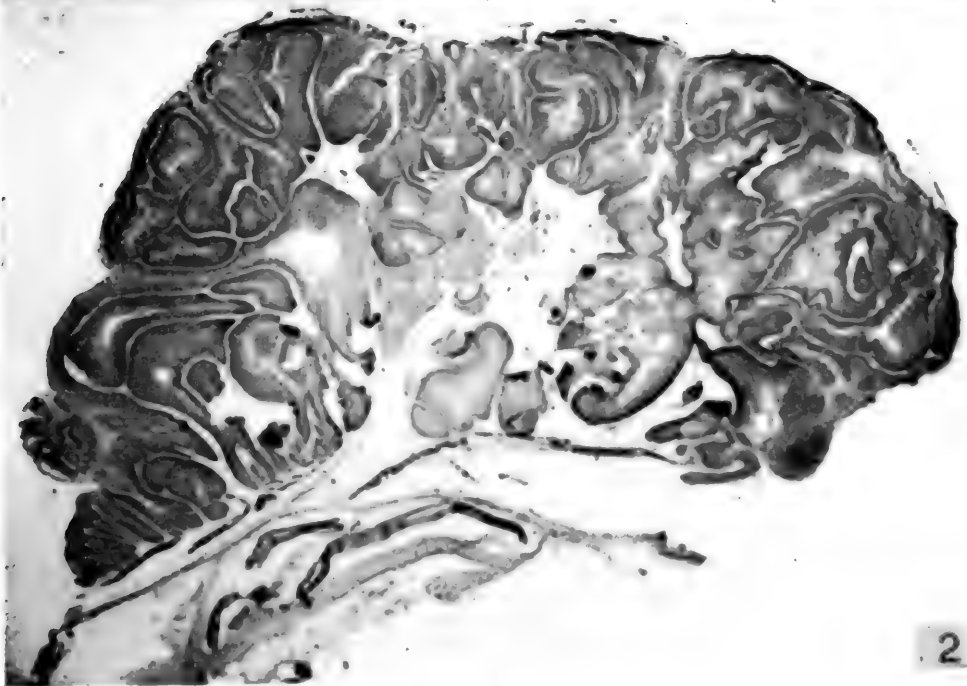
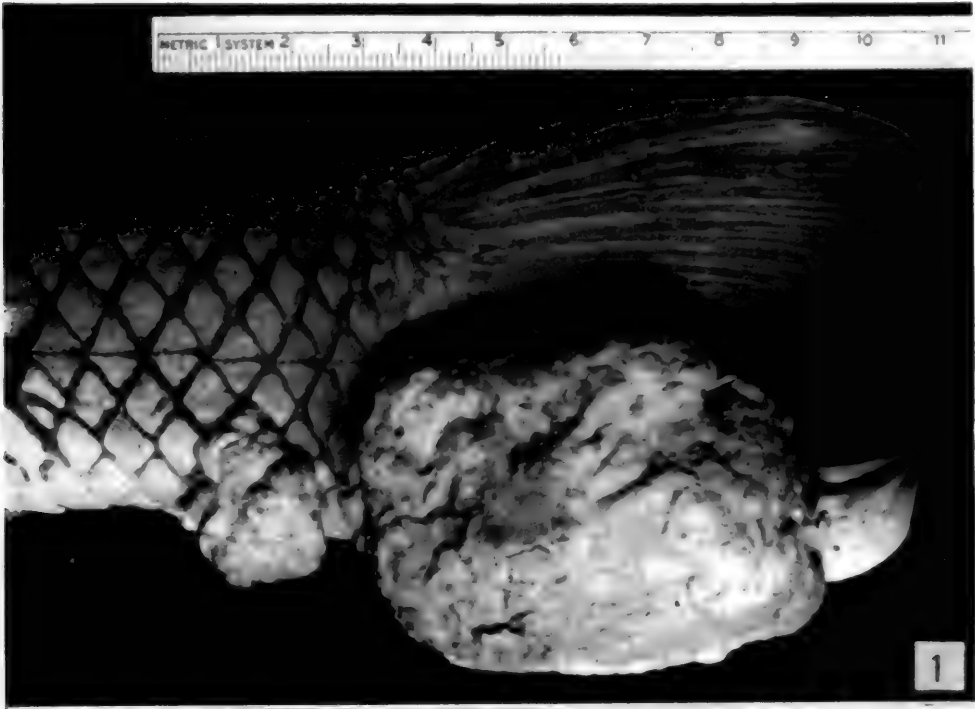
DESCRIPTION OF FIGURES 1 AND 2

Cutaneous papillomas in the common sucker, *Catostomus commersonnii*.

FIG. 1.—A large papilloma occupies the ventral half of the caudal fin; just anterior to it is a smaller tumor.

FIG. 2.—Section through the smaller of the two papillomas. The tumor has a typical papillary arrangement, the support-

ing connective tissue is scanty. The underlying structures are not involved. For details of microscopic structure see Figures 3 and 4. Mag. $\times 10$.



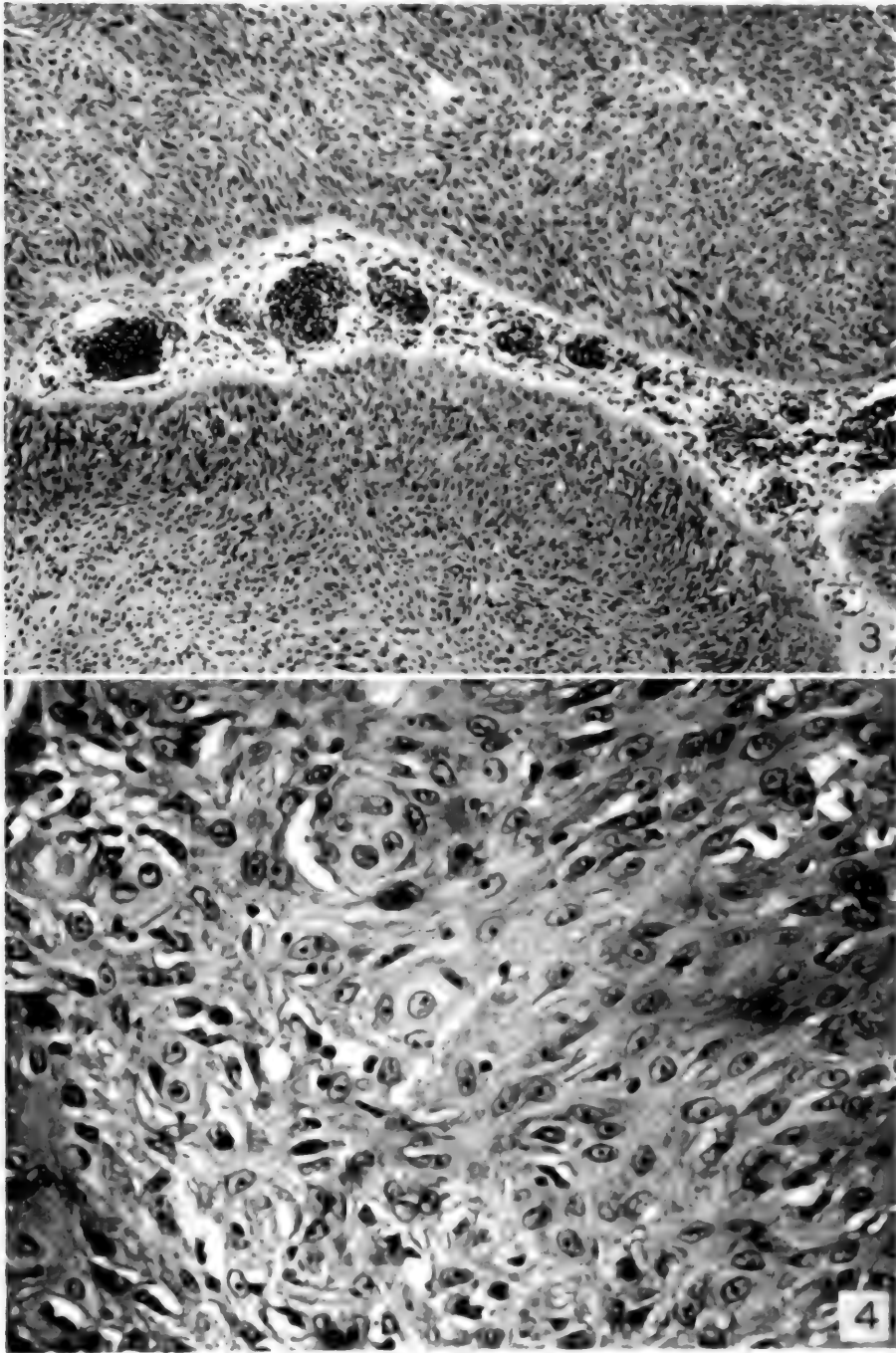
FIGS. 1-2

DESCRIPTION OF FIGURES 3 AND 4

Histologic appearance of papillomas in the common sucker, *Calostomus commersonii*.

FIG. 3.—Cellular detail from the center of the papillary growth. The epithelial character of the tissue is evident. Some of the cells have acquired a spindle shape, others are arranged in small nests, suggestive of early "pearl" formation. Mag. \times 300.

FIG. 4.—A delicate, vascular strand of loose connective tissue is surrounded by solid masses of epithelium. The basal layer of the neoplastic epithelium is composed of columnar cells. Mag. \times 80.



FIGS. 3, 4

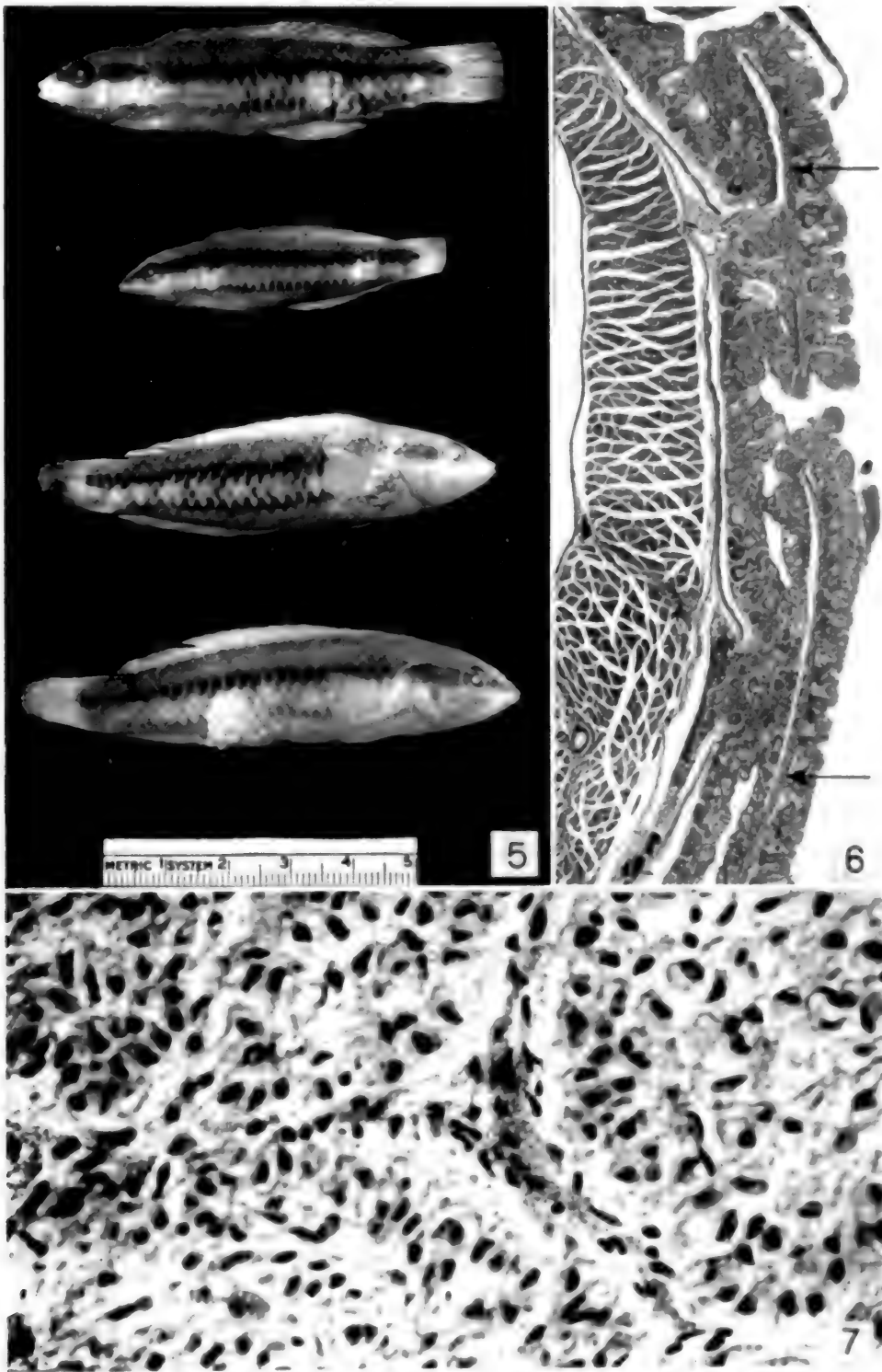
DESCRIPTION OF FIGURES 5 TO 7
Cutaneous papillomas of the slippery dick, *Iridio bivittata*.

FIG. 5. Gross appearance of the tumors. The two fish at the top of the photograph, and the one at the bottom, bear ventro-lateral tumors at the junction of the middle and caudal thirds of the body. In the fourth fish the papilloma is seen at the base of the pectoral fin.

FIG. 6. Low power appearance of a papilloma. The tumor is shown in the right half of the figure; on the left is

the trunk musculature which is separated from the epithelial tumor by a condensed, but otherwise intact connective tissue. Note the cross sections of two scales (arrows) embedded in the tumor. Mag. \times 30.

FIG. 7.—Detail of the tumor showing the finely granular cytoplasm and small nuclei of the epithelial cells. The supporting connective tissues is scant in amount. Mag. \times 500



FIGS. 5-7

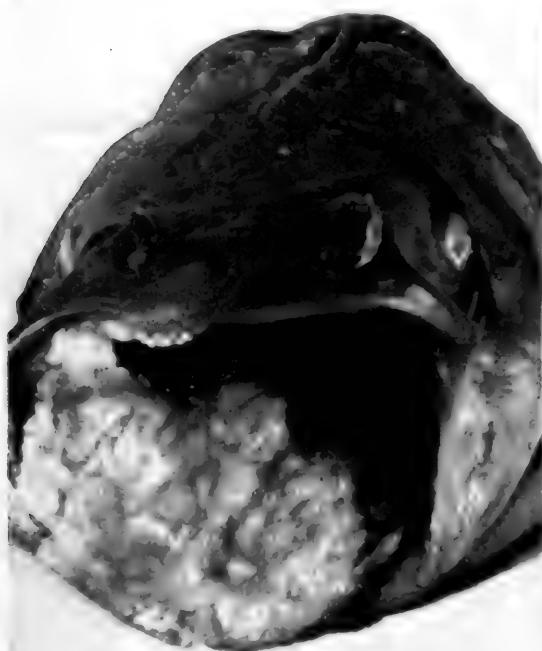DESCRIPTION OF FIGURES 8 TO 11
Epithelioma of the lip in catfish, *Ameiurus nebulosus*.

FIG. 8.—Epithelioma of the lower lip with extension to the upper lip, dental plates, and floor of the mouth.

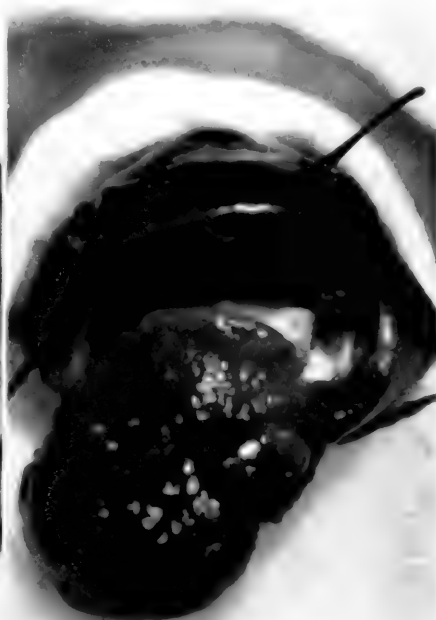FIG. 9.—Apposition tumors near the midline of the upper and lower lip and dental plates. To the right of the midline on the upper dental plate is a third tumor.

FIG. 10.—A large epithelioma occupies the entire lower lip, dental plate, anterior portion of the floor of the mouth. Externally it forms a large pendulous mass that interferes with feeding.

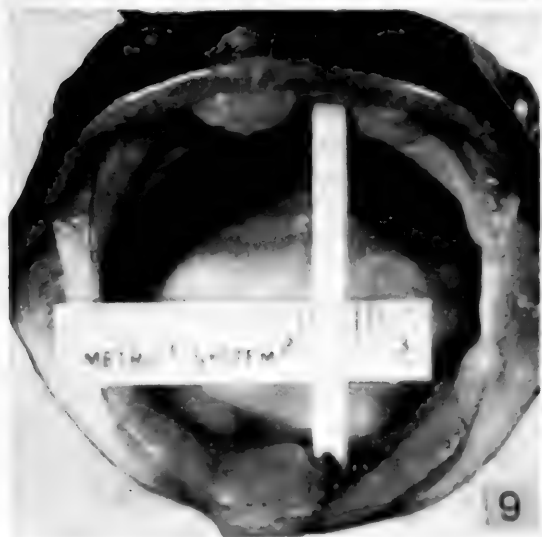FIG. 11.—Apposition tumors of the upper and lower lips.



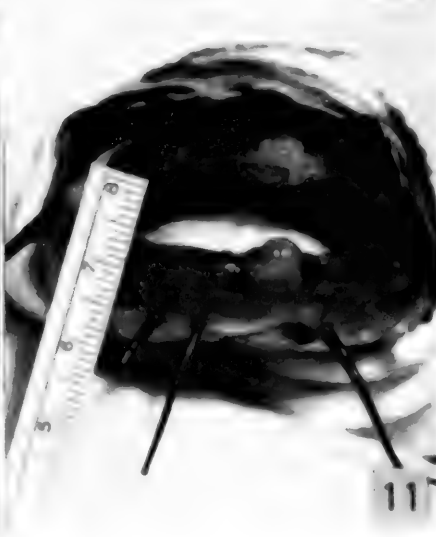
8



10



9



11

Figs 8-11

DESCRIPTION OF FIGURES 12 TO 15
Histologic appearance of epithelioma of catfish, *Ameiurus nebulosus*

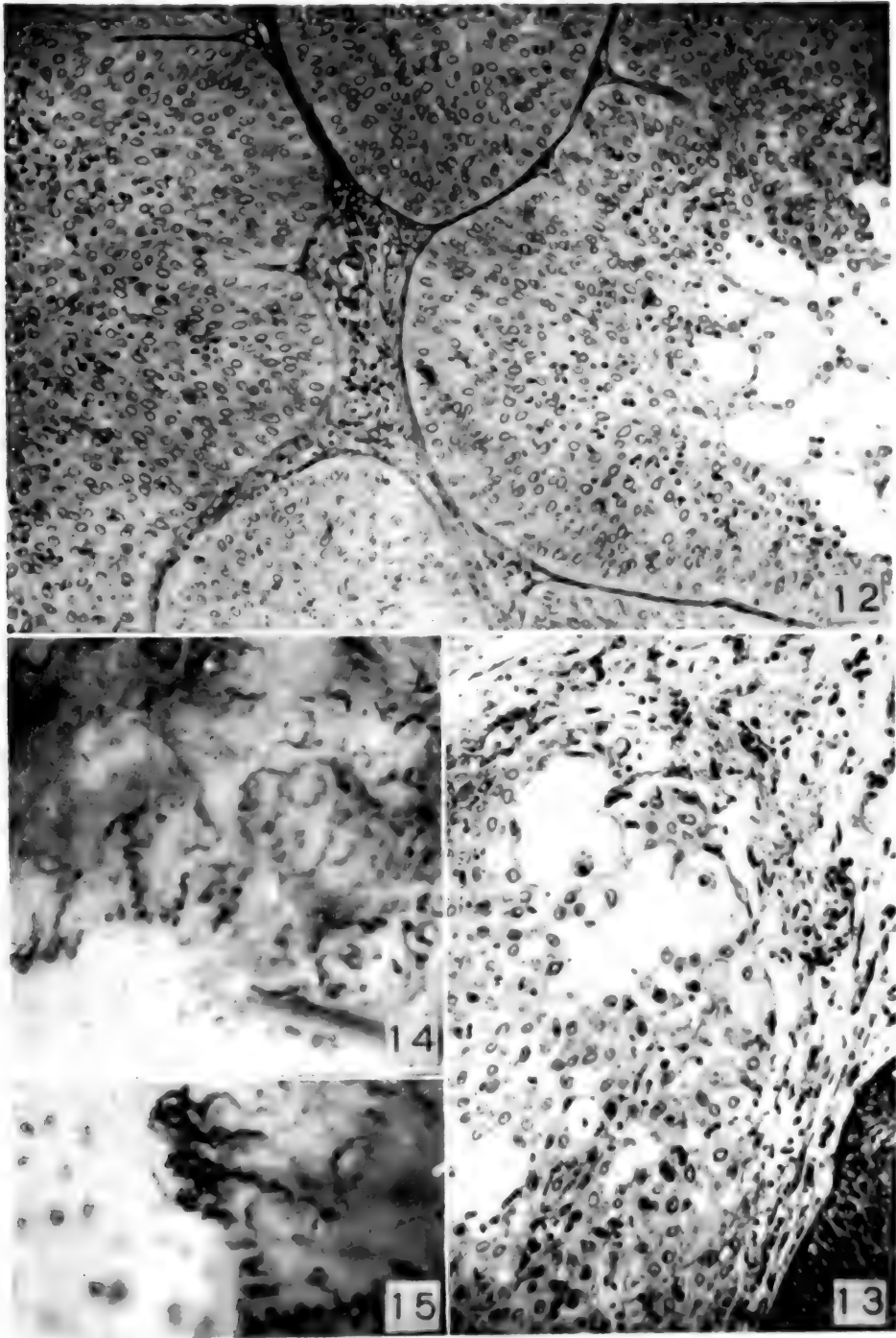
FIG. 12.—Sections through a representative tumor showing compact masses of epithelial cells which are supported by a scanty vascular stroma. Mag. \times 170.

FIG. 13.—Invasion of the adjacent connective tissue by neoplastic epithelial cells. Mag. \times 200.

FIG. 14.—Vascular bed of the living tumor (the upper two-thirds of the photograph). Note the dilatation and tortuosity of the vessels in the tumor as compared with the

delicate capillary loops in the normal tissue (lower third of photograph). Mag. \times 10.

FIG. 15.—Vascular bed of the living tumor at the margin of a growing epithelioma. The distended vessels in the tumor are seen in the right half of the figure. Note the abrupt transition between the vessels in the neoplastic area and the capillary loops of the normal lip on the left. Mag. \times 30.



FIGS. 12-15

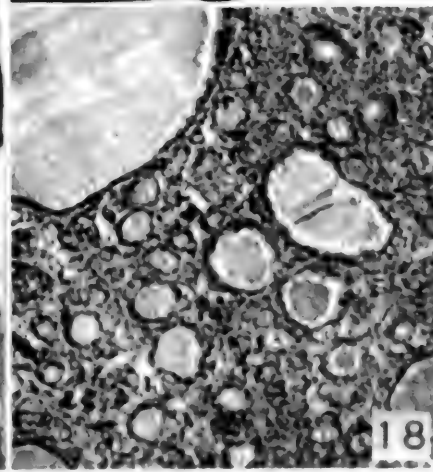
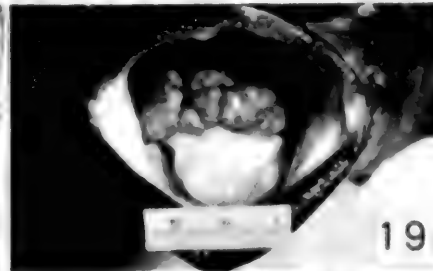
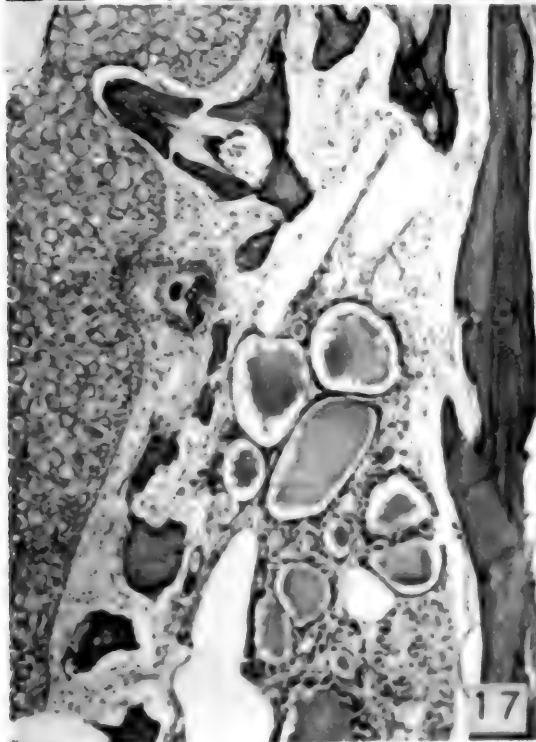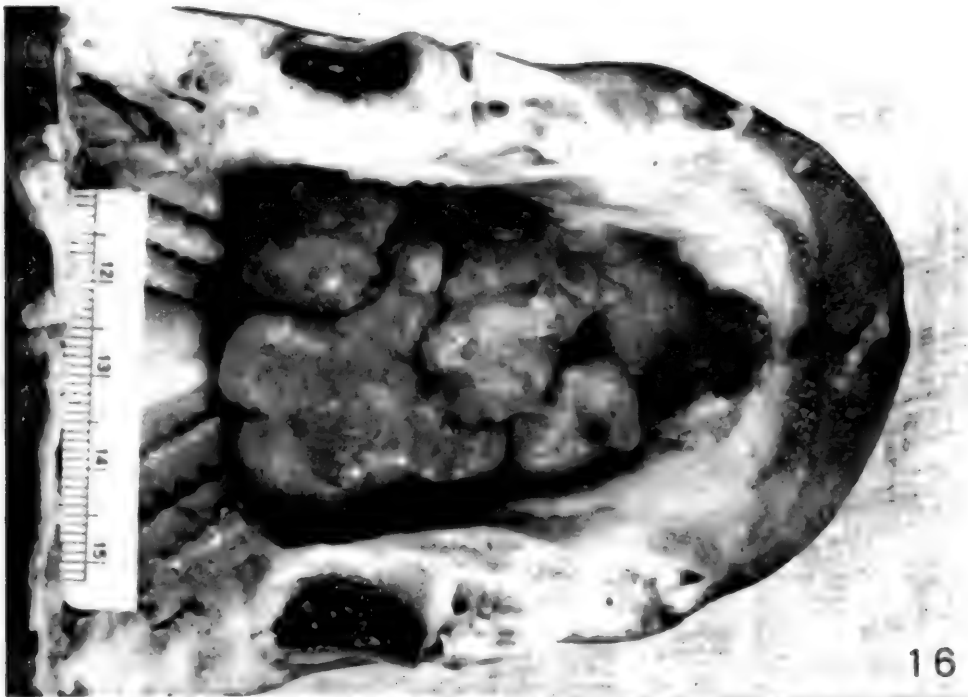DESCRIPTION OF FIGURES 16 TO 19
Thyroid "tumors" in the shark sucker, *Echeneis naucrates*.

FIG. 16.—Gross appearance of a tumor protruding through the floor of the mouth. The top of the head has been removed by a section which passed through the level of the eyes (visible in the photograph as bilateral heavy black crescents).

FIG. 17.—Thyroid tissue between the bony lamellae of a branchial arch. On the left is normal epidermis. This apparently aberrant location of thyroid tissue is normal for teleost fishes. Mag. $\times 100$.

FIG. 18.—Microscopic appearance of tumor shown in Fig. 16. Many of the acini are very small, with only a tiny lumen lined by tall columnar cells. As the acini increase in size the lining epithelial cells become flattened, and the amount of colloid increases. There are many marginal vacuoles in the colloid. Mag. $\times 70$.

FIG. 19.—Gross appearance of a tumor on the floor of the mouth in the living fish.



FIGS. 16-19

DESCRIPTION OF FIGURES 20 TO 24
Subcutaneous "fibrosarcoma" in goldfish, *Carassius auratus*.

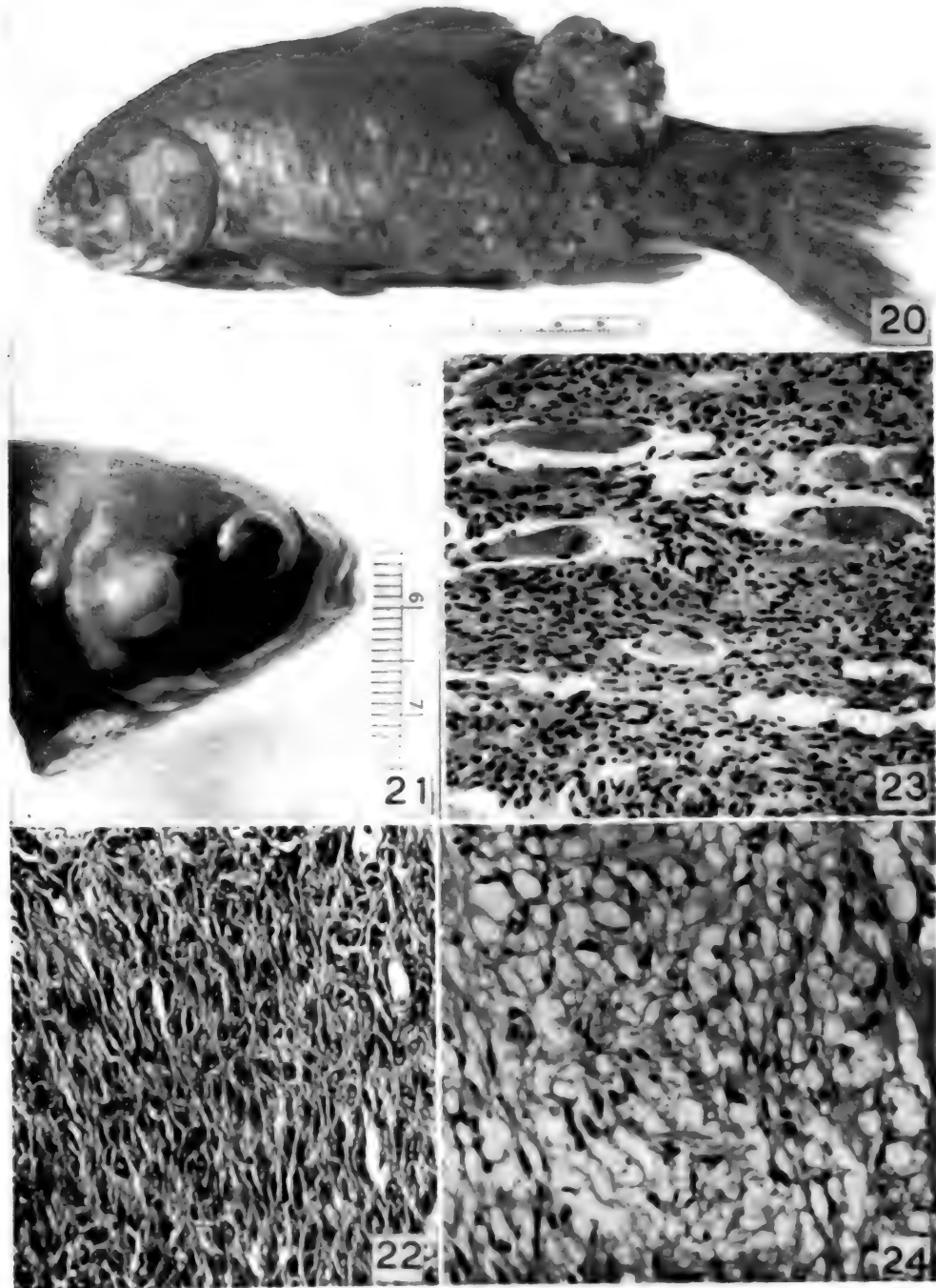
FIG. 20.—Gross appearance of a large tumor located on the side of the body.

FIG. 21.—Gross appearance of a tumor present on the right operculum near its posterior margin.

FIG. 22.—Histologic pattern of the tumor showing spindle shaped neoplastic cells in compact arrangement. **Mag. \times 300.**

FIG. 23.—Infiltration of the trunk musculature by tumor tissue. **Mag. \times 200.**

FIG. 24.—An area in which the neoplastic cells have become stellate in shape, resembling those of a myxoma. **Mag. \times 380.**



Figs. 20-24

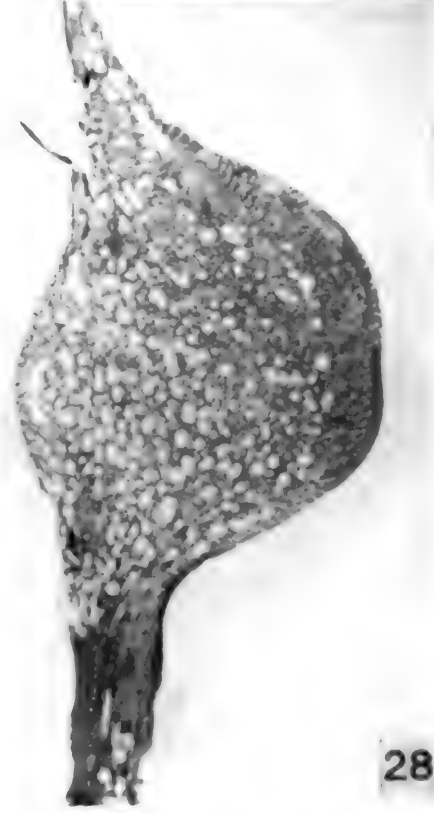
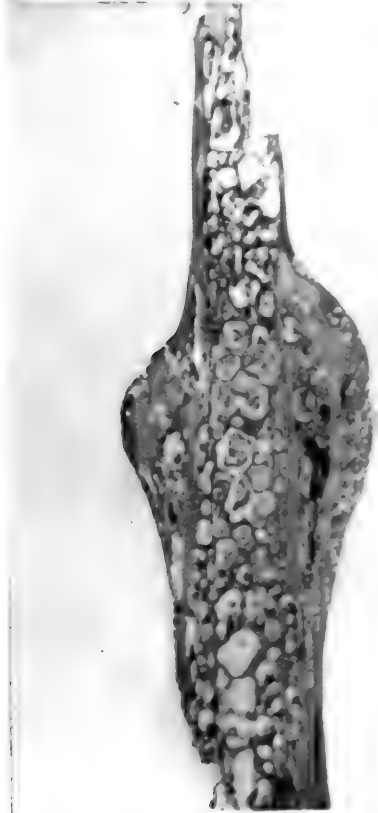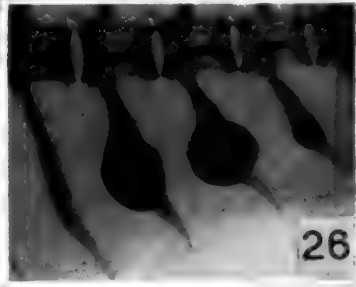
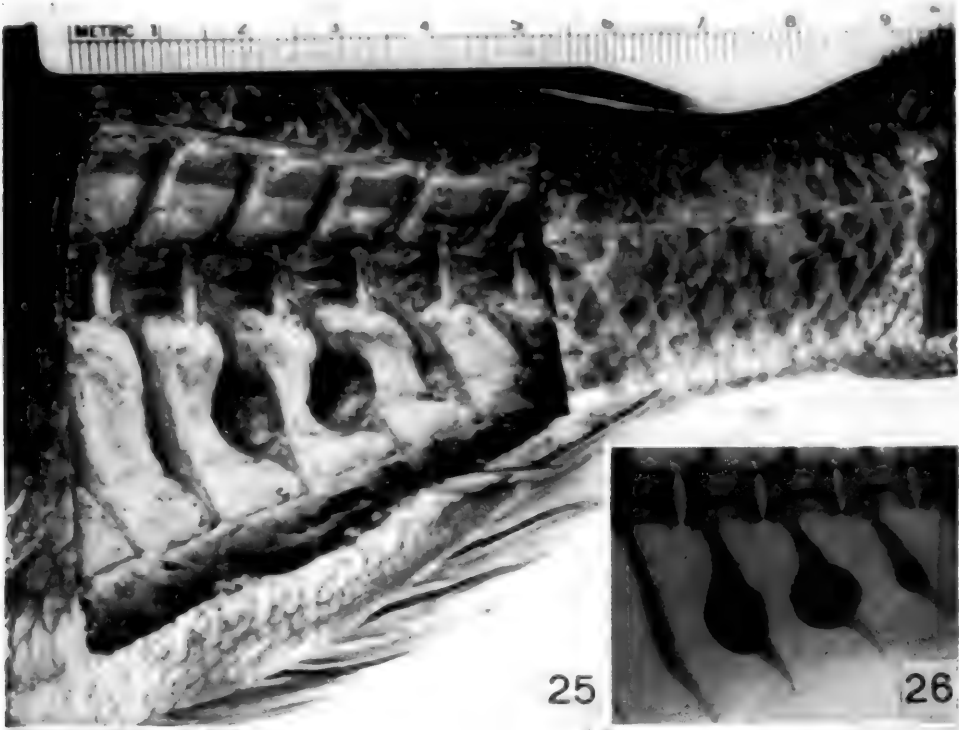
DESCRIPTION OF FIGURES 25 TO 28
Multiple osteomas in the red tai, *Pagrosomus major*.

FIG. 25.—Dissection showing the ventral (haemal) spines arising from the caudal vertebrae. The 2nd, 3rd, and 4th spines in the figure bear osteomas.

FIG. 26.—Roentgenogram of the tumors shown in the previous figure, made before dissection had been carried out.

FIG. 27.—Longitudinal section of the smallest of the tumors shown in Figure 26. New bone formation is entirely subperiosteal. Mag. \times 8.

FIG. 28.—Longitudinal section of the largest of the three osteomas shown in Figure 26. There is a marked central expansion of the spine by new formation of atypical bone. Mag. \times 6.



FIGS. 25-28

DESCRIPTION OF FIGURES 29 TO 33

"Osteomas" of the angelfish, *Chaetodipterus faber*, and on the file fish, *Alutera schoepfi*.

FIG. 29.—Osteoma of the first ventral (haemal) spine of an angelfish. The tumor is marked by an asterisk. One-half natural size.

FIG. 30.—Another example of osteoma of the first haemal spine of an angelfish.

FIG. 31.—Longitudinal section through the osteoma shown in the previous figure. Note the "annular" rings indicating

periods of arrested growth, probably seasonal. Mag. $\times 2$.

FIG. 32.—Osteoma of a bone (cleithrum) of the shoulder girdle in an angelfish. The specimen was found in a Florida Indian kitchen-midden.

FIG. 33.—Osteoma of the first interneural spine (just anterior to the dorsal fin) of a file fish. One-half natural size.

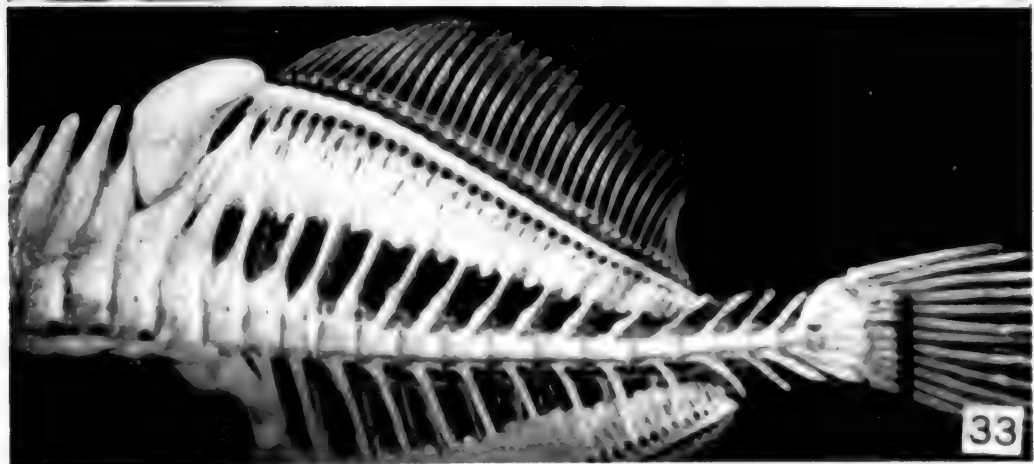
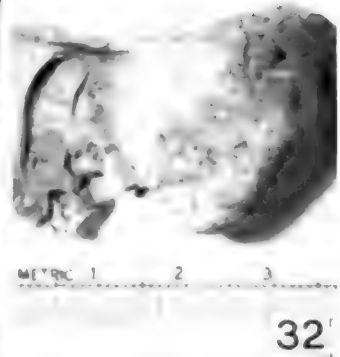

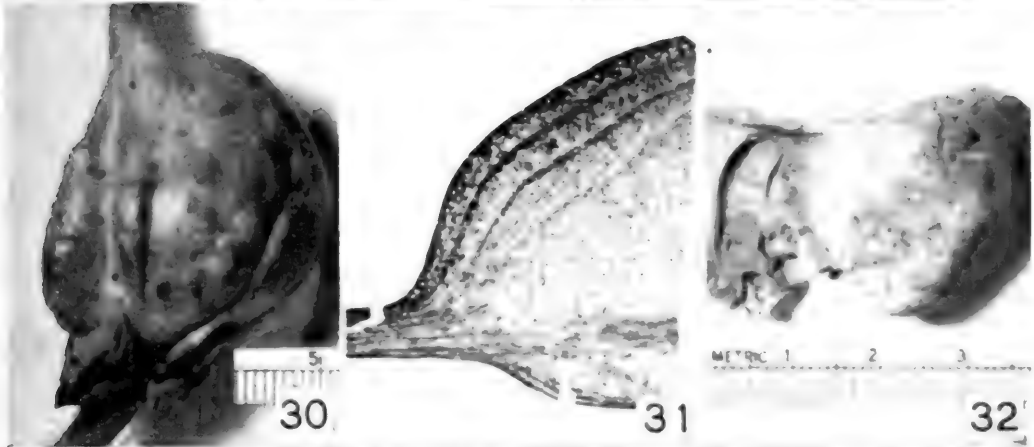
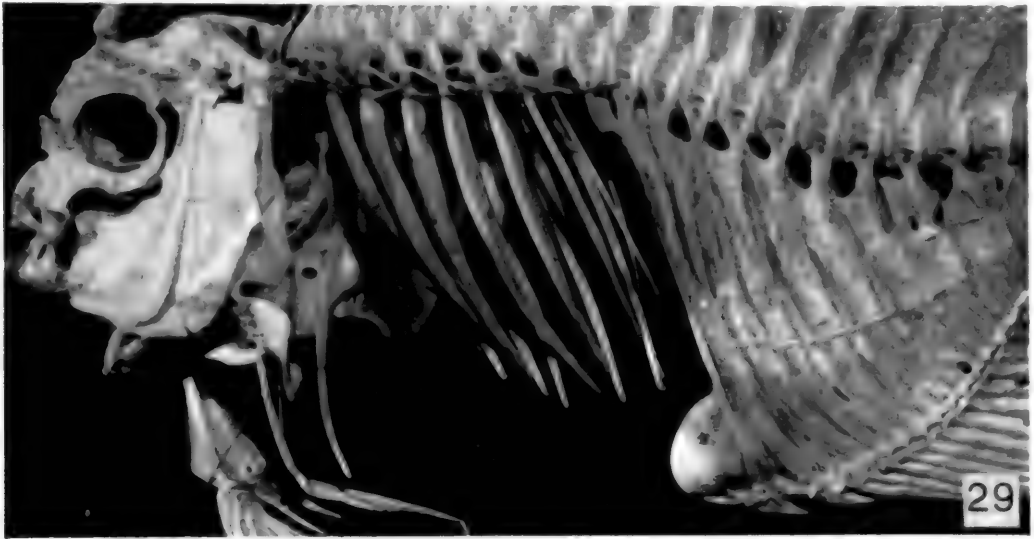


Fig. 29

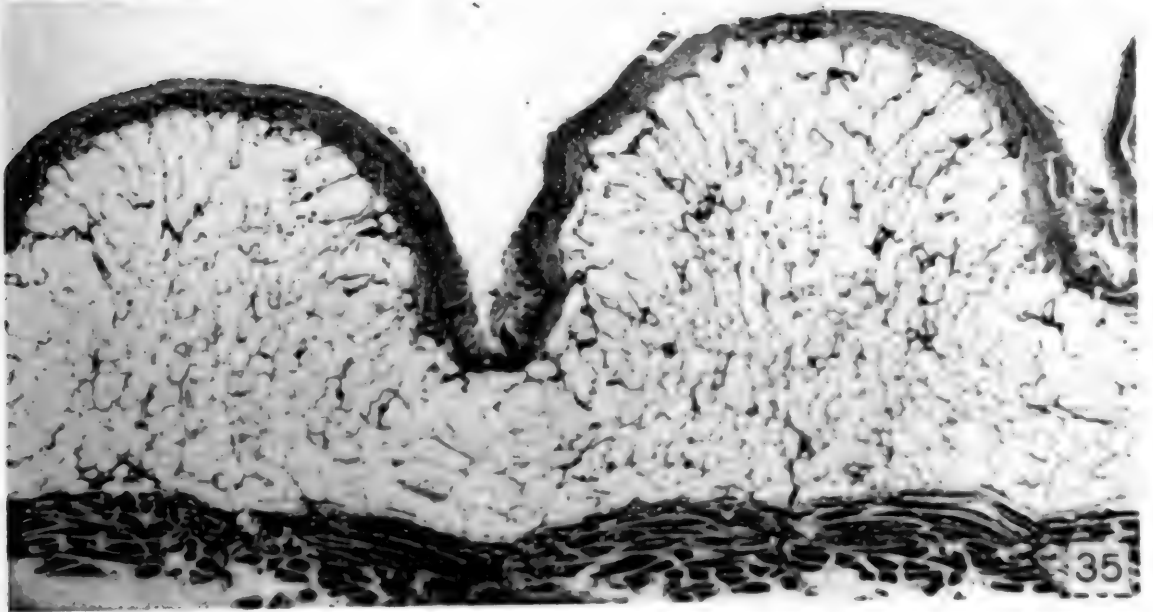
DESCRIPTION OF FIGURES 34 AND 35
Excessive accumulation of adipose tissue in a catfish, *Pygidium totae*.

FIG. 34.—Gross appearance of symmetrical, deeply lobulated, subcutaneous massive accumulations of adipose tissue in a South American catfish.

FIG. 35.—A section through the skin, adipose tissue, and trunk musculature. The overlying skin is normal, as is also the subjacent muscle. The adipose tissue is composed of adult fat cells. Mag. $\times 10$.



34



35

Figs. 34-35

DESCRIPTION OF FIGURES 36 TO 38
Tumors of the nerve sheaths in fish of the snapper family, *Lutianidae*.

FIG. 36.—Gross appearance of multiple tumors. Two tumors are present on the back, between the dorsal fin and the lateral line, a third occupies the base of the right pelvic fin, and the fourth is on the ventro-lateral aspect of the tail. One half natural size.

FIG. 37.—Relatively acellular areas composed of fibrils alternate with crowded collections of nuclei, thus giving a "palisading" appearance. Mag. $\times 280$.

FIG. 38.—Highly cellular region in which the nuclei are arranged in whorls about central bundles of fibrils. Mag. $\times 560$.

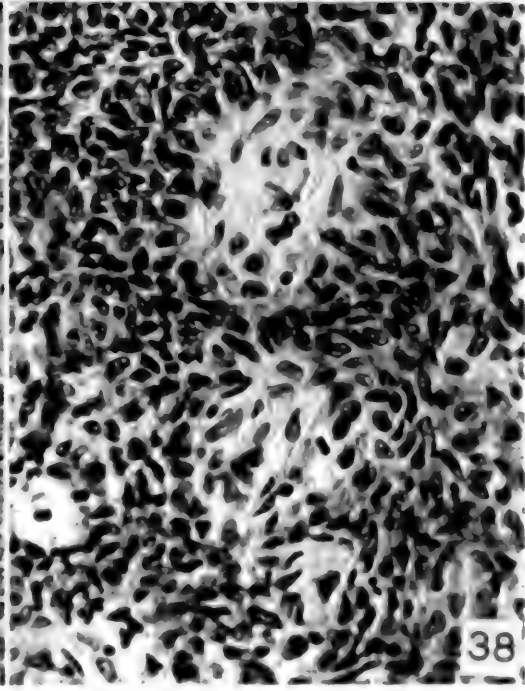
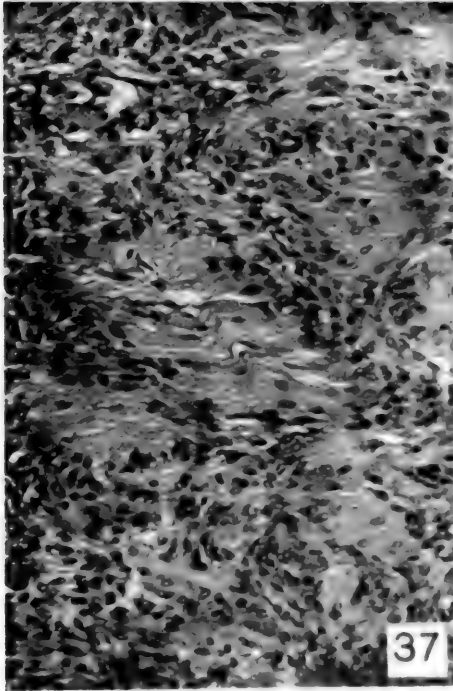
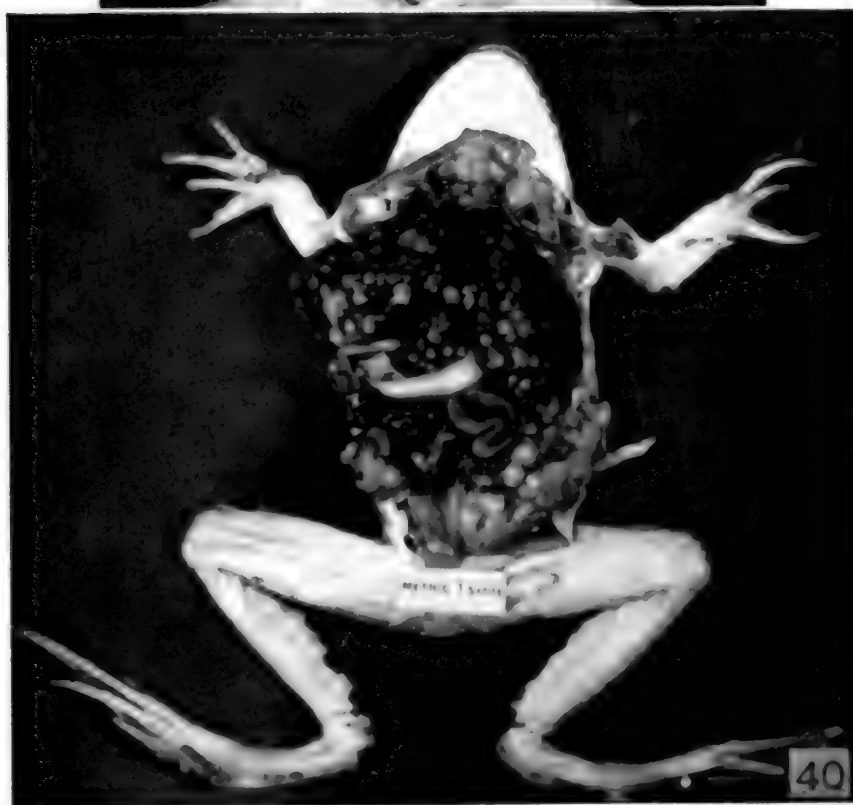
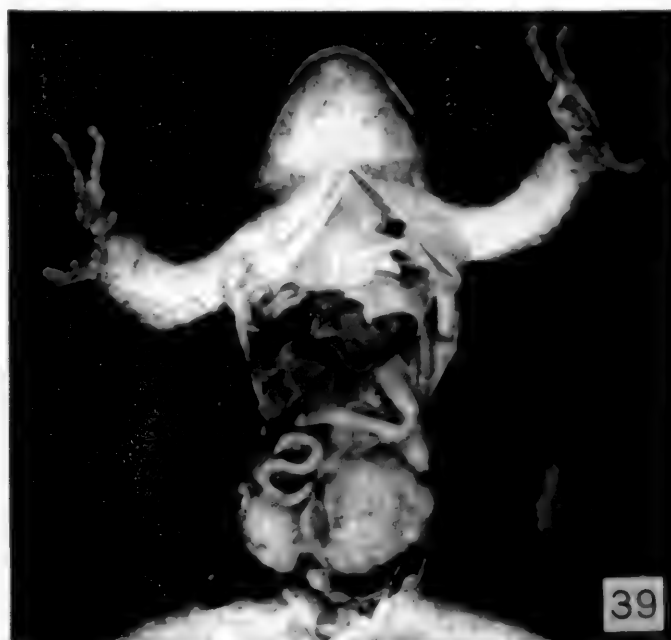

FIG. 36-38

DESCRIPTION OF FIGURES 39 AND 40
Adenocarcinoma of the kidney in the leopard frog, *Rana pipiens*.

FIG. 39.—Bilateral renal adenocarcinomas that have almost completely replaced both kidneys.

FIG. 40.—Multiple metastases to the liver, pancreas, and ovaries from bilateral kidney tumors.



FIGS. 39-40

DESCRIPTION OF FIGURES 41 TO 44

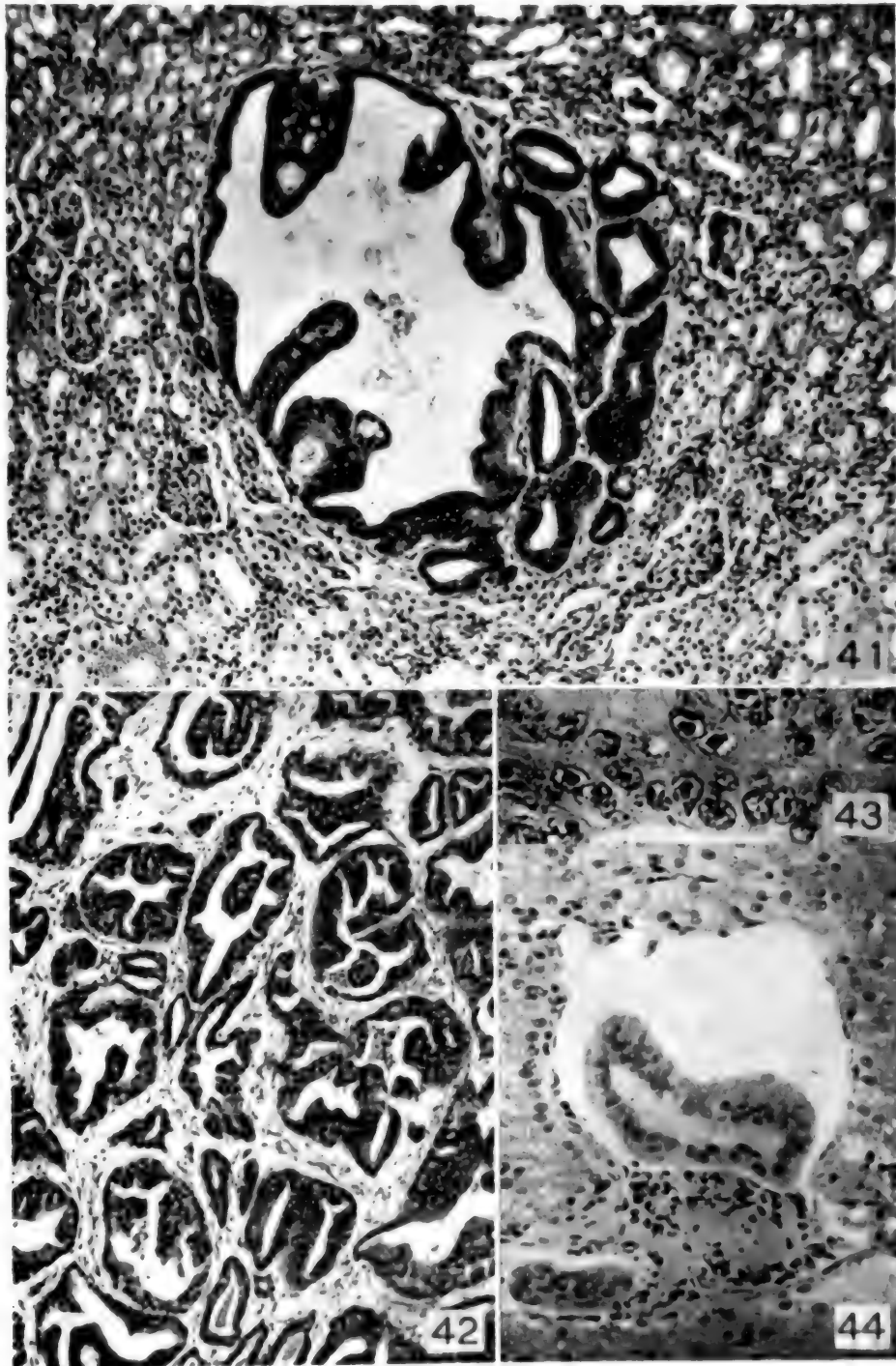
Histologic appearance of renal adenocarcinoma of the leopard frog, *Rana pipiens*.

FIG. 41.—Very early, solitary, cystic tumor surrounded by normal kidney tissue. Compare the size of the neoplastic tubules with the much smaller ones in the adjacent normal kidney. Mag. \times 95.

FIG. 42.—Microscopic appearance typical of the majority of the tumors. The neoplastic epithelium forms bizarre tubular or acinar structures supported by a moderately vascular connective tissue stroma. Mag. \times 70.

FIG. 43.—Intranuclear inclusions in neoplastic cells. The chromatin is condensed about the periphery of the nucleus, and is separated from the large central acidophilic inclusion by a clear space. Mag. \times 400.

FIG. 44.—Two large tumor emboli in vascular spaces within the liver. Mag. \times 200.



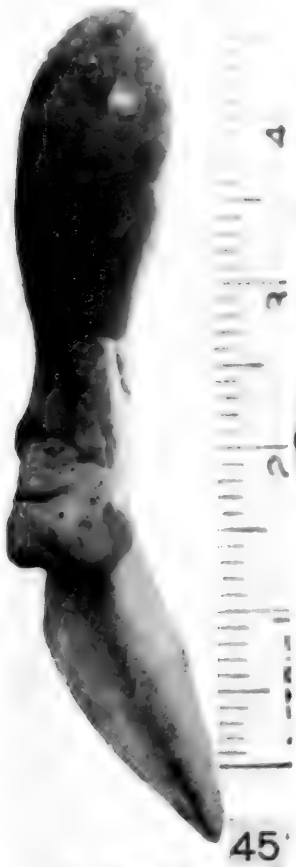
FIGS. 41-44.

DESCRIPTION OF FIGURES 45 TO 47
Tumor in a tadpole of the green frog, *Rana clamitans*.

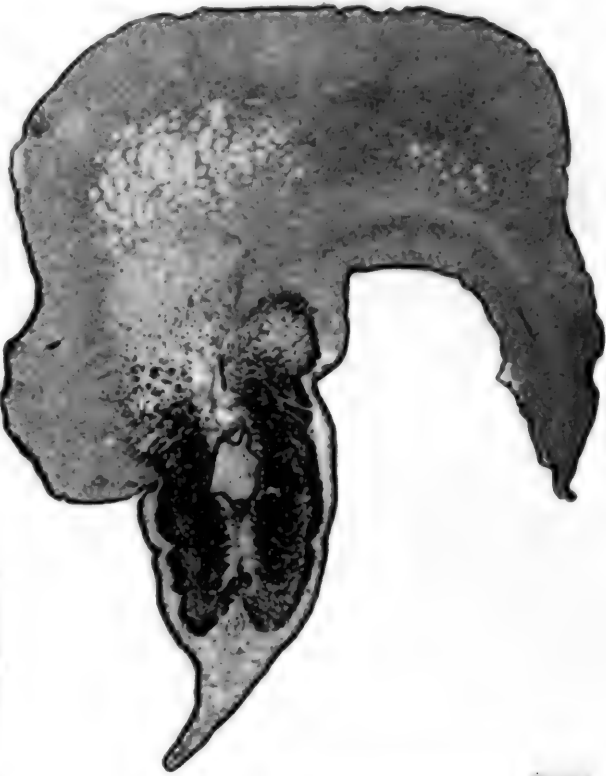FIG. 45.—A coarsely lobulated tumor on the dorsum of the tail, near its base.

FIG. 46.—Section through the neoplastic region. The neoplasm apparently arose in the subcutaneous mesenchyme and is infiltrating the dorsal myomeres. Mag. $\times 7$.

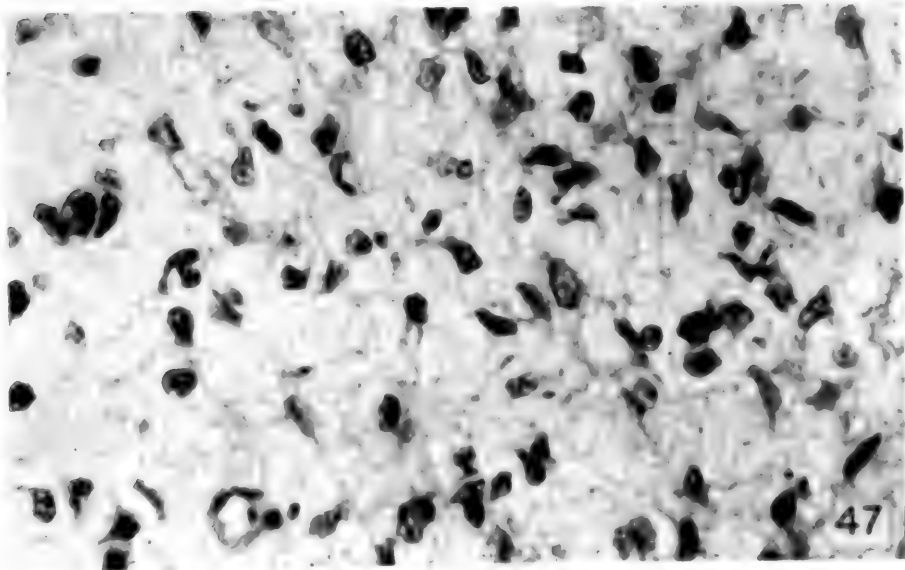
FIG. 47.—The bulk of the tumor is composed of loosely arranged stellate cells such as are characteristic of a myxoma or myxosarcoma. Mag. $\times 400$.



45



46



47

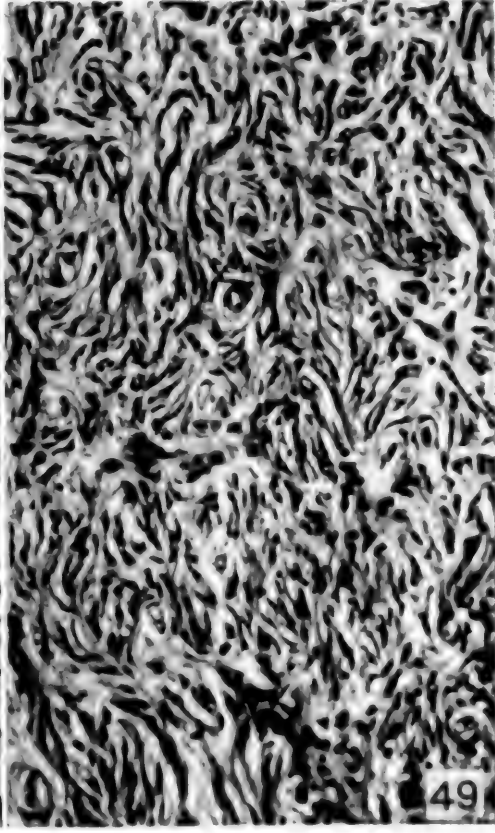
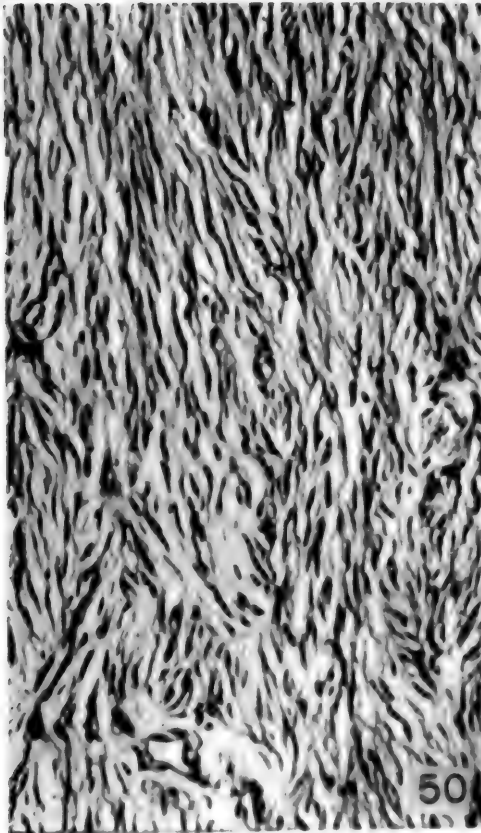
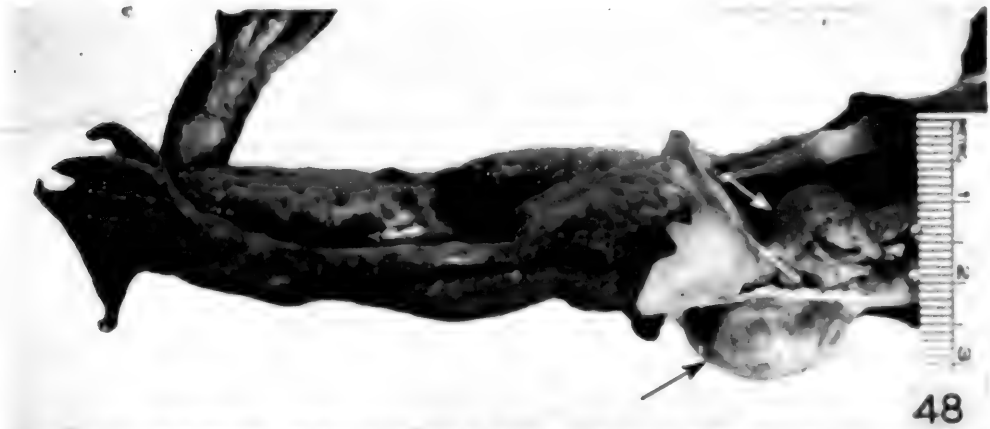FIGS. 45-47

DESCRIPTION OF FIGURES 48 TO 50
Sarcoma in a bullfrog, *Rana catesbiana*.

FIG. 48.—Gross appearance of the legs and posterior half of the trunk of a bullfrog. At the junction of the left thigh and trunk is a roughly spherical tumor, half of which lies within the coelomic cavity (white arrow); the remainder has penetrated the back muscles and forms a prominent subcutaneous mass (black arrow).

FIG. 49.—Interlacing bundles and whorls of delicate connective tissue make up the bulk of the tumor. Mag. $\times 150$.

FIG. 50.—At the periphery of the neoplasm the fibrils are arranged in parallel bundles; palisading of the nuclei is not present. Mag. $\times 150$.

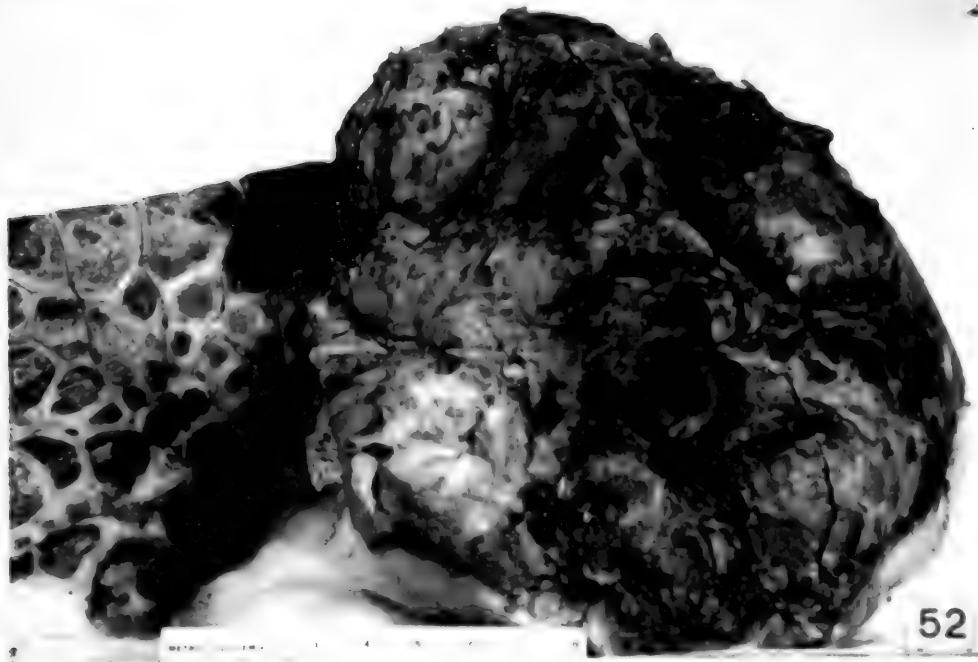
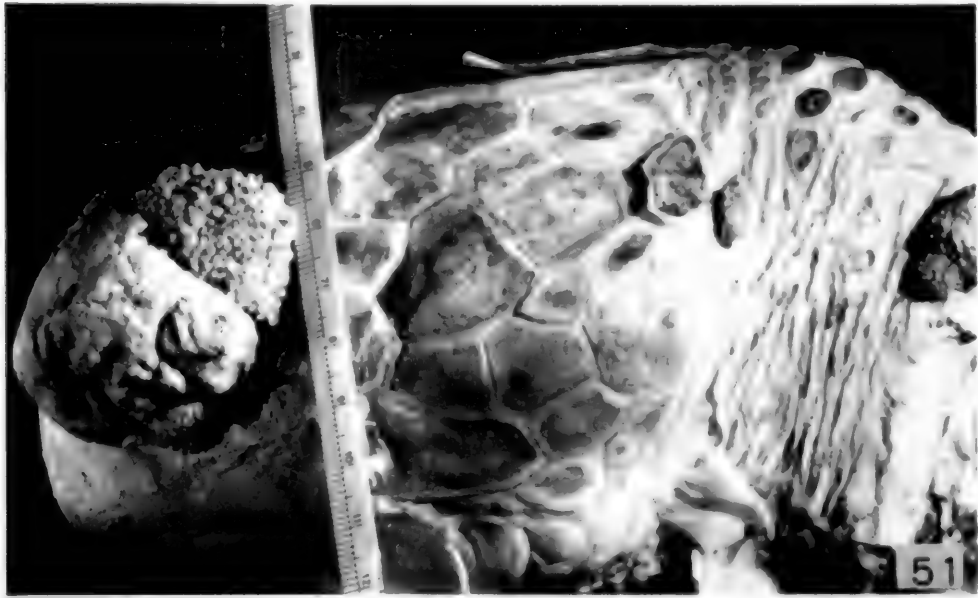
FIGS 48-50

DESCRIPTION OF FIGURES 51 AND 52
Cutaneous papillomas of the green turtle, *Chelonia mydas*.

FIG. 51.—Head and neck of turtle. At the left of the photograph a large lobulated tumor completely covers the eye. Two small papillomas are present on the dorso-lateral aspect of the neck. (Natural size).

FIG. 52.—Flipper of turtle. In the axilla is a large spherical tumor, portions of which are hemorrhagic and necrotic. (One-half natural size).



FIGS. 51-52

DESCRIPTION OF FIGURES 53 TO 56

Histologic appearance of the papillomas of the green turtle, *Chelonia mydas*.

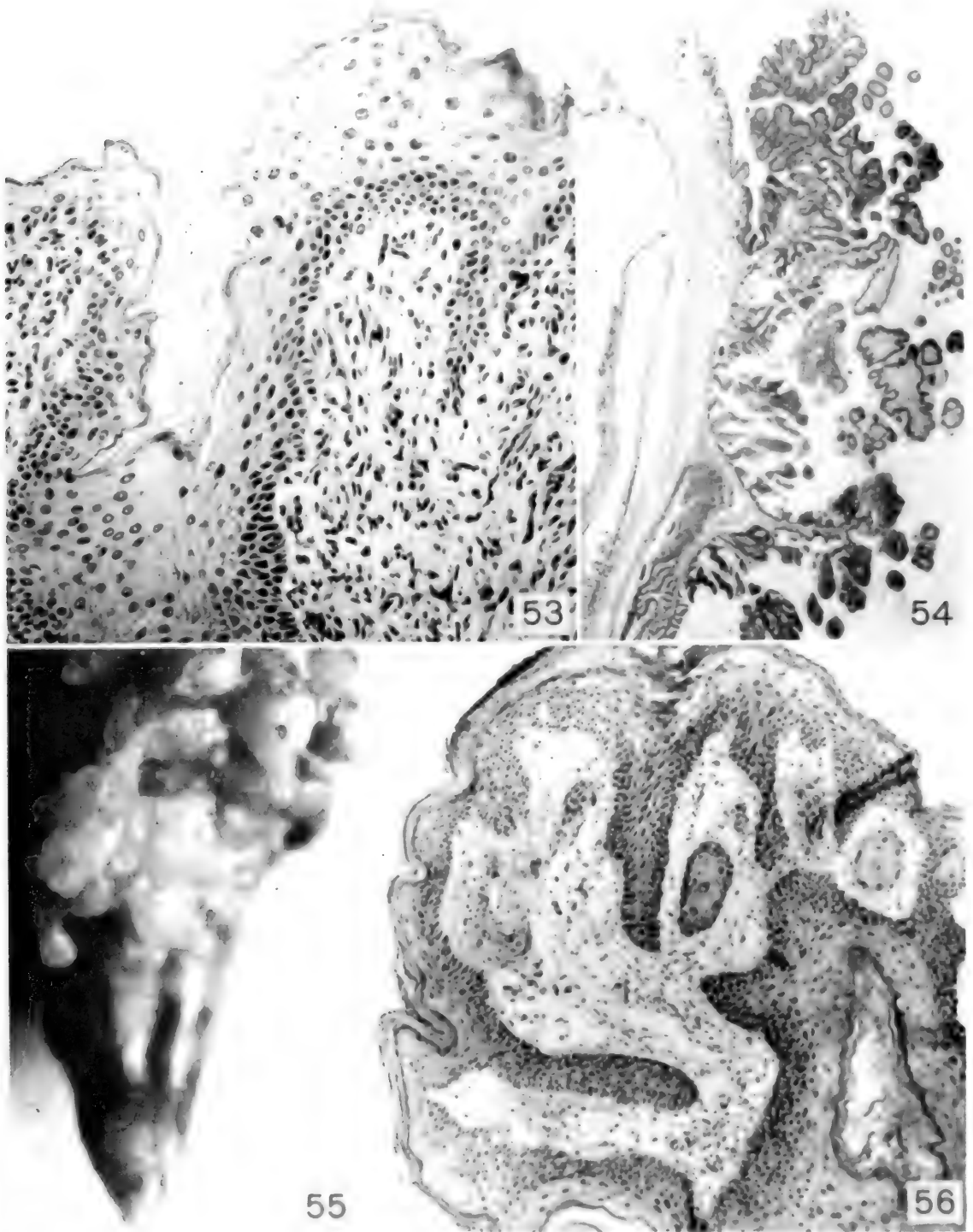
FIG. 53.—The hyperplastic epithelium of a cutaneous papilloma rests on a dense supporting stroma. Mag. \times 150.

FIG. 54.—Arborescent papilloma growing on the cornea. Mag. \times 5.

Papilloma of the musk turtle, *Sternotherus odoratus*.

FIG. 55.—Coarsely lobulated papilloma on the dorsum of the tail. Mag. \times 4.

FIG. 56.—Section of the papilloma showing hyperkeratosis and parakeratosis of the epithelium. Long pegs of epithelial cells penetrate deeply into the supporting stroma of loose, well vascularized connective tissue. Mag. \times 70.



FIGS. 53-56

DESCRIPTION OF FIGURES 57 TO 59

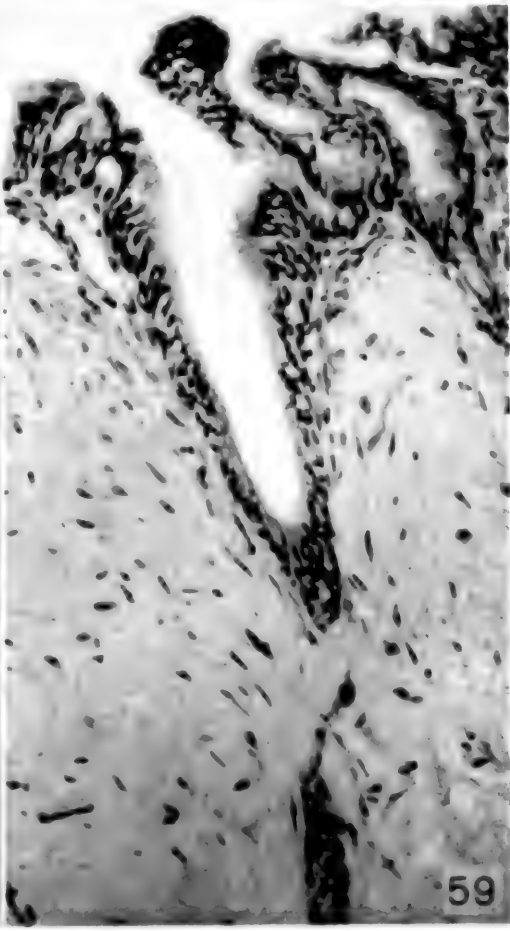
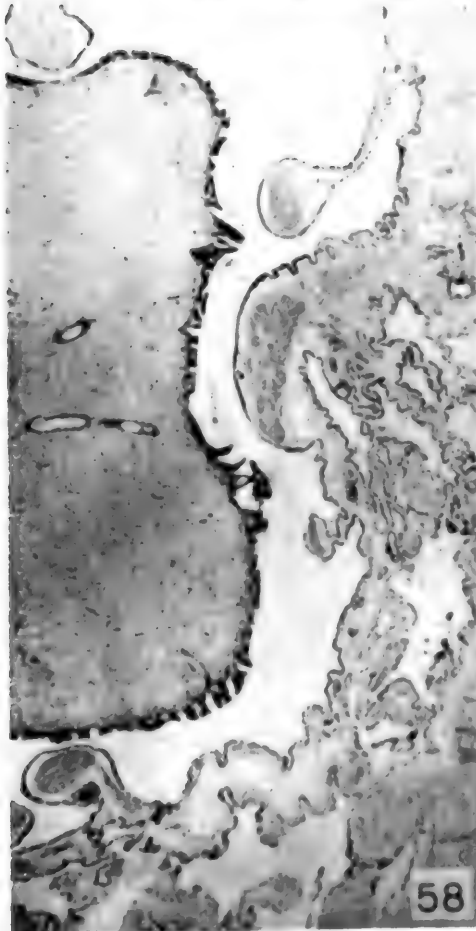
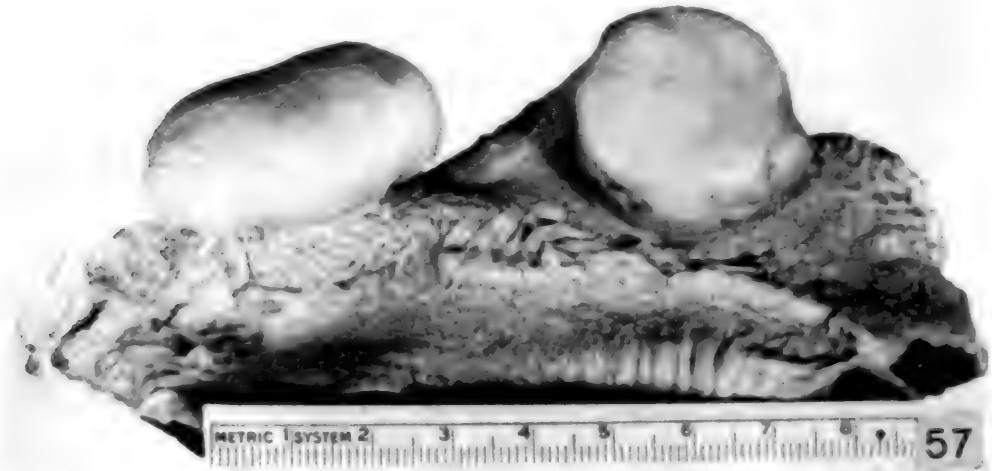Fibromas of the lung in the green turtle, *Chelonia mydas*.

FIG. 57.—Two fibromas of the lung. After incision, the elastic pulmonary parenchyma retracted away from the tumors, leaving their surfaces smooth and glistening.

FIG. 58.—The fibroma occupies the left half of the photograph. There is no evidence of infiltration of the adjacent structures, but the alveoli of the lung are compressed. Mag.

× 10.

FIG. 59.—The periphery of the tumor shown in the preceding figure. The surface is covered by normal ciliated respiratory epithelium. The underlying connective tissue comprises the bulk of the tumor; it is dense, partly hyalinized, and contains relatively few nuclei. Mag. × 150.



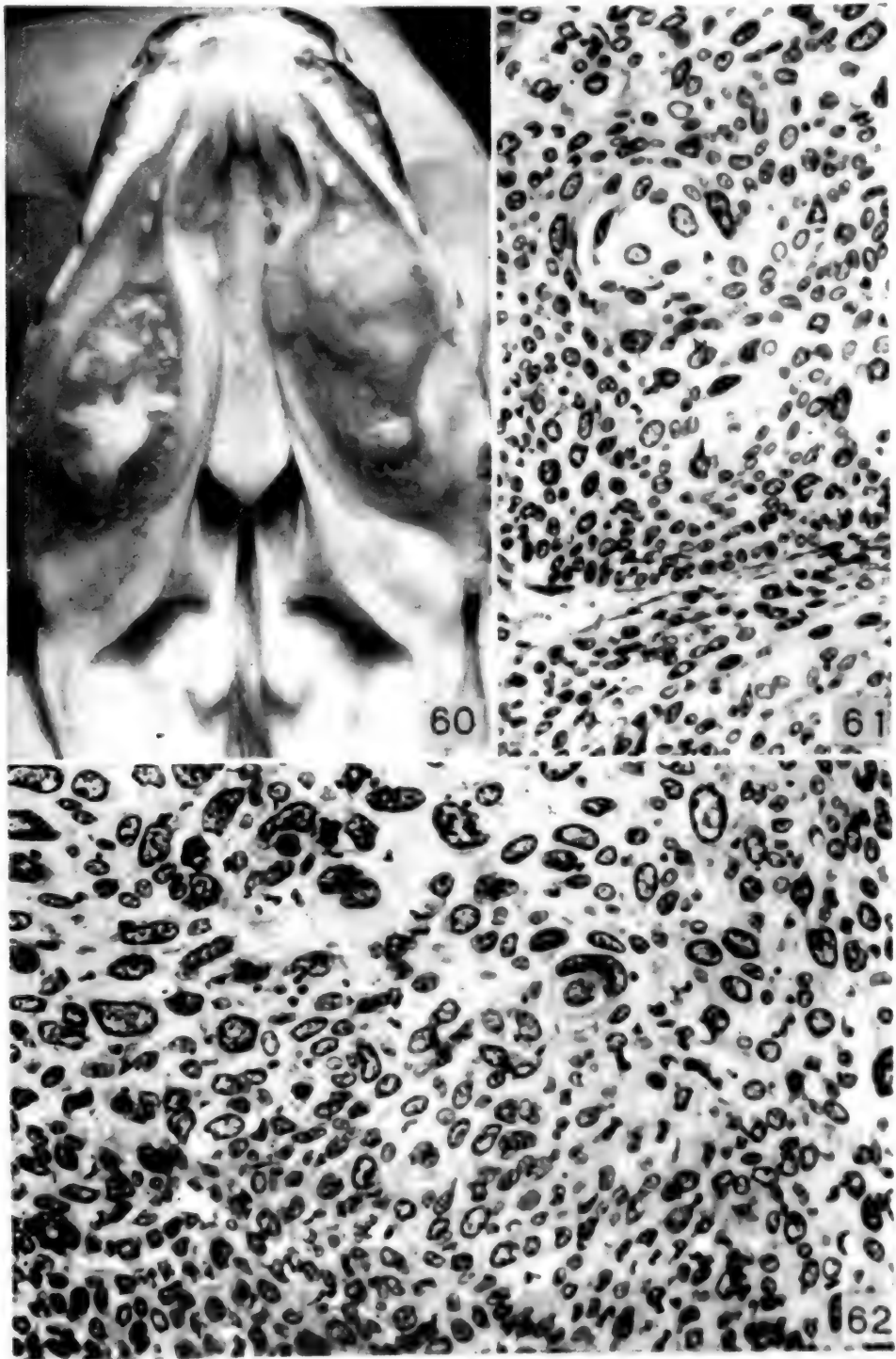
DESCRIPTION OF FIGURES 60 TO 62

Oral squamous cell carcinoma of a lizard, *Tupinambis nigropunctatus*.

FIG. 60.—Roof of the mouth in the living animal showing bilateral tumors. These arose in the epithelium of the gums and have completely destroyed several teeth. The white plaques are areas of necrosis.

FIG. 61.—In this section the neoplastic epithelial cells are in some areas arranged concentrically to form small nests or "pearls." Mag. \times 200.

FIG. 62.—The nuclei of the tumor cells are remarkably large and pleomorphic; an occasional mitotic figure is present. Intercellular bridges can be seen. Mag. \times 200.



FIGS. 60-62.

DESCRIPTION OF FIGURES 63 TO 66
Malignant melanoma in a python, *Python reticulatus*.

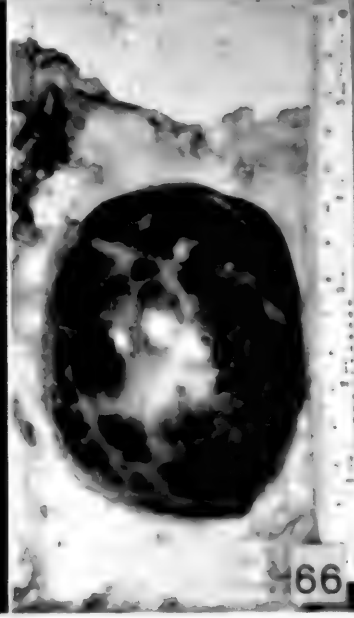
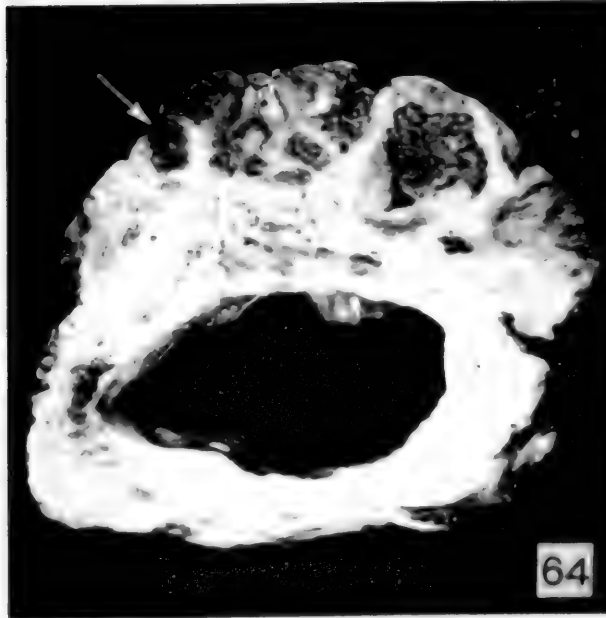
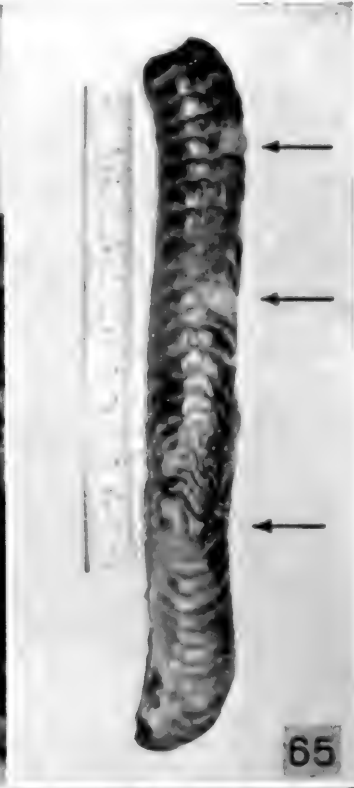
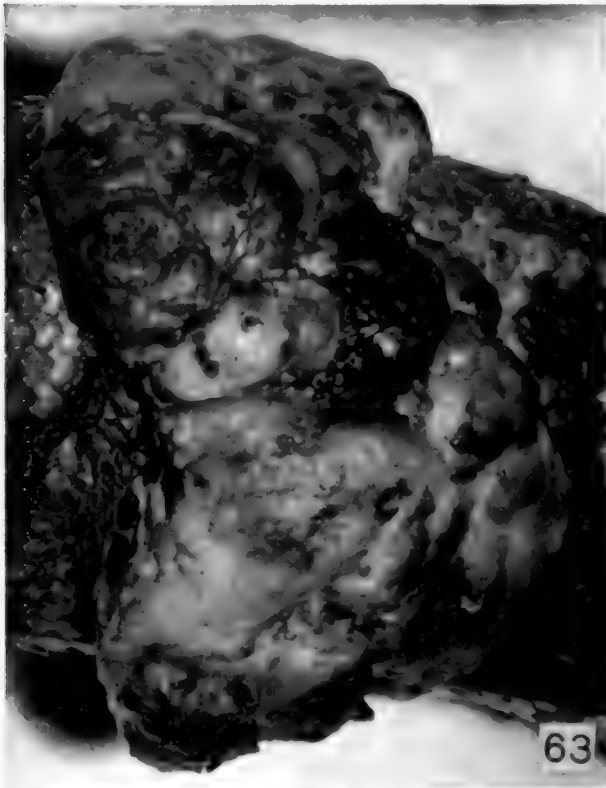
FIG. 63.—Gross appearance of the primary tumor on the lateral aspect of the body of the snake. Note the absence of scales over the coarsely lobulated surface of the neoplasm. (Two-thirds natural size.)

FIG. 64.—Cross section through the snake's body at the level of the tumor. The latter occupies about a third of the circumference of the body; it is coarsely lobulated, and contains several large areas of necrosis. Most of the tumor is

non-pigmented; however, several densely pigmented areas are present (arrow). (One-half natural size.)

FIG. 65.—Kidney bearing three non-pigmented metastatic tumor nodules (arrows). (One-half natural size.)

FIG. 66.—A deeply pigmented metastatic tumor on the parietal surface of the coelomic cavity, 20 cm. caudal to the heart. (Natural size.)



Figs. 63-66.

DESCRIPTION OF FIGURES 67 TO 70

Histologic appearance of malignant melanoma in a python, *Python reticulatus*.

FIG. 67.—Section from the primary neoplasm showing the interlacing bundles of spindle shaped neoplastic cells. In this area, only an occasional cell bears pigment granules. Mag. $\times 250$.

FIG. 68.—High power magnification of a neoplastic cell containing pigment. In the center of the photograph is an X-shaped cell with a large oval nucleus. Throughout the cytoplasm there is a uniform scattering of pigment granules. Mag. $\times 1,000$.

FIG. 69.—Metastatic tumor in the kidney. Along the left margin of the photograph is a normal renal tubule to the right of which is a sheet of neoplastic cells. The latter differ from those in the primary lesion in that they are less spindle shaped; the nuclei tend to be spherical. Mag. $\times 230$.

FIG. 70.—A region from the primary tumor in which the cell pattern has a rather pronounced neurogenic appearance. There is a suggestion of palisading of the nuclei. Mag. $\times 200$.

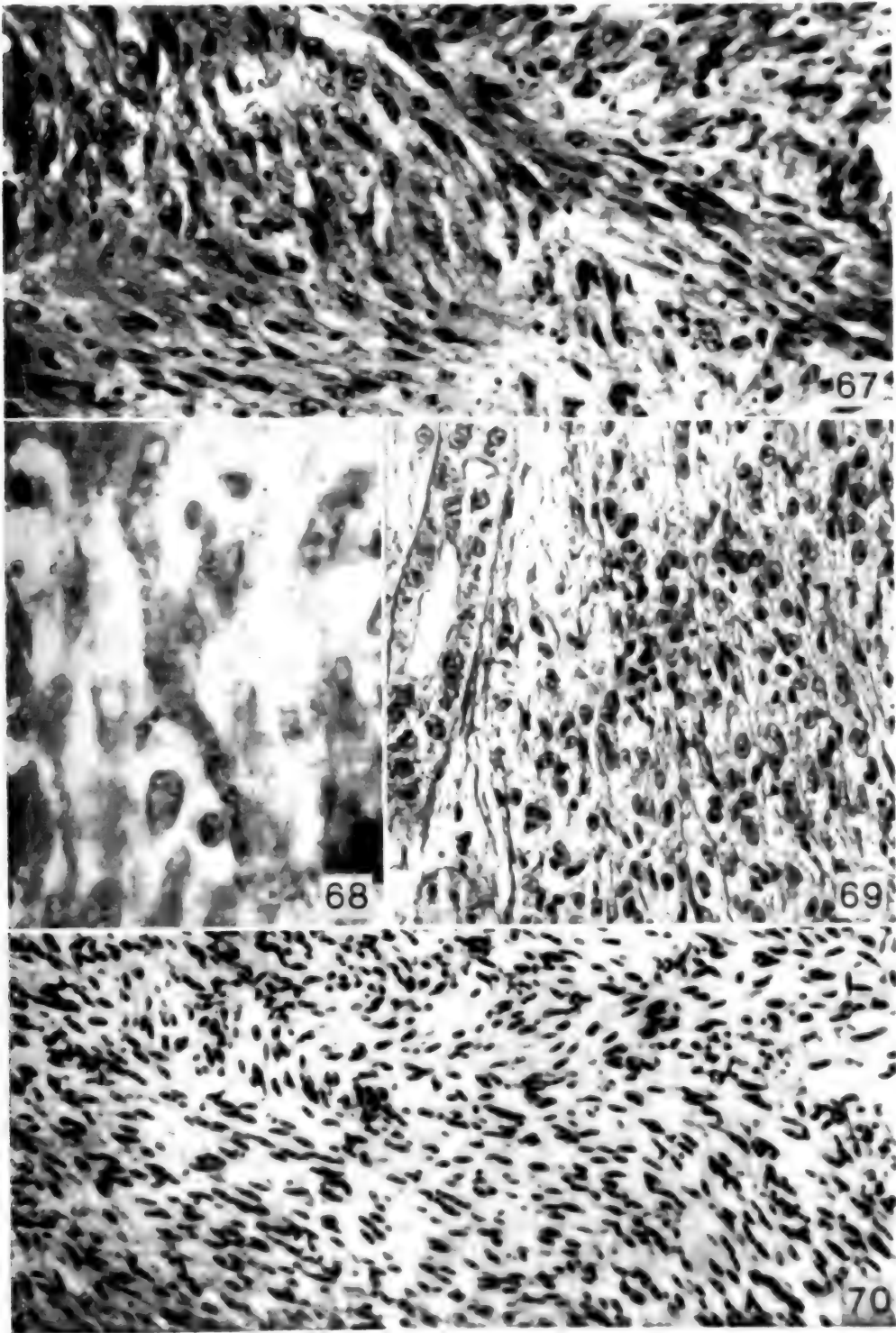


FIG. 67

NOTICE

The Index to Literature of Experimental Cancer Research, 1900 to 1935, prepared by the Donner Foundation, is now available. It is a bound volume of over 1000 pages. The Donner Foundation has generously distributed copies to the principal medical libraries of the United States and Canada,

and to some European libraries. Individuals wishing a copy for their personal use may obtain one by addressing the Donner Foundation, 2136 Land Title Building, Philadelphia 10, Pa. The price is \$10, which is less than the cost of publication.

ERRATUM

In the paper by Bernhard, Rosenbloom and Eichen, entitled "A Study of Inorganic Phosphorus Release Accompanying Glycolysis of Blood in

Cancer," Vol. 8, No. 6, p. 295, in the last line of the first paragraph, "252 mgm. per cent" should read "25 mgm. per cent."





by Schlumberger, Hans George
173 Tumors of fishes.
T8S35

Hygiene

PLEASE DO NOT REMOVE
CARDS OR SLIPS FROM THIS POCKET

UNIVERSITY OF TORONTO LIBRARY



