

JOHN A. SEAVERNS



3 9090 014 531 368

H. L. Schuch.

VETERINARY SURGERY

BY LOUIS A. MERILLAT, V. S.

VOLUME I

ANIMAL DENTISTRY AND DISEASES OF
THE MOUTH

VETERINARY SURGERY

By LOUIS A. MERILLAT, V. S.

VOLUME I

ANIMAL DENTISTRY AND DISEASES OF THE MOUTH

VOLUME II

THE PRINCIPLES OF VETERINARY SURGERY

VOLUME III

VETERINARY SURGICAL OPERATIONS

Veterinary Surgery

VOLUME I.

ANIMAL DENTISTRY

AND

DISEASES OF THE MOUTH

BY

LOUIS A. MERILLAT V. S.

PROFESSOR OF VETERINARY SURGERY IN THE CHICAGO VETERINARY COLLEGE; LATE SECRETARY AND PROFESSOR OF DENTISTRY IN THE M'KILLIP VETERINARY COLLEGE; LATE PRESIDENT OF THE CHICAGO VETERINARY SOCIETY; SECRETARY OF THE ASSOCIATION OF VETERINARY FACULTIES AND EXAMINING BOARDS OF NORTH AMERICA; MEMBER OF THE AMERICAN VETERINARY MEDICAL ASSOCIATION; MEMBER OF THE ILLINOIS STATE VETERINARY MEDICAL SOCIETY, ETC.

Illustrated

CHICAGO:
ALEXANDER EGER
1908

Entered according to Act of Congress, in the year 1905, by

ALEXANDER EGER

in the office of the Librarian of Congress at Washington.

To Mr. MYRON H. TICHENOR and Mr. LOUIS M. NEWGAS, of Chicago, U. S. A., for their appreciation of the value of animal dentistry on valuable coach and saddle horses, this volume is respectfully dedicated by

The Author.

PREFACE.

The domain of animal dentistry is too limited to fill a large volume without entering into the details of embryology, anatomy and physiology, and since these sciences are today ably covered by writers possessing special merit in each, it would appear ridiculous for a veterinary practitioner to "venture where angels fear to tread." A comprehensive understanding of the teeth in their normal state at the different periods of life, as a foundation for the intelligent treatment of their abnormalities is, however, so essential that it has been thought advisable to include an epitome of these sciences so far as they appertain to the teeth.

This Volume, with Volumes II and III, is written at the earnest solicitation of the students I have had the privilege of teaching during the past twelve years, which circumstance is the only excuse for its publication. The fact that animal dentistry is given but limited space in the surgical literature of the profession has not entered into the proposition, because the task of writing books belongs to those having the time and inclination to ponder leisurely over each single topic, and not to the busy practitioner, whose few idle moments are usually interrupted by "a call to action."

It has been the aim to cover the subject in a matter-of-fact manner, excluding all obscure, rare and imaginary conditions and including all the conditions encountered in the routine of practice. For compiling the index and for the illustrations, which are made from copies and original draw-

ings, I am particularly indebted to Mr. Alex. Eger. I have also to thank my friend, Dr. W. L. Williams, Professor of Surgery in the New York State Veterinary College, for his valuable suggestions as to the origin of teratomata of the mastoid region, and my brother Professor, Edw. Merillat, for his many original ideas which are entered throughout the text with but a single credit, viz., the operation for closing skull perforations.

With a full knowledge that the manuscript would crumble from the assault of a literary critic, I forthwith apologize to the censors of English veterinary literature.

L. A. MERILLAT.

CONTENTS.

	PAGE
PREFACE	IX
INTRODUCTION	13
CHAPTER I	18-43
Nomenclature of Teeth	18
Divisions of a Tooth	19
Structures of the Teeth	20
CHAPTER II	44-67
Evolution of the Teeth	44
Embryonic Evolution	44
Evolution of the Temporary Teeth	49
Evolution of the Permanent Teeth	58
CHAPTER III	68-126
Retrogression of the Temporary Teeth	68
Retrogression of the Permanent Teeth	68
Determination of Age	74
Routine of Examination of a Horse's Mouth to Determine Age ..	113
Anomalies of the Teeth, Natural and Artificial	117
CHAPTER IV	127-132
Function of the Teeth	127
CHAPTER V	133-151
Dental Diagnosis	133
Dental Instruments—Their Uses	135
Restraint	148
CHAPTER VI	152-256
Diseases and Irregularities of the Teeth	152
Necrosis of the Teeth of Herbivora	152
Caries	172
Abnormal Eruptions of the Teeth	175
Dental Cysts	177
Odontomata	178
Brachygnathism	179
Prognathism	181
Parvignathism	182
Projections on First Superior and Sixth Inferior Molars	184
Projections on the Superior Corners	185
Acquired Elongations of the Molars	185
Enamel Points	187
Wolf Teeth	202

	PAGE
Supernumerary Teeth	204
Elongation of Incisors.....	207
Erosion of Enamel	208
Tartar	208
Fracture of the Teeth	209
Splitting of the Molars	209
Foreign Bodies in the Mouth.....	210
Fracture of the Inferior Maxilla.....	211
Fractures of the Pre-Maxilla and Superior Maxilla.....	213
Dislocation of the Temporo-Maxillary Articulation	213
Bit Gnathitis	214
Osteomata of the Superior Maxilla	216
Carcinomata of the Palate	217
Sarcomata of the Mouth	217
Actinomyces	218
Dental Teratomata	222
Dental Fistule	224
Traumatic Stomatitis	226
Stomatitis—Infectious	227
Ulcerative Gingivitis of Dogs	229
Retention Cysts	230
Lampas	230
Secondary Chronic Nasal Catarrh	231
Chronic Perforation of the Skull	236
Application of Gutta Percha Plugs	238
Cribbing and Wind-Sucking	239
Habitual Ptyalism.....	241
Side-Reining	242
Habitual Protrusion of the Tongue.....	244
Bit Lugging.....	245
Facial Paralysis.....	248
Lacerations of the Lips.....	249
Ranula	250
Foreign Bodies in the Tongue	250
Frost Bites, Laceration of the Cheeks and Tumors of Lips and Cheeks	251
Laceration and Inflammation of Tongue	252
Aberrations of the Function of Mastication.....	253

INTRODUCTION.

Dentistry is the art of repairing the teeth or improving their utility. Human dentistry embraces the art of supplying artificial substitutes for the teeth when the original ones are lost, while animal dentistry includes the therapeutics of the secondary pathological processes and lesions in the mouth and nasal cavities, caused by the teeth. It is, however, essentially a mechanical rather than a surgical departure, and a preventive rather than a curative effort. Its province ends with the teeth and their immediate environs. Disorders of the digestion or impairment of the general health, although directly traceable to the teeth, cannot be included within the domain of dentistry. The principal object of dentistry is to promote the general health by improving the mastication and by relieving pain. It also aims at the preservation of the juvenile appearance, to which the animal dentist adds the amelioration of the driving defects of horses.

Human dentistry owes its existence to a single disease process, **caries**, while animal dentistry depends upon a single physical defect, **enamel points**. Without these two abnormalities dentistry would never have existed as an advanced art; not because there are no other serious abnormalities within the domain of dentistry, but because other abnormalities are infrequent. Few mature human beings escape caries, and few mature herbivora escape enamel points. Hence the wide requirement for dental operations in the human family, and in the chief domestic animal—the horse. As the extraction, replacement and repair of the decayed tooth is the chief occupation of the human dentist, so is cutting and floating

enamel points the principal work of the animal dentist. No student of zoology will deny that the domestic herbivora, especially the horse, suffers from frightful physical defects that are inimical to their general health and usefulness. The other defects and diseases, although frequently of serious import, demand only a small share of the animal dentist's attention because they are relatively rare. The porcine, ovine, and bovine species do not suffer to the same extent as the domestic horse on account of their different occupation and short life. Except for breeding purposes these genera seldom live beyond their maturity, and even then they are not submitted to the same artificial influences as the horse. In the canine and feline species the anatomical constitution of the teeth prevents projecting defects and their short life precludes caries, so here again the animal dentist meets only an occasional condition demanding attention. It is evident, therefore, that animal dentistry naturally centers upon the horse, the commercial value of which depends as much upon its utility as upon its general appearance. And again, mastication and insalivation are two essential digestive processes in herbivora, and of more relative importance than in carnivora and omnivora. The coarse amylaceous food of herbivora, especially the non-ruminating herbivora, requires immediate and perfect comminution and incorporation with saliva to insure perfect gastric digestion and subsequent absorption, while the artificially prepared food of man may without special detriment be passed directly to the stomach with but little mastication. The same may be said of the dog, the cat and the hog, all of which consume their food without a semblance of persistent mastication.

Then again, animal dentistry must respect the horse's mouth as the "seat of the bit" as well as the mechanism of mastication. The manner in which the horse accepts the bit

must always be a determining factor in its value. The dental defects which irritate or wound the buccal surfaces under the pressure of the complicated riggings of harness and saddle horses constitute an important feature of animal dentistry.

A summary of the exact scope of animal dentistry is as follows:

1st. The cutting and floating of the enamel points of the horse and ox.

2nd. The removal of projections which prevent perfect apposition of the dental arcades of the horse, ox and hog.

3rd. The treatment of secondary nasal catarrh resulting from diseased teeth.

4th. The extraction of all diseased teeth of all animals.

5th. The removal of tumors related to the teeth, in all animals.

6th. The treatment of stomatitis caused by the bit or by dental projections.

7th. The amelioration of driving defects resulting from dental irregularities in the horse.

8th. The treatment of faulty eruptions of the permanent or temporary dentures in the dog, the horse, the ox and the cat.

9th. Improving the appearance of the incisors of the horse.

When dentistry in animals is more generally recognized as an important if not essential feature of animal therapeutics, and when dental operations by reason of greater skill are made easier, the veterinarian will then treat the art of dentistry with the same dignity as the other branches of surgery. One object of this volume is to popularize the art of animal dentistry by describing easy methods of performing dental operations; by drawing attention to the value and necessity of dentistry, and by pointing out the advisability

of sacredly guarding dentistry from becoming obsolete in the veterinary profession, and from passing to the willing specialist, who, through deficient fundamental technical education cannot keep pace with the advancement continually being made in the other branches of veterinary surgery. Animal dentistry is unpopular, not so much because it is difficult, tedious and even dangerous, but because it is regarded as of minor importance in the veterinary colleges and by the better class of veterinary practitioners, who willingly stigmatize animal dentistry as an unimportant "side issue" by relegating dental operations to the student, the assistant, the stable-helper, the horse-shoer or the horse-dentist.

Only a few years ago, at the urgent request of a suffering patient, the family physician would condescend to pull an aching tooth, but he was never specially provoked if such a patient had consulted the watchmaker or the locksmith, who in many localities had earned enviable reputations as expert tooth-pullers, and who finally became the first recruits in the new profession of human dentistry. The duty of the veterinarian of today toward the tooth-rasping horse-shoer or the professional horse-dentist bears a striking resemblance to the relations between the physician and tooth-pulling locksmith of a few years ago. The able physician in those days willingly consigned the tooth-ache patient to the locksmith, or the barber, or the watchmaker, because dental operations were then considered as an unimportant "side issue," rather beneath the dignity of the learned therapist. But, in spite of this apathy, dentistry asserted its importance and soon became a part of the curriculum of the foremost universities of the world.

This is precisely the status of animal dentistry today. The veterinarian consigns dental operations to others, because it is rather beneath the dignity of the learned veteri-

narian to float the teeth of horses; not because it is difficult, tedious or dangerous, but because animal dentistry is regarded as a trifling accomplishment that the uneducated can master. The intimate relation of the condition of the teeth to the general health is becoming more and more recognized, and when the value and importance of veterinary dentistry is universally recognized by the veterinary profession and lay public, and when it becomes more generally admitted on all sides that the veterinary patient receives the same relative benefits from dental operations as the human subject, animal dentistry will then take its place among the useful branches of veterinary science. The limited number of patients will probably always prevent the evolution of animal dentistry into a special profession. The veterinarian will, therefore, be required to perfect himself in the practice of this art.

There were two potent factors concerned in the evolution of human dentistry—the college and the practitioner. The same influences are essential to the healthy evolution of animal dentistry. The college must devote more time to the art and the practitioner must become more proficient, even though the increasing importance of animal dentistry cannot be met by the birth of a new profession. The subject deserves to be brought out more prominently in the literature on surgical subjects, in order to foster and maintain its sesqui-special relations to veterinary surgery as a whole.

CHAPTER I.

NOMENCLATURE OF THE TEETH.

The teeth are called, **Incisors**, **Canines**, or **Molars**, according to their location, form and function; they are **superior** or **inferior** according to the jaw into which they are implanted; and **right** or **left** according to the side of the median line of the body they occupy. The incisors, naming from the median line outward, are called **centrals**, **laterals** and **corners**. The molars are numbered, **1st**, **2nd**, **3rd**, etc., from

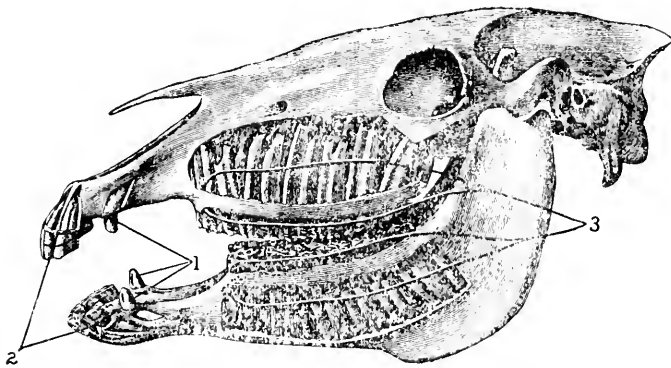


FIG. 1.

Complete Denture of a Horse.

1. The Canine denture.
2. Incisor denture.
3. Molar denture.

before backward. The subdivision of the molars into premolars and molars is useless in the herbivora, as they possess no distinguishing characteristics that would warrant such classification, and in the other animals the subdivision is more confusing than instructive.

Each tooth in the head may then be identified by refer-

ring to it as the "right-first-superior molar," the "left-fourth-superior molar," the "left-inferior-lateral," or the "left-inferior canine," etc., throughout the dental arcades.

DIVISIONS OF A TOOTH.

Anatomically a tooth is divided into the **crown**, **neck**, **fang**, **roots**, **table**, **infundibulum** and **cup**. The **crown** refers to the projecting portion, or in other words that part of a normal tooth that is visible. The **neck** is the part covered with gums, or the part between the crown and alveolar margin. The **fang** is the imbedded portion or the part between the alveolar margin and the projecting roots. The **roots** are the small projections at the imbedded extremity of the fang. The **table** refers to the grinding or contact surface. The **infundibulum** is the cavity on the table produced by the infolding of the enamel, while the **cup** refers to the unfilled portion of the infundibula of the incisors.

The surfaces of the teeth are frequently referred to as the "buccal surface," the "labial surface," or the "lingual surface." In the case of the molars the buccal surface is the external and the lingual, the internal, while in the incisors the lingual refers to the posterior surface, and the labial to the anterior.

Other names frequently used in the study of dentistry are "alveolar margin," referring to the outer border of the alveolar cavity; the "gingival margin," which refers to the outer border of the gums, and "contact margin," which implies the cutting border of a tooth such as an incisor of carnivora.

STRUCTURES OF THE TEETH.

A tooth is composed of **hard** and **soft** tissues, of which the former predominates in volume and importance. The hard tissues comprise a body of **dentine**, capped with **enamel**,

and encrusted over the remaining portion with **crusta petrosa**, or **cement**. The soft structures are the **pulp**, which occupies a cavity within the body of the tooth, the **aveolo-dental periosteum** which surrounds the external surface of the fang, the gums or **gingivae**, which cover the neck, the **blood vessels** which supply its nutrition, and the **nerves** which furnish its sensibility and tactile sense.

DENTINE.

The dentine is a hard, yellowish, sensitive substance con-

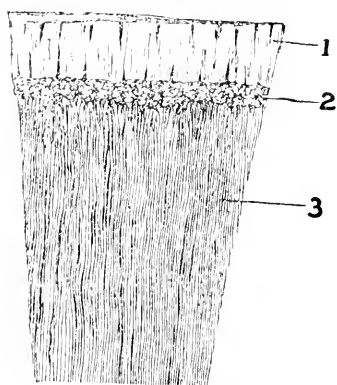


FIG. 1A.

Enamel and Dentine as Arranged at the Crown.

1. Enamel.
2. Spaces of Czermak.
3. Dentine.

(Magnified.)




Fig. 2.

Dentinal Tubules, Magnified.

stituting the major portion of the tooth's volume. It extends from the pulp cavity within to the enamel and crusta petrosa without. Chemically it shows the following composition:

Carbonate of lime.....	7.97
Phosphate of lime.....	67.54
Phosphate of magnesia.....	2.40
Fluoride of lime	a trace

Fats58
Cartilage	20.42
Soluble salts	1.

Microscopically it reveals a homogeneous substance perforated throughout with small canals (the dentinal tubules) which anastomose freely with each other and extend outward from the pulp cavity to the surface where they terminate in large lacunae (the spaces of Czermak), which in turn communicate with the canaliculi of the crusta petrosa at the fang, and **cuticle of the enamel** at the crown. The tubules are from four to five microns in diameter at the pulp cavity, and one to two microns at the surface of the dentine.

ENAMEL.

The enamel is the hardest of the dental tissues containing more than 96 per cent of inorganic matter. It is arranged upon the dentine in the form of a thin cap over the crown and extending beyond the alveolar margin over a part of the fang. In the herbivorous animals it is deeply

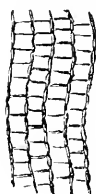


FIG. 3.
Enamel (Magnified).

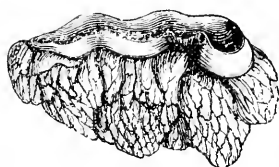
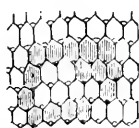

FIG. 4.
The Enamel Organ Dissected from
the First Molar of a Small
Ruminant.

folded into the table to form the well known depression characteristic of these teeth, the **infundibulum**. In the virgin tooth it covers the entire table surface, but soon wears off at that point from the mastication of food, leaving only its edges projecting at the grinding surface. In the incisor teeth it is the outer covering of both the labial and lingual surfaces, throughout the life of the animal, but in the molars

it soon becomes thickly encrusted with *crusta petrosa* on both the buccal and lingual surfaces. The molar teeth have no outer enamel covering after they have been in wear for a short time. The enamel surrounding the infundibula of the incisors is arranged in the form of an oblong or elliptical ring at the table surface, while that of the molars is folded into a very irregular boundary. The external enamel consists of an undulated plate following the course of the longitudinal ridges and grooves of the molar teeth. At the table end of the longitudinal ridges it terminates in a sharp point, constituting the "sharp teeth" of herbivora. Chemically, it consists of:

Carbonate of lime.....	4.37
Phosphate of lime.....	89.82
Fluoride of lime	a trace
Phosphate of magnesia.....	1.34
Soluble salts88
Organic matter	3.59

Microscopically it presents a thin cuticle or skin called the **cuticle of the enamel**, which is separable when a section of enamel is treated with hydrochloric acid, and hexagonal prisms projecting at a right angle from the surface of the dentine, giving the appearance of a mosaic floor.

CRUSTA PETROSA OR CEMENT.

The **crusta petrosa** is the softest of the three hard bodies composing the teeth. It is an external osseous incrustation of the fang by which the tooth is cemented to the alveolar cavity. In the virgin tooth it is but a thin layer, but as the tooth ages it becomes thick from the deposition of osseous tissue. *Crusta petrosa* covers the entire outer surfaces of the mature molars, the fangs of the incisors, the grooves in the crowns of the incisors of old animals and partly fills the

infundibula. In animals having simple teeth it is limited to the fangs. Chemically, it is composed of:

Carbonate of lime.....	7.22
Phosphate of lime.....	48.73
Fluoride of lime.....	a trace
Phosphate of magnesia.....	.99
Soluble salts82
Cartilage	41.31
Fats93

Microscopically it presents the typical characteristics of

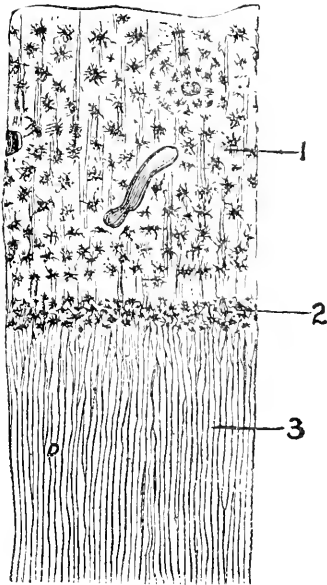


FIG. 5.

Dentine and Crusta Petrosa as Arranged at the Fang (Magnified).

1. Crusta petrosa.
2. Spaces of Cermak.
3. Dentine.

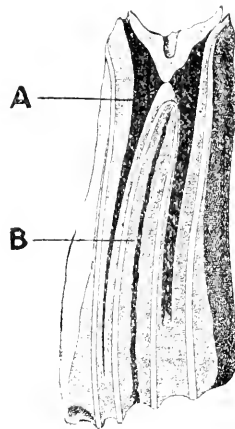


FIG. 6.

Natural Cavities of a Molar.

- A. Pulp cavity.
- B. Infundibulum.

the compact tissue of bone, the canaliculi of which communicate with those of the dentine. It is intimately associated with the alveolo-dental periosteum, which membrane is concerned in its formation.

THE PULP.

The pulp is a pultaceous substance molded to the shape of the pulp cavity, consisting of loosely arranged connective tissue, blood vessels, nerves and a limiting membrane (odontogenic membrane) which sends processes throughout the entire length and course of the dentinal tubules, and communicates with the alveolo-dental periosteum at the

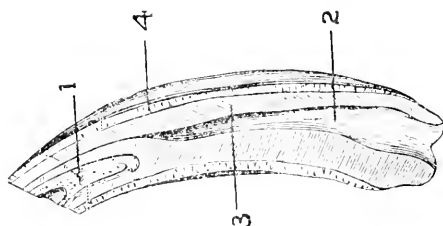


FIG. 7.

Arrangement of the Dental Tissues in an Incisor.

1. Internal enamel surrounding the infundibulum.
2. Pulp.
3. Dentine.
4. External enamel.

apical foramen. The pulp itself acts as a support for the blood vessels and nerves while the odontogenic membrane is concerned in tooth construction. In the teeth of herbivora it is constantly depositing dentinal substance in the tubules beneath the table surface to destroy the sensibility of the wearing dentine.

ALVEOLO-DENTAL PERIOSTEUM.

The alveolo-dental periosteum is a dense, tough membrane consisting chiefly of white fibrous tissue and osteoblasts. It covers the entire fang, communicates with the limiting membrane of the pulp at the apical foramen, and intermingles intimately with the gums at the neck of the

tooth. Its fibers are continuous with the stroma of the crusta petrosa and that of the alveolar wall, forming a firm connecting medium between the two. In the virgin tooth it has all the characteristics of a membrane, but it soon loses this feature and becomes confused with the crusta petrosa, which tissue it develops.

THE GUMS.

The gums, or *gingivae*, may be considered in the sense of a hypertrophy, either of the buccal mucous membrane or of the alveolo-dental periosteum, to both of which they are intimately connected. They consist of dense fibrous tissue, the fibers of which intermingle with the alveolo-dental periosteum and crusta petrosa, with the purpose of hermetically sealing the alveolar cavities from external influences.

BLOOD VESSELS.

The blood supply of the teeth is derived from the superior and inferior dental arteries, branches of the external carotid. The superior dental is given off the internal maxillary, passes into the superior dental foramen of the maxillary hiatus, through the superior dental canal as far as the infra-orbital foramen, along the roots of the third, second and first molars, and then through the premaxilla to the canines and incisors. Along the course of the dental arcades it gives off branches, for each tooth, which pass into the pulp cavity through the apical foramina. The inferior dental artery has the same general distribution via the inferior dental canal. In addition to this principal blood supply teeth receive nourishment from surrounding blood vessels by way of the alveolo-dental periosteum to the extent of preserving the integrity of the tooth should its principal supply be interrupted.

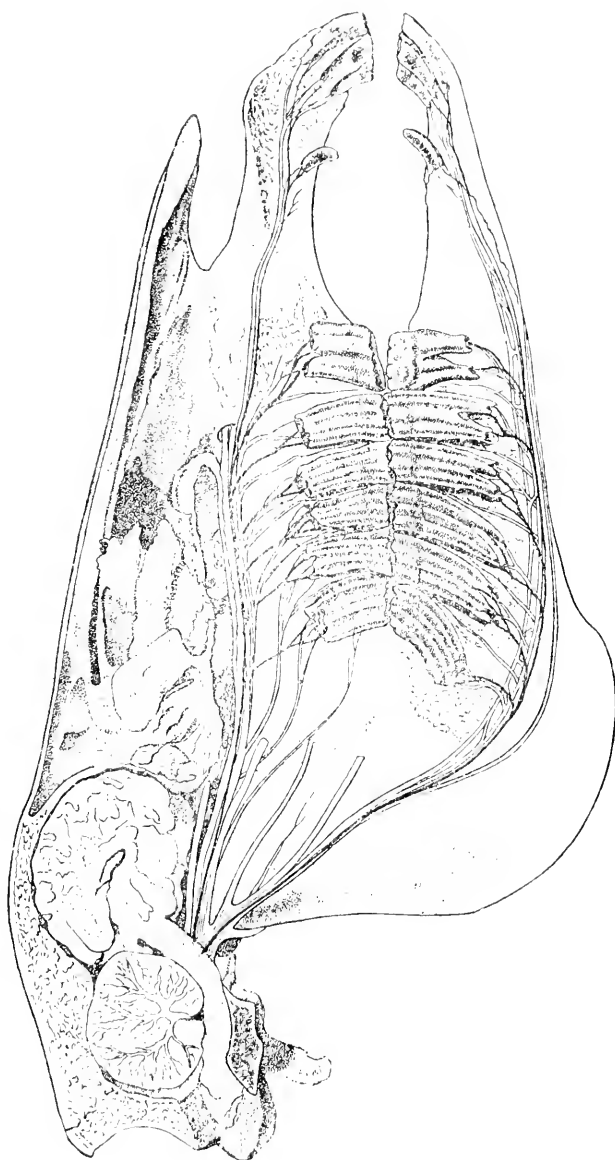


FIG. 8.
Nerve and Blood Supply of the Horse's Teeth.

THE NERVES.

The nerves are sensory and tactile, and are derived from the superior and the inferior maxillary branches of the tri-

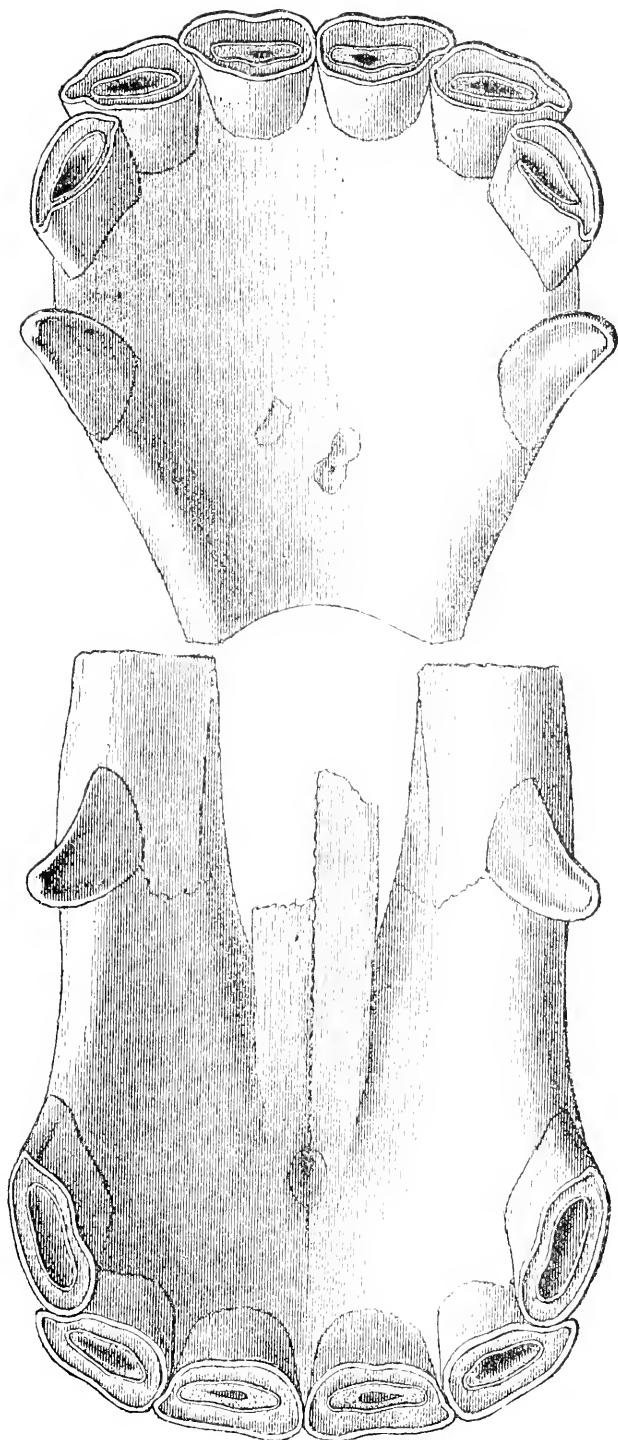


FIG. 9.
Incisor and Canine Teeth of a Mature Horse.

facial. They have the same general distribution as the arteries, the courses of which they follow into the pulp cavity.

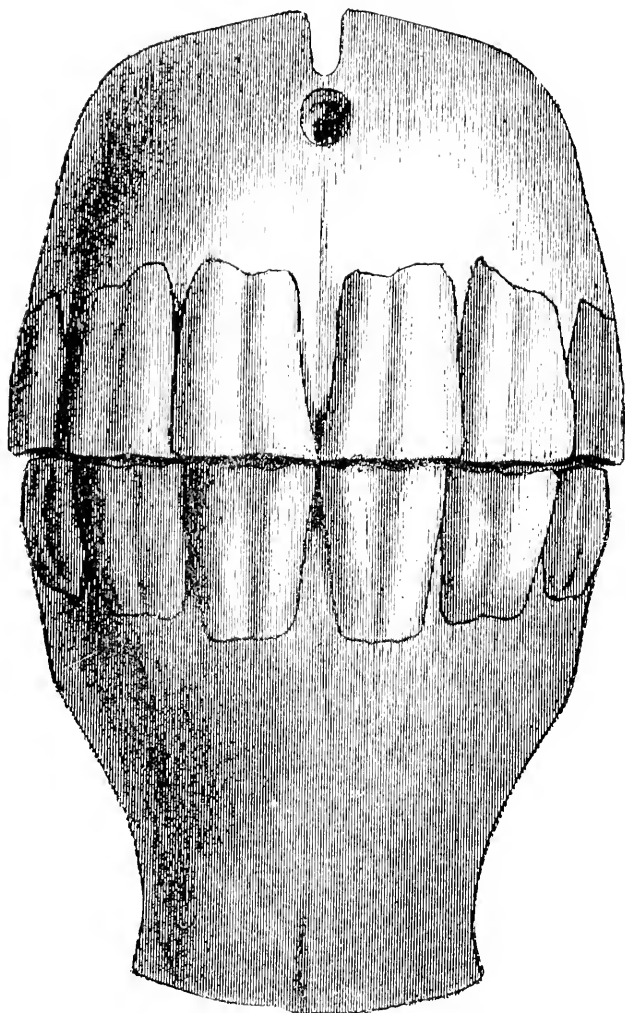


FIG. 10.

Incisor Teeth of a Mature Horse. Anterior View.

PERMANENT INCISOR TEETH OF A HORSE.

The incisor tooth of a horse presents the form of a curved pyramid with the greater curvature forward, the base outward and the apex implanted deeply into the alveolar cavity

of the same shape. The base of the pyramid, which represents the crown, is elliptical, and measuring toward the apex it becomes first oblong, then triangular, then rounded and finally biangular in the antero-posterior direction. At the table it presents the external enamel dentine, internal enamel, and infundibulum. * The labial and lingual surfaces

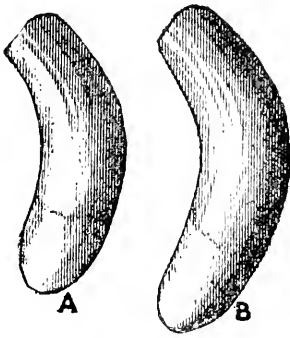


FIG. 11.

Canine Teeth of a Horse, Buccal Surface.

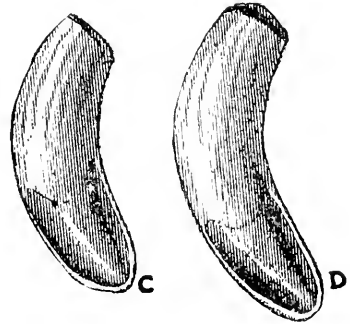


FIG. 12.

Canine Teeth of a Horse, Lingual Surface.

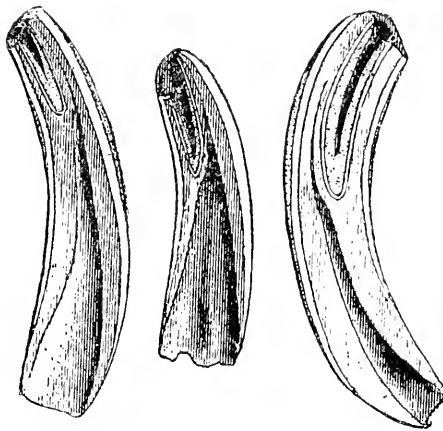


FIG. 13.

Longitudinal Sections Through Incisor Teeth.

are covered with enamel which in youth is uninterrupted with encrustations of either tartar or crusta petrosa, and is of a bluish-white color. At the apex it presents a wide open-

ing—the apical foramen—for the entrance of blood vessels and nerves.

In situ they are arranged in perfect juxtaposition in the form of a symmetrical curve with the convexity forward, and their contact with the opposing arcade is at an obtuse angle. Near the gingival margin they are separated by processes of the gums. (See Fig. 10.)

The function of the incisor teeth is that of detaching food that has been gathered by the lips, and to serve as weapons of defense. They are not concerned in mastication. For changes in the teeth, see Chapter III.

THE CANINE TEETH OF THE HORSE.

The canine teeth exist only in males and occur only as permanent teeth. They occur occasionally as rudimentary structures in the mare, but never develop the typical canine characteristics. They represent a curved tube about one centimeter in diameter, and flattened at one end—the crown. The crown is flat and presents internally two shallow perpendicular grooves divided by a rounded ridge. The fang is cylindrical and the apical foramen round and large.

The canines, so far as digestion is concerned, are useless members which the horse could well do without. They are probably intended as weapons of defense, and may serve to assist in passing coarse fibrous food from the incisors to the molars.

THE MOLARS.

The superior molars resemble an elongated square block tapering slightly toward one extremity. They present for description four surfaces, the table and apex. The external or buccal surface presents three prominent longitudinal ridges separated by two grooves, all of which traverse the entire length of the tooth, and terminate at the table in a

sharp point. The anterior and posterior surfaces are flat and smooth and come in contact with contiguous surfaces at the crown only. The internal surface is quite smooth and somewhat convex from before backward. The table presents the external crusta petrosa, the external enamel, the dentine, the internal enamel, and the internal crusta petrosa. The edges of the enamel are arranged in the form of the letter "B." (See Figs. 16, 17.) In the center of the internal




FIG. 14.

A Superior Molar, Buccal Surface.




FIG. 15.

A Superior Molar, Lingual Surface,
with Measurement.

crusta petrosa is a small black spot marking the only openings of the infundibula, which are two in number on all the superior molar teeth. The apex presents three to four roots, each having a round opening—the apical foramen. The first molar is triangular in shape, has a sharp anterior face and presents but three roots at the apex. The sixth is also somewhat triangular with its acutest angle posteriorly, and like the first, has but three roots.

The first superior molar averages 48 millimeters long, the second 55 millimeters, the third 73 millimeters, the fourth 68 millimeters, the fifth 65 millimeters, and the sixth 60 to 63 millimeters.

The inferior molars are somewhat longer and much more flattened than the superior ones. In volume, tooth for tooth, the superior ones greatly exceed them. Their surfaces are smoother, their borders less distinct, and the longitudinal ridges less prominent. The longitudinal ridges of the

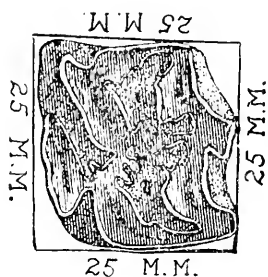


FIG. 16.

Table Surface of a Superior Molar, with Measurement.

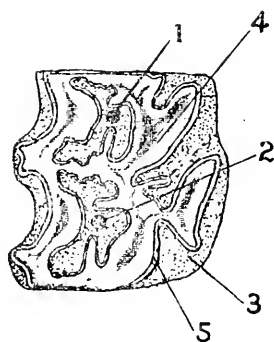


FIG. 17

Arrangement of the Dental Tissues on the Table of a Superior Molar.

1. 2. Infundibula.
3. Crusta petrosa.
4. Dentine.
5. Enamel.

internal or lingual surface are three in number and terminate at the tables in sharp enamel points similar to the external ones of the superior molars. The tables present the same dental substances as the superior, but the enamel is arranged in the form of an irregular figure, and not in the shape of the letter "B," as on the superior tables. The enamel is but a single organ and is not divided into internal and external enamel, as in the incisors and superior molars. This arrangement leaves the inferior molars without perfectly inclosed infundibula and allows all the crusta petrosa

to communicate freely. This arrangement of the enamel organ is due to the fact that its infolds are lateral and not superior. That is, the enamel does not dip deeply into the table end, but folds inwards into great ruffles along each side. They each have two roots, each of which is pierced at the apex with the foramen for the entrance of the vessels and nerves.

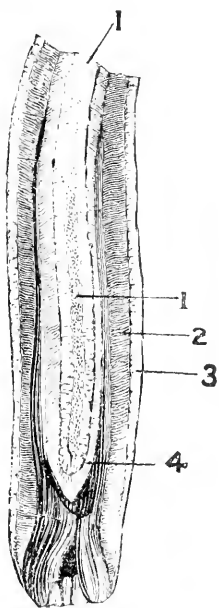


FIG. 18.

Longitudinal Section
Through a Molar.

1. I. Infundibulum.
2. Dentine.
3. Crusta petrosa and enamel.
4. Internal enamel.




FIG. 19.

An Inferior Molar,
Buccal Surface.




FIG. 20.

An Inferior Molar, Lin-
gual Surface, with
Measurement.

The superior arcades are prominently convex on the external or buccal surface, and concave on the internal or lingual surface. The width of the arcade is uniform throughout the entire length, with the exception of the extremities which taper to a narrow border anteriorly and a blunted one

posteriorly. The width between the arcades is 83 millimeters at the sixth molars, 75 millimeters at the fourth, and 57 millimeters at the first. They are from 18 to 20 centimeters long and average 25 to 28 millimeters wide.

The inferior arcades are more on a straight line than the superior ones. They are but slightly curved outward at the fourth and fifth molars, while at the second and third they may even present a slight inward curvature. Like the superior, they have a uniform width with the exception of the pointed extremities. The width between the arcades is 75 millimeters at the sixth molars, 60 millimeters at the fourth and about 50 millimeters at the first. They are from 18 to 20 centimeters long and average 17 to 20 millimeters wide.

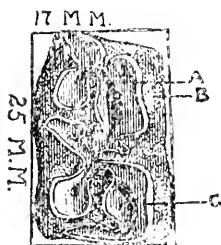


FIG. 20A.

Table Surface of an Inferior Molar, with Measurement.

In situ the molars present four arcades—right and left superior and right and left inferior—each containing six teeth, juxtaposed so closely as to give the impression of being a single body. The juxtaposition of the molars is one of the important features of the dental mechanism of herbivorous animals. This feature adds materially to the formation of a perfect, as well as a stable, grinding apparatus.

Each arcade is from 18 to 20 centimeters in length.

THE PERMANENT INCISORS OF RUMINANTS.

Ruminants have but one incisor arcade—the inferior—the superior being replaced by a dense pad of connective tissue. The incisors are eight in number, identified, count-




FIG. 21.

A Superior Molar Arcade of a Horse,
with Measurement.

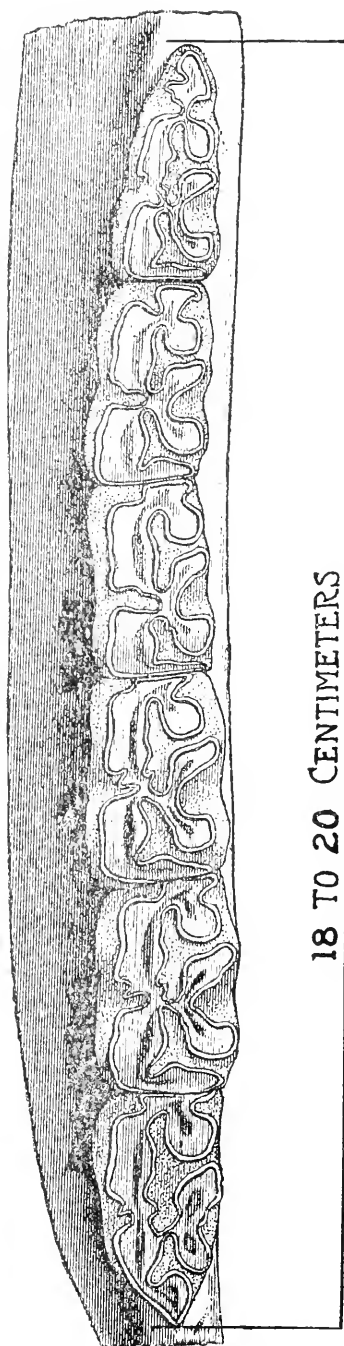


FIG. 22.

Inferior Molar Arcade of a Horse,
with Measurement.

ing from the median line outward, as : **centrals**, **laterals**, **intermediates**, and **corners**. They resemble a scoop or shovel with a tapering handle, are not juxtaposed and are always loose. The fangs are imbedded into shallow alveolar cavities and the long necks are firmly attached to the gums. They are very white in color. The labial surface is convex and the lingual one concave to fit the dental pad on the premaxilla. They diminish in size from the centrals outward, the corners being quite small.

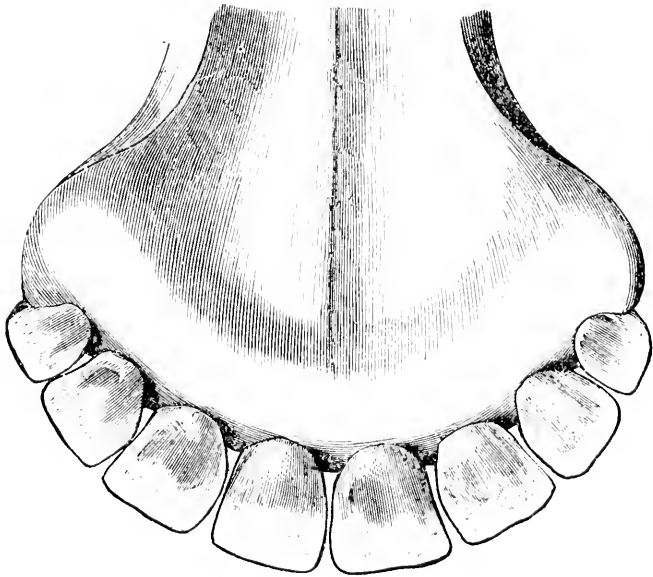


FIG. 23.
Incisor Denture of the Ox.

THE PERMANENT MOLARS OF RUMINANTS.

The **superior molars** of the large ruminants resemble those of the horse. They are arranged in two arcades of six molars each as in solipeds. The tables present the enamel, internal and external, the crusta petrosa, dentine and the infundibula. In the three posterior molars the enamel is arranged in the shape of the letter "B," as in the horse,

while the three anterior ones present more the shape of a "U" turned bottom against the tongue. The first three molars have but one infundibulum, while the last three have two. The longitudinal ridges are prominent features of the buccal surface and terminate at the table in sharp points.

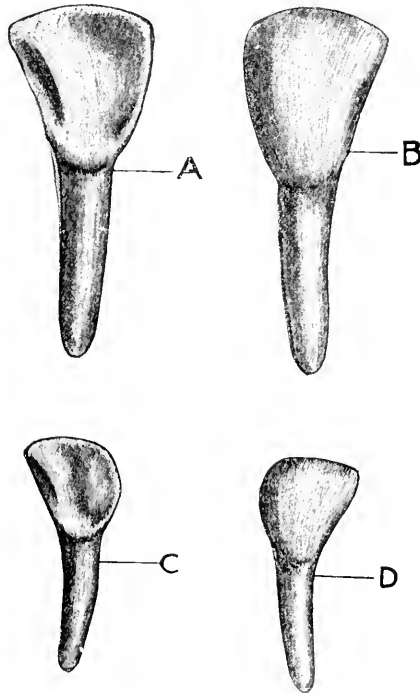


FIG. 24.
Incisor Teeth of the Ox.

- A. Lingual surface of lateral incisor.
- B. Labial surface of central incisor.
- C. Lingual surface of corner incisor.
- D. Labial surface of intermediate incisor.

The length of the posterior molars is about $8\frac{1}{2}$ centimeters, and that of the anterior about $5\frac{1}{2}$ centimeters. Each tooth presents three roots, two of which project externally and one internally.

In situ they consist of a continuous arcade, narrow anteriorly and becoming gradually wider toward the posterior

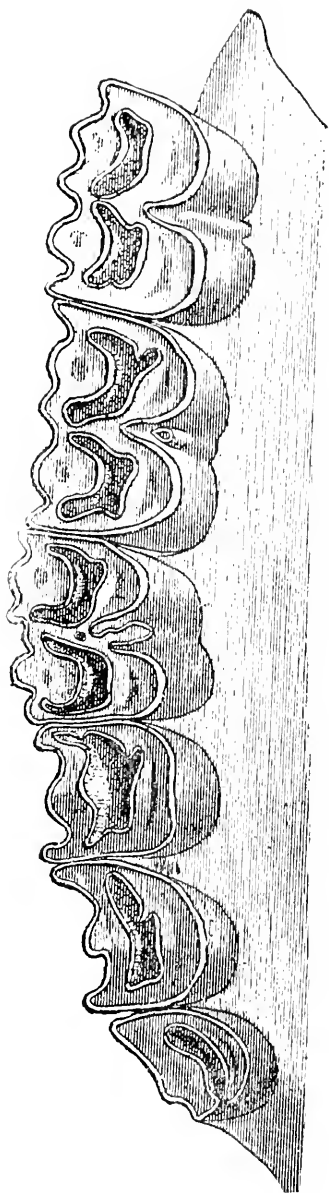


FIG. 25.
A Superior Molar Ar-
cade of an Ox.

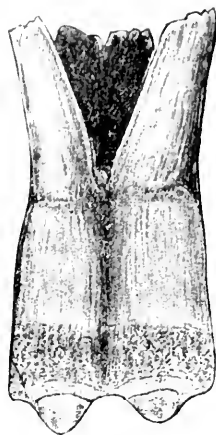


FIG. 26.
Inferior Molar of an Ox
(Labial Surface).




FIG. 27.
Inferior Molar of an Ox
(Lingual Surface).

extremity. They cannot be said to be as perfectly juxtaposed as in the horse, as the internal surface of the arcades has deep depressions at the interdientia. The arcade will average 12 centimeters long and from 15 to 22 millimeters wide.

The **inferior molars** are very narrow and closely juxtaposed, as in the inferiors of the horse, but in shape and arrangement of the enamel each tooth differs from the others. The first is triangular in shape and contains but a single ring of enamel. The second and third are rectangular and their enamel is arranged into the form of an irregular figure having five to six indentations. The fourth and fifth con-

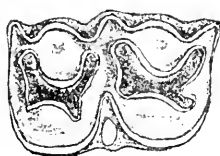


FIG. 28.

Table of a Superior Molar of the Ox.

sist of two lobes, each having a central enamel ring and infundibulum, while the sixth has three lobes with central enamel infundibula on the two anterior lobes. The arcades measure from 11 to 15 millimeters wide. The first three are from 52 to 54 millimeters long and the posterior three measure from 88 to 93 millimeters in length.

TEETH OF THE DOG.

The dog has in all forty-two teeth—six incisors, two canines and six molars in the superior jaw and six incisors, two canines and seven molars in the inferior jaw. All of the teeth of the dog are simple teeth, i. e., they are covered with enamel on the table through life. The incisors are small as compared with the other teeth, and they do not contact each other until the dog is more than a year old.

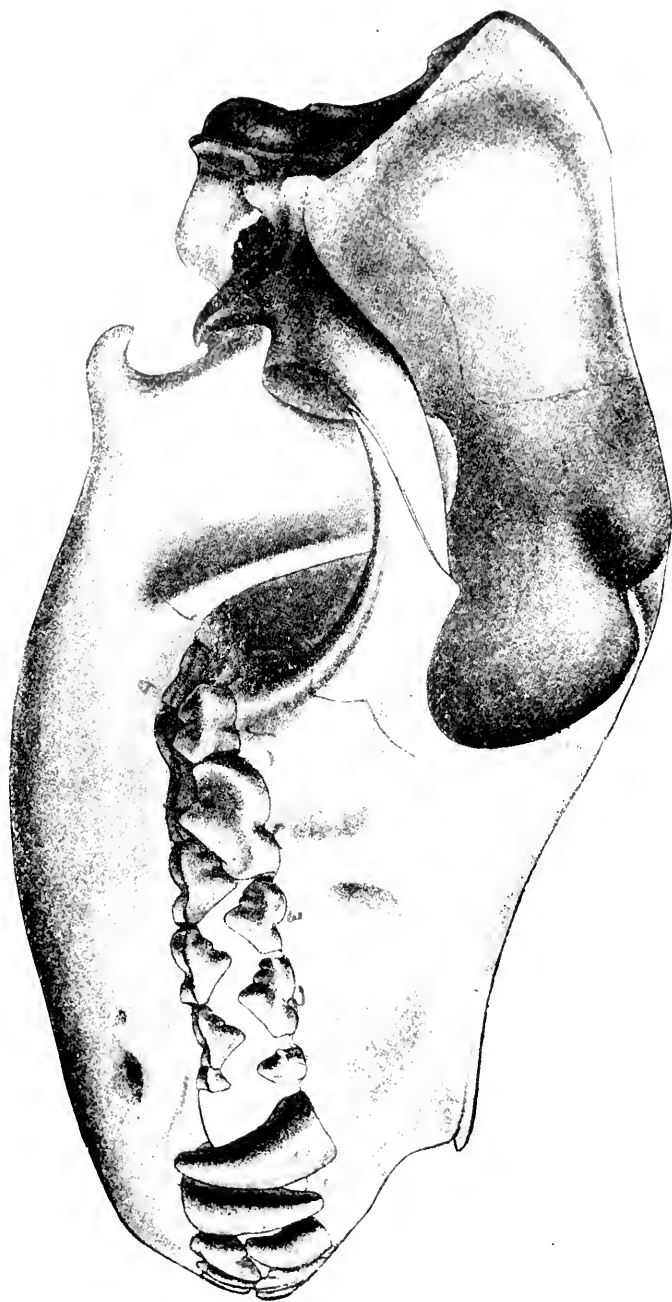


FIG. 29.

Denture of a Mature Dog. (Cornuein et Lesbire.)

The canines are the prominent features of the dog's denture. They are large, white members having deep implantations and elongated conical crowns curved backwards, which pass each other in a manner to grasp and hold firmly

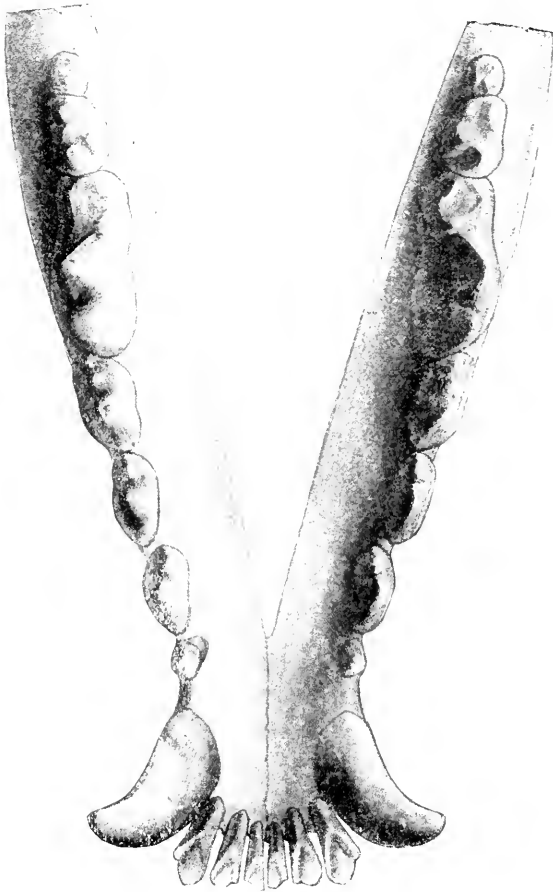


FIG. 30.

Inferior Denture of a Dog. (Cornevin et Lesbree.)

any object caught between them. The molar denture is very irregular, as is also each individual tooth. The first inferior molar of dogs is properly classified as a temporary tooth that persists in the mature animal, although it is frequently referred to as a permanent tooth having no tem-

porary predecessor. The first and second inferior molars have small conical crowns, slightly cut out internally and

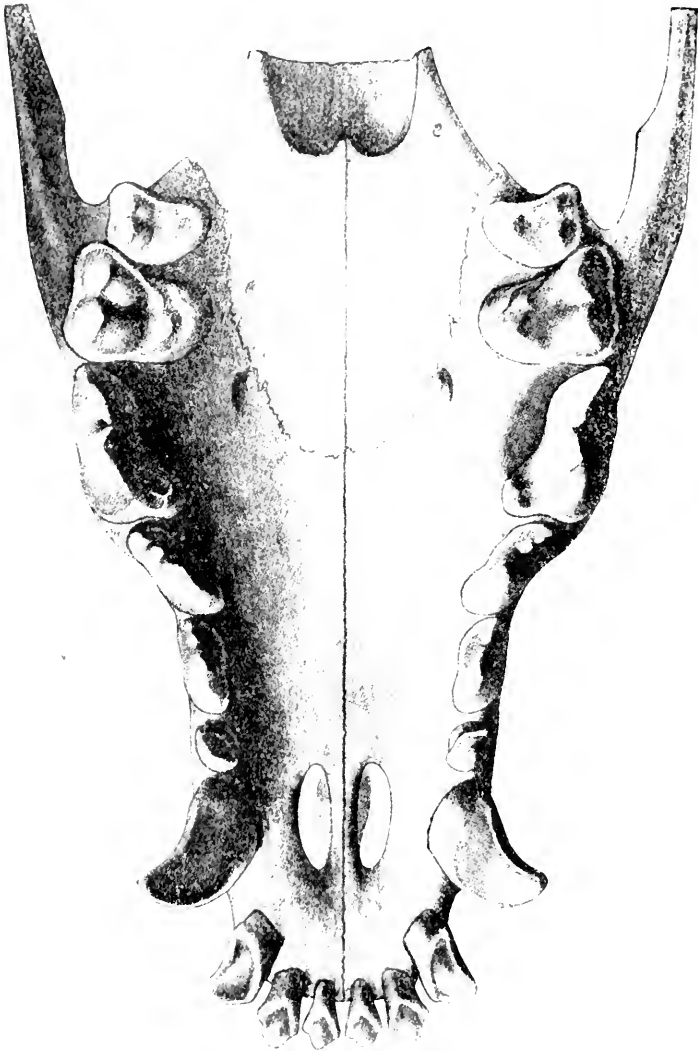


FIG. 31.

Superior Denture of an Aged Dog. (Cornevin et Lesbre.)

but a single root. The third and fourth present on the crown one large cone anteriorly and two smaller ones posteriorly; and each fang has two roots. The fifth has two small an-

terior cones, three small posterior ones on the crown, and three roots. The sixth inferior has two roots projecting backwards and presents a large crown with a number of conical projections and a deep infundibulum. The seventh is small but has three projections on the table and two roots.

The superior molars are six in number and will answer the same general description as the inferior ones, located behind the first, but their crowns are wider and more beveled from within outward.

CHAPTER II.

EVOLUTION OF THE TEETH.

The teeth are not a part of the skeleton and never, like other juxtaposed hard tissues, unite to each other or to the bones that surround them. They originate from the mucous membranes of the mouth and develop independently of the bones. They are appendages of the buccal mucosa precisely as horn, hair and hoof are appendages of the skin.

The evolution (growth) of the teeth and their subsequent retrogression (wear) occurs in such distinct successive stages from embryo to old age that the age of animals can be accurately determined at any period of life. The stages of evolution and the stages of retrogression, however, vary with each species—the horse, the dog, the ox and the cat each showing individual characteristics. The stages of evolution are distinct in all species, while those of retrogression are only apparent in the horse, the ox, the sheep and the pig. The dog, the cat and man show no visible distinct stages of wear, owing to the different anatomical construction of the teeth.

Dental evolution naturally divides itself into three periods:

- 1st. The embryonic evolution.
- 2nd. Evolution of the temporary teeth.
- 3rd. Evolution of the permanent teeth.

EMBRYONIC EVOLUTION.

In the embryo of the domestic mammal tooth formation begins at the **seventh week** of foetal life. The dental ap-

paratus at that time is represented by a whitened ridge of mucous membrane extending around the maxillary margin. This ridge (**gingival cushion**) is the matrix from which the teeth develop. At the earliest period it consists chiefly of two layers of epithelial cells and basement membrane of connective tissue. The outer layer consists of loosely arranged cells while the deep one is dense and lies in close relation to the jaw, being only divided from the latter by the thin connective tissue of the mucous membrane.

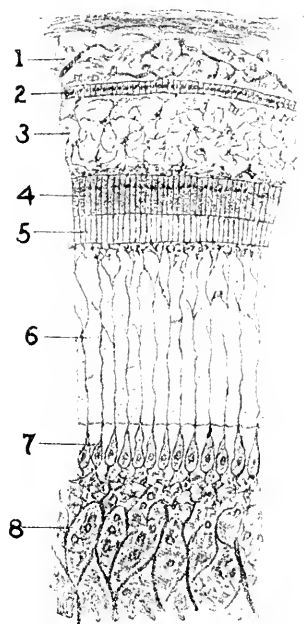


FIG. 22.

Section Through a Part of a Dental Follicle. (Cornevin et Lesbree.)

1. Crusta petrosa.
2. External enamel.
- 3, 4, 5. Internal enamel.
6. Dentine.
7. Odontoblasts.
8. Pulp.

The following changes which the gingival cushion undergoes constitute the process of tooth development: The first step in the direction of tooth formation is observed at about

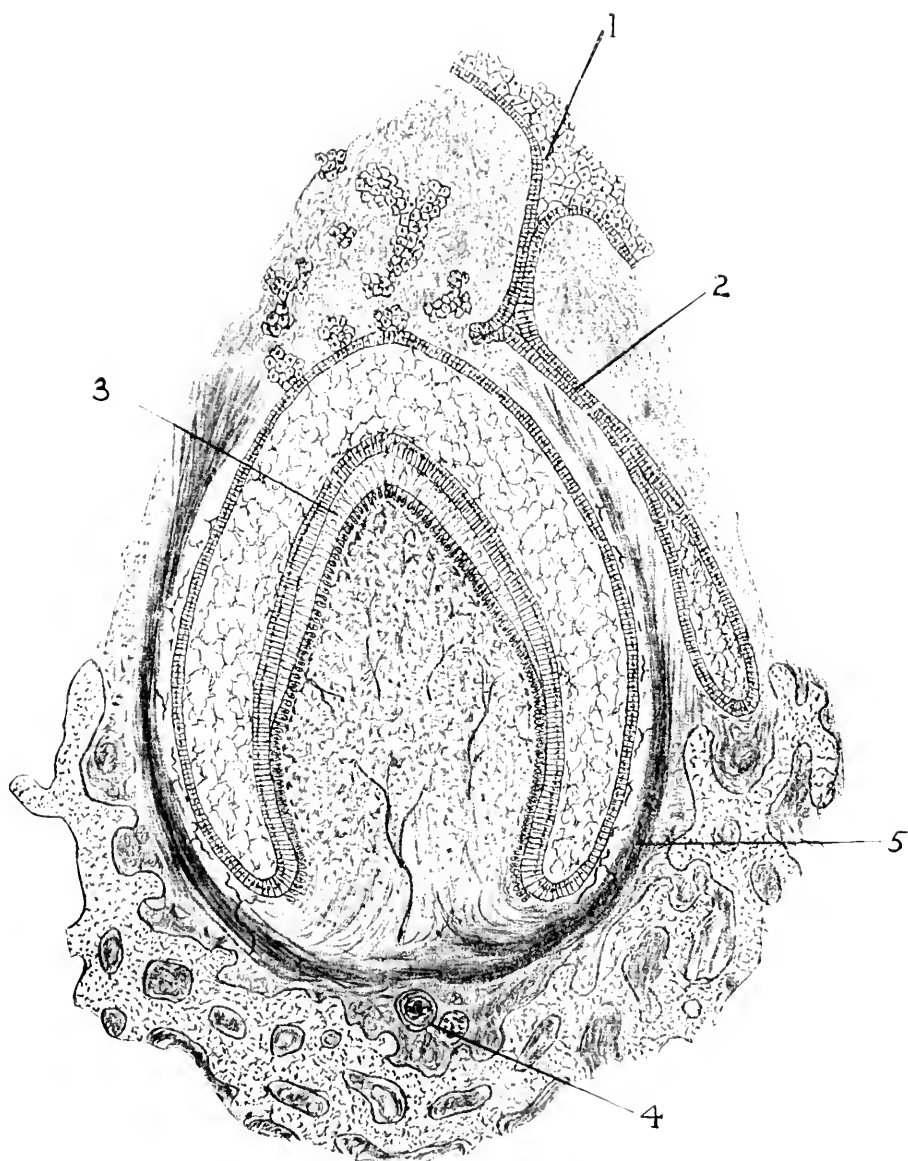


FIG. 33.

Perpendicular Section Through a Dental Papilla.

1. Epithelium of the gingival cushion.
 2. Stalk for the future permanent tooth.
 3. First dentinal formation.
 4. The jaw bone.
 5. The alveolar periosteum.
- The crescent-shaped ring represents the enamel organ.

the **eighth week** of foetal life, when the deep cellular layer of the gingival cushion begins to grow inward into the substance of the jaw, which at that period is represented by cartilage. The cartilaginous jaw at the same time grows upward around the descending epithelium until it presents a deep trough-like groove which the gingival cushion now occupies. The outer or loose layer remains without and persists through life as the gums, while the deep or dense layer pushes deeper and deeper into the jaw, becomes better organized to form the **common enamel germ**. The common enamel germ which is no more than the deep epithelial layer of the gingival cushion, is continued evenly through the whole trough, but at the **ninth** or **tenth week** of foetal life it becomes **tumefied** at regular intervals to form the first real representatives of the future teeth (the enamel germs). As the enamel germs develop into larger bodies the substance between them gradually disappears, leaving only a small mound for each temporary tooth. Simultaneously the basement layer of the gingival cushion tumefies beneath this mound and forces it upwards into a permanent body (**the dental papilla**). The dental papilla consists, therefore, of a body of connective tissue, capped with epithelium.

At the **third month** of foetal life the epithelial layer undergoes **petrification** to form the future **enamel** organ. The connective tissue **calcifies** to form **dentinal** substance, while the base of the papilla remains unchanged to form the **pulp**. While this process is going on the papilla is gradually assuming the shape and form of a tooth crown, the first division of a tooth to form. The **neck** and **fang** occur by the deposition of dentinal substance at the base of the papilla. The aperture into the pulp cavity is at first a wide one, but soon becomes narrow and takes its place at the end of the fang as an **apical foramen**, the opening through which the vessels and nerves enter the tooth. In the case of the molar

teeth several openings are formed, one for each root. The cement is **ossified connective tissue**, and is the **last** of the three hard tissues to form. It develops between the periosteum of the tooth cavity and the dental substance and is influenced in its evolution through life by both these elements.

During these evolutionary changes each tooth is enclosed within a separate sac ordinarily designated as a **dental follicle**. During the same period the jaw is undergoing great changes. It is growing upward to further enclose the follicles within itself, and is gradually separating them one from another by the formation of bony partitions (**the interdental cancellated tissue**) until each tooth occupies a deep individual compartment—the **alveolar cavity**—which the tooth fills completely at every stage of its evolution and existence and which entirely encloses both until by sheer force of its expansion it forces its way into the mouth and takes its place at the level of the dental arcade. This event marks the beginning of the second period of dental evolution.

The permanent teeth are developed much in the same manner. About the **sixteenth week** of foetal life a stalk or neck becomes disconnected from the common enamel germ and takes its place first on the side, and secondly, at the root of the temporary tooth. It undergoes the same steps of development, and by its upward growth absorbs the fang of the temporary tooth until only a mere shell remains. The permanent teeth that are not represented by temporary predecessors are formed by the backward extension of the common enamel germ. The first permanent tooth of this class—the fourth molar—has its origin in embryo, while the others which erupt later in life may not begin to form until some time after birth. The enamel germ, therefore, is not entirely a foetal structure, but exists until the last tooth is

set on its way toward maturity. (Thus far dental evolution does not vary materially in the different species).



EVOLUTION OF THE TEMPORARY TEETH.

This period of dental evolution begins when the milk teeth make their first appearance on the buccal surface, and ends when they are entirely replaced by their permanent successors. In some animals the temporary teeth erupt before birth. It is, however, at the time of birth or within a few days after that the first evidence of temporary dentition appears in all domestic animals. The end of the period varies with each species. In the horse the last temporary teeth disappear at four and a half years of age. Thus the period in the horse lasts from birth to four and a half years of age, in the ox from birth to four and a half years, in the sheep from birth to three and a half years, in the dog from birth to six months, and in the pig from birth to three years. In all the domestic animals except the dog the temporary incisors persist longer than the molars.

THE HORSE.

The central incisors erupt before birth or, in some instances, within a few days after. They are large, white teeth, occupying the entire incisor arcade and contact their opposing teeth by their anterior borders only. The posterior border is still hidden beneath the gums and only comes to the level of the anterior border after three months' wear, at which time they present the typical table of an herbivorous incisor. The cup is deep and distinct, and in its whole appearance cannot be readily recognized from that of a permanent incisor. At the earliest period after eruption two influences are at work for their destruction—the permanent tooth is gradually encroaching upon its fang while the crown is becoming shorter and shorter under the influence

of wear until at the age of two and a half years there remains only a loosened shell.

LATERAL INCISORS.

The lateral incisors make their appearance at from four to six weeks, gain the level of the arcade at four months, and are replaced by permanent incisors at three and a half years.

CORNER INCISORS.

The corner incisors appear on the buccal surface at about

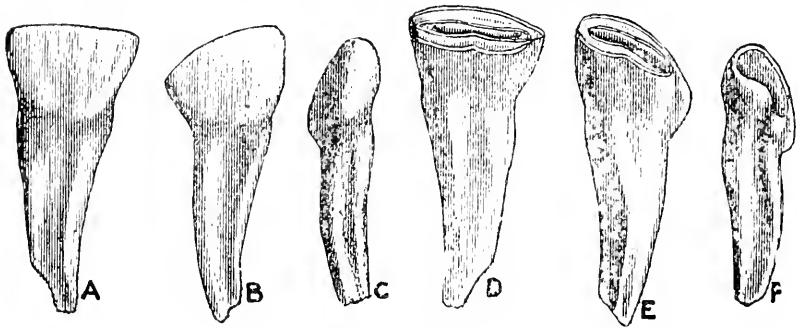


FIG. 34.

Temporary Incisor Teeth of a Horse.

A, B, C. Labial surface of central, lateral and corner.

D, E, F. Lingual surface of same.

seven months, gain the level of the arcade at ten months and are shed at four and a half years.

FIRST, SECOND AND THIRD MOLARS.

These teeth appear about the time of birth. They are large organs and occupy the whole maxillary margin behind the interdental space. At the time of eruption their tables are covered with enamel, which soon wears off to expose the dentinal tissue and cement. Their fangs are gradually lost by absorption from pressure of the growing permanent molars beneath. The first and second are shed at two and one-half years and the third at three to three and a half, leaving the molar arcades free from temporary teeth

CANINES.

The canine teeth are frequently referred to as being represented in youth by temporary predecessors. This claim cannot be accepted as entirely correct. The needle-like canines, occasionally observed in three-year-old colts, must be regarded as a freak of perverted dental evolution rather than as a part of the normal economy.

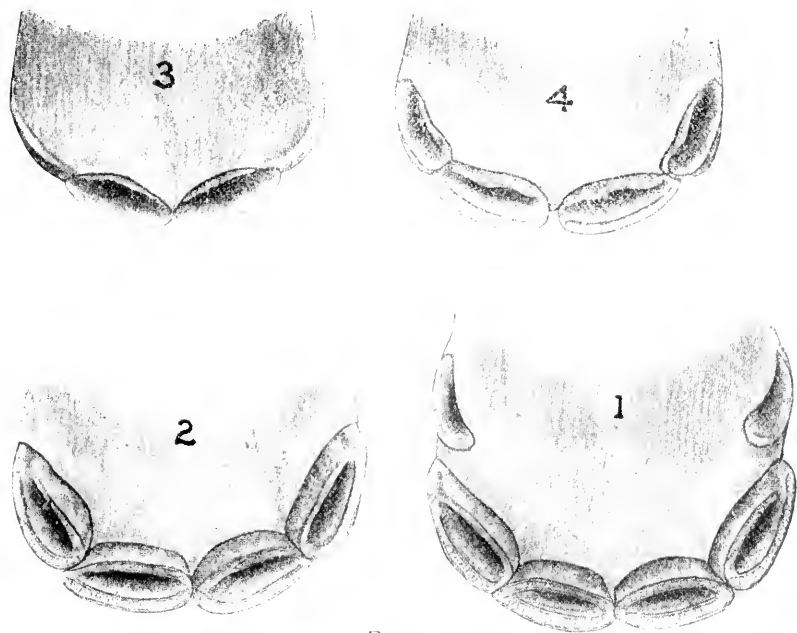


FIG. 35.
Temporary Incisors of the Colt.

- 3. Inferior incisors at birth.
- 4. Inferior incisors at ten weeks.
- 2. Inferior incisors at four months.
- 1. Inferior incisors at seven months.

THE OX.

Central Incisors*—Erupt at birth, become prominent at one month and shed at one and a half years of age.

Lateral Incisors—Erupt at birth, gain the level of the arcade at one month and shed at two and a half years.

*Lower jaw only.

Intermediate Incisors—The intermediates erupt at two weeks, gain the level of the arcade at two months and shed at three and a half years.

Corner Incisors—The corners erupt at three weeks to one month, gain the level of the arcade at three months and shed at four and a half years.

First, Second and Third Molars—As in the horse, these

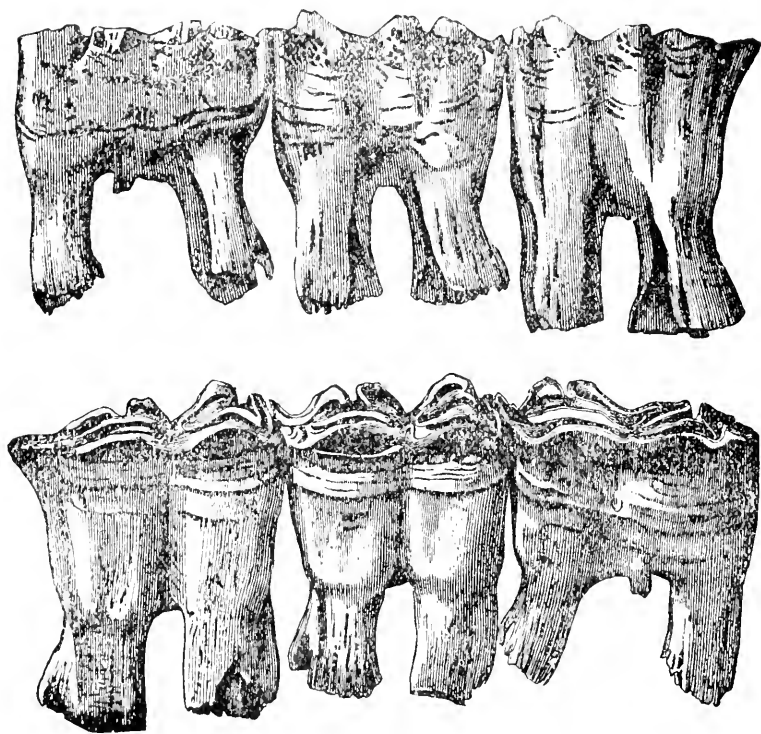


FIG. 36.

Temporary Molar Teeth of a Horse.

molars erupt at birth. The first is cast off at one and a half years, the second at two and a half years and the third at three and a half years.

THE PIG.

Central Incisors—Erupt at three to four months and are shed at three years.

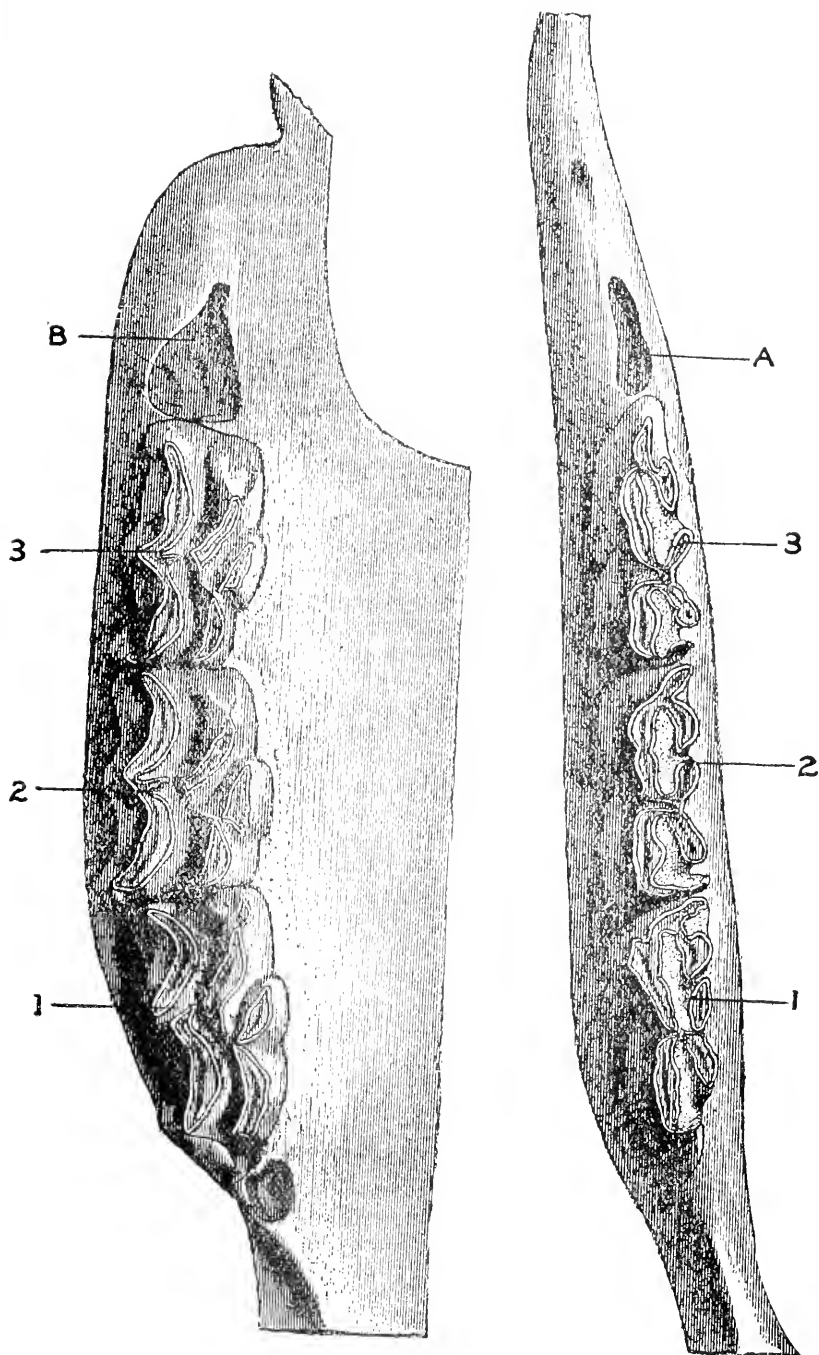


FIG. 37.

Superior and Inferior Molar Arcades of the Horse under the Age of 10 Months.

A, B. Opening for the 4th Molar.

Lateral Incisors—Erupt at four months and are shed at three years.

Corner Incisors—Erupt at birth and are shed at six months.

Canines—Erupt at birth and are shed at one year (The temporary canines of the pig are common to both sexes, but are more prominent in the male).

First Molar—The first molar of the hog has no temporary predecessor.

Second and Third Molars—Erupt at birth and are shed at two years.

Fourth Molar—Erupts at six months and is shed at two years.

THE DOG.

Central Incisors—Erupt at four weeks and are shed at four months.

Lateral Incisors—Erupt at four weeks and are shed at four months.

Corner Incisors—Erupt at four weeks and are shed at five months.

(The incisor teeth do not come in contact with one another until the age of fifteen months).

Canines—Erupt at four weeks and are shed at six months. They are common to both sexes.

First Molar—There is no temporary first molar in the dog.

Second, third and fourth molars erupt at five to six weeks and shed at six months. The fourth may be delayed until six and one-half to seven months.

At the age of seven months the temporary denture of the dog is entirely replaced by its permanent successor.

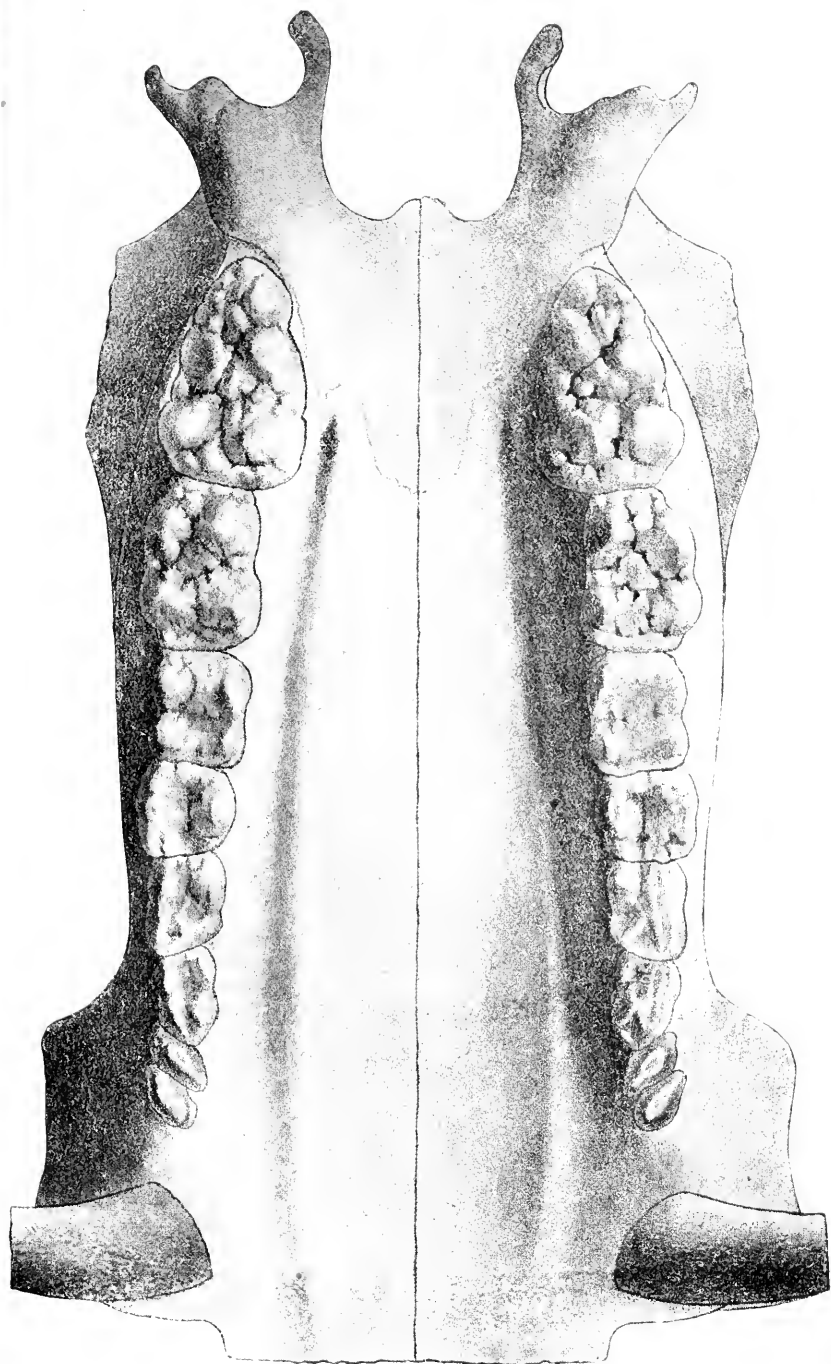


FIG. 38.

Superior Denture of a 2-Year-old Hog. (Cornevin et Lesbre.)

THE SHEEP.

Central Incisors—Erupt during the first month after birth and are shed at fifteen to eighteen months.

Lateral Incisors—Erupt during the first month, a few

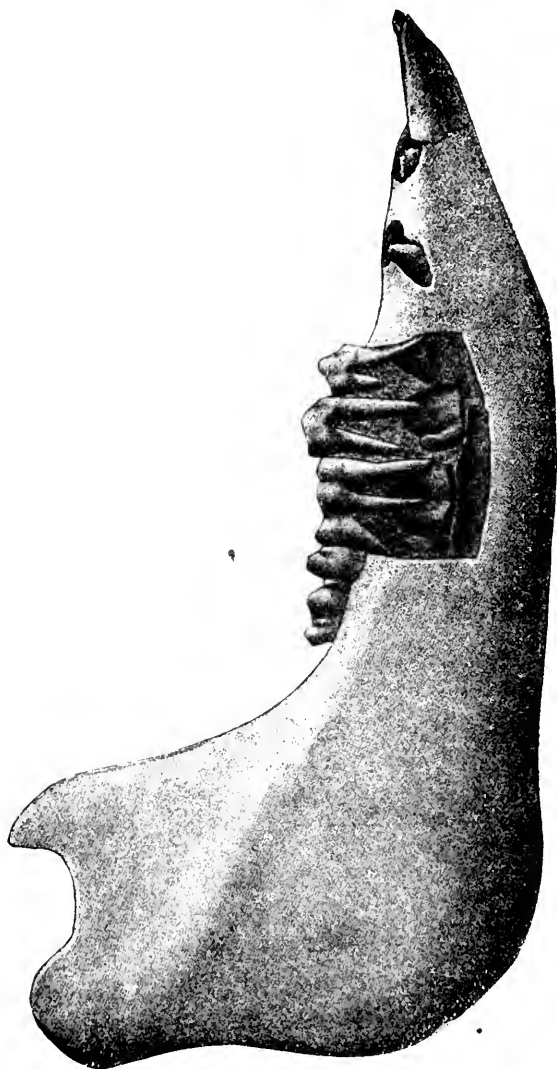

FIG. 39.
Teeth of the Hog at the Age of 8 Months. (Cornéym et Lesbre.)

days after the centrals, and are shed at twenty to twenty-four months.

Intermediate Incisors—Erupt during the second to the fourth week, a few days after the laterals, and are shed at twenty-four to thirty-three months.

Corner Incisors—Erupt about the fifth week after birth and are shed at four to four and a half years.

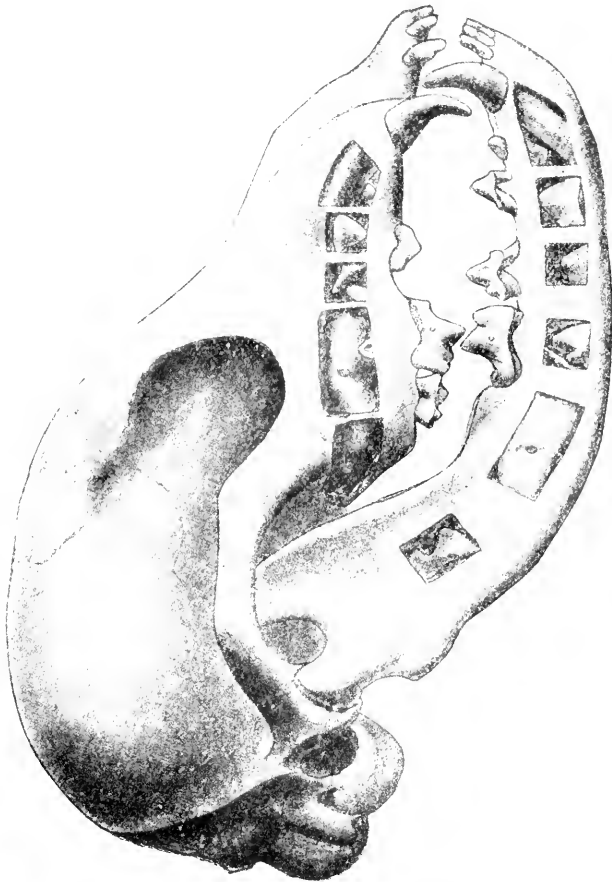


FIG. 42.
Teeth of a Dog at the Age of Three Months. (Corney et Lesbre.)

First Molar—Erupts during the first month and is shed at one and a half years.

Second Molar—Erupts with the first molar and is shed at two and a half years.

Third Molar—Erupts with the first and second and is shed at three and a half years.

EVOLUTION OF THE PERMANENT TEETH.

The development of the permanent teeth of animals begins during the foetal life. During this period they are represented only by a stalk or neck extending from the enamel germ of their temporary analogues, located first on the side

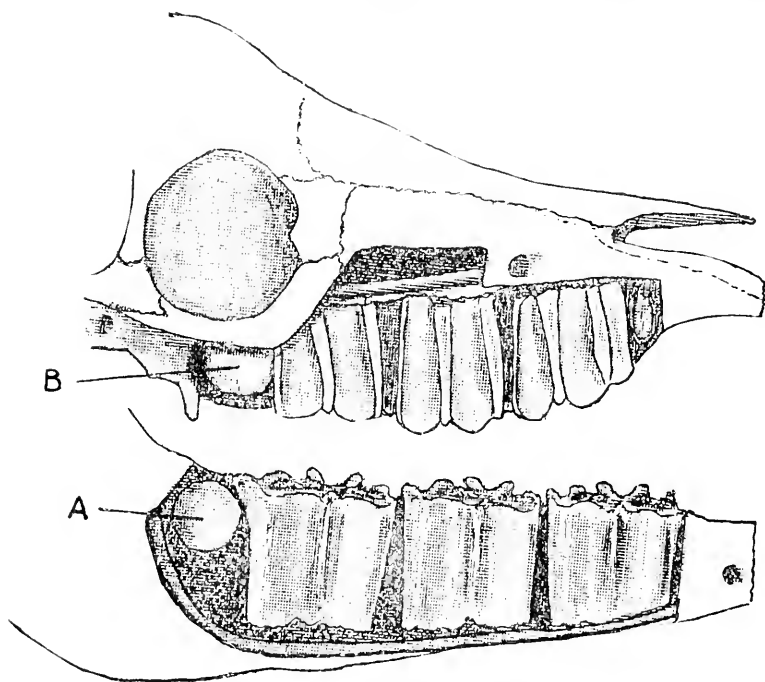


FIG. 41.

Molar Denture at Birth.

- A. Inferior 4th molar.
- B. Superior 4th molar.

and afterwards at the root. At the time of birth the germ of the central incisors and the first, second and third molars are already prominently formed at the root of the temporary teeth, and the fourth molar—the first permanent tooth to develop—consists of a rounded hypertrophy of the common enamel germ located just posterior to the third temporary molar. (Fig. 41 A. B.) The temporary molars occupy the

entire jaw behind the interdental space until the age of ten months. In the herbivora the fourth molar forces its way to the surface in the same relative position that the sixth molar occupies in the mature animal. The jaw is therefore always filled with molars, the fourth, fifth and sixth forcing their way behind their successive neighbors.

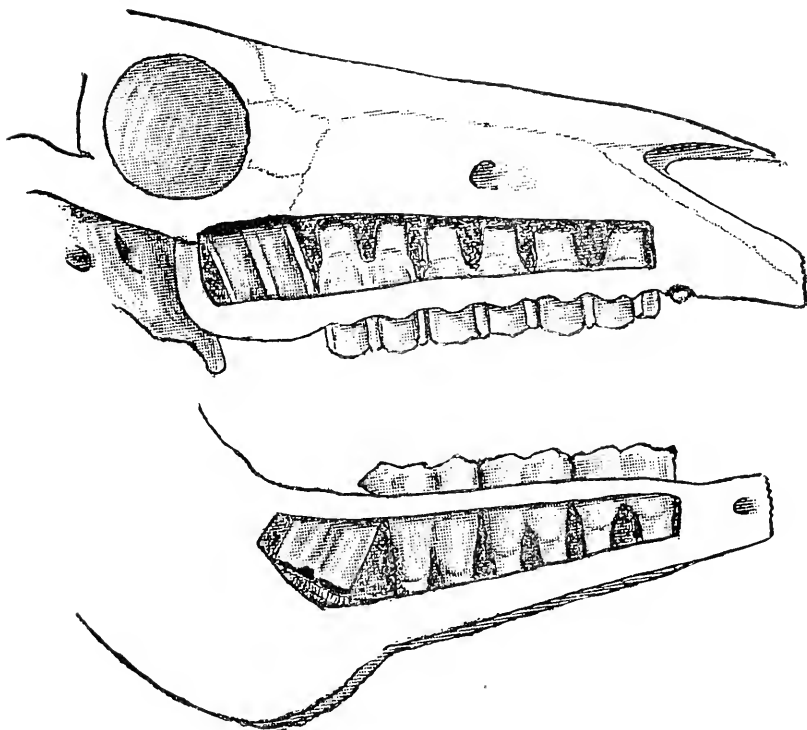


FIG. 42.

Molars of a Horse Approaching 5 to 6 Months.

During the first year the only prominent visible event in the evolution of the permanent teeth is the eruption of the fourth molar. The invisible events occurring in the germs located at the roots of the temporary are, however, of no less importance. They are developing rapidly into teeth of normal shape and size, gradually transgressing upon and shortening by absorption the fangs of the temporary teeth,

molars and incisors alike. The first, second and third molars make the most rapid progress during the first year, preparatory to their subsequent eruption one to two years hence. The incisors are less developed, the centrals are somewhat prominent preparatory to their eruption two years hence, but the lateral, intermediates—in ruminants—and the corners are merely represented by an undeveloped tooth germ. Such is the condition of development of the denture

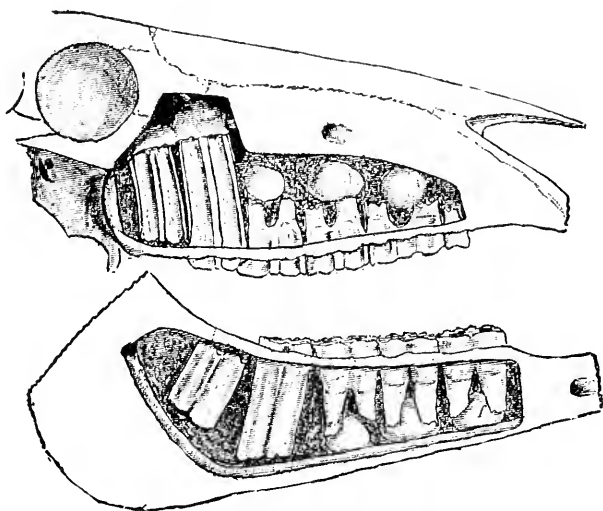


FIG. 43.

Molars of a Horse Approaching 10 Months.

of an herbivorous animal at the age of one year from whence the evolution proper begins. (See Fig. 43.)

THE HORSE.

Central Incisor—Begins to develop in embryo, assumes the shape of a tooth during the first year, reaches the level of the alveolar border at two years, expels the temporary shell at two and a half years and takes its place at the normal level of the arcade at three years of age.

Lateral Incisor—Begins to develop during the first six

months, assumes the shape of a tooth during the second year, reaches the alveolar border at three years, expels the temporary shell at three and a half years and takes its place at the level of the arcade at four years.

Corner Incisor—Is very rudimentary at one year, begins to develop at two years, assumes the shape of a tooth at three years, reaches the alveolar border at four years, expels the temporary shell at four and a half years and takes its

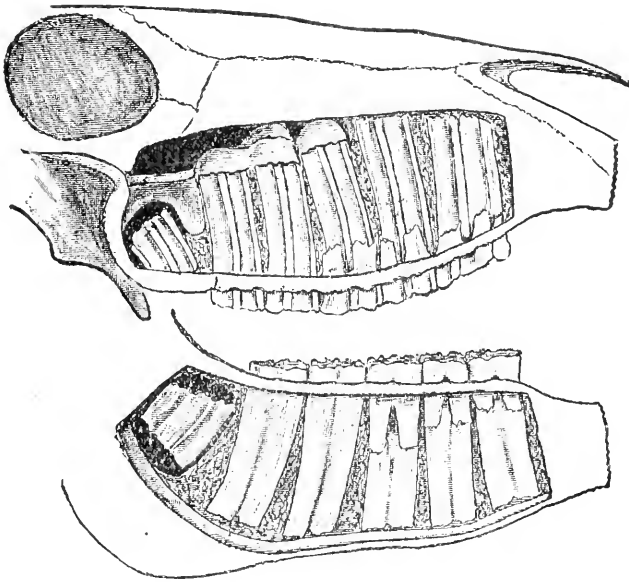


FIG. 44.

Molars of a Horse Approaching the Age of 2 Years.

place at the level of the arcade at five to five and a half years.

Canines—Erupt at the age of four to four and a half years, but may be delayed in their outward course by the hardness of the jaw. Occasionally their growth, especially of the superiors, is arrested beneath the gums until the seventh year of the animal's life. The inferior canines always erupt slightly in advance of the superior.

First, second and third molars begin to develop in the foetal life of the colt. At birth they are small, rudimentary

objects, but become tooth-like very rapidly during the first twelve months, at which time they are all morphologically and anatomically similar. During the ensuing year their growth is about equal, each growing to the level of the alveolar border. At two and a half years the first and second expel the temporary shell and become concerned actively in mastication at about three years of age. The third at two and a half years seems to be mysteriously retarded in its growth as if blocked in its outward course by the unyielding fourth molar, which has now been in active service for the past one and a half years. (See osteoma of the maxilla.) At two to two and a half years old the development of the third molar is at a standstill, until the age of three to three and a half years, when it finally expels its shell and then grows tardily outward to the level of the arcade. It is not unusual to find this molar below the level of its neighbors at four and even five years old.

Fourth Molar—The fourth molar is the most interesting of the horse's teeth. Its development begins during the last months of foetal life. At birth it consists of a small, rounded mass of rudimentary tooth substance, developing from a backward projection of the common enamel germ, and located in close contiguity to the fang of the third temporary molar. During the first ten months after birth it grows very rapidly into a shapely tooth and points to the surface at about the end of the tenth month. At twelve months it is already actively concerned in mastication, although it is morphologically defective, assuming its maximum stability only during the next two years.

Fifth Molar—The common enamel germ at the age of six months, after having formed the fourth molar projects backward to form the fifth molar. At one year old the formation is almost perfect, at one and a half years it erupts,

and at two and a half years it is found on a level with the fourth.

Sixth Molar—The sixth molar is the last of the molars to erupt, which event occurs at any time between four and five years of age. Its formation, like that of the other permanent molars, having no temporary predecessors, depends upon the backward growth of the common enamel germ. The first evidence of this molar is seen at two to two and

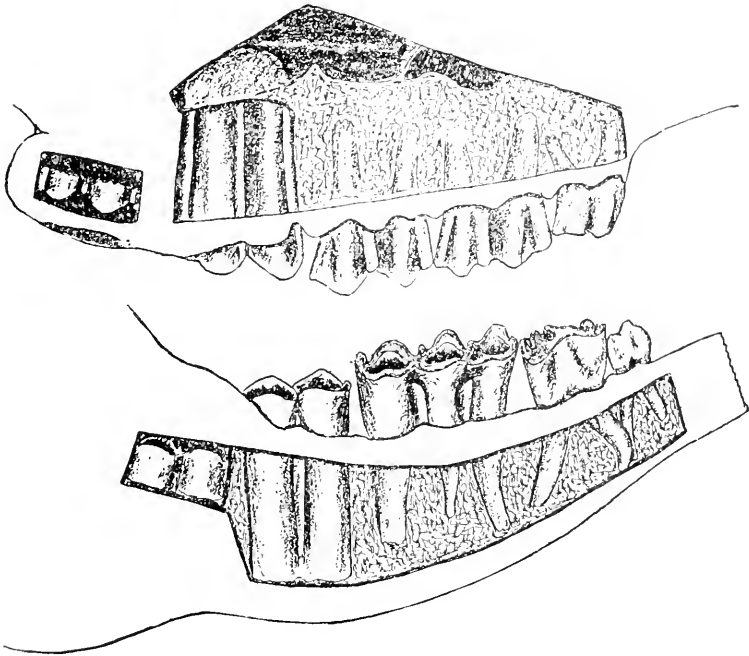


FIG. 45.

Molar Denture of the Ox at 10 Months.

a half years in the form of a rounded mass similar to that of the fourth and fifth. At this age the jaw is more unyielding and its eruption may be delayed by the resistance offered therefrom.

RUMINANTS.

Central Incisor—Reaches the alveolar margin at one year and erupts at one and a half years.

Lateral Incisor—Reaches the alveolar margin at two years and erupts at two and a half years.

Intermediate Incisor—Reaches the alveolar margin at three years and erupts at three and a half years.

Corner Incisor—Reaches the alveolar margin at four years and erupts at four and a half to five years.

First Molar—Reaches the alveolar margin at one year, expels the temporary shell at one and a half years and becomes concerned in mastication soon after.

Second Molar—Reaches the alveolar margin at two years, expels the temporary shell at two and a half years and gains the level of the first molar a month or two later.

Third Molar—Reaches the level of the alveolar margin at three years, expels the temporary shell at three and a half years and gains the table level at about four years.

Fourth Molar—Erupts at nine months and becomes concerned in mastication at ten to eleven months.

Fifth Molar—Erupts at two and a half years and gains the table level several months later.

Sixth Molar—Erupts between the ages of four and five years. As in the horse, its outward progress is hindered by the hardness of the jaws at that age.

CARNIVORA.

Central Incisor—Erupts at three to four months.

Lateral Incisor—Erupts at three to four months.

Corner Incisor—Erupts at five to five and a half months.

Canines—Erupt at five to six months, common to both sexes.

First Molar—Erupts at three months, and has no temporary predecessor.

Second Molar—Erupts at five to six months.

Third Molar—Erupts at five to six months.

Fourth Molar—Erupts at five to six months.

Fifth Molar—Erupts at four to five months.

Sixth Molar—Erupts at five to six months.

Seventh Molar—Erupts at seven months.

OMNIVORA.

Central Incisor—Erupts at two and a half years.

Lateral Incisor—Erupts at three years.

Corner Incisor—Erupts at six months.

Canine—Erupts at one year and is common to both sexes.

First Molar—Erupts at birth and is a permanent tooth.

Second Molar—Erupts at two years.

Third Molar—Erupts at two to two and a half years

Fourth Molar—Erupts at six months.

Fifth Molar—Erupts at one year.

Sixth Molar—Erupts at one and a half to two years.

Seventh Molar—Erupts at three years.

NUMBER OF PERMANENT TEETH.

	Incisors.	Canines.	Molars.	Total.
Horse	12	4	24	40
Mare	12	0	24	36
Ox	8	0	24	32
Pig	12	4	28	44
Dog	12	4	26	42
Cat	12	4	14	30
Rabbit	6	0	22	28

NUMBER OF TEMPORARY TEETH.

	Incisors.	Canines.	Molars.	Total.
Horse	12	0	12	24
Ox	8	0	12	20
Pig	12	4	12	28
Dog	12	4	24	30
Cat	12	4	10	26
Rabbit	8	0	24	32

FORMULAE OF THE TEMPORARY AND PERMANENT DENTURES OF DOMESTIC ANIMALS.

HORSE.

Temporary.

3.....3	0.....0	3.....3
Incisors:—	Canines:—	Molars:—
3.....3	0.....0	3.....3

Permanent.

3.....3	1.....1	6.....6
Incisors:—	Canines:—	Molars:—
3.....3	1.....1	6.....6

OX.

Temporary.

4.....4	0.....0	3.....3
Incisors:—	Canines:—	Molars:—
0.....0	0.....0	3.....3

Permanent.

4.....4	0.....0	6.....6
Incisors:—	Canines:—	Molars:—
0.....0	0.....0	6.....6

DOG.

Temporary.

3.....3	1.....1	3.....3
Incisors:—	Canines:—	Molars:—
3.....3	1.....1	3.....3

Permanent.

	3.....3	I.....I	6.....6
Incisors:—	Canines:—	Molars:—	
	3.....3	I.....I	7.....7

CAT.**Temporary.**

	3.....3	I.....I	3.....3
Incisors:—	Canines:—	Molars:—	
	3.....3	I.....I	2.....2

Permanent.

	3.....3	I.....I	4.....4
Incisors:—	Canines:—	Molars:—	
	3.....3	I.....I	3.....3

PIG.**Temporary.**

	3.....3	I.....I	3.....3
Incisors:—	Canines:—	Molars:—	
	3.....3	I.....I	3.....3

Permanent.

	3.....3	I.....I	7.....7
Incisors:—	Canines:—	Molars:—	
	3.....3	I.....I	7.....7

CHAPTER III.

RETROGRESSION OF THE TEMPORARY TEETH.

The temporary teeth attain their greatest capacity and length at the time of eruption, after which event they at once begin to retrogress under the influences of pressure absorption at the root and of wear from mastication at the table extremity, until only a shell remains to be expelled into the mouth. The first event of this character (shedding) occurs to the first and second molars at two and a half years, and the last to the corner incisors at four and a half years, after which time the denture is entirely free from temporary teeth. The order of shedding of the temporary teeth in solipeds is as follows:

(1) **Two and a half years**, the first and second molars and the central incisors.

(2) **Three to three and a half years**, the third molars and the lateral incisors.

(3) **Four and a half years**, the corner incisors.

This order may be made to apply to all ruminants and solipeds. In the carnivora the destruction of the temporary denture is remarkably rapid, as at the age of seven months no temporary teeth remain.

RETROGRESSION OF THE PERMANENT TEETH.

The retrogression of the permanent teeth is the most important feature of dentistry of animals. It includes the **wear** and eventual **destruction** of the teeth. The teeth of solipeds and ruminants attain their maximum **length and volume** the **second year after eruption**. During the first year they

gain in length and volume by expansion of the fang, but lose slightly by wear. The growth, however, exceeds the wear during the first year. During the second year the wear and growth are about equal. The greatest length of the teeth is therefore attained during the second twelve months of their existence within the mouth. During the succeed-

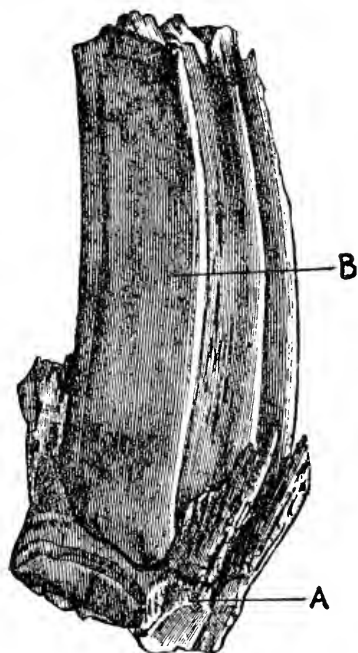


FIG. 46.

The Destruction of a Temporary Tooth by the Permanent.

- A. Temporary shell.
- B. Permanent tooth.

ing years the teeth **do not grow**, but instead undergo a gradual and regular process of destruction under two influences:

(1) Wear from mastication, which slowly shortens the length of the tooth.

(2) Receding of the alveolar margin, which gradually shortens the depth of the alveolar cavity.

In the herbivorous animals both of these influences are

at work to a remarkable degree, while in the carnivora and omnivora only the second influence is concerned in the destructive process. In the herbivora the length of the teeth varies from the long, three or four-inch tooth of the young subject, to the short, half-inch tooth of extreme old age (from the wear of mastication), while the alveolar cavity varies from the exceedingly deep excavation of youth to the shallow, flattened cavity of old age. The diminution in the depth of the alveolar cavity occurs in all the animals, and is solely responsible for senile self-extraction in the animals having simple teeth. In the animals having simple teeth the table retains its enamel covering through life, and the tooth does not diminish in length from wear.

1. **Wear from mastication.**—When the teeth of the ruminant and soliped first enter into the process of mastication they are covered with enamel over the grinding surface. The enamel in addition dips deeply into the body of the tooth around the infundibula. As soon as wear begins the surface enamel of the table at once wears off, exposing the dentine and leaving only the edges of the enamel organ on the grinding surface. The dentine, ordinarily a sensitive substance, becomes hard and insensitive along the table surface, by the deposit of dentinal cells within its tubules. The area of insensitiveness extends throughout the entire table and to the depth of one to two millimeters during the first year of wear, but in the subsequent three or four years it descends to the depth of one centimeter or even more. At the age of ten to twelve years it has descended to more than one-third of the entire tooth in the molars, and to the depth of about two centimeters in the incisors. When the animal has passed the age of eighteen the tooth is practically a dead organ so far as the sensibility of the dentine is concerned. That the stimulus to the proliferation of dentinal cells (osteodentine) is wear is demonstrated in the fact that teeth

that do not contact opposing teeth (e. g., brachygnathism) are sensitive to the very tips.

During youth and through the prime of life the active tooth wears at the rate of about two millimeters each year. In the aged animal the loss is slower. In the case of the

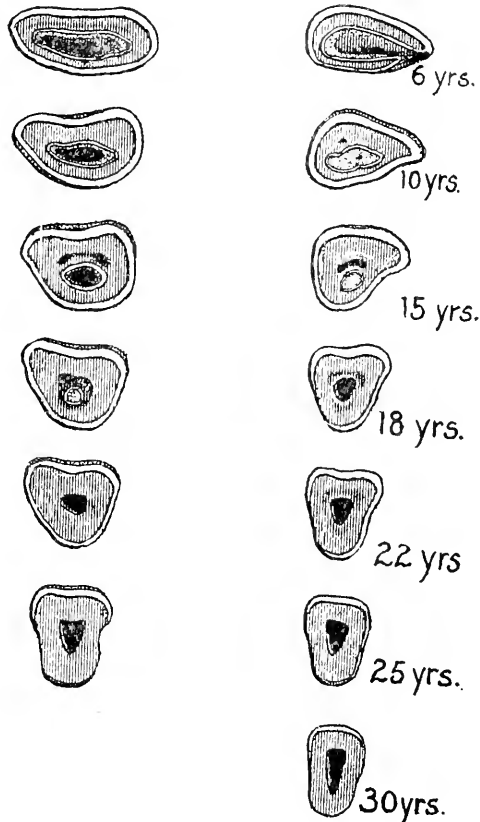


FIG. 47.

An Illustration of the Change in Shape of the Incisor Tables as a Result of Wear, from 6 Years to 30 Years.

visible teeth (the incisors) the wear brings to the surface of the table a constantly changing picture, by exposing to view the different consecutive parts of the tooth, from the flattened table of youth to the triangular table of old age.

The most striking change in the teeth from wear occurs

to the incisor teeth, especially the inferiors, which furnish the best evidence of the age after the fifth year. First, by changes in the infundibulum and then by change in the shape of the table surface. The infundibulum of the tooth is produced by the infolding of the enamel into the body of the tooth to a depth of one and a half to two and a half centimeters. The bottom of the cavity thus formed is filled with *crusta petrosa*, but the outer end is empty and constitutes the cup, which becomes blackened by the chemical action of foods and saliva. The infundibula of the incisors are shaped like a flattened cone with the apex inward and the elliptical opening outward. When the tooth is but a virgin, the cup, made more apparent by its dark color, presents an elliptical opening at the table surface, but as the crown wears away it becomes shorter and more rounded and disappears entirely when the crown has worn as far as the *crusta petrosa* that fills the bottom of the infundibula. Thereafter the infundibula are not dark but are recognized by their surrounding enamel, at first still elliptical, but finally becoming small circular rings located well toward the posterior border of the tables. In the study of dental wear the cup must not be mistaken for the infundibulum, as "cup" refers only to the unfilled portion of the infundibulum. The cups of the incisor teeth disappear three years after eruption, and the infundibulum about ten years to fifteen years after.

The molar teeth have two infundibula extending deeply into the fang. They are entirely filled with *crusta petrosa* and would entirely escape notice but for the presence of a small dark spot in the center.

In shape the tables change even more than in their infundibula. In the young tooth the table is flattened from before backward, but as the crowns wear away the other parts of the tooth come to the surface. The table becomes

first triangular, then round and finally in extreme age flattened from side to side. The triangular shape makes its appearance almost as soon as the cups disappear in the central and lateral incisors, while the corners maintain their oblong shape until after the age of twelve, and even never become as distinctly triangular as the former. (See Fig. 47.)

2. **Receding of the alveolar margin** is more prominent in the herbivora than in the other species, although it constitutes a feature of dental retrogression in all animals. Through its influence the teeth lose their implantation by gradual stages until in extreme old age they are held in position only by the gums and small pits in the jaw, which retain the remaining roots.

In the incisor arcades the alveolar margin recedes much faster than the teeth wear at the table, which circumstance results in the elongation of the crowns as the animal becomes older. In rare cases the reverse occurs and the crowns become shorter with age, but this incident results only when the teeth are defective in quality. The long crowns of the incisor teeth of old horses due to the receding jaw, is responsible for the general impression that the teeth grow in length and that they are longer in old than in young horses.

The receding process is also responsible for the gradual change in the inclination (angle) of the incisor teeth. The angle formed by the incisor teeth at the contact point is obtuse in the young, but changes gradually into a very acute one in the aged animal. This change is the result of the great curvature in the incisor tooth, which in the young animal is implanted into a deep curved cavity. As the tooth wears the part projecting forwards becomes exposed and the increased inclination results. **The incisor teeth, like all teeth of herbivora, are longest in the young animal, but**

have a longer exposed portion (crown) in the aged subject, owing to the receding of the alveolar margin.

A SUMMARY OF DENTAL EVOLUTION AND RETROGRESSION APPLIED TO THE DETERMINATION OF AGE.

The age of the horse is determined by the examination of the incisor teeth, and in certain instances the molars, as follows:

- (1) From **birth to one year** by the evolution of the temporary incisors.
- (2) From **one year to two and a half years** by the eruption of the fourth and fifth molars and the evolution of the temporary incisors.
- (3) From **two and one-half years to five years** by the retrogression of the temporary incisors, the evolution of the canines and the evolution of the sixth molar.
- (4) From **five and a half years to nine years** by the retrogression of the infundibula of the inferior incisors.
- (5) From **nine years to old age** by:
 - (1) Changes in the shape of the tables of the inferior incisors.
 - (2) Changes in the anterior face of the superior incisor arcades.
 - (3) Changes in the inclination of the incisor arcades.
 - (4) Changes in the crown of the canines.
 - (5) Changes in the molars.

FROM BIRTH TO ONE YEAR.

The colt at birth, or within a day or two after, has four incisor teeth—the superior and inferior nippers, and three

molars in each arcade, the first second, and third. The crowns of the incisors are short and contact only at the anterior margin. The infundibula are wide, elliptical and deep, and their posterior boundaries are buried within the gums. At one month the posterior edges of the infundibula are exposed and the lateral incisors are breaking through the gums. Two weeks later their crowns answer the same description as the centrals at birth. During the next eight or nine months there is no great change in the arcades except the elongation of the crowns, which resemble a cone broken off at its apex. The tenth month is marked by the



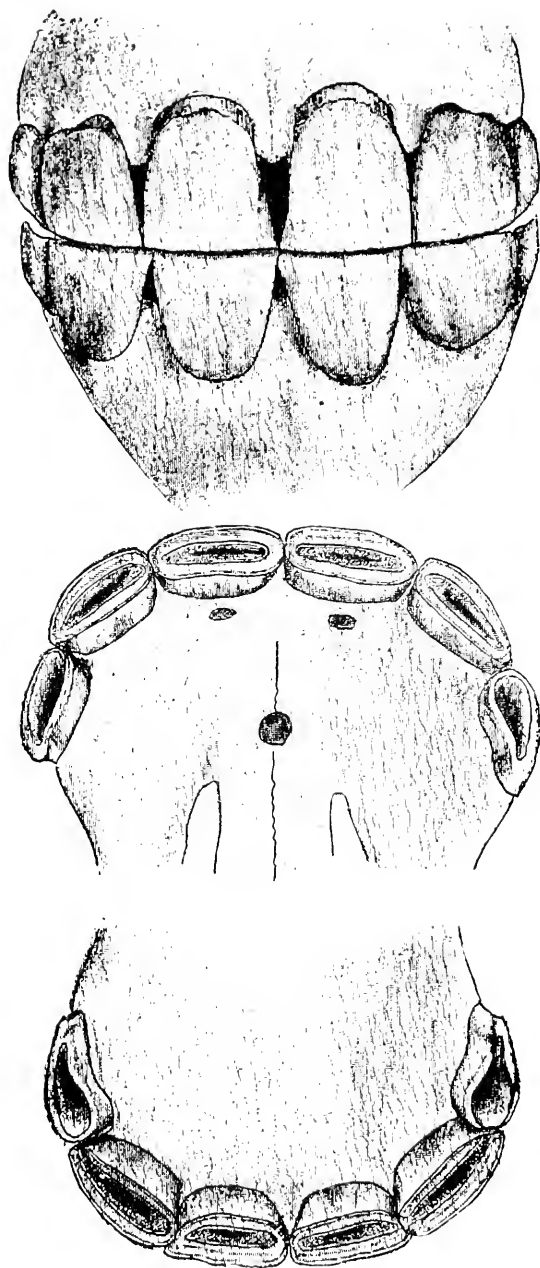
FIG. 47A.

Inferior Incisors at Birth.

eruption of the corner incisors and the fourth permanent molars.

FROM ONE TO TWO AND A HALF YEARS.

The absence of any prominent event during this period makes the determination of age rather difficult. The incisor teeth become large and prominent in all the features of teeth, and are not easily recognized from permanent teeth. If unassisted by the colt-appearance of the subject the mouth during the last part of this period is readily mistaken for a full mouth of permanent incisors. When any doubt exists the examination of the molars will reveal the presence of but four teeth in each arcade. At the age of two to two and a half years the fifth molar will be found breaking through the gums. The incisors are white, have a some-



FIGS. 48 AND 49.

Anterior View of the Incisor Denture at 12 Months.
Incisors (Table View) at 12 Months.

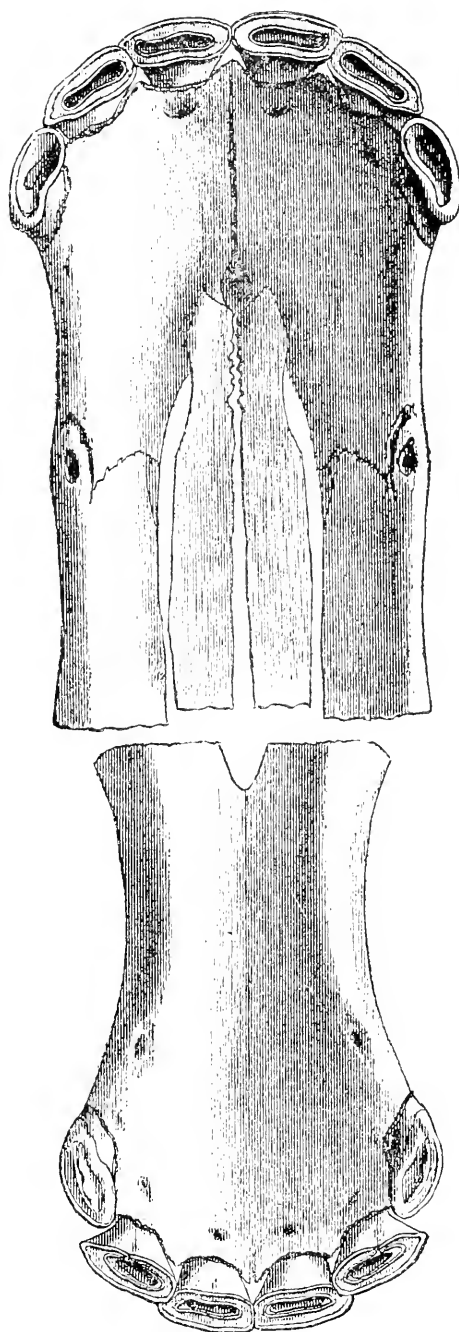


FIG. 50.

Incisor Denture at 15 Months (Table View).

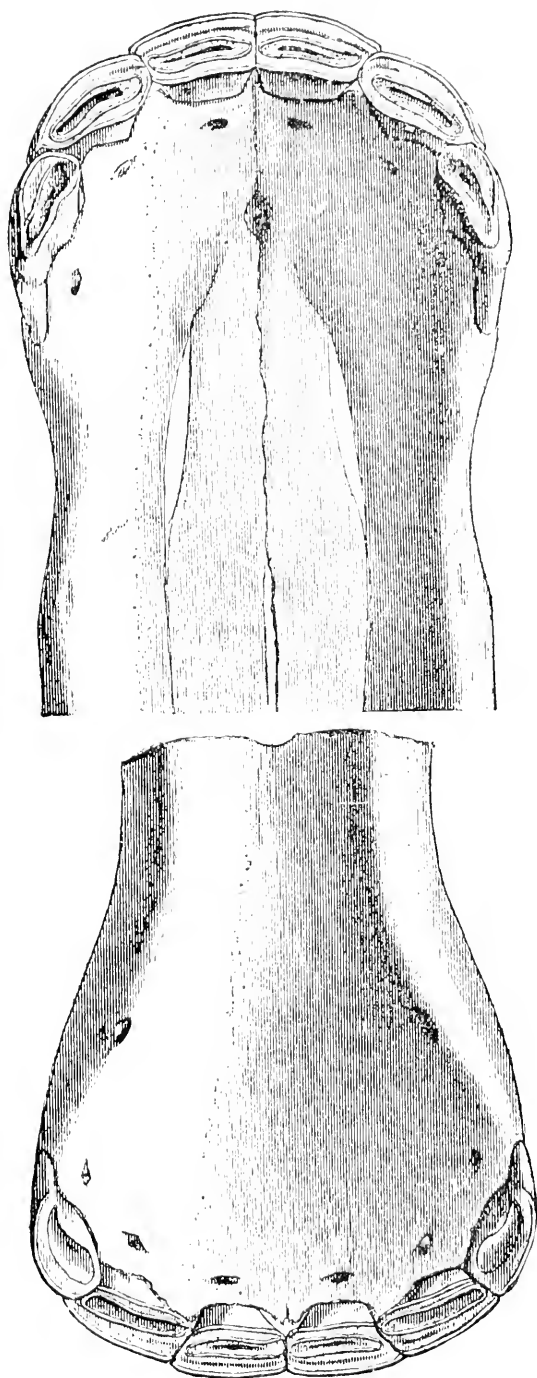


FIG. 51.

Incisor Denture of a Colt at 18 Months (Table View).

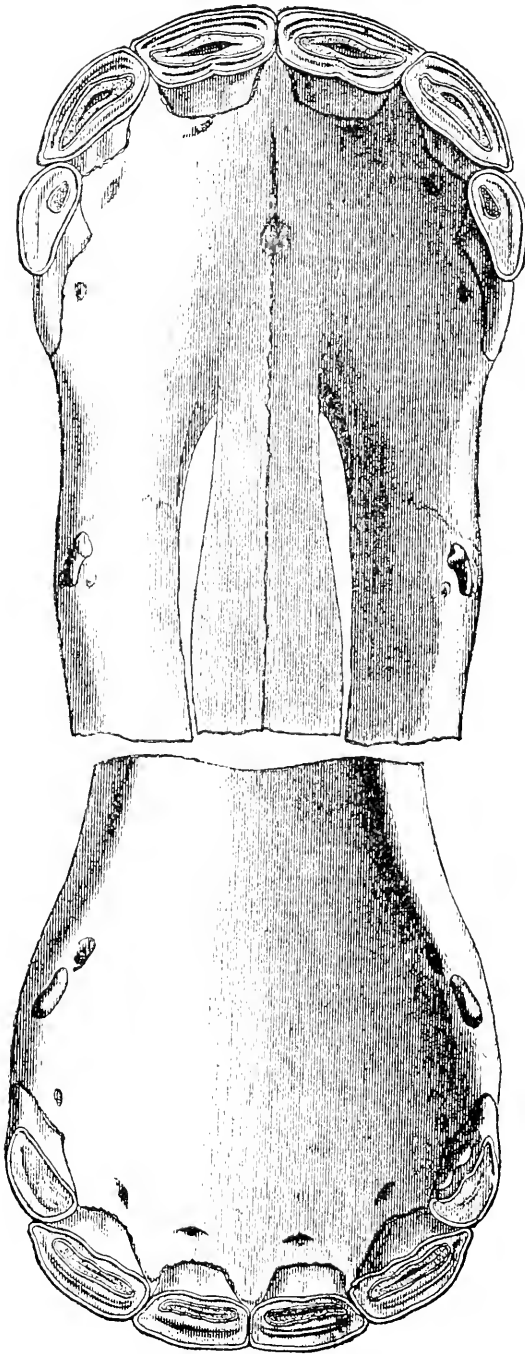


FIG. 52.
Incisor Denture at 2 Years (Table View).

what prominent neck and are separated with gums shaped as an inverted cone. The crowns do not contact one another throughout their entire length, as in the horse five and a half to six years old, for which the two-year-old might be mistaken. The absence of canines (in the male) will also assist in making the differentiation. The confusion is most likely to occur in the examination of a thoroughbred or trotter with a well developed muscular system, and the habits of an older horse from training.

FROM TWO AND A HALF TO FIVE YEARS.

The determination of age during this period is more simple and more certain than at any other period of the horse's life, owing to the three successive prominent events occurring during this period. At two and a half years the central temporary incisors are readily recognized by being loose preparatory to shedding. At three years old they are cast off and the permanent successors, broad and shiny, are seen protruding beneath, leaving an interrupted surface in the arcade. At three and a half to four years the laterals undergo the same transformation, and at four and a half to five, the corners. The five-year-old mouth is recognized by the deep, oblong infundibula of the centrals and laterals and the undeveloped condition of the corners. The latter are bluish-white, have a short crown and do not contact their opponents. The posterior edge of the table is still buried within the gums. The canines are already visible in both the jaws, but especially in the inferior, and the molar arcades are completed. At two and a half years the first and second molars cast off the temporary shells, at three the third molar casts off its predecessor, and at four to four and a half the sixth molar erupts, leaving at the end of this period a full mouth of permanent teeth.

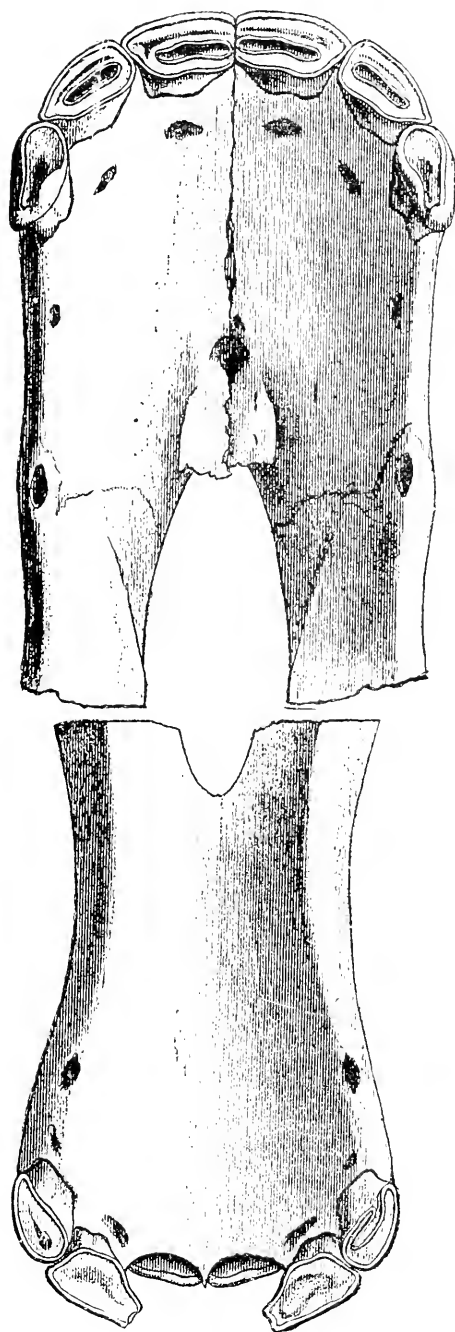


FIG. 53.

Incisor Denture Approaching $2\frac{1}{2}$ Years (Table View).

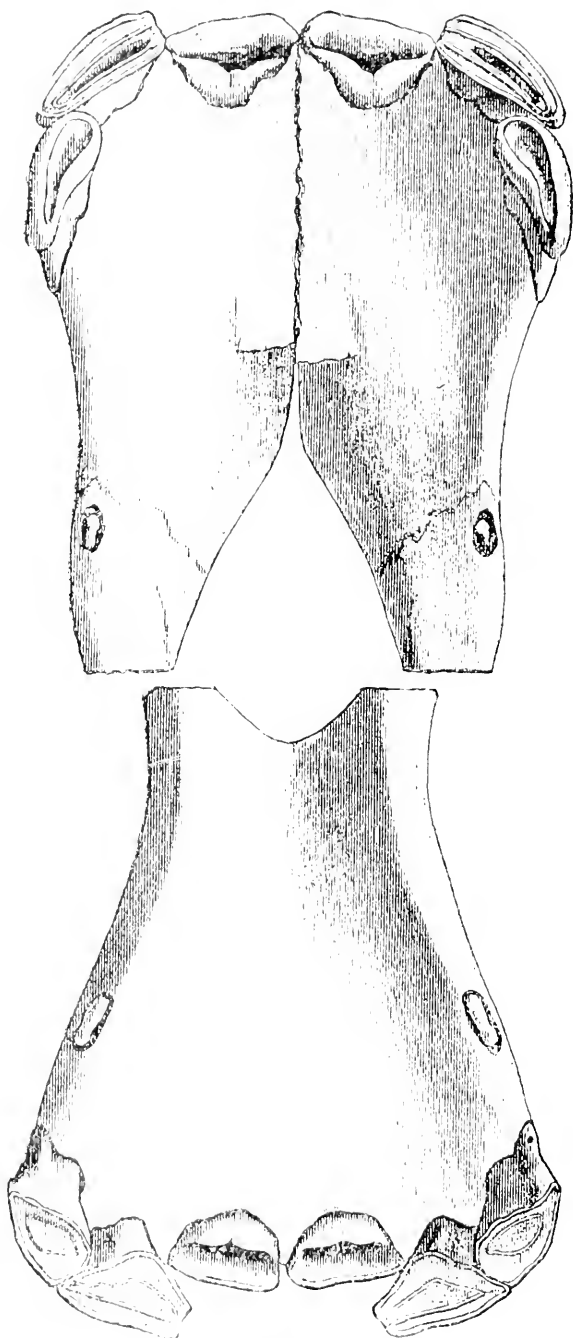


FIG. 54.

Incisor Denture at 2½ Years (Table View).

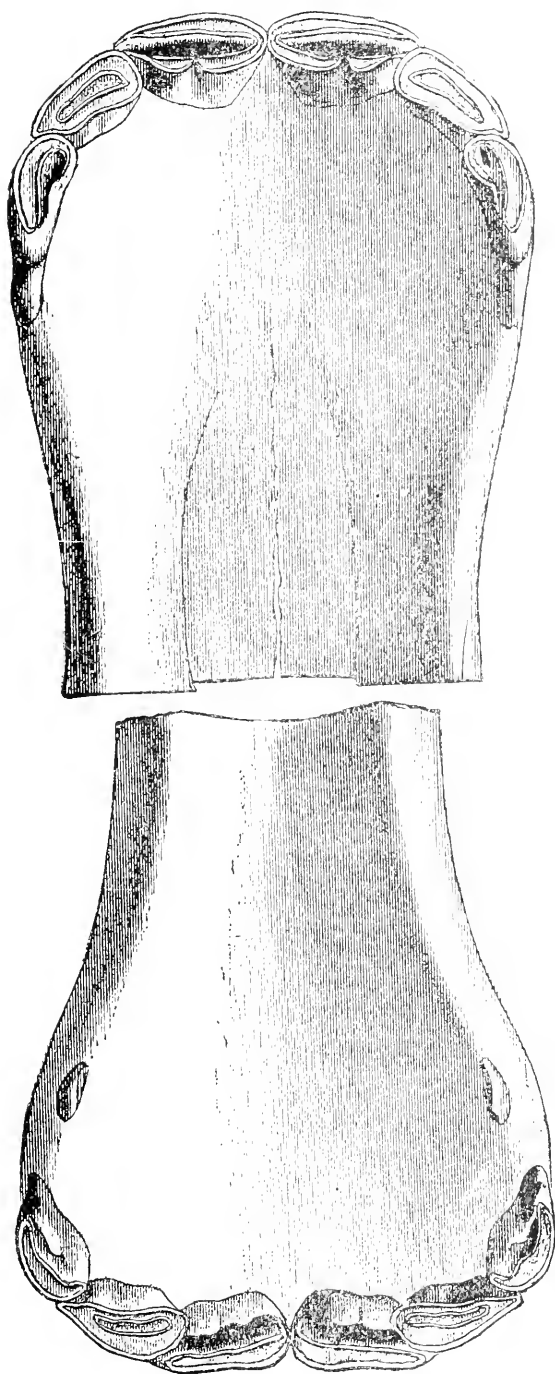


FIG. 55.
Incisor Denture at 3 Years (Table View).

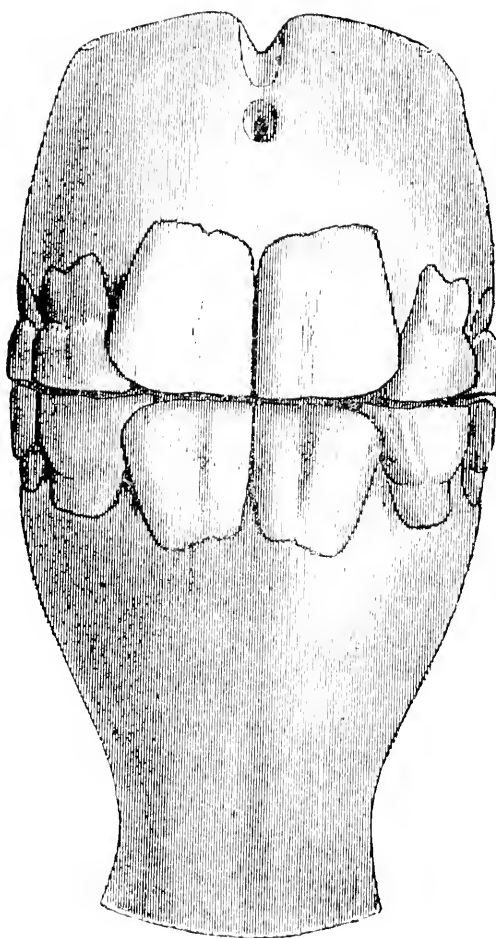


FIG. 56.

Incisor Denture at 3 Years (Anterior View)

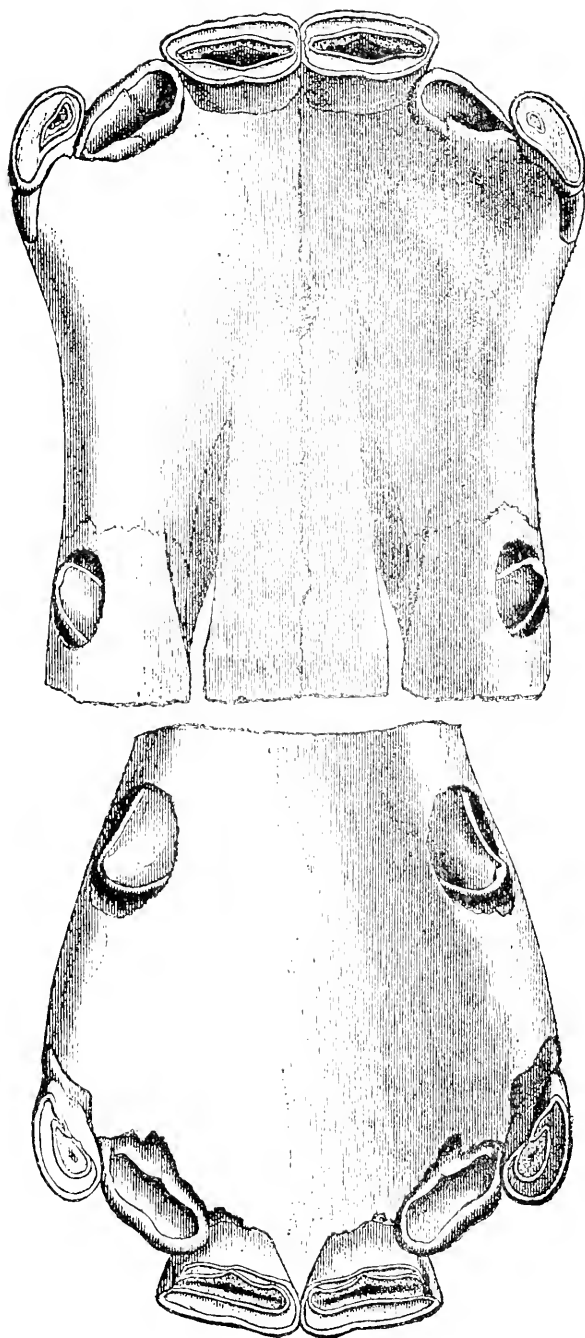


FIG. 57.

Incisor Denture at $3\frac{1}{2}$ Years (Table View).

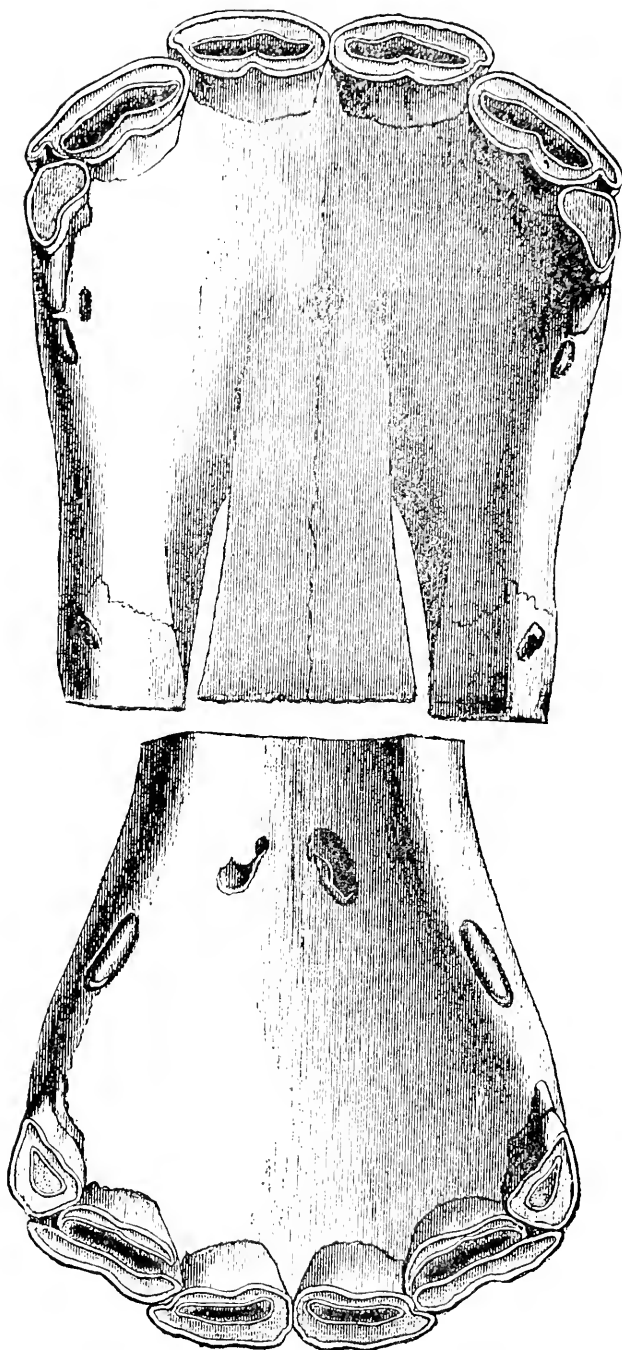


FIG. 58.

Incisor Denture at 4 Years (Table View).

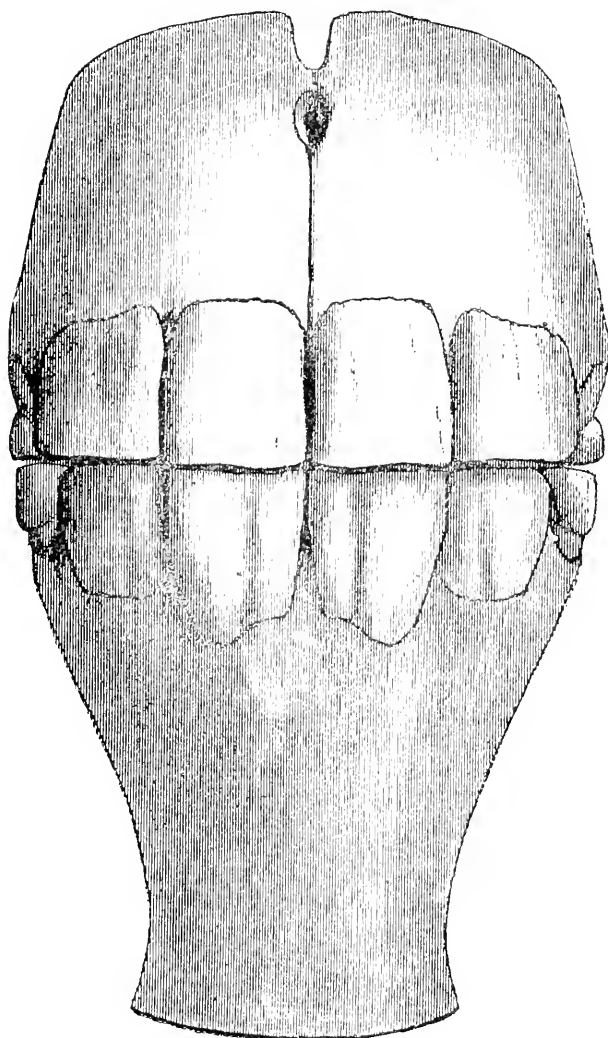


FIG. 59.
Incisor Denture at 4 Years (Anterior View).

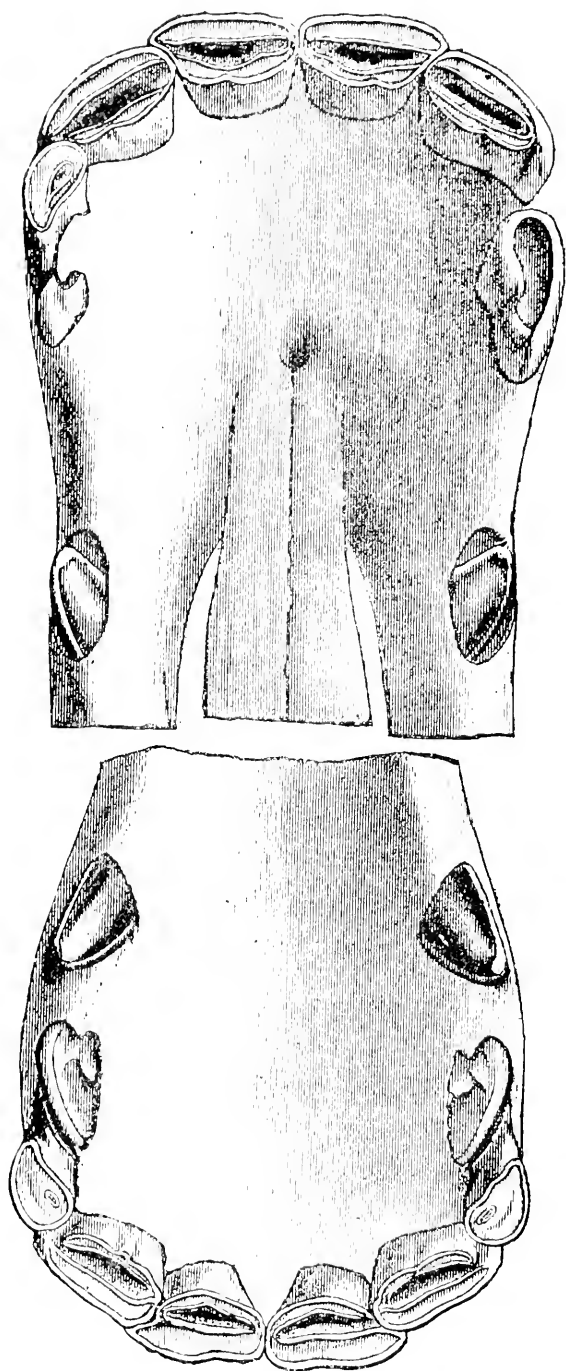


FIG. 60.

Incisor and Canine Dentures at 4½ Years (Table View).

FROM FIVE TO EIGHT YEARS.

The age during this period is determined by changes in the infundibula of the inferior incisors, the cups of which disappear in regular succession, beginning with the centrals. In some instances a small round spot remains for several years in the center of the infundibulum, but this event must be regarded as equivalent to the disappearance. The disappearance of the blackened cup is marked by the appearance of the crusta petrosa filling the bottom of the infundibulum. At six years old the central cup disappears, at seven the lateral cup, and at eight the corner one has become shallow and rounded. The cup of the corner inferior incisor is more persistent than that of the centrals and laterals, and may remain quite prominent even at the age of ten to eleven years. Its change in shape from elliptical to round is equally valuable in the determination of the age at that period.

FROM NINE YEARS TO OLD AGE.

After the age of nine years the retrogressive changes continue incessantly, but without any prominent event to mark the exact age. The age of the horse is henceforth only estimated.

Nine years—The age of nine years is easily determined by the appearance of the crusta petrosa groove at the gingival margin of the superior corner incisor and the slight downward curvature of the gums at that point. The infundibula of the inferior incisors are nearer to the posterior border of the tables of the centrals, which are now quite triangular. The inferior corner incisors are still oblong, present a rounded black cup and are beginning to show the first sign of increased inclination of the incisor arcades. The anterior surfaces of the teeth are becoming yellow.

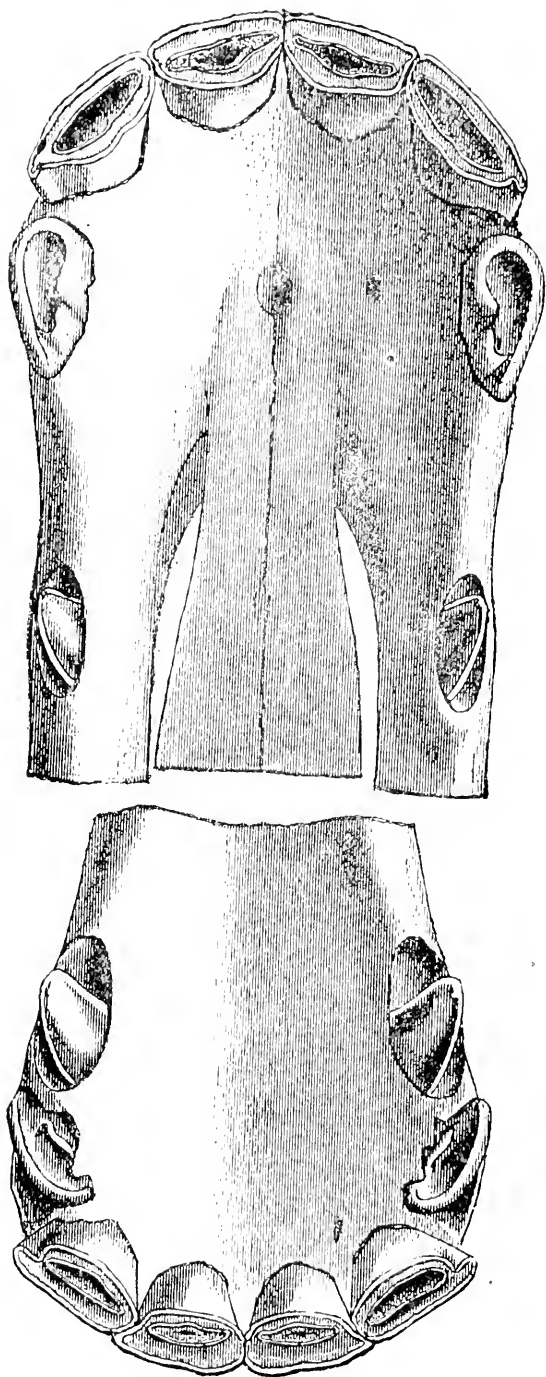


FIG. 61.

Incisor Denture Approaching 5 Years (Table View).

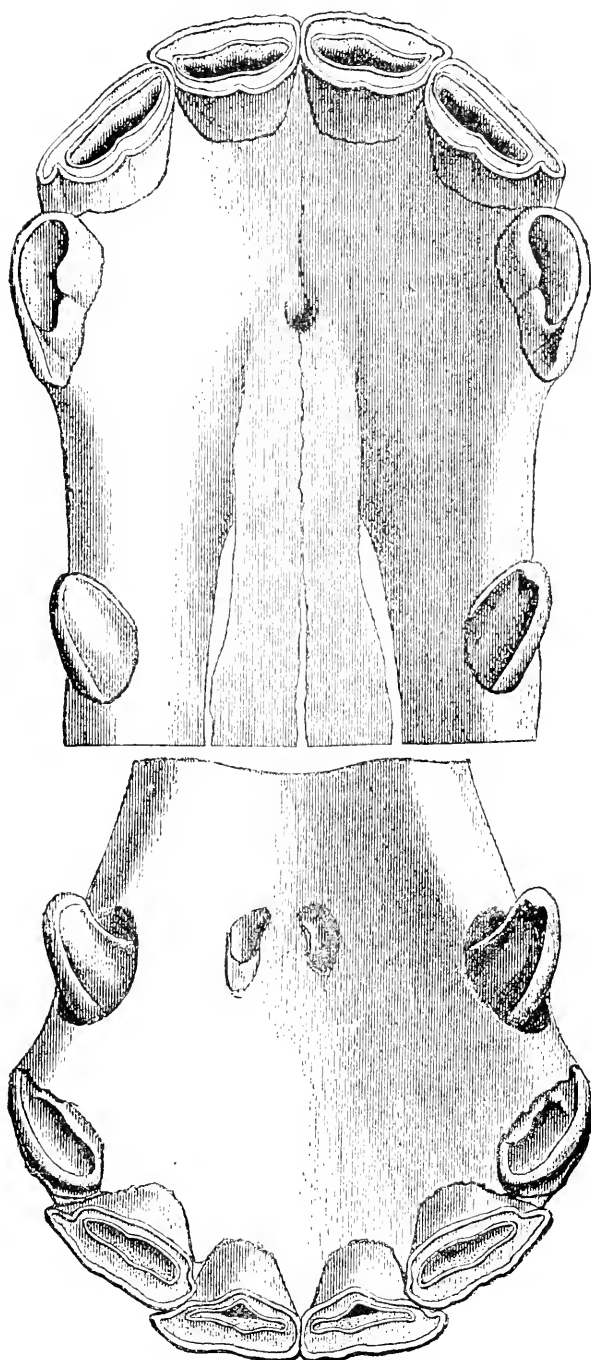


FIG. 62.

Incisor Denture at 5 Years (Table View).

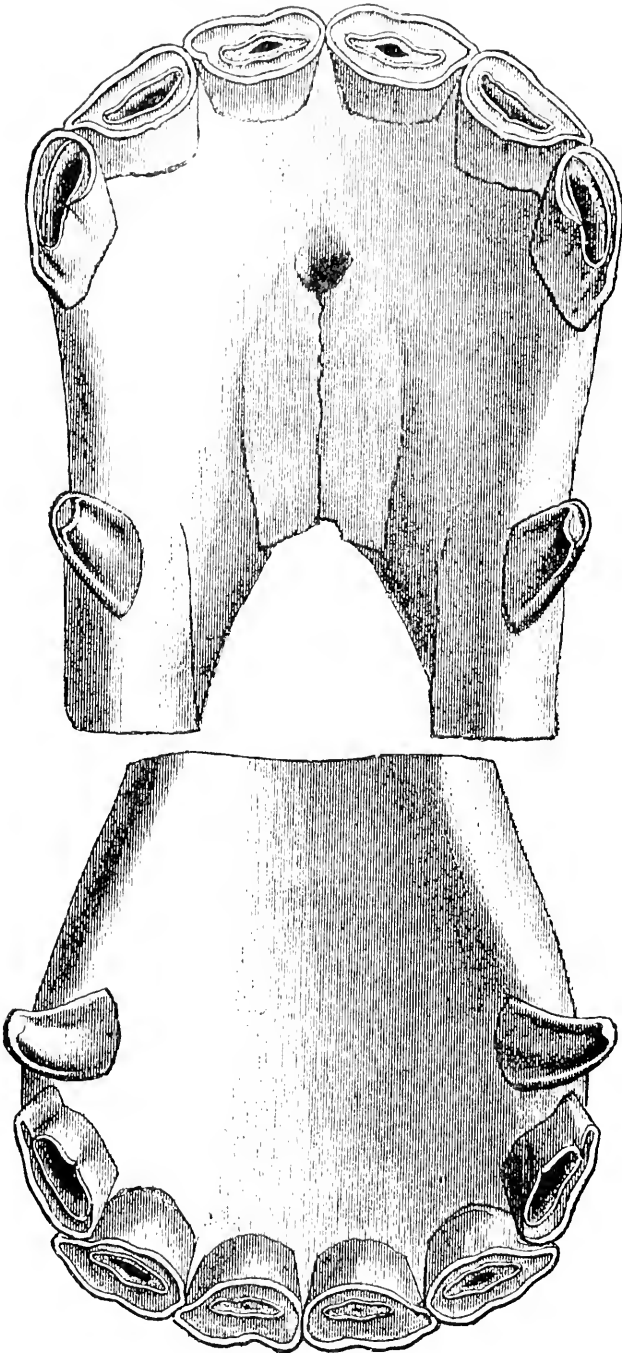


FIG. 63.

Incisor Denture at 5½ Years (Table View).

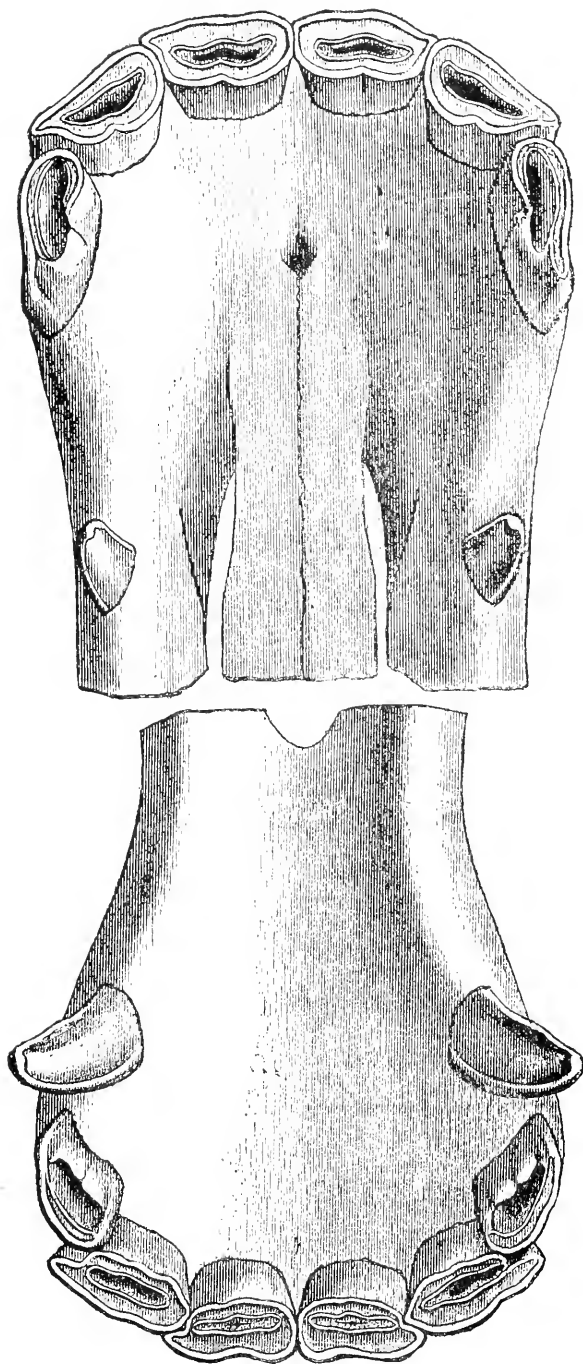


FIG. 64.

Incisor Denture at 6 Years (Table View).

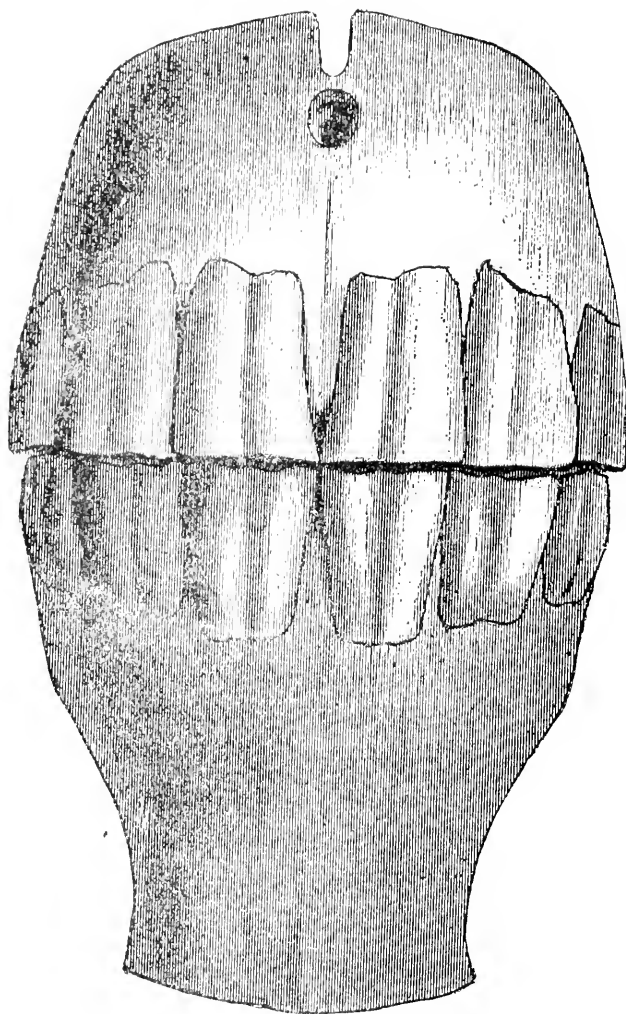


FIG. 65.

Incisor Denture at 6 Years (Anterior View).

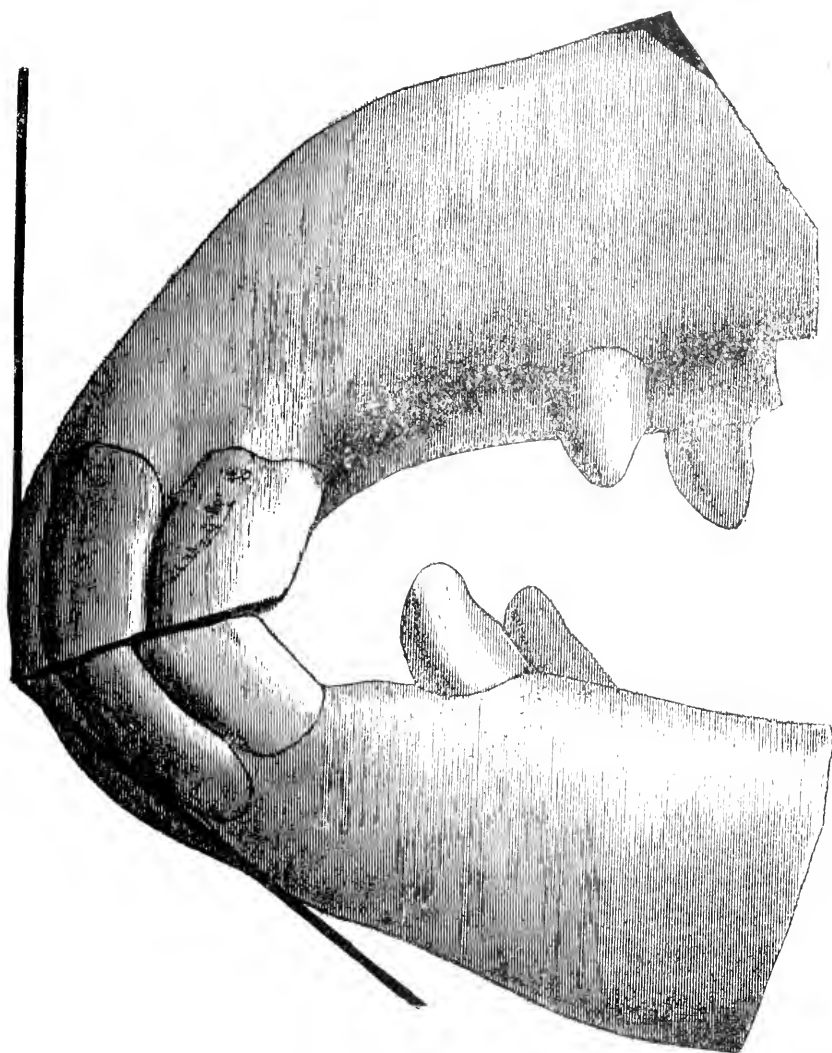


FIG. 65A.

Incisor Denture at 6 Years (Lateral View), with Dark Lines Showing Inclination

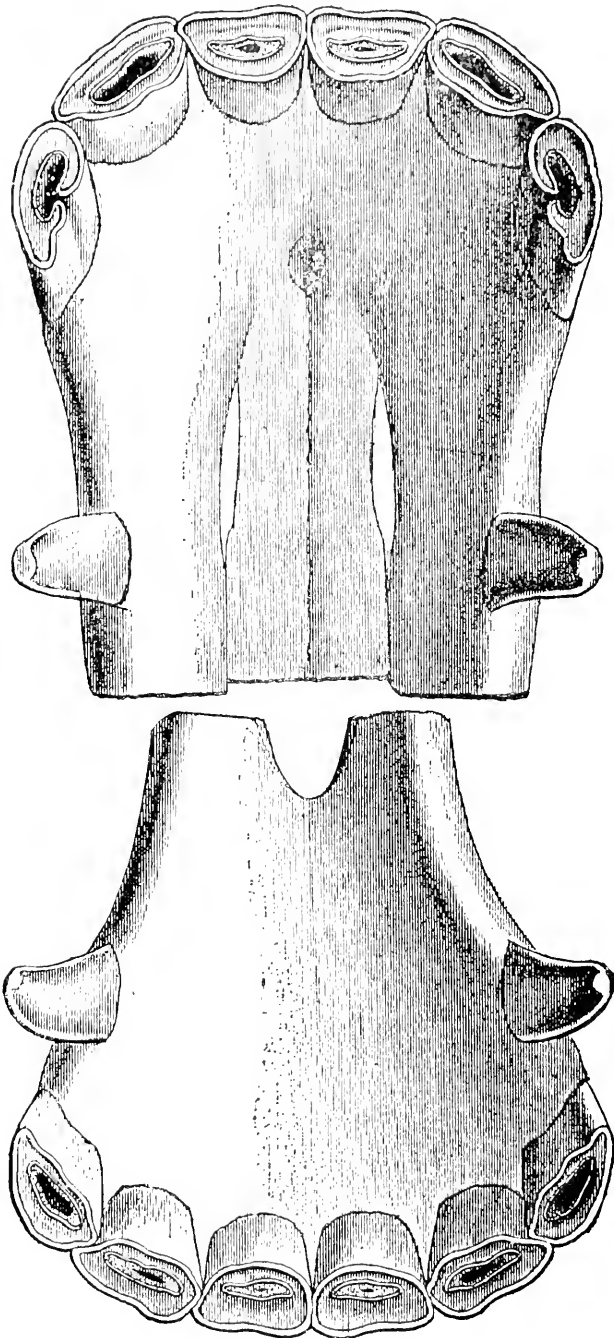


FIG. 66.

Incisor Denture at 6½ Years (Table View).

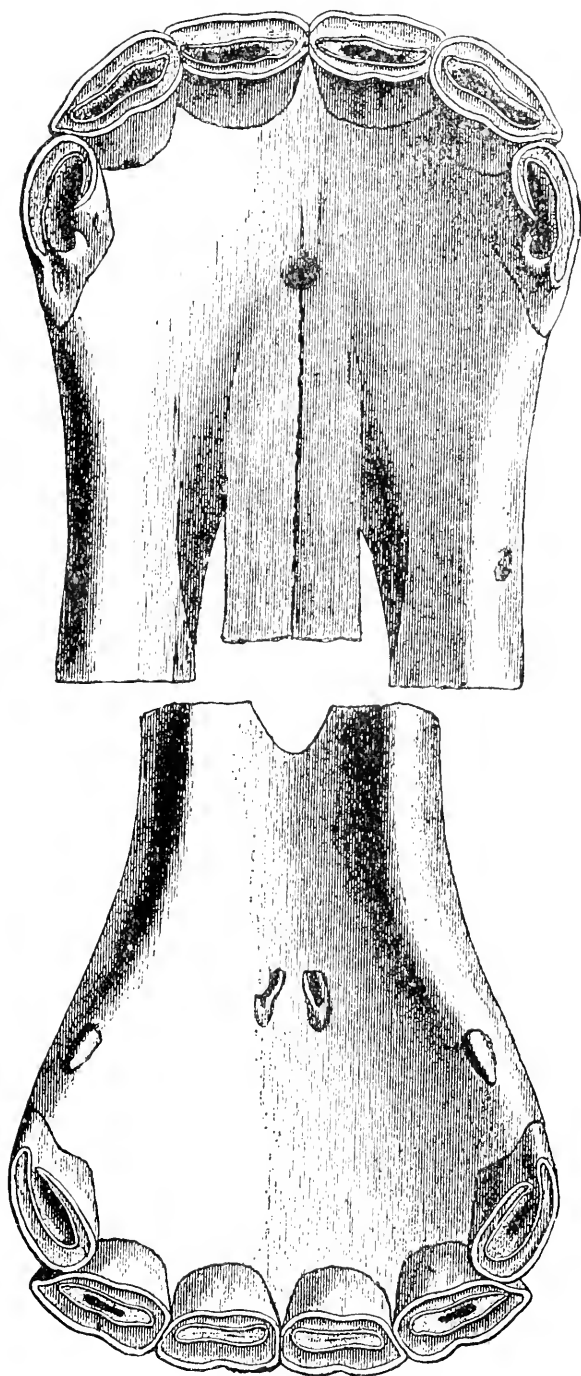


FIG. 66A.

Incisor Denture of a Mare at 6½ Years (Table View).

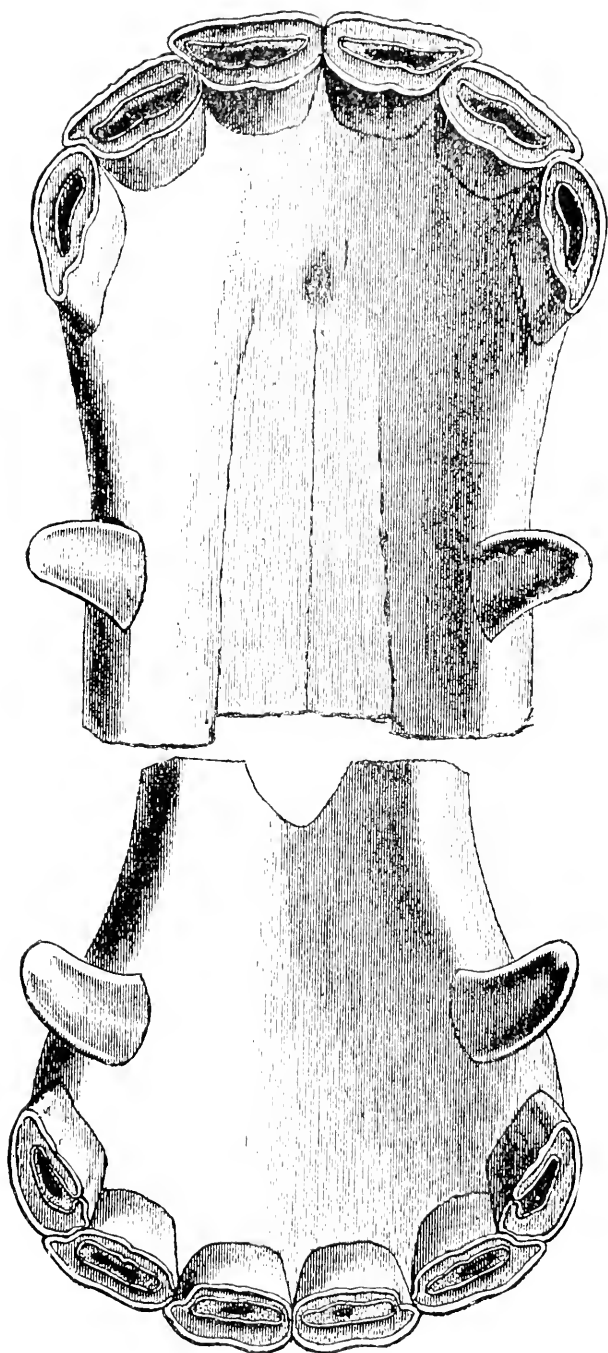


FIG. 67.

Incisor Denture at 7 Years (Table View).

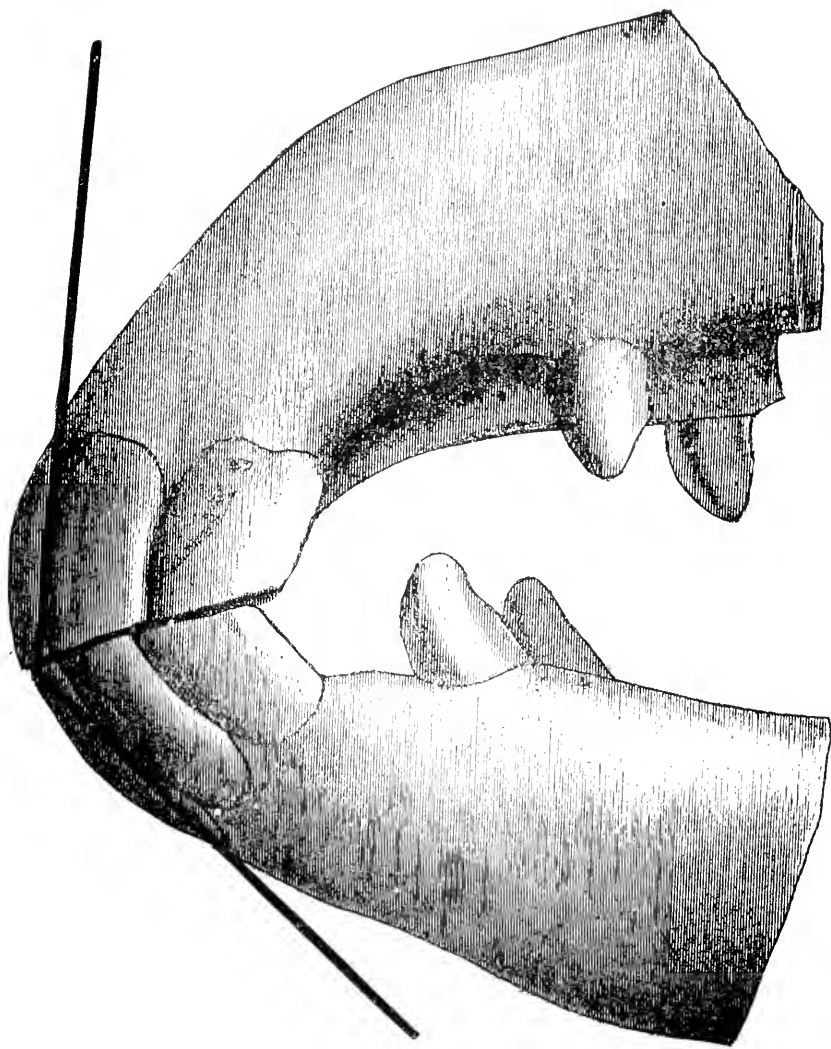


FIG. 68.

Incisor Denture at 7 Years, Dark Lines Showing Inclination.

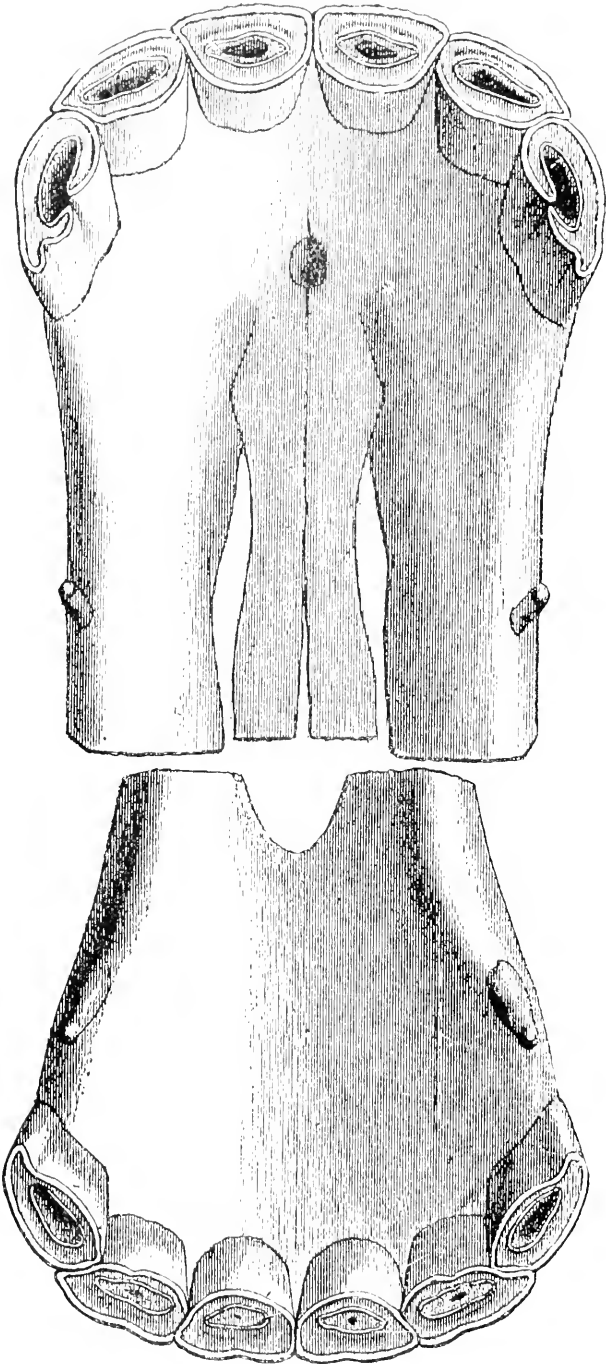


FIG. 69.

Incisor Denture of a Mare at 7 Years (Table View).

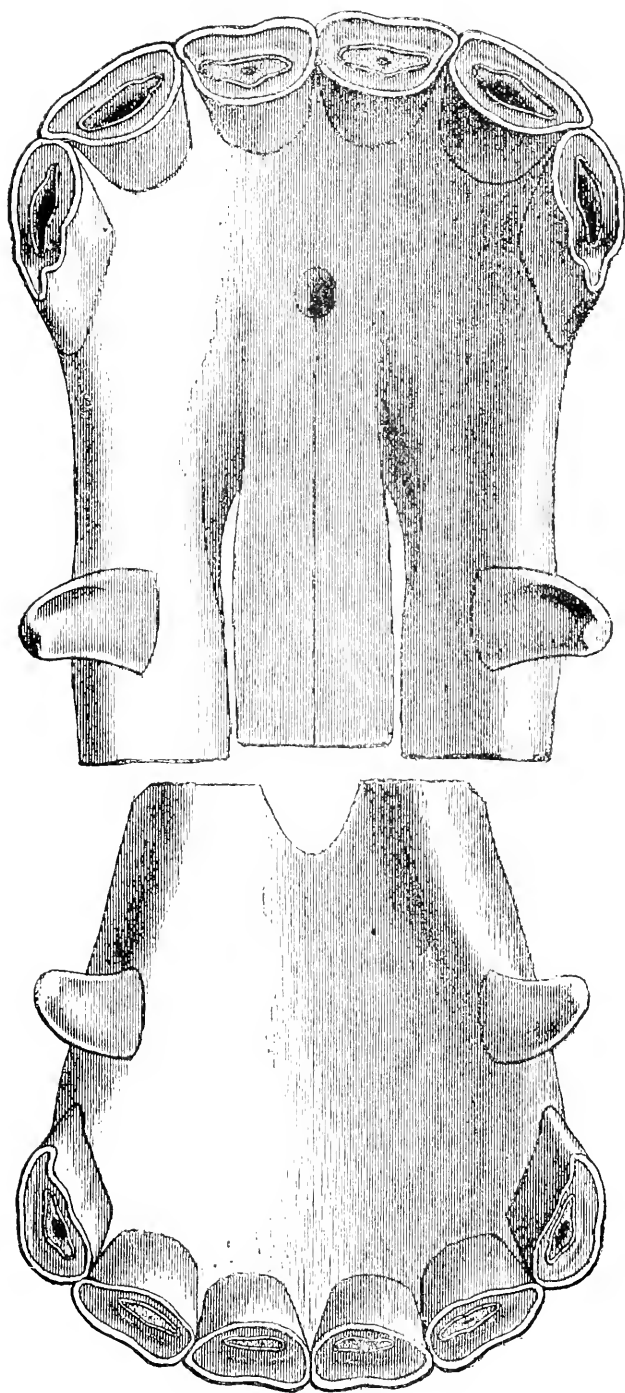


FIG. 70.

Incisor Denture at 8 Years (Table View).

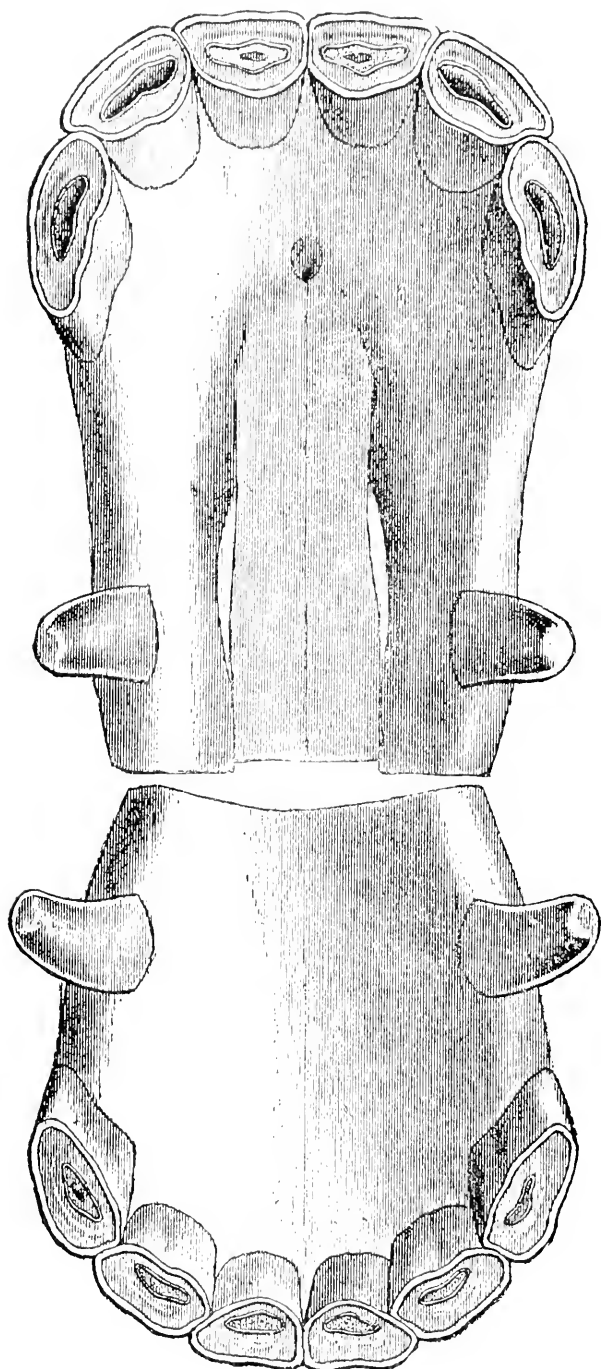


FIG. 71.

Incisor and Canine Dentures at 9 Years (Table View).

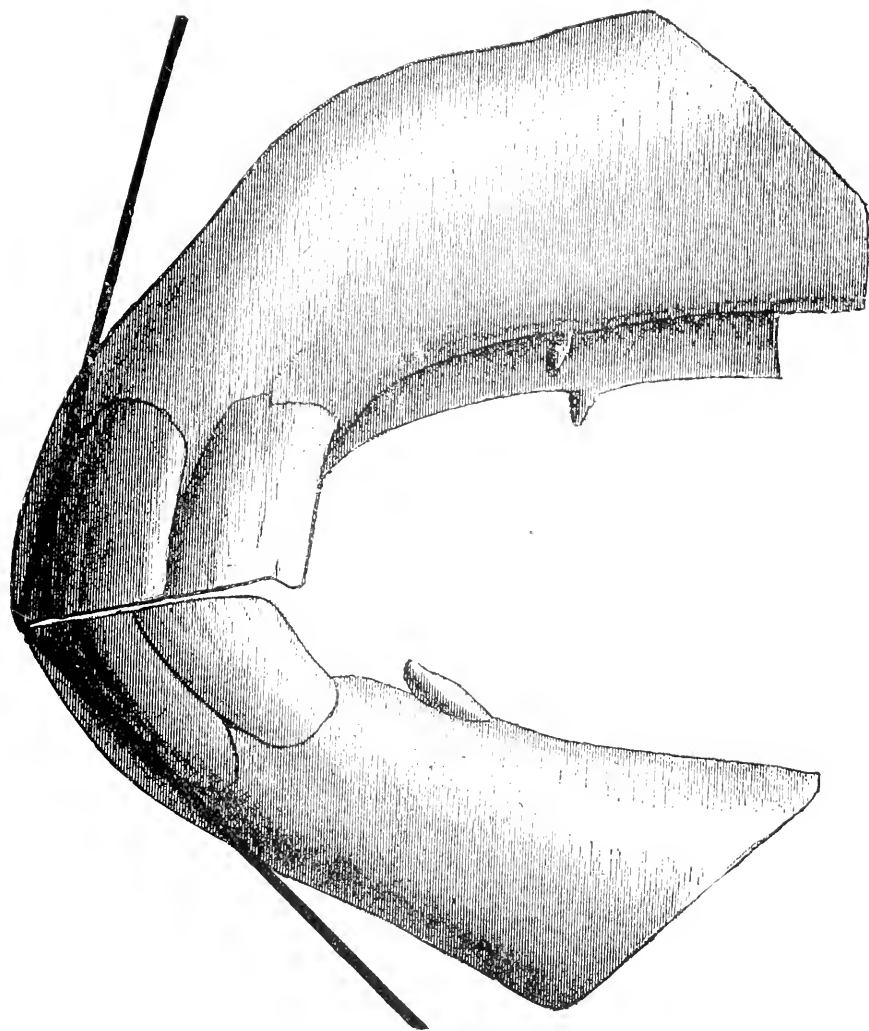


FIG. 72.

Incisor Denture at 9 Years, with Dark Lines Showing the Inclination.

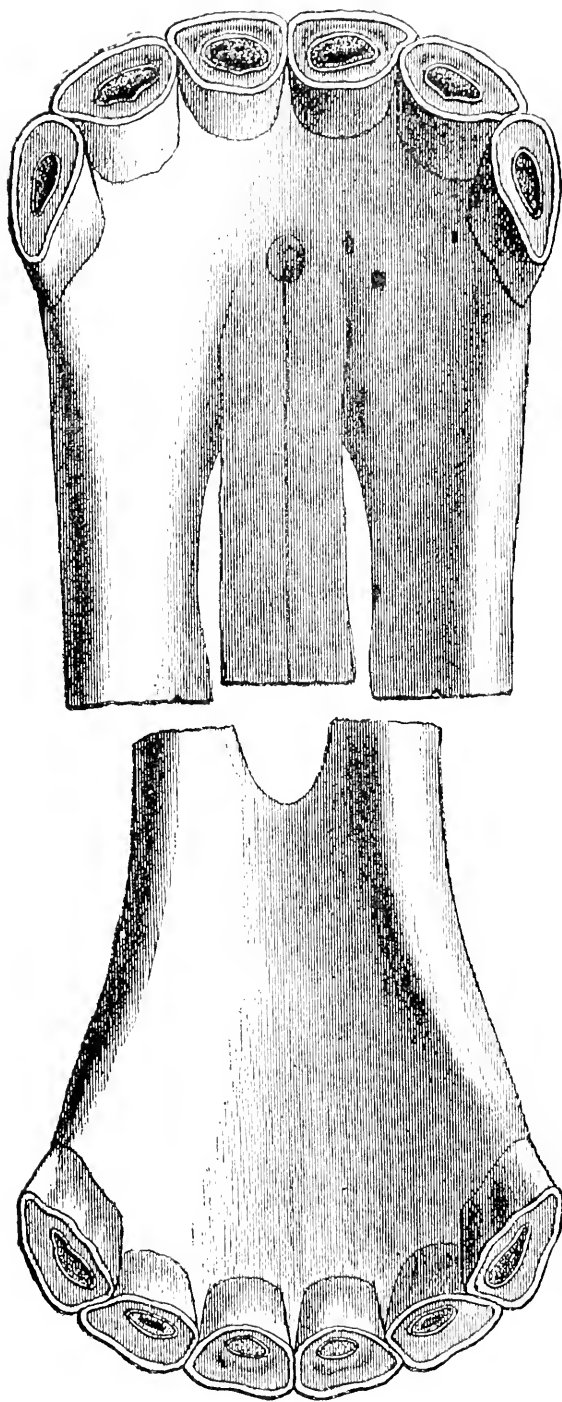


FIG. 73.

Incisor Denture of a Mare at 9 Years (Table View).

Ten to twelve years—The inferior centrals and laterals are more triangular, the cups of the inferior corners are disappearing entirely, the enamel around the infundibula of the centrals and laterals is changing from oblong to round, the crusta petrosa groove on the superior corners is two to three millimeters long and is appearing on the laterals and centrals, and finally the length of the crowns of the superior incisors is markedly increased. The crowns of the canines are large and are becoming rounded at the gingival margin. The inclination of the incisor arcades is now a marked feature of the mouth and is recognized by a mere glance at the lateral aspect of the arcades. (Figs. 74, 75, 76.)

Thirteen to fifteen years—The crusta petrosa groove on the superior corner incisor is nearing the middle of the crown, the tables are markedly triangular, the crowns of the superior incisors are becoming widely separated from the gums, and are becoming narrow near the gingival margin, the infundibula of the central and lateral inferior incisors are now but small circles of enamel—the enamel island—projecting above the level of the dentine and located well toward the posterior aspect of the table, and the gingival margin of the superior central incisors is much lower than that of the laterals. The crowns of the canines are round at the gingival margin (Fig. 77.)

Sixteen to twenty years—The inclination of the incisor arcades is so pronounced that the inferior incisors project forward almost on a straight line with the jaw, the superior corner incisor is grooved almost to the contact border, the crusta petrosa grooves extend well downward over the crowns of all the incisors, the crown of the centrals is shorter than that of the laterals, the infundibula have either disappeared entirely or exist only in the form of small projections of enamel near the posterior border of the tables of the inferior incisors, the crowns of all the superior

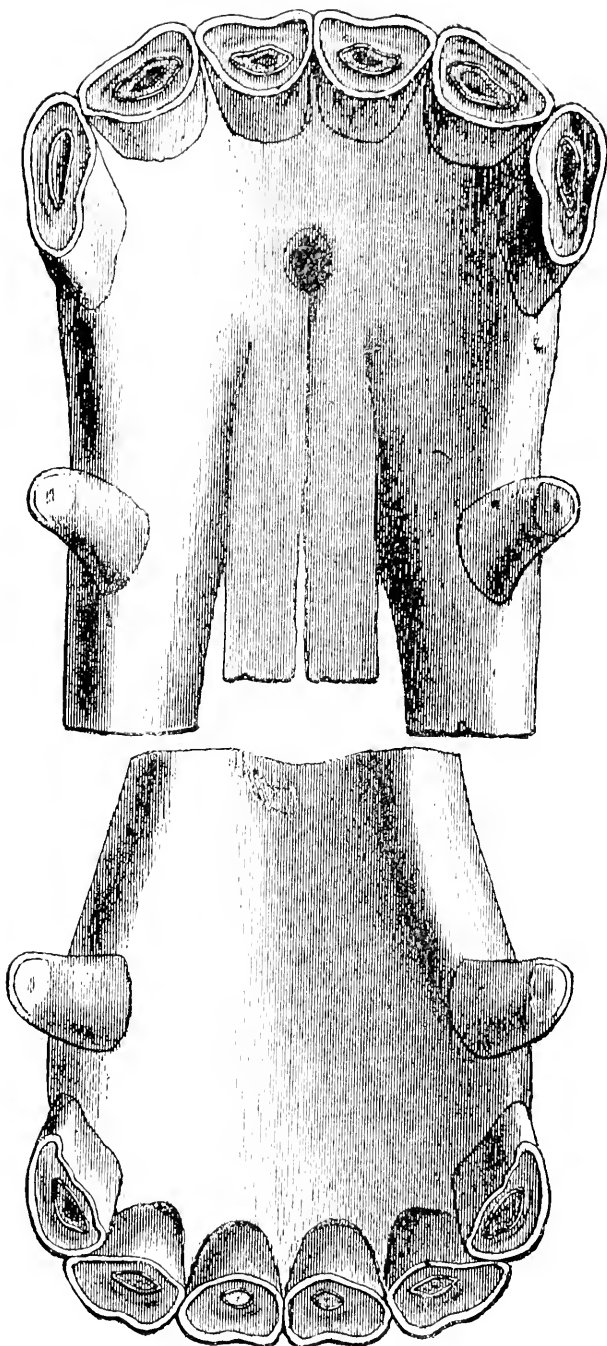


FIG. 74.

Incisor and Canine Dentures at 10 Years (Table View).

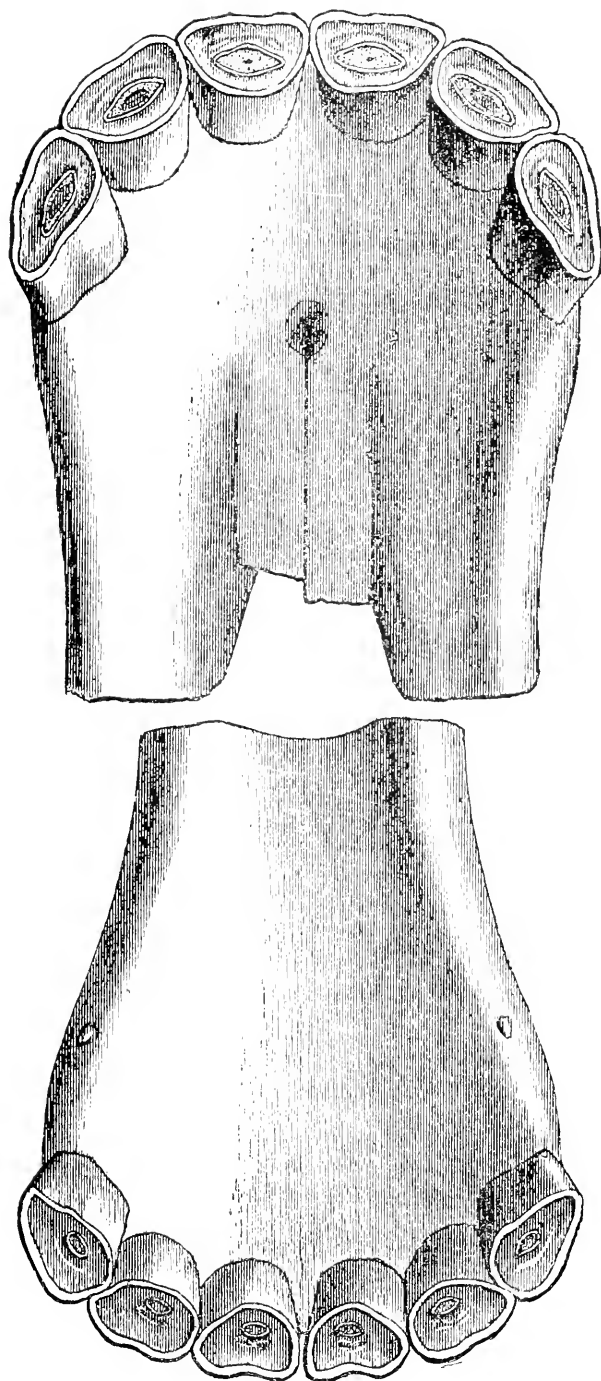


FIG. 75.
Incisor Denture at 12 Years (Table View).

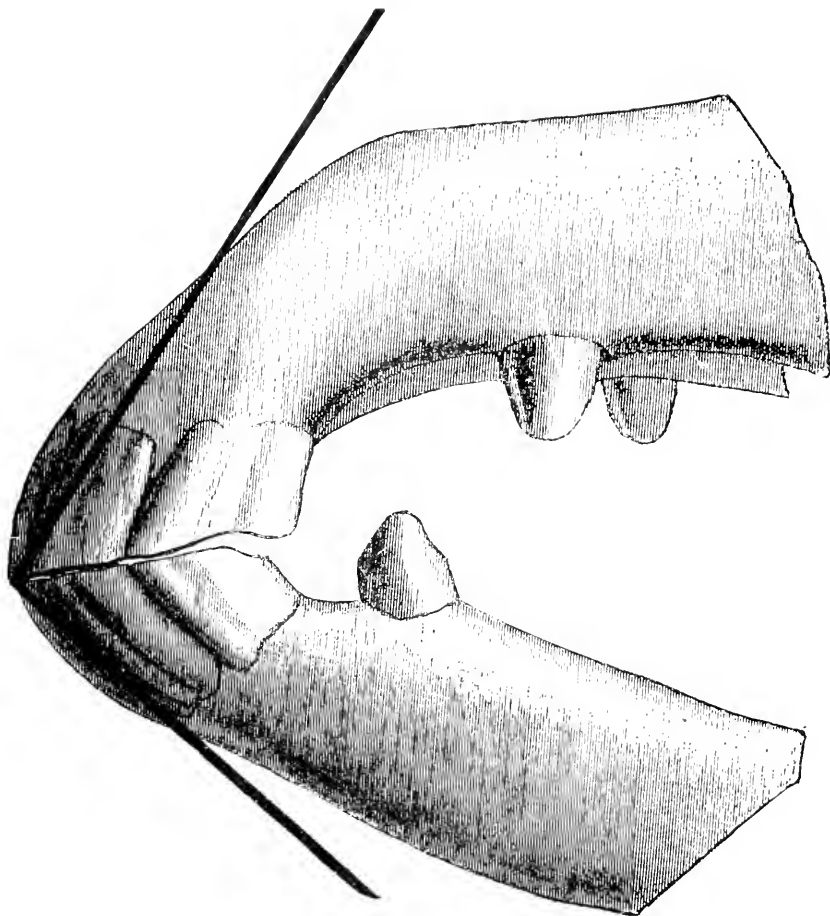


FIG. 76.

Incisor Denture Between the Ages of 10 and 12, Inclusive, with Dark Lines Showing the Inclination.

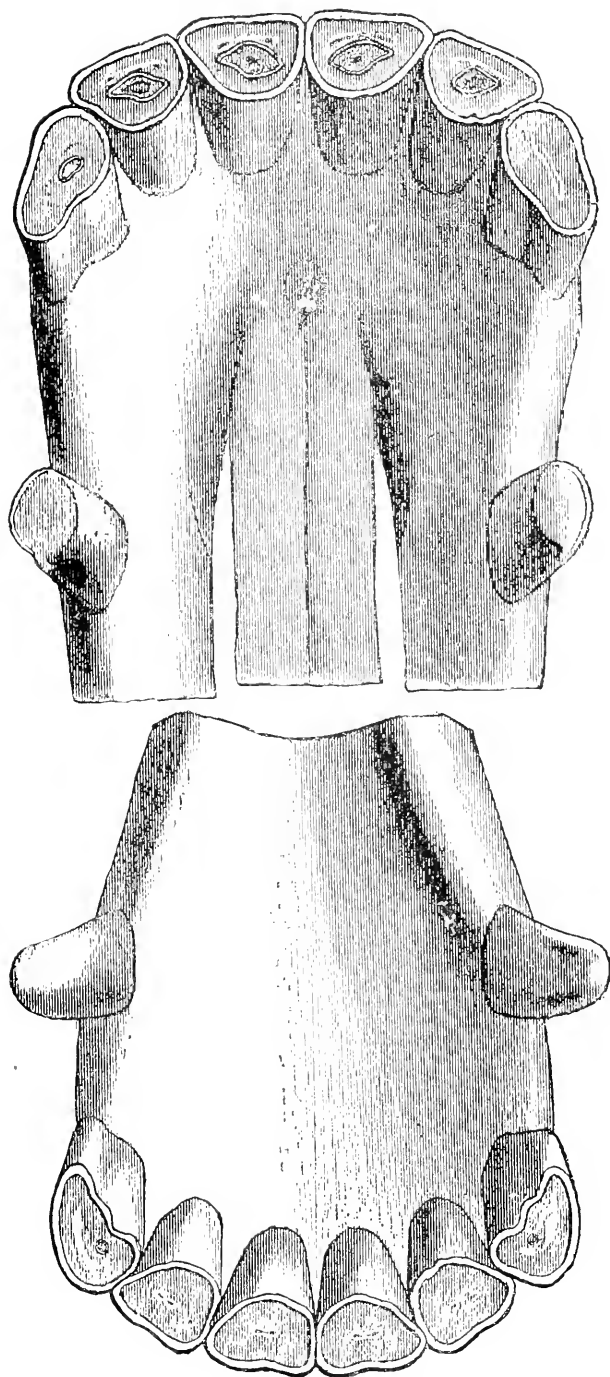


FIG. 77.

Incisor and Canine Dentures at 13 and 15 Years (Table View).

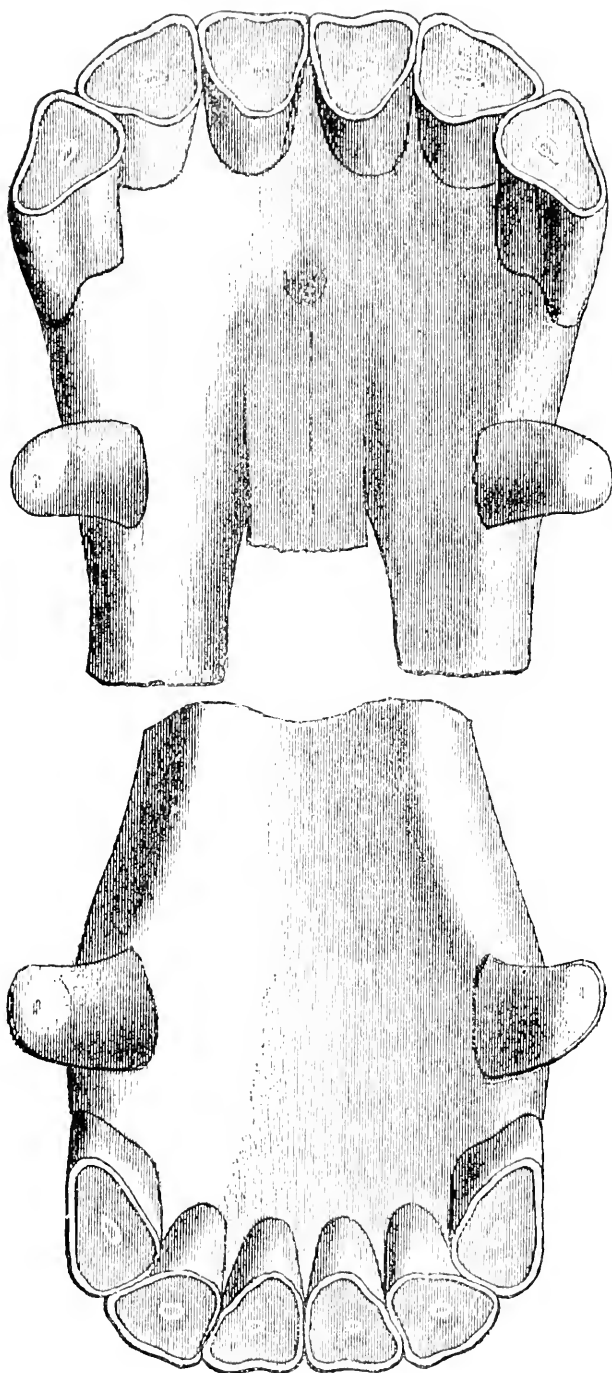


FIG. 78.

Incisor and Canine Dentures at 16 to 20 Years (Table View).

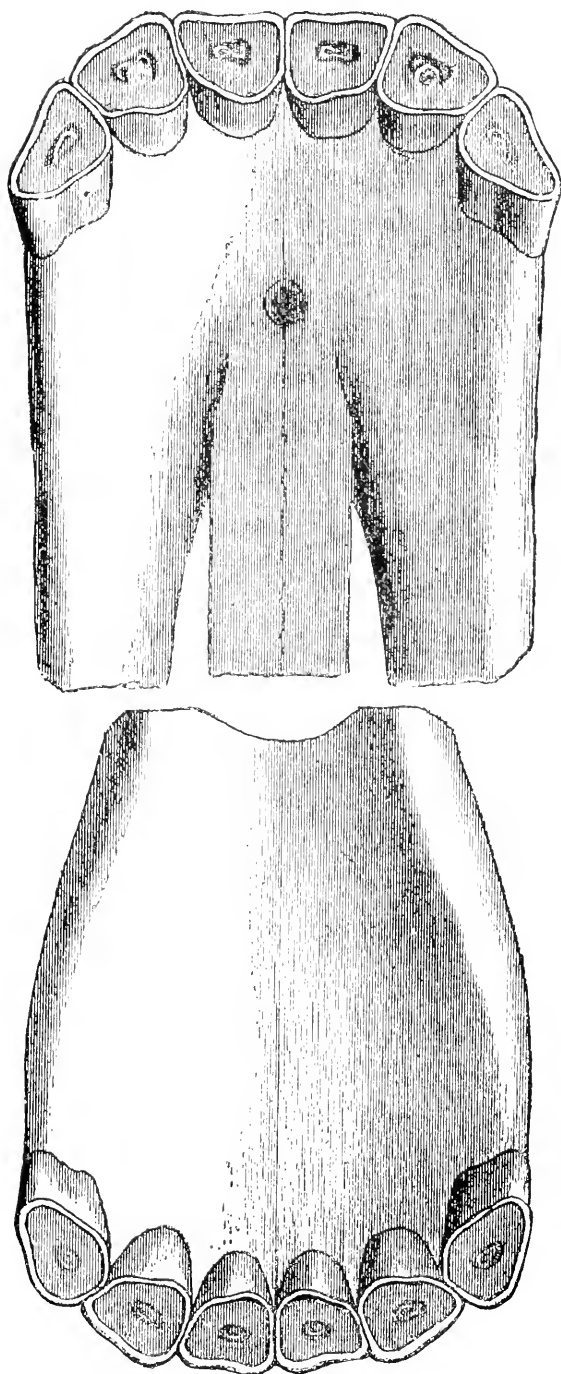


FIG. 78A.

Incisor Denture of a Mare from 16 to 20 Years (Table View).

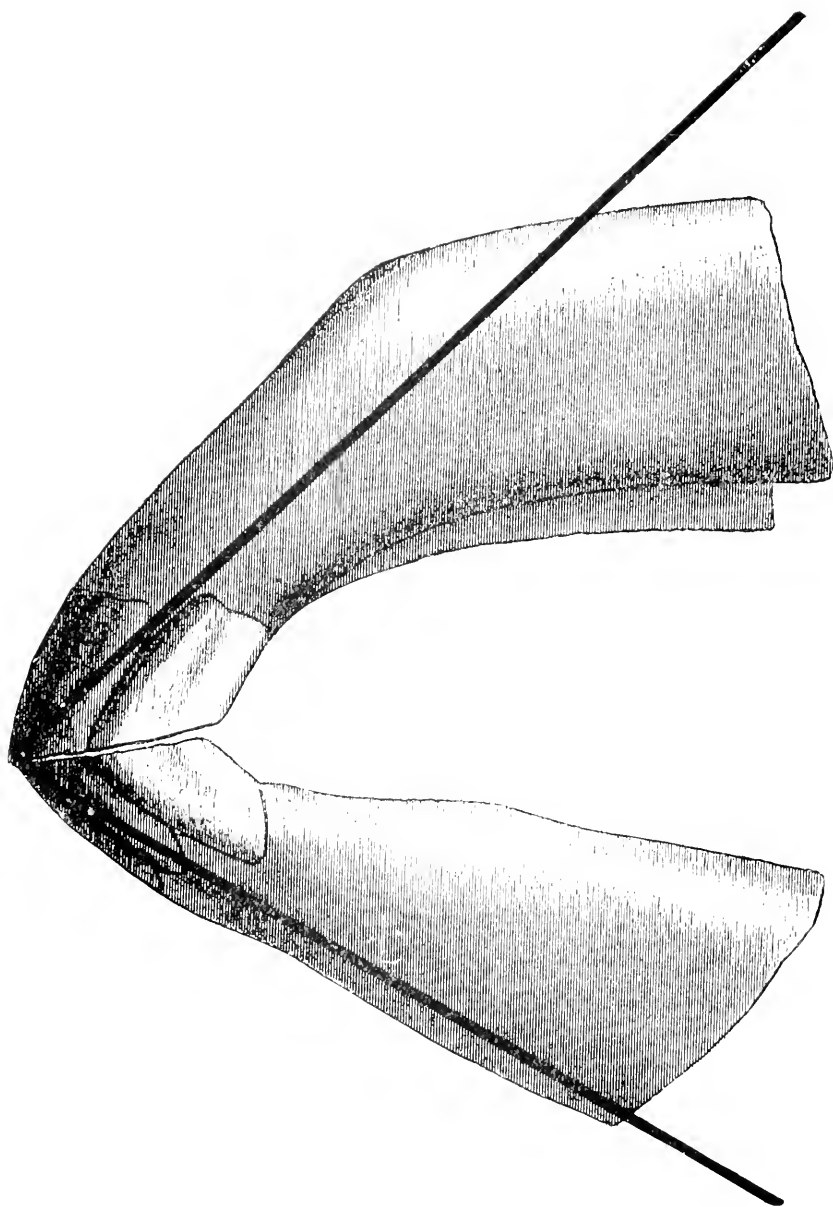


FIG. 79.

Incisor Denture at 16 to 25 Years, with Dark Line Showing Average Inclination.

incisors, with the possible exception of the corners, are long and completely conceal the inferior incisors from an anterior view when the mouth is closed, the contact edge of the superior incisor arcade overlaps that of the inferior, and finally the tables of the central inferior incisors are becoming circular and even flattened from side to side. (Figs. 78, 79.)

Twenty to twenty-five years—The mouth presents all the features of the foregoing paragraph with the exception that the enamel island, representing the last vestige of the infundibulum, has entirely disappeared and is replaced by either a light or dark spot—the **dental star**—which represents the obliterated pulp cavity. The tables are round and the external enamel around them projects beyond the surface of the dentine within, and the crowns of the superior incisors are widely separated with gums and are very narrow at the gingival end. (Fig. 79.)

Old age—The mouth of an old horse may present either very long or very short (worn out) incisor teeth. If long, the implantation can be disturbed on manipulation and can almost be extracted with the fingers. If short, the crowns at the tables are separated one from another by the gums, the crowns are round and the tables of the inferior centrals are flattened from side to side. The canines are round and the molars are uneven, easily extracted, and their roots can be felt along the gingival margin. Often a number of molars are absent from self-extraction.

ROUTINE OF THE EXAMINATION OF A HORSE'S MOUTH TO DETERMINE THE AGE.

1. The horse is approached on the left side and the lips are opened laterally, the left hand elevating the upper lip as the right depresses the under one, thus exposing the lateral aspect of the incisor arcades. A glance at the inclination

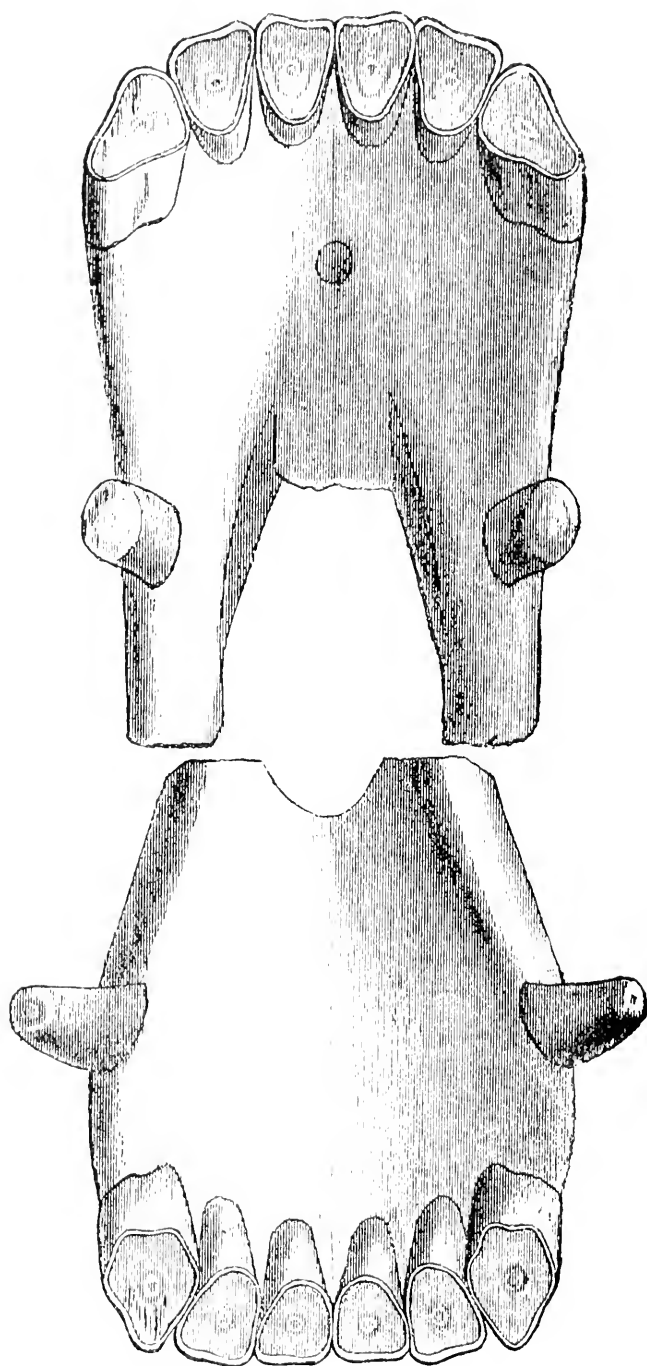


FIG. 79A.

Incisor and Canine Dentures at 20 to 25 Years (Table View).

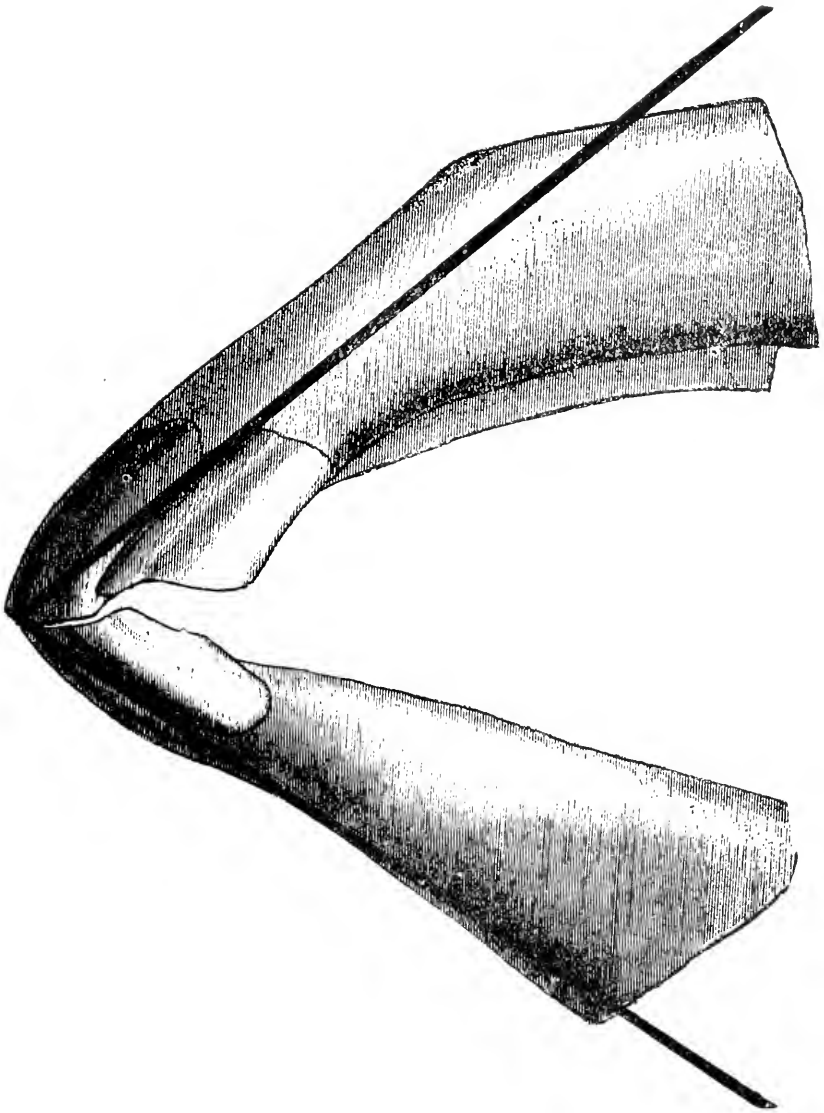


FIG. 80.

Incisor Denture of an Old Horse, with Dark Lines Showing the Inclination.

will determine whether the horse is old or young. If young a second glance is taken to determine whether the exposed teeth are permanent or temporary.

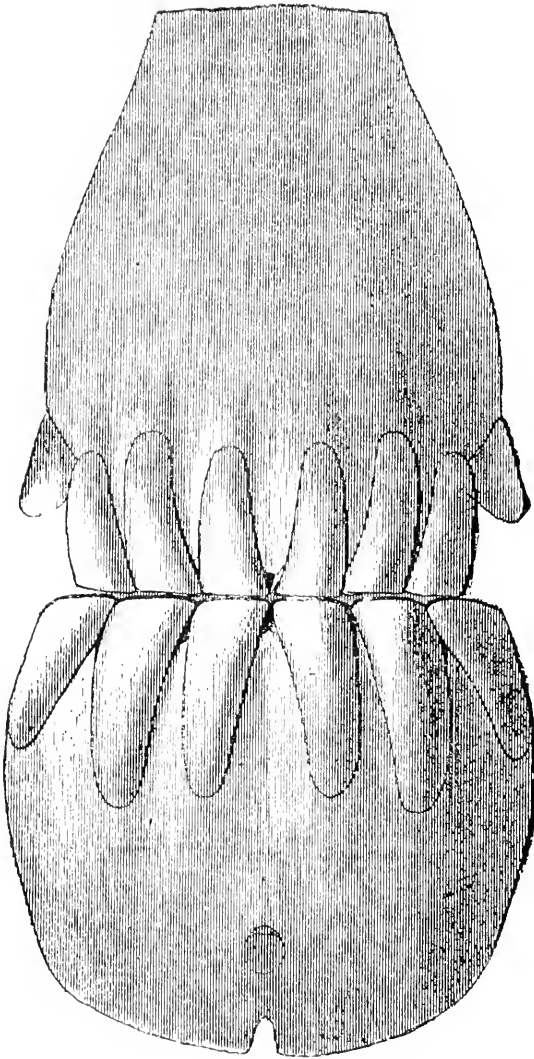


FIG. 81.

Anterior View of the Incisor Denture of an Extremely Old Horse.

2. Without releasing the hold the inspector steps to the front of the horse, elevates the upper lip with the left hand and slips the second and third finger of the right into

the interdental space, the first to expose the superior arcade and the latter to cause the horse to open the mouth slightly. From this position the length, color, crusta petrosa grooves, contiguity of the crowns, and the gingival margin of the superior arcade are inspected.

3. Without changing positions the left hand is now placed gently into the interdental space as the right one depresses the lower lip to expose the tables of the incisor teeth to determine the shape of the tables, the absence, existence or size of the cups, and the shape of the internal enamel surrounding the infundibula.

4. If deemed necessary, without changing the position the left hand is slipped upward along the left molar arcades, to determine the number and condition of the molar teeth.

ANOMALIES OF THE TEETH, NATURAL AND ARTIFICIAL.

Nature's anomalies in dental evolution and retrogression are of such common occurrence that any set rules for the determination of age will frequently mislead the diagnostician. This is especially the case when one or two features of dental growth and wear are depended upon. The common anomalies of the teeth are:

- (1) Anomalies of eruption.
- (2) Anomalies of the texture of the dental tissues.
- (3) Anomalies of the infundibula.
- (4) Anomalies of the cups of the infundibula.
- (5) Anomalies due to the character of the food.

(1) **Eruption** of the teeth will vary **slightly** in different breeds and from climate and artificial influences. In the well-bred horse, the thoroughbred, hackneys and American trotters, in which the development is forced from colthood, the temporary teeth erupt several months earlier than in the horse reared under more natural conditions, and the

same precocity will be observed in the shedding of the temporary teeth, from the increased amount of hard food ingested at an age when the teeth are still defective in texture. In the one-year-old race horse that is trained and fed to force the development of the muscular system the teeth will share in the development providing the unnatural requirement does not impair the general health.

(2) **The texture of the teeth** varies in different animals of the same class reared under the same conditions, from causes too obscure to recognize. Deficiency in the inorganic proximate principles of food in certain districts has been observed to yield horses with soft teeth. The variation in the texture of the teeth will either hasten or retard the retrogression of the teeth. When the teeth are hard the events by which age is determined will be retarded, and as a consequence the animal will appear young. When the teeth are soft the reverse occurs and the animal appears older. The anomalies caused by the varied density of the tooth substance are precocious or retarded changes in the cups, infundibula, shape of the tables and length of the crowns. One of the most pronounced results of soft teeth is the shortening instead of elongation of the incisor crowns as the animal becomes old.

(3) **The infundibula** of the incisor teeth may vary greatly as to their depth. They may be very shallow in some animals and very deep in others, and thus prove misleading when depended upon alone in the determination of age.

(4) **The cups of the infundibula** are equally subject to variations, due to the amount of crusta petrosa in the bottom of the infundibula. In some teeth the infundibula are almost full of crusta petrosa, while others contain but a small amount. When full the cup disappears early, and when empty it persists longer. This anomaly is not con-

using if the shape of the infundibula is taken into account.

(5) **Character of the food** will hasten or retard the wear of the teeth to a remarkable degree. Grazing, which requires the use of the incisor teeth to detach the food, has a



FIG. 81A.
Gouge.

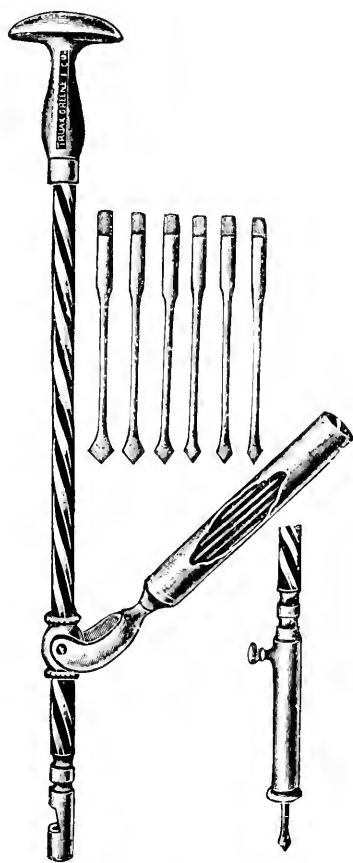


FIG. 81B.
Bishoping Drills.

precocious influence, while stable feeding, which exacts but little work from the incisors, retards the wear.

Artificial anomalies refer to alterations in the appearance of the incisor teeth by the use of instruments. Deviation from the normal may result from:

- (1) Shortening of the crowns of the incisors, espe-

cially the superior, with the incisor nipper and file.

(2) Polishing the anterior surface of the superior incisors.

(3) Renewal of the cups by drilling and staining.

1. **Shortening of the crowns** of the superior incisors will deceive only the novice or the careless expert. The artificially shortened crown is promptly recognized by the interrupted contact of the anterior margin of the arcades, if not by the other retrogressive changes which cannot be effaced. The operation is performed with an ordinary incisor nipper and file. The first step is to cut off the anterior end of the superior corners where they contact the laterals, and then file them to the length decided upon. Then using this length as a guide, a groove is filed across the entire arcade, over the laterals and centrals. The teeth are then cut off along the groove and filed to a regular, smooth edge, and beveled backwards to give the appearance of a normal superior table. If the nipper alone is used without first grooving the arcade, the enamel may chip upward and ruin the appearance of the whole arcade.

2. **Polishing the crowns**—After shortening the arcade the anterior face is scraped of all its tartar and crusta petrosa with a curette, and then whitened with emery paper to give the appearance of young teeth. This operation is also performed with a small revolving emery wheel applied to the flexible shaft of a dental engine. By this means the grooves, as well as the incrustations, can be removed. The typical bluish-white color of young enamel can, however, not be imitated, and besides, the yellow color will soon return.

3. **Renewal of the cups** (Bishoping) is the most important of the artificial attempts to make horses appear younger, and if performed intelligently upon horses that are not too old, together with the above operations, even the vaunted

expert may blunder. The operation consists of cutting large cups in the inferior corners, smaller ones in the laterals and mere dots in the centrals and then staining them with




FIG. 82A.
Wheel Drill.

FIG. 82.
Dental Engine.

FIG. 82B.
The Polishing Wheel.

silver nitrate. The cupping process is performed with an engraver's gouge, revolving hand drill, or by the modern ingenious implement in vogue in the Chicago horse market,

consisting of the foot engine used by human dentists, equipped with a circular cutting wheel, by which cups of perfectly normal shape and size can be made.

Modus operandi: The horse is backed into a single stall

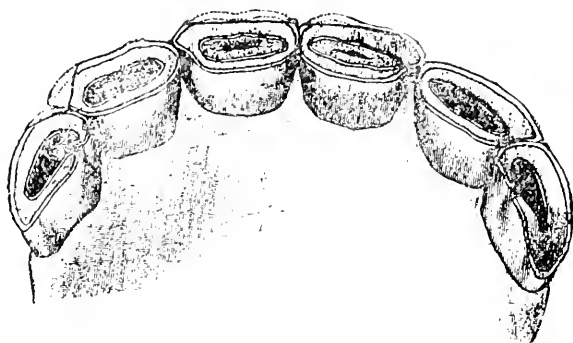


FIG. 83.

An 8-Year-Old Mouth Made "6" by "Bishoping."

and secured in the dental halter. An assistant works the dental engine with the foot. The operator holding the hand-piece of the flexible shaft in the right hand and the jaw in

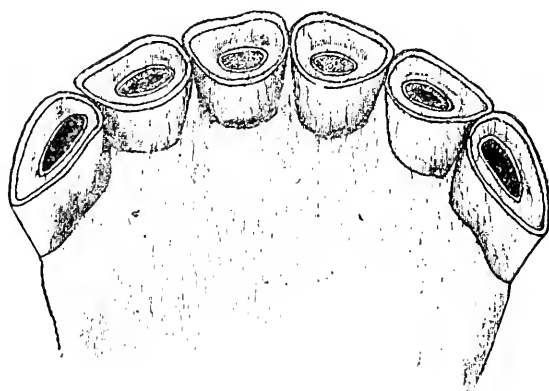


FIG. 84.

A 9 or 10-Year-Old Mouth Made "7" by "Bishoping."

the other, cuts first a large elliptical cup with sharp commissures in the table of the corner incisors, then smaller ones in the laterals and small dots in the centrals. As the wheel revolves with great velocity, the cupping is the work of but

a moment, if the horse stands complacently. When the corner tooth has but a small table it is enlarged by filing and the cup is cut across its entire length. The cup in the corners is frequently made with a rounded belly internally and a sharp commissure externally to give a more confusing if

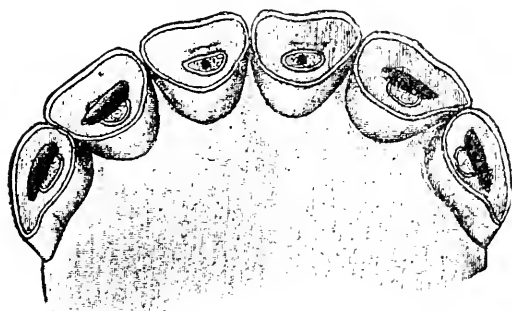


FIG. 85.

not more natural appearance. When the cupping process is complete the arcade is dried and kept free from saliva by wrapping the jaw behind the teeth with a cloth or towel. The cups are then stained by applying a saturated solution of silver nitrate with a stick and then drying it immediately

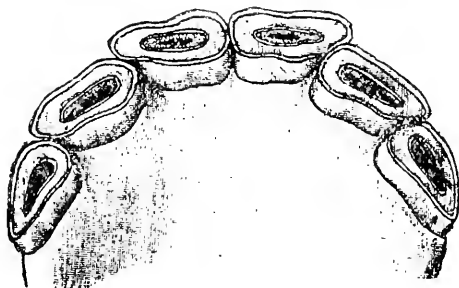


FIG. 86.

Effect of "Bishoping" Teeth of 9 to 12-Year-Old Horses.

by plunging the head of a burning match into it. The drying process immediately blackens the cavity. If the stain flows over the table of the tooth it is filed off.

Shortening, polishing, cupping and staining the incisor teeth of a nine or ten-year-old horse may be so cleverly per-

EVOLUTION AND RETROGRESSION OF THE TEETH TABULATED.

DATE.	CENTRAL.	LATERAL.	CORNER.	CANINE.	FIRST MOLAR.	SECOND MOLAR.	THIRD MOLAR.	FOURTH MOLAR.	FIFTH MOLAR.	SIXTH MOLAR.
BIRTH.	Temporary tooth erupts.	Temporary tooth erupts.	Temporary tooth erupts.	Temporary tooth erupts.			
SIX MONTHS.	Growing.	Temporary tooth erupts.	Growing.	Growing.	Growing.			
TEN MONTHS.	In wear.	In wear.	Temporary tooth erupts.	Temporary tooth in wear.	Temporary tooth in wear.	Temporary tooth in wear.	Erupts.		
TWO AND ONE-HALF YEARS.	Temporary tooth loosens.	do.	In wear.	Temporary tooth sheds. Permanent erupts.	Temporary tooth sheds. Permanent erupts.	do.	Reaches its greatest length. 68 M. M.	Erupt	
THREE YEARS.	Temporary tooth sheds. Permanent erupts.	do.	do.	Gains 2 M. M. in length.	Gains 2 M. M. in length.	Temporary tooth sheds. Permanent erupts.	Loses 2 M. M. in length.	Gains 2 M. M. in length.	
THREE AND ONE-HALF YEARS.	In wear.	Temporary tooth loosens.	do.	Reaches its greatest length. 48 M. M.	Reaches its greatest length. 55 M. M.	Gains 2 M. M. in length.	Loses 1 M. M. in length.	Reaches its greatest length. 65 M. M.	Is piercing the jaw.
FOUR YEARS.	Cup very deep.	Temporary tooth sheds. Permanent erupts.	do.	Is piercing the jaw.	Loses 1 M. M. in length.	Loses 1 M. M. in length.	Reaches its greatest length. 73 M. M.	Loses 1 M. M. in length.	Loses 1 M. M. in length.	Erupt
FOUR AND ONE-HALF YEARS.	do.	In wear.	Temporary tooth loosens.	Inferior tooth erupts.	do.	do.	Loses 1 M. M. in length.	do.	do.	Gains 2 M. M. in length.
FIVE YEARS.	Cup becomes shallow.	Cup very deep.	Temporary tooth sheds. Permanent erupts.	Superior tooth erupts.	do.	do.	do.	do.	do.	Reaches greatest length. 63 M. M.
FIVE AND ONE-HALF YEARS.	Cup disappearing.	do.	In wear.	Growing.	do.	do.	do.	do.	do.	do.

EVOLUTION AND RETROGRESSION OF THE TEETH TABULATED—CONTINUED.

DATE.	CENTRAL.	LATERAL.	CORNER.	CANINE.	FIRST MOLAR.	SECOND MOLAR.	THIRD MOLAR.	FOURTH MOLAR.	FIFTH MOLAR.	SIXTH MOLAR.
SIX YEARS.	Cup disappears from inferior.	Cup becomes shallow.	Cup very deep.	Growing.	Loses 1 M. M. in length.	Loses 1 M. M. in length.	Loses 1 M. M. in length.	Loses 1 M. M. in length.	Loses 1 M. M. in length.	Reaches greatest length. 6.3 M. M.
SEVEN YEARS.	Infundibulum becomes shorter.	Cup disappears from inferior.	Cup becomes shallow.	Has a long flat crown.	do.	Loses 1.5 M. M. in length.	Loses 2 M. M. in length.	Loses 2 M. M. in length.	Loses 2 M. M. in length.	Loses 1.5 M. M. in length.
EIGHT YEARS.	Infundibulum becomes round.	Infundibulum becomes shorter.	Cup disappearing from interior.	do.	do.	do.	do.	do.	Loses 1.5 M. M. in length.	do.
NINE YEARS.	Infundibulum round.	Infundibulum becomes round.	Cement groove appears on gingival margin of superior.	Point becomes blunt.	do.	Loses 1 M. M. in length.	do.	do.	do.	Loses 1 M. M. in length.
TEN TO TWELVE YEARS.	Crowns becoming long. Inclination increasing.		Cement groove long.	Crown becoming round at gingival margin.	Loses 2 M. M. in length.	Loses 2 M. M. in length.	do.	do.	do.	do.
TWELVE TO FIFTEEN YEARS.	Crowns long and inclination increasing. Infundibula circular.		Cement groove 1 to 1.5 C. M. in length in superior.	Crowns round and table blunted.	Loses 4 M. M. in length.	Loses 4 to 6 M. M. in length.	Loses 5 to 6 M. M. in length.	Loses 5 to 6 M. M. in length.	Loses 4 to 6 M. M. in length.	Loses 3 M. M. in length.
FIFTEEN TO TWENTY YEARS.	Crowns long. Inclination increasing. Infundibula near posterior border of table.		Cement groove extends to table margin on superior.	do.	Loses 4 M. M. in length.	Loses 5 to 6 M. M. in length.	Loses 8 to 10 M. M. in length.	Loses 12 to 15 M. M. in length.	Loses 8 to 10 M. M. in length.	Loses 4 to 5 M. M. in length.
TWENTY TO TWENTY-FIVE YEARS.	Tables biangular. Infundibula absent. Crowns long.		Crown short. Table beveled from within outward.	Short and point outward.	Loses 4 M. M. in length.	Loses 4 to 5 M. M. in length.	Loses 5 to 8 M. M. in length.	Loses 10 to 12 M. M. in length.	Loses 5 to 8 M. M. in length.	Loses 3 to 4 M. M. in length.
TWENTY-FIVE TO THIRTY YEARS.	Reach maximum inclination. Tables inferior biangular. Internal enamel absent. Dental star in each table.		do.	do.	Loses 4 M. M. in length.	Loses 4 to 4.5 M. M. in length.	Loses 4 to 5 M. M. in length.	Loses 4 to 6 M. M. in length.	Loses 3 to 4 M. M. in length.	Loses 3 M. M. in length.
.....	Estimate total loss in length of molars.	25-30 M. M.	30-40 M. M.	40-50 M. M.	40-50 M. M.	30-40 M. M.	25-30 M. M.

formed that the most circumspect study of the mouth may fail to detect the alteration. In these cases the cupping is limited to the removal of the crusta petrosa within the infundibula, thus leaving the cup with a perfect enamel boundary. At that age the other retrogressive changes are not pronounced and afford but little evidence to guide the diagnostician. (See Figs. 83, 84, 85, 86.)

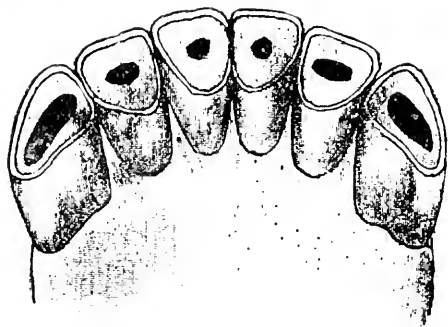


FIG. 87.

The Ridiculous Effect of "Bishoping" Aged Horses.

When horses are past the age of twelve years the results of these operations are readily detected by the interrupted contact of the incisor arcades and especially by the angle of inclination, which is never altered by any natural anomaly and which cannot be artificially changed. The shape of the tables and the absence of enamel around the cup will also lead readily to detection of the fraudulent attempts to make very old horses appear younger. (See Fig. 87.)

CHAPTER IV.

FUNCTION OF THE TEETH.

The teeth have but a passive function to perform as accessory organs of prehension, mastication and insalivation, and as organs of defense. Their uses are similar in all species, varying but slightly in detail.

The incisors serve the general purpose of **holding food**, after the lips or tongue have gathered it between them, and as a jerk of the head detaches it. In the ingestion of detached food they serve no useful purpose in any of the domestic animals. In all the domestic mammals except ruminants they are important organs of defense, and as such they are most useful in the soliped. The incisors of carnivora are so much shorter than the canines that the latter inflict the greatest harm to an enemy.

The canines of solipeds are common only to males, in which animals they have no special function to perform. In the carnivora and omnivora they serve the useful purpose of tearing attached food preparatory to mastication, besides constituting the principal organs of defense. In these animals they are common to both sexes and they lock over each other in a manner to hold fast to any object into which they are imbedded.

The molars of herbivora are the mill-stones of the mechanism of mastication. The wide, roughened tables of the superior molars, and the series of strong muscles which move the inferior ones upon them, constitutes the principal features of a perfect grinding apparatus necessary to the welfare of animals ingesting coarse, fibrous food. In these animals the molars grind the food perfectly, carefully and

persistently, and at the same time incorporate it with the abundant saliva essential to the proper digestion of amylaceous food. In ruminants the food is first passed by the molars with only nominal comminution, but when it is regurgitated during rumination it is as carefully masticated as in the non-ruminating animal. Besides the function of mastication and insalivation, the molars might correctly be classified as tactile organs, as they readily detect the presence of undesirable particles of food.

In the carnivora the molars serve to crack hard objects, as bones, into smaller particles and to divide large pieces of flesh into smaller ones simultaneously with surrounding the particles with a slimy coat of saliva to facilitate deglutition. In these animals they are not essential organs, as the food may be bolted without material impairment of the general health, while in the herbivora the molars are as essential to the life of the animal as any of the internal digestive organs.

PREHENSION.

The function of prehension is performed by the lips, incisor teeth, canine teeth and tongue. When the food has passed the incisors and canines, and the mouth is closed, it is drawn backward to the molars by suction. The organs of prehension named in the order of their importance in the different animals are as follows:

Horse: (1), the lips; (2), the incisor teeth; (3), the tongue.

Ruminants: (1), the tongue; (2), the incisor teeth and dental pad; (3), the lips.

Carnivora: (1), the canine teeth; (2), the tongue; (3), the incisor teeth; (4), the lips. In the ingestion of liquids the tongue alone performs the function by dashing the liquid well backward into the mouth.

Omnivora: (1), the incisor teeth; (2), the canine teeth; (3), the lips; (4), the tongue.

(In sheep and goats the lips are very motile and serve to gather attached food as in the horse.)

MECHANISM OF MASTICATION.

The organs of mastication comprise: The superior maxillary, the inferior maxillary, the premaxilla, the molar teeth, the tongue, the hard palate, the cheeks, and the masseter, the internal pterygoid, the temporalis, the digastricus, the external pterygoid, the stylo-maxillaris and the sterno-maxillaris muscles.

The superior maxillary is an immovable bone, closely united by sutures to its contiguous facial and cranial bones, and to its fellow by a wide, flat process extending across the mouth to form its bony roof. It receives into six deep cavities the imbedded portions of the superior molar arcade, and with its fellow and premaxilla constitutes the **upper jaw**. Its function is to hold taut the superior molars and to form the roof of the mouth.

The inferior maxillary is a movable bone articulating with the squamous temporal by a diarthrosis having imperfect rotatory and perfect ginglymoid motion. It is a single bone consisting of a small body anteriorly with two large branches extending posteriorly to the temporo-maxillary articulation. At the anterior extremity of the body it receives the six incisor teeth and along the superior margin of each branch the six inferior molars. Its function in mastication is to serve as a carriage for the inferior molars, a medium for the attachment of the muscles which move it and to assist in forming the bony boundary of the mouth.

The premaxilla is an irregular bone, which, with its fellow completes the upper jaw anteriorly and contains the

alveolar cavities for superior incisor teeth. It consists of a body and two branches extending backward. The upper branch passes upward and backward along the superior maxilla to the base of the nasal peak, where it enters into the formation of the **maxillo-nasal notch**. The lower branch is a thin plate loosely attached to its fellow and the superior maxilla to complete the roof of the mouth anteriorly.

The tongue of animals is a very strong, motile, musculo-membranous organ, having a fixed attachment to the spur process of the hyoid bone posteriorly, and a free extremity anteriorly. It is held to the floor of the mouth by its mucous membrane. Its upper surface is thickly paved with epithelium. It is a tactile, gustatory, prehensile and masticating organ. In mastication it serves the useful purpose of keeping the food between the molars while grinding, and to assist in its backward passage when mastication is complete.

The hard palate is a dense fibrous cushion covering the entire roof of the mouth from the incisor teeth to the soft palate. It presents a number of transverse bars which meet in a longitudinal raphe. It serves the purpose of preventing food from slipping freely outward, and to assist the tongue in passing food backward.

The cheeks are composed of the buccinator muscle covered externally with the skin and internally with the buccal mucous membrane. It is a loose curtain attached just beyond the alveolar border of each molar arcade. In mastication it serves to keep the food between the teeth and to complete the lateral boundaries of the mouth.

The masseter muscle is a thick, wide and short muscle located on the lateral aspect of the lower jaw. Its fixed attachment is the maxillary spine and zygoma and its movable insertion the external face of the lower jaw. Its function is that of closing the jaws and drawing the inferior maxillary slightly forward.

The pterygoid internus muscle occupies the same relative position on the internal aspect of the ramus as the masseter does externally. Its fixed attachment is the palatine crest and the movable insertion the internal face of the lower jaw. Its function is that of producing lateral motion and assisting the masseter to close the jaws, as follows: The left muscle acting alone draws the jaw to the right and the right one to the left, and when acting together they assist the masseter in closing the mouth.

The temporalis muscle occupies the space over the parietal bones, and is inserted to the coronoid process and anterior border of the ramus of the jaw. Its function is that of closing the jaw, and when acting singly it produces lateral motion.

The pterygoid externus is a short, thick muscle situated internally and in front of the temporo-maxillary articulation. It originates on the sphenoid bone and is inserted at the neck of the jaw just below the condyle. Acting together they pull the jaw forward and singly they produce a lateral motion.

The stylo-maxillaris originates at the styloid process of the occipital and is inserted to the posterior border of the ramus of the jaw. Its function is that of drawing the jaw backward and depressing it.

The digastricus muscle is located in the maxillary space, originating on the styloid process with the stylo-maxillaris and is inserted along the inner border of the ramus toward the symphysis. Its function is that of retracting and depressing the jaw.

The sterno-maxillaris muscle originates on the cariniform cartilage of the sternum and is inserted at the angle of the jaw. Its function is that of depressing the jaw.

The lower jaw is moved in every direction by the muscles of mastication; it is advanced, retracted, elevated, depressed

and drawn to either side at will. In ruminants the lateral motion is pronounced while in the carnivora it is prevented by the interlocking of the canine teeth, the beveled molars and the ginglymoid character of the articulation. In solipeds the lateral motion is nominal. The antero-posterior motion is prominent in rodents and is possible to a normal degree in herbivora. The upward movement, which is the most forcible, is of course a prominent movement in all animals, but is an exceptionally powerful one in the solipeds and ruminants.

Mastication is effected in about the following manner. The mouth is opened by gravity, aided by the stylo-maxillaris and digastricus muscles; it is then swung to the side and slightly forward by the pterygoids, temporalis and masseter, and then diagonally upward by the combined effort of the masseter, internal pterygoid and temporalis. During these movements the tongue and buccinator are engaged in keeping the bolus in position to be caught between the teeth as they come together.

Mastication is unilateral, only one side of the mouth is used at a time. Herbivora will chew on one side for a few minutes and then shift the next bolus to the other, at their will.

CHAPTER V.

DENTAL DIAGNOSIS.

Examination of the incisors (see page 113).

Examination of the horse's mouth preceding the usual dental operations is done in the standing position, by **palpation** and **inspection**.

Palpation of the mouth.—As the horse's mouth is a dark, deep cavern its examination for the detection of the common irregularities must depend chiefly upon manual exploration. For this purpose the mouth speculum or a gag may be used. The expert, however, requires neither, but passes the hand with the greatest freedom, ease and leisure to any and all parts of the mouth, without inconvenience to the horse or injury or danger to himself. To accomplish that valuable attainment the halter is removed and the head is held from being thrown upward by an assistant holding one hand on the nose and the other on the poll. The diagnostician stands directly facing the horse, and passes the right hand into the left commissure of the mouth, across the interdental space into the space between the tongue and molar teeth on the opposite (left) side. The palm of the hand faces the teeth and the dorsum the tongue. In this position the tongue of the horse is not forced into any uncomfortable attitude and the mouth is not forcibly opened. The hand may then be passed gently backward to the fauces and the fingers may be extended over the tables of the teeth without danger or injury. The secret of success is in not opening the mouth too wide and in engaging the horse by keeping the hand constantly moving. When the hand is

kept stationary in the mouth resistance is immediately offered.

The right side is palpated with the left hand and vice versa. Prior to the molar examination or immediately after,

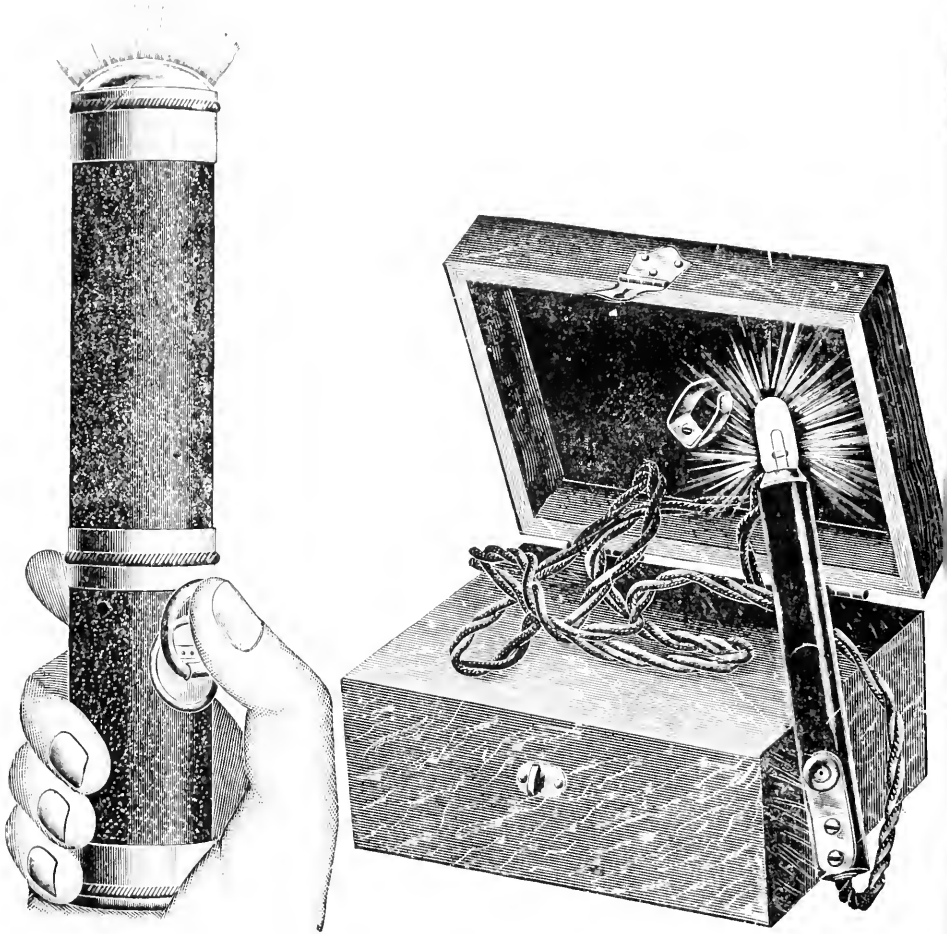


FIG. 88.

"Search Lights."

the interdental space, first below and then above, is palpated with the palmar surface of the thumbs to locate possible bit lesions or wolf teeth.

The novice may use the mouth speculum, which will admit of free palpation of the teeth with the exception of the

external borders of the molar arcades. The hand cannot be admitted freely into the mouth unless the speculum is opened wide enough to provoke resistance, and besides the cheek is drawn taut against the teeth and prevents palpation of the borders of the molars.

Inspection of the mouth.—Beyond the first two molars the mouth cannot be satisfactorily inspected in the standing position. Only gross abnormalities can be seen, and these only to an unsatisfactory degree. With the aid of a mouth speculum and artificial light,—a reflector or incandescent light,—with the head raised and the operator standing on an elevation it is possible to inspect the teeth, but in this procedure the tongue and the resistance to such forcible manipulations offered by the horse, materially interfere. A perfect inspection of the mouth can only be made in the recumbent posture with the head turned upward and the speculum adjusted, and then only by the aid of good light,—a reflector if necessary. By pulling the tongue to first one side and then the other, every part of the mouth can be **seen** and **felt**, and in addition abnormalities can be searched for with steel picks.

DENTAL INSTRUMENTS—THEIR USES.

FLOATS AND FLOAT BLADES.

Floats are the principal instruments of the animal dentist. They are to the animal dentist what the drill and dental engine are to the human dentist. The float is a simple contrivance consisting of a handle, shaft and head to receive the blade which may be either a rasp or file. The entire length should not exceed nineteen inches, divided as follows: Handle, $5\frac{1}{2}$ inches; shaft, $10\frac{1}{2}$ inches, and head, 3 inches. The head is open to receive the blade at either end and is perforated with two openings to receive the screws with which the blade is kept taut. There are many patent affairs

on the market, some simple and others complex, which hold the blade solid by various means. Some are equipped with a mechanism by which the head can be placed at different angles with the aim of combining two instruments in one, i. e., the straight and the angular float. All these inventions to date are but poor imitations of the old reliable simple screw-head float, and are neither durable nor practical, and few will hold the blade as solid as the old pattern.

These instruments are generally designated as the House floats; they have been in use for more than thirty years, and as they offer but little chance for improvement they will probably always retain the prestige of being the most satis-




FIG. 89.



FIG. 89A.

Straight and Angular Floats, with Lines showing the Proper Angle of Each.

factory instrument of their kind. Two styles are recommended—the straight float and the angular float.

The **Straight Float** is used to file the lower arcades and the posterior two-thirds of the superior arcades, and to facilitate its passage to the remotest teeth its head must be on a straight line with the handle, i. e., when the handle lies flat upon a plane the head,—face downward,—must do likewise throughout its entire length. The posterior end of the arcades, especially the inferior, cannot be reached with a float of any other shape without opening the horses's mouth wide enough to provoke resistance.

The **Angular Float** is used to file the anterior third or half of the superior arcades, which, owing to the inward cur-

vature of their external borders, cannot be conveniently reached with an instrument of any other shape. The angular float should be of the same **size** and **length** as the straight one. When its head lies, face downward, upon a plane, the center of the handle should be elevated two and one-half inches above the plane. The short-handled floats of greater angles are much less convenient.

The Float Blades should be of the rasp variety, tempered hard enough to wear well and yet not so hard as to chip from filing the hard enamel points of the molars. In the straight float the cutting edges of the rasp must point backward,—toward the handle,—and in the angular they must point forward. This arrangement is intended to train the hands to make the float cut on its outward course instead of its inward course, and thereby prevent prodding the back of the mouth.

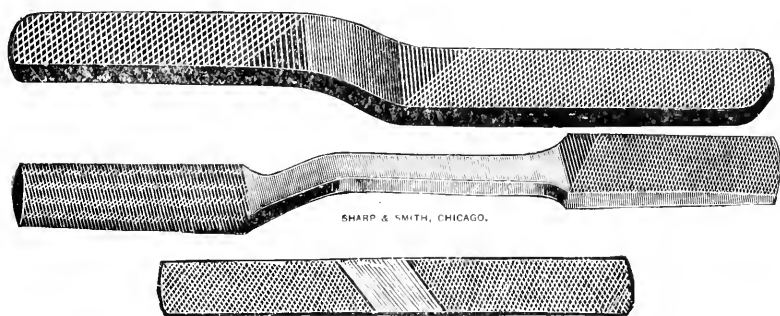


FIG. 96.

THE FLAT FILE AND RASP.

The flat file and rasp should be twelve inches long, rounded at the extremities and have a file on one side and a rasp on the other. It is used to round the first superior and first inferior molars, and to shorten the canines and incisors.

THE CLOSED MOLAR-TRIMMER OR CUTTER.

The closed trimmers are nineteen to twenty inches long, including the handles, and have a head consisting of a box

joint and two cutting jaws, one to one and a quarter inches long, which come together in perfect apposition. The cutting surface is dropped three-eighths of an inch below the level of the instrument better to enable the grasping of small points. It should be made with a box joint, the center of which is no more than two and a quarter inches from the end of the cutting jaws. The forks and handles should be of no less than five-sixteenths inch steel.

This instrument was primarily intended to trim the enamel points along the arcades, both superior and inferior, and it is still being used for this purpose by some veterinary practitioners. Its use for this purpose cannot, however, be sanctioned, owing to the difficulty of placing them accurately upon the small enamel points located posteriorly on the ar-



FIG. 91.

Closed Molar Trimmer.

cadec. The smallness of the points, the motility of the head and the great distance between the hands and the cutting end of the instrument, makes their applicability difficult in the hands of the unskilled. Even in the hands of the skilled dentist their use amounts to the cutting of whatever happens to be caught between the jaws.

The closed trimmer should be used only in cutting the projections at the extremities of the arcades—the first superior and sixth inferior molars—for which purpose they are indispensable.

THE OPEN MOLAR-CUTTER.

The open molar-cutter of the double-lever variety is also an indispensable part of the dental outfit, and owing to the laborious work it must perform it should be powerful enough to cut any projecting tooth promptly. The style recom-

mended is twenty-four to twenty-five inches long and has a head consisting of a box joint and two cutting jaws no more than one inch long which approximate within one-quarter of an inch when the instrument is closed. Six inches from the center of the box joint is a second one, to increase the lever-

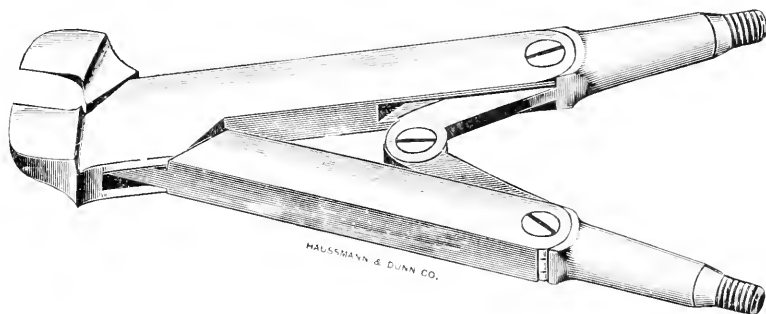


FIG. 92.

The Open Molar Lever Cutter.

age. The fork between the joints is of three-quarter inch (square) bar steel, while that from the last joint and handles is of five-sixteenth steel.

This instrument must possess strength at the expense of its neatness. It can be opened wide enough to receive any



FIG. 92A.

Plain Open Molar Cutter.

elongation of the horse's molars and will promptly cut, with only nominal effort, any tooth its jaws may grasp.

The single joint open molar-cutters, unless made much stronger and longer, will frequently disappoint the operator and will always require a number of strenuous efforts before a large tooth will yield.

THE WOLF-TOOTH SEPARATOR AND FORCEPS.

The wolf-tooth separator is a nine-inch instrument having a box joint and bayonet-point head, which contains two cutting or wedging jaws approximating each other closely at the end but open slightly along the cutting surface. This instrument is made use of to extract wolf teeth by wedging them between the wolf tooth and molar to disturb the alveo-




FIG. 93.
Wolf-Tooth Separator.

lar implantation and then pry them out. Their use to disturb the tooth may precede the use of the ordinary wolf tooth extractor which, in view of the utility of the separator, may be entirely dispensed with in veterinary dentistry. The separator may, in addition, be used to extract the shedding

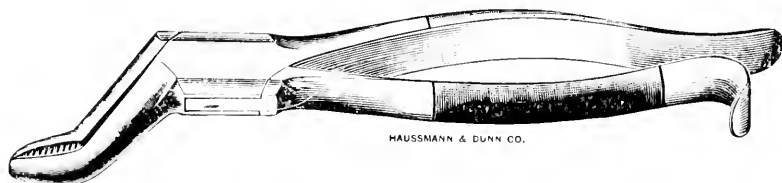


FIG. 93A.
Wolf-Tooth Forceps.

incisors, shedding molar caps, incisors and canines of dogs and fractured incisors of horses.

THE MOLAR SEPARATOR.

The molar separator is twenty inches long and has a head consisting of a box joint and two wedge-shaped jaws, projecting at a right angle, the edges of which come together when the instrument is closed. It is used for the purpose of loosening the decayed molar prior to the application of out-

ward force with the extracting forceps. Its jaws are wedged alternately, into the interdientia on either side of the decayed tooth until the implantation is disturbed.




FIG. 94.

Open Molar Separator, for Superior Arcades.

THE CLOSED MOLAR EXTRACTOR.

The closed molar extractor is twenty inches long and has jaws no more than one inch long and five-eighths of an inch wide, projecting at a right angle from the head. The forks




FIG. 94A.

Closed Molar Separator, for Inferior Arcades.

and handles are strong enough to prevent springing when pressed forcibly together. The jaws approximate within one-eighth of an inch and are furrowed internally to prevent slipping from the tooth. This instrument is indispensable in



FIG. 95.

Closed Molar Extractor.

the extraction of molars, most of which are split into narrow plates that cannot be held with an open forceps. It is used chiefly to extract split molars, but may be utilized to advantage even when the crown is whole. The dental equip-

ment containing only one extractor should, therefore, contain the closed variety instead of the open, which can only be applied in the extraction of molars having full crowns.



FIG. 96.

Closed Molar Extractor, with Curved Handles.

THE OPEN MOLAR EXTRACTOR.

The open molar extractor answers the same general description as the closed, with the exception that the jaws are five-eighths of an inch apart when the instrument is closed, and that the forks form an abrupt drop of one inch, five inches from the head. The object of the curved or drop forks is to prevent the handles from striking the incisor teeth before the tooth is lifted from its cavity. The closed extrac-

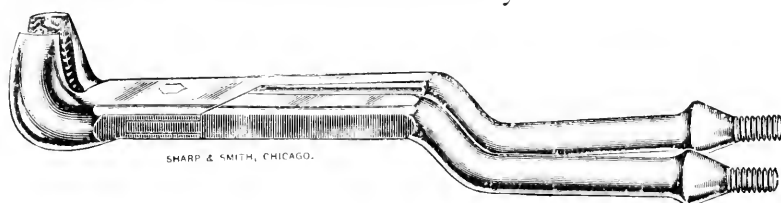


FIG. 97.

Open Molar Extractor.

tor may be similarly curved, but owing to the fact that when they are applied to the entire crown the handles are wide enough apart to pass the incisors between them, the curve is not as essential as in the open ones.

THE ANGULAR MOLAR-CUTTER.

The angular molar-cutter is twenty inches long, and is of the same size and pattern as the closed molar trimmer. Its jaws extend from the head at an angle of about forty-five degrees, and open in the shape of a V to fit the triangular crown of the first inferior molar.

This instrument is used solely for the purpose of beveling

the first inferior molars and to cut projections of nominal size on the first superior molars. It is a useful instrument, but not an essential one. The same work on the superior




FIG. 98.
Angular Molar Cutter.

molars can be accomplished with the closed cutter and file, and the first inferior can be beveled with the file to the desired point without cutting.

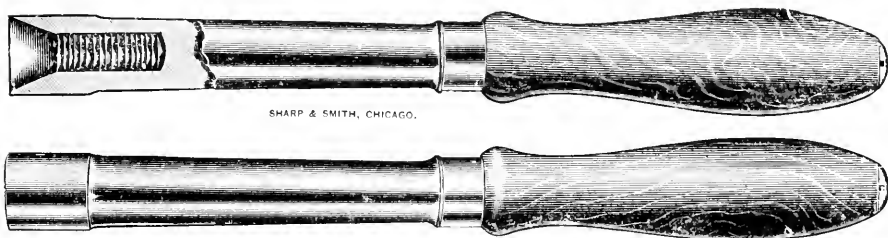


FIG. 98A.
Handles for Figs. 92, 92A, 94, 94A, 95, 97 and 98.

THE INCISOR NIPPERS.

The incisor nippers is a simple instrument about ten inches long, with a screw joint to bring the power nearer the cutting edge. It has cutting jaws which curve claw-like from




FIG. 99.
Incisor Nipper.

the head and come in perfect apposition when the instrument is closed. The cutting surface should be no less than five-eighths of an inch wide. This instrument is used to shorten the incisors and canines. It may also be used to

cut the sharp elongation at the extremity of the first superior molar.

THE MOLAR CROWN CUTTER.

The molar crown cutter or claw cutter, as it is occasionally called, answers the same general description as the oper molar-cutter, with the exception that the cutting jaws drop at a right angle from the head and curve toward each other like a pair of claws. The jaws have a cutting edge of no less than three-quarters of an inch, and part three-sixteenths of an inch when the instrument is closed. They are used to

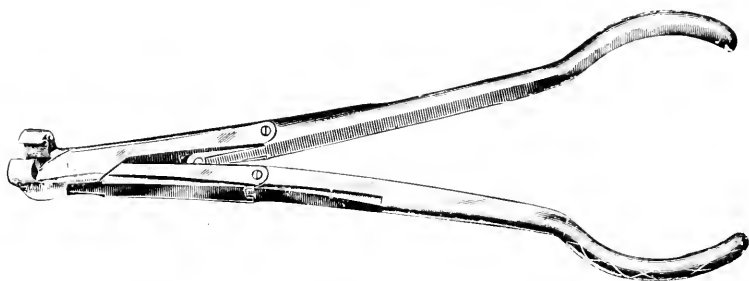


FIG. 100.

Molar Crown Cutter.

remove the crown opposing a decayed tooth, or that of a decayed one when extraction is not deemed advisable.

THE MOUTH SPECULUM.

The mouth speculum is indispensable in a dental practice. It may consist of a simple oblong loop of one-quarter inch iron bar, a wooden gag to insert between the molar teeth, or a double bar that is made to open as wide as necessary with a screw. These simple affairs may be made to answer the purpose of the more costly and complicated ratchet speculum, which has recently come into quite general use. The ratchet speculum consists of two cups to fit the incisor arcades, upper and lower, connected to the ratchet mechanism by means of curved bars following the line of the lips to a point behind the commissure of the mouth, thus

leaving the fissure oris free from obstruction. They have the advantage also of opening the mouth to any width de-

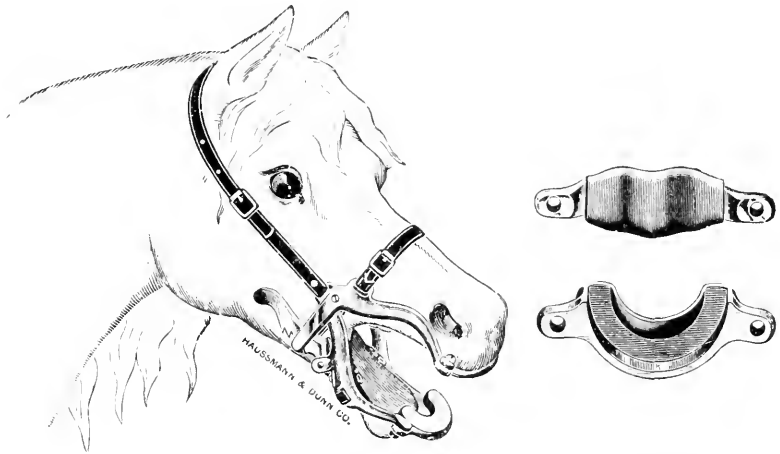


FIG. 101.

sired, and the disadvantages of being none too reliable. The ratchet may break or slip when the jaws of a powerful horse

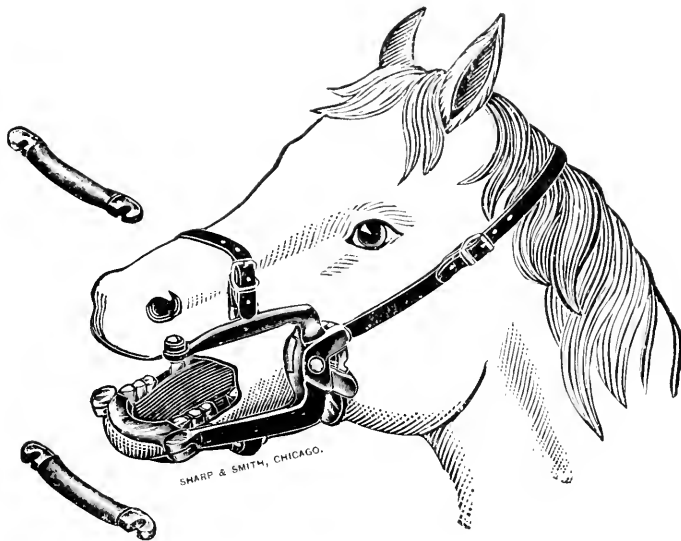


FIG. 102.

are set against its strength. Slipping of the ratchet is a very frequent accident after the catches have become worn from constant use.

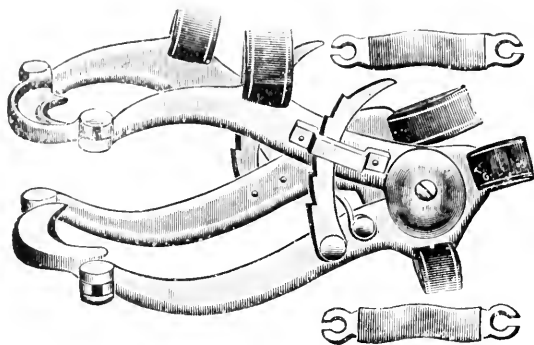


FIG. 103.

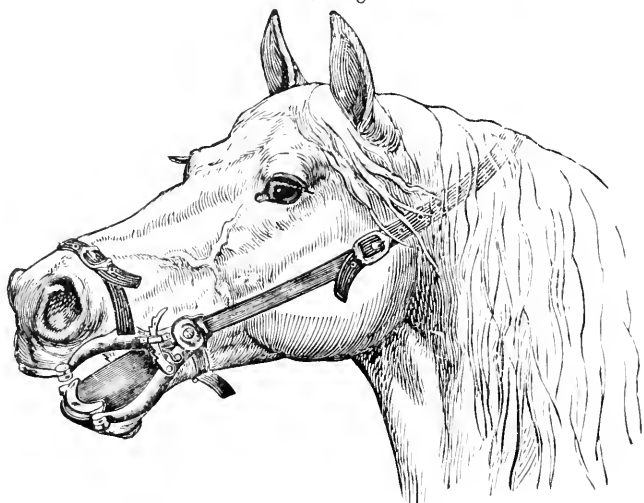


FIG. 103A.

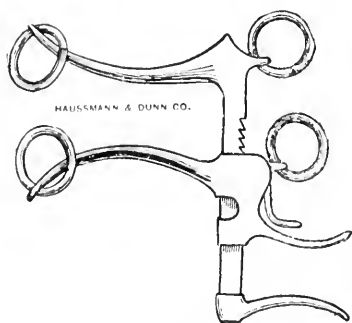


FIG. 103B.

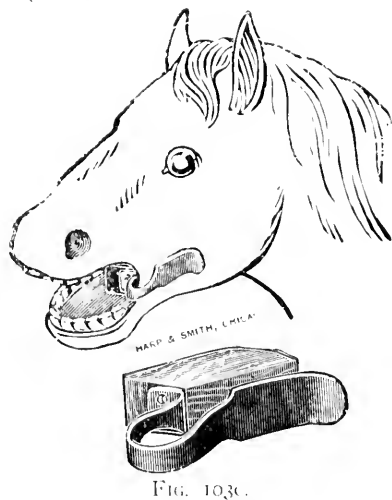


FIG. 103C.

The mouth speculum is used only for operation in the recumbent position, and especially when an animal is under the influence of an anaesthetic. In the standing posture it is useful only to the plebe and novice. It obstructs the free use of large instruments in the standing position, and is unnecessary for the minor operations.

THE TOOTH CHISEL.

The tooth chisel is a recent invention, the artifice of an Iowa veterinarian. It consists of a strong band of iron shaped as a horseshoe. At one heel is a chisel inserted as a lag screw, while on the other heel is a head to receive the blows of the hammer. The chisel end is passed into the mouth while the other heel is kept outside. Its object is to break or loosen teeth that cannot be grasped with forceps. It is undoubtedly an instrument of some value, especially in the extraction of broken fangs, as it can be equipped with chisels of different dimensions and shapes to meet each requirement.

OTHER INSTRUMENTS.

The above is a description of the more essential instruments of a dental outfit for a veterinary practitioner. It is, however, undeniable that many others might be added to the advantage of the dental branch of veterinary surgery. There is room for the addition of many instruments of various shapes, styles and patterns suitable for special purposes. For example, extractors for the superior arcades should be wider than those for the inferior; those for the right side might be curved toward the left, and those for the left side toward the right, so as to bring the instrument out of the mouth at the median line; those for the last molars might be longer and have smaller heads and shorter jaws, to pass more freely between the teeth; and finally all cutters, separators and extractors might be made specially for superior,

inferior, posterior, anterior, right or left work to the advantage of the dental surgeon.

At the present time there is no standard dental instrument. Each manufacturer and each practitioner has his particular idea as to what constitutes the appropriate style of instrument for each particular purpose, and as a result an unfortunate state of chaos exists in the veterinary dental instrument shop. This unfortunate condition makes the veterinary dental instrument costly, as the manufacturer cannot reduce the cost by making them in large quantities.

A change for the better in this connection will come when the dental operations are regarded as being of sufficient importance to warrant the adoption of standard methods of operating, which in turn will create a demand for standard instruments.

Trephines, chisels, punches, curettes, and the dissecting instruments used in animal dentistry are too well known to demand description here.

RESTRAINT.

Floating, filing and trimming the teeth of horses can be accomplished without provoking resistance—enough to demand any forcible means of restraint. The minor dental operations are accepted with remarkable complacency in the great majority of horses. The only necessary restraint is to prevent the horse from backing away from the operator and from elevating the muzzle out of the reach of the hands and instruments. This is done by backing the horse into a single stall and securing the head at a comfortable height on the pillar reins with the **dental halter**. The ordinary leather halter is not satisfactory for this purpose because one side or the other will press against the cheek and prevent the free passage of instruments along the teeth.

The dental halter consists of a leather-covered iron loop

fifteen inches long and nine inches wide, with a single poll strap and a ring on each side for the tie ropes. The poll strap is of two-inch heavy leather with numerous buckle-holes to make it adjustable to any sized head. The tie ropes are ordinary half-inch hemp, long enough to encircle the pillar or to reach the pillars of a stall of any ordinary width. Whenever the tie ropes, owing to the construction of the stall, cannot be tied low enough on the pillars to hold the



FIG. 104.

Horse Properly Secured for the Simple Dental Operations.

head down to the proper height, a third rope or strap is tied to the lower end of the halter, passed between the fore legs around the withers and back again between the fore legs to the halter. By this addition a horse can be secured in an open room, field or box stall with only the assistance of one person to steady the head. (Fig. 105.)

In the absence of the dental halter dental operations should be performed with the aid of an assistant, to hold

the head with one hand on the poll and the other over the nasal bones.




FIG. 105.

A Satisfactory Method of Securing a Horse for Simple Dental Operations, Without the Use of Pillar Reins.

Major operations, i. e., repulsion of teeth, etc., and minor operations upon vicious horses, require the recumbent posi-

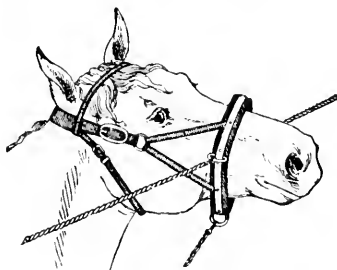


FIG. 105A.

Lucas' Dental Halter.

tion and the use of the mouth speculum. The operating table is *par excellence* the best restraining apparatus for such

operations because it brings the head to a comfortable height for inspection and operation.

Anaesthetics are seldom necessary to perform dental operations and frequently they are harmful in that they favor the aspiration of blood and saliva into the trachea. Local anaesthetics are not applicable in any form to the dental operations upon animals.

Floating, filing, trimming and cutting the teeth should be performed in the standing position. The extraction of teeth may require the recumbent, but only occasionally. Trephining the skull can be performed in the standing posture with the aid of the twitch and dental halter, but the repulsion of teeth must never be attempted without recumbent restraint.

Chiseling, punching and sawing operations require perfect restraint in the recumbent position.

CHAPTER VI.

DISEASES AND IRREGULARITIES OF THE TEETH.

NECROSIS OF THE TEETH OF HERBIVORA.

Synonyms:—Alveolar-periostitis. Peridentitis. Pericementitis. Pulpitis. Dentitis; Caries (erroneous). Decayed teeth.

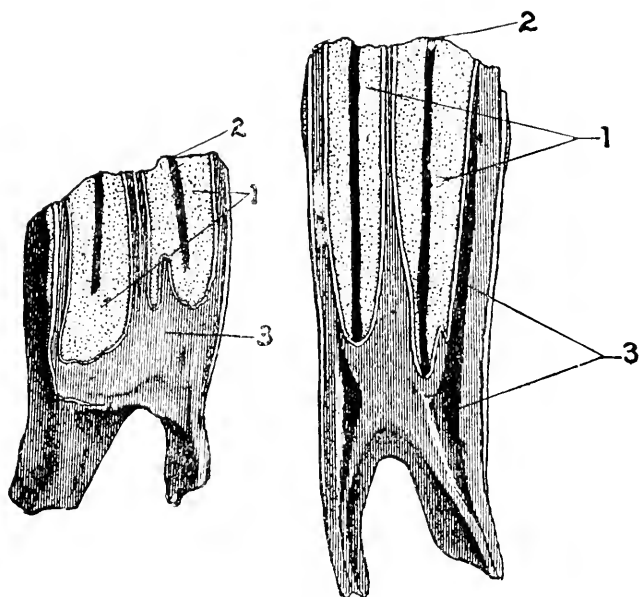


FIG. 106.

Molars Predisposed to Decay by an Open Channel Through the Crusta Petrosa of the Infundibula.

1. 1. The infundibula.
2. 2. Openings of channel at table.
3. 3. Pulp cavity. (In the short [old] tooth the pulp cavity is already closed.)

Definition:—A total necrosis of one or more molars of herbivorous animals, of inflammatory origin, due to a primary or secondary infective inflammation of the pulp.

Etiology:—The entrance of food into an imperfectly

closed infundibulum is the cause of more than 95 per cent of the decayed molars of the horse. The crista petrosa, which should hermetically seal the infundibula, is found wanting and thus leaves an entrance channel for infectious matter. The pulp is therefore the first structure to be involved in the inflammatory process, from which source it traverses through the apical foramina to the blood vessels, alveolar periosteum and bone. In rare cases the infectious matter is admitted directly to the alveolar periosteum through imperfect gums, the space between the teeth, or through the exposure of the periosteum while shedding the temporary predecessor. Cystic tumors located directly upon the root,

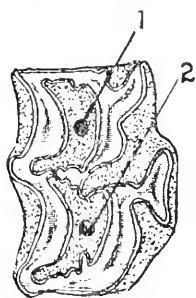


FIG. 107.

Table View of Tooth Shown in Figure 106.

1, 2. Openings of the infundibula, through which food enters the tooth.

atheromatous degeneration of the radicals of the superior dental artery, and external violence are the determining causes in a few instances. In these latter circumstances the pulp is the last structure to be involved in the inflammatory process. Systemic disturbances, especially a "ricket diathesis" induced by organic diseases or poor quality or insufficient forage during the period of growth, are predisposing influences.

Pathological Anatomy:—Pulpitis, either primary or secondary, is the basis from which to study the decayed molar of the horse. The disease process begins with **pulpitis** and ends finally in **self-extraction of the tooth**. Between these

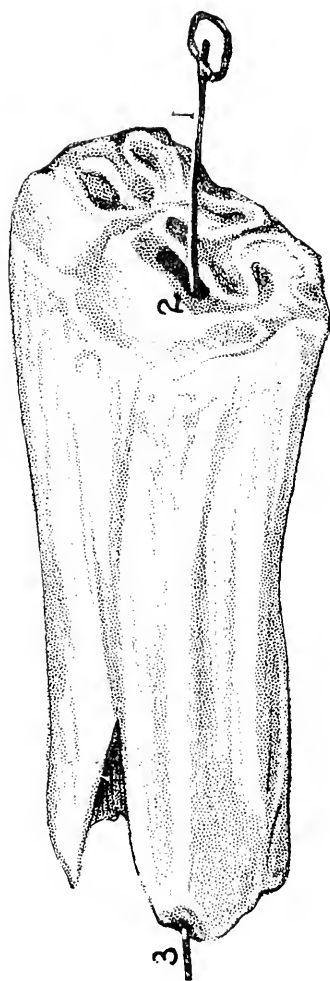


FIG. 108.

Necrosis of an Inferior Molar in the Early Stage, with Perforation from Table to Root.

two events the following chain of abnormalities occur: (1) extension of the inflammation to the blood vessel, nerves and periosteum; (2) abscess formation at the root pointing through the peridental plate into the sinuses or surface of the skull; (3) destruction of the blood supply of the tooth; (4) death, desiccation and splitting of the tooth; (5) impaction and decomposition of food in the cavity between the split section; (6) osteitis and necrosis of the alveolar border from pressure of the split sections; (7) self-extraction. The duration of the process is from three to fifteen years. The above chain of conditions is, of course, not followed to the letter in every instance. For example, an

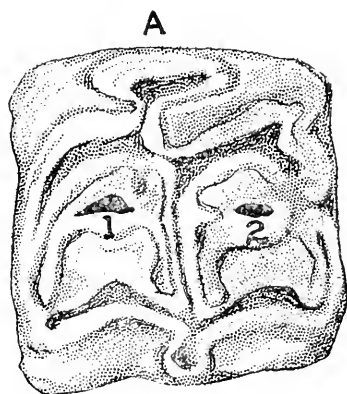


FIG. 109.

intense periostitis may rapidly loosen a tooth from its cavity and, by admitting infectious matter around it, produce extensive osteitis of the jaw. In the young animals the great length of the tooth, and in the inferior denture, gravity, prevents the self-rejection of the tooth from its cavity, and as a result the loose, dead tooth perpetuates and augments the inflammation and tumefaction of the surrounding bones. This condition is seen principally in the inferior molars when the primary lesion has been alveolar periostitis. Primary pulpitis caused by the open infundi-

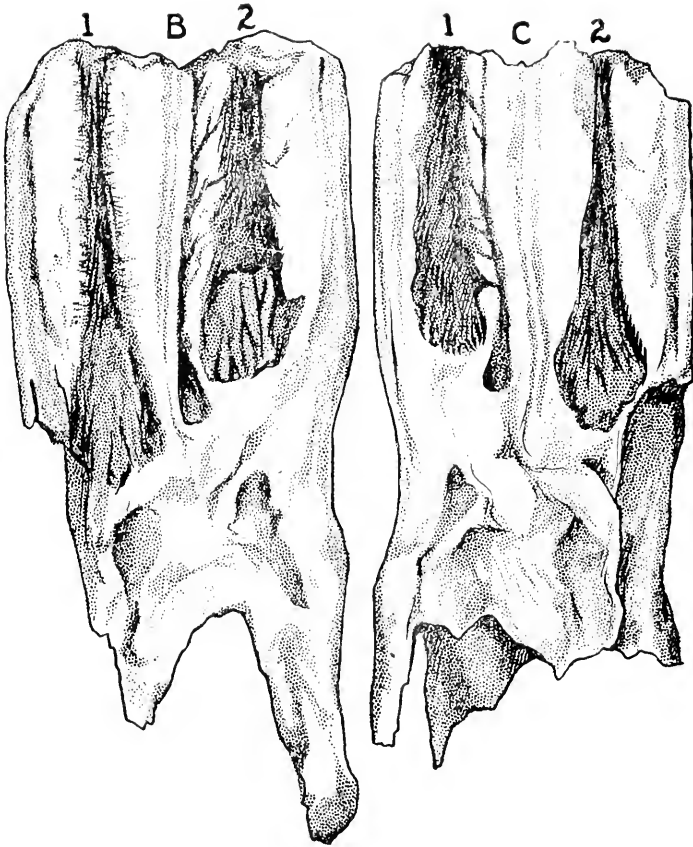


FIG. 110.

A Superior Molar in the Early Stage of Decay.

A. The table.

1, 2. Openings into the tooth admitting food.

B, C. The same tooth split longitudinally to reveal its internal condition.

bulum in the inferior arcades frequently points to the surface of the jaw and constitutes the well known dental fistula of the inferior maxilla. (See Fig. 108.)

The incisor and canine teeth are not susceptible to the condition.

Diagnosis:—The molar tooth of the horse reaches the advanced stage of decay unobserved in most instances, as the incipient stages progress without clinical signs or apparent discomfort to the animal. The fetid breath, fistula or tumefaction of jaws or mouth usually create the first suspicion of decayed teeth. In the absence of these outward signs they are only encountered accidentally in palpations of the mouth during dental operations. The earliest diagnosis of a decayed molar is made when the infective inflammation extends rapidly into the respiratory mucous membrane, before any gross changes occur in the tooth. In these cases the unilateral fetid nasal discharge leads to an examination for abnormal (open) infundibula in one of the superior molars. Anorexia, rejection of partially masticated food, dislike for cold water or turning the head to one side while masticating, are occasional signs of decay in the incipient stage, but the diagnosis must be confirmed by better evidence.

The relative decay of the teeth of horses will assist materially in locating the offending member. The fourth superior molar, owing to its position in the center of the arcade and its unstable neighbors during the second year of colthood, is the most common seat of the disease. Out of a total of two hundred decayed teeth observed, one hundred and nineteen were fourth superior molars. The fifth superior, the third superior and fourth inferior were next in order, while the remainder were divided quite evenly among the first superiors, the sixth superior and the remaining inferior molars. The second superior was not found decayed until

the two hundred and thirty-second case was investigated, showing that this tooth is not frequently decayed.

Treatment:—(1) Removal of the tooth; and, (2), removal of the opposing crown. Removal is the palpable duty in dealing with the decayed tooth of the horse, but in the

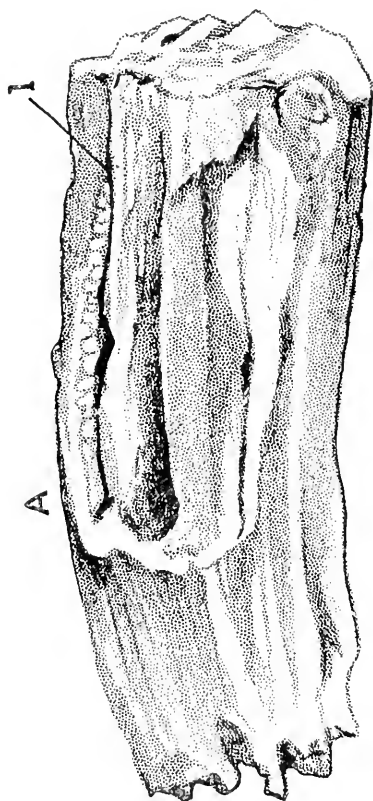


FIG. 111.

Advanced Stage of Necrosis in a Superior Molar.

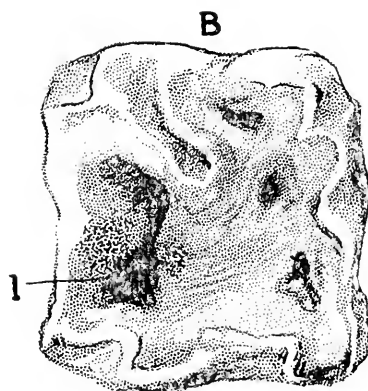


FIG. 112.

A. The tooth.

B. The table.

1, 1. The opening through which the tooth became infected.

uncomplicated case removal is warranted only when it can be accomplished in a simple manner (forcep extraction). When a decayed molar produces no apparent inconvenience and is too short to grasp firmly with the forceps, removal of

the opposing crown is ample remedy pending the development of serious complications. A decayed molar, although a foreign (dead) body, may become encysted in a protecting wall and cause no further trouble. The operation of removing a tooth crown is accomplished with a claw cutter. (Fig. 100.) The removal of teeth is accomplished by either of the following methods:

- (1) By extraction with forceps.
- (2) By repulsion with punch and mallet.
- (3) By removal of the external alveolar plate.
- (4) By splitting with chisel and mallet.

(1) EXTRACTION WITH FORCEPS.

Equipment:—Open molar extractor, closed molar extractor, separating forceps, hardwood fulcra of assorted sizes, and if operation is performed in the recumbent position, a mouth speculum.

Indications:—Forcep extraction should be adopted as the universal method to remove molars having crowns long enough to grasp firmly. Even though trephining may be necessary to reach the existing secondary condition, forcep extraction should, if possible, precede the trephining.

Restraint:—Choice between the standing and recumbent positions must be decided by the probable **complacency of the patient** and the **skill** of the operator. For the **standing position** the horse is backed into a single stall and confined to the pillars with the dental halter. The head must be brought downward within easy reach. If the operation is resisted by forcible movements of the jaw a mouth speculum may be applied. The mouth speculum should, however, be avoided if possible, as it will interfere with the free use of the instruments. For the **recumbent** position the patient is placed in a dorso-lateral attitude with the mouth speculum adjusted and the head inclining upward. Anaesthesia is not

advisable, owing to the greater danger of blood flowing into the trachea.

Modus operandi:—The first requirement is to loosen the tooth. It is safe to assert that the tooth that cannot be loosened cannot be lifted from its cavity without fracture, or injury to the teeth upon which the fulcrum is placed. The loosening process is accomplished by wedging the molar separator into the interdentalia, first on one side, then on the other until it can be easily closed in the spaces. Torsion is then applied with the extracting forceps until the tooth is felt to be well loosened. Undue haste or the application of great force must be avoided and care must be taken to prevent fracture in a sudden movement of the head. The extractor is now adjusted firmly to the crown and the fulcrum block placed as near its head as possible. Gradual, firm outward traction will readily bring the tooth from its implantation. When the tooth is divided into two or more fragile segments the manipulation must be carefully executed to prevent fracture.

Accidents:—The extraction of molars is not entirely without danger. The possible misfortunes are: (1) Fracture of the tooth which will necessitate removal by some more complicated method; (2) wounding the palatine artery with the jaw of the forceps; (3) excessive hemorrhage from the dental artery.

1. **Fracture of the decayed tooth** that is uncomplicated with secondary disorders may be treated by the simple removal of the opposing crown. If there are catarrhal or fistulous complications repulsion will be necessary.

2. **Palatine hemorrhage** is serious and unless arrested will endanger life. The accident occurs as a result of the horse chewing forcibly upon the end of the internal jaw of the forcep while being adjusted to the superior tooth. As soon as the accident occurs the operation must cease and

the mouth must be packed full of cotton, waste, oakum or any other packing material that can be promptly furnished. When there is delay in procuring a suitable packing the finger must be kept over the wound to temporarily arrest the flow of blood. After the mouth is packed full the jaws are closed tightly by encircling them with a dozen wraps of cord and the patient is backed into a stall and kept on the pillar reins for five to six hours, when the packing may be safely removed.

3. **Hemorrhage from the dental artery** may occasionally be very profuse, but it is never serious. It is arrested by packing the cavity with wadding of cotton or oakum.

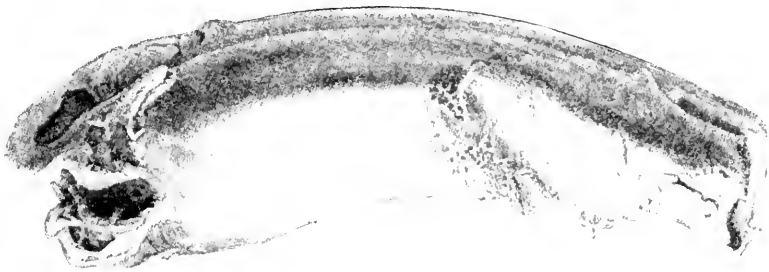


FIG. 113.

Decayed Tooth Due to Primary Alveolar Periostitis (Ostertag).

After-care:—The tooth cavity must be wadded with fresh packing every day for a week, at which time a careful examination of the cavity must be made to remove sequestra or fractured segments of bones, which may delay prompt healing of the wound. In two years the opposing tooth will have elongated into the vacant space and will require trimming to the level of its arcade.

(2) REPULSION OF TEETH WITH PUNCH AND Mallet.

Equipment—Three-quarter-inch circular trephine, one inch circular trephine, bone chisel, punch, iron mallet, scalpel, artery forcep, dissection forceps, mouth speculum, curette, razor, antiseptics and packing materials.

Indications:—Trephining the skull to repulse teeth is indicated when the tooth crown is too short to grasp with the forcep, and when there is a complication of fistula or catarrh of the sinuses. In secondary catarrh of the sinuses with more or less accumulation of purulent matter, trephining is



FIG. 114.
Mallet.

an essential adjunct to tooth extraction, even though the extraction is accomplished with the forceps. Trephining is performed to evacuate the accumulated secretion and to admit the free irrigation of the catarrhal mucous membrane,



FIG. 114A.
Straight Punch.

as well as for the purpose of admitting the punch to repulse the tooth.

The following are the molars that are removed by repulsion: Fourth and fifth superior, sixth superior of old horses,




FIG. 114B.
Curved Punches.

first, second, third and fourth inferior and the fifth and sixth inferior when accompanied with considerable tumefaction of the jaw.

Restraint:—The recumbent position, lateral posture, af-

affected side uppermost, with a mouth speculum securely adjusted, is the proper attitude for the repulsion of teeth. The standing posture is never satisfactory. The operating table is **par excellence** the best method, as the head can be more firmly secured than with the casting harness. General anaesthesia is sometimes harmful, as in the unconscious state blood readily finds its way into the lungs.

Location of the openings:—The opening in the skull must be situated so that the punch can be placed on a

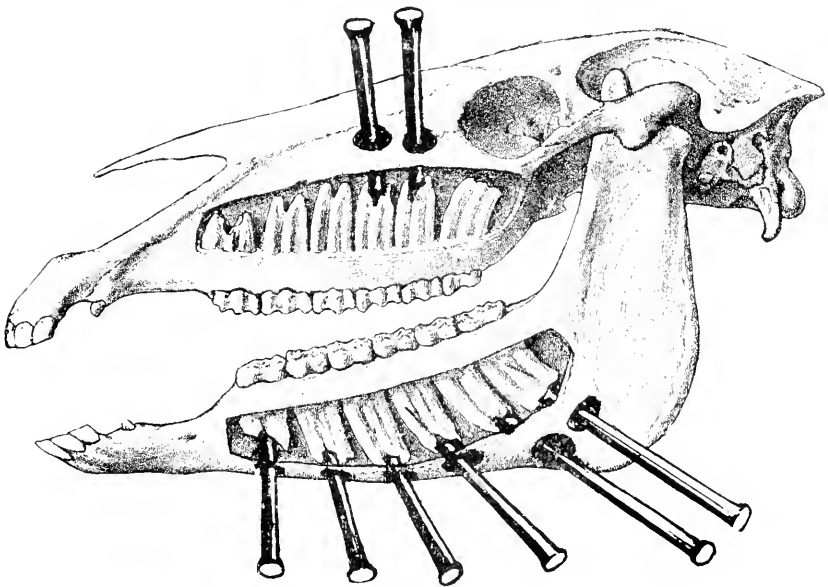


FIG. 115.

Cut Representing the 8 Teeth Which Can Be Repulsed and the Location of the Opening for Each.

straight line with the long axis of the tooth. (See Fig 116.) The transverse range will vary slightly with the age of the horse. In the young horse well toward the median line of the head and in the old one nearer the maxillary spine. The longitudinal range will vary according to the tooth to be repulsed, the fourth, fifth or sixth. The exact seat is determined after the animal is secured and otherwise prepared for the operation. The hand is placed into the mouth and a

finger pressed against the cheek opposite the decayed tooth, and from the bulge thus made in the cheek externally a measurement is made upward to a point indicated by the animal's age. In the young horse a slight variation must be made for the backward direction of the fifth molar. The sixth molar in young animals is reflected backward beneath the eye and cannot be satisfactorily repulsed.

For the inferior molars the openings are made at the very border of the jaw in every case except for the fifth and sixth, in which instance it is made upon the most prominent part of the tumefaction caused by the diseased process. For the third, fourth and fifth inferior molars, due allowance must be made for the marked backward direction of their fangs. (See Fig. 115.)

The openings must be made with due deference for the following important structures:

- (1) Steno's duct.
- (2) Lachrymal canal.
- (3) Glossofacial artery and vein.
- (4) Superior dental canal and contents.
- (5) Inferior dental canal and contents.
- (6) Superior maxillary division of the trifacial nerve near its exit from the skull.

In the repulsion of the superior teeth complicated with catarrh a single additional opening is made to drain the frontal sinus and to give free access to the maxillary sinus, as well as to drain the frontal sinus into the nasal fossa. This opening is located in an oblique direction downward and inward four centimeters from the nasal canthus. (See Fig. 151.)

Opening the Skull:—This step of the operation requires the consecutive dissection of (1) the skin, (2) the subcutaneous areolar tissue and muscles, (3) the periosteum, (4) the bone, and (5) the mucous membrane.

Repulsion of the Tooth:—The right hand is placed in the mouth with a finger pressing firmly against the tooth while the left hand directs the punch. The assistant is then directed to strike firmly with the mallet until the impression of the blow is felt by the finger against the tooth, and then forcibly until it is driven from its cavity. Failure to transmit an impression into the mouth is an indication that the punch is not advantageously located.

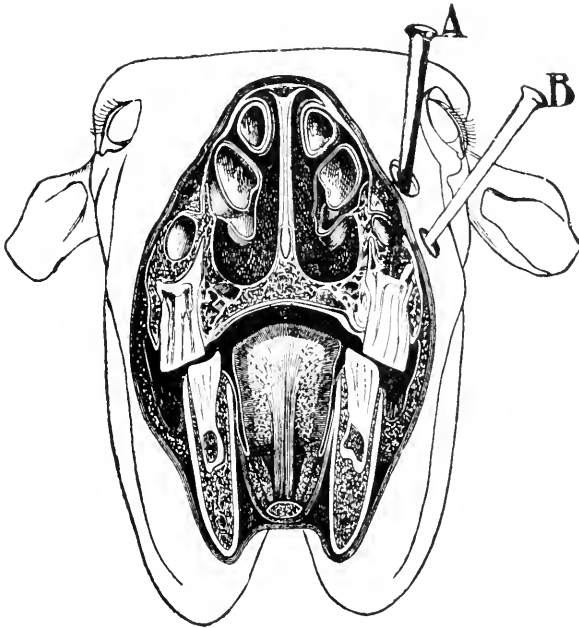


FIG. 116.

Cut Representing the Proper and the Improper Methods of Placing the Punch to a Tooth to Be Repulsed.

- A. Proper method; punch on a straight line with tooth.
- B. Improper method.

Aftercare:—As soon as the tooth is removed the patient is made to resume the standing position. The frontal sinus, maxillary sinus and nasal fossa are then freely opened into each other by breaking down the fragile septa separating them. The cavities are then emptied, irrigated, and wadded with antiseptic cotton. Daily irrigation with 3 per cent zinc

sulphate solution and renewal of the wadding for two weeks or until the discharge ceases, is the necessary after-care.

Sequelae:—(1) Alveolo-nasal fistula, (2) persistence of the catarrh and reaccumulation of pus in the sinuses, (3) persistence of the opening (chronic nasal fistula), (4) septicaemia, (5) deglutition pneumonia.

1. **Alveolo-nasal fistula**, allowing the free passage of food from the mouth to the nasal cavities or sinuses is a common result of repulsion of teeth of the upper jaw in aged horses or from allowing food to pack tightly into the tooth cavity before it has had an opportunity to close. They also occur spontaneously in decay of the first molar or from extraction with the forceps. In the old horse they are prevented by the application of a gutta percha plug between the crowns of the teeth bounding the vacant cavity and in the young horse by preventing the packing of food into the cavity. A tight wadding placed between the crowns after repulsion will not interfere with the healing and closure of the cavity. The treatment of the chronic dento-nasal fistula consists of removing the impacted food from the nasal cavity or sinus by trephining and the application of a permanent plug of gutta percha into the channel. To prevent further packing against the plug the opposing crown is removed. For fistula of the first molar the surgeon may choose between this method and the obliteration of the channel by removing the external alveolar plate and the opposing crown.

2. **Persistence of the catarrh** will demand a second operation and more precise after-care. This sequel is the result of failure to properly drain the sinuses into the nasal cavity, or careless and dilatory irrigation.

3. **Dental fistula or chronic sinuses of the lower jaw**, have their origin in bone necrosis, failure to remove the entire tooth or the proper tooth. Reopening of the wound and removal of the insulting agent is the remedy.

4. **Septicaemia** is the result of improper method of operating, the use of septic irrigation fluids, or neglect to irrigate properly.

5. **Deglutition pneumonia** results from the flow of blood, antiseptic fluid or pus into the lower air passages during the operation. It is caused either from anaesthesia or the use

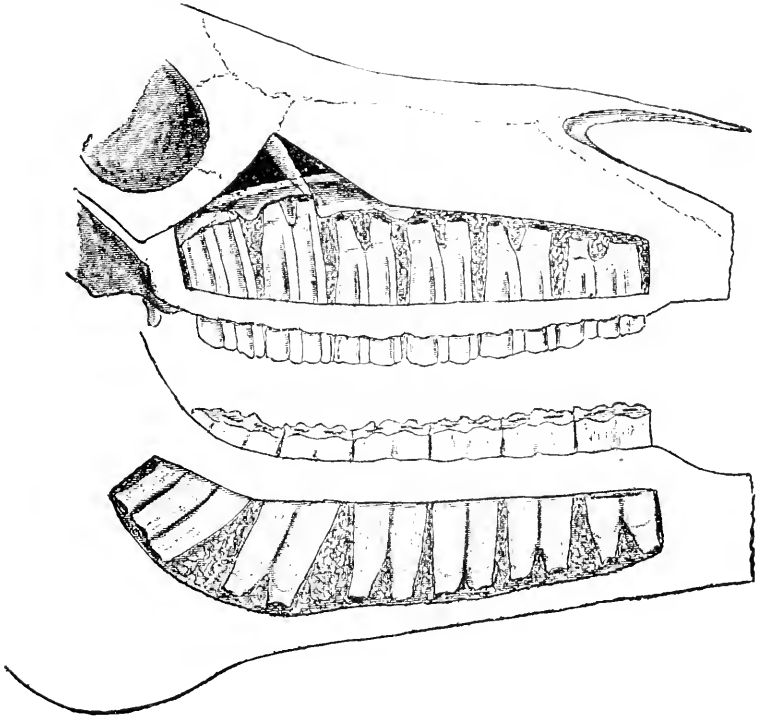


FIG. 117.

*Molar Denture of a Young Horse, in Which Extraction is Difficult, Owing to the Deep Implantation.

of the speculum, which prevents deglutition of fluids which fall into the pharynx.

(3) REMOVAL OF THE EXTERNAL ALVEOLAR PLATE.

(Williams' Operation).

Equipment:—Bone chisel, narrow-blade saw, scalpel, dissecting forceps, artery forceps, mouth speculum, antiseptics, and mouth gag.

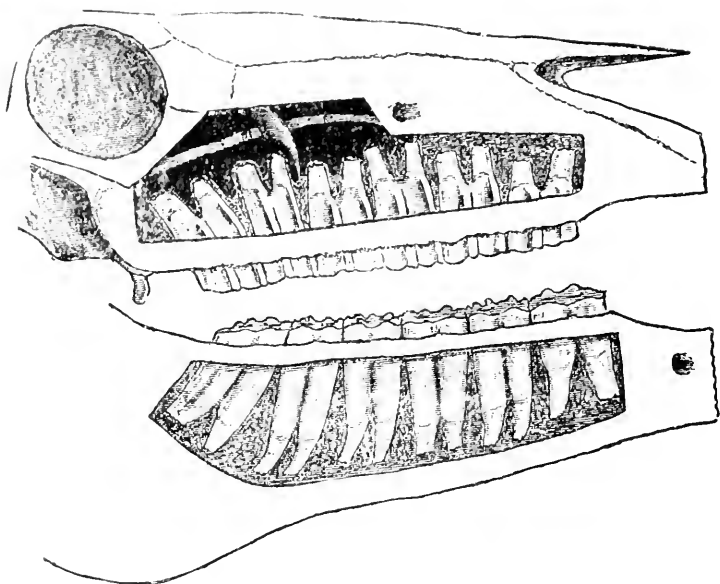


FIG. 118.
Molar Denture of Mature Middle Aged Horse.

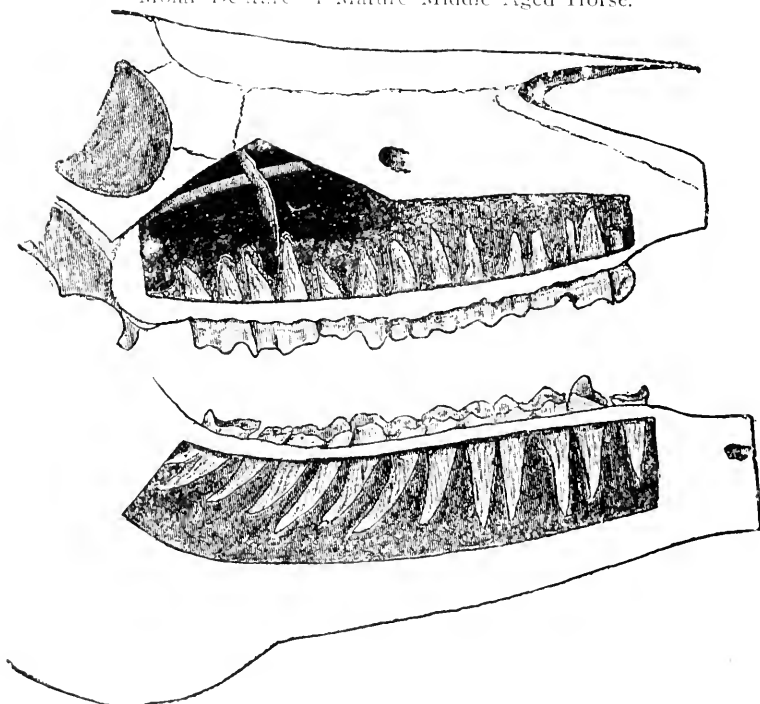


FIG. 119.
Molar Denture of an Aged Horse, in Which Extraction is Easy, Owing to the Shallow Implantation.

Restraint:—Lateral recumbent position, under chloroform anaesthesia or local cocainization, preferably the former.

Indications:—This operation should be adopted universally for the removal of the first, second and third superior molars. Applied to the fourth or fifth superior molars a deformity of the face results from the removal of the extremity of the maxillary spine, and besides it has no advantages



FIG. 120.
Chisel.



FIG. 121.
Saw.

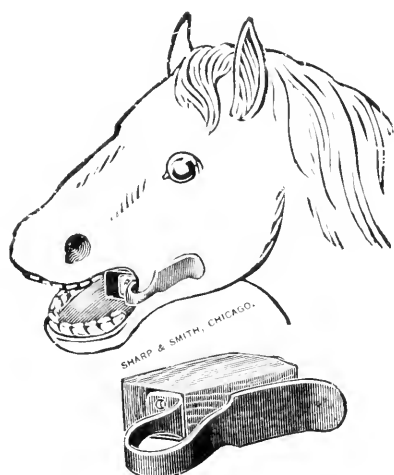


FIG. 121A.
Mouth Gag.

The Most Appropriate Speculum for
Williams' Operation.

over repulsion for these teeth. It may also be applied to removal of the first, second and third inferior molars, but in these it has no special advantages over repulsion. For the first three superior molars, especially the third and second, the operation is almost indispensable, and it out-classes repulsion because the almost perpendicular wall of the skull at this point prevents the placing of the punch on a straight line with the tooth, and finally, in repulsing the third tooth the opening, if properly placed, necessitates division of the

superior maxillary branch of the fifth cranial nerve near its exit from the infraorbital foramen.

1st step.—Clip, shave and disinfect a liberal space at seat of operation.

2nd step.—Make a longitudinal (parallel to long axis of skull) incision two inches long through the skin and muscles directly over the root of the affected tooth.

3rd step.—Separate the soft tissues from the bone from the incision to the gingival margin in the mouth.

4th step.—Saw through the skull along the interdendum on each side of the tooth; then chisel the bone flap loose superiorly.

5th step.—Pry the released plate of bone loose with the chisel, and remove with the forceps.

6th step.—Release and elevate the tooth by prying with chisel and mallet.

7th step.—Close incision with sutures and arrest hemorrhage by packing from within the mouth.

8th step.—Remove crown of opposing molar to prevent packing of food into the cavity.

After-care.—Remove the packing in twenty-four hours. Irrigate daily with mild antiseptic solution, and keep incision well protected with clay paste.

(4) REMOVAL OF TEETH BY SPLITTING WITH CHISEL.

This operation is indicated for the removal of the first superior or first inferior molars when the crowns cannot be held in the forceps. It is performed in the recumbent position with the aid of a mouth speculum. Recently an inventor has placed upon the market a tooth chisel shaped like a horseshoe, that can be used to chisel any molar tooth. Such an instrument is of service in splitting and removing badly diseased fangs when major methods are unwarranted, and to serve as a wedge to dislodge the remaining fangs of

teeth accidentally fractured in attempts to extract them with the forceps.

EXTRACTION OF THE INCISORS.

Owing to the deep implantation and curvature of the fang, the incisors cannot be readily extracted by any ordinary method, except in extreme old age, when the fang has become shortened. During youth and middle age their ex-

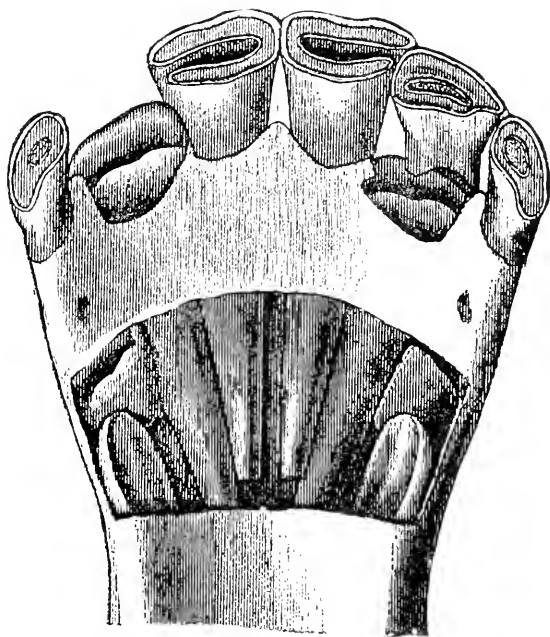


FIG. 122.

Cut Showing the Great Length and Curvature of the Incisors, that Prevents Forcep Extraction.

traction can only be accomplished by removal of the anterior alveolar plate and then prying the tooth out with a chisel or elevator. The subject is placed in the recumbent position and the mouth tied shut with several wraps of sash cord around the muzzle. With knife and forceps the mucous membrane and gums are removed over the fang, the periosteum is scraped off with a curette and the bone removed

with a chisel. When the fang is exposed throughout its entire length the chisel is driven under the tooth and it is pried out.

The incisors of the solipeds and ruminants are seldom decayed to the point requiring extraction. Longitudinal fractures from falls or blows may loosen a part of an incisor and provoke decay of the remaining portion, and occasionally a persistent temporary with a long fang may demand attention to improve the appearance of the mouth, but aside from these instances extraction is seldom required. The temporary incisors are frequently extracted to give the horse the appearance of being one year older, or when the shedding is delayed beyond the usual period.

EXTRACTION OF THE CANINES OF HORSES.

The deep, curved alveolar cavity of the horse's canines, like the incisors, prevents forcep-extraction, in the young animal. They are removed only in the recumbent posture, by the removal of the external alveolar plate and prying with the chisel as in the case of the incisor.

The canines are seldom decayed except from pulpitis and periostitis following injuries to the tooth or jaw.

CARIES.

Synonyms:—Caries dentium, decayed teeth, ulceration of teeth. (It must not be confounded with alveolar periostitis of herbivora).

Definition:—Caries signifies rottenness. As a diseased process it might be appropriately defined as a biochemic decomposition of the dentinal substance originating at one or more points of a tooth. It might also be defined as a progressive disintegration of a tooth's substance, penetrating from the surface toward the center.

Etiology:—The exciting cause of caries is erosion or frac-

ture of the enamel covering, through which channel acids and **micro-organisms** gain access to the sensitive parts of the tooth. The acids dissolve the calcium salts as the micro-organisms decompose the organic material, producing conjointly a gradual gnawing away of the substance. The progress of disintegration is frequently arrested by the formation of a protecting wall around the cavity not unlike the pyogenic wall of an abscess of the soft tissues. This process is due to the calcification of the intra-tubular substance of the dentine. In other events it progresses until the entire tooth has become destroyed.

The acids responsible for the dissolution of the calcareous matter of the tooth reach the teeth by being ingested as such, or by the transformation of food products into acid substances. The micro-organisms are the putrefactive parasites which normally inhabit the mouth and which only become pathogenic at the proper opportunity. Efforts to isolate a specific organism have thus far failed.

The predisposing causes are numerous. Impairment of the general health during the period of dental evolution, rickets, pregnancy, irregularities of the arcades, meat diet and uncleanness of the mouth are the chief conditions responsible for the disease.

Susceptible animals. In man caries is the most common of all pathological conditions. Few mature human beings escape its ravages upon the teeth. It is essentially a disease of mature life, although when the predisposing causes are legion even the temporary teeth may be attacked to a remarkable extent. In the domestic animals it is observed occasionally in the old dog, hog and cat. Solipeds and ruminants are comparatively free from caries. In these animals decay of the teeth takes the form of an inflammatory disintegration. (Necrosis, see page 152). In rare cases the dissolution of the herbivorous tooth may undergo a disin-

tegrating process which neither resembles caries (the non-inflammatory condition) nor necrosis (the inflammatory condition), and as a result leaves the impression that caries is existent in the herbivorous animals. Caries, the disease of human teeth having its uniform cause, course and termination, **is not seen in the herbivora**, and the short lives of the other domestic animals places the disease among the rare disorders in veterinary practice.

Treatment:—The carious tooth of dogs, cats and pigs is treated by prompt extraction. Leveling, burnishing and stopping the carious cavity, which constitutes the universal treatment of the disease in the human tooth is an attainment not expected of a veterinarian at the present time, and the




FIG. 122A.

White's Dog Speculum.

rarity of the indications will doubtless always prevent its introduction into the veterinary college curriculum.

EXTRACTION OF THE TEETH OF DOGS.

When the teeth of carnivora are loosened from disease their extraction is easily accomplished with the forceps, but when the implantation is not disturbed they can seldom be extracted without fracture. The canines, especially, are firmly imbedded into a curved cavity and will defeat any ordinary method of removal.

The extraction of the teeth of dogs is best accomplished by first disturbing the implantation with a cutting bone forceps along each side of the fang before applying the extracting forceps. The molars, canines and incisors may be

treated in the same manner. A handy method of securing a dog for tooth extraction is to tie a piece of tape around each jaw behind the canine teeth, then an assistant stands astride of the dog, pinches the head taut between his knees and holds the mouth open with the tape as the operator applies the instruments. This method is even preferable to the operating table, which places the mouth in an awkward position for extraction.

ABNORMAL ERUPTIONS OF THE TEETH.

Shedding of the **incisor teeth** depends upon "growth pressure" from the permanent successors. If the forming tooth

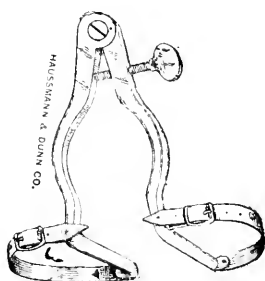


FIG. 122B.

Baker's Dog Speculum.

does not adjust itself directly upon the apex of the temporary fang the latter may remain wedged between two contiguous teeth through life. If this same condition exists in all the incisors the result is a complete double set of incisors.

When such abnormalities are observed early enough the temporary teeth should be extracted. In later years they are best left undisturbed.

The **canine teeth** frequently remain covered with the gums for several years after their usual period of eruption, and thus cause a more or less painful irritation to the mouth. The condition is observed most frequently in the six and seven-year-old driving horse by the resistance such animals

offer to the adjustment of the bridle or by shaking the head while driving. The condition is met by lancing the gums, which is best done with the curved scissors.

The **molar teeth** having temporary predecessors, the first, second and third, for obscure reasons occasionally cease to grow sufficiently to force out the temporary ones, and as the latter are not sufficiently stable to perform the function of mastication, the whole area becomes infected and the result is a large tumefaction of the jaw. When the temporary teeth are extracted the dead undeveloped permanent

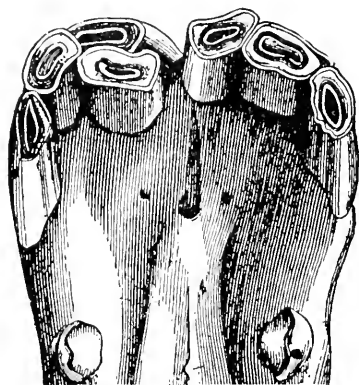


FIG. 123.

A Persisting Temporary Tooth Due to Faulty Eruption of Its Permanent Successor.

ones are found lying loosely beneath them. This condition is found chiefly on the lower jaw. The condition will always respond promptly to the removal of both the temporary and permanent teeth involved in the process. One, two or all three teeth may be affected.

On the superior jaw **osteoma of the maxilla** over the third, second or first molars is often produced by backward pressure of the permanent teeth when their downward growth is blocked by a wedged temporary tooth.

These conditions occur in young horses from two to five years old and are often mistaken for decayed teeth or tumors

of more serious import. They may be unilateral or bilateral. If the temporary tooth is already shed the condition must be treated on the expectant plan. Blisters and time will remove the condition in from two months to one year. They seldom persist longer. Removal of the greater portion of the tumor by trephining it from apex to base with a large trephine will hurry the recovery, but there is some danger of producing a chronic fistula that is difficult to heal.

DENTAL CYSTS.

Dental cysts is the name we apply to cystic growths occurring along the course of the artery supplying the tooth. They vary in size from small sacs the size of a marble to growths that entirely fill the sinuses and even cause bulging of the facial bones. They are probably the result of atheromatous degeneration in the wall of the nutrient artery of the molar tooth. They frequently become infected and cause alveolar-periostitis, chronic nasal catarrh, or both. Regardless of size, they completely destroy the nutrition of the tooth by obliterating the nutrient vessel, and after they expel their contents the dead tooth, entirely stripped of its periodontal covering, is left projecting into the sinus. During the early stages of the resulting catarrh a diagnosis of the real condition, before operation, is impossible. A tooth so affected will finally become loosened and thereby for the first time reveal the true cause of the catarrh. In rare instances the projecting root becomes encysted in a new mass of fibrous tissue and remains intact through life. The dental cyst explains the nature of the cause of some of these obscure cases of chronic nasal catarrh which are described as primary. When recognized these cysts are treated by repulsion of the affected tooth, which is located by palpation or inspection after the skull has been trephined. The disease

is confined to the fourth, fifth and sixth superior molars, and it originates in the young animal.

ODONTOMATA.

Synonym:—Tooth tumors.

Definition:—A dentinal growth of non-inflammatory origin, occurring on the fangs of the teeth.

Etiology:—The cause of these growths is obscure. They

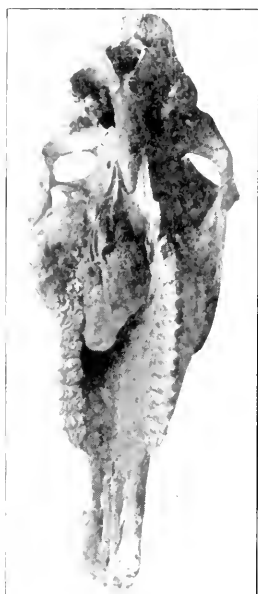


FIG. 124.

A Large Odontoma of the 6th Superior Molar.

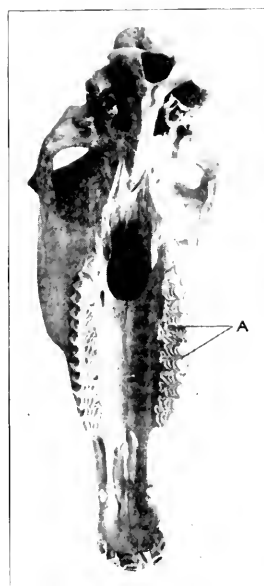


FIG. 125.

Odontomata of the 3rd and 4th Superior Molars.

are probably the result of some perversion of their foetal evolution.

Symptoms:—The odontoma may exist unobserved until attempt is made to extract the tooth to which it is attached. The tooth will be easily loosened, but in spite of all efforts it cannot be lifted from its cavity. There is usually a slight tumefaction of the skull over its fang. In the superior arcades and on the posterior teeth of the inferior arcades they

are occasionally determined by monstrosity of the crown. The crown will be found expanded in all directions, often extending well toward the median line of the palate. They may weigh upward to five or six pounds.

Treatment:—The odontoma causing no inconvenience is left undisturbed. When ablation becomes necessary through decay of the tooth or infection of the surrounding peri-

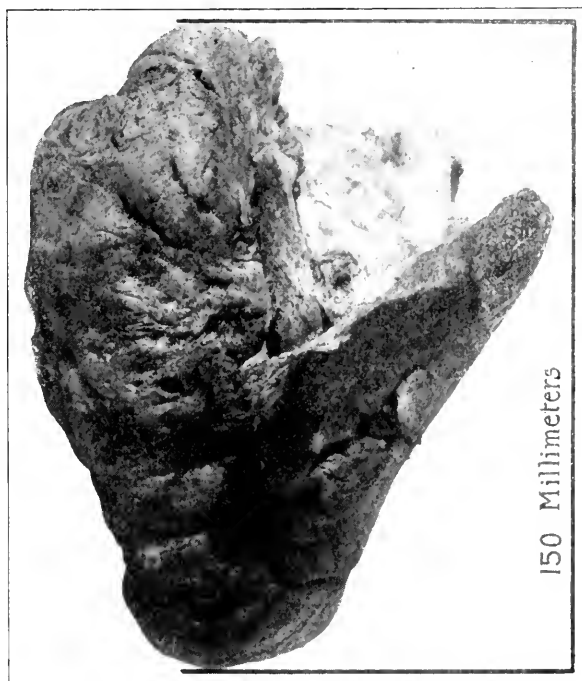


FIG. 126.

An Odontoma of the 2nd Inferior Molar Weighing 5 Pounds. The White Portion Is the Table Surface of the Original Tooth.

teum, they are removed by first trephining and chiseling the skull over the most prominent part of the tumor, and then dividing it into sections until repulsion is possible.

BRACHYGNATHISM.

Synonyms—Parrot mouth. Receding jaw. Receding chin.

Definition—A congenital deformity in which the superior incisors overlap the inferior.

Etiology—A congenital deformity of obscure cause. The deformity consists of a deficiency in the proper length of the inferior maxillary, or an abnormal elongation of the premaxilla.

Symptoms—Overlapping of the inferior incisor by the superior ones with more or less elongation of the first superior and sixth inferior molars. The condition becomes more

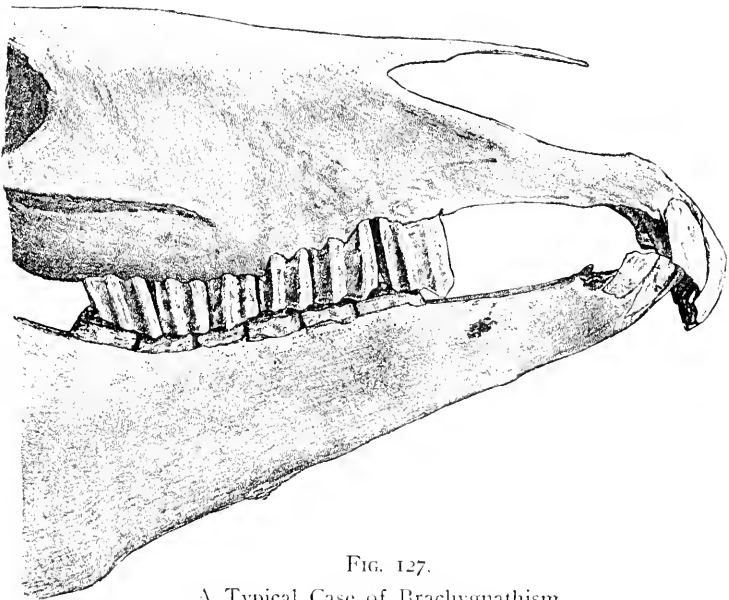


FIG. 127.
A Typical Case of Brachygnathism.

and more aggravated with age. As the molars wear away the inferior incisors reach the palate behind the superior incisors. Nature, however, seems to meet the condition by hardening of the palate and rounding the premaxilla so as to accommodate the gradual transgression of the inferior incisors. There will be difficulty in the prehension of attached food, and the animal will be difficult to keep in good condition.

Treatment—Parrot mouth is a defect for which horses

must be condemned in an inspection for soundness. The inferior incisors must be shortened by filing from time to time, and the elongated molars must be trimmed to the level of the other teeth. Shortening the superior incisor is useless and inadvisable. Filing or cutting a considerable portion of either the inferior or superior incisors is harmful, as these teeth, having never been subjected to the influence of wear,

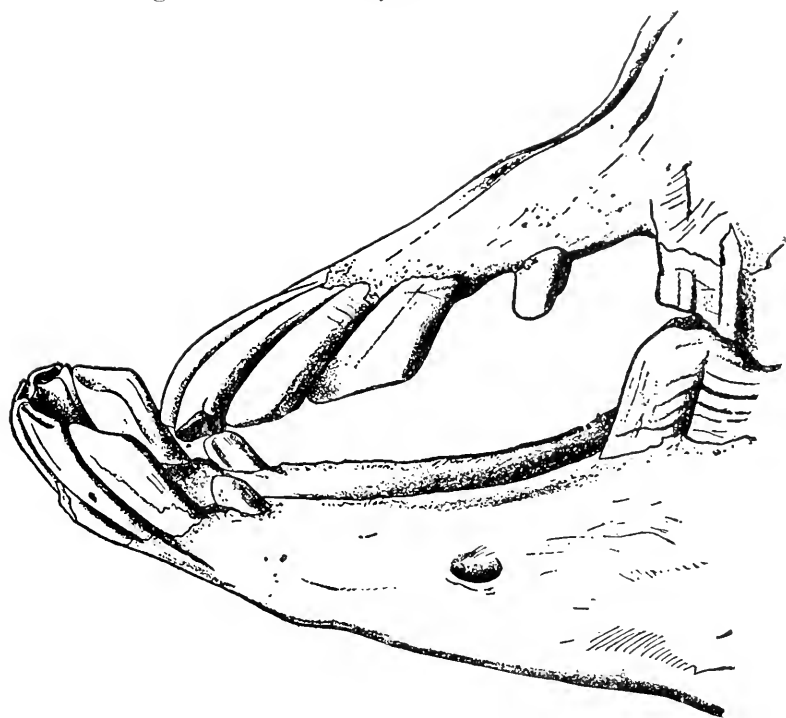


FIG. 128.

A Typical Case of Prognathism.

are sensitive to the very tables, and will bleed if much of the crown is removed.

PROGNATHISM.

Synonyms—Undershot. Prominent jaw. Prominent chin.

Definition—A congenital deformity in which the inferior incisors overlap the superior. The deformity consists of a

deficiency in the proper length of the premaxilla or an elongation of the inferior maxilla.

Symptoms—Prognathism exists most frequently in dogs in which animals it is characteristic of certain breeds. It is, however, occasionally encountered in the horse, the molars sharing the abnormality.

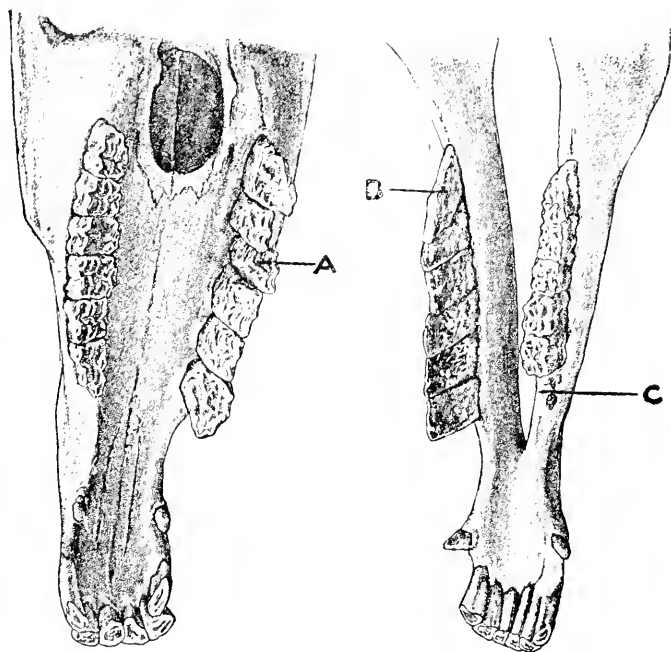


FIG. 129.

A Typical Case of Parvognathism (Ostertag).

- A, B. The beveled molars.
- C. 1st inferior molar absent.

Treatment—In the dog, none. In the horse the superior incisor crowns are shortened from time to time by filing and the molars are kept level.

PARVIGNATHISM.

Synonyms—Scissor mouth. Beveling of the molars.

Definition—A congenital deformity consisting of a deficiency in the proper width of the lower jaw, or more prop-

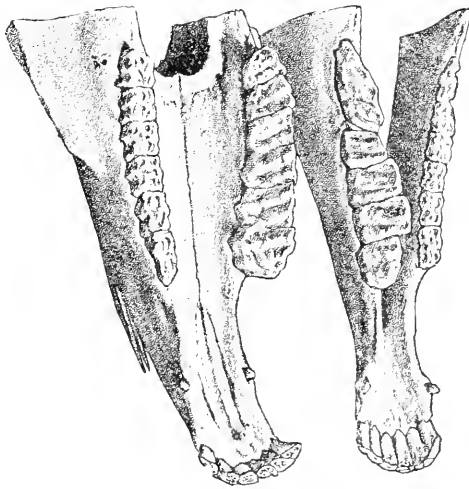


FIG. 130.

Parvognathism, with Beveling of the Buccal Surface of the Inferior Molars

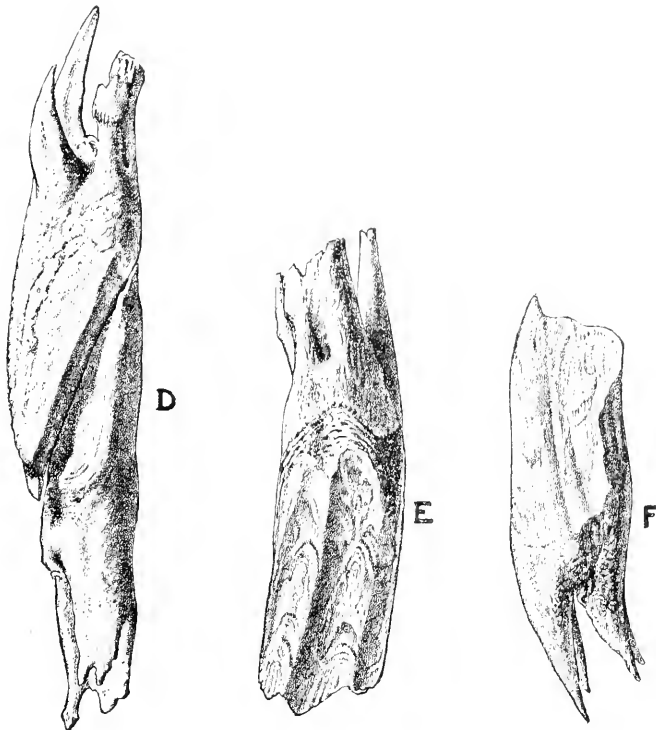


FIG. 131.

Samples of Beveled Molars Removed.

erly speaking, a deficiency in the proper distance between the inferior arcades, causing a beveling of the molars.

Symptoms—The beveling is usually confined to but one side. The molars of one superior arcade become beveled from without inward entirely obstructing the lateral motion toward the affected side. The condition is frequently complicated with decay of one or more molars, and mastication is almost impossible in the advanced stage. Parvignathism is one of the most serious irregularities of the horse's mouth.

Treatment—With the large lever cutter (Fig. 92), the beveled crowns of the entire superior and inferior arcades must be trimmed almost to the level of the gums, beginning with the first molars, and the decayed teeth, if any, must be removed. This treatment, while placing one-half of all the molars entirely "out of commission," will be met by prompt relief to the patient.

PROJECTIONS ON THE FIRST SUPERIOR AND SIXTH INFERIOR MOLARS.

Definition—A universal irregularity existing in the molar arcades of all mature horses, consisting of sharpened points of enamel at the anterior end of the superior arcades and the posterior end of the inferior arcades.

Etiology—The aggravated forms due to such gross deformities as brachygnathism or congenital or acquired deficiency in the proper length of one or both arcades are not included in this category. The large elongations occurring at the extremities in either of the molar arcades are usually due to a deficiency in the length of the opposing arcade, but in this minor irregularity the lengths of the arcades are equal. These points are caused by the position of the muscles of mastication. The fixed attachments of all the muscles of mastication except the masseter and external

pterygoid are located posteriorly, and therefore lift the jaw slightly backward at each contraction. The absence of any muscle with an anterior fixed attachment to antagonize this backward traction is the cause of these universal irregularities. The masseter's influence in that connection is insufficient.

Treatment—In driving horses the anterior ones wound the mucosa and require filing.

PROJECTIONS ON THE SUPERIOR CORNERS.

(See Fig. 72.)

At about the age of seven years there appears on the superior corner incisor a sharp enamel point which in most instances will disappear during the three ensuing years. This irregularity is due to a congenital deficiency in the dimension of the inferior corners. They disappear under the influence cited in the preceding paragraph, i. e., the backward traction by the muscles of mastication.

ACQUIRED ELONGATION OF THE MOLARS.

Definition—Projections of the molars into vacant cavities on the opposing arcades.

Etiology—The common cause of elongation of this variety is the loss of a molar by extraction. They occur also from the decayed molar that offers no adequate wearing surface for its opponent. Occasionally in old age the molars become excavated from a defect in texture.

Symptoms—Defective mastication, rejection of food, accumulation of food beneath the buccinator and tumefaction of the jaw are the signs usually directing the attention to such teeth. Palpation and inspection will reveal a large tuberos projection involving one or two teeth in one arcade, and a vacant tooth cavity or a decayed tooth, in the

opposing one. In the aggravated forms there will also be a considerable excavation of the jaw in the vacant cavity. Owing to the frequency of decay in the fourth superior molar the condition appears chiefly in the region of the fourth inferior molar.

Treatment—Trimming to the level of the arcade with the lever cutter in young animals and extraction in the aged patient. In horses more than fifteen years old the implantation is so unstable that the cutting process may loosen the tooth.

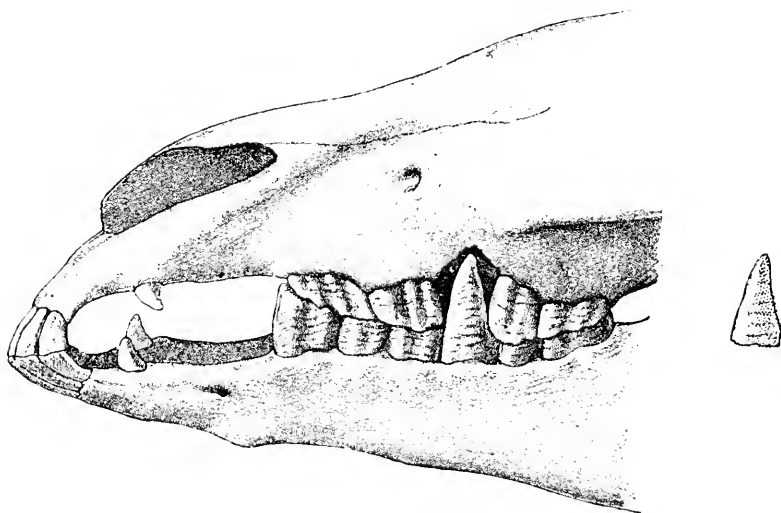


FIG. 132.

Typical Case of Elongation of the 4th Inferior Molar (Ostertag).

OPERATION OF CUTTING ELONGATIONS.

Restraint—Standing position with the dental halter and without the use of the speculum. The speculum will prevent placing the cutter evenly over the crown of the tooth.

Equipment—Dental halter, open molar cutter, floats and file.

Modus Operandi—For the left side guide the head of the cutter to the tooth with the left hand, as the other hand supports them by the handles. Place the left handle

of the cutter against the chest and open it with the right hand, then adjust the jaws over the base of the elongation. Retract the left hand and cut off the tooth with both hands. In the superior arcades the great volume of the elongation may necessitate the application of considerable force. Care

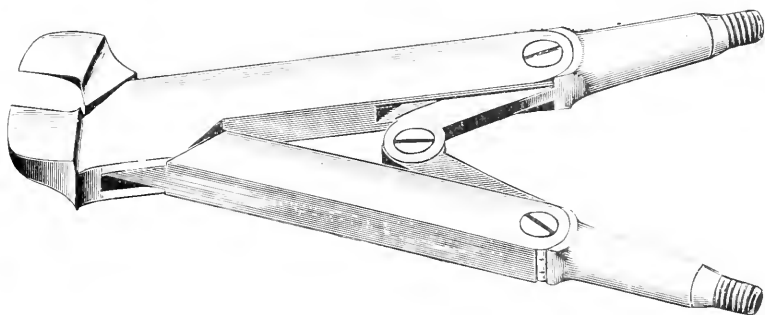


FIG. 132a. (Also FIG. 92.)
The Open Molar Lever Cutter.

must be taken in aged horses, and in the case of the molars at the extremities of the arcades, that the tooth is not loosened by a sudden movement of the patient's head. After cutting the elongation the arcade is leveled with the floats




FIG. 132b. (Also FIG. 98a.)
Handles for Figs. 92, 92A, 94, 94A, 95, 97 and 98.

and file. Small pointed projections on the inferior arcades may be cut with the closed molar trimmers when they are too narrow for the large opening of the lever cutter.

ENAMEL POINTS.

Synonyms—Sharp teeth. Lateral enamel projections. Enamel points of herbivora.

Definition—Sharp points of enamel at the table extrem-

ity of the longitudinal ridges of the molars, occurring along the buccal border of the superior arcades and the lingual border of the inferior.

Etiology—Enamel points are not pathological. They are a normal part of the dental mechanism, serving the purpose of a rake to maintain fibrous forage between the teeth. Being normal structures their causes are strictly of an intended, predisposing character, namely:

- (1) The relative narrowness of the inferior molars.
- (2) The relative narrowness of the lower jaw.
- (3) The ginglymoid character of the temporo-maxillary articulation, limiting the lateral motion of the jaw.
- (4) The longitudinal ridges, the enamel of which renders possible the formation of points.
- (5) The herbivorous characteristic of which three substances of unequal densities are in wear.
- (6) The normal wear of the teeth.

Symptoms—Under strictly natural conditions they are not harmful, but from the artificial influences to which the horse is subjected they frequently wound the buccal surfaces. The widely accepted impression that they limit mastication by obstructing the free lateral swing of the jaw is not founded upon facts. Their sole harmful effect is the wounding of the mucous membrane. The wounds are usually located on the cheek **opposite the first and second, and fifth superior molars**. The former are caused by the friction of the bit and bridle and the latter by the forcible movements of the masseter muscle. The lesions vary from slight erosions of the mucous membrane to large ulcer-like patches one inch in diameter. Other parts of the cheek and the tongue are seldom wounded. They attain the greatest size between the ages of 5 and 8 years.

Wounds of the cheeks which are being perpetually ag-

gravated by enamel points limit mastication and favor gastric indigestion. In drivers, runners and saddle horses they are the greatest sources of annoyance. The expert reinsman will promptly recognize their presence by the horse's behavior in harness. Lugging, side-reining, ptyalism, tenderness about the seat of bit, manifestations of pain from the bridle are symptoms of these lesions.

Treatment—The treatment consists of filing with the floats and file. Trimming with the closed molar trimmers (Fig. 91) preceding the filing cannot be defended by any logical argument. If this instrument could be accurately adjusted to the very tips of the points, as they are intended, they would materially lessen the labor of the operation, but as only the very skillful operator can properly accomplish this feat, the use of the trimmers should be dispensed with in the interest of judicious and scientific dentistry. A few carefully directed strokes of the float equipped with the rasp blade will rapidly blunt the sharp projections to the desired point. Rounding the borders of the molars is harmful. **The aim in dressing the teeth of a horse should be to simply blunt the enamel points along the course of the arcades and to "round up" the first superior and first inferior molars as smooth as an ivory ball.** The wounds from the bridle are thus prevented and there will be no interference with mastication from the too liberal use of instruments along the whole arcade. The closed incisor trimmers are indispensable to trim the projection at the extremities of the arcades, and on the first inferior molar the angular trimmer may be used. (Fig. 98.)

OPERATION OF TRIMMING AND FLOATING THE MOLARS.

Equipment—Straight float, angular float, closed molar trimmers, twelve-inch file, a pail of water, and the dental halter.

Restraint—The horse is secured in the standing position, backed into a single stall and fastened to the pillar with the dental halter. The halter ropes are fastened to the pillars low enough to hold the head at the proper height. When the construction of the pillars prevents tying the ropes low enough, an additional rope is fastened from the halter at the lower extremity of the iron band and passed between the forelegs around the withers, and back again between the legs to the halter, for the purpose of preventing the head from being held too high. This method is also serviceable in securing horses in a loose box or paddock where stalls are wanting. (See Fig. 105.)

The mouth speculum must be dispensed with, as it positively interferes with the free use of the instruments and provokes resistance, which is otherwise avoided. The twitch also is contra-indicated, even on the vicious animal.

The aim in securing the horse, as in performing the operation, is to avoid the use of any force that will be resented.

Examination of the Mouth—First, the incisors are inspected to determine the age and the presence of any harmful disorders or irregularities. Then the palmar surface of the thumbs is passed along the interdental space of the lower jaw to locate possible bit lesions, and without withdrawing them they are turned upward against the interdental space of the upper jaw to palpate for wolf teeth. Third, the molars are palpated by passing the hand backwards between the tongue and molar arcades. (See diagnosis.)

Modus Operandi—The canines may first be blunted with the twelve-inch file, to prevent wounding the hands, but the blunting process must be limited to the very tips of the crowns, owing to the fact that a short blunt canine gives the appearance of age, and thus leaves an opportunity for just criticism.

The second step of the operation consists of trimming the

ends of the arcades, with the closed molar trimmers, but only when the projections are long enough to warrant their use. The first superior molar and the sixth inferior alone require this treatment, in the normal mouth.

The remainder of the operation—the floating and filing—is performed as follows:

1st. Float the posterior two-thirds of the right superior arcade, with the straight float, the anterior one-third with the angular float, and then blunt the anterior end of the first molar with the twelve-inch file.

2nd. Observe the same routine on the left superior arcade.



FIG. 89.




FIG. 89A.

Straight and Angular Floats, with Lines showing the Proper Angle of Each.

3rd. Float the entire left inferior arcade with the straight float, and bevel smoothly the anterior end of the first molar with the twelve-inch file.

4th. Observe the same routine on the right inferior arcade.

5th. Extract wolf teeth, if any exist, and complete the operation by blunting any sharp projection, on the superior molar, that may exist behind them, and which could not have been reached prior to their extraction.

It will be observed that in the above routine the arcades beginning with the right superior, are dressed consecutively. The work on each one is completed before passing to the next, until all four have been perfectly attended to. The

only objection to this order of manipulations is the loss of time consumed in changing instruments. When speed is a consideration, all the work required of each instrument is completed before the instrument is laid aside, as follows:

1st. Float the posterior two-thirds of the superior arcades, and all of both inferior arcades, with the straight float.

2nd. Float the anterior one-third of the superior arcades, with the angular float.

3rd. Blunt and bevel the ends of the arcades with the twelve-inch file.

Whatever is adopted, it will be found advantageous to

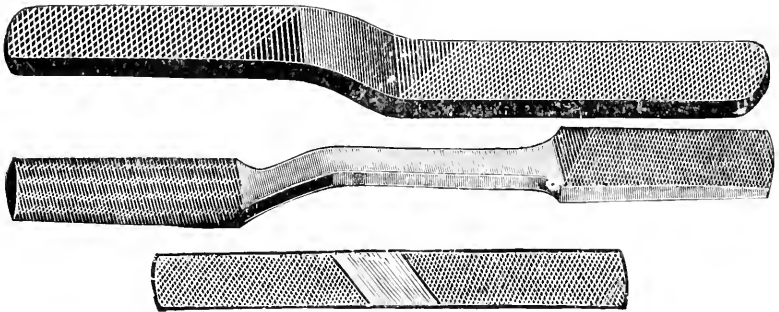


FIG. 90.

form the habit of following the routine in either plan, in order to avoid omissions and unnecessary examinations of the mouth to determine the amount of filing that has been done. It is an error to use the floats promiscuously and to repeatedly palpate to note the results. Such methods provoke resistance, which is avoided in more systematic work.

METHOD OF USING THE FLOATS AND FILES IN THE FORE-GOING OPERATION.

It is undeniable that one operator can float the teeth of horses, and in fact, use any of the dental instruments without provoking the least resistance, while another will have more or less trouble with every animal approached. So marked is the difference in this connection that bystand-

ers frequently gain the impression that some operators exert a mysterious influence over their patients. The secret lies solely in avoiding the use of force. A horse will resent forcible opening of the jaw, forcible insertion of the hand backwards into the molar region, forcible restraint, and injury to the soft structures inflicted by improperly directed instruments. In avoiding these manipulations the secret is found. Forcible opening of the mouth is unnecessary in

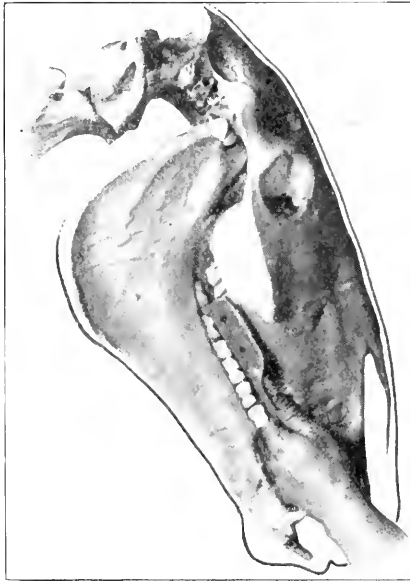


FIG. 133.

Position of Hands to Float the Right Superior Molar Arcade.

using the float. As only the edges of the arcades are floated the instrument may be passed unobstructed to their very end without opening the mouth more than half an inch. In the lower arcades the hand must be passed into the interdental space to guide the shaft of the float, and, as a result, the mouth is opened slightly more than in floating the superior ones, but to prevent resentment, the hand in the interdental space must not be used to force the mouth open when the animal attempts to close upon it. Its pres-

ence there is simply to guide the float and not to open the mouth. Injury to the hand is prevented by keeping it where it cannot be squeezed when the mouth is closed. Resistance is usually provoked in this manner by forcibly attempting to prevent closure of the mouth in fear of being bitten. The operator must learn to place the hand only where it cannot be bitten or squeezed, and the horse must be permitted to use its jaw *ad libitum*. The dental operation must not be a

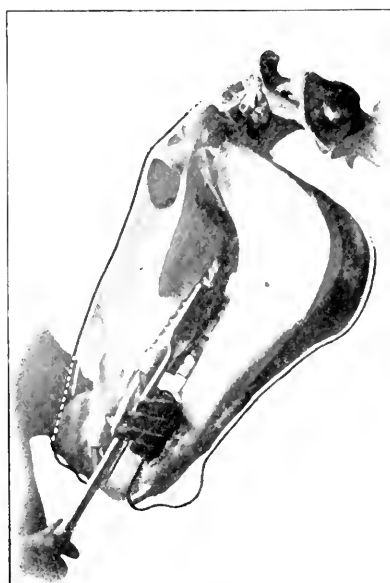

FIG. 134.

Position of Hands to Float the Left Superior Molar Arcade.

fight for superiority in strength between the dentist's hand and the patient's jaw. The following position of the hands to guide the instruments will serve the purpose.

For the right superior arcade place the tips of the fingers of the left hand palm upwards, into the interdental space, just in front of the commissure, or, in other words, in front of the first superior molar. Work the float with the right hand and guide its shaft with the **palmar surface of the fingers** of the left. In this position the finger tips are not

passed beyond the outer border of the jaw (upper branch of the premaxilla) but are fortified gently upon it. The float head is kept flat against the outer edge of the arcade and not upon the table surface. (See Fig. 133.)

For the left superior arcade pass the left hand, palm upward, through the interdental space, from right to left, until the tips of the fingers protrude slightly from the left commissure, and let the thumb rest easily on the palate in the re-

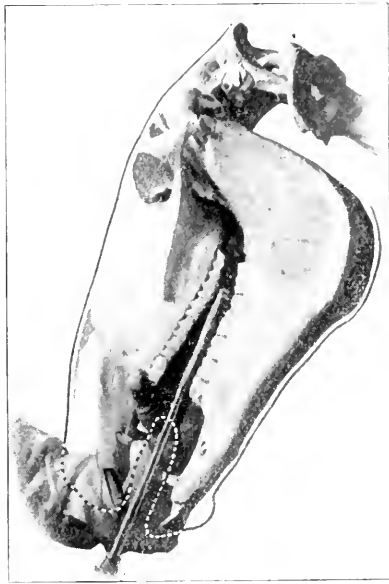


FIG. 135.

Position of the Hands to Float the Left Inferior Molar Arcade.

gion of the first superior molar. Work the float with the right hand and guide the shaft with the **palmar surface of the fingers of the left**. (See Fig. 134.)

For the left inferior arcade pass the left hand, palm downward, through the interdental space, from right to left, under the tongue, and when the left border of the tongue is reached with the finger tips, direct the hand upward between the tongue and left arcades (the dorsal surface to the tongue and palmar surface to the arcades), and let the thumb pro-

trude through the left commissure. In this position the anterior end of the arcade lies between the thumb and first finger, and the wrist is kept flat on the interdental space of the lower jaw, to keep the tongue from slipping beneath it. The float is worked with the right hand, and the shaft is guided by the **palmar surface of the base of the thumb**. The float head is kept flat against the internal border of the arcade, and not on the table. (See Fig. 135.)

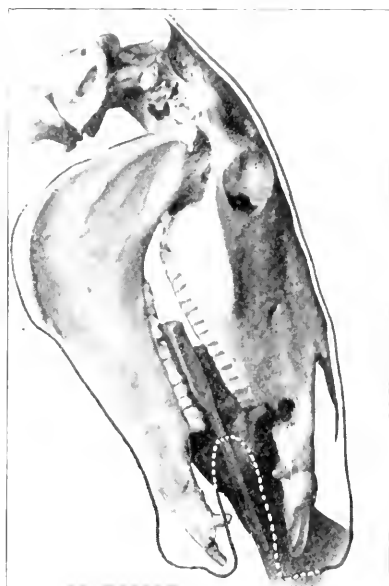


FIG. 136.

Position of the Hands to Float the Right Inferior Molar Arcade.

For the right inferior arcade place the right hand in the same relative position as the left was placed for the opposite inferior arcade, and work the float with the left hand. Although the left hand is the awkward one, it is advisable to train it to accomplish this feat, as it is the only position that will give universal satisfaction. Another method consists of placing the left hand upright into the interdental space and guiding the shaft between the second and third, or third and fourth fingers. Still another method consists

of passing the left hand into the interdental space, through the right commissure, grasping the free end of the tongue firmly with the fingers and then passing it gently out of the opposite commissure. In this position the float is worked with the right hand, and the shaft is guided by the wrist, which is slightly arched upward into the roof of the mouth. The right inferior arcade is more difficult to float than the others and as a result is usually found neglected posteriorly. (See Fig. 136.)

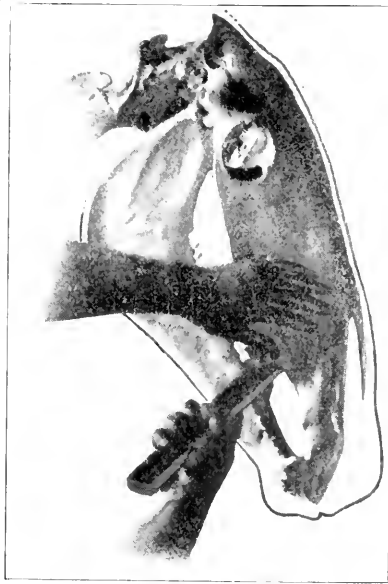


FIG. 137.

Position of the Hands and File to Blunt the Right First Superior Molar.

To blunt the right first superior molar place the left hand into the right commissure between the cheek and the molar arcades, then pass the twelve-inch file (in the right hand) through the interdental space from the opposite commissure to its finger tips. Work the file with the right hand and guide it around the end and side of the arcade with the finger tips of the left. Change positions to round the arcade anteriorly and internally as follows: Place the left hand toward the nasal roof and the thumb into the commissure to

retract and elevate it, then work the file with the right hand. (See Figs. 141-137.)

To blunt the left first superior molar place the right hand in the left commissure, between the cheek and teeth, then pass the twelve-inch file through the interdental space from the opposite side to the finger tips of the right hand. Work the file with the left hand and guide it with the finger tips of the right. Change the position to blunt the anterior end of

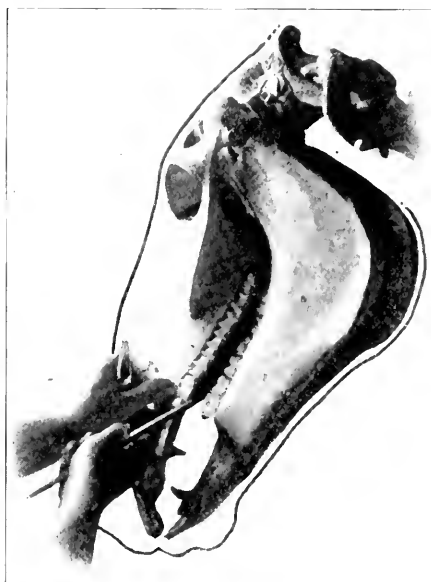


FIG. 138.

Second Position of the Hands and File to Blunt the Left First Superior Molar.

the tooth, as follows: Place the palm of the left hand over the nose and with the thumb retract and elevate the commissure of the mouth, then work the file with the right hand as in filing the opposite side. (See Fig. 138.)

To bevel the right first inferior molar place the palm of the left hand on the inferior border of the lower jaw, and retract and depress the commissure with the thumb, then work the file with the right hand. (Fig. 139.) Change the position

as follows: Pass the file through the interdental space from left to right, and hold it upon the tooth with the thumb of the left hand, then work the file by short movements of both hands.

To bevel the left first inferior molar open the mouth gently by grasping the tongue and turning it perpendicularly in the interdental space; then work the file over the molar with the right hand. The beveling process may be pre-

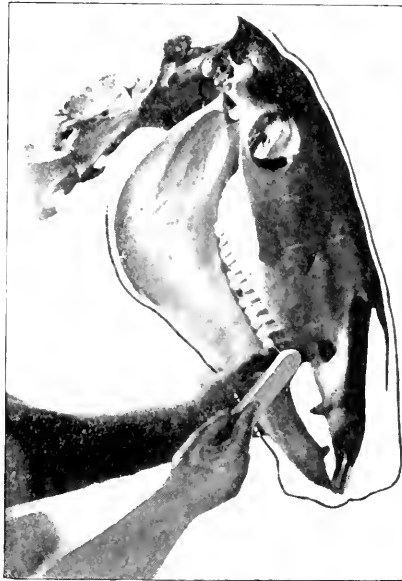


FIG. 139.

First Position of the Hands and File to Bevel and Blunt the Right First Inferior Molar.

ceded, to advantage, by first trimming the anterior angle of the crowns with the angular cutter. (See Fig. 140)

The above is simply "a" method by which the sharp points on the molars may be blunted with but little labor, and without provoking resentment from the horse. Other methods may serve the same purpose, providing they can be carried out without the use of force.

Occasionally a horse that has been roughly handled or

one that has never become accustomed to being handled about the head, will resent the attempt to open the mouth when first approached. Such animals can never be conquered by force or rough treatment, sufficiently to enable the operator to properly carry out the procedure, but by the use of kindness and gentle manipulations to first gain the patient's confidence, few dental operations need be abandoned on account of resentment. It will be found that

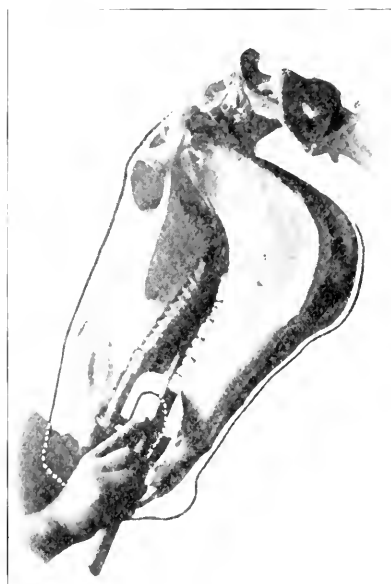

FIG. 140.

Position of the Hand and File to Bevel and Blunt the Left First Inferior Molar.

the most resistance is offered by such horses while the float is being adjusted to the teeth or while the hand is being placed in position to receive the float, and that the resistance immediately ceases as soon as the filing begins. The remarkable fact that a horse will stand "at attention" while the rasping proceeds suggests itself as a method of taking advantage of a resisting horse. Instead of first placing the hand into the interdental space, the float may first be

promptly passed into the mouth, and as the horse becomes attracted by the unusual sound and sensation produced by the filing no further resistance may be offered and the hand may then be placed unresented into the interdental space to guide the float.

Enamel points will recur in about three months, but not to a sufficient degree to produce injury until the twelfth to the eighteenth month after the operation. At the age of five

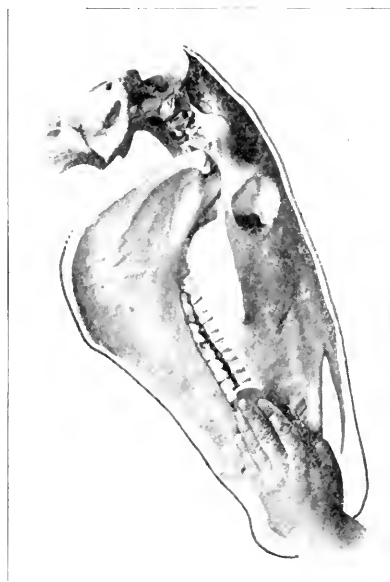


FIG. 141.

Position of the Hands and File to Complete the Blunting Process on the Superior Molars, Externally.

to eight years their recurrence is more rapid than in aged animals.

Modifications—When one of the arcades contains a decayed or elongated molar the normal arcades are floated and filed before any attention is given to the abnormal one. The painful part of the operation is performed last to avoid the resistance that might be provoked thereby, and when a tooth is extracted, to avoid working in a bloody mouth.

In very vicious animals the recumbent position may be necessary to properly trim the molar teeth, but such animals are rarely encountered. In our experience with upwards of fifty thousand horses only two such cases have been met—one was a trotting bred stallion and the other a hackney gelding. Both of these animals would resent any attempt to place a float into the mouth by striking viciously with the fore feet. In such cases the veterinarian is warranted in resorting to an appropriate means of restraint, in the recumbent position.

FLOATING THE TEETH OF THE OX.

The ox carries the head low, has an unyielding tongue and a strong jaw and is so unaccustomed to being handled about the mouth that it makes a rather unwelcome subject for dental operations. These obstacles are met by securing the head and neck to the post of the stall, in an upward inclination, and by keeping the mouth open with a strong speculum consisting of an oblong loop of iron placed within the interdental space. The ordinary horse speculum is too frail to withstand the forcible jaw of an ox.

The superior arcades are floated with the hand in the same position as in the horse, but in the inferior ones it is kept in the interdental space and not between the tongue and teeth. The float is directed from within outward to follow the direction of the arcades.

Enamel points are less harmful in the ox owing to the toughness of the buccal mucosa, yet buccal wounds from sharp teeth are not uncommon in animals past the age of three years.

WOLF TEETH.

Synonyms—Remnant teeth. Supernumerary teeth. Supplementary teeth. Eye teeth.

Definition—The wolf teeth may be defined as retrogressive teeth representing the premolars of the prehistoric

horse. They are not the result of accidental dental development but a constant normal part of the equine denture undergoing degeneration under the influence of selection, as the "wisdom teeth" of man are disappearing under the influence of civilization. The use of the bit through innumerable generations appears to have rid the interdental space of the premolars.

Wolf teeth are constant in foetal life in both the inferior and superior dentures, and many of them never develop to the point of eruption, but instead degenerate, and become incorporated with the maxilla. Those which finally erupt vary from small homogeneous masses of soft dentine to well

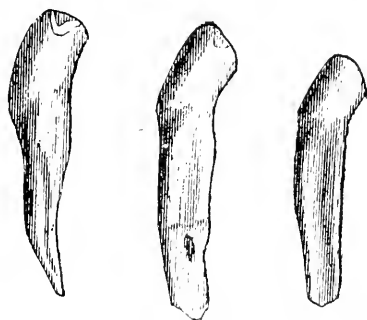


FIG. 142.
Wolf-Teeth.

developed teeth possessing all the distinguishing characteristics of the herbivorous molar.

Symptoms—Wolf teeth are harmless with the exception of their possible interference with the overcheck bit or complicated coach-horse rigging, such as bridoons. They have no effect upon the eyes, and are diagnosed solely by palpation. Their position is the interdental space of the upper jaw, more or less closely related to the first molar. In some instances they are located on the inner aspect of the molar and occasionally on the lower jaw.

Treatment—The wolf tooth should be extracted, as it serves no useful purpose and may at some time interfere

with the biting rigging of a driving horse. In the treatment of eye affection their extraction is particularly advisable, owing to the popular prejudice against them.

They are difficult to extract without fracture because their location prevents direct outward traction and because of the impossibility of perfectly immobilizing the head and especially the lower jaw. Their removal is accomplished by first disturbing their implantation with the **wolf tooth separator** (Fig. 93) prior to the application of outward traction with the forceps, or with the separator alone.



FIG. 143.

Supernumerary Incisors of a 6-Year-Old Gelding.

SUPERNUMERARY TEETH.

Definition—Teeth existing in excess of the normal number in any of the arcades, are designated as supernumerary. They must be differentiated from wolf teeth, which are normal structure and from persisting temporary teeth, due to displacement of the permanent tooth germ.

Etiology—The supernumerary teeth result from the projection of more than one stalk from the common enamel germ. This occurrence is frequent if not universal, but under normal development, all the stalks degenerate as a chief one predominates. Whenever two or more keep pace with one another until tooth development is well advanced, the

result is the formation and growth of more than one tooth at a given point. Some such teeth may never erupt, but remain imbedded in the jaw along the arcade.

An additional seventh molar frequently occurs behind the sixth in either arcade. This incident is the result of the

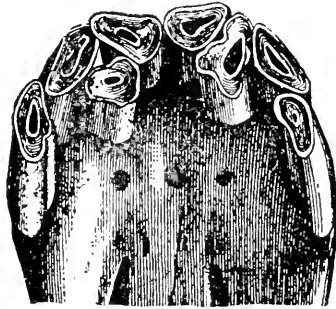


FIG. 144.

Supernumerary Incisors of a 9-Year-Old Horse.

backward extension of the common enamel germ from precocity of the sixth molar.

Symptoms—The abnormality is observed chiefly in the incisor arcades which may contain an entire double row of teeth. In most instances one or two additional incisors are

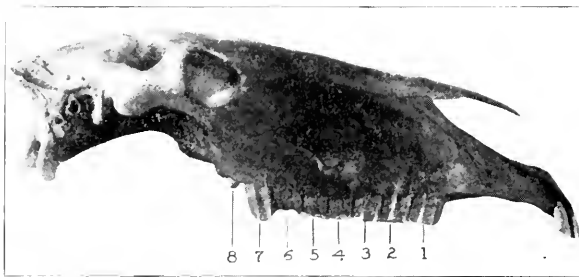


FIG. 145.

Supernumerary Molars.

observed projecting in an irregular fashion to the table level of the arcade. The lateral incisors are most frequently the seat of the abnormality.

In the molar arcades they may remain hidden through

life, or remain unobserved until their existence is revealed in the treatment of diseased conditions—extracting, trephining, etc.

Treatment—As long as the supernumerary tooth produces no apparent harm no treatment is advisable. In the incisor arcades their extraction gives even a worse appearance to the arcade than if they had been left undisturbed. When encountered within the sinuses in the course of dental operations they are removed or left undisturbed, according to whether they are involved in the morbid process.

ELONGATIONS OF THE INCISORS.

As decay or loss of incisor teeth is a rare condition acquired elongations of the incisors by growth into vacant cavities are also rare. The gradual lengthening of the whole superior incisive arcade as an animal becomes older is a natural condition resulting from a gradual receding of the alveolar border, and the constant increase in the inclination.

The common impression, especially among laymen, that the elongation of the incisors prevents contact of the molar denture is erroneous. The only detriment is the evidence they furnish of the real age of the animal, on which account alone their shortening is advisable. Shortening the superior incisors of the old horse is always harmful in proportion to the amount removed. Prehension of attached food is impaired.

SHORTENING THE INCISOR TEETH.

The incisor teeth of the horse are reduced in length for the purpose of disguising the evidence they furnish as to the age of the subject. The popular impression that they prevent contact of the molars is as positively ridiculous as it is physically impossible. The incisors can only wear as fast as the molars will permit them, and vice versa. In rare instances the veterinarian is required to reduce their length,

to hide the crowns beneath the lips, when the latter no longer cover them completely, in which case only the operation is excusable.

The operation is performed only upon the superior arcade, as the inferior one is seldom inspected for its senile changes.

Modus Operandi—**First**, cut off the internal table angle of each corner tooth and file them to the length decided upon, and then use the length as a guide for reducing the remainder of the arcade. **Second**, file a deep groove, through the enamel across the laterals and centrals connecting the new table level of the corners. **Third**, cut off the laterals with

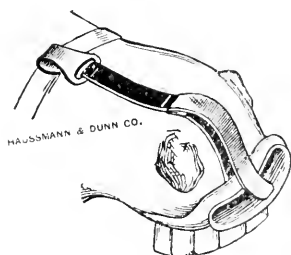


FIG. 145A.




FIG. 145B.

Lip Retractor and Mouth Gag, useful in shortening incisor teeth.

the nippers and file them to the level of the corners. **Fourth**, cut off the centrals and file them to the level of the laterals. **Fifth**, bevel the tables backwards by patient filing. **Sixth**, remove the crusta petrosa and tartar and polish with emery paper.

In cutting the incisors great care is necessary to prevent chipping of the enamel, which accident will leave an unsightly defect in the arcade. The accident is prevented by cutting the transverse groove completely through the enamel and by not grasping too much substance with the nippers. It is preferable to cut an incisor tooth by small sections, rather than by grasping the entire crown.

EROSION OF THE ENAMEL.

Definition—A disease of the anterior face of the superior incisor teeth, characterized by a gradual upward denuding of the external enamel covering.

Etiology—The cause depends solely upon a faulty construction of the teeth, both anatomically and morphologically. The disease occurs in animals having an observable softness of all the teeth. The dentine is devoid of its characteristic hardness and the crusta petrosa is deficient in quality as well as quantity. Defective cementing of the enamel to a soft underlying dentine favors the gradual breaking and wearing away of the former. Iron feed boxes, cribbing and the habit of gnawing hard objects hurry the denuding process, but are never solely responsible.

Treatment—Polishing with emery paper to give a better appearance is the only possible help.

TARTAR.

Definition—An accumulation of calcareous matter along the gingival margin of the teeth.

Etiology—Tartar simulates calculi in other parts of the body. It is the result of the chemical action of saliva and mucus on the calcium salts of the food. It is composed of

Phosphates	80.
Mucus	11.5
Ptyaline	1.
Animal matter	7.5

Symptoms—Tartar occurs as a yellow incrustation along the gums. In animals it is found mostly on the canines and incisors; on the canines it frequently accumulates in large quantities and gives the crown the appearance of a monstrosity (odontoma). It is differentiated from the latter by being readily removed, and from the normal crusta petrosa

by its lighter color and by not adhering firmly to the crown.

Treatment—Tartar is removed with a curette or file. It produces slight irritation of the gums.

FRACTURE OF THE TEETH.

Fracture of the teeth occurs to the incisors from falling or stumbling on hard pavements, blows or kicks from other animals. The molars seldom sustain such injuries. Fracture of incisors is usually complicated with considerable contusion and laceration of the lip. The fractured loose sections must be removed and the lip treated according to the character of the injury.

SPLITTING OF THE MOLARS.

Synonym—Fissuring of the molars.

Definition—A condition peculiar to the molars of herbivorous animals consisting of a division of a **decayed molar** into **two** or **three** plate-like segments.

Etiology—Splitting of the teeth is an incident of the advanced stage of decay. It is not a separate entity nor an accident. Pulpitis, alveolar periostitis and the subsequent necrosis following these inflammatory conditions, deprive the tooth of its nutrition and moisture, and the resulting desiccation, predisposed by the "layer arrangement" of the tooth, favors splitting and fissuring as a termination of the disease process. In the long process of decay which the molar teeth undergo, splitting is the incident preceding the final ejection of the tooth from its cavity—self-extraction.

Fissuring limited to the buccal or lingual surface of the crown in the absence of any gross lesion is also of common occurrence to the back molars of both arcades. This condition is evidently due to an inadequate union between the external enamel and dentine of the crown, and greatly re-

sembles the abnormality of the incisors known as "erosion" or "denuding." It is a harmless condition in itself, but should be regarded as evidence of a poor quality of teeth.

Pathological Anatomy—The incident occurs most frequently to the superior molars, but is seen also in the inferior ones. The splitting may be limited to the crown or may extend through the entire length of the tooth. In the greatest number of cases it terminates just beyond the alveolar margin on the lingual side of the tooth, dividing it into two very unequal segments, one of which comprises the principal part of the tooth, and the other a thin shell consisting of the *crusta petrosa* and external enamel.

In other instances the tooth is broken into three segments—two lateral shells and a central large one, which includes the fang and roots.

In rare cases a superior molar is divided into two equal portions by splitting from table to root between the two layers of the internal enamel.

The condition is complicated with considerable osteitis and necrosis from lateral pressure against the alveolar margin, and from the decomposition of impacted food. In the old case the opposing tooth will be found elongated and the tongue and cheek may be severely wounded from friction of the protruding segments.

Treatment—Removal of the tooth and leveling of the opposing arcade. (See extraction.)

FOREIGN BODIES IN THE MOUTH.

Foreign bodies become lodged in the mouth of all the domestic animals. In the horse and ox pieces of corncob and sticks of wood become wedged between the superior arcades, and pins, tacks and splinters lodge between the teeth. In the dog, cat and pig, pieces of bones are frequently found.

In one case a tack was found firmly lodged in the infundibulum of the lateral superior incisor.

Diagnosis—Attention is attracted to disturbed mastication, rejection of partially masticated food, disinclination to eat, ptyalism and later to the fetor caused by pressure necrosis, and the decomposition of food.

Treatment—Removal of the object followed by irrigations of the mouth with solution of borax, alum or boric acid.

FRACTURE OF THE INFERIOR MAXILLA.

Varieties:

- (1) Simple fracture of the neck of one ramus.
- (2) Simple fracture of the neck of both rami.
- (3) Simple fracture of one ramus along the molar arcade.
- (4) Fracture of the angle without dental complications.
- (5) Comminuted fracture along the molar arcade.
- (6) Fracture near the articulation.

Etiology—Kicks from horses sustained as the victim is walking through the stable aisle is the most common cause of fractures of the inferior maxilla. Collisions with vehicles and cars and other forms of violence seldom fracture this bone. Solutions in the continuity of the ramus from bit gnathitis is an occasional cause (see page 214). And finally too forcible blows on a misdirected punch while repulsing teeth occasionally fractures the jaw. In the dog and cat the bite sustained during a fight is the chief cause of this injury.

Symptoms—The diagnosis of fractured inferior maxilla is by no means a simple matter under all circumstances. The subject is usually presented several days after the accident, at which time the tumefaction will require differentiation from other diseased condition characterized by enlargement of

the inferior maxilla. In the recent case the diagnosis is equally difficult owing to the liability of the fracture remaining a subperiosteal one until displacement occurs from movements of the jaw, some days later, at which time the condition continues to be masked by swelling.

Deformity at the angle, crepitation or movement of the fractured ends felt within the mouth as the jaw is moved with the other hand, and the loosening of one or more molars, will confirm a diagnosis, but in the absence of these plain pathognomonic symptoms the nature of the injury may remain masked until an abscess forms and points to the



FIG. 146.

A Well Healed Comminuted Fracture of the Inferior Maxilla, with Dental Complications.

surface and thereby admits direct palpation of the bone. Fracture of the neck of one or both rami is easily recognized by palpation.

In addition to the above phenomena there is always a serious disturbance to mastication. There will be little inclination to eat during the first days, but finally, from sheer starvation, food will be ingested unmasticated, in which condition it will be found in the feces. The subject will lose flesh rapidly, become emaciated, suffer from colics and probably die.

Treatment—The principal treatment consists of feeding crushed food and liquid food, in order to prevent unnecessary

use of the jaw. Appliances to immobilize the fracture are never satisfactorily retained, and prove of little service. When abscesses form their contents are evacuated and the wound searched for comminuted segments. The loose teeth must be extracted.

In fracture of both rami near the incisor teeth, in small animals amputation can be successfully performed.

Prognosis—In young animals even the severe comminuted fractures may reunite by an extensive deposit of new bone, and the patient make a rather tardy recovery with considerable permanent tumefaction of the jaw. In old animals the bad fracture is always fatal. Fractures of one ramus near the neck is not serious and will reunite with but little deformity and only slight interference with the general health. Fractures without dental complication are less serious than those involving the molar teeth.

FRACTURES OF THE PREMAXILLA AND SUPERIOR MAXILLA.

Although the premaxilla is an exposed bone, its fracture is remarkably rare. The superior branch is occasionally fractured from a kick, and the body from a fall upon the incisor teeth. The superior maxillary is frequently fractured conjointly with the other facial bones as a result of kicks or other of the usual forms of violence. Owing to the fixed articulations of these bones fractures recover promptly and without much deformity. Crushing of the maxillary spine leaves a somewhat unsightly blemish, but otherwise these lesions are not serious.

DISLOCATION OF THE TEMPORO-MAXILLARY ARTICULATION.

Etiology—This dislocation is possible only in the carnivora. In the herbivora the arrangement of the condyle and

coronoid process prevents luxation. In the dog it occurs while masticating bones, or in yawning.

Pathological Anatomy—The dislocation is a forward one in all instances and like all luxations is accompanied with considerable injury to the binding and secretory ligaments. It is usually bilateral, but may be unilateral.

Symptoms—Inability to close the mouth is the pathognomonic symptom. The jaw will be locked open and cannot be closed by force. In the unilateral luxation the jaw is open but is turned to one side.

Treatment—A piece of hard wood two feet long and about one-half inch thick, wide enough to rest along both inferior arcades, is firmly fastened to the lower jaw (within the mouth) by wrapping with strong cord. The stick thus adjusted is then used as a lever to depress the jaw posteriorly. When sufficient pressure is brought to bear the condyle snaps into its cavity.

BIT GNATHITIS.

Synonyms—Bit contusions. Fractured jaw. Bit sores.

Definition—A traumatic inflammation of the interdental space of the lower jaw produced by bruising with the bit.

Etiology—Bit gnathitis is caused by the use of harsh bits, especially curb bits. The straight or snaffle bit will occasionally produce the trouble in horses inclined to "pull" heavily upon reins in the hands of a powerful reinsman. Habitual "pullers" are the susceptible subjects, when attempts are made to control them by the use of harsh riggings. The condition is seen most frequently in the coach horse, saddle horse, hunter and polo ponies, and in the light harness horse that is difficult to control.

Pathological Anatomy—The lesion consists of an intense local stomatitis, periostitis and osteitis occurring simultaneously. The inflammatory action may be confined to a small

circumscribed area at the very edge of the jaw, or extend across the entire ramus to the inferior border. The process subsides by the separation of the bone from the soft surrounding structures, and by the exfoliation of a sequestrum the size of which will vary with the extent and severity of the pre-existing inflammation. Complete division of the ramus may result in the extremely aggravated forms.

Symptoms—Tenderness manifested in adjusting the bit, ptyalism, side reining and disinclination to "take" the bit are prominent symptoms. Palpation and inspection of the interdental space will reveal a wound in the mucous membrane. The abrasion is usually large enough to expose the edge of the jaw, which is easily felt with the finger. In other cases the mucous membrane may remain intact with the exception of a small almost imperceptible opening which, if enlarged with a bistoury, will reveal the bare jaw beneath. In the early stage, before the abscess points, there may be considerable swelling externally across the ramus, giving the appearance of an external trauma. In the advanced state of the process, the bare bone is found to be loose and easily removed. With this event the process terminates and the wound heals rapidly, but leaves a tenderness of the "seat of the bit" for several months.

Treatment—Bit gnathitis must be treated on the expectant plan until the exfoliating process is complete, that is until the sequestrum is well loosened. To prevent the burrowing of pus downward, as well as to hurry the exfoliation, the edge of the jaw may be exposed by a free longitudinal incision. The incision is then kept free from food by daily irrigations until the sequestrum is sufficiently loosened to be easily lifted with a small lever or curette. Undue haste in the removal of the sequestrum is harmful by retarding the final closure of the wound. About five days after removal of the sequestrum the bottom of the wound is curetted to

remove small roughened projections that might delay the cicatrization.

During the inflammatory period and until the sequestrum is removed the bit must not be used, unless, when the wound is small, it can be adjusted at a safe distance above.

OSTEOMATA OF THE SUPERIOR MAXILLA.

Definition—A non-inflammatory tumefaction on the superior maxillary of young horses, due to obstructed downward growth of the permanent molars.

Etiology—This abnormality occurs chiefly over the fang of the third superior molar, the last of the permanent molars, having temporary predecessors to erupt. At the period of its eruption, three years old, it frequently finds its downward course blocked in a wedge-shaped space, between the second and fourth molars, which occupy fixed positions in the jaws. The growth of the tooth in its blocked position produces pressure against the skull and a tumor results.

Pathological Anatomy—Osteoma of the maxilla is a non-inflammatory growth due to a proliferation of bone cells somewhat loosely arranged. Their macroscopic appearance is that of dense cancellated tissue, unlike the osteophyte of inflammatory origin. They are diffused over the anterior end of the superior maxilla and are occasionally bilateral.

Differential Diagnosis—They are differentiated from osteoporosis by the absence of any general symptoms, the absence of any abnormality in the lower jaw and by their anterior location, and from growth of traumatic origin by the absence of heat, pain or swelling of the soft tissues; from odontomata by the age of the patient.

Symptoms and Treatment—(See abnormal eruptions, page 175).

CARCINOMATA OF THE PALATE.

The palate of the horse, opposite the fourth, fifth and sixth molars, is frequently the seat of carcinomatous growths.

They begin by the appearance of one or more malignant looking foci, and gradually invade more and more widely into the surrounding tissues. They usually perforate the bony palate and establish a free communication between the mouth and nasal cavities. In the old cases that are allowed to survive, the process may extend backward to the ethmoid and sphenoid bones and from the point of origin through the fauces into the pharynx. They become complicated with an offensive catarrh of the nasal mucosa and with more or less

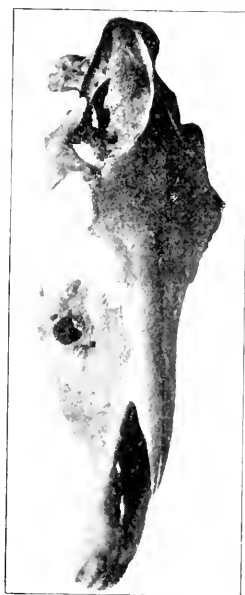

FIG. 147.

The Effect of a Carcinoma Beginning at the Palate of a Young Horse. disturbance to the eye. One case coming to our notice excavated a large opening externally through the malar and lachrymal bones and totally destroyed the globe of the eye and its appendages. The condition is of course incurable and is met by recommending the killing of the patient. (Fig 147.)

SARCOMATA OF THE MOUTH.

Sarcomatous growths in the palate of the horse are of frequent occurrence. They begin in the periosteum of the

palate, usually in the region of the fifth molar, and traverse upward between the teeth and along the alveolar border. They are first observed by the appearance of a diffused swelling of the palate extending along the molars and transversely across the raphe. They extend upward into the alveolar cavities around two, three, or even four molars, into the sinuses, and even produce bulging of the facial bones. The molars loosen and fall out or are easily extracted with the fingers, and their removal is always followed by severe hemorrhage. After the teeth are removed the cavities rapidly fill with sarcomatous tissue, which will bleed profusely when disturbed by mastication. The course of the process is slow in the early stages but very rapid after the teeth have be-

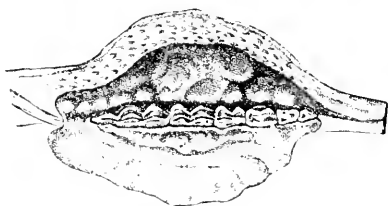


FIG. 148.

A Sarcoma of the Jaw Involving the Entire Molar Arcade.

come seriously involved. They occur as clinical conditions in horses past the age of ten years, but probably escape notice during the early period of growth. They belong in the category of incurable diseases. The disease must not be designated "osteosarcoma," a condition we have never had the opportunity of seeing in the domestic animals, although its existence is not doubted. (See Fig. 148.)

ACTINOMYCOSIS.

Synonym—Lumpy jaw.

Definition—Actinomyces is a chronic infectious disease due to the actinomyces, characterized by the formation of a neoplasm at the seat of infection.

Susceptible Animals—Ox, sheep, swine, horse and man. The disease is not entirely foreign to any of the domestic

or wild herbivora and omnivora, and it has been produced experimentally in rodentia and carnivora.

Etiology—The cause of lumpy jaw is the growth of the actinomyces in an infected tissue. The organism is a saprophyte of forage, through which medium it gains entrance into the body by inhalation into the air passages and by ingestion into the digestive tract. Eruption of teeth, dental irregularities and wounds produced by fibrous forage produce favorable channels of entrance, hence the frequency of the disease about the mouth and pharynx. The organism is, however, capable of producing its pathogenicity in the

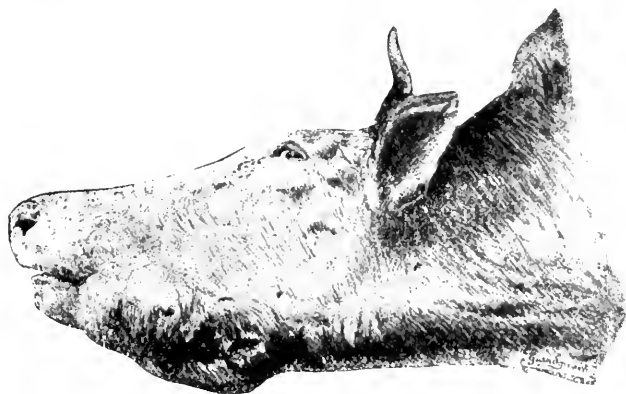


FIG. 148A.

Lumpy Jaw in the Ox.

nasal cavities, lungs, stomach and liver where wounds are not etiological factors.

Affected Organs—Mouth, lips, nostrils, tongue, jaws, salivary glands, Schneiderian membrane, velum, pharynx, rumen, omasum, liver, lungs, and mammae.

Diagnosis—The early signs of actinomycosis located in visible parts of the body, consist of the formation of one or more wart-like nodes which may, when first noticed, be only the size of a pea. These nodes contain a calcareous or caseous center. In the tongue the condition usually remains unnoticed until the organ has become indurated (wooden tongue). In the jaw the disease is first manifested by the

appearance of a more or less diffused tumefaction of the inferior maxilla (lumpy jaw) or by rounded exostoses. As the soft structures become involved more and more by spreading of the diseased process, the head may assume an unsightly appearance from the enormity of the swelling. The condition is further complicated by dental disorders—loosen-

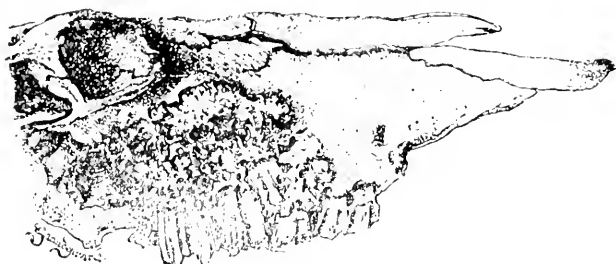

FIG. 148B.

Actinomycotic Superior Maxillary in the Ox.

ing of the teeth. In the pharynx the disease is manifested by tumefaction of the parotid region and by dysphagia and dyspnoea. Actinomycosis of the lungs and other internal structures is diagnosed only at the autopsy. Symptoms of organic disorder may lead a diagnostician to suspect the ex-

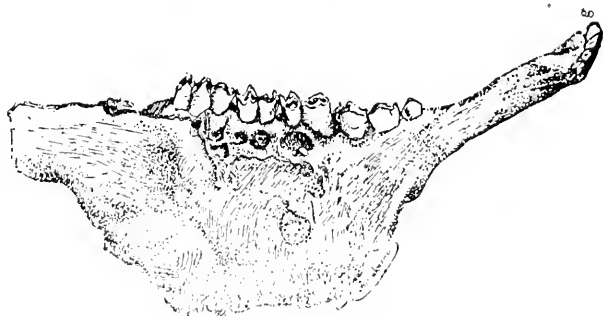

FIG. 148C.

Actinomycotic Inferior Maxillary in the Ox.

istence of the disease in districts where actinomycosis is prevalent, but a positive diagnosis of it in the internal structures is not possible in the living animal.

Treatment—In the operable actinomycotic tumor ablation is the most effectual line of treatment. To further

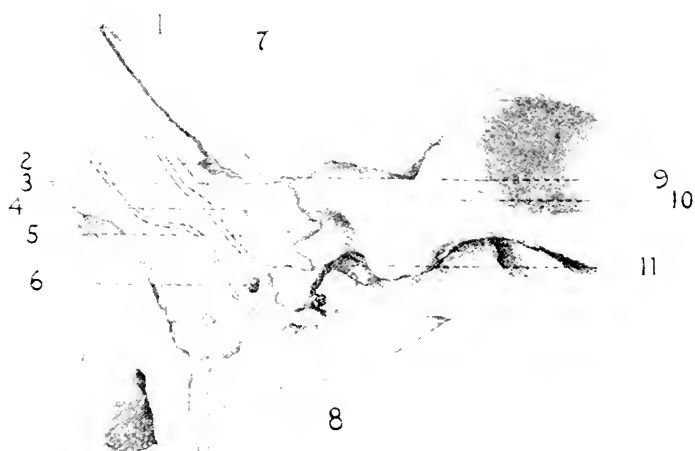


FIG. 149.

Dental Teratoma and Conchal Fistula. (Williams)

1. Mouth of the conchal fistula.
2. Bottom of the fistulous tract.
3. Gubernaculum dentis.
4. 9. Bony plates from the temporal bone.
5. The tooth.
6. External auditory meatus.
7. Wall of the fistulous tract.
8. Petrous temporal bone.
10. Zygoma.
11. Temporo-maxillary articulation.

assure destruction of the organism the surgical wound may be treated with powdered copper sulphate at intervals of four to five days during the healing process. The inoperable tumor on the surface of the body is injected with a solution containing some form of iodine. Lugol's solution, potassium iodide, 2 per cent, or tincture of iodine, may be used for this purpose. Internally potassium iodide will prove beneficial. The loose teeth must be extracted and the caustic treatment applied to the entire diseased area when possible.

DENTAL TERATOMATA.

Synonyms—Dentigerous cysts, dental cysts, mastoid fistulae.

Definition—An abnormality of early embryonic origin in which one or two teeth develop on the temporal bones near the base of the ear. It is a common abnormality of solipeds but occurs occasionally in other mammals.

Etiology—The cause of dental teratomata is found in an aberration of the embryonic evolution of the teeth, guttural pouch and external ear, the mechanism of which is so complicated as to be susceptible to variations. The condition is closely allied to conchal fistula, with which it is frequently associated.

Symptoms—Dental teratomata of the mastoid region exist from the time of birth, although they may escape detection until maturity. They appear at the surface in the form of a fistulous opening below the base of the ear or along the margin of the conchal cartilage, discharging a limited quantity of a viscid mucoid secretion. The channel is lined with a well organized epithelial membrane continuous with the skin at the orifice. They are susceptible to pathological conditions which may for the first time direct attention to their presence. When they become infected the resulting osteitis,

periostitis and dentitis augment the discharge, and change its character into a fetid, purulent secretion, and the region becomes painful to the touch.

When opened by incision the cyst is found to contain a tooth or two, which vary from the size of a hazel nut to that of a full sized molar. The smaller ones are quite round,

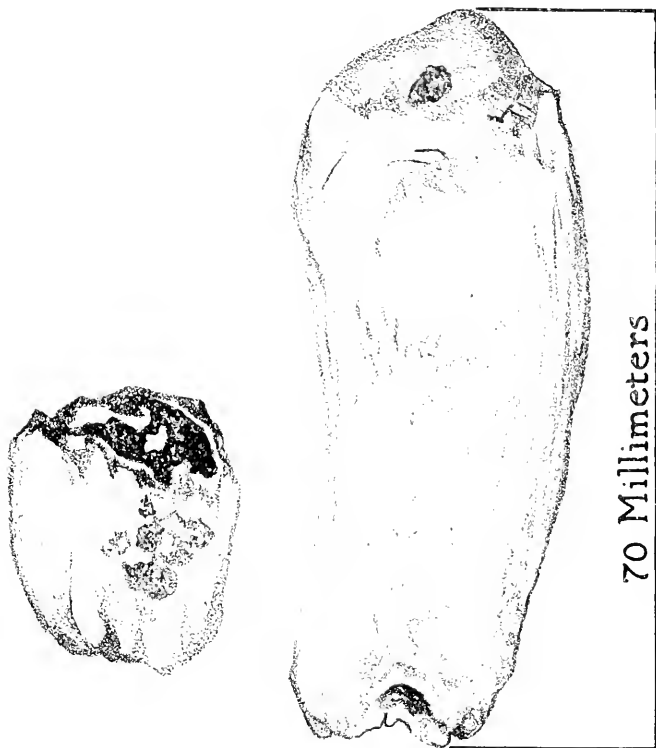


FIG. 150.

Two Teeth Removed from the Squamous Temporal Bone of a Clydesdale Mare.

while the larger ones assume the typical tooth dimensions.

Treatment—The patient is placed in the lateral recumbent position, preferably under the influences of an anaesthetic. A liberal incision is made over the tumefaction so as to expose the hard object within. This will always be found to be a tooth. When a part projects it can be extracted with

an ordinary Wolf tooth forceps, but frequently the surroundings will require chiseling to first loosen it from its cavity. When removed the cavity must be searched for a possible second tooth, and if the canal is long, as in the case of conchal fistula, the entire lining must be resected to prevent a perpetual discharge.

DENTAL FISTULAE.

Definition—A fistulous tract related to the teeth, extending from within the mouth to the outer surface of the jaw.

Etiology—Dental fistulae result from the outward pointing of an abscess accompanying a decayed molar. The entrance channel may be the infundibula or alveolar periosteum. In the upper jaw they are occasionally caused by defective gums admitting food along the external surface of the second or third molar, in the grooves between the prominent longitudinal ridges which exist on these teeth, and in the lower jaw they may in rare instances result from external violence. And again, sequestra of bones allowed to remain between the alveolar plates after the repulsion of teeth may produce a chronic fistulous opening.

Pathological Anatomy—In addition to the lesions accompanying a decayed molar (see page 152) the dental fistula is nothing more than a tract through the bone from the apex of the tooth to the surface of the jaw.

Symptoms—They are seen most frequently on the lower jaw opposite the apex of the second, third, fourth, fifth and sixth molars. In the upper jaw the second and third molars are the teeth usually responsible for the condition. They appear as small openings, always near the border of the jaw, which discharge a limited amount of pus. In the old case the skin is drawn inward by the process of cicatrization. The jaw around the offending molar is thickened to a perceptible

extent. The diagnosis is confirmed by an examination of the dental arcade. When the tract is direct a small probe may be passed from the external opening to the mouth, but ordin-

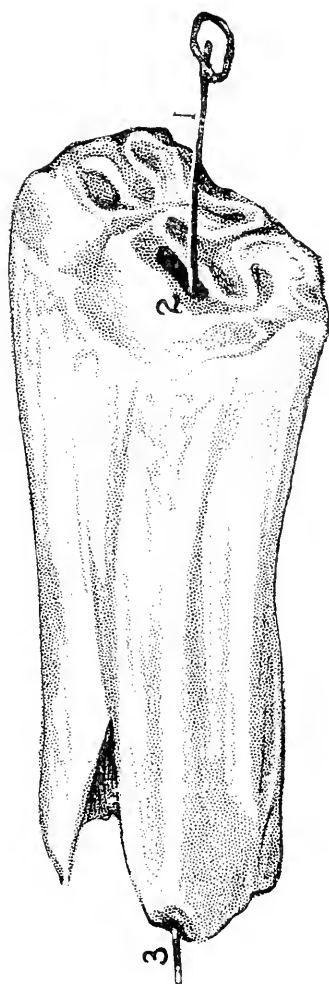


FIG. 150A.

Inferior Molar Responsible for a Fistula of the Jaw in a 7-Year-Old Horse.

arily it pursues a tortuous course through the bone and comes to the surface at a point more or less remote from the affected tooth.

Treatment—The treatment of the dental fistula should

first be limited to the extraction of the offending molar with the forceps. If after four weeks the tract still exists the skull plate around the opening is trephined and the tract well curetted along its course into the alveolar cavity.

TRAUMATIC STOMATITIS.

Definition—Stomatitis signifies inflammation of the mucous membrane of the mouth.

Etiology—Primary, traumatic stomatitis is a common disease of all the domestic animals. It is seen in the most aggravated forms from the accidental ingestion of irritants and from the administration of irritating medicines. Among the other causes are dental irregularities, severe bits, traction on the tongue and the prehension of sharp objects. But in these instances the inflammation is of a circumscribed rather than a diffused character.

The mucosa of herbivora is well protected against wounding by masticating coarse food. Beards of cereals will, however, occasionally penetrate through it around the anterior portion of the mouth and produce an alarming stomatitis simultaneously in a number of animals before the cause is discovered.

Pathological Anatomy—A simple inflammatory process promptly terminating in resolution. Purulent, catarrhal or necrotic inflammations of the mouth are rare. The severity and extent depend, therefore, upon the trauma.

Symptoms—Ptyalism, champing the jaws, disturbed prehension and mastication and a disinclination to eat are the principal symptoms. The mucous membrane is sensitive to the touch and the patient will resent examinations. On inspection there will be redness and in the severe case desquamation of the superior surface of the tongue.

Treatment—Stomatitis is not a serious disease. Removal of the cause, the administration of soft diet, and demulcent

or mild, astringent solutions, is the only necessary treatment. A useful mouth wash for the treatment of either circumscribed or diffused stomatitis is:

R.

Alum

Sodii boras aa..... 30

Spirits gaultheria 10

Aqua q.s. ad..... 480

M et sig.

Inject free'y into the
mouth three to four times
daily.

STOMATITIS, INFECTIOUS.

Synonyms—Contagious pustular stomatitis; aphthous stomatitis; contagious aphtha.

Definition—An infectious inflammatory condition of the buccal mucosa characterized by the formation of a multiplicity of pustules.

Etiology—Infectious stomatitis evidently owes its existence to a specific virus, the identity of which is unknown.

Symptoms—Contagious aphtha usually occurs simultaneously in a number of horses belonging to the same stable. Outbreaks often occur at race tracks, fairs or sale stables in which few of the exposed animals escape. The virus is evidently carried into the mouth through the medium of watering places, pails, cleaning utensils, bridles, etc. The first clinical symptom observed is ptyalism and slight anorexia, which is followed by the rapid development of many small pimples which point and leave an ulcer. In some cases the skin around the commissures of the mouth becomes infected and leaves behind a depigmentated spot at the seat of each ulcer.

Treatment—Infectious stomatitis runs a favorable course

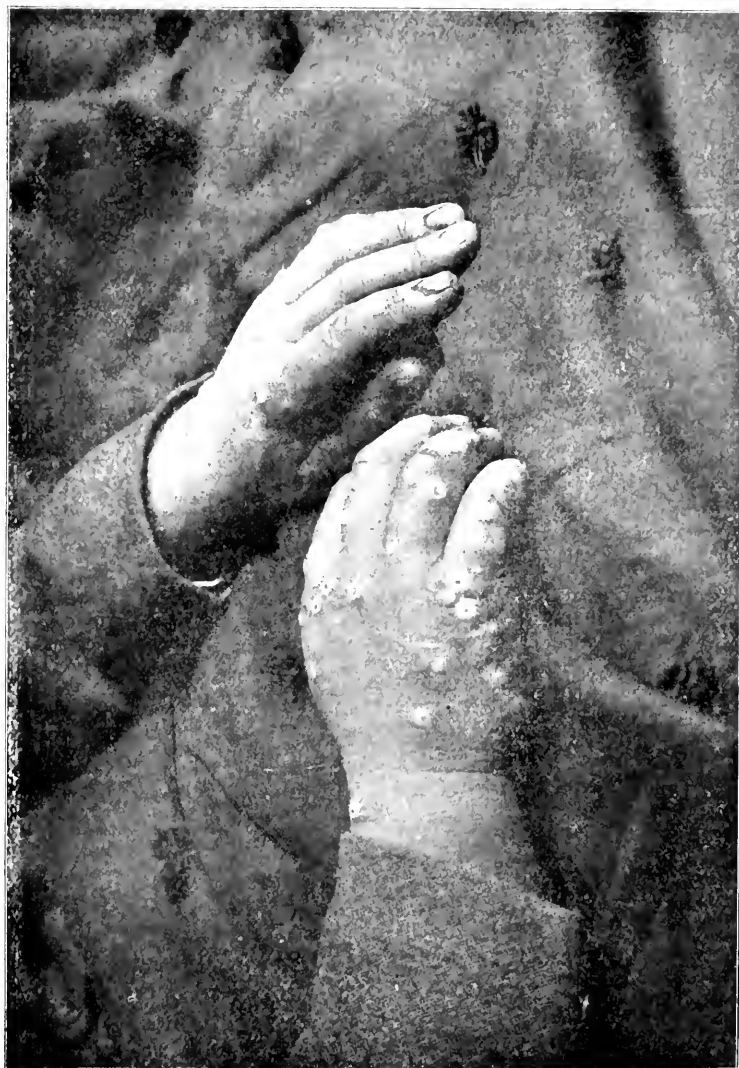

FIG. 150B.
Human Hands Said to Have Been Infected from a Horse Suffering from Infectious Stomatitis

in every case and it requires but little treatment. Preventive measures are the most important and these consist of isolation of the affected animals and the disinfection of the infected stalls, implements, feed boxes, etc.

(For a more complete description see works on General Medicine.)

ULCERATIVE GINGIVITIS OF DOGS.

Definition—Ulcerative gingivitis is a disease of young carnivorous animals beginning as an inflammation of the gums. It however spreads rapidly to the surrounding mucosa, alveolar periosteum and jaw.

Etiology—The cause of the disease is undoubtedly the propagation of microbes which habitually inhabit the mouth of meat eating animals, and which become pathogenic under the influence of a lowered vitality of the animal. Attempts to isolate a specific microbe have thus far failed.

Symptoms—Foetid breath occurring simultaneously with red or bluish red gums are the first distinguishing symptoms. The teeth are found to be coated with an excess of tartar around the gingival margin, and in the more advanced stage they are loosened and easily extracted. The gums, cheeks and tongue may become the seat of numerous ulcers as the disease progresses, but often this feature is wanting. The process usually terminates favorably or fatally in from one to two weeks, according to its severity and the vitality of the patient, or it may become chronic and last as long as four to five weeks.

Treatment—The first treatment should consist of extracting the loose teeth and removing, with the curette, all of the tartar from the stable ones. The mouth is then washed freely with mild antiseptics, boric acid and borax water being the most appropriate ones for the purpose. A 50 per cent solution of tincture of iodine painted carefully

over the gums, ulcers and vacant tooth cavities after the saliva has been wiped away will frequently arrest the process, and would undoubtedly prove a specific if its toxicity did not prevent its repetition.

RETENTION CYSTS.

Besides the large cyst that occurs in the fraenum of the tongue (ranula), the mucous membrane of the mouth of horses is occasionally the seat of mucoid cysts varying from the size of a millet seed to that of a pea. The common location is around the commissures, either superiorly or inferiorly. Anatomically they consist of a dilated mucous follicle resulting from an obstructed outlet. They are perfectly benign and yield to evacuation of the contents by incision.

TUMORS OF THE MUCOUS MEMBRANE OF THE MOUTH.

The following is an enumeration of the various tumors affecting the mucous membrane of the mouth:

- (1) Actinomycosis, see page 218.
- (2) Sarcoma, see page 218.
- (3) Carcinoma, see page 217.
- (4) Ranula, see page 250.
- (5) Retention cysts, see page 230.

LAMPAS.

Definition—Tumefaction of the hard palate just behind the superior incisor arcade.

Etiology—Lampas is a physiological condition occurring from dental nutrition during the growth of the teeth. It occurs at a time when the crowns of the teeth are still too short to overlap the first bars of the palate. In old horses

the palate may project beyond the level of the arcade from wear of the incisors, when the latter are soft in texture.

Symptoms—Tumefaction and redness of the first bars of the palate. Sensitiveness is not a characteristic feature. The bars project to the level or below the tables of the incisors.

Treatment—The popular impression that lampas is inimical to the welfare of an animal necessitates the application of efforts to diminish the size of the tumefaction. This is done by scarification and actual cautery. The latter is the effectual method. The thermo-cautery is par excellence the neatest method of satisfying the popular prejudice against them. Confine the horse with the dental halter and twitch, and elevate the head. Pass a round stick through the interdental space and hold it, together with the tongue, in the left hand. Hold the mouth open by downward pressure upon the stick and tongue and keep the upper lip elevated with the twitch, and then with the right hand cauterize the first two or three bars until they shrink below the table level.

SECONDARY CHRONIC NASAL CATARRH.

Synonyms—Chronic nasal catarrh. Unilateral chronic rhinitis. Nasal gleet. Ozena. Purulent accumulations in the facial sinuses.

Etiology—Primary chronic nasal catarrh is a rare disease in the herbivorous animals. The chronic nasal catarrh of the horse and ox has its origin in the surrounding structures and hence can only be described as a secondary condition. The primary lesion can usually be found in the superior dental arcades. Decayed teeth, usually the fourth superior molar, are responsible for 95 per cent of the cases. Alveolo-nasal fistula, fractures, foreign bodies, parasites, glanders, tumors and chronic bronchitis constitute the primary lesions of the other five per cent.

Pathological Anatomy—The features of a typical case are: Purulent or muco-purulent catarrh of the affected side, accumulation of the secretions in the recesses of the sinuses, over-filling of the sinuses and bulging of the bones, pressure necrosis of the turbinated bones and the septa of the sinuses, outward discharge of the secretion, alveolar periostitis and necrosis of a molar.

Diagnosis—The pathognomonic symptom is the **chronic, fetid, unilateral** discharge from the nostril occurring simultaneously with a dental disorder on the affected side. The decayed tooth in the early stage of decay may be difficult to locate, but owing to the frequency of this cause a special examination of the superior dental arcade must be made before the other causes are given any consideration. Negative results from the palpation or inspection of the teeth with or without a mouth speculum is not sufficient reason to exclude the decayed tooth as a cause. The patient must be placed in a recumbent position, a mouth speculum adjusted, and by the aid of good light each tooth, beginning with the fourth, must be carefully examined with a sharp steel pick. Diseased teeth which would otherwise have escaped notice are in this manner found to have one or both infundibula admitting food into the pulp cavity. When the teeth have been excluded by this circumspect investigation the attention may be directed to the other possible causes, but in no case of chronic catarrh must the examination of the teeth be omitted. Even in the bilateral catarrhs the lesion may be found on one side of the head and in many instances decayed teeth co-exist on both sides of the head.

Differential Diagnosis—Nasal gleet is differentiated from **glanders** by the mallein test; from **guttural pouch catarrh** by the profuse discharge during mastication in the latter disease; from bronchitis by the absence of cough and constitutional disturbance, and by the frothy bubbles usually

contained in secretion coming from the lower air passages.

Treatment—The treatment includes: (1) Removal of the primary lesion; (2) evacuation of the accumulated secretions from the sinuses, and, (3) irrigation of the diseased mucous membrane. Internal medication is of little value in terminating nasal catarrh. Local applications in the form of douches are equally useless.




FIG. 151.

Correct Locations of Openings to Perfectly Drain the Sinuses of a Horse's Head. The upper opening drains the frontal sinus outward, and by perforating its floor in the turbinated bone, it also drains the sinus into the nasal cavity. The dotted line on the lower opening shows the direction to elongate the orifice when a tooth is to be repulsed.

OPERATION OF TREPHINING THE SKULL FOR NASAL CATARRH.

Equipment—Two scalpels, three-fourths inch circular trephine, one inch circular trephine, dissecting forceps, chisel, artery forcep, needles and thread (punches and mallet if teeth are to be repulsed), razor, wadding of cotton or oakum and antiseptics.

Restraint—Horses may be trephined in the standing position with the dental halter and twitch. When teeth are to be repulsed or when any chiseling of the bone is necessary the recumbent position is essential.

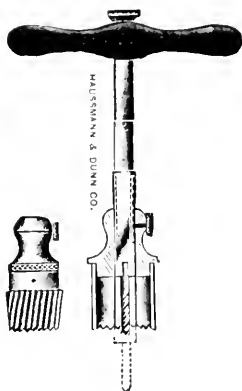


FIG. 151A.

Plain Circular Trephine.

1st Step—Clip, shave and disinfect the space intervening between the maxillary spine and longitudinal suture of the nasal bones.

2nd Step—First open the maxillary sinus about one inch

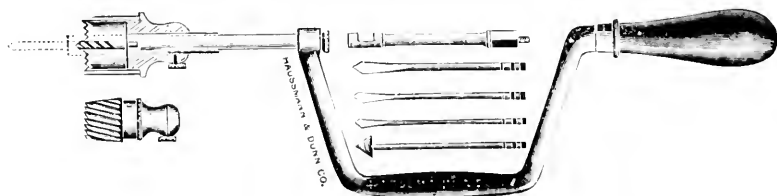


FIG. 151B.

Assorted Trephines and Tooth Drills, with Brace.

from its external border and one inch from the anterior extremity, but vary in the antro-posterior direction according to tooth to be repulsed.

3rd Step—Make a T-shaped incision through the skin with the base of the T pointing to the median line of the head.

4th Step—Dissect the muscle and connective tissue from the bone and arrest the hemorrhage.

5th Step—Cut a circular ring in the periosteum slightly larger than the diameter of the trephine to prevent tearing it beyond the area of the circle.

6th Step—Remove the skull plate with the three-fourths inch trephine.

7th Step—If a tooth is to be repulsed, enlarge the open-

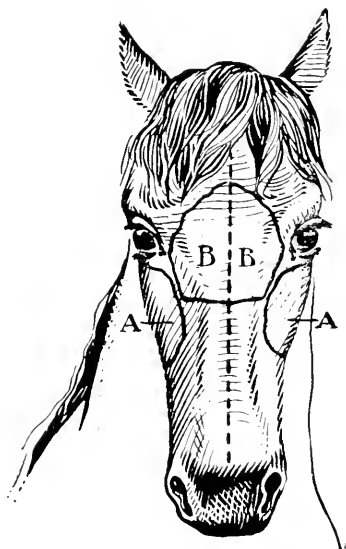


FIG. 152.

Surgical Areas of the Sinuses.

A, A. Maxillary sinuses.

B, B. Frontal sinuses.

ing toward the median line of the head with chisel and mallet, so that the punch can be placed on a straight line with the tooth.

8th Step—(See repulsion of teeth, page 161).

9th Step—Open the skull with the one-inch trephine, at a point 4 to 5 centimeters obliquely downward and inward from the nasal canthus. (See Fig. 151.)

10th Step—Break down the thin, bony septa with the

fingers so as to freely drain the frontal sinus into the maxillary sinus and nasal cavity.

11th Step—Empty and irrigate the sinuses in the standing position and wad the openings with oakum or cotton.

12th Step—Suture the transverse incision of the T-shaped wound, leaving the longitudinal one for wadding and drainage.

After-care—Irrigate with 3 per cent zinc sulphate solution daily. Prevent food from entering the cavity by wadding the tooth cavity.

Note—The two openings above referred to are the only ones necessary to drain the sinuses of the horse's head. Openings higher up along the frontal sinus serve no useful purpose. The important feature of the operation is to drain the sinuses into the nasal cavity by breaking down the bony septa. Unless there is **free** flow from the upper opening to the nostrils the trephining operation for nasal catarrh is a useless procedure.

CHRONIC PERFORATION OF THE SKULL.

Definition—Under this head we include the openings of the skull covering the facial sinuses or nasal cavities, that persist after the regenerative process has ceased.

Etiology—The chronic or persistent perforations of the skull of horses follow large surgical openings necessary to remove nasal tumors, severe contusions of the skin complicated with comminuted fractures of the skull plate, attended with sloughing of the injured area, and circular trephine openings followed by necrosis of the surrounding bone. The sequel is most liable to occur in old horses from the diminished nutrition of the bone tissue and periosteum. It is seldom seen in young animals, except in accidental perforation of large dimensions, accompanied with loss of a large area of common integument. Surgical perforations, al-

though quite large, will always heal eventually in the young horse but may threaten to become permanent in horses past the age of eighteen years. The most aggravated forms occur from comminuted fractures.

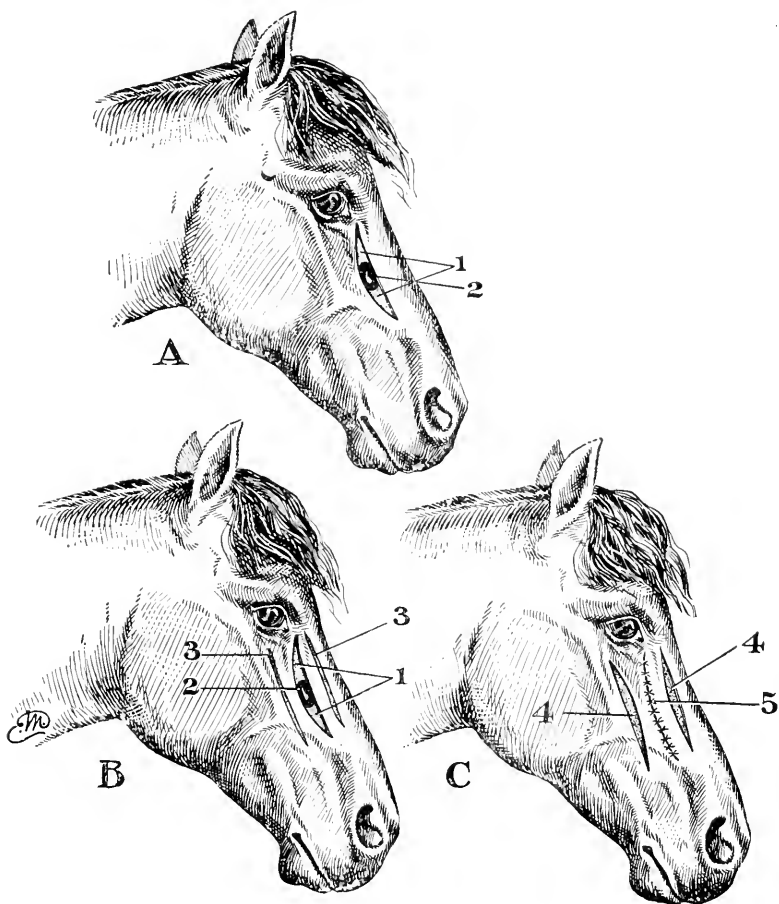


FIG. 153.

Prof. Edw. Merillat's Operation for Closing Chronic Skull Perforations.

A. 3rd step of operation.

1, 2. "Melon slice" resection of the skin. See description.

B. 4th step of operation. See description.

C. 6th step of operation. See description.

Treatment—Large perforations accompanied with loss of considerable skin may be incurable, but when the orifice

is of nominal dimensions its closure is effected by the following operative intervention:

1st Step—Secure the subject in the lateral recumbent position without anaesthesia.

2nd Step—Shave the hair from the surgical area and disinfect with mercuric chloride solution 1-500.

3rd Step—(Fig. 153A.) Make a “melon-slice” resection of the skin, extending above and below the orifice, so as to include the orifice within its widest portion.

4th Step—(Fig. 153B.) Make a longitudinal incision (Fig. 153B. 3. 3.) through the skin on each side of and about one inch from the orifice, extending the entire length of the resected skin.

5th Step—Loosen from the bone all of the skin between the longitudinal incisions.

6th Step—(Fig. 153C. 5.) Suture the “melon-slice” wound with interrupted stitches, bringing the raw edges into perfect apposition.

7th Step—Protect the whole area with a clay dressing.

After-care—Maintain perfect protection during eight days and then remove the sutures. Apply astringent lotions to the gaping longitudinal wounds (Fig. 153C. 4. 4.) which will heal by granulations.

APPLICATION OF GUTTA PERCHA PLUGS.

An artificial filling for the vacant alveolar cavity subsequent to the extraction of molars is indicated when the cavity refuses to close and thereby admits food into the nasal cavities or sinuses, in chronic dento-nasal fistula and in wadding a recently made tooth cavity that cannot receive daily attention.

The filling suitable for this purpose is a gutta percha mixture known to the human dentist as “temporary stop-

ping." It is hard at the temperature of the body but readily becomes pliable with heat.

Modus Operandi—Soften a liberal amount of the filling in hot water and roll it into an egg-shaped mass, larger than the cavity to be filled; then, with the aid of a speculum to open the mouth, force the mass into the cavity to mold it to the proper shape and dimensions. Then remove it and trim off the superfluous portion, re-heat and re-adjust to the cavity, leaving its exposed end beneath the table level of the arcade.

The gutta percha plugs should reach beyond the alveolar margin, but not to the bottom of the alveolar cavity, and to prevent disturbance from mastication the opposing crown should be removed with the claw-cutter. (Fig. 100.)

When applied as temporary filling it should be removed after five or six days to clean the cavity of accumulated secretions, and then be readjusted for one week more, at which time a tooth cavity is usually safely filled.

CRIBBING AND WIND-SUCKING.

Definition—Cribbing and wind-sucking are identical, the latter being an aggravated form of the former. Cribbing may be defined as a pertinacious habit of the horse, characterized by attempts to ingest air, while wind-sucking may be defined as the same habit in which the attempt is successful.

Etiology—The actual cause of cribbing is yet to be satisfactorily demonstrated. Idleness and the empty manger are circumstances generally accepted as favoring the acquirement of the habit. Nervousness, gastric indigestion and obscure neuroses, are also mentioned among the possible etiological factors. These assertions are based only upon speculation, and are doubted most by those who have had the widest range of observation. It may, however, be safely

stated that the habit is one of domestication, a stable habit or pastime having its origin in some unknown cause.

Symptoms—Grasping an object with the teeth, contracting the inferior cervical muscles, and uttering the characteristic grunt consecutively, is the clinical picture of the typical cribber. Some subjects follow this phenomena by the deglutition of a considerable quantity of air at each attempt, until marked tympany of the abdomen becomes apparent. Others again succeed in the deglutition without grasping an object with the teeth.

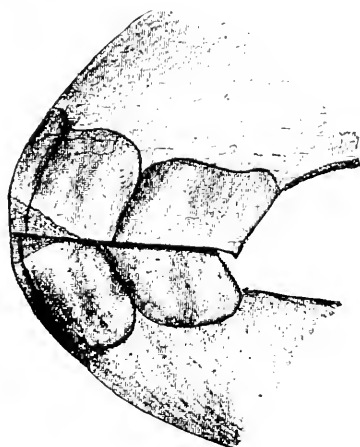


FIG. 153A.

The Mouth of a Young Cribber.

Treatment—The application of a wide leather strap tightly around the throat will prevent the ingestion of air and diminish in number the attempts at cribbing. If the strap is equipped with tacks that will prick the throat when the attempt is made the cribbing will cease while the strap is in place. A second method consists of removing from the stall all objects that can be grasped with the teeth.

The surgical intervention once recommended, consisting of a myotomy of the sterno-maxillary muscle in the upper third of the cervical region, has become obsolete through the revelation of its uselessness as a permanent remedy.

The pertinacity of the cribbing habit was demonstrated by Mr. A——, of Des Plaines, Ill., in the case of a large Shetland pony that acquired the habit at the age of three years. This pony was confined in a polished hardwood cage with the walls inclined at an angle of forty-five degrees from above downwards and outwards, for three years, during which time special care was taken to prevent any contact with objects that could be touched with the teeth. At the end of three years it was experimentally placed into a stall with a manger. In less than ten seconds the cribbing begun and continued until returned to the hardwood cage.

HABITUAL PTYALISM.

Synonym—Slobbering.

Definition—A habit of carriage horses characterized by an excessive flow of saliva from the mouth while driving.

Etiology—Habitual ptyalism of carriage horses is caused by the abnormal curbing of the neck in horses inclined to “pull” heavily upon the reins. The position of the head assumed under such circumstances prevents the free deglutition of the saliva secreted, which in the “pulling horse” is always excessive. Besides, the mind of the “pulling” carriage horse is so occupied with the bit that no deglutition is attempted.

Ptyalism is also caused by sensitiveness of the mouth, wounds, bit gnathitis, and other forms of stomatitis, but these causes constitute an entirely different entity than that referred to in this paragraph.

Symptoms—An excessive flow of saliva while driving in the absence of any lesion of the mouth determines a case of habitual ptyalism. The secretion is churned into a stringy froth, and is blown by the wind over the harness, horse, carriage and even the coachman. There is also a tendency towards “champing” the bit when the reins are relaxed.

Treatment—In the treatment of pyalism of carriage horses, the first requisite is to remove all dental irregularities that would tend to provoke a flow of saliva by irritating the buccal surface. The front molars must especially be well rounded. Wounds of the interdental space must be healed and wolf teeth extracted. The attention must then be directed to the biting. The bridoon is removed and the head is checked with an overdraw passing beneath the chin. The reins are placed in the “cheek” or “half-check” loop of the curb bit; or, if the horse cannot be managed thus, a rubber cover is placed over the bit and the rein attached to the middle or lower bar. The bridle is fitted neatly so as




FIG. 154.

The Best Bit for a Side Pulling Light Harness Horse.

to bring the bit to a comfortable position near the inferior molars. “Dropping the bit” a habit of coachmen to gain advantage of a “pulling” horse must be avoided. And finally, by patient “schooling,” the horse must be taught to drive with a “light line.”

SIDE REINING.

Definition—A habit of driving horses consisting of constant inclination to carry the head to one side of the median line of the body.

Etiology—The habit of side reining is due to an ingenious attempt to take advantage of the reinsman by placing the

head in a more advantageous position for leverage. Such animals often have serious lesions of the jaws, but these are effects rather than causes of the habit. The habit is often acquired by driving an ambitious, prompt horse with a "loafer."

The horse that drives on but one line without pulling heavily and shifts gradually to one side of the street belongs to an entirely different class. In this incident the cause is

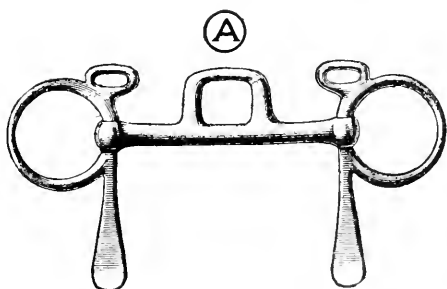


FIG. 155.

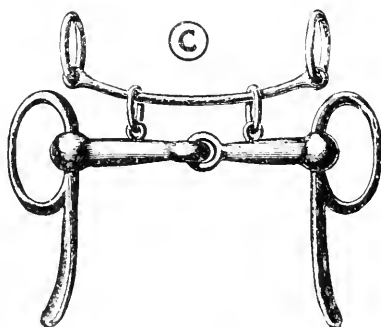


FIG. 156.

The suitable bit to equip with the flexible rubber hose. See description below.

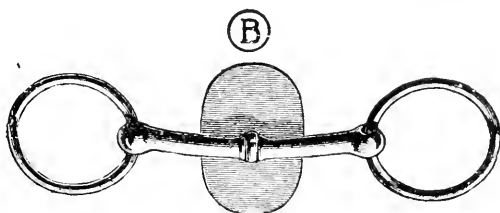


FIG. 157.

Tongue Lolling Bits.

- A. Port bit.
- B. Spoon bit.
- C. Combined snaffle and overcheck bit.

always due to some defect in the locomotory apparatus. Spavin or other slight painful condition of the hind extremity is the usual cause of this defect.

Treatment—The side reining horse must first be treated for defects of the teeth and lesions of the interdental space.

The first molars must be well rounded to prevent buccal wounds. The bit is then kept on a straight line with the jaws by means of washers fastened inside the rings. A comfortable check is used, and the horse is driven only with one well mated in promptness.

HABITUAL PROTRUSION OF THE TONGUE.

Synonym—Tongue lolling.

Definition—The habit of extending the end of the tongue from the commissure of the mouth while driving.

Etiology—The habit may be first acquired in an attempt to protect an abrasion of the mouth from further injury, but its continuation is due to the relief to the respirations. When the tongue is dropped from the fauces the lumen of the pharynx is increased and the respirations are facilitated sufficiently to induce a continuation of the habit. Paralysis of the tongue, in which retraction is impossible, is entirely another condition, occurring as a result of progressive bulbar paralysis—a fatal disease.

Treatment—Dental irregularities must be corrected and the head while driving must be elevated with the overdraw check to bring the air passages toward a straight line. The mouth may be closed with a nose band attached to the bridle. Attaching the check bit to the main bit by means of a flexible rubber hose, will frequently prevent the habit.

When these measures fail, amputation of the tongue is the only recourse.

OPERATION OF AMPUTATION OF THE TONGUE.

Restraint—Lateral recumbent position under chloroform anaesthesia.

1st Step—Make a circular incision, convexity forward, from the center of one border to the center of the opposite, so as to make one-half of a dove-tail flap.

2nd Step—Turn the tongue upward to expose the lower surface, and by a similar incision complete the inferior half of the dove-tail.

3rd Step—Close the wound with interrupted sutures.

After Care—Feed on soft diet and remove sutures in eight days. Amputation of the tongue produces a temporary inconvenience in the prehension of liquids but is otherwise a harmless operation. The above method leaves a flat extremity similar to that of a normal tongue.

BIT-LUGGING.

Definition—A fault or habit of coach, light-harness and saddle horses, consisting of a constant or periodical tendency to pull heavily upon the bit.

Etiology—Dental irregularities, while never the primary cause of the habit, irritate the seat of the bit and render its cure impossible, by aggravating the animal's temper.

The whip, reinsman or equestrian recognizes three distinct classes of bit-luggers. The **first** is the young horse that lugs from failure to understand the nature of the complicated biting riggings applied for the first time; the **second class** comprises the mature horse that has developed the habit from improper training; and the **third class** is the lugger by nature that will "pull to the end of the road" in spite of the punishment inflicted by severe bits.

Complications—Bit gnathitis from severe pressure and lacerations of the buccal surface opposite the first and second superior molars from friction of the cheek against the sharp enamel points are certain to result in the lugging horse, and in turn these injuries, which are frequently of no small proportions, are prone to augment a bad disposition.

Treatment—The treatment of bit-lugging belongs more to the domain of that part of horse training known as "bitting" or "mouthing" a horse than that of dentistry. The

latter is, however, an essential feature of the cure. The proficient teacher of the horse of quality will always demand that the anterior extremities of the molar arcades be rid of all projections that may irritate the buccal surfaces, as a prerequisite to the development of the tactile sense of the seat of the bit. The dental operation for this purpose consists of trimming and filing the anterior molars smooth and round with the angular cutter and file. The horse must, in addition, be made to become gradually accustomed to the

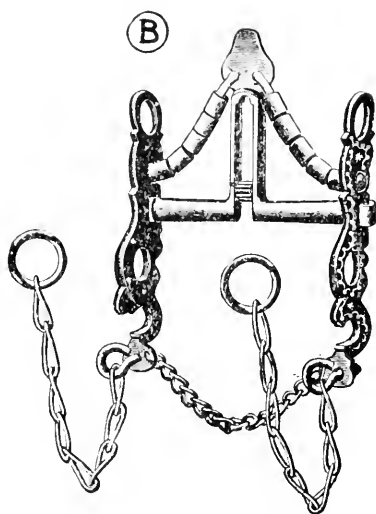


FIG. 158.

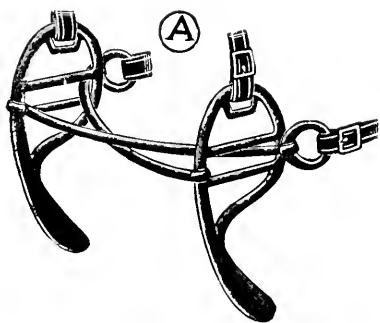


FIG. 159.

Bits for Confirmed Luggers.

A. J. L. C. bit.

B. California curb, and port.

complicated riggings. In the coach and saddle horse the dumb-jockey is indispensable, to develop the sensibility of the mouth. It should be equipped with a soft bit one to one and a half inches in diameter to develop the tactile sense over as large an area as possible, and the elastic reins should be made tighter from day to day as the horse becomes more and more accustomed to its mechanism. Among the best coachmen it is the custom to equip the dumb-jockey with a

straight and snaffle bit on alternate days. The light harness horse is trained to the bit by jogging in the breaking cart with the simplest possible riggings and all forcible restraint is avoided, the aim being to drive the youngster with a "light hand" and teach it to respond to the slightest touch instead of pulling heavily upon the bit.

The habitual confirmed lugger that has formed the habit from the faulty first lessons may be improved by handling in the same manner, and in addition careful attention must be given to the wounds of the mouth, by attending to the teeth and application of bits that will control the horse and at the same time inflict no further injury. If the jaw is sore, for example, the covered port bit may be serviceable by protecting the wounded part and transferring the punishment to the palate, while if the palate is sore the straight curb may be applied, and the lines attached to the lower bar, the object point being to prevent the unnecessary aggravation of the horse's disposition. In the light harness horse habitual lugging may be palliated considerably by proper over-checking. The higher the horse is checked the easier it will be to control. The chin-overdraw is probably the best rigging for this purpose, owing to the fact that the mouth is kept closed, and that there is no over-check bit to irritate the interdental space. In this connection it must, however, be understood that what will answer for one horse will prove useless for another, and vice versa.

The confirmed lugger of the third class is incurable except by giving plenty of hard work to lower its spirit, which in many cases may impair the animal's health before the habit is abandoned. In such animals more than the others the anterior molars must be free from points to mutilate the soft structures. Beveling the first inferior molars from the gingival margin backward over the crown to the posterior border of the table has often been practiced for the purpose

of preventing the bit from lodging against the teeth, or to prevent grasping the bit between them, but this operation is never effectual in palliating the lugging habit. In the young horse it is harmful in that the sensitive dentinal substance is thus exposed to the surface. Extraction of the first inferior molar is likewise ineffectual.

The veterinarian's full duty ends when all sharp points are removed from the molars, and when appropriate bits have been recommended.

FACIAL PARALYSIS.

Synonyms—Bell's paralysis. Paralysis of the lips. Paralysis of the seventh cranial nerve.

Definition—A partial or complete unilateral motor paralysis of the muscles controlled by the seventh cranial nerve.

Etiology—Facial paralysis is caused by injuries to the mastoid region where the seventh nerve leaves the cranial cavity. The contusion is sustained by hanging in the halter in the recumbent position, striking the head to the floor during surgical restraint or in the struggles of painful diseases, or from blows.

Symptoms—The upper lip is drawn to the opposite side, the corner of the lower lip is dropped so as to show its mucous membrane, the nostril draws inward during inspiration and in the severe case food will accumulate in the cheek from paralysis of the buccinator. When the paralysis is partial these symptoms are less pronounced. Bilateral facial paralysis occurs occasionally when both sides of the head are contused simultaneously from the above causes. In such cases the symptoms presented are total inability to move either lip, difficulty to retain food between the teeth and audible inspirations from vapidty of the nostrils.

Differential Diagnosis—Facial paralysis of this variety is recognized from that of central origin by the sensibility of

the paralyzed region determined by pricking the parts with a pin.

Treatment—Removal of the cause, liniments, blister and massage along the course of the seventh nerve will hasten the recovery. The return of motion to the parts usually occurs in from six weeks to three months. If the injury was severe enough to destroy the continuity of the axis cylinders of the nerve the paralysis may continue through life.




FIG. 160.
Facial Paralysis, Right Side.

LACERATIONS OF THE LIPS.

Injuries to the lips are of considerable import in the horse, owing to their prehensile and tactile functions, and because of the unsightliness of a permanent division of their continuity.

Etiology—Contact with sharp objects. Falls on hard pavement. Dog bites.

Treatment—The labial wound, which includes division of the border of the lip, requires scrupulous attention in order to prevent a permanent defect. Perfect disinfection

by prolonged irrigation with weak antiseptic solution is the first necessary step. The wound is first brought together with mattress or button suture to immobilize the edges, and then closed neatly with interrupted stitches. A thick coating of collodion will still further hold the parts in apposition and serve as a protection against injury and infection. The patient must be fed only upon gruel, and tied on the pillar rein for at least six days.

RANULA.

Definition—A cystic tumor, belonging to the class of retention cysts, located under the free extremity of the tongue.

Susceptible Animals—Dog, cat, ox and man. Rare in the horse.

Etiology—Ranula is generally supposed to be caused by obstruction of one of the ducts of the sublingual salivary gland.

Diagnosis—Disturbed prehension and mastication; palpation and inspection.

Treatment—Ranula is an obstinate disease and will yield to no treatment except total resection of the entire cyst wall. Evacuation of the contents and injections of irritants, iodine, ammonia, silver nitrate, etc., is never a lasting success.

ACTINOMYCOSIS OF THE TONGUE.

(See pages 218-19.)

FOREIGN BODIES IN THE TONGUE.

Pins, needles, tacks, spicula of wood, bones or iron frequently become lodged deeply into the substance of the tongue near its base. The condition is manifested by disturbed mastication, ptyalism, rejection of partially masticated food and disinclination to eat freely. The penetration is usually well under the base of the tongue at a location that defies detection by an ordinary palpation or inspection

of the mouth. With the aid of a mouth speculum palpation of the base of the tongue will reveal a hard, painful area in the center of which the penetrating body will be found protruding. The treatment consists of removal of the foreign body and free incision across the infected area, followed by mild astringent irrigations, alum, borax, sodium chloride, or boric acid solutions.

FROST BITES.

Frozen tongues are common in horses having the habit of protruding the tongue while driving (tongue lolling), and not infrequently the injury thus sustained will cause necrosis of the entire free extremity. Radical treatment must be deferred until the extent of the frozen area becomes apparent by the appearance of a well defined line of demarcation. Amputation will hasten recovery.

LACERATIONS OF THE CHEEKS.

Lacerations of the cheek that mutilate or divide the buccinator muscle transversely may prove a permanent detriment to animals by destroying its necessary elasticity and contractility. Constant packing of food in the cheek or restriction to the movements of the jaw (cicatricial trismus) are frequent results. It is therefore evident that these wounds should receive intelligent and circumspect attention. Careful disinfection, ingenious closure and drainage, and immobilization of the parts should not be omitted in the treatment.

TUMORS OF THE LIPS AND CHEEKS.

Carcinomata, sarcomata, actinomycosis, warts and retention cysts are the classes of tumors usually found on these organs. The growths should be promptly removed when first observed to prevent their diffusion over too great an area. Pedunculated warts are removed by surgical abla-

tion or ligation and the diffused ones by the use of caustics. Copper sulphate and arsenic are specific against warts. Quittman recommends the external and internal use of Fowler's solution as a specific remedy against warts covering a large surface. Retention cysts usually yield to simple evacuation of their contents by a free incision. Widely spread carcinomata and sarcomata are incurable.

LACERATION OF THE TONGUE.

Etiology—Traction on the tongue in examining the mouth or administration of medicines is the common cause of laceration of the fraenum. The body of the organ sustains injury from the tie chain, iron work of the stall or by being bitten by animals in the neighboring stall. Sudden fright while sleeping with the tongue between the incisor teeth is the probable cause of the mysterious lacerations of the tongues of horses.

Symptoms—Ptyalism, disinclination to eat and drink, champing of the jaws, rejection of food and in the later stages of severe lacerations, fetor, are the chief symptoms.

Treatment—Reposition and retention of the lacerations with sutures and amputation. (Operation of amputation see page 244.)

Prognosis—The tongue is well nourished and will heal well when sutured if the blood supply is not too greatly disturbed. In the horse amputation of the free extremity causes only temporary inconvenience in the prehension of liquids. In the ox, dog and cat loss of the free extremity is a permanent impediment in the prehension of food.

INFLAMMATION OF THE TONGUE.

Synonym—Glossitis.

Etiology—Ingestion of irritants, administration of irritating medicaments, bit bruises, wounds from dental irregu-

larities, pin punctures, etc. Specific inflammations of the tongue are seen in actinomycosis and infectious stomatitis.

Symptoms—Same as **lacerations of the tongue**.

Treatment—Removal of the cause; soft food; mild astringent irrigations; alum, borax, boric acid.

Prognosis—Seldom serious. Necrosis of the extremity may require amputation.

ABERRATIONS OF THE FUNCTION OF MASTICATION.

The common aberrations of mastication in animals are quidding, ejecting, bolting, and wadding of food.

QUIDDING.

Definition—Quidding refers to that aberration in which the food is rolled and shifted about in the mouth and then finally ejected into the manger.

Etiology and Symptoms—This abnormality occurs in three distinct forms: (1) From dental irregularities which produce pain when attempt is made to masticate, or from some lesion of the temporo-maxillary articulation. In these cases the food is not comminuted, but is simply rolled about in the mouth and ejected in large masses soaked with saliva. (2) From senile dissolution of the molar arcades. The molars will be found irregular, short in the crowns and frequently loosened in their cavities, and the food will be ejected, as in the former cases, because the molars are no longer capable of performing their function. (3) From a neurosis affecting the nerves of deglutition. In this variety of quidders the food is finely comminuted before being ejected into the manger. The condition is seen most frequently in horses past the age of fifteen years.

Treatment—The quidding horse must be treated according to the cause. Sometimes the extraction of a tooth,

the trimming of an elongation, or the filing of enamel points which wound the mucous membrane, will promptly cure the aberration. In cases of senile origin, loose teeth are extracted and the elongations are carefully blunted without further disturbing their implantations. The food should be of a character requiring but little mastication. Ground corn, ground oats, cut hay and bran, given dry, is the most suitable diet to prolong the life of an old animal so afflicted.

In the third form the aberration may often be overcome by withholding hay from the food allowance. For reasons difficult to explain, hay is the foodstuff usually quidded. Corn, oats, barley and bran are seldom ejected in this form. In addition, the molars must be well examined to exclude them as the cause of the disorder.

EJECTING FOOD.

The ejection of food, partially or completely masticated, occurs as a symptom of quidding, from causes enumerated above, and from abnormalities of the mouth or teeth that produce pain when mastication is attempted. A split molar tooth that wounds the buccal surface, carcinoma of the palate, sarcoma of the jaw, foreign bodies in the tongue or cheek, and a decaying molar, are among the lesions often responsible for this condition.

BOLTING FOOD.

Bolting food refers to the aberration of eating rapidly and without sufficient comminution. It is more of a habit than a disease, and is often acquired by allowing animals to become too hungry. The nose-bag method of feeding is prolific in the production of the habit, which is still further augmented by dental disorders that induce animals to avoid persistent mastication. The habit causes indigestion and colics, and results in the loss of no small amounts of food, that is found unmasticated in the feces. The treatment

consists of first attending to the molar teeth, and of feeding in such a manner as to effectually prevent rapid eating. Nose-bag feeding should be discontinued. When horses are fed in harness the grain should be spread upon the ground over a large surface. In the stable the feed box is taken out and the grain is spread over the entire surface of the hay manger or upon the floor along the front of the stall. Rapid eating under these circumstances is impossible and the habit will soon be abandoned. Specially appointed feeding troughs which allow the food to flow slowly outward as it is eaten are commendable.

WADDING OF FOOD IN THE CHEEK.

The accumulation of food between the cheek and molar arcades is a common aberration. It is caused frequently by a serious dental disorder—fissured molar, loss of the outer half of a molar crown, elongation that wounds the cheek, etc. The most obstinate form of this disorder, however, is due to a defect in the buccinator muscle. The defect may be either a partial or complete paralysis, which may be either co-existent with a general facial paralysis (see facial paralysis, page 248) or which may exist as a circumscribed paralysis of the muscle itself. The cause of the paralysis, when circumscribed, is usually a trauma of the buccinator branch of the seventh nerve as it passes superficially over the masseter. A lacerated wound over the masseter, that divides the continuity of the branches of the nerve, is always liable to be followed by this condition.

Impactions of food in the cheek are also caused by wounds of the buccinator muscle which interfere with its normal contractility. A trivial surgical or accidental wound may disturb the function of this highly motile muscle sufficiently to interfere with its function throughout the remainder of the animal's life. And finally cicatrices of the

buccal mucosa which destroy its sensibility are sufficient injury to be followed by this aberration of mastication.

The treatment must vary with the cause. When due to a dental disorder a cure is at hand by correcting the defect. The cicatricial forms are incurable, but can be benefited somewhat by thoroughly beveling the buccal border of the superior molar arcade. The paralytic form is either curable or incurable, according to the severity and duration of the injury.

INDEX

- A**BERRATIONS of the Function of
Mastication253
Abnormal Eruption of the Teeth....173
Accidents160
Acquired Elongation of Molars....185
Actinomycosis218, 251
Age—Determination of.....71, 113
Age—Birth to One Year.....74
Age—One to Two and One-half
Years75
Age—Two and One-half to Five
Years80
Age—Five to Eight Years89
Age—Nine to Old Age.....89
Age—Twenty to Twenty-five Years.....113
Age—Old Age.....113
Age—Routine of Examination to De-
termine a Horse's113
Alveolar Cavity48
Alveolar Margin—Receding of.....73
Alveolar Periostitis152
Alveolar Plate—Removal of Exter-
nal167
Alveolo-Dental Periosteum19, 21
Alveolo-Nasal Fistula166
Amputation of the Tongue.....241
Animal Dentistry—Scope of.....15
Anomalies—Artificial119
Anomalies of the Teeth Natural
and Artificial117
Anorexia157
Aphtha—Contagious227
Apthous Stomatitis227
Apical Foramen47
Application of Gutta Percha Plugs.....238
Arcades—Inferior34, 35
Arcades—Superior33, 35
Artificial and Natural Anomalies of
the Teeth117
Artificial Anomalies119
- B**ELL'S Paralysis245
Beveling of the Molars.....182
Beveling of Left First Inferior
Molar199
Beveling of Right First Inferior
Molar198
Bishoping120 to 126
Bites—Frost251
Bit Contusions214
Bit Gnathitis214
Bit Lugging245
Bit Sores214
- Blood Vessels19
Blunting of Left First Superior
Molar198
Blunting of Right First Superior
Molar197
Bodies in the Mouth—Foreign....210
Bolting Food254
Brachygnathism179
- C**ANINES118, 51, 54, 61, 64, 65, 127
Canine Teeth of the Horse
.....27, 28, 30, 175
Carcinomata251
Carcinomata of the Palate.....217
Caries152, 172
Caries Dentium172
Catarrh Chronic and Primary
Chronic Nasal231
Catarrh—Persistence of166
Catarrh—Secondary Chronic Nasal.....231
Champing241
Character of the Food.....119
Cheeks—Lacerations of the.....251
Cheeks—The130
Cheeks—Tumors of the Lips and.....251
Chin—Prominent181
Chin—Receding179
Chronic Nasal Catarrh231
Chronic Nasal Catarrh Primary and
Secondary231
Chronic Perforation of the Skull....236
Chronic Rhinitis Unilateral231
Chronic Sinuses of Lower Jaw.....166
Cement19, 22
Central Incisors
.....49, 51, 52, 54, 56, 60, 63, 64, 65
Common Enamel Germ47
Complete Denture of a Horse.....18
Contagious Aphtha227
Contagious Pustular Stomatitis....227
Contusions—Bit214
Corner Incisors
.....50, 51, 52, 54, 57, 61, 64, 65
Cribbing239
Crowns—Polishing the120
Crowns—Shortening of120
Custa Petrosa19, 22, 23
Cupping the Incisor Teeth123
Cups of the Infundibula118
Cups—Renewal of the120
Cuticle of the Enamel22
Cysts—Dental177, 222
Cysts—Retention230, 251

D ECAYED Teeth	152, 172
Decayed Tooth Fracture of	160
Deglutition Pneumonia	167
Dental Artery Hemorrhage from the	161
Dental Cysts	177, 222
Dental Diagnosis	133
Dental Evolution and Retrogression Applied to Determination of Age—Summary of	74
Dental Follicle	48
Dental Fistula	166, 224
Dental Halter	148
Dental Instruments Their Uses	135
Dental Papilla	47
Dental Teratomata	222
Dental Tissues Arrangement of in Incisor	21
Dentigerous Cysts	222
Dentinal Substance	47
Dentine	19, 20, 23
Dentitis	152
Denuding	210
Destruction of Temporary Tooth by the Permanent	69
Determination of Age	74
Determination of Age—Routine of Examination to	113
Diagnosis Dental	133
Digastricus Muscle—The	131
Diseases and Irregularities of Teeth	152
Dislocation of the Temporo-Maxillary Articulation	213
Divisions of a Tooth	19
Dog—Denture of	39, 40, 41, 42, 43
Dog Speculums	174, 175
Dog—Temporary Teeth of	54
Dogs—Ulcerative Gingivitis of	229
E JECTING Food	254
Elongation of the Molars—Acquired	185
Elongation Operation of Cutting	186
Elongations of the Incisors	206
Embryonic Evolution	44
Enamel	19, 21
Enamel—Cuticle of the	22
Enamel—Erosion of the	208
Enamel Germ—Common	47
Enamel Organ	47
Enamel Points	187
Enamel Points of Herpivora	187
Erosion of the Enamel	208, 210
Eruptions of the Teeth	117
Eruptions of the Teeth Abnormal	175
Evolution and Retrogression of the Teeth Tabulated	121, 125
Evolution—Embryonic	44
Evolution of Permanent Teeth	58
Evolution of Temporary Teeth	49
Examination of the Mouth	190
Extraction of the Canines of Horses	172
Extraction of the Incisors	171

Extraction of the Teeth of Dogs	174
Extraction with Forceps	159
Eye Teeth	202

F ACIAL Paralysis	245
Facial Sinuses—Purulent Accumulations in	231
Fang	47
File Flat and Rasp	137
Fissuring of the Molars	209
Fistula Alveolo-Nasal	166
Fistula Dental	166, 224
Fistulae Mastoid	222
Float The Angular	136
Float The Straight	136
Floating and Filing	191
Floating and Trimming Molars	189
Floating the Teeth of the Ox	202
Floats and Files Methods of Using on Molars	192
Floats and Float Blades	135, 136
Follicle Dental	48
Food-Bolting	254
Food Character of the	115
Food Ejecting	254
Food Wadding of in the Cheek	225
Foramen Apical	47
Foreign Bodies in the Mouth	210
Foreign Bodies in the Tongue	250
Formulae of Temporary and Permanent Dentures of Animals	66, 67
Fracture of Decayed Tooth	160
Fracture of the Inferior Maxilla	211
Fracture of the Teeth	209
Fractured Jaw	214
Fractures of the Premaxilla and Superior Maxilla	213
Frost Bites	251
Functions of the Teeth	127

G ERM—Common Enamel	47
Gingivae	19
Gingival Cushions	45
Gingivitis of Dogs—Ulcerative	229
Gleet—Nasal	231
Glossitis	252
Gnathitis Bit	214
Gutta Percha Plugs Applications of	238

H ABITUAL Protrusion of the Tongue	244
Habitual Ptyalism	241
Hard Palate—The	130
Hard Tissues	19
Hemorrhage from the Dental Artery	161
Hemorrhage Palatine	160
Horse—Complete Denture of	18
Horse—Temporary Teeth of	49

I NCISOR Nippers	143
Incisor Teeth of the Ox	37, 51

Incisor Teeth—Shedding of.....	175
Incisor Teeth—Shortening.....	123, 206
Incisor Teeth—Polishing, Cupping and Staining the	123
Incisors	18, 127
Incisors—Central	
..... 49, 51, 54, 56, 60, 63, 64, 65	
Incisors—Corner	
..... 50, 52, 54, 57, 61, 64, 65	
Incisors—Elongation of	206
Incisors—Extraction of	171
Incisors—Inferior	51
Incisors—Intermediate	51, 57, 64
Incisors—Lateral	
..... 50, 51, 54, 56, 60, 64, 65	
Incisors—Permanent of Horse.....	27, 28
Incisors—Permanent of Ruminants..	34
Incisors—Temporary of Horse.....	50
Infectious Stomatitis	227
Inferior Arcades	34, 35
Inferior Incisors	51
Inferior Maxilla—Fracture of the.....	211
Inferior Maxillary	129
Inferior Molars.....	32, 33, 34, 39
Inferior Molar of Ox.....	38
Inflammation of the Tongue.....	252
Infundibula—The	118
Infundibula—Cups of the.....	118
Infundibulum	19, 21
Inspection of the Mouth.....	135
Instruments—Dental—Their Uses ..	135
Intermediate Incisors	51, 57
Introduction	13
Irregularities and Diseases of Teeth.	152

J AW—Fractured	214
Jaw—Prominent	181
Jaw—Receding	179

L ACERATIONS of the Cheeks.....	251
Lacerations of the Lips.....	249
Lacerations of the Tongue	252
Lampas	230
Lateral Enamel Projections	187
Lateral Incisors	
..... 50, 51, 54, 56, 60, 64, 65	
Lips and Cheeks—Tumors of the.....	251
Lips—Lacerations of the.....	249
Lips—Paralysis of the	245
Lolling—Tongue	244
Lugging—Bit	245
Lumpy Jaw	218

M ARGINS of the Teeth.....	20
Masseter Muscle—The	130
Mastication—Mechanism of.....	129
Mastoid Fistulae	222
Maxillary—The Inferior	127
Maxillary—The Superior	127
Maxillo-Nasal Notch	130
Mechanism of Mastication.....	129
Merillat's (Prof. Ed's) Operation for Closing Chronic Skull Perfora-	

tions	237
Micro-Organisms	173
Molar Crown Cutter	144
Molar Cutter—Angular	142
Molar Cutter—Or Trimmer Closed.....	137
Molar Cutter—Open	138
Molar Extractor—Closed	141
Molar Extractor—Open	142
Molar Separator	140
Molar—Fourth	51
Molar—Natural Cavities of.....	23
Molar Teeth	176
Molars	18, 30, 127
Molars—Acquired Elongation of.....	185
Molars—Fissuring of the.....	209
Molars—Fourth and Fifth.....	62, 64, 65
Molars—Sixth	63, 64, 65
Molars—First, Second and Third 50, 54, 57, 61, 64, 65	
Molars—Inferior	32, 33, 34, 39
Molars—Permanent of Ruminants..	36
Molars—Projections on	184
Molars—Splitting of the.....	209
Molars—Superior	30, 31, 32
Molars—Trimming and Floating 189, 191, 192	
Mouth—Inspection of the.....	135
Mouth—Palpation of the	133
Mouth—Sarcomata of the.....	217
Mouth Speculum	144, 145, 146
Muscle—The Digastricus	131
Muscle—The Masseter	130
Muscle—The Pterygoid Externus ..	131
Muscle—The Pterygoid Internus ..	131
Muscle—The Sterno Maxillaris.....	131
Muscle—The Stylo Maxillaris	131
Muscle—The Temporalis	131

N ASAL Catarrh—Chronic, Primary Chronic and Secondary Chronic 231	
Nasal Gleet	231
Natural and Artificial Anomalies of the Teeth	117
Neck	47
Necrosis of the Teeth of Herbivora 152, 154	
Nerve and Blood Supply of Horses' Teeth	25
Nerves	19
Nippers—Incisor	143
Nomenclature of the Teeth.....	18

O DONTOMATA	178
Opening the Skull	164
Operation of Cutting Elongations.....	186
Operation of Trimming and Float- ing Molars	189
Osteo-Dentine	70
Osteoma of the Maxilla	176
Osteomata of Superior Maxilla.....	216
Ox—Floating Teeth of	202
Ox—Temporary Teeth of	51

Ozena 231

PALATE Carcinomata of the... 217
 Palate—The Hard 139
 Palatine Hemorrhage 160
 Palpation of the Mouth 133
 Papilla—Dental 47
 Paralysis—Bell's, Facial, of the Lips,
 of the Seventh Cranial Nerve... 248
 Parrot Mouth 179
 Parvignathism 182
 Perforation of the Skull—Chronic... 236
 Pericementitis 152
 Peridentitis 152
 Permanent Incisor Teeth of Horse
 27, 28
 Permanent Incisors of Ruminants... 34
 Permanent Molars of Ruminants... 37
 Permanent Teeth—Evolution of... 58
 Permanent Teeth—Number of... 65
 Permanent Teeth—Retrogression of... 68
 Persistence of Catarrh 166
 Pig—Temporary Teeth of 52
 Polishing the Crowns 120
 Polishing Incisor Teeth 123
 Poll Strap 149
 Predisposing Causes 173
 Preface 9, 10
 Prehension 128
 Premaxilla—Fractures of the 213
 Premaxilla—The 129
 Primary Chronic Nasal Catarrh... 231
 Prognathism 181
 Projections on the First Superior
 and Sixth Inferior Molars... 184
 Projections on Superior Corners... 185
 Prominent Chin 181
 Prominent Jaw 181
 Protrusion of the Tongue—Habitual... 244
 Pterygoid Externus Muscle—The... 131
 Pterygoid Internus Muscle—The... 131
 Ptyalism—Habitual 241
 Pulling 241
 Pulp 19, 24, 47
 Pulpitis 152, 153
 Purulent Accumulations in Facial
 Sinuses 231
 Pustular Stomatitis—Contagious... 227

QUIDDING 253

RANULA 250
 Receding Chin 179
 Receding Jaw 179
 Receding of Alveolar Margin... 71
 Reining—Side 242
 Remnant Teeth 202
 Removal of External Alveolar Plate... 167
 Removal of Teeth by Splitting with
 Chisel 170
 Renewal of the Cups 120
 Repulsion of Teeth with Punch and
 Mallet 161

Repulsion of the Tooth 165
 Restraint 148
 Retention Cysts 239, 251
 Retrogression and Evolution of the
 Teeth Tabulated 124, 125
 Retrogression of the Permanent
 Teeth 68
 Retrogression of Temporary Teeth... 68
 Rhinitis—Unilateral Chronic 231
 Routine of Examination of Horse's
 Mouth to Determine the Age... 113

SARCOMATA 251
 Sarcomata of the Mouth... 217
 Scissor Mouth 182
 Search Light 134
 Secondary Chronic Nasal Catarrh... 231
 Septicæmia 167
 Seventh Cranial Nerve—Paralysis
 of 248
 Sharp Teeth 187
 Shedding of the Incisor Teeth... 175
 Sheep—Temporary Teeth of 56
 Shortening of the Crowns 120
 Shortening of the Incisor Teeth... 123
 Side Reining 242
 Sinuses—Chronic of Lower Jaw... 166
 Skull—Chronic Perforation of the... 236
 Skull—Opening the 164
 Skull—Trephining the 162
 Skull—Trephining for Nasal Catarrh... 233
 Slobbering 241
 Soft Tissues 19
 Sores—Bit 214
 Splitting of the Molars 209
 Staining the Incisor Teeth 123
 Sterno Maxillaris Muscle—The... 131
 Stomatitis—Apthous 227
 Stomatitis—Contagious Pustular... 227
 Stomatitis—Infectious 227
 Stomatitis—Traumatic 226
 Structures of the Teeth 19
 Stylo Maxillaris—The 131
 Summary of Dental Evolution and
 Retrogression Applied to Deter-
 mination of Age 74
 Superior Maxilla—Fractures of the... 213
 Superior Arcades 33, 35
 Superior Maxillary 129
 Superior Molars 30, 31, 32
 Superior Molar Arcade of Ox... 38
 Superior Molar Table of Ox 39
 Surfaces of the Teeth 19
 Supernumerary Teeth 202, 204
 Supplementary Teeth 202
 Susceptible Animals 173

TABLE of Superior Molar of Ox... 39
 Tabulated Evolution and Re-
 trogression of Teeth... 124, 125
 Tartar 208
 Teeth—Abnormal Eruptions of the... 175
 Teeth—Anomalies of the Natural and
 Artificial 117

Teeth—Canine of Horse ..	27, 28, 175
Teeth—Decayed	152, 172
Teeth—Diseases and Irregularities of	152
Teeth—Eruption of the	117
Teeth—Evolution and Retrogression Tabulated	124, 125
Teeth—Evolution of the	44
Teeth—Evolution of the Temporary.	49
Teeth—Eye	202
Teeth—Fracture of the	209
Teeth—Function of the	127
Teeth—Incisor of Horse (Per- manent)	27, 28
Teeth of Ruminants	36, 37, 38, 39
Teeth of the Dog	39, 40, 41, 42, 43
Teeth—Margins of the	20
Teeth—Molar	18, 30, 127, 176
Teeth—Nerve and Blood Supply (Horses')	25
Teeth—Nomenclature of the	18
Teeth—Number of Permanent	65
Teeth—Number of Temporary	65
Teeth—Repulsion of	161
Teeth—Retrogression of Permanent	68
Teeth—Retrogression of Temporary.	68
Teeth—Structures of the	19
Teeth—Supernumerary	202, 204
Teeth—Textures of the	118
Teeth—Ulceration of	172
Teeth—Wolf	202
Temporalis Muscle—The	131
Temporary Teeth—Evolution of	49
Temporary Teeth—Number of	65
Temporary Teeth—Retrogression of.	68
Temporo-Maxillary Articulation—Dis- location of	213
Teratomata—Dental	222
Texture of the Teeth	118
Tie Ropes	149

Tissue—Interdental Cancellated	48
Tissue—Ossified Connective	48
Tissues—Hard	19
Tissues—Soft	19
Tongue	130
Tongue—Foreign Bodies in	250
Tongue—Habitual Protrusion of the.	247
Tongue—Inflammation of the	252
Tongue—Laceration of	252
Tongue Lolling	244
Tongue—Operation of Amputation of the	244
Tooth—Divisions of a	19
Tooth Chisel—The	144
Tooth—Repulsion of the	165
Tooth—Self Extraction of the	153
Tooth Tumors	176
Traumatic Stomatitis	226
Trephining the Skull	162
Trephining the Skull for Nasal Catarrh	233
Trimming and Floating Molars	189
Tumefaction on Superior Maxillary.	216
Tumors of the Lips and Cheeks	251
Tumors of the Mucous Membrane of the Mouth	230

ULCERATIONS of Teeth	172
Ulcerative Gingivitis of Dogs	229
Undershot	181
Unilateral Chronic Rhinitis	231

WADDING of Food in the Cheek.	255
Warts	251
Wear from Mastication	10
Williams' Operation	167
Wind Sucking	239
Wolf Teeth	202
Wolf Tooth Forceps	140
Wolf Tooth Separator	140
Wooden Tongue	219

Woolson Family Library of Veterinary Medicine
Cummings School of Veterinary Medicine at
Tufts University
200 Westboro Road
North Grafton, MA 01536

