




3 1761 04186 6658







Digitized by the Internet Archive
in 2008 with funding from
Microsoft Corporation

CATALOGUE

OF THE

MEDICAL AND MICROSCOPICAL SECTIONS

OF THE

UNITED STATES ARMY MEDICAL MUSEUM.

PREPARED UNDER THE DIRECTION OF THE SURGEON GENERAL, U. S. ARMY.

CATALOGUE

OF

THE MEDICAL SECTION

OF THE

United States Army Medical Museum.

PREPARED UNDER THE DIRECTION OF THE SURGEON GENERAL, U. S. ARMY.

By Brevet Lieutenant Colonel J. J. WOODWARD, Assistant Surgeon, U. S. Army,
in charge of the Medical and Microscopical Sections of the Museum.

128762
—
1817/13

WASHINGTON:
GOVERNMENT PRINTING OFFICE.
1867.

$$\frac{5126}{2144} \approx 2.39$$

1
11
11
11

NOTE.

The Specimens in the Medical Section of the Museum are chiefly wet preparations. These are preserved in alcohol, in handsome glass jars, with wide mouths and ground-glass stoppers. Each stopper is made with a glass hook, from which the preparation is suspended. It is, therefore, always possible to take Specimens out of the jars when necessary to do so for study or to change discolored alcohol. The stoppers being carefully fitted, the actual loss of alcohol by evaporation has been found too small to constitute a serious objection to the plan.

The intestinal preparations are stretched upon frames made of glass rods bent into the proper form, as will be observed in the plates which represent a few of these Specimens. Frames made of glass rods variously bent are also used in several of the other portions of the Medical Section for the proper display of Specimens.

The autopsies at the Freedman's Hospital referred to in the Catalogue were made by Hospital Stewards Bond, Schafhirt and Lamb, under the immediate supervision of the officer in charge of the Medical Section, by whom also the dissection of the Specimens was directed.

CONTENTS.

	PAGE.
Chapter I.—NERVOUS SYSTEM	3
SECTION 1. BRAIN	3
2. MEMBRANES OF BRAIN	6
3. PINEAL GLAND	9
4. BLOODVESSELS OF ENCEPHALON	9
5. SPINAL CORD	10
Chapter II.—ORGANS OF CIRCULATION	13
SECTION 1. HEART	13
2. ARTERIES AND VEINS	20
3. LYMPHATIC GLANDS	22
APPENDIX TO SECTION 3. THYROID GLAND	26
Chapter III.—RESPIRATORY ORGANS	29
SECTION 1. AIR PASSAGES	29
2. LUNGS AND PLEURE	34
Chapter IV.—DIGESTIVE ORGANS	45
SECTION 1. MOUTH, PHARYNX AND OESOPHAGUS	45
2. STOMACH	46
3. INTESTINAL CANAL	49
4. PERITONEUM AND OMENTUM	86
5. LIVER	90
6. PANCREAS	97
7. SPLEEN	97
Chapter V.—URINO-GENITAL ORGANS	105
SECTION 1. KIDNEYS	105
2. SUPRARENAL CAPSULE	109
3. URINARY PASSAGES AND BLADDER	109
4. MALE ORGANS OF GENERATION	111
5. FEMALE ORGANS OF GENERATION AND FETUS	112
Chapter VI.—ORGANS OF LOCOMOTION	117
SECTION 1. MUSCLES AND FASCIA	117
2. BONES AND JOINTS	117
Chapter VII.—INTEGUMENT	123
Chapter VIII.—ANOMALIES AND MONSTROSITIES	127
INDEX OF CONTRIBUTORS	129
INDEX OF SPECIMENS	135

Chapter I. NERVOUS SYSTEM.

Section 1. BRAIN.

	NO. OF SPECIMENS.
A. Congenital anomalies	1
B. Haemorrhage	1
C. Abscess	1
D. Tumors	7
E. Tubercle	6
F. Parasites	1

Section 2. MEMBRANES OF BRAIN.

A. Acute inflammation	5
B. Dilatation of ventricles	3
C. Cysts in choroid plexus	1
D. New formations of bone	3

Section 3. PINEAL GLAND.

A. Cystic transformation	1
--------------------------------	---

Section 4. BLOODVESSELS OF ENCEPHALON.

A. Atheroma	1
B. Aneurism	1

Section 5. SPINAL CORD	1
------------------------------	---

Chapter I. NERVOUS SYSTEM.

Section 1. BRAIN.

A. Congenital Anomalies.

No. 760. Third ventricle of brain, and tissues immediately surrounding it. The middle commissure of the ventricle
A. 1. double.

Private N. M. H., "B," 94th New York, age 21. Died, March 4th, 1865, of pyæmia, after amputation of the thigh for gunshot wound.

Autopsy: Clear serum in the lateral ventricles; the posterior cornu of the left ventricle extended an inch farther back than that of the right; corpus callosum thin and soft; brain otherwise healthy, except the double commissure; weight of cerebrum, three pounds nine ounces; there were metastatic foci in lungs, and an abscess in liver.

Contributed by Acting Assistant Surgeon J. G. Keller, National Hospital, Baltimore, Md.

See Surgical Section 1535, XVIII. II. A. B. c. 9; 1504, XIX. C. B. b. 1.

B. Hæmorrhage.

No. 617. Medulla oblongata, pons varolii, cerebellum and portion of the cerebrum; the pons disorganized by an
B. 1. apoplectic clot, chiefly involving its left side. In the left lateral ventricle was a cyst containing pus, the walls of which can still be seen in the specimen.

Private T. B., "F," 35th New York, age 40. Admitted, July 8th, 1865, suffering from mild bilious fever, which readily yielded to treatment. 10th, hemiplegia of right side observed, involuntary evacuations, no paralysis of the face; the sixteenth of a grain of strychnia was given three times a day with a supporting diet. He appeared to improve slowly, but was restless and inclined to sleep. August 2th, at 3.30 p. m., apoplectic symptoms suddenly set in, and he died in fifteen minutes.

Autopsy: Body of full habit; a large quantity of blood under the tentorium; pons varolii ruptured, the tear filled with a black coagulum; lungs with old adhesions; heart hypertrophied and soft, but no valvular disease.

Contributed by Acting Assistant Surgeon W. C. Miuer, Slough Hospital, Alexandria, Va.

C. Abscess.

No. 761. Left corpus striatum, presenting an abscess-cavity the size of a small walnut.

C. 1. A man debilitated by exposure and scurvy. Admitted in February, 1865, with phlegmonous erysipelas of left elbow and forearm; this subsided and was followed by facial erysipelas, while convalescent from which, March 15th, hemiplegia set in, followed by coma, slow pulse, dilated pupils and death comatose, March 18th.

Autopsy twenty hours after death: Almost no rigor mortis; cerebral convolutions on left side much flattened; left lateral ventricle filled with greenish fetid pus; cavity of ventricle communicating with abscess-cavity in corpus striatum; the brain substance surrounding the cavity yellow and hard; no pus in right ventricle; no metastatic foci in thoracic or abdominal viscera.

Contributed by Acting Assistant Surgeon G. C. Seguin, Little Rock Hospital, Ark.

D. Tumors.

No. 531. An oval tumor (Muller's cholesteatoma), an inch and a half in diameter, slightly nodulated on the surface; its external appearance closely resembled mother of pearl. It was composed of a delicate cyst of connective tissue, beneath which were vast numbers of polygonal flattened cells, arranged concentrically in layers like those of an onion; between these cells lay a great number of cholesteroline tables. (*See Microscopical Section, Part First, XIV, D, A, 1, and Part Second, XIV, D, A, 1, 2.*) This tumor was attached to the inner surface of the frontal bone, three-quarters of an inch above the orbital plate. Suspended beneath the tumor in the jar, is a piece of dura mater with a needle-like spiculum of bone, three-fourths of an inch long, embedded. This was removed from the lesser wing of the sphenoid bone on the right side, whence it projected upwards, backwards and outwards.

History—(Acting Assistant Surgeon N. B. Dean): Private W. R., 16th Indiana Artillery, age 21, height five feet five inches, weight one hundred and sixty pounds, of a full pathetic habit, farmer. Enlisted, October 19th, 1861, at Lafayette, Ind., to serve one year; had been in service previously, but was discharged, July, 1862, on account of epileptic fits; has not been known to have had any during present enlistment, until April 7th, 1865. March 18th, 1865, admitted for a severe attack of subacute rheumatism, accompanied by considerable fever. Recovered rapidly, and by April 1st was convalescent. April 7th, had an attack of epilepsy about 5 p. m., lasting fifteen minutes. April 10th, at 1 a. m., a series of epileptiform attacks set in, which lasted till death, at 4 p. m. There was an intermission of about four minutes between each of the attacks, which were of a severe character, the first throwing him out of his bed with much violence.

Autopsy: The tumor and spiculum of bone above described; old pleuritic adhesions on both sides; lungs filled with blood; the outer part of right lung hepatized; fatty degeneration of right ventricle of heart; hypertrophy of left ventricle; mitral valves thickened; fibrinous granulations on aortic valves.

Contributed by Surgeon W. J. Woitley, U. S. Vols., Fort Strong, Va.

No. 532. An ovoid sarcomatous tumor, one and a half inches in long diameter, attached to the dura mater, just above the anterior face of the petrous portion of the temporal bone of the right side; it is composed chiefly of small cells, the largest (diameter) of an inch in diameter, with very small nuclei.

History—(Acting Assistant Surgeon H. M. Denn): Private A. McD., "K," 9th Massachusetts, age 50. Admitted, November 23d, 1862. March 29th, 1864, is in a semi-comatose condition, the vessels of the head and neck very much congested; has had several attacks, supposed to be epilepsies. March 21st, is up, about the ward, and feeling very much better. March 25th, seized suddenly. 7 a. m., entirely unconscious; vessels of head and neck much congested; the surface hot and nearly the color of a boiled lobster; pulse 100 and quick; hands clotted, with the fingers grasping the thumbs; great difficulty of breathing; throat partially stopped by a quantity of thick frothy mucus; temperature and color of extremities normal; died, quietly, at 8:30 a. m.

Autopsy six hours after death: Height, five feet five inches; body well developed and fleshy; fat covering abdomen nearly two inches thick; rigor mortis well marked; brain rather anæmic; convolutions considerably flattened, especially on the right side; the tumor above described was firm, whitish centrally, pinkish towards the surface, which was smooth and well defined; there was considerable softening of the brain tissue around it; brain otherwise normal; pericardium, loaded with fat, contained two drams of serum; heart covered largely with fat; its valves and muscular tissue healthy; arch of aorta, somewhat narrowed, showed small patches of atheroma; spleen, near its centre externally, had an opaque spot about one inch in diameter; otherwise normal.

Contributed by Surgeon J. C. McKee, U. S. Army, Lincoln Hospital, Washington, D. C.

No. 535. An oval sarcomatous tumor three inches long by two and a half wide, situated between the posterior lobes of the cerebellum, attached below to the tentorium and crura cerebelli. It was composed of spindle-shaped, nodulated, connective tissue cells, with a scanty matrix; the cells arranged after the areolar type.

(*See Microscopical Section, Part First, XIV, B, A, 5.*)

Private J. W., "E," 2d Massachusetts (re). Admitted, September 27th, 1861, with symptoms of typhoid fever; extreme tenderness of the right iliac region and retention of urine; only partly conscious; bowels constipated; pulse 90 and feeble; tongue furred, brown, dry and highly cracked. October 12th, almost complete stupor; swallows with much difficulty. Died, October 19th.

Autopsy two hours after death: Rigor mortis distinct; body much emaciated; lungs slightly congested; spleen somewhat enlarged; Peyer's patches much enlarged; between the posterior lobes of the cerebellum the tumor described; it was very consistent, cutting like cartilage.

Contributed by Assistant Surgeon R. F. Weir, U. S. Army, General Hospital, Frederick, Md.

Nos. 299 and 300. The lateral lobe of a cerebellum, divided in the median line. At the anterior superior part of the cerebellum above the torus cerebelli of a walnut. It was composed of delicate spindle-shaped cells, with numerous large oval vesicles containing atrophied nerve cells.

D 4 and 5. Private F. M., "C," 63d Ohio (re). Admitted, February 23, 1861. 23th, was feverish, with severe pain in the face, and convulsions, partly tonic convulsions; was inclined to be eccentric, silly, even idiotic; kept his eyes closed, and could not be opened, but not strictly comatose. March 23d.

Autopsy: The tumor above described, two ounces of impur serum in the lateral ventricles.

Contributed by Acting Assistant Surgeon H. M. Lilly, Hospital No. 1, Nashville, Tenn.

No. 811. Oval sarcomatous tumor of the brain two inches in its long diameter. Microscopically, composed chiefly of small fusiform cells and coated on the external surface with a delicate envelope of connective tissue. It was situated beneath the tentorium on the left side in close connection with the seventh pair of nerves, which appeared to enter it on the one side and emerge from it on the other. It was attached to the orifice of the meatus auditorius internus, and lay in a cavity hollowed in the left hemisphere of the cerebellum. When fresh, it resembled brain tissue to the naked eye. Contributed by Acting Assistant Surgeon H. M. Lilly, Hospital No. 13, Nashville, Tenn.

No. 873. Small sarcomatous tumor of the size of a pea, found projecting into the anterior cornu of the left lateral ventricle between the median line and the inner margin of the anterior portion of the left corpus striatum. The centre of the tumor was softened into a semi-fluid. Microscopical examination showed the growth to be composed of pale, delicate granulation cells, about the size of pus corpuscles.

J. A. G., dark mulatto, three years old. Attacked with pneumonia and bronchitis, March 28th, 1867. 30th, pulse 120, tongue coated, skin dry, bowels constipated, suppressed cough. April 3d, convulsions. 4th, partial paralysis of left side, with purulent discharge from the left ear, but no apparent disturbance of sight or hearing. The convulsions reappeared at intervals until death, April 14th. The father and grandfather had been subject to epilepsy, and three former children, by the same parents, had died with similar symptoms.

Autopsy twenty-four hours after death: No rigor mortis; no emaciation; eruption of miliary vesicles on the chest; membranes of brain finely congested; substance around ventricles quite soft; lateral ventricles each distended with about two ounces of serum, in which floated much flocculent lymph; choroid plexus congested; lining membranes of ventricles slightly so; the tumor, as described; fourth ventricle largely distended with serum; yellowish jelly-like deposit beneath arachnoid over pons varolii and medulla oblongata; about one ounce of serum in subarachnoid cavity; lungs somewhat congested; right lung contained an abscess the size of a walnut in its middle lobe, with purulent contents and indurated walls; middle lobe hepaticized; pleuritic adhesions between upper and middle lobes.

Contributed by Dr. L. J. Draper, Washington, D. C.
874, chap. III., sec. 2, A. 9, *abscess of lung, is also from this case.*

E. Tubercle.

No. 583. A round tubercular mass, somewhat more than half an inch in diameter, removed from near the median line in the right anterior lobe of the cerebrum.

E. 1. Private J. W. T., "A," 4th U. S. Colored. Admitted for burial, February 15th, 1865.

Autopsy: Body emaciated; extremities and face oedematous, with a large abscess of the left side of the neck; in the brain, the tumor described; adhesions of the pleura; tubercles of the lungs; twenty-eight ounces of serum in the pericardium; no clots in heart; miliary tubercles in spleen, liver and peritoneum.

Contributed by Assistant Surgeon G. M. McGill, U. S. Army, National Hospital, Baltimore, Md.
584, chap. IV., sec. 7, D. 4, *calcareous plate on surface of spleen, is also from this case.*

No. 770. A portion of the right anterior lobe of cerebrum, containing an irregular lobulated tumor about the size of a walnut, which, on its surface, was coated with a layer of immature connective tissue, and in its interior presented the microscopical characters of cheesy tubercle.

E. 2. R. S., colored, age 25. Admitted to L'Ouverture Hospital, February 22d, 1865, greatly debilitated; pulse small, weak and very frequent; tongue slightly coated; breathing short and difficult; abdomen considerably enlarged, with decided fluctuation; feet and legs oedematous; much anxiety of countenance and obtuseness of intellect; articulation difficult. Died, February 25th.

Autopsy: Cerebrum contained the tubercular tumor described; miliary tubercles in both lungs; aortic valves somewhat cartilaginous at their edges; liver enlarged; contained scattered tubercles; spleen engorged with dark blood, and contained many tubercles; kidneys fatty; omentum shrunken; two quarts of serum in abdominal cavity.

Contributed by Surgeon E. Bentley, U. S. Vols., General Hospital, Alexandria, Va.

No. 35. Medulla oblongata and cerebellum. On the upper surface of the latter, about one inch to the left of the median line, is a single spherical tubercle, half an inch in diameter.

No. 36. A portion of the tentorium of the same patient, with two isolated tubercles somewhat smaller than the last, situated on the inner surface of the dura mater, in a position corresponding to the right side of the cerebellum. No history.

Contributed by Surgeon M. Goldsmith, U. S. Vols., Louisville, Ky.

- No. 557.** A section of cerebellum, showing a spherical tubercle half an inch in diameter, seated in the upper surface near the superior vermiciform process.
E. 5. J. T., colored. Died, May 27th, 1865, of phthisis.

Autopsy: Body thin and emaciated; tubercles and vomicae in upper lobe of right lung; pleuritic adhesions of the right side; fatty kidney; liver small and pale; tubercular ulceration of ileum and colon.

Contributed by Acting Assistant Surgeon W. C. Minor, 1st Onverture Hospital, Alexandria, Va.

555, chap. VI., sec. 1, No. 3, *chazy tubercle in fascia near left internal mammary artery*; 556, chap. VI., sec. 1, No. 1, *tubercular deposits on pleural surface of diaphragm, are also from this case.*

- No. 637.** Oval tubercular tumor, the size of a pigeon's egg, from the right lobe of the cerebellum.
E. 6. M. S., colored woman, age 23. Admitted, September 23d, 1865. Had been sick a month with cough and sore throat; dullness over upper lobe of right lung and lower lobe of left lung; hæmoptysis. Died, October 23d.

Autopsy eight hours after death: Body much emaciated; rigor mortis partial; height, five feet one inch; weight, about eighty-five pounds; arachnoid congested and adherent at several points; four drachms of fluid in posterior fossæ of cranium; two drachms of serum in each lateral ventricle; membranes of cerebellum congested; the tumor as described; right lung adherent to pleura costalis and pericardium, lobes adherent to each other, tubercles throughout, abundant in the upper lobe; left lung adherent at all points and in same condition as right; pericardium contained twelve ounces of clear serum; heart pale and flabby, white clots in both ventricles and auricles, coagula of blood in left ventricle; liver, adherent to diaphragm and walls of abdomen, of a brick dust color, contained a few large cheesy tubercles, its lateral ligaments and peritoneal covering studded with tubercles; spleen, of a burnt-umber color, filled with tubercles the size of millet seeds; omentum contracted into a band, and filled with large tubercles; diaphragm covered with tubercles throughout its whole extent, more particularly on its under surface; tubercular deposits in the cortical substance of both kidneys; mucous coat of stomach thickened, a large scooped ulcer in greater curvature, about two and a half inches from pylorus, and a small one in the greater extremity of the organ; mesentery, contracted into a solid lump, filled with tubercular glands; intestines adherent to parietal peritoneum and each other, their peritoneal surface and also the parietal peritoneum covered with tubercular deposits; one large and several small ulcers in mucous membrane of ileum; two ulcers in mucous membrane of cecum.

From Freedman's Hospital, Washington, D. C.

Autopsy by Hospital Steward S. S. Bond.

634, chap. IV., sec. 2, B, 6, *ulcer of stomach*; 635, chap. IV., sec. 4, E, 16, *tubercular ulcer of ileum*; 636, chap. IV., sec. 4, E, 8, *tubercles on parietal peritoneum, are also from this case.*

F. Parasites.

- No. 566.** Four morsels of brain, the two lower of which contain echinococcus cysts, the size of a pea; the two upper ones show cavities from which the cysts have escaped.

Corporal D. M., "G," 15th F. S. Colored. Died, May 18th, 1865, of chronic diarrhoea.

Autopsy: Brain contained numerous echinococcus cysts; lungs congested, the right adherent; liver cirrhotic; Peyer's patches thickened; colon with patches of pseudo-membrane; mesenteric glands large.

Contributed by Acting Assistant Surgeon W. C. Minor, 1st Onverture Hospital, Alexandria, Va.

Section 2. MEMBRANES OF BRAIN.

A. Acute Inflammation.

- No. 793.** A portion of cerebrium, which, when fresh, presented a thin layer of pus beneath the arachnoid; this has coagulated in the alcohol into a thin whitish layer.

W. T., colored, age 47. Admitted, April 17th, 1866; too weak to sit up; justification; only partly conscious; could not answer questions. Died, April 18th.

Autop. A eighteen hours after death: A well formed, dark, stout mulatto man, five feet high, weight about one hundred and thirty pounds; rigour mortis well marked, dura mater slightly congested; membranes of brain congested; purulent fluid beneath the arachnoid; one drachm of serum in each lateral ventricle; lining membrane and choroid plexus congested; substance of brain soft; arachnoid swollen, its membranes congested; pus beneath arachnoid, two ounces of serum in posterior fossæ of cranium;

posterior portion of lower lobes of both lungs congested; large deposit of adipose tissue on surface of heart, which was dark and congested; six ounces of serum in pericardium; nutmeg liver; gall bladder contained a half ounce of viscid bile; spleen lobulated; one small supernumerary spleen; kidneys slightly fatty; much pigment in the duodenum; Peyer's patches thickened; solitary follicles of ileum enlarged and filled with pigment.

From Freedman's Hospital, Washington, D. C.

Autopsy by Hospital Steward, S. S. Bond.

No. 32. Medulla oblongata and cerebellum, the latter somewhat broken in removing it from its position; the lymph masses which originally coated the surface of the piece were, to a great extent, washed away during the transportation of the specimen to the Museum.

A. 2.

Corporal A. A. D., "K," 51st Massachusetts, age 22. February 10th, 1863, taken sick with headache and chilliness in the evening. 11th, admitted to hospital, violently delirious, pulse 90 and feeble, countenance pale, pupils contracted, skin moist, tongue furred and moist. 12th, 9 a. m., pulse 104 and stronger, bowels well opened, skin moist, eyes natural, tongue dry in centre, headache; 6 p. m., pulse 90 and stronger; midnight, very restless and violent. 13th, pulse 85. 14th, pulse 96, very restless and violent, tongue swollen and dry, throat slightly reddened, pupils contracted; 6 p. m., pulse 100, no other change. 15th and 16th, pulse 120, feeble, mind very dull, pupils dilated. February 17th, died.

Autopsy, 18th: Sinuses of brain gorged with blood; pia mater uniformly injected; deposits of yellowish lymph over cerebrum, cerebellum, pons varolii, medulla oblongata, and around spinal cord; effusion of serum with some pus in lateral ventricles; yellowish fluid in sheath of spinal cord.

Contributed by Surgeon C. A. Cowgill, U. S. Vols., Academy Hospital, Newberne, N. C.

No. 33. A piece of the right lobe of the cerebrum on which, near the middle of the longitudinal fissure, is an opaque layer of lymph.

A. 3.

Corporal E. H. B., "C," 51st Massachusetts Militia, age 22. February 11th, 1863, taken sick early in morning and admitted to hospital in the evening; pulse 106, respiration hurried, pupils natural, tongue dryish, great headache, skin moist. 12th, 4 a. m., condition the same; 9 a. m., pulse 96, tongue furred, white in centre, with brownish streaks upon sides, face red, skin moist; 6 p. m., pulse 106, skin moist, bowels freely opened. 13th, 9 a. m., pulse 96 and strong, mind wandering, nape of neck tender; 8 p. m., pulse 90 and variable, mind very confused. 14th, 9 a. m., pulse 80, tongue dry and brown, pupils contracted, conjunctivæ injected. 15th, pulse 130, very feeble, perspiring freely, low muttering delirium; 10 p. m., died.

Autopsy: All the sinuses gorged with black blood; pia mater highly injected; one ounce of serum in lateral ventricles; deposit of lymph over entire surface of cerebrum, cerebellum, medulla oblongata and spinal cord; purulent serum in sheath of cord; thoracic and abdominal viscera healthy.

Contributed by Surgeon C. A. Cowgill, U. S. Vols., Academy Hospital, Newberne, N. C.

No. 34. Medulla oblongata and cerebellum, the upper surface of the latter covered with a thin layer of lymph.

A. 4.

Private C. V. W., "E," 115th Illinois. September 13th, 1863, was brought to hospital from camp. He complained of severe pain in the head; mind wandering; vertigo; gait staggering; pulse 120, small and quick. Last two days of life, paralysis of lower extremities. Last twenty-four hours, total paralysis. Died, September 17th.

Autopsy: Body well nourished; vessels of cerebral membranes enlarged and full of black blood; dura and pia mater thickened, and nearly opaque; as soon as the dura mater was cut, serum flowed in a stream; lateral ventricles contained two ounces of turbid serum, which also flowed from the spinal canal; vessels of cord as far as examined, which was to the seventh cervical vertebra, highly injected.

Contributed by Surgeon B. Woodward, 22d Illinois, Tallahoma, Tenn.

No. 520. Posterior portions of left cerebral hemisphere, showing part of left lateral ventricle; choroid plexus roughened by pseudo-membranes, with shreds of lymph hanging from various parts of the lining membrane of the ventricle.

A. 5.

History—(Acting Assistant Surgeon S. D. Twining): Private M. S., "E," 189th New York. November 20th, 1864, admitted from City Point, Virginia. He was restless and noisy; frequent, irregular pulse; hot, dry skin; flushed face; injected eyes; dry, coated and somewhat swollen tongue; no diarrhoea. December 1st, bowels natural. 10th, pain in head; abdominal tenderness; vomiting. 11th, pulse 135; abdominal pain and tenderness increasing; bowels constipated. 16th, breathing rapid; inclined to coma. The symptoms subsequently became worse, and the patient died, comatose, December, 20th.

Autopsy—(Acting Assistant Surgeon W. C. Miner): Body emaciated; no petechæ nor spots; face pale; surface of brain congested and coated with patches of opaque green lymph; lateral, middle and fourth ventricles filled with purulent serum and sticky pus; substance of brain not softened; posterior portion of lower lobe of right lung dark red, but mostly crepitant, with mucous-pus in the minute bronchi; posterior part of upper lobe of left lung softened, dark red, but crepitant; old adhesions of both lungs; right side of heart contained a firm white clot with thick, but fluid black blood; liver pale, with yellowish spots, extending from its surface into its substance; spleen, size of fist, firm, light reddish brown; kidneys showing fatty granular degeneration; bladder distended, filling the pelvis, and reaching to within three inches of the umbilicus; mesenteric glands enlarged; oval dark spots of a bluish tinge on mucous membrane from transverse colon to rectum.

Contributed by Acting Assistant Surgeon W. C. Miner, General Hospital, Alexandria, Va., 3d Division.

B. Dilatation of Ventricles.

No. 785. Brain, with lateral ventricles dilated to about double their normal capacity; in the fresh brain, filled with serum.

B. 1. C. G., colored, age 12. Admitted, January 24th, 1866; headache; pain in right hypochondrium; tongue furred and brown; stool loath; good appetite; bowels constipated; dull and stupid. 31st, bowels obstinately constipated; urine passed involuntarily; patient recumbent and weak, with dilated pupils; quite dull; no pain; urine and feces passed involuntarily. D. 3. March 23.

Autopsy three days after death: A well-formed dark mulatto lad; height four feet nine inches; emaciated; weight, about sixty pounds; rigor mortis well marked; membranes of brain congested; lateral ventricles distended as described; a collection of pus beneath the arachnoid over cerebellum and medulla oblongata; an abscess involving the cerebellar lobes and posterior part of medulla; surrounding parts normal; about an ounce of fluid in posterior fossæ of cranium; both lungs contained a small number of crude tubercles, their posterior portions slightly congested; one ounce of fluid in each pleural cavity; white fibrinous clots in right ventricle of heart; two ounces of serum in pericardium; spleen very small, weight one ounce, contained some tubercular deposit; kidneys much congested and fatty; bladder distended with urine.

From Freedman's Hospital, Washington, D. C.

Autopsy by Hospital Steward S. S. Bond.

No. 735. Right half of cerebnum, with lateral ventricle enormously dilated, the substance of the brain being represented by a peripheral layer about a quarter of an inch in thickness.

B. 2. C. G., colored, age 21. Admitted, December 19th, 1865, with dropsy. Died, January 20th, 1866.

Autopsy forty hours after death: Negro, height five feet four inches, weight about one hundred and forty pounds; slight rigor mortis in lower extremities, none in upper; head twenty-five inches in girth; cerebnum weighed forty-two ounces; pia mater congested; lateral ventricles greatly distended, capacity of each one pint; cerebellum weighed five ounces, very soft, membranes congested; twelve ounces of serum in posterior fossæ of cranium; upper lobe of right lung contained much crude tubercle, a depression resembling a cleatrix on its anterior surface; left lung collapsed, coated with a thick layer of lymph resembling clammy skin; right pleural cavity contained a pint of clear serum; left, three quarts of bloody serum; bronchial glands much enlarged; heart small, dark and congested; aortic and mitral valves thickened; liver reddish brown, mottled with black, and studded with tubercles; spleen contained numerous large tubercles; many tubercles in omentum; kidneys congested; deposit of black pigment near pyloric orifice of stomach; duodenal glands slightly enlarged; Peyer's patches presented the shaven-bald appearance; much pigimentary deposit in large intestine; transverse colon contracted.

From Freedman's Hospital, Washington, D. C.

Autopsy by Hospital Steward S. S. Bond.

736, *chap. III., sec. 2, G. 4, concentric-like depression on surface of lung; 737, chap. II., sec. 3, A. 4, tubercular bronchial glands; 738, chap. IV., sec. 5, D. 5, tubercles of liver; 739, chap. IV., sec. 4, E. 6, tubercles of omentum, are also from this case.*

No. 791. Cerebellum, with medulla and pons attached, coated by a layer of pus, the fourth ventricle dilated to a cavity the size of a small plum; a thin layer of pus (coagulated by the alcohol) on the pons, medulla and adjacent portions of cerebellum.

B. 3. M. J., colored, age 29. Admitted, April 11th, 1866. Intense frontal headache; pain in right side; bowels obstinately constipated; tongue coated with brown fur; breath fetid. Died, April 18th.

Autopsy thirty hours after death: A stout, well-formed negro man; height, five feet nine inches; weight, about one hundred and fifty pounds; rigor mortis well marked; brain much congested; arachnoid at the base of the brain thickened and opaque; beneath it a collection of pus; slight adhesions at apex of right lung, its posterior portion slightly congested; firm adhesions at upper part of left lung; mitral and aortic valves of heart slightly thickened; four ounces of fluid in pericardium; nutmeg liver; spleen adherent to the liver and bile; kidneys lobulated, congested and fatty; mucous membrane of duodenum and jejunum thickened and congested; album congested; pigimentary deposits in Peyer's patches; solitary follicles of large intestine elevated and coated with pigment; cranium much congested.

From Freedman's Hospital, Washington, D. C.

Autopsy by Hospital Steward S. S. Bond.

C. Cysts in the Choroid Plexus.

No. 661. Choroid plexus, the vesicles of which have dilated into cysts, several of them have attained the size of small peas.

C. 1. No. 661, p. 10.

D. New formations of bone.

No. 411. Piece of dura mater, with middle two-thirds of longitudinal sinns and falx. On the left side of the median line towards the centre of the piece, is an irregular papilionian granulation, three-fourths of an inch in diameter, the interior of which is converted into an irregular mass of true osseous tissue.

Private R. M. H., "F," 150th New York, age 41. Admitted, July 9, 1861, with chronic diarrhœa and general debility. Died, August 25th.

Contributed by Assistant Surgeon Dewitt C. Peters, Jarvis Hospital, Baltimore, Md.

No. 314. A portion of dura mater, with central part of the falx attached; a plate of true bone, two inches in length, one-fourth to three-fourths of an inch in breadth, and irregular in outline and thickness, is embedded between the two layers of the falx. At the upper portion of the specimen, the falx has been dissected away so as to expose a part of the bony plate.

No history.

Contributed by Surgeon Caleb W. Horner, U. S. Vols., Hospital No. 1, Nashville, Tenn.

No. 588. An irregular osseous plate, three-fourths of an inch long, embedded in the pia mater.

D. 3. Private J. L., "D," 90th New York, age 44. Admitted, March 11th, 1865, with fever. Died, March 18th. Contributed by Assistant Surgeon Geo. M. McGill, U. S. Army, National Hospital, Baltimore, Md.

57, *chap. I, sec. A, B, I, aneurism of the basilar artery, is also from this case.*

Section 3. PINEAL GLAND.

A. Cystic Transformation.

No. 619. Medulla oblongata, with pons, crura cerebri, and parts of cerebrum, dissected so as to expose the third and fourth ventricles and the tubercula quadrigemina. The pineal gland is converted into a cyst half an inch in diameter.

No history.

Contributed by Acting Assistant Surgeon W. C. Miner, Knight Hospital, New Haven, Conn.

Section 4. BLOODVESSELS OF ENCEPHALON.

A. Atheroma.

No. 790. Brain, the arteries about the base of which are atheromatous, with some calcareous deposits.

A. 1. M. L., colored, age 56. Admitted, February 26th, 1866, with acute rheumatism and paralysis of right side. Died, March 5th.

Autopsy eighteen hours after death: Well-formed dark mulatto man, height five feet five inches, weight one hundred and forty pounds; rigor mortis partial; œdema of legs and feet; arteries of brain as described; cerebral membranes congested; about two ounces of fluid beneath arachnoid; right lung contained much pigment, lower lobe hepatised and covered with lymph; heart large, dark, congested; a thin coating of lymph on its external surface; white fibrinous clots in all its cavities; endocardium opaque; valves somewhat thickened; extensive atheroma of aorta, extending into the iliac arteries; pericardium contained

eight ounces of fluid; liver slightly fatty; kidneys fatty, on the left a cicatrix-like depression; mucous membrane of stomach and intestine somewhat congested; slight enlargement of a few of the solitary follicles of the large intestine; bladder much distended with urine, containing twenty ounces; mucous coat somewhat thickened and congested; enlargement of prostate gland to the size of a small orange.

From Freedman's Hospital, Washington, D. C.

Autopsy by Hospital Steward S. S. Bond.

789, *chap. II, sec. 2, B, 4, atheromatous aorta*; 791, *chap. V., sec. 4, C, 1, enlarged prostate gland*; 792, *chap. V., sec. 1, A, 4, cicatrix-like depression of left kidney, are also from this case.*

B. Aneurism.

- No. 587.** Aneurismal dilatation, the size of a pen, in the left side of the basilar artery.
B. 1. *See 588, chap. I., sec. 2, D, 3, for history.*

Section 5. SPINAL CORD.

- No. 871.** Portion of spinal cord, included between the fourth and seventh dorsal vertebrae; a mass of tough, pus-like lymph coats the cord beneath the dura mater, and occupied the vertebral canal between the dura mater and the diseased bodies of the sixth and seventh dorsals. Microscopical examination failed to detect any structural lesion of the cord.

J. T., colored cook, "G," 30th U. S. Infantry, age 38. Admitted, January 4th, 1867. He stated that he had been sick for three months, and after six weeks illness began to lose the use of his limbs. When admitted there was almost entire anaesthesia of lower extremities, extending upwards almost to the nipple, and partial loss of motion. He could flex and extend the thighs to one-fourth the normal extent. 11th, severe chill, followed by symptoms of acute peritonitis, from which he sunk on the 17th.

Autopsy: Pleuritic adhesions, old and recent, on both sides; a quantity of pus, serum, and much lymph in abdominal cavity; a fluctuating tumor containing pus on anterior portion of bodies of sixth, seventh and eighth dorsal vertebrae.

Contributed by Assistant Surgeon W. Thomson, U. S. Army, Post Hospital, Washington, D. C.

792, *chap. VI., sec. 2, No. 21, tubercular caries of vertebra, is also from this case.*

Chapter II. ORGANS OF CIRCULATION.

Section 1. HEART.

	NO. OF SPECIMENS.
A. Congenital anomalies	3
B. Atrophy	1
C. Hypertrophy	2
D. Diseases of the valves	15
E. Pericarditis	11
F. Tubercle	1
G. Epithelioma	1
H. Heart clots	5

Section 2. ARTERIES AND VEINS.

A. Emboli	1
B. Atheroma	5
C. Aneurism of aorta	7
D. Aneurism of other arteries	1

Section 3. LYMPHATIC GLANDS.

A. Bronchial glands	4
B. Mesenteric glands	7
C. Peripheral glands	4

Appendix to Section 3. THYROID GLAND.

D. Bronchocele	2
----------------------	---

Chapter II. ORGANS OF CIRCULATION.

Section I. HEART.

A. Congenital Anomalies.

No. 349. Heart, the apex of which is bifurcated by a fissure an inch deep, in the line of the inter-ventricular septum.
A. 1. J. O'S., citizen. Died, January 5th, 1864, of pneumonia.

Autopsy: Hepatization of the lungs; heart as described; weight twelve ounces; contained a large, moderately firm, light yellow fibrin clot.

Contributed by Assistant Surgeon C. J. Kipp, U. S. Vols., Hospital No. 1, Nashville, Tenn.

No. 787. Heart, the apex of which is distinctly bifurcated, from a colored man who died of pleurisy, consecutive to
A. 2. Bright's disease. There was fluid in both pleural cavities; the left lung coated with lymph; kidneys fatty; weight of each six ounces.

From Freedman's Hospital, Washington, D. C.

Autopsy by Hospital Steward S. S. Bond.

No. 596. A small heart in which the foramen ovale remains open; the opening passes obliquely through the inter-auricular septum, a valve-like fold of the endocardium existing on each side, by which, undoubtedly, it was kept well closed during life.

A. 3. Private M. S., "A," 17th Wisconsin. Admitted, July 22d, 1865. He had been sick over six months with camp dysentery and was greatly emaciated. Died, August 1st.

Autopsy: Petechiæ on arms, legs and chest; old adhesions of right lung; heart small, and as above described; kidneys large and fatty; lower part of ileum darkly injected; the mucous membrane coated with whitish false membrane; colon thickened, with ulcers in the caecum and sigmoid flexure.

Contributed by Acting Assistant Surgeon W. C. Miner, Slough Hospital, Alexandria, Va.

B. Atrophy.

No. 103. A small heart which weighed five and a half ounces; from a full-sized adult.

B. 1. Private H. N., 10th Massachusetts Battery, age 33. Admitted, July 30th, 1864, laboring under chronic diarrhœa, anæmia, debility, pain in the lower extremities, and severe cough. September 1st, hectic set in. Died, September 15th.

Autopsy: Height, five feet nine inches; very much emaciated; weight, about one hundred and sixty pounds; no post mortem rigidity; body covered with fine purpuric spots; lower lobe of right lung considerably congested, and on section mucous-pus exuded from many of the small bronchial tubes; left lung adherent, on section of its lower lobe a large amount of frothy sanguinous fluid exuded, in upper lobes several carnified spots about three-quarters of an inch in diameter; heart as described; liver small and very much congested; kidneys congested; several small ulcers in rectum; at the sigmoid flexure of colon an oval ulcer measuring two and three-quarters by two inches, its long diameter being across the intestinal canal; its margin was very jagged and abrupt; the cœcum and about three feet of the lower portion of the ileum were very much congested.

Contributed by Acting Assistant Surgeon H. M. Dean, Lincoln Hospital, Washington, D. C.

C. Hypertrophy.

No. 338. Heart considerably enlarged, weighing at the time of its removal from the body seventeen and a quarter
C. 1. ounces.

Private E. G., "F," 69th New York. Admitted, June 11th, 1864, for a gunshot wound of the right ankle received at Cold Harbor, Va. Died, June 25th of pyæmia. This man was thirty-seven years of age, and weighed about one hundred and fifty-five pounds. He is not known to have had any symptoms due to the enlargement of his heart.

Contributed by Acting Assistant Surgeon H. M. Dean, Lincoln Hospital, Washington, D. C.

No. 506. Hypertrophied heart, weight twenty-four and a quarter ounces; walls of left ventricle an inch in thickness; right ventricle nearly normal; valves healthy.

C. 2.

J. G., colored woman, age 50. Admitted to L'Ouverture Hospital, March 8th, 1865, suffering from general dropsy; lower extremities enormously swollen; increased area of cardiac dullness; heart's impulse diminished; pulsations of heart's apex felt in the fifth intercostal space, four and a half or five inches to the left of the median line. Patient said she had suffered nothing in the region of the heart, until two or three weeks before her admission, with the exception of occasional difficulty of breathing, when going up stairs or taking active exercise. She also complained of pain in the lower part of the abdomen, and great pain in urinating. Subsequently to her admission she suffered nightly from paroxysms of dyspnoea, unaccompanied at times by syncope. She complained frequently of a distressing sense of constriction in the precordial region. Died, March 21st.

Autopsy: Pericardium contained five ounces of serum; heart as above described; about six drachms of well-washed fibrin were intimately interwoven with the columnar carneæ about the apex of the left ventricle; about a pint of serum in each pleural cavity; both lungs congested, the left more so than the right; abdominal cavity contained about four pints of serum; left kidney was congested and softened; fibrous tumors of uterus.

Contributed by Surgeon E. Bentley, F. S. Vols., General Hospitals, Alexandria, Va.

507, chap. V., sec. 5, B. 3, *fibrous tumors of uterus, is also from this case.*

D. Diseases of the Valves.

No. 810. Aortic valves, slightly cribriform at their edges.

D. 1.

E. S., citizen, born in Switzerland, age 29. Admitted, February 6th, 1866; had been sick three weeks; was emaciated; thin, yellowish stools tinged with blood; some tormina. Died, March 15th.

Autopsy: Middle stature, fair skin, light hair, emaciated; cavity of thorax dry; heart contained a small black clot; no fluid blood found in the body; aortic valves sieve-like near their upper border; spleen slightly enlarged; gall bladder small, contained half an ounce of thick bile; stomach pale; it and the jejunum contained six ounces of light green fluid; mucous membrane of ileum much congested and of a bright red color, with enlargement of its solitary follicles and slight thickening of Peyer's patches; an ulcerated patch, an inch long and half an inch wide, near the cæcum; also a few soft patches; mucous membrane of large intestine congested throughout, of a dark red color and much thickened, especially in the rectum; there were small ulcerated patches two inches from the anus, and follicular ulcers throughout; mesenteric glands enlarged.

Contributed by Assistant Surgeon Ira Perry, 9th U. S. Colored, Post Hospital, Brownsville, Texas.

537, chap. IV., sec. 3, I. 24, *enlarged solitary follicles of ileum*; 539, chap. IV., sec. 3, I. 25, *small follicular ulcers of colon, arc from this case.*

No. 812. Aortic valves slightly cribriform at their edges.

D. 2.

Private J. G., "B," 9th U. S. Colored. Admitted, July 22d, 1865. Diagnosis—dysentery. Transferred to my ward, August 19th. Stated he had been attacked about the first of the month, while on duty with his regiment. Since entering hospital, had been in a tent, lying in his blanket on the ground. Present condition: very weak, thin; gums dark red, ulcerated and spongy; teeth loose; legs œdematous; disphagia; appetite poor; no dysentery at present, 20th, doing well, walks about, but legs œdematous, and some ulcers linger on gums and cheeks. 25th, patient apparently gaining; good appetite and spirits; mouth nearly well; was transferred to another ward. Subsequent history not known. Died, September 13th.

Autopsy: Cadaver slender; some emaciation; some œdema of legs; right cavity of thorax contained two pints of bloody serum; lower lobe of right lung hepatised, portions sink in water; pericardium contained four ounces of clear serum; heart thick, aortic valves attenuated and cribriform on the edges; liver tough; gall bladder full of healthy bile; kidneys fatty; bowels pale, otherwise normal; mesentery thickened, covered with a layer of yellowish lymph, about an ounce of which fluid I with two ounces of serum in the pelvic cavity.

Contributed by Assistant Surgeon Ira Perry, 9th U. S. Colored, Post Hospital, Brownsville, Texas.

No. 52. Tricuspid valves, with some of the surrounding heart tissue attached. The valves present irregular masses of cancerous matter.

D. 3.

Private J. L., Furnell Legion. Died, October 17th 1862, having suffered for about twenty hours with violent palpitation of the heart.

Autopsy: Heart hypertrophied and dilated; a large quantity of adipose tissue on its surface; tricuspid valve as described; considerable quantity of fibrin in right ventricle.

Contributed by Acting Assistant Surgeon G. W. Fry, Patterson Park Hospital, Baltimore, Md.

No. 579. Portion of heart, showing thickened and tendinous transformation of mitral valves.

D. 4.

Private H. L., "F," 52d New York, age 22, born in Germany. Admitted, February 10th, 1865. General appearance good, but complains of being unable to lie down from a feeling of suffocation; area of cardiac dullness more extensive; urine was albuminous, and loaded with urates; slight œdema of lower extremities. The œdema of lower extremities increased and in March became general. On the 23d of March, a tendency to sloughing made its appearance on

the dorsum of the foot, and subsequently involved other portions of the lower extremities. The patient now became delirious, jaundice set in, and he died on the 3d of April.

Autopsy: Right ventricle considerably dilated; mitral valve as described; spleen hard and large; general anasarca, with ascites, but no dropsy of the pericardium.

Contributed by Acting Assistant Surgeon E. R. Fell, Mower Hospital, Philadelphia, Pa.

- No. 461.** Portion of heart, dissected to show the mitral and aortic valves which are roughened by fibrinous vegetations.
D. 5. Private C. W., "D," 8th New York Heavy Artillery, age 20. Admitted, August 25th, 1864, with gunshot wound of head. Died, December 24th, from the consequences of the wound. No heart symptoms recorded.

Contributed by Acting Assistant Surgeon H. M. Dean, Lincoln Hospital, Washington, D. C.

- No. 599.** Heart, with bulky fibrinous deposits in mitral valves; calcareous transformation of aortic valves; left auricle and right ventricle greatly dilated, with thin walls; left ventricle with somewhat thickened walls.

D. 6. Sergeant W. H., "C," 12th Pennsylvania Cavalry. Discharged the service at Harper's Ferry, Va., but stopped in Baltimore, and died in a private house, July 7th, 1865. Was brought to hospital for burial.

Autopsy: Legs and feet oedematous; right iliac region and posterior parts of body presenting dark blue discolorations; face yellow; heart as described; it contained about eleven ounces of blood and clots; some effusion in pericardium; liver much enlarged; kidneys fatty and granular.

Contributed by Assistant Surgeon De Witt C. Peters, U. S. Army, Jarvis Hospital, Baltimore, Md.

- No. 327.** A small portion of aorta, with semi-lunar valves and a part of the inter-ventricular septum; the semi-lunar valves present small calcareous concretions; the aorta atheromatous.

D. 7. K., a contract nurse. Died during the winter of 1863-'4.

No history.

Contributed by Acting Assistant Surgeon E. Storrer, Satterlee Hospital, Philadelphia, Pa.

- No. 472.** Portion of heart, showing aortic valves, ulcerated and beset with fibrinous deposits; left ventricle greatly thickened.

D. 8. Private E. M. D., 5th Massachusetts Battery, age 20, medium stature. Admitted, October 5th, 1864; had a short time previously suffered from articular rheumatism; was anemic; tongue furred; pulse rapid and irregular; a peculiar turgescence of the face and look of anxiety; anasarca; dyspnoea and rapid tumultuous action of the heart; more comfortable sitting than reclining. 7th, dyspnoea greatly increased; imperfect vision; roaring in ears; lips livid; p. m., died.

Autopsy: Body not emaciated; face livid; right lung bound to walls of chest anteriorly by pleuritic adhesions; both lungs greatly congested; right pleural cavity contained a small quantity of fluid; two ounces of fluid in pericardium; heart greatly dilated, but no marked thickening of its walls; its right side and the great veins filled with venous blood; the left side of the heart also filled with dark-colored blood, and large flakes of fibrin were entangled among the muscular columns; small firm excrescences adherent to the edge of the mitral valve, and very large ones on the aortic valves; endocardium appeared red and injected; nutmeg liver; spleen bound down in left hypochondrium by recent adhesions.

Contributed by Acting Assistant Surgeon O. P. Sweet, Carver Hospital, Washington, D. C.

- No. 518.** Part of aorta and left ventricle, dissected so as to show the aortic valves, which are beset with fibroid vegetations in which calcareous masses are embedded; the heart, as received at the Museum, was enlarged; the walls of left ventricle, thickened.

History—(Acting Assistant Surgeon H. Lowenthal): 1st Lieutenant I. F., "H," 143d Pennsylvania. Admitted, February 2d, 1865, with pneumonia. He was anxious; excited; pulse 80; appetite poor; bowels regular; there was acute pain in the left side; had palpitations of the heart for some time previously; slight crepitant rale on both sides; the sounds of the heart weak, but clearly audible; the second sound followed by a murmur which lasted through the pause; the area of cardiac dulness somewhat increased. 13th, respiration difficult; sleeplessness; pains over the heart; no appetite; pulse 80, but weak. 14th, dyspnoea increased; at 9 a. m., great dyspnoea and prostration; died at 10 a. m.

Contributed by Surgeon W. L. Faxon, 32d Massachusetts, Depot field hospital, City Point, Va.

- No. 310.** Heart, with left ventricle laid open to show the aortic valves which are the seat of small calcareous deposits, that also involve the adjacent parts of the aorta.

D. 10. No history.

Contributed by Surgeon C. W. Horner, U. S. Vols., Hospital No. 1, Nashville, Tenn.

311 and 312, chap. II, sec. 2, B. 2 and 3, atheromatous aorta, are also from this case.

- No. 336.** Heart with the left ventricle laid open so as to expose the aortic valves, which are somewhat thickened, roughened, one of them with a considerable quantity of adherent fibrin.

D. 11. Sergeant W. L. B., "H," 3d Pennsylvania Artillery. Admitted, January 22d, 1864, with intermittent fever; had subsequently pleuro-pneumonia. Died, March 6th.

Autopsy: Both lungs in the third stage of pneumonia; pleuritic adhesions on both sides; effusion into the left pleura; four ounces of fluid in pericardium; the aortic valves as described; liver enlarged; spleen large and soft; left kidney much larger than right.

Contributed by Acting Assistant Surgeon B. B. Miles, Jarvis Hospital, Baltimore, Md.

No. 316. Heart somewhat hypertrophied, with the left ventricle laid open so as to exhibit the aortic valves, partly destroyed by an ulceration, which extends deeply into the substance of the heart just below one of the valves. A probe introduced into this ulcer, passes readily into the right auricle. The right auricle and ventricle are laid open, and the fistulous orifice is readily seen in the auricle, just above the auriculo-ventricular valve.

Private J. A. B., "11," 8th Ohio, age 22. Admitted, May 10th, 1863, for serofulous ophthalmia, with enlargement of cervical glands. Died, suddenly, August 5th.

Contributed by Assistant Surgeon C. J. Kipp, U. S. Vols., Hospital No. 1, Nashville, Tenn.

No. 716. A portion of aorta, with semi-lunar valves and part of left ventricle. The aorta atheromatous; beneath one of the valves, an ulcer, which involves the edge of the valve.

W. L., age 54. Admitted, January 5th, 1866. Diagnosis—typhoid fever. Died, January 17th.

Autopsy: Heart large, with abundant adipose tissue, weighed fifteen ounces; the walls of left ventricle one and a quarter inches thick; aortic valves as described; white clots in all the cavities; pericardium contained two ounces of fluid; both lungs adherent; left lung contained tubercles, some of them cretified, and a cavity the size of a pigeon's egg; liver and spleen large; left kidney lobulated; some congestion of small intestine, and several invaginations; solitary follicles of cecum and colon slightly enlarged.

From Freedman's Hospital, Washington, D. C.

Autopsy by Hospital Steward S. S. Bond.

No. 801. Heart cavities laid open, showing ulceration of aortic valves hypertrophy and dilatation of the left ventricle.

D. 14. History—(Acting Assistant Surgeon L. Heard); H. R., colored, age 28. Admitted to L'Overture Hospital, Alexandria, Va., December 29th, 1865, with articular rheumatism affecting the knees, elbows, and wrists.

Subsequently, symptoms of heart disease set in; patient became dropsical, and died April —, 1866.

Autopsy: A large colored man; height, six feet; weight, about one hundred and eighty pounds; red hepatization of the lower part of left lung; pericardium contained twenty-three ounces of fluid; heart and pericardium weighed fifty-two ounces; weight of heart, after removing the pericardium and clots, thirty-five and a half ounces; liver fatty, somewhat cirrhotic; right kidney, eight ounces, had a cicatrix-like depression on its outer edge; left kidney lobulated; oedema of face and limbs; effusion into abdominal cavity.

Contributed by Surgeon E. Bentley, U. S. Vols.

—92, chap. V., sec. 1, A. 5, *cicatrix-like depression on kidney and lobulated kidney, is also in this case.*

No. 212. Heart laid open so as to exhibit the aortic valves, which are the seat of calcareous deposits. The surface

D. 15. of heart and pericardium roughened by lymph.

No history.

Contributed by Assistant Surgeon C. A. McCull, U. S. Army, Mount Pleasant Hospital, Washington, D. C.

E. Pericarditis.

No. 511. Heart, with an opaque, thickened patch of irregular form, about two lines in thickness and about an inch in diameter on the anterior surface of its right ventricle.

E. 1. History—(Acting Assistant Surgeon S. D. Twining); G. W. V., Recruit, 16th U. S. Colored. Admitted,

April 5th, 1865, from Camp Casey; had been sick for some time, suffered from rheumatic pain in limbs, hips and back; tenderness over the cervical vertebrae, and acute pains in moving the head; a tumor between the fifth and sixth costal cartilages, which appeared to pulsate; in the region of this tumor, and extending to the precordial region, more or less pain, increased by pressure and deep inspiration; patient lay quietly on his back, indisposed to move; pulse natural—tongue furred; breathing quiet; appetite fair; slept poorly. 10th, a slight chill; has been feverish for two days; pulse 90 and small. 27th, pain in neck and back of head; tenderness on pressure along the whole length of the spine; head drawn forward and to the left side, the least motion causing pain. May 4th, pulse 110, strong; breathing labored; inspiration slow and slightly stertorous; expiration explosive; tongue more thickly coated; speaks with difficulty and in a whisper; pain in chest, back, neck, and back part of head; acute pain on percussion over chest and on pressure over the tumor. 8th, patient lies quiet; breathes quietly; eyes wide open; takes food when given slowly; has to be aroused to answer questions; shows his tongue readily; pulse 100 and strong; p. m., pulse 120, hard and resisting. 9th, pulse 120, softer; speaks with difficulty and in a whisper; is in a harrassed state at night. 10th, pulse 80, small; swallows with difficulty; will not show his tongue; p. m., pulse 100, small; cannot be aroused; died at 8:30 p. m.

Autopsy thirty-eight hours after death: A small man, quite emaciated; no rigor; a small tumor between the fifth and sixth costal cartilages of right side, extending laterally from the median line, about two and a half inches more on the sixth cartilage than on the fifth, some effusion about the base of the brain with thickening of pia mater between crura cerebri and over pons varolii; tubercular deposit extending over internal surface of basilar process of occipital bone and the declivity of the sphenoid; aneurismal infarcted nodule; ventricles distended with rather dark serum, in which floated some flakes of yellow lymph; superior and external surfaces of lateral ventricles, including descending cornu, lined irregularly with yellow lymph; near the central tendon of the oval-forix was a large cheesy lymphatic gland of the size of a flattened lemon; anterior surface of the third, fourth and fifth cervical vertebrae carious and involved in a large tubercular abscess under the longus colli; a

mass of softened tubercle lay on the right arches of the second and third cervical vertebrae; the bones carious on both sides; another mass of softened tubercle, included the odontoid process with the bodies of the first and second vertebrae, and, reaching upwards, joined the deposit on the basilar process of the occipital bone; a puruloid deposit of softened tubercle of the size of a walnut lay at the junction of the fourth left rib with its cartilage and reached down through the intercostal space to the rib below; the upper and internal portion of this was softened and the fourth rib was separated from its cartilage; a somewhat similar mass lay on the right side, also extending through to the pleural surface; it was half an inch from the median line, between the fifth and sixth costal cartilages, filling the entire intercostal space, and reaching outward two and a half inches; (this was the tumor that had appeared to pulsate;) old adhesions around base of right lung, dirty yellow tubercular deposits in its middle lobe; left pleural cavity contained some dark serum, left lung externally coated with lymph, internally crepitant; a line of softened tubercular deposits extended along both sides of the vertebrae in the thorax, especially on the right, behind and within the ganglia of the sympathetic nerve; some of the vertebrae carious, with ribs loosened; pericardium contained some clear serum; heart contracted and small, on the anterior face of the right ventricle a square white patch; liver soft, of a dirty yellowish brown, with hard white tubercles; kidneys pale, left one with a white cheesy deposit, size of a chestnut; spleen softened; of a peculiar yellow or amber color, on section a few spots of yellow deposit; in median line of sternum, a soft tubercular abscess; extensive tubercular deposit in prostate and vesiculae seminales.

Contributed by Acting Assistant Surgeon W. C. Miner, L'Ouverture Hospital, Alexandria, Va.

543, *chap. V., sec. 4, C. 4, tubercular prostate*; 540, *chap. VI., sec. 2, No. 5, tubercular caries of cervical vertebrae, cheesy masses involving base of brain*; 541, *chap. VI., sec. 2, No. 6, tubercular caries of bony bridges of cervical vertebrae*; 542, *chap. VI., sec. 2, No. 7, tubercular caries of sternum and ribs, are also from this case.*

No. 51. Heart, coated with an irregular layer of lymph.

E. 2. Private O. L. S., "A," 36th New York. Admitted, October 29th, 1862. Had acute rheumatism, implicating the heart, several months previously. Has now great dyspnoea, præcordial pain, palpitation of heart, headache, vertigo, cough, œdema of eye-lids, feet and hands, enormous distension of abdomen, area of cardiac dullness increased. Died, November 9th.

Autopsy: General œdema; pericardium lined by a layer of lymph and greatly distended with serum in which particles of lymph floated; heart as described; lungs congested.

Contributed by Surgeon E. Bentley, U. S. Vols., General Hospital, Alexandria, Va., Third Division.

No. 68. Heart and pericardium, coated with an irregular layer of lymph.

E. 3. Corporal W. H., "E," 5th Pennsylvania Reserves. Admitted, July 1st, 1862, with a gunshot wound, for which the right arm was removed at the shoulder joint. Died, October 4th.

Autopsy: No emaciation; œdema of the lower extremities; adhesions at the upper and back part of right lung; the lower part of the lung, together with the corresponding costal pleura and the diaphragm, covered with a thick layer of croupous lymph; the lung almost entirely collapsed; the heart pushed over to the left of the median line; the pleural cavity contained a quart or more of thick pus; left lung with recent pleuritic adhesions, and the pleural cavity containing over a pint of clear serum; tissue of the lungs healthy; pericardium, containing about six ounces of liquid, partially adherent to the surface of the heart, which was roughened with pseudo-membranous lymph; incipient cirrhosis of the liver; the left external iliac and femoral veins distended with a fibrinous clot, closely adherent to the walls of the veins, and apparently undergoing degradation in several places into granular puruloid matter.

Contributed by Acting Assistant Surgeon Joseph Leidy, Satterlee Hospital, Philadelphia, Pa.

No. 67. Heart, the outer surface of which is covered with a thick irregular layer of lymph.

E. 4. No history.
Contributed by Surgeon J. W. Bloom, 7th Michigan.

No. 211. Heart and pericardium, pericardium slit up anteriorly and considerably thickened; its inner surface and the

E. 5. outer surface of the heart, coated with an irregular, roughened layer of croupous lymph.

No history.

Contributor unknown.

No. 214. Heart, coated with an irregular layer of lymph.

E. 6. Sergeant W. P. T., "H," 1st Connecticut Cavalry, age 21. Admitted, December 2d, 1863, suffering from diphtheria; was convalescing, when acute rheumatism set in with swelling of the knees and elbows. Had attacks of rheumatism frequently before. He was convalescing and had been sitting up a week, when, on December 22d, he suddenly complained of a sharp, cutting pain in the hypogastric region; pain in the region of the heart. He died half an hour afterwards.

Autopsy: Heart as described; pericardium distended with serum.

Contributed by Acting Assistant Surgeon B. B. Miles, Jarvis Hospital, Baltimore, Md.

No. 332. Heart and pericardium, the latter slit open; the opposing surfaces plastered with pseudo-membranous lymph.

E. 7. Private J. N. P., "E," 124th New York. Had chronic rheumatism since December, 1862. Admitted, June 18th, 1863, with slight rheumatic pains in limbs. 23d, was attacked with pleuro-pneumonia, with pericarditis. Died, July 1st.

Autopsy: Right lung adherent firmly, lower part hepaticized, coated with thick pseudo-membrane; a large quantity of serum was in the thoracic cavity; lower part of left lung also hepaticized; heart as described; the lymph was of a greyish white color, and in some places of a pulpy consistence; it was readily peeled off.

Contributed by Acting Assistant Surgeon G. B. Boyd, Mower Hospital, Philadelphia, Pa.

No. 317. Heart and pericardium, coated with pseudo-membranous lymph.

E. 8. C. C. S., 1st Maine Artillery, age 17. Admitted, January 26th, 1861, with severe bronchitis consecutive to measles. He did well and was beginning to sit up, when pneumonia set in accompanied by pericarditis. Died,

March 23.

Autopsy: Pericardium contained sixteen ounces of liquid, and was lined with pseudo-membranous lymph, which also coated the heart in irregular masses; lower portions of both lungs hepaticized; considerable enlargement of the mesenteric glands.

Contributed by Surgeon E. Bentley, U. S. Vols., General Hospital, Alexandria, Va., Third Division.

No. 111. Heart, coated with pseudo-membranous lymph.

E. 9. Private D. P., "E," 141th New York, age 22. Admitted, August 27th, 1861, laboring under typhoid pneumonia, which had commenced on the 5th. He improved under treatment and was recovering appetite and spirits, when, on the afternoon of the 11th, he was seized suddenly with violent pain in the right side, retching, oppressed respiration and feeble pulse. Died, on the morning of the 13th.

Autopsy: Solidification of the left lung, except at its upper portion; the pleural cavity contained two quarts of pus; right lung congested, coated with lymph; the pleural cavity containing ten ounces of serum; pericardium distended with a seropurulent fluid, lined with tough lymph, with which the heart was also coated; liver considerably enlarged.

Contributed by Assistant Surgeon C. Bacon, jr., U. S. Army, Annapolis Junction Hospital, Md.

No. 655. Heart, coated on the external surface with large quantities of tough lymph; the tissues around the base of the heart consolidated into a solid mass.

Private H. W. T., "H," 30th Connecticut (Colored). Admitted, April 27th, 1863, much debilitated; complained of pain in the left side, extending to the left shoulder, and down the left arm; sleeps badly, dreams and starts. Died, August 24th.

Contributed by Acting Assistant Surgeon L. D. Wilcoxson, Knight Hospital, New Haven, Conn.

No. 151. Heart, the pericardium of which is everywhere completely adherent to the surface of the organ.

E. 11 Sergeant P. T. B., "M," 1st Michigan Cavalry. Admitted, October 22th, 1861, with pleurisy. Died, November 23d.

Autopsy: Right lung completely adherent, with thick layers of lymph inclosing, in places, small quantities of fluid; left lung coated with fibrous deposit, and partly compressed against the mediastinum by a large quantity of pale reddish liquid; heart completely adherent to pericardium; nigger liver; spleen enlarged.

Contributed by Acting Assistant Surgeon W. C. Miner, General Hospital, Alexandria, Va., Third Division.

F. Tubercle.

No. 662. Heart, on the surface of which, are numerous tubercles about the size of peas. The heart was firmly

F. 1. adherent to pericardium; the tubercles are connected with the cardiac layer of the pericardium, and do not involve the muscular substance of the heart.

D. Q., colored, age 26. Admitted to L'Ouverture Hospital, Alexandria, Va., May 19th, 1865, convalescent from measles. Died, November 14th.

Autopsy: Oil and extensive adhesions of the right lung; left lung coated with lymph, as was also the diaphragm; both lungs filled with yellow tubercle; heart as described; spleen filled with large tubercles; other organs normal.

Contributed by Surgeon E. Bentley, U. S. Vols., Slough Hospital, Alexandria, Va.

663, chap. IV., see 7, G. 9, tubercles of spleen, is also from this case.

G. Epithelioma.

No. 711. Heart, with a tumor the size of a pigeon's egg in the wall of the right ventricle. Microscopical examination

G. 1 showed the tumor to consist of large flat cells, closely resembling oval epithelium, but slightly smaller in size, and with longer nuclei; concentric epithelial bodies, similar to those so frequently observed in epithelioma,

see 7, G. 1.

S. H., colored, age 49. Admitted, November, 16th, 1865, with syphilis. Died, January 25th, 1866.

Autopsy: eighteen hours after death: A well-formed dark mulatto man; height, five feet six inches; weight, about one hundred and thirty pounds; rigor mortis well marked; some emaciation; phymosis; scrotum and penis oedematous; suppurating buboes

in the groins; firm pleuritic adhesions at all points on right side; slight on left side; heart weighed eleven ounces, flabby, with an abundance of adipose tissue on its surface; all the valves slightly thickened; anterior wall of right ventricle contained the tumor described; pericardium contained eight ounces of clear serum; nutmeg liver; kidneys fatty; Peyer's patches presented the shaven-beard appearance.

From Freedman's Hospital, Washington, D. C.

Autopsy by Hospital Steward S. S. Bond.

740, chap. V., sec. 4, A. 1, *phymosis and buboes, is also from this case.*

H. Heart clots.

No. 311. Heart, the several cavities of which contain large clots of well-washed fibrin. (Death polypi.)

H. 1. No history.

No. 199. Heart, laid open to expose its cavities; a tough fibrinous coagulum in the right auricle and ventricle, extending into the pulmonary artery. The end extremity of the clot in the artery shows the fibrin to be arranged in concentric layers; the left ventricle also contains a white coagulum.

Private J. W., "H," 22d Veteran Reserves, age 46. Died suddenly at Camp Randall, Madison, Wis. The heart was found enlarged and slightly fatty, with the clots above described, but no other morbid condition was observed.

Contributed by Surgeon Howard Culbertson, U. S. Vols., Harvey Hospital, Madison, Wis.

No. 638. A heart, containing fibrinous clots in all its cavities; the clots of left ventricle extended into the aorta and are long and ramifying; those of the pulmonary artery similar, but not so long.

History—(Acting Assistant Surgeon T. H. Bishop): Private W. K., "M," 1st Connecticut Cavalry, age 50. Admitted, July 20th, 1865, by transfer from Readville, Mass., laboring under consumption, with paralysis of the lower extremities. Died, September 24th.

Autopsy: Moderate emaciation; much pigment in lungs; in apex of left, a large cavity filled with pus; tubercles and small cavities throughout the lungs; heart soft and fatty; its cavities filled with fibrinous clots, which ramified into all the arteries, and extended as high as the brain; on removing the heart, they were drawn out of the vessels like pieces of tape; some serum in pericardium; liver soft, yellow and fatty; kidneys small and fatty; brain soft; some effusion of serum in the ventricles; arachnoid somewhat opaque.

Contributed by Surgeon P. A. Jewett, U. S. Vols., Knight Hospital, New Haven, Conn.

No. 783. Heart, which presents in the left ventricle, entangled among the columnæ carneæ, a number of rounded cysts, which, when fresh, were of a yellowish color, and contained in the interior a fluid resembling pus; microscopical examination showed that the cyst wall consisted of coagulated fibrin, and was not organically connected with the endocardium; the fluid in the interior of the cysts contained granules, and decomposing red and white corpuscles, especially the latter; one similar cyst was found in the right ventricle.

J. A., colored, age 50. Admitted, April 1st, 1866. Had syphilis of over a year's standing; penis gangrenous; general anasarca; constant cough; profuse rusty expectoration; valvular murmurs of a sawing or rasping character heard very distinctly; great general debility; no appetite; urine albuminous, and normal in quantity. Died, April 8th.

Autopsy thirty hours after death: A well-formed dark mulatto man; height, five feet eight inches; weight, about one hundred and thirty pounds; rigor mortis well marked; no emaciation; anasarca of lower extremities; buboes in both groins; penis partly destroyed; six ounces of serum in posterior fossæ of cranium; lower lobe of right lung partially hepatized; upper lobes œdematous; two ounces of fluid in right pleural cavity; left lung, collapsed, contained patches of hepatization; six ounces of fluid in left pleural cavity; pericardium contained twenty ounces of serum; heart large, fatty, its surface coated with crumpled lymph; no clots; left ventricle contained the cysts described; nutmeg liver; kidneys fatty; an old peritoneal adhesion involved a portion of the ileum.

From Freedman's Hospital, Washington, D. C.

Autopsy by Hospital Steward S. S. Bond.

754, chap. IV., sec. 4, C. 1 *old adhesions of ileum, is also from this case.*

No. 852. Heart, in the left ventricle of which, attached to the inter-ventricular septum, was a mass of fibrin, the size of a hen's egg, which had softened in the centre into a pus-like fluid; a portion of the walls of this abscess-like cavity, attached to the endocardium, still remains in situ.

D. P. O., age 51, native of Somersetshire, England, citizen employe. Admitted, September 4th, 1866, suffering from dry gangrene of the first, second, and third toes of the left foot, accompanied by severe pain, on pressure, in left popliteal space and along calf of leg. There was considerable œdema of both legs; respiration somewhat hurried and labored; heart sounds weakened, but otherwise normal. The patient did not complain of pain about the region of his heart at any time during his illness. The attack began two weeks previous to his admission with pain and numbness of the left foot and leg. The gangrenous slough slowly separated at the metatarso-phalangeal articulation, but the ulcer showed no disposition to cicatrize; on the contrary, the œdema began to creep slowly up the thigh, and general anasarca resulted. The heart sounds continued regular, but gradually grew weaker; the lips were purplish and the extremities congested; the patient became partially comatose, and died, October 4th.

Autopsy: Bloodvessels of brain generally congested; slight serous effusion in subarachnoid sac over the superior surfaces of the hemispheres; each pleural sac contained about one and a half pints of straw-colored serum; the lower lobes of both lungs and isolated spots in their upper lobes, were consolidated and of a dark purplish color; these portions sank in water; heart hypertrophied and as described; the endocardium in the neighborhood of cyst was ecdymosed to some extent; the pericardium healthy, and its sac contained no fluid; calcareous degeneration of the left coronary arteries; slight calcareous deposit at the base of one of the leaflets of the aortic valve; slight atheromatous deposits on the walls of the ascending aorta; both sides of heart were filled with black clots, and the organ, including clots, weighed twenty-four and a half ounces; liver congested, otherwise normal; the gall bladder contained eight gall stones, varying in size from that of a pea to that of a small marble; one of these was found covered with mucus embedded in the cystic duct; spleen small; left kidney contained two small cysts, filled with a jelly-like substance of a urinous order; the veins throughout the body were distended with blood; the lower portion of the left femoral, the left popliteal, and a part of the left posterior tibial arteries were completely occluded by emboli; the coats of these arteries, as well as those of the system generally, contained calcareous deposits, in some cases to a very marked extent.

Contributed by Assistant Surgeon H. McElderry, U. S. Army, West Point, New York.

553, chap. II., sec. 2, A, 1, *emboli in left popliteal artery and vein*; 8534, chap. IV., sec. 5, I, 6, *biliary calculi, are also from this case.*

Section 2. ARTERIES.

A. Emboli.

- No. 853.** Left popliteal artery and vein, occluded by emboli.
A. 1. See 852, chap. II., sec. 1, H, 5, *for history.*

B. Atheroma.

- No. 789.** Atheromatous aorta, with some calcareous deposit near the iliac bifurcation.
B. 1. See 790, chap. I., sec. 3, A, 1, *for history.*
- No. 311.** Arch and a part of the descending aorta; numerous atheromatous patches and calcareous deposits in many places.
B. 2.
- No. 312.** The remainder of the descending aorta and a part of the common iliaes of the same patient. The disease has advanced to a higher degree in this portion. To many of the roughened patches fibrinous clots, derived from the blood, adhere.
B. 3. See 310, chap. II., sec. 1, D, 10, *for history.*
- No. 392.** Arch of aorta in an advanced stage of atheromatous disease, with calcareous plates, from the body of a large, muscular, and active man, who died suddenly from an attack of acute laryngitis. All the arteries were carefully examined, but the only part found diseased, except the arch of the aorta, was a small portion of the right anterior tibial.
B. 4.
- Contributed by Surgeon B. B. Breed, U. S. Vols., Gratiot Street Prison Hospital, St. Louis, Mo.
- No. 722.** Lower portion of abdominal aorta, with iliaes attached, showing a number of patches of calcareous atheroma.
B. 5. L. W., a dark mulatto man, very old. Admitted, January 13th, 1866. Died, January 21th. Diagnosis—old age and diarrhoea.

Autopsy: Pericardium firmly adherent to heart; aortic and mitral valves atheromatous; aorta and its branches with atheromatous patches; liver lobulated, with a cyst containing a clot of blood on the anterior edge near the gall bladder; mucous membrane of intestines congested.

From Freedman's Hospital, Washington, D. C.

Autopsy by Hospital Steward S. S. Bond.

723, chap. IV., sec. 5, A, 2, *lobulated liver, is also from this case.*

C. Aneurism of the aorta.

No. 516. Heart, with a small aneurism of the aorta just above the semilunar valves; the sac has burst, and the blood struck its way between the middle and outer coats posteriorly to a point just above the left auricle, being prevented from communicating with the inside of the pericardium by adhesions of the latter membrane to the heart, and by large deposits of effused lymph; the lymph, being soft in texture, was torn when the pericardium was stripped off, thus making a communication between the sac of the aneurism and the outside of the heart; the sac would have contained about two ounces of fluid; the pericardium was firmly attached to nearly the whole surface of the heart and had to be torn off; mitral valves somewhat thickened and rough; aortic valves large but healthy; aorta slightly atheromatous; pulmonary and tricuspid valves healthy.

History—(Acting Assistant Surgeon David L. Haight): Private J. Z., "L," 98th Pennsylvania Veterans, age 54. Admitted, December 16th, 1864, suffering from chronic diarrhoea of one month's standing, and some cough. His diarrhoea yielded to treatment, and he was furloughed, returning about April 1st, 1865. At that time he stated that his diarrhoea was quite well, but that he suffered much pain in the region of the heart, running back to the angle of the scapula. He was somewhat short of breath and anæmic, with a dry, hacking cough; the action of the heart very strong and rapid, and a murmur was distinctly heard with its first sound. He stated that he had suffered from trouble in the region of the heart for two years, during which time, however, he had been able to do and had done duty in the field, carrying his knapsack. He re-enlisted as a veteran a short time before his admission. He continued to suffer pain in the region of the heart; had a short, dry cough, and some dyspnoea, but was up and about the ward every day, and able to go up and down stairs. On the morning of May 9th, he was suddenly seized with a sort of spasm; his breathing became labored and spasmodic, and the action of the heart intermittent; this lasted for about half an hour, when he quietly expired.

Autopsy: Heart as described; the apices of both lungs contained calcareous deposits and other indications of obsolete tubercle; colon, with somewhat enlarged solitary follicles, presenting an areola and central spot of black pigment.

Contributed by Assistant Surgeon W. F. Norris, U. S. Army, Douglas Hospital, Washington, D. C.
547, chap. IV., sec. 3, L. 2, enlarged solitary follicles of colon, is also from this case.

No. 558. Small aneurism of the aorta, just above the semilunar valves; the sac has ulcerated through into the pulmonary artery and the pericardium; probes are passed through the orifices.

Private W. C., "A," 1st Maryland Veterans, age 22. Occupation, prior to enlistment, seaman. Was in apparently good health, and doing guard duty, when he suddenly fell insensible, and expired in a few minutes.

Autopsy: Great venous congestion in brain and lungs, with distension of the large venous trunks of the neck; pericardium distended with blood, escaped from the ruptured aneurism.

Contributed by Assistant Surgeon A. Ansell, 1st Maryland Veterans, Arlington, Va.

No. 502. A dried preparation, showing the heart and the aorta to its bifurcation. There are two aneurismal dilatations, one in the arch about the size of an orange, the other of larger size in the abdominal aorta; the first involves the great vessels of the neck. The coeliac axis, superior and inferior mesenteric and renal arteries, are given off from the second.

Private C. W., "G," 1st Missouri Artillery, age 32. Admitted, October 27th, 1863. He had not been able to do duty for four or five months; first had what was thought to be rheumatism, for which he was sent to hospital at Nashville, Tenn., and thence to Louisville. On admission he complained of severe pain in the epigastric region, with a constant throbbing and beating sensation there. Immediately below the ensiform cartilage was a pulsating tumor of an oval form, less in size than a hen's egg. On auscultation, a bellows murmur was heard over the tumor. A soft bellows murmur was also heard over the apex of the heart, growing louder towards the base over the root of the left lung. There was bronchial respiration with pectoriloquy at a limited spot underneath the clavicle. He had some cough. November 15th, the pain in the region of the tumor still continues very severe; he has also pain in the back immediately posterior to the tumor, and is compelled to remain constantly in a recumbent position; feels easiest when lying with his head bent down between his knees; bowels costive. He remained in this condition until December 6th, when he was suddenly seized with severe convulsions, accompanied by total loss of consciousness. The convulsions continued until his death, December 7th.

Autopsy: A cavity in the apex of left lung, which also contained a number of tubercles; old pleuritic adhesions; aorta as described; the bodies of the last dorsal and first lumbar vertebrae were extensively eroded by the pressure of the tumor.

Contributed by Surgeon A. T. Watson, U. S. Vols., Clay Hospital, Louisville, Ky.

No. 515. Aneurism of the abdominal aorta. Death took place by rupture of the sac into the cavity of the abdomen.

C. 4. History—(Acting Assistant Surgeon D. L. Daggett): Private G. B., "C," 7th Connecticut, age 29. Admitted, June 29th, 1863, from Hilton Head, S. C., with a pulsating tumor apparently about three inches in diameter, just above and to the left of the umbilicus; the peculiar aneurismal bruit was heard with the stethoscope. The patient first noticed this swelling after extra efforts in lifting heavy boxes at Hilton Head some months before. There was not much pain, but he was feeble, sleepless, and without appetite. This condition remained unchanged for some time. Death took place very suddenly, August 17th.

Contributed by Surgeon P. A. Jewett, U. S. Vols., Knight Hospital, New Haven, Conn.

- No. 533.** Heart and arch of the aorta: a large aneurismal sac involving the aorta from its origin to just beyond the subclavian; by pressure the sac has produced atrophy of the sternum and projects as a tumor through the centre of that bone.
- C. 5.**
- C. 6.** A colored plaster cast of the same specimen.
- No history.

Contributed by J. T. Young, M. D., Providence Hospital, Washington, D. C.

- No. 862.** Aneurism of aorta, involving lower surface of middle of arch; the aneurism has ruptured into the oesophagus and burrowed anteriorly between the arterial coats.
- C. 7.**

R. M., late Ordnance Sergeant, age 40. Admitted, December 5th, 1866, with general ill health, the most prominent symptom being almost complete aphonia; there was neither cough nor expectoration. January 13th, 1867, was seized with hæmorrhage to the extent of forty-eight ounces, the blood being mixed with the food taken the preceding day; during the day several recurrences took place, the blood thrown up being crimson in color. Died the same day.

Autopsy: Lungs slightly adherent from old pleuritis; bronchi filled with blood; aneurism of arch of aorta as above described; stomach and intestines distended with blood.

Contributed by Assistant Surgeon W. Thomson, U. S. Army, Post Hospital, Washington, D. C.

D. Aneurism of the other arteries.

- No. 503.** Abdominal aorta and its branches; the superior mesenteric artery is dilated into a spherical aneurismal tumor the size of a small orange. The tumor was recognized by its position and pulsation during the life of the patient, who died of another disease.
- D. 1.**

Contributed by Surgeon M. Goldsmith, U. S. Vols., Louisville, Ky.

Section 3. LYMPHATIC GLANDS.

A. Bronchial glands.

- No. 49.** Bronchial lymphatic glands, filled with calcareous concretions.
- A. 1.** Private C. D., "E," 29th New York, age 22. Died, September 21st, 1862, of Chickahominy diarrhoea.

Autopsy: Body extremely emaciated; skin much ecchymosed, especially over the region of the liver; old adhesions of right lung; recent congestion of both lungs, which were black in section, but everywhere pervious to air; in both, a few calcified, dry, chalky tubercles about the size of pins; the black bronchial glands contained calcified deposits; granular roughness on the right cardiac auricle, and an attachment between the front of the right ventricle and the pericardium; liver dull brown, with slate-colored patch below and slate-colored spots in section about the size of a dime; in both lobes there were several tumors the size of shell-burks, white and firm; these, beneath the microscope, exhibited a fibro-plastic character; spleen larger than usual and black in section; lymphatic glands at the head of the pancreas enlarged, and contained dry, chalky deposits; mesenteric glands somewhat enlarged; stomach with characters of gastritis and ecchymosed spots in the middle portion extending from the small curvature downward in front and behind; inflammation of the duodenum and jejunum extending in a less degree into the commencement of the ileum, which at the lower part appeared entirely free; there were fifty conspicuous Peyer's patches, besides a number of solitary follicles about a line in diameter; all of them contained black pigment; intense inflammation in the cæcum, and six small patches, rather less violent, along the course of the colon; the intervening space, with slight inflammation, is healthy; testes hard and irregular, the right one being much enlarged, both presenting tubercular masses, the right presenting an accumulation of a bloody, pus-like liquid upon the surface of the gland below the tunica albuginea.

Contributed by Acting Assistant Surgeon J. Leidy, Satterlee Hospital, Philadelphia, Pa. 17 and 18, *chap. V., sec. 1, B. 1 and 2, tubercles of the testis, are also from this case.*

- No. 694.** Heart and part of trachea, bronchus and bronchial glands attached; the heart is covered with lymph; bronchial glands enlarged; on section cheesy, with deposits of black pigment, forming an irregular lobulated mass the size of a child's head.
- A. 2.**

S. W., colored, age 24. Admitted, January 6th, 1866. Died, January 9th.

Autopsy six hours after death: A well-formed, muscular negro; height, five feet six inches; weight, about one hundred and fifty pounds; scars upon the legs; some emaciation; rigour mortis well marked; dura mater congested; membranes of

brain congested; extravasation of blood beneath the pia mater over the middle lobe of right hemisphere; substance of brain congested; half a drachm of fluid in each lateral ventricle; pineal gland enlarged; four ounces of bloody serum in posterior fosse of cranium; both lungs studded with milinary tubercles; twenty-eight ounces of dark yellow serum in right pleural cavity; upper portion of lower lobe of left lung hepaticized; twelve ounces of serum in left pleural cavity; pericardium contained nineteen ounces of bloody serum; membrane thickened and covered with lymph; heart large, its external surface covered with a thick layer of lymph; bronchial glands tubercular and very much enlarged; tubercles of liver, organ congested; spleen lobulated on the edges, and filled with large tubercles; tubercles in both kidneys; mucous coat of ileum thickened; one of Peyer's patches near the ileo-cæcal valve, much thickened and slightly ulcerated; numerous follicular ulcers in cæcum; mesenteric glands enlarged; ensiform cartilage bilid.

From Freedman's Hospital, Washington, D. C.

Autopsy by Hospital Steward S. S. Bond.

635, *chap. IV., sec. 5, E. 4, tubercles of liver*; 636, *chap. IV., sec. 7, G. 10, tubercles of spleen, are also from this case.*

No. 747. Trachea and bronchi, with bronchial glands enlarged to the size of goose eggs, some of them softened into abscesses.

A. 3.

R. A., colored, age 26. Admitted, February 7th, 1866, with cough; pain, on pressure, in right side, over ribs and sternum; dullness on percussion over apices of both lungs; tongue dry and brown. 16th, pulse quite feeble and quick; patient lay with his mouth open. Died, February 19th.

Autopsy twenty-four hours after death: A well-formed negro man; height, five feet eight inches; weight, about one hundred and thirty pounds; rigor mortis well marked in lower extremities, none in upper; membrane of brain considerably congested; half an ounce of fluid in each lateral ventricle; pineal gland enlarged; an ounce of fluid in posterior fosse of cranium; posterior portion of left lung congested, upper portion contained some tubercle; a vomica of considerable size at the root of right lung, which was congested throughout, and filled with gray tubercle; pericardium contained four ounces of fluid; bronchial glands as described; heart large, dark and congested, small washed clots in all the cavities; nutmeg liver, with tubercles; tubercles of spleen; kidneys fatty; small intestine much congested, with deposit of black pigment throughout.

From Freedman's Hospital, Washington, D. C.

Autopsy by Hospital Steward S. S. Bond.

No. 737. Enlarged bronchial glands.

A. 4.

See 735, chap. 1, sec. 2, B. 2, for history.

B. Mesenteric Glands.

No. 381. A number of enlarged mesenteric glands.

B. 1.

Private M. H., "A," 142d Ohio National Guard, age 21. Admitted, July 28th, 1864, with camp fever; delirious, with slight cough; some diarrhoea, though the passages were not frequent; pulse 96. 30th, pulse 140. 31st, 112; during this night he became rapidly worse, respiration labored, pulse weak; countenance of a dusky hue. Died, August 1st.

Autopsy six hours after death. Rigor mortis marked; lungs much engorged posteriorly; liver engorged, enlarged and softened; spleen softened; coats of stomach in the region of the greater curvature much softened; Peyer's patches and solitary glands thickened and ulcerated; the ulcers becoming more prominent in the lower portion of the ileum; the mesentery was greatly thickened and its glands enlarged, some to the size of a large peach-stone.

Contributed by Assistant Surgeon W. Thomson, U. S. Army, Douglas Hospital, Washington, D. C.

376 to 380, *chap. IV., sec. 3, E. 13 to 17, ileum with Peyer's patches and solitary glands enlarged and ulcerated, are also from this case.*

No. 25. A number of mesenteric glands, varying in size from that of a pea to that of a large chestnut. The patient

B. 2.

died of diarrhoea.

Contributed by Hospital Steward A. J. Sebafhirt.

No. 552. Several feet of the ileum, with mesentery attached, showing enlarged mesenteric glands.

B. 3.

Sergeant G. H. B., "B," 31st U. S. Colored, age, 22. Admitted, January 2d, 1865, by transfer from another hospital, unaccompanied by any medical descriptive list. He presented all the signs of tubercular phthisis, and labored also under severe diarrhoea. Shortly after entering the hospital his stomach became irritable and rejected all food. He became emaciated, and died April 11th.

Autopsy: Great emaciation; the upper lobes of both lungs filled with tubercle; the right lung had three cavities, large enough to contain three or four drachms of fluid; old adhesions in right pleura; left pleural cavity filled with serum; ileum presented numerous ulcers, similar to the specimen; colon ulcerated; mesenteric glands enlarged.

Contributed by Acting Assistant Surgeon D. L. Daggett, Knight Hospital, New Haven, Conn.

551, *chap. IV., sec. 3, M. 4, tubercular ulcers of ileum, is also from this case.*

No. 132. Tubercular enlargement of the mesenteric glands. The piece consists of the duodenum, with pancreas attached. A mass of greatly enlarged mesenteric glands is suspended anteriorly in connection with the duodenum, and the head of the pancreas; posteriorly may be seen a portion of the abdominal aorta, adjoining which is a mass of enlarged lymphatic glands.

B. 4. Z. T., rebel deserter, age about 40. Admitted, December 2d, 1861. Had enlisted some three years previously in the rebel service, from Lynchburg, Va. Had deserted and entered the United States service as a teamster. Four years ago he had measles, followed by a tedious cough, with expectoration. Two years ago he was injured by a wagon wheel passing over the abdomen. At the time of admission was much emaciated, with sallow countenance and tender abdomen; dullness on percussion, and moist rales over both lungs; great dysphagia, nausea, and vomiting. Died, exhausted, December 5th.

Autopsy: Height, five feet eight and one-half inches; rigor mortis marked; body much emaciated; countenance of a light bronze hue; mucous membrane of pharynx excoriated; mucous membrane of larynx and trachea roughened, apparently from minute ulceration; both lungs studded with tubercles from the size of a small pea down to that of a pin-head; right side of the heart contained a large black clot, left side a small amount of black blood; mesenteric glands very much enlarged and softened; the intestines full of tubercular ulcers.

Contributed by Acting Assistant Surgeon H. M. Dean, Lincoln Hospital, Washington, D. C.
426, chap. III., sec. 1, A. 1, *superficial ulceration of larynx*; 437, chap. III., sec. 2, D. 4, *tubercles of lungs*; 428 to 431, chap. IV., sec. 3, M. 37 to 40, *tubercular ulceration of the intestines*, are also from this case.

No. 269. Enlarged mesenteric glands.

B. 5. History—(Acting Assistant Surgeon Alfred Stillé): Private B. W., "1," 61st Ohio. Admitted, December 18th, 1862; had just had typhoid fever, after previously suffering from dysentery; was greatly emaciated; complained of general rheumatic (scorbatic) muscular pains, and had chronic diarrhoea and oedema of the extremities. His condition gradually improved until towards the end of December, when the diarrhoea became more troublesome, and his stomach with difficulty retained any food. At this time his cough attracted attention, and on examination a large portion of the left lung was found solidified; blood and pus were mingled with his sputa; irritability of stomach and diarrhoea increased, and emaciation advanced rapidly. January 15th, 1863, crackling was heard at the summit of the left lung. From the 23d, great tenderness of the abdomen, under the least pressure, was manifested, and the vomiting continued. Died, January 27th by gradually progressive asthenia.

Autopsy, January 27th: Age about 29; emaciation extreme; adhesions over all left lung; upper lobe, with diffused tubercle, and a large cavity in the apex, containing mucopurulent matter and blood; a few small tubercles in the lower lobe; heart with a white clot in the right side, but normal; liver enlarged, brown on the surface, in section mingled brown and ochre-yellow from fatty degeneration; stomach redder than natural; spleen enlarged, not flabby, dark red in section; with the marks of an old inflammation on the convex surface; glands of the mesentery and mesocolon, all very much enlarged, and filled with tubercular matter; Peyer's patches all completely ulcerated away; the bases of many of the ulcers extending to the peritoneum; besides these there was a multitude of ulcers in the ileum about the size of three-cent pieces, which were suspected to have had their origin in solitary glands; at the edges of many of the ulcers, were small, white, opaque tubercles, from which it was suspected the ulcers had their commencement; the colon, throughout, presented a number of ulcers, from the size of a three-cent piece to that of a quarter of a dollar; the mucous membrane of the cecum was highly inflamed, and elsewhere in the colon streaks of inflammation were observed.

Contributed by Acting Assistant Surgeon J. Leidy, Satterlee Hospital, Philadelphia.
262 to 266, chap. IV., sec. 3, I. 63 to 67, *ulcerated ileum*; 267 and 268, chap. IV., sec. 3, I. 68 and 69, *ulcerated colon*, are also from this case.

No. 197. Enlarged and softened mesenteric glands.

B. 6. Private M. W., "E.," 7th Wisconsin. Admitted to Post Hospital, Camp Randall, Wis., with measles. Transferred to Harvey Hospital, June 14th, 1861. Diagnosis—tubercles mesenterica. Died, July 25th.

Contributed by Surgeon H. Culbertson, F. S. Vols., Harvey Hospital, Madison, Wis.
196, chap. IV., sec. 3, E. 59, *follicular ulceration of ileum*, is also from this case.

No. 730. Part of duodenum, with pancreas attached, showing enlarged lymphatic glands around the head of the pancreas.

B. 7. Private C. S., "B.," 14th F. S. Colored, age 18. Admitted, November 25th, 1865, suffering from scrofula. On admission the patient was very feeble and considerably emaciated; suppurating abscesses in neck and axilla. Died, January 31st, 1866.

Autopsy: Tubercles in both lungs; in the apex of left lung a large cavity, which communicated with a fistulous opening through the parietes of the chest into the axilla; tubercles of the peritoneum; tubercles of the spleen; the mesenteric glands greatly enlarged.

Contributed by Surgeon R. B. Eustace, F. S. Vols., Harewood Hospital, Washington, D. C.
727, chap. IV., sec. 1, E. 9, *tubercles of mesentery*; 728, chap. IV., sec. 1, E. 10, *tubercular peritonitis*; 729, chap. IV., sec. 7, G. 13, *tubercles of the spleen*, are also from this case.

C. Peripheral glands.

No. 582. A portion of left femoral artery and vein from just below Poupart's ligament, showing the adjacent lymphatic glands greatly enlarged.

C. 1.

Private J. R., "E," 23d U. S. Colored. Died, July 23, 1867—general serofula.

Autopsy: Body emaciated; right knee swollen, with fluctuation above and across the knee joint, and crepitation on motion of the patella; the joint was filled with flaky pus, and communicated with a large abscess above the knee, beneath the vasti muscles; the bone was covered with a soft albumen-like curd, similar in substance to the flakes in the pus; parts of the femur and the head of the tibia were denuded; both lungs adherent and filled with milinary tubercles; the lower lobe of the right lung hepaticized; spleen contained a few scattered tubercles; mesenteric glands enormously enlarged; liver adherent to diaphragm, stomach, and colon; cheesy deposits of the size of almonds were found on the surfaces of these organs, especially at the points of adhesion; scattered bands of adhesion connected the knuckles of the small intestine; peritoneum contained much black pigment, and, scattered here and there, tubercles; there was great enlargement of the lymphatic glands in the neighborhood of the saphenous opening of the left side; no intestinal ulceration.

Contributed by Acting Assistant Surgeon W. C. Miner, L'Ouverture Hospital, Alexandria, Va.

581, *chap. IV., sec. 4, E. 7, large tubercles of peritoneum, with adhesions*; 580, *chap. VI., sec. 2, No. 13, scrofulous ulceration of knee joint, are also from this case.*

No. 686. Encephaloid tumor, involving the lymphatic glands of the left supra-clavicular region, weighing one pound and three-sixteenths.

C. 2.

Private P. F., "H," 150th Illinois, age 51. The tumor was first observed about ten months before death; it grew very rapidly during the last three months. The abdominal tumor was first observed three months before death. Died, December 17th, 1865.

Autopsy: Lower extremities, left forearm and hand, swollen from dropsical effusion; body greatly emaciated, and of the peculiar hue regarded as characteristic of the cancerous cachexia; the primary tumor occupied all the supra-clavicular region, as high as the occipital bone, and extended downwards to the pleura surrounding the phrenic nerve and brachial plexus of nerves; it also compressed the large bloodvessels of the neck and the trachea; it was invested by a sac; it was situated beneath the skin, superficial fascia, platysma myoid, omohyoid and sterno-cleido-mastoid muscles; the apex of the left lung was inflamed and adherent to the pleura; the secondary tumor was located in the mesentery, and was found to occupy the epigastrium, the umbilical, a part of the left hypocondriac, the left lumbar, and the left iliac regions; it was adherent posteriorly to the lumbar muscles and spinal column; the stomach, liver, spleen, and pancreas were pushed upwards, but were not involved in the disease; the bowels were pushed to the right of the tumor. Both tumors were composed, microscopically, chiefly of large polygonal cells, with one or more large oval nuclei.

Contributed by Surgeon Howard Culbertson, U. S. Vols.

667, *chap. IV., sec. 1, F. 2, encephaloid cancer of omentum, is also from this case.*

No. 821. A lobulated melanotic tumor, weighing thirteen ounces, removed from Scarpa's space over the left thigh, apparently consisting of diseased lymphatic glands.

C. 3.

No. 826. A spindle-shaped tumor, five inches long, weighing two and a half ounces, which was situated over the left clavicle and upper portion of the sternum of same patient—probably diseased lymphatic glands.

C. 4.

R. B., colored, age 60. Admitted, June 21st, 1856. Diagnosis—remittent fever. Died, July 7th.

Autopsy eight hours after death: An old, gray-haired African; flat chest; slight rigor mortis; some little emaciation; height, five feet six and a half inches; weight, about one hundred and fifty pounds; an indurated dry ulcer on the inside of the left great toe; hard, prominent tumors, from the size of a pea to that of a walnut, over front of chest; a tumor over the left clavicle; a hard tumor in the belly of the pronator radii teres muscle of the right forearm; a large tumor on the left thigh in Scarpa's space; in removing it the femoral vessels were exposed, but were not adherent; the tumor over the clavicle had pressed on the sternum and clavicle so that the inner portion of the latter, and the upper third of the former, were black and carious; a black coagulum, about the size of a walnut, in the right corpus striatum; about an ounce of fluid in subarachnoid cavity; cartilages of ribs ossified; each pleural cavity contained an ounce of straw-colored fluid; lower lobe of each lung presented large melanotic tumors; a few scattered through the upper lobes; a black tumor on the right cardiac auricle; five ounces of straw-colored fluid in the pericardium; liver, spleen, and pancreas contained black melanotic masses; kidneys fatty, a melanotic tumor in the pelvis of right kidney; three or four small black tumors on the parietes of stomach; melanotic ulcers and patches all through the intestines; two black tumors in walls of bladder.

Microscopical examination: The specimen was received in alcohol; the melanotic masses were soft, and their character could be made out with difficulty: the nodules appeared to be composed of irregular, more or less, polygonal cells, about $\frac{1}{10}$ to $\frac{1}{8}$ inch in diameter, with large oval nuclei, containing brownish-black pigment granules; there was, however, an immense amount of pigment in free granules, whether derived exclusively from broken-up cells or not, cannot be positively stated.

From Freedman's Hospital, Washington, D. C.

Autopsy by Assistant Surgeon Edwin Bentley, U. S. Army.

827 and 828, *chap. III., sec. 2, H. 1 and 2, melanotic tumors in lungs*; 829, *chap. IV., sec. 5, F. 11, melanotic tumors in liver*; 830, *chap. IV., sec. 6, A. 1, melanotic nodules in pancreas*; 831, *chap. V., sec. 1, E. 1, melanotic tumor in pelvis of right kidney*, 825, *chap. VI., sec. 1, No. 4, melanotic tumor in pronator radii teres, are also from this case.*

D. Bronchocele.

No. 210. The thyroid gland, enlarged into an irregular **V**-shaped body, the right leg of the **V** being over three inches in length and one and a half inches in diameter, and the left over four inches in length and two in diameter; the superior thyroid arteries enlarged, especially on the left side, where the artery attains nearly the size of the common carotid. The essential conditions present, are ordinary cystic disease of the thyroid, involving alike the isthmus and lobes. The walls of some of the cysts are the seat of calcareous deposits.

No history.

Contributor unknown.

No. 595. Oval, lobulated, cystic tumor, two inches in length by an inch and a quarter in breadth, removed by extirpation from the left side of the neck, close to the outer edge of the thyroid gland: the cyst has walls of strong fibrous tissue, nearly a quarter of an inch thick, in which much calcareous matter is deposited; in its interior is one large cavity into which several smaller cavities open: it was supplied by a branch of the enlarged superior thyroid artery. The thyroid gland was not enlarged. The patient recovered from the operation.

Contributed by Surgeon G. B. Parker, U. S. Vols.

Chapter III. RESPIRATORY ORGANS.

Section 1. AIR PASSAGES.

	NO. OF SPECIMENS.
A. Ulceration of larynx and trachea	2
B. Abscess of larynx	2
C. Oedema of glottis and epiglottis	6
D. Diptheria	21
E. Foreign bodies in air passages	1

Section 2. LUNGS AND PLEURÆ.

A. Pneumonia and pleuro-pneumonia	9
B. Pyæmic foci	2
C. Pleurisy	7
D. Tubercles in lungs	8
E. Tubercular vomicae	9
F. Tubercular pleurisy	5
G. Cicatrices on surface of lungs	4
H. Cancer of lungs	2

Chapter III. RESPIRATORY ORGANS.

Section I. AIR PASSAGES.

A. Ulceration of larynx and trachea.

- No. 426.** Larynx and part of trachea, with thyroid body attached; the under surface of the epiglottis and the mucous membrane of the larynx and trachea present a number of superficial ulcers.
A. 1. See 432, chap. II., sec. 3, B. 4, for history.
- No. 6.** Anterior half of larynx, with posterior third of tongue attached; situated on the right side, below the rima glottidis, is a deep phagedenic ulcer, which has dissected between the cricoid and thyroid cartilages; the perichondrium of the cricoid is destroyed, and the cartilage itself, at the bottom of the ulcer, is of bone-like hardness from calcareous deposits. (Probably scorbutic. See remarks to No. 1, chap. IV., sec. 1, A. 1.)
A. 2. Contributed by Acting Assistant Surgeon R. K. Browne, Marine Hospital, New Orleans, La.

B. Abscess of larynx.

- No. 167.** Larynx and trachea, with enlarged bronchial glands attached, laid open posteriorly, the incision passing through the middle of an abscess-cavity; the cricoid cartilage is necrosed and lies free in the cavity.
B. 1. Private C. C., "C," 5th Pennsylvania Heavy Artillery. Admitted, October 9th, 1864, with chronic diarrhoea, from which he so far recovered as to be able to do duty about the hospital. About November 1st he was seized with fever, cough, and pain in the right lung, and numerous small abscesses formed over various parts of the chest and abdomen. December 10th, difficulty of breathing, dry cough, and pain at the upper end of the sternum. Died, suffocated, December 24th. No tenderness of the larynx on pressure, nor any disease of that organ was detected, although the attention of his attendants was directed to it during life.
- Autopsy: The abscess described had not opened either into the larynx or œsophagus; from its size and position it was, undoubtedly, the cause of death; bronchial glands enlarged, especially on the right side, one of them, at the root of the right lung, containing pus and calcareous matter; lower lobe of right lung filled with miliary tubercles, with which intercurrent pneumonia was associated; the posterior part of this lobe coated with pleuritic lymph; heart contained a firm white clot on each side; liver large and pale; spleen rather small, with a number of minute tubercles; colon, otherwise normal, presented patches of pigmentary deposits; kidneys small and granular.
- Contributed by Acting Assistant Surgeon W. C. Miner, General Hospital, Alexandria, Va., Third Division.

- No. 491.** Larynx, presenting an abscess on the right side posteriorly; the right half of the thyroid cartilage and a part of the cricoid have been removed to show its cavity.
B. 2. Private W. C., "C," 1st Wisconsin Heavy Artillery. The abscess above described obstructed respiration and required tracheotomy, December 25th, 1864. Before the operation was completed, the patient had ceased to breathe. The trachea was however opened and a silver catheter introduced; artificial respiration commenced and he gradually recovered. He was doing well on the evening of the same day, when he rose to use the chamber, and expired before he could be got to bed; artificial respiration was again resorted to, but in vain.
- Autopsy: Abscess as described; heart large and dilated; walls of right ventricle fatty; the ventricle contained a large fibrinous clot, which extended through the auricular-ventricular opening.
- Contributed by Surgeon H. Culbertson, U. S. Vols., Harvey Hospital, Madison, Wis.

(C. Edema of glottis and epiglottis.

No. 301. A portion of tongue, with larynx and part of trachea laid open from behind; there is considerable oedematous tumefaction of mucous membrane of epiglottis and subcutaneous tissue.

C. 1. Corporal S. D., "H," 24th Veteran Reserve Corps, age 22. Admitted, March 29th, 1861, convalescent from typhoid fever, and complaining of sore throat. 31st, 6 a. m., he was suddenly seized with difficulty of breathing, and expired asphyxiated.

Contributed by Surgeon T. R. Spencer, U. S. Vols., General Hospital, Alexandria, Va., Second Division.

No. 302. Larynx and trachea, laid open from behind, with well-marked edema of epiglottis; mucous membrane of larynx and trachea apparently healthy.

C. 2. Private H. S., "C," 1st Michigan Cavalry. Admitted, February 4th, 1861, with chronic diarrhoea. 23d, was suddenly seized with difficulty of breathing in the morning, and died at 4 p. m. the same day.

Contributed by Assistant Surgeon W. T. Okie, U. S. Army, Taylor Hospital, Louisville, Ky.

No. 519. Larynx and part of trachea laid open, showing epiglottis and mucous membrane of orifice of glottis much thickened; laryngotomy had been performed, the incision passing perpendicularly through crico-thyroid membrane and cricoid cartilage, in the median line.

Private W. S., "F," 19th Indiana. Admitted, February 3d, 1865, convalescent from acute bronchitis. He continued to improve till the 12th, when sore throat, enlargement of tonsils and swelling of cervical glands supervened, not, however, sufficiently severe to cause weakness until the 17th, when great dyspnoea, due to oedema of glottis, suddenly seized him; the finger introduced into the throat readily distinguished the swollen lips of the glottis and enlarged and thickened epiglottis. Some hours later, the lips became blue, respiration labored, pulse feeble and rapid, and laryngotomy was determined upon. After the operation, the patient took two or three stertorous inspirations, coughed out a few drops of blood, and died.

Autopsy: Trachea and bronchi in a state of acute inflammation; mucous membrane intensely red and much thickened throughout; lining membrane of larynx pale; mucous membrane of vocal folds and orifice of glottis very much thickened and oedematous, so as completely to close the glottidean entrance; no false membrane nor other exudation at any part of air passages. Duration of case about seven hours.

Contributed by Assistant Surgeon William F. Norris, U. S. Army, Douglas Hospital, Washington, D. C.

No. 570. Larynx and epiglottis, with mucous membrane around orifice of glottis thickened from inflammatory oedema. **C. 4.** No diphtheritic formation.

Recruit H. F. W. Died of acute laryngitis, February 13th, 1861.

No history.

Contributed by Surgeon John Neill, U. S. Vols., Hospital corner of Broad and Cherry streets, Philadelphia, Pa.

No. 650. Larynx, with portions of tongue and trachea attached; orifice of glottis closed by oedema; epiglottis greatly swollen.

C. 5. History—(Acting Assistant Surgeon M. K. Gleason); D. R. Z., "C," 7th South Carolina, (Rebel), age 30. Admitted, April 9th, 1864; teeth firmly set together; loud croupy breathing; pain over laryngeal region; dusky countenance; lips blue; breathing quick and labored; loud rale over larynx, sonorous and subcrepitant rales over both lungs; epiglottis, tonsils and surrounding parts very much swollen; tracheotomy performed one hour after admission; inserted quill tube through aperture in trachea, and patient breathed freely with marked improvement until two o'clock next night, when he had a severe chill, and rapidly sunk. Died, 8 a. m., April 10th.

Autopsy: Epiglottis and tonsils thickened and enlarged; folds of glottis swollen, producing almost complete closure; lungs normal.

Contributed by Surgeon William Watson, U. S. Vols., Post Hospital, Rock Island, Ill.

No. 652. Larynx and part of trachea, showing great thickening of epiglottis, like what is usually described as oedema of glottis; an incision into epiglottis discovered pus in connective tissue of that part.

C. 6. History—(Acting Assistant Surgeon M. K. Gleason); Private M. E., "G," 2d Arkansas Cavalry, age 26. September 25th, 1864, suddenly attacked, high febrile excitement, followed by intense headache, with pain in back and arms, lasting all night. 26th, throat very sore; cervical glands enlarged; aphonia; difficult deglutition, with much pain. Admitted to hospital 27th; much pain in head and throat, especially during paroxysms of coughing; great dyspnoea; florid, anfrused, anxious countenance; injected conjunctivae; respiration loud, thirty per minute; dry and croupy cough; expectoration scanty, clear and viscid, setting posture preferred, head thrown slightly back; throat swollen and glands enlarged; pulse 120, firm and full, tongue coated, pupils raised; skin dry and hot; bowels costive; throat tender to touch. Died, suddenly, September 28th, after attempting to rise from bed.

Autopsy: Parotid and submaxillary glands enlarged; mucous membranes engorged; epiglottis swollen, and, on puncture, yielded pus, three drachms of sero-purulent fluid in pouches of larynx; chink of glottis firmly closed.

Contributed by Surgeon William Watson, U. S. Vols., Post Hospital, Rock Island, Ill.

D. Diphtheria.

- No. 11.** Larynx laid open posteriorly, coated with a thin diphtheritic layer.
D. 1. Contributed by Acting Assistant Surgeon J. Leidy, Satterlee Hospital, Philadelphia, Pa.
- No. 528.** Larynx, with part of tongue and tonsils attached; tonsils somewhat coated with diphtheritic membrane; epiglottis oedematous; an incision made by the operation of laryngotomy in the circo-thyroid space.
D. 2. Private D. S., "K," 1st Vermont Cavalry, age 13. Admitted, December 23d, 1864, with general lassitude, chilliness, pains in limbs, anorexia, surface and conjunctivæ deeply tinged with icterus; not confined to bed. 25th, complained of sore throat, which was much inflamed, the inflammation involving both tonsils, and extending upward along the anterior palatine arch to soft palate and posterior roof of mouth. 30th, tongue, tonsils, and palate greatly swollen, highly inflamed, and obstructing the passage of solid food. 31st, has passed a restless night from dyspnoea; pulse full and quick; articulation very imperfect. January 1st, 1865, no better; dyspnoea increasing; membranous exudation of some consistence depending from uvula, which, on being partially detached, left a clean, red, highly-inflamed surface. 2d, complained of cold extremities; coughed up a thickened glairy mucus, mixed with blood and particles of membrane of a very offensive odor; dyspnoea increasing; 2, p. m., seized with dyspnoea, resulting in asphyxia and death; before tracheotomy could be performed, respiration ceased; larynx, however, opened, and artificial respiration kept up for twenty minutes, without success.
 Contributed by Assistant Surgeon R. P. Weir, U. S. Army, General Hospital, Frederick, Md.
- No. 15.** Larynx and part of trachea, laid open posteriorly, lined by thin diphtheritic membrane.
D. 3. Contributed by Acting Assistant Surgeon H. Rowe.
- No. 9.** Larynx, lined with pseudo-membrane.
D. 4. No history.
 Contributed by Acting Assistant Surgeon B. B. Miles, Annapolis Hospital, Md.
- No. 10.** Larynx and trachea, lined throughout by pseudo-membrane.
D. 5. Contributed by Assistant Surgeon H. Allen, U. S. Army, Lincoln Hospital, Washington, D. C.
- No. 8.** Larynx, lined by pseudo-membrane, which occupies its entire length, and lies free in the cavity in the form of a tube.
D. 6. Contributed by Acting Assistant Surgeon B. B. Miles, Annapolis Hospital, Md.
- No. 110.** Larynx and part of trachea, lined by thick pseudo-membrane.
D. 7. History—(Acting Assistant Surgeon E. G. Derby): Private C. W., "A," 44th New York, age 19. Admitted, October 21st, 1864, from Field Hospital, suffering with chronic diarrhoea and syphilis. November 1st, complained of sore throat. 2d, throat worse, covered with pseudo-membrane; dysphagia. During the 3d and 4th, he continued about the same. 5th, began to sink. Died, November 6th.
 Autopsy—(Acting Assistant Surgeon T. Bowen): No emaciation; encephalon normal; sides of uvula coated with pseudo-membrane; epiglottis oedematous, its under surface, larynx, and trachea lined with pseudo-membrane; pericardium contained an ounce of fluid; right pleural cavity contained three ounces of serum with shreds of floating lymph; lower part of upper lobe of right lung carnified.
 Contributed by Surgeon Edwin Bentley, U. S. Vols., General Hospitals, Alexandria, Va.
- No. 11.** Larynx and part of trachea, laid open posteriorly, lined throughout by thick diphtheritic membrane, which is loosened and turned up at its edges.
D. 8. Sergeant G. W. B., "I," 14th Connecticut. Admitted, July 15th, 1863, from battle of Gettysburg, wounded through both hips; had suffered from chronic diarrhoea six months before he was wounded; was very much exhausted, and wounds in an unhealthy state; the diarrhoea was checked, but wounds did not assume a healthy character. August 12th, complained of sore throat; uvula and tonsils very much congested. 14th, diphtheritic patches on the throat, and large flakes removed by local applications. Died, August 15th.
 Contributed by Assistant Surgeon DeWitt C. Peters, U. S. Army, Jarvis Hospital, Baltimore, Md.
- No. 110.** Larynx and trachea, lined by a thick pseudo-membranous layer.
D. 9. History—(Acting Assistant Surgeon S. Graham): Private J. F., "C," 7th New York. Admitted, August 17th, 1864, with a gunshot wound. When admitted, there were indications of diphtheria, which became fully developed on the 24th—throat became swollen, white film formed about tonsils, and great difficulty of swallowing set in, so that food was rejected through the nostrils; respiration difficult, but no cough. Died of suffocation, August 30th.
 Contributed by Surgeon N. R. Moseley, U. S. Vols., Emory Hospital, Washington, D. C.

- No. 12.** Posterior fourth of tongue, larynx and trachea; air passages laid open posteriorly; a diphtheritic layer, loosened into shreds, lines the larynx, trachea, and bronchi.
D. 10. Private J. L. B. "L." 7th Maine. Died, September 23d, 1862.
 Autopsy: Age about thirty years; body not wasted; fauces, pharynx to the commencement of œsophagus, larynx, trachea, and bronch, inflamed and lined by pseudo-membrane; tissue of lungs healthy, but bronchial tubes filled with mucus; effusion of blood in interlobular connective tissue; apex of right lung tied by an old pleuritic adhesion; stomach exhibited evidences of gastritis, more or less inflamed throughout; mucous membranes of duodenum, jejunum, and ileum slightly reddened and stained with bile; large intestine exceedingly contracted, and nearly uniformly pink throughout.
 Contributed by Acting Assistant Surgeon J. Leidy, Satterlee Hospital, Philadelphia, Pa.
- No. 13.** Larynx and trachea, laid open posteriorly; a diphtheritic membrane extends throughout into the bronchi, in the form of a hollow tube.
D. 11. Patient had typhoid fever, which left him with chronic diarrhoea. He then had measles, and was quite sick for two or three weeks. On admission, was very feeble and much emaciated; tongue furred. He improved under treatment, and became able to leave his bed most of the day. March 11th, 1863, he complained of sore throat; on examination, diphtheritic exudation was already manifest, but he still swallowed easily. 12th, difficulty in swallowing; after a certain amount had passed, all fluid returned by the nose. 13th, breathing quite laborious; tonsils much swollen, membrane upon each newly closing the fauces; surrounding parts covered with pseudo-membrane; towards evening symptoms of suffocation appeared; dyspnoea constantly increased. Died, March 14th.
 Contributed by Assistant Surgeon H. B. Buck, U. S. Vols., Columbian Hospital, Washington, D. C.
- No. 585.** Larynx and trachea, with soft palate and part of tongue attached; the mucous membrane coated with thick pseudo-membrane.
D. 12.
- No. 586.** A portion of lung of same patient, showing pseudo-membranous casts in smaller bifurcations of bronchi.
D. 13. Acting Assistant Surgeon J. T. St. J., age 25. Admitted from City Point, Va., March 3d, 1865, with diphtheria, and partial paralysis of left arm. Died, March 6th.
 Autopsy: Air passages as above described; white clot in left side of heart, mixed clot in right side; pia mater congested; slight redness of Peyer's patches; spots like ecchymosis in mucous membrane of stomach; bladder contained some albuminous urine.
 Contributed by Assistant Surgeon G. M. McGill, U. S. Army, National Hospital, Baltimore, Md.
- No. 411.** Larynx, trachea, and bronchial tubes laid open, incompletely lined by pseudo-membrane; left bronchial tube and its principal bifurcations occupied by a complete tubular cast of pseudo-membrane; the lumen of the right bronchial tube is free.
D. 14. Private J. V., "E." 46th New York, age 19. Admitted with amputation of left little finger, result of gunshot wound received before Petersburg, Va., October 12th, 1864. Symptoms of tonsillitis appeared, and diphtheria was recognised on the 23d. Died, October 26th.
 Air passages and lungs received in fresh condition at the Museum. On the left side the diphtheritic process was found to extend to the minutest bronchi, but not to the air vesicles; right lung not involved; diphtheritic layer in trachea composed of granular fibrin, in which were embedded innumerable ciliated epithelial cells, with multitudes of oval and rounded elements, apparently from the deeper layer of the tracheal epithelium; on stripping off portions of the pseudo-membranous layer, the mucous membrane was found to be deprived of all the more superficial parts of its epithelium.
 Contributed by Assistant Surgeon C. A. McCall, U. S. Army, Mount Pleasant Hospital, Washington, D. C.
- No. 7.** Anterior half of larynx, with soft palate and posterior third of tongue attached; coated by a diphtheritic layer, involving posterior surface of soft palate, under surface of epiglottis and larynx, most luxuriant at rima glottidis.
D. 15. Private D. G. H., "D." 13th New Hampshire. Died, March 1th, 1862.
 Contributed by Surgeon J. Bryant, U. S. Vols., Lincoln Hospital, Washington, D. C.
- No. 529.** Larynx, with soft palate attached; palate coated with pseudo-membrane, which also lines larynx.
D. 16. Private T. B., "C." 106th New York, age 21. Admitted, July 10th, 1861. Femur fractured at Monocacy Junction, July 9th, by conoidal ball. Amputation 10th. 15th, four ounces secondary hæmorrhage. 17th, sloughing of stump. 19th, complains of difficult respiration; pulse weak. 21st, respiration impeded; crepitant ræchus over left lung; percussion dull. Died, July 22d.
 Autopsy: Body emaciated; both lungs congested and infiltrated with serum; air passages as described.
 Contributed by Assistant Surgeon R. F. Weir, U. S. Army, General Hospital, Froelich, Md.
- No. 515.** Larynx, laid open from behind, with tongue and tonsils; epiglottis much thickened; larynx lined by a thick pseudo-membrane, which extends to tonsils and upon sides of tongue.
D. 17. Private E. C. M., "H." 9th New York Cavalry, age 23. Admitted, February 11th, 1865, from Angur Hospital, Alexandria, Va., suffering with acute pharyngitis and tonsillitis, with exudation upon the tonsils, accompanied by

fever. Disease at first appeared to yield partially to treatment, but later developed a distinct diphtheritic character; false membrane appearing on walls of pharynx and gradually extending. About a week after admission, stomach became irritable, and for two days prior to death, nothing was retained except a little water from ice melting in mouth. Fever sthenic till two days before death, when system began to suffer from imperfect aeration of blood; from that time the purple hue of skin became increasingly marked; in last two days, very little urine voided, but no uræmia observed, mind being perfectly clear till death. Died, February 24th.

Autopsy: Tonsils and larynx coated with pseudo-membrane; trachea lined throughout with firm false membrane, extending into ramifications of left bronchus; right bronchi not lined with membrane, but greatly inflamed; lungs healthy, closely adherent to thorax and diaphragm by old adhesions; a firm, well-washed clot in each ventricle of heart, right larger and more firmly attached than left.

Contributed by Assistant Surgeon H. Allen, U. S. Army, Mount Pleasant Hospital, Washington, D. C.

No. 591. Larynx, with soft palate attached; tonsils greatly enlarged, somewhat coated with pseudo-membrane;

D. 18. larynx and trachea lined with same, which, however, is not shown in specimen, it being prepared to exhibit the condition of the tonsils.

Sergeant J. W. S., "D," 1st Maine Veterans, age 24. Admitted, October 24th, 1864, with a gunshot wound of right thigh, fracturing femur just below trochanter major, received October 19th, at Cedar Creek, Va. He became greatly emaciated and broken down, but, after several months, fracture united, and he then rapidly improved; was able to sit up in the ward, and became quite fat, several sinuses, however, still discharging a considerable amount of pus. May 24th, 1865, complained of sore throat, but there were no traces of diphtheritic exudation; 10 p. m., the nurse was wakened by the patient's groans and efforts to breathe. When seen, a few minutes after, he was breathing stertorously; tonsils much swollen; fauces and posterior nares covered with diphtheritic membrane; about 12 p. m., tracheotomy was performed by Acting Assistant Surgeon F. P. Foster, and gave considerable temporary relief; but he soon relapsed, and grew gradually worse. Died, May 27th, at 4 a. m.

Autopsy: Tonsils greatly enlarged; larynx and posterior nares covered with diphtheritic membrane, which extended a considerable distance down the trachea.

Contributed by Assistant Surgeon De Witt C. Peters, U. S. Army, Jarvis Hospital, Baltimore, Md.

No. 416. Lower part of nose, with vomer and parts of superior maxillary bones attached; the nasal mucous membrane

D. 19. coated with pseudo-membrane; communicating ulcer between nostrils, in cartilaginous septum.

Private C. O. G., "H," 4th Vermont, age 31. Admitted, October 25th, 1864, with amputation of right leg for a gunshot wound received at Cedar Creek, Va., October 19th. When admitted, stump was healing favourably, and patient in good physical condition, but suffering greatly from nostalgia. 30th, diarrhoea, and tendency to sloughing in stump. November 20th, stump healthy, nearly healed, diarrhoea occasionally troubling. 23d, complains of sore throat; slight diphtheritic deposit on one tonsil; patient believed disease would be fatal. 24th, false membrane extending, involving nostrils. Died, November 26th.

Autopsy: Pseudo-membrane coated nostrils, palate, larynx, and upper part of trachea.

Contributed by Acting Assistant Surgeon G. W. Fay, Patterson Park Hospital, Baltimore, Md.

No. 391. Pseudo-membranous cast of lower part of trachea and larger bronchial tubes.

D. 20. Private A. C. W., "F," 83d Pennsylvania. Admitted, July 7th, 1864, complaining of sore throat; fauces covered with pseudo-membrane; patient had walked to hospital and seemed to be in good condition. The cast, which constitutes the specimen, was ejected on the 9th, after a hard spell of coughing; patient at first seemed comfortable and likely to do well, but soon began to sink, suffering from dyspnoea, and died thirty-three hours after ejecting the cast.

Contributed by Surgeon W. L. Faxon, 32d Massachusetts, 5th Corps Field Hospital, White House, Va.

No. 572. Larynx and part of trachea, lined with pseudo-membrane: from a child who died of diphtheria.

D. 21. Contributed by Dr. Samuel C. Smoot, Washington, D. C.

E. Foreign bodies in air passages.

No. 290. Larynx, trachea, and part of right lung air passages, laid open from before, and exhibiting a large lumbricoid

E. 1. worm, lying extended in larynx, trachea, and right bronchus; worm finding its way into air passages from œsophagus. Patient choked to death, January 20th, 1864.

Contributed by Acting Assistant Surgeon S. B. Ward, General Hospital, Alexandria, Va., Third Division.

Section 2. LUNGS AND PLEURE.

A. Pneumonia and pleuro-pneumonia.

No. 92. Perpendicular section of left lung, with pleuritic adhesions of the surface and partial hepaticization of the lower lobe.

A. 1.

Private T. K., "A," 126th New York. Admitted, December, 12th, 1862, with diarrhoea. On the 18th was moving about; in the evening, ate his supper; the same night became delirious. Died, December 19th.

Autopsy: Body not emaciated; age about 25; upon the body, especially the thighs, a number of irregular spots of purpura from the size of a flea-bite to that of a dime; blood very liquid and poured forth from incisions in the skin and all the internal organs; recent pleuritic adhesions on both sides; left lung crepitant, but engorged with a bloody liquid; upper lobe of right lung hepaticized; lower lobes congested; liver soft, Indian red in color, and large; spleen large, flabby, and in section dark Indian red, its convex surface with the marks of former inflammations; small intestine pink; the Peyer's patches thickened and mostly bright red; the lower glands a line in thickness, and contained a white deposit; mesenteric glands somewhat enlarged; mucous membrane of large intestine, dirty slate color, with streaks of inflammation here and there; at the extremity of the appendix vermiformis several irregular growths of connective tissue hardened by calcareous deposits; some atheroma of aorta.

Contributed by Acting Assistant Surgeon J. Leidy, Satterlee Hospital, Philadelphia, Pa.

See to 50, chap. IV., sec. 3, F. 1 to 3, thickened Peyer's patches; 91, chap. IV., sec. 4, D. 2, connective tissue growths on appendix vermiformis, are also from this case.

No. 313. Left lung, coated with freshly formed pseudo-membranous lymph; a part of the lower lobe hepaticized.

A. 2.

Private J. M., "B," 116th Pennsylvania, age 20. Admitted, March 26th, 1864, with pleuro-pneumonia, in a dying condition. Had previously suffered from measles. Died, March 28th.

Autopsy: A pint of serum in the cavity of the left pleura; left lung as described.

Contributed by Surgeon E. Bentley, U. S. Vols., General Hospital, Alexandria, Va., Third Division.

No. 318. Right lung, the surface of which is coated with an irregular layer of pseudo-membranous lymph; strong adhesions between the costal and pulmonary pleurae at the posterior part; lower lobe of the lung hepaticized.

A. 3.

Private A. R., 5th New York Artillery, age 49. Admitted March 22, 1861, in the second stage of pneumonia, with great dyspnoea, excessive pain in right side, livid, anxious countenance, and characteristic sputa. Died, March 27th.

Autopsy: Right lung as described; thickening and adhesions of pleura; slight pleuritis on left side; pericardium coated with lymph, but no fluid in its cavity; some of Peyer's glands enlarged.

Contributed by Surgeon E. Bentley, U. S. Vols., General Hospital, Alexandria, Va., Third Division.

No. 411. Section of right lung, from the convex surface of which the adherent pleura has been partly reflected backwards, to show the adhesions; the lung, when received at the Museum, was in a state of gray hepaticization.

A. 4.

Private M. H., "D," 11th Indiana, age 35. Admitted, October 25th, 1861, with pneumonia. Died, October 29th.

Autopsy: Body emaciated; back of a deep purple color, ecchymosed spots on the sides; pleuritic adhesions on the left side; left lung congested; right lung adherent throughout and in a state of gray hepaticization; four bird-shot were found encysted in the lower part of the costal pleura; there was, however, no visible external wound, and they had probably entered long previously; a fibrous clot in the right ventricle and pulmonary artery; liver was large and presented several bird-shot mainly encysted on the under surface of the right lobe; spleen enlarged and softened.

Contributed by Surgeon E. Bentley, U. S. Vols., General Hospital, Alexandria, Va., Third Division.

No. 65. Lower lobe of left lung, in the most depending portion of which is a large irregular abscess; the pleural surface of the lung covered with a thick layer of lymph; no tubercles present. At the time of the formation of these abscesses, the patient was convalescing from typhoid fever.

A. 5.

Contributed by Surgeon C. Page, U. S. Army, Judiciary Square Hospital, Washington, D. C.

No. 311. Partly collapsed left lung, in the lower portion of the upper lobe of which is a large cavity, lined by a firm membrane; the rest of the tissue of the lung collapsed; no tubercles.

A. 6.

History—Acting Assistant Surgeon R. A. F. Penrose: Private M. M., "B," 3d Michigan, age 20. Admitted, December 12th, 1862, with epilepsy. Having had, since April, 1862, while in the regiment, five or six "fits;" none in the hospital; was pale, weak and emaciated. 16th, went to bed complaining of a severe cold and sore throat; skin hot; pulse 115. 17th, slight dullness on percussion, and crepitant rale indistinctly heard over lower lobe of left lung. 18th, pain in left side. 20th, pulse 108; tongue clean; very much better; expectoration becoming white, though still preserving a pneumonic

character, which had existed since the 16th; lung dull on percussion. 26th, became suddenly worse; pulse 145; very feeble; respirations sixty per minute; universal dullness on percussion and enormous expectoration of matter of the color and consistency of custard. Died, February 1st, 1863.

Autopsy: No emaciation; dilatation of right ventricle of heart; its walls two lines thick; its cavity contained a large white clot; pericardium contained about a gill of liquid; left lung, attached by its anterior border to the front of the chest, completely collapsed, though the upper lobe was still pervious to air; the back part of the pleural cavity lined with a thick pseudo-membrane, and contained several quarts of pus; an abscess-cavity, lined with the same kind of membrane, and holding about half a pint of pus, in the lower lobe of the lung; bronchial mucous membrane was inflamed, but there appeared to be no inflammation of the remaining lung tissue; liver large, light brown and flabby; spleen large, soft, dull red, flabby; mucous membrane of the ileum inflamed, its general redness accompanied with one patch of intense redness about eighteen inches long, with several large ecchymosed spots; moderate inflammation of colon.

Contributed by Acting Assistant Surgeon J. Leidy, Satterlee Hospital, Philadelphia, Pa.

No. 684. Left lung, with an abscess-cavity the size of a hen's egg in the posterior part of its lower lobe.

A. 7. H. J., colored, age 15. Admitted, October 20th, 1865. Died, December 20th. Diagnosis—anasarca and diarrhœa.

Autopsy twelve hours after death: Height, five feet four inches; weight, about one hundred pounds; emaciation extreme; rigor mortis partial; one drachm of fluid in each lateral ventricle; four ounces of fluid in posterior fosse of cranium; right lung adherent to pleura costalis by a few fibrous bands; gray hepatization of its lower lobe; posterior portion of upper lobe congested; anterior portion emphysematous; no effusion in pleural cavity; left lung adherent to pleura costalis; abscess as described; no tubercles; pericardium contained four ounces of clear serum; heart small and dark; nutmeg liver; spleen congested; right kidney, nine and a half ounces in weight, very large, granular, and fatty; left kidney weighed ten ounces and in same condition as right; congestion of mucous membrane of stomach, duodenum and jejunum; mucous coat of ileum thickened; its villi hypertrophied; ulceration of its solitary follicles; mucous coat of cæcum and colon thickened with ulceration of the solitary follicles.

From Freedman's Hospital, Washington, D. C.

Autopsy by Hospital Steward S. S. Bond.

680 to 683, chap. IV., sec. 3, I. 42 to 45, *ulceration of solitary follicles of ileum and colon*; 685, chap. V. sec. 1, B. 4, *Bright's disease of kidneys, are also from this case.*

No. 315. Section of lower lobe of right lung, presenting on its surface a number of small abscesses; the tissue of the lung, when received, was in a state of red hepatization; pleura thickened and roughened.

A. 8.

Private J. B. T., "H," 6th Michigan Cavalry, age 32. Admitted, February 13th, 1864, with pleuro-pneumonia

consecutive to measles. Died, February 29th.

Autopsy: Lung as described; fatty degeneration of kidneys.

Contributed by Surgeon E. Bentley, U. S. Vols., General Hospital, Alexandria, Va., Third Division.

No. 871. Right lung, presenting an abscess about an inch in diameter in lower anterior portion of middle lobe.

A. 9.

See 773, chap. 1, sec. 1, D. 7, for history.

B. Pyæmic foci.

No. 807. Portions of lower lobe of left lung containing a number of small pyæmic foci, about the size of peas.

B. 1.

E. G., colored, age 13. Admitted, January 21st, 1866. Diagnosis—scrofula. February 23d, two abscesses in groin. April 29th, diarrhœa. May 6th, cough. Died, May 14th.

Autopsy four hours after death: A well-formed mulatto boy; weight, about ninety pounds; height, four feet nine inches; extremely emaciated; no rigor mortis; two abscesses in left groin below Poupart's ligament; considerable effusion beneath arachnoid; two drachms of fluid in each lateral ventricle; substance of brain congested, but firm; four ounces of serum in posterior fosse of cranium; left lung contained a number of dark, hard, pyæmic foci; one and a half ounces of clear serum in pericardium; heart flabby, white clots in all the cavities; liver firmly adherent at all points, externally covered with a thick layer of lymph; stomach and intestines agglutinated together into one conglomerate mass by chronic peritonitis.

From Freedman's Hospital, Washington, D. C.

Autopsy by Hospital Steward S. S. Bond.

796, chap. IV., sec. 4, C. 3, *intestines bound together by peritonitis, is also from this case.*

No. 818. Upper and middle lobes of right lung, fused together anteriorly, containing numerous metastatic foci, from the size of a pea to that of an acorn.

B. 2.

C. W., colored. Admitted, June 23d, 1866. Diagnosis—typhoid fever. Died, July 1st.

Autopsy eighteen hours after death: Rigor mortis very strong; African; well developed; curly hair; right hand slightly swollen, and cuticle loosened by action of poultices; middle finger of right hand suppurating and discharging by three circular openings

on the back of the hand; height, five feet six and three-quarter inches; weight, about one hundred and thirty-five pounds; infarcted edges of lower lobe of left lung consolidated; lymph on lower external surface; metastatic foci interspersed throughout both lungs; weight of right, twenty-five and a half ounces; of left, twenty-four and a half ounces; no abnormal fluid in cavity of chest; heart enlarged; fibrin clots in all the cavities; left ventricle enlarged and thickened; spleen very black and soft; metastatic abscesses in kidneys; bone, periosteum, tendons, &c., of right hand sound; a number of small, circum-scribed abscesses full of pus, three of which had opened, on the back of the hand.

From Freedman's Hospital, Washington, D. C.

Autopsy by Assistant Surgeon E. Bentley, U. S. Army.

C. Pleurisy.

No. 312. Right lung partially collapsed; its lower lobe thickly coated with pseudo-membranous lymph, with occasional patches over the rest of the surface.

C. 1. Private J. H. McM., "K," 5th Pennsylvania Cavalry, age 19. Admitted, March 11th, 1861, with pleurisy consecutive to measles. Died, March 23d.

Autopsy: Right lung partly collapsed; its tissue somewhat friable; its surface bright crimson; coated with lymph, as described; larynx and trachea filled with tenacious mucus; the mucous membrane inflamed.

Contributed by Surgeon E. Bentley, U. S. Vols., General Hospital, Alexandria, Va., Third Division.

No. 526. Left lung, the anterior portion coated with pseudo-membrane, by which it adhered to the anterior parietes of the chest; the posterior portion of the lung but slightly altered; this unaltered portion corresponded to the seat of a considerable serous effusion, by which the lung was compressed.

Private B. B., 5th Maryland. Died, February 9th, 1865.

Contributed by Acting Assistant Surgeon W. C. Miner, General Hospital, Alexandria, Va., Third Division.

No. 310. Right lung, collapsed and coated by a thin layer of pasty lymph.

C. 3. Private R. W., "G," 9th Michigan Cavalry, age 22. Admitted, April 18th, 1861. Died, April 25th.

Autopsy: Right lung as described; cavity of chest filled with serum; left lung with military tubercles in its upper portion, lower portion hepatic; heart flabby and containing large heart clots; effusion in pericardium; mucous membrane of intestines inflamed; kidneys enlarged.

Contributed by Acting Assistant Surgeon B. B. Miles, Jarvis Hospital, Baltimore, Md.

No. 339. Left lung, collapsed and coated with thick pseudo-membranous lymph. The patient had been under treatment for chronic pleurisy. There was a considerable quantity of purulent fluid in the cavity of the chest.

C. 4. Contributed by Acting Assistant Surgeon T. Cunningham, Shesburne Barracks, Washington, D. C.

No. 133. Right lung collapsed, its convex surface thickly coated by pseudo-membranous lymph.

C. 5. Corporal E. C., "D," 15th Pennsylvania, age 24. Admitted, October 30th, 1861, with chronic diarrhoea. Was extremely emaciated, with frequent pulse, and five or six loose dejections daily. November 11th, attention was drawn to a dry cough at night, with frequency of respiration. Died, November 18th.

Autopsy: Right pleural cavity contained one gallon of sero-purulent fluid; lung compressed as described; fifth, sixth, and seventh ribs, denuded of periosteum, were bathed in pus; on the upper surface of the liver was a large abscess, communicating with the pleural cavity by an opening in the diaphragm three by four inches in diameter; mucous membrane of lower part of ileum coated with pseudo-membrane and presented a number of small follicular ulcers; Peyer's patches slightly thickened; colon presented a number of follicular ulcers, the edges of many of which were covered with pseudo-membrane; mesenteric glands enlarged.

Contributed by Surgeon T. R. Crosby, U. S. Vols., Columbian College Hospital, Washington, D. C.

E35 and E37, chap. IV., sec. 3, 4, 5 and 6, follicular ulcers of caecum and colon; E35, chap. IV., sec. 5, C. 2, abscess of liver; E31, chap. VI., sec. 2, No. 1, seventh rib denuded of periosteum, are also from this case.

No. 331. Right lung, with trachea, bronchus and portion of thickened pleura attached; the lung is collapsed to the size of a fist, and coated with a thin layer of lymph.

C. 6. T. K., "B," 14th New York Militia. Died, December 17th, 1862.

Autopsy: No emaciation; right lung as described; cavity of pleura contained about a gallon and a half of pus; left lung somewhat inflated, especially along the anterior border; its bronchial mucous membrane inflamed, and the bronchia filled with mucus; liver indented by the purulent accumulation of right pleura, and the interlobular vessels much congested; oesophagus rather lighter pink than natural, with several patches of moderate inflammation accompanied by ecchymosis; caecum inflamed, rose red, with a multitude of ecchymoses about the size of pin-heads; several irregular small patches of follicular inflammation, accompanied by ecchymosis, in colon.

Contributed by Acting Assistant Surgeon J. Leidy, Satterlee Hospital, Philadelphia, Pa.

No. 521. Portions of the ribs of the left side, with a part of the lung adherent anteriorly; posteriorly, the lung, which is coated with pseudo-membrane and somewhat collapsed, is separated from the pleura costalis, which is similarly coated. A glass rod is passed through the orifice between the six and seventh ribs, by which the pus was evacuated.

Private G. F. B., "F," 14th New York Heavy Artillery, age 18. Admitted, December 28th, 1864. Diagnosis—pneumonia. Towards the close of January, 1865, he became convalescent. February 20th, was attacked with pain in the side attended by fever and cough. 21st, fever worse; pains more severe; friction sound over the heart. 23d, headache and slight oedema of the limbs. 23d, pulse accelerated; dyspnoea; cough and expectoration of glairy mucus. 25th, pain much increased, marked dullness in percussion over the left side. 27th, pain somewhat diminished, but very weak. March 6th, an abscess pointed between the sixth and seventh ribs; it was opened March 8th, and discharged two quarts of pus. Died, March 12th.

Autopsy—(Acting Assistant Surgeon Ensign): Left lung, collapsed, adherent anteriorly; posteriorly, the chest full of purulent liquid, which had discharged anteriorly as described; between the fourth and fifth ribs, the pus had found its way through the intercostal muscles, but had not penetrated the skin; the pericardium contained some purulent fluid, and both pericardium and heart were coated with tough layers of yellow lymph.

Contributed by Surgeon N. R. Mosely, U. S. Vols., Emory Hospital, Washington, D. C.

D. Tubercles in the lungs.

No. 667. Section of lower lobe of right lung, containing miliary tubercles (gray granulations).

D. 1. Private J. D., 31st U. S. Colored. Admitted, September 16th, 1865. Had suffered from consumption several months. Was weak, unable to sit up, and coughed frequently. October 29th, was attacked with pleurisy. November 3d, pulse 110, weak, irregular; night sweats. 9th, feet oedematous. Died, November 14th.

Autopsy: Large effusion of serum in right pleural cavity; adhesions of both lungs; five ounces of serum in pericardium; large tubercular masses in upper lobes of both lungs; in lower lobes gray granulations; tubercles on the surface of the spleen, and scattered through its substance.

Contributed by Surgeon E. Bentley, U. S. Vols., General Hospitals, Alexandria, Va.

No. 101. Section of lower lobe of left lung, stuffed with numerous crude tubercles. When received, the tubercles were of a bright yellow color, but not materially softened.

D. 2. History—(Acting Assistant Surgeon David L. Haight): Private M. C., 1st Michigan Cavalry. Admitted, June 27th, 1864, immediately after a hæmorrhage from the lungs. During the two days following his admission he had several attacks of pulmonary hæmorrhage, losing, in all, over two quarts of blood. He was in good condition, weighing one hundred and eighty pounds, and stated that he had had no cough. His mother had died of consumption. A short time after admission the physical signs of phthisis were recognized. The disease ran a rapid course, and he died August 27th. He had lost fifty or sixty pounds during his illness.

Autopsy: Both lungs adherent and infiltrated with yellow tubercles; the left lung more diseased than the right, with a small cavity at its apex.

Contributed by Assistant Surgeon W. Thomson, U. S. Army, Douglas Hospital, Washington, D. C.

No. 105. Section of upper and middle lobes of right lung, presenting a number of moderate-sized, discrete, cheesy tubercles. The patient had low fever and delirium, an abscess over the parotid, and cold abscesses of the subcutaneous tissue at various points. He was apparently convalescing, though still suffering from diarrhoea, when erysipelas set in, and he died.

Autopsy: Tubercles of the lungs and ulceration of the colon.

Contributed by Acting Assistant Surgeon D. L. Haight, Douglas Hospital, Washington, D. C.

406, chap. IV., sec. 3, L. 38, *follicular ulceration of the colon, is also from this case.*

No. 127. Section of upper lobe of left lung, infiltrated with cheesy tubercles.

D. 4. See 432, chap. II., sec. 3, B. 4, *for history.*

No. 192. Right lung with two lobes; a few tubercles at its apex.

D. 5. Private J. H., 7th New York Cavalry. Admitted, January 31st, 1865. Died, February 8th, 1865, of phthisis, consecutive to camp fever.

Autopsy: Right lung as described; left lung contained a number of large vomice; ileum of a grayish slate-color, the villi hypertrophied; at the apex of each villus a black point from deposit of pigment; Peyer's patches had been ulcerated away, and were in every stage of cicatrization, the ulcers being smooth, the gut around them puckered; colon cream colored, the solitary follicles black with pigment, and a minute depression on each.

Contributed by Acting Assistant Surgeon W. C. Miner, General Hospital, Alexandria, Va., Third Division.

189 to 491, chap. IV., sec. 3, H. 5 to 7, *cicatrizing ulcers of ileum, are also from this case.*

No. 607. Section of upper lobe of right lung, containing numerous tubercles, pleural surface covered with old adhesions. This specimen illustrates well the manner in which tubercular masses of the lungs enlarge; each tubercular mass of any size on the face of the section being, as a rule, surrounded by a number of smaller outlying tubercles.

J. M., colored, age 25; height, five feet ten inches; weight, about one hundred and forty pounds. Died, August 25th, 1865, having been admitted several months previously.

Autopsy nine hours after death: Rigor mortis marked; about three ounces of serum in pericardium; small calcareous formations on free edges of aortic valves; lungs firmly adherent, with yellow tubercles, as in specimen; a cicatrix-like depression the size of a half-dime on lower lobe of right lung; minute hard tubercles in spleen.

From Freedman's Hospital, Washington, D. C.

Autopsy by Hospital Steward A. J. Schaffert.

No. 691. Transverse section of lower lobe of left lung, infiltrated with masses of yellow tubercle.

D. 7. L. C., colored woman, age unknown. Admitted, December, 23d, 1865, with consumption and anasarca. 26th, diarrhoea. Died, January 29th, 1866.

Autopsy twenty-six hours after death: Malatto; height, five feet one inch; weight, one hundred and ten pounds; no rigor mortis; right lung congested and filled with gray tubercle, weight twenty-two ounces; about one pint of serum in right pleural cavity; upper lobe of left lung contained numerous tubercles and vomicae, rest of lung solidified with tubercle, organ adherent at all points, weight thirty ounces; one pint of fluid in left pleural cavity; four ounces of fluid in pericardium; heart contained fibrinous clots in all its cavities; anterior surface of liver covered with lymph; organ studded with miliary tubercles; spleen large, filled with tubercles, anterior surface covered with lymph; omentum filled with tubercles; abdominal cavity distended with fluid; duodenum showed a few solitary follicles ulcerated; jejunum contained similar ulcerations, occurring more frequently; in ileum the ulcerations were very numerous, each Peyer's patch containing a number of distinct ulcers, the spaces between which were slightly thickened; numerous follicular ulcers in caecum, and the whole tract of the large intestine showed, here and there, ulceration of the solitary follicles.

From Freedman's Hospital, Washington, D. C.

Autopsy by Hospital Steward S. S. Bond.

692, *chap. IV., sec. 3, M. 1, tubercular ulceration of ileum*; 693, *chap. IV., sec. 1, E. 1, tubercles of omentum, are also from this case.*

No. 773. Right lung, infiltrated with large masses of cheesy tubercle.

D. 8. J. T., age 43. Admitted, January 23d, 1866, with feet and legs frost-bitten to the knees. Mortification of left leg took place, with line of demarcation half way to the knee. Amputation performed at upper third of leg.

January 28th. Toes of right foot had sloughed off; bones removed by nippers. February 25d, symptoms of consumption recognized. Died, March 28th.

Autopsy ten hours after death: A dark mulatto boy; height, four feet six inches; weight, about fifty pounds; much emaciated; rigor mortis well marked; lower lobe of right lung firmly adherent to pleura costalis and diaphragm; lobes, firmly adherent to each other, contained large masses of cheesy tubercle; anterior portion of lower lobe a mass of tubercle, containing a cavity the size of a walnut; posterior portion hepaticized; weight, twenty-four ounces; left lung, slightly adherent to pleura costalis, contained much tubercle, weight ten ounces; no fluid in cavities; pleura costalis dotted with numerous tubercles; pericardium contained four ounces of serum; heart fatty, all its cavities contained white fibrinous clots; bronchial glands much enlarged, and filled with tubercle; liver covered with lymph superiorly, and filled with tubercle; spleen large, firmly adherent to diaphragm, and almost one mass of tubercle; tubercular ulcers throughout the small intestine, particularly in the lower part of ileum, where Peyer's patches were ulcerated through to the peritoneal coat; caecum and upper portion of large intestine exhibited healed ulcers; a number of large ulcers in rectum, covered with pseudo-membrane; kidneys, each three and a half ounces, and congested; remainder of urino-genitals normal; head not examined.

From Freedman's Hospital, Washington, D. C.

Autopsy by Hospital Steward S. S. Bond.

771, *chap. IV., sec. 3, M. 43, tubercular ulcers of ileum*; 772, *chap. IV., sec. 3, M. 44, ulceration of rectum, are also from this case.*

E. Tubercular Vomicae.

No. 169. Section of left lung, with numerous small, irregular, tubercular abscesses, especially in the upper lobe.

E. 1 Private L. K., 2d Battalion, Veteran Reserves, blacksmith, age 60. Admitted, September 5th, 1864, with emaciation; dullness on percussion over the upper part of left lung; cavernous respiration over the upper lobe of the left lung; most cough and copious mucosanguinolent expectoration; appetite good; bowels regular; pulse 90 to 110. Patient said that for the previous ten or twelve years he had been unable to work at his trade on account of ill health. Had been in service a year, but had done little duty. Died, December 5th.

Autopsy: Great emaciation; extensive pleuritic adhesions, especially on the left side; lungs full of pigment, and as above described; arch of mouth somewhat dilated, and slightly atrophic; spleen small, with minute tubercles on its peritoneal surface.

Contributed by Surgeon Thomas R. Crosby, U. S. Vols., Columbian College Hospital, Washington, D. C.

70, *chap. III., sec. 2, C. 2, cicatrix-like depression on lung*; 71, *chap. IV., sec. 7, C. 2, tubercles of spleen, are also from this case.*

No. 16. Portion of the upper lobe of the right lung, with several communicating tubercular cavities, the longest the size of a walnut; the intervening lung tissue infiltrated with tubercle.

Private J. J. "B." 107th New York, age 46. Admitted, October 18th, 1862. Had been suffering from phthisis one month, but there had been no hæmorrhages. Was much emaciated. Died, November 25th.

Autopsy: Cavities in both lungs, with tubercular infiltration.

Contributed by Acting Assistant Surgeon S. R. Skillern, Summit House Hospital, Philadelphia, Pa.

No. 213. Upper portion of the left lung, with abundant deposit of tubercles: near the apex of the upper lobe is a cavity, with tough walls, the size of an orange.

Private T. T. "E." 1st Connecticut Cavalry, age 23. Admitted, July 25th, 1863, with phthisis pulmonalis. August 18th, severe diarrhœa set in. Died, August 20th.

Autopsy: Body greatly emaciated; two small vomices in the right lung, which was filled with tubercles on the left side; numerous pleuritic adhesions and the cavity described.

Contributed by Assistant Surgeon De Witt C. Peters, U. S. Army, Jarvis Hospital, Baltimore, Md.

No. 309. Portion of the upper lobe of left lung, presenting at its lower part a tubercular cavity about the size of an English walnut.

Private J. C. "H." 11th Kentucky Cavalry, age 53. Admitted, April 18th, 1864. Died, May 31, of phthisis pulmonalis. He was a paroled prisoner.

Autopsy: Tubercles in both lungs, with the cavity described; effusion of a turbid bloody serum in left pleural cavity; adhesions of the right pleura; effusion in the pericardium; spleen soft; kidneys fatty.

Contributed by Assistant Surgeon De Witt C. Peters, U. S. Army, Jarvis Hospital, Baltimore, Md.

No. 611. A portion of left lung, presenting a tubercular abscess, the size of an egg, in the posterior upper portion of lower lobe. This abscess burst into the pleural cavity during life. In the autopsy, pus was found in the cavity of the pleura, with adhesions around a part of the orifice of the abscess.

P. W., colored woman, age 60. Admitted, September 18th, 1865, greatly emaciated, and in a dying condition. Died, September 19th.

Autopsy eighteen hours after death: Rigor; emaciation extreme; weight, about one hundred pounds; height, five feet three inches; much effusion beneath cranium; vessels of pia mater distended with dark blood; two ounces of serum collected in posterior fossæ of cranium; about one drachm of serum in each of the lateral ventricles; brain soft; both cardiac ventricles contained hard yellow clots adherent, and black coagula; hard white tubercles scattered through right lung, its upper lobe engorged with blood, a puckered cicatrix-like depression on the anterior surface of the upper lobe; right pleural cavity contained four ounces of pinkish serum; left lung engorged with blood, and filled with softened tubercular masses about the size of hazel-nuts; abscess cavity as described; left pleural cavity contained about six ounces of bloody pus; spleen small and firm; in ileum numerous ulcers with long diameter transverse to the gut, and small white tubercles on the peritoneal surface, opposite each ulcer; in middle of ileum the large ulcer described in No. 612; solitary follicles of ileum marked by a small speck of pigmentary matter in each; in cæcum and colon the solitary follicles appeared as small black spots with a pin-point puncture in each; scattered here and there in colon were a few superficial ulcers, the size of five-cent pieces, with edges apparently healing; a cystic tumor of the left ovary, about the size of an orange, filled with fat and black hair.

From Freedman's Hospital, Washington, D. C.

Autopsy by Hospital Steward A. J. Schaffhirt.

612, *chap. IV., sec. 3, M. 7, tubercular ulcer of ileum*; 613, *chap. V., sec. 5, C. 4, cyst of ovary containing fat and hair, are also from this case.*

No. 180. Upper lobe of right lung, the cut surface of which shows a large number of minute tubercles; at the top of the lobe is a cavity the size of an orange, with distinct firm walls.

Private J. H. "E." 101th Pennsylvania. Admitted, January 10th, 1865, with phthisis and distressing diarrhœa, muco-purulent expectoration, and great prostration. Died, February 6th.

Autopsy: Tubercles in both lungs, with a cavity in the right as described; pleuritic adhesions on right side; ulceration in the bowels; enlargement of mesenteric glands.

Contributed by Surgeon Thomas R. Crosby, U. S. Vols., Columbian College Hospital, Washington, D. C.

181, *chap. III., sec. 2, G. 1, cicatrix-like depression on lung*; 482 and 487, *chap. IV., sec. 3, M. 25 to 33, tubercular ulceration of the intestines, are also from this case.*

No. 633. Upper lobe of right lung, at the apex of which is a cavity the size of an orange, communicating freely with the bronchial tubes; a number of whalebones have been passed through the bronchial tubes into the cavity.

P. L., colored, age 60. Admitted, October 14th, 1865. Died, October 24th, at 5 a. m.

Autopsy nine hours after death: Rigor mortis partial; height, five feet two and a half inches; weight, about one hundred pounds; emaciation extreme; slight adhesions of left lung to diaphragm and pericardium; cavity in superior lobe; some tubercles present throughout the lung, but not extensive; right lung firmly adherent to walls of chest and diaphragm; cavity in upper lobe as described; substance of lung filled with cheesy tubercle; heart soft, flabby, pale and fat; a large white clot in aorta; aorta dilated one and a half inches in diameter; liver adherent to diaphragm; small quantity of tubercular deposit in the mesenteric glands, and on the adjoining peritoneal surface; tubercular ulceration; thickened mucous membrane and venous congestion in lower portion of ileum.

From Freedman's Hospital, Washington, D. C.

Autopsy by Hospital Steward S. S. Bond.

No. 665. Upper lobe of right lung, in which is a large cavity occupying the greater part of the lobe; through the cavity run isolated bands of lung tissue, which have been elevated on whalebones.
E. 8. J. M., colored, age 19. Admitted, September 19th, 1865, with phthisis. Died, November 11th.
 Contributed by Surgeon E. Bentley, U. S. Vols., General Hospitals, Alexandria, Va.

No. 711. Left lung, containing tubercle and coated with lymph, with an abscess the size of a pigeon's egg in the posterior portion of lower lobe.
E. 9.

P., colored, two and a half years of age. Died, February 19th, 1866.

Autopsy about twenty-four hours after death: Considerable emaciation; no rigor mortis; left lung firmly adherent to pleura costalis; its lower lobe contained the abscess described; the whole lung contained much tubercle; pericardium contained about an ounce of serum; heart large, dark, ecchymosed on its anterior surface; a few minute tubercles on anterior surface of liver; spleen large, contained numerous large tubercles.

From Freedman's Hospital, Washington, D. C.

Autopsy by Hospital Steward S. S. Bond.

715, *chap. IV., sec. 7, G. 11, tubercles of spleen, is also from this case.*

F. Tubercular pleurisy.

No. 675. Transverse section through the left side of the thorax, embracing the fifth and sixth ribs; the lung has a few tubercles scattered through it; the costal and pulmonary pleurae are adherent throughout with delicate fibrous adhesions.
E. 1.

Negro man. Died, December 22d, 1865.

Autopsy two hours after death: Much emaciation; rigor mortis very slight; a well-formed man; height, five feet seven inches; weight, about one hundred pounds; right lung, firmly adherent to pleura costalis and pericardium, filled with conical and tubercles; left lung, with scattered tubercles, also adherent; costiform cartilage bilid; pericardium contained four ounces of bloody serum; heart dark and flabby, the walls of all its cavities extremely thin; liver firmly adherent to diaphragm; left kidney lobulated, with several deposits of tubercle on its upper anterior surface; mucous membrane of stomach and small intestine congested; mucous coat of colon thickened and ulcerated.

From Freedman's Hospital, Washington, D. C.

Autopsy by Hospital Steward S. S. Bond.

676, *chap. VI., sec. 2, No. 1, hyal cartilage, is also from this case.*

No. 621. Section through right side of the chest, embracing a portion of lung with the fourth, fifth and sixth ribs; the lung contains a number of tubercles and is firmly adherent to the walls of the chest by a thick layer of lymph, which has undergone tubercular transformation.
E. 2.

No. 625. Section through the chest on left side of same case, embracing fourth and fifth ribs, the lung containing tubercles; both parietal pleurae and costalis about one-fourth of an inch thick, adherent in most places with lymph which has undergone tubercular transformation.
E. 3.

A man about middle age, greatly emaciated, presenting the rational symptoms of consumption. Died, September, 1865.

Contributed by Acting Assistant Surgeon W. C. Miner, L'Ouverture Hospital, Alexandria, Va.

626, *chap. IV., sec. 4, E. 18, tubercles of the liver; 327, chap. IV., sec. 7, G. 8, tubercles of the spleen, are also from this case.*

No. 567. Sternum, with costal cartilage attached; posteriorly a part of the left lung and the heart; on the left side the lung is adherent to the anterior wall of the chest by a mass of cheesy tubercle, which fills the anterior mediastinum and coats the front of the left lung; the part of the lower lobe of the left lung through which the section is made is converted into an irregular tubercular mass.
E. 4.

R. H., colored. Died, July 7th, 1865.

Autopsy six hours after death: Body quite warm and soft; no rigor mortis; anterior mediastinum filled with a yellowish white cheesy deposit of tubercle; a similar layer coated the anterior and outer surface of the left lung; the cheesy mass invaded the anterior interior angle of the left lung and the diaphragm; the diaphragm was separated from the lung through a part of its extent by a membranous layer of cartilaginous toughness, composed of transforming muscular tissue, in which, however, muscular fibres could still be recognized; the tubercular masses had pushed the heart to the right, so that the apex was at the center of the sternum between the fifth and sixth costal cartilages; pericardial cavity contained no fluid, being almost everywhere a flattened right lung rounded, without adhesions; pericardium contained a little fluid, with some adhesions to the heart; pericardium small, with tubercles about the size of pens.

Contributed by Acting Assistant Surgeon W. C. Miner, L'Ouverture Hospital, Alexandria, Va.

627, *chap. IV., sec. 7, G. 1, tubercles of spleen; 568, chap. VI., sec. 1, No. 2, inflammatory thickening of diaphragm, are also from this case.*

No. 688. Right side of thorax, from third to eighth ribs, inclusive; at the upper section, which passes just above the third rib, the lung is firmly adherent on every side by tough masses of cheesy lymph; at the lower section, which passes just below the eighth rib, the lung is compressed to a thin layer, not more than half an inch in thickness; the thoracic cavity is lined with a layer of cheesy lymph, which, on the costal pleura is more than three-quarters of an inch in thickness; on the pulmonary pleura somewhat thinner; the cavity between the compressed lung and walls of the chest was occupied in the fresh specimen by a purulent fluid, in which floated a large coagulum of tough yellow lymph, which is still preserved in the specimen, although considerably shrunken by the action of the alcohol; this section also passes through the right lobe of the liver, which is firmly adherent to the diaphragm; the diaphragm is much thickened, and converted into a thick, whitish, lardaceous mass, of cartilaginous firmness.

J. J., colored, age 22. Admitted, September 20th, 1865. Diagnosis—*phthisis pulmonalis*. Died, December 25th.

Autopsy twenty-four hours after death: A well-formed, dark unlatto man; height, five feet nine inches; weight, about one hundred and thirty pounds; rigor mortis partial; slight emaciation; vesicular eruption over body; left lung firmly adherent to costal pleura and diaphragm; weight sixteen ounces; somewhat congested; contained a small amount of tubercle; about two ounces of serum in left pleural cavity; right lung adherent as described; pericardium contained six ounces of clear serum; all the valves of heart thickened, white fibrous clots in all the cavities; abdominal viscera agglutinated together by firm peritoneal adhesions.

From Freedman's Hospital, Washington, D. C.

Autopsy by Hospital Steward S. S. Bond.

629, *chap. IV., sec. 4, E. 15, adhesions from tubercular peritonitis, is also from this case.*

G. Cicatrices on surface of lungs.

No. 181. Upper lobe of left lung, presenting on its convex surface a large and much puckered cicatrix-like depression.
G. 1. *See 480, chap. III., sec. 2, E. 6, for history.*

No. 170. Section of lower lobe of right lung, on the convex surface of which is a large cicatrix-like depression; the upper and middle lobes of this lung contained tubercular deposits and small abscesses, which, however, were not so marked as in the left lung.
G. 2. *See 469, chap. III., sec. 2, E. 1, for history.*

No. 511. Portion of the apex of the right lung, showing a puckered cicatrix. On cutting into the tissue from behind, a mass of fibroid tissue was found extending, irregularly, some distance into the substance of the lung.
G. 3.

Private C. W. C., "C," 40th Indiana, age 31. Admitted, October 11th, 1864. Died, October 23d.

Contributed by Acting Assistant Surgeon Herbert, Hospital No. 8, Nashville, Tenn.

No. 736. Upper lobe of right lung, containing much tubercle and a remarkable branched depression, resembling a cicatrix.
G. 4.

See 735, chap. I., sec. 2, B. 2, for history.

II. Cancer of the lungs.

No. 827. Lower lobe of the left lung, presenting a number of rounded melanotic nodules, chiefly in its lower part.
H. 1. At the point where the bronchus enters the lobe are two large oval melanotic nodules, the larger over an inch in long diameter, each enveloped in a distinct membrane.

No. 828. A portion of the lower lobe of the right lung of same patient, presenting a lobulated melanotic mass, about the size of a hen's egg, at its inferior angle.
H. 2.

See 824, chap. II., sec. 3, C. 3, for history.

Chapter IV. DIGESTIVE ORGANS.

Section 1. MOUTH, PHARYNX AND ŒSOPHAGUS.

	NO. OF SPECIMENS.
A. Scorbutic ulcers	5
B. Imperforate œsophagus	1
C. Stricture of œsophagus	1

Section 2. STOMACH.

A. Concentric atrophy of stomach	2
B. Inflammation and ulceration of stomach	7
C. Cancer of stomach	8

Section 3. INTESTINAL CANAL.

A. Diverticula of small intestine	6
B. Invaginations of small intestine	7
C. Anomalies of position with strangulation	2
D. Fever. Cases in which enlargement of solitary follicles of small intestine is the prominent lesion	41
E. Fever. Cases in which thickening and ulceration of Peyer's patches is the prominent lesion	61
F. Fever. Pulpy thickening and sloughing of Peyer's patches	17
G. Fever. Perforations and peritonitis	21
H. Fever. Granulation and cicatrization of the ulcerated Peyer's patches	13
I. Fever and dysentery. Lesions of both ileum and colon	89
K. Concentric atrophy of colon	1
L. Ulceration of colon. Dysentery, including cases commonly designated camp diarrhœa	116
M. Tubercular ulceration of intestines	45
N. Parasites in intestinal canal	11

Chapter IV. DIGESTIVE ORGANS—Continued.

Section 4. PERITONEUM AND OMENTUM.

	NO. OF SPECIMENS.
A. Atrophy of omentum	1
B. Abscess	1
C. Peritoneal adhesions	8
D. Connective tissue growths	2
E. Tubercle	18
F. Cancer	4

Section 5. LIVER.

A. Anomalies of form	2
B. Cirrhosis	5
C. Abscess	6
D. Metastatic foci	4
E. Tubercle	8
F. Cancer	11
G. Cysts	2
H. Diseases of gall-bladder	2
I. Biliary calculi	6

Section 6. PANCREAS.

A. Cancer	1
-----------------	---

Section 7. SPLEEN.

A. Anomalies of form	1
B. Atrophy	2
C. Hypertrophy	5
D. Diseases of capsule	4
E. Metastatic foci	3
F. Tumors	1
G. Tubercle	16

Chapter IV. DIGESTIVE ORGANS.

Section I. MOUTH, PHARYNX AND ŒSOPHAGUS.

A. Scorbatic ulcers.

- No. 1.** An inch and three-fourths of inferior maxillary bone, taken at symphysis, with soft parts attached; gum and periosteum dissected by a scorbatic ulceration, which separates them from the bone anteriorly and posteriorly to the distance of half an inch below alveolar process.

From a patient who died in Marine Hospital, New Orleans, in 1862; one of a number of fatal cases in same hospital, in which gangrenous ulceration of mouth and throat occurred in debilitated and anæmic (scorbatic) men.

Contributed by Acting Assistant Surgeon R. K. Browne, Marine Hospital, New Orleans, La.

For specimens from similar cases, see 6, chap. III., sec. 1, A. 2, ulceration of larynx; 2, chap. IV., sec. 1, A. 2, ulceration of gums; 3, chap. IV., sec. 1, A. 3, ulceration of tonsils; 4, chap. IV., sec. 1, A. 4, ulceration of tonsils; 5, chap. IV., sec. 1, A. 5, ulceration of tonsils.

- No. 2.** Right lateral half of inferior maxillary bone, with part of tongue attached; a scorbatic ulcer between molars and tongue has denuded the bone of periosteum.

See remarks on 1, chap. IV., sec. 1, A. 1.

Contributed by Acting Assistant Surgeon R. K. Browne, Marine Hospital, New Orleans, La.

- No. 3.** Larynx, posterior third of tongue, half-arches and tonsils, with scorbatic ulceration of tonsils, especially on right side.

See remarks on 1, chap. IV., sec. 1, A. 1.

Contributed by Acting Assistant Surgeon R. K. Browne, Marine Hospital, New Orleans, La.

- No. 4.** Larynx, posterior third of tongue, half-arches and tonsils; both tonsils the seats of foul, irregular and gangrenous ulceration.

See remarks on 1, chap. IV., sec. 1, A. 1.

Contributed by Acting Assistant Surgeon R. K. Browne, Marine Hospital, New Orleans, La.

- No. 5.** Larynx, posterior third of tongue and half-arches, with ulceration of tonsils, especially on right side, where the tonsil is foul and gangrenous; mucous follicles at root of tongue much enlarged, with gaping orifices.

See remarks on 1, chap. IV., sec. 1, A. 1.

Contributed by Acting Assistant Surgeon R. K. Browne, Marine Hospital, New Orleans, La.

B. Imperforate œsophagus.

- No. 812.** Cul-de-sac, from a case of imperforate œsophagus, in which upper portion of tube terminated on a level with bifurcation of trachea; lower portion of œsophagus communicated above with posterior surface of bifurcation of trachea. The child lived to be eleven days old; was able to swallow small quantities of liquid, which produced gurgling sound in passing through trachea. Died, September 16th, 1866.

Contributed by Surgeon Charles H. Lamb, U. S. Army, Soldier's Home, Washington, D. C.

C. Stricture of œsophagus.

- No. 193.** Larynx and trachea, with part of œsophagus and arch of aorta attached; considerable thickening of coats of œsophagus, extending from two inches below larynx to level of bifurcation of trachea; a stricture is thus formed, barely permitting passage to a small flexible probe; small fistulous orifice leading off from upper part of stricture to the right.

From the body of a pauper who died in 1856. Cause of disease appears to have been caries of cervical vertebrae, the inflammation extending to œsophagus, which was adherent to vertebrae posteriorly, and anteriorly to trachea. On opening stricture, in preparing specimen, a quantity of coffee-ground was found in the passage.

Contributed by Surgeon H. Culbertson, U. S. Vols., Harvey Hospital, Madison, Wis.

Section 2. STOMACH.

A. Concentric atrophy of stomach.

No. 63. Stomach, contracted to a tube about an inch in diameter in pyloric half, and about two inches in diameter at largest part of greater curvature.

A. 1. Private C. C. "K," 104th Pennsylvania, American, age 30. Admitted, August 9th, 1862, with chronic gastro-itis contracted in Army of the Potomac. Died, August 23d.

Autopsy: Body exceedingly emaciated; considerable ecchymosis diffused over an extent of about six inches around scrobiculus cordis; a suppurating sinus, about four inches long, between scalp, temporal fascia and frontal bone, extending from front of ear to side of forehead; bone not necrosed, and sinus appeared to have resulted from contusion; stomach, in pyloric half, contracted to an inch in diameter, and in a corresponding degree in cardiac half; small intestine moderately contracted; transverse colon distended with air; inflammation of mucous membrane of ileum and colon, and in descending portion of latter a number of blackish ulcers; intestinal glands contained deposit of black pigment.

Contributed by Acting Assistant Surgeon J. Leidy, Satterlee Hospital, Philadelphia, Pa.

61. chap. IV., sec. 3, L. 13, follicular ulcers of colon, is also from this case.

No. 786. Stomach, contracted to the capacity of three ounces.

A. 2. E. P., age 26. Admitted, April 10th, 1866, with intense pain over front of thorax, constant cough, feeble pulse, and patient very weak. Died, April 13th.

Autopsy six hours after death: A well-formed negro man; height, five feet three inches; weight, one hundred and twenty pounds; rigor mortis partial; slight emaciation; posterior portion of right lung congested; organ composed of but two lobes imperfectly marked; left lung covered with crumpled lymph; posterior portion of lower lobe slightly oedematous; one of the bronchial glands converted into a cyst, filled with pyoid fluid; bronchi filled with frothy mucus; large white fibrinous clots in all the cavities of heart; slight atheroma of aorta; two ounces of fluid in pericardium; liver nutmeg; spleen small; kidneys fatty; stomach as described; mucous membrane of small intestine congested, with much pigmentary deposit; Peyer's patches presenting the shaven-head appearance.

From Freedman's Hospital, Washington, D. C.

Autopsy by Hospital Steward S. S. Bond.

B. Inflammation and ulceration of stomach.

No. 363. Portion of greater curvature of stomach, thickened with conspicuous rugae, and coated with pseudo-membrane.

B. 1. Private L. H. J., 1st Connecticut Light Battery, age 22. Received an injury from limb of gun in fall of 1863; subsequently suffered from pain in epigastric and left hypochondriac regions, distress, fainting, nausea and vomiting after eating. Admitted to Second Division, Beaufort Hospital, April 3d, 1864, and transferred to First Division May 17th, with dyspepsia and diarrhoea. Died of chronic diarrhoea, July 17th.

Contributed by Assistant Surgeon C. T. Reber, U. S. Vols., General Hospital, Beaufort, S. C., First Division.

No. 653. Part of greater curvature of stomach, thickened and with numerous minute follicular ulcers.

B. 2. Private T. E. (H. B.), 17th United States Infantry. Admitted, July 6th, 1864, and died, August 26th, 1864, of chronic gastritis complicating chronic diarrhoea.

Contributed by Surgeon William Watson, U. S. Vols., Post Hospital, Rock Island, Ill.

No. 272. Portion of stomach, with numerous small ulcers of solitary follicles distributed over lesser curvature.

B. 3. Private C. B. D. "B," 17th United States Infantry. Admitted, August 10th, 1862, from the Army of the Potomac. Diagnosis—"Typhus."

Autopsy: Body well made; now about 22; moderately emaciated; skin of trunk discolored by diffused ecchymosis; two erysipeloid spots near base of heart; stomach with some inflammation of mucous membrane near pylorus, and some small ulcers, about a line in diameter, along lesser curvature; inflammation of ileum in patches; solitary glands enlarged; a few of Peyer's glands slightly thickened, but none necrosed; mucous membrane of colon somewhat slate-colored, with patches of inflammation, a number of ecchymoses about half an inch in diameter, and, in descending colon, some small, stellate, follicular ulcers.

Contributed by Acting Assistant Surgeon J. Leidy, Satterlee Hospital, Philadelphia, Pa.

55 to 62, chap. IV., sec. 3, D. 46 to 49, enlarged solitary follicles and thickened Peyer's patches, are also from this case.

No. 478. Portion of greater curvature of stomach, showing a number of minute ulcers.

E. 4. History—(Assistant Surgeon G. H. Baker, 20th Maine): Sergeant A. S., "A," 107th Pennsylvania, age 32. Admitted from Division Hospital at the front, January 17th, 1865, in a state of collapse. About ten days before, he passed suddenly a pint or more of blood; has since had bloody and muco-purulent stools at short intervals; superficial veins on right side of abdomen and thorax much enlarged; decubitus on right side, with feet drawn up and head elevated; evacuations small and frequent, of a dark grumous character and foetid smell. Died, January 24th.

Autopsy: Height, five feet ten inches; complete adhesion of both lungs, with deposits of tubercle in apices of both; a large abscess in under portion of liver, containing about a quart of pus; no adhesion of liver to abdominal parietes; stomach as in specimen; slight thickening of Peyer's patches; colon thickened and ulcerated.

Contributed by Surgeon W. L. Faxon, 32d Massachusetts, Depot Hospital, 5th Army Corps, City Point, Va.

No. 768. Portion of stomach, taken near pyloric orifice, presenting a cyst about the size of a pea, with thick walls;

E. 5. it contained pus. (*See Microscopical Section, Part First, VII.* G. c. 1.)

J. W., colored, age 23. Admitted, January 10th, 1865. Died, March 26th.

Autopsy thirty hours after death: A well-formed mulatto man; height, five feet eleven inches; weight, about one hundred and eighty pounds; oedema of abdomen; slight oedema of lower extremities; rigor mortis partial; left lung contained much miliary tubercle; posterior portion congested; four ounces of fluid in left pleural cavity; lower lobe of right lung firmly adherent, its posterior portion slightly congested; lung filled with miliary tubercle; sixteen ounces of fluid in right pleural cavity; bronchial glands tubercular; tricuspid valve slightly thickened; walls of left ventricle one and a quarter inches in thickness; aortic and mitral valves slightly thickened; aorta atheromatous; fibrinous clots in all the cardiac cavities, organ somewhat fatty; pericardium contained eight ounces of serum; liver filled with miliary tubercles; spleen very large, weight fifty-four ounces, filled with miliary tubercle; omentum congested and filled with tubercle; mesenteric glands enlarged and tubercular; abdominal cavity contained four pints of serum; stomach with cyst as described; solitary follicles in lower part of ileum much enlarged; Peyer's patches thickened; caecum with numerous sloughing ulcers; remainder of large intestine contained much pigmentary deposit, but not ulcerated; kidneys fatty.

From Freedman's Hospital, Washington, D. C.

Autopsy by Hospital Steward S. S. Bond.

767, chap. IV., sec. 7, G. 15, *large tubercular spleen*; 769, chap. IV., sec. 3, L. 71, *sloughing ulcers of caecum, are also from this case.*

No. 631. Part of stomach, including pyloric orifice and commencement of duodenum, about three and a half inches

E. 6. from pylorus; mucous membrane of greater curvature of stomach presents an oval ulcer about half an inch in diameter, with perpendicular edges, penetrating to muscular coat; a few minute follicular ulcers in duodenum.

See 637, chap. I., sec. 1, E. 6, for history.

No. 498. Part of stomach and duodenum; small oval ulcer has perforated stomach near pyloric valve; similar ulcer

E. 7. has perforated duodenum, just below valve.

D. B. L., mechanic, age 35. Died of peritonitis consequent upon the perforations, shortly after eating a

hearty meal.

Contributed by Surgeon H. Culbertson, U. S. Vols., Harvey Hospital, Madison, Wis.

C. Cancer of stomach.

No. 66. Lobulated carcinomatous mass surrounding lower three inches of œsophagus, involving, also, diaphragm

C. 1. and cardiac orifice of stomach.

No history.

Contributed by Acting Assistant Surgeon H. W. Ducachet, Fairfax Seminary Hospital, Va.

No. 291. Portion of greater curvature of stomach, presenting at its centre a flat, cauliflower-like, carcinomatous tumor,

C. 2. two and a half inches in diameter.

History—(Acting Assistant Surgeon H. M. Dean): P. S., "H," 2d Pennsylvania Cavalry, age 45. Admitted, February 13th, 1864, with cancer of liver and stomach. Had been in the army about seventeen years. Was wounded at Buena Vista, Chapultepec, Antietam, and at Gettysburg. Enjoyed good health until December, 1863. There was tenderness on pressure over region of liver, which was much enlarged; patient anæmic; had slight anasarca of lower extremities. 29th, had a very severe spell of vomiting. March 11th, anasarca general; thighs swollen to twice their original dimensions; serotum and prepuce much distended. Subsequently, effusion took place into abdominal cavity; vomiting continued; with these exceptions, he remained about the same until death. Died, March 20th.

Autopsy—(Acting Assistant Surgeon W. M. James): Height, five feet ten inches; body emaciated; general anasarca; each pleural cavity contained about one pint of serum; several hard deposits of cancerous matter on surfaces of both lungs and scattered through their tissue, from the size of a pin-head to that of a pea; pericardium contained two and a half ounces of

serum; adipose tissue covering heart infiltrated with serum; aortic valves contained calcareous deposits; a like deposit in free margin of mitral valve; calcareous deposits in descending aorta and iliacs; abdomen contained five quarts of serum; liver full of cancerous growths; measured eleven and a half by nine by five inches, and weighed eight and three-quarter pounds, extending from middle of sixth rib, on right side, and upper margin of eighth, on left side, downwards to within an inch of umbilicus; its upper surface adherent to diaphragm by elevated cancer nodules, varying in diameter from a half inch to one and a half; firmly adherent below to transverse colon, stomach, and duodenum; cancerous tumor, an inch and a quarter long by three-quarters of an inch wide, near centre of pancreas, of firm consistence, whitish centrally, pinkish toward margins; below this tumor another, similar in character and dimensions, also firmly connected with pancreatic tissue; stomach as described. Microscopic examination showed a well-developed fibrous stroma, in the meshes of which numerous large nucleated cells were embedded; stroma, at periphery of lobules, continuous with connective tissue of liver.

Contributed by Assistant Surgeon J. C. McKee, Lincoln Hospital, Washington, D. C.

292 to 291, *chap. IV., sec. 5, F. 3 to 5, sections of cancerous liver, are also from this case.*

No. 813. Stomach, presenting cancerous thickening extending from pyloric orifice about three inches towards greater curvature; surface of cancerous growth nodulated, in some places ulcerated.

C. 3.

W. M. Admitted to Soldier's Home, July 16th, 1866, and to hospital, August 2d, suffering from an obscure abdominal affection, with obstinate vomiting. Died, August 2th.

Autopsy: Deposit of fat around base of heart, slight atheroma of aorta just above valves; pylorus found in hypogastrum, just above summit of bladder, which was empty, the stomach enormously distended by its contents, and as described; left lobe of liver, spleen, pancreas, lesser curvature of stomach and diaphragm inter-adherent; no perforation was found.

Contributed by Surgeon C. H. Lamb, U. S. Army, Soldier's Home, Washington, D. C.

No. 69. Pyloric extremity of stomach, with a small portion of duodenum, exhibiting a group of mulberry-like carcinomatous growths on mucous membrane of stomach near pylorus.

C. 4.

Private M. B., "C." 1st U. S. Cavalry, age 32; height, five feet eight inches. Had suffered from chronic diarrhoea for six months. When he came under my charge, shortly before death, his complexion was sallow; there was extreme emaciation; no appetite; great thirst; occasional vomiting; pain in epigastrium; fugitive pains in abdomen; tenderness on pressure over colon; slight tympanites; frequent dark fluid, but generally painless passages; slight cough; fine mucous rale on right side in mammary region; feeble action of heart and wandering intellect. Died, April 11th, 1863.

Autopsy: A small portion of anterior part of upper lobe of left lung examined; hypostasis and friability posteriorly in lower lobe of right lung; lung pigment abundant; pleura somewhat thickened, and presented numerous white spots resembling milinary tubercles; two ounces of serum in pericardium; heart flabby; small dark clots in both ventricles; mesenteric glands much enlarged, nearly pure white on section, internally softened; stomach as described; colon much thickened, whitish on section, with follicular ulcers and scattered pseudo-membranous patches throughout its whole extent.

Contributed by Assistant Surgeon Geo. M. McGill, U. S. Army, Camp Allen, Falmouth, Va.

70, *chap. IV., sec. 3, L. 54, follicular ulcers of colon, is also from this case.*

No. 10. Pyloric extremity of stomach, the orifice surrounded by an irregular carcinomatous mass, the size of a small orange.

C. 5

No history.

Contributed by Surgeon J. H. Baxter, U. S. Vols., Campbell Hospital, Washington, D. C.

No. 537. Pyloric extremity of stomach, thickened into irregular cancerous nodules; a number of lymphatic glands, connected into large medullary masses are attached.

C. 6.

Private T. R., "G." 64th New York, age 55. Admitted, February 8th, 1865, from City Point, Va., with evident induration and enlargement of liver. At various times, complained of pain over region of liver; general health and appetite good. Died suddenly, March 13th.

Autopsy: Outer layer of peritoneum thickened; omentum highly injected; liver enormously enlarged, crowding intestine downwards, lungs and heart upwards, and stomach far over to left side; organ filled with numerous hard spherical nodules of a dirty yellow color, some flattened and others concave externally, varying in size from one-eighth of an inch to three inches in diameter, and occupying nearly the whole peritoneal cavity; organ adherent to diaphragm, stomach, spleen, and transverse colon; stomach as described; small encysted tumor adherent to diaphragm and pericardium.

Contributed by Surgeon Thomas Sim, U. S. Vols., Patterson Park Hospital, Baltimore, Md.

537 and 539, *chap. IV., sec. 5, F. 7 and 8, nodillary cancer of liver, are also from this case.*

No. 719. Pyloric extremity of stomach thickened into an irregular cancerous mass, extending about four inches from the pylorus; inner surface irregularly nodulated and in some places ulcerated; no adhesion. The growth is chiefly composed of narrow spindle-shaped cells.

C. 7.

W. G., age 57. Admitted, November 27th, 1866. Died, January 29th, 1866.

Autopsy forty-eight hours after death. A well-formed dark mollate; height, six feet; weight, about one hundred and fifty pounds; some emaciation; rigor mortis past; astrophytes in peritoneum granulations; right lung contained much pigment; middle lobe hepatized; lower lobe congested; left lung adherent to pleura costalis; its lower lobe congested; two ounces of serum in left pleural cavity; valves of heart thickened; aorta dilated and atheromatous; five ounces of fluid in pericardium;

a cyst of some size on under surface of left lobe of liver at anterior edge of longitudinal fissure, filled with dark-colored blood, and a smaller cyst on same surface; right kidney contained a black calculus, the size of a small pea; left kidney contained a few small cysts; stomach filled with a fluid resembling coffee-grounds; pyloric portion as described; intestines throughout contained much black pigment; solitary follicles enlarged in lower portion of ileum; ensiform cartilage bilid.

From Freedman's Hospital, Washington, D. C.

Autopsy by Hospital Steward S. S. Bond.

No. 188. Pyloric portion of stomach laid open, showing cancerous thickening, extending several inches from pylorus;
G. 8. thickness amounting at maximum to over an inch; gastric surface of mucous growth irregularly nodulated and in some places ulcerated.

Private J. B. "D," 2d United States Artillery. Admitted, May 4th, 1864, from Harwood Hospital, Washington, D. C. Had enjoyed good health up to April 20th; was then taken sick, while on picket, with severe pain in right hip and groin, gradually passing into back, right leg, knee, and ankle; had severe cough, spitting some blood, night sweats, and burning in hands and feet. Entered Harwood Hospital April 23d. When he entered Satterlee Hospital he had intense pain in back and legs, with anorexia, constipation, and great debility. 24th, increased pain in hubs, and great dyspnea. 30th, sonorous and sibilant rales heard over both lungs, front and back; pulse 140; respiration 32. June 3d, dullness on percussion in right sub-clavicular region and axillary space; oedema of feet and ankles. 10th, dyspnea increasing; pain in chest. 12th, weaker; chest pain increased; decubitus on right side. Died, June 14th. Diagnosis during life—chronic rheumatism and acute plethsis.

Autopsy twenty-four hours after death: Body emaciated; oedema of feet and ankles; large amount of purulent serum in right pleural sac, less in left; small round masses resembling tubercles scattered through upper and middle lobes of both lungs, and covering pulmonary pleura; large amount of false membrane on surface of right lung; much serum in pericardium; mitral valves thickened at margin; much serum in peritonum; large number of round yellow masses on surface of liver, extending half an inch into its structure; stomach as described.

Contributed by Acting Assistant Surgeon C. P. Tatt, Satterlee Hospital, Philadelphia, Pa.

Section 3. INTESTINAL CANAL.

A. Diverticula of small intestine.

No. 651. Piece of duodenum, upper portion, taken about six inches from stomach; about the middle of the piece, or ten inches from stomach, is a diverticulum, forming a conical pouch, terminating in a fibrinous cord about one and a half inches from the bowel; the cord attached to inner surface of umbilicus.

From a colored girl, age 12, native of Virginia. Admitted, August 29th, 1865, with typhoid fever. Died, October 27th, of perforation of bowels.

Contributed by Acting Assistant Surgeon W. C. Miner, L'Orverture Hospital, Alexandria, Va.

No. 670. Piece from middle portion of duodenum, presenting a true diverticulum about two inches long, communicating with intestine by a small constricted orifice.

J. F., dark mulatto, age 71; height, five feet five inches. Died, November 28th, 1865, of enteric fever.

From Freedman's Hospital, Washington, D. C.

Autopsy by Hospital Steward S. S. Bond.

No. 112. Piece of ileum, taken about one and a half feet from ileo-caecal valve, presenting a diverticulum about three inches long.

A. 3. Private J. L. K. "H," 2d Tennessee, age 23. Died, May 17th, 1864, after an operation for strangulated hernia.

Contributed by Acting Assistant Surgeon B. B. Miles, Jarvis Hospital, Baltimore, Md.

No. 532. Piece of ileum, with a diverticulum about two inches long.

A. 4. No history.

Contributed by Assistant Surgeon R. F. Weir, U. S. Army, General Hospital, Frederick, Md.

No. 518. Portion of ileum, presenting a large obtusely-formed diverticulum, one and a half inches long; a process of mesentery extended from the normal mesenteric attachment to apex of diverticulum.

From a patient who died of chronic dysentery.

Contributed by Assistant Surgeon B. E. Fryer, U. S. Army, Brown Hospital, Louisville, Ky.

- No. 519.** Portion of ileum, with diverticulum, about three inches long and one in diameter, near the extremity of which is a constriction, the diverticulum terminating in a small globular dilatation; a process of mesentery extended from normal mesenteric attachment to apex of diverticulum.

A. 6. From a patient who died of chronic dysentery.

Contributed by Assistant Surgeon B. E. Fryer, U. S. Army, Brown Hospital, Louisville, Ky.

B. Invaginations of small intestine.

- No. 24.** Portion of small intestine, with two invaginations at different points; no evidences of peritoneal inflammation.

B. 1. Contributed by Assistant Surgeon H. B. Chapin, U. S. Vols.

Nos. 30 and 31. Two pieces of the small intestine of the same patient, each with a well-marked invagination; no peritoneal inflammation.

Private J. W. C. "G," 49th New York, age 30. Died, October, 15th, 1862, of chronic diarrhoea.

B. 2 and 3. Autopsy: Body much emaciated; small intestine presented four intussusceptions; mucous membrane continuously inflamed, except in duodenum and commencement of jejunum; black pigment in solitary and Peyer's glands; large intestine extremely contracted, being not more than one inch in diameter throughout, except at caecum and about four inches of ascending portion; mucous membrane of colon inflamed throughout.

Contributed by Acting Assistant Surgeon J. Leidy, Satterlee Hospital, Philadelphia, Pa.

- No. 39.** Piece of small intestine, with two invaginations; no evidences of peritoneal inflammation.

B. 4. From a patient who died of chronic diarrhoea.

Contributed by Acting Assistant Surgeon E. Cones, Mount Pleasant Hospital, Washington, D. C.

- No. 44.** Portion of jejunum, with a well-marked invagination; no evidences of peritoneal inflammation.

B. 5. History—(Acting Assistant Surgeon W. L. Hammond): Private A. S., "A," United States Engineers. Admitted, January 16th, 1861, from the Army of the Potomac, with chronic diarrhoea. He was extremely emaciated; without appetite; stools foetid and scanty; no vomiting. Died, January 15th.

Autopsy: Ulceration of mucous membrane in small and large intestines; disease of mesenteric glands; enlargement of spleen; jejunum with invaginations as described.

Contributed by Surgeon E. Bentley, U. S. Vols., General Hospital, Alexandria, Va., Third Division.

- No. 15.** Piece of jejunum, presenting a well-marked invagination, without any evidence of the existence of inflammatory action.

B. 6. No history.

Contributed by Assistant Surgeon De Witt C. Peters, U. S. Army, Jarvis Hospital, Baltimore, Md.

- No. 350.** Portion of small intestine, about three feet long, in which are four well-marked invaginations; no peritoneal inflammation.

B. 7. No history.

Contributed by Acting Assistant Surgeon J. Leidy, Satterlee Hospital, Philadelphia, Pa.

C. Anomalies of position with strangulation.

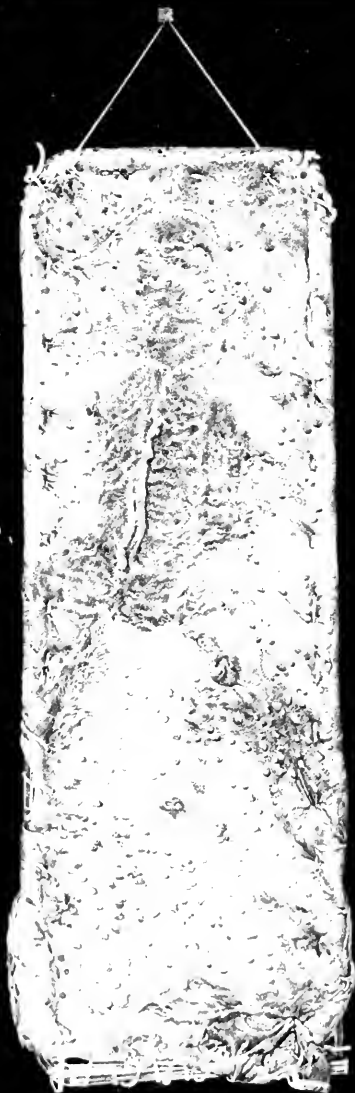- No. 505.** Piece of mesentery, in which an opening has been formed, through which several feet of the lower part of the ileum passed, and subsequently became strangulated. When received at the Museum, the cavity of the strangulated intestine was found to be full of clotted blood, the lumen of the portion of mesentery belonging to the strangulated gut separated by hemorrhagic extravasations, and the whole peritoneal surface of the piece dark from the gorged condition of the vessels.

Private C. C., "A," 5th Wisconsin. Died after an attack resembling ileus, which lasted thirty-six hours. The symptoms were great pain, obstinate vomiting, early prostration, constipation, and great distension of the abdomen.

Contributed by Surgeon H. Culbertson, U. S. Vols., Harvey Hospital, Madison, Wis.

- No. 522.** Diaphragmatic hernia, in which stomach and a large portion of greater omentum, have passed through a supralaryngeal opening of diaphragm into thoracic cavity; stomach and omentum greatly congested; stomach filled with blood.

Sergeant L. McB., "A," 14th Veteran Reserves. Admitted at 4 p. m., March 8th, 1865, with symptoms of strangulation



№ 98.

of bowels; vomiting frequent; pulse quick and feeble; countenance anxious and expressive of severe pain. He said he had never had hernia to his knowledge, and no external appearance of hernia could be detected. His symptoms increased in violence till death, 11 a. m., March 10th.

Autopsy: The diaphragmatic hernia described; left lung partly collapsed.

Contributed by Acting Assistant Surgeon I. J. Moxley, Augur Hospital, near Alexandria, Va.

See **1789, XX.** A. B. A. 22, *Surgical Section, for another illustration.*

D. Fever. Cases in which enlargement of solitary follicles of small intestines is the prominent lesion.

Nos. 81 and 85. **81.** portion of ileum, showing some thickening of Peyer's patches and enlargement of solitary follicles. **85.** from farther down the same ileum, exhibits similar conditions.

Private J. L., "A," 26th Pennsylvania, age 40, German. Admitted, December 12th, 1862. Diagnosis—diarrhoea. Died, January 23d, 1863. Diagnosis—phthisis pulmonalis.

D. 1 and 2. Autopsy: Body emaciated; right lung with old adhesions; apex contained a tubercle the size of a large pea, and several smaller ulcerated cavities; left lung with a few tubercles size of pepper grains in apex and scattered at back part of upper lobe; pericardium contained about a teacupful of liquid; heart flabby, with large white coagulum in right ventricle; spleen soft, flabby, and reddened and roughened on surface; solitary and Peyer's glands of ileum slightly enlarged and opaque; mucous membrane of colon soft, grayish, with a few red streaks of inflammation and a few ecchymosed spots.

Contributed by Acting Assistant Surgeon J. Leidy, Satterlee Hospital, Philadelphia, Pa.

No. 87. Portion of ileum, with solitary follicles somewhat enlarged.

D. 3. Private S. S. S., "K," 132d Pennsylvania, age 21, American. Admitted, December 16th, 1862. Diagnosis—typhoid fever. Died, January 9th, 1863.

Autopsy: Body very much emaciated; skin ecchymosed on trunk and extremities; mucous membrane of ileum slightly inflamed; Peyer's and solitary glands white and slightly enlarged; mucous membrane of colon intensely inflamed throughout, softened, and everywhere covered with a thin, broken layer of white pseudo-membrane, tightly adherent and composed of pyoid corpuscles; there was also a multitude of ecchymosed spots not larger than flea-bites.

Contributed by Acting Assistant Surgeon J. Leidy, Satterlee Hospital, Philadelphia, Pa.

Nos. 93 to 98. Successive portions of ileum, with enlargement of solitary follicles, and slight thickening of Peyer's patches. **No. 98** is from just above the ileo-cæcal valve.

Corporal G. S., "H," 9th Wisconsin. Admitted, December 18th, 1862, from the Army of the Potomac. **D. 4 to 9.** Diagnosis—chronic diarrhoea. Died, December 24th.

Autopsy: Age, about 30 years; body rather emaciated; abdomen presented a number of faint spots of purpura; lobular pneumonia in lower lobes of both lungs, the inflamed portions numerous, from the size of a marble to that of a walnut, and in a state of gray hepatization; bronchitis; stomach exceedingly contracted; liver apparently sound; gall-bladder enormous and distended with green bile; spleen small but healthy; pancreas and kidneys sound; inflammation of small intestine increasing in descent; Peyer's glands darkened with inflammation; solitary glands looked like yellow mustard seeds sprinkled on a red ground; large intestine streaked and spotted with ash-color and dark red on a more uniform red ground; also, some spots of ecchymosis.

Contributed by Acting Assistant Surgeon J. Leidy, Satterlee Hospital, Philadelphia, Pa.

Nos. 107 and 108. Successive portions of ileum, with solitary follicles enlarged to the size of small shot; each piece exhibits an apparently healthy Peyer's patch.

Private L. A. W., "E," 20th Michigan. Admitted, December 13th, 1862, from the Army of the Potomac. **D. 10 & 11.** Diagnosis—diarrhoea. Died, December 26th.

Autopsy: Age about 22 years; body rather emaciated; spots of purpura on trunk; recent pleurisy on both sides, most marked on right; pneumonia in lower lobes of both lungs; bronchitis; liver and spleen enlarged; moderate congestion diffused throughout ileum and colon; enlargement of solitary glands in lower part of ileum; Peyer's glands reddened; slight enlargement of solitary follicles of large intestine.

Contributed by Acting Assistant Surgeon J. Leidy, Satterlee Hospital, Philadelphia, Pa.

109, chap. IV., sec. 7, C. 3, *enlarged spleen, is also from this case.*

No. 153. Lower portion of ileum and ileo-cæcal valve with pin-head enlargement of solitary follicles.

D. 12. Private M. L. C., "I," 85th New York. Admitted, August 19th, 1862. Diagnosis—typhoid fever. Died suddenly, November 18th.

Autopsy: Extensive inflammation of ileum and cæcum; solitary follicles enlarged; mesenteric glands enlarged; liver and kidneys fatty.

Contributed by Surgeon A. C. Bournoville, U. S. Vols., Hospital at Fifth and Buttonwood streets, Philadelphia, Pa.

Nos. 237 and 238. Two successive portions of ileum, with pin-head enlargement of solitary follicles; each presents a slightly thickened Peyer's patch.

Private J. B., "F," 7th Maine. Admitted, August 10th, 1862. Diagnosis—diarrhoea. Died, October 8th.

D. 13 & 14. Autopsy: Age about 27; much emaciated; skin slightly ecchymosed; liver dull brownish-purple, in sections brown; spleen flabby, remarkably bloodless, in sections bright lake red; gall-bladder large and distended; continuous inflammation throughout small intestine, commencing feebly in duodenum and gradually increasing in intensity in the descent; ileum of a deep mation color, without any destruction of epithelium; Peyer's glands normal; solitary glands numerous and slightly thickened; intense inflammation of ascending colon; transverse colon nearly free; a moderate degree of infection here and there, accompanied by ecchymosis in descending colon, sigmoid flexure and rectum; pigment in some solitary follicles of colon.

Contributed by Acting Assistant Surgeon J. Leidy, Satterlee Hospital, Philadelphia, Pa.

No. 270. Portion of ileum, with pin-head enlargement of solitary follicles, and slight thickening of Peyer's patches.

D. 15. Private D. C., 61st New York. Admitted, July 10th, 1862, from the Army of the Potomac, then on the Peninsula. Diagnosis—typhoid fever. Died, August 24th.

Autopsy: Organs generally healthy, except that the solitary glands were thickened, and both they and Peyer's glands of a black color, resembling the bluish-black of tattooing; surrounding parts of mucous membrane pale and devoid of anything like congestion; there was slight thickening of Peyer's glands.

Contributed by Acting Assistant Surgeon J. Leidy, Satterlee Hospital, Philadelphia, Pa.

Nos. 273 to 276. Successive portions of ileum, with pin-head enlargement of solitary follicles, and some slight thickening of Peyer's glands.

D. 16 to 19. See 272, chap. IV., sec. 2, B. 3, for history.

No. 328. Portion of ileum, taken from just above ileo-cæcal valve, presenting pin-head enlargement of solitary follicles.

D. 20. Private D. C. S., "B," 2d Tennessee Mounted Infantry, age 21. Was captured at Rogersville, East Tennessee, November 6th, 1863; was confined at Belle Isle; was in hospital there some weeks. April 29th, 1864, was paroled; arrived at Annapolis, Maryland, May 21. June 7th transferred to this hospital with chronic diarrhoea. 21st, growing weaker; had effusion in pleural, pericardial, and abdominal cavities; respiration exceedingly laborious; could only lie on right side; breathing very difficult; remains up but a few minutes at a time; face, left arm, and hand greatly swollen; appetite craving. 26th, effusion decreasing; less dyspnoea; very rapid and small pulse; irregular action of heart. 27th, considerable abdominal pain on pressure in right lumbar region; appetite decreasing, weakness increasing. Died, July 12th.

Autopsy: Right lung adherent to walls of chest, and pushed into upper part of cavity by dirty yellow serum; some similar serum in left pleural cavity; peritoneum contained several ounces of similar serum; small intestine distended with gas; thin solitary follicles, somewhat enlarged; colon very thin, with enlarged solitary follicles; rectum contracted; spleen greatly enlarged, but firm.

Contributed by Assistant Surgeon C. Bacon, jr., U. S. Army, Annapolis Junction Hospital, Md.

No. 717. Portion of ileum, taken from near ileo-cæcal valve; solitary follicles enlarged, with a point of ulceration in each; a number of follicles in Peyer's patches enlarged and ulcerated; the remainder of each patch apparently normal; specimen presented shaven-head appearance when fresh.

B. B., dark mulatto, age 18. Admitted, December 1st, 1865, with phthisis. Died, January 23d, 1866.

Autopsy thirty-six hours after death: Height, five feet four inches; weight, about eighty pounds; extreme emaciation; no rigor mortis; bed sores on hips, partially healed; both lungs adherent, filled with tubercles, and large cavities in upper lobes; bronchial glands much enlarged; large heart-clots in all its cavities; Peyer's patches presented many small elevations, resembling pimples, the summit of each elevation ulcerated, remainder of patch presenting shaven-head appearance; solitary follicles enlarged and ulcerated at apices; solitary follicles of cæcum enlarged; colon contained much pigment; liver slate-colored; kidneys somewhat fatty.

From Freedman's Hospital, Washington, D. C.

Autopsy by Hospital Steward S. S. Bond.

Nos. 718 to 750. Successive portions of ileum, the last taken just above ileo-cæcal valve, with progressively enlarged solitary follicles, the largest the size of a small shot; when fresh, Peyer's patches, which are slightly thickened, presented the shaven-head appearance.

D. 22 to 24. C. C., colored. Admitted, February 29th, 1866, with pain in abdomen, diarrhoea, and tumefied abdomen. Died, February 29th.

Autopsy eighteen hours after death: Negro; height, five feet seven inches; weight, about one hundred and fifty pounds; age, about 20; rigor mortis well marked; no emaciation; membranes of brain congested; lower lobe of left lung in a state of gray hepatization, with slight pleuritic adhesions; three ounces of serum in pericardium; heart fatty, all its cavities contained thin, white, fibrous clots; outree liver; gall-bladder full; spleen with a small supernumerary spleen the size of a pigeon's egg; kidneys fatty; intestines distended throughout with flatus; solitary follicles of lower part of ileum enlarged; Peyer's patches presented shaven-head appearance.

From Freedman's Hospital, Washington, D. C.

Autopsy by Hospital Steward S. S. Bond.

No. 756. Portion of ileum, taken at ileo-cæcal valve, with pin-head enlargement of solitary follicles, and slight thickening of the Peyer's patch above the valve.

D. 25. G. A., colored, age 38; teamster. Admitted, March 9th, 1866, with intense pain in forehead and in right hypochondrium, extending up the back to right scapula; tongue coated with thick brown fur; no appetite; bowels constipated. Died, March 14th.

Autopsy thirteen hours after death: Mulatto; toes of right foot and second and third phalanges of toes of left foot absent; (*See Surgical Section, 1939, XXXIII, B. D. 3*); height, five feet eight inches; weight, one hundred and fifty pounds; rigor mortis well marked; membranes of brain congested; slight effusion beneath arachnoid; red hepatization of right lung, which was covered with lymph and slightly adherent; lobes firmly inter-adherent; left lung congested, covered with lymph, posterior portion hepaticized; pericardium coated with lymph; contained ten ounces of serum; heart with fibinous clots in all its cavities; nutmeg liver; gall-bladder full; mucous membrane of stomach congested; mucous membrane of small intestine thickened and congested; solitary follicles in lower portion of ileum congested; Peyer's patches slightly thickened and presented shaven-beard appearance; horse-shoe kidney.

From Freedman's Hospital, Washington, D. C.

Autopsy by Hospital Steward S. S. Bond.

757, chap. V., sec. 1, A. 8, horse-shoe kidney, is also from this case.

No. 762. Portion of ileum, with pin-head enlargement of solitary follicles and very slightly thickened Peyer's patches.

D. 26. R. R., colored, age 19. Admitted, February 8th, 1866. Diagnosis—phthisis. Died, March 10th.

Autopsy: Negro; height, five feet eight inches; weight, one hundred and fifty pounds; no emaciation; membranes of brain congested; slight effusion of serum beneath arachnoid; both lungs contained tubercles and were congested posteriorly; right lung presented a few small vesicæ in its upper lobe; two ounces serum in each pleural cavity; bronchial glands tubercular; pericardium contained eighteen ounces of pus-like serum, with much flaky lymph floating freely therein; patches of lymph adherent to both surfaces of pericardium; white clots in all the cavities of the heart; nutmeg liver with small tubercles scattered through its substance; gall-bladder contained two drachms of viscid bile; spleen large and filled with tubercles; kidneys somewhat fatty; Peyer's patches presented shaven-beard appearance throughout ileum; solitary follicles enlarged, particularly in lower portion of ileum near ileo-cæcal valve; colon presented a few healed ulcers, its solitary follicles enlarged.

From Freedman's Hospital, Washington, D. C.

Autopsy by Hospital Steward S. S. Bond.

763, chap. IV., sec. 5, E. 6, tubercles of liver, is also from this case.

No. 781. Portion of ileum, taken near ileo-cæcal valve, showing moderate thickening of Peyer's patches, which presented shaven-beard appearance when fresh; solitary follicles enlarged to size of pin-head, and projecting from the surface.

D. 27. W. C., colored, age 24. Admitted, April 14th, 1866, with great dyspnoea; extreme pain over left side of thorax; tongue coated a deep brown; pulse 105. Died, April 6th.

Autopsy nine hours after death: Stout negro; height, five feet four inches; weight, one hundred and fifty pounds; rigor mortis well marked; slight congestion of membranes of brain; right lung firmly adherent at all points, lower lobe congested, a few patches of red hepatization in middle lobe; left lung slightly adherent posteriorly, lower lobe somewhat congested; eight ounces serum in each pleural cavity; heart fatty, aortic and mitral valves slightly thickened, walls of left ventricle thick, large fibinous clots in all the cavities of heart; fourteen ounces serum in pericardium, both surfaces of which were covered with crumous lymph; liver fatty; gall-bladder full; small intestine congested throughout in lower ileum; Peyer's patches somewhat thickened; solitary follicles enlarged; colon contained much pigmentary deposit.

From Freedman's Hospital, Washington, D. C.

Autopsy by Hospital Steward S. S. Bond.

Nos. 192 and 193. Two successive portions of ileum, presenting thickening and ulceration of Peyer's patches; solitary glands, enlarged to little tumors one or two lines in diameter, stud the whole surface of mucous membrane, many of them presenting, at their apices, minute points of ulceration.

D. 28 & 29. The patient died of camp fever during the summer of 1863.

Contributed by Assistant Surgeon W. A. Bradley, U. S. Army, Finley Hospital, Washington, D. C.

No. 208. Portion of ileum, presenting a single much-thickened and ulcerated Peyer's patch; solitary follicles enlarged to polypoid tumors, size of small shot.

D. 30. The patient died of camp fever, December, 1862.

Contributed by Surgeon H. Bryant, U. S. Vols., Clifton Hospital, Washington, D. C.

Nos. 165 to 170. Six successive portions of ileum, with solitary follicles enlarged to size of small shot; Peyer's patches thickened and ulcerated.

D. 31 to 36. The patient was admitted in a moribund condition in the spring of 1863. He was said to have suffered from camp fever. Died twenty-four hours after admission.

Contributed by Assistant Surgeon W. Thomson, U. S. Army, Douglas Hospital, Washington, D. C.

- Nos. 280 to 283.** Four successive portions of ileum, with enlargement and thickening of Peyer's patches; solitary follicles enlarged to size of small shot and projecting as polypoid tumors from surface of mucous membrane; at the apices of many of these tumors are one or more small points of ulceration.
- D. 37 to 40.** The diagnosis was "typhus."
Contributed by Surgeon J. H. Bryant, U. S. Vols., Lincoln Hospital, Washington, D. C.

See plate opposite.

- No. 565.** Portion of ileum, taken just above ileo-cæcal valve, showing a much thickened Peyer's patch, and solitary follicles enlarged to size of small peas; villi are hypertrophied, giving to piece a peculiar velvety aspect.
- D. 41.** H. R., negro. Died, June 21th, 1865, of fever. Besides the alterations in ileum, the mesenteric glands were much enlarged, and spleen large and hard.
- Contributed by Acting Assistant Surgeon W. C. Miner, L'Ouverture Hospital, Alexandria, Va.

E. Fever. Cases in which thickening and ulceration of Peyer's patches is the prominent lesion.

- No. 202.** Portion of ileum, from just above ileo-cæcal valve, with an extensive Peyer's patch, partly injected: the individual follicles of the patch, considerably enlarged and with semi-transparent contents, can be distinctly recognized either by transmitted or reflected light.
- E. 1.** Private I. W., "D," 1st Vermont. Died, February 15th, 1864, of pneumonia consecutive to measles.
- Contributed by Assistant Surgeon W. Thomson, U. S. Army, Douglas Hospital, Washington, D. C.
- Nos. 228 to 231.** Successive portions of ileum, presenting thickening of Peyer's patches, and of some of the solitary glands.
- E. 2 to 5.** Private T. E., "D," 14th United States Infantry, age 18, American. Admitted, August 10th, 1862. Diagnosis—typhoid fever. Died, August 18th.
- Autopsy: Body not much wasted; heart and inner surface of pericardium roughened with old pseudo-membrane, but no adhesion of apposed surfaces; pneumonic engorgement of right lung; liver large; gall-bladder nearly empty; stomach distended with air, its mucous membrane presented a large reddened patch on lower part of left extremity; whitish inflamed condensation about the size of a nutmeg at upper end of spleen; adjacent gastro-splenic omentum also inflamed; mucous membrane of ileum inflamed in patches, one of which was two feet long, its lower portion being about six inches from ileo-cæcal valve; there were thirty-two Peyer's patches varying from half an inch to three inches in length, a large one dotted with black pigment, but otherwise healthy, being on each fold of ileo-cæcal valve; the next patch above also appeared healthy, but the remainder, except the first two, were much thickened and generally inflamed, though none were ulcerated; where not reddened by inflammation, they appeared opaque white; solitary glands generally invisible in jejunum, and few in ileum; but where obvious in the latter, were quite prominent and red with inflammation; colon much contracted; mucous membrane generally of a slate-color, with small patches of inflammation; its solitary glands black.
- Contributed by Acting Assistant Surgeon J. Leidy, Satterlee Hospital, Philadelphia, Pa.
- Nos. 171 to 177.** Seven successive portions of ileum, showing the most gradual transitions between the slightest thickening of Peyer's patches in the first pieces and the large ulcerated patches just above ileo-cæcal valve in the last; villi hypertrophied.
- E. 6 to 12.** Private G. B., "G," 6th Pennsylvania Cavalry. Admitted, April 26th, 1863, with typhoid pneumonia. Died, May 24.
- Contributed by Surgeon C. Page, U. S. Army, Judiciary Square Hospital, Washington, D. C.
- Nos. 376 to 380.** Successive portions of ileum, the last taken just above ileo-cæcal valve, presenting from above downwards the most gradual enlargement of Peyer's patches; the thickened patches have abrupt edges and are in many instances slightly constricted at the base, like flat "sessile fungi;" the summits are more or less ulcerated in
- E. 13 to 17.** last three pieces; many solitary follicles are also diseased, forming oval elevations ulcerated on summits, similar in character to the thickened Peyer's patches, but smaller in size.
- See 3-1, chap. II., sec. 3, B. 1, for history.*
- Nos. 112 and 113.** Successive portions of ileum, No. 113 embracing ileo-cæcal valve; each piece presents a large thickened Peyer's patch, with a few ulcerated points; the patch in No. 113 more than five inches long; in this piece there are also several ulcers of the solitary follicles.
- E. 18 & 19.** Private B. A., "H," 1st Ohio, age 25. Admitted, December 23d, 1862, suffering from typhoid fever with intercurrent erysipelas of face and head. Died, December 26th.
- Autopsy: Body fat; discolored on left side of head and neck, from erysipelas; brain healthy, but pia mater more than usual; enlarged on left side; more liquid than normal in subarachnoid space; lungs and heart healthy; liver, stomach, pancreas healthy; spleen enlarged seven by five by two and a half inches; diffused inflammation of moderate character throughout stomach and colon; intestinal glands healthy except in lower three feet of ileum, in which Peyer's patches were much enlarged and ulcerated; there were also some ulcers connected with the solitary follicles.
- Contributed by Acting Assistant Surgeon J. Leidy, Satterlee Hospital, Philadelphia, Pa.
- See 3-1, chap. IV., sec. 7, A. 5, enlarged spleen, is also from this case.*



N° 280.

Nos. 185 to 189. Five successive portions of ileum, presenting considerable thickening and ulceration of Peyer's patches and some solitary follicles.

E. 20 to 24. The patient was a soldier who died of fever during the summer of 1863. The ileum, towards its lower portion, presented patches of most intense congestion; Peyer's patches progressively thickened and ulcerated; their ulcerated surface stained of a greenish color by altered biliary matter.

Contributed by Assistant Surgeon W. A. Bradley, U. S. Army, Finley Hospital, Washington, D. C.

Nos. 398 and 399. **398**, portion of ileum, about the middle, presenting a somewhat thickened but not ulcerated Peyer's patch; solitary follicles somewhat enlarged. **399**, portion of ileum taken from just above ileo-cæcal valve of same patient, showing a Peyer's patch eight inches long, considerably thickened, with a number of minute ulcers at its upper extremity; this piece also presents a few enlarged solitary follicles.

E. 25 & 26. Private A. W., "A," 20th Maine. Admitted, August 21st, 1864, with decided typhoid symptoms; pulse about 120; tongue dry, with a brown fur; diarrhoea; about five or six alvine dejections per diem, with pain in the right side, and slight dyspnoea, but little emaciation. He continued in this state without any marked change until the 23d, when his diarrhoea nearly disappeared, but the lung symptoms increased in intensity; there was now severe pain in right side of chest, dullness on percussion, and slight crepitant rale; subsequently his diarrhoea returned, but not so severely as before; tongue continued dark colored and dry, and he sank without any marked change of symptoms, except occasional delirium. Died, August 27th.

Autopsy: No emaciation; rigor mortis marked; right lung congested, its middle lobe in a state of red hepatization; left lung in a state of hypostatic congestion posteriorly, otherwise normal; pericardium contained two ounces of fluid; a large partly-washed fibrinous clot in right side of heart; liver enlarged and pale; gall-bladder distended with viscid bile; spleen enlarged and soft; stomach dilated with gas, and flabby; about pyloric orifice red and congested; small intestine healthy to about middle of ileum, below which Peyer's patches, and mucous membrane in their vicinity, were thickened and congested; solitary follicles enlarged and prominent, and between the last Peyer's patch and ileo-cæcal valve were a few small ulcers; mucous membrane of ascending and transverse colon somewhat congested, solitary follicles being stained with black pigment; mucous membrane of descending colon more deeply congested with occasional large black spots; no ulcers.

Contributed by Acting Assistant Surgeon O. P. Sweet, Carver Hospital, Washington, D. C.

Nos. 277 and 278. Two successive portions of ileum, showing thickening and ulceration of Peyer's patches and a few solitary follicles.

E. 27 & 28. From a female patient in private practice, who died of enteric fever prior to the breaking out of the rebellion. Contributed by Acting Assistant Surgeon Fred. Schafhirt.

Nos. 201 and 205. Two successive portions of ileum, with characteristic thickening and ulceration of Peyer's patches, and some solitary follicles.

E. 29 & 30. The specimens were received during the fall of 1863, without history or memorandum.

Nos. 99 to 101. Three successive portions of ileum, with thickened and ulcerated Peyer's patches

Private A. S., "C," 73d Ohio. Admitted, December 1st, 1862. Died, January 30th, 1863.

E. 31 to 33. Autopsy: Age about 24; body emaciated; slight bronchial inflammation; right side of heart contained a large white clot; spleen flabby and unnaturally red; liver pale brown with rather darker brown intralobular spots; gall-bladder distended with muddy greenish bile; pancreas exceedingly hard; stomach and upper portion of small intestine apparently healthy; lower five feet of ileum with Peyer's patches successively and gradually enlarged, those within the last foot dark red, and surrounding mucous membrane inflamed; the most diseased was that contiguous to ileo-cæcal valve, which presented several small ulcers; colon greatly distended, its mucous membrane unnaturally red; lymphatic glands of mesentery and meso-cælon bluish black; in section, this color formed a circle just within periphery of glands; microscopically, it presented the appearance of exceedingly fine particles, apparently not crystalline, and recalled to mind the black deposits of intestinal glands of Chickahominy diarrhoea.

Contributed by Acting Assistant Surgeon J. Leidy, Satterlee Hospital, Philadelphia, Pa.

See plate opposite.

Nos. 212 and 213. Two successive portions of ileum, with thickening and ulceration of Peyer's patches.

Private G. F., "B," 20th New York, German. Admitted, July 26th, 1862. Diagnosis—chronic dysentery. Died, August 9th.

E. 34 & 35. Autopsy: Body much emaciated; right lung presented old pleuritic adhesions throughout; heart pale and flabby with opaque white patches on right ventricle about the size of a dime; similar but quite small patches on both auricles, together with some roughness of corresponding portion of pericardium; mucous membrane of ileum inflamed, and Peyer's patches, except the upper ones, thickened, and in several instances presented small ulcerations; mesenteric glands unaltered; mucous membrane of colon inflamed, especially towards each extremity.

Contributed by Acting Assistant Surgeon J. Leidy, Satterlee Hospital, Philadelphia, Pa.

Nos. 315 and 316. Two successive portions of ileum, with thickening and ulceration of Peyer's patches. Private D. S. K., "C," 130th Pennsylvania, age 24, butcher. Admitted, July 11th, 1863, with a flesh wound of right hand received at Gettysburg; this wound granulated favorably. About the 25th he began to suffer from languor and debility, but did not complain until the 29th, when he presented a furred tongue and diarrhoea (two or three passages daily). August 9th, fever increasing; patient sleepless. 10th, slight cough with sonorous and sibilant rales; tenderness in right iliac fossa. 11th, rose-colored spots on abdomen and chest; tongue dry; general abdominal tenderness; debility increasing. 15th, some delirium; mucous, sonorous and sibilant rales on right side. 17th, five or six passages, subsultus tendinum, stupor, from which, however, he can be aroused. Afternoon, gradually increasing dyspnoea; wound of hand sloughing; abdomen tender, but no tympanites. Died, August 19th.

Autopsy seven hours after death: Rigor mortis slightly marked; abdomen flat; jejunum normal; ileum congested; Peyer's patches thickened, a few near cecum ulcerated; lungs congested, especially on right side, but no hepatization.

Contributed by Acting Assistant Surgeon W. L. Wells, McClellan Hospital, Philadelphia, Pa.

No. 190. Portion of ileum, including ileo-caecal valve; Peyer's patches and some solitary follicles, considerably thickened and ulcerated.
E 38. From a patient who died of fever during the summer of 1863.

Contributed by Medical Cadet Elliot Cones, Mount Pleasant Hospital, Washington, D. C.

No. 207. Portion of ileum, taken from just above ileo-caecal valve, presenting an irregular ulceration of the last Peyer's patch: solitary follicles enlarged.
E 39. The patient died suddenly from oedema of glottis. It is said that he had suffered neither from diarrhoea nor typhoid fever. The facts of the case are however not sufficiently known to be convincing, especially when it is considered that oedema of the glottis is a not infrequent termination of the diarrhoea which follows camp fever, as is shown by several other specimens in the Museum.

Private H. F. W., "D," 33d Massachusetts. Admitted, February 9th, 1863. Diagnosis—pneumonia. From the first there was great dyspnoea and complete aphonia. Died by asphyxia, February 15th. No diarrhoea nor any abdominal symptoms observed while in hospital; prior history unknown.

Autopsy: Both lungs much congested; glottis and epiglottis oedematous to such an extent as to close orifice; mucous membrane of larynx and trachea inflamed, in larynx ulcerated; ileum presented numerous ulcers, similar to specimen; mucous membrane of colon softened and tumid.

Contributed by Medical Cadet Elliot Cones, Mount Pleasant Hospital, Washington, D. C.

No. 75. Portion of ileum, with two thickened and ulcerated Peyer's patches and several small ulcers of solitary follicles with elevated and thickened edges.
E 40. The patient had suffered from symptoms of typhoid fever, but without diarrhoea; the ileum, nevertheless, was found ulcerated after the usual manner. The most prominent complications of the disease had been the urgent head symptoms; the brain, however, was not examined.

Contributed by Surgeon C. Page, U. S. Army, General Hospital, Alexandria, Va., First Division.

No. 150. Portion of ileum, taken from just above ileo-caecal valve, with enlargement and ulceration of solitary follicles and Peyer's patches.
E 41.

Private E. B. D., "B," 27th Connecticut. Had been suffering since latter part of January, 1863, from a rather severe attack of bronchitis, for which he was treated in his quarters. Admitted to hospital, March 9th. Diagnosis—bronchitis. Pulse 108; tongue clean and moist; cough; white frothy sputa; substernal soreness; stools rather infrequent, but loose and watery. 11th, pulse 108; respirations 20; tongue furred and a little tinged with brown; one passage, watery and thin, daily. 14th, three loose passages; pulse 108; respirations 20; tongue furred and a little moist, except at tip, which was red and inclined to dryness; abdomen tender over whole course of colon. 15th, pulse 112; respirations 24; tongue becoming dry; two loose passages in preceding twenty-four hours. 16th, pulse 120; respirations 28; lips dark in patches; tongue dry and dark; very restless during night; cough loud and dry, some rusty sputa; abdomen tender all over; is stupid and cannot answer sensibly. 17th, pulse 88; respirations 24. Died, March 20th. No rose-colored spots were at any time observed, and there was no tympanites.

Autopsy: Lower portion of ileum presented from twenty to twenty-five indurated Peyer's patches, some half a dozen of which were ulcerated; ileo-caecal valve thickened with an indurated slightly ulcerated patch on caecal surface; neighboring parts of ileum and colon much congested; mesenteric glands enlarged.

Contributed by Surgeon W. O. McDonald, 27th Connecticut, Army of the Potomac.

Nos. 121 and 125. 121, portion of ileum with a thickened Peyer's patch, somewhat more than three inches long, in which may be seen several small points of ulceration. 125, portion of ileum from just above ileo-caecal valve, of same patient, presenting a large thickened and ulcerated Peyer's patch, with thickening and ulceration of solitary follicles. (*See Macroscopical Section, Part First, Vol. II, p. 8 and 9.*)
E 42 & 43.

Private D. R., "A," 32d Massachusetts, age 20. Admitted, from City Point, Va., August 30th, 1864. Had diarrhoea and at times slight rigors, for the two weeks previous; was considerably emaciated, with severe diarrhoea and

pain in both hypochondriac regions; at times involuntary evacuations from bowels, with constant anorexia; tongue coated in centre with dark dry fur. September 4th, pleurisy on right side; pulse greatly increased in rapidity; intense pain in right side; slight cough; hurried respiration. 5th, delirium, with great prostration. Died, September 6th.

Autopsy: Right lung somewhat congested; pleura pulmonalis completely covered with croupous lymph; no fluid in pleural cavity; left lung greatly congested but otherwise healthy, pleuritic adhesions; right side of heart contained a large fibrinous clot; liver enlarged, softened, and beset with adhesions; spleen attached to walls of abdomen by recent adhesions, its surface covered with lymph, and it enlarged, soft, and of a brown color; mesenteric glands enlarged; stomach red and congested at cardiac extremity, mucous membrane at pyloric end thickened and softened; both stomach and intestines were inflated with gas; small intestine healthy, except ileum, mucous membrane of which was red and congested; Peyer's patches thickened, and in lower part both Peyer's patches and solitary follicles enlarged and ulcerated; near ileo-cæcal valve the ulcers were more numerous and stained with greenish yellow pigment; a large ulcer on ileo-cæcal valve; mucous membrane of ascending colon congested; transverse and descending colon slightly congested; and solitary follicles stained with black pigment.

Contributed by Acting Assistant Surgeon O. P. Sweet, Carver Hospital, Washington, D. C.

Nos. 79 and 80. 79, portion of upper part of ileum, presenting a thickened Peyer's patch. 80, portion of same ileum, somewhat lower down, presenting two thickened and ulcerated Peyer's patches, and two smaller ulcers of solitary follicles.

E. 44 & 45. Private J. L., "G," 4th Vermont. Admitted, November 23d, 1863, moribund, and died the same day. He came from the Army of the Potomac.

Autopsy: Ileum as in the specimens; toes and anterior portion of metatarsi of both feet gangrenous.

Contributed by Assistant Surgeon W. Thomson, U. S. Army, Douglas Hospital, Washington, D. C.

Nos. 107 and 108. 107, piece from middle of ileum, with a large, slightly thickened Peyer's patch, the seat of six ulcers of small size with thickened edges. 108, from just above ileo-cæcal valve of same ileum, with an ulcerated Peyer's patch and slight prominence of solitary follicles. (*See Microscopical Section, Part First, VII, II, c.*)

E. 46 & 47.

Private L. W., "C," 7th West Virginia Cavalry, age 19. Admitted from the Army of West Virginia, August 21st, 1861. He was considerably emaciated, and had been sick for some time with fever, diarrhoea and vomiting. When admitted he appeared exhausted; pulse frequent and feeble; slight diarrhoea and incessant vomiting; under treatment, the vomiting disappeared and diarrhoea greatly improved; but he remained in a typhoid condition and died August 25th.

Autopsy: Hypostatic congestion of posterior parts of lungs; a large fibrinous clot in right side of heart; ileum presented patches of congestion with enlargement of solitary follicles; there were numerous ulcers of Peyer's patches; which, however, presented the peculiarity that three, four, or more small oval ulcers, a few lines in diameter, were seated in each patch, the remaining portions of which were nearly normal; solitary follicles of colon were the seats of pigment deposits.

Contributed by Acting Assistant Surgeon O. P. Sweet, Carver Hospital, Washington, D. C.

No. 160. Portion of ileum, with a large, somewhat thickened Peyer's patch, presenting several points of ulceration.

E. 48. H. V., "D," 171st Pennsylvania, age 19, American. Admitted, July 8th, 1863. Diagnosis—acute diarrhoea. Died, July 16th. Diagnosis—typhoid pneumonia.

Autopsy: Upper lobe of right lung highly congested, especially at apex, but floated on water; middle lobe somewhat congested, presenting evidences of bronchitis posteriorly; lower lobe intensely engorged with venous blood, which poured out in large quantities on section; lung of a dark red or purple color, in some places approaching to black; parenchyma dense, entire lobe approaching a condition of splenization; upper lobe of left lung less congested; bronchial secretion abundant on section; on posterior part of lower lobe a transudation of blood had taken place to a great extent in cellular tissue beneath pleura; this lobe in a state of lobular splenization; right lung weighed twenty-four and a half ounces; left, twenty-one and a half ounces; small intestine apparently healthy to within three feet of ileo-cæcal valve, from which point the mucous membrane became greatly congested and softened, and Peyer's patches thickened; the first ulcer was observed at this place, and was small, of a darker color than the surrounding membrane, and superficial; the specimen was taken about two feet below this point; five lumbricoid worms were found in the stomach.

Contributed by Assistant Surgeon H. Allen, U. S. Army, Lincoln Hospital, Washington, D. C.

No. 121. Portion of ileum, taken from near its middle, with a large Peyer's patch in which are five small ulcers; very many Peyer's patches of this ileum were in a similar condition.

E. 49. Private S. H., "B," 10th United States Infantry. Admitted, July 2d, 1864, with fever. Died, July 27th.

Autopsy: Body extremely emaciated; ileum inflamed, with ulcers as described; ulcers also in colon.

Contributed by Surgeon E. Bentley, U. S. Vols., General Hospital, Alexandria, Va., Third Division.

Nos. 60 and 61. 60, portion of ileum, from about its middle, with two thickened Peyer's patches, presenting a well-marked ulceration in each. 61, portion of same ileum, taken lower down, with five thickened Peyer's patches, all ulcerated.

E. 50 & 51. Private M. K., "I," 32d New York, age 24, Irish. Admitted, August 10th, 1862. Diagnosis—typhoid fever. Died, August 11th.

Autopsy: Body presented a vigorous appearance, with but slight emaciation; right lung exhibited old pleuritic adhesions;

liver circumscribed, much enlarged, of a yellowish brown, and coarsely granular, the granules being about the size of pepper-corns; spleen enlarged, being nine by five and a half by two and a half inches, but of natural color and consistence; mucous membrane of ileum reddened, and its lower Peyer's patches much thickened and ulcerated.

Contributed by Acting Assistant Surgeon J. Leidy, Satterlee Hospital, Philadelphia, Pa.
62, *chap. IV., sec. 7, C. 2, enlarged spleen, is also from this case.*

No. 201. Portion of ileum, presenting several well-marked ulcers of Peyer's patches, with thickened edges.

E. 52. Private M. W. K., "A." 67th Pennsylvania, age 23, American. Admitted, February 31, 1861. Diagnosis—chronic diarrhoea. Died, February 28th.

Contributed by Assistant Surgeon H. Allen, U. S. Army, Lincoln Hospital, Washington, D. C.

No. 226. Piece of upper portion of ileum, presenting three ulcers of Peyer's patches, of considerable size, with thickened edges.

E. 53. The patient died of camp fever, July 17th, 1862.

Contributed by Acting Assistant Surgeon A. F. Delaney, Alexandria, Va.

No. 271. Portion of ileum, with ulceration of Peyer's patches.

E. 54. The patient died of fever in the fall of 1863.

Contributed by Surgeon T. R. Crosby, U. S. Vols., Columbian College Hospital, Washington, D. C.

No. 352. Portion of ileum, taken just above ileo-cæcal valve; one large and one small ulcer in upper part of the somewhat thickened Peyer's patch in lower part of piece; above, several small rounded ulcers, four to six lines in diameter, most of them exposing the transverse muscle at their bases, and with abrupt thickened edges.

Private W. D., "I," 10th New York, age 21. Admitted, May 14th, 1861, from the field, with flesh-wound of upper third of left forearm, which readily healed. Furloughed on the 18th for thirty days; re-admitted June 18th. From that date to July 28th he performed the duties of hospital attendant, still being disqualified for duty in the field in consequence of wound. July 28th, was seized with symptoms of typhoid fever—severe pain in head, rapid pulse, (100 per minute,) tongue covered with dark fur, and nocturnal delirium. August 1st, subsultus tendinum and some dyspnoea. 3d, slight diarrhoea, at no time troublesome. 5th, worse; delirium, jaundition, flushed face; diarrhoea slight. These symptoms continued till death, August 7th.

Autopsy: Body considerably emaciated; lungs congested; pericardium contained one ounce of fluid; liver congested; gall-bladder filled with viscid bile; spleen dark colored, slightly enlarged, and congested; mesenteric glands enlarged; mucous membrane of stomach light colored, thickened, and softened; mucous membrane of small intestine soft and somewhat thickened down to lower portion of ileum, where, at different points some distance from each other, there were numerous ulcers; near ileo-cæcal valve mucous membrane was greatly thickened and congested; very large ulcers, extending down to muscular coat and surrounded by red areolæ, were found at this point; mucous membrane of colon greatly congested; solitary follicles slightly enlarged.

Contributed by Acting Assistant Surgeon O. P. Sweet, Currier Hospital, Washington, D. C.

No. 339. Portion of ileum, presenting ulcers of Peyer's patches with thickened edges.

E. 56. Private G. Y., Admitted, August 10th, 1862. Diagnosis—typhoid fever. Died, August 13th. Was delirious from time of admission.

Autopsy: Body, apparently between 35 and 40 years of age, much emaciated; abdomen and thorax exhibited about a dozen rose-colored spots; mucous membrane of small intestine inflamed throughout, slightly so at upper part, in a decided manner in lower part of ileum; Peyer's patches ulcerated, especially lower ones, which were entirely destroyed, ulceration exposing muscular coat; mucous membrane of ileum near cæcum of a livid purple; Peyer's patches and a portion of surrounding mucous and submucous tissue completely destroyed, leaving patches of exposed transverse muscular fibres, enclosed by thickened ridges of mucous membrane; mucous membrane of colon slightly inflamed and of a slate-color.

Contributed by Acting Assistant Surgeon J. Leidy, Satterlee Hospital, Philadelphia, Pa.

No. 420. Portion of ileum, taken just above ileo-cæcal valve, with several large ulcers of Peyer's patches, which penetrate in some places to transverse muscle, in others to peritonæum; some solitary follicles enlarged and ulcerated.

Private G. W., "H," 2d Maine Battery. Admitted, July 25th, 1861, in the advanced stage of camp fever. He was nearly speechless; soon became comatose, and remained so till death. Died, July 27th.

Autopsy: Body extremely emaciated; besides lesion of small intestine, there was ulceration of large intestine; fatty liver, and distended gall-bladder.

Contributed by Surgeon E. Bentley, U. S. Vols., General Hospital, Alexandria, Va., Third Division.

No. 496. Piece of lower portion of ileum, with several ulcerations extending deeply into muscular layer; when fresh the specimen was exceedingly vascular and presented well-marked pigment deposit in solitary follicles.

The patient died of fever in the fall of 1863.

Contributed by Assistant Surgeon W. Thomson, U. S. Army, Douglas Hospital, Washington, D. C.

No. 496. Portion of ileum, from just above ileo-cæcal valve, showing numerous small oval ulcers of solitary follicles, and a Peyer's patch which is the seat of a number of ulcers.

See IV., chap. II., sec. 3, B. 6, for history.

No. 191. Lower portion of ileum, including ileo-cæcal valve, with considerably thickened mucous membrane and small punched-out follicular ulcers, about size of pin-heads; near ileo-cæcal valve are several irregular ulcers of Peyer's patches, lower one of which involves a portion of ileo-cæcal valve.

E. 60. Sergeant W. A. S., "E," 14th Iowa, age 24. Admitted, October 19th, 1862. Diagnosis—typhoid fever. Died, December 25th.

Contributed by Acting Assistant Surgeon B. B. Miles, General Hospital, Annapolis, Md.

No. 702. Portion of ileum, with Peyer's patches thickened at the edges, in the centre destroyed by eroding ulcers which penetrate to the muscular coat; pin-head enlargement of solitary follicles.

E. 61. History unknown.

See *Microscopical Section, Part First, VII.* H. c. 12 and 13.

F. Fever. Pulpy thickening and sloughing of Peyer's patches.

Nos. 88 to 90. Successive portions of ileum, in each of which is an enlarged and thickened Peyer's patch. **90** is especially remarkable on account of great size and pulsatious character of thickening, and also presents several thickened solitary follicles.

F. 1 to 3. See 192, chap. III., sec. 2, A. 1, for history.

Nos. 102 to 105. Successive portions of ileum, showing various degrees of enlargement and ulceration of Peyer's patches; the extensive sloughing patch on **105** is especially worthy of note.

105. Private J. R., "B," 67th Ohio. Admitted, October 27th, 1862. Died, January 27th, 1863. Diagnosis—**F. 4 to 7.** typhoid fever.

Autopsy: Age about 22; no emaciation; back of body exhibited a purplish aspect from gravitation of blood into skin; a number of reddish spots visible on front of abdomen and chest; spleen enlarged and flabby; moderate enlargement of lower Peyer's patches; lowest solitary glands also enlarged, and a few with small ulcers at summits; ileum presented a diffuse redness with a few ecchymosed spots; mucous membrane of large intestine grayish, with a few inflamed streaks.

Contributed by Acting Assistant Surgeon J. Leidy, Satterlee Hospital, Philadelphia, Pa.

106, chap. IV., sec. 7, C. 4, *enlarged spleen, is also from this case.*

Nos. 180 to 183. Four successive portions of ileum, in each of which is a thickened ulcerated Peyer's patch; the thickening in the specimens, when fresh, was grumous in consistency, blackish in color, tinged with a livid red, and margins indistinctly defined; several solitary follicles also ulcerated.

F. 8 to 11. The patient died, May 27th, 1863. His disorder is described by the ward physician as an "obscure disease resembling typhus."

Autopsy: Peyer's patches thickened and converted into irregular sloughs as described; mesenteric glands large and soft; lower lobe of right lung hepatized; spleen extremely small.

Contributed by Surgeon T. R. Crosby, U. S. Vols., Columbian College Hospital, Washington, D. C.

Nos. 210 and 211. Successive portions of ileum. **210** presents three large superficial ulcers of Peyer's patches. **211** presents a large, irregular, pulpy slough.

211. Private R. L. T., "E," 17th United States Infantry, age 23. Admitted, August 10th, 1862. Diagnosis—**F. 12 & 13.** typhoid fever. Died, August 16th.

Autopsy: Several old pleuritic adhesions; lungs somewhat engorged with mucus; spleen of usual size, color and consistence, but its convex surface roughened, apparently from an old inflammation; mucous membrane of ileum of a pinkish cream-color with patches of inflammation; there were twenty-two Peyer's patches, varying in size from half an inch to one which was four inches in length; to the twelfth they were healthy, but with deposits of black pigment; the thirteenth was ulcerated, fourteenth appeared healthy, and remainder were all ulcerated, some even through to peritoneum; the last of series, near ileo-cæcal valve, formed a blackish-brown irregular eschar about an inch and a quarter square and a fourth of an inch thick; mucous membrane was inflamed in vicinity of ulcerated glands; solitary glands of ileum prominent, with deposit of black pigment.

Contributed by Acting Assistant Surgeon J. Leidy, Satterlee Hospital, Philadelphia, Pa.

Nos. 559 to 561. Three successive pieces of ileum, showing thickened Peyer's patches, which are the seats of sloughing ulcers; ulcer just above ileo-cæcal valve has perforated; all the pieces covered with pasty lymph on peritoneal surface.

F. 14 to 16. No history.

Contributor unknown.

No. 168. Lower portion of ileum, with ileo-cæcal valve and part of cæcum, showing three ulcerated Peyer's patches, surface of ulcers being covered by pultaceous sloughs; solitary follicles enlarged, many of them, especially near valve, ulcerated, ulcers presenting same character as those of Peyer's patches, but smaller; small sloughing ulcers on under surface of valve and in cæcum.

Private A. J. C. Admitted, November 30th, 1861, by transfer from a hospital at City Point, Va., where he had been treated for camp fever contracted before Peter-burg, Va.; pulse feeble, thread-like, about 100; skin hot and dry; tongue dry, red and gashed; teeth and gums coated with sorbes; muttering delirium; tympanites; petechiæ; sudamina; tenderness in right iliac region; epistaxis; hæmorrhage from bowels. Died, December 3d.

Autopsy: Ileum presented enlarged solitary follicles and sloughing ulcers of Peyer's patches; colon pale, but not ulcerated except in cæcum; mesenteric glands greatly enlarged; spleen softened; nutmeg liver.

Contributed by Acting Assistant Surgeon W. C. Minor, General Hospital, Alexandria, Va., Third Division.

See plate opposite.

G. Fever. Perforations and peritonitis.

Nos. 371. and 375. Two successive portions of ileum, presenting several ulcers with thickened edges. In **371**, one has penetrated to peritoneal coat, on opposite surface of which is a patch of discolored lymph. In **375**, an ulcer has perforated, and some lymph adheres to peritoneum immediately around orifice, and the piece also presents a small diverticulum; solitary follicles somewhat enlarged.

G. 1 and 2. Private W. H. M., "H," 117th New York, age 33. Admitted, August 20th, 1861, with fever and diarrhœa of four weeks' standing. Had about twelve passages daily, with tormina and tenesmus; was very much emaciated. Died, August 30th.

Autopsy: Peyer's patches ulcerated; one ulcer had perforated; peritoneum reddened, but no fluid in abdominal cavity.

Contributed by Acting Assistant Surgeon D. L. Haight, Douglas Hospital, Washington, D. C.

Nos. 369. to 373. **369**, portion of ileum, with five irregular ulcers one-quarter to one-half an inch in diameter, with thickened edges, penetrating nearly through muscular coat; solitary follicles slightly enlarged. **370**, from lower down same ileum, with three large ulcers of irregular oval shape, about an inch in diameter, thickened edges, and penetrating deeply; perforations existing in all; perforation in upper ulcer quite minute, and ulcer presents, a little to left of actual opening, another point at which perforation was about to occur; the second ulcer presents an oval perforation nearly half an inch in length; a portion of necrosed peritoneal layer attached to one edge of perforation floats free in cavity of ulcer; just above actual perforation is an isolated point in which peritoneal layer is almost perforated; the third ulcer presents an oval perforation nearly an inch in long diameter; a portion of necrosed peritoneum, similar in shape to perforation but smaller in size, occupies its centre and is attached by shreds to edges of orifice; solitary follicles slightly prominent. **371**, from lower down same ileum, with two large ulcers similar to those in **370**, one has perforated; mucous membrane of this piece thickened, and a number of minute punched-out ulcers corresponding to solitary follicles; also a pouch-like diverticulum, in mucous membrane of which are several follicular ulcers similar to those just described. **372**, from lower down same ileum, with several ulcers of moderate size, similar to the larger ones of former pieces, one of them perforated; mucous membrane thickened and presents a number of follicular ulcers. **373**, from just above ileo-cæcal valve of same patient; mucous membrane considerably thickened; numerous irregular ulcerations penetrate to muscular coat, one over two inches in long diameter; on the thickened mucous membrane, between the ulcers, are a number of solitary follicles considerably enlarged.

Private M. H., "B," 5th New York Cavalry. Admitted from Camp Stoneman, Washington, D. C., August 12th, 1861, with fever; delirium; tympanites; abdomen tender; tongue firred; pulse rapid. Died, August 29th. Diarrhœa not noticed until within four days of death.

Autopsy: Height, six feet two inches; not much emaciation; right lung filled with pigment; ileum as described, showed five perforations; solitary glands of cæcum enlarged; peritoneal layers of lymph (recent)

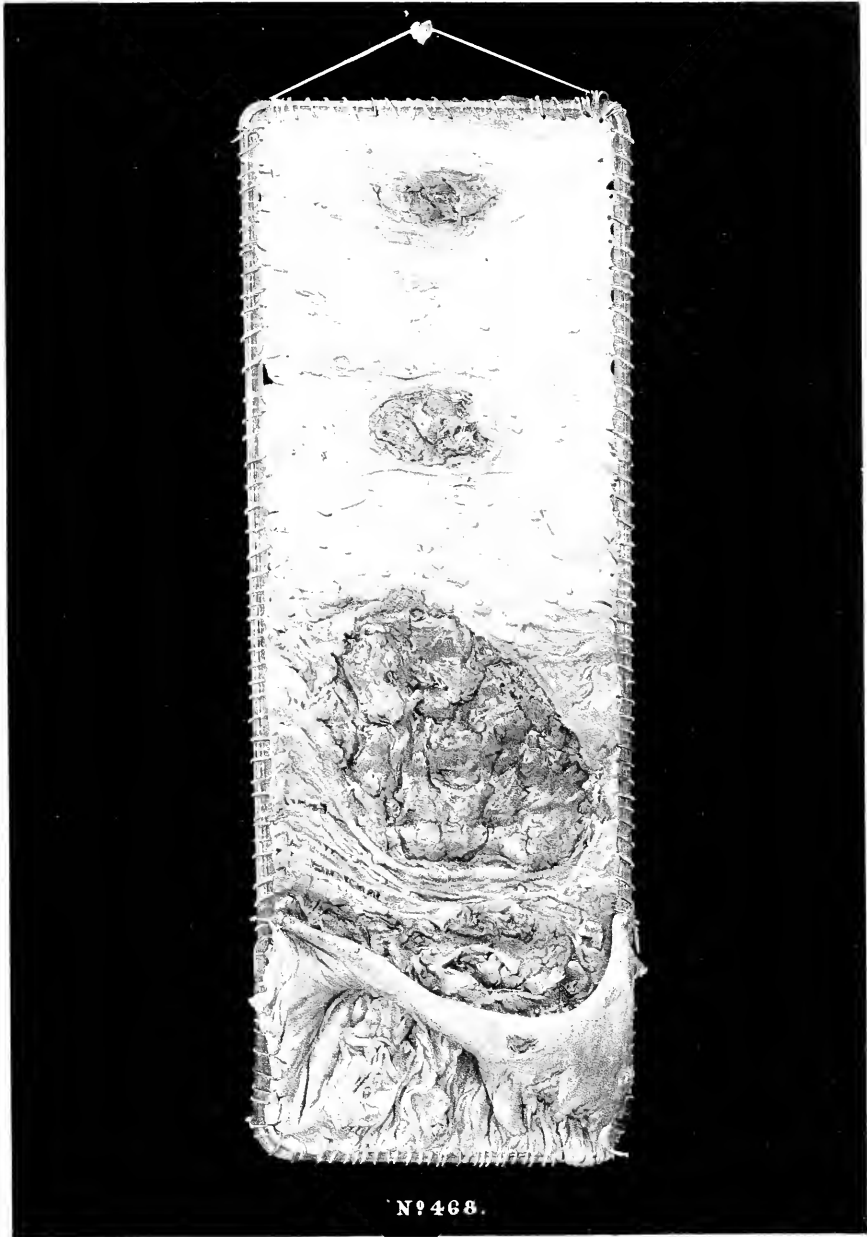
Contributed by Acting Assistant Surgeon H. M. Dean, Lincoln Hospital, Washington, D. C.

No. 77. Portion of ileum, on mucous surface of which are several excavating ulcers; two of these have perforated into **G. 8.** peritoneal cavity; peritoneal surface of piece is coated with pseudo-membranous lymph.

Lieutenant J. W. L., "B," 9th New York Cavalry. Admitted, September 21st, 1863, with stiffness and some swelling of back of neck, from blow from butt of a rebel musket received at Brandy Station, Va., August 1st. Health good, September 30th, received thirty days' leave of absence. Returned, November 11th. Had an attack of diarrhœa preceded by vomiting during absence, and seemed somewhat feeble. 14th, was up, seemed much better and expressed desire to rejoin regiment; at midnight was seized with violent pain, attributed at first to testicles, followed by abdominal tenderness, obstinate vomiting, feeble pulse, anxious countenance. Died, November 19.

Autopsy: Peritoneal surface of intestines covered with opaque lymph; a little pus in abdominal cavity; ileum presented a number of typhoid ulcers and several perforations.

Contributed by Surgeon H. W. Duanelet, U. S. Vols., Seminary Hospital, Georgetown, D. C.



№ 468.

No. 479. Portion of ileum, taken several feet above the ileo-caecal valve, with two ulcerated Peyer's patches which present a peculiar cribriform appearance: near the bottom of piece is a deep oval ulcer, the long diameter of which is transverse to the gut; at the bottom of this ulcer are two oval perforations a short distance apart; peritoneal surface is coated with a thin film of pseudo-membrane; some solitary follicles ulcerated; intestines, as received at Museum, presented several other perforations. The patient died of peritonitis consecutive to camp fever contracted before Petersburg, Va.

Contributed by Surgeon W. L. Faxon, 23d Massachusetts, Depot Hospital, City Point, Va.

No. 439. Portion of ileum presenting two deep typhoid ulcers, one of which has perforated; peritoneal surface of piece coated with pseudo-membrane.

G. 10. Private W. T. F., "C," 42d Massachusetts. Admitted, October 29th, 1861. Was taken sick about a week before with a decided chill followed by a hot skin and severe headache, with thirst and diarrhoea; two or three passages daily; no delirium, epistaxis, deafness, nor tympanites; is now wakeful, with hot skin; pulse 120; headache, thirst, scanty urine, thickly coated dry tongue, and some bronchial irritation. November 6th, symptoms have abated; tongue clearing. 12th, has continued to improve till this morning; respiration now hurried; pulse more frequent; febrile symptoms renewed; more cough; dark flushed cheeks; no physical signs of pneumonia. 15th, so much better as to desire to leave bed; expectorates rusty sputa. 16th, pulse feeble; skin cool. 17th, bilious vomiting several times last night; complains of pain in epigastrium; is cold; prostrated; pulse feeble; no mental derangement; bowels have acted once or twice daily for last few days; no tympanites; vomiting continued, assuming character of coffee-grounds. Died, at 8 p. m., November 17th.

Autopsy sixteen hours after death: Rigor mortis great; body not much emaciated; omentum inflamed; external surface of small intestine very much reddened and inflamed, and glued together with pasty yellow lymph; abdominal cavity contained two pints of yellow turbid fluid, which had an unpleasant fecal odor; perforation about one-eighth of an inch in diameter about middle of ileum; several enlarged and thickened Peyer's patches near perforation and in lower part of ileum; spleen enlarged and softened.

Contributed by Surgeon E. Bentley, U. S. Vols., General Hospital, Alexandria, Va.

No. 452. Portion of ileum, taken from just above ileo-caecal valve, presenting one large and several small ulcerations;

G. 11. the small ulcers are oval and penetrate to the muscular coat: the large one is irregular with overhanging edges, and occupies the site of a Peyer's patch, which, however, is completely ulcerated away, leaving the muscular coat exposed; near the center of this ulcer is a small oval perforation; peritoneal surface of piece coated with pseudo-membranous lymph.

Private E. J. W., "C," 179th New York. Admitted, November 30th, 1864. Died, December 5th, of peritonitis consecutive to fever.

Contributed by Acting Assistant Surgeon W. C. Miner, General Hospital, Alexandria, Va., Third Division.

No. 117. Portion of ileum, with perforating ulcer; pseudo-membranous patches on peritoneal surface.

G. 12. Private E. W. W., 5th Maine Battery. Admitted, September 1st, 1862, with gunshot wound received at battle of Bull Run. November 12th, furloughed, and while at home taken sick. Returned, February 6th, 1863, in a low, debilitated condition. March 12th, attacked by fever, with severe pain in left precordial region. 24th, had chill, followed by sharp pain in lower part of abdomen; decubitus dorsal with knees drawn up; extreme thirst; constipation; nausea; vomiting; face pallid, contracted and anxious; pulse frequent and feeble; tongue red at tip and edges, with a whitish or yellowish fur in the centre; was conscious until within an hour of death. Died, March 25th.

Autopsy: Small intestine deep red, almost black in portions, in others a brilliant red; mucous membrane of ileum, for about five feet, showed patches of ulceration, and was perforated by a large ulcer eighteen inches from colon; a large amount of serum and pus in abdominal cavity.

Contributed by Medical Cadet Abner Thorp, Columbian College Hospital, Washington, D. C.

No. 810. Portion of ileum, with a number of typhoid ulcers penetrating to muscular coat; an oval perforation exists in lowest ulcer of piece; villi hypertrophied.

G. 13. Private W. N. P., "C," 19th Wisconsin, age 18. Admitted, September 9th, 1861, from Army of Potomac, having been sick two weeks with typhoid fever. There was pain in left iliac region, which, by the 13th, extended over the whole abdomen, with tympanites; knees drawn towards abdomen; face pinched. Died, September 14th.

Autopsy: Two quarts of yellowish fluid in peritoneal cavity; agglutination of intestines by false membrane; Peyer's glands indurated at edges and ulcerated in centre; in lower part of bowel quite ulcerated away; a perforation in the middle of one patch.

Contributed by Acting Assistant Surgeon J. H. Butler, West Buildings Hospital, Baltimore, Md.

Nos. 601 to 606. 601, portion of ileum, taken just above ileo-caecal valve, showing thickening and ulceration of Peyer's patches, and enlarged solitary follicles. 605, several knuckles of ileum, taken just above the previous piece, with a small perforation; peritoneal surface of intestine coated with lymph. 606, portions of transverse colon of same patient coated with a thick layer of lymph.

W. W., colored, age 18. Height, five feet seven inches. Weight, about one hundred and fifty pounds. Admitted, August 20th, 1865, with fever. Died, August 24th.

Autopsy twelve hours after death: Rigor mortis marked; no emaciation; membranes of brain congested; about three

ounces of serum beneath arachnoid; two ounces of serum in pericardium; a pint of sero-pus in abdominal cavity; all the viscera coated with yellow, pasty lymph; peritoneal surface of ileum beneath layer of lymph reddened, with a darker spot corresponding to situation of each Peyer's patch; mucous membrane of ileum inflamed, with thickening and ulceration of Peyer's patches; a perforation in one patch; solitary follicles in lower part of ileum enlarged, the apex of each black with pigment; mesenteric glands enlarged.

From Freedman's Hospital, Washington, D. C.

Autopsy by Hospital Steward A. J. Schaffhirt.

Nos. 231 to 236. Three successive portions of ileum, presenting ulcerations with thickened edges corresponding to the sites of Peyer's patches; at bottom of largest ulcer in **235** is a perforation about a line in diameter.

T. J., nurse of ward "T." Died, October 30th, 1863. Diagnosis—peritonitis.

G. 17 to 19. Autopsy: Age about 50; body well nourished; capacity of chest much diminished by pressure of abdominal contents; acute peritonitis; peritoneum everywhere reddened and covered by thin, cream-colored pseudo-membrane; abdominal cavity filled with sero-purulent fluid; the pseudo-membrane was composed of a fibrinous substratum mixed with pus corpuscles; liver large, yellow-brown, rather soft and somewhat fatty; spleen flabby, bluish white on surface and with an old cicatrix-like mark, which, together with the subserous tissue, was spotted with black maculae; section of spleen bright Indian red and remarkably bloodless; tissue, for half a line from surface, was black, due to molecular pigment; granules of various sizes up to round masses of the size of blood corpuscles; ileum and colon somewhat pinker than natural; upper Peyer's patches healthy, those of lower three feet of ileum ulcerated, ulcers occupying only a part of the gland extending to muscular and serous coats, and having edges a line in thickness; one ulcer had perforated the bowel, the hole being circular and about a line in diameter; blood contained, if anything, fewer white corpuscles than usual; thyroid body on one side enlarged to size of hen's egg.

Contributed by Acting Assistant Surgeon J. Leidy, Satterlee Hospital, Philadelphia, Pa.

Nos. 307 and 308. Two successive portions of ileum; mucous membrane presents ulcerations of solitary follicles and Peyer's patches; peritoneal surface covered with crumpled lymph.

Private J. E. E., "G." 2d Tennessee, age 22, paroled prisoner. Admitted, April 15th, 1864, with chronic diarrhoea, and in the last stage of emaciation. Died, May 3d.

Autopsy—(Acting Assistant Surgeon R. B. Miles): A large tubercular cavity in middle lobe of left lung; two quarts of effusion in left pleura pushing heart to right side; cavity in middle lobe of right lung, upper lobe consolidated by deposition of tubercular matter, extensive adhesions of right pleura; heart pale and flabby; aortic valves thickened; spleen soft; gall-bladder empty; general peritonitis, with effusion of pasty lymph involving, especially, lower part of ileum and caecum coli; ulceration of solitary follicles of small intestine.

Contributed by Assistant Surgeon Dr. Witt C. Peters, U. S. Army, Jarvis Hospital, Baltimore, Md.

II. Fever. Granulation and cicatrization of ulcerated Peyer's patches.

Nos. 656 and 657. Successive portions of ileum. **657**, taken from just above ileo-caecal valve, showing ulcers of Peyer's patches, the bases of which are granulatory; some ulcers are filled with granulations nearly to the surface.

S. C., dark mulatto woman, age 24. Admitted, October 28th, 1863. Had a large bed-sore over sacrum and buttocks when admitted, another over trochanter major of right side. Had been ill of a fever a long time; no appetite; tongue brown in centre; skin dry and harsh; pulse quick and feeble. Died, December 2d.

Autopsy eleven hours after death; Height, five feet two inches; weight, about eighty pounds; rigor mortis well marked in lower extremities, partial in upper; the large bed-sores as described; lungs contained much pigment; right lung adherent; pericardium contained an ounce of clear serum; large, white fibrinous clots in both ventricles of heart extending into aorta and pulmonary artery; nutmeg liver; gall-bladder large and distended with bile; spleen small, edges lobulated; kidneys fatty; granulating ulcers of Peyer's patches as in specimens; anterior lip of os uteri showed a few small ulcers; similar ones in upper portion of vagina; ovaries connected by adhesions with fallopian tubes and broad ligaments.

From Freedman's Hospital, Washington, D. C.

Autopsy by Hospital Steward S. S. Bond.

657, chap. IV., sec. 5, H. 2, enlarged gall-bladder; 659, chap. V., s. c. 5, A. 2, small ulcers of os uteri and vagina, adhesions of ovaries and uterus, are also from this case.

Nos. 159 and 160. **159**, portion of ileum, taken just above ileo-caecal valve, with four typhoid ulcers, upper two completely cicatrized, lower two partially so; solitary follicles enlarged to size of pin-heads. (*See Microscopical Section,*

Part First, VII. H. C. 4.) **160**, portion of colon of same patient, near sigmoid flexure; mucous membrane much thickened, with irregular, jagged, cicating ulcers extending to muscular coat.

Private J. R., "F." 10th Vermont, age 23. Admitted, August 27th, 1864, from field hospital, Sandy Hook, Md., in a low typhoid condition; dull and inattentive; complaining of abdominal pain, and with frequent mucous discharges from bowels. 30th, discharges still frequent; skin hot and dry; pulse 100, and intermittent; much headache. September 1st,

somewhat better: from this date improved in general condition, but diarrhoea continued. Febrile symptoms returned towards latter part of September, assuming a tertian form, diarrhoea still continuing. 29th, much better; tongue cleaning at edges; appetite returning; pulse frequent; diarrhoea constant. October 3d, dull; difficult to arouse; tongue dry; involuntary dejections, mixed with blood and pus. From this period he grew rapidly worse, and died October 14th.

Autopsy: Great emaciation; cicatrizing ulcers of Peyer's patches; enlargement of solitary follicles of small intestine; extensive ulceration of colon.

Contributed by Assistant Surgeon C. Bacon, jr., U. S. Army, General Hospital, Annapolis Junction, Md.

Nos. 489 to 491. Successive portions of ileum, showing typhoid ulcers in various stages of cicatrization; villi enlarged, especially immediately around cicatrices, giving a plush-like surface to gut. (*See Microscopical Section, Part First, VII.* H. c. 14.)

H. 5 to 7. See 492, chap. III., sec. 2, D. 5, for history.

Nos. 597 and 598. 597, portion of ileum, with ileo-cæcal valve and part of cæcum; ileum thickened with patches of pseudo-membrane and a few minute ulcers near valve; a Peyer's patch, two inches above valve, presents a large oval cicatrix; cæcum coated with patches of pseudo-membrane. 598, portion of colon, thickened, with follicular ulcers and pseudo-membranous patches.

Private W. H., "G," 8th New York Cavalry, age 18, American. Admitted, July 23d, 1865, with chronic diarrhoea. Died, July 27th.

Autopsy: Sigmoid flexure of colon adherent to anterior walls of pelvis by semi-transparent bands; part of ileum behind it also adherent; lower part of small intestine congested, with pseudo-membranous patches on mucous surface, and a few small ulcers near valve; colon thickened, with follicular ulcers and patches of pseudo-membrane; mesenteric glands enlarged.

Contributed by Acting Assistant Surgeon W. C. Miner, Slough Hospital, Alexandria, Va.

Nos. 510 to 513. 510, from high up, 511 from near the middle, and 512 from low down in ileum, including ileo-cæcal valve: the pieces show pin-head enlargement of solitary follicles, with adherent shreds of mucous membrane.

513, 511 presents a large oval cicatrix, corresponding in situation with a Peyer's patch. The ileum presented a number of such cicatrices. 513, from descending colon, shows many follicular ulcers, with a few adherent shreds of mucous membrane.

Private A. McG., "K," 40th Illinois. Admitted, November 20th, 1864, with chronic diarrhoea, frequent, watery, sometimes bloody, and often involuntary stools; much emaciated; countenance pale and anxious; pain; tenesmus; retention of urine. Died, November 27th.

Contributed by Acting Assistant Surgeon H. C. May, Hospital No. 8, Nashville, Tenn.

I. Fever and dysentery Lesions of both ileum and colon.

Nos. 385 to 390. 385, piece taken from high up in the ileum; 386, from its middle; 387, from just above the ileo-cæcal valve. These pieces show progressive enlargement of the solitary follicles; Peyer's patches are but slightly thickened. (*See Microscopical Section, Part First, VII.* H. c. 2 and 3.) 388, appendix vermiformis of same patient.

I. 1 to 6. presenting a number of minute follicular ulcers. 389, portion of ascending colon of same patient, with enlarged solitary follicles and a few minute ulcers. 390, portion of transverse colon of same patient, with enlarged solitary follicles.

Private F. D., "D," 100th Pennsylvania, age 18. Admitted to hospital at City Point, Va., June 26th, 1864, and transferred to Washington, July 3d. Diagnosis—diarrhoea. Admitted to Carver Hospital, July 5th. Was considerably emaciated; tongue coated in the centre with thick gray fur; pulse rapid, but weak; had severe diarrhoea and anorexia, with inflammation of the left parotid gland, which was swollen and painful. 15th, the parotitis has terminated in suppuration; the abscess was opened to-day; the febrile symptoms continue, but there are distinct remissions during the forenoon of each day; persistent diarrhoea. 22d, patient has grown gradually worse; the integument over the parotid has sloughed; diarrhoea continues; there is deafness and low delirium, especially at night; the remissions not so distinct the last two days. Died, July 22d, in the evening.

Autopsy: Emaciation; lungs congested; heart pale and flabby; spleen enlarged; mucous membrane of stomach presented a number of red spots; Peyer's patches congested, but not thickened perceptibly, except, perhaps, the lowest; the solitary follicles of ileum enlarged to the size of pin-heads; several very minute ulcers in the ascending colon and in the vermiform appendix; solitary follicles of colon enlarged.

Contributed by Acting Assistant Surgeon O. P. Sweet, Carver Hospital, Washington, D. C.

Nos. 600 and 601. 600, portion of ileum, with enlarged solitary follicles, and a patch of Peyer slightly thickened, with two small ulcers near its middle. 601, lower portion of ileum, ileo-cæcal valve, and part of cæcum of same patient. Ileum, with enlarged solitary follicles; cæcum slightly thickened, with extremely minute follicular ulcers not much larger than pin-pricks.

Private E. B., "G," 195th Ohio, age 18. Admitted, July 29th, 1865, with diarrhoea of three or four weeks' standing. He was feeble; pulse 80, weak and compressible; tongue moist, slightly coated, tip and edges clean. August 1st,

symptoms assumed a typhoid character; tongue black and dry; delirium set in. 2d. better. 3d. much better; tongue moist; had but four stools in twenty-four hours. 5th. still improving; began to relish his food. 6th. died suddenly, having been up fifteen minutes before.

Autopsy: Enlargement of solitary follicles throughout the ileum, with slight thickening of Peyer's patches, which presented, in many instances, one or more minute ulcers; colon closely studded with minute follicular ulcers about the size of pin-pricks.

Contributed by Acting Assistant Surgeon W. C. Miner, Slough Hospital, Alexandria, Va.

Nos. 701 to 706. **701**, portion of ileum, taken from near the middle; solitary follicles enlarged; mucous membrane somewhat thickened; when fresh, pigment deposits in extremities of villi. **705**, portion of ileum of same patient, taken at ileo-caecal valve, in the same condition as No. **701**, the last Peyer's patch slightly thickened. **706**, portion of descending colon of same patient, much thickened; ulcerated, with pseudo-membrane adherent.

Private W. A., "C," 2d U. S. Colored. Admitted, January 17th, 1863, with chronic dysentery, contracted while on duty with his regiment in Florida. Was in a dying condition, with profuse haemorrhage from bowels. Died, January 23d.

Autopsy: Ileum as in specimen; colon, with greenish and brownish patches, thickened and ulcerated throughout as in specimen.

Contributed by Surgeon R. B. Bontecou, U. S. Vols., Harewood Hospital, Washington, D. C.

Nos. 116 to 118. **116**, portion of ileum, taken from just above the ileo-caecal valve, the solitary follicles enlarged to the size of pin-heads. **117**, portion of transverse colon of same patient, quite thin, with a number of irregularly oval ulcers. **118**, portion of the descending colon of same patient, with numerous irregular ulcers which unite with each other, forming large erosions, most of which involve the muscular coat and some penetrate it.

Private G. V., "D," 126th Ohio. Admitted, July 1th, 1861, from field hospital, Army of the Potomac. He was very much emaciated and suffering from symptoms resembling typhoid fever; tongue covered with a thick, dry, brown fur; teeth coated with dark sordes; tympanites; petechiae on the abdomen and chest; tenderness over the right hypocondrium; surface of the body dry, but there was little abnormal heat. The diarrhoea was quite severe but the stools feculent. After a few days the diarrhoea abated somewhat, the tongue appeared moist and there seemed to be a decided improvement. 25th, diarrhoea worse; the tongue again dry and dark colored; delirium. Died, July 30th.

Autopsy six hours after death: Body greatly emaciated; rigor mortis not marked; old pleuritic adhesions on both sides; pericardium contained two ounces of pinkish serum; liver enlarged and pale; the gall-bladder nearly filled with bile; spleen dark colored, enlarged, firm by eight inches, and firm; stomach dilated and flabby, its mucous membrane thickened and softened; solitary follicles of jejunum slightly enlarged; solitary follicles of ileum as in specimen; colon distended and thin; in the ascending colon were a number of ulcers; in the transverse colon, which made a bend downwards towards the pubis, large ulcers with ragged edges, some of them extending through the muscular coat; these ulcers increased in size towards the sigmoid flexure.

Contributed by Acting Assistant Surgeon O. P. Sweet, Carver Hospital, Washington, D. C.

Nos. 115 and 116. **115**, piece of the lower portion of ileum, with well-marked enlargement of the solitary follicles, the villi hypertrophied. **116**, portion of transverse colon of same patient, presenting numerous irregular superficial ulcers.

I. **15 & 16.** Private W. T. B., "E," 5th Illinois Cavalry, age 21. In the army two years. Had been sick for eight months. Admitted, October 10th, 1863, with intermittent fever, which was succeeded by an attack of dysentery of three or four days' duration; diarrhoea supervened with watery stools, followed in a week by another attack of dysentery. November 9th, stools small, shreddy, gelatinous and sometimes white; tenesmus very slight. Till November 1st his appetite had been ravenous, afterwards it entirely failed. Died, November 19th.

Autopsy: Lungs healthy, but presenting extensive adhesions; mesenteric glands dark and slightly enlarged; spleen rather large; in middle of jejunum a softened tract six inches long, of a deep livid red color, a similar tract a foot further on; the entire ileum of a deep livid red, softened, except just above the caecum, where the bowel appears quite healthy; solitary glands as in the specimen; caecum dark red and softened; transverse colon comparatively healthy; from beginning of descending colon to anus the mucous membrane completely eroded, except here and there a few isolated elevated spots and patches; but few of the ulcers involve the muscular coat; rectum deep red, the ulcers situated here filled with still deeper red adherent grumous clots.

Contributed by Surgeon Geo. F. French, U. S. Vols., Hospital No. 3, Vicksburg, Miss.

Nos. 197 to 200. **197, 198 and 199**, successive portions of ileum, exhibiting well-marked enlargement of the solitary follicles; Peyer's glands unchanged. **200**, portion of rectum of the same patient, presenting punched-out ulcers of the solitary follicles, several of which have extended into oval excavations of moderate size; patches of pseudo-membrane scattered over the surface.

Private H. M., "H," 134th New York. Admitted, November 12th, 1863. He had suffered from diarrhoea for six months; was much prostrated and greatly emaciated; tongue was dry; discharges from the bowels frequent and profuse. Died, December 30th.

Autopsy: Enlargement of the solitary follicles of ileum; thickening and ulceration of the colon and rectum.

Contributed by Assistant Surgeon W. E. Whitehead, U. S. Army, Hospital No. 3, Murfreesboro', Tenn.

Nos. 395 to 397. **395**, portion of ileum, with ileo-cæcal valve and part of the cæcum; the solitary follicles in the ileum are enlarged to the size of pin-heads, some of them presenting a dot-like point of ulceration at the apex; the mucous membrane of cæcum thickened and sprinkled with points of pseudo-membrane; it also presents a few scattered minute follicular ulcers. **396**, a portion of the cæcum, with the vermiform appendix of the same patient; a number of minute follicular ulcers in the mucous membrane of the cæcum at the orifice of the appendix; follicular ulcers of larger size scattered throughout the appendix. **397**, portion of sigmoid flexure and rectum of same patient, with numerous punched-out but extremely small ulcers; the surface of the mucous membrane is frosted with points of pseudo-membrane.

Private J. O., "K," 8th New York Heavy Artillery, age 16. Admitted, September 15th, 1864, laboring under chronic diarrhæa. He was very weak and much emaciated. Died, October 2d.

Autopsy: Enlargement of solitary follicles of ileum; pigment deposits in the solitary follicles of cæcum; scattered follicular ulcers in cæcum, the bases of many of them black with pigment; many follicular ulcers in transverse and descending colon and rectum; surface of mucous membrane throughout the colon more or less frosted with pseudo-membrane.

Contributed by Acting Assistant Surgeon W. H. Combs, Emory Hospital, Washington, D. C.

Nos. 838 and 839. **838**, a piece of ileum, with pin-head enlargement of solitary follicles and slight thickening of the Peyer's patch. **839**, a piece of the sigmoid flexure from same case, greatly thickened, with small follicular ulcers. See No. 840, chap. II., sec. 1, D. 1, for history.

I. 24 & 25.

Nos. 126 to 128. **126**, portion of jejunum; **127**, ileum of same patient; both with enlarged solitary follicles, which project as pin-head-like tumors from the surface of the mucous membrane; in **127** are several small ulcers. **128**, portion of the ascending colon, near cæcum, of same patient, with a few scattered follicular ulcers.

I. 26 to 28. Private D. B. D., 2d Iowa Battery, age 22. July 4th, 1863, had an attack of dysentery, when he passed a moderate amount of blood, suffering considerably from tenesmus and tormina; small white mucous stools succeeded, numbering about fourteen daily; subsequently reduced in number to five or six. The stools were streaked with blood and were very offensive. About three weeks from commencement of the attack the symptoms assumed the characteristics of diarrhæa, which has not since ceased, although at times conjoined with mild dysenteric symptoms. Two weeks in August, patient was sick with intermittent fever, the diarrhæa continuing. Admitted, October 10th, in a very low typhoid condition, from which he never recovered. Died, November 21st.

Autopsy: Old pleuritic adhesions of left lung; spleen pale; congenital anomaly of liver, the left lobe being longer than the right; patches of congestion in small intestine, especially in ileum; the solitary glands in the specimen; the enlarged glands were of the same color as the mucous membrane and delicately punctuated in their centre; transverse and descending colon and rectum reddened and spotted with deep mahogany-colored stains, here and there livid and dark-green tracts; there were a few small follicular ulcers in colon, and several large ragged ulcers extended transversely across the lower portion of rectum.

Contributed by Surgeon Geo. P. French, U. S. Vols., Hospital No. 3, Vicksburg, Miss.

Nos. 815 to 821. **815** to **817**, successive portions of ileum; Peyer's patches much thickened and ulcerated; solitary follicles enlarged to rounded tumors nearly the size of peas, many of them ulcerated at the apices; villi greatly hypertrophied. **818** cæcum, **819** from the ascending, **820** from the transverse, and **821** from the descending colon; the solitary follicles in all enlarged to tumors the size of peas, with ulcerated apices; the tumors are largest in the transverse and descending colon.

I. 29 to 35. History—(Acting Assistant Surgeon G. P. Hanawalt): Private G. H., "B," 12th U. S. Infantry, age 25. Admitted, August 25th, 1866. Diagnosis—typhoid fever. Had been taken sick about August 1st, while a prisoner in the guard-house. On admission, he was found quite stupid, but could readily be aroused. In the afternoon of the 26th he became delirious, and during the night constant watching and restraint were required to keep him in bed. 27th, stupor. Died, August 28th.

Autopsy: Arachnoid at the base of the brain opaque; some effusion of lymph just below the medulla oblongata in the posterior portion of the spinal cord; intestines as described in the specimen; other viscera healthy.

Contributed by Assistant Surgeon W. Thomson, U. S. Army, Post Hospital, Washington, D. C.

Nos. 356 to 359. **356**, portion of ileum, with pin-head enlargement of solitary follicles, the Peyer's patches very slightly thickened. **357**, portion of ascending, **358** of transverse, and **359** of descending colon of the same patient, somewhat thickened, and presenting numerous follicular ulcers, which, in the transverse colon especially, I. 36 to 39. have, in many instances, extended into large irregular but rather oval excavations, exposing the muscular coat; the descending colon, much thickened, is frosted with pseudo-membrane.

Private W. B., "B," 56th Massachusetts. Admitted, July 5th, 1864, with fever, considerably emaciated, petechiæ on abdomen, tongue thickly covered in its centre with a dark fur, pulse 120 and slight diarrhæa. About July 20th, was better; able to walk about the ward. 25th, after imprudence in diet, was attacked with severe diarrhæa; anorexia; tongue red and dry; pulse 80. Died, August 2d, greatly emaciated.

Autopsy: Right pleural cavity entirely obliterated by old pleuritic adhesions; lungs contained much black pigment; large fibrinous clot in right side of heart; pericardium contained half an ounce of fluid; gall-bladder nearly filled with bile; spleen

pale and very firm; solitary follicles of ileum enlarged; mucous membrane of colon thickened and softened, thickness greatly increasing in descending colon, about sigmoid flexure and rectum; mucous membrane was very thick and presented a peculiar spongy appearance; follicular ulcers throughout colon, in transverse colon especially, have coalesced into large eroding excavations.

Contributed by Acting Assistant Surgeon O. P. Sweet, Carver Hospital, Washington, D. C.

Nos. 851 and 855. **851**, portion of ileum, with a Peyer's patch somewhat thickened, and solitary follicles the size of pin-heads. **855**, portion of colon of same patient, with minute follicular ulcers.

I. 40 & 41. Recruit **M. K.** Was struck by lightning during a violent thunder-storm, while standing under or against a poplar tree near his post, September 14th, 1866. The left side of his cap was torn open; the facing of the metal button of that side thrown off; the hair of his left temple and behind the ear singed and burnt; the left foot was torn widely open from the outside seam forwards and upwards, and the stocking within it torn, while the right foot was torn open by two small rips in front of the outside seam, and about an inch apart, one above the other. No other external marks. The coat was buttoned closely about him; none of its buttons, nor those of the vest nor pants, affected.

Autopsy sixteen hours after death: A stout, muscular man; slight purplish stasis of back part of neck; partial rigor of arms; fixed rigidity of fingers and lower extremities; hair of left temple and behind ear singed away; a faint dull yellow or amber-colored line extended from hair way down left side of neck forward to sternal head of clavicle, then irregularly double down the left of median line of chest over sternum, more irregularly down the abdomen to the left of umbilicus, becoming indistinct just before reaching hair of pubes, which was burnt over middle of ramus of left side, and upon left side of scrotum; the yellow line became again distinct upon the inside of the left thigh, in a direction downwards and backwards, was lost over popliteal space, became again distinct on back of left calf by burnt hairs, continued to the outside and forwards in front of external malleolus, where it ended. A similar but fainter burnt line of hairs could be traced on back of right calf, passing also downwards, outwards, and forwards to terminate in front of external malleolus of that side; some blood oozed from left ear; there was very slight stasis at posterior part of back; pupils widely dilated; scalp quite free from blood; no fracture of skull; opposite the left parietal protuberance, between fissures of Rolando and Sylvius, was a marked effusion of blood under the membrane; considerable serum in the lateral ventricles and spinal membranes; under the lines on the skin above described, there was no anatomical change observable; old adhesions of left lung posteriorly; heart large and fatty, filled with soft black blood on right side; an opaque white spot on front of left ventricle; stomach partly filled with food, with reddened rugae; (he had taken supper about an hour before); the partly digested food, of a yellowish cream-color, was found throughout the small intestines; Peyer's patches near ileo-caecal valve reddened, somewhat thickened, and slightly honey-combed; the solitary glands were somewhat enlarged, especially at lower end of ileum; colon contained normal yellow feces; its mucous membrane presented a few minute ulcers; spleen black and friable, but without fluid blood; gall-bladder almost entirely empty; urinary bladder half filled with urine.

Contributed by Assistant Surgeon W. C. Miner, U. S. Army, Fort Columbus, New York Harbor.

Nos. 680 to 683. **680**, portion of ileum, much thickened, with hypertrophied villi and ulceration of the solitary follicles. **681**, ileum and ileo-caecal valve from same case, thickened, and in the same condition as the last; some of the solitary follicles enlarged, but not ulcerated. **682**, caecum from same case, much thickened, with minute follicular ulcers. **683**, portion of colon from same case, in the same condition as the caecum.

See 684, chap. III., sec. 2, A, 7, for history.

Nos. 353 to 355. **353**, portion of ileum taken just above the ileo-caecal valve, showing a large thickened Peyer's patch; some of the solitary follicles slightly enlarged. **354**, portion of ascending colon of the same patient, presenting numerous ulcers with abrupt edges, varying from the size of a pin-head to that of a five-cent piece. **355**, portion of transverse colon of the same patient, presenting a number of minute follicular ulcers.

Private P. Q., "E," 11th New York, age 48. Admitted, July 5th, 1861. Had scurvy look; was considerably emaciated; pulse 90; tongue moist, but covered with a gray fur; anorexia; severe diarrhoea. He continued about the same till the 10th, when he began to improve, the diarrhoea being somewhat checked and his appetite better. 26th, was seized with severe pain in the right side, dullness on percussion and other evidences of pleurisy with effusion. The diarrhoea now became aggravated and the anorexia returned. Died, August 1st.

Autopsy: Old pleuritic adhesions of left lung, lower lobe greatly congested; right pleural cavity about half full of fluid, some new adhesions; posterior portion of right lung in a state of hypostatic congestion; a partially washed clot in the right side of heart; about three ounces of fluid in pericardium; liver enlarged, pale and fatty; gall-bladder filled with viscid bile; spleen enlarged and soft; cortical substance of kidneys very pale; mucous membrane of stomach thickened and congested; mucous membrane of small intestine congested; in the lower three feet of the ileum, Peyer's patches were thickened, and presented a spongy appearance at their centres, in ascending colon there were several large ulcers with ragged edges, which contained a quantity of black pigment; mucous membrane thickened and softened; in transverse colon less numerous and smaller ulcers; in descending colon these ulcers again became larger.

Contributed by Acting Assistant Surgeon O. P. Sweet, Carver Hospital, Washington, D. C.

No. 707 and 708. **707**, portion of ileum, taken at ileo-cæcal valve, slightly thickened, its villi hypertrophied; Peyer's patches and a few of the solitary follicles thickened and ulcerated. **708**, portion of cæcum of same patient, slightly thickened, showing ulceration of a few of the solitary follicles; before immersion in alcohol, each of the ulcers I. 49 & 50. appeared to be on the summit of a small truncation the size of a pea.

Private J. W., "F," 2d U. S. Colored. Admitted, January 17th, 1866, in a moribund condition; tongue parched; teeth and lips covered with sordes. Died, January 18th.

Autopsy: Ileum and colon as in the specimen.

Contributed by Surgeon R. B. Bontecou, U. S. Vols., Harewood Hospital, Washington, D. C.

Nos. 232 and 233. **232**, a portion of ileum, presenting several irregular ulcers. **233**, a portion of colon from the same patient, presenting several large irregular ulcers invading the muscular coat.

Private P. G., "D," 1st New Jersey, age 21. Admitted, August 9th, 1862. Diagnosis—diarrhœa. Died, I. 51 & 52. August 31st. Diagnosis—dysentery.

Autopsy: Body emaciated and in an unusually advanced state of decomposition; recent peritonitis; all the viscera agglutinated with pseudo-membrane, and the intervals occupied with an abundance of sero-purulent liquid; inflammation of mucous membrane of ileum and colon; thickening of the upper Peyer's glands, and ulceration of the lower ones; no less than three near the ileo-cæcal valve presented perforations; a number of ulcers in the colon, and a large one had very nearly perforated; the solitary glands were thickened and contained black pigment.

Contributed by Acting Assistant Surgeon J. Leidy, Satterlee Hospital, Philadelphia, Pa.

Nos. 698 and 699. **698**, portion of ileum, taken some little distance from the ileo-cæcal valve, thickened and presenting adherent pseudo-membrane. **699**, portion of rectum, from the same patient, much thickened, with large ulcers in mucous membrane, and patches of adherent pseudo-membrane; between the large ulcers are numerous small follicular ulcers.

Private J. C., "D," 2d U. S. Colored. Admitted, January 11th, 1866. Diagnosis—typhoid fever. Died, January 12th.

Autopsy forty hours after death; Negro: height, five feet six inches; weight, one hundred and thirty pounds; slightly emaciated; rigor mortis well marked; left lung contained at its base a small number of crude tubercles, upper lobe was slightly congested; upper lobe and posterior portion of inferior lobe of right lung slightly congested; about three ounces of serum in each pleural cavity; pericardium contained about two ounces of clear yellow serum; heart large and flabby, dark, on its surface numerous ecchymosed spots, large white fibrinous clots in all the cavities, ramifying through the pulmonary artery and aorta and their branches; aortic valves atheromatous; liver bronze-color; gall-bladder filled with bile; kidneys fatty, the left kidney large; omentum, contracted into a band, firm, dark, and congested; mucous membrane of duodenum thickened, its solitary follicles slightly enlarged near the pylorus; slight thickening and congestion of the mucous membrane of the jejunum; ileum was covered with pseudo-membrane, particularly in its lower portion; in the upper portion Peyer's patches, slightly thickened, in the lower portion they presented a few points of commencing ulceration; mucous coat of colon covered with pseudo-membrane, with great thickening, and a number of large but superficial ulcers.

From Freedman's Hospital, Washington, D. C.

Autopsy by Hospital Steward S. S. Bond.

Nos. 161 to 163. **161**, portion of ileum, presenting a thickened Peyer's patch, with two well-marked ulcerations. **162** and **163**, successive portions of the colon of the same patient, with numerous ulcerations and pseudo-membranous patches.

I. 55 to 57. Private C. S. P., "C," 1st Delaware Cavalry, age 29, American. Admitted, January 25th, 1863, with diarrhœa. Said he had been ship-wrecked on the coast of New Jersey, in the winter of 1852, had his feet frost-bitten, and had not been in good health since. He passed little urine at a time, but frequently, so that the quantity passed in twenty-four hours was nearly normal. 27th, had a slight chill last night; mouth somewhat dry; tongue slightly coated and of a brownish color; pulse 100, easily compressible; eyes somewhat suffused; respiration natural. February 2d, pulse 100; complained of loss of sleep. 5th, pulse about the same; skin continues dry; less heat of surface than heretofore; still complains of want of sleep; tongue moister and not so dark. 10th, pulse 95; tongue and mouth moist; skin more natural; slight moisture about the forehead and neck. 15th, pulse 90; tongue clean; slight perspiration. 18th, still improving, pulse 90, fuller and softer; again complains of sleeplessness. March 1st, is able to sit up and walk several steps unsupported; moderate appetite. 7th, slight diarrhœa set in. 15th, discharges from the bowels very frequent since preceding night, consisting of thin mucus; complete prostration; refused nourishment. This diarrhœa continued unchecked until death, March 19th.

Autopsy: Pericardium contained about four ounces of serum; stomach hanging perpendicularly, the pyloric end reaching two inches below the umbilicus; mucous membrane of lower portion of jejunum dark red and soft; ileum not so red as the jejunum, but presenting many ulcerated patches with raised edges; colon very much thickened and presented ulcers and pseudo-membranous patches as in the specimens; rectum in the same state as the colon; gall-bladder large and filled with bile; the left kidney greatly enlarged, perhaps six times its normal size, and presenting numerous cysts, filled with fluid, varying in size from a line to three-quarters of an inch in diameter; the capsule was much thickened and firmly adherent; the right kidney about twice its usual size, and in other appearances resembling the left.

Contributed by Surgeon Thos. Antisell, U. S. Vols., Harewood Hospital, Washington, D. C.

161, *chap. V., sec. 1, C. 4, cysts of left kidney, is also from this case.*

Nos. 700 and 701. portion of ileum, taken at ileo-caecal valve, showing thickening and ulceration of Peyer's patches, with enlargement of some of the solitary follicles. **701.** vermiform appendix and caecum of same patient, showing a number of ulcers of some size and depth.

I. 58. & 59. Unknown malatto. Admitted, January 16th, 1866. Died, January 17th.

Autopsy thirty-six hours after death. Height, five feet seven inches; age, about twenty-two years; weight, one hundred and forty pounds; slight rigor mortis in lower extremities; umbilical hernia; both lungs filled with crude tubercle; numerous vesicles in their upper portions; left lung, posteriorly, firmly adherent; right lung adherent at its apex; pericardium contained twelve ounces of clear serum; heart flabby, with large, firm, white clots in all the cavities; nutmeg liver; enlargement of the solitary follicles, with a few small ulcers and deposits of pigment in duodenum; numerous ulcers throughout entire length of jejunum, many of which extended through the mucous and muscular coats, with small tubercles opposite them on the peritoneal coat; ileum with numerous ulcers of Peyer's patches and the solitary follicles; numerous ulcers in caecum, the remaining solitary follicles with deposits of black pigment; colon contained much pigment and a few small ulcers.

From Freedman's Hospital, Washington, D. C.

Autopsy by Hospital Steward S. S. Bond.

No. 321. Small portion of the ileum, with part of the caecum, both presenting numerous ragged ulcers.

I. 60. History—(Assistant Surgeon T. W. Stull, 8th Illinois Cavalry): Private N. H. D., "A," 8th Illinois Cavalry. Admitted, June 18th, 1861. Had headache; suffused and painful eyes; pulse 100 and small; skin hot and dry; tongue coated with dark yellow fur, the edges livid; loss of appetite; dull pain in hips and lower extremities; bowels loose. Says he has not felt well for several weeks; was previously in good health. 19th, better; pulse 80, 24th, pulse 120 and full; vomited a little greenish glairy fluid in the morning; exacerbation of fever in the afternoon. 25th, skin moist and cool; pulse 96. 29th, seemed comfortable; pulse 102. 30th, was suddenly seized previous evening with sharp pain in region of bladder and penis; urine suppressed; this morning the pain extended over the whole abdomen, which was very tender to the touch; countenance anxious; pulse 120 and small; lay on right side with thighs flexed; skin moist and cool except over the abdomen; slight hicough. July 1st, seems easier; passed several ounces of urine in the morning; pulse 101; bowels somewhat tympanitic; during the morning, however, was taken suddenly worse and the pain in the region of the bladder returned. Died, July 2d.

Autopsy: There was a perforation of the ileum about four inches from the ileo-caecal valve, and very extensive inflammation of the peritoneum extending over the entire surface of that membrane, with extensive adhesions.

Contributed by Surgeon A. Hard, 8th Illinois Cavalry, Washington, D. C.

No. 86. Lower portion of ileum and part of caecum, the ileum presenting an ulcerated Peyer's patch, and ulceration of several of the solitary follicles; the caecum, a number of small, irregular, excavating ulcers, with thickened overhanging edges.

Private R. G., "E," 2d Massachusetts, age 25, English. Admitted, December 18th, 1862. Diagnosis—phthisis. Died, December 31st.

Autopsy: Body not much emaciated; skin waxen; no spots of pupura; recent pleurisy, with pseudo-membranous attachment on both sides; tubercular deposits throughout both lungs, and several small cavities the size of filberts at their apices; bronchitis; enlargement of bronchial glands; heart soft, flabby, its cavities distended with currant-jelly-like clots; spleen of medium size with condensation and blackening of portions of its structure; mesenteric glands somewhat enlarged; a few ecchymosed spots in the ileum; ulceration of the lower Peyer's glands; extensive ulceration of the mucous membrane of caecum; a few small tubercles here and there in the walls of the much-contracted colon; small, irregular, ecchymosed patches in ascending and descending colon.

Contributed by Acting Assistant Surgeon J. Leidy, Satterlee Hospital, Philadelphia, Pa.

No. 76. Lower four inches of ileum, with part of caecum; the ileum is thickened and ulcerated; the ulcers, about twenty, extend through the sub-mucous connective tissue to the muscular coat; they vary from one to eight lines in long diameter; the edges are rounded, thickened and overhanging; small follicular ulcers in the caecum.

Private G. F. S., "K," 11th New York. Admitted, July 20th, 1863. Diagnosis—chronic diarrhoea. About the 1st of August he passed into a typhoid condition, with low delirium. Died, August 21st.

Autopsy: lower twenty inches of ileum inflamed and ulcerated as in the specimen.

Contributed by Assistant Surgeon W. Witt C. Peters, U. S. Army, Jarvis Hospital, Baltimore, Md.

Nos. 262 to 268. successive portions of ileum, exhibiting large deep ulcerations, invading the muscular coat and extending in many points quite to the peritoneum. There were many larger ulcerations in this ileum than those here preserved, but the thin peritoneal coat incinerated so rapidly that it was impossible to keep them intact. **267 and 268.** portions of the colon of the same patient, exhibiting a number of large ulcers and many smaller ones.

See 269, chap. II., *sc.* 3, B. 5, for history.

Nos. 619 **619**, piece from the upper part of the ileum, with a long, somewhat thickened Peyer's patch. **620**, piece from the middle of ileum of same patient, with two thickened ulcerated Peyer's patches. **621**, piece from the ileo-cæcal valve of same patient, with ulcerated and sloughing Peyer's patches, the solitary follicles enlarged, the villi hypertrophied. (*See Microscopical Section, Part First, VII, Pl. C. 7.*) **622**, portion of ascending colon of same patient, with considerable enlargement of the solitary follicles, the apices of some of them ulcerated.

C. H., colored woman, age 18. Admitted, September 15th, 1865, in a semi-comatose condition; tongue coated with a thick yellowish fur; diarrhoea; skin moist and cool; pulse 130 and feeble; dullness on percussion over right lung; no tympanites. Died, September 19th.

Autopsy twelve hours after death: Rigor mortis well marked; height, five feet two inches; weight, about one hundred and twenty pounds; slight effusion beneath arachnoid; right lung firmly adherent and congested; left lung adherent by white bands, upper lobe congested; a firm white clot in right ventricle; pericardium contained two ounces of serum; kidneys fatty; on the anterior surface of left kidney, near the pelvis, a metastatic focus about the size of a five-cent piece; duodenum and jejunum inflamed in patches; ileum inflamed throughout; in its upper third Peyer's patches were slightly thickened, presenting the "shaved-chair" appearance; in its middle the enlargement and thickening were more marked, and nearly all the patches presented one or more points of ulceration, which, in some, had coalesced, forming small ragged ulcers; in the lower third the thickening was very great, the whole of the surface of the patches being ulcerated or sloughing; throughout the whole length of small intestine the villi were much enlarged; solitary follicles of the colon were enlarged to the size of split peas, surrounded by a vivid red areola, some of them were ulcerated at the apex, with slough attached, others were surrounded by a narrow band of ulceration, having the enlarged follicle in the centre; a recent menstrual corpus luteum in right ovary; small cysts in upper part of cervix uteri.

From Freedman's Hospital, Washington, D. C.

Autopsy by Hospital Steward A. J. Schafhirt.

623, chap. V., sec. 5. A. 1, cysts of cervix uteri, is also from this case.

Nos. 116 **116** and **117**, successive portions of ileum. **116** exhibits a considerable number of superficial ulcers; to in **117**, superficial ulcers and pseudo-membranous patches. **118**, colon of the same patient, greatly thickened and irregularly covered with a pseudo-membranous layer.

I. 74 to 76. Private T. S., "F," 121 New York, age 23. Admitted, September 12th, 1863, with chronic diarrhoea of about a month's duration; emaciation extreme; hair dry and long; eyes dim, but no ulceration of the cornea; abdomen much depressed; skin furfuraceous, of a dull yellowish slate-color; feet and toes persistently cold and bluish around the toes. October 13th, he began to sink rapidly, but afterwards partially recovered from a condition bordering upon death, and for several weeks improved so much that temporary hopes were entertained of his recovery. Died, November 19th.

Autopsy six hours after death: Height, five feet nine inches; rigor mortis not marked; body much emaciated; lungs dry and collapsed, with much pigment; tubercles at apex of right lung; fibrin clots in both sides of heart; liver fatty; gall-bladder contained eight ounces of tarry bile; ileum and colon as in specimen.

Contributed by Assistant Surgeon H. Allen, Lincoln Hospital, Washington, D. C.

Nos. 317 **317** to **319**, successive portions of the upper part of ileum, presenting large irregular ulcers of Peyer's glands, penetrating to the muscular coat. **320**, portion of the colon of the same patient, somewhat thickened and presenting numerous large irregular ulcerations, which penetrate to the muscular coat. A number of enlarged mesenteric glands are attached to the peritoneal surface of the piece.

I. 77 to 80. Private J. R. R., "H," 82d New York. Admitted, December 14th 1862. Diagnosis—chronic diarrhoea and phthisis. Died, December 31st.

Contributed by Acting Assistant Surgeon E. B. Vandye, Christian Street Hospital, Philadelphia, Pa.

Nos. 608 **608**, portion of ileum, taken ten inches above the ileo-cæcal valve, showing a much-thickened Peyer's patch, which presents a honeycomb appearance; there are also several oval ulcers which penetrate to the muscular coat. (*See Microscopical Section, Part First, VII, Pl. C. 5.*) **609**, portion of ascending colon of the same patient, showing a number of oval ulcers, which penetrate to the muscular coat. **610**, portion of descending colon of the same patient, with large ulcers penetrating to the muscular coat.

C. F., dark mulatto woman, age 26, nursing an infant three months old. Admitted, September 5th, 1865, with typhoid fever. Had been suffering from fever, headache, and pain in the abdomen for four weeks; some emaciation; pulse 120 and feeble; skin hot and dry; tongue coated with thick yellow fur; anorexia and thirst; bowels moved once a day, feces greenish; urine high-colored and burning; abdominal tenderness; diarrhoea set in subsequently. Died, September 13th.

Autopsy sixteen hours after death: Emaciation great; rigor mortis marked; slight engorgement in lower lobes of lungs; duodenum inflamed; jejunum inflamed in patches; ileum inflamed throughout; Peyer's patches enlarged and thickened gradually from above downwards; in the lower third of the ileum the thickened patches each presented one or more points of ulceration; near the valve some of the patches were entirely ulcerated away, exposing at the base the fibres of the muscular coat; on the valve, and for about four inches above it, the whole mucous surface was a mass of enlarged and thickened Peyer's patches, each presenting several points of ulceration; ascending colon inflamed with large, deep, transverse, oval ulcers, with

overhanging edges, some of them more than two inches in diameter; there were also a few enlarged solitary follicles the size of peas, some of which were ulcerated on the apex; transverse colon presented a few small round ulcers penetrating to the muscular coat; descending colon inflamed in patches and having in the sigmoid flexure a group of small oval ulcers, and slightly enlarged solitary follicles, with specks of pigment on each; a few small ulcers in the rectum.

From Freedman's Hospital, Washington, D. C.

Autopsy by Hospital Steward A. J. Schafhirt.

Nos. 101 and 102. **101**, portion of ileum; **102**, of descending colon, the mucous membrane of both coated with pseudo-membrane in the colon small follicular ulcers.

I. 84 & 85. Private M. K., "G," 2d New York Heavy Artillery, age 33. Admitted, August 21st, 1861, from field hospital, Army of the Potomac, greatly emaciated. Had severe diarrhoea, fifteen or twenty dejections during twenty-four hours; pulse weak and easily compressed; tongue moist and thinly coated with gray fur. 25th, the faecal discharges very frequent and involuntary. Died, August 25th.

Autopsy: Post-mortem rigidity great; body much emaciated; large collection of sordes on teeth; right side of heart contained a fibrinous clot, left side filled with dark blood; pericardium contained two ounces of fluid; liver slightly enlarged and congested; gall-bladder filled with viscid bile; spleen dark colored, small and firm; mucous membrane of stomach congested and red, presenting signs of severe inflammation about the cardiac orifice; in lower portion of the ileum the Peyer's glands congested, the congestion increasing toward the ileo-cæcal valve; mucous membrane of colon congested, thickened and rough with pseudo-membrane; small ulcers in lower part of the descending colon.

Contributed by Acting Assistant Surgeon O. P. Sweet, Carver Hospital, Washington, D. C.

Nos. 156 to 159. **156**, piece of the lower part of ileum, considerably thickened and presenting numerous superficial ulcers and pseudo-membranous patches. **157 to 159**, successive portions of the colon of the same patient, greatly thickened, with numerous follicular ulcerations and pseudo-membranous patches.

I. 86 to 89. Private W. S. C., "E," 29th Michigan, age 22. Admitted, January 2d, 1863, with chronic diarrhoea. Died March 11th.

Contributed by Surgeon Thomas Antisell, U. S. Vols., Harwood Hospital, Washington, D. C.

K. Concentric atrophy of colon.

No. 158. Piece of transverse colon very much contracted.

K. 1. Private B. K., "G," 2d Connecticut Heavy Artillery, age 43, Irish. Admitted, October 23d, 1861, with gunshot wound of knee, for which amputation was performed November 7th. Died of secondary hæmorrhage November 14th.

Autopsy: Lungs small; liver very large; stomach distended with air; colon and rectum much contracted; the hæmorrhage proceeded from the femoral artery, the ligature having sloughed away.

Contributed by Surgeon Thos. Sim, U. S. Vols., Patterson Park Hospital, Baltimore, Md.

L. Ulceration of colon. Dysentery, including the cases commonly designated Camp Diarrhoea.

No. 660. Portion of descending colon, on the mucous surface of which are a number of cysts the size of large peas; the colon is somewhat thickened. When received at the Museum the mucous surface was cream-colored; the cysts yellow at the apex, their bases and the tissues immediately surrounding them of a livid blue; they contained a yellow, semi-transparent, jelly-like substance, which, microscopically, was faintly granular, with a number of small granular cells, similar to the cells of the solitary follicles; in the alcohol many of the cysts have collapsed, and present the appearance of ulcers.

Private T. B. C., "A," 19th Mississippi (Rebel.) Admitted from Army Square Hospital, August 17th, 1865, with penetrating gunshot wound of chest, received at Petersburg, Va., November 5th, 1861. He died August 19th, 1865, from the consequences of the wound. He had diarrhoea from the time he was first brought under observation.

Contributed by Assistant Surgeon W. F. Norris, U. S. Army, Douglas Hospital, Washington, D. C.

No. 517. A piece of descending colon, showing abundant solitary follicles, which are somewhat enlarged. When fresh, each follicle presented a central spot of black pigment, and was surrounded by an areola of pigment deposited in the adjoining follicles of Lieberkuhn. (See *Microscopical Section, Part First, VII. I. C. 3.*)

See 516, chap. II., sec. 2, C. I. for history

No. 217. A portion of descending colon, the mucous membrane of which is considerably thickened, and presents numerous well-marked follicular ulcers.

L. 3.

Private A. W., "C," 2d New Jersey. Admitted from the Army of the Potomac, February 16th, 1863, in a dying condition. Had been taken sick early in December with fever, without chills, but accompanied by delirium. Diarrhœa set in during the fever and continued after it had disappeared. During the previous two or three weeks his bowels had been moved eight or ten times a day. He died on the day of his admission.

Autopsy: Body much emaciated; mucous membrane of descending colon and sigmoid flexure thickened, softened, and with numerous ulcerations one-eighth to one-half an inch in diameter; mucous membrane of the rest of the colon thickened, softened, and of a greenish-gray color; cæcum very much congested; Peyer's patches thickened, and patches of inflammation throughout the whole length of the small intestine; smaller curvature of the stomach congested; lungs, liver and kidneys apparently healthy; spleen adherent to liver.

Contributed by Surgeon Chas. Page, U. S. Army, Judiciary Square Hospital, Washington, D. C.

Nos. 218 and 219. Two successive portions of colon, presenting numerous follicular ulcers, some of which, in 219, have coalesced into an irregular excavating ulcer of considerable size.

L. 4 and 5. Private C. F., "B," 1st New York. Admitted, February 15th, 1863, with chronic diarrhœa. Had been taken sick in the Army of the Potomac. Died, February 16th.

Autopsy: Body much emaciated; right lung compressed against the anterior and upper part of the thorax by about two quarts of moderately thick, not offensive, pus; pleura costalis covered by a thick pseudo-membrane; mucous membrane of descending colon and sigmoid flexure thickened, softened, and presenting numerous follicular ulcers, with some of more considerable size; small intestine and stomach healthy; spleen very small.

Contributed by Surgeon Chas. Page, U. S. Army, Judiciary Square Hospital, Washington, D. C.

Nos. 220 and 221. Two successive portions of colon, the mucous membrane greatly thickened and presenting numerous follicular ulcers. 220 is slightly coated with pseudo-membrane.

L. 6 and 7. Private R. P., "C," 3d New Jersey. Admitted, February 15th, 1863, from the Army of the Potomac, in a dying condition. Died, February 16th.

Autopsy: Body emaciated; mucous membrane of colon softened, thickened, purple in color, with numerous follicular ulcers; mucous membrane of lower part of ileum thickened and presenting a number of small ulcers, especially in its lower portion; the rest of the small intestine and the stomach healthy; spleen rather small.

Contributed by Surgeon Chas. Page, U. S. Army, Judiciary Square Hospital, Washington, D. C.

No. 227. Portion of colon, presenting numerous follicular ulcers; some of them have extended into irregular, jagged excavations.

L. 8.

Private R. A. E., "H," 1st Vermont Cavalry, a paroled prisoner, age 26. Admitted, September 16th, 1862, with chronic diarrhœa. Died, November 1th.

Contributed by Acting Assistant Surgeon B. B. Miles, Annapolis Hospital, No. 1, Md.

No. 119. Portion of colon, presenting numerous follicular ulcers, many of which are circular in form, with the diseased follicle remaining in the centre.

L. 9.

Corporal W. P., "H," 16th New York Cavalry. Admitted, July 13th, 1864, with diarrhœa. Died, July 24th. Autopsy: Great emaciation; lower lobe of right lung extensively inflamed, slight pleuritic adhesions; liver large and fatty; spleen much enlarged and congested; intussusceptions of ileum and numerous ulcers of the intestinal mucous membrane, extending from two feet above the ileo-cæcal valve to the anus.

Contributed by Surgeon E. Bentley, U. S. Vols., General Hospital, Alexandria, Va., Third Division.

No. 438. Portion of transverse colon, presenting numerous follicular ulcers and slightly frosted with pseudo-membrane.

L. 10.

Private R. B., "H," 6th Ohio Cavalry, age 47. Admitted to hospital, November 14th, 1864, in the advanced stage of chronic diarrhœa. Died, November 15th.

Contributed by Surgeon N. R. Moseley, U. S. Vols., Emory Hospital, Washington, D. C.

No. 831. Portion of colon, with extremely minute follicular ulcers.

L. 11.

Private A. D., "B," 2d Battery, U. S. Colored, age 35. Entered my ward, October 6th, 1865. Had had diarrhœa, with some blood and straining, for more than a month; was thin; just able to walk about; some tenderness in the right lumbar and left iliac regions; five or six semi-solid stools daily, with muco-purulent matter and blood; occasionally pain and tenesmus; anorexia; pulse 93 and irritable. October 26th, was transferred to another ward apparently improved. Died, November 2d.

Autopsy: Not much emaciated; three inches above the ileo-cæcal valve was an ulcerated patch, three inches long by three-fourths of an inch wide, red and raw, entirely through the mucous membrane; colon somewhat congested and presenting extremely minute follicular ulcers; kidneys about one-third larger than natural.

Contributed by Assistant Surgeon Ira Perry, 9th U. S. Colored, Post Hospital, Brownsville, Texas.

No. 837. Portion of sigmoid flexure, thickened and presenting a number of irregular ulcers of moderate size; some adherent pseudo-membrane.
L. 12.

Private J. T., "G," 11th U. S. Colored, age 40. Admitted, July 25th, 1865. Had diarrhoea some weeks while with his regiment; much fatigue duty and poor diet. He was thin, weak, dispirited, with seven to ten stools daily, and some abdominal tenderness. October 11th: Has been doing well until within a few days; got his feet wet and ate heartily; diarrhoea came on with violence, and continued with some fever. Died, November 3d.

Autopsy: Costal cartilages ossified; portal circle congested, especially the superior mesenteric veins; ileum contracted; colon congested throughout; middle coat of sigmoid flexure and rectum two or three lines thick and white like cartilage; it presented a number of follicular ulcers.

Contributed by Assistant Surgeon Ira Perry, 9th U. S. Colored, Post Hospital, Brownsville, Texas.

No. 64. A portion of descending colon, considerably thickened and presenting numerous follicular ulcers, varying in size from mere points to three lines in diameter.
L. 13.

See 63, chap. IV., sec. 2, A. 1, for history.

See plate opposite.

No. 141. Portion of descending colon, the mucous surface of which presents numerous follicular ulcers.

L. 14. C. C. T., "C," 114th Illinois, age 32, pedler. Had had a tendency to diarrhoea during the previous seven years.

Sometime before had hæmoptysis. Lost a brother by phthisis. Was attacked in March with diarrhoea, which continued intermittently till September 29th, 1863. Dysentery set in, with from eight to fifty bloody stools daily. A typhoid state set in, and for a short time there was delirium. After two weeks the stools diminished in number (three to five daily); after the first few days the stools became small, jelly-like and white. Throughout there was anorexia with great thirst and moderate œdema of lower extremities. Admitted, October 12th, November 1st, extremely emaciated; respiration 18 a minute; pulse 120, weak and fluctuating; tongue smooth and rather dry; slight sordes which has existed for about a fortnight. Died, November 3d.

Autopsy: Isolated calcified tubercles in the middle of the upper lobe of each lung, and pleuritic adhesions at both apices; calcified tubercles in the mesenteric glands; dark mahogany-colored patches of inflammation here and there along the whole tract of ileum, becoming more diffuse and intense toward the cæcum, where there is a greenish discoloration and softening of the mucous membrane; about three or four feet from the cæcum, a few enlarged solitary follicles; mucous membrane of ileum near cæcum intersected transversely by ragged elevated granulations and granular ulcerations, which increase in size and number as they approach the cæcum; one or two of Peyer's patches are studded with minute ulcers; cæcum and ascending colon, with numerous minute points of ulceration of a dark red color, penetrating the muscular coat; in the transverse colon numerous ulcers, many extending almost through the muscular coat; they are from the size of a pin-head to that of a pea; the descending colon and rectum, exhibited numerous elevated mahogany-colored patches of inflammation, and the rectum was roughened with superficial granular ulcerations and shreds of exudation of lymph; the mucous membrane of the colon was thickened, especially at its extremities.

Contributed by Surgeon Geo. F. French, U. S. Vols., Hospital No. 3, Vicksburg, Miss.

No. 203. Portion of the descending colon, thickened and presenting well-marked follicular ulcers.

L. 15. Private S. G., "G," 122d New York. Admitted, February 15th, 1863, with diarrhoea. Died, April 3d.

Contributed by Surgeon Chas. Page, U. S. Army, Judiciary Square Hospital, Washington, D. C.

No. 206. A portion of colon, thickened and presenting numerous punched-out follicular ulcers; many of them have extended into irregular burrowing excavations of considerable size.
L. 16.

Contributor unknown.

No. 279. A portion of colon, with its mucous membrane much thickened and numerous follicular ulcers, many of them penetrating to the muscular coat; there are also small patches of adherent pseudo-membrane.

L. 17. F. W., "G," 72d Pennsylvania. Admitted, July 30th, 1862, with chronic dysentery. Died, August 3d.

Autopsy: The mucous membrane of the ileum and the Peyer's glands inflamed and thickened, but not ulcerated; mucous membrane of colon inflamed, especially towards its two extremities; its middle portion was mottled, red, gray and slate-color, its extremities dark red; throughout its entire extent there were innumerable ulcers about the size of peas, many of them extending to the muscular coat.

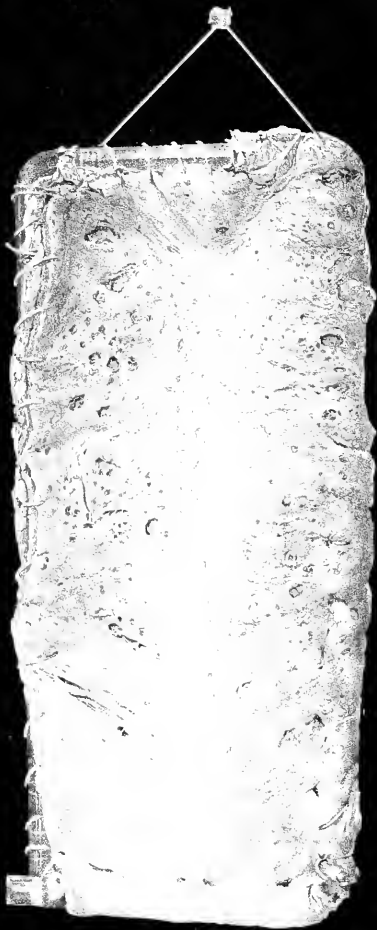Contributed by Acting Assistant Surgeon J. Leidy, Satterlee Hospital, Philadelphia, Pa.

No. 285. A portion of colon, with mucous membrane greatly thickened, and presenting numerous irregular deep ulcers; some adherent pseudo-membrane. The patient died of chronic diarrhoea during the summer of 1863.
L. 18.

Contributed by Surgeon E. L. Welling, 11th New Jersey, Field Hospital, Army of the Potomac.

No. 286 and 287. Two successive portions of colon, with mucous membrane greatly thickened, and presenting numerous follicular ulcers; some adherent pseudo-membrane. The patient died of chronic diarrhoea in the field hospital, Army of the Potomac.

L. 19 & 20. Contributed by Surgeon E. L. Welling, 11th New Jersey, Field Hospital, Army of the Potomac.



№ 64.

Nos. 296 and 297. **296**, a portion of ascending colon, near the cæcum; **297**, portion of the right extremity of the transverse colon of the same patient; in both the mucous membrane is considerably thickened and presents follicular ulcers, which are most numerous in **296**.

L. 21 & 22. Private D. B. J., "H," 145th Pennsylvania, age 29, Irish. Admitted, March 24th, 1864. Had suffered from chronic diarrhoea about four months, and was in a greatly exhausted condition. Died comatose, March 30th.

Autopsy: Mucous membrane of colon thickened, softened and ulcerated; tubercles in both lungs, especially in the upper lobe of the right, where there was also an abscess containing about an ounce of fluid; spleen contained numerous tubercles.

Contributed by Surgeon E. Bentley, U. S. Vols., General Hospital, Alexandria, Va., Third Division.

298, chap. IV., sec. 7, G. 1, tubercles of spleen, is also from this case.

No. 616. Portion of colon, presenting follicular ulcers and superficial excavations.

L. 23. History—(Acting Assistant Surgeon W. G. Small): Private J. E. S., "C," 62d New York, American, age

45. Admitted, October 22d, 1864, with chronic diarrhoea and general exhaustion; dejections frequent, slimy and partially fecal. Under treatment, he improved at first, but the diarrhoea returned at intervals; occasionally he manifested symptoms of mental aberration; his appetite was capricious. February 23d, 1865, was attacked with convulsions. Died, February 24th.

Autopsy six hours after death: Body much emaciated; rigor mortis slight; about two ounces of serum beneath arachnoid; much pigment in both lungs, the posterior part of lower lobe of left lung cartified; much serum in both pleural cavities; pericardium contained a small quantity of serum; mucous membrane of transverse and descending colon, sigmoid flexure and rectum thickened, presenting follicular ulcers and superficial excavations; in the sigmoid flexure some whitish pseudo-membrane.

Contributed by Assistant Surgeon G. M. McGill, U. S. Army, National Hospital, Baltimore, Md.

Nos. 118 and 119. Successive portions of colon, with pin-head ulcers of the solitary follicles, the orifices of which are, for the most part, surrounded by a permanent fringe of pseudo-membrane.

L. 24 & 25. Private P. B., "D," 62d New York. Admitted, August 12th, 1862, with intermittent fever. Died, August 26th. Diagnosis—diarrhoea and phthisis.

Contributed by Acting Assistant Surgeon E. Hartsborne, Hospital Fifth and Buttonwood Streets, Philadelphia, Pa.

Nos. 119 to 123. Successive portions—**119** and **120** of ascending colon, **121** of transverse, **122** and **123** of descending colon, all with thickened mucous membrane and deep follicular ulcers.

L. 26 to 30. Private J. H. K., "H," 4th Iowa Cavalry. Had diarrhoea nine months previous to decease. It commenced with an attack of dysentery, with frequent bloody stools, which, after the first day or two, greatly diminished in number, becoming mucous and gelatinous. At the end of five weeks the disease passed into diarrhoea, since which time diarrhoea and dysentery alternated. November 16th, pulse frequent and feeble; tongue dry, red and covered with a ragged white and yellow fur. Admitted, October 10th, 1863. Died, November 17th.

Autopsy: A few calcareous tubercles and cicatrices in the apex of each lung; spleen the size of a small kidney; deep vascular congestion of the duodenum and jejunum; intestines full of a yellowish-green fluid; at the beginning of the ileum the inflammation deepened, was diffused and had gone on to softening; the inflammation not continuous, but interrupted here and there by a healthy tract a few inches long; at the lower end of the ileum a few of Peyer's patches were a little prominent; the large intestine, with the exception of the cæcum, thickened, cutting like cartilage; cæcum deep red, with softening of the mucous coat; the rest of the colon presented a whitish base, mottled and discolored with livid purple spots and stasis; the whole colon thickly studded with small ulcers, with here and there a large one; the ulcers deep, and involved the submucous coat to which the thickening was limited; there were also patches of adherent pseudo-membrane, especially in the lower part of the colon.

Contributed by Surgeon Geo. F. French, U. S. Vols., Hospital No. 3, Vicksburg, Miss.

Nos. 129 to 131. **129**, portion of transverse colon, considerably thickened, and presenting a number of follicular ulcers; **130** and **131**, successive portions of descending colon, with more numerous follicular ulcers; in **131** the ulcers have, for the most part, extended into irregular erosions, which occupy the greatest portion of the surface

L. 31 to 33. of the mucous membrane.

Private W. G., 2d Iowa Battery, age 33, intemperate; was never hardy, but had been healthier since he entered the army; had been subject to ague for years; since entering the service had diarrhoea occasionally. July 5th, 1863, at "Big Black," had a mild attack of dysentery, but continued to walk about till October 10th, when he was admitted to hospital. In a short time improved and went into convalescent camp, but had a relapse of dysentery about the first of November. The stools were, at first, copious and bloody, but soon became small and gelatinous, continuing so till death, November 20th. Had no flatulence nor tormina; appetite was moderately good throughout.

Autopsy: Pneumonia of lower lobe of each lung; pericardium contained much serum, and was roughened with soft yellow lymph; spleen soft and attached to the diaphragm at its upper end by a strong fibrous adhesion, and on its free surface slightly roughened with a few ragged, white, fibrous shreds, a glassy white cartilaginous patch, about an inch square, in the centre of

its free surface; in small intestine a few small tracts of moderately diffuse inflammation, and somewhat softened; similar inflammation in cæcum and ascending colon; ulcers sparse and not deep in transverse colon, increasing in number and size downward to the anus; mucous membrane of colon livid and dark; the ulcers had ragged, elevated and everted edges, and contained a dirty, yellowish-white flocculent lymph, which, when with difficulty removed, disclosed a very deep red, smooth base; in the lower half of the colon, and especially in the rectum, the mucous and muscular coats were greatly hypertrophied.

Contributed by Surgeon Geo. F. French, U. S. Vols., Hospital No. 3, Vicksburg, Miss.

Nos. 393 and 394. **393**, portion of ascending, **394**, of transverse colon, with numerous follicular ulcers somewhat over a line in diameter. The mucous membrane is thickened and presents in **394** some thin scanty patches of pseudo-membrane.

L. 34 & 35. Private A. H. M., "G," 31st Maine. Admitted, September 9th, 1861, from the Army of the Potomac, with chronic diarrhœa and bronchitis. Was much emaciated and very weak; somewhat flighty; vomited occasionally; the abdomen was flat, somewhat painful on pressure; the stools thin and frequent; tongue moist; pulse feeble and thready. Died, September 16th.

Autopsy: Lungs much shrunken, with hypostatic engorgement; bronchi filled with frothy fluid; liver small and green; gall-bladder full of green bile; stomach contained three or four ounces of dark greenish fluid, its mucous membrane softened, small intestine normal; colon as in specimen.

Contributed by Assistant Surgeon W. Thomson, U. S. Army, Douglas Hospital, Washington, D. C.

Nos. 178 and 179. **178**, portion of the sigmoid flexure; **179**, portion of rectum of same patient. The mucous membrane in both pieces is thickened and softened, presenting numerous ulcers of the solitary follicles, and is slightly coated with pseudo-membrane.

L. 36 & 37. The patient died of chronic diarrhœa in the spring of 1863, in the field hospital at Windmill Point, Va. Contributed by Surgeon E. L. Welling, 11th New Jersey, Army of the Potomac.

No. 106. A portion of descending colon, presenting numerous follicular ulcers in which the swollen solitary follicles remain as prominent points in the centre of the ulcers, which extend circularly around them. (*See Microscopical Section, Part First, Vol. I, c. 6.*)

See 405, chap. III., sec. 2, D. 3, for history.

Nos. 56 to 59. **56**, portion of ascending colon, somewhat thickened, with patches of pseudo-membrane adherent to the surface; ulceration of the solitary follicles. **57**, from further along the same colon, with more numerous and better-marked follicular ulcerations. **58**, from transverse colon of the same patient, presents fewer ulcerated follicles, but the pseudo-membranous patches are more abundantly present. **59**, from the descending colon of the same patient, in a similar condition to **58**, but the ulcerated follicles less numerous; many of the solitary follicles in each of these pieces converted into cysts about the size of peas.

Private W. P., "D," 65th New York. Admitted, December 16th, 1862, supposed to be laboring under phthisis. He had suffered also from chronic diarrhœa. Died, February 1st 1863.

Autopsy: Body extremely emaciated; about a gill of liquid in the pericardium; heart somewhat enlarged; dilatation of the right ventricle, the walls of which were about two lines thick, and the cavity contained a large and recent white fibrinous clot; inferior anterior angle of left lung affected with pleuro-pneumonia, forming an indurated mass the size of an egg, and lying by recent pseudo-membrane to the neighboring pleura; the base of the lower lobe was affected with recent pleurisy, as indicated by engorgement of the subserous capillaries, and a band of pure white pseudo-membrane, about two lines wide, fringing the lower and anterior margin of the lung; inflammation of the tracheal and bronchial mucous membranes; liver nearly uniformly brown; gall-bladder empty; spleen small, indurated and attached throughout by old adhesions; stomach and small intestine distended with air; the lower fifteen inches of the ileum affected with pseudo-membranous inflammation; Peyer's glands containing black deposits; colon contracted, its mucous membrane exceedingly corrugated, inflamed, generally of a slate-color, with darker patches and spots of the same, and pseudo-membranous matter adherent from one end to the other; the pseudo-membranous matter adhered tightly, was fibro-granular in structure, and replaced the columnar epithelium, which appeared normal in the intervals of the pseudo-membranous shreds; the dark coloring was produced by the deposit of black globules about half the size of blood disks and smaller; many of the solitary follicles of the colon were ulcerated, and some of them converted into cysts.

Contributed by Acting Assistant Surgeon J. Leidy, Sutterlee Hospital, Philadelphia, Pa.

55, chap. IV., sec. 7, D. 1, spleen with peritoneal adhesions, is also from this case.

Nos. 151 and 155. Two successive portions of colon, greatly thickened, presenting numerous follicular ulcers and pseudo-membranous patches.

L. 43 & 44. Private H. B. A., "G," 7th New York, age 30. Admitted, January 11th, 1863, with chronic diarrhœa. Died, January 29th.

Contributed by Assistant Surgeon H. Allen, U. S. Army, Lincoln Hospital, Washington, D. C.

- Nos. 436 and 437.** **436**, appendix vermiformis and a portion of cæcum, presenting numerous follicular ulcers: **437**, portion of descending colon, presenting follicular ulcers, the edges of many of which are surrounded by a fringe-like layer of pseudo-membrane.
- L. 45 & 46.** See 433, *chap. III., sec. 2, C. 5, for history.*
- No. 162.** Piece of colon, taken near the sigmoid flexure, the mucous membrane thickened; minute follicular ulcers and pseudo-membranous frosting.
- L. 47.** Private J. F. B., "1." 8th New York Heavy Artillery. Admitted, September 9th, 1864, with chronic diarrhœa. He was much emaciated, and had from ten to fifteen stools daily; improved till October 17th, when, however, he had a relapse, and died October 23d.
- Contributed by Acting Assistant Surgeon R. B. Hitz, Douglas Hospital, Washington, D. C.
- No. 527.** Portion of transverse colon, thickened; shreds of pseudo-membrane adherent; a number of follicular ulcers.
- L. 48.** When first received at the Museum, many of the solitary follicles, converted into cysts, projected above the surface of the gut; the vesicles, however, subsequently collapsed, and the excavations thus left resemble the other ulcers.
- Private J. F., "B," 16th Pennsylvania Cavalry, age 23. Admitted, November 14th, 1864, with intermittent fever and chronic diarrhœa. Died, December 27th.
- Contributed by Surgeon N. R. Moseley, U. S. Vols., Emory Hospital, Washington, D. C.
- No. 78.** A portion of transverse colon, with pseudo-membranous patches; scattered over the mucous surface are numerous small punched-out follicular ulcers.
- L. 49.** Private B. A. S., "L." 31st South Carolina, (Rebel.) Admitted, October 26th, 1863, with chronic diarrhœa of five months' standing. Died, November 1st.
- Contributed by Assistant Surgeon W. H. Gardner, U. S. Army, Point Lookout Hospital, Md.
- Nos. 110 and 111.** Two successive portions of descending colon, with irregular patches of pseudo-membrane on the mucous surface; some of the solitary follicles present the characteristic pin-head and punched-out ulcerations.
- L. 50 & 51.** Corporal R. S., "B," 6th Maine, age 40, American. Admitted, November 13th, 1862. Diagnosis—phthisis pulmonalis. Died, December 29th. Diagnosis—chronic diarrhœa.
- Autopsy: Body exceedingly emaciated; lower extremities œdematous, especially the left; both lungs attached throughout by old pleuritic adhesions; right lung contained in its apex a cavity about the size of a walnut; left lung for the most part healthy, there being several condensed masses, indicating lobular pneumonia in the back part of the lower lobe; old adhesions on upper surface of liver, which was somewhat fatty in appearance, being yellowish-brown and soft; old adhesions on convex surface of spleen, which was small and in section pale; mesenteric glands enlarged, many of them to the size of a pigeon's egg, and filled with soft, pasty, tubercular matter; large intestine with moderate diffused inflammation, accompanied by small patches of greater intensity; these patches were covered with shreds of pseudo-membrane and desquamated epithelium; the lower part of the sigmoid flexure and rectum were intensely inflamed, accompanied by pseudo-membrane and desquamated epithelium; the mucous membrane of the colon was exceedingly soft; some of the solitary follicles were ulcerated.
- Contributed by Acting Assistant Surgeon J. Leidy, Satterlee Hospital, Philadelphia, Pa.
- Nos. 121 and 125.** **121**, portion of transverse, and **125**, of descending colon, with pseudo-membranous patches and a few follicular ulcers.
- L. 52 & 53.** Private B. F. L., "G," 93d Indiana, age 20. Had lung fever five years ago; said whenever he took cold he had severe pain in left side after a full inspiration; had had a dry cough some time. August 1st, 1863, had a mild attack of diarrhœa, which in about two weeks gradually changed into dysentery, with tenesmus and bloody stools. When the dysentery was at its height, the stools varied in number from twenty to forty, soon diminishing, however, to eight or ten daily; in appearance sometimes gelatinous, sometimes mucous and white. About the middle of October his appetite, previously excellent, failed. November 1st, pulse 84; tongue pale in centre, red on edges with slight white fur at base; stools small and variably white, flocculent, gelatinous or shreddy. Admitted, October 10th. Died, November 21st.
- Autopsy: Strong pleuritic adhesions over anterior surface of left lung; spleen about the size of a kidney, with an abnormal congenital fissure in its upper end; a few tracts of inflammation here and there through small intestine, with moderate softening; about the same degree of inflammation and softening in cæcum; descending colon and rectum bright red; transverse colon dark and livid; for about sixteen inches above the anus, the bowel was almost bared of its mucous coat by ulcers which exposed the whitish muscular coat; some of the ulcers were ragged, others round or oval, and all limited to the mucous coat and filled with a dirty-white adherent lymph, causing them to appear raised above the surface.
- Contributed by Surgeon Geo. F. French, U. S. Vols., Hospital No. 3, Vicksburg, Miss.
- No. 70.** A portion of the sigmoid flexure, thickened, with ulceration of the solitary follicles and scattered pseudo-membranous patches.
- L. 54.** See 69, *chap. IV., sec. 2, C. 4, for history.*

- No. 222.** Portion of colon, thickened, presenting a few follicular ulcers and numerous pseudo-membranous patches.
L. 55. Private D. W., "G," 27th New York. Admitted February 15th, 1863, from the Army of the Potomac. He stated that he had suffered more or less from diarrhoea ever since his enlistment in May, 1861, suffering always most after marching. About the 1st of December, 1862, he was confined to his bed and was not up afterward. Died, February 17th 1863.
 Autopsy: Hepatization of lower lobe of the left lung, with pleuritic adhesions; mucous-membrane of colon inflamed and thickened; ulcers, especially in the caecum and sigmoid flexure; pseudo-membranous patches covered much of the surface of the mucous membrane.
 Contributed by Surgeon C. Page, U. S. Army, Judiciary Square Hospital, Washington, D. C.
- No. 83.** Appendix vermiformis, presenting several ulcers on the mucous surface.
L. 56. G. D. K., American, age 26. Admitted, March 31st, 1863, with chronic diarrhoea of many months' standing. Died, April 14th.
 Autopsy: Numerous ulcers were found in the lower three feet of the ileum, and the upper portion of the colon, as well as in the appendix.
 Contributed by Assistant Surgeon P. S. Conner, U. S. Army, New Orleans, La.
- Nos. 132 to 137.** Successive portions of colon, with numerous ulcers in the mucous membrane. **132** and **133** from the ascending colon, **131** and **135** from the transverse, and **136** and **137** from the descending colon. The ulcers are oval in shape and vary from the size of a three-cent piece to that of a quarter of a dollar; they are deepest in the descending colon, but even in the transverse many penetrate quite through the muscular coat.
L. 57 to 62. Private W. B. T., "B," 95th Ohio, age 25. Had been in the army fifteen months; diarrhoea much of the time. Admitted to field hospital, September 1-1th, 1863, with a severe attack of dysentery; stools bloody; tenesmus severe; almost constant pain over ascending colon; in about a week the stools began to assume a gelatinous appearance; for four days after the commencement of the attack, the number of stools was twenty to forty, but subsequently they diminished in number to from three to five daily; they were sometimes of dark, jelly-like consistence, sometimes shredly, flocculent or white. October 12th, transferred to Marine Hospital. October 1-8th, complained of severe pain in the right hypochondriac region, which in a few days subsided into a dull heavy ache; cold night-sweats were frequent; slight sores appeared a fortnight before death. November 1-8, slight oedema of lower extremities; greatly emaciated; pulse rapid and tremulous; tongue parched and dry. Died, November 21.
 Autopsy: Abscess in the anterior superior part of right lobe of liver, containing twenty ounces of pus, which had the odor of sour milk; right lobe of liver glued with strong adhesions to diaphragm; left kidney fatty and considerably larger than right, it was of a livid green color, its pelvis contained a puruloid fluid; at upper part of ileum, for about twelve inches, extreme dark red discoloration and softening of the mucous coat; farther on the mucous membrane was here and there of a livid green; colon of a mottled greenish color, with here and there dark red spots and numerous ulcers; in the lower half of the colon the ulcers were very numerous, some had rough ragged borders, in others the borders were smooth; the cavities of some were lined with a white, opaque, adherent lymph; in some places what were supposed to be cicatrices; the ulcers though very irregular, were mostly oval, and extended transversely across the bowel; close to the appendix vermiformis were two perforations through the caecum, one nearly the size of a dime, the other the size of a pea; feculent matter had escaped into abdominal cavity, discoloring the wall of the abdomen contiguous to the caecum; there were extensive adhesions of the upper part of the caecum to the right iliac fossa, and around the point of perforation the intestine was glued to the wall of the cavity.
 Contributed by Surgeon Geo. F. French, U. S. Vols., Hospital No. 3, Vicksburg, Miss.
- Nos. 151 and 152.** Two successive portions of the colon, with thickened mucous membrane; in **151** a large, irregular ulcer extending to the muscular coat; **152**, several such.
L. 63 & 64. Private L. Y., "B," 6th Ohio Cavalry, age 20, American. Admitted, August 17th, 1863, with chronic diarrhoea. Had been sick four weeks; was greatly emaciated; pulse feeble and irregular; dejections bloody and frequent; pain along the whole course of the colon, but no tympanites. Died, August 26th.
 Contributed by Acting Assistant Surgeon S. Dorsey, Harewood Hospital, Washington, D. C.
- Nos. 71 to 74.** Two successive portions of colon, with mucous membrane much thickened, surface irregularly eroded by superficial ulcers, the scanty intervening portions thickened, giving to the whole a granulated appearance.
L. 65 to 68. Private A. H., "G," 8th Maine. Admitted, November 16th, 1862, with chronic diarrhoea. Was very much emaciated, and had been sick about two months. Had frequent copious evacuations, without fever or tenesmus; skin dry; urine scanty and high-colored; pain during micturition; pain along track of colon; some little nausea, and a sinking sensation in abdomen. Died, December 4th.
 Autopsy: Colon and rectum as in specimens.
 Contributed by Assistant Surgeon E. T. Dade, U. S. Vols., Hospital No. 3, Beaufort, S. C.
- No. 115.** Portion of colon, considerably thickened, with several large superficial ulcers which invade the sub-mucous connective tissue, but do not extend to the muscular coat; the largest is an irregular quadrilateral, nearly two inches in each direction.
L. 69. Private T. W. G., "H," 110th Pennsylvania, age 31. Admitted, October 17th, 1863, with chronic diarrhoea. Died, December 12th.
 Contributed by Acting Assistant Surgeon W. H. Combs, Emory Hospital, Washington, D. C.

No. 362. Portion of transverse colon, with numerous superficial ulcers.
L. 70. Private L. W. K., "H," 45th Pennsylvania. Admitted, September 9th, 1864, with a hacking cough; no expectoration; troublesome diarrhoea; much emaciated; had severe night-sweats; pulse about 90; had been sick several weeks. 27th, was suddenly seized with great dyspnoea which passed off in a few hours, but returned with violence on the morning of the 30th. Died, September 30th.

Autopsy: Right lung congested; in left pleural cavity a large effusion of greenish-yellow sero-purulent fluid, which completely compressed the lung against the vertebral column; both lung and costal pleura were covered with a thick layer of lymph; heart covered with a layer of fibrinous lymph, and considerable effusion of serum, in which shreds and flakes of lymph floated free, in the pericardium; liver adherent to the diaphragm, adhesions old and tough; spleen contracted and firm; a few ulcers in ileum; colon ulcerated and thickened throughout its entire extent; right kidney, situated over the second lumbar vertebra, converted into a large cyst containing several ounces of a clear amber-colored liquid; a patulous ureter led from it and emptied into the bladder at its usual place; the urine was albuminous.

Contributed by Assistant Surgeon W. F. Norris, U. S. Army, Douglas Hospital, Washington, D. C.
 361, chap. V., sec. 1, A. 11, kidney converted into a cyst, is also from this case.

No. 769. Cæcum, with large sloughing ulcers; solitary follicles of ileum slightly enlarged.
L. 71. See 768, chap. IV., sec. 2, B. 5, for history.

Nos. 191 and 195. Two successive portions of colon, with many follicular ulcers, and a number of large, irregular, burrowing ulcers, which invade the muscular coat, some penetrating even to the peritoneum.

L. 72 & 73. Sergeant A. L. M., "E," 152d New York, age 24, American. Had suffered from chronic diarrhoea for some time; was attacked by measles March 1st, 1863; dysentery followed. Admitted, March 6th. Died, April 1st. Contributed by Assistant Surgeon W. Thomson, U. S. Army, Douglas Hospital, Washington, D. C.

Nos. 288 and 289. Two successive portions of colon, with the mucous membrane thickened; follicular ulcers; the surface of the mucous membrane coated with pseudo-membrane. In 288 is one, in 289 several large eroding ulcers, which have destroyed the mucous coat and expose the transverse fibres of the muscular layer.

L. 74 & 75. Private J. M., "L," 108th New York, age 24. Admitted, February 13th, 1863. Was taken sick at Acquia Creek, Va. When admitted was emaciated; feeble; pulse 110; tongue clean and red; stools frequent and liquid. 27th, somewhat better; pulse 95; tongue clean and moist; some appetite; stools less frequent. March 2d, pulse 85; skin moist, tongue clean but rather dry; bowels moved three times during the day; some tenderness in umbilical and left iliac regions. 13th, better; countenance more cheerful; abdominal tenderness disappeared; still very feeble and much emaciated. 17th, worse; tympanites; abdominal tenderness, especially over the descending colon; tongue and skin dry. 18th, very weak; pulse 140; tongue and skin dry; thirst; considerable tympanites; whole abdomen tender; much pain in the epigastric region; two light-yellow stools in the last twenty-four hours; no tenesmus; micturition painful. Died, March 25th.

Autopsy: Pleuritic adhesions of the lower lobe of right lung; nutmeg liver; spleen somewhat indurated; stomach much contracted; lower part of small intestine with patches of inflammatory congestion; colon, with mucous membrane somewhat thickened, plastered over with pseudo-membranous matter of a whitish color, and presented numerous large ulcerations similar to those in the specimens.

Contributed by Assistant Surgeon W. Thomson, U. S. Army, Douglas Hospital, Washington, D. C.

No. 181. Portion of descending colon, the mucous membrane thickened, somewhat coated with pseudo-membrane, and presenting numerous irregular ulcers of variable depth.

L. 76. Private A. W., "A," 9th Missouri Cavalry. Admitted November 11th, 1862, with chronic diarrhoea of six months' duration. Died, February 1st, 1863.

Autopsy: Mucous membrane of the entire colon and rectum thickened and ulcerated; at points the muscular coat was penetrated.

Contributed by Surgeon H. Callertson, U. S. Vols., General Hospital, Rolla, Missouri.

No. 400. A portion of colon, with a few follicular ulcers and a number of somewhat extensive erosions.

L. 77. Private D. McD., "F," 39th Massachusetts. Admitted, September 9th 1864, from the Army of the Potomac.

Had suffered from frequent attacks of diarrhoea; during the summer had also had intermittent fever. For three weeks prior to his admission, he had been in field hospital. He was emaciated and feeble; conjunctiva yellow; tongue furred; pulse 80; abdomen flat and tender, especially over the colon; slight cough. 29th, was seized with nausea, vomiting, and increased tenderness in the abdomen. Died, September 30th.

Autopsy four hours after death: Rigor mortis well marked; both lungs firmly adherent, their apices presented several dense fibrinous spots resembling cicatricies, and contained a number of cretified tubercles, some of which were quite hard, others of a cheesy consistence; peritonitis; the viscera coated with patches of yellow lymph, and slightly reddened; the recto-vesical cul-de-sac filled with a thin yellowish pus; small intestine normal, except that a diverticulum existed; large intestine greatly thickened and presented extensive irregular ulcers.

Contributed by Assistant Surgeon W. F. Norris, U. S. Army, Douglas Hospital, Washington, D. C.

- Nos. 383 and 384.** **383**, portion of ascending, **384**, of transverse colon; the mucous membrane in both thickened, presenting numerous large excavating ulcers, occupying a large portion of its surface; detached shreds of mucous membrane coated with lymph hang from the edges of the ulcers.
- L. 78 & 79.** History—(Acting Assistant Surgeon A. G. Coleman); Private E. C., 2d Battalion Veteran Reserve Corps, age 60. Came to "Surgeon's call," August 6th, 1864, complaining of diarrhoea. Had had frequent attacks of diarrhoea for the previous six months; debilitated; complexion sallow and pale; tongue furred; pulse quick and small; skin hot and dry; thirst, anorexia, foul breath, slight nausea and eructation, flatulence, gripping pains and tenesmus; the stools were from ten to fifteen a day, consisting chiefly of thin frothy mucus mixed with blood. 20th, admitted to hospital. Died, August 25th.
- Autopsy: Little emaciation; lungs dry, with abundant pigment; colon extensively ulcerated, as in specimen; gall-bladder distended with thick greenish bile.
- Contributed by Assistant Surgeon H. Allen, U. S. Army, Fairfax Seminary Hospital, Alexandria, Va.
- Nos. 367 and 368.** **367**, portion of transverse, **368**, of descending colon; in both, the mucous membrane is thickened and presents numerous large irregular ulcers.
- L. 80 & 81.** Private P. D., "B," 1st Maryland, age 22. Admitted, September 20th, 1861, with chronic diarrhoea. Died, September 23d.
- Autopsy: The whole colon was soft and ulcerated, the ulcers presenting a dark greenish base; the mucous membrane between coated with pseudo-membrane in patches.
- Contributed by Surgeon X. R. Moseley, U. S. Vols., Emory Hospital, Washington, D. C.
- Nos. 122 and 123.** **122**, portion of transverse, **123**, of descending colon, presenting large eroding ulcers which penetrate in **122** to the muscular coat, and several of them in **123** to the peritoneum, the mucous membrane much thickened.
- L. 82 & 83.** Private C. W. A., 7th Maine Battery, age 16. Admitted, July 4th, 1861, with chronic diarrhoea. He had been suffering for five weeks; was emaciated; much debilitated, and unable to walk; tongue whitish; appetite impaired; thirst great; pulse 90 to 100; gripping pains in the bowels, with tenesmus. 6th, the pains in the bowels have disappeared; the stools diminished from ten to twelve to seven per day. 12th, anorexia. Died, July 17th, greatly emaciated.
- Autopsy: Colon as in the specimens; some ulceration in lower part of ileum.
- Contributed by Surgeon E. Bentley, U. S. Vols., General Hospital, Alexandria, Va., Third Division.
- No. 195.** Portion of transverse colon, which is thickened and presents numerous excavating ulcers, which penetrate to the muscular coat.
- L. 84.** Private C. P., "F," 25th Wisconsin, age 15. Admitted, July 12th, 1864. Diagnosis—chronic rheumatism. Died, August 1st. Diagnosis—inflammation of bowels.
- Contributed by Surgeon H. Culbertson, U. S. Vols., Harvey Hospital, Madison, Wis.
- No. 703.** Portion of rectum, much thickened, ulcerated and coated with pseudo-membrane, which in many places hangs in shreds.
- L. 85.** Private W. B., "H," 2d U. S. Colored, Admitted, January 13th, 1866, with dysentery of four weeks' standing, contracted while on duty with his regiment in Florida; was not much emaciated. Died, January 29th.
- Autopsy: Colon thickened and ulcerated throughout; the rectum as in specimen.
- Contributed by Surgeon R. B. Boutecou, U. S. Vols., Harewood Hospital, Washington, D. C.
- Nos. 361 to 366.** **361**, portion of ascending, **365**, of transverse, and **366**, descending colon, near the rectum; mucous membrane somewhat thickened and presents numerous excavating ulcers, many of which penetrate to the muscular and some even to the peritoneal coat. These ulcers appear to have extended by burrowing in the submucous connective tissue, beneath the follicular layer; as a consequence, the latter hangs out in more or less extensive shred-like fringes, which are especially remarkable in **366**.
- Private P. B., 27th New York Battery. Admitted, September 9th, 1861, with chronic diarrhoea. Had been sick for a long time, did not know how long, but thought it more than two months; was extremely emaciated; twenty to thirty passages of yellowish, then, feculent matter daily; pulse 100 and feeble. Died, September 17th.
- Autopsy: Mucous membrane of colon ulcerated as in the specimens; lower Peyer's patches presented the shaven-beard appearance; solitary glands of ileum slightly prominent.
- Contributed by Acting Assistant Surgeon D. L. Haight, Douglas Hospital, Washington, D. C.
- No. 109.** Portion of descending colon, showing large, irregular ulcers, which expose the mucous coat; sloughs of dead mucous membrane hang in shreds from the edges of the ulcers. (*See Microscopical Section, Part First, VIII, 1, c, 17.*)
- Private W. H. B., "I," 26th Michigan. Admitted, August 30th, 1861, from field hospital, with acute dysentery; was not greatly emaciated; had been ill but a few days; rapid pulse; tongue covered with a dark, dry fur; anorexia; frequent stools, consisting mostly of mucus and blood; almost constant tenesmus. September 5th, great gastric weakness; ten or fifteen

offensive stools during twenty-four hours; severe pain in the abdomen, and tenesmus. 8th, involuntary discharges of large quantities of bloody mucus; raving delirium. Died, September 9th.

Autopsy eight hours after death: Emaciation slight; rigor mortis well marked; slight adhesion of right lung; pericardium contained two ounces of fluid; right side of heart contained a large fibrinous clot; liver enlarged, soft and pale; gall-bladder distended with bile; spleen enlarged and firm, of a dark slate-color; kidneys pale; mesenteric glands enlarged; mucous membrane of ileum congested, its solitary follicles enlarged; sloughing ulcers in descending colon, the sloughs, of dark color and fetid odor, were separating, some having already been thrown off, leaving the circular fibres of the muscular coat in view; in the transverse and descending colon, the mucous membrane had nearly all sloughed away, and in some places the slough appeared to extend nearly or quite through the muscular coat.

Contributed by Acting Assistant Surgeon O. P. Sweet, Carver Hospital, Washington, D. C.

No. 819. Portion of colon, much thickened, with jagged and extensive ulcers, at the edges of which the mucous membrane hangs in shreds; some adherent pseudo-membrane in those portions of mucous membrane which are not destroyed.

L. 90.

G. W., negro, age 50. Admitted to Freedman's Hospital, August 23, 1866. Diagnosis—chronic diarrhoea. Died, August 4th.

Autopsy six hours after death: Rigor mortis marked; no emaciation; height, five feet two and a half inches; weight, about one hundred and thirty-five pounds; scattered tubercles in both lungs, with adhesions anteriorly, especially the right side; edges of tricuspid valves thickened; walls of left ventricle hypertrophied; fibrin clots in all the cavities of heart; colon thickened, extensively ulcerated, with elevated patches of pseudo-membrane; liver hard, rounded, and with amber-colored metastatic foci in the right lobe; gall-bladder distended; spleen very small; cortical substance of kidneys waxy.

Contributed by Assistant Surgeon E. Bentley, U. S. Army, Washington, D. C.

No. 673. Portion of transverse colon, thickened, and presenting numerous follicular ulcers with some adherent pseudo-membrane.

L. 91.

Private T. P., "B," 1st Connecticut Heavy Artillery, age 30. Admitted, September 27th, 1865, with chronic diarrhoea; was somewhat emaciated; had been sick about a month; he had from six to eight thin dark-brown stools daily, with gripping pain. November 10th, extreme emaciation, with œdema of ankles and hands. Died, December 1st.

Autopsy: Colon thickened and with follicular ulcers, as in the specimen; gall-bladder moderately full of bile.

Contributed by Surgeon E. Bentley, U. S. Vols., Slough Hospital, Alexandria, Va.

No. 666. Portion of descending colon, much thickened and coated with patches of pseudo-membrane; many minute follicular ulcers.

L. 92.

Private C. C., "K," 195th Ohio, age 19. Admitted, October 10th, 1865, with chronic dysentery; evacuations frequent, painful, and scanty. Died, October 15th.

Autopsy: Old adhesions of both lungs; colon thickened and coated with pseudo-membrane, as in the specimen.

Contributed by Surgeon E. Bentley, U. S. Vols., General Hospital, Alexandria, Va.

Nos. 138 to 143. Successive portions of colon, exhibiting numerous superficial ulcers, with scattered pseudo-membranous patches. **138** and **139** from the ascending, **140** and **141** from the transverse, and **142** and **143** from the descending colon. The mucous membrane is considerably thickened, especially in the descending colon.

L. 93 to 98. Private H. E., "C," 5th Minnesota. Taken sick in June with intermittent fever and diarrhoea, which, sometime in July, ran into dysentery. He rallied, and was able to walk about for a week or two, but suffered a relapse, and was admitted October 10th, 1863. There was considerable œdema of lower extremities, with copious bloody stools, attended with moderate febrile action and dry tongue; subsequently the stools became dark and slimy, varying from five to twelve a day; appetite at first good, but soon failed. Died, October 31st.

Autopsy: Mesenteric glands enlarged; entire tract of large intestine eroded with ulcers, many of them superficial, but some penetrating to the muscular coat; mucous membrane thickened, especially in the cæcum.

Contributed by Surgeon George F. French, U. S. Vols., Hospital No. 3, Vicksburg, Miss.

No. 521. Portion of colon, coated with pseudo-membrane, with a few superficial ulcers.

L. 99.

Private L. K. S., "D," 14th Connecticut, age 35. Admitted, February 12th, 1865. Diagnosis—chronic diarrhoea. Had been sick for about six months; was received by transfer from Harewood Hospital, Washington, D. C., much emaciated and very feeble; had from four to eight thin stools daily. Died, March 15th.

Autopsy nineteen hours after death: Slight rigor mortis; great emaciation; omentum a mere sheet of thin membrane, no fat anywhere; adhesion of free extremity of vermiform appendix to peritoneum, just under umbilicus; the sigmoid flexure in left hypochondrium; adhesions in vicinity of caput coli; left kidney found in front of the promontory of the sacrum, its hilum upon its upper anterior surface; renal artery given off from bifurcation of aorta; spermatic arteries arose about an inch above bifurcation of aorta; spleen small and corrugated; liver small; the whole extent of mucous lining of intestine soft and thin; numerous roundish ulcerated patches in ascending colon.

Contributed by Surgeon P. A. Jewett, U. S. Vols., Knight Hospital, New Haven, Conn.

525, chap. V., sec. 1, A. 10, anomalous position of kidney, is also from this case.

No. 360. Portion of descending colon, the surface of which is thickly covered with pseudo-membranous lymph.
L. 100. When fresh the pseudo-membranous layer was of a bright yellow color, and the livid crimson mucous membrane could be seen in patches. (*See Microscopical Section, Part First, VII. 1, C. 22.*)

The patient was admitted September, 1861, in a dying condition, and expired shortly after his admission.

Contributed by Assistant Surgeon W. Thomson, U. S. Army, Douglas Hospital, Washington, D. C.

No. 223 Three successive portions of colon, with the mucous membrane greatly thickened and covered with a pseudo-membranous layer. In **221** and **225** there are many follicular ulcers, which, in three or four patches, have extended into vast eroding excavations, the largest one a and a half inches by one inch.

L. 101 to 103. Private J. G. B., "F." 37th Massachusetts. Had diarrhoea slightly for some months. December 27th, 1862, was attacked with menses and a severe cough, with cessation of the diarrhoea; while convalescing from this attack he suffered two relapses, on account of exposure, and entered hospital February 15th, 1863, quite weak, with some cough and a diarrhoea which had recently come on. His appetite was fair; tongue clean and moist; pulse 111. There was no special change until the 20th, when he began to sink, and died February 22d.

Autopsy twenty-seven hours after death: Body emaciated; rigor mortis slightly marked; abdomen collapsed; muscles pale; right lung exhibited scattered yellow tubercles in the upper and middle lobes, with mucus-pus in the bronchial tubes; left lung presented one cavity in the upper lobe as large as a hen's egg, with a number of smaller ones from the size of a pea to that of a hazel-nut; these cavities had yellow opaque walls about one line in thickness; there were some yellow tubercles in this lung, and its lower edge was oedematous; bronchial glands hard, enlarged and filled with black pigment; heart small; liver showing a marked difference between the red and yellow portions, the latter being comparatively large and pale; stomach contained a thin mucus mixed with bile, but its mucous membrane and that of the duodenum and jejunum was normal; mesenteric glands small and pale; Peyer's glands normal; small intestine smeared over with thick adhesive mucus stained with greenish-yellow bile, which was darker in the lower part of the jejunum, but lighter through the ileum; one or two small ulcers near the ileo-caecal valve; colon contained thin yellow faeces; throughout its whole length the mucous membrane was greatly thickened, with patches of pseudo-membrane; the descending colon and rectum presented numerous ulcers of various sizes from one-fourth of an inch to two inches in diameter, the membrane being softened, thickened and undermined for some distance around the margin of the large ulcers.

Contributed by Surgeon C. Page, U. S. Army, Judiciary Square Hospital, Washington, D. C.

See plate opposite.

No. 382. Fibrinous cast, fourteen inches long, from the rectum, composed of ordinary croupous lymph.

L. 104. Private W. H. M., "B." 4th California, age 35. Attacked with diarrhoea while marching from Fort Mojave, Arizona Territory, to Drum Barracks, December 11th, 1863. The attack was mild and he continued on foot for two days. The attack passed into dysentery, with bloody mucus in the faeces, on the third day; on the seventh day, retention of urine. On reaching Los Angeles, December 24th, he was suffering from retention of urine, frequent discharges of bloody mucus, with painful tenesms, accompanied by prolapsus of the rectum. Admitted to Drum Barracks, December 25th. The cast was found in his bed, January 1st, 1864. Catheterism was continued up to January 15th, when he was able to void water without the instrument. February 3d, he was able to leave his bed and walk about, without assistance; the diarrhoea subsequently returned, and the patient died April 25th.

Contributed by Surgeon S. S. Todd, 4th California, Drum Barracks, California.

No. 281. Portion of colon, with its mucous membrane greatly thickened, and numerous irregular deep ulcers, some of them penetrating to the peritoneal coat. The patient died of diarrhoea during the winter of 1862.

Contributed by Assistant Surgeon Warren Webster, U. S. Army, Douglas Hospital, Washington, D. C.

No. 118. A portion of descending colon, presenting large, deep and irregular ulcers.

L. 106. Private D. S., "F." 2d New York Heavy Artillery. Admitted from the Army of the Potomac, September 29th, 1864, with chronic diarrhoea; was much emaciated, and, in addition to the usual symptoms of the advanced stage of chronic diarrhoea, had jaundice and frequent bilious vomiting. The abdomen was flat and tender; there was stupor, low delirium and involuntary stools. Died, September 17th.

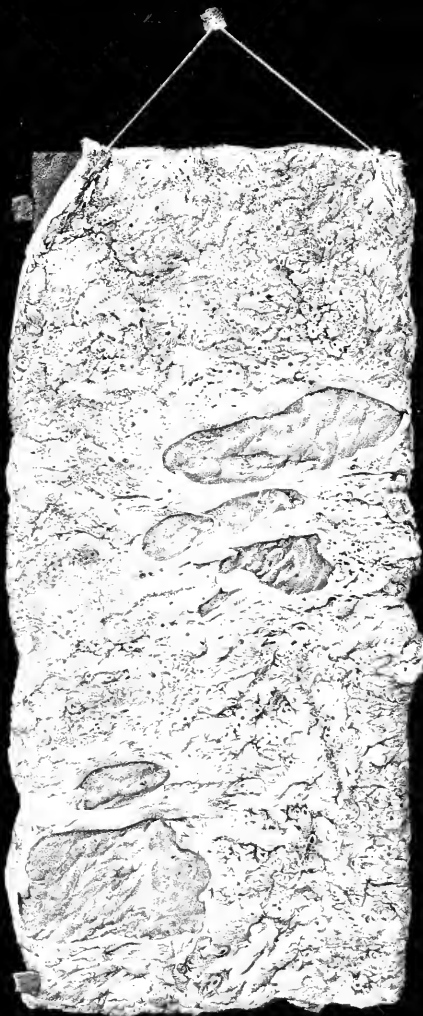
Autopsy: Body emaciated; intensely jaundiced; mucous membrane of colon greatly thickened throughout and presented numerous large, irregular, ragged ulcers, most of which involved the muscular coat; at the caecum a perforation the size of a dime; peritonum roughened; colon adherent to the right lobe of the liver for an extent of two inches; liver contained numerous metastatic foci, from a quarter to half an inch in diameter, which were chiefly situated in the right lobe and on the course of the branches of the portal vein; many of them contained a small drop of yellow fluid in the centre, consisting, as seen under the microscope, of disorganized liver tissue, granular matter and fat globules, but no pus.

Contributed by Assistant Surgeon Wm. F. Norris, U. S. Army, Douglas Hospital, Washington, D. C.

113, chap. IV., sec. 5, D. 3, metastatic foci in liver, is also from this case.

No. 13. Portion of caecum, with large, irregular, superficial ulcers, one of which has perforated. The mucous membrane hangs in shreds from the edges of several of the ulcers.

L. 107. Private W. E. K., "H." 6th Maine, age 21, American. Admitted, August 10th, 1862. Diagnosis—debility, apparently convalescent from typhoid fever; had diarrhoea. Died, August 13th, suddenly, without symptoms of peritonitis.



№ 224

Autopsy: Body very much emaciated; skin of trunk somewhat ecchymosed; bed-sores on hips; about a gill of liquid in pericardium; stomach contracted and empty, some of the rugae along its greater curvature highly injected; mucous membrane of ileum inflamed in patches from a few inches to a foot or more in length; Peyer's glands thickened, some of them reddened by inflammation, but none ulcerated; solitary glands inconspicuous; mucous membrane of colon slate-colored, with small red inflamed patches; it also presents a number of large ulcers, extending to the muscular coat: one of these, within the cæcum, had perforated; the perforation appears to have occurred just previous to death, as it had not given rise to peritonitis, except some injection of the peritoneum in the immediate vicinity of the aperture in the right iliac fossa.

Contributed by Acting Assistant Surgeon J. Leidy, Satterlee Hospital, Philadelphia, Pa.

No. 618. Portion of cæcum, with ileo-cæcal valve and lower part of ileum; a perforating ulcer in the cæcum.

L. 108. Private C. B. K., 10th Wisconsin Battery, age 32. Admitted, January 10th, 1865, with diarrhoea, extremely irritable stomach, and pain in the right iliac fossa. About the third day after admission low fever set in, with muttering delirium at night. Died, January 17th.

Autopsy: Body emaciated; hepatization of lower lobes of both lungs; in right iliac region peritoneal adhesions, which gave way on traction, exhibiting a perforation in the cæcum; escape of fecal matter into the abdominal cavity had been prevented by the adhesions; there was an abscess beneath the right iliac fascia containing about two ounces of dark-colored offensive pus; lower third of ileum and the colon presented inflammatory spots, with softening and ulceration of the mucous membrane; liver enlarged and congested.

Contributed by Assistant Surgeon George M. McGill, U. S. Army, National Hospital, Baltimore, Md.

No. 322. Portion of ascending colon, thickened, and presenting a number of ragged and irregular ulcers, two of which had perforated.

L. 109. Private F. G., "K," 8th Illinois Cavalry, age 27, German. Admitted, May 6th, 1864. Had been under treatment in camp with diarrhoea, alternating with constipation; breath very offensive; obstinate diarrhoea supervened, with fever of an adynamic type. This state continued with anorexia and emaciation till May 18th, when hemorrhage from the bowels set in. Died, May 23d.

Autopsy: Mucous membrane of small intestine softened and ulcerated in patches; mucous membrane of colon, from the cæcum to the rectum, ragged with irregular ulcers, were several perforations.

Contributed by Surgeon A. Hard, 8th Illinois Cavalry, Washington, D. C.

Nos. 329 to 331. 329, portion of ileum, taken from just above the ileo-cæcal valve, presenting a few superficial ulcers. 330, portion of transverse colon of same patient, presenting several ulcers, which penetrate to the muscular coat. 331, portion of the descending colon of same patient, similar to the transverse colon; two of the ulcers had perforated.

L. 110 to 112. Musician T. B., 2d Pennsylvania Heavy Artillery. Admitted, July 25th, 1861, with diarrhoea, in an extremely exhausted condition. Died, July 30th.

Contributed by Assistant Surgeon H. Allen, U. S. Army, Fairfax Seminary Hospital, Alexandria, Va.

Nos. 602 and 603. 602, portion of transverse colon, thickened, and presenting on the mucous surface, a number of cysts of about the size of peas, with a few ulcers corresponding to ruptured cysts. 603, a portion of descending colon of the same patient, presenting a few smaller cysts, with several cicatrices of former ulcers. When received at the Museum, the colon was of a pale cream-color, with livid bluish discolorations around the cysts. The cysts contained a semi-transparent yellowish matter, resembling calves-foot jelly; with the microscope, a few delicate nucleated cells were observed embedded in this matter.

Private T. K. "E," 28th Massachusetts, age 29, Irish. Admitted, April 18th, 1865, with gunshot fracture of thigh, received near Petersburg, Va., March 25th. May 10th was attacked with diarrhoea, with mucous stools, which continued till death. Died, July 30th, of erysipelas of the thigh, terminating in gangrene. (Amputation had not been performed.)

Autopsy eight hours after death: Rigor mortis well marked; tubercles at the apices of both lungs; left lung coated with recent lymph; small intestine normal; colon as in specimen.

Contributed by Acting Assistant Surgeon G. K. Smith, Army Square Hospital, Washington, D. C.

See *Surgical Section*, **1105, 1111**. A. B. b. 77.

Nos. 165 and 166. 165, portion of ileum, taken from near the middle, with enlargement of the solitary follicles and slight thickening of Peyer's patches. 166, portion of the transverse colon of the same patient, presenting several small ulcers; near the right edge of the piece, below the middle, are several ulcers in different stages of cicatrization. (See *Microscopical Section, Part First*, **VIII**, l. c. 15 and 16.)

Private L. S., "A," 186th New York. Admitted, December 1st, 1864. Diagnosis—typhoid fever. Said he has had diarrhoea several months. Died, December 10th.

Autopsy: Ileum, with patches of congestion and enlarged solitary follicles, with slight thickening and pigment deposit in Peyer's patches; near the ileo-cæcal valve some ulceration of the solitary follicles; in the ileum, about three and a half feet from ileo-cæcal valve, an intestinal diverticulum two and a half inches long; colon ulcerated, especially at its extremities; in transverse colon several of the ulcers were cicatrizing.

Contributed by Acting Assistant Surgeon W. C. Miner, General Hospital, Alexandria, Va., Third Division.

M. Tubercular ulceration of intestines

No. 692. A portion of ileum, taken at the ileo-cæcal valve, with tubercular ulceration of Peyer's patches and of some of the solitary follicles; on the peritoneal surface of the piece, especially opposite the ulcers, are several small tubercles.

M. 1.

See 691, chap. III., sec. 2, D. 7, for history.

No. 771. Portion of ileum, with several small tubercular ulcers; the villi around the edges of the ulcers hypertrophied; tubercular deposits on peritoneal surface opposite the ulcers.

M. 2.

R. F., mulatto, age 33. Admitted, February 31, 1866, with phthisis. Died, March 29th.

Autopsy twenty hours after death: Height, six feet; weight, about one hundred and sixty pounds; rigor mortis well marked; no emaciation; membranes of brain slightly congested; tubercles in both lungs, especially the right, which contained several vomicae and was coated with crumpled lymph; lower lobe of left lung hepatized; six ounces fluid in right pleural cavity, four ounces in left; pericardium contained five ounces of serum; heart fatty; aorta atheromatous; liver and spleen contained a few miliary tubercles; kidneys fatty; a number of large scooped tubercular ulcers in the ileum, with deposits of tubercle on the peritoneal surface opposite; a few tubercular ulcers in colon.

From Freedman's Hospital, Washington, D. C.

Autopsy by Hospital Steward S. S. Bond.

No. 776. Portion of ileum, from just above the ileo-cæcal valve, with numerous tubercular ulcers on the mucous coat; tubercular deposits on the peritoneal surface.

M. 3.

A. G., mulatto woman, age 18. Admitted, July 5th, 1865. Diagnosis—jaundice. August 23d, acute pneumonia supervened. 26th, pain on pressure over whole abdomen; bowels constipated. 30th, diarrhoea, with typhoid symptoms. September 6th, weak; pulse 110; headache; sleepless; bowels constipated. October 17th, coughing frequently; collipative night-sweats. March 3d, 1866, diarrhoea; extreme emaciation; too weak to sit up; little appetite. Died, March 30th.

Autopsy thirty-five hours after death: Height, five feet five inches; weight, one hundred and ten pounds; rigor mortis partial; extreme emaciation; bed-sores on buttocks; membranes of brain congested; both lungs contained many tubercles; large vomicae in left lung; left lung adherent; sixteen ounces of serum in right pleural cavity; bronchial glands enlarged and tubercular; pericardium contained six ounces of serum; heart somewhat fatty; atonic liver, containing many miliary tubercles; gall-bladder full of viscid bile; spleen contained many crude tubercles; mesenteric glands tubercular, very much enlarged, some the size of a hen's egg; tubercles in both kidneys; an ulcer near the pyloric orifice of stomach; mucous coat thickened; a large number of tubercular ulcers throughout small intestine; opposite to each ulcer, on the peritoneal surface, numerous tubercles; mucous membrane of colon much thickened and presented numerous tubercular ulcers.

From Freedman's Hospital, Washington, D. C.

Autopsy by Hospital Steward S. S. Bond.

No. 551. Piece of ileum, taken from just above ileo-cæcal valve, showing a number of tubercular ulcers. On the peritoneal surface, opposite to the principal ulcer, can be seen several minute tubercles.

M. 4

See 552, chap. II., sec. 3, B. 3, for history.

No. 671. Portion of ileum, taken from near the ileo-cæcal valve, showing a Peyer's patch, which is moderately thickened, and presents a considerable number of distinct tubercular ulcers.

M. 5.

S. G., mulatto, age 31. Admitted, September 5th, 1865, with phthisis. Died, December 17th.

Autopsy sixteen hours after death: Height, five feet three inches; weight, about one hundred and twenty pounds; some emaciation; rigor mortis well marked; both lungs contained numerous tubercles, with vomicae in the upper lobes, upper portion of both adherent—these conditions being most decided on the right side; firm white clot in both ventricles of heart, extending into the great vessels; congestion of mucous membrane of stomach, duodenum and jejunum; Peyer's patches slightly thickened, with a number of separate ulcers in each patch, the extent of the lesion increasing in the lower portion of the ileum; colon distended with feces, its mucous membrane ulcerated; liver and spleen small; kidneys fatty.

From Freedman's Hospital, Washington, D. C.

Autopsy by Hospital Steward S. S. Bond.

No. 798. Portion of ileum, with small tubercular ulcerations of mucous membrane, and tubercles on peritoneal surface opposite the ulcers.

M. 6.

A negro woman. Died, May 16th, 1866. No history.

Autopsy. Height, five feet; weight, one hundred pounds; slight emaciation; membranes of brain finely congested; both lungs adherent, containing numerous tubercles; a cavity the size of an orange in upper lobe of right lung; two large cavities and several smaller in upper lobe of left lung; pericardium contained a pint of serum; heart somewhat fatty; liver, extending

down to umbilicus, presented the nutmeg appearance, and extremely fatty; gall-bladder full of bile; numerous tubercular ulcers throughout both large and small intestine, with tubercular deposits on the peritoneal surface opposite the ulcers; fallopian tubes enlarged and contained a cheesy matter.

From Freedman's Hospital, Washington, D. C.

Autopsy by Hospital Steward S. S. Bond.

793, *chap. V., sec. 5, C. 1, fallopian tubes distended and filled with cheesy matter is also from this case.*

No. 612. Portion of ileum, taken from near its middle, showing a Peyer's patch, seven inches long, completely destroyed by tubercular ulceration; on the peritoneal surface of the piece a number of tubercles can be observed, some of them the size of bird-shot.

See 611, chap. III., sec. 2, E. 5, for history.

No. 808. Portion of ileum, with tubercular ulceration of Peyer's patches; tubercular deposits on the peritoneum opposite the ulcers.

M. 8. J. E., light mulatto, age 20. Admitted, May 31, 1866. Died, May 4th.

Autopsy twenty-eight hours after death: Height, six feet; weight, one hundred and fifty pounds; rigor mortis partial; some emaciation; small flat osteophytes on inner surface of calvarium; membranes of brain congested; both lungs adherent, filled with tubercles; numerous vomicae in upper portions; four ounces fluid in each pleural cavity; liver fatty; gall-bladder contained half an ounce of bile; spleen lobulated; kidneys fatty; extensive tubercular ulceration of small and large intestines, with deposits of tubercle on peritoneal surface opposite the ulcers.

From Freedman's Hospital, Washington, D. C.

Autopsy by Hospital Steward D. S. Lamb.

809, *chap. VI., sec. 2, No. 3, small flat osteophytes on inner surface of calvarium, is also from this case.*

No. 725. Portion of ileum and caecum, with tubercular ulcers; a few tubercles on the peritoneal surface of the ileum.

M. 9. M. S., mulatto woman. Admitted, January 31st, 1866, with phthisis. Died, February 11th.

Autopsy thirty-six hours after death: Age, about 30; height, five feet five inches; weight, about one hundred and thirty pounds; not much emaciation; rigor mortis well marked in lower extremities, very slight in upper; bed-sore on right buttock; numerous osteophytes in Paechionian granulations; right lung firmly adherent and filled with tubercles; its upper lobe hepatized, middle lobe emphysematous, lower lobe congested; left lung firmly adherent; both lobes contained large vomicae; whole lung filled with tubercle and hepatized; left pleural cavity contained about a pint of serum; pericardium contained six ounces of serum; abdominal cavity filled with serum; tubercular ulcers in small intestine and colon; liver fatty, firmly adherent at all points by fibrous bands; gall-bladder contained half an ounce of yellow bile; kidneys fatty; right kidney somewhat lobulated and presenting a number of cysts.

From Freedman's Hospital, Washington, D. C.

Autopsy by Hospital Steward S. S. Bond

725, *chap. V., sec. 1, C. 13, cysts of kidneys, is also from this case.*

Nos. 211 to 260. a series of pieces taken successively from high in the jejunum to near the ileo-caecal valve, with numerous ulcers, most of which are associated with tubercles of the peritoneum, and have their long

261. diameter transverse to the length of the intestine. **261.** portion of the colon of the same patient, thickened, ulcerated, and presenting pseudo-membranous patches.

M. 10 to 27. Private A. Y., "K," 3d Vermont, age 23, American. Admitted, August 10th, 1862. Diagnosis—rheumatism. Died, September 15th. Diagnosis—tuberculosis and diarrhoea.

Autopsy: Body much emaciated, with an echylosed condition of the skin about the pit of the stomach; right lung with adhesions of an old pleurisy, tubercular deposit in its apex, and tubercular masses, from the size of a cherry-stone to that of a peach-stone, some of them softening in the centre, scattered through its substance; left lung with old adhesions at its back part and containing about twenty tubercular masses from the size of a cherry-stone to that of a shell-bark; heart pale, devoid of fat; liver dull-brown; stomach moderately contracted; its mucous membrane presenting a few slightly injected patches; mesenteric glands much enlarged, with tubercular deposits; intestines contracted, with inflammation of the mucous membrane from the duodenum to the anus; there were patches of tubercles in the peritoneum beneath the position of every Peyer's gland; the tubercles were opaque, white, and about a line in diameter; the Peyer's glands were all ulcerated and surrounded by thick hardened edges; circumscribed peritonitis accompanied the patches of tubercles; similar patches, with ulcers of the mucous membrane, were exhibited high up in the jejunum; inflammation of the mucous membrane of the colon (most acute at the two extremities) was associated with a number of ulcers, patches of pseudo-membrane, desquamated epithelium, and blackened solitary glands.

Contributed by Acting Assistant Surgeon J. Leidy, Satterlee Hospital, Philadelphia, Pa.

Nos. 182 to 187. **182.** piece of the upper part of jejunum, presenting three small tubercular ulcers. **183.** piece from the upper part of ileum of same patient, with a large oval tubercular ulcer, the long diameter of which is transverse to the gut. **181.** piece from the lower part of ileum of same patient, with a Peyer's patch, which is the seat of three small tubercular ulcers. **185.** piece of ileum, with ileo-caecal valve and part of the caecum of same patient; a transverse ulcer just above the valve; ulcers in the caecum. **186.** the vermiform appendix of same patient, deeply ulcerated. **187.** piece of transverse colon of same patient, presenting several ulcers.

See 180, chap. III., sec. 2, E. 6, for history.

Nos. 677 to 679. **677**, portion of ileum, presenting a somewhat thickened Peyer's patch, in which are a considerable number of minute ulcers. **678**, portion of ileum of same patient, taken from near the ileo-caecal valve, with a part of the caecum attached; the large Peyer's patch just above the valve presents a considerable number of small ulcers; some of the solitary follicles are also ulcerated; when fresh, the solitary follicles and the Peyer's patches were the seat of black pigment deposit; the ulcers in this piece and **677** are quite minute and have elevated edges. **679**, portion of colon of same patient, somewhat thickened, in which the solitary follicles, which are slightly ulcerated, were the seat of black pigment deposit.

M. B., mulatto woman, age 36. Admitted, December 17th, 1865. Diagnosis—consumption and anasarca. Died, December 27th.

Autopsy thirty hours after death: Height, five feet five inches; weight, about ninety pounds; great emaciation; rigor mortis well marked; membranes of brain congested; tubercles in both lungs; right lung firmly adherent, and with cavities in its upper lobe; left lung slightly adherent, its lower lobe in a state of gray hepatization; four ounces of fluid in right pleural cavity; three ounces of serum in left pleural cavity; pericardium contained two ounces of clear serum; white fibrinous clots in all the cavities of heart; kidneys fatty; duodenum slightly congested, with solitary follicles enlarged, and a few ulcers; enlargement and ulceration of solitary follicles of jejunum and ileum, with thickening of Peyer's patches, which presented the shaven-head appearance, and numerous distinct pin-head ulcers with elevated edges; solitary glands of colon filled with pigment, a few ulcerated; uterus about double its natural size.

From Freedman's Hospital, Washington, D. C.

Autopsy by Hospital Steward S. S. Bond.

Nos. 128 to 131. **128**, piece of upper portion of jejunum, presenting near its middle a large ulcer, the long diameter of which is transverse to the length of the intestinal canal. On the peritoneal surface opposite the ulcer are a number of small tubercles. **129**, a piece taken from high up in the ileum of the same patient, with two similar ulcers. **M. 37 to 40.** **130**, from just above the ileo-caecal valve, presents a slightly thickened Peyer's patch, in which are a number of small ulcers, and several small isolated ulcers connected with the solitary follicles. The villi throughout the small intestine were hypertrophied. **131**, a portion of caecum with vermiform appendix. An irregular ragged ulceration surrounds the orifice of the appendix, the mucous membrane of which is ulcerated throughout; the caecum presents a number of large irregular ulcers.

See 132, chap. II., sec. 3, B. 1, for history.

Nos. 163 and 161. **163**, piece from upper portion of ileum, presenting near its centre a group of small, irregular ulcers; a number of minute tubercles on the peritoneal surface opposite the ulcers. **161**, rectum with part of the skin surrounding the anus; the mucous membrane thickened and presents numerous small follicular ulcers; in the skin, close to the anus, two small fistulous orifices, communicating with an abscess-cavity rather larger than a walnut, which is situated in the areolar tissue just outside of the sphincter ani.

Private M. C., 2d Battalion Veteran Reserves. (Transferred to this Corps for amputation of left arm.) Admitted, August 25th, 1861, with diarrhoea; there was nausea, griping and eight to twelve feculent passages daily. Some weeks later he complained of cough and pain in upper part of left side of chest. There was dullness on percussion over the upper part of left lung, with rale respiration and slight mucous rale. The diarrhoea, meanwhile, continued with five or six passages daily. He began to emaciate, became low spirited, lost appetite and took to his bed. About two weeks before his death, an abscess formed near the anus, which opened after a few days, discharging a thick dark pus. Died, December 13th.

Autopsy: Great emaciation; pericardium filled with serum mixed with lymph; both lungs contained tubercles and vomicae, the upper part of the left lung being most extensively diseased; liver and kidneys fatty; mesenteric glands enlarged; small intestine presented numerous ulcers similar to those in the specimen; mucous membrane of the colon thickened and presenting numerous ulcers; vermiform appendix adherent to upper part of rectum, and the cavities of the two communicated through an ulceration; near the anus the abscess above described.

Contributed by Acting Assistant Surgeon W. C. Miner, General Hospital, Alexandria, Va., Third Division.

Nos. 771 and 772. **771**, A portion of ileum from just above the ileo-caecal valve, showing tubercular ulceration of the last Peyer's patch and of several of the solitary follicles. **772**, a portion of rectum, with patches of superficial ulceration, covered with thick pseudo-membrane. **M. 43 & 44.** See 773, chap. III., sec. 2, D. 5, for history.

No. 720. **M. 45.** Portion of transverse colon, showing a number of minute follicular ulcers; near the middle of the piece is a large tubercle at base, running obliquely to the axis of the gut; on the peritoneal surface opposite the nœc a considerable number of tubercles; a few minute ones scattered on other portions of the peritoneal surface.

F. W., mulatto boy, age 14. Admitted, May 24th, 1865, suffering from serofulous ophthalmia. Symptoms of phthisis first not seen until the middle of October. Died, February 4th, 1866, of profuse and sudden hæmorrhage from the lungs.

Autopsy twenty-two hours after death: Height, four feet nine inches; weight, about eighty pounds; some emaciation; rigor mortis well marked; both lungs adherent, filled with tubercles and presenting a number of small vomicae, in upper lobe of left lung a large one; three ounces of serum in right, one ounce in left pleural cavity; bronchial glands very much enlarged; heart somewhat fatty; eight ounces of fluid in pericardium; liver adherent, its anterior surface coated with lymph, on section it is congested, and contained some tubercles; spleen adherent and filled with tubercle; mesenteric glands much enlarged;

two large tubercular ulcers in the ileum near the ileo-caecal valve; the rest of the small intestine normal; a few of the solitary follicles of caecum enlarged; in ascending colon one large tubercular ulcer, involving the mucous and muscular coats; on the peritoneal surface opposite the ulcer were numerous tubercles; a similar ulcer in the transverse colon, but much larger; with these exceptions, the large intestine was normal; abdominal cavity filled with serum, and intestines slightly adherent to abdominal peritoneum

From Freedman's Hospital, Washington, D. C.

Autopsy by Hospital Steward S. S. Bond.

721, chap. IV., sec. 4, E. 2, *tubercles of the omentum, is also from this case.*

N. Parasites in intestinal canal.

- No. 111.** A lumbricoid worm, vomited by Private G. C. H., "A," 8th New York Heavy Artillery.
N. 1. Contributed by Acting Assistant Surgeon John Morris, Lincoln Hospital, Washington, D. C.
- No. 17.** *Tenia solium*, about twenty-five feet long, with the head.
N. 2. Private J. J. B., "F," 96th New York, age 29. First saw the joints in his stools about three months before admission; had, on an average, three stools daily, passing about ten joints, half an inch long, at each stool; very little emaciation; appetite variable; vomited, while in hospital, several lumbricoid worms. The specimen was voided after the use of turpentine and castor oil.
 Contributed by Acting Assistant Surgeon J. F. Kennedy, Seminary Hospital, Washington, D. C.
- No. 18.** *Tenia solium*, nine separate individuals, each varying from two to five feet long, none of them with the head.
N. 3. Private J. H. O., U. S. A., age 25, American. Stated that three years previously, while in Texas, he first noticed segments of tenia in his evacuations; had passed, at various times, large quantities of worm, the longest segments about twenty-five feet in length.
 Contributed by Assistant Steward J. F. Cramer, Judiciary Square Hospital, Washington, D. C.
- No. 19.** The specimen consists of two portions *tenia solium*, one fifteen, the other one foot long. No history.
N. 4. Contributed by Surgeon Geo. F. French, U. S. Vols., Hospital No. 3, Vicksburg, Miss.
- No. 113.** Incomplete *tenia solium*, nine feet four inches long.
N. 5. Sergeant J. E. R., "E," 10th New Jersey, age 28. Anthelmintic—pumpkin seeds.
 Contributed by Acting Assistant Surgeon Wm. E. Sparrow, Alexandria, Va.
- No. 115.** An incomplete *tenia solium*, twenty-five feet in length—no head; passed by the officer who presented it, in July, 1861. Anthelmintic—pumpkin seeds. Dr. W. first noticed the symptoms produced by the presence of the worm in 1855, while serving in the East with the British Foreign Legion. Symptoms were paleness of the face and lips; alternate loss and excess of appetite; vomiting in the morning; bloating of the abdomen, with sensations of contraction of the throat, and a peculiar feeling as if some foreign body were moving in the bowels. Anthelmintics had hitherto failed to afford permanent relief.
 Contributed by Acting Assistant Surgeon Iwanoff Willentzki, General Hospital, Alexandria, Va., Second Division.
- No. 775.** Fragment of *tenia solium*, four and a third feet long—no head; passed by Private J. R., "F," 1st U. S.
N. 7. Veterans, age 30, who had been suffering for some time with symptoms of tapeworm, and had passed numerous fragments.
 Contributed by Assistant Surgeon De Witt C. Peters, U. S. Army, Fort McHenry, Baltimore, Md.
- No. 811.** Upper extremity of *tenia solium*, four feet long. For head of the specimen, *see Microscopical Section, Part First, XV., A. a. 1.*
N. 8. Private A. V., "F," 3d Battalion, 16th U. S. Infantry, German. In February, 1865, at Carthagena, Spain, was attacked with abdominal pains and passed about five feet of tapeworm. Was then 23 years old, and had previously enjoyed good health. Had a similar attack in London, in November, 1865, and again at Sibley Barracks, April 12th, 1866, July 9th, passed the specimen. Anthelmintic employed—pumpkin seeds.
 Contributed by Acting Assistant Surgeon A. I. Comfort, Sibley Barracks, Nashville, Tenn.
- No. 832.** *Tenia solium*, six feet long, expelled from the bowels of a soldier of the 3d Battalion, 16th U. S. Infantry,
N. 9. Sibley Barracks, Nashville, Tenn. The head and a few of the adjacent segments are preserved for microscopical examination. (*See Microscopical Section, Part First, XV., A. a. 1.*)
 Contributed by Acting Assistant Surgeon A. I. Comfort, Sibley Barracks, Nashville, Tenn.

- No. 50.** Two pieces of tænia lata, measuring together about thirty-five feet,—no head; passed by H. K., who had been voiding segments of the worm for about a year.
N. 10. Contributed by Acting Assistant Surgeon J. E. Wilson, Jackson Hospital, Memphis, Tenn.
- No. 51.** Several pieces of tænia lata, in all eighty feet long.
N. 11. No history.
 Contributed by Medical Storekeeper H. Stevens, U. S. Army, Memphis, Tenn.

Section I. PERITONEUM AND OMENTUM.

A. Atrophy of omentum.

- No. 731.** Portion of transverse colon, from which hangs the greater omentum, condensed into an oval cord, about an inch and a half in diameter and twelve inches long, terminating below in an irregular fringe. The patient died of ascites due to chronic peritonitis. Folds of small intestine found glued together by close adhesions; thoracic viscera, liver, spleen and kidneys healthy.
A. 1. * Contributed by Surgeon E. Bentley, U. S. Vols., General Hospital, Alexandria, Va.

B. Abscess.

- No. 153.** Portion of transverse colon, presenting two perforations communicating with a large irregular abscess-cavity lying between colon, stomach and liver.
B. 1. Major J. L., 15th New York. Admitted, November 18th, 1864, from Division Hospital at front. Diagnosis—remittent fever. Stomach very irritable, with frequent vomiting, but no abdominal tenderness. 23d, swelling over left lobe of liver; not tender on pressure; subsided next day, and patient commenced vomiting large quantities of offensive greenish liquid; copious stools of a bloody slime mixed with pus. December 1st, a careful examination detected no abdominal tenderness. Died, December 3d.
 Autopsy: Right lung adherent to walls of chest; stomach filled with dark green fluid; left lobe of liver adherent to transverse colon, stomach, and omentum; abscess-cavity of some size situated on under surface of liver near transverse fissure, between liver, colon and stomach, which had discharged by two orifices into transverse colon and also into abdominal cavity; intestines contained much thick viscid pus; pus also found in peritoneal sac.
 * Contributed by Surgeon W. L. Faxon, 32d Massachusetts, Depot Hospital, 5th Army Corps, City Point, Va.

C. Peritoneal adhesions.

- No. 781.** Kneekles of ileum, presenting old and fully-formed adhesions.
C. 1. See 783, chap. II., sec. 4, B. 4, for history.
- No. 715.** Small portion of anterior edge of spleen and portion of left lobe of liver, attached to each other by well-organized false membrane. Both organs were considerably enlarged.
C. 2. C. G., light mulatto, age 13. Admitted, October 13th, 1865, with acute diarrhoea, cough, and œdema of face and extremities. Died, January 17th, 1866.
 Autopsy sixteen hours after death: No rigor mortis; height, five feet; weight, about ninety pounds; emaciation extreme; two ounces of serum beneath arachnoid; abundant pigment and a large quantity of tubercle in both lungs; twelve ounces of serum in right peritoneal cavity, four ounces in left; white clots in all the cavities of the heart; liver weighed fifty-two ounces, and contained scattered tubercles; spleen indurated, weighed twenty-two ounces; liver and spleen adherent by their anterior edges as in specimen; abdominal cavity distended with serum.
 From Freedman's Hospital, Washington, D. C.
 Autopsy by Hospital Steward S. S. Bond.
- No. 806.** Section through abdominal viscera, showing intestines bound together by well-developed adhesions.
C. 3. See 807, chap. III., sec. 2, B. 4, for history.

No. 651. Perpendicular section through abdominal viscera, showing intestines adherent to each other, and mesenteric glands greatly enlarged, the whole forming a solid mass.

C. 4. History—(Acting Assistant Surgeon J. B. Young): Private W. R., "F," 3d Georgia Cavalry, (Rebel,) age 36. Admitted, November 29th, 1864. Diagnosis—scurvy. Had had diarrhoea, which disappeared before admission; complained of dyspnoea; intercostal spaces prominent; abdomen distended. Died, January 3d, 1865.

Autopsy: Miliary tubercles in both lungs; considerable effusion in both pleural cavities; abdomen distended with much serum; viscera inter-adherent by well-developed fibrous tissue.

Contributed by Surgeon Wm. Watson, U. S. Vols., Post Hospital, Rock Island, Ill.

No. 731. Portions of left lobe of liver and of spleen adherent together; scattered tubercles in substance of liver and on its under surface; large tubercles stuff the spleen; convex surface of each organ coated with pseudo-membrane.

C. 5. A young colored girl who died about two weeks after delivery.

Autopsy: Thoracic and abdominal viscera glued together by inflammation into a solid mass; lungs and spleen stuffed with cheesy tubercles; liver and kidneys presented a few tubercles scattered through their substance; the peritonitis was associated with tubercle on peritoneal surface of viscera, and was most developed in upper part of abdominal cavity.

Contributed by Surgeon E. Bentley, U. S. Vols., Alexandria, Va.

732, *chap. V., sec. 1, D. 1, tubercles of kidneys; 733, chap. V., sec. 5, D. 3, womb two weeks after delivery, are also from this case.*

Nos. 562 and 563. 562. perpendicular section through abdominal viscera, about three inches to the right of median line, showing several knuckles of intestine closely adherent to each other, to liver, and to greater omentum. 563. section through abdominal viscera, about three inches to left of median line, of same patient; on one side of

C. 6 and 7. upper part of specimen is the spleen, which contains a number of tubercles; on the other side, a portion of greater curvature of stomach; the greater omentum is much thickened, and between its posterior surface and the small intestines a cavity exists, which was found filled with pus; except this cavity, all the abdominal viscera were adherent to each other.

Private J. R., "D," 31st U. S. Colored. Admitted, April 5th, 1865, by transfer from David's Island, New York Harbor. Very weak; suffering from pain in abdomen; cough; anorexia; some fever; mind clear; abdomen swollen, quite hard at its upper part, and fluctuation, due to liquid effusion, at its lower part. Fever increased; patient became delirious in a few days; moaned and screamed continually; refused food and medicine; had involuntary evacuation of urine and feces. Died, April 10th.

Autopsy: Abdominal viscera in the condition described; no record of state of thoracic viscera.

Contributed by Acting Assistant Surgeon W. B. Casey, Knight Hospital, New Haven, Conn.

No. 533. Perpendicular section through liver, transverse colon and small intestine on right side, the several viscera and omentum bound together by old adhesions.

C. 8. History—(Acting Assistant Surgeon L. Hearl): Private J. N., "B," 23d U. S. Colored, age 20. Admitted, August 9th, 1864, from City Point, Va., with amputation of left arm in middle third for gunshot fracture received before Petersburg, Va., July 30th. December 23d, stump was healed and patient appeared in good condition. February 20th, 1865, intermittent fever set in. March 1st, chills and fever had disappeared; appetite improved; tongue slightly furred; bowels regular; pulse 80 and of fair strength; abdomen slightly swollen, tense, and tender on pressure. 10th, patient about the same; able to walk about; had no cough. 25th, gradual loss of muscular strength; progressive emaciation; otherwise the same. He continued to lose ground gradually; appetite failed; pulse grew smaller, weaker and more frequent. Died, May 3d.

Autopsy: Lower lobe of right lung coated with yellow lymph, a few tubercles the size of beans in its upper lobe, cheesy mass the size of a walnut in lower lobe; miliary tubercles in left lung; pericardium distended with serum; nutmeg liver; fatty kidneys; abdominal viscera inter-adherent, as in specimen.

Contributed by Acting Assistant Surgeon W. C. Miner, L'Ouverture Hospital, Alexandria, Va.

D. Connective tissue growths.

No. 53. A spherical tumor, three-fourths of an inch in diameter, attached by a small peduncle one-half inch long to peritoneal surface of ileum, and composed of connective tissue with irregular calcareous deposits, giving it a bone-like hardness.

D. 1. Private E. L., "F," 93d Illinois, age 21, American. Admitted, October 17th, 1863, with chronic diarrhoea. Died, November 13th.

Autopsy: Great emaciation; pleuritic adhesions on left side; a few hard calcareous tubercles in apex of left lung; softened tubercles in upper lobe of right lung; posterior parts of both lungs slightly congested; heart cavities contained partly-washed clots; patches of congestion in stomach and small intestine; large deep ulcers with indurated and jagged edges in colon; mesenteric glands enlarged; gall-bladder distended with thin yellow bile; tumor above described attached to ileum.

Contributed by Assistant Surgeon C. J. Kipp, U. S. Vols., Hospital No. 1, Nashville, Tenn.

- No. 91.** Portion of caecum with appendix vermiformis; numerous tumefactions of connective tissue hardened by calcareous deposits, at extremity of appendix.
D. 2. *See 92, chap. III., sec. 2, A. 1, for history.*

E. Tubercle.

- No. 693.** Portion of omentum, in which several tubercles, the size of millet seeds, are embedded.
E. 1. *See 691, chap. III., sec. 2, D. 7, for history.*
- No. 721.** Portion of omentum, containing a large number of minute tubercles.
E. 2. *See 720, chap. IV., sec. 3, M. 45, for history.*
- No. 778.** Portion of omentum, containing tubercular deposits.
E. 3. J. A. S., mulatto woman, age 20. Admitted, February 6th, 1866. Diagnosis—consumption. Died, March 31st.

Autopsy fifty-four hours after death: Height, five feet; weight, one hundred and ten pounds; rigor mortis in lower extremities, none in upper; some emaciation; small-pox pits upon face; right lung, firmly adherent at all points, infiltrated with tubercle, and contained numerous vomice; left lung, covered with a thick coating of plastic lymph, contained much tubercle and a few small vomice; eight ounces of serum in left pleural cavity; heart fatty; ten ounces of serum in pericardium; nutmeg liver; some tubercle in spleen; Lidsheys tubulated and fatty; entire tract of small intestine exhibited large tubercular ulcers, with ragged irregular edges, penetrating to peritoneal coat, with tubercular deposits on peritoneal surface; caecum showed a large number of small similar ulcers; remainder of large intestine presented follicular ulcers throughout the whole tract, especially in ascending colon; two pints of serum in abdominal cavity; tubercles of omentum; fibrous tumor in uterus.

From Freedman's Hospital, Washington, D. C.

Autopsy by Hospital Steward S. S. Bond.

779, chap. V., sec. 1, A. 2, tubulated kidneys; 780, chap. V., sec. 5, B. 4, fibrous tumor of uterus, are also from this case.

- Nos. 612 and 613.** **612**, some knuckles of femur, with numerous small tubercles connected with peritoneal coat and peritoneal surface of mesentery; there are also numerous peritoneal adhesions. **613**, portion of omentum of same patient, thickened, its fat atrophied, and presented numerous yellow tubercles.
E. 4 and 5. M. A. S., mulatto, age 41. Admitted, September 4th, 1865. She had miscarried the day before admission, at third month of pregnancy; syphilitic cicatrices on external organs of generation; a pustular eruption over body; ringworm eruptions on face. October 24th, much emaciated; too weak to sit up; appetite capricious, sometimes enormous, at others entirely wanting. Died, November 29th.

Autopsy: Height, five feet one inch; weight, about eighty pounds; emaciation extreme; no rigor mortis; tubercle the size of a pea on upper surface of right lobe of cerebellum, near medulla oblongata; both lungs somewhat adherent, lower lobes congested; much pigment in both lungs, and a few miliary tubercles; four ounces of serum in left pleural cavity, two ounces in right; pericardium contained half an ounce of clear serum; heart small and fatty, small white clot in each ventricle, extending into pulmonary artery and aorta; liver small, fatty, and firmly adherent to diaphragm; a few tubercles in each kidney; spleen dotted with deposits of white tubercle the size of peas; deposits of white tubercle on under surface of diaphragm; peritoneal surface of stomach covered with small tubercles, hanging like grapes, with narrow necks; intestines adherent to parietal peritoneum and to each other; a cavity, with walls of dirty-yellow lymph, was formed in lower portion of abdomen immediately over bladder, containing about a pint of fecal matter and pus; uterus enlarged and ulcerated internally and on posterior lip of os; ovaries and fallopian tubes, coated with the same dirty lymph which lined the cavity above described; a few small ulcers, with irregular edges and gray bases, at upper portion of vagina, adjoining os uteri.

From Freedman's Hospital, Washington, D. C.

Autopsy by Hospital Steward S. S. Bond.

611, chap. V., sec. 1, D. 2, tubercles of kidneys; 615, chap. V., sec. 5, A. 3, ulceration of mucous membrane of womb, are also from this case.

- No. 739.** Portion of greater omentum containing numerous minute tubercles.
E. 6. *See 735, chap. I., sec. 2, B. 2, for history.*
- No. 541.** Section through diaphragm, liver, and stomach, which are mutually adherent; numerous oval, flattened masses of cheesy tubercular matter, about the size of almonds, on diaphragm and surfaces of liver and spleen.
E. 7. *See 542, chap. II., sec. 3, C. 1, for history.*
- No. 636.** Portion of peritoneum, taken from a abdominal parietes to right of median line; the surface is the seat of numerous tubercles, which have coalesced in many places into a thick, irregular layer.
E. 8. *See 637, chap. I., sec. 1, E. 6, for history.*

Nos. 727 and 728. **727**, knuckle of small intestine with mesentery attached, showing tubercles of mesentery and a few peritoneal adhesions. **728**, several knuckles of intestine, taken lower down, with peritoneal adhesions and tubercles, and innumerable shreds of false membrane, in which here and there small tubercles are embedded.

E. 9 & 10. See 730, *chap. II., sec. 3, B. 7, for history.*

Nos. 751 to 753. **751**, a few knuckles of small intestine, presenting several pedunculated tubercles, some of which have undergone cretification; in the mesentery is a pultaceous, semi-cretified mass of tubercular matter the size of a pigeon's egg; hanging in the jar, is a similar semi-cretified mass, from another portion of mesentery. **752**,

E. 11 to 13. portion of colon, with meso-colon attached, from the same patient; in the meso-colon, is a mass similar to those in **751**; there are a number of delicate adhesions connected with side of colon. **753**, womb and appendages of same patient, with numerous peritoneal adhesions connected with the ovaries; in these adhesions are several cretified masses similar to those above described.

A. P., colored girl, age 15. Admitted, January 23d, 1866. Diagnosis—serofulous abscess of hip. Died, March 9th.

Autopsy six hours after death: Height, five feet three inches; weight, about sixty pounds; extreme emaciation; rigor mortis partial; abscess, opening over right iliac region, not connected with hip joint; a similar one on left thigh, outer aspect, four inches below great trochanter; bed-sores over back and buttocks; hip joint healthy; slight congestion of posterior portion of right lung, which was somewhat adherent; left lung coated with lymph, posterior portion slightly congested; four ounces of serum in each pleural cavity; right kidney contained a cyst filled with cheesy matter; mesenteric glands much enlarged; peritoneal adhesions, in which and in mesentery and meso-colon were a number of collections of semi-solid tubercular matter, partly cretified; an abscess in sheath of left psoas muscle, connected below with abscess on thigh, above with superficial caries of lower six dorsal and upper three lumbar vertebrae.

From Freedman's Hospital, Washington, D. C.

Autopsy by Hospital Steward S. S. Bond.

754, *chap. V., sec. 5, E. 1, hymen*; 755, *chap. VI., sec. 2, No. 8, tubercular caries of vertebra, are also from this case.*

No. 661. Several knuckles of intestine, beset with numerous thread-like adhesions, and presenting on the peritoneal surfaces of intestines and mesentery a number of tubercles of different sizes.

E. 14. Private D. C., "H," 27th U. S. colored, age 21. Admitted, September 16th, 1865, with phthisis. Died, October 15th.

Autopsy: Right lung with old adhesions, tubercles and lobular pneumonia; left lung with old adhesions and a few tubercles, and at apex a deposit of calcified tubercular matter the size of a walnut; bronchial glands much enlarged; heart small and flabby; tubercles on peritoneal surface of liver; small tubercle in spleen; tubercles on peritoneum; tubercular peritonitis.

Contributed by Surgeon E. Bentley, U. S. Vols., L'Ouverture Hospital, Alexandria, Va.

No. 689. Several knuckles of intestine, with firm peritoneal adhesions, and numerous tubercular masses, the size of peas, on peritoneum.

E. 15. See 688, *chap. III., sec. 2, F. 5, for history.*

No. 635. From middle of ileum, showing a tubercular ulcer, an inch and a half in diameter, on the mucous surface;

E. 16. peritoneal surface covered with numerous tubercles, many of which hang like polypi by narrow necks from the surface.

See 637, *chap. I., sec. 1, E. 6, for history.*

No. 761. Portion of ileum, taken just above ileo-caecal, showing a number of tubercles on peritoneal surface.

E. 17. W. C., mulatto, age 27. Admitted, November 28th, 1865, with contused wound of face; was on light duty in hospital until March 16th, 1866, when he was attacked with chills and fever, paroxysms returning every day until death. Died, November 19th.

Autopsy twenty-four hours after death: Height, five feet eight inches; weight, about one hundred and thirty pounds; some emaciation; rigor mortis partial; both lungs contained miliary tubercles, congested posteriorly and coated with lymph; two ounces of fluid in right pleural cavity; bronchial glands enlarged and tubercular; pericardium contained twelve ounces of serum; liver contained miliary tubercles; right lobe firmly adherent to diaphragm; spleen filled with tubercles; mucous coat of small intestine thickened and congested; solitary follicles of ileum enlarged; numerous tubercles on peritoneal surface; thickening of mucous coat and pigment deposit throughout entire tract of colon; in lower colon a few healed ulcers.

From Freedman's Hospital, Washington, D. C.

Autopsy by Hospital Steward S. S. Bond.

765, *chap. IV., sec. 5, E. 7, tubercles of liver, is also from this case.*

No. 626. Small section of upper posterior portion of right lobe of liver, embedded in the surface of which are a number of cheesy tubercles, about the size of almonds, connected with the peritoneal coat.

E. 18. See 624, *chap. III., sec. 2, F. 2, for history.*

E. Cancer.

No. 157. Section through liver, spleen, and stomach; anterior edge of left lobe of liver and lower edge of spleen fused together by a cancerous growth; upper surface of stomach connected with lower surface of liver by bands of pseudo-membrane.

Private A. B., "K," 2d Connecticut Heavy Artillery, age 40. Admitted, October 5th, 1864. Diagnosis—phthisis. There was decided flattening of right side of chest, with dullness on percussion over right lung; some expectoration of a dark mucopurulent matter; trunk and lower extremities oedematous; appetite good; bowels costive; skin dry, but of natural temperature. Died, November 13th.

Autopsy eleven hours after death: Rigor mortis firm; no emaciation; a gelatinous tumor, the size of a large pea, embedded in right hemisphere, near posterior edge of corpus callosum; in inferior horn of each lateral ventricle was a cystic tumor, size of a nutmeg; heart pressed towards left side; firm adhesions of both pleure; the left pleural cavity containing about four ounces of bloody serum, the right nearly obliterated by adhesions; in upper lobe of left lung and throughout right lung were numerous small cancer nodules; omentum the seat of a cancerous formation of considerable size, in the growth of which it had shrunken and become thickened, contracting adhesions with adjacent parts till it had formed an irregular mass, adherent to whole length of anterior edge of liver and anterior edge of spleen; the cancerous mass surrounded pyloric extremity of stomach, which however had contracted no adhesions to it, and was also connected closely with the colon; there were many peritoneal adhesions; stomach and intestines normal, as were also the liver, spleen, pancreas, and kidneys; no cancer nodules observed in any of these organs.

Contributed by Surgeon E. Bentley, U. S. Vols., General Hospital, Alexandria, Va.

No. 687. Large cephaloid tumor of omentum; weight, three and a half pounds.

F. 2. *See 686, chap. II., sec. 3, C. 2, for history.*

Nos. 617 and 618. **617.** several knuckles of small intestine, the peritoneal surface of which presents adhesions and numerous nodules of cancer about the size of peas. **618.** piece of omentum from same patient, almost devoid of fat, and containing a number of cancer nodules.

F. 3 & 4. H. W., dark mulatto girl, age 18. Admitted, August 2d, 1865. Died, November 8th.

Autopsy: Osteophytes in the Pacchionian granulations; four ounces of serum in pericardium; both lungs adherent, with a few cancer nodules scattered through their substance, and numerous similar nodules on pleural surfaces; four ounces of bloody serum in left pleural cavity; liver adherent to diaphragm, with cancer nodules scattered over its surface and through its substance, which was congested; spleen small, contained cancer nodules throughout its substance; omentum as in specimen; stomach, intestines, and mesentery bound by adhesions into one conglomerate mass, with cancer nodules embedded in the adhesions and on peritoneal surface; mesenteric glands very large; uterus ulcerated; both ovaries converted into carcinomatous masses, in each of which was a cyst, the size of an orange, filled with a creamy fluid; that on the left side was firmly adherent to the intestines, and was ruptured in removing it from the body.

From Freedman's Hospital, Washington, D. C.

Autopsy by Hospital Steward S. S. Bond.

646 chap. V., sec. 5, C. 5, cancer of uterus and ovaries, is also from this case.

Section 5. LIVER.

A. Anomalies of form.

No. 672. Portion of liver, showing an unusually large pons hepatis.

A 1 S. S., color 1, age 72. Died, November 29th, 1865, of valvular disease of heart.

From Freedman's Hospital, Washington, D. C.

Autopsy by Hospital Steward S. S. Bond.

No. 723. Liver, the upper surface of which has a number of deep grooves, giving it a lobulated appearance.

A 2 *See 722, chap. II., sec. 2, B. 5, for history.*

B. Cirrhosis.

- No. 209.** Cirrhoted liver, small, nodulated; interlobular connective tissue well developed; weight thirty-six ounces.
B. 1. No history.
 Contributed by Acting Assistant Surgeon L. Wells, Seminary Hospital, Georgetown, D. C.
- No. 351.** Cirrhoted liver, seven and a half by six and one-fourth by three and a half inches; weight, fifty-one ounces.
B. 2. Corporal H. D., "K," 106th Pennsylvania. Died, July 14th, 1864, from gunshot wound of right shoulder, for which resection of head of humerus had been performed.
 Autopsy: Pleuritic adhesions of right lung; spleen enlarged and firm; fibrinous clots in both ventricles of heart; liver small and cirrhoted.
 Contributed by Acting Assistant Surgeon H. M. Dean, Lincoln Hospital, Washington, D. C.
- No. 415.** Antero-posterior section through right lobe of a cirrhoted liver; interlobular tissue very much developed and surface of liver nodulated; the organ has shrunk to about one third the normal size.
B. 3. No history.
 Contributed by Acting Assistant Surgeon Fred. Schafhirt.
- Nos. 450 and 451.** **450**, central portion of liver, in a condition of well-marked cirrhosis. **451**, small section of right lobe of same liver, in a similar condition.
B. 4 and 5. Private J. H. V., "D," 6th New York Heavy Artillery, age 37. Admitted, June 30th, 1864, with pneumonia. Died, July 24th.
 Autopsy: Gray hepatization of lower part of right lung; fibrinous clot in right ventricle of heart; liver as in specimen.
 Contributed by Acting Assistant Surgeon H. M. Dean, Lincoln Hospital, Washington, D. C.

C. Abscess.

- No. 333.** Portion of right lobe of liver, presenting numerous large, irregular, communicating abscess-cavities.
C. 1. Private D. O'K., "F," 6th Maine, age 45, Irish. Admitted, December 18th, 1862, with intermittent fever. Died, January 22d, 1863, of peritonitis.
 Autopsy: Body exceedingly emaciated; skin tinged with bile; heart and pericardial serum tinged with bile; right auricle and ventricle each with a white opaque membranous patch on its surface the size of a quarter-dollar; lungs with old adhesions throughout, but otherwise healthy; liver enormous, extending down front of abdomen so as to cover half the remaining contents, its surface dull-brown and coarse y nodulate; right lobe presented a large multilocular abscess, containing a pint or more of thick, greenish, yellow pus, left lobe contained a smaller similar abscess; gall-bladder very small, filled with bile resembling coal-tar in color and consistence; peritonitis; small and large intestines covered with thin, recent, pseudo-membranous matter; spleen small; ileum with mucous membrane considerably inflamed and blackened; colon exceedingly contracted, not more than three-fourths of an inch in diameter in the middle of its course, and all appearance of sacculi obliterated, its mucous membrane greenish-black, with streaks of inflammation and a few ecchymosed spots; intestines contained a small quantity of brownish mucus, which was exceedingly fetid.
 Contributed by Acting Assistant Surgeon J. Leidy, Satterlee Hospital, Philadelphia, Pa.
- No. 435.** Portion of liver, presenting on its upper surface an abscess the size of a child's head.
C. 2. See 433, chap. III., sec. 2, C. 5, for history.
- No. 501.** Portion of liver, with an abscess which has opened on its diaphragmatic surface and formed a cavity lined by pseudo-membrane between diaphragm and liver; it discharged externally between tenth and eleventh ribs; a portion of integument remains around external orifice; a portion of ascending colon and right kidney attached to piece show the general position of abscess.
 Private F. B., "H," 13th Wisconsin, age 19. Admitted, December 7th, 1864, with acute hepatitis. Died, January 14th, 1865.
 Contributed by Surgeon H. Culbertson, U. S. Vols., Harvey Hospital, Madison, Wis.

No. 668. Portion of right lobe of liver, showing two large abscess-cavities on its upper surface.
C. 4. Private P. R., "I," 1st Veteran Reserve, age 41. Admitted, September 30th, 1865. He had suffered from chronic diarrhoea for several months, and was much emaciated; stools from six to ten, daily. October 18th, complained of violent pain, apparently in the kidneys. Died, October 21st.

Autopsy: Hypostatic congestion of posterior parts of both lungs; four ounces of bloody serum in right pleural cavity; right lobe of liver, adherent to abdominal walls, presented three abscesses, each containing about four ounces of thick flaky pus; spleen very large and soft; colon ulcerated throughout, some ulcers very large and penetrating to muscular coat.

Contributed by Assistant Surgeon De Witt C. Peters, U. S. Army, Post Hospital, Fort McHenry, Md.

No. 669. Portion of right lobe of liver, in upper surface of which is a large abscess-cavity the size of a child's head.
C. 5. History—(Medical Cadet H. C. Morrison): Private J. S. B., "H," 1st U. S. Vols., age 45. Admitted, November 2d, 1865. He stated that about two weeks before, he had a chill on each of two successive days,

the chills preceded by a feeling of languor and disinclination for exertion, anorexia, etc. When admitted he was in a state of prostration and anxiety, with faltering voice; respiration 34 per minute; pulse 81 and weak; tongue dry, and slightly covered with a brown fur and with tip and edges red; tympanites and tenderness in right iliac fossa; a pain in right side; bowels somewhat constipated. 4th, somewhat weaker; had slight diarrhoea; stools thin and slimy; troubled with a cough; expectoration slightly stained with blood; some pain in stomach. Died, November 1th. There was no jaundice during the progress of the case.

Autopsy twelve hours after death: Rigor mortis well marked; much pigment in lungs and bronchial glands; lower lobe of right lung firmly adherent to diaphragm; liver greatly enlarged, so that the diaphragm was pushed up to third rib; a large abscess in right lobe, containing forty ounces of thick flaky pus; remainder of liver showed no disease; spleen small and very soft; intestines congested in several places, and Peyer's glands somewhat thickened, but not ulcerated, nor could any ulcers be found elsewhere in the intestinal tract.

Contributed by Assistant Surgeon De Witt C. Peters, U. S. Army, Fort McHenry, Baltimore, Md.

No. 742. Central portion of liver, with abscess-cavities and lymph adherent to surface.

C. 6. Private L. R., age 50, intemperate, German, formerly a wealthy merchant of Rio Janeiro, four years in the United States, and over two in the army. Admitted, November 25th, 1865, having been indisposed for several weeks; he was very weak and anemic; of a pale yellowish waxy hue; gums pale; skin flabby, dry and harsh; abdomen much swollen and pendulous; hepatic dullness extending upwards to right nipple, and but little below edge of ribs; great emaciation, fullness and weight in region of liver, pain and tenderness upon pressure when breathing deeply or coughing; was unable to lie on right side; frequent, short and dry cough; thirst; anorexia; eructations of wind; had had no passage from bowels for eight days. 26th, felt easier, but had a sharp pain following each deep inspiration or cough. 28th, could lie on right side, pain and cough having much decreased; abdomen less hard but still distended; no thirst; appetite poor; mind depressed; patient morose. December 2d, appetite improved; weakness increased; frequent hiccough; light and insufficient sleep. 12th, weakness much increased; unable to get up without help; complained several times of feeling chilly; cheeks and eyelids oedematous; tongue dry; complete anorexia; very somnolent; a large tumor in right hypochondrium, extending downwards below line of naval, feeling rather soft and not distinctly limited, tender on pressure; integuments oedematous; stools consisted of small clay-colored lumps, mixed sometimes with a little blood and a few drops of a puriform fluid. 13th, tumor extended down into hypogastrium and was the seat of dull aching pain; patient rapidly sinking. Died, December 14th.

Autopsy: Extensive hypostatic congestion of dependent parts; abdominal integuments oedematous, and very fatty; extremities emaciated; on opening peritoneal cavity a brownish pus poured out mixed with blood, the quantity of this fluid in the peritoneal cavity amounting to about sixteen pints; mesentery, intestines and omentum coated with and adherent by abundant layers of organized lymph; transverse colon as low down as umbilicus; liver adherent; between liver and diaphragm a large sac containing pus, elevating diaphragm as high as nipple; left lobe of liver enlarged, nearly reaching to spleen, fatty, and rather soft, and of yellowish color; on superior surface of right lobe was an unopened abscess, four and three-eighths inches in diameter, containing thick pus, close to which and separated only by a very thin wall, was a second abscess, with an opening the size of a half-dollar communicating with peritoneal cavity; the pus of this abscess was of the same character as that found in the abdomen, the abscess four and five-eighths by five and three-fourths inches in diameter, irregular, and lined with a thick pseudo-membrane; spleen small and shrunken; its coat wrinkled; edges somewhat indented.

Contributed by Surgeon S. Kneeland, U. S. Vols., Post Hospital, Mobile, Ala.

D. Metastatic foci.

No. 117. Section of right lobe of liver, presenting a number of abscess-cavities, about the size of a walnut, which contained thin pus.

Captain G. McC., militia, "C," 31st U. S. Colored, age 36. Admitted, August 9th, 1861, with gunshot wound of left hand and another of hip; had existed about February 1st, 1861, and shortly afterwards was attacked with cancer which continued with occasional intermission up to date of admission. Wounds healed kindly with simple dressings, but cancer continued and typhoid symptoms set in with obstinate hiccough. Died, October 8th. The condition of the soft parts mucous membrane was, unfortunately, not recorded.

Contributed by Surgeon E. Bentley, U. S. Vols., General Hospital, Alexandria, Va.

- No. 295.** Portion of liver, presenting a number of metastatic foci.
D. 2. Musician J. P., 14th U. S. Infantry, age 16. Died, April 11th, 1864, after an illness of eighteen days. He joined the regiment on the 24th of the previous month, having been exposed to the severities of a snowstorm, and sleeping in the snow on the road. From the 31 of April, the date of admission, he had colliquative diarrhoea accompanied by quotidian chills, but no nausea nor vomiting.
 Autopsy: Metastatic foci in liver; pericarditis; extensive peritonitis; other organs apparently healthy.
 Contributed by Assistant Surgeon E. DeW. Breneau, U. S. Army, Army of the Potomac.
- No. 119.** Section of right lobe of liver, containing numerous metastatic foci from a quarter to half an inch in diameter.
D. 3. See 448, chap. IV., sec. 3, L. 106, for history.
- No. 850.** Two portions of liver; the upper one presents on its superior surface, about two inches from anterior edge, near attachment of suspensory ligament, an abscess-cavity about an inch in diameter; this had discharged into the peritoneal cavity between liver and diaphragm, the pus being limited by subsequent peritonitis; an abscess-cavity of large size had thus formed, a part of the walls of which cover upper surface of piece. The lower portion is a section of right lobe of liver, with several metastatic foci.
 History—(Acting Assistant Surgeon W. H. Grafton): Sergeant S. C., "A," 12th United States Infantry. Admitted, November 22d, 1866, from Camp Angur. He complained of colic, to which he stated he had been subject periodically for several years; had previously been treated in this hospital for diarrhoea; was weak; anorexia complete; great pain in abdomen. 25th, had a spell of vomiting. December 3d, hepatic abscess diagnosed; had troublesome and painful cough. 8th, restless and feverish. 20th, tumor over region of liver, very prominent and painful; on being punctured, discharged slightly. 21st, a greater discharge of liver-colored matter was obtained. 26th, hectic fever appeared. From this time patient's strength gradually failed. Diarrhoea set in on the 31st; rigors and exacerbation of fever at irregular intervals; opening was enlarged and gave exit to clots of coagulated blood and fibrinous matter. January 2d, 1867, gangrenous action set in at abscess-opening, and gradually spread. Died, January 7th.
 Autopsy: Viscera, except liver, healthy; liver presented the abscess described and numerous metastatic foci, varying in size from one-fourth to one inch in diameter, of yellow color, and consisting microscopically of granules and debris of liver tissue; matter from the abscess had burrowed its way under the integument four inches toward the right side, deoiding the under surface of sixth rib of periosteum; there were firm adhesions to diaphragm and parts adjacent to opening.
 Contributed by Assistant Surgeon W. Thomson, U. S. Army, Post Hospital, Washington, D. C.

E. Tubercle.

- No. 628.** Section of liver, showing a number of small cavities, the contents of which were cheesy, with moderately firm cheesy walls.
E. 1. Private R. B., "C," 11th Vermont, age 45, Irish. Admitted, September 12th, 1864, with fever; rapid pulse; dry, furred tongue; great dyspnoea and marked constitutional depression, with dullness on percussion and bronchial respiration over both lungs. Died, September 18th.
 Autopsy: Both lungs congested, and presented abundant tubercular deposits; tubercular abscesses in liver.
 Contributed by Assistant Surgeon H. S. Schell, U. S. Army, Cuyler Hospital, Germantown, Pa.
- No. 614.** Left lobe of liver, presenting numerous tubercles in connection with its peritoneal coat and scattered through its substance.
E. 2. S. M., colored girl, age 15. Admitted in September, 1865, with phthisis pulmonalis; very much emaciated; prostrated; pulse 115 and very feeble; tongue moist; tympanites, and tenderness on pressure over abdomen; night sweats. Died a few days subsequently.
 Autopsy: Great emaciation; right lung firmly adherent; tubercles in both lungs, most abundant in right; pericardium distended with serum; tubercles in liver, spleen, and kidneys.
 From Freedman's Hospital, Washington, D. C.
 Autopsy by Acting Assistant Surgeon W. Ellis.
 615, chap. V., sec. 1, D. 3, *tubercles of kidney, is also from this case.*

- No. 690.** Small section of right lobe of liver, showing two tubercles about the size of peas.
E. 3. S. T., negro, age 27. Admitted, September 9th, 1865. Had a hard tumor on anterior border of trapezius muscle of right side; stiff neck; swimming of head; thick yellowish coating on tongue; obstinate constipation. November 6th, unable to sit up on account of pain in head and neck. Died, November 9th.
 Autopsy five hours after death: Height, five feet ten inches; weight, one hundred and sixty pounds; no emaciation nor rigor mortis; venous congestion of cerebral membranes; about an ounce of fluid beneath arachnoid; medulla oblongata softened and bathed in pus, which ran out to the amount of three ounces on depressing the head; pericardium contained one

ounce of serum; left lung slightly adherent; liver weighed eighty ounces, very large, of bluish-purple color; contained several tubercles about the size of peas; spleen shriveled, contained several yellow tubercles; Peyer's patches presented shaven-board appearance.

From Freedman's Hospital, Washington, D. C.

Autopsy by Hospital Steward S. S. Bond.

- No. 695.** Small section from right lobe of liver, showing numerous minute tubercles on cut surface and peritoneum.
E. 4. See 694, *chap. II., sec. 3, A. 2, for history.*
- No. 738.** Portion of left lobe of liver, with tubercles from the size of a pin's head to that of a pea.
E. 5. See 735, *chap. I., sec. 2, B. 2, for history.*
- No. 763.** Section of liver, with small tubercles scattered through its substance.
E. 6. See 762, *chap. IV., sec. 3, D. 26, for history.*
- No. 765.** Section of right lobe of liver, with miliary tubercles scattered through its substance.
E. 7. See 764, *chap. IV., sec. 4, E. 17, for history.*
- No. 867.** Irregular calculus, probably a crested tubercle, nearly an inch in diameter, composed chiefly of carbonate of lime, from middle superior portion of right lobe of liver of a paroled prisoner, who died, March 25th, 1865, of cerebro-spinal meningitis.
E. 8.
- Contributed by Assistant Surgeon Geo. M. McGill, U. S. Army, Hicks Hospital, Baltimore, Md.

F. Cancer.

- Nos. 215 and 216.** Two sections of liver, **215** presenting a considerable number of large nodules of soft cancer; in **216**, which is the right extremity of right lobe, the central portion of a large medullary mass had softened into a pus-like fluid, which escaped on making section, leaving irregular cavities in specimen. The tumors consisted chiefly of small polygonal and triangular, irregular nucleated cells; fibrous stroma scanty.

F. 1 & 2. History—(Acting Assistant Surgeon J. C. Nelson): Private T. S., 6th Rhode Island Battery. Admitted, July 30th, 1863; complained of pain and tenderness in hepatic region; conjunctiva and general surface of skin jaundiced; suffered from nausea, vomiting, and slight diarrhoea; right hypochondrium and epigastrium tumefied; liver enlarged and nodulated. The patient stated that he had suffered no inconvenience until a few weeks before admission when he began to feel weight and pain in abdomen. August 29th, oedema of lower extremities had supervened, which, however, did not become extreme. 27th, comatose, with small pulse, slow respiration, and cold extremities. Died, August 29th.

Autopsy: Liver weighed thirteen pounds, filled with cancerous tumors varying in size from that of a robin's egg to that of an orange, the interior of the largest softened into a pus-like fluid; intestines somewhat contracted, with thickening of coats; other viscera healthy.

Contributed by Assistant Surgeon C. A. McCull, U. S. Army, Mount Pleasant Hospital, Washington, D. C.

- Nos. 292 to 294.** **292**, section of left lobe of liver, the hepatic tissue almost entirely replaced by cancerous masses. **293**, from left extremity of right lobe, from same patient, in a similar condition. **294**, from right portion of right lobe, from same patient, the quantity of hepatic tissue much larger, but filled with numerous tumors varying in size from that of a pea to that of an egg.
F. 3 to 5. See 294, *chap. IV., sec. 2, C. 2, for history.*

- No. 321.** Central portion of liver, in which are embedded a number of large medullary nodules; a medullary tumor, **F. 6**, four inches in long diameter, oval, smooth, and nodulated, lies just below the portal vein.

Rev. L. M., late Chaplain 12th Wisconsin; resigned chaplaincy about seven months before death on account of ill health; had suffered before resignation with chronic diarrhoea; when seen a few days before death, had dull pain in epigastric region; occasional vomiting; indigestion and emaciation; enlarged area of hepatic dullness, extending to umbilical region; constipation; sallow complexion; taxis showed the liver to be enlarged, with nodules on its surface, and also a well-defined tumor in umbilical region. The patient stated that the disease had progressed rapidly within the last three months. Died, May 21st, 1864.

Autopsy, May 23d: Liver enlarged on its anterior surface by several round and slightly elevated tumors, each about an inch and a quarter in diameter, with a few vessels ramifying over the surface; these bodies were a little harder than the liver structure, their centres were softened, and yielded, on scraping, a soft white matter, in which the microscope showed numerous cells containing nuclei, and granules were seen; on applying acetic acid, the cell walls were dissolved, the nuclei remaining unchanged; the same disease was present in the pylorus, involving duodenum, a portion of upper part of mesentery and transverse colon; mesenteric glands not enlarged; stomach distended with a coles-ground fluid.

Contributed by Surgeon H. Culbertson, U. S. Vols., Hurvy Hospital, Madison, Wis.

Nos. 538 and 539. **538.** liver, filled with numerous large medullary masses; its weight, after having been some time in alcohol, was nine pounds eight ounces. **539.** a plaster cast of same liver, colored after nature.
See 537, chap. IV., sec. 2, C. 6, for history.

F. 7 and 8.

No. 697. Portion of left lobe of liver, containing several nodules of scirrhus cancer, the largest about the size of a plum.
F. 9. J. S., light mulatto, age 41. Admitted, January 5th, 1866. Diagnosis—bilious diarrhea. Died, January 7th. Autopsy forty-eight hours after death: Rigor mortis well marked; height, five feet six inches; weight, about one hundred and twenty pounds; some emaciation; membranes of brain slightly congested; extravasation of blood on upper portion of left middle lobe beneath pia mater; right lung contained much pigment; upper lobe hepaticized; contained a large vomica and much tubercle, posterior portion of lower lobe congested; ten ounces of fluid in right pleural cavity; posterior portion of left lung congested; contained much pigment and tubercle; three ounces of fluid in left pleural cavity; pericardium contained three ounces of fluid; heart fatty, small white clots in all its cavities; liver adherent at all points, weight sixty-eight ounces, very fatty, and contained numerous masses of white matter throughout its whole substance, varying in size from a pea to a large plum, and composed chiefly of nucleated cells of irregular shape and moderate size; spleen adherent, very soft, dark, reddish brown; kidneys fatty; stomach and small intestine congested; Peyer's patches presented shaven beard appearance; caecum presented numerous follicular ulcers.

From Freedman's Hospital, Washington, D. C.

Autopsy by Hospital Steward S. S. Bond.

No. 571. Section of liver, with several melanotic masses, the largest the size of a walnut, from the same patient as
F. 10. No. 396 in the Boston Medical Society's Museum. *For history of case, see American Journal of Medical Science, for 1848.*

Contributed by Dr. J. B. S. Jackson, on behalf of Museum of Medical Society, Boston, Mass.

No. 829. Section of liver, presenting several melanotic nodules, the largest over three-fourths of an inch in diameter.
F. 11. *See 824, chap. II., sec. 3, C. 3, for history.*

G. Cysts.

No. 639. Perpendicular section through right lobe of liver, showing a great number of cysts and sinuous passages, the largest nearly a quarter of an inch in diameter; these are dilated gall-ducts, which, in the recent specimen, contained a yellowish serum-like fluid.

G. 1. History—(Acting Assistant Surgeon S. D. Twining): Private C. L., "G," 23d U. S. Colored, age 21. Admitted, October 20th, 1865. Diagnosis—intermittent fever. 21st, some fever, a decided chill in the afternoon. 22d, some fever during the day with feeble pulse, no chill. 23d, pulse 100. 24th, pulse 120, quick and full; skin hot and dry; slight muttering delirium; restless; wakeful; respiration 60 per minute; urine dark, with much sediment; bowels constipated. 25th, pulse quick and jerking; did not sleep; bowels constipated. 26th, sleepless; tongue dark brown and coated; respiration 62 per minute; delirium; bowels moved last night, stools thin and yellow; abdominal tenderness; tympanites; jaundice appearing. 27th, pulse 110 and weaker; bowels constipated; tongue dry and brown; slept a little toward morning. Died, October 28th.

Autopsy: Effusion into ventricles of brain; some serum in left thoracic cavity; some thickening of Peyer's patches; the rest of the intestines normal; liver large, right lobe completely honeycombed by dilated gall-ducts, which contained a serum-like liquid; left lobe normal, but stained with bile; gall-bladder small, containing some viscid bile, the rugae of its mucous surface unusually prominent.

Contributed by Surgeon E. Bentley, U. S. Vols., Slough Hospital, Alexandria, Va.

No. 641. Portion of anterior edge of liver, with gall-bladder attached; on anterior edge, between right lobe and gall-bladder, is a cyst the size of a horsechestnut, which contained a yellowish semi-solid substance, in which the microscope showed, besides abundant granules, numerous echinococcus claws.

J. A., light mulatto, age 51. Admitted, October 23d, 1865. Diagnosis—intermittent fever, general debility and incontinence of urine. Died, November 11th.

Autopsy four hours after death: Height, five feet ten inches; weight, about one hundred and twenty pounds; rigor mortis partial; no emaciation; two ounces of serum in pericardium; heart flabby; liver contained the cyst described; spleen small; calcareous deposits in mesenteric glands; both kidneys enlarged; the right about the size of a child's head, its cavity distended with pus, giving off two ureters, which were enlarged and filled with pus; the left kidney about half as large as right, with its cavity and ureter also distended with pus; bladder much thickened and distended with pus; prostate gland enlarged; membranous portion of urethra, unfortunately, not examined.

From Freedman's Hospital, Washington, D. C.

Autopsy by Hospital Steward S. S. Bond.

640, chap. V., sec. 3, A. 5, *distended kidneys and bladder, double ureter on right side, is also from this case.*

II. Diseases of gall-bladder.

- No. 37.** Gall-bladder, considerably distended.
H. 1. Private J. F. "L." 14th Pennsylvania Cavalry, age 52. Admitted July 25th, 1863, with delirium tremens and diarrhoea. Died August 3d.
 Autopsy: Abscess in lower lobe of right lung; liver hypertrophied; gall-bladder enormously enlarged (from six to eight inches long); ileum ulcerated and presented a perforation.
 Contributed by Assistant Surgeon De W. C. Peters, U. S. Army, Jarvis Hospital, Baltimore, Md.
- No. 658.** Portion of liver, showing greatly enlarged gall-bladder, which projects two inches beyond anterior edge of organ.
H. 2.
See 656, chap. IV., sec. 3, H. 1, for history.

I. Biliary calculi.

- No. 173.** Oval biliary calculus, flesh-colored externally, internally a number of concentric layers, some about the same color as external surface, others lighter; weight, 3.3295 grammes; specific gravity, 1.067, 1.09; composition, cholesterolin.
I. 1.
 From the gall-bladder of Private J. D. H. "K," 33d Massachusetts, age 27. Died, November 28th, 1863, of pyæmia consecutive to an amputation for gunshot wound.
 Contributed by Assistant Surgeon C. J. Kipp, U. S. Vols., Hospital No. 1, Nashville, Tenn.
- No. 171.** Three slate-colored biliary calculi, the largest about the third of an inch in diameter, of irregular polygonal shape, composed chiefly of cholesterolin.
I. 2.
 From the gall-bladder of Private N. J. O., 42d Alabama (Rebel), who died January 29th, 1864, from a gunshot wound.
 Contributed by Assistant Surgeon C. C. Byrne, U. S. Army, Field Hospital, Chattanooga, Tenn.
- No. 175.** Fragments of biliary calculus the size of a hazel-nut, iron-rust color externally; grayish white and glistening internally; composition chiefly cholesterolin.
I. 3.
 Contributed by Acting Assistant Surgeon J. Leidy, Satterlee Hospital, Philadelphia, Pa.
- No. 176.** A number of fragments of a biliary calculus passed by stool; in an attached phial is a small quantity of purified cholesterolin obtained from some of the fragments.
I. 4.
 From a medical man who has suffered from a number of attacks of hepatic cholæ.
 Analysis, by Professor Worndley, Columbus, Ohio, of one of the calculi passed by this patient, gave the following: Cholesterolin, 5.3; biliary resin, 3.7; coloring matter, 7.6; earthy salts, 3.1.
 Contributed by Surgeon J. Y. Cantwell, 82d Ohio.
- No. 177.** Oval biliary calculus, three-fourths of an inch in diameter, from the gall-bladder of a dissecting-room cadaver;
I. 5. it is brown and somewhat nodulated externally, and presents mottled yellowish and brownish concentric layers; composition chiefly cholesterolin.
- No. 853.** Eleven biliary calculi, the largest the size of a hazel-nut, removed from the gall-bladder after death; the calculi present irregular facets, and were composed chiefly of cholesterolin.
I. 6.
See 552, chap. II., sec. 1, H. 5, for history.

Section 6. PANCREAS.

A. Cancer.

- No. 830.** Portion of pancreas, presenting a number of melanotic nodules, the largest about the size of a pea.
A. 1. See 824, chap. II., sec. 3, C. 3, for history.

Section 7. SPLEEN.

A. Anomalies of form.

- No. 306.** Spleen presenting on its covered edge four deep fissures, giving it a lobulated character.
A. 1. From an American 21 years of age.
 Contributed by Surgeon E. Bentley, U. S. Vols., General Hospital, Alexandria, Va., Third Division.
 305, chap. V., sec. 1, A. 1, *lobulated kidney, is also from this case*
- No. 531.** Deeply lobulated spleen, with six supernumerary spleens attached; the latter vary from one inch to less than half an inch in diameter.
A. 2. Private H. P., "I," 146th New York, German, age 31. Died, April 21st, 1865, after resection of hip performed for gunshot fracture of left femur.
 See 3235, XII, A. v. d. 11, *Surgical Section*.
 Contributed by Assistant Surgeon W. F. Norris, U. S. Army, Douglas Hospital, Washington, D. C.
- No. 412.** Two supplementary spleens, about the size of shell-barks; found one just above, and the other just below the true spleen.
A. 3. Private S. E. A., "G," 1st Maryland Heavy Artillery. Died, July 31st, 1864, of pyæmia consecutive to a gunshot wound received before Petersburg, Va.
 Contributed by Surgeon E. Bentley, U. S. Vols., General Hospital, Alexandria, Va., Third Division.
- No. 836.** Spleen, somewhat enlarged, five inches long, with two supernumerary spleens, each about an inch and a half in diameter.
A. 4. Private G. H., "E," 31th Indiana, age 30. Admitted, December 15th, 1865, with scurvy. Died, January 22d, 1866.
 Contributed by Assistant Surgeon Ira Perry, 9th U. S. Colored, Post Hospital, Brownsville, Texas.

C. Hypertrophy.

- No. 26.** Spleen of a patient who died of typhoid fever, macerated and washed to remove the pulp; many Malpighian corpuscles of the size of small shot, can be observed; the spleen was large and soft.
C. 1. Contributed by Assistant Surgeon J. W. S. Goutley, U. S. Army.
- No. 62.** Enlarged spleen, nine by five and a half by two and a half inches.
C. 2. See 00, chap. IV., sec. 3, E. 50, for history.
- No. 109.** Enlarged spleen, seven and a half by five by three inches, with some peritoneal adhesions about its lower part.
C. 3. See 107, chap. IV., sec. 3, D. 10, for history.
- No. 106.** Enlarged spleen, seven by four by one and a half inches.
C. 4. See 102, chap. IV., sec. 3, F. 4, for history.
- No. 111.** Enlarged spleen, seven by five by two and a half inches.
C. 5. See 112, chap. IV., sec. 3, E. 18, for history.

B. Atrophy.

No. 716. Spleen, extremely small, weighing half an ounce.

B. 1. H. N., colored, age 21. Admitted, December 16th, 1865. Diagnosis—pleurisy. Died, February, 26th, 1866.

Autopsy forty hours after death: Height five feet ten inches, weight about one hundred and fifty pounds; rigor mortis partial: both lungs adherent posteriorly, coated anteriorly with thick yellow lymph, which also lined the pleura costalis: an ounce of serum in each pleural cavity: pericardium contained six ounces of clear serum: heart large and fatty, fibrinous clot in right auricle: liver large, its surface bronzed, a reddish-brown on section: spleen very small; kidneys fatty; slight thickening of Peyer's patches in lower portion of ileum.

From Freedman's Hospital, Washington, D. C.

Autopsy by Hospital Steward S. S. Bond.

No. 712. Atrophied spleen, weighing about two ounces.

B. 2. Private N. D., "C," 5th U. S. Colored, mulatto. Was attacked by scurvy two weeks after landing at Brazos, Texas. Had sore mouth, swelled legs, and a few sores on legs; these symptoms were much improved

by the use of the American aloë, till October 1st, when diarrhoea set in. November 1st, 1861, was admitted to my ward; he was weak, confined to bed, and had eight to twelve evacuations daily. 25th, seemed to be failing; discharges few; appetite poor; pains in back, hips, arms, wrists and neck; abdomen tender on slight touch, but bore pressure; pulse 68; mouth and throat dry and bluish. Died, December 7th.

Autopsy: Emaciation; abdomen flat; extreme attenuation of pulmonary and aortic valves; spleen weighed less than two ounces, of a red color; the last fifteen inches of ileum narrow, only three-fourths of an inch in diameter; mucous membrane thickened and red; caput coli pale; ascending colon slightly dilated; remainder of large intestine contracted to about an inch in diameter; mucous membrane of a bluish tinge, no signs of ulceration; mesenteric glands enlarged.

Contributed by Assistant Surgeon Ira Perry, 9th U. S. Colored, Post Hospital, Brownsville, Texas.

D. Diseases of capsule.

No. 55. Spleen, on the surface of which are the remains of numerous peritoneal adhesions.

D. 1. *See 56, chap. IV., sec. 3, L. 39, for history.*

No. 710. Spleen, slightly enlarged, with thickened capsule and peritoneal adhesions.

D. 2. Private S. S., "D," 19th U. S. Colored. Landed at Brazos, Texas, in July, 1865, suffering from scurvy in a mild form, which gradually increased in intensity. August 10th, gums turgid, almost covering teeth, bled easily. During October these symptoms of scurvy disappeared. 29th, admitted with chronic diarrhoea, which continued, checked at intervals, with occasional bloody stools; poor appetite; thirst. Died suddenly, November 27th.

Autopsy: Aortic valves very much attenuated; abdomen contained four ounces of reddish serum; peritoneum thickened, completely adherent to abdominal viscera; liver, stomach, spleen, bowels, kidneys and bladder formed one semi-solid mass, the adhesions interspersed with white roundish tubercles one-eighth to one-fourth of an inch in diameter; gall-bladder contained half an ounce of bile; kidneys enlarged one-third and thick; mesenteric glands enlarged; no ulceration of intestines.

Contributed by Assistant Surgeon Ira Perry, 9th U. S. Colored, Post Hospital, Brownsville, Texas.

No. 782. Spleen, presenting several puckered cicatrices, especially on its convex surface.

D. 3. B., mulatto. Died, April 5th, 1866.

Autopsy: Anasarca; a number of osteophytes in pacchionini granulations; two ounces of serum in right pleural cavity; six ounces of bile in pericardium adherent to heart, firm white clots in ventricles; nutmeg liver; spleen light and coarse, with several central like depressions; kidneys fatty; Peyer's patches thickened, one or two of them ulcerated; urinary tubercles of ileum enlarged.

From Freedman's Hospital, Washington, D. C.

Autopsy by Hospital Steward S. S. Bond.

No. 581. Small portion of spleen, presenting on the surface a calcareous plate of irregular oval shape, and about half an inch in transverse diameter.

D. 4. *See 583, chap. I., sec. 4, L. 4, for history.*

E. Metastatic foci.

Nos. 325 and 326. Two perpendicular sections of spleen, which is lobulated, considerably enlarged, and irregularly infiltrated with metastatic masses. When received at the Museum, the spleen was so soft as to be easily torn with the finger, of a livid blood-color in part, partly bluish-black; the metastatic foci bright yellow, and consisting entirely of granular matter, in which were embedded the partly disintegrated anatomical elements of normal splenic structure.

E. 1 and 2. Private N. L., "F," 6th Wisconsin. Admitted, April 21st, 1864, from field. Diagnosis—typho-malarial fever. He stated that he had been sick for about a week with fever, coming on with chills; when admitted, was much prostrated; bowels loose; tongue dry, coated and brown in color with red edges. A few days after admission he complained of a pain in the side; respiration was accelerated; there was some cough. About June 1st, he began to show symptoms of hectic; had fever at irregular intervals, and profuse sweats. Died, June 23d.

Autopsy twenty-four hours after death: Body much emaciated; rigor mortis moderate; left pleural cavity contained about a pint and a half of purulent fluid; lung compressed against spinal column; right pleural cavity contained about six ounces of serum; lung healthy; mucous membrane of stomach and of entire intestinal canal thickened and softened; solitary glands of ileum enlarged and prominent, but not ulcerated; the patches of Peyer presented the appearance of the "newly-shaved chin." Liver about one-third larger than normal, and contained a large number of metastatic foci, consisting, microscopically, of granules and debris of liver tissue; spleen as in specimens.

Contributed by Assistant Surgeon G. A. Mursick, U. S. Vols., Stanton Hospital, Washington, D. C.

No. 523. Spleen, incised transversely; at junction of upper and middle thirds of incision is a metastatic focus the size of a small walnut.

E. 3. Private P. D., "A," 157th New York, intemperate. Admitted, February 29th, 1865. Died of pneumonia, March 4th.

Autopsy: Spots of purpura scattered over lower extremities, the largest a quarter of an inch in diameter; lower lobes of both lungs hepatized, sinking in water, upper lobe little affected; on outer side of lower lobe of left lung, was a stellate, sunken cicatrix, beneath which was a collection of tubercular matter the size of a butternut; a large white clot in right ventricle of heart, a smaller one in left; spleen adherent to diaphragm and presented the metastatic focus above described; weight of organ twelve ounces; ileum ulcerated; a small ulcer near middle of greater curvature of stomach; remainder of intestine healthy, except scattered patches of congestion; mesenteric glands enlarged.

Contributed by Surgeon W. L. Faxon, 32d Massachusetts, Depot Hospital, City Point, Va.

F. Tumors.

No. 313. An oval tumor, the size of a walnut, consisting of layers of partially developed connective tissue, arranged concentrically; the most central part of the growth is cretified; taken from the substance of the spleen, which was otherwise healthy.

F. 1.

No history.

Contributed by Surgeon C. W. Horner, U. S. Vols., Hospital No. 1, Nashville, Tenn.

G. Tubercle.

No. 298. Spleen, with a number of small tubercles, just beneath peritoneum.

G. 1. See 296, chap. IV., sec. 3, L. 21, for history.

No. 471. Spleen, with numerous very minute tubercles embedded in the peritoneal coat.

G. 2. See 469, chap. III., sec. 2, E. 1, for history.

No. 561. Spleen, laid open by a longitudinal incision, showing in interior and on external surface numerous tubercles. From a negro who died June 11th, 1865, of phthisis pulmonalis, accompanied by diarrhoea.

G. 3. Autopsy: Tubercles and cavities in lungs; tubercles in spleen; minute miliary tubercles in liver; tubercular ulcers of small intestine.

Contributed by Acting Assistant Surgeon W. C. Miner, L'Ouverture Hospital, Alexandria, Va.

No. 569. Section of small spleen, showing a number of cheesy tubercles about the size of peas.

G. 4. See 567, chap. III., sec. 2, F. 4, for history.

No. 630. Spleen, weighing twenty ounces, filled with yellow tubercles, varying in size from a millet seed to a large cherry.
G. 5.

From a negro who died of phthisis, August 19th, 1863. He had tubercles of lungs; tubercular ulceration of bowels, and tubercular enlargement of mesenteric glands.

Contributed by Acting Assistant Surgeon W. C. Miner, Slough Hospital, Alexandria, Va.

No. 631. A small spleen, weighing four ounces, containing quite a number of tubercles, which vary in size from a millet seed to half an inch or more in diameter.
G. 6.

M. P., dark mulatto, age 19. Admitted, August 31st, 1865, with phthisis. Died, October 31st.

Autopsy thirty-six hours after death: No rigor mortis; height, five feet nine inches; weight, about one hundred and ten pounds; both lungs adherent, contained much tubercle; vomica in upper lobe of right lung; three ounces of serum in left pleural cavity, sixteen ounces in right; five ounces of fluid in pericardium; small fibinous clot in left cardiac ventricle, tubercles in liver; spleen as described, and of a bluish slate-color; no ulcerations of intestines.

From Freedman's Hospital, Washington, D. C.

Autopsy by Hospital Steward S. S. Bond.

No. 632. Spleen, weighing thirteen ounces, containing numerous tubercles the size of hazel-nuts.

G. 7. Private T. S., "F," 5th U. S. Colored. Admitted, February 22d, 1861, for wounds received at the battle of Olustee, Fla. The wounds did well, but, about two weeks after admission, he had rigors which presented an intermittent type and yielded to quinine and stimulants; in about two weeks there was another chill, accompanied by night-sweats, which yielded to quinine and opium; he, however, became debilitated with anæmia, and died, May 14th. His wounds had been healed for some time prior to his death.

Autopsy: Heart small; tubercles in lungs, liver, and spleen; peritoneum studded with tubercles; two quarts of serum in abdominal cavity; transverse and descending colon very small, about three-fourths of an inch in diameter, but otherwise normal; the small intestine distended with gas to an inch and a half or two inches in diameter, otherwise normal.

Contributed by Assistant Surgeon E. D. Buckman, U. S. Vols., Hospital No. 6, Beaufort, S. C.

No. 627. Spleen, containing numerous large, cheesy tubercles.

G. 8. See 624, chap. III., sec. 2, F. 2, for history.

No. 663. Section of spleen, with numbers of large cheesy tubercles embedded.

G. 9. See 662, chap. II., sec. 1, F. 1, for history.

No. 696. Section of spleen, presenting numerous discrete tubercles, varying from mere points to the size of peas.

G. 10. See 694, chap. II., sec. 3, A. 2, for history.

No. 709. Spleen slightly enlarged; weight, when fresh, thirteen ounces; containing tubercles the size of peas.

G. 11. Private S. W., "I," 29th U. S. Colored. Landed at Brazos, Texas, about July 1st, 1865; noticed scorbutic sore mouth two days afterwards. Admitted, July 16th; mouth very sore; legs swelled; under treatment improved very much, but about October 1st took cold by exposure to rain, and got rapidly worse. Transferred to my ward, November 5th; had great tenderness on pressure over costal cartilages; considerable dullness on percussion over whole thorax; abdomen tender and slightly tumefied; no appetite; micturition frequent; urine deep red; slight expectoration; subdued cough; pulse small and irritable; no diarrhoea. Died suddenly, November 15th.

Autopsy: Not much emaciated; abdominal cavity contained four pints of yellow serum; peritoneum and mesentery presented numerous milinary tubercles; intestines contracted; liver high up under ribs, full size, light-red or yellowish in color; surface and substance presented many tubercles, two to six lines in diameter; spleen as in specimen, and of a carmine color; pleura, lungs, pericardium, diaphragm, perities of thorax, spleen and liver adherent in one mass; heart normal, but aortic valves thin; interior of pericardium normal.

Contributed by Assistant Surgeon Ira Perry, 9th U. S. Colored, Post Hospital, Brownsville, Texas.

No. 711. Spleen, considerably enlarged; weight, thirty-two ounces when fresh; filled with tubercles the size of peas.

G. 12. Private J. D. S., "H," 3rd U. S. Colored. Admitted, September 22d, 1865. Diagnosis—dysentery. Transferred to my ward, October 23d; appearance emaciated; epigastrium and left hypochondrium enlarged and protuded; patient distressed and very weak; no diarrhoea. Died, October 26th.

Autopsy: Thoracic viscera anæmic; aortic valves very thin, erubition along the free borders; liver one-third larger than natural, deep red color, with very minute tubercles externally and internally; spleen dark-red, and as in specimen; lower surface of diaphragm studded with tubercles similar to those in spleen; no lesion noticed in bowels.

Contributed by Assistant Surgeon Ira Perry, 9th U. S. Colored, Post Hospital, Brownsville, Texas.

o. 729. Tubercles of spleen.

G. 13. See 729, chap. II., sec. 3, B. 7, for history.

- No. 745.** Spleen, enlarged, with a number of small tubercles; an opaque spot on lower part of its concave surface.
G. 14. *See 744, chap. III., sec. 2, E. 9, for history.*
- No. 767.** Spleen of great size; weight, fifty-four ounces; filled with miliary tubercles.
G. 15. *See 768, chap. IV., sec. 2, B. 5, for history.*
- No. 835.** Spleen, containing numerous tubercles about the size of peas; weight, when fresh, ten ounces.
G. 16. Private B. S., "K," 19th U. S. Colored, age 25, negro. Admitted, December 24th, 1865, much debilitated; had suffered from scurvy, the symptoms of which had abated; had some diarrhoea at times and dyspnoea after walking or taking a hearty meal. From February 10th, 1866, to his death, he had much dyspnoea, with hurried respiration and general distress. Died, February 18th.
- Autopsy: No emaciation; left lung adherent and partially filled with gray miliary tubercles; pleura costalis converted into an uneven layer of compact tissue, yellowish, half an inch thick, with a gritty sound on cutting; a similar layer coated lower lobe of right lung; in this thickened structure were lobular masses of yellow tubercles from the size of a pea to two inches long, one inch wide and three-fourths of an inch thick; right lung everywhere adherent; small masses of hard and soft tubercles in its upper and middle lobes; lower lobe converted into a jelly-like mass; pericardium contained eight ounces of serum; heart pale, hypertrophied, and white clots in all the cavities; liver large, of a light-yellow color; spleen reddish in color, with tubercles as in specimen; mesenteric glands enlarged and soft.
- Contributed by Assistant Surgeon Ira Perry, 9th U. S. Colored, Post Hospital, Brownsville, Texas.

Chapter V. URINO-GENITAL ORGANS.

Section 1. KIDNEYS.

	NO. OF SPECIMENS.
A. Anomalies of form and position	11
B. Bright's disease	8
C. Cysts	15
D. Tubercle	3
E. Cancer	1
F. Renal calculi	3

Section 2. SUPRARENAL CAPSULE.

A. Tubercle	1
-------------------	---

Section 3. URINARY PASSAGES AND BLADDER.

A. Dilatation from stricture of urethra or other obstructions	7
B. Ulceration of mucous membrane of bladder	1

Section 4. MALE ORGANS OF GENERATION.

A. Syphilitic ulceration	2
B. Tubercles of testes	3
C. Diseases of prostate	4

Section 5. FEMALE ORGANS OF GENERATION, AND FÆTUS.

A. Diseases of uterine and vaginal mucous membrane	4
B. Fibrous tumors of uterus	4
C. Diseases of ovaries and fallopian tubes	5
D. Uterus after parturition	3
E. Miscellaneous	8

Chapter V. URINO-GENITAL ORGANS.

Section I. KIDNEYS.

A. Anomalies of form and position.

No. 305. Right kidney, presenting on its anterior surface several deep depressions, marking out distinct lobules.
A. 1. *See 306, chap. IV., sec. 7, A. 1, for history.*

No. 779. Lobulated kidneys.
A. 2. *See 778, chap. IV., sec. 4, E. 3, for history.*

No. 803. Lobulated kidney, the arteries of which enter above by two trunks, one anteriorly and one posteriorly. This kidney was situated at brim of pelvis and belonged to left side; left renal artery originated in the normal position and ran down to the kidney; left suprarenal capsule in its normal situation or a little above it; kidney and suprarenal capsule of right side normal in position; body otherwise normal in its anatomy, except that the left vertebral artery came off as a separate branch from arch of aorta.

R. G., colored woman, age 24. Admitted to Freedman's Hospital, January 31st, 1866, with phthisis. Died, April, 1866. Contributed by Surgeon E. Bentley, U. S. Vols., Washington, D. C.

No. 792. Left kidney, presenting on its surface a cicatrix-like depression.
A. 4. *See 790, chap. I., sec. 4, A. 1, for history.*

No. 802. Kidneys; the left, which is uppermost in the jar, lobulated, the right presenting a singular cicatrix-like depression on its outer edge.
A. 5. *See 801, chap. II., sec. 1, D. 14, for history.*

No. 23. Horse-shoe kidney; the two kidneys are joined together at their inferior extremities by an isthmus of kidney tissue about an inch and a half in length; each kidney has its ureter and bloodvessels complete.
A. 6. Corporal I. W., "F," 55th Pennsylvania. Admitted, December 9th, 1862, with chronic diarrhoea. Died,

December 25th.

Contributed by Assistant Surgeon F. T. Dade, U. S. Vols., Hospital No. 3, Beaufort, S. C.

No. 335. Two kidneys, united at their lower extremities by a narrow isthmus; each kidney is further noteworthy by presenting two pelves, two ureters and two sets of bloodvessels. The ureters united within an inch and a half of bladder for their external surfaces, the canals, however, remaining distinct as far as bladder.

Private W. P., Hawkins' Rebel Cavalry. Died, January 20th, 1864, of a wound received at battle of Chickamauga. Contributed by Assistant Surgeon C. J. Kipp, U. S. Vols., Hospital No. 1, Nashville, Tenn.

No. 757. Horse-shoe kidney; fusion has taken place at inferior extremity; one ureter on each side.
A. 8. *See 756, chap. IV., sec. 3, D. 25, for history.*

No. 551. Double kidney on right side; left kidney is transferred to right side and is situated just below position of right kidney, with which it is intimately fused; left suprarenal capsule preserves its normal position; conformation of pelvis of right kidney approaches closely to normal; pelvis of left kidney divides into branches, corresponding to the several calyces; right ureter normal in position and relations; left ureter crosses in front of the great vessels and behind sigmoid flexure to left side of rectum, thence descending to its natural point of entrance into bladder; right renal artery crosses to kidney behind vena cava; left renal artery, about three and a half inches lower down, crosses to kidney in front of vena cava; besides this, a second renal artery is given off from bifurcation of aorta, and crosses in front of right common iliac to lower portion of left kidney; the two renal veins run parallel with each other, both opening into right side of vena cava, the left two and a half inches further down than right; besides, the principal renal vein of left kidney, there is a branch rather larger than a quill, which empties into left common iliac vein, and which proceeds from that part of left kidney which is supplied by the arterial branch above mentioned as given off from bifurcation of aorta; left spermatic vein empties into left suprarenal vein, which passes from the capsule behind aorta into vena cava; in addition to the above anomalies there is but one vesicula seminalis—namely, on left side.

Lieutenant A. M. B., "A," 29th Virginia, (Rebel.) Died, April 20th, 1865, of a gunshot wound. (*See Surgical Section, 4081, XIII. A. B. b. 3, and 1085, XVIII. II. A. B. b. 36.*)

Contributed by Acting Assistant Surgeon G. K. Smith, Armoury Square Hospital, Washington, D. C.

- No. 525.** Left kidney, situated beneath bifurcation of aorta; aorta at bifurcation gives off three renal arteries, one of which bifurcates so that four renal arteries enter substance of kidney—two at the pelvis, the others on its upper part.
See 524, chap. IV., sec. 3, L. 99, for history.
- No. 361.** Right kidney, converted into a cyst about the size of a small orange; the wall fibrous and about four lines thick; it is connected by a patulous ureter to urinary bladder; two renal arteries the size of crow-quills proceed from aorta at point of bifurcation, and ramify upon walls of cyst; the cyst was found over second lumbar vertebra; left kidney apparently healthy, but the patient had had albumen in his urine.
See 362, chap. IV., sec. 3, L. 70, for history.

B. Bright's disease.

- No. 46.** Anterior half of right kidney, cortical substance considerably thickened; surface of kidney, when fresh was light yellow, mottled by the course of the congested blood vessels; cortical substance on section was pale yellow, thickened and streaked by the congested veins; pyramids natural. Microscopical examination showed a granular condition of epithelium of tubuli uriniferi; many cells contained fat globules; interlobular connective tissue hypertrophied.

Private E. J., "B." 49th New York, age 22, American. Admitted, January 22d, 1864, with pneumonia. February 9th, a diphtheritic appearance of throat was recognised. Died, February 11th.

Autopsy: Fauces and larynx covered with a diphtheritic layer; lower lobes of both lungs hepatized; extensive adhesions between pulmonary and costal pleurae; both kidneys as in specimen.

Contributed by Surgeon E. Bentley, U. S. Vols., General Hospital, Alexandria, Va., Third Division.

- No. 530.** Left kidney, enlarged; weight, eleven ounces, when taken from body; when received at Museum, kidneys were of a tawny yellow color, mottled on surface; epithelium of tubuli uriniferi filled with oil drops; connective tissue cells of matrix multiplying.

History—(Acting Assistant Surgeon D. L. Haight): Private J. E. W., "I." 10th New York Heavy Artillery. Admitted, December 24th, 1864; legs, face and eyelids oedematous. He stated that some three weeks previous to admission he had caught a severe cold by being exposed to dampness and lying on ground; within a day or two his legs began to swell, and they continued to do so until he came to hospital. He also stated that he had had syphilis, and at date of admission his body was covered with copper-colored spots; his urine gave, by heat and nitric acid, an abundant deposit of albumen, and showed, microscopically, abundant casts filled with oil globules; some blood also in urine. Died, March 1st, 1865.

Autopsy: Tissues all oedematous; abdominal cavity contained about sixteen pints of fluid; right kidney weighed ten ounces; left, eleven ounces; both in the condition above described.

Contributed by Assistant Surgeon W. F. Norris, U. S. Army, Douglas Hospital, Washington, D. C.

- No. 766.** Both kidneys, much enlarged; weight of each, eight ounces; were of a yellowish-fawn color, mottled with reddish streaks and spots of congestion, when fresh; epithelium of tubuli uriniferi exceedingly granular, with numerous free oil drops.

Corporal G. M., "K." 195th Ohio. Admitted, December 8th, 1865, suffering with acute rheumatism; had been under treatment at regimental hospital eight days; for two weeks previous to attack had been intoxicated most of the time; when admitted, his left lower extremity was very much swollen and painful; left elbow and wrist tender and painful; tongue dry and dark brown; stomach and bowels irritable; abdomen tympanitic; stools frequent, light-colored and watery; pulse 100 and weak; skin dry; mental faculties dull. 9th, vomited twice the previous night; passed no urine; half an ounce of mucus and urine obtained by use of catheter. 10th, total suppression of urine; bowels moved twice in the night; stools more consistent, but light colored. 11th, suppression of urine continued; patient aroused with difficulty; pulse scarcely perceptible. Died, *infra* 11th.

Autopsy: Surface sallow; no emaciation; old pleuritic adhesions at posterior portion and apex of right lung, a portion of its middle lobe hepatized, old cicatrices on anterior surface; heart large, otherwise normal; liver fawn-colored and enlarged; spleen large, kidneys as described.

Contributed by Surgeon E. Bentley, U. S. Vols., General Hospitals, Alexandria, Va.

- No. 685.** Kidneys, enlarged and fatty. Bright's disease.
B. 4 *See 684, chap. III., sec. 2, A 7, for history.*

- Nos. 20 and 21.** **20**, left kidney, with pelvis distended into a single, large, multilocular cyst; the medullary substance has disappeared, and the cortical substance reduced to a layer about two lines in thickness. **21**, section of right kidney of same patient, enlarged and fatty.

B. 5 and 6. Corporal J. H., "C." 121 New York. Admitted, September 15th, 1862, with chronic diarrhoea. Died, October 21st. No attention was drawn to the kidneys during life.

Autopsy: Kidneys as described; bladder small and contracted.

Contributed by Medical Cadet Kingston, Douglas Hospital, Washington, D. C.

Nos. 863 and 864. **863**, left kidney, with lobulated cyst the size of a walnut at its lower end, the remainder in a state of fatty degeneration. (*See Microscopical Section, Part First, IX. A. c. 1 and 2.*) **864**, right kidney, presenting a number of cysts half an inch in diameter. Much adipose tissue in pelvis of both kidneys.

B. 7 and 8. T. M., discharged, Irish, age 14. Admitted, August 6th, 1866, feeble; had been sick for the previous seven months; feet oedematous; urine highly albuminous; he suffered from severe attacks of asthma. Died, January 23d, 1867, having been comatose the previous twenty-four hours.

Autopsy: Heart enlarged; aortic valves incompetent, and presented calcareous deposits; left kidney weighed fourteen and a half ounces, three-fourths of it having undergone fatty degeneration, the remaining fourth having been converted into a lobulated cyst; right kidney weighed eight ounces, contained a number of large cysts; much adipose tissue in pelvis of each kidney; other viscera healthy.

Contributed by Assistant Surgeon W. Thomson, U. S. Army, Post Hospital, Washington, D. C.

C. Cysts.

Nos. 27 to 29. **27**, anterior half, and **28**, posterior half, of left kidney, which is considerably enlarged; weight, fourteen ounces; in its substance are innumerable cysts, varying in size from a pin-head to a chestnut. **29**, right kidney of same patient, laid open, larger than left; weight, twenty-four ounces; filled with cysts, the largest of which attains the size of an English walnut.

C. 1 to 3. Private A. A. E., 2d Vermont Sharpshooters. Died, December 26th, 1862, of chronic diarrhoea. No attention was drawn to kidneys during life.

Autopsy: Extensive ulceration of colon; kidneys as described.

Contributed by Surgeon J. S. Hildreth, U. S. Vols., Judiciary Square Hospital, Washington, D. C.

No. 161. Left kidney, seven by five inches; filled with cysts of various sizes, from a line to three-fourths of an inch in diameter, variously filled with yellow, bluish, greenish and brownish serum.

See 161, chap. IV, sec. 3, l. 55, for history.

Nos. 155 and 156. **155**, right kidney, presenting several small cysts on its surface; pelvis of kidney much enlarged and ureter distended to nearly half an inch in diameter. **156**, left kidney of same patient, laid open, showing a number of small cysts on its external surface; the section passes through several cysts of which the largest attains the size of a shell-bark; the ureter of this kidney was also distended.

C. 5 and 6. Private J. W. B., "F," 25th New York Cavalry, age 52. Admitted, December 6th, 1864, with acute bronchitis, and very feeble. Died, December 18th.

Autopsy: body well developed; height five feet nine inches; plenra slightly adherent; about three ounces of fluid in each pleural cavity; both lungs much congested; fibrinous clot in left cardiac ventricle; bladder contained forty-six ounces of urine; ureters distended to about half an inch in diameter; kidneys as in specimens.

Contributed by Acting Assistant Surgeon H. M. Dean, Lincoln Hospital, Washington, D. C.

No. 500. Left kidney, presenting on its surface two cysts, the largest about the size of a walnut.

C. 7. Private C. B. E., "A," 2d Vermont. Admitted, December 2d, 1864, and died, December 30th, of chronic diarrhoea.

Autopsy: Lungs filled with tubercle, extensive pleuritic adhesions; intestine ulcerated; left kidney as above described.

Contributed by Acting Assistant Surgeon B. B. Miles, Jarvis Hospital, Baltimore, Md.

No. 501. Anterior superior portion of left kidney, presenting on surface two small cysts, the largest the size of a large pea.

C. 8. Corporal N. T. G., "H," Cole's Maryland Cavalry. Admitted, January 23d, 1864, with phthisis pulmonalis.

Died the same day.

Autopsy: Plenra adherent; tubercles and vomice in both lungs; ileum ulcerated; both kidneys presented a few small cysts on the surface.

Contributed by Acting Assistant Surgeon B. B. Miles, Jarvis Hospital, Baltimore, Md.

Nos. 508 and 509. **508**, right kidney, **509**, left kidney, both containing numerous cysts, the largest about half an inch in diameter; they were filled with a yellowish serum.

C. 9 & 10. Private J. B. W., "B," 30th Maine, age 30. Admitted, March 15th, 1865, with typhoid fever. No symptoms indicated disease of kidneys. Died, March 25th.

Contributed by Assistant Surgeon Walter Ure, U. S. Vols., Depot Field Hospital, Winchester, Va.

- No. 671.** Two kidneys, presenting numerous cysts of moderate size.
C. 11. A. G., mulatto, age 79. Admitted, March 11th, 1865. Diagnosis—debility from old age. Incontinence of urine existed for a few days before death. Died, November 26th.
 Autopsy twenty-eight hours after death: Rigor mortis well marked; some emaciation; both lungs adherent, with abundant pigment; lower lobe of right lung in a state of gray hepatization; three ounces of serum in each pleural cavity, a large dark fibrous clot in right; two ounces of serum in pericardium; a white clot in left ventricle extending through aorta into left carotid artery, from which it was drawn to the length of twenty inches; aortic valves semi-cartilaginous in consistency, and aorta dilated to one and a half inches in diameter; liver adherent to diaphragm, capsule on anterior surface of right lobe thickened; spleen small and lobulated, its capsule thickened; kidneys contained cysts as in specimen; Peyer's patches presented the shaven-beard appearance; pigment in solitary follicles of colon.
 From Freedman's Hospital, Washington, D. C.
 Autopsy by Hospital Steward S. S. Bond.
- No. 718.** Left kidney, presenting on its anterior surface, adjoining pelvis, a cyst the size of a walnut; before having
C. 12. shrunk by action of alcohol, the cyst was the size of a hen's egg, and contained transparent serum.
 W. H., mulatto, age about 50. Died suddenly, January 23d, 1866.
 Autopsy: Tubercles in both lungs with intercurrent pneumonia on right side; enlarged bronchial glands; tubercles of liver; larger sloughing ulcers in cecum and ascending and transverse colon; left kidney as above; right kidney normal.
 From Freedman's Hospital, Washington, D. C.
 Autopsy by Hospital Steward S. S. Bond.
- No. 726.** Somewhat lobulated right kidney, presenting on its surface a few cysts which, when fresh, contained a
C. 13. serum-like liquid.
See 725, chap. IV., sec. 3, M. 9, for history.
- No. 822** **823.** right kidney, **823.** left kidney, presenting innumerable cysts, the largest the size of a hen's
and egg, the smallest of extreme minuteness; in each kidney the renal artery, before approaching the pelvis, sends
823. off a small branch to upper portion of organ.
C. 14 & 15. H. T., negro, age 23. Admitted to Freedman's Hospital, September 5th, 1865; tongue covered with a thick brown fur; frontal headache; bowels costive; slight pain on pressure over right hypochondrium; incontinence of urine; patient dragged his leg after him when walking; arms and legs constantly trembled; unable to stand up without support; mind wandering; partial deafness; good appetite. Discharged, November 28th, apparently cured. Readmitted, April 14th, 1866, with general anasarca; great dyspnoea and cough. Died, July 9th.
 Autopsy twenty-four hours after death: No rigor mortis; slight emaciation; lower extremities oedematous; height five feet seven and a quarter inches; about two ounces of fluid in sub-arachnoid cavity; left pleural cavity contained sixty-four ounces of reddish-yellow serum; lungs hepatized in patches; heart fatty; marks of former pericarditis on its surface; patches of atheroma on first portion of arch of aorta; liver cirrhotic; spleen soft; kidneys dark red and congested, full of cysts as above.
 Contributed by Assistant Surgeon E. Bentley, U. S. Army, Washington, D. C.

D. Tubercle.

- No. 732.** Right kidney, presenting several tubercles the size of peas.
D 1 *See 731, chap. IV., sec. 4, C. 5, for history.*
- No. 611.** Portion of right kidney, showing several tubercular nodules the size of peas.
D 2 *See 612, chap. IV., sec. 4, E. 4, for history.*
- No. 615.** Left kidney, with a few small tubercles embedded in its cortical substance
D 3. *See 614, chap. IV., sec. 5, E. 2, for history.*

E. Cancer.

- No. 831.** Right kidney, the pelvis of which is occupied by a rounded melanotic nodule, about one and a half inches in
E 1 diameter.
See 824, chap. II., sec. 3, C. 3, for history.

F. Renal calculi.

- No. 592.** Small, soft calculus, chiefly composed of earthy phosphates with urates, from left kidney.
F. 1. Private S., 10th Alabama, (Rebel.) Died, March, 1-64.
 Contributed by Surgeon Thomas H. Bache, U. S. Vols., West's Buildings Hospital, Baltimore, Md.
- No. 593.** A number of calculi, varying in size and shape, some of them mace-shaped; the largest weighs sixty-five grains, weight of all one hundred and twenty-three grains; composition chiefly oxalate of lime, mixed, however, with some phosphates.
F. 2. Private L. W., "E," 8th Iowa Cavalry. Admitted, February 6th, 1864, with chronic diarrhoea. Died, February 24th, of peritonitis.
 Autopsy: Pus in abdominal cavity; peritoneum coated with pseudo-membrane; mucous membrane of intestine similarly coated; lower part of colon ulcerated; pelvis and calyces of left kidney contained eighteen concretions.
 Contributed by Surgeon J. W. Foye, U. S. Vols., Hospital No. 19, Nashville, Tenn.
- No. 594.** Horse-shoe-shaped calculus, weighing 4.3-15 grammes; the nucleus, which forms about half the calculus, is composed of oxalate of lime; the external layers, especially in the cornua, are composed of a mixture of oxalate of lime with urates and phosphates.
F. 3. Contributed by Acting Assistant Surgeon Bowen, Episcopal Hospital, Philadelphia, Pa.

Section 2. SUPRARENAL CAPSULES.

A. Tubercle.

- No. 811.** Left suprarenal capsule, infiltrated with yellow tubercle.
A. 1. Private J. G., "A," 118th U. S. Colored, age 20. Admitted about August 10th, 1865. Symptoms of scurvy appeared while with his regiment about the middle of the previous July, and increased in intensity up to time of admission. When admitted, was weak, languid and dispirited; gums turgid, swollen, of a dark-purple color, and readily bled; teeth loose; tongue foul; voice husky; bowels loose. September 1st, symptoms of scurvy nearly disappeared; diarrhoea not essentially different; three to eight stools a day. 25th, diarrhoea nearly disappeared; patient on his legs, hopeful and with good appetite. October 1st, still improving; transferred to convalescent ward. 8th, somewhat delirious on rising in the morning; respiration disordered; dullness on percussion over lower lobe of right lung. Died, October 10th.
 Autopsy: Scurbitic ulcerations in mouth; lower lobe of right lung hepatized, sinking in water; suprarenal capsules large, with structure altered, apparently tubercular; liver hard, of a rusty-brown color, with scattered tubercles; mucous membrane of the last twelve inches of ileum, dark red and thickened; mucous membrane of ascending and transverse colon dark red; descending colon and rectum only an inch in diameter, with firm, white and thickened walls; mucous membrane mottled in dark patches.
 Contributed by Assistant Surgeon Ira Perry, 9th U. S. Colored, Post Hospital, Brownsville, Texas.

Section 3. URINARY PASSAGES AND BLADDER.

A. Dilatation from stricture of urethra or other obstructions.

- No. 536.** Urinary organs; right kidney, with greatly dilated pelvis; pyramids encroached upon; kidney dilated into a multilocular cyst, the walls of which are composed of the atrophied renal tissue; pelvis of left kidney greatly distended; ureters dilated to size of forefinger; muscular coat of bladder hypertrophied, the thickened bundles of muscles forming an areolar arrangement, through the meshes of which a number of hernie of mucous membrane have taken place forming oval cysts, the largest of which is over two inches, the smallest about a quarter of an inch in diameter; these cysts communicate with cavity of bladder by a comparatively narrow orifice.
A. 1. Private W. P., "G," 122d Ohio, age 43. Admitted, November 12th, 1864, in articulo mortis. He was greatly emaciated, and had constant involuntary evacuations of urine and feces.
 Autopsy: Urinary organs as described; stricture of membranous portion of urethra, still permitting however the passage of urine.
 Contributed by Assistant Surgeon R. F. Weir, U. S. Army, General Hospital, Frederick, Md.

Nos. 576 to 578. **576.** left kidney, with pelvis and ureter enormously dilated; kidney contained numerous cysts. **577.** section of right kidney of same patient, in which it appears that the larger cysts are dilatations of calyces, the smaller probably of tubuli uriniferi. **578.** portion of bladder of same patient, with some inches of right ureter attached; a ureter irregularly dilated, in many places to thickness of thumb; bladder greatly thickened, and near insertion of ureter presents a cyst-like hernia of mucous membrane the size of a walnut.

Private J. W. S., "A," 5th Massachusetts Cavalry. Admitted from Baltimore, September 12th, 1864. Micturition difficult; ine-entrance of urine, which also kept his clothes constantly wet; urine turbid and ammoniacal; stricture near neck of bladder detected by use of bougie. He did not improve under treatment, and was about to be discharged the service, when, January 2d, 1865, he was seized with a severe chill followed by fever, with intense pain in epigastrium, nausea, vomiting, and partial suppression of urine. Died, January 12th.

Contributed by Acting Assistant Surgeon A. S. Gibbs, Mower Hospital, Philadelphia, Pa.

No. 610. Kidneys, ureters, and bladder; right kidney very greatly enlarged, with two pelves, each greatly distended; **A. 5.** from each pelvis proceeds a separate ureter, the two uniting about three inches from bladder, and distended to the thickness of a man's finger; left kidney also enlarged; pelvis distended; ureter the size of a finger; muscular coat of bladder more than half an inch in thickness; prostate slightly enlarged; vasa deferentia distended.

See 611, chap. IV., sec. 5, G. 2, for history.

No. 759. Urinary organs; pelves of kidneys distended; ureters thicker than a man's thumb; right ureter, just above entrance into bladder, distended into a cyst the size of a child's head; left ureter, at a corresponding point, distended into a cyst the size of a man's head; bladder with a muscular coat much thickened and disposed in interlacing bands; urethra free from stricture; prostate not materially enlarged.

The patient, who was an old man, was admitted in March, 1866, suffering with retention of urine. A large tumor, supposed to be the enlarged gall-bladder, was felt in lower portion of abdomen; after vain attempts to pass catheter into bladder, it was decided to puncture bladder through rectum; this was done and nearly two gallons of urine drawn off; the patient, however, did not rally, and died a few hours after the operation.

Autopsy: Trocar had penetrated the large cyst on left side; the efforts at catheterization had somewhat lacerated membranous portion of urethra; the difficulty of catheterization had arisen from the bladder being pushed up in pelvis by the enormous cyst-like distension of ureters; nature of obstructions by which the primary disease of the passages was induced could not be ascertained.

Contributed by Dr. C. M. Ford, Providence Hospital, Washington, D. C.

No. 796. Stricture of urethra, extending from membranous portion about two and a half inches forward; canal very small, but patulous up to time of death; bladder greatly distended, muscular coat hypertrophied; ureters distended to the thickness of a finger; pelves of kidneys considerably dilated.

History—(Acting Assistant Surgeon L. Heard.) G. L., mulatto, age 75; height, five feet eight inches; weight, about one hundred and forty pounds. Admitted to L'Ouverture Hospital, April 8th, 1866; complained of pain in lower extremities, particularly in knees and ankles; no swelling whatever; able to go about the ward. About the 20th, a cold storm of rain and wind came on, and from some exposure he was suddenly taken with symptoms of inflammation of the lungs, with dulness on percussion over base of each lung posteriorly; pulse 100 and non-resisting; dyspnoea quite urgent; expectoration moderate and slightly colored. Died, April 20th. During the whole time the patient was in hospital, no complaint of difficulty in micturition was made.

Autopsy sixteen hours after death: Rigor mortis slight; posterior part of middle and lower lobes of right lung in a state of red hepatization, as was also the posterior portion of lower lobe of left lung; remaining portions crepitant; urinary organs as in specimen.

Contributed by Surgeon E. Bentley, U. S. Vols., General Hospital, Alexandria, Va.

B. Ulceration of mucous membrane of bladder.

No. 12. Bladder, the mucous membrane of which presents a number of superficial ulcerations and is irregularly coated with pseudo-membrane; there was a partial stricture in membranous portion of urethra, posteriorly, to which the mucous membrane was ulcerated for about two inches; there was also a perineal abscess involving the prostate glands.

J. C., age 45. First seen November 26th, 1866, suffering from swollen testicle; pain in course of urethra; desire to urinate every few minutes. After eight days' treatment he had apparently recovered. Subsequently had an attack of pneumonia. Died, March 15th, 1867.

Autopsy: Thoracic and abdominal viscera healthy, except slight adhesions in lower portion of abdominal cavity; membranous and prostatic portions of urethra dilated; mucous membrane ulcerated; abscess the size of an orange in perineum involving the prostate; it had not opened; bladder contained about ten ounces of turbid urine, in which floated numerous flakes of coagulated lymph; its walls were somewhat thickened; the lining membrane presented superficial ulcers, covered in patches with a coating of plastic lymph, which, in some places, hung like shreds.

Contributed by Dr. S. S. Bond, Washington, D. C.

Section 4. MALE ORGANS OF GENERATION.

A. Syphilitic ulceration.

No. 710. External organs of generation of a male negro; phymosis, edema, suppurating buboes in groins.
A. 1. See 741, *chap. II., sec. 1, G. 1, for history.*

No. 797. External genitals; glans penis destroyed by phagedenic ulceration, with phagedenic superficial ulceration of perineum and in the fold between scrotum and groin.
A. 2. T. M., mulatto, age 22. Admitted, April 7th, 1866. Died, May 7th.

Autopsy twenty hours after death: Height, six feet one inch; weight, about one hundred and fifty pounds; rigor mortis well-marked; phagedenic ulceration of external genitals as in specimens; lower lobe of right lung in a state of red hepatization; three ounces of serum in right pleural cavity; heart slightly fatty; ten ounces of serum in pericardium; nutmeg liver; capsule of spleen much thickened and firmly adherent to diaphragm; kidneys fatty.

From Freedman's Hospital, Washington, D. C.

Autopsy by Hospital Steward S. S. Bond.

B. Tubercles of testis.

Nos. 17 and 18. **17**, right testicle, containing numerous tubercular masses, especially in its anterior inferior parts. **18**, left testicle of same patient, with two large tubercular masses in its inferior portion.
See 19, chap. II., sec. 3, A. 1, for history.

B. 1 and 2.

No. 38. Testicle, laid open from before, a large tubercular mass in its superior portion, smaller masses along anterior surface, between tunica albuginea and gland. The organ was removed by the operation of castration, May 6th, 1863; seven months previously it became enlarged, red, hard and painful; fistulous orifices opened and a fetid ichor was discharged. The patient recovered from the operation. Subsequent history unknown.

Contributed by Assistant Surgeon C. C. Byrne, U. S. Army, Armory Square Hospital, Washington, D. C.

C. Diseases of prostate.

No. 791. Greatly enlarged prostate gland.
C. 1. See 741, *chap. II., sec. 1, G. 1, for history.*

No. 816. Bladder, with thickened rugous walls and prostate gland much enlarged; the enlargement affects chiefly the third lobe, which projects into the cavity of bladder, forming a rounded tumor the size of an English walnut.
C. 2. C. P., negro, age 70. Admitted to Freedman's Hospital, September 12th, 1866; extremely feeble; palsied; poor appetite; involuntary discharges from bowels; incontinence of urine. Died, September 24th.

Autopsy: Height, five feet nine and a half inches; weight, one hundred and fourteen and a half pounds; talipes valgus; both lungs, especially upper lobe of left, and upper and middle lobes of right, filled with tubercles; pericardium closely adherent to heart; insufficiency of aortic valves; pulmonary valves calcareous; liver cirrhotic, left lobe very small, right rounded and thickened; spleen full of tubercle; right kidney contained in its cortex a fibrous mass about half an inch in diameter, the left contained a well-marked cyst; prostate gland as in specimen.

Contributed by Assistant Surgeon E. Bentley, U. S. Army, Washington, D. C.

No. 815. Posterior portion of bladder, with vesiculae seminales and prostate attached; left lobe of prostate, enlarged to size of a small walnut, has been split open and exhibits a mass of softened tubercle the size of a hazel-nut.
C. 3. B. S., negro, age 40. Admitted to Freedman's Hospital, July 4th, 1866, with an abscess of upper third of left thigh, involving hip and back. About September 1st abdominal dropsy appeared, affecting also the scrotum and penis; the effusion increased so much as to disturb respiration, when the patient was in the reclining posture. 10th, about five p. m. he had a congestive chill. Died, September 11th.

Autopsy: height, five feet six inches; much emaciated; abdomen distended; large bubo in left groin; scrotum, prepuce and lower limbs oedematous; lower lobes of lungs hepatized and adherent posteriorly; sixteen ounces of fluid in each pleural cavity; bronchial glands enlarged, containing softened tubercle; kidneys fatty; tubercles in the lymphatic glands, which are involved in bubo; also in prostate, which presented on left side a mass of softened tubercle about the size of a hazel-nut.

Contributed by Assistant Surgeon E. Bentley, U. S. Army, Washington, D. C.

- No. 513.** Bladder, with prostate and vesiculae seminales attached; both prostate and vesicles filled with tubercular deposits and considerably enlarged; central portion of mass had softened into a tubercular abscess, which discharged into posterior portion of urethra; a probe has been introduced into orifice of abscess.
C. 4.
See 541, chap. II., sec. 1, E. 1, for history.

Section 5. FEMALE ORGANS OF GENERATION AND FÆTUS.

A. Diseases of uterine and vaginal mucous membrane.

- No. 623.** Uterus and ovaries, with cysts the size of peas projecting into upper portion of cavity of cervix; a recent corpus luteum in left ovary.
A. 1.
See 619, chap. IV., sec. 3, I. 70, for history.
- No. 659.** Minute ulcers of os uteri and upper part of vagina; adhesions of ovaries to fallopian tubes and broad ligaments; peritoneal adhesions on fundus uteri.
A. 2.
See 656, chap. IV., sec. 3, H. 1, for history.
- No. 615.** Uterus and appendages, with foul ragged ulcers of uterine mucous membrane; small ulcers on posterior lip of os; peritoneal surface of piece coated with foul pseudo-membrane, which in the fresh specimen was discolored with fecal matter.
A. 3.
See 619, chap. IV., sec. 1, E. 4, for history.
- No. 800.** Female organs of generation; vagina and uterus, opened posteriorly, presenting a number of superficial ulcerations, the largest between the labia majora and minora on right side, the others between labia majora and thigh, in vestibule, and about the orifice of vagina.
A. 4.
 Autopsy: Light mulatto; height, five feet eleven inches; weight, one hundred and fifty pounds; body ecchymosed posteriorly and covered with syphilitic scars; lungs congested and adherent; liver fatty; spleen adherent and soft; genital organs as described.
 From Freedman's Hospital, Washington, D. C.
 Autopsy by Hospital Steward S. S. Bond.

B. Fibrous tumors of uterus.

- No. 833.** Uterus presenting a number of fibrous growths embedded in its parietes, some projecting externally, some internally; length of organ three and a half inches, greatest breadth four inches.
B. 1.
 J. L., colored. Admitted to Freedman's Hospital, June 21th, 1866, with paralysis. Died, July 3d.
 Autopsy: Two ounces of coagulated blood in left lateral ventricle of brain, an old vertical cicatrix in corpus striatum of right side, extending from summit to base; two ounces of fluid in sub-arachnoid cavity; middle lobe of right lung contained several small tubercles; liver fatty.
 Contributed by Assistant Surgeon E. Bentley, U. S. Army, Washington, D. C.
- No. 788.** Fibrous tumor of uterus, presenting a nodulated surface, and weighing twenty-five ounces; microscopical examination showed the tumor to consist of white fibrous tissue, and non-striated muscular filar cells. (*See Microscopical Section, Part First, XIV., B. v. 1.*)
B. 2.
 From a negro who died in the Baltimore Almshouse in March, 1866.
 Contributed by Assistant Surgeon Geo. M. McGill, Hicks Hospital, Baltimore, Md.
- No. 507.** Uterus, much enlarged; weight, eleven ounces; cervix elongated; body of organ enlarged, with a number of fibrous tumors varying from the size of a pea to that of a walnut; length of uterine cavity, as measured by a sound, three and five eighths inches; a number of cysts in right ovary, some of the smaller ones pedunculated.
B. 3.
See 506, chap. II., sec. 1, C. 2, for history.
- No. 780.** Fibrous tumor, the size of a small hen's egg, embedded in left anterior wall of uterus and projecting into its cavity. (*See Microscopical Section, Part First, XIV., B. v. 2.*)
B. 4.
See 778, chap. IV., sec. 1, I. 3, for history.

C. Diseases of ovaries and fallopian tubes.

- No. 799.** Uterus, ovaries and fallopian tubes, the latter distended to about one-fourth of an inch in diameter and stuffed with cheesy tubercular matter.
C. 1.
See 798, chap. IV., sec. 3, M. 6, for history.
- Nos. 589 and 590.** **589**, tumor of left ovary; **590**, tumor of right ovary; both tumors consist of multilocular cysts with tough walls of connective tissue; no sarcomatous nor cancerous masses; the uterus has been split in two, half remaining with each tumor, showing its anatomical connections; the tumors, having risen out of pelvis, produced, by traction, some elongation of the cervix, with modification of shape of os uteri; cavity of uterus measures three and a half inches.
C. 2 and 3.
 From a colored woman.
 Contributed by Acting Assistant Surgeon W. C. Miner, L'Ouverture Hospital, Alexandria, Va.
- No. 613.** Left half of uterus, with ligaments and ovary attached; the ovary contains a cyst the size of an orange filled with hair and fat; the cyst has contracted adhesions to surrounding parts.
C. 4.
See 611, chap. III, sec. 2, E. 5, for history.
- No. 616.** Uterus and appendages; uterine mucous membrane ulcerated; ovaries connected with uterus by a dense sarcomatous mass; the ovaries represented by cysts filled with yellow creamy matter.
C. 5.
See 617, chap. IV., sec. 4, P. 3, for history.

D. Uterus after parturition

- No. 337.** Uterus five days after delivery.
D. 1.
 From a colored girl, age 19, under treatment for syphilis; delivered in the ninth month of her first pregnancy of a dead foetus, and died on the fifth day afterwards with typhoid symptoms.
 Contributed by Surgeon E. Bentley, U. S. Vols., General Hospital, Alexandria, Va., 31 Division.
- No. 713.** Uterus at about the sixth month, with placenta and membranes in situ.
D. 2.
 From a woman of about 20 years of age, who had been treated for phthisis in a civil hospital; had aborted at sixth month, and died a few days after.
 Autopsy: Masses of white tubercles in upper lobes of both lungs; several abscesses about the size of hens' eggs in spleen; a large clot in vagina; uterus as in specimen.
 Contributed by Hospital Steward A. M. Signier.
- No. 733.** Female organs of generation about two weeks after parturition; peritoneal surface of uterus coated with croupous lymph.
D. 3.
See 731, chap. IV., sec. 4, C. 5, for history.

E. Miscellaneous.

- No. 751.** External organs of generation, with hymen.
E. 1.
 From a young mulatto girl.
See 751, chap. IV., sec. 4, E. 11, for history.
- No. 851.** Uterus and ovaries; right ovary presented a corpus luteum composed of a red blood clot three-fourths of an inch in diameter; a cyst, one third of an inch in diameter, attached by a narrow pedicle to the fimbriated extremity of left fallopian tube; another, half an inch in diameter, attached directly to right fallopian tube.
E. 2.
 From a colored woman who died of fever.
 Autopsy: Prominent elevation of Peyer's patches and solitary follicles; follicular ulceration of colon; ovaries as described.
 From Freedman's Hospital, Washington, D. C.
 Autopsy by Hospital Steward D. S. Lamb.
- No. 795.** Fibrous tumor of ovary, about the size of a child's head; a thick fibro-muscular cyst attached, which, in alcohol, has contracted to a little smaller than the tumor; the cyst contains an attached placenta, from which depends a well-formed female foetus, at about four and a half months. (*See Microscopical Section, Part First,*
X. M. c. 1.)
 Contributed by Dr. George McCook, Pittsburgh, Pa.

- No. 857.** Fetus of about four months, aborted by a colored woman in the fall of 1865.
E. 4. Contributed by Dr. J. W. Van Arman, Washington, D. C.
- No. 758.** Gravid uterus at seven and a half months, containing fetus and membranes: umbilical cord twisted twice around the child's head.
E. 5. Mrs. ———, age about 30; pregnant for the third time; had intermittent fever: labor came on March 1st, 1865; the patient, who was very feeble, died exhausted in a few hours.
Autopsy: Much serum in abdominal cavity; some evidences of peritonitis; spleen large and dark; liver large; gall bladder distended; the blood from a superficial vein showed a preponderance of white corpuscles.
Contributed by Assistant Surgeon De Witt C. Peters, U. S. Army, Post Hospital, Fort McHenry, Md.
- No. 81.** Embryo of ten weeks, with membranes complete: the membranes have been slit open.
E. 6. Contributed by Hospital Steward Fred. Schafhirt.
- No. 777.** Female pelvis, with ligaments
E. 7
- No. 113.** Embryo of five months, with placenta and ruptured membranes attached.
E. 8. Contributed by Dr. C. M. Ford, Providence Hospital, Washington, D. C.

Chapter VI. ORGANS OF LOCOMOTION.

	NO. OF SPECIMENS.
Section 1. MUSCLES AND FASCIA	4
Section 2. BONES AND JOINTS	21

Chapter VI. ORGANS OF LOCOMOTION.

Section 1. MUSCLES AND FASCIA.

- No. 556.** Portion of diaphragm, with cheesy tubercular deposits on its pleural surface.
1. *See 557, chap. I., sec. 1, E. 5, for history.*
- No. 568.** A section of lower lobe of left lung, adherent to diaphragm; lung tissue contains a few minute tubercles; diaphragm infiltrated with a cartilage-like mass of proliferating connective tissue, in the midst of which, by the microscope, atrophying muscular fibres were readily recognized.
2. *See 567, chap. III., sec. 2, F. 4, for history.*
- No. 555.** Sternum and costal cartilages; cheesy tubercular deposits on left side, near internal mammary artery, and opposite third, fourth, sixth and seventh costal cartilages.
3. *See 557, chap. I., sec. 1, E. 5, for history.*
- No. 825.** Spindle-shaped melanotic tumor, five inches long, two inches broad, weighing six ounces, which occupies the belly of pronator radii teres muscle of right forearm.
4. *See 824, chap. II., sec. 3, C. 3, for history.*

Section 2. BONES AND JOINTS.

- No. 676.** Lower part of sternum, with bifid ensiform cartilage.
1. *See 675, chap. III., sec. 2, F. 1, for history.*
- No. 303.** Calvarium, presenting on right side of sagittal suture, about two inches posterior to coronal suture, a perforation about one-eighth of an inch in diameter; on the inner side it is seen that the perforation leads to an irregular conical excavated fossa, on the inner surface of right parietal bone and corresponding in its position with one of the Pacchionian granulations; near the fossa is another of similar character, which, however, does not penetrate to an unusual depth.
2. Contributed by Assistant Surgeon De Witt C. Peters, U. S. Army, Jarvis Hospital, Baltimore, Md.
- No. 809.** Calvarium with small flat osteophytes on its inner surface.
3. *See 808, chap. IV., sec. 3, M. 8, for history.*
- No. 434.** Seventh rib, with its pulmonary side denuded of periosteum, and presenting on its surface several new formations of bone; this condition was caused by the burrowing of pus from an abscess.
4. *See 433, chap. III., sec. 2, C. 5, for history.*
- Nos. 510 to 512.** **510**, portion of base of cranium, with cervical vertebrae attached; anteriorly the carious bodies of the vertebrae have been denuded by a burrowing abscess, which communicates by two passages through the anterior occipito-atloid space with base of brain; posteriorly the spinal cord can be seen in situ; the dura mater spinalis surrounded externally by a cheesy mass, which is most abundant in region of atlas and axis; basilar process of occipital bone, declivity of sphenoid and sella turcica are covered with a mass of tubercular matter, which is situated chiefly beneath the softened and altered dura mater. **511**, bony bridges and spinous processes of second, third and fourth cervical vertebrae, with soft tubercular deposits between external periosteum and bone, especially on right side; some newly formed bone on left. **512**, lower part of sternum with cartilages and parts of ribs attached; on right side, at attachments of cartilages of fifth and sixth ribs to sternum, is a softened tubercular mass which involves substance of sternum on right side and sternal extremities of cartilages; a whole-bone has been passed into internal mammary artery to show its relations; on left side, at junction of fourth rib with its cartilage, is a similar tubercular mass; the extremity of the rib carious and detached from its cartilage; in the neighborhood of this mass, connected with the fascia, are several tubercular deposits about the size of peas.
5 to 7. *See 544, chap. II., sec. 1, E. 1, for history.*

No. 755. Tubercular caries of lower six dorsal and upper three lumbar vertebrae.
8. *See 751, chap. IV., sec. 4, E. 11, for history.*

No. 757. Ninth, tenth, eleventh and twelfth dorsal, and first, second and third lumbar vertebrae; body of last dorsal almost entirely destroyed by caries; bodies of eleventh dorsal and first lumbar nearly so; spine curved at an angle of one hundred degrees; large tubercular cavity in body of second lumbar; bodies of remaining vertebrae of piece appear more or less worn-away on surface; articular processes of last dorsal and first lumbar firmly united by bony ankylosis; similar ankylosis between ninth and tenth, and tenth and eleventh dorsals; the articulation between eleventh and twelfth still exists as such, though numerous processes and outgrowths from neighborhood of articular surfaces of both bones exist; there is a large oval articular surface between spinous processes of second and third lumbar vertebrae.

From a rebel deserter, employed as a teamster by the Quartermaster's Department, who died of phthisis pulmonalis.

Autopsy: Tubercles of lungs; abdominal cavity filled with pus; two psoas abscesses; the one on right side had discharged into abdominal cavity; that on left side had not opened and was filled with cheesy pus; the abscess on right, partly filled with similar matter, communicating with the diseased vertebrae; anterior vertebral ligament and periosteum of bodies of several vertebrae, above and below curvature, were separated from bodies of vertebra by burrowing pus; the abscesses had already made their appearance in groin.

Contributed by Dr. N. S. Lincoln, Teamster's Hospital, Washington, D. C.

No. 713. Sixth to tenth dorsal vertebrae, with parts of ribs attached; masses of softened tubercular matter on each side between sixth and seventh dorsal vertebrae; the bodies of these vertebrae carious; spinal canal has been laid open, exposing the cord, which, however, does not appear to have suffered any actual compression.

D. B., colored, age 23. Admitted to L'Ouverture Hospital, June 24, 1865, with symptoms of dyspepsia; in a few weeks he seemed greatly relieved, was able to take free exercise in open air and to render some assistance in ward; he, however, continued weak without any perceptible cause, and about September 1st, there was a manifest aversion to take exercise, with loss of muscular power and signs of inability to use lower extremities; he was inclined to bend forward and had some pain in back, with tenderness on pressure over sixth and seventh dorsal vertebrae. About October 1st there was manifest paraplegia, loss of motion being far greater than of sensation; in a few weeks the limbs were completely paralyzed as respects motion; pain and tenderness in region of back alone noticed increased; appetite, however, good; pulse 80 and of fair strength; bowels constipated; urine passed involuntarily; bed-sores, about hips and sacrum, almost imperceptibly occurred. December 15th, anorexia; pulse small and weak; decided failure of vital powers. Died, December 29th.

Autopsy: Head of peculiar shape, anterior posterior diameter being great as compared with lateral, which was very small; brain more than ordinarily hard; medullary substance unusually white; upper and middle lobes of right lung firmly adherent; a tubercular cavity in posterior part of middle lobe, the surrounding lung tissue hardened; left pleural cavity contained ten ounces of yellowish serum; lung firmly adherent at apex; deposition of yellowish lymph over unattached portion of upper lobe; tubercular cavity in posterior upper part of lower lobe; neighboring lung tissue hardened and attached to sides of vertebrae; considerable tubercular deposit on each side of bodies of sixth and seventh dorsal vertebrae, in the stage of softening bones, denuded and carious; kidneys slightly fatty.

Contributed by Surgeon E. Bentley, U. S. Vols., Alexandria, Va.

No. 575. Pelvis, in which the os sacrum is light and spongy, especially on left side, with irregular new formations of bone on anterior surface; thin layers of new-formed bone coat the inner and outer surfaces of a large part of left ilium; the new-formed bone on inner surface of left ilium rises into an irregular exostosis of moderate size; a large abscess existed in specimen, as received at Museum, filled with cheesy pus, which anteriorly formed in front of sacrum and in hollow of left ilium a tumor of considerable size, the pus lying external to iliac periosteum; an irregular abscess-cavity posteriorly involving left half of sacrum and posterior half of outer surface of ilium; this abscess-cavity was filled with cheesy pus, communicated with abscess within pelvis, and opened by several fistulous orifices through skin on upper part of left buttock.

From a negro affected with serfelia, who had abscesses in various parts of body and phthisis pulmonalis.

Contributed by Acting Assistant Surgeon W. C. Miner, L'Ouverture Hospital, Alexandria, Va.

No. 811. Tubercular caries of lower two dorsal vertebrae, of lumbar vertebrae and of sacrum, involving ischium and crest of ilium of both sides.

Private J. T., "E," 37th U. S. Colored, age 23. Admitted, February 20th, 1866, from Hicks Hospital, with severe pain much increased on pressure over lumbar region, with paraplegia, great constitutional debility and serofulous cachexia. He stated that his sickness commenced while in hospital at Fortress Monroe, Va., with first bitten feet; he had pain in the back, increasing early until he was unable to use his lower extremities. An abscess formed and was opened shortly after his admission into this hospital; the opening continued to discharge profusely a quantity of very fetid and empy pus; at times he was considerably troubled with incontinence of urine. About three weeks before his death another large abscess formed lower down over sacro-lumbar junction; it was opened and discharged one and a half pints of fetid, empy pus, followed by a quantity of yellow inspissated matter, in which little specks of necrosed bone were seen; carious bone was seen through both of these openings. He continued to grow weaker daily, and was found dead in his bed early in the morning, April 10th, after having eaten his supper as usual the night before.

Autopsy: Large amount of about three ounces of purulent fluid escaped from subarachnoid space upon opening dura mater; vessels of piamater somewhat congested, surfaces of meningeal and pia mater covered with a thick layer of yellowish pus; area of heart of left lateral ventricle contained about two drachms of pus; third ventricle also contained a small quantity of

purulent matter; fourth ventricle full of pus; entire surface of spinal cord covered with pus; left lung adherent; both lungs and bronchial glands full of black pigment; heart somewhat enlarged, its cavities filled with whitish fibinous clots; liver fatty; gall-bladder filled with greenish-yellow bile; mesenteric glands enlarged, some containing deposits of tubercular matter; about eight ounces of yellowish serum in peritoneal cavity; lumbar, sacral, coccygeal and lower dorsal vertebrae carious, as in specimen; lymphatic glands in inguinal and pelvic regions infiltrated with curly pus; pus beneath sheaths of both psoas muscles, the greater portion of these muscles being destroyed; curious abscesses of right fifth rib, and of left second and fourth, at cartilaginous junctions; sternum carious from fifth costal junction down; innominate bones studded with spots of caries.

Contributed by Acting Assistant Surgeon H. McElderry, Post Hospital, Fort McHenry, Baltimore, Md.

No. 580. Right knee joint, in which the articular surfaces of femur, tibia and patella have been destroyed by serofulous ulceration; the bones for some distance beyond the articulation are coated by flat, irregular plates of new-formed bone.

See 582, chap. II., sec. 3, C. 1, for history.

No. 588. Lower part of right femur, patella and upper parts of bones of legs; the articular extremities spongy, eroded, presenting several cavities, the largest of which is in head of tibia, and is over an inch in length; anterior surface of patella and surfaces of tibia, fibula and femur, near articulation, roughened by irregular, new formations of bone.

From a case of tubercular inflammation of joint in Freedman's Hospital.

Contributed by Assistant Surgeon E. Bentley, U. S. Army, Washington, D. C.

No. 860. Small, irregular, new formations of bone about the upper edges of articular faces of scaphoid bone of left foot and adjoining edges of astragalus and internal cuneiform bones; ankylosis of last two phalanges of little toe; supernumerary sesamoid bone between last two phalanges of great toe.

From a negro man who died in the spring of 1866.

From Freedman's Hospital, Washington, D. C.

Autopsy by Hospital Steward D. S. Lamb.

No. 856. Right innominate and femur, cotyloid ridge of acetabulum fringed by arthritic new formations of bone; its concavity lined by porous new-formed bone; head of femur atrophied, its neck distorted; arthritic new formations on edges of patella and anterior surfaces of femoral condyles.

From Freedman's Hospital, Washington, D. C.

Autopsy by Hospital Steward A. M. Squier.

No. 859. Left knee joint, articular surfaces much deformed, giving the leg a considerable bow inward; edges of articular surfaces of all the bones beset by arthritic new formations.

From the body of a colored woman who died in the spring of 1866.

From Freedman's Hospital, Washington, D. C.

Autopsy by Hospital Steward S. S. Bond.

No. 574. Portion of sacrum, showing caries in lower anterior portion, in connection with which a pelvic abscess had existed.

18. From a case of constitutional syphilis.

No history.

Contributed by Surgeon E. Griswold, U. S. Vols., Judiciary Square Hospital, Washington, D. C.

No. 866. Section of an enchondromatous tumor of shoulder, of great size. (*For description, see Boston Medical and Surgical Journal, Vol. 70, page 169. See Surgical Section, 1656, XXXI, B. A. 16; Microscopical Section, Part First, XIV, A. A. 1.*)

Contributed by Dr. J. B. S. Jackson, Boston, Mass.

No. 22. Skull, with diploe greatly thickened, in some places nearly to half an inch; inner surface of cranium irregularly roughened; rami of lower jaw soft and porous; in outer portion of falx major was a large osteophyte; several smaller ones near middle of falx.

From the body of a white woman of unknown history, found in a dissecting room.

Contributed by Acting Assistant Surgeon A. M. Squier.

No. 872. Third to eleventh dorsal vertebrae, inclusive, with tubercular caries involving bodies of sixth to ninth dorsals, inclusive; the destruction of the osseous tissue is greatest in the bodies of the seventh and eighth.

121. *See 874, chap. 1., ser. 5, 1, for history.*

Chapter VII. INTEGUMENT.

SEVEN SPECIMENS.

Chapter VII. INTEGUMENT.

- No. 323.** Piece of integument from back of left arm, presenting several small carbuncles.
1. From a soldier of the Veteran Reserves, who was taken sick in May, 1864, with idiopathic erysipelas of the hand and forearm; he became comatose on the second day, and small carbuncles, similar to those in specimen, appeared over whole body; he died on third day.
Contributed by Acting Assistant Surgeon T. Cunyngnam, Sherburne Barracks, Washington, D. C.
- No. 805.** Fœtus, at term, with whole scalp covered with an irregular, lobulated, luxuriant vascular fungus, which extends somewhat upon the face, disfiguring features, and involves, though in a much slighter manner, the upper part of trunk and shoulders.
2. The mother was a healthy young mulatto woman.
Contributed by Surgeon E. Bentley, U. S. Vols., L'Ouverture Hospital, Alexandria, Va.
- No. 629.** Integument of front of thorax of a very dark mulatto, over which ramifies an irregular branching keloid growth; the integument between the branches of this new formation healthy, with enlarged sebaceous glands; a few hairs beset the growth. Microscopical examination showed the growth to be composed of tough connective tissue, with small papillæ and thin epidermis; vascularity scanty, and the whole tissue resembling an old scar from a burn.
3. (See *Microscopical Section, Part First, XIV. B A. 3.*)
From a colored man who died of mania-a-pota, September 15th, 1865.
From Freedman's Hospital, Washington, D. C.
Autopsy by Hospital Steward A. J. Shafhirt.
- No. 301.** Plaster cast of part of left leg, with elephantiasis tuberosa, presenting a livid patch somewhat larger than the hand, from which project innumerable smooth tubercles, varying from the size of a small shot to that of a large pea.
4. Private J. B. B., "E," 15th Kentucky. Admitted, June 24th, 1863, with leg as shown in specimen. He stated that he suffered from the disease nine years previously, but after a year it disappeared; it presented itself again about a month prior to admission, and had extended. The patient's general health and appearance were excellent; he suffered no pain while at rest, but the part "ached" when he attempted to walk; said he had never had syphilis.
Contributed by Assistant Surgeon C. C. Gray, U. S. Army, Hospital No. 8, Nashville, Tenn.
- No. 875.** Two portions of skin, showing the eruption of small-pox on the 18th day; the upper portion from over the epigastrium, the lower, from the lower third of the leg.
5. B. C., colored, age 21, not vaccinated. Admitted, June 8th, 1866, with confluent small-pox; eruption had appeared on 6th. He did well until the 19th or 20th day, when, in addition to severe furuncular inflammations on various parts of his body, pneumonia supervened. Died, June 24th.
The pustules were drying on various parts of the body before pneumonia occurred.
Contributed by Assistant Surgeon T. G. Mackenzie, U. S. Army, Kalorama Hospital, Washington D. C.
- No. 876.** Three portions of skin, showing the eruption of small-pox on the 14th day; the upper portion from lower third of leg; the left lower one, from over thorax; the right lower, from upper third of forearm.
6. E. K. H., U. S. General Service, age 30, recently unsuccessfully vaccinated. Admitted, June 15th, 1866, with confluent small-pox; the eruption had appeared on the 13th. He died in convulsions on the 27th.
Contributed by Assistant Surgeon T. G. Mackenzie, U. S. Army, Kalorama Hospital, Washington, D. C.
- No. 877.** Portion of skin from upper third of right forearm, showing the eruption of small-pox on the 11th day.
7. D. S. colored, age 80, recently successfully vaccinated. Admitted, June 30th, 1866, with discrete small-pox; he was much debilitated and had albuminous urine. Died comatose, July 7th.
Contributed by Assistant Surgeon T. G. Mackenzie, U. S. Army, Kalorama Hospital, Washington, D. C.

Chapter VIII. ANOMALIES AND MONSTROSITIES.

THIRTEEN SPECIMENS.

Chapter VIII. ANOMALIES AND MONSTROSITIES.

- No. 550.** Hand, in which the metacarpal bone of thumb, much expanded laterally, presents two articular facets at its phalangeal extremity, on outer one of which two thumb phalanges are situated, and on inner, three finger phalanges; both finger and thumb phalanges of diminutive size.
Contributed by Surgeon F. G. Snelling, U. S. Vols., Medical Director 18th Army Corps, Newbern, N. C.
- No. 724.** 2. Left foot, in which the last metatarsal bone, presents at its anterior extremity two articular heads, one of which supports a toe composed of three phalanges; the outer one a toe composed of two phalanges.
Contributor unknown.
- Nos. 516 and 517.** **516.** middle and ring fingers of left hand, firmly united by their lateral margins throughout their whole length, presenting a single nail of double width with an indentation corresponding to the division of the last two fingers. **517.** middle and ring fingers of right hand of same patient, dissected to show the bones; phalanges of middle finger normal, but nail adheres to that of ring finger; second phalanx of ring finger bifid; ulnar branch much the largest; third phalanx, which carries a nail of unusual breadth and is nearly an inch in transverse diameter at its base, has an articular surface uniting it with each branch of second phalanx.
No history.
Contributed by Medical Cadet Elliott Cones, Mount Pleasant Hospital, Washington, D. C.
- No. 868.** Cast of left hand, with double thumb.
5. Private J. A. H., 15th Massachusetts Battery, age 43. Admitted, October 29th, 1864, with chronic rheumatism. Returned to duty January 2d, 1865.
Contributed by Surgeon J. C. McKee, Lincoln Hospital, Washington, D. C.
- Nos. 869 and 870.** Casts of both hands, each with a sixth finger on the ulnar side.
Private T. H., "I." 99th New York. Admitted, September 6th, 1865, with chronic diarrhoea. Transferred to hospital at David's Island, N. Y. Harbor, October 2nd.
6 and 7. Contributed by Acting Assistant Surgeon J. H. Armsby, Ira Harris Hospital, Albany, N. Y.
- No. 711.** 8. Skeleton of a hemicephalus fetus at term; parietal bones, ascending portion of frontal, and squamous portions of the two temporals wanting; frontal bone rounded off above orbits, and its anterior surface becomes continuous with orbital process; edges of temporal and occipital bones rounded off in like manner; in the cup-shaped conical cavity was a rudimentary brain, covered superiorly by imperfectly developed integument.
Contributor unknown.
- No. 801.** 9. Hemicephalus fetus at term. The mother was a young mulatto woman.
Contributed by Surgeon E. Bentley, U. S. Vols., Washington, D. C.
- No. 82.** 10. Hemicephalus fetus, which died a few minutes after birth at full term.
Contributed by Surgeon H. Culbertson, U. S. Vols., Harvey Hospital, Madison, Wis.
- No. 861.** 11. Monstrous fetus at full term; lived fifteen minutes after birth; fourth child; third pregnancy; other children healthy and well formed. The following are the anatomical conditions:—thymus gland well developed; each lung consists of a single lobe; stomach large, with hour-glass contraction about the middle; liver lobated; no gall-bladder; testes in abdominal cavity; small intestine terminates in a cul-de-sac on left side, largely distended with mæconium; no large intestine; pancreas and spleen normal; an irregular body, one inch long, on left side, supposed to represent left kidney, but no ureters nor bladder could be made out; no pelvic cavity nor external opening of anus; double club forearm and hand; arrest of development in both thighs, which resemble stumps, the left being the largest.
Contributed by Dr. F. Howard, Washington, D. C.
- No. 817.** 12. Mole, with cavity containing a rudimentary fetus; the abnormal ovum forms a sac three and a half inches long, with an oval cavity and walls of various thicknesses, half an inch at the thickest part; to one part of anterior surface of cyst thus formed, an embryo half an inch long is attached by its fetal extremity.
This mole was expelled, November 5th, 1866, by a patient who had last menstruated in the previous August.
Contributed by Assistant Surgeon H. McElderry, U. S. Army, West Point, N. Y.
- No. 865.** 13. Monstrous pig, with a single body; two normal forelegs and a double head fused together; there are two snouts, each with two nostrils; two mouths, with upper and lower jaw-teeth each; the inner surfaces of both jaws fused together; the outer eye on each side apparently perfect; the inner eyes represented by a single aperture, leading to an undeveloped rudiment, with a few black bristles for eyebrows; outer ear of each head normal; inner ear absent; vault of cranium deficient; brain rudimentary.
Contributed by Surgeon H. Culbertson, U. S. Vols., Harvey Hospital, Madison, Wis.

INDEX

OF

CONTRIBUTORS TO THE MEDICAL SECTION.

A.

- Allen, H.—p. 31, No. 10; p. 32, No. 515; p. 57, No. 160; p. 58, No. 201; p. 69, Nos. 116 to 118; p. 71, Nos. 151 and 155; p. 78, Nos. 383 and 384; p. 81, Nos. 329 to 331.
- Ansell, A.—p. 21, No. 558.
- Antisell, Thomas—p. 67, Nos. 161 to 163; p. 70, Nos. 156 to 159; p. 107, No. 161.
- Armsby, J. H.—p. 127, Nos. 869 and 870.

B.

- Bache, Thomas H.—p. 109, No. 592.
- Bacon, C., jr.—p. 18, No. 111; p. 52, No. 328; p. 62, Nos. 159 and 160.
- Baxter, J. H.—p. 48, No. 40.
- Bentley, E.—p. 5, No. 770; p. 14, No. 506; p. 16, No. 801; p. 17, No. 51; p. 18, Nos. 317 and 662; p. 25, Nos. 821 and 826; p. 31, No. 410; p. 31, Nos. 313, 318 and 111; p. 35, Nos. 315 and 818; p. 36, No. 312; p. 37, No. 667; p. 40, No. 665; p. 41, Nos. 827 and 828; p. 50, No. 11; p. 57, No. 121; p. 58, No. 420; p. 61, No. 439; p. 71, No. 419; p. 73, Nos. 296 and 297; p. 78, Nos. 122 and 123; p. 79, Nos. 819, 673 and 666; p. 86, No. 731; p. 87, No. 731; p. 89, No. 661; p. 90, No. 157; p. 92, No. 417; p. 95, Nos. 829 and 639; p. 97, Nos. 830, 306 and 112; p. 99, No. 298; p. 100, No. 663; p. 105, Nos. 305, 803 and 802; p. 106, Nos. 16 and 766; p. 108, Nos. 822 and 823, 732 and 831; p. 110, No. 796; p. 111, Nos. 816 and 815; p. 112, Nos. 833 and 507; p. 113, Nos. 337 and 733; p. 117, No. 825; p. 118, No. 713; p. 119, No. 858; p. 123, No. 805; p. 127, No. 801.
- Bloom, J. W.—p. 17, No. 67.
- Bond, S. S.—p. 110, No. 42.
- Bontecou, R. B.—p. 24, No. 730; p. 64, Nos. 761 to 706; p. 67, Nos. 707 and 708; p. 78, No. 703; p. 89, Nos. 727 and 728; p. 100, No. 729.
- Bournonville, A. C.—p. 51, No. 153.
- Bowen, ————p. 109, No. 591.
- Boyd, G. B.—p. 17, No. 332.
- Bradley, W. A.—p. 53, Nos. 192 and 193; p. 55, Nos. 185 to 189.
- Breed, B. B.—p. 20, No. 392.
- Breneman, E. De W.—p. 93, No. 295.
- Browne, R. K.—p. 29, No. 6; p. 45, Nos. 1, 2, 3, 4 and 5.
- Bryant, J.—p. 32, No. 7; p. 53, No. 208; p. 54, Nos. 280 to 283.
- Buck, H. B.—p. 32, No. 13.
- Buckman, E. D.—p. 100, No. 632.
- Butler, J. H.—p. 61, No. 810.
- Byrne, C. C.—p. 96, No. 171; p. 111, No. 38.

C.

- Cantwell, J. Y.—p. 96, No. 476.
- Casey, W. B.—p. 87, Nos. 562 and 563.
- Chapin, H. B.—p. 50, No. 24.
- Combs, W. H.—p. 65, Nos. 395 to 397; p. 76, No. 115.

- Comfort, A. I.—p. 80, Nos. **811** and **832**.
 Conner, P. S.—p. 76, No. **83**.
 Coues, E.—p. 50, No. **39**; p. 56, Nos. **190** and **207**; p. 127, Nos. **516** and **517**.
 Cowgill, C. A.—p. 7, Nos. **32** and **33**.
 Cramer, J. F.—p. 85, No. **18**.
 Crosby, T. R.—p. 36, No. **133**; p. 38, No. **169**; p. 39, No. **180**; p. 41, Nos. **181** and **170**; p. 58, No. **271**; p. 59, Nos. **180** to **183**; p. 75, Nos. **136** and **137**; p. 83, Nos. **182** to **187**; p. 91, No. **135**; p. 99, No. **171**; p. 117, No. **131**.
 Culbertson, Howard—p. 19, No. **199**; p. 21, No. **197**; p. 25, No. **686**; p. 29, No. **191**; p. 45, No. **193**; p. 47, No. **198**; p. 50, No. **505**; p. 58, No. **196**; p. 77, No. **181**; p. 78, No. **195**; p. 90, No. **687**; p. 91, No. **501**; p. 94, No. **321**; p. 127, Nos. **82** and **865**.
 Cunyngnam, T.—p. 36, No. **339**; p. 123, No. **323**.

D.

- Dade, F. T.—p. 76, Nos. **71** to **74**; p. 105, No. **23**.
 Daggett, D. L.—p. 23, No. **552**; p. 82, No. **551**.
 Dean, H. M.—p. 13, Nos. **103** and **338**; p. 15, No. **161**; p. 21, No. **132**; p. 29, No. **126**; p. 37, No. **127**; p. 60, Nos. **369** to **373**; p. 81, Nos. **128** to **131**; p. 91, Nos. **351**, **150** and **151**; p. 107, Nos. **155** and **156**.
 Delaney, A. P.—p. 58, No. **226**.
 Dorsey, S.—p. 76, Nos. **151** and **152**.
 Draper, L. J.—p. 5, No. **873**; p. 35, No. **871**.
 Ducachet, H. W.—p. 47, No. **66**; p. 60, No. **77**.

E.

- Ellis, W.—p. 33, No. **611**; p. 108, No. **615**.

F.

- Faxon, W. L.—p. 15, No. **518**; p. 33, No. **391**; p. 47, No. **178**; p. 61, No. **179**; p. 86, No. **153**; p. 99, No. **523**.
 Fay, G. W.—p. 33, No. **116**.
 Fell, E. R.—p. 11, No. **579**.
 Ford, C. M.—p. 110, No. **759**; p. 111, No. **113**.
 Foye, J. W.—p. 109, No. **593**.
 French, George F.—p. 61, Nos. **115** and **116**; p. 65, Nos. **126** to **128**; p. 72, No. **111**; p. 73, Nos. **119** to **123**, and **129** to **131**; p. 75, Nos. **121** and **125**; p. 76, Nos. **132** to **137**; p. 79, Nos. **138** to **143**; p. 85, No. **19**.
 Fry, G. W.—p. 11, No. **52**.
 Fryer, B. E.—p. 49, No. **518**; p. 50, No. **519**.

G.

- Gardner, W. H.—p. 75, No. **78**.
 Gibbs, A. S.—p. 110, Nos. **576** to **578**.
 Goldsmith, M.—p. 5, Nos. **35** and **36**; p. 22, No. **503**.
 Gouley, J. W. S.—p. 97, No. **26**.
 Gray, C. C.—p. 123, No. **301**.
 Griswold, E.—p. 119, No. **571**.

H.

- Haight, D. L.—p. 37, No. **105**; p. 60, Nos. **371** and **375**; p. 71, No. **106**; p. 78, Nos. **361** to **366**.
 Hard, A.—p. 67, No. **321**; p. 81, No. **322**.
 Hartshorne, E.—p. 73, Nos. **118** and **119**.
 Herbut, ————p. 11, No. **511**.
 Hildreth, J. S.—p. 107, Nos. **27** to **29**.
 Hitz, R. B.—p. 75, No. **162**.
 Horner, Caleb W.—p. 9, No. **311**; p. 15, No. **310**; p. 20, Nos. **311** and **312**; p. 39, No. **313**.
 Howard, F.—p. 127, No. **861**.

J.

- Jackson, J. B. S.—p. 25, No. **571**; p. 119, No. **866**.
 Jewett, P. A.—p. 19, No. **638**; p. 21, No. **515**; p. 79, No. **521**; p. 106, No. **525**.

K

- Keller, J. G.—p. 3, No. **760**.
 Kennedy, J. F.—p. 85, No. **47**.
 Kingston, ———p. 106, Nos. **20** and **21**.
 Kipp, C. J.—p. 13, No. **319**; p. 16, No. **316**; p. 87, No. **53**; p. 96, No. **473**; p. 105, No. **335**.
 Kneeland, S.—p. 92, No. **712**.

L

- Laub, C. H.—p. 45, No. **812**; p. 48, No. **813**.
 Leidy, Joseph—p. 17, No. **68**; p. 22, No. **19**; p. 24, No. **269**; p. 31, No. **11**; p. 32, No. **12**; p. 34, Nos. **92** and **311**; p. 36, No. **331**; p. 46, Nos. **63** and **272**; p. 50, Nos. **30**, **31** and **350**; p. 51, Nos. **81**, **85**, **87**, **93** to **98** and **107** and **108**; p. 52, Nos. **237**, **238**, **270** and **273** to **276**; p. 54, Nos. **228** to **231** and **112** and **113**; p. 55, Nos. **99** to **101** and **212** and **213**; p. 57, Nos. **60** and **61**; p. 58, No. **239**; p. 59, Nos. **88** to **90**, **102** to **105**, and **210** and **211**; p. 62, Nos. **231** to **236**; p. 67, Nos. **232** and **233**; p. 68, Nos. **86** and **262** to **268**; p. 72, Nos. **61** and **279**; p. 74, Nos. **56** to **59**; p. 75, Nos. **110** and **111**; p. 80, No. **13**; p. 83, Nos. **211** to **261**; p. 88, No. **91**; p. 91, No. **333**; p. 96, No. **475**; p. 97, Nos. **62**, **109**, **106** and **111**; p. 98, No. **55**; p. 111, Nos. **17** and **18**.
 Lilly, H. M.—p. 4, Nos. **299** and **300**; p. 5, No. **811**.
 Lincoln, N. S.—p. 118, No. **573**.

M

- McCall, C. A.—p. 16, No. **212**; p. 32, No. **411**; p. 94, Nos. **215** and **216**.
 McCook, George—p. 113, No. **795**.
 McDonald, W. O.—p. 56, No. **150**.
 McElderry, H.—p. 19, No. **852**; p. 20, No. **853**; p. 96, No. **853**; p. 118, No. **811**; p. 127, No. **817**.
 McGill, G. M.—p. 5, No. **583**; p. 9, No. **588**; p. 10, No. **587**; p. 32, Nos. **585** and **586**; p. 48, No. **69**; p. 73, No. **616**; p. 75, No. **70**; p. 81, No. **618**; p. 94, No. **867**; p. 98, No. **581**; p. 112, No. **788**.
 McKee, J. C.—p. 4, No. **813**; p. 47, No. **291**; p. 94, Nos. **292** to **291**; p. 127, No. **868**.
 Mackenzie, T. G.—p. 123, Nos. **875**, **876** and **877**.
 May, H. C.—p. 63, Nos. **510** to **513**.
 Miles, B. B.—p. 15, No. **336**; p. 17, No. **214**; p. 31, No. **988**; p. 36, No. **310**; p. 49, No. **412**; p. 59, No. **191**; p. 71, No. **227**; p. 107, Nos. **500** and **501**.
 Miner, W. C.—p. 3, No. **617**; p. 6, Nos. **557** and **566**; p. 7, No. **520**; p. 9, No. **619**; p. 13, No. **596**; p. 16, No. **514**; p. 18, No. **451**; p. 25, No. **582**; p. 29, No. **467**; p. 36, No. **526**; p. 37, No. **192**; p. 40, Nos. **621**, **625** and **567**; p. 49, No. **651**; p. 54, No. **565**; p. 60, No. **468**; p. 61, No. **152**; p. 63, Nos. **189** to **191**, **597** and **598**, and **600** and **601**; p. 66, Nos. **851** and **855**; p. 81, Nos. **465** and **166**; p. 84, Nos. **463** and **464**; p. 87, No. **553**; p. 88, No. **581**; p. 89, No. **626**; p. 99, Nos. **561** and **569**; p. 100, Nos. **630** and **627**; p. 112, No. **513**; p. 113, Nos. **589** and **590**; p. 117, Nos. **556**, **568**, **555** and **510** to **512**; p. 118, No. **575**; p. 119, No. **580**.
 Morris, John—p. 85, No. **411**.
 Moseley, N. R.—p. 31, No. **410**; p. 37, No. **521**; p. 71, No. **438**; p. 75, No. **527**; p. 78, Nos. **367** and **368**.
 Moxley, I. J.—p. 50, No. **522**.
 Mursick, G. A.—p. 99, Nos. **325** and **326**.

N

- Neill, John—p. 30, No. **570**.
 Norris, W. F.—p. 21, No. **516**; p. 30, No. **519**; p. 70, Nos. **660** and **517**; p. 77, Nos. **362** and **400**; p. 80, No. **448**; p. 93, No. **419**; p. 97, No. **531**; p. 106, Nos. **361** and **530**.

O

- Okie, W. T.—p. 30, No. **302**.

P

- Page, C.—p. 34, No. **65**; p. 54, Nos. **171** to **177**; p. 56, No. **75**; p. 71, Nos. **217**, **218** and **219**, and **220** and **221**; p. 72, No. **203**; p. 76, No. **222**; p. 80, Nos. **223** to **225**.
 Parker, G. B.—p. 26, No. **595**.
 Perry, Ira—p. 14, Nos. **810** and **812**; p. 65, Nos. **838** and **839**; p. 71, No. **831**; p. 72, No. **837**; p. 97, No. **836**; p. 98, Nos. **712** and **710**; p. 100, Nos. **709** and **711**; p. 101, No. **835**; p. 109, No. **811**.
 Peters, De Witt C.—p. 9, No. **11**; p. 15, No. **599**; p. 31, No. **14**; p. 33, No. **591**; p. 39, Nos. **213** and **309**; p. 50, No. **15**; p. 62, Nos. **307** and **308**; p. 68, No. **76**; p. 85, No. **775**; p. 92, Nos. **668** and **669**; p. 96, No. **37**; p. 111, No. **758**; p. 117, No. **303**.

R.

Reber, C. T.—p. 46, No. **363**.
 Rowe, H.—p. 31, No. **15**.

S.

Schafhirt, A. J.—p. 23, No. **25**.
 Schafhirt, Fred.—p. 55, Nos. **277** and **278**; p. 91, No. **115**; p. 114, No. **81**.
 Schell, H. S.—p. 93, No. **628**.
 Seguin, G. C.—p. 3, No. **761**.
 Sim, Thomas—p. 48, No. **537**; p. 70, No. **158**; p. 95, Nos. **538** and **539**.
 Skillern, S. R.—p. 39, No. **16**.
 Smith, G. K.—p. 81, Nos. **602** and **603**; p. 105, No. **551**.
 Smoot, Samuel C.—p. 33, No. **572**.
 Snelling, F. G.—p. 127, No. **550**.
 Sparrow, Wm. E.—p. 85, No. **113**.
 Spencer, T. R.—p. 39, No. **301**.
 Squier, A. M.—p. 113, No. **713**; p. 119, Nos. **856** and **92**.
 Stevens, H.—p. 86, No. **51**.
 Storror, E.—p. 15, No. **327**.
 Sweet, O. P.—p. 15, No. **172**; p. 55, Nos. **398** and **399**; p. 56, Nos. **421** and **125**; p. 57, Nos. **107** and **108**; p. 58, No. **352**; p. 63, Nos. **385** to **390**; p. 64, Nos. **116** to **118**; p. 65, Nos. **356** to **359**; p. 66, Nos. **353** to **355**; p. 70, Nos. **101** and **102**; p. 78, No. **109**.

T.

Thomson, W.—p. 10, No. **871**; p. 22, No. **862**; p. 23, No. **381**; p. 37, No. **101**; p. 53, Nos. **165** to **170**; p. 54, Nos. **202** and **376** to **380**; p. 57, Nos. **79** and **80**; p. 58, No. **196**; p. 65, Nos. **815** to **821**; p. 71, Nos. **393** and **391**; p. 77, Nos. **191** and **195**, and **288** and **289**; p. 80, No. **360**; p. 93, No. **850**; p. 107, Nos. **863** and **861**; p. 119, No. **872**.
 Thorp, Abner—p. 61, No. **117**.
 Todd, S. S.—p. 80, No. **382**.
 Tutt, C. P.—p. 49, No. **188**.

U.

Ure, Walter—p. 107, Nos. **508** and **509**.

V.

Van Arnum, J. W.—p. 111, No. **857**.
 Vandyke, E. B.—p. 69, Nos. **317** to **320**.

W.

Ward, S. B.—p. 33, No. **290**.
 Watson, A. T.—p. 21, No. **502**; p. 30, Nos. **650** and **652**; p. 46, No. **653**; p. 57, No. **651**.
 Webster, Warren—p. 80, No. **281**.
 Weir, R. P.—p. 4, No. **535**; p. 31, No. **528**; p. 32, No. **529**; p. 49, No. **532**; p. 109, No. **536**.
 Welling, E. L.—p. 72, Nos. **285** and **286** and **287**; p. 71, Nos. **178** and **179**.
 Wells, W. L.—p. 56, Nos. **315** and **316**; p. 91, No. **209**.
 Whitehead, W. E.—p. 61, Nos. **197** to **200**.
 Wilcoxson, L. D.—p. 18, No. **655**.
 Willentski, Iwanoff—p. 59, No. **115**.
 Wilson, J. E.—p. 86, No. **50**.
 Wolfley, W. J.—p. 4, No. **531**.
 Woodward, B.—p. 7, No. **31**.

Y.

Young, J. T.—p. 22, No. **533**.

Specimens from Autopsies made at the Freedman's Hospital by Employees of the Museum.—p. 6, Nos. **637** and **793**; p. 8, Nos. **785**, **735** and **791**; p. 9, No. **790**; p. 13, No. **787**; p. 16, No. **716**; p. 18, No. **711**; p. 19, No. **783**; p. 20, Nos. **789** and **722**; p. 22, No. **691**; p. 23, Nos. **717** and **737**; p. 35, Nos. **681** and **807**; p. 38, Nos. **607**, **691** and **773**; p. 39, Nos. **611** and **633**; p. 40, Nos. **711** and **675**; p. 41, Nos. **688** and **736**; p. 46, No. **786**; p. 47, Nos. **768** and **631**; p. 48, No. **719**; p. 49, No. **670**; p. 52, Nos. **717** and **718** to **750**; p. 53, Nos. **756**, **762** and **781**; p. 61, Nos. **601** to **606**; p. 62, Nos. **656** and **657**; p. 66, Nos. **680** to **683**; p. 67, Nos. **698** and **699**; p. 68, Nos. **700** and **701**; p. 69, Nos. **619** to **622**, and **608** to **610**; p. 77, No. **769**; p. 82, Nos. **692**, **771**, **776**, **671** and **798**; p. 83, Nos. **612**, **808** and **725**; p. 84, Nos. **677** to **679**, **771** and **772**, and **720**; p. 86, Nos. **781**, **715** and **806**; p. 88, Nos. **693**, **721**, **778**, **612** and **613**, **739** and **636**; p. 89, Nos. **751** to **753**, **689**, **635** and **761**; p. 90, Nos. **617** and **618**, **672** and **723**; p. 93, No. **690**; p. 94, Nos. **695**, **738**, **763** and **765**; p. 95, Nos. **697** and **611**; p. 96, No. **658**; p. 98, Nos. **716** and **782**; p. 100, Nos. **631** and **696**; p. 101, Nos. **715** and **767**; p. 105, Nos. **779**, **792** and **757**; p. 106, No. **685**; p. 108, Nos. **671**, **718**, **726** and **611**; p. 110, No. **610**; p. 111, Nos. **710**, **797** and **791**; p. 112, Nos. **623**, **659**, **615**, **800** and **780**; p. 113, Nos. **799**, **613**, **616**, **751** and **851**; p. 117, Nos. **676** and **809**; p. 118, No. **755**; p. 119, Nos. **860**, **856** and **859**; p. 123, No. **629**.

INDEX

OF

SPECIMENS IN THE MEDICAL SECTION.

<i>Spec.</i>	<i>Page.</i>	<i>Spec.</i>	<i>Page.</i>	<i>Spec.</i>	<i>Page.</i>	<i>Spec.</i>	<i>Page.</i>	<i>Spec.</i>	<i>Page.</i>	<i>Spec.</i>	<i>Page.</i>	<i>Spec.</i>	<i>Page.</i>
No. 1	45	No. 56	74	No. 111	75	No. 166	53	No. 221	71	No. 276	52	No. 331	81
No. 2	45	No. 57	74	No. 112	54	No. 167	53	No. 222	76	No. 277	55	No. 332	17
No. 3	45	No. 58	74	No. 113	54	No. 168	53	No. 223	80	No. 278	55	No. 333	91
No. 4	45	No. 59	74	No. 111	97	No. 169	53	No. 221	80	No. 279	72	No. 331	36
No. 5	45	No. 60	57	No. 115	76	No. 170	53	No. 225	80	No. 280	54	No. 335	105
No. 6	29	No. 61	57	No. 116	69	No. 171	54	No. 226	58	No. 281	54	No. 336	15
No. 7	32	No. 62	97	No. 117	69	No. 172	54	No. 227	71	No. 282	54	No. 337	113
No. 8	31	No. 63	46	No. 118	69	No. 173	54	No. 228	54	No. 283	54	No. 338	13
No. 9	31	No. 61	72	No. 119	73	No. 174	54	No. 229	54	No. 281	80	No. 339	36
No. 10	31	No. 65	34	No. 120	73	No. 175	54	No. 230	54	No. 285	72	No. 340	36
No. 11	31	No. 66	47	No. 121	73	No. 176	54	No. 231	54	No. 286	72	No. 311	34
No. 12	32	No. 67	17	No. 122	73	No. 177	54	No. 232	67	No. 287	72	No. 312	36
No. 13	32	No. 68	17	No. 123	73	No. 178	74	No. 233	67	No. 288	77	No. 313	34
No. 14	31	No. 69	48	No. 121	75	No. 179	74	No. 231	62	No. 289	77	No. 311	19
No. 15	31	No. 70	75	No. 125	75	No. 180	59	No. 235	62	No. 290	33	No. 315	35
No. 16	39	No. 71	76	No. 126	65	No. 181	59	No. 236	62	No. 291	47	No. 316	16
No. 17	111	No. 72	76	No. 127	65	No. 182	59	No. 237	52	No. 292	94	No. 317	18
No. 18	111	No. 73	76	No. 128	65	No. 183	59	No. 238	52	No. 293	94	No. 318	34
No. 19	22	No. 71	76	No. 129	73	No. 181	77	No. 239	58	No. 291	94	No. 319	13
No. 20	106	No. 75	55	No. 130	73	No. 185	55	No. 240	59	No. 295	93	No. 350	50
No. 21	106	No. 76	68	No. 131	73	No. 186	55	No. 241	59	No. 296	73	No. 351	91
No. 22	119	No. 77	61	No. 132	76	No. 187	55	No. 242	55	No. 297	73	No. 352	58
No. 23	105	No. 78	75	No. 133	76	No. 188	55	No. 243	55	No. 298	99	No. 353	66
No. 24	50	No. 79	57	No. 134	76	No. 189	55	No. 244	53	No. 299	4	No. 351	66
No. 25	23	No. 80	57	No. 135	76	No. 190	56	No. 245	53	No. 300	4	No. 355	66
No. 26	97	No. 81	114	No. 136	76	No. 191	59	No. 246	53	No. 301	20	No. 356	65
No. 27	107	No. 82	127	No. 137	76	No. 192	53	No. 247	53	No. 302	30	No. 357	65
No. 28	107	No. 83	76	No. 138	79	No. 193	53	No. 248	53	No. 303	117	No. 358	65
No. 29	107	No. 84	51	No. 139	79	No. 191	77	No. 249	53	No. 301	123	No. 359	65
No. 30	50	No. 85	51	No. 140	79	No. 195	77	No. 250	53	No. 305	105	No. 360	80
No. 31	50	No. 86	68	No. 141	79	No. 196	58	No. 251	53	No. 306	97	No. 361	106
No. 32	7	No. 87	51	No. 142	79	No. 197	64	No. 252	53	No. 307	62	No. 362	77
No. 33	7	No. 88	59	No. 143	79	No. 198	64	No. 253	53	No. 308	62	No. 363	46
No. 34	7	No. 89	59	No. 141	72	No. 199	61	No. 254	53	No. 309	39	No. 361	78
No. 35	5	No. 90	59	No. 145	64	No. 200	64	No. 255	53	No. 310	15	No. 365	78
No. 36	5	No. 91	88	No. 146	64	No. 201	58	No. 256	53	No. 311	20	No. 366	78
No. 37	96	No. 92	34	No. 147	61	No. 202	51	No. 257	53	No. 312	20	No. 367	78
No. 38	111	No. 93	51	No. 148	73	No. 203	72	No. 258	53	No. 313	99	No. 368	78
No. 39	50	No. 91	51	No. 149	73	No. 201	55	No. 259	53	No. 311	9	No. 369	60
No. 40	48	No. 95	51	No. 150	56	No. 205	55	No. 260	53	No. 315	56	No. 370	60
No. 41	9	No. 96	51	No. 151	76	No. 206	72	No. 261	53	No. 316	56	No. 371	60
No. 42	110	No. 97	51	No. 152	76	No. 207	56	No. 262	68	No. 317	69	No. 372	60
No. 43	80	No. 98	51	No. 153	51	No. 208	53	No. 263	68	No. 318	69	No. 373	60
No. 44	50	No. 99	55	No. 151	74	No. 209	91	No. 264	68	No. 319	69	No. 371	60
No. 45	50	No. 100	55	No. 155	74	No. 210	26	No. 265	68	No. 320	69	No. 375	60
No. 46	106	No. 101	55	No. 156	70	No. 211	17	No. 266	68	No. 321	94	No. 376	54
No. 47	25	No. 102	59	No. 157	70	No. 212	16	No. 267	68	No. 322	21	No. 377	54
No. 48	25	No. 103	59	No. 158	70	No. 213	39	No. 268	68	No. 323	133	No. 378	54
No. 49	25	No. 104	59	No. 159	70	No. 211	17	No. 269	24	No. 321	68	No. 379	54
No. 50	25	No. 105	59	No. 160	57	No. 215	94	No. 270	52	No. 325	69	No. 380	54
No. 51	26	No. 106	97	No. 161	67	No. 216	94	No. 271	58	No. 326	99	No. 381	23
No. 52	14	No. 107	51	No. 162	67	No. 217	94	No. 272	46	No. 327	15	No. 382	80
No. 53	27	No. 108	51	No. 163	67	No. 218	71	No. 273	52	No. 328	52	No. 383	78
No. 54	17	No. 109	97	No. 161	107	No. 219	71	No. 274	52	No. 329	81	No. 381	78
No. 55	98	No. 110	75	No. 165	53	No. 220	71	No. 275	52	No. 330	21	No. 385	63

Spec.	Page.	Spec.	Page.	Spec.	Page.	Spec.	Page.	Spec.	Page.	Spec.	Page.	Spec.	Page.	Spec.	Page.
No. 111	18	No. 196	58	No. 551	82	No. 606	61	No. 661	8	No. 716	15	No. 771	84	No. 825	117
No. 112	49	No. 197	21	No. 552	23	No. 607	38	No. 662	18	No. 717	52	No. 772	84	No. 826	35
No. 113	114	No. 198	47	No. 553	87	No. 608	69	No. 663	100	No. 718	108	No. 773	38	No. 827	41
No. 114	24	No. 199	13	No. 554	105	No. 609	69	No. 664	89	No. 719	48	No. 774	82	No. 828	41
No. 115	91	No. 200	107	No. 555	117	No. 610	69	No. 665	40	No. 720	84	No. 775	85	No. 829	95
No. 116	33	No. 501	91	No. 556	117	No. 611	39	No. 666	79	No. 721	88	No. 776	82	No. 830	97
No. 117	92	No. 502	21	No. 557	6	No. 612	83	No. 667	37	No. 722	97	No. 777	111	No. 831	108
No. 118	89	No. 503	92	No. 558	21	No. 613	113	No. 668	92	No. 723	90	No. 778	88	No. 832	85
No. 119	93	No. 504	107	No. 559	59	No. 614	93	No. 669	92	No. 724	127	No. 779	105	No. 833	112
No. 120	91	No. 505	50	No. 560	59	No. 615	108	No. 670	49	No. 725	83	No. 780	112	No. 834	71
No. 151	91	No. 506	14	No. 561	59	No. 616	73	No. 671	108	No. 726	108	No. 781	53	No. 835	101
No. 152	61	No. 507	112	No. 562	87	No. 617	3	No. 672	30	No. 727	89	No. 782	98	No. 836	97
No. 153	86	No. 508	107	No. 563	87	No. 618	81	No. 673	79	No. 728	89	No. 783	19	No. 837	72
No. 154	18	No. 509	107	No. 564	99	No. 619	69	No. 674	82	No. 729	100	No. 784	86	No. 838	65
No. 155	107	No. 510	63	No. 565	54	No. 620	69	No. 675	40	No. 730	21	No. 785	8	No. 839	65
No. 156	107	No. 511	63	No. 566	6	No. 621	69	No. 676	117	No. 731	87	No. 786	46	No. 840	14
No. 157	90	No. 512	63	No. 567	40	No. 622	69	No. 677	81	No. 732	108	No. 787	13	No. 841	109
No. 158	70	No. 513	63	No. 568	117	No. 623	112	No. 678	84	No. 733	113	No. 788	112	No. 842	14
No. 159	62	No. 514	41	No. 569	99	No. 624	40	No. 679	94	No. 734	86	No. 789	30	No. 843	4
No. 160	62	No. 515	32	No. 570	99	No. 625	40	No. 680	66	No. 735	8	No. 790	9	No. 844	5
No. 161	15	No. 516	127	No. 571	95	No. 626	40	No. 681	66	No. 736	41	No. 791	111	No. 845	111
No. 162	75	No. 517	137	No. 572	39	No. 627	100	No. 682	66	No. 737	33	No. 792	105	No. 846	111
No. 163	84	No. 518	15	No. 573	118	No. 628	93	No. 683	66	No. 738	91	No. 793	6	No. 847	127
No. 164	84	No. 519	30	No. 574	118	No. 629	123	No. 684	35	No. 739	88	No. 794	8	No. 848	35
No. 165	81	No. 520	7	No. 575	118	No. 630	100	No. 685	106	No. 740	111	No. 795	113	No. 849	79
No. 166	81	No. 521	37	No. 576	110	No. 631	100	No. 686	25	No. 741	18	No. 796	140	No. 850	93
No. 167	29	No. 522	50	No. 577	110	No. 632	100	No. 687	90	No. 742	92	No. 797	111	No. 851	113
No. 168	60	No. 523	99	No. 578	110	No. 633	39	No. 688	41	No. 743	118	No. 798	82	No. 852	19
No. 169	38	No. 524	79	No. 579	11	No. 634	47	No. 689	99	No. 744	101	No. 799	113	No. 853	20
No. 170	41	No. 525	106	No. 580	119	No. 635	59	No. 690	93	No. 745	101	No. 800	112	No. 854	96
No. 171	99	No. 526	36	No. 581	88	No. 636	88	No. 691	38	No. 746	98	No. 801	16	No. 855	66
No. 172	15	No. 527	75	No. 582	25	No. 637	6	No. 692	82	No. 747	23	No. 802	105	No. 856	66
No. 173	96	No. 528	31	No. 583	5	No. 638	19	No. 693	88	No. 748	52	No. 803	105	No. 857	119
No. 174	96	No. 529	32	No. 584	98	No. 639	55	No. 694	22	No. 749	52	No. 804	127	No. 858	111
No. 175	96	No. 530	106	No. 585	32	No. 640	110	No. 695	91	No. 750	52	No. 805	123	No. 859	119
No. 176	96	No. 531	4	No. 586	32	No. 641	95	No. 696	100	No. 751	89	No. 806	86	No. 860	119
No. 177	96	No. 532	19	No. 587	10	No. 642	88	No. 697	95	No. 752	89	No. 807	35	No. 861	119
No. 178	47	No. 533	22	No. 588	9	No. 643	88	No. 698	67	No. 753	89	No. 808	83	No. 862	127
No. 179	61	No. 534	97	No. 589	113	No. 644	108	No. 699	67	No. 754	113	No. 809	117	No. 863	22
No. 180	39	No. 535	4	No. 590	113	No. 645	112	No. 700	68	No. 755	118	No. 810	61	No. 864	167
No. 181	41	No. 536	109	No. 591	33	No. 646	113	No. 701	68	No. 756	53	No. 811	118	No. 865	107
No. 182	83	No. 537	148	No. 592	109	No. 647	90	No. 702	50	No. 757	105	No. 812	145	No. 866	127
No. 183	83	No. 538	95	No. 593	109	No. 648	90	No. 703	78	No. 758	114	No. 813	48	No. 867	119
No. 184	83	No. 539	95	No. 594	109	No. 649	9	No. 704	61	No. 759	110	No. 814	85	No. 868	91
No. 185	83	No. 540	117	No. 595	26	No. 650	30	No. 705	64	No. 760	3	No. 815	65	No. 869	127
No. 186	83	No. 541	117	No. 596	13	No. 651	87	No. 706	61	No. 761	3	No. 816	65	No. 870	127
No. 187	83	No. 542	117	No. 597	63	No. 652	30	No. 707	67	No. 762	53	No. 817	65	No. 871	127
No. 188	49	No. 543	112	No. 598	63	No. 653	46	No. 708	67	No. 763	91	No. 818	65	No. 872	110
No. 189	63	No. 544	16	No. 599	15	No. 654	49	No. 709	100	No. 764	89	No. 819	65	No. 873	119
No. 190	63	No. 545	11	No. 600	63	No. 655	18	No. 710	98	No. 765	91	No. 820	65	No. 874	5
No. 191	63	No. 546	11	No. 601	63	No. 656	62	No. 711	100	No. 766	106	No. 821	65	No. 875	35
No. 192	37	No. 547	70	No. 602	81	No. 657	62	No. 712	98	No. 767	101	No. 822	108	No. 876	123
No. 193	45	No. 548	19	No. 603	81	No. 658	96	No. 713	113	No. 768	47	No. 823	108	No. 877	123
No. 194	29	No. 549	50	No. 604	61	No. 659	112	No. 714	127	No. 769	77	No. 824	25	No. 878	123
No. 195	78	No. 550	127	No. 605	61	No. 660	70	No. 715	86	No. 770	5				

CATALOGUE

OF THE

MICROSCOPICAL SECTION

OF THE

United States Army Medical Museum.

PREPARED UNDER THE DIRECTION OF THE SURGEON GENERAL, U. S. ARMY,

By Brevet Major EDWARD CURTIS, Assistant Surgeon, U. S. Army.

WASHINGTON:
GOVERNMENT PRINTING OFFICE
1867.

CONTENTS.

	PAGE.
Part First.—MOUNTED PREPARATIONS FOR THE MICROSCOPE	5
NOTE.....	5
I. CONNECTIVE TISSUE SYSTEM.....	7
II. EXTERNAL TEGUMENTARY SYSTEM.....	11
III. MUSCULAR SYSTEM.....	21
IV. OSSEOUS SYSTEM.....	27
V. VASCULAR SYSTEM.....	33
VI. NERVOUS SYSTEM.....	39
VII. DIGESTIVE ORGANS.....	45
VIII. RESPIRATORY ORGANS.....	67
IX. URINARY ORGANS AND SUPRARENAL GLANDS.....	73
X. SEXUAL ORGANS, OVA AND FETAL APPENDAGES.....	85
XI. ORGAN OF VISION.....	89
XII. ORGAN OF HEARING.....	95
XIII. ORGAN OF SMELL.....	99
XIV. PATHOLOGICAL GROWTHS.....	103
XV. PARASITES.....	107
XVI. ARTICLES OF FOOD AND CLOTHING, AND MATERIA MEDICA.....	111
XVII. DIATOMS AND OTHER TEST OBJECTS.....	119
XVIII. MISCELLANEOUS.....	127
Part Second.—PHOTOGRAPHIC NEGATIVES OF MICROSCOPIC OBJECTS	131
NOTE.....	131
I. CONNECTIVE TISSUE SYSTEM.....	135
II. EXTERNAL TEGUMENTARY SYSTEM.....	136
III. MUSCULAR SYSTEM.....	137
IV. OSSEOUS SYSTEM.....	138
V. VASCULAR SYSTEM.....	140
VI. NERVOUS SYSTEM.....	140
VII. DIGESTIVE ORGANS.....	141
VIII. RESPIRATORY ORGANS.....	144
* * * * *	
XIV. PATHOLOGICAL GROWTHS.....	145
XV. PARASITES.....	145
XVI. ARTICLES OF FOOD AND CLOTHING, AND MATERIA MEDICA.....	146
XVII. DIATOMS AND OTHER TEST OBJECTS.....	147
XVIII. MISCELLANEOUS.....	149
Part Third.—PHOTOMICROGRAPHS PRESENTED TO THE MUSEUM	151
INDEX OF PREPARERS OF SPECIMENS	153
INDEX OF SPECIMENS	157
INDEX OF NEGATIVES	161

Part First.

MOUNTED PREPARATIONS FOR THE MICROSCOPE.

ERRATA.

Page 81, third line from above, for **123** read **113**.

Page 142, first line, for **27** read **21**.

Page 142, nineteenth line from above, for **145** read **144**.

Page 142, twenty-third line from above, for **146** read **145**.

NOTE.—These preparations, with the exception of three hundred and sixty opaque injections by Professor Hyrtl, of Vienna, and a few others, are mounted on slips of glass three inches long by one wide. Each slide is labelled with the name of the object, the menstruum in which it is mounted, the date of preparation, and the Museum and Catalogue numbers of the specimen. The large majority of the specimens have been prepared in the Microscopical Department of the Museum—the greater part by Acting Assistant Surgeon J. C. W. Kenyon, U. S. Army; the remainder by Assistant Surgeon Edward Curtis, U. S. Army, and Hospital Steward E. M. Schaeffer, U. S. Army. Where a specimen has not been prepared in the Museum, the name of the preparer is appended to the description.

The preparations of Professor Hyrtl consist of opaque fine injections in various colors, to show the arrangement of the capillaries in the different structures of the body. They are mounted dry in small slips of wood, having a black background, and are to be viewed by reflected light.

In the following Catalogue, the range of objectives that may be advantageously used with each preparation is given. By "low powers" is meant object glasses below an $\frac{8}{16}$; by "moderate" those between an $\frac{8}{16}$ and a $\frac{1}{4}$; by "high" those from a $\frac{1}{4}$ upwards.

I. CONNECTIVE TISSUE SYSTEM.

A. CONNECTIVE TISSUE PROPER.

B. WHITE FIBROUS TISSUE.

C. YELLOW ELASTIC TISSUE.

D. ADIPOSE TISSUE.

A. FROM MAN | B. FROM ANIMALS | C. PATHOLOGICAL.

I. CONNECTIVE TISSUE SYSTEM.

A. CONNECTIVE TISSUE PROPER.

A. FROM MAN.

- 1120, 1121 and 1615.** Three preparations of connective tissue from finger, with transparent carmine injection, showing the arrangement of the bloodvessels. Specimens **1120** and **1121** show, also, adipose tissue. For low and moderate powers.
A. 1.
- 1620.** Connective tissue from finger, with transparent carmine injection, showing the capillaries running together in groups; also, yellow elastic tissue. For low and high powers.
A. 2.
- 25.** Opaque injection (red) of the vessels of the subcutaneous connective tissue of the face. For low powers.
A. 3. Prof. Joseph Hyrtl, Vienna, Austria.
- 26.** Opaque injection (red) of the vessels of the subcutaneous connective tissue of the scrotum. For low powers.
A. 4. Prof. Joseph Hyrtl, Vienna, Austria.

For other illustrations, see **II.** A. A. 1, 7, 8, 11, 12; **VII.** II. A. 2; **VIII.** II. C. 1 to 8, 10 to 14; **VII.** I. C. 1, 3, 4, 6 to 11, 15; **XI.** II. A. 2.

See also Part Second, **I.** A. A. 1; **VII.** I. C. 2, 3.

B. FROM ANIMALS.

- 1665.** Connective tissue from kitten, showing very numerous connective tissue corpuscles, stained with carmine; also small arteries and veins. For high powers.
B. 1.
- 1633.** Connective tissue of caterpillar, stained with carmine. For low and high powers.
B. 2. Assistant Surgeon J. S. Billings, U. S. Army.

For other illustrations, see **II.** A. B. 1; **III.** B. B. 6, 15 (Specimen **1971**); **V.** C. B. 4; **VI.** E. B. 5; **VII.** B. B. 2, 3; **VII.** II. B. 8, 13; **VII.** O. B. 1, 3 to 6; **VII.** P. B. 1; **VII.** Q. B. 1; **IX.** A. B. 27; **XII.** A. B. 1, 2.

C. PATHOLOGICAL.

See **II.** A. C. 1, 2; **VII.** II. C. 1 to 14; **VII.** I. C. 1, 2, 4 to 8, 12 to 23; **XIV.** B. A. 3.

See also Part Second, **I.** A. C. 1; **VII.** H. C. 4.

B. WHITE FIBROUS TISSUE.

B. FROM ANIMALS.

- 1267.** Fibrous tissue from tendo Achillis of cat and kitten, showing in the specimen from the cat the fibrillated structure of the tissue, and in that from the kitten very numerous elongated nuclei stained with carmine ("germinal matter" of Beale).
B. 1. Dr. Lionel S. Beale, London, England.

For other illustrations, see **III.** C. B. 1, 2.

C. YELLOW ELASTIC TISSUE.

A. FROM MAN.

See **I.** A. A. 2; **VIII.** C. A. 3; **XIV.** B. A. 3.

B. FROM ANIMALS.

See **VIII.** B. B. 1, 2.

D. ADIPOSE TISSUE.

A. FROM MAN.

21. Opaque injection (red) of the vessels in a perpendicular section through the panniculus adiposus of the palm of the hand. For low powers.
A. 1. Prof. Joseph Hyrtl, Vienna, Austria.

353. Opaque injection (yellow) of the vessels of adipose tissue. For low powers.
A. 2. Prof. Joseph Hyrtl, Vienna, Austria.

For other illustrations, see **I.** A. A. 1; **II.** A. A. 1, 7, 8; **II.** D. A. 2; **III.** B. C. 2.

See also Part Second, **II.** A. A. 1.

B. FROM ANIMALS.

See **II.** A. B. 9; **III.** B. B. 11; **III.** B. C. 1; **V.** C. B. 3; **VI.** E. B. 4; **VII.** O. B. 1 to 5; **VII.** P. B. 1; **VII.** Q. B. 1.

II. EXTERNAL TEGUMENTARY SYSTEM.

A. SKIN.

B. NAILS, CLAWS AND HOOFES.

C. HAIRS.

D. CUTANEOUS GLANDS.

A. FROM MAN. | B. FROM ANIMALS. | C. PATHOLOGICAL.

II. EXTERNAL TEGUMENTARY SYSTEM.

A. SKIN.

A. FROM MAN.

- 1203 to 1206.** Series of four perpendicular sections of scalp of negro, stained with red aniline, showing very beautifully all the structures of the scalp, their arrangement and minute anatomy. For low and high powers.
A. 1. *See Part Second, II, A. A. 1 to 4.*
- 1627, 1629 and 530.** Three preparations of scalp of human fetus, stained with carmine, showing the skin and young hair bulbs at the period when they consist entirely of cells. For moderate and high powers.
A. 2. Assistant Surgeon J. S. Billings, U. S. Army.
- 1112 to 1118.** Series of seven perpendicular sections of skin from ala of nose of negro, showing the general arrangement of the structures of the skin, especially the size and character of the sebaceous glands. For low powers.
A. 3.
- 1221 & 1225.** Two perpendicular sections of skin from axilla of negro, showing the large sudoriparous glands of this region and their position beneath the cutis. For low powers.
A. 4.
- 1172.** Perpendicular section of skin from sole of foot, showing the spiral course of the sweat ducts through the thick epidermis. For low powers.
A. 5.
- 1173 & 1171.** Two perpendicular sections of skin from sole of foot, showing the relative thickness of the cutis and epidermis and the sudoriparous glands and their ducts. For low powers.
A. 6. These specimens make beautiful objects for the polariscope.
See Part Second, II, A. a. 5.
- 1192 to 1195.** Four perpendicular sections of skin from sole of foot, faintly stained with red aniline, showing the general arrangement and minute anatomy of the various structures of the skin. For low and moderate powers.
A. 7. Assistant Surgeon J. J. Woodward, U. S. Army.
- 1207.** Perpendicular section of skin and subcutaneous tissue, stained with carmine, showing very beautifully the general arrangement and minute anatomy of the various structures. For high and low powers.
A. 8. Assistant Surgeon J. S. Billings, U. S. Army.
- 1196 to 1201.** Six perpendicular sections of epidermis from sole of foot, stained with carmine, showing the cellular structure of this tissue. For moderate powers.
A. 9.
- 1170.** Horizontal section of epidermis from sole of foot, exposing its inner surface, showing the depressions in the epidermis corresponding to the papillæ of the corium, and their arrangement in rows. For low powers.
A. 10.
- 1983 to 2002.** Twenty perpendicular sections of skin from under surface of finger, with transparent Prussian blue injection and carmine staining; showing the general arrangement and minute anatomy of all the structures of the skin. The staining defines beautifully the cellular elements of the rete mucosum, the connective tissue of the cutis vera and the sudoriparous glands. Specimens **1998 to 2002** show also several tactile corpuscles of Meissner in the papillæ. For low and high powers.
A. 11.
- 2003 to 2011.** Nine preparations, same as **A. 11**, embracing but little of the cutis vera. Specimens **2009 to 2011** show tactile corpuscles.
A. 12.
- 2013 & 2029.** Two perpendicular sections of skin from under surface of toe, with transparent carmine injection, showing the arrangement of the capillaries in the several structures of the skin. For low powers.
A. 13.

- 1171.** Surface of corium from finger, with opaque injection (red), showing the arrangement of the capillaries of the papillæ. For low powers.
A. 14.
- 1.** Opaque injection (red) of the vessels of skin from forehead. For low powers.
A. 15. Prof. Joseph Hyrtl, Vienna, Austria.
- 2.** Opaque injection (white) of the vessels of skin from vertex, from a new-born child; seen from below. For low powers.
A. 16. Prof. Joseph Hyrtl, Vienna, Austria.
- 3.** Opaque injection (red) of the vessels of skin from vertex, from an adult; seen from above. For low powers.
A. 17. Prof. Joseph Hyrtl, Vienna, Austria.
- 4.** Opaque injection (red) of the vessels in a perpendicular section through the mons veneris, showing a few hair roots. For low powers.
A. 18. Prof. Joseph Hyrtl, Vienna, Austria.
- 5.** Opaque injection (red) of the vessels of skin from between the eyebrows. For low powers.
A. 19. Prof. Joseph Hyrtl, Vienna, Austria.
- 6.** Opaque injection (red) of the vessels of skin from lower eyelid. For low powers.
A. 20. Prof. Joseph Hyrtl, Vienna, Austria.
- 7.** Opaque injection (red) of the vessels of skin from upper eyelid. For low powers.
A. 21. Prof. Joseph Hyrtl, Vienna, Austria.
- 8.** Opaque injection (red) of the vessels of skin from cheek. For low powers.
A. 22. Prof. Joseph Hyrtl, Vienna, Austria.
- 9.** Opaque injection (red) of the vessels of skin from the chin. For low powers.
A. 23. Prof. Joseph Hyrtl, Vienna, Austria.
- 10.** Opaque injection (red) of the vessels of skin from upper lip; external surface. For low powers.
A. 24. Prof. Joseph Hyrtl, Vienna, Austria.
- 11.** Opaque injection (red) of the vessels of skin from perineum, showing the apertures of numerous sebaceous glands. For low powers.
A. 25. Prof. Joseph Hyrtl, Vienna, Austria.
- 12.** Opaque injection (red) of the vessels of skin from back of hand. For low powers.
A. 26. Prof. Joseph Hyrtl, Vienna, Austria.
- 13.** Opaque injection (red) of the vessels of skin from palm of hand. For low powers.
A. 27. Prof. Joseph Hyrtl, Vienna, Austria.
- 14.** Opaque injection (red) of the vessels of skin from concha of the ear. For low powers.
A. 28. Prof. Joseph Hyrtl, Vienna, Austria.
- 15.** Opaque injection (red) of the vessels of skin from back of finger. For low powers.
A. 29. Prof. Joseph Hyrtl, Vienna, Austria.
- 16.** Opaque injection (red) of the vessels of skin from back of toe. For low powers.
A. 30. Prof. Joseph Hyrtl, Vienna, Austria.
- 17.** Opaque injection (red) of the vessels of skin from apex of index finger. For low powers.
A. 31. Prof. Joseph Hyrtl, Vienna, Austria.
- 18.** Opaque injection (red) of the vessels of skin from apex of great toe. For low powers.
A. 32. Prof. Joseph Hyrtl, Vienna, Austria.
- 19.** Opaque injection (red) of the vessels of skin from apex of little toe. For low powers.
A. 33. Prof. Joseph Hyrtl, Vienna, Austria.

20. Opaque injection (red) of the vessels of skin from sole of foot of a young girl. For low powers.
A. 34. Prof. Joseph Hyrtl, Vienna, Austria.

21. Opaque injection (red) of the vessels of skin from sole of foot of gypsy who never wore boots. For low powers.
A. 35. Prof. Joseph Hyrtl, Vienna, Austria.

For other illustrations, see **II. B. A. 1.**

B. FROM ANIMALS.

1087 to 1091. Eight perpendicular sections of skin of rat, stained (except specimen **1091**) with carmine, showing the general arrangement and minute anatomy of the structures of the skin; also the characteristics of the hair of the rat. For low and high powers.
B. 1.

1257 & 1258. Two preparations of skin of frog, with transparent Prussian blue injection (nearly faded) and carmine staining, showing the arrangement of the capillaries, pigment cells, cutaneous follicles, and, in specimen **1258**, the hexagonal nucleated cells of the epidermis. For low and high powers.
B. 2.

1259, 1260 and 372 to 371. Five preparations of skin of frog, with transparent carmine injection, showing the arrangement of the capillaries and pigment cells. For low powers.
B. 3.

1255 & 1256. Two preparations of skin of toad, with transparent Prussian blue injection (nearly faded) and carmine staining, showing the arrangement of the capillaries, pigment cells, cutaneous follicles, and, in specimen **1256**, the hexagonal nucleated cells of the epidermis. For low and high powers.
B. 4.

1266. Skin of tree toad (*Hyla viridis*), with transparent Prussian blue injection (nearly faded) and carmine staining, showing capillaries, pigment cells and cutaneous follicles. For low and high powers.
B. 5. Dr. Lionel S. Beale, London, England.

1261. Portions of young and old cuticle of newt, stained with carmine, showing the young tissue almost entirely composed of cells and the old tissue composed of polygonal epithelial scales with large nuclei. For high powers.
B. 6. Dr. Lionel S. Beale, London, England.

1611. Skin of snake (*Coleberatrix*), showing the lozenge-shaped scales, the orifices for the bloodvessels at the angles of the scales, and the arrangement of the pigment. For low powers.
B. 7. Assistant Surgeon J. S. Billings, U. S. Army.

103. Skin of snake, with opaque injection (blue), showing the arrangement of the bloodvessels. For low powers.
B. 8. Dr. S. A. Jones, Englewood, N. J.

1262. Perpendicular section of skin of mouse, showing the position and relation of the hairs and hair follicles. For low and moderate powers.
B. 9.

2012. Entire foot of frog, with transparent carmine injection, showing the arrangement of the capillaries in the web between the toes. For low powers.
B. 10.

30. Opaque injection (red) of the vessels of the papilla tactus from toe of lion. For low powers.
B. 11. Prof. Joseph Hyrtl, Vienna, Austria.

31. Opaque injection (red) of the vessels of the papilla tactus from sole of foot of bear. For low powers.
B. 12. Prof. Joseph Hyrtl, Vienna, Austria.

32. Opaque injection (red) of the vessels of skin from near the ankle joint of calf. For low powers.
B. 13. Prof. Joseph Hyrtl, Vienna, Austria.

33. Opaque injection (red) of the vessels of skin from near the ankle joint of tapir. For low powers.
B. 14. Prof. Joseph Hyrtl, Vienna, Austria.

- 31.** Opaque injection (red) of the vessels of skin from near the ankle joint of horse. For low powers.
B. 15. Prof. Joseph Hyrtl, Vienna, Austria.
- 39.** Opaque injection (red) of the vessels of skin from sole of foot of *Ardea cinerea*. For low powers
B. 16. Prof. Joseph Hyrtl, Vienna, Austria.
- 40.** Opaque injection (yellow) of the vessels of skin of *Rana esculenta*. For low powers.
B. 17. Prof. Joseph Hyrtl, Vienna, Austria.
- 41.** Opaque injection (yellow) of the vessels of skin of *Salamandra maculosa*. For low powers.
B. 18. Prof. Joseph Hyrtl, Vienna, Austria.
- 42.** Opaque injection (yellow) of the vessels of skin of *Triton Alpestris*. For low powers.
B. 19. Prof. Joseph Hyrtl, Vienna, Austria.
- 43.** Opaque injection (red) of the vessels of skin of *Bombinator igneus*. For low powers.
B. 20. Prof. Joseph Hyrtl, Vienna, Austria.
- 44.** Opaque injection (yellow) of the vessels of foot of *Triton cristatus*; seen from above. For low powers.
B. 21. Prof. Joseph Hyrtl, Vienna, Austria.
- 45.** Opaque injection (yellow) of the vessels of skin of *Proteus anguineus*; seen from below. For low powers.
B. 22. Prof. Joseph Hyrtl, Vienna, Austria.
- 339.** Opaque injection (red) of the vessels of erectile caruncula in neck of *Melicer*. For low powers.
B. 23. Prof. Joseph Hyrtl, Vienna, Austria.

For other illustrations, see **XII.** A. B. 1, 2.

C. PATHOLOGICAL.

- 863 to 875.** Series of thirteen perpendicular sections of human skin of leg from a case of variola; stained with carmine.
C. 1. This series consists of sections through a fully-developed variolous pustule, from the thickened skin near the margin of the pustule to its centre, and shows the following pathological conditions: First, a hypertrophy of the papillæ of the corium near the margin of the pustule, and thickening of the rete mucosum of the epidermis by cell-multiplication. Secondly, a separation of the horny layer of the epidermis from the rete mucosum; the cavity so formed being filled (in the specimens) by the coagulated contents of the pustule. Thirdly, the appearance of a lining membrane to this cavity, formed of flattened epithelial cells similar to those of the free surface of healthy epidermis. At this stage the papillæ of the corium are shorter than natural and blunt at their apices, and active cell-multiplication is seen in the connective tissue of the corium. Finally, near the centre of the pustule the under portion of the lining wall of the cavity gives way, the rete mucosum degenerates into a mass of ill-defined cells and granules, and the corium suffers a superficial ulceration, all signs of papillæ being gone. For low and high powers.
- 876 to 887.** Series of twelve perpendicular sections of human skin of leg, from same case as **C. 1.**, stained with carmine.
C. 2. These sections pass through the central portion of a pustule, showing conditions similar to those above described, and also a thinning and final rupture of the horny layer of the epidermis at the apex of the pustule. For low and high powers.
- 358.** Opaque injection (yellow) of the vessels of cicatricial tissue from an arm stump. For low powers.
C. 3. Prof. Joseph Hyrtl, Vienna, Austria.

For other illustrations, see **XIV.** B. A. 3.

B. NAILS, CLAWS AND HOOFS.

A. FROM MAN.

- 2014.** Perpendicular section, cut longitudinally, of posterior portion of nail and bed of nail from finger, with transparent carmine injection, showing the relations of the nail to the structures of the skin and the arrangement of the capillaries in the bed of the nail. For low powers.
- A. 1.**
- 2015.** Same as **A. 1.**, but embracing only a portion of the body of the nail and its bed.
- A. 2.**
- 22.** Opaque injection (red) of the vessels of matrix of nail of thumb. For low powers.
- A. 3.** Prof. Joseph Hyrtl, Vienna, Austria.
- 23.** Opaque injection (red) of the vessels of matrix of nail of great toe. For low powers.
- A. 4.** Prof. Joseph Hyrtl, Vienna, Austria.

B. FROM ANIMALS.

- 35.** Opaque injection (red) of the vessels of matrix of hoof of horse; anterior zone with pyramidal papillae. For low powers.
- B. 1.** Prof. Joseph Hyrtl, Vienna, Austria.
- 36.** Opaque injection (red) of the vessels of matrix of hoof of horse; posterior zone with longitudinal folds. For low powers.
- B. 2.** Prof. Joseph Hyrtl, Vienna, Austria.
- 37.** Opaque injection (red) of the vessels of matrix of hoof of bull; anterior zone. For low powers.
- B. 3.** Prof. Joseph Hyrtl, Vienna, Austria.
- 38.** Opaque injection (red) of the vessels of matrix of hoof of bull; posterior zone. For low powers.
- B. 4.** Prof. Joseph Hyrtl, Vienna, Austria.

C. HAIRS.

A. FROM MAN.

- 111 to 113.** Three preparations of hair from head of white child, mounted in balsam, showing only the delicate longitudinal striation of the cortical substance. For moderate and high powers.
- A. 1.**
- 114 & 115.** Two preparations of the same hair as **A. 1.**, mounted in water, showing the transverse ridges produced by the overlapping edges of the epidermic scales. For moderate and high powers.
- A. 2.** See *Part Second*, **II. C. A. 1.**
- 1270 to 1272.** Three preparations of hair from head of adult white male, showing the structure of the cuticle and cortical substance as developed by the action of caustic soda. For moderate and high powers.
- A. 3.**
- 1273 & 1274.** Two preparations of hair from head of adult negro male, after treatment with caustic soda. The intense blackness of the hair prevents any points of structure being made out. For low powers.
- A. 4.**
- 1275 & 1276.** Two preparations of eyelashes of adult negro male, after treatment with caustic soda. For low powers.
- A. 5.**
- 1279 to 1281.** Three preparations of hair from head of adult white male, after boiling in sulphuric acid, showing the fibre cells of the cortex. For moderate and high powers.
- A. 6.**

- 1613 & 1611.** Two preparations of hair from beard of white male, showing hairs with medullary substance. For moderate and high powers.
A. 7.
- 1284 to 1286.** Three preparations of transverse sections of hair from head of white adult male, showing the different sizes and shapes of the hairs and the relative thickness of the various structures composing the hair. For moderate and high powers.
A. 8.
- 1287 & 1288.** Two preparations of transverse sections of hair from pubes of white adult male, similar in character to **A. 8.**
A. 9. *See Part Second, II, C. A. 2.*
- 1289 & 1290.** Two preparations of transverse sections of hair from head of adult male mulatto, similar in character to **A. 8.**
A. 10.
- 1175 to 1177.** Three preparations of hair from head of male mummy from Egypt; the hairs are perfectly preserved. For moderate and high powers.
A. 11.
- 1178 to 1180.** Three preparations of hair from head of female mummy from Egypt, similar to **A. 11.**
A. 12.
- 1181 to 1183.** Three preparations of false hair found braided in with the hair of **A. 12.**
A. 13.

For other illustrations, see II, A. A. 1, 2; XI, II, A. 1, 2.

See also Part Second, II, A. A. 1, 2.

B. FROM ANIMALS.

- 1293 & 1294.** Two preparations of hair from body of mouse. For moderate and high powers.
B. 1.
- 1295.** Whiskers of mouse. For moderate and high powers.
B. 2.
- 1296.** White hairs of cat. For moderate and high powers.
B. 3. *See Part Second, II, C. B. 2.*
- 1297 & 1298.** Two preparations of whiskers of cat. For moderate and high powers.
B. 4.
- 1350 to 1395.** Series of forty-six preparations of hair of various species of bat, taken both from the back and belly. For moderate and high powers. The following are the species:
B. 5.
- | | |
|-------------------------------------|---|
| <i>Vesperugo ntidus</i> | (Specimens 1350 to 1353 .) |
| <i>Vesperugo lucifugus</i> | (Specimens 1351 to 1357 .) |
| <i>Myotis crepuscularis</i> | (Specimens 1358 to 1361 .) |
| <i>Antrozous pallidus</i> | (Specimens 1362 to 1365 .) |
| <i>Myotis nasutus</i> | (Specimens 1366 to 1369 .) |
| <i>Scotophilus hesperus</i> | (Specimens 1370 to 1373 .) |
| <i>Lasiurus northwesterni</i> | (Specimens 1374 to 1377 .) |
| <i>Lasiurus cinereus</i> | (Specimens 1378 to 1381 .) |
| <i>Scotophilus nocturgans</i> | (Specimens 1382 and 1383 .) |
| <i>Scotophilus fuscus</i> | (Specimens 1384 to 1387 .) |
| <i>Vesperugo subulatus</i> | (Specimens 1388 to 1391 .) |
| <i>Myotis Californicus</i> | (Specimens 1392 to 1395 .) |

See Part Second, II, C. B. 3.

For other illustrations, see II, A. B. 1, 2; XI, A. B. 1, 2; XVI, B. 1.

See also Part Second, II, C. B. 1; XVI, B. 1.

C. PATHOLOGICAL.

- 1101.** Hair and part of follicle from human leg in morbus pillaris, showing the hair coiled up within the follicle.
C. 1. For moderate and high powers.

D. CUTANEOUS GLANDS.

A. FROM MAN.

1229 to 1231. Three preparations of sudoriparous glands from axilla of negro, showing the large size of the glands and their convoluted structure. For low powers.

A. 1.

1268 & 1132. Two preparations of sudoriparous glands and adipose tissue from finger, with transparent carmine injection, showing the arrangement of the bloodvessels. For low and moderate powers.

A. 2.

For other illustrations, see **II.** A. A. 1, 3, 5, 6, 7, 8, 11; **II.** A. C. 1, 2.

See also Part Second, **II.** A. A. 1, 3, 5.

B. FROM ANIMALS.

17. Opaque injection (yellow) of the vessels of cutaneous glands, from leg of *Salamandra maculosa*. For low powers.

B. 1.

Prof. Joseph Hyrtl, Vienna, Austria.

18. Opaque injection (yellow) of the vessels of cutaneous glands of *Bufo vulgaris*. For low powers.

B. 2.

Prof. Joseph Hyrtl, Vienna, Austria.

For other illustrations, see **XII.** A. B. 1, 2.

III. MUSCULAR SYSTEM.

A. SMOOTH MUSCLE.

B. STRIPED MUSCLE.

C. TENDONS.

D. APONEUROSES AND FASCLE.

E. BURSE

A. FROM MAN. | B. FROM ANIMALS | C. PATHOLOGICAL.

III. MUSCULAR SYSTEM.

A. SMOOTH MUSCLE.

A. FROM MAN.

See **II.** A. A. 1; **VII.** II. A. 2; **VII.** II. C. 1 to 14; **VII.** I. C. 1 to 10, 12 to 23; **X.** M. c. 1; **XIV.** B. A. 1, 2.
See also Part Second, **II.** A. A. 3, 4.

B. FROM ANIMALS.

1119. Muscular coats of intestine of mouse, showing the individual smooth muscular fibres, with their nuclei stained with carmine. For high powers.
B. 1.

1312. Same as **B. 1**, with transparent Prussian blue injection. For high powers.
B. 2.

1973 & 1974. Two preparations, similar to **B. 2** from kitten.
B. 3.

For other illustrations, see **VII.** G. B. 3; **VII.** II. B. 8, 13.

B. STRIPED MUSCLE.

A. FROM MAN.

27. Opaque injection (red) of the vessels of the platysma myoides muscle. For low powers.
A. 1. Prof. Joseph Hyrtl, Vienna, Austria.

311. Opaque injection (red) of the vessels of the diaphragm. For low powers.
A. 2. Prof. Joseph Hyrtl, Vienna, Austria.

For other illustrations, see **III.** B. C. 2; **IV.** B. A. 16; **XI.** H. A. 2.

B. FROM ANIMALS.

508 & 509. Two preparations of striped muscle from cat, with transparent carmine injection, showing the individual muscular fibres with the transverse striae, and the arrangement of the long capillary loops. For high powers.
B. 1.

1100. Same as **B. 1**, but does not show well the striae on the muscular fibres.
B. 2.

1138 & 1139. Two preparations of striped muscle of kitten, with transparent Prussian blue injection and carmine staining, showing the nuclei of the sarcolemma stained, and the arrangement of the capillaries; also the minute anatomy of small bloodvessels. For high powers.
B. 3.

1140. Same as **B. 3**. The injection and staining have faded to a great extent. Shows beautifully the individual muscular fibres with their transverse striae, also a nerve trunk subdividing over the muscle. For high powers.
B. 4.

888 to 902. Fifteen preparations, same as **B. 3**. The injection and staining are very brilliant, and the specimens show the individual muscular fibres with striae and nuclei, the minute anatomy of bloodvessels, and the arrangement of the capillary loops. For high powers.
B. 5.

- 1651 to 1661.** Eight preparations of striped muscle of kitten, stained with carmine, showing most beautifully the striae on the fibres and the nuclei of the sarcolemma; also connective tissue, bloodvessels and nerves.
B. 6. Specimens **1656** and **1661** show a portion of a good-sized nerve trunk. Specimen **1661** shows also the sarcolemma drawn beyond the extremities of the muscular fibres, with nuclei still attached. For high powers.
- 1181 to 1191.** Eight preparations of striped muscle of mouse, with transparent Prussian blue injection and carmine staining, showing the striated fibres and nuclei and the arrangement of the capillary loops; and, in specimen **1187**, the anatomy of small bloodvessels. For high powers.
- 171 to 178.** Five preparations of striped muscle of mouse, with transparent carmine injection and blue staining, showing the arrangement of the capillary loops, and, faintly, the striae on the muscular fibres. For moderate and high powers.
- 533.** Portion of diaphragm of mouse, showing striated muscular fibres and a branching nerve trunk. For high powers.
B. 9. Assistant Surgeon J. S. Billings, U. S. Army.
- 1618.** Same as **B. 9**, with carmine staining of the nuclei of the sarcolemma; shows very beautifully the structure of a small artery and vein. For high powers.
B. 10. Assistant Surgeon J. S. Billings, U. S. Army.
- 1101 to 1108.** Eight preparations of striped muscle of mouse, with transparent Prussian blue injection (faded in many of the specimens) and carmine staining, showing very beautifully striated muscular fibres, nuclei of the sarcolemma, bloodvessels, nerves and adipose tissue. Specimen **1101** is particularly rich in nerves.
 For high powers.
See Part Second, III. B. 6. 3, 4
- 1095 to 1099.** Five preparations of striped muscle of chicken, with transparent carmine injection, showing the striated muscular fibres and the arrangement of the capillaries. For high powers.
B. 12. *See Part Second, III. B. 6. 1, 2.*
- 1226 to 1228.** Three preparations of striped muscle of chicken, similar to **B. 12**.
B. 13.
- 1123 to 1128.** Six preparations of striped muscle of tadpole, stained with carmine, showing the striated muscular fibres and the nuclei of the sarcolemma. For high powers.
B. 14.
- 1967 to 1971.** Five preparations of striped muscle of kitten with transparent Prussian blue injection and carmine staining, showing the striae of the muscular fibres, the nuclei of the sarcolemma, and the arrangement of the capillaries. Specimen **1971** shows also the minute anatomy of connective tissue. For high powers.
B. 15.
- 2016 to 2021.** Six preparations, same as **B. 15**
B. 16.
- 2022.** Occipito-frontalis muscle of kitten, with transparent carmine injection, showing the arrangement of the bloodvessels. For low powers.
B. 17.
- 2015.** Same as **B. 15**; the staining is not so brilliant.
B. 18.
- 318.** Opaque injection (yellow) of the vessels of the mylo-hyoid muscle of *Salamandra*. For low powers.
B. 19. Prof. Joseph Hyrtl, Vienna, Austria.
- 319.** Opaque injection (yellow) of the vessels of the mylo-hyoid muscle of *Python reticulatus*. For low powers.
B. 20. Prof. Joseph Hyrtl, Vienna, Austria.
- 320.** Opaque injection (yellow) of the vessels of the mylo-hyoid muscle of *Rana temporaria*. For low powers.
B. 21. Prof. Joseph Hyrtl, Vienna, Austria.
- 321.** Opaque injection (yellow) of the vessels of the constrictor faucium muscle of *Aspius rapar*. For low powers.
B. 22. Prof. Joseph Hyrtl, Vienna, Austria.

For other illustrations, see II. A. 6. 1; IV. B. 6. 7; V. A. 6. 1; VI. E. 6. 3; VII. C. 6. 2, 7, 8; VIII. C. 6. 1; VIII. F. 6. 1; XII. A. 6. 1, 2.

C. PATHOLOGICAL.

- 1232 to 1212** Seventeen preparations of human striped muscle infested with the *Trichina spiralis*, showing the parasites, and some enclosed in a cyst between the muscular fibres, and some not yet encysted. For moderate and high powers.
- 1669 to 1671.** C. 1.
- 1479 to 1495.** Seventeen preparations, same as C. 1, stained with carmine, showing the parasites, and also bloodvessels, nerves and adipose tissue. For moderate and high powers.
- 1111 to 1115.** Five preparations of striped muscle of rat infested with trichinae, with transparent carmine injection, showing the parasites encysted and the arrangement of the capillaries of the muscle. For moderate and high powers.
- 1109.** Striped muscle of mouse infested with trichinae, showing the parasites encysted; also the ramifications of nerve fibres over the muscle, and adipose tissue. For moderate and high powers.
- 1116 to 1118.** Three preparations, same as C. 4, but stained with carmine.
- C. 5.** See Part Second, XV. A. B. 1 to 3.
- 1561.** Striped muscle of hog infested with trichinae, showing the encysted parasites in very great numbers. For moderate powers.
- C. 6.** Procured from Messrs. J. W. Queen & Co., Philadelphia, Pa.

C. TENDONS

A. FROM MAN.

- 1111.** Small tendon from finger, with transparent carmine injection, showing the arrangement of the bloodvessels around the tendon. For low powers.
- A. 1.**
- 323.** Opaque injection (red) of the vessels of tendo Achillis. For low powers.
- A. 2.** Prof. Joseph Hyrtl, Vienna, Austria.

B. FROM ANIMALS.

- 1037 to 1039.** Three preparations of tendon of rat with carmine staining and transparent Prussian blue injection (nearly faded), showing the structure of the fibrous tissue composing the tendon. The elongated nuclei are rendered distinct by the staining. For high powers.
- B. 1.**
- 1011.** Tendon of cat, prepared same as B. 1., and illustrating the same points.
- B. 2.** For other illustrations, see I. B. B. 1.

D. APONEUROSES AND FASCLE.

A. FROM MAN.

- 321.** Opaque injection (red) of the vessels of sheath of tendo Achillis. For low powers.
- A. 1.** Prof. Joseph Hyrtl, Vienna, Austria.
- 326.** Opaque injection (red) of the vessels of the fascia lata. For low powers.
- A. 2.** Prof. Joseph Hyrtl, Vienna, Austria.

E. BURSE.

B. FROM ANIMALS.

- 195.** Opaque injection in two colors (arteries white, veins green) of bursa from *Dromaius* of New Holland. For low powers.
- B. 1.** Prof. Joseph Hyrtl, Vienna, Austria.

IV. OSSEOUS SYSTEM.

A. CARTILAGE AND PERICHONDRIUM.

B. BONE.

C. PERIOSTEUM.

D. MEDULLARY SUBSTANCE.

E. LIGAMENTS.

F. SYNOVIAL MEMBRANES.

A. FROM MAN. | B. FROM ANIMALS. | C. PATHOLOGICAL.

IV. OSSEOUS SYSTEM.

A. CARTILAGE AND PERICHONDRIUM.

A. FROM MAN.

1051. Section of cartilage from unossified portion of condyle of femur of boy. The cartilage cells have shrunk so as to leave wide interspaces between the cell proper and the capsule. For high powers.

1052. Same as **A. 1.** cut in the immediate vicinity of newly-formed bone, showing active multiplication by division of the cartilage cells. Here, too, the cells have shrunk from the capsules. For high powers.

531. Section of cartilage from head of tibia, from a seven months' fetus, stained with carmine, showing the very numerous cells of the young cartilage. For high powers.
Assistant Surgeon J. S. Billings, U. S. Army.

1015 & 1016. Two sections of cartilage from wrist joint of child, with transparent carmine injection, showing the capillaries of the young cartilage. For moderate powers.

For other illustrations, see IV. B. A. 16 to 18.

B. FROM ANIMALS.

1018. Section of cartilage of cat, stained with carmine, showing very numerous cartilage cells. For high powers.

1265. Sections of cartilage of kitten, at birth and at the age of five weeks, stained with carmine, showing the relative number of cartilage cells. For high powers.
Dr. Lionel S. Beale, London, England.

1012. Sections of articular cartilage from knee joint of ox, stained with carmine, showing capsules, cells and nuclei perfectly defined. For high powers.
See Part Second, IV. A. B. 1, 2.

1013. Same as **B. 3.** without the staining.

906 to 916. Eleven preparations, consisting of perpendicular sections of articular cartilage from knee joint of calf, stained with carmine, showing capsules, cells and nuclei well defined, and the different character and arrangement of the cells near the free and attached surfaces of the cartilage. For high powers.

917 to 923. Seven sections of rib cartilage of calf, stained with carmine, showing capsules, cells, nuclei and blood-vessels. For high powers.

921 to 931. Eight sections of rib cartilage of calf, stained with carmine, showing very beautifully the various stages in the formation of young cells by multiplication by division; also bloodvessels. For high powers.
See Part Second, IV. A. B. 3 to 9.

1330 to 1336 and 1316 to 1318. Ten sections of cartilaginous vertebra of sturgeon, stained with carmine, showing sparsely scattered cartilage cells. For high powers.

B. 8.

1010. Transverse section of rib cartilage from kitten, stained with carmine, showing cartilage cells and capsules. For high powers.
Assistant Surgeon J. S. Billings, U. S. Army.

For other illustrations, see IV. B. B. 7 to 9; VII. C. B. 7; VIII. B. B. 2, 4; XII. A. B. 1, 2; XIII. B. B. 1.

B. BONE.

A. FROM MAN.

1062. Longitudinal section of compact substance of shaft of femur, showing the Haversian canals and the arrangement of the lacunae and canaliculi. In the specimen, the balsam has filled many of the canaliculi, rendering them invisible. For moderate and high powers.

A. 1.

1063. Same as **A. 1.**, embracing a greater extent of bone, and with the canaliculi perfectly preserved. For moderate and high powers.

A. 2.

See Part Second, IV., B. A. 1, 1.

1064. Transverse section of portion of shaft of femur, extending across the entire thickness of the compact substance, showing the arrangement of the Haversian systems, the lacunae and canaliculi. A little of the spongy tissue is preserved on the inner edge of the section. For moderate and high powers.

A. 3.

1065. Section similar to **A. 3.**

A. 4.

1066. Section similar to **A. 3.**

A. 5.

1067. Section similar to **A. 3.**, but showing very little spongy tissue.

A. 6.

1080. Transverse section of portion of shaft of femur, extending across the entire thickness of the compact substance, stained with carmine, showing very well the lamellar structure of the bone substance. For moderate and high powers.

A. 7.

See Part Second, IV., B. A. 2.

1071. Longitudinal section of portion of compact substance of rib, embracing the surface of junction with the costal cartilage, showing the Haversian systems, lacunae and canaliculi. For moderate and high powers.

A. 8.

1068. Horizontal section through one lateral half of condyle of lower jaw, showing the arrangement of the compact and spongy substance, as well as their minute anatomy. For low and high powers.

A. 9.

1069. Same as **A. 9.**, but embracing nearly the entire diameter of the condyle.

A. 10.

1070. Vertical section through the long axis of condyle of lower jaw and ramus of the condyloid process, showing the arrangement and minute anatomy of the compact and spongy tissues. The thin layer of compact substance on the articular surface of the condyle is wanting over the outer half of the section.

A. 11.

For low and high powers.

1072. Vertical section through the posterior projection of inner condyle of femur of a young boy, in whom much of the condyle was still cartilaginous; shows a mesh-work of spongy tissue, bordered by a narrow ring of more compact substance. Parts of this ring have been broken off in the section. For low and high powers.

A. 12.

high powers.

1079 to 1081. Three preparations of parietal bone of fetus, stained with carmine, showing the cells and nuclei of the young lacunae colored by the carmine. For moderate and high powers.

A. 13.

Assistant Surgeon J. S. Billings, U. S. Army.

1030. Similar to **A. 13.** a transparent Prussian blue injection fills some of the vessels of the bone. For moderate and high powers.

A. 14.

Assistant Surgeon J. S. Billings, U. S. Army.

1031. Portion of orbital plate of frontal bone of fetus, with partial transparent Prussian blue injection, showing the Haversian canals and closely aggregated lacunae of the young bone. For moderate and high powers.

A. 15.

Assistant Surgeon J. S. Billings, U. S. Army.

1682. Section through one and portion of another of the bones of the tarsus of new-born infant, stained with carmine.

A. 16. Only a small central portion in the bones is as yet ossified, and the specimen shows the process of ossification of cartilage and the minute anatomy of cartilage, perichondrium and muscle, a few muscular fibres remaining attached to the bones. For moderate and high powers.

Assistant Surgeon J. S. Billings, U. S. Army.

1019 & 1050. Two sections of portion of condyle of femur of young boy, showing the ossification of cartilage. For

A. 17. moderate and high powers.

1616. Lower extremity of fetus, at the eighth week, stained with carmine, showing ossification in the shafts

A. 18. of the long bones, and the almost exclusively cellular composition of the young cartilage. For low and high powers.

Assistant Surgeon J. S. Billings, U. S. Army.

For other illustrations, see Part Second, IV. B. A. 3.

B. FROM ANIMALS.

1081. Transverse section of shaft of bone of albatross, embracing the entire circumference of the bone. Most

B. 1. of the canaliculi are invisible from the use of too fluid balsam in the mounting. For moderate and high powers.

J. Bourgogne, Paris, France.

1082. Transverse section of spongy tissue from vertebra of whale. Most of the canaliculi are filled with

B. 2. balsam. For low and high powers.

J. Bourgogne, Paris, France.

1083. Section labelled by the preparator: "Transverse section of bone of Ostrich." The section is, however,

B. 3. parallel to the Haversian canals. For moderate and high powers.

J. Bourgogne, Paris, France.

1011. Transverse section of compact substance of fossil bone of whale. Most of the canaliculi are filled with

B. 4. balsam. For moderate powers.

C. M. Topping, London, England.

158. Piece of fossil bone from the neighborhood of Richmond, Va., asserted to be a "marl-stone," curing

B. 5. syphilis, hydrophobia, bites of serpents, &c., and offered for sale as such. Shows the Haversian canals, but is too thick to show lacunae and canaliculi. For low powers.

159 to 161. Three preparations of scales of gar-fish, showing the osseous structure of the scales. For low and high

B. 6. powers.

1623 & 1678. Two preparations consisting of horizontal sections of sternum of mouse, with cartilages, articulating

B. 7. extremities of ribs, and portions of muscle attached, stained with carmine, showing the minute anatomy and mutual relations of the several structures enumerated. For low and high powers.

Assistant Surgeon J. S. Billings, U. S. Army.

1683 & 1681. Two horizontal sections through one lateral half of head of tibia of young puppy, stained with carmine,

B. 8. showing the process of ossification of cartilage. For high powers.

Assistant Surgeon J. S. Billings, U. S. Army.

1017. Section of cartilage and young bone from cat, stained with carmine, showing the process of ossification

B. 9. of cartilage. For high powers.

For other illustrations, see VII. C. B. 7.

C. PATHOLOGICAL.

1073. Transverse section of portion of compact substance of shaft of human femur, from a case of osteo-

C. 1. myelitis, showing large cavities produced in the bone by ulceration, apparently starting from the walls of the Haversian canals. For low and high powers.

1071. Same as **C. 1**, but embracing a portion of healthy bone. Is too thick for minute study. For low and

C. 2. moderate powers.

- 1075.** Transverse section of portion of compact substance of shaft of human fibula from the vicinity of a fracture, showing a narrow deposit of new bone from periosteal inflammation. For low and high powers.
C. 3. Assistant Surgeon J. J. Woodward, U. S. Army.
- 1076.** Transverse section of sequestrum from human bone, embracing compact and spongy tissue. Upon a portion of the outer surface there is a deposit of new bone. For moderate and high powers.
C. 4.
- 1077 & 1078.** Two transverse sections through a mass of young callus in the vicinity of a fracture, from human femur, showing the structure of new bone. For low and high powers.
C. 5.
- 1079.** Transverse section of compact substance of shaft of human femur, with a small portion of callus attached to the outer surface, from the vicinity of a fracture. The earthy constituents of the bone have been removed by maceration in acid. For moderate and high powers.
C. 6.
- 1085.** Longitudinal section of a chicken bone through a consolidated fracture, showing the rounded extremities of the bones riding past each other, but connected by an arch of new spongy bone. For low and high powers.
C. 7.
- Hospital Steward A. J. Schafhirt, U. S. Army.

C. PERIOSTEUM.

A. FROM MAN.

- 325.** Opaque injection (yellow) of the vessels from the anterior tunicelle. For low powers.
A. 1. Prof. Joseph Hyrtl, Vienna, Austria.
- 327.** Opaque injection (yellow) of the vessels of the pericranium. For low powers.
A. 2. Prof. Joseph Hyrtl, Vienna, Austria.
- 329.** Opaque injection (yellow) of the vessels of periosteum of tibia. For low powers.
A. 3. Prof. Joseph Hyrtl, Vienna, Austria.

C. PATHOLOGICAL.

- 330.** Opaque injection (red) of the vessels of inflamed periosteum, from a syphilitic node of tibia. For low powers.
C. 1. Prof. Joseph Hyrtl, Vienna, Austria.

D. MEDULLARY SUBSTANCE.

A. FROM MAN.

- 351.** Opaque injection in two colors (arteries white, veins blue) of the vessels of medullary substance from femur. For low powers.
A. 1. Prof. Joseph Hyrtl, Vienna, Austria.

E. SYNOVIAL MEMBRANES.

A. FROM MAN.

- 1059 to 1061.** Three preparations of synovial fringes from finger joint, with transparent carmine injection, showing the arrangement of the capillary loops. For low powers.
A. 1. *See Part Second, IV, E, v. 1*
- 328.** Opaque injection (red) of the vessels of synovial membrane from knee joint. For low powers.
A. 2. Prof. Joseph Hyrtl, Vienna, Austria.

V. VASCULAR SYSTEM.

A. HEART.

B. PERICARDIUM

C. ARTERIES.

D. VEINS.

E. CAPILLARIES.

F. LYMPHATIC VESSELS.

G. LYMPHATIC GLANDS.

H. BLOOD AND LYMPH.

A. FROM MAN | B. FROM ANIMALS. | C. PATHOLOGICAL.

V. VASCULAR SYSTEM.

A. HEART.

A. FROM MAN.

- 315.** Opaque injection (yellow) of the vessels of the substance of heart of fetus. For low powers.
A. 1. Prof. Joseph Hyrtl, Vienna, Austria.
- 316.** Opaque injection (red) of the vessels of papillary muscle of heart. For low powers.
A. 2. Prof. Joseph Hyrtl, Vienna, Austria.
- 317.** Opaque injection (yellow) of the vessels of trabeculae carneae of heart. For low powers.
A. 3. Prof. Joseph Hyrtl, Vienna, Austria.

B. FROM ANIMALS.

- 1081 to 1086.** Three transverse sections through wall of auricle of bullock's heart, showing the arrangement of the muscular bundles composing the wall. For low and high powers.
B. 1.
- 322.** Opaque injection (yellow) of the vessels of trabeculae carneae of heart of *Hexanchus griscus*. For low powers.
B. 2. Prof. Joseph Hyrtl, Vienna, Austria.

C. ARTERIES.

A. FROM MAN.

- 319.** Opaque injection (red) of vasa vasorum of aorta. For low powers.
A. 1. Prof. Joseph Hyrtl, Vienna, Austria.

For other illustrations, see **III.** B. c. 2.

B. FROM ANIMALS.

- 526.** Portion of aorta of mouse and arterial branches, stained with carmine, showing (best in the smaller vessels) the structure of the coats. For moderate and high powers.
B. 1.
- 436 to 438.** Three preparations of arteries and veins in muscular tissue of kitten, stained with carmine, showing the general character of the structure of the vessels. For moderate and high powers.
B. 2.
- 439 and 440.** Two preparations of arteries and veins from kitten, stained with carmine, showing the minute anatomy of the walls of the vessels; also nerves and adipose tissue. For moderate and high powers.
B. 3.
- 1666 to 1668.** Three preparations of arteries, veins and capillaries from kitten, stained with carmine, showing very perfectly the minute anatomy of the walls of the vessels and of nerves and connective tissue. For moderate and high powers.
B. 4.

For other illustrations, see **I.** A. B. 1; **II.** A. B. 1; **III.** B. B. 3, 5, 6, 7 (Specimen **1187**), 10, 11; **VI.** D. B. 9 (Specimen **1211**); **VI.** E. B. 3 to 5; **VIII.** B. B. 2, 3; **VII.** O. B. 1, 3 to 6; **VII.** Q. B. 4.

D. VEINS.

A. FROM MAN.

See III. B. C. 2.

B. FROM ANIMALS.

See I. A. B. 1; II. A. B. 1; III. B. B. 3, 5, 6, 7 (Specimen 1187), 10, 11; V. C. B. 2 to 4; VI. E. B. 3 to 5; VII. B. B. 2, 3; VIII. O. B. 1, 3 to 6; VIII. Q. B. 1.

E. CAPILLARIES.

A. FROM MAN.

See III. B. C. 2.

B. FROM ANIMALS.

See II. A. B. 1; III. B. B. 3 to 5, 6, 7 (Specimen 1187), 11; V. C. B. 4; VI. D. B. 9 (Specimen 1211); VI. E. B. 5; VII. B. B. 2, 3; VIII. O. B. 1, 3 to 6; VIII. P. B. 1; VIII. Q. B. 1.

F. LYMPHATIC VESSELS.

A. FROM MAN.

28. Opaque injection (yellow) of the lymphatic vessels of the seroum. For low powers.
A. 1. Prof. Joseph Hyrtl, Vienna, Austria.

351. Opaque injection (white) of the lymphatic vessels on the out-side of a gravid uterus. For low powers.
A. 2. Prof. Joseph Hyrtl, Vienna, Austria.

C. PATHOLOGICAL.

39. Opaque injection (yellow) of lymphatic vessels of the skin of the leg in elephantiasis. For low powers.
C. 1. Prof. Joseph Hyrtl, Vienna, Austria.

352. Opaque injection (yellow) of subarachnoid lymphatic plexus from a hydrocephalic child. For low powers.
C. 2. Prof. Joseph Hyrtl, Vienna, Austria.

G. LYMPHATIC GLANDS.

A. FROM MAN.

287. Opaque injection in two colors (arteries white, veins blue) of small lymphatic glands from the mesenteric. For low powers.
A. 1. Prof. Joseph Hyrtl, Vienna, Austria.

288. Same as **A. 1.** from a large gland (arteries red, veins yellow). For low powers.
A. 2. Prof. Joseph Hyrtl, Vienna, Austria.

II. BLOOD AND LYMPH.

A. FROM MAN.

608. Human blood corpuscles, dried. For high powers.
A. 1. *See Part Second, V. II. A. 1 to 4.*

B. FROM ANIMALS.

387. Blood corpuscles of pigeon, dried. For high powers.
B. 1. *See Part Second, V. II. B. 1.*

609 to 612. Four preparations of blood corpuscles of frog, dried. For high powers.
B. 2. *See Part Second, V. II. B. 2.*

613 to 617. Five preparations of blood corpuscles of toad, dried. For high powers.
B. 3.

618 to 621. Seven preparations of blood corpuscles of lizard (*Menopoma Allegheniensis*). For high powers.
B. 4.

2018 to 2050. Three preparations of blood corpuscles of *Triton*. For high powers.
B. 5.

VI. NERVOUS SYSTEM.

A. CEREBRUM.

B. CEREBELLUM.

C. PONS VAROLII AND MEDULLA OBLONGATA.

D. SPINAL CORD.

E. NERVES.

F. GANGLIA.

G. MEMBRANES OF BRAIN AND SPINAL CORD.

A FROM MAN. | B. FROM ANIMALS. | C. PATHOLOGICAL.

VI. NERVOUS SYSTEM.

A. CEREBRUM.

B. FROM ANIMALS.

496 to 507 Fifteen preparations consisting of sections of cerebrum of mouse, with transparent carmine injection, showing the arrangement of the excessively minute capillaries. For moderate powers.
and
1513 to 1515.

B. 1.

1960, 1961 Four sections of cerebrum of kitten, with transparent carmine injection, showing the arrangement of the capillaries in the several portions of the cerebrum. Specimens **1961, 2033** and **2034** embrace the entire thickness of the cerebrum. For low powers.
and
2033, 2034.

B. 2.

B. CEREBELLUM.

A. FROM MAN.

331. Opaque injection (red) of the vessels of the cortical substance of cerebellum. For low powers.
A. 1. Prof. Joseph Hyrtl, Vienna, Austria.

C. PONS VAROLII AND MEDULLA OBLONGATA.

A. FROM MAN.

1551. Transverse section of medulla oblongata through the olivary bodies, stained with carmine, showing the general arrangement of the component parts of the cord, and also individual nerve cells and fibres. For low and high powers.
A. 1. Dr. R. T. Edes, Hingham, Mass.

1547. Transverse section of medulla oblongata at the region of the decussation of the anterior pyramids; similar in character to **A. 1.**
A. 2. Dr. R. T. Edes, Hingham, Mass.

D. SPINAL CORD.

A. FROM MAN.

1552. Transverse section of upper cervical portion of spinal cord, stained with carmine, showing the general arrangement of the component parts of the cord, and also individual nerve cells and fibres. For low and high powers.
A. 1. Dr. R. T. Edes, Hingham, Mass.

1612. Transverse section of spinal cord stained with carmine. The section has cracked in many places in the process of mounting and does not show well under the high powers.
A. 2. Assistant Surgeon J. S. Billings, U. S. Army.

- 1619.** Same as **A. 2.**, without the staining.
A. 3. Assistant Surgeon J. S. Billings, U. S. Army.
- 335.** Opaque injection (yellow) of the vessels of central part of spinal cord. For low powers.
A. 4. Prof. Joseph Hyrtl, Vienna, Austria.

B. FROM ANIMALS

- 1550.** Transverse section of spinal cord of dog through the cervical enlargement, stained with carmine, showing the general and minute anatomy of the cord. For low and high powers.
B. 1. Dr. R. T. Edes, Hingham, Mass.
- 1518.** Transverse section of spinal cord of dog through the lumbar enlargement, stained with carmine; similar in character to **B. 1.**
B. 2. Dr. R. T. Edes, Hingham, Mass.
- 375.** Transverse section of spinal cord of cat, stained with carmine, showing the general and minute anatomy of the cord. For low and high powers.
B. 3. Dr. S. A. Jones, Englewood, N. J.
- 1119 to 1159.** Eleven transverse sections of spinal cord of cat, with transparent Prussian blue injection (almost entirely faded) and carmine staining, showing the general and minute anatomy of the cord. The central canal of the cord is still extant, and many of the specimens show the columnar epithelium lining the canal. The sections are particularly well suited for study with the higher powers.
B. 4.
- 1160 to 1166.** Seven preparations, consisting of transverse sections of spinal cord of kitten, with transparent Prussian blue injection and carmine staining, showing the general anatomy of the cord, and, partially, the arrangement of the capillaries. For low and moderate powers.
B. 5.
- 1621.** Transverse section of spinal cord of kitten, with transparent Prussian blue injection, showing the arrangement of the capillaries of the cord. For low and moderate powers.
B. 6. Assistant Surgeon J. S. Billings, U. S. Army.
- 376 to 385.** Ten transverse sections of spinal cord of calf, stained with carmine, showing the general and minute anatomy of the cord. For low and high powers.
B. 7.
- 1167 to 1169.** Three preparations, same as **B. 7.** but cracked in mounting, and not well adapted for high powers.
B. 8.
- 1208 to 1211.** Seven preparations of scraps of spinal cord of calf, teased out so as to show nerve cells and fibres and their mutual relations; stained with carmine. Specimen **1211** shows also very beautifully a small artery and capillaries. For high powers.
B. 9.
- 1215 to 1218.** Four preparations of isolated multipolar nerve cells, with their processes attached, from spinal cord of calf; stained with carmine. For high powers.
B. 10.
- 1558.** Same as **B. 10.**
B. 11. Prof. Joseph Gerlach, Erlangen, Bavaria.
See Part Second, VI, D n. 1.
- 1556.** Tanga of axis fibres teased out from white substance of spinal cord of calf and stained with carmine. For high powers.
B. 12. Prof. Joseph Gerlach, Erlangen, Bavaria.
- 1519.** Transverse section of spinal cord of *Enys insculpta* through the cervical enlargement, stained with carmine, showing the general and minute anatomy of the cord. For low and high powers.
B. 13. Dr. R. T. Edes, Hingham, Mass.
- 1962 to 1965.** Four transverse sections of cervical portion of spinal cord of kitten, with transparent carmine injection, showing the arrangement of the capillaries. For low powers.
B. 14.

E. NERVES.

A. FROM MAN.

- 1512.** Nerve from finger, with transparent carmine injection, showing the dense mesh-work of capillaries surrounding the nerve. For low powers.
A. 1.
- 517.** Pacinian body from finger, with transparent carmine injection, showing the arrangement of the capillaries over the surface of the body. For low powers.
A. 2.
- 331.** Opaque injection (red) of the vessels of the ischiatic nerve. For low powers.
A. 3. Prof. Joseph Hyrtl, Vienna, Austria.
- 332.** Opaque injection (yellow) of the vessels of the posterior root of the second sacral nerve. For low powers.
A. 4. Prof. Joseph Hyrtl, Vienna, Austria.
- 333.** Opaque injection (yellow) of the vessels of the sympathetic nerve. For low powers.
A. 5. Prof. Joseph Hyrtl, Vienna, Austria.

For other illustrations, see II. A. A. 8, 11 (Specimens 1998 to 2002), 12 (Specimens 2009 to 2011); III. B. C. 2.

B. FROM ANIMALS.

- 602.** Nerve from neck of mouse, with transparent carmine injection, showing the arrangement of the capillaries around the nerve. For low powers.
B. 1.
- 518.** Nerve of rat, with transparent Prussian blue injection and carmine staining. Only a few of the vessels are filled by the injection. The staining brings out the connective tissue corpuscles of the neurilemma, and from the cut extremities of the nerve the nerve pulp projects in globular masses. For moderate and high powers.
B. 2.
- 1010.** Nerves from rat, with transparent Prussian blue injection and carmine staining, showing the individual nerve fibres composing the bundles, the corpuscles of the neurilemma, and also muscular fibres, arteries and veins. For moderate and high powers.
B. 3.
- 857.** Pacinian bodies in situ in mesentery of cat, with transparent Prussian blue injection, showing the structure of the Pacinian bodies and their relations to the nerves; also arteries, veins, and adipose tissue. For moderate and high powers.
B. 4.
- 858.** Same as **B. 4.** without the injection, and stained with carmine. The staining brings out more distinctly the structure and relations of the Pacinian bodies. Shows also arteries, veins, capillaries and connective tissue. For moderate and high powers.
B. 5.

For other illustrations, see II. A. B. 1; III. B. B. 4, 6, 9, 11; III. B. C. 4; V. C. B. 3, 4; VI. F. B. 1; VII. B. B. 2, 3; VII. C. B. 8; VII. M. B. 1 (Specimen 939); VII. O. B. 1, 3, 5; VII. Q. B. 1, 4; IX. A. B. 11; XII. A. B. 1, 2.

F. GANGLIA.

B. FROM ANIMALS.

- 1622.** Three nerve ganglia, with connecting nerve trunks attached, from a caterpillar. Vessels of the trachea are also shown passing to the ganglia and nerve trunks, and there breaking up into great numbers of extremely fine ramifying branches. For moderate and high powers.
B. 1.

Assistant Surgeon J. S. Billings, U. S. Army.

G. MEMBRANES OF BRAIN AND SPINAL CORD.

A. FROM MAN.

- 350.** Opaque injection (white) of the vessels of choroid plexus, from lateral ventricle of cerebrum. For low powers.
A. 1. Prof. Joseph Hyrtl, Vienna, Austria.

B. FROM ANIMALS.

- 1277 A 1278.** Two preparations of choroid plexus of cat, with transparent carmine injection, showing the arrangement of the vessels of the plexus, and the epithelial cells covering them. For low and high powers.
B. 1.
- 1213.** Choroid plexus of rat, with transparent carmine injection, showing the arrangement of the vessels of the plexus. For low powers.
B. 2.
- 1966.** Portion of pia mater of kitten, with transparent carmine injection, showing the arrangement of the bloodvessels. For low powers.
B. 3.

VII. DIGESTIVE ORGANS.

- A. MUCOUS MEMBRANE OF MOUTH AND FAUCES.
- B. SALIVARY AND POISON GLANDS.
- C. TONGUE
- D. TEETH.
- E. PHARYNX.
- F. ŒSOPHAGUS.
- G. STOMACH.
- H. SMALL INTESTINE.
- I. LARGE INTESTINE AND CLOACA.
- K. LIVER AND GALL-BLADDER.
- L. CHEMICAL CONSTITUENTS OF BILE.
- M. PANCREAS.
- N. SPLEEN.
- O. MESENTERY.
- P. OMENTUM.
- Q. PERITONEUM.

A. FROM MAN. | B. FROM ANIMALS. | C. PATHOLOGICAL.

VII. DIGESTIVE ORGANS.

A. MUCOUS MEMBRANE OF MOUTH AND FAUCES.

B. FROM ANIMALS.

- 196.** Opaque injection (yellow) of the vessels of the mucous membrane of mouth of *Triton cristatus*. For low powers.
B. 1. Prof. Joseph Hyrtl, Vienna, Austria.
- 197.** Opaque injection (yellow) of the vessels of the fornix of mouth of *Salamandra maculosa*. For low powers.
B. 2. Prof. Joseph Hyrtl, Vienna, Austria.
- 198.** Opaque injection (yellow) of the vessels of the palate of *Salamandra maculosa*. For low powers.
B. 3. Prof. Joseph Hyrtl, Vienna, Austria.

B. SALIVARY AND POISON GLANDS.

A. FROM MAN.

- 276.** Opaque injection in two colors (arteries yellow, veins red) of parotid gland. For low powers.
A. 1. Prof. Joseph Hyrtl, Vienna, Austria.
- 277.** Opaque arterial injection (yellow) of submaxillary gland. For low powers.
A. 2. Prof. Joseph Hyrtl, Vienna, Austria.

B. FROM ANIMALS.

- 1662.** Portion of salivary gland from kitten, stained with carmine, showing the racemose character of the gland and the nuclei of the pavement epithelium of the lobules. For low and high powers.
B. 1.
- 1663.** Portion of duct of salivary gland of kitten, stained with carmine, showing the structure of the duct, and also arteries, veins, capillaries, nerves and connective tissue. For moderate and high powers.
B. 2.
- 1661.** Portion of salivary gland, with duct attached, from kitten, stained with carmine, similar in character to **B. 1** and **2**; shows also arteries, veins, capillaries, nerves and connective tissue. For low and high powers.
B. 3.
- 280.** Opaque injection in two colors (arteries yellow, veins red) of parotid gland of *Simia Capucina*. For low powers.
B. 4. Prof. Joseph Hyrtl, Vienna, Austria.
- 289.** Opaque injection in two colors (arteries red, veins yellow) of poison gland of *Aspis Haje*. For low powers.
B. 5. Prof. Joseph Hyrtl, Vienna, Austria.

U. TONGUE.

A. FROM MAN.

- 306.** Opaque injection (yellow) of the vessels on the under surface of tongue. For low powers.
A. 1. Prof. Joseph Hyrtl, Vienna, Austria.
- 307.** Opaque injection (yellow) of the vessels in a section of tongue. For low powers.
A. 2. Prof. Joseph Hyrtl, Vienna, Austria.
- 308.** Opaque injection (red) of the vessels of the papillæ circumvallatæ of tongue. For low powers.
A. 3. Prof. Joseph Hyrtl, Vienna, Austria.

B. FROM ANIMALS.

- 388 to 391.** Series of seven preparations of epidermis of upper surface of cat's tongue, from tip to root, showing the large recurved papillæ. For low powers.
B. 1.
- 911 to 950.** Series of ten perpendicular sections of tongue of cat, cut transversely, with transparent carmine injection, showing the arrangement of the capillaries and muscular bundles in the tongue and the structures of the mucous membrane. For low and moderate powers.
B. 2.
- 951 to 953.** Three perpendicular sections of tongue of kitten, cut transversely, with transparent carmine injection; similar in character to **B. 2**.
B. 3.
- 105.** Perpendicular section of small portion of tongue of dog, with transparent Prussian blue injection, showing the arrangement of the capillary loops in the long papillæ of the tongue. For low powers.
B. 4. Assistant Surgeon J. S. Billings, U. S. Army.
- 106.** Perpendicular section of portion of tongue of dog, cut longitudinally, with transparent Prussian blue injection; similar in character to **B. 4**, but embracing more of the substance of the tongue.
B. 5. Assistant Surgeon J. S. Billings, U. S. Army.
- 555 to 566.** Twelve preparations, consisting of perpendicular sections of tongue of mouse, cut transversely, with transparent carmine injection, showing the arrangement of the capillaries in the substance of the tongue and mucous membrane, and the character of the papillæ. For low and moderate powers.
B. 6.
- 536 to 512.** Series of seven perpendicular sections of tongue of chicken, cut transversely, with transparent carmine injection, showing the relations and anatomy of the various structures—muscle, cartilage, bone and dense epidermis—composing the organ, and the arrangement of the capillaries. For low and high powers.
B. 7.
- 531.** Perpendicular section of portion of tongue of *Iguana*, with transparent Prussian blue injection and carmine staining, showing the arrangement of the muscular elements of the tongue, especially the muscular fibres passing up to the summit of the erectile papillæ, the arrangement of the capillaries, and also some nerve fibres.
B. 8. In one or two of the papillæ branched muscular fibres are seen. For low and high powers.
 Assistant Surgeon J. S. Billings, U. S. Army.
- 309.** Opaque injection (red) of the vessels of the filiform papillæ of tongue of lion. For low powers.
B. 9. Prof. Joseph Hyrtl, Vienna, Austria.
- 310.** Opaque injection (yellow) of the vessels of tongue of *Salamandra*. For low powers.
B. 10. Prof. Joseph Hyrtl, Vienna, Austria.
- 311.** Opaque injection (yellow) of the vessels of tongue of frog. For low powers.
B. 11. Prof. Joseph Hyrtl, Vienna, Austria.

C. PATHOLOGICAL.

- 513 to 551** Fifteen preparations consisting of perpendicular sections of tongue of rat infested with the *Trichina spiralis*, with transparent carmine injection, showing the parasites lying encysted between the muscular fibres. The specimens show also the normal arrangement of the elements of the rat's tongue. For low and moderate powers.
add
1219 to 1221.
C. 1.

D. TEETH.

A. FROM MAN.

- 395.** Longitudinal section of incisor tooth. The enamel has all been broken off in the course of preparation
A. 1. Shows only the dentine. For low and high powers.
- 396.** Longitudinal section of incisor tooth. As in **A. 1**, the enamel is wanting. Shows only the dentine.
A. 2. For low and high powers.
- 397.** Longitudinal section of incisor tooth. This section retains most of the enamel, but is much thicker than
A. 3. the preceding. It embraces the central cavity of the tooth, and shows the osseous cement lining the inner surface of the fang. For low and high powers.
- 398.** Longitudinal section of molar tooth, showing all the structures of the tooth. For low and high
A. 4. powers.

B. FROM ANIMALS.

- 399.** Longitudinal section of teeth of rat with portion of lower jaw attached, and transverse section of another
B. 1. tooth, showing all the structures of the teeth. For low and high powers.
 J. Bourgogne, Paris, France.
- 400.** Longitudinal section of molar tooth of sheep, showing its various structures. For low and high powers.
B. 2. J. Bourgogne, Paris, France.
- 401.** Transverse section of same as **B. 2.** For low and high powers.
B. 3. J. Bourgogne, Paris, France.
- 402.** Section of portion of molar tooth of elephant, showing enamel and dentine. For low and high powers.
B. 4. J. Bourgogne, Paris, France.

E. PHARYNX.

B. FROM ANIMALS.

- 527.** Portion of pharynx of *Iguana*, with transparent Prussian blue injection, showing a dense layer of
B. 1. pigment cells with anastomosing processes. For moderate powers.
 Assistant Surgeon J. S. Billings, U. S. Army.
- 510.** Epidermis from pharynx of *Iguana*, slightly stained with carmine, showing the spike-shaped papillæ.
B. 2. For moderate powers.
 Assistant Surgeon J. S. Billings, U. S. Army.
- 1951.** Portion of mucous membrane from pharynx of kitten, with transparent carmine injection, showing the
B. 3. arrangement of the bloodvessels. For low and moderate powers.
- 199.** Opaque injection (white) of the vessels of pharynx of *Salamandra maculosa*. For low powers.
B. 4. Prof. Joseph Hyrtl, Vienna, Austria.

F. ŒSOPHAGUS.

B. FROM ANIMALS.

- 1510.** Portion of œsophagus of mouse, with transparent carmine injection, showing the arrangement of the
B. 1. capillaries and muscular layers. For moderate and high powers.
- 569 & 570.** Two preparations of œsophagus of chicken, with transparent carmine injection, showing the arrangement
B. 2. of the capillaries. For low powers.

G. STOMACH.

A. FROM MAN.

- 157.** Opaque injection in two colors (arteries white, veins blue) of mucous membrane of stomach, near the cardiac orifice. For low powers.
A. 1. Prof. Joseph Hyrtl, Vienna, Austria.
- 158.** Same as **A. 1.**, from near the pylorus. For low powers.
A. 2. Prof. Joseph Hyrtl, Vienna, Austria.
- 159.** Same as **A. 1.** (arteries yellow, veins red), from the fundus of the stomach.
A. 3. Prof. Joseph Hyrtl, Vienna, Austria.
- 160.** Opaque injection in two colors (arteries white, veins red) of the submucous connective tissue of stomach.
A. 4. Prof. Joseph Hyrtl, Vienna, Austria.
- 161.** Opaque injection in two colors (arteries yellow, veins red) of muscular coat of stomach.
A. 5. Prof. Joseph Hyrtl, Vienna, Austria.
- 178.** Opaque injection in two colors (arteries white, veins red) of pylorus.
A. 6. Prof. Joseph Hyrtl, Vienna, Austria.

B. FROM ANIMALS.

- 173.** Portion of muscular coat of stomach of cat, with transparent carmine injection, showing the arrangement of the capillaries. For low and moderate powers.
B. 1.
- 567.** Portion of stomach of toad, with transparent Prussian blue injection and carmine staining, showing the arrangement of the glands and capillaries. The mucous surface is towards the observer. For low and moderate powers.
B. 2.
- 568.** Perpendicular sections of stomach of toad, with transparent Prussian blue injection and carmine staining, showing the anatomy of the several coats of the stomach. For low and high powers.
B. 3.
- 1955 & 1956.** Two perpendicular sections of stomach of kitten, embracing the entire circumference of the organ, with transparent carmine injection, showing the arrangement of the capillaries in the several coats of the stomach, and the epithelium in situ on the mucous membrane. For low and high powers.
B. 4.
- 1972.** Portion of muscular coat of stomach of kitten, with transparent carmine injection, showing the arrangement of the capillaries. For low powers.
B. 5.
- 181.** Opaque injection in two colors (arteries yellow, veins red) of the vessels in a transverse section of proventriculus of goose. For low powers.
B. 6. Prof. Joseph Hyrtl, Vienna, Austria.
- 182.** Same as **B. 6.** in longitudinal section. For low powers.
B. 7. Prof. Joseph Hyrtl, Vienna, Austria.
- 183.** Opaque injection (yellow) of the vessels in a transverse section of glands of proventriculus of *Pero cristatus*.
B. 8. Prof. Joseph Hyrtl, Vienna, Austria.
- 184.** Opaque injection in two colors (arteries white, veins blue) of the vessels on the external aspect of glands of proventriculus of *Columba*. For low powers.
B. 9. Prof. Joseph Hyrtl, Vienna, Austria.
- 185.** Opaque injection in two colors (arteries yellow, veins red) of the vessels on the internal aspect of proventriculus of *Ardea cinerea*. For low powers.
B. 10. Prof. Joseph Hyrtl, Vienna, Austria.

- 186.** Opaque injection in two colors (arteries yellow, veins red) of the vessels on the internal surface of muscular stomach of *Gallina*. For low powers.
B. 11. Prof. Joseph Hyrtl, Vienna, Austria.
- 187.** Opaque injection in two colors (arteries white, veins blue) of muscular stomach of *Strix Bubo*. For low powers.
B. 12. Prof. Joseph Hyrtl, Vienna, Austria.
- 200.** Opaque injection in two colors (arteries white, veins blue) of stomach of *Proteus*. For low powers.
B. 13. Prof. Joseph Hyrtl, Vienna, Austria.
- 205.** Opaque injection (white) of the vessels of stomach of *Triton cristatus*. For low powers.
B. 14. Prof. Joseph Hyrtl, Vienna, Austria.
- 207.** Opaque injection in two colors (arteries red, veins white) of stomach of *Salamandra*, near the pylorus.
B. 15. For low powers. Prof. Joseph Hyrtl, Vienna, Austria.
- 215.** Opaque injection in two colors (arteries yellow, veins green) of stomach of *Rana ridibunda*. For low powers.
B. 16. Prof. Joseph Hyrtl, Vienna, Austria.
- 219.** Opaque injection in two colors (arteries yellow, veins blue) of pylorus of *Rana esculenta*. For low powers.
B. 17. Prof. Joseph Hyrtl, Vienna, Austria.
- 232.** Opaque injection in two colors (arteries white, veins blue) of stomach of *Coluber tessellatus*. For low powers.
B. 18. Prof. Joseph Hyrtl, Vienna, Austria.
- 233.** Opaque injection in two colors (arteries white, veins green) of stomach of *Anguis fragilis*. For low powers.
B. 19. Prof. Joseph Hyrtl, Vienna, Austria.
- 212.** Opaque injection in two colors (arteries yellow, veins red) of stomach of *Acipenser Sturio*. For low powers.
B. 20. Prof. Joseph Hyrtl, Vienna, Austria.
- 213.** Opaque injection (red) of vessels of pylorus of *Acipenser Sturio*. For low powers.
B. 21. Prof. Joseph Hyrtl, Vienna, Austria.
- 211.** Same as B. 21, from *Acipenser Ruthenus*. For low powers.
B. 22. Prof. Joseph Hyrtl, Vienna, Austria.
- 216.** Opaque injection (red) of vessels of muscular coat of stomach of *Acipenser Sturio*. For low powers.
B. 23. Prof. Joseph Hyrtl, Vienna, Austria.
- 219.** Opaque injection in two colors (arteries white, veins blue) of stomach of *Cobitis fossilis*. For low powers.
B. 24. Prof. Joseph Hyrtl, Vienna, Austria.
- 250.** Opaque injection (white) of vessels of muscular coat of stomach of pike. For low powers.
B. 25. Prof. Joseph Hyrtl, Vienna, Austria.

C. PATHOLOGICAL.

- 1327 to 1329 and 1313 to 1315.** Six perpendicular sections of human stomach, in the immediate vicinity of a small cyst, stained with carmine, showing thickening of the walls of the stomach, especially of the muscular coat. For low and high powers.
C. 1. From Specimen 768, *Medical Section*, chap. IV., sec. 2, B. 5.

II. SMALL INTESTINE.

A. FROM MAN.

- 108 to 110.** Three preparations of mucous membrane of ileum, dissected from the other coats of the intestine, showing the villi and orifices of the glands of Lieberkuhn. For low and moderate powers.
A. 1.
- 101.** Perpendicular section of ileum, stained with red aniline, showing the minute anatomy of the several coats of the intestine. For low and high powers.
A. 2.
- 1563.** Portion of muscular coat of small intestine of negro infant, with transparent carmine injection, showing the arrangement of the capillaries. For low and moderate powers.
A. 3.
- 571 to 576 and 1111.** Seven preparations, consisting of portions of jejunum, with opaque injection (red), showing the arrangement of the capillary loops in the villi. For low powers.
A. 4.
- 577, 578 and 1112, 1511.** Four preparations, same as **A. 4**, but with yellow instead of red injection.
A. 5.
- 162.** Opaque injection in two colors (arteries yellow, veins blue) of mucous membrane of duodenum. For low powers.
A. 6. Prof. Joseph Hyrtl, Vienna, Austria.
- 163.** Opaque injection (red) of the vessels of mucous membrane of jejunum. For low powers.
A. 7. Prof. Joseph Hyrtl, Vienna, Austria.
- 161.** Opaque injection in two colors (arteries white, veins yellow) of ileum from a new-born child. For low powers.
A. 8. Prof. Joseph Hyrtl, Vienna, Austria.
- 165.** Opaque injection in two colors (arteries yellow, veins blue) of mucous membrane of ileum, near the ileo-caecal valve, from a child two years old. For low powers.
A. 9. Prof. Joseph Hyrtl, Vienna, Austria.
- 166.** Opaque injection in two colors (arteries yellow, veins blue) of muscular coat of ileum. For low powers.
A. 10. Prof. Joseph Hyrtl, Vienna, Austria.
- 167.** Opaque injection (white) of the vessels of a Peyer's patch. For low powers.
A. 11. Prof. Joseph Hyrtl, Vienna, Austria.
- 168.** Opaque injection in two colors (arteries yellow, veins red) of a Peyer's patch. The glands are filled with chyle. For low powers.
A. 12. Prof. Joseph Hyrtl, Vienna, Austria.
- 169.** Opaque injection (yellow) of the chyliferous vessels of the intestinal villi. For low powers.
A. 13. Prof. Joseph Hyrtl, Vienna, Austria.
- 170.** Same as **A. 13**, with opaque injection (red) of the arteries. For low powers.
A. 14. Prof. Joseph Hyrtl, Vienna, Austria.

B. FROM ANIMALS.

- 535.** Perpendicular section of small intestine of puppy, showing the very long villi. For low powers.
B. 1. Assistant Surgeon J. S. Billings, U. S. Army.
- 1053 & 1051.** Two preparations, consisting of perpendicular sections of duodenum of cat, with transparent carmine injection, showing the arrangement of the capillaries in the several coats of the intestine, and also the glands of Brunner. For low and moderate powers.
B. 2.

- 605 & 606.** Two perpendicular sections of jejunum of cat, with transparent carmine injection, showing the arrangement of the capillaries in the several coats of the intestine, and also the epithelium of the villi. For low and moderate powers.
B. 3.
- 1222 & 1223.** Two preparations, similar to **B. 3.**
B. 4.
- 1282 & 1283.** Two perpendicular sections of ileum of cat, with transparent carmine injection, showing the arrangement of the capillaries in the several coats, and also the glands of a Peyer's patch. For low and moderate powers.
B. 5.
- 1560.** Perpendicular section through entire circumference of small intestine of cat, with transparent carmine injection, showing the arrangement of the capillaries in the several coats of the intestine, and also the epithelium in situ upon the villi. For low and moderate powers.
B. 6.
 Prof. Joseph Gerlach, Erlangen, Bavaria.
- 951 to 961.** Eight preparations, same as **B. 6.**, and showing the same points.
B. 7.
- 962 to 967.** Seven perpendicular sections of small intestine of cat, with transparent Prussian blue injection (faded to a considerable extent) and carmine staining; showing the minute anatomy of the structures of the several coats of the intestine. For low and high powers.
and
607.
B. 8.
- 603.** Perpendicular section of mucous coat of small intestine of cat, with transparent Prussian blue injection and carmine staining, showing the capillary loops in the villi and the structure of the follicles of Lieberkuhn. For low and high powers.
B. 9.
- 595.** Oblique section, same as **B. 9.**
B. 10.
- 756 to 758.** Three perpendicular sections through the entire circumference of small intestine of cat, with transparent Prussian blue injection and carmine staining, showing the capillary loops in the villi and the individual cells of the columnar epithelium of the villi, with their nuclei stained. For low and high powers.
B. 11.
- 1311 to 1316** Five preparations, consisting of perpendicular sections of small intestine of kitten, with transparent Prussian blue injection and carmine staining, showing the arrangement of the capillaries in the several coats of the intestine and the epithelium in situ on the villi. For low and moderate powers.
and
1575 & 1576.
B. 12.
- 1317 to 1321.** Eight preparations, same as **B. 12.** The injection has faded to a great extent, but the sections show the minute anatomy of the various structures of the walls of the intestine. In many places there are instructive transverse sections of the villi. For low and high powers.
B. 13.
- 1325.** Perpendicular section of small intestine of kitten, with transparent carmine injection, showing the arrangement of the capillaries and the epithelium in situ on the villi. For low and moderate powers.
B. 14.
- 759.** Same as **B. 14.**, embracing the entire circumference of the intestine.
B. 15.
- 581 to 587,** Sixteen preparations, consisting of portions of small intestine of rat, with transparent carmine injection, showing the capillary loops in the villi and over the surface of the mucous membrane. The inner surface of the intestine is towards the observer. For low and moderate powers.
760 to 767,
and
1300 to 1303.
B. 16.
- 1313.** Same as **B. 16.**, showing also a solitary gland, with its vessels injected.
B. 17.
- 588 to 590** Five preparations, consisting of portions of mucous membrane of small intestine of mouse with transparent carmine injection, showing the capillary loops in the villi. For low and moderate powers.
and
1304 & 1305.
B. 18.

- 1306.** Same as **B. 18**, showing a small Peyer's patch and the orifices of the follicles of Lieberkühn. For low and moderate powers.
B. 19.
- 768.** Same as **B. 18**, showing the orifices of the follicles of Lieberkühn. For low and moderate powers.
B. 20.
- 591 to 591 and 769 to 771.** Seven preparations of villi of small intestine of mouse, with transparent carmine injection, showing the arrangement of the capillaries in the villi. For low and moderate powers.
B. 21. See *Part Second*, **VIII.** 11. **B. 1.**
- 772 to 776.** Five perpendicular sections through entire circumference of small intestine of mouse, with transparent carmine injection, showing the capillaries in the villi and intestinal walls and the epithelium of the villi in situ. For low and moderate powers.
B. 22.
- 777.** Perpendicular section through entire circumference of small intestine of mouse, with transparent Prussian blue injection and carmine staining, showing the capillaries and the round nuclei of the substance of the villi. For low and high powers.
B. 23.
- 601.** Portion of small intestine of mouse, with transparent Prussian blue injection and carmine staining, showing the arrangement of the capillaries, the orifices of the follicles of Lieberkühn, and, better than **B. 23**, the round nuclei of the substance of the villi. For low and high powers.
B. 24.
- 596 & 1326.** Two preparations of villi from small intestine of chicken, with double transparent injection (artery blue, veins and capillaries red), showing the arrangement of the vessels of the villi. For low powers.
B. 25.
- 597 to 599.** Three preparations of villi from small intestine of chicken, with transparent carmine injection, showing the arrangement of the vessels in the villi. For low powers.
B. 26.
- 581 to 583.** Three preparations of portions of small intestine of frog, with transparent carmine injection, showing the arrangement of the bloodvessels in the intestinal walls. For low powers.
B. 27.
- 778 to 782.** Five preparations of portions of small intestine of toad, with transparent carmine injection, similar in character to **B. 27**. For low powers.
B. 28.
- 783.** Portion of ileum of sheep, with opaque injection (red), showing the arrangement of the vessels in the villi. For low powers.
B. 29.
- 781 to 786.** Three preparations of small intestine of chicken, with opaque injection (bluish white), showing the capillary networks in the villi. For low powers.
B. 30.
- 580.** Same as **B. 30**, injected with red.
B. 31.
- 600 & 601.** Two preparations of villi from small intestine of chicken, with double opaque injection (artery bluish white, veins yellow; capillaries, some filled from the artery, some from the veins), showing the arrangement and mutual relations of the bloodvessels in the villi. For low powers.
B. 32.
- 1957 & 1958.** Two preparations, same as **B. 15**.
B. 33.
- 179.** Opaque injection in two colors (arteries yellow, veins red) of intestinal villi of *Capra hca*. For low powers.
B. 34. Prof. Joseph Hyrtl, Vienna, Austria
- 188.** Same as **B. 34**, from *Struthio Camelus*, (arteries white, veins blue). For low powers.
B. 35. Prof. Joseph Hyrtl, Vienna, Austria.
- 189.** Same as **B. 35**, from *Tetrao Colchurnix*. For low powers.
B. 36. Prof. Joseph Hyrtl, Vienna, Austria
- 190.** Same as **B. 35**, embracing isolated villi only. For low powers.
B. 37. Prof. Joseph Hyrtl, Vienna, Austria.

- 191.** Same as **B. 35**, from *Rhea Americana*. For low powers.
B. 38. Prof. Joseph Hyrtl, Vienna, Austria.
- 192.** Opaque injection (white) of chyliferous vessels of villi of *Ovis tarbo*. For low powers.
B. 39. Prof. Joseph Hyrtl, Vienna, Austria.
- 193.** Same as **B. 39**, from *Corvus Corone*. For low powers.
B. 40. Prof. Joseph Hyrtl, Vienna, Austria.
- 201.** Opaque injection (white) of small intestine of *Proteus*. For low powers.
B. 41. Prof. Joseph Hyrtl, Vienna, Austria.
- 202.** Same as **B. 41**, from near the cloaca. For low powers.
B. 42. Prof. Joseph Hyrtl, Vienna, Austria.
- 201.** Opaque injection in two colors (arteries white, veins blue) of small intestine of *Triton cristatus*. For low powers.
B. 43. Prof. Joseph Hyrtl, Vienna, Austria.
- 208.** Opaque injection in two colors (arteries white, veins green) of small intestine of *Salamandra*. For low powers.
B. 44. Prof. Joseph Hyrtl, Vienna, Austria.
- 209.** Same as **B. 44**, from near the cloaca. For low powers.
B. 45. Prof. Joseph Hyrtl, Vienna, Austria.
- 213.** Opaque injection in two colors (arteries white, veins blue) of small intestine of *Bufo viridis*. For low powers.
B. 46. Prof. Joseph Hyrtl, Vienna, Austria.
- 211.** Same as **B. 46**, from near the cloaca. For low powers.
B. 47. Prof. Joseph Hyrtl, Vienna, Austria.
- 216.** Opaque injection in two colors (arteries yellow, veins green) of small intestine of *Rana ridibanda*. For low powers.
B. 48. Prof. Joseph Hyrtl, Vienna, Austria.
- 217.** Same as **B. 48**, from near the cloaca. For low powers.
B. 49. Prof. Joseph Hyrtl, Vienna, Austria.
- 221.** Opaque injection in two colors (arteries yellow, veins blue) of small intestine of *Rana temporaria*. For low powers.
B. 50. Prof. Joseph Hyrtl, Vienna, Austria.
- 222.** Same as **B. 50**, from *Pelobates fuscus*. For low powers.
B. 51. Prof. Joseph Hyrtl, Vienna, Austria.
- 223.** Same as **B. 50**, from near the cloaca of *Alytes obstetricans*, (arteries red, veins blue). For low powers.
B. 52. Prof. Joseph Hyrtl, Vienna, Austria.
- 221.** Same as **B. 50**, from *Rana esculenta*, (arteries white, veins red). For low powers.
B. 53. Prof. Joseph Hyrtl, Vienna, Austria.
- 225.** Same as **B. 50**, from *Bufo vulgaris*, (arteries yellow, veins red). For low powers.
B. 54. Prof. Joseph Hyrtl, Vienna, Austria.
- 226.** Same as **B. 50**, from *Hyla viridis*, (arteries red, veins yellow). For low powers.
B. 55. Prof. Joseph Hyrtl, Vienna, Austria.
- 228.** Opaque arterial injection (white) of the villi of *Pseudopus serpentinus*. For low powers.
B. 56. Prof. Joseph Hyrtl, Vienna, Austria.

- 229.** Same as **B. 56**, in two colors (arteries white, veins red). For low powers.
B. 57. Prof. Joseph Hyrtl, Vienna, Austria.
- 230.** Same as **B. 57**, from *Psammosaurus griscus*. For low powers.
B. 58. Prof. Joseph Hyrtl, Vienna, Austria.
- 231.** Same as **B. 57**, from *Vipera Ammodytes*. (arteries yellow, veins red). For low powers.
B. 59. Prof. Joseph Hyrtl, Vienna, Austria.
- 231.** Opaque injection in two colors (arteries white, veins blue) of small intestine of *Coluber Esculapii*. For low powers.
B. 60. Prof. Joseph Hyrtl, Vienna, Austria.
- 235.** Same as **B. 60**, from *Camaleo Africanus*. For low powers.
B. 61. Prof. Joseph Hyrtl, Vienna, Austria.
- 236.** Same as **B. 60**, in one color (red), from *Geochelonia tabulata*. For low powers.
B. 62. Prof. Joseph Hyrtl, Vienna, Austria.
- 237.** Same as **B. 62**, from near the cloaca. For low powers.
B. 63. Prof. Joseph Hyrtl, Vienna, Austria.
- 238.** Same as **B. 60**, from *Phalassochelys Couana*, (arteries yellow, veins blue). For low powers.
B. 64. Prof. Joseph Hyrtl, Vienna, Austria.
- 239.** Opaque injection in two colors (arteries yellow, veins blue) of the ileo-caecal valve of *Enys Europæa*. For low powers.
B. 65. Prof. Joseph Hyrtl, Vienna, Austria.
- 240.** Opaque injection in two colors (arteries white, veins red) of small intestine of *Testudo Græca*. For low powers.
B. 66. Prof. Joseph Hyrtl, Vienna, Austria.
- 241.** Opaque injection in two colors (arteries yellow, veins blue) of muscular coat of small intestine of *Testudo Græca*. For low powers.
B. 67. Prof. Joseph Hyrtl, Vienna, Austria.
- 247.** Opaque injection in two colors (arteries yellow, veins blue) of small intestine of *Acanthias vulgaris*. For low powers.
B. 68. Prof. Joseph Hyrtl, Vienna, Austria.

C. PATHOLOGICAL.

- 116 to 122.** Series of seven perpendicular sections of human ileum, from a case of fatal diarrhoea following convalescence from fever, showing enlargement and protrusion of the solitary glands; stained with yellow aniline.
C. 1. The series consists of sections through two glands from periphery to centre, showing the glands enlarged to the size of small pin-heads and projecting from the surface of the intestine, pushing the mucous coat before them. There is active cell-multiplication in the connective tissue beneath them. In all but specimen **122** a portion of a Peyer's patch is also seen. For low and high powers.
From the same intestine as Specimen 159, Medical Section, chap. IV, ser. 3, 11, 3.
See Part Second, VII, 11, C, 1 and 2.
- 123 to 129.** Series of seven perpendicular sections of human ileum, from a case of camp fever, showing enlargement and protrusion of the solitary glands; stained with yellow aniline. The series embraces sections through two solitary glands, exhibiting the same conditions as in **C. 1**. All but specimens **124** and **128** show also a Peyer's patch. Very numerous bloodvessels are seen in the connective tissue layer. For low and high powers.
From the same intestine as Specimens 385 to 387, Medical Section, chap. IV, ser. 3, 1, 1 to 3.
- 130 to 135.** Series of six perpendicular sections of human ileum, from the same case as **C. 2**, showing an enlarged solitary gland situated at the junction of two valvulae conniventes; stained with yellow aniline. The sections show also a Peyer's patch with commencing ulceration, and very numerous bloodvessels in the connective tissue layer. For low and high powers.
From the same intestine as Specimens 385 to 387, Medical Section, chap. IV, ser. 3, 1, 4 to 7.

411 to 413. Series of three perpendicular sections of human ileum, showing an enlarged and slightly protuberant solitary gland. An original staining with red aniline has almost entirely faded. The solitary gland shows points of softening in its centre. Not very well suited for high powers.

C. 4.

1686 to 1717. Series of thirty-two perpendicular sections of human ileum, from a case of typhoid fever, showing a Peyer's patch greatly thickened and protuberant, but not yet ulcerated; stained, some with red and some with yellow aniline. The patch is seen to have lost its glandular structure, and to form, with the altered connective tissue in its vicinity, a mass consisting of closely aggregated adventitious cells, fed by numerous bloodvessels. The sections pass through various portions of the diseased patch, from periphery to centre. Suited for high powers, under which the progressive stages of cell-multiplication in the connective tissue are beautifully shown.

From the same intestine as Specimen 608, Medical Section, chap. IV. sec. 3, I. 81.

See Part Second, VII. H. c. 3.

416. Perpendicular section of human ileum, from a case of typhoid fever, showing a condition of a Peyer's

C. 6. patch similar to C. 5; stained with red aniline. For low and high powers.

See Part Second, VII. H. c. 4.

1718 to 1711. Series of twenty-four perpendicular sections of human ileum, from a case of typhoid fever, showing progressive stages of disease in a Peyer's patch, from a slight thickening, where the glands of the patch can still be recognized, to complete structural degeneration and final jagged ulceration; stained with yellow aniline. Suited for high powers, which show the minute anatomy of the structural changes.

From the same intestine as Specimens 619 to 624, Medical Section, chap. IV. sec. 3, I. 70 to 72.

417 to 455. Series of nine perpendicular sections of human ileum, from a case of camp fever, showing progressive stages of thickening and ulceration of a Peyer's patch; stained with red aniline. The ulcers are seen to originate in the individual glands of the patch, which, after softening and disintegrating, burst into the cavity of the intestine, establishing thus minute ulcers, which subsequently spread. For low and high powers.

From the same intestine as Specimens 121 and 125, Medical Section, chap. IV. sec. 3, E. 42 and 43.

See Part Second, I. A. c. 1; VII. H. c. 5 to 8.

456 & 457. Series of two perpendicular sections of human ileum, from the same case as C. 8, showing three

C. 9. disintegrated glands of a Peyer's patch at the point of rupture; stained with red aniline. For low and high powers.

From the same intestine as Specimens 121 and 125, Medical Section, chap. IV. sec. 3, E. 42 and 43.

See Part Second, VII. H. c. 9.

462 to 465. Series of four perpendicular sections of human ileum, from a case of camp fever, showing several

C. 10. disintegrated glands of a Peyer's patch before rupture, and, in the first three specimens of the series, several shallow ulcers; stained with yellow aniline. For low and high powers.

From the same intestine as Specimens 407 and 408, Medical Section, chap. IV. sec. 3, E. 46 and 47.

See Part Second, VII. H. c. 10.

466 to 469. Series of four perpendicular sections of human ileum, from the same case as C. 10, showing a deep

C. 11. smooth ulcer in a Peyer's patch, extending down to the muscular coat, and, in the last three specimens, one disintegrated gland of the patch not yet ruptured; stained with yellow aniline. For low and high powers.

From the same intestine as Specimens 407 and 408, Medical Section, chap. IV. sec. 3, E. 46 and 47.

See Part Second, VII. H. c. 11 to 14.

1742 to 1759. Series of eighteen perpendicular sections of human ileum, from a case of camp fever, showing an excavating ulcer extending deep into the connective tissue layer of the intestine, and, in specimens 1745

C. 12. to 1750, various stages of ulceration of a solitary gland; stained, some with red and some with yellow aniline. The first section of the series passes through the thickened intestine just beyond the edge of the ulcer, showing cell-multiplication in the connective tissue and enlarged bloodvessels; also a portion of a Peyer's patch. The remaining sections pass through various portions of the ulcer, from periphery to centre. For low and high powers.

From the same intestine as Specimen 702, Medical Section, chap. IV. sec. 3, E. 61.

See Part Second VII. H. c. 15 to 18.

1760 to 1771. Series of twelve perpendicular sections of human ileum, from the same case as C. 12, showing an

C. 13. excavating ulcer of similar character to the preceding, but larger and extending down to the muscular coat; also, in specimens 1762 to 1767, commencing disintegration of the solitary glands; stained, some with red and some with yellow aniline. For low and high powers.

From the same intestine as Specimen 702, Medical Section, chap. IV. sec. 3, E. 61.

- 170 to 172.** Series of three perpendicular sections of human ileum, showing a typhoid ulcer of a Peyer's patch in process of healing; stained with red aniline. The walls of the cicatrix are seen to consist for the most part of condensed connective tissue, embedded in which are a few of the original glands of the patch. For low and high powers.
C. 14.
- From the same intestine as Specimens 189 to 191. Medical Section, chap. IV, sec. 3, II. 5 to 7.
 See Part Second, VIII, II. C. 19.*

- 360.** Opaque injection (red) of the vessels of human small intestine in cholera morbus. For low powers.
C. 15. Prof. Joseph Hyrtl, Vienna, Austria.

I, LARGE INTESTINE.

A. FROM MAN.

- 171.** Opaque injection in two colors (arteries yellow, veins red) of mucous membrane of caecum. For low powers.
A. 1. Prof. Joseph Hyrtl, Vienna, Austria.
- 172.** Same as **A. 1.** from the vermiform appendix. For low powers.
A. 2. Prof. Joseph Hyrtl, Vienna, Austria.
- 173.** Same as **A. 1.** from the ascending colon. For low powers.
A. 3. Prof. Joseph Hyrtl, Vienna, Austria.
- 174.** Same as **A. 1.** from the descending colon, (arteries yellow, veins blue). For low powers.
A. 4. Prof. Joseph Hyrtl, Vienna, Austria.
- 175.** Opaque injection in two colors (arteries white, veins red) of the submucous connective tissue of the colon. For low powers.
A. 5. Prof. Joseph Hyrtl, Vienna, Austria.
- 176.** Opaque injection in two colors (arteries white, veins blue) of rectum. For low powers.
A. 6. Prof. Joseph Hyrtl, Vienna, Austria.
- 177.** Opaque injection in two colors (arteries yellow, veins red) of ilco-caecal valve. For low powers.
A. 7. Prof. Joseph Hyrtl, Vienna, Austria.
- 180.** Opaque injection in two colors (arteries yellow, veins red) of the pouches of the rectum. For low powers.
A. 8. Prof. Joseph Hyrtl, Vienna, Austria.

B. FROM ANIMALS.

- 107.** Horizontal section of mucous membrane of large intestine of cat, with transparent Prussian blue injection and carmine staining, showing the follicles of Lieberkuhn in transverse section, with epithelium in situ, and the arrangement of the capillary network between the follicles. For moderate and high powers.
B. 1.
- 579.** Same as **B. 1.**; the injection and staining have, in a great measure, faded. For moderate powers.
B. 2.
- 787.** Perpendicular section through entire circumference of caecum of cat, with transparent carmine injection, showing the arrangement of the capillaries in the intestinal walls and the very large solitary glands. For low powers.
B. 3.
- 1555.** Same object as **B. 3.**, with transparent carmine injection and imperfect blue staining; similar in character to **B. 3.**
B. 4. Professor Joseph Gerlach, Erlangen, Bavaria.
- 635.** Horizontal section of mucous membrane of large intestine of rat, with transparent carmine injection, showing the network of capillaries between the follicles of Lieberkuhn. For low powers.
B. 5.
- 632 to 634.** Three preparations of portions of large intestine of mouse with transparent carmine injection, showing the arrangement of the capillaries. For low powers.
B. 6.

- 788 & 789.** Two perpendicular sections of large intestine of mouse, with transparent carmine injection, showing the arrangement of the capillaries in the intestinal walls. For low and moderate powers.
B. 7.
- 790.** Perpendicular section through entire circumference of large intestine of mouse, with transparent Prussian blue injection and carmine staining, showing the arrangement and relations of the several coats of the intestine and the capillaries. For low and moderate powers.
B. 8.
- 625 to 631.** Seven preparations of portions of large intestine of frog, with transparent carmine injection, showing the arrangement of the bloodvessels. For low powers.
B. 9.
- 791 to 798.** Eight preparations of portions of large intestine of toad, with transparent carmine injection; similar in character to **B. 9.** Specimen **796** shows also the cysts of a parasitic worm. The worm itself has altered since mounting so as to be no longer recognizable. For low powers.
B. 10.
- 799.** Same object as **B. 10.**, with transparent Prussian blue injection and carmine staining. The staining has failed to bring out any points of structure, and the preparation shows only the injected vessels. For low powers.
B. 11.
- 636.** Cloaca of chicken, with opaque injection (red), showing the arrangement of the capillaries. For low powers.
B. 12.
- 637.** Portion of large intestine of cat, with opaque injection (yellow), showing the capillary network between the follicles of Lieberkuhn. For low powers.
B. 13.
- 46.** Opaque injection (yellow) of the vessels of cloacal outlet of female *Triton taeniatus*. For low powers.
B. 14. Prof. Joseph Hyrtl, Vienna, Austria.
- 191.** Opaque injection in two colors (arteries yellow, veins red) of villi of cloaca of *Cygnus olor*. For low powers.
B. 15. Prof. Joseph Hyrtl, Vienna, Austria.
- 203.** Opaque injection in two colors (arteries white, veins blue) of the vessels of cloaca of *Proteus*. For low powers.
B. 16. Prof. Joseph Hyrtl, Vienna, Austria.
- 206.** Same as **B. 16**, from *Triton cristatus*, (arteries white, veins red). For low powers.
B. 17. Prof. Joseph Hyrtl, Vienna, Austria.
- 210.** Same as **B. 16**, in one color (red) from *Salamandra*. For low powers.
B. 18. Prof. Joseph Hyrtl, Vienna, Austria.
- 212.** Same as **B. 16**, from *Bufo viridis*. For low powers.
B. 19. Prof. Joseph Hyrtl, Vienna, Austria.
- 218.** Same as **B. 16**, from *Rana ridibunda*, (arteries yellow, veins green). For low powers.
B. 20. Prof. Joseph Hyrtl, Vienna, Austria.
- 227.** Same as **B. 16**, from *Bufo palmarum* (arteries red, veins green). For low powers.
B. 21. Prof. Joseph Hyrtl, Vienna, Austria.
- 211.** Opaque injection in two colors (arteries yellow, veins red) of border of anus of *Salamandra*. For low powers.
B. 22. Prof. Joseph Hyrtl, Vienna, Austria.
- 220.** Opaque injection in two colors (arteries yellow, veins green) of cecum of *Rana esculenta* at the ileo-caecal valve. For low powers.
B. 23. Prof. Joseph Hyrtl, Vienna, Austria.
- 215.** Opaque injection (yellow) of the vessels of large intestine of *Acipenser Ruthenus*. For low powers.
B. 24. Prof. Joseph Hyrtl, Vienna, Austria.
- 218.** Opaque injection in two colors (arteries yellow, veins blue) of villi in the beginning of large intestine of *Acanthias vulgaris*. For low powers.
B. 25. Prof. Joseph Hyrtl, Vienna, Austria.

C. PATHOLOGICAL.

- 638.** Perpendicular section of human colon, from a case of chronic diarrhoea, showing slight thickening of the connective tissue layer; stained with yellow aniline. Cell-multiplication is commencing in the connective tissue adjoining the mucous coat. For low and high powers.

See Part Second, **VII**, l. c. 1 to 4.

- 639 to 641.** Series of three perpendicular sections of human colon, showing enlargement of the solitary glands and slight thickening of the connective tissue layer; stained with red aniline; cell-multiplication is well marked in the connective tissue adjoining the solitary glands. For low and high powers.

Assistant Surgeon J. J. Woodward, U. S. Army.

- 642 to 650.** Series of nine perpendicular sections of human colon, from a case of mild chronic diarrhoea, showing slight enlargement of the solitary glands; stained with yellow aniline. For low and high powers.

From the same intestine as Specimen **517**, Medical Section, chap. **IV**, sec. 3, l. 2.

See Part Second, **VII**, l. c. 5.

- 651 & 652.** Series of two perpendicular sections of human colon, showing an enlarged solitary gland. Shows, under the high powers, the cell-multiplication in the connective tissue adjoining the enlarged gland, but the other structures of the intestine are not well preserved. For high powers.

Assistant Surgeon J. J. Woodward, U. S. Army.

- 653 to 658.** Series of six perpendicular sections of human colon, showing enlargement and commencing ulceration of the solitary glands; stained with yellow aniline. The solitary glands are considerably enlarged; there is thickening of the submucous connective tissue, and, in the last three specimens of the series, the mucous

membrane has commenced to ulcerate over the summits of the solitary glands. For low and high powers.

See Part Second, **VII**, l. c. 6 to 8.

- 659 to 667.** Series of nine perpendicular sections of human colon, showing shallow ulceration of the mucous membrane around an enlarged solitary gland; stained with yellow aniline. As usual, there is considerable cell-multiplication in the connective tissue in the neighborhood of the diseased spot. For low and high

powers.

From the same intestine as Specimen **106**, Medical Section, chap. **IV**, sec. 3, l. 38.

See Part Second, **VII**, l. c. 9.

- 668.** Perpendicular section of human colon, showing ulceration around two very much enlarged solitary glands; stained with yellow aniline. The mucous coat has entirely disappeared from over the solitary glands, and there is a furrow of ulceration around the circumference of the gland reaching down to the connective tissue layer; in the latter layer there is the usual cell-multiplication evident. For low and high powers.

- 669.** Perpendicular section of human colon, showing ulceration of the mucous coat around an enlarged solitary gland, with commencing ulceration of the gland itself; stained with red aniline. The ulceration is more extensive than in **C. 7**; there is the usual thickening in the connective tissue layer. For low and

high powers.

Assistant Surgeon J. J. Woodward, U. S. Army.

- 670 to 672.** Series of three perpendicular sections of human colon, showing commencing ulceration of a solitary gland, similar to that shown in **C. 7** and **8**, but with little change in the connective tissue layer; stained with yellow aniline. The mucous membrane has cracked in many places in these specimens in the course

of preparation. For low and high powers.

- 673 to 677.** Series of five perpendicular sections of human colon, showing enlarged solitary glands and a shallow ulcer of the mucous coat, extending about half-way through the thickness of the layer; stained with yellow aniline. For low and high powers.

- 678 to 682.** Series of five perpendicular sections of human colon, showing a few enlarged solitary glands and shallow ulceration of the mucous membrane, similar to that shown in **C. 10**, stained with yellow aniline. The mucous layers have not been preserved in these sections. For low and high powers.

- 683 to 685.** Series of three perpendicular sections of human colon, showing the following forms of ulcers: a narrow ulcer, extending to the mucous layer below, and cutting into the connective tissue at the sides so as to give an oval bag-like edge of mucous membrane; shallow ulcers of the mucous coat, and a wide ulcer, extending down to the mucous coat. The connective tissue of the intestine is much thickened, and, in the extreme of the ulcer, has its normal appearance entirely, being transformed into masses of closely-packed, ill-formed cells. Stained with yellow aniline. For low and high powers.

See Part Second, **VII**, l. c. 10 to 13.

- 686.** Perpendicular section of human colon, from the same case as **C. 12**, showing deep ulcers extending nearly to the muscular coat. The various tissues present the same characteristics as those mentioned in **C. 12**. Stained with red aniline. For low and high powers.
- 687 to 691.** Series of five perpendicular sections of human colon, showing the same variety of ulcers and conditions of the tissues of the intestine as those described under **C. 12**. In the first two specimens of the series the sections pass through a small excavating ulcer beyond the line where it pierces the mucous coat, exhibiting thus a cavity in the connective tissue layer bridged over by mucous membrane and bordered by walls of dense altered connective tissue. Stained with yellow aniline. For low and high powers.
See Part Second, VII. I. c. 16.
- 1520 to 1531.** Series of twelve perpendicular sections of human colon, showing a deep smooth ulcer extending to the muscular coat. The first six specimens of the series, like the first two of **C. 14**, show ulceration of the connective tissue alone. In the remainder of the specimens the sections pass through the centre of the ulcer. There is but little change in the connective tissue layer. The mucous coat has cracked badly in the process of preparation. Stained with yellow aniline. For low and high powers.
From the same intestine as Specimen 166, Medical Section, chap. IV, sec. 3, L. 116.
- 1532 to 1537.** Series of six perpendicular sections of human colon, from the same case as **C. 15**, showing deep ragged ulcers of the intestine. In all the specimens but the last the structures of the mucous coat have entirely disappeared, and a ragged mass of shreds represents the inner half of the thickness of the intestine. In the last specimen a portion of mucous membrane and a very much enlarged solitary gland can still be recognised. Stained with red aniline. For low and high powers.
From the same intestine as Specimen 166, Medical Section, chap. IV, sec. 3, L. 116.
See Part Second, VII. I. c. 17.
- 692 to 702.** Series of eleven perpendicular sections of human colon from a case of chronic dysentery, showing extensive ulcers reaching to the muscular coat. The connective tissue in the neighborhood of the ulcers is, as usual, altered in character by the products of cell-multiplication. Stained with yellow aniline. For low and high powers.
From the same intestine as Specimen 109, Medical Section, chap. IV, sec. 3, L. 89.
See Part Second, VII. I. c. 18.
- 703 to 710.** Series of eight perpendicular sections of human colon, showing extensive and deep ulcers and altered connective tissue, similar to the appearances described in **C. 17**; stained, some with red and some with yellow aniline. For low and high powers.
- 711 & 712.** Series of two perpendicular sections of human colon, showing ulcers and conditions of the connective tissue similar to those described in **C. 17**; stained with red aniline. For low and high powers.
See Part Second, VII. I. c. 19 and 20.
- 713 & 714.** Series of two perpendicular sections of human colon, showing extensive disease of the mucous and connective tissue coats of the intestine. These layers have both entirely lost their normal structure and are blended into a mass of closely aggregated ill-formed cells. Stained with yellow aniline. For low and high powers.
- 715 to 728.** Series of fourteen perpendicular sections of human colon, showing extensive ulcers of various depths, and great thickening, from cell-multiplication, in the connective tissue layer; stained with carmine, except specimens **716, 727** and **728**. For low and moderate powers.
- 729 to 731.** Series of three perpendicular sections of human colon, showing the structure of the so-called pseudo-membranous exudation. The mucous membrane is considerably thickened, and near its upper surface has lost its normal structure, having degenerated into a dense mass indistinctly cellular in its character. The follicles of Lieberkühn gradually lose themselves in this altered tissue, and, in the lower portions of the mucous layer, where they can still be seen, are separated from each other by new cell-growths. The mucous membrane is ulcerated in many places, and the connective tissue layer is greatly thickened, and shows active cell-multiplication. Stained with red aniline. For low and high powers.
From the same intestine as Specimen 360, Medical Section, chap. IV, sec. 3, L. 100.
See Part Second, VII. I. c. 21 and 22.
- 732 to 755.** Series of twenty-four perpendicular sections of human colon, showing a condition of the intestinal structures similar to that described under **C. 22**, but with the morbid changes not so far advanced; stained, some with red and some with yellow aniline. For low and high powers.

K. LIVER AND GALL-BLADDER.

A. FROM MAN.

- 861.** Portion of human gall-bladder with opaque injection (red), showing the arrangement of the capillaries.
A. 1. For low powers.
- 251.** Opaque injection in three colors (artery red, portal vein blue, hepatic veins white) of surface of liver.
A. 2. For low powers.
 Prof. Joseph Hyrtl, Vienna, Austria.
- 252.** Same as **A. 2**, in two colors (artery yellow, portal vein red), from a fetus. For low powers.
A. 3. Prof. Joseph Hyrtl, Vienna, Austria.
- 253.** Same as **A. 2**, in section of the organ. For low powers.
A. 4. Prof. Joseph Hyrtl, Vienna, Austria.
- 251.** Same as **A. 2**, in four colors (artery white, portal vein blue, hepatic veins red, bile-ducts yellow). For
A. 5. low powers.
 Prof. Joseph Hyrtl, Vienna, Austria.
- 255.** Same as **A. 4**, (artery white, portal vein red, bile-ducts yellow). For low powers.
A. 6. Prof. Joseph Hyrtl, Vienna, Austria.
- 256.** Opaque injection in two colors (arteries white, veins red) of gall-bladder. For low powers.
A. 7. Prof. Joseph Hyrtl, Vienna, Austria.

B. FROM ANIMALS.

- 818.** Section of liver of sheep with transparent carmine injection through the portal vein, showing the
B. 1. arrangement of the capillaries in the lobules. An original Prussian blue injection through the hepatic
 veins has entirely faded from the specimen. For low and moderate powers.
- 800 to 803.** Six sections of liver of sheep, with double transparent injection (portal vein carmine and hepatic veins
and Prussian blue), showing the peripheral portion of the capillary plexus in the lobules filled with the red,
859 & 860. and the central portion with the blue injection. In specimen **860** all the capillaries are filled with the
B. 2. red, and the commencement of the intralobular veins alone with blue. For low and moderate powers.
See Part Second, VII. K. v. 1 and 2
- 801 to 815.** Twelve sections of liver of sheep, with transparent Prussian blue injection and carmine staining, showing
B. 3. the capillaries of the lobules filled with the injection, and interlacing with the network of hepatic cells—
 the individual cells, with their nuclei, being rendered beautifully distinct by the staining. For moderate
 and high powers.
- 816 & 817.** Two sections of liver of rabbit, with opaque yellow injection, showing the arrangement of the capillaries
B. 4. in the lobules. For low powers.
- 1539.** Portion of gall-bladder of mouse, with transparent carmine injection, showing the arrangement of the
B. 5. bloodvessels in the walls of the bladder. For low powers.
- 529 & 818.** Two preparations of portions of gall-bladder of *Iguana*, with transparent Prussian blue injection, showing
B. 6. the arrangement of the capillaries in the walls of the bladder. For low powers.
 Assistant Surgeon J. S. Billings, U. S. Army.
- 1959.** Portion of liver of sheep, with triple transparent injection (portal vein red, hepatic vein blue, bile-ducts
B. 7. yellow), showing the mutual relations of the vessels in the lobules. Only a few of the bile-ducts are
 filled with the injection. For low powers.
- 257.** Opaque injection in two colors (portal vein yellow, hepatic vein red) of liver of *Macacus Cynomolgus*.
B. 8. For low powers.
 Prof. Joseph Hyrtl, Vienna, Austria.

- 258.** Same as **B. 8**, from *Sus scrofa*, in three colors (artery white, portal vein yellow, hepatic vein red). For low powers.
B. 9. Prof. Joseph Hyrtl, Vienna, Austria.
- 259.** Same as **B. 8**, from *Lupus Cuniculus*, (portal vein white, hepatic vein red). For low powers.
B. 10. Prof. Joseph Hyrtl, Vienna, Austria.
- 260.** Same as **B. 8**, from *Erinaccus Europæus*. For low powers.
B. 11. Prof. Joseph Hyrtl, Vienna, Austria.
- 261.** Same as **B. 10**, from *Mustela Martes*. For low powers.
B. 12. Prof. Joseph Hyrtl, Vienna, Austria.
- 262.** Same as **B. 8**, from *Picus Martius*, (artery yellow, vein red). For low powers.
B. 13. Prof. Joseph Hyrtl, Vienna, Austria.
- 263.** Same as **B. 8**, (red portal injection only), from *Columba Palumbus*. For low powers.
B. 14. Prof. Joseph Hyrtl, Vienna, Austria.
- 264.** Same as **B. 13**, from *Tetrao Urogallus*. For low powers.
B. 15. Prof. Joseph Hyrtl, Vienna, Austria.
- 265.** Same as **B. 8**, from *Rana Alpina*, (portal vein red, hepatic vein green). For low powers.
B. 16. Prof. Joseph Hyrtl, Vienna, Austria.
- 266.** Same as **B. 8**, from *Pelobates fuscus*, (portal vein white, hepatic vein blue). For low powers.
B. 17. Prof. Joseph Hyrtl, Vienna, Austria.
- 267.** Same as **B. 8**, from *Bipes Pallasii*, (portal vein red, hepatic vein blue). For low powers.
B. 18. Prof. Joseph Hyrtl, Vienna, Austria.
- 268.** Same as **B. 8**, from *Vipera Berus*, (portal vein red, hepatic vein yellow). For low powers.
B. 19. Prof. Joseph Hyrtl, Vienna, Austria.
- 269.** Same as **B. 10**, from *Coluber Austriacus*. For low powers.
B. 20. Prof. Joseph Hyrtl, Vienna, Austria.
- 270.** Same as **B. 8**, from *Emys Europæa*, (arteries white, portal vein red). For low powers.
B. 21. Prof. Joseph Hyrtl, Vienna, Austria.
- 271.** Same as **B. 8**, from *Lacerta viridis*, (portal vein yellow, hepatic vein blue). For low powers.
B. 22. Prof. Joseph Hyrtl, Vienna, Austria.
- 272.** Same as **B. 8**, from *Lucioperca Sandra*, (artery white, portal vein blue). For low powers.
B. 23. Prof. Joseph Hyrtl, Vienna, Austria.
- 273.** Same as **B. 10**, from *Acipenser Ruthenus*. For low powers.
B. 24. Prof. Joseph Hyrtl, Vienna, Austria.
- 274.** Same as **B. 8**, (red portal injection only), from *Chimæra monstrosa*. For low powers.
B. 25. Prof. Joseph Hyrtl, Vienna, Austria.
- 275.** Opaque injection (green) of the vessels of gall-bladder of *Lota*. For low powers.
B. 26. Prof. Joseph Hyrtl, Vienna, Austria.

L. CHEMICAL CONSTITUENTS OF BILE.

A. FROM MAN.

- 862.** Tabular crystals of cholesterine from a gall-stone. For moderate powers.
A. 1. *See Part Second, XIV. D. A. 1 and 2.*

M. PANCREAS.

A. FROM MAN.

278. Opaque injection in two colors (arteries yellow, veins blue) of pancreas. For low powers.
A. 1. Prof. Joseph Hyrtl, Vienna, Austria.

279. Opaque injection (red) of the ramification and terminal vesicles of the pancreatic duct. For low powers.
A. 2. Prof. Joseph Hyrtl, Vienna, Austria.

B. FROM ANIMALS.

933 to 939. Seven preparations of portions of pancreas of cat, with transparent carmine injection, showing the arrangement of the capillaries around the lobules of the gland. Specimen **939** shows also a Pacinian body. For low powers.
B. 1.

290. Opaque arterial injection (white) of pancreas of *Crocodilus Niloticus*. For low powers.
B. 2. Prof. Joseph Hyrtl, Vienna, Austria.

292. Opaque injection in two colors (arteries white, veins green) of pancreas of *Proteus anguineus*. For low powers.
B. 3. Prof. Joseph Hyrtl, Vienna, Austria.

N. SPLEEN.

A. FROM MAN.

281. Opaque injection in two colors (arteries yellow, veins blue) of section of spleen. For low powers.
A. 1. Prof. Joseph Hyrtl, Vienna, Austria.

B. FROM ANIMALS.

286. Opaque venous injection (red) of spleen of *Acipenser Ruthenus*. For low powers.
B. 1. Prof. Joseph Hyrtl, Vienna, Austria.

C. PATHOLOGICAL.

285. Opaque injection (red) of the vessels in a section of hypertrophied spleen, from a case of quanta intermittent fever. For low powers.
C. 1. Prof. Joseph Hyrtl, Vienna, Austria.

O. MESENTERY.

A. FROM MAN.

355. Opaque injection in two colors (arteries yellow, veins blue) of mesentery. For low powers.
A. 1. Prof. Joseph Hyrtl, Vienna, Austria.

B. FROM ANIMALS.

851 to 855. Five preparations of mesentery of cat, with transparent Prussian blue injection and carmine staining, showing very beautifully the minute anatomy of connective tissue, adipose tissue, bloodvessels and nerves. For moderate and high powers.
B. 1.

856. Portion of mesentery of cat, with transparent carmine injection, showing the arrangement of the bloodvessels, and also adipose tissue. For low powers.
B. 2.

819 to 821. Three preparations of mesentery of kitten, with transparent Prussian blue injection and carmine staining, showing the same structures as **B. 1.** Specimen **819** shows also, very beautifully, several Pacinian bodies. For moderate and high powers.

822. Portion of mesentery of kitten, stained with carmine (very imperfectly), showing connective tissue, bloodvessels and adipose tissue. For moderate and high powers.
B. 4. Assistant Surgeon J. S. Billings, U. S. Army.

1307 & 1308. Two preparations of mesentery of dog, with transparent Prussian blue injection and carmine staining, showing the same structures as **B. 1.** For moderate and high powers.

823. Same as **B. 5**; the staining is much more brilliant.
B. 6.

For other illustrations, see VI. E. B. 4 and 5.

P. OMENTUM.

B. FROM ANIMALS.

2035. Omentum of kitten, stained with carmine, showing the minute anatomy of connective and adipose tissue and capillaries. For moderate and high powers.
B. 1.

Q. PERITONEUM.

B. FROM ANIMALS.

1631. Portion of peritoneum of young mouse, stained with carmine, showing numerous and large corpuscles in the young peritoneum, beautifully defined by the staining; also bloodvessels, nerves and adipose tissue. For moderate and high powers.

Assistant Surgeon J. S. Billings, U. S. Army.

819 & 850. Two preparations of peritoneum of frog, with transparent carmine injection, showing the arrangement of the bloodvessels. For low powers.
B. 2.

821 & 825. Two preparations of peritoneum of toad, with transparent carmine injection, showing the arrangement of the bloodvessels. For low powers.
B. 3.

826 & 827. Two preparations same as **B. 3**, but also stained with carmine, showing the nucleated epithelial cells of the peritoneum in situ; also a very abundant network of nerves, with the nuclei of the neurilemma beautifully defined, and arteries, veins and capillaries. For low and high powers.
B. 4.

VIII. RESPIRATORY ORGANS.

A. LARYNX.

B. TRACHEA AND BRONCHI.

C. LUNGS, GILLS AND AIR-BLADDER.

D. PLEURE.

E. THYROID GLAND.

F. THYMUS GLAND.

A. FROM MAN. | B. FROM ANIMALS. | C. PATHOLOGICAL.

VIII. RESPIRATORY ORGANS.

A. LARYNX.

A. FROM MAN.

- 56.** Opaque injection (red) of the vessels of mucous membrane of larynx. For low powers.
A. 1. Prof. Joseph Hyrtl, Vienna, Austria.

B. FROM ANIMALS.

- 63.** Opaque arterial injection (yellow) of glottis of *Rana esculenta*. For low powers.
B. 1. Prof. Joseph Hyrtl, Vienna, Austria.

B. TRACHEA AND BRONCHI.

A. FROM MAN.

- 57.** Opaque injection in two colors (arteries white, veins green) of mucous membrane of trachea. For low powers.
A. 1. Prof. Joseph Hyrtl, Vienna, Austria.

B. FROM ANIMALS.

- 1617.** Portion of posterior wall of trachea of mouse, faintly stained with carmine, showing the free extremities of three of the cartilaginous rings, and the fibrous connecting layer abounding in elastic tissue. For moderate and high powers.
B. 1. Assistant Surgeon J. S. Billings, U. S. Army.

- 828.** Horizontal section of portion of trachea of puppy, with transparent Prussian blue injection, showing the relations and minute anatomy of the cartilaginous rings and the fibrous connecting layer. For moderate and high powers.
B. 2. Assistant Surgeon J. S. Billings, U. S. Army.

- 829.** Portion of air tube of wasp and branches; shows also several muscular fibres; partially stained with carmine. For high powers.
B. 3.

- 1975.** Portion of trachea of kitten, with transparent Prussian blue injection and carmine staining, showing the epithelium of the mucous membrane in situ, the anatomy of the cartilaginous rings, and the arrangement of the bloodvessels. For low and high powers.
B. 4.

- 2030.** Transverse section of trachea of kitten, with transparent carmine injection, showing the extent of the cartilaginous rings around the circumference of the section, and the arrangement of the bloodvessels. For low powers.
B. 5.

- 76.** Opaque injection (yellow) of the vessels in the trachea of *Coluber Austriacus*. For low powers.
B. 6. Prof. Joseph Hyrtl, Vienna, Austria.

C. PATHOLOGICAL.

- 58.** Opaque injection (blue) of the vessels of human bronchus in chronic catarrh. For low powers.
C. 1. Prof. Joseph Hyrtl, Vienna, Austria.

C. LUNGS, GILLS AND AIR-BLADDER.

A. FROM MAN.

519 to 523 and 830 to 838. Fourteen preparations of lung, with transparent carmine injection, showing the network of capillaries in the walls of the air vesicles. For low and moderate powers.
A. 1.

1551. Portion of lung, with transparent Prussian blue injection and faint carmine staining, showing the network of capillaries in the walls of the air vesicles, and in a few places the connective tissue corpuscles of the parenchyma of the lung. For low and high powers.

Prof. Joseph Gerlach, Erlangen, Bavaria.

839. Portion of lung of baby, with very imperfect transparent Prussian blue injection, showing the fibrous trabeculae and tessellated epithelium of the air vesicles in situ. For high powers.
A. 3. Assistant Surgeon J. S. Billings, U. S. Army.

19. Opaque injection (white) of the air vesicles of the lung of a new-born child. For low powers.
A. 4. Prof. Joseph Hyrtl, Vienna, Austria.

52. Opaque injection in three colors (arteries blue, veins red, air cells white) of lung. For low powers.
A. 5. Prof. Joseph Hyrtl, Vienna, Austria.

53. Opaque arterial injection (red) of a section of lung. For low powers.
A. 6. Prof. Joseph Hyrtl, Vienna, Austria.

51. Opaque injection in two colors (arteries white, veins red) of lung of six months' fetus which had never breathed. For low powers.
A. 7. Prof. Joseph Hyrtl, Vienna, Austria.

B. FROM ANIMALS.

810. Portion of lung of dog, with transparent Prussian blue injection, showing the network of capillaries in the walls of the air vesicles. For low and moderate powers.
B. 1.

521 & 811. Two preparations of lung of frog, with transparent carmine injection, showing same as **B. 1.** For low powers.
B. 2.

812 to 814. Three preparations of lung of toad, similar to **B. 2.**
B. 3. See *Part Second*, **VIII**, C. B. 1.

525. Portion of lung of newt, similar to **B. 2.**
B. 4.

528. Portion of lung of *Iguana*, similar to **B. 2.**
B. 5.

55. Opaque injection in two colors (arteries red, air cells yellow) of lung of *Somia Satyr.* For low powers.
B. 6. Prof. Joseph Hyrtl, Vienna, Austria.

60. Opaque arterial injection (white) of lung of *Melagris Gallopavo.* For low powers.
B. 7. Prof. Joseph Hyrtl, Vienna, Austria.

61. Same as **B. 7.** of gills of *Protus anguineus.* For low powers.
B. 8. Prof. Joseph Hyrtl, Vienna, Austria.

62. Same as **B. 7.** (red) of *Protus anguineus.* For low powers.
B. 9. Prof. Joseph Hyrtl, Vienna, Austria.

- 61.** Same as **B. 7**, (yellow), of *Rana esculenta*; external surface of lung in collapse. For low powers.
B. 10. Prof. Joseph Hyrtl, Vienna, Austria.
- 65.** Same as **B. 10**; internal surface in expansion. For low powers.
B. 11. Prof. Joseph Hyrtl, Vienna, Austria.
- 66.** Same as **B. 7**, of *Salamandra*; internal surface in collapse. For low powers.
B. 12. Prof. Joseph Hyrtl, Vienna, Austria.
- 67.** Same as **B. 7**, of *Triton cristatus*. For low powers.
B. 13. Prof. Joseph Hyrtl, Vienna, Austria.
- 68.** Opaque injection in two colors (arteries blue, veins white) of lung of *Bipus Pallasii*. For low powers.
B. 14. Prof. Joseph Hyrtl, Vienna, Austria.
- 69.** Same as **B. 14**, of *Varanus Niloticus*; external surface, (arteries white, veins red). For low powers.
B. 15. Prof. Joseph Hyrtl, Vienna, Austria.
- 70.** Same as **B. 15**, of *Uromastix Spinipes*; internal surface. For low powers.
B. 16. Prof. Joseph Hyrtl, Vienna, Austria.
- 71.** Same as **B. 14**, of *Vipera Ammodytes*; internal cellular aspect, (arteries green, veins yellow). For low powers.
B. 17. Prof. Joseph Hyrtl, Vienna, Austria.
- 72.** Same as **B. 17**, of *Coluber Esculapii*, (arteries yellow, veins red). For low powers.
B. 18. Prof. Joseph Hyrtl, Vienna, Austria.
- 73.** Same as **B. 15**, of *Seps chalcides*. For low powers.
B. 19. Prof. Joseph Hyrtl, Vienna, Austria.
- 74.** Same as **B. 18**; posterior end of the lung, very scantily supplied with bloodvessels, (arteries white, veins blue). For low powers.
B. 20. Prof. Joseph Hyrtl, Vienna, Austria.
- 75.** Same as **B. 14**, of *Crocodilus Niloticus*, (arteries red, lymphatic vessels yellow). For low powers.
B. 21. Prof. Joseph Hyrtl, Vienna, Austria.
- 77.** Same as **B. 15**, of *Emys Europea*. For low powers.
B. 22. Prof. Joseph Hyrtl, Vienna, Austria.
- 78.** Same as **B. 14**, of *Testudo Graeca*, (arteries blue, veins red). For low powers.
B. 23. Prof. Joseph Hyrtl, Vienna, Austria.
- 79.** Opaque injection in two colors (arteries blue, veins white) of gills of *Heranchas griseus*. For low powers.
B. 24. Prof. Joseph Hyrtl, Vienna, Austria.
- 80.** Same as **B. 24**, of *Cartharia minor*. For low powers.
B. 25. Prof. Joseph Hyrtl, Vienna, Austria.
- 81.** Same as **B. 24**, of *Anguilla murana*, (arteries white, veins red). For low powers.
B. 26. Prof. Joseph Hyrtl, Vienna, Austria.
- 82.** Same as **B. 24**, of *Sitarus gbanis*, (arteries white, veins blue). For low powers.
B. 27. Prof. Joseph Hyrtl, Vienna, Austria.
- 83.** Same as **B. 24**, of *Lucioperca Sandra*, (arteries yellow, veins white). For low powers.
B. 28. Prof. Joseph Hyrtl, Vienna, Austria.
- 84.** Same as **B. 28**, embracing only a single lamina. For low powers.
B. 29. Prof. Joseph Hyrtl, Vienna, Austria.

- 85.** Opaque arterial injection (red) of branchiae succenturiate of *Lota communis*. For low powers.
B. 30. Prof. Joseph Hyrtl, Vienna, Austria.
- 86.** Opaque arterial injection (white) of vascular body in air-bladder of eel. For low powers.
B. 31. Prof. Joseph Hyrtl, Vienna, Austria.
- 87.** Opaque venous injection (yellow) of retina mirabilia unipolaria in the air-bladder of *Lota*. For low powers.
B. 32. Prof. Joseph Hyrtl, Vienna, Austria.
- 88.** Same as B. 32, of *Percu fariatilis*, in two colors (arteries white, veins blue). For low powers.
B. 33. Prof. Joseph Hyrtl, Vienna, Austria.

C. PATHOLOGICAL.

- 50.** Opaque injection (red) of the air vesicles of adult human lung with incipient emphysema. For low powers.
C. 1. Prof. Joseph Hyrtl, Vienna, Austria.
- 51.** Opaque injection in three colors (arteries white, veins red, air cells blue) of inflamed lung: the air cells, filled with exudation, have not allowed free entrance to the blue injection. For low powers.
C. 2. Prof. Joseph Hyrtl, Vienna, Austria.

D. PLEURE.

C. PATHOLOGICAL.

- 59.** Opaque injection (yellow) of the subpleural lymphatic plexus of an oedematous lung. For low powers.
C. 1. Prof. Joseph Hyrtl, Vienna, Austria.
- 356.** Opaque injection (yellow) of newly formed vessels in an inflamed pleura. For low powers.
C. 2. Prof. Joseph Hyrtl, Vienna, Austria.
- 357.** Opaque injection (red) of the vessels in a very old pseudo-membrane of the pleura. For low powers.
C. 3. Prof. Joseph Hyrtl, Vienna, Austria.

E. THYROID GLAND.

A. FROM MAN.

- 282.** Opaque injection (yellow) of the vessels of thyroid gland of fetus. For low powers.
A. 1. Prof. Joseph Hyrtl, Vienna, Austria.
- 283.** Same as A. 1 from the atrophied gland of a woman eighty years old. For low powers.
A. 2. Prof. Joseph Hyrtl, Vienna, Austria.

C. PATHOLOGICAL.

- 281.** Opaque arterial injection (yellow) of thyroid gland, from a scrofulous subject. For low powers.
C. 1. Prof. Joseph Hyrtl, Vienna, Austria.

IX. URINARY ORGANS AND SUPRARENAL GLANDS.

A. KIDNEYS AND WOLFFIAN BODIES.

B. URETERS.

C. BLADDER.

D. URETHRA.

E. CHEMICAL CONSTITUENTS OF URINE.

F. ORGANIC DEPOSITS IN URINE.

G. SUPRARENAL GLANDS.

A. FROM MAN | **B.** FROM ANIMALS. | **C.** PATHOLOGICAL.

IX. URINARY ORGANS AND SUPRARENAL GLANDS.

A. KIDNEYS AND WOLFFIAN BODIES.

A. FROM MAN.

- 975.** Section of cortical portion of kidney, stained with carmine, showing the arrangement of the convoluted uriniferous tubules and Malpighian bodies. For low powers.
A. 1. Dr. S. A. Jones, Englewood, N. J.
- 976 & 977.** Two sections of cortical portion of kidney, with (very imperfect) transparent Prussian blue injection. The injection fills a few of the interlobular arteries, and the capillaries of the Malpighian bodies. For low powers.
A. 2. Dr. S. A. Jones, Englewood, N. J.
- 1772 to 1778.** Seven sections of cortical and medullary portions of kidney, with transparent carmine injection. The injection is very perfect, and the specimens show the mutual relations of the various systems of vessels. For low and moderate powers.
A. 3.
- 1538.** Same as **A. 3.**, but embracing only the cortical portion of the kidney. For low powers.
A. 4.
- 2023 to 2025.** Three sections of cortical and medullary portions of kidney, with double transparent injection (artery red, vein blue) and carmine staining. The red injection fills only a few of the Malpighian bodies; the blue venous injection is more perfect. The staining shows the arrangement of the straight and convoluted uriniferous tubules, and defines the epithelium of the tubes in situ and the cellular elements of the stroma of the kidney. The fibrous tunica of the Malpighian bodies and its lining epithelium are beautifully shown. For low and high powers.
A. 5.
- 89.** Opaque injection (yellow) of the vessels of the Malpighian bodies in a section of cortical substance of kidney from a new-born child. For low powers.
A. 6. Prof. Joseph Hyrtl, Vienna, Austria.
- 90.** Opaque injection in two colors (Malpighian bodies yellow, veins blue) of the vessels on the surface of the cortical portion of kidney; from a child two years old. For low powers.
A. 7. Prof. Joseph Hyrtl, Vienna, Austria.
- 91.** Same as **A. 7.**, in vertical section. For low powers.
A. 8. Prof. Joseph Hyrtl, Vienna, Austria.
- 93.** Opaque venous injection (blue) of pyramid; vertical section. For low powers.
A. 9. Prof. Joseph Hyrtl, Vienna, Austria.
- 91.** Same as **A. 9.**, horizontal section, (arteries red, veins yellow) For low powers.
A. 10. Prof. Joseph Hyrtl, Vienna, Austria.
- 95.** Opaque venous injection (yellow) of surface of kidney. For low powers.
A. 11. Prof. Joseph Hyrtl, Vienna, Austria.
- 96.** Opaque injection (yellow) of the straight uriniferous tubules in the medullary portion of the kidney, showing the tubules bifurcating. For low powers.
A. 12. Prof. Joseph Hyrtl, Vienna, Austria.
- 97.** Opaque injection (yellow) of the convoluted uriniferous tubules in the cortical portion of the kidney. For low powers.
A. 13. Prof. Joseph Hyrtl, Vienna, Austria.

B. FROM ANIMALS.

- 815 & 816.** Two sections of cortical and medullary portions of kidney of dog, with transparent Prussian blue injection, showing the vessels of the Malpighian bodies and the capillary plexus of the substance of the kidney partially filled by the injection. For low and moderate powers.
B. 1.
- 817.** Same as **B. 1**, with transparent carmine injection, showing all the vessels of the kidney filled by the injection. For low and moderate powers.
B. 2.
- 1621.** Section of cortical portion of kidney of dog, with partial transparent Prussian blue injection, showing the vessels of the Malpighian bodies and the capillary plexus of the substance of the kidney interfusing with the convoluted uriniferous tubules. For low and moderate powers.
B. 3.
- Assistant Surgeon J. S. Billings, U. S. Army.
- 1625 & 1626.** Two preparations, same as **B. 3**, including also some of the medullary portion of the kidney.
B. 4. Assistant Surgeon J. S. Billings, U. S. Army.
- 1628 & 1632.** Two preparations, same as **B. 4**, with faint carmine staining, showing the uriniferous tubules better defined.
B. 5. Assistant Surgeon J. S. Billings, U. S. Army.
- 981 to 983.** Three sections of cortical and medullary portions of kidney of small dog, with transparent carmine injection. The injection fills only the capillaries of the Malpighian bodies and then affluents arteries. The convoluted uriniferous tubules are seen composing the bulk of the renal substance. For low powers.
B. 6.
- 1779 & 1780.** Two sections of cortical portion of kidney of dog, with transparent Prussian blue injection and carmine staining, showing the capillaries of the Malpighian bodies and substance of the kidney, and, very beautifully, the convoluted uriniferous tubules sharply defined by the staining. For low and high powers.
B. 7.
- 1781.** Same as **B. 7**; embracing also some of the medullary portion of the kidney.
B. 8.
- 1782.** Portion of capsule of kidney of dog, with double transparent injection (arteries red, veins and capillaries blue), showing the arrangement of the vessels. For low powers.
B. 9.
- 1783.** Same as **B. 9**; the blue has mostly faded.
B. 10.
- 1309.** Same as **B. 9**; showing also the cells of the substance of the capsule and some nerves. For low and high powers.
B. 11.
- 981.** Section of cortical and medullary portion of kidney of cat, with transparent carmine injection; showing all the vessels of the kidney filled by the injection. For low and moderate powers.
B. 12. Boulogne Freres, Paris, France.
- 1781 to 1788.** Five preparations, same as **B. 12**.
B. 13.
- 1789 & 1790.** Two preparations, same as **B. 13**, with the sections passing through the entire kidney perpendicularly and parallel to the axis of the pyramids.
B. 14.
- 1791 & 1792.** Two preparations, same as **B. 14**, cut transversely to the axis of the pyramids, exhibiting the straight tubules of the medullary portion in transverse section.
B. 15.
- 1793 & 1794.** Two sections of medullary and cortical portions of kidney of cat, with transparent Prussian blue injection and carmine staining. The injection fills only the capillaries of the Malpighian bodies. The sections show the uriniferous tubules with epithelium in situ splendidly defined by the staining; also the epithelium of the inner surface of the Malpighian capsules. For moderate and high powers.
B. 16.
- 1795 to 1797.** Three sections of cortical and medullary portions of kidney of rat, with transparent Prussian blue injection, showing all the vessels of the kidney filled by the injection. For moderate powers.
B. 17.

- 1798 to 1802.** Five preparations, same as **B. 17**, but with the injection mostly faded in the cortical portion.
B. 18.
- 1561 to 1571 and 1803 to 1809.** Eighteen sections of cortical and medullary portions of kidney of rat, with transparent Prussian blue injection and carmine staining. The injection has mostly faded in the cortical portion. The staining defines very beautifully the straight and convoluted uriniferous tubules, showing their arrangement and relations. In specimens **1570** and **1804** to **1807**, the individual epithelial cells in situ in the tubules are also clearly shown. For low and high powers.
B. 19.
- 968.** Section of cortical portion of kidney of sheep, with partial transparent Prussian blue injection. The injection fills only some of the interlobular and afferent arteries and capillaries of the Malpighian bodies. For low powers.
B. 20.
- 969 & 970.** Two sections of cortical and medullary portions of kidney of sheep, with transparent Prussian blue injection and carmine staining. The injection is similar to that in **B. 20**; the staining shows the arrangement and relations of the uriniferous tubules. For low and moderate powers.
B. 21.
- 971 to 973.** Three preparations, same as **B. 21**, but with the injection mostly faded.
B. 22.
- 978 & 979.** Two sections of cortical portion of kidney of pig, stained with carmine, showing the minute anatomy and relations of the Malpighian bodies and uriniferous tubules. For moderate and high powers.
B. 23. Dr. S. A. Jones, Englewood, N. J.
- 1810 to 1813.** Four sections of cortical and medullary portions of kidney of ox, with opaque yellow injection, showing the arrangement of the various bloodvessels of the kidney. For low powers.
B. 24.
- 1977.** Section of cortical and medullary portions of kidney of rabbit, with double transparent injection (artery red, veins blue). The arterial injection fills all the vessels of the cortical portion; the venous, a few of the straight vessels of the medullary portion. For low powers.
B. 25.
- 1976.** Same as **B. 25**. The blue venous injection fills some of the capillary plexus in the cortical substance, meeting the red in many places in the same vessel.
B. 26.
- 2026 to 2028.** Three preparations of capsule of kidney of dog, with transparent Prussian blue injection and carmine staining, showing the arrangement of the bloodvessels, and the cellular elements of the stroma of the capsule, beautifully defined by the staining. For low and high powers.
B. 27.
- 98.** Opaque injection (yellow) of fasciculated uriniferous tubules in the cortical portion of kidney of *Cynocephalus Hamadryas*. The white spots are deposits of uric salts. For low powers.
B. 28. Prof. Joseph Hyrtl, Vienna, Austria.
- 99.** Opaque injection in two colors (arteries yellow, veins red) of a vertical section of cortical and medullary portions of kidney of *Ovis Musimon*. For low powers.
B. 29. Prof. Joseph Hyrtl, Vienna, Austria.
- 100.** Same as **B. 29**, from a bear, (arteries red, uriniferous tubules white). For low powers.
B. 30. Prof. Joseph Hyrtl, Vienna, Austria.
- 101.** Same as **B. 29**, from *Lepus Caniculus*, (arteries red, veins white). For low powers.
B. 31. Prof. Joseph Hyrtl, Vienna, Austria.
- 102.** Opaque injection (white) of Malpighian bodies in kidney of *Pteropus Egyptianus*. For low powers.
B. 32. Prof. Joseph Hyrtl, Vienna, Austria.
- 103.** Same as **B. 32**, from *Lutra vulgaris*, (red). For low powers.
B. 33. Prof. Joseph Hyrtl, Vienna, Austria.
- 104.** Same as **B. 33**, from *Meles Taxus*. For low powers.
B. 34. Prof. Joseph Hyrtl, Vienna, Austria.
- 105.** Same as **B. 32**, from *Sus scrofa*: veins also injected (blue). For low powers.
B. 35. Prof. Joseph Hyrtl, Vienna, Austria.

- 106.** Same as B. 32, from *Halmaturus Brunii*, (yellow). For low powers.
B. 36. Prof. Joseph Hyrtl, Vienna, Austria.
- 107.** Same as B. 36, from *Equus Caballus*. For low powers.
B. 37. Prof. Joseph Hyrtl, Vienna, Austria.
- 108.** Same as B. 32, from *Camelopardalis Giraffa*. For low powers.
B. 38. Prof. Joseph Hyrtl, Vienna, Austria.
- 109.** Same as B. 33, from *Felis Lynx*. For low powers.
B. 39. Prof. Joseph Hyrtl, Vienna, Austria.
- 110.** Same as B. 33, from *Ornithorhynchus paradoxus*. For low powers.
B. 40. Prof. Joseph Hyrtl, Vienna, Austria.
- 111.** Same as B. 33, from *Castor Fiber*, in section of cortical substance. For low powers.
B. 41. Prof. Joseph Hyrtl, Vienna, Austria.
- 117.** Same as B. 32, from *Festinus gallus*. For low powers.
B. 42. Prof. Joseph Hyrtl, Vienna, Austria.
- 118.** Same as B. 42, with uriniferous tubules in transverse section of the kidney. For low powers.
B. 43. Prof. Joseph Hyrtl, Vienna, Austria.
- 119.** Opaque injection (yellow) of the uriniferous tubules in cortical portion of kidney of *Falco Esalon*
B. 44. For low powers.
Prof. Joseph Hyrtl, Vienna, Austria.
- 120.** Opaque injection (yellow) of uriniferous tubules in section of kidney of *Tetrao tetrix*. For low powers.
B. 45. Prof. Joseph Hyrtl, Vienna, Austria.
- 121.** Opaque injection (yellow) of Malpighian bodies in kidney of *Rana Alpina*. For low powers.
B. 46. Prof. Joseph Hyrtl, Vienna, Austria.
- 122.** Same as B. 46, from *Proteus anguinus*. For low powers.
B. 47. Prof. Joseph Hyrtl, Vienna, Austria.
- 123.** Same as B. 46, from *Salamandra maculosa*. For low powers.
B. 48. Prof. Joseph Hyrtl, Vienna, Austria.
- 124.** Same as B. 46, from *Triton cristatus*, with the transitus of the arteries (white) into the renal veins
B. 49. (blue). For low powers.
Prof. Joseph Hyrtl, Vienna, Austria.
- 125.** Same as B. 46, from a tadpole, in two colors (arteries yellow, veins red). For low powers.
B. 50.
- 126.** Same as B. 50 from *Salamandra atra*. For low powers.
B. 51. Prof. Joseph Hyrtl, Vienna, Austria.
- 127.** Same as B. 50, from *Triton taeniatus*. For low powers.
B. 52. Prof. Joseph Hyrtl, Vienna, Austria.
- 128.** Same as B. 46, from *Bufo vulgaris*. For low powers.
B. 53. Prof. Joseph Hyrtl, Vienna, Austria.
- 129.** Same as B. 46, from *Bufo Pallasii*; dorsal surface of kidney. For low powers.
B. 54. Prof. Joseph Hyrtl, Vienna, Austria.
- 130.** Same as B. 46, from *Uperla Cherson*; ventral surface of kidney. For low powers.
B. 55. Prof. Joseph Hyrtl, Vienna, Austria.
- 131.** Same as B. 50, from *Colaptes lacertina*. For low powers.
B. 56. Prof. Joseph Hyrtl, Vienna, Austria.

- 132.** Same as **B. 46**, from *Tropidonotus Natriz*. For low powers.
B. 57. Prof. Joseph Hyrtl, Vienna, Austria.
- 133.** Same as **B. 46**, from *Chrysolamprus ocellatus*; section of the kidney. For low powers.
B. 58. Prof. Joseph Hyrtl, Vienna, Austria.
- 134.** Same as **B. 58**, from *Chersus marginatus*, (red). For low powers.
B. 59. Prof. Joseph Hyrtl, Vienna, Austria.
- 135.** Same as **B. 50**, from *Bufo palmarum*, (renal veins green). For low powers.
B. 60. Prof. Joseph Hyrtl, Vienna, Austria.
- 136.** Opaque injection (red) of afferent or portal vein on the dorsal surface of kidney of *Hyla viridis*. For low powers.
B. 61. Prof. Joseph Hyrtl, Vienna, Austria.
- 137.** Opaque injection in two colors (arteries white, renal veins red) of dorsal face of kidney of *Anguis fragilis*. For low powers.
B. 62. Prof. Joseph Hyrtl, Vienna, Austria.
- 138.** Opaque injection in two colors (portal vein red, uriniferous tubules white) of dorsal surface of kidney of *Zacholus Austriacus*. For low powers.
B. 63. Prof. Joseph Hyrtl, Vienna, Austria.
- 139.** Opaque injection in three colors (arteries white, renal vein blue, ureter yellow) of ventral face of kidney of *Coluber Merromii*. For low powers.
B. 64. Prof. Joseph Hyrtl, Vienna, Austria.
- 140.** Same as **B. 64**, from *Aspis Haje*. For low powers.
B. 65. Prof. Joseph Hyrtl, Vienna, Austria.
- 141.** Same as **B. 64**, from *Coluber leopardinus*, (uriniferous ducts white). For low powers.
B. 66. Prof. Joseph Hyrtl, Vienna, Austria.
- 142.** Same as **B. 66**, from *Coluber Esculapii*. For low powers.
B. 67. Prof. Joseph Hyrtl, Vienna, Austria.
- 143.** Same as **B. 63**, from *Coluber viridi-flavus*, (uriniferous ducts yellow, portal vein red). For low powers.
B. 68. Prof. Joseph Hyrtl, Vienna, Austria.
- 144.** Same as **B. 64**, from *Trigonacepholus*, (arteries yellow, veins blue, uriniferous tubules white). For low powers.
B. 69. Prof. Joseph Hyrtl, Vienna, Austria.
- 147.** Opaque injection in three colors (arteries yellow, portal vein green, uriniferous tubules white) of dorsal face of kidney of *Bipes Pallasii*. For low powers.
B. 70. Prof. Joseph Hyrtl, Vienna, Austria.
- 148.** Same as **B. 70**, from *Crocodilus Niloticus*, (arteries white, portal vein red, uriniferous ducts green). For low powers.
B. 71. Prof. Joseph Hyrtl, Vienna, Austria.
- 149.** Same as **B. 70**, from *Bipes Pallasii*, in four colors, (arteries white, portal vein blue, uriniferous tubules yellow, renal vein red). For low powers.
B. 72. Prof. Joseph Hyrtl, Vienna, Austria.
- 150.** Opaque injection (red) of portal vein on dorsal face of kidney of *Scuturus affricatus*, (uriniferous ducts white). For low powers.
B. 73. Prof. Joseph Hyrtl, Vienna, Austria.
- 151.** Opaque injection (yellow) of Malpighian bodies in the kidney of *Scyllium Canicula*. For low powers.
B. 74. Prof. Joseph Hyrtl, Vienna, Austria.

- 152.** Same as **B. 74**, from *Sitarus glanis*. For low powers.
B. 75. Prof. Joseph Hyrtl, Vienna, Austria.
- 153.** Same as **B. 74**, from *Conger Myrus*. For low powers.
B. 76. Prof. Joseph Hyrtl, Vienna, Austria.
- 154.** Same as **B. 74**, with tubuli uriniferi also injected, from *Abramis Brama*. For low powers.
B. 77. Prof. Joseph Hyrtl, Vienna, Austria.
- 155.** Opaque injection (yellow) of tubuli uriniferi in kidney of *Tinea chrysis*. For low powers.
B. 78. Prof. Joseph Hyrtl, Vienna, Austria.
- 156.** Same as **B. 78**, from *Ilus melanotus*. For low powers.
B. 79. Prof. Joseph Hyrtl, Vienna, Austria.
- 818.** Opaque injection in two colors (yellow and red) of vessels of Wolffian body of fetal horse, showing true Malpighian bodies. For low powers.
B. 80. Prof. Joseph Hyrtl, Vienna, Austria.

For other illustrations, see **IX, B. B. 1.**

C. PATHOLOGICAL.

- 1814 & 1815.** Two sections of cortical and medullary portions of human fatty kidney, with transparent Prussian blue injection and carmine staining. The fat has all been removed in the process of preparation, but the contours of the uriniferous tubules are seen to be lost over a great part of the sections. The specimens show the cellular elements of the kidney splendidly defined by the carmine. For moderate and high powers.
C. 1. From *Specimen 862, Medical Section, chap. V, sec. 1, B. 7.*
- 1816 & 1817.** Two preparations, same as **C. 1**, but with the injection and staining in great part faded.
C. 2. From the same specimen as **C. 1.**
- 92.** Opaque injection (yellow) of the vessels of human kidney in Bright's disease. For low powers.
C. 3. Prof. Joseph Hyrtl, Vienna, Austria.

B. URETERS.

A. FROM MAN

- 980.** Mucous membrane of ureter of child, with transparent carmine injection, showing the arrangement of the bloodvessels. For low powers.
A. 1
- 116.** Opaque injection in two colors (arteries white, veins blue) of pelvis of kidney. For low powers.
A. 2 Prof. Joseph Hyrtl, Vienna, Austria.

B. FROM ANIMALS.

- 971.** Ureter of frog, with transparent carmine injection, showing the arrangement of the bloodvessels. A small portion of the kidney remains attached and shows a few Malpighian bodies with the capillaries injected. For low powers.
B. 1
- 115.** Opaque injection (yellow) of the ramifying branches of the ureter on the ventral surface of the kidney of *Pseudis serpentina*. For low powers.
B. 2 Prof. Joseph Hyrtl, Vienna, Austria.
- 116.** Same as **B. 2** from *Leontas Melogalis*. For low powers.
B. 3 Prof. Joseph Hyrtl, Vienna, Austria.

C. BLADDER.

A. FROM MAN.

- 112.** Opaque injection (red) of the vessels in the mucous membrane of the bladder. For low powers.
A. 1. Prof. Joseph Hyrtl, Vienna, Austria.
- 123.** Same as **A. 1.**, of the muscular layer. For low powers.
A. 2. Prof. Joseph Hyrtl, Vienna, Austria.

B. FROM ANIMALS.

- 985.** Portion of bladder of cat, with transparent carmine injection, showing the arrangement of the bloodvessels, and, in some places, the epithelium of the mucous coat in situ. For low and high powers.
B. 1.
- 991.** Portion of bladder of mouse, with transparent carmine injection, showing the arrangement of the capillaries. For low and moderate powers.
B. 2.
- 316.** Opaque injection in two colors (arteries white, veins red) of bladder of *Salamandra*. For low powers.
B. 3. Prof. Joseph Hyrtl, Vienna, Austria.

D. URETHRA.

A. FROM MAN.

- 111.** Opaque injection (red) of the vessels in the urethra. For low powers.
A. 1. Prof. Joseph Hyrtl, Vienna, Austria.

C. PATHOLOGICAL.

- 986 to 990.** Five sections of slough of mucous membrane of human urethra. The slough, in the form of a tubular grayish cast, was drawn from the urethra of a patient who had been using injections of chloride of zinc for the cure of gonorrhoea. The sections show sufficient indications of connective and fibrous tissue, bloodvessels and urethral glands, to prove the cast to be a true slough. For history of the case, see the *Boston Medical and Surgical Journal*, vol. 69, page 323. The portion of the slough from which the sections were cut was presented by Dr. J. B. S. Jackson, of Boston, Mass.
C. 1.

E. CHEMICAL CONSTITUENTS OF URINE.

A. FROM MAN.

- 992 & 993.** Two preparations of various forms of crystals of urea, artificially prepared. Many of the crystals have lost their sharp outline from partial solution. For moderate powers.
A. 1.
- 991.** Large rhomboidal crystals and glomeruli of uric acid, natural deposit. For low and moderate powers.
A. 2. Assistant Surgeon J. J. Woodward, U. S. Army.
- 995.** Small quadrate tabular crystals of uric acid, natural deposit. For moderate and high powers.
A. 3. Assistant Surgeon J. J. Woodward, U. S. Army.
- 996.** Barrel-shaped and fusiform crystals of uric acid, natural deposit. For moderate powers.
A. 4. Assistant Surgeon J. J. Woodward, U. S. Army.
- 997.** Large rhomboid, crucial and spindle-shaped crystals of uric acid, artificially crystallized. For low powers.
A. 5.

- 998.** Very large irregular crystals of uric acid, artificially crystallized. For low powers.
A. 6.
- 999.** Small hexagonal tabular plates of uric acid, artificially crystallized. For moderate and high powers.
A. 7.
- 1000.** Small rhomboid and cylindrical crystals of uric acid, artificially crystallized. For moderate powers.
A. 8.
- 1002.** Minute dumb-bell crystals of urates mixed with fusiform crystals of uric acid, natural deposit. For moderate and high powers.
A. 9. Assistant Surgeon J. J. Woodward, U. S. Army.
- 1003 & 1001.** Two preparations of minute spheroidal crystals of urate of soda with a few prismatic crystals of triple phosphate of magnesia and ammonia, natural deposit. For moderate and high powers.
A. 10.
- 1005.** Dumb-bell and spheroidal crystals of urate of soda with projecting spicula, and foliaceous crystals of basic phosphate of magnesia and ammonia, artificially crystallized. For moderate powers.
A. 11.
- 1006 to 1008.** Three preparations of dumb-bell and spheroidal crystals of urate of soda, with granular masses of the amorphous urates and prismatic crystals of triple phosphate of magnesia and ammonia, natural deposit. For moderate and high powers.
A. 12.
- 1011.** Minute ovoid plates of oxalate of lime, artificially crystallized. For high powers.
A. 13.
- 1013 to 1017.** Five preparations of overlapping hexagonal plates of cystine, natural deposit. For moderate powers.
A. 14.
- 1018.** Rosettes of minute hexagonal plates of cystine, recrystallized from ammoniacal solution. For moderate and high powers.
A. 15. Assistant Surgeon J. J. Woodward, U. S. Army.
- 1019 & 1192.** Two preparations of prismatic crystals of triple phosphate of magnesia and ammonia, natural deposit; mounted in a watery menstruum. For low and moderate powers.
A. 16.
- 1020.** Same as A. 16; mounted in glycerine jelly.
A. 17.
- 1023.** Same as A. 16; mounted dry.
A. 18.
- 1021.** Large foliaceous crystals of basic phosphate of magnesia and ammonia, natural deposit. For low powers.
A. 19. Assistant Surgeon J. J. Woodward, U. S. Army.
- 1022.** Same as A. 19; mounted dry.
A. 20.
- 1021 to 1027.** Four preparations of rosettes and peniform crystals of phosphate of lime, artificially crystallized. For moderate powers.
A. 21.
- 1028.** Various forms of crystals of phosphates, stained yellow with bile, natural deposit; from a case of jaundice. For moderate powers.
A. 22. Assistant Surgeon J. J. Woodward, U. S. Army.
- 1029 to 1033.** Five preparations of amorphous phosphate of lime and octahedral and dumb-bell crystals of oxalate of lime, natural deposit. For high powers.
A. 23.

B. FROM ANIMALS.

- 1001.** Small acicular and spindle-shaped crystals of hippuric acid; from urine of horse. For moderate powers.
B. 1. Assistant Surgeon J. J. Woodward, U. S. Army.
- 1012.** Spherical crystals of carbonate of lime; from urine of horse. For moderate powers.
B. 2. Assistant Surgeon J. J. Woodward, U. S. Army.

F. ORGANIC DEPOSITS IN URINE**A.** FROM MAN.

- 1035.** Granular casts of the uriniferous tubes, and pus corpuscles: from a case of Bright's disease. For high powers.
A. 1.
- 1036.** Granular casts of the uriniferous tubes, blood corpuscles and prisms of triple phosphates: from a case of Bright's disease. For high powers.
A. 2. Presented by Surgeon T. Sim, U. S. Vols.

G. SUPRARENAL GLANDS.**A.** FROM MAN.

- 115.** Opaque injection (yellow) of the vessels in the suprarenal gland: from a new-born child.
A. 1. Prof. Joseph Hyrtl, Vienna, Austria



X. SEXUAL ORGANS, OVA AND FETAL APPENDAGES.

- A. TESTES.
- B. TUNICA VAGINALIS.
- C. VASA DEFERENTIA.
- D. VESICULÆ SEMINALES.
- E. PROSTATE AND COWPER'S GLANDS.
- F. PENIS.
- G. SEMEN.
- H. VULVA.
- I. VAGINA.
- K. UTERUS.
- L. FALLOPIAN TUBES AND OVIDUCTS.
- M. OVARIES.
- N. MAMMARY GLANDS.
- O. OVA.
- P. FETAL APPENDAGES.

A. FROM MAN. | B. FROM ANIMALS. | C. PATHOLOGICAL.

X. SEXUAL ORGANS, OVA AND FŒTAL APPENDAGES.

A. TESTES.

B. FROM ANIMALS.

336. Opaque injection in two colors (arteries white, veins red) of testis of *Protus*. For low powers.
B. 1. Prof. Joseph Hyrtl, Vienna, Austria.

337. Opaque injection (yellow) of the vessels of testis of *Salamandra maculosa*. For low powers.
B. 2. Prof. Joseph Hyrtl, Vienna, Austria.

F. PENIS.

A. FROM MAN.

338. Opaque injection (red) of the vessels of the corpus cavernosum. For low powers.
A. 1. Prof. Joseph Hyrtl, Vienna, Austria.

G. SEMEN.

A. FROM MAN.

1191. Human spermatozoa. For high powers.
A. 1. J. Bourgogne, Paris, France.

B. FROM ANIMALS.

1319. Spermatozoa of horse. For high powers.
B. 1. J. Bourgogne, Paris, France.

2012 to 2011. Three preparations of spermatozoa of rabbit. For high powers.
B. 2.

K. UTERUS.

A. FROM MAN.

310. Opaque injection (red) of the vessels in a non-gravid uterus. For low powers.
A. 1. Prof. Joseph Hyrtl, Vienna, Austria.

311. Opaque injection (red) of the vessels in the neck of the uterus. For low powers.
A. 2. Prof. Joseph Hyrtl, Vienna, Austria.

L. FALLOPIAN TUBES AND OVIDUCTS.

B. FROM ANIMALS.

311. Opaque injection in two colors (arteries white, veins red) of oviduct of *Triton Alpestris*. For low powers.
B. 1. Prof. Joseph Hyrtl, Vienna, Austria.

315. Same as **B. 1.** (gravid), from *Salamandra*, (arteries white, veins yellow). For low powers.
B. 2. Prof. Joseph Hyrtl, Vienna, Austria.

M. OVARIES.

A. FROM MAN.

- 312.** Opaque injection (red) of the vessels of a Graafian vesicle after conception. For low powers.
A. 1. Prof. Joseph Hyrtl, Vienna, Austria.

B. FROM ANIMALS.

- 313.** Opaque injection in two colors (arteries white, veins blue) of ovary of *Triton Alpestris*. For low powers.
B. 1. Prof. Joseph Hyrtl, Vienna, Austria.

C. PATHOLOGICAL.

- 1337 to 1312.** Six sections through the walls of a cyst of human ovary, in which was lodged a foetus in a case of extra-uterine pregnancy. The sections are stained with carmine and show the muscular structure of the walls of the cyst. For moderate and high powers.
C. 1. From Specimen **795**, *Medical Section, chap. V, sec. 5, E. 3.*

N. MAMMARY GLANDS.

A. FROM MAN.

- 291.** Opaque injection (red) of the lactiferous tubules and terminal vesicles in the mammary gland. For low powers.
A. 1. Prof. Joseph Hyrtl, Vienna, Austria.

O. OVA.

B. FROM ANIMALS.*

- 1199.** Ova of *Tania solium*. For high powers.
B. 1. Dr. S. A. Jones, Englewood, N. J.

For other illustrations, see **XV**, A. A. 1 to 3.

P. FETAL APPENDAGES.

A. FROM MAN.

- 1195.** Portion of placenta, with transparent carmine injection, showing the bloodvessels of the part. For low and moderate powers.
A. 1. Presented by Surgeon T. Sim, U. S. Vols.
- 317.** Opaque injection in two colors (arteries white, veins red) of placenta. For low powers.
A. 2. Prof. Joseph Hyrtl, Vienna, Austria.

XI. ORGAN OF VISION.

A. SCLEROTICA AND CORNEA.

B. CHOROID AND IRIS.

C. RETINA.

D. CRYSTALLINE LENS.

E. VITREOUS HUMOR AND HYALOID MEMBRANE.

F. CONJUNCTIVA.

G. LACHRYMAL GLANDS AND DUCTS.

H. EYELIDS.

A. FROM MAN. | B. FROM ANIMALS. | C. PATHOLOGICAL.

XI. ORGAN OF VISION.

A. SCLEROTICA AND CORNEA.

B. FROM ANIMALS.

- 1818.** Portion of cornea of cat, with transparent carmine injection, showing the fine capillary loops around the circumference of the cornea. For low powers.
- B. 1.**
- 1310.** Transverse sections of cornea of frog, faintly stained with carmine, showing the laminated structure of the cornea and the long fusiform corneal cells. For high powers.
- B. 2.**
- 1311.** Portion of membrane of Descemet, from cornea of frog, stained with carmine, showing the nucleated epithelium in situ upon its inner surface. For high powers.
- B. 3.**

B. CHOROID AND IRIS.

A. FROM MAN.

- 1553.** Portion of vascular layer of choroid, with transparent carmine injection, showing the arrangement of the capillaries in the membrana choriocapillaris. For low powers.
- A. 1.** Prof. Joseph Gerlach, Erlangen, Bavaria.
- 297.** Opaque injection (yellow) of the vessels of the ciliary processes. For low powers.
- A. 2.** Prof. Joseph Hyrtl, Vienna, Austria.
- 298.** Opaque injection (white) of the vessels of the choroid. For low powers.
- A. 3.** Prof. Joseph Hyrtl, Vienna, Austria.
- 301.** Opaque injection (white) of the vasa vorticosa of the choroid. For low powers.
- A. 4.** Prof. Joseph Hyrtl, Vienna, Austria.

B. FROM ANIMALS.

- 1819 to 1821.** Three preparations of portions of choroid from eye of white rabbit, with transparent carmine injection, showing the arrangement of the capillaries. For low and moderate powers.
- B. 1.**
- 1822 & 1823.** Two preparations of portions of ciliary processes and iris from eye of rabbit, with transparent carmine injection, showing the arrangement of the capillaries. For low and moderate powers.
- B. 2.**
- 511 & 515.** Two preparations of portions of choroid, ciliary body and iris from eye of chicken, with transparent carmine injection, showing the arrangement of the bloodvessels in the several structures, and the pigment of the choroid and ciliary processes. For low and moderate powers.
- B. 3.**
- 511.** Ciliary processes from eye of rabbit, with opaque yellow injection, showing the vessels of the processes.
- B. 4.** For low powers.
- 513.** Same as **B. 4.**, with opaque red injection.
- B. 5.**
- 386 & 512.** Two preparations of ciliary processes from eye of dog, with opaque yellow injection, showing the vessels of the processes. For low powers.
- B. 6.**

- 1263.** Marsupium from eye of chicken, with transparent carmine injection, showing the arrangement of the bloodvessels and the masses of pigment. For low and moderate powers.
B. 7.
- 1978.** Posterior portion of choroid from eye of cat, with transparent carmine injection, showing the arrangement of the bloodvessels, the pigment cells, and the absence of pigment in the tapetum. For low and moderate powers.
B. 8.
- 299.** Opaque injection (yellow) of the vasa vorticiosa of choroid of *Salamandra*. For low powers.
B. 9. Prof. Joseph Hyrtl, Vienna, Austria.
- 302.** Opaque injection (white) of the vessels of iris of *Anguilla Marina*. For low powers.
B. 10. Prof. Joseph Hyrtl, Vienna, Austria.
- 303.** Opaque injection (yellow) of the vessels of choroid of *Rana esculenta*. For low powers.
B. 11. Prof. Joseph Hyrtl, Vienna, Austria.
- 301.** Opaque injection (yellow) of the vessels of choroid and iris of *Salamandra*. For low powers.
B. 12. Prof. Joseph Hyrtl, Vienna, Austria.

C. PATHOLOGICAL.

- 296.** Opaque injection (yellow) of the vessels of human iris with coloboma. For low powers.
C. 1. Prof. Joseph Hyrtl, Vienna, Austria.

C. RETINA.

A. FROM MAN.

- 1559.** Portion of retina, with transparent carmine injection, showing the arrangement of the fine capillaries of the retina. For low and moderate powers.
A. 1. Prof. Joseph Gerlach, Erlangen, Bavaria.
- 300.** Opaque injection (yellow) of the arteria centralis retinae and its branches. For low powers.
A. 2. Prof. Joseph Hyrtl, Vienna, Austria.

B. FROM ANIMALS.

- 1821 to 1827.** Four preparations of retina from eye of cat, with transparent carmine injection, showing the arrangement of the fine retinal capillaries. For low and moderate powers.
B. 1.
- 1980.** Portion of retina from eye of kitten, with transparent carmine injection, showing the arrangement of the fine retinal capillaries. For low and moderate powers.
B. 2.

D. CRYSTALLINE LENS.

A. FROM MAN.

- 305.** Opaque injection (yellow) of the vessels of the capsule of the lens, with lens in situ, from eye of fetus. For low powers.
A. 1. Prof. Joseph Hyrtl, Vienna, Austria.

B. FROM ANIMALS.

- 532.** Capsule of crystalline lens from eye of puppy, with transparent Prussian blue injection, showing the arrangement of the bloodvessels in the young capsule. For low and moderate powers.
B. 1. Assistant Surgeon J. S. Billings, U. S. Army.

1828. Crystalline lens in situ in its capsule, from eye of frog, with opaque yellow injection, showing the ramifying vessels of the capsule; shows also, by transmitted light, the laminated structure of the lens. For low and moderate powers.

1979. Crystalline lens, with posterior capsule attached, from eye of kitten, with transparent carmine injection, showing the arrangement of the capillaries in the capsule. For low powers.

F. CONJUNCTIVA.

A. FROM MAN.

2031. Portion of conjunctiva from eye of six-months' fetus, with transparent carmine injection, showing the arrangement of the capillaries. For low powers.

291. Opaque injection (yellow) of the vessels of the conjunctiva. For low powers.
A. 2. Prof. Joseph Hyrtl, Vienna, Austria.

295. Same as **A. 2.**, (red), from the ball of the eye. For low powers.
A. 3. Prof. Joseph Hyrtl, Vienna, Austria.

C. PATHOLOGICAL.

293. Opaque injection (red) of the vessels of inflamed conjunctiva. For low powers.
C. 1. Prof. Joseph Hyrtl, Vienna, Austria.

H. EYELIDS.

A. FROM MAN.

1129 to 1137. Nine perpendicular sections of upper eyelid of negro, showing the general arrangement and relations of the various structures of the lid. For low powers.
A. 1.

1981. Perpendicular section of upper eyelid of a six-months' fetus, with transparent carmine injection. The injection is imperfect, but the specimen shows the general arrangement of the structures of the eyelid, and, with a high power, muscular fibres, young connective tissue, the epithelium lining the duct of a Meibomian gland and free edge of the eyelid, and the cellular elements of the young hair-bulbs. For low and high powers.
A. 2.

B. FROM ANIMALS.

516. Nyctitating membrane from eyelid of chicken, with transparent carmine injection, showing the arrangement of the bloodvessels. For low powers.
B. 1.

2032. Nyctitating membrane from eyelid of kitten, with transparent carmine injection, showing the arrangement of the bloodvessels. For low powers.
B. 2.

XII. ORGAN OF HEARING.

A. EXTERNAL EAR.

B. MIDDLE EAR, MEMBRANA TYMPANI AND EUSTACHIAN TUBE.

C. INTERNAL EAR.

A. FROM MAN.

B. FROM ANIMALS. |

C. PATHOLOGICAL.

XII. ORGAN OF HEARING.

A. EXTERNAL EAR.

B. FROM ANIMALS.

1829 & 1830. Two sections of pinna from rat, with transparent Prussian blue injection and carmine staining, showing the minute anatomy and general arrangement of the various structures of the pinna. For low and high powers.
B. 1.

1831. Same as **B. 1.**, with the injection faded.
B. 2.

B. MIDDLE EAR, MEMBRANA TYMPANI AND EUSTACHIAN TUBE.

B. FROM ANIMALS.

1833. Two tympanic membranes from frog, with transparent carmine injection, showing the arrangement of the zone of capillaries around the ear-drum. For low powers.
B. 1.

C. INTERNAL EAR.

B. FROM ANIMALS.

1557. Lamina spiralis from ear of rat, with transparent carmine injection, showing the general structure of the lamina and the arrangement of the capillaries. For moderate and high powers.
B. 1. Prof. Joseph Gerlach, Erlangen, Bavaria

XIII. ORGAN OF SMELL.

A. SCHNEIDERIAN MEMBRANE.

B. OTHER STRUCTURES OF THE NOSE.

A. FROM MAN | **B.** FROM ANIMALS. | **C.** PATHOLOGICAL.

XIII. ORGAN OF SMELL.

A. SCHNEIDERIAN MEMBRANE.

A. FROM MAN.

- 312.** Opaque injection (red) of the vessels in the Schneiderian membrane over the inferior turbinated bone.
A. 1. For low powers.
Prof. Joseph Hyrtl, Vienna, Austria.
- 313.** Same as **A. 1.**, (white); from the septum narium. For low powers.
A. 2. Prof. Joseph Hyrtl, Vienna, Austria.

B. OTHER STRUCTURES OF THE NOSE.

B. FROM ANIMALS.

- 1982.** Transverse section of nasal fossae of kitten, with transparent carmine injection, showing the mutual relations of the various structures, the arrangement of the capillaries, and, with a high power, the anatomy of cartilage. For low and high powers.
B. 1.

XIV. PATHOLOGICAL GROWTHS.

A. CARTILAGINOUS TUMORS.

B. FIBROUS AND CONNECTIVE TISSUE TUMORS.

C. CANCERS.

D. CHOLESTERINE TUMORS.

A. FROM MAN. | B. FROM ANIMALS.

XIV. PATHOLOGICAL GROWTHS.

A. CARTILAGINOUS TUMORS.

A. FROM MAN.

- 1055 to 1058** Twelve sections of a portion of a very large enchondromatous tumor from shoulder, stained with carmine.
and The tissue of the tumor is seen to be true cartilage. For high powers.
1831 to 1811. From Specimen 866, *Medical Section, chap. VI, sec. 2, No. 19*
A. 1.

B. FIBROUS AND CONNECTIVE TISSUE TUMORS.

A. FROM MAN.

- 1812 to 1817.** Six sections of fibrous tumor of uterus, stained with carmine, showing smooth muscular fibre intermixed with fibrous tissue. For moderate powers.
A. 1. From Specimen 788, *Medical Section, chap. V, sec. 5, B. 2*.
- 1818 to 1851.** Seven sections of fibrous tumor of uterus, stained with carmine, showing dense fibrous tissue and smooth muscle. For moderate and high powers.
A. 2. From Specimen 780, *Medical Section, chap. V, sec. 5, B. 4*.
- 1211 to 1251.** Eleven perpendicular sections through a keloid growth from the breast of a negro, stained with carmine, showing great hypertrophy of the fibrous stroma of the true skin. The structures of the skin are preserved but are forced apart by the growth of new tissue. For low and high powers.
A. 3. From Specimen 629, *Medical Section, chap. VII, No. 3*.
- 1855 to 1861.** Ten sections of fibro-plastic tumor of clitoris, stained with carmine, showing a stroma of dense connective tissue with very distinct fusiform cells enclosing masses of many-nucleated round cells and free nuclei. From a girl of fifteen years; had been growing for about one year; removed by Dr. George McCoy, Washington, D. C., June, 1866; has not recurred to date of publication. For low and high powers.
A. 4.
- 361 to 369.** Nine sections of a sarcomatous tumor of brain. The tissue of the tumor consists of closely-aggregated spindle-shaped connective tissue corpuscles embedded in the meshes of a fibrous stroma. Partially stained with red aniline. For high powers.
A. 5. From Specimen 535, *Medical Section, chap. I, sec. 1, D. 3*.
- 2036 to 2011.** Six sections of fibroid tumor of uterus, stained with carmine, showing dense fibrous tissue. For moderate and high powers.
A. 6.
- 359.** Opaque injection (red) of the vessels in a fibrous tumor of the uterus. For low powers.
A. 7. Prof. Joseph Hyrtl, Vienna, Austria.

C. CANCERS.

A. FROM MAN.

- 903 to 905.** Three preparations of small scraps from an encephaloid cancer of the liver, showing masses of closely-packed roundish cells. The cells have altered by keeping, and the nuclei can no longer be distinguished. For high powers.
A. 1.

D. CHOLESTERINE TUMORS.

A. FROM MAN.

370 & 371. Two preparations of scraps of a cholesteatoma growing on the inner face of the frontal bone. The tabular plates of cholesterine, which were abundant in the fresh specimen, have almost all dissolved, and the sections show only the meshwork of hexagonal cells that compose the matrix of the tumor. For high powers.

From Specimen 531, Medical Section, chap. I, sec. 1, D. 1.
See Part Second, XIV. D. A. 1 and 2.

XV. PARASITES.

A. ANIMAL.

B. VEGETABLE.

A. FROM MAN.

|

B. FROM ANIMALS.

XV. PARASITES.

A. ANIMAL.

A. FROM MAN.

- 1865 to 1869.** Five preparations of young joints of *Tenia solium*. For low powers
A. 1. See Specimens **811** and **832**, Medical Section, chap. **IV**, sec. 3, N. 8 and 9.
- 1500, 2016
and
2017.** Fully formed proglottides of *Tenia solium*; three preparations. For low powers.
A. 2. Dr. S. A. Jones, Englewood, N. J.
- 1197.** Female *Trichocephalus dispar*. The worm has broken in two across the abdomen, and great numbers of
A. 3. ova are scattered over the field. For low and high powers.
- 1870.** *Acarus Scabiei*. For low and moderate powers.
A. 4. See Part Second, **XV**, A. A. 3.

For other illustrations, see **III**, B. c. 1 and 2.
See also Part Second, **XV**, A. A. 1, 2, 4, 5.

B. FROM ANIMALS

- 1196.** *Cysticercus*, from hare. For low powers.
B. 1.
- 1562.** *Trichina spiralis*, from hog. For low and high powers
B. 2. Procured from Messrs. J. W. Queen & Co., Philadelphia, Pa.

For other illustrations, see **III**, B. c. 3 to 6; **VII**, C. c. 1; **VII**, I. B. 10 (Specimen **796**).
See also Part Second, **XV**, A. A. 1 to 3.

B. VEGETABLE.

A. FROM MAN.

- 1291 & 1292.** Two preparations of *Achorion Schenckii*, from a case of favus of the leg. For high powers.
A. 1.

**XVI. ARTICLES OF FOOD AND CLOTHING, AND
MATERIA MEDICA.**

A. ARTICLES OF FOOD.

B. ARTICLES OF CLOTHING.

C. MATERIA MEDICA. {
A. CRYSTALS.
B. ROOTS.
C. STEMS.
D. LEAVES.
E. FLOWERS.
F. FRUITS.

XVI. ARTICLES OF FOOD AND CLOTHING, AND MATERIA MEDICA.

A. ARTICLES OF FOOD.

- 1396 & 1397.** Sections of bean; two preparations. For moderate and high powers.
A. 1.
- 1398 to 1400.** Sections of roasted bean; three preparations. For moderate and high powers.
A. 2.
- 1402 & 1403.** Sections of grain of rice; two preparations. For moderate and high powers.
A. 3.
- 1404 to 1406.** Sections of roasted grain of rice; three preparations. For moderate and high powers.
A. 4.
- 1407 to 1409.** Sections of kernel of Indian corn; three preparations. For moderate and high powers.
A. 5.
- 1410 to 1412.** Sections of roasted kernel of Indian corn; three preparations. For moderate and high powers.
A. 6.
- 1413.** Starch grains from Indian corn. For moderate and high powers.
A. 7.
- 1414 to 1416.** Sections of rye grain; three preparations. For moderate and high powers.
A. 8.
- 1417 to 1419.** Sections of roasted rye grain; three preparations. For moderate and high powers.
A. 9.
- 1420 to 1422.** Sections of wheat grain; three preparations. For moderate and high powers.
A. 10.
- 1423 to 1425.** Sections of roasted wheat grain; three preparations. For moderate and high powers.
A. 11.
- 1426 to 1428.** Sections of barley grain; three preparations. For moderate and high powers.
A. 12.
- 1429 to 1431.** Sections of roasted barley grain; three preparations. For moderate and high powers.
A. 13.
- 1433.** Sections of oat grain. For moderate and high powers.
A. 14.
- 1434 to 1436.** Sections of roasted oat grain; three preparations. For moderate and high powers.
A. 15.
- 1437 to 1439.** Sections of pea; three preparations. For moderate and high powers.
A. 16.

- 1110.** Sections of toasted pea. For moderate and high powers.
A. 17.
- 1113 to 1115.** Sections of unripe acorn; three preparations. For moderate and high powers.
A. 18.
- 1116.** Sections of roasted unripe acorn. For moderate and high powers.
A. 19.
- 1117 to 1119.** Sections of Hazel-nut; three preparations. For moderate and high powers.
A. 20.
- 1150 to 1152.** Sections of Irish potato; three preparations. For moderate and high powers.
A. 21.
- 1153 & 1151.** Sections of roasted Irish potato; two preparations. For moderate and high powers.
A. 22.
- 1155 to 1157.** Sections of fragments of tapioca; three preparations. For moderate and high powers.
A. 23.
- 1158 & 1159.** Sections of fragments of sago; two preparations. For moderate and high powers.
A. 24.
- 1160 to 1162.** Arrow-root starch; three preparations. For moderate and high powers.
A. 25. *See Part Second, XVI. A. 1.*
- 1163 to 1165.** Investing membrane of coffee berry; three preparations. For moderate and high powers.
A. 26.
- 1166 & 1167.** Sections of coffee berry; two preparations. For moderate and high powers.
A. 27.
- 1168 to 1173.** Sections of roasted coffee berry; six preparations. For moderate and high powers.
A. 28. *See Part Second, XVI. A. 2.*
- 1171, 1175,** Series of six preparations of crystals of caffeine, showing various sizes of the acicular crystals. For
1189, 1190, moderate and high powers.
1191 & 1193.
A. 29.
- 1176 to 1178.** Horizontal sections embracing upper surface of tea leaf; three preparations. For moderate and high
A. 30. powers.
- 1179 to 1181.** Horizontal sections embracing under surface of tea leaf; three preparations. For moderate and high
A. 31. powers.
- 1182 & 1183.** Sections of capsicum seed; two preparations. For moderate and high powers.
A. 32.
- 1181 to 1186.** Sections of black mustard seed; three preparations. For moderate and high powers.
A. 33.
- 1187.** Sections of white mustard seed. For moderate and high powers.
A. 34.
- 1188.** Specimen of commercial powdered mustard, showing extensive adulteration with wheat flour. For
A. 35. moderate and high powers.
- 2119 & 2120.** Two preparations of crystals of caffeine. For low powers.
A. 36.

B. ARTICLES OF CLOTHING.

- 1874 to 1881.** Eight preparations of white wool. For moderate and high powers.
B. 1. *See Part Second, XVI. B. 1.*
- 1882 to 1886.** Five preparations of cotton fibres. For moderate and high powers.
B. 2. *See Part Second, XVI. B. 2.*
- 1887 to 1891.** Five preparations of fibres of flax. For moderate and high powers.
B. 3. *See Part Second, XVI. B. 3.*
- 1892 to 1896.** Five preparations of fibres of silk. For moderate and high powers.
B. 4. *See Part Second, XVI. B. 4.*

C. MATERIA MEDICA.

A. CRYSTALS.

- 2103 & 2101.** Two preparations of crystals of amygdalin. For low and moderate powers.
A. 1.
- 2105 & 2106.** Two preparations of crystals of codeia. For low powers.
A. 2.
- 2107 & 2108.** Two preparations of crystals of morphia. For low powers.
A. 3.
- 2109 & 2110.** Two preparations of crystals of muriate of morphia. For low and moderate powers.
A. 4.
- 2111 & 2112.** Two preparations of crystals of piperin. For low powers.
A. 5.
- 2113 to 2116.** Four preparations of crystals of sulphate of quinia. For moderate powers
A. 6.
- 2117 & 2118.** Two preparations of crystals of strychnia. For low and moderate powers.
A. 7.

B. ROOTS

- 2058.** Two transverse sections of root of *Althaea officinalis*: one partially stained with red aniline, and one unstained. For moderate and high powers.
B. 1. Assistant Surgeon J. S. Billings, U. S. Army.
- 2059.** Two transverse sections of root of *Angelica Archangelica*, stained with red aniline. For low and moderate powers.
B. 2. Assistant Surgeon J. S. Billings, U. S. Army.
- 2060.** Two oblique sections of root of *Aram triphyllum*: one stained with red aniline, and one unstained. For moderate and high powers.
B. 3. Assistant Surgeon J. S. Billings, U. S. Army.
- 2061.** Two transverse sections of root of *Asarum Canadense*: one stained with red aniline, and one unstained. For low and high powers.
B. 4. Assistant Surgeon J. S. Billings, U. S. Army.
- 2062.** Same as **B. 4.**, with fainter staining.
B. 5. Assistant Surgeon J. S. Billings, U. S. Army.

- 2063.** Two transverse sections of rhizoma of *Acorus Calamus*; one stained with red aniline, and one unstained.
B. 6. For low and moderate powers.
 Assistant Surgeon J. S. Billings, U. S. Army.
- 2064.** Transverse section of root of *Cocculus palmatus*. For low and high powers.
B. 7. Assistant Surgeon J. S. Billings, U. S. Army.
- 2065.** Two transverse sections of root of *Gentiana lutea*; one stained with red aniline, and one unstained. For low and moderate powers.
B. 8. Presented by Assistant Surgeon J. S. Billings, U. S. Army.
- 2066.** Two transverse sections of root of *Glycyrrhiza glabra*; one stained with red aniline, and one unstained.
B. 9. For low and high powers.
 Assistant Surgeon J. S. Billings, U. S. Army.
- 2067.** Two transverse sections of root of *Cephaelis Ipecacuanha*; one stained with red aniline, and one unstained. For low and high powers.
B. 10. Assistant Surgeon J. S. Billings, U. S. Army.
- 2068.** Two transverse sections of rhizoma of *Iris Florentina*; one stained with blue and red aniline, and one unstained. For low and high powers.
B. 11. Assistant Surgeon J. S. Billings, U. S. Army.
- 2069.** Four sections, two transverse and two longitudinal, of root of *Krameria trandra*, stained with red aniline. For low and moderate powers.
B. 12. Assistant Surgeon J. S. Billings, U. S. Army.
- 2070.** Two transverse sections of root of *Cissampelos Pareira*; one stained with red aniline, and one unstained.
E. 13. For low and high powers.
 Assistant Surgeon J. S. Billings, U. S. Army.
- 2071.** Three transverse sections of rhizoma of *Podophyllum peltatum*; one stained with carmine, one with blue aniline, and one unstained. For low and high powers.
B. 14. Assistant Surgeon J. S. Billings, U. S. Army.
- 2072.** Two sections of root of *Rheum*, from East Indies; one stained with red aniline, and one unstained. For low and high powers.
B. 15. Assistant Surgeon J. S. Billings, U. S. Army.
- 2073.** Same as **B 15**, from Turkey. For low and high powers.
B. 16. Assistant Surgeon J. S. Billings, U. S. Army.
- 2074.** Two transverse sections of rhizoma of *Sanguinaria Canadensis*; one stained with red aniline, and one unstained. For low and high powers.
B. 17. Assistant Surgeon J. S. Billings, U. S. Army.
- 2075.** Two longitudinal sections of bark of root of *Sassafras officinale*; one stained with red aniline, and one unstained. For low and high powers.
B. 18. Assistant Surgeon J. S. Billings, U. S. Army.
- 2076.** Two transverse sections of bulb of *Scilla maritima*; one stained with red aniline, and one unstained.
B. 19. For low and moderate powers.
 Assistant Surgeon J. S. Billings, U. S. Army.
- 2077.** Two transverse sections of root of *Polygala Senega*; one stained with blue and red aniline, and one unstained. For low and moderate powers.
B. 20. Assistant Surgeon J. S. Billings, U. S. Army.
- 2078.** Two transverse sections of root of *Aristolochia Serpentaria*. For low and moderate powers.
B. 21. Assistant Surgeon J. S. Billings, U. S. Army.

- 2079.** Four transverse sections of root of *Spigelia Marilandica*: three stained with red aniline, and one unstained.
B. 22. For low and moderate powers.
 Assistant Surgeon J. S. Billings, U. S. Army.
- 2080.** Five sections, two transverse and three longitudinal, of root of *Valeriana officinalis*. For low and moderate powers.
B. 23. Assistant Surgeon J. S. Billings, U. S. Army.
- 2081.** Two sections, same as **B. 23**, one longitudinal and one transverse: stained with carmine.
B. 24. Assistant Surgeon J. S. Billings, U. S. Army.
- 2082.** Two transverse sections of rhizoma of *Zinziber officinale*; the upper one stained with red aniline, and the lower with carmine. For low and high powers.
B. 25. Assistant Surgeon J. S. Billings, U. S. Army.

C. STEMS.

- 2083.** Four longitudinal sections of bark of *Cinchona Calisaya*: one stained with red aniline, and the others unstained. For low and moderate powers.
C. 1. Assistant Surgeon J. S. Billings, U. S. Army.
- 2081.** Two transverse sections of bark of *Cinnamomum Zeylanicum*; one stained with red aniline, and one unstained. For low and moderate powers.
C. 2. Assistant Surgeon J. S. Billings, U. S. Army.
- 2085.** Sections of wood of *Guaiaecum officinale*. For low and high powers.
C. 3. Assistant Surgeon J. S. Billings, U. S. Army.
- 2086.** Longitudinal sections of bark of *Daphne Genkium*. For low and moderate powers.
C. 4. Assistant Surgeon J. S. Billings, U. S. Army.

E. FLOWERS.

- 2087.** Four sections, two transverse and two longitudinal, of unexpanded flowers of *Caryophyllus aromaticus*: one transverse and one longitudinal section stained with red aniline, the others unstained. For low and moderate powers.
 Assistant Surgeon J. S. Billings, U. S. Army.
- 2088.** *Lupulina*. For low and high powers.
E. 2. Assistant Surgeon J. S. Billings, U. S. Army.

F. FRUITS.

- 2089.** Section of fruit of *Juniperus communis*. For low and moderate powers.
F. 1. Assistant Surgeon J. S. Billings, U. S. Army.
- 2090.** Two sections of seed of *Linum usitatissimum*; one stained with red aniline, and one unstained. For low and moderate powers.
F. 2. Assistant Surgeon J. S. Billings, U. S. Army.

XVII. DIATOMS AND OTHER TEST OBJECTS.

A. MIXED DIATOMS.

B. SELECTED DIATOMS.

- A. EUNOTIE.E.
- B. FRAGLARI.E.E.
- C. SURRELE.E.E.
- D. STRIATELE.E.E.
- E. MELOSIRE.E.
- F. COSCINODISCE.E.
- G. EUPODISCE.E.
- H. BIDDULPHIE.E.
- I. ANGULIFERE.E.
- K. CHETOCERE.E.
- L. COCCONEIDE.E.
- M. CYMBELLE.E.
- N. GOMPHONEME.E.
- O. NAVICULE.E.

C. OTHER TEST OBJECTS.

XVII. DIATOMS AND OTHER TEST OBJECTS.

A. MIXED DIATOMS.

- 1897.** Diatoms from Rappahannock Cliff, Va. For high powers.
A. 1. From material presented by Count L. F. Pourtales, Washington, D. C.
- 1898.** Diatoms from Hollis Cliff, Va. For high powers.
A. 2. From material presented by Count L. F. Pourtales, Washington, D. C.
- 1899.** Diatoms from Monterey, Cal. For high powers.
A. 3. From material presented by Count L. F. Pourtales, Washington, D. C.
- 1900.** Diatoms from Monterey; lower stratum. For high powers.
A. 4. From material presented by Count L. F. Pourtales, Washington, D. C.
- 1901.** Diatoms from Piscataway, Md. For high powers.
A. 5. From material presented by Count L. F. Pourtales, Washington, D. C.
- 1902 & 1903.** Diatoms from Bermuda; two preparations. For high powers.
A. 6. From material presented by Count L. F. Pourtales, Washington, D. C.
- 1904 & 1905.** Diatoms from Barbadoes; two preparations. For high powers.
A. 7. From material presented by Count L. F. Pourtales, Washington, D. C.
- 1906.** Diatoms from Barbadoes, Springfield district. For high powers.
A. 8. From material presented by Count L. F. Pourtales, Washington, D. C.
- 1907 to 1910.** Diatoms from Para River; four preparations. For high powers.
A. 9. From material presented by Count L. F. Pourtales, Washington, D. C.
- 1517.** Sub-peat diatoms from New Hampshire. For high powers.
A. 10. Procured from Messrs. J. W. Queen & Co., Philadelphia, Pa.
- 1911.** Diatoms from Bemis Lake, N. H. For high powers.
A. 11. Arthur M. Edwards, Esq., New York.
- 1912 & 1913.** Diatoms from Richmond earth, Va.; two preparations. For high powers.
A. 12.
- 1911.** Diatoms from Para River. For high powers.
A. 13. W. F. Beach, Esq., Louisville, Ky.
- 1915.** Diatoms from Portland, Me. For high powers.
A. 14. W. F. Beach, Esq., Louisville, Ky.
- 1916.** Diatoms from Cold Spring, Cape May. For high powers.
A. 15. W. F. Beach, Esq., Louisville, Ky.

B. SELECTED DIATOMS.

A. EUSOTHEL.

- 1580.** Various forms of *Epithemia*. For high powers.
A 1 J. Bourgogne, Paris, France.
- 1917.** *Hemantidium*; Quebec. For high powers.
A 2 W. F. Beach, Esq., Louisville, Ky.

B. FRAGILARIEE.

- 1918.** *Nitzschia linearis*. For high powers.
B 1 W. F. Beach, Esq., Louisville, Ky.
- 1919 to 1923.** Five preparations of *Amphipleura pellucida*. For high powers.
E 2 W. S. Sullivan, Esq., Columbus, Ohio.
- 1921 to 1926.** Three preparations of *Amphipleura pellucida*. For high powers.
B 3 W. F. Beach, Esq., Louisville, Ky.
- 1589.** *Amphipleura magna*; near Empire Mines, Isthmus of Panama. For high powers.
E 4 Arthur M. Edwards, Esq., New York.
- 1927.** *Amphipleura Sullivanii*; Cuba. For high powers.
E 5 W. F. Beach, Esq., Louisville, Ky.

C. SCIRELLIEE.

- 1928 to 1930.** Three preparations of *Synedra rotunda*. For high powers.
C 1 W. F. Beach, Esq., Louisville, Ky.
- 1606.** *Siccatousus* (tossil); California. For high powers.
C 2 Arthur M. Edwards, Esq., New York.

D. STRIATELLIEE.

- 1931.** *Rhabdonema*. For high powers.
D 1 W. F. Beach, Esq., Louisville, Ky.
- 1599.** *Grammatophora marina*; coast of England. For high powers.
D 2 Arthur M. Edwards, Esq., New York.
- 1511.** *Grammatophora serpentina*; Fayal. For high powers.
D 3 Procured from Messrs. J. W. Queen & Co., Philadelphia, Pa.
- 1585.** *Grammatophora*. For high powers.
D 4 Procured from Messrs. J. W. Queen & Co., Philadelphia, Pa.
See Part Second, XXXI, B, d, 1 and 2.
- 1505.** *Grammatophora*; New Hampshire. For high powers.
D 5 J. Bourgogne, Paris, France.
- 1509.** *Grammatophora marina*. For high powers.
D 6 Procured from Messrs. J. W. Queen & Co., Philadelphia, Pa.
- 1510.** *Grammatophora subtilissima*; Greenport, Long Island. For high powers.
D 7 Assistant Surgeon J. J. Woodward, U. S. Army.
- 2091 & 2092.** Two preparations of *Grammatophora*. For high powers.
D 8 C. M. Topping, London, England.

E. MELOSIREL.

1602. *Podosira Franklinii*; California. For high powers.
E. 1. Arthur M. Edwards, Esq., New York.

1603. *Podosira cerrina*; California. For high powers.
E. 2. Arthur M. Edwards, Esq., New York.

F. COSCINODISCÆ.

1598. *Coscinodiscus robustus*; California. For high powers.
F. 1. Arthur M. Edwards, Esq., New York.

1932 & 1933. Two preparations of *Coscinodiscus*. For high powers.
F. 2.

1931. *Coscinodiscus*. For high powers.
F. 3. Christian Febiger, Esq., Wilmington, Del.

1935. *Coscinodiscus*, *Craspedodiscus* and *Heliopelta*; Nottingham, Md. For high powers.
F. 4. W. F. Beach, Esq., Louisville, Ky.

1936. *Actinoecylus* and *Coscinodiscus*; Nottingham, Md. For high powers.
F. 5. W. F. Beach, Esq., Louisville, Ky.

1587. *Actinoecylus Stoddertii*; Sandwich Islands. For high powers.
F. 6. Arthur M. Edwards, Esq., New York.

1588. *Actinoecylus Iris*; Sandwich Islands. For high powers.
F. 7. Arthur M. Edwards, Esq., New York.

1600. *Heliopelta* and *Coscinodiscus*; Nottingham, Md. For high powers.
F. 8. Arthur M. Edwards, Esq., New York.
See Part Second, XVII. B. F. 3.

1937. *Heliopelta* and *Coscinodiscus*; Bermuda. For high powers.
F. 9. Procured from Messrs. J. W. Queen & Co., Philadelphia, Pa.
See Part Second, XVII. B. F. 1 and 2.

1502. *Arachnoidiscus Ehrenbergii*; California. For high powers.
F. 10. Procured from Messrs. J. W. Queen & Co., Philadelphia, Pa.

1590. *Arachnoidiscus* (fossil); California. For high powers.
F. 11. Arthur M. Edwards, Esq., New York.

1591. *Arachnoidiscus* (recent); California. For high powers.
F. 12. Arthur M. Edwards, Esq., New York.
See Part Second, XVII. B. F. 4 and 5.

G. EUPODISCÆ.

1592. *Aulacodiscus crux*; Nottingham, Md. For moderate and high powers.
G. 1. Arthur M. Edwards, Esq., New York.

1593. *Aulacodiscus formosus*; Bolivian guano. For moderate and high powers.
G. 2. Arthur M. Edwards, Esq., New York.

1591. *Aulacodiscus Germanicus*; Wilmington River, Ga. For moderate and high powers.
G. 3. Arthur M. Edwards, Esq., New York.

1595. *Aulacodiscus Rogersii*; Nottingham, Md. For high powers.
G. 4. Arthur M. Edwards, Esq., New York.

1596. *Aulacodiscus scaber*; Chincha guano. For high powers.
G. 5. Arthur M. Edwards, Esq., New York.

H. BIDDULPHIÆ.

- 1516.** *Estonia nreosa*; California. For moderate and high powers.
H. 1. Procured from Messrs. J. W. Queen & Co., Philadelphia, Pa.

I. ANGULIFERÆ.

- 1607.** *Triceratium*; Florida. For high powers.
I. 1. Arthur M. Edwards, Esq., New York.
- 1609.** *Triceratium striolatum*; Sandwich Islands. For high powers.
I. 2. Arthur M. Edwards, Esq., New York.
- 1610.** *Triceratium luteus*; Wilmington River, Ga. For high powers.
I. 3. Arthur M. Edwards, Esq., New York.

K. CHETOCERÆ.

- 1938.** *Bactriastrum furcatum*; Wilmington River, Ga. For high powers.
K. 1. W. F. Beach, Esq., Louisville, Ky.

L. COCCONIDÆ.

- 1597.** *Cocconis* (fossil); Monterey, Cal. For high powers.
L. 1. Arthur M. Edwards, Esq., New York.

M. CAMBELLÆ.

- 1939.** *Cymbella*. For high powers.
M. 1. W. F. Beach, Esq., Louisville, Ky.
- 1910.** *Cocconema parvum*. For high powers.
M. 2. W. F. Beach, Esq., Louisville, Ky.
- 1911.** *Amphora hyalina*; Cape May. For high powers.
M. 3. W. F. Beach, Esq., Louisville, Ky.

N. GOMPHOSEMELÆ.

- 1512.** *Gomphonema*. For high powers.
N. 1. J. Bourgogne, Paris, France.

O. NAVICULÆ.

- 1518.** *Navicula major*. For high powers.
O. 1. J. Bourgogne, Paris, France.
- 1583.** *Navicula cryptosphaula*. For high powers.
O. 2. Procured from Messrs. J. W. Queen & Co., Philadelphia, Pa.
- 1608.** Various forms of *Navicula*, sub-peat deposit; Bemis Lake, N. H. For high powers.
O. 3. Arthur M. Edwards, Esq., New York.
See Part Second, XXII, B, o. 2 and 3.
- 1912 & 1913.** Two preparations of *Navicula rhomboides*; Bemis Lake, N. H., and Cherryfield, Me. For high powers.
O. 4. Arthur M. Edwards, Esq., New York.
See Part Second, XXII, B, o. 1.
- 1503.** *Navicula rhomboides*. For high powers.
O. 5. J. Bourgogne, Paris, France.
- 1601.** *Navicula cuspidata*; Washington, Pa. For high powers.
O. 6. Arthur M. Edwards, Esq., New York.

- 1581 & 1582.** Two preparations of *Naricula (Pinaularia) viridis*. For high powers.
O. 7. Procured from Messrs. J. W. Queen & Co., Philadelphia, Pa.
- 1508.** *Naricula tumida*. For high powers.
O. 8. J. Bourgogne, Paris, France.
- 1914.** *Naricula Plestrum*; Bemis Lake, N. H. For high powers.
O. 9. Arthur M. Edwards, Esq., New York.
- 1605.** *Stauroneis*; Laconia, N. H. For high powers.
O. 10. Arthur M. Edwards, Esq., New York.
See Part Second, XVII. B. o. 4.
- 1915.** *Pleurosigma Balticum*. For high powers.
O. 11. W. F. Beach, Esq., Louisville, Ky.
- 1578.** *Pleurosigma Balticum*. For high powers.
O. 12. J. Bourgogne, Paris, France.
- 1586.** *Pleurosigma formosum*. For high powers.
O. 13. C. M. Topping, London, England.
See Part Second, XVII. B. o. 5 and 6.
- 1916.** *Pleurosigma tenac*; brackish water, Delaware. For high powers.
O. 14. W. F. Beach, Esq., Louisville, Ky.
- 1506.** *Pleurosigma angulatum*. For high powers.
O. 15. J. Bourgogne, Paris, France.
See Part Second, XVII. B. o. 7 to 19.
- 1507 & 1917.** Two preparations of *Pleurosigma angulatum*. For high powers.
O. 16. Assistant Surgeon J. J. Woodward, U. S. Army.
- 1918.** *Pleurosigma angulatum*; England. For high powers.
O. 17. W. F. Beach, Esq., Louisville, Ky.
- 1919 & 1950.** Two preparations of *Pleurosigma Spenceri*. For high powers.
O. 18. W. F. Beach, Esq., Louisville, Ky.
- 1579.** *Pleurosigma attenuatum*. For high powers.
O. 19. J. Bourgogne, Paris, France.
- 1951.** *Pleurosigma attenuatum*. For high powers.
O. 20. *See Part Second, XVII. B. o. 19.*
- 1581.** *Pleurosigma Hippocampus*. For high powers.
O. 21. Procured from Messrs. J. W. Queen & Co., Philadelphia, Pa.
- 1952.** *Amphiprora pulchra*. For high powers.
O. 22. W. F. Beach, Esq., Louisville, Ky.
- 1953.** *Mostogloia*; Cape May. For high powers.
O. 23. W. F. Beach, Esq., Louisville, Ky.
- 2093 & 2094.** Two preparations of *Pleurosigma formosum*. For high powers.
O. 24. C. M. Topping, London, England.
- 2095 & 2096.** Two preparations of *Pleurosigma angulatum*. For high powers.
O. 25. C. M. Topping, London, England.
- 2097 & 2098.** Two preparations of *Pleurosigma Spenceri*. For high powers.
O. 26. C. M. Topping, London, England.

- 2099 & 2100.** Two preparations of *Pleurosigma attenuatum*. For high powers.
O. 27. C. M. Topping, London, England.

C. OTHER TEST OBJECTS.

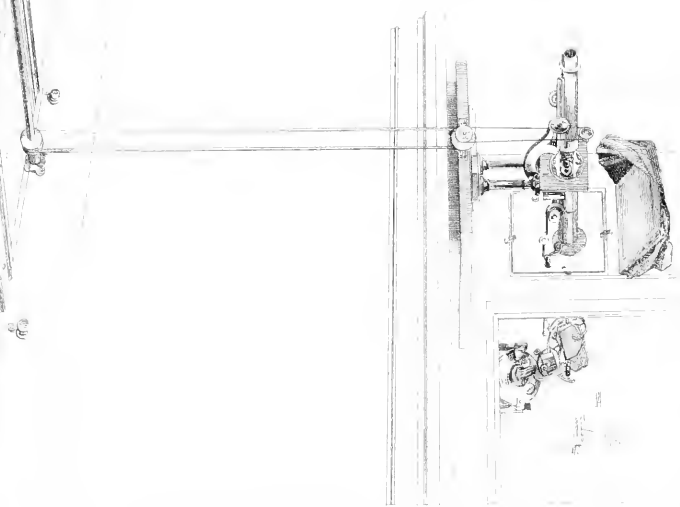

- 1513.** Scales of *Podura*. For high powers.
C. 1. Smith, Beck & Beck, London, England.
- 1511 & 1515.** Scales of *Podura*. For high powers.
C. 2. Assistant Surgeon J. J. Woodward, U. S. Army.
- 2101 & 2102.** Two preparations of scales of *Podura*. For high powers.
C. 3. Procured from Messrs. Powell & Lealand, London, England.

See Part Second, **XVII.** C. 1 to 4.

XVIII. MISCELLANEOUS.

XVIII. MISCELLANEOUS.

- 1601.** *Polycystina*; Barbadoes. For high powers.
Arthur M. Edwards, Esq., New York.
- 444.** Wing of fly. For low and high powers.
- 1498.** Fungus from mouldy straw. For high powers.
- 2051 & 2052.** Two preparations of crystals of sulphate of lime. For moderate powers.
See Part Second, XVIII. (negative 1.)
- 1501.** Sediment from Potomac water. For high powers.
- 932.** Spiral vessels in stem of *Leontodon Taraxacum*, stained with purple aniline. For high powers.
Assistant Surgeon J. S. Billings, U. S. Army.
- 1009.** Three transverse sections of stem of *Leontodon Taraxacum*. For moderate and high powers.
Assistant Surgeon J. S. Billings, U. S. Army.
- 1031.** Five transverse sections of stem of *Rosa centifolia*; central section stained with purple aniline, the rest with carmine. For low and high powers.
Assistant Surgeon J. S. Billings, U. S. Army.
- 1269.** Transverse section of stem of Judas tree, stained with both carmine and purple aniline. For low and high powers.
Assistant Surgeon J. S. Billings, U. S. Army.
- 1299.** Transverse section of broom straw. For moderate and high powers.
Assistant Surgeon J. S. Billings, U. S. Army.
- 1501.** Transverse section of rose stem, stained with both carmine and purple aniline. For low and high powers.
Assistant Surgeon J. S. Billings, U. S. Army.
- 1832.** Pollen of violet. For high powers.
Assistant Surgeon J. S. Billings, U. S. Army.
- 2053.** Sprig of moss, stained with red aniline. For low and moderate powers.
Assistant Surgeon J. S. Billings, U. S. Army.
- 2054.** Transverse sections of leaf-bud of maple, stained with carmine. For low and high powers.
Assistant Surgeon J. S. Billings, U. S. Army.
- 2055.** Horizontal section of leaf of *Filix mas*, exposing the under surface of the leaf, stained with blue aniline.
For low and high powers.
Assistant Surgeon J. S. Billings, U. S. Army.
- 2056.** Same as specimen **2055**, containing three sections; central piece stained with carmine, the others with red aniline. For low and high powers.
Assistant Surgeon J. S. Billings, U. S. Army.
- 2057.** Enveloping membrane of seed of ivy. For moderate and high powers.
Assistant Surgeon J. S. Billings, U. S. Army.



Part Second.

PHOTOGRAPHIC NEGATIVES OF MICROSCOPIC OBJECTS.

NOTE.—These negatives are on sheets of plate glass seven inches square, and were prepared in the Microscopical Department of the Museum by Assistant Surgeon Edward Curtis, U. S. Army, mainly from the Museum Cabinet of Specimens. Most of them have been photographed by means of the object-glasses of the microscope alone; but, in some cases, where great amplification has been desired, the power of the objective has been increased by inserting a concave lens, properly corrected, (“amplifier”), into the body of the microscope in the position usually occupied by the eyepiece. In some of the earlier negatives also, the ordinary eyepieces were used in conjunction with the object-glass. In each case the particular objective or combination used, and the number of diameters that the object appears magnified, are given in the description of the negative.

The rationale of the process employed in the production of these negatives is as follows: To secure a perfectly steady and at the same time an intense light, the direct rays of the sun are reflected upon the plane mirror of the microscope from the mirror of a Silbermann’s heliostat. The beam so obtained is thrown upon a piece of greased ground glass inserted into the short body of the microscope below the achromatic condenser. An intense “white cloud” illumination is thus obtained, perfectly free from the spectral interference lines that would result from the use of the unmodified rays of the sun, and so steady as to allow of long exposures with the high powers.* The object upon the stage of the microscope, illuminated by this light—condensed, if necessary, by an achromatic condenser below the stage—is magnified by the object-glass of the instrument; and the image so formed, being brought to a focus upon the plane of the surface of the sensitive plate, yields the photographic impression. In order to insure perfect *photographic* sharpness of definition in the object-glass, the objectives used for photography are specially corrected so as to bring to one focus the rays in the violet end of the spectrum, where the actinic power resides, instead of mean white light, as is the case with ordinary achromatic objectives. Violet light alone is then used to illuminate the object, this being obtained practically pure by interposing in the solar beam reflected from the mirror a shallow cell, with plate glass sides, containing a solution of the ammonio-sulphate of copper. Sharp photographic definition is thus secured, and at the same time, since the visual and chemical foci are here identical, the source of error encountered in the use of ordinary objectives, from the want of coincidence between these two foci, is entirely obviated. The blue copper solution is also of use in absorbing the heat rays of the solar beam. The concave amplifiers used in combination with the objectives are also specially corrected for violet light.†

* On certain objects, with very low powers, and on some of the finely marked diatoms, with very high powers, the ground glass may be advantageously omitted and the direct rays of the sun used.

† The objectives and amplifiers of this description are those mentioned in the Catalogue as made by Mr. Wales; those of other makers that have been used are the ordinary achromatic lenses.

The apparatus devised and in present use at the Museum is figured in the plate facing the preceding page. For the sake of convenience a camera-box and table are dispensed with, and the operating room, having a window facing to the south, is itself converted into a camera by wooden shutters on the inside of the window, sufficient non-actinic light to enable the operator to move about freely being admitted through yellow panes in a sashed door. A small yellow pane is also let into one of the window shutters to enable the operator to watch the sky during an exposure and see when clouds are about to obscure the sun. The microscope, with its body in a horizontal position, stands on a shelf on the inner window sill, its feet fitting into brass cleets to insure accuracy of position. Covering the portion of the window towards which the microscope points is a stout immovable shutter, having a square opening to receive a movable piece which fits into it with a rebate and is held in position by four wooden buttons. An aperture is cut in this movable shutter (see fig. 1) of the same diameter as the short body of the microscope and in a direct line with it; and a light tight connection is made between the two by a sliding brass tube (*b*) fitted to the shutter. This aperture can be opened and closed at will, to make the exposures, by a brass plate (*e*) playing over the outer face of the shutter on a pivot, which, passing through the shutter, is worked by a handle (*d*) from within the room. This brass plate is sunk into a shallow space cut in the shutter so as not to project beyond its surface. Over the plate and covering the aperture is fastened the glass cell (*c*) containing the blue copper solution. Immediately below the edge of this cell a piece of brass tubing (*f*), thirteen inches long, is screwed to the shutter, carrying at its extremity the microscope mirror (*g*) accurately centred opposite the aperture in the shutter. This mirror is adjustable from within the room by means of two steel rods (*h h*) attached to its framework by ball and socket joints, and projecting into the room through small holes in the shutter. One of these rods moves the mirror upon its vertical, the other upon its horizontal axis. The heliostat stands on an iron shelf outside the window, in such a position that its mirror is a few inches only distant from the microscope mirror and in a northwesterly direction from it.

The frame for the plate-holder, instead of standing upon a table, is supported upon a narrow walnut car, running upon an iron track ten feet long, laid upon the floor at right angles to the plane of the window (see plate). This car consists essentially of a base made of four pieces of wood joined together so as to leave an opening in the centre eight inches square, and two stout uprights, connected by a crosspiece, which rise from the side pieces of this base and have a V-shaped way cut on their inner faces to receive the sliding sides of the top of the car. This top can thus be adjusted

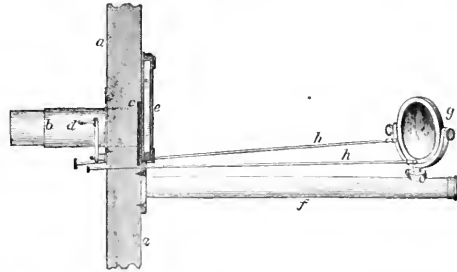


FIG. 1. Section of movable shutter, with apparatus attached: *a*, shutter; *b*, sliding brass tube to join the short body of the microscope; *c*, brass plate to close the aperture in the shutter; *d*, handle to work the same from within the room; *e*, glass cell containing the blue copper solution; *f*, brass tube carrying the microscope mirror; *g*, mirror; *h h*, steel rods to adjust the mirror from within the room.

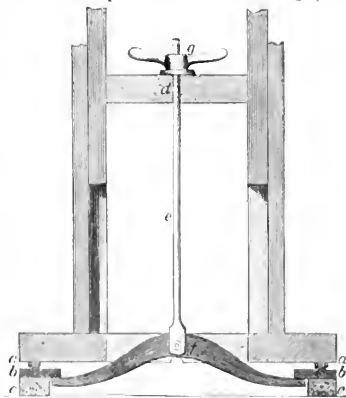


FIG. 2. Transverse section of car and track, to show the rails and the apparatus for clamping the car to the same: *a a*, small brass wheels, cross-rod; *b b*, flat iron rails, with V-shaped projection to fit the groove in the wheels; *c c*, wooden rails; *d*, cross-piece connecting the sides of the car; *e*, vertical iron rod passing through the same; *f*, cast-iron cross-piece to clamp under the iron rails; *g*, screw nut, with handles to elevate the same.

This top can thus be adjusted

to any height, and clamped in position by wooden binding screws, so that negative plates of different sizes may be used, if desired, and centred to the axis of the microscope body. The track (see fig. 2) consists of two wooden rails (*c c*) an inch high, screwed to the floor, upon which in turn are screwed flat iron rails (*b b*) whose inner edges project half an inch beyond the wooden rails. These iron rails are cast with a \wedge -shaped projection on their upper faces and the base of the car is furnished with small brass wheels (*a a*) correspondingly grooved to run on these projections. The car can be firmly fixed upon the track at any position by the following means (see fig. 2): Through a hole in the centre of the crosspiece (*d*) connecting the sides of the car, runs a vertical iron rod (*e*), supporting at its lower extremity a cast iron crosspiece with flat ends (*f*), which hangs transversely to the direction of the track through the central opening in the base of the car. The ends of this crosspiece reach under the projecting inner edges of the flat iron rails (*b b*) and are made to clamp against their under surfaces by a nut with handles (*g*) screwing on the upper part of the iron rod, and binding on an iron washer on the wooden crosspiece (*d*) through which the rod runs. The car can thus be fixed upon the track at any distance from the microscope within ten feet, and the distance that the surface of the negative is from the stage of the microscope in any given position of the car is determined by a scale of feet laid off upon the floor close to one of the rails, and a scale of inches on the side of the base of the car. (See plate.)

To obtain the final focus of the image upon the plate in the plate-holder, the following contrivance is used (see fig. 3): A perfectly straight cylindrical iron shaft (*a*) runs the entire length of the track, midway between the two rails, and at such a height as just to clear a groove on the under surface of the base of the car. This shaft has a shallow square groove cut in it along its entire length, and is supported at each extremity by brass bearings, attached to the floor, in which it turns freely. To the posterior crosspiece of the base of the car is fastened a bent brass bearing (*b*), projecting into the square opening in the base of the car and supporting two bevel gear wheels (*c*) working into each other. The upper and horizontal one of these wheels is turned by a vertical iron rod (*d*) attached to it, which is furnished at its upper extremity with a large milled head (*e*) and is supported by a collar (*f*) attached to the crosspiece connecting the sides of the car. The lower and vertical wheel is pierced to allow the passage of the long shaft (*a*), and from the surface of the bore a small square iron tongue projects, exactly fitting the longitudinal groove in the shaft. By this means, no matter what may be the position of the car upon the track, the operator can rotate the shaft (*a*) through the pressure of this tongue upon the sides of the groove, by turning the milled head (*e*) connected with the bevel wheels. At the same time the car can be moved freely over the track, the iron tongue running smoothly to and fro in the groove of the shaft. This long shaft (*a*) is made to turn the fine adjustment wheel of the microscope by the following means (see plate): Attached to the edge of the shelf upon which the microscope stands is a short iron axle parallel to the grooved shaft below, which turns freely in two flat brass bearings, and supports two wheels. One of these, a small brass wheel,

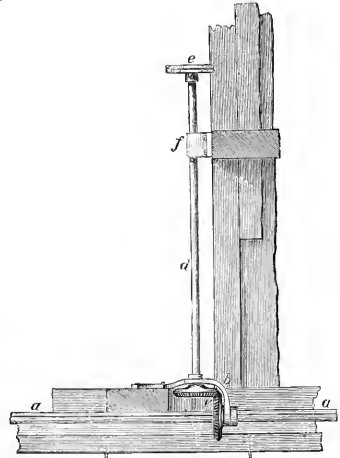


FIG. 3. Longitudinal section of posterior half of car, to show the apparatus for obtaining the focus of the image upon the plate in the plate-holder: *a*, grooved iron shaft running the whole length of the track and passing under the car; *b*, bent brass bearing supporting two bevelled gear wheels; *c*, bevelled gear wheels; *d*, vertical iron rod attached to the upper wheel; *e*, milled head on the upper extremity of the same; *f*, collar to support the iron rod.

is grooved and connected by a silk thread, removable at pleasure, with the fine adjustment wheel of the microscope, which is also grooved. The other, a large wooden wheel, is connected permanently by a flat leathern band with a similar wheel attached to the long iron shaft below.

The steps in the process of photographing by the above described apparatus are as follows: The movable shutter, with the apparatus attached, is buttoned in position, the heliostat set in place on the shelf outside the window and properly adjusted so as to throw the rays reflected from its mirror upon the microscope mirror at the extremity of the rod on the shutter. The window shutters may now be closed and need not again be opened. The microscope is then placed in the proper position upon the shelf inside the window, and the silk thread adjusted which connects the fine adjustment wheel with the wheel on the edge of the shelf. The operator then, sitting on a stool in front of the microscope and inserting an eyepiece, views the object as in the ordinary use of the instrument. This he is enabled to do without discomfort or injury to the eye, since the light transmitted by the solution of the ammonio-sulphate of copper, though *photographically* intense, is *luminously* comparatively feeble, and is also deprived of a large proportion of its heat rays in its passage through that medium. While thus seated at the microscope the operator makes the necessary adjustments of the stage, achromatic condenser, diaphragms, &c., having perfect control of the illumination by means of the steel rods attached to the mirror without the window and projecting into the room through the shutter. While making these adjustments he commands the fine adjustment wheel by the fingers in the usual way, the wheel readily slipping under the thread that connects it with the wheel on the shelf below. These adjustments being made and the best view and proper illumination of the object secured, the eyepiece is removed, and a black velvet hood, attached around the edges of a hinged shelf projecting from the shutter (see plate), is lowered so as to envelope all of the microscope but its body, thus preventing any leakage of light by the side of the objective. The operator now goes to the car, adjusts its position, noting its distance from the microscope by the scale on the floor and side of the base of the car, as already described, and clamps it firmly in place. He then sits down behind it and receives the image upon the surface of a piece of plate glass held in the plate-holder, viewing it with an eyepiece held against the glass plate, whose focus corresponds exactly with the anterior surface of this plate. He next turns the milled head that operates on the apparatus for turning the fine adjustment wheel of the microscope, until the image, viewed as just described, appears in exact focus upon the surface of the plate-glass screen. The aperture in the shutter is then closed by means of the brass plate with handle inside the room, the sensitive plate substituted for the plate-glass screen in the plate-holder, and the exposure made by opening and closing the aperture in the movable shutter by the means already described. The time of the exposure is noted by the beats of a metronome, adjusted to strike at second intervals, the dimness of the yellow light in the room rendering the use of a watch inconvenient. Having obtained the negative, a stage micrometer is substituted for the object photographed, and its divisions, as projected upon a piece of ground glass held in the plate-holder, are carefully traced upon paper. By comparing these with a standard scale, the exact amplification of the object, as represented in the negative, is readily calculated. Other negatives, representing the same magnifying power, can then be taken at any time by using the same objective and placing the car at the same distance from the microscope. The ordinary wet collodion process is the one used in the preparation of the negatives.

I. CONNECTIVE TISSUE SYSTEM.

(SUBDIVISIONS SAME AS IN PART FIRST.)

A. CONNECTIVE TISSUE PROPER.

A. FROM MAN.

- 57.** View of portion of connective tissue layer of intestine, showing connective tissue corpuscles with anastomosing processes, and faintly striated intercellular substance.
A. 1. Magnified 238 diameters; $\frac{1}{2}$ -inch objective (Wales).

For other illustrations, see VII. I. c. 2 and 3.

C. PATHOLOGICAL.

- 117.** View of portion of connective tissue layer of small intestine in the vicinity of an ulcerated Peyer's patch, from a case of camp fever, showing active multiplication by division of the connective tissue corpuscles.
C. 1. Magnified 106 diameters; $\frac{1}{10}$ -inch objective (Wales).

Photographed from Specimen 119, Part First, VII. H. c. 8.

For other illustrations, see VII. II. c. 4.

D. ADIPOSE TISSUE.

A. FROM MAN.

See II. A. A. 1.

II. EXTERNAL TEGUMENTARY SYSTEM.

(SUBDIVISIONS SAME AS IN PART FIRST.)

A. SKIN.

A. FROM MAN.

- 2.** View from perpendicular section of scalp of negro, giving a bird's-eye view of the positions and relations of the various structures of the scalp, and panniculus adiposus.
Magnified 22 diameters: $1\frac{1}{2}$ -inch objective (Zeutmayer).

Photographed from Specimen 1206, Part First, II, A. A. 1.

- 3.** Portion of hair and follicle in section of scalp. The walls of the follicle have shrunk away from the hair.
Magnified 250 diameters: $\frac{1}{10}$ -inch objective (Tolles).

Photographed from the same Specimen as A. 1.

- 1.** View from section of scalp, showing an arrector pili muscle dividing to embrace a sebaceous gland.
Magnified 150 diameters: $\frac{1}{2}$ -inch objective (Tolles).

Photographed from the same Specimen as A. 1.

- 5.** View from section of scalp, showing an arrector pili muscle in its course through the skin.
Magnified 500 diameters: $\frac{1}{10}$ -inch objective (Tolles) and eyepiece.

Photographed from the same Specimen as A. 1.

- 16.** View from perpendicular section of skin from sole of foot, showing the thick epidermis, papillae, corium, sudoriferous glands and ducts.

Magnified 25 diameters: $1\frac{1}{2}$ -inch objective (Zeutmayer) and eyepiece.

Photographed from Specimen 1171, Part First, II, A. A. 6.

C. HAIRS.

A. FROM MAN.

- 115.** Human hair from head of white child, showing the overlapping epidermic scales.

Magnified 370 diameters: $\frac{1}{4}$ -inch objective (Wales).

Photographed from Specimen 1111, Part First, II, C. A. 2.

- 116.** Transverse section of hair from pubes of adult white male, showing the cuticle, cortex, and medullary substance in section.

Magnified 370 diameters: $\frac{1}{4}$ -inch objective (Wales).

Photographed from Specimen 1288, Part First, II, C. A. 9.

For other illustrations, see II, A. A. 1 and 2.

B. FROM ANIMALS.

- 117.** Two hairs, one large and one small, from polar bear.

Magnified 370 diameters: $\frac{1}{4}$ -inch objective (Wales).

- 118.** White hairs from body of cat.

Magnified 370 diameters: $\frac{1}{4}$ -inch objective (Wales).

Photographed from Specimen 1296, Part First, II, C. B. 3.

- 119.** Hairs from back of bat (*Nyctinomus nasutus*).
B. 3. Magnified 370 diameters; 4-inch objective (Wales).
Photographed from Specimen 1366, Part First, III. C. B. 5.

For other illustrations, see XVI. B. 1.

D. CUTANEOUS GLANDS.

A. FROM MAN.

See II. A. A. 1, 3 and 5.

III. MUSCULAR SYSTEM.

(SUBDIVISIONS SAME AS IN PART FIRST.)

A. SMOOTH MUSCLE.

A. FROM MAN.

See II. A. A. 3 and 4.

B. STRIPED MUSCLE.

B. FROM ANIMALS.

- 62.** Portion of striped muscle of chicken, showing the individual muscular fibres, with their transverse striæ.
B. 1.

Magnified 250 diameters; 4-inch objective (Wales) and amplifier (Tolles).

See Part First, III. B. B. 12 and 13.

- 63.** Single striped muscular fibre of chicken, showing the transverse striæ.
B. 2.

Magnified 250 diameters; 4-inch objective (Wales) and amplifier (Tolles).

See Part First, III. B. B. 12 and 13.

- 102.** Striped muscular fibre of mouse, showing the transverse striæ and the nuclei of the sarcolemma.
B. 3.

Magnified 337 diameters; 4-inch objective (Wales).

Photographed by Assistant Surgeon J. J. Woodward, U. S. Army.

Photographed from Specimen 1101, Part First, III. B. B. 11.

- 125.** Same object as **B. 3.** The nuclei of the sarcolemma are better defined, though the striæ are fainter.
B. 4.

Magnified 370 diameters; 4-inch objective (Wales).

C. PATHOLOGICAL.

See XV. A. B. 1 to 3.

IV. OSSEOUS SYSTEM.

(SUBDIVISIONS SAME AS IN PART FIRST.)

A. CARTILAGE AND PERICONDRIUM.

B. FROM ANIMALS.

- 6.** View from section of articular cartilage from knee joint of ox, showing multiplication by division of the cartilage cells and nuclei within the capsules.

B. 1. Magnified 250 diameters: $\frac{1}{10}$ -inch objective (Tollés).

Photographed from Specimen 1012, Part First, IV, A. B. 3.

- 7.** View from section of articular cartilage from knee joint of ox, showing several young cartilage cells still enclosed in one capsule. The outlines of the capsule are not well defined.

B. 2. Magnified 216 diameters: $\frac{1}{10}$ -inch objective (Tollés) and eyepiece.

Photographed from the same Specimen as B. 1.

- 81.** View from section of rib cartilage of calf, showing single mononucleated cartilage cells in their capsules.

B. 3. Magnified 370 diameters: $\frac{1}{4}$ -inch objective (Wales).

Photographed from Specimen 931, Part First, IV, A. B. 7.

- 85.** Same subject as **B. 3**, illustrating the first step in cell-multiplication. Near the centre of the field is a cartilage cell containing two young nuclei in close juxtaposition, produced by division of the parent nucleus.

B. 4. Magnified 370 diameters: $\frac{1}{4}$ -inch objective (Wales).

Photographed from the same Specimen as B. 3.

- 86.** Same subject as **B. 3**, illustrating the commencement of the second step in cell-multiplication. As in **B. 4**, there is a single cell with two nuclei, but the nuclei are here widely separated, and the cell itself is ready to divide.

B. 5. Magnified 370 diameters: $\frac{1}{4}$ -inch objective (Wales).

Photographed from the same Specimen as B. 3.

- 87.** Same subject as **B. 3**, illustrating the second step in cell-multiplication. The cell has now divided, and two cells, each with its nucleus, are seen enclosed in a single capsule.

B. 6. Magnified 370 diameters: $\frac{1}{4}$ -inch objective (Wales).

Photographed from the same Specimen as B. 3.

- 88.** Same subject as **B. 3**, illustrating the commencement of the third step in cell-multiplication. Four young cells are seen still enclosed in one capsule, but the latter is commencing to subdivide.

B. 7. Magnified 370 diameters: $\frac{1}{4}$ -inch objective (Wales).

Photographed from the same Specimen as B. 3.

- 89.** Same subject as **B. 3**, illustrating the third and last step in cell-multiplication. The capsule has divided, and young cells, each with nucleus and capsule of its own, are seen in various degrees of separation from each other.

B. 8. Magnified 370 diameters: $\frac{1}{4}$ -inch objective (Wales).

Photographed from the same Specimen as B. 3.

- 103.** View from section of rib cartilage of calf, showing a group of young cartilage cells.

B. 9. Magnified 357 diameters: $\frac{1}{4}$ -inch objective (Wales).

Photographed by Assistant Surgeon J. J. Woodward, U. S. Army.

Photographed from Specimen 930, Part First, IV, A. B. 7.

B. BONE.

A. FROM MAN.

- 19.** View from longitudinal section of shaft of femur, showing the lacunæ and canaliculi of the compact substance.

A. 1. Magnified 178 diameters; $\frac{1}{2}$ -inch objective (Tolles) and eyepiece.

Photographed from Specimen 1063, Part First, IV. B. A. 2.

- 20.** View from transverse section of shaft of femur, showing the Haversian systems and the lamellar structure of the compact substance.

A. 2. Magnified 178 diameters; $\frac{1}{2}$ -inch objective (Tolles) and eyepiece.

Photographed from Specimen 1080, Part First, IV. B. A. 2.

- 126.** View from transverse section of shaft of humerus, showing the Haversian systems, lacunæ and canaliculi, in the compact substance.

A. 3. Magnified 180 diameters; $\frac{1}{10}$ -inch objective (Wales).

- 127.** View from longitudinal section of shaft of femur, showing lacunæ and canaliculi.

A. 4. Magnified 180 diameters; $\frac{1}{10}$ -inch objective (Wales).

Photographed from Specimen 1063, Part First, IV. B. A. 2.

C. PATHOLOGICAL.

- 26.** View from transverse section of portion of compact substance of shaft of human femur, from a case of osteomyelitis, showing large cavities produced in the bone by ulceration, apparently starting from the walls of the Haversian canals.

C. 1. Magnified 38 diameters; $1\frac{1}{2}$ -inch objective (Wales).

Photographed from Specimen 1073, Part First, IV. B. C. 1.

F. SYNOVIAL MEMBRANES.

A. FROM MAN.

- 59.** View of synovial fringes from finger joint with transparent carmine injection, showing the capillary loops.

A. 1. Magnified 105 diameters; $\frac{1}{10}$ -inch objective (Wales).

Photographed from Specimen 1059, Part First, IV. F. A. 1.

V. VASCULAR SYSTEM.

(SUBDIVISIONS SAME AS IN PART FIRST.)

II. BLOOD AND LYMPH.

A. FROM MAN.

- 64.** Human blood corpuscles. Water was added to the blood and many of the corpuscles are crenated.
A. 1. Magnified 457 diameters; $\frac{1}{4}$ -inch objective (Wales).
- 65.** Human blood corpuscles, dried on a slide. Taken a little out of focus so as to show the corpuscles with a dark centre and light border.
A. 2. Magnified 750 diameters; $\frac{1}{4}$ -inch objective (Wales).
- 66.** Human blood corpuscles, dried on a slide. Taken in exact focus.
A. 3. Magnified 1116 diameters; $\frac{1}{4}$ -inch objective and amplifier (Wales).
- 122.** Human blood corpuscles, dried on a slide. Taken a little out of focus, like **A. 2.**, so as to show a dark centre with a light border.
A. 4. Magnified 370 diameters; $\frac{1}{4}$ -inch objective (Wales).

See Part First, V. H. A. 1.

B. FROM ANIMALS.

- 123.** Blood corpuscles of pigeon, dried on a slide.
B. 1. Magnified 370 diameters; $\frac{1}{4}$ -inch objective (Wales).
Photographed from Specimen 387, Part First, V. H. B. 1
- 124.** Blood corpuscles of frog, dried on a slide.
B. 2. Magnified 370 diameters; $\frac{1}{4}$ -inch objective (Wales).
See Part First, V. H. B. 2.

VI. NERVOUS SYSTEM.

(SUBDIVISIONS SAME AS IN PART FIRST.)

D. SPINAL CORD.

B. FROM ANIMALS.

- 22.** Thin, stained, multipolar nerve cells, with their processes attached, from spinal cord of cat.
B. 1. Magnified 180 diameters; $\frac{1}{4}$ -inch objective (Wales).
Photographed from Specimen 1558, Part First, VI. D. B. 11.

VII. DIGESTIVE ORGANS.

(SUBDIVISIONS SAME AS IN PART FIRST.)

II. SMALL INTESTINE.

B. FROM ANIMALS.

- 90.** Four villi from small intestine of mouse, with transparent carmine injection, showing the capillary loops in the villi.

Magnified 84 diameters; $\frac{3}{16}$ -inch objective (Wales).

Photographed (by the electric light) from Specimen 591, Part First, VII. II. B. 21.

C. PATHOLOGICAL.

- 91.** View from perpendicular section of human ileum, showing enlargement and protrusion of the solitary glands. The section passes a little to one side of the centres of the glands.

Magnified 12 diameters; 3-inch objective (Wales).

Photographed from Specimen 417, Part First, VII. H. C. 1.

- 19.** Same subject as **C. 1**, the section passing through the centres of the glands.

Magnified 12 diameters; 3-inch objective (Wales).

Photographed from Specimen 421, Part First, VII. II. C. 1.

- 93.** View from perpendicular section of human ileum, showing a thickened and protuberant Peyer's patch, which has entirely lost its glandular structure.

Magnified 12 diameters; 3-inch objective (Wales).

Photographed from Specimen 1688, Part First, VII. II. C. 5.

- 58.** View from perpendicular section of human ileum, showing the minute anatomy of the diseased condition exhibited in **C. 3**. The view embraces the connective tissue layer of the intestine and portion of the altered Peyer's patch, and shows active cell-multiplication of the connective tissue corpuscles and degeneration of the Peyer's patch into a confusedly granular mass.

Magnified 105 diameters; $\frac{1}{16}$ -inch objective (Wales).

Photographed from Specimen 446, Part First, VII. H. C. 6.

- 17.** View from perpendicular section of human ileum, showing commencing ulceration in the glands of a Peyer's patch, and thickening of the submucous connective tissue.

Magnified 12 diameters; 3-inch objective (Wales).

Photographed from Specimen 447, Part First, VII. H. C. 8.

- 18.** View from perpendicular section of human ileum, showing various stages of ulceration of the glands of a Peyer's patch.

Magnified 12 diameters; 3-inch objective (Wales).

Photographed from Specimen 455, Part First, VII. H. C. 8.

- 23.** View from same object as **C. 6**.

C. 7. Magnified 33 diameters; $\frac{1}{4}$ -inch objective (Zentmayer) and eyepiece.

- 21.** View from same object as **C. 6**.

C. 8. Magnified 37 diameters; $\frac{3}{16}$ -inch objective (Zentmayer).

- 25.** View from perpendicular section of human ileum, showing two excavated glands of a Peyer's patch at the point of rupture.

Magnified 35 diameters; $\frac{1}{16}$ -inch objective (Zentmayer).

Photographed from Specimen 457, Part First, VII. II. C. 9.

- 27.** View from perpendicular section of human ileum, showing several glands of a Peyer's patch softened and disintegrated in their centres.
C. 10. Magnified 26 diameters: $\frac{1}{4}$ -inch objective (Zentmayer) and eyepiece.
Photographed from Specimen 165, Part First, VII. II. c. 10.
- 16.** View from perpendicular section of human ileum, showing a deep smooth ulcer in a Peyer's patch extending down to the muscular coat of the intestine.
C. 11. Magnified 12 diameters: $\frac{3}{16}$ -inch objective (Wales).
Photographed from Specimen 166, Part First, VII. II. c. 11.
- 29.** View from perpendicular section of human ileum, embracing the same ulcer as **C. 11.**
C. 12. Magnified 35 diameters: $\frac{3}{16}$ -inch objective (Zentmayer).
Photographed from Specimen 167, Part First, VII. II. c. 11.
- 27.** View of one lateral half of same object as **C. 12.**
C. 13. Magnified 66 diameters: $\frac{3}{16}$ -inch objective (Zentmayer) and eyepiece.
- 28.** Duplicate of **C. 13.**
C. 14.
- 113.** View from perpendicular section of human ileum, close to an excavating ulcer, showing part of the connective tissue layer eroded. Also a solitary gland commencing to soften.
C. 15. Magnified 12 diameters: $\frac{3}{16}$ -inch objective (Wales).
Photographed from Specimen 1715, Part First, VII. II. c. 12.
- 115.** View from another section of the same series as **C. 15**, passing through the centre of the excavating ulcer, and showing a point of ulceration in the centre of the solitary gland.
C. 16. Magnified 12 diameters: $\frac{3}{16}$ -inch objective (Wales).
Photographed from Specimen 1717, Part First, VII. II. c. 12.
- 116.** View from another section of the same series as **C. 15** and **16**, showing the excavating ulcer as in **C. 16**, and an established ulcer in the solitary gland.
C. 17. Magnified 12 diameters: $\frac{3}{16}$ -inch objective (Wales).
Photographed from Specimen 1750, Part First, VII. II. c. 12.
- 130.** View from another section of the same series as **C. 15**, showing the excavating ulcer.
C. 18. Magnified 12 diameters: $\frac{3}{16}$ -inch objective (Wales).
Photographed from Specimen 1756, Part First, VII. II. c. 12.
- 15.** View from perpendicular section of human ileum, showing a typhoid ulcer of a Peyer's patch in process of healing.
C. 19. Magnified 12 diameters: $\frac{3}{16}$ -inch objective (Wales).
Photographed from Specimen 1711, Part First, VII. II. c. 14.

I. LARGE INTESTINE AND CLOACA.

C. PATHOLOGICAL.

- 32.** View from perpendicular section of human colon, showing slight thickening of the connective tissue layer.
C. 1 Magnified 12 diameters: $\frac{1}{4}$ -inch objective (Zentmayer) with the front lens removed.
Photographed from Specimen 638, Part First, VII. I. c. 1.
- 31.** View from same object as **C. 1**, more highly magnified, showing commencing cell-multiplication in the submucous connective tissue.
C. 2 Magnified 35 diameters: $\frac{3}{16}$ -inch objective (Zentmayer).
- 11.** View from same object as **C. 1**, more highly magnified. Similar to **C. 2.**
C. 3 Magnified 56 diameters: $\frac{1}{4}$ -inch objective (Zentmayer) and eyepiece.

- 15.** View from same object as **C. 1**, embracing the lower portion of the mucous, and upper portion of the connective tissue layers.
C. 4. Magnified 200 diameters; $\frac{1}{3}$ -inch objective (Tolles) and eyepiece.
- 31.** View from perpendicular section of human colon, showing two enlarged solitary glands.
C. 5. Magnified 12 diameters; 3-inch objective (Wales).
Photographed from Specimen 650, Part First, VII. I. c. 3.
- 38.** View from perpendicular section of human colon, showing two solitary glands, one considerably enlarged.
C. 6. Magnified 12 diameters; 3-inch objective (Wales).
Photographed from Specimen 656, Part First, VII. I. c. 5.
- 37.** View from perpendicular section of human colon, showing commencing ulceration over the summits of several solitary glands.
C. 7. Magnified 12 diameters; 3-inch objective (Wales).
Photographed from a Specimen belonging to the series, VII. I. c. 5, which has since spoiled and is not catalogued.
- 39.** View from perpendicular section of human colon, showing commencing ulcers, same as in **C. 7**.
C. 8. Magnified 12 diameters; 3-inch objective (Wales).
Photographed from Specimen 658, Part First, VII. I. c. 5.
- 40.** View from perpendicular section of human colon, showing shallow ulceration of the mucous membrane around a solitary gland.
C. 9. Magnified 12 diameters; 3-inch objective (Wales).
Photographed from Specimen 662, Part First, VII. I. c. 6.
- 30.** View from perpendicular section of human colon, showing a small excavating ulcer and wide shallow ulcers of the mucous coat.
C. 10. Magnified 12 diameters; 3-inch objective (Wales).
Photographed from Specimen 683, Part First, VII. I. c. 12.
- 13.** View from another section of the same series as **C. 10**, passing nearer the centre of the small excavating ulcer.
C. 11. Magnified 12 diameters; 3-inch objective (Wales).
Photographed from Specimen 681, Part First, VII. I. c. 12.
- 91.** Duplicate of **C. 11**.
C. 12.
- 8.** View of the small ulcer represented in **C. 11**, more highly magnified.
C. 13. Magnified 33 diameters; $\frac{8}{10}$ -inch objective (Zentmayer).
9. Duplicate of **C. 13**.
C. 14.
- 10.** Same as **C. 13**, more highly magnified.
C. 15. Magnified 75 diameters; $\frac{8}{10}$ -inch objective (Zentmayer) and eyepiece.
- 11.** View from perpendicular section of human colon, showing a deep wide ulcer extending down to the muscular coat, a shallow ulcer of the mucous coat, and an excavated ulcer of the connective tissue layer.
C. 16. Magnified 12 diameters; 3-inch objective (Wales).
Photographed from Specimen 687, Part First, VII. I. c. 14.
- 92.** View from perpendicular section of human colon, showing deep ragged ulcers of the mucous and connective tissue layers.
C. 17. Magnified 12 diameters; 3-inch objective (Wales).
Photographed from Specimen 1535, Part First, VII. I. c. 16.
- 36.** View from perpendicular section of human colon, showing deep and extensive ulcers.
C. 18. Magnified 12 diameters; 3-inch objective (Wales).
Photographed from Specimen 691, Part First, VII. I. c. 17.

- 12.** View from perpendicular section of human colon, showing deep and extensive ulcers.
C. 19. Magnified 12 diameters; 3-inch objective (Wales).
Photographed from Specimen 711, Part First, VII. I. c. 19.
- 11.** View from perpendicular section of human colon, showing deep and extensive ulcers.
C. 20. Magnified 12 diameters; 3-inch objective (Wales).
Photographed from Specimen 712, Part First, VII. I. c. 19.
- 79.** View from perpendicular section of human colon, showing great thickening and so-called pseudo-membranous exudation.
C. 21. Magnified 12 diameters; 3-inch objective (Wales).
Photographed from Specimen 731, Part First, VII. I. c. 22.
- 118.** View of portion of mucous membrane of the same section as **C. 21**, showing the minute anatomy of the pathological changes in that tissue.
C. 22. Magnified 106 diameters; $\frac{1}{10}$ -inch objective (Wales).

K. LIVER AND GALL-BLADDER.

B. FROM ANIMALS

- 17.** View from section of liver of sheep, injected, showing the capillaries of the lobules.
B. 1. Magnified 21 diameters; 11-inch objective (Zentmayer) and eyepiece.
Photographed from Specimen 859, Part First, VII. K. B. 2.
- 18.** Same object as **B. 1**.
B. 2. Magnified 48 diameters; $\frac{1}{10}$ -inch objective (Zentmayer) and eyepiece

L. CHEMICAL CONSTITUENTS OF BILE.

A. FROM MAN.

See **XIV. D. A. 1 and 2.**

VIII. RESPIRATORY ORGANS.

(SUBDIVISIONS SAME AS IN PART FIRST.)

(1) LUNGS, GILLS AND AIR-BLADDER.

B. FROM ANIMALS.

- 97.** View from preparation of lung of toad, with transparent carmine injection, showing the capillary network in the walls of the air vesicles.
B. 1 Magnified 30 diameters; 3-inch objective (Wales).
Photographed from Specimen 812, Part First, VIII. C. B. 3.

XIV. PATHOLOGICAL GROWTHS.

(SUBDIVISIONS SAME AS IN PART FIRST.)

D. CHOLESTERINE TUMORS.

A. FROM MAN.

- 12.** View of scrap of a cholesteatoma, showing the tabular plates of cholesteroline.
A. 1. Magnified 190 diameters; $\frac{1}{4}$ -inch objective (Tolles) and eyepiece.
Photographed from a piece of the same tumor that furnished Specimens 370 and 371, Part First.
- XIV. D. A. 1.**
- 13.** Same subject as **A. 1**, showing cholesteroline plates and the hexagonal cells that composed the matrix of the tumor.
A. 2. Magnified 190 diameters; $\frac{1}{4}$ -inch objective (Tolles) and eyepiece.

XV. PARASITES.

(SUBDIVISIONS SAME AS IN PART FIRST.)

A. ANIMAL.

A. FROM MAN.

- 101.** Human flea (*Pulex irritans*).
A. 1. Magnified 32 diameters; $\frac{1}{2}$ -inch objective (Zentmayer).
- 105.** Human head louse (*Pediculus capitis*).
A. 2. Magnified 32 diameters; $\frac{1}{2}$ -inch objective (Zentmayer).
- 106.** Itch mite (*Acarus scabiei*).
A. 3. Magnified 180 diameters; $\frac{1}{10}$ -inch objective (Wales).
Photographed from Specimen 1870, Part First, XV. A. A. 4.
- 107.** Pimple mite (*Demodex folliculorum*).
A. 4. Magnified 180 diameters; $\frac{1}{10}$ -inch objective (Wales).
- 108.** Two claws of crab louse (*Phthirus pubis*).
A. 5. Magnified 180 diameters; $\frac{1}{10}$ -inch objective (Wales).

B. FROM ANIMALS.

- 60.** Encysted *Trichina spiralis* in situ in muscle of mouse.
B. 1. Magnified 105 diameters; $\frac{1}{10}$ -inch objective (Wales).
- 61.** *Trichina spiralis* from muscle of mouse.
B. 2. Magnified 183 diameters; $\frac{1}{2}$ -inch objective (Wales).
- 83.** Encysted *Trichina spiralis* in situ in muscle of mouse.
B. 3. Magnified 370 diameters; $\frac{1}{4}$ -inch objective (Wales).
Photographed from Specimen 1116, Part First, III. B. C. 5.

XVI. ARTICLES OF FOOD AND CLOTHING, AND MATERIA MEDICA.

(SUBDIVISIONS SAME AS IN PART FIRST.)

A. ARTICLES OF FOOD.

- 121.** Starch grains of arrow-root.
A. 1. Magnified 370 diameters; $\frac{1}{2}$ -inch objective (Wales).
Photographed from Specimen 1161, Part First, XVI. A. 25.
- 120.** View from section of roasted coffee berry.
A. 2. Magnified 370 diameters; $\frac{1}{2}$ -inch objective (Wales).
Photographed from Specimen 1171, Part First, XVI. A. 25.

B. ARTICLES OF CLOTHING.

- 110.** White woolen hair.
B. 1. Magnified 370 diameters; $\frac{1}{2}$ -inch objective (Wales).
Photographed from Specimen 1877, Part First, XVI. B. 1.
- 111.** Tangle of cotton fibres.
B. 2. Magnified 370 diameters; $\frac{1}{2}$ -inch objective (Wales).
Photographed from Specimen 1882, Part First, XVI. B. 2.
- 112.** Tangle of fibres of flax.
B. 3. Magnified 370 diameters; $\frac{1}{2}$ -inch objective (Wales).
Photographed from Specimen 1889, Part First, XVI. B. 3.
- 113.** Fibre of silk.
B. 4. Magnified 370 diameters; $\frac{1}{2}$ -inch objective (Wales).
Photographed from Specimen 1892, Part First, XVI. B. 4.

XVII. DIATOMS AND OTHER TEST OBJECTS.

(SUBDIVISIONS SAME AS IN PART FIRST.)

B. SELECTED DIATOMS.

D. STRIATELLEE.

- 133.** *Grammatopora*, showing the transverse striae.
D. 1. Magnified 522 diameters; $\frac{1}{10}$ -inch objective (Wales).
Photographed from Specimen 1585, Part First, XVII. B. D. 4.
- 131.** Same object as **D. 1.**, more highly magnified.
D. 2. Magnified 1291 diameters; $\frac{1}{10}$ -inch objective and amplifier (Wales).

E. COSCINODISCEE.

- 82.** *Coscinodiscus ophthalanthus*.
F. 1. Magnified 370 diameters; $\frac{1}{10}$ -inch objective (Wales).
Photographed from Specimen 1937, Part First, XVII. B. F. 9.
- 78.** *Heliopelta Lecuenerhækii*.
F. 2. Magnified 235 diameters; $\frac{1}{10}$ -inch objective (Wales).
Photographed from Specimen 1937, Part First, XVII. B. F. 9.
- 81.** *Heliopelta Lecuenerhækii*.
F. 3. Magnified 370 diameters; $\frac{1}{10}$ -inch objective (Wales).
Photographed from Specimen 1600, Part First, XVII. B. F. 8.
- 80.** *Arachnoidiscus Ehrenbergii*.
F. 4. Magnified 370 diameters; $\frac{1}{10}$ -inch objective (Wales).
Photographed from Specimen 1591, Part First, XVII. B. F. 12.
- 128.** Same object as **F. 4.**
F. 5. Magnified 522 diameters; $\frac{1}{10}$ -inch objective (Wales).

O. NAVICULEE.

- 119.** *Navicula rhomboides*, with the markings resolved into squares.
O. 1. Magnified 850 diameters; $\frac{1}{10}$ -inch objective and amplifier (Wales).
Photographed from Specimen 1912, Part First, XVII. B. O. 4.
- 131.** *Navicula scrians*, with the markings resolved.
O. 2. Magnified 522 diameters; $\frac{1}{10}$ -inch objective (Wales).
Photographed from Specimen 1608, Part First, XVII. B. O. 3.
- 132.** *Navicula (Pinnularia) rividis*.
O. 3. Magnified 370 diameters; $\frac{1}{10}$ -inch objective (Wales).
Photographed from Specimen 1608, Part First, XVII. B. O. 3.
- 129.** *Stauroneis*, with the circular bead-like markings perfectly resolved.
O. 4. Magnified 522 diameters; $\frac{1}{10}$ -inch objective (Wales).
Photographed from Specimen 1605, Part First, XVII. B. O. 10.
- 99.** *Pleurosigma farmosum*, with the markings resolved.
O. 5. Magnified 337 diameters; $\frac{1}{10}$ -inch objective (Wales).
Photographed by Assistant Surgeon J. J. Woodward, U. S. Army.
Photographed from Specimen 1586, Part First, XVII. B. O. 13.

- 100.** Portion of same frustule as **O. 5.**, more highly magnified.
O. 6. Magnified 2540 diameters; $\frac{1}{4}$ -inch objective and amplifier (Wales).
 Photographed by Assistant Surgeon J. J. Woodward, U. S. Army.
- 95.** View of slide of *Pleurosigma angulatum*, to show the minute size of the frustules.
O. 7. Magnified 12 diameters; 3-inch objective (Wales).
- 96.** Same object as **O. 7.**, more highly magnified.
O. 8. Magnified 118 diameters; $\frac{1}{10}$ -inch objective (Wales).
- 138.** *Pleurosigma angulatum*, with the markings resolved into dots on viewing the negative with a lens.
O. 9. Magnified 170 diameters; $\frac{1}{10}$ -inch objective (Wales).
- 139.** *Pleurosigma angulatum*, (same frustule as in **O. 9.**), with the markings resolved into dots.
O. 10. Magnified 250 diameters; $\frac{1}{10}$ -inch objective (Wales).
- 140.** *Pleurosigma angulatum*, (same frustule as in **O. 9.**), with the markings resolved into dots.
O. 11. Magnified 370 diameters; $\frac{1}{10}$ -inch objective (Wales).
- 141.** *Pleurosigma angulatum*, (same frustule as in **O. 9.**), with the markings resolved into dots.
O. 12. Magnified 522 diameters; $\frac{1}{10}$ -inch objective (Wales).
- 137.** Portion of valve of *Pleurosigma angulatum*, (same frustule as in **O. 9.**), with the markings resolved into perfectly defined circular spots.
O. 13. Magnified 2540 diameters; $\frac{1}{4}$ -inch objective and amplifier (Wales).
- 98.** Portion of valve of *Pleurosigma angulatum*, similar to **O. 13.**
O. 14. Magnified 2540 diameters; $\frac{1}{4}$ -inch objective and amplifier (Wales).
 Photographed by Assistant Surgeon J. J. Woodward, U. S. Army.
- 67.** Portion of valve of *Pleurosigma angulatum*, similar to **O. 13.**
O. 15. Magnified 2540 diameters; $\frac{1}{4}$ -inch objective and amplifier (Wales).
- 73.** Portion of valve of *Pleurosigma angulatum*, (same frustule as in **O. 15.**), similar to **O. 15.**
O. 16. Magnified 2311 diameters; $\frac{1}{10}$ -inch objective (Powell and Lealand).
- 75.** Portion of valve of *Pleurosigma angulatum*, showing the circular markings four-tenths of an inch in diameter.
O. 17. Magnified 19050 diameters; enlarged from negative 67 (**O. 15.**).
- 76.** Portion of valve of *Pleurosigma angulatum*, similar to **O. 17.**
O. 18. Magnified 19050 diameters; enlarged from negative 73 (**O. 16.**)
See Part First, XXIII, B, o. 15 to 17.
- 101.** *Pleurosigma attenuatum*, with the markings resolved.
O. 19. Magnified 337 diameters; $\frac{1}{4}$ -inch objective (Wales).
 Photographed by Assistant Surgeon J. J. Woodward, U. S. Army.

Photographed from Specimen 1951, Part First, XXIII, B, o. 20.

C, OTHER TEST OBJECTS.

- 135.** Scales of *Podara*, showing the spikes.
C. 1. Magnified 322 diameters; $\frac{1}{10}$ -inch objective (Wales).
 Photographed from Specimen 1515, Part First, XXVII, C, 2.
- 136.** Portion of one of the same scales of *Podara* as in **C. 1.**, showing the spikes.
C. 2. Magnified 1650 diameters; $\frac{1}{10}$ -inch objective (Powell and Lealand).
- 142.** Scale of *Podara* (same scale as in **C. 2.**), showing the spikes.
C. 3. Magnified 1650 diameters; $\frac{1}{10}$ -inch objective and amplifier (Wales).
- 146.** Scale of *Podara*, showing the spikes perfectly resolved into a dark contour and bright centre.
C. 4. Magnified 1400 diameters; $\frac{1}{10}$ -inch objective and amplifier (Wales).

XVIII. MISCELLANEOUS.

- I.** Crystals of sulphate of lime.
Magnified 17 diameters; $1\frac{1}{2}$ -inch objective (Zeutmayor).
Photographed from Specimen 2052, Part First, XVIII.
- 109.** Portion of eye of fly.
Magnified 180 diameters; $\frac{1}{10}$ -inch objective (Wales).
- 111.** Threads of spider's web.
Magnified 370 diameters; $\frac{1}{4}$ -inch objective (Wales).



Part Third.

PHOTOMICROGRAPHS PRESENTED TO THE MUSEUM.

1. A volume of thirty-one photomicrographs from negatives taken by Dr. R. L. Maddox, of Southampton, England, representing the following objects—magnifying powers not stated:

<i>Pleurosigma angulatum.</i>	Parasite of martin.
<i>Pleurosigma formosum.</i>	Male parasite of sparrow.
<i>Pleurosigma decorum.</i>	Female parasite of sparrow.
<i>Actinosphania splendens.</i>	Sycamore leaf insect.
<i>Actinosphania splendens</i> (more highly magnified).	Tongue of drone fly.
<i>Heliopelta Lecanuchakii.</i>	Eye of drone fly.
Dise from Barbadoes earth.	Tongue of blow fly.
<i>Empodiscus Ralfsii.</i>	Foot of fly.
<i>Pinnularia.</i>	Spiracle of <i>Dytiscus</i> .
<i>Naxicula didyma.</i>	Head of female gnat.
Transverse section of spine of <i>Echinus</i> .	Section of tooth of <i>Myliobatis</i> .
<i>Auliscus oralis.</i>	Seed of <i>Ecerinocarpus</i> .
<i>Licinophora flabellata.</i>	Pupa case of gnat.
Male flea of mole.	Larva of gnat.
Female flea of mole.	Blood discs of newt.
Male flea of pigeon.	

Presented by Dr. Maddox.

2. Two stereoscopic photomicrographs from negatives taken by Dr. R. L. Maddox, of Southampton, England, representing the following objects—magnifying powers not stated:

Coscinodiscus radiatus; *Biddulphia Rhombus*.

Presented by Dr. Maddox.

3. A volume of sixteen photomicrographs from negatives taken by Professor Joseph Gerlach, of Erlangen, Bavaria, representing the following objects:

Blood corpuscles of frog; magnified 250 diameters.
Passage of muscular fibre into tendon; magnified 250 diameters.
Human ovum in situ in Graafian follicle; magnified 50 diameters.
Epithelial scales from cavity of mouth of man; magnified 320 diameters.
Striped muscular fibre of man; magnified 250 diameters.
Axisfibræ from white substance of spinal cord of calf, stained with carmine; magnified 250 diameters; printed in carmine.
Human choroid, injected; magnified 25 diameters; printed in carmine.
Section of human cerebellum, stained with carmine; magnified 15 diameters; printed in carmine.
Villi of intestine of cat, injected; magnified 50 diameters; printed in carmine.
Membrana chorio-capillaris from human eye, injected; magnified 25 diameters; printed in carmine.
Bile-ducts in human liver, injected with Berlin blue; magnified 120 diameters; printed in aniline blue.
Venous loops in papilla of human kidney, injected with Berlin blue; magnified 50 diameters; printed in aniline blue.

Lymphatic vessels of connective tissue of calf, injected with Berlin blue; magnified 15 diameters; printed in aniline blue.

Transverse section of human bone; magnified 250 diameters.

Smooth muscular fibre of man; magnified 300 diameters.

Human blood corpuscles; magnified 500 diameters; printed in the coloring matter of pig's blood.

Presented by Professor Gerlach.

4. Six photomicrographs of shells of *Foraminifera*, from negatives taken by Count L. F. Pourtales, of Washington, D. C., representing specimens of the following genera—magnifying powers not stated:

Globigerina; *Polystomella*; *Marginulina*; *Nobosaria*; *Dentalina*.

Presented by Count Pourtales.

5. Seven photomicrographs from negatives taken by Assistant Surgeons William Thomson and W. F. Norris, U. S. Army, representing the following objects—magnifying powers not stated:

Perpendicular section of skin from sole of foot.

Idem, from a different specimen.

Section of human kidney.

Idem, more highly magnified.

Perpendicular section of upper eyelid of negro.

Longitudinal section of shaft of human femur.

Transverse section of the same.

Presented by Assistant Surgeons Thomson and Norris, U. S. Army.

6. Fourteen photomicrographs from negatives taken by Dr. C. F. Crehore, of Boston, Mass., representing the following objects—magnifying powers not stated:

Cornea of rabbit, injected; 3-inch objective (Wales). Photographed by the magnesium light. (Two prints.)

Section of kidney of rabbit, injected; 3-inch objective (Wales). Photographed by the magnesium light.

Tongue of rabbit, injected; 4-inch objective (Tolles). Photographed by the magnesium light.

Same as above; ½-inch objective (Wales). Photographed by the magnesium light.

Transverse section of bone; ½-inch objective (Wales). Photographed by sunlight.

Section of tooth of *Mytilus*; ½-inch objective (Wales). Photographed by sunlight.

Cascinidiscus; ½-inch objective (Wales). Photographed by the magnesium light uncondensed.

Same as above. Photographed by sunlight.

Tooth of saw-fish; 3-inch objective (Wales). Photographed by the magnesium light.

Branchial foot of *Nereis*; 3-inch objective (Wales). Photographed by the magnesium light.

Cascinidiscus; ½-inch objective (Wales). Photographed by sunlight.

Print from an enlarged transparent positive, copied from the negative of the above by a 3-inch objective (Wales) and the magnesium light.

Origin of the auditory and facial nerves; 3-inch objective (Wales). Photographed by the magnesium light.

Presented by Dr. Crehore.

7. Two photomicrographs from negatives taken by Surgeon H. Culbertson, U. S. Vols., representing the plume of a gnat's wing, and a young spider's claw. Taken with a 1-inch objective—magnifying power not stated.

Presented by Surgeon Culbertson, U. S. Vols.

8. Photomicrograph from a negative taken by Professor O. N. Rood, of New York, representing a portion of valve of *Platystrophia angulatum*; magnified 7000 diameters.

Presented by Professor Rood.

9. Photomicrograph from a negative taken by Mr. L. M. Rutherturd, of New York, representing a scale of *Podura*—magnifying power not stated.

Presented by Mr. Rutherturd.

10. Six photomicrographs from negatives taken by Mr. J. H. Woodworth, of Dublin, Ireland, representing the following objects:

Asthma verrucosa; magnified 200 diameters.

Tetractinum Varus; magnifying power not stated.

Skin of *Synapta*; magnified 40 diameters.

Foot of *Dytiscus*; magnified 20 diameters.

Small sucker from same; magnifying power not stated.

Varus scaber; magnifying power not stated.

Presented by Mr. Woodworth.

INDEX

OF

PREPARERS OF SPECIMENS

IN THE

MICROSCOPICAL SECTION.

B.

- Beach, W. F.—p. 121, 1914, 1915, 1916; p. 122, 1917, 1918, 1921, 1925, 1926, 1927, 1928, 1929, 1930, 1931; p. 123, 1935, 1936; p. 124, 1938, 1939, 1940, 1941; p. 125, 1945, 1946, 1948, 1949, 1950, 1952, 1953.
- Beale, Lionel S.—p. 9, 1267; p. 15, 1266, 1264; p. 29, 1265.
- Billings, J. S.—p. 9, 1633; p. 13, 1627, 1629, 530, 1207; p. 15, 1611; p. 24, 533, 1618; p. 29, 531, 1010; p. 30, 1679, 1680, 1681, 1630, 1631; p. 31, 1682, 1616, 1623, 1678, 1683, 1684; p. 41, 1612; p. 42, 1619, 1621; p. 43, 1622; p. 48, 405, 406, 531; p. 49, 527, 510; p. 52, 535, p. 62, 529, 818; p. 65, 822, 1631; p. 69, 1617, 828; p. 70, 839, 528; p. 76, 1624, 1625, 1626, 1628, 1632; p. 92, 532; p. 115, 2058, 2059, 2060, 2061, 2062; p. 116, 2063, 2064, 2065, 2066, 2067, 2068, 2069, 2070, 2071, 2072, 2073, 2074, 2075, 2076, 2077, 2078; p. 117, 2079, 2080, 2081, 2082, 2083, 2084, 2085, 2086, 2087, 2088, 2089, 2090; p. 129, 932, 1009, 1031, 1269, 1299, 1501, 1832, 2053, 2054, 2055, 2056, 2057.
- Bourgogne Frères.—p. 76, 981.
- Bourgogne, J.—p. 31, 1081, 1082, 1083; p. 49, 399, 400, 401, 402; p. 87, 1491, 1349; p. 122, 1580, 1505; p. 124, 1512, 1518, 1503; p. 125, 1508, 1578, 1506, 1579.

E.

- Edes, R. T.—p. 41, 1551, 1517, 1552; p. 42, 1550, 1518, 1519.
- Edwards, Arthur M.—p. 121, 1911; p. 122, 1589, 1606, 1599; p. 123, 1602, 1603, 1598, 1587, 1588, 1600, 1590, 1591, 1592, 1593, 1594, 1595, 1596; p. 124, 1607, 1609, 1610, 1597, 1608, 1912, 1913, 1601; p. 125, 1911, 1605; p. 129, 1604.

F.

- Febiger, Christian.—p. 123, 1934.

G.

- Gerlach, Joseph.—p. 42, 1558, 1556; p. 53, 1560; p. 58, 1555; p. 70, 1554; p. 91, 1553; p. 92, 1559; p. 97, 1557.

H.

Hyrtl, Joseph.—p. 9, **25, 26**; p. 10, **21, 353**; p. 14, **1, 2, 3, 4, 5, 6, 7, 8, 9, 10, 11, 12, 13, 14, 15, 16, 17, 18, 19**; p. 15, **20, 21, 30, 31, 32, 33**; p. 16, **31, 39, 10, 11, 12, 13, 14, 15, 339, 358**; p. 17, **32, 23, 35, 36, 37, 38**; p. 19, **17, 38**; p. 23, **27, 311**; p. 24, **318, 319, 320, 321**; p. 25, **323, 321, 326, 195**; p. 32, **325, 327, 329, 330, 351, 328**; p. 35, **315, 316, 317, 322, 319**; p. 36, **28, 351, 29, 352, 287, 288**; p. 41, **331**; p. 42, **335**; p. 43, **331, 332, 333**; p. 44, **350**; p. 47, **196, 197, 198, 276, 277, 280, 289**; p. 48, **306, 307, 308, 309, 310, 311**; p. 49, **199**; p. 50, **157, 158, 159, 160, 161, 178, 181, 182, 183, 181, 185**; p. 51, **186, 187, 200, 205, 207, 215, 219, 232, 233, 212, 213, 241, 216, 219, 250**; p. 52, **162, 163, 161, 165, 166, 167, 168, 169, 170**; p. 54, **179, 188, 189, 190**; p. 55, **191, 192, 193, 201, 202, 204, 208, 209, 213, 211, 216, 217, 221, 222, 223, 224, 225, 226, 228**; p. 56, **229, 230, 231, 231, 235, 236, 237, 238, 239, 240, 241, 247**; p. 58, **360, 171, 172, 173, 174, 175, 176, 177, 180**; p. 59, **16, 191, 203, 206, 210, 212, 218, 227, 211, 220, 215, 218**; p. 62, **251, 252, 253, 251, 255, 256, 257**; p. 63, **258, 259, 260, 261, 262, 263, 261, 265, 266, 267, 268, 269, 270, 271, 272, 273, 274, 275**; p. 64, **278, 279, 290, 292, 281, 286, 285, 355**; p. 69, **56, 63, 57, 76, 58**; p. 70, **49, 52, 53, 54, 55, 60, 61, 62**; p. 71, **64, 65, 66, 67, 68, 69, 70, 71, 72, 73, 74, 75, 77, 78, 79, 80, 81, 82, 83, 84**; p. 72, **85, 86, 87, 88, 59, 51, 59, 356, 357, 282, 283, 281**; p. 75, **89, 90, 91, 93, 91, 95, 96, 97**; p. 77, **98, 99, 100, 101, 102, 103, 104, 105**; p. 78, **106, 107, 108, 109, 110, 111, 117, 118, 119, 120, 121, 122, 123, 124, 125, 126, 127, 128, 129, 130, 131**; p. 79, **132, 133, 134, 135, 136, 137, 138, 139, 140, 141, 142, 143, 144, 147, 148, 149, 150, 151**; p. 80, **152, 153, 154, 155, 156, 318, 92, 116, 145, 146**; p. 81, **112, 113, 316, 114**; p. 83, **145**; p. 87, **336, 337, 338, 340, 341, 344, 345**; p. 88, **342, 343, 291, 317**; p. 91, **297, 298, 301**; p. 92, **299, 302, 303, 304, 296, 300, 305**; p. 93, **291, 295, 293**; p. 101, **312, 313**; p. 105, **359**.

J.

Jones, S. A.—p. 15, **103**; p. 42, **375**; p. 75, **975, 976, 977**; p. 77, **978, 979**; p. 88, **1199**; p. 109, **1500, 2046, 2047**.

P.

Powell & Lealand (Specimens procured from).—p. 126, **2101, 2102**.

Q.

Queen, J. W. & Co. (Specimens procured from).—p. 25, **1561**; p. 109, **1562**; p. 121, **1517**; p. 122, **1511, 1585, 1509**; p. 123, **1937, 1502**; p. 124, **1516, 1583**; p. 125, **1581, 1582, 1584**.

S.

Schaffhirt, A. J.—p. 32, **1685**.

Sim, T. (Specimens presented by).—p. 83, **1036**; p. 88, **1195**.

Smith, Beck & Beck—p. 126, **1513**.

Sullivan, W. S.—p. 122, **1919, 1920, 1921, 1922, 1923**.

T.

Topping, C. M.—p. 31, **1014**; p. 122, **2091, 2092**; p. 125, **1586, 2093, 2091, 2095, 2096, 2097, 2098**; p. 126, **2099, 2100**.

W.

Woodward, J. J.—p. 13, **1192, 1193, 1191, 1195**; p. 32, **1075**; p. 60, **639, 640, 641, 651, 652, 669**; p. 81, **991, 995, 996**; p. 82, **1002, 1018, 1021, 1022, 1028, 1001, 1012**; p. 122, **1510**; p. 125, **1507, 1917**; p. 126, **1514, 1515**.

Prepared in the Museum.—p. 9, 1120, 1121, 1615, 1620, 1665; p. 13, 1233, 1264, 1295, 1206, 1142, 1143, 1144, 1145, 1146, 1147, 1148, 1224, 1225, 1172, 1173, 1174, 1171, 1166, 1197, 1198, 1199, 1200, 1201, 1170, 1983, 1984, 1985, 1986, 1987, 1988, 1989, 1990, 1991, 1992, 1993, 1994, 1995, 1996, 1997, 1998, 1999, 2000, 2001, 2002, 2003, 2004, 2005, 2006, 2007, 2008, 2009, 2010, 2011, 2013, 2039; p. 14, 1171; p. 15, 1087, 1088, 1089, 1090, 1091, 1092, 1093, 1094, 1257, 1258, 1259, 1260, 372, 373, 374, 1255, 1256, 1262, 2012; p. 16, 863, 864, 865, 866, 867, 868, 869, 870, 871, 872, 873, 874, 875, 876, 877, 878, 879, 880, 881, 882, 883, 884, 885, 886, 887; p. 17, 2011, 2015, 411, 412, 413, 414, 415, 1270, 1271, 1272, 1273, 1274, 1275, 1276, 1279, 1280, 1281; p. 18, 1613, 1614, 1284, 1285, 1286, 1287, 1288, 1289, 1290, 1175, 1176, 1177, 1178, 1179, 1180, 1181, 1182, 1183, 1293, 1294, 1295, 1296, 1297, 1298, 1350, 1351, 1352, 1353, 1354, 1355, 1356, 1357, 1358, 1359, 1360, 1361, 1362, 1363, 1364, 1365, 1366, 1367, 1368, 1369, 1370, 1371, 1372, 1373, 1374, 1375, 1376, 1377, 1378, 1379, 1380, 1381, 1382, 1383, 1384, 1385, 1386, 1387, 1388, 1389, 1390, 1391, 1392, 1393, 1394, 1395, 1401; p. 19, 1229, 1230, 1231, 1268, 1432; p. 23, 1119, 1312, 1973, 1974, 508, 509, 1100, 1138, 1139, 1140, 888, 889, 890, 891, 892, 893, 894, 895, 896, 897, 898, 899, 900, 901, 902; p. 24, 1654, 1655, 1656, 1657, 1658, 1659, 1660, 1661, 1184, 1185, 1186, 1187, 1188, 1189, 1190, 1191, 474, 475, 476, 477, 478, 1101, 1102, 1103, 1104, 1105, 1106, 1107, 1108, 1095, 1096, 1097, 1098, 1099, 1226, 1227, 1228, 1123, 1124, 1125, 1126, 1127, 1128, 1967, 1968, 1969, 1970, 1971, 2016, 2017, 2018, 2019, 2020, 2021, 2022, 2045; p. 25, 1232, 1233, 1234, 1235, 1236, 1237, 1238, 1239, 1240, 1241, 1242, 1669, 1670, 1671, 1672, 1673, 1674, 179, 480, 481, 482, 483, 484, 485, 486, 487, 488, 489, 490, 491, 492, 493, 494, 495, 1111, 1112, 1113, 1114, 1115, 1109, 1116, 1117, 1118, 1141, 1037, 1038, 1039, 1041; p. 29, 1051, 1052, 1045, 1046, 1048, 1049, 1043, 906, 907, 908, 909, 910, 911, 912, 913, 914, 915, 916, 917, 918, 919, 920, 921, 922, 923, 924, 925, 926, 927, 928, 929, 930, 931, 1330, 1331, 1332, 1333, 1334, 1335, 1336, 1346, 1347, 1348; p. 30, 1062, 1063, 1064, 1065, 1066, 1067, 1080, 1071, 1068, 1069, 1070, 1072; p. 31, 1049, 1050, 458, 459, 460, 461, 1017, 1073, 1074; p. 32, 1076, 1077, 1078, 1079, 1059, 1060, 1061; p. 35, 1084, 1085, 1086, 526, 436, 437, 438, 439, 440, 1666, 1667, 1668; p. 37, 608, 387, 609, 610, 611, 612, 613, 614, 615, 616, 617, 618, 619, 620, 621, 622, 623, 624, 2018, 2049, 2050; p. 41, 496, 497, 498, 499, 500, 501, 502, 503, 504, 505, 506, 507, 1513, 1514, 1515, 1960, 1961, 2033, 2034; p. 42, 1149, 1150, 1151, 1152, 1153, 1154, 1155, 1156, 1157, 1158, 1159, 1160, 1161, 1162, 1163, 1164, 1165, 1166, 376, 377, 378, 379, 380, 381, 382, 383, 384, 385, 1167, 1168, 1169, 1208, 1209, 1210, 1211, 1212, 1213, 1214, 1215, 1216, 1217, 1218, 1962, 1963, 1964, 1965; p. 43, 1512, 517, 602, 518, 1040, 857, 858; p. 44, 1277, 1278, 1243, 1966; p. 47, 1662, 1663, 1664; p. 48, 388, 389, 390, 391, 392, 393, 394, 941, 942, 943, 944, 945, 946, 947, 948, 949, 950, 951, 952, 953, 555, 556, 557, 558, 559, 560, 561, 562, 563, 564, 565, 566, 586, 587, 588, 589, 540, 541, 542, 543, 544, 545, 546, 547, 548, 549, 550, 551, 552, 553, 554, 1219, 1220, 1221; p. 49, 395, 396, 397, 398, 1951, 4540, 569, 570; p. 50, 473, 567, 568, 1955, 1956, 1972; p. 51, 1327, 1328, 1329, 1313, 1314, 1315; p. 52, 408, 409, 410, 404, 1563, 574, 572, 573, 574, 575, 576, 1141, 577, 578, 1442, 1514, 1053, 1054; p. 53, 605, 606, 1222, 1223, 1282, 1283, 954, 955, 956, 957, 958, 959, 960, 961, 962, 963, 964, 965, 966, 967, 607, 608, 595, 756, 757, 758, 1314, 1315, 1316, 1575, 1576, 1317, 1318, 1319, 1320, 1321, 1322, 1323, 1324, 1325, 759, 584, 585, 586, 587, 760, 761, 762, 763, 764, 765, 766, 767, 1300, 1301, 1302, 1303, 1313, 588, 589, 590, 1304, 1305; p. 54, 1306, 768, 591, 592, 593, 594, 769, 770, 771, 772, 773, 774, 775, 776, 777, 604, 596, 1326, 597, 598, 599, 584, 582, 583, 778, 779, 780, 781, 782, 783, 784, 785, 786, 580, 600, 601, 1957, 1958; p. 56, 416, 417, 418, 419, 420, 421, 422, 423, 424, 425, 426, 427, 428, 429, 430, 431, 432, 433, 434, 435; p. 57, 441, 442, 443, 1686, 1687, 1688, 1689, 1690, 1691, 1692, 1693, 1694, 1695, 1696, 1697, 1698, 1699, 1700, 1701, 1702, 1703, 1704, 1705, 1706, 1707, 1708, 1709, 1710, 1711, 1712, 1713, 1714, 1715, 1716, 1717, 416, 1718, 1719, 1720, 1721, 1722, 1723, 1724, 1725, 1726, 1727, 1728, 1729, 1730, 1731, 1732, 1733, 1734, 1735, 1736, 1737, 1738, 1739, 1740, 1741, 447, 448, 449, 450, 451, 452, 453, 454, 455, 456, 457, 462, 463, 464, 465, 466, 467, 468, 469, 1742, 1743, 1744, 1745, 1746, 1747, 1748, 1749, 1750, 1751, 1752, 1753, 1754, 1755, 1756, 1757, 1758, 1759, 1760, 1761, 1762, 1763, 1764, 1765, 1766, 1767, 1768, 1769, 1770, 1771; p. 58, 470, 471, 472, 497, 579, 787, 635, 632, 633, 634; p. 59, 788, 789, 790, 625, 626, 627, 628, 629, 630, 631, 794, 792, 793, 794, 795, 796, 797, 798, 799, 636, 637; p. 60, 638, 642, 643, 644, 645, 646, 647, 648, 649, 650, 653, 654, 655, 656, 657, 658, 659, 660, 661, 662, 663, 664, 665, 666, 667, 668,

670, 671, 672, 673, 674, 675, 676, 677, 678, 679, 680, 681, 682, 683, 684, 685,
 p. 61, 686, 687, 688, 689, 690, 691, 1520, 1521, 1522, 1523, 1524, 1525, 1526, 1527,
 1528, 1529, 1530, 1531, 1532, 1533, 1534, 1535, 1536, 1537, 692, 693, 694, 695,
 696, 697, 698, 699, 700, 701, 702, 703, 704, 705, 706, 707, 708, 709, 710, 711, 712,
 713, 714, 715, 716, 717, 718, 719, 720, 721, 722, 723, 724, 725, 726, 727, 728, 729,
 730, 731, 732, 733, 734, 735, 736, 737, 738, 739, 740, 741, 742, 743, 744, 745, 746,
 747, 748, 749, 750, 751, 752, 753, 754, 755; p. 62, 861, 848, 800, 801, 802, 803, 859,
 860, 801, 805, 806, 807, 808, 809, 810, 811, 812, 813, 814, 815, 816, 817, 1539,
 1959; p. 63, 862; p. 64, 933, 934, 935, 936, 937, 938, 939, 851, 852, 853, 854, 855, 856;
 p. 65, 819, 820, 821, 1307, 1308, 823, 2035, 819, 850, 824, 825, 826, 827; p. 69, 829,
 1975, 2030; p. 70, 519, 520, 521, 522, 523, 830, 834, 832, 833, 834, 835, 836, 837,
 838, 840, 524, 811, 812, 813, 814, 525; p. 75, 1772, 1773, 1774, 1775, 1776, 1777,
 1778, 1538, 2023, 2024, 2025; p. 76, 815, 816, 817, 981, 982, 983, 1779, 1780, 1781,
 1782, 1783, 1309, 1784, 1785, 1786, 1787, 1788, 1789, 1790, 1791, 1792, 1793,
 1794, 1795, 1796, 1797; p. 77, 1798, 1799, 1800, 1801, 1802, 1564, 1565, 1566, 1567,
 1568, 1569, 1570, 1571, 1572, 1573, 1574, 1803, 1804, 1805, 1806, 1807, 1808,
 1809, 968, 969, 970, 971, 972, 973, 1810, 1811, 1812, 1813, 1977, 1976, 2026, 2027,
 2028; p. 80, 1814, 1815, 1816, 1817, 980, 974; p. 81, 985, 991, 986, 987, 988, 989,
 990, 992, 993, 997; p. 82, 998, 999, 1000, 1003, 1004, 1005, 1006, 1007, 1008, 1011,
 1013, 1014, 1015, 1016, 1017, 1019, 1492, 1020, 1023, 1024, 1025, 1026, 1027,
 1029, 1030, 1034, 1032, 1033; p. 83, 1035; p. 87, 2042, 2043, 2044; p. 88, 1337, 1338,
 1339, 1340, 1344, 1342; p. 91, 1818, 1340, 1344, 1819, 1820, 1824, 1822, 1823, 514,
 515, 511, 513, 386, 512; p. 92, 1263, 1978, 1824, 1825, 1826, 1827, 1980; p. 93, 1828,
 1979, 2031, 1429, 1430, 1431, 1432, 1433, 1434, 1435, 1436, 1437, 1984, 516, 2032;
 p. 97, 1829, 1830, 1834, 1833; p. 101, 1982; p. 105, 1055, 1056, 1057, 1058, 1834, 1835,
 1836, 1837, 1838, 1839, 1840, 1841, 1842, 1843, 1844, 1845, 1846, 1847, 1848,
 1849, 1850, 1851, 1852, 1853, 1854, 1244, 1245, 1246, 1247, 1248, 1249, 1250,
 1251, 1252, 1253, 1254, 1855, 1856, 1857, 1858, 1859, 1860, 1864, 1862, 1863,
 1864, 364, 362, 363, 364, 365, 366, 367, 368, 369, 2036, 2037, 2038, 2039, 2040,
 2041, 903, 904, 905; p. 106, 370, 371; p. 109, 1865, 1866, 1867, 1868, 1869, 1497,
 1870, 1496, 1294, 1292; p. 113, 1396, 1397, 1398, 1399, 1400, 1402, 1403, 1404,
 1405, 1406, 1407, 1408, 1409, 1410, 1411, 1412, 1413, 1414, 1415, 1416, 1417,
 1418, 1419, 1420, 1421, 1422, 1423, 1424, 1425, 1426, 1427, 1428, 1429, 1430,
 1431, 1433, 1434, 1435, 1436, 1437, 1438, 1439; p. 114, 1440, 1443, 1444, 1445,
 1446, 1447, 1448, 1449, 1450, 1451, 1452, 1453, 1454, 1455, 1456, 1457, 1458,
 1459, 1460, 1464, 1462, 1463, 1464, 1465, 1466, 1467, 1468, 1469, 1470, 1471,
 1472, 1473, 1474, 1475, 1489, 1490, 1491, 1493, 1476, 1477, 1478, 1479, 1480,
 1481, 1482, 1483, 1484, 1485, 1486, 1487, 1488, 2119, 2120; p. 115, 1874, 1875,
 1876, 1877, 1878, 1879, 1880, 1884, 1882, 1883, 1884, 1885, 1886, 1887, 1888,
 1889, 1890, 1891, 1892, 1893, 1894, 1895, 1896, 2103, 2104, 2105, 2106, 2107,
 2108, 2109, 2110, 2111, 2112, 2113, 2114, 2115, 2116, 2117, 2118; p. 121, 1897,
 1898, 1899, 1900, 1904, 1902, 1903, 1904, 1905, 1906, 1907, 1908, 1909, 1910,
 1912, 1913; p. 123, 1932, 1933; p. 125, 1954; p. 129, 444, 448, 2054, 2052, 1504.

INDEX

OF

SPECIMENS IN THE MICROSCOPICAL SECTION.

NOTE.—Numbers marked N. C. (not catalogued) represent Specimens that have been prepared in the Museum and subsequently exchanged for preparations of other makers.

<i>Spec.</i>	<i>Page.</i>	<i>Spec.</i>	<i>Page.</i>	<i>Spec.</i>	<i>Page.</i>	<i>Spec.</i>	<i>Page.</i>	<i>Spec.</i>	<i>Page.</i>	<i>Spec.</i>	<i>Page.</i>	<i>Spec.</i>	<i>Page.</i>	<i>Spec.</i>	<i>Page.</i>
1	14	52	70	103	77	151	80	205	51	256	62	307	48	358	16
2	14	53	70	101	77	155	80	206	59	257	62	308	48	359	105
3	14	54	70	105	77	156	80	207	51	258	63	309	48	360	58
4	14	55	70	106	78	157	50	208	55	259	63	310	48	361	105
5	14	56	69	107	78	158	50	209	55	260	63	311	48	362	105
6	14	57	69	108	78	159	50	210	59	261	63	312	101	363	105
7	14	58	69	109	78	160	50	211	59	262	63	313	101	364	105
8	14	59	72	110	78	161	50	212	59	263	63	314	23	365	105
9	14	60	70	111	78	162	52	213	55	264	63	315	35	366	105
10	14	61	70	112	81	163	52	214	55	265	63	316	35	367	105
11	14	62	70	113	81	164	52	215	51	266	63	317	35	368	105
12	14	63	69	114	81	165	52	216	55	267	63	318	24	369	105
13	14	64	71	115	83	166	52	217	55	268	63	319	24	370	106
14	14	65	71	116	80	167	52	218	59	269	63	320	24	371	106
15	14	66	71	117	78	168	52	219	51	270	63	321	24	372	15
16	14	67	71	118	78	169	52	220	59	271	63	322	35	373	15
17	14	68	71	119	78	170	52	221	55	272	63	323	25	374	15
18	14	69	71	120	78	171	58	222	55	273	63	324	25	375	42
19	14	70	71	121	78	172	58	223	55	274	63	325	32	376	42
20	15	71	71	122	78	173	58	224	55	275	63	326	25	377	42
21	15	72	71	123	78	174	58	225	55	276	47	327	32	378	42
22	17	73	71	124	78	175	58	226	55	277	47	328	32	379	42
23	17	74	71	125	78	176	58	227	59	278	64	329	32	380	42
24	10	75	71	126	78	177	58	228	55	279	64	330	32	381	42
25	9	76	69	127	78	178	50	229	56	280	47	331	43	382	42
26	9	77	71	128	78	179	54	230	56	281	72	332	43	383	42
27	23	78	71	129	78	180	58	231	56	282	72	333	43	384	42
28	36	79	71	130	78	181	50	232	54	283	72	334	41	385	42
29	15	80	71	131	78	182	50	233	51	284	64	335	42	386	91
30	15	81	71	132	79	183	50	234	56	285	64	336	87	387	37
31	15	82	71	133	79	184	50	235	56	286	64	337	87	388	48
32	15	83	71	134	79	185	50	236	56	287	36	338	87	389	48
33	15	84	71	135	79	186	51	237	56	288	36	339	16	390	48
34	16	85	72	136	79	187	51	238	56	289	47	340	87	391	48
35	17	86	72	137	79	188	54	239	56	290	64	341	87	392	48
36	17	87	72	138	79	189	54	240	56	291	88	342	88	393	48
37	17	88	72	139	79	190	54	241	56	292	64	343	88	394	48
38	17	89	75	140	79	191	55	242	51	293	93	344	87	395	49
39	16	90	75	141	79	192	55	243	51	294	93	345	87	396	49
40	16	91	75	142	79	193	55	244	51	295	93	346	81	397	49
41	16	92	80	143	79	194	59	245	59	296	92	347	88	398	49
42	16	93	75	144	79	195	25	246	54	297	91	348	80	399	49
43	16	94	75	145	79	196	47	247	56	298	91	349	35	400	49
44	16	95	75	146	80	197	47	248	59	299	92	350	44	401	49
45	16	96	75	147	79	198	47	249	51	300	92	351	36	402	49
46	59	97	75	148	79	199	49	250	51	301	91	352	36	403	15
47	19	98	77	149	79	200	51	251	62	302	92	353	10	404	52
48	19	99	77	150	79	201	55	252	62	303	92	354	32	405	48
49	70	100	77	151	79	202	55	253	62	304	92	355	64	406	48
50	72	101	77	152	80	203	59	254	62	305	92	356	72	407	58
51	72	102	77	153	80	204	55	255	62	306	48	357	72	408	52

Spec.	Page.	Spec.	Page.	Spec.	Page.	Spec.	Page.	Spec.	Page.	Spec.	Page.	Spec.	Page.	Spec.	Page.
109	52	187	25	565	47	613	60	721	61	799	59	877	16	955	53
110	52	188	25	566	48	611	60	722	61	800	62	878	16	956	53
111	17	189	25	567	50	615	60	723	61	801	62	879	16	957	53
112	17	190	25	568	50	616	60	724	61	802	62	880	16	958	53
113	17	191	25	569	49	617	60	725	61	803	62	881	16	959	53
114	17	192	25	570	49	618	60	726	61	804	62	882	16	960	53
115	17	193	25	571	52	619	60	727	61	805	62	883	16	961	53
116	56	194	25	572	52	650	60	728	61	806	62	884	16	962	53
117	56	195	25	573	52	651	60	729	61	807	62	885	16	963	53
118	56	196	41	574	52	652	60	730	61	808	62	886	16	964	53
119	56	197	41	575	52	653	60	731	61	809	62	887	16	965	53
120	56	198	41	576	52	654	60	732	61	810	62	888	23	966	53
121	56	199	41	577	52	655	60	733	61	811	62	889	23	967	53
122	56	500	41	578	52	656	60	734	61	812	62	890	23	968	77
123	56	501	41	579	58	657	60	735	61	813	62	891	23	969	77
124	56	502	41	580	54	658	60	736	61	814	62	892	23	970	77
125	56	503	41	581	54	659	60	737	61	815	62	893	23	971	77
126	56	504	41	582	54	660	60	738	61	816	62	894	23	972	77
127	56	505	41	583	54	661	60	739	61	817	62	895	23	973	77
128	56	506	41	584	53	662	60	740	61	818	62	896	23	974	77
129	56	507	41	585	53	663	60	741	61	819	65	897	23	975	75
130	56	508	23	586	53	664	60	742	61	820	65	898	23	976	75
131	56	509	23	587	53	665	60	743	61	821	65	899	23	977	75
132	56	510	49	588	53	666	60	744	61	822	65	900	23	978	77
133	56	511	91	589	53	667	60	745	61	823	65	901	23	979	77
134	56	512	91	590	53	668	60	746	61	824	65	902	23	980	70
135	56	513	91	591	54	669	60	747	61	825	65	903	105	981	76
136	35	514	91	592	54	670	60	748	61	826	65	904	105	982	76
137	35	515	91	593	54	671	60	749	61	827	65	905	105	983	76
138	35	516	93	594	54	672	60	750	61	828	69	906	29	984	76
139	35	517	43	595	53	673	60	751	61	829	69	907	29	985	74
140	35	518	43	596	54	674	60	752	61	830	70	908	29	986	74
141	57	519	79	597	54	675	60	753	61	831	70	909	29	987	74
142	57	520	79	598	54	676	60	754	61	832	70	910	29	988	74
143	57	521	79	599	53	677	60	755	61	833	70	911	29	989	74
144	129	522	70	600	54	678	60	756	53	834	70	912	29	990	74
145	N. C.	523	70	601	54	679	60	757	53	835	70	913	29	991	74
146	57	524	70	602	43	680	60	758	53	836	70	914	29	992	74
147	57	525	70	603	53	681	60	759	53	837	70	915	29	993	74
148	57	526	35	604	51	682	60	760	53	838	70	916	29	994	74
149	57	527	49	605	53	683	60	761	53	839	70	917	29	995	74
150	57	528	70	606	53	684	60	762	53	840	70	918	29	996	74
151	57	529	62	607	53	685	60	763	53	841	70	919	29	997	74
152	57	530	13	608	37	686	61	764	53	842	70	920	29	998	74
153	57	531	18	609	37	687	61	765	53	843	70	921	29	999	74
154	57	532	92	610	37	688	61	766	53	844	70	922	29	1000	74
155	57	533	24	611	37	689	61	767	53	845	76	923	29	1001	74
156	57	534	29	612	37	690	61	768	54	846	76	924	29	1002	74
157	57	535	52	613	37	691	61	769	54	847	76	925	29	1003	74
158	31	536	48	614	37	692	61	770	54	848	62	926	29	1004	74
159	31	537	48	615	37	693	61	771	54	849	65	927	29	1005	74
160	31	538	48	616	37	694	61	772	54	850	65	928	29	1006	74
161	31	539	48	617	37	695	61	773	54	851	64	929	29	1007	74
162	57	540	48	618	37	696	61	774	54	852	64	930	29	1008	74
163	57	541	48	619	37	697	61	775	54	853	64	931	29	1009	74
164	57	542	48	620	37	698	61	776	54	854	64	932	29	1010	74
165	57	543	48	621	37	699	61	777	54	855	64	933	64	1011	74
166	57	544	48	622	37	700	61	778	54	856	64	934	64	1012	74
167	57	545	48	623	37	701	61	779	54	857	43	935	64	1013	74
168	57	546	48	624	37	702	61	780	54	858	43	936	64	1014	74
169	57	547	48	625	59	703	61	781	54	859	62	937	64	1015	74
170	58	548	48	626	59	704	61	782	54	860	62	938	64	1016	74
171	58	549	48	627	59	705	61	783	54	861	62	939	64	1017	74
172	58	550	48	628	59	706	61	784	54	862	63	940	N. C.	1018	74
173	50	551	48	629	59	707	61	785	54	863	16	941	4	1019	74
174	24	552	48	630	59	708	61	786	54	864	16	942	4	1020	74
175	24	553	48	631	59	709	61	787	58	865	16	943	4	1021	74
176	24	554	48	632	58	710	61	788	59	866	16	944	4	1022	74
177	24	555	48	633	58	711	61	789	59	867	16	945	4	1023	74
178	24	556	18	634	58	712	61	790	59	868	16	946	4	1024	74
179	25	557	18	635	58	713	61	791	59	869	16	947	4	1025	74
180	25	558	18	636	59	714	61	792	59	870	16	948	4	1026	74
181	25	559	18	637	59	715	61	793	59	871	16	949	4	1027	74
182	25	560	18	638	60	716	61	794	59	872	16	950	4	1028	74
183	25	561	18	639	60	717	61	795	59	873	16	951	4	1029	74
184	25	562	18	640	60	718	61	796	59	874	16	952	4	1030	74
185	25	563	18	641	60	719	61	797	59	875	16	953	4	1031	74
186	25	564	18	642	60	720	61	798	59	876	16	954	53	1032	74

Spec.	Page.	Spec.	Page.	Spec.	Page.	Spec.	Page.	Spec.	Page.	Spec.	Page.	Spec.	Page.	Spec.	Page.	Spec.	Page.
1033	82	1111	25	1189	24	1267	9	1345	51	1423	113	1501	129	1579	125		
1031	129	1112	25	1190	24	1268	19	1346	29	1424	113	1502	123	1580	123		
1035	83	1113	25	1191	21	1269	129	1347	29	1425	113	1503	124	1581	125		
1036	83	1114	25	1192	13	1270	17	1348	29	1426	113	1504	129	1582	125		
1037	25	1115	25	1193	13	1271	17	1349	87	1427	113	1505	122	1583	124		
1038	25	1116	25	1194	13	1272	17	1350	18	1428	113	1506	125	1584	125		
1039	25	1117	25	1195	13	1273	17	1351	18	1429	113	1507	122	1585	122		
1040	43	1118	25	1196	13	1274	17	1352	18	1430	113	1508	125	1586	125		
1041	25	1119	23	1197	13	1275	17	1353	18	1431	113	1509	122	1587	123		
1042	29	1120	9	1198	13	1276	17	1354	18	1432	19	1510	122	1588	123		
1043	29	1121	9	1199	13	1277	44	1355	18	1433	113	1511	122	1589	122		
1044	31	1122	N. C.	1200	13	1278	44	1356	18	1434	113	1512	124	1590	123		
1045	29	1123	24	1201	13	1279	17	1357	18	1435	113	1513	126	1591	123		
1046	29	1124	24	1202	N. C.	1280	17	1358	18	1436	113	1514	126	1592	123		
1047	31	1125	24	1203	13	1281	17	1359	18	1437	113	1515	126	1593	123		
1048	29	1126	24	1204	13	1282	53	1360	18	1438	113	1516	124	1594	123		
1049	31	1127	24	1205	13	1283	53	1361	18	1439	113	1517	124	1595	123		
1050	31	1128	24	1206	13	1284	18	1362	18	1440	114	1518	124	1596	123		
1051	29	1129	93	1207	13	1285	18	1363	18	1441	52	1519	N. C.	1597	124		
1052	29	1130	93	1208	42	1286	18	1364	18	1442	52	1520	61	1598	123		
1053	52	1131	93	1209	42	1287	18	1365	18	1443	114	1521	61	1599	122		
1054	52	1132	93	1210	42	1288	18	1366	18	1444	114	1522	61	1600	123		
1055	105	1133	93	1211	42	1289	18	1367	18	1445	114	1523	61	1601	124		
1056	105	1134	93	1212	42	1290	18	1368	18	1446	114	1524	61	1602	123		
1057	105	1135	93	1213	42	1291	109	1369	18	1447	114	1525	61	1603	123		
1058	105	1136	93	1214	42	1292	109	1370	18	1448	114	1526	61	1604	129		
1059	29	1137	93	1215	42	1293	18	1371	18	1449	114	1527	61	1605	125		
1060	32	1138	23	1216	42	1294	18	1372	18	1450	114	1528	61	1606	122		
1061	32	1139	23	1217	42	1295	18	1373	18	1451	114	1529	61	1607	124		
1062	30	1140	23	1218	42	1296	18	1374	18	1452	114	1530	61	1608	124		
1063	30	1141	25	1219	48	1297	18	1375	18	1453	114	1531	61	1609	124		
1064	30	1142	13	1220	48	1298	18	1376	18	1454	114	1532	61	1610	124		
1065	30	1143	13	1221	48	1299	129	1377	18	1455	114	1533	61	1611	15		
1066	30	1144	13	1222	53	1300	53	1378	18	1456	114	1534	61	1612	41		
1067	30	1145	13	1223	53	1301	53	1379	18	1457	114	1535	61	1613	18		
1068	30	1146	13	1224	53	1302	53	1380	18	1458	114	1536	61	1614	18		
1069	30	1147	13	1225	53	1303	53	1381	18	1459	114	1537	61	1615	9		
1070	30	1148	13	1226	24	1304	53	1382	18	1460	114	1538	75	1616	31		
1071	30	1149	42	1227	24	1305	53	1383	18	1461	114	1539	62	1617	69		
1072	30	1150	42	1228	24	1306	54	1384	18	1462	114	1540	49	1618	24		
1073	31	1151	42	1229	19	1307	65	1385	18	1463	114	1541	52	1619	42		
1074	31	1152	42	1230	19	1308	65	1386	18	1464	114	1542	43	1620	9		
1075	32	1153	42	1231	19	1309	76	1387	18	1465	114	1543	41	1621	42		
1076	32	1154	42	1232	25	1310	91	1388	18	1466	114	1544	41	1622	43		
1077	32	1155	42	1233	25	1311	91	1389	18	1467	114	1545	31	1623	31		
1078	32	1156	42	1234	25	1312	23	1390	18	1468	114	1546	N. C.	1624	76		
1079	32	1157	42	1235	25	1313	53	1391	18	1469	114	1547	31	1625	76		
1080	30	1158	42	1236	25	1314	53	1392	18	1470	114	1548	42	1626	76		
1081	31	1159	42	1237	25	1315	53	1393	18	1471	114	1549	42	1627	13		
1082	31	1160	42	1238	25	1316	53	1394	18	1472	114	1550	42	1628	76		
1083	31	1161	42	1239	25	1317	53	1395	18	1473	114	1551	41	1629	13		
1084	35	1162	42	1240	25	1318	53	1396	113	1474	114	1552	41	1630	30		
1085	35	1163	42	1241	25	1319	53	1397	113	1475	114	1553	91	1631	30		
1086	35	1164	42	1242	25	1320	53	1398	113	1476	114	1554	70	1632	76		
1087	15	1165	42	1243	44	1321	53	1399	113	1477	114	1555	58	1633	9		
1088	15	1166	42	1244	105	1322	53	1400	113	1478	114	1556	42	1634	65		
1089	15	1167	42	1245	105	1323	53	1401	18	1479	114	1557	97	1635	N. C.		
1090	15	1168	42	1246	105	1324	53	1402	113	1480	114	1558	42	1636	N. C.		
1091	15	1169	42	1247	105	1325	53	1403	113	1481	114	1559	92	1637	N. C.		
1092	15	1170	13	1248	105	1326	54	1404	113	1482	114	1560	53	1638	N. C.		
1093	15	1171	14	1249	105	1327	51	1405	113	1483	114	1561	25	1639	N. C.		
1094	15	1172	13	1250	105	1328	51	1406	113	1484	114	1562	109	1640	N. C.		
1095	24	1173	13	1251	105	1329	51	1407	113	1485	114	1563	52	1641	N. C.		
1096	24	1174	13	1252	105	1330	29	1408	113	1486	114	1564	77	1642	N. C.		
1097	24	1175	18	1253	105	1331	29	1409	113	1487	114	1565	77	1643	N. C.		
1098	24	1176	18	1254	105	1332	29	1410	113	1488	114	1566	77	1644	N. C.		
1099	24	1177	18	1255	15	1333	29	1411	113	1489	114	1567	77	1645	N. C.		
1100	23	1178	18	1256	15	1334	29	1412	113	1490	114	1568	77	1646	N. C.		
1101	24	1179	18	1257	15	1335	29	1413	113	1491	114	1569	77	1647	N. C.		
1102	24	1180	18	1258	15	1336	29	1414	113	1492	82	1570	77	1648	N. C.		
1103	24	1181	18	1259	15	1337	88	1415	113	1493	114	1571	77	1649	N. C.		
1104	24	1182	18	1260	15	1338	88	1416	113	1494	87	1572	77	1650	N. C.		
1105	24	1183	18	1261	N. C.	1339	88	1417	113	1495	88	1573	77	1651	N. C.		
1106	24	1184	24	1262	15	1340	88	1418	113	1496	109	1574	77	1652	N. C.		
1107	24	1185	24	1263	15	1341	88	1419	113	1497	109	1575	53	1653	N. C.		
1108	24	1186	24	1264	15	1342	15	1420	113	1498	129	1576	53	1654	24		
1109	25	1187	24	1265	29	1343	51	1421	113	1499	85	1577	N. C.	1655	24		
1110	N. C.	1188	24	1266	15	1344	51	1422	113	1500	109	1578	125	1656	24		

<i>Spec.</i>	<i>Page.</i>	<i>Spec.</i>	<i>Page.</i>	<i>Spec.</i>	<i>Page.</i>	<i>Spec.</i>	<i>Page.</i>	<i>Spec.</i>	<i>Page.</i>	<i>Spec.</i>	<i>Page.</i>	<i>Spec.</i>	<i>Page.</i>	<i>Spec.</i>	<i>Page.</i>	<i>Spec.</i>	<i>Page.</i>
1657	24	1715	57	1773	75	1831	97	1889	115	1947	135	2005	13	2063	116		
1658	24	1716	57	1774	75	1832	129	1890	115	1948	125	2006	13	2064	116		
1659	24	1717	57	1775	75	1833	97	1891	115	1949	125	2007	13	2065	116		
1660	24	1718	57	1776	75	1834	105	1892	115	1950	125	2008	13	2066	116		
1661	24	1719	57	1777	75	1835	105	1893	115	1951	125	2009	13	2067	116		
1662	47	1720	57	1778	75	1836	105	1894	115	1952	125	2010	13	2068	116		
1663	47	1721	57	1779	76	1837	105	1895	115	1953	125	2011	13	2069	116		
1664	47	1722	57	1780	76	1838	105	1896	115	1954	49	2012	15	2070	116		
1665	9	1723	57	1781	76	1839	105	1897	121	1955	50	2013	13	2071	116		
1666	35	1724	57	1782	76	1840	105	1898	121	1956	50	2014	17	2072	116		
1667	35	1725	57	1783	76	1841	105	1899	121	1957	54	2015	17	2073	116		
1668	35	1726	57	1784	76	1842	105	1900	121	1958	54	2016	24	2074	116		
1669	25	1727	57	1785	76	1843	105	1901	121	1959	62	2017	24	2075	116		
1670	25	1728	57	1786	76	1844	105	1902	121	1960	41	2018	24	2076	116		
1671	25	1729	57	1787	76	1845	105	1903	121	1961	41	2019	24	2077	116		
1672	25	1730	57	1788	76	1846	105	1904	121	1962	42	2020	24	2078	116		
1673	25	1731	57	1789	76	1847	105	1905	121	1963	42	2021	24	2079	117		
1674	25	1732	57	1790	76	1848	105	1906	121	1964	42	2022	24	2080	117		
1675	N. C.	1733	57	1791	76	1849	105	1907	121	1965	42	2023	75	2081	117		
1676	N. C.	1734	57	1792	76	1850	105	1908	121	1966	44	2024	75	2082	117		
1677	N. C.	1735	57	1793	76	1851	105	1909	121	1967	21	2025	75	2083	117		
1678	31	1736	57	1794	76	1852	105	1910	121	1968	24	2026	77	2084	117		
1679	30	1737	57	1795	76	1853	105	1911	121	1969	24	2027	77	2085	117		
1680	30	1738	57	1796	76	1854	105	1912	121	1970	24	2028	77	2086	117		
1681	30	1739	57	1797	76	1855	105	1913	121	1971	24	2029	13	2087	117		
1682	31	1740	57	1798	77	1856	105	1914	121	1972	50	2030	69	2088	117		
1683	31	1741	57	1799	77	1857	105	1915	121	1973	23	2031	93	2089	117		
1684	31	1742	57	1800	77	1858	105	1916	121	1974	23	2032	93	2090	117		
1685	32	1743	57	1801	77	1859	105	1917	122	1975	60	2033	41	2091	122		
1686	57	1744	57	1802	77	1860	105	1918	122	1976	77	2034	41	2092	122		
1687	57	1745	57	1803	77	1861	105	1919	122	1977	77	2035	65	2093	125		
1688	57	1746	57	1804	77	1862	105	1920	122	1978	92	2036	105	2094	125		
1689	57	1747	57	1805	77	1863	105	1921	122	1979	93	2037	105	2095	125		
1690	57	1748	57	1806	77	1864	105	1922	122	1980	92	2038	105	2096	125		
1691	57	1749	57	1807	77	1865	109	1923	122	1981	93	2039	105	2097	125		
1692	57	1750	57	1808	77	1866	109	1924	122	1982	101	2040	105	2098	125		
1693	57	1751	57	1809	77	1867	109	1925	122	1983	13	2041	105	2099	126		
1694	57	1752	57	1810	77	1868	109	1926	122	1984	13	2042	87	2100	126		
1695	57	1753	57	1811	77	1869	109	1927	122	1985	13	2043	87	2101	126		
1696	57	1754	57	1812	77	1870	109	1928	122	1986	13	2044	87	2102	126		
1697	57	1755	57	1813	77	1871	N. C.	1929	122	1987	13	2045	24	2103	115		
1698	57	1756	57	1814	80	1872	N. C.	1930	122	1988	13	2046	109	2104	115		
1699	57	1757	57	1815	80	1873	N. C.	1931	122	1989	13	2047	109	2105	115		
1700	57	1758	57	1816	80	1874	115	1932	123	1990	13	2048	37	2106	115		
1701	57	1759	57	1817	80	1875	115	1933	123	1991	13	2049	37	2107	115		
1702	57	1760	57	1818	91	1876	115	1934	123	1992	13	2050	37	2108	115		
1703	57	1761	57	1819	91	1877	115	1935	123	1993	13	2051	129	2109	115		
1704	57	1762	57	1820	91	1878	115	1936	123	1994	13	2052	129	2110	115		
1705	57	1763	57	1821	91	1879	115	1937	123	1995	13	2053	129	2111	115		
1706	57	1764	57	1822	91	1880	115	1938	124	1996	13	2054	129	2112	115		
1707	57	1765	57	1823	91	1881	115	1939	124	1997	13	2055	129	2113	115		
1708	57	1766	57	1824	92	1882	115	1940	124	1998	13	2056	129	2114	115		
1709	57	1767	57	1825	92	1883	115	1941	124	1999	13	2057	129	2115	115		
1710	57	1768	57	1826	92	1884	115	1942	124	2000	13	2058	115	2116	115		
1711	57	1769	57	1827	92	1885	115	1943	124	2001	13	2059	115	2117	115		
1712	57	1770	57	1828	93	1886	115	1944	125	2002	13	2060	115	2118	115		
1713	57	1771	57	1829	93	1887	115	1945	125	2003	13	2061	115	2119	114		
1714	57	1772	75	1830	97	1888	115	1946	125	2004	13	2062	115	2120	114		

INDEX

OF

NEGATIVES IN THE MICROSCOPICAL SECTION.

NOTE.—Numbers marked N. C. (not catalogued) represent Negatives which are no longer printed from, they having been superseded by better Negatives of the same objects subsequently obtained.

<i>Neg.</i>	<i>Page.</i>	<i>Neg.</i>	<i>Page.</i>	<i>Neg.</i>	<i>Page.</i>	<i>Neg.</i>	<i>Page.</i>	<i>Neg.</i>	<i>Page.</i>	<i>Neg.</i>	<i>Page.</i>	<i>Neg.</i>	<i>Page.</i>	<i>Neg.</i>	<i>Page.</i>
1	139	20	139	39	143	58	141	77 N. C.	96	148	115	136	134	147	
2	136	21	142	40	143	59	139	78	147	97	144	116	136	135	148
3	136	22	140	41	143	60	145	79	144	98	148	117	136	136	148
4	136	23	141	42	144	61	145	80	147	99	147	118	136	137	148
5	136	24	141	43	143	62	137	81	137	100	148	119	137	138	148
6	138	25	141	44	141	63	137	82	137	101	148	120	146	139	148
7	138	26	139	45	142	64	140	83	145	102	137	121	146	140	148
8	143	27	142	46	132	65	140	84	138	103	138	122	140	141	148
9	143	28	142	47	141	66	140	85	138	104	145	123	140	142	148
10	143	29	142	48	141	67	148	86	138	105	145	124	140	143	142
11 N. C.		30	143	49	141	68 N. C.		87	138	106	145	125	137	144	142
12	145	31	142	50 N. C.		69 N. C.		88	138	107	145	126	139	145	142
13	145	32	142	51 N. C.		70 N. C.		89	138	108	145	127	139	146	148
14	142	33 N. C.		52 N. C.		71 N. C.		90	141	109	149	128	147	147	135
15	143	34	143	53 N. C.		72 N. C.		91	141	110	146	129	147	148	141
16	136	35 N. C.		54 N. C.		73	148	92	143	111	146	130	142	149	147
17	144	36	143	55 N. C.		74 N. C.		93	141	112	146	131	147		
18	144	37	143	56 N. C.		75	148	94	143	113	146	132	147		
19	139	38	143	57	135	76	148	95	148	114	149	133	147		





R
891
U5
v.2-3

U.S. Army Medical Museum
Catalogue

Biological
* Medical

PLEASE DO NOT REMOVE
CARDS OR SLIPS FROM THIS POCKET



UNIVERSITY OF TORONTO LIBRARY

